APPLIED VETERINARY HISTOLOGY

THIRD EDITION



William J. Banks

APPLIED VETERINARY HISTOLOGY

Downloaded From Vet-eBooks.com

APPLIED VETERINARY HISTOLOGY

WILLIAM J. BANKS, DVM, MS, PhD
Professor, Department of Veterinary Anatomy and Public Health
Associate Dean, Academic Programs
College of Veterinary Medicine
Texas Veterinary Medical Center
Texas A&M University
College Station, Texas

THIRD EDITION

Mosby
A *Harcourt Health Sciences Company*
St. Louis Philadelphia London Sydney Toronto

Downloaded From Vet-eBooks.com

Mosby
A Harcourt Health Sciences Company

Publisher: George Stamathis
Editor: Robert W. Reinhardt
Assistant Editor: Melba Steube
Production Editor: George B. Stericker, Jr.
Designer: Gail Morey Hudson

THIRD EDITION
Copyright © 1993 by Mosby, Inc.

Previous editions copyrighted 1981, 1986

All rights reserved. No part of this publication may be reproduced, stored in a retrieval system, or transmitted, in any form or by any means, electronic, mechanical, photocopying, recording, or otherwise, without prior written permission from the publisher.

Permission to photocopy or reproduce solely for internal or personal use is permitted for libraries or other users registered with the Copyright Clearance Center, provided that the base fee of $4.00 per chapter plus $.10 per page is paid directly to the Copyright Clearance Center, Inc., 222 Rosewood Drive, Danvers, MA 01923. This consent does not extend to other kinds of copying, such as copying for general distribution, for advertising or promotional purposes, for creating new collected works, or for resale.

Printed in the United States of America

Mosby, Inc.
11830 Westline Industrial Drive
St. Louis, Missouri 63146

Library of Congress Cataloging-in-Publication Data

Banks, William J.
Applied veterinary histology / William J. Banks.—3rd ed.
p. cm.
Includes bibliographical references and index.
1. Veterinary histology. I. Title.
1. Veterinary histology. I. Title.
SF757.3.B36 1992 92-10984
636.089'1018—dc20

ISBN 0-8016-6610-4

01 02 03 04 CL/MY 9 8 7 6 5 4 3

Dedicated to the memory of

DR. JARRETT W. NEWBREY

(1943-1990)

OUTSTANDING TEACHER, RESPECTED COLLEAGUE,
AND TREASURED FRIEND

Downloaded From Vet-eBooks.com

Preface to the Third Edition

Veterinary medical educators have spent the past 5 years carefully evaluating the professional veterinary medical education process. This evaluation has included in-depth self-assessments of teaching and learning processes and many content issues. The primary driving force has been to ensure that graduates would be capable of meeting the challenges placed upon them by society now and into the twenty-first century.

I was privileged to have been an active participant in the strategic planning process at Louisiana State University and A&M College and am privileged to be part of strategic implementation at Texas A&M University. I have been impacted significantly by these experiences. More importantly, they and the insights derived therefrom have been translated directly into this textbook.

The issues of information management, information integration, and use of the vast veterinary medical database in problem-solving are just a few hallmarks in the ongoing processes of strategic planning and implementation. Concerted attempts have been made in this edition to improve the presentation. The text has been reduced by more than 15%. Synonyms and eponyms, for the most part, have been removed; all histological names are in accordance with the *Nomina Anatomica Veterinaria,* a few synonyms and eponyms being retained for clarification purposes.

New tables have been added, and all diagrams, all flow charts, and some illustrations have been updated and redrawn. There are some 1065 illustrations (micrographs, drawings, flow charts), and 108 are in full color. Several new micrographs have been added.

I have throughout most of my professional life been a proponent for and involved in the delivery of integrated courses. A body of knowledge has more meaning and relevance when it is integrated into the knowledge base of other disciplines rather than being taught as a "stand alone" discipline. Thus, this textbook has evolved into an integrated and applied format over its extended life.

I am convinced now more than ever that the concepts of horizontal and vertical integration are not only applicable to modern medical education but also essential for its improvement. I undertook the revision of this textbook girded in the belief that an integrated presentation would foster more learning than would any other approach.

The organizational scheme has not changed. Functional and clinical applications are interwoven throughout the histological presentation. Five sections—*Introduction to Histology, Cell Biology, Histology, Comparative Organology,* and *Introduction to Exfoliative Cytology*—still comprise the backbone of the book.

All sections have been updated, reorganized, shortened, and rewritten. Brevity and clarity have been the objectives. *Section I* provides perspective upon which veterinary medical students can build their knowledge. *Section II* (Cell Biology) provides the necessary background for the remainder of the text materials. *Section III* (Histology) includes the classical tissues. *Section IV* (Comparative Organology) remains the bulk of the endeavor. *Section V* (Introduction to Exfoliative Cytology) has been improved, but its substance is not changed.

Students are still the primary focus of this textbook. It is written for them. Their feedback remains critically important. To date, their feedback has shown that it is a project worth continuing and improving. I had hoped from the onset that students would continue to use this textbook beyond their histology courses and beyond their first year in veterinary medical school. They tell me that, in fact, they use the book throughout their formal education. I consider that most gratifying.

Despite its functional and clinical considerations, the book is still a textbook of histology. Some of the information it contains will add to your general knowledge about the biomedical sciences without having some direct application to the practice of medicine. That should not be a cause for concern. As a veterinary medical practitioner, you will be exptected to have command of a wide variety of biomedical information.

The warm and friendly encouragement about this text from my students and colleagues has always been a source of great personal satisfaction. Their words have been the basis for my striving to produce a continually improving product. The continued input of students and colleagues is sought.

Information about errors, inaccuracies, or incomplete or confusing discourse would be much appreciated.

Many people deserve special credit for their assistance with this project. They have helped to make it what it is. The mistakes, however, are mine. The omissions, too, are mine. Hopefully, both will prove to be minimal.

Finally, I thank the many students from whom I continue to learn so much.

William J. Banks

College Station, Texas

Preface to the Second Edition

Embarking upon the original edition of this textbook about fourteen years ago represented the quest of a long-standing desire to write a textbook of veterinary histology. Although the completion of the project was as gratifying as envisioned originally, my feelings of gratification were gradually but continually eroded and replaced by a growing awareness of the shortcomings and ephemeral nature of the book. The need to modify, to improve, and to update—to maintain pace with the burgeoning wealth of knowledge—became the ultimate responsibility and source of satisfaction.

The encouragement of my veterinary colleagues and students has been a continual source of motivation. Students, especially, have always been willing to share their thoughts about the utility, clarity (or lack thereof), and appropriateness of various materials. Their feedback has been influential. Their positive comments have been a source of great personal satisfaction; their negative but constructive comments have become the grist of the mill of improvement. That seems appropriate! This book is for them.

The approach used in this textbook reflects clearly my personal philosophy about educational experiences in a medical curriculum. Disciplinary information, histology notwithstanding, should be coherent, integrated, and relevant. Indeed, the author is fortunate to be teaching in a professional veterinary medical curriculum that permits the expression of this philosophy. The knowledge and insights of veterinary histology must afford students the opportunity to expand their clinical problem-solving ability. Just as importantly, the integration of histology with other bodies of knowledge demonstrates the existence, ultimately, of one body of knowledge viewed through the perspective of different disciplinary windows. These are the principles that have governed the generation of the content of this book.

Students of veterinary medicine seem to have less and less time to learn more and more about the expanding body of knowledge encompassed by their profession. A teaching-type textbook becomes a valuable vehicle in maximizing their learning and minimizing the amount of time spent in the process. Opinions expressed by first-year students who have used the textbook at Colorado State University and other institutions indicate that this book complements their learning. Their complimentary comments about the book are gratifying. Too often, however, books purchased for a course do little else than collect dust on an obscure portion of a bookshelf upon completion of the specific course. Worse yet, they may be doomed by being recirculated through a previously-owned-book dealer. The most gratifying comments about this textbook have been from juniors, seniors, and graduates. They have related to me their continual use of the textbook throughout their education. If the book can become an "old friend" and help periodically throughout the total learning process, then the effort has been truly worthwhile.

The expansion of the knowledge base of a discipline is usually sufficient justification for expansion of textbooks. The broadening of the author's perspectives is also a reasonable justification. Both are operable in this situation. Although the new edition of this textbook has expanded, the inclusion and exclusion of new information has been approached judiciously. The problem for most authors, this one notwithstanding, is not what to include-definitive tomes are usually heavier than they are useful—but what to exclude and still achieve the varied goals of the textbook. The primary goal, however, remains being a useful book for students who must integrate structural and functional information.

The pertinent histology has been updated and expanded. I have resisted the temptation, however, of wholesale inclusion of ultrastructural information and electron micrographs. When included, it was done to enhance understanding and add to the coherence of a particular subject. Similarly, functional information has been expanded selectively and updated.

Histology is a visual science; the student learns the subject while looking through a microscope. The cryptic puzzles of tissue artchitecture are best deciphered when comparisons are possible. For this reason, the textbook is replete with illustrations. Numerous light and electron micrographs are complemented by many scientific illustrations, diagrams, and flow charts. The new edition contains almost 1100 illustrations, of which 109 are in color. Over 100 illustrations have been added. Most are new, but 21 are replacements for old illustrations that needed updating or improvement. Many of the illustrations are classic, visually describing features of microscopic architecture. Some are speculative and represent attempts by the author and artists to present a visual story of some topics about which our knowledge is incomplete. Finally, flow charts have been used to show relationships and integrate the visual knowledge into a coherent story. The illustrative materials should facilitate the learning process.

The use of color micrographs in this edition has not changed from the previous edition. All of the color micrographs are grouped on plates following Section III. Although the use of color has many advantages, its use is not essential for learning histology. (Color-blind individuals have always performed well in my histology classes.) The grouping of color micrographs and their minimal use within the textbook are simply cost saving devices. If color were used throughout this book, then neither of us could afford the book.

Magnifications as reported within the caption of each initial illustration for a chapter seems to be a source of confusion. The original magnifications are reported for light micrographs, because that is what the student will see when looking through a microscope at a comparable magnification. That was the particular magnification I used when photographing the sample originally. The photographic enlargement factor does not translate readily during use of the microscope. Generally, most negatives of light microscopic materials for the text have been enlarged four to five times. Final magnification of electron micrographs is reported, because that is the typical stage of examination—after photographic enlargement.

Every chapter in this edition has been subjected to careful scrutiny. Three chapters have been added. The information

for one chapter is new, whereas the information for the other two chapters was extracted from larger chapters in the previous edition. All the chapters have been reorganized in an attempt to facilitate identification and retrieval of specific information.

The basic organization of the textbook has not changed. Functional and clinic applications are interwoven throughout the histologic story. The textbook is organized into five sections: Introduction to Histology, Cell Biology, Histology, Comparative Organology, Introduction to Exfoliative Cytology. Some of the particulars relating to changes in this edition follow.

Section I, Introduction to Histology, has been updated, reorganized, and expanded. This section is intended to provide perspective for the new student of histology. Understanding most of the content of this section will complement the information in the remainder of the text and enhance learning.

Section II, Cell Biology, has been enlarged and many parts have been updated and rewritten. Most students entering a veterinary medical curriculum have an adequate background in cell biology. The inclusion of Chapter 4 in this textbook completes the story about cells and provides the necessary background for the remainder of the text materials. Mastery of the subject matter within this section is essential.

Section III, Histology, encompasses the classic tissues. Chapter 6, Extracellular Matrix, is new and the material included affords a comprehensive treatment of extracellular substances, including interstitial fluids. All of the other chapters in this section have been modified and reorganized. Many parts have been rewritten.

Section IV, Comparative Organology, still remains the bulk of the endeavor. Structure and function have been expanded, rewritten, and reorganized. Every chapter in this section has been altered.

Section V, Introduction to Exfoliative Cytology, has been improved, but the substantive materials have not been changed.

Exhaustive attempts have been made to integrate structural and functional considerations within the construct of being applicable to clinical medicine and surgery. The book, however, is still a textbook of histology. Some of the information will add to your general knowledge about the biomedical sciences without much apparent application to the practice of medicine directly. Hopefully, the book will continue to provide the necessary information in a comprehensible and enjoyable manner while enhancing learning. Also, I hope that students will continue to use it long after their initial exposure to histology has been completed.

The input of many colleagues and students has been invaluable. I respectfully request that they continue to comment about the book to me. Notification of errors, inaccuracies, or inadequate discourse would be appreciated greatly.

Finally, the textbook is not intended to be a definitive tome on the subject. Rather, it is simply one person's perceptions of a rapidly expanding, vast, dynamic, and exciting body of knowledge.

William J Banks
Fort Collins, Colorado

Downloaded From VetBooks.ir

Acknowledgments

Many colleagues, students, and friends have made significant contributions to this edition. Indeed, I am indebted to many individuals who contributed directly and indirectly to its improvement. Direct criticisms, subtle suggestions, intense discussions, and even blatant disagreements have been the basis for improving the third edition of this textbook.

The staff of the Histology Preparation Laboratory of the Department of Anatomy, College of Veterinary Medicine and Biomedical Sciences, Colorado State University, was most helpful. They willingly assisted me with the generation of new histological specimens for inclusion in the original edition of this book. The vast histological specimen library of the Department was always available to me through them. Their contribution persists in this current edition.

Similarly, the staff of the Histology Laboratory, School of Veterinary Medicine, Louisiana State University and A&M College, contributed to the previous edition and their input remains viable in this edition.

Various individuals scrutinized many chapters and gave willingly of their time, expertise, and interest. Dr. M.J. Burke, DVM, MS, MD, past graduate student, current chief resident of neurosurgery at the University of Colorado Medical Center in Denver, respected colleague, and treasured friend, was a constant source of encouragement. His critical evaluations and our lively discussions are apparent on most pages of the book. He has given generously to his teacher.

Many veterinary students over the years at Colorado State University, Louisiana State University, and Texas A&M University have offered helpful suggestions for improvement of the text. I am especially indebted to these young colleagues for their insightful and constructive commentary. The telephone calls and letters from students across the country have also been a great source of encouragement.

The micrographs, negatives, and samples supplied by colleagues for all editions are gratefully acknowledged. My appreciation especially to Drs. M. Carry, C.J. Connell, D.L. Eisenbrandt, J.J. England, G.P. Epling, R.A. Kainer, D.E. Kelly, J.W. Newbrey, H.O. Nornes, R.W. Norrdin, J.E. Rash, J. Storz, M.A. Thrall, W. Todd, T. Al-Bagdadi R.P. Amann, R.A. Kainer, T. Spurgeon, N.J. Wilsman, and C. Farnum, and to Ms A. Sheppard. The permission granted by other authors and publishing companies to use selected copyrighted materials is, likewise, appreciated. Finally, the cooperation of Dr. A. Peters (Boston University) is acknowledged with gratitude.

The staff of Biomedical Media, College of Veterinary Medicine and Biomedical Sciences, Colorado State University, was invaluable in generating the earlier editions of this book. Most medical illustrations and diagrams are the result of their original efforts. I am indebted to these talented artists.

The staff of Media Resources, College of Veterinary Medicine, Texas A&M University contributed importantly to the current edition. The cheerful and talented support of Ms. Janet Hestand made the project enjoyable. The cooperation and support of the Director, Ms. Merrie Mendenhall, as also appreciated. The enthusiastic and willing support of the photography staff, Ms. Elizabeth Morgan and Mr. Anthony Rydzewski, was most timely and appreciated.

Many colleagues deserve a special note of appreciation. The encouragement and thoughtful suggestions of Drs. L.R. Whalen, D. J. Hillmann, W.G. Hank, M.A. Littlefield-Chabaud, and P.A. Melrose were especially valuable. These people were always willing to discuss various apsects of the book.

The protracted discussions on immunology specifically and veterinary education in general with Dr. Ian Tizard were also invigorating. I especially appreciated the opportunity to read selected chapters of the newest edition of his textbook while it was still in manuscript. The assistance of Dr. R.C. Burghardt with photomicroscopy was most appreciated.

The continual input of Dr. R.A. Kainer, Professor Emeritus, Department of Anatomy, Colorado State University, to this project was valuable and appreciated. Our many hours of discussions over the past 20 years have been an especially enjoyable part of compiling the text.

The inventors of the microcomputer and the authors of the word processing software used in this project deserve special recognition. I began writing this book in the precomputer era and have continued into the computer era. I don't think manuscript production without a computer would be much fun anymore.

My wife, Patricia G. Banks, deserves special recognition and a particularly heartfelt expression of thanks for her patience, understanding, support, encouragement, and assistance. They have made the completion of this edition possible.

My daughters—Amie, Victoria, Melanie, and Kristin—also deserve special thanks for their encouragement and understanding. Kristin's help, particularly with some routine tasks, was great.

The able staff of Mosby–Year Book, Inc., the new publisher of this text, has made the project both enjoyable and gratifying. I am pleased to acknowledge the assistance of the Editor for this project, Mr. R.W. Reinhardt, and the Publisher, Mr. George Stamathis, for their support, encouragement, and enthusiasm in all aspects of my authoring endeavors. The patience and friendship of George Stamathis are especially valued. He continues the fine tradition of professional expertise and support that he established as Editor for this book when he was on the staff of the original publisher. I also wish to express my deepest appreciation to the current design, editing, and production staffs, especially George B. Stericker.

To my numerous students, teachers, and colleagues—from whom I have learned so much—my sincere appreciation is expressed.

William J. Banks

College Station, Texas

Contents

SECTION I
GENERAL PRINCIPLES OF HISTOLOGY

1 **Insights into Histology,** 2
Tissues—the Elements of Organization, 2

2 **Methods of Histology,** 4
Paraffin Technique, 5
Principles of Staining, 6
Selected Preparation Techniques, 7

3 **Microscopy and Interpretation,** 12
Microscopy, 12
Interpretation, 15

SECTION II
CELL BIOLOGY

4 **Cells—Structure and Function,** 22
General Cell Characteristics, 22
Chemical and Physical Properties, 22
Biological Properties, 23
Morphological Features, 23
Nucleus, 26
Cytoplasm, 28
Cell Membranes, 29
Structure and function, 29
Transport and functions, 31
Membranes as receptors, 31
Cytoplasmic Membranous Compartments, 31
Ribosomes and rough endoplasmic reticulum, 31
Agranular endoplasmic reticulum, 33
Golgi complex, 34
Mitochondria, 34
Lysosomes, 35
Peroxisomes, 36
Cytoplasmic Skeleton and Inclusions, 37
Microtubules, 37
Cytoskeletal components, 41
Cytoplasmic inclusions, 41
Cell Division, 43

SECTION III
HISTOLOGY

5 **Epithelia,** 48
General Characteristics, 48
Simple Epithelia, 49
Stratified Epithelia, 51
Transitional Epithelium, 53
Grandular Epithelia, 53
Special Epithelia, 57
Surface Specializations of Epithelia, 59
Regeneration and Repair of Epithelia, 63

6 **Extracellular Matrix,** 68
Extracellular Components, 68
Fibers, 68
Collagen, 68
Reticular fibers, 72
Elastic fibers, 73
Ground Substance, 73
Tissue Fluid, 77
Body Fluids and Ground Substance, 77
Hydrostatic and osmotic relationships, 77
Alterations to Fluid Exchange, 80

7 **Proper Connective Tissues and Adipose Tissue,** 82
General Characteristics, 82
Resident Cell Populations, 83
Transient Cell Populations, 87
Embryonal Connective Tissues, 89
Proper Connective Tissues, 89
Special Connective Tissues, 92
Adipose Tissue, 93
Macrophage System, 94
Regeneration and Repair, 95

8 **Supportive Tissue—Cartilage,** 96
General Characteristics, 96
Matrical Components, 97
Fibers, 97
Ground Substance, 97
Staining of Cartilage, 98
Ultrastructure of Cartilaginous Matrices, 98
Types of Cartilage, 100
Hyaline Cartilage, 100
Elastic Cartilage, 103
Fibrous Cartilage, 103
Maintenance and Repair of Cartilage, 105

9 **Supportive Tissues—Bone,** 107
General Characteristics, 107
Matrical Components, 107
Envelopes of Bone, 108
Periosteum, 108
Endosteum, 110
Cellular components, 111
Relationships of Cells, 111
Mesenchymal Cells, 111
Osteoprogenitor Cells, 111
Osteoblasts, 111
Osteocytes, 113
Osteoclasts, 113
Types of Bone, 115
Configurations of Bone, 116
Organization of Bone, 116
Lamellae, 116
Osteons, 116
Bone Remodeling, 120
General Features, 120
Basic Metabolic Unit, 121
Histological Evidence of Remodeling, 121
Bone-Endocrine Relationships, 121
Calcium Regulatory System, 124
Mechanisms of Action, 124
"In Concert" Influences of Hormones, 125

10 **Osteogenesis,** 127
Development of Bone, 127
Mechanisms of Development, 127
Intramembranous Ossification, 127
Endochondral Ossification, 130
Model formation, 131
Model growth, 135
Modeling activity, 138
Hormones and bone development, 140

11 **Blood,** 142
Peripheral Blood, 142
General Characteristics, 142
Mammalian Blood Cells, 142
Erythrocytes, 142
Granulocytes, 146
Agranulocytes, 147
Platelets, 149
Formed Elements—Species Variations, 149
Avian Blood Cells, 150
Erythrocytes, 150
Granulocytes, 151
Agranulocytes, 151
Thrombocytes, 152

Hemostasis, 152
Coagulation, 152

12 Hematopoiesis, 155

Development of Blood, 155
General Characteristics, 155
Bone Marrow, 155
Erythropoiesis, 156
Granulocytopoiesis, 157
Thrombocytopoiesis, 157
Agranulocytopoiesis, 157
Kinetics of Blood, 158
Erythrokinetics, 159
Granulokinetics, 159
Agranulokinetics, 161
Evaluation of Blood and Bone Marrow, 161

13 Muscle Tissue, 163

General Characteristics, 163
Smooth Muscle, 163
Histological Structure, 163
Ultrastructural Features, 163
Functional Correlates, 166
Skeletal Muscle, 166
Histological Structure, 166
Ultrastructural Features, 166
Myofibrillar Organization, 167
Contractile Mechanism, 167
Relaxation/Contraction Morphology, 174
Types of Muscle Fibers, 176
Functional Correlates, 176
Cardiac Muscle, 177
Histological Structure, 177
Ultrastructural Features, 177
Functional Correlates, 180
Repair and Regeneration, 180

14 Nervous Tissue, 182

General Characteristics, 163
Neurones, 182
General Properties, 182
Classification, 182
Neuronal Components, 185
Cell bodies, 185
Dendrites, 187
Axons, 187
Information Transfer, 188
Focal Sites of Transmission, 188
Electrotonic transmission, 188
Synapses, 188
Neurochemical Transmission, 189
Presynaptic components, 189
Postsynaptic components, 190
Neuroglia, 192
Central Glial Elements, 192
Peripheral Glial Elements, 193
Cellular Investments of Neurons, 193
Neuronal Processes, 193

SECTION IV
COMPARATIVE ORGANOLOGY

15 Organization of Organs, 204

Parenchyma and Stroma, 204
Tubular Organs, 204
General Form, 204
Tunica Mucosa, 204
Tela Submucosa, 204
Tunica Muscularis, 204
Tunica Adventitia and Tunica Serosa, 204
Surface and Glandular Modifications, 204
Organization of Solid Organs, 207
Membranes as Simple Organs, 207
Mucous Membranes, 207
Serous Membranes, 207

16 Musculoskeletal System, 210

General Characteristics, 210
Bone as an Organ, 210
Physical Properties of Bones, 210
Biomechanical Properties of Bone, 213
Biological Properties of Bone, 213
Fracture Repair, 215
Influential Factors, 215
Stages of Fracture Repair, 215
Types of Repair Mechanisms, 216
Primary-intention healing, 216
Secondary-intention healing, 216
Articulations, 218
General Characteristics, 218
Types of Articulations, 219
Fibrous, cartilaginous, and osseous joints, 219
Synovial joints, 219
Synovial Fluid, 224
Muscle as an Organ, 225
Muscle-Tendon Relationships, 225
Tendons, 225
Muscle-Nerve Relationships, 228

17 Nervous System, 232

Anatomical Considerations, 232
Physiological Considerations, 236
Reflex Arc, 237
Peripheral Organizational Components, 238
Sensory Ganglia, 238
Motor Ganglia, 238
Neuronal Processes, 238
Nerve trunks, 238
Histological organization, 240
Afferent terminals, 240
Efferent terminals, 242
Central Organizational Components, 243
Meninges, 243
Pachymeninx, 243
Leptomeninges, 243
Cerebrospinal Fluid, 243
Choroid plexus, 243
Dynamic relationships, 243
Brain-Associated Barriers, 248
Blood/cerebrospinal fluid barrier, 248
Blood/brain barrier, 248
Specific Organs, 248
Spinal cord, 248
Brain stem, 249
Cerebrum, 249
Autonomic Nervous System, 253
Organization, 253
System characteristics, 253
Sympathetic and Parasympathetic Divisions, 253
Sympathetic nervous system, 253
Parasympathetic nervous system, 253
Functional Correlates, 255
Synaptic Relationships, 255
Transmitters, 255
Cholinergic receptors, 255
Adrenergic receptors, 256
Adrenal Medulla, 257
Pharmacological Considerations, 257
Neuronal Response to Injury, 257

18 Cardiovascular System, 260

Mural Organization, 260
Exchange System, 260
High-Pressure System, 263
Low-Pressure System, 266
High- and Low-Pressure Systems Compared, 266
Heart, 266
Mural Organization, 266
Cardiac Activity, 273
Regulatory mechanisms, 273
Specialized chemoreceptors, 274
Specialized baroreceptors, 274
Neuroregulation, 274
Autonomic reflex activity, 274
Lymphatic Vessels, 275

19 Lymphatic System and Immunity, 277

General Characteristics, 277
Diffuse, Unencapsulated Lymphatic Tissue, 277
Dense, Unencapsulated Lymphatic Tissue, 277
Dense, Encapsulated Lymphatic Tissue, 278
Lymph Node, 278
Hemal Nodes and Hemolymph Nodes, 283
Spleen, 283
Thymus, 289
Bursa of Fabricius, 292
Immunity, 292
Nonspecific Immunity, 292
Specific Immunity, 292
Humoral antibody response, 293
Cell-mediated immune response, 294
Hypersensitivity Reactions, 294
Type I hypersensitivity, 294
Type II hypersensitivity, 295
Type III hypersensitivity, 296
Type IV hypersensitivity, 296
Autoimmunity, 296

20 Integumentary System, 298

General Characteristics, 298
Mammalian Integument, 298
Typical Skin, 298

Organization of the Skin, 298
Specialized Skin Regions, 300
Hairs, 300
Special Skin Cells, 303
Glands of the Mammalian Skin, 305
Sebaccous and tubular glands, 305
Glands of the perianal region, 306
Mammary gland, 306
Miscellaneous glands, 311
Hooves and Claws, 311
Equine Foot, 311
Structure of the hoof, 311
Corium of the foot, 317
Ruminant and Porcine Claws, 317
Claws of Carnivores, 317
Integumentary Appendages, 317
Repair of the Skin, 318
Avian Integument, 322

21 Digestive System I—Alimentary Canal, 326

General Characteristics, 326
Oral Structures, 326
Teeth, 331
Development, 331
Cellular and Matrical Components, 335
Association Structures, 336
Types of Dentition, 336
Pharynx, 336
Esophagus, 336
Glandular Stomach, 338
Structure, 338
Glandular Regions, 339
Histophysiology, 344
Compound Stomach, 345
Structure, 345
Histophysiology of Ruminant Digestion, 349
Small Intestine, 350
Structure, 350
Regions of the Small Intestine, 351
Histophysiology of the Small Intestine, 353
Large Intestine, 354
Structure, 354
Regions of the Large Intestine, 354
Histophysiology of the Large Intestine, 356
Avian Digestive System, 356

22 Digestive System II—Extramural Organs, 360

Salivary Glands, 360
Liver, 363
Histological Organization, 363
Histophysiology of the Liver, 369
Gallbladder, 371
Exocrine Pancreas, 371

23 Urinary System, 374

Kidney, 374
Nephron, 375
Renal Corpuscle, 375
Tubular Components, 378
Collecting Duct System, 379
Stromal Elements, 382
Juxtaglomerular Complex, 383
Histophysiology of the Kidney, 384
Urinary Passages, 387

24 Respiratory System, 390

Respiratory Tract, 390
Conductive Components, 390
Nasal Cavity, 390
Nasopharynx, 391
Larynx, 391
Extrapulmonary Bronchi, 392
Lung, 392
Conductive Components, 392
Intrapulmonary bronchi, 393
Bronchioles, 394
Transitional Components, 395
Respiratory bronchioles, 395
Alveolar ducts, saccules, and alveoli, 397
Blood/Air Barrier, 400
Stromal Elements, 400
Histophysiology of the Lung, 400
Exchange of gases, 400
Regulation of respiration, 403
Avian Respiratory System, 404

25 Endocrine System, 408

General Characteristics, 408
Hypophysis Cerebri, 408
Adenohypophysis, 409
Pars distalis, 409
Pars tuberalis, 411
Pars intermedia, 411
Histophysiology of the adenohypophysis, 411
Regulation of the adenohypophysis, 412
Neurohypophysis, 412
Epiphysis Cerebri, 413
Thyroid Gland, 414
Parathyroid Glands, 416
Adrenal Glands, 416
Adrenal Cortex, 419
Histophysiology, 422
Adrenal Medulla, 423
Endocrine Pancreas, 424
Miscellaneous Endocrine Glands, 425

26 Male Reproductive System, 429

Testes, 429
Genital Ducts, 432
Spermatogenesis, 432
Testicular Secretions, 438
Accessory Glands, 439
Urethra, 442
Copulatory Organ, 444

27 Female Reproductive System, 446

Mammals, 446
Ovary, 446
Ovarian Cycle, 447
Uterine Tubes, 452
Uterus, 452
Vagina, 455
Vulva, 456
Cyclical Changes, 456
Comparative Placentology, 457
Distribution of chorionic villi, 457
Extraembryonic membrane contributions, 460
Degree of implantation, 461
Configuration of chorionic attachments, 461
Fetal and maternal contributions, 461
Birds, 465

28 Eye and Ear, 469

Eye, 469
Fibrous Tunic, 471
Sclera, 471
Cornea, 472
Vascular Tunic, 473
Choroid, 473
Ciliary body and process, 475
Iris, 477
Compartments of the Eye, 479
Anterior compartment, 479
Posterior compartment, 479
Lens, 479
Nervous tunic, 481
Organization of the retina, 481
Ocular fundus, 483
Photoreceptor cells, 483
Retinal blood supply, 484
Ocular Adnexa, 484
Eyelids, 484
Nictitating membrane, 484
Lacrimal apparatus, 484
Ear, 488
External Ear, 488
Middle Ear, 488
Inner Ear, 488
Vestibular Apparatus, 488
Auditory Apparatus, 491

SECTION V EXFOLIATIVE CYTOLOGY

29 Introduction to Exfoliative Cytology, 498

Cytology of Selected Organs and Systems, 498
Nervous System, 498
Hemic-Lymphatic System 498
Integumentary System, 500
Digestive System, 500
Urinary System, 500
Respiratory System, 500
Glandular Organs, 503
Reproductive System, 503
Body Cavities, 504
Visual System, 506
Musculoskeletal System, 506

Downloaded From Vet-eBooks.com

COLOR PLATES

Plate I. Various stains of selected tissues and organs.

I.1, Haired skin. The stratified squamous epithelium stains *purple,* the dense collagenous tissue of the dermis stains *blue.* The hairs are *yellow;* the associated sebaceous glands *red.* (×40, Masson's trichrome.)

I.2, Bovine haired skin. The hair follicle in the center of the field is surrounded by *yellow*-staining dense collagenous tissue of the dermis. Note the sebaceous gland in the upper left portion of the micrograph. (×40, hematoxylin-phloxine-safran.)

I.3, Dense collagenous tissue (regular). Collagenous fibers are stained pink. Note the sections of arterioles, a venule, and nerve fibers in the upper portion of the micrograph. (×40, H & E.) (This is one of the most common staining combinations used in histology.)

I.4, Porcine cerebellum. Piriform cells are the large, *pink*-staining cells at the interface between the granular *(right)* and molecular *(left)* layers of this organ. (×40, H & E.)

I.5, Porcine cerebellum similar to that of **I.4.** The large *dark*-staining cells are piriform cells. This staining technique permits visualization of the neuronal processes. (×40, silver impregnation.)

I.6, Feline ovary. Two vesicular follicles occupy the center of the field. The *pink* band around the oocyte is the zona pellucida. Primordial follicles are evident along the right margin of the micrograph. (×40, H & E.)

I.7, Feline ovary similar to that of **I.6.** The vesicular follicle in the center of the field is more mature and larger than those in the previous micrograph. (×40, Lendrum's phloxine tartrazine.)

I.8, Canine proximal femoral growth plate. This physis was associated with development of the femoral head. The hyaline cartilage of the growth plate and primary spongiosa stains *dark blue;* bone stains *pale blue.* The bone marrow imparts a high cellularity to the primary spongiosa. (×40, Alcian blue.)

I.9, Ground lamellar bone about 75 μm thick. *Pale*-staining areas are old bone; *orange* indicates newer bone. *Red*-staining areas represent the newest bone. The *green* band internal and adjacent to the newest bone *(red)* is the osteoid seam. A resorption space is apparent *(upper left.)* (×40, tetrachrome stain.)

I.10, Tetracycline-labeled ground bone section from the fracture repair site of an equine third carpal bone. The *fluorescent* bands indicate new bone deposition at the time of serial injections of an antibiotic. (×40, fluorescent microscopy.)

I.11, Elastic cartilage. A perichondrium *(yellow)* surrounds the mass of cartilage. (×40, pentachrome stain.)

I.12, Equine intestinal mucosa. Goblet cells are stained *purple.* (×40, PAS.)

Downloaded From Vet-eBooks.com

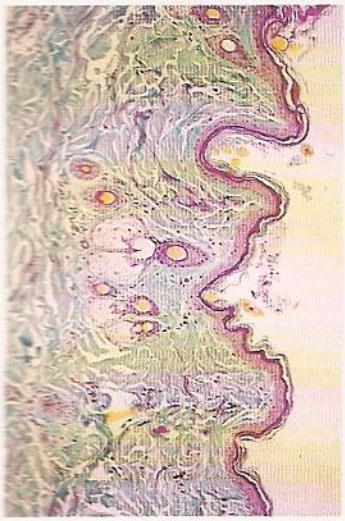

I.1

I.2

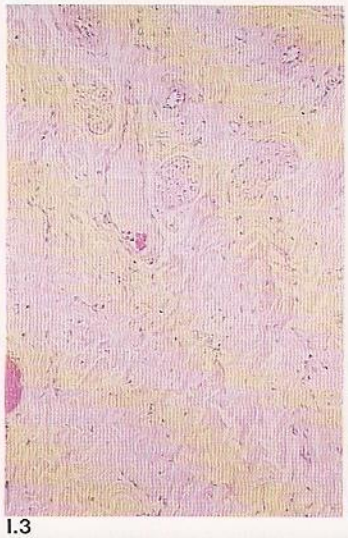

I.3

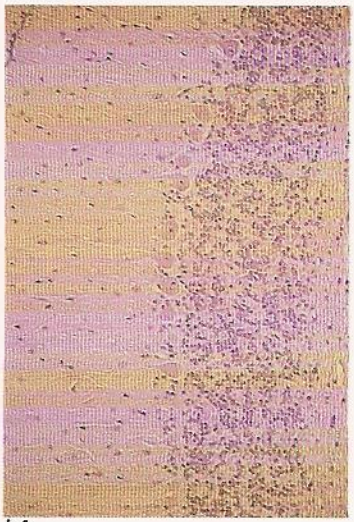

I.4

I.5

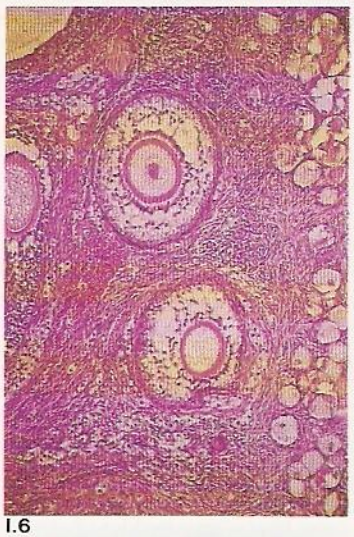

I.6

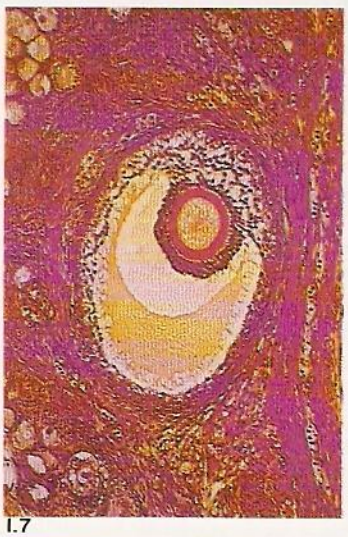

I.7

I.8

I.9

I.10

I.11

I.12

PLATE I

Downloaded From Vet-eBooks.com

Plate II. Characteristics of selected cells.

II.1, Porcine testicular interstitial cells. These steroid-producing cells occupy the interstitial space between seminiferous tubules. They have an acidophilic, foamy cytoplasm due to the leaching of lipid products from the cytoplasm. (×400, H & E.)

II.2, Seminiferous tubule of a porcine testis. A sustentacular cell *(lower center)* has a large triangular nucleus positioned along its basal border. The cytoplasm is difficult to discern. Identification of the cell is predicated upon nuclear morphology. Sustentacular cells form an effective blood-testis barrier. Spermatocytes *(round nucleus)* and spermatozoa *(elongated nucleus)* (×400, H & E.)

II.3, Steroid-producing cells of the zona fasciculata of an equine adrenal cortex. The cells have vesicular nuclei. The cytoplasm is foamy and acidophilic due to the leaching of lipids during processing. (×400, H & E.)

II.4, Multinucleated osteoclast. Its acidophilic, finely granular cytoplasm contains many vacuoles. Note the brush border at the cell-bone interface. These cells are fusion products of macrophages or their precursors They remove bone and cartilage. The osteoclast and chondroclast are the same cell. Although the names are used interchangeably, osteoclast is more common (even when the cell is associated with cartilage). (×400, H & E.)

II.5, Osteoblasts from developing bone. The osteoblasts line the surface of a spicule of bone *(center)*. An active cell has a vesicular nucleus and a basophilic cytoplasm. The basophilia is from extensive quantities of RER. A negative-staining Golgi zone is apparent in one of the cells *(left center)*. The cells assume an epithelioid appearance when active. (×400, H & E.)

II.6, Mesenchymal cells from loose collagenous tissue. A large nucleus is the prominent feature. Definitive identification, however, is virtually impossible by histological section alone. The slightly basophilic cytoplasm is visible as the perikaryon. Cellular processes are difficult to distinguish from collagenous fibers also present. (×400, H & E.)

II.7, Cells of a bovine abomasum (glandular stomach). These round to oval cells with acidophilic cytoplasm are parietal cells. Their cytoplasmic granularity results from numerous mitochondria. They secrete hydrochloric acid. The foamy cells in the center of the field secrete mucus. (×400, H & E.)

II.8, Serous cells associated with the olfactory mucosa. The cuboidal cells have a centrally positioned nucleus surrounded by a finely granular, acidophilic cytoplasm. (×400, H & E.)

II.9, Mucous cells from the glands associated with an equine ureter. The low columnar cells have a foamy cytoplasm and a basally positioned and flattened nucleus. (×400, H & E.)

II.10, Cross section through a pancreatic acinus *(arrow)*. These cells have an apical acidophilia and a basal basophilia. The basophilia results from an accumulation of ribosomes and RER in the basal part of the cell. The apical acidophilia is from zymogen granules. (×400, Gomori's chrome alum-hematoxylin.) (Courtesy R. A. Kainer.)

II.11, Neuronal cell and amphicyte in a dorsal root ganglion. The ganglion cell has a large, vesicular nucleus with a prominent nucleolus. Chromophilic substance is barely evident as a focal cytoplasmic basophilia. A nerve fiber is sectioned longitudinally *(right)*. (×400, H & E.)

II.12, Longitudinal section of skeletal muscle. The striations are due to registration of the myofibrils. A *dark* A band is separated by a *light* I band. The I band contains a Z line. The *arrow* indicates connective tissue elements of the endomysium. (×400.) (Courtesy R. A. Kainer.)

Downloaded From Vet-eBooks.com

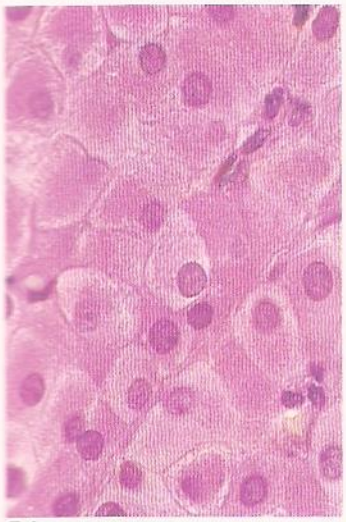

II.1

II.2

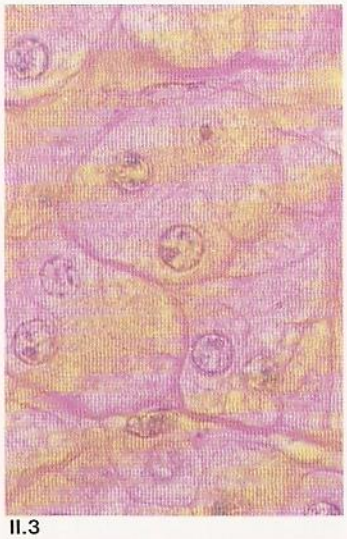

II.3

II.4

II.5

II.6

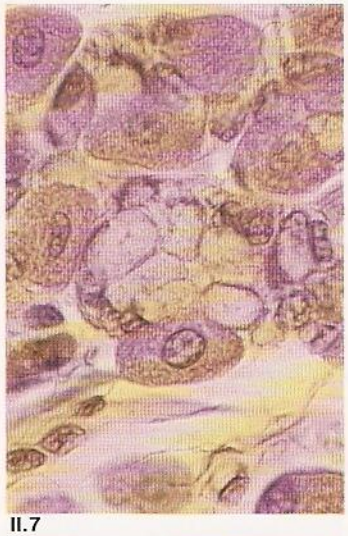

II.7

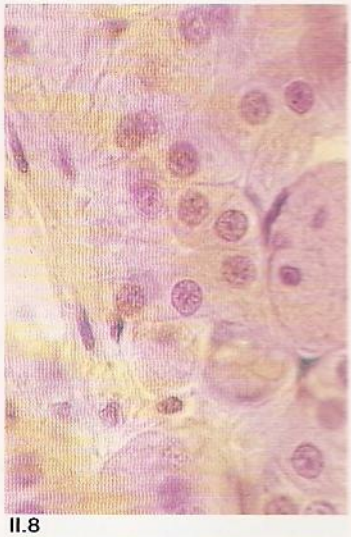

II.8

II.9

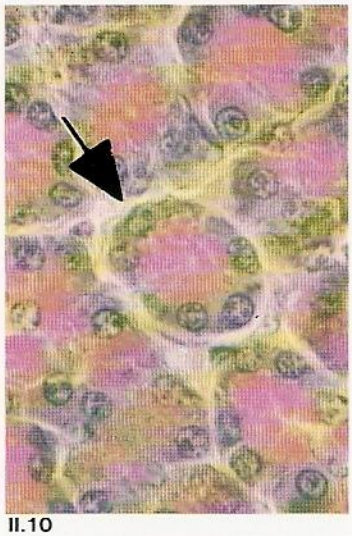

II.10

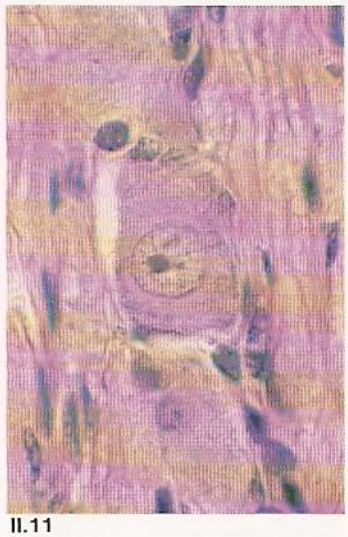

II.11

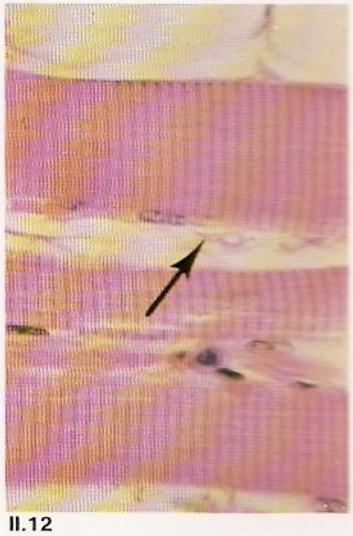

II.12

PLATE II

Downloaded From Vet-eBooks.com

Plate III. Surface and glandular epithelia.

Lining epithelia

III.1, Simple cuboidal epithelium of a salivary duct. (×100, hematoxylin-phloxine-safran.)

III.2, Simple columnar epithelium of a canine stomach. The apical borders of the cells are clear. (×100, H & E.)

III.3, Simple columnar epithelium and goblet cells of a feline jejunum. The pale *blue*-staining cells are goblet cells. (×100, Mallory's azan.)

III.4, Simple columnar epithelium and goblet cells of equine intestinal mucosa. The goblet cells and striated border are stained purple. (×100, PAS.)

III.5, Cornified, stratified squamous epithelium of a canine muzzle. The pale-staining material *(top)* is keratin. Note the epidermal pegs and dermal papillae. (×100, H & E.)

III.6, Noncornified, stratified squamous epithelium of a canine esophagus. (×100, hematoxylin-phloxine-safran.)

III.7, Pseudostratified ciliated columnar epithelium with goblet cells from a murine trachea. Bundles of smooth muscle fibers are present in the lamina propria mucosae. (×100, H & E.)

Glandular epithelia

III.8, Adenomere of an apocrine tubular gland surrounded by dense collagenous tissue. (×100, Masson's trichrome.)

III.9, A section of sebaceous glands within the dermis. These branched alveolar glands are associated with a hair follicle. The hair is the *yellow* oval. (×100, Masson's trichrome.)

III.10, Equine pyloric glands. Note the typical mucous cell characteristics. (×100, H & E.)

III.11, Mucous and serous cells within adenomeres of glands associated with a respiratory mucosa. (×100, H & E.)

III.12, Hepatocytes from a porcine liver. The epithelial cells are arranged in cords. (×100, H & E.)

Downloaded From Vet-eBooks.com

III.1

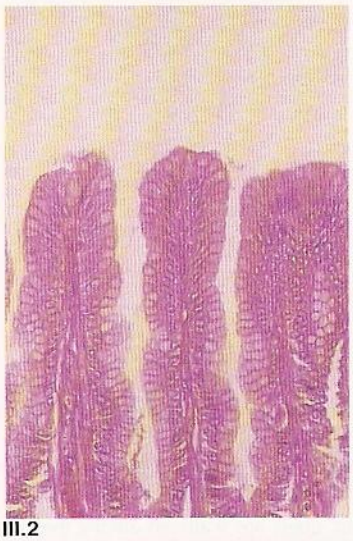

III.2

III.3

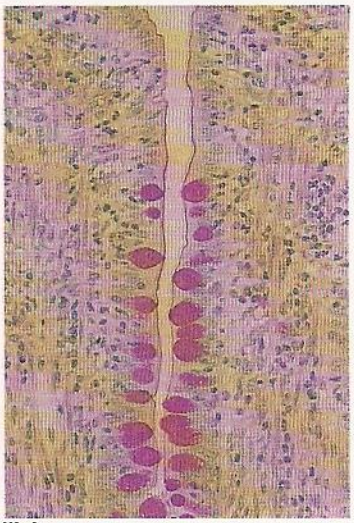

III.4

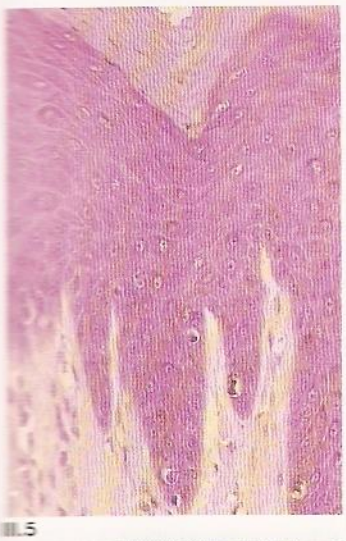

III.5

III.6

III.7

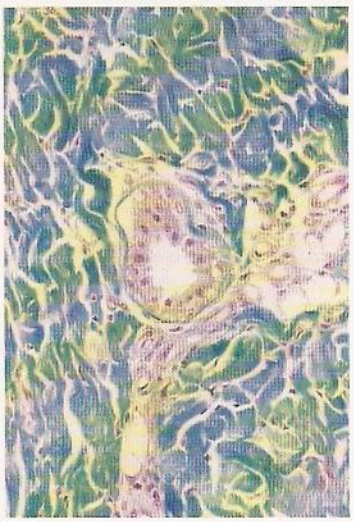

III.8

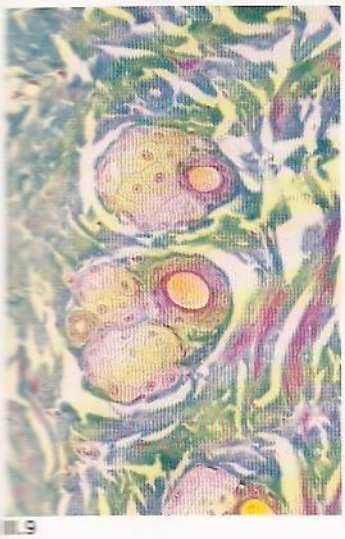

III.9

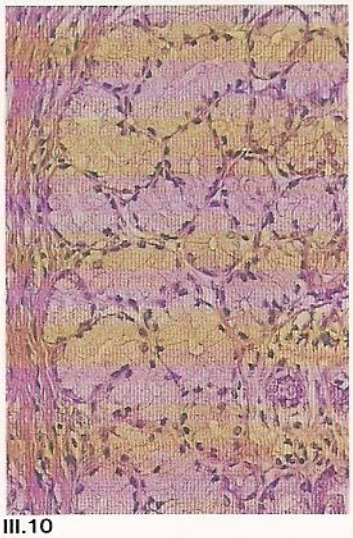

III.10

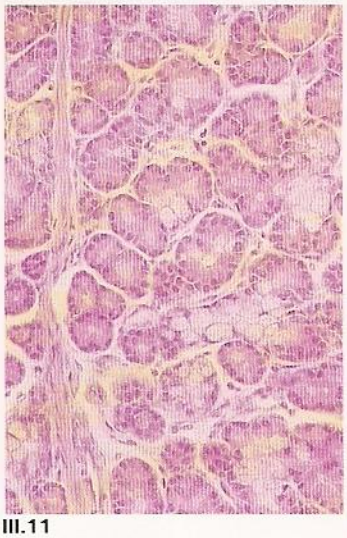

III.11

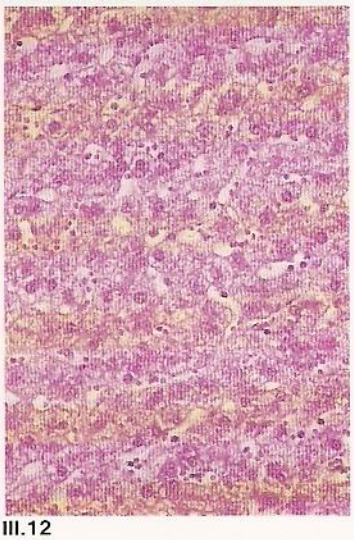

III.12

PLATE III

Downloaded From Vet-eBooks.com

Plate IV. Connective tissue.

Proper connective tissue

IV.1, Loose collagenous tissue. The connective tissue is composed of a loose array of pink-staining collagenous fibers and typical cells of the resident population. A venule *(top left),* arteriole *(top right)* and a nerve fiber *(lower left)* are evident. (×100, H & E.)

IV.2, Hyperplastic loose collagenous tissue of the pharyngeal mucosa. Many mononuclear cells comprise part of the resident cellular population. They perform immunological protective functions in regions exposed to continual antigenic insult. (×100, H & E.)

IV.3, Dense collagenous tissue (irregular) of a dermis. *Pink*-staining elastic fibers are scattered among the collagenous fibers. (×100, hematoxylin-phloxine-safran.)

IV.4, Longitudinal section of a nuchal ligament from a lamb. Elongated nuclei are interspersed between *pink*-staining, wavy fibers. (×100, H & E.)

IV.5, Longitudinal section of a tendon. The flattened, dense nuclei of fibroblasts are scattered among the *pink*-staining collagenous fibers of this dense collagenous tissue. The cytoplasm of the cells is not apparent. (×100, H & E.)

IV.6, Longitudinal section of a tendon. The cells are scattered among the *yellow*-staining, collagenous fibers of this dense collagenous tissue. Some loose collagenous tissue elements and part of a sectioned blood vessel are apparent along the left margin of the micrograph. (×100, van Gieson.)

Supportive tissue

IV.7, Section of growing hyaline cartilage. Note the *dark*-staining nuclei of chondrocytes within the chondrocytic lacunae. The matrix stains a *dark purple*. The tissue is surrounded by a perichondrium, whose fibrous layer blends insensibly with the surrounding connective tissue. (×100, H & E.)

IV.8, A section of mature hyaline cartilage. The homogeneous, pink-staining matrix is a conspicuous feature of this tissue. The territorial and interterritorial matrical staining differences are not apparent in this section. The perichondrium occupies the upper portion of the micrograph. (×100, H & E.)

IV.9, Hyaline cartilage associated with a developing bone. The articular cartilage *(top)* and growth plate *(diagonally from right central to lower central)* are both hyaline cartilage. The epiphyseal *(upper left)* and metaphyseal *(lower right)* bone stains *pink* and contains cores of *pale* calcified cartilage that stain similarly to the hyaline cartilage of the articular surface and growth plate. This is calcified cartilage upon which bone has been deposited. (×100, H & E.)

IV.10, Section of elastic cartilage. The elastic fibers are *red* and are especially obvious in the *yellow*-staining, young cartilage adjacent to the perichondrium *(bottom).* (×100, pentachrome stain.)

IV.11, Fibrocartilage from a canine meniscus. Note the columns of chondrocytes between the collagenous fibers. (×100, H & E.)

IV.12, Osteons within the compact bone of a diaphysis. The limit of the osteon *(lower center)* is the *pale* reversal line. (×100, Mallory's.)

Downloaded From Vet-eBooks.com

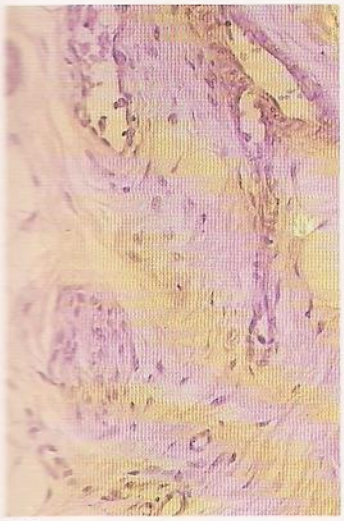

IV.1

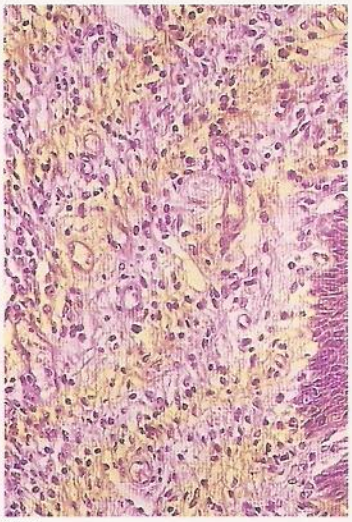

IV.2

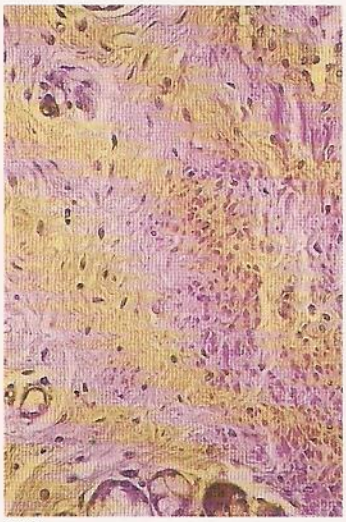

IV.3

IV.4



IV.5

IV.6

IV.7

IV.8

IV.9

IV.10

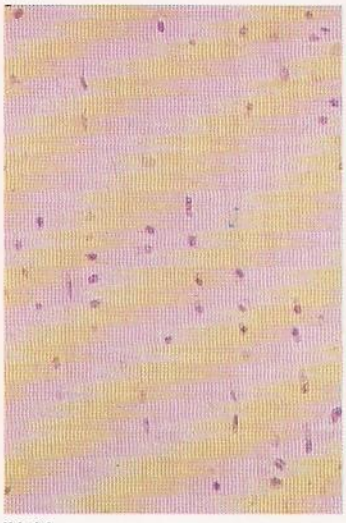

IV.11

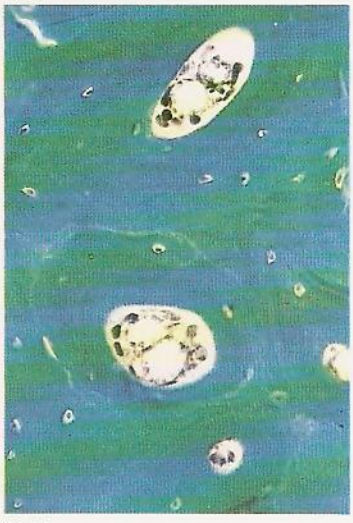

IV.12

PLATE IV

Downloaded from Vet-eBooks.com

Plate V. Muscular, nervous, and adipose tissue.

Muscular tissue

V.1, Longitudinal section of a sheet of smooth muscle from the tunica muscularis of an intestine. The relatively homogeneous, acidophilic staining of smooth muscle is obvious. (×100, H & E.)

V.2, Cross section of bundles of smooth muscle. Note that not all cells contain a visible nucleus. The nuclei, if not evident, are above or below the plane of section in these spindle-shaped cells.(×100, H & E.) (Courtesy R. A. Kainer.)

V.3, Longitudinal section of skeletal muscle. (×100, H & E.) (Courtesy R. A. Kainer.)

V.4, Cross section of skeletal muscle. The muscle fibers are *gray*, and the endomysial connective tissue is *blue*. (×100, Masson's trichrome.)

V.5, A longitudinal section of cardiac muscle. Striations are not as well defined as in skeletal muscle. The fibers are not oriented in parallel array as they are in skeletal muscle. (×100, H & E.)

V.6, Cross section of cardiac muscle. (×100, H & E.)

Nervous tissue

V.7, Longitudinal section of a myelinated nerve. (×100, H & E.)

V.8, Longitudinal section of a myelinated nerve. (×100, osmium tetroxide.)

V.9, Cross section of a fascicle of a myelinated nerve. (×100, H & E.)

V.10, Section of a brain stem of a pig. A large neuron occupies the center of the field. The cytoplasmic *blue*-staining material is chromophilic substance. The small, *dark*-staining nuclei are those of neuroglial cells. (×100, Nocht's stain.)

Adipose tissue

V.11, Yellow adipose tissue. (×100, H & E.)

V.12, Brown adipose tissue. (×100, H & E.)

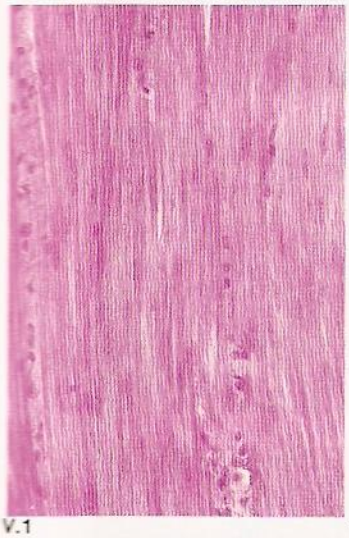

V.1

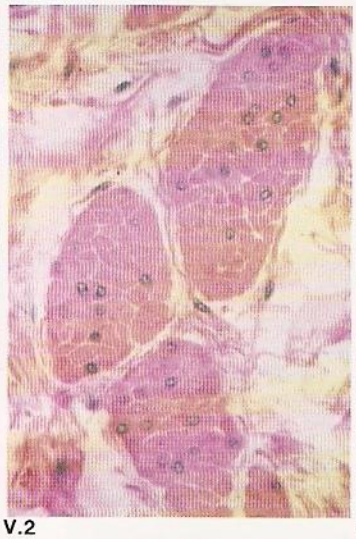

V.2

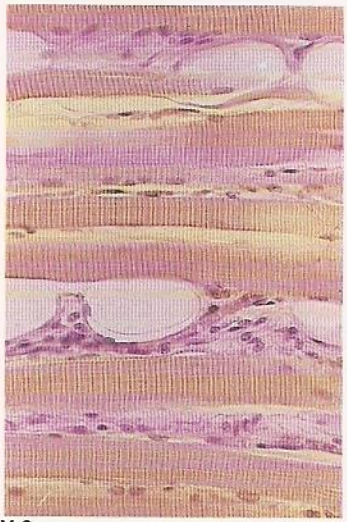

V.3

V.4

V.5

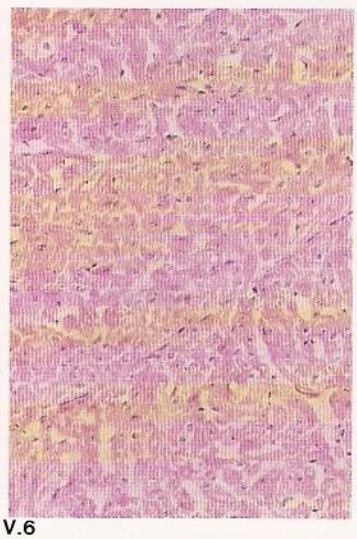

V.6



V.7

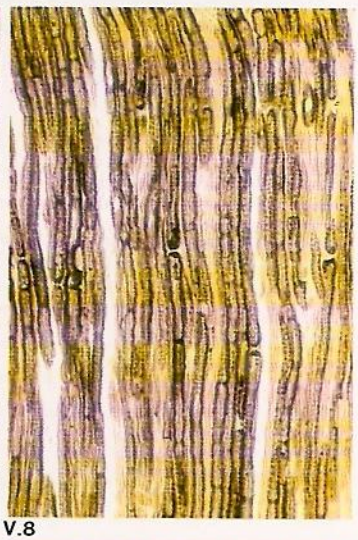

V.8

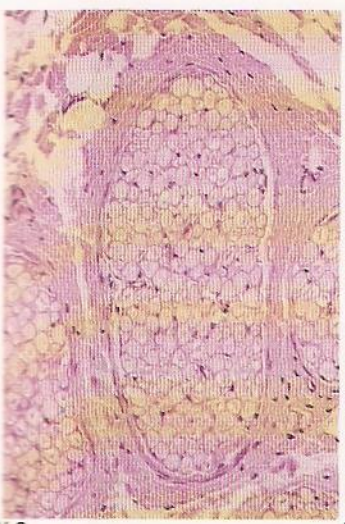

V.9

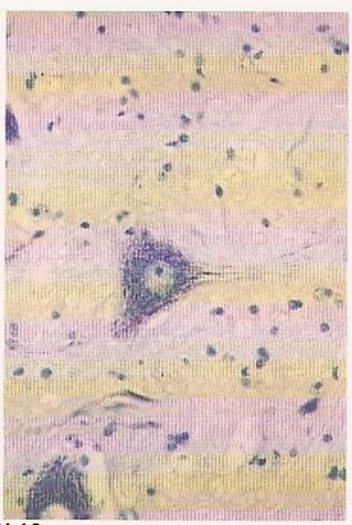

V.10

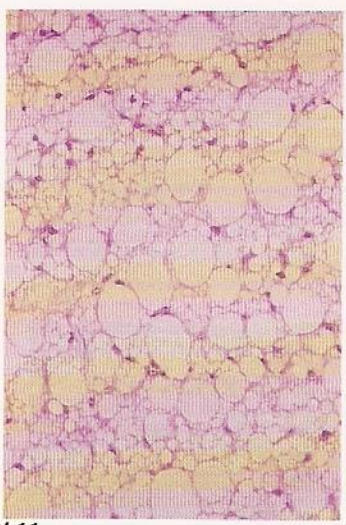

V.11

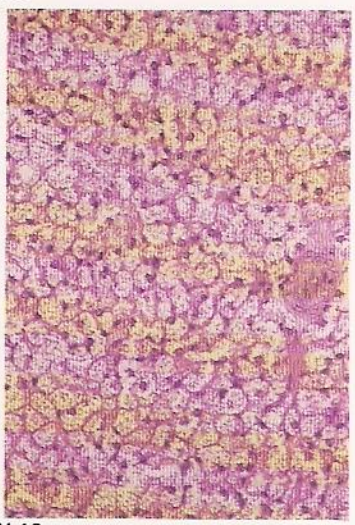

V.12

PLATE V

Plate VI. Peripheral blood cells. All the blood smears were stained with a Romanowsky stain and photographed at 400×.

Neutrophils

VI.1, Canine peripheral blood smear.

VI.2, Feline peripheral blood smear.

VI.3, Equine peripheral blood smear.

VI.4, Bovine peripheral blood smear.

Lymphocytes

VI.5, Canine peripheral blood smear.

VI.6, Feline peripheral blood smear.

VI.7, Equine peripheral blood smear.

VI.8, Bovine peripheral blood smear.

Monocytes

VI.9, Canine peripheral blood smear.

VI.10, Feline peripheral blood smear.

VI.11, Equine peripheral blood smear.

VI.12, Bovine peripheral blood smear.

Eosinophils

VI.13, Canine peripheral blood smear. (Courtesy M. A. Thrall.)

VI.14, Feline peripheral blood smear. (Courtesy M. A. Thrall.)

VI.15, Equine peripheral blood smear. (Courtesy R. A. Kainer.)

VI.16, Bovine peripheral blood smear. (Courtesy M. A. Thrall.)

Basophils

VI.17, Canine peripheral blood smear.

VI.18, Feline peripheral blood smear.

VI.19, Equine peripheral blood smear.

VI.20, Bovine peripheral blood smear.

Miscellaneous blood cells

VI.21, Canine lymphocyte. Note the indented nucleus.

VI.22, Canine rubricyte in a peripheral blood smear.

VI.23, Toxic neutrophilic bands in a feline peripheral blood smear. Note the Barr body.

VI.24, Erythrophagocytosis by a blood monocyte.

Downloaded From Vet-eBooks.com

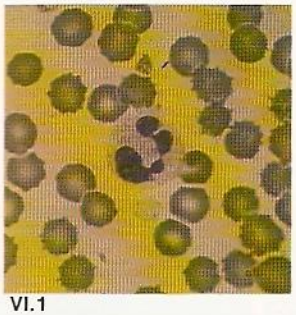
VI.1

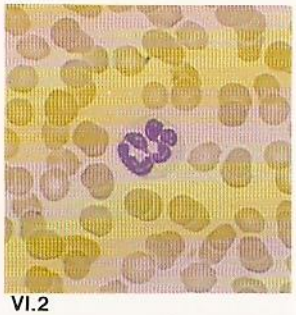
VI.2


VI.3


VI.4

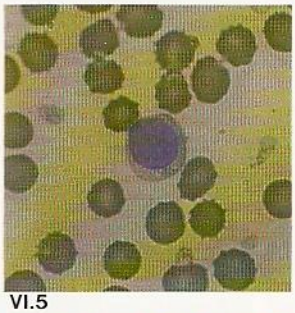
VI.5

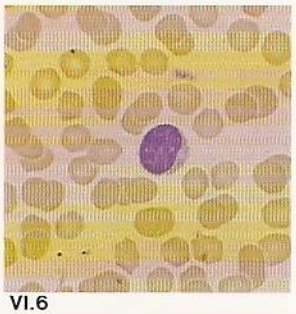
VI.6

VI.7

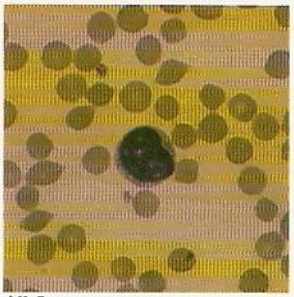
VI.8


VI.9

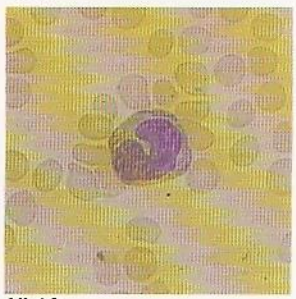
VI.10

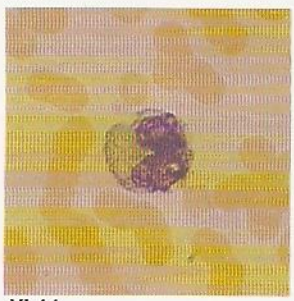
VI.11


VI.12

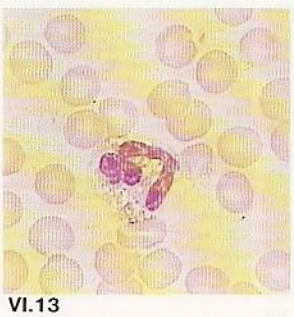
VI.13

VI.14

VI.15

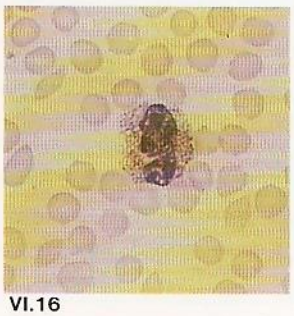
VI.16

VI.17

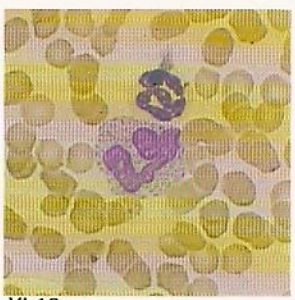
VI.18

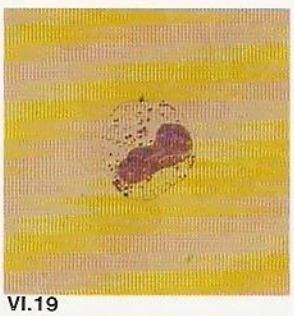
VI.19

VI.20

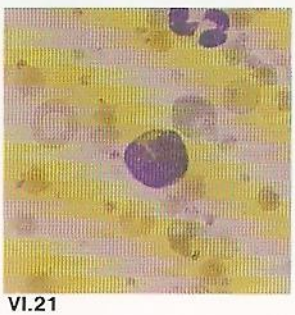
VI.21


VI.22

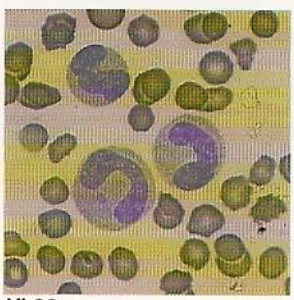
VI.23


VI.24

PLATE VI

Downloaded From Vet-eBooks.com

Plate VII. Peripheral blood and exfoliative cytology. All the specimens were attained with a Romanowsky stain and photographed at 400×.

Miscellaneous blood cells

VII.1, A feline neutrophilic band with toxic granulation.

VII.2, A bovine lymphocyte with azurophilic granules.

VII.3, A canine monocyte *(top)*, neutrophilic band cell *(middle)*, and a neutrophil *(bottom)*.

VII.4, Polychromasia in a canine peripheral blood smear.

VII.5, Canine peripheral blood cells. *Top to bottom*, platelet, monocyte, rubricyte, and metarubricyte.

Exfoliative cytological preparations

VII.6, Cerebrospinal fluid tap. Note the macrophage with hemosiderin in a CSF sample from a dog with head trauma.

VII.7, Aspirate of a reactive canine lymph node. Note the large lymphoblasts *(upper left)*, mature lymphocytes, plasma cells *(center)*, and a Mott cell *(lower right)*. Note also the spoke-wheel configuration of the plasma cell nucleus, apparent in sectioned materials, but not obvious in smeared samples. A lymphoglandular body is in the *center* of the field just below the plasma cell.

VII.8, Aspirate of a canine popliteal lymph node. Metastatic mast cell tumor cells *(upper left)*, plasmablast *(upper center)*, and plasma cell *(upper right)* are present. Mast cell granules from ruptured cells are scattered throughout the sample.

VII.9, Transitional epithelial cells from an impression smear of the urinary bladder of a normal dog

VII.10, Tracheal wash from a normal dog. Ciliated columnar cells are present.

VII.11, Tracheal wash from a dog with chronic bronchitis. Vacuolated macrophages, neutrophils, and a reactive lymphocytes are present.

VII.12, Impression smear of thyroid follicular cells from a normal dog.

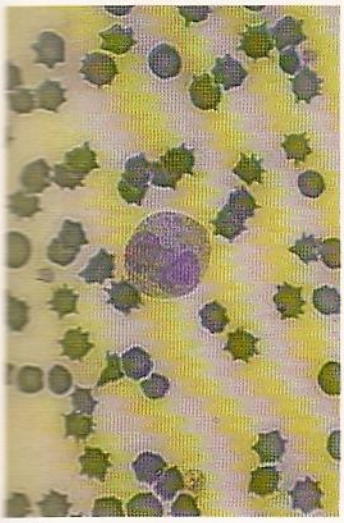

VII.1

VII.2

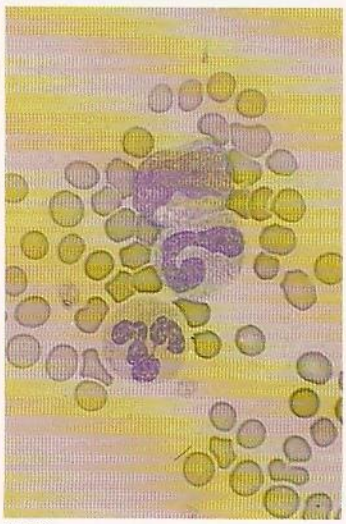

VII.3

VII.4



VII.5

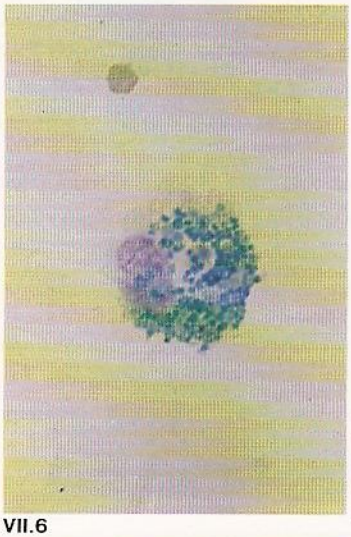

VII.6

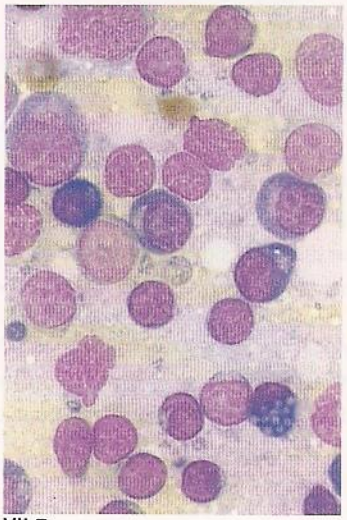

VII.7

VII.8

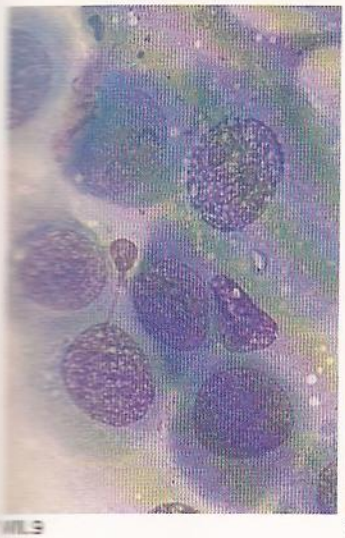

VII.9

VII.10

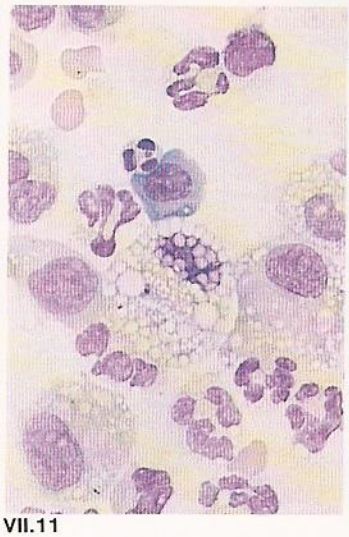

VII.11

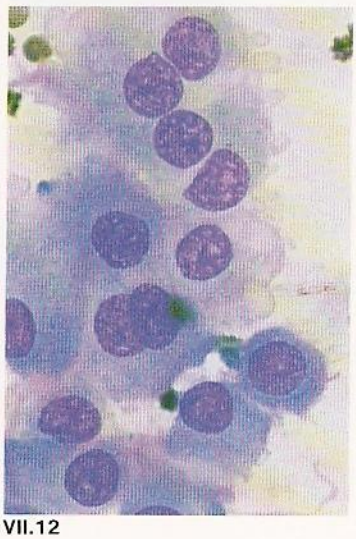

VII.12

PLATE VII

Downloaded From Vet-eBooks.com

Plate VIII. Exfoliative cytology. All the specimens were stained with a Romanowsky stain and photographed at 400×.

VIII.1, Impression smear of thyroid follicular cells from a normal dog. The cells contain *dark blue* cytoplasmic granules.

VIII.2, Aspirate of a canine salivary gland. The vacuolated cells are secretory cells. Note the contamination of the sample with blood.

VIII.3, Aspirate of a normal canine prostate gland. Note the size and shape of the normal epithelial cells.

VIII.4, An aspirate of a canine hyperplastic prostate gland. The cells are more columnar than normal.

VIII.5, Aspirate of a canine prostate gland with adenocarcinoma. The large, binucleated cell has prominent nucleoli. Note the size difference of th cell. (×400.)

VIII.6, Aspirate of a canine prostate gland with squamous cell metaplasia. The cells are squamous, with pyknotic nuclei and abundant cytoplasm.

VIII.7, Canine vaginal smear during early estrus. Cornified epithelial cells have many bacteria on their surfaces. Some erythrocytes are present.

VIII.8, Canine vaginal smear during diestrus. Intermediate epithelial cells contain neutrophils.

VIII.9, Smear of fluid obtained by abdominal centesis from a normal horse. A cluster of mesothelial cells, some macrophages, and some neutrophi are present.

VIII.10, Smear of fluid obtained by abdominal centesis from a normal horse. Erythrocytes and a neutrophil with a pyknotic nucleus *(center)* are preser

VIII.11, Smear of a conjunctival scraping from a normal dog. The epithelial lining cells are typical.

VIII.12, Smear of a conjunctival scraping from a dog with keratoconjunctivitis sicca. Goblet cells are prominent features of the sample.

Downloaded From Vet-eBooks.com

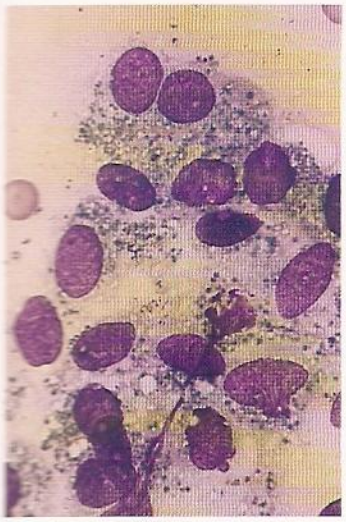

VIII.1

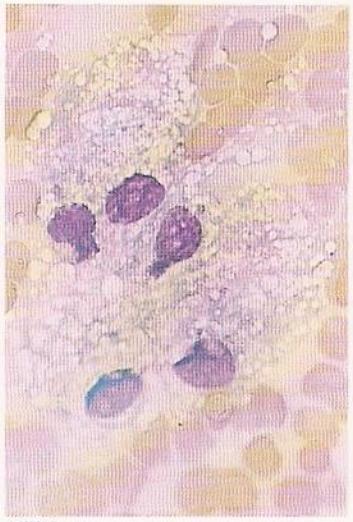

VIII.2

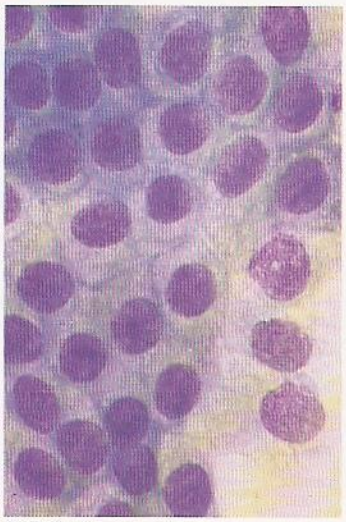

VIII.3

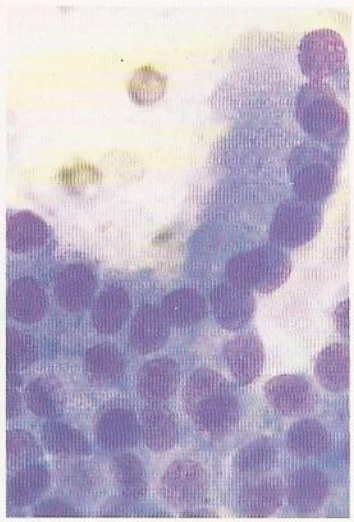

VIII.4

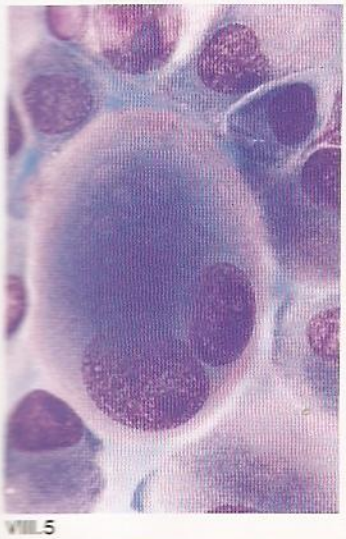

VIII.5

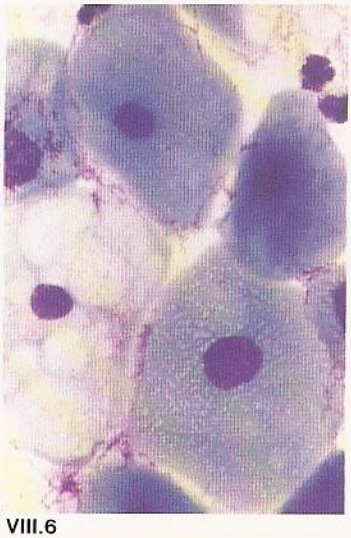

VIII.6

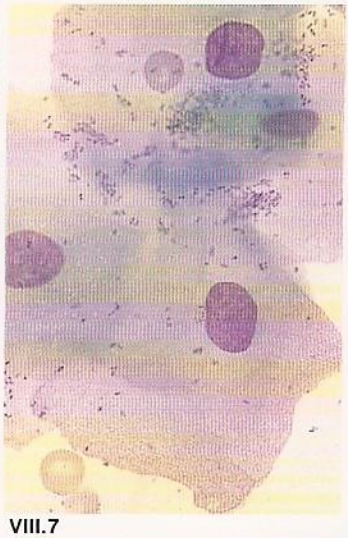

VIII.7

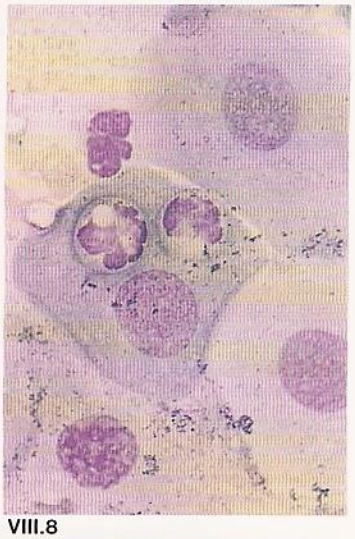

VIII.8

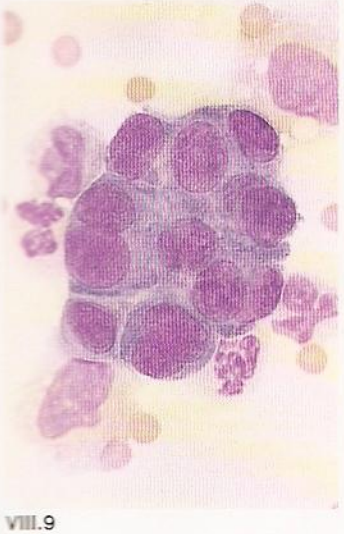

VIII.9

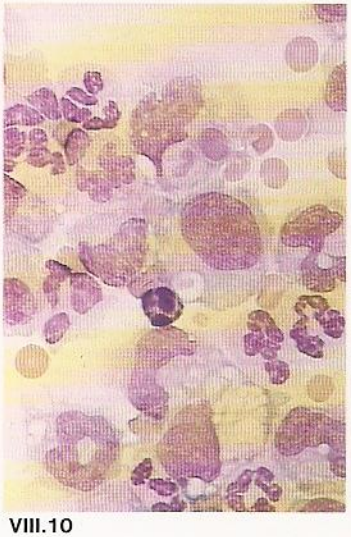

VIII.10

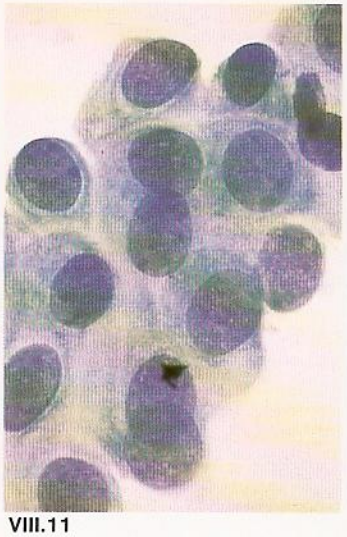

VIII.11



VIII.12

PLATE VIII

Downloaded From Vet-eBooks.com

SECTION I

GENERAL PRINCIPLES OF HISTOLOGY

Downloaded From Vet-eBooks.com

CHAPTER 1

Insights into Histology

As you begin the study of a new discipline, the placement of the knowledge, ideas, and techniques to be acquired into the proper context and perspective may be difficult. You may have questions concerning the nature, scope, depth, and relevance of the discipline. These questions are justifiable. The following short discourse will answer some of these questions for you.

As a student of the biomedical sciences, you have set for your ultimate goal understanding the organism in health and disease. Health maintenance or wellness depends upon preventing disease and maintaining normal structure and function. The aim of diagnosis and treatment of disease is return of the organism to normal structure and function. The living organism is the sum of its constituent parts and much more. Thus, studying the constituent parts is essential to gaining insights about the healthy and diseased organism. Histology is one of those relevant biomedical disciplines affording insights through an in-depth study of the structure and function of the constituent parts.

Anatomy is a branch of biomedical science concerned with the external and internal structure of the organism. Although it was once considered a descriptive science only, its multiple objectives exceed the limits of mere description. Descriptions of basic architectural patterns of cells, tissues, organs, and organisms are fundamental to the discipline, but an understanding of the structural basis of function is also essential.

Anatomy is usually divided into disciplines based on the nature of the component parts and the methods by which they are studied. **Gross anatomy** includes structural features studied by direct visual inspection, palpation, and dissection. **Histology** is the study of structures not visible to the unaided eye.

Although histology began as a descriptive, subgross, anatomical science, it is now a hybridization of anatomy, physiology, chemistry, and physics. The classical histology implied a purely descriptive science. The modern histology **(microscopic anatomy)** is a sophisticated science concerned about tissue structure and function from multidisciplinary approaches.

Organology is the study of organ structure and function. Although organ studies may be approached from different perspectives, organs are commonly studied with a microscope. Thus, this branch of science falls within the purview of histology. **Comparative organology** emphasizes structural and functional organ differences and/or similarities between and among various animal groups. The knowledge encompassed by this discipline is essential for your progress as a veterinary medical student.

The expansion of any discipline, including histology, is linked with the technical advances of many disciplines. Advances in physics and engineering have led to the development of the light microscope, the transmission electron microscope, the scanning electron microscope, and other sophisticated optical instruments. The transmission and scanning electron microscopes are the tools of **ultrastructural cytology,** a body of knowledge encompassed by histology. Insights from inorganic chemistry, organic chemistry, and biochemistry apply to cells and tissues. Histology, then, includes the specialized subdisciplines of **histochemistry** and **cytochemistry.** Many other modern methods contribute to the integrated body of knowledge of histology: autoradiography, fluorescence techniques, immunocytochemistry, and culture techniques.

Finally, histology is an integral component of medical education. The discipline affords insights into normal structure and function at the microscopic level of organization. Histology also serves as the basic building block for understanding disease processes. Cell and tissue responses to the insults associated with disease processes are the purview of **histopathology.**

TISSUES—THE ELEMENTS OF ORGANIZATION

The term **histology,** derived from the Greek *histos* (web) and *logos* (study), means the study of tissues. The etymological derivation of the English word **tissue** is from the French *tissu,* which means "texture or weave." This word was introduced into the medical sciences by a French gross anatomist and physician, Marie F.X. Bichat, in the late 18th century. He became fascinated by the various textures and weaves of the many structures he noted during his detailed gross dissections. His observations resulted in the publication of a book describing more than 20 different tissues. This brilliant anatomist, considered by most to be the Father of Histology, did not use a microscope to found this discipline. Shortly after his death at the turn of the 19th century, the term histology was coined.

The original idea of 20 tissues comprising the body was useful in establishing the discipline. Today most histologists recognize four basic tissue types, with each type consisting of several subtypes. Some histologists believe adipose tissue warrants a separate classification and support the idea of five basic tissues. The diverse organs result from the unique aggregation, association, and interdependence of these basic tissue types. The tissues are the building blocks upon which the organs are constructed in logical, orderly, and consistent ways.

An understanding of tissues is essential for a comprehensive grasp of organ structure and function. Just as the organism is the sum of its organs, so are the organs the sum of their tissue components. The tissues are also the products of their cellular and extracellular constituents. Cells and extracellular substances are the consequence of their biochemical composition.

A logical approach to histology is one beginning with biochemistry, progressing to the cells, continuing to the tissues, and culminating with a study of organs. You will have had some biochemistry and cytology by this stage of your scientific growth and development. It is essential, therefore, to discuss the next order of organization—the tissues.

A tissue is a group of similar, identical, or dissimilar cells and their extracellular products performing a specific function or a spectrum of related functions. This is a workable definition, with some problems. In those instances in which the cells are identical, the recognition of a single tissue is obvious. In some tissues the cells may be similar. In this circumstance the identification of a single tissue can still be

Downloaded From Vet-eBooks.com

accomplished. In others, cellular dissimilarity may imply multiple tissues incorrectly. In all situations, however, the functional relationships of the constituent cells unify them as cellular contributors to specific tissue types. Some tissues are characterized by scant amounts of extracellular materials whereas others have tremendous amounts of these materials. Again, their functional relationships satisfy the definition. Extremes in structural and functional properties still satisfy the basic definition. Any grouping scheme is prone to interpretative problems, because **man classifies, nature doesn't.**

The **basic** or **simple tissues** are epithelia, connective tissues, muscular tissues, nervous tissues, and perhaps adipose tissue. The organs consist of various quantities and types of these tissues in specific architectural patterns. The basic tissues are covered in detail in Section III.

The basic tissues, then, are the building blocks of a complex organizational hierarchy. Your building a comprehensive knowledge of histology is an essential base for understanding the animal in health and disease.

Downloaded From Vet-eBooks.com

CHAPTER 2

Methods of Histology

Technological progress in various scientific disciplines affords histologists many ways to study cells and tissues. The information desired usually dictates the use of one approach over another or the use of combined approaches. The maximal information attainable with any technique requires familiarity with the technique, an understanding of information output, and an appreciation of its advantages and disadvantages. The following will acquaint you with diverse techniques available to examine living cells, dead cells, and cell components. Histologists use these methods to solve histological problems.

Cell culture permits direct observation of living cells. It is routine because of the use of antibiotics. Cell culture also allows the continual observation, manipulation, and testing of explanted cells without donor jeopardy (Figs. 2-1 and 2-2). It facilitates studying cell differentiation, cell transformations, cytogenetics, cellular metabolism, cell-to-cell interactions, host-parasite relationships, and other biological processes. Cell culture is indispensable in diagnostic virology (Figs. 2-3 and 2-4), vaccine development, and vaccine production.

Implantation of **transparent viewing chambers** and the **exteriorization** and **transillumination** of organs and tissues complement direct observation. Although exteriorization techniques limit observation time, insights about microcirculation and the response of tissues and organs to chemotherapeutical agents have been obtained. Transparent viewing chambers extend the observation period. Neovascularization, cellular differentiation and movement, and other vital processes are studied by these techniques. The anterior chamber of the eye is a naturally occurring viewing chamber used in this approach.

The selective uptake of **vital** and **supravital stains** has added to our understanding of cell function, cell structure, and extracellular matrix materials. These stains have low toxicity; they may be injected into a living organism (vital) or used on living cells removed from the organism (supravital).

Oxytetracycline, a broad-spectrum antibiotic, is also a vital stain. At therapeutic dosages, this drug selectively stains all surfaces where bone, cementum, and dentin form (Figs. 2-5 and 2-6). Insights concerning rates of bone formation, turnover, and maintenance have been obtained through carefully timed, spaced, serial administration of the drug.

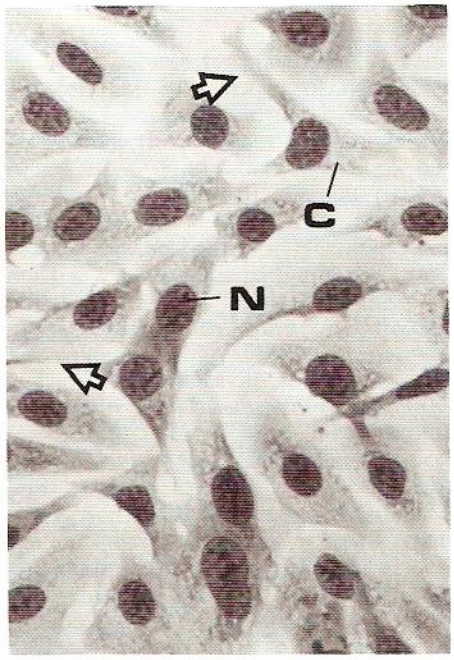

Figure 2-2. Medium-power micrograph of a monolayer of normal bovine fetal spleen cells. The nuclei *(N)* are vesicular and the foamy and granular cytoplasm *(C)* has processes *(open arrows)* imparting a stellate or spindle appearance. (×100, Giemsa stain.) (Courtesy H. Storz.)

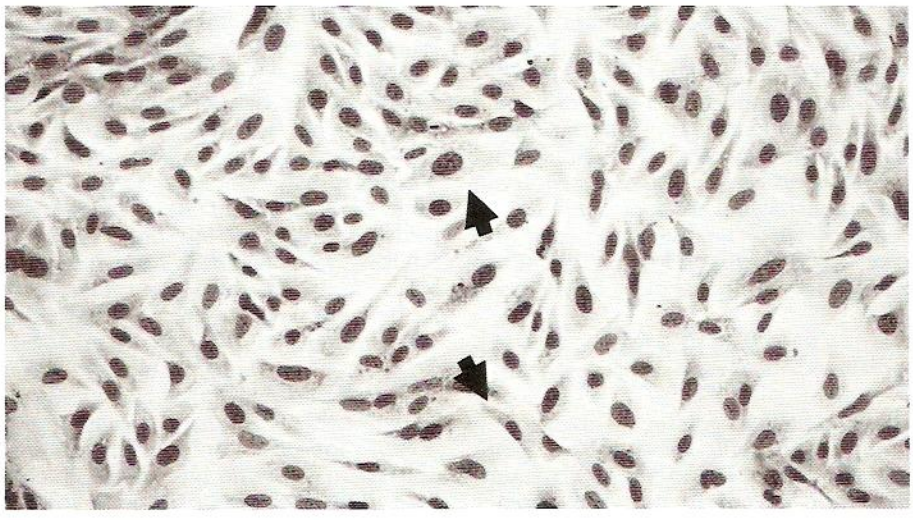

Figure 2-1. Low-power micrograph of a monolayer of normal bovine fetal spleen cells. Contact inhibition results in the formation of a monolayer of stellate- and spindle-shaped cells *(arrows)*. (×40, Giemsa stain.) (Courtesy H. Storz.)

Lithium carmine and trypan blue are vital dyes for studying phagocytosis. Janus green B and neutral red are supravital stains used to study mitochondria and lysosomes.

The separation and purification of cell fractions through **differential centrifugation** and **density gradient centrifugation** are aids for studying biochemical and metabolic phenomena.

The simplest method for the direct observation of living cells is to remove them from the organism, place them on a slide, and examine them with a **phase-contrast microscope** (Fig. 3-4) or **dark-field microscope.**

Examining living cells and tissues is difficult microscopically, because they are

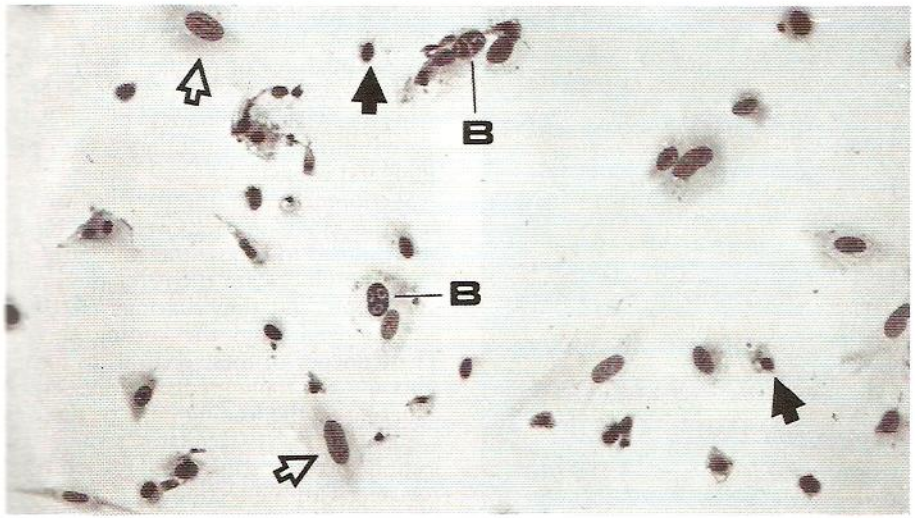

Figure 2-3. Low-power micrograph of a monolayer of bovine fetal spleen cells 48 hours postinfection with a parvovirus. The cells have been altered from the infection. The even distribution of cells as a monolayer is not apparent. Most of the cells are round and have withdrawn their cytoplasmic processes. Some nuclei are normal *(open arrows)*; others are pyknotic *(solid arrows)*. Some cells contain nuclear inclusion bodies *(B)*. (×40, Giemsa stain.) (Courtesy H. Storz.)

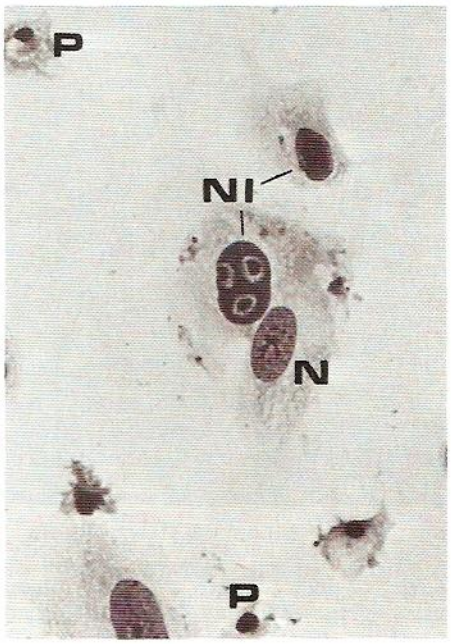

Figure 2-4. Medium-power micrograph of a monolayer of bovine fetal spleen cells 48 hours postinfection with a parvovirus. Pyknotic nuclei *(P)*, normal nuclei *(N)*, and nuclei with inclusion bodies *(NI)* are apparent. Note the altered cell shapes. Compare with Figure 2-2. (×100, Giemsa stain.) (Courtesy H. Storz.)

transparent and thick. The refractive indices of cell components are similar; they preclude easy identification and differentiation. Superimposition artifacts and excessive absorption of light also limit the useful and reliable information obtainable from unprocessed living materials. These problems are reduced when thin tissue sections are obtained, stained, and examined. This approach requires extensive tissue handling and processing, but this approach is the standard for histological studies.

To minimize structural alterations, tissues and cells for microscopic examination are usually killed by fixatives. Subsequent processing ends with the tissues' being embedded in a material to simplify thin sectioning.

PARAFFIN TECHNIQUE

The paraffin technique for preparing samples is simple and reliable. Although cell and tissue modifications result, the processed samples are reliably accurate and permit inferences to the in vivo situation. The paraffin technique is the most common method used in preparing specimens for histology courses, diagnostic histopathology, and morphological research with light microscopy.

Acquisition. Sample acquisition is a critical step. Obtaining the sample requires knowing gross anatomy. Once the desired sample is identified, its removal must be atraumatic. Most living tissues are fragile entities and their morphology changes from excessive handling and poor removal techniques. **A "tissue conscience" is as important to the histologist as it is to the surgeon.** Dull and dirty scalpels or scissors and excessive pressure or traction during sampling alters tissue components.

Most cells and tissues degenerate when separated from their ideal environments. Tissues must be removed rapidly and deftly; they should reach the fixative in the shortest time possible to inactivate autolytic enzymes.

Fixation. Chemical fixation is used on histological specimens for the primary purpose of stopping **postmortem autolysis.** By denaturing protein, fixatives inactivate the autolytic enzymes responsible for postmortem changes. The frequently used chemical fixatives are **formaldehyde, glutaraldehyde, paraformaldehyde, ethyl alcohol, acetic acid, picric acid, potassium dichromate, mercuric chloride, chromic acid,** and **osmic acid.** Each has specific properties, resulting in various advantages and disadvantages.

Some chemical agents are **coagulative fixatives.** They induce changes in cells similar to those occurring when heat is applied to an egg. Macromolecular conformation is altered by coagulative fixatives (e.g., ethanol and methanol). These fixatives induce marked structural changes.

Others are described as **additive fixatives.** These achieve fixation by chemically reacting with cellular biochemical components. They do not induce the marked morphological changes characteristic of coagulative fixatives. The aldehydes (formaldehyde, paraformaldehyde, and glutaraldehyde) are additive fixatives useful in histological studies.

A 10% solution of neutral-buffered formalin is the most common fixative. It consists of 10 volumes of commercial formalin (40% formaldehyde in water) and 90 volumes of phosphate-buffered water.

The action of most fixatives is multiple: they (1) **prevent postmortem autolysis by inactivating hydrolytic enzymes,** (2) **facilitate sectioning of the tissues by hardening them,** (3) **enhance staining by acting as a mordant,** (4) **minimize the leaching of many constituents resulting from subsequent processing,** (5) **stabilize structural components in as near in vivo conditions as possible,** and (6) **protect the histologist through their antiseptic properties.**

Immersion of the sample into the fixative must occur immediately upon removal from the organism. Trimming of the tissue block in fixative should produce a sample only a few millimeters thick. This permits thorough penetration (and fixation) of the entire sample. **The ideal ratio of fixative volume to tissue volume is about 30:1.**

The actual time required for complete fixation varies with the fixative diffusion properties, the concentration of the fixative, and the density of the tissue. Most formaldehyde fixation is achieved within 24 hours.

Downloaded From Vet-eBooks.com

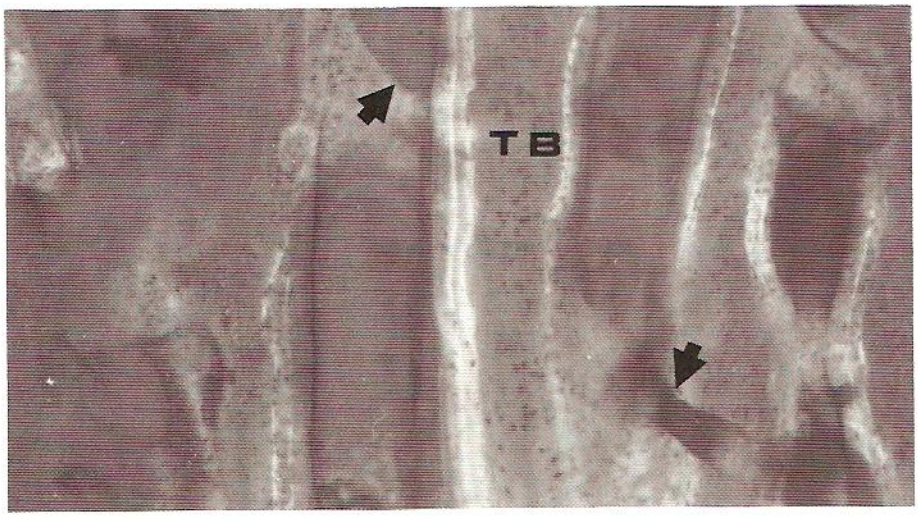

Figure 2-5. A 50 μm section of trabecular bone from an equine third carpal bone undergoing repair. Tetracycline at therapeutic dosages (5 mg/lb) was administered at 10-day intervals and the sample was obtained 20 days after the initial injection. Two bright bands of fluorescence within trabecular bone *(TB)* indicate the uptake of tetracycline at the times of injection. The interval between the two labels indicates the amount of bone formed during the 10-day interim. *Solid arrows* are for orientation and comparison of this micrograph with Figure 2-6. (×40, oxytetracycline-labeled, fluorescence microscopy.)



Figure 2-6. Bright-field micrograph of the same tissue field in Figure 2-5. The coupling of fluorescence and bright-field microscopy affords valuable insights about the morphological and dynamic changes accompanying fracture repair. (×40.)

Dehydration and clearing. Various chemicals are part of this procedure. When paraffin or a similar substance is infiltrated into a sample to permit sectioning, water must first be removed. Water comprises about 75% of most tissues normally. After extensive washing in water to remove excess fixative, the sample is dehydrated in preparation for embedding.

Many **dehydrating agents** are used (ethanol, butanol, dioxane, isopropanol), but the most common is ethanol. Tissue samples are immersed in increasing alcohol concentrations until total dehydration occurs with absolute ethanol. The samples are processed through a **clearing agent,** because dehydrating and embedding agents are not miscible in each other. Clearing agents are miscible in dehydrating and embedding agents. The clearing agent replaces the dehydrating fluid; the embedding agent replaces the clearing substance.

Embedding. The cleared specimens are processed through solutions containing increasing paraffin concentrations. The embedding reagents are maintained at their melting points (50° to 68° C) throughout the infiltration process, but the heat required may induce some morphological changes in the tissues. Commercial mixtures of purified paraffin and plastic polymers are effective embedding materials. The infiltrated samples are placed into molds, surrounded with paraffin, and cooled.

Sectioning. After the paraffin hardens and the molds are removed, the blocks are trimmed to expose the embedded tissue. The blocks are then mounted on a **microtome** and thin shavings **(sections)** are removed from the cutting surface. The tendency of these sections to form a ribbon—the trailing edge of one section adhering to the leading edge of the subsequent section—facilitates sample collection. Because some compression is associated with the sectioning process, ribbons may be floated on a warm water bath, subsequently stretched, and picked up on slides. Portions of the ribbons may be affixed to slides and placed on a warming table to minimize compression artifacts.

A **rotary microtome** can cut thin sections 1 μm (micron, micrometer) thick. Most specimens for histological examination are sectioned between 5 and 7 μm and collected on glass slides.

Staining and mounting. Sections of paraffin-embedded materials affixed to glass slides simplify the remaining steps of staining and mounting. Most tissue stains are soluble in water or alcohol; the paraffin must be removed before staining. Rehydration occurs and then the slides are stained. The specimens are dehydrated, cleared, and covered with a mounting medium that is miscible with the clearing agent. A coverslip is applied to produce a permanent preparation.

PRINCIPLES OF STAINING

General features. Most examinations of histological sections occur with bright-field microscopy. Cell and tissue components are similar optically; studying them is difficult without enhancing their optical properties through stains. Many stains and stain combinations are used in the histology laboratory (Plate I), because stain reactivity with cells and tissues varies. Some stains are specific for certain cell and/or extracellular components, others are not. Hematoxylin (H) and eosin (E) are general stains frequently used together.

Stains are useful, and the information obtained is maximized when the principles of staining are understood. The detailed chemical reactions for all stains are not understood completely; however, many staining mechanisms are known, and these afford the additional advantage of some chemical insights concerning cell and tissue constituents.

Basic and acidic stains. Most stains

used in histology are water-soluble salts described as **acidic** or **basic stains.** If the coloring component is in the acidic radical, the stain is designated acidic. If in the basic radical, the stain is designated basic.

Acidic and basic staining depends upon the anionic and cationic charges associated with cell and tissue proteins. The net charge on these stains results from the total number and nature of their ionizable radicals and environmental pH.

Basic cell components react with acidic stains through the **neutralization** reaction, resulting in the formation of a colored salt and water. Acidic cell and tissue components react with basic stains similarly. Basic cell and tissue components are **acidophilic;** they react with acidic dyes. Acidic components are **basophilic;** they react with basic dyes.

Hematoxylin and eosin. Neutralization is the mechanism of H&E staining. The basic dye, **hematoxylin,** is applied first. It imparts a blue to purple color to acidic cell components such as chromatin and some secretory products. Then **eosin,** the acidic dye, is applied; it imparts a pink to red color to basic cell components such as cytoplasm and many extracellular products.

Romanowsky stains. The **modified Romanowsky stains** are useful dye combinations containing methylene blue and eosin. Methylene blue is oxidized to form azure dyes. Combinations of methylene blue and the azure dyes (azure A, azure B, azure C) are called **polychromed methylene blue** and have a broad staining range for acidic components. Eosin is the acidic counterstain. This stain combination (Romanowsky and eosin) is used commonly for blood smears and bone marrow samples (Plate VI).

Periodic acid–Schiff stain. The **periodic acid–Schiff (PAS)** stain is useful for histological studies. The procedure involves two steps to achieve the characteristic reactivity. The first reaction is the oxidation of α-amino alcohols and/or 1,2-glycol groups to aldehydes by periodic acid. These aldehydes are then exposed to the Schiff reagent. The Schiff reagent has basic fuchsin decolorized from its original red-violet by the addition of sulfurous acid. The subsequent reaction of the aldehydes with the reagent forms a complex that restores the magenta color. Hematoxylin is the usual counterstain. Many carbohydrates and carbohydrate-protein complexes are PAS-positive (Plate I, *12*).

SELECTED PREPARATION TECHNIQUES

The amount and kind of information obtainable from histological studies are limited only by the approaches used. If structural relationships are the only concern, then the paraffin technique is useful. Many shortcomings are apparent, however: (1) **the fixation employed;** (2) **the heat required during subsequent processing;** (3) **the use of organic solvents that have harsh effects upon the cells;** (4) **the necessity for thick sections (5 to 7 μm) to facilitate observation;** and (5) **the time required to complete the procedure.**

Diverse technical approaches provide different information.

Cytological studies. Cytological studies are useful adjuncts when tissue architecture is a minimal concern (Chapter 29).

Freezing techniques. A concern for the altered morphology and function resulting from fixation and subsequent processing has been an impetus for the development of techniques that would be less harsh than those employed routinely. Reducing processing time has also been an impetus. Freezing techniques have been developed to satisfy these and other concerns. Frozen sections, such as intraoperative biopsy samples, are processed rapidly for examination.

The **freeze drying technique** is one in which fresh biopsy samples are frozen to liquid nitrogen temperatures (−170° C) while under vacuum. The resulting sublimation of water precludes the need for fixation, dehydration, and clearing. Samples are then embedded, sectioned, and stained. The ability to conduct chemical studies on such tissues is of special interest. Valuable insights concerning enzyme localization and activity have been obtained. Tissues prepared by this technique have fewer artifacts than those prepared by conventional chemical fixation.

Samples prepared by the **frozen section technique** afford advantages similar to those in the previously described technique; however, some damage occurs in the sample due to ice crystal formation, and section thinness is limited. Tissue samples are frozen rapidly to −40° C and cut within an apparatus that maintains this temperature. The cutting device, a **cryotome,** is a rotary microtome contained within this closed, cold environment.

Histochemistry and cytochemistry. These techniques are attempts to localize and characterize chemical substances within intact cells and tissues that chemists can readily characterize in test tubes. The procedures range from simple to complex, but the governing principle is simple. If a chemical constituent can be complexed with a stain to enhance its visualization, it lends itself to study. The precision of visualization and interpretation is a function of (1) **the specificity of the staining reaction,** (2) **the localization and stability of the component being studied,** and (3) **the degree to which the substance being examined is altered by processing techniques.**

Most chemical cell and tissue constituents can be examined by histochemical and cytochemical methods: minerals (Fig. 2-7), carbohydrates, fats, proteins, and enzymes (Fig. 2-8).

The term **histochemistry** is usually applied to studies conducted with light microscopy; **cytochemistry** is applicable to electron microscopy. Freezing techniques and/or moderate chemical fixatives are used for enzymes studies because of the denaturing effects of chemical fixatives. Electron microscopic studies of cytochemical events require that the trapped end-products be electron dense for visualization and localization to occur (Fig. 2-8).

Methacrylate technique. The paraffin technique is a quick, easy, and reliable method for histology. Despite its advantages, however, some disadvantages exist. The resolution of fine detail is not possible with specimens sectioned between 5 and 7 μm. Also the heat and harsh organic solvents required of the paraffin technique induce artifactual cell and tissue changes.

Electron microscopy offers the advantage of greatly improved resolution. This enhanced resolution accrues from electron beam characteristics and the ability to cut plastic-embedded specimens approximately 40 nm and less. Unfortunately, harsh chemicals must be used during the processing techniques. A definite structural gap existed between the cytological features demonstrable with light microscopy and the paraffin technique and those features demonstrable with electron microscopy and plastic embedding and sectioning techniques.

Glycol methacrylate (GMA) is a water-soluble plastic embedding medium that permits many harsh chemicals (dehydration and clearing agents) and the heat required of the paraffin technique to be avoided. Accordingly, the introduction of processing artifacts is reduced. The GMA technique is a hybridization of light microscopy and electron microscopy, bridging the gap between these methods. Additionally, GMA-embedded specimens can be sectioned in the 0.5 to 4 μm range. **Thin sectioning enhances the cytological detail observable with a light microscope.**

GMA embedding is useful in histochemical and cytochemical techniques. Determination of specific enzyme activity is enhanced when harsh chemicals are avoided; and because exposure to water is avoided or at lease minimized, water-soluble substances are retained within cells and tissues.

Glycol methacrylate techniques can complement the standard techniques of light microscopic evaluation.

Downloaded From Vet-eBooks.com

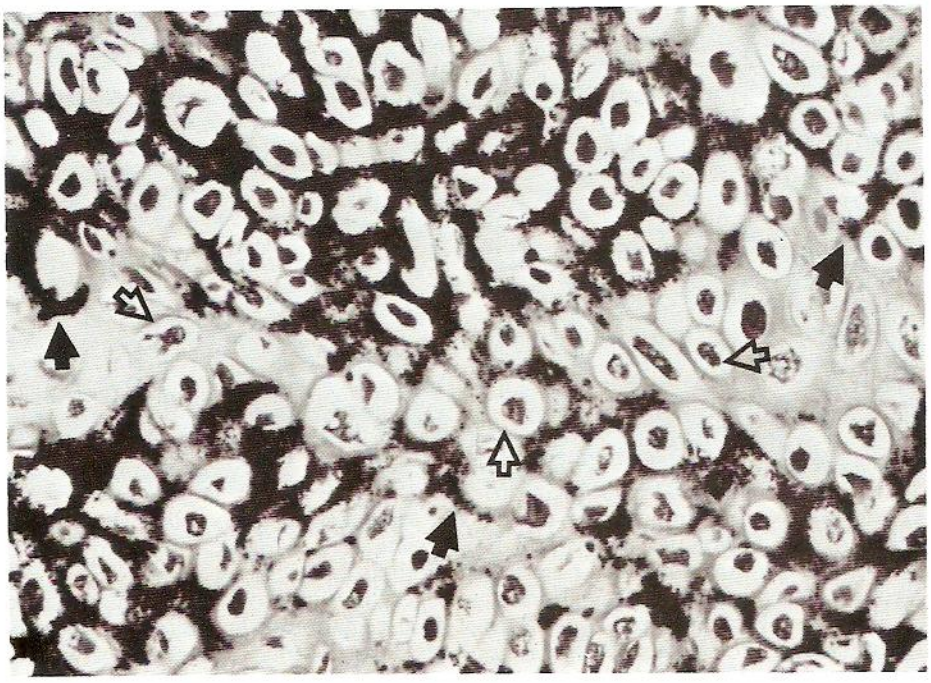

Figure 2-7. Section of developing cervine antler. The antler contains cartilage. The cartilage consists of chondrocytes *(open arrows)* surrounded by the matrix secreted by the cells. Mineralization of the cartilage *(solid arrows)* occurs before bone formation is initiated. The individual mineralization foci *(solid arrows)* coalesce during development *(dark-staining areas)*. (×80, von Kossa stain.)

Autoradiography. This technique is useful for histological studies of dynamic cellular processes. Tissue sections are incubated with radioactively labeled substances. The radioactive markers are usually soft beta emitters. The sections are then coated with a photographic emulsion that is exposed by the radiation. The latent image in the photographic emulsion is developed routinely. Staining of the sections allows visualization of the silver grains superimposed on the section (Fig. 2-9). These sections may be examined with light or electron microscopes because the silver grains are black and electron dense. Insights into cell synthesis, secretion, and mitosis result from these methods.

Immunocytochemistry. This technique is useful with light and electron microscopic investigation for the identification and localization of potentially antigenic substances. A purified extract of the desired substance is prepared and injected as an **antigen** (Ag) into another animal. The animal develops an immune response and produces **antibodies** (Ab); the antibodies are then isolated and purified. The subsequent treatment is determined by the nature of the specific immunochemical technique utilized.

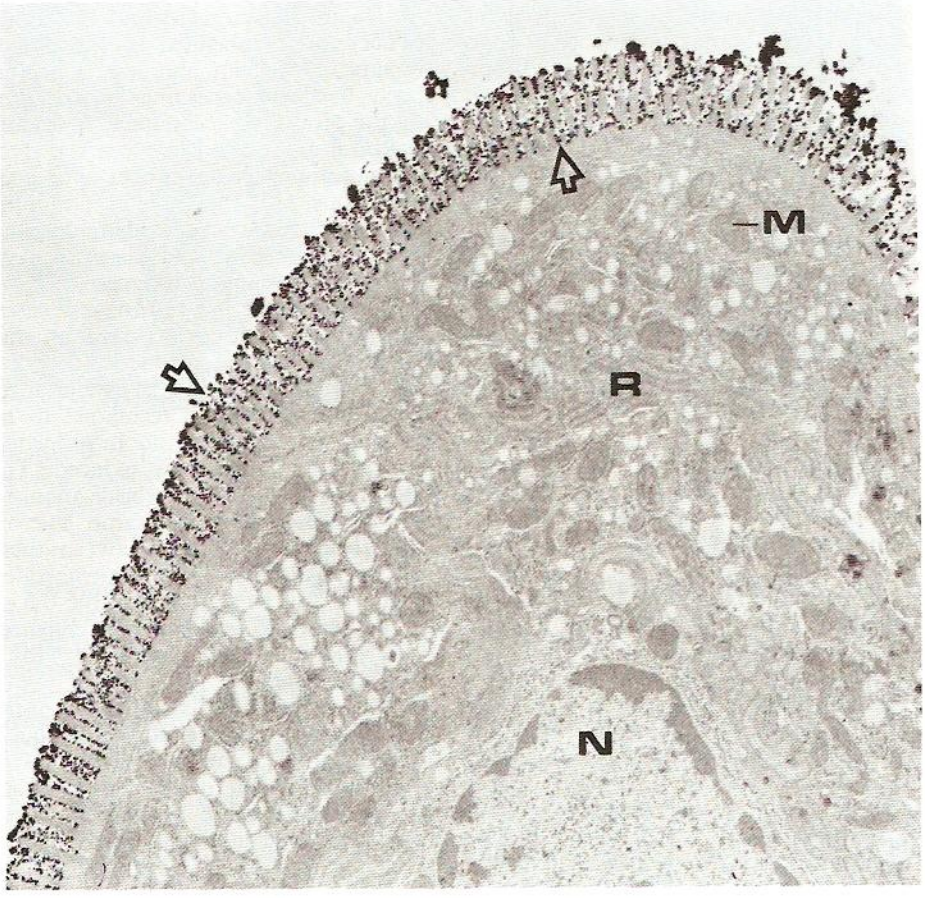

Figure 2-8. Electron micrograph of a murine intestinal lining cell. The dense granules *(open arrows)* associated with the microvilli represent reaction foci for the enzyme alkaline phosphatase. *M*, Mitochondria; *R*, rough endoplasmic reticulum; *N*, nucleus. (×6000, modified Gomori technique.)

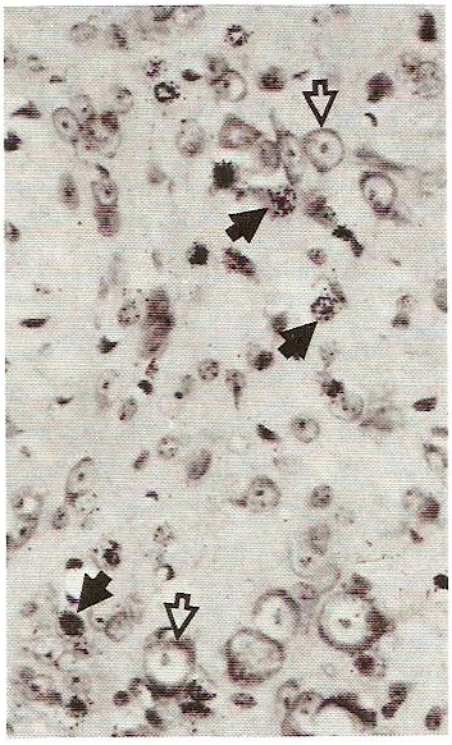

Figure 2-9. Autoradiograph of the substantia gelatinosa of the developing spinal cord of a mouse. The nuclei of some neurons *(open arrows)* are unlabeled; the nuclei of others *(solid arrows)* are labeled with tritiated thymidine. The electron-dense, dark-staining, silver grains are positioned over labeled nuclei. (×100.) (Courtesy M. Cary and H.O. Nornes.)

In the **direct fluorescent antibody technique** a fluorescent dye, usually fluorescein isothiocyanate (FITC), is complexed with the antibody. The Ab-FITC complex then interacts with the specimen. Subsequent washing removes all the reagent except that forming an Ag-Ab-FITC complex. Examination with an ultraviolet light source allows fluorescent antigen localization (Fig. 2-10). In the **indirect fluorescent antibody technique,** an additional step is required to produce an **antiglobulin** (An) to the originally-produced antibody. The fluorescent tag is attached to the antiglobulin. The sample is incubated as described previously with a resultant Ag-Ab-An-FITC complex being formed. This technique has the advantage of increasing reaction intensity and sensitivity by allowing more complexes to form. The markers used in this technique are not confined to fluorescent dyes. The enzyme **peroxidase** may be conjugated to the Ab or the An. Reactive complex visualization is achieved by the histochemical demonstration of peroxidase activity. **Ferritin** may be complexed with an Ab or An. Ferritin contains 23% iron, is electron dense, and permits reaction visualization with the electron microscope. Investigations using these techniques are not confined to classical antigens. Any substance inducing a humoral Ab response in another animal may be localized via this technology.

Transmission electron microscopy. The preparation of biological materials for electron microscopy involves procedures similar to those described for the paraffin technique.

The sample must be obtained atraumatically. Any careless handling and/or introduction of contamination during this phase will be observed readily at the levels of magnification used. Fixation, usually accomplished with paraformaldehyde or glutaraldehyde and/or osmic acid, must be excellent; it is usually achieved at 4° C. Dehydration is similar to that for light microscopic preparations. Clearing agents are used in the manner described previously to permit specimen embedding in plastics.

Plastic embedding, the precision of the cutting instruments, and the use of glass or diamond knives simplify the acquisition of thin specimens (30 to 60 nm thick). Thin sections are essential to allow the electron beam to pass through the specimen. If specimens are too thin, insufficient scatter occurs. Thick specimens absorb too much of the electron beam. Heavy metal stains (osmic acid, lead, uranium) are used to stain cell and extracellular constituents. These heavy metals, dispersed differentially throughout the specimen, account for the electron beam scattering and image formation (Fig. 2-11).

During the sectioning process, 1 to 2 μm tissue sections are often examined for purposes of orientation. These thick sections are useful for histological study (Fig. 2-12).

Scanning electron microscopy. Preparation techniques for this microscopy are similar to those used for transmission electron microscopy, but sectioning and staining are not required. The specimens used in this technique afford a natural or artificially induced surface. They are acquired, fixed, and dried by **critical point drying** (to minimize surface tension distortion) and are then coated with a conductor, usually gold, which backscatters secondary electrons to a collector. Such specimens require minimal treatment yet afford insights into three-dimensional relationships (Fig. 15-8).

Freeze fracturing. This technique uses the rapid freezing of samples with liquid nitrogen (or Freon) and bypasses the need for chemical fixation and dehydration. Frozen samples are mounted on plates within a special apparatus. The plates are moved slightly, and the specimens fractured. Metals vaporized from a heated source coat the fractured surfaces and form ultrathin metallic replicas. The metallic replicas are removed from the fractured tissues and are used as the sample examined with the transmission electron microscope. This technique affords high resolution insights into the architecture of real and induced surfaces—plasmalemma, cytomembranes, other organelles, matrical components, and inclusions (Fig. 2-13).

Figure 2-10. Direct fluorescent antibody reaction of bovine lung cells for IBR virus. Both cells are positive for the virus, as evidenced by the bright fluorescence associated with them. (×400.) (Courtesy J.J. England.)

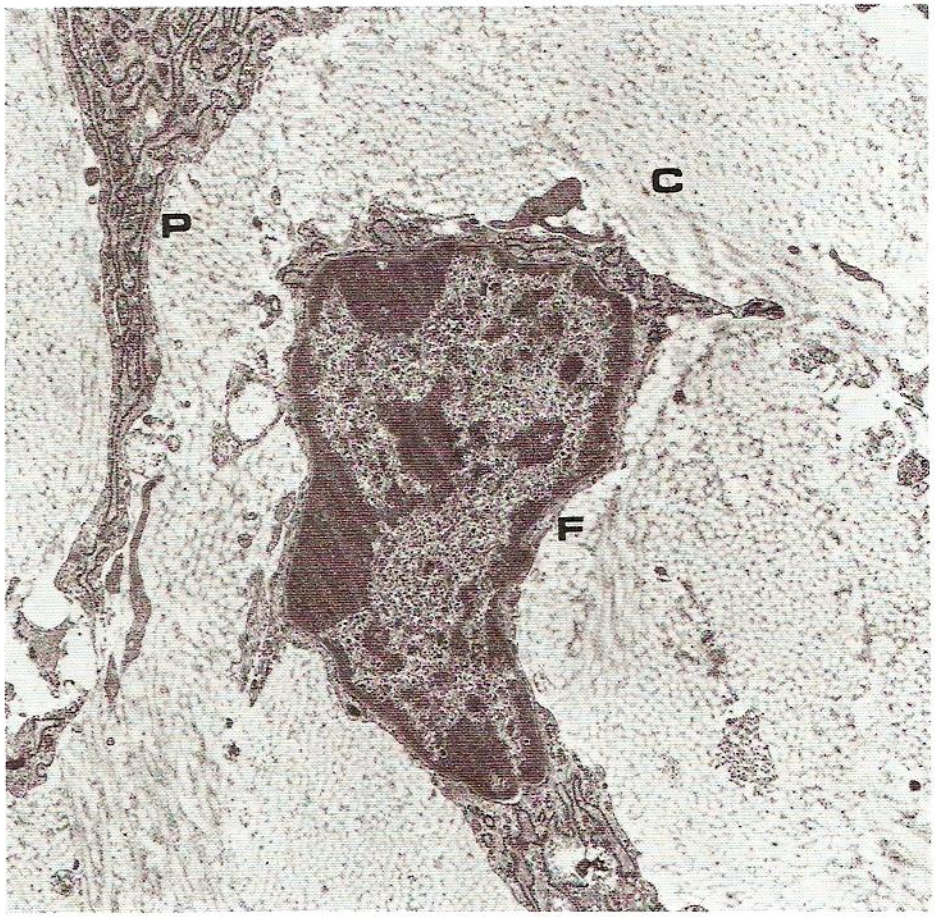

Figure 2-11. Electron micrograph of a section of cervine dermis. The fibroblast *(F)* is surrounded by collagen fibers *(C)* cut in longitudinal and cross section. *P,* Cytoplasmic processes of another fibroblast. (×6000.)

Downloaded From Vet-eBooks.com

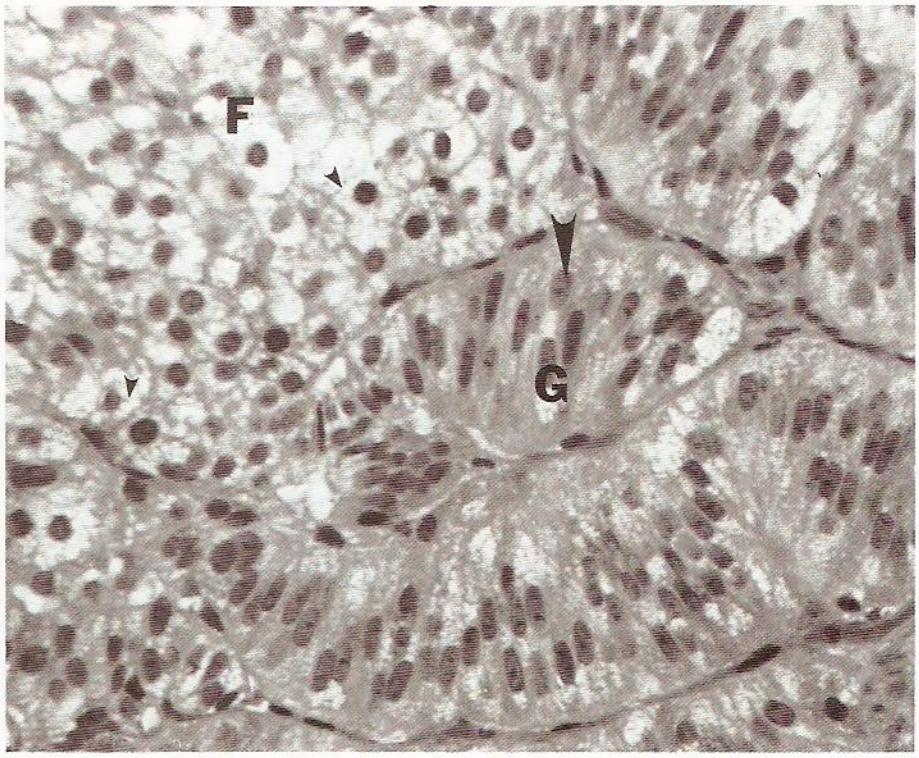

Figure 2-12. Light micrograph of a glycol methacrylate–embedded, 2 μm section of a canine adrenal gland. The sample is a section of the adrenal cortex. The cells of the zona fasciculata *(F)* and zona glomerulosa have excellent detail. Note the foamy appearance of the spongiocytes *(small arrowheads)* and the nuclear detail *(large arrowhead)* of the cells. (×100.)

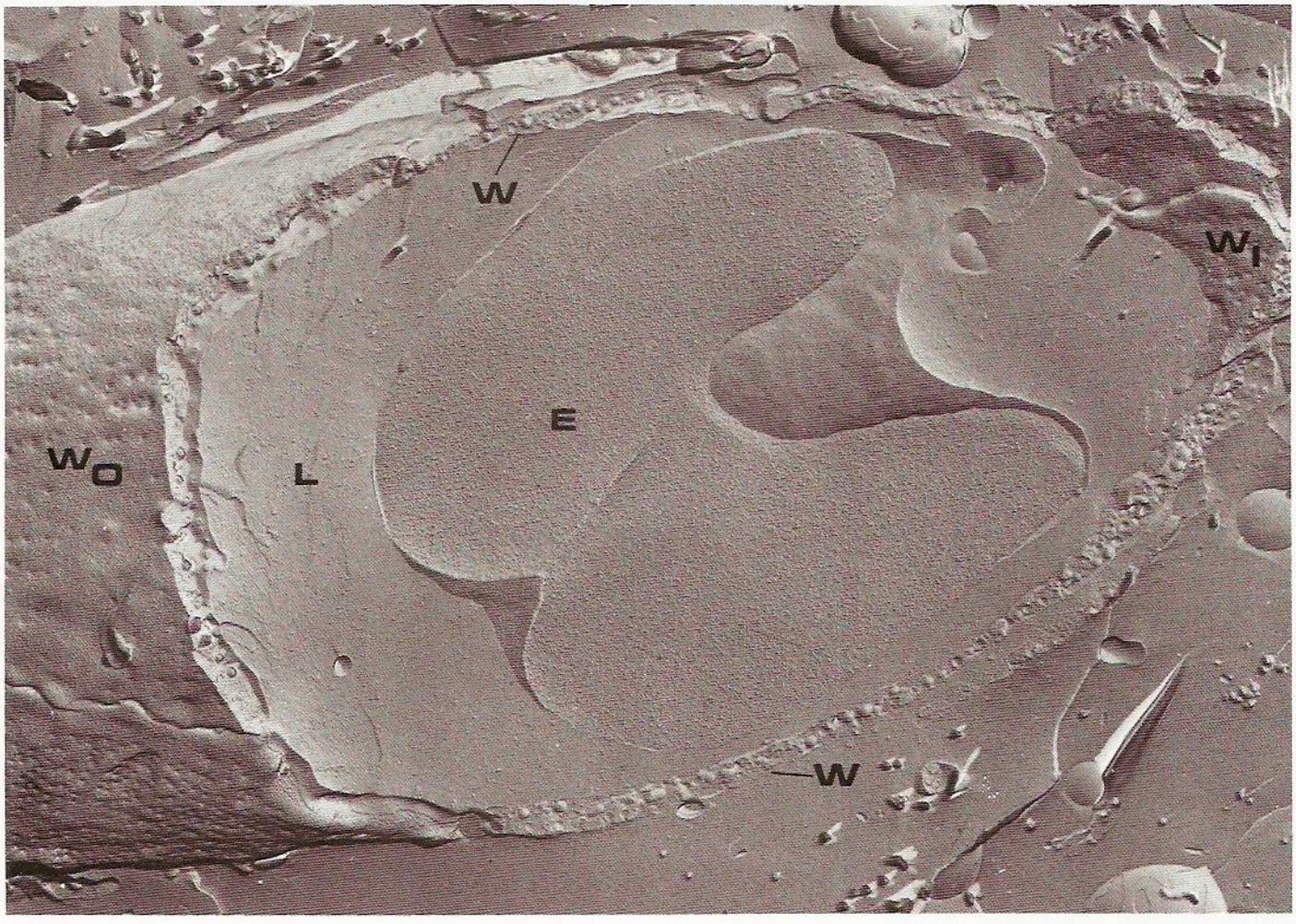

Figure 2-13. Electron micrograph of a freeze fractured capillary. An erythrocyte *(E)* occupies the lumen *(L)* of the capillary. The wall of the capillary has been fractured in longitudinal *(W)* and cross section. The inner (W_i) and outer (W_o) surfaces of the capillary wall are apparent. (×20,500.) (Courtesy J.E. Rash.)

ADDITIONAL READINGS

Albers B, et al: *Molecular biology of the cell,* ed 2, New York, 1989, Garland Publishing.

Baker JR: *Cytological techniques: the principles underlying routine methods,* ed 5, New York, 1966, John Wiley & Sons.

Davenport HA: *Histological and histochemical techniques,* Philadelphia, 1960, WB Saunders.

Gahan PB: *Autoradiography for biologists,* New York, 1972, Academic Press.

Gomori G: *Microscopic histochemistry: principles and practice,* Chicago, 1952, University of Chicago Press.

Hayat MA: *Basic electron microscopy techniques,* New York, 1972, Van Nostrand Reinhold.

Hayat MA: *Principles and techniques of scanning electron microscopy: biological applications,* vol I, New York, 1974, Van Nostrand Reinhold.

Hayat MA: *An introduction to biological scanning electron microscopy,* Baltimore, 1978, University Park Press.

Hearle JWS, Sparrow JT, Cross PM: *The use of the scanning electron microscope,* New York, 1972, Pergamon Press.

Humason GL: *Animal tissue techniques,* ed 3, San Francisco, 1972, WH Freeman.

Koehler JK (ed): *Advanced techniques in biological electron microscopy,* New York, 1973, Springer-Verlag.

Koss LG: *Diagnostic cytology and its histopathologic bases,* ed 2, Philadelphia, 1968, JB Lippincott.

Lillie RD: *H.J. Conn's Biological stains,* ed 9, Baltimore, 1977, Williams & Wilkins.

Pearse AGE: *Histochemistry: theoretical and applied,* ed 3, vols I and II, Baltimore, 1968, Williams & Wilkins.

Pease DC: *Histological techniques for electron microscopy,* ed 2, New York, 1964, Academic Press.

Wischnitzer S: *Introduction to electron microscopy,* ed 3, New York, 1981, Pergamon Press.

Downloaded From Vet-eBooks.com

CHAPTER 3

Microscopy and Interpretation

To study histology effectively, you must understand preparation techniques and the many ways cells and tissues can be examined. Both dictate and/or limit the information obtainable from histological specimens. Your interpretation skill is also an essential component of histology.

Table 3-1. Linear Measurements

	Abbreviation	Relationships
Centimeter	cm	1 cm = 10^{1} mm, 10^{4} μm, 10^{7} nm, 10M^{8} Å
Millimeter	mm	1 mm = 10^{-1} cm, 10^{3} μm, 10^{6} nm, 10^{7} Å
Micrometer (micron)	μm	1 μm = 10^{-4} cm, 10^{-3} mm, 10^{3} nm, 10^{4} Å
Nanometer (millimicron)	nm	1 nm = 10^{-7} cm, 10^{-6} mm, 10^{-3} μm, 10^{1} Å
Angstrom	Å	1 Å = 10^{-8} cm, 10^{-7} mm, 10^{-4} μm, 10^{-1} nm

MICROSCOPY

As a new student of histology, you face the challenge of conceptualizing this realm of structure and appreciating the functional and spatial relationships of the histological components (Table 3-1 and Fig. 3-1).

The ability of a microscope to magnify is important to histology, but the ability to display points close to each other as separate images is the significant consideration. **The display of closely spaced objects as separate images is the resolving power of a lens or lens system.** Resolution is defined as

$$R + 0.61\ \lambda/NA$$

The resolving power (R) in (in angstroms) is determined by the wavelength (λ) (also in angstroms) of the illuminating source and the numerical aperture *(NA)* of the objective lens. The numerical aperture for a lens, n sine α, is the refractive index (n) multiplied by the sine of the half angle formed between the specimen and the maximal lens opening. This describes the light gathering properties of lenses. Wavelengths of about 5000 Å are used commonly in light microscopes, and the numerical aperture of good oil-immersion objective lenses is about 1.4. The resolving power for a system with these values would be about 2200 Å. Any components closer than 2200 Å would not be seen as separate objects. A reasonable estimate of the theoretical resolving power of an optical system is $\lambda/2$.

Spherical aberration, the inability of a curved surface to bring monochromatic light to a single focus, can decrease resolution. **Chromatic aberration,** the manifestation of multiple focal points through the differential refraction of polychromatic light, can also negatively affect image quality. In quality optical systems, lenses are corrected for these aberrations.

Bright-field microscope. The bright-field microscope used in histology (Fig. 3-2) has a resolution limit of about 2200 Å. Stained sections are necessary for maximal effectiveness of this type of microscope because of living tissue transparency.

The resolution of bright-field microscopes can be increased by using a light source with a shorter wavelength. Wavelengths shorter than 4000 Å are not transmitted through glass lenses. The ultimate resolution with this microscope is a function of lens characteristics, not wavelength.

Ultraviolet microscope. This type of microscope uses an ultraviolet radiation source emitting wavelengths between 1000 and 3000 Å. An estimate of resolution of this system is between 500 and 1500 Å. Quartz lenses are needed so these short wavelengths can enter the optical system. Photographic techniques must be used, because ultraviolet radiation cannot be seen and will damage retinas and living organisms. The primary application of this microscope is in microspectrophotometry as an adjunct to histochemical studies.

Fluorescence microscope. This visible light microscope uses an ultraviolet light source. The monochromatic radiation excites molecules, which absorb photon energy, and reemit wavelengths in the visible spectrum (Plate I, *10*). Barrier filters prevent the shorter wavelengths from reaching the retina. This microscope is used in fluorescent antibody techniques (Chapter 2).

Dark-field microscope. This instrument is a modified bright-field microscope. The usual condenser is replaced by one that causes light to strike the image

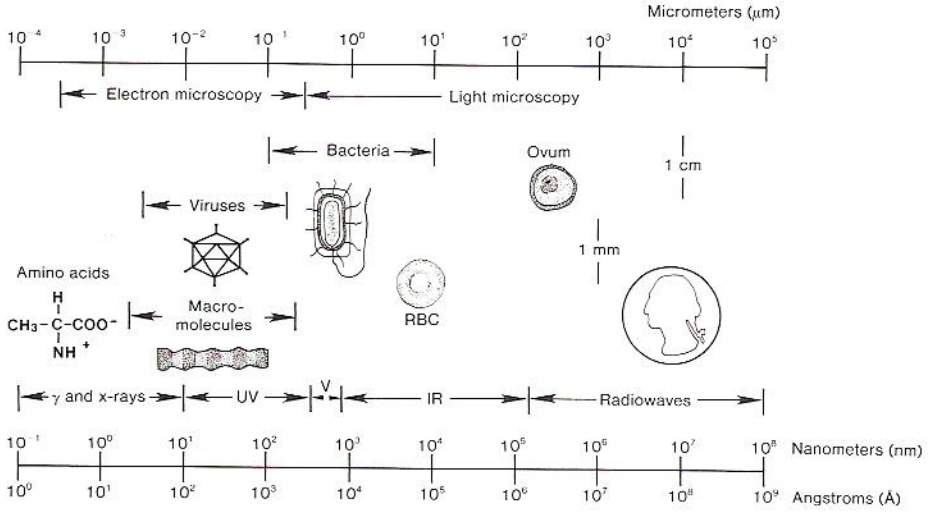

Figure 3-1. Scalar relationships and relative sizes of biological and nonbiological entities.

at an oblique angle. No direct illumination reaches the objective lens. Light reaching this lens is that scattered at the boundaries between components with different refractive indices. Cells and other tissue components appear bright against a dark background. The limits of resolution are similar to those of the bright-field microscope. Dark-field microscopes enable one to examine living, unstained specimens.

Phase-contrast and interference microscopes. These are discussed together because they use light similarly.

The **phase-contrast microscope** is a modified light microscope requiring a special condenser (**Zernike condenser**) and a phase plate. The alignment of optical components is achieved with a **focusing telescope.** When living or unstained specimens are transilluminated, various constituents transmit phase-altered light as a function of their slightly different refractive indices and thicknesses. This **phase-altered (deviated) light** interacts with the **normophasic (undeviated) light** to produce an image. The image created through constructive and destructive interference results in a visible altered intensity. **Phase-contrast microscopes convert undetectable phase differences into amplitude differences visible to the human retina** (Fig. 3-3). This microscopy is useful for studying living and unstained specimens (Fig. 3-4).

The same principles govern the **Normarski interference phase microscope.** Its singlemost important advantage is the three-dimensional imaging of cells and tissues (Figs. 3-5 and 3-6).

Polarizing microscope. Many substances contained within or secreted by cells have an ordered molecular structure. When a beam of polarized light passes through such substances, the transmitted

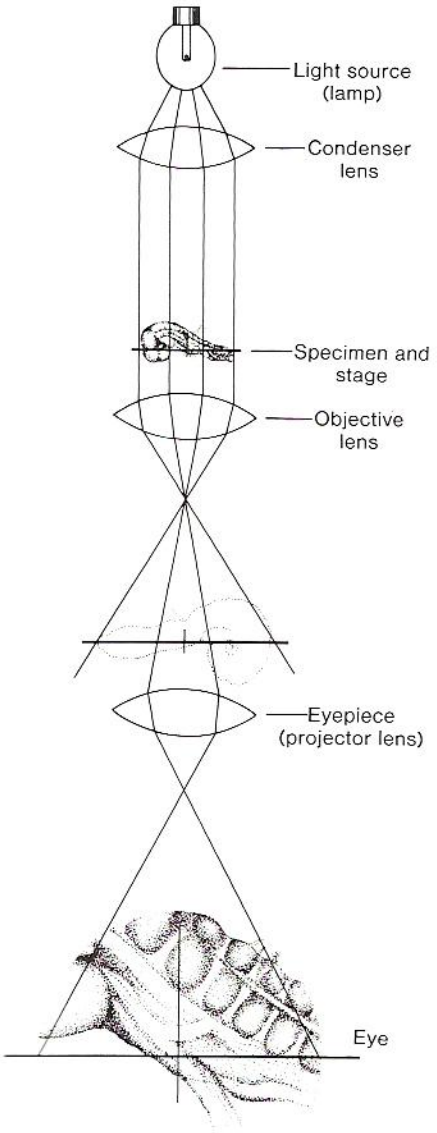

Figure 3-2. Optical pathway in a bright-field microscope. The light passes through glass lenses and the specimen before forming an image on the retina. See Figure 3-8.

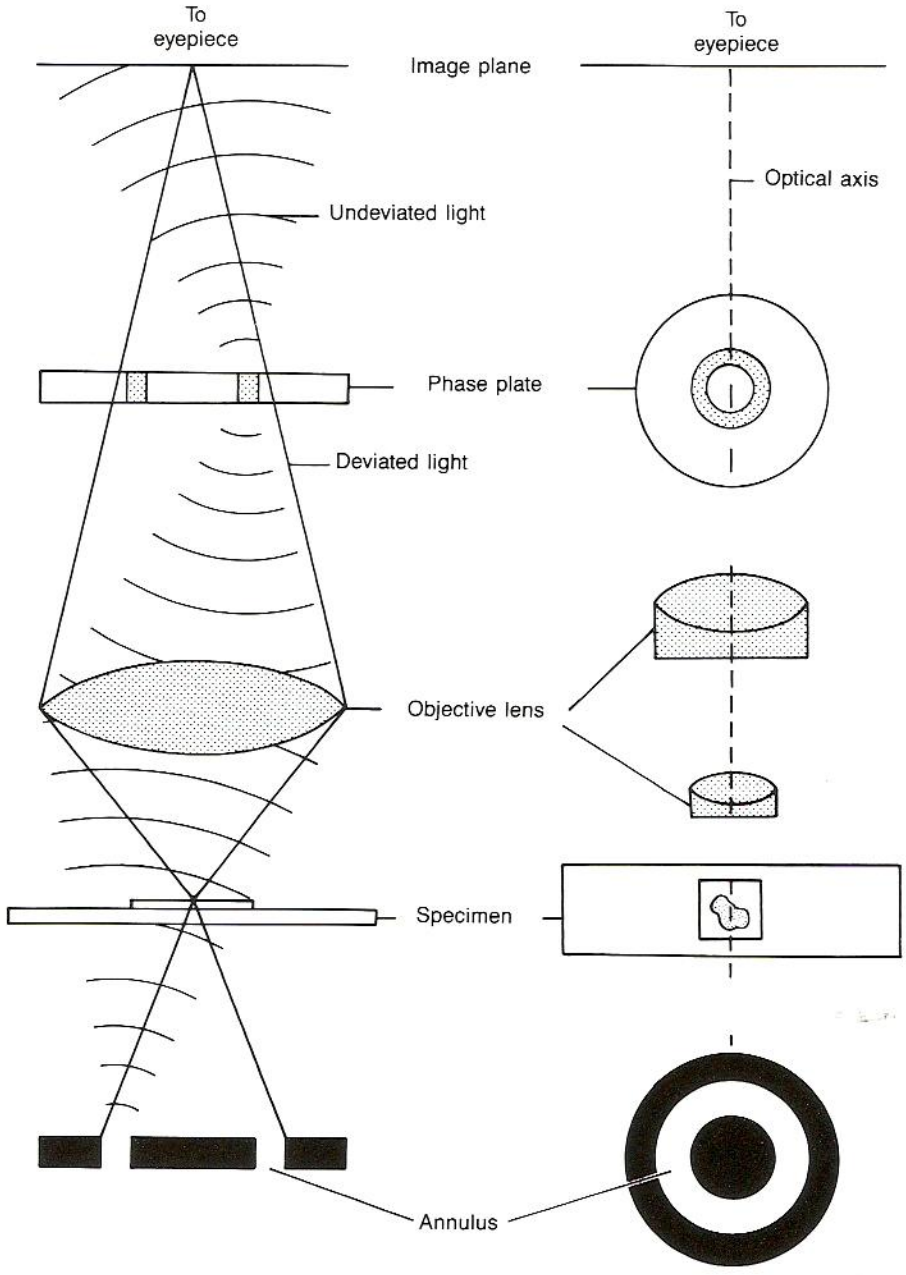

Figure 3-3. Optical pathway and primary constituents of a phase-contrast microscope. The annulus presents a ring of light to the objective lens, separating the undeviated and deviated light rays from each other. The phase plate, built into the back focal plane of the objective lens, retards the central (undeviated) beam by ¼ lambda and absorbs about 75% of this central light. The retardation becomes interference at the image plane, accounting for contrast enhancement.

Downloaded From: LWW Books.com

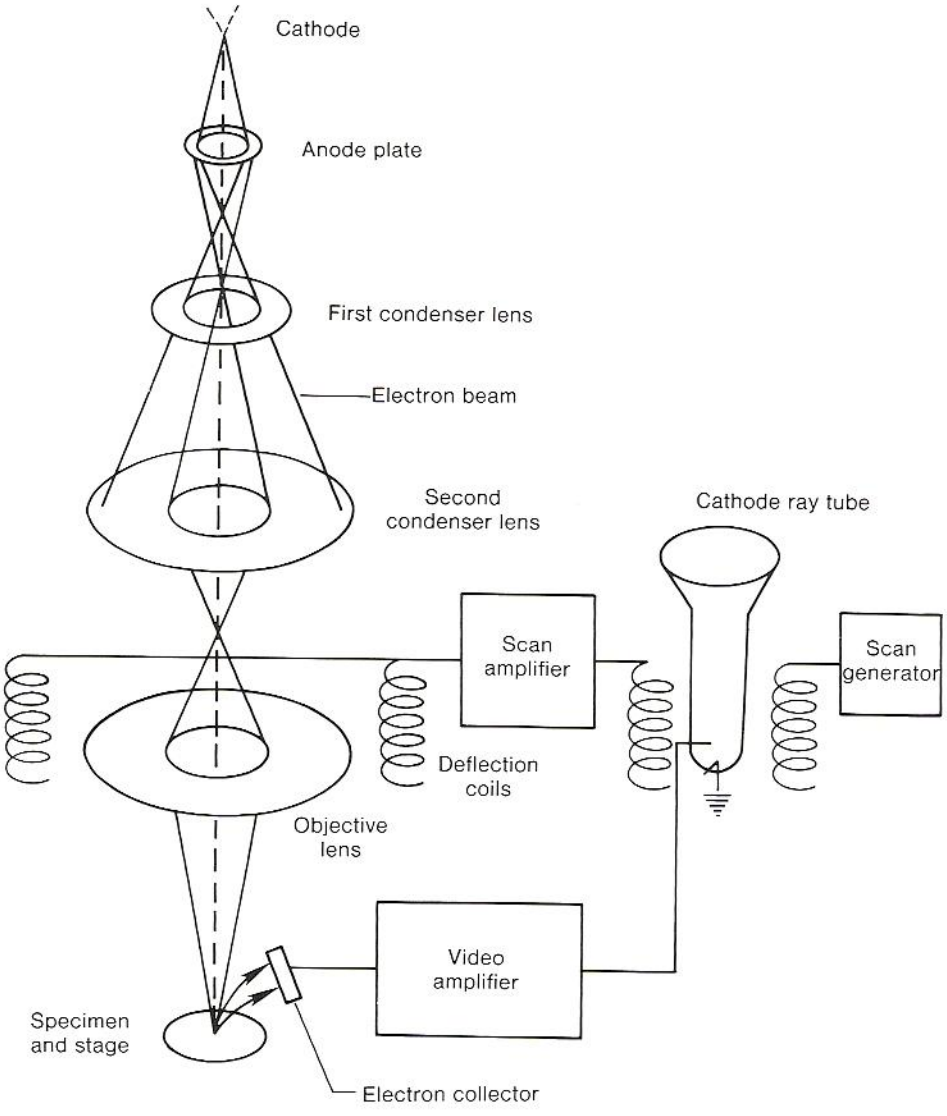

Figure 3-9. Electron pathway in a scanning electron microscope (SEM). The electrons pass through the column to the objective lens. The objective lens focuses the electron beam on the specimen while deflection coils move the beam back and forth across the specimen. The detector picks up backscattered electrons. The signal is converted to an image on a CRT. Micrographs are obtained by photographing the CRT display.

obtained. The histologist knows the organ of origin and probably noted its gross structure (normal or abnormal). The study of histology without gross anatomical orientation creates an artificial didactic situation, especially during examinations, requiring you to rely upon microscopic features only to identify cells, tissues, and organs.

All sections of known or unknown origin are best examined first with the unaided eye. Many microscopic features are evident with this cursory yet effective first step. The distribution of staining properties (basophilia, acidophilia), the presence or absence of hollow spaces (lumina), and the characterizing architecture may direct your attention to certain regions of a section. Besides, such an examination, if conducted carefully, limits the number of interpretive possibilities.

A desire "to want to see more" by going directly to the highest magnification may result in disorientation. Each increase in magnification gives a narrower field of vision. It is best to pass through each stage of magnification noting the specific features of each field. You gets more information about less tissue with each magnifications increase. An examination may end with the oil-immersion lens. Often, the desired information about tissues is obtainable without the use of this lens.

Color and morphology. If you learn and understand morphology, then color is not important. Color should be an aid to learning and study. Electron micrographs, an important part of the study of histology, are black and white. The sooner you can rely on morphology independent of tinctorial properties, the sooner you will understand histology. The judicious use of color in this text is intended as an aid to study.

Sectioning and morphology. Three challenges face you in preparing a histological section.

The first is to realize that fixed, processed, stained, and sectioned pieces of the body represent reasonable samples of body constituents. The structural and functional relationships visible on the slide are a captured moment in the life of the organism or a part of the organism. If the sample is representative, reasonable inferences about the organism and/or its constituent parts can be made.

The second challenge is to assess the reliability of a tissue section. Does the section from any organ truly represent the entire organ? The answer is yes, if the sample was obtained carefully. You must

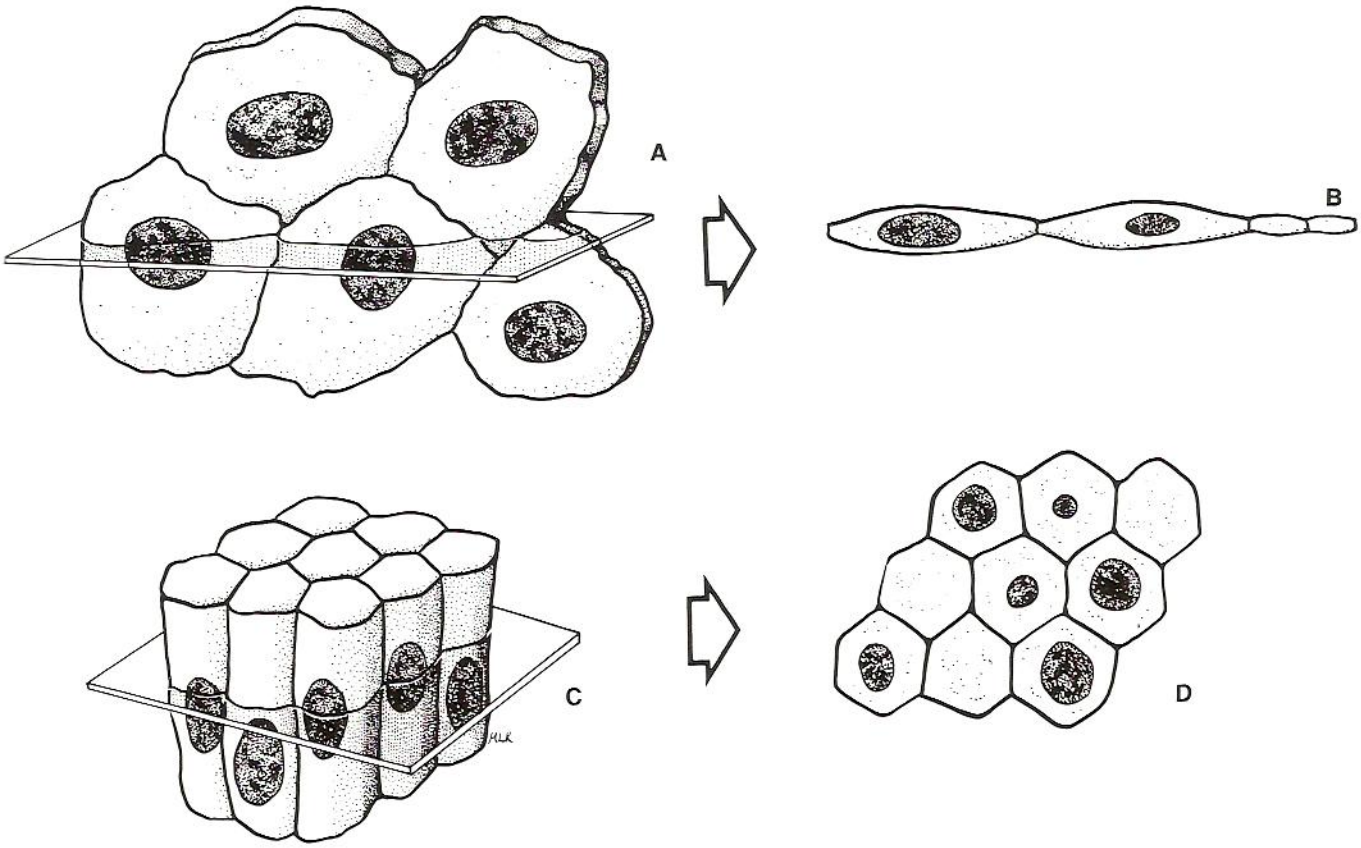

Figure 3-10. Apparent alteration of cell shape with different views. **A,** The flattened or pancake-shaped cells appear round in surface view. **B,** After sectioning in a plane perpendicular to the surface, the cells appear flattened and elongated. The cells are a variable length, the nuclei are different sizes, and two of the cells appear to be devoid of nuclei. **C,** Some cells appear as columns when viewed from the side. **D,** After sectioning in a plane parallel to the surface, the cells appear more like those in **A** than **C.** Whereas their hexagonal shape is obvious in section, it would not have been obvious in a true side view. The uniform cells now appear to have nuclei of different sizes, and some cells appear to be devoid of nuclei.

accept samples as representative and then proceed to convert them mentally into a three-dimensional and dynamic picture.

The third challenge is to convert biplanar sections into a three-dimensional whole. Scientists have good reasons for working with sections. Sections are an expeditious way of gaining insights into the constituent parts and the organism without examining every milligram of the organism. Your ability to convert these biplanar images to a three-dimensional whole will be an important part of histology.

Items in our everyday lives are easily conceptualized. Often in histology, however, you must think three-dimensionally from a single plane of section about unfamiliar items. A section normal to the long axis of pancake-shaped or flattened cells gives misleading information about cell shape (Fig. 3-10). In both instances the third dimension must be considered.

Correlating three-dimensional structure with biplanar images of familiar items is useful. The first slice perpendicular to the long axis of a hard-boiled egg rarely causes concern about the absence of a yolk. Progressive sectioning will eventually "produce and lose" the yolk. The three-dimensional relationship of the yolk and white accounts for its sectioned structure.

Similar problems are encountered in tissue sections. Although all cells have nuclei, not all the nuclei will be encountered in a single section (plane) of a given tissue (Fig. 3-10). You can be as confident about the presence of a nucleus as you are about the presence of a yolk. Misinterpretations of three-dimensional structure and components can occur with sectioning of an egg. Similar misinterpretations can occur in histology. The following considerations help to minimize such interpretative errors: familiarity with what is sectioned, increasing the number of sections, and faith in the accumulated knowledge of histology relating to three-dimensional structure.

The tissue components of many organs are disposed in patterns with various architectural features. Sectioning the familiar lemon demonstrates the appearance of a specific slice of this fruit (Fig. 3-11). Organ sections also appear differently as a function of the sectioning plane. You should be aware of these different representations when slides are being examined.

Some solid tubular organs may be cut longitudinally, cross sectioned, or sliced obliquely. Their representation may be compared with different planes of section of a coaxial cable (Fig. 3-12). The altered appearance of the cable, especially in the oblique section (Fig. 3-12, *C*), can give the misleading impression of discontinuity between components.

Some elongated, hollow, tubular structures (Fig. 3-13) may assume various shapes in section. These shapes, if not carefully examined and interpreted, can give false impressions of the real nature of these structural entities.

Histological artifacts. Processing histological samples induces changes in cells and tissues. You should learn to distinguish constant and predictable changes from those alterations resulting from capricious handling and/or processing of samples—**artifacts.**

Excessive shrinkage and/or swelling can alter tissues. Incomplete embedding

Downloaded From Vet-eBooks.com

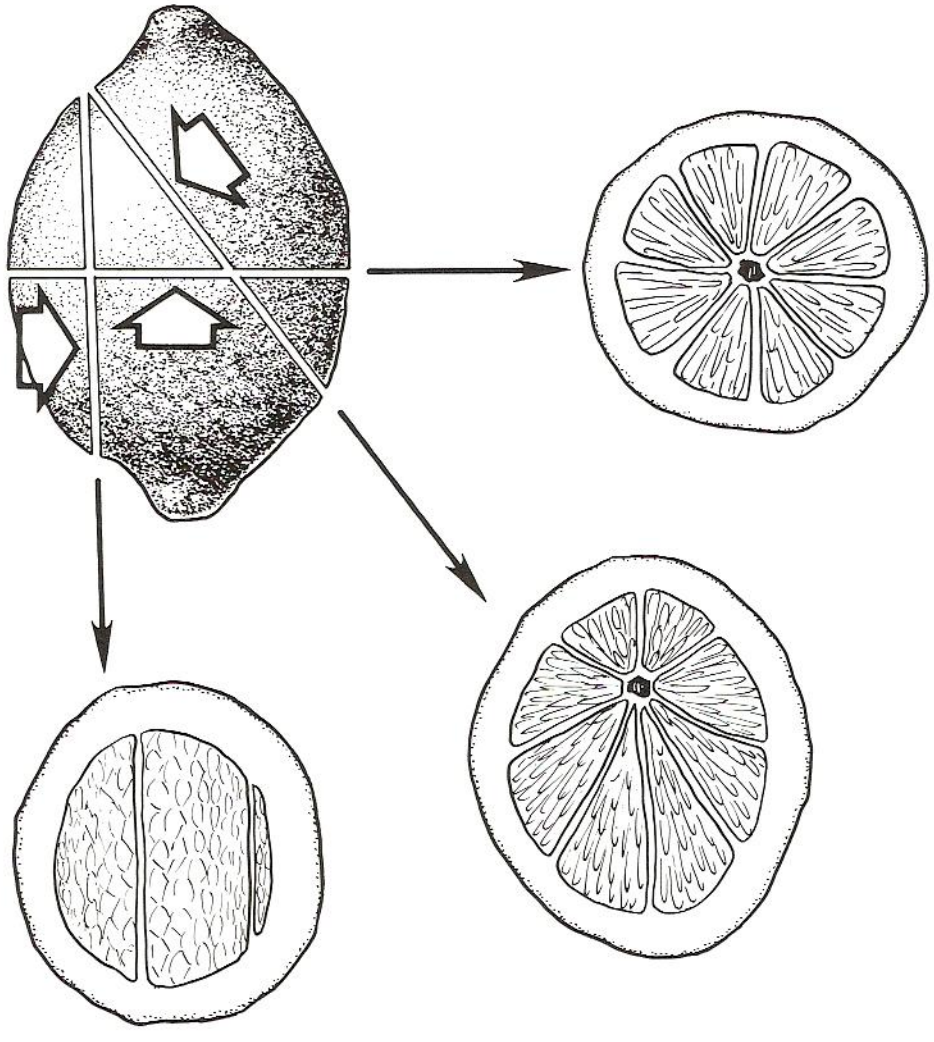

Figure 3-11. Apparent alteration of the architectural subdivisions of a lemon as a function of different planes of section. Cross sections, oblique sections, and parasagittal sections of this familiar fruit afford different perspectives of its internal organization.

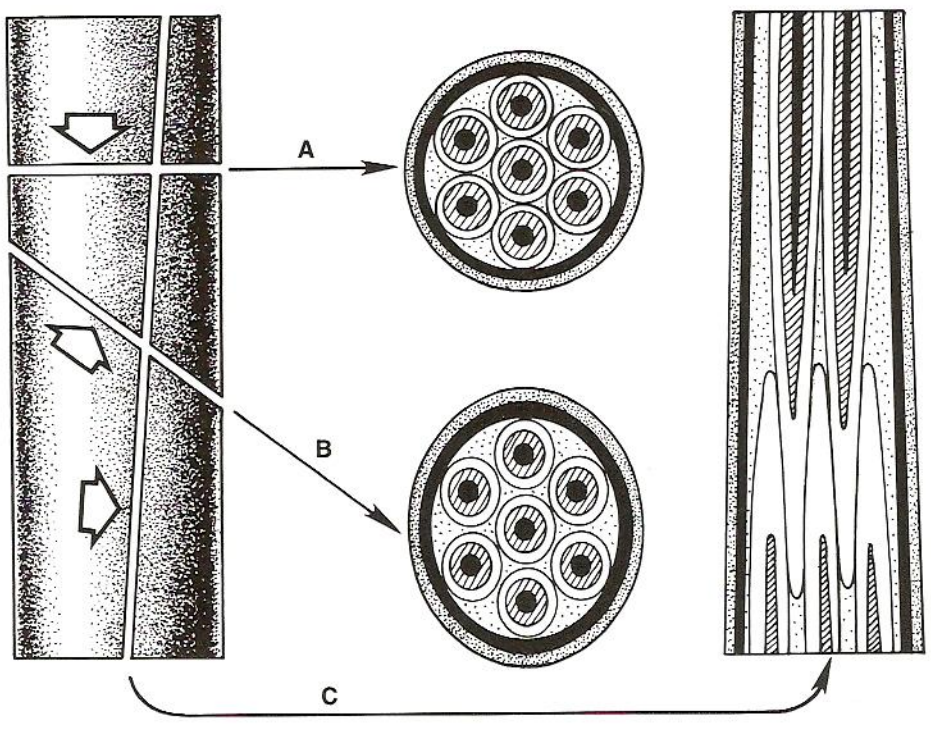

Figure 3-12. Apparent alteration of internal constituents of a coaxial cable as a result of different planes of section. (Redrawn and modified from Ham AW: *Histology*, ed 6, Philadelphia, 1969, JB Lippincott.)

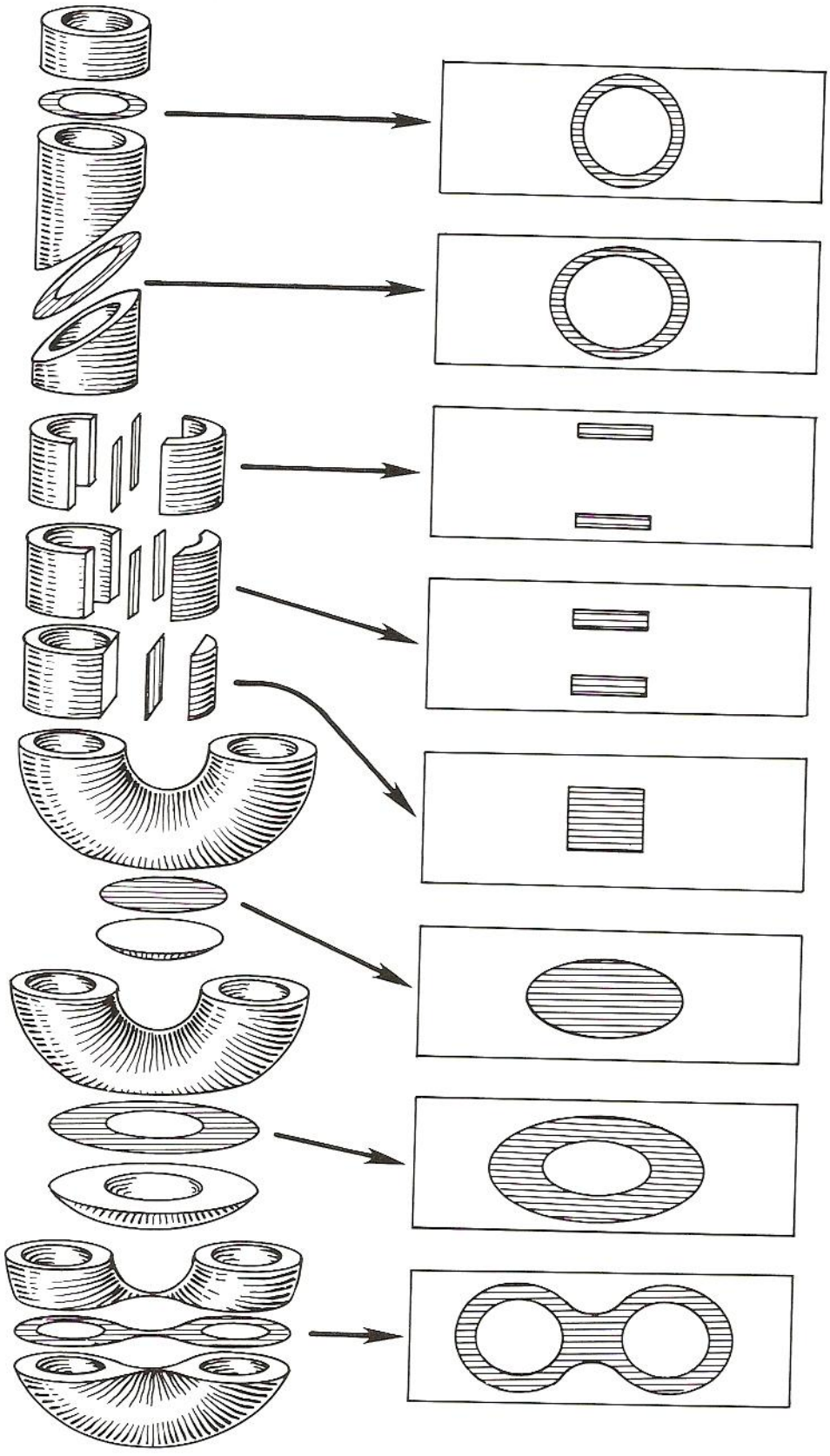

Figure 3-13. Appearance of a hollow, tubular structure in various planes of section. (Redrawn and modified from Ham AW: *Histology*, ed 6, Philadelphia, 1969, JB Lippincott.)

Downloaded From Vet-eBooks.com

often results in loss of a region of a tissue during sectioning. Incomplete stain removal may appear as excessive stain precipitates. Improper knife angles during sectioning can impart a wavy characteristic to the tissue. The thick portion appears more dense because of superimposition artifacts. Poorly sharpened knives scratch the paraffin block during sectioning. If a section is not stretched onto the slide, then folds or wrinkles become apparent. Excessive stretching of paraffin sections can also distort spatial relationships.

ADDITIONAL READINGS

Bachet J, Mirsky AE: *The cell: biochemistry, physiology, and morphology,* vol I, New York, 1959, Academic Press.

Bradbury S: *An introduction to the optical microscope,* New York, 1984, Oxford University Press.

Bullivant S: Freeze-etching and freeze-fracturing. In: Koehler J (ed): *Advanced techniques in biological electron microscopy,* New York, 1973, Springer-Verlag, pp 66-112.

Causey G: *Electron microscopy: a textbook for students of medicine and biology,* Baltimore, 1962, Williams & Wilkins.

Cosslett VE: *Modern microscopy or seeing the very small,* Ithaca NY, 1968, Cornell University Press.

Elias H: Three-dimensional structure identified from single sections, *Science* 174:993, 1971.

Elias H, Pauly JE: *Human microanatomy,* ed 3, Philadelphia, 1971, FA Davis.

Freshney RI: *Culture of animal cells: a manual of basic technique,* New York, 1987, Liss.

Grivet P: *Electron optics,* ed 2, vols I and II, New York, 1972, Pergamon Press.

Hall T, et al: *Microprobe analysis as applied to cells and tissues,* New York, 1974, Academic Press.

Hayat MA: *Introduction to biological scanning electron microscopy,* Baltimore 1978, University Park Press.

Needham GH: *The practical use of the microscope including photomicrography,* Springfield Ill, 1958, Charles C Thomas.

Pollister AW (ed): *Physical techniques in biological research,* ed 2, vol III, New York, 1969, Academic Press.

Rogers AW: *Techniques of autoradiography,* ed 3, New York, 1979, Elsevier/North Holland.

Sjostrand FS: *Electron microscopy of cells and tissues: instrumentation and techniques,* vol I, New York, 1967, Academic Press.

Weibel ER: Stereological principles for morphometry in electron microscopic cytology. Bourne GH, et al (eds), *Int Rev Cytol* 26: 235, 1969.

Wischnitzer S: *Introduction to electron microscopy,* ed 3, New York, 1981, Pergamon Press.

Woldseth R: *X-Ray energy spectrometry,* Burlingame Calif, 1973, Kevex Corporation.

Wren LA: *Understanding and using the phase microscope,* Newton Highlands Mass, 1963, Unitron Instrument Co.

SECTION II

CELL BIOLOGY

CHAPTER 4

Cells—Structure and Function

GENERAL CELL CHARACTERISTICS

Chemical and Physical Properties

Protoplasm. The cell is a regulated, integrated, dynamic, balanced, and maintained accumulation of biochemical substances, salts, and water **(protoplasm).** The molecular components of protoplasm vary, but some generalizations about its chemical nature are possible. The diversity accounts for cell variability.

Water constitutes about 75% of protoplasm and occurs both bound and free. **Bound water**, which is less than 10% of total water, is involved in the structure of chemical components. **Free water** is involved in the chemical events of protoplasm and is the solvent in which all the miscible substances are dissolved. It is also the phase in which other substances are suspended, imparting colloidal properties to protoplasm.

A **colloid** is an aggregate of atoms or molecules dissolved in but separated from the solvent phase. A colloid contains particles of a size sufficient to prevent their passing through a semipermeable membrane. Proteins possess colloidal properties and may exist in protoplasm as **sols** or **gels.** Sols are colloidal suspensions with fluid-like properties; gels are semisolid. Both are viscous with gelatinous characteristics. Protoplasmic proteins, as sols or gels, account for many cell properties.

Crystalloids pass through semipermeable membranes when dissolved in water. Important crystalloids are glucose and many ions. **K^+ is the primary protoplasmic cation; HCO_3^- and $SO_4^=$ are the primary protoplasmic anions; Na^+ and Cl^- are the primary extraprotoplasmic ions.**

Nucleic acids, proteins, carbohydrates, and lipids are the common biochemicals of protoplasm. These can occur as **macromolecules** composed of smaller monomeric subunits.

Nucleic acids and nucleotides. Nucleic acids are the repository of information essential for life. They contain the genetic code and are blueprints for protein synthesis. Nucleic acids are macromolecules of repeating **nucleotides.** Nucleotides are composed of a **pentose sugar, phosphoric acid,** and a **nitrogenous base.** The nitrogenous bases are **purines (adenine, guanine)** or **pyrimidines (cytosine, thymine, uracil).**

Nucleic acids occur in two groups. **Deoxyribonucleic acid (DNA)** contains the sugar **deoxyribose** whereas **ribonucleic acid (RNA)** contains the sugar **ribose.** The bases in DNA are adenine, cytosine, guanine, and thymine; in RNA, uracil replaces thymine.

DNA is the primary nucleic acid of the nucleus, but small quantities also occur in mitochondria. RNA occurs in the nucleus but is especially apparent in the cytoplasm. Both nucleic acids are complexed with proteins to form **nucleoproteins.**

The amount of DNA is constant, but it must double before mitosis to ensure that daughter cells receive the species-specific amount. This amount is halved in the gametes (via meiosis) to ensure the proper amount being restored during fertilization.

Different types of RNA occur in cells. **Ribosomal RNA (rRNA),** about 85% of cytoplasmic RNA, is complexed with protein as **ribonucleoprotein. Messenger RNA (mRNA),** which is **encoded (transcribed)** by a single strand of DNA, carries the sequencing information for protein synthesis to the ribosomes. **Transfer RNA (tRNA)** complexes with cytoplasmic amino acids and carries them to mRNA to effect the synthesis of proteins **(translation).**

The acidic nature of these compounds ensures their staining with a basic dye. Many basophilic cell components contain nucleic acids. The basic nature of some proteins with which nucleic acids associate impart an acidophilia. The nucleolus is an example.

Although nucleotides are essential components of nucleic acids, nucleotides are not limited to nucleic acids. **Adenosine triphosphate (ATP),** a high energy storage compound, releases energy when a phosphate bond is broken, and the compound is converted to **adenosine diphosphate (ADP).** The conversion process

$$ADP \longrightarrow ATP$$

is the means of energy storage and release upon demand.

Cyclic adenosine monophosphate (cAMP) is a free nucleotide considered a second cell messenger. Upon stimulation of specific cell surface receptors, increased **adenyl cyclase** activity causes an augmented formation of cAMP from ATP. The cAMP stimulates enzymatic reactions and may be a factor in gene regulation.

Proteins. **Proteins** are needed for cell architectural and metabolic integrity. These macromolecules consist of repeating amino acid units joined covalently to each other. This **peptide linkage** is formed when the carboxyl group (—COOH) of one amino acid reacts with the amino group ($—NH_2$) of another. The specific amino acid sequence in a protein is the **primary structure.** If the number of amino acids produces a molecular weight greater than 10,000 daltons, the molecule is a protein; if less than 10,000, a **polypeptide.**

The regular, coiled conformation of peptide chains is the **secondary structure.** This pertains to the **α-helix** of fibrous proteins. Some peptides are folded sufficiently to impart a globular configuration called the **tertiary structure.** The **quaternary structure** results from the association of a number of globular and/or fibrous proteins. The fibrous proteins of cells include fibrinogen, myosin, keratin, and tropocollagen. The globular proteins include enzymes, some hormones, and the membrane structural proteins.

Proteins occur as **simple (native)** or **conjugated** proteins. Simple proteins yield only amino acids upon hydrolysis; conjugated proteins yield amino acids and nonproteinaceous groups. Examples of simple proteins are the albumins, globulins, and histones. **Nucleoproteins** are macromolecules consisting of a nucleic acid and protein. **Chromoproteins** have a metal imparting pigmentation to the protein (hemoglobin). **Glycoproteins** or **mucoproteins** have carbohydrate groups (mucin and some matrix components of cartilage and bone). **Lipoproteins** have a lipid group, of which some cell membrane components are examples. **Phosphoproteins** contain a phosphorus group (casein).

Proteins stain with the conventional acidic and basic stains used in histology.

Carbohydrates. Carbohydrates are classified into three types. **Monosaccharides** have the formula $(CH_2O)_n$ and include the pentose sugars (n = 5) ribose and deoxyribose as well as the hexose sugars (n = 6) glucose, fructose, and galactose. The monosaccharides are immediate energy sources (glucose) and the building blocks of complex molecules. These polymers may consist of unaltered monosaccharides, amino sugars, uronic acids, or a combination of these monomers. **Amino sugars** have one hydroxyl group replaced by a primary amine. Such a replacement in glucose forms glucosamine. These forms of the monosaccharides occur in the polysaccharides of connective tissue matrices.

The union of two monosaccharides via a glycosidic linkage forms a **disaccharide,** such as maltose and sucrose. Addition of monomeric units forms long chain saccharides.

A chain of 10 or more monosaccharides is called a **polysaccharide. Glycogen** is a polysaccharide used to store energy for the cell. Other polysaccharides include the **glycosaminoglycans** (hyaluronic acid, heparin, chondroitin sulfates, dermatan sulfate, and keratan sulfate). Many polysaccharides beside those listed occur in conjugated proteins. These mucoproteins, or glycoproteins, are structural or functional components or products of cells. Glycosaminoglycans complexed with core proteins are called **proteoglycans.** They are components of connective tissue ground substance.

Most carbohydrates can be stained for light microscopy.

Lipids. Lipids are heterogeneous compounds with various functions. **Neutral fats** are esters of fatty acids and glycerol stored within cells as high energy sources. Hydrolysis of fats yields the previously esterified components. The fatty acids may undergo beta oxidation with the acetyl groups being activated as acetyl–coenzyme A. Acetyl–coenzyme A can enter the tricarboxylic acid (TCA) cycle.

Phospholipids are fats with one fatty acid being replaced by a phosphoric acid and a nitrogen-containing compound, such as choline, ethanolamine, or serine. Lecithin, cephalin, and sphingomyelin are examples, respectively. These compounds are cell membrane and myelin sheath constituents. They have polar (hydrophilic) and nonpolar (hydrophobic) ends; they effectively achieve chemical and physical compartmentalization of the cell.

Sterols are lipids with complex ring structures. Cholesterol, a cell membrane component, may be considered the prototype compound. Many sterols are hormones (estrogen, testosterone, progesterone, gluco- and mineralocorticoids.

Some lipids are complexed with sugars as **glycolipids**—cerebrosides and gangliosides, essential components of cell membranes. **Waxes** are similar to the neutral fats, except they consist of long chain fatty acids. The waxes serve protective functions. Lipids can be demonstrated in histological specimens, but lipid solvents must be avoided. Commonly employed lipid dyes are the Sudan stains and osmium tetroxide.

Biological Properties

The metazoon is a complex array of many cells depending upon one another for various functions. These cells interact in such a way as to maintain an ideal internal environment in which all constituent cells may flourish. This **division of labor** requires that cells perform specific functions beyond those simply essential for their own survival. The following activities characterize cells:

Metabolism is the sum of all chemical reactions occurring within cells. **Anabolic** reactions result in the synthesis of new molecular components essential for growth, maintenance, and repair. **Catabolic** reactions result in the degradation of cellular components or products with energy release. **Internal respiration,** or the chemical utilization of foodstuffs for heat and energy production, is an example of catabolism. Not all cells have the same metabolic activity or requirements. The bases for the similarities and differences are the protoplasmic constituents.

Irritability is a property of cells enabling them to respond to environmental stimuli. This property accounts for their biological behavior. **Conductivity** is the special property of some cells (neurons, muscle) to transmit waves of excitation along their cell membranes, a special form of information transfer.

Contractility is a form of reactivity. Most cells change shape, but muscle cells are adapted uniquely to change shape by shortening along their long axes. This allows them to accomplish work.

Homeostasis requires endocytotic and exocytotic processes, essential features of all cells. The movement of materials into the cell is **endocytosis**. Some fluids and dissolved substances diffuse through the plasmalemma. Other fluids gain entry via vacuoles formed in the cell membrane that eventually "pinch off" within the cytoplasm during **pinocytosis.** The uptake of solid matter is a special form of endocytosis **(phagocytosis).** The egress of materials is **exocytosis.** The outward movement of metabolic waste products is **excretion;** the outward movement of products synthesized by cells is **secretion.**

Growth, maintenance, and **reproduction** of the protoplasm are universal characteristics. Molecular components are added and replaced continually.

Morphological Features

The division of labor and specialization among component cells of metazoons result in functionally diverse and interdependent cell populations. This specialization is so precise that functional inferences can be made from structure alone; the converse is also true. Despite the degree of specialization, most cells have many common characteristics (Fig. 4-1).

Shape. Animal cell shape is often described as spheroidal, but specialization influences shape. Cell contact, pressure, and the ability to alter shape also determine morphology. Thus cells may be round (Fig. 4-2), stellate (Fig. 4-3), spindle-shaped (Fig. 4-4), elongated (Fig. 4-5), columnar (Fig. 4-6), squamous (Fig. 4-7), cuboidal (Fig. 4-8), and other shapes.

Spatial organization. Despite diverse cell shapes, the organelles are usually spatially positioned in an organized and predictable manner. The nuclei of round, spheroidal, cuboidal, or spindle-shaped cells are usually round and located centrally (Fig. 4-2); other shapes may be apparent (Fig. 4-9). Nuclei are ovoid and oriented parallel to the long axis in elongated cells (Figs. 4-10 and 4-11). Nuclear position and shape correlate with the position of other organelles and cell shape.

The Golgi complex is usually located in a juxtanuclear position, but the position of other components varies with specific cell types.

Many cells are spatially polarized (Fig. 4-12). The nuclei of such cells are generally positioned eccentrically, and a corresponding orderly spatial relationship of other components exists. Such organizational patterns are usually associated with secretory activity, as in epithelial cells.

Size. No correlation exists between the organism's size and the size of its cells. Some cells are visible with the unaided eye; others, with a microscope. Some cells are a few micrometers in diameter; the red blood corpuscle (RBC) ranges from 4 to 7 μm in diameter depending on the species. **(RBCs appear in most histological sections; they are effective built-in micrometers.)** The ovum may be 300 μm in diameter. Striated muscle cell length may be in inches; neuronal process length may be several feet. Even within the narrow limits of microscopic observation, various sizes exist. Giant cells, such as megakaryocytes, are larger than developing RBCs (Fig. 4-13). Similarly, striated muscle cells are larger than the fibroblasts associated with them. Most mammalian cells are 10 to 30 μm.

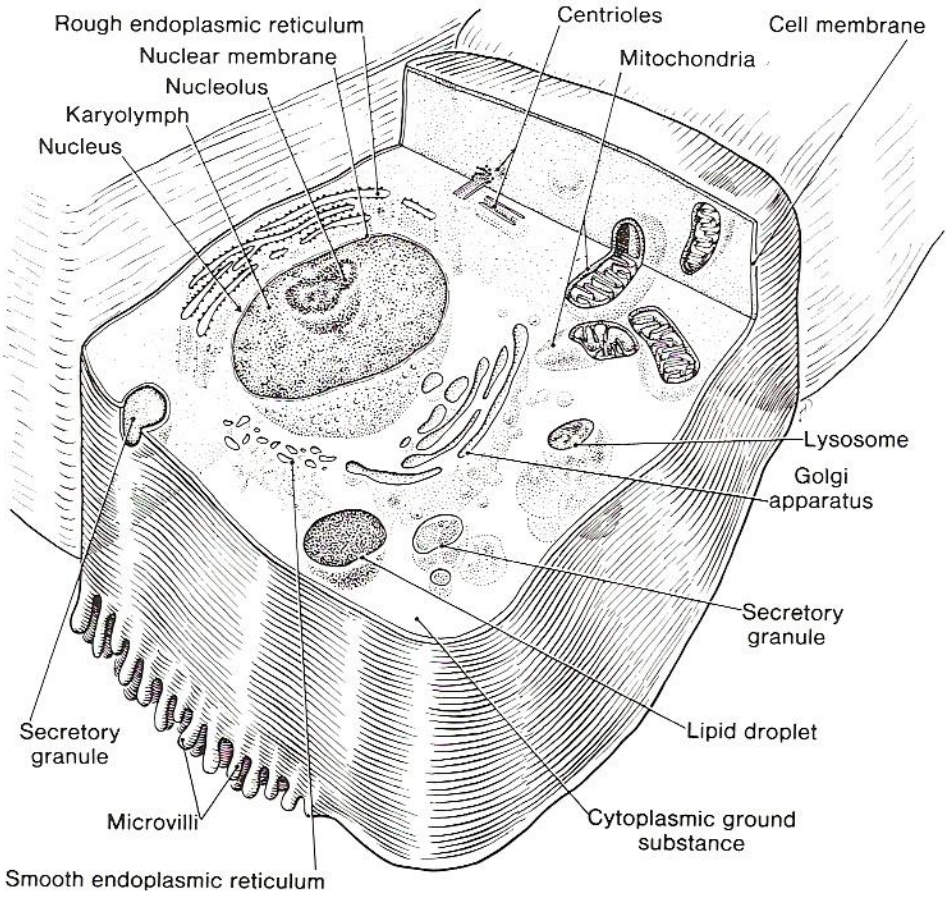

Figure 4-1. A typical cell. Major components are included and labeled.

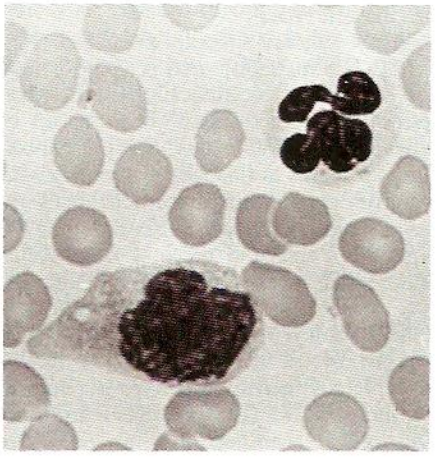

Figure 4-2. Round cells. The cell with a lobulated nucleus *(top)* is a feline leukocyte. The elongated cell with a round nucleus *(bottom)* is a different leukocyte. (×400.) The background cells are erythrocytes devoid of nuclei.

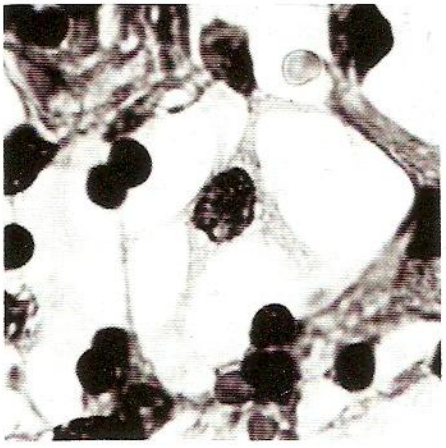

Figure 4-3. Stellate cell. A reticular cell from a canine lymph node is in the center of the field. The elongated cytoplasmic processes impart a star-shaped appearance to it. (×160.)

Figure 4-4. Spindle-shaped cells. The elongated and flattened cells are mesenchymal cells from a sample of bovine loose connective tissue. They may appear stellate in a different plane of section. (×400.)

Figure 4-5. Elongated cells. The elongated, multinucleated cells are skeletal muscle fibers. Each joins end-to-end with adjacent cells. (×40.)

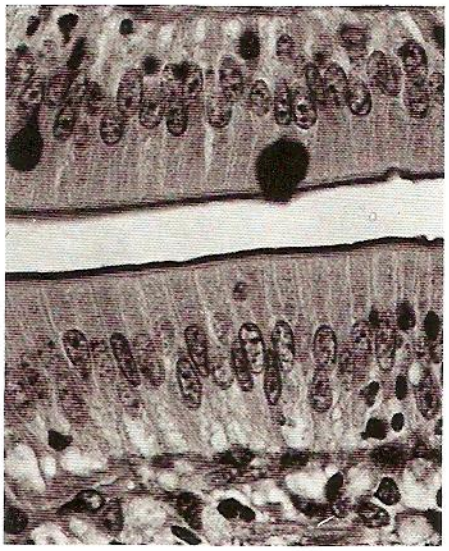

Figure 4-6. Columnar cells. These lining cells are longer than they are wide. The shape of the nuclei typically matches the shape of the cells. Compare this micrograph with the drawing of columnar cells (Fig. 3-10). (×160.)

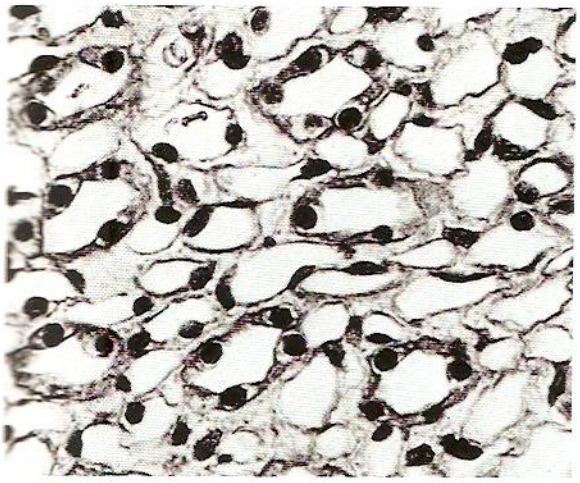

Figure 4-7. Squamous cells of the tubules of a canine kidney. The tubules are lined by flattened cells with prominent nuclei. The cytoplasm appears as thin rims of dark-staining material. The perikaryon is the only notable cytoplasmic region in most of the cells *(center)*. Cytoplasmic processes are obvious in some of the cells *(lower left* and *lower center)*. (×160.)

Figure 4-8. Cuboidal cells. These cuboidal cells line the lumen of a tubule from a canine kidney. Although the cells appear as squares in biplanar section, the cells have a cuboidal shape in three dimensions. (×100.)

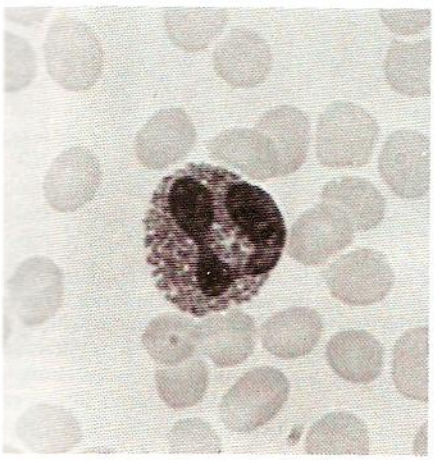

Figure 4-9. A round cell with lobulated nucleus. The nuclear configuration is typical for this feline eosinophil. (×400.)

Downloaded From Vet-eBooks.com

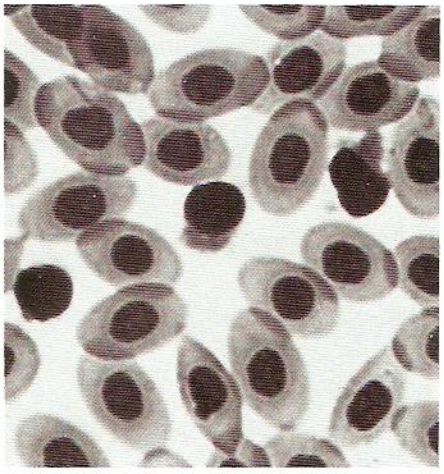

Figure 4-10. Avian erythrocytes. The elongated cells contain elongated nuclei oriented parallel to the long axis of the cells. (×400.) Compare with Figure 4-6.

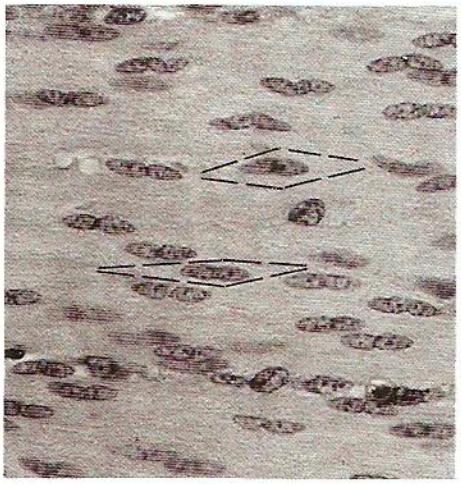

Figure 4-11. Smooth muscle cells from a canine intestine. The approximate margins of the cells are indicated by *dashed lines*. The elongated nuclei are oriented along the long axes of the cells. (×160.)

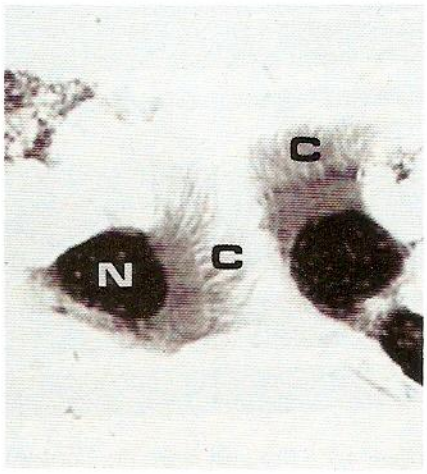

Figure 4-12. Polarized cells. These ciliated cells were exfoliated from the epithelial lining of a canine trachea. The nuclei *(N)* are displaced basally. The apical borders have cilia *(C)*. Polarization of cellular components, as evidenced by basal displacement of the nuclei, is a typical epithelial characteristic. (×160.)

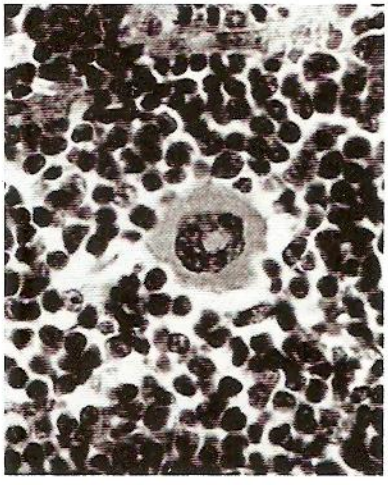

Figure 4-13. A megakaryocyte and other cells of the bone marrow. The megakaryocyte in the center of the field is many times larger than the cells surrounding it. (×100.)

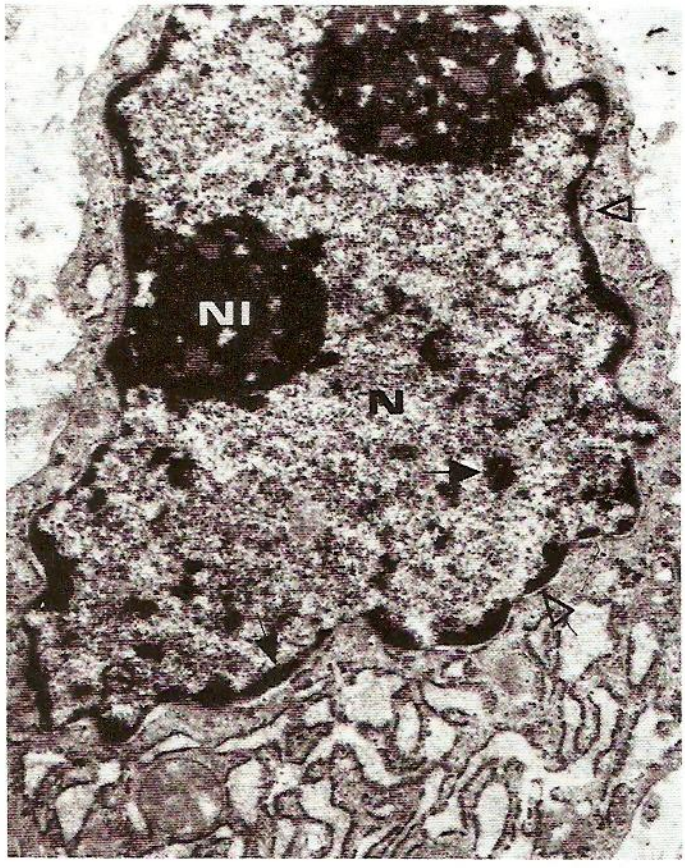

Figure 4-14. Electron micrograph of a fibroblast of loose collagenous tissue. The nucleus *(N)* contains two nucleoli *(NI)*. Heterochromatin *(solid arrows)* is interspersed with euchromatin. The nuclear envelope *(open arrows)* surrounds the nucleus. The condensation of heterochromatin along the peripheral margin of the nucleus precludes seeing the inner nuclear membrane at this magnification. (×16,000.)

NUCLEUS

The nucleus controls cell activities through information encoded in its DNA molecules. This information is the basis for all cell characteristics, because all nuclei of a given animal have the same genetic information. Specialized cells manifest the differential expression of genetic information by the repression or derepression of specific gene loci.

Some functional correlations with nuclear morphology are possible. The most obvious of these is the structure of dividing **(mitotic)** and nondividing **(intermitotic, interphase,** or **vegetative)** cells.

In the interphase nucleus, four distinct components may be seen—**nuclear membrane, karyolymph, chromatin,** and **nucleolus** (Fig. 4-14).

Downloaded From Vet-eBooks.com

Figure 4-15. Multinucleated cells of bone. The osteoclasts contain a variable number of nuclei. The multinucleations result from cellular fusion rather than nuclear division without cytoplasmic division. (×100.)

Number, shape, and position. Cells are usually mononucleated (Figs. 4-2 to 4-4, 4-6, and 4-8 to 4-10). Some, however, are **binucleated,** and others are **multinucleated** (Fig. 4-15). Extremes range from the mammalian RBC (which has no nucleus) (Figs. 4-2 and 4-9) and certain cells of the lens to the spermatozoon (in which the cell bulk is a nucleus).

Nuclear morphology varies with cell shape. Round to oval cells usually have a similarly shaped nucleus (Figs. 4-3, 4-8, and 4-10); elongated cells usually have an elongated nucleus (Figs. 4-5, 4-6, and 4-11). Others have crescent-shaped or lobulated nuclei (Figs. 4-2 and 4-9). Many other nuclear shapes also exist. Identical cells within a specific cell population usually have identical nuclei.

Nuclei may be centrally, paracentrally, or eccentrically positioned. Specific cell types, however, are characterized generally by similarly positioned nuclei. Definite spatial relationships are identifiable between the nucleus, cytoplasmic organelles, and inclusions. These are especially apparent when a cell has a distinct polarity (Fig. 4-12).

In some cells the nucleus may be the only dominant feature (Fig. 4-4), because these cells (stellate or squamous cells) have small amounts of cytoplasm difficult to resolve with light microscopy (Fig. 4-7).

Envelope. A dark, basophilic line between the nucleus and cytoplasm is apparent with light microscopy (Figs. 4-2 to 4-4). This membrane is a condensation of nuclear and cytoplasmic components, as well as stain, on each side of the **nuclear membrane** or **nuclear envelope.** The electron microscope (Fig. 4-16) reveals two membranes comprising the nuclear envelope, the **inner** and **outer nuclear membranes.** Each measures about 7.5 nm and is separated from the other by a **perinuclear space** or **cistern** varying from 40 to 70 nm wide.

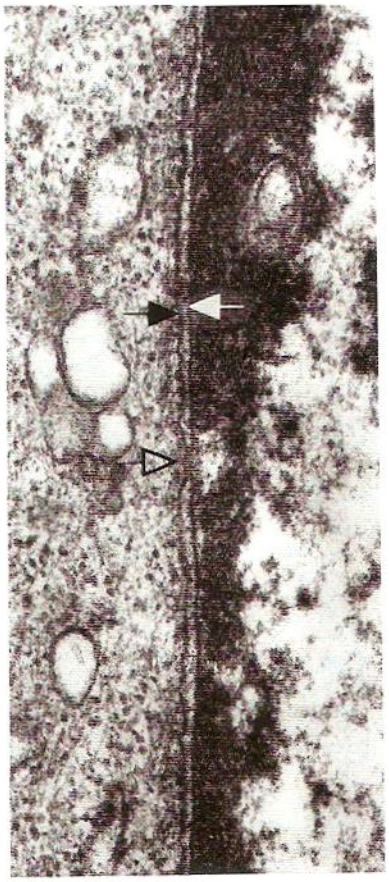

Figure 4-16. Electron micrograph of the nuclear membrane of a fibroblast. The outer nuclear membrane *(black arrow)* is separated from the inner nuclear membrane *(white arrow)* by the nuclear cistern. Heterochromatin obliterates portions of the inner nuclear membrane. A nuclear pore *(open arrow)* is apparent. (×52,000.)

The perinuclear space and the outer nuclear membrane are continuous with the rough endoplasmic reticulum (RER) (Fig. 4-17). **Ribosomes** are often attached to the outer nuclear membrane. The intimate relationship of RER to the nuclear membrane is apparent near the end of mitosis. RER forms the nuclear envelope. Thread-like intermediate filaments line the surface of the inner nuclear membrane. These filaments consist of subunits called **lamins.**

The inner and outer nuclear membranes appear discontinuous. Points of discontinuity or fusions between the inner and outer membranes are **nuclear pores** (Fig. 4-18). Nuclear pores are approximately 70 nm in diameter. When sectioned perpendicular to the nuclear membrane, they seem covered by a septum (diaphragm) thinner than the membranes limiting the pore margins (Fig. 4-16). On face view these structures appear complex (Figs. 4-18 and 4-19). Filamentous material contributes to a centrally positioned **annulus.** This morphology indicates open communication between the nucleus and cytoplasm. The architecture provides a selective complex for the inward passage of certain proteins and the outward passage of RNA. A typical cell has 3000 to 4000 pores, or about 11 pores/μm^2 of membrane.

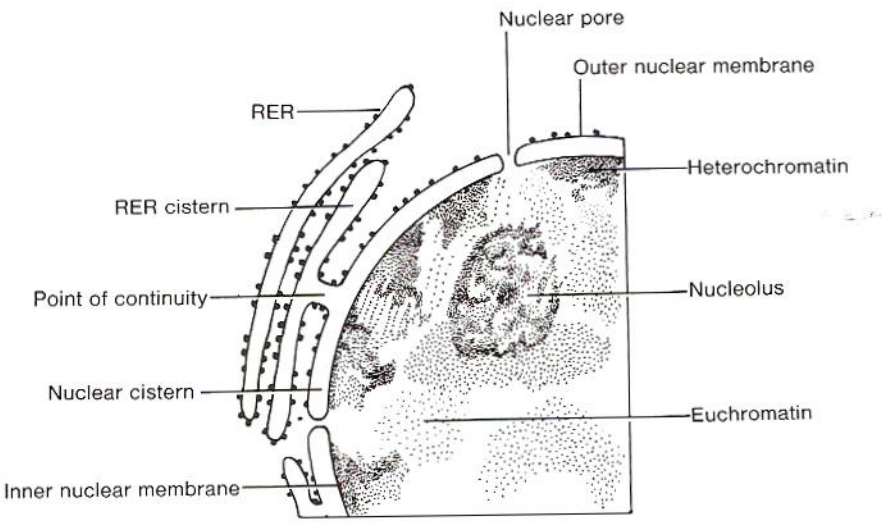

Figure 4-17. Part of a nucleus and RER as visualized by electron microscopy. The perinuclear cistern continues with the RER cistern. Ribosomes decorate the outer nuclear membrane.

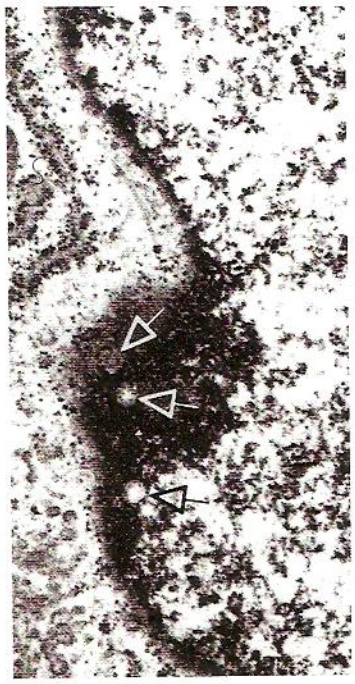

Figure 4-18. Electron micrograph of the face view of a nuclear membrane. The nuclear pores *(open arrows)* are not simple openings between the nucleus and the cytoplasm. An annulus *(upper arrow)* and particulate matter *(middle arrow)* characterize the apertures. (×23,000.)

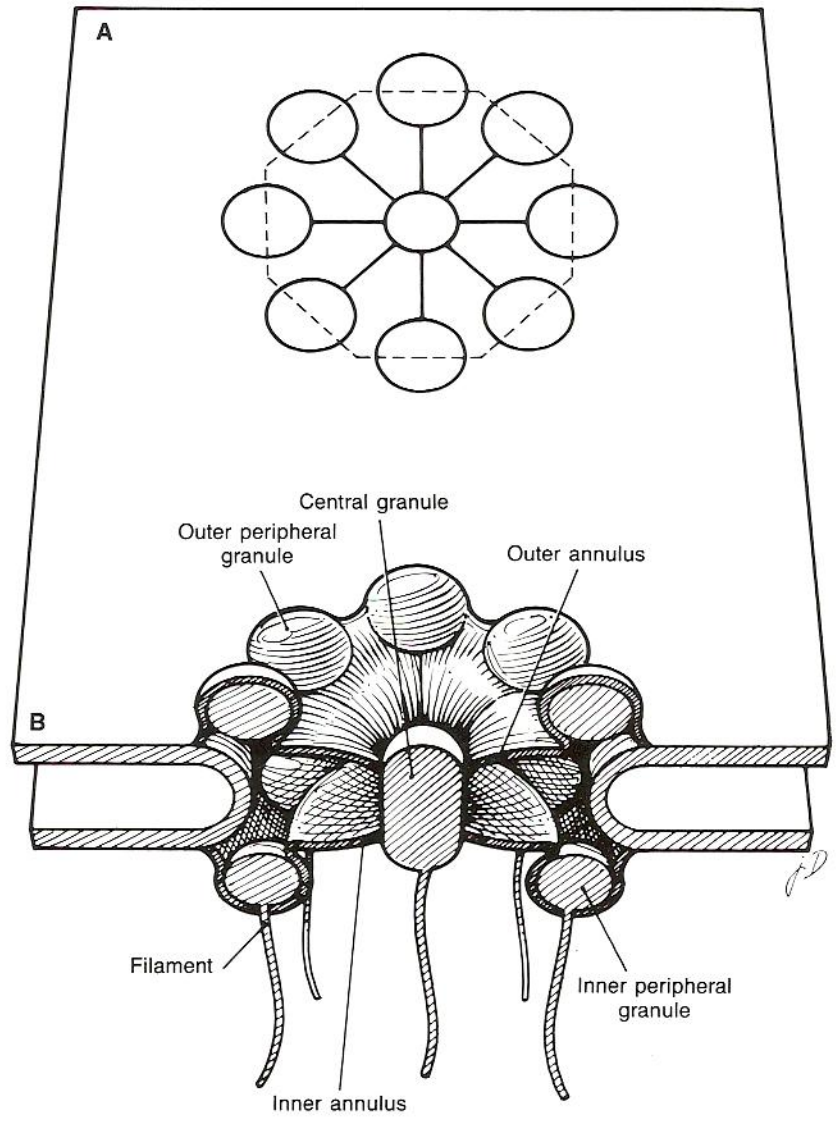

Figure 4-19. Nuclear pore. **A,** Face view. The pore has octagonal symmetry. **B,** Cross section. The pore consists of inner and outer annuli joined by a central granule. Peripherally positioned granules are associated with both annuli. Nuclear filaments radiate from the central and peripheral granules.

Complexes identical to nuclear membranes (with pores) occur in the cytoplasm as isolated or stacked structures called **(annulate lamellae).** Their function is unknown.

Matrix. The limiting membrane encloses the **nuclear matrix (nuclear ground substance).** This **nuclear sap** or **karyolymph** is the soluble phase of nuclear material.

Chromatin. **Chromatin** occurs within the nucleus suspended in the nuclear matrix. The term chromatin describes any nuclear area containing DNA. Different types of chromatin occur in the interphase. **Heterochromatin** stains intensely with basic dyes and is condensed (Figs. 4-12 and 4-14). **Constituitive heterochromatin** consists of chromosome regions permanently coiled and never expressed. **Facultative heterochromatin** is coiled in some cells and expressed, uncoiled **(euchromatin)** in other cells and expressed. Euchromatin stains lightly, becomes dispersed, and is metabolically active (Figs. 4-14 and 4-20). Various heterochromatin and euchromatin ratios alter nuclear appearance, from **condensed** (much heterochromatin) to **open** or **vesicular** (little heterochromatin). The chromatin distribution is a diagnostic feature of some cells. The amount of euchromatin is an indicator of potential protein synthesis. The more heterochromatin there is, the less active the cell; the more euchromatin, the greater is the potential for protein synthesis (Figs. 4-14 and 4-20).

Some heterochromatin is distinguishable as **Barr bodies,** which are condensations of one of the X chromosomes. The female contains two X chromosomes. One is condensed and inactive, and forms a Barr body (Plate VI, *23*); the other is euchromatic.

Nucleolus. The **nucleolus** (or "little nucleus") is a prominently staining, highly refractive, smooth-surfaced body of various shapes within the nucleus (Fig. 4-20). Single or multiple nucleoli may characterize specific nuclei, particularly in cells involved in protein synthesis. It is also a prominent feature of **blastoid** and **malignant cells.**

Examination of electron micrographs reveals this structure as a discrete body that is not membrane-bound (Fig. 4-21). Nucleoli attach to chromosomes at the **nucleolar organizing sites,** wherein occur the **cistrons** for rRNA synthesis. The nucleolus consist of a **fibrillar center** with DNA that is not undergoing transcription, a **dense fibrillar part** with RNA being formed, and a **granular part** with maturing ribosomal particles. The nucleolus is the center for the synthesis of ribosomal RNA.

CYTOPLASM

General characteristics. The amount of cytoplasm varies in living cells. The types, kinds, and numbers of morphological and biochemical components dictate

Downloaded From Vet-eBooks.com

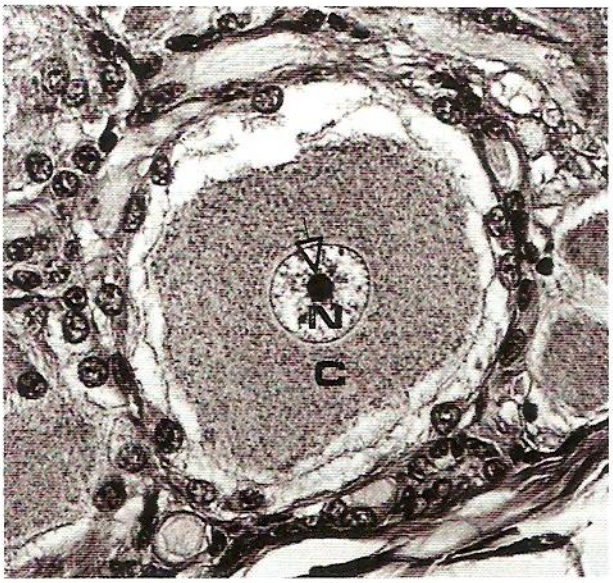

Figure 4-20. A ganglion cell. The cytoplasm *(C)* contains a vesicular nucleus *(N)* in which euchromatic material predominates. A prominent nucleolus *(arrow)* is present. (×100.)

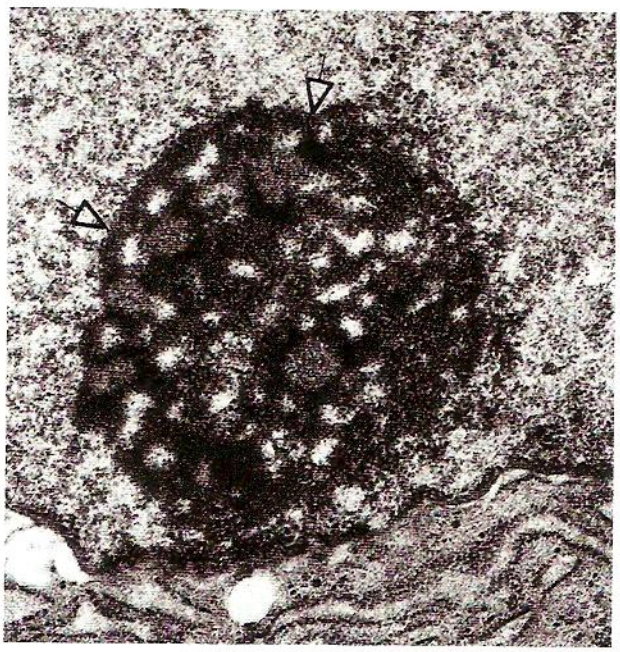

Figure 4-21. Electron micrograph of a nucleolus. Dense fibrillar components *(arrows)* are interspersed with granular material. (×25,000.)

functional specialization and contribute to histological identification.

The bulk of cytoplasm is a mixture of water, protein, carbohydrates, and organic and inorganic salts. The physical state of cytoplasm is in constant flux; sol-gel properties are apparent. Cytoplasmic streaming (movement) occurs within the fluidlike central cytoplasm **(endoplasm),** which is full of typical organelles. A narrow band of gellike peripheral cytoplasm (**ectoplasm**) free of organelles is apparent in free and motile cells.

The cytoplasm of mature somatic cells is generally **acidophilic;** however, it may be totally or focally **basophilic,** as well as totally or focally **chromophobic** or **neutrophilic.** Many cytoplasmic components contribute to cell characteristics.

Cell Membranes

The boundary layer between the protoplasm and its surrounding environment is the **plasma membrane.** It circumscribes the protoplasm and defines the cell's limits. The **nucleus** is membrane-bound within the protoplasm and contains nucleoplasm.

The plasma membrane and nuclear membrane are complex structures whose biochemical components impart gel properties. Proteins contribute to this characteristic. As **hydrophilic** (water-loving) **colloids, proteins permit the movement of crystalloids and water to and from the cell,** as well as between the nucleus and cytoplasm. **Lipid membrane components permit the movement of lipid-soluble substances through them.**

The cell consists of orderly aggregations of macromolecules compartmentalizing it into regions of specific form and function. These compartments **(organelles)** consist of cytomembranes with specific enzymes and/or nucleic acids. The remainder of the protoplasm consists of fluid with many essential substances.

Structure and function

Membranes and glycocalyx. The **plasma membrane (plasmalemma** or **cell membrane)** encloses the cytoplasm and contacts the extracellular environment. The cell membrane is about 8 nm thick. The 200 nm resolution of the white light microscope precludes resolving the plasmalemma as a distinct entity. Despite this, **cell limits** are discernible because of the condensation of structural protein and contiguous materials, addition of stain, and the presence of a **cell coat.**

No definitive structure has been determined for the plasma membrane. It is a trilaminar structure composed of two **osmiophilic** bands separated by an **osmiophobic** band with electron microscopy (Fig. 4-22). Each band is about 2.5 nm wide and corresponds to a sandwich-like relationship with two layers of protein laid upon a layer of lipid (protein-lipid-protein). This structural design comprised the **unit membrane concept** and was believed applicable to all membrane

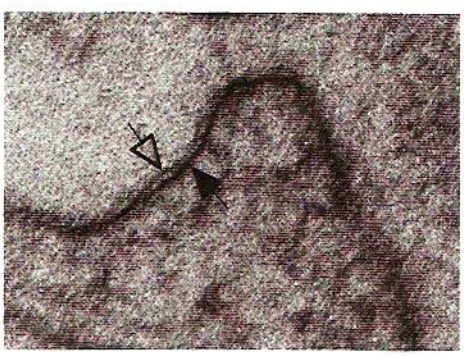

Figure 4-22. Trilaminar plasma membrane. The outer, thinner lamina *(open arrows)* is separated by a translucent space from the inner, thicker lamina *(solid arrows).* (×215,000.)

Downloaded From Vet-eBooks.com

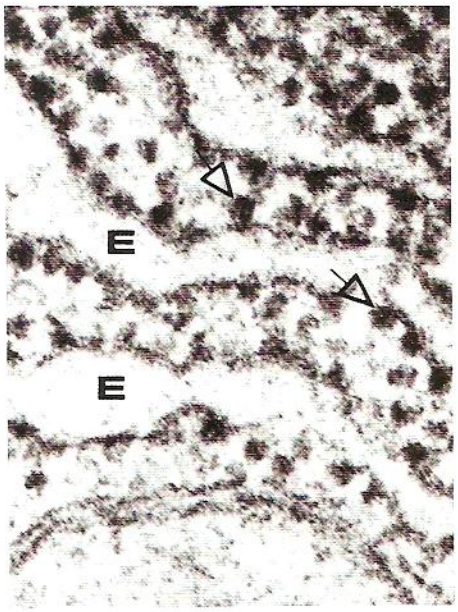

Figure 4-23. Globular cytoplasmic membranes. The cisterns *(E)* of the granular endoplasmic reticulum are membrane-bound and studded with ribosomes *(open arrows)*. The trilaminar appearance is not evident. Rather, the membrane components appear to be globular. (×156,000.)

systems. Too many structural and chemical variations have been observed to consider this concept applicable to all membranes (Fig. 4-23).

Various technologies have contributed to our knowledge of membrane structure. All seem to confirm the lipid-globular protein, mosaic model (Fig. 4-24). The model is a bimolecular leaflet of phospholipids with their hydrophilic (polar) groups directed outwardly and their hydrophobic (nonpolar) groups directed inwardly. Proteins are embedded within the lipid bilayer and project variously from either surface. Polysaccharides, projecting from the outer surface, are attached to proteins. The changing protein positions, properties, and constituents (enzymes, receptor sites, antigenic sites, permeability sites) impart a fluid nature **(fluid mosaic model)** corresponding to physiological activities. **The hydrophilic, globular proteins account for the selective permeability of certain water-soluble substances and may function as pores; the lipid components explain the relative ease of passage of lipid-soluble substances.**

The periphery of the plasma membrane is covered by a carbohydrate-rich layer. This **glycocalyx (cell coat)** probably occurs on all cells and is well developed on some. It appears as "fuzzy" material with the electron microscope (Fig. 4-25). The glycocalyx is attached to and integrated into the structure of the plasmalemma as glycoproteins and glycolipids. Cell coat polysaccharides account for its positive reaction with periodic–acid Schiff (Fig. 4-26).

The functions of the cell coat vary. **Cellular recognition** may be achieved based upon its specific biochemical components. Cells in cultural monolayers mediate **contact inhibition** through the cell coat. Cell-to-cell **adhesion** and attachment to connective tissue is achieved through **cell adhesion molecules (CAMs)** located in the glycocalyx. **Absorption** and **digestion** of some materials involve the glycocalyx and are associated with **antigenicity.**

Lipid and protein constituents, as described for the fluid mosaic model, occur in the membranes of organelles.

Properties and functions. Studies of various membranes have broadened our basic understanding, but a clear definition of membrane structure is still elusive. All membranes contain a lipid bilayer, but the specific proteins, lipids, and carbohydrates vary. The lipids

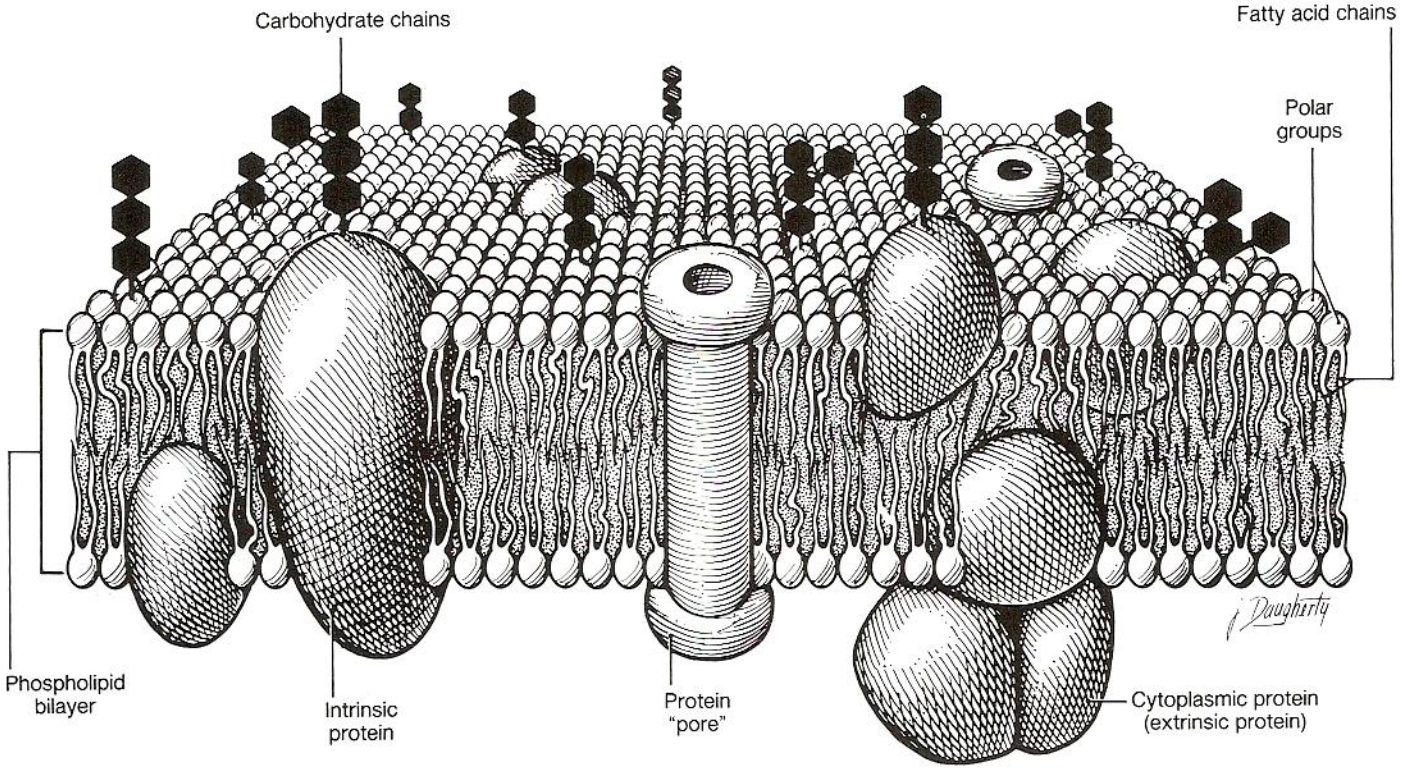

Figure 4-24. Fluid mosaic model of the plasma membrane. Intrinsic proteins are embedded within a sea of lipids. The lipid bilayer consists of phospholipids whose hydrophilic heads project outwardly and hydrophobic tails project inwardly. Carbohydrates, as components of glycoproteins and glycolipids, project above the membrane as components of the glycocalyx. Conformational changes of intrinsic proteins account for the pore characteristics associated with membranes.

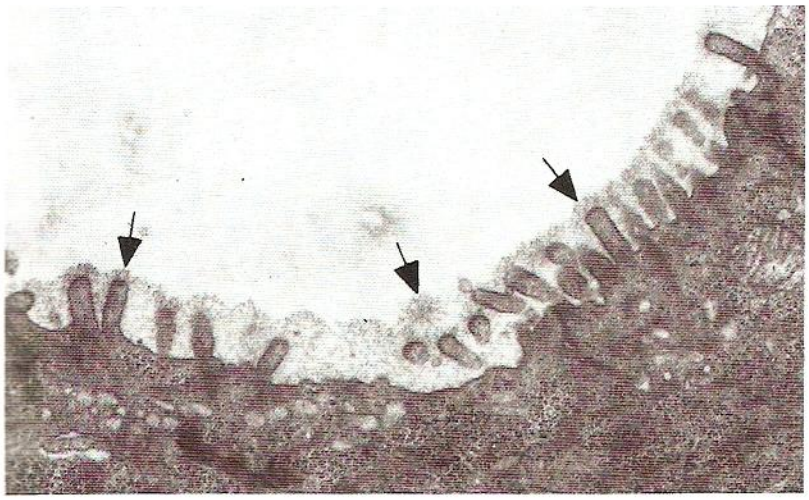

Figure 4-25. Electron micrograph of the glycocalyx. The glycocalyx *(arrows)* covers the microvilli and apical surfaces of these murine intestinal cells. (×14,000.) (Courtesy A. M. Sheppard.)

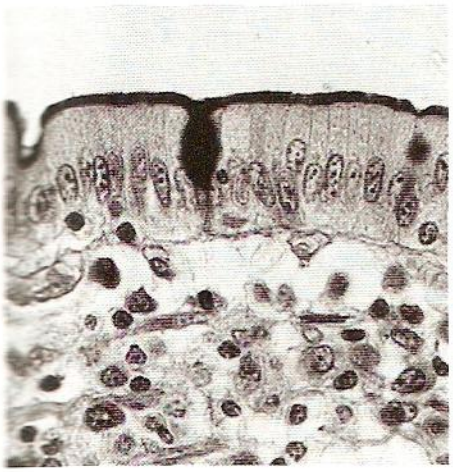

Figure 4-26. The glycocalyx as visualized with light microscopy and special staining. The apical striated border of these intestinal lining cells is covered by a dark-staining glycocalyx. (×160, PAS.)

are primarily phosphatidylcholine, phosphatidylethanolamine, phosphatidylserine, sphingomyelin, and cholesterol. The carbohydrates are part of the glycocalyx.

Membrane proteins are classified as **peripheral proteins** or **integral (intrinsic) proteins.** Peripheral proteins are attached to the outer or inner portions of the membranes. The intrinsic proteins are predominantly located in the polar regions of the bilayer and may extend from the outer to the inner surface as **transmembrane proteins.** The following functions relate to membranes and their protein constituents: **selective permeability, differential transport, compartmentalization, energy conversions, structural integrity, carrier molecules, pores or channels, enzymes, receptor molecules, adhesion, cellular recognition,** and **transmission.**

Membrane fluidity, or the movement of various components, occurs within the membrane. Short chain, unsaturated fatty acids increase fluidity due to the rotational movement at C=C bonding. Long-chain, unsaturated fatty acids and cholesterol decrease membrane fluidity. Aggregates of lipids may also move laterally as free entities or in association with their protein constituents. Membrane fluidity is partially responsible for the dynamic changes associated with specific membrane foci.

Transport functions

Passive transport. Various mechanisms describe the passive transport of substances across the plasma membrane. Despite the diverse processes, **all passive transport mechanisms depend upon concentration gradients.**

Facilitated diffusion is also called **carrier-mediated transport.** A carrier membrane protein facilitates sugar and amino acid transport. **Na^+-dependent facilitated diffusion** is a transport mechanism for certain amino acids and sugars that depends on a sodium transport system.

Active transport. This is an energy-requiring process moving substances against their concentration or electrochemical potential gradients. The process may also augment the spontaneous "downhill" movement of molecules. The relative external/internal concentration gradient for Na^+ dictates that equilibrium would be reached eventually. Cells need a Na^+ pump to move Na^+ out of the cell constantly. Energy is supplied by a Na^+-dependent ATPase.

Membranes as receptors

Receptors. Proteins serve as receptor molecules in cell membranes. Receptors unite with substances serving as messengers between or within cells. The union of the messenger with the receptor is usually associated with measurable changes in cell behavior. The union could induce alterations in carrier molecules altering transport functions.

The number and distribution of receptors (and carrier molecules) can change. An increased amount of a messenger (or a transported substance) may increase the number of receptor (and carrier) molecules—**up regulation.** The same increases under a different set of circumstances could cause the number of receptor (and carrier) molecules to decrease—**down regulation.**

The alteration of transport functions in response to the union of a messenger molecule with a receptor is called **chemical gating.** Pore alterations may depend upon protein conformational changes. Electrical potentials can alter molecular orientation within membranes and alter transport functions. Pores or channels resulting from potential changes are called **electrical gates.**

Cellular messengers. Intercellular communication is achieved with **primary messengers.** Their union with appropriate receptors usually initiates a cascade of intracellular events dependent upon information transfer by **second messengers** or **intracellular messengers,** such as **calcium, cAMP,** and **cyclic guanidine monophosphate (cGMP).** The influence of calcium as an intracellular messenger is mediated through **calmodulin.**

Many primary messengers mediate their effects through cAMP. The initiating event is the activation of **adenyl cyclase.** This enzyme converts ATP to cAMP, which then mediates its influence by activating a **protein kinase.** Protein kinases phosphorylate other effector proteins (enzymes), rendering them active or inactive. The effector protein stimulates or inactivates a specific biological behavior. A **phosphodiesterase** activation degrades cAMP to 5′-AMP, which terminates protein kinase activity and returns the specific activity to the prestimulation level. Cyclic AMP affects membrane permeabilities, releases stored products, modifies rates of reactions, and induces enzyme synthesis.

Cytoplasmic Membranous Compartments

Ribosomes and rough endoplasmic reticulum

Morphology and function. The cytoplasm of many cells is either totally or focally basophilic. These areas contain RNA and protein, **ribonucleoprotein**

Downloaded From Vet-eBooks.com

Figure 4-27. Electron micrograph of a fiber-forming cell. The cytoplasm contains many profiles of RER. Some are tubular *(T)* configurations; others are cisternal *(E)* profiles. Ribosomes *(open arrows)* and polyribosomes *(solid arrows)* are abundant. (×20,000.)

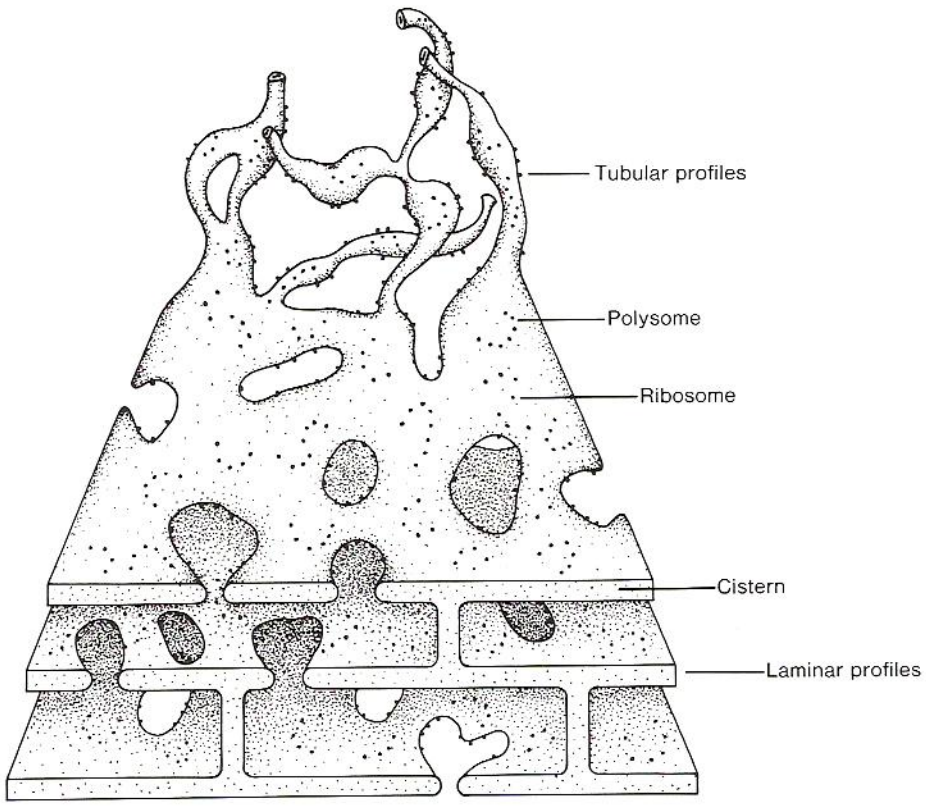

Figure 4-28. RER. The anastomotic plates and tubules may be scattered randomly or placed in an orderly array throughout the cytoplasm.

(RNP). Although tRNA and mRNA are present in the cytoplasm, the primary contributor to this staining property is rRNA. **Ribosomes** are small cytoplasmic granules consisting of approximately 60% RNA and 40% protein. These structures occur in the cytoplasm as single units, **free ribosomes,** or as multiple units, **polyribosomes** or **polysomes** (Fig. 4-27). **The free ribosomes and polysomes, which are responsible for the synthesis of proteins for intracellular use, characterize differentiating and growing cells.**

An extensive network of tubules, flattened vesicles, and cisterns extends throughout the cytoplasm of many cells. When ribosomes and polysomes are attached to this network (reticulum), the organelle is called the **granular (rough) endoplasmic reticulum (RER)** (Figs. 4-23, 4-27, and 4-28). In many cells this organelle is scattered randomly throughout the cytoplasm; the distribution of plasma cell RER imparts a total cytoplasmic basophilia. In others its distribution is associated with cell polarity. The pancreatic acinar cell, for example, has a basally positioned basophilia due to the polarized position of RER (Fig. 4-29 and Plate II, *10*). **The proteins synthesized on the ribosomes of the RER are primarily for extracellular use. A cell with a vesicular nucleus, prominent nucleolus, and cytoplasmic basophilia usually has a high potential for protein synthesis.**

Protein synthesis. The process of protein synthesis is summarized graphically in Figure 4-30. The **transcription** of mRNA occurs on the euchromatic DNA and requires the enzyme **RNA polymerase.** A ribosome consists of two unequal **subunits** of rRNA synthesized in the nucleolus, transported to, and subsequently assembled within the cytoplasm. The two subunits perform different functions in protein synthesis. A slender strand of mRNA runs between the subunits linking ribosomes as polyribosomal units.

The messenger leaves the nucleus encoded with the proper information relating to amino acid sequencing. The initiating event of transcription is the binding of the 5′ end of the mRNA to the smaller ribosomal subunit. This information is vested in **(codons),** which are various triplet combinations of nucleotides.

Transfer RNA is synthesized in the nucleus and is active in the cytoplasm. A specific tRNA exists for each amino acid. Individual amino acids are transferred

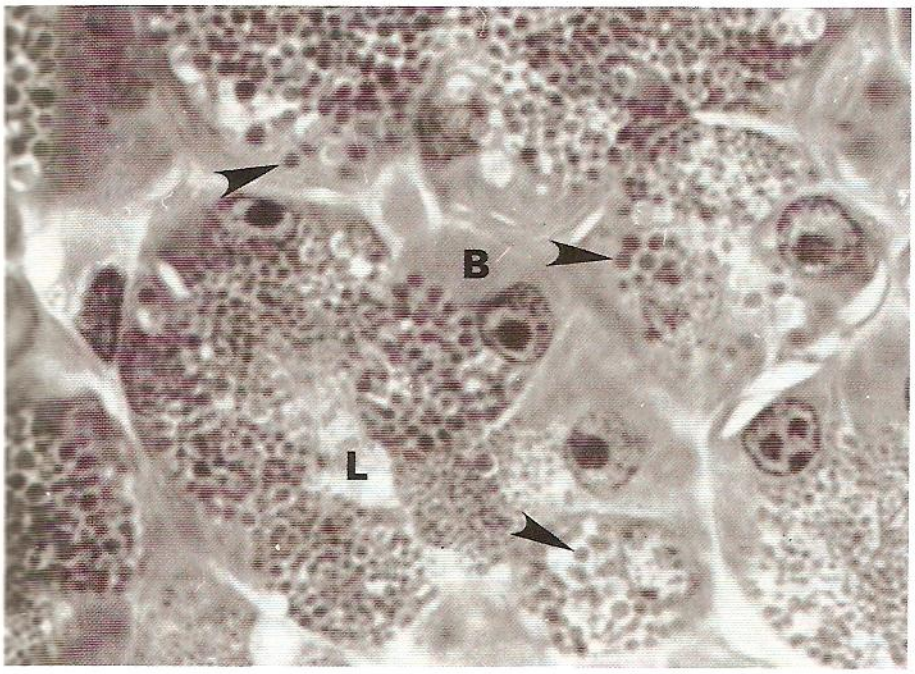

Figure 4-29. Adenomeres of a canine pancreas. This 2 μm plastic-embedded section has excellent detail. Zymogen granules *(arrowheads)* are preserved well. The basophilia *(B)* of the basal part of the cells is obvious. This cell is highly polarized. (×160.) (Glycol methacrylate–embedded section.) Compare this light micrograph with Figure 4-48. See also Plate II, 9, to compare with these figures.

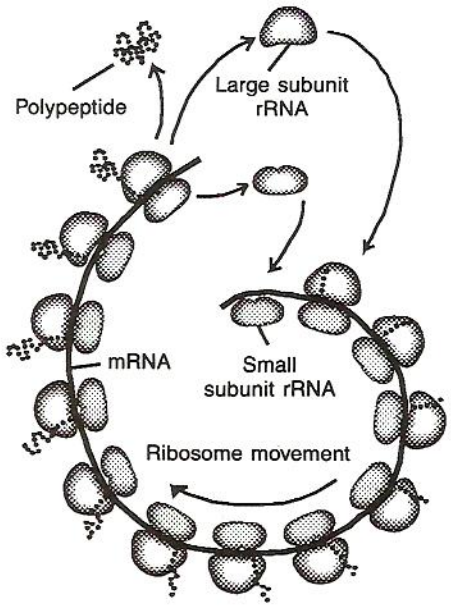

Figure 4-30. Translation of mRNA and the synthesis of polypeptides. The translation process begins with binding of the small and large subunits of rRNA to the 5′ end of the mRNA. The combined subunits move along the mRNA clockwise toward the 3′ end of the mRNA. With each combination of mRNA and rRNA with a tRNA complex, a new amino acid is added to the lengthening polypeptide chain. Upon completion of the polypeptide, the two subunits dissociate and separate from the mRNA. (Redrawn and modified from Alberts B, et al: *Molecular biology of the cell,* ed 2, New York, 1989, Garland Publishing.)

from the cytoplasmic pool to an appropriate tRNA by the activity of at least one of ten specific **aminoacyl-tRNA synthetases.** Its enzyme activity causes the activation of one amino acid and joins it to tRNA as an **aminoacyl-tRNA complex.** The different aminoacyl-tRNAs necessary to form a polypeptide are selected individually and sequentially by specific codons of the mRNA.

Attachment of the tRNA to an **initiator codon** of mRNA initiates polypeptide synthesis. Two tRNA binding sites exist on the ribosome—the **acceptor (A) site** and the **peptidyl (P) site.** The aminoacyl-tRNA binds initially to the A site, moves to the P site, and carries the mRNA with it, exposing the next codon. The vacated A site now becomes occupied by another aminoacyl-tRNA complex. A peptide linkage forms between the two amino acids. The aminoacyl-tRNA complex advances again, releases the initial tRNA, carries the mRNA with it, and exposes another codon. This cycle of attachment, advance, peptide linkage formation, and tRNA release and attachment continues until the 3′ end **(terminal codon)** of the messenger is reached. The lengthening polypeptide is always attached to the new aminoacyl-tRNA complex that joins the A site. The ribosomes contribute actively to the translation process by catalyzing the peptide linkage formation.

The tRNA is subsequently released from the messenger, and the ribosome moves along the mRNA. Another tRNA is then ready to read the next mRNA codon. Released tRNA is available for the transfer of another specific amino acid; the released ribosomes are available for repeated nonspecific utilization. The specificity for the protein resides in the mRNA. This assembly process of amino acids into polypeptides is called **translation.** Assembly is a rapid process; some experimental data indicate approximately 10 msec per amino acid.

The length of the mRNA determines the number of ribosomes associated with it and thus the length of the polypeptide chain. Secretory proteins gain access to the tubules or cisterns of the RER, are translocated to the Golgi apparatus, and emerge as **condensing vacuoles** that are converted to **secretory granules.**

Signal hypothesis. The mechanisms governing the fate of newly formed polypeptides—intracellular use or extracellular transport—are explained by the **signal hypothesis.** According to this hypothesis, mRNAs for secretory proteins have a **signal codon** sequence to produce an amino-terminal **leader peptide** attached to proteins for secretion. The leader peptide serves as a **signal peptide** directing the secreted protein to the RER membrane. The signal peptide joins with a **signal-recognition particle (SRP),** which cycles between the cytosol and the RER membrane. This complex binds with an **SRP receptor (docking protein)** on the RER membrane. Translocation occurs across the membrane as the ribosome continues its translation. Upon entry into the cisterns, the signal peptide is cleaved from the nascent polypeptide by a **signal peptidase** located on the RER.

Agranular endoplasmic reticulum

The **smooth (agranular) endoplasmic reticulum (SER)** is not as extensive as its granular counterpart, except in certain cell types. The SER is not associated with ribosomes and polyribosomes but consists of anastomosing tubules (Fig. 4-31). Although SER is distinct from RER, the two sets of profiles are connected.

Smooth endoplasmic reticulum is more diverse than its morphology would imply—**glycogen and lipid synthesis and transport, biotransformation, and ion storage and transport.** Glycogen and SER profiles are usually associated with each other. The enzyme **glucose-6-phosphatase** is a component of this organelle in liver cells, wherein it is involved in the biotransformation of various substances. SER, through its drug metabolizing enzymes, biotransforms many endogenous

Downloaded From: YesDental.com

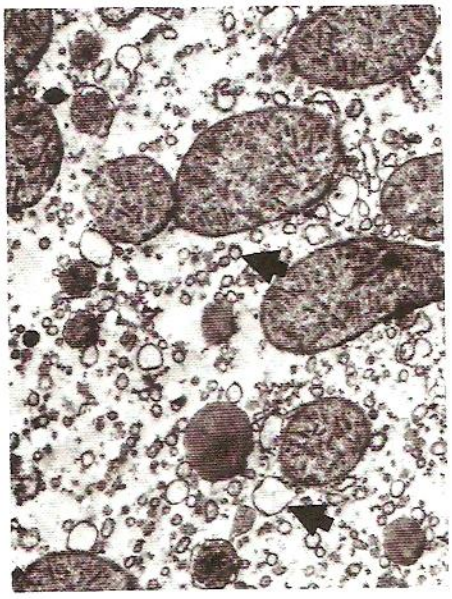

Figure 4-31. Electron micrograph of the SER of a hepatocyte. Although the cell has been ruptured, the tubular profiles *(arrows)* of the organelle are obvious. Mitochondria and RER profiles are also present. (×11,400.)

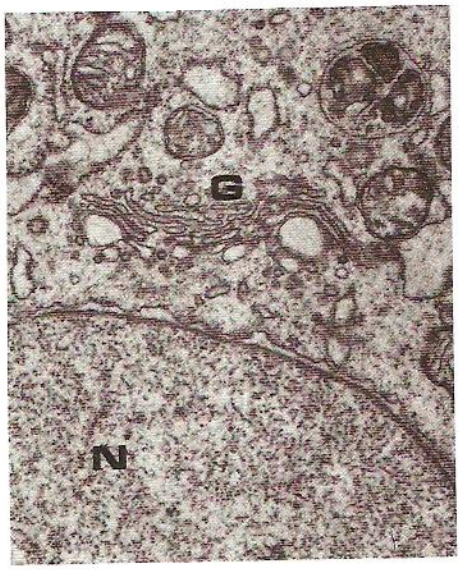

Figure 4-32. Electron micrograph of a Golgi complex *(G)* positioned close to the nucleus *(N)*. (×20,000.)

and exogenous substances. The involvement of this organelle in lipid metabolism varies. In intestinal lining cells, fatty acid resynthesis into fats and their transport to cell borders occur within the SER. Steroid hormone and lipoprotein synthesis occurs in this organelle. The sarcoplasmic reticulum is a special SER of muscle cells used for Ca^{++} sequestration and subsequent transport.

Golgi complex

Structure. The **Golgi complex** may be seen with light microscopy with special stains impregnating the organelle as a positive image. The organelle is a network of tubules and vacuoles scattered throughout the cell, sometimes in more than one focus, or is juxtaposed to the nucleus and confined to a discrete region. With H&E, an extensive Golgi complex provides a negative image due to its chromophobic staining properties. The position of the Golgi complex reflects polarization; the apparatus is supranuclear, located between the nucleus and the apical cell surface.

Electron microscopy has contributed to an understanding of the morphology of this organelle (Fig. 4-32). The Golgi apparatus consists of parallel arrays of smooth-surfaced membranes disposed as flattened saccules with peripheral dilated cisternae. The entire complex assumes a semilunar configuration of polarity. The **convex face (*cis*, forming,** or **proximal face)** is associated and ultimately fuses with **transfer vesicles** from the RER. Many fenestrations characterize this surface. The **concave face (*trans*, maturing,** or **distal face)** is associated with **secretory vesicles** in various stages of condensation and maturation (Fig. 4-33).

Function. The membranes of the Golgi stack are in constant flux. "New membrane" is added by the incorporation of transfer vesicles, and "old membrane" is lost at the mature face through secretory vesicles. Exocytosis involves the fusing of membrane-bound vesicles from the Golgi apparatus with the plasmalemma. The translocation of membranes from the immature face through the stack to the mature face contributes to the plasmalemma and the glycocalyx.

The Golgi complex alters and packages secretory units for intracellular and extracellular use. Glycosylation of glycoproteins and collagenous precursors is a posttranslational function, using **glycosyl transferases** to accomplish the transfers. The Golgi also adds sugars to lipids during the synthesis of glycolipids. Sulfation of glycosaminoglycans also occurs in this organelle. Post-translational proteolysis **(hydrolases)** occurs commonly, converting prosecretory proteins into secretory proteins. The complex is also responsible for glycosaminoglycan synthesis. It also forms lysosomes.

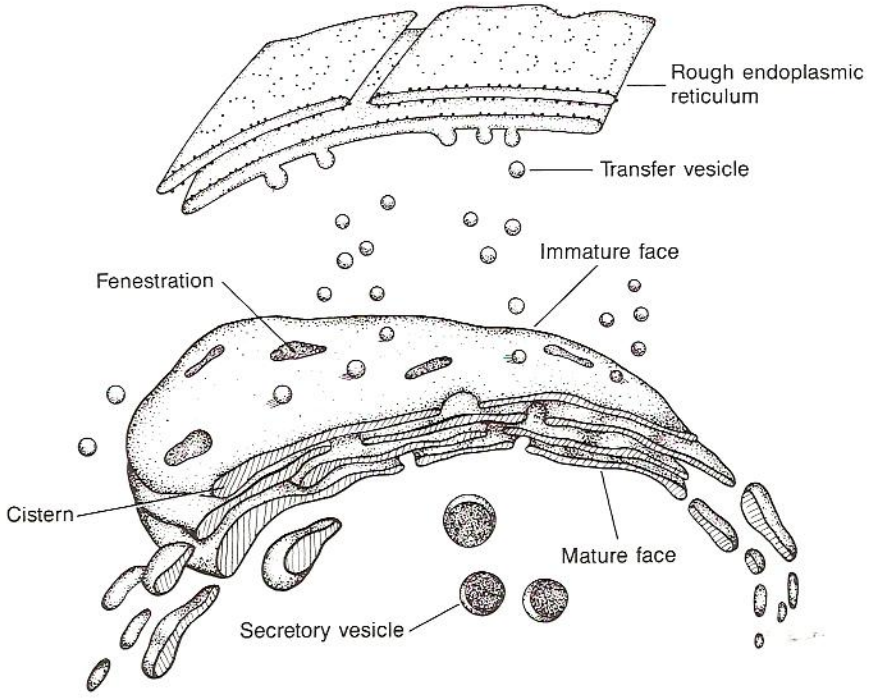

Figure 4-33. Golgi complex and its relationship to the RER. Transfer vesicles bud from the RER and fuse with the immature face. Materials enter the stack at the immature face, traverse the stack, and emerge as presecretory vesicles that then mature into secretory vesicles.

Mitochondria

Mitochondria appear as threads or granules with various stains for light microscopy. Special stains stain them specifically. Their shape is varied, even within a specific cell type. They are pleomorphic, ranging from round to oval or from elongated to filamentous. Mitochondrial numbers vary with the cell's energy requirements. Although most mitochon-

Figure 4-34. Typical mitochondria are in the orthodox conformation. Cristae are prominent, because the mitochondrial matrix is not very dense. (×27,000.) Compare the density of this mitochondrial matrix with that in Figure 4-36.

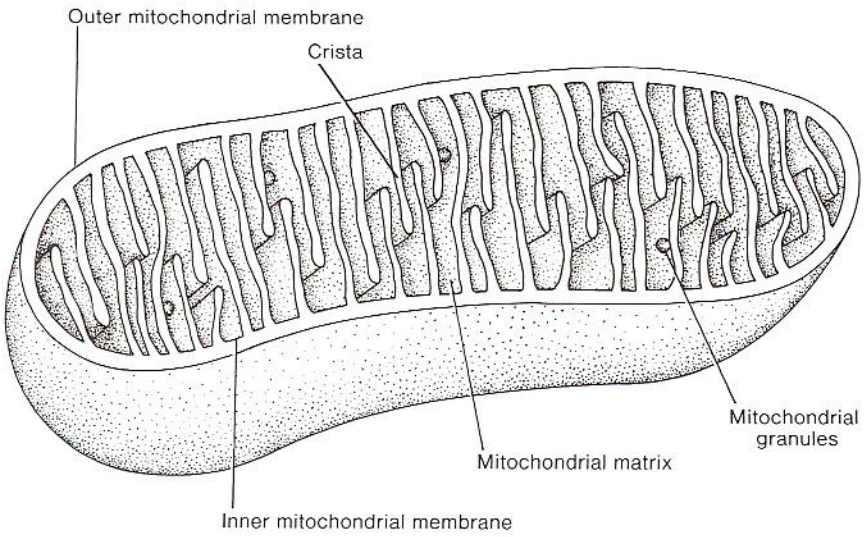

Figure 4-35. Typical mitochondrion with components labeled.

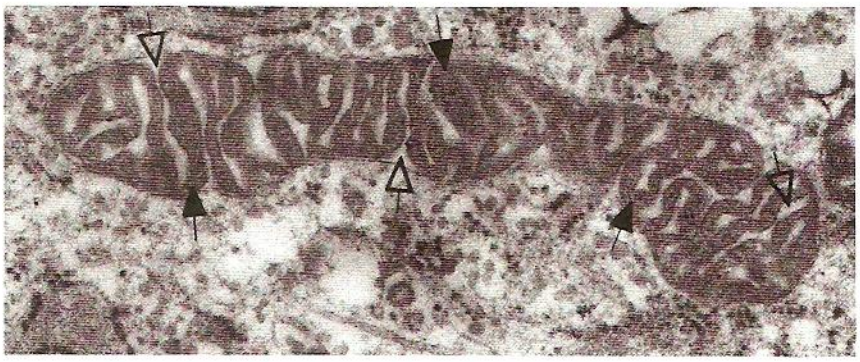

Figure 4-36. Electron micrograph of a mitochondrion in the condensed conformation. The cristae *(open arrows)* are separated from each other by a condensed mitochondrial matrix *(solid arrows)*. (×48,000.)

dria are 2 to 3 μm long, some can exceed a length of 10 μm.

Mitochondria are seen by electron microscopy as double-membrane organelles (Fig. 4-34). An **outer mitochondrial membrane** has a smooth contour, is approximately 7 nm thick, and defines the periphery of the organelle. An **inner mitochondrial membrane** is approximately 8 nm thick and is modified into plate-like or tubular folds **(cristae).** The cristae are separated by a **mitochondrial matrix** that is homogeneous and finely granular but of varying density. Electron-dense granules **(mitochondrial granules)** occur within the matrix (Fig. 4-35).

Mitochondria change conformation. A change in conformation is linked with **inactive** or **active oxidative phosphorylation.** The **orthodox conformation** occurs with inactive oxidative phosphorylation and is seen structurally as the "typical" picture of mitochondria (Fig. 4-34). The **condensed conformation** is associated with an active oxidative phosphorylation during which mitochondria have an enlarged intermembranous space and a condensed mitochondrial matrix (Fig. 4-36).

The inner mitochondrial membrane and mitochondrial matrix contain all the enzymes of the citric acid cycle, oxidative phosphorylation, and fatty acid oxidation. The primary role of mitochondria is the production of energy. Mitochondria also contain DNA and RNA. They possess some genetic and protein synthetic potential. As such, they are capable of replication, although the exact method (budding or division) is yet to be determined.

Lysosomes

Structure. **Lysosomes** are membrane-bound particles rich in **hydrolytic enzymes.** They occur in most cells and assume many shapes and sizes **(polymorphism).** By light microscopy some of the granules of basophils, eosinophils, and neutrophils can be seen to demonstrate the characteristic structure and staining properties of these particles (Fig. 4-37).

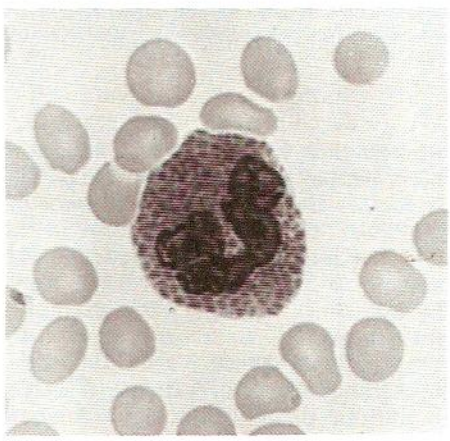

Figure 4-37. A feline basophil. The small, specific granules scattered throughout the cell are lysosomes. ×400.

Lysosomes are particles in various stages of formation, maturation, and activity. Primary lysosomes form similarly to secretory granules. The hydrolytic enzymes are synthesized in the RER

Downloaded From Vet-eBooks.com

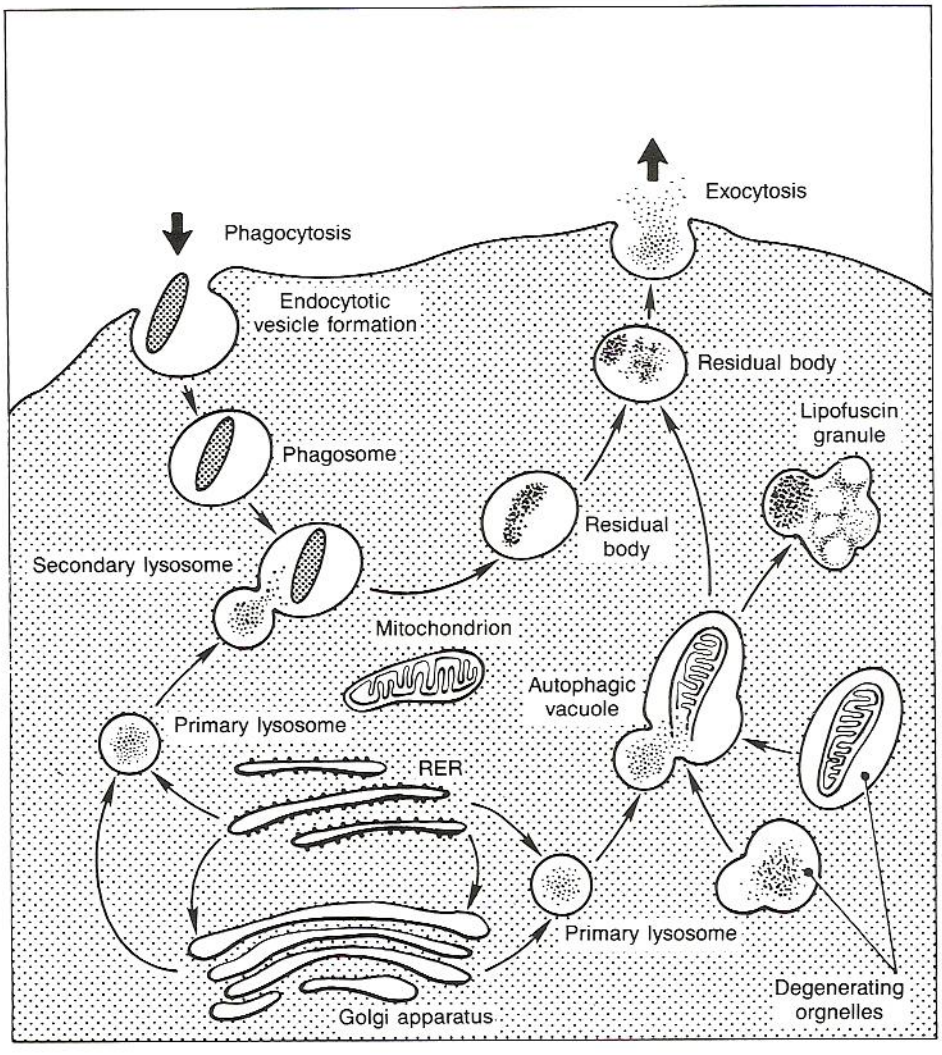

Figure 4-38. Lysosomal activity during phagocytosis and autophagocytosis. Particulate matter engulfed by the cell in endocytotic vesicles enters the cytoplasm within phagosomes. Primary lysosomes produced by the Golgi complex and/or the RER fuse with the phagosomes to form activated or secondary lysosomes. The digestion of particulate matter culminates in the formation of a residual body retained within the cell or extruded by the cell through exocytosis. Foci of degenerating organelles may be engulfed initially by membranes of the RER. Fusion with primary lysosomes forms autophagic vacuoles (secondary lysosomes). Residual bodies and/or lipofuscin granules result from autophagocytosis.

whereas their segregation and packaging occur within the Golgi apparatus. The lysosomes are "secretory granules for intracellular use." They may form in the GERL (Golgi endoplasmic reticulum lysosome), a Golgi-associated RER, thereby bypassing the Golgi complex during their formation.

Figure 4-38 depicts lysosomal particles in various stages of activity. Vacuoles bud from the Golgi complex and are transformed into **dense bodies (primary lysosomes, inactive lysosomes).** The fate of primary lysosomes depends upon the activity with which they are associated, **endocytosis** or **autophagocytosis.**

Endocytosis. Endocytosis is subdivided into **phagocytosis** and **pinocytosis.** In **phagocytosis,** particulate matter is engulfed by the cell as membrane-bound vesicles **(phagosomes).** The union of a primary lysosome and phagosome produces a **secondary** or **active lysosome,** called a **phagolysosome.** Upon completion of the digestive activity of this newly formed structure, or during an arrest in the activity, a resulting **residual body** is formed. The latter, upon completion of the digestive function, is extruded from the cell.

During **pinocytosis** (Gr *pinein,* to drink) fluid material is engulfed by the cell in **pinocytotic vesicles (pinosomes).** These vesicles may fuse with primary lysosomes and appear within a dense body as vesicles. The primary lysosome with engulfed vesicles is called a **multivesicular body.** After digestion the multivesicular body is assumed to be converted to a primary lysosome for future use or a residual body is formed.

Some fluids enter cells through receptor activity by **receptor mediated pinocytosis.** Large droplets filled with fluid **(macropinosomes)** and visible with the light microscope also occur. They, too, may fuse with lysosomes.

Autophagocytosis. During **autophagocytosis** a sequence occurs similar to that of phagocytosis. Organelles and insoluble portions of cytoplasm degenerate or become functionless. These regions appear as **foci of cytoplasmic degeneration.** All such cytoplasmic components are engulfed by primary lysosomes and are referred to as **autophagic vacuoles** or **cytolysosomes.** Their fate is similar that of phagolysosomes.

Function. Lysosomes are part of a continually dynamic process and should not be considered simply as "garbage dumps." They are responsible for routine digestive properties and protective functions. They contain, in fact, some 50 acid hydrolases—including **phosphatases, nucleases, proteases, sulfatases, peptidases, glycosidases,** and **lipases.**

The hydrolyzed products, once released from the lysosomes, are available for reutilization by the cell. Nevertheless, their intracellular functions have led to the general misconception that they are exclusively refuse factories—scavenging, digesting, and sequestering various materials throughout the life cycle. Lysosomal enzymes also function outside the cell. Collagenases, proteases, and other hydrolases can destroy extracellular matrices. Lysosomes are responsible for protecting the body against foreign materials by digesting this particulate material. The organelle is also responsible for destroying cells through **autolysis.** Under normal conditions routine cellular death **(necrobiosis)** is mediated through autolysosomal function **(autolysis).** In pathological conditions lysosomes can account for abnormal cell death **(necrosis)** via autolytic processes as well.

Lysosomes degrade biologically active molecules that regulate cellular activities related to growth, nutrition, metabolism, and differentiation. Receptor-mediated endocytosis is significant in the flow of internalized substances to various organelles. Some of these substances are delivered to lysosomes for degradation. The basis for this selective sorting of compounds to various cellular compartments is a subject of current research.

Peroxisomes

Peroxisomes are spherical or ovoid organelles smaller than mitochondria. Special staining techniques demonstrate them with light microscopy. They can

also be identified by the presence of certain enzymes.

With the electron microscope peroxisomes can be seen to be bound by a single membrane enclosing a matrix containing a crystalloid particle (nucleoid). Cells with altered lipid metabolism have an increased number of peroxisomes. Peroxisomes have been identified in liver cells, renal lining cells, macrophages, and other cell types.

The enzymes occurring within peroxisomes include **catalase, oxidases, alcohol dehydrogenases, amino transferases, and others.** The oxidases produce energy by oxidizing substrates with molecular O_2. Catalase controls the amount of hydrogen peroxide (H_2O_2) this organelle produces. Amino transferases remove the amino group from amino acids, producing substrates for the generation of glucose **(gluconeogenesis).** Alcohol dehydrogenase degrades alcohol (as well as antifreeze).

Cytoplasmic Skeleton and Inclusions

Microtubules

Structure and function. **Microtubules** occur in various cells and serve various functions. Except in the case of the mitotic spindle apparatus, they are difficult to identify by light microscopy. Even then, they appear as fibers rather than tubules. With the electron microscope they are resolved as hollow, rodlike organelles with an outside diameter of 20 to 26 nm and a wall 5 to 7 nm thick (Fig. 4-39). They may be several micrometers long.

Microtubules occur scattered throughout the cytoplasm of many cell types and are preferentially distributed in certain cells. Because they contribute to cell shape, they may be considered a part of the cytoplasmic skeleton. They occur in cilia, in flagella, and in the manchette of spermatids. Also they occur in the axoplasm of neurons, wherein they serve a transport function, and are an integral component of the spindle apparatus during mitosis.

Microtubules consist of monomers called **tubulin,** which is a heterodimer of subunits called α- and β-tubulins, each with a molecular weight of 60,000 daltons. The dimers are arranged to form a **protofilament** (Fig. 4-40). Initial assembly of microtubules appears to occur as coiled tubular protofilaments in association with the centrioles. Protofilamentous growth is accompanied by polymerization at the ends or **nucleation sites** of the tubule.

Centrioles. The **centrioles** of resting cells are two small bodies contained within an area called the **centrosphere.** These bodies are usually inconspicuous in resting cells, but special stains can be used to demonstrate them with the light microscope.

The two small bodies observed by light microscopy are resolved with the electron microscope as cylindrical units 150 nm in diameter and approximately 500 nm long (Fig. 4-40) oriented perpendicular to each other. Each cylinder is composed of nine groups of three tubules. The nine groups are eccentrically positioned within the cylinder. Fibrous material connects the terminal tubules of one group to the terminal tubules of adjacent groups. Also fibrous material connects the peripherally located groups to the center of the centriole.

Centrioles duplicate themselves and associate with the microtubules of the spindle apparatus during mitosis. A dense cytoplasmic region in the centrosphere has been associated with microtubule formation as a **microtubular organization center.**

Cilia and flagella. **Cilia** and **flagella** are surface modifications of cells used for motility. An exception to this generalization exists, however. Two types of cilia have been identified. **Stereocilia** are nonmotile, long, branched cellular processes (Fig. 4-41); they lack the complex organization normally associated with cilia and may be considered long microvilli. **Kinocilia,** often simply called cilia, are the motile, cellular processes.

Kinocilia are characteristic of epithelial cells, wherein they function for movement; but some cells use cilia as sensory receptors. Typical ciliated cells have numerous cilia ranging in length from 2 to 10 μm (Fig. 4-42). Male gametes have a single flagellum between 100 and 200 μm long. Ciliary and flagellar diameters may be 0.3 to 0.5 μm.

An array of microtubules organized in a typical 9 + 2 pattern is called an **axoneme** (Fig. 4-43). Nine peripheral pairs of microtubules surround two centrally positioned microtubules. The components of these doublets share some protofilaments (Fig. 4-44). **Subunit A** is a complete microtubule that contains 13 protofilaments. **Radial spokes** and projecting arms **(inner** and **outer arms)** are attached to it. ATPase activity is localized to the inner and outer arms of subunit A. This enzyme was named **dynein** (force protein) because of its role in the mechanochemical transduction of energy for ciliary motility. **Subunit B** is an incomplete microtubule attached to subunit A. Adjacent peripheral doublets are joined to each other by protein bridges called **nexins.** Similarly, peripheral doublets are joined by the radiating spokes to the central sheath surrounding the central pair of microtubules (Fig. 4-45). (The same organization is characteristic of flagella.)

Basal bodies form as centrioles within cells developing cilia (and flagellae). The new centrioles migrate to the cell's periphery subjacent to the plasmalemma. New dimers are added at the distal nucleation sites, and the nascent axonemes grow into a sheath of plasma membrane and cytoplasmic matrix to form the new cilia. **Rootlets** develop in association with the proximal ends of the basal bodies to anchor these structures in the cytoplasm. Also a striated structure, the **basal foot,** develops and attaches laterally to the basal bodies.

Ciliary motility. Movement of cilia is necessary for the transport of materials across an epithelial surface. These structures are essential components of the **mucociliary apparatus**—the combination of mucus secretion and ciliary motility that protects an underlying epithelial lining.

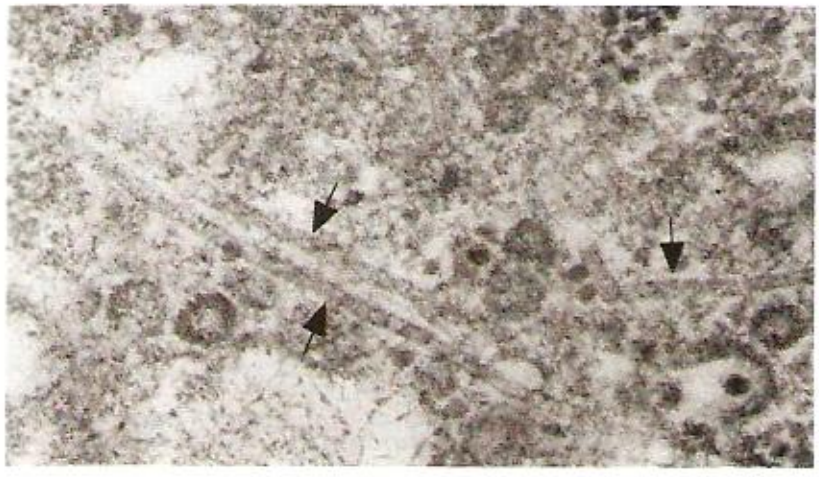

Figure 4-39. Electron micrograph of microtubules. The microtubules *(arrows)* are scattered throughout the cytoplasm. The distribution of microtubules is very specific and/or highly organized in some cells and in certain stages of the mitotic cycle.

Downloaded From Vet-eBooks.com

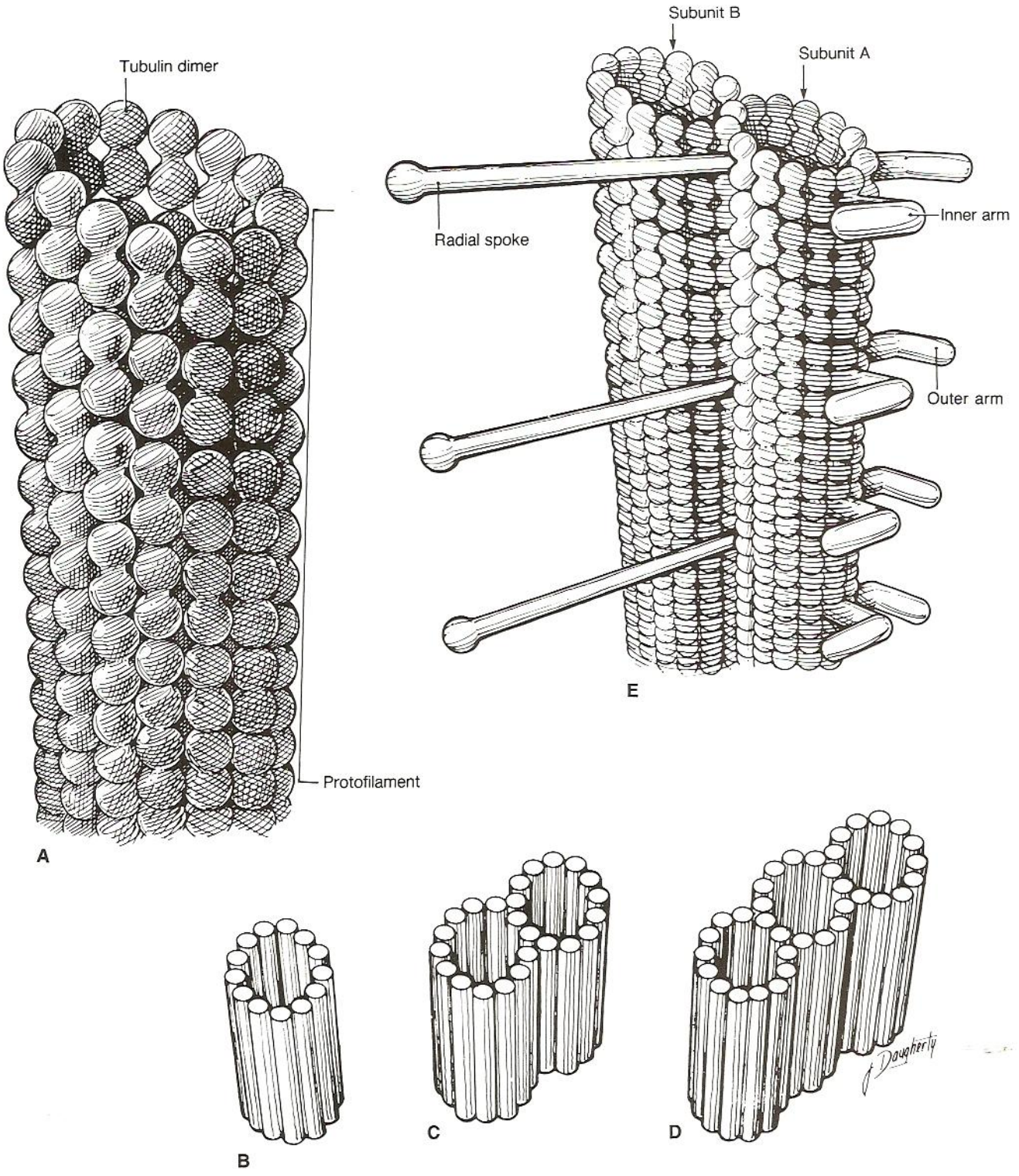

Figure 4-40. Microtubular organization. **A,** The microtubules consist of dimeric units called tubulin. Tubulin dimers are organized as linear arrays called protofilaments. **B,** Dimeric units are represented as protofilaments. Thirteen protofilaments comprise a microtubule. **C,** Pairs of microtubules as occur in cilia and flagella. Protofilaments are shared by constituent microtubules. **D,** Microtubular triplets as occur in centrioles. Protofilaments are also shared by microtubules in this configuration. **E,** Microtubular doublets as occur in cilia. Subunit *A* consists of 13 protofilaments. Inner and outer arms and radial spokes are attached to it. Subunit *B* is incomplete and shares some protofilaments with subunit *A*.

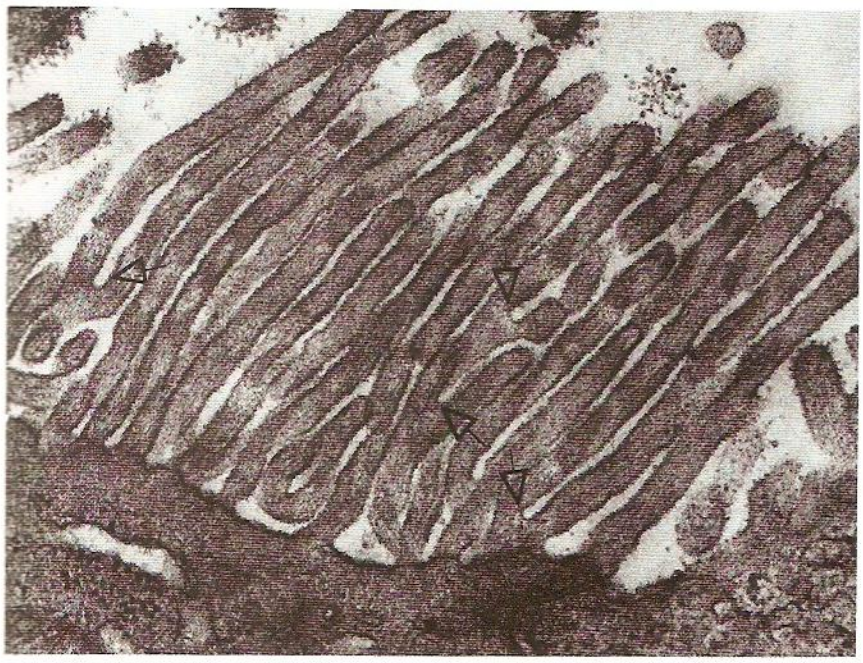

Figure 4-41. Electron micrograph of stereocilia in a lining cell of the trachea of a mouse. The stereocilia are branched *(arrows)* and lack the internal organization of kinocilia. (×46,000.)

Figure 4-42. Low-magnification scanning electron micrograph of cilia from the trachea of a 9-month-old dog. (Courtesy N. J. Wilsman and C. E. Farnum.)

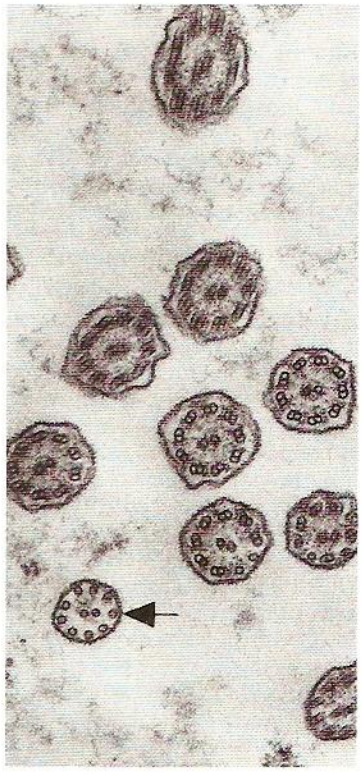

Figure 4-43. Electron micrograph of cross sections of cilia. The doublets and central pair of microtubules are apparent. The configuration of the peripheral microtubules is altered at the tip of the cilium *(arrow)*. (×44,000.)

Downloaded From Vet-eBooks.com

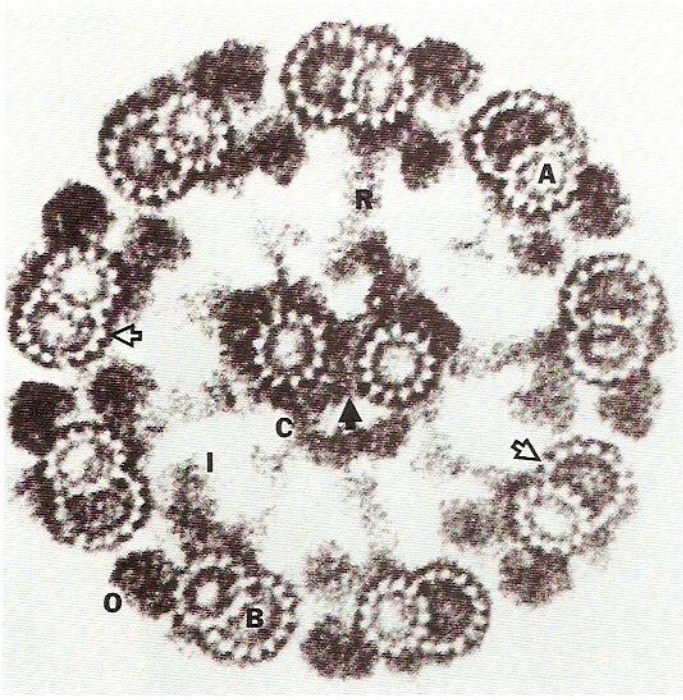

Figure 4-44. High-magnification transmission electron micrograph of a normal ciliary axonemic profile following demembranization and tannic acid staining. *R*, Radial spoke; *A*, subunit A; *B*, subunit B; *C*, central sheath; *solid arrow*, bridge; *open arrows*, protofilaments; *O*, outer arm; *I*, inner arm. Compare this micrograph with Figure 4-45. (Courtesy N. J. Wilsman and C. E. Farnum.)

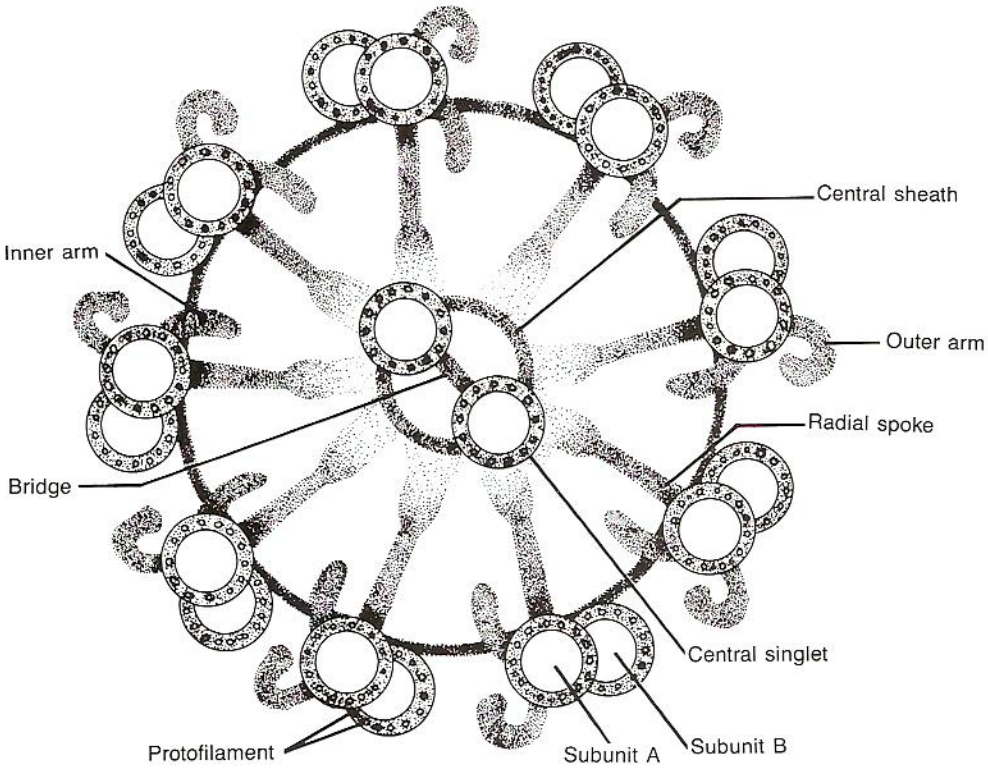

Figure 4-45. An axoneme. Compare this with the actual micrograph (Fig. 4-44).

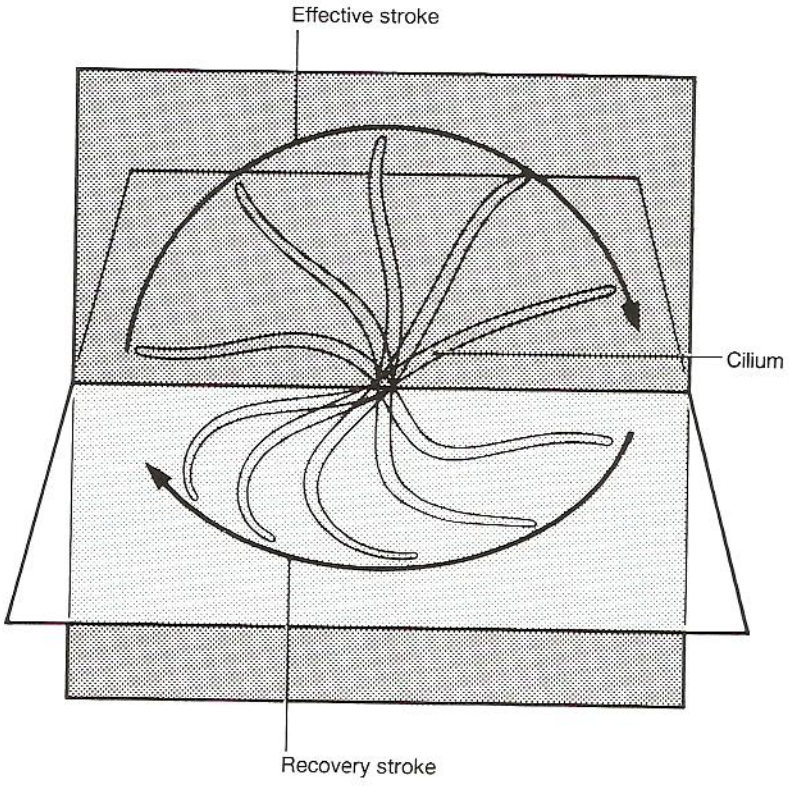

Figure 4-46. Two-phase ciliary beat. The cilium is rigid during the effective stroke. It then relaxes, bends, and returns to its starting point during the recovery phase.

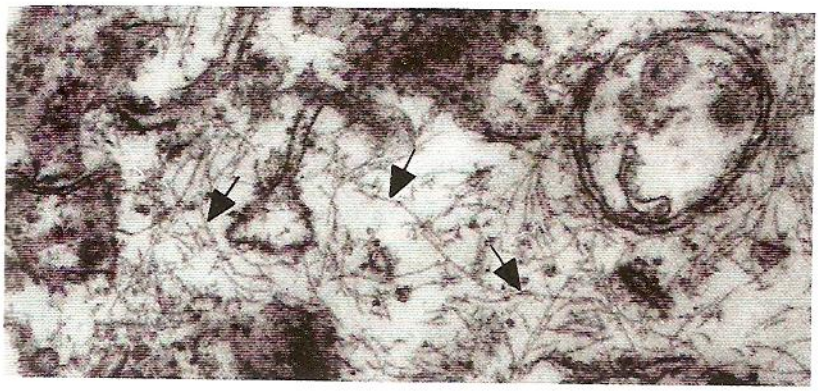

Figure 4-47. Electron micrograph of cytofilaments. The cell was ruptured during processing. Because much of the normal cytoplasmic matrix was lost during processing, the cytofilaments *(arrows)* are observed easily. (×52,000.)

The cilia of a cell may beat in synchrony with each other **(isochronal rhythm)** or out of synchrony **(metachronal rhythm).** In a metachronal rhythm all the cilia within a particular row beat in synchrony but those in successive rows are slightly asynchronous with those in adjacent rows. The result is a wave of activity similar to the response of a field of grain to a gentle breeze.

A ciliary beat cycle consists of an effective stroke and a recovery stroke. During the **effective stroke** the cilium is rigid and beats generally in the direction of the cross-sectional axis between the pair of central microtubules (Fig. 4-46). During the **recovery stroke,** it relaxes, bends, and returns to the starting position.

Cytoskeletal components

Filaments. Three types of **cytofilaments** have been identified. **Microfilaments** are composed of **actin** and have a 5 to 6 nm diameter (Figs. 13-5 and 13-26). **Myosin filaments** are 10 nm in diameter (Fig. 13-15) and are the contractile elements of cells. **Intermediate filaments (IF)** are noncontractile, 8 to 10 nm diameter elements forming the supportive network of the cytoplasm (Fig. 4-47). They are fibrous proteins constructed like woven rope and are intermediate in size between actin and myosin filaments.

Type I IF proteins are **keratins,** which strengthen cells and concentrate to form impermeable skin layers. They are the primary component of hairs, feathers, nails, hooves, and epidermis.

Type II IF proteins are **vimentin, desmin,** and **glial fibrillary acidic proteins.** Vimentin enmeshes the nucleus and may dictate nuclear location. Desmin filaments occur in muscle cells, wherein they anchor the myofilaments. Glial fibrillary acidic proteins form filaments in glial cells.

Type III IF proteins are **neurofilaments,** which contribute to the structural and transport framework of neurons.

Type IV IF proteins are the **nuclear lamins,** which provide structural support along the inner nuclear membrane.

Cytoplasmic inclusions

Secretory inclusions. The secretory products of cells include enzymes, acids, proteins, and mucosubstances. The morphology of the secretory products is as diverse as the products themselves. Lysosomes were described previously. **Zymogen granules,** membrane-bound packets of enzyme precursors for extracellular use, typify many protein-secreting cells. These secretory products, appearing as granules in a subluminal position, are derived from the distal face of the Golgi complex. They mature, move toward the lumen, and are secreted at the apical cell surface (Fig. 4-48).

Some cells secreting **mucosubstances** are characterized, as in the case of the **goblet cell** (Fig. 4-49), by a very foamy cytoplasm (Plate II, *9*). The secretion of lipid materials is associated with cells possessing a foamy but acidophilic cytoplasm. The foamy appearance results from the fact that the lipids have been leached from the cytoplasm. Cells from the adrenal cortex typify this kind of secretory inclusion (Fig. 4-50 and Plate II, *3*).

Some cells secrete products invisible by light microscopy. Cells of the connective and supportive tissues secrete proteoglycans, glycosaminoglycans, and glycoproteins without light microscopic evidence of this activity.

The serous cells of some glands secrete a watery or **serous** product without alterations at the secretory surface. The accumulation of light microscopically visible products is also not evident (Fig. 4-51 and Plate II, *8*).

Nutritive inclusions. Glycogen is stored in many cells, including liver and

Downloaded From Vet-eBooks.com

Figure 4-48. Electron micrograph of pancreatic acinar cells. The approximate limits of one cell *(outer dashed line)* are indicated. The apex *(A)* of the cell borders the lumen *(L)*. The apical portion of the cell *(inner dashed line)* contains numerous zymogen granules *(G)*. The basal portion *(B)* contains the nucleus *(N)*, RER, and mitochondria. (×7000.) Compare this electron micrograph with the light micrograph (Fig. 4-29). Note that the distribution of acidophilic and basophilic staining corresponds to the distribution of specific organelles and inclusion bodies. See also Plate II, 9, to compare with these figures.

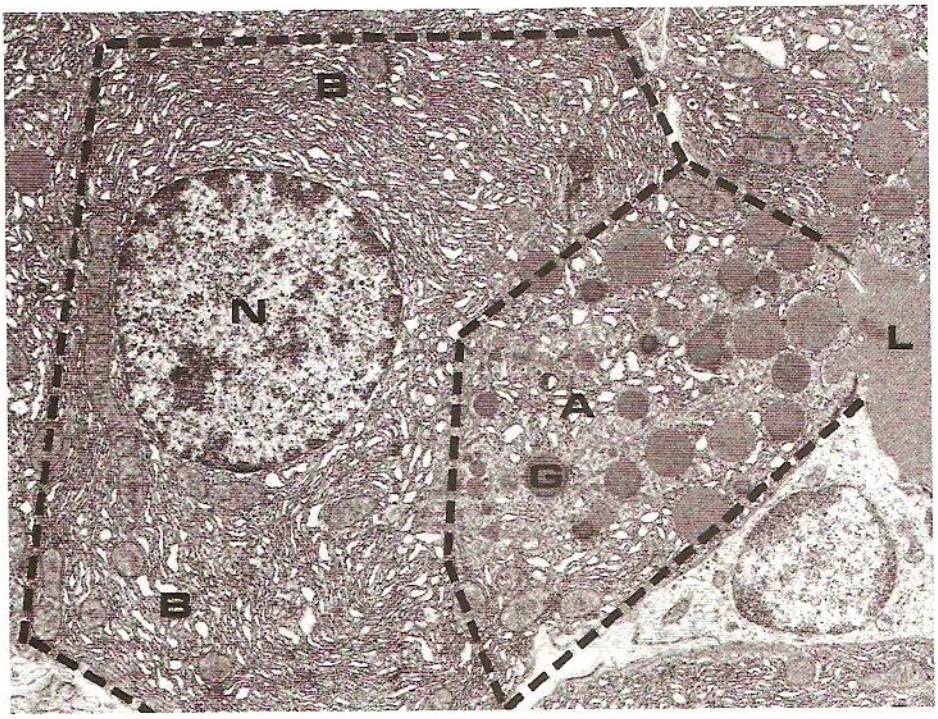

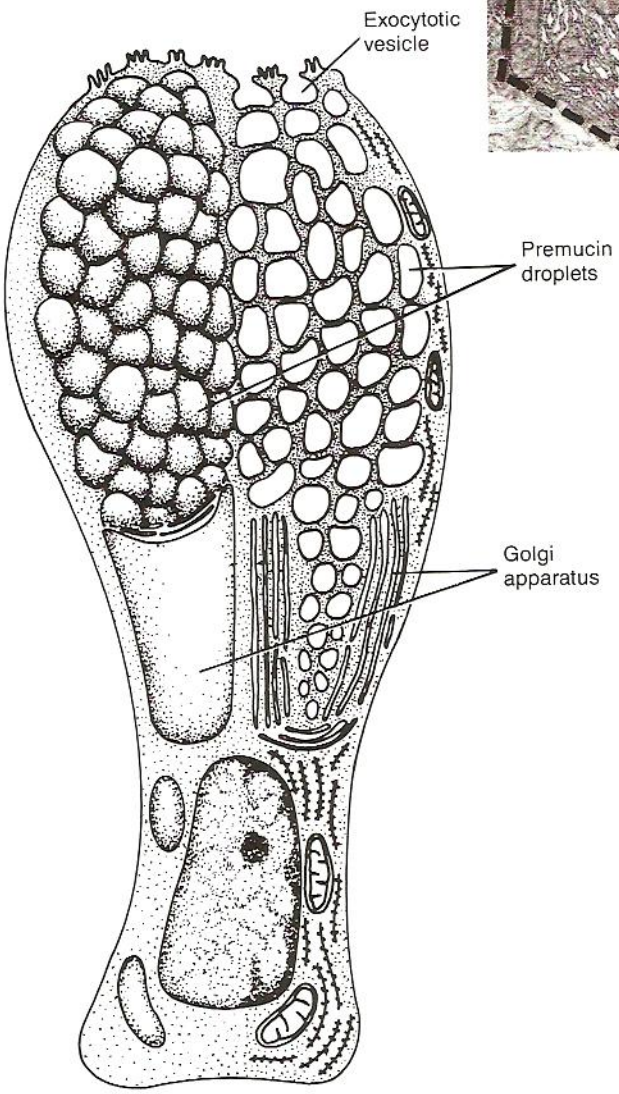

Figure 4-49. A goblet cell. Premucin droplets occupy the bulk of cytoplasmic volume and displace other cytoplasmic components peripherally and basally. They fuse with the cytoplasmic face of the apical plasmalemma as exocytotic vesicles, depositing mucinogen at the cell surface.

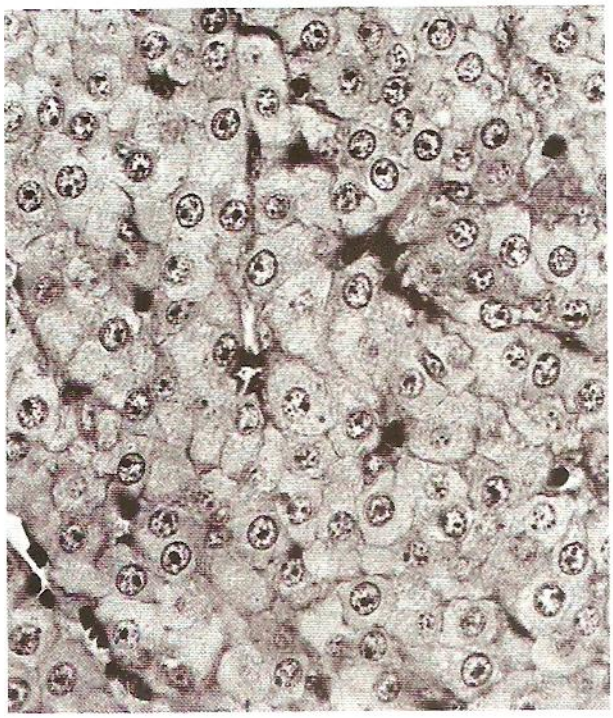

Figure 4-50. Lipid-containing cells from the adrenal cortex. The pyramidal cells have a foamy appearance due to their content of lipid. The foamy appearance is imparted to the cells because the lipids were actually removed from the cells during processing by the paraffin technique. (×160.)

Downloaded From Vet-eBooks.com

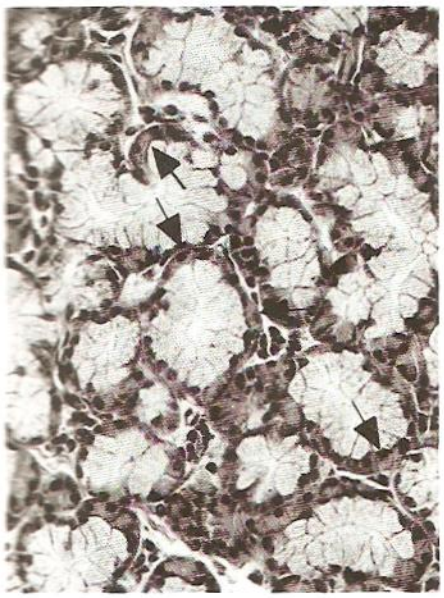

Figure 4-51. Serous and mucous cells from an equine salivary gland. The dark-staining cells (*arrows*) are serous cells. The light-staining, pyramidal cells are mucous cells. The serous cells are disposed around the mucous cells as demilunes. (×160.)

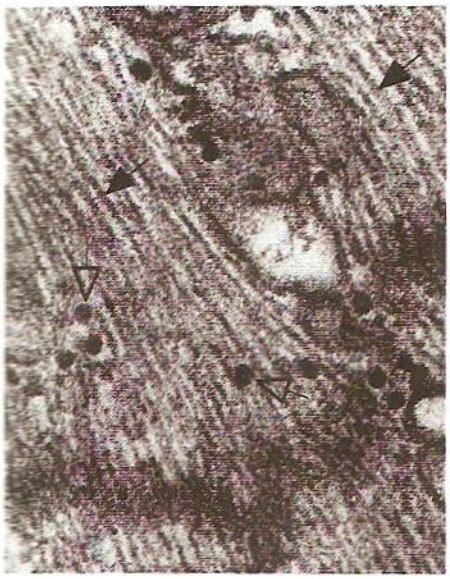

Figure 4-52. Electron micrograph of glycogen particles. The β particles (*open arrows*) are scattered among the myofilaments (*solid arrows*) of a striated muscle cell. (×51,000.)

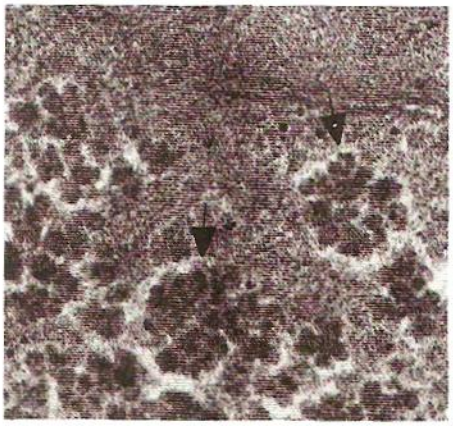

Figure 4-53. Electron micrograph of glycogen "rosettes." The *arrows* point to α particles. (×133,000.)

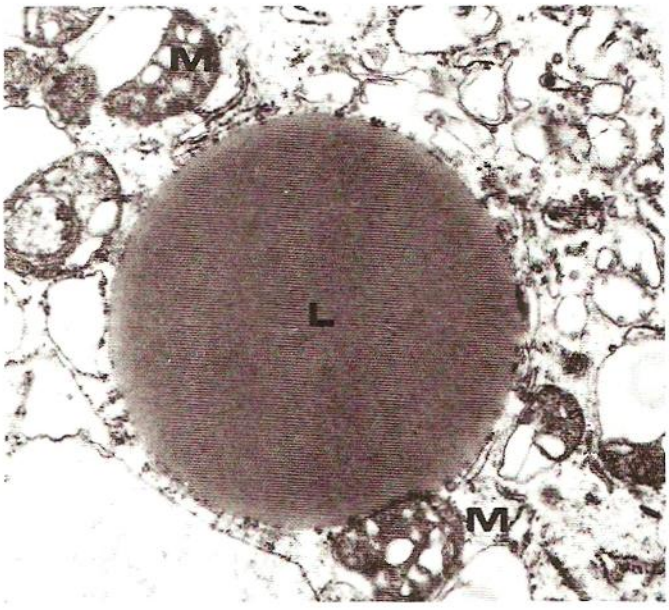

Figure 4-54. Electron micrograph of a lipid droplet from a murine ascites tumor cell. The droplet (*L*) is not membrane-bound. Condensed mitochondria (*M*) are also present. (×20,000.)

skeletal muscle cells. It requires special processing for light microscopic demonstration. With the electron microscope it appears either as single particles ranging from 15 to 30 nm in diameter with an irregular outline (**β particles**) (Fig. 4-52) or as accumulations in the form of **rosettes (α particles)** (Fig 4-53).

Lipid droplets within cells are storage packets of triglycerides. Although various cells store them, their ultimate storage occurs in adipocytes. Special processing is needed to demonstrate lipids by light microscopy. With the electron microscope they appear free in the cytoplasm as osmiophilic bodies of varying density (Fig. 4-54). In intestinal lining cells triglycerides are membrane-bound.

Miscellaneous inclusions. Many inclusions occur within various cells. The most notable are **pigment granules. Melanin** is the brown pigment producing coloration in scattered foci throughout the body. **Lipofuscin** is a gold-brown pigment that occurs in residual bodies as a terminal inclusion of lysosomal activity. It accumulates with age and thus is often referred to as the "wear and tear" pigment. Altered cell function is generally associated with its accumulation in nerve cells and cardiac muscle cells. **Hemosiderin** is a red-brown pigment resulting from the degradation of hemoglobin.

CELL DIVISION

Cell cycle. The **replacement** of dead cells with new ones is a continual occurrence. Some cells, such as those of the skin, are replaced at regular intervals; others, such as cardiac muscle cells, are not replaced. The body has the ability to replace most cells. Besides being able to replace worn out cells, however, it **must retain the ability to replace a given cell with an identical cell.** The mechanism of this faithful replication is **mitosis.**

The **cell cycle** is the passage of a cell through interphase and mitosis; the **gen-**

Downloaded From Vet-eBooks.com

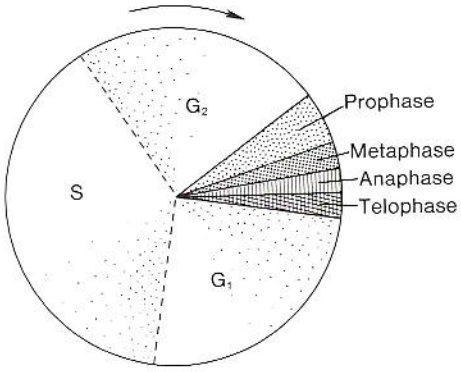

Figure 4-55. The cell cycle. Generation times of mammalian cells are variable but may average about 20 hours. The mitotic phase is shortest, approximately 2 hours. The duplication phase *(S)* is longest, about 7 hours. Specific generation times characterize specific cells of the body.

eration time is the time required to complete one cycle (Fig. 4-55).

Histological techniques allow for the recognition only of interphase and mitosis; autoradiographic techniques are needed for insights relating to other stages of the cell cycle. Through the use of tritiated thymidine (a DNA precursor), subdivisions of the interphase can be made apparent.

The **preduplication** or **presynthesis (G_1) phase** is the period before the uptake of labeled thymidine. It is the **vegetative phase,** when a cell conducts its "routine functions." Also, if the cell has a potential for mitosis, the metabolites necessary to support mitotic activity are accumulated during this stage. Most of the cells or accumulations of cells examined in histology will be in the vegetative phase of the cell cycle. The G_1 phase is protracted in somatic cells. Such protracted phases of vegetative activity are referred to by some authors as the G_0.

The **duplication phase (S)** is the stage during which DNA replication occurs, as evidenced by the nuclear uptake of labeled thymidine. Not all chromatin is duplicated simultaneously. The end result, however, is the duplication of chromosomes and a doubling of the DNA complement.

The **postduplication** or **postsynthesis (G_2) phase** is named for the termination of DNA replication; however, much synthetic activity characterizes it. The synthesis of histones and of RNA occurs during this stage.

The **interphase** of a cell cycle is the active phase responsible for a variety of events—increase in the total mass of a cell, increase in the nuclear and nucleolar mass, the duplication of chromatic material, the synthesis of RNA and proteins, and the conduction of routine cellular functions. Compared with the interphase, the mitotic phase of the cell cycle is a short, single-focus event.

Differentiation and mitotic potential. During the early stages of embryonic and fetal growth, most cells have a high potential for division as well as the potential to become a variety of cells. As development ensues, the **differentiation** of varied cellular populations becomes apparent. A consequence of this **specialization** (through differentiation) is the **reduction or loss of a cell's potentiality** and a **reduction or loss of its reproductive capacity (mitotic potential).**

Generally, highly specialized cells possess a low capacity for duplicating or an inability to duplicate themselves. Neurons (Fig. 4-20) and cardiac muscle cells (Fig. 13-23) are examples.

Specialized cell populations usually have specific cells associated with them from which other members of their populations differentiate. These are called **stem cells.** The basal cell population of the epidermis (stem cells) is an example of a residual cell population within a community of specific cells that retains the ability to replace cells lost from the skin surface. These stem cells are capable only of forming "epidermal" cells. Other examples will be discussed in subsequent sections.

The **mesenchymal cell** is similar to the aforementioned. It is a stem cell possessing both a high potentiality and a high reproductive capacity. It is an undifferentiated cell capable of specializing into a variety of cell types—muscle cells, bone cells, cartilage cells, blood cells, etc. It is scattered throughout the body in association with many cell populations, retaining this ability for mitosis and multiple expression. It may be apparent around small blood vessels in the **perivascular space.** The mesenchymal cell is a stellate or fusiform cell with scant cytoplasm and a large, vesicular nucleus. Its ultrastructural features conform to the relationships discussed regarding euchromatin, ribosomes, polyribosomes, and RER.

Some cells, such as hepatocytes, achieve a high degree of differentiation but still retain a high reproductive capacity after an injury.

In order to maintain the reproductive capacity described, dividing cells commit one daughter cell to the differentiation process and retain the other in an undifferentiated state for future division.

Divisional sequence. The continuum of the divisional process has been arbitrarily divided into five stages—**interphase, prophase, metaphase, anaphase,** and **telophase.** The last four stages actually comprise **mitosis.**

During **prophase** (Figs. 4-56 and 4-57) the chromatin undergoes a progressive condensation culminating with the chromosomes' becoming distinct entities in late prophase. As the nuclear

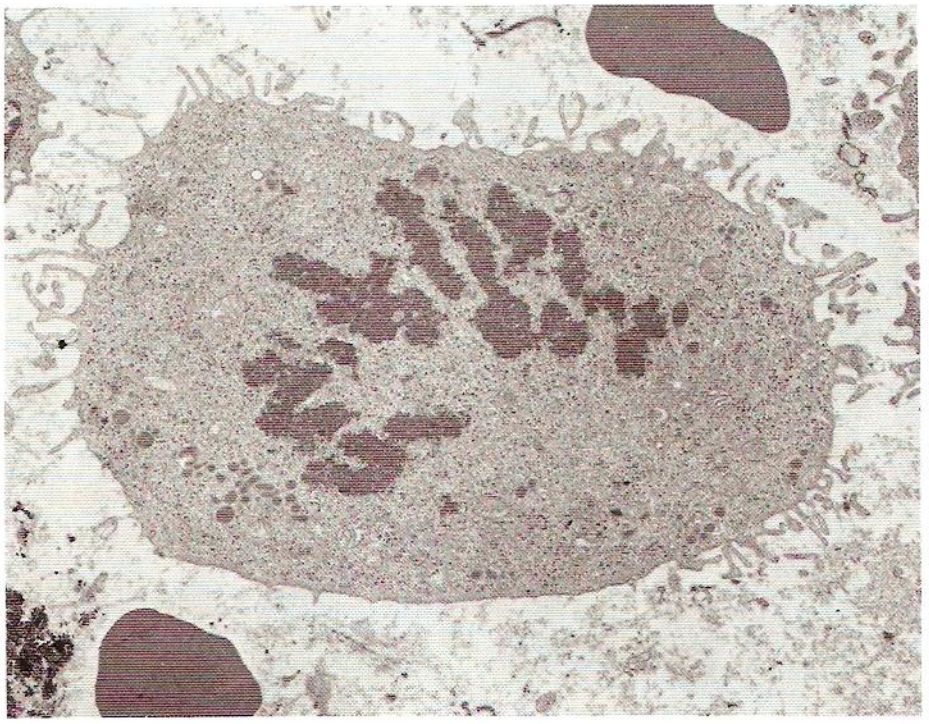

Figure 4-56. Electron micrograph of a dividing mesenchymal cell from the connective tissue space. The cell is in prophase. The chromosomes have condensed, and the nuclear membrane has disintegrated, but the spindle fibers have not yet formed. The mesenchymal cell has a high mitotic potential. (×2000.)

Downloaded From Vet-eBooks.com

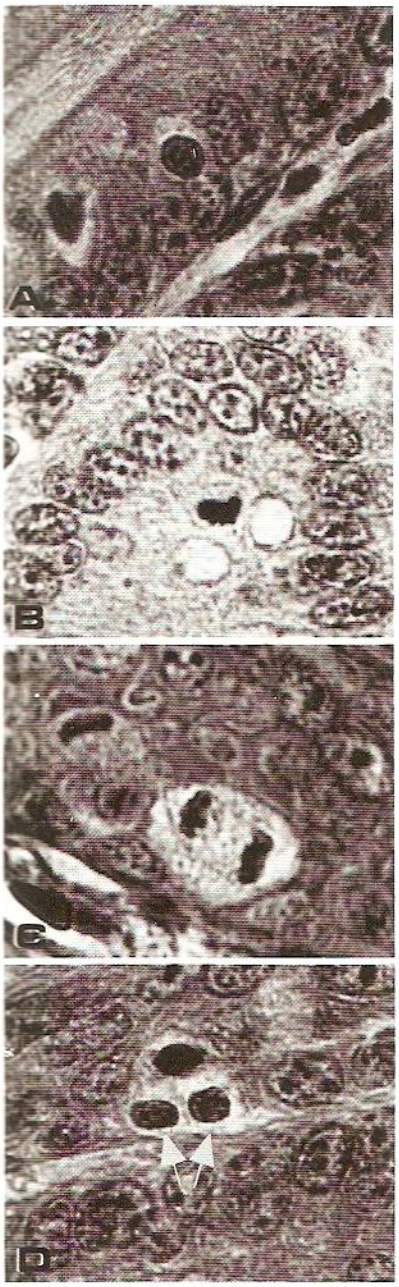

Figure 4-57. Mitosis in lining cells of an intestinal crypt. Prophase is initiated, **A,** and the chromosomes migrate to the equatorial plane during metaphase, **B.** During anaphase, **C,** the chromosomes move toward the poles. During telophase, **D,** daughter cells *(arrows)* are formed. The cell above the daughter cells has entered prophase.

membrane disintegrates in late prophase, the nucleolus disappears. The **centrosphere** divides in the cytoplasm, each part containing a pair of **centrioles.** The centrioles move toward opposite poles. **Spindle fibers,** composed of microtubules, are apparent between the migrating centrospheres.

During **metaphase** (Fig. 4-57) the chromosomes migrate toward and align themselves on the **equatorial plane** of the cell. Microtubules attach themselves to the **centromere;** each chromosome is composed of two **chromatids** attached at the centromere. The alignment is random; **homologous chromosomes** do **not** align themselves as pairs. This is an important distinction between **mitosis** and **meiosis.**

With the splitting of the two chromatids at the centromere, daughter chromosomes begin to migrate to the opposite cellular poles. These events mark the beginning of **anaphase** (Fig. 4-57). Thus anaphase is characterized by the beginning of **karyokinesis.**

The reconstitution of the nuclear membrane marks the start of **telophase** (Fig. 4-57). The chromosomes disperse while the nucleus enlarges. **Cytokinesis,** initiated peripheral to the equatorial plane, is completed and two identical daughter cells result.

ADDITIONAL READINGS

General

Albers B, et al: *Molecular biology of the cell,* ed 2, New York, 1989, Garland.

Bloom W, Fawcett DW: *A textbook of histology,* ed 9, Philadelphia, 1968, WB Saunders.

Brachet J, Mirsky AE: *The cell: biochemistry, physiology, and morphology* (6 vols), New York, 1959-1964, Academic Press.

Bresnick E, Schwartz A: *Functional dynamics of the cell,* New York, 1968, Academic Press.

DeRobertis EDP, Nowinski WW, Saez FA: *Cell biology,* ed 4, Philadelphia, 1965, WB Saunders.

DuPraw EJ: *Cell and molecular biology,* New York, 1968, Academic Press.

Fawcett DW: *Atlas of fine structure: the cell, its organelles and inclusions,* Philadelphia, 1967, WB Saunders.

Ham AW, Cormack DH: *Histology,* ed 8, Philadelphia, 1979, JB Lippincott.

Lentz TL: *Cell fine structure: an atlas of drawings of whole-cell structure,* Philadelphia, 1971, WB Saunders.

Matthews JL, Martin JH: *Atlas of human histology and ultrastructure,* Philadelphia, 1968, Lea & Febiger.

Porter KR, Bonneville MA: *Fine structure of cells and tissues,* ed 3, Philadelphia, 1968, Lea & Febiger.

Sandborn EB: *Cells and tissues by light and electron microscopy,* New York, 1970, Academic Press.

Nucleus

Bennett HS: Fine structure of cell nucleus, chromosomes, nucleoli, and membrane, *Rev Mod Phys* 31:297, 1959.

Dalton AJ, Haguenau F (eds): *Ultrastructure in biological systems. The nucleus,* vol 3, New York, 1968, Academic Press.

Monneron A, Bernard W: Fine structural organization of the interphase nucleus in some mammalian cells, *J Ultrastruct Res* 27:266, 1969.

Moses NJ: Studies on nuclei using correlated cytochemical, light and electron microscopic techniques, *J Biophys Biochem Cytol* 2:397, 1956.

Wischnitzer S: The submicroscopic morphology of the interphase nucleus, *Int Rev Cytol* 34:1, 1973.

Nuclear Envelope

Abelson HT, Smith GH: Nuclear pores: the pore-annulus relationship in thin sections, *J Ultrastruct Res* 30:558, 1970.

Barnes BG, Davis JM: The structure of nuclear pores in mammalian tissues, *J Ultrastruct Res* 3:131, 1959.

Fawcett DW, Chemes H: Changes in distribution of nuclear pores during differentiation of male germ cells, *Tiss Cell* 1:147, 1979.

Franke W: Isolated nuclear membranes, *J Cell Biol* 31:619, 1966.

Franke W, Kartenbeck J: Structure of nuclear membranes isolated from brain cells, *Experientia* 25:396, 1969.

Franke WW, et al: The nuclear envelope and the architecture of the nuclear periphery, *J Cell Biol* 91:39s, 1981.

Kessel RG: Fine structure of the pore-annulus complex in the nuclear envelope and the annulate lamellae of germ cells, *Z Zellforsch* 94:441, 1969.

Maul GC: On the octagonality of the nuclear pore complex, *J Cell Biol* 51:558, 1971.

Maul GC: The nuclear and cytoplasmic pore complex: structure, dynamics, distribution, and evolution, *Int Rev Cytol Suppl* 6:76, 1977.

Wiener J, Spiro D, Lowenstein WR: Ultrastructure and permeability of nuclear membranes, *J Cell Biol* 27:107, 1965.

Yoo BY, Bailey ST: The structure of pores in isolated pea nuclei, *J Ultrastuct Res* 18:651, 1967.

Chromatin

Barr ML: The significance of sex chromatin, *Int Rev Cytol* 19:35, 1966.

Bujard H: Electron microscopy of single stranded DNA, *J Molec Biol* 49:125, 1970.

Dales S: A study of the fine structure of mammalian somatic chromosomes, *Exp Cell Res* 19:577, 1960.

Osgood EE, et al: Electron micrographic studies of the expanded and uncoiled chromosomes from human leukocytes, *Ann NY Acad Sci* 113:717, 1963.

Priest JH, Shikes RH: Distribution of labeled chromatin, *J Cell Biol* 47:99, 1970.

Watson JD: *Molecular biology of the gene,* New York, 1965, WA Benjamin.

Nucleolus

Bernhard W, Granboulan N: Electron microscopy of the nucleolus in vertebrate cells. In Dalton AJ, Haguenau F (eds): *Ultrastructure in biologic systems: the nucleus, vol 3,* New York, 1968, Academic Press, p 81.

Vincent VS, Miller OJ Jr (eds): The nucleolus, its structure and function, *Natl Cancer Inst Monogr,* vol 23, 1965.

Cellular Membranes

Bolis L, Pethica BA: *Membrane models and the formation of biological membranes,* Amsterdam, 1968, North Holland Publishing.

Dalton AJ, Haguenau F (eds.): *Ultrastructure in biological systems: the membranes,* vol 4, New York, 1968, Academic Press.

Davson H: Growth of the concept of the paucimolecular membrane. *Circulation* 26:1022, 1962.

Finean JB: The molecular organization of cell membranes, *Progr Biophys* 16:143, 1966.

Hendler RW: Biological membrane ultrastructure, *Physiol Rev* 51:66, 1971.

Korn ED: Structure of biological membranes, *Science* 153:1492, 1966.

Robertson JD: The ultrastructure of cell membranes and their derivatives, *Biochem Soc Sympos* 16:3, 1959.

Rothman JE, Lenard J: Membrane asymmetry, *Science* 195:743, 1977.

Singer SJ, Nicolson GL: The fluid mosaic model of the structure of cell membranes, *Science* 175:720, 1972.

Sjostrand FS: A comparison of plasma membranes, cytomembranes and mitochondrial membrane elements with respect to ultrastructural features, *J Ultrastruct Res* 9:561, 1963.

Sjostrand FS: A new repeat structural element of mitochondrial and certain cytoplasmic membranes, *Nature* 199:1262, 1963.

Vanderkooi G, Green DE: New insights into biological membrane structure, *Bioscience* 21:409, 1971.

Ribosomes and Granular Endoplasmic Reticulum

Alfrey VG: Nuclear ribosomes, messenger RNA, and protein synthesis, *Exp Cell Res* 9:183, 1963.

Blobel G, Dobberstein B: Transfer of proteins across membranes. II. Reconstitution of functional rough

Downloaded From: Yes-Radio.com

microsomes from heterologous components, *J Cell Biol* 67:852, 1975.
Haguenau F: The ergastoplasm: its history, ultrastructure and biochemistry, *Int Rev Cytol* 7:425, 1958.
Kreibich G, Ulrich BL, Sabatini DD: Proteins of rough microsomal membranes related to ribosome binding. I. Identification of ribophorins I and II, membrane proteins characteristic of rough microsomes, *J Cell Biol* 77:64, 1978.
Palade GE: A small particulate component of the cytoplasm, *J Biophys Biochem Cytol* 1:59, 1955.
Palade GE: Intracellular aspects of the process of protein synthesis, *Science* 189:347, 1975.
Porter KR: Observations on a submicroscopic basophilic component of the cytoplasm, *J Exp Med* 97:727, 1953.
Rich A: Polyribosomes, *Sci Am* 209:44, 1963.
Siekevitz P, Zamecnik C: Ribosomes and protein synthesis, *J Cell Biol* 91:53s, 1981.
Spirin AS, Gavrilova LP: *The ribosome*, New York, 1969, Springer-Verlag.

Smooth Endoplasmic Reticulum

Cardell RR: Smooth endoplasmic reticulum in rat hepatocytes during glycogen deposition and depletion, *Int Rev Cytol* 48:221, 1977.
Christensen AK: Fine structure of testicular interstitial cells in the guinea pig, *J Cell Biol* 26:911, 1965.
Christensen AK, Fawcett DW: The fine structure of the interstitial cells of the mouse testis, *Am J Anat* 118:551, 1966.
DePierre JW, Dallner G: Structural aspects of the membrane of the endoplasmic reticulum, *Biochim Biophys Acta* 415:411, 1975.
Ito S: The endoplasmic reticulum of gastric parietal cells, *J Biophys Biochem Cytol* 11:333, 1961.
Remmer H, Merker HJ: Effects of drugs on the formation of smooth endoplasmic reticulum and drug metabolizing enzymes, *Ann NY Acad Sci* 123:79, 1965.

Golgi Complex

Beams HW, Kessel RG: The Golgi apparatus: structure and function, *Int Rev Cytol* 23:209, 1968.
Berlin JD: The localization of acid mucopolysaccharides in the Golgi complex of intestinal goblet cells, *J Cell Biol* 32:760, 1967.
Caro LG, Palade GE: Protein synthesis, storage, and discharge in the pancreatic exocrine cell. An autoradiographic study, *J Cell Biol* 20:473, 1964.
Farquhar MG, Palade G: The Golgi apparatus (complex)—(1954-1981)—from artifact to center stage, *J Cell Biol* 91:77s, 1981.
Hodge AJ, McLean SD, Mercer FV: A possible mechanism for the morphogenesis of lamellar systems in plant cells, *J Biophys Biochem Cytol* 2:597, 1956.
Jamieson JD, Palade GE: Intracellular transport of secretory proteins in the pancreatic exocrine cell. I. Role of the peripheral elements of the Golgi complex, *J Cell Biol* 34:597, 1967.
Neutra M, Leblond CP: Synthesis of the carbohydrate of mucus in the Golgi complex as shown by electron microscope radioautography of goblet cells from rats injected with glucose-H_3, *J Cell Biol* 30:119, 1966.
Neutra M, Leblond CP: The Golgi apparatus, *Sci Am* 220:100, 1969.

Mitochondria

Ashwell M, Work T: The biogenesis of mitochondria, *Ann Rev Biochem* 39:251, 1970.
Claude A, Fullom EF: Electron microscopic study of isolated mitochondria, *J Exp Med* 81:51, 1945.
Fernandez-Moran H, et al: A macromolecular repeating unit of mitochondrial structure and function, *J Cell Biol* 22:63, 1964.
Green DE, Young JH: Energy transduction in membrane systems, *Am Sci* 59:92, 1971.
Hackenbrock CR: Ultrastructural basis for metabolically linked mechanical activity in mitochondria. II. Reversible ultrastructural changes in metabolic steady state in isolated liver mitochondria, *J Cell Biol* 30:269, 1966.
Hackenbrock CR: Ultrastructural basis for metabolically linked mechanical activity in mitochondria. II. Electron transport-linked ultrastructural transformations in mitochondria. *J Cell Biol* 37:345, 1968.
Hall D, Palmer J: Mitochondrial research today, *Nature* 221:717, 1969.
Lehninger AL: *The mitochondrion*, New York, 1964, Benjamin.
Munn EA: *The structure of mitochondria*, New York, 1974, Academic Press.
Wagner P: Genetics and phenogenetics of mitochondria, *Science* 163:1026, 1969.
Weber NE, Blair PV: Ultrastructural studies of beef heart mitochondria. I. Effects of adenosine diphosphate on mitochondrial morphology, *Biochem Biophys Res Commun* 36:987, 1969.

Lysosomes

Bainton DF: The discovery of lysosomes, *J Cell Biol* 91:66s, 1981.
DeDuve C: Lysosomes, *Sci Am* 208:5, 1963.
Gahan PB: Histochemistry of lysosomes, *Int Rev Cytol* 21:1, 1967.
Gordon GB, Miller LR, Bensch KG: Studies on the intracellular digestive process in mammalian tissue culture cells, *J Cell Biol* 25:41, 1965.
Novikoff AB, Essner E, Quintana N: Golgi apparatus and lysosomes, *Fed Proc* 23:1010, 1964.

Centrioles and Basal Bodies

Randall J, Hopkins JM: Studies on cilia, basal bodies and some related organelles. II. Problems of genesis, *Proc Linnean Soc Lond* 174:37, 1963.
Szollosi D: Centrioles, centriolar satellites, and spindle fibers, *Anat Rec* 148:343, 1964.
Wolfe J: Basal body fine structure and chemistry, *Adv Cell Molec Biol* 2:151, 1972.
Yamada E: Some observations on the fine structure of the centriole in the mitotic cell, *Kurume Med J* 5:36, 1958.

Peroxisomes

Hruban Z, Rechcigl M Jr: Microbodies and related particles: morphology, biochemistry, and physiology, *Int Rev Cytol suppl I*, 1969.

Microtubules, Filaments, and Fibrils

Behnke O: Studies on isolated microtubules. Evidence for a clear space component, *Cytobiologie* 11:366, 1975.
Brody I: The ultrastructure of the tonofilaments in the keratinization process, *J Ultrastruct Res* 4:265, 1960.
Franke WW, et al: Different intermediate sized filaments distinguished by immunofluorescence microscopy, *Proc Natl Acad Sci* 75:5034, 1978.
Gibbons IR: Cilia and flagella of eukaryotes, *J Cell Biol* 91:107s, 1981.
Haimo LT, Rosenbaum JL: Cilia, flagella, and microtubules, *J Cell Biol* 91:125s, 1981.
Huxley HE: Electron microscopic studies in the structure of natural and synthetic protein filaments from striated muscle, *J Molec Biol* 7:281, 1963.
Inoue S, Stephens RE (eds): *Molecules and cell movement*, New York, 1975, Raven.
Lazarides E: Review article: Intermediate filaments as mechanical integrators of cellular space, *Nature* 283:249, 1980.
Ledbetter MC, Porter KR: Morphology of microtubules of plant cells, *Science* 144:872, 1964.
Sandborn E, et al: Cytoplasmic microtubules in mammalian cells, *J Ultrastruct Res* 11:123, 1964.
Slatterback DB: Cytoplasmic microtubules. I. Hydra, *J Cell Biol* 18:367, 1963.
Soifer D (ed): The biology of cytoplasmic microtubules, *Ann N Y Acad Sci* 253:1, 1975.
Wessels NK: How living cells change their shape, *Sci Am* 225:76, 1971.

Inclusions

Billingham RE, Silvers WK: The melanocytes of mammals, *Q Rev Biol* 35:1, 1960.
Bjorkerud S: The isolation of lipofuscin granules from bovine cardiac muscle, *J Ultrastruct Res* 5:5, 1963.
Napolitano L: The differentiation of white adipose cells. An electron microscope study, *J Cell Biol* 18:663, 1963.
Revel JP: Electron microscopy of glycogen, *J Histochem Cytochem* 12:104, 1964.

Cell Division

Baserga R: *The biology of cell reproduction*, Cambridge, Mass, 1985, Harvard University Press.
Flemming W: Contributions to the knowledge of the cell and its vital processes, *J Cell Biol* 25:3, 1965 (translation of the 1880 work).
Mazia D: How cells divide, *Sci Am* 105:101, 1961.
Mazia D: Fibrillar structure in mitotic apparatus. In Warren KB (ed): *Formation of cell organelles*, New York, 1967, Academic Press.
Rappaport R: Cytokinesis in animal cells, *Int Rev Cytol* 31:169, 1986.

Downloaded From: Yes-Books.com

SECTION III

HISTOLOGY

CHAPTER 5

Epithelia

GENERAL CHARACTERISTICS

Form. Epithelia are cell aggregates covering or lining the body and organ surfaces. They are composed of cells closely related structurally and/or functionally. They have little **intercellular substance** between them, and thus a **high cellular density.** Their close contacts and junctional complexes form effective barriers between the underlying connective tissue and their apical surface environment.

The free cell margin contacting the environment is called the **apical** or **luminal border.** The **basal border** contacts the connective tissue, and the **lateral surface** contacts adjacent cells. These cells have apical/basal modifications imparting a distinct and well-developed **cellular polarity,** reflected in the distribution of their constituent organelles.

Epithelia are separated from the underlying connective tissues by a **basement membrane.** Because epithelial tissues are avascular, they are dependent upon the underlying connective tissue for metabolic support.The apical, lateral, and basal borders of epithelial cells have many modifications.

Functional correlates. Epithelial cells are modified to serve many essential functions.

Protection from mechanical, microbial, desiccative, and ultraviolet radiational injury is achieved in various ways. The body is protected from these insults by its thickened and pigmented epithelial covering—the epidermis. The lining of the body tubes (digestive, respiratory, and genitourinary tracts) is subjected to mechanical injury, microbial invasion, and other insults. **Transport** of particulate matter along epithelial surfaces affords protection.

Secretion is an indispensable epithelial function. Waxy secretions of epithelial cells lubricate the covering epithelium and its associated structures—hairs or feathers. Epithelial cell secretions moisten and protect lining epithelia. Other cells secrete large quantities of a watery substance. During a 24-hour period, for example, the salivary glands of herbivores may secrete 10 to 15 gallons of this watery product. In some animals sweat formation serves as a **thermoregulator** by providing a mechanism for evaporative cooling. In the dairy cow specific epithelial cells of the udder form 50 to 100 pounds of milk per day. Some epithelial cells synthesize and secrete digestive enzyme precursors. These examples of secretion characterize cells elaborating their products onto a lining or covering epithelium—cells of the **exocrine glands** or **glands of external secretion.**

Absorption of materials occurs through the epithelial cells of the lungs, gastrointestinal tract, and renal tubules. Absorptive functions are highly selective and specific.

Sensory functions are served by epithelia in diverse ways.

1. The nervous system is derived from epithelial cells, specifically **neuroectodermal cells,** that lose their typical epithelial characteristics, acquiring new ones that suit them ideally for intercellular communication. Epithelial cells serving as sensory receptors are energy transducers.
2. Hormones are secreted by **endocrine cells** into the surrounding microenvironment; these cross endothelial cells and are transported to target cells via the blood.
3. Other epithelial cells, such as those lining the **vascular** and **lymphatic systems,** ensure that functional exchange occurs between the blood and lymphatic channels and the rest of the somatic cells. Similar cells lining the body cavities **(celomic spaces)** facilitate the movement of visceral organs over smooth, lubricated surfaces.
4. Specific epithelial cells reserved for perpetuation of the species (in the **gonads**) produce gametes.

Not all epithelial cells perform all these functions. Some perform many of these functions simultaneously. **The lining cells of epithelia form an effective barrier or interface that prevents both the free outward movement of vital tissue fluid components and the ingress of certain materials into the underlying fluid compartment.** Some epithelial cells are effective barriers; others permit leakage across the lining.

Origin of epithelia. During early development the embryo differentiates into three distinct germ layers—**ectoderm, mesoderm,** and **endoderm.** The outer covering (ectoderm) is separated from the inner lining (endoderm) by an intermediate packing layer (mesoderm). Most epithelia are derivatives of the ectoderm and endoderm; a few are derived from mesoderm.

Diverse epithelial structures originate from ectoderm. Most of them relate to the external surfaces. The endoderm differentiates into many epithelial derivatives lining the inner aspect of the developing organism. The mesoderm differentiates into tissues between these two layers (muscle, bone, cartilage, connective tissue).

The mesoderm also forms two kinds of epithelial cells. One population **(mesothelium)** lines the body cavities. **The name mesothelium means squamous cells derived from mesoderm lining the body cavities.** The other population **(endothelium)** lines the heart, arteries, veins, capillaries, and lymphatic vessels. **The term endothelium means squamous cells derived from mesoderm lining the vascular and lymphatic channels.**

Unique relationships. Epithelial tissues are avascular and depend upon the connective tissue for nutrients and waste removal. For those tissues "embedded within" the connective tissue this dependency is less obvious than in epithelia. Any separation of epithelia from the underlying connective tissue may have disastrous effects upon the integrity of this cell boundary.

The intimate relationship between epithelia and their underlying connective tissues requires a "glue" to hold them together, the **basement membrane.** This membrane, a consistent modification associated with the basal border of epithelial cells, varies in thickness but is usually visible by light microscopy. Although it is difficult to see with routine H&E, it can be demonstrated with silver stains and PAS.

The **glands of internal secretion (endocrine glands)** secondarily lose their attachment to a surface lining. One surface (usually basal) is still associated with the connective tissue. The other (usually apical) becomes associated intimately with the vasculature.

Classification. The classification and

Downloaded From Vet-eBooks.com

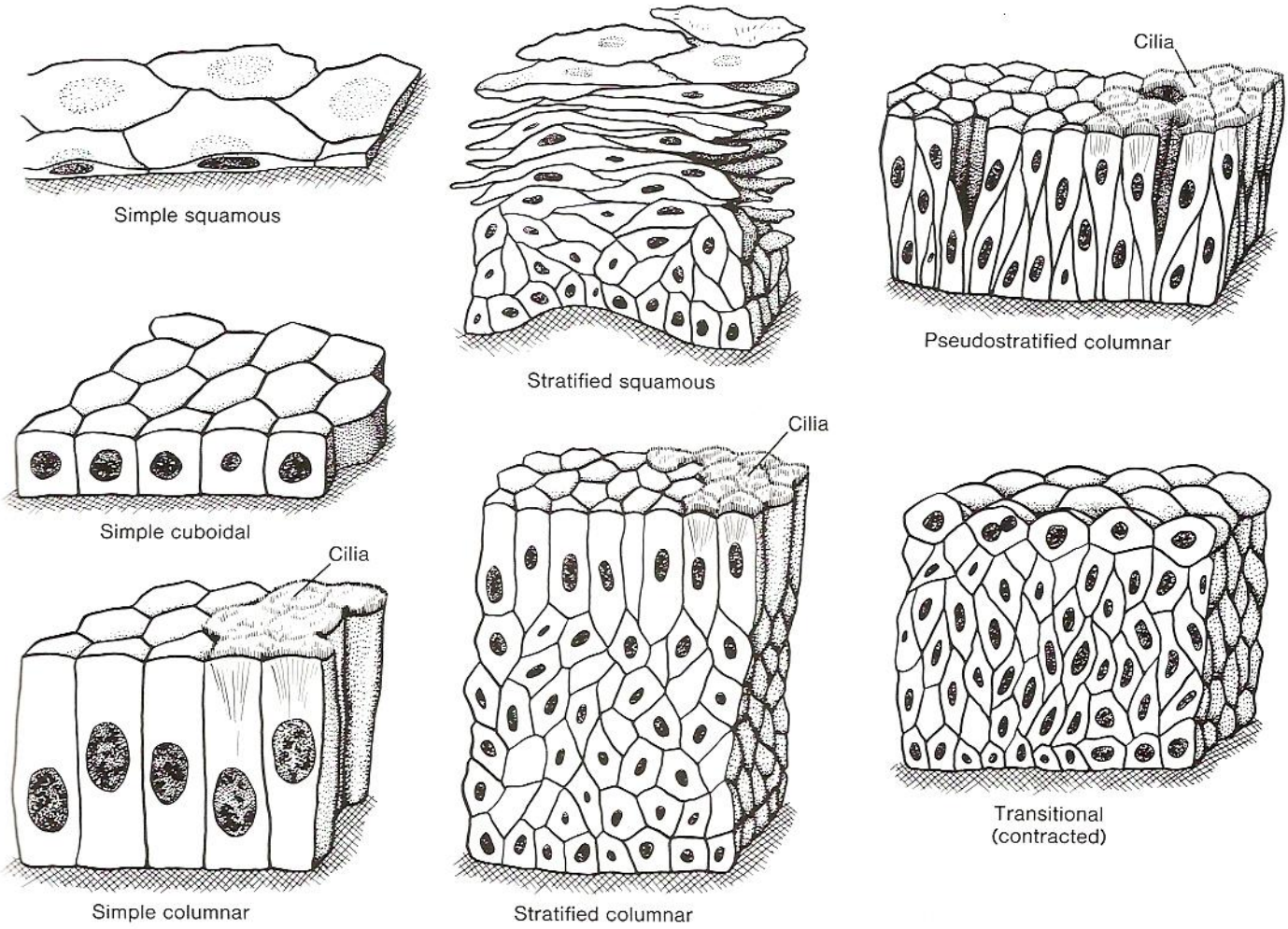

Figure 5-1. Types of epithelial tissue. Simple cuboidal, simple columnar, stratified columnar, and pseudostratified columnar epithelia may be ciliated.

naming of epithelial tissues are based upon the number of cells layered on each other and the predominant or surface cell shape (Fig. 5-1). An epithelial lining may be **simple** (one cell layer), **stratified** (more than one cell layer), **pseudostratified** (one cell layer appearing as more than one), or **transitional** (layers subject to change).

Simple epithelia are named after the predominant cell type—**squamous, cuboidal,** or **columnar.** Pseudostratified epithelia consist predominantly of columnar cells touching the basement membrane. The pseudostratified epithelia are simple linings. Stratified epithelia are named for the shape of the apical or luminal cell: **squamous, cuboidal,** or **columnar.** Transitional epithelium can vary the number of layers apparent.

SIMPLE EPITHELIA

Simple squamous epithelium. This tissue has thin cells, the cytoplasm of which is barely visible by light microscopy (Fig. 5-2). The nucleus often appears as a

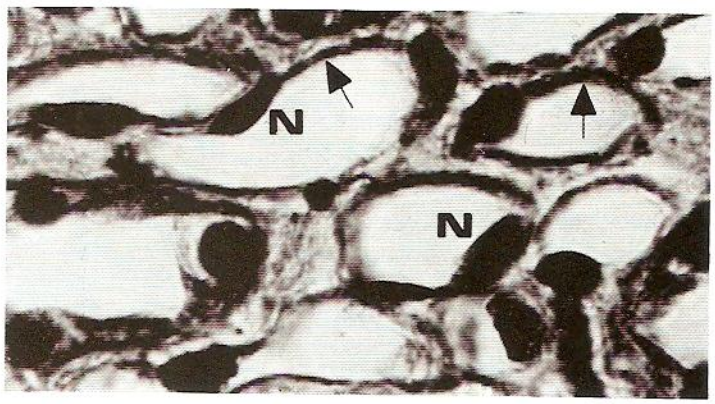

Figure 5-2. Simple squamous epithelial lining of a canine kidney tubule. The dark nuclei *(N)* are the obvious components of the cells. The cytoplasm, which is barely visible *(arrows),* appears as thin rims or processes. The lining cells are actually pancake-shaped, folded upon themselves and adjacent cells as tubules. (X160.)

Downloaded From Vet-eBooks.com

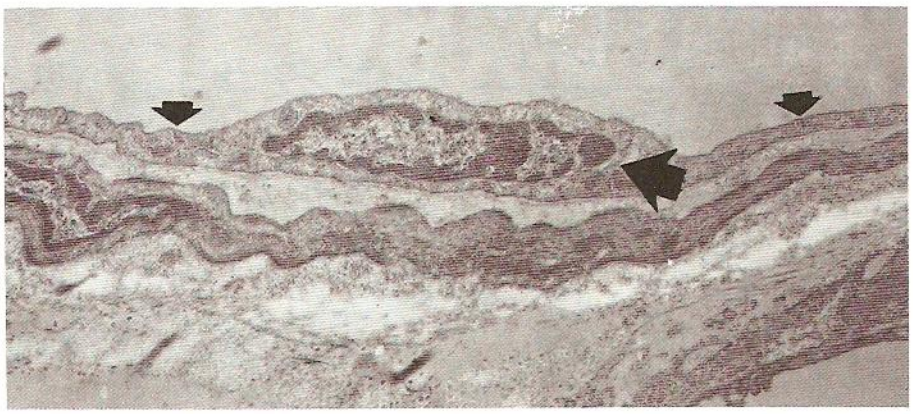

Figure 5-3. Electron micrograph of a simple squamous epithelial lining cell in a pulmonary alveolus. The nucleus *(large arrow)* protrudes into the lumen. The attenuated lateral projections of cytoplasm *(small arrows)* comprise the major lining component of the alveolus, through which gaseous exchange occurs. (X120,000.) (Courtesy G. P. Epling.)

Figure 5-4. Cuboidal epithelial lining of a collecting tubule from the equine kidney. Nuclei occur within a homogeneous cytoplasm. The cellular limits of some cells are apparent *(arrows)*. Although they appear as squares in histological sections, these cells are actually cubic structures when viewed three-dimensionally. (X320.)

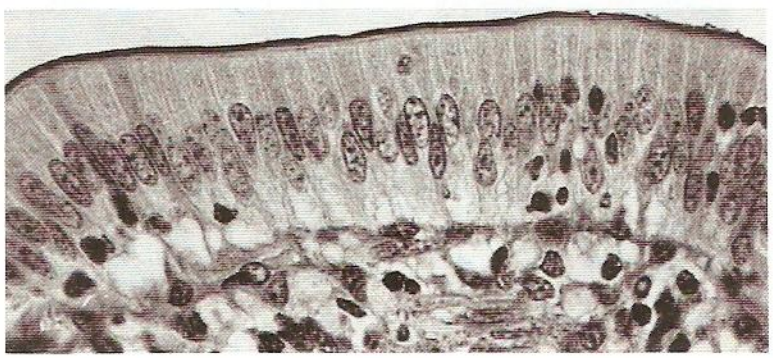

Figure 5-5. Columnar cells from the duodenum of a bird. Elongated and basally positioned nuclei accentuate the cellular polarity. The lining cells depicted are absorptive cells. (X320.) Compare with Figure 3-10.

prominent bulge at the free surface. The cytoplasm is expansive, and nuclei of adjacent cells are separated from each other by long cytoplasmic processes. In many instances the cytoplasm, though expansive, appears absent. Electron micrographs verify its presence and nature (Fig. 5-3). In surface views these cells are polygons, but they appear spindle-shaped when cut perpendicular to the free surface or basal border (Fig. 3-10, *A* and *B*).

The morphology of squamous cells is suited for the transport of materials across a reduced cytoplasmic mass (Figs. 5-51 and 5-52). The endothelial lining of blood vessels allows movement of fluids, crystalloids, and some colloids. Squamous epithelium of the lung, thin segments of the renal loop of Henle, and celomic space mesothelium permit the passage of fluids and or gases.

OCCURRENCE. Lining of celomic spaces (mesothelium); lining of the heart blood and lymphatic vessels (endothelium); functional lining of lung; small ducts of many glands; specific portions of renal tubules and Bowman's capsule; membranous labyrinth of the inner ear

Simple cuboidal epithelium. The cells of this tissue are cubes. They appear as squares in sections perpendicular to the apical border (Fig. 5-4). From surface views they may appear as squares or hexagons. Nuclei are located in a central or **paracentral** position. Lateral cell borders may or may not be distinct. This epithelium is associated generally with secretion and absorption.

OCCURRENCE. Secretory and ductal portions of many glands; certain tubules of the kidney; specific portions of the respiratory tree; surfaces of the lens and iris; surface epithelium of the ovary; specific tubules of the testis; pigmented epithelium of the retina (Plate III, *1*)

Simple columnar epithelium. These cells are taller than they are wide (Fig. 5-5). Their nuclei are elongated and generally displaced toward the basal border. A distinct cell polarity is obvious. Usually the nuclei are registered within a distinct row, but they may form two rows due to cell crowding.

These cells are associated typically with secretory processes. Most exocrine glands are composed of these cell types. Absorption is another function of columnar cells. Various apical border modifications suit them ideally for these functions.

OCCURRENCE. Lining of glandular stomach, small intestine and large intestine; middle portions of the respiratory tree; lining of the uterus and uterine tubes; lining of the secretory and conducting portions of many glands; lining of the cholecyst (Plate III, *2* to *4*)

Pseudostratified epithelium. All cells of this epithelium reside upon the basement membrane, but only the columnar cells reach the luminal surface. In section this epithelium, based on the number of

Downloaded From Vet-eBooks.com

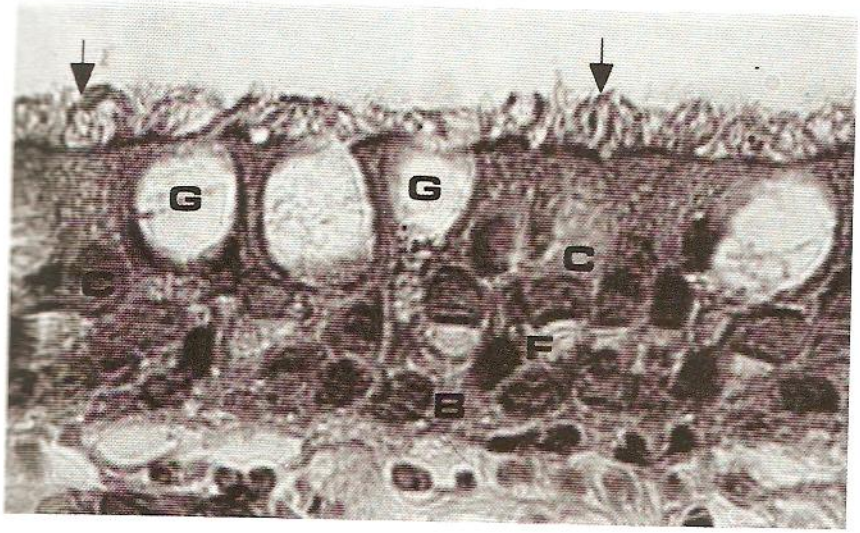

Figure 5-6. Pseudostratified ciliated columnar epithelial cells from an ovine trachea. All cells of this epithelial lining are in contact with the basement membrane, but not all of the cells reach the luminal surface. Compare with Figure 5-1. An apparent "stratification" is evident because of the arrangement of nuclei in the basal *(B)*, fusiform *(F)*, and columnar *(C)* cells. Cilia *(arrows)* occur along the luminal border. Goblet cells *(G)* are also present. (X320.)

nuclei per unit area, appears overcrowded with cells (Figs. 5-6 and 5-35). The basal and middle parts of the lining are congested with the nuclei of basal, fusiform, and columnar cells. **Goblet cells** may be present. **Cilia** occur frequently on the luminal surfaces of the columnar cells. This epithelium is termed a **pseudostratified columnar** or **pseudostratified ciliated columnar epithelium.**

It is a lining epithelium for some tubular organs in which its cilia expand their function to surface transport. Cilia provide protection by moving particulate matter while goblet cells supply a viscous protective layer. Particulate matter within this layer is moved by cilia toward the exterior by the **mucociliary apparatus.** (Surface transport within the uterine horns facilitates fertilization.)

Pseudostratified epithelium is an interface between simple and stratified epithelia, permitting gradual thickening of a lining. These relationships are usually apparent within an excretory duct of a gland opening upon a stratified or pseudostratified epithelial lining.

OCCURRENCE. Lining of upper respiratory tract (Plate III, 7); lining of specific regions of urogenital system; ducts of glands at points of transition between simple/stratified and simple/pseudostratified epithelia

STRATIFIED EPITHELIA

Stratified squamous epithelium. This epithelium has many cell layers of **keratinocytes** derived from a single basal layer. It is a thickened epithelium occurring at foci that require protection for the underlying tissues (Fig. 5-7). It may be thin with a few cell layers, or thick with many cell layers.

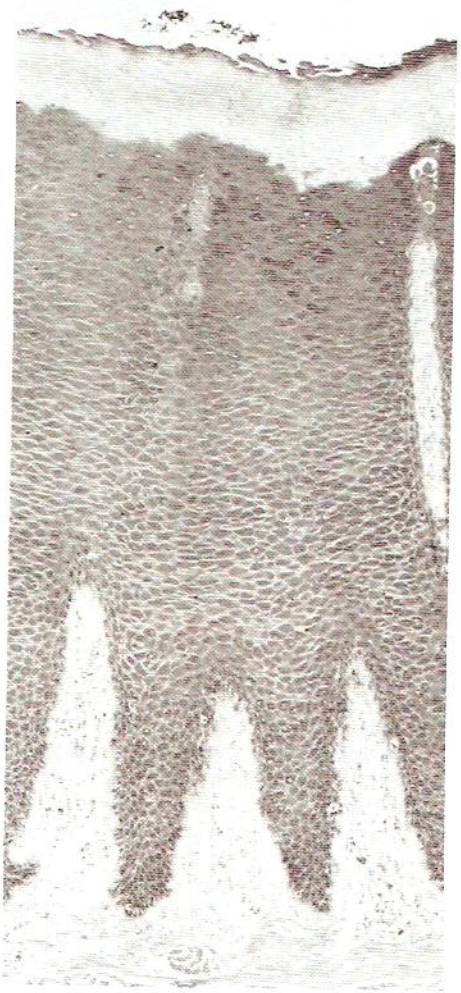

Figure 5-7. Stratified squamous epithelium of the canine muzzle. The epithelium, intimately associated with underlying connective tissue, is cornified *(light-staining material at the top of the field)*. (X25.)

The **basal layer (stratum basale)** has a single layer of pyramidal, cuboidal, or columnar cells (Fig. 5-8). It resides upon the basement membrane as a stem cell population.

The **stratum spinosum** has light-staining cells that flatten toward the surface. Cells shrunk by processing demonstrate intercellular spaces with many cellular processes (Fig. 5-9). These **spines** are processes of contiguous cells joined by **desmosomes**—which pattern is responsible for naming this layer the **spinous cell layer.** Spinous cells also contribute to the stem cell population of this tissue. **Mitoses within the basal and intermediate layers replace desquamated cells.**

The **stratum granulosum** may be several cell layers thick or absent. The granular spindle-shaped cells of this layer contain basophilic **keratohyalin** granules (Fig. 5-10). These are precursors to **keratin.** Degenerative changes in the cells, as evidenced by pyknotic nuclei, are also characteristic.

The **stratum lucidum** is not a typical feature of the epidermis of domestic animals. When present (canine digital pads, epidermis of the nose, perioplic epidermis, teat), the cells are flattened, pale-staining, or slightly acidophilic. This layer has dead or dying cells with indistinct or missing nuclei. Several layers of cells may be present.

The **stratum corneum** (Fig. 5-11) is well-developed with closely packed dead cells in regions typified by a high degree of **cornification** (canine digital pads, equine hoof). The remainder of the skin is less cornified, but this stratum is still present. Cells slough from this layer.

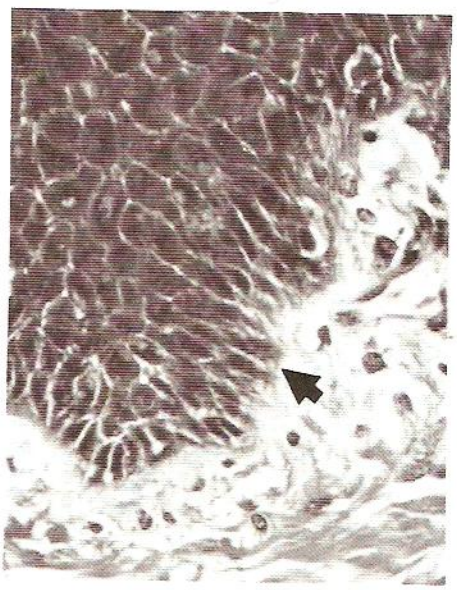

Figure 5-8. Stratified squamous epithelium of the canine muzzle. The stratum basale *(arrow)* is depicted. (X400.) Figures 5-9 to 5-12 were obtained from different regions of the same epithelial lining.

Downloaded From Vet-eBooks.com

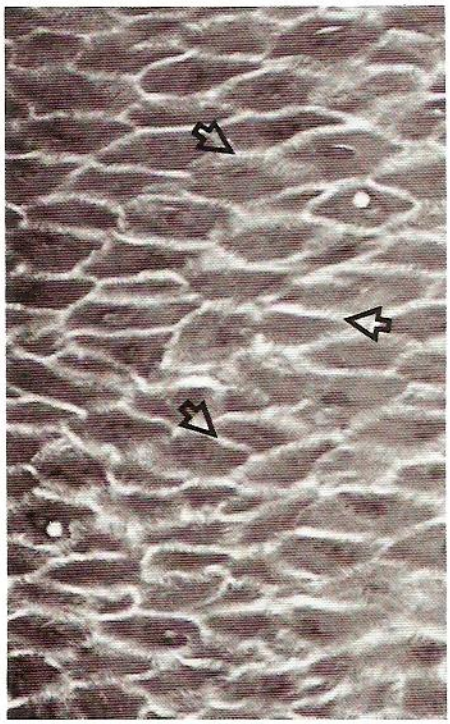

Figure 5-9. Stratified squamous epithelium of the canine muzzle. The stratum spinosum is depicted. Spinous processes *(arrows)* are apparent between contiguous cells. (X400.)

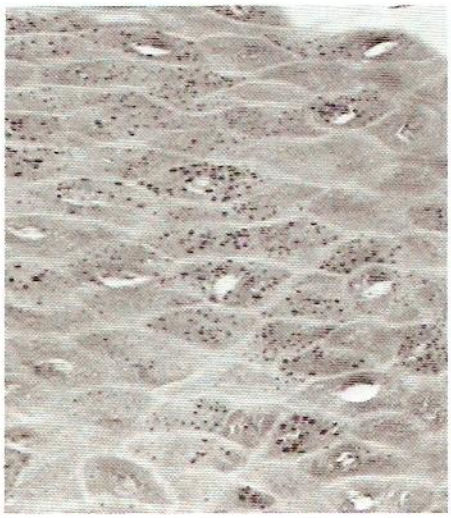

Figure 5-10. Stratified squamous epithelium of the canine muzzle. The stratum granulosum is depicted. This layer is the region of transition between the stratum spinosum and the stratum corneum. (X400.)

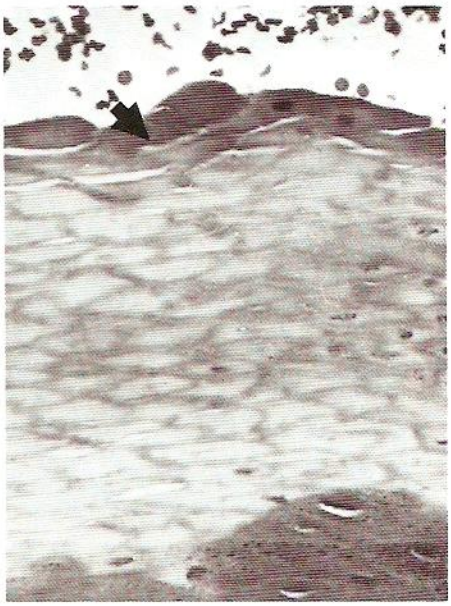

Figure 5-11. Stratified squamous epithelium of the canine muzzle. The stratum corneum comprises the majority of the micrograph. A portion of the stratum granulosum is visible *(bottom)* Cells are shed from this surface *(arrow)*. (X400.)

Less or no cornification occurs in the oral and aboral parts of the digestive tube and along its length (esophagus, nonglandular portions of the ruminant stomach). The degree of cornification depends upon the pressure and abrasion to which the epithelium is subjected.

Not all typical layers of this tissue are present at all locations (Fig. 5-12). The transition from basal layer to stratum corneum may occur without other layers being present. The stratum basale is the constant and distinct layer.

Stratified squamous epithelium is a thick tissue in most locations. The interface between its basal cell layer and the associated connective tissue is usually smooth but may be highly interdigitated. This latter relationship is what provides a large surface area for diffusion and adhesion.

The cornified layer protects against desiccative and mechanical damage. Even those epithelia that are not cornified, or are only minimally cornified, protect against mechanical damage. Ruminant dental pads assist mastication with minimal abrasive damage from foodstuffs. The upper digestive tract of ruminants is protected from roughened foodstuffs by this epithelium. The epithelium also serves an absorptive function in ruminants.

OCCURRENCE. Two categories:

cornified—general body surface; buccal cavity; anal region; ruminant forestomach (Plate III, *5*)

noncornified—vestibular region of respiratory system; oral, esophageal, and anal portions of digestive system; cornea of eye; conjunctiva; portions of the male and female urogenital systems (Plate III, *6*)

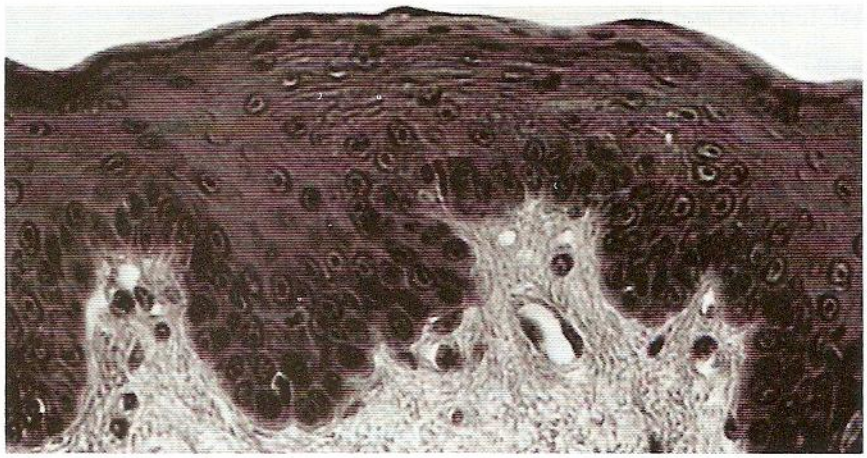

Figure 5-12. Noncornified stratified squamous epithelium from the feline buccal cavity. (X125.)

Stratified cuboidal epithelium. This epithelium has two cell layers (Fig. 5-13). The basal layer consists of polygonal cells serving as stem cells covered by a superficial layer of cuboidal cells. Stratified cuboidal epithelium has a limited occurrence, providing a gradual transition from one epithelial type to another.

OCCURRENCE. Specific portions of the genital system; ducts of various glands; zones of transition between simple and stratified or pseudostratified epithelia

Stratified columnar epithelium. This tissue may consist of two, three, or more layers of cells (Fig. 5-14). The basal and luminal cells may be separated from each other by intermediate cell types. The basal cells are cuboidal, the intermediate cells polygonal, and the apical cells columnar. This tissue is sometimes difficult to distinguish from pseudostratified epithelium.

Stratified cuboidal and columnar epithelia are presumed to serve only a lining function. Their interdigitation between the simple epithelia of glands and the stratified or pseudostratified epithelia of lining surfaces affords a gradual transition from one epithelial type to another.

Downloaded From LatestBooks.com

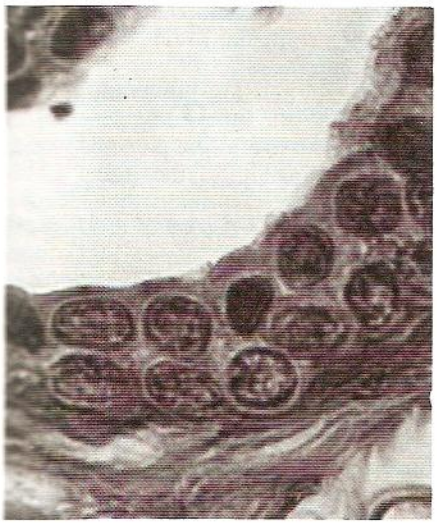

Figure 5-13. Bistratified cuboidal epithelium of a duct from a feline salivary gland. The occurrence of this tissue is limited generally to points of transition from simple to stratified epithelia and simple to pseudostratified epithelia. (X400.)

OCCURRENCE. **Zones of transition between columnar or pseudostratified and stratified epithelia; portions of the upper respiratory tract; ducts of some glands**

TRANSITIONAL EPITHELIUM

Transitional epithelium is actually a pseudostratified epithelium, although it appears stratified. All cells, including superficial ones, are anchored to the basement membrane by long, thick cytoplasmic processes. The tissue changes shape in response to pressure applied from the luminal surface. Because it is associated only with the urogenital system, it is sometimes called **urothelium.**

In the relaxed state, urothelium may be six or seven layers thick (Fig. 5-15), with the luminal cells cuboidal and their apical borders bulging into the lumen. During distention the thickness of the epithelium is reduced (Fig. 5-16), with as few as two or three layers remaining, and the tissue may be mistaken for stratified squamous epithelium.

The tissue accommodates to the stretching that results from an increased luminal volume. It thus prevents the movement of water from connective tissue spaces into the luminal space occupied by hypertonic urine.

OCCURRENCE. **Lining of regions of the urinary tract**

GLANDULAR EPITHELIA

General features and classification. Single cells and populations of cells secrete many products. Surface linings accomplish diverse secretory functions. Various mechanisms are used to accomplish these activities. The relationship of glands to surrounding tissues is also varied. Glands may be classified according to (1) their number of cells, (2) the relationship of glandular to lining and surrounding tissues, (3) the pattern of multicellular glands, and (4) the method of secretion and type of secretory product.

Number of cells in a gland. Glands are either unicellular or multicellular.

Unicellular glands are specialized cells scattered throughout an epithelial lining. The most common unicellular gland is the goblet cell (Fig. 5-6)—found in the respiratory, digestive, and urinary tracts (Plate III, *3* and *4*).

Until active, the goblet cell cannot be distinguished from other columnar cells. When activity begins, droplets appear in the cytoplasm. These accumulate until the entire apical and middle parts of the cell are filled and swollen with **premucin** (Fig. 5-17). The droplets impart a foamy and basophilic appearance to the cytoplasm. The remainder of the cytoplasm and nucleus is displaced to the narrow basal region of the cell.

Expulsion of the mucoid substances may be explosive or gradual. If explosive, the cell returns to a columnar shape and the process begins again. If gradual, the continuing process does not alter the shape of the cell.

Multicellular glands are diverse secretory units. Entire sheets of epithelia may perform a secretory function, as in the lining of the glandular stomach.

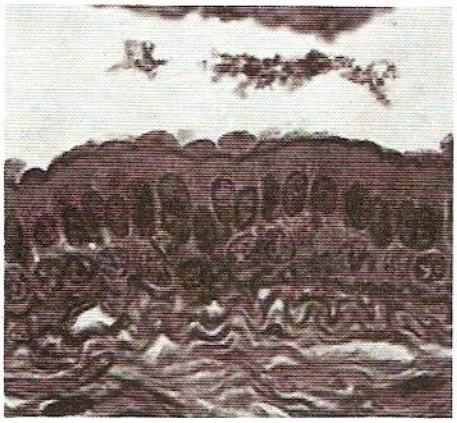

Figure 5-14. Bistratified columnar epithelium of a duct from a feline salivary gland. The function and distribution of this tissue are similar to those of bistratified cuboidal epithelium. (X400.)

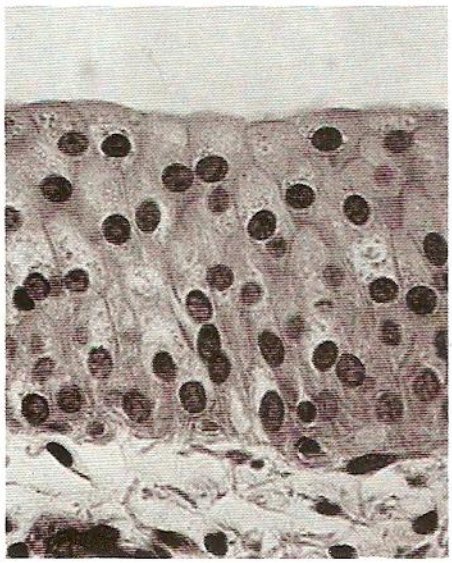

Figure 5-15. Transitional epithelium of the bovine bladder. The thickness of the tissue, as evidenced by the number of "nuclear layers," indicates the tissue is relaxed or contracted. (X160.) Compare with Figures 5-1 and 5-16.

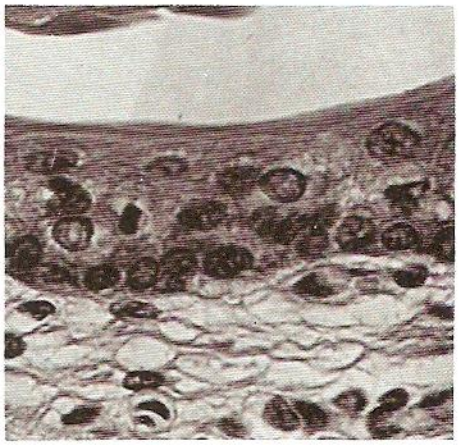

Figure 5-16. Transitional epithelium of the canine bladder. The reduced thickness of the tissue, as indicated by the reduced number of nuclear layers, indicates that the tissue is distended or stretched. Compare with Figures 5-1 and 5-15. (X160.)

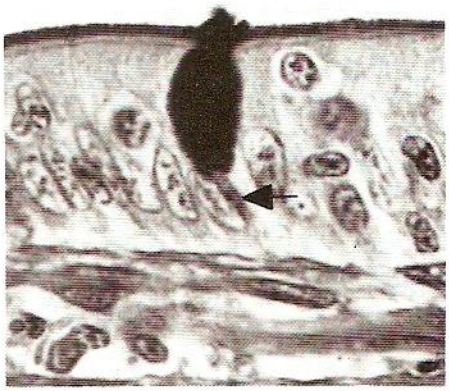

Figure 5-17. A goblet cell within the lining epithelium of the feline jejunum. The bulk of the goblet cell *(dark oval mass)* contains premucin droplets. The nucleus *(arrow)* is displaced basally. Note the extrusion of the secretory product upon the apical border of the cells. Compare with Figure 5-6. (X250, Alcian blue and PAS.)

Downloaded From Vet-eBooks.com

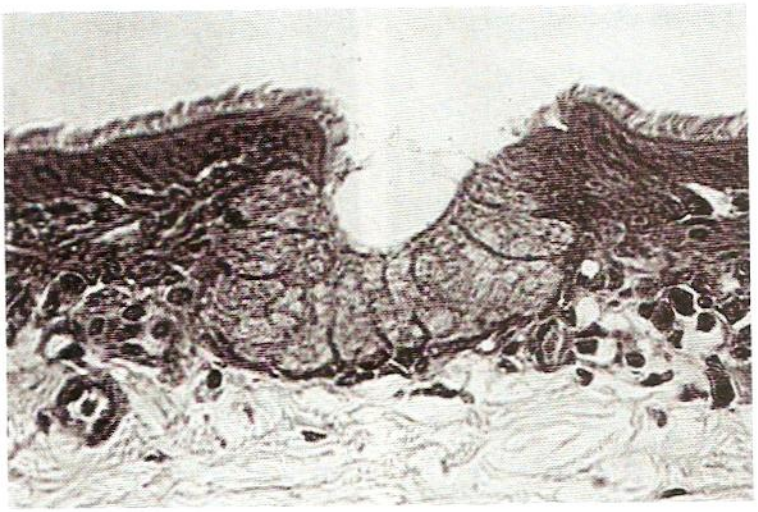

Figure 5-18. Intraepithelial gland from the avian respiratory mucosa. (X200.)

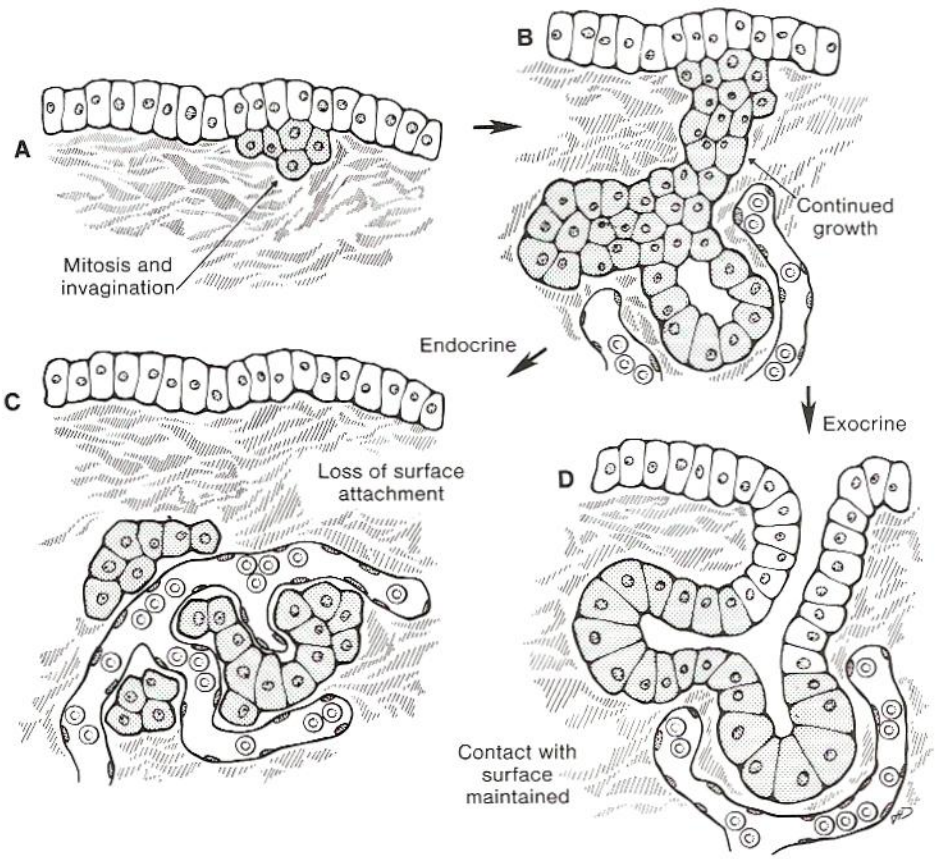

Figure 5-19. Exocrine and endocrine gland development. Lining cell mitotic activity causes an invagination of the epithelium (and accompanying basement membrane) into the space occupied by the connective tissue, **A.** Continued mitotic activity and growth establish a mass of cells, **B,** outside the plane of the lining epithelium "within the connective tissue space." The mass of cells is attached to the surface lining epithelium (and is surrounded by a basement membrane). Subsequent disintegration of the surface attachment isolates the cord or clumps of epithelial cells within the connective tissue space as endocrine cells in close association with capillaries, **C.** The persistent attachment of lining and glandular cells to each other and the formation of a lumen establish an exocrine gland, **D.**

Intraepithelial glands, which are rare, are accumulations of secretory cells within an epithelial lining (Fig. 5-18). They occur in the lining of the upper respiratory and male genital systems.

Great diversity of form and function occurs in multicellular glands residing outside the epithelial lining. (**Outside,** in this context, means that the glandular tissues, though continuous with the lining epithelium, are not in the same plane as the lining epithelium.) These glands occur commonly.

Their true relationship to the lining is obscured by the morphological complexity they assume and the plane of section. Their relationship to the lining is best understood by examining their development (Fig. 5-19). A cord of dividing cells invaginates into the underlying connective tissue space. These cells do **not** actually invade the space but are separated from it by the basement membrane. A tube develops within the cord while the remaining cells proliferate and differentiate into secretory cells, forming an **adenomere.** The tube connecting the adenomere to the epithelial surface is the basis for gland classification.

Relationship to lining and surrounding tissues. A persistent duct between the surface and the adenomere makes the gland an **exocrine** gland. The growth of the adenomeres and associated ducts is not limited to the example cited. Very elaborate duct and secretory shapes may develop. Whether a simple or complex arrangement, all exocrine glands secrete

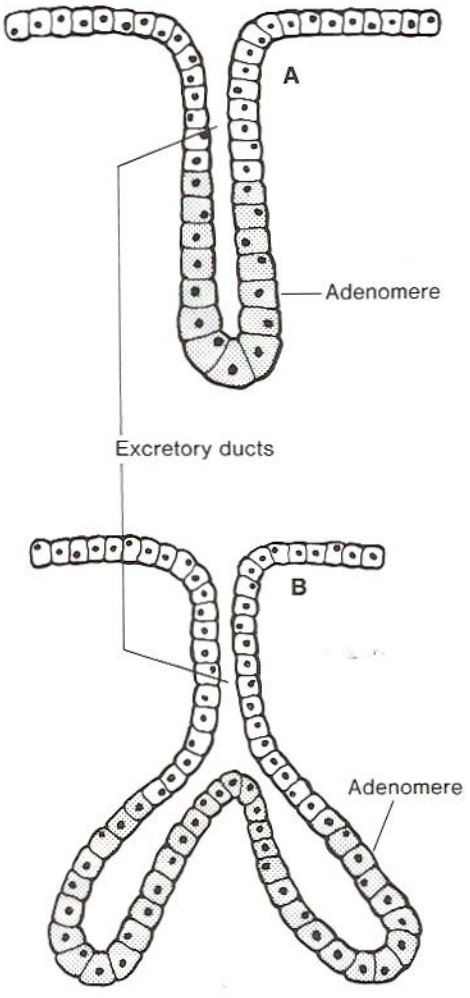

Figure 5-20. Tubular glands. The adenomeres may be straight, **A,** or branched, **B.**

into a system of ducts eventually opening at an epithelial surface.

Endocrine glands lose their connection to an epithelial surface (Fig. 5-19), and the adenomeres do not assume tubular shapes. The secretory cells arrange themselves in cords or clumps and deposit their **hormones** into the vascular beds within the adjacent connective tissue space.

Organization of multicellular glands. Multicellular glands assume various shapes in extraepithelial positions. In a single section of these glands, the three-dimensional relationships can only be implied. The following classification is based on serial sections and three-dimensional reconstructions of them.

Multicellular exocrine glands are **simple** or **compound.** The **secretory end pieces (adenomeres)** may be **tubular** (a hollow cylinder), **alveolar** or **acinar** (globular or pear-shaped), or **tubuloalveolar** (combination of both) (Fig. 5-20).

In a **simple gland** the adenomere secretes into an unbranched duct. The adenomeres may be **straight** (intestinal glands) (Fig. 5-20), **coiled** (sweat glands) (Fig. 5-21), or **alveolar.** The adenomeres may branch and still secrete into a single duct system. In this instance, they are called **branched tubular** glands (intestinal submucosal glands) (Fig. 5-22) or **branched alveolar** glands (sebaceous glands) (Fig. 5-23).

Figure 5-21. Coiled, tubular sweat glands from ovine skin. The coiled nature of the gland is responsible for the discontinuities between glandular components apparent in section *(small arrows)*. The excretory duct *(large arrow)* eventually connects the adenomere to the surface. (X9.)

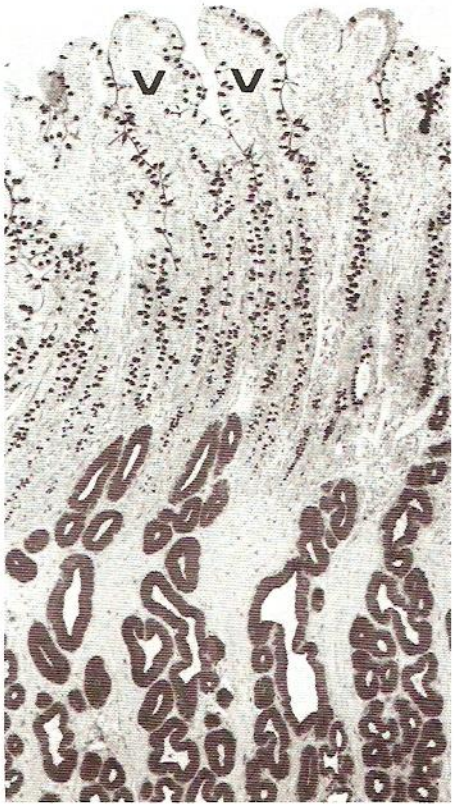

Figure 5-22. Submucosal glands of a canine duodenum. The branched tubular glands, *dark-staining,* are continuous to the surface *(top)* through the intestinal crypts. *V* denotes villi. (X16, Alcian blue and PAS.)

Many subdivisions of the duct system and adenomeres occur in **compound** glands (Fig. 5-24). They may be **compound tubular** glands (salivary glands), **compound acinar** glands (pancreas), or **compound tubuloalveolar** glands (salivary and mammary glands).

The naming of ductal subdivisions is based on the organizational pattern (Fig. 5-25). The large **excretory duct** connects to the surface upon which the gland empties its secretion. Most glands are subdivided into smaller units called lobes. **Lobar ducts** drain the secretory products of lobes and connect to the excretory duct. The large continuations of the lobar ducts within a lobe are called **intralobar ducts.** Smaller units of lobes are called lobules. Lobules are drained by **lobular ducts.** The continuation of the lobular duct within a lobule is called the **intralobular duct.** This duct continues with the secretory portion of the gland. A similar organizational scheme applies to many glandular organs.

Method of secretion. Three secretory methods occur.

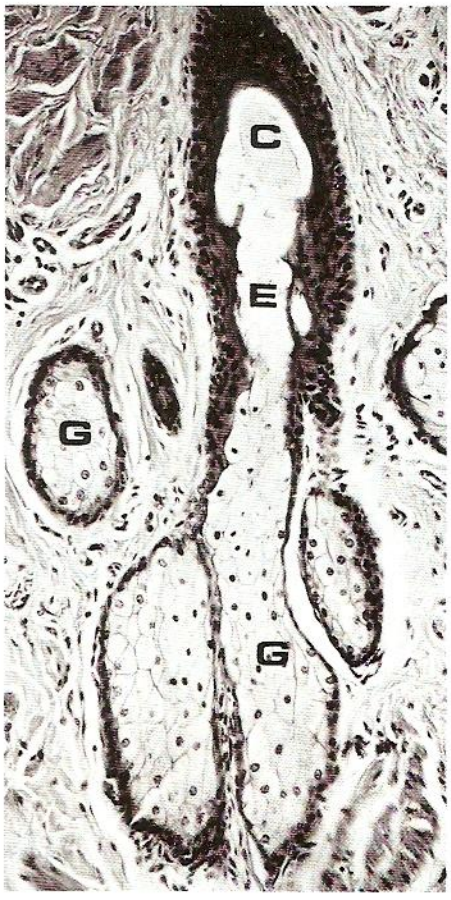

Figure 5-23. Alveolar gland from ovine skin. Sebaceous glands *(G)* are branched, alveolar glands. The glands are connected to the root canal *(C)* of a hair follicle through an excretory duct *(E).* (X40.)

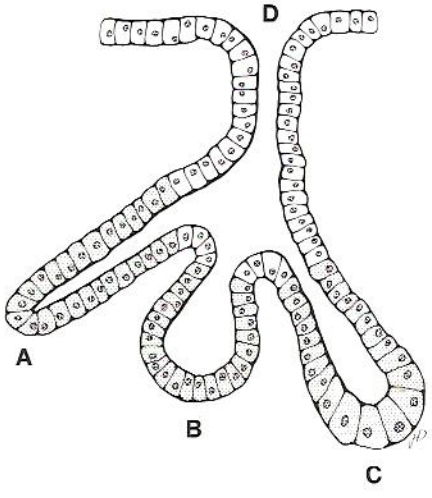

Figure 5-24. Configurations of the adenomeres of compound glands. Tubular *(A),* acinar or alveolar *(B),* or tubuloalveolar *(C)* adenomeres open into a branched duct system *(D).*

In the **merocrine** method, the cell only contributes the actual product produced. The membrane of the secretory droplet fuses with the plasma membrane; this fusion opens the product to the extracellular space (Figs. 4-48, 4-49, and 5-26).

Downloaded From Vet-Books.com

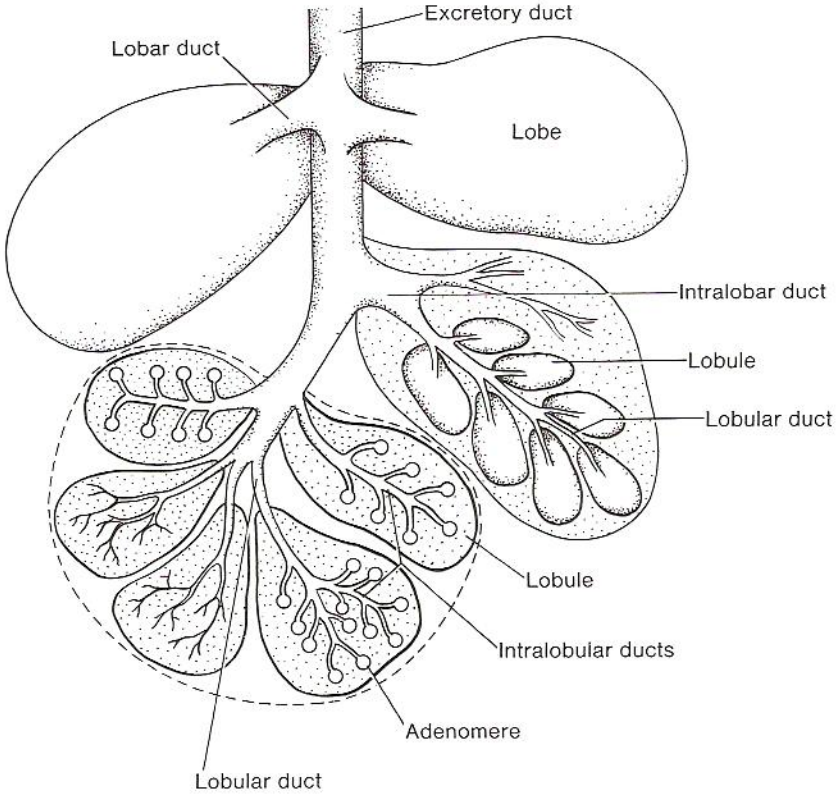

Figure 5-25. Subdivisions of a compound gland. One lobe *(dashed line)* is enlarged to show the intralobular relationships. The flow of secretory product is from adenomere to intralobular duct to lobular duct to intralobar duct to lobar duct to excretory duct to surface. This pattern (or a slight modification of it) typifies many organs (lungs, pancreas, kidneys) besides those described as typically glandular.

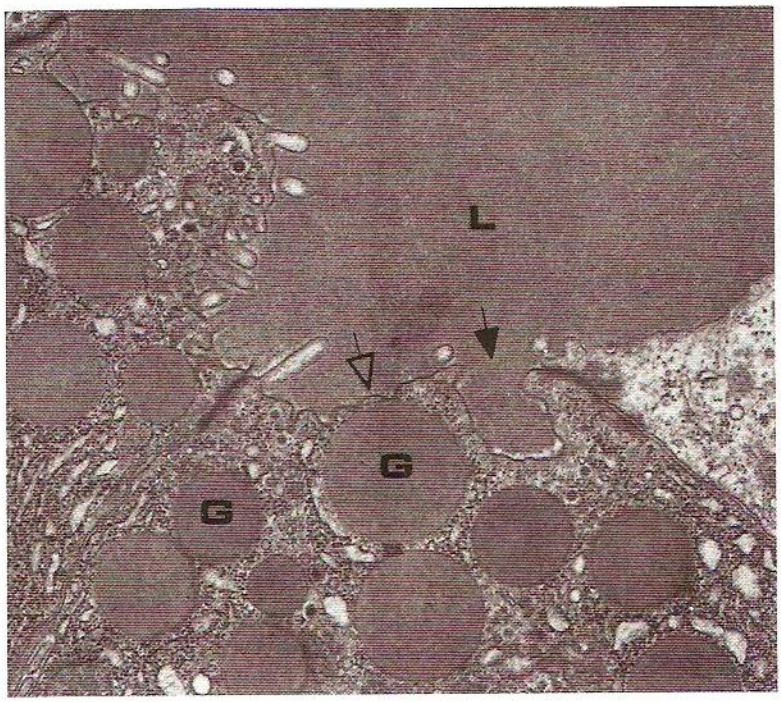

Figure 5-26. Electron micrograph of the luminal border of pancreatic acinar cells. The lumen *(L)* is filled with secretory material from the zymogen granules *(G)* emptying their contents onto the apical surface via exocytosis. One granule *(solid arrow)* may have fused with the cell membrane while another *(open arrow)* is about to fuse with the cell membrane. (X22,000.)

This exocytotic method is typical of most glands (Fig. 5-26).

In the **apocrine** method the product and some apical cytoplasm are secreted. Blebs along the apical surface are present during this exocytotic process (Fig. 5-27). The method is typical of most sweat glands in domestic species, some human sweat glands, and some mammary gland products (Plate III, *8*).

In the **holocrine** method the entire cell becomes the secretory product. Because cells are shed continually by this method, glandular function would cease if cellular replacement did not occur. The continued function of holocrine glands is assured by a supply of stem cells.

In sebaceous glands, which secrete by the holocrine method, stem cells are located at the alveolar periphery along the basement membrane (Fig. 5-28). Mitotic activity of these cells forces them toward the lumen, and they begin to accumulate lipids. They then undergo necrobiosis and become the secretory product (Plate III, *9*).

In the gonads and hematopoietic organs also, cells are elaborated that become the "secretory products" of these glands (Fig. 5-29).

Serous and mucous units. Two types of secretory cells occur. Although not all secretory cells can be included in this scheme, is applicable to digestive, respiratory, and reproductive glands.

The **serous cell** is a wedge-shaped or pear-shaped cell usually possessing a finely granular, acidophilic cytoplasm (Fig. 5-30). The rounded nucleus is central or paracentral in position. The lateral margins of the cell are usually indistinct. Serous cells secrete a clear, watery fluid containing enzymes

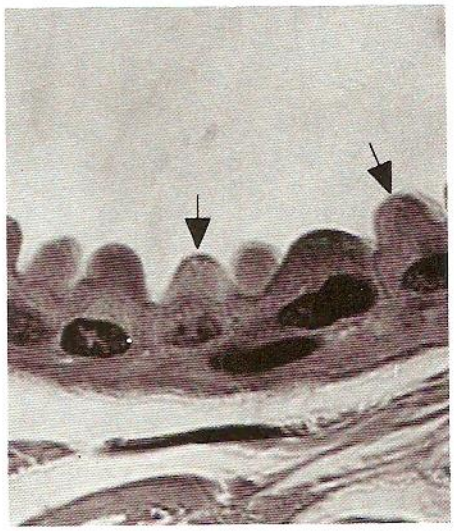

Figure 5-27. Apocrine tubular sweat glands of ovine skin. The apical blebs *(arrows)* indicate the apocrine method of secretion. (X500.)

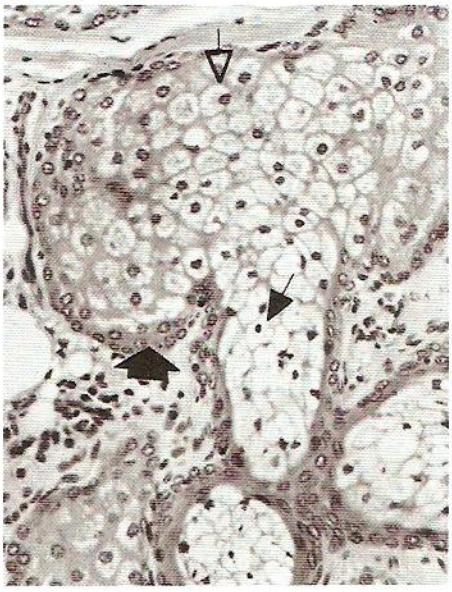

Figure 5-28. Sebaceous glands of an ovine orbital sinus. The cells located at the periphery of the adenomere *(large solid arrow)* are stem cells. They divide, and one of the daughter cells moves toward the lumen; the other remains at the base of the adenomere as another stem cell. As the cells move toward the lumen, they undergo degenerative changes characterized by lipid accumulation *(open arrow)* and pyknotic nuclei *(small solid arrow)*. The cells die and become the secretory product. The retention of one of the daughter cells as a future stem cell ensures continued activity of the gland. (X50.)

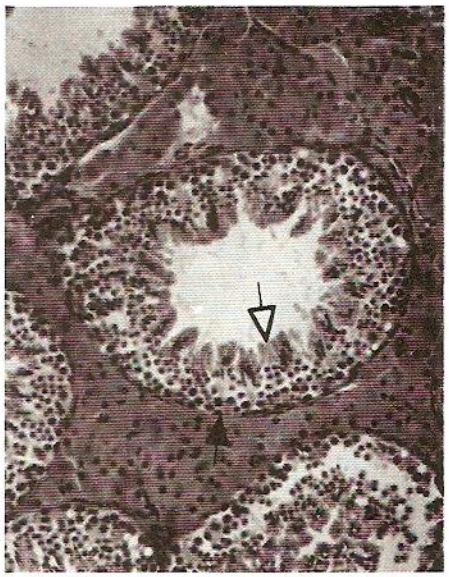

Figure 5-29. Seminiferous tubules of a porcine testis. Developing spermatozoa *(open arrow)* line the luminal surface of the seminiferous tubules. The developing germ cells constitute the "secretory product" of the tubules, whose stem cells are located at the periphery. (X40.)

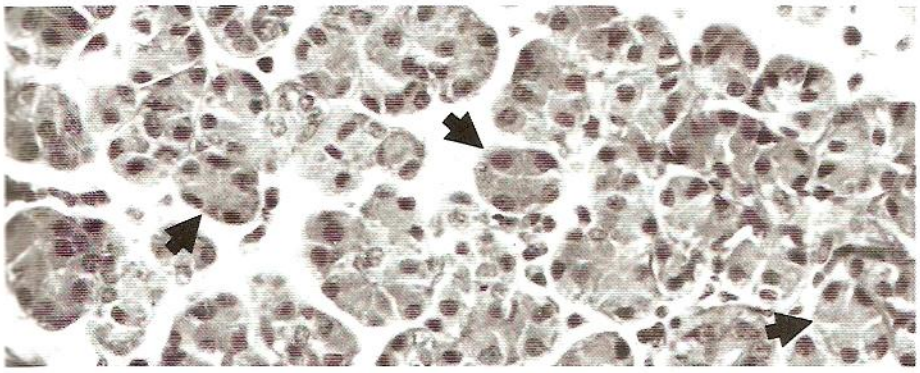

Figure 5-30. Serous cells of an adenomere from a salivary gland. The serous cells *(arrows)* are pyramidal cells with round, paracentrally positioned nuclei. The dark cytoplasm is granular and acidophilic. (X160.)

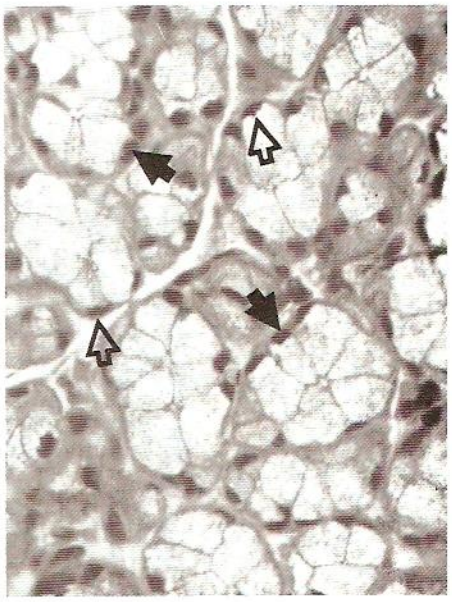

Figure 5-31. Mucous adenomeres from a salivary gland. The mucous adenomere *(solid arrows)* consists of mucous cells that are pyramidal. The cytoplasm of these cells is foamy, and the flattened nuclei *(open arrows)* are positioned basally. Note that some of the cells appear to be devoid of nuclei. (X100, glycol methacrylate 2 μm section.)

The **mucous cell** is a pear-shaped cell with a foamy and basophilic cytoplasm (Fig. 5-31). A marked polarity is apparent; the hyperchromatic, flattened nucleus is basal. Mucous cells produce a viscous fluid rich in glycoproteins.

Mixed glands may have both serous and mucous cells in various arrangements (Plate III, *11*, and Fig. 5-32). An entire gland may possess separate serous and mucous adenomeres (Fig. 5-33). Serous and mucous cells may be mingled with each other and discharge their products at the luminal surface (Fig. 5-34). **Serous demilunes** may be attached to a mucous adenomere (Fig. 5-32). In this instance small canals **(secretory canaliculi)** connect the serous cells with the luminal surface.

SPECIAL EPITHELIA

Epithelial tissues perform specialized functions at certain loci. Among these tissues are **ciliated epithelium, sensory epithelium, pigment epithelium,** and **myoepithelium.**

Ciliated epithelia have kinocilia and stereocilia. The **kinocilia** are usually associated with cells of pseudostratified columnar or simple columnar epithelia. Isolated cells or most cells within the epithelial layer may be ciliated. The **stereocilia** increase surface area for secretion (Fig. 5-35).

Some epithelial cells are modified to receive and transmit **sensory** information. These cells occur in organs receiving optic, olfactory, gustatory, auditory, and kinesthetic sensations. A **neurosensory epithelial cell** is a nerve cell modified as a receptor and transmitter of information. The cells receive, transduce, and transmit the information along their axons. Pho-

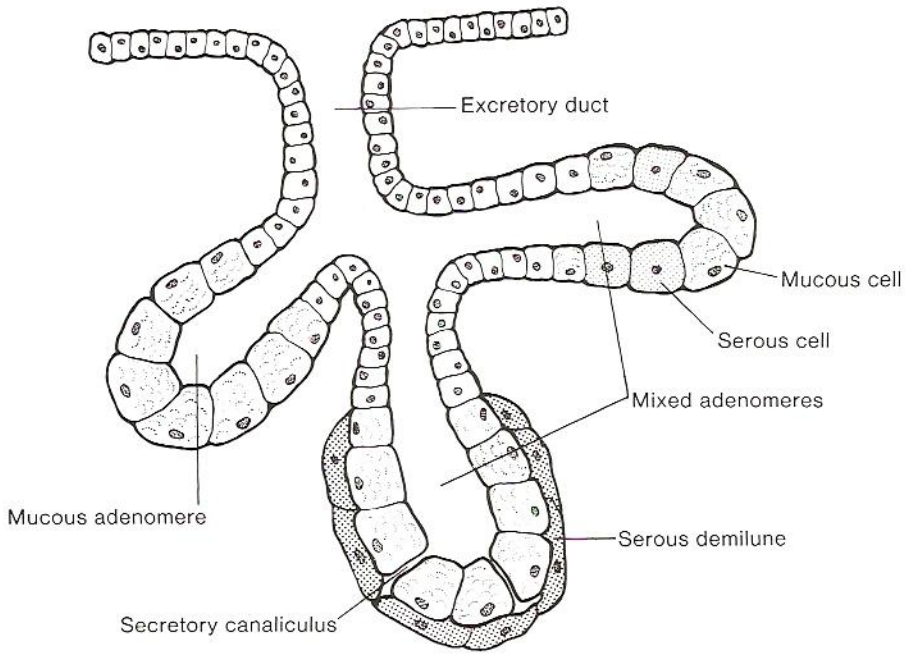

Figure 5-32. Adenomeres of a salivary gland. Salivary glands may be serous, mucous, or mixed (seromucous). The adenomeres therefore also must be serous, mucous, or mixed. Mixed glands achieve their condition in various ways. They may consist of separate serous and mucous adenomeres; mucous adenomeres may have serous demilunes associated with them; or serous and mucous cells may be intermingled within a single adenomere.

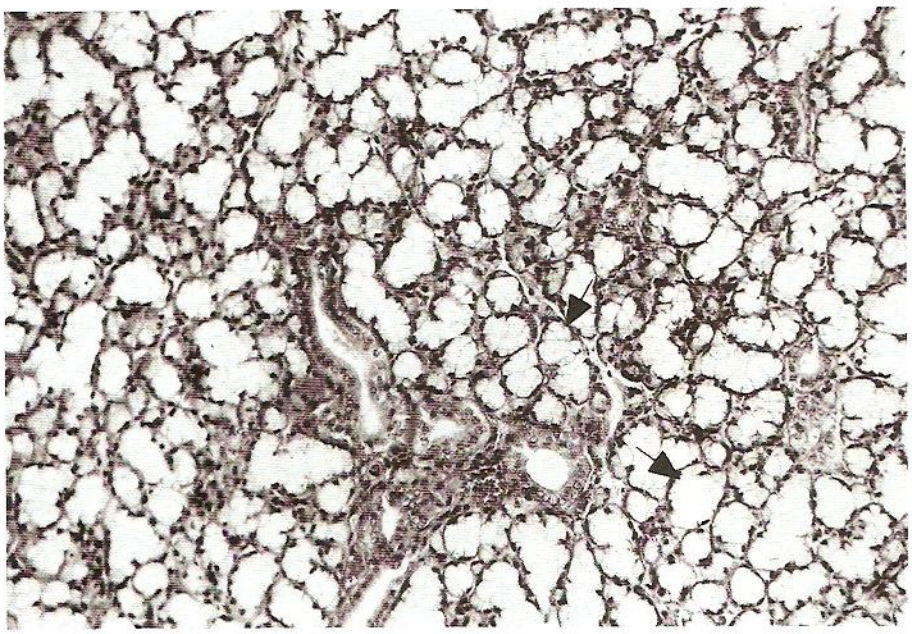

Figure 5-33. Canine salivary gland. The mucous adenomeres *(arrows)* comprise the bulk of the gland. (X40.)

Downloaded From Vet-eBooks.com

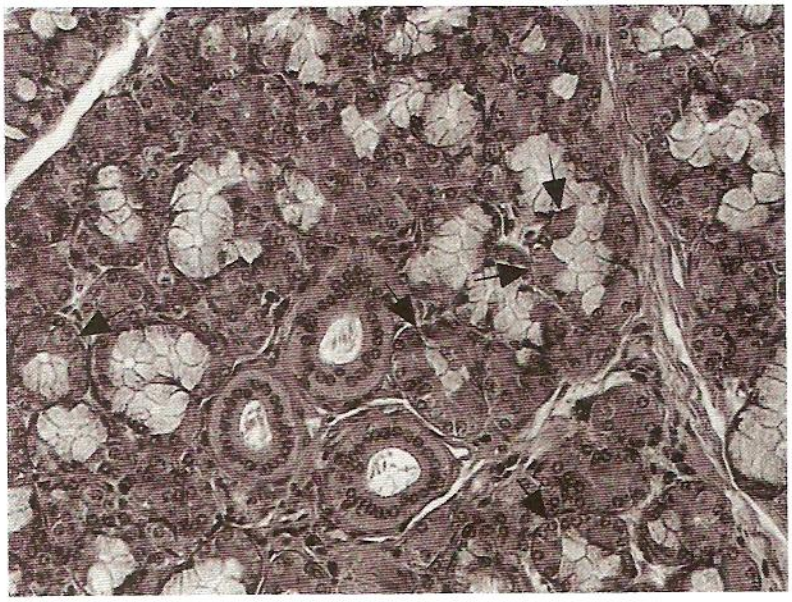

Figure 5-34. Porcine salivary gland. The *arrows* point to regions within adenomeres in which serous cells are intermingled among mucous cells. (X63.)

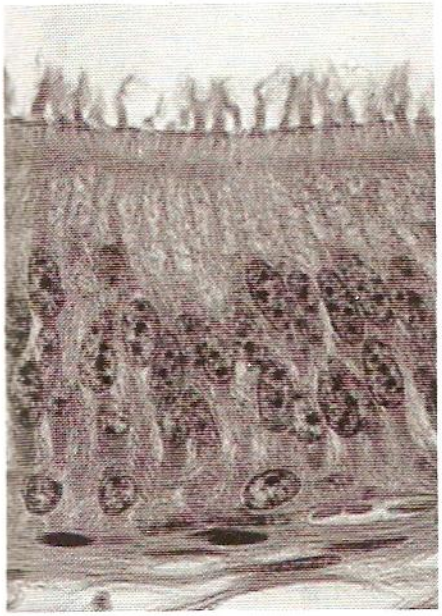

Figure 5-35. Stereocilia of the equine ductus epididymidis. (X200.)

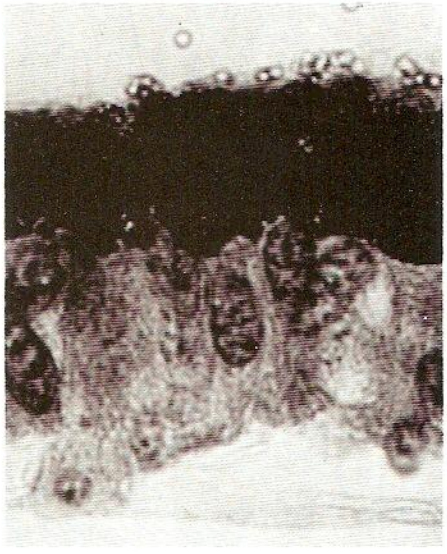

Figure 5-36. Pars ciliaris retinae of a canine eye. The pigment epithelium at the *top* of the micrograph is obscured by the pigment. The columnar cells in the *lower* portion of the micrograph comprise a separate layer. (X320.)

toreceptor and olfactory cells are examples of these types of epithelial cell. A **sensory epithelial cell** is a nonneural cell that is the sensory receptor for gustatory, auditory, and vestibular sensations. These cells receive, transduce, and transmit the information to neurons.

Various cells typically possess different **pigments.** In one instance an entire sheet of epithelium, the pigment epithelium of the retina (Fig. 5-36), is modified to contain large quantities of melanin.

Myoepithelia are specialized **basket cells** associated with the adenomeres of most exocrine glands. They are spindle-shaped and surround the adenomeres (Fig. 5-37). Their origin is epithelial, they contain myofibrils, and their contractions move secretory products into ducts. They are associated with the salivary, sweat, and mammary glands.

Surface Specializations of Epithelia

Cell-to-cell modifications. The lateral surfaces of epithelial cells are modified to hold cells together, to serve as diffusion barriers, to assist diffusion between epithelial cells, and to permit intercellular communication. The lateral surface modifications include alterations of the glycocalyx, lateral plasma membranes, and filamentous components of the cytoplasm.

The points of epithelial cell attachments to each other are visible with light microscopy. This apicolateral alteration of the cell surface appears as a continuous and collarlike alteration around the entire cell. With electron microscopy it is seen as a complex of different structural alterations between adjacent cells. Thus the name **junctional complex** is used. The discrete units of junctional complexes may comprise continuous modifications along contiguous cell surfaces. Such bands of alteration are confined to distinct zones; thus, they are described as zonular (L *zonula*, small zone). Others, disposed as discrete patches or spots of alteration, are described as "spot welds" along contiguous surfaces. They are called macular (L *macula*, a spot) alterations. Junctional complexes (Fig. 5-38) may consist of various components.

The **tight junction (zonula occludens)** (Fig. 5-39) is the common component of junctional complexes. The outer and dense laminae of contiguous cell membranes fuse, with a loss of intercellular space. Cytoplasmic condensation may be apparent on both side of the junction. When this type of junction is well-developed, the epithelium forms an effective barrier between the lumen and connective tissue.

The **intermediate junction (zonula adherens)** (Fig. 5-39) is usually associated with a tight junction and is characterized by the juxtaposition of adjacent cell membranes. They are separated by a 20 to 90 nm space filled with a mucosubstance as the adhesive material. These junctions, too, extend around the apicolateral portion of the cell much like a belt. The adjacent cytoplasmic condensations contain many intermediate filaments continuous with those of the **terminal web.** Intermediate filaments are anchored to the membrane by electron-dense plaques on the cytoplasmic side of the membrane. Intermediate junctions anchor the intermediate filaments of the terminal web, thereby providing support for movement of microvilli. **Actin** filaments extend from the terminal web into the terminal portions of microvilli.

A **desmosome (macula adherens)** (Gr *desmos,* bond; *sōma,* body) does not encircle the cell totally. These structures are scattered along the cell margins at dis-

Downloaded From Vet-eBooks.com

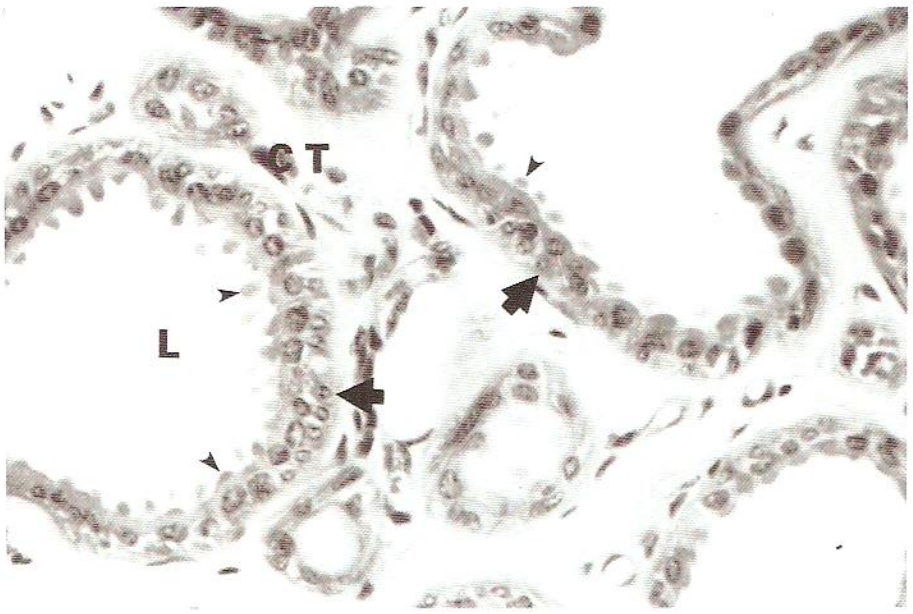

Figure 5-37. A section of apocrine tubular glands from an ovine inguinal pouch. The coiled adenomeres are separated by connective tissue *(CT)*. Apical blebs *(small arrowheads)* characterize the luminal surface of these secretory cells. Myoepithelial cells *(large arrows)* surround the adenomeres and help to express the secretory product from the gland. *L* is the glandular lumen. (X100.)

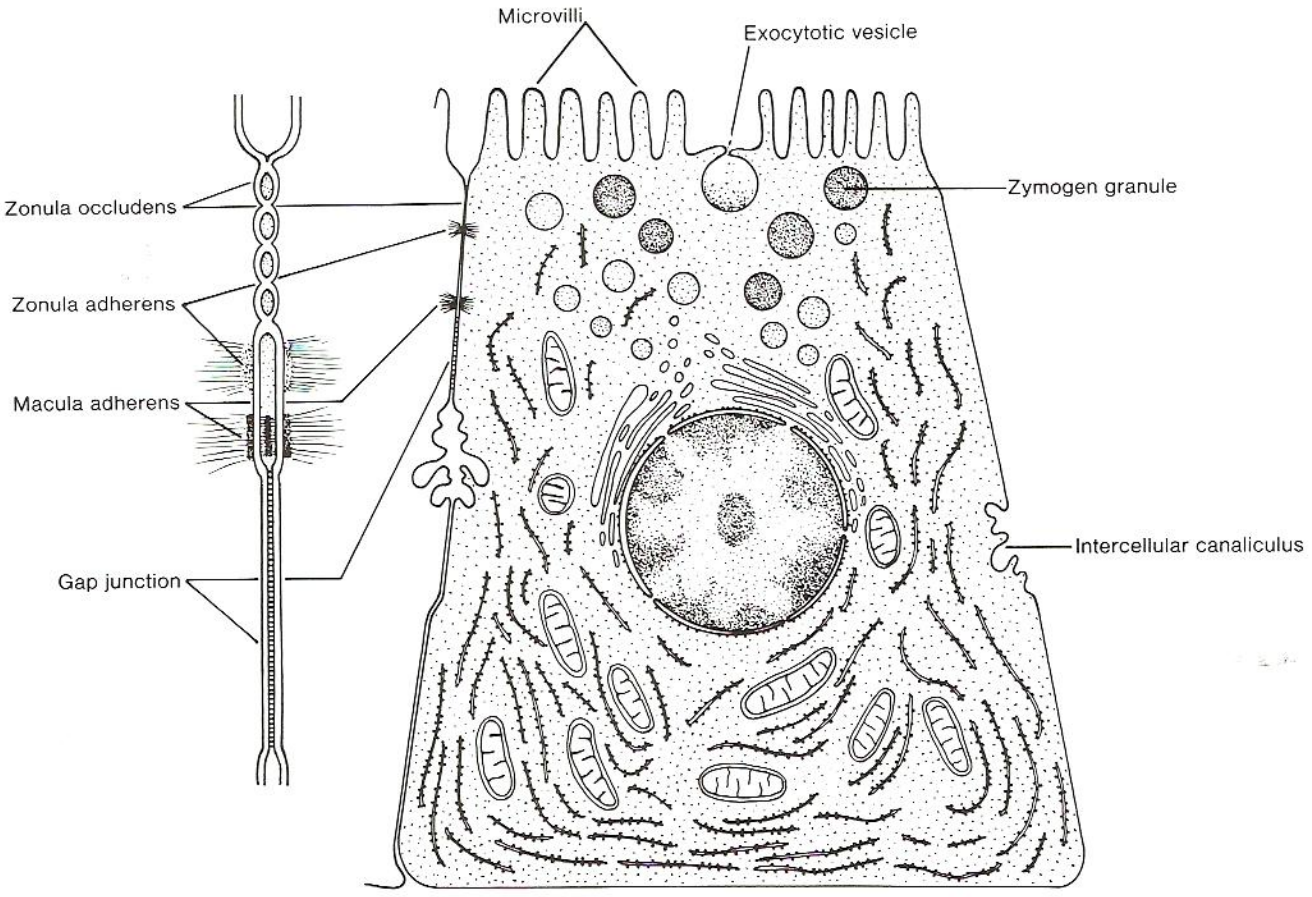

Figure 5-38. Secretory cell as visualized with the electron microscope. Apical and lateral cellular membranous modifications are illustrated. (Redrawn and modified from Bloom W, Fawcett DW: *A textbook of histology*, ed 10, Philadelphia, 1975, WB Saunders.)

crete locations, functioning as spot welds between cells (Fig. 5-39). They are not confined to junctional complexes. The cytoplasmic margins of each cell membrane are coated by an electron-dense **attachment plaque** in which intermediate filaments are embedded (Fig. 5-40). These filaments originate in the cytoplasm, form hairpin loops in the dense material associated with the desmosomes, and return to the cytoplasm. Desmosomes, therefore, play a role in the cytoskeletal architecture of the cell. A space of 25 nm between adjacent cell membranes is typical, and a dense **desmosomal core** fills the intercellular space. Two families of glycoproteins (**desmocollins** and **desmogleins**) occur within the core. These transmembrane proteins are responsible for **adhesive recognition** between cells.

The **gap junction (nexus, close junction, communicating junction)** is similar to the tight junction but is separated by a 20 nm intercellular space (Fig. 5-41). Face views show that these areas are

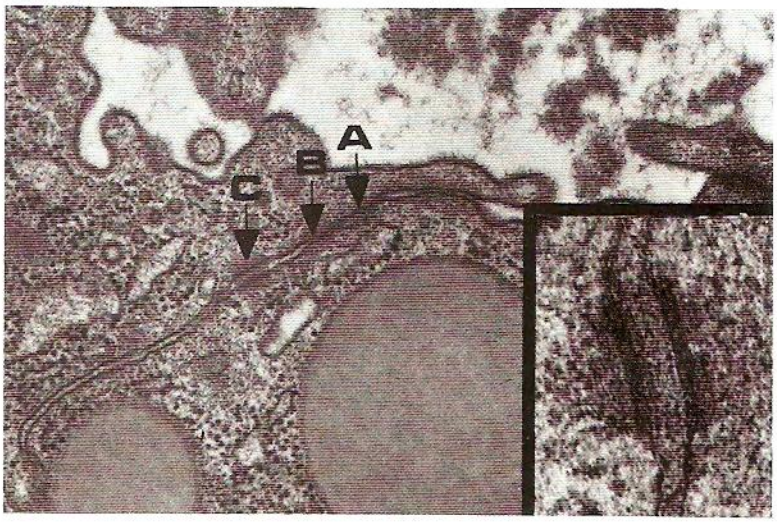

Figure 5-39. Electron micrograph of junctional complexes between contiguous pancreatic acinar cells. A tight junction *(A)*, intermediate junction *(B)*, and desmosome *(C)* are indicated. (X41,000.) *Inset:* High magnification of a desmosome. (X146,000.)

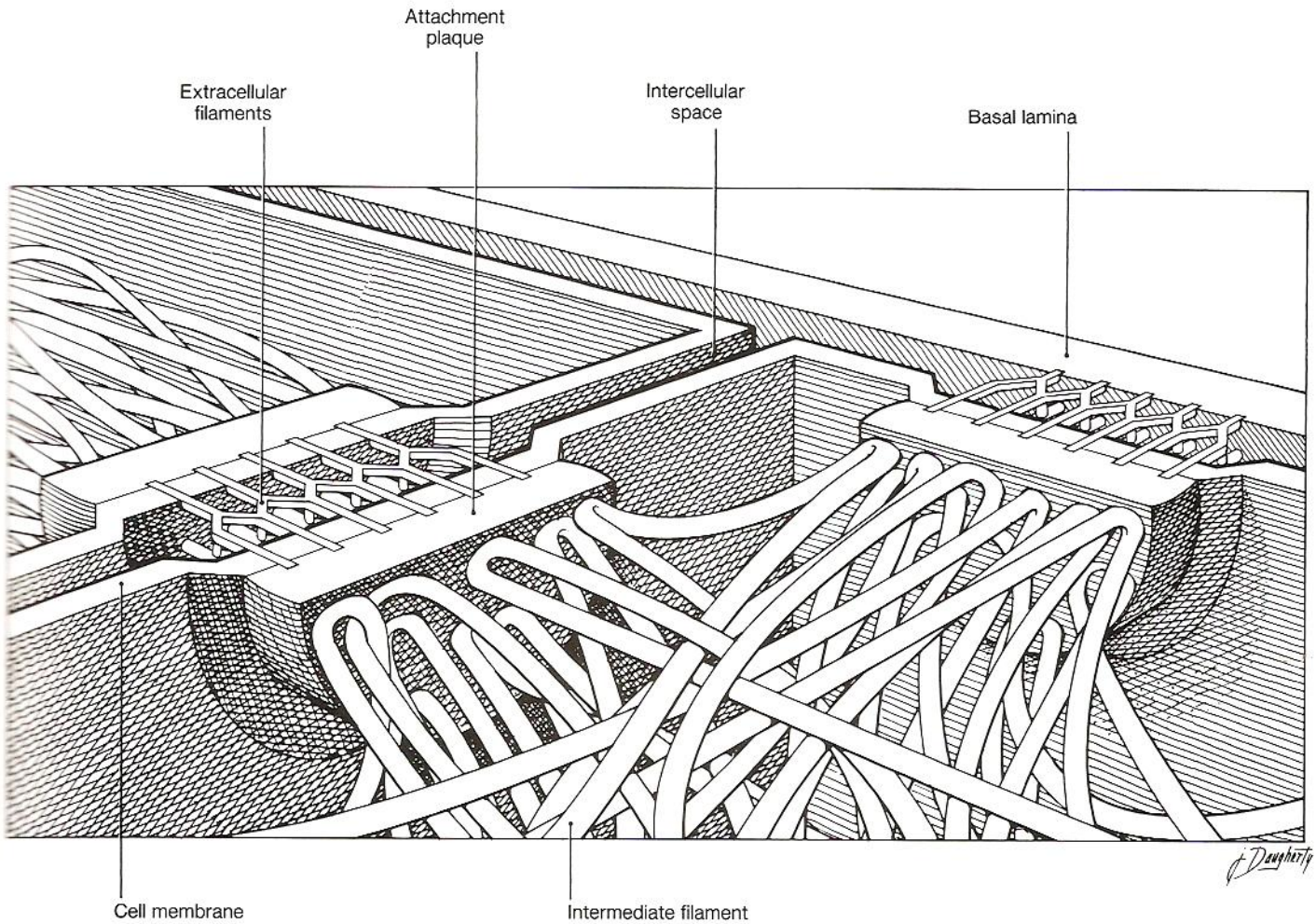

Figure 5-40. Interrelationships of a desmosome *(left)* and hemidesmosome *(right)*. Intermediate filaments originate in the cytoplasm and attach to the plaques. Extracellular filaments attach to contiguous cell membranes or basal lamina. They pass through the cell membrane and attach in the plaques.

Downloaded From Vet-eBooks.com

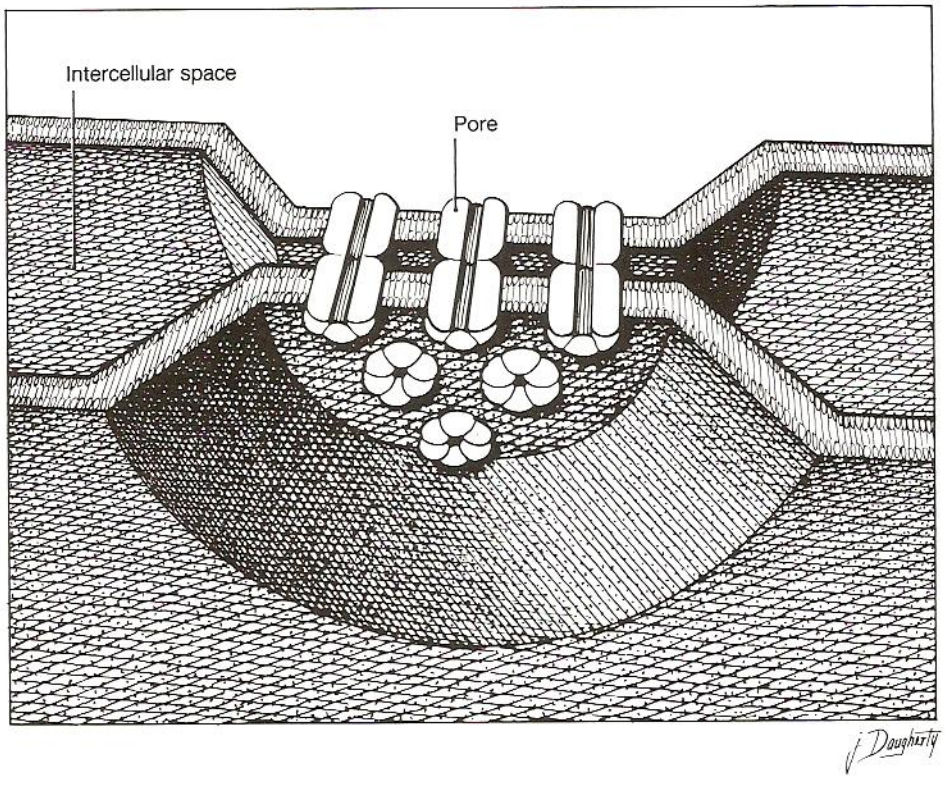

Figure 5-41. Gap junction. Pores are cylindrical structures between contiguous cells permitting the movement of ions and small molecules (e.g., cAMP) between cells.

Figure 5-42. Electron micrograph of surface modifications between adjacent murine intestinal lining cells. Lateral interdigitations *(large arrow)* are apparent, an intermediate junction *(small arrow)* is visible near the apical cellular surface, and a desmosome *(small arrow)* in the middle of the micrograph. (X25,000.) (Courtesy A.M. Sheppard.)

composed of an ordered array of hexagonal subunits, **connexons.** These subunits consist of contiguous proteins extending through the cell membranes in contact with each other. Gap junctions provide **ionic coupling** for coordinated and synchronous cell activities. These structures facilitate **metabolic cooperation;** nucleotide precursors and cAMP pass between cells through these structures.

The remaining 15 nm space between cells is occupied by the glycocalyx. The glycocalyx, as well as other junctional alterations, is coupled with cellular interdigitations to ensure maximal cellular adhesion (Fig. 5-42).

Basal border modifications. The modifications associated with the basal border are varied. Generally, all epithelial tissues are separated from the underlying or surrounding connective tissue by a layer called the **basement membrane.** It is demonstrable with PAS or silver impregnation but not with H&E staining (Figs. 5-43 and 5-44).

The ultrastructural detail of the basement membrane has been elucidated (Fig. 5-45). The light microscopic entity includes the basal cell membrane, amorphous cell coat, some dense material, and associated connective tissue fibrils. With electron microscopy, some dense materials (50 to 70 nm wide) underlie the basal cell membrane and closely follow the contour of this membrane as a **basal lamina.** This **lamina densa** or **basal lamina** is separated from the cell membrane by a clear zone, the **lamina lucida,** which is the modified cell coat. The lamina densa contains glycoproteins and collagenous fibers as a fine feltwork. A thicker layer of collagenous fibers **(lamina fibroreticularis)** projects into the underlying connective tissue space.

The basal lamina is produced by the non–connective tissue cells residing upon it—epithelial cells, muscle cells, adipocytes, neurolemmal cells. The synthesis of the basal lamina also includes the synthesis of various types of collagen comprising it.

Downloaded From Vet-eBooks.com

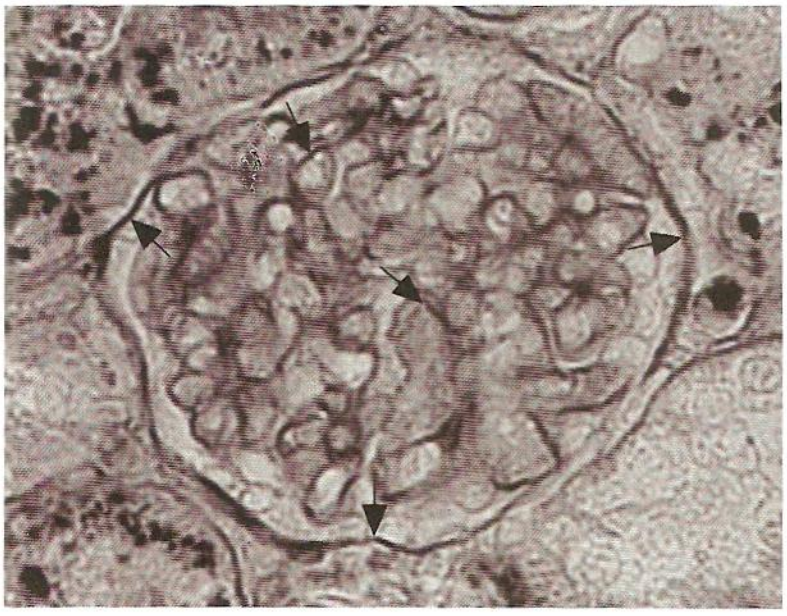

Figure 5-43. Glomerulus of a canine kidney stained with PAS. The basement membrane *(arrows)* is defined clearly. Compare with Figure 5-44. (X250.)

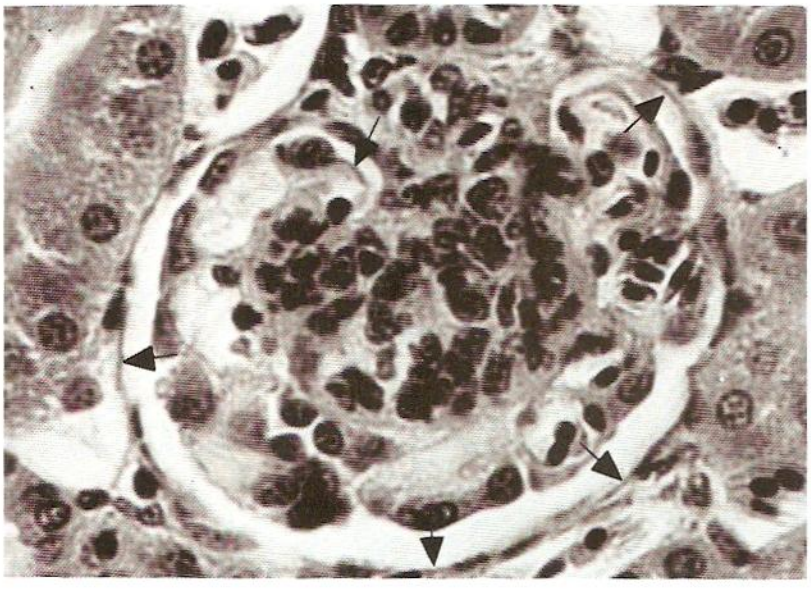

Figure 5-44. Glomerulus of a canine kidney stained with H&E. The cellular limits *(arrows)* are visible, but the basement membrane is not. Compare with Figure 5-43. (X250.)

The basal cell membranes may possess many infoldings (Fig. 5-46). This modification is apparent in cells involved in transport activities. Regardless of the cell's function, however, small bulblike invaginations of the cell membrane (**caveolae**) exist (Fig. 5-47) that pinch off and form **pinocytotic vesicles** (Fig. 5-47). These two structures represent mechanisms for **endocytotic** and/or **exocytotic** activity (Fig. 5-48). The basal membrane is important because all nutrients and waste products must pass through it. It also has many receptors for hormones and connective tissue components.

Hemidesmosomes (half-desmosomes) occur along the basal cell membrane (Figs. 5-40 and 5-49). They anchor cytoskeletal elements to basal cell membranes. They provide points of adhesion to the connective tissue through the basal lamina.

Apical border modifications. Apical border modifications differ from those of other surfaces. The cell membrane is also different from that at the other borders. In intestinal lining cells it contains **disaccharidases** and **transpeptidases** for digestive purposes. In renal lining cells this membrane contains **alkaline phosphatase** and **leucine aminopeptidase,** enzymes involved in transcellular transport. In endothelial cells the apical membrane contains vasoactive, coagulative, and antithrombotic substances, (including **angiotensin converting enzyme, Factor VIII,** and **thrombomodulin**).

Microvilli occur on the surfaces of most cells and vary in size, distribution, and organization. Their prime function is to increase the absorptive surface. Microvilli achieve their maximal development in epithelia. They are slender, cylindrical processes oriented perpendicular to the luminal surface.

Microvilli of intestinal epithelial cells form a **striated** or **brush border** (Fig. 5-50). These processes are 1 to 1.5 μm long and approximately 0.1 μm in diameter. They are juxtaposed in a parallel arrangement (Fig. 5-51). The microvillar cores contain actin filaments bound by proteins, **fimbrin** and **villin.** This complex attaches to the membrane at the apex of the microvillus. Myosin filaments have been noted at the base of microvilli attaching to intermediate filaments of the terminal web. These relationships provide a mechanism for controlled microvillar movement.

Certain renal lining cells have microvilli. These are not in as orderly an arrangement as those described previously (Fig. 5-52). In the past this arrangement was called a **brush border** and the highly ordered array a **striated border.** Now these terms are used synonymously. Both modifications increase surface area. The glycocalyx associated with microvilli is prominent.

Kinocilia (Fig. 5-53) and **stereocilia** (Fig. 4-40) are typical apical modifications of specialized epithelial cells.

The **caveolae** and **pinocytotic vesicles** of the apical border are similar in structure and function to those modifications of the basal border (Figs. 5-47 and 5-48).

REGENERATION AND REPAIR OF EPITHELIA

Epithelial tissues are subjected to harsh environments resulting in cells being damaged and lost. The lives of epithelial cells are finite; therefore epithelial layers require renewal and replacement. Usually this need is met by the presence of stem cells in the epithelial lamina. Various epithelial tissues accomplish this activity in different ways.

Simple epithelial membranes composed of squamous, cuboidal, or columnar cells are not highly differentiated for secretory and/or absorptive functions.

Downloaded From: Vet-eBooks.com

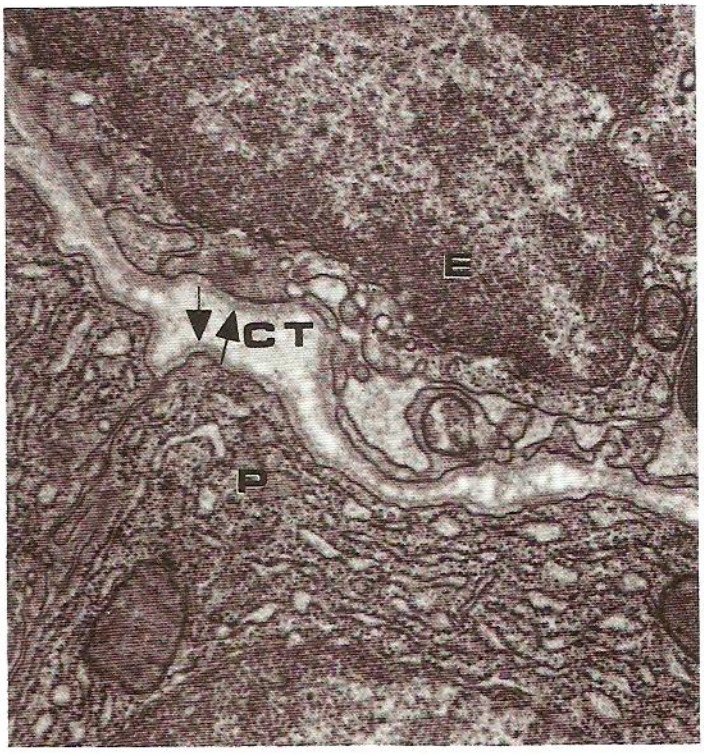

Figure 5-45. Electron micrograph of pancreatic acinar cells, associated connective tissue, and capillary endothelium. The pancreatic acinar *(P)* and endothelial *(E)* cells are underlaid by individual basal laminae *(arrows)*. Intervening is connective tissue space *(CT)*. (X25,000.)

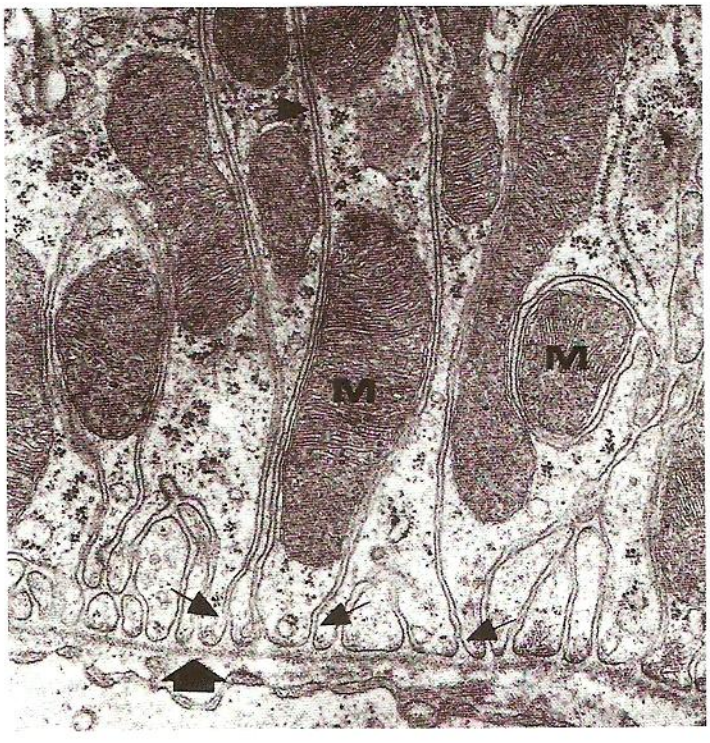

Figure 5-46. Electron micrograph of a lining cell in proximal convoluted tubule of a canine kidney. Numerous basal cellular membranous infoldings are evident *(small arrows)*. Mitochondria *(M)* are contained within the cytoplasm between the membranes. The basal lamina *(large arrow)* is apparent. (X18,000.)

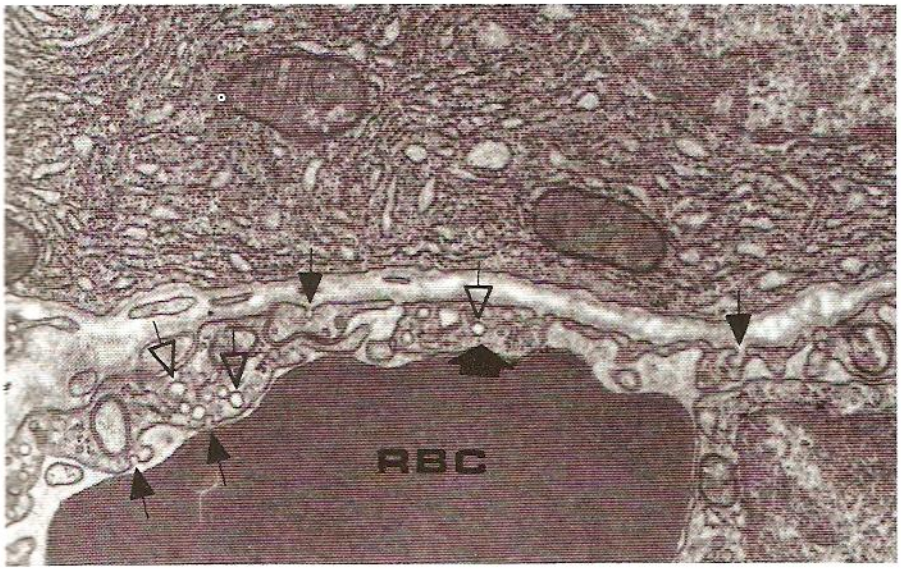

Figure 5-47. Electron micrograph of a capillary. An erythrocyte *(RBC)* is surrounded by capillary endothelium *(large solid arrow)*. Pinocytotic vesicles *(open arrows)* and caveolae *(solid arrows)* are apparent. (X18,000.) Compare with Figure 5-48.

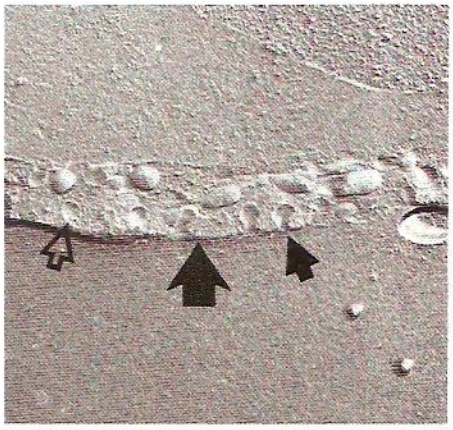

Figure 5-48. Electron micrograph of a freeze fractured capillary. The capillary endothelium *(large arrow)* contains pinocytotic vesicles *(open arrow)* and caveolae *(solid arrow)*. (X43,000.) Compare with Figure 5-47. (Courtesy J.E. Rash.)

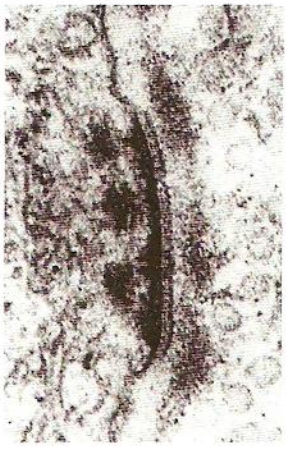

Figure 5-49. Electron micrograph of the basal border of a murine intestinal lining cell. A hemidesmosome is visible in the center of the field. (X91,000.)

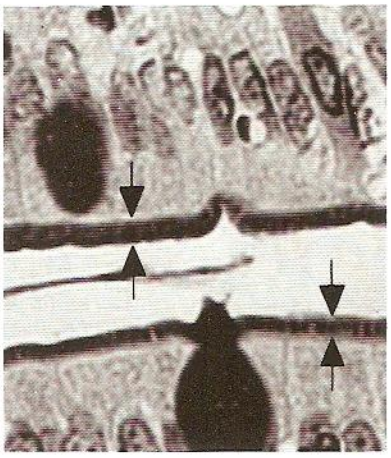

Figure 5-50. Equine jejunum. The striated border *(arrows)* results from the orderly arrangement of microvilli. It appears prominent and dark because of staining of the glycocalyx. (X250, Alcian blue and PAS.)



Figure 5-51. Electron micrograph of the striated border of a murine intestinal lining cell. The microvilli, arranged in an orderly manner, are covered by a glycocalyx *(small arrows)* and contain actin filaments *(large arrows)*. (X70,000.)

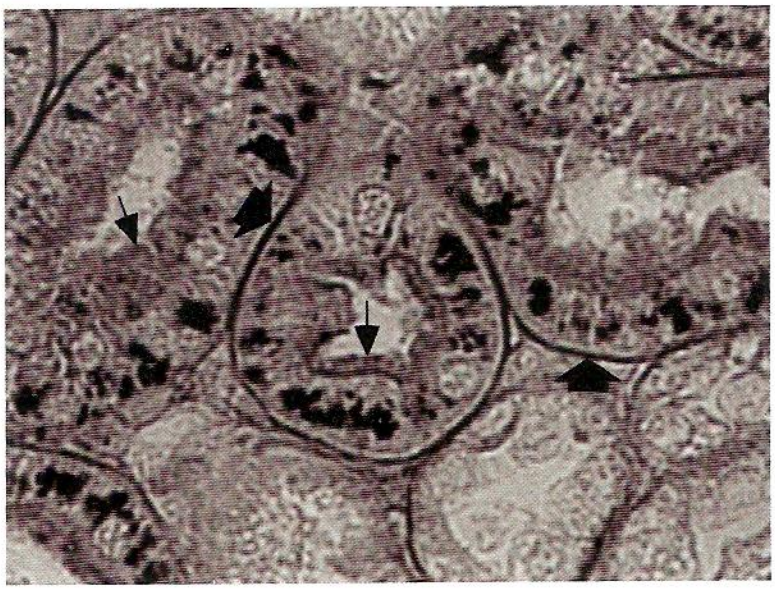

Figure 5-52. Brush borders of the lining cells of the proximal convoluted tubules of a canine kidney. The brush borders *(small arrows)* are indicated. The basement membranes are defined clearly *(large arrows).* (X250, toluidine blue and PAS.)

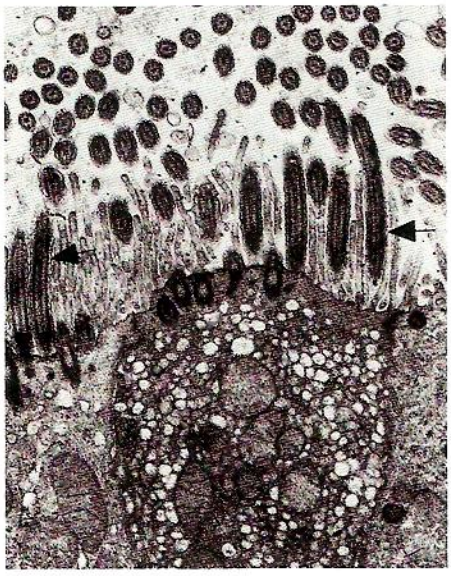

Figure 5-53. Electron micrograph of ciliated cells from a murine trachea. The arrows point to cilia. (X8000.)

They retain a high mitotic potential and serve as stem cells. This applies to typical epithelial lining cells as well as endothelial and mesothelial cells.

In those epithelial membranes characterized by columnar cells specialized for absorptive or secretory functions (stomach, intestine), the specialization is accompanied by an attendant reduction in mitotic potential. Such cellular laminae are dependent upon stem cells for cellular replacement. The location of the stem cells in these simple epithelia varies. In the small intestine, epithelial lining cells of the villi are shed at the tips of these surface modifications. The stem cells are located in intestinal crypts. Mitotic activity occurs in the cryptal cells. Their daughter cells migrate along the glandular epithelium of the crypts, ascend the lateral shoulders of the villi, and are shed at the apices of the villi.

The basal cells of stratified epithelia are the stem cells. The basal and fusiform cells of pseudostratified columnar epithelia can differentiate into lining cells and goblet cells. Similar relationships are assumed to occur in the replacement of transitional epithelium.

The replacement of lost cells in stratified squamous epithelia is necessary, because cells are constantly being shed at the surface. Replacement is the function of the stratum basale and stratum spinosum. Wound repair of the epidermis and underlying dermis has been studied, and it has been determined that the process depends on both the nature and the extent of injury. (See Chapter 20.)

ADDITIONAL READINGS

Epithelium

Brody I: The keratinization of epidermal cells of normal guinea pig skin revealed by electron microscopy, *J Ultrastruct Res* 2:482, 1959.

Dunn JS: The fine structure of the absorptive epithelial cells of the developing small intestine of the rat, *J Anat* 101:57, 1967.

Fawcett DW: *An atlas of fine structure,* Philadelphia, 1965, WB Saunders.

Hackemann M, Grubb C, Hill KR: The ultrastructure of normal squamous epithelium of the human cervix uteri, *J Ultrastruct Res* 22:443, 1968.

Hicks RM: The fine structure of the transitional epithelium of rat ureter, *J Cell Biol* 26:25, 1965.

Matthews JL, Martin JH: *Atlas of human histology and ultrastructure,* Philadelphia, 1971, Lea & Febiger.

Porter KR, Bonneville MA: *Fine structure of cells and tissues,* ed 4, Philadelphia, 1973, Lea & Febiger.

Severs NJ, Hicks RM: Analysis of membrane structure in transitional epithelium of rat urinary bladder, *J Ultrastruct Res* 69:279, 1979.

Zelickson AS: *Ultrastructure of normal and abnormal skin,* Philadelphia, 1967, Lea & Febiger.

Glandular Epithelium

Bullough WS, Ebling FJ: Cell replacement in the epidermis and sebaceous glands of the mouse *J Anat* 86:29, 1952.

Ekholm R, Edlund Y: Ultrasrtucture of the human exocrine pancreas, *J Ultrastruct Res* 2:453, 1959.

Gabe M, Arvy L: Gland cells. In Brachet J, Mirsky AE (eds): *The cell: biochemistry, physiology, morphology,* vol 5, New York, 1961, Academic Press, pp 1-88.

Junqueria LC, Hirsh GC: Cell secretion: a study of pancreas and salivary glands, *Int Rev Cytol* 5:323, 1956.

Parks HF: Morphological study of the extrusion of secretory materials by the parotid glands of mouse and rat, *J Ultrastruct Res* 6:449, 1962.

Scott BL, Pease DC: Electron microscopy of the salivary and lacrimal glands of the rat, *Am J Anat* 104:115, 1959.

Kurosumi K, Shibasaki S, Ito T: Cytology of the secretion in mammalian sweat glands, *Int Rev Cytol* 87:253.

Special Epithelia

Arstila A, Wersall J: The ultrastructure of the olfactory epithelium of the guinea pig, *Acta Otolaryngol [Stockh]* 64:187, 1967.

Edwards E, Duntley S: The pigments and color of living skin, *Am J Anat* 65:1, 1939.

Fitzpatrick TB, Szabo G: The melanocyte: cytology and cytochemistry, *J Invest Dermatol* 32:197, 1959.

Frisch D: Ultrastructure of mouse olfactory mucosa, *Am J Anat* 121:87, 1967.

Lundquist PG, Kimura R, Wersall J: Ultrastructural organization of the epithelial lining in the endolymphatic duct and sac in the guinea pig, *Acta Otolaryngol [Stockh]* 57:65, 1963.

Rhodin J, Dulhan T: Electron microscopy of the tracheal ciliated mucosa in rat, *Z Zellforsch* 44:345, 1956.

Travill AA, Hill MF: Histochemical demonstration of myoepithelial cell activity, *Q J Exp Physiol* 48:423, 1963.

Surface Specializations

Barber VC, Boyde A: Scanning electron microscopic studies of cilia, *Z Zellforsch* 84:269, 1968.

Claude P, Goodenough DA: Fracture faces of zonulae occludentes from "tight" and "leaky" epithelia, *J Cell Biol* 58:390, 1973.

Curtis ASG: Cell contact and adhesion, *Biol Rev* 37:82, 1962.

Farquhar MG, Palade GE: Junctional complexes in various epithelia, *J Cell Biol* 17:375, 1963.

Fawcett DW: Physiologically significant specializations of the cell surface, *Circulation* 26:1105, 1962.

Fawcett DW: Surface specializations of absorbing cells, *J Histochem Cytochem* 13:75, 1965.

Fawcett DW, Porter KR: A study of the fine structure of ciliated epithelia, *J Morphol* 94:221, 1954.

Goodenough DA: The structure and permeability of isolated hepatocyte gap junctions, *Cold Spring Harb Symp* 40:37, 1975.

Granger B, Baker RF: Electron microscope investigation of the striated border of intestinal epithelium, *Anat Rec* 107:423, 1950.

Hashimoto K, Gross BG, Lever WF: Electron microscopic study of apocrine secretion, *J Invest Dermatol* 46:378, 1966.

Hudspeth AJ, Jacobs R: Stereocilia mediate transduction in vertebrate hair cells, *Proc Natl Acad Sci USA* 76:1506, 1979.

Ito S: The surface coat of enteric microvilli, *J Cell Biol* 27:475, 1965.

Kelly D: Fine structure of desmosomes, hemidesmosomes and an adepidermal globular layer in developing newt epidermis, *J Cell Biol* 28:51, 1966.

Downloaded from Ebi-ebooks.com

Kurtz SM, Feldman JD: Experimental studies on the formation of the glomerular basement membrane, *J Ultrastruct Res* 6:19,1962.

Pierce GB Jr, Midgley AR Jr, Sri Ram J: The histogenesis of basement membranes, *J Exp Med* 117:339, 1963.

Satir P: Cilia, *Sci Am* 204:61, 1961.

Sorokin SD: Reconstruction of centriole formation and ciliogenesis in mammalian lungs, *J Cell Sci* 3:207, 1968.

Staehelin AL: Structure and function of intercellular junctions, *Int Rev Cytol* 39:191, 1974.

Susi FR, Belt WD, Kelly JW: Fine structure of fibrillar complexes associated with the basement membrane in human oral mucosa, *J Cell Biol* 34:686, 1967.

Repair and Regeneration

Hunt TK, Van Winkle W Jr (eds): *Fundamentals of wound management in surgery—wound healing: normal repair,* South Plainfield NJ, 1976, Chirurgecom Inc.

Leblond CP, Walker BE: Renewal of cell populations, *Physiol Rev* 36:255, 1956.

Odland GF, Ross R: Human wound repair. I. Epidermal regeneration, *J Cell Biol* 39:135, 1968.

Peacock EE Jr, Van Winkle W Jr (eds): *Surgery and biology of wound repair,* Philadelphia, 1970, WB Saunders.

Potten CS (ed): *Stem cells: their identification and characterization,* Edinburgh, 1983, Livingstone.

Ross R, Odland GF: Human wound repair. II. Inflammatory cells, epithelial-mesenchymal interactions, and fibrogenesis, *J Cell Biol* 39:152, 1968.

Weiss P: The biological foundations of wound repair, *Harvey Lect* 55:13, 1961.

Downloaded From Vet-eBooks.com

CHAPTER 6

Extracellular Matrix

EXTRACELLULAR COMPONENTS

The **matrix** of a connective tissue is the amorphous ground substance and fibers between the cells. The matrical components of the connective tissues impart the specific biomechanical properties for characterizing these tissues. The pliability, elasticity, and stretch characteristics of connective tissues relate to their constituent collagenous and elastic fibers; the ability to resist compression relates to their constituent glycosaminoglycans (GAGs). Similarly the compressive and tensile Properties of articular (hyaline) cartilage relate to its GAGs and collagenous fibers, respectively.

The common fibrous proteins of connective tissue are **collagenous, elastic,** and **reticular fibers.**

Glycoproteins are macromolecules in which one or more saccharide chains (e.g., glucosamine, galactose, fucose) and sialic acid are linked covalently to a polypeptide. The terminology applied to these substances is not standardized. Many **enzymes, membrane proteins, receptors,** and **plasma proteins** are glycoproteins containing less than 50% carbohydrate. Salivary **mucins** are glycoproteins consisting of more than 50% carbohydrate. **Proteoglycans** are considered structural glycoproteins consisting of more than 95% carbohydrate, but these substances may be distinguished from each other based on the amount of protein and the types of polysaccharide side chains. **Collagen** is a structural glycoprotein, but it is considered a separate group because of its short galactose and glucosylgalactose side chains. Also, sialic acid is not present. Other structural glycoproteins include **fibronectin, chondronectin,** and **laminin.**

GAGs are polysaccharides containing amino sugars. These polysaccharides become complexed to proteins as **proteoglycans.** Many proteoglycans and hyaluronic acid combine with each other in cartilage to form **proteoglycan aggregates.**

Fibers

Collagen

General properties. Collagen is the most widespread and most abundant structural protein—the liver contains about 4% collagen; hyaline cartilage is nearly 50% collagen; the dermis is 72% collagen; tendons and ligaments are predominantly collagen. In all these organs collagen provides tensile strength and resists stretching.

Collagen is the polymerized product of soluble precursor molecules secreted by fibroblasts, osteoblasts, chondroblasts, and other cells. In contrast to its pure structural function in most locations, it has structural and optical functions in the eye.

The appearance of collagen fibers varies in different types of tissues. In light microscopic sections stained with H&E the fibers are pink-staining. The degree of collagen fiber staining, the three-dimensional orientation of the fibers, and their association with certain ground substance components combine to alter their appearance. In the dermis the highly polymerized fibers of dense collagenous tissue are thick, wavy, and randomly oriented. The bundles are of indefinite length, with a diameter between 1 and 12 μm (Fig. 6-1). The length, thickness, and random orientation of the fibers are apparent in stretch preparations of loose collagenous tissue (Fig. 6-2).

The dense collagenous tissue of tendons and ligaments has fibers difficult to resolve as individual units. The fibers are highly polymerized, tightly packed, and functionally oriented in an ordered manner in response to the tensile forces exerted upon them. Collagen fibers in loose collagenous tissue are randomly oriented and thin.

In the supportive tissues the presence of collagen fibers is not evident with routine techniques. The indices of refraction of collagen and intermingled ground substance are sufficiently similar to mask the collagen.

Chemical characteristics. Electron microscopy and appropriate staining reveal unique features of this ubiquitous structural protein. Alternating dark- and light-staining patterns are apparent. One dark band and one light band form a 67 nm period repeated throughout the fiber's length. This periodicity results from the precise registration of the monomers that polymerize to form collagen. The monomers, known as **tropocollagen,** have three smaller units called **α-chains.** Each α-chain consists of approximately 1000

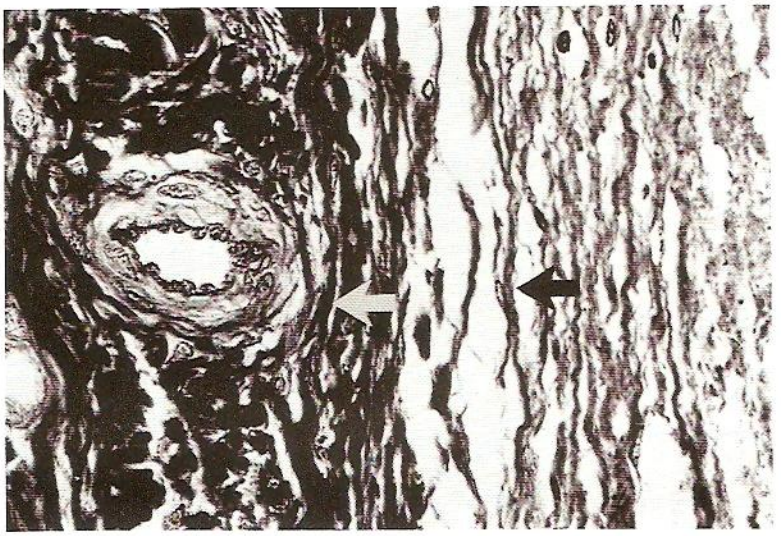

Figure 6-1. Collagen fibers of the capsule of an adrenal gland. Coarse fibers *(white arrow)* and fine fibers *(black arrow)* comprise the capsule of the organ. (X160, Azan stain.)

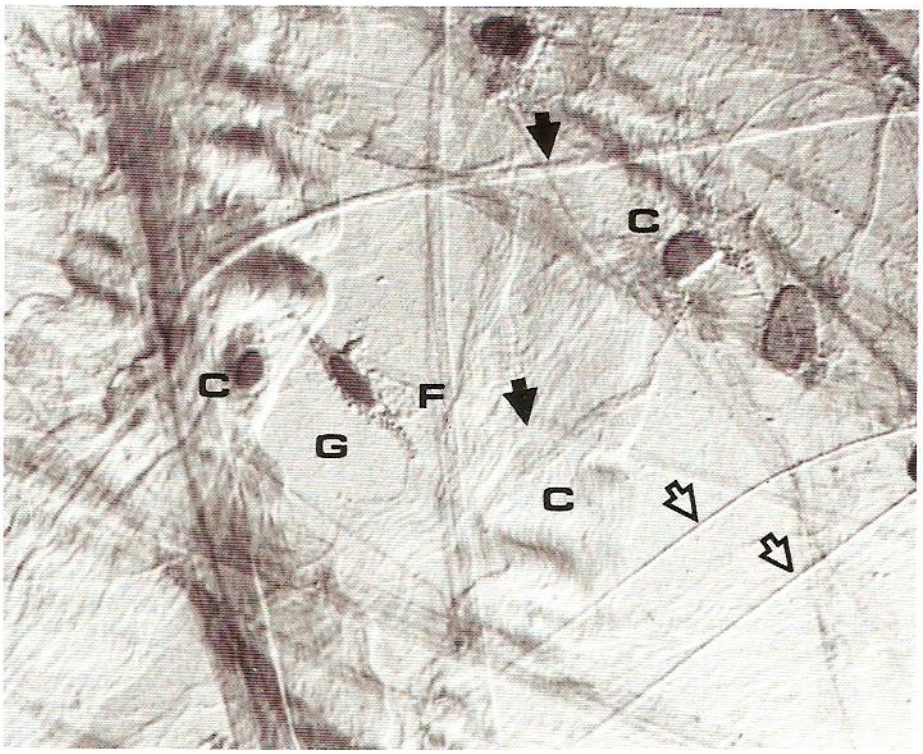

Figure 6-2. Nomarski interference contrast micrograph of a stretch preparation of loose collagenous tissue from a murine subcutis. *F*, Fibroblast; *G*, ground substance; *open arrows*, elastin; *solid arrows*, collagen; *C*, bundles of collagen fibers. (X160.)

amino acids. The total molecular weight is about 95,000 daltons.

Different types of α-chains have been identified and named based on composition and sequencing of constituent amino acids. The α-chains have a repetitive amino acid sequence in which every third amino acid is glycine (Gly). Collagen has an unusually high quantity of proline. Proline and hydroxyproline occupy about every fourth position and account for 20% to 25% of the amino acid residues. Two hydroxylated derivatives of proline, **3-hydroxyproline** and **4-hydroxyproline,** occur only in collagen. Hydroxylysine (Hyl) does not occur often in α-chains but is nevertheless a significant component. It is the site for the addition of sugars and the site of intermolecular cross linkages.

The α-chains of tropocollagen have a unique secondary structure. Each is a left-handed, integral residue helix in which three residues exist per turn. The occurrence of glycine at every third position permits the tight winding of the polypeptide. Hydrogen bonding does not contribute to the stability of the helix. Three α-chains are wound around each other to produce a right-handed, triple-helical molecule called tropocollagen. Hydrogen bonding stabilizes the helical pattern between associated α-chains. Short, nonhelical regions exist at the C and N termini of the α-chains. These regions are important in intermolecular cross linkage.

Initial chromatographic studies of collagen derived from bone and the dermis of the skin determined that tropocollagen consists of three α-chains, two that are identical and a third that is different. This collagen, now known as **type I,** has two α-chains designated α_1 and one α-chain designated α_2. The composition of type I collagen is $[\alpha_1(I)]_2\ \alpha_2(I)$. Since then, many collagens have been isolated and some of their constituent α-chains have been characterized. These chains differ from the α_1 chains of type I collagen $[\alpha_1(I)]$ and the α_2-chains of type I collagen $[\alpha_2(I)]$. Table 6-1 lists the types, occurrence, and selected features of the collagens identified. **Types I, II,** and **III** are **interstitial collagens** whereas **type IV** is **basement membrane collagen.** Other collagens **(types V to XI)** have been isolated from various organs but most have not been characterized completely. Many more genetic collagens probably will be isolated. The adaptive advantage of types I, II, and III is clear, but little understanding is available concerning the adaptive advantage of types IV to XI.

Synthesis and secretion. Not many years ago the accepted dogma was that only the fibroblastic family (mesenchymal cell, fibroblast, chondroblast, osteoblast) synthesized and secreted collagen. Today it is known that cells from almost every tissue secrete collagen (and GAGs) at some point in their life cycle. Often they synthesize and secrete more than one type of collagen.

The synthesis of collagenous precursors is similar to the synthesis of other proteins (Fig. 6-3). The generation of different types of collagen is contingent upon the ability to synthesize different polypeptide chains (α-chains). Many enzymes are involved in post-translational alterations to the collagenous precursors—including "signal" peptidase, prolylhydroxylase, lysylhydroxylase, galactosylhydroxylysl-transferase, glucosylgalactosylhydroxylysl-transferase, procollagen carboxypeptidase, procollagen aminopeptidase, and lysyl oxidase. The extensive posttranslational alterations to collagen are unique. They complicate synthesis and afford opportunities for errors in production that are recognizable as diseases.

The terminology used in the following description is consistent with most of that used in literature on the subject. I have taken some liberties with names to present a coherent story (Fig. 6-3).

The initial translational product is a **preprocollagen chain** that has a primary structure of $(X\text{-}Y\text{-glycine})_{333}$. Additionally, the amino-terminal and carboxy-terminal portions have propeptides attached consisting of 180 and 300 amino acids, respectively. The preprocollagen chains have "signal peptides" attached to them. These signal sequences direct the transfer of molecules from polyribosomes across the membrane of the RER to the cisterns of this organelle. Membrane-bound en-

Table 6-1. Types and Composition of Collagen

	Occurrence	Selected Features
Interstitial collagens		
I $[\alpha_1(I)]_2\alpha_2(I)$	Bone, loose and dense connective tissue, vascular media, GI tract wall, cornea	Low content of Hyl and sugars, large-diameter banded fibers
II $[\alpha_1(II)]_3$	Cartilage, cornea	Moderate content of Hyl and sugars, small-diameter banded fibers
III $[\alpha_1(III)]_3$	Reticular connective tissue, cornea	Low content of Hyl and sugars, small-diameter banded fibers, argyrophilia
Basal laminar collagen		
IV $[\alpha_1(IV)]_2\alpha_2(IV)$	Basal laminae	Very high content of Hyl and sugars, meshwork of nonbanded fibrils
Other collagens		
V $[\alpha_1(V)]_2\alpha_2(V)$	Extraembryonic membranes, muscle, tendon sheaths	High content of Hyl and sugars, thin nonbanded layers around cells
VI $[\alpha_1(VI)]_2\alpha_2(VI)$	Distribution pattern similar to that of type I	Fibrils with 100 nm period
VII $[\alpha_1(VII)]_3$	Attaches basal lamina to connective tissue	High content of Hyl
VIII $[\alpha_1(VIII)]_3$	Vascular and corneal endothelia	
IX $\alpha_1(IX)\alpha_2(IX)\alpha_3(IX)$	Cartilage	
X $[\alpha_1(X)]_3$	Cartilage, hypertrophic zone of growth plates	
XI Not clear	Cartilage	

Hyl, Hydroxylysine.

zymes (signal peptidases) remove the signal peptides on the luminal side of the RER membrane. The shortened chains, **procollagen chains** (pro-α-chains), are polypeptides without signal peptides.

The pro-α-chains become associated with each other in a nonorderly array. The first pro-α-chain modifications occur as the polypeptides pass through the RER membrane. The amino acids 3-hydroxyproline, 4-hydroxyproline, and hydroxylysine are characteristic of collagen. Proline and lysine are incorporated during translation. **Prolylhydroxylase** and **lysylhydroxylase** hydroxylate these amino acids as they pass into the RER lumen. Their hydroxylation is essential for the proper extracellular transport of collagen. Also triple helix formation depends upon hydroxylation. (When the hydroxylation step is interrupted, fiber-forming cells accumulate an abnormal form of collagen called **protocollagen.**) The hydroxylation proceeds as the pro-α-chains aggregate and move through the RER cisterns.

Aggregation of the pro-α-chains within the RER cisterns results in the formation of **procollagen.** A modification of this process is the formation of disulfide bonds within the amino and carboxy terminals. The amino terminal is involved in intrachain disulfide bonding, the carboxy terminal in interchain disulfide bonds.

Additional modifications to procollagen involve some hydroxylysyl residues. Glycosylation, necessary for helical stabilization, transport, and secretion, occurs within the RER and Golgi complex. **Galactosylhydroxylysyl-transferase** uses **uridine diphosphate (UDP)–galactose** as a source of galactose to add to certain hydroxylysyl residues. **Glucosylgalactosylhydroxylysyl-transferase** uses **UDP-glucose** as a source of glucose to be added to galactosylhydroxylysyl residues. The resulting molecule, **procollagen,** is a hydroxylated and glycosylated macromolecule (with disulfide bonds) registered in a triple helical pattern. The molecule passes through the Golgi complex and is extruded from the cell.

Procollagen is the secretory product of collagen-producing cells. Additionally, these cells secrete the enzymes necessary for the completion of the synthetic process. Extracellular processing is a significant component in the generation of collagen.

Extracellular alterations and self-assembly. The first step in extracellular procollagen processing is the removal of most of the nonhelical extension peptides at the C and N termini (Fig. 6-4). The role of these extension peptides is uncertain. They seem to help with the formation of the helix, and they may ease intracellular and extracellular transport. Their fate after cleavage is also uncertain. Two enzymes are necessary to cleave the terminal peptides—**procollagen carboxypeptidase** cleaves the C-terminal peptide, **procollagen aminopeptidase** removes the N-terminal peptide. The activity of these enzymes results in the formation of the insoluble **tropocollagen** (which is composed of three α-chains). Tropocollagen is a helical structure along 95% of its length; the remaining 5% is attributable to the residual, nonhelical C- and N-terminal peptides. The tropocollagen molecule is approximately 290 nm long by 1.5 nm wide.

Spontaneous self-assembly of tropocollagen into collagen fibers follows removal of the terminal peptides. The primary structure of the constituent α-chains provides the necessary information for proper registration of the components. The final step in the assembly process ensures that the tensile strength of collagen will be established. This requires the formation of intermolecular cross linkages, occurring between the nonhelical components of constituent tropocollagens. Cross linkage is achieved through the oxidative deamination of lysyl and hydroxylysyl residues into aldehydes by **lysyl oxidase.** Then aldol condensation and Schiff base formation with Amadori rearrangement result in stabilized intramolecular and intermolecular cross linkages.

Polymerization: microfibrils to fibers. Various techniques have provided insight into the architecture of the tropocollagenous monomers into the polymerization product—collagen fibrils. The **quarter-stagger model** was proposed as a reasonable explanation of the **axial periodicity** characterizing collagen. According to this model, the tropocollagenous molecules overlap each other by one quarter of their length. A 280 nm tropocollagenous molecule would be divisible into 70 nm repetitive units. The model afforded valuable insights but was less than perfect.

The length of tropocollagen is about 290 nm, and the axial periodicity is 67 nm. The quarter stagger model was modified to include a hole region of about 40 nm between the linearly oriented tro-

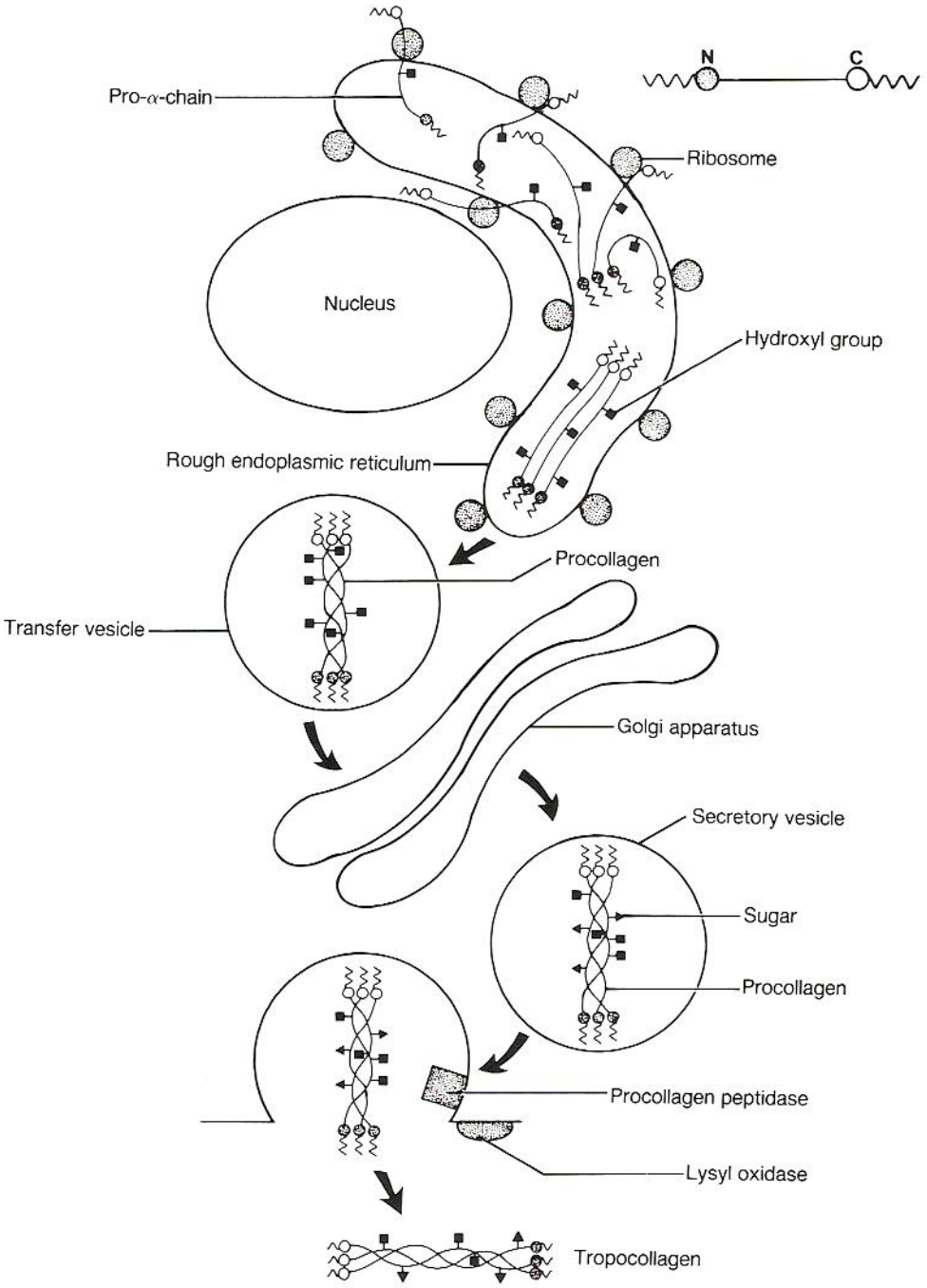

Figure 6-3. Synthesis and secretion of procollagen. The mRNA for procollagen is formed in the nucleus by transcription. It enters the cytoplasm and attaches to ribosomes of the RER. Translation results in the formation of *preprocollagen chains*. These are *pro-α-chains* to which a signal peptide is appended. The signal peptide is clipped from the polypeptide as the polypeptide enters the RER. Hydroxylation of proline and lysine occurs as the pro-α-chains enter the cisterns of the RER. Pro-α-chains become aggregated in triplets called procollagen. Transfer vesicles are incorporated into the immature face of the Golgi complex. Glycosylation within the Golgi complex leads to the formation of stabilized procollagen molecules. The procollagen molecules leave the mature face of the Golgi complex within secretory vesicles. The secretory vesicles fuse with the plasma membrane as exocytotic vesicles. A procollagen peptidase, located either within the secretory vesicles or on the cell membrane, cleaves the tailpieces, resulting in the formation of tropocollagen. Cross linkage between tropocollagen molecules occurs through the activity of lysyl oxidase. (Redrawn and modified from Hunt TK, Dunphy JE [eds]: *Fundamentals of wound management, New York, 1979, Appleton-Century-Crofts.)*

Downloaded From Vet-eBooks.com

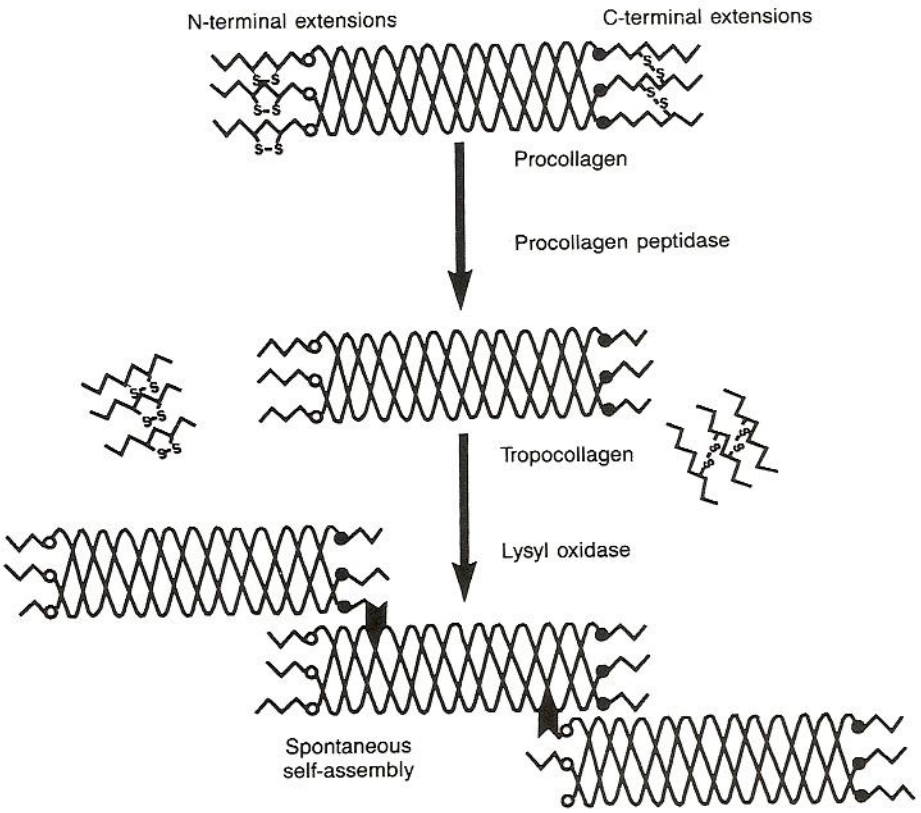

Figure 6-4. Formation of tropocollagen and its subsequent spontaneous self-assembly.

these types of preparations and appears light. Naturally, just the reverse staining pattern occurs with positively stained materials observed with the electron microscope (Fig. 6-6). Additionally, 12 bands (I to XII) are visible in sectioned and positively stained preparations.

Microfibrils less than 40 nm in diameter are visible with electron microscopy. Further microfibrillar polymerization results in **fibril** formation (about 0.5 μm in diameter) visible with light microscopy. Bundles of fibrils form the characteristic **fibers** of light microscopy.

Functional correlates. Disruptions in the many posttranslational events result in disease processes. Collagen diseases are due to the following: a deficiency of lysylhydroxylase **(Ehlers-Danlos VI),** an inability to remove the amino terminal of a collagenous precursor **(Ehlers-Danlos VII, dermatosparaxis** of sheep and cattle), and a deficiency of lysyl oxidase **(Ehlers-Danlos V). Lathyrism,** either naturally occurring or experimentally induced, results from feeding excessive quantities of the sweet pea (*Lathyrus* sp) or an extract from this plant, β-amino propionitrile (BAPN). This lathyritic agent inhibits lysyl oxidase. Cross linkages are also inhibited, and the tensile strength of the collagen is reduced. The agent has been useful in explaining the mechanisms involved in cross linkages.

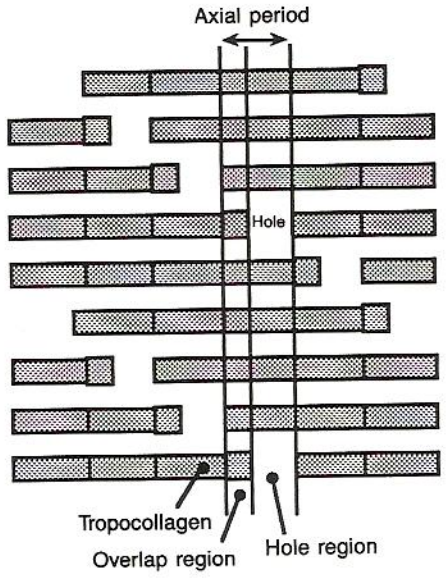

Figure 6-5. Overlap/hole modification of the quarter stagger model. (Redrawn and modified from Glimcher M: *Handbook of physiology-endocrinology*, ed7, Baltimore, 1976, Williams & Wilkins.)

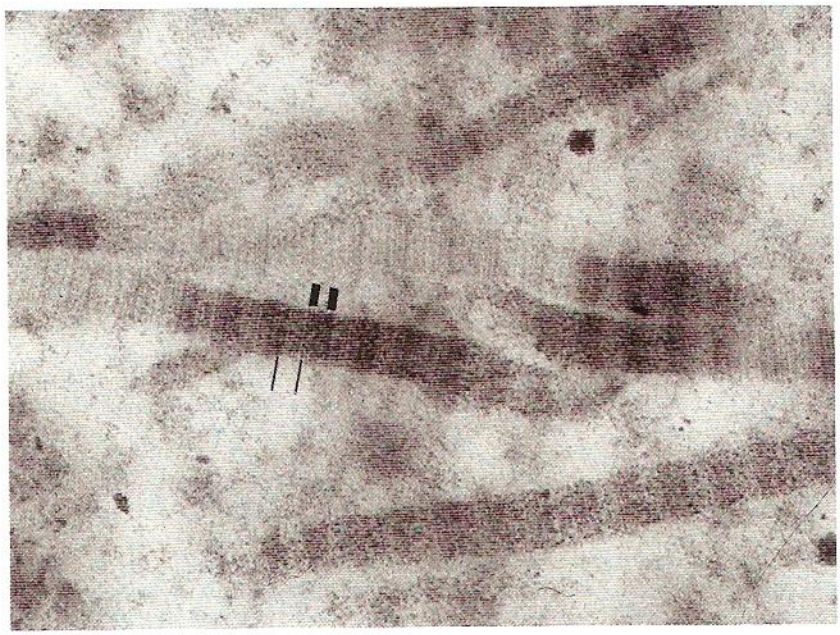

Figure 6-6. Electron micrograph of sectioned collagen. The periodic banding is obvious. The dark band *(thick bars)* and light band *(thin bars)* comprise the typical 64 nm period. (X94,000.)

pocollagenous molecules (Fig. 6-5). The 67 nm axial periodicity results from the precise end-to-gap-to-end arrangement. All tropocollagens are arranged in this manner. The N terminal of a molecule overlaps the C terminal of an adjacent tropocollagen by 27 nm, not the entire 67 nm repetitive unit length. Thus the axial periodicity of collagen has **overlap zones** (27 nm) and **hole zones** (40 nm). The hole zone typically fills with stain in negatively stained preparations for electron microscopy and appears dark. The overlap zone does not fill with stain in

Reticular fibers

The reticular fibers (type III collagen) of light microscopy cannot be shown with routine stains. As such, these fibers are indistinguishable from collagenous fibers; but reticular fibers are visible with special silver stains (Fig. 6-7). The fibers

Downloaded From TestBooks.com

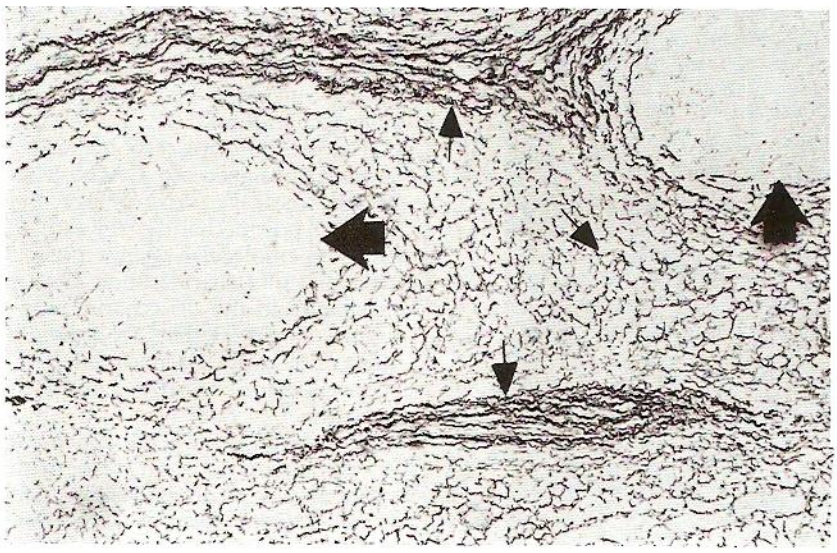

Figure 6-7. Reticular fibers within a canine lymph node. The argyrophilic fibers *(small arrows)* are arranged in dense and loose aggregates. Areas devoid of fibers *(large arrows)* are the germinal centers of secondary lymph nodules. (X40, Snook's reticulum stain.)

Figure 6-8. Elastic fibers of loose connective tissue. Although the fibers *(arrows)* are difficult to demonstrate with routine stains, they can be seen with special staining techniques. (X160, Verhoeff's stain.)

are termed **argyrophilic** (silver-loving) because of their silver affinity.

Reticular fibers were named on the basis of their forming a delicate, finely branched network (L *rete,* net) of fibers in close association with the individual cells of various tissues and organs. They occur frequently with basement membranes and are components of most tissues and organs. Reticular fibers form a delicate network around bundles of collagen fibers in tendons/ligaments and around individual smooth muscle fibers. They form the stroma in many other locations. The organs of the hemic-lymphatic system use these fibers as the primary means of connective tissue support.

Fibroblasts secrete the collagenous, and reticular fibers the proper, connective tissues.

Elastic fibers

The elastic fibers of light microscopy are not shown easily with routine stains. With H&E the discerning eye will note that they stain a brighter pink than collagen fibers do. Elastic fibers are observed readily with special staining techniques as long, thin, or wavy (Fig. 6-8). If broken, they become wavy (Figs. 6-2 and 6-9).

Elastic fibers consist of two distinct components visible by electron microscopy. The primary component, **elastin,** forms an amorphous electron-dense mass (Fig. 6-10). A glycoprotein is present that forms microfibrils intimately associated with the **amorphous mass.** The microfibrils surround and are embedded within the amorphous mass of elastin. The secondary component, **microfibrillar protein,** is secreted as a supporting network to mold the amorphous mass into cylindrical structures. Absence of microfibrillar protein probably precludes elastin from assuming its fibrous nature. Neither of these components has an axial periodicity that should be confused with the periodicity of collagen.

Elastin has a limited but significant distribution in quadruped animals. The **nuchal ligament** is composed of dense elastic tissue. Elastin also contributes to lung compliance, and it is a constituent of cartilage in a limited number of foci. Finally, it is the main constituent of proper connective tissues.

Elastin and the microfibrillar glycoproteins are produced by fibroblasts and smooth muscle cells. The elasticity of blood vessels and the lungs depends upon normal elastic fibers. Damaged elastic fibers contribute to the pathogenesis of atherosclerosis and pulmonary emphysema.

Ground Substance

General properties. The fibrous and cellular components of proper connective tissues are easily demonstrated in routine preparations for light microscopy. These components are bathed by an aqueous medium continuous with the vascular, extracellular, and intracellular spaces. The cells, fibers, and aqueous media **(tissue fluid, interstitial fluid)** are held by a viscous gel-like material called **amorphous ground substance.** The ground substance is the secretory product of the characteristic cells of the tissue—fibroblasts, osteoblasts, chondroblasts—and consists primarily of carbohydrates. The carbohydrates, varying in type and quantity, comprise the viscous gel phase of the interstitial space. The tissue fluid and all its dissolved substances comprises the fluid phase of the interstitial space **(interstitium).** The ground substance and the interstitial fluid, though distinct entities, are inseparable.

The ground substance helps to characterize the properties of the tissues. The free and bound water of the interstitium ensures an ample water supply. In addition, all transport to and from the cells must occur through this aqueous medium. A proper amount of tissue fluid must be maintained. Too little **(dehydration)** or too much **(edema)** tissue fluid can have devastating effects.

The ground substance, composed of water-soluble components, is observed rarely with routine paraffin techniques.

Downloaded from Vet-eBooks.com

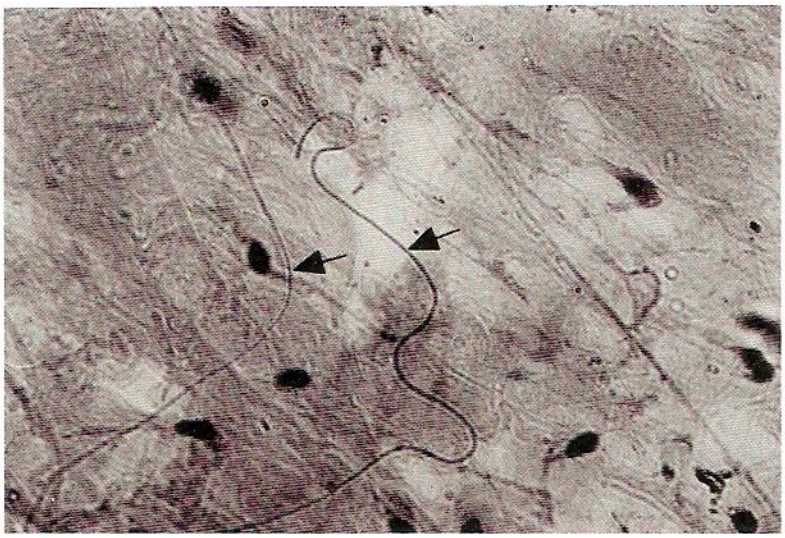

Figure 6-9. Elastic fibers in a stretch preparation of loose collagenous tissue from the subcutis of a mouse. The broken elastic fibers *(arrows)* appear wavy. Other cellular and fibrous components are out of the plane of focus. (X160.)

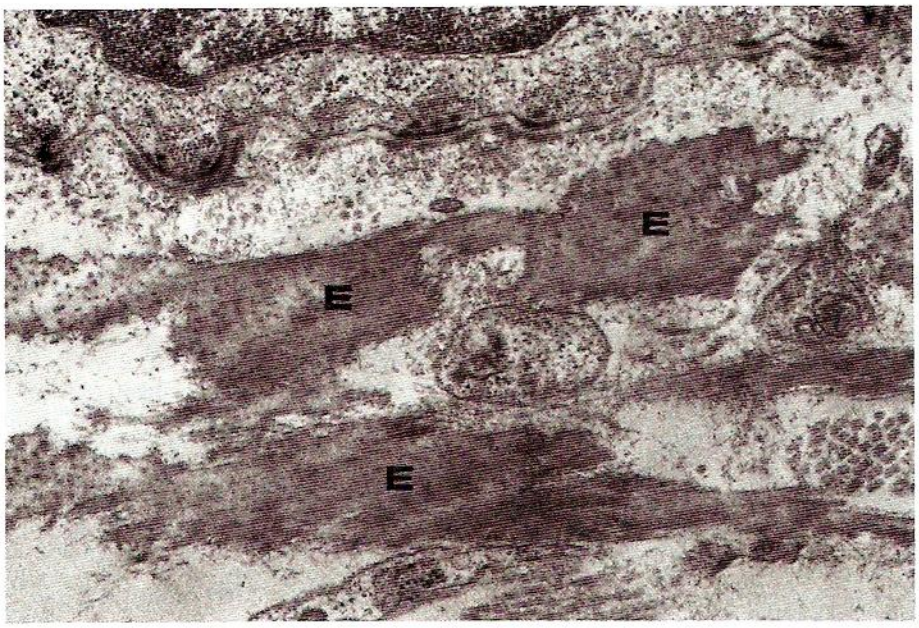

Figure 6-10. Electron micrograph of elastic fibers. The irregularly shaped elastic fibers *(E)* are scattered throughout the connective tissue. (X26,000.)

Freezing techniques must be used to preserve this material for staining. The obvious spaces between cells and fibers in proper connective tissue are artifacts of preparation. In the living organism those "spaces" are occupied by ground substance.

Materials must diffuse or filter through and/or around the ground substance. Large molecules and microorganisms have much difficulty moving through the ground substance. The virulence of bacteria is related to various factors, one of which is their ability to spread or invade the body beyond a particular site of entry. Many bacteria have developed the ability to produce **hyaluronidase.** This enzyme or **spreading factor** breaks down the ground substance and facilitates their spread. Some bacteria also produce **collagenase;** this enzyme aids their dispersion by degrading collagen.

Glycosaminoglycans (GAGs). The viscous, semifluid, gelatinous ground substance of most connective tissues consists predominantly of carbohydrates. The carbohydrates are **polysaccharides** (that have been called **mucopolysaccharides** and **mucosubstances).** Although new terminology has been adopted for these substances, some old terminology remains. A group of diseases characterized by the inability to metabolize some of these substances properly is called the **mucopolysaccharidoses.**

The predominant carbohydrates of the ground substance are **GAGs.** The term literally means an amino sugar (glycosamino-) polysaccharide (-glycan). GAGs are high–molecular weight polymers of repeating disaccharide units. One monosaccharide in the disaccharide unit is an **amino sugar**—either **N-acetylglucosamine** or **N-acetylgalactosamine.** The other monosaccharide is either a **uronic acid** or **galactose.**

The GAGs are a heterogeneous group of carbohydrates with some common properties. They are **polyanions** that bind water in large quantities. The repeating units contain one hexosamine. The sugars are linked through β-1,3 or β-1,4 glycosidic linkages, but a β-1,6 linkage also occurs.

The compounds differ in various ways. Their polyanionic nature depends upon sulfate groups, carboxylate groups, or both. Each repeating unit is different, but a specific disaccharide repeating unit characterizes a particular GAG. The length of the polymers also is different. All GAGs, except hyaluronic acid, are complexed as proteoglycans. Lastly, the distribution of GAGs varies throughout connective tissues (Table 6-2).

Hyaluronic acid (Fig. 6-13) is a long-chain polymer whose disaccharide units are glucuronic acid and glucosamine **(glucuronate β-1,3–N-acetylglucosamine β-1,4).** This long, unbranched compound contains 2500 disaccharide units, has a molecular weight of about 2×10^6, and is the most commonly occurring GAG in connective tissues. It is the only one that is not sulfated. It is also the only one that is not complexed to proteins routinely. Its secondary associations with

Table 6-2. Type and Distribution of Glycosaminoglycans

	Distribution
Hyaluronic acid	Synovial fluid, umbilical cord, vitreous humor, loose connective tissue
Chondroitin	Cornea
Chondroitin-4-sulfate	Cartilage, bone, cornea, aorta
Chondroitin-6-sulfate	Cartilage, nucleus pulposus, sclera, tendons, umbilical cord
Keratan sulfate	Cartilage, bone, cornea, nucleus pulposus
Dermatan sulfate	Aorta, cardiac valves, ligamentum nuchae, sclera, skin, tendons
Heparin	Mast cells
Heparin sulfate	Cell surfaces

Downloaded From Vet-eBooks.com

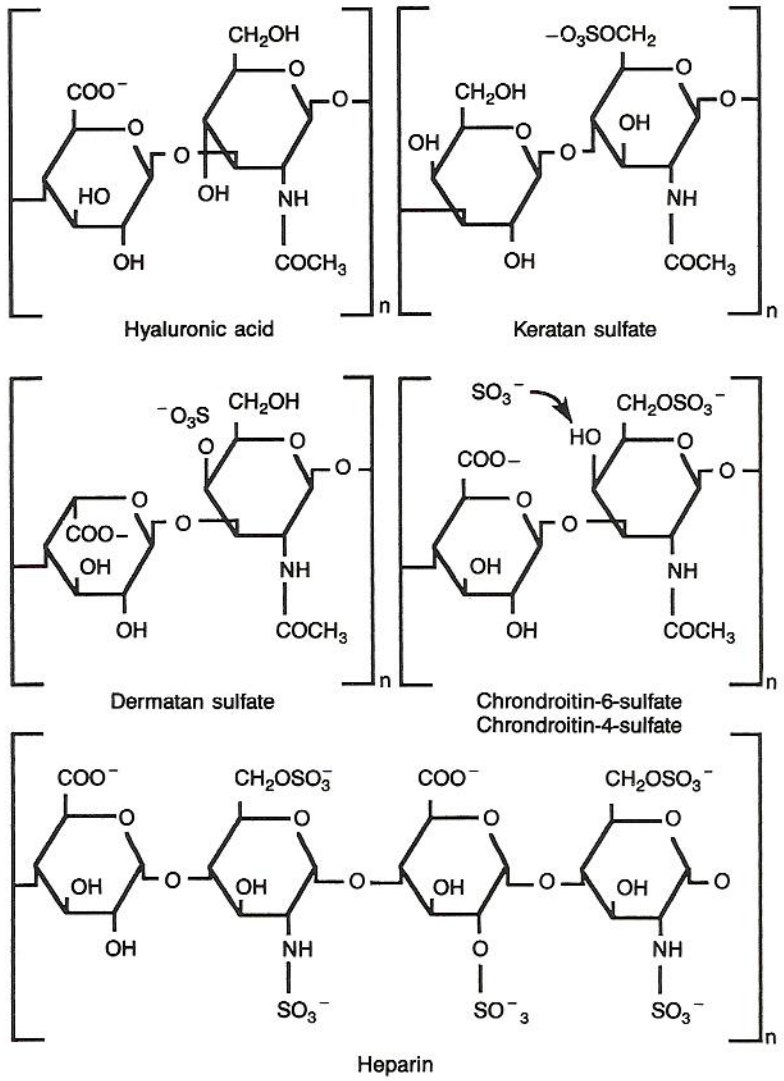

Figure 6-11. Chemical composition of selected glycosaminoglycans. The chain length *(n)* varies among these substances: hyaluronic acid (n = 2500), keratan sulfate (n = 10 to 20), dermatan sulfate (n = 120), chondroitin sulfates (n = 60), heparin (n = 15). The structure of heparin illustrates some features that characterize the molecule. The actual sequence depicted has been chosen arbitrarily. Iduronic acid may substitute for glucuronic acid. Also, few of the NH groups are acetylated but all are sulfated.

proteoglycans form large aggregates typical of cartilaginous matrices.

The **chondroitin sulfates** (Fig. 6-11) are polymers of repeating units of glucuronic acid and galactosamine **(glucuronate β-1,3–N-acetylgalactosamine β-1,4).** The position of the sulfate determines the isomer formed—**chondroitin-4-sulfate** or **chondroitin-6-sulfate.** The significance of the positioning of the sulfates is not understood. These isomers do have a differential distribution relating to the tissue, age, and state of health of the organism. Each polysaccharide has 30 to 50 disaccharide units with a molecular weight between 15,000 and 25,000 daltons.

Dermatan sulfate (Fig. 6-11) differs from chondroitin-4- and -6-sulfates by having iduronic acid substituted for glucuronic acid. The molecular weight is 20,000 to 50,000 daltons, and the chain length is approximately twice that of the chondroitins.

Keratan sulfate (Fig. 6-11) is the most heterogeneous GAG. The polymer has repeating disaccharide units of glucosamine and galactose **(N-acetylglucosamine β-1,3–galactose β-1,4).** The polysaccharide chains are short, each with about 15 disaccharides. The molecular weight of this compound varies between 5000 and 10,000 daltons. The degree of sulfation also varies and can exceed more than one sulfate per disaccharide unit. **Keratan sulfates I and II have been isolated.** KS I is a corneal component, KS II a skeletal tissue component. These GAGs achieve branching through β-1,6 glycosidic linkages, and they may contain additional monosaccharides such as mannose, fucose, sialic acid, and N-acetylgalactosamine.

Two types of heparins exist. **Heparin** is formed from repeating disaccharide units consisting of glucosamine and glucuronic acid or iduronic acid (Fig. 6-11). The linkages in heparin are α-glycosidic linkages. Few glucosamine groups are N-acetylated, but all have sulfate groups. The sulfate content per disaccharide is approximately 2.5 per unit. Heparin is a product of mast cells, serving as an anticoagulant and lipid-clearing agent, with a molecular weight between 6000 and 20,000 daltons. **Heparin sulfate** contains more acetylated groups and fewer sulfate groups than heparin. It has an extracellular distribution and has been associated with cellular surface coats.

Sialic acid, though not a GAG, is a constituent of GAGs and a contributor to the synthesis of GAG chains, especially as they occur in glycoproteins. Sialic acid has two components—N-acetylglucosamine complexed with lactic acid.

Proteoglycans. These substances are conjugates of GAGs and protein. Because they contain at least 95% carbohydrate, they act more like sugars than like proteins.

A typical proteoglycan has a **core protein** with a molecular weight of about 20,000 daltons. Many GAGs are complexed to it (Fig. 6-12). Such a molecule, containing about 100 chondroitin sulfate chains, about 110 keratan sulfate chains, and about 15 other oligosaccharides, has a molecular weight of approximately 2.5×10^6 daltons. Specific regions of the core protein have been identified—**chondroitin sulfate–binding region, keratan sulfate–binding region,** and **hyaluronic acid–binding region.** The keratan sulfate–binding region is characterized also by the attachment of oligosaccharides. The hyaluronic acid–binding site is involved in the formation of **proteoglycan aggregates.**

The polyanionic nature of proteoglycans suits them ideally for their biological functions. Proteoglycans do the following:

1. Increase viscosity within the synovial fluid
2. Contribute to compressive properties of tissues
3. Function as a depot for excessive water storage in the interstitial space (edema)
4. Ensure a readily available source of water for the cells
5. Add to the stability and support provided by connective tissues
6. Assist with water volume maintenance and electrolyte distribution

Proteoglycan synthesis requires many of the processes involved in glycoprotein

Downloaded From Vet-eBooks.com

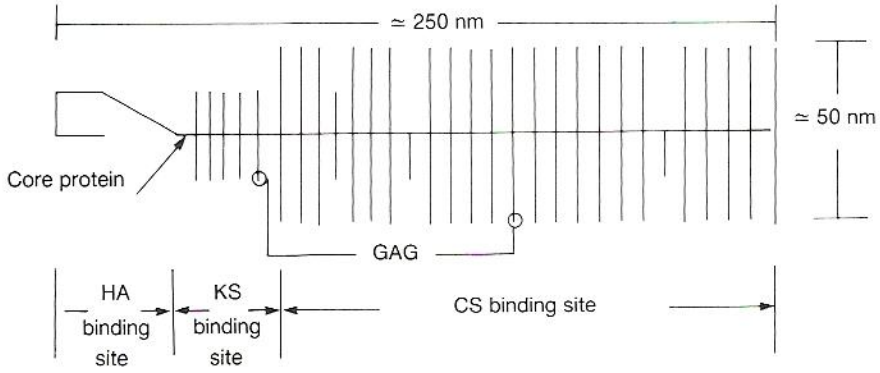

Figure 6-12. Typical glycoprotein (simplified). The oligosaccharides have not been included. *HA,* Hyaluronic acid; *KS,* keratan sulfate; *CS,* chondroitin sulfate; *GAG,* glycosaminoglycan.

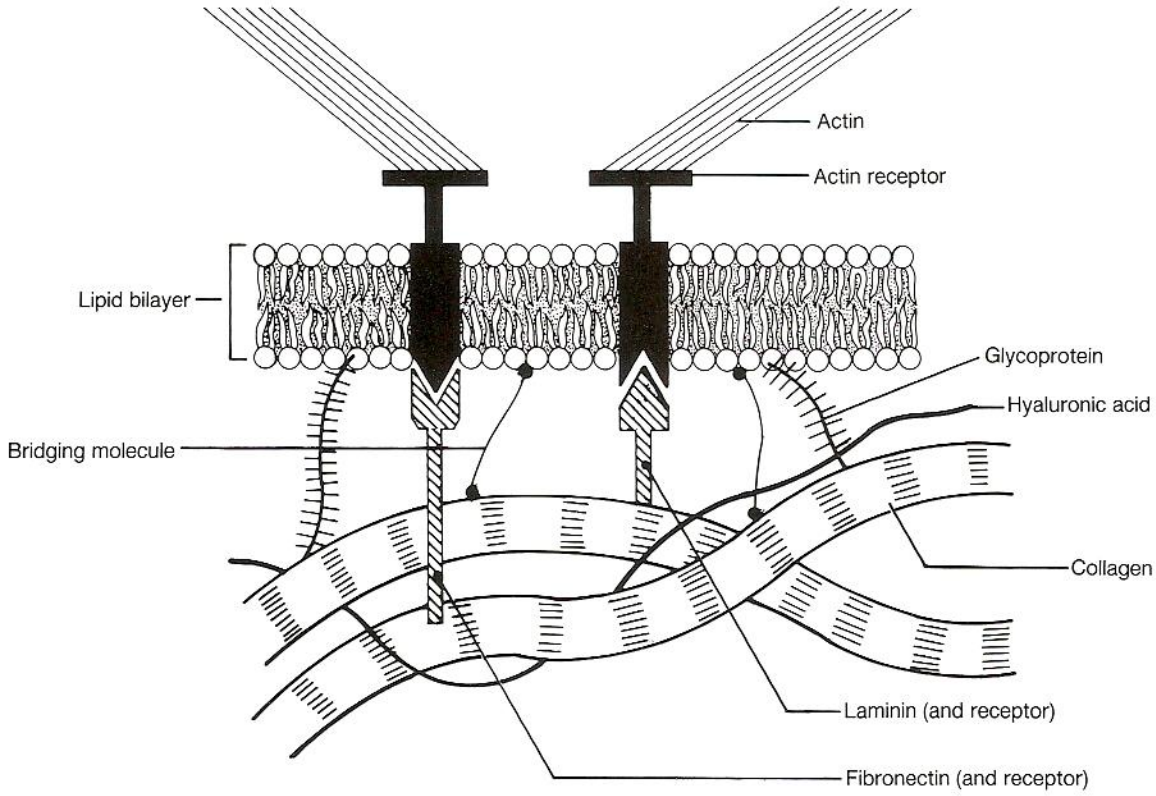

Figure 6-13. Relationship of extracellular molecules to the cell membrane. This model, a theoretical composite of various models that have been proposed, assumes that receptor molecules exist within the membrane for most if not all the extracellular molecules.

synthesis. Core protein is synthesized within the RER and moves into the Golgi complex, where polysaccharide attachment, elongation, and sulfation occur. The formation of polysaccharide chains depends upon the activity of six different **glycosyltransferases,** whereas sulfation occurs because of the sulfate donation from **3′-phosphoadenine 5′-phosphosulfate (PAPS).**

Degradation of proteoglycans within the connective tissue space depends upon the sequential action of **proteases, glycosidases, deacetylases,** and **sulfatases.**

Staining of GAGs. The sulfated GAGs stain with the basic component of routine staining preparations. As acidic substances, they are basophilic. They stain blue with H&E. They also can bind certain stains whose color changes once the binding is achieved. This property is called **metachromasia.**

PAS reactivity is not usually characteristic of GAGs and proteoglycans. The PAS procedure demonstrates glycoproteins, because the 1,2 glycol groups of attached sugars are oxidized readily during the oxidation time used normally for this stain.

Other structural proteins. Several other structural proteins are involved in tissue integrity.

Fibronectin (L *fibra,* fiber; *nectere,* to tie) is a product of various cells in culture (fibroblasts, myoblasts, some epithelial cells), with a molecular weight of approximately 230,000 daltons. This glycoprotein contains about 5% carbohydrate. Three types of fibronectin have been identified. A **plasma fibronectin** circulates in the blood and is believed to enhance blood clotting, wound healing, and phagocytosis. **Cell surface fibronectin** serves to bind cell surfaces to associated matrices. This glycoprotein appears early in the embryo and has been identified as a basement membrane component. **Matrix fibronectin** occurs in the extracellular matrix, assisting with cell adhesion to and migration through the matrix.

Laminin is a large glycoprotein with a molecular weight of about 660,000 daltons. It is a component of basal laminae that attach nonconnective tissue cells to collagenous fibers.

Tenascin, entactin, and **nidogen** are additional adhesive glycoproteins contributing to the cell/basal lamina/matrix

interface. It is estimated that over 40 additional adhesive molecules are involved in this interface. Figure 6-13 illustrates the possible relationships between cell, basal lamina, and matrix.

Chondronectin is a large glycoprotein connecting chondrocytes to collagenous fibers in a manner similar to that described for fibronectin.

TISSUE FLUID

Body Fluids and Ground Substance

Body water. The total volume of water in the body constitutes about 65% of the body's weight. This percentage is related more directly to the mass of lean tissues than to the actual body weight. Lean animals contain a higher percentage of water than do obese animals. Water volume is distributed unequally; tissues and organs contain different but characteristic amounts of water. This unequal distribution of water is divisible into two compartments—**extracellular fluid** and **intracellular fluid** (Fig. 6-14). Approximately 24% of the total fluid volume is extracellular and includes the **plasma (4%), interstitial** or **tissue fluid (15%),** and **transcellular fluid (5%).** Transcellular fluids occur in the body cavities, hollow visceral organs, and the eye and as glandular secretions. The remaining 41% of the fluid is intracellular. These separate fluid compartments are exchangeable and in a state of flux.

Plasma, tissue fluid, and lymph. The **plasma** or intercellular fluid phase of the blood contains crystalloids and plasma proteins (albumin, globulins, fibrinogen). The proteins do not leave the blood in significant quantities normally; only water and crystalloids freely access the connective tissue space. **Tissue fluid** is plasma without most of its proteins. The tissue fluid gaining access to the lymphatic capillaries is called **lymph.** Lymph contains significant quantities of proteins. Plasma proteins entering the interstitium are returned to the general circulation via lymphatic vessels.

Ground substance and tissue fluid. The unique characteristics of the connective tissues are attributable to the nature of the constituent GAGs. These substances, as proteoglycans, bind most of interstitial fluid. Despite the interchangeability of all fluids, large fluid volumes do not leave the vascular bed, traverse the interstitial space, and enter the cell as intracellular water. Actual fluid flow through the interstitium does occur, but the movement is achieved by **diffusion**—the movement of fluid and dissolved substances molecule by molecule down their concentration gradients through the intercellular space.

If five molecules were to enter the interstitium from the vascular bed, then five would leave the interstitium and enter the cells, vascular beds, or lymphatic capillaries. The five molecules leaving the interstitium would not be the same ones that entered. Such movement is the result of a "domino" or cascade effect upon the tissue fluid and all dissolved ions within the interstitium. Diffusion is a rapid and efficient mechanism for transport of materials through the interstitial space.

Because dissolved substances and water are essential for normal cellular function, the interstitium assumes a transport role critically important to the well-being of cells. Unfortunately, routine preparations of proper connective tissues do not show the components except as spaces between constituent fibers and cells.

Vascular and tissue fluids. Metabolites and oxygen must traverse the tissue fluid before the cells are reached. Metabolic waste products traverse the tissue fluid and are transported in the blood to their appropriate sites of excretion (kidneys) or exchange (lungs). Although a basal lamina and endothelial barrier separate the vascular compartment from the extravascular compartment (tissue fluid compartment), these spaces may be considered a continuum based on the movement of fluids, crystalloids, and gases between these two compartments. These dissolved substances diffuse randomly to or from the vascular compartment through spaces between endothelial cells or through fenestrations within endothelial cells. Pinocytotic vesicles, which may be apparent in the endothelial cells, do not account for the rapid movement of diffusible particles and water. They may help in the transcapillary movement of macromolecules between the two fluid compartments. The selective permeability of endothelial cells precludes, except for a small amount, the transport of macromolecules (proteins) across this barrier.

The movement of fluid and dissolved substances is governed by hydrostatic and osmotic pressure relationships regulating the delicate fluid balance within the body. The hydrostatic pressure (HP) within the capillary beds continuously moves fluid and its dissolved substances into the connective tissue space. Continuous loss of fluid from the vascular space would occur were it not for the osmotic pressure of the plasma proteins of the capillary beds, pulling fluid from the interstitial space back into the capillary space. Although these simple relationships represent the essence of the mechanism, the maintenance of fluid balance is more complicated than that.

Hydrostatic and osmotic relationships

The movement and distribution of fluid depend upon the balance of four factors—**capillary hydrostatic pressure (HP), interstitial HP, capillary colloid osmotic pressure (COP),** and **interstitial COP.**

Capillary pressures. Precise measurements of **capillary HP** are difficult to obtain. A reasonable estimate of **arterial capillary HP** is 25 mm Hg whereas a similarly reliable estimate of **venous capillary HP** is 10 mm Hg. The arterial capillary HP is due to the mechanical activity of the heart and peripheral vascular elements. Vascular smooth muscle contributes actively to the maintenance of peripheral blood pressure. Based upon their physical characteristics (modulus of elasticity), collagen fibers and elastic fibers contribute passively to the maintenance of peripheral blood pressure. The reduced HP on the venous side of the capillary bed is a consequence of fluid loss and the inability of the walls of the capillaries to contribute significantly to intravascular HP.

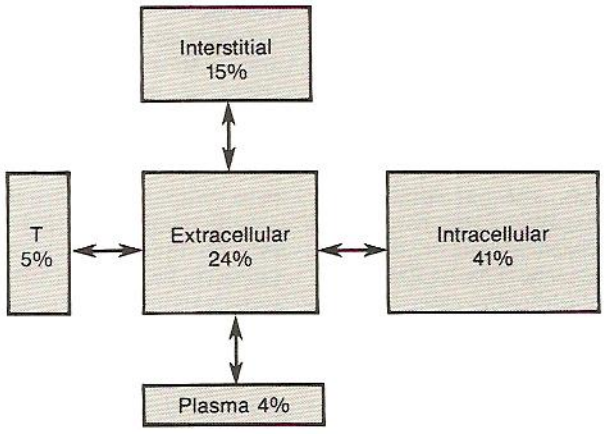

Figure 6-14. Distribution of fluids within the animal body. The percentages are based upon water comprising 65% of the body weight. The 24% extracellular fluid consists of transcellular fluids *(T)*, plasma, and interstitial fluid. The fluids move freely between all fluid compartments.

The **capillary COP** is from proteins and ions dissolved in the plasma. The proteins contribute because they do not move readily across the semipermeable "capillary membrane." Also the **Gibbs-Donnan equilibrium effect** essentially increases the osmotic pressure by approximately 50% more than exerted by the proteins alone. The negative charges of the proteins are balanced by the positive charges of the cations, predominantly Na^+, increasing the number of particles and the osmotic pressure.

The COP of plasma is approximately 28 mm Hg. The plasma concentration and size of albumin dictate that this plasma protein contributes 70% to 75% of the osmotic pressure. Because very few plasma proteins diffuse into the interstitial space, the COP on the venous side of the circulation stays the same. **This pressure is the single significant factor influencing the return of fluid to the capillary bed.**

Interstitial pressures. The **interstitial HP** has been just as difficult to determine as the capillary HP. The interstitial HP referred to in this discussion results from the pressure exerted by the free fluid. The interstitial HP is −6.3 mm Hg. This negative or subatmospheric HP within the interstitial space is explained by direct measurements, by the mathematical necessity of balancing all pressures across the capillary wall, and by the suction effect of the lymphatic capillaries upon the interstitial space. The negative HP within the interstitium tends to "suck" fluids out of the capillaries and to hold elements of the tissues close together.

Although many proteins occupy the extracellular space, very little protein leaks from the vascular bed to be transported within the tissue fluid. Nevertheless, this small amount of protein makes the **interstitial COP** approximately 5 mm Hg, or some 18% of the capillary COP.

Mechanisms of exchange. The random movement of crystalloids and ions across the capillary wall is augmented by filtration. Filtration is the movement of fluids and dissolved solutes across the capillary boundary.

Arterial CHP is 25 mm Hg, exceeding the interstitial HP, which is −6.3 mm Hg. The **effective HP (EHP)** of the arterial capillary bed is the sum of both pressures (31.3 mm Hg) (Fig. 6-15). The intravascular pressure tends to push fluid into the interstitium, while the negative pressure within the interstitium tends to suck fluids into the interstitial space. Both combine to move fluids into the extracellular space.

The plasma proteins, principally albumin, contribute to the COP of the blood. This is approximately 28 mm Hg in the arterial capillary bed; the COP of the tissue fluid is about 5 mm Hg. The **effective COP (ECOP)** in the arterial capillary bed is 23 mm Hg, favoring the movement of water into the capillary bed (Fig. 6-16). (Remember that, when separated by a semipermeable membrane, water moves from the area of low osmotic pressure or low solute concentration to the area of high osmotic pressure or high solute concentration.) The **net driving force** (EHP minus ECOP) in the arterial capillary is 8.3 mm Hg (Fig. 6-14). Therefore the movement of fluids from the capillary bed to the connective tissue compartment occurs normally under the influence of a **filtration pressure** of 8.3 mm Hg (Fig. 6-16).

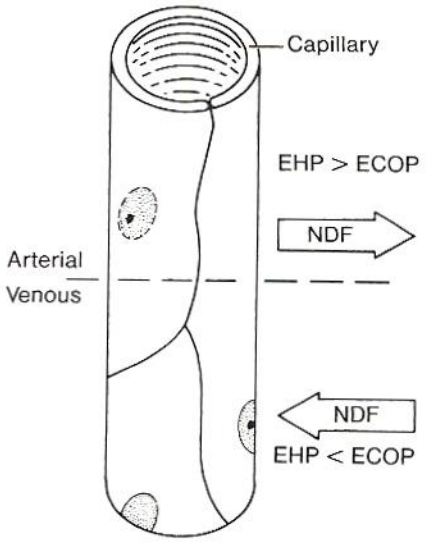

Figure 6-15. Filtration across the capillary bed. Movement of fluids and solutes from the capillary bed into the connective tissue space occurs on the arterial side of the capillary bed because the *EHP* is greater than the *ECOP* in this region. The net driving force *(NDF)* is reversed on the venous side of the capillary bed, because the *ECOP* is greater than the *EHP*.

The net outward driving force ensures that fluids will be "pushed" into the tissue fluid space, and a gradual change in the governing parameters ensures that they will return to the venous side of the capillary bed (Fig. 6-15). As fluids leave the capillary bed, the HP within the venous capillary is reduced to 10 mm Hg while the tissue HP is maintained at −6.3 mm Hg. The sum of these values is the EHP on the venous side of the capillary bed. The EHP (16.3 mm Hg) in the venous capillary still favors the movement of fluid into the interstitial space. The COP of the blood and tissue fluid remains somewhat constant at 28 and 5 mm Hg, respectively. The ECOP in the venous capillary is the difference between these pressures or 23 mm Hg inward. A net driving force of 6.7 mm Hg (**reabsorption pressure**) favors the return of fluids to this portion of the capillary.

The filtration pressure (8.3 mm Hg) moves about 0.3% of the plasma fluid volume into the connective tissue compartment during a 24-hour period. The reabsorption pressure (6.7 mm Hg) moves about 90% of the filtered fluid from the connective tissue space back into the vascular bed. The remaining 10% of the fluid not returned to the vascular bed would destroy these filtration and reabsorption relationships were it permitted to remain in the interstitium. However, the fluid and a small amount of protein are returned to the general circulation via the lymphatic vessels.

This exchange mechanism accounts for the continuous fluid formation and turnover throughout the body. Although the numerical parameters vary slightly between specific locations, the relationships between HP and COP do not. This mechanism ensures that cells are bathed continuously in a fluid environment conducive to their homeostasis. This mechanism is also important in the formation of urine.

Lymphatic channels and fluid balance. All connective tissue spaces, directly or indirectly, contain lymphatic capillaries as blind-ended structures originating within the interstitium. Most organs, but not even all lymphatic organs, have lymphatic capillaries. These vessels are the medium through which potential residual fluid (10% of which had been filtered) is returned to the cardiovascular system indirectly. Ninety percent of the filtered plasma fluid is returned to the cardiovascular system directly. Although the amount of protein that moves into the interstitium during a given short period is small, more than 50% of the plasma proteins leak into the interstitium daily. Their return is essential for the maintenance of proper osmotic pressures

Downloaded From Vet-ebooks.com

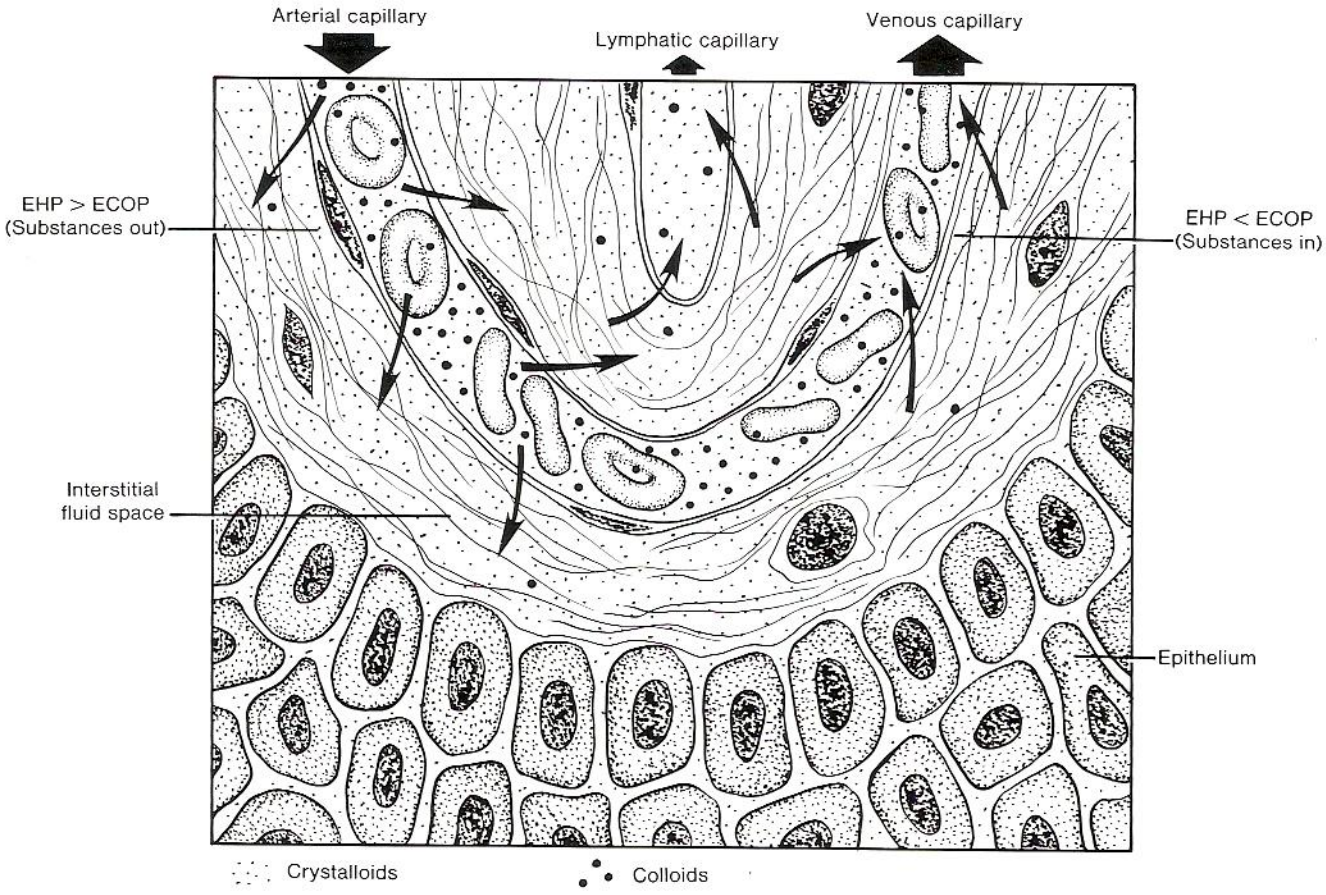

Figure 6-16. Normal movement of fluids and crystalloids between the capillary bed and the fluid space (connective tissue compartment). The basal lamina is not shown but separates the connective tissue from the nonconnective tissues. Substances move into the connective tissue compartment on the arterial side of the capillary bed and are returned to the capillary bed on the venous side. Few colloids escape into the interstitial space. The labels used for this figure are applicable to Figures 6-15 to 6-20. (Figs. 6-16 to 6-20 were redrawn and modified from Ham AW: *Histology*, ed 7, Philadelphia, 1974, JB Lippincott.)

within the vascular system and extracellular space.

Lymphatic channels are branching vessels that drain most of the body. The peripheral portions are the lymphatic capillaries. These fuse to form larger venules; venules fuse to form larger veins; larger veins coalesce to form the cisterna chyli, continuing with the thoracic duct. The thoracic duct returns lymph to the general circulation at the subclavian or external jugular veins (species variable).

Lymphatic capillaries are permeable structures with gaps between adjacent endothelial cells. The gaps are covered by cytoplasmic processes **(marginal folds)** forming one-way valves. The valves open inwardly to permit the ingress of fluid but close to prevent fluid from moving back into the interstitial space. Collagenous and reticular fibers are **anchoring filaments** that connect the endothelial cells to the connective tissue space. The sparse remnants of the basal lamina are the points of endothelial attachment for the anchoring filaments.

This morphology permits a one-way slow flow. The amount of lymph flow in the thoracic duct is about 2 ml/kg/hr. Despite this sluggish rate, the entire plasma volume is exchanged every 24 hours. Exercise increases lymph flow by as much as 15 times the normal rate at rest. Lymph flow is affected by tissue fluid pressure, skeletal muscle contraction, lymphatic vessel contraction, arterial pulsations, and body movements.

Fluid moves into the lymphatic capillaries despite the normal negative interstitial HP. As lymph capillaries expand, they suck fluid into their lumina. Periodic compression of the connective tissue space causes a transitory rise in pressure, propelling fluid into the lymph capillaries. Any factor causing an increased interstitial fluid pressure, except lymph obstruction, causes an increase in the lymph flow. These factors include increased capillary HP, decreased capillary COP, increased interstitial COP, and increased capillary permeability.

Lymphatic vessels have valves ensuring a one-way flow (centrally) when the luminal volume of the vessel is reduced due to body movement, skeletal muscle contraction, or contractions of the smooth muscle lining the wall of larger lymphatic vessels. Arterial pulsations also compress the fluid volume with the lymph vessels, because these vessels are companions to each other. Decreased luminal volume in one segment propels the fluid centrally. Upon return to normal luminal size, the fluid is trapped in the adjacent segment by closing of the one-way valve. A progressive series of contractions, either intrinsic or extrinsic, causes the lymph to move continually in one direction.

The mechanisms affecting large lymph vessels apply equally to lymph capillaries. The transitory accumulation of plasma proteins in the interstitium aids in the pumping activity of lymph capillaries. Fluid return to the venous circulation is accompanied by an accumulation of plasma proteins in the interstitium, which increases the interstitial COP. The increased interstitial COP decreases tissue fluid return to the venous capillaries, and the result is an increased interstitial HP. This increased pressure functions as a pump, returning both fluid and protein to the lymph capillaries. Thus it can be seen that the periodic washout of fluid from the interstitium returns essential plasma proteins and fluid to the general circulation.

Downloaded From Vet-eBooks.com

Alterations to Fluid Exchange

Many factors can influence and alter the delicate balance existing among the fluid components of the vascular system, lymphatic system, and connective tissue compartment. Alterations (excessive or inadequate water intake, electrolyte imbalances, protein deficiencies, inflammatory processes, systemic diseases) can be manifested as a localized or generalized disruption of fluid balance.

Fluid accumulation. **Edema** is the retention and subsequent accumulation of tissue fluid resulting when the interstitial HP becomes positive. Systemic and/or regional edematous conditions do not occur readily. As a clinical manifestation, edema is usually the result of serious disease processes. Two specific mechanisms provide a safety margin for fluid accumulation. The ground substance can absorb about 30% more fluid than present normally. Lymph flow mechanisms provide an additional margin of safety. This flow is influenced by the negative interstitial HP, lymphatic capillary pumping and interstitial protein washout mechanism. Lymph flow provides a mechanism requiring a 70% increase in capillary HP before edema is observed. Also an approximately 70% reduction of capillary COP is necessary before an edematous condition is achieved. Despite these safety factors, edema does occur. Four basic mechanisms disrupt normal exchange and account for the excessive formation of tissue fluid.

Lymphatic obstruction (Fig. 6-17) prevents tissue fluid return to the circulation, resulting in a fluid increase within the connective tissues. This increases the tissue fluid HP. An accumulation of proteins occurs in the connective tissue compartment, increasing the connective tissue COP and attracting and holding more water. Certain parasitic diseases and metastatic tumors may cause lymph obstruction. Solid tumors may grow around and occlude lymph channels.

Increased capillary permeability (Fig. 6-18) results in plasma leakage into the connective tissue. An increased interstitial COP due to these excess proteins increases the tissue fluid. The blood also diminishes its ability to re-attract water into the capillaries. Inflammation, allergic reactions, toxic substances, and burns may cause edema due to increased capillary permeability.

Decreased vascular COP (Fig. 6-19) is associated with a decreased concentration of plasma proteins. Such a deficiency diminishes the ability to attract fluid into the blood from the connective tissue. Hypoproteinemia may result from liver disorders, excessive protein loss in the urine, protein malnutrition, excessive protein loss through the digestive tract, and parasitism.

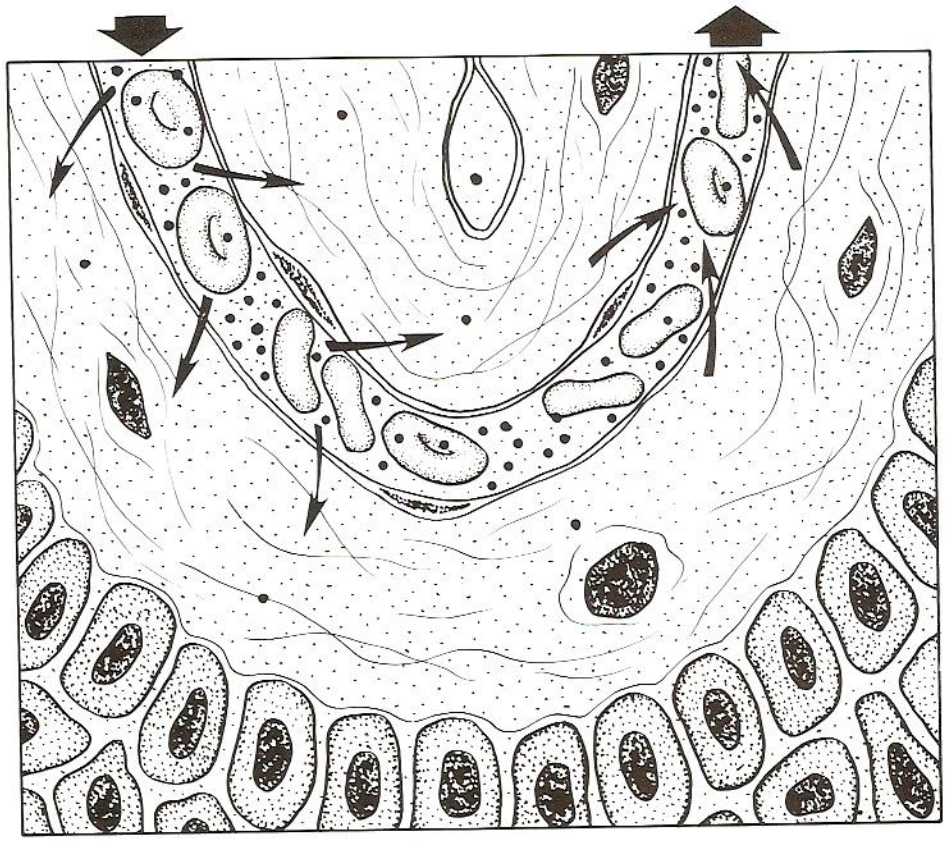

Figure 6-17. Altered tissue fluid formation and exchange due to lymphatic obstruction. Lymphatic obstruction causes excessive fluid and colloids to accumulate in the interstitial fluid space. The interstitial compartment swells and alters cell and matrix component relationships.

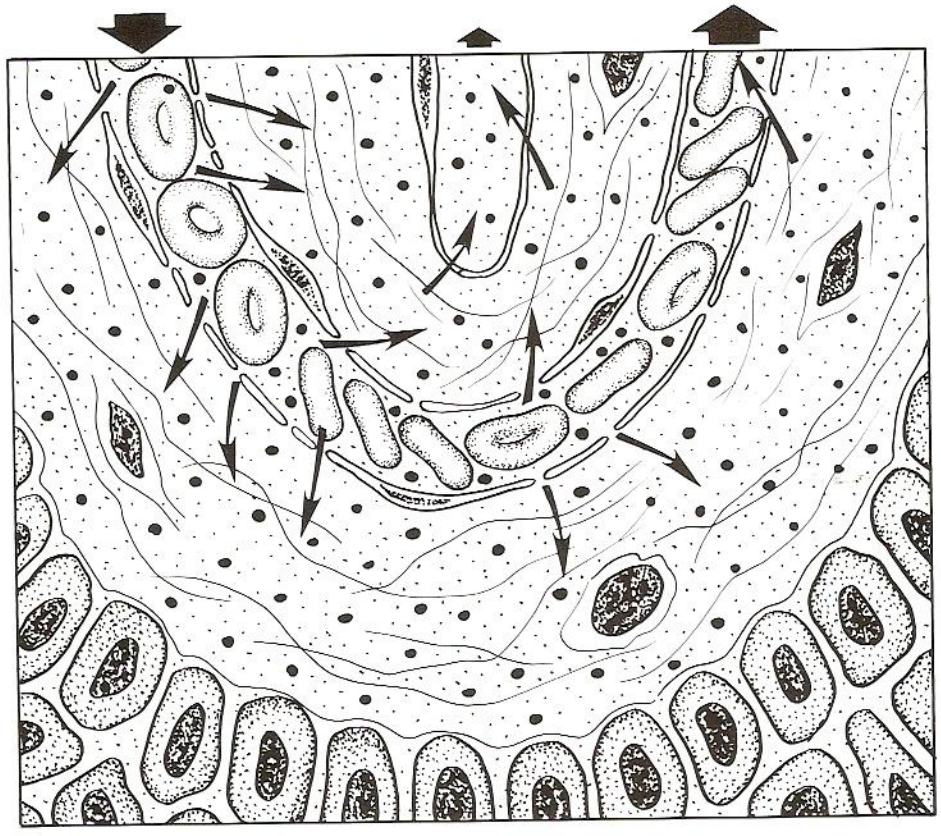

Figure 6-18. Altered tissue fluid formation and exchange due to an increase in capillary permeability. The movement of colloids into the interstitial space causes the space to swell.

Downloaded From Vet-eBooks.com

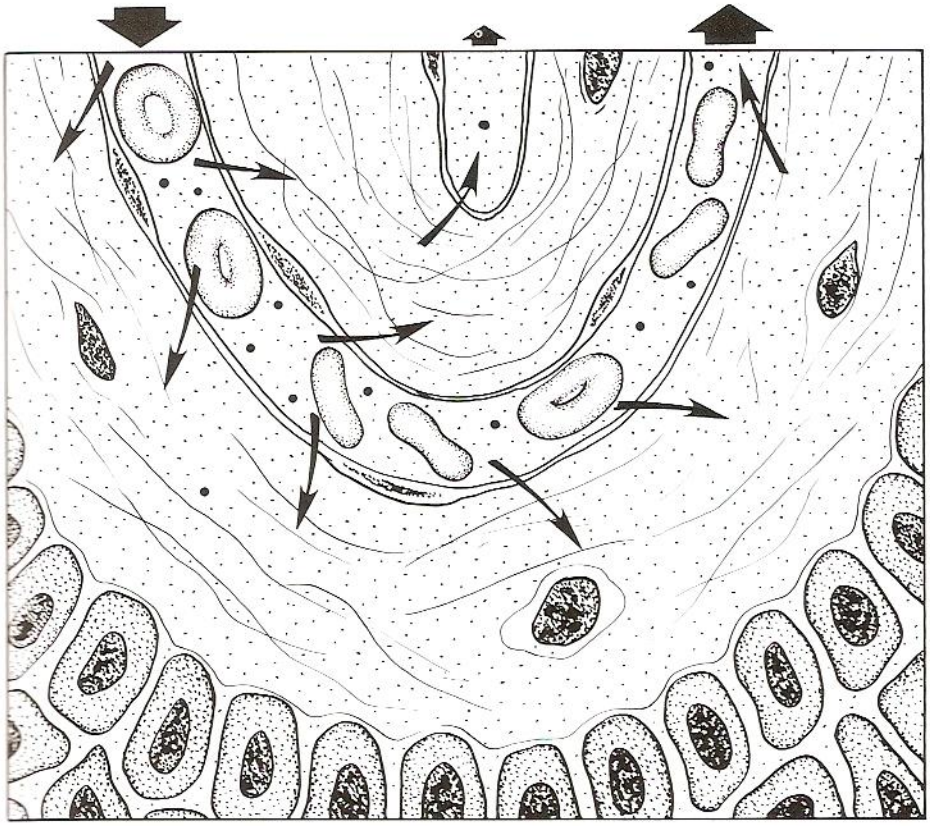

Figure 6-19. Altered tissue fluid formation and exchange due to a decrease in the COP. The capillary bed has a diminished ability to attract fluids. The fluids accumulate in the interstitial space, and swelling results.

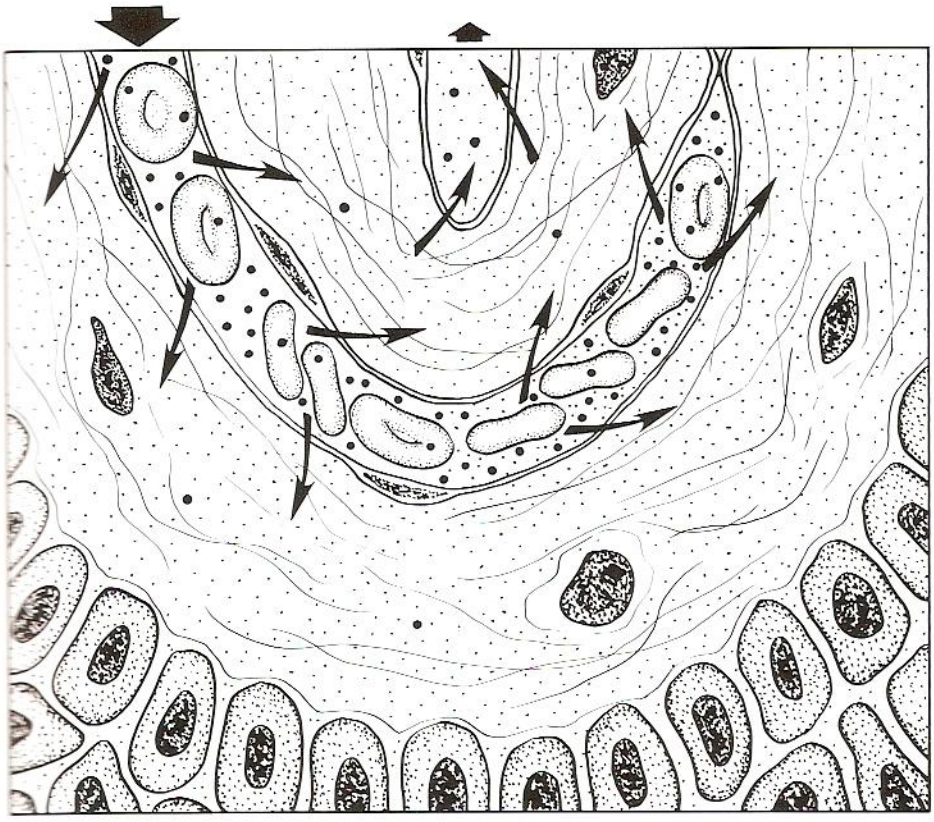

Figure 6-20. Altered tissue fluid formation and exchange due to an increase in the capillary HP induced by venous obstruction. The capillary HP increases and fluids are retained within the interstitial space. Swelling results.

Increased capillary HP (Fig. 6-20) is the result of venous obstruction. When the hydrostatic pressure exceeds the capillary COP, fluids are retained in the connective tissue compartment. Increased capillary HP may be due to **congestive heart failure, inflammation of veins, increased pulmonary resistance,** or **tight bandages.** Generally, elevated venous blood pressure causes edema.

The real significance of the altered exchange associated with these problems is not the swelling. The swelling expands the connective tissue compartment and may compromise the nutritional environment of cells. Diffusion distances for metabolites are increased and waste products of metabolism accumulate.

ADDITIONAL READINGS

Bensley SH: On the presence, properties, and distribution of the intercellular ground substance of loose connective tissue, *Anatomy* 60:93, 1934.

Burgeson E: Structure and biology of proteoglycans, *Ann Rev Cell Biol* 4:229, 1988.

Chain E, Duthie ES: Identity of hyaluronidase and the spreading factor, *Br J Exp Pathol* 21:234, 1940.

Eyre DR: Collagen: molecular diversity in the body's protein scaffold, *Science* 207:1315, 1980.

Fahrenback WH, Sandberg LB, Cleary EG: Ultrastructural studies on early elastogenesis, *Anat Rec* 155:563, 1966.

Ghadially FN: *Ultrastructural pathology of the cell and matrix: a text and atlas of physiological and pathological alterations in the fine structure of cellular and extracellular components*, ed 2, London, 1982, Butterworths.

Ginsberg V, Robbins P (eds): *Biology of carbohydrates*, vol 1, New York, 1981, John Wiley.

Greenlee TK Jr, Ross R, Hartman JL: The fine structure of elastic fibers, *J Cell Biol* 30:59, 1966.

Gross J: Collagen, *Sci Am* 204:120, 1961.

Hall DA: *The ageing of connective tissue*, New York, 1976, Academic Press.

Hay ED: Extracellular matrix, *J Cell Biol* 91:205s, 1981.

Hynes RO: Fibronectins, *Sci Am* 254:42, 1986.

Hynes RO: Integrins. A family of cell surface receptors, *Cell* 48:549, 1987.

Lillie RD: Histochemistry of connective tissues, *Lab Invest* 1:30, 1952.

Mancini RE: Connective tissue and serum proteins, *Int Rev Cytol* 14:193, 1963.

Martin GR, Timpl R: Laminin and other basement membrane components, *Ann Rev Cell Biol* 3:57, 1987.

Martin GR, et al: The genetically distinct collagens, *Trends Biochem Sci* 10:285, 1985.

Miller EJ: Biochemical characteristics and biological significance of the genetically distinct collagens, *Molec Cell Biochem* 13:165, 1976.

Petruska AJ, Hodge JA: A subunit model for the tropocollagen macromolecule, *Proc Natl Acad Sci USA* 51:871, 1964.

Prockop DJ, et al: The biosynthesis of collagen and its disorders, *N Engl J Med* 301:13, 1979.

Ruoslahti E: New collagens, new concepts, *Ann Rev Cell Biol* 4:551, 1988.

Schubert M: *A primer on connective tissue biochemistry*, Philadelphia, 1968, Lea & Febiger.

Snodgrass MJ: Ultrastructural distinction between reticular and collagenous fibers with an ammoniacal silver stain, *Anat Rec* 187:191, 1977.

Spicer SS, Horn RG, Leppi TJ: Histochemistry of connective tissue mucopolysaccharides. In Uy R, Wold F: Post-translational covalent modifications of proteins, *Science* 198:890, 1977.

Wagner BM, Smith DE (eds): *The connective tissue*, Baltimore, 1967, Williams & Wilkins, pp. 251-303.

Watt FM: The extracellular matrix and cell shape, *Trends Biochem Sci* 11:482, 1986.

Downloaded From Vet-eBooks.com

CHAPTER 7

Proper Connective Tissues and Adipose Tissue

GENERAL CHARACTERISTICS

Form and function. Connective tissues are a diverse group of structures. They consist of heterogeneous populations of cells separated from each other by copious amounts of **extracellular material (intercellular substance).** The fibrous and amorphous components comprise the connective tissue **matrix.** The fibers may impart a feltwork or weavelike consistency to the matrix. The **ground substance** is the amorphous component consisting of **glycosaminoglycans** and **proteoglycans.** These substances fill the intercellular and interfibrillar spaces and form a three-dimensional framework connecting and supporting other tissues and organs. The relative number and types of cells and the amount and types of matrical components vary in response to structural and functional needs (Fig. 7-1).

Connective tissues **connect** one tissue or organ to another and **suspend** organs from the body wall or other organs. Various connective tissues **insulate** organs from mechanical damage, and they account for the **form** of the organs. They are an important line of **defense,** because many protective cells are part of their cell populations. Some connective tissues are the means by which infective agents spread throughout a region or to other regions via established fascial planes. The connective tissues also serve a **nutritive** function. Not only do vascular beds have to traverse connective tissues to reach other tissues, metabolites likewise have to move through the connective tissue space to reach individual cells.

Heat regulation, water utilization, and **food storage** are also important functions. These tissues aid in **support** and **locomotion** with other tissues. Additionally, some play an important role in **repair** and **regeneration.** Most connective tissues can regenerate and/or repair themselves after injury. Some nonconnective tissues are unable to repair themselves and must rely upon certain connective tissues to replace damaged components.

Origin of connective tissue. All connective tissues are derivatives of mesoderm. This compartment of mesenchyme begins early in development as a well-defined, well-delineated, and continuous space bounded by the ectoderm and the endoderm. Many tissues develop within this space. The **mesenchymal cell** is the stem cell for all mesodermal derivatives (Fig. 7-2).

Development is characterized by a continuous and progressive "invasion" of the connective tissue compartment by invagination of cells from the ectoderm and endoderm. The continuous development of cavities within the mesoderm (celomic spaces), the differentiation of vascular elements (endothelium), and the formation of muscles and supportive tissues all tend

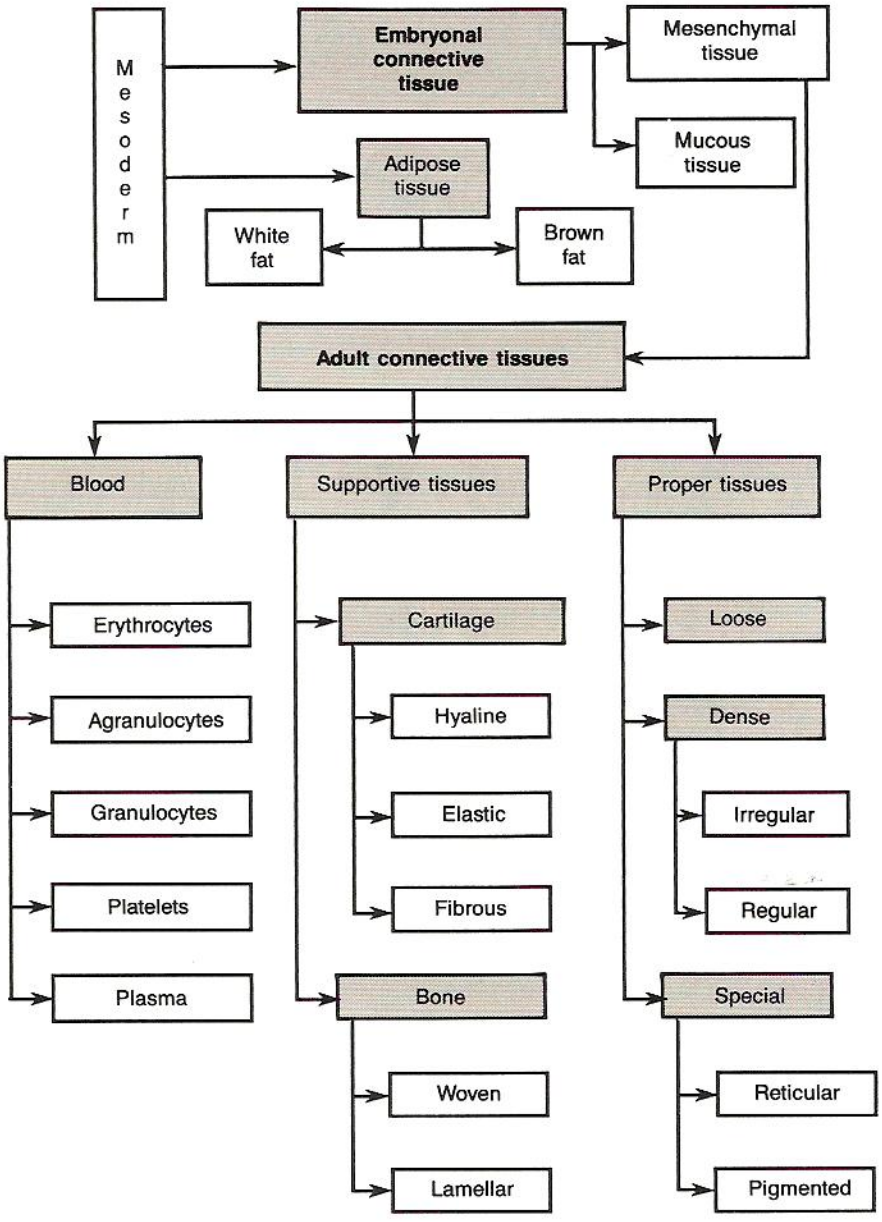

Figure 7-1. Organizational scheme of connective tissue.

Downloaded From Vet-eBooks.com

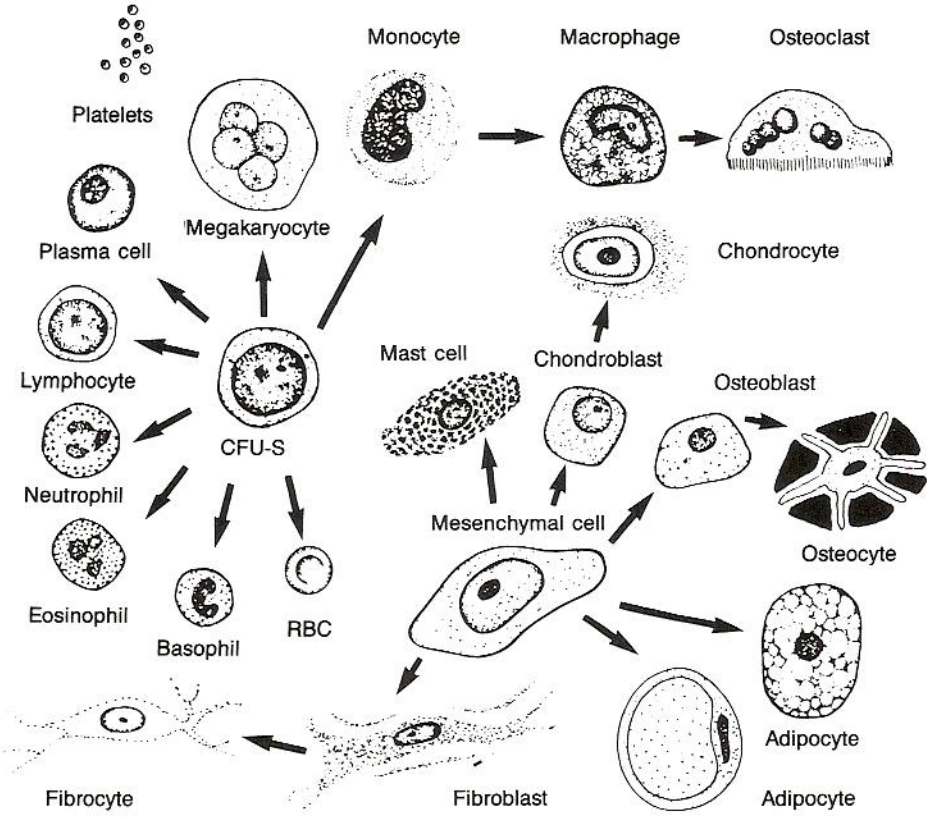

Figure 7-2. Connective tissue cell derivatives. All connective tissue derives directly from mesenchymal cells. Mature blood cells derive from the colony-forming unit (CFU). The relationship of the *CFU-S* (stem cell) to the mesenchymal cell is not clear. Detailed relationships among these cells are discussed in subsequent chapters.

to infringe upon this compartment. The net result is conversion of the connective tissue compartment into a tortuous, irregular, and "apparently" discontinuous array of spaces (Fig. 7-3).

Those elements invaginating into or developed within the connective tissue never actually enter the connective tissue compartment. They are separated from it by the ever-present basal lamina. The relationship is similar to attempting to enter the air-filled space of a balloon by pushing a finger into it. The finger never gains access to the space but is always covered by the wall of the balloon. The basal lamina is analogous to this wall.

As ectodermal and endodermal derivatives infringe upon the connective tissue compartment, they essentially "push" the basal lamina in front of them. Even nonconnective elements developing within the mesenchyme secondarily develop a basal lamina. **The basal lamina separates all connective tissues from nonconnective tissues.** A few noteworthy exceptions exist.

The basal lamina may be considered the peripheral limit of the connective tissue compartment. Cells of connective and supportive tissues are devoid of a basal lamina. Adipose tissue is highly cellular, has little intercellular matrix, and each cell is covered by a basal lamina. As with muscle, adipose tissue may be considered a separate and distinct tissue.

Unique relationships. The connective tissue compartment is intimately associated with all tissues. Metabolites carried by the vascular system must leave the capillaries and cross the basal lamina of the endothelial cell. They traverse the connective tissue compartment within interstitial fluid and cross another basal lamina before being incorporated into a nonconnective tissue cell. Waste products of metabolism follow the reverse sequence. Connective tissue cells are bathed continuously by this fluid **(connective tissue fluid** or **interstitial fluid).** This fluid, also called **extracellular fluid (ECF),** comprises a vast compartment. The peripheral limits of the ECF compartment correspond to the limits of the connective tissue space as delimited by the basal lamina.

The connective tissue space is the compartment within which the organism mounts specific (humoral antibodies, cell-mediated immunity) and nonspecific immune responses (phagocytosis). The resident populations of cells (macrophages and mast cells) and transient populations of cells (neutrophils, eosinophils, plasma cells) contribute to protection.

Classification. The relationships among these tissues are outlined in Figure 7-1. Four criteria are used to classify connective tissues— **predominant cell type or types, type of fibrous components of the matrix, number of fibers in a unit volume of the matrix,** and **orderliness of the matrical components.**

RESIDENT CELL POPULATIONS

The cell population of any connective tissue will vary with the tissue and its physiological state at the time observed. However, some cells of connective tissues are encountered frequently. These may be called the **resident cell population.**

Mesenchymal cells. The **mesenchymal cell** is a stellate or spindle-shaped cell with a high nuclear to cytoplasmic ratio. It has a large, vesicular nucleus rich in euchromatin (Fig. 7-4). The cytoplasm is acidophilic and scant. In most preparations the cytoplasm is indistinguishable from surrounding matrical components (Plate II, *6*). At the ultrastructural level the predominant cytoplasmic organelle is the polyribosome (Fig. 7-5). The combination of prominent euchromatin and extensive free polyribosomes indicates the high protein synthesis potential of this cell. Few other organelles are apparent.

Although mesenchymal cells are scattered throughout the connective tissue space, they are usually difficult to iden-

Downloaded From Vet-eBooks.com

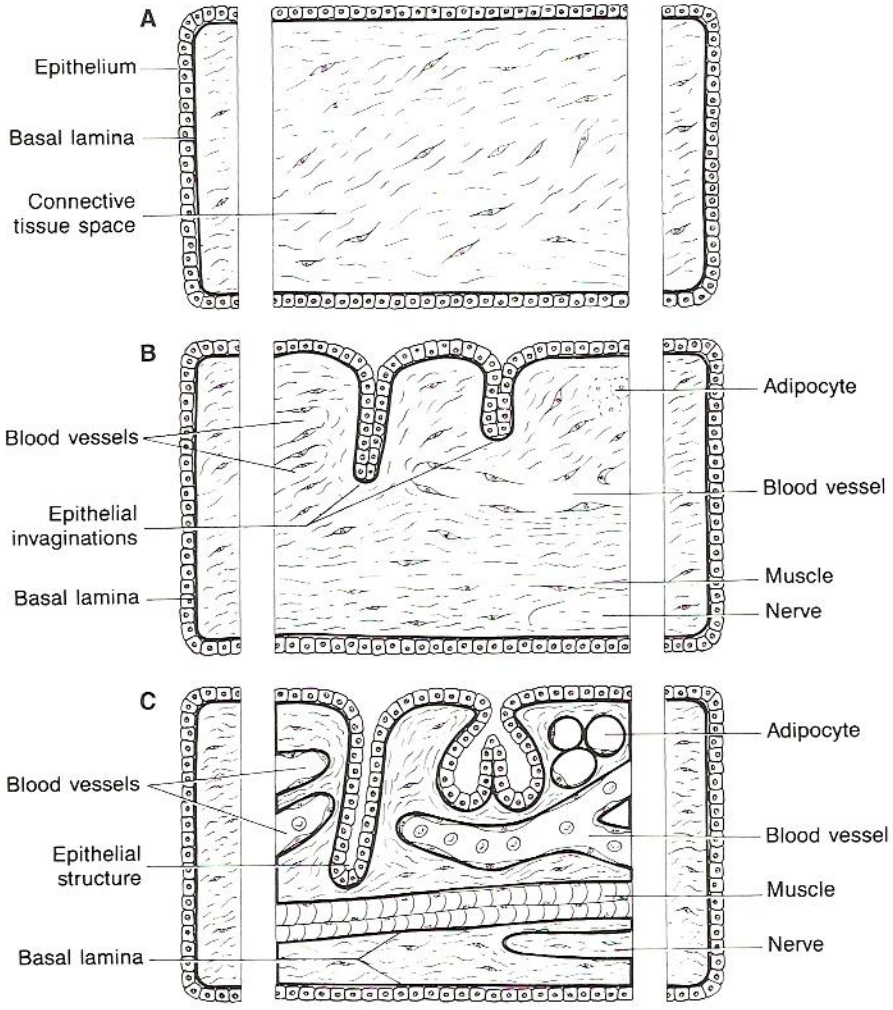

Figure 7-3. Connective tissue space and basal lamina. Although the connective tissue space, as defined by the peripherally positioned basal lamina, is continuous, it is represented as discontinuous in these diagrams to imply its vastness. A single closed compartment in a diagram does not do justice to it. **A,** Early in development the connective tissue space may be visualized as a compartment consisting exclusively of connective tissue components—mesenchymal cells, fibroblasts, fibers, and amorphous matrix materials. The boundary of the compartment is defined by the basal lamina *(dark black line)*. **B,** As development progresses, various cells differentiate within or invade the compartment. **C,** Complete development of components intimately associated with the connective tissue has been achieved. Although the connective tissue compartment is reduced in volume and irregularly shaped, its integrity is maintained. Nothing has actually gained access to the compartment. The basal lamina still separates connective tissue components from nonconnective tissue components.

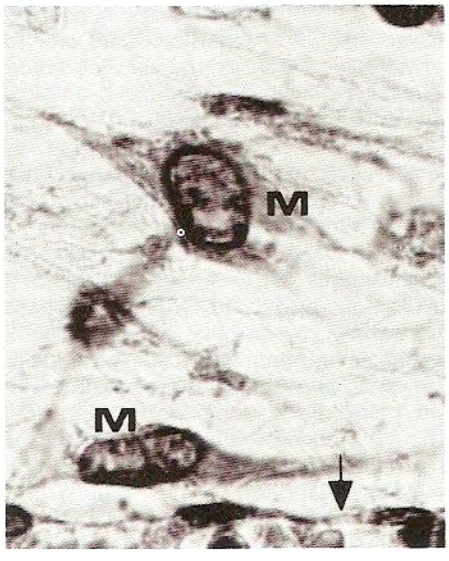

Figure 7-4. Mesenchymal cells from a perivascular space within loose collagenous tissue. The cells *(M)* are typical and occur close to a capillary bed. The *arrow* points to endothelial cells of the capillary. (X400.)

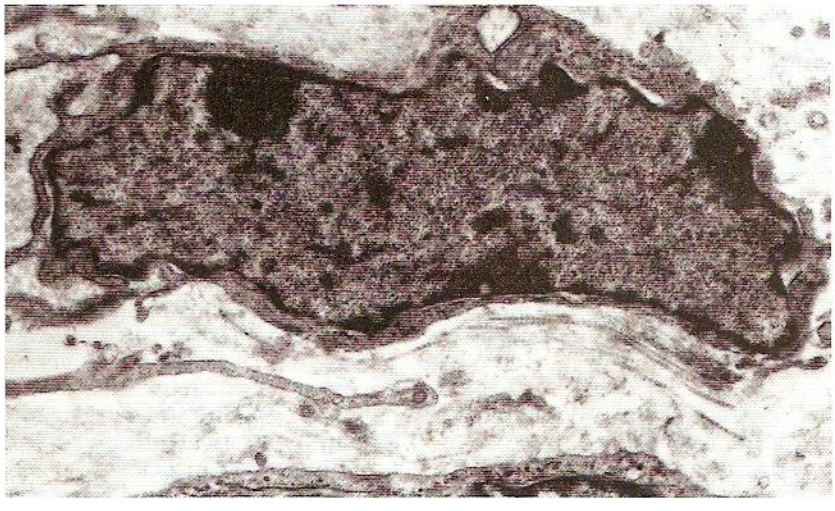

Figure 7-5. Electron micrograph of a mesenchymal cell. The ratio of nuclear to cytoplasmic volumes is large. (X12,000.)

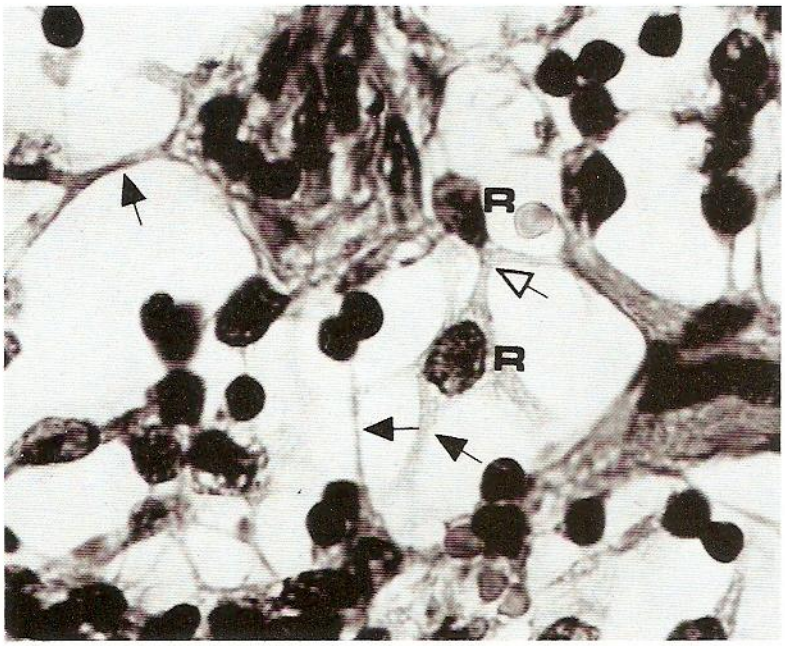

Figure 7-6. Reticular cells of the medullary region of a canine lymph node. The cells *(R)* extend cytoplasmic processes *(solid arrows)*, which contact similar processes of other reticular cells. These relationships form the cellular reticulum characterizing these organs. Points of contact between the stellate cells *(open arrows)* are occasionally apparent. (X320.)

Figure 7-7. Fibroblasts of loose collagenous tissue. The cytoplasm is barely visible whereas the vesicular nuclei are quite apparent. Collagen fibers are oriented randomly throughout the section. (X340.)

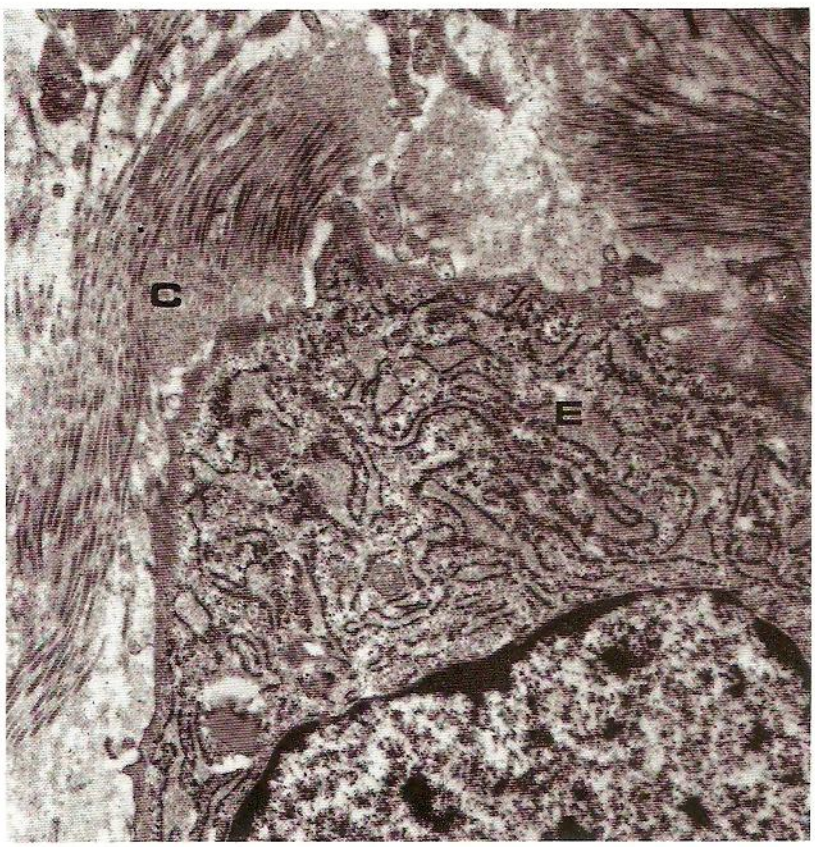

Figure 7-8. Electron micrograph of a fibroblast. The cell contains extensive quantities of RER profiles *(E)* filled with a granular material. Collagenous fibers *(C)* are present in the connective tissue space. (X6000.)

tify. They may be most prominent in the perivascular region. These cells are probably the primary means through which **metaplasia** occurs.

Reticular cells. The **reticular cell** is a stellate or spindle-shaped cell occurring in myeloid tissue and lymphatic organs. It generally forms a **cellular reticulum** in association with a fibrous stroma of reticular fibers. The nucleus is round to oval and vesicular (Fig. 7-6). The cytoplasm is extensive and slightly basophilic. The cytoplasmic processes of these cells are in contact with each other and account for the typical **cellular meshwork** or **reticulum.** The reticular cell occurs in association with reticular fibers and is the characteristic resident cell of reticular connective tissue. It is probably a fibroblast.

Fibroblasts. The **fibroblasts,** or fiber-forming cells of the proper connective tissues, are the most frequently encountered cells. Young fibroblasts are stellate or spindle-shaped cells with long cellular processes. The large, oval or round nucleus is vesicular and has a prominent nucleolus (Fig. 7-7). Basophilic cytoplasm is abundant. This active form of the cell has an abundant RER and a well-developed Golgi complex (Fig. 7-8).

Inactive fibroblasts **(fibrocytes)** have nuclei with more heterochromatin than their active counterparts. Fibrocytes are spindle-shaped cells with a scant, acidophilic cytoplasm, if it is visible. A corre-

Downloaded From Vet-eBooks.com

Figure 7-9. Macrophages in a stretch preparation of loose collagenous tissue. The nuclei of the macrophages *(arrows)* are typical. The other cell and matrix components are out of the plane of focus. (X100.)

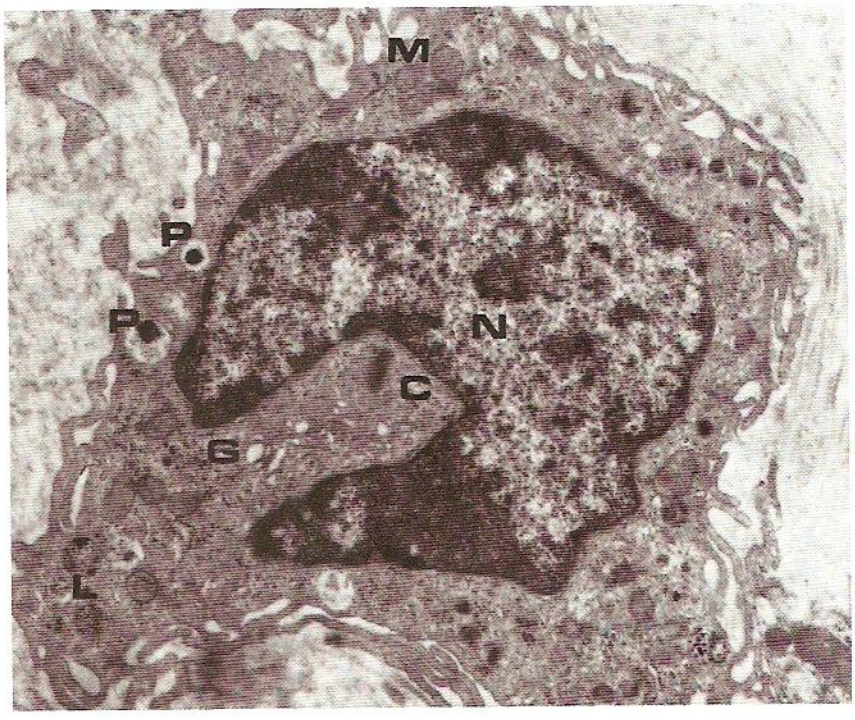

Figure 7-10. Electron micrograph of a macrophage from loose collagenous tissue. The horseshoe-shaped nucleus *(N)* is typical. The Golgi complex *(G)* is well-developed and juxtanuclear. One of the centrioles *(C)* is visible. Mitochondria *(M)* are scattered throughout the cell. Phagosomes *(P)* and lysosomes *(L)* are typical features of active macrophages. (X26,000.)

sponding reduction in their intracellular organelles is characteristic.

Fibrosis, the formation of fibrous connective tissue as a reaction to chronic insult, results from the activity of these cells. Similarly, repair of matrix after injury **(laceration, surgical incision, inflammation)** results from fibroblastic activity. Excessive quantities of fibrous connective tissue **(granulation tissue),** especially characteristic of connective tissue repair in the horse, result from fibroblastic activity.

The fibroblast secretes procollagen; however, the cell's role in polymerization and spatial orientation of procollagen is unknown. The cell and mechanical stresses may contribute to the spatial arrangement of collagen.

Macrophages. **Macrophages** are the resident phagocytic cells of connective tissues. As **fixed** cells, they are most prominent in the pericapillary space. They also may be fixed along the length of collagen fibers. They become **wandering** or **ameboid** upon activation by numerous stimuli.

Macrophages vary from spindle-shaped in the fixed stage to round or oval with blunt cellular processes during their wandering activities. The nucleus is smaller than the fibroblast nucleus and is dark because of a coarse heterochromatin. Lastly, the nucleus is often indented; it is **bean-shaped** (Fig. 7-9). The cell is usually polarized, with the indentation of the nucleus facing the bulk of the cytoplasm. The basophilic cytoplasm may possess a juxtanuclear, pale-staining region.

At the ultrastructural level the prominent organelles are the Golgi complex (in the nuclear indentation), RER, and lysosomes (Fig. 7-10). With light and electron microscopy ingested particles may be apparent if the cell is active.

Macrophages originate from monocytes. Within the confines of the blood vascular system **(intravascular)** this cell is called a monocyte. Once it enters the connective tissue compartment **(extravascular),** it is called a **histiocyte** or macrophage.

Macrophages also fuse to form **giant cells.** Macrophage fusion in response to foreign material may be an attempt to increase surface area for phagocytosis. These **foreign body giant cells** effectively wall off, enclose, or encircle foreign materials. Nodular inflammatory lesions **(granulomas)** consist of these cells encircling foreign matter.

Macrophages fulfill multiple roles important to the organism. They are involved in endocytosis, contributing actively to pinocytosis and phagocytosis of fluids and particulate matter. The uptake may occur independent of or through surface receptors. They also phagocytize pathogenic organisms that have been coated with serum recognition factors called **opsonins.** These are immunoglobulins and components of complement (C3), and the mechanism of their action relies upon recognition of the serum components through appropriate receptors, not recognition of the organism.

Macrophages contribute to diverse activities (Table 7-1) and also synthesize and secrete diverse substances, including **lysosomal hydrolases, proteinases, lysozyme, coagulation factors, complement proteins, prostaglandins, leukotriene C, platelet activating factor (PAF), interleukin-1, endogenous pyrogen, α_2-macroglobulin, and various metabolites of O_2, tumor necrosis factor–α (TNF-α, cachexin).**

Macrophages also actively participate in the immune response.

Pericytes. **Pericytes** are specific cells intimately contacting the endothelium of the small vessels with which they are associated (Fig. 7-11). They are invested with a basal lamina except at the point of contact with the endothelial cell (Fig. 7-12). Some of these cells are contractile; thus they may control the size of the vascular lumen. Others have not been shown as contractile and their function is unknown.

Mast cells. **Mast cells** occur variably in the connective tissue space but commonly reside along the pathway of small vessels. Usually they are found in small clusters. They vary in size and shape in

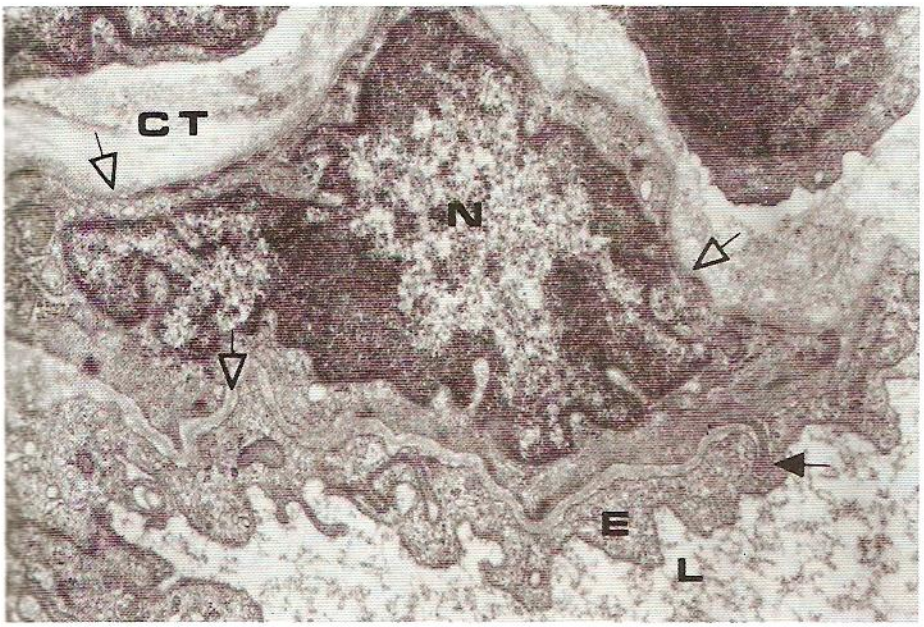

Figure 7-11. Electron micrograph of a pericyte from a bovine lung. The nucleus *(N)* of the pericyte is prominent. The cell is in close association with an endothelial cell *(E)* defining the capillary lumen *(L)*. The basal lamina *(open arrows)* surrounds the pericyte and separates it from the connective tissue *(CT)* and endothelium. The region indicated by the *solid arrow* is enlarged in Figure 7-12. (X17,000.) Courtesy G. P. Epling.)

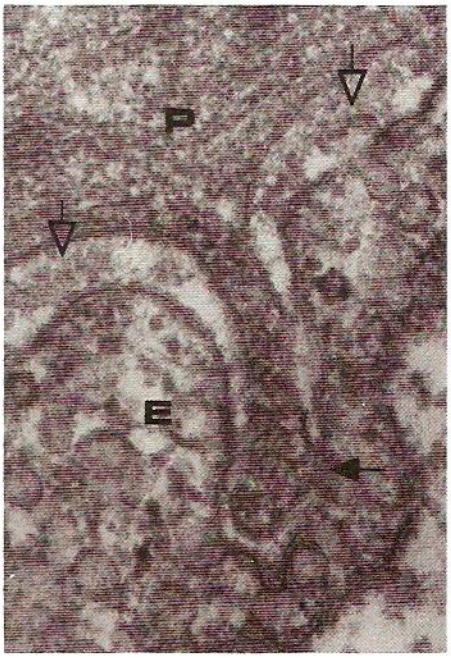

Figure 7-12. An electron micrograph of the contact between a pericyte and an endothelial cell within a bovine lung. The pericyte *(P)* and endothelial cell *(E)* are separated by a basal lamina *(open arrows)*, except at a single contact point *(solid arrow)*. (X125,000.) (Courtesy G. P. Epling).

Table 7-1. Macrophage Activities

	Participation through
	Secretion of
Bacterial destruction	Hydrolases, proteases,lysozyme, oxygen metabolites, complement components
Hemostasis	Coagulation Factors V, VII,IX, and X; platelet activating factor
Cell regulation and proliferation	Interleukin 1, interferon,fibriblast-stimulating factors
Inflammation/Fever	Interleukin 1, prostaglandins,complement components, oxygen metabolites
Tumor destruction	Tumor necrosis factor–α (TNF-α, cachexin), proteases, oxygen metabolites
	Formation of
Sequestering foreign materials	Multinucleated giant cells and granulomas
Removal of support tissues	Multinucleated giant cell—osteoclasts, chondroclasts

different species, generally being ovoid with a small, pale, ovoid, and centrally located nucleus. The prominent feature is the presence of basophilic granules in the cytoplasm (Fig. 7-13). It is not uncommon to observe these highly refractile granules surrounding the mast cell. Mast cells may rupture during preparatory techniques. The water-soluble granules are preserved rarely by routine techniques.

Mast cells have a long life and long turnover time. They are not polymorphonuclear basophils. Basophils and mast cells are different, derived from different bone marrow precursors. Both, however, contain and secrete similar substances. Among the substances stored in these cells are **histamine, heparin, eosinophilic chemotactic factor, N-acetyl-β-glucosaminidase,** and **β-glucuronidase.**

Histamine increases vascular permeability and smooth muscle contraction. Heparin is an anticoagulant; it prevents the possible clotting of fibrinogen in the local environment. Heparin also acts as a **clearing agent** in blood, serving as a cofactor for the enzyme **lipoprotein lipase.** This enzyme is a secretory product of endothelial cells that promotes the clearance of chylomicrons from the blood. The glucosaminidase and glucuronidase contribute to the hydrolysis of connective tissue GAGs. The remaining stored substances are involved in immune responses (Chapter 19).

Some of the nonstored substances released by these cells are **leukotriene C** and other **arachidonic acid derivatives, platelet activating factor (PAF),** and **products of O_2 metabolism.**

Adipocytes. These cells are discussed subsequently (p. 93).

TRANSIENT CELL POPULATIONS

Most transient cells are protective but are considered residents in some connective tissues. Their numbers usually vary. The **transient cell population** includes **plasma cells, melanocytes, lymphocytes, monocytes, neutrophils, eosinophils,** and **basophils.** Only the plasma cell and pigment cell are discussed here; the blood cells are discussed in Chapter 10.

Plasma cells. **Plasma cells** provide immediate and prolonged protection against antigens. They synthesize and secrete large quantities of **humoral antibodies (immunoglobulins)** as part of the specific immunological response. These cells may occur generally in the connective tissue space but occur specifically in regions subjected continually to antigenic challenge. They are part of the resident cell population of connective tissues of the gastrointestinal, genitourinary, and respiratory tracts.

The plasma cell is easily demonstrated by routine techniques. It is round with a definite polarity. The basophilic cytoplasm contains an eccentrically placed and round nucleus (Fig. 7-14). The nu-

Downloaded From Vet-eBooks.com

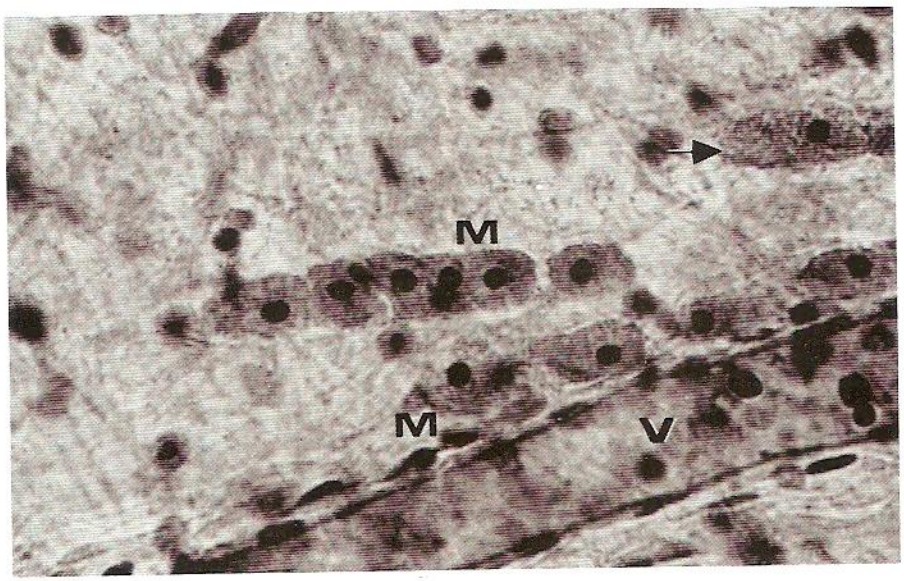

Figure 7-13. Mast cells in a stretch preparation of murine subcutis. These cells *(M)* are aligned along the blood vessel *(V)* path. A ruptured mast cell *(arrow)* has extruded its granules into the surrounding environment. Ruptured mast cells are frequently observed in histological preparations as a result of harsh handling during processing. (X160.)

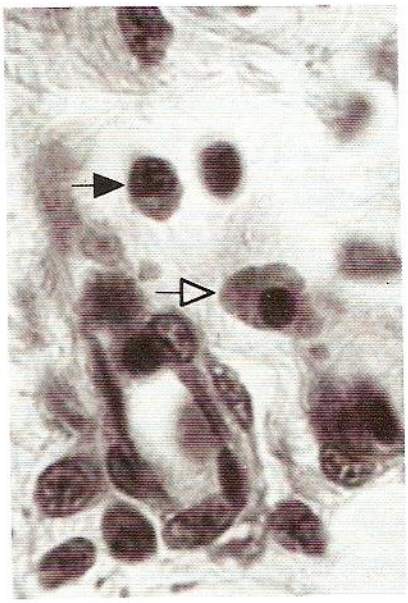

Figure 7-14. A plasma cell of loose collagenous tissue *(solid arrow)*. This is a typical cell. The position of its nucleus and the negative Golgi area can be appreciated. A macrophage *(open arrow)* is also present. Note the difference between these two cells. (X160.)

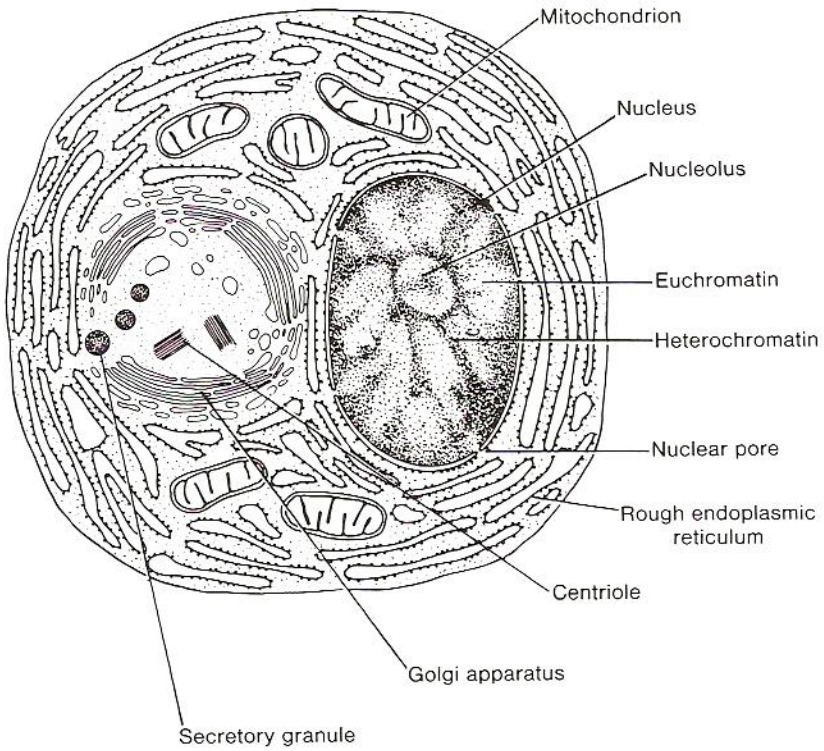

Figure 7-15. A plasma cell as seen with the electron microscope. The constituent organelles are indicated. Note the spoke-wheel configuration of the chromatin, extensive RER, and well-developed Golgi complex.

cleus contains extensive heterochromatin that is sometimes arranged as the spokes of a wheel. A juxtanuclear, pale-staining, Golgi region is often apparent. The basophilia of the cytoplasm is due to the extensive development of RER and free ribosomes (Fig. 7-15).

Melanocytes. Pigment-bearing cells are associated with various organs. Some actively produce the pigment; others get it passively. The primary pigment is **melanin. Melanoblasts** are derived from neural crest ectoderm. They migrate throughout the body and reside eventually in or close to the epidermal basal layer within the basement membrane. They have the potential to produce melanin but do not do so until they arrive at their place of residence. When they begin to synthesize melanin, they are termed **melanocytes** (Fig. 7-16).

Melanocytes extend cell processes throughout the epidermal layers and pass their pigment to other cells. The epidermal recipients of this pigment are morphologically indistinguishable from melanocytes. These passive recipients are termed **melanophores.** Melanocytes rarely occur in the connective tissue compartment. The pigmented cells of this compartment have either passively received the pigment or have phagocytosed the pigment. Thus they are **melanophores** or **chromatophores.**

A simple histochemical test, the **dihydroxyphenylalanine (DOPA) reaction,** is used to decide which cells are melanocytes. Only melanocytes are capable of converting DOPA into melanin because of the presence of the enzyme **tyrosinase.** A **protyrosinase** is produced in the RER, passes through the Golgi complex, and is part of secretory vesicles. The pigment passes through four stages before becoming mature melanin granules.

The primary function of these cells is to protect the body from ultraviolet radiation. Melanoblasts and melanocytes can be involved in the formation of rapidly spreading and, therefore, potentially dangerous cancerous growths.

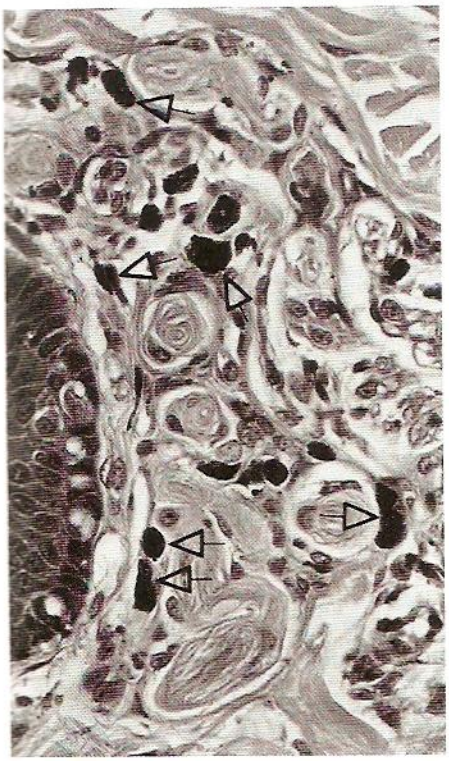

Figure 7-16. Pigment-bearing cells *(open arrows)* in connective tissue of the dermis. (X100.)

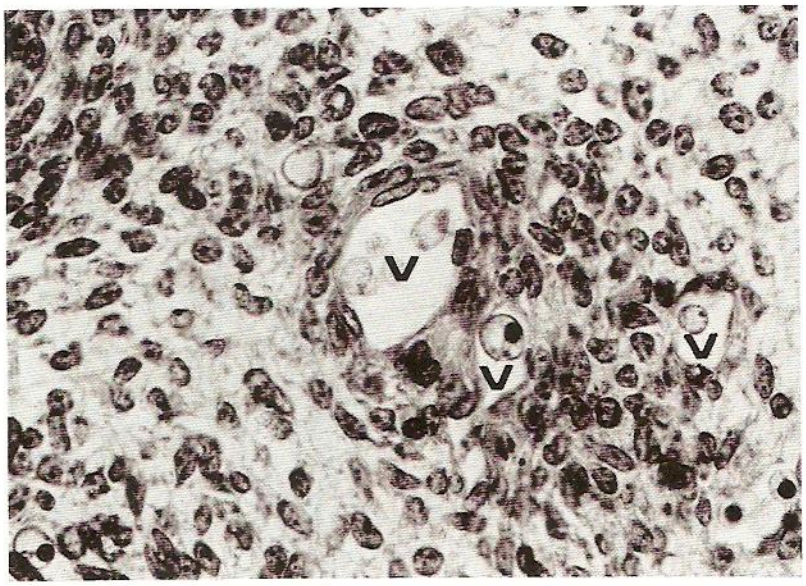

Figure 7-17. Mesenchymal connective tissue from a limb bud of a hamster. Vessels *(V)* are scattered among the mesenchymal cells. The mesenchymal connective tissue would have eventually differentiated into other tissues derived from the mesoderm. Mesenchymal connective tissue is a transitory connective tissue during development. (X160.)

Figure 7-18. Mucous connective tissue of the ovine umbilical cord. (X160.)

EMBRYONAL CONNECTIVE TISSUES

Mesenchymal connective tissue. This unspecialized mesodermal tissue of the embryo is a transitory tissue and disappears rapidly from the developing organism as differentiation occurs (Fig. 7-17). Its primary constituents are mesenchymal cells, which form many cellular contacts and give the appearance of a **cellular reticulum.** Differentiating fibroblasts are also present. Pale-staining interstices contain GAGs and delicate collagen or reticular fibrils. Mesenchymal cells can also produce small quantities of fibers and ground substance.

This tissue is the precursor for **proper** and **special connective tissues, cartilage, bone, blood,** and **muscle.** In adults it is reduced to isolated and scattered foci of mesenchymal cells in those tissues derived from it.

Mucous connective tissue. **Mucous connective tissue** is characteristic of the umbilical cord (Fig. 7-18). It has a cellular reticulum of **fibroblasts** and a few scattered **mesenchymal cells.** The matrix is composed of **mucin** and delicate collagen fibers. The ground substance appears granular with proper fixation.

In developing embryos this tissue occurs in subepidermal regions and the umbilical cord. In adults it is usually a transitory stage during the repair of supportive tissues. It also occurs normally in the comb and wattles of gallinaceous birds. It is present in specific portions of the lamina propria mucosae of the ruminant omasum.

PROPER CONNECTIVE TISSUES

Loose collagenous tissue. **Loose collagenous tissue** is the most ubiquitous connective tissue. It is composed of a loose array of randomly oriented **collagen, reticular,** and **elastic fibers.** Delicate collagen fibers predominate. All the cells described previously, except reticular cells, may occur in this tissue. The predominant cell type is the fibroblast or fibrocyte (approximately 90%). The prevalent ground substance component is hyaluronic acid, but some chondroitin sulfate and dermatan sulfate are also present. These matrical components impart a soft, pliable, and elastic quality to the tissue (Fig. 7-19).

A stretch preparation of subcutis serves as an example of loose collagenous tissue (Fig. 7-20). Randomly oriented, delicate collagen and elastic fibers are apparent. Reticular fibers are also present. Many vessels and scattered fat cells can be seen.

Loose collagenous tissue appears dif-

Downloaded From Vet-eBooks.com

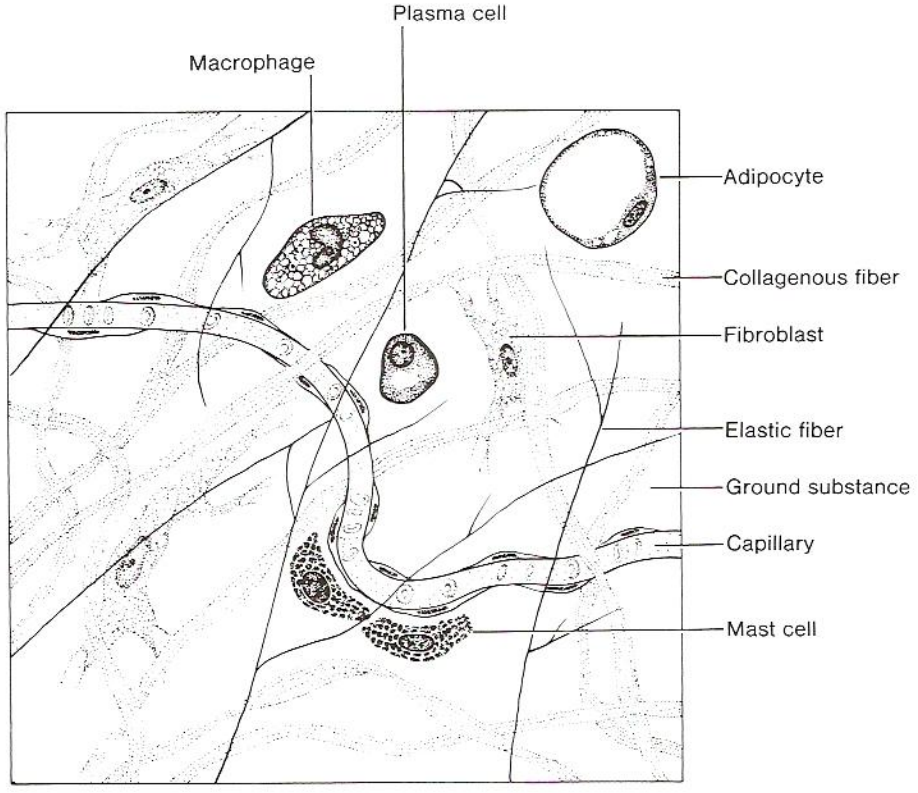

Figure 7-19. Loose collagenous tissue. The major components are labeled.

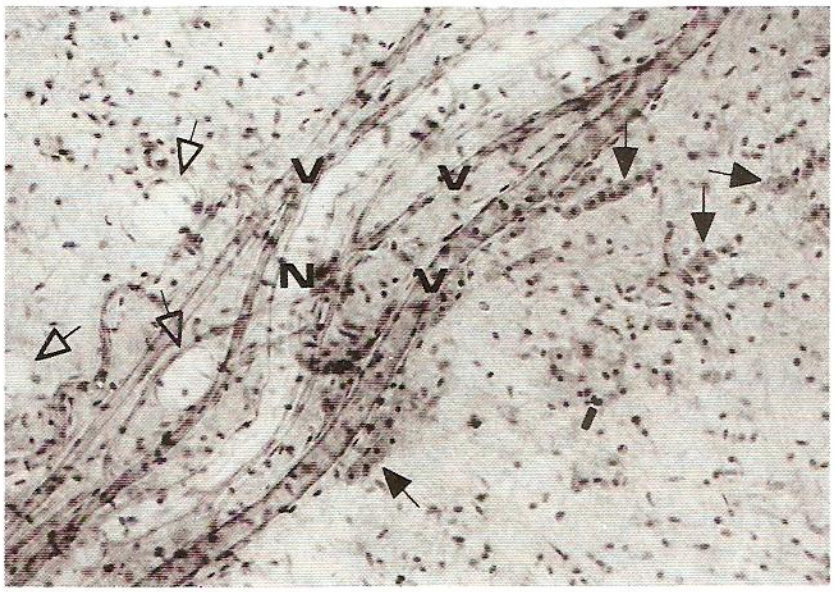

Figure 7-20. Stretch preparation of loose collagenous tissue from a murine subcutis. Vessels *(V)* and a nerve *(N)* traverse the tissue. Mast cells *(solid arrows)*, a macrophage *(bar)*, and adipocytes *(open arrows)* are present. The remainder of the nuclei are those of fibroblasts. (X40.)

ferent in section (Fig. 7-21). The interlacing, randomly oriented, and delicate bundles of fibers with cells scattered between are typical.

In a section of loose collagenous tissue associated with the digestive tract a very different-appearing tissue is observed (Fig. 7-22). Although the typical fibers and cells are present, the predominant feature is the presence of defensive cells—lymphocytes, plasma cells, and macrophages. This appearance is typical in regions subjected to constant insult. The previous example of this tissue (Fig. 7-21) would appear similar in response to an insult (Plate IV, *2*).

MORPHOLOGICAL FEATURES. A fine network of collagen, reticular, and elastic fibers loosely arranged in random array is apparent. Collagen fibers and fibroblasts predominate. Large numbers of cells occur within a stroma of few fibrous components. Cellular constituents vary with location and physiology.

OCCURRENCE. Subepithelial connective tissue, mesenteries, between muscles and nerves, components of most organs (Plate IV, *1*)

Dense collagenous tissue—irregular. This tissue is closely related to loose collagenous tissue. All the fibrous and cellular elements of loose collagenous tissue may occur in dense collagenous tissue. Usually the fibroblasts and thick, wavy collagen fibers are the predominant features (Fig. 7-23). The collagen fibers form a coarse network within which few cells are located.

MORPHOLOGICAL FEATURES. A coarse network of collagen fibers with some reticular and elastic fibers is apparent. The number of cells is reduced and the number of fibers is increased compared to loose connective tissue.

OCCURRENCE. Subepidermal connective tissue, capsules of organs (Plates I, *3*, and IV, *3*)

Dense collagenous tissue—regular. The significant feature of this tissue is the orderly, parallel orientation of collagen fibers (Fig. 7-24). Although distinct bundles of fibers are present, they do not appear as such in routine preparations. The

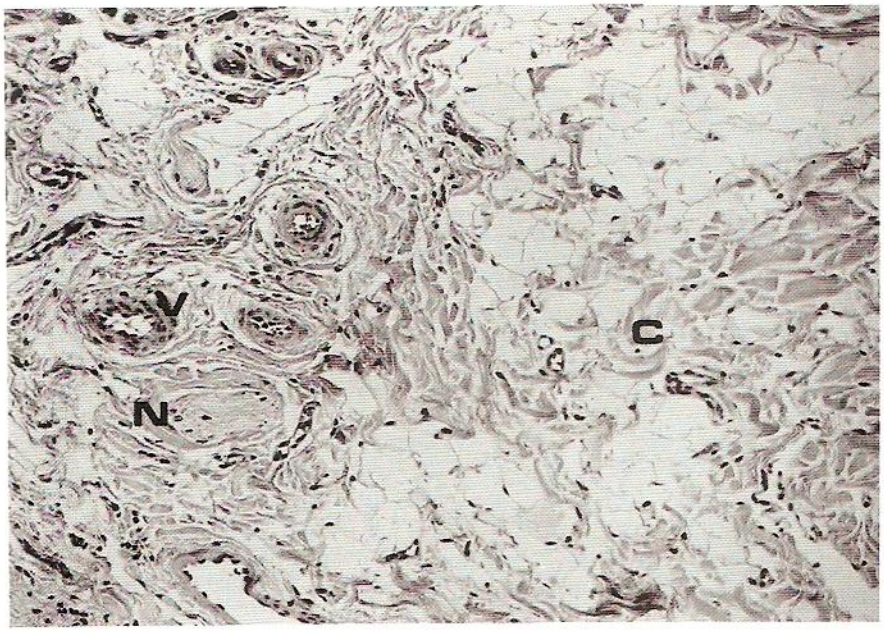

Figure 7-21. Section of loose collagenous tissue. Collagen fibers *(C)*, nerves *(N)*, and blood vessels *(V)* are scattered throughout the tissue. Fibroblasts and adipocytes are also present. (X40.)

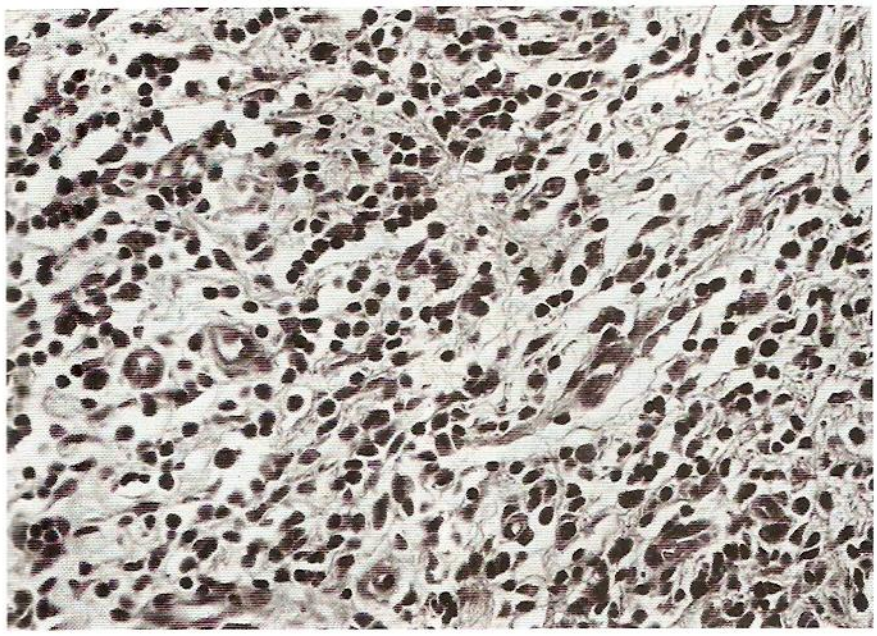

Figure 7-22. Section of loose collagenous tissue from the upper digestive tract. The basic components are similar to those in Figure 7-21. The numerous dark nuclei are of mononuclear cells—lymphocytes, macrophages, plasma cells. These mononucleated cells impart a hyperplastic appearance to the tissue. The cellular population of loose collagenous tissue is typical of regions subjected continually to antigenic insult. (X100.)

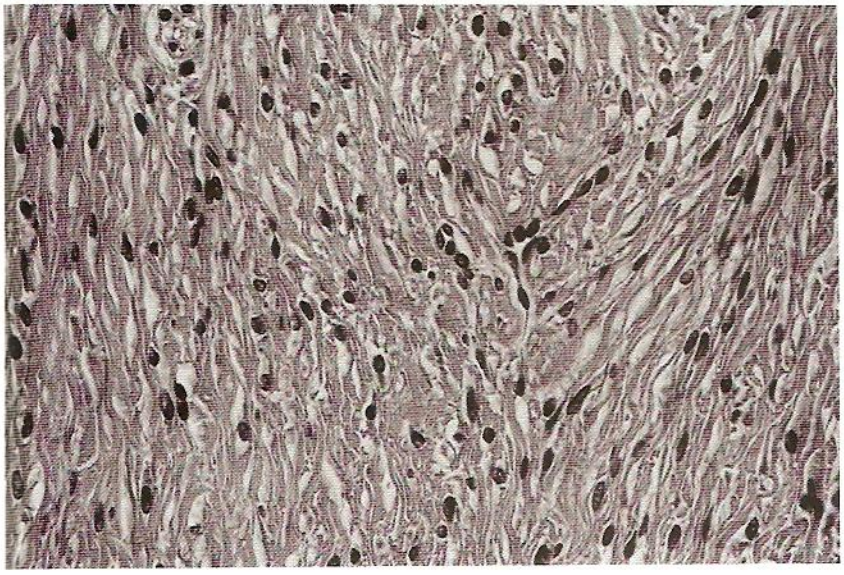

Figure 7-23. Section of dense collagenous tissue (irregular) from the tunica albuginea of a canine testis. Collagen fibers and fibroblasts are the predominant elements. (X100.)

Downloaded from Vet-Ebooks.com

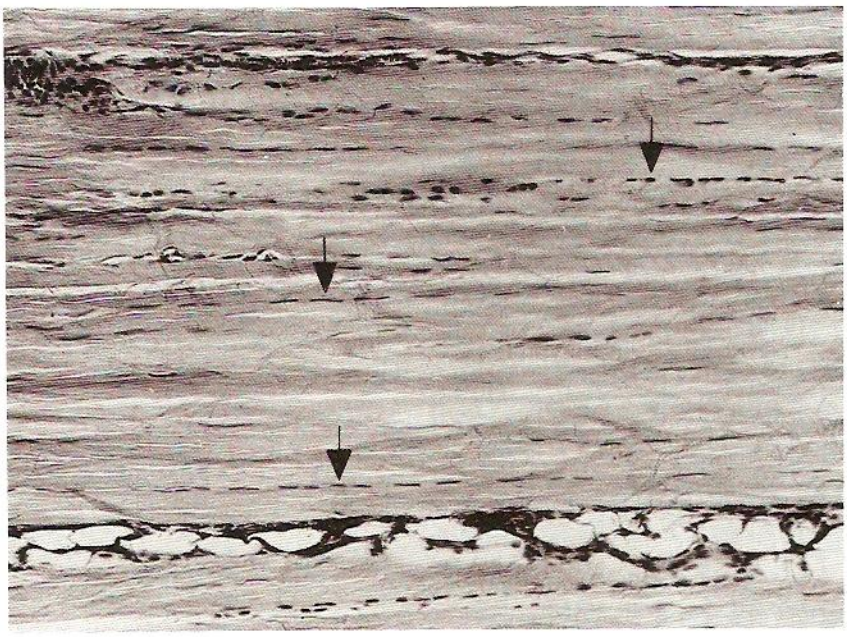

Figure 7-24. Section of dense collagenous tissue (regular) from a tendon. The fibrocytes *(arrows)* are oriented parallel to the collagen fibers. (X40.)



Figure 7-25. Longitudinal section of elastic connective tissue from a canine nuchal ligament. The dark profiles are fibroblastic nuclei, some of which have been displaced from their interfibrillar positions. (X100.)

fibers form a homogeneous, pink-staining background with H&E. The fibrocytes seem to delimit the extent of individual bundles. The dark-staining nuclei vary from oval to thin and elongated. The thin cytoplasmic processes are not distinct. The nuclei and fibers may appear wavy. Although other cell types may be present normally, they are rare.

This tissue predominates in **tendons** and **ligaments.** Individual bundles of these highly organized fibers are held together by loose collagenous tissue in which a few blood vessels and nerves are observed. The ordered arrangement resists the great amount of tensile stress applied to tendons and ligaments.

MORPHOLOGICAL FEATURES. Few cells—mostly fibrocytes—are present. Heavy collagen fibers appear as a somewhat homogeneous background matrix between cells. Fibrocytes are arranged in a longitudinal orientation. Cells and fibers may appear wavy. Collagen stains a light pink with H&E.

OCCURRENCE. Tendons (attachments of muscle to bone), ligaments (attachments of bone to bone), aponeuroses (thin, sheetlike tendons) (Plate IV, *5* and *6*)

Elastic connective tissue. This tissue is a modification of the type previously discussed. Elastic fibers and fibroblasts predominate (Fig. 7-25). The fibers are larger than collagen fibers, and they branch and anastomose with each other. Individual elastic fibers are surrounded by loose collagenous tissue. This tissue may be confused with dense collagenous tissue. Upon careful examination, however, the presence of bright pink-staining fibers (H&E) becomes obvious. With special staining, the elastic fibers are evident (Fig. 7-26).

In cross section the large fibers and extrafibrillar nuclei (Fig. 7-27) of the fibroblasts are apparent.

MORPHOLOGICAL FEATURES. Elastic fibers in parallel and branched array predominate. Fibers stain intensely pink with H&E. Fibroblasts predominate; few other cell types are present.

OCCURRENCE. Nuchal ligament (ligamentum nuchae), some dorsal ligaments of spinal column, mural elements of arteries (Plate IV, *4*)

SPECIAL CONNECTIVE TISSUES

Reticular connective tissue. The predominant fiber in this tissue is the reticular fiber. It forms a fibrous network complemented by a network of reticular cells. Because this type of tissue is associated with **cytogenic organs (cell-producing),** careful examination is required to observe the fixed reticular cells and fibrous reticulum through the mass of varied free cells normally present. Many free cells **(stem cells, reticular cells, lymphocytes, agranulocytes, plasma cells, macrophages)** may be present.

In a section of spleen that has been flushed with physiological saline to remove the free cells, the cellular reticulum is apparent. With special staining techniques for reticular fibers, the fibrous reticulum is also easily observed (Fig. 6-7). Ordinary staining does not demonstrate this tissue definitively, but its association with certain cell types and organs is a reliable key to its identification.

Reticular fibers also constitute the finest interstitial connective tissue intimately associated with the cells of many organs. In this instance the defensive cells are absent or occur with a frequency similar to that expected in loose collagenous tissue. In these regions the predominant cell is the fiber-forming reticular cell.

MORPHOLOGICAL FEATURES. A fine reticulum of fibers and cells is apparent; the fibers are argyrophilic. The tissue is usually associated with cytogenic organs that produce defensive cells.

OCCURRENCE. Stroma (fibrous support) of lymphatic and hematopoietic organs; finer interstitial connective tissue of some organs

Pigmented connective tissue. This is loose collagenous tissue in which pig-

Downloaded From Vet-eBooks.com

Figure 7-26. Longitudinal section of elastic fibers from a canine nuchal ligament. Only the elastic fibers are stained. (X40, Verhoeff's stain.)

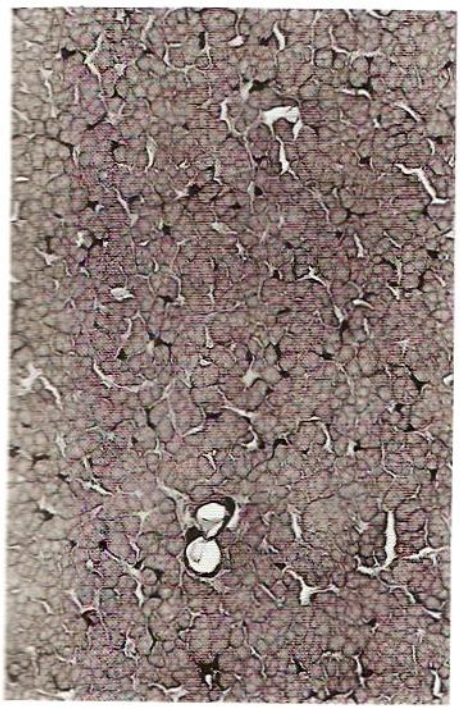

Figure 7-27. Cross section of the elastic connective tissue of a canine nuchal ligament. (X80.)

ment-containing cells occur (Fig. 7-16). It is of limited but significant occurrence.

MORPHOLOGICAL FEATURE. Pigment-bearing cells are present.

OCCURRENCE. Iris and choroid coat; connective tissue associated with pigmented skin

ADIPOSE TISSUE

Form and function. Adipose tissue is composed of a homogeneous cell population, **adipocytes** or **fat cells,** occurring as single cells, groups of cells, or extensive masses of cells. Although it has blood vessels, nerves, and elements of loose collagenous and/or reticular connective tissue, its predominant feature is the adipocyte.

Whereas adipose tissue may exist in association with all loose collagenous tissues, predilection sites do occur; adipose tissue may form an extensive subcutaneous sheet, the **panniculus adiposus.** Extensive quantities of this tissue often occur in association with the visceral, parietal, and connecting mesothelial membranes of the celomic cavities. Adipose tissue occurs in areas devoid of other tissue components—the axillary region, the inguinal region.

Most organs contain some adipose tissue. Even the popular prime cuts of beef are a mixture of skeletal muscle, connective tissue, and adipose tissue (marbling).

This tissue is a readily available source of energy. The stored fats of adipose tissue contain more energy per gram than corresponding quantities of proteins or sugars. (Fats supply 9 calories per gram, carbohydrates and proteins each 4 calories per gram.) Adipose tissue is an important contributor to thermoregulation; its somatic distribution aids in heat conservation. Adipose tissue is also an important mechanical insulator through its distribution with the visceral organs and greater omentum. The rich deposit of adipose tissue within the digital cushion of the equine foot is a device for absorbing concussive forces. The adipose tissue of synovial membranes absorbs shock and stabilizes joints.

Morphologically, two types of adipose tissue are identified—**white** and **brown.**

Origin of adipose tissue. The questions of the precise origin of fat cells and the relationship of white fat cells to brown fat cells have not been answered satisfactorily. The special stem cell for adipocytes is probably the mesenchymal cell. This can account for specific predilection sites instead of adipocytes' being spread ubiquitously throughout the body because of the fibroblastic accumulation of fat. Besides, the presence of a basal lamina around individual adipocytes is difficult to explain if they are differentiated from fibroblasts. The occurrence of age and species differences, the propensity to accumulate fat, and the anatomical sites in which the accumulation takes place all support the idea of separate populations of fat cells.

White adipose tissue. This tissue is also called **white fat, unilocular fat,** and **ordinary adipose tissue** (Plate V, *11*). Its cells are very large, ranging to about 130 μm. They are spherical and may appear polyhedral. **Unilocular fat cells,** the predominant cell of this tissue, have a signet-ring appearance (Fig. 7-28). The bulk of the cytoplasm is occupied by a single large fat droplet rimmed by a thin margin of cytoplasm. The nucleus, which is usually displaced to one side of the cell, accounts for this signet-ring pattern. In most planes of section the nucleus is not apparent (Fig. 7-29).

In routine paraffin sections of fat cells the space occupied by the lipids is all that remains; the lipid solvents used in the process dissolve the fats. Special preparation techniques such as freezing and special stains (osmium tetroxide, Sudan stains) are required to demonstrate the lipids of fat cells (Fig. 7-30).

The lipids of these cells are triglycerides and certain fatty acids, which are mobilized through enzymatic hydrolysis by lipases. Free fatty acids then enter the blood as an available source of energy.

White adipose tissue is subdivided into smaller units (lobules) by loose connective tissue septa. Reticular fibers extend from these septa and surround individual fat cells. The extensive vascular supply and nerves of this tissue gain access via these connective tissues.

Lipid droplets of white fat cells are not membrane-bound but are rimmed by a condensation of cytoplasm that may contain some cytofilaments.

Brown adipose tissue. This tissue has **multilocular fat cells** (Plate V, *12*). The predominant feature of these cells is the presence of many small fat droplets within the cytoplasm (Fig. 7-31). The round nucleus is not displaced to one side of the cell but may assume any position. Unless the special preparatory precautions just mentioned are taken, the lipids will be leached from these cells and an acidophilic and foamy appearance im-

Downloaded From Vet-eBooks.com

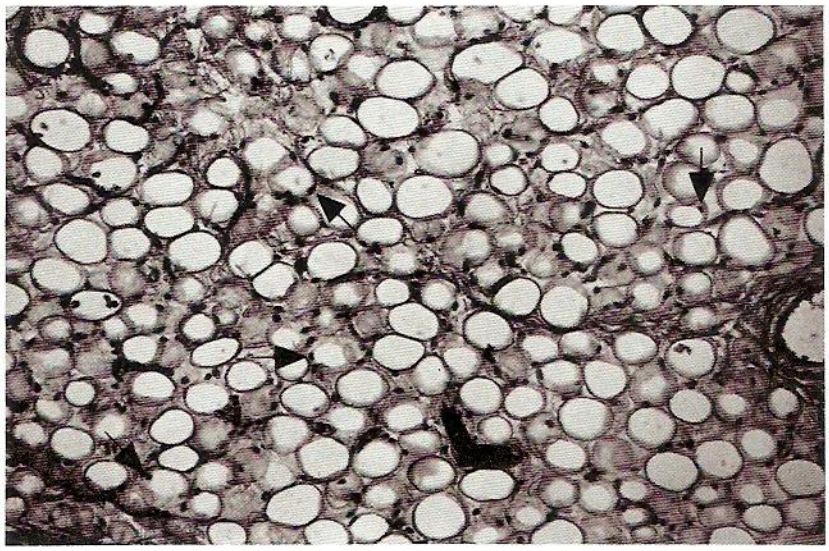

Figure 7-28. Section of yellow adipose tissue. The *arrows* point to nuclei of those cells in a typical signet-ring configuration. (X40.)

Figure 7-30. Special stain for lipids. The large lipid droplets *(L)* remain as dominant features of the cytoplasm. The cellular margins are indicated by the *arrow*. (X125, osmium tetroxide stain.)

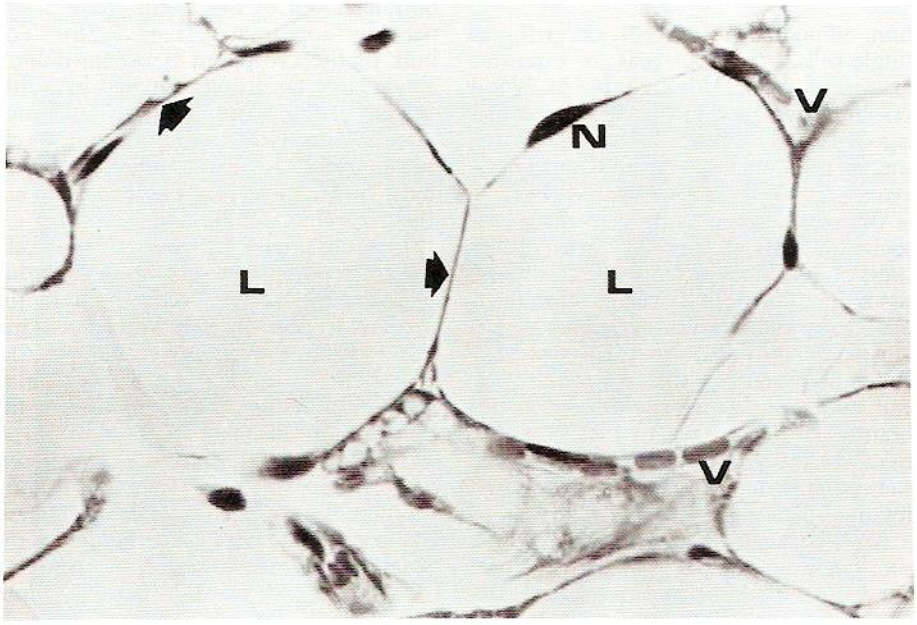

Figure 7-29. Section of adipocytes from yellow adipose tissue. The signet-ring configuration is obvious. The nucleus *(N)* is displaced to one side of the cell. The cytoplasm is reduced to a thin margin at the periphery of the cell *(arrows)*. The spaces that had been occupied by the lipid droplets *(L)* are the predominant cytoplasmic features. Vessels *(V)* occur within the associated connective tissue. (X160.)

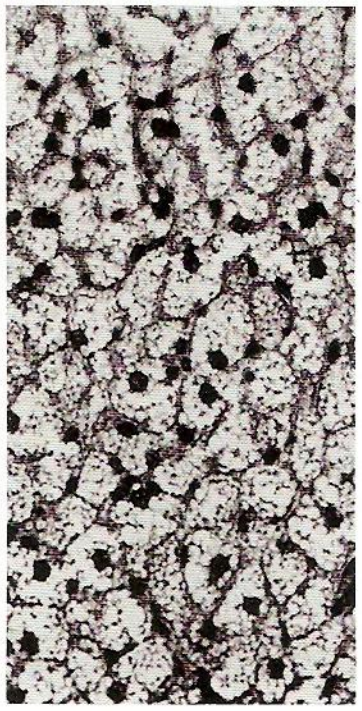

Figure 7-31. A section of multilocular adipose tissue. Spaces that had been occupied by individual lobules of lipids are apparent within the cells. (X100.)

parted to the cytoplasm (Fig. 7-31).

The brown color of this tissue results from many mitochondria and high quantities of the cytochrome oxidase system. Brown fat cells contain more mitochondria, and the tissue is better vascularized and innervated, than white fat cells. The lobular characteristics impart a glandular appearance to the tissue.

The metabolism of the stored lipids releases heat, warms the blood, and raises the body temperature. Brown adipose tissue has a limited but specific distribution. It develops during the prenatal period and is confined generally to the axilla, interscapular region, mediastinum, mesenteries, and perirenal region. The tissue may help young animals to resist postnatal cold extremes. Hibernating rodents, similarly, have brown adipose tissue deposits in the regions specified. These depots help with body temperature maintenance during hibernation.

Adipose tissue tumors. Two types of fat cell tumors occur in domestic animals, especially dogs. The **benign lipoma** is difficult to distinguish from typical white adipose tissue histologically. The **malignant liposarcoma** cells may look like multilocular fat cells histologically.

MACROPHAGE SYSTEM

Many cells can ingest particulate matter (phagocytosis). Some have an exceptional ability to do it. The **fixed** and **wan-**

dering **macrophages** of the connective tissue compartment possess this ability and are important cellular defense components. The ability of macrophages to range far within connective tissues affords a ready and mobile defense force associated with almost every tissue and organ. Many organs integrate phagocytic cells into their tissue architecture. Unfortunately, it is easy to lose sight of the common phagocytic function of these cells, because they are named differently in different loci—microgliocytes, blood monocytes, von Kupffer cells, alveolar macrophages, littoral cells of sinusoids (Table 7-2).

This common phagocytic function was first recognized by Metchnikoff in the late nineteenth century. He looked upon these cells as a diffuse cellular system of "big eaters" and coined the name **macrophage system.** Other cells, namely specialized endothelial lining cells and the cellular stroma ("phagocytic reticular cell") of certain organs, were believed to have well-developed phagocytic activity. The original system of phagocytes was expanded conceptually to include these reticular and endothelial cells. Thus the name **reticuloendothelial system** was coined.

Table 7-2. Cells of the Macrophage System

	Location
CFU-S* (uncommitted)	Bone marrow Bone circulation
CFU-GM† (committed)	Bone marrow
Precursors	Bone marrow
Monocytes	Bone marrow Blood circulation
Macrophages	Connective tissue (histiocytes) Lymphatic organs (fixed and wandering) Liver (stellate macrophages, formerly called von Kupffer cells) Bone marrow Lung (alveolar and septal) Central nervous tissue (microgliocytes) Body cavities (fixed and wandering)

*Colony-forming unit—spleen: pluripotent stem cell for all blood cells.
†Committed stem cell for granulocytes and monocytes.

The bulk of evidence today disproves any contribution by the reticular cell and endothelial cell to the reticuloendothelial system. Specialized macrophages provide the phagocytic activity ascribed to these cells. The name reticuloendothelial system has fallen into disfavor. A more descriptive term, gaining increasing acceptance, is the **mononuclear phagocyte system** or **macrophage system,** the latter having been proposed by Metchnikoff almost 100 years ago.

This system includes many mononuclear cells of different organs that function through phagocytosis to protect against foreign materials and microorganisms. These cells rid the body of dead constituent cells, remove matrical materials, and assist with the processing of antigens.

REGENERATION AND REPAIR

The fibroblast is the primary cell responsible for regeneration and repair within proper connective tissue. Old and/or damaged cells are continuously removed and replaced by new fibroblasts. Similarly, damaged and chemically altered matrix is removed and replaced by new components. The macrophage is the key cell in this removal activity.

The ability of fibroblasts to mediate repair or regeneration is predicated upon several factors. Because they can divide, they serve as their own "stem cell" in times of need. Additionally, mesenchymal cells are scattered throughout connective tissue, especially in a pericapillary position. Mitotic activity and subsequent differentiation of some of these cells serve to replenish the fibroblastic population.

Fibrous connective tissue also may mediate the repair of other tissues. After an acute myocardial infarction, degenerative cardiac muscle is replaced by a scar of fibrous connective tissue. Skeletal muscle that has been injured severely is replaced similarly by a connective tissue scar. The result of chronic inflammation is the deposition of abnormal quantities of fibrous connective tissue, **fibrosis.** The formation of fibrous connective tissues in the repair process of other tissues may limit, reduce, or obliterate the normal function of the repaired tissue.

ADDITIONAL READINGS

Carpenter JC, Perrelet A, Orci L: Morphological changes of the adipose cell membrane during lipolysis, *J Cell Biol* 72:104, 1977.

Chapman JA, Gough J, Elves MW: An electron microscopic study of the in vitro transformation of human leucocytes. II. Transformation to macrophages, *J Cell Sci* 2:371, 1967.

Cohn ZA, Fedorko ME, Hirsch JG: The in vitro differentiation of mononuclear phagocytes. IV. The ultrastructure of macrophage differentiation in the peritoneal cavity and in culture, *J Exp Med* 123:747, 1966.

Cohn ZA, Fedorko ME, Hirsch JG: The in vitro differentiation of mononuclear phagocytes. V. The formation of macrophage lysosomes, *J Exp Med* 123:757, 1966.

Dean RT, Jessup W (eds): *Mononuclear phagocytes: physiology and pathology,* Amsterdam, 1985, Elsevier.

Downey H: The development of histiocytes and macrophages from lymphocytes, *J Lab Clin Med* 45:499, 1955.

Fawcett DW: An experimental study of mast cell degranulation and regeneration, *Anat Rec* 121:29, 1955.

Harrington JS: Fibrogenesis, *Environ Health Perspec* 9:271, 1974.

Hayward JS, Lyman CP, Taylor CR: The possible role of brown fat as a source of heat during arousal from hibernation, *Ann NY Acad Sci* 131:441, 1965.

Hunt TK, Van Winkle W Jr: *Fundamentals of wound management in surgery—wound healing: normal repair,* South Plainfield NJ, 1976, Chirurgecom.

Kolouch F Jr: The lymphocyte in acute inflammation, *Am J Pathol* 15:413, 1939.

Leibovich SJ, Ross R: The role of macrophages in wound repair, *Am J Pathol* 78:71, 1975.

Litt M: Eosinophils and antigen-antibody reaction, *Ann N Y Acad Sci* 116:964, 1964.

Maximow AA: Morphology of mesenchymal reactions, *Arch Pathol Lab Med* 4:557, 1927.

Movat HZ, Fernando NVP: The fine structure of connective tissue. I. The fibroblast, *Exp Molec Pathol* 1:509, 1962.

Movat HZ, Fernando NVP: The fine structure of connective tissue. II. The plasma cell, *Exp Molec Pathol* 1:535, 1962.

Nathan CF: Secretory products of macrophages, *J Clin Invest* 70:319, 1987.

Padawar J (ed): Mast cells and basophils, *Ann N Y Acad Sci* 103:1, 1963.

Heldon H, Hellenberg CH, Winegard AI: Observations on the morphology of adipose tissue, *Diabetes* 11:378, 1962.

Smith RE, Hock RJ: Brown fat: thermogenic effector of arousal in hibernation, *Science* 140:199, 1963.

Weinstock A, Albright JT: The fine structure of mast cells in normal human gingiva, *J Ultrastruct Res* 17:245, 1967.

West GB: Function of mast cells, *J Pharm Pharmcol* 14:618, 1962.

Downloaded From Vet-eBooks.com

CHAPTER 8

Supportive Tissue—Cartilage

GENERAL CHARACTERISTICS

Form and function. Cartilage has an amorphous, gel-like matrix secreted by constituent cells embedded in their secretions. Chondrocytic secretions form a firm but resilient matrix. These qualities suit cartilage to its roles in **weight-bearing, movement,** and **organ integrity.**

The mesenchymal cells from which cartilage cells arise reside at the periphery of the cartilage in a membrane known as the **perichondrium** (capsule of the cartilage).

The chondroblastic line of differentiation at a perichondral surface is the means by which new chondrocytes are added to cartilage. The new cells deposit matrix upon preexisting cartilage by **appositional growth.** Once the chondroblasts become embedded in their products as chondrocytes, growth does not cease. Chondrocytes divide within the confines of their **lacunae.** This mitotic activity from within, **interstitial growth,** causes expansion of the resilient matrix. **Most cartilages use appositional and interstitial mechanisms for growth.**

Cartilage is an avascular tissue. Although large blood vessels pass through it, there are no intracartilaginous capillaries directly supplying its nutritional needs. All metabolites must diffuse from the periphery to the cells in the depths of the tissue. The solid ground substance of cartilage complicates the movement of fluid and dissolved substances to and from the cells. Despite the diminished diffusion and the increased distances over which it must occur, chondrocytes flourish. They thrive in an environment with diminished oxygen concentrations. The movement of metabolites and waste products becomes more difficult with age. The natural fate of cartilage is to mineralize. This increases the problem of percolation of metabolites through the matrix. The older cells die, phagocytic cells remove the tissue, and bone develops in place of the tissue.

Sensory innervation of cartilage occurs through sensory nerve endings scattered within the fibrous perichondrium.

Cartilage is the primary support tissue of the fetus. Cartilaginous support structures develop in association with the upper and lower respiratory tract, the pinna and external auditory meatus, and the auditory tube. These cartilaginous structures continue to develop during adolescence and are maintained in the adult. Much of the fetal and neonatal cartilaginous mass develops as part of the musculoskeletal system. Certain structures, such as fibrocartilaginous intervertebral discs and fibrocartilaginous attachments of ligaments and tendons to bone, continue to develop as integral parts of the musculoskeletal system. Much of the hyaline cartilage of the developing organism is involved directly in bone development. The small amounts of cartilage in the growing postnatal and adult organisms do not reflect the importance of cartilage as a supportive tissue.

Origin of cartilage. Sites within which cartilage is going to develop in the fetus are identifiable initially as hyperplastic sites of **mesenchymal cell condensation.** The mesenchymal cells withdraw their cellular processes, become round, and form dense populations of cells within **chondrogenic centers.** The mesenchymal cells subsequently differentiate into chondroblasts, enlarge, and secrete the matrix. As the matrix increases, the cells become separated further from each other and each cell surrounds itself in its secretions.

The space occupied by each cell is a **lacuna.** The space occupied by a chondrocyte is usually quite similar to that occupied by a fibroblast. The lacuna associated with the chondrocyte is readily apparent by light microscopy because of the consistency of the matrix. The lacuna is an artifact of preparation and sectioning techniques.

Interstitial and appositional growth mechanisms, as the names imply, are most active during development and growth. The potential for these activities diminishes in the adult. However, this type of activity is a significant component of fracture repair processes in young and adult organisms.

Cells of cartilage. Cartilage has a homogeneous cell population. Mesenchymal cells, either in an embryonic chondrogenic center or in the perichondrium, differentiate into active cells synthesizing and secreting large quantities of matrix. These **chondroblasts** surround themselves with their secretions and eventually become isolated within their lacunae. At this point the cells are **chondrocytes.** They maintain and remove matrix materials. They perform functions similar to those of chondroblasts, but their level of activity diminishes compared with chondroblasts. The chondroblast/chondrocyte line is the same cell in a different stage of its life cycle. Chondrocytic subpopulations have been identified based upon matrical, ultrastructural, and histochemical properties.

Another cell may be observed in cartilage, especially during developmental stages. It is a multinucleated giant cell, the **chondroclast,** which is responsible for the removal of cartilage matrix and cells. Chondroclasts and **osteoclasts** are morphologically and functionally identical. They are multinucleated giant cells resulting from fusion of macrophages. As chondroclasts "eat" their way through cartilage, chondrocytes are released and die.

The chondroblastic, fibroblastic, and osteoblastic cell lines are closely related populations of cells. All originate from mesenchymal cells. All secrete collagen and GAGs. Yet, each produces components that impart distinctive characteristics to its associated matrix. Under varying circumstances fibrous connective tissues, cartilage, and bone occur in regions where they are not expected. This abnormal transformation of a specific, adult, fully differentiated tissue into another differentiated type is called **metaplasia.** Cartilage and bone can form de novo in fibrous connective tissue. Bone and fibrous connective tissue can form at sites occupied by cartilage. Cartilage and fibrous connective tissue can form in sites occupied by bone. The stem cells associated with these tissues are responsive to subtle but significant changes in their environments. Under such circumstances, perichondral stem cells, which under normal conditions would differentiate into cartilage cells, may produce one or both of the other fiber-producing cells. Similarly, stem cells of the covering of bone (periosteum) may differentiate into all three cell types.

Classification. Three types of cartilage exist. Their classification uses the relative amounts of amorphous matrix and the

Downloaded From: ClassicBooks.com

amount and types of fibers embedded within the matrix. They are **hyaline cartilage, elastic cartilage,** and **fibrocartilage.**

MATRICAL COMPONENTS

Fibers

The predominant fibers of cartilage are fine collagen fibers. In hyaline cartilage they occur in a random pattern throughout the matrix. In routine preparations they remain obscure, because their index of refraction is similar to that of the ground substance.

In fibrocartilage the collagen fibers are obvious, because they are the primary constituents of cartilage and the amount of ground substance is reduced. This tissue has characteristics similar to cartilage and dense collagenous tissue.

The fibers of elastic cartilage include both collagen and elastic fibers. Elastic fibers are seen with normal and special staining techniques.

Ground Substance

The primary constituents of ground substance are the **GAGs.** Minor differences in the quantities of specific GAGs relate to age and location. Chondroitin-4-sulfate and chondroitin-6-sulfate are most abundant. Chondroitin-6-sulfate is more common in adult cartilage; chondroitin-4-sulfate is more common in the cartilage of young animals. Small quantities of hyaluronic acid are present in cartilage. Keratan sulfate concentrations increase with age.

GAGs are complexed with a **core protein** to form **proteoglycans.** Proteoglycans can form large aggregates once they have been secreted by the cells. These **proteoglycan aggregates** may achieve molecular weights in excess of 5.0×10^6 daltons. The aggregation phenomenon is dependent upon hyaluronic acid. Although hyaluronic acid occurs in low quantities in cartilage, its role in the structure of cartilaginous ground substance is significant (Fig. 8-1). Hyaluronate may comprise as little as 0.01% of the proteoglycan aggregate, yet may bind with as much as 250 times its weight in proteoglycans.

Link proteins seem to stabilize the aggregates into large compounds with bottle brush–like configurations. The proteoglycan aggregates stabilize the matrix, define its volume, and provide compressive properties.

The stability of the matrix results from the chemical linkage of proteoglycans to hyaluronic acid and collagen fibers (Fig. 8-2). This ensures the appropriate spatial orientation of matrical constituents. Proper spatial orientation is essential for the binding of interstitial fluid. These macromolecules define spatial volumes by entrapping the surrounding interstitial fluid. The proteoglycans can absorb solvent volumes that are as much as 50 times their dry weight. This property contributes significantly to the volume definition of the tissue.

Defective GAG and proteoglycan synthesis, secretion, and aggregation are associated with a decreased tissue volume because of the decreased ability to absorb water. Bone length and shape depend upon volume definition during endochondral ossification. Alterations in bone development, as exemplified in **chondrodystrophy**, have been related to the synthesis of defective proteoglycans.

The absorption of water by proteoglycan aggregates imparts a vast hydrodynamic domain to them. Proteoglycan aggregates are reversibly resistent to compressive forces. Subjecting proteoglycan aggregates to centrifugal force decreases their volume in proportion to the applied force. Upon removal of the force, these macromolecules return to their original volume. Recall that these substances are polyanions. As the molecular domain of a proteoglycan decreases, the charge density and constraints on mobility within the molecule increase. These factors, coupled with the noncompressible property of water, account for the compressive properties of cartilaginous tissues.

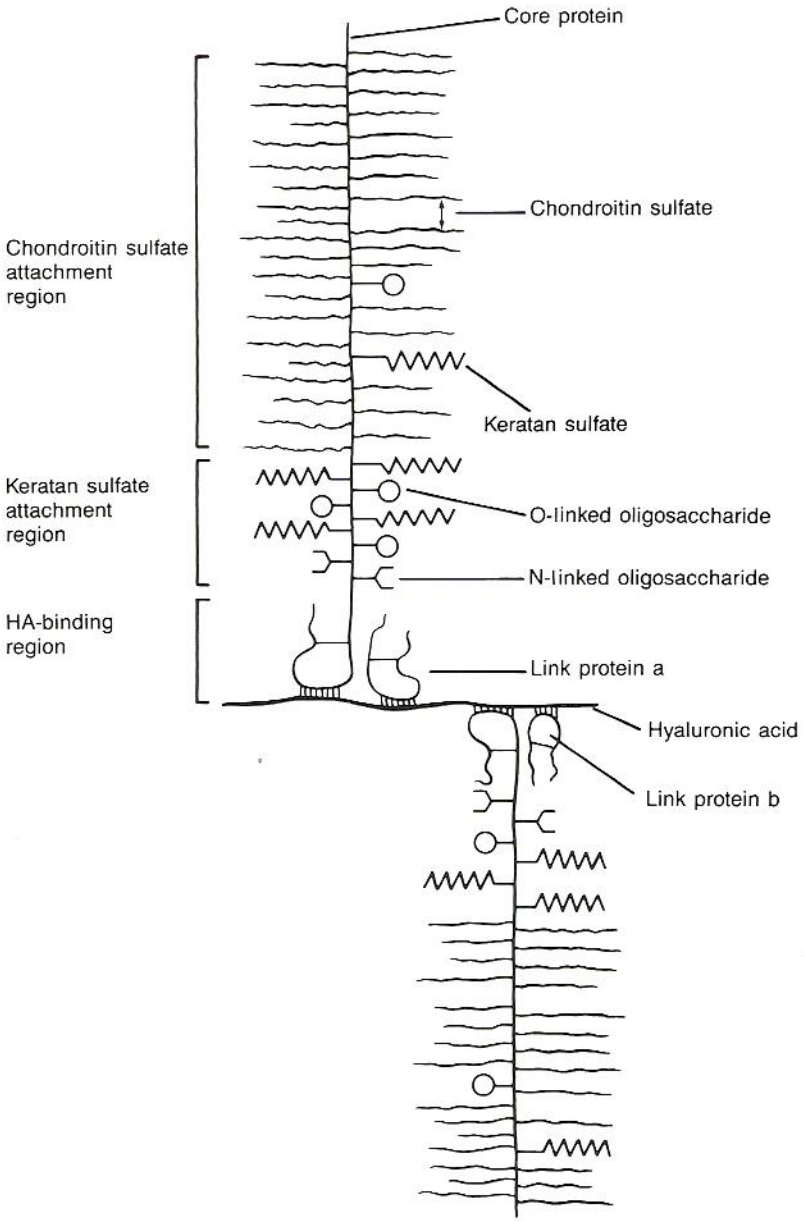

Figure 8-1. Structure of a proteoglycan aggregate from cartilage. The appropriate features are labeled. Oligosaccharides are linked to the core proteins through either an oxygen *(O-linked)* or a nitrogen *(N-linked)* bond. (Redrawn and modified from Hascall VC: In Ginsberg V, Robbins P (eds): *Biology of carbohydrates*, New York, 1981, John Wiley & Sons, vol 1, p 7.)

Downloaded From Vet-eBooks.com

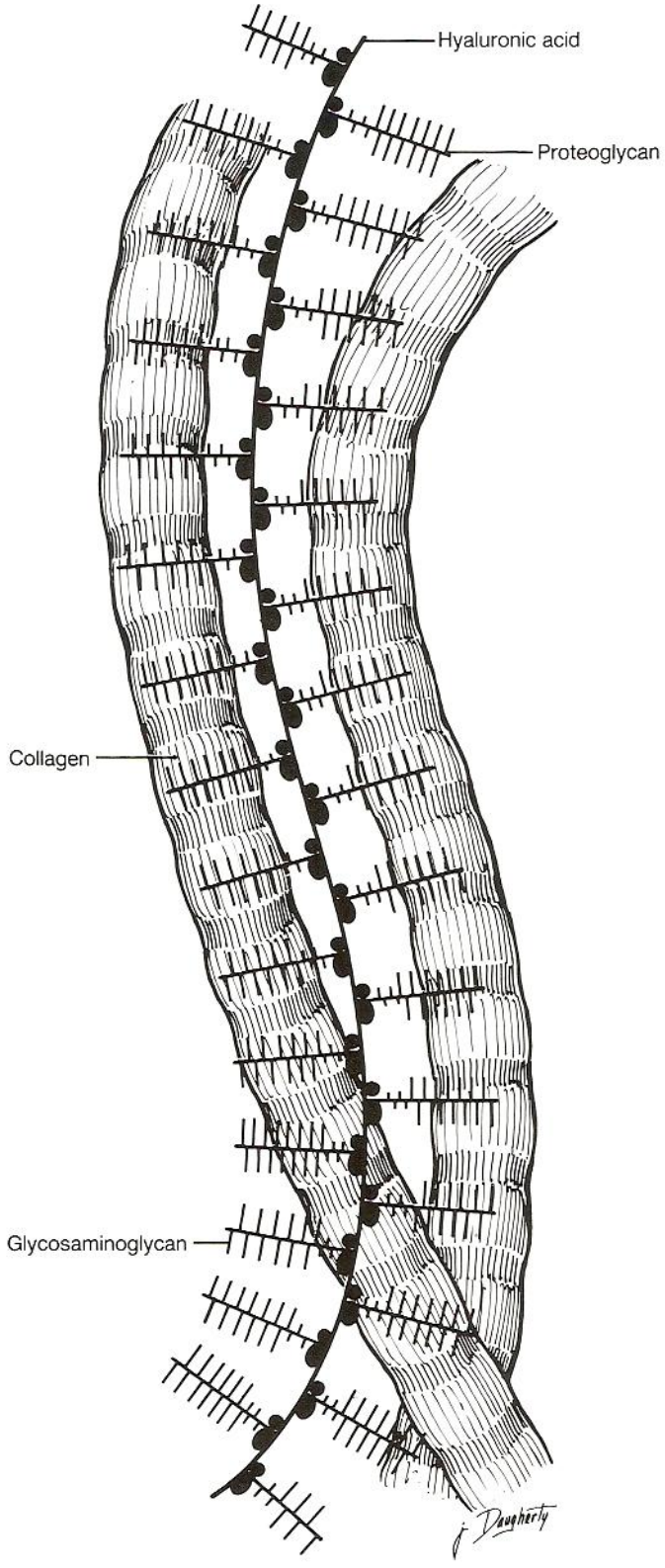

Figure 8-2. Relationship of proteoglycan aggregates to collagen fibers in cartilage. The GAGs of constituent proteoglycans are linked electrostatically to the collagenous components. In cartilage the collagen provides tensile properties whereas the proteoglycans provide compressive properties. The linkages between GAGs and collagen fibers provide a rigid matrical framework for this tissue.

Weight-bearing on articular surfaces is contingent upon this physical characteristic. Loss of or the inappropriate synthesis and aggregation of these compounds or their constituents decrease the hydrodynamic domain of the remaining or resulting proteoglycan aggregates. This decreases the amount of water contained within the cartilaginous matrix and increases its compressibility. Decreasing the ability to resist compression increases the possibility of damage to the tissue. Alteration to the tissue in this manner may be a factor in the development of **degenerative joint disease**.

Staining of Cartilage

The presence of sulfate groups on these compounds imparts an acidic nature to the matrix. As such, the ground substance of cartilage is basophilic and stains appropriately with routine stains (H&E). The matrix of most cartilages does not stain uniformly (Fig. 8-3). Young cartilage may be acidophilic; the matrix of the perilacunar margin (**capsular** or **territorial matrix**) of old cartilage stains intensely basophilic. The region of the matrix between individual cells or groups of cells, the **interterritorial matrix,** stains less intensely basophilic than the territorial matrix. The staining properties relate to the sulfate and carboxylate groups (basophilic components) and the acidophilic nature of the collagen. In young cartilage with fewer sulfate groups, collagen acidophilia dominates the staining. In mature cartilage, the basophilic components dominate.

The metachromatic staining properties of cartilage depend upon the constituent GAGs. Metachromatic stains are useful to show these substances.

Not all cartilage stains the same. Tracheal, intervertebral disc, and articular cartilage stains differently. Also, young hyaline cartilage of an articular surface stains differently from old cartilage of a similar surface.

Although the sulfated glycosaminoglycans of cartilaginous matrix are periodic acid–Schiff (PAS) negative, cartilaginous matrix stains positive with PAS. All of the molecules responsible for this stain reactivity have not been determined, but they are probably collagen and other structural glycoproteins.

Ultrastructure of Cartilaginous Matrices

The cells and matrix of hyaline cartilage appear differently when viewed with electron microscopy (Fig. 8-4). The chondrocytic lacunae are not apparent. Fibrillar and granular materials are next to the cells. Some collagenous fibers are

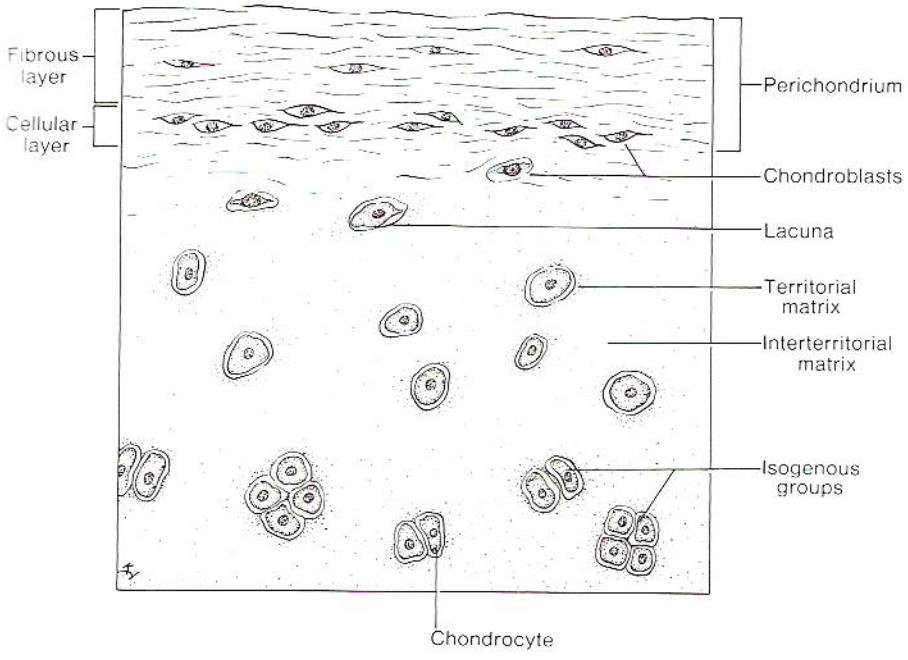

Figure 8-3. Typical hyaline cartilage. Mitosis of cells within the perichondrium results in appositional growth. Mitotic activity within the matrix produces both isogenous groups (cell nests) and interstitial growth.



Figure 8-4. Electron micrograph of growing cartilage. The cellular margin *(solid arrow)* and lacunar margin *(open arrow)* are separated from each other by a lacunar *(L)* or territorial matrix. The territorial matrix is composed of granular materials (matrix granules), fibrillar materials, and some cellular processes, but banded collagen is not evident. (X6800.) (Courtesy J. W. Newbrey.)

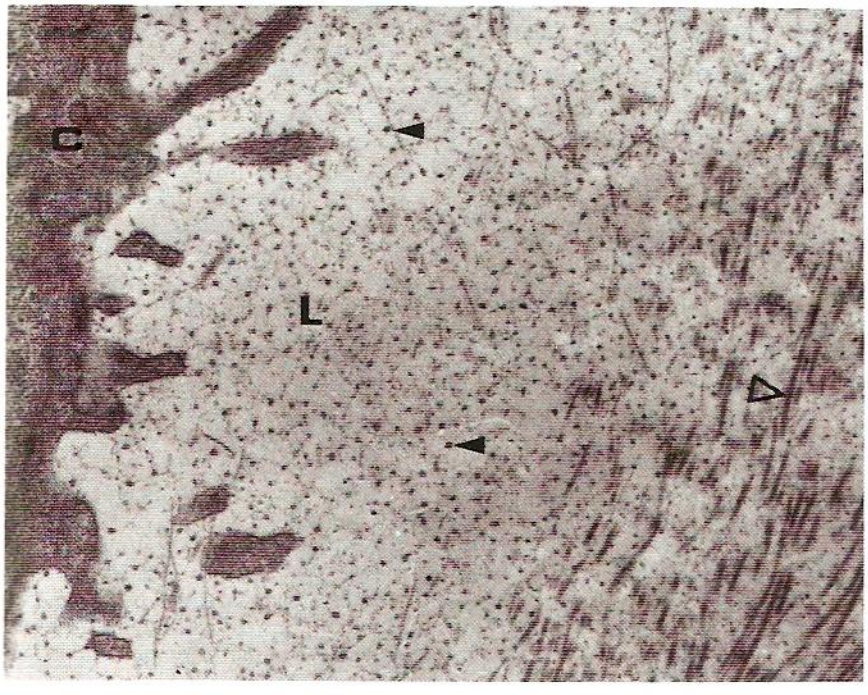

Figure 8-5. Electron micrograph of growing cartilage. The chondroblast *(C)* has cellular processes extending into and through the lacunar *(L)* or territorial matrix. Matrix granules *(solid arrowheads)* are evident in both the territorial and the interterritorial matrices. The matrix granules within the territorial matrix occur in juxtaposition to microfibrils. The interterritorial matrix is characterized by matrix granules interspersed among banded collagenous fibers *(open arrowhead)*. This preparation was stained with ruthenium red, an electron-dense stain for GAGs. (X15,000.) (Courtesy J. W. Newbrey.)

also apparent (Fig. 8-5). There is, then, a continuum of matrical materials from the cellular margin to the matrix proper.

Three matrical zones are visible with the electron microscope—pericellular, territorial, and interterritorial. The **pericellular matrix,** which is immediately next to the cell, has granules and fibrillar materials (Fig. 8-4). The retraction of the cell from this interface accounts for the lacunae that are observed by light microscopy. The **territorial matrix (capsular matrix, lacunar matrix)** has fibrillar and granular materials (Figs. 8-4 and 8-5). The granular materials, **matrix granules,** consist of proteoglycan aggregates. These granules typically stain with GAG-specific stains and are removed by appropriate enzymes. Banded collagen fibrils are not evident in this region. Fibrillar materials, **microfibrils,** probably represent diverse substances, nonbanded collagen, noncollagenous proteins (core proteins), and hyaluronic acid (Fig. 8-6). The **interterritorial matrix** contains banded collagen (type II). Fibrillar materials and matrix granules also comprise this matrix.

Matrix granules appear free in the matrix, in intimate association with mi-

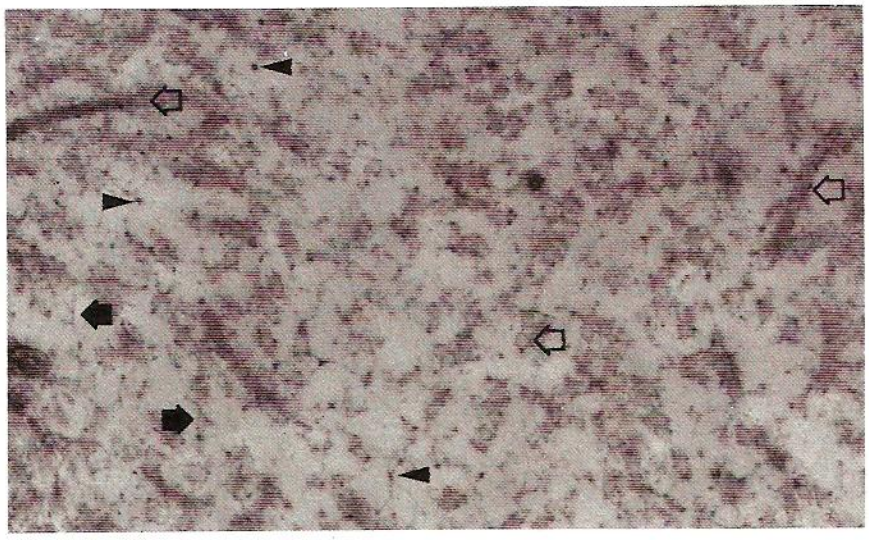

Figure 8-6. Electron micrograph of the matrix of growing cartilage. The sample was stained with ruthenium red, an electron-dense stain used to demonstrate GAGs. The intimate relationship of the biochemical matrical components is shown. Matrix granules *(small solid arrowheads)*, microfibrils *(large solid arrows)*, and sectioned collagen fibers *(open arrows)* are evident. Note the intimate juxtaposition of matrix granules to microfibrils and collagen. The microfibrils are known to be hyaluronic acid. Some of the collagen fibers are cut in longitudinal section, others in cross section. Hyaluronic acid, other GAGs, and collagen are linked biochemically to each other within the matrix. (X36,000.) (Courtesy J. W. Newbrey.)

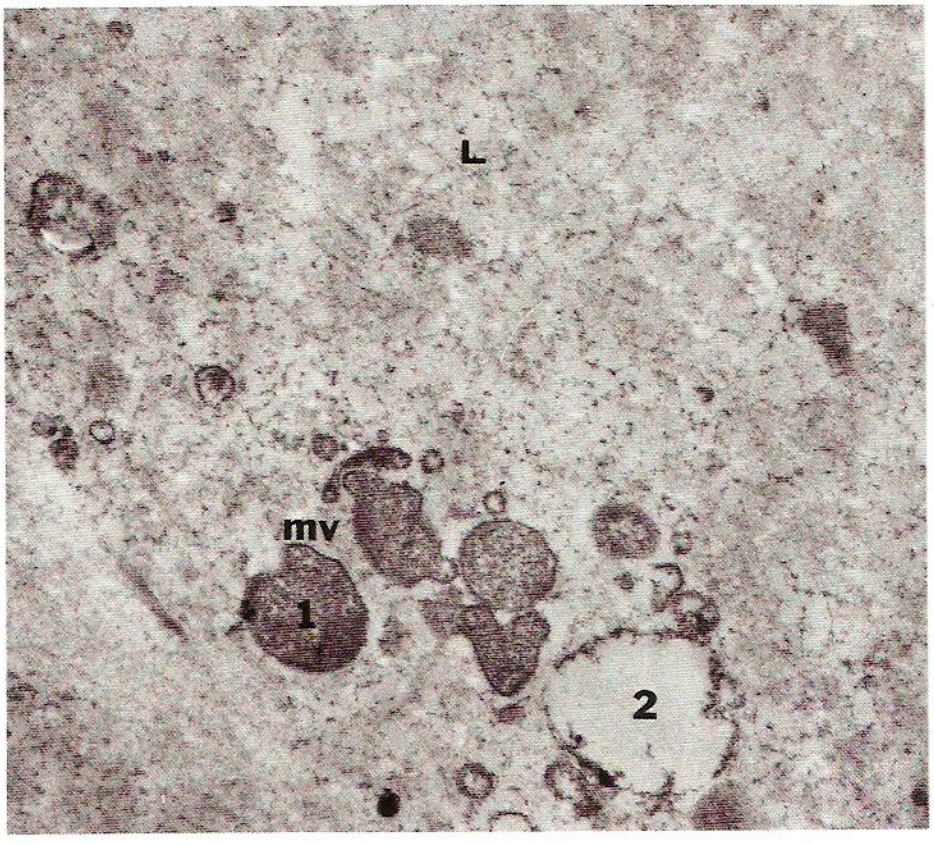

Figure 8-7. Electron micrograph of mineralizing cartilage. Two types *(1,2)* of matrix vesicles *(mv)* are present within the matrix. The matrix vesicles are foci for the initiation of cartilage mineralization. They usually occur within or close to the interterritorial matrix. The lacunar or territorial matrix *(L)* is indicated. (X34,000.) (Courtesy J. W. Newbrey.)

crofibrils, and juxtaposed to collagen fibrils (Fig. 8-6). All matrix components bond chemically to each other (Fig. 8-2). Additionally, cytoplasmic processes project from the cells and extend into the matrix. **Matrix vesicles** are present in certain foci with hyaline cartilage. These membrane-bound vesicles pinch off from the cells or cell processes and remain in the matrix. They occur in the mineralization zone of growth plate hyaline cartilage and are the sites used by the cartilage for initiating growth plate mineralization (Fig. 8-7).

TYPES OF CARTILAGE

Hyaline Cartilage

Grossly, hyaline cartilage has a white, glassy appearance (Gr *hyalos,* glass). In histological section this avascular tissue is separated from the surrounding tissue by a **perichondrium** (Fig. 8-8), which is analogous to the capsule of other organs. The perichondrium has **fibrous** and **cellular** parts. The fibrous portion is dense collagenous tissue that usually blends imperceptibly with the surrounding connective tissue. The cellular part contains mesenchymal cells serving as stem cells for chondroblasts and fibroblasts of the fibrous perichondrium (Fig. 8-9). The cells are a prominent part of the perichondrium only in young growing cartilage.

In young cartilage a definite gradation from **mesenchymal cells** to **chondroblasts** to **chondrocytes** is apparent (Fig. 8-10). As mesenchymal cells differentiate into chondroblasts, these cells secrete matrix and surround themselves in their secretions. This activity forms small **lacunae** (lakes) in which the cells reside without any contact with other cells or the surface. The lacunae of cartilage being without cells in some sections is an artifact of sectioning. The lacunae and the cells within them are flattened, with their long axes parallel to the surface. The matrix of this region is generally acidophilic.

Maturation of the chondroblasts into chondrocytes is marked by cellular hypertrophy, lacunar enlargement, and a change in lacunar shape from flat to ovoid (Fig. 8-11). Chondrocytes also cluster as **isogenous groups** or **cell nests.** These clusters are the daughter cells of single chondrocytes that underwent mitosis (interstitial growth). The isogenous groups in growth plates assume a columnated pattern (Fig. 8-12).

Chondrocytes appear as smooth-surfaced cells withdrawn from the lacunar margins (Fig. 8-13). With electron microscopy, many cellular processes are seen intimately contacting and extending into the matrix (Fig. 8-14).

Downloaded From VetBooks.com

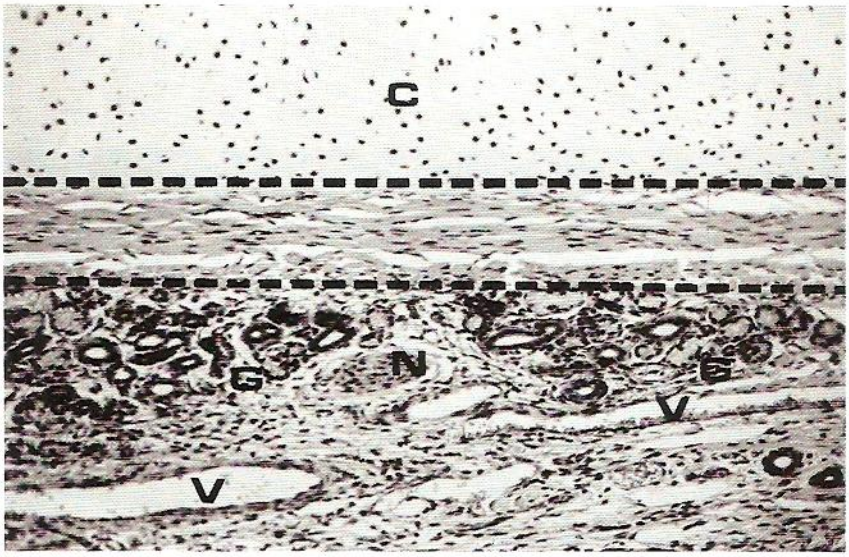

Figure 8-8. Cartilage and associated tissue of an ovine turbinate. The cartilage *(C)* is surrounded by a perichondrium *(dashed lines)*. The peripheral loose collagenous tissue *(below the perichondrium)* contains nerves *(N)*, glands *(G)*, and blood vessels *(V)*. (X40.)

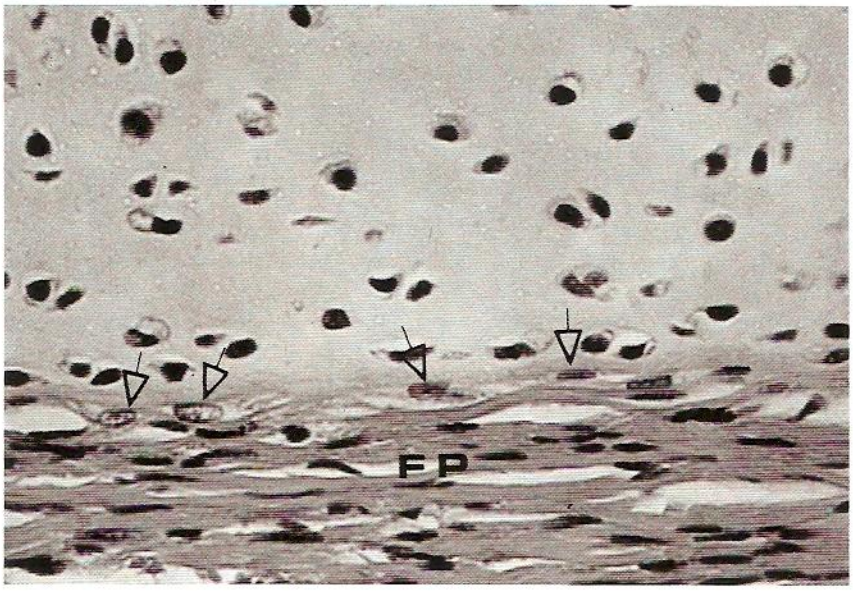

Figure 8-9. Perichondrium of cartilage. The fibrous perichondrium *(FP)* consists of collagen fibers and fibroblasts. The cellular perichondrium *(arrows)* consists of mesenchymal cells and chondroblasts. It is more evident in growing animals. (X160.)

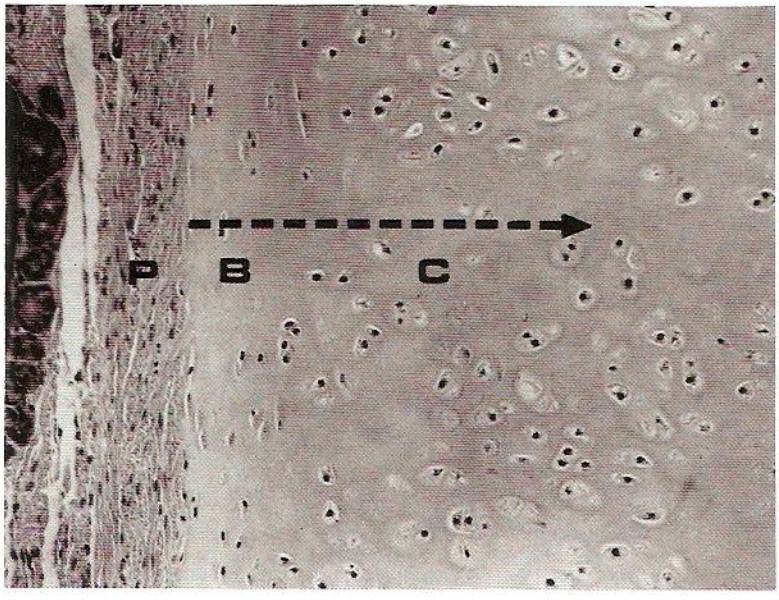

Figure 8-10. Growing cartilage from a feline larynx. The fibrous perichondrium *(P)* is peripheral to the layer in which chondroblasts *(B)* are evident. Enlargement of chondroblasts and their differentiation into chondrocytes *(C)* are apparent. A *dashed line* indicates the progression of differentiation. (X40.)

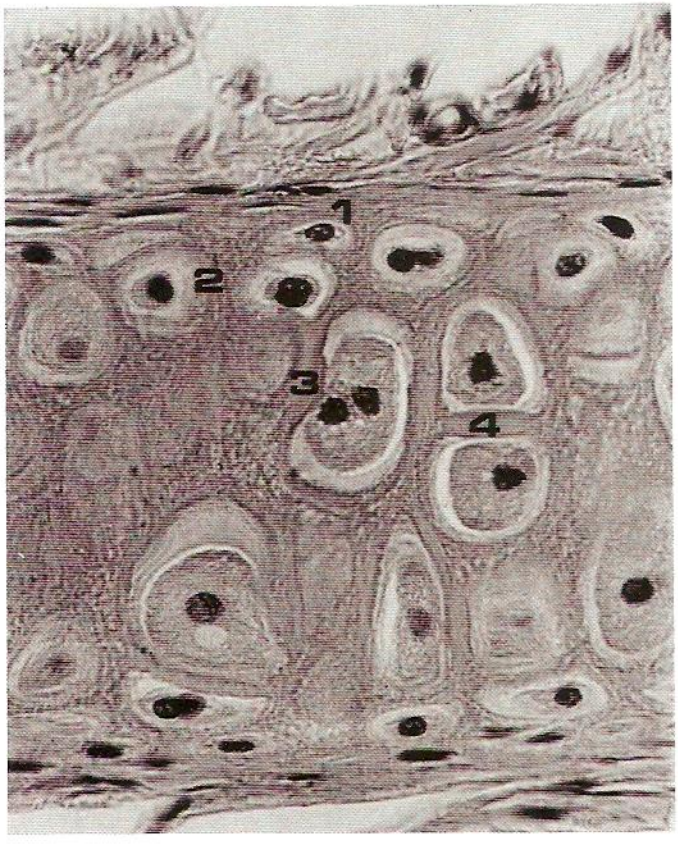

Figure 8-11. Growing elastic cartilage of a porcine pinna. Chondroblasts *(1)* enlarge to become chondrocytes *(2)*. Chondrocytes may divide *(3)* to form isogenous groups *(4)*. Interstitial growth consists of new cells and matrix added from within the mass of the cartilage. (X160.)

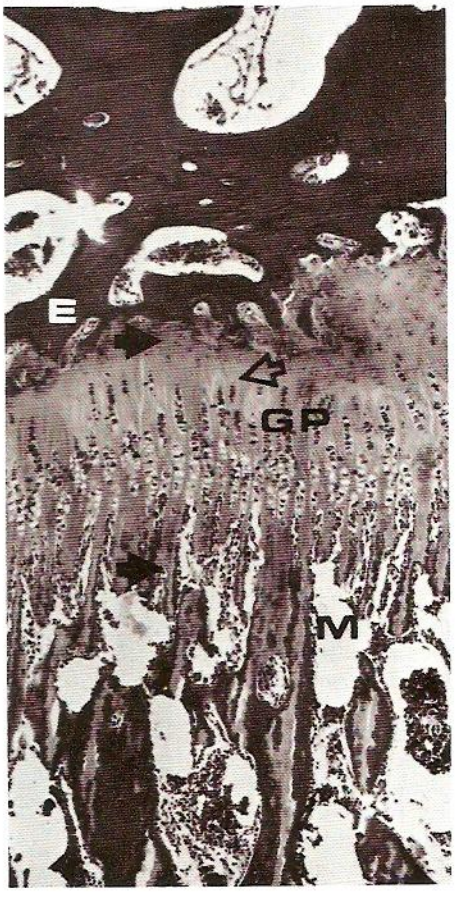

Figure 8-12. Growth plate of a developing bone. In general, the growth plate *(GP)* consists of hyaline cartilage insinuated between the epiphyseal endplate *(E)* and the complex tissues of the metaphysis *(M)*. The approximate limits of the physis are indicated by *solid arrows*. Stacks of young chondrocytes *(open arrow)* divide and form ordered columns of maturing cells. Each column represents a unique configuration of an isogenous group. The physis, therefore, grows by interstitial growth. (X16.)

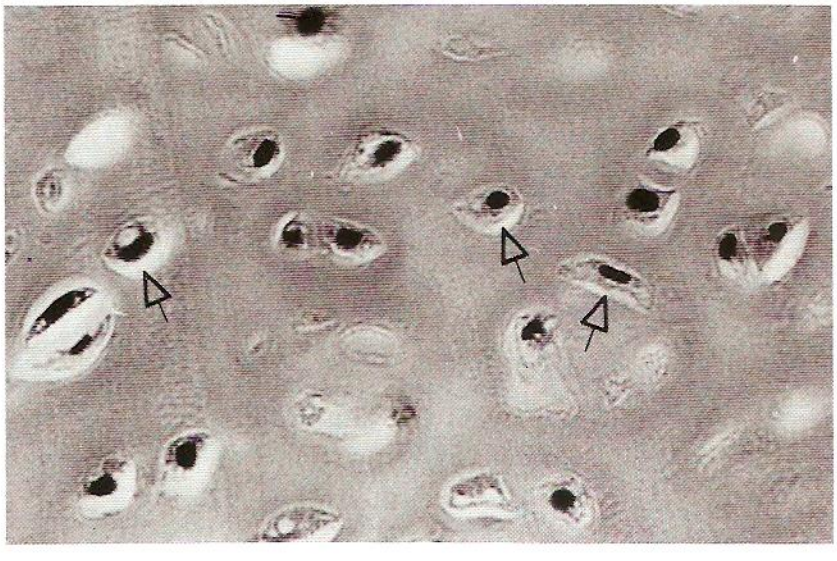

Figure 8-13. Mature chondrocytes within hyaline cartilage. The chondrocytes may occur as single cells or as components of isogenous groups. The lacunae *(open arrows)* are features of light microscopy, because the cell limits artifactually shrink away from the margin of the matrix during processing. (X100.)

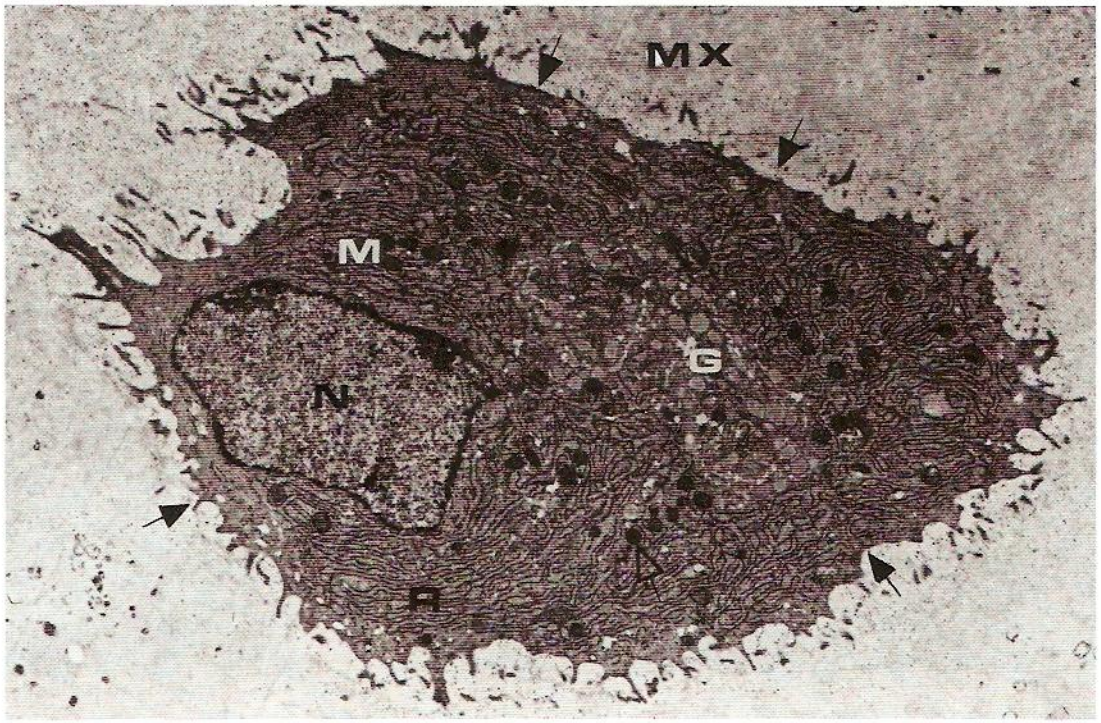

Figure 8-14. Electron micrograph of a chondrocyte. The nucleus *(N)* is vesicular. The cytoplasm has an extensive Golgi complex *(G)* and RER *(R)*. Mitochondria *(M)* and dense bodies *(open arrows)* are also present. The interface *(solid arrows)* between the cell and its matrix *(MX)* is very close. Cell processes extend into the matrix. Note that a lacunar space is not evident. (X5000.)

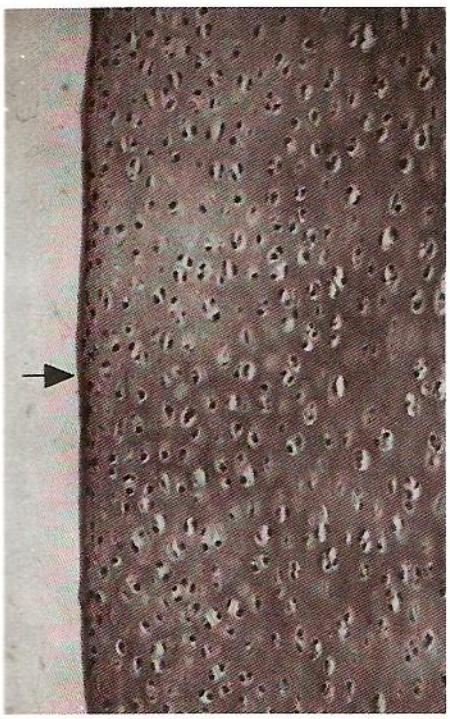

Figure 8-15. Articular surface of the proximal head of a canine humerus. The hyaline cartilage of the articular surface *(arrow)* is devoid of a perichondrium. (X38.)

The lacunar margins of individual chondrocytes or isogenous groups are more basophilic than other portions of the matrix. This marked basophilia delimits the **capsule** or **territorial matrix** of these cells; the lighter region of basophilia marks the **interterritorial matrix.**

Although the perichondrium is generally a consistent feature of hyaline cartilage, **articular hyaline cartilage secondarily loses its perichondrium** (Fig. 8-15).

MORPHOLOGICAL FEATURES. A few cells are embedded within a gel-like matrix that appears afibrillar. The limits of the tissue are usually well marked by a perichondrium. The matrix generally stains with basic dyes.

OCCURRENCE. Most bone-forming sites of the fetus and young animal; articular cartilages; airways of the respiratory tree; support structures of the nose and larynx (Plate IV, *8* and *9*)

Elastic Cartilage

Grossly, this tissue is yellow and more resilient than hyaline cartilage due to the presence of elastic fibers. Other than having elastic fibers, it is identical with hyaline cartilage. In some foci more isogenous groups than those typical of hyaline cartilage may be apparent. The elastic fibers are demonstrable with H&E as pink-staining fibers scattered throughout the matrix (Fig. 8-16). They are easily shown with special staining techniques (Fig. 8-17).

MORPHOLOGICAL FEATURES. Identical with those of hyaline cartilage, except for the presence of elastic fibers. Isogenous groups may be observed more frequently.

OCCURRENCE. External ear (pinna); external auditory canal; auditory tube; parts of the laryngeal cartilages; epiglottic cartilage (Plates I, *11*, and IV, *10*)

Fibrous Cartilage

Fibrocartilage has a limited occurrence but imparts additional strength to cartilage and dense collagenous tissue. It is an intermediate form between dense collagenous tissue and cartilage. Because visible collagenous fibers predominate, it may be considered a modified dense collagenous tissue. Features of cartilage and dense collagenous tissue are also apparent at the ultrastructural level.

Large collagenous **fascicles** (bundles) occur in orderly array and are separated by isolated portions of cartilage (Fig. 8-18). The chondrocytes, which reside between the fascicles, secrete small quantities of typical cartilaginous matrical materials. The classical appearance of this tissue is the **herringbone pattern** (Fig. 8-19), in which collagenous bundles are oriented to each other as a V. Typically, the orientation of the fibers may not appear as orderly as described (Fig. 8-20).

Fibrocartilage usually occurs at points of transition between dense collagenous tissue and cartilage and between dense collagenous tissue and bone. Fibrous cartilage imparts additional strength to these points of transition and/or attachment. Also, this tissue is a significant constitu-

Downloaded From Vet-eBooks.com

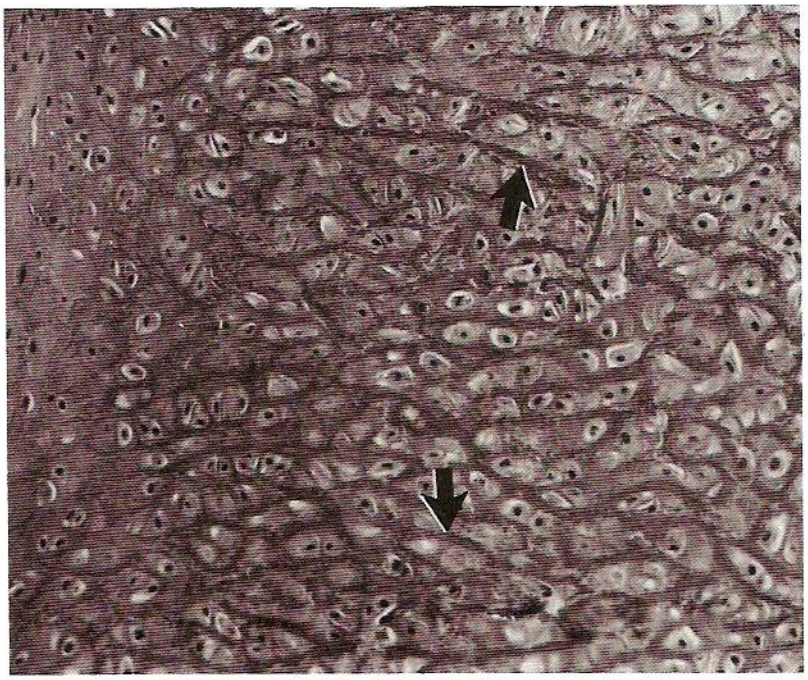

Figure 8-16. Elastic cartilage from a bovine epiglottis. The elastic fibers *(arrows)* are predominant features of the matrix. (X40.)

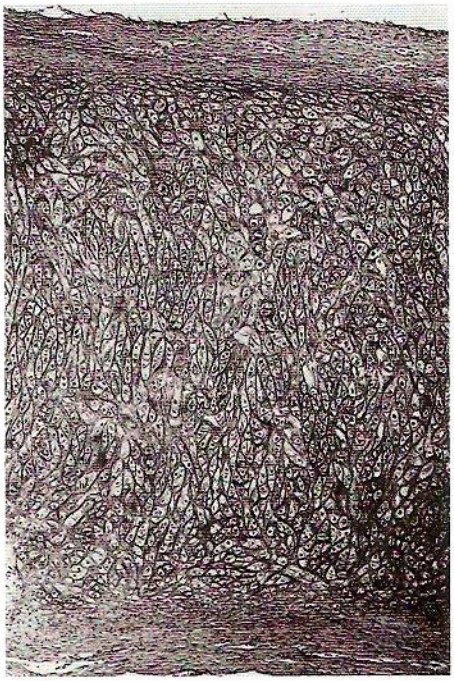

Figure 8-17. Special staining of elastic cartilage. The elastic fibers are black. (X13, Verhoeff's stain.)

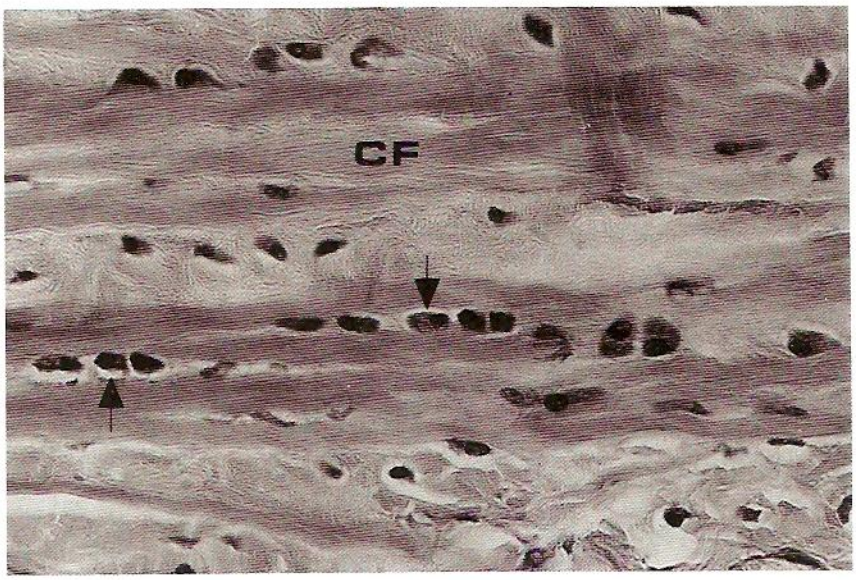

Figure 8-18. Fibrocartilage. The collagen fibers *(CF)* are predominant features of this tissue. Chondrocytes within their lacunae *(arrows)* are spaced in an orderly manner between the fibers. (X100.)

Downloaded from Yes Dental.com

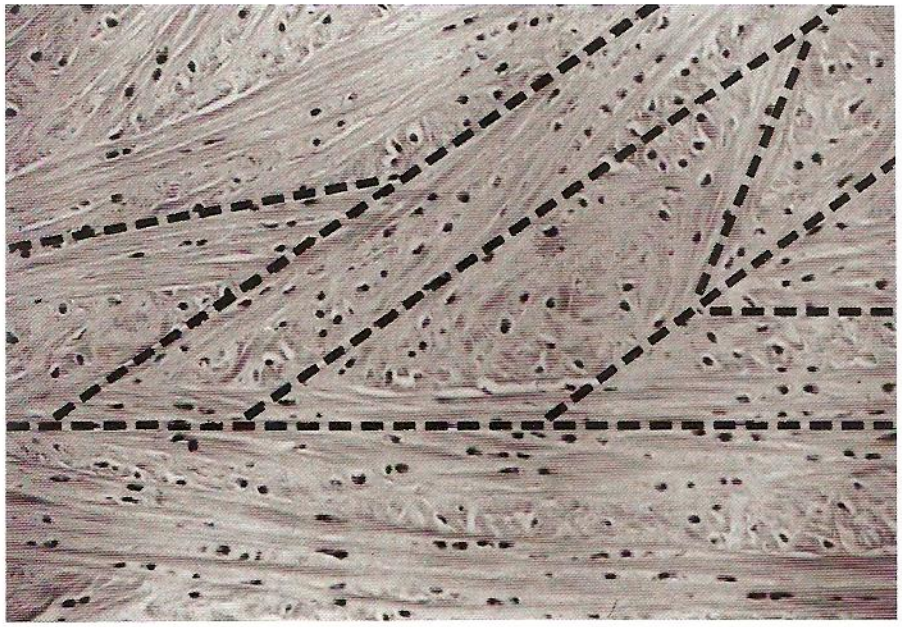

Figure 8-19. Fibrocartilage from the meniscus of a canine stifle. The herringbone configuration *(dashed lines)* is readily apparent in this section. (X40.)

Figure 8-20. Fibrocartilage from an intervertebral disc. The herringbone configuration is not as apparent in this section as it is in Figure 8-19. (X39, Verhoeff's stain.)

ent of articulations. **This tissue does not have a perichondrium.**

MORPHOLOGICAL FEATURES. **Coarse collagenous bundles in parallel and/or V-shaped orientation predominate. Chondrocytes and limited amounts of matrical materials occur between the bundles.**

OCCURRENCE. **Intervertebral discs; attachments of certain tendons and ligaments to bone; menisci (Plate IV, *11*)**

MAINTENANCE AND REPAIR OF CARTILAGE

Avascular cartilaginous tissues depend totally upon diffusion of metabolites from capillaries. Nutritional compromise of chondrocytes leads to degenerative changes apparent especially in thick cartilage of aged animals. Mineralization of the matrix is a common sequel to this aging process.

Growth plate cartilage normally undergoes mineralization. This "normal" process may be interpreted as an acceleration of the aging process. When the cells are displaced away from their blood supply, they may be compromised nutritionally and mineralization of the matrix results.

The actual maintenance of the matrix is the responsibility of chondrocytes, which remove and replace fibrous and amorphous components. The intense basophilia of the capsular matrix reflects the ability of chondrocytes to add highly sulfated GAGs to the matrix.

Cartilage repair is not achieved to the same degree in all types of cartilage. The same type of cartilage does not achieve the same degree of repair in different locations. The animal's age is also a significant factor.

The perichondrium ensures a supply of mesenchymal cells. The continued proliferation and differentiation of mesenchymal cells of the perichondrium, a feature of young, growing animals, are complemented by interstitial growth. Damage to hyaline or elastic cartilage during this period is repaired by appositional and interstitial growth.

In adults the perichondrium is not active and some of its regenerative ability diminishes. Interstitial growth potential is also lost. Repair of adult cartilage is mediated by a fibrous connective tissue derived from the perichondrium or the dense collagenous tissue of adjacent fascia. The newly added tissue, called "granulation tissue" by some authors, may be transformed gradually into cartilage. The new cartilage may retain a fibrocartilaginous character.

Fibrocartilage reacts differently to injury. It is a dense tissue without a perichondrium. Its vascular supply is limited, especially in the menisci of the stifle joint and the intervertebral discs, to a few foci at the periphery. These vascular relationships, coupled with a paucity of stem cells, generally preclude good healing. Meniscal damage and intervertebral disc rupture usually compromise the vascular supply sufficiently to warrant the general statement that fibrocartilaginous repair potential is poor. This applies also to the fibrocartilaginous interface at attachment points of ligaments and tendons to bone. However, careful surgical management of meniscal tears in the canine stifle, with particular attention to peripherally positioned vessels, results in satisfactory repair.

The hyaline cartilage of the articular surface is without a perichondrium. Interstitial growth is active until adulthood, and superficial damage to the articular surface may be repaired by this mechanism. Any minor blemish to the matrix of the articular surface in young or adult animals may be repaired by increased secretion of matrix components.

In adults articular cartilage repair varies with the extent and location of the damage. On the weight-bearing surface, superficial damage can be repaired only through compensatory secretion by the chondrocytes. If the damage were to extend through the cartilage to the subchondral bone **(full-thickness defect)**, then a number of possibilities for repair exists. Stem cells in the subchondral region may differentiate into fibrous connective tissue, fibrocartilage, or bone. Under carefully controlled experimental conditions these stem cells may give rise to hyaline cartilage when subjected to continuous passive motion. Full-thickness defects of cartilage may be repaired by transplanting autologous perichondral grafts over the damaged surface. The replacement of the hyaline cartilage by bone represents a degenerative change known as **osteoarthrosis.**

Downloaded From Vet-eBooks.com

Along the peripheral non–weight-bearing surface of the articular cartilage, damage generally leads to replacement with fibrocartilage.

The most ideal repair results in the replacement of a specific tissue with an identical type of tissue. The repair of cartilage, especially that of the articular surface of the adult, is less than ideal. The replacement tissues do not have the same properties; therefore, structure and function are usually compromised.

ADDITIONAL READINGS

Amprino R: On the incorporation of radiosulfate in the cartilage, *Experientia* 11:65, 1955.

Anderson HC: Vesicles associated with calcification of the matrix of epiphyseal cartilage, *J Cell Biol* 41:59, 1969.

Cameron DA, Robinson RA: Electron microscopy of epiphyseal and articular cartilage matrix in the femur of the newborn infant, *J Bone Joint Surg* 40:163, 1958.

Goodman GC, Lane N: On the site of sulfation in the chondrocyte, *J Cell Biol* 21:353, 1964.

Goodman GC, Porter KR: Chondrogenesis studies with the electron microscope, *J Biophys Biochem Cytol* 8:719, 1960.

Hall BK (ed): *Cartilage*, vols I to III, New York, 1983, Academic Press.

Kuettner KE, et al: Lysosome in epiphyseal cartilage. II. The effect of egg white lysozyme on mouse embryonic femurs in organ cultures, *J Cell Biol* 44:329, 1970.

Lane JM, Weiss C: Review of articular cartilage collagen research, *Arthritis Rheum* 18:553, 1975.

Larsson SE, Kuettner KE: Microchemical studies of acid glycosaminoglycans from isolated chondrocytes in suspension, *Calcif Tiss Res* 14:49, 1974.

Maroudas A: Distribution and diffusion of solutes in articular cartilage, *Biophys J* 10:365, 1970.

Meachin G: The effect of scarification on articular cartilage in the rabbit, *J Bone Joint Surg* 45(B):150, 1963.

Nemeth-Csoka M: The influence of inorganic phosphate and citrate anions on the effect of glycosaminoglycans during collagen fibril formation, *Exp Pathol* 14:40, 1977.

Palfrey AJ, Davies DV: The fine structure of the chondrocyte, *J Anat* 100:213, 1966.

Pritchard JJ: A cytological and histochemical study of bone and cartilage formation in the rat, *J Anat* 86:259, 1952.

Salter RB, Harris DJ, Clements ND: The healing of bone and cartilage in transarticular fractures with continuous passive motion, *Orthop Trans* 2:77, 1978.

Sheldon H, Robinson RA: Studies on cartilage. I. Electron microscope observations on normal rabbit ear cartilage, *J Biophys Biochem Cytol* 4:401, 1958.

Skoog T, Johansson SH: The formation of articular cartilage from free perichondrial grafts, *Plast Reconstructr Surg* 57:1, 1976.

Sokoloff L (ed): *The joints and synovial fluid*, New York, 1978, Academic Press.

Spycher MA, Moor H, Ruettner JR: Electron microscopic investigations on aging and osteoarthritic human articular cartilage. II. The fine structure of freeze-etched aging hip joint cartilage, *Z Zellforsch* 98:512, 1969.

Svajger A: Chondrogenesis in the external ear of the rat, *Z Anat Entwicklungsgesch* 131:236, 1970.

Thyberg J, Friberg U: The lysosomal system in endochondral growth, *Progr Histochem Cytochem* 10:1, 1978.

Downloaded From Vet-eBooks.com

CHAPTER 9

Supportive Tissues—Bone

GENERAL CHARACTERISTICS

Form and function. Bone is a connective tissue with its cells embedded in a mineralized, gel-like substance. The method of secretion and the manner in which the cells become embedded in the matrix are similar to those mechanisms in cartilage. The distinctive mineral consists predominantly of **hydroxyapatite (HAP) crystal.** The organic matrix of bone is predominantly collagen.

Bone cells **(osteocytes)** contact each other and surface cells (osteoblasts) through cellular processes located in small canals **(canaliculi)** in the matrix. Bone is a well-vascularized tissue. Mineralized bone matrix is minimally expandable, so bone can grow only by apposition. This requires a copious supply of **stem cells.**

Bone stem cells, osteoblasts, and osteoclasts are located in covering envelopes called **periosteum** and **endosteum.** These envelopes and their associated cells cover all surfaces of bone (except some in old age).

Once bone is formed, its mineral is not irreversibly sequestered but may be mobilized by distinct mechanisms. Bone functions as a dynamic sink for Ca^{++} and phosphate (as well as other bone-seeking substances). Bone is metabolically active and constantly changing. Its extensive vascular supply gives some insight into its viability and metabolic activity. The cells of bone are responsive to many and varied stimuli. Many hormones act "in concert" upon bone, influencing directly its cellular activity and, indirectly, its intercellular substance. Mechanical forces acting upon bone influence the amount of bone in the skeleton as well as its three-dimensional distribution.

All essential physiological activities conducted by other tissues are conducted by bone. Bone cells perform these activities within the confines of a mineralized matrix. The turnover of bone matrix may be evaluated by direct observation. **The matrix of bone is a record of the events occurring previously.**

Classification. Bone is either **woven (immature, fibrous)** or **lamellar (mature).** Both tissues can be arranged differently into distinct **configurations.** These configurations, **cancellous (spongy, trabecular)** bone or **compact bone** (Fig. 9-1), are visible grossly, radiographically, and microscopically.

Bone is both a tissue and an organ. **As a tissue, it grows only by apposition. As an organ, it grows by appositional and interstitial mechanisms.**

MATRICAL COMPONENTS

The matrix of bone is a major portion of its tissue mass. The extracellular matrix, occupying 92% to 95% of the tissue volume, consists of various organic and inorganic constituents—**collagen, sugars, glycoproteins, proteoglycans, glycosaminoglycans (GAGs), peptides, lipids, organic ions, inorganic ions, and water.** Many factors influence the types and quantities of these constituents—age, species, state of health, bone type, bone configuration. The organic matrix is about 22% of the weight of a bone sample; the inorganic materials are 69%. Bone contains about 9% water.

Organic matrix. The **organic matrix** of bone **(osteoid)** consists of a fibrous **stroma** and **amorphous ground substance. Collagen** is about 90% of the organic matrix. The remaining 10% is the amorphous ground substance. Conjugated proteins, small amounts of proteoglycans, and very small amounts of lipids are components of the matrix. Interfibrillar substances may function as foci for the initiation of mineralization.

Sialoproteins, glycoproteins, and **phosphoproteins** have been isolated from bone. Sialoproteins and phosphoproteins bind Ca^{++} and may also contribute to the mineralization process. Plasma proteins (albumin, α_2HS-glycoprotein, γ-carboxy glutamic acid–containing proteins) have been isolated from bone, but their function has not been determined.

Proteoglycans with chondroitin-4-sulfate, keratan sulfate, and hyaluronic acid are present. The onset of mineralization occurs with the removal of matrix proteoglycans. Proteoglycans function as initiators and inhibitors of mineralization. Phospholipids may also be involved.

The amount of skeletal water varies with the animal's age and the degree to which the skeleton is mineralized.

Inorganic matrix. About half the maximal mineral-holding capacity of bone exists at the time of its initial mineralization. In approximately a year a given sample of bone achieves 100% mineralization.

HAP crystal is the predominant salt within a mature sample of bone, but many salts participate in the phase transitions from initiation to maturity. HAP has the chemical formula $Ca_{10}(PO_4)_6(OH)_2$. Several substitutions occur in vivo, reducing the theoretical Ca^{++}:phosphate molar ratio to less than the 1.66 expected. Among the substituted elements and compounds are Na^+, Mg^{++}, $CO_3^=$, F^-, Pb^{++}, Sr^{++}, citrate, phosphate esters, diphosphonates, pyrophosphates, and amino acids.

Functional correlates. The tensile properties of bone, or the resistance to elongatation when loaded, are greatest when a bone is loaded along its long axis. Such loading corresponds, generally, to the orientation of osteons within diaphyseal compacta and the general orientation of stacked laminae of collagenous fibers in osteons. **The tensile properties of bone relate directly to the tensile properties of its constituent collagenous fibers.** The ability of a bone to resist tensile stress is about half its ability to resist compressive stress. **Compressive stress properties relate to the mineral content of bone.**

The collagen of bone is usually organized into highly ordered arrays. In **mature bones** this organizational pattern is manifested as layers of collagenous fibers deposited upon each other in a helical pattern; each layer of the helix is oriented at a different angle to the previous layer (Fig. 9-2). The pattern of fiber orientation, responsible partially for the tensile properties of bone, imparts a lamellar appearance to mature bone especially apparent with polarizing microscopy (Fig. 3-7).

The microcrystalline structure of HAP provides a surface area of about 200 m^2 per gram of crystal. The three-dimensional array of the crystal provides an enormous surface area for absorption and exchange of materials between itself and the surrounding, metastable fluid of the extracellular compartment.

Preparation of bone samples. The histological study of bone may be ap-

Downloaded From Vet-eBooks.com

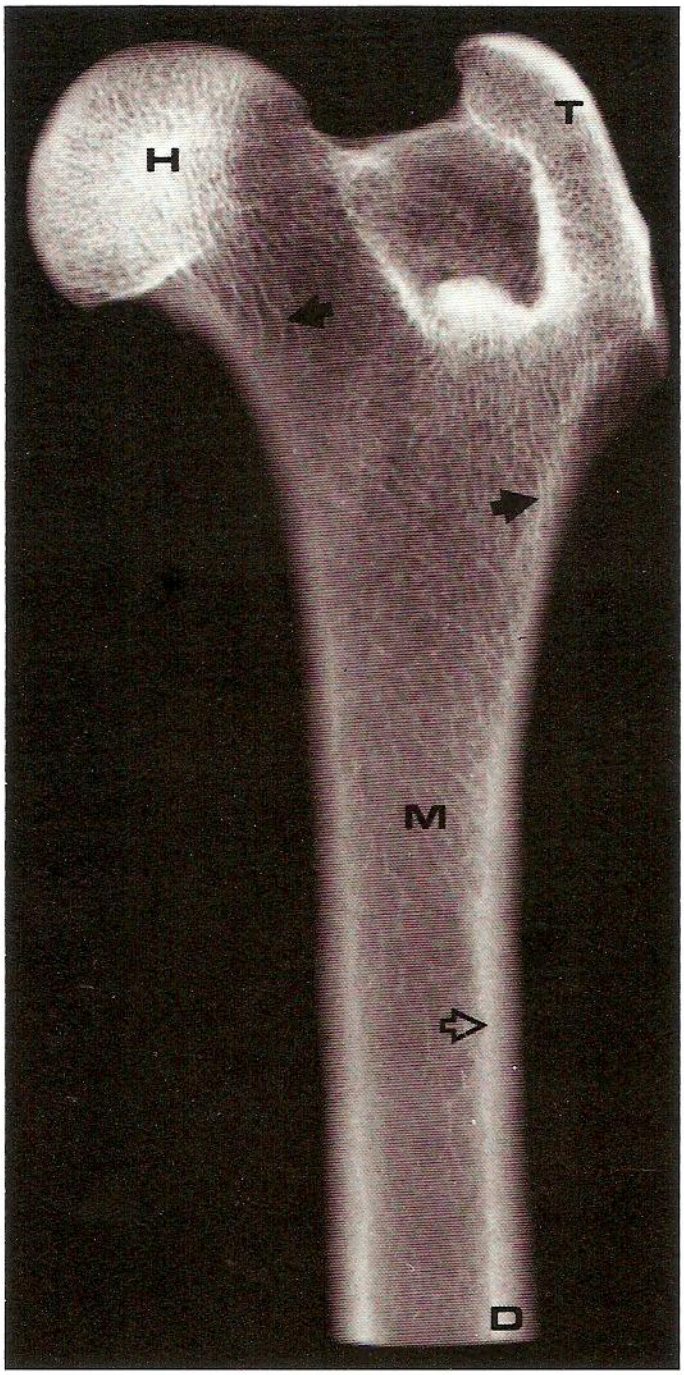

Figure 9-1. Radiograph of the proximal portion of a longitudinally sectioned canine femur. Note the cancellous *(solid arrow)* and compact *(open arrows)* bone. *H*, Head; *T*, greater trochanter; *M*, marrow cavity; *D*, diaphysis.

proached by examination of **demineralized** and/or **mineralized** sections. Demineralization is accomplished by either **chelation** or **acid hydrolysis,** resulting only in removal of the mineral phase of bone and leaving the organic **osteoid.** Thin sections of bone may be obtained for study by this approach. Sections of bone so prepared retain near normal matrical relationships. Good cytological detail is also retained.

Mineralized samples must be cut with a diamond-tipped saw blade or ground on an abrasive material. Sample thicknesses of 50 to 100 μm can be obtained. Cytological detail is not retained with this method, but the matrix supplies valuable information about cell activity. **Unless specified in the legend, micrographs of bone used in this book have been obtained from demineralized sections.**

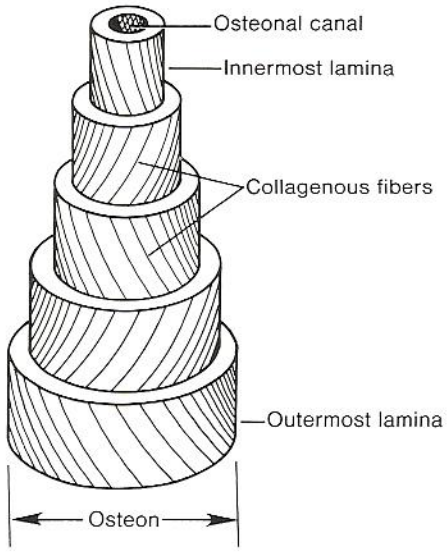

Figure 9-2. Osteon. The concentric laminae of bone have been partially removed to show the orientation of collagen fibers within each lamina. In this example, collagen fibers within the laminae are oriented at approximately 90° to each other. The osteon is an elongated structure (cylinder) consisting of successive laminae of bone matrix. The relationship of the fibers to the apatite crystals is not indicated.

ENVELOPES OF BONE

The cells of bone are distributed throughout the tissue in two distinct loci. Osteocytes are located within the osseous matrix. The other cells are located on bone surfaces within distinct envelopes, **periosteum** and **endosteum.** The cells of these envelopes appear structurally identical, but they are not identical functionally. Differential responses of these subsets occur during growth, aging, and disease.

Periosteum

The **periosteum** is the outer covering of an entire bone, except the articular surfaces (Fig. 9-3). It must be incised to expose underlying osseous tissue. The periosteum has fibrous and cellular layers. The fibrous layer is dense collagenous tissue considered the **capsule** of the organ (Fig. 9-4). Collagen fibers of ligaments and tendons blend with and pass through this fibrous capsule before becoming anchored in the osseous tissue beneath it. The cells of the periosteum are mesenchymal cells, osteoprogenitor cells, osteoblasts, and osteoclasts. The periosteum is well-vascularized.

This envelope produces, maintains, remodels, and repairs the diaphysis. It responds to various insults, resulting in **periosteal new bone** formation.

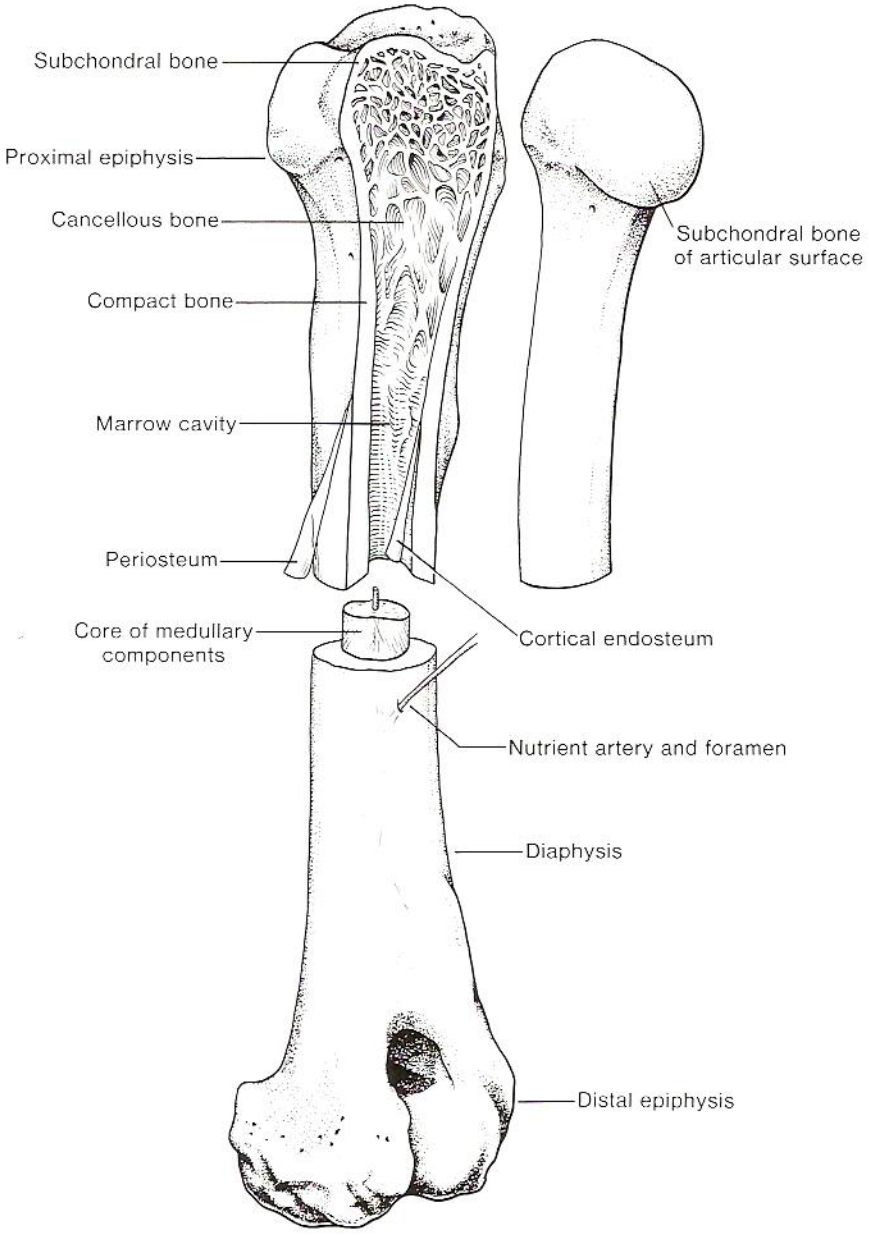

Figure 9-3. Canine humerus. The preparation of this specimen resulted in removal of the articular cartilage. The periosteum covers all external bone surfaces except those of the articulations. The endosteum covers all internal bone surfaces. Compare with Figure 9-6.

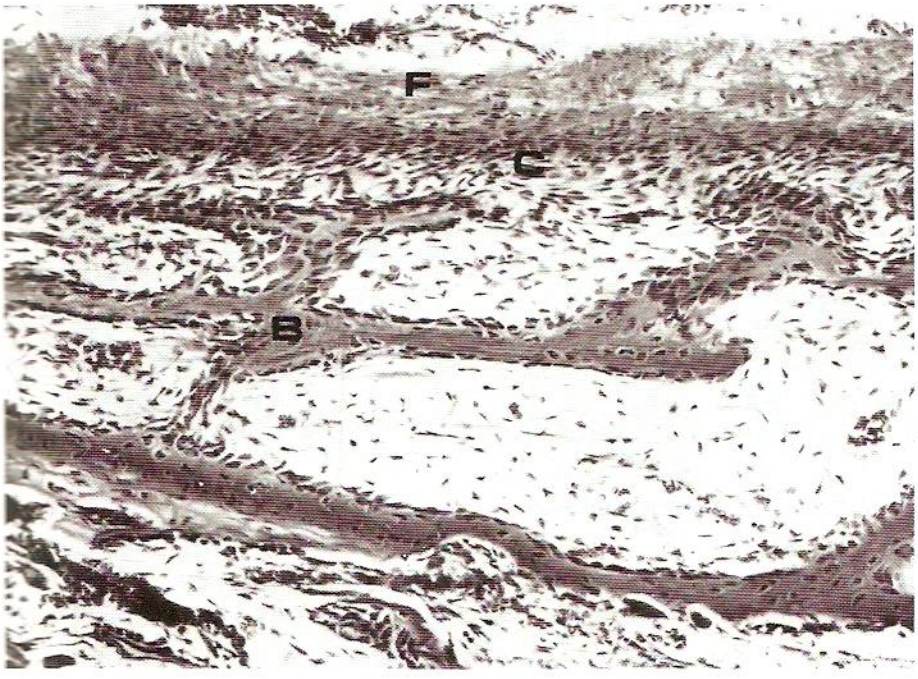

Figure 9-4. Periosteum of a developing long bone. The fibrous *(F)* portion of the periosteum consists of dense collagenous tissue whereas the cellular *(C)* portion consists of different types of bone cells. The cellular portion is evident especially during growth and fracture repair, as well as in response to insults other than fracture. Bone spicules *(B)* have formed as a result of periosteal activity. (X40.)

Downloaded from Vet-eBooks.com

Endosteum

The **endosteum** is the inner and internal covering of bone (Fig. 9-5). The compact bone adjacent to the marrow cavity, the trabecular bone of the marrow cavity, and the osteonal canals within the compact bone are lined by endosteum. Three endosteal divisions are named based on their anatomical distribution—cortical, trabecular, and osteonal.

The **cortical endosteum** covers the compact bone and defines the peripheral limit of the marrow cavity (Fig. 9-6). It continues with the **trabecular endosteum,** covering the osseous trabeculae of the marrow cavity. In most long bones the trabeculae and their associated envelopes are confined generally to the proximal and distal epiphyses and metaphyses (Fig. 9-6). The cortical and trabecular endosteums are the inner linings of bone. The **osteonal endosteum** lines the osteonal canals (Fig. 9-7) and is the internal lining of bone. It is continuous with the periosteal and cortical endosteums. The osteonal endosteum provides cell continuity from the external surface through the substance of bone to the inner surface of gross bones.

The cells of the endosteum are identical to those within the periosteum, but endosteal cells occur within a loose collagenous tissue (Fig. 9-5).

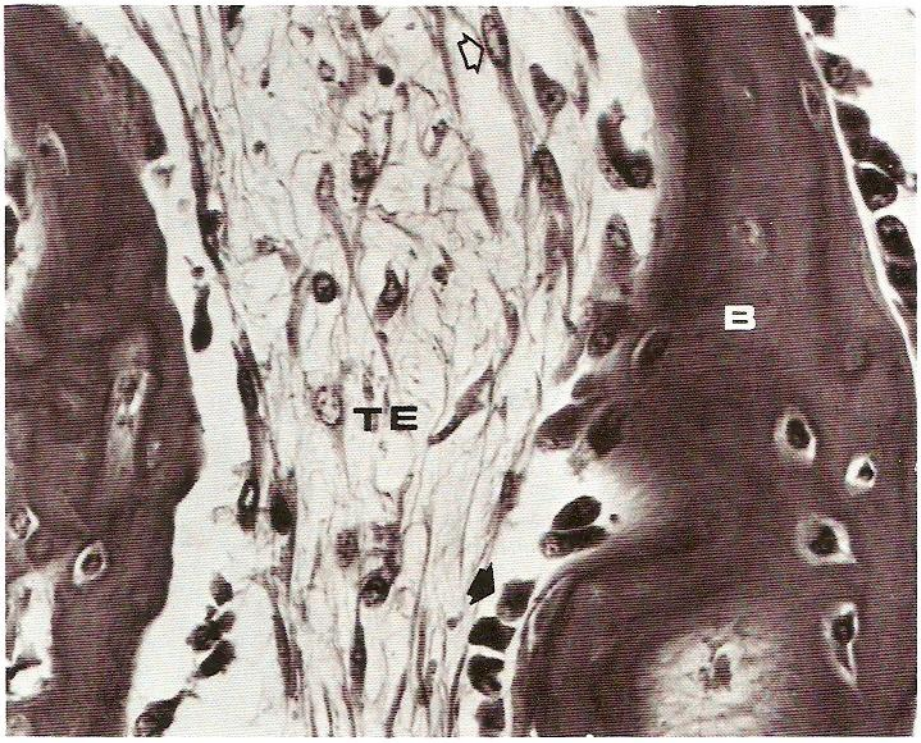

Figure 9-5. Trabecular endosteum within a bovine fetal jaw. Loose collagenous tissue comprises this endosteum *(TE)*. Stem cells *(open arrow)* are the source of both trabecular endosteum and bone. Osteoblasts *(solid arrow)* occur at the interface between the endosteal connective tissue and bone. Some of these spindle-shaped cells (as is true of the stem cells) could be osteoprogenitors. *B,* Bone. (X100.)

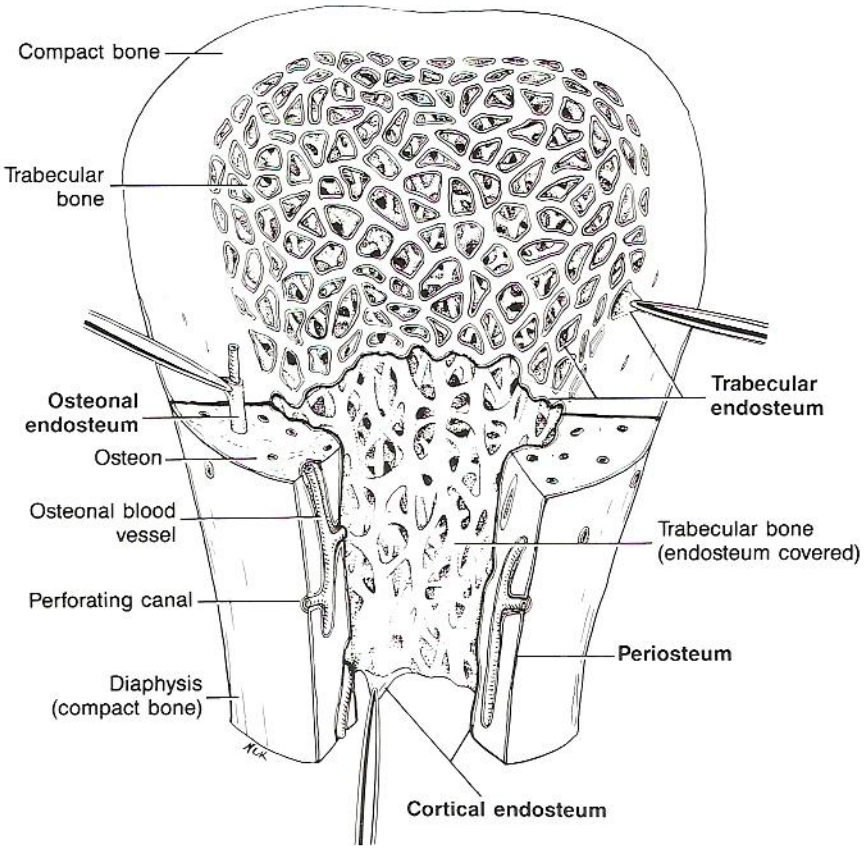

Figure 9-6. Sectioned long bone. The endosteum covers all internal bone surfaces. Compare with Figures 9-3 and 9-7.

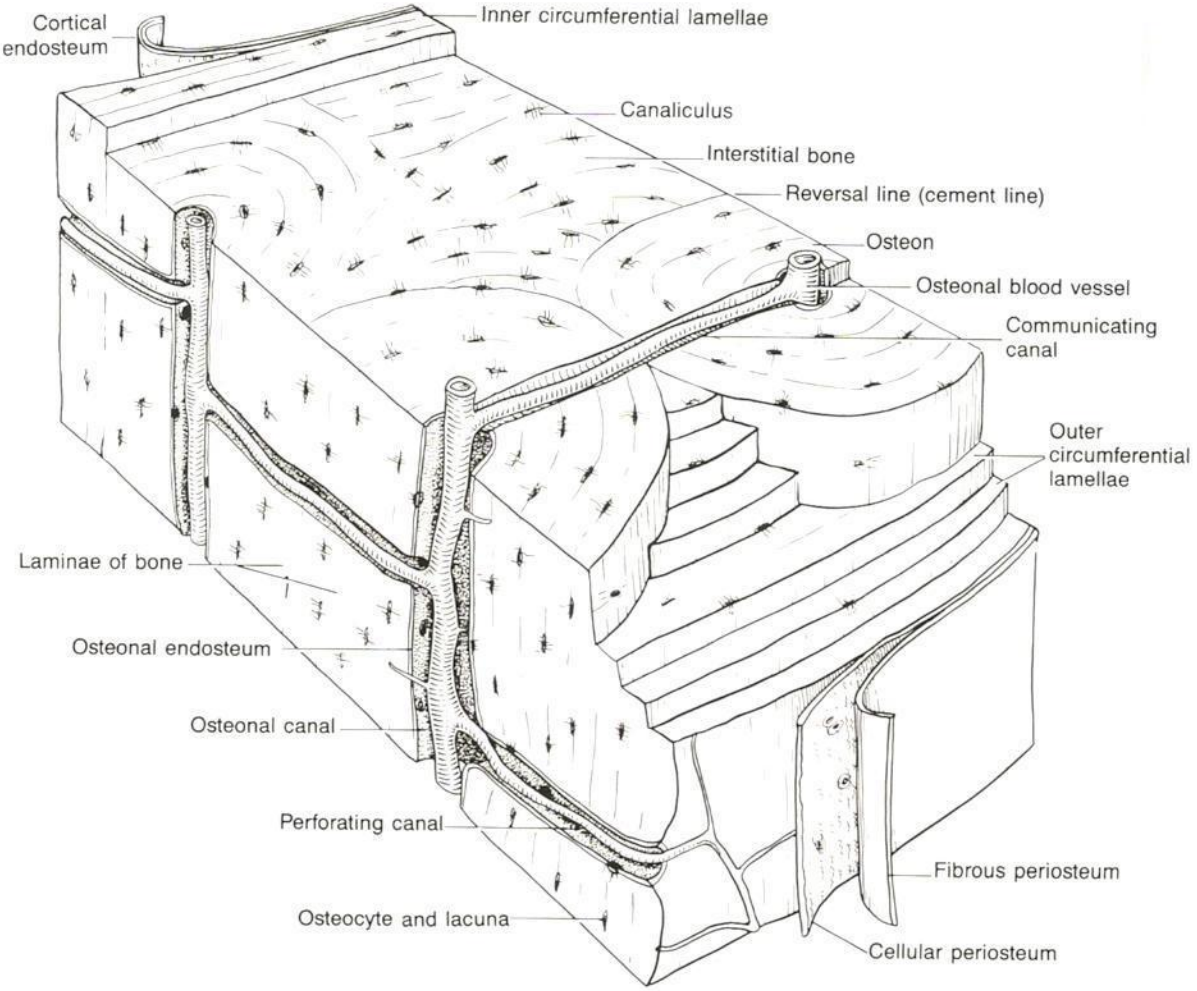

Figure 9-7. Section of compact bone from a diaphysis. All typical structures have been included and labeled. Not all cross sections of diaphyseal bone, however, will consist of all these features.

Developmentally, the periosteum gives rise to and is continuous with all divisions of the endosteum through **perforating canals** (Figs. 9-6 and 9-7).

CELLULAR COMPONENTS

Relationships of Cells

Current evidence establishes two distinct lines of bone cells—osteogenic and osteoclastic. **Osteogenic cells** start with **osteoprogenitor cells** differentiating from mesenchymal cells. The progenitor cells are mitotic and differentiate into **osteoblasts.** Osteoblasts continue their life cycle as **osteocytes. Bone-lining cells** also occur on bone surfaces. **Osteoclasts** are **multinucleated giant cells** forming as fusion products of macrophages. Both cell lines are essential for the proper maintenance of the skeleton.

Mesenchymal Cells

Although **mesenchymal cells** (Fig. 9-8) are present in osseous envelopes, they do not differentiate into all the typical mesenchymal cell derivatives. They acquire a limited potency early in development. Some populations are osteogenically competent and differentiate into osteoprogenitor cells.

Osteoprogenitor Cells

Osteoprogenitor cells look like mesenchymal cells. They are identified by their location on bone surfaces as cells peripheral to osteoblasts (Fig. 9-8). They are the only bone cells capable of mitosis. The presence of mitotically active osteoprogenitor cells ensures the stem cells needed for growth, maintenance, remodeling, and repair.

Osteoblasts

Osteoblasts are the bone-forming cells. They secrete procollagen and other organic matrical components. They also store the mineral used in mineralization.

Active osteoblasts are hypertrophied, become polarized, and assume epithelioid

Figure 9-8. Stem cells of bone located within an endosteal envelope. These are mesenchymal cells *(M)*, but they may be mesenchymal or osteoprogenitor cells. A spicule of bone *(B)* is covered by osteoblasts. (X100.)

Downloaded From VetBooks.com

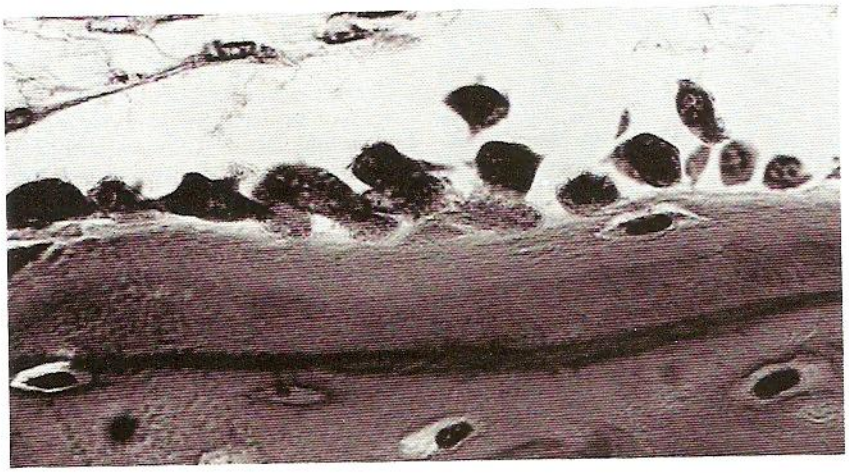

Figure 9-9. Active lining cells upon a bone surface. The cuboidal and columnar cells are active osteoblasts. (Compare with Plate II, 5.) (X160.)

characteristics (Fig. 9-9). The single nucleus, with a prominent nucleolus, is displaced to the end of the cell away from the bone surface. The cytoplasm is moderately basophilic due to the high content of rRNA. A well-developed Golgi complex and many mitochondria are characteristic (Plate II, 5).

Calcium is essential for the proper operation of various cell systems. Ca^{++} exchanges for Na^{+} at osteoblastic plasma membranes, and active transport mechanisms involving Mg^{++} and ATP help maintain low levels of intracellular Ca^{++}. Excess intracellular Ca^{++}, which is cytotoxic, is sequestered by various organelles and Ca^{++}-binding proteins. Mitochondrial Ca^{++} sequestration occurs in **mitochondrial granules.** The sequestered Ca^{++} can move between the granules and the cytosol. Osteoblasts have many mitochondrial granules storing Ca^{++} and releasing it on demand.

Osteoblastic activity along a bone-forming surface is synchronized. The cells produce about 2 μm^3 osteoid/day that accumulates, layer upon layer, until a definitive **osteoid seam** approximately 10 to 15 μm thick is apparent. This osteoid seam is a lighter pink (H&E) than the mineralized osteoid (Fig. 9-10). It is organic matrix that has never been, but ultimately will become, mineralized. It is set apart from the remaining osteoid by a dark-staining **reversal band,** the region from which centripetal mineralization of the osteoid seam progresses. The osteoid seam is apparent with mineralized sections and special staining techniques (Plate I, 9).

The secretory activity of the osteoblast is biphasic.

The first phase is the synthesis and secretion of organic materials as osteoid seam. Tropocollagen polymerizes outside the cell and becomes oriented in an orderly manner (Fig. 9-2). This orientation may result from osteoblastic influences and/or response to stress.

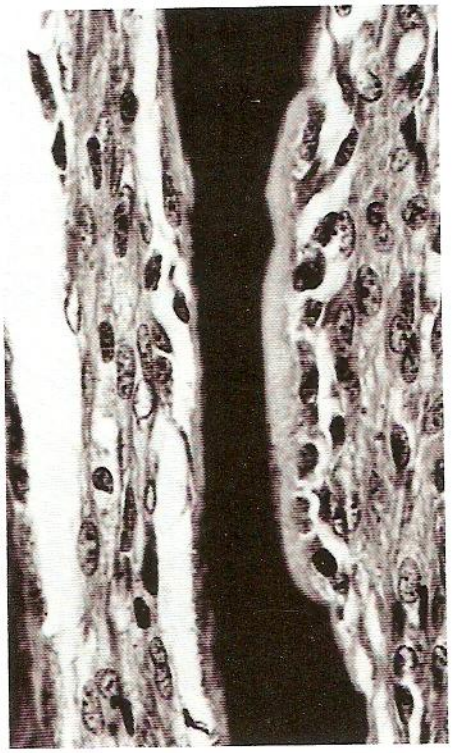

Figure 9-10. Osteoid seam in a demineralized section of bone. The light-staining region adjacent to and at the right of the black portion (spicule) is the osteoid seam. (X140.)

The second phase is mineralization of the osteoid seam. Calcium released from osteoblasts reacts with collagen. Mineralization occurs first on and then within the collagen. The attachment of some GAGs to collagen may prevent mineralization of the seam during the first phase. Subsequent removal of these substances may facilitate matrix mineralization. Initial mineralization accounts for about half the total holding capacity of the matrix. Progressive addition of mineral occurs over several months at the expense of water.

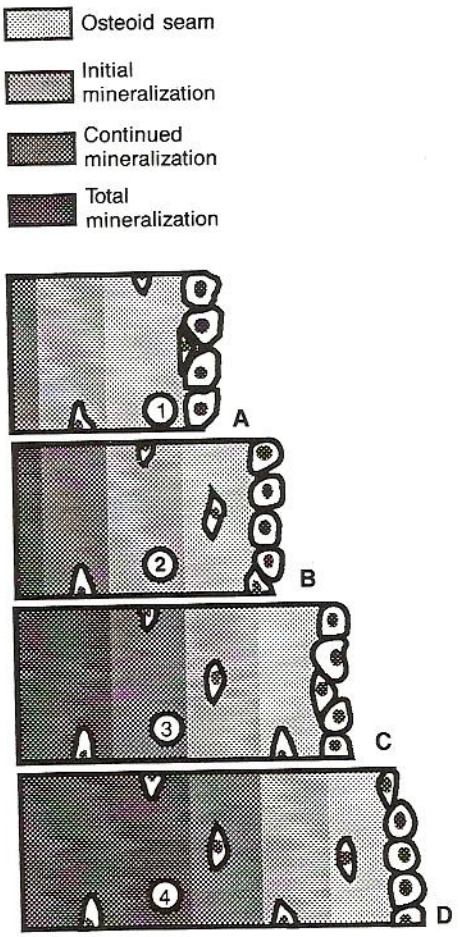

Figure 9-11. Biphasic activity of osteoblasts during osteogenesis. Bone formation in an adult occurs on preexisting bone surfaces. The initial stage of osteoblastic activity culminates with the formation of osteoid seam upon a preexisting bone surface, **A.** Initial mineralization occurs within the most recent osteoid seam, **B.** New osteoid seam forms while older osteoid seams become progressively more mineralized, **C.** This activity continues, **D,** until a specified amount of bone forms. Numbers *1* to *4* indicate the sequential fate and relative position of the initial osteoid seam that had been formed.

The progressive formation and mineralization of osteoid seam account for the highly ordered and laminar nature of mature bone (Fig. 9-11). Disruptions and/or alterations in this orderly sequence change the quantity and quality of bone formed.

If the first phase does not occur, continual osteoclasia without the balanced formation by osteoblasts results in a quantitative reduction in bone—a **quantitative osteopenia. A quantitative osteopenia is a reduction in bone mass/unit volume.** The bone present is normal; there just is not enough of it. **Cushing's syndrome, disuse osteoporosis,** and se-

Downloaded From Vet-eBooks.com

nile **osteoporosis** are diseases characterized by quantitative bone changes.

If the second phase of the osteoblastic activity does not occur, the organic matrix does not become mineralized. This results in a qualitative change in bone—a **qualitative osteopenia. The qualitative bone changes result from too little mineral in the matrix.** There may be adequate to excessive amounts of matrix with insufficient amounts of mineral. **Rickets, renal secondary hyperparathyroidism,** and **nutritional secondary hyperparathyroidism** are examples of diseases associated with qualitative bone changes.

As the osteoblasts secrete their products and retreat before the advancing front of osteoid, a few cells (about one out of every 10) become embedded in their own secretions.

Osteocytes

Osteocytes are osteoblasts that have become embedded in their own secretions. These cells are sometimes observed shortly after they have become embedded in the osteoid seam as **osteoid osteocytes** (Fig. 9-12). Once mineralization occurs, these cells are simply osteocytes.

The cytoplasm of osteocytes is either weakly basophilic or weakly acidophilic. The **lacuna** and its cell may be round to lenticular. Osteocytes are often retracted from their lacunar surfaces as fixation artifacts. Occasionally, lacunae may appear empty; this could be either a sectioning artifact or an indication of pathology.

Osteocytic processes are prominent features but are not readily seen with light microscopy. The **canaliculi (or little canals within which osteocytic processes occur)** are easily observed in mineralized sections (Fig. 9-13). Canaliculi become visible in paraffin sections by reducing the quality of the light. They form an extensive communicative network between osteocytes (Fig. 9-13). The osteocytic processes and associated canaliculi extend to and are in contact with the cells at the periosteal and endosteal surfaces (Fig. 9-14). Osteocytic contacts facilitate coordination of their and surface cell activities. These contacts provide for the coordinated activity of the **osteocyte-osteoblast pump,** a mechanism involved in the homeostatic maintenance of plasma Ca^{++} levels.

The osteocytes maintain the matrix. They synthesize and secrete matrical materials, but their activity level is less than that of osteoblasts. They are also capable of removing matrix by a process termed **osteocytic osteolysis.** Their ability to add and remove bone matrix is a vital function. Their functional duplicity ensures the maintenance of skeletal volume and proper levels of Ca^{++} in the plasma. The 23,000 osteocytes/mm^3 of tissue affords an extensive lacunar surface upon which these cells are able to function.

Osteoclasts

Osteoclasts are **multinucleated giant cells** that remove bone and are derivatives of macrophages. They are able to dissolve bone mineral and digest organic matrix. By releasing organic acids (citrate, lactate) they decrease the pH of the microenvironment. This dissolves bone mineral and enhances the activity of secreted lysosomal enzymes. Acid hydrolases hydrolyze the organic matrix. The process of bone removal by osteoclasts is called **osteoclasia.**

These cells have few to many nuclei and a foamy, acidophilic cytoplasm (Fig. 9-15). They are polarized, with nuclei that are displaced away from the bone (Plate II, *4*). The border adjacent to the bone is a **brush** (or **ruffled**) **border** (Fig. 9-16) that terminates in a peripheral smooth zone serving as a tight seal to confine pH changes to the region under the border.

Osteoclasts reside on surfaces in concavities called **resorption lacunae** (Fig. 9-15) but may be artifactually separated from this surface by sectioning. Osteoclasts also occur along surfaces on which bone is forming, or an entire surface may be occupied by osteoclasts. Osteoclasts also develop within compact bone. In

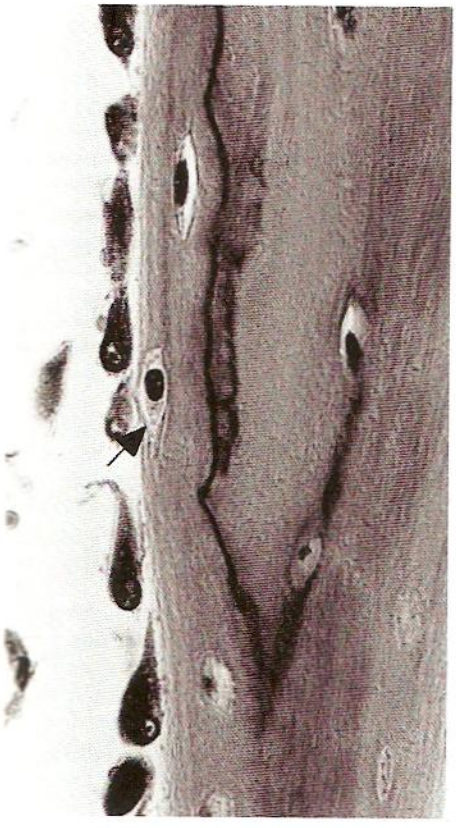

Figure 9-12. Osteocytes. An osteoblast was recently incorporated into bone as an osteoid osteocyte *(arrow)*. The flattened cells on the surface are bone-lining cells. (X160.)

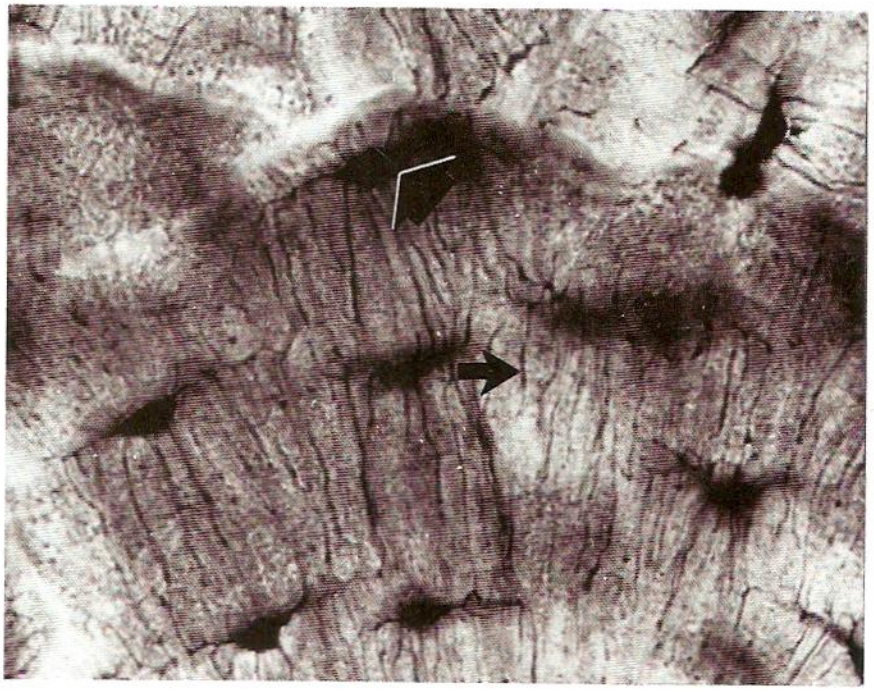

Figure 9-13. Portion of the canalicular system of bone. Osteocytic lacunae *(large arrow)* are continuous with canaliculi *(small arrow)*. The canaliculi form an extensive communication and transport network throughout the matrix of bone. (X200, ground bone section.)

Downloaded From VetBooks.com

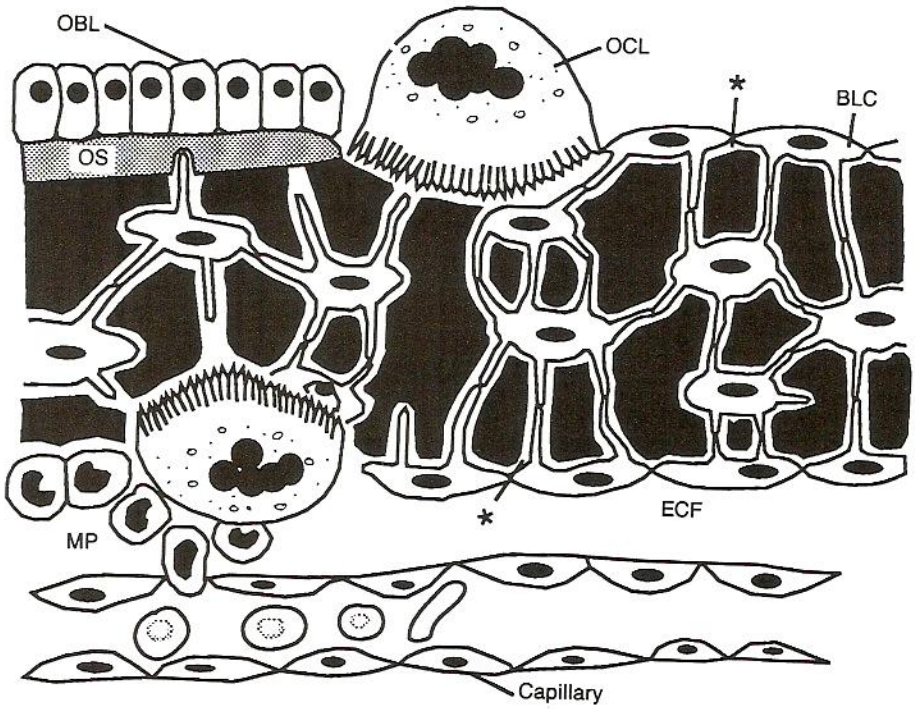

Figure 9-14. Relationships of bone, cell, fluid, and vessel. Osteoblasts *(OBL)*, osteoclasts *(OCL)*, and bone lining cells *(BLC)* line all bone surfaces. Osteocytes, contained within the bone *(black)*, communicate with each other and the surface cells through cellular processes contained within canaliculi. Fluid leaving the capillary bed becomes extracellular *(ECF)*. Calcium ions and ECF enter the bone fluid (*) by moving between the lining cells. The surface lining cells actively return calcium to the ECF. This return process is augmented by parathyroid hormone. Bone fluid is different from ECF in that it fills the spaces within the bone (*), bathes all the interosseous crystalline surfaces, and fills the canalicular and lacunar spaces. Osteoclasts form as fusion products of macrophages *(MP)* or their precursors exiting the vascular bed and taking residence upon the bone surfaces. New bone, as unmineralized osteoid seam *(OS)*, is apparent beneath the osteoblasts.

Figure 9-15. A spicule of bone and multiple foci of osteoclasia. The spicule *(B)* is being removed and/or remodeled by many osteoclasts *(solid arrows)*. The boundaries of resorption lacunae are indicated by *white bars*. Note the brush or ruffled borders *(open arrows)* and their relationships to the serrated margins of the bone. (X100, Masson's trichrome.) (See also Plate II, 4.)

Downloaded From Vet-eBooks.com

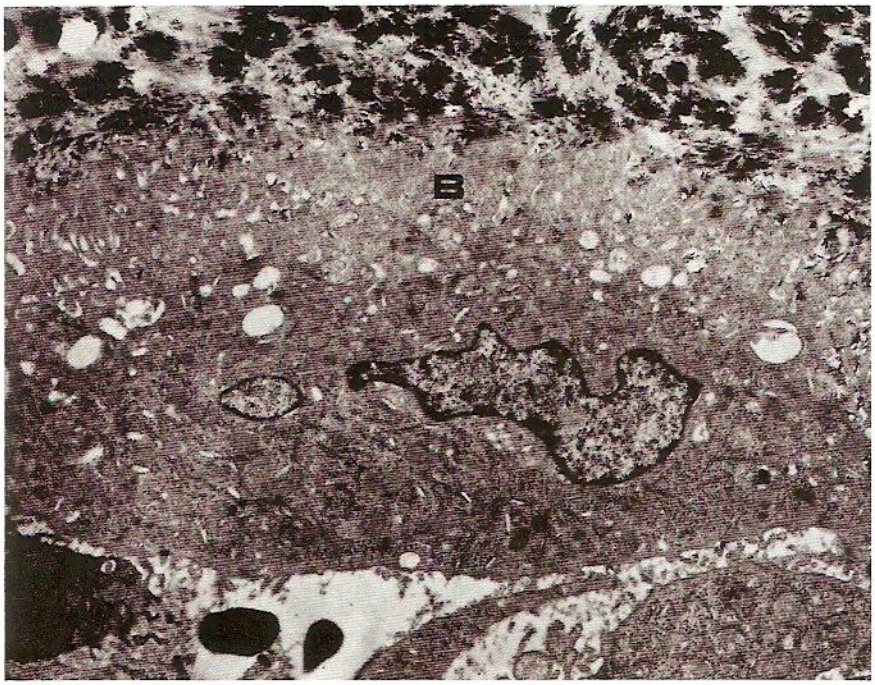

Figure 9-16. Electron micrograph of an osteoclast. The cell is multinucleated and polarized. The brush or ruffled border *(B)* is in contact with the bone surface. (X5000.)

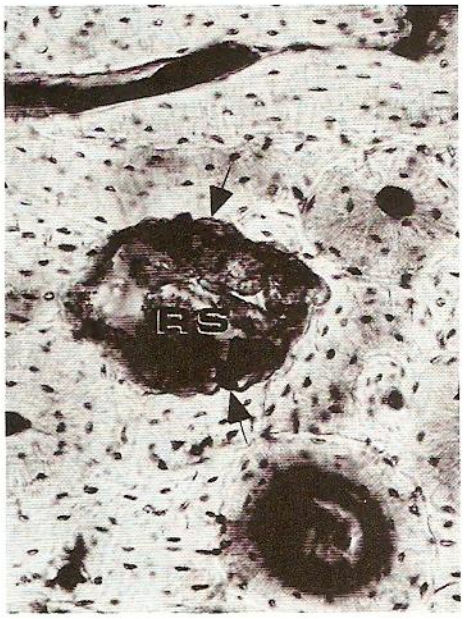

Figure 9-17. Resorption space *(RS)* in bone. Note that it has serrated edges *(arrows)* due to the confluence of resorption lacunae. (X40, ground bone section.)

this instance, resorption lacunae are continuous with each other as a **resorption space** (Fig. 9-17). The resorption space is the cross-sectional representation of a cylinder of bone being removed by osteoclasia. The serrated edges of resorption lacunae are evidence of bone resorption.

Bone-lining cells. Most bone surfaces are covered by flat, squamous cells with an elongated nucleus. These cells, called **bone-lining cells,** cover bone surfaces at which neither bone formation nor bone resorption is occurring (Figs. 9-12, 9-14, and 9-18). They have been called **inactive osteoblasts, osteoprogenitor cells, flattened mesenchymal cells,** and **surface osteocytes.**

These cells may be an ion barrier separating the extracellular fluid compartment from the bone fluid compartment (Fig. 9-14). They also may regulate Ca^{++} and inorganic phosphate (P_i) concentrations, thereby controlling crystallization on bone surfaces. The communication of surface lining cells with osteocytes ensures coordinated and synchronized bone formation and resorption.

Bone-lining cells are probably resting or exhausted osteoblasts. Their fate has not been determined.

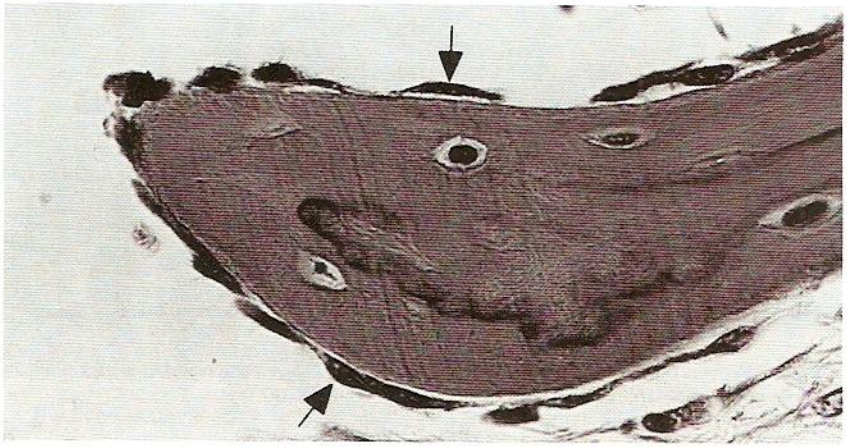

Figure 9-18. Bone-lining cells *(arrows)* may be any one of a number of cells covering bone surfaces. The *empty space* above and to the left of the bone is an artifact of processing. (X160.)

TYPES OF BONE

All bones consist of either woven (immature) or lamellar (mature) osteoid tissue (Fig. 9-19).

Immature bone is woven bone. It is cellular, and its lacunae are large, round, and randomly dispersed throughout the matrix (Fig. 9-20). Bundles of collagenous fibers are arranged in a random pattern. The organic matrix is basophilic, stains unevenly, and has less mineral than mature bone has.

Immature bone forms in fetal ossification centers and the primary spongiosa of developing bones. It is also the first bone at fracture repair sites. Woven bone occurs in some bone tumors, in alveolar bone associated with teeth, and at points of ligamentous and tendinous attachments to bone.

Woven bone may vary from cancellous to compact, but osteons are rarely composed of it. It is a temporary tissue, replaced by lamellar bone, affording support during development and repair.

Mature bone is lamellar. It constitutes the bulk of the adult skeleton, and its lacunae are lenticular (Fig. 9-21). Lacunae are also dispersed in an orderly fashion throughout the matrix, with collagenous fibers deposited helically at varying angles in successive lamellae. Thus an ordered pattern of birefringence is seen with polarizing microscopy (Figs. 3-7 and 9-2). The demineralized organic matrix of mature bone stains lightly and evenly with acidic dyes.

Downloaded From Vet-eBooks.com

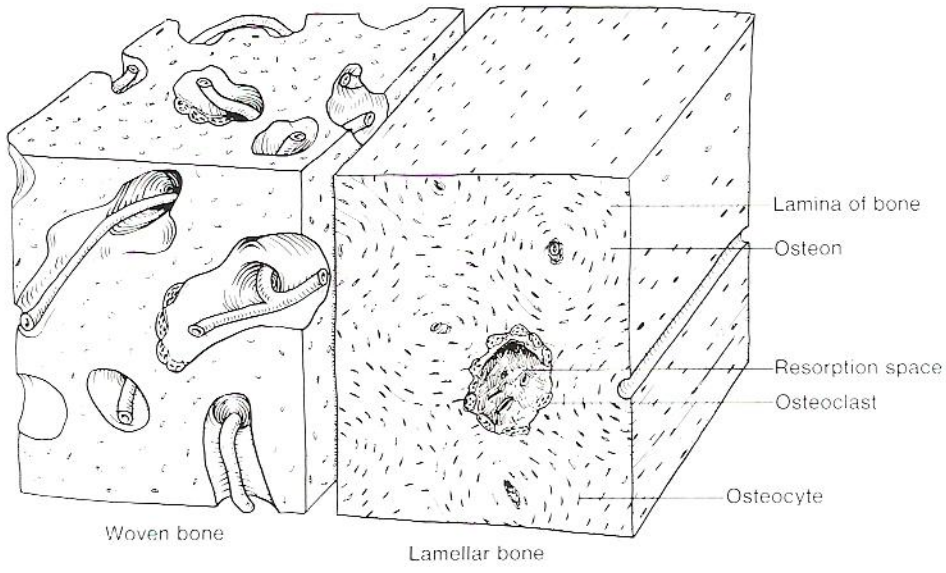

Figure 9-19. Organizational differences between woven and lamellar bone. Note especially the difference in disposition of the osteocytic lacunae. Lamellar bone comprises the bulk of the adult skeletal mass whereas woven bone is of only limited occurrence.

Figure 9-20. Woven bone in a developing bovine mandible. Note the mottled appearance of the matrix, large osteocytes, and random orientation of the cells. (X100.)

CONFIGURATIONS OF BONE

Cancellous bone is arranged as spicules or trabeculae that are actually **plates** of bone when examined three-dimensionally. These spicules may be either woven or lamellar bone. In the adult skeleton they are lamellar. Cancellous bone has more interosseous space than compact bone has (Fig. 9-22). A high **bone porosity** is the basis for its classification.

Compact bone has a high amount of osseous tissue in a given volume (Fig. 9-23). It may be arranged into **laminae (lamellae)** or **osteons.**

ORGANIZATION OF BONE

Lamellae

Bone deposition in successive laminae is typical of the periosteal and endosteal surfaces. These lamellae are deposited in sheets called **outer circumferential lamellae (periosteal lamellar bone)** (Fig. 9-24). The cortical endosteum forms **inner circumferential lamellae (endosteal lamellar bone)** (Fig. 9-25). These continue as part of the marrow cavity bone trabeculae.

Osteons

Osteonal bone is the lamellar bone of **osteons** (Figs. 9-26 and 9-27). It is disposed in concentric laminae or sheets around an **osteonal canal** (Fig. 9-28). The periphery of the osteons is marked by a **reversal line.** The osteonal canal contains blood vessels, vasomotor nerves, and endosteal cells.

Primary osteons form at the periosteal surface as small cylinders composed of a few concentric bone laminae within compact bone (Fig. 9-24). They add strength, smooth surfaces, and new blood vessels to bone. Their formation demonstrates envelope continuity and es-

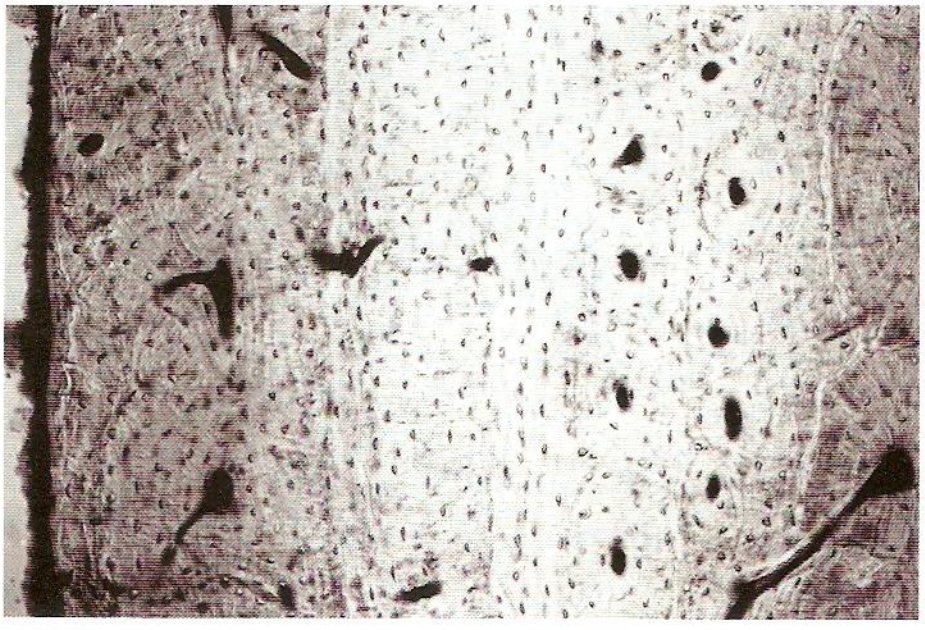

Figure 9-21. Lamellar bone. The lamellar nature of such bone is indicated by the ordered disposition of osteocytic lacunae within circumferential, primary osteonal, and secondary osteonal bone. (X40, ground bone section.)

Downloaded From TestBooks.com

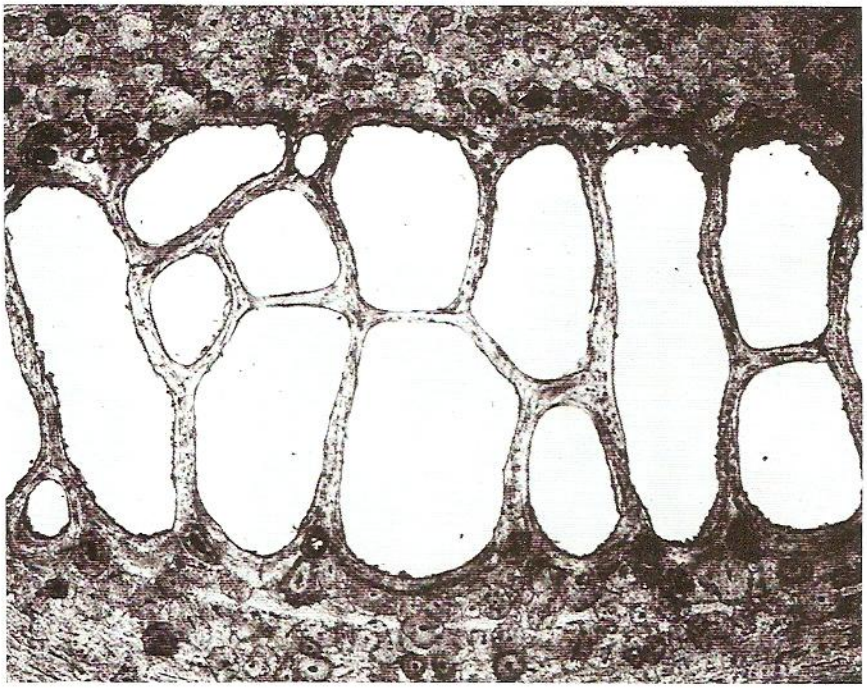

Figure 9-22. Cancellous bone within the marrow cavity of a cervine rib. The amount of interosseous space exceeds the amount of bone that is present. (X10, ground bone section.)

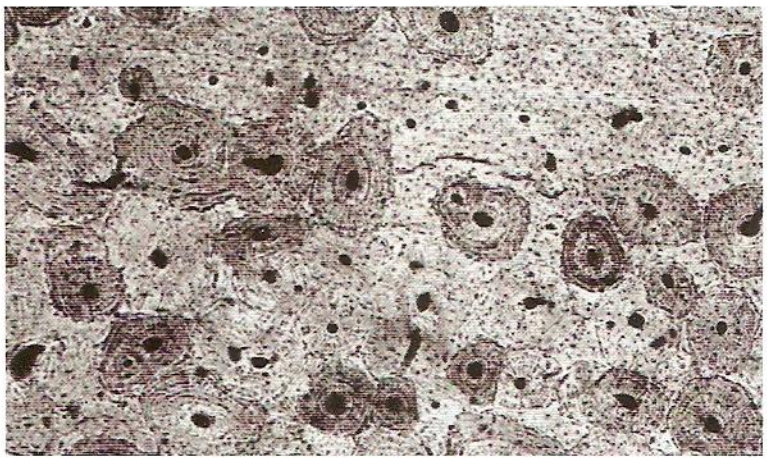

Figure 9-23. Compact bone of an adult canine humerus. The interosseous space is reduced appreciably and is confined to the osteonal and communicating canals. This section of bone consists of portions of outer circumferential lamellae, interstitial, and osteonal bone. (X16, ground bone section.)

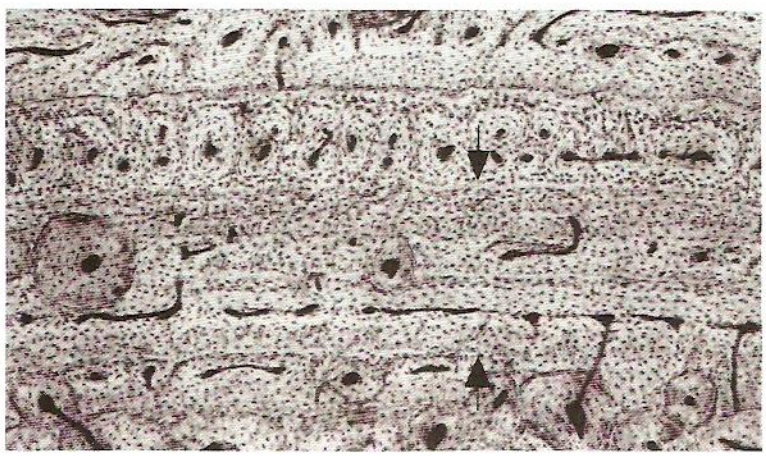

Figure 9-24. Transverse section of periosteal bone from a growing animal. Outer circumferential lamellae occur between the *arrows*. The lamellae alternate with layers of primary osteons. (X16, ground bone section.)

Downloaded From Vet-eBooks.com

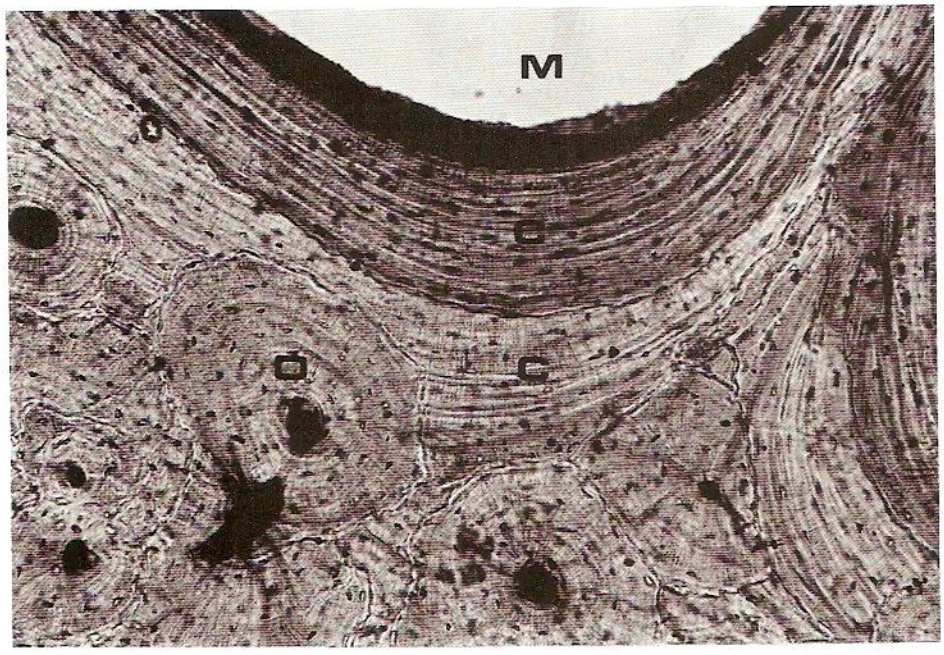

Figure 9-25. Inner circumferential lamellae. The marrow cavity *(M)* is bordered by the inner circumferential bone *(C)*. An osteon *(O)* has formed within part of the inner circumferential bone from remodeling. (X40, ground bone section.)

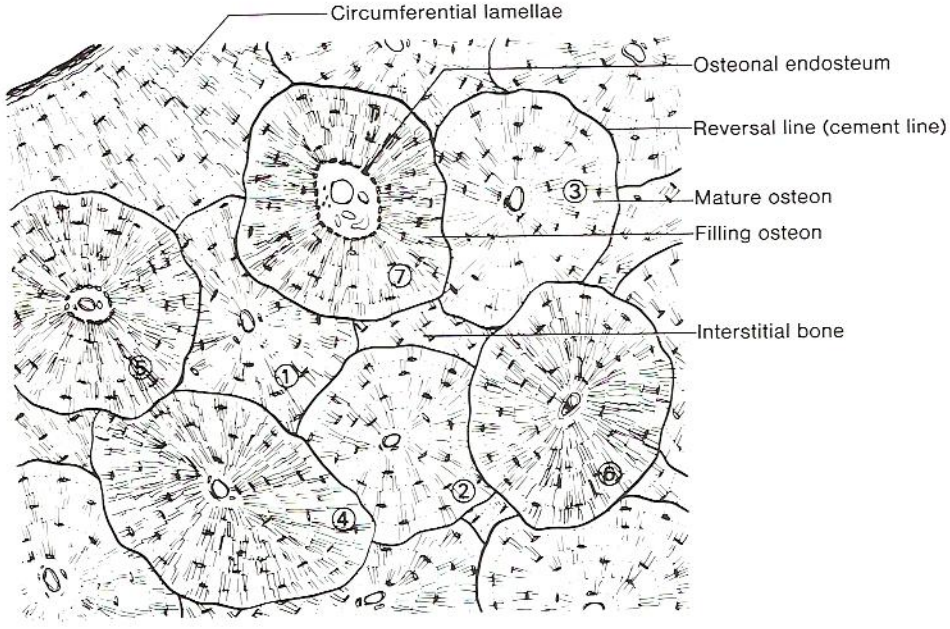

Figure 9-26. Cross section of mature bone. All the osteons are secondary osteons, formed as a result of remodeling activity. Interstitial remnants are due to the formation of osteons *1*, *2*, and *3*, the first generation of secondary osteons. Osteons *4*, *6*, and *7* (second generation) infringed during their formation upon osteons *1*, *2*, and *3*. Osteon *5* (third generation) infringed during its formation upon the first- and second-generation osteons.

Downloaded From TestBooks.com

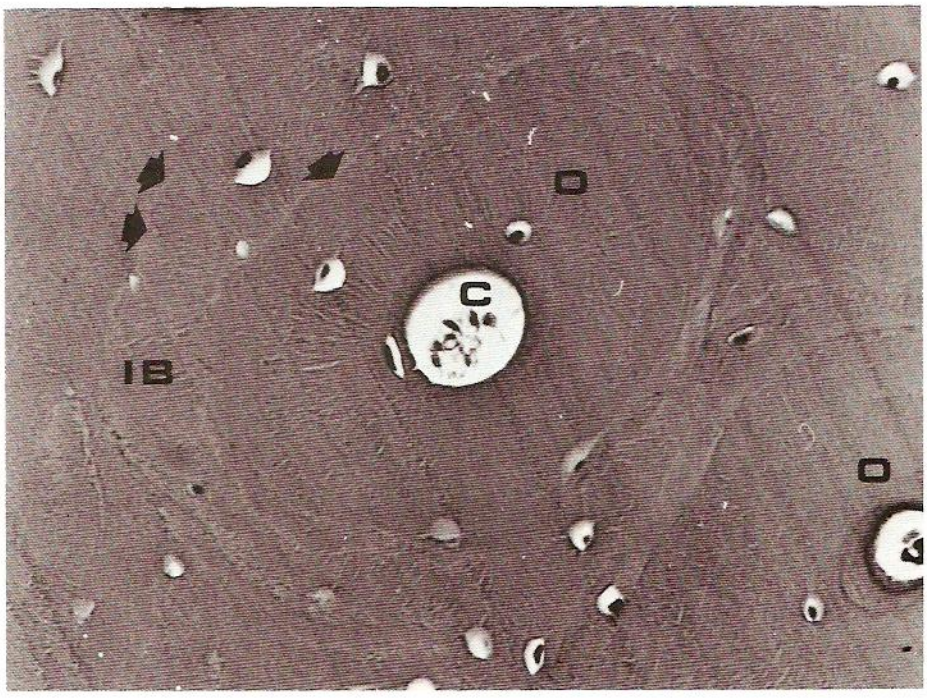

Figure 9-27. Cross section of compact bone. The limit of a secondary osteon *(O)* is the reversal line *(solid arrow)*. A remnant of a previous generation osteon as interstitial bone *(IB)* is apparent. The reversal line of the old osteon is also visible *(double arrows)*. The osteonal canal *(C)* contains endosteum. (X100.)

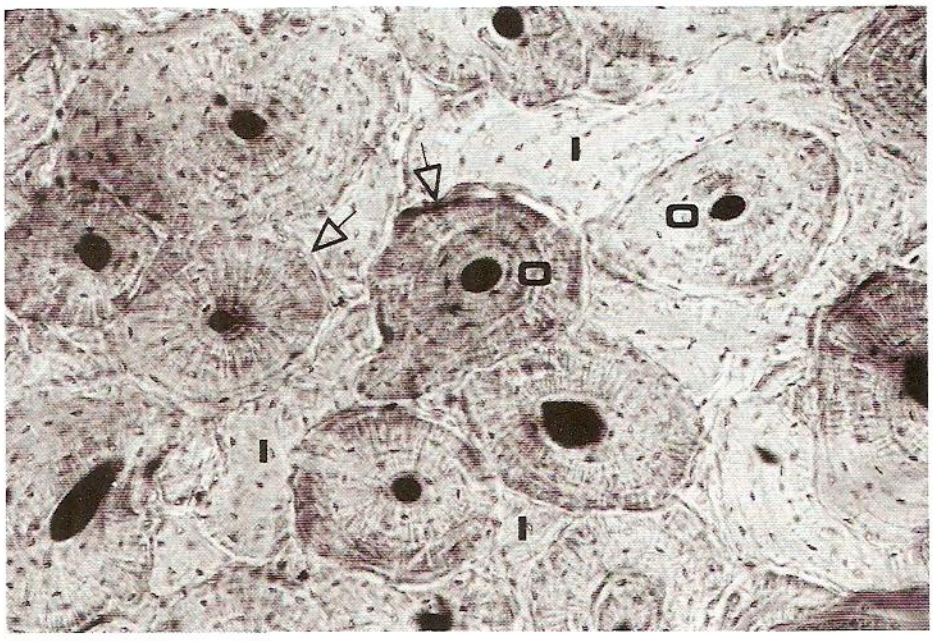

Figure 9-28. Osteons and interstitial remnants within the compacta. *I*, Interstitial bone; *O*, osteons. All the osteons in this section are mature. The osteonal canals, dark regions within the osteons, are small. *Open arrows* point to reversal lines. (X40, ground bone section.)

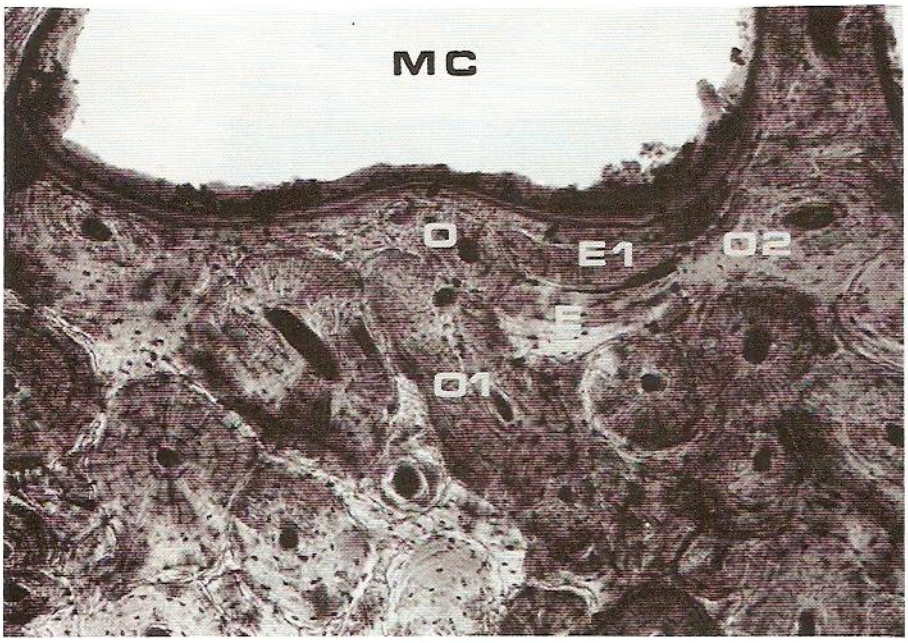

Figure 9-29. Secondary osteons and interstitial bone. The marrow cavity *(MC)* is bordered by remnants of inner circumferential lamellae *(E1)* interrupted by an osteon *(O)*. Osteons *(O1, O2)* also interrupt the endosteal bone *(E)*. Compare with Figures 9-25, 9-26, and 9-28. (X25, ground bone section.)

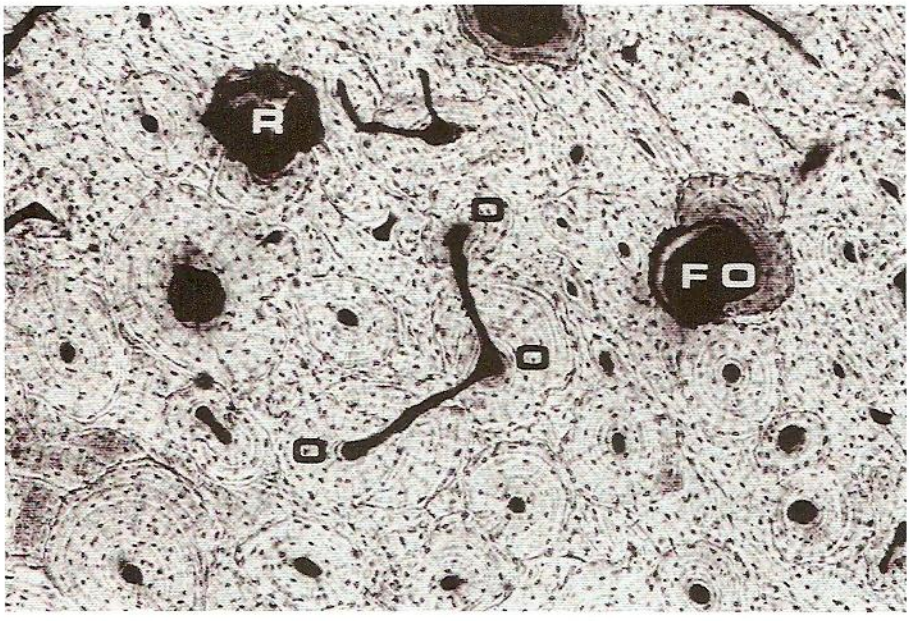

Figure 9-30. Section of compact bone. Communicating canals connect three osteonal canals *(O)*. A resorption space *(R)* and a filling osteon *(FO)* are present. (X25, ground bone section.)

tablishes the origin of osteonal endosteum from periosteum.

Secondary osteons are cylinders of concentric bone laminae formed within compact bone. The only prerequisite for their formation is a preexisting tunnel within bone. The most obvious tunnel is the canal of a primary osteon. Osteoclasts remove bone and expand the limits of the osteonal canal. The limit of this osteoclasia is the reversal line. The reversal line, then, is the **peripheral limit of bone removal and is the surface upon which osteoblasts deposit new bone once osteoclasia ceases in that region.** The centripetal deposition of successive bone laminae results in the formation of new secondary osteons (Figs. 9-27 and 9-28). These bone resorptive and formative activities (remodeling) destroy previously formed osteons, build new osteons, and form remnants of osteonal and circumferential bone, called **interstitial bone** (Figs. 9-28 and 9-29). Secondary osteons may abut on each other, be separated by segments of interstitial bone, or become isolated within circumferential bone.

Osteons are the structural units of bone. They are long cylinders with a hollow cavity, may be extensively branched, and usually occur in regions of high bone stress. These entities may be likened to reinforcing rods in concrete.

The blood vessels of bone are entrapped during development but are connected with vessels at the periosteal or cortical endosteal surface through large **perforating canals.** Osteonal vessels anastomose extensively with each other through **communicating canals** (Figs. 9-7 and 9-30).

BONE REMODELING

General Features

The biomechanical properties of the musculoskeletal system depends upon the normal architectural associations between bone, muscle, cartilage, and fibrous connective tissue. Although the gross anatomical features of bones do not change appreciably throughout adult life, changes occur constantly within the substance of bone. The process accounts for the removal and replacement of microscopic packages of bone without alteration to the visible skeletal volume. The essence of the process is to accomplish turnover while maintaining the architectural and physiological competence of individual skeletal units—called **remodeling.**

This lifelong activity is not a unique feature of bone. All elements of the body undergo similar replacement phenomena; however, the tissue architecture and mineralized matrix impose unique temporal and spatial dependencies. The remodeling process involves the removal of packets of old lamellar bone and their replacement with new lamellar bone. Remodeling activity occurs on all bone surfaces; all of the envelopes of bone are involved. The osseous envelopes, then, are responsible for the turnover and maintenance of their contained volume of osseous tissue. Their effectiveness in maintaining the human skeletal mass throughout adulthood is not equivalent. Cortical and trabecular endosteal envelopes are associated with a skeletal loss (negative skeletal balance), while the activity of the osteonal envelope is in perfect balance. Periosteal activity is generally manifested as a positive balance. Although all of the envelopes contribute to skeletal balance, they do so differentially. Trabecular bone is more labile than osteonal bone. Trabecular endosteal remodeling activity may be as much as three times greater than osteonal endosteal remodeling activity.

Many stimuli result in remodeling activity. Bone is responsive to the following diverse stimuli: (1) As the vascular supply moves away from osteocytes, some of them die; repositioning of vessels within the bone substance to minimize osteocytic death is a consequence; removal of dead bone becomes an essential stimulus. (2) Continual stress upon the skeleton results in the formation of microfractures that must be repaired. (3) Increased biomechanical stress upon bone necessitates the repositioning or reorientation of osteons; also such stress may require the replacement of primary osteons and circumferential lamellar bone with secondary osteons. (4) As a reservoir for the storage of minerals, bone responds to dietary influences; malabsorption of Ca^{++} or dietary deficiencies of this ion may result in increased remodeling activity. (5) Immobilization and the disuse attributed to convalescence during fracture repair is characterized by increased remodeling. **(Increased and decreased stress are stimuli for increased remodeling.)** (6) Altered endocrine signals, endocrine diseases and the prolonged use of certain chemotherapeutic agents increase the remodeling activity of the skeleton.

Remodeling is a normal process. This process can be increased in response to any, all, or a combination of the previously described circumstances.

Basic Metabolic Unit

The evidence of remodeling is recorded in the matrix. You can use various structures to determine the extent of this process—primary and secondary osteons, interstitial bone, resorption spaces, and the amount of bone present at a specific locus of compact bone. These structural features provide insights about the changes occurring in the matrix, as well as the balance of activity between formative and resorptive processes.

The cells responsible for formative and resorptive processes are the osteoblasts and osteoclasts. Together, these cells and their progenitors combine to form a functional unit called the **basic metabolic unit (BMU)** or **bone remodeling unit.** The events associated with the BMUs are part of the **ARF** sequence, where **A** is **activation, R** is **resorption,** and **F** is **formation.**

$$\mathbf{A} \longrightarrow \mathbf{R} \longrightarrow \mathbf{F}$$

A new BMU begins its activity upon a bone surface in response to various stimuli. The nature of the activation has not been determined, but it must begin with stimulation of macrophages or their progenitors within the osseous envelopes.

In the normal adult skeleton the amount of bone does not change. New bone is added only at the expense of old bone. Resorption, then, is accomplished by osteoclasts removing a discrete quantity of bone. These cells are able to remove about 5000 to 20,000 μm^3 of bone/day/osteoclastic nucleus. This is the equivalent of resorbing the amount of bone produced by 10 to 40 osteoblasts per osteoclastic nucleus. Osteoclasia is the mechanism for "creating space" for the new bone. Formation is initiated in a local region by stimulating osteoprogenitor cells to differentiate into osteoblasts. Osteoblastic activity culminates in the formation of a new packet of bone serving as a bone structural unit.

The amount of bone in the skeleton should not vary during the adult life of the organism. Despite this stability, packets of the skeleton are removed continually. The amount of bone removed and replaced by a BMU is designated ΔB.BMU. If the skeleton were in perfect balance, ΔB.BMU would equal 0. The amount of bone removed and replaced under this circumstance would be equal (i.e., resorption equal to formation [R = F]). A progressive loss of bone occurs when ΔB.BMU is less than 0 ($-\Delta$B.BMU) or resorption exceeds formation (R > F). Incremental accumulations of bone result when ΔB.BMU is greater than 0 ($+\Delta$B.BMU) or resorption is less than formation (R < F). The absolute amount of bone loss or gain is governed by the magnitude of the ΔB and the number of BMUs activated.

The period required for a BMU to pass through the ARF sequence is termed sigma (σ). If ΔB.BMU = 0 is considered the steady state, then the time required to pass through the ARF sequence in response to a stimulation and return to the steady state is σ; or σ is the time required to remove and subsequently reform the same amount of bone. Sigma consists of two subperiods: the resorption period (σ_r) is the time required to complete the osteoclasia; the formative period (σ_f) is the time necessary to form the same amount of new bone. Therefore

$$\sigma = \sigma_r + \sigma_f$$

Immediate advantages accrue to the organism as a consequence of BMU activation. During the σ_r period Ca^{++} becomes available generally. Even though skeletal volume is ultimately maintained (ΔB.BMU = 0), the transitory availability of Ca^{++} through the BMU activity may satisfy a temporary need. Sigma values normally range in months but may extend to years in abnormal skeletons.

Histological Evidence of Remodeling

Remodeling phenomena occur in all bone envelopes. The following descriptions of the remodeling activity of the osteonal endosteum apply equally to the other osseous surfaces; however, the three-dimensional spatial arrangements are different.

In any cross section of compact bone certain features will be apparent—resorption spaces, mature osteons, and filling osteons. The temporal and spatial relationships of these structures become more apparent when a longitudinal section is compared to cross sections (Figs. 9-31 to 9-33). Macrophage activation to osteoclasts occurs at a given point in an osteon in response to an activating stimulus. The osteoclasts proceed down the tunnel formed by the osteonal endosteal/bone interface and remove bone both longitudinally and centrifugally. This cavitation process expands the diameter of the osteonal canal, the peripheral limit of which becomes the **reversal line.** While osteoclastic activity progresses away from the point of activation via the **cutting cone,** osteoprogenitor cells differentiate into osteoblasts at the same origination point. So formation follows resorption. Eventually osteoclastic activity ceases but the osteoblasts continue to form new bone by apposition from the original reversal line. This centripetal process results in the formation of a new osteon. **Tetracycline labels may be given at timed intervals to determine bone apposition rates at a given locus** (Figs. 2-5 and 9-35 and Plate I, *10*).

The resorption space is a cross-sectional representation of a sequence of events that resulted in the removal of an entire cylinder of bone (Figs. 9-32 and 9-33). Filling osteons are osteons in various stages of the formation process that eventually culminate in mature osteons (Figs. 9-26, 9-28 to 9-30, and 9-34). The timing of these events from osteoclastic activation to mature osteon formation is measured normally in months. BMU activity resulted in the formation of secondary osteons, mature osteons, filling osteons, resorption spaces, and interstitial bone.

BONE-ENDOCRINE RELATIONSHIPS

Calcium is involved in or regulates diverse functions within the organism. These include: neuronal and muscular excitability, synaptic and neuromuscular junctional transmission, muscular contraction (activation contraction coupling), exocytosis (activation secretion coupling), membrane structure and permeability, cell adhesion, coagulation, intracellular communication, and skeletal structure.

It is not surprising that elaborate mechanisms evolved to control the Ca^{++}

Downloaded From Vet-Ebooks.com

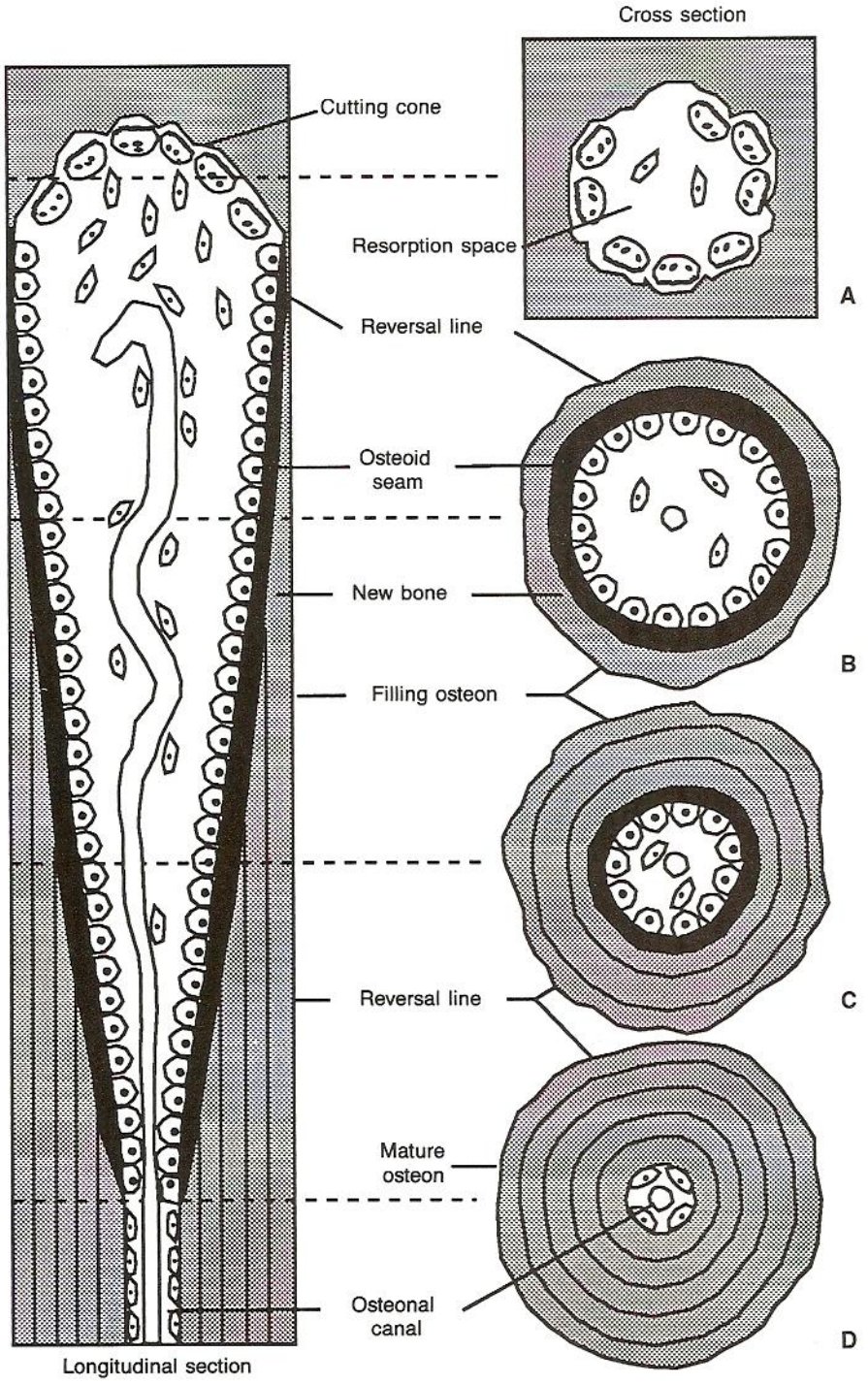

Figure 9-31. Longitudinal and cross sectional representations of an osteonal remodeling unit. The cutting cone, initiated at *D*, moves along the osteonal canal, removing bone longitudinally and centrifugally. Point *A* represents the cutting cone. Gradual refilling with new bone (points *B* and *C*) has resulted in the formation of a new osteon. Because the cavitation of the bone occurred initially at point *D*, the temporal relationships caused point *D* to have more new bone as a mature osteon than the rest of the cross sectional representatives would have as filling osteons (*B* and *C*). Eventually the filling osteons of points *B* and *C* will be converted to mature osteons. Thus the reversal line truly represents a reversal of function: it is the point at which osteoblastic activity replaces osteoclastic activity and it forms the peripheral limit of the osteon.

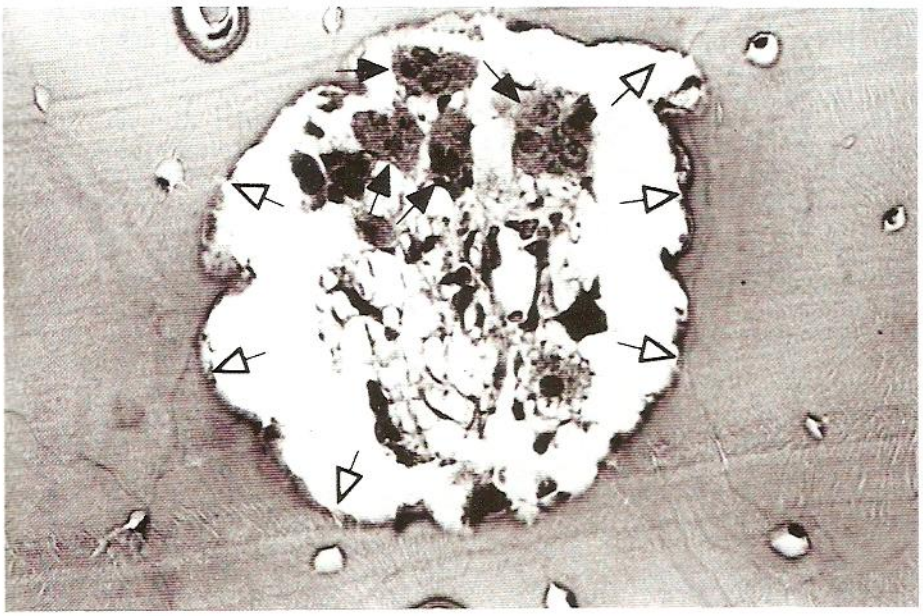

Figure 9-32. Resorption space. The border of the resorption space is serrated because of the confluence of resorption lacunae *(open arrows)*. Osteoclasts *(solid arrows)* have been displaced from the lacunae by the sectioning techniques. (X125.) Compare with Figures 9-15 and 9-30.

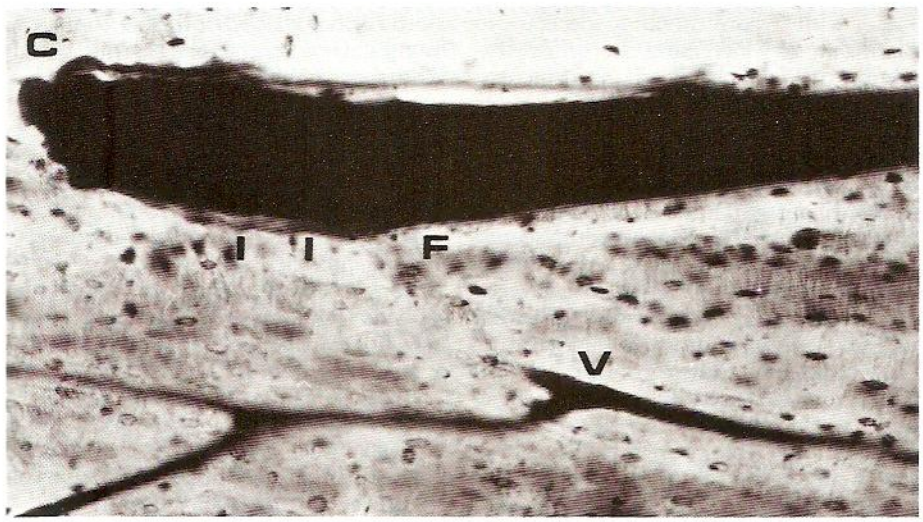

Figure 9-33. Longitudinal section of compact bone undergoing remodeling. The cutting cone *(C)* is the front of osteoclasia. The reversal line *(bars)* is the peripheral limit of the newly forming osteon *(F)*. The vessel *(V)* and osteonal endosteal elements comprise a narrow osteonal canal before and after cavitation of the bone. (X40, ground bone section.)

available to the organism on a minute-to-minute basis. The physicochemical nature of the Ca^{++}/P_i system and the metabolic requirements of the cells demand that regulation be precise. The skeleton must provide a depot for storage of these ions during periods of excess and must provide a source of ions when intrinsic sources are reduced. The gastrointestinal and renal systems complement these important skeletal functions.

The total plasma Ca^{++} concentration ($[Ca^{++}]$) of mammals is about 10 mg/dl (1 mg/100 ml). Under normal conditions this value remains constant, shows no species variability, and is independent of both diet and aging. The total plasma $[Ca^{++}]$ (10 mg/dl or 2.5 mM) is divisible into two distinct forms—nondiffusible, protein-bound Ca^{++} and diffusible Ca^{++}. **Nondiffusible, protein-bound Ca^{++}** accounts for an average 40% of the total Ca^{++} or 4 mg/dl (1 mM). Since plasma proteins remain relatively constant under normal conditions, the amount of bound Ca^{++} does not deviate significantly from this value. The **diffusible Ca^{++}** (6 mg/dl or 1.5 mM) is divisible into two subunits: **free Ca^{++}** accounts for about 83% of the diffusible fraction (5 mg/dl or 1.25 mM); **complexed Ca^{++}** is the remaining 17% (1 mg/dl or 0.25 mM), attached to citrate, bicarbonate, orthophosphate, and pyrophosphate.

Free Ca^{++} moves readily into the interstitial space. The $[Ca^{++}]$ within the extracellular space is the same as within the plasma. Similar concentrations characterize the fluid spaces within the osseous tissue. The intracellular $[Ca^{++}]$ is 10^{-6} to 10^{-7} M.

Most of the Ca^{++} within the body, about 99%, is in the skeleton as HAP crystal. Despite the surface exposure and potential physicochemical exchange, only 1% or less is exchanged in this manner. This does not mean that the rest of the mineral is irreversibly sequestered in the skeleton. Cell mechanisms make virtually every milligram of "sequestered bone mineral" available for exchange. Minor deviations from 10 mg/dl are compensated by physicochemical mechanisms. Major perturbations to this parameter require cell responses to appropriate hormones. These mechanisms ensure the organism maintaining a continual normocalcemic state rather than ranging from hypercalcemia after a meal to hypocalcemia before the next meal.

Inorganic phosphate (P_i) is an abundant ion, but the plasma concentration of this substance varies more than Ca^{++}.

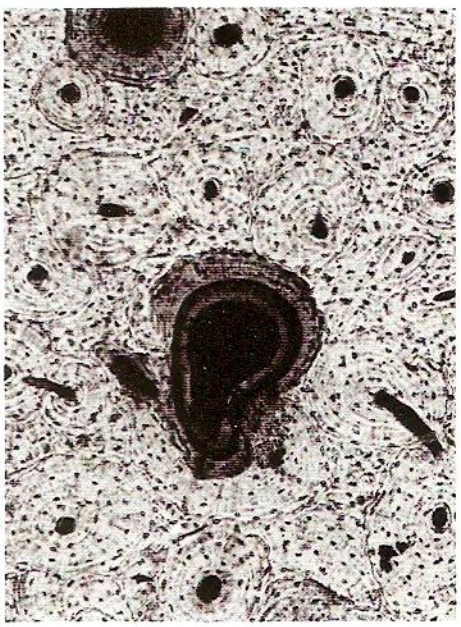

Figure 9-34. Refilling osteon. The osteon in the center of the field is filling. Compare its morphology with that of the osteon in Plate II, 9. The osteon at the top of the field is immature and inactive. (An osteoid seam is not apparent.) The remaining osteons are mature. (X25, ground bone section.)

Downloaded From Vet-eBooks.com

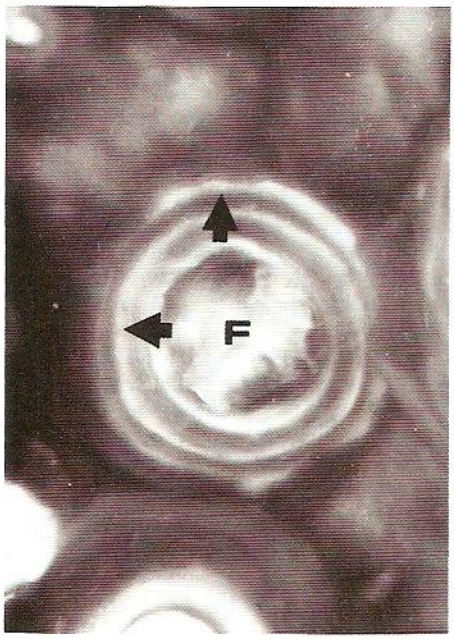

Figure 9-35. A 50 μm section of the cortex of a canine bone. The successive layers of fluorescence *(arrows)* indicate the active deposition of bone in a filling osteon *(F)*. (Courtesy RW Norrdin.) Compare with Plate I, *10*.

Generally, plasma P_i concentrations are about one-half that of plasma Ca^{++}, about 5 mg/dl. A useful but abridged relationship is that the solubility products of Ca^{++} and P_i equal a constant

$$k = [P_i] \times [Ca^{++}])$$

Calcium Regulatory System

Control substances. Parathormone (PTH) is a polypeptide secretory product of the chief cells of the parathyroid glands. Parathormone is the **hypercalcemic factor.** Release of this hormone in response to **hypocalcemia** causes an elevation of plasma $[Ca^{++}]$. The normal range of plasma $[Ca^{++}]$ is called **normocalcemia;** elevation above normal is **hypercalcemia.**

Calcitonin (CT) is the secretory product of thyroid gland parafollicular cells. Calcitonin is the **hypocalcemic factor.** The release of the hormone from the parafollicular cells in response to elevated levels of plasma Ca^{++} causes a depression of the plasma $[Ca^{++}]$.

Vitamin or hormone D is the third major substance involved in the regulation of Ca^{++}. As a vitamin, it is required in the diet, but hormone D is also synthesized by the body.

Vitamin D_3 or **cholecalciferol** is ingested in small amounts and is synthesized in the skin sebaceous glands. The synthesis of hormone D from **7-dehydrocholesterol** requires photoactivation of the substance by ultraviolet radiation. Hormone D_3 is then transported to the liver, where it is hydroxylated to **25-hydroxycholecalciferol (25-HCC** or **25-$(OH)D_3$).** If a Ca^{++} demand exists, 25-HCC is converted to **1,25-dihydroxycholecalciferol (1,25-DHCC** or **1,25-$(OH)_2D_3$)** within the mitochondria of renal tubular epithelial cells. If the organism does not have a need for Ca^{++} at the time, 25-HCC is converted to **24,25-dihydroxycholecalciferol (24,25-DHCC** or **24,25-$(OH)_2D_3$)** within the mitochondria of renal tubular epithelial cells.

Vitamin D_2 (calciferol) is formed by the irradiation of ergosterol, a plant sterol. This compound, once ingested and absorbed, undergoes transformations similar to those described for D_3. Vitamin D_2 is active in mammals but is inactive in birds.

Mechanisms of Action

Effects of hormones. PTH is the principle hormone responsible for the minute-to-minute, homeokinetic maintenance of the plasma Ca^{++} concentration. The most important biological effects of this hormone include (1) elevation of plasma Ca^{++} with a corresponding decrease in plasma P_i, (2) increasing the urinary excretion of P_i (phosphaturia), (3) increasing the urinary conservation of Ca^{++}, (4) increasing the rate of skeletal remodeling, (5) increasing the rate of osteocytic osteolysis, (6) facilitating the formation of 1,25-dihydroxyvitamin D_3 by exerting a trophic effect upon the 1-hydrolase system, and (7) increasing the Ca^{++} and P_i absorption from the small intestine by having a direct effect upon the formation of 1,25-DHCC.

PTH release results in the elevation of plasma Ca^{++}. The effects upon the skeleton result in the release of 1.66 moles of Ca^{++} for each mole of P_i. Calcium and P_i are absorbed from the small intestine in equimolar concentrations. So, two of the mechanisms cause both ions to be elevated in the blood. These mechanisms do not satisfy the relationship dictated by the equation $[Ca^{++}] \times [P_i] = k$. The parathyroid/renal axis adjusts elevated Ca^{++} while reducing P_i. The renal tubular reabsorption of Ca^{++} is enhanced, while the renal tubular reabsorption of P_i is blocked under the influence of PTH.

The effects of calcitonin upon osteoclastic and osteocytic cells is antagonistic to the action of PTH. The effect of calcitonin upon the kidney complements the action of parathormone. Calcitonin also manifests an inhibitory effect upon the intestinal absorption of Ca^{++} and P_i. The effects of calcitonin within the regulatory system include (1) the reduction of plasma Ca^{++} and P_i, (2) the inhibition of parathormone-stimulated osteoclasia and osteocytic osteolysis, (3) the indirect inhibition of Ca^{++} and P_i absorption from the small intestine, and (4) the short term stimulation of osteoblastic activity.

Calcitonin reduces plasma Ca^{++}. The effects of CT upon the gut may be indirect, inhibiting the synthesis of 1,25-DHCC. The precise and direct role of CT upon the kidney is not clear.

The dual regulation of Ca^{++} by PTH and CT is more precise than would be possible with one hormone alone. PTH seems to protect against hypocalcemia; CT seems to be an emergency-type hormone, protecting against postprandial hypercalcemia. As polypeptide hormones, both exert their effects through cAMP.

The active metabolites of hormone D are another aspect of the dual regulatory mechanisms involved in Ca^{++} homeokinesis: Increased Ca^{++} need favors the formation of 1,25-DHCC. The intestine responds by increasing its absorption of Ca^{++} and P_i. Osteoclasia and osteocytic osteolysis are increased by 1,25-DHCC. This metabolite is necessary for intestinal cells to respond to PTH. The precise effects of 1,25-DHCC upon the kidneys need further clarification. The compound is inhibitory to the parathyroid glands. The specific functions of 24,25-DHCC also need to be clarified. This compound has a negative influence upon PTH production, and it may facilitate the deposition of Ca^{++} in bone. The mechanisms by which both active metabolites mediate their effects are typical of the steroid hormones.

Target organ responses. The integrated functions of the target organs (small intestine, kidney, bone) in this regulated system are the essential mediators of Ca^{++} homeokinesis.

The **small intestine** absorbs Ca^{++} and P_i. The 1,25-DHCC metabolite enhances this activity by activating absorptive cells and by synthesizing and secreting **Ca^{++}-binding proteins (CaBPs).**

Diets with reduced Ca^{++} enhance the synthesis of CaBPs; thus Ca^{++} absorptive efficiency is increased. This relationship may serve as part of the rationale for dietary reduction of Ca^{++} in dairy cows just before parturition. Such reductions decrease the incidence of milk fever (parturient paresis) by inducing the cow to increase absorptive efficiency just before the increased demands imposed upon her by milk letdown. Additionally, the PTH/bone axis is activated.

The effects of CT upon this target organ are not clear. The inhibitory effect upon gut absorption may be through its negative influence on the synthesis of 1,25-DHCC. PTH exerts its influence through a positive effect on the synthesis of 1,25-DHCC.

The **renal** component of the regulatory

Downloaded From Vet-eBooks.com

system is responsible for the conservation and/or excretion of Ca^{++} and P_i. The differential activity of the renal tubular epithelial cells is the essential contributor to the elevation of plasma Ca^{++} levels. Receptors for PTH occur within the basilar membrane of the lining cells of the proximal and distal convoluted tubules. Enhancement of distal convoluted tubular reabsorption under PTH influence seems to be an important mediator of the homeokinetic Ca^{++} maintenance. Phosphorus is usually reabsorbed from the filtrate within the proximal convoluted tubule; selective resecretion occurs within the distal convoluted tubule. PTH stimulation of proximal convoluted tubular lining cells blocks the reabsorption of P_i from the filtrate within this segment of the nephron. The resulting **phosphaturia** elevates urinary P_i, decreases plasma P_i, and tends to favor the elevation of plasma Ca^{++}.

The effects of CT upon the kidney are not clear. CT receptors have been demonstrated in the epithelial cells of the nephron loop and the distal convoluted tubule.

PTH has a trophic effect upon the 1-hydroxylase system within the renal tubular lining cells. Although these active metabolites of hormone (1,25-DHCC and 24,25-DHCC) are synthesized within the kidney, their effects upon the kidney need clarification.

Not only does **bone** serve as a mineral sink to prevent excesses in plasma Ca^{++} levels, it must also be a source of minerals to prevent hypocalcemia. Osteoblasts and osteocytes function, respectively, to form and maintain bone. They work together to remove bone. Similarly, osteoclasts augment the pool of circulating metabolites through their lytic activity. All bone cells contribute to the homeokinetic maintenance of plasma Ca^{++}.

Osteocytes and osteoblasts are linked structurally through their cell processes within the canaliculi. Functionally they are linked as an **osteocyte-osteoblast pump.** The immediate effect of PTH stimulation is activation of this pump. The activated pump mobilizes mineral from the "depths" of bone and transports it to the surface, whereupon the mineral enters the circulating pool. The initial action is **osteocytic osteolysis.** Osteocytes secrete organic acids and various hydrolases (proteases, collagenases) into the lacunar environment. The subsequent enlargement of lacunae is associated with released organic and inorganic materials from the lacunar surfaces. The Ca^{++} may move down its concentration gradient to the surface cells through canaliculi or may be transported actively through the cellular processes to the osteoblasts. Each osteocyte does not mobilize much mineral, but its cellular density ensures that enough mineral is mobilized to alter blood Ca^{++} levels. **Osteocytic osteolysis and the osteocyte-osteoblast pump are the rapid, minute-to-minute, PTH-responsive mechanisms for increasing the concentration of plasma Ca^{++}.**

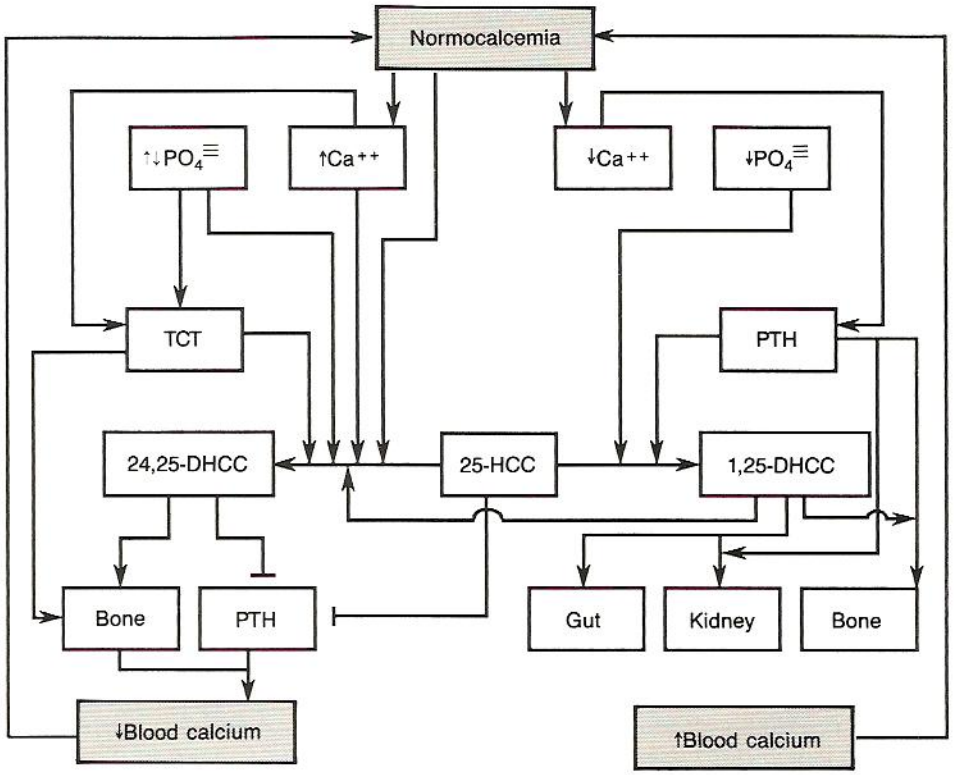

Figure 9-36. Relationships of various substances in the regulation of calcium. *Arrows,* Stimulation; *bars,* blockage or inhibition.

Osteoclastic participation in mineral mobilization is an adjunctive mechanism stimulated by PTH. Hours are required to measure the responsiveness of these cells to PTH. Osteoclasts are capable of mobilizing large quantities of mineral from beneath the "sealed" microenvironment of the ruffled border. The mechanism by which this mobilization is achieved is similar to that described for osteocytes. Organic acids and hydrolases are essential secretions. Degraded materials are ingested by the osteoclasts, processed further, and ultimately moved to the extracellular environment.

CT manifests its effect upon bone by blocking osteoclasia and osteocytic osteolysis. This effect, however, is transitory. Also bone formation is an initial response to calcitonin. The 1,25-DHCC is necessary for bone cells to respond to parathormone.

Various disorders exist in which abnormalities of mineral metabolism are manifested as clinical disease entities. **Hypocalcemic tetany (eclampsia)** in the bitch associated with parturition and milk letdown is a life-threatening situation. Hypercalcemia can be a complication of various metabolic bone diseases. One of the consequences is the **metastatic calcification** of normal tissues.

The response of this system to hypocalcemia and hypercalcemia is illustrated in Figure 9-36.

"In Concert" Influences of Hormones

Specific hormones and influences. The elaborate PTH/CT/vitamin D regulatory system is a precise mechanism for Ca^{++} homeostasis. The complexity of this regulatory scheme is compounded by the "in concert" effect of many other hormones. The mechanisms by which these hormones exert their influences, for the most part, have not been elucidated. Interaction with the Ca^{++} regulatory system is an attractive choice.

The gonadal hormones exert many effects upon the mature skeleton that are species-variable. The removal of the ovaries or their dysfunction with age results in an estradiol deficiency. This deficiency, notable in women with the onset of menopause, is associated with a reduction of skeletal mass. The osteoporosis results from an altered remodeling. Estrogen and the other sex steroids (testosterone) probably exert an inhibitory influence upon osteoclasia. Removal of the

Downloaded From Vet-eBooks.com

inhibition causes an increased remodeling characterized by a $-\Delta$B.BMU in which resorption is increased, but formation is normal. Some experimental evidence has shown that the administration of sex steroids interfaces with the conversion of 25-HCC to 1,25-DHCC. The sex steroids may mediate their effect through the metabolic pathways for vitamin D.

The relationship of the glucocorticosteroids to bone is well established. Osteoporosis is often a complication of **Cushing's syndrome** or the improper use of these hormones therapeutically. The adrenocorticoids also have an inhibitory effect upon Ca^{++} absorption from the small intestine and Ca^{++} conservation by the kidneys. The osteoporosis of this syndrome is characterized by an inhibition of osteoclastic activity that is less than the inhibition of osteoblastic activity. The ΔB.BMU still results in skeletal loss. The precise mechanisms are not known; some evidence suggests that interference of vitamin D metabolism may be involved. Also, the inhibition of protein synthesis may be a factor.

The thyroid hormones (T_3 and T_4) are known to influence bone remodeling and metabolism. **Hyperthyroidism** is associated with hypercalcemia and increased skeletal remodeling. **Thyrotoxicosis** may interfere with the generation of circulating levels of 25-HCC.

The somatotropin/somatomedin axis is the important mechanism for growth hormone (somatotropin) to exert its influence upon the growing and repairing skeleton. These hormones may mediate their effects and satisfy the increased demand for Ca^{++} by stimulating the production of 1,25-DHCC.

A reduced skeletal mass has also been associated with **diabetes mellitus.** This defect may result from a Ca^{++} malabsorption problem in the small intestine. Experiments with animals show that a defect in the generation of 1,25-DHCC may be part of the disease process. Insulin, then, may also influence vitamin D metabolism.

Prolactin increases circulating levels of 1,25-DHCC. Also, the prostaglandins (A, B, E, and F), especially prostaglandin E_2 (PGE_2), are strong promoters of bone resorption. It is interesting to speculate that this effect may be mediated through vitamin D metabolism.

The "in concert" effects of the hormones upon the skeleton have been known for years. The mechanisms by which these effects are mediated remain speculative. The Ca^{++} regulatory system of PTH/CT/vitamin D provides a functional substrate upon which all of the other hormones exert their influence.

ADDITIONAL READINGS

Amprino R, Engstrom A: Studies on x-ray absorption and diffraction of bone tissue, *Acta Anat* 15:1, 1952.

Ascenzi R, Bonucci E, Bocciarelli DS: An electron microscope study of primary periosteal bone, *J Ultrastruct Res* 18:605, 1967.

Belanger LF, et al: Resorption without osteoclasts (osteolysis). In Sognnaes RF (ed): *Mechanisms of hard tissue destruction.* AAAS, Washington DC, 1963.

Bourne GH (ed): *The biochemistry and physiology of bone.* vols 1 to 3, New York, 1972, Academic Press.

Cohen J, Harris WH: The three dimensional anatomy of Haversian systems, *J Bone Joint Surg* 40A:419, 1958.

Cooper RR, Milgram JW, Robinson RA: Morphology of the osteon: an electron microscopic study, *J Bone Joint Surg* 48A:1239, 1966.

Christakos S, Norman AW: Interaction of the vitamin D endocrine system with other hormones, *J Mineral Electrolyte Metab* 1:231, 1978.

DeLuca HF: The kidney as an endocrine organ for the production of 1,25-dihydroxyvitamin D_3; a calcium-mobilizing hormone, *N Engl J Med* 289:359, 1973.

Fischman DA, Hay ED: Origin of osteoclasts from mononuclear leukocytes in regenerating newt limbs, *Anat Rec* 143:329, 1962.

Frost HM: *Bone remodelling dynamics,* Springfield Ill, 1963, Charles C Thomas.

Frost HM: *The physiology of cartilaginous, fibrous, and bony tissue,* Springfield Ill, 1972, Charles C Thomas.

Frost HM: Bone mass and the mechanostat: a proposal, *Anat Rec* 219:1, 1987.

Gonzales F, Karnovsky MJ: Electron microscopy of osteoclasts in healing fractures of rat bone, *J Biophys Biochem Cytol* 9:299, 1961.

Gothlin G, Erricsson JLE: The osteoclast, *Clin Orthop* 120:201, 1976.

Hancox NM: *Biology of bone,* Cambridge, 1972, University Press.

Heller-Steinberg M: Ground substance, bone salts, and cellular activity in bone formation and destruction, *Am J Anat* 89:347, 1951.

Hobdell MH, Boyde A: Microradiography and scanning electron microscopy of bone sections, *Z Zellforsch* 94:487, 1969.

Jee WSS, Nolan PD: Origin of osteoclasts from the fusion of phagocytes, *Nature* 200:225, 1963.

Jotereau FV, LeDouarin NM: The developmental relationship between osteocytes and osteoclasts: a study using quail-chick nuclear marker in endochondral ossification, *Dev Biol* 63:253, 1978.

Kincaid SA, VanSickle DC: Bone morphology and postnatal osteogenesis: potential for disease, *Vet Clin North Am* 13:3, 1983.

Little K: *Bone behavior,* New York, 1973, Academic Press.

Martin JH, Matthew JL: Mitochondrial granules in chondrocytes, osteoblasts, and osteocytes, *Clin Orthop* 68:273, 1970.

Mathews JL: Bone structure and ultrastructure. In: Urist MR (ed): *Fundamental and clinical bone physiology,* pp 4-44, Philadelphia, 1980, JB Lippincott.

Nichols G Jr, Wasserman RH (eds): *Cellular mechanisms for calcium transfer and homeostasis,* New York, 1971, Academic Press.

Owen M: Histogenesis of bone cells, *Calc Tiss Res* 25:205, 1978.

Parfitt AM: Mechanisms of calcium transfer between blood and bone and their cellular basis: morphological and kinetic approaches to turnover, *Metabolism* 25:809, 1976.

Parfitt AM: Quantum concept of bone remodeling and turnover: implications for the pathogenesis of osteoporosis, *Calcif Tiss Res* 28:1, 1979.

Queener SF, Bell NH: Calcitonin: a general survey, *Metabolism* 24:555, 1975.

Rasmussen H, Goodman DBP: Relationships between calcium and cyclic nucleotide in cell activation, *Physiol Rev* 57:421, 1977.

Sumner-Smith G (ed): *Bone in clinical orthopaedics: a study in comparative osteology,* Philadelphia, 1982, WB Saunders.

Urist MR (ed): *Fundamental and clinical bone physiology,* Philadelphia, 1980, JB Lippincott.

Walker DG: Experimental osteopetrosis, *Clin Orthop* 97:158, 1973.

Walker DG: Spleen cells transmit osteopetrosis in mice, *Science* 190:785, 1975.

Walker DG: Bone resorption restored in osteopetrotic mice by transplant of normal bone marrow and spleen cells, *Science* 190:784, 1975.

Downloaded From Vet-Books.com

CHAPTER 10

Osteogenesis

DEVELOPMENT OF BONE

General characteristics. Osteogenic processes begin in the fetus and continue throughout life. Because osteoblasts develop in two different environments, two types of normal ossification processes are described—intramembranous and endochondral.

Ossification vs. mineralization. **Ossification** is a process in which a complex sequence of spatially and temporally linked events leads to bone formation. **Mineralization,** a part of ossification, is the process by which the organic matrix of bone acquires its usual complement of inorganic components.

Bone formation may occur in foci not normally occupied by osseous tissue. This **pathological (metaplastic) ossification** may be observed in otherwise normal tissues of scars, tracheal and laryngeal cartilage, lateral cartilages of the equine foot, and other organs. **Calcification** of normal tissues, occurring as a part of persistent hypercalcemia, is termed **metastatic calcification.** The calcification of degenerative or dead tissues is termed **dystrophic calcification.** Precipitation occurs during hypocalcemia, because the concentrations of Ca^{++} and phosphorus (P_i) exceed their solubility product.

Developmental modeling and remodeling. The cellular mechanism of bone formation is the same during development as in the adult organism. The essence of the process is the biphasic activity of osteoblasts.

Intramembranous ossification is responsible for the attainment of the final shape of some bones not preformed in cartilage. Endochondral ossification is responsible for diaphyseal elongation and epiphyseal shape and size. Elongation is complemented by activities increasing the transverse diameters of developing diaphyses.

Both ossification processes are used to accomplish skeletal development. After development of bone in a membranous or cartilaginous environment, subsequent bone formation occurs on pre-existing bone surfaces by apposition. Continued deposition leads to bone growth. The **modeling** of bones is the combined result of osteoblastic and osteoclastic activity. The balance of these combined activities favors bone deposition during growth.

Although osteogenic processes most noticeably occur during adolescence, they are not confined to this period. Bone deposition and removal, without any significant gross alteration, occurs throughout life. This **remodeling** process complements adolescent bone modeling. Remodeling activity is an essential skeletal development and growth feature. As the body mass increases, the skeleton compensates to carry the additional load effectively. New osteon formation, repositioning of secondary osteons, and proper trabecular bone placement are part of skeletal development, growth, and maintenance achieved by remodeling.

MECHANISMS OF DEVELOPMENT

Intramembranous Ossification

Sequence of histogenesis. The bones destined to form, either totally or partially, in this manner are the skull, mandible, and clavicle. These are not weight-bearing structures.

The first recognizable stage of skeletal development during the embryonic period is **mesenchymal condensation.** Initially, these regions appear hyperplastic. They are characterized by mesenchymal cells crowded within a homogeneous, fluid ground substance. The subsequent tissue envelopment occurs when **fibroblasts** differentiate from mesenchymal cells. **Collagen fibers** are randomly scattered among the many cells. Some of the mesenchymal cells will become **osteoprogenitor cells.**

The next step in this differentiation is the appearance of osteoblasts (Fig. 10-1). Although bone matrix is not always visible during early differentiation stages, secretions by these cells produces recognizable osteoid within early ossification centers (Figs. 10-2 to 10-4).

Progressive development produces

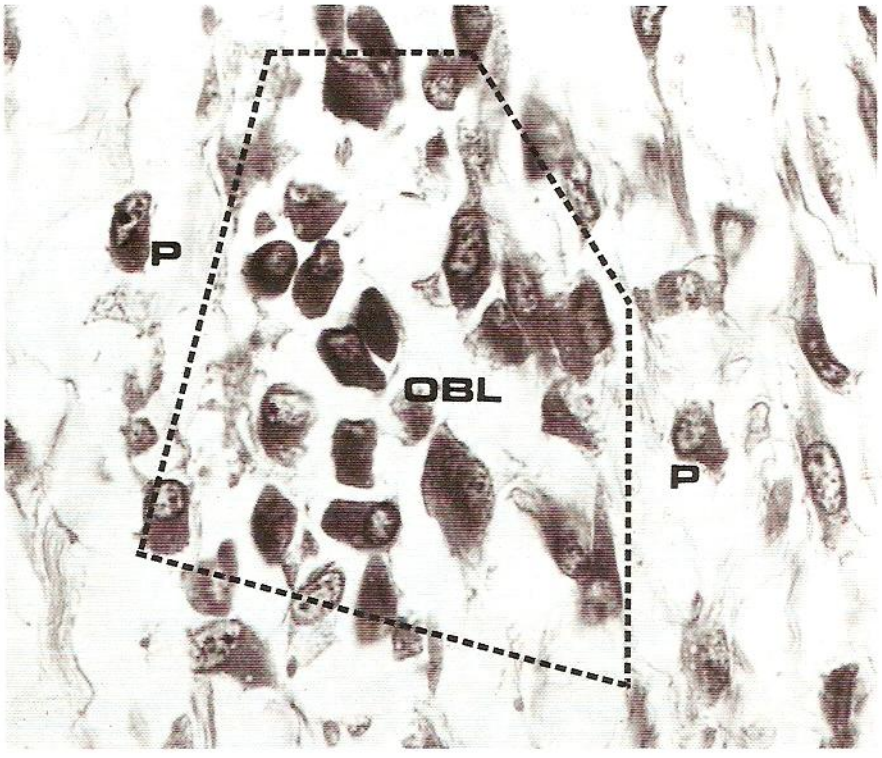

Figure 10-1. Differentiation of osteoblasts within an intramembranous ossification center of a bovine fetal jaw. The *outlined area* is an ossification center that contains osteoblasts *(OBL).* The light-staining cells at the periphery may be osteoprogenitor cells *(P).* (X160.)

Downloaded From Vet-eBooks.com

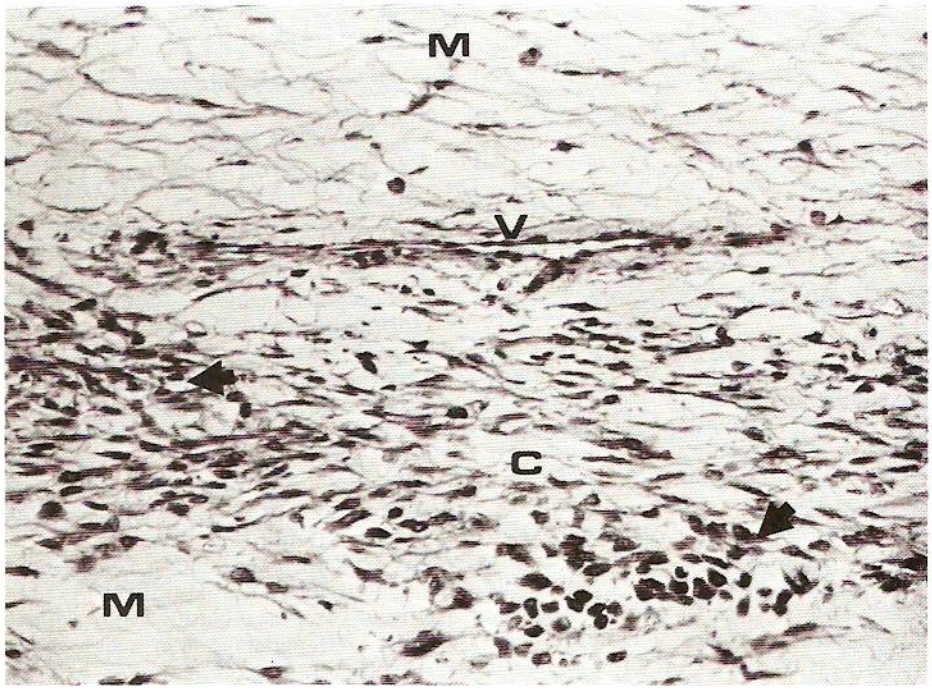

Figure 10-2. Presumptive ossification center in a bovine fetal jaw. The mesenchyme *(M)* surrounds an area of mesenchymal condensation *(C)*. Dark-staining cells *(arrows)* are osteoblasts. Bone matrix has not been formed at these sites yet. A blood vessel *(V)* has developed in association with the ossification center. (X40.)

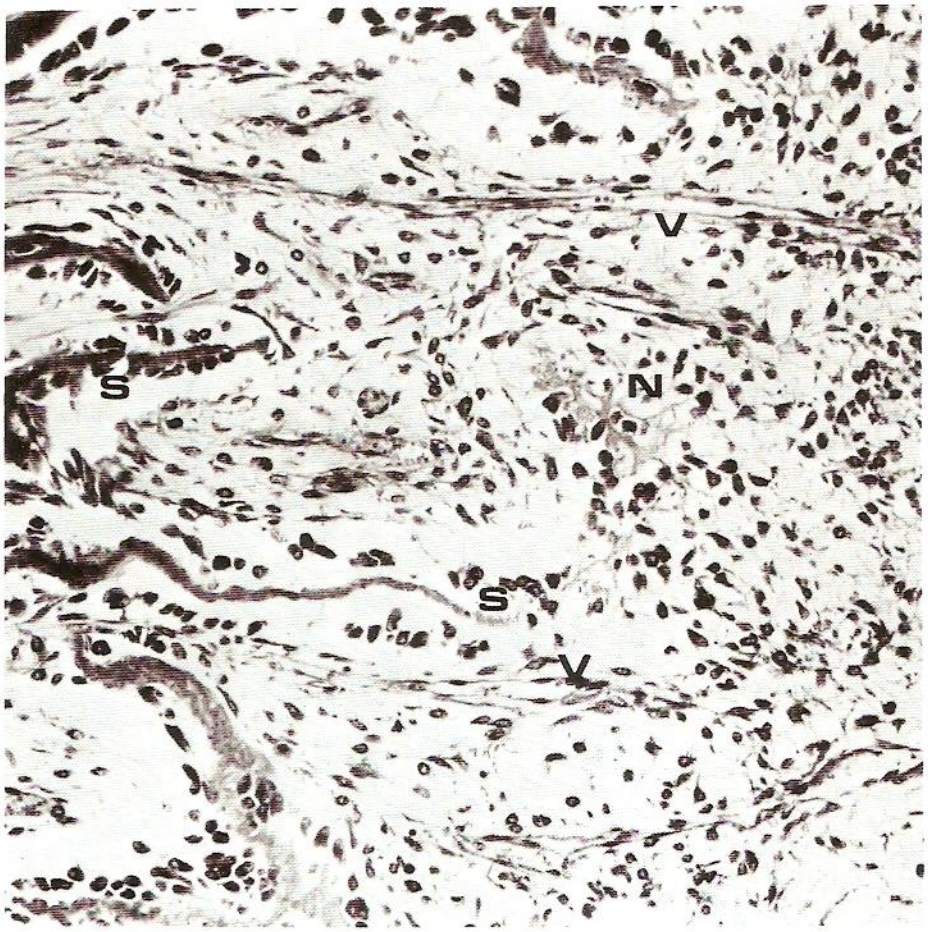

Figure 10-3. Bone matrix formation within an ossification center within a bovine fetal jaw. New matrix formation *(N)* is evident. Continued activity of osteoblasts forms progressively larger spicules of bone *(S)*. An extensive vascular bed *(V)* is developing also. (X40.)

identifiable bone spicules (Fig. 10-5). A fibrocellular connective tissue with numerous blood vessels surrounds the developing bone. As osteoblasts deposit bone appositionally, some cells remain entrapped in their secretions as osteocytes. The bone deposited in these ossification centers is **woven bone** (Figs. 10-5 and 10-6).

Woven bone is a temporary structure during development. Its production decreases with time, while lamellar bone formation increases progressively. Osteoclasts remove woven bone (Fig. 10-6). Ultimately, only lamellar bone remains.

Osteoblastic and osteoclastic activities are integral parts of bone formation. Active osteoblasts form bone, osteoclasts remove woven and lamellar bone. This combination moves osseous spicules through space (Fig. 10-6). Spicules of bone form, move through space, coalesce, and form recognizable gross structures. Loose and dense collagenous tissues develop in association with the bone. Similarly, vascular beds develop within the mesenchyme of developing bones.

The covering envelopes associated with developing spicules are typical. They develop simultaneously with bone within the ossification center. The osseous coverings could be called trabecular endosteal envelopes because of their association with bone spicules. The peripheral covering becomes the periosteum. Complete distinction of the various envelopes is possible when some definitive shape is apparent.

Progressive expansion of the ossification center increases the size of the developing bone and alters the configuration of the osseous tissue. Isolated foci become more typically cancellous bone (Fig. 10-6). Osteons may form in the cancellous bone as some of it becomes compact bone. The cancellous nature of the bone within the forming marrow cavity is retained.

The periosteum continually deposits bone laminae in a compact configuration, strengthening the bone and increasing its diameter. Cortical endosteal osteoclasts continually remove bone, expanding the

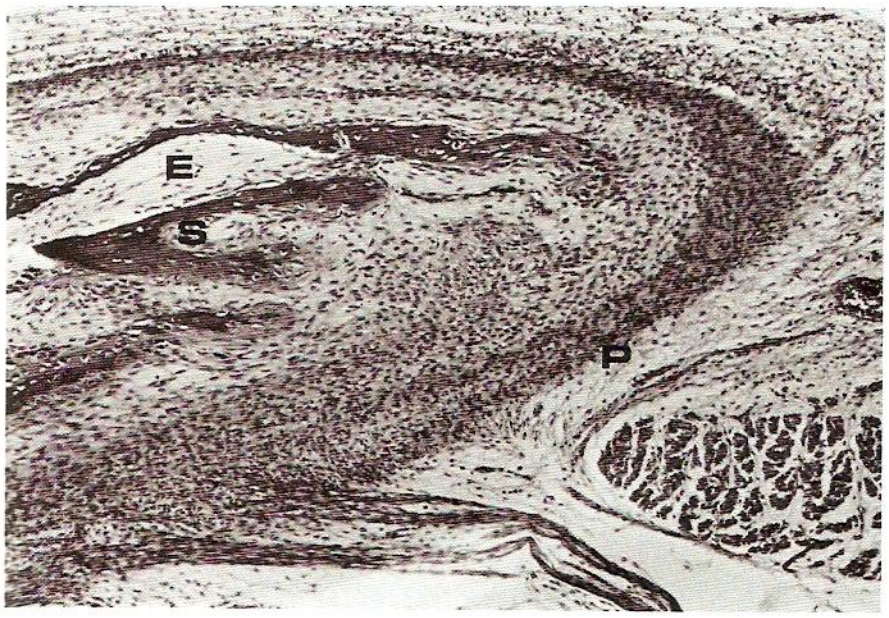

Figure 10-4. Ossification of a bovine fetal jaw. The developing bone site is demarcated clearly from surrounding mesenchyme by the condensation of mesenchymal cells forming a periosteum *(P)*. Bone spicules *(S)* and endosteal elements *(E)* are apparent within the ossification center. (X20.)

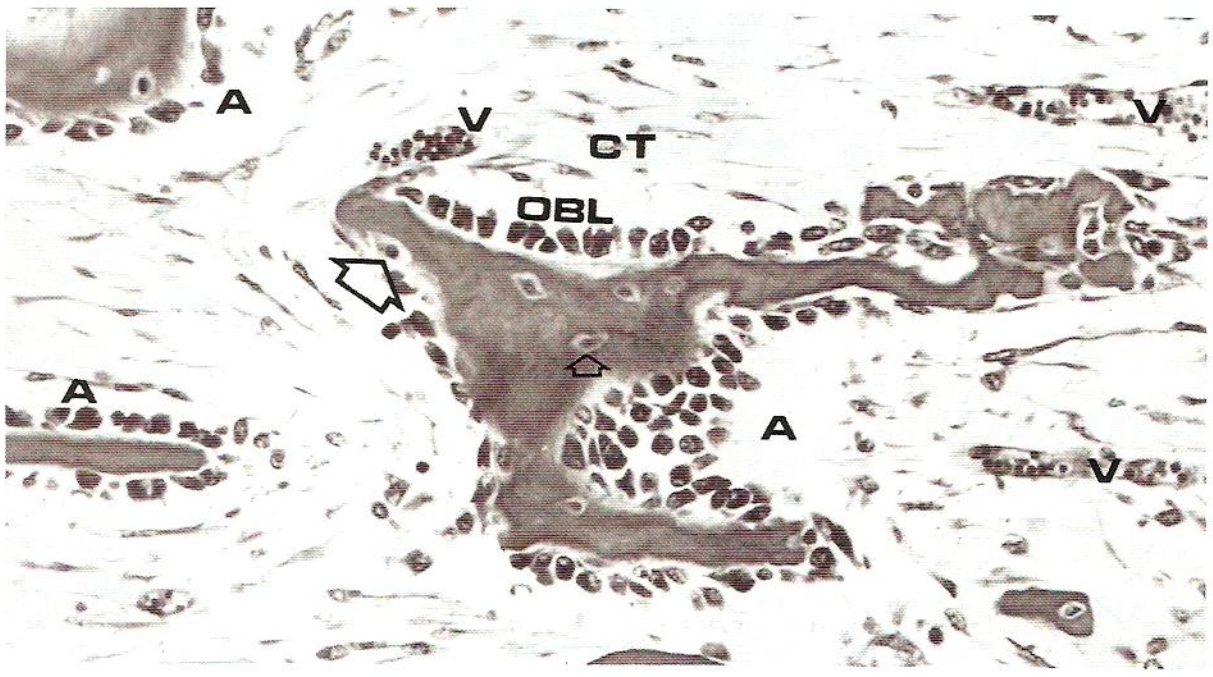

Figure 10-5. Spicules of bone within an ossification center of a bovine fetal jaw. The spicules are surrounded by endosteum consisting of fibrocellular connective tissue *(CT)*. Blood vessels *(V)* are evident. The endosteum is separated artifactually from the bone *(A)*. Osteoblasts *(OBL)* become entrapped in bone *(large arrow)* and are recognized eventually as typical osteocytes *(small arrow)*. Spicules will coalesce as they grow. (X63.)

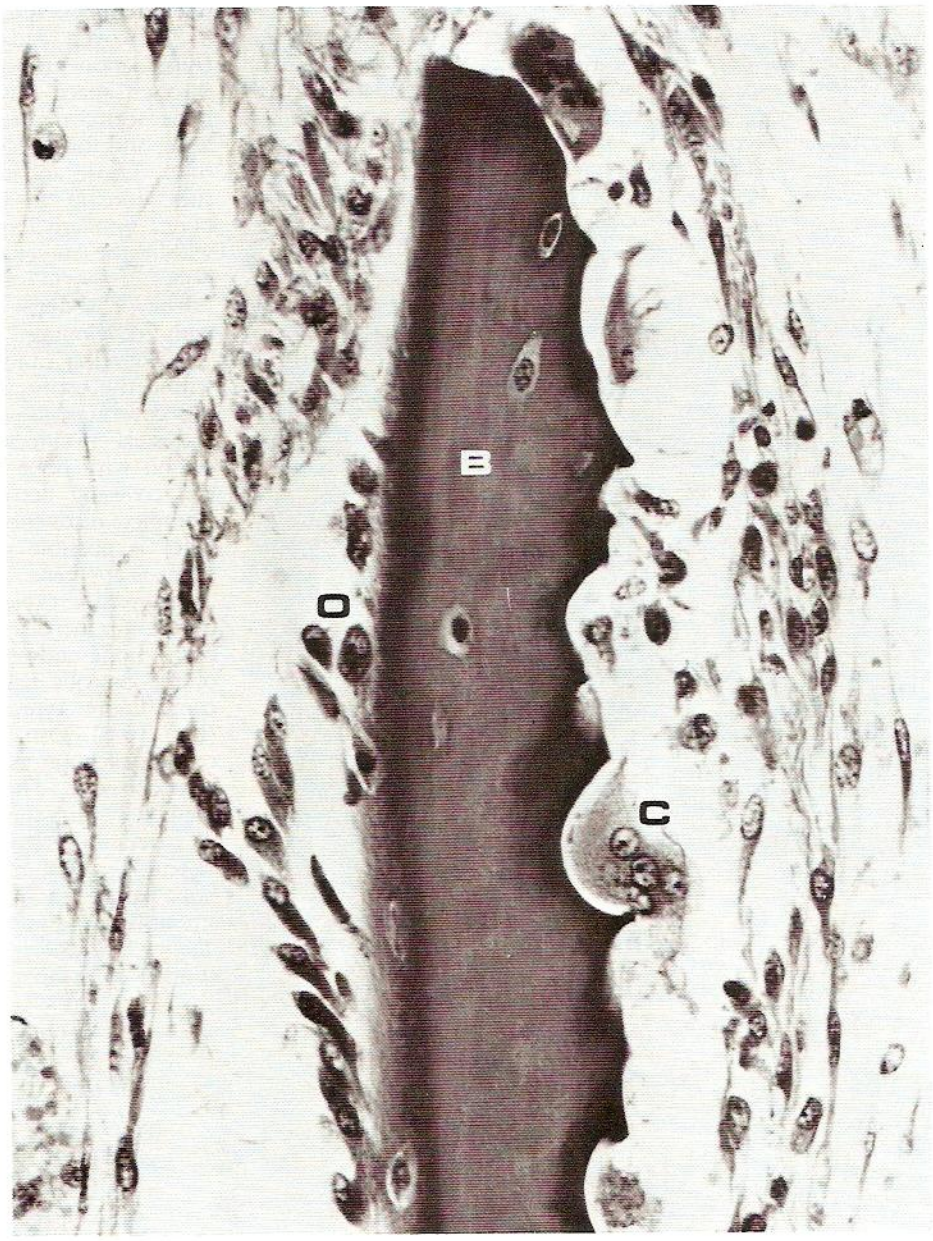

Figure 10-6. Bone spicule in an intramembranous ossification center within a bovine fetal jaw. Osteocytes have been incorporated into the spicule *(B)*. Osteoblastic *(O)* and osteoclastic *(C)* activity is evident. Both types of cells are always associated with bone developmental processes. The spicule consists of woven bone. Osteoclastic activity is evident along its right margin; osteoblastic activity, along its left margin. With time this spicule would have moved from right to left. (X100.)

marrow cavity while maintaining the essential thickness of the compact bone. The bone formed by periosteal osteogenic activity is removed by cortical endosteal osteoclasia until the definitive diameter of the structure is achieved.

The essence of this ossification is the de novo formation of bone in mesenchyme. Continual bone addition and removal produces a definitive shape with an appropriate distribution of cancellous and compact bone.

Endochondral Ossification

General features. **Endochondral, enchondral,** and **intracartilaginous ossification** are synonyms for this process of bone development within cartilage. The hyaline cartilage models are miniature versions of adult bones (Fig. 10-7). The cartilage is removed gradually and replaced continuously by bone.

Endochondral ossification forms the weight-bearing bones. Elongation is achieved in such a way that the animal is able to bear weight while growing.

Premature termination of endochondral ossification is considered an abnormality in most species. In some dog breeds, however, an early cessation of endochondral ossification results in shortened bones considered normal. **Achondroplasia (chondrodystrophy, chondrodysplasia)** is the premature termination of endochondral ossification. Achondroplasia is generalized in Bulldogs and Pekingeses, restricted to the head in Boxers and Boston Terriers, and localized to the limbs in Dachshunds and Basset Hounds.

Functions. Endochondral ossification **elongates** most of the skeletal mass during growth. This function starts before and continues during actual weight-bearing. The rate at which growth progresses, the duration of the process, and the direction of the process in three-

Downloaded From Vet-eBooks.com

Figure 10-7. Developing manus of a hamster. The bones of the manus (phalanges and metacarpals) are preformed in cartilage. The metacarpal bones *(M)* and phalanges *(P)* are miniature versions of the adult structures. Note the appearance of the metacarpophalangeal and interphalangeal joints early in development. (X10.)

dimensional space is affected by genetic, nutritional, metabolic, and mechanical factors. Most of an organism's definitive height occurs through growth plate activity. The continuous addition of cartilage to the growth plate and the subsequent replacement of the growth plate by bone accounts for elongation.

Endochondral ossification **contributes to the shape, size, spatial orientation, and alignment of bone articulations.** Normal locomotor function is directly related to modeling aspects of this process. Most long bones have epiphyses whose diameters are larger than diaphyseal diameters. Endochondral ossification activity within secondary ossification centers and differential bone cell activities within the periphery of metaphyses are essential for the attainment of proper epiphyseal shape and size. The enlarged epiphyses provide biomechanical advantages.

Endochondral ossification **forms most of the cancellous bone.** Cancellous bone reduces the skeletal mass without compromising the ability to bear weight, because the trabeculae are positioned for maximal mechanical advantage.

Model formation

Chondrogenic centers. Mesenchymal cell condensation characterizes regions in which bones develop by this process. (Figs. 10-8, *A*, and 10-9). The developing matrix contributes to cell differentiation. Early stage matrix production has hyaluronic acid, which may be required for the aggregation of mesenchymal cells. As cytodifferentiation continues, chon-

Downloaded From VetBooks.com

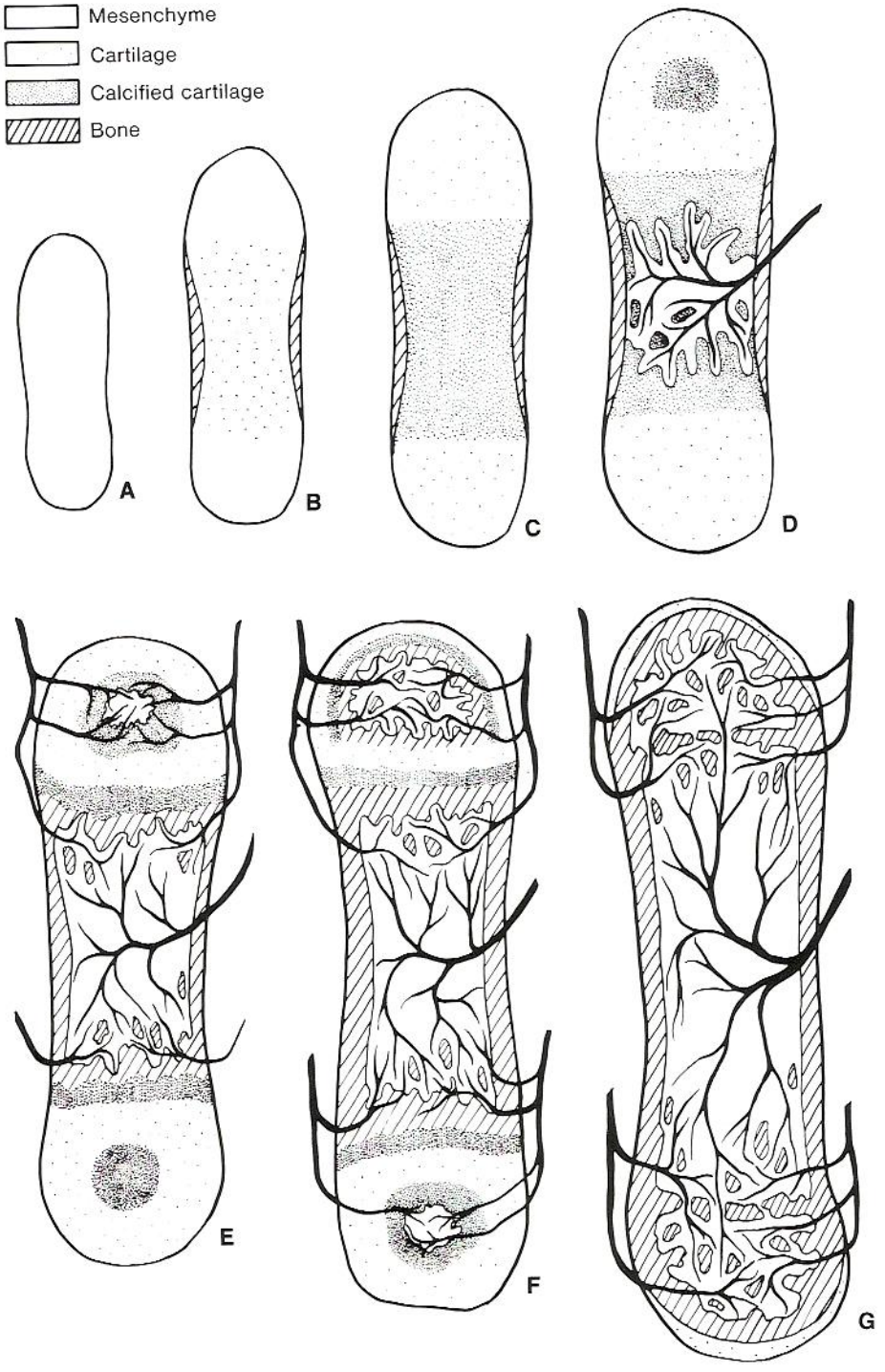

Figure 10-8. Sequence of events typifying long bone development by endochondral ossification. Refer to the text for a complete description of the process.

droitin sulfates increase with the removal of hyaluronate. The condensation, resulting from aggregation and mitotic activity, appears hyperplastic. The relationships of future bones are apparent in the presumptive bone-forming sites.

The cells eventually differentiate into chondroblasts and form a **chondrogenic center** called a **cartilaginous model** (Fig. 10-10). Commensurate with this, mesenchymal cells at the periphery of the model condense and form a **perichondrium** enclosing the model. Perichondral appositional growth, complemented by interstitial growth, lengthens and thickens the model. As adjacent bone-forming sites lengthen, the proximal and distal perichondrial envelopes degenerate, forming a synovial cavity between the developing bones (Fig. 10-10). These denuded sites become the articular surfaces. Subsequently the model depends exclusively upon continuing interstitial growth.

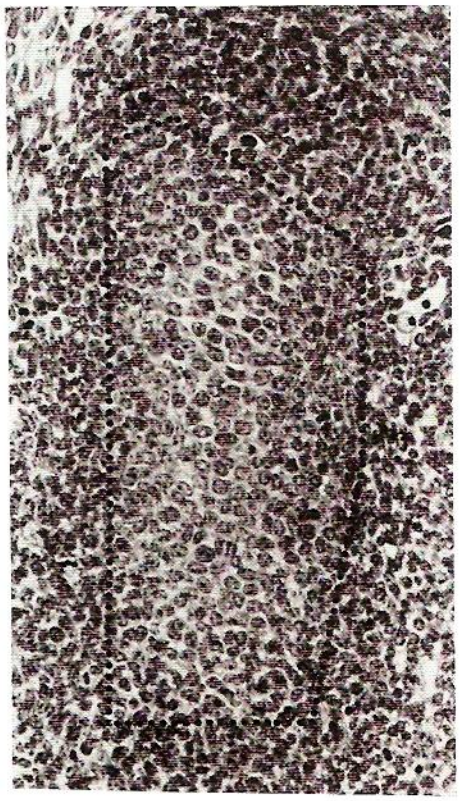

Figure 10-9. Mesenchymal condensation in a presumptive bone-forming site, a fetal hamster humerus. The mesenchymal condensation is outlined. A perichondrium will differentiate at the periphery of the condensation. (X60, periodic acid–Schiff).

The progressive lengthening and thickening of the model is associated with chondrocytic maturation. Those differentiating first occupy the center of the model. The young cells, located proximally and distally, mature toward the center. Young cells and their lacunae become progressively larger with maturation. Eventually the lacunae of contiguous cells become sufficiently large to reduce the intervening matrix to a thin separating rim. Such older cells are hypertrophic. At the same time these maturation events are occurring, the perichondrium in the middle of the model is invaded by blood vessels. Then, some cells in this envelope differentiate into osteoblasts and osteoclasts; thus the **periosteum** is formed (Fig. 10-8, *B*). This envelope forms woven bone circumscribing the chondrogenic model (**collar** or **sleeve bone**) of the newly forming diaphysis. The **diaphyseal ossification center** has been established (Fig. 10-8 *C*).

Primary ossification center. The continued latitudinal expansion of the **primary ossification center (diaphyseal ossification center)** depends upon the continued periosteal osteogenic activity. Elon-

Downloaded From Vet-eBooks.com

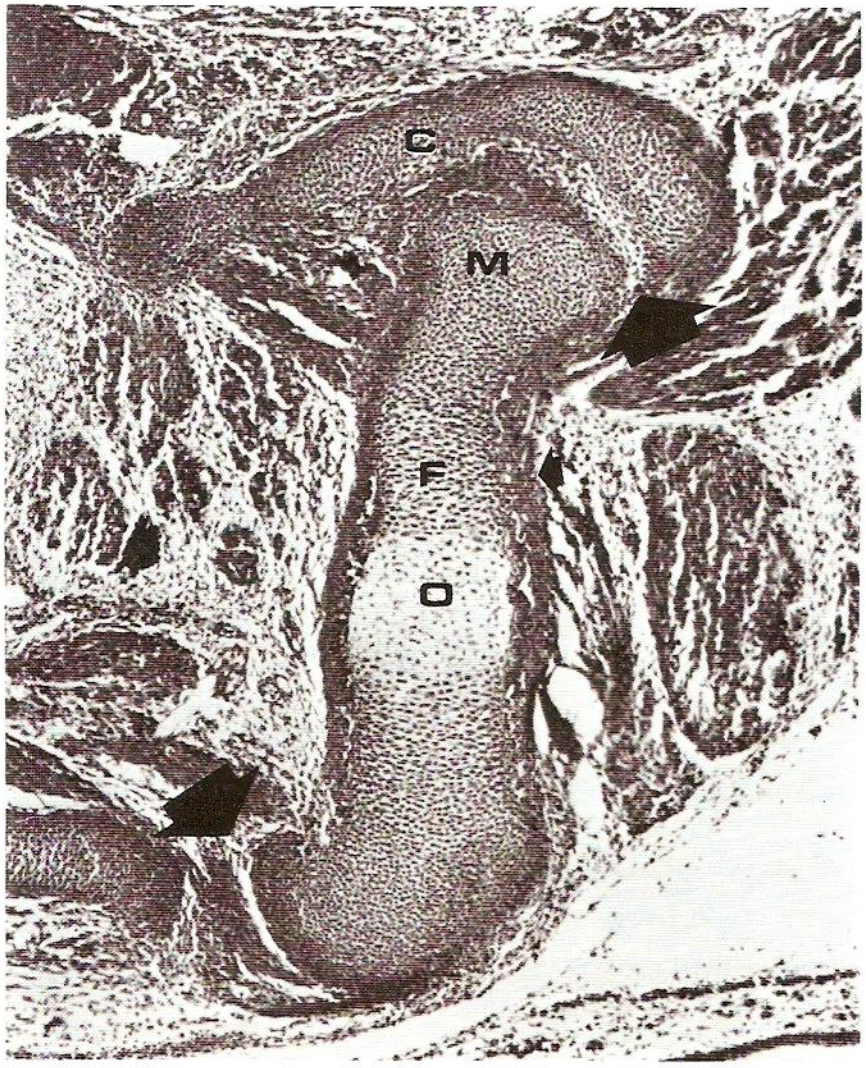

Figure 10-10. Developing model of the os coxa and femur in a canine fetus. The general forms of the femur *(F)* and os coxa *(C)* are apparent at this early stage of development. Most of the model is composed of mesenchymal cells *(M)*. The center of the model *(O)*, composed of cartilage, is the early ossification center. The model is surrounded by a perichondrium *(small arrow)*. The mesenchyme has disintegrated in the regions of the acetabulum and stifle; thus these joints are evident at this early stage of development *(large arrows)*. (X16.)

gation depends upon continued cartilage production and its replacement within the confines of the surrounding sleeve bone (Fig. 10-8, *C*). The matrix associated with hypertrophic chondrocytes in the center of the primary ossification center eventually becomes calcified. Although the hypertrophic chondrocytes participate in the calcification process, all chondrocytes eventually die in the process.

The cartilaginous model is avascular, despite blood vessels being located at the periphery as part of the periosteum. Also **the cartilaginous model is devoid of stem cells.** All chondrogenic center mesenchymal cells differentiate into chondrocytes. Continued development of the model depends upon neovascularization and repopulation with stem cells.

Periosteal bud formation. Calcified cartilage is dead tissue, and it must be removed from the expanding ossification center. Macrophages invade the center of the calcified cartilage from the perivascular region of the periosteum. This cavitation (phagocytic) process creates spaces within the calcified cartilaginous mass, which become filled with capillaries and perivascular cells (Fig. 10-8, *D*). Many **periosteal buds** penetrate the model after the initial osteoclastic wave. One of these buds will become the **nutrient artery.**

Periosteal bud invasion results in **removal of calcified cartilage, neovascularization of the model,** and **repopulation of the model with appropriate stem cells.**

The essence of this ossification process is the formation of bone within cartilage. The osteoclastic removal of calcified cartilage creates spaces and new surfaces within the cartilaginous model. These surfaces are the ones upon which woven bone is deposited. **Bone replaces cartilage; cartilage is not converted into bone.** The bone formed on these surfaces at the periphery of the model is continuous with the collar bone around the model. The repopulation of the model with stem cells establishes the endosteal envelopes. The marrow cavity results from osteoclasia, and the development of myeloid tissue within it is integral to bone development.

Sleeve bone formation. Bone deposition at the periphery of the cartilaginous model results from the perichondrium's being converted into a periosteum. This has been described as intramembranous ossification. The first spicules of sleeve bone are from the newly formed periosteum. The new bone forms **upon** the chondral model within a vascularized environment. This is followed by bone apposition on preexisting bone. The difference between this pattern of ossification and intramembranous ossification is the use of cartilage for initial bone formation. It seems prudent to call this mechanism of sleeve bone formation **epichondral ossification.**

Continued growth—primary center. Chondrocytes continue to divide at the proximal and distal ends of the model, increasing bone length (Fig. 10-11). The periosteum adds new bone, so the diaphysis maintains a longitudinal relationship with the growing cartilage. Continued apposition of periosteal new bone also increases the diaphyseal diameter. The chondrocytes continue to mature, and their matrices ultimately calcify. **Capillary loops** with their pericapillary osteoclasts remove more cartilage and create new surfaces for bone formation (Fig. 10-12).

Matrix removal at the apex of the capillary loop is accomplished by mononucleated cells. Multinucleated giant cells are not observed often in these foci. The macrophages have not fused at this point in the process, but osteoclasts are apparent away from the advancing front of chondroclasia.

The chondrocytes are arranged into columns of isogenous groups. The chondroid material between each chondrocyte is a **transverse septum.** Successive removal of transverse septa results in confluence of contiguous chondrocytic lacunae. The remaining intercolumnar matrices, **longitudinal septa,** become the calcified cartilaginous surfaces for new woven bone deposition. The longitudinal septa appear as calcified cartilaginous spicules separated by spaces filled with capillary loops and perivascular cells. In actuality, the longitudinal septa are the tunnel walls upon which bone deposition occurs. (Imagine pushing a blunt object into a mass of clay until many holes are

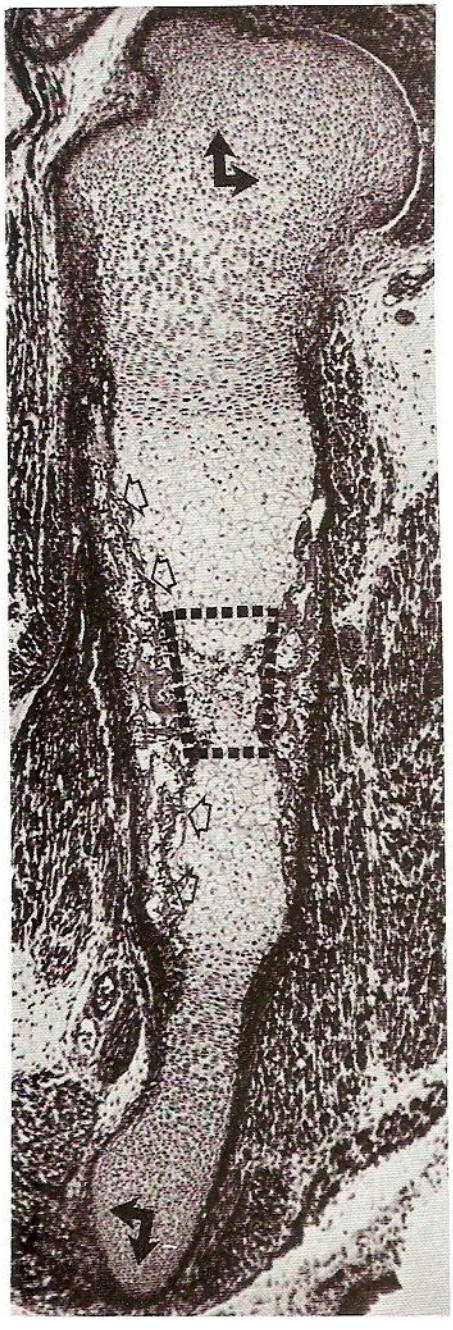

Figure 10-11. Progressive development of the primary ossification center of a fetal hamster humerus. The *outlined area* is the primary ossification center. Periosteum of the collar bone has developed *(open arrows)*. The bone continues to grow in the directions indicated *(solid arrows)*. (X7.)

separated by thin rims of clay. The tubular, clay-lined tunnels are analogous to the longitudinal septa and intervening spaces.)

Some bones develop from a single ossification center. In these instances the expanding osseous replacement reduces the growing cartilage to a zone beneath the articular cartilage. This zone of growth **(growth cartilage)** supplies new chondrocytes to the maturation sequence within the primary ossification center. Spicules of calcified cartilage and woven bone are used for lamellar bone deposition. The region of the ossification center containing these three tissues (calcified cartilage, woven bone, lamellar bone) is called the **primary spongiosa** (Fig. 10-13). Gradually, calcified cartilage, woven bone, and some lamellar bone are removed by osteoclasia and replaced totally by lamellar bone. The **secondary spongiosa** is the part of the ossification center consisting of spicules of lamellar bone.

In some bones trabeculae of the primary spongiosa extend from proximal growth cartilage through the marrow cavity to the distal growth cartilage. In these bones the secondary spongiosa expands longitudinally toward each growth cartilage. Upon cessation of growth, cancellous bone extends from both epiphyses through the marrow cavity. In other bones the secondary spongiosa is a narrow zone of lamellar bone, because osteoclasia removes all osseous trabeculae

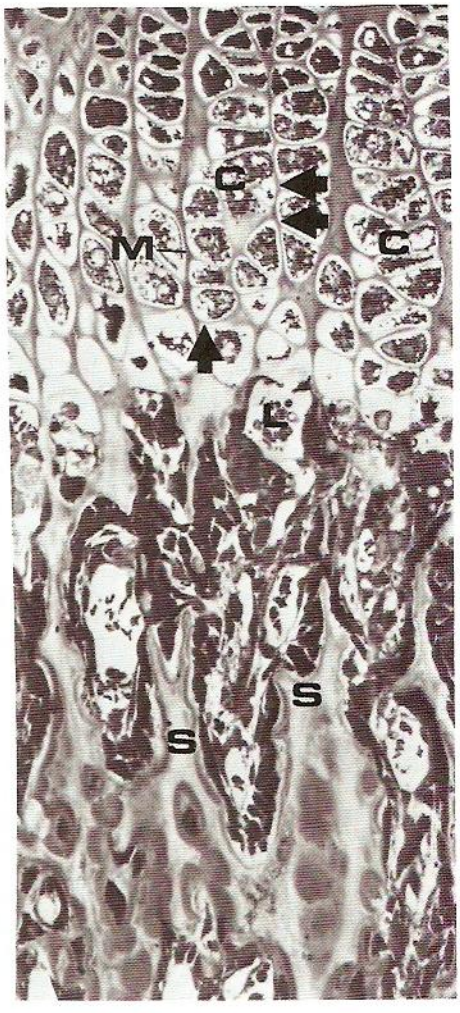

Figure 10-12. Removal of calcified cartilage within the primary ossification center of a murine femur. The chondrocytes *(C)* within their lacunae are separated from each other by thin rims of cartilaginous matrix *(M)*. Transverse septa *(arrow)* do not mineralize in most animals, although longitudinal septa *(double arrows)* do. Capillary loops *(L)* are surrounded by many perivascular cells. The lacunae are opened by osteoclasts, which remove the transverse septa. The contiguous lacunar surfaces and intervening matrix become the surfaces *(S)* or longitudinal septa upon which woven bone deposition occurs. (X160, plastic-embedded 1 μm section.)

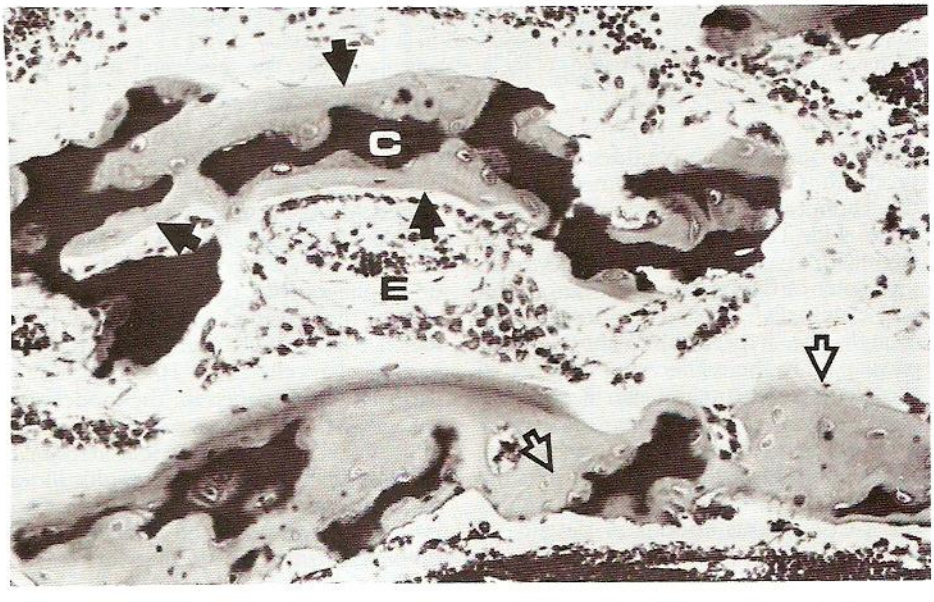

Figure 10-13. Tissues of the primary spongiosa. Spicules of bone contain cores of calcified cartilage *(C)*. Woven bone *(open arrows)* comprises the bulk of the osseous tissue. Lamellar bone formation is apparent upon the spicules *(solid arrows)*. Elements of the endosteum and myeloid tissue fill the interosseous spaces. (X40, aldehyde fuchsin.)

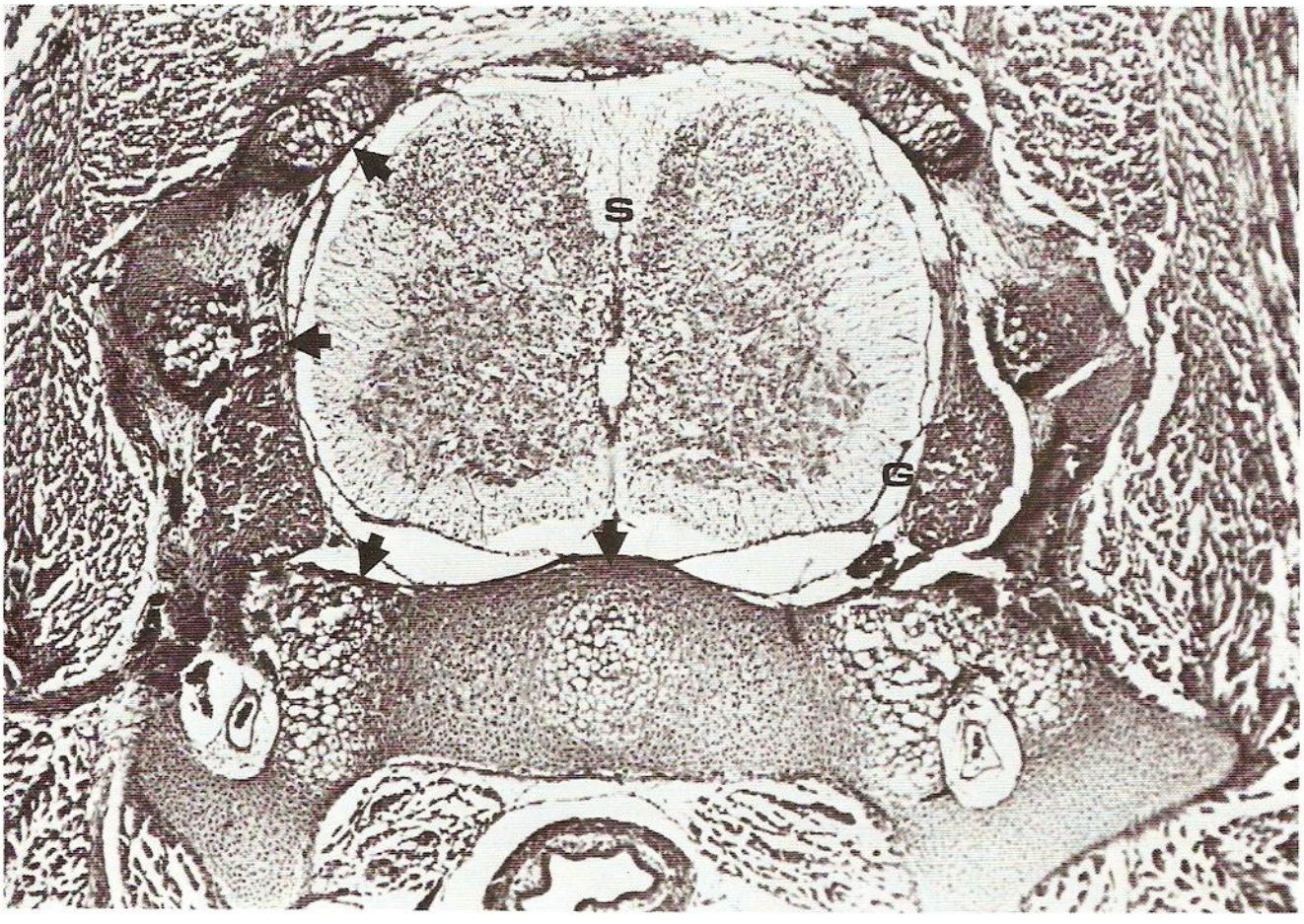

Figure 10-14. Developing cervical vertebra of a fetal hamster. Many ossification centers *(arrows)* characterize this irregular bone. The developing spinal cord and a dorsal root ganglion *(G)* are apparent within the spinal canal. (X10.)

from the marrow cavity. Upon cessation of growth, the secondary spongiosa is confined to the proximal and distal epiphyses as trabecular bone, and the marrow cavity is devoid of bone.

While progressive elongation has been occurring, the periosteum has been increasing the length and diameter of the organ. The increasing bone diameter accompanies an increased marrow cavity diameter. Simultaneously the trabecular endosteum forms bone at the point of **metaphyseal osseous replacement** and removes bone if the marrow cavity is to be hollow.

Model growth

Secondary ossification centers. Most long bones have at least three ossification centers. Whereas the primary ossification center forms the diaphysis, the **secondary (proximal and distal) ossification centers** form the proximal and distal epiphyses (Fig. 10-8, *D* and *E*). All ossification centers developing subsequent to the primary ossification center are secondary centers. Irregularly shaped bones have numerous ossification centers, each one responsible (generally) for a single irregularity (Fig. 10-14). Each secondary ossification center is the development center for "separate bones," fusing secondarily with the primary ossification center to form the definitive bone. Sometimes fusion does not occur. **Elbow dysplasia,** for example, can result from the nonunion of the anconeal ossification center **(ununited anconeal process)** with the rest of the ulna.

Some temporal and spatial relationships within the secondary centers differ from those within the primary centers. At some point branches from epiphyseal vessels either actively invade or are incorporated into the cartilage of the presumptive epiphyses. These vessels occur within a network of tunnels, called **cartilage canals** (Fig. 10-15), that contain arterioles and venules connected by a terminal glomerulus ensheathed in perivascular connective tissue.

The periglomerular cartilaginous matrix undergoes calcification. Osteoclasts and their precursor macrophages initiate calcified cartilage removal. The margins of the spaces formed serve as surfaces for woven bone formation. Continued radial chondroclasia and complementary osteogenesis occur within the coalescing marrow cavity of the secondary ossification center. Myeloid tissue also develops within this center.

The morphological features and timing sequence of secondary ossification center events are a variation of diaphyseal ossification center events. The cascade of events following vascular invasion is postponed, presumably until the appropriate stimulation occurs. Despite these differences, an ossification center forms. This new ossification center defines the growing limits of the epiphyseal cartilage and delimits a band of cartilage between the primary and secondary ossification centers (Fig. 10-16). The formation of this band or **growth plate** is a consequence of secondary ossification center formation.

Growth plates. Cartilage of the model is reduced to the articular surface and to a plate between the forming bone of the epiphyseal and diaphyseal centers (Fig. 10-17). This cartilaginous plate is called the **growth plate (physis).**

Cartilage is added to the secondary ossification center by interstitial growth from the subarticular growth cartilage and the epiphyseal side of the growth plate. These zones of proliferative cells continue with each other at the periphery

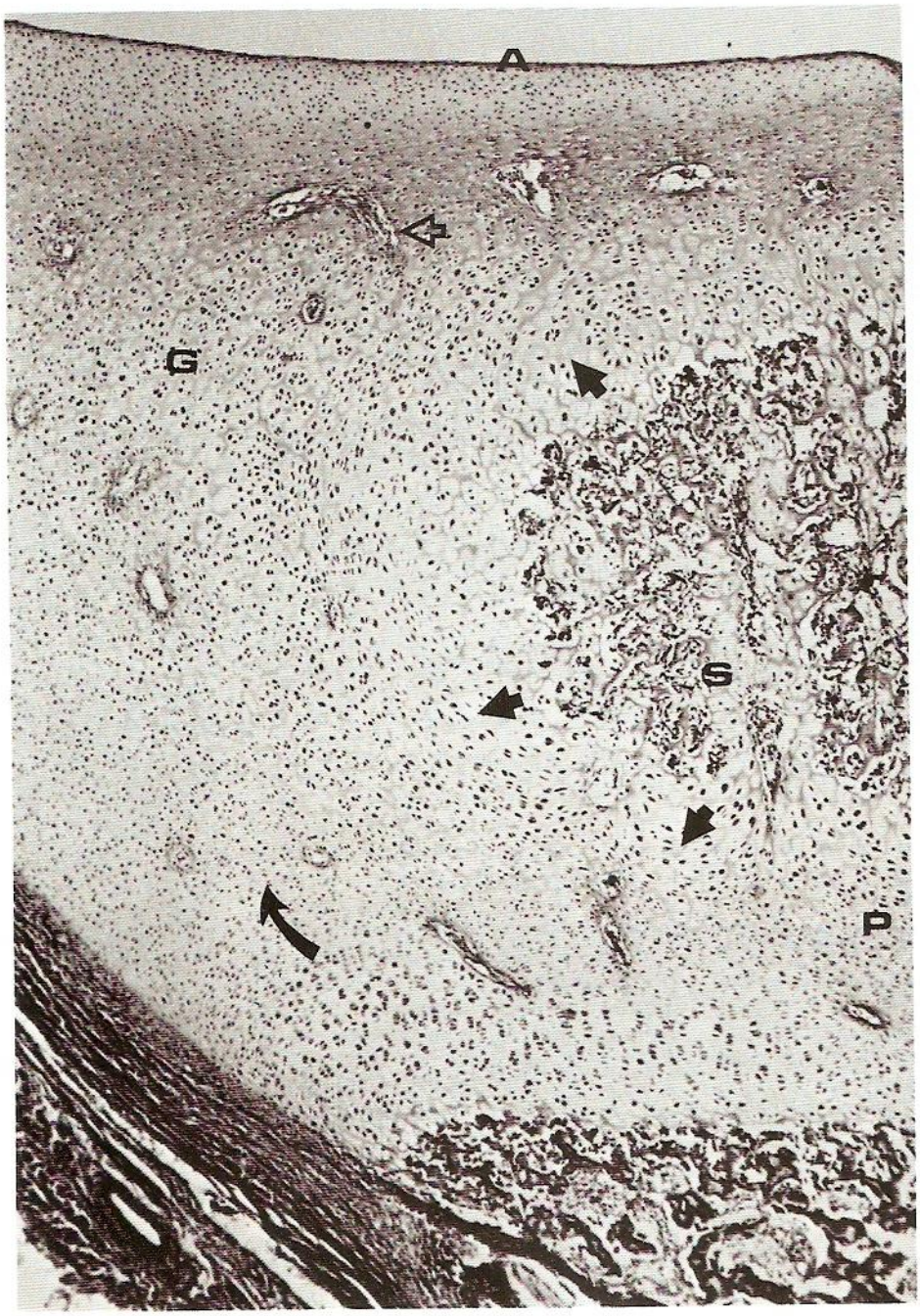

Figure 10-15. Longitudinal section through a developing secondary ossification center. The cartilage of the epiphysis includes the articular cartilage *(A)*, growing cartilage *(G)*, and presumptive growth plate cartilage *(P)*. The continuity of the growth plate cartilage *(curved arrows)* with the articular cartilage often is maintained throughout development. The secondary ossification center expands progressively *(solid arrows)*, reducing the epiphyseal and growth plate cartilage to narrow zones. The *open arrow* points to a cartilage canal. The band of cartilage beyond the extent of the cartilage canals is destined to become articular cartilage. (X10.)

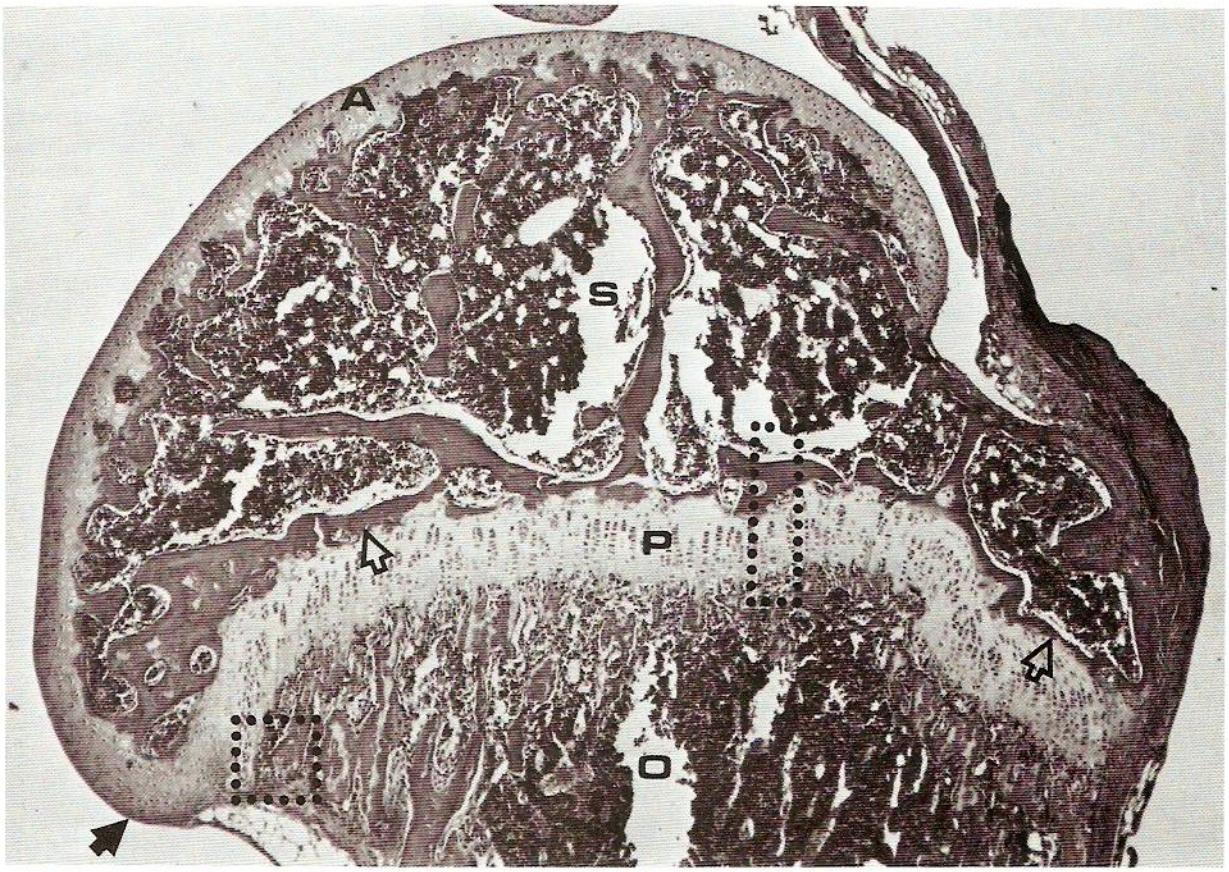

Figure 10-16. Ossification centers and growth plate of the proximal humerus of a growing gerbil. The growth plate *(P)* separates the primary *(O)* from the secondary *(S)* ossification center and is continuous with the articular cartilage *(arrow)*. Spicules of bone, calcified cartilage, and myeloid tissue fill both ossification centers. The spaces are artifacts of sectioning. The endplate *(open arrows)* resides upon the proximal margin of the physis. The presence of the endplate indicates that the growth plate no longer contributes to formation of the epiphysis. Rather, continued growth and expansion of the secondary ossification center depend upon growing cartilage deep to the articular cartilage. The *square area* is the union of the diaphysis with the growth plate. The *rectangular area* is represented in Figures 10-17 and 10-22. Compare with Plate IV, *10*. (X10.)

of the epiphyseal cartilage. The proliferative zone of the growth plate adds new cartilage cells to the diaphyseal and epiphyseal ossification centers simultaneously for a variable but short amount of time. Eventually, **epiphyseal osseous replacement** adjacent to the growth plate overrides the proliferative capacity of the cartilage on this side of the growth plate. An **endplate** of epiphyseal bone forms next to the cartilage (Figs. 10-9 and 10-16)—with two direct consequences:

1. The growth and shaping of the epiphysis become the exclusive function of the epiphyseal subarticular growth cartilage.
2. The growth plate contributes only cartilage to the diaphyseal (primary) ossification center.

The formation of the growth plate occurs as a consequence of secondary ossification center formation (Figs. 10-8, *E* and *F*, 10-15, and 10-17). Continued diaphyseal elongation results from growth plate interstitial growth. Mitotic activity within the growth plate constantly adds new cells and moves the epiphysis further from the center of the diaphysis. This tends to thicken the growth plate, although the plate maintains a relatively constant thickness throughout its existence. The thickness is maintained because the proliferative rate of reserve chondrocytes equals the rate of metaphyseal osseous replacement. Accordingly, diaphyseal elongation coincides with growth plate movement through space. Growth stops and the growth plate becomes thinner and closes when the cartilage proliferative rate is exceeded by the rate of metaphyseal osseous replacement. Growth plates close at different times in different bones in different species. Closure times for specific growth plates in specific bones of a given species occur at a given time. Metaphyseal trabecular bone continues through the plate to the epiphyseal trabecular bone (Fig. 10-8, *F* and *G*).

Zones of the growth plate. The organization of the growth plate is similar to the ossification center before plate formation. Events within the plate are identical to those of the primary ossification center. Growth plates are the proximal and distal limits of the expanding primary ossification center.

Five zones occur within the growth plate (Figs. 10-17 and 10-18).

The **zone of resting chondrocytes** is next to the epiphyseal endplate. These nondividing cells seem to weld the growth plate to the epiphysis.

The **zone of proliferative chondrocytes** consists of thin, wedge-shaped, actively mitotic cells. The stacks of cells provide for elongation by adding new cells to the plate.

In the **zone of maturing chondrocytes** cell and lacunar size increase progressively, and lacunae become more round than in the proliferative and resting zones. The cells are in columns.

The **zone of hypertrophied chondrocytes** is a narrow region adjacent to the maturation zone. The cells are large, and the intercellular substance is reduced. Transverse septa are thin. Longitudinal septa eventually undergo calcification. This zone is the weakest region of the growth plate. Fracture of a growth plate **(epiphysiolysis)** generally occurs through this zone.

The **zone of calcified cartilage** consists of cells whose matrix has undergone cal-

Downloaded From Vet-eBooks.com

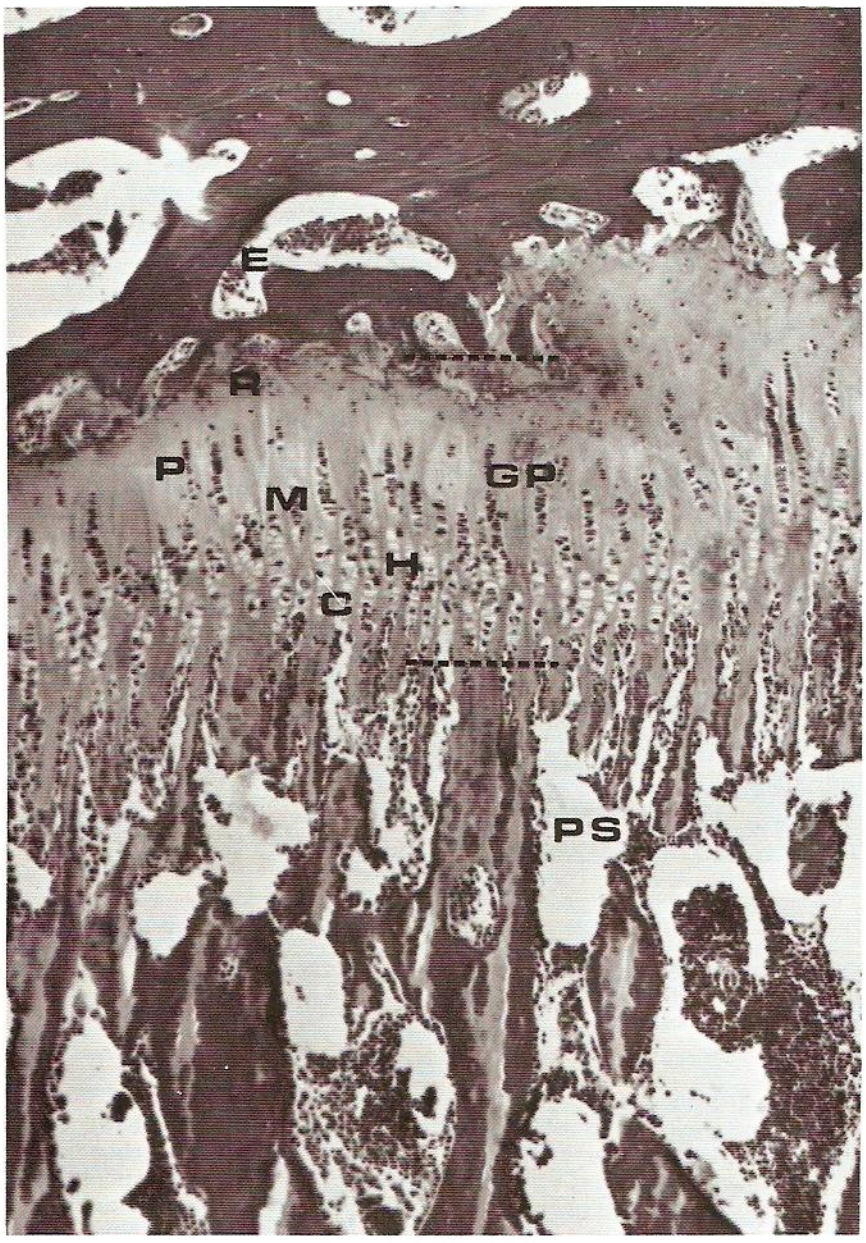

Figure 10-17. Micrograph of a definitive growth plate. The endplate *(E)* has formed on the epiphyseal side of the growth plate, thus ending the physeal contribution to the shape and growth of the epiphysis. The approximate limits of the growth plate *(GP)* are indicated by the *dashed lines*. The growth plate maintains a relatively constant thickness until closure begins. The cells within are columnated and divisible into distinct yet related groups or zones. *R,* Reserve or resting chondrocytes; *P,* proliferative chondrocytes; *M,* maturing chondrocytes; *H,* hypertrophied chondrocytes; *C,* zone of calcified cartilage. The primary spongiosa *(PS)* is just below the physis. (X50.)

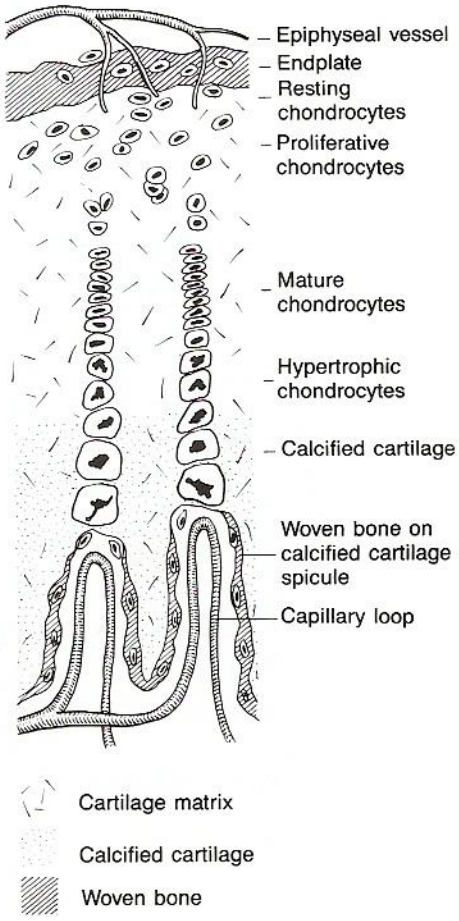

Figure 10-18. Physis. The morphological features are labeled. Compare this with Figure 10-17.

cification. Calcification is usually confined to longitudinal septa, but portions of or all transverse septa may also be mineralized in some species.

Perivascular cells of the capillary loops in the zone of calcified cartilage remove the transverse septa (Fig. 10-19). Chondrocytic lacunae become confluent, and their contiguous surfaces are used for woven bone deposition. These surfaces actually are the longitudinal septa. In longitudinal section they appear as fingerlike projections into the metaphysis (Plate I, *8*). In actuality, they are tunnels (Fig. 10-20).

The relationships of the primary and secondary spongiosa to the growth plate are identical to those of the primary ossification center (Fig. 10-23).

Modeling activity

These activities combine to produce the definitive shapes characteristic of bones. Modeling and remodeling activities complement each other.

Diaphyseal growth. The attainment of definitive length is a growth plate function. Although some length occurs before plate formation, the majority of length results from interstitial growth of plate cartilage.

The continual apposition of bone by the periosteum increases the diaphyseal diameter (Fig. 10-21). The increased outside diameter accompanies an increased marrow cavity diameter. To accomplish this, the periosteum forms bone while the cortical endosteum removes bone. The net effect is that the cortical compacta becomes a periosteal derivative.

The marrow cavity of most long bones is filled with myeloid tissue, but bone is sparse. The primary and secondary spongiosa is removed during development. Metaphyseal osseous replacement occurs within the primary spongiosa by the trabecular endosteal envelope. The same envelope removes calcified cartilage and woven bone and adds lamellar bone. Ultimately, lamellar bone totally replaces the temporary tissues within the secondary spongiosa. In a typical long bone the secondary spongiosa is difficult to observe, because trabecular endosteal osteoclasia removes these spicules (resulting in a marrow cavity devoid of bone).

Downloaded From Vet-eBooks.com

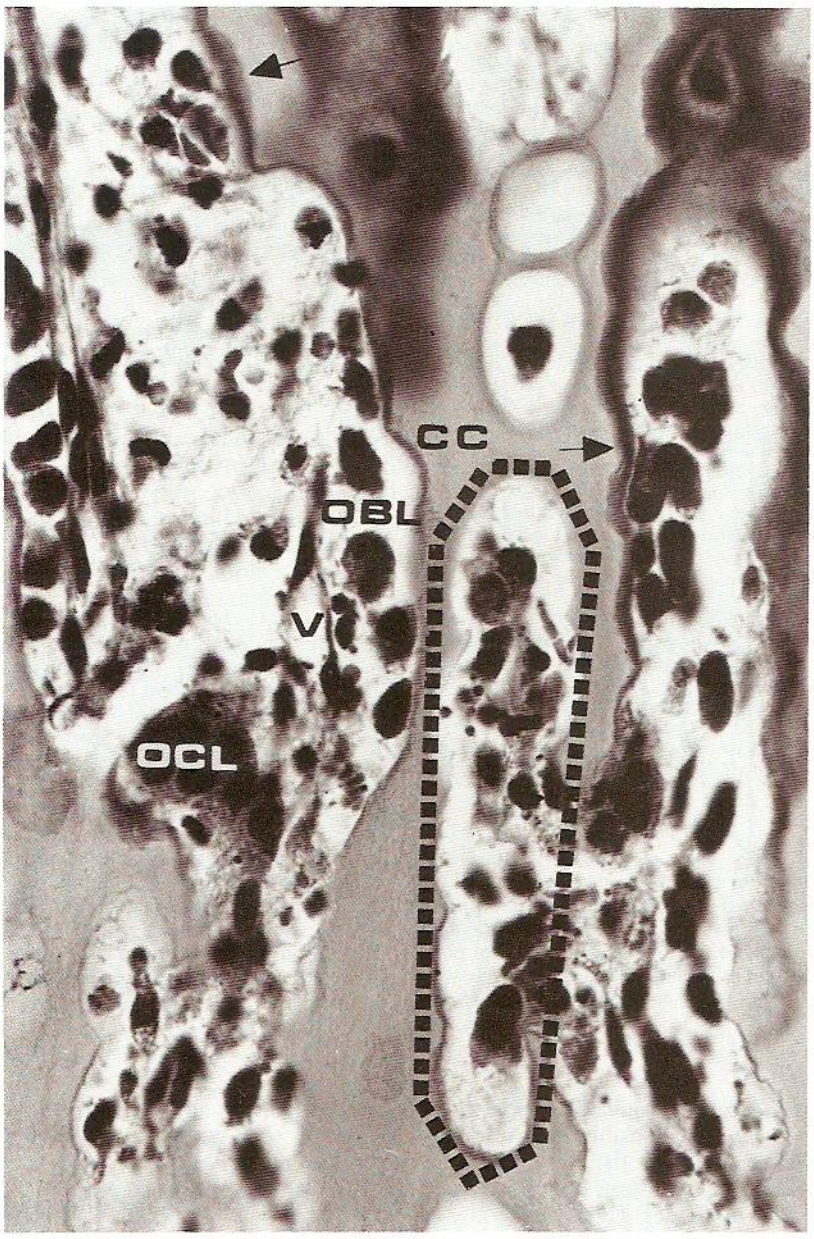

Figure 10-19. Osteoblastic and osteoclastic activity adjacent to the growth plate. Confluent lacunae and their remaining longitudinal septa *(outlined region)* are the surfaces upon which osteoblasts *(OBL)* deposit woven bone *(arrows)*. Osteoblasts and osteoclasts *(OCL)* comprise a major portion of the perivascular cell populations associated with numerous vascular loops *(V)*. (X160.)

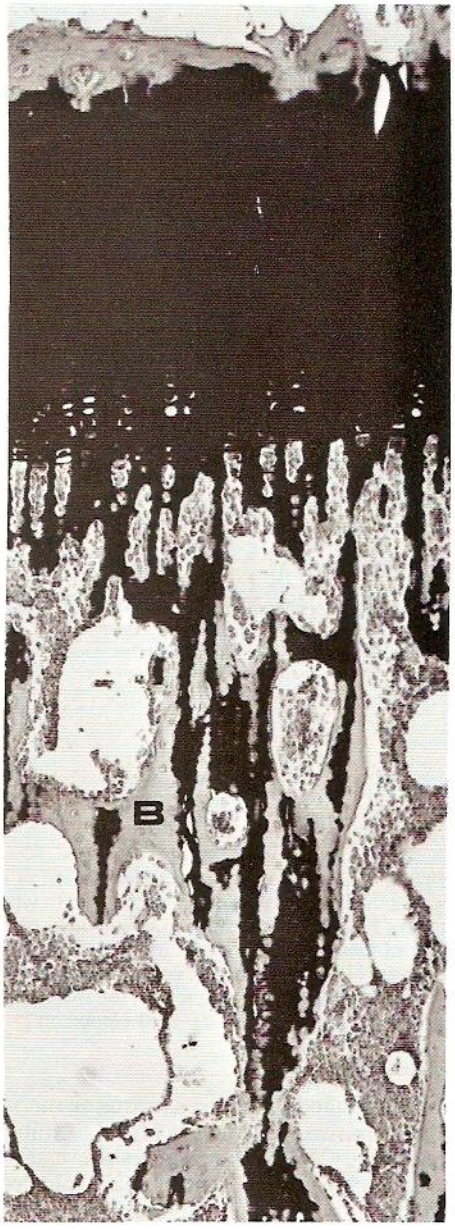

Figure 10-20. Growth plate and primary spongiosa. Fingerlike projections of dark-stained material, (calcified cartilage) extend from the growth plate into the primary spongiosa. The progressive deposition of bone *(B)* is coupled with the continual removal of calcified cartilage. (X16, aldehyde fuchsin.)

The differential activity of these envelopes during growth is one reason the envelopes are distinguishable from each other functionally. The periosteum forms bones while the cortical endosteum removes bone. The trabecular endosteum of the primary spongiosa forms bone while the same envelope within the secondary spongiosa removes bone to form a hollow marrow cavity.

The periphery of the growth plate joins the cylindrical diaphysis by the spicules of bone covering the cores of calcified cartilage. This margin is the only point of contact and union between these two structures. As new bone is deposited

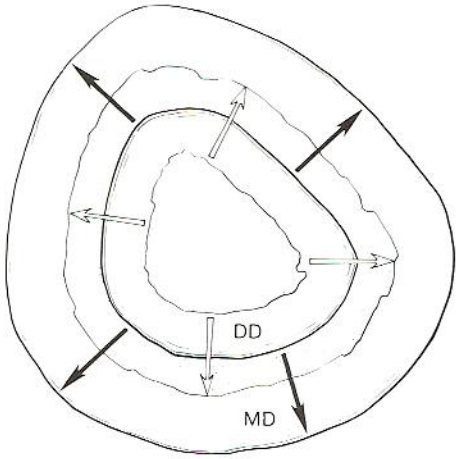

Figure 10-21. Latitudinal movement of the diaphysis during growth. The developing diaphysis *(DD)* grows in width through osteogenic activity of the periosteum *(solid arrows)*. As periosteal bone is added, the cortical endosteum removes bone via osteoclastic activity *(open arrows)*. The net result is a diaphysis with both an increased diameter and an increased marrow cavity diameter (*MD*, mature diaphysis). Also, these related activities cause most of the diaphysis of a long bone to be derived from the periosteum.

Downloaded From Vet-eBooks.com

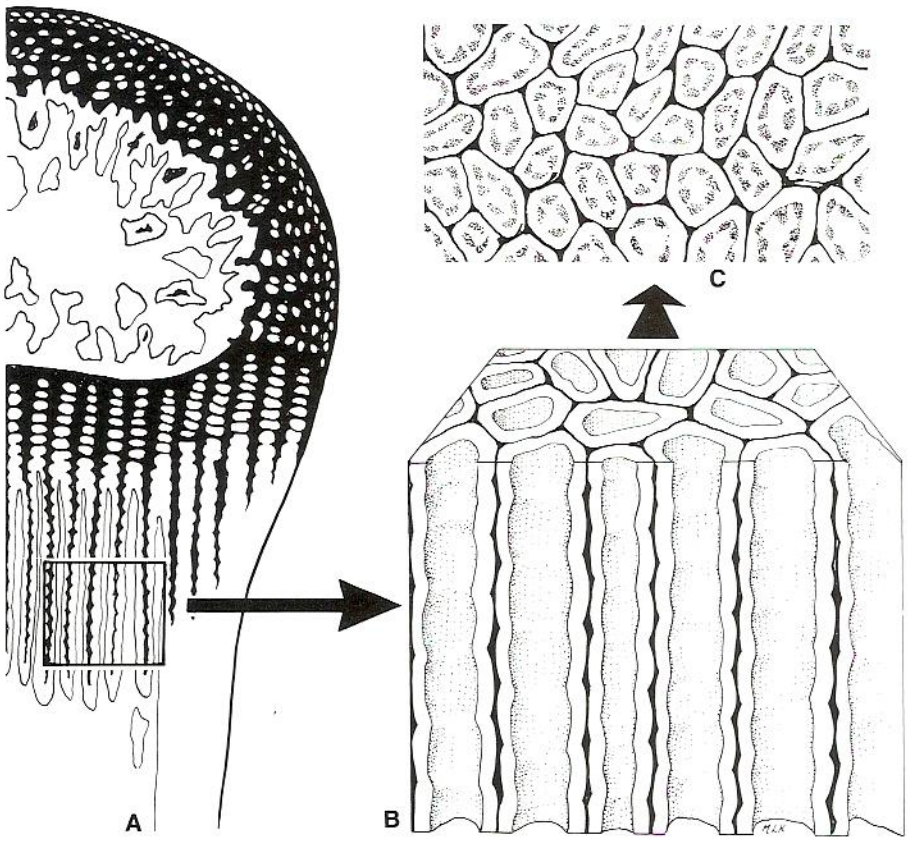

Figure 10-22. Morphological relationships of components of the primary spongiosa. The retained longitudinal septa of calcified cartilage with woven bone deposited on their surfaces appear as spicules or fingerlike projections in longitudinal section, **A.** The spicules are actually the peripheral margins of tunnels when viewed in three dimensions, **B.** The walls of the tunnels are formed of bone deposited upon a peripheral core of calcified cartilage. The tunnels become filled progressively with bone at their points of union with the diaphysis, **C.** (Redrawn and modified from Ham AW: *Histology*, ed 7, Philadelphia, 1974, JB Lippincott.)

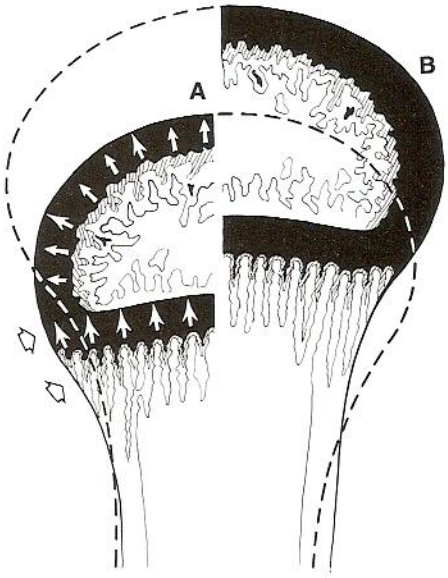

Figure 10-23. Modeling of epiphyses. The epiphyses of long bones are generally larger than the diaphyses. The growth plate and growth cartilage subjacent to the articular cartilage are responsible for longitudinal movement of the epiphyses through space. Interstitial growth of these components *(white arrows)* moves the epiphyses and articular surface from *A* to *B*. The epiphyseal flaring is accomplished by bone being resorbed by periosteal osteoclasts *(open arrows)*, while deposition along the inner surface of the bone is accomplished via the trabecular endosteum associated with the tunnels of the primary spongiosa that are continuous with the diaphysis. (Redrawn and modified from Ham AW: *Histology*, ed 7, Philadelphia, 1974, JB Lippincott.)

upon calcified cartilage, osseous tissue is also deposited on spicules of the forming diaphysis. The two structures are essentially welded to each other. The spicules of bone, which in reality are tunnels of bone, are the surfaces upon which layers of bone are deposited (Fig. 10-22). This also provides osseous continuity between the growth plate and diaphysis.

Epiphyseal growth. The epiphysis of a long bone is the part developing from an ossification center distinct from the shaft (Fig. 10-15). Furthermore, it is initially separated from the shaft by a growth plate. In adults an epiphysis consists of bone covered by articular cartilage. During development three distinct cartilaginous zones are apparent within the **chondroepiphysis.** The **presumptive articular cartilage** has a superficial maturing zone and a mitotically active zone positioned deep. An **acidophilic cartilage** zone is subjacent to the presumptive articular cartilage zone. The acidophilic cartilage is underlaid by the **growth cartilage** feeding chondrocytes into the endochondral ossification process of the epiphysis. A zone of mitotically active cells is peripheral to a deep maturing zone. The activity of these zones is responsible for the definitive characteristics of the adult epiphysis.

The epiphyses of long bones are larger than the diaphyses (Fig. 10-23). The epiphyses and metaphyses have a distinct flare. After formation of the epiphyseal endplate, growth of the epiphysis occurs independently of events transpiring within the diaphyseal ossification center. The growth cartilage subjacent to the articular cartilage supports the expanding epiphysis. Naturally, the growing diaphysis must maintain a proper relationship with the enlarged epiphysis. This occurs by selected modeling activities in the metaphysis. During growth, bone is resorbed on the periosteal side of the metaphysis; it is added to the metaphyseal trabeculae (tunnels), which join the endosteal side of the diaphysis. This facilitates the characteristic flaring.

Perichondral ring. The point of transition between the periosteum and articular cartilage is the **perichondral ring.** This ring of perichondrium covers the periphery of the growth plate. It thus supports the latitudinal expansion of the growth plate through appositional growth to maintain pace with the expanding diaphysis and epiphysis.

Hormones and bone development

Specific hormones and effects. Differentiation, mitosis, carbohydrate synthesis and secretion, protein synthesis and secretion, Ca^{++} metabolism, and phagocytosis are essential cell activities of connective, cartilaginous, osseous, and vascular tissues during development. These activities are influenced by many factors.

The effects of **estrogens** upon endochondral ossification are diverse, complex, and species-specific. Generally the estrogens inhibit linear growth by favoring growth plate closure by accelerating metaphyseal osseous replacement and inhibiting proliferative chondrocytes. **Testosterone** exerts an effect similar to the estrogens. Skeletal maturation depends upon the presence of this hormone, because it favors bone formation. Its presence is important for normal growth plate closure.

Excessive **glucocorticoids** inhibit skeletal growth and retard the development of

Downloaded From Free-Books.com

secondary ossification centers. A decreased proliferation and chondrocytic hypertrophy is a consistent developmental problem with excessive glucocorticoids. This phenomenon is mediated through the inhibitory effects of glucocorticosteroids upon protein synthesis. Osteoblastic activity within the primary and secondary spongiosa is also reduced. Similarly glucocorticoids decrease periosteal and endosteal osteoblastic activity of growing bones.

Growth hormone mediates its effect upon the growing skeleton by regulating the mitotic rate of proliferative chondrocytes. Excess growth hormone before growth plate closure results in **pituitary gigantism.** After growth plate closure, excesses result in pronounced periosteal new bone formation, called **acromegaly.**

Although the **thyroid hormones** (T_3 and T_4) affect the metabolic activity of most cells, their effects upon the developing skeleton are manifested primarily in the cartilage. **Thyroxine** (T_4) is necessary for chondrocytic proliferation and maturation. It also affects the proliferation and modulation of osteogenic cells of the primary and secondary spongiosa.

ADDITIONAL READINGS

Anderson CE, Parker J: Electron microscopy of the epiphyseal cartilage plate, *Clin Orthop* 58:225, 1968.

Ascenzi A, Bendetti L: An electron microscope study of the foetal membranous ossification, *Acta Anat* 37:370, 1962.

Bassett AL: Current concepts of bone formation, *J Bone Joint Surg* 44A:1217, 1962.

Bonucci E: Fine structure of early cartilage calcification, *J Ultrastruct Res* 20:33, 1967.

Boskey AL: Current concepts of the physiology and biochemistry of calcification, *Clin Orthop* 157:225, 1981.

Bridges CH, Moffitt PG: Influence of variable content of dietary zinc on copper metabolism of weanling foals, *Am J Vet Res* 51(2):275, 1990.

Brighton CT: Structure and function of the growth plate, *Clin Orthop* 136:22, 1978.

Brookes M: Cortical vascularization and growth in foetal trabecular bones, *J Anat* 97:597, 1963.

Clark ER, Clark EL: Microscopic observations on new formation of cartilage and bone in the living animal, *Am J Anat* 70:167, 1942.

Crelin E, Koch W: An autoradiographic study of chondrocytic transformation into chondroclasts and osteocytes during bone formation in vitro, *Anat Rec* 158:473, 1967.

Farnum CE, Wilsman NJ: The pericellular matrix of growth plate chondrocytes: A study using post-fixation with osmium ferrocyanide, *J Histochem Cytochem* 31:765.

Frost HM: Tetracycline-based histological analysis of bone remodeling, *Calcif Tiss Res* 3:211, 1969.

Frost HM: *Bone remodeling and skeletal modeling errors,* Springfield Ill, 1973, Charles C Thomas.

Haines R: Cartilage canals, *J Anat* 68:45, 1933.

Holtrop ME: The ultrastructure of the epiphyseal plate. II. The hypertrophic chondrocyte, *Calcif Tiss Res* 9:140, 1972.

Kincaid SA, Van Sickle DC: Bone morphology and postnatal osteogenesis: potential for disease, *Vet Clin North Am* 13:3, 1983.

Kuettner KE, et al: Lysozyme in epiphyseal cartilage, *J Cell Biol* 44:329, 1970.

Matthews JL, et al: Calcium incorporation in the developing cartilaginous epiphysis, *Calcif Tiss Res* 1:33, 1968.

Odegaard J: Growth of the mandible studied with the aid of metallic implants, *Am J Orthop* 57:145, 1970.

Schenk RK, Spiro D, Wiener J: Cartilage resorption in the tibial epiphyseal plate of growing rats, *J Cell Biol* 34:275, 1967.

Schenk RK, Weiner J, Spiro D: Fine structural aspects of vascular invasion of the tibial epiphyseal plate of growing rats, *Acta Anat* 69:1, 1968.

Scherft JP: The ultrastructure of the organix matrix of calcified cartilage and bone in embryonic mouse radii, *J Ultrastruct Res* 23:333, 1968.

Simmons DJ (ed): *Nutrition and bone development,* New York, 1990, Oxford University Press.

Weinmann JP, Sicher H: *Bone and bones,* St Louis, 1955, CV Mosby.

Wilsman NJ, et al: Morphological evidence of a functional heterogeneity among physeal chondrocytes in growing swine, *Am J Vet Res* 42:1547, 1981.

Young RW: Cell proliferation and specialization during endochondral osteogenesis in young rats, *J Cell Biol* 14:357, 1962.

Downloaded From Vet-eBooks.com

CHAPTER 11

Blood

PERIPHERAL BLOOD

General Characteristics

Blood consists of a fluid matrix and many cells (Table 11-1). A fibrous component **(fibrin)** is also present during blood clotting.

The fluid phase (matrix) is called **plasma.** Various cells and/or cell fragments are suspended within it. Upon removal of **fibrinogen** and **fibrin,** the remaining fluid is **serum.**

Blood has many functions. Oxygen and carbon dioxide **transport** complements pulmonary (external) and cell (internal) respiration. Several **buffer systems** occur in blood—carbonates, phosphates, hemoglobin, proteins. All food substances must pass through the blood; thus blood provides **nutrition.** An **excretory** function is obvious, through metabolic waste product removal. The **maintenance of the fluid volume** occurs by balancing the blood-vascular, tissue, cell, and lymphatic fluids. This fluid volume supports **heat regulation.** The transport of hormones involves blood in **regulatory** functions. The blood affords **protection** through its cells and suspended materials (antibodies, antitoxins, etc.).

Plasma. **Plasma** is the straw-colored and transparent fluid matrix of blood. It is apparent when a blood sample with anticoagulant added has been centrifuged or the formed elements have been allowed to settle to the bottom of a collection vial. It comprises 35% to 50%, but many factors (age, degree of hydration, disease, athletic conditioning) can affect this percentage.

Plasma is 90% water and 10% dissolved substances and solids. Inorganic ions (Na^+, K^+, Cl^-, HCO_3^-, Ca^{++}, etc.) are about 1% of the plasma. Plasma proteins (albumins, globulins, fibrinogen) comprise about 7% of the total plasma. Other organic substances (urea, uric acid, amino acids, fatty acids, glycerol, etc.) constitute 1%. Plasma normally contains some hormones, enzymes, pigments, vitamins, and dissolved gases.

Many characteristics of plasma relate to its protein components, which maintain intravascular colloid osmotic pressure, transport various plasma constituents (hormones, waste products), the clotting mechanism, and protection by humoral antibodies (immunoglobulins). Electrophoretic separations are used commonly to characterize plasma or serum proteins. Such characterizations demonstrate plasma proteins consisting of albumin, α-globulins (α_1, α_2), β-globulins (β_1, β_2), γ-globulins, and fibrinogen. The globulin components are subject to species variations.

The liver produces albumin, fibrinogen, and about three-quarters of the globulins. The remaining globulins are produced by lymphatic cells. Plasma is the immediate source of proteins when tissue proteins are depleted. Plasma proteins in the tissue fluid space are imbibed by macrophages via pinocytosis. The proteins are digested into their constituent amino acids, secreted, and used locally or transported to the blood for distribution. The available amino acids in the blood is in equilibrium with circulating plasma proteins and tissue proteins.

Albumin is a small protein with a molecular weight of about 70,000 daltons. It accounts for nearly half the total plasma protein and nearly 70% of the intravascular osmotic pressure. Albumin contributes to the concentration gradient between blood and extracellular fluid. It also binds and transports hormones (thyroxine), metabolites (bilirubin), and drugs (barbiturates).

The **α-globulins** contribute to intravascular osmotic pressure and are carrier molecules: copper by **ceruloplasmin,** hemoglobin by **haptoglobin,** thyroxine by **thyroxine binding globulin,** cortisol by **transcortin.** Lipoproteins of this fraction also transport triglycerides, fatty acids, vitamins, and other substances. This fraction also contains cholinesterase, alkaline phosphatase, lactic dehydrogenase, and factors involved in coagulation (Factors V, IX, and X).

The **β-globulins** contribute to osmotic pressure and are also transport molecules; iron is transported by **transferrin** and hemin by **hemopexin.** Lipoproteins, complement, fibrinogen, and coagulation factors (VII, VIII) are present also.

The **γ-globulins** consist of the immunoglobulins (Chapter 17), blood group globulins, and the cryoglobulins.

The subsequent descriptions are based upon Wright's or Giemsa staining.

Mammalian Blood Cells

Erythrocytes

Form and function. **Erythrocytes** are also called **red blood cells (RBCs), red blood corpuscles,** and **rubricytes.** They are anucleated, biconcave, round disc in most mammalian species (Fig. 11-1), oval in the Camelidae (camel, dromedary, llama, and alpaca). The diameter range is 3.5 to 7.5 μm.

The biconcavity may be apparent in smear preparations because of differential light transmission from the periphery to the center (Figs. 11-2 and 11-3). RBCs may swell in hypotonic media and shrink in hypertonic media. They are pink in sections stained by routine procedures. Within the capillary beds and larger vessels, and even as extravasated blood, they may stack upon each other in a typical **rouleau** formation. This formation indicates how they move through capillaries. The occurrence of RBCs outside the vascular bed is usually a preparation artifact in normal tissues.

RBCs are modified to carry oxygen to tissues (as **oxyhemoglobin**) and to carry some carbon dioxide away from tissues (as **carboxyhemoglobin**). Most cell organelles (nucleus, Golgi, mitochondria, etc.) are lost during differentiation, and the bulk of the RBC is **hemoglobin.** The structural modification as a biconcave disk facilitates movement of RBCs through capillary beds (Fig. 11-4).

Erythrocytic variants. Many RBC structural variations occur. Some result from improper sample processing; others from disease processes. Some morphological changes cannot be explained. During the examination of blood smears from different species, many of the following changes may be observed:

1. Erythrocytic variants occur in blood during **anemias.** A **regenerative anemia** occurs when the bone marrow attempts to produce new RBCs to compensate for those lost. In a **nonregenerative anemia** the bone marrow is not responsive to peripheral RBC needs.
2. Immature RBCs, normally confined to the bone marrow, may access the peripheral circulation. One of these immature forms is a **metarubricyte** (Fig. 11-5). Normally RBC nuclei

Downloaded From Vet-Books.com

Table 11-1. Blood Parameters of Selected Domestic and Laboratory Species*

	Parameter Packed Cell Vol (PCV) (%)	Hb (gm/100 ml)	RBC ($\times 10^6$/ml)	Total Protein†	Platelets ($\times 10^3$/ml)	MCV‡ ($\times 10^{-15}$L)	RBC (μm)	MCHC (g/dl)	M/E	WBC ($\times 10^3$/ml)
Dog	45	15	6.8	6.0-7.5	550	70	7.0	34	1.2	11.5
Cat	37	12	7.5	6.0-7.5	450	45	5.9	33	1.6	12.5
Horse	42	15	9.5	6.0-8.0	330	46	5.4	35	1.6	9.0
Ox	35	11	7.0	6.0-8.0	500	52	5.7	33	0.7	8.0
Sheep	38	12	12.0	6.0-7.5	400	33	4.5	34	1.1	8.0
Goat	35	10	13.0	6.0-7.5	450	27	4.1	32	0.7	9.0
Pig	42	13	6.5	6.0-7.0	520	63	6.0	32	1.8	16.0
Rabbit	48	12	5.6	6.0-7.2	500	61	6.8	32	1.0	7.9
Rat	45	15	8.5	6.1-7.1	532	60	6.9	32	1.6	11.5
Guinea pig	40	14.5	5.6	5.1-6.3	500	65	7.5	30	1.5	10.8
Domestic fowl	36	10.3	2.8	4.0-5.2	27.6	127	10.7 × 7.1	29		16.6

*These average parameters vary with age, sex, strain, and breed of animal.
†Range of values.
‡*MCV*, Mean corpuscular volume; *MCHC*, mean corpuscular hemoglobin concentration; *M/E*, myeloid/erythroid ratio.

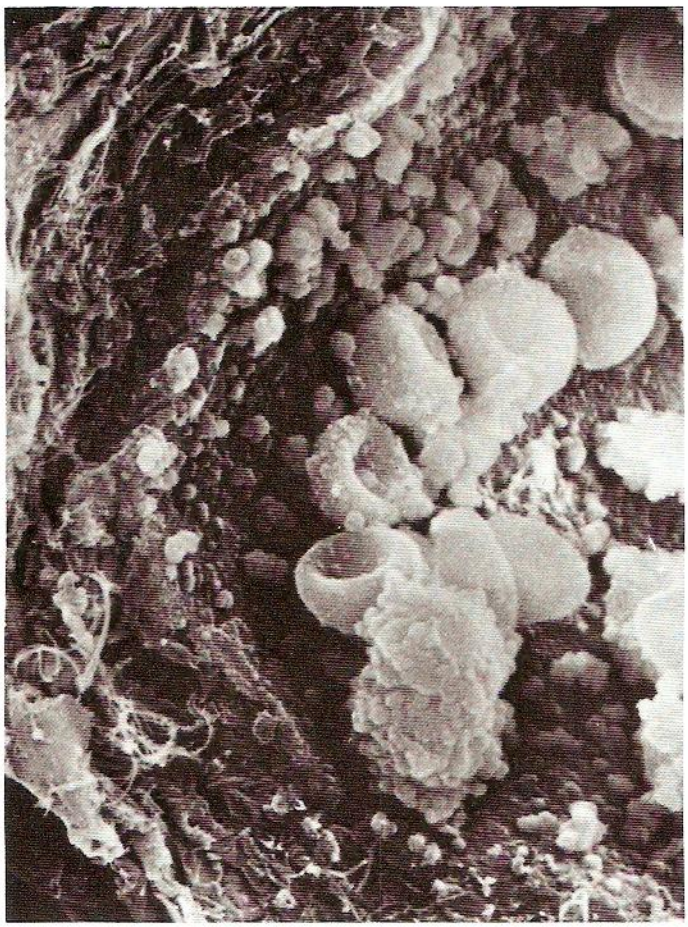

Figure 11-1. Scanning electron micrograph of canine erythrocytes. The freeze fractured sample is from the testis. The large, globular structure with numerous processes is a white blood cell. Note the central depression in the erythrocytes. Some of the erythrocytes are bowl-shaped. (X4000.) (Courtesy C. J. Connell.)

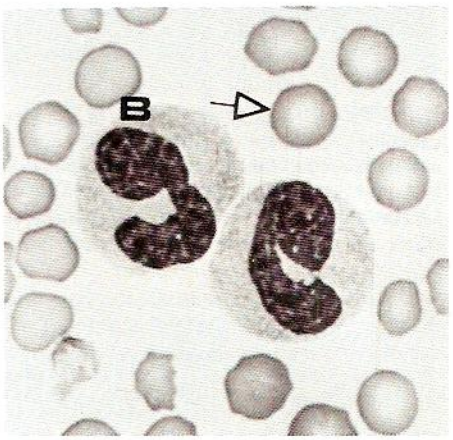

Figure 11-2. Feline peripheral blood smear. The large cells in the center of the field are immature neutrophils (neutrophilic band cells) *(B)*. Central pallor is apparent in some red blood corpuscles *(arrow)*. The concavity and, therefore, the central pallor are neither equally developed nor equally apparent in all species. (X400.)

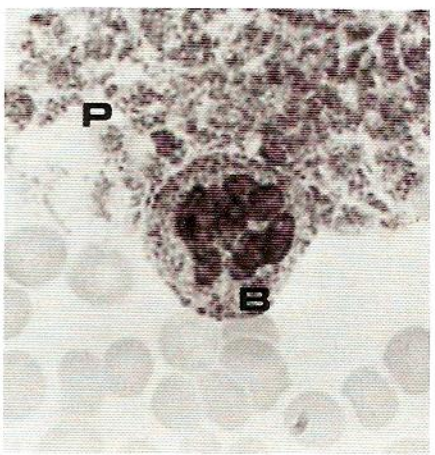

Figure 11-3. Feline peripheral blood smear. A basophil *(B)* is surrounded by aggregated platelets *(P)* and erythrocytes. Variations in central pallor within this small population of erythrocytes are apparent.

are extruded before the cells enter the vascular bed. Metarubricytes in the peripheral circulation usually indicate regeneration.

3. Immature cells (**reticulocytes**) with ribosomal remnants also enter the peripheral circulation. These RBCs have a diffuse cytoplasmic basophilia (Fig. 11-6). Positive identification requires seeing basophilic granules or a fibrillar network with supravital stains (new methylene blue). **Polychromatophilic erythrocytes** are immature cells with a cy-

Downloaded From Vet-eBooks.com

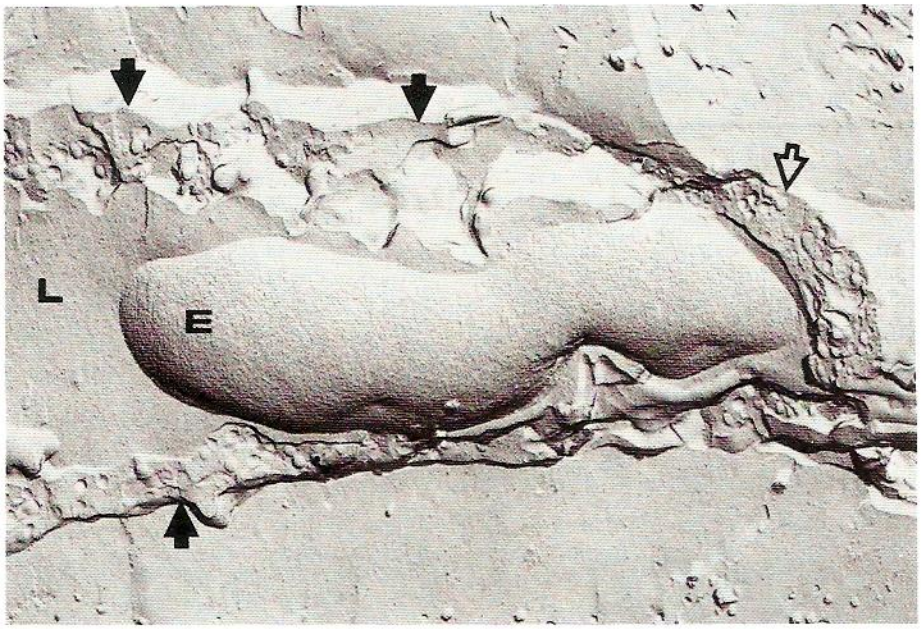

Figure 11-4. Electron micrograph of a freeze fractured capillary and erythrocyte. The collapsed capillary is identified on the basis of its endothelial lining in both longitudinal section *(solid arrows)* and cross section *(open arrows)*. The capillary lumen *(L)* contains a single erythrocyte *(E)* conforming to the shape of the capillary. Erythrocytes are capable of adjusting their shape to that of the capillary. Compare with Figure 2-13. (X25,600.) (Courtesy J. E. Rash.)

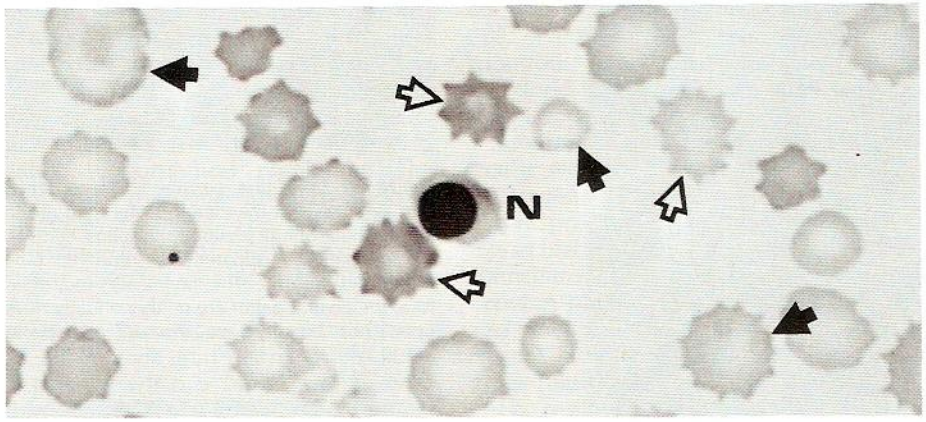

Figure 11-5. Peripheral blood smear from a piglet with a regenerative anemia. A nucleated erythrocyte (metarubricyte) occupies the center of the field *(N)*. Acanthocytes *(open arrows)* are present. Note the different sizes of the erythrocytes *(solid arrows)*. This condition is called anisocytosis. (X400, Giemsa stain.)

toplasm having a mixed affinity for the acid and basic dyes of Romanowsky stains. **Polychromasia** describes the condition of the blood when these entities are present (Plate VII, *4*). The reticulocyte and the polychromatophilic RBC are the same cell stained differently. Polychromasia indicates regeneration and should not be confused with RBC **basophilic stippling,** apparent with a Romanowsky stain (Fig. 11-7). The latter indicates regeneration in cats, cattle, and sheep, but it can also indicate heavy metal poisoning resulting in defective RBC formation. Basophilic stippling is not observed with new methylene blue.

4. **Howell-Jolly (HJ) bodies** are nonrefractile, eccentrically positioned, nuclear remnants within RBCs. Although they indicate increased RBC production, they are observed routinely in 1% of feline and equine RBCs.
5. **Erythrocyte refractile (ER) bodies** are visible in unstained wet mounts as slight protrusions from the cell's periphery. They are small, circular

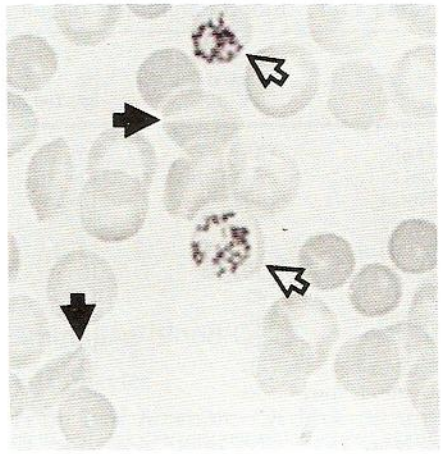

Figure 11-6. Canine peripheral blood smear. The reticulocytes *(open arrows)* are surrounded by large erythrocytes (macrocytes) and small erythrocytes (microcytes). The range of sizes in erythrocytes is called anisocytosis. Note the leptocytes *(solid arrows)*. (X400, new methylene blue stain.)

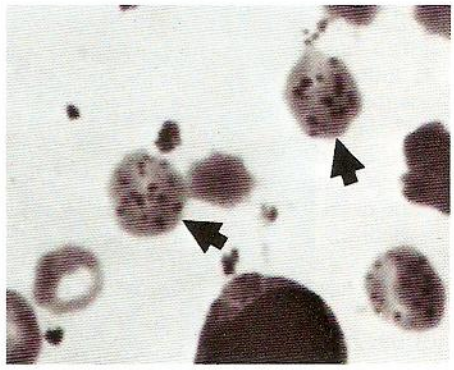

Figure 11-7. Bovine peripheral blood smear. Basophilic stippling *(arrows)* is apparent. (X400, Giemsa stain.)

pale areas that may be observed with Wright's stain (Fig. 11-8) in 10% of normal feline RBCs. **Heinz bodies** are peripherally positioned, intracytoplasmic masses of altered hemoglobin appearing as pale areas with Romanowsky stains and as refractile blue-black spheres with new methylene blue. Heinz bodies and ER bodies are the same structures. They result from the oxidation of hemoglobin by certain agents. Feline hemoglobin is more susceptible to oxidation than that of other species.

Although the size of RBCs varies, this parameter is constant for a given species. RBCs of normal size and hemoglobin content are called **normocytes** (Figs. 11-2 and 11-3). Any alteration in this normal size is **anisocytosis** (Fig. 11-9). Cells larger than normal are **macrocytes;** cells smaller than normal, **microcytes.** Anemias in domestic animals are sometimes

Downloaded From Vet-eBooks.com

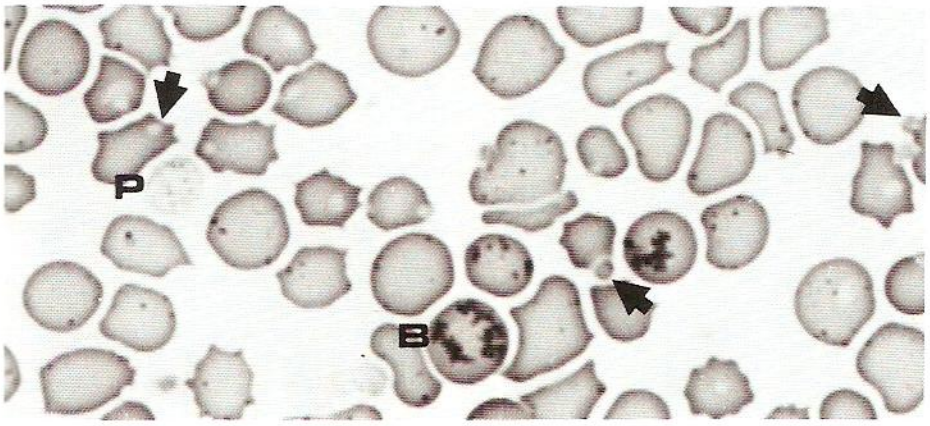

Figure 11-8. Feline peripheral blood smear. Basophilic stippling *(B)* and Heinz bodies *(solid arrows)* are evident. *P,* Platelet. (X400, Wright's stain.)

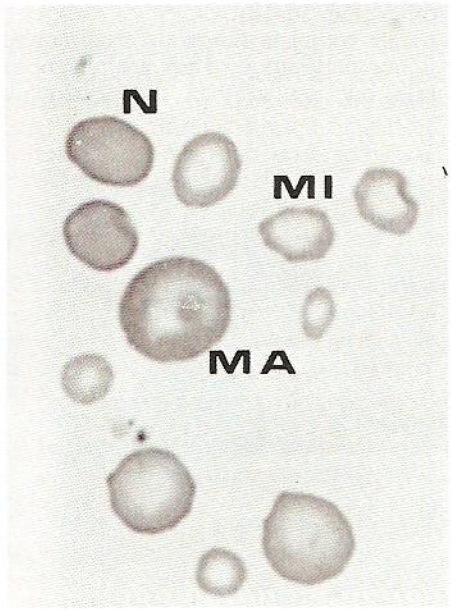

Figure 11-9. Anisocytosis in a porcine peripheral blood smear. Macrocytes *(MA),* normocytes *(N),* and microcytes *(MI)* are evident. The microcytes are hyperchromatic. (X400, Giemsa stain.)

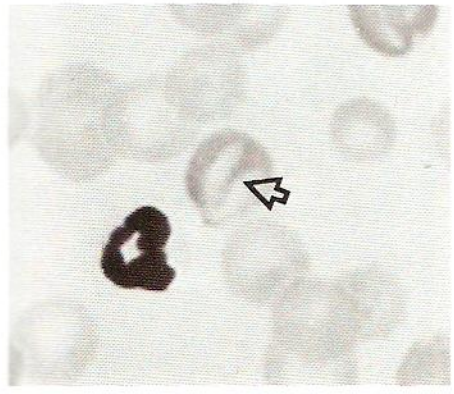

Figure 11-10. A fold cell in a peripheral blood smear of canine blood. A fold of membrane *(arrow)* crosses the central area of pallor. (X400.)

classified (on the basis of cell size) as normocytic, macrocytic, or microcytic. A **normocytic anemia** is commonly associated with various chronic diseases (infections, malignancies, nephritis). The most common cause of **macrocytic anemia** in domestic animals is the increased production and subsequent release of reticulocytes in response to blood loss or destruction. Because this anemia is self-correcting, it is called **transitory** or **pseudomacrocytic.** A true **macrocytic anemia** results from arrest of bone marrow maturation in which immature (large) cells enter the peripheral blood. The most common cause of a **microcytic anemia** is iron deficiency from chronic blood loss.

The number of RBCs per cubic millimeter varies inversely with RBC size. An increased number is called **polycythemia,** a decreased number **oligocythemia.**

Deviations from normal RBC shape are termed **poikilocythemia.** Alterations to shape result from disease processes and/or faulty processing techniques.

1. **Acanthocytes** have spinelike or blunt processes. These cells can result from various diseases (Fig. 11-5). Similar changes arise during processing in which slow-drying fluids create a hypertonic solution. Then the cells are called **crenated cells.**

2. **Bowl- or cup-shaped erythrocytes** appear to have "punched-out" centers when observed in stained smears. RBCs normally assume a parabolic shape when passing through capillaries (Fig. 2-13), (but some cytoplasmic stromal defects do not permit them to return to this normal biconcave configuration.

3. **Leptocytes** are RBCs with a decreased volume and a normal to increased surface area (Fig. 11-10). Leptocytes are target cells or folded cells. A **target cell** has a dense central zone surrounded by a clear zone with another dense zone at the periphery of the cell. These altered densities are generally attributed to a heterogeneous distribution of hemoglobin. **Folded cells** have a folded membrane across the cell.

4. **Ovalocytes** are elliptical RBCs encountered periodically. They are normal in avian, piscine, and cameline blood.

5. **Poikilocytes** are RBCs with various abnormal configurations. Most commonly they may have a "teardrop" shape. They can indicate both disease and slow drying problems during processing. **Schistocytes** are erythrocytic fragments with irregular shapes (Fig. 11-11). A spheroid cell with a decreased volume compared to its diameter and without central pallor is a **spherocyte.** Although it may be associated with other disease processes, it occurs in autoimmune problems. **Stomatocytes** have a linear region of central pallor (Fig. 11-12) and are associated with hereditary erythrocytic membrane defects.

The homogeneous staining of RBCs is a function of the amount and distribution of hemoglobin. The normal amount and distribution of hemoglobin are termed **normochromic.** A decreased hemoglobin content is **hypochromasia.** Bone marrow reticulocyte release and iron deficiency result in hypochromasia. Reticulocytes contain hemoglobin, but the cells are larger than normal. A **macro-**

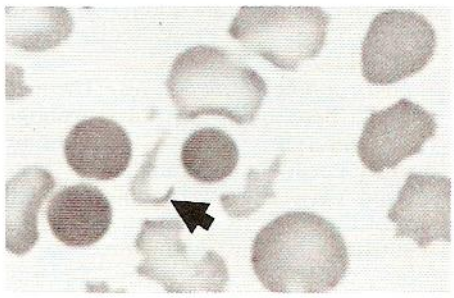

Figure 11-11. Canine peripheral blood smear. The *arrow* points to a schistocyte. (X400, Wright's stain.)

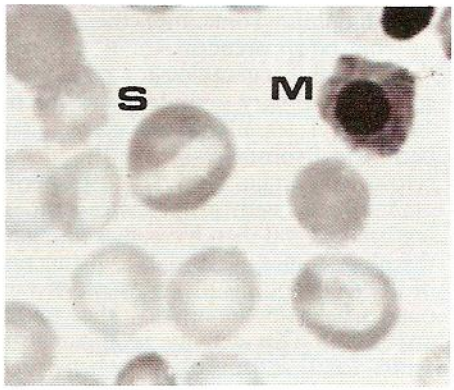

Figure 11-12. Canine peripheral blood smear. *S,* Stomatocyte; *M,* metarubricyte. (X400.)

Downloaded From Vet-eBooks.com

Table 11-2. WBC Differential Counts for Selected Domestic and Laboratory Species*

	Cells†					
	Mature Neutrophils	Immature Neutrophils‡	Lymphocytes	Monocytes	Eosinophils	Basophils
Dog	70	3	20	5.0	4.0	Rare
Cat	60	3	32	2.8	5.2	Rare
Horse	52	2	39	4.4	4.1	0.5
Ox	28	2	57	5.0	8.8	0.5
Sheep	30	Rare	62	2.5	5.0	0.5
Goat	36	Rare	56	2.5	5.0	0.5
Pig	37	3	53	5.0	3.5	0.5
Rabbit	43	2	42	9.0	2.0	4.0
Rat	28	1	62	5.0	2.0	1.0
Guinea pig	42	3	45	7.0	5.0	1.0
Domestic fowl	26	—	64	6.0	2.0	2.0

*These average parameters vary with age, sex, strain, and breed of animal.
†Values are percentages of total WBCs.
‡Values represent upper limits of normalcy.

cytic hypochromic anemia is typically a regenerative disorder in all domestic animals except the horse, whose bone marrow does not release immature RBCs. A **microcytic hypochromic anemia** results from an iron deficiency of chronic blood loss (ectoparasites, endoparasites, gastric ulcers).

Granulocytes

Granulocytes are **white blood cells (WBCs, leukocytes)** with specific granules and lobed or segmented nuclei. They are protective cells functioning within the vascular bed and extravascular tissues (Table 11-2).

Neutrophilic granulocytes. The **neutrophil, heterophil,** or **polymorphonuclear leukocyte (PMN)** is the most frequently encountered granulocyte (Plates VI and VII). The cell is about twice the size of the RBC (9 to 12 μm) and has a segmented nucleus with three to five lobes connected by a nucleoplasmic strand (Figs. 11-13 to 11-15). The specific granules may vary from light pink to purple depending upon the stain used; thus the name **heterophil.** In some species (rabbit, guinea pig) they stain with acid dyes, and the cells are called **pseudoeosinophils.** Sometimes the particles may not be apparent.

Neutrophilic granulocytes contain **lysosomes (primary granules)** and **specific (secondary) granules.** The latter contain bactericidal substances. After the phagocytosis of certain bacteria, first specific granules fuse with phagosomes containing bacteria and then lysosomes fuse with the phagosomes. Thus the main function of the neutrophil is phagocytosis of various particles, bacteria, and other microorganisms. This activity is apparent in acute local inflammation when great numbers of these cells become connective tissue residents.

Neutrophilic bacterial phagocytosis is facilitated by **complement** and certain plasma proteins functioning as **opsonins.** Bactericidal activity occurs through specific granule **lysozyme,** which is a hydrolase degrading bacterial cell wall glycosides. Other hydrolases of lysosomes (e.g., **myeloperoxidase, acid phosphatase, β-galactosidase,** and **5′-nucleosidase**) aid the degradation process. **Myeloperoxidase** activity and H_2O_2 form superoxides that are bactericidal. Lysozyme and **lactoferrin** occur in specific granules. Lactoferrin is a bacteriostatic substance.

Eosinophilic granulocytes. The **eosinophil** or **acidophil** is the next most frequently encountered granulocyte (Plate VI). Its diameter is about 12 to 14 μm. The nucleus is bilobed but may be polymorphic (Fig. 11-16). The acidophilic granules are the distinguishing feature. They are uniform within a cell, but they do vary from species to species (Fig. 11-15). They are especially large in equids (Fig. 11-17). These granules are lysosomes (Fig. 11-18).

The complete function of eosinophils is not understood. They are phagocytic cells but less so than the neutrophils.

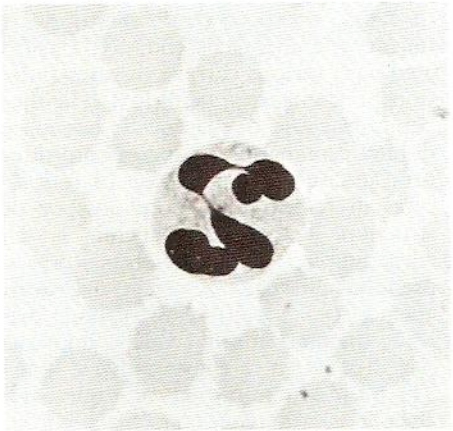

Figure 11-13. Canine peripheral blood smear. A neutrophil (PMN) occupies the center of the field. (X400.)

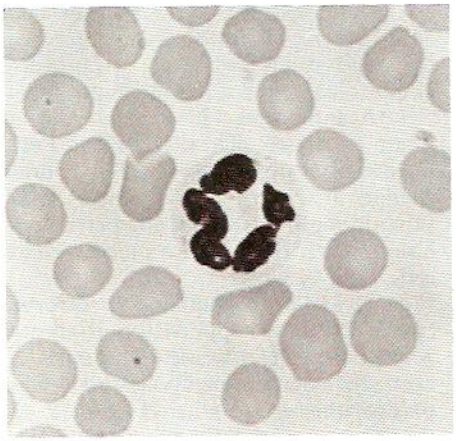

Figure 11-14. Feline peripheral blood smear. A neutrophil occupies the center of the field. Compare with Figure 11-3. (X400.)

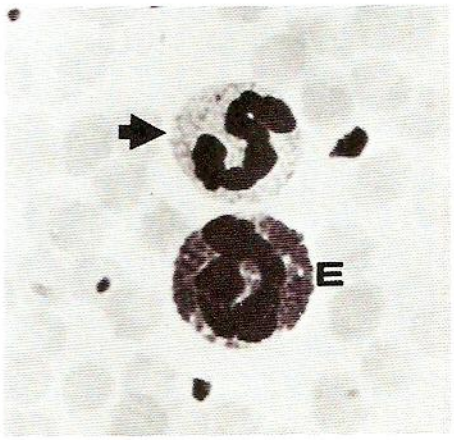

Figure 11-15. Ovine peripheral blood smear. An eosinophil *(E)* and a neutrophil *(arrow)* are present. (X400.)

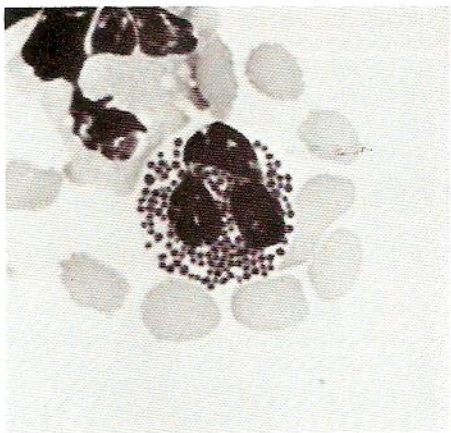

Figure 11-16. Bovine peripheral blood smear. An eosinophil occupies the center of the field. (X400.)

Figure 11-17. Equine peripheral blood smear. An eosinophil occupies the center of the field. Note the characteristic shape of the specific granules of eosinophils in this species. (X400.)

Their numbers increase during allergic reactions (type I hypersensitivity) and parasitic infections. These cells are mobilized rapidly during parasitic infections. In response to invasion, eosinophils surround the parasite, degranulate, and release antilarval substances that kill the parasite.

They become numerous in the extracellular space at sites of antibody/antigen reactions. Eosinophilic responses are unclear in these circumstances. These cells, however, may inactivate histamine by releasing **histaminase.**

Basophilic granulocytes. The **basophil** or **basophilic leukocyte,** the least numerous of the granulocytes (Plate VI), is about the same size as the neutrophil (9 to 12 μm). The nucleus is usually bilobed, although more lobes may be present. The **specific granules** are round, coarse, size-variable, basophilic, and metachromatic (Figs. 11-19 and 11-20). They usually stain darker than the nucleus and may partially obscure it.

Their precise function is obscure, but they may increase in certain types of parasitism (canine heartworm disease). These cells are phagocytic and contain large quantities of histamine. Their histamine content is released in response to allergic stimulation.

Basophils are also phagocytic and function to control microbial invasion. This cell also releases the same substances released by mast cells and enhances the inflammatory response. (See Chapter 7.)

The neutrophil, eosinophil, and basophil comprise a **microphage system** affording protection against microbial agents of disease.

Agranulocytes

The **agranulocytes** are white blood cells without specific granules, but granules may be present. They are round cells with more or less rounded nuclei.

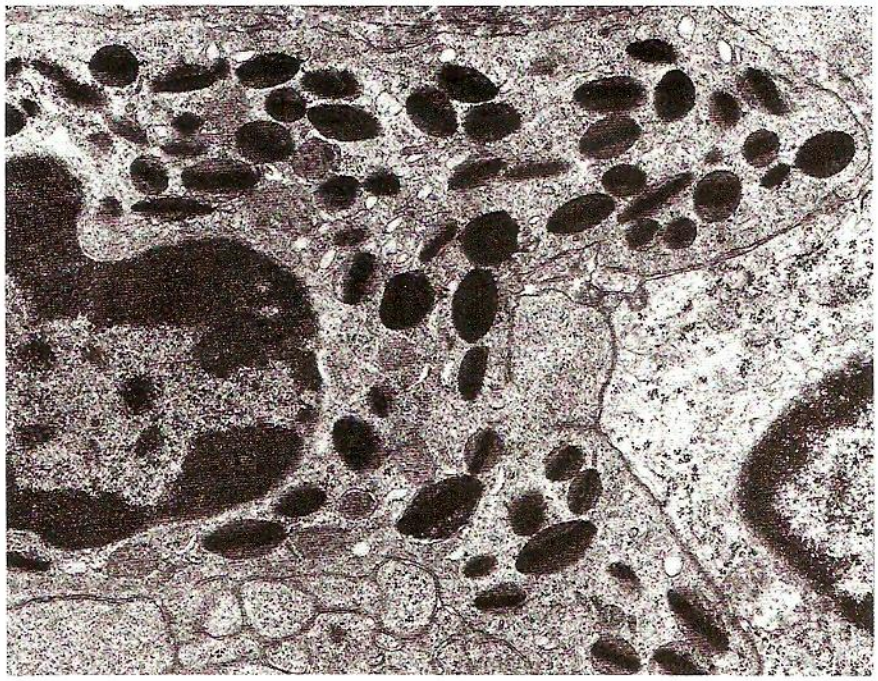

Figure 11-18. Electron micrograph of an eosinophil. The dark bodies are the specific granules of the cell. (X17,000.) (Courtesy A. M. Sheppard.)

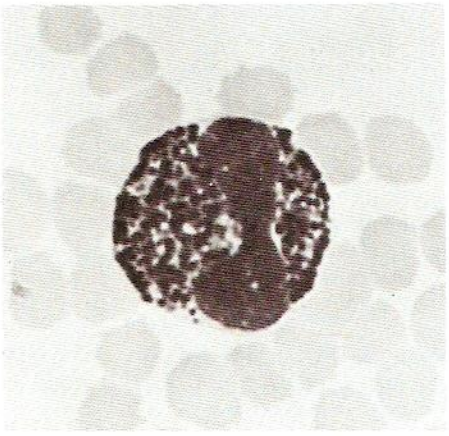

Figure 11-19. Equine peripheral blood smear. A basophil occupies the center of the field. (X400.)

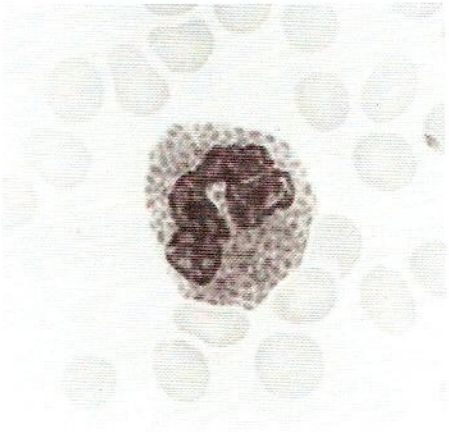

Figure 11-20. Feline peripheral blood smear. A basophil occupies the center of the field. Note the light-staining specific granules, which characterize this species. (X400.)

Lymphocytes. The **lymphocytes** are usually the most frequently seen agranulocytes (Plate VI). They have a high nuclear/cytoplasmic ratio (Fig. 11-21). The nucleus is usually round, has peripherally condensed heterochromatin, and is sufficiently dense to obscure the nucleolus. A nuclear indentation may be seen (Fig. 11-22). The clear basophilic cytoplasm may contain some nonspecific, azurophilic granules (Fig. 11-23 and Plate VII,2). The predominant cytoplasmic organelles are ribosomes, polyribosomes, and RER. The Golgi complex and mitochondria are scant.

Small lymphocytes have a diameter of 5 to 10 μm and are the predominant lymphocytes in the circulating blood. **Medium-sized lymphocytes** range from 10 to 18 μm. The medium-sized lymphocytes are sometimes difficult to distinguish from monocytes. **Large lymphocytes** typically occur in lymphatic tissue.

Immunological techniques permit the identification of B and T lymphocytes.

B lymphocytes (B cells) produce **antibodies (immunoglobulins)** and are the basis for the blood-borne or **humoral antibody immunity** (Chapter 19). Their cell surfaces have specific

Downloaded From Vet-eBooks.com

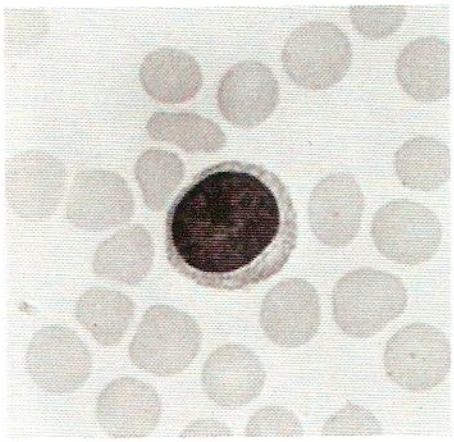

Figure 11-21. Feline peripheral blood smear. A lymphocyte occupies the center of the field. (X400.)

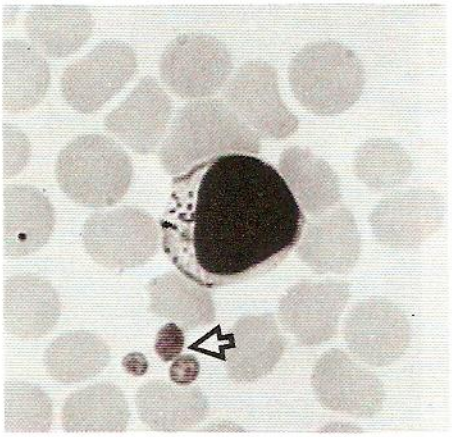

Figure 11-23. Equine peripheral blood smear. A lymphocyte occupies the center of the field. Note the azurophilic granules within the cytoplasm. The *arrow* points to platelets. (X400.)

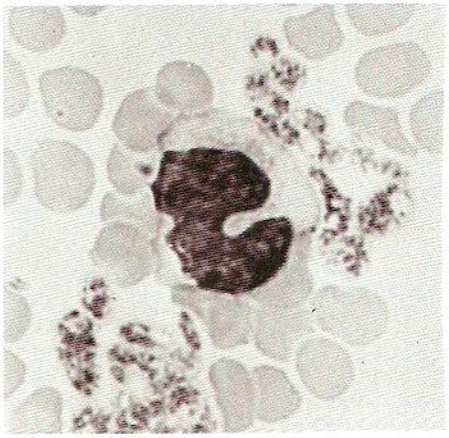

Figure 11-24. Feline peripheral blood smear. A monocyte occupies the center of the field and is surrounded by erythrocytes and aggregated platelets. The monocytic nucleus has been described as having a "spaghetti and meatball" appearance. (X400.)

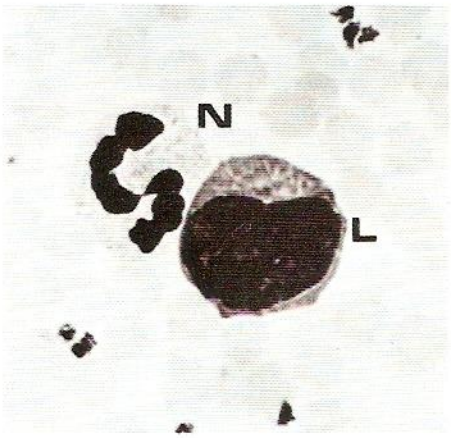

Figure 11-22. Ovine peripheral blood smear. A lymphocyte *(L)* is adjacent to a neutrophil *(N)*. (X400.)

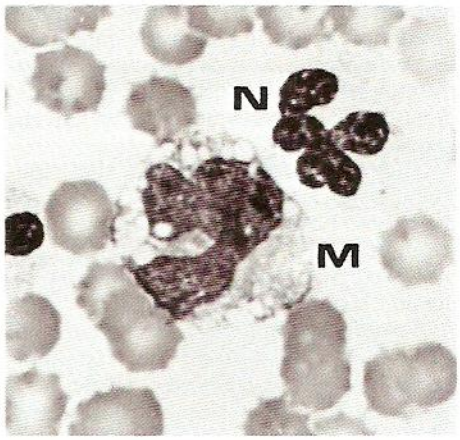

Figure 11-25. Canine peripheral blood smear. A monocyte *(M)* and neutrophil *(N)* are apparent. (X400.)

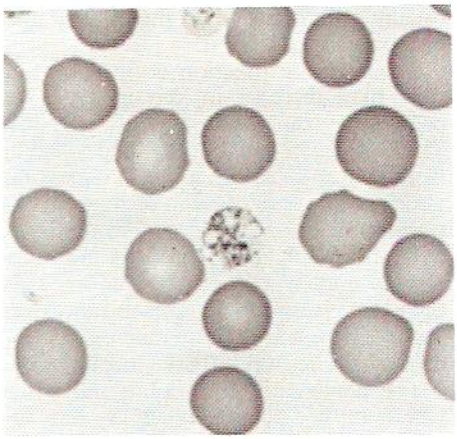

Figure 11-26. Canine peripheral blood smear. A platelet is apparent in the center of the field. (X400.)

receptors for antigen, immunoglobulin Fc, and C3b. They occur in bone marrow, the bursa of Fabricius (in birds), and the germinal centers of lymph nodules and splenic follicles.

T lymphocytes (T cells) are a functionally diverse population of cells. They are responsible for **cell-mediated immunity** (Chapter 19). In response to antigenic stimulation (Chapter 19), they may become cytotoxic T cells, T helper cells, T suppressor cells, or memory cells, or they may produce transfer factors and lymphokines.

Transfer factors are extracts of lymphocytes conferring specific cell-mediated reactivity on a normal recipient of the extract. These factors may be a ribonucleoprotein. **Lymphokines** are biologically active, nonantigen-specific, low–molecular weight proteins (25,000 to 75,000 daltons). They are synthesized and secreted by activated T cells primarily, although B cells may produce them in response to nonspecific stimulation. Over 90 different lymphokine-mediated activities have been characterized. Lymphokines influence cellular populations (macrophages, lymphocytes, granulocytes) by changing their behavior. Some of the lymphokines are **MIF (migration inhibition factor), MAF (macrophage aggregating factor), MCF (macrophage chemotactic factor), MF (mitogenic factor), IFN (interferon),** and **BF (lymphocyte blastogenic factor).** MIF prevents macrophage migration; MAF causes macrophage aggregation; MF stimulates lymphocytic mitosis; MCF attracts macrophages; IFN prevents viral replication; BF induces blast formation and lymphocytic mitosis.

T cell surfaces generally have a Thy-1 or θ antigen. Other surface differences and stimulation responses also distinguish T and B cells. T cells occur in the thymus, the paracortical zones of lymph nodules, and the periarteriolar zone of splenic corpuscles.

Most circulating lymphocytes are T cells. The life span of lymphocytes may vary from hours to years. The long-lived B and T lymphocytes are believed to be **memory cells.**

Monocytes. **Monocytes** are the largest blood cells (Plate VI), with diameters of 16 to 25 μm. The nucleus is kidney-shaped, but it may be round or trilobed (Fig. 11-24). The nuclear chromatin is lighter and more reticulated than that of the lymphocytic nucleus (Fig. 11-25). The cytoplasm is generally gray, but the even distribution of clear granules imparts a ground-glass appearance. Scattered azurophilic granules contribute to this staining. The nucleus is an excellent distinguishing feature.

Monocytes are phagocytic cells that become macrophages once they enter the extravascular space. Following their access to connective tissue and under appropriate stimulation, these cells may fuse to form **foreign body giant cells** and **osteoclasts.**

Downloaded from VetBooks.com

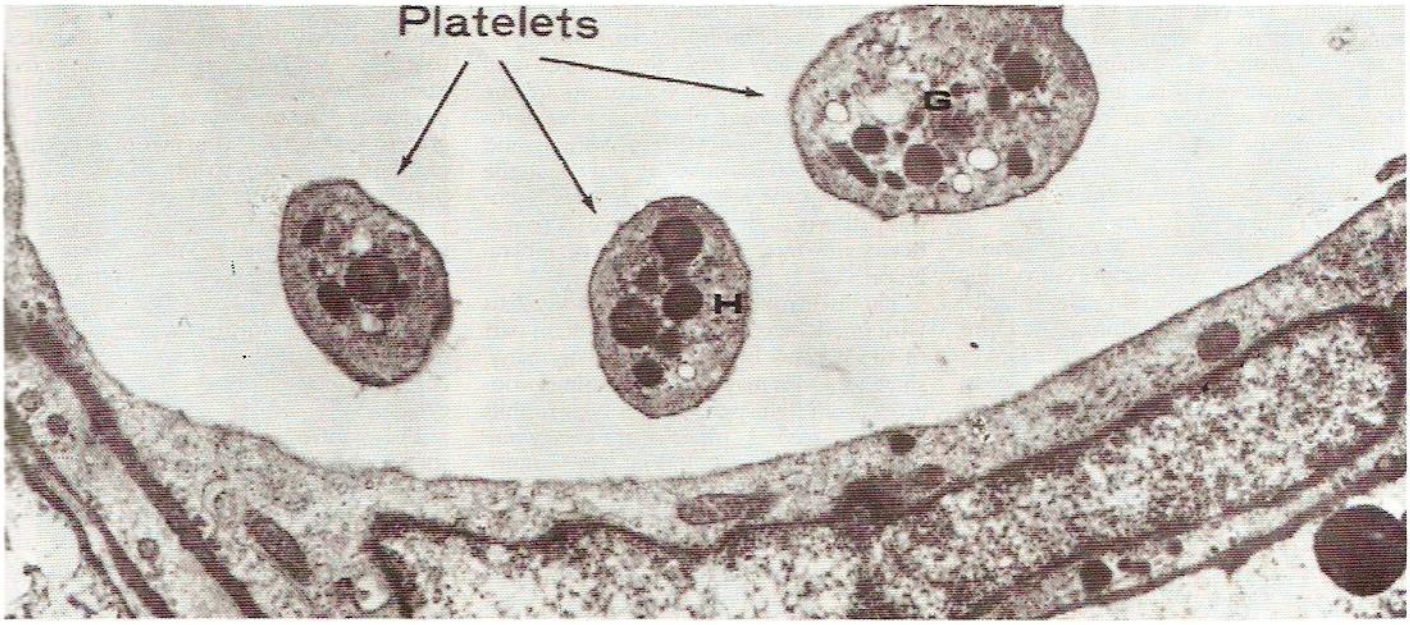

Figure 11-27. Electron micrograph of platelets within a capillary. *G*, Granulomere; *H*, hyalomere. (Reprinted with permission from Bloom W, Fawcett DW: *Textbook of histology*, ed 10, Philadelphia, 1975, WB Saunders.)

Plasma cells. The morphology and general function of **plasma cells** are discussed in Chapter 7; their origin in Chapter 12; and their immunological function in Chapter 19.

Platelets

Blood platelets (thrombocytes) are small discs 2 to 4 μm in diameter (Fig. 11-26). They are cytoplasmic fragments of **metamegakaryocytes.** Platelets are membrane-bound, round to oval fragments containing a central, basophilic region **(chromomere)** and a pale, homogeneous peripheral zone **(hyalomere).** The chromomere contains mitochondria, endoplasmic reticular profiles, and granules (Figs. 11-27 and 11-28). The hyalomere may contain some glycogen. A homogeneous cytoplasmic matrix with microtubules is typical.

Platelets function in hemostasis. Although their role in stopping hemorrhage may be their most prominent function, they serve various functions. By virtue of their serotonin content, they are mediators of vasoconstriction. They combine with bacteria and thus aid phagocytosis by serving as **opsonins.** They may also serve a similar function by combining with viral particles.

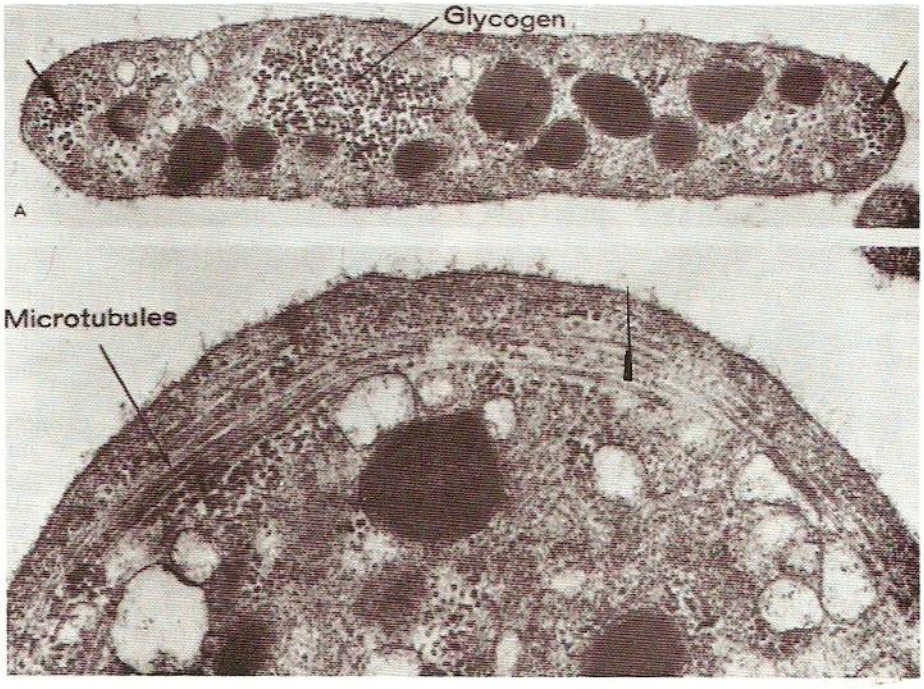

Figure 11-28. Electron micrographs of platelets sectioned along the narrow surface *(upper)* and parallel to the flat surface *(lower)*. Glycogen granules are obvious within the granulomere. Microtubules *(arrows)* are apparent within the hyalomere. (Upper, X31,000; lower, X45,600.) (Reprinted with permission from Bloom W, Fawcett DW: *Textbook of histology*, ed 10, Philadelphia, 1975, WB Saunders.)

Formed Elements—Species Variations

The blood cells of selected species are compared in color Plates VI and VII.

Canine blood cells. The average size of the canine RBC is 7 μm. These cells usually have a well-defined central pallor. Leptocytes are sometimes present. Although HJ bodies and nucleated RBCs are occasionally seen, they are not normal for the species. Reticulocytes are less than 1% of the RBCs in adults. Rouleau formation occurs.

The neutrophil has an irregularly lobed nucleus, the lobes of which are usually joined by a narrow strand of nucleoplasm. The cytoplasm stains faintly a pink-gray color and contains fine, diffuse granules. The eosinophil has granules varying in number and size that stain faintly with acid dyes. Usually part or all of the nucleus is seen, because the granules are localized to a small region of the

Downloaded From Vet-eBooks.com

cytoplasm. The cell shape varies. The basophil contains granules also varying in size and number. The staining intensity of these granules varies, and their number is rarely sufficient to cover the nucleus or fill the cytoplasm. Because basophilic granules are water-soluble and easily removed during processing, this cell may be confused with a monocyte.

The small lymphocyte is the predominant cell in peripheral blood. Azurophilic granules rarely occur in these cells. Monocytes contain fine azurophilic granules and large nuclei. The nucleus is typically C-shaped with large blunt ends, but the cell and nucleus are usually pleiomorphic.

Feline blood cells. The average size of feline RBCs is 5.9 μm. These cells stain uniformly, and the central pallor is not usually as prominent as in canine RBCs. HJ bodies may occur in 1% of normal RBCs. Nucleated RBCs may be seen in the peripheral blood. Rouleau formation is a prominent feature.

The neutrophil contains a large, usually coiled, nucleus. Nuclear lobes are connected by filaments or thin strands of nuclear materials. Fine, pink granulations occur within a gray cytoplasm. Eosinophilic granules are rod-shaped, refractile, and numerous. They generally cover the nucleus. Basophils are rarely encountered but contain many, small, round, light-staining, lavender granules with occasional large dark granules.

The small lymphocyte is the predominant agranulocyte in feline peripheral blood. It has a dull, blue, granular cytoplasm; and cytoplasmic vacuoles may occur.

Equine blood cells. The average size of equine RBCs is 5.4 μm. Rouleau formation occurs rapidly. Although in blood smears, single RBCs with a slight central pallor may be seen, many will overlap in rouleau formation. HJ bodies may occur in normal RBCs. One striking feature is the absence of immature erythrocytic forms. **Reticulocytosis,** even in anemia, is extremely rare.

The neutrophilic nucleus has many foci of clumped heterochromatin. Interlobar filaments are rare. The gray cytoplasm contains fine, pink granules. The eosinophil is the identifying feature of equine blood. The granules are large and round to oval, stain a bright red-orange, and generally obscure most of the nucleus. They define the cell contour. The basophil contains purple granules scattered throughout the cytoplasm. Their shape and size are irregular, and they may cover the nucleus.

Most peripheral lymphocytes are small, but large lymphocytes may be the same size as monocytes. Azurophilic granules also occur. The monocytic nucleus most typically is kidney-shaped. Small azurophilic granules and small vacuoles may be scattered throughout the cytoplasm.

Bovine blood cells. Small RBCs and the absence of rouleau formation are the reasons that bovine blood does not sediment readily. Anisocytosis is normal, and the smallest RBC may be only half the diameter of the largest. Normally, a central pallor is difficult to observe. Also, reticulocytes rarely occur in the peripheral blood.

The neutrophil has a lobed nucleus with one lobe connected to the main part of the nucleus by a filament. The many, small granules may vary in staining properties from light pink to red. Neutrophils are the second most common white blood cell of bovine blood. The eosinophil contains many, small, round, red granules filling the cytoplasm and partially covering the nucleus. The lobed nucleus is usually a C-shaped structure. The basophil, though rare, is typical.

The lymphocyte is the primary leukocyte. Small, medium, and large lymphocytes occur in the peripheral blood. The large lymphocytes are easily confused with monocytes. Although the small and medium lymphocytes are typical, the large ones are light-staining and have an eccentrically positioned kidney-shaped nucleus, pale blue cytoplasm, and many azurophilic granules. Cytoplasmic vacuolations may be apparent. Monocytes vary in size, and their nuclear morphology also is variable; a cloverleaf nucleus may be observed occasionally. The monocytes may be confused with large and medium-sized lymphocytes. Monocytic cytoplasm stains more darkly and is more granular than that of lymphocytes. The rare occurrence of azurophilic granules in monocyte cytoplasm is a useful distinguishing feature.

Ovine blood cells. The RBCs of sheep are smaller than those of bovids. A faint central pallor is observed, as well as a limited amount of rouleau formation. All other characteristics of ovine RBCs are similar to those of the bovid.

The neutrophilic nucleus is typically multilobed, with each lobe connected by fine filaments. The faintly staining, pink cytoplasm contains diffuse small granules and some large granules. As with bovine blood, these cells do not occur as frequently as in other nonruminant species. The eosinophil contains uniform, oval, and refractile red-orange granules filling the cytoplasm and partially covering the nucleus. The basophil has dark granules with a red halo.

The lymphocytes vary from small to large but are difficult to categorize by size. All lymphocytes have nuclei with a smooth chromatin network that may stain with a red tint. Although the single nucleus is usually round, or oval and smooth, binucleated cells occur. The cytoplasm stains blue. Azurophilic granules may also be observed. The monocytes have oval, indented, or trilobed nuclei. Strands of dark-staining chromatin impart a lacy texture to the nucleus. The ground-glass–appearing cytoplasm stains more intensely than that of the large lymphocytes. Azurophilic granules are rare.

Caprine blood cells. The RBCs of goats are the smallest among domestic animals. They are round or triangular and devoid of a central pallor. Anisocytosis and rouleau formation are not common in adult blood. Juvenile blood is characterized by anisocytosis and poikilocytosis.

The neutrophil is similar to that of sheep, except fewer lobes occur. The number of neutrophils is similar to that in other ruminants. The eosinophil contains a C-shaped to mono-, bi-, or trilobed nucleus. The bluish cytoplasm has many small, round, red-staining granules. The basophil is typical. The purple granules have a red halo, imparting a reddish tint to the cytoplasm.

Lymphocytes are small, medium, and large. The nuclei are generally round to oval, but occasionally a kidney-shaped one is seen. The chromatin pattern of large lymphocytic nuclei differentiates these cells from monocytes. Large lymphocytes have coarsely clumped heterochromatin, and nucleoli or nucleoli-like structures are present. Azurophilic granules of various sizes may be present. The monocytes are similar to those in sheep.

Porcine blood cells. Crenation and rouleau formation are constant, but the occurrence of a central pallor is variable.

The neutrophil has a dark-staining nucleus that may be coiled. The lobes are connected by strictures rather than filaments. The pale blue cytoplasm has pale-staining, small granules. The eosinophil contains orange granules filling the cytoplasm, making the cell margin indistinct, and partially obscuring the nucleus. The basophil has red-purple granules with coccoid or dumbbell shapes.

The small lymphocytes are typical. The nucleus fills the cell and may be surrounded by a thin rim of pale blue cytoplasm. Large lymphocytes have a more vesicular nucleus than smaller cells do. Azurophilic granules occur variably, tend to be rod-shaped, and are distributed along the cellular margin. The monocyte is typical, without conspicuous azurophilic granules.

Avian Blood Cells

Erythrocytes

Avian RBCs range from 10 to 13 μm long and 6 to 7 μm wide. They are oval and have oval nuclei (Fig. 11-29). The elongated nucleus is about half the cell's dimensions. The heterochromatin has a

Downloaded From Vet-eBooks.com



Figure 11-29. Erythrocytes in an avian peripheral blood smear. (X400.)

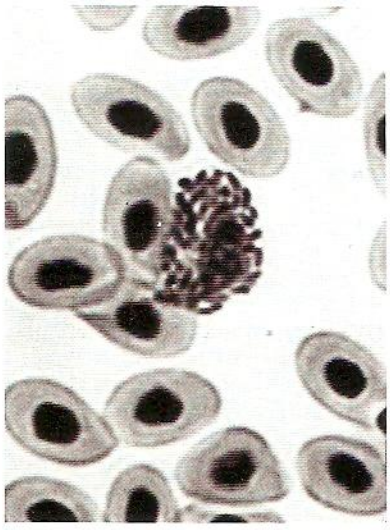

Figure 11-30. Avian peripheral blood smear. A heterophil occupies the center of the field. (X400.)

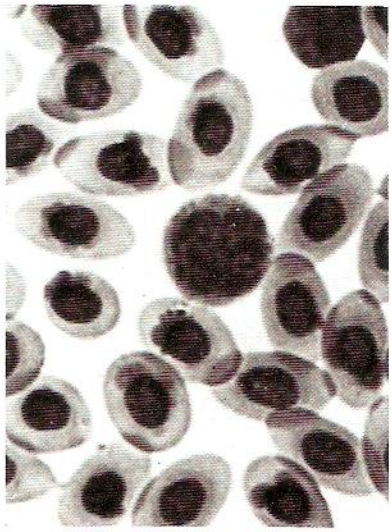

Figure 11-32. Avian peripheral blood smear. A lymphocyte occupies the center of the field. (X400.)

uniform distribution within the oval nucleus. A nucleolus is not apparent. The cytoplasm may vary from orange-pink to red. Many artifactual changes can alter the cell's configuration and staining affinity. Fish and amphibian RBCs are similar to avian RBCs.

Granulocytes

Heterophils. The avian **heterophil** is the neutrophil in other species. It has a diameter of 6 to 9 μm. Despite its ameboid properties, it is usually a round cell in blood smears. The multilobed nucleus may have as many as five lobes, and the heterochromatin is coarsely clumped. The distinguishing feature is the presence of brightly stained, fusiform, eosinophilic rods randomly scattered throughout the cell (Fig. 11-30). These are easily dissolved in an aqueous medium, and all that may remain is a red-staining **central body** or **vacuole.** As a result the normally clear cytoplasm usually becomes acidophilic. Then the heterophil may be easily confused with an eosinophil.

Eosinophils. The avian **eosinophil** has a diameter of 5 to 9 μm and a multilobed nucleus with coarsely clumped heterochromatin. The cytoplasm, though usually obscured by tightly packed granules, stains a pale clear blue (Fig. 11-31). This characteristic distinguishes eosinophils from heterophils in which the rods have been partially dissolved. The granules of some eosinophils may appear as homogeneous bodies. In larger cells the granules appear to be composed of three or four subunits combined in such a manner that a clear space is present in the center of the complex. The eosinophilic granule is more refractile than that of the heterophil.

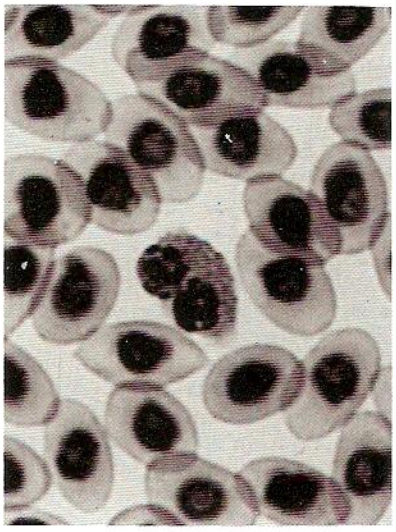

Figure 11-31. Avian peripheral blood smear. An eosinophil occupies the center of the field. (X400.)

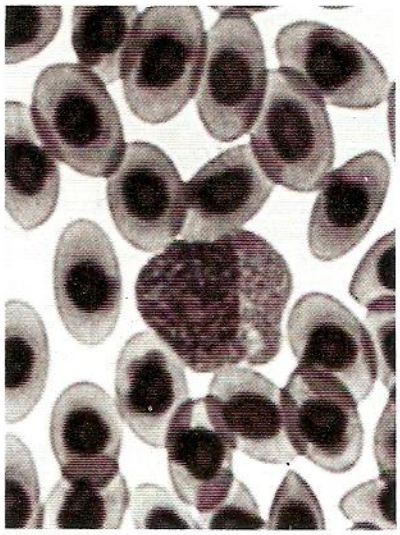

Figure 11-33. Avian peripheral blood smear. A monocyte is apparent in the center of the field. (X400.)

Basophils. The **basophil** of birds is similar to that of mammalian species.

Agranulocytes

Lymphocytes. Avian **lymphocytes** are about the same size as comparable mammalian cells. Small, medium, and large lymphocytes have been described. The cell is generally round with an even contour (Fig. 11-32), but cytoplasmic blebs are apparent. The nucleus is usually centrally located, although some cells may be polarized. Coarsely clumped heterochromatin typifies this structure. Also the nuclear to cytoplasmic ratio is high. A sharp indentation in the nucleus may be noted. The cytoplasm stains faintly and is homogeneous, or it may stain intensely and be flocculated with basophilic material. The flocculation is either fine and slightly reticulated or heavy and coarsely reticulated. Some magenta-staining granules may be evident.

The previous discussion of mammalian B cells and T cells applies to B and T cells in birds.

Monocytes. The avian **monocyte** is the largest of mature agranulocytes. Usually its diameter approximates the diameter of its nucleus. Although it normally is round, many other configurations attest to its ameboid characteristics (Fig. 11-33). Its nuclear/cytoplasmic ratio is smaller than that of the lymphocyte. Its kidney-shaped nucleus contains a fine heterochromatin reticulum. The

Downloaded From Vet-eBooks.com



Figure 11-34. Avian peripheral blood smear. Thrombocytes are apparent in the center of the field. (X400.)

juxtanuclear indentation reveals orange granules or may be tinged orange. The ground-glass appearance of the cytoplasm, azurophilic granules, and juxtanuclear characteristics are diagnostic features for the monocyte.

Thrombocytes

The **thrombocytes** of birds and other submammalian vertebrates are nucleated cells. They are smaller than RBCs and have average dimensions of 5 × 9 μm. The centrally located, elongated nucleus is coarsely granular with heterochromatin (Fig. 11-34). The cytoplasm is finely reticulated and basophilic, and it may contain azurophilic granules.

Besides functioning in hemostasis similarly to mammalian platelets, avian thrombocytes are **trephocytic** and **phagocytic.**

HEMOSTASIS

Hemostasis is a complex series of interactions culminating in the termination of blood loss after vascular injury.

Response of the vasculature. Vasoconstriction immediately follows the rupture of a vessel, resulting from one or a combination of factors—localized spasm (contraction) of intramural smooth muscle, reflex activity involving vasomotor nerves, the localized release of vasoconstrictor substances (especially serotonin). Vasoconstricting compounds maintain vasoconstriction for 20 to 60 minutes after injury, reducing blood loss and facilitating the aggregation of platelets at the injury site. The denuded or damaged endothelial surface exposes subendothelial collagen, and damaged cells release **ADP.** These events facilitate platelet aggregation by increasing surface adhesiveness. The contact with the exposed collagen activates intrinsic coagulative mechanisms. **Plasminogen** is also released at the injury site.

Platelet function. Platelets aggregating at injury sites are transformed into sticky, irregularly shaped structures with pseudopodia extending into the injury and between the individual platelets. The aggregation process causes a **release reaction** in which the platelets secrete products stored in their granulomeres. The products include **adenine diphosphate (ADP), serotonin, histamine, platelet phospholipids (PF3s),** and enzymes that cause the formation of plasma **thromboxane A.** Thromboxane A and ADP activate other platelets, causing them to adhere to the original aggregate. PF3s catalyze several reactions involved in thrombin formation. This release reaction, called **degranulation,** continues the aggregation of more platelets.

Erythrocytes contain high concentrations of ADP. Their entrapment and rupture within the plug release more ADP, enhancing the aggregation of platelets. The reversible process of **platelet plug** formation stops blood loss. These temporary plugs can be washed away from the site, and rebleeding occurs as a consequence. Additional mechanisms are required to transform the temporary plug into an irreversible aggregation of platelets.

Permanency is imparted to the platelet plug through platelet **viscous metamorphosis** and **fibrin generation.** Viscous metamorphosis is an irreversible structural platelet change within the plug. Filaments with contractile properties appear in the platelets. Actin and myosin polymerize and form definitive platelet microfilaments. The actual mechanisms by which contractile proteins, platelets, and fibrinous strands achieve clot retraction are not known. Fibrin attaches to platelet pseudopodia; contraction of actin/myosin complexes probably exerts tension on the fibrinous strands. This may account for **clot retraction.** Fibrin deposition on the platelet aggregate may be the activation mechanism for viscous metamorphosis. Calcium is essential for clot contraction; cAMP has been implicated as the regulator of viscous metamorphosis.

Platelet or **hemostatic plug** formation is compromised in animals with coagulation disorders **(coagulopathies).** Mechanisms normally limiting plug formation at vascular injury sites include the following: dilution of activated clotting constituents by continued blood flow, endothelial cell release of prostaglandins (causing vasodilation and inhibiting platelet aggregation), and antithrombin III inactivation of coagulation factors. These mechanisms, coupled with inadequate generation of fibrin, result in continuous bleeding from sites of vascular injury.

Coagulation

General mechanisms. **Coagulation** is a series of interactions in which the blood loses its fluid characteristics and becomes a semisolid mass. "Irreversible clot" formation (resulting from the interaction of damaged tissue, platelets, and fibrin) is integral to this process. Fibrin formation is due to a process involving tissue and/or blood factors.

The blood and tissue factors, except Factor IV, are proteins. Activation of the fibrin-producing mechanism that originates in the tissues is called the **extrinsic pathway.** Activation of a fibrin-producing mechanism within the blood is called the **intrinsic pathway.** These two pathways converge upon the activation of Factor X, in the **common pathway,** leading to fibrin formation. The coagulation scheme is outlined in Figure 11-35.

The sequence of events leading to coagulation occurs in three stages—**stage I, the formation of a prothrombin converting factor; stage II, the conversion of prothrombin to thrombin by prothrombin converting factor; stage III, the induction of fibrin formation from fibrinogen by thrombin.**

Extrinsic pathway. The **extrinsic pathway** generates **prothrombin activator substance** in response to the blood's contacting extravascular tissues. Coagulation by this pathway is rapid, occurring in less than a minute in severe tissue trauma. This pathway is not subject to disruption by natural inhibitors influencing the intrinsic pathway.

The initial contact of blood with extravascular tissues causes the release of **tissue phospholipids** (from cellular membranes) and **tissue thromboplastin (Factor III).** Factor III, calcium, and **Factor VII** form a complex acting enzymatically with tissue phospholipids to convert **Factor X** to **activated Factor X.** The remaining process is the common pathway.

Intrinsic pathway. The **intrinsic pathway** generates **prothrombin activator substance** when blood damage occurs directly or through contact with collagenous fibers or other subendothelial elements. The inherent ability to clot is the basis for the name of this pathway. Perturbations cause the inactive **Factor XII** to change configuration and become a proteolytic enzyme called **activated Factor XII. Kallikrein** and high–molecular weight **kininogen** may mediate Factor XII activation. The damage that initiates the activation of Factor XII also disrupts platelets, causing the release of **platelet phospholipids,** a factor called **platelet factor 3 (PF3).** PF3 influences subsequent steps of the cascading pathway. Activated Factor XII acts enzymatically to convert

Downloaded From Vet-eBooks.com

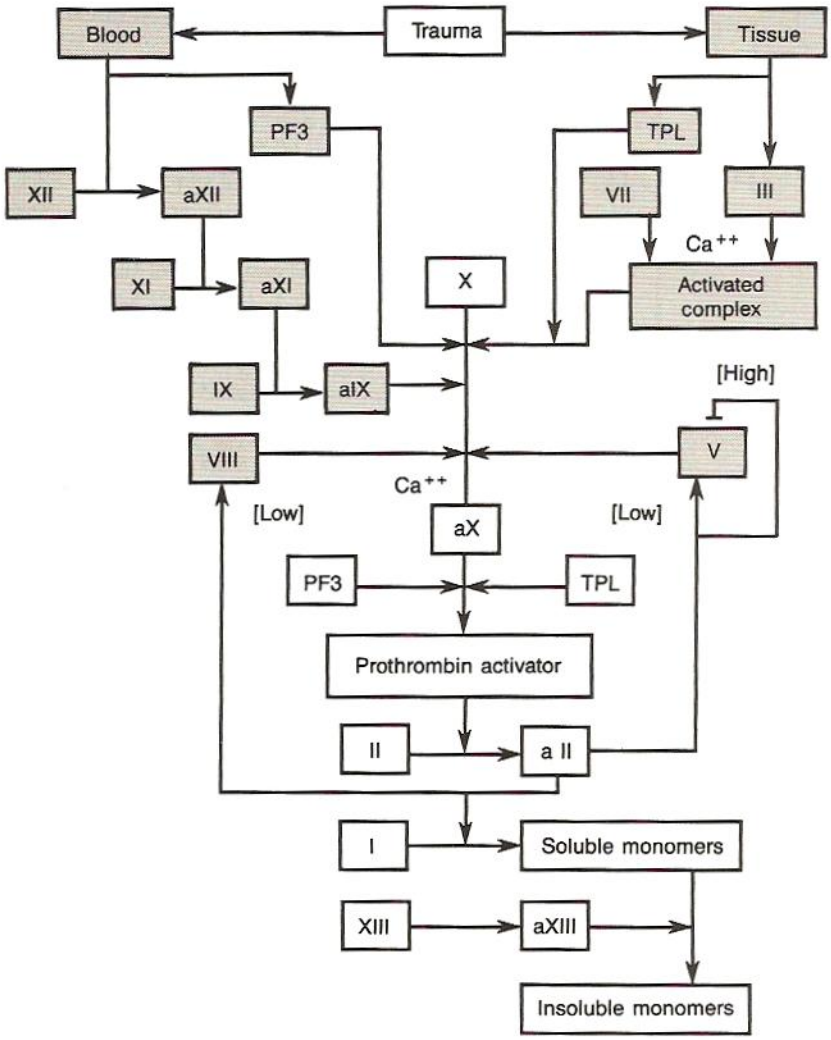

Figure 11-35. Coagulation schemes. The extrinsic pathway begins with tissue trauma and terminates with the activation of Factor X. The intrinsic pathway begins with blood trauma and terminates with the activation of Factor X. The common pathway begins with the activation of Factor X. a, Activated; *TPL*, tissue phospholipid; *PF3*, platelet factor 3.

Factor XI into **activated Factor XI.** This conversion occurs rapidly. Activated Factor XI acts enzymatically upon **Factor IX** to convert it rapidly to **activated Factor IX.** Activated Factor IX, along with **Factor VII** and PF3, activates **Factor X.** Bleeding problems attributable to decreased platelets (**thrombocytopenia**) are manifested because of the inability to activate Factor X via the intrinsic pathway.

Common pathway. The **common pathway** begins with the activation of **Factor X,** brought about by the combination of various substances (Factor III, calcium, Factor VII, and tissue phospholipids) involved in the extrinsic pathway. Similarly PF3, Factor IX, and Factor VII combine to activate Factor X through the intrinsic pathway.

Activated Factor X combines with **Factor V** and platelet and/or tissue phospholipids to form **prothrombin activator substance.** Prothrombin activator substance then initiates the activation of **Factor II (prothrombin)** to **activated Factor II (thrombin).** The major role of thrombin is to convert **fibrinogen (Factor I)** to **soluble fibrin monomers.** Fibrin monomers are cross linked by **activated Factor XIII** to form insoluble fibrin polymers. The polymerization process stabilizes the fibrinous clot. Trace amounts of thrombin also increase the activities of Factors V and VIII. High concentrations of thrombin cause digestion of Factor V. Thus thrombin production both increases and subsequently decreases its own production.

Functional correlates. The liver is an essential organ for normal coagulation mechanisms: most coagulation factors, except Factor VIII, are synthesized by the hepatocytes. Factor VIII is synthesized primarily by endothelial cells. Proper coagulation depends upon normal hepatocytes, because the half-lives of the coagulation factors vary from a few hours to a few days.

Vitamin K is a fat-soluble vitamin produced by the intestinal flora in sufficient quantities that deficiencies should not occur. Its absorption depends upon bile salt production. Liver disease can cause a vitamin K malabsorption and subsequent deficiency. The synthesis of coagulation Factors II, VII, IX, and X is vitamin K–dependent. Without this vitamin, bleeding problems can occur.

Regulation of coagulation is necessary to prevent a positive feedback effect. The most important blood anticoagulants are those removing thrombin. A natural coagulation inhibitor, an α-globulin called **antithrombin III (AT III),** implements its anticoagulant properties by complexing with the coagulation factors called **serine proteases.** The serine proteases (those coagulation factors with serine at their enzymatic site) are Factors II, VII, IX, X, XI, and XII. The complexes, such as AT III–Factor II, are then removed from the blood by the liver. Heparin functions as an anticoagulant by enhancing the inhibition of coagulation through AT III.

Clot formation and fibrinolysis. Despite the so-called irreversibility of blood clots, they are not permanent structures. The cascading effects of the clotting and coagulation mechanisms, once initiated, do not continue unregulated under normal circumstances. The fibrinolytic mechanism is outlined in Figure 11-36. Unfortunately, not all the details of this mechanism are understood.

The cessation of clot formation assists with ultimate clot removal. One limiting factor in clot formation is fibrin's ability to absorb the generated thrombin. The absorptive process limits both clot growth and clot spread.

The dissolution of an insoluble clot depends upon enzymatic digestion by a serine protease called **plasmin** or **fibrinolysin.** Its precursors occur as plasma proteins called **plasminogen** or **prefibrinolysin.** A delicate balance exists between plasmin activators and plasmin inhibitors. The precursor molecules, some of which become entrapped within forming clots, are activated by various substances—activators released from damaged endothelial cells, activated Hageman factor (Factor XII), thrombin, and lysosomal enzymes from damaged tissues. Once generated, plasmin digests fibrin, fibrinogen (Factor I), prothrombin (Factor II), and Factors V, VII, and XII. Plasmin not only digests clots, it interferes with the coagulation mechanism by digesting coagulation factors.

An α_2-globulin called **antiplasmin** normally inhibits plasmin generation. The incorporation of plasmin precursors into the forming thrombus may serve as a device to protect the plasmin-generation mechanism from antiplasmin inhibition. Also fibrinolysin generation within the

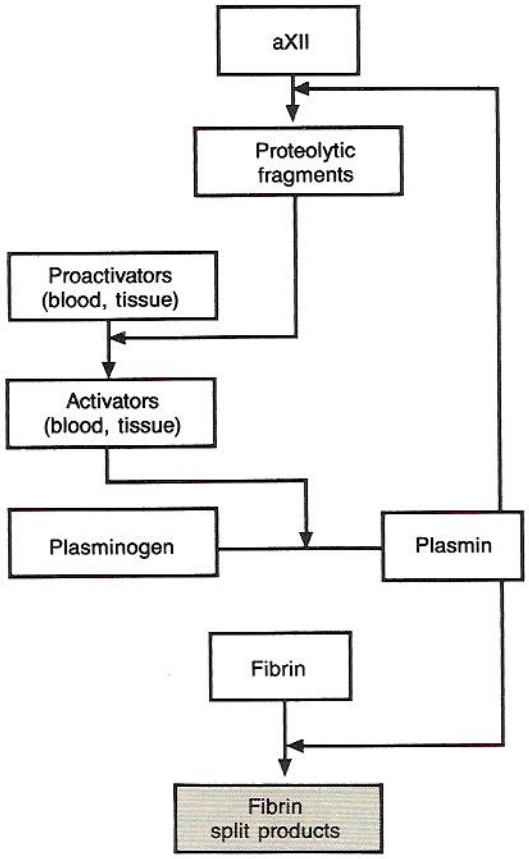

Figure 11-36. Fibrinolytic mechanism. Plasmin degrades fibrin into fibrin split products and exerts a positive feedback influence upon activated Hageman factor.

thrombus limits the proteolytic activity to localized fibrin accumulations. This localized entrapment precludes plasmin from digesting circulating factors, an effect that could compromise the ability to achieve subsequent coagulation.

Certain bacteria use the plasmin system to assist their spread throughout the body. Streptococcal organisms release an activator enzyme, called **streptokinase,** that activates plasmin. Plasmin dissolves clots within blood, lymphatic fluid, and tissue fluid. This facilitates bacterial spread throughout a fluid environment, rather than their being confined within the semisolid environment of a clot.

ADDITIONAL READINGS

Erythrocytes

Baker RF: Ultrastructure of red blood cells, *Fed Proc* 26:1785, 1967.

Fisher JW, Gordon AS: Conference: erythropoietin, *Ann NY Acad Sci,* vol 149, 1968.

Hevesy G, Ottesen J: Life-cycle of the red corpuscle of the hen, *Nature* 156:534, 1945.

Hillman RS, Finch CA: *The red cell manual,* ed 4, Philadelphia, 1974, FA Davis.

Kochler JK: Freeze-etching observations on nucleated erythrocytes with special reference to the nuclear and plasma membranes, *Z Zellforsch* 85:1, 1972.

Jain NC, Zinkl JG (eds): Symposium on clinical hematology, *Vet Clin North Am* 11:187, 1981.

London IM: Iron and heme: crucial carriers and catalysts. In Wintrobe MM (ed): *Blood, pure and eloquent,* New York, 1980, McGraw-Hill.

Marks P, Rifkind RA: Protein synthesis: its control in erythropoiesis, *Science* 175:955, 1972.

Schalm OW: Hematologic characteristics of autoimmune hemolytic anemia in the dog, *Calif Vet* 23:19, 1969.

Granulocytes

Archer GT, Hirsch JC: Motion picture studies of degranulation of horse eosinophils during phagocytosis, *J Exp Med* 118:287, 1963.

Beeson PB, Bass DA: *The eosinophil,* Philadelphia, 1977, WB Saunders.

Dolowy WC, Cornet J, Henson D: Particles in leukocytes of normal human beings after negative staining in electron microscopy, *Nature* 209:1358, 1966.

Dvorak AM, Dvorak HF: The basophil, *Arch Pathol Lab Med* 103:551, 1979.

Hamre CJ: Origin and differentiation of heterophil, eosinophil and basophil leucocytes of chickens, *Anat Rec* 112:339, 1952.

Hersh IG, Cohn ZA: Degranulation of polymorphonuclear leucocytes following phagocytosis of microoganisms, *J Exp Med* 112:1005, 1960.

Miller F, DeHarven E, Palade GE: The structure of eosinophil leucocytes granules in rodents and in man, *J Cell Biol* 31:349, 1966.

Natt MP, Herrick CA: Variation in the shape of the rodlike granule of the chicken heterophil leucocyte and its possible significance, *Poult Sci* 33:828, 1954.

Zucker-Franklin D: Electron microscopic study of human basophils, *Blood* 29:878, 1967.

Agranulocytes

Elves MW: *The lymphocytes,* London, 1966, Lloyd Luke.

Fiore-Donati L, Hanna MG Jr: *Lymphatic tissue and germinal centers in immune response,* New York, 1969, Plenum.

Gowans JL: The life history of lymphocytes, *Br Med Bull* 15:50, 1959.

Gowans JL: The immunological activities of lymphocytes, *Prog Allergy* 9:1, 1965.

Greaves MR, Owen JJT, Raff MC: *T and B lymphocytes: origins, properties, and roles in immune responses,* New York, 1975, North-Holland.

Hoshino T, et al: Early development of thymic lymphocytes in mice, studied by light and electron microscopy, *Anat Rec* 164:47, 1969.

Mackay LJ, Jarrett WFH, Coombs RRA: Two populations of lymphocytes in a cat, *Vet Rec* 96:41, 1975.

Movat HZ, Fernando NVP: The fine structure of the lymphoid tissue during antibody formation, *Exp Molec Pathol* 4:155, 1965.

Tizard IR: *An introduction to veterinary immunology,* ed 3, Philadelphia, 1987, WB Saunders.

Tompkins EH: The monocyte, *Ann NY Acad Sci* 59:732, 1955.

Zinkl JG: The leukocytes, *Vet Clin North Am* 11:237, 1981.

Platelets and Thrombocytes

Behnke O: Electron microscopic observations on the membrane systems of the rat blood platelet, *Anat Rec* 158:121, 1967.

Carlson HC, Sweeney PR, Tokaryk JM: Demonstration of phagocytic and trephocytic activities of chicken thrombocytes by microscopy and vital staining techniques, *Avian Dis* 12:700, 1968.

Clarke JA, Hawkey C, Salisbury AJ: Surface ultrastructure of platelets and thrombocytes, *Nature* 233:401, 1969.

Rodman NF, Mason RG: Platelet-platelet interaction: relationship to hemostasis and thrombosis, *Fed Proc* 26:95, 1967.

Simpson CF: Ultrastructural features of the turkey thrombocyte and lymphocyte, *Poult Sci* 47:848, 1968.

Comparative Hematology

Afonsky D: Blood picture in normal dogs, *Am J Physiol* 180:456, 1955.

Archer RK: *Haematological techniques for use in animals,* Oxford, 1965, Blackwell Scientific.

Benjamin MM: *Outline of veterinary clinical pathology,* ed 3, Ames, 1978, Iowa State University Press.

Calhoun ML, Brown EM: Hematology and hematopoietic organs. In Dunne HW (ed): *Swine diseases,* Ames, 1975, Iowa State University Press, pp 33-75.

Diggs LW, Sturm D, Bell A: *The morphology of human blood cells,* Chicago, 1970, Abbott Laboratories.

Ferguson LC, Irwin MR, Beach BA: On variation in the blood cells of healthy cattle, *J Infect Dis* 76:24, 1945.

Holman HH: A negative correlation between size and number of the erythrocytes of cows, sheep, goats and horses, *J Pathol Bacteriol* 64:379, 1952.

Lucas AM: A discussion of synonymy in avian and mammalian hematological nomenclature, *Am J Vet Res* 20:887, 1959.

Rich LJ: *The morphology of canine and feline blood cells with equine references,* St Louis, 1974, Ralston Purina.

Schalm OW, Jain NC, Carroll EJ: *Veterinary hematology,* ed 3, Philadelphia, 1975, Lea & Febiger.

Winthrobe MM: *Clinical hematology,* ed 7, Philadelphia, 1974, Lea & Febiger.

Wintrobe MM, Shumacker HB Jr, Schmidt WJ: Values for number, size and hemoglobin content of erythrocytes in normal dogs, rabbits, and rats, *Am J Physiol* 114:502,1936.

Hemostasis

Bennett B, Douglas AS: Blood coagulation mechanism, *Clin Haematol* 2:3, 1973.

Day HJ: Role of platelets in hemostasis and thrombosis, *Ser Haematol* 8:23, 1975.

Dodds WJ: The diagnosis, management and treatment of bleeding disorders. I and II, *Mod Vet Pract* 58:680, 756, 1977.

Hall DE: *Blood coagulation and its disorders in the dog,* London, 1972, Ballière Tindall.

Kirk RW (ed): *Current veterinary therapy VI. Small animal practice,* Philadelphia, 1977, WB Saunders, p 421.

CHAPTER 12

Hematopoiesis

DEVELOPMENT OF BLOOD

General Characteristics

Blood cell replacement (**hematopoiesis**) occurs through stem cell activities confined to specific regions. During early prenatal development, hematopoiesis begins in the mesenchyme as yolk sac-associated blood islands. Hematopoietic activity becomes widespread in the fetal liver, spleen, thymus, lymph nodes, and bone marrow. Postnatal formation of RBCs, granulocytes, and platelets is confined primarily to the red bone marrow. The spleen is also involved, to a lesser degree.

During early development the thymus is the primary lymphocytopoietic organ. The spleen and remaining lymphoid tissues then produce agranulocytes throughout the life of the organism.

Colony-forming unit. The current concept is that a **colony-forming unit (CFU)** is the pluripotent blood stem cell (Fig. 12-1). Because this cell was identified from spleen colony studies, it is designated CFU-S. The CFU-S is responsible for the differentiation and proliferation of cell clones called **colonies.** CFU-Ss occur in the classical hematopoietic tissues and also circulate in the blood, differentiating into and proliferating as the various blood cells.

The CFU-S is a small cell, with a diameter between 7 and 10 μm and ultrastructural features similar to those of a small lymphocyte. Some scientists call this cell a **candidate stem cell,** because the evidence for its function is all indirect.

Developmental determinants. In culture, colonies of specific blood cells develop from CFUs in response to specific inducer substances. **Erythropoietin** induces a committed stem cell to produce morphologically identifiable RBC precursors. A **burst-forming unit–erythropoietic (BFU-E)** is an early progenitor in the series giving rise to committed stem cells. The committed progenitor for the series is the **CFU-E (colony-forming unit of the RBC line of differentiation** or **CFU-erythrocytic).** Various other factors, including **granulopoietin** and **thrombopoietin,** serve as the basis for identifying six distinctive lines of differentiation—**erythrocytic (CFU-E), megakaryocytic (CFU-Meg), granulocytic and monocytic (CFU-GM), eosinophilic (CFU-EO), B lymphocytic (CFU-BL),** and **T lymphocytic (CFU-TL).** Little is known about the origin of basophils.

Besides the various inducer or regulatory factors, other substances can influence the proliferation and differentiation of stem cells—the environment, the marrow cellular populations, and cell-to-cell interactions. The **hematopoietic inductive environment (HIM),** which differs within different hematopoietic organs, may be set by the stromal cells.

Trends in development. The differentiation of mature RBCs and granulocytes includes sequential changes that typify development (Fig. 12-2). Early cells are large and become smaller with maturation. In the RBC series the nucleus is extruded from the cell. The nucleus of early cells is light-staining and acidophilic. With maturation it becomes darker and basophilic. Similarly, the cytoplasm of early cells is basophilic and becomes progressively acidophilic. Stem cell nuclei are large, round, and light-staining. Their chromatin forms a fine reticulum. With maturation the nuclei become indented, lobed, or segmented, and the chromatin stains more darkly and is clumped.

Early cells do not usually have granules. In the granulocytic series they are nonspecific and are replaced or augmented by specific granules. Early cells have one or more nucleoli, but these are not apparent as development moves toward maturation. Also mitotic activity is high in primitive cells during normal development. Similar trends are also characteristic of the agranulocytic series.

Bone Marrow

Marrow tissue is a hypercellular and highly vascularized connective tissue. It is contained within the **medullary cavity (marrow cavity)** in all bones. During development and growth all the marrow is **red bone marrow.** By adulthood the red bone marrow is confined to a limited number of loci: sternebrae, ribs, vertebrae, and cranial bones. The other sites will have been replaced by **yellow bone marrow.**

The peripheral limit of the marrow is the cortical endosteum, while trabecular endosteum occurs within the marrow substance. The acquisition of blood-cell formative and blood-cell destructive functions, though acquired secondarily, is maintained throughout life.

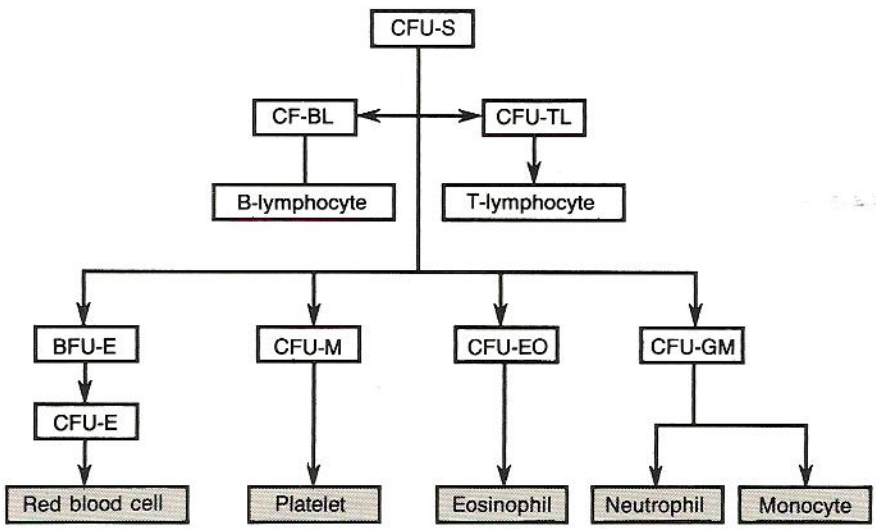

Figure 12-1. Origin and differentiation of blood cells from a pluripotent stem cell.

Downloaded From Vet-eBooks.com



Figure 12-2. Cellular changes associated with the differentiation of blood cells. **A,** The large, pale-staining nucleus becomes progressively smaller with development; the nucleus is extruded in the erythrocytic series; the basophilic cytoplasm becomes progressively lighter as development progresses. **B,** Nuclear and cytoplasmic size is reduced during development; more heterochromatin becomes obvious during progress toward the mature cell. **C,** The stages of development of erythrocytes can be compared to the generalities shown in **A** and **B.** (Modified and redrawn from Diggs LW, Sturm D, Bell A: *The morphology of blood cells*, North Chicago, 1954, Abbott Laboratories.)

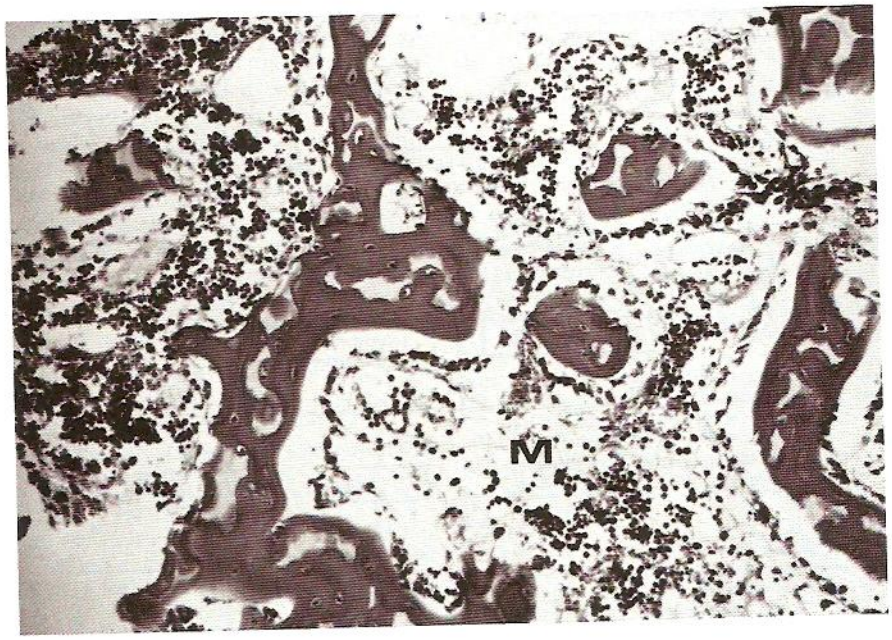

Figure 12-3. Red bone marrow within the medullary cavity of a developing bone. The bone marrow *(M)* occupies the interosseous spaces between the developing osseous and calcified cartilaginous spicules of the primary spongiosa. (X40.)

Red bone marrow. The red color of bone marrow results from the accumulation of RBCs, RBC precursors, and their contained pigment. **Red bone marrow** is often called **myeloid tissue.** RBCs, granulocytes, platelets, and agranulocytes are produced within it.

The marrow consists of arteries, veins, sinuses, a reticular fiber framework, free cells of the blood cell lineages, macrophages, and some adipose tissue (Fig. 12-3). It is divisible into two compartments: vascular and hematopoietic. The **vascular compartment** includes all bone marrow vessels. The sinuses are lined by endothelial cells with macrophages positioned as perivascular cells. The **hematopoietic compartment** consists of irregular islands of tissue between the vascular beds. It includes reticular cells, reticular fiber stroma, CFUs, macrophages, intermediate and mature blood cell forms, adipose tissue, and other typical connective tissue cells (plasma cells, mast cells) (Fig. 12-4). Red bone marrow produces blood cells.

Yellow bone marrow. Adipose tissue replaces most blood cell–producing elements of the hematopoietic compartment. Under conditions of stress (including disease), the **yellow bone marrow** can revert to an active hematopoietic tissue.

Erythropoiesis

Cytology of differentiation. The following cells comprise the erythrocytic series: **proerythroblast, basophilic erythroblast, polychromatophilic erythroblast, acidophilic erythroblast, reticulocyte, mature red blood corpuscle** (Figs. 12-1 and 12-2).

The **proerythroblast (rubriblast)** is the earliest recognizable form of this series. Its nucleus is primitive, being vesicular with a prominent nucleolus. A thin rim of dark blue cytoplasm surrounds the nucleus. The nuclear/cytoplasmic ratio is high.

The **basophilic erythroblast (prorubricyte)** is smaller than the proerythroblast, has coarse nuclear chromatin and a basophilic cytoplasm. Its nucleolus is not defined or is absent. Mitotic activity is high.

The **polychromatophilic erythroblast (rubricyte)** is a small cell with a small, round, and dense nucleus. Nucleoli are not apparent. Its cytoplasm begins with a mottled basophilia, becomes polychromatophilic, and finally has an acidophilic appearance. These changes are linked with a progressive increase in hemoglobin and a progressive decrease in ribonucleoprotein (Plate VII, *2* and *22*). Mitotic activity is high.

The **acidophilic orthochromatic erythroblast (metarubricyte)** has a cytoplasm similar to that of mature RBCs (Plate VII, *5*). Its nucleus becomes condensed and eventually pyknotic. The nucleus is lost either by simple extrusion from the cell or by

Downloaded From Vet-eBooks.com

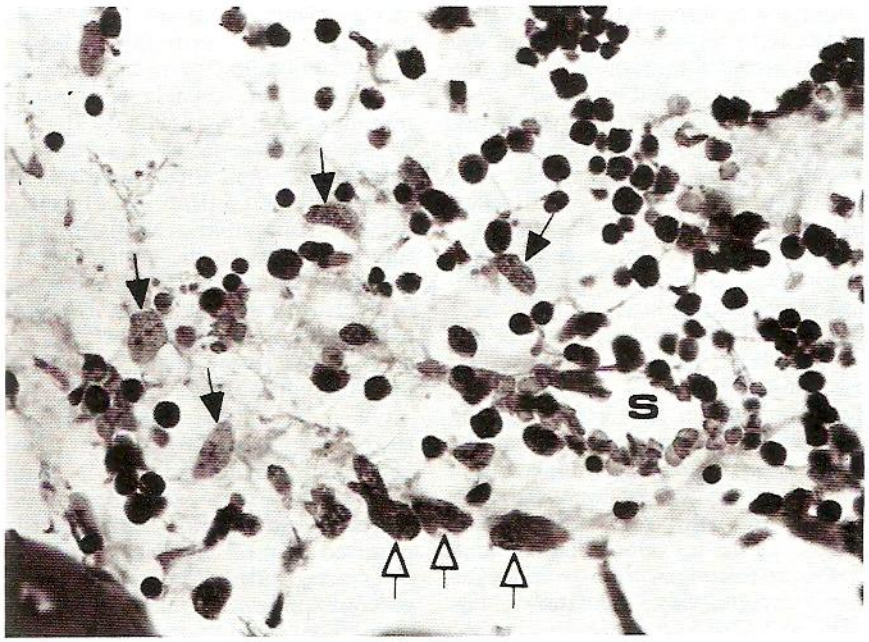

Figure 12-4. Elements of red bone marrow. Reticular cells *(solid arrows)* comprise a cytoreticulum and produce the reticular fiber stroma. Many free blood cells are in various stages of development. A sinus *(S)* and osteoblasts *(open arrows)* are apparent. The osteoblasts were separated artifactually from their osseous surface. (X160.)

karyolysis. The resulting enucleated cell is the **reticulocyte.** The cytoplasm is diffusely basophilic, and with special staining techniques a fine reticulum is apparent. Ribosomes, polyribosomes, and mitochondria are still present and account for an increased cytoplasmic basophilia. Some reticulocytes occur normally in the peripheral blood. Hemoglobin accumulation results in a mottled cytoplasmic appearance. Hemoglobin synthesis increases and organelles decrease during this stage. A continuation of this process forms the mature RBC.

The circulating erythrocytes of the embryo are nucleated and probably represent metarubricytes.

Granulocytopoiesis

The cytodifferentiation known as **granulocytopoiesis** includes a reduction in size, a decreased nuclear/cytoplasmic ratio, a decreased cytoplasmic staining intensity, and the appearance of specific granules.

Cytology of differentiation. The following cells comprise the granulocytic series: myeloblast, promyelocyte, myelocyte, metamyelocyte, mature granulocyte, band cell (Figs. 12-1 and 12-2).

The **myeloblast** has a 15 to 20 μm diameter. Its basophilic cytoplasm is unevenly stained, being darker at the periphery than in the perinuclear region. Its nucleus is large, finely reticular, and red-staining. Two or more nucleoli may be observed. The myeloblast is larger than the rubriblast and has more cytoplasm.

The **promyelocyte** is a large cell. Its nucleus is round with coarse chromatin. Nucleoli are not readily observed. Its cytoplasm, though basophilic, contains acidophilic regions. Acidophilic and basophilic granules are present. There is a gradual decrease in **nonspecific granules (primary granules).** The primary or **azurophilic** granules are lysosomes. Primary granule synthesis is initiated in this stage. These granules form in large numbers but decrease toward the mature granulocyte. Promyelocytic mitotic activity is high.

The **myelocyte** may be basophilic, eosinophilic, or neutrophilic when it is identified by the staining affinity, size, and shape of its specific granules. Its nucleus is smaller and its chromatin more coarse than in the previous stages. A nucleolus is not present. The nucleus is oval, and a slight indentation may be apparent. The decreased cytoplasmic basophilia is complemented by an increased number of **specific granules.** Mitotic activity is high.

The nature of the specific granules varies with the specific granulocytes. The neutrophilic myelocyte and its mature progeny have two granules. The primary granules are lysosomes. The specific granules may contain some lysosomal enzymes, but bacteriocidal and bacteriostatic substances are common. The specific granules of eosinophils are lysosomes. Basophilic granules are lysosomes and granules with vasoactive substances.

The **basophilic, eosinophilic,** and **neutrophilic metamyelocyte** has a bean-shaped or horseshoe-shaped nucleus. Its cytoplasm is slightly acidophilic and filled with specific granules of the individual cell line. Progressive indentation results in the lobed nucleus of **mature granulocytes.**

Neutrophilic granulocytes are the predominant granulocytes of the mycloid tissue and peripheral blood. Immature neutrophils are commonly encountered in the peripheral blood. A **neutrophilic metamyelocyte** is also called a **juvenile.** The progressive nuclear indentation results in a **neutrophilic band cell** (Plates VI, *23,* and VII, *1* and *3*). The nucleus of this cell is horseshoe-shaped. The subsequent nuclear lobulation produces a mature cell called a **neutrophil.**

Thrombocytopoiesis

Cytology of differentiation. The cells comprising the platelet formation series are **megakaryoblast, promegakaryocyte, megakaryocyte, metamegakaryocyte, and platelets** (Fig. 12-1).

The rare **megakaryoblast** has a lightly basophilic cytoplasm and a red-staining, finely granular nucleus. The peripheral cytoplasm has pseudopodia and a few foamy vacuoles.

The **promegakaryocyte** is larger than the previous cell type, and two nuclei may be present. The cytoplasm is slightly basophilic and contains many basophilic granules. Foamy, cytoplasmic blebs may be apparent at the periphery.

The **megakaryocyte** is larger than the promegakaryocyte. Karyokinesis occurs, and as many as 32 nuclei may form. These fuse to form the cell's typical lobed nucleus. The cytoplasmic volume is large and acidophilic. Vacuoles and pale-staining areas are scattered among the evenly distributed, lightly basophilic granules.

The **metamegakaryocyte** is the largest cell in the series. It is similar to the megakaryocyte, except cytoplasmic granules aggregate and platelets appear at its periphery.

The cells in this series get larger and increase the number of nuclei per cell—the reverse of the trend in the aforementioned series. Mitosis **(endomitosis)** occurs in which nuclear separation **(karyokinesis)** is not accompanied by a cytoplasmic separation **(cytokinesis).**

Platelets form from metamegakaryocytes by an exocytotic process; they pinch off from the cell surface.

Agranulocytopoiesis

General characteristics. Agranulocytes (lymphocytes, monocytes, macrophages, and plasma cells) develop in the lymphoid organs and bone marrow. The development of these cells is not as clearly

Downloaded From Vet-eBooks.com

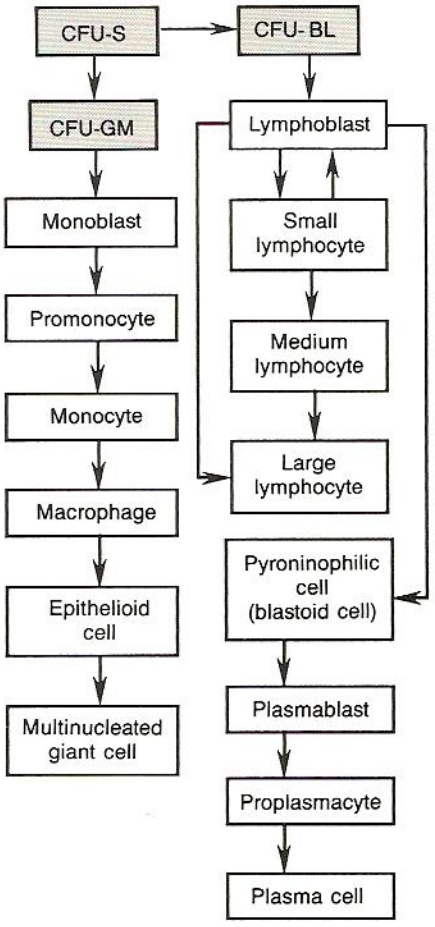

Figure 12-5. Established relationships among agranulocytes.

defined as it is for the previous series. Figure 12-5 is a summary of the known relationships.

Lymphocytopoiesis and plasma cells. The mononucleated leukocytes are derivatives of CFUs—CFU-GM (for granulocytes and monocytes), CFU-BL (for B lymphocytes), CFU-TL (for T lymphocytes).

Lymphoblasts are the largest cells of this series. They have large, round vesicular nuclei with one or more prominent nucleoli and a basophilic cytoplasm. Progressive differentiation and mitosis result in a cell, called a **large lymphocyte,** with a nucleus containing coarsely clumped heterochromatin. These are referred to as **prolymphocytes** or **medium lymphocytes** by some authors. Subsequent division results in **small lymphocytes.** Any lymphocyte can enter the peripheral circulation.

Small lymphocytes are not fixed postmitotic cells. Under appropriate stimulation they can dedifferentiate into lymphoblasts capable of producing more small lymphocytes. Also, with appropriate antigenic stimulation, the small lymphocyte is converted to an **immunoblast.** Small lymphocytes undergo a blastoid transformation into **plasmablasts. Plasmablasts** and **proplasmacytes** are not distinct and identifiable cytological intermediates in the **plasma cell** series.

Origin of lymphocytes. During embryonic life, stem cells are produced sequentially in the yolk sac, liver, and spleen (Fig. 12-6). Lymphocytes differentiate in the liver and spleen. Stem cells then populate the bone marrow, which functions as the major source for two lymphocyte populations.

One stem cell population (CFU-TL) leaves the bone marrow and populates the thymus. These cells proliferate and differentiate within this organ. During **peripheralization** lymphocytes from the thymus **(T lymphocytes)** populate specific regions of lymph nodes and the periarteriolar zone of splenic corpuscles, becoming the basis for cell-mediated immunity and interacting with B lymphocytes to induce antibody formation (Fig. 12-6).

The organs involved in the development of **B lymphocytes** in mammals have not been characterized completely. Stem cells leave the bone marrow and populate the bursal equivalent. In birds these cells infiltrate the bursa of Fabricius and subsequently populate secondary lymphatic organs. It seems that B cells in mammals complete their development in the spleen. After populating the spleen and other lymphopoietic organs, these cells populate the secondary lymphatic organs—**germinal centers of lymphatic nodules.** The B cells produced here synthesize antibodies (humoral antibody response) and are capable of transformation into plasma cells (Fig. 12-6).

Monocytopoiesis. Monocytes originate in the bone marrow from CFU-GMs. The stem differentiates further and becomes committed as a CFU-M. Immature monocytes in the bone marrow are larger than, but similar to, their mature counterparts. The large oval or round nucleus has numerous nucleoli. These **promonocytes** are difficult to distinguish from granulocytic precursors.

KINETICS OF BLOOD

The finite existence of blood cells requires that old and/or damaged cells be removed from the circulation and new elements be added. Many organs participate in blood cell formation and destruction. The bone marrow, spleen, and other organs that contain macrophages are also involved in blood cell destruction. The liver contributes to iron metabolism and retains its fetal potential for hematopoiesis. Gastrointestinal system components contribute to erythrogenesis by absorbing iron and producing **intrinsic factor.** Intrinsic factor exists in humans but may not occur in domestic animals. The kidney regulates erythropoiesis through its generation of **erythropoietin.** The balance between production and

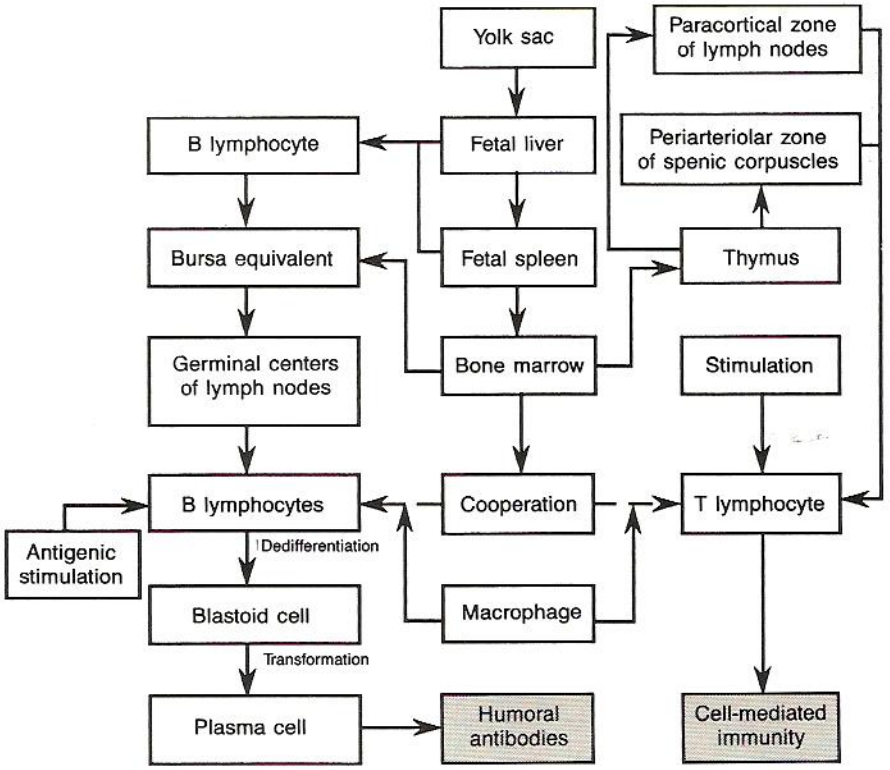

Figure 12-6. Origin, fate, and function of B and T lymphocytes.

turnover is affected by disruptions to the normal contributions by these organs.

Erythrokinetics

Life cycle of erythrocytes. The extrusion of its nucleus, the synthesis of its hemoglobin, and its biconcave shape all ensure that the RBC will have maximal oxygen-carrying capacity and a high volume to surface ratio. The ultimate stimulation for erythropoiesis is **tissue hypoxia** (Fig. 12-7).

The kidney and other organs respond to hypoxia by releasing **renal erythropoietic factor (REF), erythrogenin.** Renal hypoxia may cause the release of a prostaglandin (E_2) that sequentially activates cyclic adenosine monophosphate, a protein kinase, and the synthesis of renal erythropoietic factor. This factor reacts with a plasma α-globulin originating in the liver to produce **erythropoietin (EP).** Then EP stimulates CFU-Es to differentiate into proerythroblasts. EP does not seem to influence the mitotic activity of BFU-Es, but the division of these cells gives rise to numerous CFU-Es. EP also induces proerythroblasts, basophilic erythroblasts, and early polychromatophilic erythroblasts to increase their mitotic activity. Removal of the kidneys does not result in a loss of EP. Other organs, most likely the liver, produce this regulatory substance.

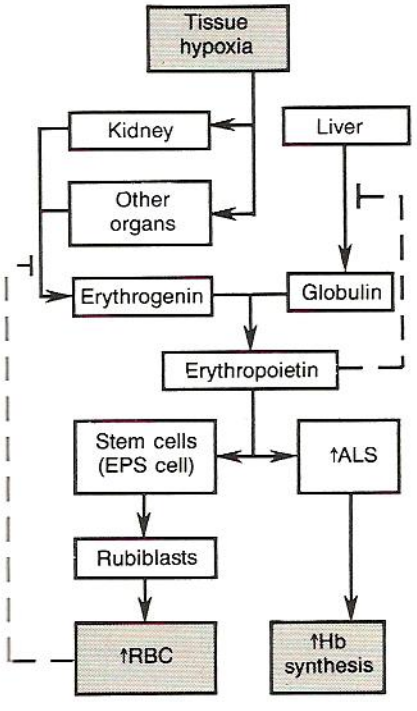

Figure 12-7. Factors in the regulation of erythropoiesis. *Arrows* represent direction of flow and/or stimulation. *Bars* represent inhibition. *EPS cells,* Erythropoietin-sensitive cells; *ALS,* aminolevulinic acid synthetase; *Hb,* hemoglobin.

Although such stimulation is immediate, increased numbers of RBCs are not noted in the peripheral circulation for about 3 days. The normal proliferation and differentiation cycle within the bone marrow takes 3 to 5 days. Deleted mitoses and the early release of immature forms can occur, but the number of erythrocytes is not increased.

A progenitor cell (CFU-E) and its descendants undergo four mitoses in a span of 5 days to produce 16 erythrocytes. Mitotic activity ceases in the late polychromatophilic erythroblast stage.

The BFU-Es circulate in the blood, but the CFU-Es seem to be confined to the hematopoietic tissues. The circulating levels of the BFU-Es is increased during severe anemia and may be the means by which yellow bone marrow becomes reactivated.

The life span of domestic animal RBCs is variable (Table 12-1). Reticulocytes occur rarely in normal blood of animals with an average RBC life span greater than 100 days. As RBCs age, they are removed from circulation by macrophages, especially those of the spleen. Because the number of RBCs is a homeostatic parameter of the blood, erythropoiesis must equal erythroclasia. A medium-sized dog produces and destroys about 5×10^7 RBCs/minute.

Hemoglobin synthesis, destruction, and reutilization. **Hemoglobin** is a **chromoprotein** that consists of **heme** and **globin.** Heme is a protoporphyrin plus ferrous iron synthesized in mitochondria. Hemoglobin constitutes about 95% of the mature RBC dry weight. Variations in the amino acid sequence account for different types of hemoglobin (embryonic, fetal, and adult).

Old RBCs are removed from the circulation by macrophages. Although the spleen is the primary organ for erythroclasia, this also occurs in the bone marrow and liver. Subtle membrane alterations and increased RBC fragility probably account for the phagocytosis. All components of the hemoglobin molecule are reutilized (Fig. 12-8).

Hemoglobin is split into its two components. The globin is hydrolyzed to its component amino acids. Iron is removed, leaving the protoporphyrin, and becomes bound to plasma transferrin. It is thus transported to the bone marrow for reutilization. Ferritin and hemosiderin are iron storage forms in bone marrow and splenic macrophages.

The protoporphyrin is converted to **biliverdin** and then to **bilirubin.** Bilirubin is transported in the plasma bound to plasma proteins in the **unconjugated** form of bilirubin. Bilirubin enters hepatocytes and is conjugated to a glucuronide by the activity of the enzyme **glucuronyl transferase.** This **conjugation to bilirubin glucuronide** is a biotransformation process, making bilirubin water-soluble. Trace amounts of bilirubin reenter the circulation and are excreted by the kidney as **urobilinogen.**

Most conjugated bilirubin is secreted by hepatocytes as the major bile pigment. Bilirubin absorbed by the small intestine recirculates to the liver via the **enterohepatic circulation.** Further alteration of bilirubin occurs in the intestine. The resultant compounds, **urobilin** and **stercobilin,** are eliminated in the feces and impart the characteristic color to fecal material.

An excessive amount of bilirubin imparts a yellow hue to the tissues. This condition, **jaundice (icterus),** occurs under various circumstances. Excessive RBC destruction **(hemolytic jaundice)** is characterized by increased quantities of unconjugated bilirubin. Bile duct obstructions are characterized by increased quantities of conjugated bilirubin.

Table 12-1. Average Life Span of Erythrocytes

	Days
Canid	120
Felid	73
Equid	145
Bovid	159
Ovid	110
Caprid	125
Porcid	67

Granulokinetics

Neutrophils. **Neutrophils** proliferate and mature within the bone marrow (Fig. 12-9). Those released into the blood comprise **circulating** and **marginal pools.** They eventually leave the blood and permanently enter the **tissue pool.**

Five mitoses characterize a neutrophil's development. Myeloblasts and progranulocytes each divide once whereas myelocytes divide three times. Myelocytes become mature neutrophils in 5 days. A 3-to-5-day lag period occurs before a response from the bone marrow is noted in the peripheral blood. However, an increase in circulating neutrophils can occur rapidly by mobilizing marginal pool neutrophils. The marginal pool consists of neutrophils positioned along the walls of small vessels. This pool may equal the circulating pool (in dogs) or be two to three times the circulating pool (cats).

The half-life of neutrophils within the circulating pool is about 6 hours, and the pool is replaced about every 10 to 12 hours directly from the maturation pool. With normal neutrophil utilization the canine bone marrow has roughly a 5-day cell supply. Mature cells are the first neu-

Downloaded From Vet-eBooks.com

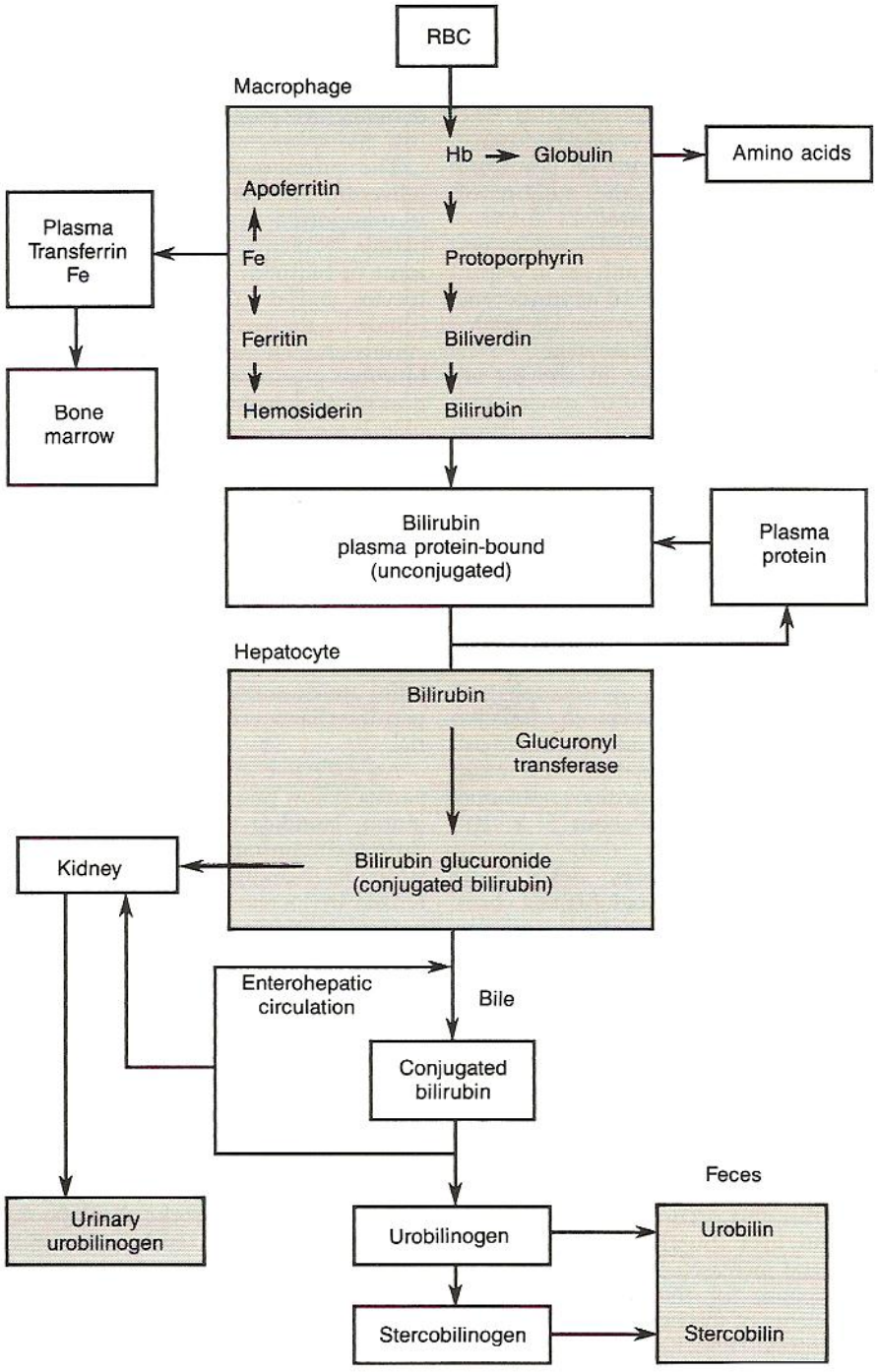

Figure 12-8. Extravascular metabolism of hemoglobin. Refer to the text for a complete description of the process.

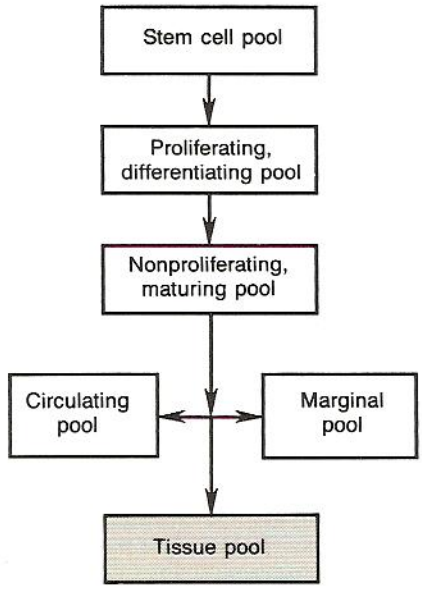

Figure 12-9. Flow and distribution of neutrophils within various pools in the body. The proliferating, differentiating pool consists of myeloblasts, progranulocytes, and myelocytes. The nonproliferating, maturing pool consists of metamyelocytes, band cells, and mature cells.

trophils mobilized from the maturation pool. As the demand for neutrophils increases, younger cells are released from the bone marrow. Even neutrophilic myelocytes may occur in the circulation during periods of extreme demand and excessive depletion of the maturation pool.

Neutrophilia is an increased number of circulating neutrophils. **Neutropenia** is a decreased number. A neutrophilia with a slight to moderate increase in the number of immature neutrophils (>3%) is called a **regenerative left shift.** A **degenerative left shift** is characterized by a low to slightly elevated neutrophil count in which the immature forms outnumber the mature neutrophils. A **right shift** is characterized by an increased number of older cells in which nuclear hypersegmentation is obvious.

Regulation of neutrophils. Many factors involved in the specific and nonspecific immune response—complement fragments, bacterial products, and tissue enzymes—influence granulocytic production and migration. Additionally, a glycoprotein called **colony-stimulating factor (CSF)** influences the mitotic activity of CFU-GMs and subsequent neutrophilic intermediates. This factor is released by macrophages responding to local inflammation, endotoxin, and some immunologic mediators. Prostaglandin release by macrophages inhibits the proliferative activity of the CFU-GM. Neutrophils also secrete a substance called **colony inhibiting activity (CIA),** which limits the proliferative activity of the CFU-GM despite normal levels of CSF being present. **Neutrophil-releasing activity (NRA)** or **leukocytosis-inducing factor (LIF)** is a circulating substance causing the release of immature neutrophils into the general circulation. Endotoxin induces an increased level of LIF.

Eosinophils. The maturation pattern, production time, life span, and circulation of the eosinophil are similar to those described for the neutrophil. The production time for the eosinophil is 3 to 6 days. Although circulating numbers of eosinophils are low, approximately 300 cells to every circulating eosinophil constitute the maturation pool. About 100 cells for every circulating cell constitute the proliferating pool.

The ultimate stimulation for an eosinophilia is the release of histamine from degranulated mast cells; however, this does not always result in **eosinophilia (eosinophilic leukocytosis).** Circulating histamine probably accounts for that. Various factors involved with immune respon-

Downloaded From Vet-eBooks.com

siveness are associated with increased numbers of eosinophils locally or in the circulation. Additionally, an **eosinophilopoietin** may exist.

Basophils. The small numbers of these cells within the body complicate kinetic studies of them. Their life span is 10 to 12 days. The functions of basophils are similar to those of mast cells.

Agranulokinetics

Lymphocytes. T lymphocytes are more numerous in the peripheral blood than B lymphocytes. T cells are long-lived, remaining in the body for months or years. Thymocytes are short-lived (3 to 4 days), and most degenerate within the thymus. B cells responsible for the **primary immune response** are short-lived; those responsible for the **secondary immune response** are long-lived. Accurate data concerning the life span of lymphocytes are difficult to obtain because of lymphocyte recirculation.

Large and medium-sized lymphocytes of the bone marrow, spleen, and lymph nodes seem to generate in about 8 hours. Small lymphocytes within these organs may require at least 4 days. In dogs, a sufficient number of lymphocytes enter the blood from the thoracic duct to indicate that all lymphocytes may be replaced every 12 hours.

Except for thymocytes, the common stimulator for lymphopoiesis is the presence of an antigen.

Circulating lymphocytes can gain access to lymph nodes by leaving the circulation through venules in the paracortical zones of lymph nodes. These venules are called **postcapillary venules.** Once inside the parenchyma of the lymph node, the lymphocytes may return to the vascular bed via the postcapillary venules; or they may enter the lymph node within the circulation and exit the blood at the postcapillary venules; or they may enter the efferent lymphatics and eventually return to the circulation through the thoracic duct. This **recirculation** phenomenon ensures that immunocompetent cells will be distributed widely and exposed to an antigen. Evaluation of lymphatic outflow from lymph nodes shows that 95% of these lymphocytes may be of blood origin and 5% of nodal origin. T cells appear to recirculate as much as five times faster than B cells.

Lymphocytosis is an increased number of lymphocytes. **Lymphopenia** is a decreased number. Certain types of disease processes cause a lymphocytosis (bacterial infection); others (viral) cause a lymphopenia.

Monocytes. **Monocytes** exist in a marginal pool along the luminal surface of endothelial cells that may be five times as large as the circulating pool. Because young monocytes leave the bone marrow rapidly, the maturation pool is small. Once they have gained access to the vascular compartment, they enter the tissues randomly. The tissue pool of macrophages (histiocytes) may be 400 times greater than the circulating pool of monocytes. Whereas the circulating half-life of human monocytes is about 8 days, the life span of histiocytes probably exceeds 100 days.

The regulation of monocyte proliferation is not understood completely. Those factors influencing the CFU-GM and resulting in an augmented neutrophil production influence the monocytes similarly.

EVALUATION OF BLOOD AND BONE MARROW

Whole blood evaluations invariably involve the use of substances inhibiting coagulation. **Anticoagulants** include **EDTA (ethylenediamine tetraacetic acid), heparin, sodium citrate,** and various salts of oxalic acid **(sodium oxalate, potassium oxalate)**. Heparin interferes with fibrin generation by functioning as an antithrombin and antithromboplastin. The other compounds arrest coagulation by forming insoluble salts with Ca^{++}. Often hematological evaluation requires the use of a blood sample with an anticoagulant added, a clotted blood sample for serum evaluations, and a blood smear for qualitative and quantitative evaluations.

Peripheral blood parameters. **Erythrocyte and white blood cell (WBC) counts** can be accomplished with automated systems; but the use of a **hemocytometer** is a quick, easy, and inexpensive counting method. RBCs and total WBCs are reported as the number of cells per cubic millimeter of blood. Often RBCs are not counted but the **packed cell volume (PCV)** is determined. The PCV is a valuable parameter related to RBC numbers and size.

The **differential count** of WBCs is accomplished on a stained blood smear. The count identifies the frequency of different WBCs when 100 or 200 WBCs are counted. Identification of mature and immature forms is a part of this subjective evaluation. It is customary to note other cell characteristics (anisocytosis, polychromasia, toxicity), the presence of nucleated RBCs, and any other notable features. A differential leukocyte count generates **relative values.** The percentages are converted to **absolute values** by multiplying the total WBC count by the percentage occurrence of each cell type, mature and immature.

The **mean corpuscular volume (MCV)** characterizes the RBC size. It is calculated by multiplying the PCV by 10 and dividing by the RBC count. The MCV is expressed in femtoliters (1×10^{-15} liter).

Hemoglobin concentration is determined with a **hemoglobinometer.** This simple technique determines **oxyhemoglobin** by its light absorption. Although the values obtained this way are less accurate (± 10%) than wet chemical methods for **cyanomethemoglobin,** they are useful for clinical evaluations.

The **mean corpuscular hemoglobin concentration (MCHC)** is used for distinguishing anemias as **normochromic** or **hypochromic.** The MCHC (g/dl) is calculated by dividing the hemoglobin concentration (g/dl) by the PCV and multiplying by 100.

The **erythrocyte sedimentation rate** is determined by using a tube of blood to which an anticoagulant has been added and noting the amount of RBC settling in a given time.

Total protein determinations can be made on serum or plasma sample by refractometry. **Electrophoresis** can also be accomplished. The **albumin/globulin (A/G) ratio,** normally 0.7 to 1, is a valuable diagnostic parameter determined by electrophoresis.

Bone marrow evaluation. Bone marrow evaluations can be used to gain more insights concerning peripheral blood. Different biopsy sites are used in different domestic animals. A bone marrow evaluation requires familiarity with the cytology of differentiation. A differential count of 500 cells is a valuable parameter. The **myeloid/erythroid (ME) ratio** is determined by dividing the total number of granulocytic cells by the total number of nucleated erythrocytic cells of the marrow differential count.

ADDITIONAL READINGS

Development of Blood

Ackerman GA: Ultrastructure and cytochemistry of the developing neutrophil, *Lab Invest* 19:290, 1968.

Barr RD, Whang-Peng J, Perry S: Hematopoietic stem cells in human peripheral blood, *Science* 190:284, 1975.

Behnke O: An electron microscope study of the megakaryocyte of the rat bone marrow. I. The development of the demarcation membrane system and the platelet surface coat, *J Ultrastruct Res* 24:412, 1968.

Calhoun LM: Bone marrow of horses and cattle, *Science* 104:423, 1946.

Calhoun LM: A cytological study of costal marrow. I. The adult horse, II. The adult cow, *Am J Vet Res* 15:181, 395, 1954.

Campbell FR: Nuclear elimination from the normoblast of fetal guinea pig liver as studied with electron microscopy and serial sectioning techniques, *Anat Rec* 160:539, 1968.

Chamberlain JK, Lichtman MA: Marrow cell egress: specificity of the site of penetration into the sinus, *Blood* 52:959, 1978.

Fedorko M: Formation of cytoplasmic granules in human eosinophilic myelocytes: an electron microscopicautoradiographic study, *Blood* 31:188, 1968.

Johnson FR, Roberts DB: The growth and division of human small lymphocytes in tissue culture: an electron microscopic study, *J Anat* 98:303, 1964.

Kaihotsu N: Electron microscopic studies on the maturation process of neutrophilic leucocytes, *Kobe J Med Sci* 13:47, 1967.

Downloaded From Vet-eBooks.com

Kato K: Monophyletic scheme of blood cell formation for clinical and laboratory reference, *J Lab Clin Med* 20:1243, 1935.
Loutit JF: Transplantation of haemopoietic tissue, *Br Med Bull* 21:118, 1965.
Metcalf D: Hematopoietic colonies—in vitro cloning of normal and leukemic cells, *Recent Results Cancer Res*, vol 61, 1977.
Mohandas N, Prenant M: Three-dimensional model of bone marrow, *Blood* 51:633, 1978.
Moore MAS: Regulatory role of macrophages in hematopoiesis, *J Reticuloendothel Soc* 20:89, 1976.
Osoba, D.: Precursors of thymic lymphocytes, *Ser Haematol* 7:427, 1974.
Pease DC: An electron microscopic study of red bone marrow, *J Hematol* 11:501, 1956.
Quesenberry OP, Levitt L: Hematopoietic stem cells, *N Engl J Med* 301:755, 1979.
Scott RE, Horn RG: Fine structural features of eosinophil granulocyte development in human bone marrow, *J Ultrastruct Res* 33:16, 1970.
Stanley ER, et al: Colony stimulating factor and the regulation of granulopoiesis and macrophage production, *Fed Proc* 34:2272, 1975.
Tavassoli M: The marrow-blood barrier, *Br J Haematol* 41:297, 1979.
Wetzel BK, Horn RG, Spicer SS: Fine structural studies on the development of heterophil, eosinophil and basophil granulocytes in rabbits, *Lab Invest* 16:349, 1967.
Wu AM, et al: A cytological study of the capacity for differentiation of normal hemopoietic colony-forming cells, *J Cell Physiol* 69:177, 1967.
Yamada E: The fine structure of the megakaryocyte in the mouse spleen, *Acta Anat* 29:267, 1957.

Kinetics

Everett NB, Caffrey RW, Rieke WD: Recirculation of lymphocytes, *Ann NY Acad Sci* 113:887, 1964.
Finch CA: Some quantitative aspects of erythropoiesis, *Ann NY Acad Sci* 77:410, 1959.
Firth JL: Life-span, recirculation, and transformation of lymphocytes, *Int Rev Exp Pathol* 5:1, 1966.
Giblett ER: The plasma transferrins, *Prog Med Genet* 2:34, 1962.
Graber SE, Krantz SB: Erythropoietin and the control of red cell production, *Ann Rev Med* 29:51, 1978.
Greenwalt TJ, Jamieson GA: *Formation and destruction of blood cells*, Philadelphia, 1970, JB Lippincott.
Jamuar MP, Cronkite EP: The fate of blood granulocytes, *Exp Hematol* 8:884, 1980.
Lajtha LG, et al: Kinetic properties of hemopoietic stem cells, *Cell Tiss Kinet* 2:39, 1969.
Leblond CP, Walker BE: Renewal of cell populations, *Physiol Rev* 36255, 1956.
Morley AA: A neutrophil cycle in healthy individuals, *Lancet* 2:1220, 1966.
Perutz MF: The hemoglobin molecule, *Proc R Soc (Lond) (Biol) Ser B* 173:1113, 1969.
Schalm OW: Interpretation of leukocyte responses in the dog, *J Am Vet Med Assoc* 142:147, 1963.
Schalm OW, Hughes J, Hardy D: Dynamics of the neutrophilic leukocyte and a unique response in acute indigestion in the cow, *Calif Vet* 21:20, 1967.
Weed RI: The importance of erythrocyte deformability, *Am J Med* 49:147, 1970.

Downloaded From Vet-eBooks.com

CHAPTER 13

Muscle Tissue

GENERAL CHARACTERISTICS

The structural element of muscular tissue is the **muscle cell (muscle fiber),** and its well-developed characteristic is **contractility.** Muscle is most of the "flesh" (Gr *sarkos*) or "meat" of an organism. It is also the primary mural element of tubular organs. Muscle fibers are elongated cells with a cytoplasm containing typical organelles and **myofilaments** composed of the proteins **actin** and **myosin.** The myofilaments are grouped as **myofibrils.**

Muscle contractility is the means by which work is accomplished for locomotion, expression of secretions from glands, movement of blood through the cardiovascular system, and movement of materials through the digestive system.

Functionally, muscle may be **voluntary** or **involuntary.** Structurally, it may be **smooth (nonstriated)** or **striated.** The following classification applies: **smooth muscle—nonstriated, involuntary; skeletal muscle—striated, voluntary; cardiac muscle—striated, involuntary.**

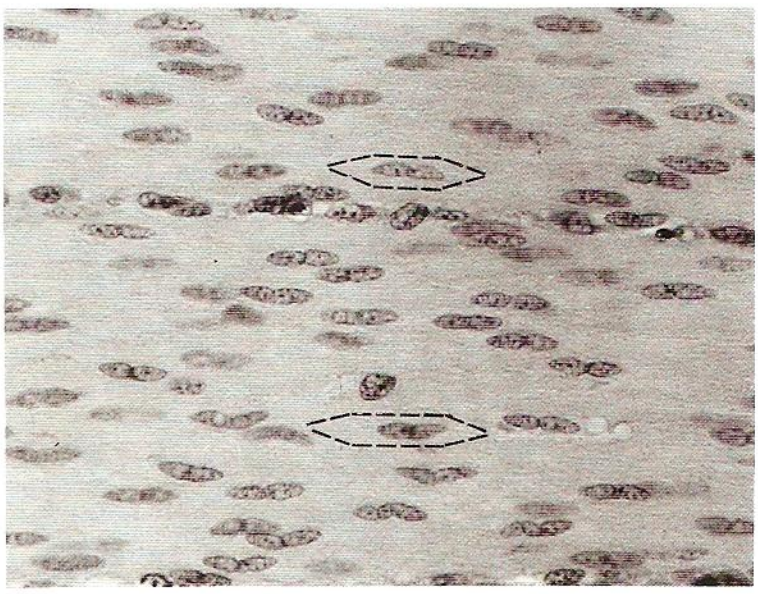

Figure 13-1. Longitudinal section of smooth muscle. *Dashed lines* represent the approximate cellular limits. The elongated nuclei are oriented parallel to the long axis of the muscle fiber. Cellular limits are difficult to discern in longitudinal sections of sheets of smooth muscle. Some of the torpedo-shaped nuclei appear to be twisted. This indicates that the cells are contracted. (×160.)

SMOOTH MUSCLE

Histological Structure

Smooth muscle fibers are elongated, spindle-shaped cells with finely tapered ends. The central region, with the nucleus, is located in the widest part of the cell. These cells may be as short as 20 μm (mural elements of a small tubule) or as long as 0.5 mm (the wall of a gravid uterus). This appearance is not always apparent in a single section. Often, the cells are packed tightly and blend as a homogeneous mass (Fig. 13-1 and Plate V, *1* and *2*). The elongated, cylindrical nucleus is round at the ends and contains a fine chromatin network with peripheral heterochromatin. Two to several nucleoli may be apparent. The nuclei may be twisted and wrinkled or may assume a helical shape, indicating active contraction during fixation or passive distortion at death. The cytoplasm is homogeneous, bright-staining, and acidophilic.

In longitudinal section, smooth muscle cells appear as described previously. Because of their shape, not all nuclei are seen in a given section. The cells are staggered, with the thickest portion of one adjacent to the tapered portion of another.

In cross section the cells are round to oval (Fig. 13-2). The nuclei are round and centrally located and, again, may not be seen in all cells sectioned.

Smooth muscle fibers associate with fine reticular fibers (Fig. 13-3). Each is surrounded by a basement membrane with reticular fibers embedded in it. Muscle fibers may be associated with connective tissue as in the dermis. Muscle cells occur in extensive sheets ranging from a few to many layers thick. The fine reticular fibers surrounding individual cells are continuous with the connective tissue surrounding the entire sheet.

These sheets are often arranged so that the muscle fibers of one sheet are at "right angles" to the muscle fibers of another. In cross sections through a tubular organ such as the gut, one sheet ("circularly oriented" and inner) is sectioned longitudinally. The adjacent sheet ("longitudinal" and outer), at 90° to the other, is cross sectioned (Fig. 13-4). In longitudinal sections the reverse pattern occurs. (Generally, the inner layer of muscle is disposed as a tighter helix than the outer layer.)

Ultrastructural Features

Smooth muscle ultrastructure reflects its light microscopic appearance (Fig. 13-5). The elongated and finely granular nucleus has peripheral heterochromatin. The organelles occur in the perinuclear region, especially at the nuclear poles. Mitochondria, RER, free ribosomes, and a small Golgi complex are present. Parallel, discontinuous, spirally oriented bundles of myofilaments occur in the cytoplasm. These bundles vary in thickness and are oriented along the long axis of the cell. Roundish amorphous **dense bodies** are scattered throughout the cytoplasm in association with the plasmalemma. They appear to be attachment points for the myofilaments (Fig. 13-5) and are analogous to the Z lines in skeletal muscle.

The plasma membrane contains many invaginations called caveolae, and many pinocytotic vesicles are juxtaposed to it (Fig. 13-5). The basal lamina covers the

Downloaded From Vet-eBooks.com

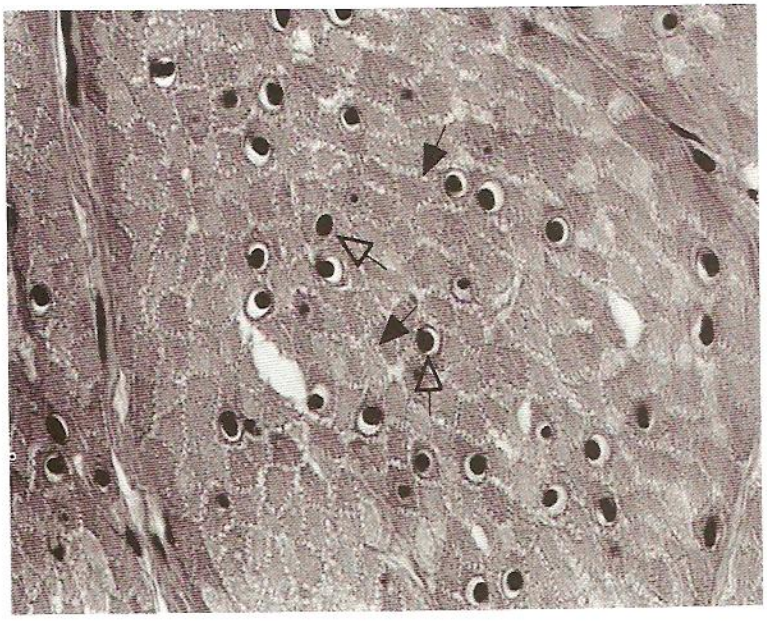

Figure 13-2. Cross section of smooth muscle. The nuclei *(open arrows)* and cellular limits *(solid arrows)* are apparent. Most of the nuclei are out of the plane of section. (×160.)

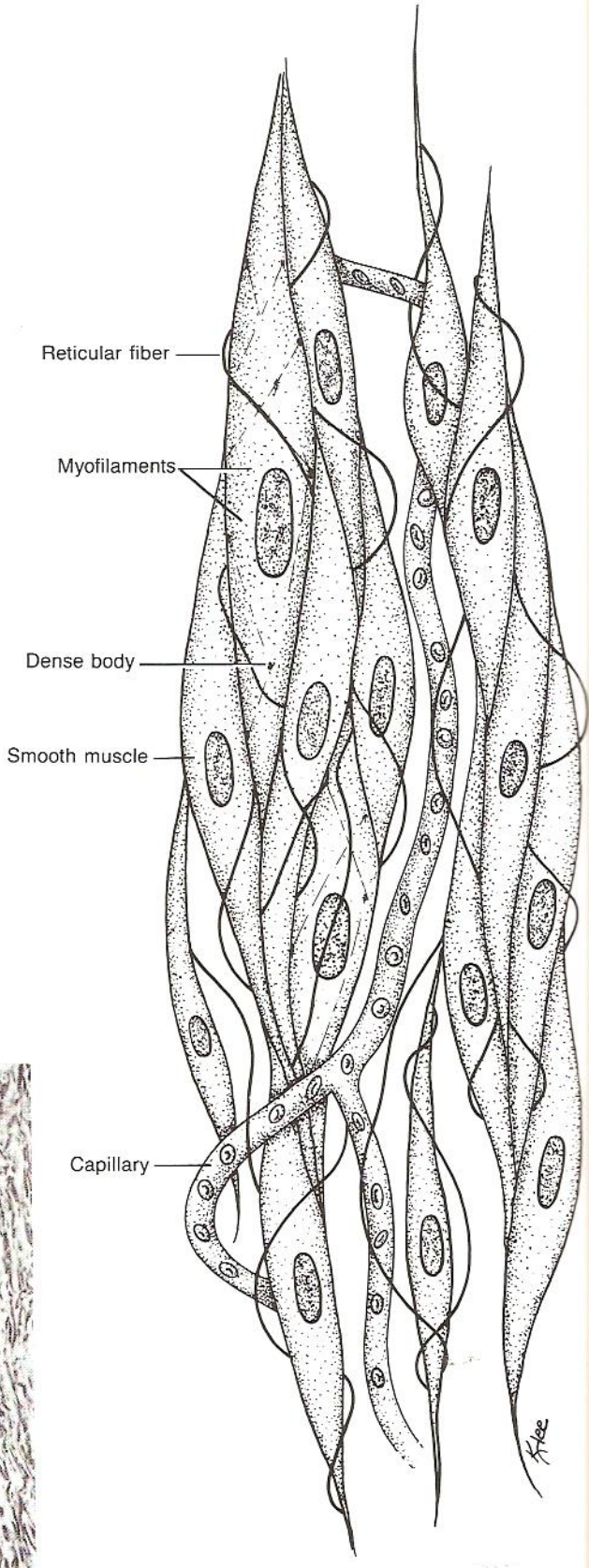

Figure 13-3. Relationships between smooth muscle cells and the associated tissue. Myofilaments are scattered throughout the cytoplasm and are attached to the surface and within the cytoplasm by dense bodies.

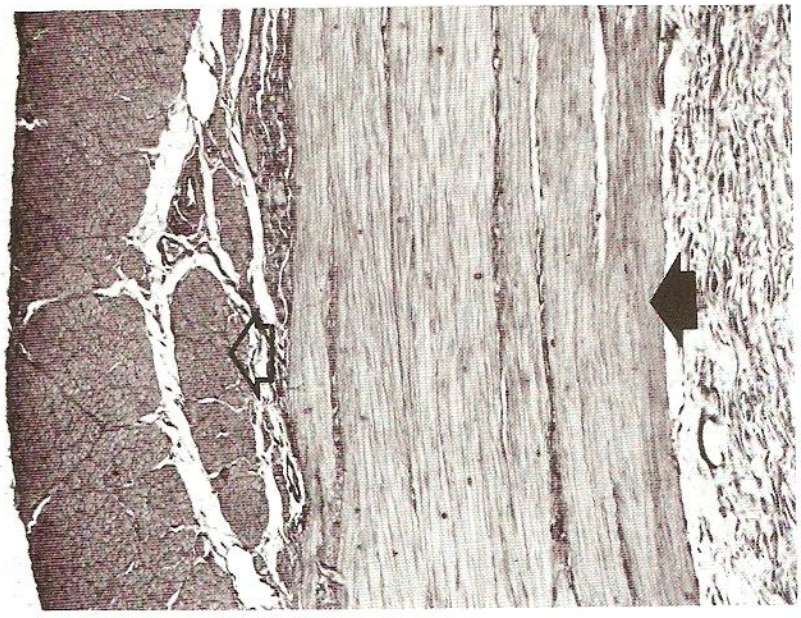

Figure 13-4. Cross section of the tunica muscularis of the gastrointestinal tract wall. The inner circular muscle *(solid arrow)* is sectioned longitudinally. The outer longitudinal muscle *(open arrow)* is cross sectioned. (×40.)

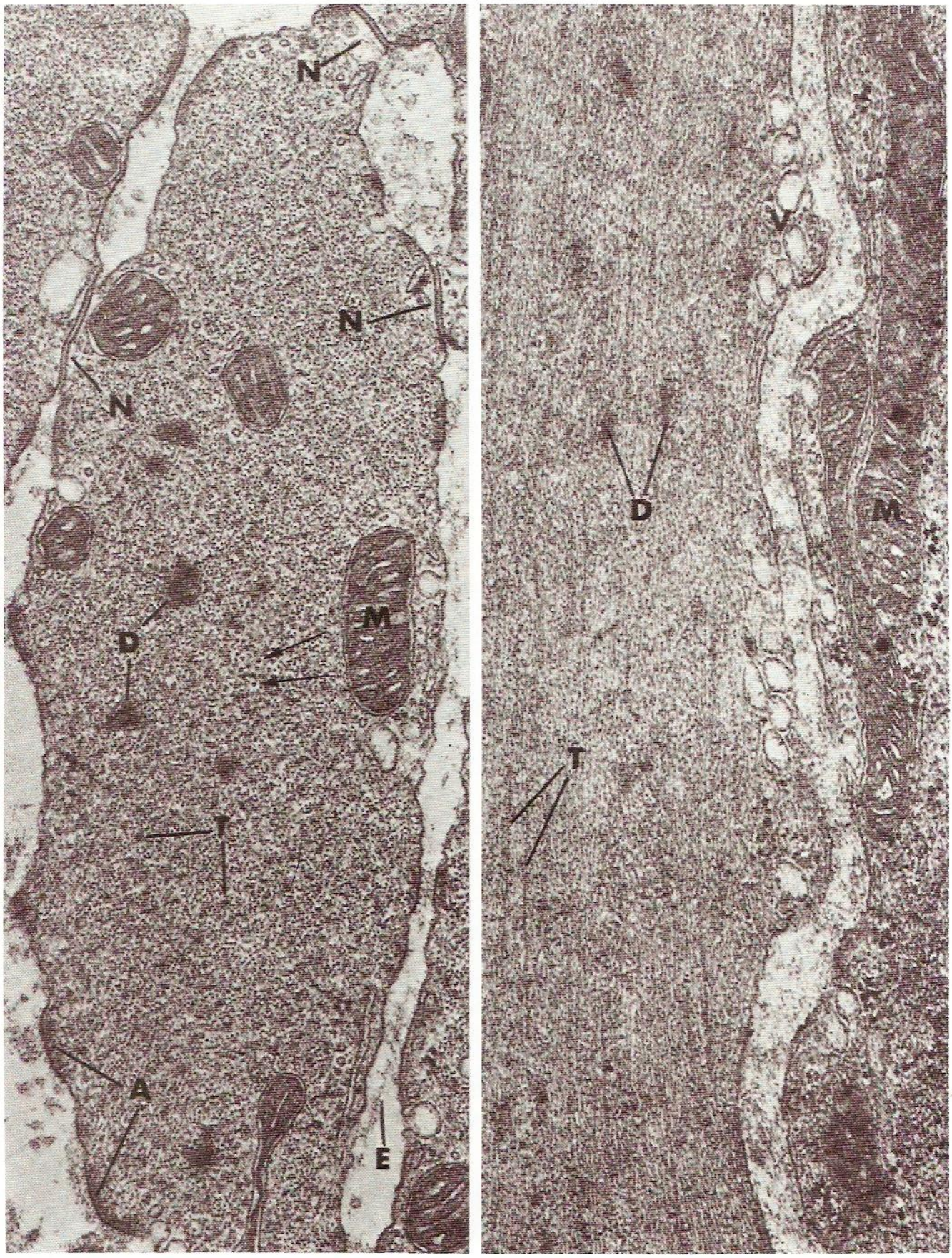

Figure 13-5. Electron micrograph of smooth muscle cells from a rat small intestine. The cells on the *left* are cut transversely. Thick filaments *(T)*, probably myosin, are scattered among numerous thin actin filaments. A third type of filament *(arrows)* is noncontractile and intermediate in size. Attachment plaques *(A)* anchor the myofilaments to the cell membrane. Dense bodies *(D)* anchor the filaments within the cytoplasm. Nexi *(N)* between adjacent cells are apparent. Mitochondria *(M)* are present. The cells on the *right* are sectioned longitudinally. Pinocytotic vesicles *(V)* are evident along the cell membrane. *E*, Basal lamina. (×89,600.) (Reprinted with permission from Copenhaver WM, Kelly DE, Wood RL: *Bailey's Textbook of histology*, ed 17, Baltimore, 1978, Williams & Wilkins.)

entire cell except at points of cell-to-cell contact, the **nexi** (Fig. 13-5). A **nexus** or **gap junction** is a contact point between adjacent cells facilitating the spread of excitation from one cell to another. These are regions of low electrical resistance.

Functional Correlates

Smooth muscle is slow to contract, but its sustained contraction resists fatigue. The contractions are probably based upon a sliding filament mechanism. Upon contraction an elongated, smooth-surfaced cell becomes shortened, with many surface dimples. The dimples result from cytoplasmic bulging between points of contact between the **anchoring plaques** on the plasma membrane. This imparts the characteristic cell thickening and twisting during contractions. Such twisting and the absence of an orderly sarcomere permit smooth muscle cells to shorten more in proportion to their length than skeletal muscle cells.

Calcium is essential to the activation and sustaining of smooth muscle contractions. Most likely, the influx and outflow of calcium are associated with the SER and caveolae.

Although neuronal stimulation can initiate smooth muscle contraction, not all smooth muscle cells are innervated. The spread of excitation occurs by nexi, which activate adjacent cell contractions. Cell distortion can be transmitted to adjacent cells by the generation of forces through the connective tissue coverings. Smooth muscle also responds to humoral agents. One of the most important stimuli to contraction of smooth muscle is its responsiveness to stretch. This local stimulus is vital to the normal functioning of hollow visceral organs.

Smooth muscle may be considered a single morphological entity; yet additional distinctions within this tissue type are possible on the basis of physiological and pharmacological properties.

Vascular smooth muscle or **multiunit smooth muscle** has a high-density innervation, but not all cells are innervated. Nexi are not observed between adjacent cells. Neurotransmitter release from nondirected synapses probably accounts for the stimulation of noninnervated adjacent cells.

Visceral smooth muscle or **single-unit smooth muscle** has a lower innervation density than multiunit smooth muscle. Visceral smooth muscle cells act as single units; excitation spreads by ephaptic conduction. This smooth muscle also has **rhythmic** and **tonic contractions**—the former responding to the periodic self-activation of "pacemaker cells" within the muscle mass, the latter constituting the partial contraction or **tone** of smooth muscle. An **intermediate type** of smooth muscle has an innervation density greater than that observed in single-unit smooth muscle, and nexi are present.

Smooth muscle is also excited or inhibited by hormones of the gastrointestinal tract. Uterine smooth muscle is responsive to the hormones associated with estrus, pregnancy, and parturition. Epinephrine, likewise, has an influence on smooth muscle.

Smooth muscle is a wall component of hollow visceral organs. The intramural muscle mass contributes to luminal size, wall tone, and the movement of materials through the organs. Smooth muscle is not confined to the hollow viscera; it occurs also in the eye and orbit (iris, ciliary body, eyelid, third eyelid, periorbita) and capsules of the spleen and hemal nodes. In the vascular system the smooth muscle of the vessel wall actively contributes to peripheral resistance, which assists in the maintenance of blood pressure.

SKELETAL MUSCLE

Histological Structure

The skeletal muscle fiber is an elongated cell with slightly tapered or blunt ends. Most fibers are between 1 and 40 mm. They vary from 10 to 100 μm in diameter and are multinucleated and striated (Fig. 13-6). The oval nuclei, with peripheral heterochromatin, are located at the periphery of the cells. Some appear centrally located, but this is an artifact of sectioning; that is, the section may be close to the plasmalemma above or below the observation plane.

Cross striations, or dark and light bands, are oriented perpendicular to the muscle fiber long axis (Plate V, *3*). Upon higher magnification the regularity of the banding is resolved (Fig. 13-7). Lighter **I bands** separate darker **A bands. Z lines** are dense striations within the I bands (Plate II, *12*). **A sarcomere, the unit of muscular contraction, includes the myofilaments contained between adjacent Z lines.**

Individual muscle fibers are unbranched, parallel to each other, and separated by loose collagenous tissue. A basement membrane separates the connective tissue and muscle fibers.

In cross section the peripheral relationship of the nuclei to the muscle fibers is observed more readily (Fig. 13-8). Also the myofibrils appear as clumps of acidophilic dots (Plate V, *4*).

Ultrastructural Features

Sarcomeric morphology has been clarified with the electron microscope (Fig. 13-9). One sarcomere extends between two adjacent Z lines in a myofibril and includes half the I bands on each side of the A band (Fig. 13-10). Actin myofilaments occur alone within the I bands. The A bands contain thin actin filaments and thick myosin filaments. Two separate actin filaments extend from each Z line through the A band. The gap between their ends within the A band is the H band. Upon contraction the I band shortens, the H band disappears, and a dense M line forms in the space previously occupied by the H band.

A small and inactive Golgi complex is

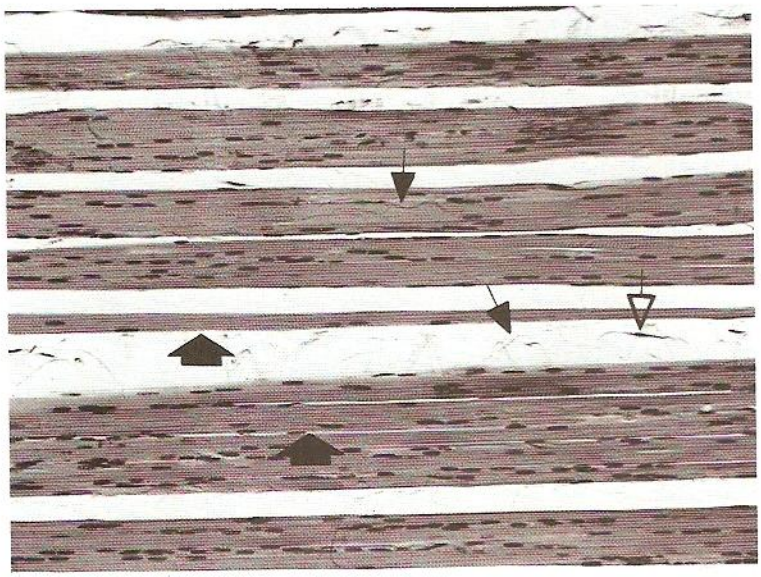

Figure 13-6. Longitudinal section of skeletal muscle. Individual muscle fibers *(large arrows)* are striated and multinucleated. Compare the muscle fiber size with the size of the connective tissue cell *(open arrow)*. Endomyseal connective tissue *(solid arrows)* surrounds the muscle fibers. (×40.)

Downloaded From VetBooks.com

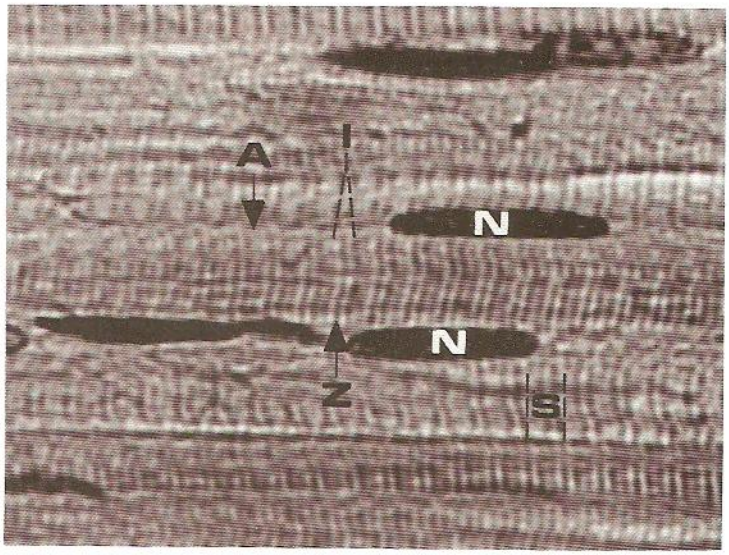

Figure 13-7. Skeletal muscle. Note the nuclei *(N)*, A band *(A)*, I band *(I)*, and Z lines *(Z)*. The sarcomeres *(S)* are registered with each other. The sarcomere below the *S* is outlined with *dashed lines* and extends from Z line to Z line. (×400.)

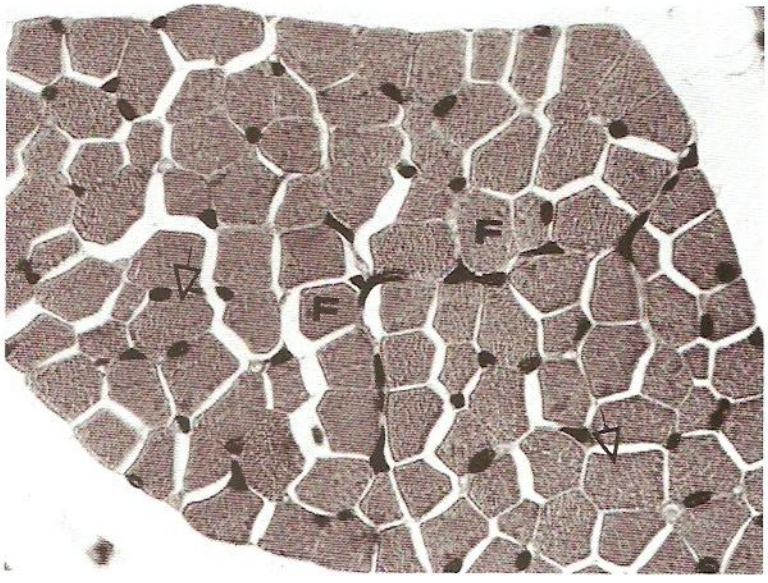

Figure 13-8. Cross section of skeletal muscle. The fibers *(F)* are grouped in bundles or fascicles *(arrows)*. Note the nuclei positioned peripherally. (×160.)

juxtaposed to many of the nuclei. Mitochondria are numerous, occurring at nuclear poles, (beneath the plasmalemma) and interdigitated among the myofibrils. The intimate relationship between mitochondria and myofibrils is significant in the contractile mechanism.

The **SER** is a network of cisterns and tubules occurring among and on the myofibrillar units (Fig. 13-11). Most tubular profiles are oriented longitudinally to the myofibrils. At specific loci within the cell the tubules become confluent and form **terminal cisterns** oriented perpendicular to the long axis of the cell. At these specific loci two terminal cisterns are separated by a transversely oriented slender **transverse tubule.** Each tubule is a plasmalemmal invagination, part of the **transverse tubular system (T tubular system).** Two terminal cisterns and a transverse tubule form a **triad** (Figs. 13-11 and 13-12). In amphibians the triads are located at Z lines. In mammals they are located at A-I junctions, resulting in two triads per sarcomere.

Substances within the transverse tubules are actually outside the cell, because these tubules are slender invaginations of the cell membrane (Fig. 13-13).

Myofibrillar Organization

Myofibrils are composed of the myofilaments **actin** and **myosin** (Fig. 13-14). The disposition and registration of the myofilaments within and between sarcomeres account for the typical skeletal muscle striations.

Myosin is a thick filament approximately 10 nm in diameter by 1.5 μm long. It is the principal component of the A band, wherein these parallel filaments are separated by a distance of 45 nm. Thick filaments have a smooth and thick central portion tapering toward each end. The slender portions of the filaments have radial projections. The isolation and dissociation of thick filaments yield **myosin.**

Myosin is a cone-shaped molecule approximately 150 nm long with a globule or head at one end. The thick filaments of the A band are formed by the association of myosin molecules such that the elongated, rod-shaped part of each molecule projects toward the thicker central portion of the filament. The globular heads project in the opposite direction and account for the radial projections associated with slender portions of the thick myosin filaments. Digestion of myosin with trypsin yields two major fragments, **light meromyosin (LMM)** and **heavy meromyosin (HMM).** The LMM fragment is the rod-shaped portion of the molecule; the HMM fragment constitutes the radially projecting globular head.

The thin **actin** filaments have a 5 nm diameter and a 1 μm length. They originate from the Z line, comprise the I band exclusively, and extend into the A band between thick myosin filaments. Each thin filament of actin consists of two strands of **fibrous (F) actin** disposed in a double helix. F actin is a polymer of about 200 **globular (G)** actin monomers. A fibrous protein, **tropomyosin,** occupies the space between the F actin strands. **Troponin,** a globular protein, occupies a specific locus at each half-turn in the helix. Tropomyosin and troponin are regulatory proteins in the contractile mechanism.

Contractile Mechanism

The contraction of skeletal muscle starts at the motor endplate (Fig. 13-11). The action potential reaches the presynaptic region, and **acetylcholine** is released. The activation of cholinergic receptors culminates in the generation of endplate potentials. These result in an action potential's spreading along the cell membrane into the cell via the transverse sarcotubular system. The inward movement of a wave of depolarization causes the release of Ca^{++} from the SER and

Text continued on p. 174.

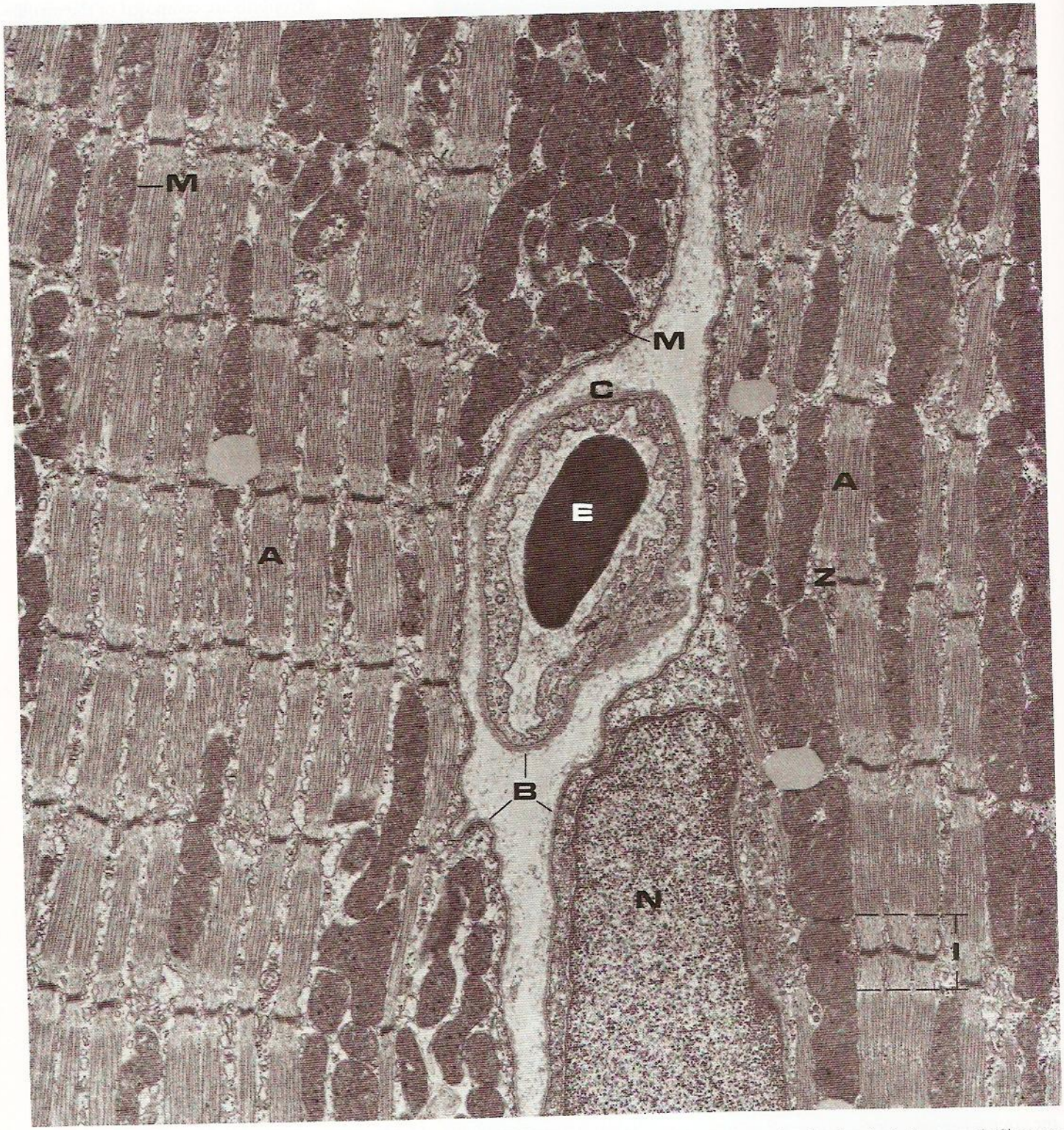

Figure 13-9. Electron micrograph of a longitudinally sectioned skeletal muscle from the extrinsic eye muscles of a slow loris. Two muscle fibers are separated by the endomyseal connective tissue space, which is bounded by a basal lamina *(B)*. The connective tissue space contains a capillary *(C)* with an erythrocyte *(E)*. Caveolae and pinocytotic vesicles are contained within the endothelial cell of the capillary. The A bands *(A)* or anisotropic bands are darker than the I bands *(I)* or isotropic bands. Z lines *(Z)* occur in the middle of the I bands. Mitochondria *(M)* occur between the myofibrils and beneath the plasmalemma (i.e., they are subplasmalemmal). A nucleus *(N)* of one muscle fiber is included in the section. (×14,600.) (Courtesy D.E. Kelly and included with permission from Copenhaver WM, Kelly DE, Wood RL: *Bailey's Textbook of histology*, ed 17, Baltimore, 1978, Williams & Wilkins.)

Downloaded From Vet-eBooks.com



Figure 13-10. Electron micrograph of myofibrils from the psoas muscle of a rabbit. The dark A bands *(A)* contain a lighter H band *(H)*. An M line *(M)* bisects the H band. The light I bands *(I)* contain a dark Z line *(Z)*. (×52,000.) (Reprinted with permission from Copenhaver WM, Kelly DE, Wood RL: *Bailey's Textbook of histology*, ed 17, Baltimore, 1978, Williams & Wilkins.)

Downloaded From Let-eBooks.com

Figure 13-11. Electron micrograph of longitudinal sections through two fibers of amphibian skeletal muscle. The longitudinally oriented *(L)* and terminal cisterns *(C)* of the sarcoplasmic reticulum extend between the myofibrils. The terminal cisterns and transverse tubules *(T)* form triads at the level of the Z line *(Z)*. Mitochondria *(M)* occur in subsarcolemmal and interfibrillar positions. A nerve ending *(N)* forms a neuromuscular complex with the muscle cell. Note the clear (ACH-containing) presynaptic vesicles *(V)* within the neuronal ending and the junctional folds *(J)* of the sarcolemma. The plasmalemma of the muscle cells and axonal terminal are covered by a basal or external lamina *(open arrows)*. The connective tissue *(CT)* between the muscle fibers contains collagen in longitudinal and cross section. (×26,000.) (Courtesy D. E. Kelly and included with permission from Copenhaver WM, Kelly DE, Wood RL: *Bailey's Textbook of histology*, ed 17, Baltimore, 1978, Williams & Wilkins.)

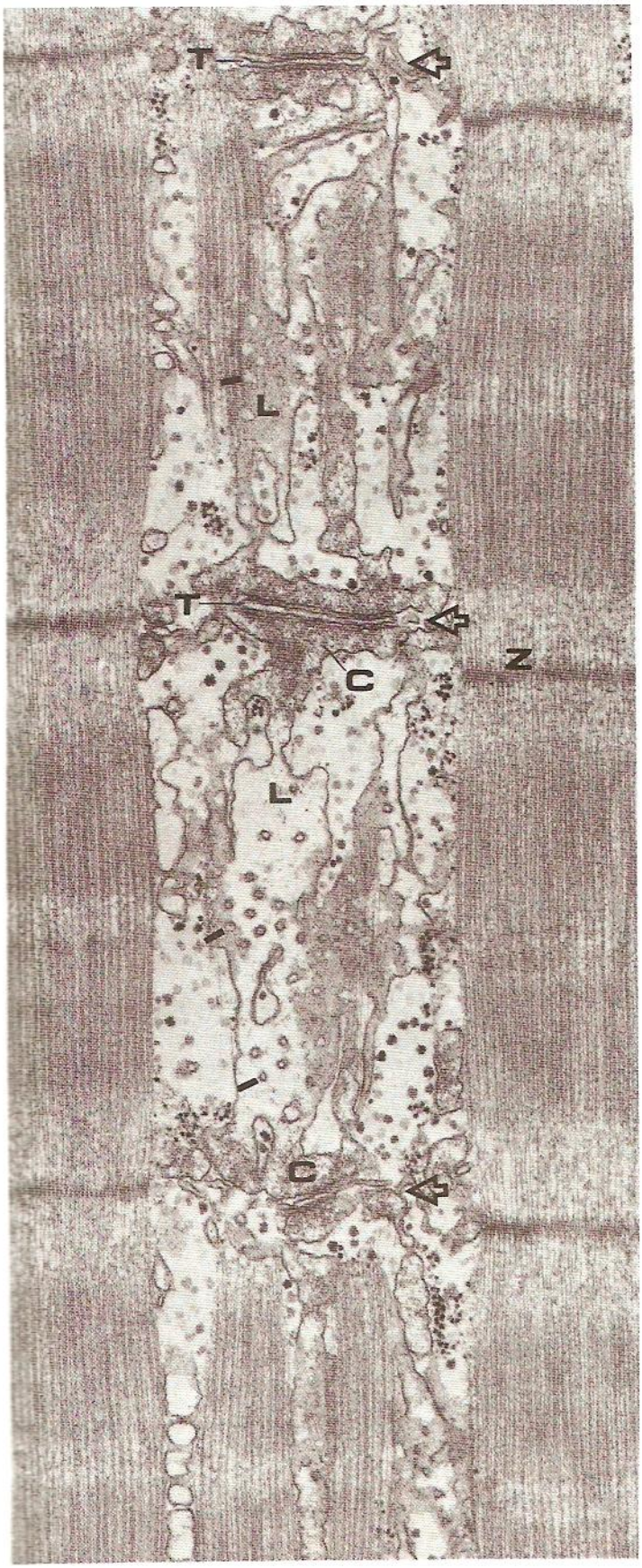

Figure 13-12. Electron micrograph of a longitudinal section of amphibian skeletal muscle. The triads *(open arrows)* occur at the level of Z lines *(Z)*. The membranes of the longitudinal components *(L)* of the SER contain many perforations *(bars)*. Longitudinal components terminate as dilated cisterns *(C)* in association with transverse tubules *(T)*. Two cisterns and a transverse tubule comprise a triad. Three triads are evident in this section. Dark-staining glycogen granules are scattered throughout the cytoplasm. (×34,000.) (Courtesy D. E. Kelly and included with permission from Copenhaver WM, Kelly DE, Wood RL: *Bailey's Textbook of histology*, ed 17, Baltimore, 1978, Williams & Wilkins.)

Downloaded From Vet-eBooks.com

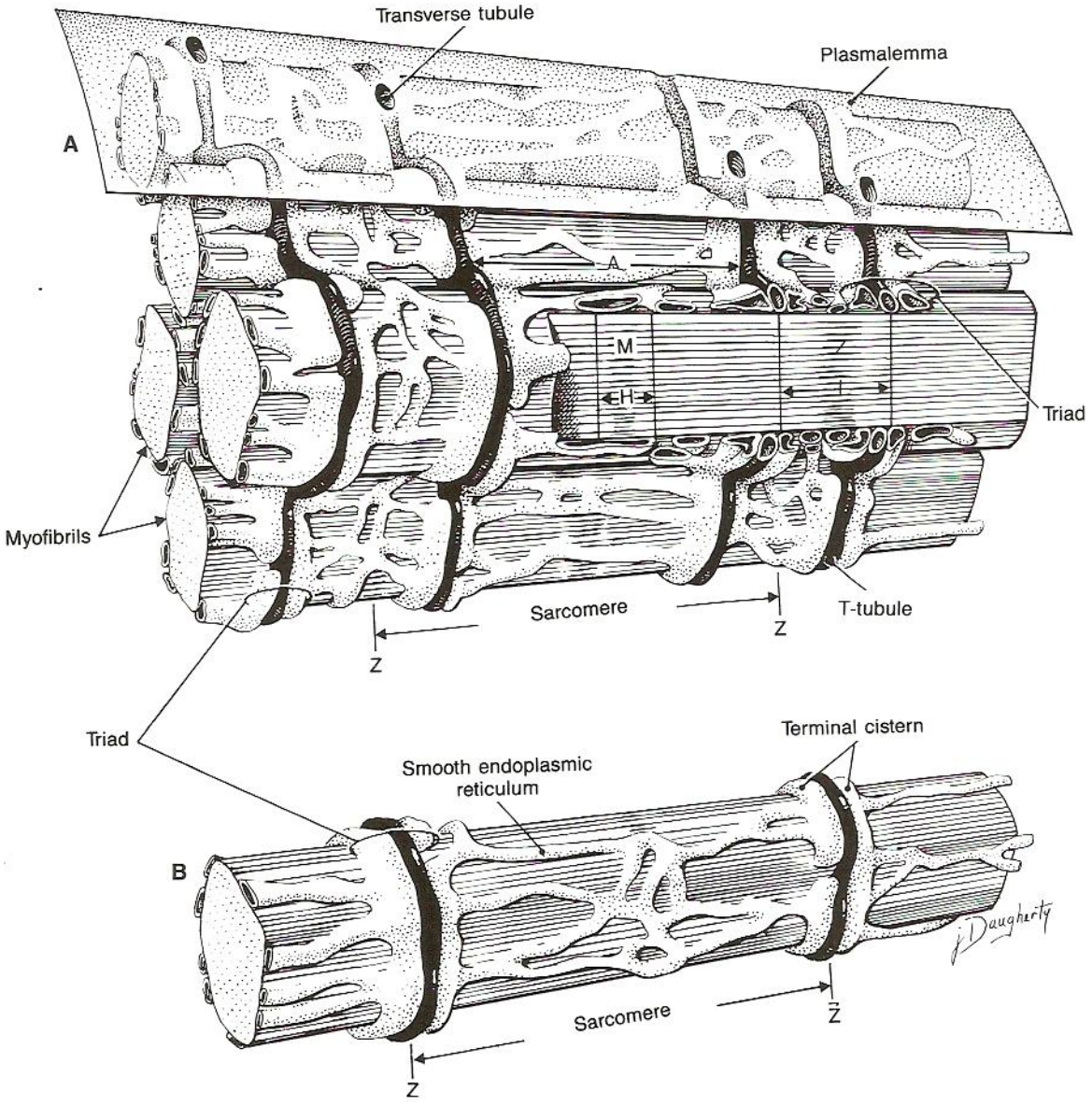

Figure 13-13. Relationships of myofibrils, SER, and T tubules in mammalian skeletal and cardiac muscle. **A,** Skeletal muscle. **B,** Cardiac muscle. The triads of mammalian skeletal muscle occur at the A/I junctions; thus two triads characterize each sarcomere. The triads of cardiac muscle and amphibian skeletal muscle occur at the Z lines (Z). The T tubules are invaginations of the plasmalemma surrounding the myofibrils at specific locations in association with the terminal cisterns of the SER. (Redrawn and modified from Peachey LD: *J Cell Biol* 25:209, 1965.)

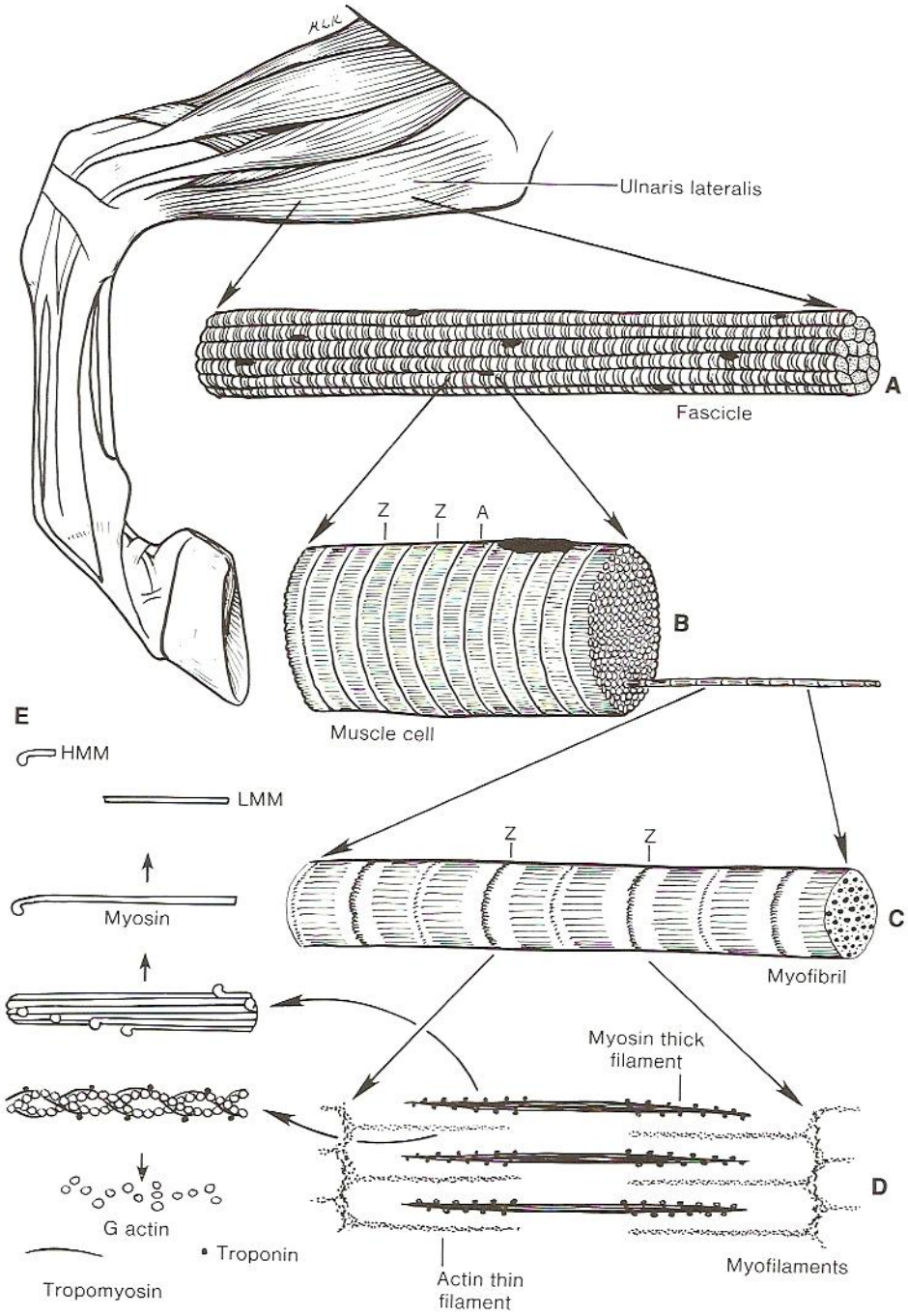

Figure 13-14. Gross, histological, ultrastructural, and biochemical relationships of skeletal muscle in the equine thoracic limb. Low-magnification examination of a muscle fascicle with the light microscope reveals elongated striated cells, **A.** High-magnification light microscopy, **B,** demonstrates Z lines, A bands, and I bands. Examination of myofibrils with the electron microscope, **C** and **D,** reveals the intimate relationships between myofilaments of the sarcomere. Biochemical analyses, **E,** have been used to characterize the thin and thick myofilaments. (Redrawn and modified from Bloom W, Fawcett DW: *A textbook of histology*, ed 9, Philadelphia, 1968, WB Saunders.)

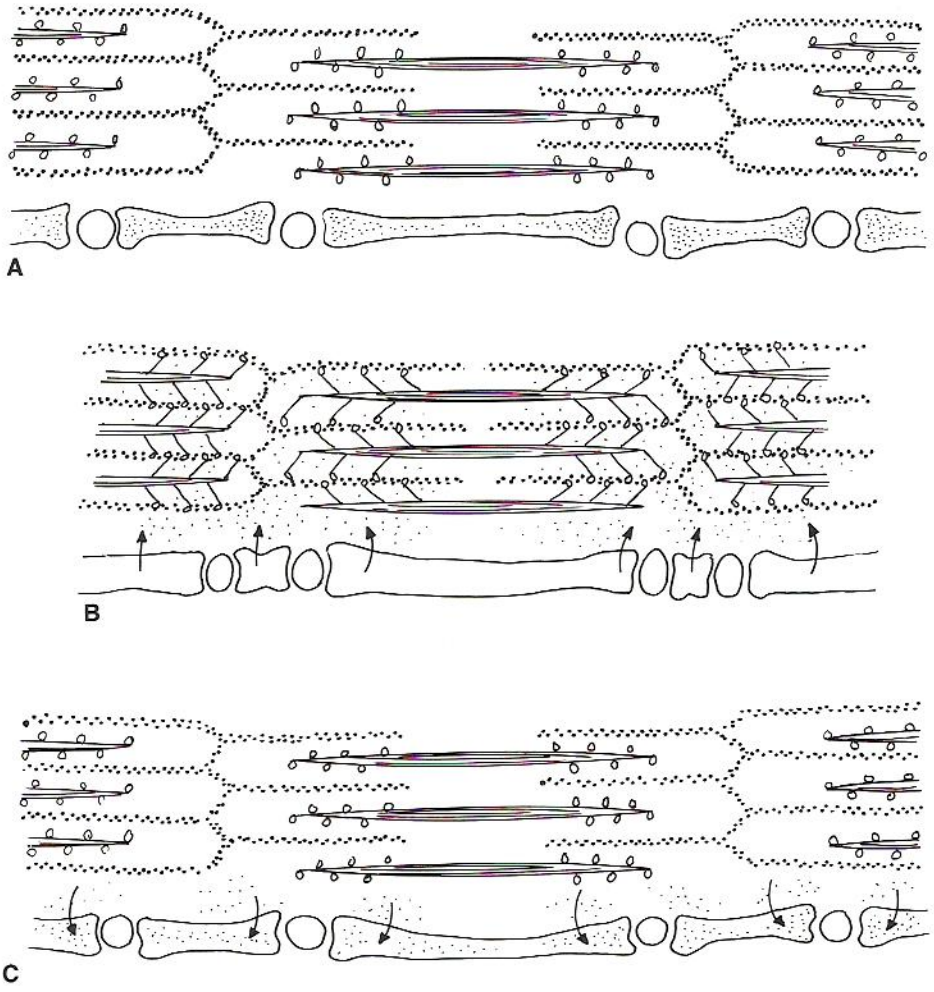

Figure 13-15. Calcium and the contractile mechanism. During relaxation, **A,** calcium is stored in the SER. A wave of depolarization moves along the plasmalemma and alters the membrane potential of the transverse tubules. The altered membrane potential induces a change in the SER permitting the movement of Ca^{++} into the cytoplasm, **B.** The inhibition is removed, and the globular heads of myosin contact the G actin monomers. Resumption of the resting state, **C,** is achieved upon return of Ca^{++} to the SER profiles.

initiates contraction (Fig. 13-15). These events comprise **excitation-contraction coupling.**

Calcium is sequestered within the SER bound to a Ca^{++}-binding protein called **calsequestrin.** The release of Ca^{++} from the SER into the cytoplasm probably evokes a conformational change in troponin and causes the movement of tropomyosin. Tropomyosin, which normally blocks the active sites of actin and myosin during relaxation, is displaced sufficiently to remove this inhibition and permit interaction between the globular heads (HMM) and G actin monomers (Fig. 13-16).

This interaction is viewed as a four-stage process.

During **stage 1** a free myosin head binds ATP. Myosin, functioning as an actin-activated ATPase, hydrolyzes ATP.

During **stage 2** the myosin holds the hydrolysis products (ADP and P_i) close to it.

In **stage 3** the myosin loosely binds to an actin, which triggers the release of the P_i and causes a tight binding to the actin molecule.

In **stage 4** a conformational change occurs in the myosin heads and produces a unidirectional powerstroke.

Subsequently ADP is released, a new ATP attaches to the myosin head, and the head detaches from the actin.

Contraction is the sequential connection, disconnection, and reconnection between the globular heads and G actin in one direction. Each reconnection to adjacent G actin results in the incremental shortening of the sarcomere at rates up to 15 μm/second. Myosin "walking the actin " is summed as sarcomeric shortening and contraction of the muscle fiber. This energy-efficient process results in 50% to 70% of the energy used as work. By comparison an internal combustion engine is about 10% to 20% efficient.

ATP also supplies energy for the active transport or pumping of Ca^{++} from the cytoplasm to the SER, where it is stored in the terminal cisterns.

Relaxation/Contraction Morphology

The previously described events represent the **sliding-filament hypothesis** of muscle contraction. These events, observed by light and electron microscopy, coincide with the sarcomeric morphology (Fig. 13-17). At rest, the sarcomere appears as described previously with the ultrastructure.

The morphology of contraction depends upon the degree of contraction. As muscles contract, they become shorter and wider than their resting length and width. The I bands decrease in length and are eventually obliterated when 50% contraction is achieved. The H band changes proportionally with I band alterations. Although the A band does not change length during normal contraction

Downloaded From Free-Books.com

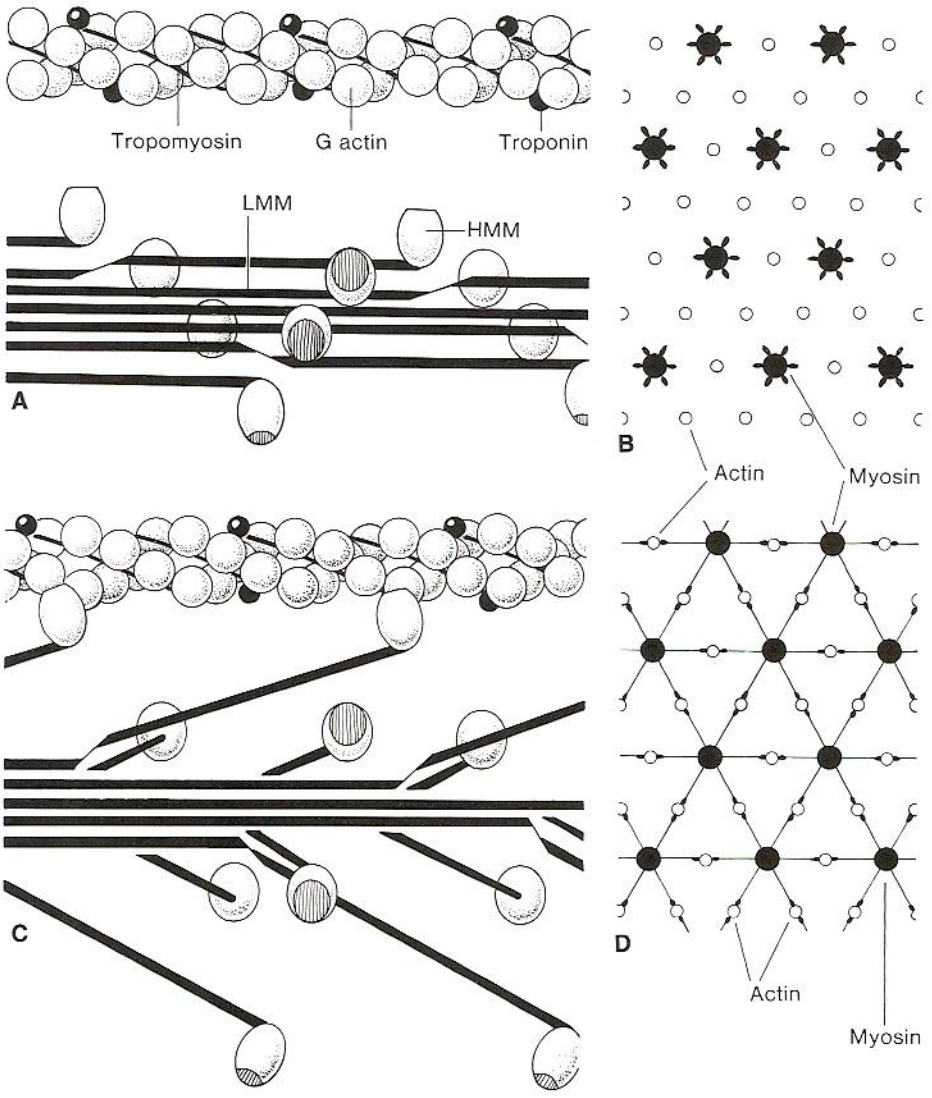

Figure 13-16. Relationships between actin and myosin during relaxation and contraction. The globular heads radiate around the myosin thick filament in close association with the actin thin filaments (**A**). A cross section (**B**) through myofilaments reveals that six actin thin filaments surround each myosin but actin thin filaments are shared by adjacent myosin thick filaments. Upon contraction (**C**), the globular heads swing laterally and contact G actin monomers. Each actin thin filament is contacted by two globular heads (**D**). The scales between the longitudinal (**A** and **C**) and cross sectional (**B** and **D**) representations are not equal. (Redrawn and modified from Ham AW: *Histology*, ed 7, Philadelphia, 1974, JB Lippincott.)

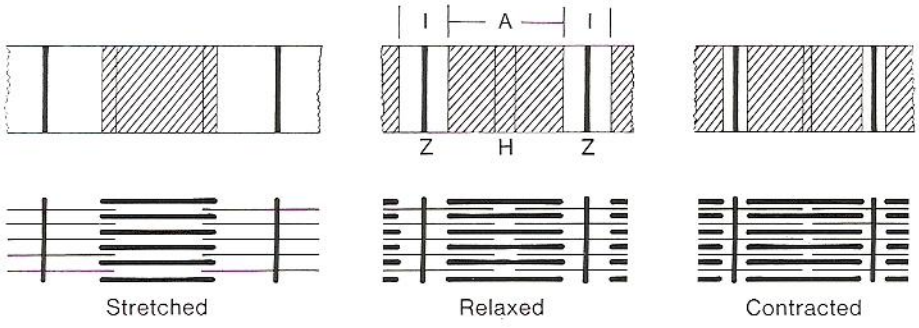

Figure 13-17. Sarcomeric banding and relationships of the myofilaments during three different physiological conditions. Refer to the text for a complete description.

Downloaded From Vet-eBooks.com

cycles, an M line may appear as actin filaments slide past the myosin filaments and overlap or interact in the center of the A band. During extremes in contraction, a **contraction zone** may appear adjacent to the Z line and represent an overlap of myosin thick filaments at the Z line.

When muscle is stretched, the length of the A band remains constant while the I band and H band lengths are increased.

Types of Muscle Fibers

Grossly, skeletal muscle is not a homogeneous mass. Obvious coloration differences are apparent between species and among individual muscles within the same species. These differences range from a deep red through an intermediate shade to a pale color. The two extremes are termed **red** and **white** muscle. The hindlimb red muscles of domestic fowl may be contrasted with their pectoral white muscles. Further studies have correlated specific histochemical and ultrastructural characteristics with different physiological properties.

Based upon metabolic characteristics demonstrable with histochemical techniques, three types of muscle fibers are identifiable (Fig. 13-18)—type I (slow-twitch, oxidative), type IIa (fast-twitch, oxidative-glycolytic), type IIb (fast-twitch, glycolytic). **Red muscle** consists predominantly of type I fibers. These muscles have slow contraction cycles and use aerobic metabolism, with glucose and fatty acids as the primary energy sources. **White muscle** consists of type II fibers. These muscles have fast contraction cycles and use aerobic metabolism, with glucose as the primary source of energy. Muscles consist of mosaic patterns of these fiber types. Specific distribution patterns in specific muscles of different animals and individuals are functional adaptations to diverse behaviors.

Type I muscle fibers are small cells with many mitochondria and abundant **myoglobin.** The mitochondrial respiratory pigments (**cytochrome system**) and the myoglobin impart the red color. The many mitochondria, with their many cristae, occupy interfibrillar and subplasmalemmal positions. SER profiles, especially in the region of the H band, are more complex than described previously. Also Z lines are thick. A capillary bed surrounds these muscle fibers. Oxygen transport from the capillaries to the mitochondrial cytochrome system is facilitated by myoglobin. Prolongation of contraction and relaxation times means these fibers are not fatigued easily. Storage of oxygen by myoglobin may preclude fatigue.

Type II muscle fibers are large cells with small amounts of myoglobin and few mitochondria. SER profiles are simple, and Z lines are thin. The scant amount of myoglobin requires oxygen to be transferred directly from the capillaries to the few mitochondria. Type IIa fibers are fast-contracting and fatigue-resistant. Type IIb fibers are fast-contracting and easily fatigued, because lactic acid accumulates readily.

Functional Correlates

Contraction depends upon ATP as an energy source. There is an insufficient supply of ATP in a muscle cell to sustain contraction for a long time. Most muscle cells have stores of ATP that would last less than 1 second. Active and continual contraction requires rapid ATP replenishment. This occurs through glycolysis and the tricarboxylic acid cycle. Muscle fibers have developed a backup and storage system for rapid ATP replenishment. This system uses a **phosphagen, creatine phosphate (CP, phosphocreatine),** to store phosphate bond energy (Fig. 13-19).

During periods of low demand ATP reacts with **creatine** to form creatine phosphate. The ratio of CP:ATP is about 30:1. The ATP for CP generation derives from glucose metabolism through glycolytic and tricarboxylic acid (TCA)

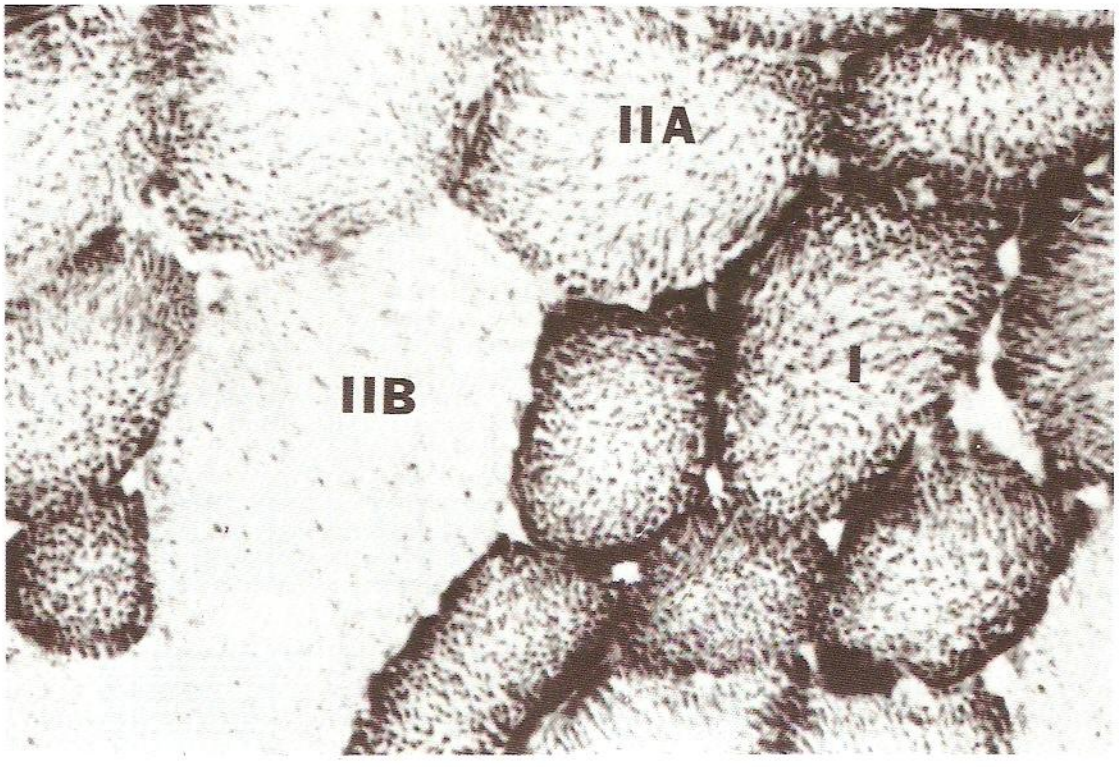

Figure 13-18. Muscle fibers stained histochemically for mitochondrial NAD-reductase. The biopsy sample was obtained from the middle gluteal muscle of a Quarter Horse mare. *I*, Slow-twitch, oxidative, fatigue-resistant; *IIA*, fast-twitch, oxidative-glycolytic, fatigue-resistant; *IIB*, fast-twitch, glycolytic, non–fatigue-resistant. (×16.) (Courtesy T. Spurgeon.)

Downloaded From VetBooks.com

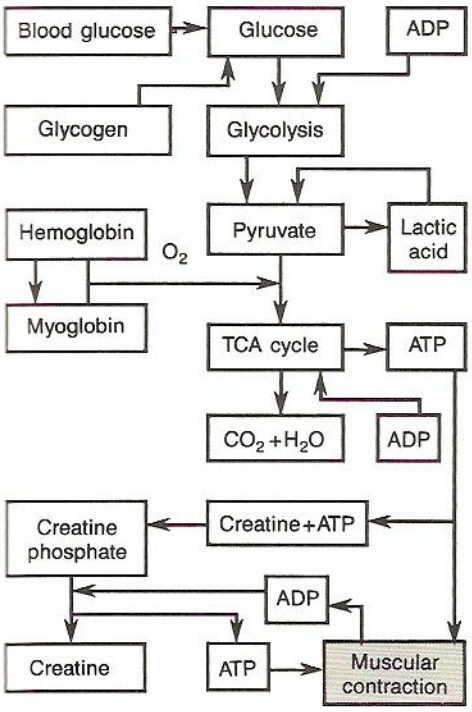

Figure 13-19. Energy sources and muscle contraction. Muscle metabolism is discussed in the text.

pathways. The TCA cycle is 19 times more efficient in ATP production than glycolysis is.

During periods of exercise ATP degrades constantly to ADP and CP constantly rephosphorylates ADP to make more ATP available. The enzyme **creatine phosphokinase (CPK)** catalyzes this phosphorylation. As long as an adequate oxygen supply is maintained during exercise, the high ATP yield from aerobic metabolism continuously forms CP.

During strenuous exercise the oxygen supply is inadequate to drive the TCA cycle. Muscle metabolism then switches to anaerobic mechanisms. Pyruvic acid is converted to lactic acid instead of being metabolized to carbon dioxide and acetyl–coenzyme A. This results in a diminished supply of ATP, an inadequate formation of CP, and the accumulation of lactic acid. The lactate accumulation involves an **oxygen debt** that must be satisfied during the conversion of lactate back to pyruvate. Lactate leaks from the cell and causes a localized vasoconstriction, exacerbating the problems. It is carried via blood to the liver, where it is metabolized. The local lactate accumulation accounts partially for the muscular soreness associated with strenuous exercise. Lactate is converted back to pyruvate within the muscle as the oxygen supply relative to contractile activity is increased.

Contraction energy comes from the degradation and metabolism of glycogen stored in muscle cells. Aerobic respiration is the energy source for protracted muscular activity. Such events depend upon adequate glycogen stores and an increased oxygen consumption ability. Anaerobic respiration is an energy source for short, demanding periods of muscular activity. Because the CP-ATP system is depleted rapidly, these energy sources are essential for the activities described.

Besides being the energy source for contraction, ATP is essential for Ca^{++} movement from the cytoplasm into the SER. ATP depletion results in Ca^{++} accumulation and the inability of myosin globular heads to be released from the G actin. This contraction after the cessation of stimulation may account for **muscle cramps** as well as **rigor mortis.**

Blood Ca^{++} reduction is associated classically with a **hypocalcemic tetany.** Despite the depletion of extracellular Ca^{++}, muscle cells do not readily lose their intracellular Ca^{++}. Hypocalcemia results in a hyperexcitability of motor nerve fibers and muscle cells resulting in the tetanic stimulation and response of the muscle fibers. Hypocalcemic tetany usually occurs as a sequel to acute Ca^{++} loss. Canine **eclampsia** (hypocalcemic tetany in the postpartum lactating female) is a classic example. Tetany, however, is not always a sequel to acute Ca^{++} loss. **Bovine milk fever (postparturient paresis)** is a hypocalcemia characterized by a flaccid paralysis rather than tetany.

Skeletal muscle adapts to the functional demands made upon it by increasing in size. The increased muscle mass results from individual muscle fiber **hypertrophy.** Cytoplasm and the amount of contractile proteins increase. Hypertrophy results from an increased number of myofibrils, not an increase in myofibrillar thickness. A thickness limit probably exists beyond which efficiency is lost. Myofibrils are known to split during the growth process.

Disuse of a muscle or group of muscles leads to **atrophy.** Atrophy is a decrease in size of individual fibers and a loss of contractile protein. The atrophy of disuse may result from confinement, immobilization associated with fracture repair, or loss of motor nerve input. Muscle contraction maintains the integrity of skeletal elements. Muscular atrophy is also a clinical sign of neurological diseases involving the **final common pathway (lower motor neuron, α-motor neuron).** Neuronal stimulation and exercise are essential for the maintenance of muscular mass.

CARDIAC MUSCLE

Histological Structure

Cardiac muscle is similar to skeletal muscle; both are striated. However, cardiac muscle is involuntary. In the ensuing discussion only those features characteristic of cardiac muscle are presented. If a specific characteristic is omitted, the student is to assume that it is similar to that found in skeletal muscle.

Six morphological features of cardiac muscle are distinctive aids in identification.

1. Cardiac muscle fibers are branched (Plate V, *5* and *6*). In any given section longitudinally, transversely, and obliquely sectioned fibers may be observed (Fig. 13-20).
2. The connective tissue surrounding each cardiac muscle fiber is prominent.
3. The cardiac muscle cell nucleus is centrally located and surrounded by a pale-staining cytoplasmic region—referred to as the **perinuclear halo** (Fig. 13-21).
4. The cytoplasm of cardiac muscle cells has myofilaments arranged in the manner described previously. Bundles of myofilaments, however, reflect the branching of the muscle fibers.
5. The striations readily apparent in skeletal muscle are not as prominent in cardiac muscle.
6. Distinct, transversely oriented, dark-staining bands are scattered throughout cardiac muscle. These **intercalated discs** are points of end-to-end contact between contiguous muscle fibers. They appear as stepwise striations in the muscle mass (Fig. 13-22).

Ultrastructural Features

The ultrastructural characteristics of cardiac muscle cells are similar to those described for skeletal muscle (Fig. 13-23). Only the significant differences are discussed herein. The **intercalated discs** are contact and adhesion points between adjacent cardiac muscle cells. They are composed of junctional complexes between terminal Z lines (Fig. 13-24), including **desmosomes, gap junctions,** and **fasciae adherentes.** Focal areas of dense filamentous materials are the attachment points of actin filaments to the plasmalemma. The fascia adherens is similar to the zonula adherens of epithelial tissues, but the fasciae adherentes are irregular and discontinuous regions. The desmosomes are typical and are adhesion points between cells. The laterally oriented cell interfaces consist of nexi. Fasciae adherentes couple cells together mechanically.

The SER consists of longitudinally oriented and anastomotic profiles. Although terminal cisterns are absent, SER profiles make intimate contact with **transverse tubules (T tubules).** These complexes generally occur at the level of Z lines. T tu-

Downloaded From Vet-eBooks.com

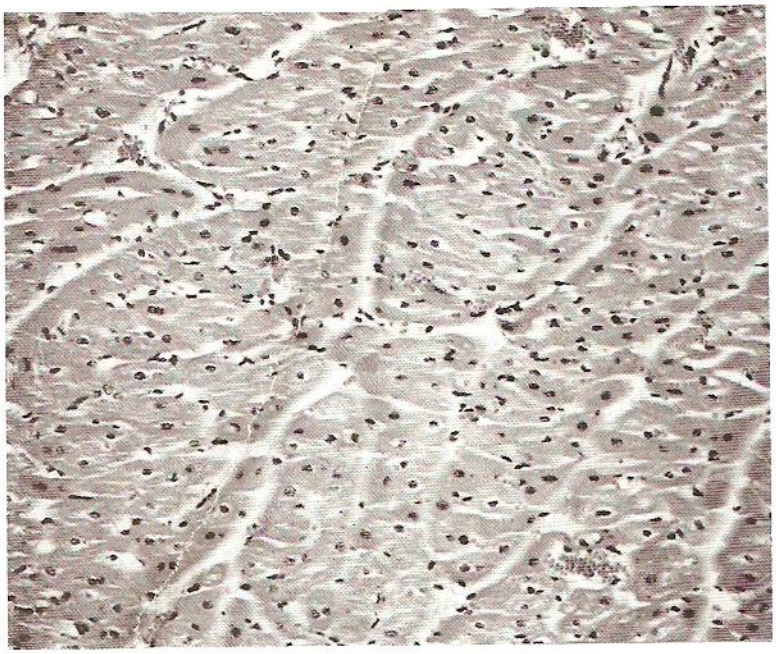

Figure 13-20. Section of cardiac muscle. The branched fibers contain nuclei located in the center of the cytoplasm. (×40.)

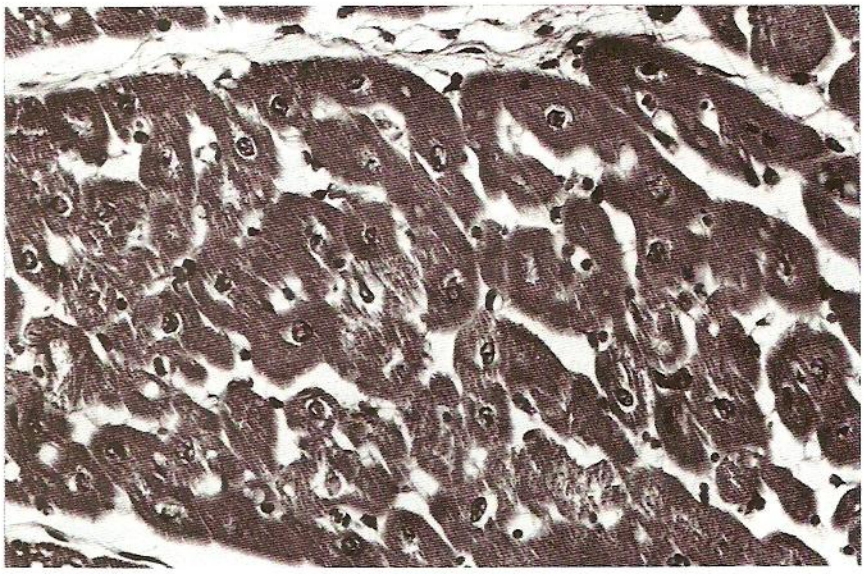

Figure 13-21. Section of cardiac muscle. The central location of nuclei and the perinuclear halos are prominent features of the branched muscle fibers. (×100.)

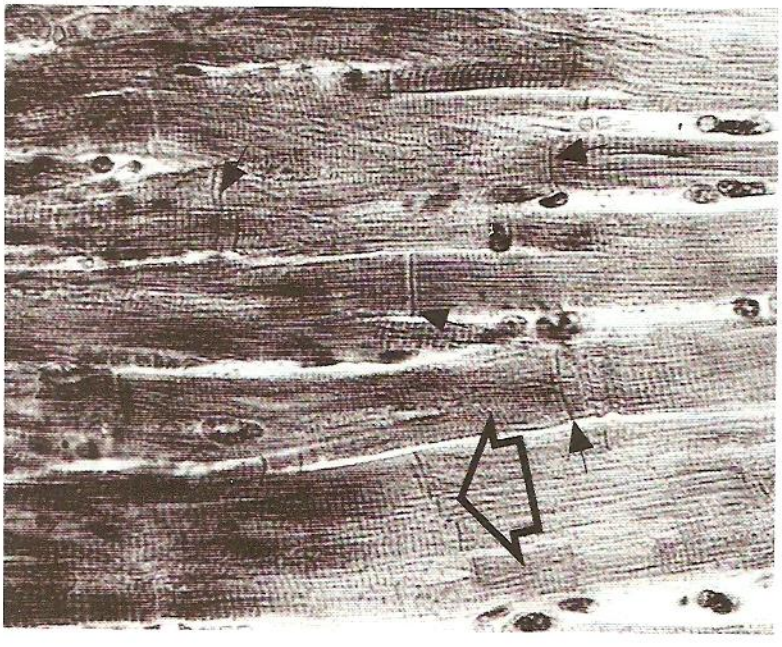

Figure 13-22. Intercalated discs of cardiac muscle. The discs *(solid arrows)* mark the end-to-end relationships of adjacent muscle cells. They may have straight boundaries or a staggered arrangement *(large arrow).* (×160.)

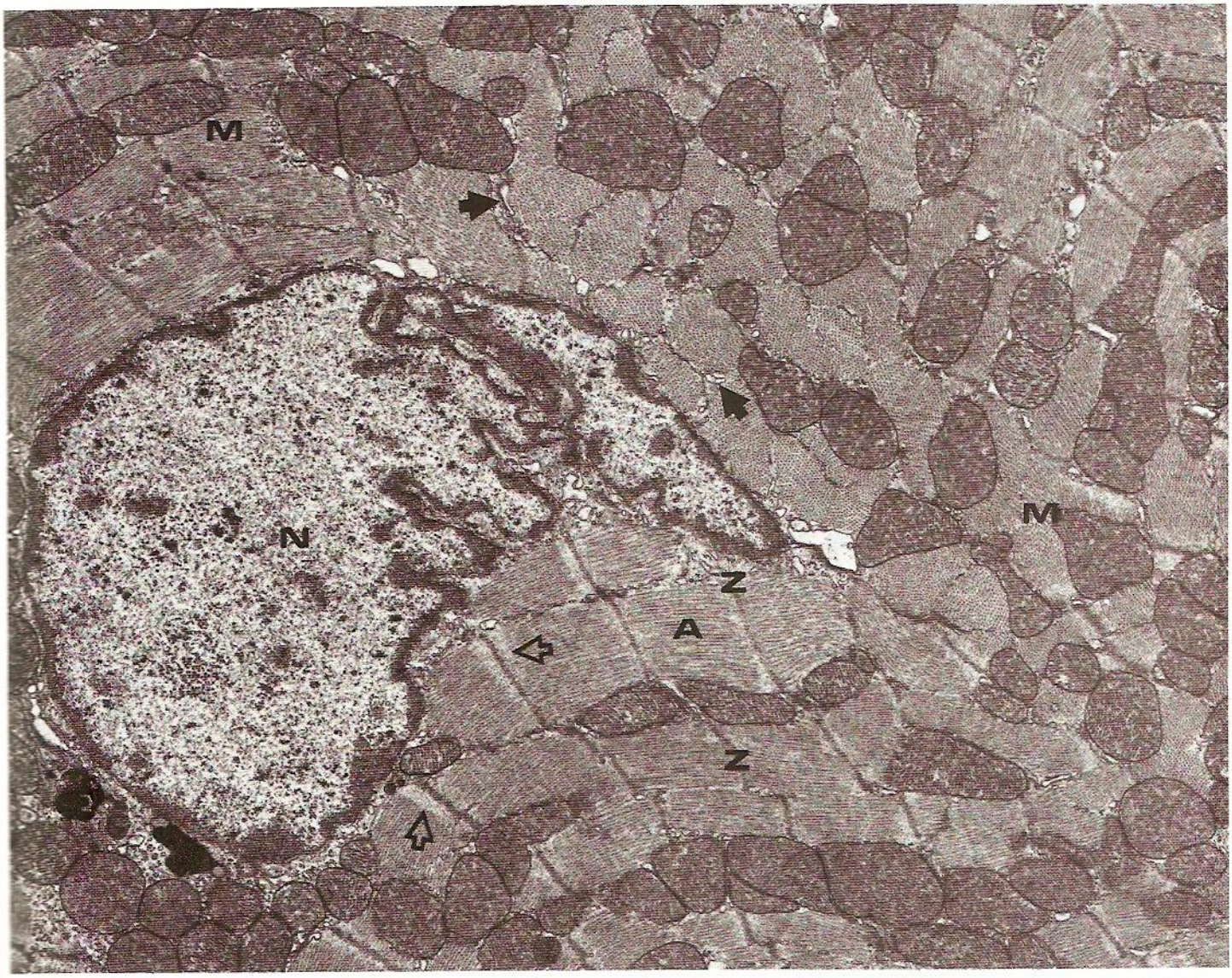

Figure 13-23. Electron micrograph of a cardiac muscle cell. The nucleus *(N)* is surrounded by bundles of myofilaments that are longitudinally and cross sectioned. Z lines *(Z)* are not registered with each other, and I bands *(open arrows)* are almost obliterated. A bands *(A)* are adjacent to Z lines. Many mitochondria *(M)* surround the nucleus and are scattered among the myofibrils. Profiles of the SER *(solid arrows)* surround the myofibrils. (×11,400.)

Downloaded From Vet-eBooks.com

Figure 13-24. Electron micrograph of an intercalated disk. The tortuous path of the disk is apparent. Desmosomes *(D)* are components of the disk. Myofilaments *(F)* extend from Z lines *(Z)* and terminate at the disk. Note the mitochondria *(M)*. (×26,000.)

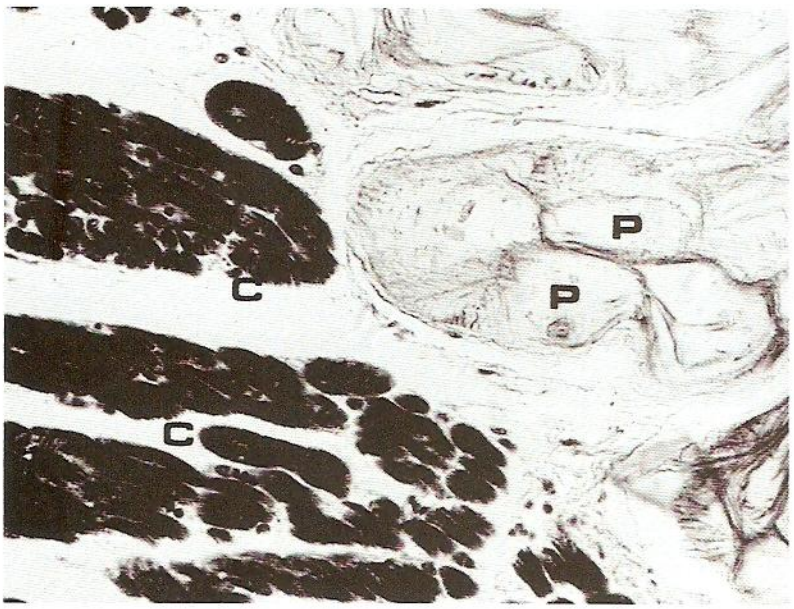

Figure 13-25. Cardiac muscle cells and conducting cells. Note that the conducting cells *(P)* are larger than the muscle cells *(C)*. (×100, phosphotungstic acid–hematoxylin [PTAH].)

bules are larger than their counterparts in skeletal muscle and contain basal laminar material. Mitochondria occur in greater numbers than in skeletal muscle.

Cardiac muscle fibers of the atria contain dense membrane-bound granules, **atrial granules,** that contain **atrial natriuretic factor (ANF).** This factor reduces arterial blood pressure and causes a diuresis and natriuresis. It also inhibits hormones involved in water and Na^+ regulation (aldosterone, renin, ADH). Receptors for this substance have been located on spongiocytes of the adrenal zona glomerulosa, renal glomeruli, and regions of the brain involved in water regulation. The substance may have a significant role in general fluid balance.

Functional Correlates

The cardiac muscle contractile mechanism is the same as in skeletal muscle. The spontaneous and rhythmic contraction of cardiac muscle is unique whereas the interfibrillar spread of excitation is similar to that in visceral smooth muscle. The presence of **pacemaker cells** establishes a beat modifiable by autonomic nerves.

Cardiac muscle cells have an extensive vascular supply, abundant mitochondria, and large quantities of myoglobin. Hypoxic conditions leading to anaerobic metabolism cannot support cardiac muscle contraction because of inadequate energy production.

The cardiac muscle cell is capable of hypertrophy, which accounts for its increased size during growth. Hypertrophy is one of the mechanisms by which the heart responds to an increased work load.

Cardiac conducting cells are specialized cardiac fibers modified as impulse-conducting cells (Fig. 13-25). They conduct impulses from the A-V node through the interventricular septum to the ventricles. In cross section the cardiac conducting fibers are larger than typical cardiac muscle cells. They also have an abundant pale-staining, acidophilic cytoplasm rich in glycogen. Myofibrils are few and, when present, are usually located peripherally. Nuclei are centrally located. In longitudinal section these fibers appear as swollen cardiac muscle cells with scattered myofibrils. They are joined to cardiac muscle cells by intercalated discs.

REPAIR AND REGENERATION

Mitotic activity occurs in smooth muscle cells, but it may not be a major factor in repair and regeneration. New smooth muscle cells may also be derived from pericapillary mesenchymal cells. The regeneration of smooth muscle is limited; healing occurs primarily through forming a connective tissue scar.

The regeneration of damaged skeletal muscle fibers is also limited. Healing occurs primarily by scar tissue formation. There are instances, however, during which new skeletal muscle fibers are derived from **myoblasts. Satellite cells** may be myoblasts persisting from fetal into adult life. These cells proliferate, fuse,

Downloaded From VetcellBooks.com

and form typical skeletal muscle cells. The simultaneous formation of scar tissue rarely permits the return to 100% function.

Cardiac muscle cells do not regenerate. Repair is achieved by the formation of scar tissue.

ADDITIONAL READINGS

Smooth Muscle

Ashton TT, Somlyo AV, Somlyo AP: The contractile apparatus of vascular smooth muscle: Intermediate high voltage stereo electron microscopy, *J Mol Biol* 98:17, 1975.

Cooke P: A filamentous cytoskeleton in vertebrate smooth muscle fibers, *J Cell Biol* 68:539, 1976.

Kelly RE, Rice RV: Ultrastructural studies on the contractile mechanism of smooth muscle, *J Cell Biol* 42:683, 1969.

Gabella G: Fine structure of smooth muscle, *Proc Trans R Soc Lond (Biol)* 265:7, 1973.

Gabella G, Blundell D: Nexuses between smooth muscle cells of the guinea pig ileum, *J Cell Biol* 82:239, 1979.

Garamvolgyi N, Vizi ES, Knoll J: The regular occurrence of thick filaments in stretched mammalian smooth muscle, *J Ultrastruct Res* 34:135, 1971.

Lane BP: Alterations in cytological detail of intestinal smooth muscle cells in various stages of contraction, *J Cell Biol* 27:199, 1965.

McNutt NS, Weinstein RS: The ultrastructure of the nexus, *J Cell Biol* 47:666, 1970.

Osvaldo-Decima L: Smooth muscle in the ovary of the rat and monkey, *J Ultrastruct Res* 29:218, 1970.

Small JV: Studies on isolated smooth muscle cells: the contractile apparatus, *J Cell Sci* 24:327, 1977.

Skeletal Muscle

Averill DR: Diseases of the muscle, *Vet Clin North Am* 10:223, 1980.

Braund KG, Hoff EJ, Richardson K: Histochemical identification of fiber types in canine skeletal muscle, *Am J Vet Res* 39:561, 1978.

Cardinet GH III: Neuromuscular diseases: the diagnosis and classification of muscle diseases in the dog. Fourth Kal Kan symposium, pp 1-10, 1980.

Close RI: Dynamic properties of skeletal muscle, *Physiol Rev* 52:129, 1972.

Cohen C: The protein switch of muscle contraction, *Sci Am* 233:36, 1975.

Franzini-Armstrong C: The structure of a simple Z line, *J Cell Biol* 58:630, 1973.

Franzini-Armstrong C, Porter KR: The Z disc of skeletal muscle, *Z Zellforsch* 61:661, 1964.

Granger BL, Lazarides E: The existence of an insoluble Z disc scaffold in chicken skeletal muscle, *Cell* 15:1253, 1978.

Hanson J, Huxley HE: Structural basis of the cross-striations in muscle, *Nature* 172:530, 1953.

Huddart H: *The comparative structure and function of muscle*, Oxford, 1975, Pergamon Press.

Huxley AF: Muscular contraction, *J Physiol [Lond]* 243:1, 1974.

Huxley AF: The contraction of muscle, *Sci Am* 199:67, 1958.

Jones JK, et al: Paramyosin: molecular length and assembly, *Science* 163:1196, 1969.

Knappeis GG, Carlsen F: The ultrastructure of the M line in skeletal muscle, *J Cell Biol* 38:202, 1968.

Peachey LD: The sarcoplasmic reticulum and transverse tubules of the frog's sartorius, *J Cell Biol* 25:209, 1965.

Shafia SA, et al: The fine structure of fiber types in normal human muscle, *Anat Rec* 156:283, 1966.

Squire JM: Muscle filament structure and muscle contraction, *Ann Rev Biophys Bioeng* 4:137, 1975.

Cardiac Muscle

Atlas SA: Atrial natriuretic factor: a new hormone of cardiac origin, *Rec Prog Horm Res* 42:207, 1986.

Cantin M, Genest J: The heart as an endocrine gland, *Sci Am* 254:76, 1986.

Johnson EA, Sommer JR: A strand of cardiac muscle. Its ultrastructure and the electrophysiological implication of its geometry, *J Cell Biol* 33:103, 1967.

Katz AM: Contractile proteins of the heart, *Physiol Rev* 50:63, 1970.

Legato MJ: Sarcomergenesis in the human myocardium, *J Molec Cell Cardiol* 1:425, 1970.

Rhodin JA, Missier P, Reid LC: The structure of the specialized impulse-conducting system of the steer-heart, *Circulation* 24:349, 1961.

Simpson FO, Oertelis SJ: Relationship of the sarcoplasmic reticulum to the sarcolemma in sheep cardiac muscle, *Nature* 189:758, 1961.

Sommer JR, Waugh RA: The ultrastructure of the mammalian cardiac muscle—with special emphasis on the tubular membrane systems, *Am J Pathol* 82:191, 1976.

Spiro D: The ultrastructure of heart muscle, *Trans NY Acad Sci* 24:879, 1962.

Downloaded From Vet-eBooks.com

CHAPTER 14

Nervous Tissue

GENERAL CHARACTERISTICS

Nervous tissue is distributed throughout the soma intimately associated with most tissues. The anatomical unit of nervous tissue is the **neuron.** Neurons are modified to receive and transmit stimuli. These functions are the basis for complex visceral and somatic behavior. Neurons receive stimuli from the internal **(interoception)** and external **(exteroception)** environment, instantaneously integrating and associating this information and subsequently transmitting it to muscle and glands.

The properties of **irritability** and **conductivity** suit neurons to their tasks, and their well-developed cell processes ensure contact throughout the body. These cell processes are the anatomical bases for transmission. Intimate contact between neurons and cell processes occurs through **synapses.**

Neurons are intimately associated with other cells called the **neuroglia. Neurons and the neuroglia constitute nervous tissue.** The neuroglia furnishes protection, nutrition, and structural integrity to nervous tissue.

NEURONS

General Properties

Although no single description encompasses all neurons, they do have common characteristics despite diverse three-dimensional morphology. A neuron has a **cell body (cyton** or **soma)** and cell processes **(dendrites** and an **axon)** (Fig. 14-1). The **perikaryon** is part of the cell body surrounding the nucleus.

All nervous tissue components, with the exception of microgliocytes, are derivatives of neuroectoderm. Nervous tissue is modified epithelium (Chapter 17).

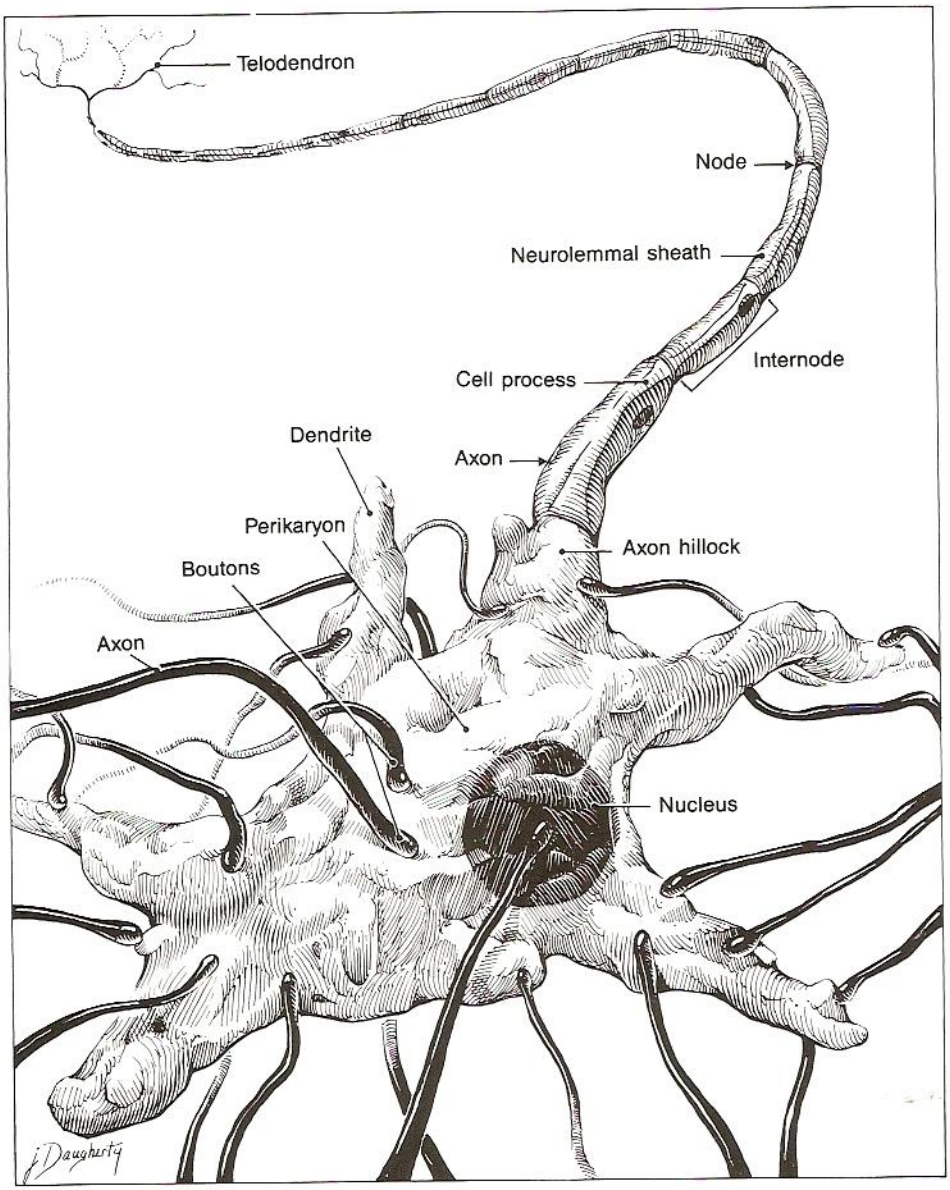

Figure 14-1. A multipolar neuron. The dendrites, cell body, axon, and telodendrion are conspicuous. According to the Bodian classification the dendrites, cell body, and initial segment of the axon comprise the dendritic zone, which receives afferent information. The axon carries information away from this zone. The telodendrion is the site of interaction (point of information transfer) with an effector or another neuron.

Classification

Morphological diversity of neurons is manifested in many ways as adaptations to diverse functional demands (Fig. 14-2). Neurons are either transmission neurons or neurosecretory neurons (Fig. 14-3).

Conducting neurons. **Transmission (conducting) neurons** comprise the majority of neurons and are the cells that secrete neurotransmitters at synapses. Generally they have dendrites, a cell body, and an axon. Various morphological features are used to classify them (Fig. 14-4).

Multipolar neurons have many dendrites and a single, long or short axon. Those with a long axon are ventral horn

Downloaded From Vet-eBooks.com

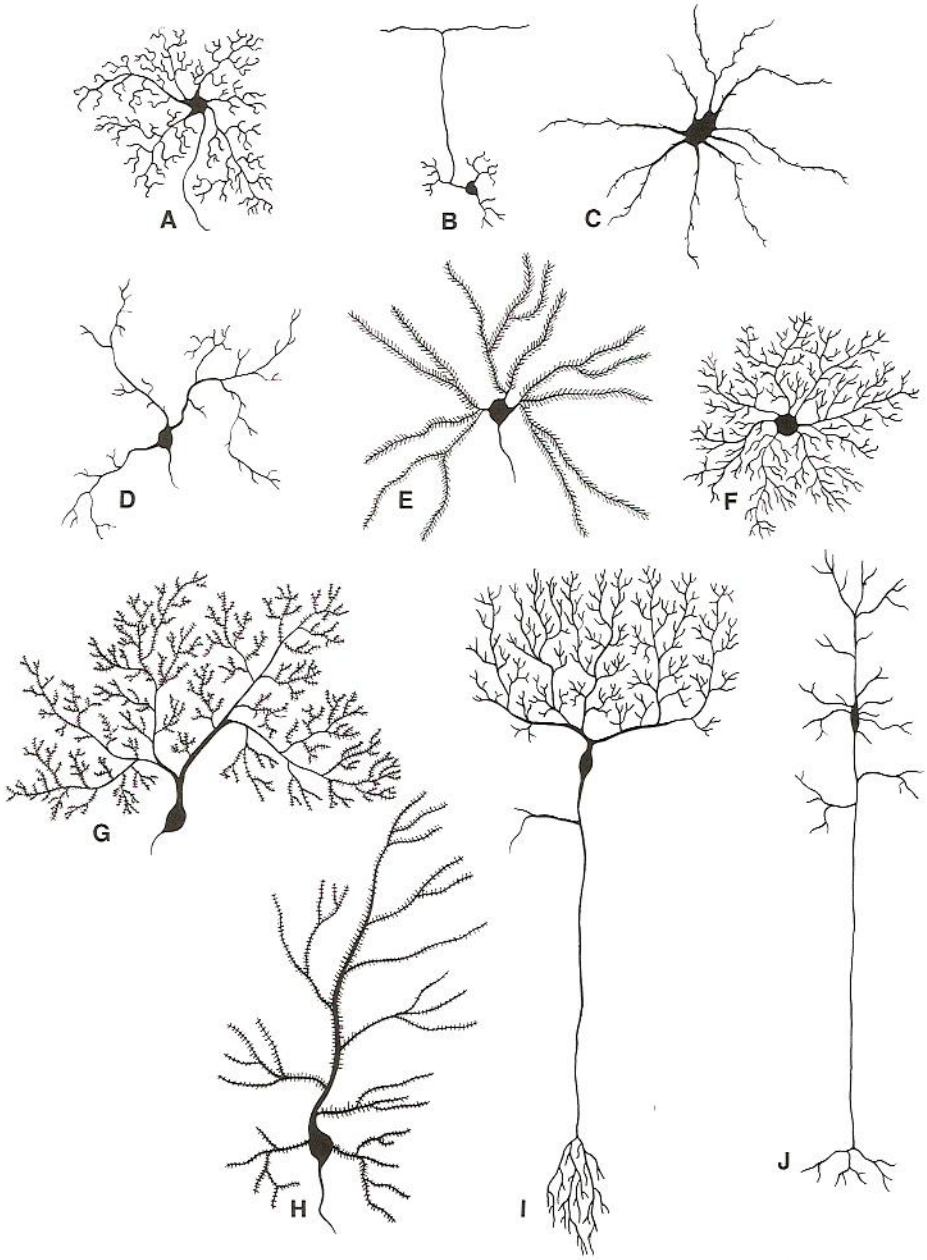

Figure 14-2. Neuronal components of the CNS. **A,** Neuron of an olivary nucleus; **B,** Granule cell of a cerebellar cortex; **C,** neuron from a reticular formation; **D,** large neuron of the spinal nucleus of a trigeminal nerve; **E,** neuron of a basal ganglion; **F,** neuron of a thalamic nucleus; **G,** piriform cell of a cerebellar cortex; **H,** pyramidal cell of a cerebral cortex; **I,** piriform cell with its long axon and telodendrion; **J,** pyramidal cell with its long axon and telodendrion. (Redrawn and modified from Truex RC, Carpenter MB: *Human neuroanatomy,* ed 5, Baltimore, 1966, Williams & Wilkins.)

Downloaded From Vet-eBooks.com

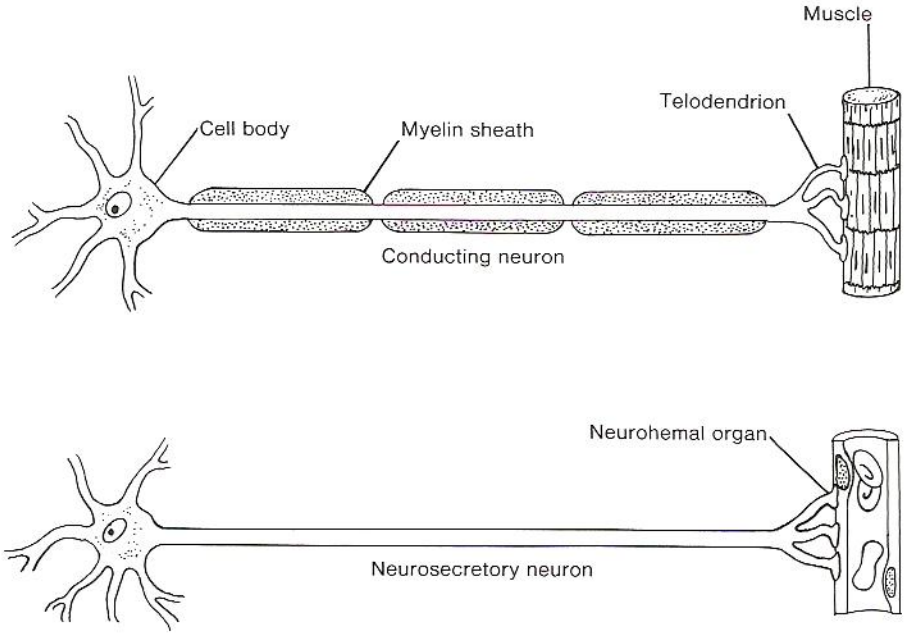

Figure 14-3. Conducting and neurosecretory neurons. Conducting neurons occur more commonly than neurosecretory neurons. Despite their limited distribution, however, neurosecretory neurons are important members of the endocrine system.

cells of the spinal cord gray column (α-motor neurons), sympathetic and parasympathetic preganglionic neurons, sympathetic postganglionic neurons, and other motor cells. Those with a short axon are interneurons and cells of the cerebral and cerebellar cortex.

Bipolar neurons have one main dendrite and an axon; the processes are located at opposite poles of the cell body. These cells receive special visceral and somatic stimuli.

True unipolar neurons have only an axon and occur only during development.

Pseudounipolar neurons have an axon and a dendrite fused close to the cell body but separated from it. Both processes appear structurally as axons. These cells are typical of the cranial and spinal ganglia.

Some neurons (e.g., the retinal amacrine cells) do not have axons and are called **anaxonic neurons.**

Neurosecretory neurons. These synthesize **neurosecretory substances,** transport them along axons as **neurosecretory bodies,** and release them into the blood. The axonal terminal–blood vessel relationship is intimate and forms **neurohemal organs** (Fig. 14-3). Some hypothalamic neurosecretory cells secrete **oxytocin** and **antidiuretic hormone.** Others secrete **releasing factors (releasing hormones)** or **inhibiting factors (inhibiting hormones)** (Chapter 25).

Bodian classification. Classical discussions of neuronal component functions have included the following concepts: (1) dendrites carry information to the cell body **(afferent);** (2) axons carry information from the cell body **(efferent);** (3) this information is transferred to the next element in the series, another neuron or effector organ, and the process repeats itself. Thus the neuron or chains of neurons are established as the structural basis of behavior.

Although the cell body's relationship to these afferent (dendritic) and efferent (axonal) neuronal components varies, the location of the cell body for specific neurons is constant. The specific location of the cell body relative to a tissue's geometric organization is not important when the excitation, conduction, and information transfer functions are considered.

According to the **Bodian classification,** the three functionally significant zones are dendritic, axonic, and telodendritic (Fig. 14-5). The **dendritic zone** is the neuronal region subjected to excitatory and inhibitory stimulation. It includes dendrites, cell body, and the initial axonal segment. Impulses impinging upon these surfaces produce graded receptor potentials propagating passively to the **initial segment (trigger zone).** Such propagation may or may not generate an action potential. The **axonic zone** includes the initial segment of the axon (the axis cylinder and part of the arborizing axonal terminal). It is the all-or-none conducting part of the neuron. The **telodendritic zone** includes those terminal modifications permitting information transfer to the next element in the pathway. The electrical or chemical activity of the telodendria produces a graded response in the next element of the series.

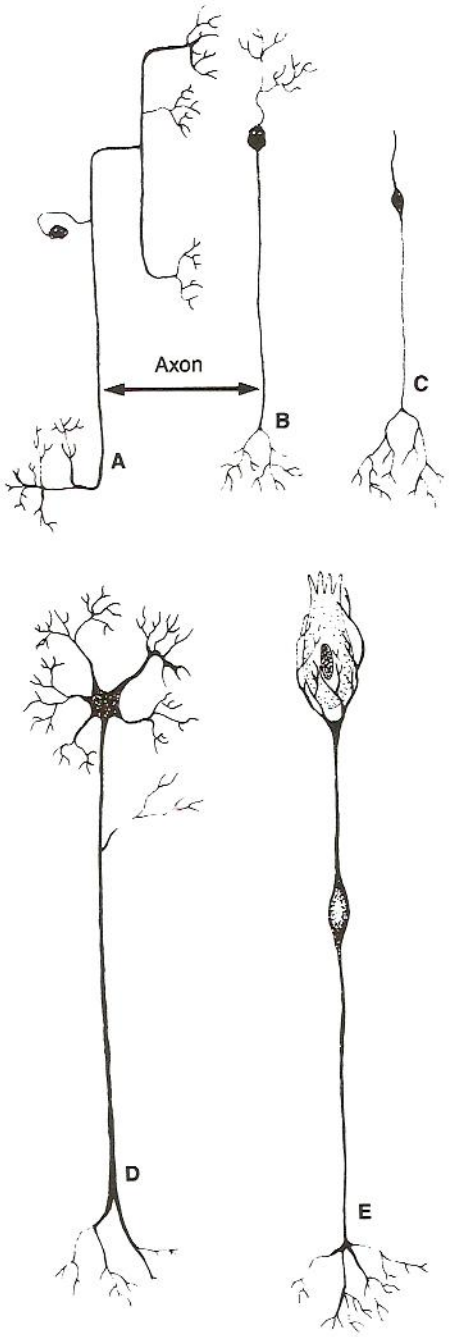

Figure 14-4. Neuronal components of the PNS. **A,** Neuron of a spinal ganglion; **B,** α-motor neuron; **C,** olfactory neuron; **D,** sympathetic ganglion cell; **E,** epithelial receptor and bipolar neuron from the membranous labyrinth of the inner ear. Part of the axon and the telodendrion of the spinal ganglion cell **(A)** occur within the CNS; the remainder of the axon, the cell body, and the dendritic zone are in the PNS. The α-motor neuronal cell body (with associated dendritic zone) and part of the axon are in the CNS, and the remainder of the axon and telodendrion are in the PNS. (Redrawn and modified from Copenhaver WM, Kelly DE, Wood RL: *Bailey's Textbook of histology,* ed 17, Baltimore, 1978, Williams & Wilkins.)

Downloaded From Vet-eBooks.com

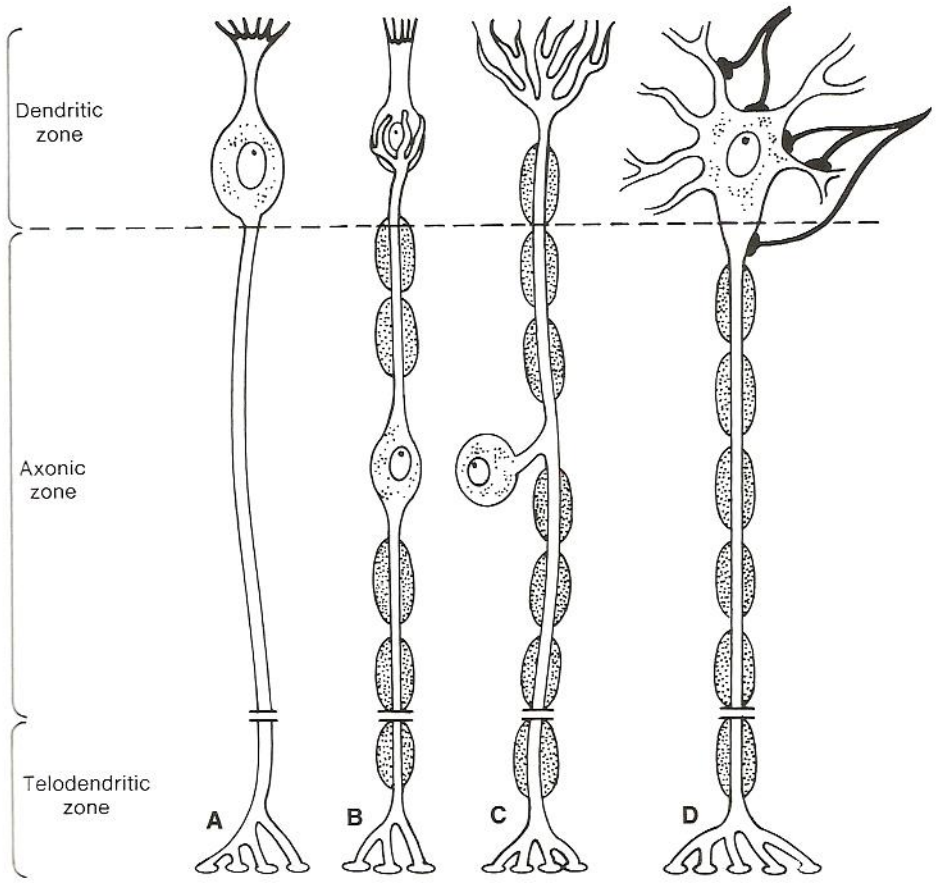

Figure 14-5. Zones ascribed to various neurons by the Bodian classification. The position of the cell body varies, but three distinct zones are apparent. The cell body occurs independently of the ability of the neuron to transmit an action potential. The initial segment, although an anatomical part of the axon, is actually part of the dendritic zone of the cell. **A,** Olfactory neuron; **B,** epithelial cell and bipolar neuron of the membranous labyrinth of the inner ear; **C,** dorsal root ganglion cell; **D,** α-motor neuron.

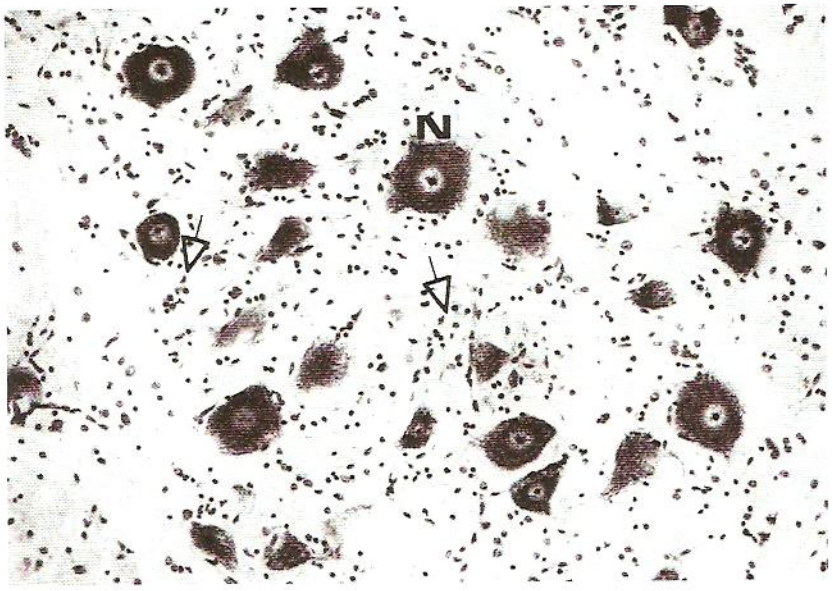

Figure 14-6. Nervous tissue from a porcine brain stem. The neurons *(N)* are distributed among many neuroglial cells *(open arrows)*. The cell body at *N* is dark-staining. The round pale-staining nucleus, with a prominent nucleolus, is located centrally. (×40.)

Neuronal Components

Cell bodies

The neuronal cell body varies from 4 to 135 μm in diameter. A prominent, round, large, vesicular nucleus is usually located centrally. A prominent nucleolus is also present (Fig. 14-6).

The cytoplasm is granular and basophilic. The abundant, granular basophilic inclusions **(chromaphilic substance** or **bodies)** are scattered throughout the perikaryon and the dendritic cytoplasm (Fig. 14-7) but are not present in the axon. A clear region, the **axon hillock,** delimits the axonal origin in the perikaryon (Fig. 14-8). Chromaphilic substance varies in shape, size, and distribution within the neuron. Also the amount of this material varies with the neuron's functional state. Chromaphilic bodies are prominent in α-motor neurons. The granules are clusters of RER, free ribosomes, and free polysomes (Fig. 14-9). Neurons renew as much as a third of their proteins per day.

Chromaphilic substance is labile and may dissolve **(chromatolysis)** when the cell body and/or its processes are injured. The dissolution of chromaphilic substance accompanies an increased quantity of SER, an increased amount of free ribosomes and polysomes, and an increased total cell RNA content. Although chromatolysis is now considered a restorative process, it may still indicate neuron degeneration. The restorative aspects of this change depend upon the neurons involved and the severity and location of cellular injury.

Golgi complex functions relate to lysosome formation, the condensation and segregation of cellular products, and plasmalemmal replenishment. A neuron is a secretory cell. Most secretory cells have a prominent Golgi complex. Secretory vesicles are transported a short distance from the Golgi stack to the apical cell membrane. This region of most secretory cells is specialized for exocytosis. The neuron performs the same activities, but the distances over which secretory vesicles must travel are great. The portion of the neuronal plasma membrane specialized for exocytosis is the terminal part of the axon. The presynaptic terminal, then, is homologous to the apical part of a typical secretory epithelial cell.

Mitochondria occur in large numbers within the cell body; the organelle is especially prominent in axonal terminals (Fig. 14-9). **Lipofuscin** occurs in nerve cells and may be linked to their high rate of cellular metabolism and organelle turnover. Lipofuscin is thought to occur within residual bodies from autophagocytic phenomena. Its presence may indicate cell dysfunction. **Neurofilaments** and **neurotubules (microtubules)** occur in the

Downloaded From Vet-eBooks.com

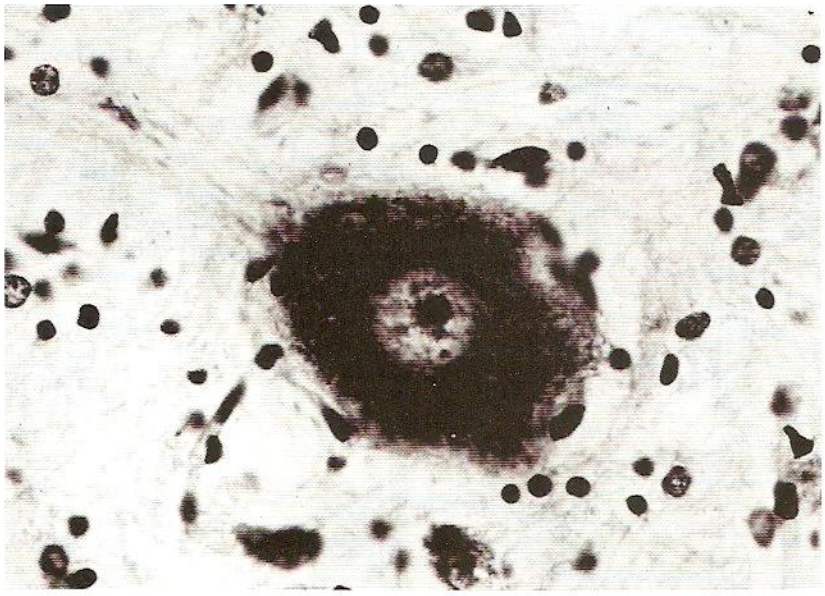

Figure 14-7. Chromophilic substance of a neuron. The chromophilic substance is the dark-staining material within the cytoplasm. The nuclei of cells surrounding the neuron are those of neuroglial cells. Note the size difference between neurons and neuroglial cells. (×160.)

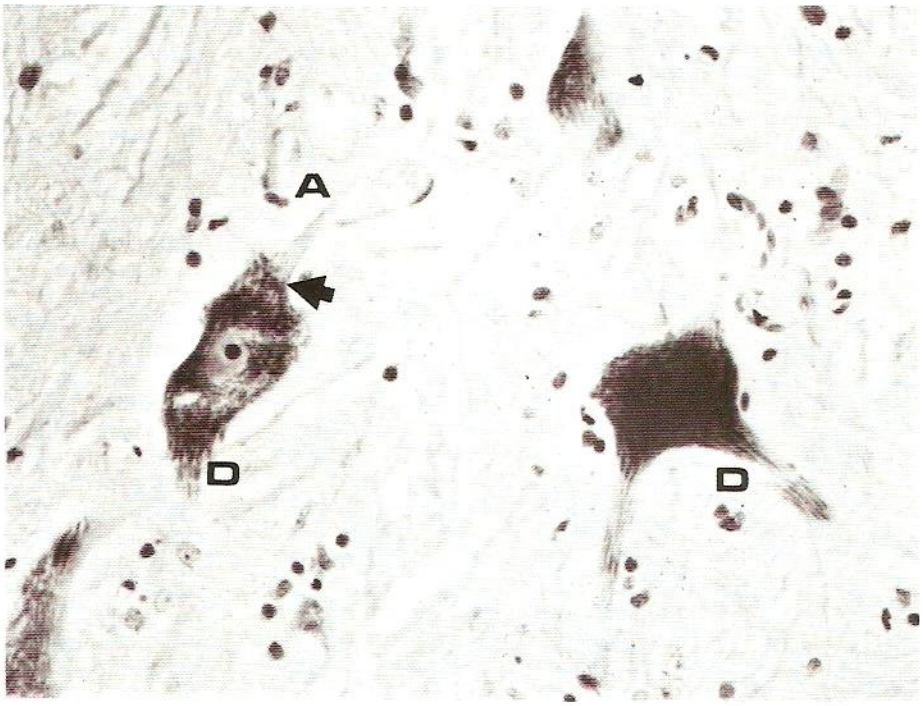

Figure 14-8. Neurons from a canine brain stem. The axon hillock *(arrow)*, devoid of chromophilic substance, clearly denotes the origin of the axon within the cell body. The initial segment of the axon is important in generating action potentials. *A*, Axon; *D*, dendrites. (×100, Nocht's stain.)

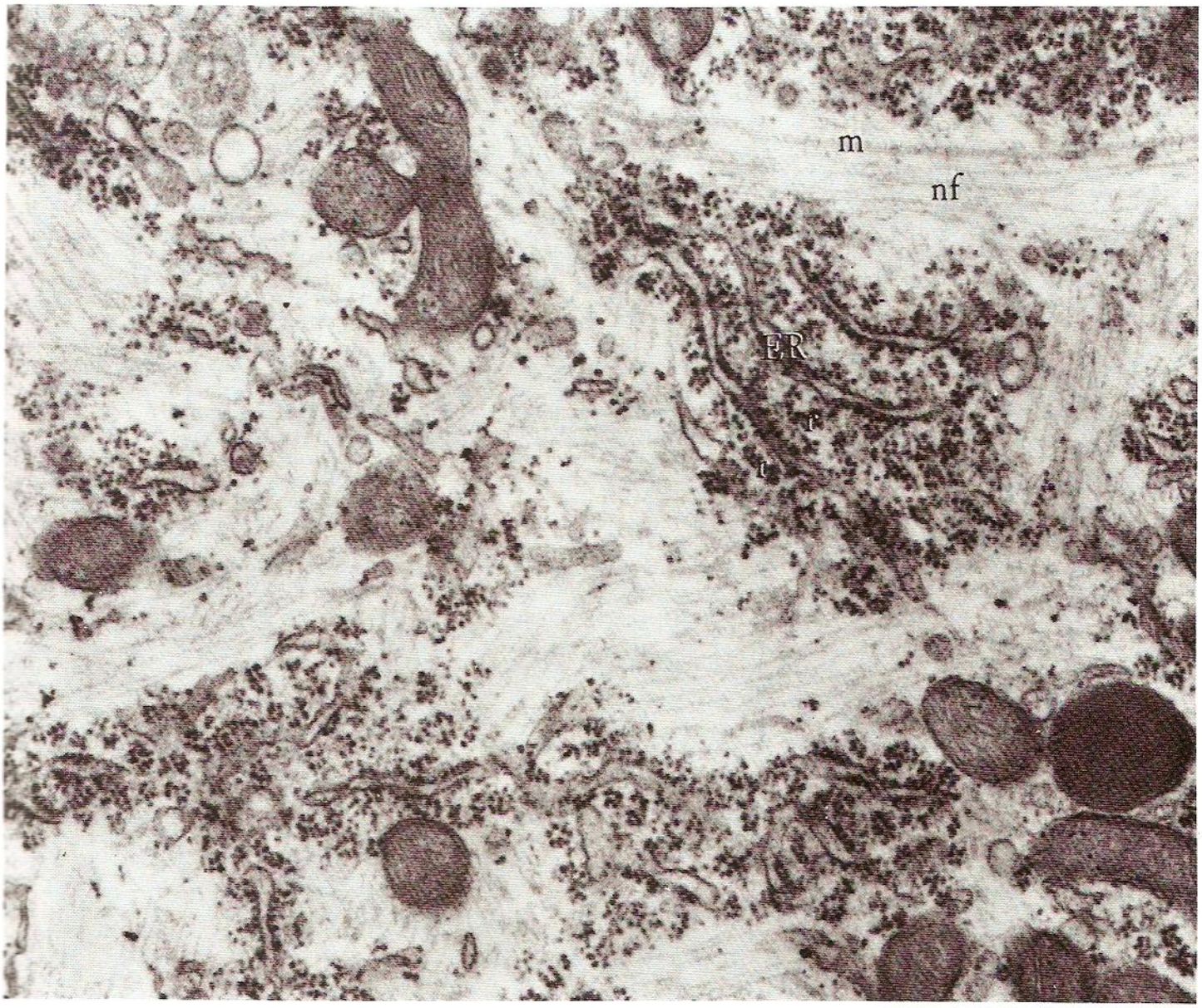

Figure 14-9. Electron micrograph of the cytoplasm of a murine dorsal root ganglion cell. The cytoplasm contains discrete chromophilic substance composed of rough endoplasmic reticulum *(ER)* and free ribosomes *(r)* and polysomes. Many neurofilaments *(nf)* and microtubules *(m)* are scattered throughout the cytoplasm. ×49,000. (Reprinted with permission from Peters A, Palay SL, Webster HF: *The fine structure of the nervous system: the neurons and supporting cells,* Philadelphia, 1976, WB Saunders.)

cell body and processes (Fig. 14-9). Although the plasmalemma is typical morphologically and conforms to the fluid mosaic model, it is not structurally and functionally uniform.

Dendrites

The **dendrites** are cell processes, increasing a cell's surface area. They are like tree branches (Gr *dendron,* tree). The dendritic processes usually are shorter than the axon, branch continuously, and taper gradually (Fig. 14-1). The dendritic and cell body surfaces are covered with many **spines** or **gemmules** representing synaptic connections with **axon terminals** of other nerve cells. The cytoplasmic content of these processes is similar to that of the cell body. Nissl substance occurs only proximally in the processes, but neurotubules, neurofilaments, and mitochondria occur throughout the processes.

Axons

Structure. The **axon** arises from the **axon hillock** of the perikaryon (Figs. 14-1 and 14-8). This single process has a smooth surface and a uniform diameter. The axonal cytoplasm contains mitochondria, neurotubules, neurofilaments, and SER. Chromaphilic substance does not occur in the axon hillock and axon.

The axon branches extensively as the **telodendrion** before terminating on an effector. The axonal plasma membrane is typical, with functional and morphological alterations at various points along its course. The **initial segment** extends from the point of cell body emergence to the point of myelin initiation, which is the first 50 to 100 μm of the axon. Also the initial segment has a lower excitatory threshold than the dendrites and cell body. Nodes occur along myelinated axons as focal discontinuities in the myelin sheath. The axon at these points is covered by cytoplasmic processes of the glial cells; it may be thicker at the nodes. Functionally the nodes account for **saltatory conduction** of impulses (i.e., a jumping of the depolarization wave from

Downloaded From Vet-eBooks.com

node to node). Axon terminals are variously modified to facilitate information transfer.

Axonal transport. In the axon, materials move constantly away from **(somatofugal)** and toward **(somatopetal)** the cell body. Somatofugal **cytoplasmic flow** may be **slow** or **fast.** Most materials within the axoplasm move slowly at rates of 0.5 to 5 mm/day and are believed to consist of large molecules utilized in axonal maintenance, turnover, and repair. Some materials, however, move very rapidly (10 to 200 mm/day). They use neurotubules for their transport and are involved with axonal synaptic functions. The cell body responds to alterations in its axon, because information flows **retrograde** toward the cell body (somatopetally).

INFORMATION TRANSFER

Focal Sites of Transmission

Electrotonic transmission

Electrotonic transmission in nervous tissue occurs at specific sites called **ephapses, electrotonic junctions,** or **electrical synapses.** In the tissues discussed previously these points of electrical transmission between cells were called **gap junctions (nexi)** (Figs. 13-5 and 14-10). Electrical stimulation of cells related in this manner allows the unpolarized spread of excitation by ionic current between junctional components. The contributing cell membranes function as a single unit, and transmission is achieved rapidly. Ephapses are confined generally to the retina and a few sites within the central nervous system of vertebrates.

Synapses

Structure. **Synapses** are **electrochemical transmission sites** between neurons or neurons and effector cells. The electrical activity of the **presynaptic** cell membrane causes the release of a neurotransmitter substance that traverses the intercellular space and links to a **receptor site** on the adjacent **postsynaptic** cell membrane. **The union of the neurotransmitter with the receptor results in excitation or inhibition.** The release, diffusion, and union of the neurotransmitter substance at the receptor site result in **synaptic delay.**

The following description applies to most synapses. Axonal terminations are the **presynaptic** membranous elements whereas adjacent cell membranes are the **postsynaptic** membranous elements. The pre- and postsynaptic membranes are separated by an intercellular space **(synaptic cleft)** varying in width from 6 to 20 nm (Fig. 14-11) and containing electron-dense materials and fine filaments. The fine filaments or fibrous materials appear attached to the pre- and postsynaptic membranes, projecting from each component like brush bristles. Glycoproteins and glycolipids occur within the cleft. These substances probably are modified glycocalyx materials holding the synaptic members together. Pre- and postsynaptic components can be isolated as discrete units **(synaptosomes)** from disrupted nervous tissue.

This type of morphology typifies a **directed synapse;** the target area on the postsynaptic member is small but the distance to the target is short. The least di-

Figure 14-10. Electrical synapse between a mossy fiber *(At)* and a granule cell dendrite *(Den)* within the cerebellum of a viper. Note the intimate juxtaposition of the *pre*synaptic and *post*synaptic membranes diverging at the margins (△) of the gap junction to form punctate junctions. Synaptic vesicles *(SV)* are also present within the mossy fibers. Although this form of communication between mammalian neurons is not common, it is important for other cells (epithelial and muscle) and some neurons. (×305,000.) (Reprinted with permission from Peters A, Palay SL, Webster HF: *The fine structure of the nervous system: the neurons and supporting cells,* Philadelphia, 1976, WB Saunders.)

Downloaded From Vet-eBooks.com

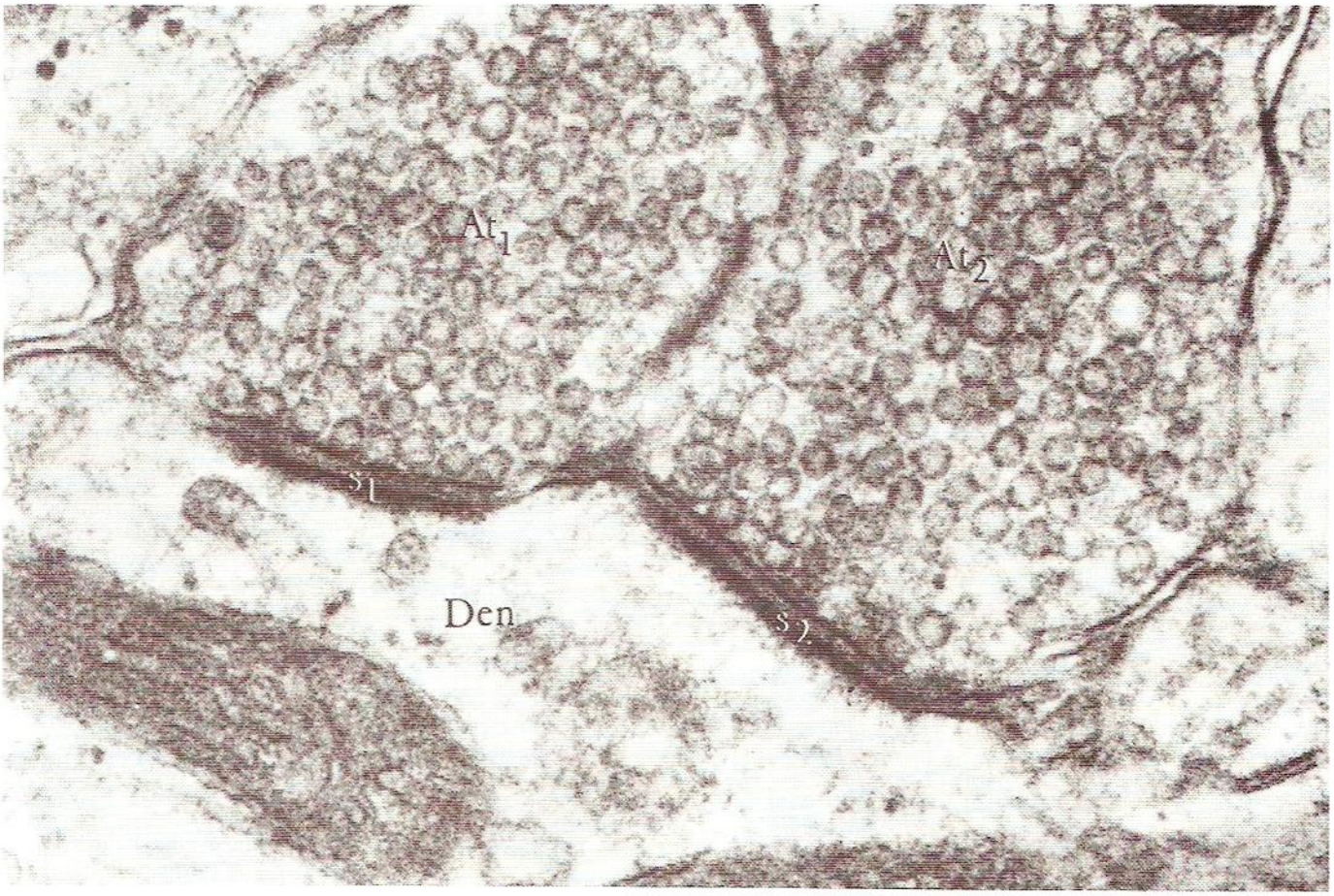

Figure 14-11. Two asymmetrical synapses (S_1 and S_2) of a rat visual cortex. Two axon terminals (At_1 and At_2) have synapsed with a dendrite *(Den)* of a stellate cell. The presynaptic and postsynaptic membranes are separated by a cleft containing dense intercellular material. The postsynaptic membrane also has dense material associated with its cytoplasmic face. Note the many vesicles in the axon terminals. (×100,000.) (Reprinted with permission from Peters A, Palay SL, Webster HF: *The fine structure of the nervous system: the neurons and supporting cells,* Philadelphia, 1976, WB Saunders.)

rected synapses are those associated with neurohemal organs. Adrenergic terminals may be intermediate or **nondirected** in their relationships with effector targets; the localized release of neurotransmitters has a widespread influence on these effector cells.

Filamentous densities of the postsynaptic membrane form the **subsynaptic web.** The presynaptic terminal consists of mitochondria, neurofilaments, neurotubules, and **synaptic vesicles.** Cytoplasmic densities may be associated with both the pre- and the postsynaptic membrane **(symmetrical synapse)** or with either membrane **(asymmetrical synapse).** Intermediate forms also exist. Chemical synapses have a distinct morphological presynaptic to postsynaptic polarity manifested as a unidirectional flow of information from the presynaptic to the postsynaptic membrane.

Appositional relationships. The presynaptic portion of the axon expands into bulblike processes called **end bulbs, end feet, boutons,** or **boutons terminaux** (Fig. 14-12). Enlargements along the course of the axon are called **boutons en passage.** They occur along the axons of unmyelinated nerves or at nodes of myelinated nerves. Axonal terminals form synapses with various parts of other neurons (Fig. 14-13). The **neuromuscular junction** is a special synaptic relationship between neurons and striated muscle. (See Chapter 16.)

Neurochemical Transmission

Presynaptic components

Neurotransmitters. **Neurotransmitters** are chemical compounds linking presynaptic neurons to postsynaptic neurons or effector organs. Many compounds have been implicated as neurotransmitters; only a few qualify **(acetylcholine, dopamine, norepinephrine, δ-aminobutyric acid, serotonin, histamine, glycine, glutamate).** Despite the diversity of compounds, **a neuron characteristically secretes only one neurotransmitter.**

The presynaptic enlargement contains

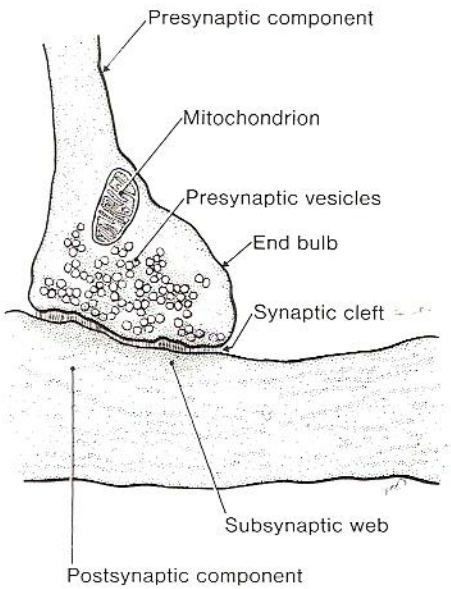

Figure 14-12. Morphology of a synapse. The primary constituents are labeled. Synaptic morphology varies.

Downloaded From Vet-eBooks.com

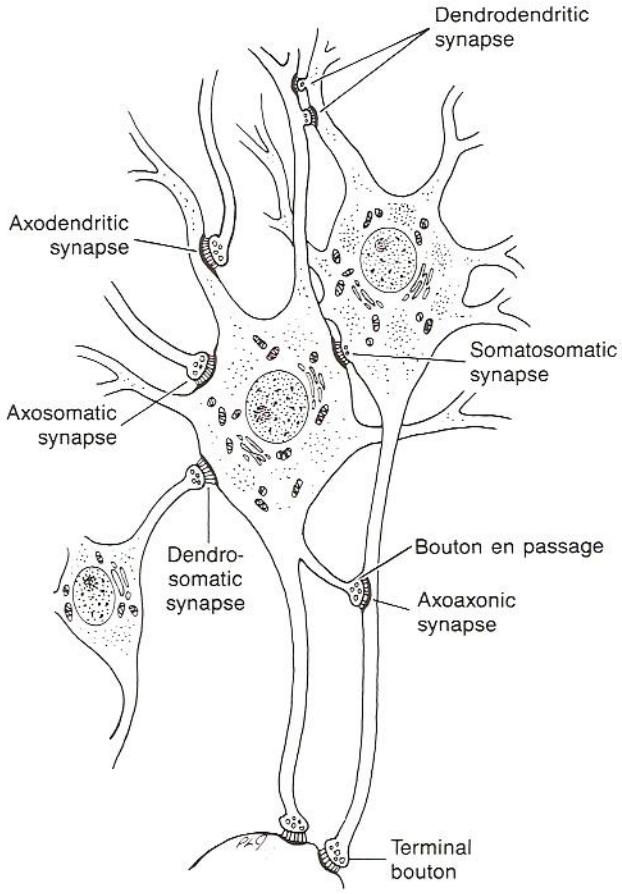

Figure 14-13. Synaptic patterns. Although the synapses depicted are asymmetrical, other patterns exist.

many **synaptic vesicles.** Neurotransmitter substances are contained within or are bound to these vesicles. Upon appropriate presynaptic electrical stimulation by an action potential, exocytosis occurs. The action potential opens voltage-gated Ca^{++} channels, permitting the entry of Ca^{++} into the axonal terminal. Neurotransmitters are released in discrete, fixed amounts called **quanta.** Each synaptic vesicle, containing several thousand molecules, is a single quantum. Calcium influx increases the quanta released upon stimulation. The Ca^{++} may bind to the inside of the presynaptic member at **release** or **active sites**, causing a transient vesicular binding to the membrane. The vesicles open, release their contents, close, and reenter the cytosol.

Two distinct synaptic vesicles are identifiable. **Clear vesicles** occur in neuronal terminals with **acetylcholine** as the neurotransmitter. **Dense core** or **granular vesicles** occur in neurons releasing **norepinephrine** or other catecholamines.

Cholinergic terminals. Acetylcholine is synthesized from choline and **acetyl-coenzyme A** in a reaction catalyzed by **choline acetylase** (Fig 14-14). The enzyme is active in cholinergic terminals. Acetylcholine is stored in clear synaptic vesicles at synaptic terminals. It is released into the synaptic cleft upon appropriate stimulation. **Acetylcholinesterase** occurs in the postsynaptic cell membrane. It hydrolyzes and inactivates this neurotransmitter at cholinergic receptor sites.

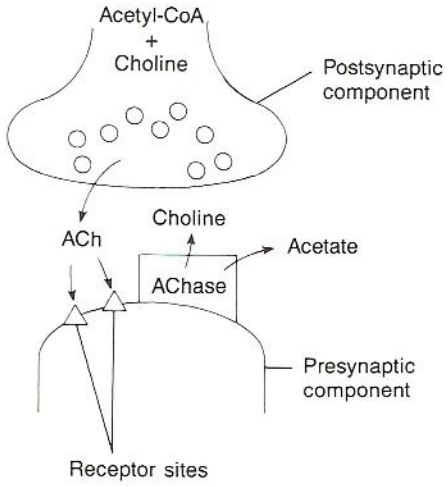

Figure 14-14. Cholinergic synapse. After attachment at the receptor sites, acetylcholine *(ACh)* is degraded to acetate and choline by acetylcholinesterase *(AChase)*. The acetate diffuses into surrounding tissues, but the choline is returned to presynaptic terminals.

Acetylcholine is the neurotransmitter used by the α-motor neurons of the spinal cord and the cranial nerves innervating skeletal muscle. Preganglionic sympathetic and parasympathetic neurons are cholinergic; postganglionic parasympathetic neurons are also cholinergic. Acetylcholine is a neurotransmitter used by various brain cells.

Adrenergic terminals. The synthesis of dopamine, norepinephrine, and epinephrine occurs according to Figure 14-15. Some of the synthesis occurs within the dense-core vesicles of **adrenergic neurons.** Phenylalanine or tyrosine enters the metabolic pathway for **catecholamine** synthesis. (Catecholamines are compounds consisting of an *o*-dihydroxybenzene ring and an alkylamine side chain.) **Tyrosine hydroxylase** is an oxidase that converts tyrosine to **L-dihydroxyphenylalanine (L-DOPA).** This is the rate-limiting step in synthesis. The L-DOPA is decarboxylated within the cytoplasm to **dopamine.** In noradrenergic nerves, dopamine is converted to **norepinephrine** by **dopamine β-hydroxylase,** an oxidase located within dense-core vesicles. Norepinephrine is converted to **epinephrine** in the adrenal medulla by **methyl transferase.**

Norepinephrine is the neurotransmitter of sympathetic postganglionic nerves. Adrenergic nerves are also located within specific brain stem foci. Dopaminergic nerves also occur within specific brain foci. Sympathetic ganglia also contain **small intensely fluorescent (SIF) cells** that are dopaminergic.

The most important step in terminating norepinephrine and epinephrine activity is their reentry into adrenergic neuronal terminals (Fig.14-16), wherein they are oxidized by a mitochondrial enzyme, **monoamine oxidase (MAO).** The deaminated metabolites enter the blood and are excreted in the urine. The kidney and liver may also deactivate norepinephrine and epinephrine. **Catechol-O-methyl-transferase (COMT)** of the kidney, liver, and postsynaptic membrane probably assists with deactivation. The inactivated metabolites resulting from COMT and MAO activity may be conjugated with glucuronides through the hepatic enzyme **glucuronyl transferase** and subsequently secreted in the bile.

Postsynaptic components

Receptors. A **receptor** on or within the postsynaptic membrane is a molecular structure with which a single neurotransmitter substance reacts. The site may be an enzyme and/or a membrane structural protein. Conformational changes of the receptor protein after its fusion with the neurotransmitter account for membrane permeability alterations following this in-

Downloaded From Vet-eBooks.com

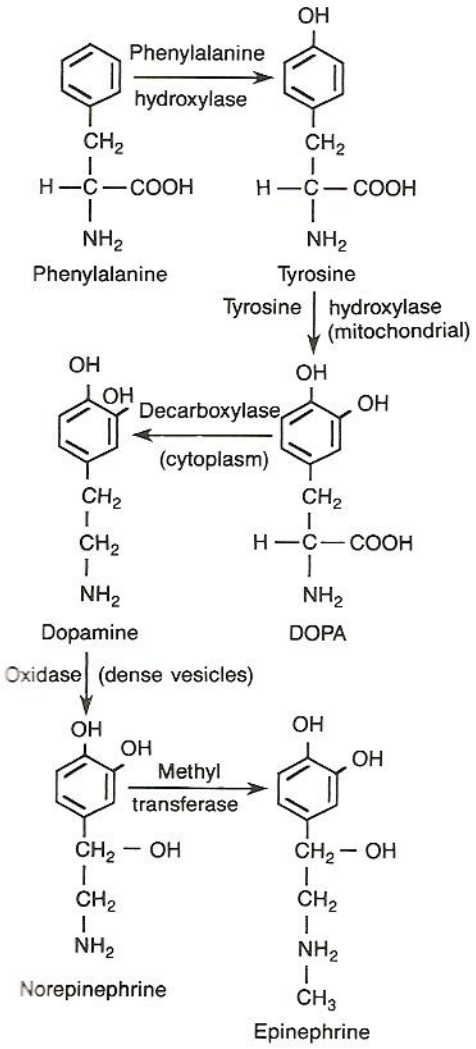

Figure 14-15. Biosynthesis of catecholamines.

teraction. The stimulation of a receptor site results in excitation or inhibition.

Excitation from receptor stimulation causes a decreased polarity (hypopolarization) of the postsynaptic membrane. Chemical gates or channels occur at the receptor sites. Activation opens them and increases the permeability of the membrane to Na^+ and K^+. These events reduce the negativity of the membrane potential due to a net inward flow of positive charges. The alteration in polarity can be measured electrically as an **excitatory postsynaptic potential (EPSP).**

Inhibition from receptor stimulation causes an increased polarity (hyperpolarization) of the postsynaptic membrane. This altered polarity is measurable as an **inhibitory postsynaptic potential (IPSP).** The receptor site functions as a chemical gate in which stimulation results in a flow of chloride ions (in some cases K^+), increasing the negative potential (hyperpolarization) beyond the normal resting potential.

The potential for excitation or inhibition of the postsynaptic membrane resides with the receptor site. A given neurotransmitter may elicit excitatory and inhibitory postsynaptic events.

The generation of an EPSP means the postsynaptic membrane permeability status is more likely to lead to an action potential, whereas the generation of an IPSP means that the permeability status and increased potential is less likely to lead to an action potential. The **spatial** and **temporal summation** of EPSPs and IPSPs determines the response of the postsynaptic element (neurons or effector organs).

Cholinergic sites. The fusion of acetylcholine with neuromuscular junction receptor sites results in Na^+ influx, cell membrane depolarization above the action potential threshold, and cell activation. In the heart acetylcholine fusion with cardiac muscle receptor sites increases K^+ permeability, stabilizes the diastolic membrane potential, and inhibits the effector organ. Thus the single neurotransmitter acetylcholine produces two different physiological effects from different acetylcholine receptors.

Adrenergic sites. Adrenergic receptor sites are responsive to **norepinephrine,** the neurotransmitter substance of adrenergic fibers. They are also responsive to **epinephrine,** the secretion of the adrenal medulla. Norepinephrine manifests **local effects,** but epinephrine effects occur **throughout the body.**

The differential effects of epinephrine and norepinephrine (and other drugs) upon adrenergic receptor sites define α- and β-receptors. Epinephrine and norepinephrine stimulate α-receptors; β-receptors likewise respond to epinephrine and, to a lesser extent, norepinephrine. Classically, α-receptors mediate postsynaptic element activation, such as smooth muscle contraction, resulting in vasoconstriction.

α-Receptors are now divided into α_1- and α_2-types. α_1-Receptors are the classical excitatory receptors, except for their effects upon intestinal smooth muscle. α_2-Receptors occur on presynaptic components of cholinergic and adrenergic nerves. They inhibit the prejunctional release of acetylcholine and norepinephrine. The placement of α_2-receptors at these prejunctional sites increases local regulation of their release.

β-Receptors are now also divided into two types—β_1- and β_2-. β_1-Receptor cardiac stimulation causes an increase in the rate **(positive chronotropy)** and in the strength **(positive inotropy)** of contractions. β_2-Receptors both stimulate the myocardium and inhibit intestinal smooth muscle. Their activation is manifested as inhibition of bronchiolar, vascular, and uterine smooth muscle contraction. Stimulatory β_2-receptors are located on presynaptic terminals. Their epinephrine responsiveness amplifies the sympathetic effect achieved by an increase in norepinephrine from the nondirected synapses.

Current evidence indicates that α- and β-receptors may be different conformations of a single metabolically controlled molecular entity. Such modulation, with its concomitant functional manifestations, would permit the organism to respond to varying normal and pathological conditions. Induced changes might also contribute to or result from disease processes. These conformational changes

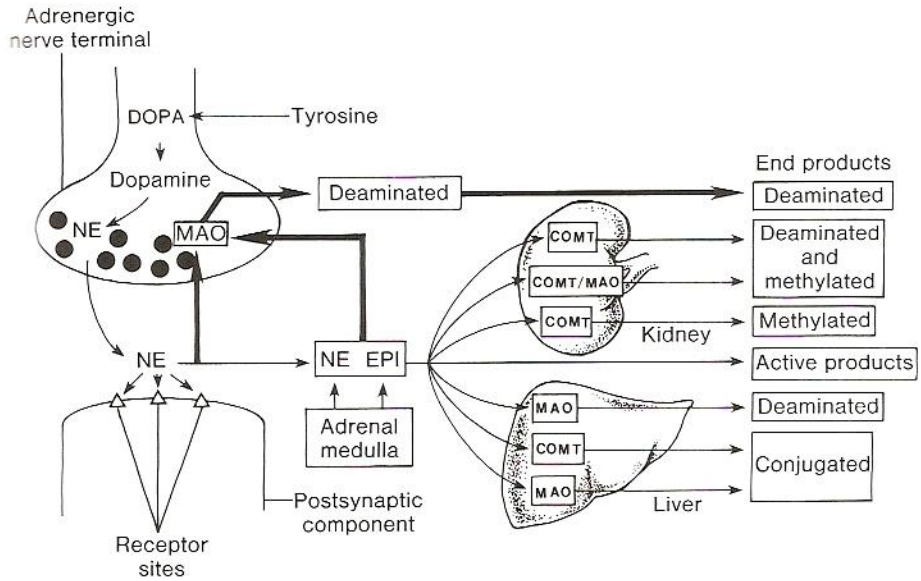

Figure 14-16. Secretion and degradation of norepinephrine *(NE)* and epinephrine *(EPI)*. Deaminated, methylated, and conjugated products are removed from the body by excretion and elimination. The most important inactivation process involves the deamination of norepinephrine and epinephrine by adrenergic nerve terminals.

Downloaded From Vet-eBooks.com

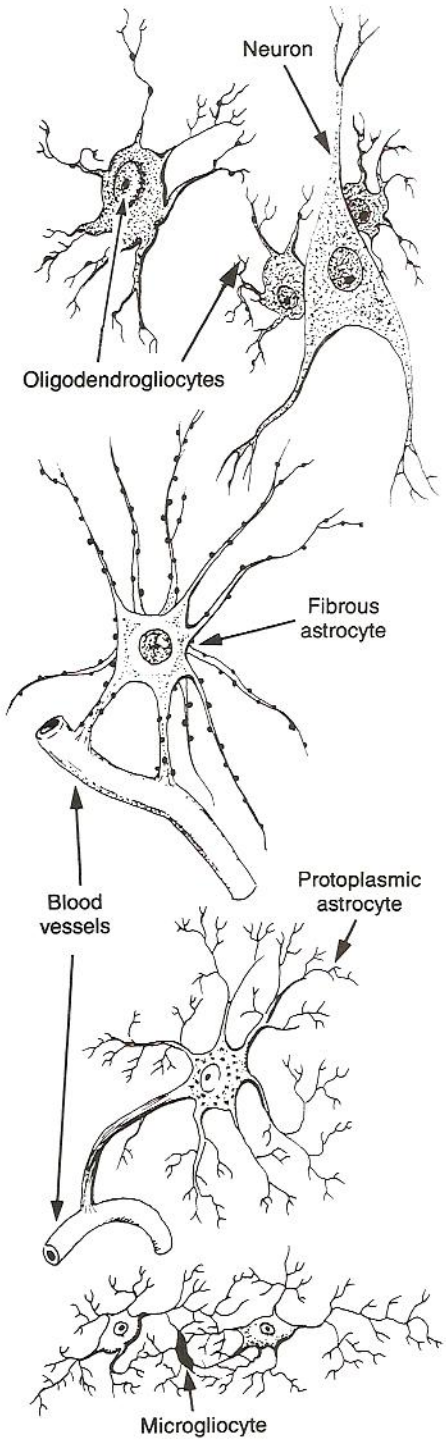

Figure 14-17. Morphology of central neuroglial cells as visualized with silver staining techniques. (Redrawn and modified from Copenhaver WM, Kelly DE, Wood RL: *Bailey's Textbook of histology*, ed 17, Baltimore, 1978, Williams & Wilkins.)

may account for intraspecific and interspecific differences noted upon adrenergic stimulation in domestic animals.

NEUROGLIA

Development of the central nervous system (CNS) results in the differentiation of two distinct cell populations. Both populations, neurons and neuroglia, form complex geometric patterns. The **neuroglial cells,** serving as the supportive network or nervous system stroma, are the "neural glue" binding neurons together. Besides a supportive function, they perform protective and nourishing functions as well as other activities vital to neurons.

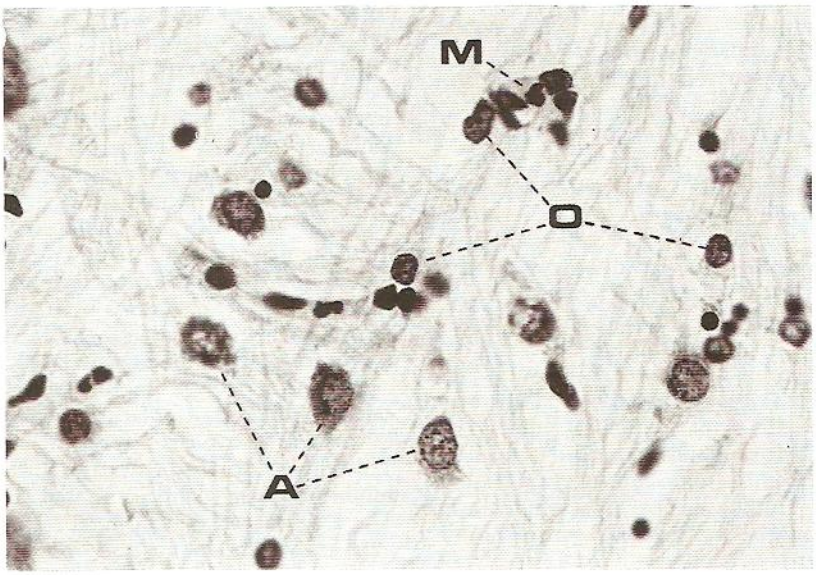

Figure 14-18. Neurogliocytes from a porcine brain stem. *O,* Oligodendrogliocytes; *A,* astrocytes; *M,* microgliocytes. (×160.)

Large neuroglial cells **(macroglia)** include oligodendrogliocytes, astrocytes, ependyma, amphicytes, neurolemmal cells, and Müller cells. The small neuroglial cells **(microglia)** are the microgliocytes. The neuroglia may also be divided on the basis of its association with the CNS or peripheral nervous system (PNS). The **central glia** includes oligodendrogliocytes, astrocytes, ependyma, Müller cells, and microgliocytes. The **peripheral glia** includes amphicytes and neurolemmal cells.

Routine staining is not useful for demonstrating the neuroglial cell bodies and cytoplasmic processes (Fig 14-17). Glial elements are identified by nuclear morphology.

Neuropil is a complex, feltlike network of axonal and dendritic processes with neuroglial elements of gray matter in which CNS neuronal cell bodies are embedded. It is the field within which synapsis occurs.

Central Glial Elements

Oligodendrogliocytes. **Oligodendrogliocytes** are the most numerous neurogliocytes (Fig. 14-18). They have a small, oval, or round nucleus containing much heterochromatin. The nucleus may vary from large and pale to small and dark. It is smaller and rounder than the astrocyte nucleus. Oligodendrogliocytes have scant cytoplasm and few cell processes. Residing between nerve cell processes, cell bodies, and capillaries, they may be **interfascicular, perineuronal,** or **perivascular.** The perineuronal cells probably perform nutritional functions, for in some regions of the feline brain they cover as much as 90% of the cell body surface area. Oligodendrogliocytes form myelin within the CNS.

Astrocytes. **Astrocytes** are the second most frequently encountered neurogliocytes of the CNS (Fig. 14-18). They are divided into **fibrous** and **protoplasmic** types, the latter having more cytoplasm than the former. The fibrous type is abundant in the white matter; the protoplasmic type, in the gray matter. Both have a large, round or oval, pale-staining nucleus. Fine chromatin granules are clumped peripherally.

Astrocytes are part of the structural support of the brain and spinal cord, imparting a weavelike texture and supportive framework around neuronal processes. Astrocytes also form the **outer glial limitans,** which repair nervous tissue defects and forms CNS scars. Astrocytes can become hypertrophic, hyperplastic, and phagocytic. They isolate neuronal receptor surfaces by performing an insulating function.

Microgliocytes. **Microgliocytes** have a scant cytoplasm with a small, dark nucleus (Fig. 14-18). The nucleus may be round, indented, or irregularly shaped. The cell body has numerous short processes. These cells are members of the macrophage system, because they are capable of phagocytosis in response to minor injury. Subsequent to extensive injury, phagocytic cells migrate from blood vessels and accom-

Downloaded From Vet-eBooks.com

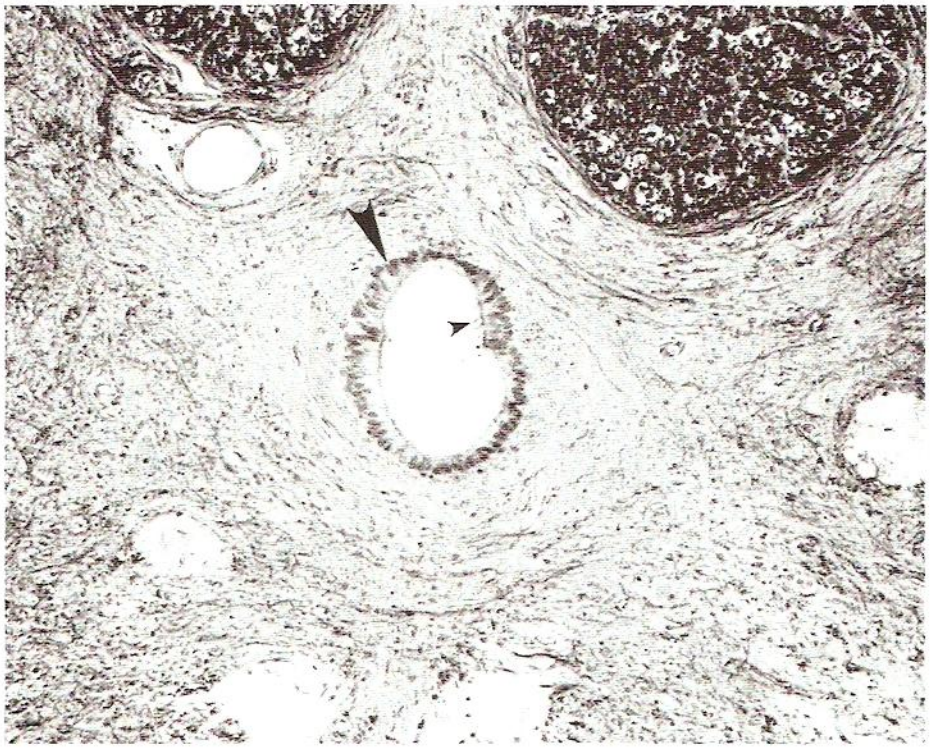

Figure 14-19. Central canal of a canine spinal cord. The canal *(large arrowhead)* is lined by columnar cells. Some of the cells are ciliated *(small arrowhead)*. (×40, myelin stain.)

plish functions ascribed to microgliocytes.

***Müller cells*. Müller cells** are columnar cells. They span the thickness of the neural retina (pars optica retinae) and form the inner limiting membrane of that structure.

***Ependyma*. Ependymal cells** line the neural canal (Fig. 14-19). The squamous to columnar epithelial lining is observed in adults as the lining of the spinal cord central canal and the four brain ventricles (Fig. 14-20). This lining is especially prominent and modified where the **choroid plexuses** are formed. Embryonic ependyma consists of low cuboidal or low columnar ciliated cells. The latter are retained in adults as islands of cilia projecting from the brushlike luminal border. These cells have large, pale nuclei with one or more nucleoli. In adults the basal borders reside on a basement membrane separated from the nervous tissue. In younger animals the basal modifications are complex and cell processes may extend through the mantle layer of the developing nervous tissue.

Ependymal cells contribute to the formation of cerebrospinal fluid (CSF). This formative process occurs at scattered sites throughout the ventricular system. Ciliated cells move CSF through the ventricular system. Nerve endings within the ependymal lining impart a sensory function to this layer of cells. The ependymal cells transport hormones.

Tanycytes are specific cells of the ependymal lining occurring principally in the median eminence. Their processes span from the third ventricle wall to the portal venous plexus. They may be involved in transport of neurosecretions.

The **subependymal organ** may replace neurons and neuroglial cells during development for some time after neuroepithelial mitosis ended.

Peripheral Glial Elements

***Ganglion gliocytes*. Ganglion gliocytes (amphicytes)** are neuroglial cells surrounding the neurons of ganglia (Fig. 14-21). Some investigators believe that amphicytes are neurolemmal cells.

***Neurolemmal cells*. Neurolemmal cells** are associated with neuronal processes (Fig. 14-22). They surround these fibers and form myelin and are probably also related to oligodendrogliocytes.

CELLULAR INVESTMENTS OF NEURONS

The neurons of the nervous system are intimately associated with neuroglial cells. Oligodendrogliocytes establish unique relationships with central neurons through myelin sheath formation on neuronal cell processes. Neurolemmal cells form similar relationships in the periphery.

Ganglion cells are neurons located in the peripheral nervous system. Accumulations of these cells are called **ganglia.** The neuronal cell bodies are covered by a layer of **ganglion gliocytes** (Fig. 14-21). Amphicytes usually form a continuous covering over sensory ganglion cells, although the covering may be incomplete in autonomic ganglia (Fig. 14-23). Amphicytes end at points of neurolemmal cell initiation. The distinction between amphicytes and neurolemmal cells may be artificial.

NEURONAL PROCESSES

***Unmyelinated nerve fibers*.** The neurolemmal cell is the cellular investment of peripherally located neuron cell processes. **Unmyelinated fibers** are small fibers that are either unmyelinated or invested by only a trace of myelin. Such fibers are contained within elongated invaginations in the neurolemmal cell (Fig. 14-24). The fibers are not within the neurolemmal cell cytoplasm but are covered by the plasmalemma of the investing cell. Such investments are called **neurolemmal sheaths.** The juxtaposed plasmalemmal components of the neurolemmal cell encircling the axons are called **mesaxons.** A single neurolemmal cell can invest many neuronal processes.

Because a single neurolemmal cell invests a neuronal process only over a lim-

Downloaded From Vet-eBooks.com

Figure 14-20. Electron micrograph of an ependymal cell from the lining of a murine lateral ventricle. A tuft of cilia contains microtubules *(m)* that originate from a basal body *(bb)*. A basal foot *(arrow)* and ciliary rootlet *(x)* protrude laterally from the basal body. A fibrogranular *(fg)* aggregate is also apparent and may be confused with the ciliary rootlet. Mitochondria *(mit)*, granular endoplasmic reticulum *(ER)*, free ribosomes *(r)*, vesicles *(v)*, microtubules *(m_1)*, filaments *(f)*, and multivesicular bodies *(mvb)* are apparent. (Reprinted with permission from Peters A, Palay SL, Webster HF: *The fine structure of the nervous system: the neurons and supporting cells*, Philadelphia, 1976, WB Saunders.)

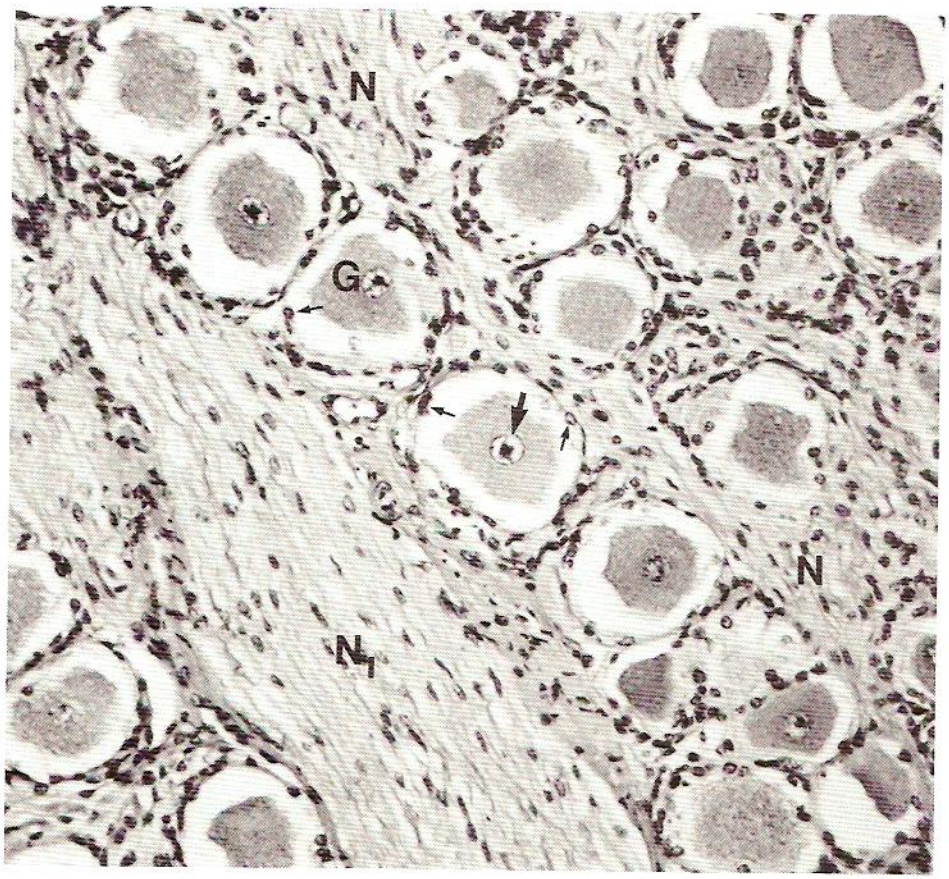

Figure 14-21. Ganglion gliocytes (amphicytes) and ganglion cells of a canine dorsal root ganglion. The amphicytes *(arrows)* surround the ganglion cells. They have been separated from the ganglion cells artifactually by processing. *N*, Neuronal processes. (×125.)

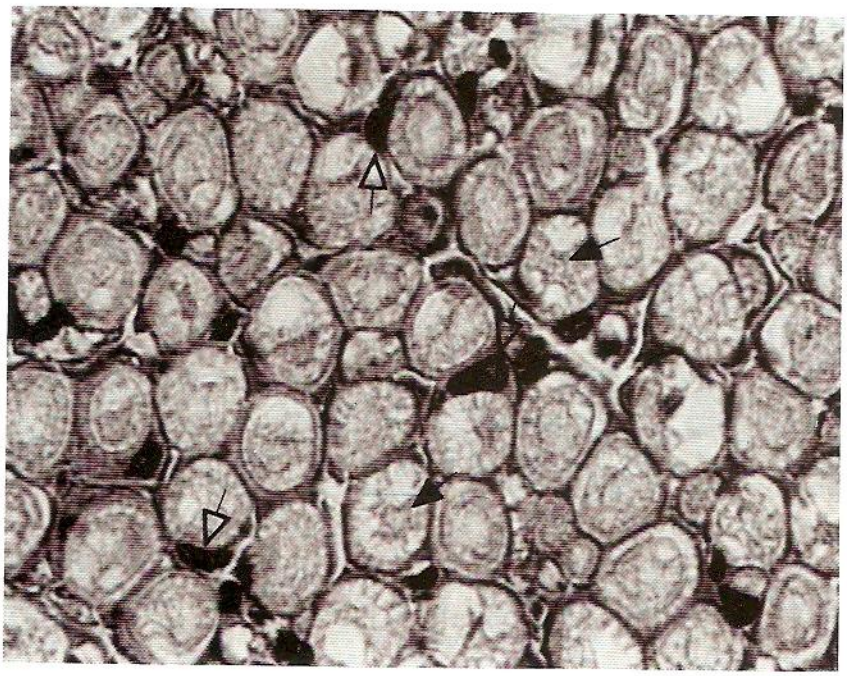

Figure 14-22. Cross section of a nerve. The neurolemmal cells *(open arrows)* surround the neuronal cell processes. The axoplasm *(solid arrows)* is surrounded by the myelin sheath. (×160.)

Downloaded From Vet-eBooks.com

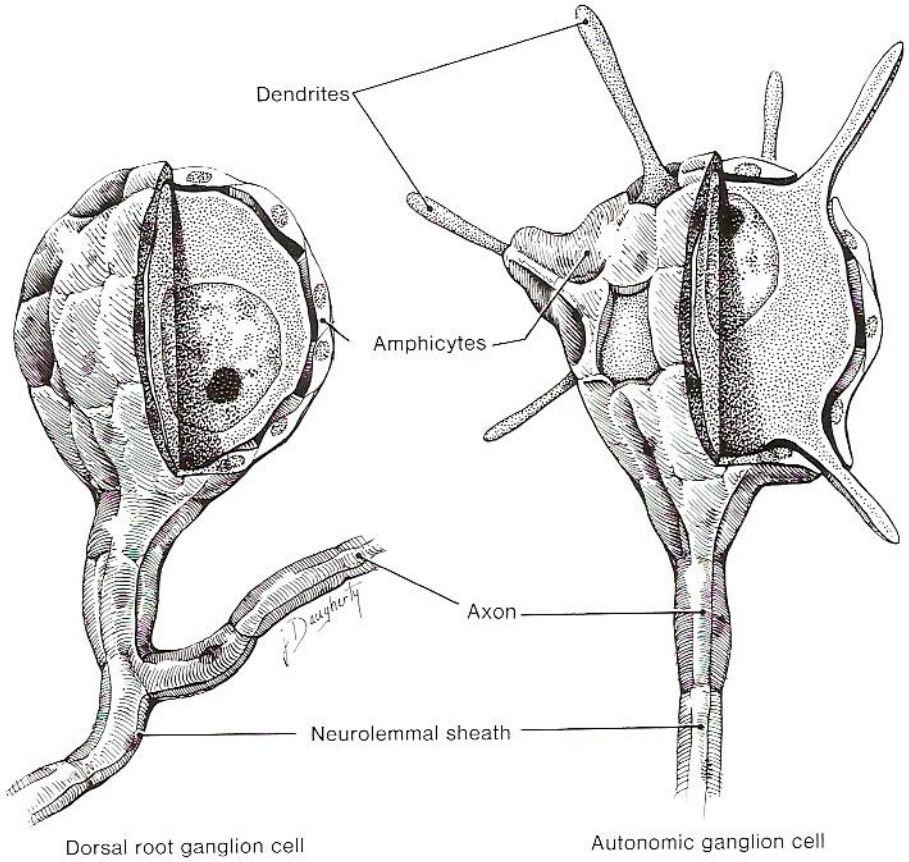

Figure 14-23. Amphicytes in different types of ganglion cells. Note that they form a complete covering around the dorsal root ganglion. The covering around autonomic ganglia may be incomplete. The pseudounipolar neurons of a dorsal root ganglion have only a single cellular process extending from the cell body. These are sensory cells. The multipolar neurons of autonomic ganglia have many dendrites and a single axon perforating the amphicytic covering. These are motor neurons.

ited distance, the neurolemmal sheath is composed of many juxtaposed neurolemmal cells. A basal lamina, located peripheral to the neurolemmal sheath, covers the neurolemmal cell and separates it from the surrounding connective tissue space (Fig. 14-24). Unmyelinated nerve fibers are small processes with relatively slow impulse conducting speeds.

Myelinated nerve fibers. These nerve fibers are the largest and most rapidly conducting in the body. The myelin functions in a manner similar to insulation on an electrical wire. Oligodendrogliocytes and neurolemmal cells form myelin. Although the methods by which they do this and the end products of this action are slightly different, the result is that the nerve fiber becomes invested with a myelin sheath.

The neuronal process contains cytoplasm and is limited by a cell membrane (Fig. 14-22). The space adjacent to the axon is occupied by the myelin sheath. In routine preparations the removal of lipids alters the appearance of these membranous whorls. All that remains is the nonlipid component of the myelin sheath, **neurokeratin** (Fig. 14-25). Fingerlike projections of neurokeratin appear as the spokes of a wheel. The neurolemmal cells are peripheral to the remnants of the myelin sheath. They have a large, vesicular nucleus with chromatin clumped peripherally. The cytoplasmic, circumscribing remnants of neurolemmal cells comprise the **neurolemmal sheath.**

Breaks in continuity between contiguous neurolemmal cells are called **nodes** (Fig. 14-26). The nodes are constrictions along the nerve fiber at which the myelin stops, but the processes of the neurolemmal cell continue to contact the plasmalemma (Figs. 14-27 and 14-28). Although the myelin sheath stops at the node, the axon continues uninterruptedly through the nodal region (Fig. 14-29).

The myelin sheath consists of continuous whorls formed by the cytoplasmic processes of neuroglial cells (Figs. 14-24, 14-29, and 14-30). An **inner mesaxon** is formed by the juxtaposed cellular processes of neurolemmal cells adjacent to the nerve cell processes. An **outer mesaxon** is in the same relationship at the periphery of the myelin. The outer portion of the myelin sheath is covered by the cytoplasm of neuroglial cells responsible for myelination. A basal lamina covers the neurolemmal cells.

The juxtaposition of successive layers of plasma membrane accounts for myelination. The outer leaflets of contiguous membranes fuse to form the **intraperiod lines** whereas the inner leaflets of adjacent plasma membranes fuse to form the **major dense lines** as the cytoplasm is extruded from the encircling process (Fig. 14-31).

Myelination. **Myelination** of a nerve cell process results from the relationship established between these processes and neurolemmal cells or oligodendrogliocytes (Fig. 14-32).

During **peripheral myelination** a single neuronal process occupies an invagination along a neurolemmal cell. A tonguelike projection of the neurolemmal cell winds around the axon (Fig. 14-32). As the cytoplasm within this process is lost, the plasma membranes become juxtaposed and fused. The degree of myelination, or thickness of the myelin sheath, is proportional to the number of whorls occurring during this process (Figs. 14-24 and 14-32). A single neurolemmal cell is responsible for the internodal myelina-

Downloaded From Vet-eBooks.com

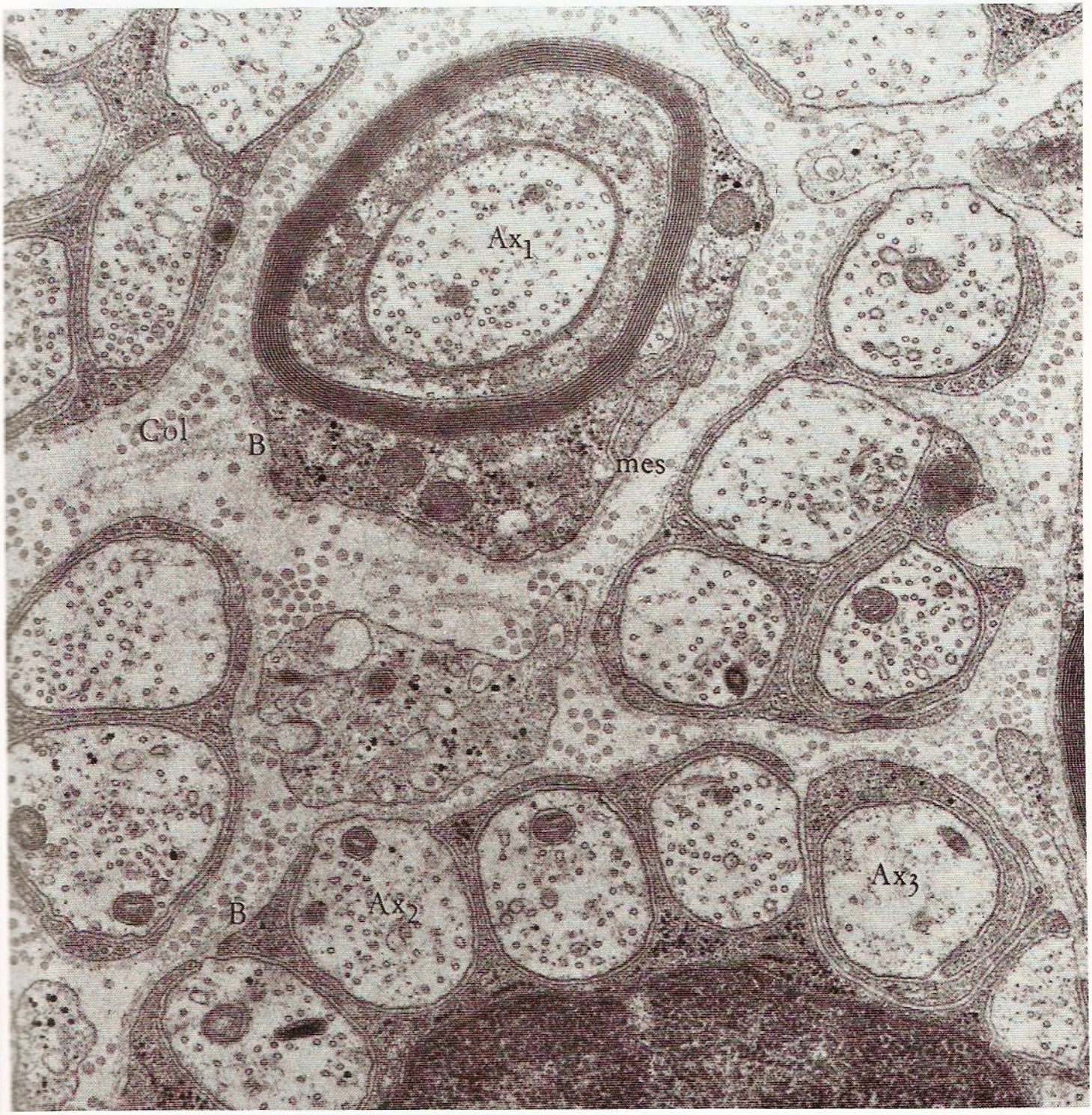

Figure 14-24. Cross section of the ischiatic nerve of an adult rat. A myelinated nerve fiber *(top)* is surrounded by a basal lamina *(B)* and collagen fibers *(Col)*. The axon (Ax_1) is juxtaposed to the neurolemmal cell cytoplasm. Note the outer mesaxon *(mes)* and its continuity with the myelin. Other axons are unmyelinated. Note also the neurolemmal cell relationship to Ax_2, which is covered incompletely. A finger-like process of the neurolemmal cell surrounds Ax_3. The collagen fibers are part of the endoneurium. (×48,000.) (Reprinted with permission from Peters A, Palay SL, Webster HF: *The fine structure of the nervous system: the neurons and supporting cells,* Philadelphia, 1976, WB Saunders.)

Downloaded From Vet-eBooks.com

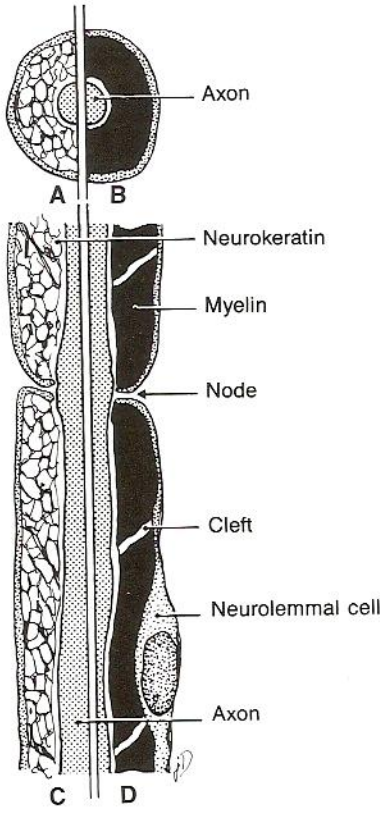

Figure 14-25. Sectioned nerve. **A** and **B,** Cross sections; **C** and **D,** longitudinal sections. The techniques and stains used to demonstrate the nerve alter the way it appears in section. The paraffin technique is represented in **A** and **C.** The myelin appears vacuolated because of protein remnants called neurokeratin. Preservation of the lipids and staining with osmium **(B** and **D)** represent the nerve fiber differently. Compare **A** and **C** with Figures 14-22 and 14-26, and **B** and **D** with Figures 14-27 and 14-28. (Redrawn and modified from Bloom W, Fawcett DW: *A textbook of histology,* ed 10, Philadelphia, 1975, WB Saunders.)

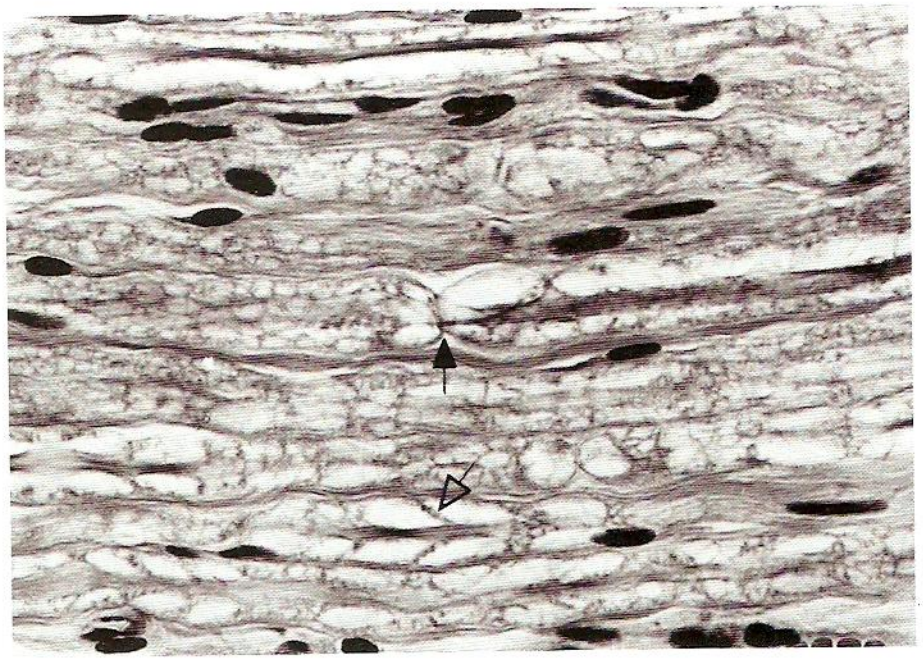

Figure 14-26. Longitudinal section through nerve fibers. The *solid arrow* points to a node, the *open arrow* a myelin cleft. (×160.)

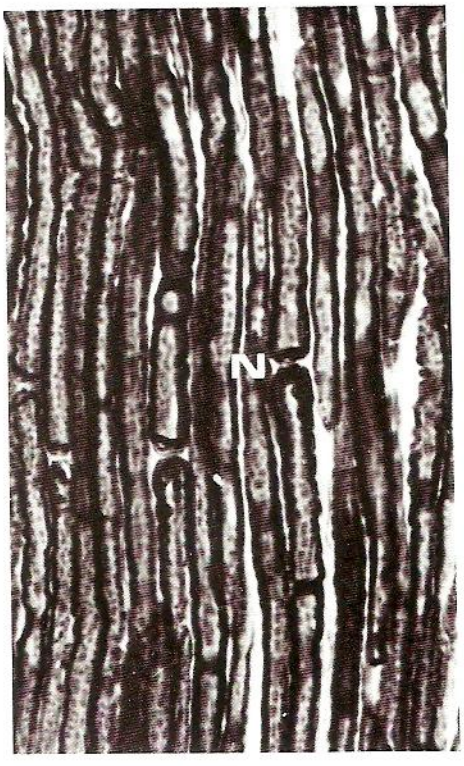

Figure 14-27. Longitudinal section of an ischiatic nerve stained with osmium tetroxide. *N,* Node. Compare with Figure 14-26. (×100.)

Downloaded From: http://...



Figure 14-28. Cross section of an ischiatic nerve stained with osmium tetroxide. The axonal processes are unstained. Compare with Figure 14-24. (×100.)

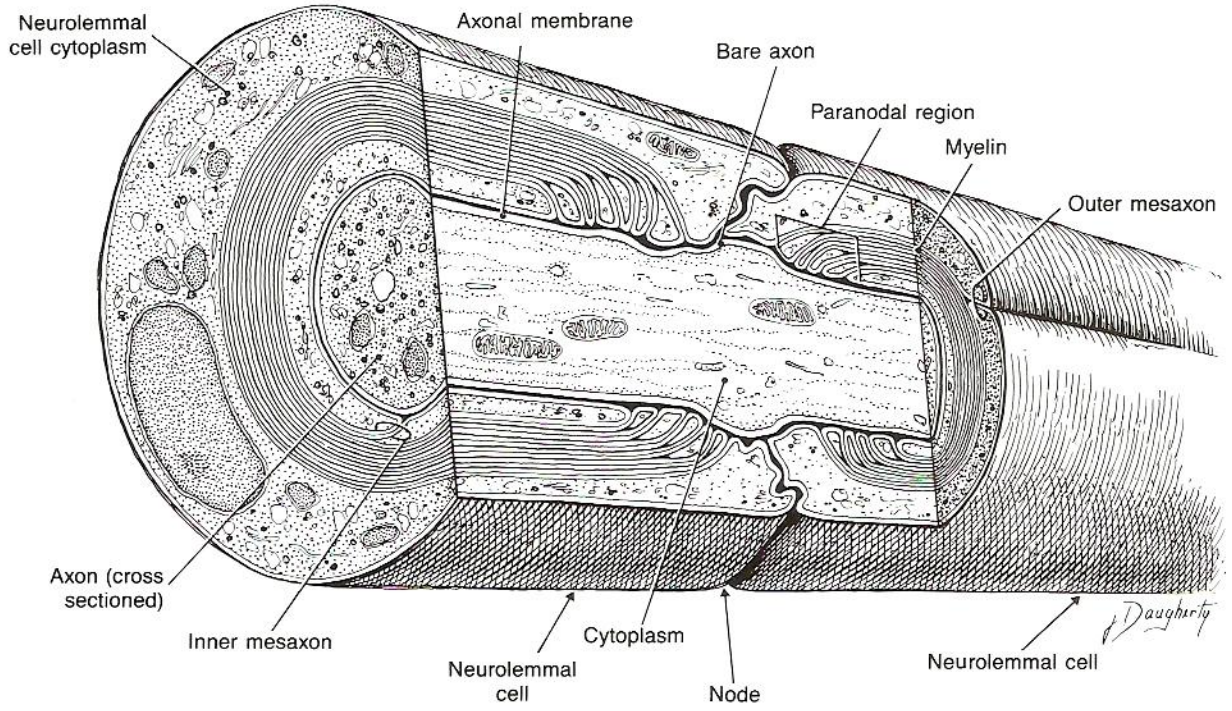

Figure 14-29. Components of a myelinated neuronal cell process. The anatomy typifies relationships between a neurolemmal cell and a neuronal cell process. The relationships between oligodendrogliocytes and neuronal cell processes are different. (Redrawn and modified from Bloom W, Fawcett DW: *A textbook of histology*, ed 10, Philadelphia, 1975, WB Saunders.)

Downloaded From Vet-eBooks.com

Figure 14-30. Cross section of a myelinated nerve fiber from the ischiatic nerve of an adult rat. The axon *(Ax)* is surrounded by a myelin sheath composed of spiraled sheets of the neurolemmal cell plasma membrane. Note the inner mesaxon *(mes$_i$)* and outer mesaxon *(mes$_o$)*. *SC*, Neurolemmal cell; *B*, basal lamina; *Col*, collagen fibers. Major dense period lines *(DL)* and intraperiod lines *(IL)* are constituents of the myelin sheath. (×100,000.) (Reprinted with permission from Peters A, Palay SL, Webster HF: *The fine structure of the nervous system: the neurons and supporting cells*, ed 10, Philadelphia, 1976, WB Saunders.)



Figure 14-31. Electron micrograph of myelin. Note the *dark* major period lines and the *light* interperiod lines. (×154,000.)

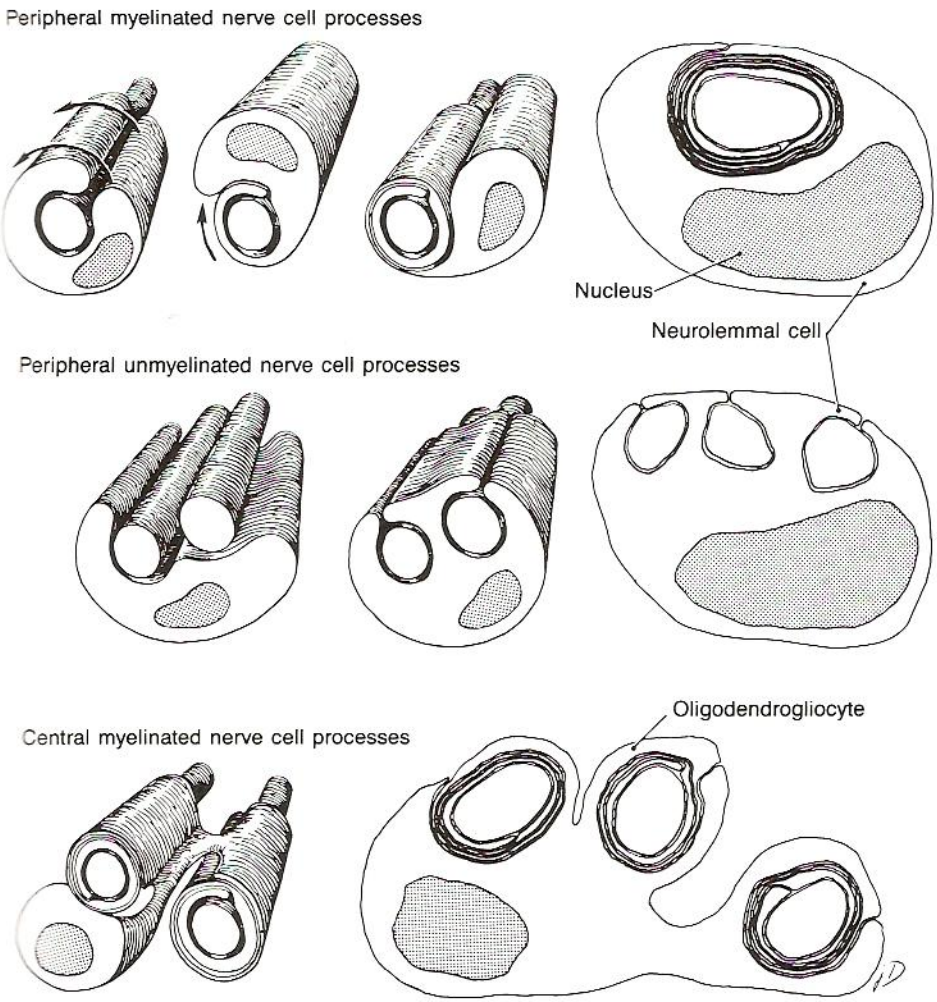

Figure 14-32. Myelination in the CNS and PNS. The relationship of neurolemmal cells to unmyelinated neuronal processes is also depicted. See text for a complete description of the process.

tion of one neuronal process and one internodal region.

Although **central myelination** by oligodendrogliocytes is similar to peripheral myelination, a few differences exist (Fig. 14-32): connective tissue elements are not intimately associated with CNS nervous tissue; adjacent myelinated neuronal processes are not separated by a basal lamina; the repetitive unit of intraperiod and major dense lines is narrower in central myelin than in peripheral myelin; centrally myelinated neuronal processes do not have much oligodendrogliocytic cytoplasm associated with the myelin sheath; the cell body of the oligodendrogliocytes is not juxtaposed to the myelin sheaths but is connected to them by cell processes (one oligodendrogliocyte may myelinate more than one internodal region along the same fiber).

The neurogliocytes maintain the myelin sheath and produce myelin after the demyelination accompanying some diseases and injuries. (See Chapter 17.)

ADDITIONAL READINGS

Cellular Components

Bodian D: The generalized vertebrate neuron, *Science* 137:323, 1962.

Bondareff W, Hyden H: Submicroscopic structure of single neurons isolated from rabbit lateral vestibular nucleus, *J Ultrastruct Res* 26:399, 1964.

Eccles JC: *The physiology of nerve cells,* Baltimore, 1957, Johns Hopkins Press.

Fogelson MH, et al: Oligodendroglial lamellar inclusions, *Arch Neurol* 19:150, 1968.

Glees P: *Neuroglia: morphology and function,* Springfield, Ill, 1955, Charles C Thomas.

Grafstein B, Forman DS: Intracellular transport in neurons, *Physiol Rev* 60:1167, 1980.

Hamberger A, Hansson H, Sjostrand F: Surface structure of isolated neurons, *J Cell Biol* 47:319, 1970.

Luse SA: Ultrastructure of reactive and neoplastic astrocytes, *Lab Invest* 7:401, 1958.

Palay SL, Palade GE: The fine structure of neurons, *J Biophys Biochem Cytol* 1:69, 1955.

Peters A, Palay S, Webster HF: *The fine structure of the nervous system: the neurons and supporting cells,* Philadelphia, 1976, WB Saunders.

Quarton GC, Melnechuk T, Schmitt FO: *The neurosciences,* New York, 1967, Rockefeller University Press.

Sandborn EB: Electron microscopy of the neuron membrane systems and filaments, *Can J Physiol Pharmacol* 44:329, 1966.

Schwartz JH: The transport of substances in nerve cells, *Sci Am* 242:152, 1980.

Stevens CF: The neuron, *Sci Am* 241:54, 1979.

Vaughn JE: an electron microscopic analysis of gliogenesis in rat optic nerve, *Z Zellforsch* 94:293, 1969.

Neuronal Processes

Bischoff A, Moor H: Ultrastructural differences between the myelin sheaths of peripheral nerve fibers and CNS white matter, *Z Zellforsch* 81:303, 1967.

Cravioto H: The role of Schwann cells in the development of human peripheral nerves, *J Ultrastruct Res* 12:634, 1965.

Douglas WW, Ritchie JM: Mammalian nonmyelinated nerve fibers, *Physiol Rev* 42:297, 1962.

Hursh JB: Conduction velocity and diameter of nerve fibers, *Am J Physiol* 127:131, 1939.

Napolitano LM, Scallen TJ: Observations on the fine structure of peripheral nerve myelin, *Anat Rec* 163:1, 1969.

Peters A: Observations on the fine structure of peripheral nerve myelin, *Anat Rec* 98:125, 1964.

Downloaded From Vet-eBooks.com

Uzman BG, Nogueira-Graf G: Electron microscope studies of the formation of nodes of Ranvier in mouse sciatic nerves, *J Biophys Biochem Cytol* 3:589, 1957.

Transmission

Akert K, Waser PG (eds): Mechanisms of synaptic transmissions, *Progr Brain Res,* vol 31, 1969.

DeRobertis EDP: *Histophysiology of synapses and neurosecretion,* New York, 1964, Macmillan.

Dewey MM, Barr L: Intercellular connection between smooth muscle cells: the nexus, *Science* 137:670, 1962.

Gobel S, Dubner R: Axo-axonic synapses in the main sensory trigeminal nucleus, *Experientia* 24:1250, 1968.

Grundfest H: Synaptic and ephaptic transmission. In Quarton GC, et al (eds): *The neurosciences,* New York, 1967, Rockefeller University Press, pp 353-372.

Jones DG: The morphology of the contact region of vertebrate synaptosomes, *Z Zellforsch* 95:263, 1969.

Kandel FR, Schwartz JH: *Principles of neuroscience,* ed 2, New York, 1985. Elsevier/North Holland.

Katz B: *Nerve, muscle and synapse,* New York, 1966, McGraw-Hill.

Katz B: *The release of neural transmitter substances,* Springfield Ill, 1969, Charles C Thomas.

Kelly RB, et al: Biochemistry of neurotransmitter release, *Ann Rev Neurosci* 2:399, 1979.

Priedkalns J, Oksche A: Ultrastructure of synaptic terminals in nucleus infundibularis and nucleus supraopticus of Passer domesticus, *Z Zellforsch* 98:135, 1969.

Takeno K, Nishio A, Yanagiya I: Bound acetylcholine in the nerve ending particles, *J Neurochem* 16:47, 1969.

Downloaded From Vet-eBooks.com

SECTION IV

COMPARATIVE ORGANOLOGY

Downloaded from PeterBooks.com

CHAPTER 15

Organization of Organs

All organs form from various combinations of the basic tissues. Specific cells, different tissue constituents, and unique geometric patterns are distinguishing features of organs.

PARENCHYMA AND STROMA

The distinguishing cell types of an organ constitute its parenchyma; these cells perform the functions characterizing the organ.

The parenchyma is often the epithelial component. Neurons characterize the organ functions of the nervous system. Secretory epithelial cells characterize the function of the glandular stomach. The testicular seminiferous tubules and the small intestinal secretory and absorptive cells perform the characteristic functions of these organs. The definition is not confined to epithelia. Skeletal muscle fibers are the parenchyma of muscles. Cardiac muscle cells are the fibers of the heart.

The parenchyma is bound by various connective tissues. **The connective tissue of an organ is its stroma.** The stroma transmits the blood and lymph vessels and nerve fibers essential to nutritional and regulatory support of the organ.

TUBULAR ORGANS

General Form

Most tubular organs have four concentric layers called **tunics** (Fig. 15-1). From the luminal surface to the periphery, they are the tunica mucosa, tela submucosa, tunica muscularis, and tunica adventitia (or tunica serosa). All tunics may be present, one or more may be eliminated, or one or more may be modified to meet specific local needs. These variations and other characteristics permit organ identification.

Tunica Mucosa

The tunica mucosa is the luminal coat; it has three layers (Fig. 15-2)—lamina epithelialis mucosae, lamina propria mucosae, and lamina muscularis mucosae.

The **lamina epithelialis mucosae** is the epithelial layer. It may have one or more types of epithelial cells depending upon the specific organ function. This layer is a consistent lamina of the tunica mucosa. A basement membrane is also a constant feature.

The **lamina propria mucosae,** an essential connective tissue space underlying the epithelial layer, is usually loose collagenous or reticular connective tissue. Small vessels, nerves, and infoldings of the lamina epithelialis mucosae infringe upon it. The connective tissue of this space may have many protective cells either free or within lymph nodules. The lamina propria mucosae nourishes and controls the epithelium.

The **lamina muscularis mucosae,** of variable occurrence, constitutes one or more smooth muscle layers. Inner circular and outer longitudinal layers may be apparent. The smooth muscle sheets within this lamina are usually continuous despite the lamina's variable occurrence. This lamina is the means by which local mobility of organs is achieved, and it also expresses secretions from glands invaginating into the lamina propria mucosae. It is thus a sharp demarcation between the lamina propria mucosae and the tela submucosa.

Tela Submucosa

The **tela submucosa** consists of loose collagenous tissue more coarsely arranged than the connective tissue of the lamina propria mucosae (Fig. 15-3). Large blood vessels, nerves, nerve plexuses, and autonomic (intramural) ganglia are present. In some organs glands may also be present. This tunic permits motility of the tunica mucosa. When a lamina muscularis mucosae is not present, the lamina propria mucosae and the tela submucosa together are called the **lamina propria-submucosa.**

Tunica Muscularis

The **tunica muscularis** is usually well-developed and consists of two muscle layers (Fig. 15-4), although it may be absent in some organs. The layers are generally smooth muscle, but skeletal muscle may be present. The most common arrangement is to have an inner circular and an outer longitudinal layer. The inner circular layer is disposed in a tighter helix than the outer, more loosely oriented, layer. Vascular and neural plexuses and autonomic ganglion cells separate the two. This tunic is responsible for the tone of a hollow organ, size of the lumen, and movement of materials through the organ.

Tunica Adventitia and Tunica Serosa

The **tunica adventitia** is loose collagenous tissue covering an organ. Blood vessels, nerves, ganglia, and adipose tissue may be present. This outer covering is part of organs that are not intimately associated with celomic spaces.

The **tunica serosa** is the most peripheral layer of organs associated with the celomic cavities (Fig. 15-5). It consists of mesothelium and connective tissue.

Vessels, lymphatics, and nerves gain access to an organ through the tunica adventitia and tunica serosa. These tunics suspend organs, either through union of the tunica adventitia with surrounding connective tissue or by reflection of the mesothelium and associated connective tissue as **mesenteries.**

Surface and Glandular Modifications

Tubular organs use many methods to increase their surface area (Fig. 15-6). The cells of a flattened tunica mucosa may evaginate into the lumen of the organ and form villous projections (Figs. 15-6, *B,* and 15-7), rugae (Fig. 15-6, *F*), and other effaceable or noneffaceable folds. The cells of the tunica mucosa may invaginate into the lamina propria mucosae independent of (Fig. 15-6, *F*) or in association with (Fig. 15-6, *C*) surface projections. This usually results in a thickened lamina propria mucosae.

Elements of the lamina muscularis mucosae may interdigitate between invaginations of the lamina epithelialis mucosae and extend into the evaginations of the tunica mucosa (Fig. 15-6, *C, D,* and *F*). Glands within the lamina propria mucosae are **mucosal glands.** Those of the lam-

Downloaded From Vet-eBooks.com

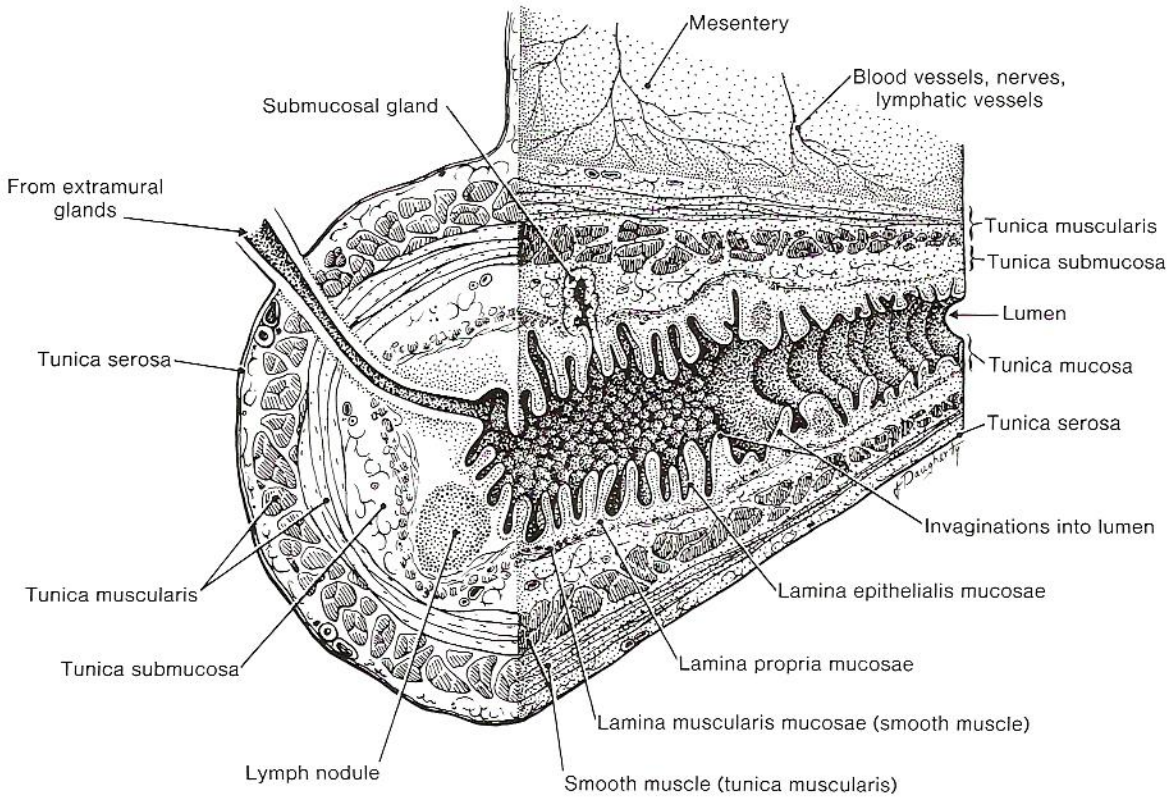

Figure 15-1. Tubular visceral organ. Refer to text for a complete description of the components.

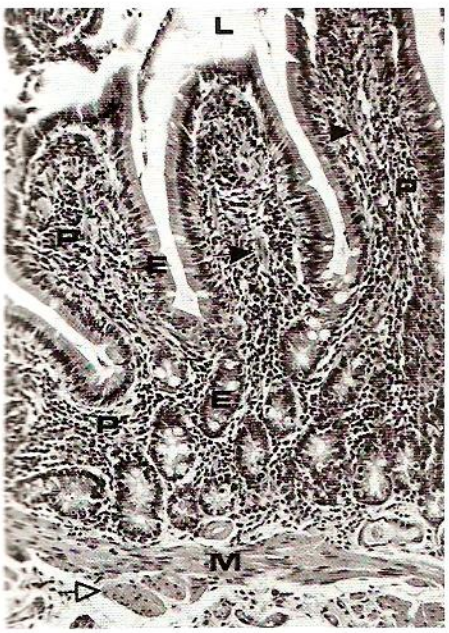

Figure 15-2. Tunica mucosa of an equine duodenum. The lamina epithelialis mucosae *(E)* is adjacent to the lumen *(L)* and invaginates into the lamina propria mucosae *(P)*. The lamina propria is hyperplastic. The lamina muscularis mucosae *(M)* consists of inner circular and outer longitudinal layers *(open arrow)* of smooth muscle. Extensions of the lamina muscularis *(solid arrows)* are apparent within the lamina propria. (×29.)

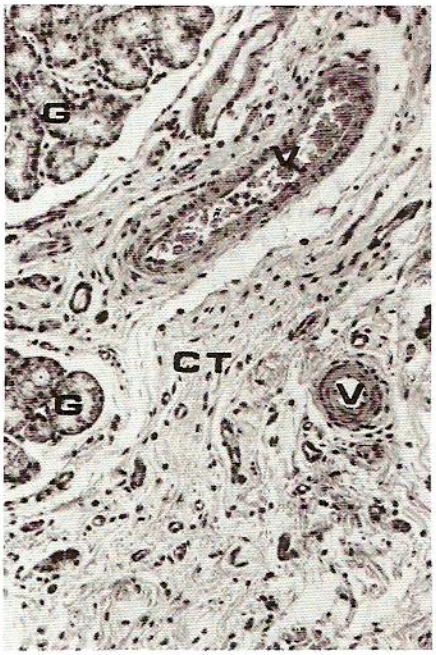

Figure 15-3. Tunica submucosa of an equine duodenum. The loose collagenous tissue *(CT)* surrounds vessels *(V)* and glands *(G)* within the tunica. Nerves and lymphatic vessels are also present. (×34.)

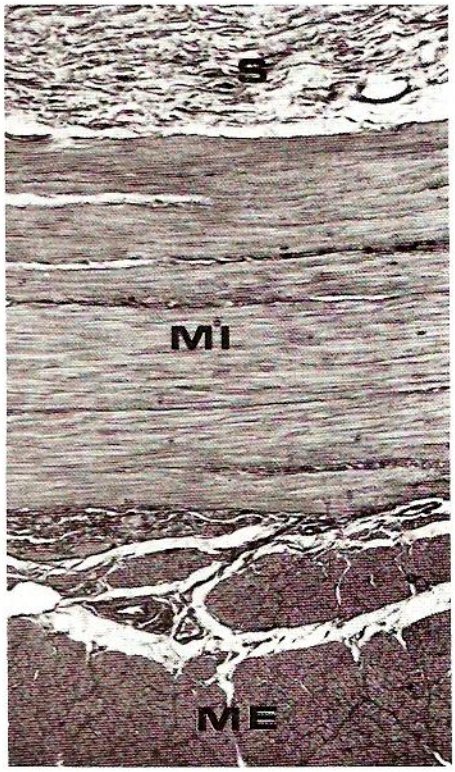

Figure 15-4. Tunica muscularis of a feline stomach. The tunica is peripheral to the tunica submucosa *(S)*. It consists of inner *(MI)* and outer *(ME)* layers of smooth muscle. Compare with Figure 13-4. (×40.)

Downloaded From Vet-eBooks.com

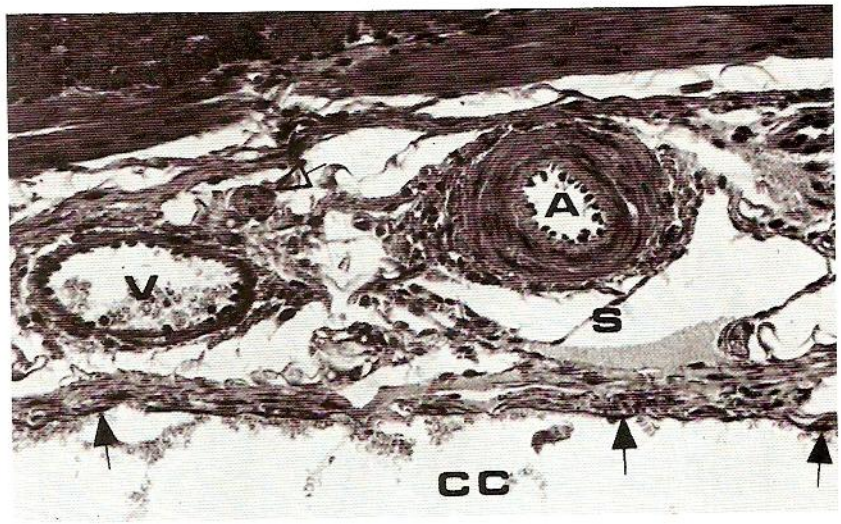

Figure 15-5. Tunica serosa of a feline stomach. The tunica (visceral peritoneum) is the outer covering of organs intimately associated with the peritoneal cavity. This cavity (also known as the celomic cavity, CC) is bounded by mesothelial cells *(solid arrows)* that contribute to the visceral and parietal serosal membranes. Subserosal connective tissue *(S)* is areolar. Note the arteries *(A)*, veins *(V)*, and nerves *(open arrow)*. The spaces within the connective tissue are artifacts of sectioning. (×63.)

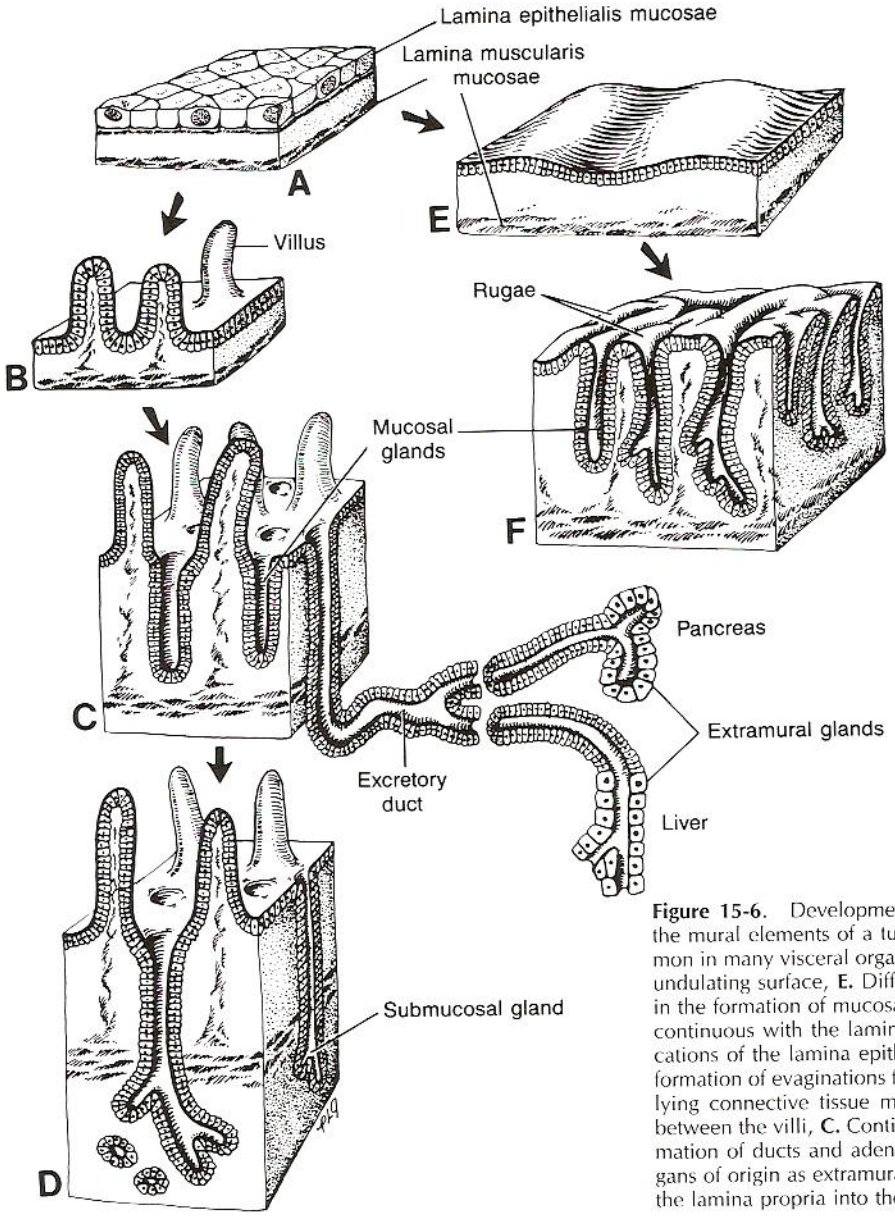

Figure 15-6. Development of surface modifications and glands associated with the mural elements of a tubular visceral organ. **A,** A flat epithelial surface is common in many visceral organs. Differential growth of the epithelium may result in an undulating surface, **E.** Differential growth also may become exaggerated, resulting in the formation of mucosal glands located within the lamina propria mucosae but continuous with the lamina epithelialis mucosae, **F.** Alternatively, surface modifications of the lamina epithelialis and underlying lamina propria may result in the formation of evaginations from the surface called villi, **B.** These surfaces and underlying connective tissue may then develop complementary invaginations (glands) between the villi, **C.** Continued growth of the epithelial lining may result in the formation of ducts and adenomeres of glands that are displaced away from their organs of origin as extramural glands. The growth of lamina epithelialis cells through the lamina propria into the tunica submucosa establishes submucosal glands, **D.**

Downloaded From Let-ebooks.com

Figure 15-7. Scanning electron micrograph of villi from the jejunum of a mouse. Note how the villi project from the mucosal surface into the lumen of the organ. (Courtesy D.L. Eisenbrandt.)

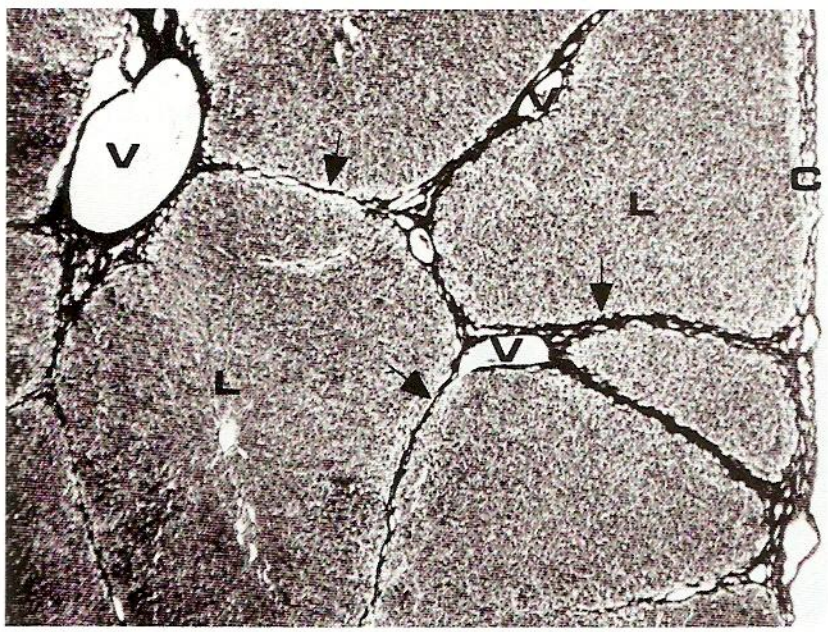

Figure 15-8. Organization of a solid organ (porcine liver). The connective tissue capsule *(C)* is continuous with large trabeculae *(arrows)* that subdivide the organ into small anatomic units (lobules). Fine reticular fibers extend a short distance into the lobules *(L)*. Large vessels *(V)* are visible within the trabeculae (Snook's reticulum). (×10.)

ina epithelialis mucosae may perforate the lamina muscularis mucosae, and their adenomeres may occupy the tela submucosa as **submucosal glands** (Fig. 15-6, *D*). Sometimes the lamina epithelialis mucosae is continuous with glands positioned remotely from the lumen (Fig. 15-6, *C*). This relationship typifies that of the liver and pancreas to the gut lumen.

ORGANIZATION OF SOLID ORGANS

The parenchyma and stroma are also distinct entities of solid organs (Fig. 15-8). Small, parenchymatous units may be surrounded by a fine meshwork of loose collagenous or reticular connective tissue. Small units of parenchyma may be grouped as larger units surrounded by a coarse loose collagenous tissue, or the connective tissue of these small groups may continue with coarse loose collagenous tissue **trabeculae.** In either case, the connective tissue is progressively more dense and is continuous with the dense collagenous tissue of the **capsule**. This continuity affords structural support and facilitates the entry and/or exit of vessels and nerves.

MEMBRANES AS SIMPLE ORGANS

Mucous Membranes

Mucous membranes include some or all of the components of the tunica mucosa. They consist of a **moistened epithelial lining** and an **underlying connective tissue** (Fig. 15-9). These membranes are kept moist by secretions from cells within the lamina epithelialis mucosae and/or glands located within the lamina propria mucosae or tela submucosa. The lamina epithelialis mucosae may be stratified squamous, cuboidal, columnar, or pseudostratified columnar epithelium. A mucous membrane consisting of stratified squamous epithelium (cornified or noncornified) is called a **cutaneous mucous membrane.** It typically occurs as part of the digestive and reproductive tracts (Fig. 15-10). Mucous membranes lined by transitional epithelium occur in the urinary tract (Fig. 15-11).

Serous Membranes

Serous membranes consist of a layer of mesothelium and associated connective tissue (Fig. 15-12). They line the celomic spaces and are moistened by the fluids within these spaces.

Serosal investments of visceral organs are significant contributors to the repair of these organs. Fibrin deposition in the

Downloaded From Vet-eBooks.com

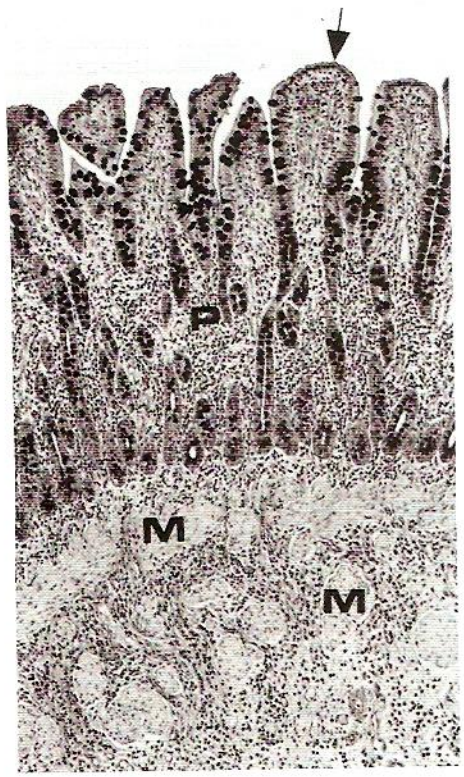

Figure 15-9. Mucous membrane lined by simple columnar epithelium from a canine jejunum. The epithelium *(arrow)* invaginates into the lamina propria mucosae *(P)*. The lamina muscularis mucosae *(M)* consists of smooth muscle oriented in longitudinal and circular configurations. The dark-staining cells of the lamina epithelialis mucosae are goblet cells and other mucus-secreting cells. (×16, Alcian blue and PAS.)

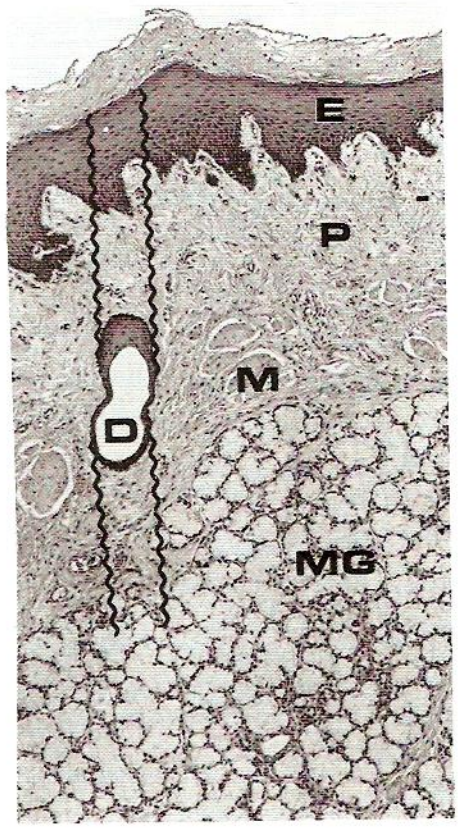

Figure 15-10. Mucous membrane lined by stratified squamous epithelium from a porcine esophagus. This combination of epithelial tissue, with or without keratinization, and underlying connective tissue is called a cutaneous mucous membrane. The lamina epithelialis mucosae *(E)* is covered by a mucoid secretory product and underlaid by the lamina propria mucosae *(P)*. The lamina muscularis mucosae *(M)* is discontinuous. Mucosal glands *(MG)* are responsible for the moistened surface. The secretory products of these glands reach the surface *(wavy lines)* through the excretory duct *(D)* and its continuations. (×16.)

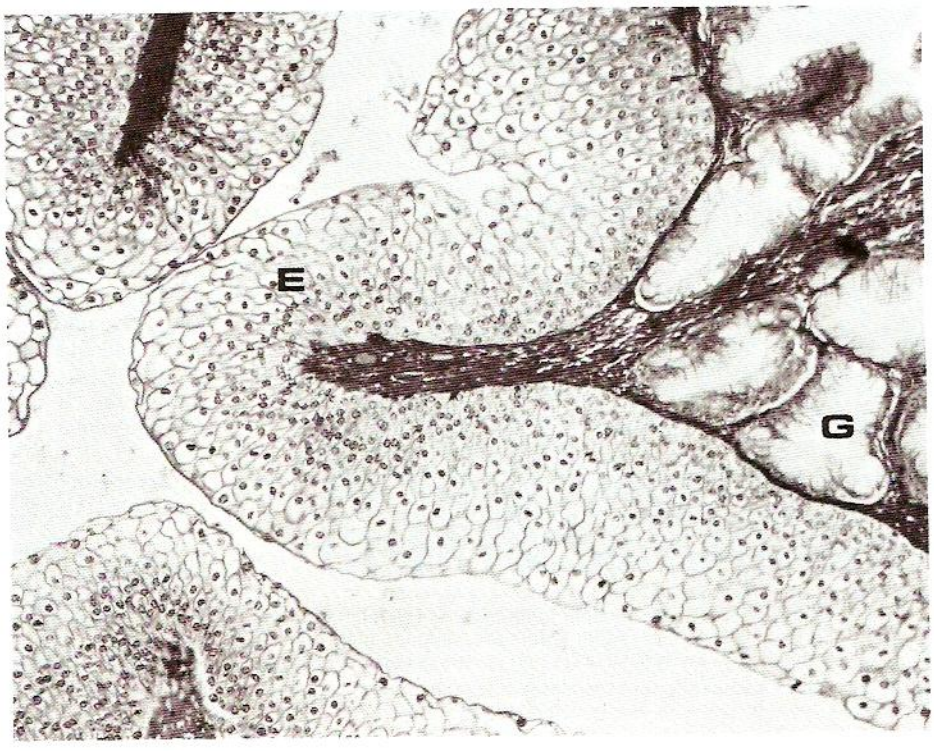

Figure 15-11. Transitional mucous membrane from an equine ureter. Mucous glands *(G)* moisten the surface of the epithelium *(E)*. (×40.)

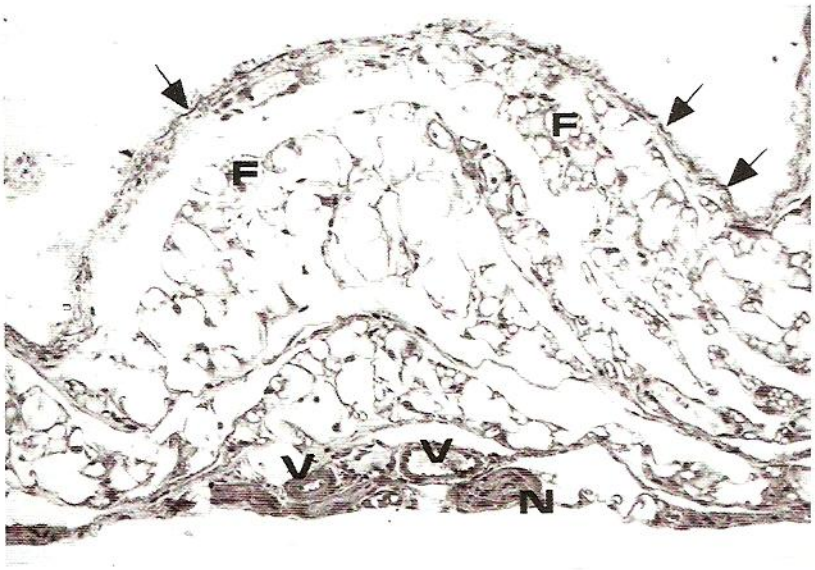

Figure 15-12. Serous membrane (tunica serosa). The mesothelium *(solid arrows)* and its associated loose collagenous tissue contain typical components, including adipocytes *(F)*, vessels *(V)*, and nerves *(N)*. Compare with Figure 15-5. (×40.)

submesothelial and subserosal connective tissue decreases leakage after repair by sealing the wound. Excessive and/or rough handling of the peritoneum can cause fibrin deposition in focal regions. Fibroblastic secretion of collagen in such regions is the basis for **adhesions.**

ADDITIONAL READINGS

Specific references for the subject material of this chapter are included in subsequent chapters covering specific organs.

Downloaded From Vet-eBooks.com

CHAPTER 16

Musculoskeletal System

GENERAL CHARACTERISTICS

All basic tissues contribute to the musculoskeletal system. Bone gives support and serves as attachment points for the muscles to perform work. Skeletal muscle converts contractility into the work of support and locomotion. Dense collagenous tissue in ligaments and tendons attaches bone to bone and muscle to bone. Cartilage facilitates growth and is the substrate for bone-to-bone contact (articular surfaces). Loose collagenous tissue binds the system together and provides space for blood vessels, lymphatics, and nerves.

BONE AS AN ORGAN

Physical Properties of Bone

Density and composition. The basis of many of bone's mechanical properties is its **density.** Bone density is reported as mass per unit volume of fully hydrated, defatted bone. Compact bone density is in the range of 1.9 to 2.1. Trabecular bone is approximately 15% less. These figures represent the density of osseous tissue only.

The mineral content of bone (69%) contributes to bone density. Newly formed bone, which is incompletely mineralized, is **low density** whereas older bone approaching complete mineralization is **high density.**

The ash content of a bone is the inorganic residue following incineration of a sample. **Ash/unit volume** is about 69% of the defatted dry weight.

A reduction in bone mass without a change in ash content is a quantitative change. It results from increased remodeling. The skeletal mass is reduced, but the quality of remaining bone is normal in the **quantitative osteopenias—osteoporosis.**

A reduction in ash content with or without a decrease in bone mass indicates a qualitative change in bone. The **qualitative osteopenias (rickets, osteomalacia)** occur as incompletely, inappropriately, or nonmineralized osteoid. Osteoid seams are thickened and/or increased in number.

Radiographic density is equivalent to **tissue density, not bone density.** The radiographic manifestation of tissue density is the sum of all tissue densities present at a particular locus (Fig. 16-1).

Figure 16-1. Comparison of bone density, ash/unit volume, and radiographic density. **A,** Cube of dense cortical bone with normal density, translating radiographically as a specified amount of radiolucency or radiodensity. The ash/unit volume is normal. **B,** Cube of bone that, despite numerous vacuities (osteonal canals, resorption spaces, perforating canals), has a normal bone density and a normal ash/unit volume. These parameters are typical of quantitative bone changes. The same parameters could apply to a cube obtained from trabecular bone, in which case the cavities would represent interosseous spaces associated with cancellous bone. The bone density of these samples would be normal. The radiographic density of sample **B** would be less than that of sample **A.** The radiographic density under such circumstances might represent either normalcy or abnormal circumstances depending on the amount of bone loss that had occurred. **C,** Cube of bone similar to sample **A** that may not contain the proper amount of mineral. Such changes are characteristic in bone. The bone density and ash/unit volume would be less than normal and distinguishable from the parameters for samples **A** and **B.** The radiographic density of sample **C** would be similar and indistinguishable from the radiographic density of sample **B. D,** Cube of bone with decreased mineral (qualitative change) and increased cavities and/or increased interosseous spaces (quantitative change). This bone would have a low density and low ash/unit volume. The decreased density would result from the qualitative change, not the quantitative change. The radiographic density of sample **D** would be much less than normal. Based upon radiographic density only, it would not be possible to distinguish between samples **B, C,** and **D.**

Piezoelectricity. Bone reacts to mechanical energy by converting (transducing) it into a usable signal (stimulus). This property of bone results from the crystalline nature of hydroxyapatite and the ordered arrangement of collagen. The transduced information, in the form of electrical energy, affects the cells' electrical environment and controls their behavior. This generation of an electrical potential resulting from a separation of ions in response to mechanical stimulation is termed **piezoelectricity.** It explains the predictable responsiveness of bone to mechanical loading (Fig. 16-2).

Biomechanical Properties of Bone

Stress and strain. The magnitude, direction, duration, and rate at which a force (**stress**) is applied to bone influence its responsiveness. The stress may fracture the structure or may alter its relationship to the remaining skeletal mass. Bone responds to applied stress by developing **strain** within it. The strain is a measure of structural deformation. **Tensile strain** results in structural elongation. **Compressive strain** results in structural shortening. **Flexure, shearing,** and **torque** are also influential stresses.

The collagen fibers of bone impart tensile strength; the hydroxyapatite crystals impart compressive strength. **Because the tensile properties of bone are less than the compressive properties, bone fracture generally occurs in tension.**

Flexure-drift relationships. A flexural stress of sufficient magnitude may cause bone to bend (Fig. 16-3). When this occurs, compressive strain develops along its concave surface while tensile strain develops along its convex surface. Repeated or maintained application of the force can cause the bone to drift toward its concave surface (Fig. 16-4). This movement depends upon a separation of charge resulting from piezoelectricity. Osteoblastic activity occurs on the compressive (concave) surface with a negative potential. Osteoclastic activity occurs on the tensile (convex) surface with a positive potential.

This osseous spatial adjustment develops under various circumstances—the autocorrection of misaligned fracture fragments, the osseous remodeling associated with the subluxation and luxation of joints, any other alteration in normal weight-bearing. This does not imply that bones with natural curvatures will eventually become straight. Nor does it suggest that the opposite will occur under normal circumstances.

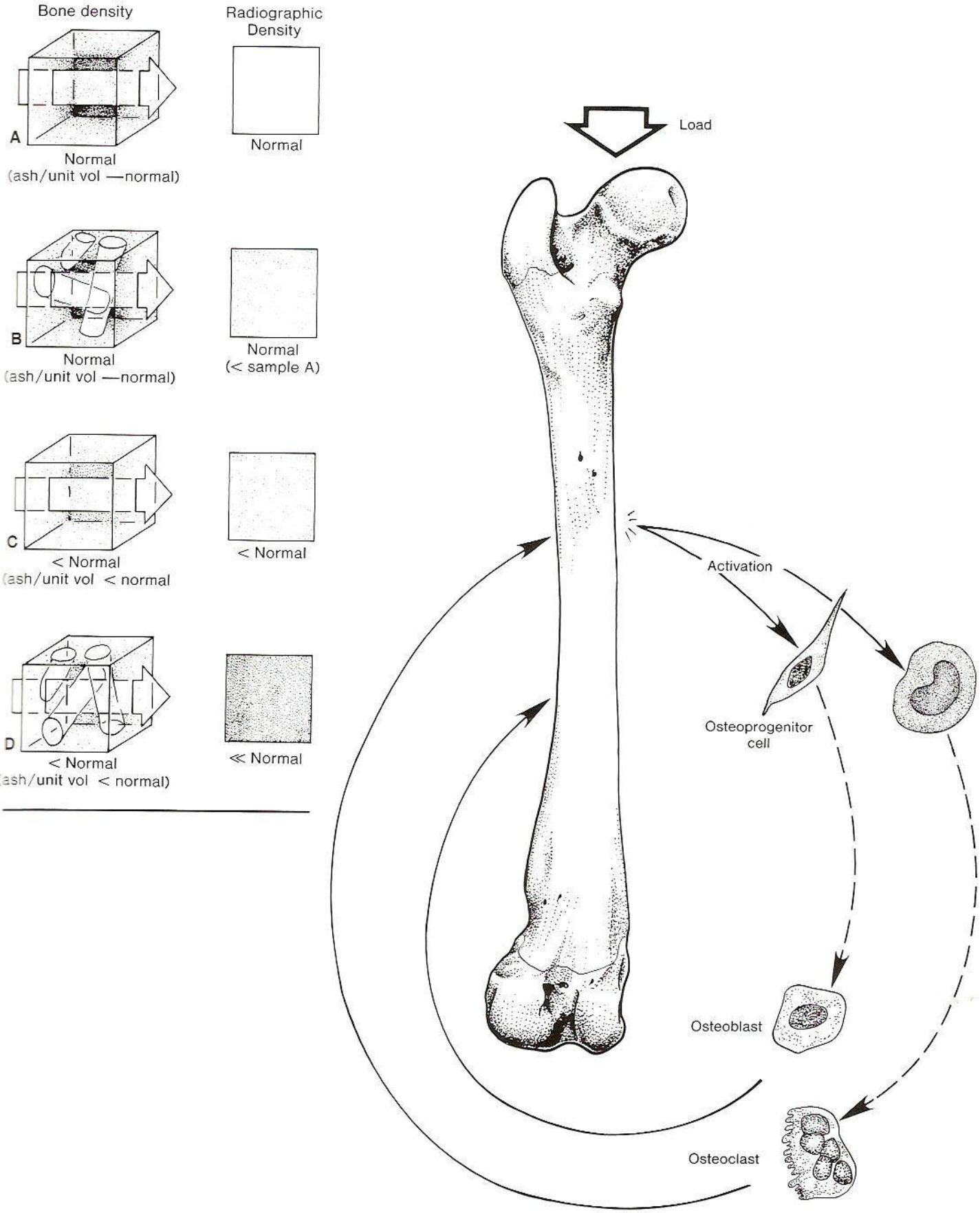

Figure 16-2. Responsiveness of bone to mechanical stimuli. The loading of a bone, especially if abnormal, activates osteoprogenitor cells and macrophages within the osseous envelopes. This activation determines the type of response—formation or resorption—manifested by the bone.

Downloaded From Vet-eBooks.com

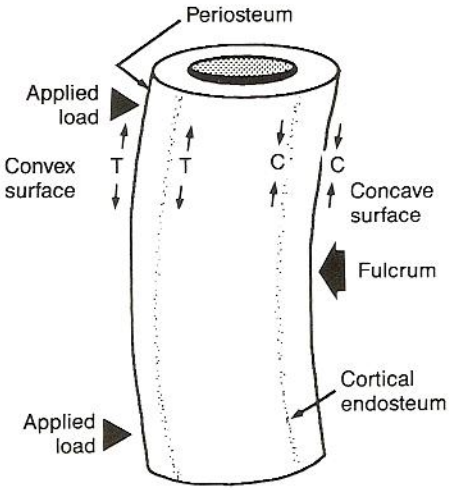

Figure 16-3. Strain developed within a loaded living bone. Such loading of bone induces compressive strain along the concave surface and tensile strain along the convex surface. The tension and compression are greatest in the periosteum.

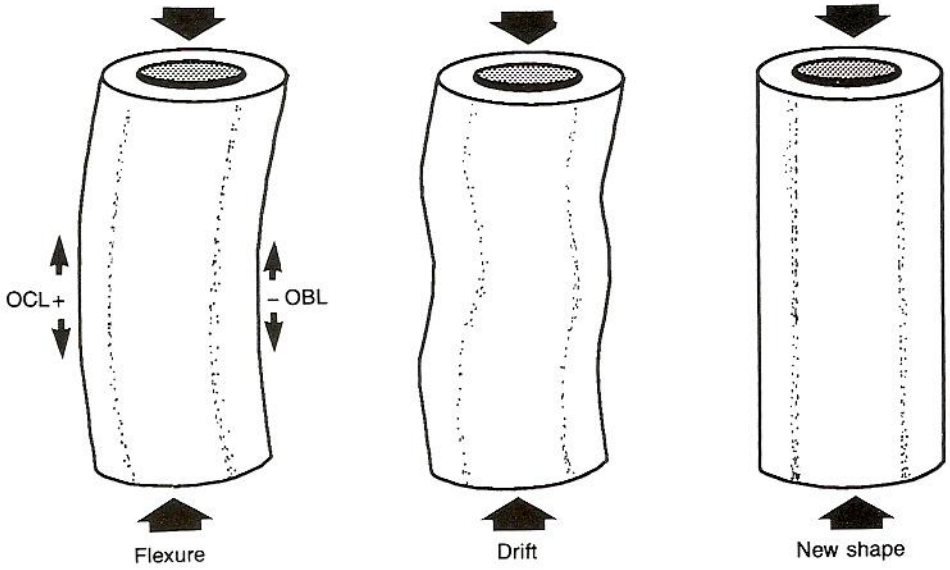

Figure 16-4. Flexure-drift relationships in bone. The sustained force induces a flexure associated with separation of charges (biopotential). The concave surface, associated with compression, drifts as a result of osteoblastic *(OBL)* activity. The convex surface, under tension, drifts as a result of osteoclastic *(OCL)* activity. The new shape of the bone is due to the predictable activity of bone cells under specified loading conditions. Bones tend to drift toward the concave surface.

Adaptive bone behavior depends upon intermittent deformation and the generation of strain. High strain rates (vigorous activity) are more potent stimuli for adaptive behavior than is less vigorous activity. Periosteal remodeling is proportional to the strain generated. Endosteal remodeling increases with increased or decreased strain.

Cartilage and bone modeling. Stress influences growth plate orientation, cell columnation within the plate, and growth plate responses to altered stress patterns.

Two types of growth plates or growth cartilage structures exist (Fig. 16-5). One, the **compression growth plate,** is subject generally to compressive forces. The capital femoral growth plate and the epiphysis are examples. The other, a **tension growth plate,** is subject generally to tensile forces. The femoral greater trochanter is an example of a traction (tension) epiphysis.

The application of normal, even, and sustained compression upon compression growth plates causes an even growth of the plate and proper spatial orientation of the bone. These plates, however, are differentially responsive to compression. Increased compression within the "normal range" accelerates growth whereas an increased compression in the "abnormal range" retards growth. An uneven and sustained load can result in an altered orientation of the growth plate and associated articular surface.

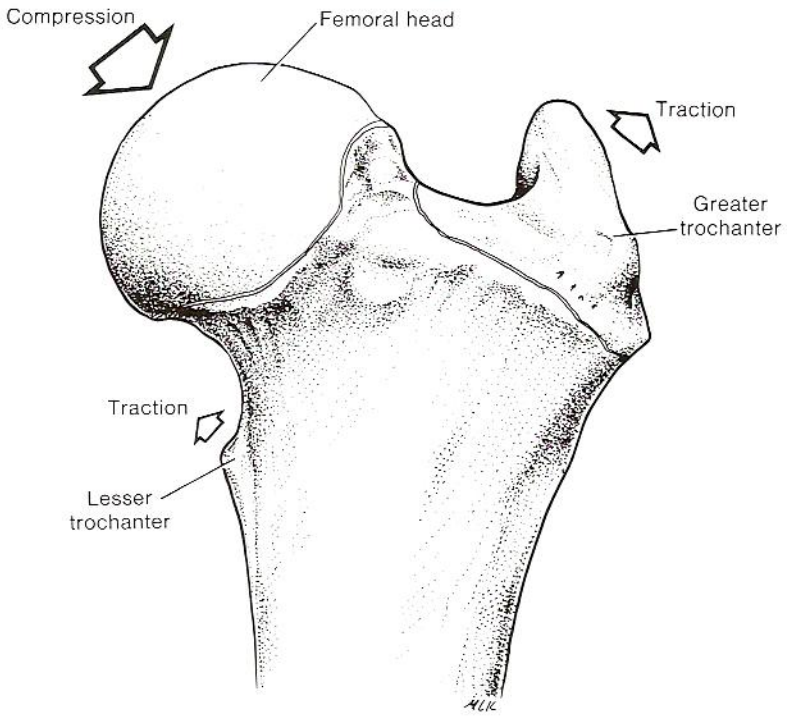

Figure 16-5. Pressure and traction epiphyses of the proximal femur.

These principles are used in correcting angular limb deformities (Fig. 16-6). Some foals are born with deformed carpi (and other joints) in which the distal portion of the limb projects laterad **(carpus valgus).** If this is attributable to the distal radial growth plate, the principles of growth plate response to compression apply. A fixation device bridged across the medial aspect of the distal radial physis is anchored in the adjacent metaphysis and epiphysis. As the plate continues to grow, nonphysiological compression retards growth of the plate on that side. The lateral aspect of the plate continues to grow normally. Eventually the lateral growth compensates and corrects the limb. The fixation device is then removed.

Downloaded From Vet-eBooks.com

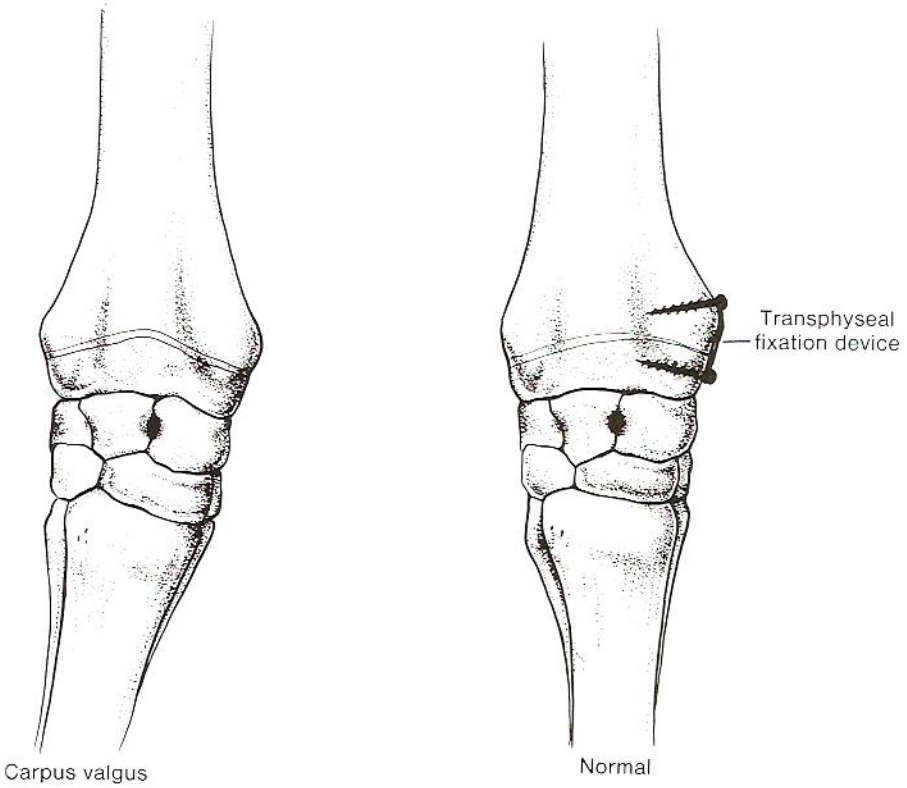

Figure 16-6. Use of a transphyseal fixation device to correct an angular limb deformity in a foal attributable to an altered growth rate in the distal radial physis. Nonphysiological compression retards the physis after the application of the devise. The lateral side, growing normally, straightens the limb. If the device is not removed after straightening, a medial deviation will result.

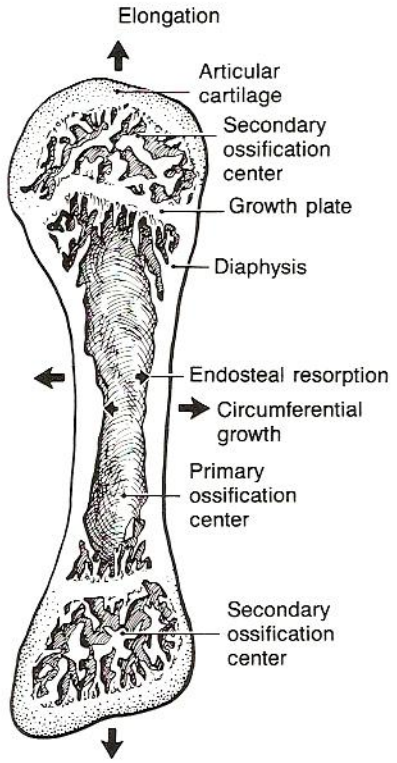

Figure 16-7. Growth of a long bone. The growth plate is responsible for elongation. The periosteum adds new bone whereas the cortical endosteum removes bone. These combined activities result in circumferential growth of the diaphysis and enlargement of the marrow cavity.

Biological Properties of Bone

Dynamic properties. The behavioral properties of bone are **endochondral ossification, remodeling, modeling, repair,** and **Ca^{++} metabolism.** Modeling and fracture repair are discussed herein.

The long bones move through space as they grow (Fig. 16-7). This growth phenomenon is the result of integrated cell and tissue activity. The growth plate elongates bone. The final shape of the distal and proximal heads results from the secondary ossification centers. The periosteum thickens the diaphysis while the endosteum thins the diaphysis. These two envelopes control the diaphyseal movement through space. Many factors influence growth plate and diaphyseal activity. **Modeling** is the sum of these activities, resulting in definitive bone forms.

Vascular, neural, and lymphatic components. The blood supply to a typical long bone is through the **nutrient, metaphyseal, epiphyseal,** and **periosteal arteries.** Vascular relationships vary in growing and mature bones (Fig. 16-8).

The **nutrient artery** enters the long bone shaft through an oblique canal. It then divides into proximal and distal divisions and branches throughout the marrow cavity. This vessel is the primary source of blood to the marrow. Nutrient arterial branches penetrate the cortex and become osteonal for the inner two thirds of the cortex. Proximal and distal nutrient arterial branches anastomose with the metaphyseal arteries.

The **metaphyseal arteries** gain access to the marrow cavity through foramina in the proximal and distal metaphyses. These vessels anastomose with nutrient arterial branches.

Many **epiphyseal arteries** enter the epiphyses through small foramina and contribute to the supportive role of anastomotic primary ossification center vessels. They also supply the nutritional needs of the growth plate proliferative zone. Before plate closure the epiphyseal capillary beds are independent of the primary ossification center capillary loops. Upon plate closure, the epiphyseal vessels anastomose with the primary ossification center vessels.

Epiphyseal vessel entry into an epiphysis varies with articular cartilage distribution over the epiphysis (Fig. 16-9). The vessels usually enter the epiphysis through the perichondral ring. When a discontinuity exists between the articular cartilage and the growth plate, the epiphyseal arteries perforate the area of discontinuity. The first configuration may subject the epiphysis to vascular compromise when a growth plate fractures.

Periosteal arterioles entering cortical bone provide blood to the outer cortical third at points of heavy fascial attachment. At cortical regions overlaid by loosely attached periosteum, the outer cortex is supplied by vessels derived from the medullary cavity. These patterns are typical of bones with more than one ossification center. Minor deviations occur in specific bones.

Venous drainage mimics the afferent blood supply. The metaphysis is drained by numerous **metaphyseal veins. Cortical venous channels** drain the deep cortex, and **periosteal venous channels** drain the superficial cortex. The medullary cavity is also drained directly to the outside by **emissary veins** perforating the osseous substance and the **nutrient vein.**

A dual circulation characterizes the growth plate vascular supply. Capillary loops, as branches of anastomotic nutrient and metaphyseal vessels, are half of the dual circulation. The capillary extensions of epiphyseal arteries are the other half. The metaphyseal capillary loops support osseous replacement activities of the primary ossification center. The epiphyseal capillaries provide nutrition to the growth plate.

Lymph vessels have not been demonstrated within bone, but lymphatics occur within the periosteum.

Nerves exist within the marrow cavity and osteonal canals. They are probably vasomotor fibers. Pain is associated with nerve endings in the fibrous coverings of

Downloaded From VetBooks.com

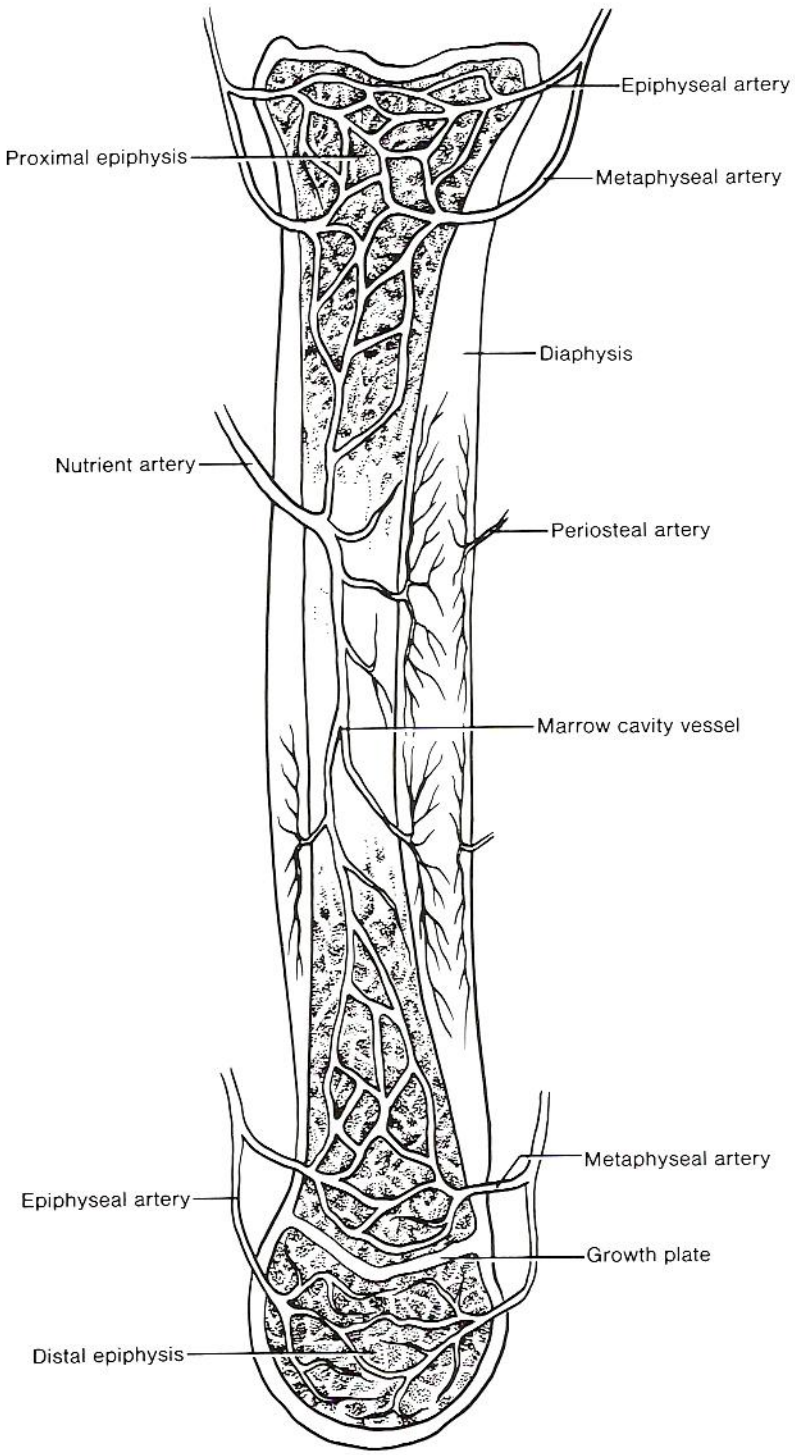

Figure 16-8. Typical blood supply to a long bone. Before growth plate closure the epiphyseal and metaphyseal vasculatures are separate. After closure these vessels anastomose.

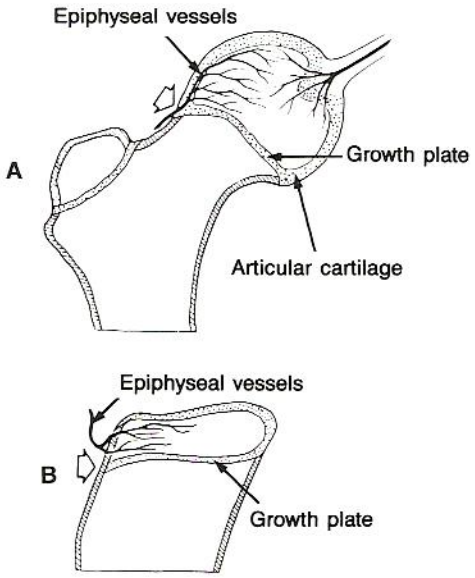

Figure 16-9. Two patterns of blood supply to an epiphysis. **A,** When cartilage covers the articular surface entirely and is continuous with the growth plate, epiphyseal vessels enter the epiphysis by traversing the perichondral ring at the periphery of the physis *(arrow)*. Fractures of the physis or neck can disrupt the vascular supply. **B,** When an epiphysis is covered partially by articular cartilage, the epiphyseal vessels enter the epiphysis at the gap *(arrow)*. These vessels are less apt to be disrupted from growth plate fractures. (Redrawn and modified from Dale GG, Harris WJ: J Bone Joint Surg 40(B):116, 1958.)

bones (periosteum, fibrous joint capsule).

Vascular relationships—functional correlates. Muscular activity is linked to osseous blood flow. Muscle contraction temporarily occludes venous channels and elevates bone marrow vascular pressure. This pumplike action is important to vascular drainage and bone structure. Prolonged limb immobilization during fracture repair is associated with a reduced bone mass **(quantitative osteopenia)** proximal and distal to the fracture site.

Periosteum removal at points of heavy fascial attachments locally devitalizes the outer third of the cortex. Revascularization from the medullary vessels ensures that these problems will be temporary.

In adult bones the epiphyseal/metaphyseal/nutrient arterial anastomoses ensure that damage to one of these components has no adverse effects upon bone. However, epiphyseal vessel disruption during growth can result in premature closure of the growth plate or epiphyseal **avascular necrosis.**

FRACTURE REPAIR

Influential Factors

Fractures disrupt structural integrity. Attendant changes may alter function, cause a loss of function, or effect changes elsewhere that are symptomatic of fracture. Facilitation of repair occurs through various management procedures, but bone responds to fracture only by **primary-** (or **first-**) **intention** and **secondary-** (**second-**) **intention** healing mechanisms.

Nutritional and metabolic factors. A well-balanced **diet** is an essential repair component. **Age** is also a factor; older animals tend to have less osteogenic activity than younger animals. The presence of intercurrent **disease** may alter the process. **Infection** has a devastating effect on repair.

Stability, vasculature and reduction. Other factors affect the fracture repair process—**the stability and immobilization of the fracture site, the maintenance of vascular integrity, the ability to return the fracture fragments to their original relationships (reduction).** The practitioner generally exercises some influence over these factors.

Osseous factors. Bone is not a homogeneous biological building material. It has diverse components, each of which affects its fracture repair properties. Intermolecular collagen cross linking accounts for its tensile properties. Defects in collagen cross linkage reduce bone tensile properties. Age changes in bone are accompanied by an increased amount of collagenous cross linkages. Such changes, also associated with increased mineralization, tend to make older bones stiffer and more brittle than younger bones. The compliant nature of young skeletons generally leads to **greenstick fractures.**

The amount of cortical or cancellous bone influences bone's mechanical properties. The rate at which a load is applied to cortical bone affects its ability to resist the load. Cortical bone also manifests its strongest properties when loaded parallel to its long axis. Cancellous bone's mechanical properties differ from those of compact bone. As cancellous bone spicules fracture, the total specimen becomes weaker until ultimate failure occurs.

Because the ability to absorb compressive energy is about twice the ability to absorb tensile energy, **bones tend to fail in tension.** For this reason rigid internal fixation devices are generally applied to bone's tension band side.

Stages of Fracture Repair

Fracture repair is a continuum of events progressing from the impact through injured site remodeling. It is useful to divide the process into stages relating to the predominant activity apparent.

Impact stage. A sufficient amount of energy must be absorbed to result in bone failure. The direction, magnitude, and rate of bone loading interact with many biological properties to produce various fractures. This stage may have no functional loss or varying degrees of impaired function. Hemorrhage and other sequelae are to be anticipated. Contamination or infection generally accompanies devitalization of hard and soft tissue.

Induction stage. This stage may not be a distinct entity, for its events occur throughout repair. Cells must differentiate into new cell populations. Local vascular changes, tissue hypoxia, and increased H^+ concentration are probably stimulatory. Alterations to this stage lead to delayed union or nonunion.

Inflammatory stage. This stage results from disruption of the vasculature—hemorrhage and hematoma. Hypoxia and acidosis characterize the environment. The resultant necrosis allows inflammatory cell invasion. The processes of migration, chemotaxis, recognition, opsonization, and phagocytosis are performed by the invading inflammatory cells.

Inflammation is an essential feature of fracture repair. Devitalized tissue is removed; the hematoma is reorganized and also removed. If inflammation does not occur or is insufficient, repair will be protracted or stopped. If inflammation is excessive, repair may be protracted or not accomplished. This typically occurs with infected fracture repair sites **(osteomyelitis).**

Reparative stage. This stage involves activities progressing from induction through inflammation to callus formation, all of which restore anatomical continuity between fracture fragments. This stage, too, is an artificial division of events, however, because repair contin-

ues uninterruptedly throughout the entire process.

Remodeling. Stimulated bone metabolic units are responsible for the reorganization of osseous tissue during repair. Complete success ensures that the fracture site will not be identifiable by radiographic or histological techniques.

Types of Repair Mechanisms

Although the fracture repair process can be a complicated event, it uses basic processes—**remodeling, intramembranous ossification,** and **endochondral ossification.** The circumstances associated with repair dictate the mechanisms that mediate it. Primary-intention healing is direct bone formation involving remodeling and intramembranous ossification. Secondary intention healing is indirect bone formation involving the three mechanisms.

The descriptions of primary- and secondary-intention bone healing are stereotypical. Many variations exist, and a single fracture may use both types during healing.

Primary-intention healing

Primary-intention healing is the direct formation of bone without an extensive, intermediary, cartilaginous, supportive structure **(callus).** This description is based upon the following assumptions: good vascular integrity, adequate immobilization, excellent reduction, smooth-ended fracture fragments, and the use of a metallic plate across the fracture site.

Contact repair. Contact repair is the simplest fracture repair (Fig. 16-10). The circumstances associated with primary intention healing are operable. **Remodeling is used for contact repair.**

Soft tissue injury and inflammation occur after the impact. As a result of the fracture, vascular channels are disrupted. This causes bone and endothelial cell death a short distance from the fracture gap. The fracture site is then bordered by dead bone to the first viable vascular anastomoses. Perivascular and endothelial cell proliferation occurs at those anastomoses. The events resulting from the insult stimulate BMUs, and these cause new tissue and vessels to grow toward the fracture site. Osteoclasts remove bone from damaged osteonal canals as in remodeling. Their cutting cones cross the fracture site and establish the surfaces for new osteons. Osteoblasts deposit lamellar bone and establish fracture fragment continuity by bridging the small gap with new osteons. The situation is analogous to drilling holes (resorption spaces) in a piece of wood and using dowels (secondary osteons) to hold the wood together.

The side of the bone opposite the plate may form a small periosteal callus. The size and extent of the callus relate to fracture stability.

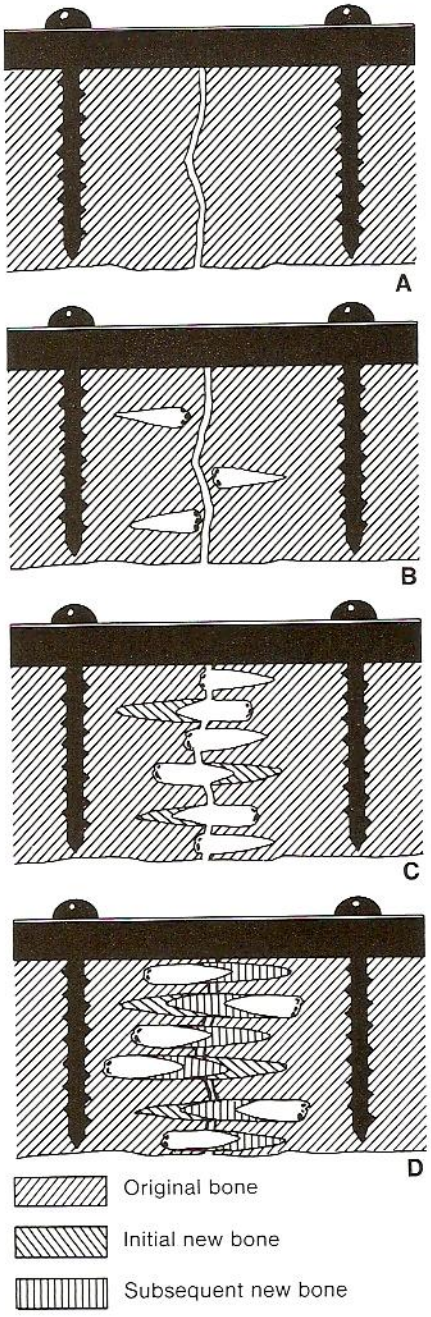

Figure 16-10. Gap-type primary-intention healing in which rigid internal fixation was achieved with screws and a bone plate. After the open reduction of the fracture site, **A,** osteonal remodeling units become activated, **B.** The remodeling units cross the gap and establish a basis for osteon bridging of the fracture site, **C.** The cutting cones form the cavity in which initial new bone formation occurs. The process continues, **D,** until new bone subsequently bridges the gap. Regions in the fracture gap between remodeling units may be "spot welded" with woven bone. The new osteons achieve fracture repair.

Gap repair. Small spaces (gaps) may remain between the fracture fragments when rigid fixation is achieved without perfect gap reduction. This can occur with irregular fracture fragments. Then the space will fill temporarily with woven bone, serving as a spot weld between the fragments. **Intramembranous ossification and remodeling are used for gap repair under this circumstance.** Canalization and new osteon formation occur as described with contact repair. Gap repair may be compared to uniting two pieces of wood with dowels in which irregularities between the pieces are filled with wood putty. Contact repair and gap repair commonly occur simultaneously. A comminuted fracture with a large butterfly fragment, if rigidly immobilized, will use both mechanisms of primary-intention healing.

Secondary-intention healing

Secondary-intention healing involves the formation of an external cartilaginous support structure, **callus,** during repair. It is the repair sequence expected when casts, pins, and other devices are used. **It occurs when vascular integrity may have been compromised and immobilization, stability, and reduction are not perfect.** The following description assumes that these apply to a closed, transverse, noncomminuted fracture in which the fracture fragments are smooth and fixation is achieved externally. **Intramembranous ossification, endochondral ossification, and remodeling are the contributing mechanisms through which repair is achieved.**

Impact stage. The energy absorbed upon impact determines the damage manifested. Because of bone's physical characteristics, it fractures more readily with rapid than slow loading. The impact causes the break and attendant soft tissue damage, with tissue devitalization by disrupting vascular beds (Fig. 16-11). Clot formation exacerbates the vascular damage to soft and hard tissues. Periosteum, marrow elements, endosteum, and bone die adjacent to the gap as far as the first functional vascular anastomosis. Bone death is evidenced by osteocytic degeneration and empty osteocytic lacunae.

Induction and inflammatory stages. The significance of these was discussed previously. They end when the cardinal signs of inflammation (redness, pain, swelling, and heat) are no longer apparent (Fig. 16-12).

Reparative stage. This stage involves development of a bone callus.

Induction through callus formation begins with reorganization and invasion of the hematoma by phagocytic and fibroblastic cells. Endosteal stem cells initiate osteogenic and endothelial cell mitosis (Fig. 16-12). New cells and blood vessels migrate toward the fracture site, invade the hematoma, and bridge the gap with a fibrocellular hyperplastic tissue

Downloaded From Vet-eBooks.com

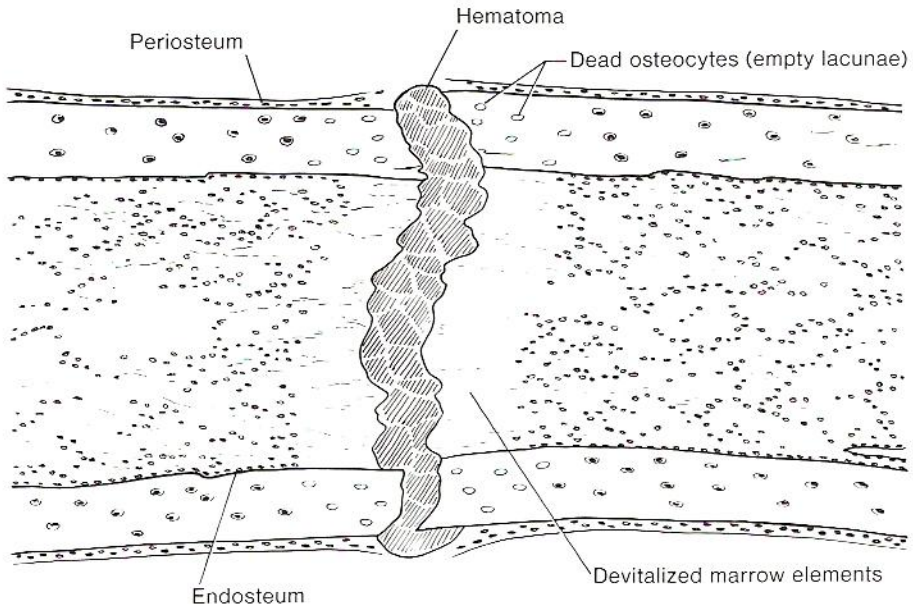

Figure 16-11. Hematoma formation after a fracture. Refer to the text for a complete description of the events involved in the fracture repair sequence as represented in Figures 16-10 to 16-16. (Figs. 16-11 to 16-17 are based on and modified from the descriptions by Ham and Harris, in Bourne GH (ed): *The biochemistry and physiology of bone*, ed 4, vol 3, New York, 1971, Academic Press, pp 337-339.)

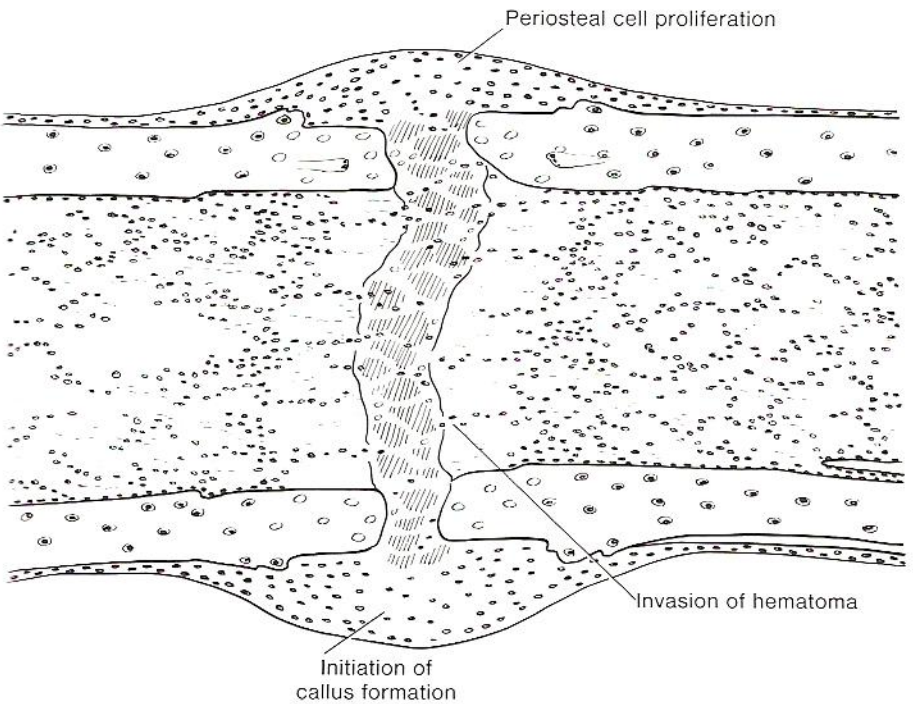

Figure 16-12. Induction of cells from the marrow cavity, periosteum, and endosteum. Invasion of the hematoma has occurred and callus formation is beginning.

(Fig. 16-15). Thus a **bone precursor** forms within the marrow cavity and fracture gap. The new endosteal bone (woven bone) is the **internal (endosteal) callus** (Fig. 16-13).

Concomitant with these endosteal events periosteal cells proliferate and produce a hypercellular mass that differentiates into bone and cartilage (Fig. 16-13).

Callus is the new tissue forming around, within, and adjacent to the fracture site. It begins with fibrocellular tissue forming from the envelopes and it ends with bone crossing the fracture gap. Many terms describe it—**internal, endosteal, external, periosteal, bridging, permanent, provisional, temporary, soft,** and **hard.** Despite these names, only one callus forms during fracture repair. It changes character as the originating fibrocellular tissue develops into bone, proliferates, and remodels.

The proliferation of periosteal osteogenic cells (occurring initially within an adequate vasculature) produces **periosteal new bone** along the fracture margin some distance from the fracture gap. Eventually this proliferating cell layer bridges the fracture gap and forms a thickened cell layer peripheral to the regressing hematoma—an **external callus.** Because osteogenic cells here may proliferate faster than their associated periosteal vessels, they differentiate into chondroblasts. Thus the external callus has new bone peripherally and cartilage adjacent to the fracture gap. Periosteum covers these tissues (Fig. 16-14). As the cartilaginous mass continues to grow, it is further separated from its blood supply. Chondrocytes along the cartilage/bone interface hypertrophy and their associated matrix becomes mineralized. From within outward a progression occurs—calcified cartilage to hypertrophic chondrocytes to maturing chondrocytes to proliferating cells. Vascular invasion and osseous replacement start at the cartilage/bone interface and continue until woven bone replaces cartilage. This process is a reiteration of endochondral ossification. The formation of external callus under such repair circumstances indicates normal repair. In other circumstances, however, external callus may indicate complications to repair leading to **delayed union** or **nonunion. The primary function of the external callus is to stabilize the fracture site.**

New tissue development from endosteal envelopes (Figs. 16-13 and 16-14) occurs simultaneously with events in the periosteum. Proliferating trabecular and cortical endosteal cells invade the regressing hematoma, forming bone attached to the inner bone surface on each side of the fracture—an **internal callus.** The bone bridges the gap and is continuous with bone on the opposite side of the fracture. Two significant features characterize the internal callus. **Bone forms directly without a cartilaginous intermediary. The internal callus actually mediates fracture repair.**

Remodeling stage. Cancellous woven bone forms in the internal and external calluses. Progressive appositional growth converts this configuration into dense cancellous and compact bone (Fig. 16-14). The new bone forming at or adjacent to the fracture site is bonded to dead and live bone. At this point in repair the marrow cavity may be occluded with bone, the fracture gap filled with bone, and the fracture surrounded by an

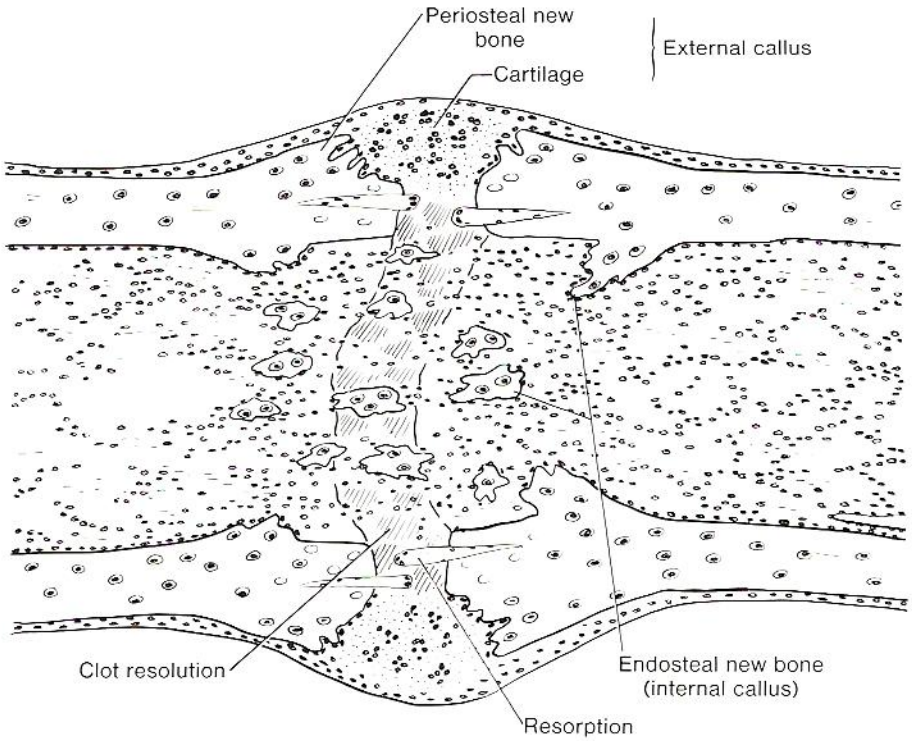

Figure 16-13. Periosteal and endosteal bone formation at the fracture site. Bone formation in the callus has begun.

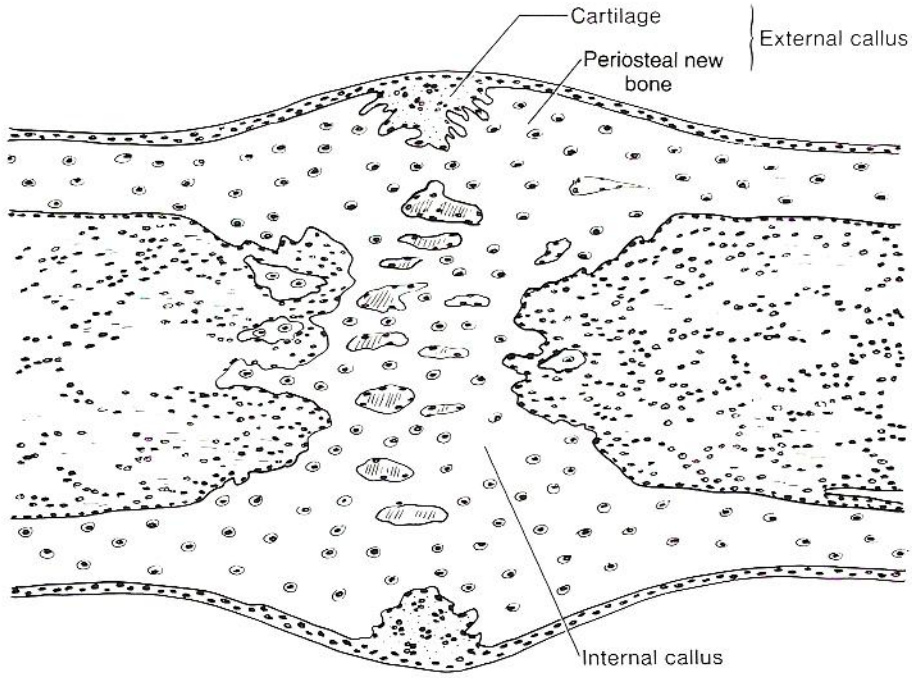

Figure 16-14. Fracture site bridged with new bone. External and internal callus is established.

expanded sleeve of bone. Osteoclasts remove the surplus bone (Fig. 16-15). Remodeling activity, as described with primary-intention healing, produces new osteons traversing the fracture site. Eventually only the diaphyseal cortical bone remains (Fig. 16-16).

Circumstances of repair. "Simply placing feline bones in the same room is enough to bring about repair" is an expression of the ease with which repair occurs in this species. Although such a statement applies to cats, a similar statement can be made about other species as well. Some bones, and certain regions of specific bones, heal more easily than others. Return of the anatomical unit to perfect function is the management objective.

The return of fracture fragments to the prefracture configuration is known as **reduction.** Three circumstances are part of the reduction process—distraction, displacement, and angulation.

Distraction implies that reduction is not perfect, because a gap remains between the fracture fragments. Although perfect reduction of distracted fragments is difficult to achieve, the gap should never exceed one-half the diameter of the distracted fragments. The prognosis for successful repair decreases as the gap increases. With rigid immobilization the primary problem is requiring the bone to create new bone within the gap. Cancellous bone grafts may have to be used when fragments are distracted markedly. Such grafts provide a temporary scaffold upon which new bone formation occurs.

Displacement is the improper registration of fracture fragments such that the cortices and marrow cavity are not perfectly aligned. Small overlaps still permit repair to be achieved. Flexure-drift principles usually apply to the correction of minor displacement problems. Return to normal function may be delayed with improperly registered fragments.

Angulation between fracture fragments will not alter repair, even if the fragments are at a 45°-angle to each other. Repair can be achieved under these circumstances, but return to function may be impossible. Angulation problems less than 20° repair normally and autocorrect by flexure-drift mechanisms.

Strength of fracture sites. The flexural strength of a cylindrical object is defined mathematically. The rectangular moment of inertia (I_o) is a measure of the resistance of such an object to flexural stresses. Accordingly,

$$I_o = 1/4\ \pi r^4$$

Because all values on the right side of the equation, except the radius, are constants, the rigidity or resistance of a cylindrical object to flexural stress is a function of the fourth power of the radius (r^4). Doubling the radius produces a sixteenfold flexural strength increase. Periosteal callus increases the flexural strength of a repairing fracture.

The contact area between fracture fragments also affects fracture site strength, which increases as the square of the area ($a = \pi r^2$). Because large surface areas have many cells, metaphyseal fractures heal faster than diaphyseal fractures.

ARTICULATIONS

General Characteristics

The means of joining two or more bones together are called joints or articu-

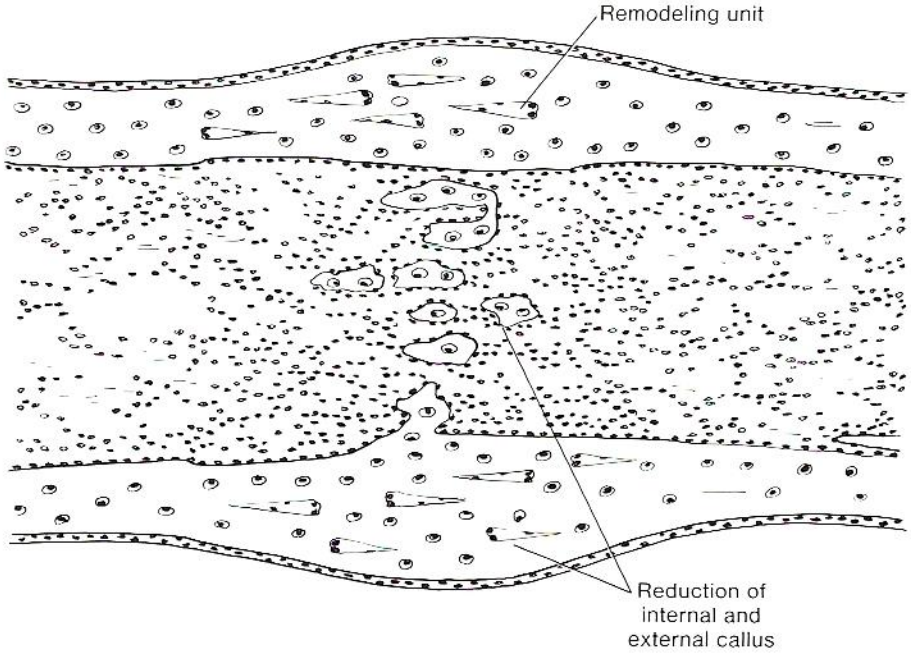

Figure 16-15. Remodeling of internal and external callus. The bone mass is reduced and remodeled.

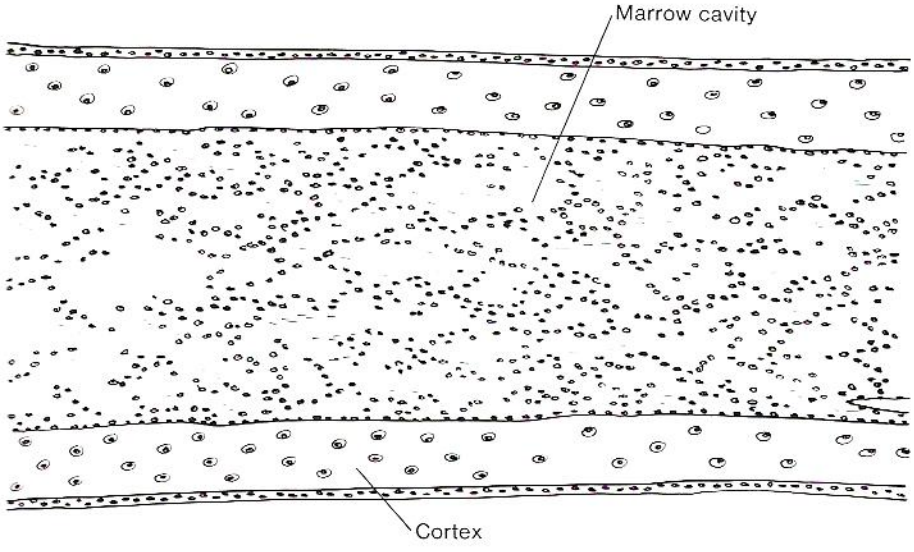

Figure 16-16. Return of bone to its prefracture configuration.

lations. These structures provide for weight-bearing, locomotion, stability, and growth.

Composition and classification. Bones are held together by other connective tissues. Some joints have a single connective tissue type; others may consist of more than one connective tissue. The following tissues may contribute to articulations: hyaline cartilage, fibrocartilage, dense collagenous tissue, loose collagenous tissue, bone, and adipose tissue. The most widely accepted classification scheme is that predicated upon the predominant type of tissue characteristic of the joint.

Fibrous joints are those formed by dense collagenous tissue. **Cartilaginous joints** consist of hyaline and/or fibrous cartilage. **Osseous joints** consist of bone. **Synovial joints** consist of many tissues.

Functions. Joints perform the following functions: **stabilize and unite two or more bones without movement, stabilize and unite two or more bones with some movement, facilitate movement between two or more bones, facilitate the growth of bones, resist the predominant stress manifested at a joint surface.** Joints may serve one, a combination of, or all of these functions.

Types of Articulations

Fibrous, cartilaginous, and osseous joints

Syndesmoses. A **syndesmosis** is the union of bone surfaces by dense collagenous tissues. This is typical, as in the skull, when bones develop from separate ossification centers. The bone edges mark the limits of the **fontanelles.** The fontanelles contain the joint connective tissue and precursor cells for bone. Progressive closure of the fontanelles forms **sutures.** Because bone precursor cells remain at the site, syndesmoses are replaced by **synostoses.**

Synchondroses. A **synchondrosis** is the union of two bones by hyaline cartilage (Fig. 10-16). The most common example is the growth plate. This joint permits a unidirectional diaphyseal growth while joining the diaphyseal and epiphyseal bones. Some synchondroses permit a two-dimensional growth of fused bones. The ultimate fate of a synchondrosis is conversion to a synostosis.

Symphyses. The predominant tissue in a **symphysis** is fibrocartilage. Dense collagenous tissue and hyaline cartilage may be constituents. The ends of the contributing bones are covered by hyaline cartilage. The symphysis pubis and intervertebral joints are examples (Figs. 16-17 and 16-18).

Synostoses. A **synostosis,** fusion of bones by bone, ensures stability and immobility.

Synovial joints

Diarthroidal joints (synovial joints, true joints) are the commonest bone-to-bone union. They permit a great degree of motion and are significant in clinical practice.

Origin and nature. Presumptive bone centers are separated by mesenchyme. As chondrogenic centers elongate, the intervening mesenchyme degenerates; the remaining mesenchyme forms the contributing synovial membrane components (Fig. 16-19). The articular surface perichondrium degenerates simultaneously. The joint space develops from a cavitation process within the mesoderm. Mesothelial cells do not develop within a synovial joint; the synovial space is lined by epithelioid cells not underlaid by a basal lamina.

The components of diarthroses are **articular cartilage** and **articular capsule** (Fig. 16-20). All the tissues mentioned previously as components of joints are either involved directly with synovial joints or closely associated with them.

Histological structure. The articular surface is composed of hyaline cartilage (Fig. 16- 21), which accounts for the bulk of this tissue in adults (Plate IV, *9*). The hyaline cartilage, devoid of a perichondrium, is divisible into four poorly

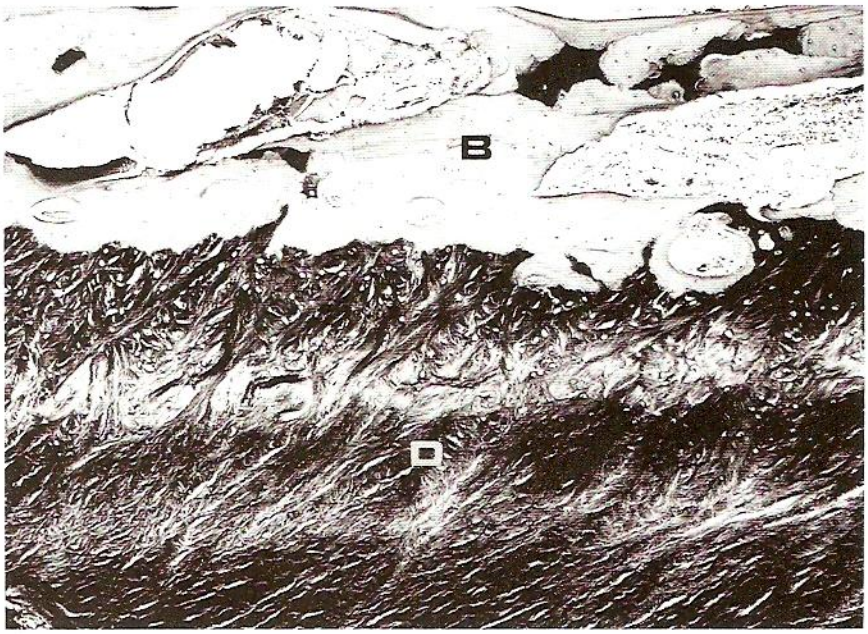

Figure 16-17. Portion of an intervertebral disc from a dog. The bone *(B)* of a vertebral body is connected to an adjacent vertebral body by an intervertebral disc *(D)*. The fibrocartilage of the annulus fibrosus is apparent as alternating bands of light- and dark-staining materials. (×160, periodic acid–Schiff [PAS].)

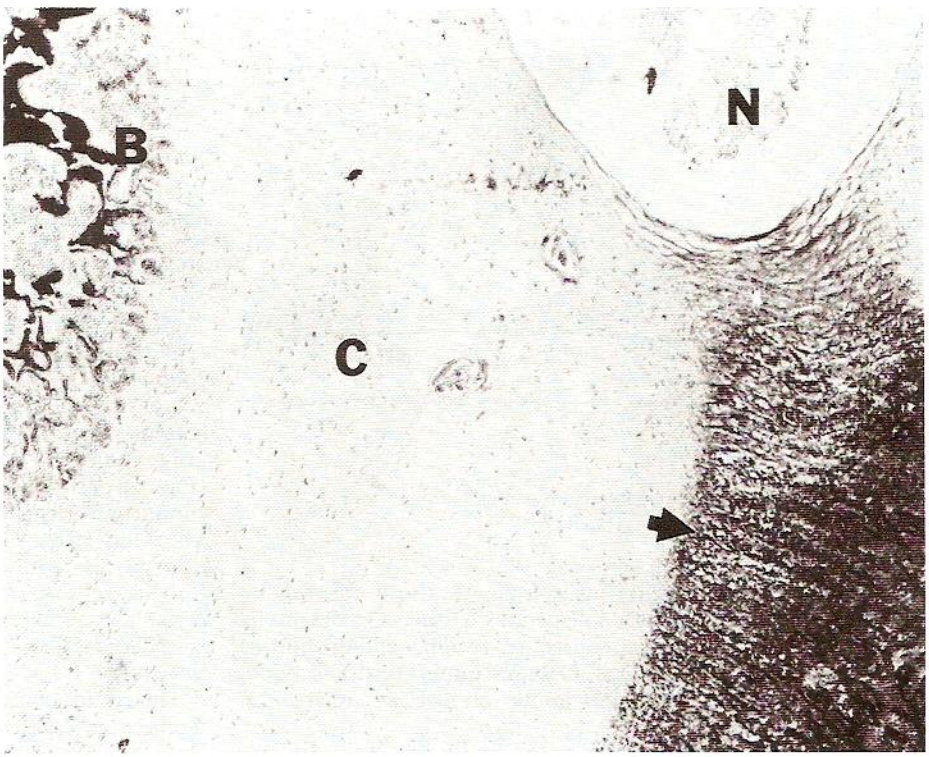

Figure 16-18. Developing cervical vertebra and intervertebral disc of a cat. The developing annulus fibrosus *(arrow)* consists of fibrocartilage. Remnants of the nucleus pulposus *(N)* are apparent. The cartilage *(C)* contributes to the developing vertebral body *(B)* through endochondral ossification. (×25.) (Specimen courtesy M.J. Burke.)

Downloaded From VetBooks.com

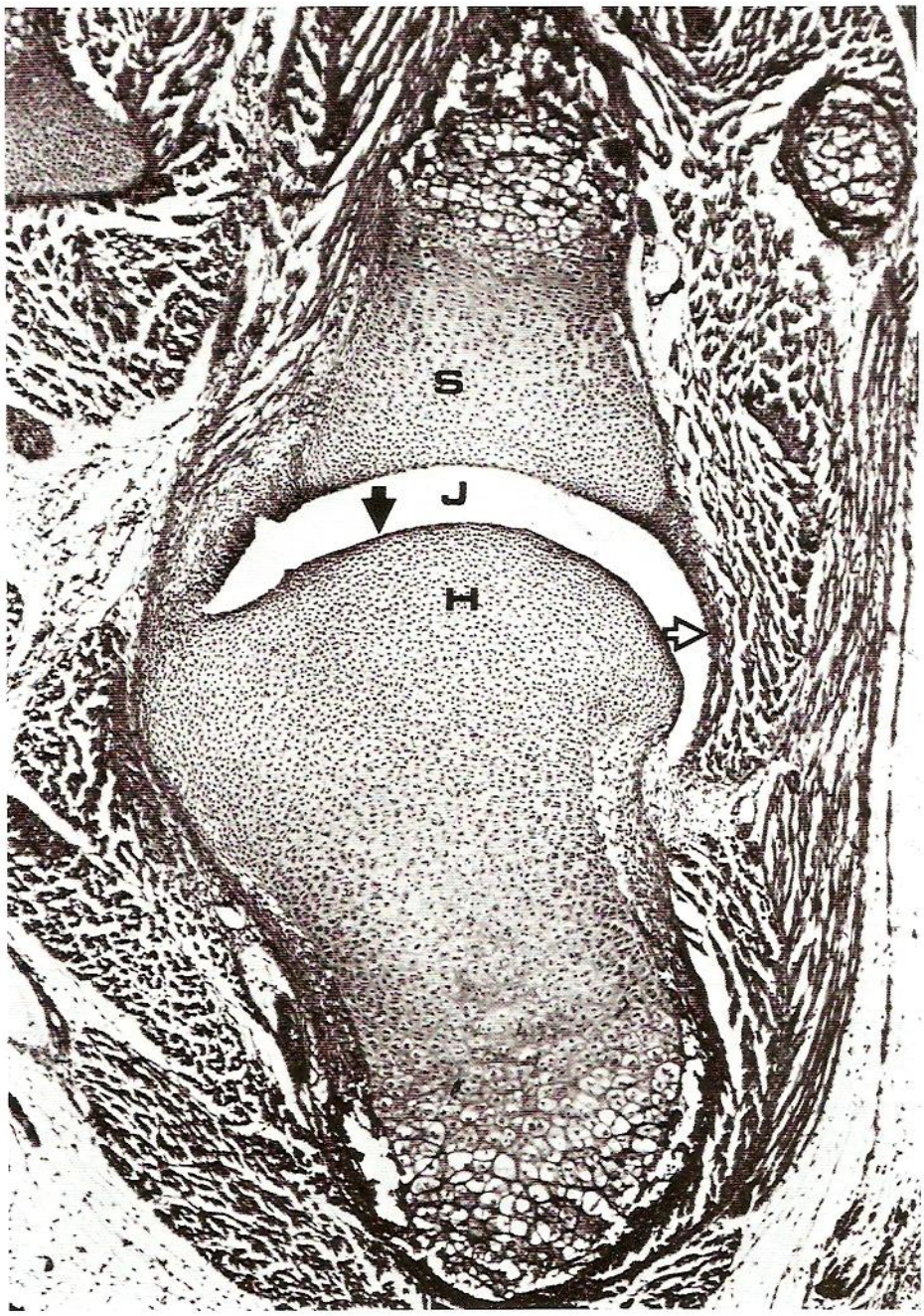

Figure 16-19. Developing scapulohumeral articulation in a fetal dog. The scapula *(S)* and humerus *(H)* are separated by the joint space *(J)*. The synovial membrane *(open arrow)* has been formed. Note that the articular cartilage *(solid arrow)* is devoid of a perichondrium. (×10.)

Downloaded From Vet-eBooks.com

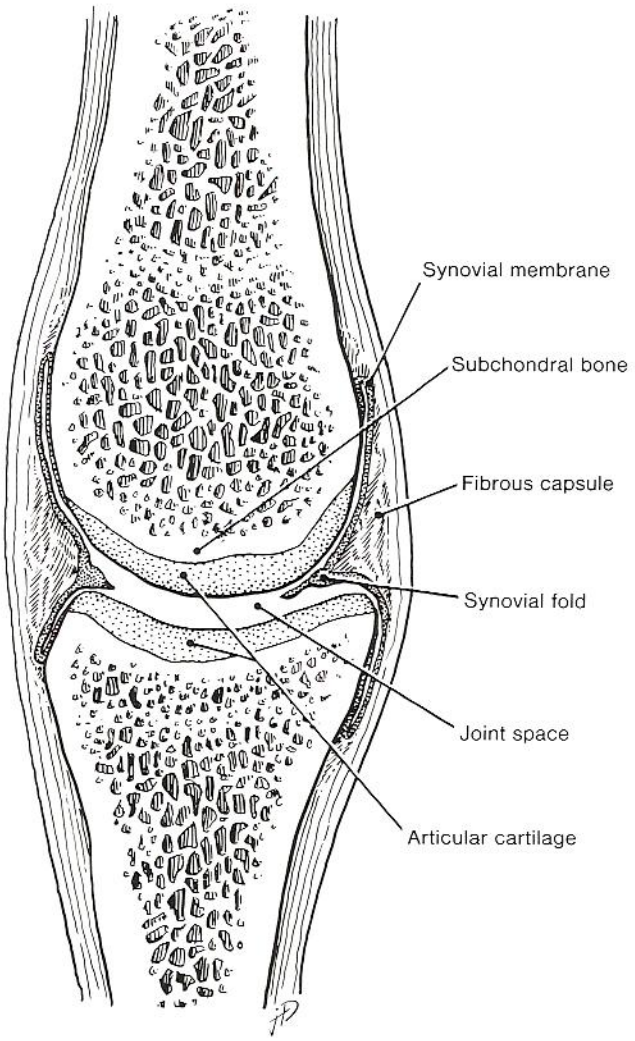

Figure 16-20. Synovial joint with the primary components labeled.

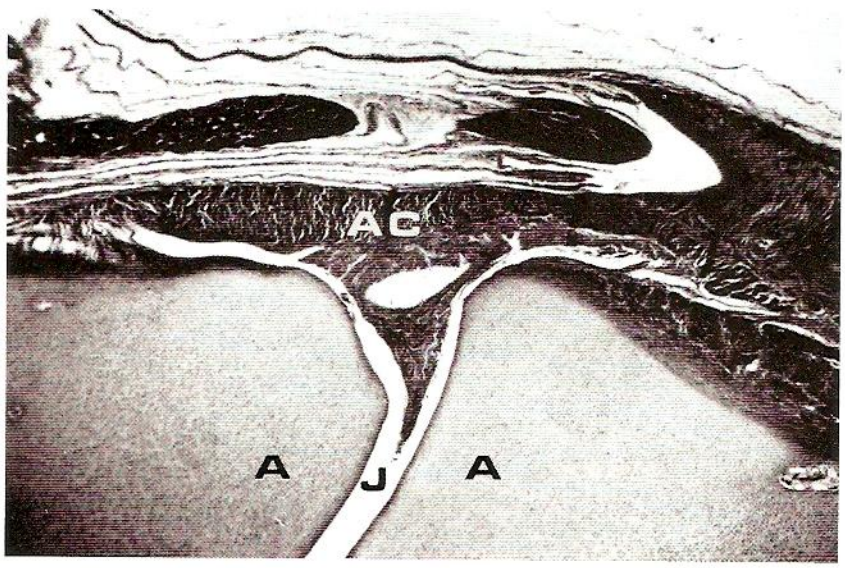

Figure 16-21. Portion of a developing synovial joint. Ligaments and muscles traverse the lateral aspects of the joint in the upper part of the micrograph. The articular capsule *(AC)* surrounds the joint and projects into the joint cavity *(J)*. The articular surfaces *(A)* are composed of hyaline cartilage. (×10.)

defined zones (Fig. 16-22)—superficial, intermediate, deep, and mineralized.

The **superficial (surface) layer** has small, flattened chondrocytes, with their long axes oriented parallel to the articular surface. The **intermediate (transitional) zone** has round cells in various maturational stages. These cells may be arranged in columns oriented perpendicular to the articular surface. The **deep zone** has mature and hypertrophic cells. The **mineralized zone** occurs at articular cartilage union with the underlying epiphyseal compact bone **(subchondral zone)**. The superficial edge of advancing mineralization appears as **tidemarks** (Fig. 16-22).

During development the interstitial growth of the **presumptive articular cartilage** occurs from a deep mitotic region. (See "Epiphyseal growth," p. 140.) These cells divide, move toward the surface, and mature (Fig. 16-23). The attainment of skeletal adulthood marks the end of effective articular chondrocytic mitoses. Chondrocytic mitoses, however, are evident in degenerative joint disease as **chondrones.** These cellular nests are ineffective attempts at repair.

The **articular capsule** has a fibrous layer (fibrous capsule) and a synovial membrane (Figs. 16-20 and 16-21). The **fibrous layer** is dense collagenous tissue with some elastic fibers. It blends with the proper joint ligaments. The fibrous capsule and some ligaments attach circumferentially at a **perichondral ring (transition zone)** between the fibrous periosteum and the articular cartilage. The inner surface of the fibrous capsule is lined by the **synovial membrane** (Fig. 16-24). The synovial membrane reflects upon, blends with, and attaches to the non–weight-bearing articular surface. It delimits the closed space of the joint cavity.

The synovial membrane has lining cells and subsynovial connective tissue (Fig. 16-25). The connective tissue blends with the fibrous capsule. The lining (epithelioid) cells are flat or round and form a membrane from one to four cells thick. They are fibroblast-like (B) cells; no basal lamina lies between them and the subsynovial connective tissue. Macrophage-like (A) cells are also components of the lining. They may be different functional stages of the same cell, because intermediate forms exist. These cells secrete synovial fluid components and are phagocytic.

Prominent synovial membrane infoldings into the synovial space are called **synovial folds,** and slender projections **synovial villi.**

Types of synovial membranes. Synovial membranes are named for the tissue juxtaposed to them. The **fibrous type** is associated with the fibrous capsule, proper ligaments, and tendons crossing

Downloaded From Vet-eBooks.com

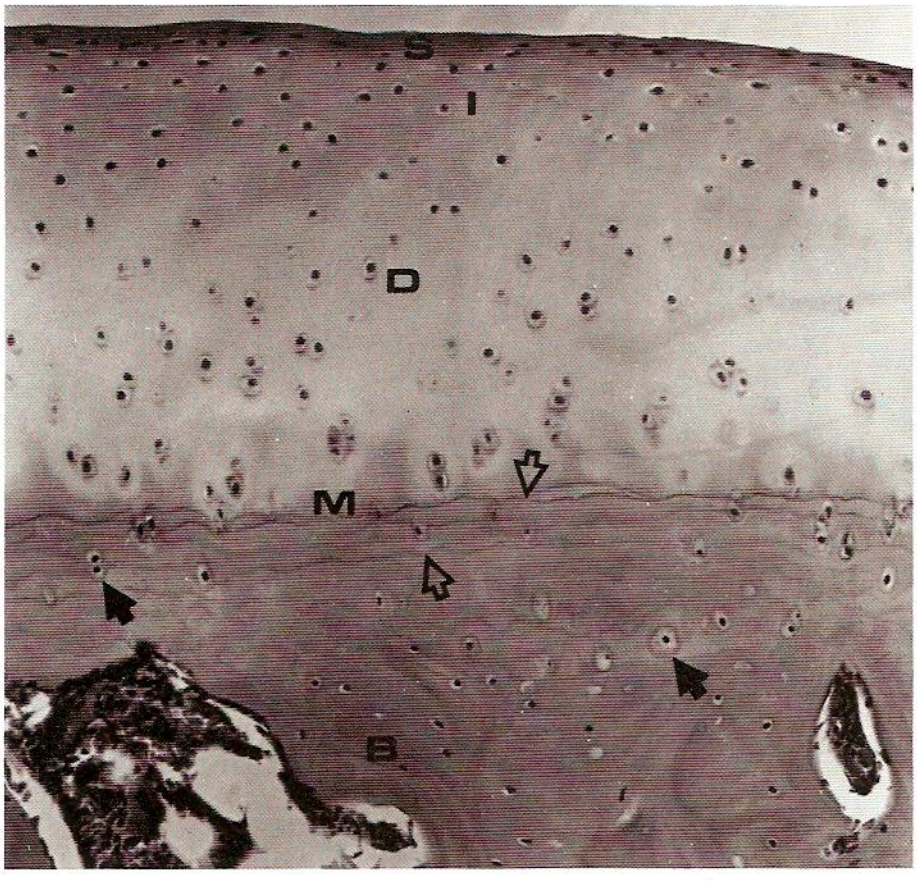

Figure 16-22. Mature articular cartilage and subchondral bone from the head of a feline femur. The superficial *(S)*, intermediate *(I)*, deep *(D)*, and mineralized *(M)* zones of the articular cartilage are evident. Tidemarks *(open arrows)* represent the advancing wave of cartilage mineralization. Pockets of calcified matrix *(solid arrows)* occur deep to the tidemarks adjacent to subchondral bone *(B)*. Note the relatively smooth interface between subchondral bone and articular cartilage. (×40.)

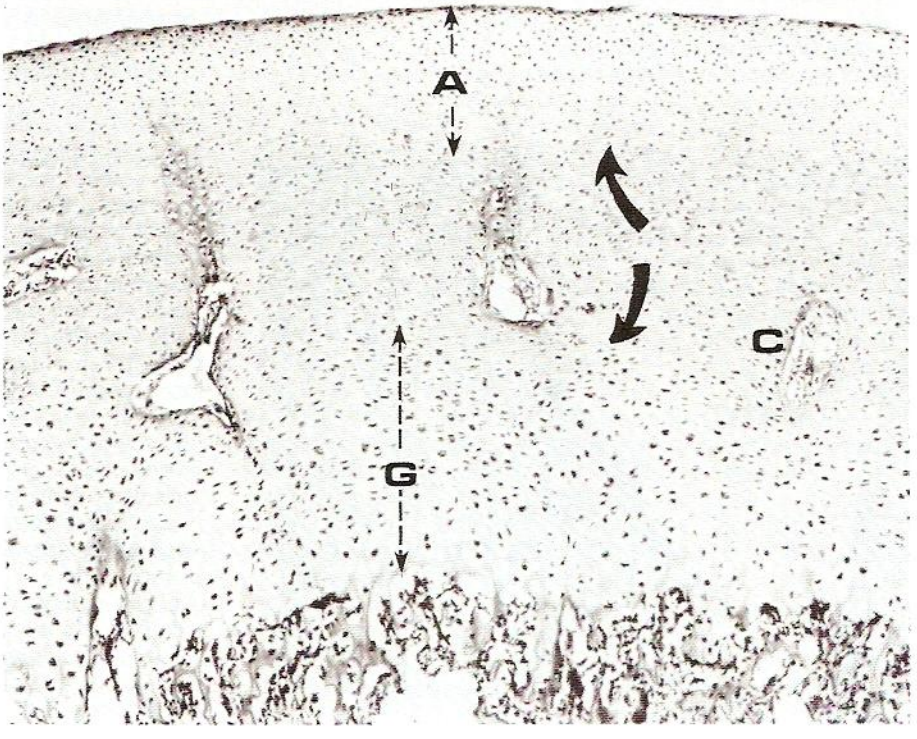

Figure 16-23. Section of a canine growing bone before the formation of a secondary ossification center. Cartilage canals *(C)* are scattered throughout the chondroepiphysis. Presumptive articular cartilage *(A)* is not invaded by cartilage canals. The presumptive growth plate is apparent. Cartilage is "fed" into the developing articular surface and growth plate from a mitotic zone in the general region of the bases of the *curved arrows*. (×25.)

Downloaded From Vet-Ebooks.com

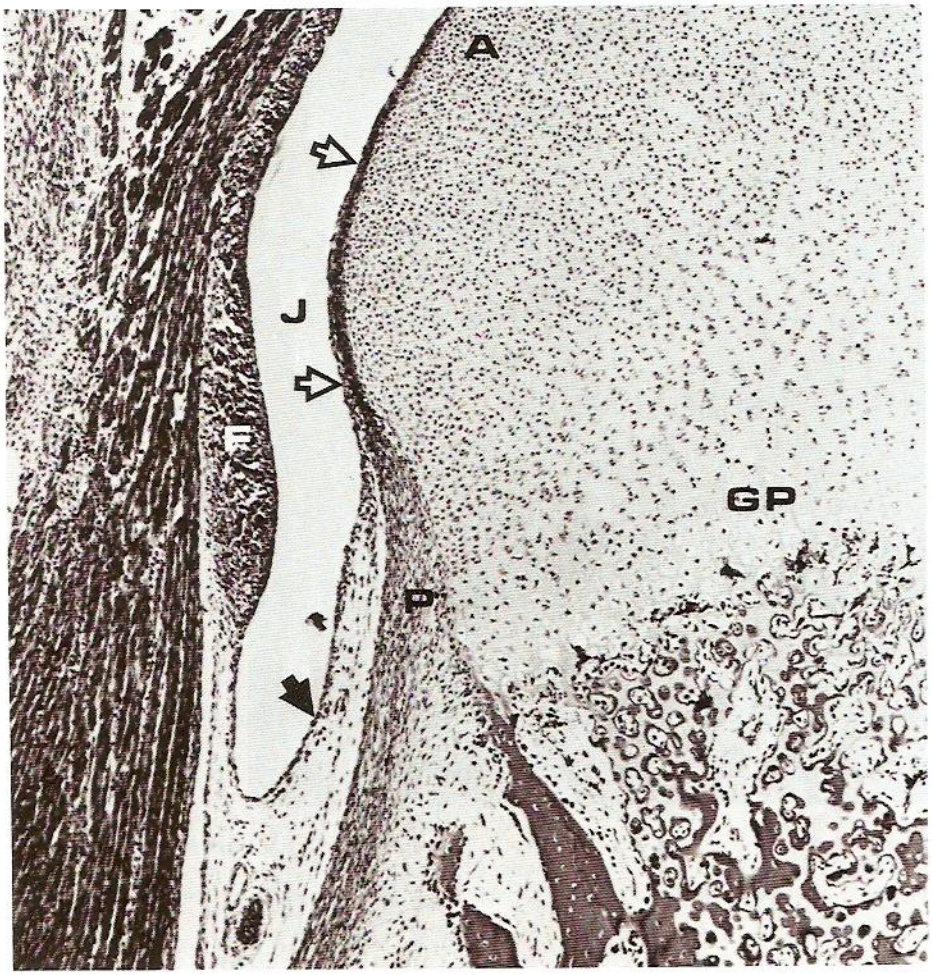

Figure 16-24. Periarticular relationships in a developing bone. The joint space *(J)* is outlined by the synovial lining *(solid arrow)* and the articular cartilage *(A)*. The fibrous capsule *(F)* is peripheral to the synovial lining cells. The synovial lining cells are reflected on the non–weight-bearing surface of the articular surface *(open arrows)*. The presumptive growth plate *(GP)* is bounded peripherally by the perichondral ring *(P)*. (×16.)

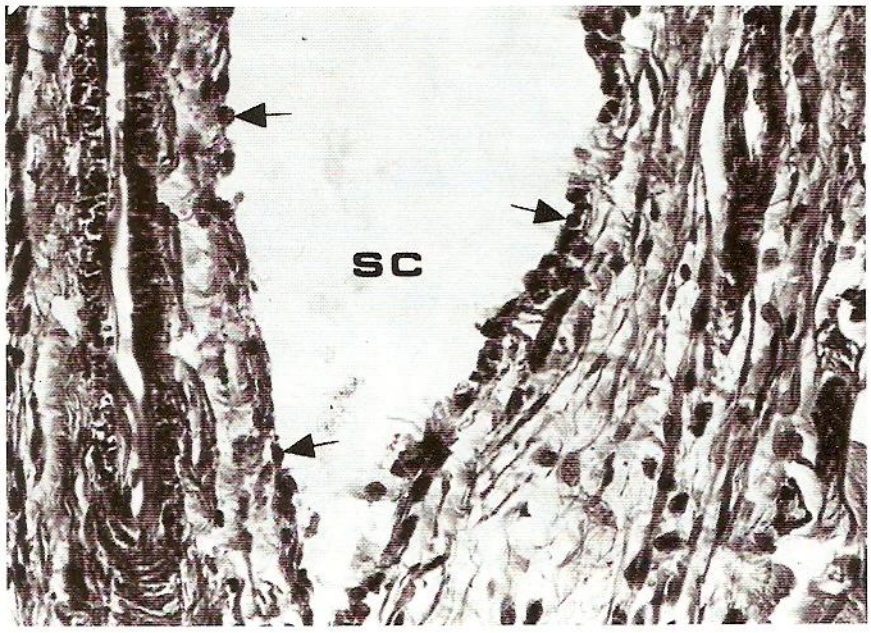

Figure 16-25. Synovial membrane. The synovial cavity *(SC)* is delimited by a fibrous synovial membrane. Flattened fibroblasts *(arrows)* are the predominant lining cells. (×100.)

the joint. The cells lining the synovium rest upon the fibroclastic tissue of these components. The **areolar** synovial membrane is separated from the fibrous capsule by loose collagenous tissue, permitting extensive mobility of the membrane. The **adipose** synovial membrane is associated with adipose tissue that is integral to some synovial joints.

Perichondral ring. The **perichondral ring** was described previously as a **transition zone** between the diaphyseal periosteum and the articular cartilage (Fig. 16-26). Wholly perichondral, it is the attachment site of the fibrous capsule and many ligaments. In growing bones it is positioned as a belt or ring at the peripheral margin of the growth plate. Stimulation of this region is followed by developmental anomalies (e.g., excessive lateral cartilage and/or bone deposition by endochondral ossification). In adult bones it retains its position relative to the closed growth plate along with its cartilage-producing potential.

If trauma involves tearing of the fibrous capsule and/or the ligaments at their perichondral ring attachments, then cartilage or bone formation via endochondral ossification can be expected. These bone spurs are called **periarticular osteophytes.**

Anchoring fibers are the collagenous attachments of fibrous capsules, ligaments, and tendons to bone. They are incorporated in bone during development (Fig. 16-31) when the bone (or cartilage) grows around them. **Periarticular osteophytosis** is an attempt by the perichondral ring to reanchor fibers that have been torn. It may compromise joint function.

Synovial Fluid

Synovial fluid is a transudate from the blood altered by the secretory activity of synovial lining cells. These cells add glycosaminoglycans, principally **hyaluronic acid,** to the synovial fluid. Synovial fluid's viscosity, which derives primarily from the hyaluronic acid, is a conspicuous feature. Low–molecular weight proteins identical to plasma proteins occur in low concentrations. Lysosomal enzymes and proteoglycan degradation products of the lining cells and cartilaginous matrix are components. The "weeping" of articular cartilage also adds some components.

The turnover and absorption of synovial fluid are not completely understood.

Three functions are ascribed to synovial fluid—lubrication, nutrition, and protection.

Lubrication. **Lubrication** of joint surfaces has been attributed to the high viscosity of synovial fluid, but the process is more dynamic and complex than this. Two mechanisms of mechanical lubrica-

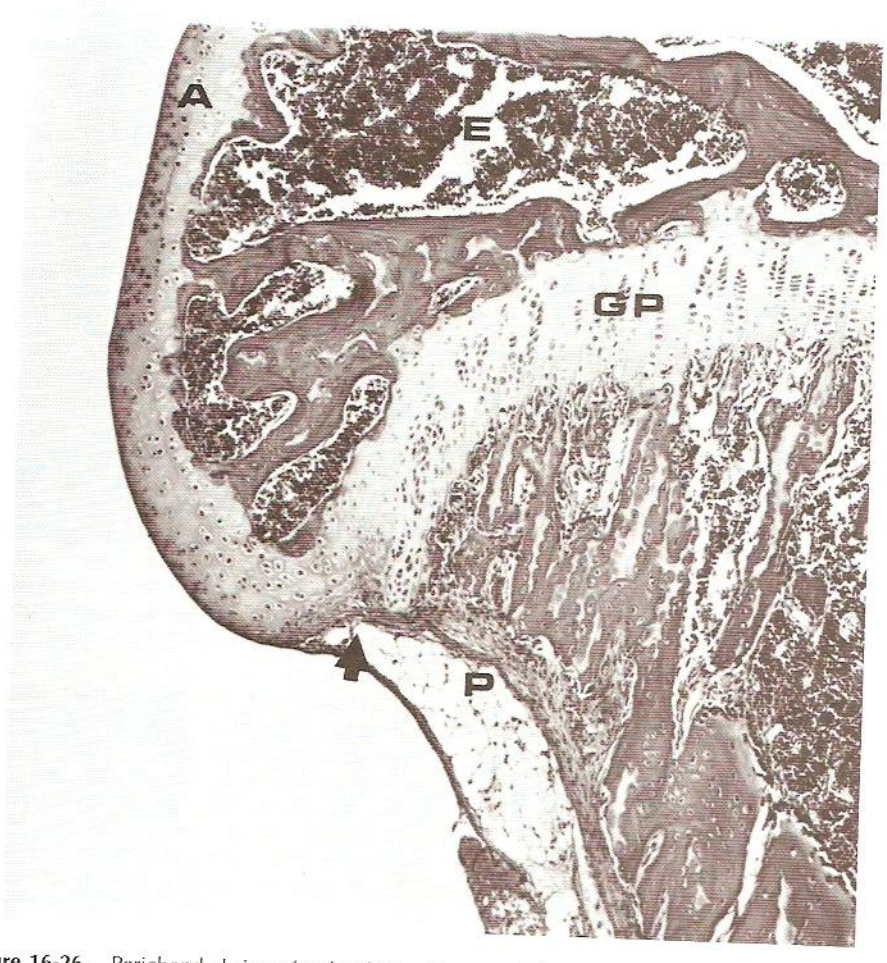

Figure 16-26. Perichondral ring of a developing humerus. The ring *(arrow)* surrounds the peripheral limits of the growth plate *(GP)* at the transition point between articular cartilage *(A)* and periosteum *(P)*. *E*, Epiphyseal ossification center. (×16.)

tion, fluid film and boundary, apply to synovial joints.

Fluid film lubrication occurs when a lubricating film completely separates opposing surfaces. Four types of fluid film lubrication (hydrodynamic, hydrostatic, elastohydrodynamic, and squeeze film) have been implicated in joint surface lubrication. This type of lubrication functions whenever articular surfaces are loaded at various rates.

Boundary lubrication occurs when surface-absorbed molecules maintain the lubricating properties. A glycoprotein yet to be characterized is believed to be the boundary lubricant of articulations. Boundary lubricants function independently of load and rate of loading.

Mixed lubrication (a combination of fluid film and boundary lubrication) occurs under different circumstances.

Three other types of lubrication mechanisms unique to articular cartilage have been identified, but their significance is controversial.

Weeping lubrication arises from the load-dependent squeezing of substances against the cartilage surface. The substances move back into the matrix when the load is removed.

Boosted lubrication results when water separates from the synovial fluid and moves into the matrix, increasing synovial fluid's viscosity and lubricating properties.

Lipid lubrication results when the lipid constituents of articular cartilage reduce the coefficient of friction between opposing surfaces.

As stated, the lubrication process is complex and probably involves a combination of mechanisms. The high viscosity of synovial fluid results from hyaluronic acid. Intuitively, then, you could assume that viscosity and hyaluronic acid are what account for synovial fluid's lubricating properties. These assumptions are reasonable; however, the digestion of hyaluronate reduces this viscosity, and the removal of hyaluronate does not alter the fluid's lubricating properties. The glycoprotein mentioned earlier as having been isolated but not characterized is probably responsible for synovial fluid's lubricating properties.

Nutrition and protection. **Nutrition and protection** of the articular cartilage are also functions of synovial fluid.

The weeping of articular cartilage may be a mechanism for the diffusion of nutrients and waste products. Articular chondrocytes are ideally suited for anaerobic metabolism.

The lubricating properties of synovial fluid protect against mechanical damage. The presence of lysosomal enzymes protects against foreign bodies and microbes. Synovial fluid is a good growth medium for microbiological agents. Synovial cells and/or articular chondrocytes may secrete a plasminogen system activator preventing the formation of clots within synovial fluid or on articular surfaces.

Functional correlates. Despite the secretory activity of its lining cells (altering tissue fluid), the joint space is an expanded portion of the connective tissue space. The synovial tissues are well vascularized, with large capillaries (many of which are fenestrated) ensuring a rapid exchange of tissue fluid. The mechanisms governing tissue fluid exchange apply. Extensive lymphatic capillaries occur in this region.

The fibrous capsule and associated ligaments are well-innervated. Pain and proprioception are carried by the neuronal processes. Postganglionic fibers of the sympathetic nervous system (vasomotor nerves) are also present.

Synovial fluid characterization is an invaluable aid for diagnosing joint abnormalities (Table 16-1).Radiology is commonly used. Although the articular cartilage is radiolucent, the radiographic interface between joint surfaces is visible because of mineralized cartilage and subchondral bone beneath each surface. Subchondral bone is the articular cartilage support component. Many changes in articular cartilage are accompanied by subchondral bone changes. Thus an **evaluation of the subchondral bone** is also useful diagnostically.

Repair of articular cartilage. Full-thickness articular surface damage does not repair itself appropriately. Abortive attempts at repair usually lead to degenerative joint disease. (Articular cartilage repair is discussed in Chapter 8.)

Continuous passive motion of damaged joints has been effective experimentally in stimulating full-thickness articular cartilage repair by hyaline cartilage, and the technique may have future clinical application.

MUSCLE AS AN ORGAN

Muscle-Tendon Relationships

Organization. Tissue constituents of muscles as organs include skeletal muscle fibers, loose and dense collagenous tissues, vessels, lymphatics, and nerves. Individual muscle fibers are the structural

Table 16-1. Synovial Fluid Analysis of Selected Conditions

	Normal	Trauma	Sepsis
Clarity	Clear	Clear-bloody	Cloudy
Color	Straw	Straw-xanthochromic-bloody	Pink to gray Green
Viscosity	High	High	Low
Mucin clot	Good	Good	Poor
Fibrin clot	0	0 to slight	Minimal to marked*
pH	7.0 to 7.8	7.0 to 7.8	Decreased
Total protein	1.0 to 5	Variable	Increased
RBCs	0	Variable†	+
WBCs	500 to 3000‡	Normal to slight increase	30,000
Cytology	Healthy cells	Healthy cells	Toxic/degenerative
Monocytes	90%	70% to 80%	10% to 20%*
Neutrophils	10%	20% to 30%	80% to 90%*

*Varies with the type of agent.
†Positive if acute; 0 if chronic.
‡Some species variations: horse, 500; dog, 3000.

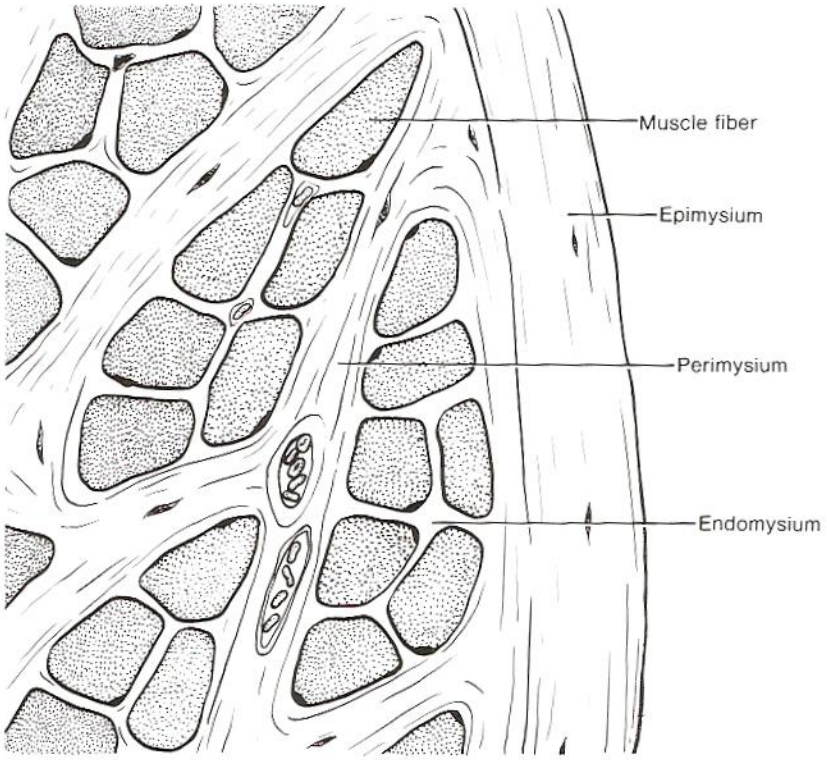

Figure 16-27. Connective tissue investments of skeletal muscle.

units and parenchyma of gross muscle masses.

Grossly, skeletal muscle masses are distinct entities separated by a dense collagenous tissue called **fascia.** Fascia may be considered the capsule of the organ and is called **epimysium** by histologists (Fig. 16-27). It extends into the muscle mass and forms a covering **(perimysium)** around individual muscle bundles. Individual fibers within bundles **(fascicles)** are separated by a delicate collagenous tissue, the **endomysium.** The connective tissue investments are continuous. They bind the components as a single structural unit and allow nerves and vessels to reach the fibers (Fig. 16-28). Lymphatic vessels are present in the epimysial and perimysial connective tissue but are not components of the endomysium.

Myotendinous junctions. The connective tissue investments of muscles are continuous with the connective tissues by which they are anchored. This continuity converts the mechanical activity of contraction into work. The **muscle-tendon junction** is also the point where actin filaments attach to the plasmalemma (Fig. 16-29). The collagen of the tendon is attached to the basal lamina at invaginations along the plasmalemma. The increased length of muscle during growth occurs by the addition of new sarcomeres at this junction.

Tendons

Morphology. A **tendon,** composed of dense collagenous tissue (regularly arranged), connects muscles to their attachments (Fig. 16-29). Whereas the tensile strength of a muscle is in the range of 80 psi, that of tendons may be 225 times larger. Thus, heavy muscle masses function effectively through small tendinous attachments. The ability of an animal to perform work depends upon tendons' moving or gliding great distances through associated soft tissues.

Tendons consist of collagenous bundles bound by perimysium-like connective tissue called **endotendon (endotenon)** (Fig. 16-29). Blood vessels and nerves are also present within tendons. The entire tendon is surrounded by a connective tissue sheath, **epitendon (epitenon),** that is similar to the epimysium. Loose collagenous tissue, adipose tissue, or synovial sheaths between tendons and their fibrous sheaths are called **paratendon (paratenon).**

Tendons are enclosed within **tendon sheaths (synovial sheaths)** at friction points along their paths. These sheaths consist of two layers of flattened cells. The inner layer (tendinous part) is associated with the epitendon and provides a smooth surface for movement. The outer layer (parietal part) is attached to surrounding paratendinous tissues. The intervening space between the two layers is filled with a lubricating fluid similar to synovial fluid. The synovial membranes of joints may establish similar relationships to tendons such that the intervening space between the sheath layers is continuous with the joint space. The **mesotendon** is a zone of continuity and contact between the inner and outer layers of the synovial sheath. Blood vessels and nerves enter the tendon through the mesotendon. The relationship between a tendon and its sheath is similar to that of a cylinder laid upon a slightly inflated balloon and then pushed into the balloon (Fig. 16-30). The cavity of the balloon is analogous to the lubricating space between the sheath layers. To provide proper lubrication, the inner part is attached to the epitendon; the entire tendon and inner part move within the synovial fluid space as a unit.

Fibrocartilage, often the tissue interface between a tendon and its osseous or cartilaginous attachment, strengthens origin and insertion points. The attachment of a tendon to bone or cartilage occurs through **anchoring fibers** (Fig. 16-31). Intrinsic attempts to reattach anchoring fibers to bone are characterized by this process of **periosteal new bone growth (exostosis).**

Extrinsic and intrinsic repair. Two requirements must be met for repair phenomena to return tendons to normal

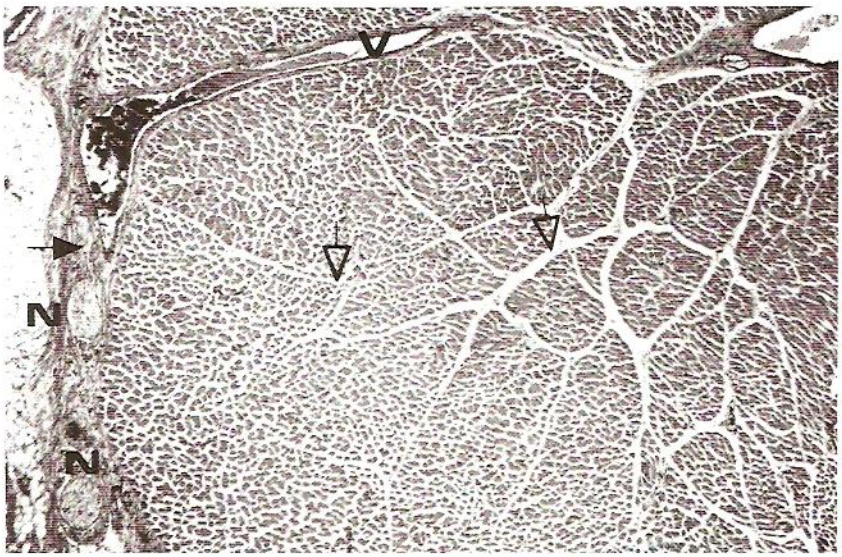

Figure 16-28. Cross section of a skeletal muscle. Groups (fascicles) of fibers are surrounded by the perimysium *(open arrows)*. This connective tissue is continuous with the epimysial *(solid arrows)* and endomysial connective tissues. Note the nerves *(N)* and vessels *(V)* within the perimysium. (×10.)

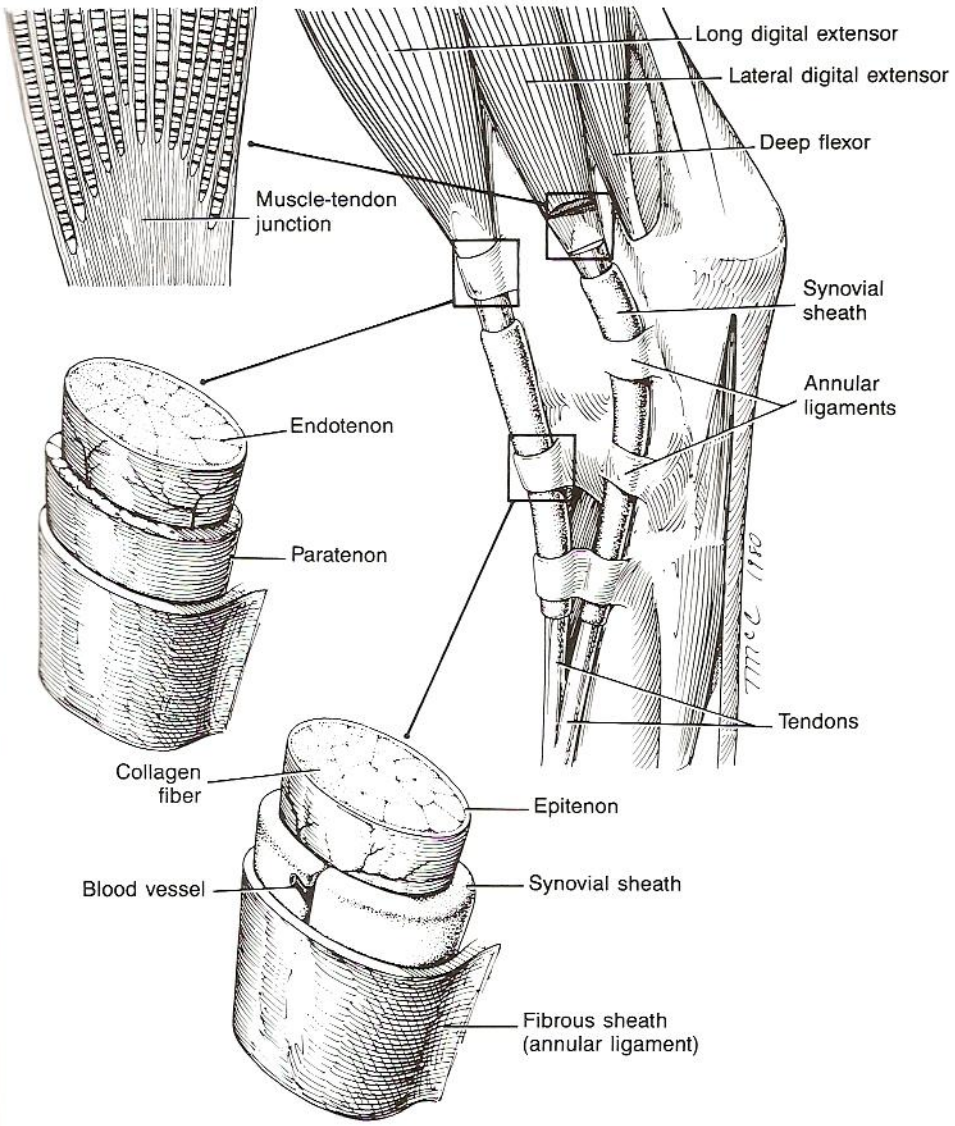

Figure 16-29. Superficial muscles and tendons associated with the equine tarsus (components labeled).

function. **The tendon's tensile properties must be restored,** and **its ability to glide must be maintained.** Fibroblast proliferation and procollagen secretion and polymerization are essential for tensile property restoration. Contributions from paratendinous fibroblasts can impair the necessary gliding property. This **extrinsic repair** is essential for tendon restoration, but it can cause **adhesions** (collagenous connections) between the tendon and the surrounding tissues. Although the paratendinous tissue contributions (fibroblasts and capillaries) are significant, tendons also undergo **intrinsic repair.** The fibroblasts originate within the tendon in this repair.

Repair sequence. The sequence of tendon repair occurs in distinct yet interrelated stages corresponding to those described for fracture repair.

During the **insult stage** partial or complete tendon severing results in tendon damage and other soft tissue damage and devitalization. Hemostasis may exacerbate devitalization. Because the blood supply to tendons within synovial sheaths is segmental, the location and extent of the lesion in relation to the blood supply are determinants in the amount of devitalization. The synovial fluid within the sheath is also a source of nourishment to joint tissues, and its disruption has the effect of complicating repair.

The **induction stage** is probably an artificial separation of events occurring throughout the repair process. The stimulus for new cell induction during repair may be hypoxia. Fibroblasts proliferate within and adjacent to the tendon and new capillaries rapidly invade the tendon from the paratendinous tissues.

The **inflammatory stage** occurs as a sequel to tissue damage, and the amount of inflammation depends upon the extent of the damage. The cardinal signs of inflammation are apparent throughout this stage. An excessive inflammation can result in an excessive collagen formation **(fibrosis)** at the repair site.

The **fibroblastic stage** is characterized by proliferation of fibroblasts and their procollagen secretion. The epitendon and endotendon fibroblasts are responsible for intrinsic repair. These regions become hyperplastic, and collagen is deposited randomly within the repair site. The synovial sheath and paratendinous tissues also contribute cells and collagen as the extrinsic aspect of the repair process.

During the **maturation stage** the collagen fibers become oriented parallel to the tendon's long axis, fuse, and interdigitate with other fibers. The tendon eventually separates from the surrounding paratendinous tissues. The degree to which this separation occurs determines the extent to which normal function is restored. Collagenous adhesions from the

Downloaded From Vet-eBooks.com

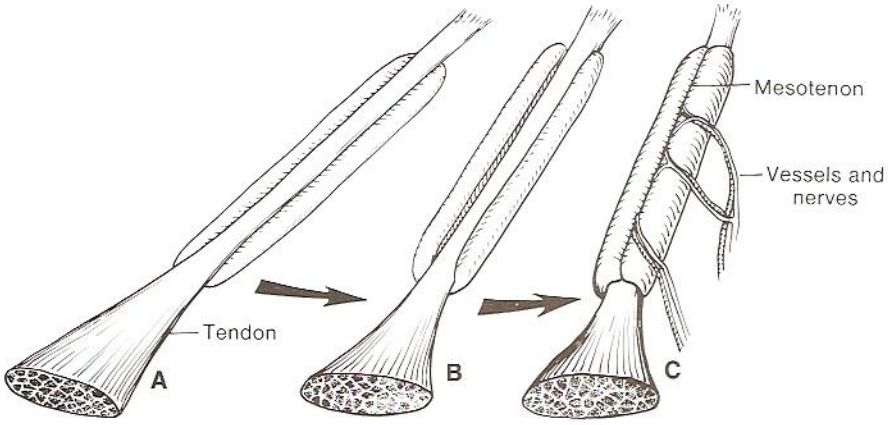

Figure 16-30. Development of a tendon sheath around a tendon. **A,** Initial tendinous invagination into sheath; **B,** continued invagination and encirclement of the tendon; **C,** established relationship.

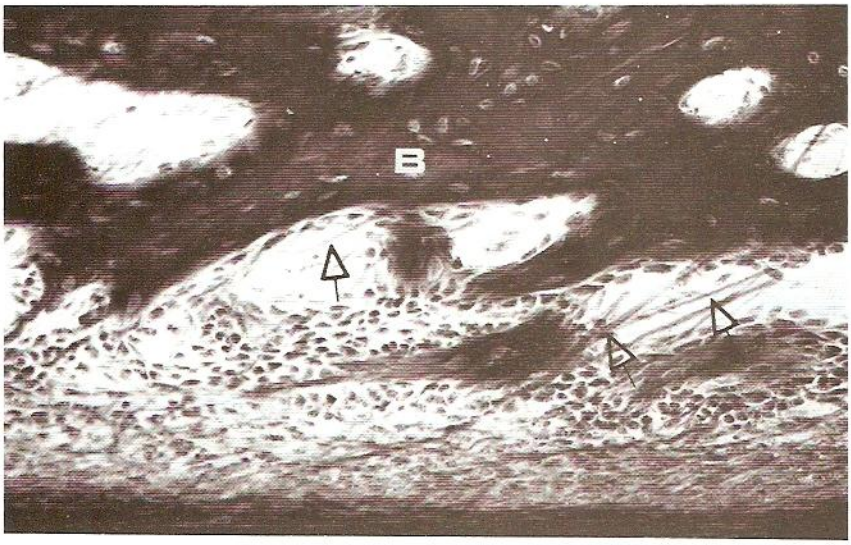

Figure 16-31. Attachment of muscle to bone through dense collagenous tissue. Anchoring fibers *(arrows)* attach the connective tissue to the bone *(B).* (×40.)

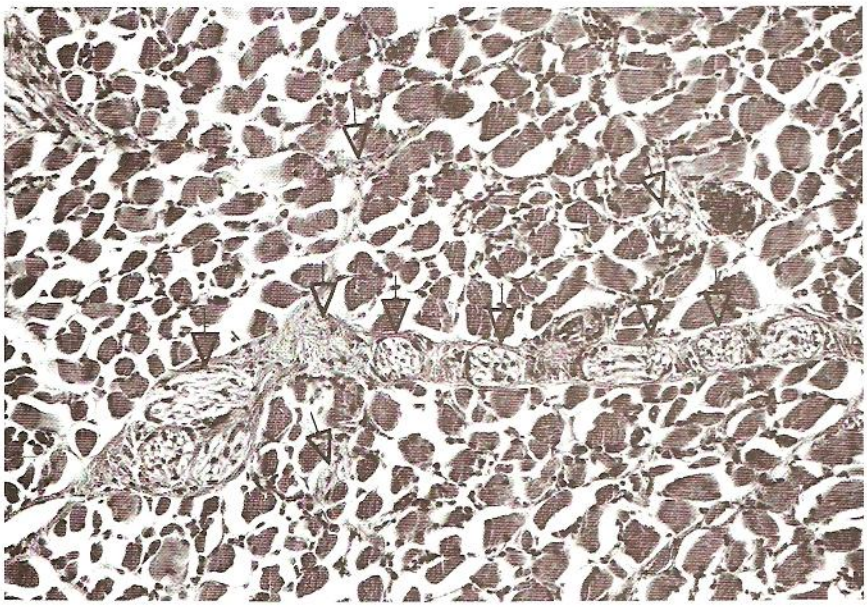

Figure 16-32. Nerves and muscles. The nerve fibers *(arrows)* innervate the adjacent musculature. (×40.)

tendon to the paratendinous tissues limit functional gliding.

Many factors influence successful repair of a tendon. Careful management of these histological events can result in return to near-normal function.

The events responsible for the repair of a torn tendon from its attachments to bone are similar to those just described. The important difference is the **necessity to reestablish the attachments of anchoring fibers.**

Muscle-Nerve Relationships

Motor unit. Large nerve fibers enter the epimysial connective tissue space, branch throughout the perimysium, and send fine terminals into the endomysium (Fig. 16-32). Low innervation ratios characterize the antigravity muscles or coarse body movers; high innervation ratios characterize the muscles of fine movement. The muscle fibers and the nerve innervating them are called a **motor unit.** A motor unit includes the cell body located in the ventral gray column of the spinal cord, the axon as it passes through the white matter of the spinal cord, the continuation of the axon in the ventral root, the axon within the main stem and the dorsal or ventral branches of the spinal nerve, the myoneural junction, and the muscle fibers. (This concept applies to the equivalent components of the cranial nerves.)

Myoneural junction. The union of a neuronal terminal and the muscle fiber(s) is called the **motor endplate** or **myoneural junction** (Figs. 16-33 and 16-34). As an axon approaches a muscle fiber, the myelin sheath terminates (Fig. 16-35). The neurolemmal cell continues and covers the contact point with the muscle fiber. The terminal arborization extends into recesses in the muscle called **synaptic troughs (primary synaptic clefts).** The **subneural apparatus** consists of plasmalemmal modifications, called **secondary synaptic clefts,** including many plasmalemmal and basal lamina infoldings (Fig. 13-11). The axon and plasma membrane are always separated by the intervening basal lamina.

The neuromuscular junction is a directed chemical synapse. The axon telodendria contain many small vesicles and mitochondria. The vesicles, **synaptic vesicles,** contain the neurotransmitter acetylcholine, which is released into the synaptic trough upon nerve stimulation.

Synaptic vesicles undergoing exocytosis do not fuse with the inner surface of the presynaptic membrane randomly. A series of **dense bars** is present along the inner surface of the presynaptic membrane opposite the apex of the postsynaptic membranous folds. Synaptic vesicles align themselves along the edges of

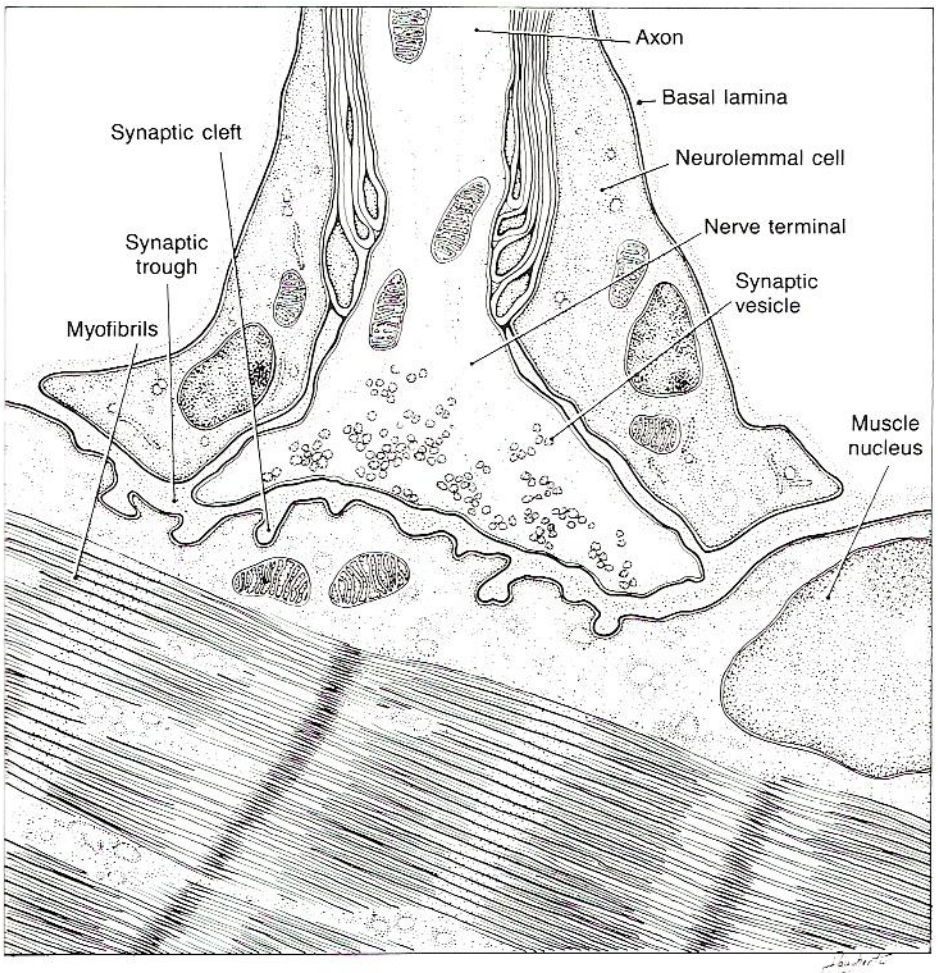

Figure 16-33. Myoneural junction (components labeled). Compare with Figure 13-11.

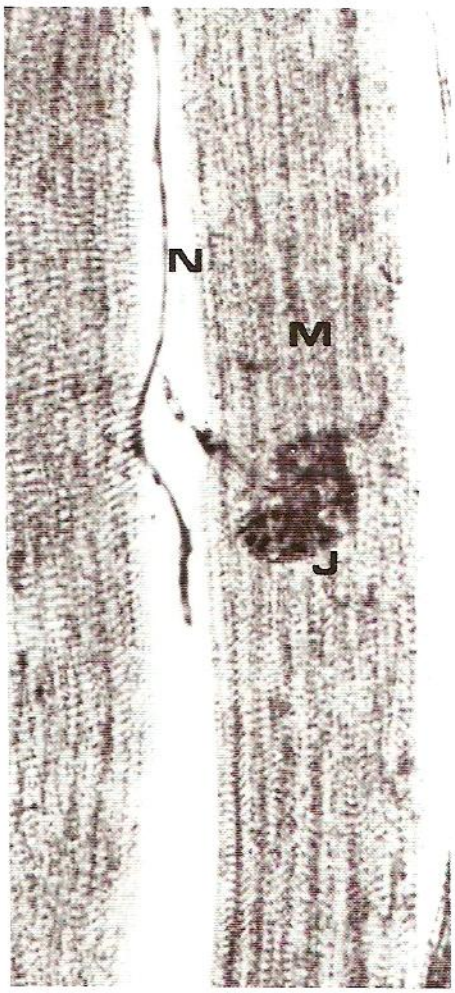

Figure 16-34. Neuromuscular junction. A branch of a nerve fiber *(N)* terminates as a neuromuscular junction *(J)* upon the muscle fiber *(M)*. (×100, gold impregnation.)

these bars. This combination of dense bars and aligned synaptic vesicles is called an **active zone.** An active zone is actually the specialized region within synapses where neurotransmitter release occurs. Once the neurotransmitter is released, the vesicle is recycled for use by the neuron. (Active zones are features of most neurons. The morphology and frequency of attachment sites vary.)

Acetylcholine binds to receptor sites on the apex of the membranous folds of the subneural apparatus. Neurotransmitter and receptor interaction opens chemically gated Na^+ channels, permitting Na^+ entry into the muscle cell. The rapid Na^+ influx causes a rise in the endplate membrane potential, called the **endplate potential.** Once the endplate potential raises the local membrane potential to threshold, an action potential results. Subsequent depolarization spreads from this site as an action potential and activates the muscle cell. The motor endplate is a synapse.

Neuromuscular spindle apparatus. **Neuromuscular spindles** occur throughout muscles. They maintain the tone of a muscle and minimize the possibility of damage from excessive muscle stretching. Spindles mediate their activity through a **stretch reflex** involving two neurons at the level of the spinal cord.

Neuromuscular spindles consist of muscle fibers, nerve endings, and connective tissue (Fig. 16-35). A loose collagenous tissue capsule separates the smaller **intrafusal** spindle fibers from the ordinary and larger **extrafusal** fibers of the muscle mass. Intrafusal fibers vary in length from 2 to 10 mm and are approximately 200 μm in diameter. Two types of intrafusal fibers occur, a **nuclear bag fiber** (Fig. 16-36) and a **nuclear chain fiber** (Fig. 16-37). Of the 20 fibers forming a spindle, the nuclear chain fibers outnumber the nuclear bag fibers by a two or three to one ratio. Both fibers are attached to the capsule at their poles.

Both types of fiber are typically striated but have distinct **equatorial regions.** The nuclear bag fiber has an enlarged center filled with nuclei and devoid of contractile elements. The smaller and shorter nuclear chain fibers do not have expanded centers, but large nuclei are prominent and contractile elements are missing in their central region.

Many afferent and efferent nerve endings associate with these fibers (Fig. 16-35). Afferent endings innervating the equators of both fibers are called **primary endings (annulospiral endings).** When the equators are stretched, the fibers transmit an impulse to the spinal cord resulting in the contraction of extrafusal fibers of the same muscle mass. The same input signal from the primaries causes inhibition of the antagonistic muscle mass. This accounts for the stretch reflex (Fig. 16-38).

The input from the primaries notifies higher brain centers at a subconscious level about the rate of muscle lengthening or stretching and the actual length of the muscle.

Afferent **secondary endings (flower spray endings)** originate on each side of the equatorial region (Fig. 16-35). Their precise function is not understood. They transmit information about muscle length to the CNS at a subconscious level.

Small **γ-efferents** innervate intrafusal fibers at their respective poles (Fig. 16-35). γ-Efferents establish the stretch on equatorial regions, thereby raising or lowering primary ending discharge threshold. This varies spindle sensitivity to stretching.

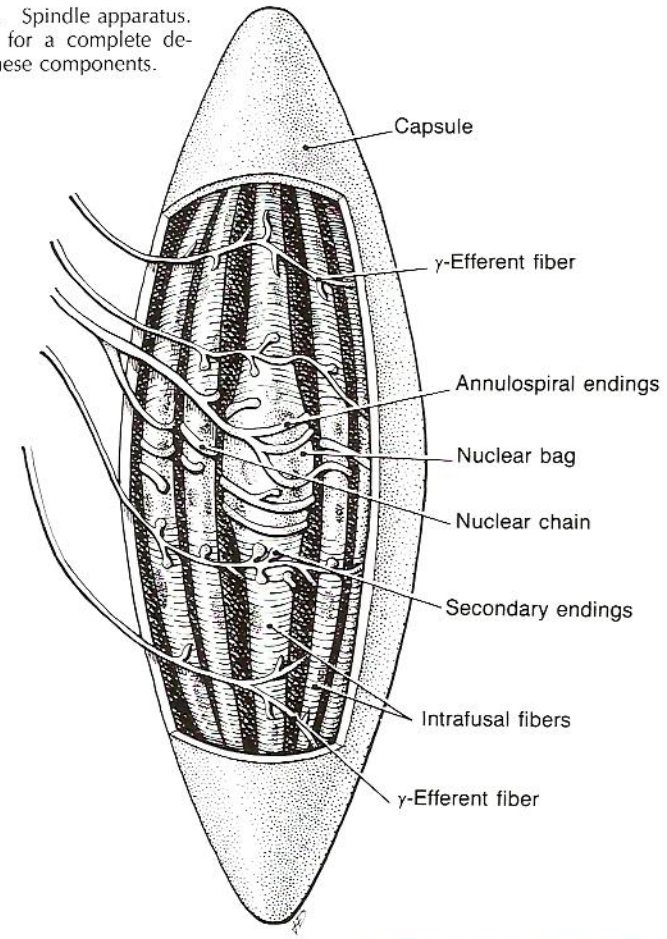

Figure 16-35. Spindle apparatus. Refer to text for a complete description of these components.

When extrafusal fibers contract, the equatorial tension decreases, causing a regional collapse. By γ-efferent discharge, equatorial regional tension is maintained throughout the contraction range, ensuring a constant informational input to the spinal cord and higher brain centers about the stretch of a particular muscle mass.

Neurotendinous relationships. **Neurotendinous organs (Golgi tendon organs)** are located in tendons close to muscle/tendon junctions. The Golgi tendon organs consist of collagenous fibers contained within a connective tissue capsule. Many cells and afferent terminals are also present. They transmit information about the tension on tendons and the amount of muscle mass contraction. With excessive tension on a tendon the afferent discharge inhibits further contraction. Although the information is transmitted at a subconscious level throughout the range of muscular contraction, these organs minimize the possibility that tendons will be torn from their points of attachment to bone or muscle.

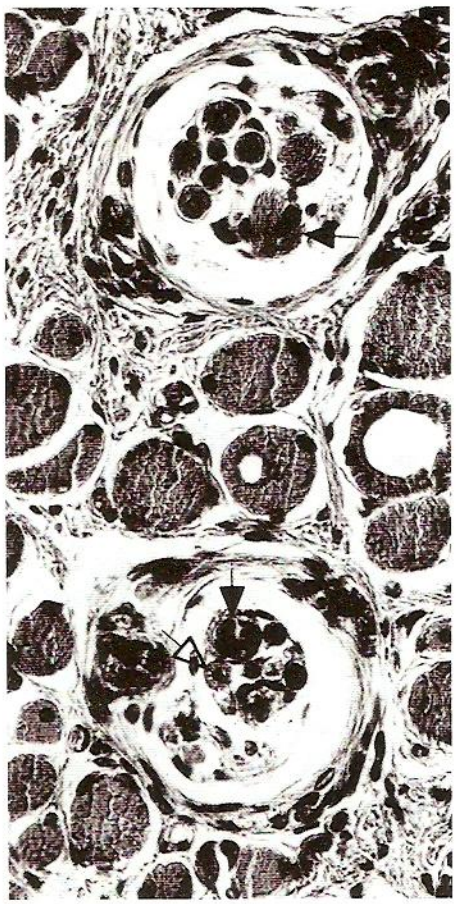

Figure 16-36. Cross sections of two spindle apparatus from the extraocular musculature of an elk, showing the nuclear bag *(solid arrows)* and nuclear chain *(open arrow)* regions. Note the connective tissue capsule separating the small intrafusal fibers from the large extrafusal fibers. (×100.)

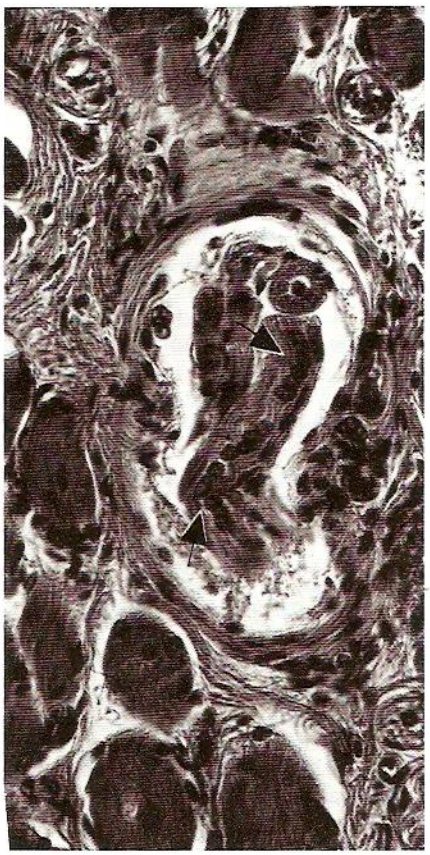

Figure 16-37. Oblique section of a spindle apparatus from the extraocular musculature of an elk. *Arrows* point to the equatorial regions of nuclear chain fibers. (×100.)

Downloaded From VetBooks.com

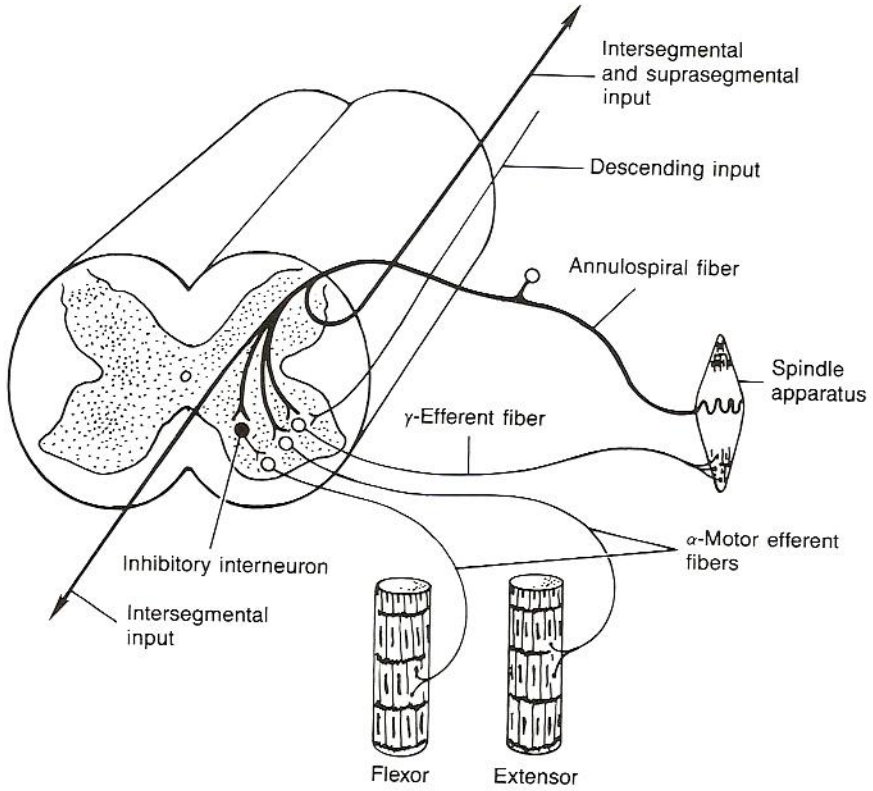

Figure 16-38. Myotatic reflex. Stimulation of the spindle apparatus by stretching induces the firing of annulospiral afferent fibers. Collaterals synapse with α-motor neurons in the ventral gray column, causing extensor contractions. A synapse with an interneuron inhibits flexor contractions. Collaterals from the annulospiral fibers descend and ascend the spinal cord to intersegmental and suprasegmental levels.

The input from spindles and neurotendinous organs is at a subconscious level, but conscious input occurs through other mechanisms. Naked nerve endings (Ruffini-like) are embedded within joint capsular connective tissue. Subjected to the compression and tension associated with joint movement, they transmit **kinesthetic** information (i.e., information concerning the relative positions of various parts of the body).

ADDITIONAL READINGS

Bone as an Organ

Arnold JS: Quantitation of mineral of bone as an organ and tissue in osteoporosis, *Clin Orthop* 17:167, 1960.

Butler WF: Age changes in alcian blue staining of glycosaminoglycans in sheep articular cartilage, *Res Vet Sci* 22:303, 1977.

Cooke AF, Dowson D, Wright V: Lubrication of synovial membrane, *Ann Rheum Dis* 35:56, 1976.

Cooper RR, Milgram JW, Robinson RA: Morphology of the osteon. An electron microscopic study, *J Bone Joint Surg* 48A:1239, 1966.

Elliot HC: Studies on articular cartilages. I. Growth mechanisms, *Am J Anat* 58:127, 1936.

Frost HM: New concepts of bone remodelling and of the nature of osteoporoses, *J Med Surg* I:41, 1961.

Frost HM: *Bone remodelling dynamics,* Springfield Ill, 1963, Charles C Thomas.

Frost HM: *The physiology of cartilaginous, fibrous and bony tissue,* Springfield Ill, 1972, Charles C Thomas.

Frost HM: *Bone modeling and skeletal modeling errors,* Springfield Ill, 1973, Charles C Thomas.

Frost HM: A chondral modeling theory, *Calcif Tiss Res* 28:181, 1979.

Haines RW: The development of joints, *J Anat* 81:33, 1947.

Hancox NM: *Biology of bone,* New York, 1972, Cambridge University Press.

Hirohata K, Morimoto K: *Ultrastructure of bone and joint diseases,* New York, 1971, Grune & Stratton.

Ketchum LD: Tendon healing. In Hunt TK, Dunphy JE (eds): *Fundamentals of wound management,* New York, 1979, Appleton-Century-Crofts, pp 500-523.

Kincaid SA, Van Sickle DC: Regional histochemical and thickness variations of adult canine articular cartilage, *Am J Vet Res* 42:209, 1981.

Koch JL: The laws of bone architecture, *Am J Anat* 21:177, 1917.

Radin EL, Swann DA, Weisser PA: Separation of a hyaluronate free lubricating fraction from synovial fluid, *Nature* 228:337, 1970.

Roy S: Ultrastructure of articular cartilage in experimental hemarthrosis, *Arch Pathol* 86:69, 1968.

Silberberg M, Silberberg R, Hasler M: Fine structure of articular cartilage in mice receiving cortisone acetate, *Arch Pathol* 82:569, 1966.

Sokoloff L, Bland JH: *The musculoskeletal system,* Baltimore, 1975, Williams & Wilkins.

Urist MR (ed): Symposium: Articular cartilage in health and disease, *Clin Orthop* 64:3, 1969.

Wilson FC: *The musculoskeletal system,* Philadelphia, 1975, JB Lippincott.

Fracture Repair

Ham AW, Harris WR: Repair and transplantation of bone. In Bourne GH (ed): *The biochemistry and physiology of bone,* vol 3, New York, 1971, Academic Press, pp 337-399.

Heppenstall RB: Fracture and cartilage repair. In Hunt TK, Dunphy JE (eds): *Fundamentals of wound management,* New York, 1979, Appleton-Century-Crofts, pp 524-551.

Peacock EE, Jr, Van Winkle W Jr: *Surgery and biology of wound repair,* Philadelphia, 1970, WB Saunders.

Perrin S: Cortical bone healing, *Acta Orthop Scand Suppl,* vol 125, 1969.

Sumner-Smith G (ed): *Bone in clinical orthopaedics: a study in comparative osteology,* Philadelphia, 1982, WB Saunders, p 435.

Urist MR (ed): *Fundamental and clinical bone physiology,* Philadelphia, 1980, JB Lippincott, p 416.

Muscle as an Organ

Bowman JP Jr: *The muscle spindle and neuronal control of the tongue: implications for speech,* Springfield Ill, 1971, Charles C Thomas.

Cohen LA: Contributions of tactile musculo-tendinous and joint mechanisms to position sense in human shoulder, *J Neurophysiol* 21:563, 1958.

Cooper S: Afferent impulses in the hypoglossal nerve on stretching the cat's tongue, *J Physiol* 126:32P, 1954.

Lentz TL: Development of the neuromuscular junction, *J Cell Biol* 47:423, 1970.

Mathews PBC: Muscle spindles and their motor control, *Physiol Rev* 44:219, 1964.

Nystrom B: Muscle-spindle histochemistry, *Science* 155:1424, 1967.

Sokoloff L, Bland JH: *The musculoskeletal system,* Baltimore, 1975, Williams & Wilkins.

Spiro AJ, Beilin RL: Histochemical duality of rabbit intrafusal fibers, *J Histochem Cytochem* 17:348, 1969.

Wilson FC: *The musculoskeletal system,* Philadelphia, 1975, JB Lippincott.

Yelin H: A histochemical study of muscle spindles and their relationship to extrafusal fiber types in the rat, *Am J Anat* 125:31, 1969.

CHAPTER 17

Nervous System

The nervous system is a complex of organs formed by nervous tissue, connective tissue, and vascular components. Its complexity is based upon neurons communicating with each other and effector cells. The system perceives stimuli, processes the information, and causes the appropriate responses contributing to **homeostasis.** The neuron is the anatomical unit of an intercommunicating network of cells and cell processes.

The nervous system has two anatomical subdivisions, the **central nervous system (CNS)** and the **peripheral nervous system (PNS).** The CNS consists of the brain, its extensions, and the spinal cord. The units contain many pools of segregated neurons interconnected by cell processes. The PNS includes the nerve trunks (cranial and spinal nerves), accumulations of peripherally positioned neuronal cell bodies, and neuronal terminals. The PNS receives stimuli, transduces them into useful information as action potentials, and transmits this information to the CNS. The information elicits a segmental or intersegmental response (reflex). The information is transmitted over ascending pathways to higher (suprasegmental) levels responsible for the integration, association, and interpretation of information. The appropriate response, transmitted over neuronal processes forming descending pathways, is carried eventually to the effector organs (glands and muscles) by the nerve trunks of the PNS.

The PNS may be subdivided into the **somatic nervous system** and the **autonomic nervous system.** The somatic nervous system includes those neurons carrying information from the external environment to the CNS and back to skeletal muscles. The autonomic nervous system functions similarly. Although the origin of its input varies, the subsequent evocation of a response involves the visceral organs.

Conducting neurons allow the organism to respond immediately and for short periods to environmental stimuli. Neurosecretory neurons, because of their influence on the endocrine system, permit gradual and long-term responses to environmental stimuli.

ANATOMICAL CONSIDERATIONS

Development. The basic form of the vertebrate CNS is a dorsal, hollow, tubular structure derived from a thickened plate of **neuroectoderm** (Fig. 17-1). The **neural plate** is a longitudinal thickening dorsal to the notochord during the presomite stage. The neural plate invaginates to form the **neural groove;** its lateral margins grow centrally and fuse along the longitudinal axis to form the **neural tube.** As these two layers of ectoderm separate from each other, a longitudinally oriented mass of cells segregates as the **neural crest cells.**

The rostral end of the neural tube accumulates developing nerve cells and is characterized by the development of vesicles destined to differentiate into various brain components (Fig. 17-2). This process of **cephalization** is identifiable early in development by the appearance of three vesicles—prosencephalon, mesencephalon, and rhombencephalon (Fig. 17-3).

The **prosencephalon** divides into two vesicles, the telencephalon and the diencephalon. The **telencephalon** grows extensively and covers the rostral portions of the vesicles as the **cerebral hemispheres.** The **diencephalon** differentiates into the thalamus and its various subdivisions **(epithalamus, thalamus, metathalamus, subthalamus,** and **hypothalamus)** and associates with the developing eye **(optic vesicle).**

Throughout this development the rostral neural tube becomes tortuous, but the neural tube lumen maintains its patency and continuity. The lumen of the telencephalon is the two **lateral ventricles;** the lumen of the diencephalon is the donut-shaped **third ventricle.** The third ventricle communicates with the lateral ventricles through two laterally positioned **interventricular foramina.**

The **mesencephalon** does not subdivide into other vesicles but gives rise directly to the midbrain. The constricted portion of the lumen of the neural tube in the midbrain is called the **mesencephalic aqueduct.** It connects the third ventricle rostrally and the **fourth ventricle** caudally.

The fourth ventricle develops with the **rhombencephalon.** It subdivides into the metencephalic and myelencephalic vesicles. The **metencephalon** gives rise to the cerebellum dorsally and the pons ventrally. The **myelencephalon** becomes the medulla oblongata. It ends at the foramen magnum; the spinal cord continues caudally. Continued brain growth is contingent upon the continuing differentiation of the five vesicles (Fig. 17-3).

Cell differentiation, development, and orientation. The rapid growth of the neural tube results from marked proliferation of its neuroepithelial cells. The neuroepithelium segregates into neural crest cells, neuroblasts, and glioblasts.

Neural crest cells separate from the neural tube and differentiate into many cell types, some of which maintain their relationship with the nervous system (Fig. 17-4). **Neuroblasts** differentiate into CNS neurons. **Glioblasts** differentiate into CNS neuroglial cells (Fig. 17-4).

Although the extent of proliferation varies in different parts of the neural tube, the differentiation pattern, organization, and orientation are maintained throughout its wall (Fig. 17-5). The innermost zone, which lines the lumen of the tube, is termed the **germinal** or **matrix layer.** It consists of dividing neuroepithelial cells. Their daughter cells migrate peripherally forming a centrally positioned **mantle layer.** The neuroblasts of this layer may send processes rostrad and/or caudad to form the outermost **marginal layer;** or the processes may perforate the neural tube to become PNS motor nerves. Glioblasts differentiate into neuroglial cells and assume their typical relationships to neurons in the three layers. At the end of CNS development, the three layers will have become the white matter (marginal layer), the gray matter (mantle layer) and the ependymal layer (germinal or matrix layer). Additional neuroepithelial cell division during development accounts for additional neuronal pools typical of these adult structures.

A longitudinal groove, the **sulcus limitans,** is present in the neural tube wall from the mesencephalon caudad. A plane through the sulcus divides the neural

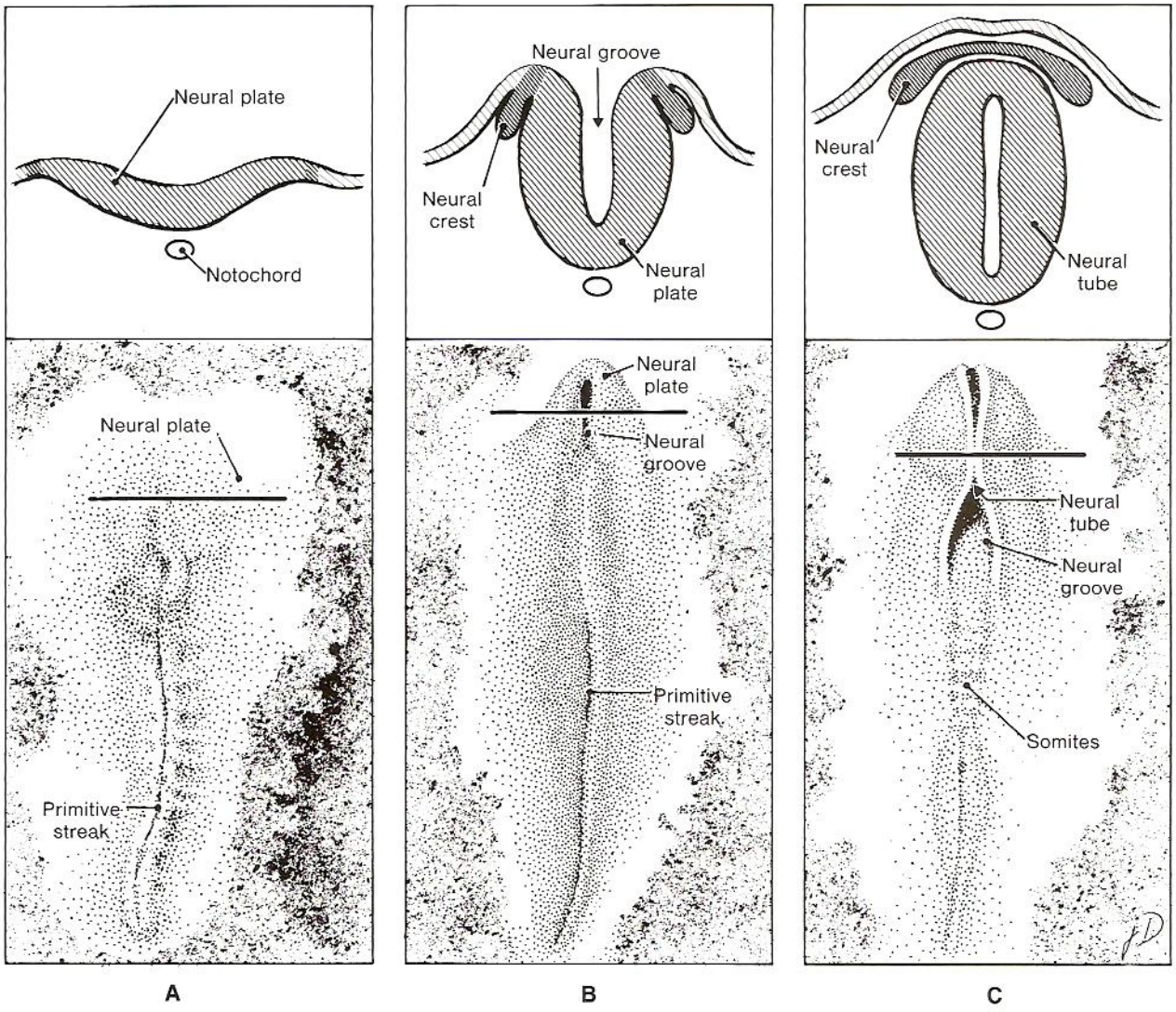

Figure 17-1. Neural tube development. *Upper,* Cross sections; *lower,* dorsal views. **A,** The ectoderm thickens as the neural plate during the presomite stage of development. **B,** The neural plate continues to thicken and forms an invagination, the neural groove. **C,** The neural groove closes as a neural tube and neural crest cells are differentiated.

Downloaded From Vet-eBooks.com

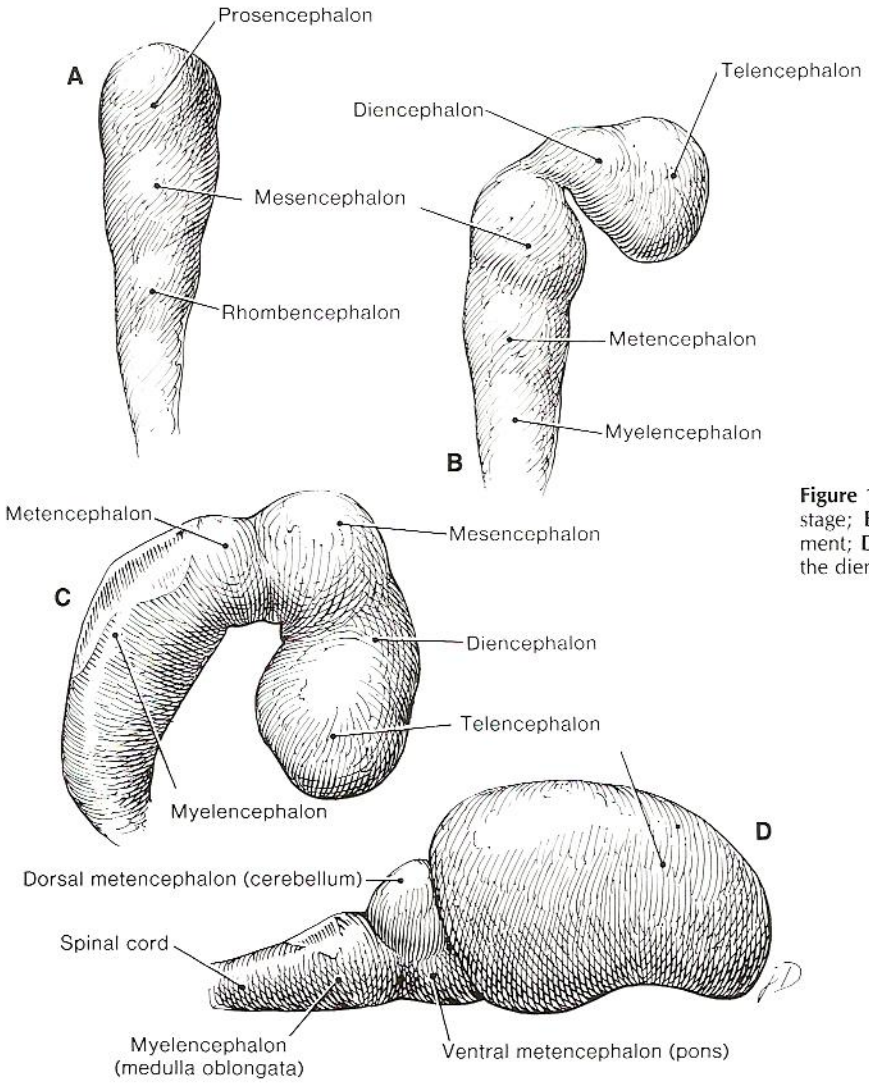

Figure 17-2. Cephalization of the neural tube. **A,** Three-vesicle stage; **B,** five-vesicle stage; **C,** continued growth and development; **D,** telencephalic vesicles overgrow the other vesicles, and the diencephalon becomes located deep to the telencephalon.

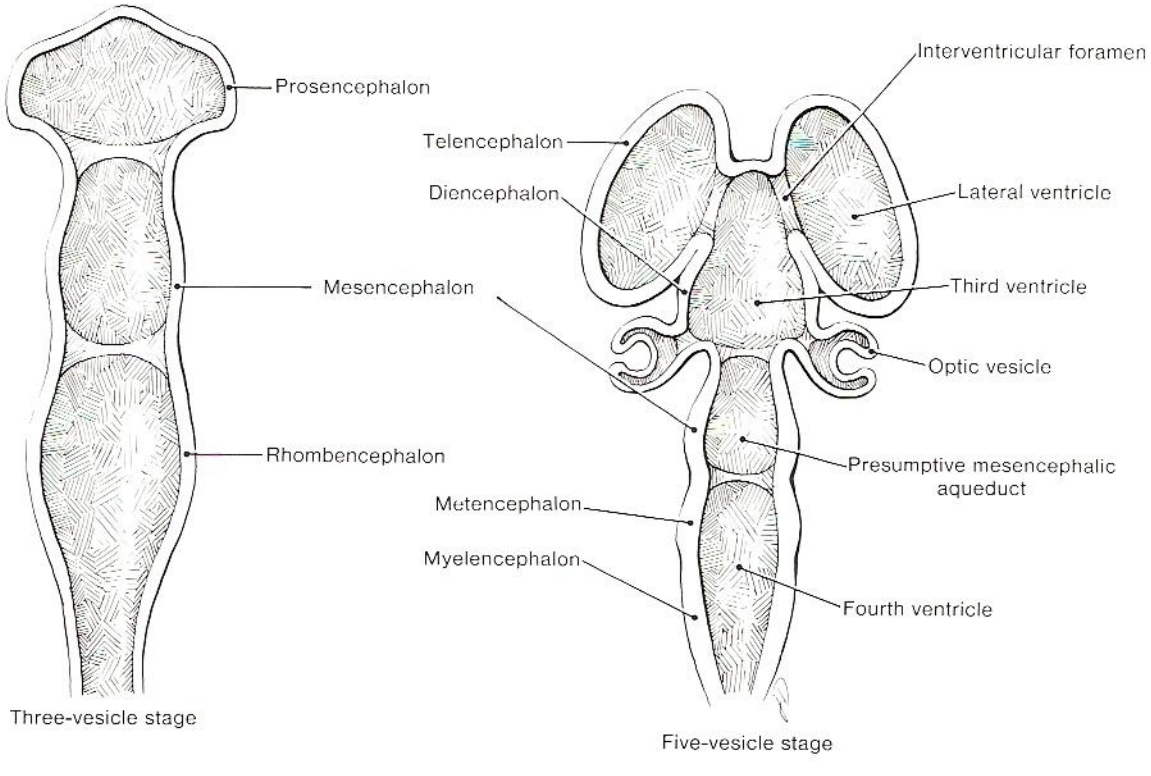

Figure 17-3. Frontal sections through the three-vesicle and five-vesicle stage of brain development.

Downloaded From Vet-eBooks.com

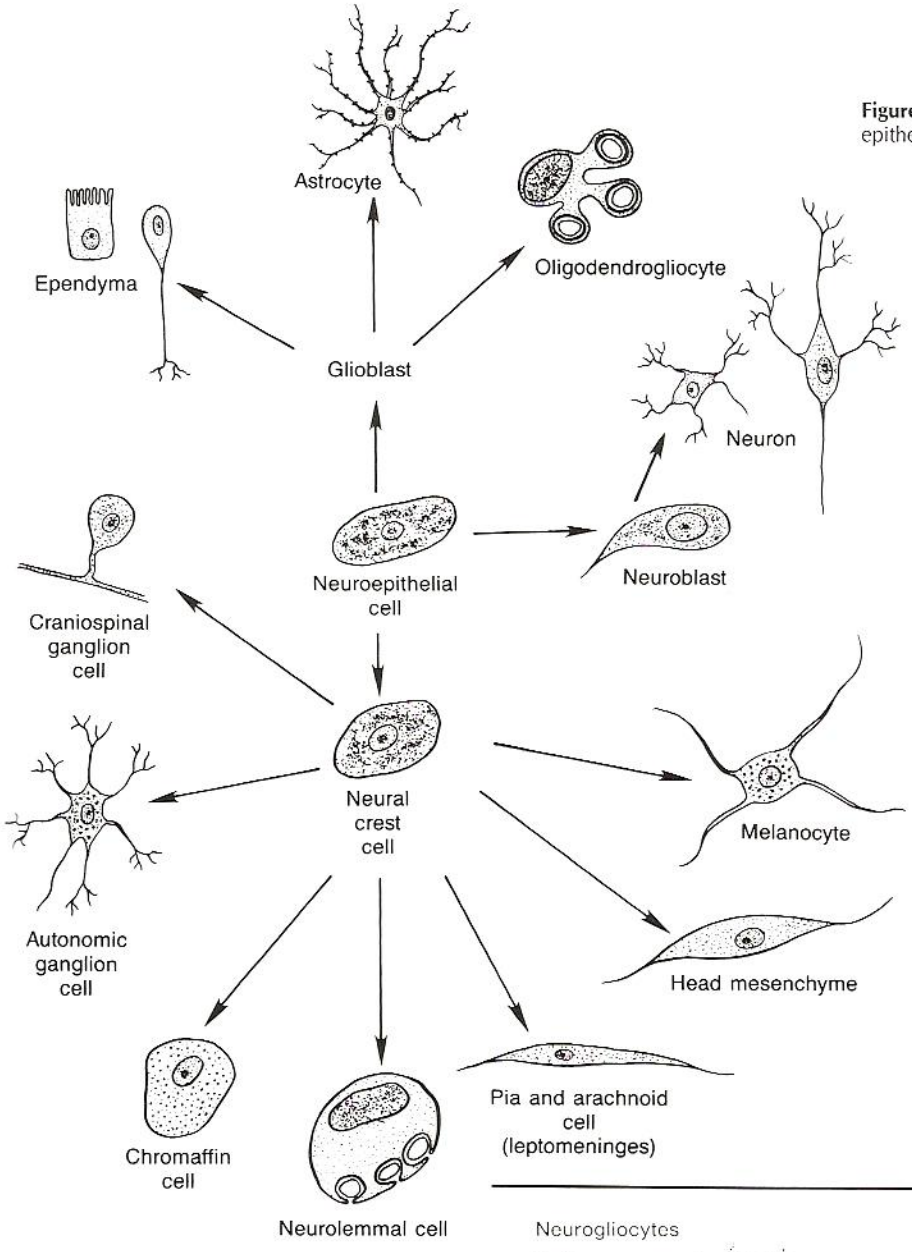

Figure 17-4. Cellular intermediates and derivatives of neuroepithelial cells.

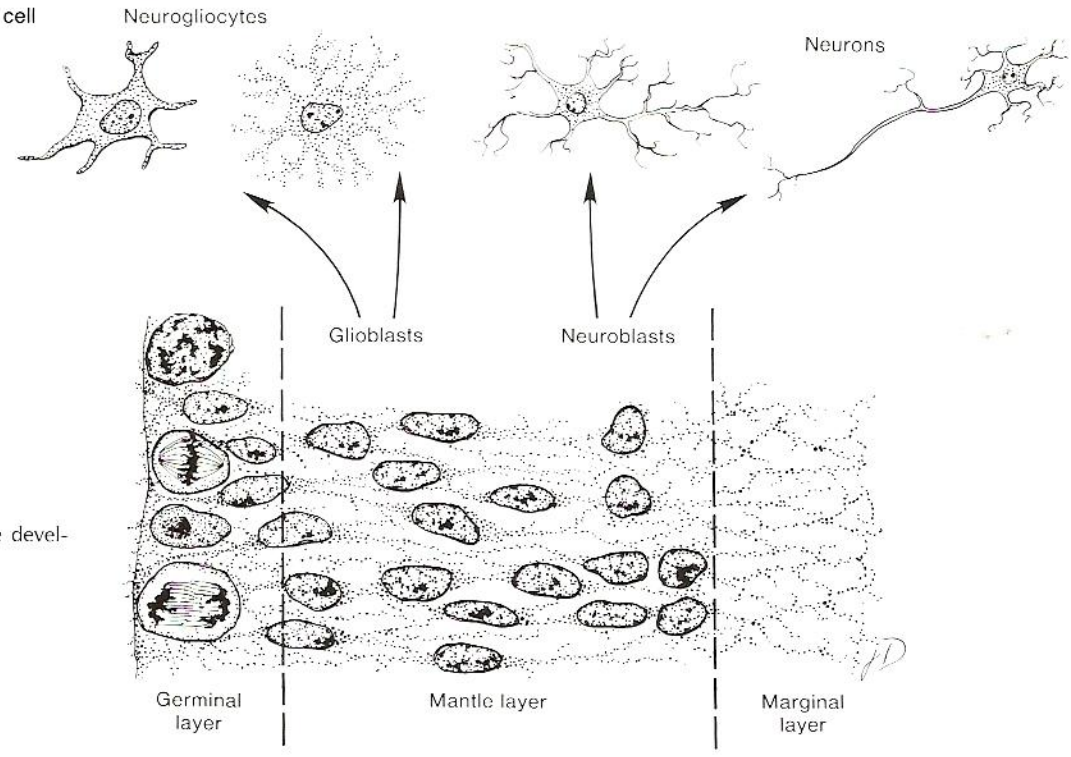

Figure 17-5. Cross section through the developing neural tube (zones indicated).

Downloaded From Yes-Dental.com

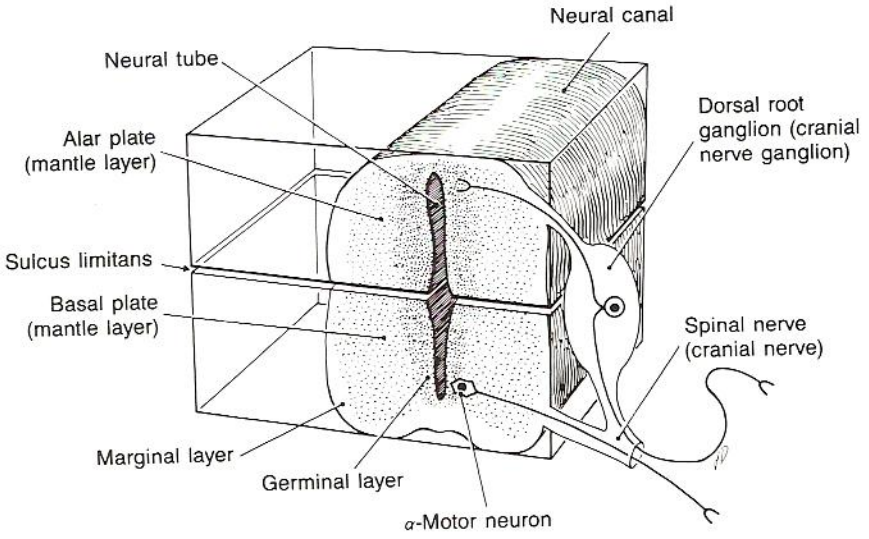

Figure 17-6. Relationships of the alar and basal plates in the developing neural tube.

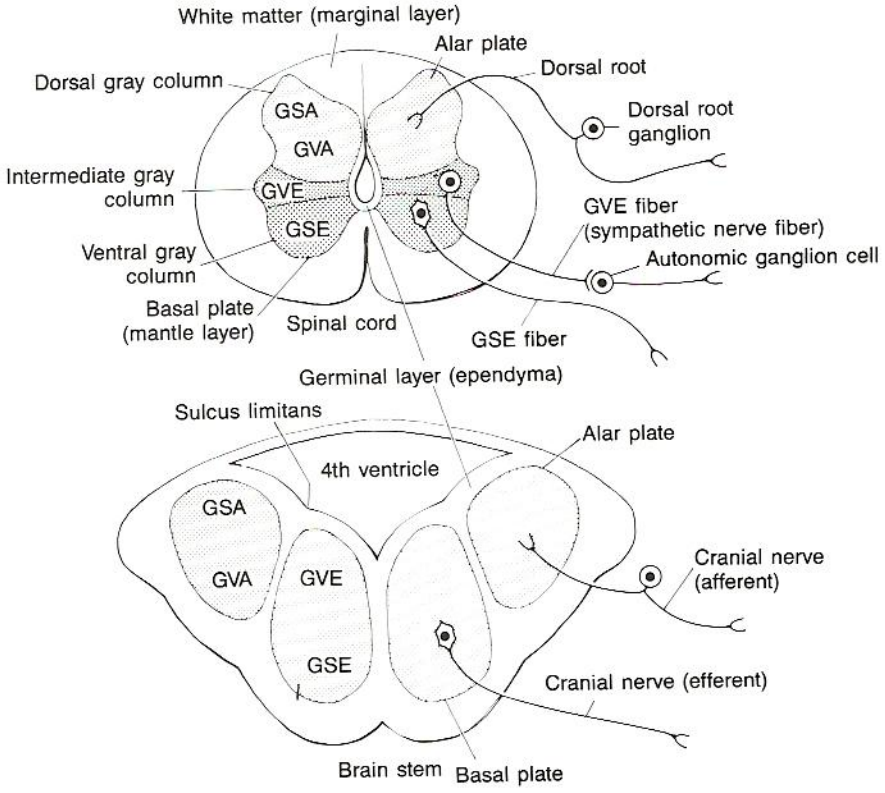

Figure 17-7. Relationships of the alar and basal plates in the spinal cord and brain stem. Refer to text for an explanation of the functional classification of components.

tube into two distinct anatomical and functional regions—the alar and basal plates (Fig. 17-6). The mantle layer of the dorsal plate (**alar plate**) is associated with sensory input into the CNS. The mantle layer of the ventral plate (**basal plate**) is associated with motor output from the CNS. Within the spinal cord these two plates assume the relationships described (Fig. 17-7). Within the brain stem, the relative positions of these two plates is maintained; however, the altered growth in this region accounts for the lateral position of the alar plate and the medial position of the basal plate (Fig. 17-7). The relative positions of the neuronal pools forming these plates or columns are maintained in the neural tube from the mesencephalon caudally into the spinal cord.

PHYSIOLOGICAL CONSIDERATIONS

Functional organization. The brief discussion of CNS development has indicated that the motor fibers exiting the CNS to innervate effector organs originate from the motor plate. These neurons contribute to the PNS. Similarly, neuronal process ingrowth from cranial and spinal ganglion cells contributes to both the PNS and the CNS. Many neuronal processes (axons), originating from afferent neuronal terminals (dendritic zones), are components of these systems. The classification of the nervous system on a purely anatomical basis deemphasizes the contribution that these systems make to each other. Functionally the neurons and their processes may be considered from **(1) the location of the dendritic zone, (2) the location of the axon telodendria,** and **(3) the type of information transmitted by the nerve fibers** (Table 17-1).

Efferent systems. Information carried over nerve trunks is either going to or exiting from the CNS. The **motor** or **efferent fibers** innervate the body effectors. Their dendritic zones and cell bodies are located in the spinal cord and brain stem gray matter (basal plate). Their axonal processes form the cranial, spinal, and splanchnic nerves.

Those neurons with axon telodendria distributed generally throughout the body to the skeletal muscle mass comprise the **general somatic efferent (GSE) system.** They are called **lower motor neurons,** the **final common pathway,** or **α-motor neurons.**

Those neurons with axon telodendria distributed generally to cardiac and smooth muscle and glands comprise the **general visceral efferent (GVE) system.** They are the efferent limb of the autonomic nervous system and are a **two-neuron system.**

The embryological origin of skeletal muscles within the branchial arches provides a special designation for the nerve fibers innervating them. These muscle fibers are associated with visceral functions, and their innervating neurons constitute the **special visceral efferent (SVE) system.**

Afferent system. **Sensory** or **afferent fibers** arise from dendritic zones scattered throughout the body. They carry information to the brain and spinal cord and contribute to the alar plate. Their cell bodies, dendritic zones, and some axons comprise the PNS. These fibers contribute to the cranial, spinal, and splanchnic nerves. Their telodendria are located in the CNS.

Those neurons with the dendritic zones scattered throughout the body

Table 17-1. Functional Organization of the Cranial and Spinal Nerves

	Information Carried	Location of Telodendritic and Dendritic Zones	Nerves involved*
Efferent			
GSE	Contraction	Skeletal muscle	III, IV, VI, XII, all spinal nerves
GVE	Contraction, secretion	Smooth and cardiac muscle and glands	III, VII, IX, X, XI, all spinal nerves
SVE	Contraction	Branchial arch skeletal muscle	V, VII, IX, X, XI
Afferent			
GSA	Pain, touch, temperature, general proprioception	Somatopleure derivatives	V, VII, IX, X, all spinal nerves
SSA	Optic, auditory, vestibular	Retina, membranous labyrinth	I, VIII
GVA	Mechanical, chemical	Splanchnopleure derivatives	VII, IX, X
SVA	Taste, smell	Tongue, olfactory mucosa	VII, IX, X, I

*Roman numerals refer to cranial nerves.

GSE, General somatic efferent; *GVE*, general visceral efferent; *SVE*, somatic visceral efferent; *GSA*, general somatic afferent; *SSA*, special somatic afferent; *GVA*, general visceral afferent; *SVA*, special visceral afferent.

generally and responding to external stimulation by pain, touch, and temperature form the **general somatic afferent (GSA) system. General proprioception (GP)** arises from neurons whose dendritic zones are located in muscles, tendons, and joint capsules. They respond to changes in tension and length and add valuable (conscious and unconscious) information about body position and the relative positions of body parts. The GSA system is considered by some authors to include the GP system. All cranial nerves with GSE and SVE probably transmit GP information.

The dendritic zones of neurons integral to the eye and ear constitute the **special somatic afferent (SSA) system.** Vestibular functions of the ear comprise **special proprioception (SP)** and are considered part of the SSA system by some authors. The SSA system provides information about the organism's relationship to the environment.

Those neurons whose dendritic zones are located in the walls of the visceral organs constitute the **general visceral afferent (GVA) system.** They respond to mechanical and chemical alterations within and/or associated with these organs.

Some organs are modified for the perception of **special visceral afferent information—olfactory and gustatory sensations.**

Reflex Arc

Any activity (movement of a limb, secretion of glands, increased heart rate, pupillary constriction) in response to a stimulus requires an afferent-to-efferent pathway linkage. The involuntary activity resulting from this is called a **reflex.** The afferent and efferent limbs, and the interneurons that may contribute, form the **reflex arc.** The reflex is a short-term, stereotypical response serving the organism's immediate needs.

Monosynaptic and polysynaptic reflexes. Reflexes are not uniform events. Anatomically they may vary from **monosynaptic** (involving only two neurons) to **polysynaptic** (involving more than two neurons). Reflex motor activity does not occur as an event isolated from the rest of the nervous system but (invariably) involves segmental, intersegmental, and suprasegmental contributions.

The **monosynaptic reflex** or **stretch reflex** is the simplest neuronal arrangement in a reflex arc (Fig. 17-8). A pseudounipolar neuron with its cell body located in the **dorsal root ganglion** has its axon in a stretch receptor receiving GP information. Its axon is part of the **spinal nerve** and **dorsal root** and extends into the **dorsal gray column** of the spinal cord. The axon telodendrion synapses with the dendritic zone of neurons located in the **ventral gray column.** Upon sufficient stimulation, excitatory postsynaptic potentials (EPSP) result in an action potential in these **α-motor neurons.** Their axons exit the spinal column, form the **ventral root,** and continue in the **spinal nerve.** The telodendria of the GSE fibers innervate the skeletal muscle responsive to proprioceptive stimulation.

Inhibition is achieved by placing an **interneuron** in the circuit. Interneuron stimulation results in the generation of IPSPs in the α-motor neuron of the antagonistic muscle mass. That α-motor neuron becomes hyperpolarized, and the antagonistic muscle mass relaxes. At the same time branches from the proprioceptive fibers ascend the spinal cord to transmit GSA information to higher brain centers (cerebrum, cerebellum). Suprasegmental transmission is complemented by branches from the fibers ascending and descending to other spinal cord segments (intersegmental).

A **multisynaptic (polysynaptic) reflex** involves more than two neurons in the reflex arc (Fig. 17-8). The **withdrawal reflex** is a multisynaptic pathway. Excessive pressure applied to the interdigital region of a canine forelimb results in withdrawal (flexion) of the forelimb. The GSA information is transmitted as described previously; however, an additional neuron is

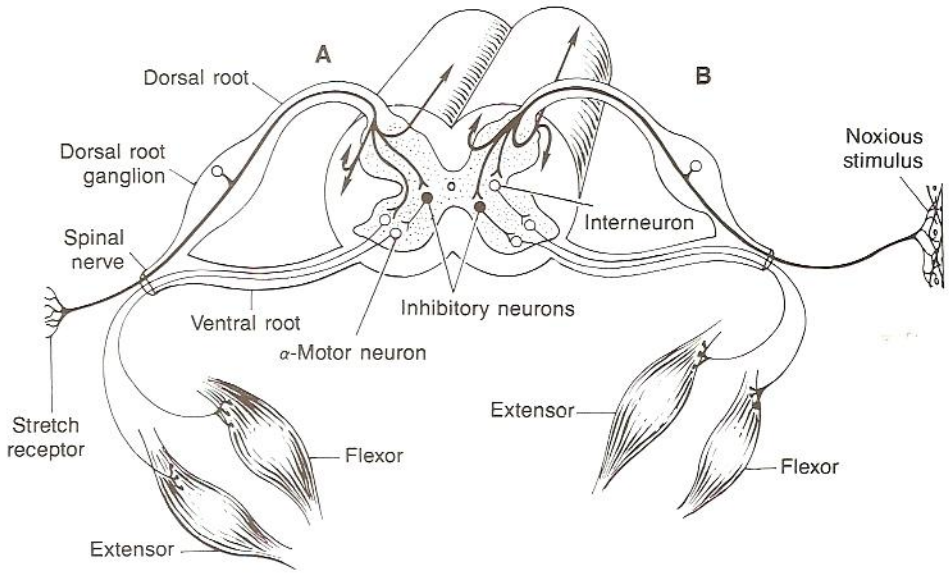

Figure 17-8. Stretch reflex, **A,** and withdrawal reflex, **B.** The stretch reflex is monosynaptic; the axon telodendrion of the afferent neuron synapses with the α-motor neuron to the extensors. The withdrawal reflex is multisynaptic; the axon telodendrion of the afferent fiber synapses with an interneuron. The interneuron synapses with the α-motor neuron to the flexors.

Downloaded From Vet-eBooks.com

added to the circuit. The excitation of the α-motor neurons innervating the flexors must be complemented by extensor inhibition. Segmental, intersegmental, and suprasegmental relationships also pertain. The withdrawal and myotatic reflexes demonstrate **reciprocal innervation.** Excitation of specific flexors requires inhibition of antagonistic extensors. The converse is also true.

Cranial nerve reflex patterns. Multisynaptic reflex activity occurs with the cranial and visceral nerves. The reflexes associated with cranial nerves follow the same basic pattern but may involve more than one nerve. One cranial nerve may serve as the afferent limb, and another as the efferent limb. Naturally they are connected by interneurons. Although the spatial arrangement of cranial nerve reflexes is different from that of spinal nerve reflexes, they are logical if you keep in mind the relationships between the alar (sensory) plate and the basal (motor) plate.

The V-VII reflex arc is an example of such a relationship. Noxious stimuli to the head (cornea, palpebra, muzzle) are transmitted as GSA information to the sensory region of the trigeminal nerve (V). An interneuron connects this region to the motor nucleus of the facial nerve (VII). The GSE fibers of VII innervate the skeletal muscles responsible for the response (squint, blink, menace).

Figure 17-9. Cells of a dorsal root ganglion. The neurons *(N)* are surrounded by amphicytes *(solid arrows)*. Note the axon hillock of one neuron *(open arrow)*. (×63, iron hematoxylin.)

PERIPHERAL ORGANIZATIONAL COMPONENTS

Sensory Ganglia

Nerve cell body accumulations outside the CNS are called **ganglia.** (Accumulations within the CNS are **nuclei.**) Ganglia are either **craniospinal (sensory)** or **autonomic (motor).** The craniospinal ganglia are **cranial ganglia** of the cranial nerves and **dorsal root ganglia** of the spinal nerves. The autonomic ganglia are **paravertebral** and **prevertebral** within the sympathetic nervous system. Parasympathetic ganglia are **terminal ganglia.** They may be close to, upon, or within organ walls. Those within the walls of organs are **intramural ganglia.**

Ganglia vary in size. They are surrounded by a capsule whose fine collagenous and reticular fibers extend into the organ. Blood vessels, axons, dendrites, peripheral neuroglia, and nerve cell bodies are enmeshed within the supportive framework. Amphicytes are intimately associated with the nerve cell bodies.

Craniospinal ganglia. The ganglion cells (pseudounipolar neurons) of spinal nerves are located in **dorsal root ganglia** and are components of all sensory nerves (probably including all cranial nerves). The ganglion cells of the optic nerve are located in the retina. Those of the remaining cranial nerves (I, V, and VII to XI) are patterned after the dorsal root ganglia. (The ganglion cells of cranial nerve VIII are bipolar neurons.)

The **dorsal root ganglia,** as representative craniospinal ganglia, are encapsulated, globular structures (Plate II, *11*). Each neuron is surrounded by amphicytes (Figs. 14-11 and 17-9). These flattened or cuboidal cells intimately contact the perikarya and often indent the cell bodies, continuing with the neurolemmal sheath of the axon. Axons comprise the rest of the organ.

Motor Ganglia

Sympathetic and parasympathetic ganglia. The **sympathetic ganglia** and multipolar neurons comprising them are smaller than the dorsal root ganglia and their constituent cells. Nerve fibers are scattered diffusely throughout them. **Parasympathetic ganglia** are similar to sympathetic ganglia. **Intramural ganglia** are not as structured as either of these (Fig. 17-10). Parasympathetic ganglia have few multipolar neuronal cell bodies and processes. In most instances their perikarya are devoid of amphicytes; however, fibroblasts may replace the amphicytes. They, too, are motor ganglia.

Neuronal Processes

Nerve trunks

Peripheral neuronal processes are organized into nerve trunks of varying size following the pattern described for the organization of solid organs (Fig. 17-11).

Spinal nerves. The nerve trunks or nerves are aggregations of axons connecting the brain, brain stem , and spinal cord to peripheral dendritic zones or axon telodendria. The **spinal nerves,** formed by the dorsal and ventral roots contain afferent and efferent fibers (Table 17-1). All spinal nerves contain GSA, GSE, and GVE components. The **visceral nerves,** which supply the thoracic, abdominal, and pelvic cavities, are similar to the spinal nerves. They consist of GVA and GVE components.

Cranial nerves. The cranial nerves are organized in different patterns. Dorsal and ventral roots are not apparent. The nerves consist of trunks that are sensory only (I, II, and VIII), motor only (III, IV, VI, and XII), or sensory and motor (V, VII, IX, X, and XI). The mixed (sensory and motor) cranial nerves are similar to the spinal nerves. The sensory cranial nerves deviate slightly from the basic pattern. The olfactory (I), optic (II), and vestibulocochlear (VIII) nerves consist of

Downloaded from VetBooks.com

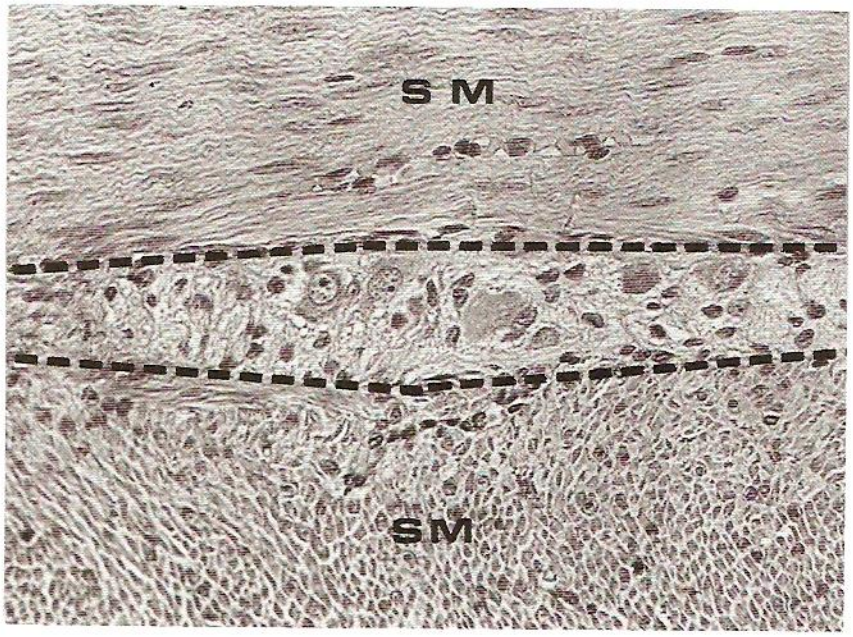

Figure 17-10. Intramural ganglion from a myenteric plexus. *Dashed lines* mark the approximate limits of the ganglion, which is interdigitated between two masses of smooth muscle *(SM)* of the tunica muscularis. (×100.)

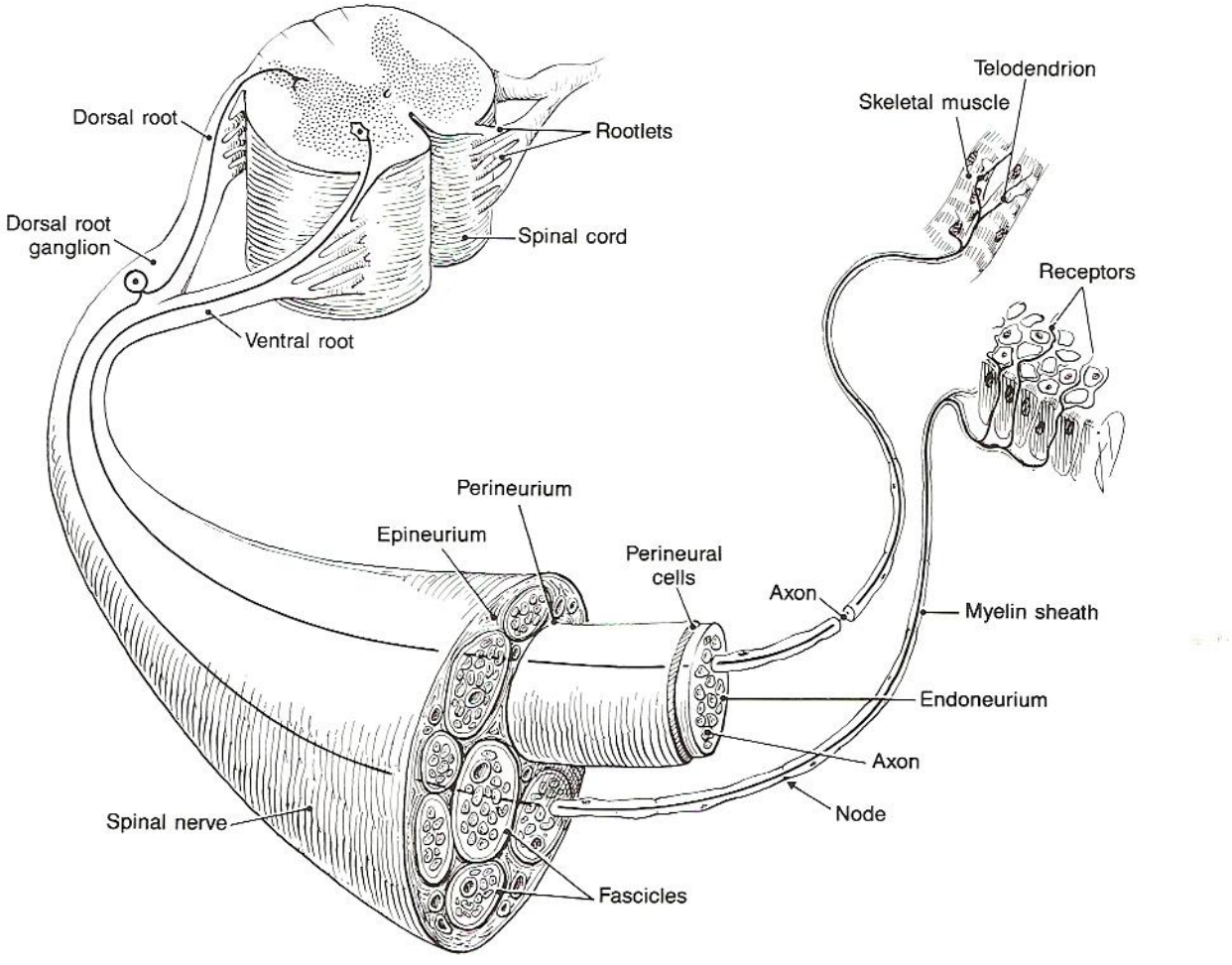

Figure 17-11. Investments of a spinal nerve and its relationship to the CNS. Spinal nerves are mixed nerves; their axons carry both sensory and motor information.

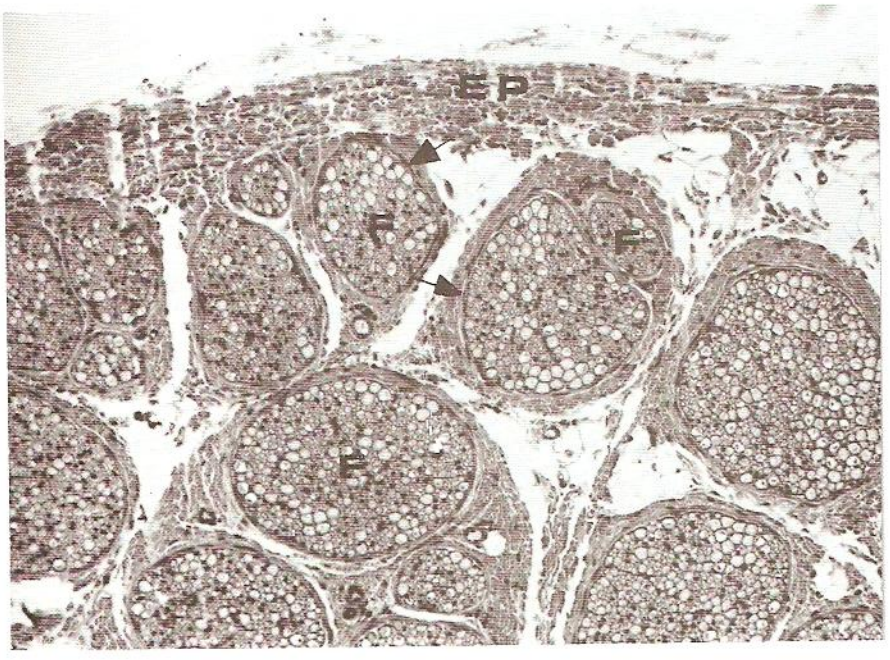

Figure 17-12. Organization of a nerve trunk. The epineurium *(EP)* covers all fascicles *(F)*. Individual fascicles are surrounded by the perineurium. *Solid arrows* indicate the perineural cell sheath investing individual fascicles deep to the perineurium. (Compare with Fig. 17-15.) The endoneurium surrounds individual nerve cell processes. (×40.)

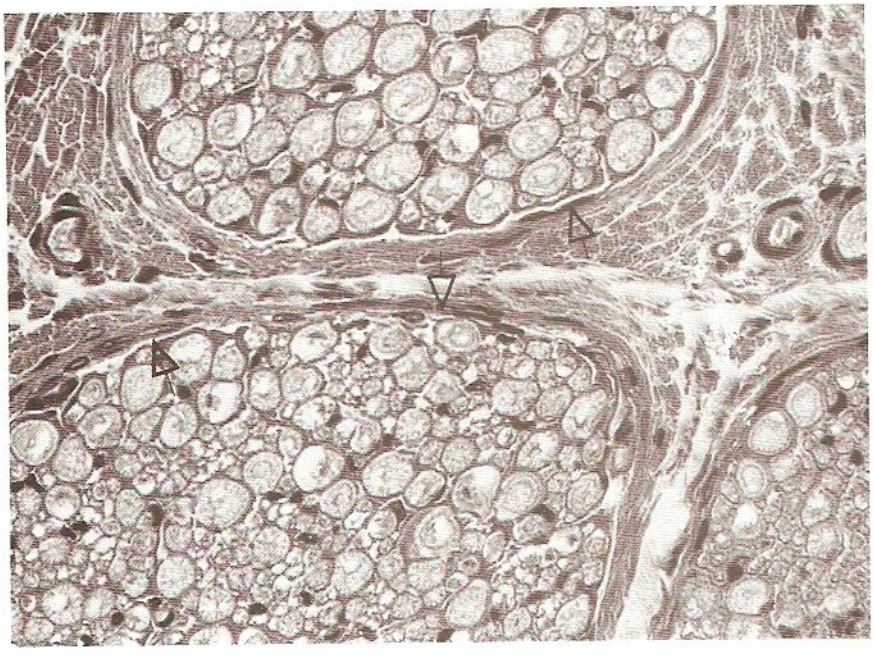

Figure 17-13. Section of a nerve and its investments. Layers of perineural cells *(arrows)* surround individual fascicles deep to the perineurium. (×160.)

axons of ganglion cells located in the olfactory bulbs, ganglionic layers of the retina, and vestibular and spiral ganglia, respectively. The motor cranial nerves are similar to the ventral roots and efferent fibers of spinal and visceral nerves. Their cell bodies are located within specific nuclei of the brain stem motor column.

Histological organization

Epineurium. Nerves consist of **fascicles** of neuronal fibers invested with connective tissue (Fig. 17-11). The outermost covering of nerves is the **epineurium** (Plate V, *7* and *9*, and Figs. 17-11 and 17-12). The epineurium, considered the capsule of these organs, consists of irregular dense collagenous tissue.

Perineurium. The **perineurium** is the moderately dense collagenous tissue investment of individual nerve fascicles. It contains 1 to 10 layers of cells (Figs. 17-12 to 17-14). As fascicles divide and become smaller, the perineurium becomes thinner.

Perineural cells form alternating cell layers between layers of collagenous and reticular fibers. They may be continuous with or derived from the leptomeninges. Although called fibroblasts, they are surrounded by basal laminae. At points of intimate contact, tight junctions are apparent. Based on these characteristics, perineurial cells are epithelioid.

Ultimately a single neuronal process is covered by a single layer of perineural cells. Capsules of afferent terminals may be formed by perineural cells; naked neuronal processes emerge from their single perineural cell investment at their terminations.

Endoneurium. The **endoneurium** is the loose collagenous tissue extending from the neurolemmal cell surface to the inner layer of perineural cells (Figs. 17-14 and 17-15). Fibroblasts in the endoneurium do not have a basal lamina associated with them. The endoneurium also contains many capillaries. As capillaries enter the endoneurium from the perineurium, they carry extensions of perineural cells with them.

Functional correlates. These investments provide support for delicate structures. The sheaths contribute to elasticity and preclude tearing during normal ranges of motion.

The perineurium and endoneurium help maintain a constant environment for neuronal processes. The perineuronal and endothelial cells of the endoneurial capillaries form an incomplete **blood/nerve barrier,** preventing certain substances from gaining entry to the endoneurium. Breaks exist at three sites—the terminations of neuronal processes where the perineurium ends, blood vessel entry sites into the endoneurium at the ends of the perineural cells, and the points at which collagen fibers perforate the perineurium.

Afferent terminals

The afferent terminals are transducers converting various modalities (pain, touch, warmth, pressure, etc.) into a form usable by the nervous system. Anatomical features establish whether they will be free and diffuse or encapsulated.

Free and diffuse endings. The **free and diffuse nerve endings** are most numerous. Although they occur primarily in the epidermis, they can also be seen in mucous and serous membranes, muscles, joints, and visceral connective tissue. The diffusely arborized fibers may be myeli-

Downloaded From TestBook.com

Figure 17-14. Transmission electron micrograph of the perineurium and endoneurium of a murine ischiatic nerve. Fibroblasts *(Fb)* and fibroblastic processes *(Fb)* alternate with layers of collagen *(Col)* in the perineurium. Note, however, that these fibroblasts are surrounded by a basal lamina *(B)*. Microfilaments among other typical organelles are visible within these cells. A neurolemmal cell *(SC)* within the endoneurium is covered by a basal lamina *(B)* whereas an endoneural *(En)* fibroblast *(Fb_1)* is not. Junctional complexes *(arrow)* also characterize the attachments of adjacent fibroblastic cells within a given cellular lamina. (Reprinted with permission from Peters A, Palay SL, Webster HF: *The fine structure of the nervous system: the neurons and supporting cells*, Philadelphia, 1976, WB Saunders.)

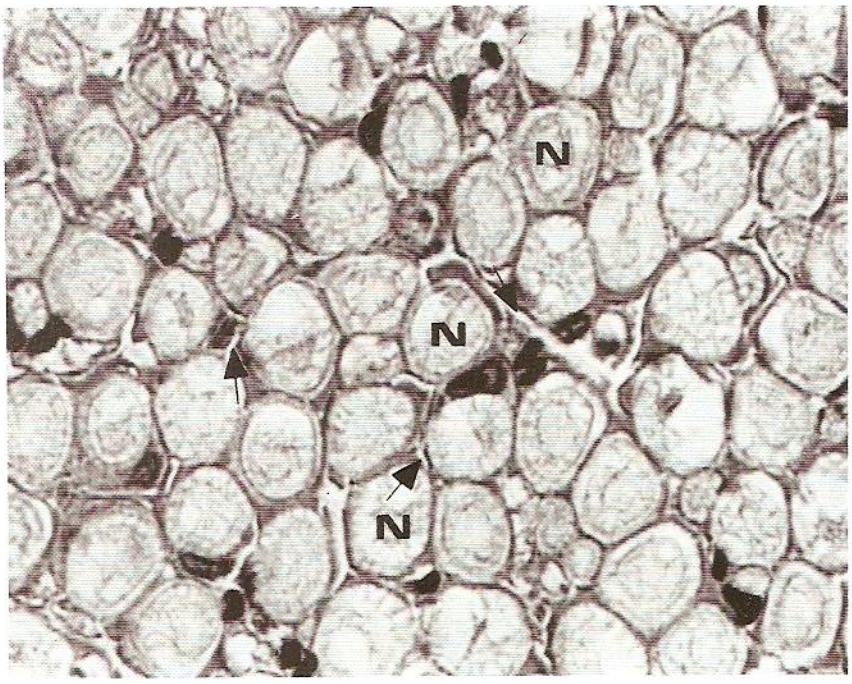

Figure 17-15. Section of a nerve and its investments. Individual nerve cell processes *(N)* are surrounded by the endoneurium *(arrows)*. Note the axons and neurokeratin of the altered myelin sheaths. (×320.)

nated or unmyelinated and may terminate as flattened or bulblike endings scattered among epithelial or connective tissue cells (Fig. 17-16). They are usually considered touch receptors.

Modified free nerve endings are associated with deep epidermal cells **(tactile epithelioid cells)**, and their terminal branches are flattened or disklike against these cells. They generally occur in hairless skin and receive stimulation that is pain associated.

Encapsulated endings. The **encapsulated receptors** may have slight to heavy encapsulation (Fig. 17-16).

Tactile corpuscles are numerous encapsulated receptors of hairless skin (Fig. 17-17) occurring in the dermal papillae of the soles and palms. The corpuscles are about 100 μm long and approximately 25 μm wide. They are slightly encapsulated and contain the terminals of one or more nerves arranged in a helix around a helical cell mass. They look like fir cones.

Krause's endbulbs are encapsulated, spherical receptors located in the skin and associated mucous membranes (especially the conjunctiva). Their neuronal terminal enters a granular mass within the capsule and terminates, either singly or in bundles, as a slightly expanded ending. This corpuscle is a cold temperature receptor.

Golgi-Mazzoni corpuscles are similar to but smaller and more thickly encapsulated than tactile corpuscles. They are believed to be pressure receptors of the connective tissue of hairless skin and associated mucous membranes. They also occur in the dermis of the glans penis, the digital pads of carnivores, and the connective tissue associated with the hoof.

Genital corpuscles are similar to and larger and more encapsulated than Golgi-Mazzoni corpuscles. They may also be lobulated. The number of neuronal processes entering the capsule varies from 1 to 10. They arborize and form a spiral, interlacing network of naked neuronal terminals. These corpuscles, occurring in the clitoris and glans penis, are pressure receptors.

Lamellated corpuscles are the largest encapsulated nerve endings (Fig. 17-16). They may be 3 to 4 mm long. A single axon enters the corpuscle and terminates in a bulb surrounded by granular material. Concentric layers of perineural cells, connective tissue cells, and capillaries impart an onionlike appearance (Fig. 17-18). The corpuscles are ubiquitous pressure receptors. They occur in the deep connective tissue, mesenteries, and serous membranes as well as in the connective tissue of visceral organs, muscle, tendons, and ligaments.

Herbst corpuscles are smaller versions of lamellated corpuscles that function as pressure receptors in the tongues and beaks of birds.

Ruffini corpuscles consist of neuronal process arborizations interlacing throughout a granular mass enclosed by a connective tissue capsule. They are probably heat receptors, but Ruffini-like receptors are associated with kinesthetic sensations.

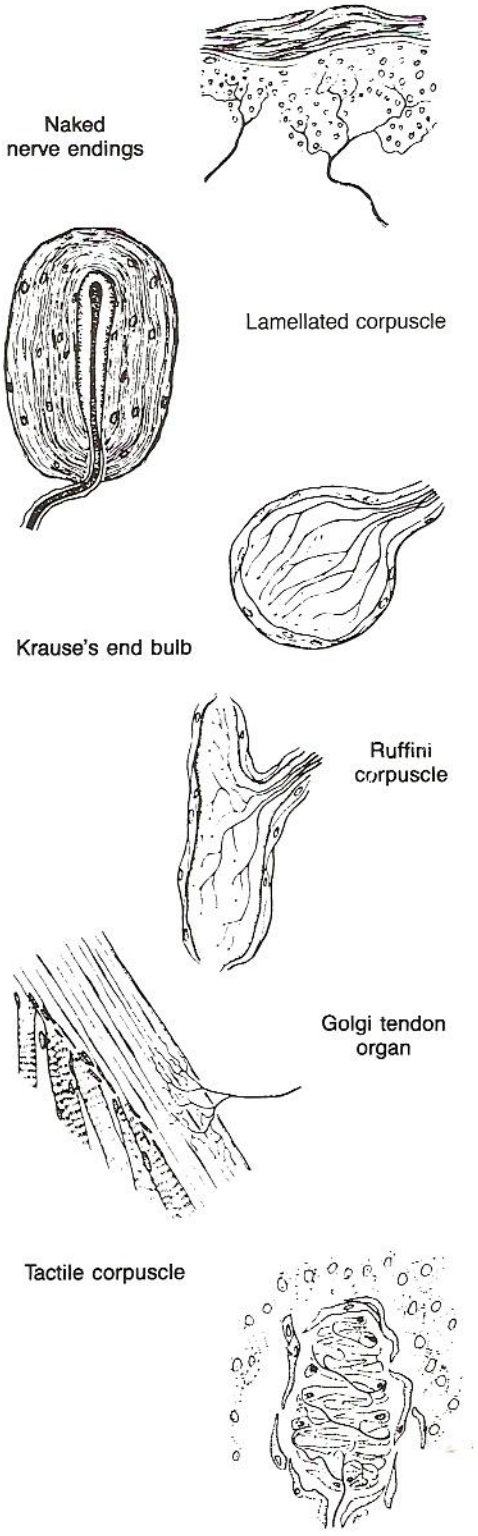

Figure 17-16. Various types of receptors.

Efferent terminals

Neuromuscular spindles and **Golgi tendon organs** were described previously.

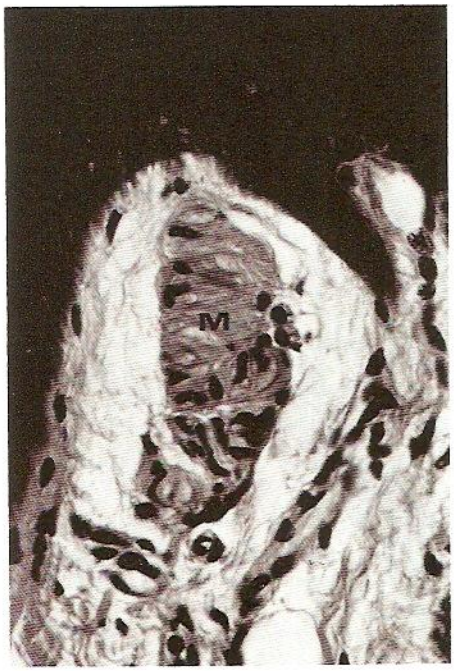

Figure 17-17. Section of the skin. A tactile corpuscle *(M)* is surrounded by dermis. (×117.)

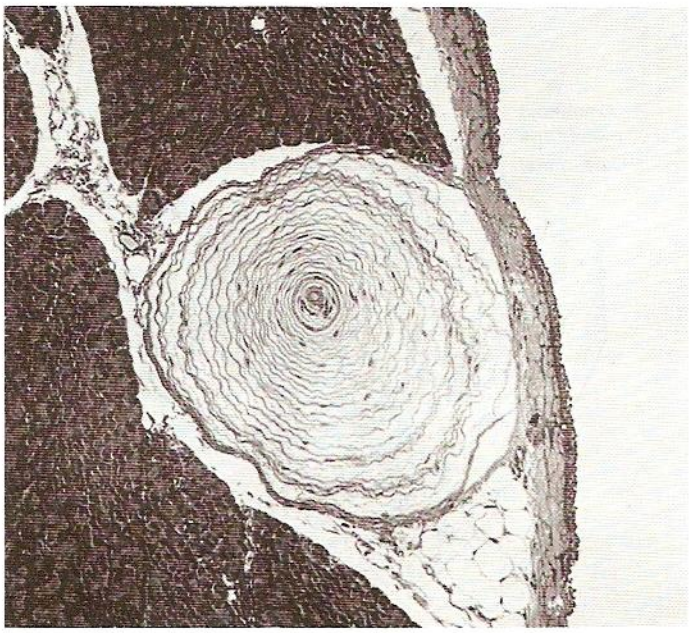

Figure 17-18. Cross section of a lamellated corpuscle in the connective tissue of a feline pancreas. The concentric layers impart an onionlike appearance. (×25.)

CENTRAL ORGANIZATIONAL COMPONENTS

Meninges

The CNS is protected by its placement within the bones of the skull and spinal column. Additional protection is afforded by its association with fibrous connective tissue (Fig. 17-19). These tissues are disposed as three fibrous membranes totally enclosing the system—dura mater, arachnoidea, and pia mater. The dura mater is also called the **pachymeninx;** the arachnoid and pia mater are called the **leptomeninges.** These membranes are associated with **cerebrospinal fluid (CSF)** and the CNS vascular supply.

Pachymeninx

The **dura mater** is a tough fibrous covering of the brain and spinal cord consisting of collagen, some elastic fibers, and blood vessels (Fig. 17-20). It consists of an **outer layer** (the fibrous periosteum of the inner surface of cranial bones, which contains many blood vessels associated with the cranial bones) and an **inner poorly vascularized layer** (blending insensibly with the outer or periosteal layer). These layers are distinct in specific regions, where they separate and form the **dural sinuses.** The dural sinuses collect cerebrospinal fluid and return it to the vascular system. The dura is separated from the arachnoid by a potential **subdural space.**

The spinal cord dura mater is a single layer **(meningeal dura)** separated from the vertebral periosteum by the **epidural space** (Fig. 17-21), which contains loose collagenous tissue, adipose tissue, veins, and venous sinuses. The epidural space is used for the administration of some anesthetics **(epidural anesthesia).**

Leptomeninges

Arachnoidea. The **arachnoidea** is a distinct fibrous membrane with many fibrous trabeculae on its inner surface (Fig. 17-22). Both the membrane and its trabeculae consist of fine collagen fibers and elastic fibers. The extensive trabecular network extends to the pia mater and forms the supportive framework for the **subarachnoid space.** This space, occupied by CSF, contains blood vessels scattered on the floor in the pia mater. Protrusions of component tissues from it extend through the inner layer of the dura mater and form **arachnoid granulations** projecting into the dural sinuses. CSF from the subarachnoid space is returned to the blood vascular system through these projections.

Pia mater. The **pia mater** is the innermost protective membrane of the brain and spinal cord (Figs. 17-20 and 17-22), extending into the many depressions and fissures of those organs. It consists of fine collagen and elastic fibers and small vessels. Covered by a continuous membrane of fibroblasts, it nevertheless allows the entry of blood vessels along with some connective tissue.

Cerebrospinal Fluid

Choroid plexus

Histological organization. The ependymal lining of the brain's ventricular system and the spinal cord's central canal is retained in adults. In specific areas (roof and walls of the ventricles) the ependyma is associated with the vascular pia mater. Usually the pia mater is separated from the ependyma by many neurons and neuroglia. Juxtaposition of pia mater and ependyma occurs in regions where neurons and neuroglia do not develop.

The juxtaposition of pia mater (with its blood vessels and connective tissue) and ependyma forms the **choroid plexus** (Fig. 17-23). The choroid plexus has three distinct components—ependyma, tela choroidea, and a vascular (choroid) plexus (Fig. 17-24). The **ependyma** is a thin layer of epithelial cells, **lamina epithelialis,** lining the ventricular space associated with the peripherally positioned pia mater (Fig. 17-25). The cuboidal or columnar cells of this lamina have well-developed brush borders and are joined along their lateral margins by tight junctions (Fig. 17-26). The **tela choroidea** is a thin, weblike connective tissue layer. The **vascular plexus,** contained within the delicate tissue, projects into the ventricular system as extensive folds (villi).

Dynamic relationships

General features. The CSF, a clear colorless fluid produced by the choroid plexus, fills the brain's ventricular system

Downloaded From Vet-eBooks.com

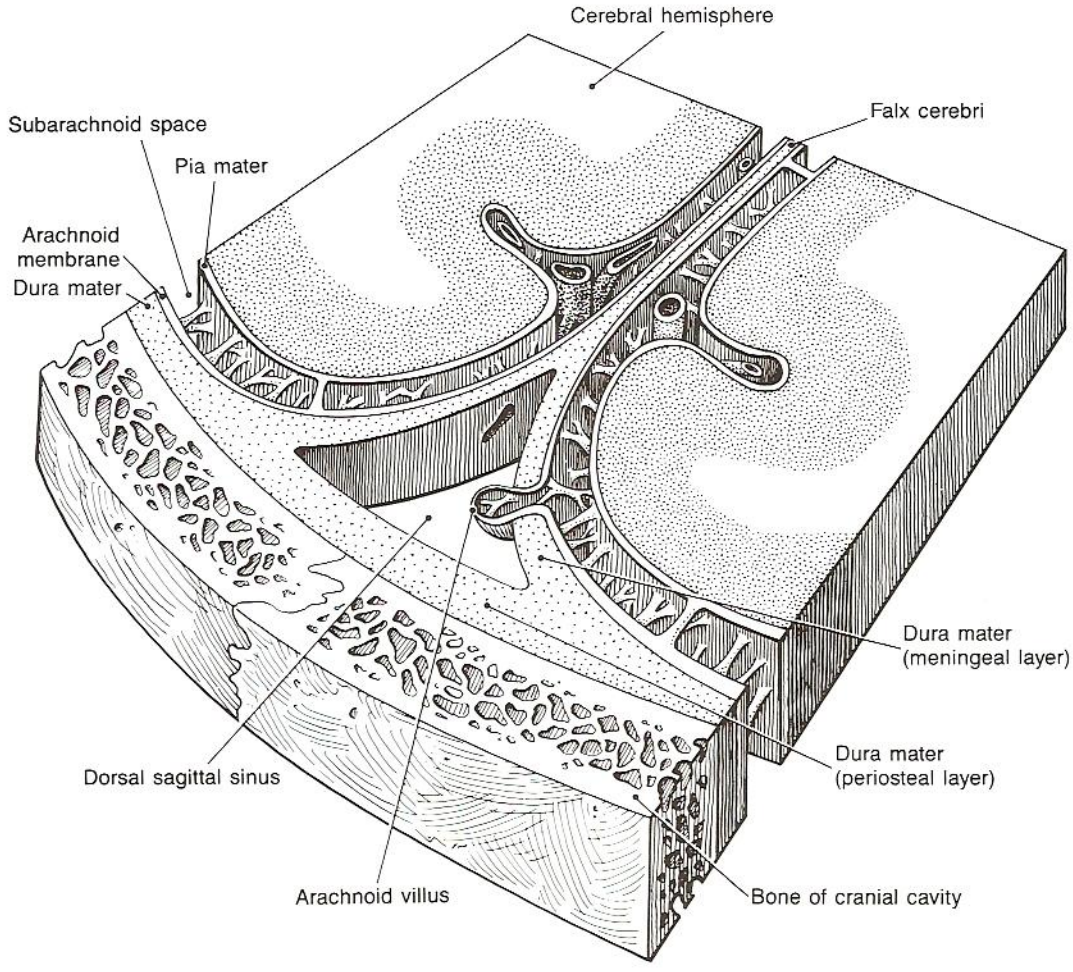

Figure 17-19. Relationships of the cranial meninges in cross section. Separation of the two layers of dura mater forms the dorsal sagittal sinus and falx cerebri.



Figure 17-20. Scanning electron micrograph of the meninges of the spinal cord of a young dog. *DM*, Dura mater; *A*, arachnoidea; *SS*, subarachnoid space; *PM*, pia mater: *arrows*, arachnoid trabeculations. (Reprinted with permission from Peters A, Palay SL, Webster HF: *The fine structure of the nervous system: the neurons and supporting cells*, Philadelphia, 1976, WB Saunders.)

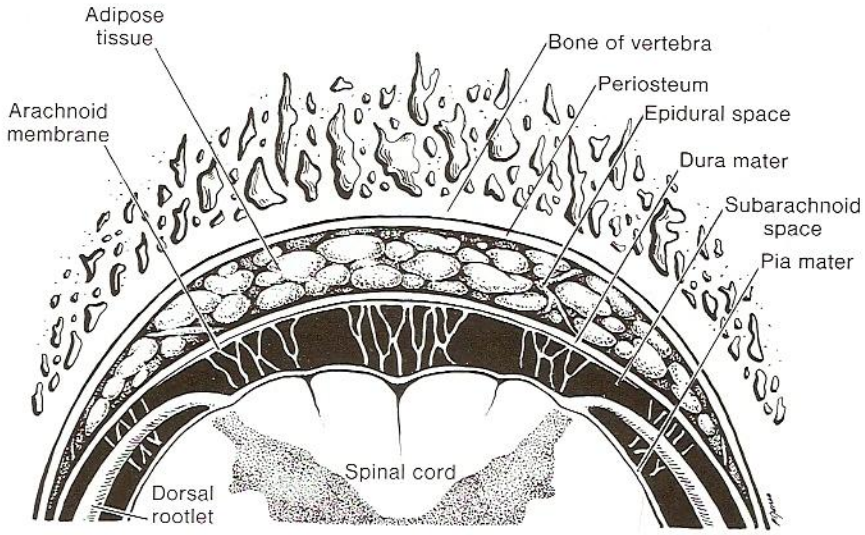

Figure 17-21. Relationships of the spinal meninges in cross section. The dura mater of the spinal cord is separated from the periosteum by the epidural space.

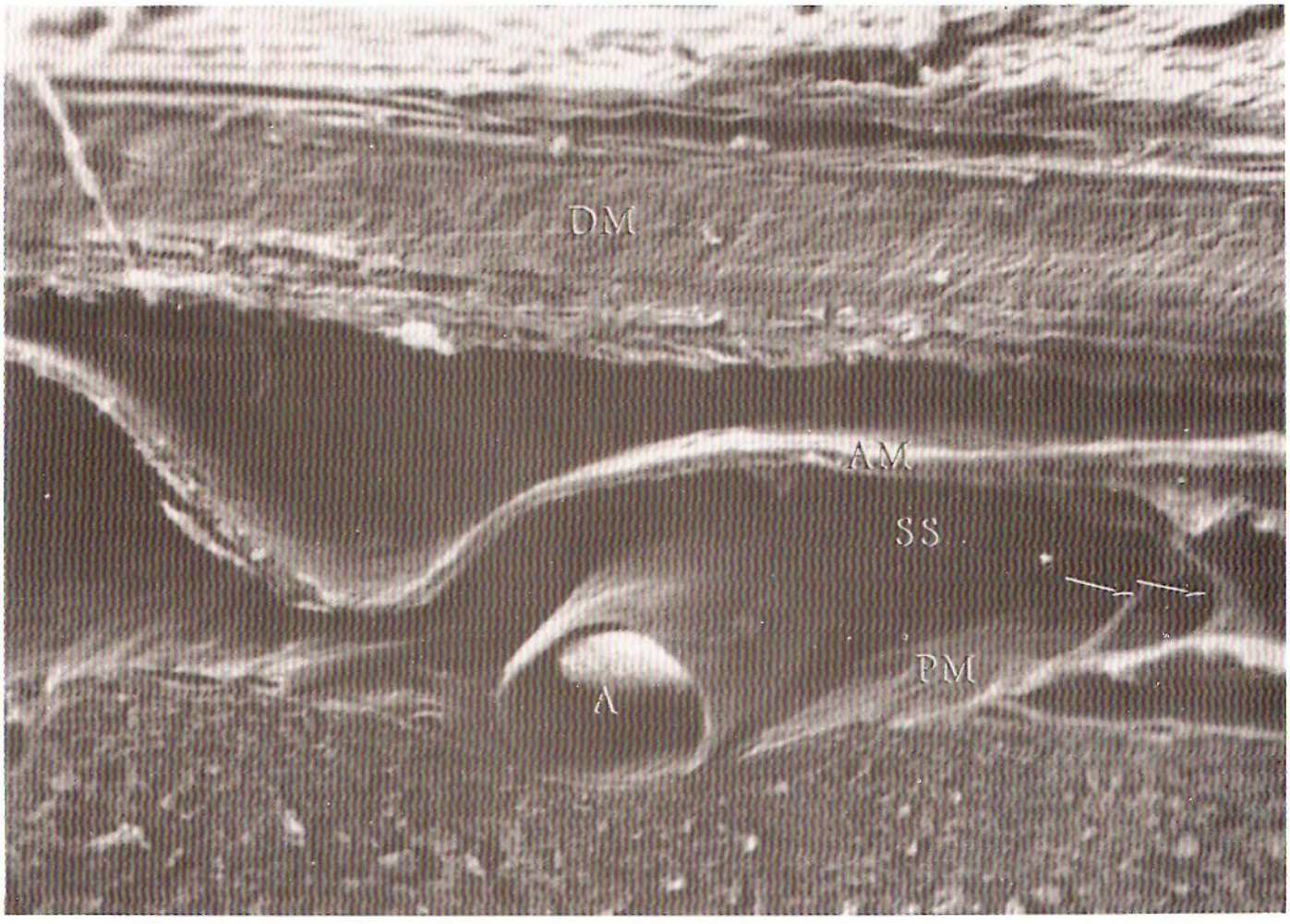

Figure 17-22. Scanning electron micrograph of the meninges of the cerebral hemisphere of a young dog. *DM*, Dura mater; *AM*, arachnoid membrane; *SS*, subarachnoid space; *A*, arachnoidea; *PM*, pia mater; *SS*, subarachnoid space; *arrows*, subarachnoid trabeculations. A "subdural space" is an artifact of preparation. (Reprinted with permission from Peters A, Palay SL, Webster HF: *The fine structure of the nervous system: the neurons and supporting cells*, Philadelphia, 1976, WB Saunders.)

Downloaded From Vet-eBooks.com

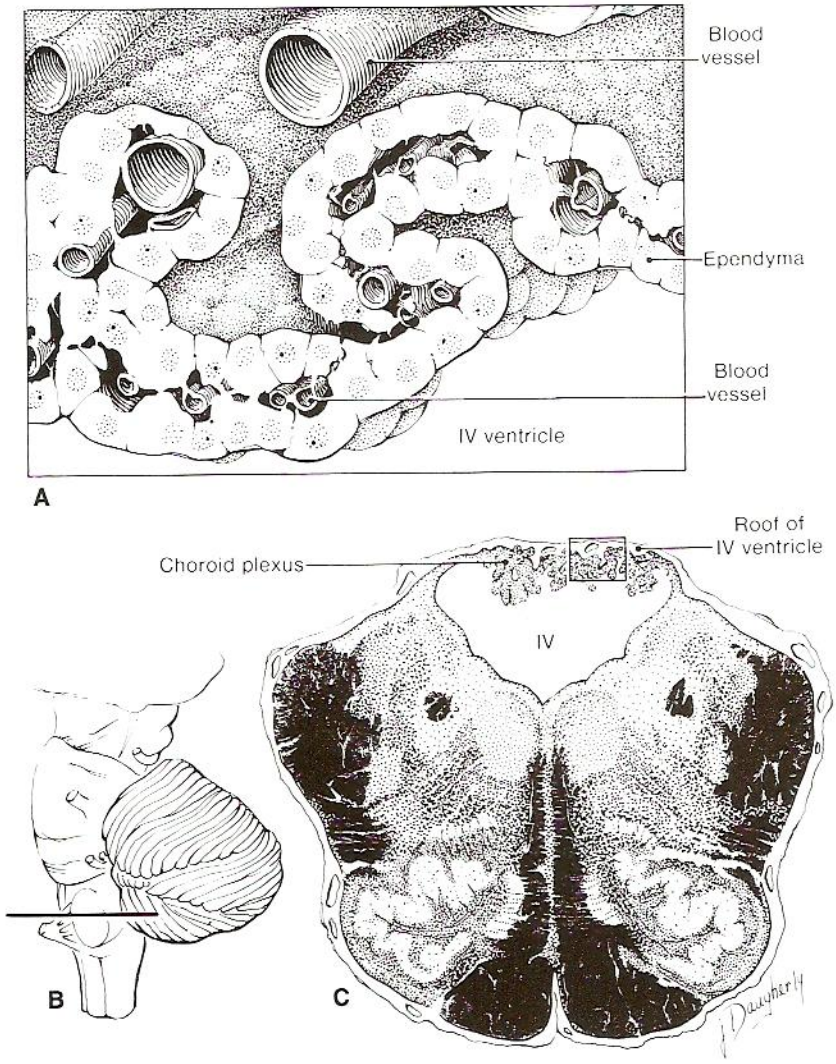

Figure 17-23. Choroid plexus and its relationship to the fourth ventricle. **A,** Artist's interpretation of a scanning electron micrograph. **B,** Human midbrain and cerebellum. **C,** Level of the horizontal line in **B.**

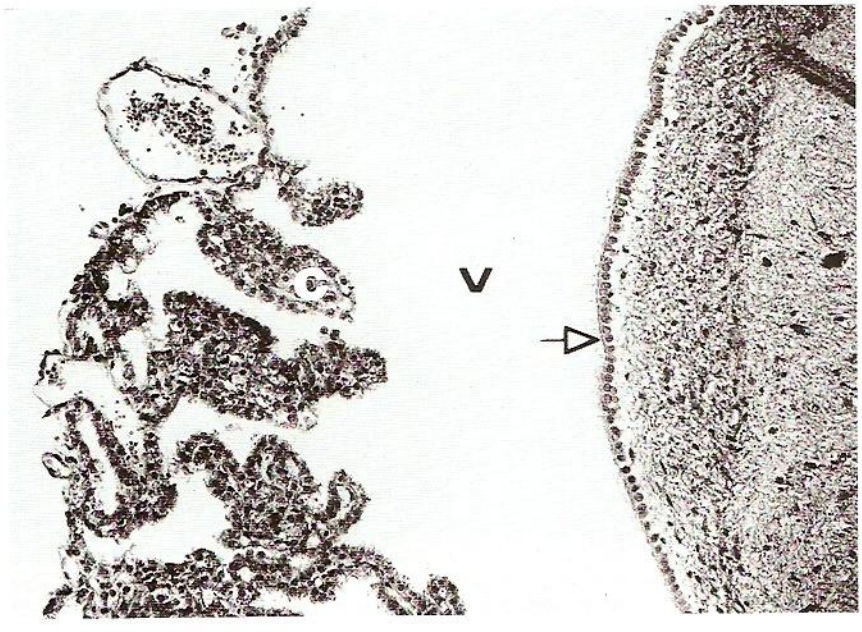

Figure 17-24. The choroid plexus *(C)* is suspended from the roof of the fourth ventricle *(V).* Ependymal cells *(arrow)* covering the nervous tissue of the brain stem adjacent to the fourth ventricle are integral components. (×40.)

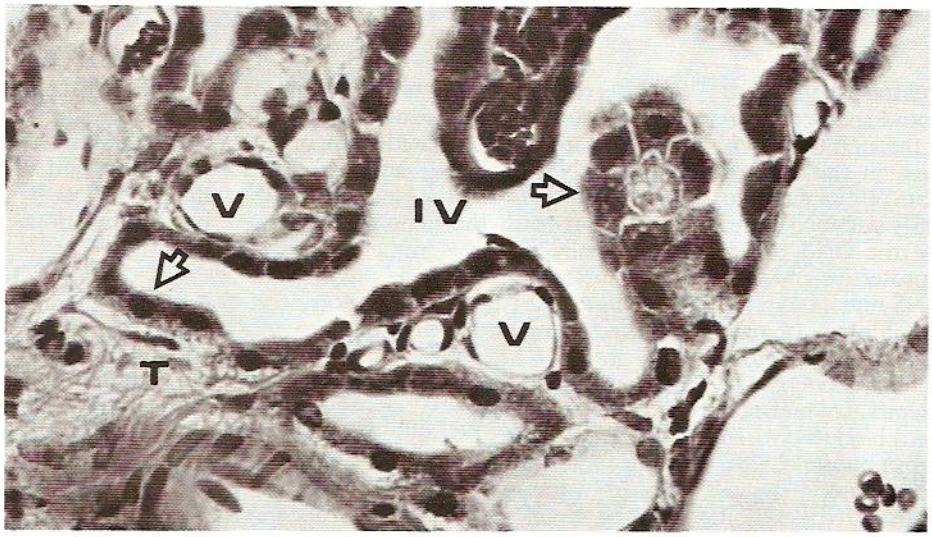

Figure 17-25. Components of the choroid plexus of the fourth ventricle *(IV)*. The ependymal cells *(arrows)* are associated intimately with vessels *(V)* of the choroid plexus. Connective tissue components of the tela choroidea *(T)* are evident. (×125.)

Figure 17-26. Transmission electron micrograph of the choroid plexus of a murine lateral ventricle. *mit,* Mitochondria; *Ly,* lysosome; *G,* Golgi complex; *Nuc,* nucleus; *ER,* endoplasmic reticulum; *mv,* microvilli. Junctional complexes *(J)* and many interdigitated foldings characterize the cellular interfaces *(arrow)*. A basal lamina *(B)* and connective tissue space with cell processes *(x)* separate the lining cells from the capillary *(Cap)* endothelium *(End)*. (Reprinted with permission from Peters A, Palay SL, Webster HF: *The fine structure of the nervous system: the neurons and supporting cells,* Philadelphia, 1976, WB Saunders.

Downloaded From UptoBooks.com

and the spinal cord's central canal. It also occupies the subarachnoid space, in continuity with this space through two laterally positioned foramina in the roof of the fourth ventricle. It is not confined to these spaces, however, but penetrates into and permeates all the CNS tissue, serving as a hydraulic protective and supportive medium for CNS nutrition.

As much as 40% of CSF may be produced at sites other than the choroid plexus—the ependymal lining cells of the ventricular system, the leptomeninges, and the brain and spinal cord blood vessels.

Formation of cerebrospinal fluid. CSF is produced as an **ultrafiltrate** or **dialysate** of the blood and through **active secretion** by ependymal cells. The principles of tissue fluid formation apply generally to its formation. Although CSF normally is formed at a constant rate, its production rate is independent of blood hydrostatic pressure, being instead influenced by vascular colloid osmotic pressure. The selective permeability and active secretion of ependymal cells account for significant differences between CSF and tissue fluid. The CSF contains less Ca^{++}, K^{+}, glucose, and protein and more Mg^{++}, Na^{+}, and Cl^{-} than tissue fluid.

Circulation of the cerebrospinal fluid. The bulk of CSF is produced by the plexuses of the lateral ventricles. The fluid flows into the third ventricle through the lateral ventricular foramina, and additional fluid is added by the choroid plexus of the third ventricle. It continues its flow caudad through the cerebral aqueduct into the fourth ventricle, where more fluid is added by the choroid plexus of that ventricle. Although some CSF continues caudad into the central canal of the spinal cord, this flow pattern is not dynamic.

CSF enters the subarachnoid space via foramina in the fourth ventricle roof, where it contacts and bathes all aspects of the brain and spinal cord. It returns to the vasculature by passing through **arachnoid granulations** projecting into the **dural venous sinuses.** The arachnoid villi function as pressure-dependent, unidirectional flow valves. Excessive pressure in the dural sinuses can collapse the granulations and shut down the return of CSF, but production continues normally. Impediments to proper circulation of CSF cause **hydrocephalus.**

Functions of cerebrospinal fluid. CSF helps maintain a constant extracellular environment. The fluid, bathing all cells, is in dynamic equilibrium with the extracellular fluid. The specific gravity of CSF provides CNS hydrostatic cushioning. The weight of the brain in CSF is reduced to about one third of what it would be in air.

The free movement of CSF into the extracellular environment means that this fluid serves as a transport medium for various substances. Because lymphatic channels are not associated with organs of the CNS, the CSF and associated spaces may perform this function. Substances can reach the brain through the CSF. Finally, receptors in the fourth ventricle are responsive to H^{+} concentrations in CSF. The fluid, therefore, contributes to respiratory function.

Brain-Associated Barriers

Blood/cerebrospinal fluid barrier

The unique composition of CSF results from the high degree of regulation imposed upon its formation. The anatomical interface between blood and CSF consists of various components from without inward—diaphragmed and fenestrated capillary endothelium, basal lamina, delicate connective tissue, basal lamina, and ependymal cells. These form the **blood/CSF barrier** (Fig. 17-27). A minimal barrier is formed by the juxtaposition of endothelial cells and ependymal cells and the fusion of their basal laminae. Perforations in the capillary endothelial cells imply that there is a restricted movement of tissue fluid into the tela choroidea; therefore the ependyma probably performs a barrier function.

The movement of CSF into the nervous tissue and the equilibrium of CSF and extracellular fluid maintain the proper environment for neuron function. The movement of materials between these spaces is selective, but selectivity is not the exclusive domain of the interfacing anatomical components. Transport relates to structural and functional properties of endothelial cells, ependymal cells, and the materials being transported.

Blood/brain barrier

Blood vessels within the subarachnoid space are bathed by CSF and separated from the neural tissue by the pia mater (Fig. 17-27). As large blood vessels penetrate the neural tissue, they are separated from the pia mater by a pericapillary space. This perivascular space becomes smaller and is obliterated when the capillaries are juxtaposed to neuroglial cells (astrocytes) forming the **outer glial limitans.** Juxtaposition of neuroglial cells between capillary beds and neurons provides the anatomical basis for a blood-neuron interface. The astrocytes have footlike processes intimately associated with the basal lamina of endothelial cells. Despite this morphology, neurons and neuroglia are bathed continuously by the CSF (Fig. 17-27). Also some materials move readily from the capillary bed between neuroglial cells and gain access to the neurons. **The blood/brain barrier is formed by the endothelial cells of the brain capillaries.**

Endothelial tight junctions, glial foot processes, specialized transport systems within endothelial cells (carrier-mediated transport), and the specific properties of the substances being transported impart barrier functions to these endothelial cells.

Specific Organs

Spinal cord

Spinal cord morphology varies at the cervical, thoracic, lumbar, and sacral levels. The following pattern, however, is similar at all levels.

The cord is round to oval and surrounded by meninges (Fig. 17-28). It is divided into two distinct regions, gray matter and white matter.

The **gray matter,** arranged in an H or butterfly pattern, consists of nerve cell bodies, unmyelinated fibers, some myelinated fibers, protoplasmic astrocytes, oligodendrogliocytes, microgliocytes, and blood vessels with fine perivascular connective tissue fibers. Although neurons are present throughout the gray matter, they are especially distinct in the **ventral columns.** The large multipolar neurons of the columns (α-motor neurons) give rise to axons carrying information to skeletal muscle. Medium-sized neurons, located in the **lateral columns** of the throacolumbar segments, give rise to axons connecting with autonomic ganglia. Small neurons characterize the **dorsal columns.** Their axons project up and down the spinal cord. The spinal canal (lined by ependyma) is contained within the **central intermediate substance** or **gray commissure.**

The **white matter** has myelinated and unmyelinated fibers, scattered neuroglial elements, and blood vessels. A **dorsal funiculus** occupies the region between dorsal columns; a **lateral funiculus** is between adjacent dorsal and ventral columns; and a **ventral funiculus** is between ventral columns.

Spinal cord diameter is not uniform from the cervical to sacral regions. Because most of the thoracic limb is innervated by the cervical segments of the spinal cord, there is an enlargement at this level. The **cervical (brachial) enlargement** or **intumescence** occurs between levels C6 and T1. A similar enlargement, the **lumbar intumescence,** occurs in the spinal cord associated with the pelvic limb between segments L4 and S2. The enlargements result from greater quantities of white and gray matter in these portions of the spinal cord than in other segments.

The white matter is also divisible into specific regions characterized by ascend-

Downloaded From VetBooks.com

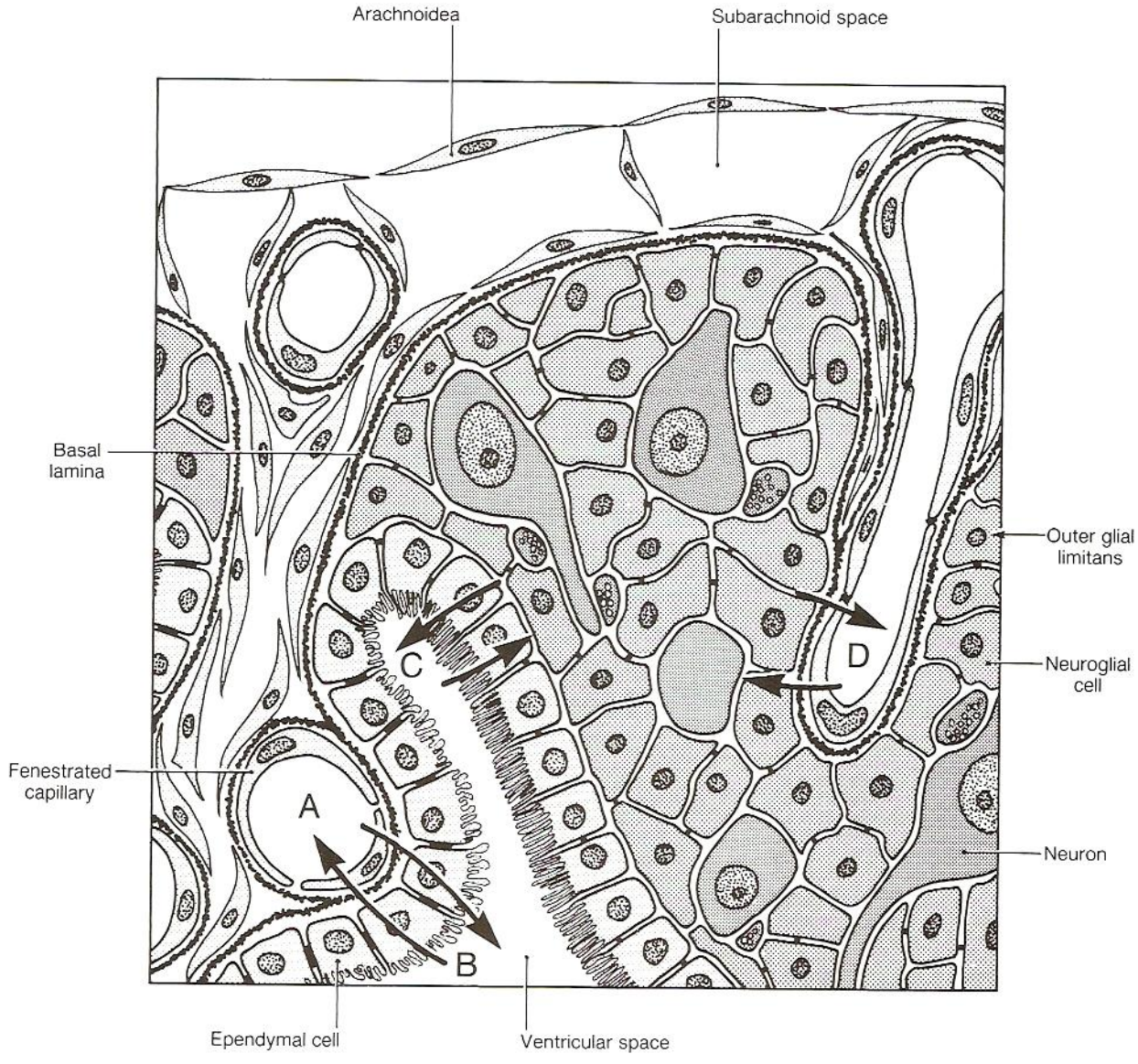

Figure 17-27. Blood/CSF and blood/brain barriers. **A,** Tissue fluid forms by ultrafiltration of the plasma. **B,** Ependymal cells modify the ultrafiltrate as cerebrospinal fluid. **C,** CSF enters the substance of the nervous tissue, freely bathing the neurons and neuroglia. **D,** Endothelial cells serve as the blood/brain barrier. Fluid and dissolved substances enter the nervous tissue, bathing the neurons and neuroglia.

ing and descending fiber tracts. Species differences exist in the distribution, size, and relative positions of tracts within the spinal cord.

Brain stem

The brain stem is a complex structure continuous with the spinal cord caudally and higher brain centers rostrally. The structures forming it are derived from the myelencephalon, metencephalon, mesencephalon, and diencephalon. Various nuclei and tracts are distributed in specific patterns throughout the brain stem (Plate V, *10,* and Fig. 17-29). The general pattern of nerve cell body and tract distribution for the cranial nerves rostral to the myelencephalon follows the alar and basal plate relationships described earlier (p. 232). Additional nuclei occur within the region, and many ascending and descending tracts exist.

Cerebellum. The cerebellum is also divided into gray and white matter (Fig. 17-30), the white matter covered by a thin layer of gray matter. Three distinct zones of gray matter are apparent—outer molecular layer, central layer of piriform cells, and deep granular layer. The granular layer is contiguous to the white matter (Plate I, *4* and *5*).

The outer **molecular layer** has some small neurons and many unmyelinated fibers. The **piriform cells** of the **central layer** are prominent, large, and pyramidal (Figs. 17-31 and 17-32). The neurons of the inner **granular layer** are small and tightly packed. Details of the connections among these cells, as well as the connections with **mossy** and **climbing fibers,** are available in texts of neuroanatomy.

Cerebrum

The diverse and complex functions of the cerebrum are reflected in its cytoarchitecture. Although six layers of cells have been described, the degree of layer development varies with the area of cerebral cortex being studied (Fig. 17-33). The gray (outer) region of the cerebral cortex consists of the following cellular regions: **molecular layer, outer granular layer, pyramidal cell layer, inner granular layer, ganglion** or **inner pyramidal cell layer,** and **polymorphic cell layer.**

Throughout these regions are neuroglial elements, myelinated and unmyelinated axons, and vessels. The student is referred to a text of neuroanatomy

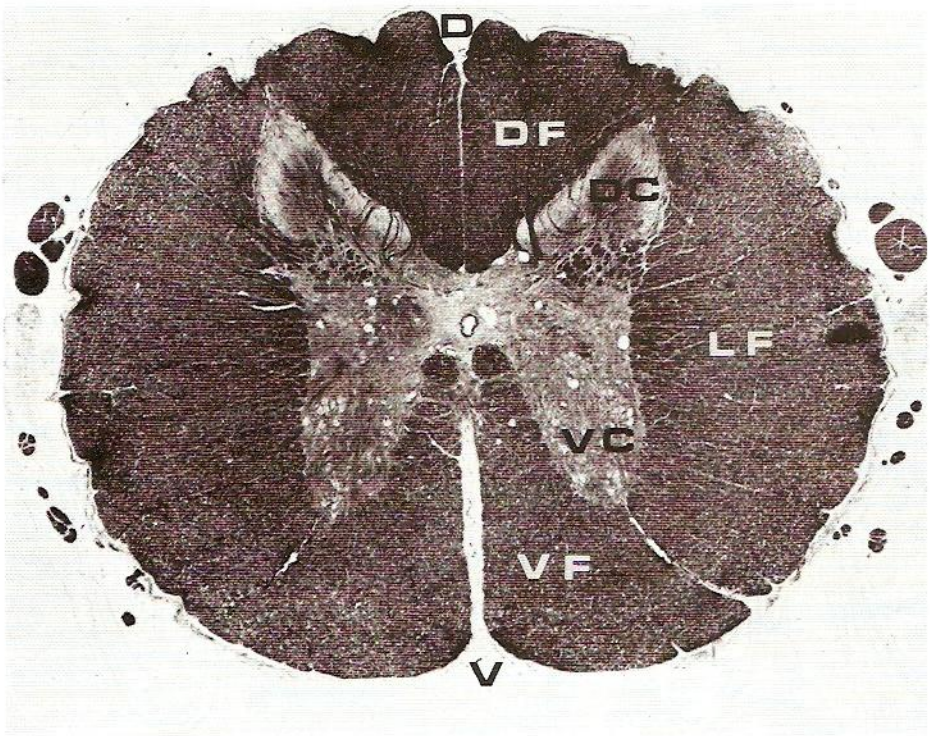

Figure 17-28. Typical section through the cervical region of the human spinal cord. The dorsal *(DC)* and ventral *(VC)* columns are prominent gray matter components. The dorsal *(DF)*, lateral *(LF)* and ventral *(VF)* funiculi comprise the white matter. *D*, Dorsal; *V*, ventral. (×4, myelin stain.)

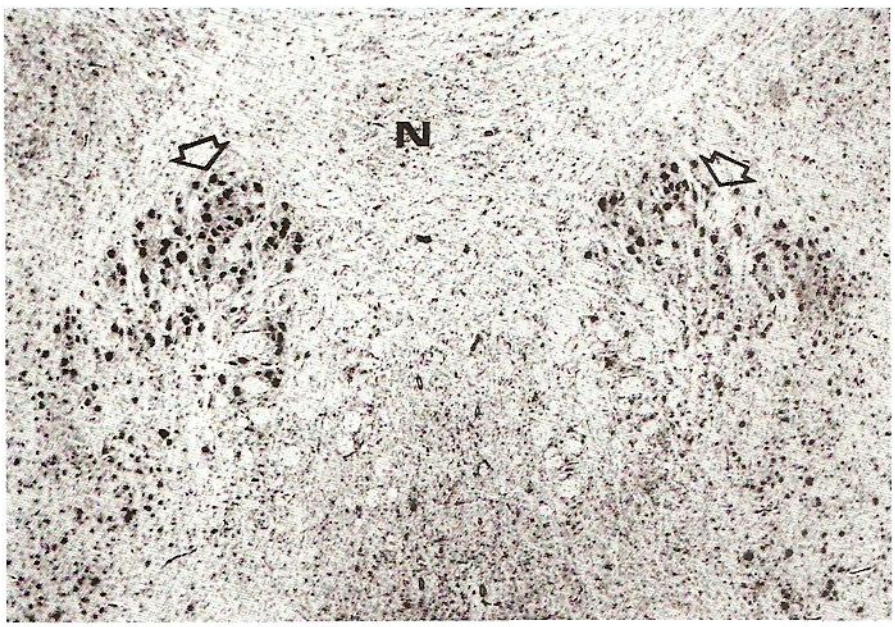

Figure 17-29. Frontal section through the brain stem of a pig. Note the nerve cell bodies of two prominent nuclei *(arrows)* within the rest of the nervous tissue *(N)*. (×4.)

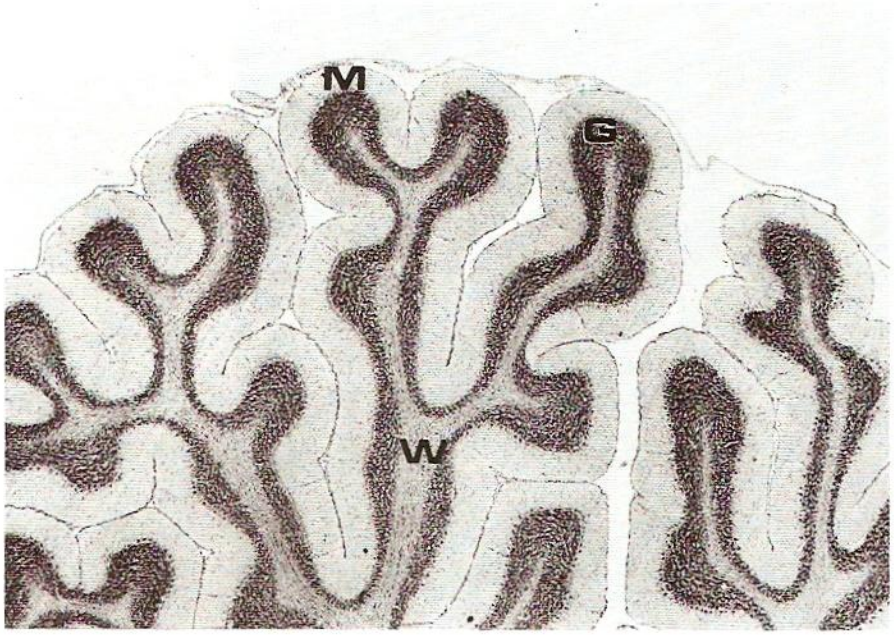

Figure 17-30. Section through a cerebellum. The molecular layer *(M)* and the granular layer *(G)* are peripheral to the white matter *(W)*. (×4.)

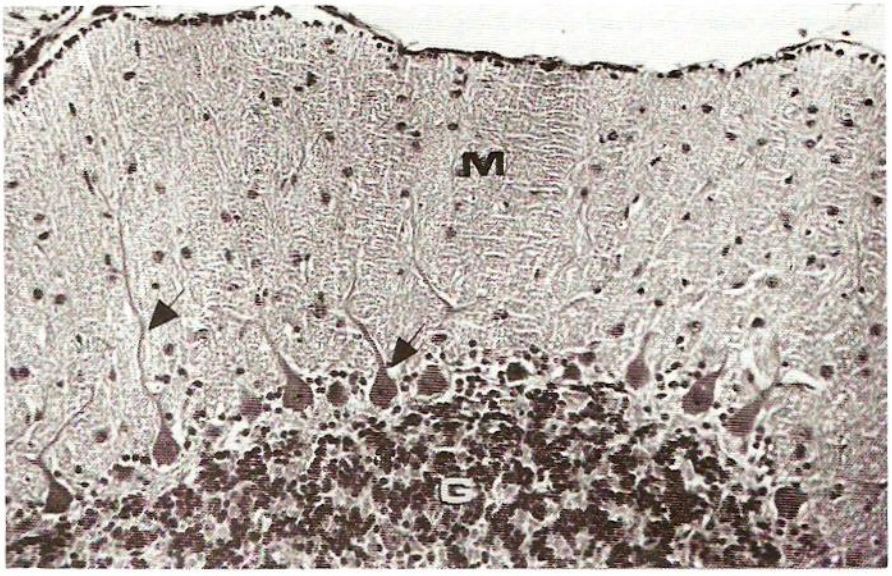

Figure 17-31. Piriform cells of a cerebellum. The cells *(arrows)* occur at the interface between the molecular *(M)* and granular *(G)* layers. (×4.)

Downloaded From Vet-Ebooks.com

Figure 17-32. Piriform cell of a cerebellum. The cell *(P)* has dendritic processes *(arrows)* extending into the molecular layer. Its axon extends through the granular layer *(G)* and synapses with neurons in the cerebellar nuclei. (×100, silver stain.)

Figure 17-33. Section through a cerebrum. The occurrence and distribution of layers of the gray matter differ in various regions. (×10.)

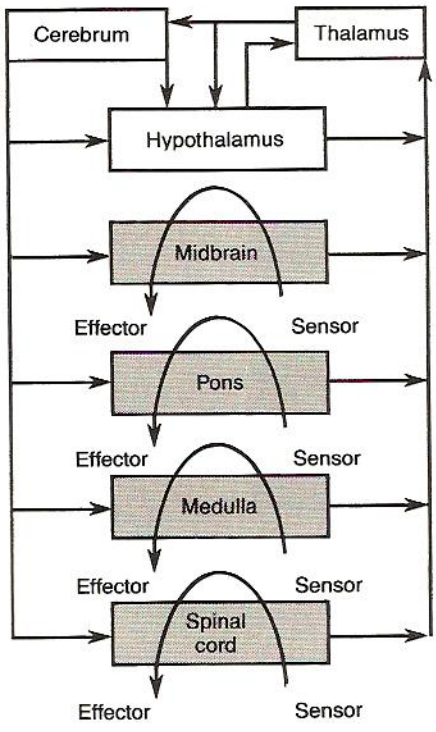

Figure 17-34. Components of the autonomic nervous system. *Solid lines on the right* are afferent pathways to the thalamus; *solid lines on the left* are efferent pathways from the cerebrum and hypothalamus; *arches* through the midbrain, pons, medulla, and spinal cord are reflexes.

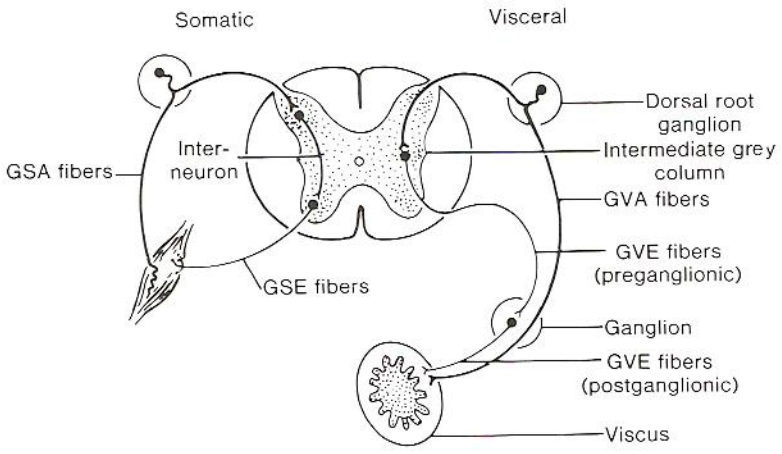

Figure 17-35. A somatic versus a visceral reflex arc. Note the additional neuron located in a ganglion in the visceral reflex.

for further discussion of the cerebral cortex.

AUTONOMIC NERVOUS SYSTEM

Organization and Characteristics

The regulation of a constant and optimal internal environment (**homeostasis** or **homeokinesis**) is the function of the autonomic nervous system (ANS) and is complemented by the endocrine system. These systems function to provide fine control of the many parameters permitting normal cell behavior.

The influence of the ANS is exerted on four effectors—(1) smooth muscle (e.g., intestines, urinary bladder, blood vessels), (2) cardiac muscle, (3) exocrine glands (salivary, sweat, mucous), and (4) some endocrine glands (adrenal medulla).

Components—central and peripheral. Often the ANS is presented as an efferent (motor) system linking the CNS to the aforementioned effectors. The efferent portion of this system may be the most obvious, but the autonomic regulation of visceral function requires more than efferent pathways. The ANS consists of **sensors, afferent pathways, central integration centers, control centers, efferent pathways,** and **effectors.** These all function to maintain the internal environment. The system has both central and peripheral components (Fig. 17-34). ANS receptors are located throughout the body.

Afferent input. The common modalities monitored by the receptors are as follows: stretch, distention, pressure, and chemical changes.

Impulses from these receptors are transmitted via GVA fibers to the CNS. Upon entry into the spinal cord, a reflex pathway is established through an **interneuron.** The afferent information also ascends to higher centers (suprasegmental) and may be at a conscious (e.g., visceral pain) or unconscious level. The impulses reach the **hypothalamus,** the integration center of the ANS. The hypothalamus, then, influences metabolic centers in the midbrain, pons, and medulla. Efferent fibers originating in these centers and the spinal cord innervate visceral effectors via specific cranial, spinal, and splanchnic nerves. These fibers, carrying general motor impulses to the visceral effectors, are referred to as **GVE fibers.**

Because the ANS regulates visceral functions, GVA fibers are essential. Sensory ANS information is not restricted to that transmitted by GVA fibers. All sensory systems (GVA, SVA, SSA, and GSA) supply input to the ANS. The essential efferent limb consists of GVE fibers.

Reflex arc—basis of regulation. The ANS is designed to function spontaneously through the **reflex arc.** The hypothalamus modulates the response. Through integrative hypothalamic functions, ANS effectors maintain a basic level of activity (**tone**) modifiable by afferent input and efferent output.

In a polysynaptic somatic reflex (Fig. 17-35):

1. GSA fibers reach the **dorsal root** from the spinal nerve and enter the **dorsal gray column.**
2. A synapse occurs with an **interneuron.**
3. The interneuron synapses with a neuron in the **ventral gray column (α-motor neuron).**
4. GSE fibers enter the **ventral root** and **spinal nerve** and subsequently reach the skeletal muscle effector.

In the typical autonomic reflex:

1. GVA fibers reach the **dorsal root** and enter the **dorsal gray column.**
2. A synapse occurs with a neuron **(preganglionic neuron)** located in the **intermediate gray column.**
3. This axon exits the spinal cord and synapses with a second neuron **(postganglionic neuron)** located in a motor ganglion.
4. The GVE impulses are transmitted over postganglionic fibers (axons) to the visceral effectors.

It is my opinion that **consistency with the terminology applied to a somatic reflex requires considering the first or preganglionic neuron as the interneuron and the second (postganglionic) neuron as the lower motor neuron.** The cell bodies of postganglionic neurons are located in **vertebral (paravertebral), prevertebral (collateral),** or **terminal (peripheral) ganglia.** The unmyelinated axons of postganglionic neurons terminate on visceral effectors. **The autonomic reflex, then, always consists of at least an afferent, a preganglionic,** and **a postganglionic neuron.**

Sympathetic and Parasympathetic Divisions

The ANS is divided into **sympathetic** and **parasympathetic nervous systems.** Part of the rationale for this is the location of the preganglionic neuron. These neurons occur in three regions of the CNS—**brain stem, thoracolumbar spinal cord,** and **sacral spinal cord** (Fig. 17-36).

In the sympathetic nervous system the cell bodies of the preganglionic neurons are located in the intermediate gray column of the **thoracolumbar spinal cord.** These neurons extend from the first thoracic to the fifth lumbar cord segment (thus the term **thoracolumbar system**). In the parasympathetic nervous system the cell bodies of preganglionic neurons are located in the **brain stem** in **nuclei of cranial nerves III, VII, IX, X,** and **XI** and in the **sacral segments of the spinal cord,** the **craniosacral system.**

Sympathetic nervous system

Many patterns characterize pre- and postganglionic sympathetic nerve fiber distribution. Notably, the postganglionic fibers are long and synapses between the pre- and postganglionic neurons occur some distance from their effectors. **Synapses in the paravertebral ganglia occur for fibers distributed to the periphery generally. Synapses in prevertebral ganglia are for fibers distributed to deep visceral organs.**

Specific nerves may be identified, but most nerves and prevertebral ganglia form extensive plexuses intimately associated with major arteries. Generally, preganglionic fibers originating cranial to T5 are distributed cranially and those caudal to T5 caudally. The extent of the ganglionated sympathetic trunk is actually greater than the site of origin of preganglionic fibers. The trunk extends from the cranial cervical region to the cranial caudal region. In the cervical region the sympathetic trunk is enclosed with the vagus nerve in a common sheath, forming the **vagosympathetic trunk.**

Parasympathetic nervous system

The spatial relationships between GVA fibers and the GVE fibers of the sacral portion of the parasympathetic nervous system follow the basic pattern just discussed. Afferent information reaches the spinal cord via the pelvic and splanchnic nerves. The cell bodies for the fibers reside in the dorsal root ganglia. These neurons synapse with preganglionic neurons in the intermediate horn. Preganglionic fibers are then distributed to the viscera by the pelvic nerve and plexus. Their terminal ganglia are the sites for synapses with postganglionic neurons. Generally these synapses occur within organ walls in intramural ganglia. The postganglionic fibers are very short.

Afferent information at the sacral cord level ascends the spinal cord to higher brain centers and may also be carried via the splanchnic nerves or the vagus nerve and then to higher centers.

The reflex pattern of the cranial parasympathetic nervous system is organized in a different way from that described for autonomic spinal reflexes. These differences relate to different embryological events of spinal cord and brain stem development.

The parasympathetic nuclei of cranial nerves III, VII, IX, X, and XI are homologous to the intermediate gray columns of the spinal cord (thoracic, lumbar, and sacral segments). These nuclear regions are the sites of origin of preganglionic parasympathetic fibers. Synapses with postganglionic neurons occur in terminal ganglia located close to or within the organs innervated.

Afferent information may enter the

Downloaded From VetBooks.com

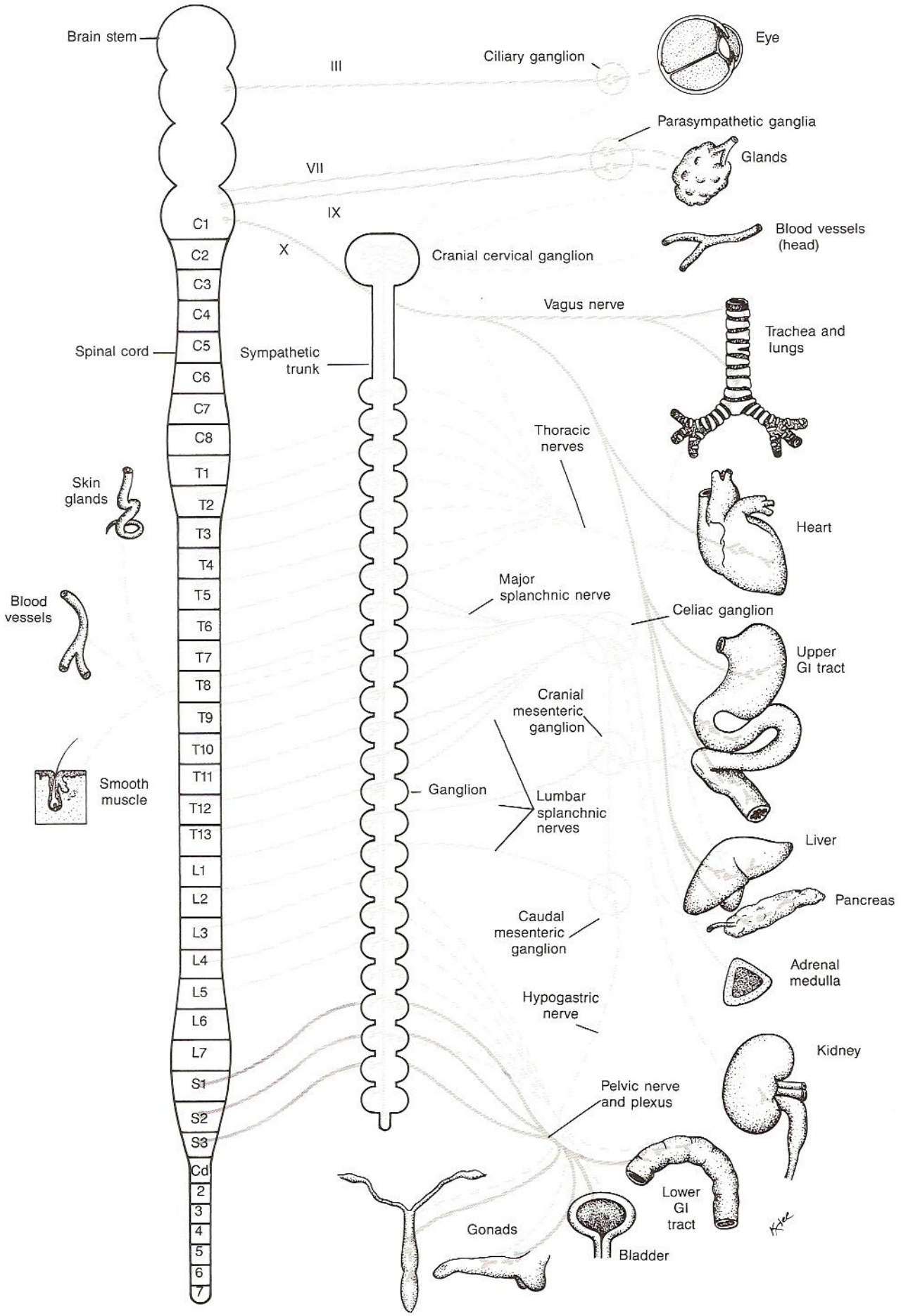

Figure 17-36. The human autonomic nervous system, simplified for clarity. Not all possible permutations are shown. Moreover, the fusion of nerves into each other is not typical of the anatomy but is used to reduce the number of lines on the drawing. The sympathetic innervation of the integument (arrector pili muscles, vessels, glands) is indicated for only one segment to the *left* to reduce the complexity of the drawing. The innervation of other visceral organs is shown to the *right*. The specific pathways of the sympathetic innervation to the cervical organs via the vertebral nerve are not shown. Sympathetic nerves are *black*, parasympathetic nerves *gray*. Preganglionic fibers are *solid*, postganglionic fibers *dashed*.

Downloaded from Library

brain stem in various ways and from various sources. The cell bodies of afferent fibers are located in specific sensory ganglia homologous to the dorsal root ganglia. (One exception is the use of SSA information.) Upon entry into the brain stem these afferent fibers project rostrad and caudad in the **solitary tract.** They end on interneurons of the **nucleus of the solitary tract,** whose fibers synapse (directly or indirectly) with the preganglionic neurons of cranial nerves VII, IX, X, and XI. Despite the altered organizational patterns, all components for an autonomic reflex are present.

Functional Correlates

Dual innervation. Most visceral organs have a dual innervation. The functional influence of the sympathetic and parasympathetic innervation upon these organs is synergistic. One system may enhance visceral functions; the other may inhibit these functions. They work together to achieve homeostasis.

There are notable exceptions to the previous generalities. Both divisions seem to stimulate salivary and pancreatic secretion. Also, not all organs have a dual innervation. The adrenal medulla, spleen, pilomotor muscles, sweat glands, and probably the blood vessels are innervated exclusively by the sympathetic division. The parasympathetic division provides the exclusive innervation for ciliary and pupillary sphincter muscles; the sympathetic division innervates the pupillary dilator.

Comparison of systems. For those organs innervated exclusively by sympathetic nerves, tone variations are still possible. Most vessels are constricted partially by the basal level tone of this system. An increased level causes **vasoconstriction,** a decreased level **vasodilation.**

The preganglionic fibers of the ANS are myelinated and relatively slow-conducting B fibers. Each fiber potentially may diverge to many postganglionic neurons, giving rise to mostly unmyelinated C fibers. By comparison with the somatic system, the autonomic output is diffuse and slow.

The two systems differ in their degree of responsiveness. These differences may be explained, in part, by different **innervation ratios.** The relatively short preganglionic fibers of sympathetic nerves synapse with many neurons some distance from the organs innervated, permitting a diffuse response over the long postganglionic fibers to the organs innervated. This innervation ratio of preganglionic axons to ganglion cells may be 1:20 or more.

The relatively long preganglionic fibers of parasympathetic nerves synapse with many neurons close to or within the organs innervated, permitting a more discrete and limited response than its sympathetic counterpart. In some organs the innervation ratio seems to be 1:1. Estimates of the ratio of preganglionic vagal fibers to ganglion cells of the submucosal plexus are as high as 1:8000. The distinction between the two systems based upon discreetness of response does not apply to all sites.

Innervation ratios, alone, do not distinguish the two systems. Postganglionic synapses with effector cells are described as **intermediate forms** of **directed synapses.** Local effects of adrenergic neurotransmitters, or the degree of nondirectedness, may exceed the local effects of acetylcholine upon its effectors.

Synaptic Relationships

Transmitters

Specific substances. Synapses between pre- and postganglionic neurons and between the postganglionic neuron and effector organs are typical. **Neurotransmitters** act upon receptors to affect responsiveness. The principal ANS neurotransmitters are **acetylcholine (ACh)** and **norepinephrine (NE)** (Fig. 17-37).

Pre- and postganglionic fibers. Sympathetic and parasympathetic preganglionic fibers and parasympathetic postganglionic fibers release ACh; they are **cholinergic fibers.** Sympathetic postganglionic fibers release NE; they are **adrenergic fibers.**

Cholinergic receptors

These receptors are discussed in Chapter 14; additional information now relates their ANS functions. Drugs mimicking ACh are **cholinergic drugs.** ACh receptor sites are **cholinergic receptors.** Although ACh is released by preganglionic sympathetic and parasympathetic nerves and postganglionic parasympathetic nerves, preganglionic and postganglionic receptor sites differ. These two sites manifest different responses to two plant alkaloids, muscarine and nicotine.

Muscarinic sites. **Muscarine** has little effect upon autonomic ganglion cells, but it does mimic the stimulatory effect of ACh upon effector organs innervated by postganglionic parasympathetic nerves. These ACh-receptor sites are termed **muscarinic receptors** (Fig.17-37). Other drugs acting similarly are **muscarinic drugs.**

Certain drugs block the effects of ACh at its preganglionic or postganglionic receptor sites. These types of drugs are called **anticholinergic drugs.** Anticholinergic drugs specifically blocking the receptor sites of postganglionic parasympathetic nerves are **antimuscarinic drugs.**

Muscarinic receptors are present as prejunctional receptors on adrenergic terminals. Stimulation of these receptors inhibits the release of NE; thus, local inhibitory control of these terminals tends to amplify the parasympathetic influence on effector organs.

Nicotinic sites. **Nicotine** mimics the effect of ACh on autonomic ganglion cells and on the receptors of the motor endplates of skeletal muscle. In small amounts it stimulates these receptor sites. In large doses it blocks autonomic ganglion cell transmission and the stimulation of skeletal muscle. These receptor sites are called **nicotinic receptors,** and the drugs manifesting such effects are **nicotinic drugs** (Fig. 17-37). Neuromuscular junctions are slightly different nicotinic receptors.

Response to stimulation. Receptor site uniqueness at the postganglionic parasympathetic synapses is important clini-

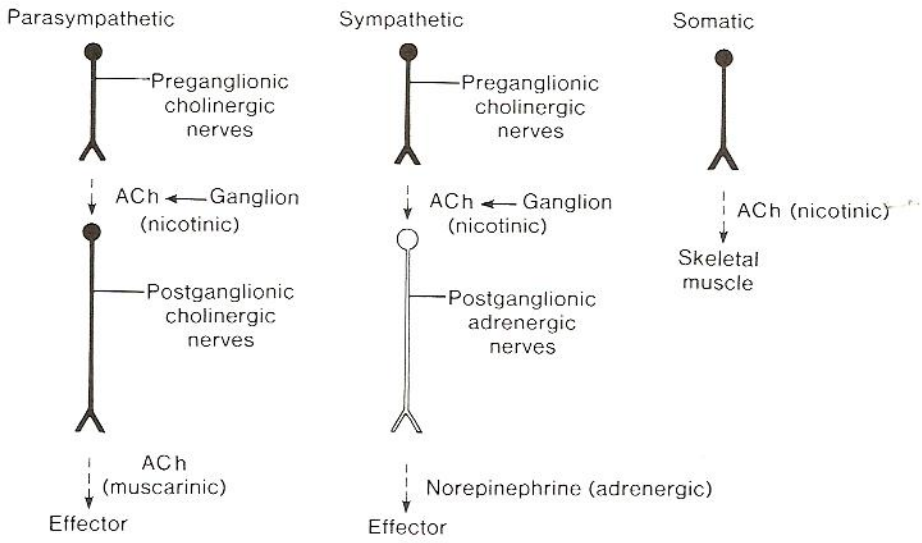

Figure 17-37. Cholinergic and adrenergic nerves. Refer to the text for a complete description of these relationships.

Downloaded From Vet-eBooks.com

cally. The selective blockage of muscarinic sites can be achieved by the judicious use of antimuscarinic drugs.

Although all cholinergic receptors respond to ACh, not all result in activation of the effector organs. Activation of specific receptor sites can manifest excitatory or inhibitory effects upon the effector organ by the generation of EPSPs or IPSPs (p. 191). Cholinergic stimulation of the heart results in a decreased heart rate; similar stimulation of the pupillary sphincter muscle and smooth muscle of the gastrointestinal tract results in contraction of these muscles. Generally the muscular sphincters of the alimentary canal relax or decrease tone upon cholinergic stimulation.

Adrenergic receptors

Classification of receptor sites. The different effects of catecholamines upon effector cells have been the basis for identifying α- and β-adrenergic receptors. Norepinephrine is a strong α-stimulator but a weak β-stimulator. Epinephrine is a strong α- and β-stimulator. Isoproterenol is a strong β-stimulator but a weak α-stimulator. Since the original descriptions of these major subdivisions, other drugs have been used to identify subpopulations of these receptors—α_1-, α_2-, β_1-, and β_2-. (See Chapter 14.)

Alpha-adrenergic sites. The classical stimulatory effects of α-receptor activation are attributed to α_1-adrenergic receptors. Stimulation of α_1-receptors results in vasoconstriction, pupillary dilation, and pilomotor smooth muscle contraction. Stimulation of these receptors in the wall of the intestine decreases smooth muscle tone.

The effects of α_2 stimulation at postjunctional sites (on the effector cells) have not been clarified completely. These receptors have been identified on some vascular smooth muscle; they stimulate the muscle fibers.

α_2-Receptors have been identified on prejunctional adrenergic and cholinergic terminals. Prejunctional α_2-receptors on adrenergic terminals inhibit the release of neurotransmitters and function as mediators of a local negative feedback mechanism. Prejunctional α_2-receptors on cholinergic terminals function similarly: they inhibit the release of ACh. The prejunctional effect upon cholinergic terminals would tend to amplify the local adrenergic effect by decreasing local parasympathetic tone.

α-Adrenergic receptors also mediate metabolic effects. α_1-Receptors affect hepatic glycogenolysis whereas α_2-receptors inhibit lipolysis in adipocytes. Additionally, stimulation of α_2-receptors causes platelet aggregation. The mechanisms by which α-receptors manifest their effects are not understood completely. The receptors may use calcium and cyclic adenosine monophosphate.

Beta-adrenergic sites. β_2-Receptors usually affect smooth muscle inhibition in blood vessels, intestines, bronchioles, uterus, and splenic capsule. Some gland secretions are inhibited by β_2-receptor stimulation.

Prejunctional β_2-receptors located on adrenergic terminals are stimulatory to the adrenergic terminals in response to epinephrine. This type of interaction tends to amplify the local effects of sympathetic discharge.

The β_1-receptor is an exception to the postjunctional inhibitory role of β-receptors. β_1-Receptor stimulation is excitatory to the heart muscle and has a positive chronotropic and positive inotropic effect upon the cardiac muscle mass. The effects of β-receptor stimulation are mediated through cAMP.

Distribution of α- and β-receptors. Many organs contain either α- or β-receptors and react accordingly. Some organs contain both α- and β-receptors. Vessels of the dermis, mucosa, kidney, and other visceral organs have more α- than β-receptors. Vessels of the heart and skeletal muscle have more β- than α-receptors. In gut wall smooth muscle the α- and β-receptors are inhibitory.

Adrenergic varicosities. The postganglionic neurons of the sympathetic nervous system are excellent examples of intermediate nondirected synapses. The axonal terminals arborize extensively, and the branches have many beads or varicosities along the tract (Fig. 17-38). The varicose axonal terminals of adjacent neurons overlap extensively. The overlap helps to account for the diffuse effects of sympathetic discharge.

Each varicosity is a presynaptic member releasing NE. The synaptic clefts associated with these varicosities are wide; norepinephrine spreads some distance to influence effector cells.

Many local factors influence the activity of adrenergic varicosities of vascular smooth muscle (Fig. 17-38). Such modulation may reduce or amplify the output of adrenergic terminals and have the effect of isolating the local neuroeffector activity from the rest of the system. Metabolic factors inhibiting such release include: acidosis, increased K^+ concentrations, hyperosmolality, adenosine and adenine nucleotides. These local factors are associated with increased muscular activity. Local modulation, in this instance, inhibits norepinephrine release; the vascular tone decreases, and vasodilation is achieved.

α_2-Receptors and muscarinic receptors on the varicosities inhibit the release of NE. These substrates, then, tend to self-regulate or amplify the desired local effect, respectively. Histamine, a strong vasodilator, also has a inhibitory effect upon these varicosities.

Cutaneous blood vessels and associated adrenergic varicosities respond to reduced temperature. Reduced temperatures increase the effector site affinity for the neurotransmitter and decrease the uptake of NE into the varicosity. Despite the neurotransmitter release in this circumstance, the desired vasoconstriction and heat conservation are achieved.

The stimulation of prejunctional β_2-receptors by epinephrine augments the sympathetic tone locally by increasing norepinephrine release from noradrenergic varicosities.

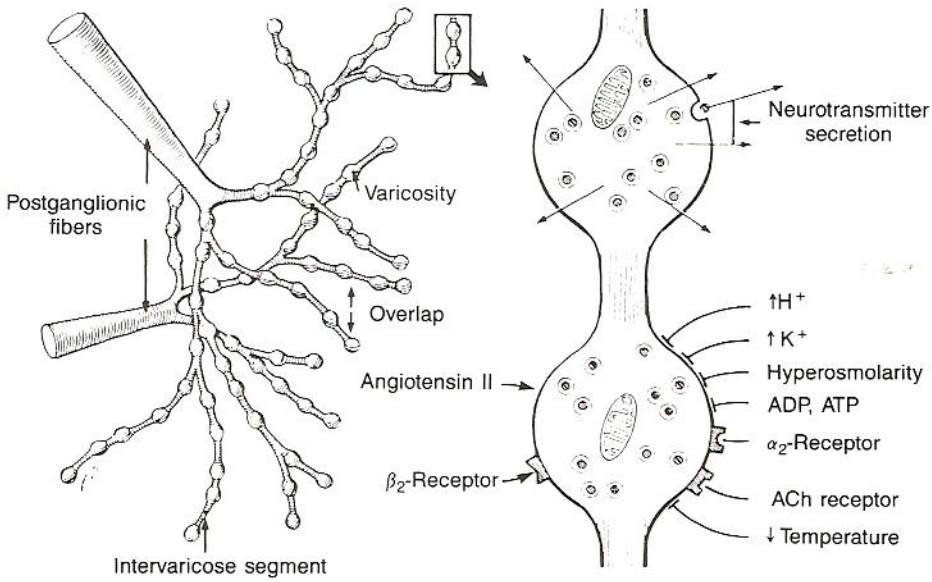

Figure 17-38. Adrenergic varicosities and the local factors that influence the release of neurotransmitter substance. Refer to the text for a complete description of these influences.

Adrenal Medulla

Relationship to the autonomic nervous system. The adrenal medulla is a unique organ innervated by **preganglionic sympathetic nerves.** The anatomical basis for this is simple. The cells of the adrenal medulla are derived from neural crest ectoderm. The chromaffin cells of the adrenal medulla, therefore, are **postganglionic neurons.** These cells secrete epinephrine and norepinephrine (about 85:15).

Functions. The adrenal medulla is an important part of the sympathetic nervous system. It is the means by which generalized sympathetic overflow manages to affect all cells (Fig. 17-39). Adrenal medullary secretions, primarily epinephrine, have the following effects: they (1) facilitate adrenergic transmission, (2) increase heart rate (β_1), (3) increase cardiac contraction strength (β_1), (4) elevate glycogenolysis **(diabetogenic),** and (5) release free fatty acids from adipose tissue. These effects ready the animal body for stress such as that accompanying violent muscular activity, hypotension, hypoxia, fear, anger, anxiety. At the same time, blood is shunted from the vessels of the skin (α-receptors) and viscera ($\alpha > \beta$) to the vessels of skeletal muscle ($\beta > \alpha$). This surge of adrenal medullary activity is the "fight or flight" reaction. It prepares the animal for stress threatening its physical well-being and/or homeostasis. The examining room is a good place to observe its effects.

As is true for the rest of the sympathetic nervous system, the adrenal medulla is not essential to life, as long as emergencies are minimized. Demonstration of complete sympathectomy is difficult if nonstressful conditions are maintained.

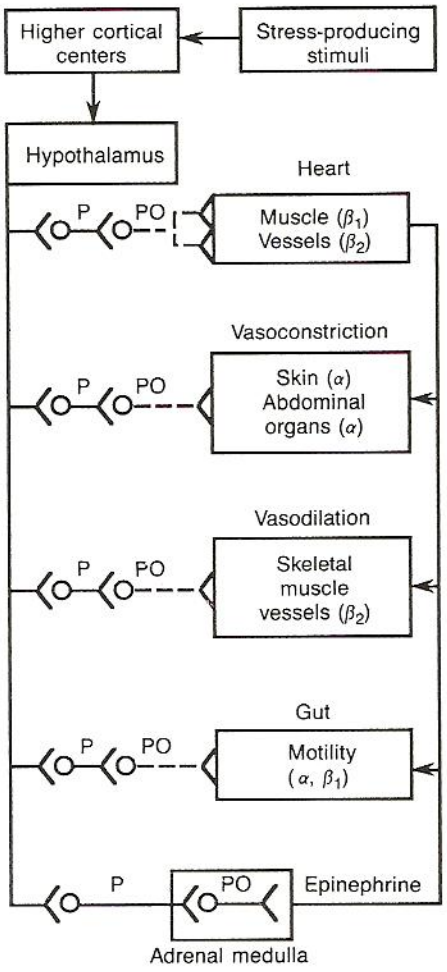

Figure 17-39. Relationship of the adrenal medulla to the sympathetic nervous system. The innervated organs react to neural stimulation as indicated. The release of epinephrine complements the neural stimulation. *P,* Preganglionic neuron; *PO,* postganglionic neuron.

Pharmacological Considerations

The autonomic drugs are those chemicals that mimic or intensify **(agonists)** or block **(antagonists)** the effects of sympathetic and parasympathetic neurotransmitters.

Drugs can achieve their mimetic effects by several mechanisms. Some (the **congeners**) are sufficiently similar to the neurotransmitter that they are able to **combine with the receptor site** and elicit the effector response. (The similarity between epinephrine, norepinephrine, and dopamine is apparent in Figure 14-15.) Some can **cause the release of neurotransmitter** from the axon telodendria. Some **inhibit the enzyme activity** responsible for degradation of the neurotransmitter, causing it to accumulate and prolong the effector response.

Drugs can also achieve a blocking effect in several ways. Certain compounds are sufficiently similar to the neurotransmitters that they bind with receptor sites and **competitively inhibit** the normal neurotransmitter–receptor site reaction. Others prevent the release or synthesis of the neurotransmitter substances.

Drugs that act in the manner described are classified into four general categories—parasympathomimetic, parasympatholytic, sympathomimetic, and sympatholytic. Two classes of drugs affect the parasympathetic nervous system.

Parasympathetic system. Two classes of drugs affect the parasympathetic nervous system.

Parasympathomimetics mimic the effects of parasympathetic neuronal stimulation of the effector organs. Drugs in this category are also called **cholinergics** or **cholinomimetics.** They are effective at ganglionic synapses (parasympathetic and sympathetic), parasympathetic postganglionic neuroeffector junctions, and neuromuscular junctions of skeletal muscle. Other cholinergics are inhibitors of acetylcholinesterase (AChase). They bind with the AChase and reduce the hydrolysis and subsequent inactivation of ACh.

Parasympatholytics or **anticholinergics** block the effects of parasympathetic neuronal stimulation. Drugs in this category actually inhibit muscarinic receptors **(antimuscarinics).** Some effector organs (e.g., sweat glands and some blood vessels in skeletal muscle) have muscarinic receptors but are innervated by sympathetic postganglionic cholinergic nerves. Some smooth muscle cells have cholinergic receptors but lack cholinergic innervation.

Sympathetic system. The catecholamines and other compounds constitute a rather complex group of drugs that partially or completely mimic the effects of sympathetic postganglionic neuronal discharge.

The **sympathomimetics** or **adrenergics** are **α- and β-stimulators.** Some selectively stimulate one receptor but not the other.

The **sympatholytics** (also called **antiadrenergics**) may be **α-adrenergic** or **β-adrenergic blocking agents.**

NEURONAL RESPONSE TO INJURY

Neuronal specialization is accompanied by a loss of mitotic potential. Among the many complexities relating to neuronal functions, and as yet to be explained, is the dynamic interaction that occurs between neurons and their effector organs. Neuronal death results in the irreplaceable loss of that cell and its processes. Neurons or neuronal pools that lose their innervation undergo **transneuronal (transsynaptic) reactions.** Transneuronal reactions also affect the neurons "innervating" damaged neurons. Thus, presynaptic and postsynaptic neurons may be affected and the reactions can range from subtle to degenerative.

Neuroglial cells, especially astrocytes, fill in the space previously occupied by the neurons or neuronal pools. Neuron and effector organ relationships function in a similar manner. The denervation of skeletal muscle leads to its atrophy, which is reversed upon reinnervation. The disruption of an axonal process results in myelin sheath degeneration. Similarly, the loss of myelin sheaths from disease processes affects the functional integrity of the axons. (The axons are unable to transmit action potentials.) The exact trophic relationships and influences between these components have not been clarified, but they have an **obligatory symbiosis.**

Neuronal processes damaged within the PNS cause degenerative and regener-

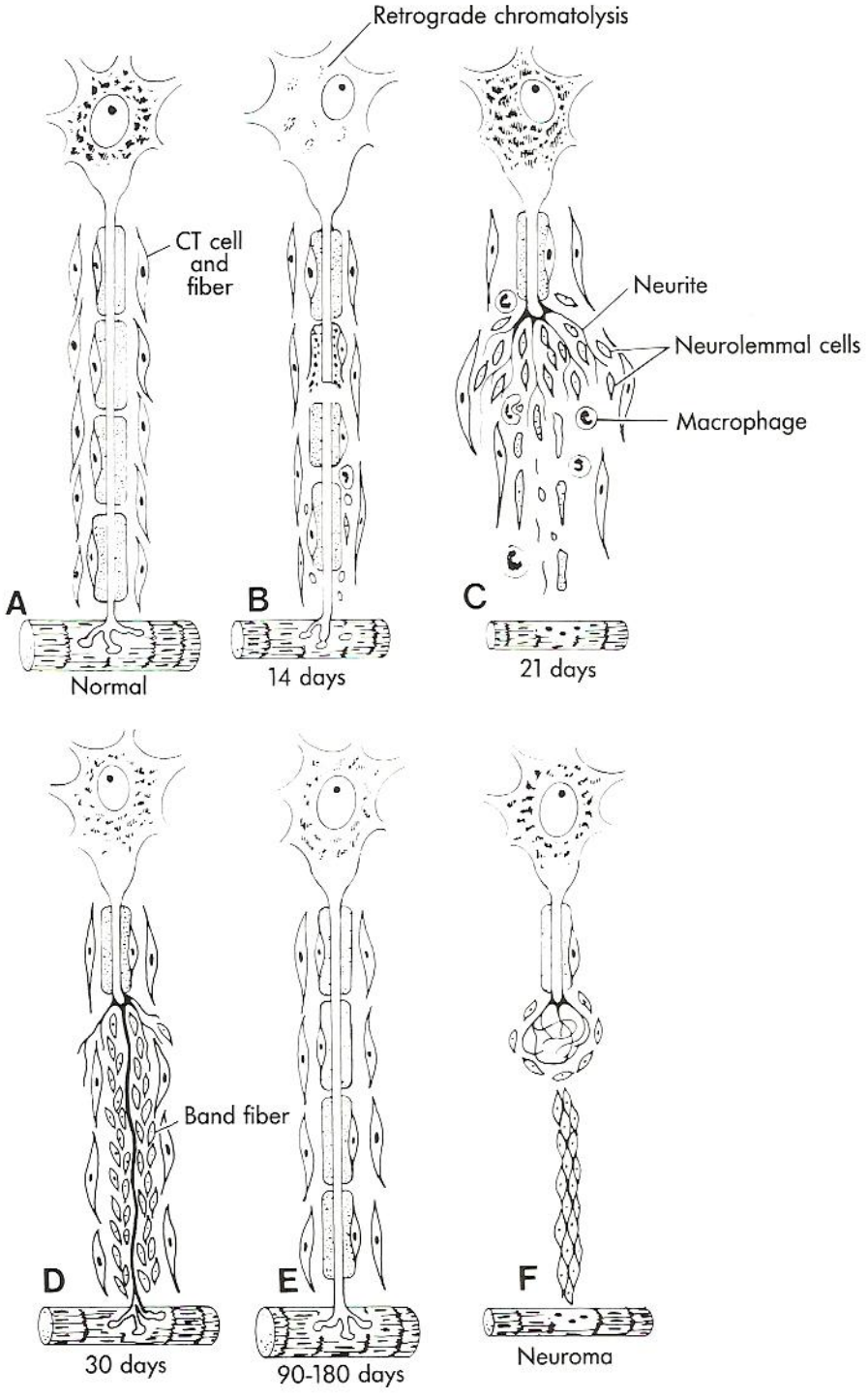

Figure 17-40. Degeneration and regeneration of a nerve fiber. **A,** Normal neuromuscular relationships. **B,** Primary neural degeneration. The myelin sheath is degenerating, and the muscle is undergoing neurogenic atrophy. **C,** Reactivity to neural degeneration. Neurolemmal cells have become reactive, and macrophages have invaded the region. Neurites are beginning to grow from the proximal stump of the axon. Distal degeneration is almost complete, and muscular atrophy is progressing. **D,** Band fiber formation. Neurolemmal cells establish themselves as band fibers to guide the predominant neurite. **E,** Reestablishment of innervation. The relationships have returned to normal. **F,** Neuroma formation. A whorled arrangement of growing neurites, neurolemmal cells, and connective tissue establishes the neuroma. (Redrawn and modified from Junqueira LC: *Basic histology*, Los Altos Calif, 1975, Lange; and from Quarton GC, Melnechuk T, Schmitt FO (eds): *The neurosciences*, New York, 1967, Rockefeller University Press.)

ative alterations in the cell process that may involve the nerve cell body. Neurons within the CNS react similarly to damage, but the time frame for regeneration is slower than with their peripheral counterparts. Neuronal changes in response to injury are referred to as **primary** and secondary degeneration.

Sequence of events. When a nerve is severed, it does not regenerate.

The transection results in damage proximal and distal to the injury site (Fig. 17-40). Proximally the **primary degeneration,** which may include myelin sheath disintegration and partial axonal loss, extends over a few internodal segments (Fig. 17-40, *B*). The nature of the injury dictates the degree of proximal involvement. The proximal portion of the axon, maintaining its continuity with the nerve cell body, soon begins to undergo regeneration and new axonal branches **(neurites)** radiate from the stump (Fig. 17-40, *C*).

After separation of the distal segment from the neuronal cell body, the axonal terminal undergoes degeneration first, **terminal degeneration.** Subsequent degeneration of the myelin sheath and axon occurs. This process, **secondary degeneration,** results in progressive degenerative distal segment changes. The axon, separated from the trophic influence of the neuronal cell body, assumes a beaded appearance, breaks up into irregular fragments, and eventually disintegrates. The myelin sheath undergoes similar alterations in association with the fragmented axon. These changes occur within the limits of the endoneurium. The peripheral connective tissue fibers form a cylindrical envelope around the reacting nerve fiber.

Macrophages invade the **zone of trauma** and assist with debris removal. Neurolemmal cells enlarge and proliferate. Reactive neurolemmal cells remove cellular detritus and myelin fragments some distance from the regions from the zone of trauma. Neurolemmal cell proliferation results in the formation of **band fibers (cellular tubes)** along the length of the disintegrated distal segment (Fig. 17-40, *D*). Band fibers are guide tubes for proximal segment neurites to extend into the distal fragment and eventually to the neuron or effector organ. When a neurite establishes contact with the pathway supplied by the band fibers, the remaining neurites degenerate (Fig. 17-40, *E*).

The changes occurring in the axon are accompanied by cell body alterations. **Retrograde chromatolysis** occurs within the cell body very rapidly (Fig. 17-40, *B*). Eventually the nerve fiber is restored to its original relationship and regeneration is achieved (Fig. 17-40, *E*). The transection of a nerve may result in the opening of a large gap between the proximal and distal segments or the distal segment may be missing, as would result from an amputation. In either case the neurites and associated cells may form a large, painful nodule called a **neuroma** (Fig. 17-40, *F*). Neuroma formation is not a problem in dogs but is one in horses. Neuromas can be a significant complication of digital neurectomies

used as salvage operations for **navicular disease**. The folding and suturing of the epineurium over the transected proximal fragment **(epineural capping)** decrease the occurrence of these neuromas in horses.

Neuronal fiber regeneration within the CNS occurs at a much slower rate than within the PNS. The absence of band fiber formation from oligodendrogliocytes may account for the slow progression of repair. Peripheral regeneration occurs at a rate of 2 to 4 mm/day, but complete disintegration and phagocytosis of severed distal segments within the CNS may take 6 months. Importantly, functional regeneration within the CNS probably does not occur.

ADDITIONAL READINGS

General

Chrisman CL (ed): Symposium on advances in veterinary neurology, *Vet Clin North Am* 10:1, 1980.

DeLahunta A: *Veterinary neuroanatomy and clinical neurology,* ed 2, Philadelphia, 1983, WB Saunders.

Ettinger SJ (ed): *Textbook of veterinary internal medicine: diseases of the dog and cat,* vol I, Philadelphia, 1975, WB Saunders.

Hoerlein BF: *Canine neurology: diagnosis and treatment,* ed 3, Philadelphia, 1978, WB Saunders.

Kandel ER, Schwartz JH: *Principles of neural science,* New York, 1981, Elsevier/North Holland.

Quarton GC, Melnechuk T, Schmitt FO (eds): *The neurosciences,* New York, 1967, Rockefeller University Press.

Peripheral Nervous System

Bradley WG: *Disorders of peripheral nerves,* Oxford, 1974, Blackwell.

Cauna N: Structure of digital touch corpuscles, *Acta Anat* 32:1, 1958.

Cauna N, Mannan G: The structure of human digital pacinian corpuscles (corpuscula lamellosa) and its functional significance, *J Anat* 92:1, 1958.

Dyck PJ, et al: *Peripheral neuropathy,* ed 2, vol I, Philadelphia, 1984, WB Saunders.

Fernand VSV, Young JZ: The sizes of the nerve fibers of muscle nerves, *Proc R Soc [Biol]* 139:38, 1951.

Gamble HJ, Eames RA: An electron microscope study of the connective tissue of human peripheral nerve, *J Anat* 98:655, 1964.

Griffiths IR, Duncan ID, Lawson DD: Avulsion of the brachial plexus. 2. Clinical aspects, *J Small Anim Pract* 15:177, 1974.

Grillo MA: Electron microscopy of sympathetic tissues, *Pharmacol Rev* 18:387, 1966.

Hess A: The fine structure of young and old spinal ganglia, *Anat Rec* 123:399, 1955.

Heuser JE, et al: Synaptic vesicle exocytosis captured by quick freezing and correlated with quantal transmitter release, *J Cell Biol* 81:275, 1979.

Jones LM, et al: *Veterinary pharmacology and therapeutics,* ed 4, Ames, 1977, Iowa State University Press.

Kunos G: Adrenoreceptors. In George R, et al (eds): *Annual review of pharmacology and toxicology,* vol 18, Palo Alto Calif, 1978, Annual Reviews.

Kuntz A: *The autonomic nervous system,* Philadelphia, 1953, Lea & Febiger.

Meyers FH: *Review of medical pharmacology,* ed 5, Los Altos Calif, 1976, Lange.

Ortiz-Picon JM: The neuroglia of the sensory ganglia, *Anat Rec* 121:513, 1955.

Schanthavcerappa TR, Bourne GH: The "perineural epithelium," a metabolically active, continuous protoplasmic cell barrier surrounding peripheral nerve fasciculi, *J Anat* 96:527, 1962.

Sheperd JT, Vanhoutte PM: Local modulation of adrenergic neurotransmission, *Circulation* 64:655, 1981.

Spencer PJ, Schaumberg HH: The pathology of dying back polyneuropathies, *Prog Neuropathol* 3:253, 1977.

Central Nervous System

Bradbury M: *The concept of a blood-brain barrier,* New York, 1979, Wiley & Sons.

Barringer JR: A simplified procedure for spinal fluid cytology, *Arch Neurol* 22:305, 1970.

Elliott HC: Studies on the motor cells of the spinal cord, *Am J Anat* 70:95, 1942.

Globus EG, Scheibel AB: Pattern and field in cortical structure, *J Comp Neurol* 131:155, 1967.

Hartley WJ: Lower motor neuron disease in dogs, *Acta Neuropathol* 2:334, 1963.

Herndon RM: The fine structure of the Purkinje cell, *J Cell Biol* 18:167, 1963.

Maxwell DS, Pease DC: Electron microscopy of the choroid plexus, *Anat Rec* 124:331, 1956.

Palmer AC: Pathogenesis and pathology of the cerebellovestibular syndrome, *J Small Anim Pract* 11:167, 1970.

Weed LH: Meninges and cerebrospinal fluid, *J Anat* 72:181, 1938.

Wright JA: Evaluation of cerebrospinal fluid in the dog, *Vet Rec* 103:48, 1978.

Yeo JD: A review of experimental research in spinal cord injury, *Paraplegia* 14:1, 1976.

Downloaded From VetBooks.com

CHAPTER 18

Cardiovascular System

The cardiovascular system consists of components to pump, transport, and distribute required elements to the cells and tissues (Fig. 18-1).

The histology of vessel construction is inseparable from the hemodynamic role that vessels fulfill. The arterial system carries a low blood volume under high pressure at high velocity. The capillary system has a large blood volume under diminished pressures and velocities. The venous system transports a high blood volume at low pressures and velocities.

MURAL ORGANIZATION

Various mural patterns accommodate pressure-volume relationships. The basic scheme consists of tunica intima, tunica media, and tunica adventitia (Figs. 18-2 and 18-3).

The **tunica intima** has three subdivisions—endothelium, subendothelial coat, and internal elastic membrane (Figs. 18-2 to 18-4). The **endothelium** is typical squamous epithelium lining the lumen. It is a consistent feature of all blood vessels and the heart. Typically the nuclei are prominent and may bulge into the lumen; the marginal cytoplasm is difficult to discern. The cells reside upon a basement membrane separating the endothelium from the peripheral fibroelastic connective tissue and fibroblasts of the **subendothelial coat.** These elements are generally oriented parallel to the long axis of the vessel. Smooth muscle fibers may be present, as well as cells normally occupying connective tissue spaces. The **internal elastic membrane** is a condensation of elastic fibers separating the tunica intima from the tunica media.

The **tunica media** consists of a mixture of smooth muscle cells, collagen fibers, elastic fibers, and fibroblasts (Figs. 18-2, 18-3, and 18-5). The smooth muscle cells are arranged in a circular pattern around the lumen intimately associated with collagen and elastic fibers. In large vessels **nervi** and **vasa vasorum,** the nerve and blood supplies of the vessels, occur within this tunic.

An **external elastic membrane** may be present at the junction between the tunica media and tunica adventitia. It, too, is a condensation of elastic fibers demarcating the media from the adventitia. The **tunica adventitia** is formed of this membrane and dense fibroelastic connective tissue (Figs. 18-2, 18-3, and 18-5). It is difficult to distinguish the end of the adventitia from the beginning of the surrounding connective tissue. Nervi and vasa vasorum also ramify in the tunica adventitia.

Not all vessels contain all the aforementioned elements; nor, if present, are all the elements represented equally in every vessel. The endothelium is the only constant feature.

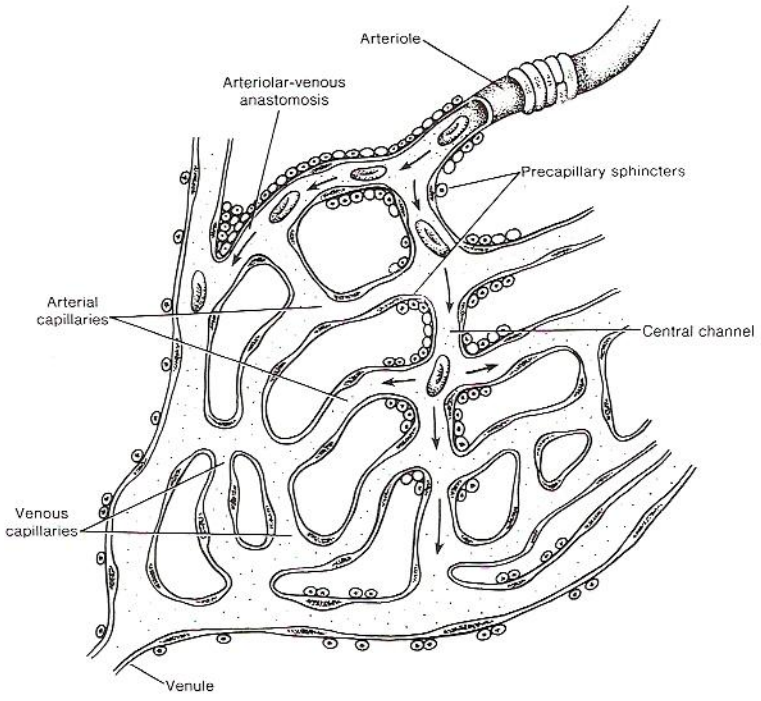

Figure 18-1. Relationships of capillaries to arterioles and venules. The central channel, surrounded by smooth muscle, is the metarteriole. Contraction of its smooth muscle shunts blood through the capillary bed. (Redrawn and modified from Copenhaver WM, Kelly DE, Wood RL: *Bailey's Textbook of histology,* Baltimore, 1978, Williams & Wilkins.)

EXCHANGE SYSTEM

Endothelium. The **endothelial cells** form the **blood-tissue boundary,** through which all blood-borne substances must pass to reach the cells. They are the basis for exchange and exclusion. Transcytotic and endocytotic processes move materials from the blood through or around the endothelial cells into the subendothelial space.

Transcytosis is an active process for materials gaining access to the **subendothelial space** either through or around the endothelium. It is the predominant means for moving fluids and molecules via **vesicles** and through **fenestrations** and **diaphragms.** Receptors also facilitate the movement of certain molecules (by **receptor-mediated transcytosis**).

Endocytosis includes **phagocytosis, pinocytosis,** and **receptor-mediated endocytosis** involving **coated vesicles.**

The simplicity of endothelial cell structure does not accurately reflect their diverse and complex metabolic activities. These cells are also involved in the metabolism of vasoactive substances, synthesis of hemostatic factors, and secretion of other diverse products (Table 18-1).

Capillaries. **Capillaries** are the means by which metabolites gain access to and waste products leave the connective tis-

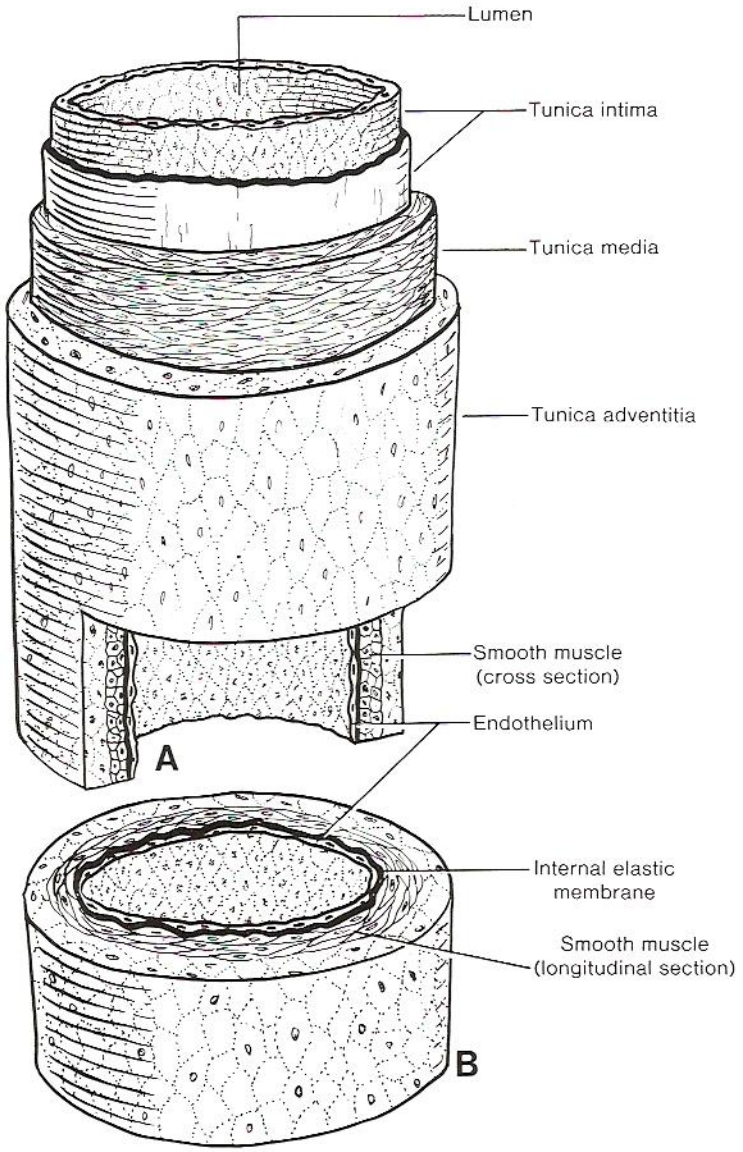

Figure 18-2. Mural organization of an artery. When cut longitudinally **(A)**, the smooth muscle of the tunica media is cross sectioned. When the vessel is cut in cross section **(B)**, the smooth muscle is cut longitudinally.

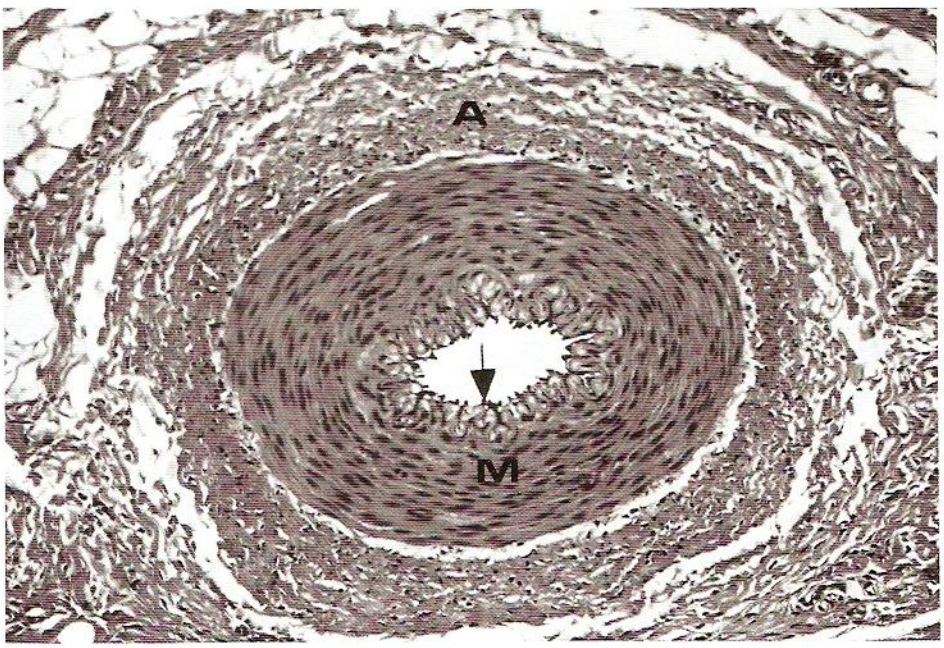

Figure 18-3. Mural elements of a muscular artery. The three components are tunica intima *(arrow)*, tunica media *(M)*, and tunica adventitia *(A)*. (×40.)

Downloaded From Vet-eBooks.com

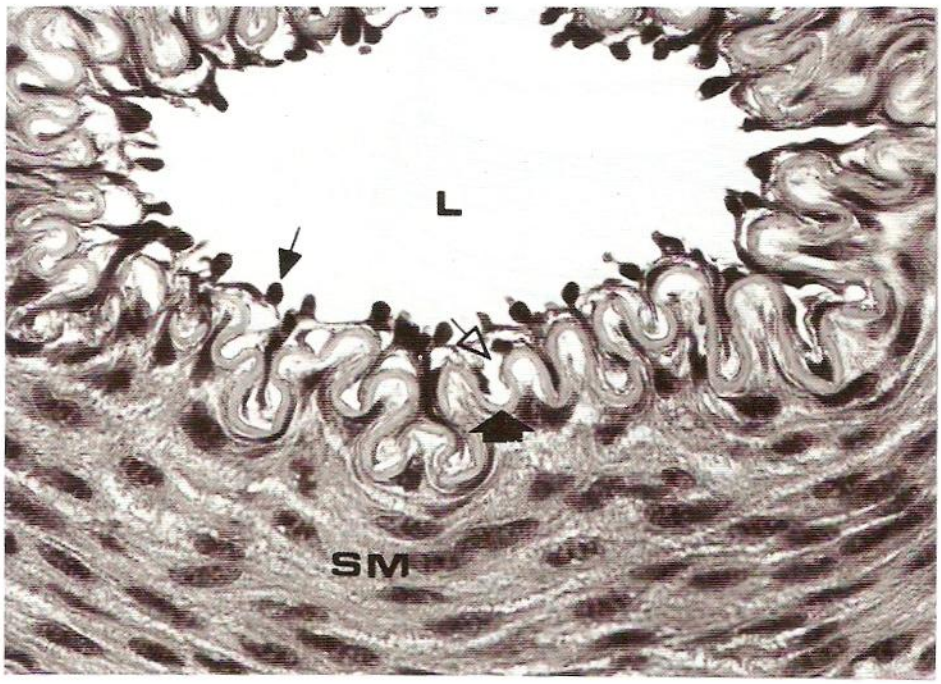

Figure 18-4. Tunica intima of a muscular artery. The lumen *(L)* of the vessel is lined by endothelium *(solid arrow)*, the cells of which protrude into the lumen. The protrusion results from agonal contractions of the tunica media during sample acquisition. The accentuation of the subendothelial space *(open arrow)* is an artifact of preparation. The internal elastic membrane *(large solid arrow)* is adjacent to the smooth muscle *(SM)* of the tunica media. (×160.)

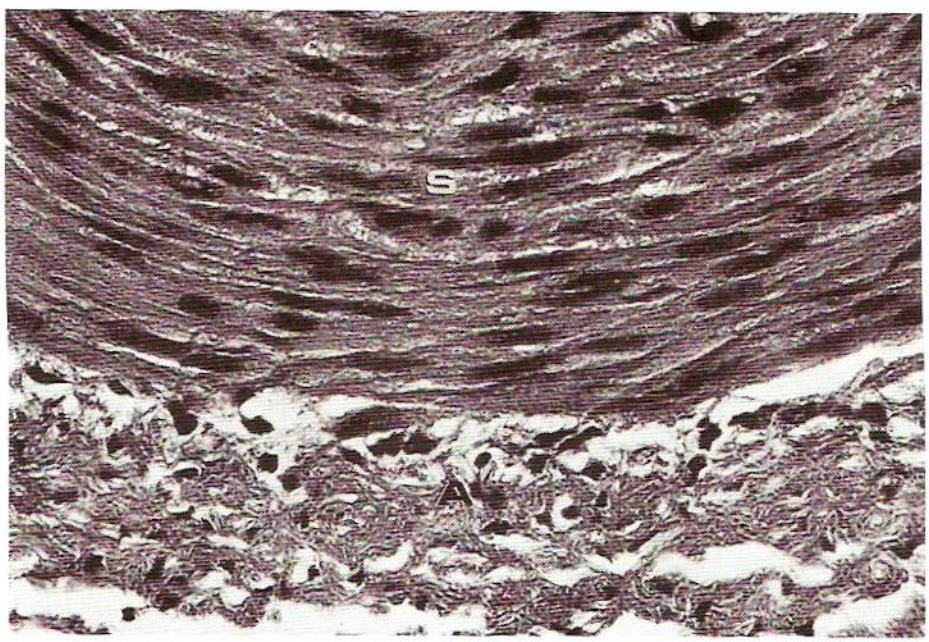

Figure 18-5. Tunica media and tunica adventitia of a muscular artery. The tunica media contains smooth muscle cells *(S)* whereas the tunica adventitia *(A)* consists of fibroelastic connective tissue. (×160.)

Downloaded From Vet-eBooks.com

Table 18-1. Endothelial Cell Activities

	Participation Through
Vasoconstriction	Angiotensin I conversion to angiotensin II
Catecholamine degradation	Catechol-O-methyltransferase (COMT), monoamine oxidase (MAO)
Vasodilation	Production of prostacyclin (PGI_2)
Hemostasis	Synthesis and secretion of tissue factor, Factor VIII, plasminogen inhibitor, antithrombin III, plasminogen activator
Connective tissue interface	Synthesis and secretion of collagens IV, V, and VIII, thromobospondin, entactin, laminin, fibronectin, proteoglycans
Antigen presentation	Traps antigens → synthesizes interleukin 1 → produces class II histocompatibility antigens

sue space. They are simple endothelium-lined tubes with a diameter of 7 to 9 μm. They can accommodate a single RBC at a time and often are surrounded by a basal lamina (Fig. 18-6).

In sections viewed with the light microscope, a thin rim of acidophilic cytoplasm marks the extent of the capillary (Fig. 18-7). The dark nucleus of the endothelial cell occurs along the margin of the lumen and may bulge into it. Capillaries are accompanied by connective tissue cells, thin collagen fibers, and reticular fibers. Among the many cells closely associated with them are fixed macrophages, mesenchymal cells, and perivascular cells.

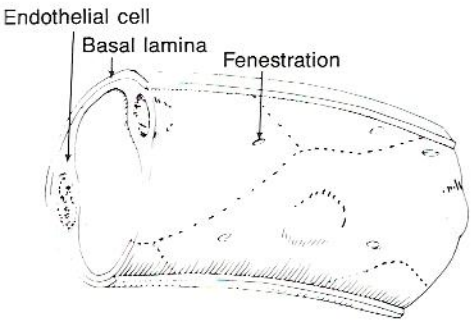

Figure 18-6. Fenestrated capillary. The basal lamina completely covers the abluminal surface of the endothelium.

All capillaries are similar when viewed by light microscopy, but ultrastructural studies demonstrate five types — continuous, fenestrated, and sinusoidal as well as sinusoids and venous sinuses.

Continuous capillaries have no interruptions or pores in the endothelial cells (Fig. 18-8). They occur typically in muscle, lungs, and the nervous system. **Fenestrated (perforated) capillaries** have pores scattered throughout the endothelial walls (Fig. 18-9). The pores may be covered by a diaphragm thinner than the cell membrane. These capillaries occur in the endocrine glands, intestines, and kidneys, where fluid transport is important. They have a complete basal lamina. **Sinusoidal capillaries** are larger and more irregularly shaped than continuous and fenestrated capillaries. A basal lamina is not a prominent feature. Their endothelial cells are not phagocytic, and macrophages are not associated with the cells. These capillaries characterize the endocrine organs and the aortic and carotid bodies.

Sinusoids are larger than sinusoidal capillaries. The basal lamina is not a prominent feature and in most sinusoids is absent. These vessels occur in the bone marrow and liver. Hepatic sinusoids differ from other sinusoids in having lining (endothelial) cells with macrophages (Fig. 18-10). **Venous sinuses** are larger than sinusoids. The basal lamina is discontinuous, and the lining cells are not phagocytic.

Various cells assume intimate relationships with the capillary endothelium. They are called **pericapillary (perivascular) cells** and include **macrophages, fibroblasts, mesenchymal cells, mast cells,** and **pericytes.** Pericytes are smooth muscle cells intimately associated with the capillary endothelium — and are probably smooth muscle cells of the **metarterioles** and **precapillary sphincters** (Fig. 18-1).

Figure 18-7. Capillaries in loose collagenous tissue. The connective tissue *(CT)* contains a blood capillary *(C)* and a lymphatic capillary *(L)*. (×160.)

HIGH-PRESSURE SYSTEM

Arterioles. There is a gradual transition from capillaries to arterioles. A **metarteriole** is a branch of an arteriole with a discontinuous layer of smooth muscle fibers surrounding it (Fig. 18-1). These vessels are sphincters; they control the blood flowing through the **central** or **thoroughfare channel,** coursing through the capillary bed, and joining the venous side of the circulation. **Precapillary sphincters** are capillaries with a single layer of smooth muscle fibers controlling blood flow through the metarterioles into the capillary bed proper. Contraction of these vessels stops flow in the specific capillary bed. A capillary bed bypass may be achieved by arteriolar-venular anastomoses (Fig. 18-1).

Arterioles have a diameter less than 100 μm (Fig. 18-11). The smallest arterioles have a tunica intima with no subendothelial coat. The only recognizable elements are the endothelium and thin internal elastic membrane, the latter appearing as a bright scalloped line (Fig. 18-12). The tunica media has one to three layers of smooth muscle among which are scattered some fine collagenous and elastic fibers. An external elastic membrane is not present, and the loose collagenous tissue of the tunica adventitia blends insensibly with the surrounding connective tissue.

It is not unusual to observe a scalloped endothelial layer, whose individual cells

Downloaded From Vet-eBooks.com

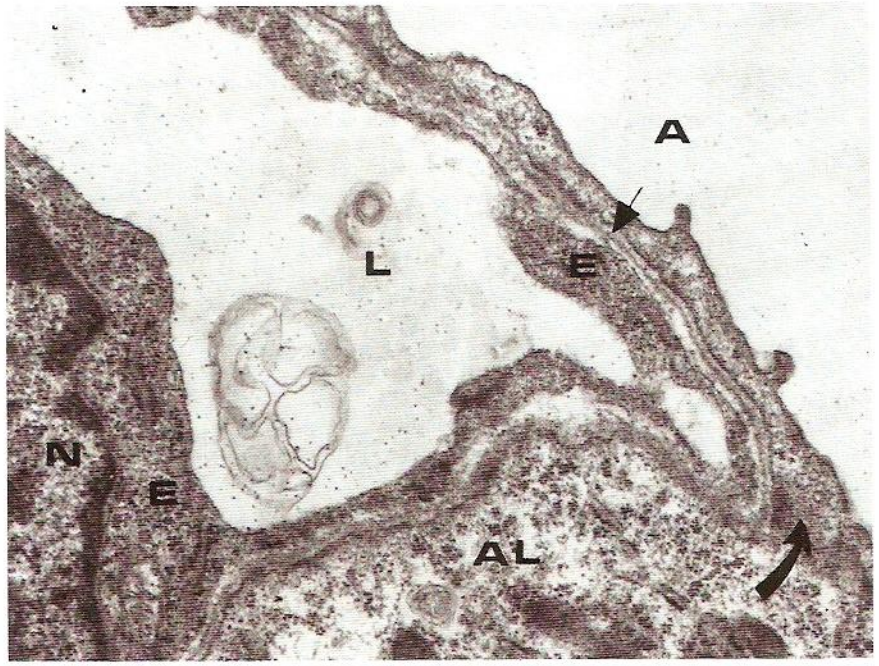

Figure 18-8. Electron micrograph of a continuous capillary from a bovine lung. The alveolus *(A)* is defined by the perikaryon of the alveolar lining cell *(AL)* and the attenuated cellular process of the lining cells *(curved arrow)*. The lumen of the capillary *(L)* is delimited by the endothelial cells *(E)* and its nucleus *(N)*. The basal lamina *(small arrow)* is complete and the endothelial lining is continuous. (×20,000).

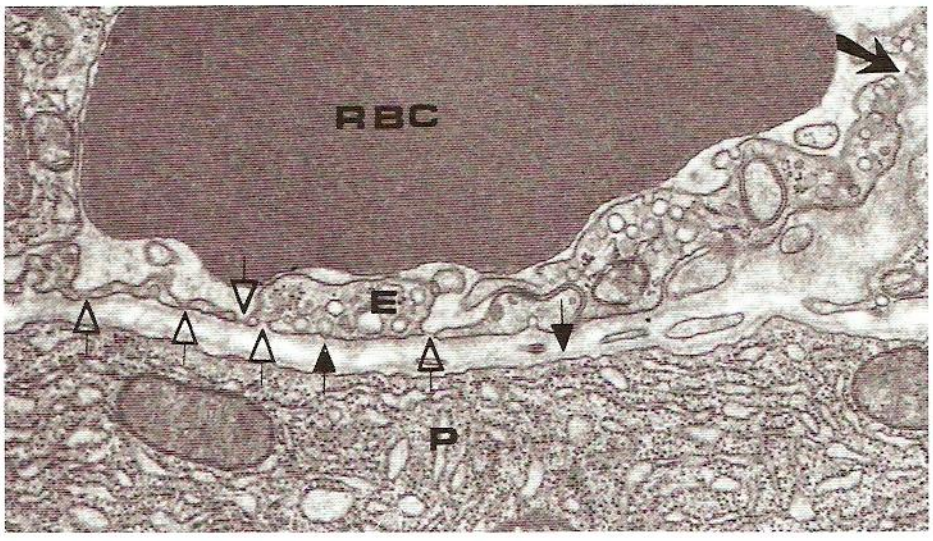

Figure 18-9. Electron micrograph of a fenestrated capillary. The endothelium *(E)* of the capillary is separated from a pancreatic acinar cell *(P)* by two basal laminae *(small solid arrows)*. The capillary contains an erythrocyte *(RBC)*. Many fenestrations *(open arrows)* are covered by diaphragms whereas one fenestration *(large solid arrow)* is not. (×25,000).

Downloaded From Vet-eBooks.com

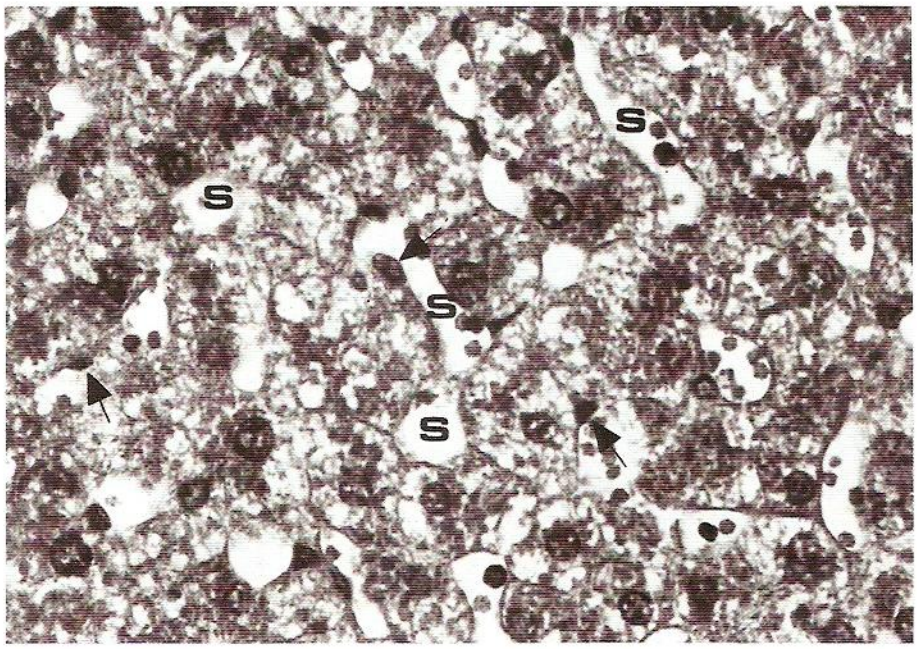

Figure 18-10. Sinusoids of a liver. These channels *(S)* are lined by phagocytic cells *(arrows)* and endothelial cells (×160.)

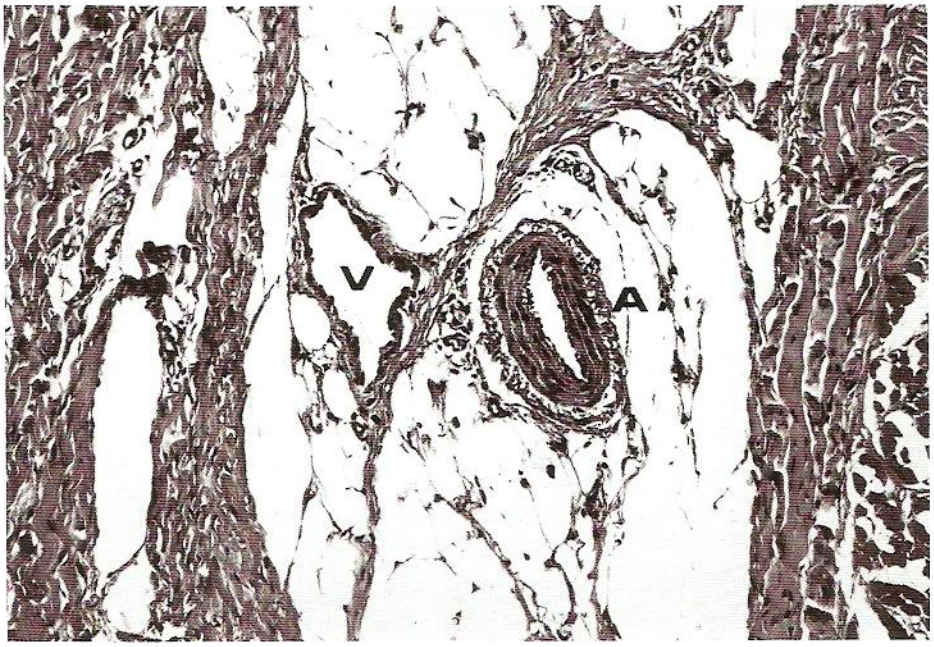

Figure 18-11. Arteriole and venule. The arteriole *(A)* has three layers of smooth muscle in the tunica media. The companion venule *(V)* does not contain smooth muscle. (×40.)

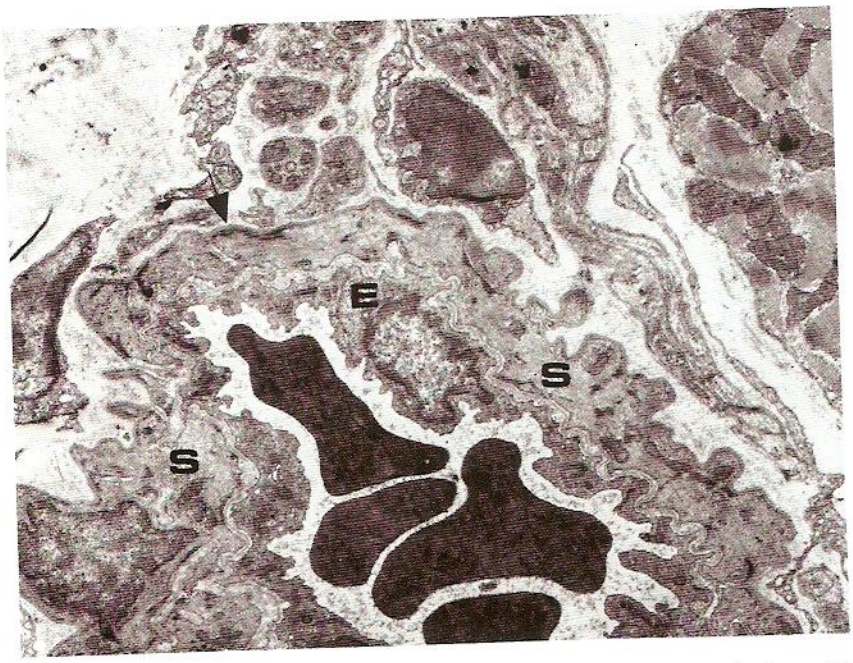

Figure 18-12. Electron micrograph of an arteriole. Smooth muscle *(S)* surrounds the endothelial cell *(E)*. A basal lamina *(arrow)* is apparent at the peripheral border of the smooth muscle cell. (×14,000). (Courtesy G.P. Epling.)

protrude into the lumen (Fig. 18-13). This results from excessive vessel contraction at the time of fixation.

Small and medium arteries. There is no sharp line of distinction between arterioles and small arteries. The small and medium-sized arteries are also termed **muscular** or **distributing arteries** (Fig. 18-3). The tunica intima is typical. An external elastic membrane is often well-defined, and the tunica adventitia is characteristic.

Elastic arteries. The **elastic arteries** are the largest arteries (Fig. 18-14). Compared to their luminal volume, they have a rather thin wall. All the elements of the tunica intima are present. The endothelium is polygonal rather than (expectedly) flat. The subendothelial layer has fibroblasts and smooth muscle cells in a loose collagenous tissue. An internal elastic membrane is present. The membrane is not always distinct, however, because the tunica media has many elastic fibers oriented as repeating elastic membranes. Between the coarse elastic fibers are fine collagen fibers, fine elastic fibers, fibroblasts, and smooth muscle cells. A distinct external elastic membrane is not present. The adventitial tissue is thin and blends with the surrounding connective tissue.

LOW-PRESSURE SYSTEM

Capillaries and venules. **Venous capillaries** have diameters up to 20 times those of capillaries and gradually acquire other mural elements. In contradistinction to arterial capillaries, venous capillaries usually associate with connective tissue first and later develop mural smooth muscle. **Venules** are simple endothelial tubes surrounded by loose collagenous tissue (Fig. 18-11). Smooth muscle investment occurs as they become small veins. The tunica adventitia of these vessels is thick compared to the tunica media.

Small and medium veins. These vessels are lined by a thin tunica intima consisting of polygonal endothelial cells and a very small subendothelial connective tissue layer (Fig. 18-15). The tunica media is thin, consisting of circularly oriented muscle cells as well as both collagen and fine elastic fibers. The tunica adventitia is well-developed and forms the bulk of the wall.

Many of these veins have **valves** (Fig. 18-16), which are evaginations from the tunica intima into the vessel lumen. Valves are lined by flattened endothelial cells with a core of subendothelial connective tissue (Fig. 18-17). They are especially prominent in vessels located below the heart.

Large veins. The tunica intima is thicker than in smaller veins, and an internal elastic membrane may be present. The tunica media consists primarily of collagen fibers and elastic fibers with a reduced or absent smooth muscle component. The well-developed tunica adventitia is the thickest part of the wall. Scattered smooth muscle bundles may be present within this coat and oriented parallel to the vessel's long axis. Valves are absent in the venae cavae and the hepatic portal vein.

HIGH- AND LOW-PRESSURE SYSTEMS COMPARED

The mural elements of a vein are less distinct than those of its companion artery.

COMPARATIVE FEATURES. Following are specific features for comparison:

1. Blood rarely occurs in sectioned arteries but is typically present in veins.
2. The tunica media is well-developed in arteries, but the tunica adventitia is well-developed in veins.
3. Luminal diameters are greater than mural thicknesses in veins, but luminal diameters of arteries are smaller than mural thicknesses.
4. During agonal changes, veins are subject to irregular contractions, but arteries contract more regularly.
5. Internal elastic membranes may be present in arterioles but are usually confined to large veins.
6. The tunica adventitia of veins is usually the thickest coat of the wall.

HEART

Mural Organization

The heart is a thick-walled, muscularized pump. Its mural elements are organized similarly to those of vessels. It consists of three coats—an inner (endocardium), a middle (myocardium), and an outer (epicardium) layer (Fig. 18-18).

Endocardium. The **endocardium,** the cardiac counterpart of the tunica intima, has an endothelium, a subendothelial coat, and a subendocardial coat (Fig. 18-19). In the **endothelium** polygonal cells are continuous with the endothelial lining of the vessels. In the **subendothelial coat** fine collagen and elastic fibers are continuous with a deeper or more peripheral **subendocardial coat** of loose collagenous tissue. The latter contains collagen fibers and elastic fibers, adipose cells, smooth muscle fibers, blood vessels, and nerves. Besides attaching the endocardium to the myocardium, this coat contains the heart's impulse-conducting system in the ventricles.

Myocardium. The **myocardium** is comparable to the tunica media (Fig. 18-20). It consists of cardiac muscle, connective tissue fibers, nerves, and blood vessels (Chapter 13).

Epicardium. The **epicardium** is actually a serous membrane—the **visceral pericardium** of gross anatomy (Fig. 18-21). The mesothelium resides upon a thin layer of loose collagenous tissue, the **subepicardial coat.**

Cardiac skeleton. The cardiac muscle and valves are supported by a skeleton of dense collagenous tissue, cartilage, or bone. The cardiac skeleton includes (1)

Downloaded From Vet-eBooks.com

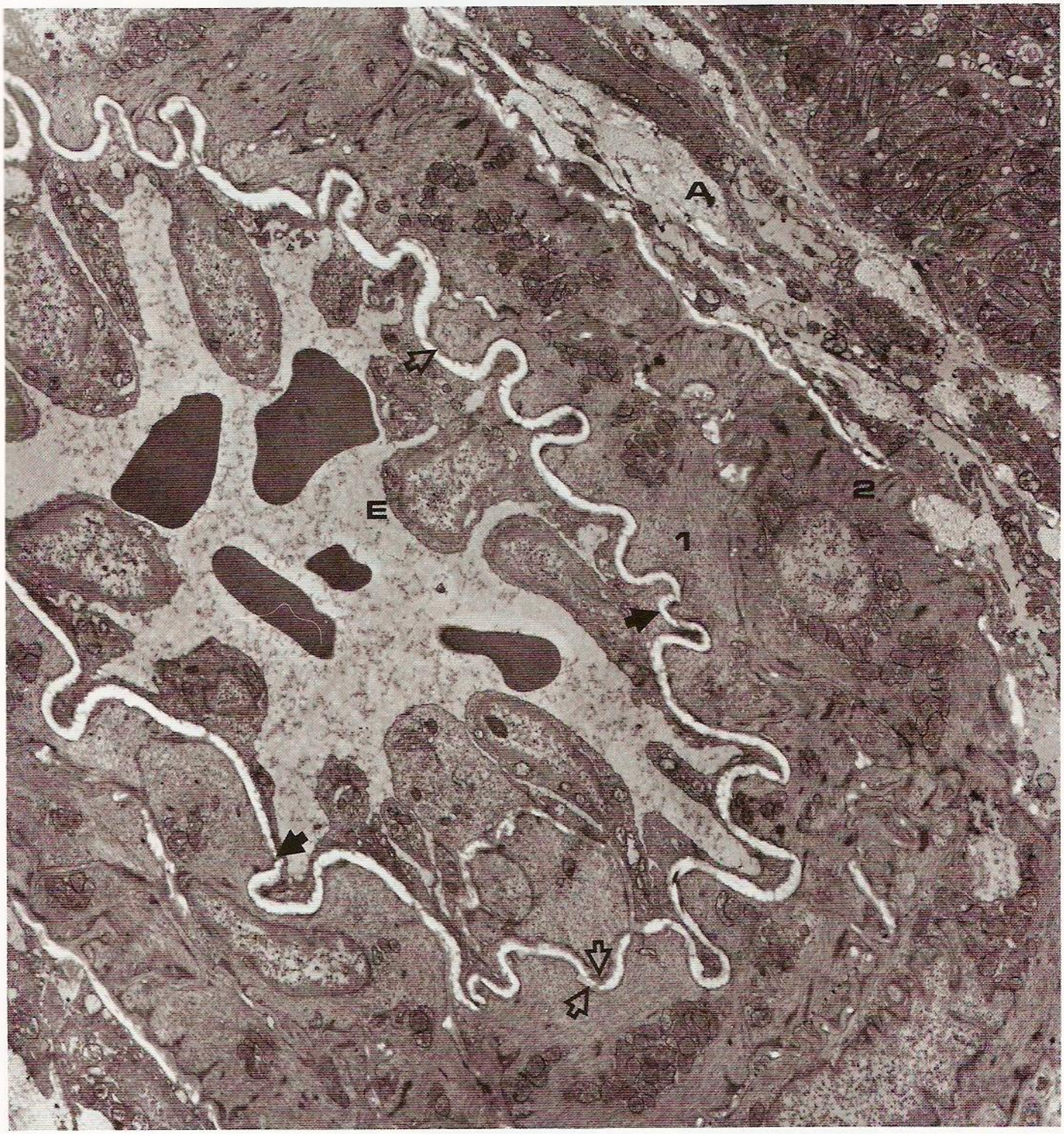

Figure 18-13. Electron micrograph of an arteriole with a scalloped border. Contraction of the vessel has caused the protrusion of the endothelial perikaryons into the lumen *(E)*. The internal elastic membrane is folded for the same reason *(solid arrows)*. Two smooth muscle cells *(1,2)* comprise the tunica media. Portions of the basal lamina are apparent on the luminal and abluminal surfaces of the internal elastic membrane *(open arrows)*. Elastic fibers, collagen, and fibroblasts are apparent in the adventitial connective tissue.

Downloaded From Vet-eBooks.com

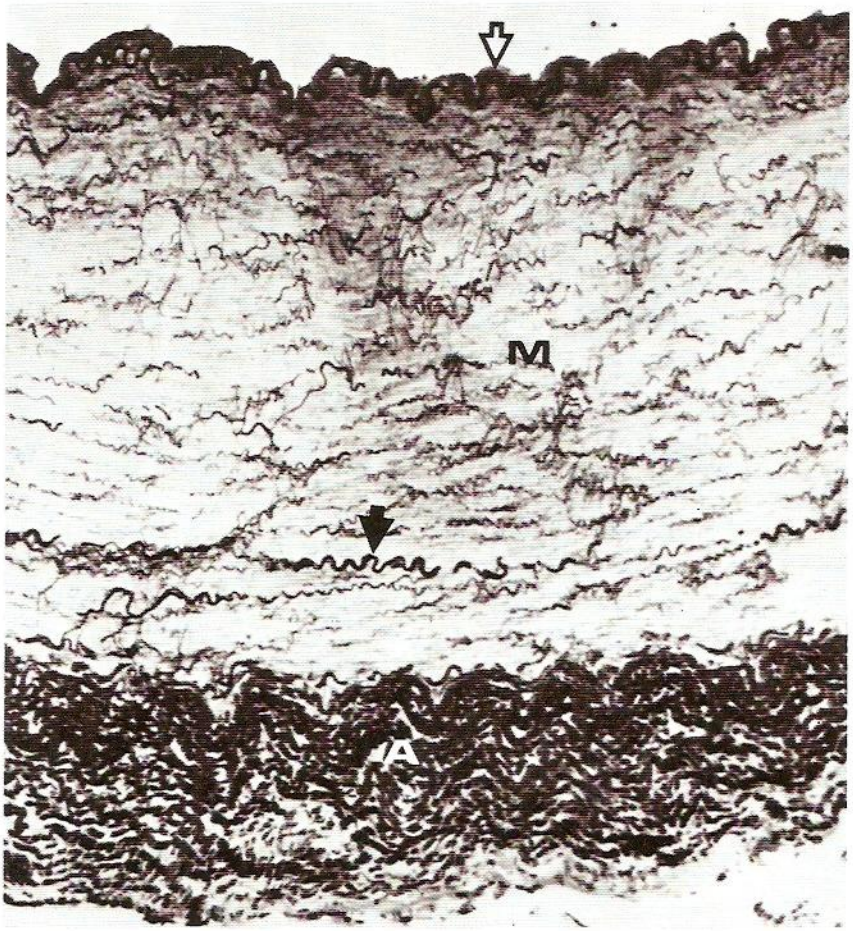

Figure 18-14. Section of an elastic artery. This section of aorta is stained for elastic fibers. The tunica intima contains a well-defined internal elastic membrane *(open arrow)*. The tunica media *(M)* consists of smooth muscle *(not stained)* and elastic fibers *(solid arrow)*. The tunica adventitia *(A)* has numerous elastic fibers also. (×25, orcein stain.)

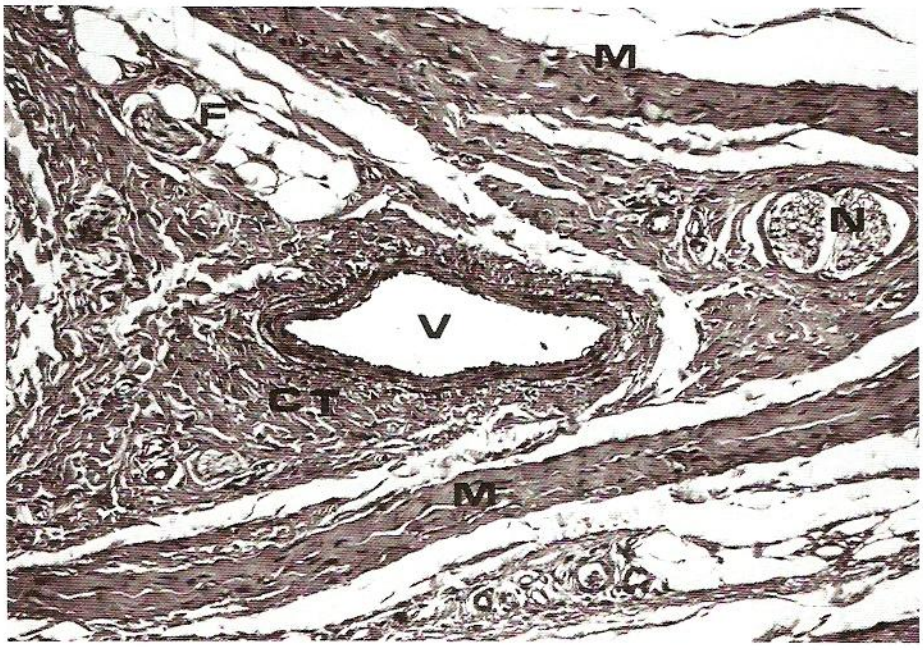

Figure 18-15. Section of a small vein. The vein *(V)* is surrounded by connective tissue *(CT)*. Adipocytes *(F)*, nerves *(N)*, and skeletal muscle are also present. (×40.)

Downloaded From VetBooks.com

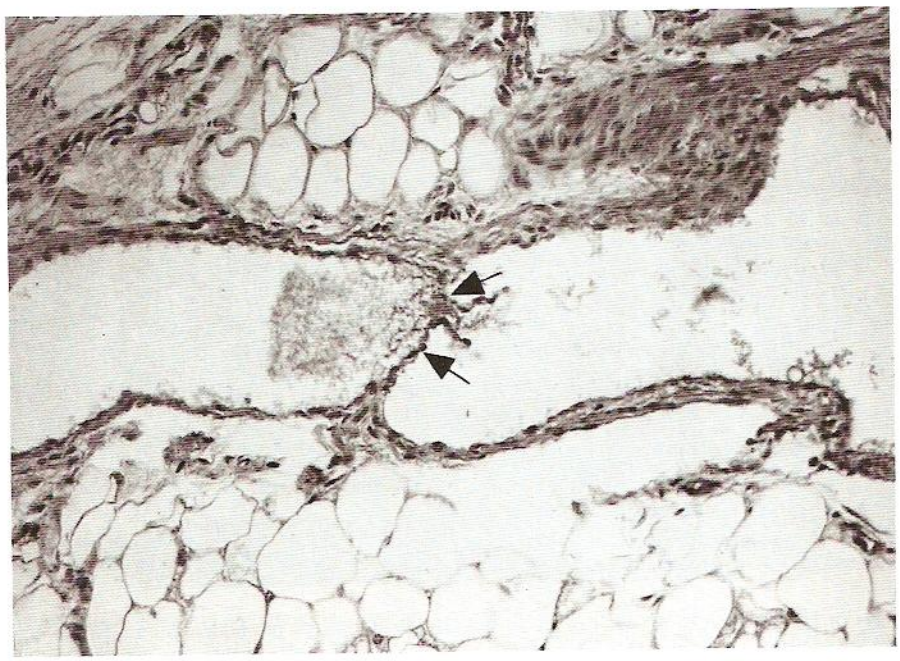

Figure 18-16. Valve in a vein. The cusps *(arrows)* are intimal modifications that prevent blood flow reversal. (×50.)

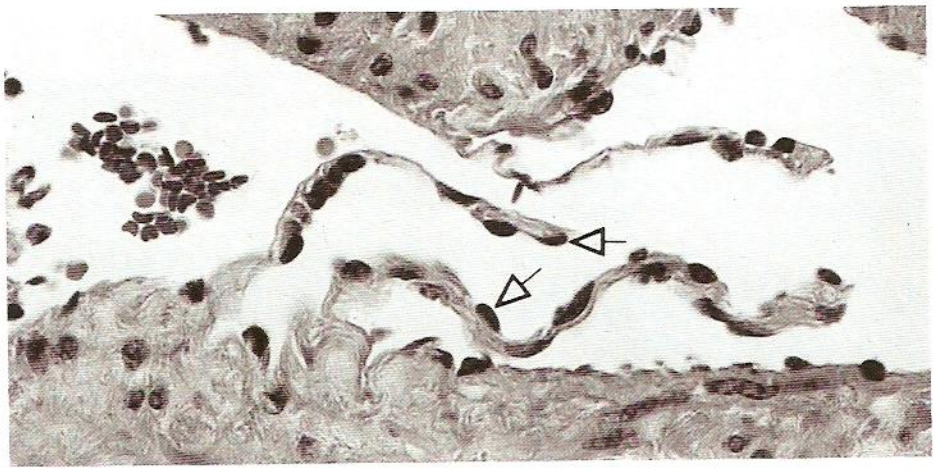

Figure 18-17. Components of a valve. The cusps are composed of endothelial cells *(arrows)* surrounding a core of subendothelial connective tissue. (×160.)

Downloaded From Vet-eBooks.com

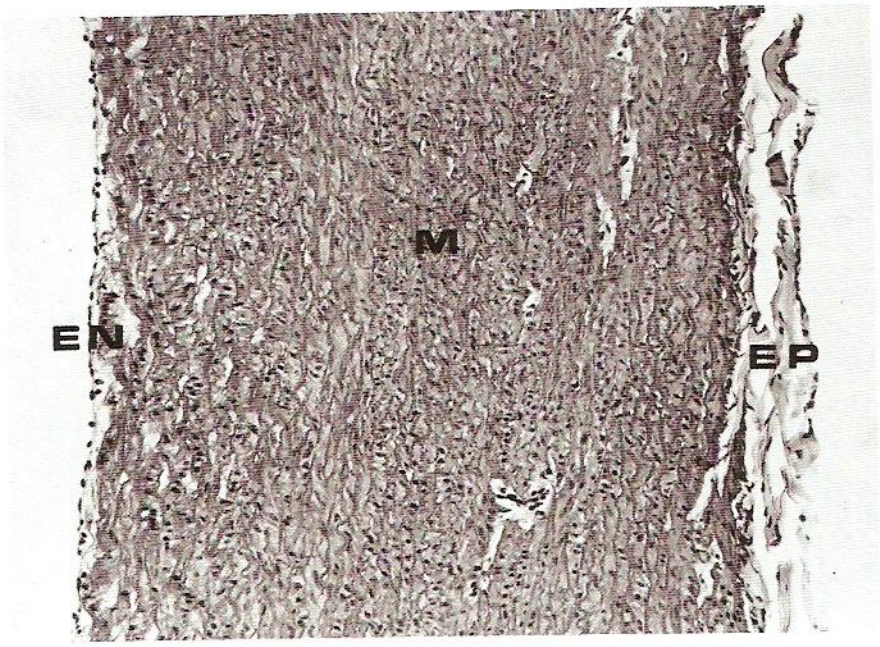

Figure 18-18. Section of the wall of an atrium. The wall consists of endocardium *(EN)*, myocardium *(M)*, and epicardium *(EP)*. The epicardium is also called tunica serosa and visceral pericardium. (×40.)

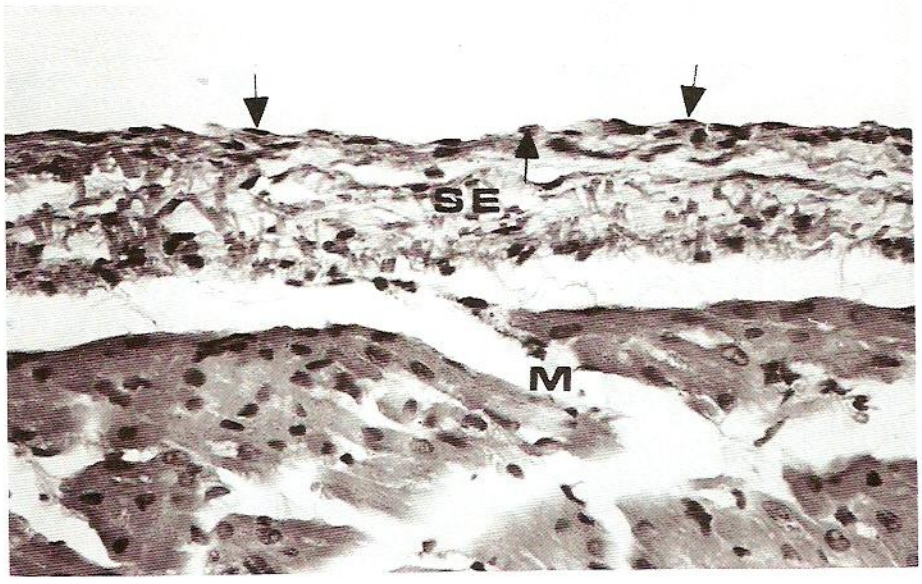

Figure 18-19. Section of atrial endocardium. The endothelium *(arrows)* is underlaid by subendothelial connective tissue *(SE)* that is adjacent to the myocardium *(M)*. (×100.)

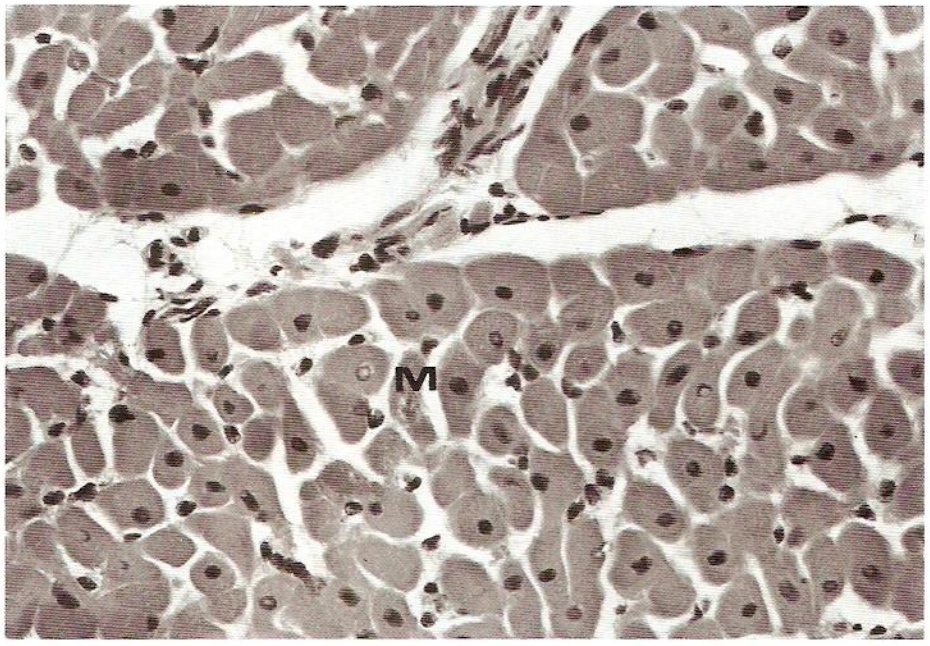

Figure 18-20. Section of ventricular myocardium. Most of the cardiac muscle cells are in cross section. The myocardium consists of cardiac muscle cells separated by a well-vascularized endomysium. (×100.)

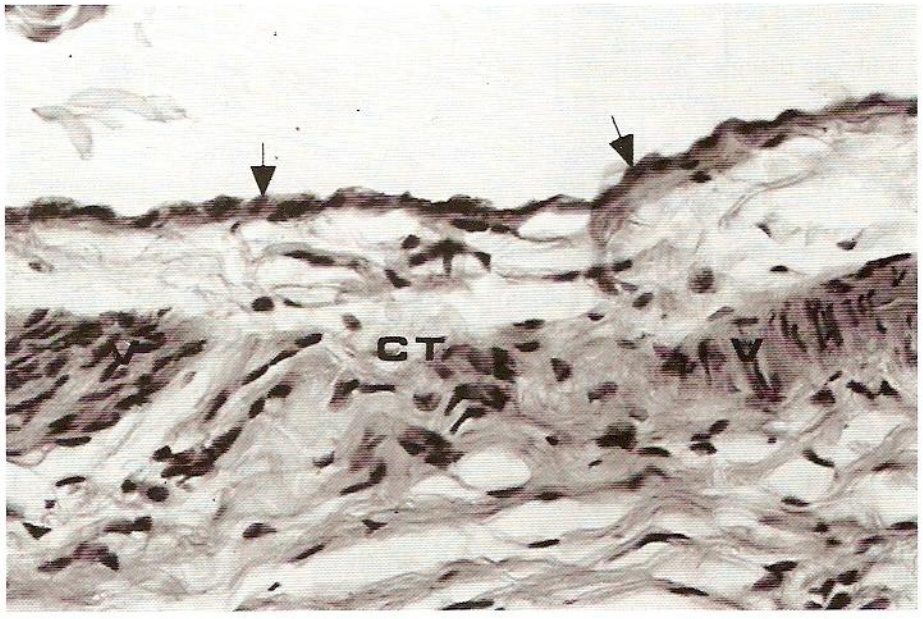

Figure 18-21. Section of atrial epicardium. The mesothelial lining *(arrows)* resides upon a layer of connective tissue *(CT)*. The smooth muscle is part of vessels *(V)* that have been sectioned obliquely. (×100.)

Downloaded From Vet-eBooks.com

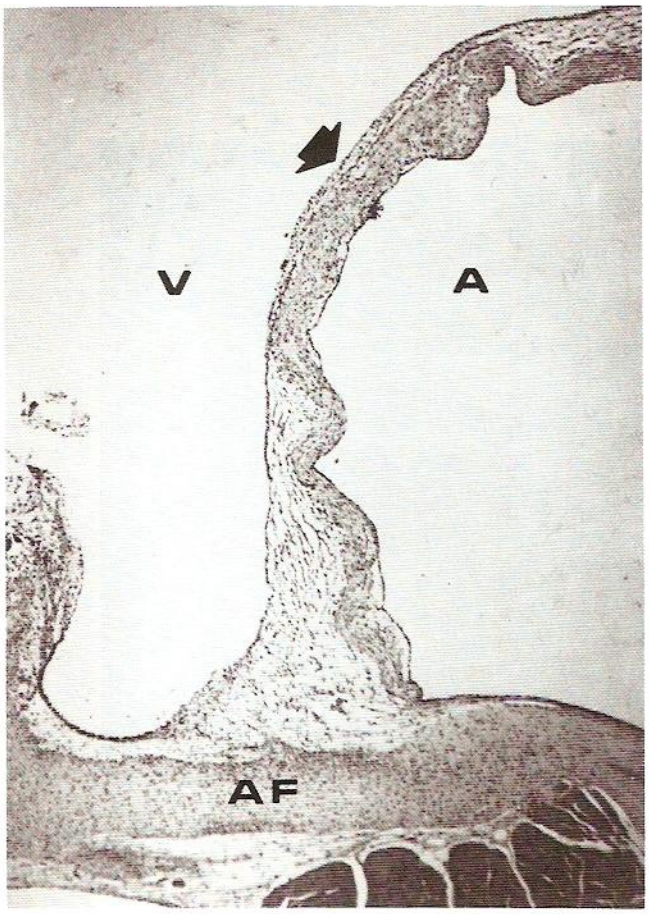

Figure 18-22. Section of part of an atrioventricular valve. The valve *(arrow)* separates the ventricle *(V)* from the atrium *(A)*. The connective tissue of the fibrous ring *(AF)* is continuous with the connective tissue core of the valve. The valve is covered by endothelium. (×10.)

four fibrous rings, (2) a fibrous triangle, and (3) a membranous septum.

The **four fibrous rings** surround the two semilunar valves (of the pulmonary artery and aorta) and the right and left atrioventricular valves. They continue with the **fibrous triangle,** a mass of fibrous tissue between the atrioventricular canals. Similarly they are continuous with the **fibrous tissue of the membranous interventricular septum.** These skeletal elements are origins and insertions for the cardiac muscle mass.

In the ox ossification of the fibrous ring of the aortic semilunar valve forms the **os cordis.**

Cardiac valves. The cardiac valves are evaginations of the endocardium into the cardiac lumen (Fig. 18-22). The connective tissue of the fibrous rings continues as a supportive core in the valves between the two endocardial layers. The connective tissue of the atrioventricular valves continues with the collagen fibers of the tendinous cords, which attach to the ventricular surfaces of the valves. A layer of endocardium reflects over these tendinous cords and continues with the endocardium of the papillary muscles. Elastic fibers are more numerous on the side of the valve facing the back pressure.

The **semilunar valves** are similar to the **atrioventricular valves.** A dense nodule of collagen or cartilage (the **semilunar valve nodule**) may be present on the edge of the three cusps.

Cardiac conduction system. Cardiac muscle is modified for conduction and contraction. Despite this ability, a specialized impulse-generating-and-conducting system is necessary to ensure the proper origination of impulses and the proper sequencing of atrial and ventricular contractions. The generating and conducting system consists of the sinoatrial (SA) node, the atrioventricular (AV) node, and the atrioventricular bundle (Fig. 18-23). Conducting cardiac fibers comprise this system (Fig. 18-24).

The **SA node,** positioned in the right atrial wall at the confluence of the major vessels entering it, contains conducting fibers described as **pacemaker cells.** The wave of depolarization spreads radially throughout the atrial myocardial mass and eventually reaches the **AV node.**

The conducting cardiac fibers converge at the **atrioventricular bundle,** close to the ventricles. The atrioventricular bundle courses craniad and ventrad through

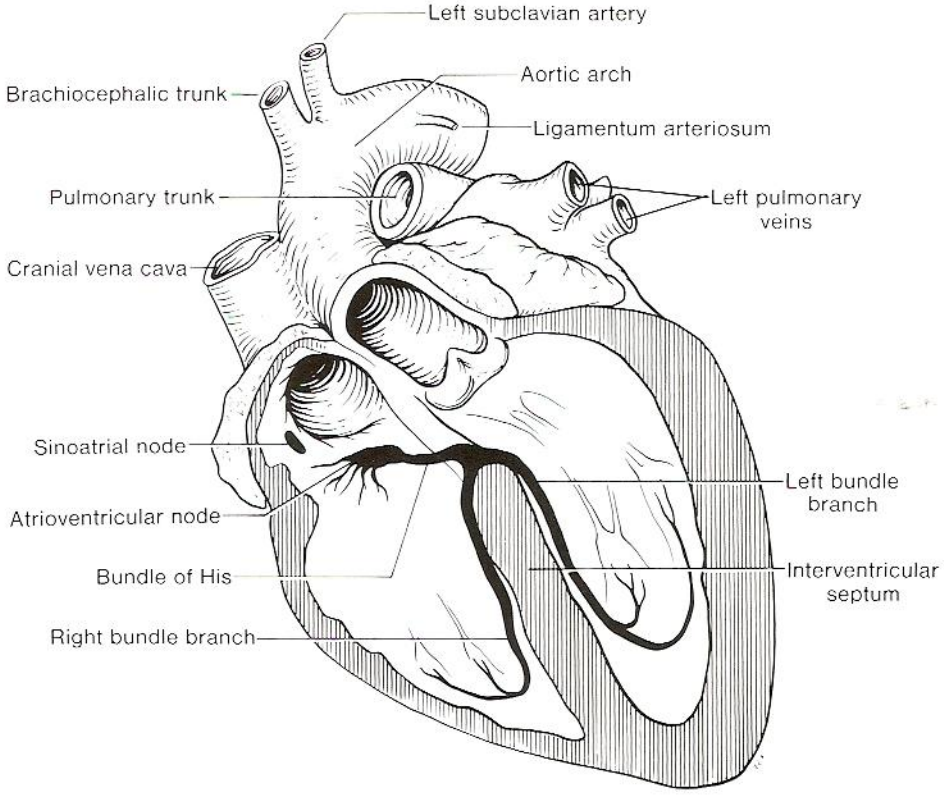

Figure 18-23. Canine heart, showing the conduction system and major components.

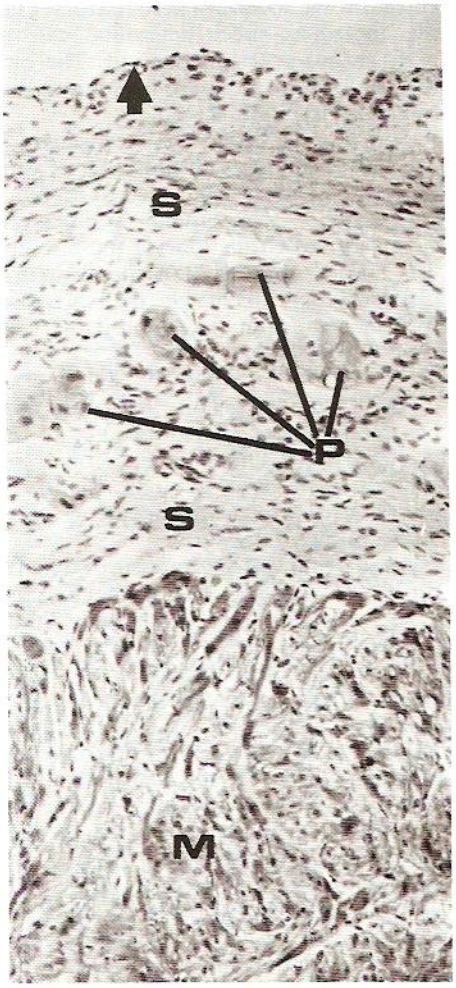

Figure 18-24. Subendocardial cardiac conducting cells of a porcine heart. The *arrow* points to endothelium. *S* denotes subendothelium, *P* cardiac conducting cells, *M* myocardium. The cardiac conducting cells are part of the bundle branches of the ventricles. (×40.)

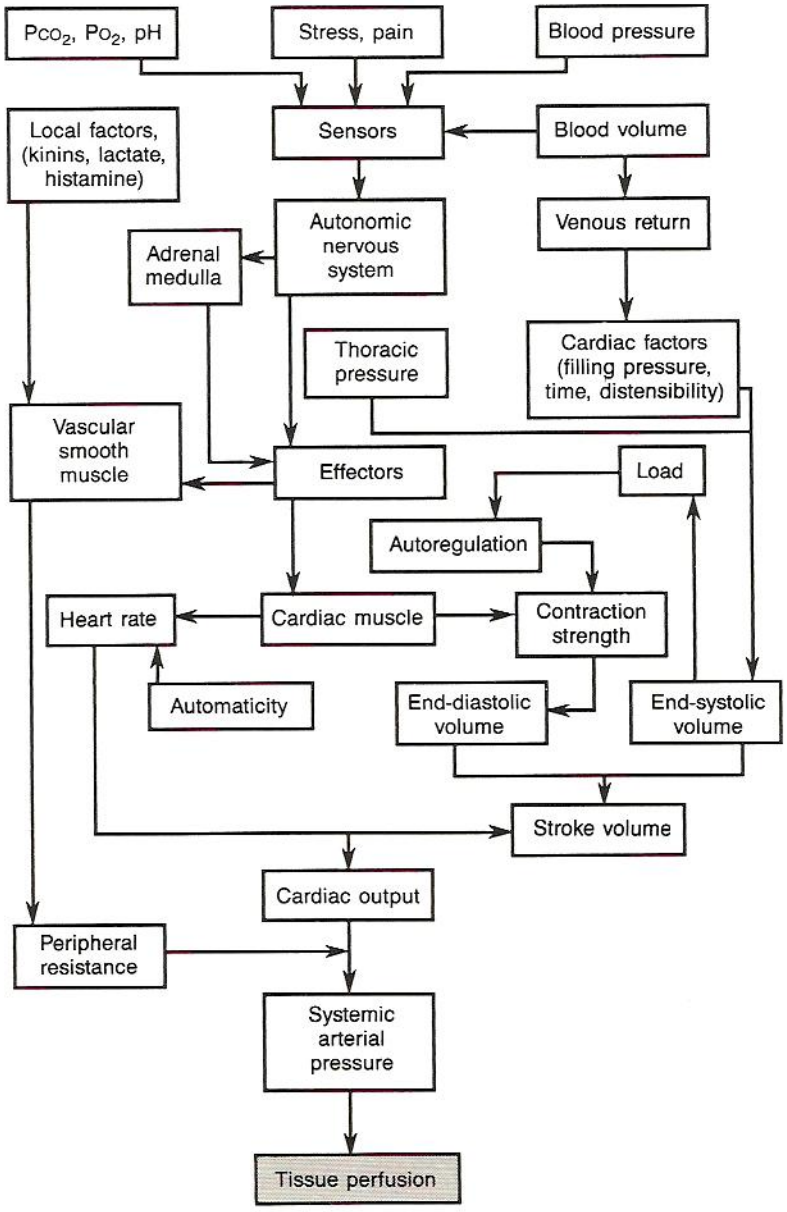

Figure 18-25. Influences upon the cardiovascular system that affect tissue perfusion.

the fibrous triangle and extends into the membranous septum, dividing into the **right** and **left bundle branches.**

The impulse-generating-and-conducting system affords advantages to the myocardial mass. The cells of the SA node have a pacemaker function because of their rapid rate of depolarization and repolarization. This normally precludes **ectopic foci** from assuming that role. The initial spread of excitation over the atrial musculature ensures filling of the ventricles. The AV nodal conduction delay facilitates maximal ventricular filling prior to contraction. The atrioventricular bundles speed impulses toward the apex, permitting the wave of contraction to proceed from apex to base and ensuring maximal blood ejection.

Cardiac blood vessels, lymphatic vessels, and nerves. The heart is richly vascularized through its coronary arteries. These vessels originate from the aortic arch immediately distal to the aortic valve. The extensive myocardial capillary network is an obvious feature. Lymphatic vessels occur in the three cardiac coats. Many nerve fibers from the ANS innervate the myocardial mass as well as the nodes and smooth muscle of the coronary vessels.

Cardiac Activity

Regulatory mechanisms

Many factors influence the cardiovascular system—myogenic, neurogenic, humoral, chemical, metabolic, barometric, and volumetric. Cardiovascular regulation is the sum effect of these influences on the heart and peripheral vessels.

The essence of this regulation is to ensure an adequate amount of blood to the tissues, **tissue perfusion** (Fig. 18-25). Proper tissue perfusion depends upon the presentation of an adequate blood volume to the capillaries, under appropriate pressure.

Types of influences. The **myogenic** influence upon the heart relates to pacemaker cell automaticity. **Neurogenic** influences from the ANS can increase or decrease the rate of depolarization of SA nodal pacemakers. A **hormonal influence** on the cardiovascular α- and β-receptors is exerted by epinephrine from the adrenal medulla. A **chemical influence** is exerted by special receptors sensitive to the partial pressures of CO_2 and O_2 and pH. **Barometric** or blood pressure changes influence neurogenic cardiac regulation. The heart is also capable of **homeometric autoregulation**—ejecting a greater stroke volume against increased aortic pressure. **Volumetric influences** are manifested as an integral part of regulation, because the

Downloaded From Vet-eBooks.com

heart tends to eject whatever is returned to it. This stroke volume/diastolic filling relationship is known as **Starling's law of the heart** and is dependent upon changes in myocardial fiber length **(heterometric autoregulation). Pain** may have a stimulatory or inhibitory effect upon cardiac activity. Added to the above are many local autoregulatory factors that affect tissue perfusion, including the kinins, lactate, histamine, CO_2, and O_2.

Specialized chemoreceptors

The **carotid bodies** and **aortic bodies** are specialized chemoreceptors exerting an influence upon the cardiovascular and respiratory systems through their responses to blood levels or partial pressure (P) of carbon dioxide (Pco_2) and oxygen (Po_2).

Carotid bodies. The **carotid bodies** are small nodules of cells positioned with the common carotid arteries. They are vascularized receptors consisting of parenchymal cells enclosed by a capsule of connective tissue. Two distinct cells are apparent. **Type I cells (glomus cells)** are large, contain a round nucleus, and are usually clumped together in small groups. Many nerve fibers ramify throughout the carotid bodies and terminate on Type I cells. The glomus cells are surrounded by **Type II cells (sustentacular cells).** The precise mechanism by which Type I cells function has not been determined.

Glomus cells have ultrastructural features of sensory and effector (secretory) cells; their innervation appears to be both afferent and efferent. The carotid bodies are innervated by GVA and GVE fibers from the glossopharyngeal nerve.

Aortic bodies. The **aortic bodies** are similar to the carotid bodies. Although they have not been studied as extensively as the carotid bodies, they probably function in a similar manner, being innervated by fibers from the vagus nerve.

Specialized baroreceptors

The **carotid sinus** and **aortic sinus** are specialized receptors responsive to alterations in blood pressure. The carotid sinus is a dilation of the internal carotid artery as it originates from the common carotid artery. The tunica media of the carotid sinus has fewer smooth muscle fibers and more elastic and collagen fibers than do adjacent portions of the artery. Many afferent terminals from the glossopharyngeal nerve (IX) ramify in the tunica adventitia of this structure. The vagus nerve (X) innervates the aortic sinus. These receptors stimulate central control centers, resulting in a reflex bradycardia, dilation of the splanchnic vessels, and a fall in systemic blood pressure.

Neuroregulation

Central components and afferent input. The hypothalamic influence upon the cardiovascular system is mediated through various autonomic nerve centers—vasomotor centers, the motor nuclei of cranial nerves, and the lateral gray columns of the thoracic and lumbar spinal cord. Hypothalamic control is manifested as a basal **tone** altered in response to various afferent input.

The **vasopressor region, cardiac stimulator center,** and **vasodepressor region** are diffuse regions within the medullary reticular formation. The **cardiac inhibitory center** or **vagal dorsal motor nucleus** is a discrete nucleus within this region.

Physiological correlates. The dual innervation of the myocardium provides an effective and precise means for cardiac regulation. This activity is determined by the balance exerted between inhibitory cholinergic fibers of the vagus nerve and stimulatory adrenergic fibers of the sympathetic nerves.

Cardiac stimulation by sympathetic nerves results in a **positive chronotropy** (increased heart rate), a **positive inotropy** (increased strength of contraction), and a **positive dromotropy** (increased velocity of conduction). An increased vagal tone has the opposite effect.

The heart rate of a resting animal is primarily under the inhibitory influence of the vagus nerve's exerting a braking effect upon the resting heart rate. Bilateral vagotomy or the use of antimuscarinic drugs results in tachycardia. Massive vagal stimulation or the use of muscarinic drugs can reduce the heart rate (bradycardia) to the point of sinus arrest. Sympathectomy or the use of β_1-blocking agents produces **bradycardia;** sympathetic stimulation or the administration of β-stimulators causes **tachycardyia.** The chronotropic effects upon the heart are mediated through an altered nodal tissue depolarization rate. A change in the slope of the prepotential determines the rapidity of nodal firing.

Although the sympathetic nerves exert a marked positive inotropy upon the ventricular myocardium, the negative inotropic effect of the vagus is not equivalent. The mechanism by which these nerves exert their inotropic effects is not clear. The positive inotropy exerted through β_1-receptor activity is mediated by cAMP. Many xanthines, which decrease the breakdown of cAMP by the inhibition of phosphodiesterase activity, are also positive inotropes. The cardiac glycosides and other antiarrhythmic drugs are believed to exert their positive inotropy upon the myocardium by the inhibition of Na^+/K^+-dependent ATPase. The increased intercellular Na^+ followed by an influx of Ca^{++} causes enhanced excitation-contraction coupling.

The dromotropic effect is manifested as an alteration in atrial and ventricular conduction speeds, as well as an alteration in nodal delay. It complements the chronotropic effect. These factors plus the inotropic effect determine cardiac performance or **cardiac output. The cardiac output is the heart rate multiplied by the stroke volume.**

The adrenergic receptors located in coronary vessel smooth muscle are β_2-receptors. The heart is required to do more work under sympathetic stimulation. Coronary vessel dilation via these receptors ensures that a blood supply to the myocardium will match the increased work demands imposed upon it.

Autonomic reflex activity

Arterial pressoreceptor reflex. Arterial baroreceptors are located throughout the body as integral components of vessel walls. They respond to alterations in the blood vessel stretch accompanying alterations in blood pressure.

An increase in blood pressure stretches the vessel wall and causes an increased rate of discharge (Fig 18-26). This information reaches the vasomotor centers and stimulates the vasodepressor region while blocking the vasopressor region, effectively decreasing the sympathetic tone to the cardiovascular system. Concomitantly, these afferents reach the cardiac inhibitory center (dorsal motor nucleus of the vagus nerve) and vagal tone to the heart is increased. Thus an increased blood pressure reflexively results in a decreased cardiac output and peripheral vasodilation. This combination effectively lowers the blood pressure. A decrease in blood pressure has the reverse effect upon the cardiovascular system (Fig. 18-26).

The specific arterial pressoreceptor reflex involving the carotid sinus is called the **carotid sinus reflex.** It is a negative feedback loop in cardiovascular homeostasis. Baroreceptor stimulation inhibits the cardiovascular system. One notable exception to this generality exists: when the heart is operating under the influence of increased vagal tone, stretching of the right atrium causes an increased heart rate **(Bainbridge reflex).**

Chemoreceptor reflexes. These reflexes use the carotid and aortic bodies. Medullary receptors on the floor of the fourth ventricle near the obex are also involved. The receptors for chemical reflexes are sensitive to Po_2, Pco_2, and pH.

The carotid body, as an example, consists of a glomus of cells that is one of the most vascularized organs. It receives approximately 200 times more blood than the rest of the body on a milliliter per minute per gram basis. An increased discharge, as in the baroreceptor reflex, causes a release of central inhibition. The primary effects, however, are mediated through the respiratory centers. Minimal cardiac effects are noted, since peripheral hypoxia depresses cardiac activity; a central hypoxia stimulates cardiac activity.

Downloaded From Vet-eBooks.com

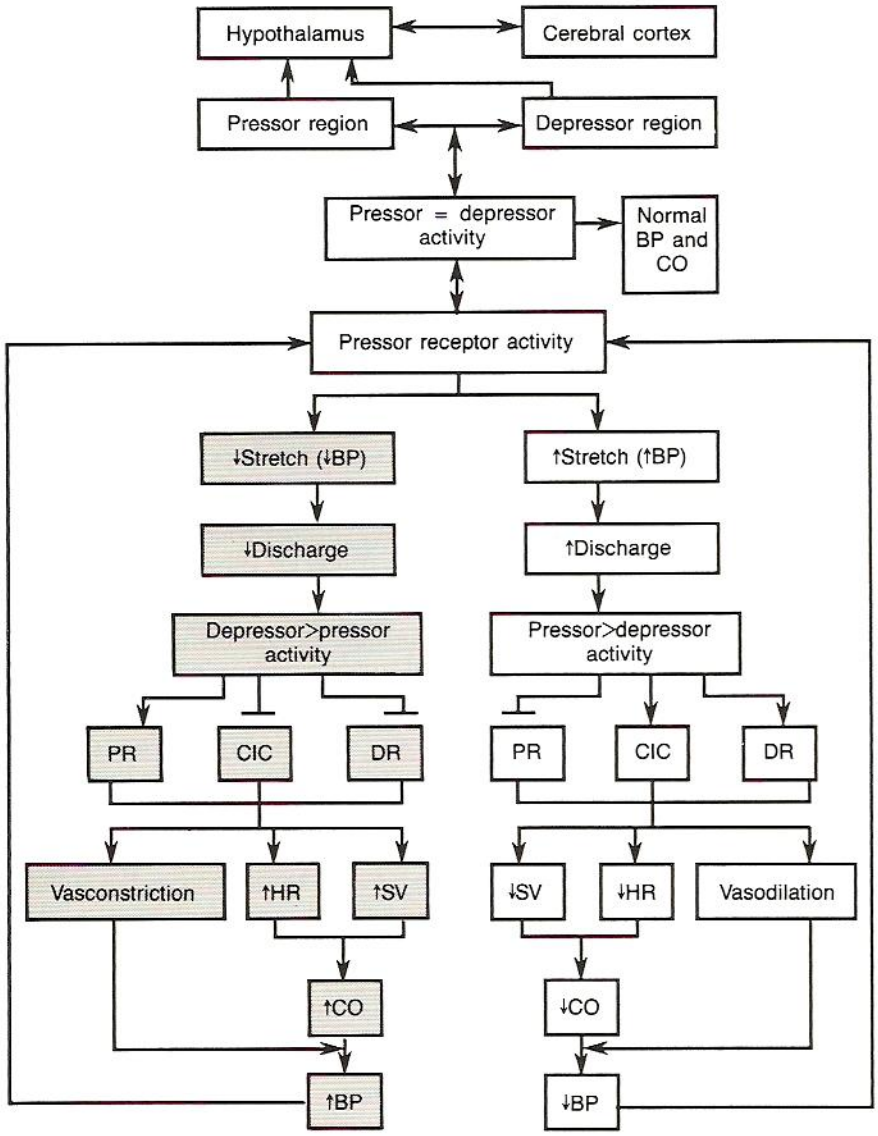

Figure 18-26. Effects of the arterial pressoreceptor reflex upon blood pressure. *PR,* Pressor region; *CIC,* cardiac inhibitory center (dorsal motor nucleus of the vagus nerve); *DR,* depressor region; *SV,* stroke volume; *HR,* heart rate; *CO,* cardiac output; *BP,* blood pressure. *Arrows* indicate the direction of flow or stimulation; *bars,* inhibition. An increased discharge rate inhibits the *PR* but stimulates the *CIC* and *DR;* a decreased blood pressure results. The reverse occurs when a decrease in blood flow causes decreased receptor discharge.

Chemoreceptors help to coordinate pulmonary and cardiac activity to ensure proper ventilation and perfusion ratios.

It is possible that blood flow to the brain can be impaired without stimulation of the carotid or aortic receptors. Under these circumstances the medullary receptors are important monitors of P_{CO_2} and pH. **Cerebral ischemia,** then, leads to increased activity in the cardiovascular and respiratory systems.

Pain. Most sensory modalities are involved in the reflex activity associated with cardiovascular regulation. Pain manifests diverse influences upon the system. Generally, a painful stimulus causes a rise in blood pressure through increased activity of the vasopressor centers. Vasoconstriction and increased cardiac output account for a rise in blood pressure.

Severe cutaneous and deep visceral pain usually has the opposite effect—bradycardia and decreased blood pressure. A **vagovagal reflex** involving the visceral organs occurs under various circumstances but may be especially significant during abdominal surgery.

LYMPHATIC VESSELS

Lymph capillaries are similar to continuous blood capillaries and are most difficult to distinguish from each other in section (Fig. 18-7). They are partially or completely devoid of a basement membrane, and their abluminal surfaces may have microvilli anchoring the vessel in the connective tissue space. Also they are generally devoid of formed elements; however, agranulocytes may be encountered.

The larger vessels are not well-organized. Although there may be three mural regions, these are poorly defined. Generally, lymphatic vessels have thinner walls than other veins of a corresponding size do and valves occur in smaller lymph vessels than in correspondingly sized veins.

ADDITIONAL READINGS

Vasculature

Abramson DI: *Circulation in the extremities,* New York, 1976, Academic Press.

Ahmed MM: The fine structure of endothelium in coronary arterioles, *Acta Anat* 69:327, 1968.

Bennet HS, Luft JH, Hampton JC: Morphological classification of vertebrate blood capillaries, *Am J Physiol* 196:381, 1959.

Bruns RR, Palade GE: Studies on blood capillaries. I. General organization of blood capillaries in muscle, *J Cell Biol* 37:244, 1968.

Cliff WJ: *Blood vessels,* New York, 1976, Cambridge University Press.

Fernando NVP, Movat HZ: The capillaries, *Exp Molec Pathol* 3:87, 1964.

Hayes JR: Histological changes in constricted arteries and arterioles, *J Anat* 101:343, 1967.

Keech MK: Electron microscope study of the normal rat aorta, *J Biophys Biochem Cytol* 7:533, 1960.

Leak LV, Burke JF: Fine structure of the lymphatic capillary and the adjoining connective tissue area, *Am J Anat* 118:785, 1966.

Rhodin JAG: Fine structure of vascular walls in mammals with special reference to smooth muscle component, *Physiol Rev* 42:447, 1962.

Simonescu N: Cellular aspects of transcapillary exchange, *Physiol Rev* 63:1536, 1983.

Wood JE: *The veins: normal and abnormal function,* Boston, 1965, Little, Brown.

Heart

Bolton GR: *Handbook of canine electrocardiography,* Philadelphia, 1975, WB Saunders.

Eckner FAO, et al.: Alterations of the gross dimensions of the heart and its structures by formalin fixation: a quantitative study, *Virchows Arch Pathol Anat* 346:318, 1969.

Ettinger SJ, Suter PF: *Canine cardiology,* Philadelphia, 1970, WB Saunders.

Ghidoni JJ, Liotta D, Thomas H: Massive subendocardial damage and accompanying prolonged ventricular fibrillation, *Am J Pathol* 56:15, 1969.

Hogan PM, Davis LD: Evidence for specialized fibers in the canine right atrium, *Circ Res* 23:387, 1968.

James TN, Sherf L: Ultrastructure of myocardial cells, *Am J Cardiol* 22:389, 1968.

James TN, Sherf L, Urthaler F: Fine structure of the bundle branches, *Br Heart J* 36:1, 1974.

Langer GA, Brady AJ: *The mammalian myocardium,* New York, 1974, John Wiley & Sons.

Merkin RJ: Position and orientation of heart valves, *Am J Anat* 125:375, 1969.

Mitomo Y, Nakao K, Angrist A: The fine structure of the heart valves of the chicken, *Am J Anat* 125:147, 1969.

Muir AR: Observations on the fine structure of the Purkinje fibers in the ventricles of the sheep's heart, *J Anat* 91:251, 1957.

Nabors CE, Ball CR: Spontaneous calcification in hearts of DBA mice, *Anat Rec* 164.153, 1969.

Rhodin JAG, Delmissier P, Reid LC: The structure of the specialized conducting system of the steer heart, *Circulation* 24:349, 1961.

Regulation

Aars H: The baroreflex in arterial hypertension, *Scand J Clin Lab Invest* 35:97, 1975.

Armour JA, Randall WC: Functional anatomy of canine cardiac nerves, *Acta Anat* 91:510, 1975.

Denn MJ, Stone HL: Autonomic innervation of the dog coronary arteries, *J Appl Physiol* 41:30, 1976.
Feigl EO: Sympathetic control of coronary circulation, *Circ Res* 20:262, 1967.
Feigl EO: Carotid sinus reflex control of coronary blood flow, *Circ Res* 23:223, 1968.
Feigl EO: Parasympathetic control of coronary blood flow in dogs, *Circ Res* 25:509, 1969.
Granger HS, Guyton AC: Autoregulation of the total systemic circulation following destruction of the central nervous system in the dog, *Circ Res* 25:379, 1969.
Gross D: Pain and autonomic nervous system, *Adv Neurol* 4:93, 1974.
Osborne MP, Butler PJ: New theory for receptor mechanism of carotid body chemoreceptors, *Nature* 254:701, 1975.

Downloaded From VetraBooks.com

CHAPTER 19

Lymphatic System and Immunity

GENERAL CHARACTERISTICS

Form and function. The lymphatic and vascular systems form a functional unit, the **hemic-lymphatic system,** that is a **secondary defense system.** The **primary defense system** is the skin and mucous membranes. The hemic-lymphatic system **produces defensive cells, transports materials via the lymphatic vessels, filters lymph and blood, phagocytizes,** and **is involved in the production of immunoglobulins.** Filtration is complemented by phagocytosis. The phagocytic function is achieved by aggregation of phagocytic cells as the **macrophage system.**

Classification of lymphatic tissues. The tissues and organs of the lymphatic system are grouped into morphological divisions:

- Diffuse and unencapsulated (subepithelial accumulations associated with the respiratory, digestive, and urogenital tracts)
- Dense and unencapsulated (subepithelial accumulations associated with the respiratory, digestive, and urogenital tracts)
- Dense and encapsulated (scattered throughout the body [lymph nodes, spleen, hemal nodes, hemolymph nodes, thymus, bursa of Fabricius])

DIFFUSE, UNENCAPSULATED LYMPHATIC TISSUE

Lymphoid cells (mononuclears) are distributed throughout the body and include lymphocytes, monocytes, plasma cells, and macrophages. They may occur with sufficient frequency in connective tissues to impart a hypercellular nature to the tissues (Fig. 19-1). In those organs subjected to continual insult from foreign materials (respiratory, digestive, and urogenital tracts) they are part of the resident population of connective tissue cells.

DENSE, UNENCAPSULATED LYMPHATIC TISSUE

Lymphocytic populations are organized into solitary small, spheroidal or ovoid, aggregates called **nodules. Primary nodules (follicles)** consist of uniformly small lymphocytes. Some of these

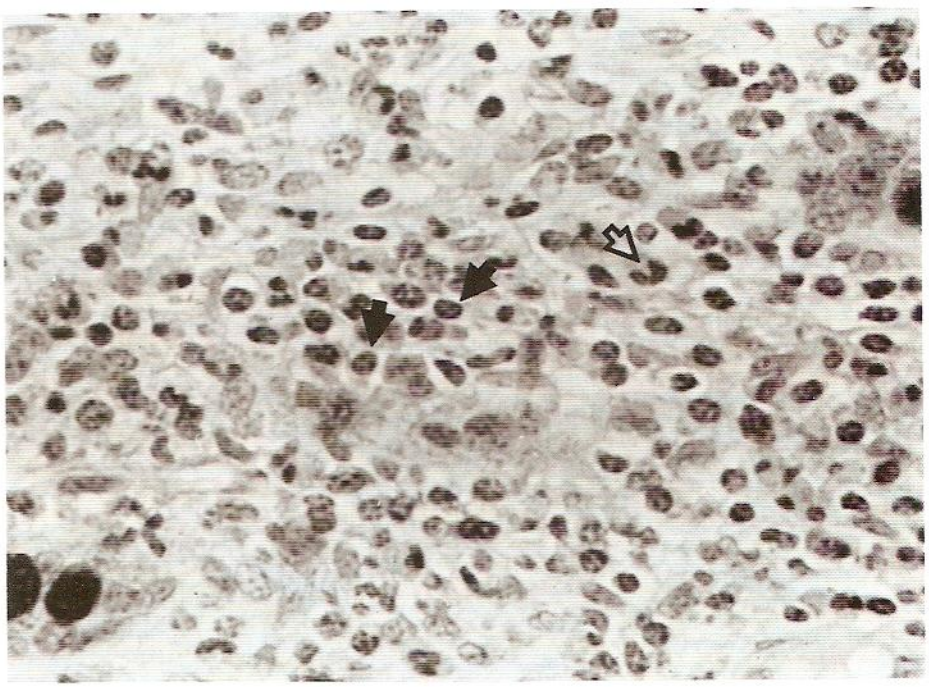

Figure 19-1. Section of lamina propria mucosae associated with the gastrointestinal tract. The tissue is hyperplastic. Numerous plasma cells *(solid arrows),* macrophages *(open arrow),* and other mononucleated cells are present. (×160.)

nodules have a light-staining central zone (large lymphocytes and macrophages) that stains lightly because of its large cells, light cytoplasm, and pale-staining nuclei. **Secondary nodules** have a central zone (called the **germinal center**) that is surrounded by dark-staining small lymphocytes (the **corona, crescent,** or **mantle zone**).

Solitary nodules occur in the connective tissue of most organs, especially the digestive, respiratory, and urogenital tracts (Fig. 19-2). Lymphoid cells migrate from the nodules into the connective tissue. The tissues surrounding these nodules are drained by lymphatic vessels. Some nodules have capsules.

Avian lymphatic tissue. Many birds (excluding swamp birds, shorebirds, and seabirds) do not have lymph nodes. Solitary accumulations of lymph nodules characterize their digestive tract, serous membranes, and skin (Fig. 19-3).

Mammalian lymphatic tissue. Accumulations of large and even confluent lymph nodules (Fig. 19-4) occur throughout the mammalian body. Aggregated lymph nodules in the pharnyx are called tonsils. Such collections in the small intestine are called **Peyer's patches** and are part of the **gut-associated lymphatic tissue (GALT).**

Tonsils are solitary or aggregated nodules and diffuse mononuclears in the pharyngeal mucosa (Fig. 19-5). They have large germinal centers with dense cortices, and infiltration of mononuclears into the surrounding pharyngeal mucosa is usually evident.

Although tonsils are similar, two types have been defined based upon their relationships with the surface epithelium—tonsils with crypts and tonsils without crypts. A **crypt** is a blind and sometimes branched invagination of the surface epithelium. Along with its lymphatic tissue it comprises a **tonsillar follicle** (Fig. 19-6). A group of tonsillar follicles constitutes a **tonsil with crypts. A tonsil without crypts** is formed by a single layer of lymphatic tissue secondarily protruding into the lumen or slightly folded to increase its surface area (Fig. 19-5). The in-

Downloaded From Vet-eBooks.com

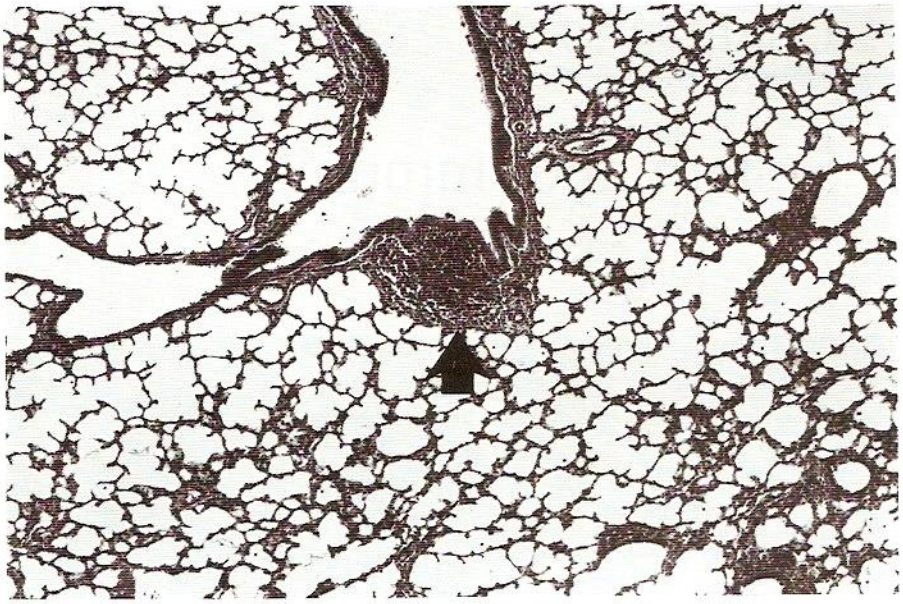

Figure 19-2. Solitary lymph nodule in a lung. The nodule *(arrow)* is associated closely with a bronchiole. (×16.)

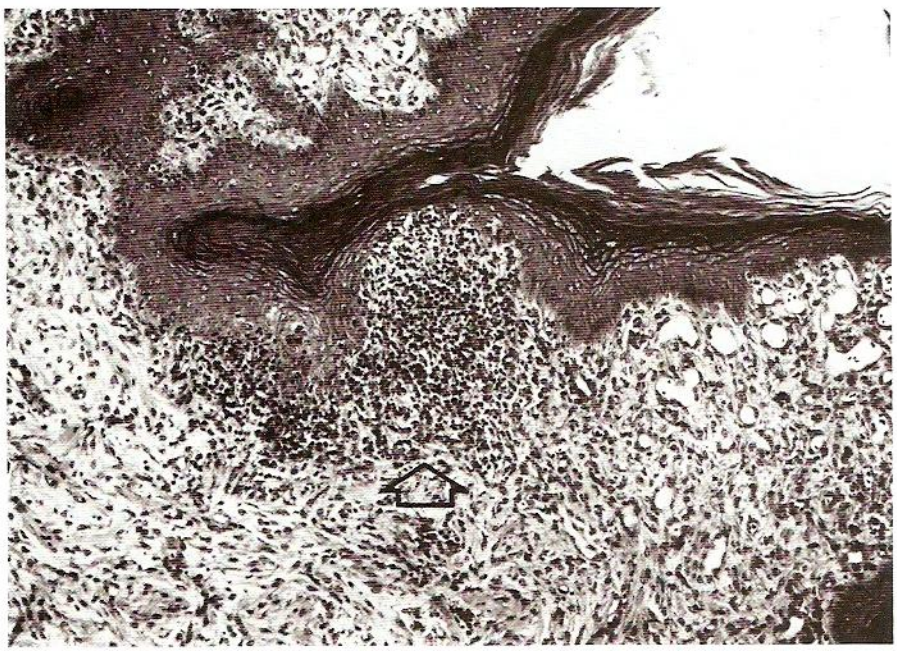

Figure 19-3. Lymphatic tissue in the dermal connective tissue of an avian comb. The dermis contains a lymphatic nodule *(arrow)* and loose lymphatic tissue.

vaginations of the tunica mucosa are significant, because they serve as foci of infection and inflammatory processes.

OCCURRENCE

Tonsils with crypts (follicular tonsils): palatine tonsils in humans, horses, ruminants, and swine; lingual tonsils in humans, horses, ruminants, and swine; tubal tonsils in swine; paraepiglottic tonsils in sheep, goats, and swine

Tonsils without crypts: palatine tonsils in carnivores; pharyngeal tonsils in all domestic animals except carnivores; tubal tonsils in ruminants

Tonsils do not possess afferent lymphatic channels, but efferent channels do drain the aggregated nodules.

DENSE, ENCAPSULATED LYMPHATIC TISSUE

Lymph Node

Histological structure. **Lymph nodes (glands)** are dense, encapsulated organs occurring constantly in specific regions called **lymphocenters.** They are usually

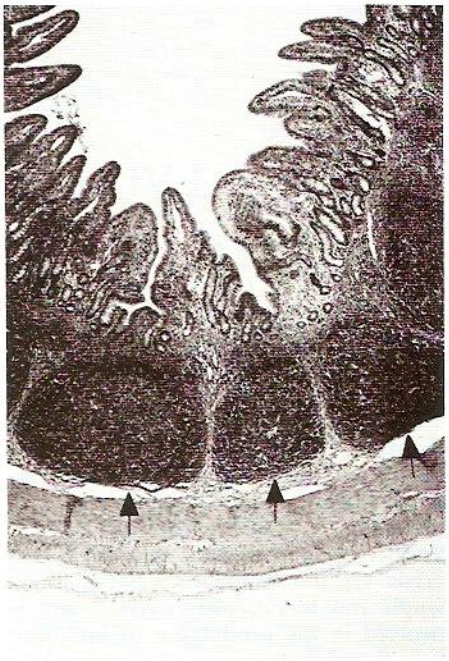

Figure 19-4. Lymphatic nodule aggregates (Peyer's patches) in the wall of an ileum. The patches *(arrows)* are also called gut-associated lymphatic tissue (GALT). (×8.)

bean-shaped and vary in size from a millimeter to several centimeters (Fig. 19-7).

The capsule and trabeculae are dense collagenous tissue. The fine stromal elements are reticular fibers (Fig 19-8). The reticular fibers are secreted by **reticular cells** (probably fibroblasts). Both the fibers and the cells form an extensive network throughout the lymph node. Interspersed among this **fibrous reticulum** and **cytoreticulum** are the free cells (lymphocytes, plasma cells, macrophages) of the lymphatic system.

Diffusely spaced lymphocytes occupy the cortex in association with **lymph nodules (follicules).** There are primary and secondary nodules. The **primary type** has tightly packed small lymphocytes throughout. The **secondary type** has a central pale region of large lymphocytes and macrophages (Fig. 19-9). This central region stains lightly because of its large cells, their pale-staining cytoplasm, and the pale-staining euchromatin. The secondary nodules (Fig. 19-10) have a germinal center surrounded by a zone of small lymphocytes. This zone, called the **mantle zone** or **corona,** stains darkly because of the small size of its cells, their reduced cytoplasmic mass, and the nuclear heterochromatin.

The **cortex** of a lymph node can be divided into three zones—**nodular, internodular,** and **deep** (Fig. 19-7). The internodular and deep cortices comprise the **paracortical region** or **diffuse cortex** of some authors. B cells are concentrated in the primary nodules and in the germinal centers of secondary nodules. T cells occupy the paracortical region. B cell differ-

Downloaded From Vet-eBooks.com

Figure 19-5. Tonsil without crypts. Nodular *(N)* and loose *(L)* lymphatic tissue is the primary constituent of this structure *(arrow)*. The tunica mucosa is folded slightly. Extensive infiltration of lymphocytes into the lamina propria mucosae and lamina epithelialis mucosae is evident. The epithelial lining is not readily apparent *(center)* because of cell infiltration. (×10.)

Figure 19-6. Tonsil with crypts. Nodular *(N)* and loose lymphatic tissues are the primary components. The lamina epithelialis mucosae *(E)* is folded extensively and forms deep crypts *(C)* or invaginations. (×10.)

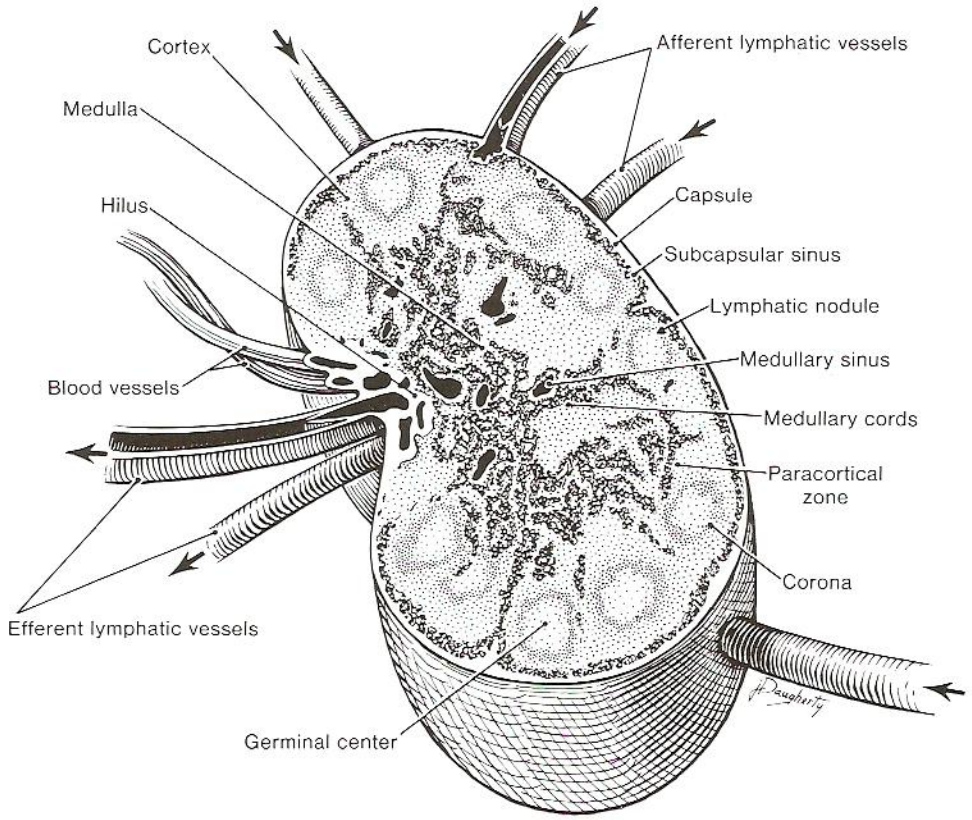

Figure 19-7. Typical lymph node.

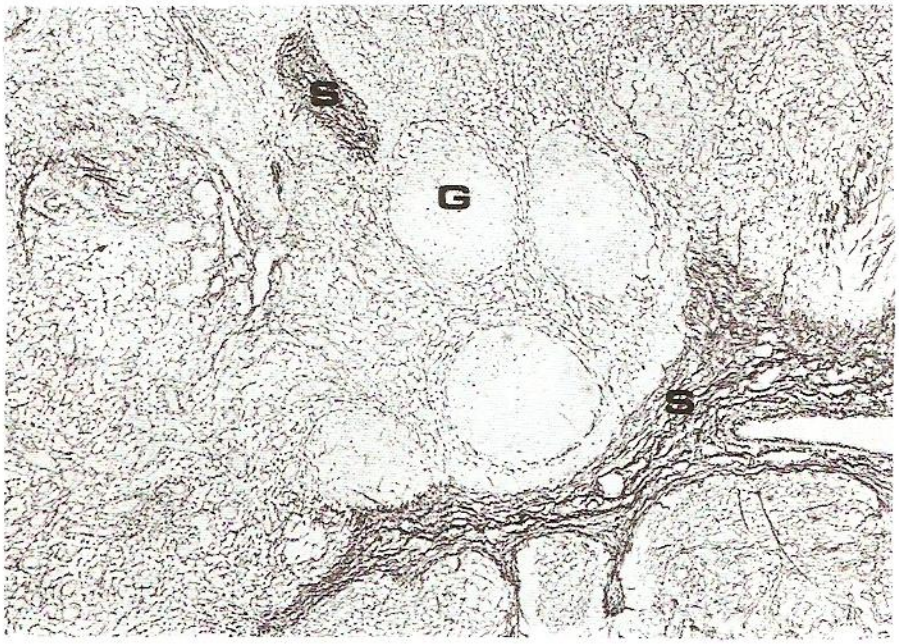

Figure 19-8. Stromal elements of a lymph node. The trabecular stroma *(S)* consists of reticular and collagen fibers. Other interstitial regions are composed of reticular fibers exclusively. The germinal centers *(G)* contain a paucity of fibrous elements. (×16, Snook's reticular stain.)

Downloaded from VetBooks.com

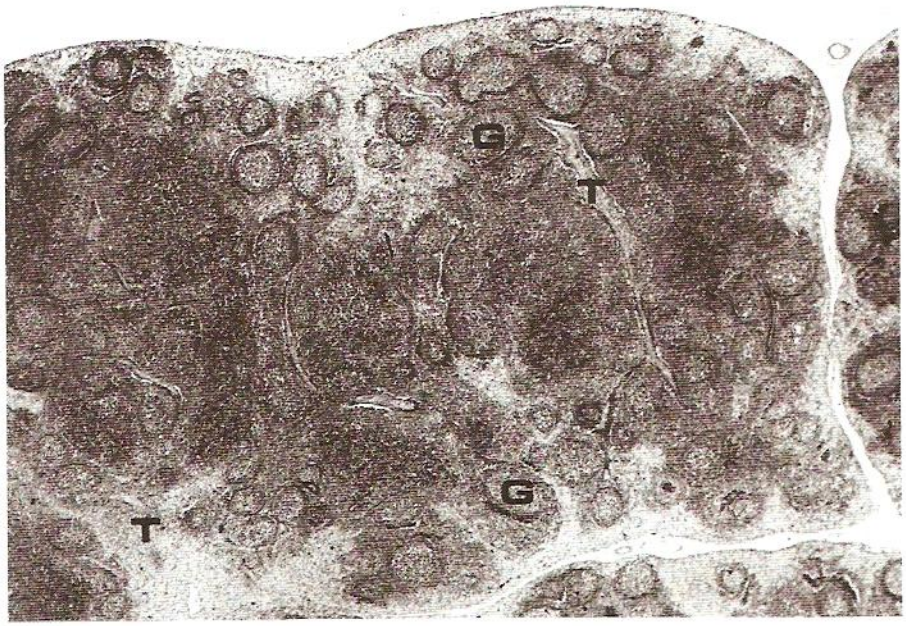

Figure 19-9. Section of an equine lymph node. The cortex consists of nodules with germinal centers *(G)*, trabeculae *(T)* and sinuses. (×4.)

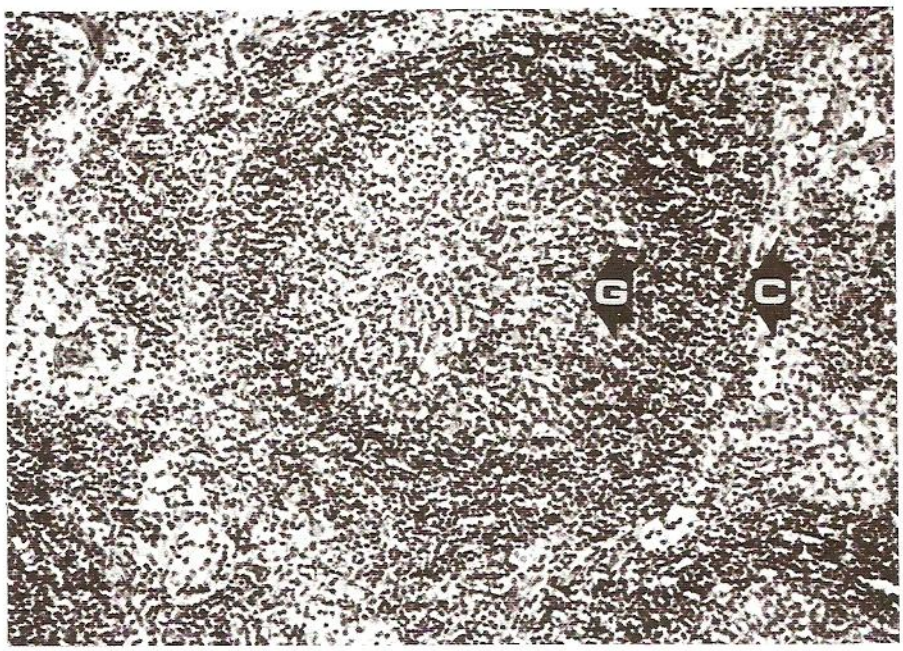

Figure 19-10. Nodule from a lymph node of an immunologically competent animal. Note that it consists of a central germinal center *(G)* and an outer corona *(C)*. (×40.)

Downloaded From Vet-eBooks.com

entiation occurs in the germinal center, and leads to the formation of plasma cells (which immediately move to the periphery of the nodule).

The **medulla** of a node consists of branching trabeculae of reticular fibers and cells surrounded by medullary sinuses and lymph capillaries. They are described as **medullary cords** (Fig. 19-11). The free cells include lymphocytes, plasma cells, and macrophages.

Dendritic cells are stellate cells with a fine network of interlacing processes. These cells trap antigens for presentation to T and B cells. In the T cell zone of lymph nodes, dendritic cells are called **interdigitating cells (IDCs);** and in the B cell zone, **follicular dendritic cells (FDCs).** (See "Antigen-presenting cells," p. 293.)

Lymph circulation. **Afferent vessels** enter a lymph node at the capsule and empty into a prominent **subcapsular (marginal) sinus.** Percolation of lymph continues through the **cortical sinuses** and nodules into the **medullary sinuses.** The latter are confluent with **efferent lymphatic vessels** at the hilus. Flow through a lymph node is unidirectional—capsule to hilus.

Blood vessels and nerves. Arteries enter a lymph node at the hilus and are distributed via trabeculae throughout the node. The venous drainage is typical, but **postcapillary venules** lined by thickened endothelial cells have been identified and are involved in the **recirculation** of lymphocytes from the blood. Lymphocytes leave the blood through these venules and pass to nodules (B cells) or the paracortical zone (T cells). These cells then leave the node through efferent lymphatic vessels. After passage through the efferent system they enter the venous system from the thoracic duct for redistribution throughout the body with the arterial blood. Eventually they reach a lymph node or other lymphatic tissue and the cycle is repeated. Thus the majority of circulating lymphocytes keep moving between the blood and lymphatic organs.

Most of the nerves entering at the hilus are vasomotor. Some, independent of the vasculature, occur within the trabeculae and capsule and medullary cords.

Species characteristics. The **porcine lymph node** has the reverse of the pattern observed in other species (Fig. 19-12). Lymph nodules are located in the central region of the organ, and medullary cords with related cell aggregates in the periphery.

The medullary cords of porcine lymph nodes consist of a dense reticulum of cells, probably reticular cells and macrophages, that may be less permeable to cell traffic than in other species and is believed to support an efficient filter system.

Despite the inverted organizational pattern, cortical (nodular) and paracortical components appear to function similarly to such tissues in other species as regards B and T cell distribution. Recirculation of lymphocytes (T cells in particular) may be more efficient in porcine than in conventional lymph nodes. The **efferent output** is devoid of lymphocytes, which contrasts with the high number of circulating lymphocytes in the peripheral circulation. Porcine lymphocytes recirculate directly from postcapillary venules to blood vessels. This is consistent with the observed rapid antigen recognition and immune responses noted in pigs. The **afferent input** occurs at the nodal periphery. Acellular efferent lymph emerges from the hilus. Thus lymph flow through a porcine lymph node is conventional despite the inverted morphology.

Such reverse lymph node morphology also occurs in elephants, rhinoceroses, dolphins, hippopotamuses, peccaries, warthogs, and wild pigs.

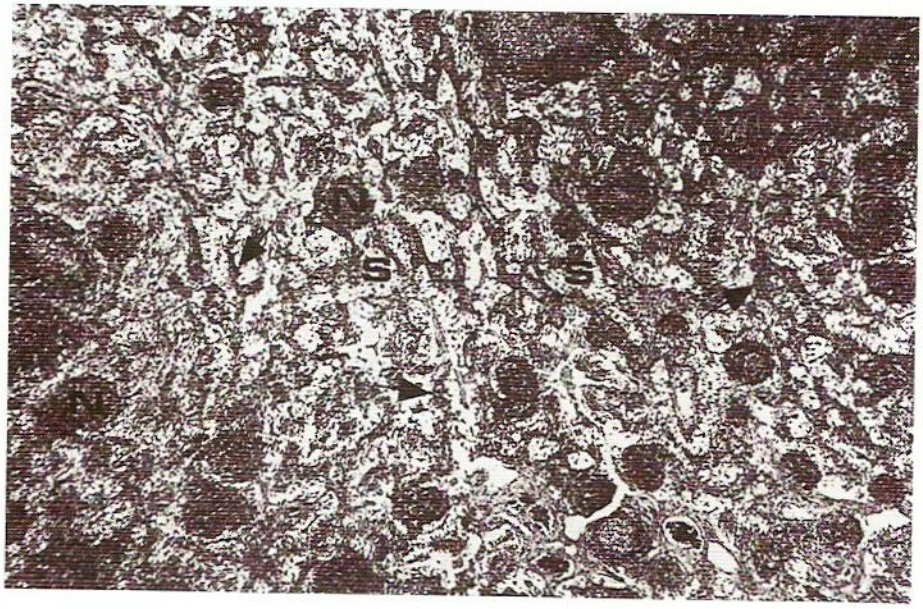

Figure 19-11. Medulla of a canine lymph node. Nodules *(N)* are apparent at the periphery. Medullary cords *(arrows)* and sinuses *(S)* are the primary constituents of the medulla. (×10.)

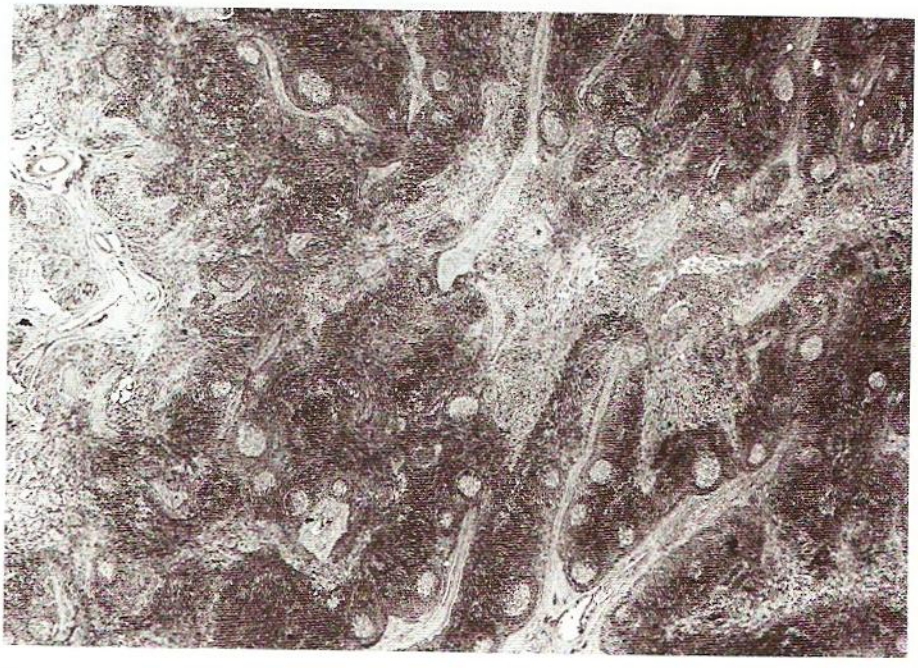

Figure 19-12. Section of a porcine lymph node. The organization of the node is reversed from that occurring in other mammals. (×10.)

Downloaded From Vet-eBooks.com

Lymph node variations are observed in many species. In horses, for example, cortical nodular fusion is common. In oxen the nodules have large germinal centers. Age and physiological state can cause variations in lymph node morphology.

Functional correlates. Lymph nodes produce lymphocytes, filter lymph, phagocytose foreign materials, and form antibodies. Extensive mitotic activity within lymph nodules gives rise to B lymphocytes.

Lymphatic capillaries are permeable to foreign materials (macromolecules, particulate matter, microbial agents) and connective tissue cells (Fig. 19-13). As a result these vessels can transport various materials and cells to the lymph nodes, wherein filtration and phagocytosis occur. The permeability of the endothelium lining the nodal lymphatic channels facilitates these basic protective functions. The free movement of particulate matter, microbial agents, and cells from the lymphatic channels to the lymph node (with subsequent access to blood vessels and efferent lymphatic vessels) also facilitates the spread of infectious agents and the metastasis of cancer cells.

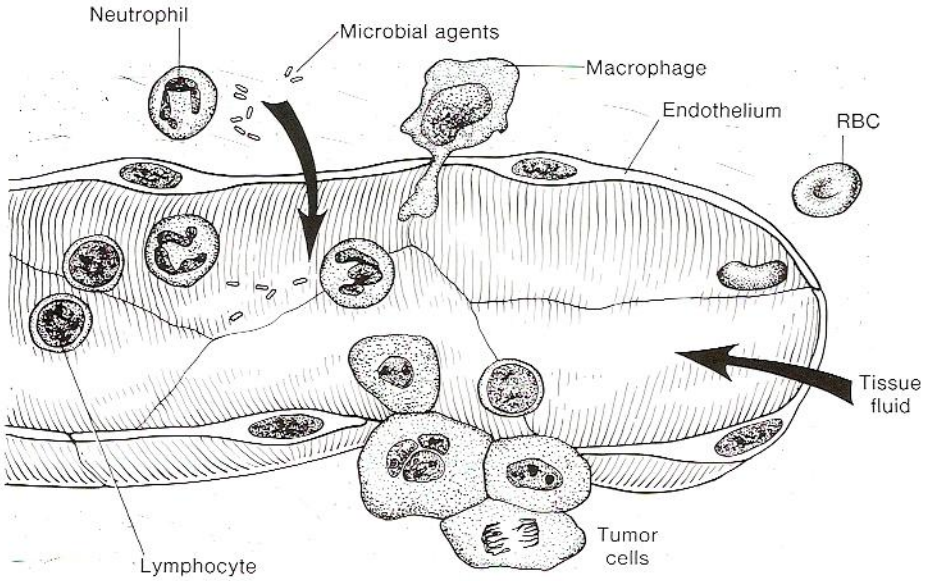

Figure 19-13. Initial portion (lymphatic capillary) of lymphatic channels. White blood cells, some RBCs, proteins, particulate matter, parasites, microbial agents, and a few tumor cells readily gain access to lymphatic vessels. Whereas such access serves as a method of involving the lymph nodes in the organism's defense by transporting foreign materials, infectious agents may spread to other parts of the body via the lymphatic system. Also some tumors metastasize through the lymphatic system.

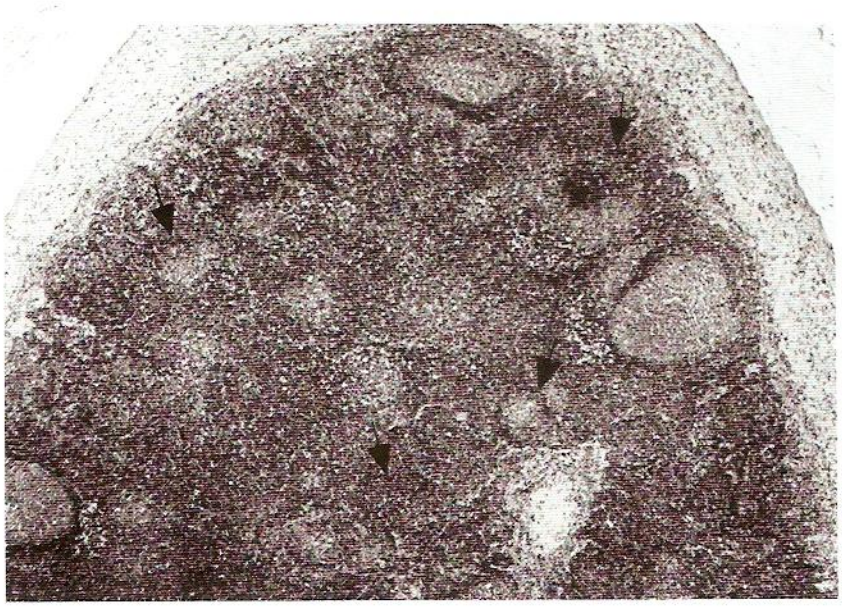

Figure 19-14. Bovine hemal node. The organ is similar to a lymph node; however, its sinuses *(arrows)* are engorged with blood. (×10.)

Hemal Nodes and Hemolymph Nodes

Hemal nodes have sinuses that are filled with blood, not lymph (Fig. 19-14), and lymph vessels are not apparent. The capsule and trabeculae contain smooth muscle fibers. These nodes, described as miniature spleens, look much like typical lymph nodes.

Hemal nodes occur in ruminants retroperitoneally along the vertebral column, in association with some visceral organs, and in the jugular furrow.

Hemolymph nodes may be hemorrhagic lymph nodes, but evidence exists that they are normal and distinct entities. The blood and lymph intermix in the sinuses. These nodes may be an intermediate form of lymphatic organ. They occur in the perirenal (sheep, goat) and lumbar (ox) regions and may be mistaken for **hemorrhagic lymph nodes**.

Spleen

The **spleen,** the largest mass of lymphatic tissue (Fig. 19-15), has multiple functions—blood cell formation, hemoglobin and iron metabolism, red blood cell destruction, blood filtration, blood storage, phagocytosis, and immune response.

Histological structure. The connective tissue of the spleen's serous membrane blends with its capsular dense collagenous tissue. Dense collagenous trabeculae extend into the parenchyma, dividing it into small compartments (Fig. 19-16). Smooth muscle fibers and elastic fibers are present in the capsule and trabeculae (Fig. 19-17). Reticular fibers, produced by reticular cells, are the primary stromal elements. The arrangement of the capsular and trabecular smooth muscle is species variable. Large volume changes are accommodated, and smooth muscle facilitates the discharge of blood from the organ.

The spleen has phagocytic sinuses, a reticular fiber stroma, a cytoreticulum, and a free cell parenchyma. A distinct cortex or medulla, however, is not apparent. Nodules are scattered within the cellular parenchyma—**white pulp** and **red pulp.** Lymph nodules **(splenic corpuscles)** and **periarterial lymphatic sheaths (PALs)** form the white pulp (Fig. 19-18). An arteriole **(nodular arteriole)** occupies the central or paracentral

Downloaded From Vet-eBooks.com

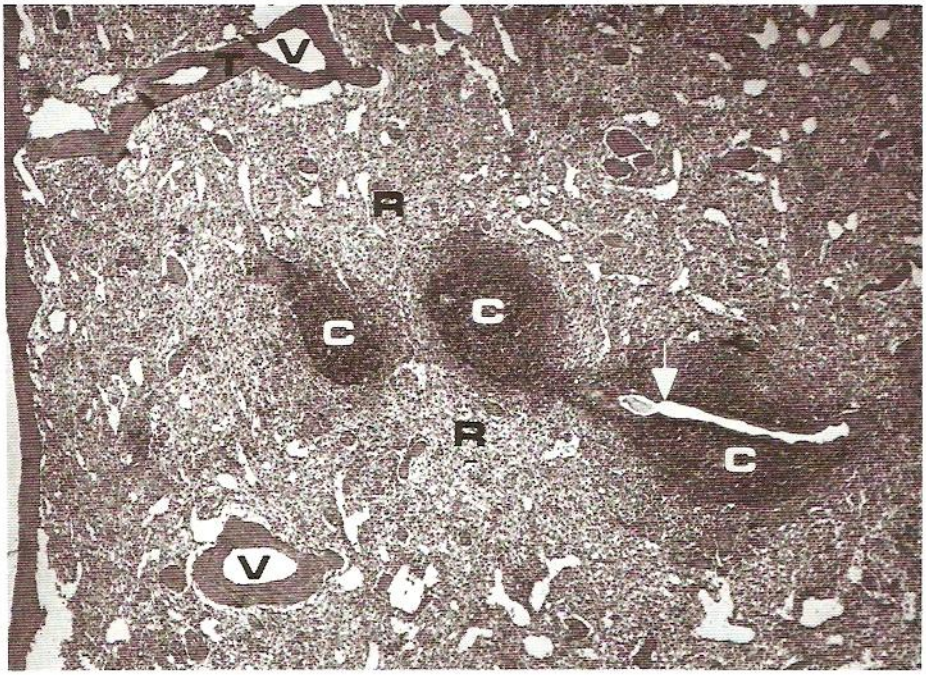

Figure 19-15. General organization of the spleen. Trabeculae *(T)* invaginate parenchyma from the capsule. Note that they contain arteries and veins *(V)*. The parenchyma consists of splenic corpuscles *(C)*. Nodular arterioles *(arrow)* occur within the corpuscles. The corpuscles are surrounded by red pulp *(R)*. (×10.)

Figure 19-16. Stromal elements of the spleen. The trabeculae *(T)* consist of dense collagenous tissue; the remaining stromal elements are reticular fibers. Splenic corpuscles *(C)* are delineated by the red pulp *(R)*. The germinal centers of the corpuscles contain a paucity of stromal elements. (×40, Snook's reticular stain.)

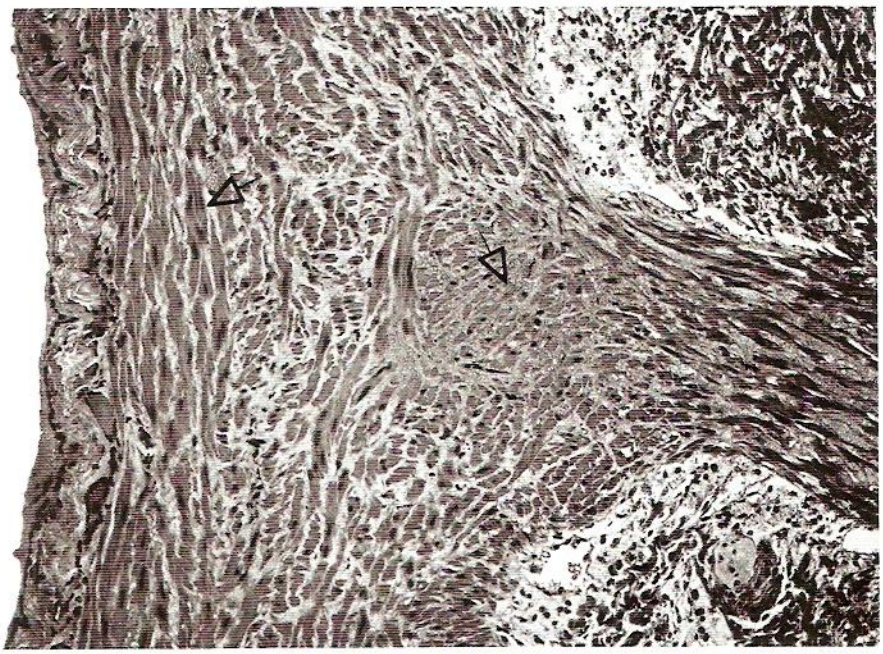

Figure 19-17. Smooth muscle *(arrows)* in the capsule and trabeculae of a cervine spleen. (×40.)

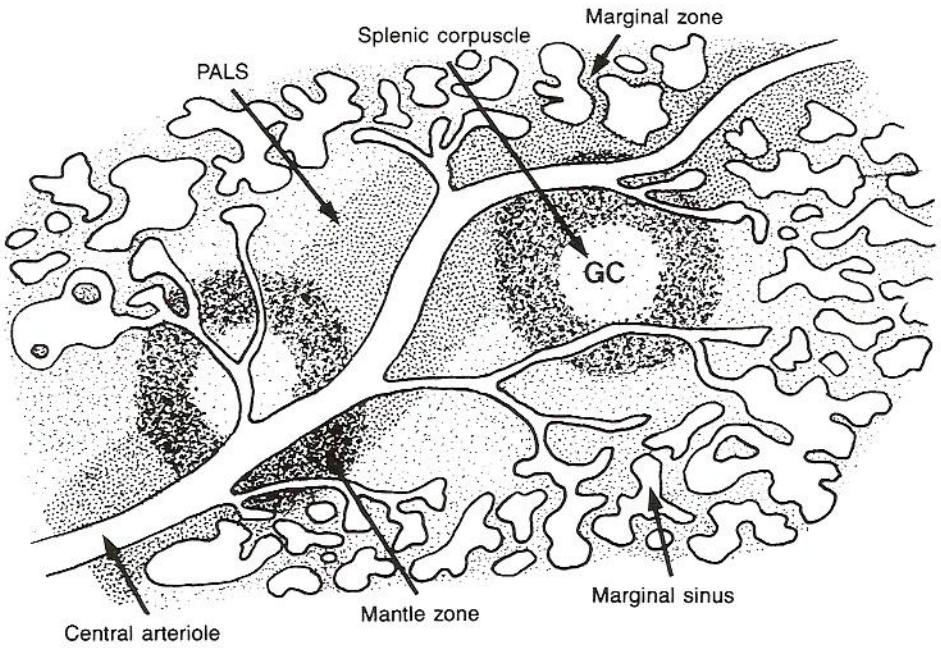

Figure 19-18. Components of white pulp. *PALS,* Periarterial lymphatic sheaths; *GC,* germinal center of the corpuscle.

Downloaded From Vet-eBooks.com

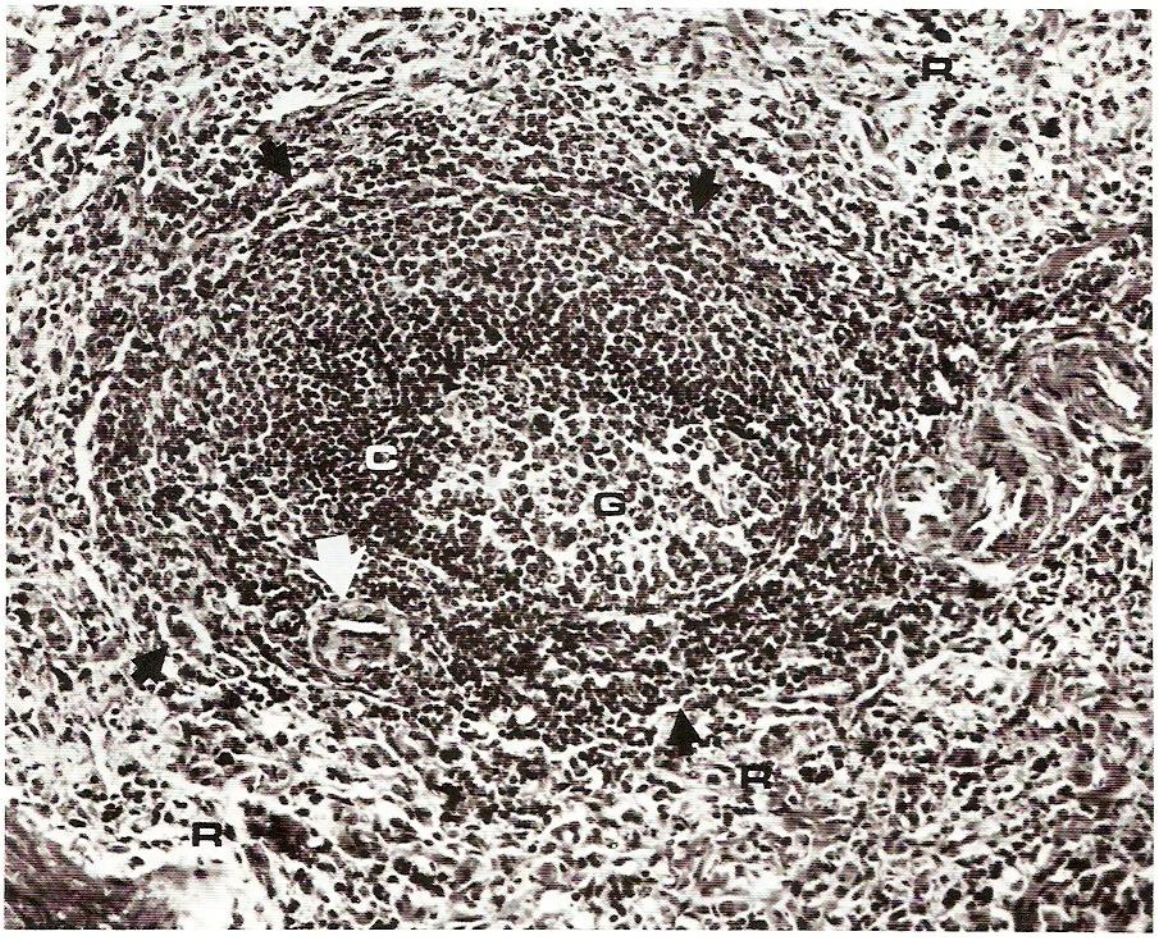

Figure 19-19. Splenic corpuscle and red pulp of a canine spleen. A germinal center *(G)*, corona *(C)* or mantle layer, and paracentral arteriole *(white arrow)* are apparent. The marginal zone *(black arrow)* separates the nodule from the red pulp *(R)*. (×40.)

position within each nodule (Fig. 19-15) though it may not be observable in every section; the section plane may parallel it. Nodule presence depends upon the same factors influencing the germinal centers in lymph nodes.

White and red pulp. The **white pulp** is dense lymphatic tissue intimately associated with trabecular artery branches. Nodular enlargements **(splenic corpuscles)** are randomly distributed along the course of arteries within it and are intercalated with PALS (Figs. 19-19 and 19-20). The composition, nature, and distribution of splenic corpuscle components are similar to those of lymph nodule components; however, each germinal center of a splenic nodule is surrounded by a **mantle zone,** which is continuous with the PALS, whereas the white pulp peripheral limits are interfaced with red pulp by a **marginal zone,** consisting of sinuses, a sheath of dendritic cells, macrophages, and a layer of lymphatic cells. T cells occupy both PALS and marginal zones; B cells occupy corpuscles and marginal zones.

The regions between splenic corpuscles and trabeculae are the **red pulp,** named for its extensive vascularity. The red pulp contains splenic sinuses and cords (Figs. 19-21 and 19-22). The splenic sinuses are discontinuous and lined by phagocytic cells. They open into splenic cords. The cords are composed of granulocytes, granulocyte progenitors, fiber-producing reticular cells, and phagocytic cells. In

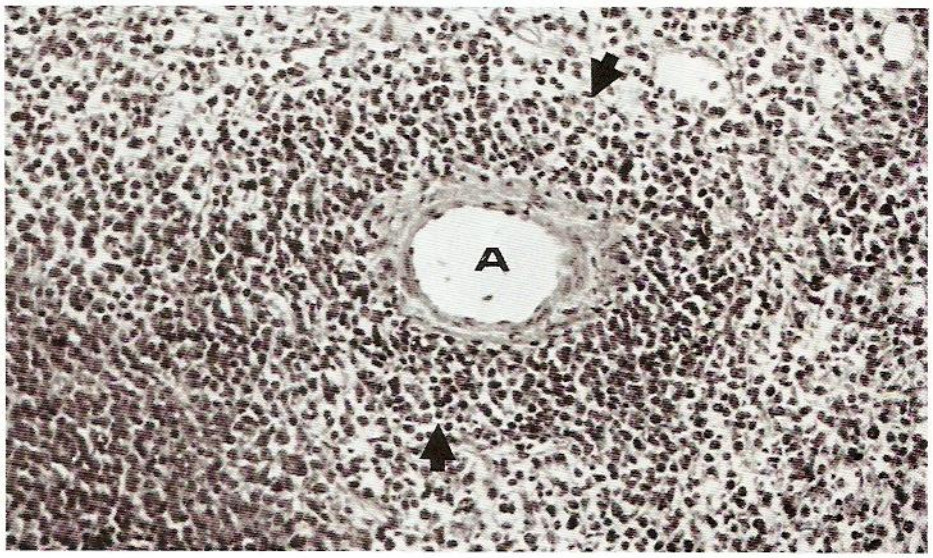

Figure 19-20. Periarteriolar sheath of lymphatic tissue. A condensation of white pulp constituents *(arrows)* surrounds an arteriole *(A)*. T lymphocytes occur within this locus. (×40.)

Downloaded From Vet-eBooks.com

Figure 19-21. Red pulp of a canine spleen flushed with physiological saline during acquisition. Most of the free cells have been removed. Note the splenic cords *(arrows)*, splenic sinusoids *(S)*, and venous sinuses *(V)*. (×100.)

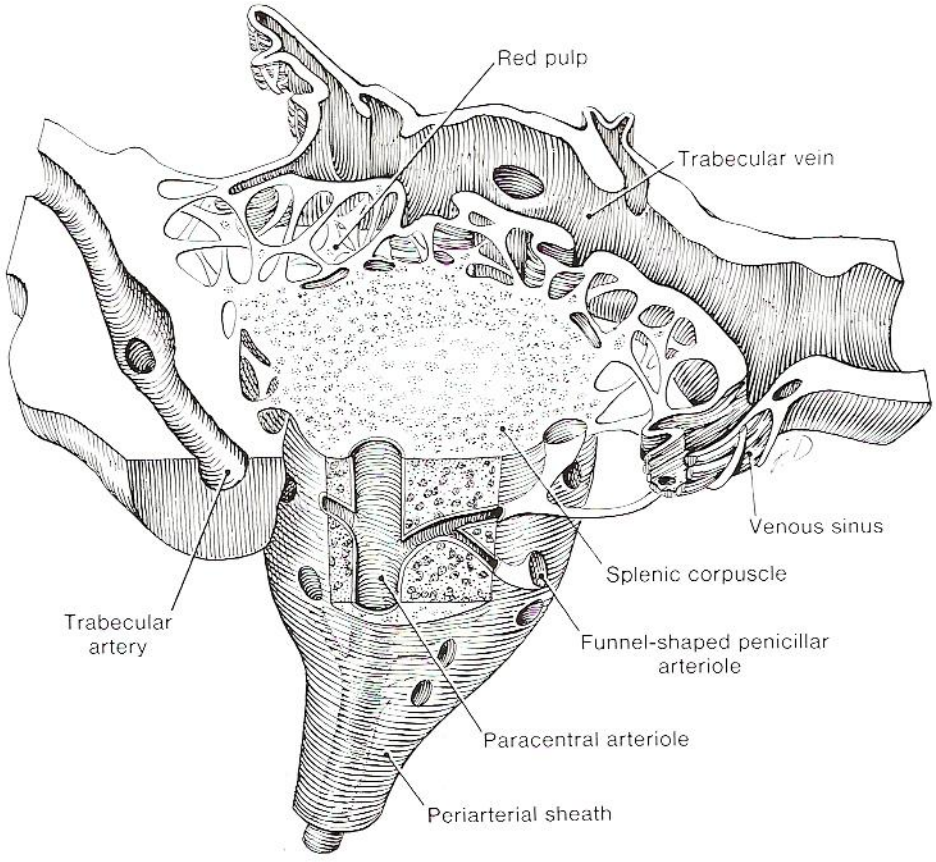

Figure 19-22. Portion of the spleen.

Downloaded From Vet-eBooks.com

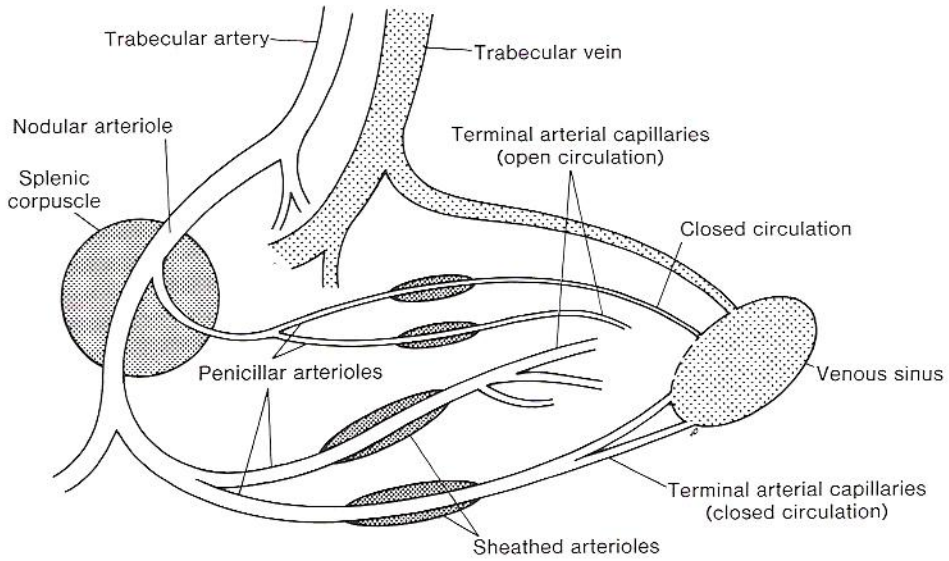

Figure 19-23. Open and closed splenic circulations. Both are integral parts of the physiological movement of blood through the spleen.

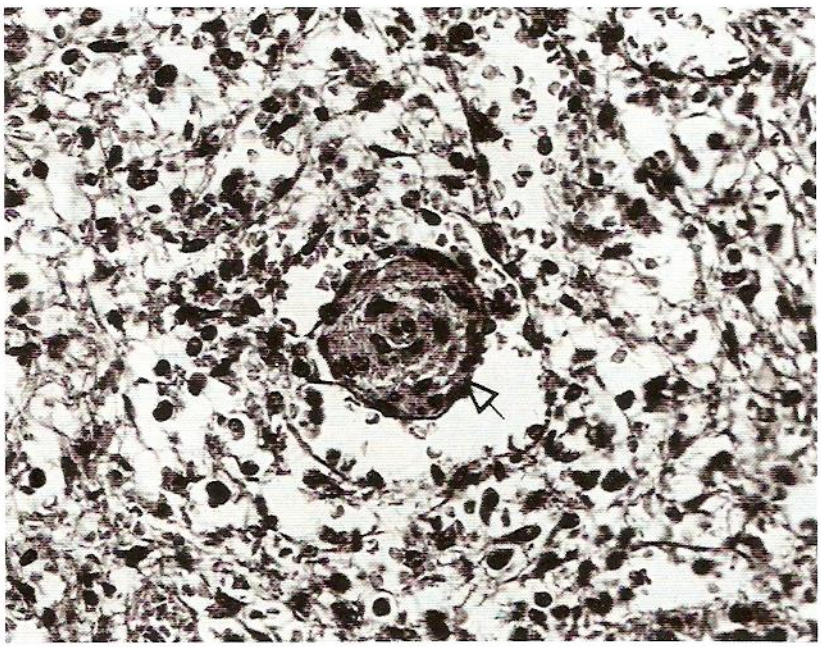

Figure 19-24. Sheathed arteriole from the red pulp of a canine spleen evacuated and flushed with physiological saline during acquisition. The sheathed arteriole *(arrow)* is surrounded by concentric whorls of reticular cells, defensive cells, and reticular fibers. (×100.)

some species smooth muscle fibers also occur. The sinuses and cords are integrated filtration and phagocytic units with many fixed and wandering macrophages. These phagocytic cells remove cell detritus, damaged erythrocytes, and foreign substances from the blood. A yellow-brown pigment, **hemosiderin** (a breakdown product of hemoglobin), is usually present in the phagocytic cells of the sinuses and cords.

Splenic circulation. Splenic arteries enter at the hilus and divide into **trabecular arteries** (Fig. 19-23). Upon entering the splenic parenchyma, trabecular arteries accumulate lymphocytes in their adventitia and this lymphocytic sheath becomes continuous with the splenic nodules. Once in the nodules, the vessels become **nodular arterioles.** Branches from these vessels supply capillaries in the white pulp and its marginal region. The capillaries empty into either the **red pulp sinuses** or the **pulp veins.** Nodular arterioles emerge from the white pulp and divide into smaller branches, **penicillar arterioles.** Penicillar arterioles are divisible into **red pulp arterioles, sheathed arterioles,** and **terminal arterial capillaries.** Sheathed arterioles have walls thickened by concentric cells and fiber laminae (Fig. 19-24). Arteriolar sheaths range from compact structures with cells tightly packed to spongy structures with infiltrating plasma. Macrophages, granulocytes, RBCs, and platelets are present. The arteriolar sheaths have a high capacity for phagocytosis and are a major locus for the removal of blood-borne particulate matter. The arteriolar sheaths may also regulate blood flow through intermittent engorgement with blood. In some animals (horses) the sheaths contain antigen presenting cells (APCs). The name **periarteriolar macrophage sheath (PAMS)** has been proposed for these structures.

Three theories of splenic circulation have predominated in thoughts concerning blood flow through this organ. The **closed theory** postulated a direct link from terminal arteriolar capillaries to venous sinuses. The **open theory** postulated an indirect link from terminal arteriolar capillaries through the red pulp reticulum to venous sinuses. The **physiological theory** postulated that normal conditions would dictate the nature of blood flow through the organ.

The last now seems to be correct. A **blood/spleen barrier** forms, directing either an open or a closed blood flow depending upon functional demands. **Barrier cells** contract, move, and effectively provide direct shunts to the venous sinuses that bypass the red pulp. The barrier cells are probably contractile reticular cells innervated directly by sympathetic fibers or stimulated by nondirected synapses.

Species characteristics. Three types of spleens have been described—**defensive, intermediate,** and **storage.** Defensive spleens have few trabeculae and muscle fibers but abundant lymphatic tissue (lagomorphs, humans). The storage type has many trabeculae and smooth muscle fibers. It is relatively large with minimal white pulp (horses, dogs, cats). Intermediate forms occur in ruminants and swine. Red blood corpuscular destruction is typical of all spleens and is well-demonstrated in horses and swine.

Lymph vessels and innervation. The spleen does not receive afferent lymph vessels. Efferent lymph vessels occur in the white pulp, trabeculae, capsule, and hilus.

Some myelinated axons occur in the spleen and are probably sensory nerves. Predominant are the sympathetic fibers to vascular and capsular smooth muscle, contractile reticular cells, and trabeculae.

Physiological correlates. The spleen is not essential for life. After splenectomy,

Downloaded From Vet-eBooks.com

other organs, especially the bone marrow, assume some of its functions.

The spleen removes foreign particles, microbial agents, and old or degenerating blood cells from the circulation. Filtration and removal of blood-borne materials are achieved by splenic architecture and the macrophage system. Sluggish blood flow through splenic cords and marginal zones enhances phagocytosis by the perivascular macrophages of splenic cords. Although the lungs, liver, and bone marrow contribute to this cleansing function, the spleen has the greatest capacity for it. Its ability to separate blood cells from plasma complements the cleansing function. The sympathetic stimulation of splenic veins increases pressure within the spleen, forces plasma into the lymph channels, and concentrates RBCs within splenic cords.

The storage function of some spleens is enhanced by the separation phenomenon. Equine and carnivore spleens can have a reservoir capacity for RBCs approximating one third the circulating blood volume. Sympathetic discharge in response to stress (physical examination, venipuncture) causes splenic capsular contraction, which results in the discharge of a concentrated mass of RBCs into the circulation with a corresponding increase in the packed cell volume. Some drugs (anesthetics, tranquilizers) cause a splenic engorgement manifested as a decreased packed cell volume.

The splenic storage function also extends to platelets. The spleen can store up to one third of all circulating platelets. Splenectomy may cause a **thrombocytosis** whereas enlargement may result in **thrombocytopenia.**

The sluggish splenic blood flow facilitates removal of aged or damaged erythrocytes. Cells unable to deform as they move through the spleen (e.g., spherocytes in **autoimmune hemolytic anemia**) are subject to **erythrophagocytosis.** Similarly, the spleen is capable of removing particulate matter (HJ bodies, Heinz bodies) and parasites from RBC surfaces.

The spleen is a hematopoietic organ during fetal and neonatal life. Although this is not a significant function in adults, it is retained throughout adulthood. The spleen may also be a storage depot for the maturation of RBCs.

The spleen functions in cell-mediated and humoral antibody responses through its B and T lymphocytes.

Thymus

The thymus originates with the parathyroid glands from the third and fourth pharyngeal pouches. Its anlagen separate from the parathyroids, occupying part of the cranial mediastinum, thoracic inlet, and ventral cervical region.

Most endodermally derived structures (liver, pancreas, and other glands) are solid organs, with the epithelium becoming the obvious parenchyma. As vascularization develops, the densely packed mass of thymic epithelial cells becomes a loosely arranged cell reticulum. Subsequent invasion by lymphocyte progenitors from the bone marrow converts the gland into a **lymphoepithelial organ,** with the parenchyma consisting of **thymocytes.** While the gland grows, epithelial **(epithelial-reticular)** cells become stellate cells attached to each other by desmosomes. Some form continuous sheets that constitute the peripheral limits of a system of labyrinths occupied by thymocytes and stellate-shaped epithelial-reticular cells. The deep portion **(medulla)** has fewer thymocytes than the outer portion **(cortex).** The formation of lobules, containing cortical and medullary components, follows vascular invasion developmentally.

Histological structure. Both lobes of the thymus are covered by a capsule of loose collagenous tissue from which septa of similar tissue arise and divide the organ into lobules (Fig. 19-25). These septa extend to the corticomedullary junction. The incomplete septation causes lobules to be continuous with each other. Reticular connective tissue forms the bulk of the perivascular stroma.

Epithelial-reticular cells assume two shapes integral to thymic structure and function. The organ periphery is lined by a sheet of these cells (Fig. 19-26). Complete sheets also ensheathe the thymic vessels. The cell sheets form labyrinths at the periphery (discussed previously). Epithelial-reticular cells also assume stellate shapes within the labyrinths, constituting a cell reticulum (Fig. 19-26). Processes of adjacent cells, both within the labyrinths and at their surfaces, are attached to each other by desmosomes. Thus epithelial-reticular cells delimit the labyrinths as well as form a supportive **cytoreticulum.**

The thymus has a distinct **medulla** and **cortex** (Fig. 19-25) with dense accumulations of small lymphocytes **(thymocytes)** obliterating the cytoreticulum formed by the epithelial-reticular cells (Fig. 19-27). The thymocytes of the medulla are not as densely packed as those of the cortex, and thus the medulla appears lighter than the cortex. The definitive feature is the presence of **thymic corpuscles** in the medulla (Fig. 19-28). These acidophilic bodies have a 20 to 100 μm diameter. They are concentric whorls of epithelial-reticular hyaline-appearing cells in various degenerative stages that can undergo cornification and even mineralization. High concentrations of immunoglobulin A (IgA) are present within bovine thymic corpuscles, and pyknosis and karyolysis are common. The corpuscles are often observed in advanced stages of involution. Peripherally located corpuscular cells tend to continue with the cell stroma. Their exact thymic function is unknown.

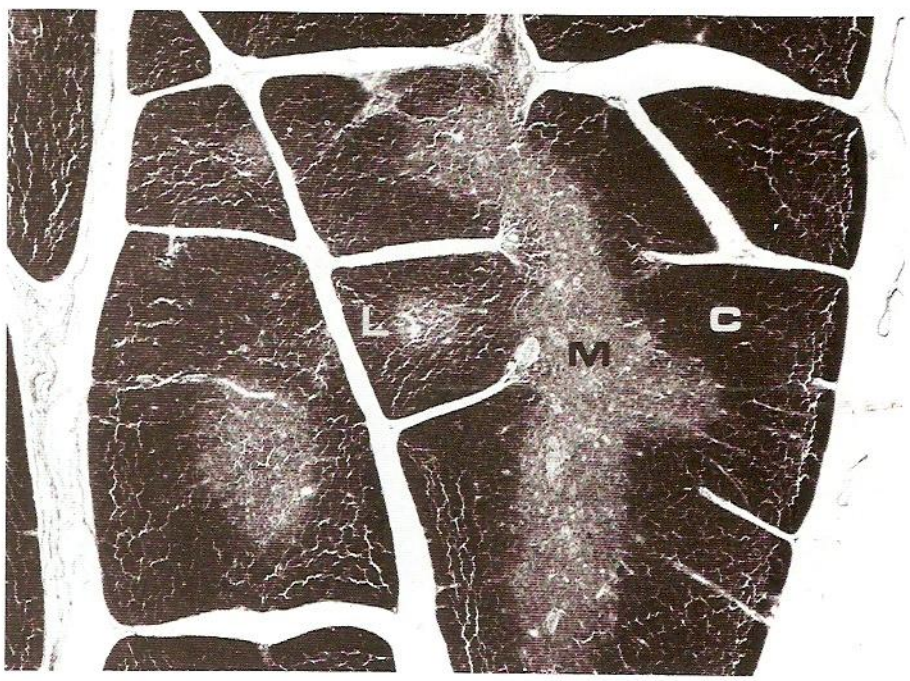

Figure 19-25. Section of a canine thymus. The loose collagenous tissue capsule covers the organ and divides it into distinct lobules *(L)*. The light-staining medulla *(M)* is surrounded by a dark-staining cortex. The thymus may be considered one large nodule; individual nodules do not occur within the organ. (×10.)

Downloaded From Vet-eBooks.com

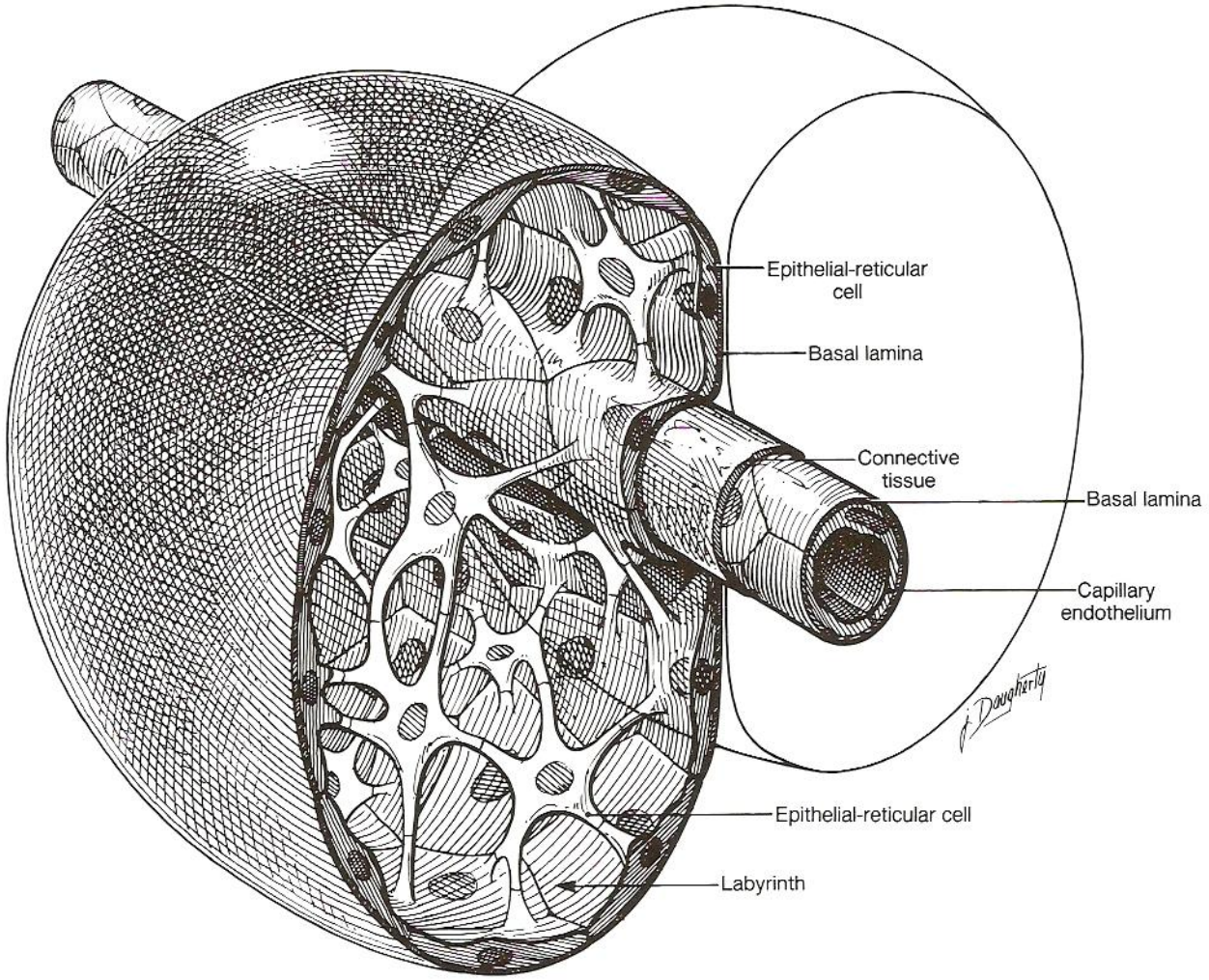

Figure 19-26. Thymic labyrinths and their relationships to epithelial-reticular cells. Note that the vasculature and connective tissue are separated from the labyrinthine spaces by epithelial-reticular cells. The labyrinths are filled with thymocytes.

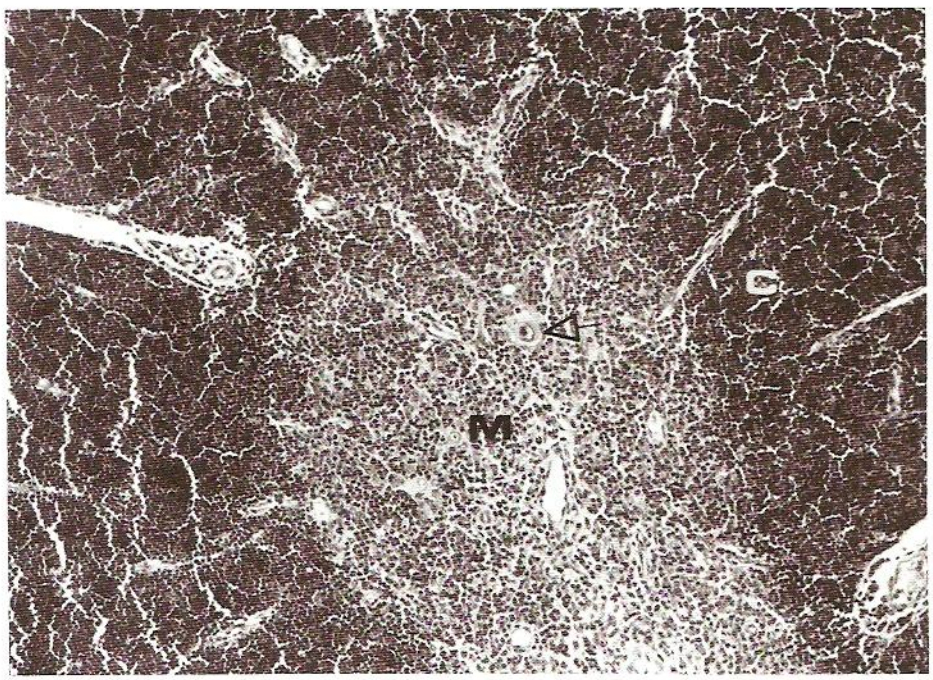

Figure 19-27. Cortex and medulla of a canine thymus. The cortex *(C)* contains more dense aggregations of thymocytes than the medulla *(M)*. Note the characteristic thymic corpuscle *(arrow)*. (×40.)

Downloaded From Vet-eBooks.com

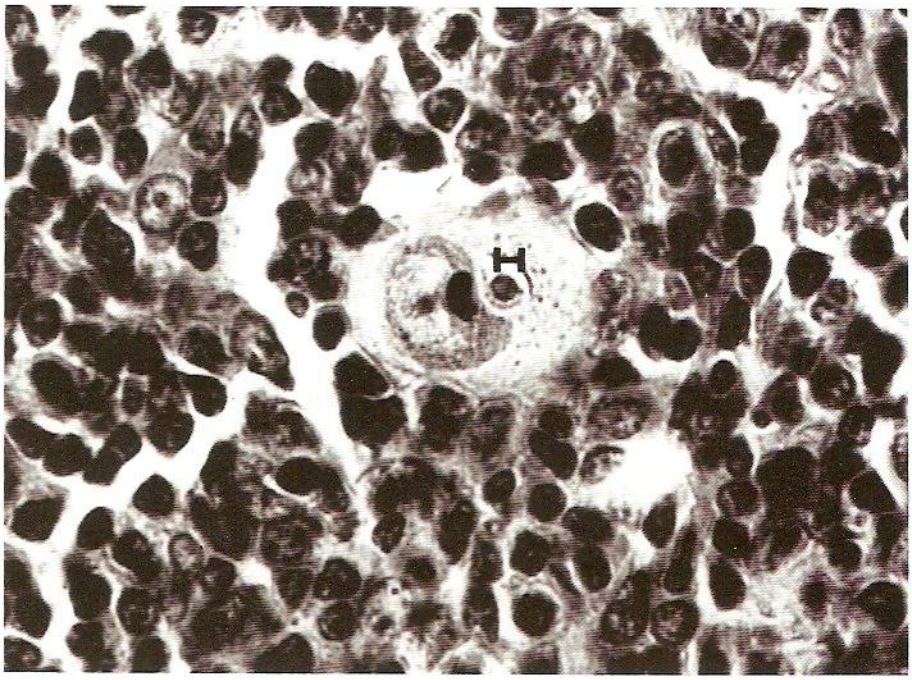

Figure 19-28. Thymic corpuscle from a canine thymus. This corpuscle *(H)* is a morphological feature of the medullary portion of the gland. (×320.)

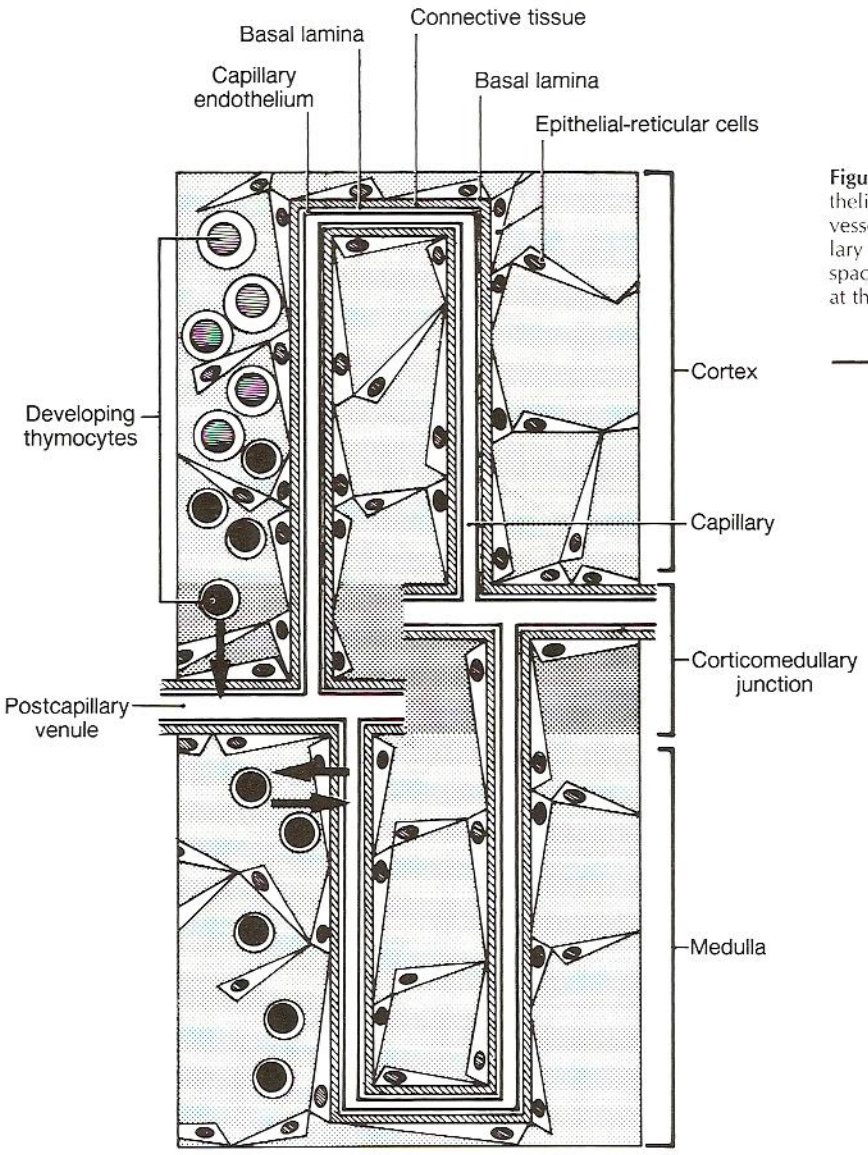

Figure 19-29. Organization of the thymic/blood barrier. Epithelial-reticular cells separate the labyrinths from the blood vessels. The cortical barrier is functional whereas the medullary barrier is not. Cells move freely between the vascular spaces of the postcapillary venules and the labyrinthine spaces at the corticomedullary junction.

Blood vessels and the thymic/blood barrier. Although some vessels are confluent with thymic venules in the capsule, most reverse their direction, forming arcades within the cortex and draining into venules of the corticomedullary junction and medulla.

The **thymic arteries** ramify within the interlobular connective tissue and enter the organ substance at the corticomedullary junction of the lobules (Fig. 19-29). Arterial capillaries penetrate and traverse the cortex to the periphery of the cortical parenchyma. The capillaries of the cortex are impermeable to macromolecules.

Arteriolar branches from the corticomedullary vessels enter the medulla, branch into capillaries, and return as medullary veins to the corticomedullary junction. Postcapillary venules are permeable to macromolecules and lymphocytes.

The **thymic/blood barrier** consists of epithelial-reticular cell vascular bed investments within the thymic parenchyma (Figs. 19-26 and 19-29). The permeability characteristics of the cortex limit the term "barrier" to the cortex. The medul-

Downloaded from Vet-Books.com

lary and corticomedullary junctional vessels are sufficiently permeable to macromolecules and lymphocytes that their postcapillary venules function in a manner similar to those vessels described with lymph nodes. The postcapillary venules do not contribute to a blood/thymic barrier, and the relationships of epithelial-reticular cells and vessels throughout the gland do not match the different barrier functions.

Lymph vessels and innervation. Afferent lymph vessels are not associated with the thymus. Efferent lymph vessels occur in the connective tissue peripheral to the lobules.

Although some nerves occur freely within the parenchyma, most nerve fibers of the gland (which are derived from the vagus and sympathetic nerves) innervate vascular mural elements.

Physiological correlates. The thymus is the primary mammalian lymphatic organ. Lymphocytes (thymocytes), which differentiate in the thymus, leave the organ and populate secondary lymphatic organs (lymph nodes, spleen, tonsils, bone marrow) and other aggregates of scattered lymphatic nodules with T cells. The movement of thymocytes through postcapillary venules to secondary lymphatic organs **(peripheralization)** is a significant aspect of cell-mediated immunity.

A gradual and continuing thymic involution accelerates after puberty and is characterized by a decrease in organ weight, a loss of cortical lymphocytes, infiltration by adipose cells, and an increase in thymic corpuscles. Eventually, adipose infiltration replaces the gland.

The thymic role in immunity is aptly demonstrated by neonatal thymectomy in some species. The result is an impaired delayed hypersensitivity. The ability to produce an antibody-mediated response is also impaired, because antibody production requires T cell assistance.

Thymosin, the humoral factor derived from and secreted by thymic epithelial cells, substitutes for a thymus in thymectomized mice. **Thymopoietin, thymic humeral factor,** and **serum thymic factor** are humoral factors enhancing T cell responsiveness.

Bursa of Fabricius

The bursa of Fabricius occurs in birds (Fig. 19-30). It is a blind sac opening into the dorsal proctodeal wall of the cloaca. The wall of the organ is extensively folded and covered by a simple columnar or pseudostratified columnar epithelium. Lymph nodules are located between epithelial folds, and germinal centers are present.

IMMUNITY

Different species and individuals within a species, except for identical twins, possess a unique chemical identity. Although individuals of a species have similar chemical constituents, their specific macromolecular composition is different. Various mechanisms have been developed by the body to protect it from foreign materials. **These mechanisms maintain chemical uniqueness by excluding all foreign materials.**

Nonspecific Immunity

Nonspecific responses are integral to an organism's resistance to exogenous macromolecules and various disease agents. The innate genetic composition of some organisms precludes successful invasion of them by certain disease agents. Specific anatomical, physiological, and biochemical factors afford nonspecific protection. The skin, mucociliary apparatus, lacrimation, urination, defecation, and pH are all part of nonspecific mechanisms. Neutrophilic phagocytosis, lysosomal and β-lysin secretion, and the properdin system are also part of nonspecific protection.

Specific Immunity

The **specific immune response** is a protective mechanism permitting the body to recognize and respond to specific foreign materials. The foreign materials capable of eliciting this response have a unique surface configuration **(antigenic determinant)** and are called **antigens.** Macrophages, lymphocytes, and plasma cells mount a **humoral antibody** or **cell-mediated immune response** to antigenic stimulation.

Histocompatibility. Recognition of self and nonself resides in three populations of cells—T cells, B cells, and antigen-presenting cells. T cells function to kill foreign cells and to assist B cells with antibody formation. Antigen-presenting cells interact with both cell populations to facilitate their immune responses. The separate and combined activities of these cells are regulated by cell surface proteins called **histocompatibility antigens**.

Genes located close to each other on one chromosome comprise the **major histocompatibility complex (MHC).** This complex directs the production of three classes of glycoproteins that constitute the **major histocompatibility antigens** occurring on the surfaces of all cells of a given animal.

Class I MHC antigens, present on the surfaces of all somatic cells, are involved in the regulation of graft rejection, cytotoxic T cell activity, and the presentation of fragmented viral products from virus-infected cells.

Class II MHC antigens are transmembrane glycoproteins occurring on the surfaces of T cells, B cells, endothelial cells, and antigen-presenting cells, (e.g., macrophages, dendritic cells, intraepidermal macrophages). These antigens may also occur on the surfaces of stromal cells (reticular cells) in myelolymphoid organs. Class II antigens permit immune surveillance and the differentiation of self and

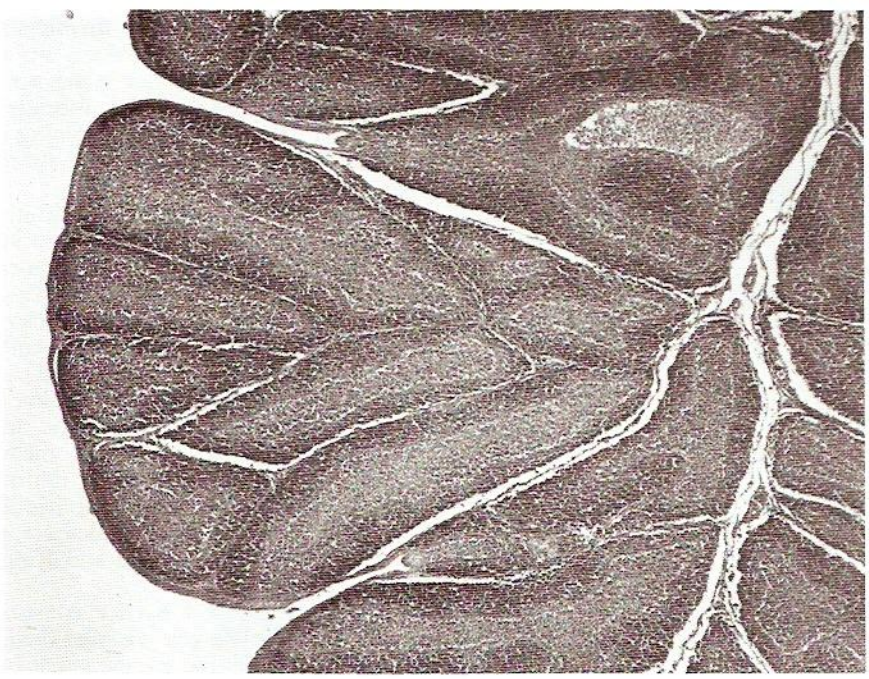

Figure 19-30. Section of the avian bursa of Fabricius. Lymphatic nodules are aggregated in such a way as to impart architectural characteristics similar to those of the thymus. (×10.)

Downloaded From Vet-eBooks.com

nonself. These antigens regulate the interactions of immune cells, the response and non-response of the organism, and the intensity of the immune response.

Class III MHC antigens are components of the complement system, which includes plasma proteins involved in immune responses, inflammation, and hemostatic mechanisms. One of these class III MHC antigens is the C3 surface receptor of phagocytic cells.

Lymphokines. **Lymphokines** are biologically active, non–antigen specific (non-immunoglobulin), low–molecular weight (25,000 to 75,000 daltons) proteins released from lymphocytes. They influence many cell populations and behaviors. Almost 100 cell activities associated with different lymphokines have been identified (Table 19-1). Some of these substances are secreted by monocytes **(monokines)** and by other cells. Perhaps the general term **cytokine** is appropriate.

Antigen-presenting cells. Lymphokines and macrophages are important elements of immune responsiveness. A heterogeneous population of cells called **antigen-presenting cells (APCs)** is also important in immune responses. The APCs include **B cells, endothelial cells, interdigitating cells (IDCs), follicular dendritic cells (FDCs),** and **intraepidermal macrophages (Langerhans cells).** The IDCs and FDCs are also macrophages.

The APCs have class II MHC antigens and many immunoglobulin (Fc) receptors on their surfaces. The APCs attach many immunoglobulins (Igs) to their surfaces through their Fc receptors. The Igs are able to interact with foreign antigens. This configuration, coupled with the class II MHC antigens, is a potent stimulator for antigen-sensitive responses.

The strategic positioning of APCs throughout the body ensures that these cells will be exposed to foreign materials. It also ensures that they will contact the cells responsible for the specific immune responses.

Table 19-1. Selected Lymphokines and Monokines

Name	Abbreviation	Activity
Regulating Substances		
Interleukin-1	IL-1*	Induce and activate T cells
Interleukin-2	IL-2	Induce T cell proliferation
Interleukin-3	IL-3	CFU-S stimulation for T cell line
Interleukin-4	IL-4	B cell, T cell, and mast cell proliferation; increase B cell class II MHC antigen
Interleukin-5	IL-5	Stimulate B cell proliferation
Interleukin-6	IL-6†	Activate T cells; stimulate B cell maturation and secretion
Interferon-δ	IFN-δ	Stimulate class II MHC antigens; activate macrophages
Lymphocyte blastogenic factor	BF	Induce lymphocyte blast formation and mitosis
Macrophage Regulating Substances		
Macrophage inhibition factor	MIF	Prevent macrophage migration
Macrophage fusion factor	MFF	Induce multinucleated giant cell formation
Macrophage chemotactic factor	MCF	Attract macrophages
Cytotoxic Substances		
Lymphotoxins		Destroy cells other than lymphoctes
Tumor necrosis factor–a (cachexin)	TNF‡	Kill tumor cells
Perforins		Kill specific target cells

*From APCs; remainder are from T cells unless otherwise specified.
†Over 12 ILs have been defined.
‡From macrophages.
MHC, Major histocompatibility complex.

Humoral antibody response

Cell mechanism. The humoral antibody response is a function of B lymphocytes. Their responses requires the interaction of macrophages, APCs, and T cells.

The foreign antigen is processed by an APC and is fixed to the surface of the APC while being presented to the B cell. The APC has foreign antigens and class II MHC antigens on its surface. It secretes interleukin-1 **(IL-1)**, which activates **T helper cells (T4)** and to a lesser degree B cells. The T helper cells secrete two interleukins when they interact with the APC. The interleukins cause the B cells to proliferate and subsequently differentiate.

Stimulated B cells express new surface antigens followed by mitotic activity. Under the influence of T cell interleukins the B cells differentiate into two distinct populations. The B cells become transformed into blast cells, proliferate, and produce a population of sensitized B lymphocytes and plasma cells **(clonal expansion).** This population includes effector cells, which produce **antibodies (immunoglobulins)** and **memory cells.** Memory cells are inactive but are capable of responding to the antigen (Ag) at some future time.

The initial response to an Ag, resulting in antibody (Ab) production, is called the **primary response.** A measurable Ab titer to a specific Ag is apparent after a variable but relatively long time **(latent period).** Subsequent exposure to the Ag can activate memory cells and previously sensitized APCs. This second exposure, producing a more rapid and greater Ab-producing reaction than the primary response, is called the **secondary** or **anamnestic response.**

Immunoglobulins. An **immunoglobulin** is a Y-shaped molecule with Ag reaction sites located at the ends of the arms (Fig. 19-31). A small chain is attached parallel to each of the arms. **Light** and **heavy chain** components result from appropriate chemical treatment. The **Fc fragment** is the part responsible for its biological properties—activation of complement, binding to cells, opsonization.

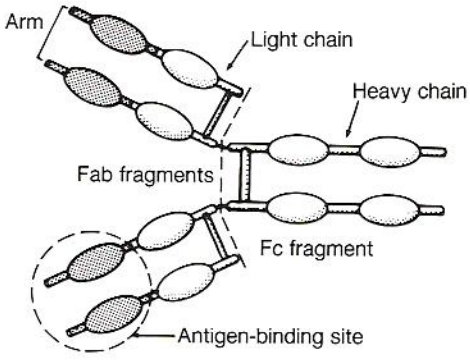

Figure 19-31. Typical immunoglobulin. A light chain is attached to each arm. A heavy chain includes an arm and half the tailpiece. Two Fab fragments and an Fc fragment result from hydrolysis along the *dashed line* (hinge region). The Fab fragments contain the Ag-binding sites. The Fc fragment is responsible for the biological properties of the molecule.

Downloaded From Vet-eBooks.com

Abs bind to specific Ags and facilitate their removal from the body. This binding may

- Result in the precipitation of Ab-Ag complexes (with subsequent phagocytosis)
- Inhibit the uptake of certain (viral) antigens by cells
- Induce the lysis of microbial agents by the activation of complement
- Facilitate the clearance of various agents by macrophages (opsonization)

Antibodies (immunoglobulins, Ig) are plasma proteins of the globulin fraction. Several classes have been identified—IgG, IgM, IgA, IgE, and IgD.

IgG comprises about 80% of all immunoglobulins. Because it is small, it leaves the vascular bed readily. It is the major Ab produced in response to infections and immunizations and the predominant immunoglobulin of the anamnestic response. Its half-life is species-variable (dog, 7 to 8 days; ox, 23 days).

IgM comprises about 10% of the immunoglobulins. It is a large pentameric compound with protective functions probably confined to the vascular system. Although it is the predominant Ig of the primary response, it is also produced anamnestically. It functions similarly to IgG and is the first fetal antibody response, although it has less specificity than IgG.

IgA comprises about 10% of the immunoglobulins. It is the major immunoglobulin in external secretions, affording primary antibody protection for the respiratory, gastrointestinal, and genitourinary mucous membranes and the eye. It may assume polymeric forms. The dimeric form passes through intestinal epithelial cells, salivary gland cells, and hepatocytes. During this passage a **secretory** or **transport piece** of protein is added to the dimeric structure, forming **secretory IgA.** The secretory piece increases the resistance of secretory IgA to proteolysis. Secretory IgA may prevent microbial adherence to epithelial surfaces. Protection of mucosal surfaces by IgA may be broad spectrum. An anamnestic response is not characteristic.

IgE constitutes less than 1% of the immunoglobulins, although it possesses some unique characteristics integral to type I hypersensitivity reactions.

IgD is a lymphocyte surface Ab occurring in laboratory animals, humans, pigs, and chickens. It has not been demonstrated in other domestic mammals.

Cell-mediated immune responses

T cells are the population of lymphocytes responsible for **cell-mediated immunity (CMI)**. Programmed to recognize and respond to specific Ags, they comprise a heterogeneous population. All mature T cells have **T3 surface antigens,** the majority also have a **T4 surface antigen,** and the remainder a **T8 surface antigen**. Those cells with T4 surface antigens are **T helper (T4) cells;** those with T8 surface antigens, **suppressor** or **cytotoxic (T8) cells.**

Three types of cells are necessary to activate T cells—APCs, T helper cells, and effector cells. A foreign epitope in association with a class I MHC antigen on the surface of an APC is recognized. Following the interaction of these surface sites, the effector (T8) cell is induced to express **interleukin-2 (IL-2) receptors**.

T helper cells also recognize a foreign epitope and the class II MHC antigen on the APC surface. Following interactions with its receptors and the APC surface antigens, the T helper cell is induced by the release of IL-1 from the APC to secrete IL-2. The released IL-2 attaches to the effector cell, causing mitosis **(blastoid transformation)** and clonal expansion. This expansion produces two subsets of activated T cells—**effector cells** and **memory cells.** Some activated or sensitized T cells become **cytotoxic lymphocytes (T killer cells).** Upon intimate contact with the foreign cells activating them, T lymphocytes cause them to lyse through the release of **perforin** and **nucleases**. The T lymphocytes also secrete **lymphokines.**

Whereas some T cells serve as helper cells, others serve as suppressor cells. The **T suppressor cells** limit T and B cell responsiveness, interfere with T helper cell interactions with B cells, or limit the responsiveness of B cells to Ag stimulation. Suppressor T cells and macrophages are involved in the **tolerance phenomenon,** the inability to respond to Ag stimulation. Tolerance to self-antigens is an essential T suppressor cell function.

Hypersensitivity Reactions

Type I hypersensitivity

The **type I hypersensitivities (allergies, anaphylaxis)** may be generalized or localized reactions of mast cells and basophils to certain Ags mediated by IgE. Because of its cellular binding activity, IgE is called a **cytotrophic antibody.** The interaction of Ag, IgE, and reactive cells involves the release of pharmacologically active substances, the most significant of which is **histamine.** Although the type I hypersensitivity reaction serves protective functions through its induction of an acute inflammatory response and the elimination of Ag substances, it has deleterious side effects that can be life-threatening.

Certain Ags may induce IgE production, but not all individuals can produce this immunoglobulin. The production of IgE in response to Ag stimulation **(atopy)** is genetically determined.

Upon initial exposure to the exciting Ag, the B cell population reacts by secreting IgE. Mast cells and basophils, which have specific receptors for the Fc portions of this immunoglobulin, bind IgE. After reexposure to the same Ag, the Ag binds with the Ag-binding fragments of IgE. This Ab-Ag reaction causes degranulation and/or lysis of these cells with the subsequent release of various active substances.

The substances released include histamine, serotonin, eosinophilic chemotactic factor of anaphylaxis (ECF-A), platelet-activating factor (PAF), prostaglandins, leukotrienes (LTs), and bradykinin.

Histamine is the most important of these substances. Many of the stereotypical tissue responses relate directly to the activity of this compound. The primary effects of histamine are directed to smooth muscle and glands. Most blood vessels dilate and increase their permeability. The increased permeability is responsible for production of the characteristic wheal and flare of this reaction. The vascular smooth muscle of some organs, however, contracts in response to histamine. The nonvascular smooth muscle constituents of the lung, stomach, intestine, uterus, and urinary bladder contract in response to histamine stimulation. Excessive pulmonary mucous secretion, salivation, and lacrimation are typical exocrine responses.

Histamine exerts its influence on target cells through **histamine receptors** located on surface membranes. Based upon the activities of histamine antagonists, two receptors have been identified—H_1 and H_2. Membrane permeability alterations to Ca^{++} and/or release of Ca^{++} from intracellular, sequestered stores result from stimulation of these receptors. The cause and effect relationship of histamine stimulation and increased cAMP needs clarification.

Serotonin occurs in mast cells of laboratory rodents and large ruminants. Its effects are directed to cardiac and smooth muscle fibers. Vasoconstriction and increased cardiac activity are typical. Increased vascular permeability also occurs in laboratory rodents.

ECF-A is a small polypeptide released from mast cells upon stimulation. It attracts eosinophils to sites of mast cell stimulation and degranulation and is also responsible for the withdrawal of eosinophils from the reactive region.

PAF is a phospholipid that induces aggregation of platelets and causes them to release their contents. This promotes serotonin release and prostaglandin synthesis.

A family of compounds called **eicosanoids** is derived from a 20-carbon fatty acid with double bonds known as arachidonic **(eicosatetraenoic)** acid. The family includes **prostaglandins, thromboxanes, prostacyclin,** and **leukotrienes** (LTs) (p. 426).

Downloaded From Vet-eBooks.com

Five types of LTs have been identified and designated—LTA, LTB, LTC, LTD, and LTE. Smooth muscle contraction and increased vascular permeability occur as a result of LTC_4 and LTD_4 activity (p. 427), the compounds that heretofore have been described as the **slow-reacting substances of anaphylaxis.** The LTs are responsible for a slow onset of, but sustained, smooth muscle contraction. LTB is a neutrophilic and eosinophilic chemotactic factor. **Prostaglandin $F_{2\alpha}$** promotes vascular and nonvascular smooth muscle contraction. Other prostaglandins (**PGE**) and **prostacyclin (PGI_2)** inhibit vascular and nonvascular smooth muscle contraction. The effects manifested by prostaglandins and prostacyclins locally are dependent upon the types and quantities of substances released from specific tissues. **Thromboxanes** function in a manner similar to $PGF_{2\alpha}$.

Kinins are vasodilator peptides activated from **kininogens** by the enzymatic action of **kallikreins (kininogenases).** They also increase vascular permeability. Tissue kallikreins are derived from activated platelets; they may also be activated from the plasma (Fig. 19-32). Plasma kallikreins are produced by the liver. Kallikreins are **serine proteases**—enzymes with serine at their active site.

Two types of kininogens occur in the plasma. A **low–molecular weight (LMW) kininogen** diffuses into the connective tissue space and becomes the substrate for tissue kallikrein. A **high–molecular weight (HMW) kininogen** remains in the plasma and is the essential substrate for plasma kallikrein. The **kallikrein-kinin system** is thus an active part of vasoregulatory mechanisms and a contributory component of type I hypersensitivity.

Eosinophils are integral components and modulators of type I hypersensitivity reactions. They release enzymes (histaminase, arylsulfatase, phospholipase D) that neutralize the active substances secreted by mast cells. **Histaminase** degrades histamine whereas **arylsulfatase** inactivates the LTs. Additionally, **phospholipase D** deactivates platelet activating factor. Moreover, eosinophils secrete **PGE**which are inhibitors of histamine secretion and stimulators of vasodilation.

Additional regulation of this process is directed toward the neuroregulation of mast cells. Neuroregulation of mast cell degranulation is achieved through their complement of α- and β-adrenergic receptors. α-Stimulation enhances degranulation whereas β-adrenergic stimulation depresses mast cell degranulation. Both effects are mediated through cAMP.

The clinical manifestations of type I hypersensitivities vary. Cutaneous reactivity is manifested by swelling and **erythema (wheal and flare)** associated with insect bites. Generalized atopic reactivity **(anaphylactic shock)** may be manifested as cardiopulmonary distress and/or gastrointestinal upset. The type of response is species-specific, since various organs **(shock organs)** of domestic species and humans react differently to these active substances. Numerous Ags **(allergens)** are capable of inducing localized and/or generalized type I reactions.

Type II hypersensitivity

Type II hypersensitivity, also called **cytotoxic** or **cytolytic reactivity,** involves immunoglobulins (IgG, IgM), complement, neutrophils, macrophages, and tissue Ags.

Cytotoxic reactions are characterized by the reaction of circulating Abs (IgG, IgM) with Ags that are attached to cell surfaces or Ags that have become intimate components of cell surfaces. The binding of immunoglobulins with these Ags activates the complement system. The subsequent binding of complement at the site of Ag-Ab reaction results in the lysis of surface-modified cells. Alternatively, the Ag-Ab reaction at the cell surface permits the adherence of phagocytic cells (neutrophils and macrophages) to the cell surface. Cell lysis and phagocytosis result. These processes are enhanced when complement is bound to the Ag-Ab complex. Additionally, the release of hydrolases by the phagocytic cells causes surrounding tissue damage.

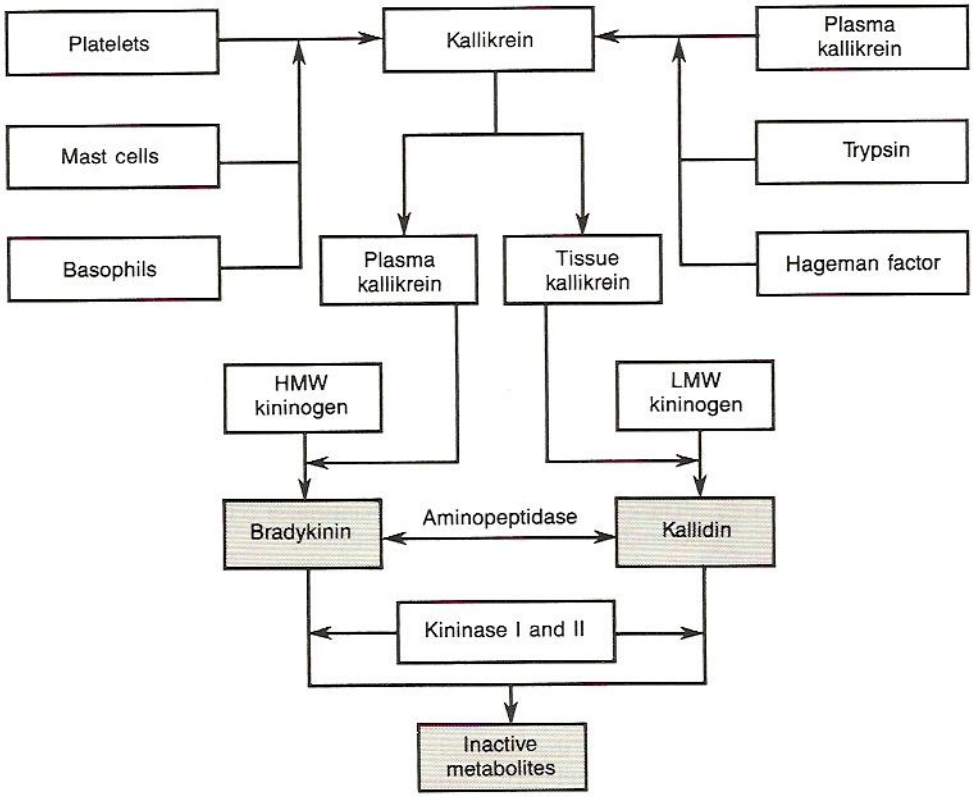

Figure 19-32. The kallikrein-kinin system. This system is a contributory component of the Type I hypersensitivity reaction.

Downloaded From Vet-eBooks.com

Reactions to incompatible transfusions, **neonatal isoerythrolysis, RH factor incompatibility (erythroblastosis fetalis), autoimmune hemolytic anemia, immune thrombocytopenia,** and certain other immune-mediated disease processes are characterized by type II hypersensitivity reactions.

Type III hypersensitivity

The **type III hypersensitivity** response is also called the **toxic complex reaction.** Ags result in the formation of immune complexes that activate the complement system. Initiation of the complement cascade results in the release of factors that cause platelet aggregation, mast cell degranulation, and neutrophil accumulation. Extensive tissue damage, inflammation, and necrosis result.

Type III reactions are characterized by two responses to Ags—the Arthus reaction and serum sickness. The **Arthus reaction** results from localized accumulation of immune complexes. The generalized circulation of immune complexes initiates the second response, **serum sickness.** Type III reactions may be manifested when excessive amounts of Ag-Ab complexes are formed.

Arthus reaction. The Arthus reaction results when an Ag to which the organism can respond is introduced into the subcutis, as might occur after a vaccination booster injection. The Ag within the connective tissue reacts with IgG. Some controversy exists relating to the function of IgE in this reaction. The immune complexes IgE and Ag may cause the release of vasoactive amines from mast cells. The resultant increase in vascular permeability may permit the leakage of IgG from the vascular bed and may facilitate the formation of Ag and IgG immune complexes. Importantly, the immune complex IgG fixes complement.

Various products of the complement cascade (C3a, C5a, C3b, C567) initiate helpful and damaging sequelae. The release of C567 attracts neutrophils to the local area whereas C3b facilitates the adherence of neutrophils to the immune complexes. The opsonizing influence of C3b results in phagocytosis and clearance of the immune complexes. **Anaphylatoxins** (C3a, C5a) cause mast cell degranulation and the release of vasoactive substances. The release of hydrolases (collagenases, elastases, proteases) by the neutrophils causes the localized damage that characterizes the Arthus reaction. Vascular wall damage exacerbates the localized response by attracting more neutrophils, which release more hydrolases. Damaged endothelial cells also release kallikreins and aid in the generation of kinins. The resultant hemorrhage leads to clot formation and necrosis of the tissues that have been deprived of their vascular supply **(ischemic necrosis).** The complement cascade induction of platelet aggregation also exacerbates tissue necrosis. The severe localized inflammatory response of the Arthus reaction may be observed in dogs either infected or vaccinated with live **adenovirus type I (infectious canine hepatitis virus)** and is manifested as "blue eye." **Hypersensitivity pneumonitis** is a type III response to actinomycete spores. **Staphylococcal hypersensitivity dermatitis** is also an example of a type III reaction. Arthus reactions, however, can occur in any localized focus of Ag-Ab accumulation.

Serum sickness. **Serum sickness** involves similar initiating mechanisms as have been described for the Arthus reaction. Some complexes (i.e., the insoluble ones) are cleared by macrophages. The soluble complexes circulate throughout the vascular system and eventually deposit themselves on vascular endothelial cells. Their deposition initiates those events attributable to various complement factors described for the Arthus reaction. Severe damage to the kidney **(glomerulonephritis)** can result when these complexes are deposited within the glomerulus. Although the precise mechanism of kidney damage is not understood, it occurs without the involvement of neutrophils. Mesangial, endothelial, and epithelial cell proliferation, as well as basement membrane alterations, cause excessive protein loss in the urine. **Arteritis and arthritis** are also sequelae.

Type IV hypersensitivity

Type IV hypersensitivity, also called **delayed hypersensitivity** and **CMI,** does not require immunoglobulins and occurs initially over a period of 8 to 12 days. Cytotoxic lymphocytes, lymphokines, and macrophages are contributing components. The infiltration of mononuclear cells into regions of antigen concentration is the characteristic histological feature. The rejection of foreign skin grafts, the response to intradermal injections of tuberculin, and the skin reactivity to certain contact agents and arthropods are examples of type IV hypersensitivity reactions.

Autoimmunity

The essence of immune mechanisms is the ability to recognize those substances that are "self" and those that are foreign. The inability to recognize self results in the formation of autoantibodies and the destruction of somatic tissues. Various mechanisms are proposed to explain this self-destructive phenomenon. Autoantibodies may be produced against body components that normally are not "seen" by the lymphocytes following damage that results in exposure to the surveillance cells. New Ags may be developed within the body as a result of viral influence and/or the incorporation of foreign materials with normal body components. These and other mechanisms are likely responsible for activation of the immune processes against "self." Autoimmunity is manifested as types I to IV hypersensitivity reactions. **Systemic lupus erythematosus, autoimmune thyroiditis, myasthenia gravis,** and **rheumatoid arthritis** are examples of autoimmune or **immune-mediated diseases.**

ADDITIONAL READINGS

Adams DO: The granulomatous inflammatory response: a review, *Am J Pathol* 84:164, 1976.

Binns RM: Organisation of the lymphoreticular system and lymphocyte markers in the pig, *Vet Immunol Immunopathol* 3:95, 1982.

Breaven MA: Histamine, *N Engl J Med* 294:30, 1976.

Burnet FM: The thymus gland, *Sci Am* 207:50, 1962.

Clark SL Jr: The reticulum of lymph nodes in mice studied with the electron microscope, *Am J Anat* 110:217, 1962.

Clark AD, MacLennon KA: The many facets of thymic involution, *Immunol Today* 7:204, 1986.

Cohn ZA: The structure and function of monocytes and macrophages, *Adv Immunol* 9:163, 1968.

Edwards VD, Simon GT: Ultrastructural aspects of red cell destruction in the normal rat spleen, *J Ultrastruct Res* 33:187, 1970.

Feuerstein G, Hallenbeck JM: Leukotrienes in health and disease, *FASEB J* 1:186, 1987.

Fujisaki S: The fine structure of Hassall's corpuscles and reticular cells in the mouse thymus, *Acta Med Biol* 14:107, 1966.

Goldstein AL, Chirigos MA (eds): *Lymphokines and thymic hormones,* New York, 1981, Raven Press.

Hayes TG: The marginal zone and marginal sinus in the spleen of the gerbil. A light and electron microscopic study, *J Morphol* 141:205, 1973.

Hoshino T, et al: Early development of thymic lymphocytes in mice studied by light and electron microscopy, *Anat Rec* 164:47, 1969.

Jaroslow BN: Genesis of Hassall's corpuscles, *Nature* 215:408, 1967.

Kay AB: The role of the eosinophil, *J Allergy Clin Immunol* 64:90, 1979.

Levin PM: The development of the tonsil of the domestic pig, *Anat Rec* 45:189, 1930.

Metz SA: Anti-inflammatory agents as inhibitors of prostaglandin synthesis in man, *Med Clin North Am* 65:713, 1981.

Meyer A: Hemal nodes in bovines and goats, *Am J Anat* 21:359, 1917.

Moe RE: Electron microscopic appearance of the parenchyma of lymph nodes, *Am J Anat* 114:341, 1964.

Movat HZ, Fernando NVP: The fine structure of the lymphoid tissue during antibody formation, *Exp Molec Pathol* 4:155, 1965.

Murray RG, Murray A, Pizzo A: The fine structure of thymocytes of young rats, *Anat Rec* 151:17, 1965.

Payne F, Breneman WR: Lymphoid areas in endocrine glands in the fowl, *Poult Sci* 31:155, 1952.

Peck HM, Hoerr NL: The intermediary circulation in the red pulp of the mouse spleen, *Anat Rec* 109:447, 1951.

Raviola E, Karnovsky MJ: Evidence for a blood-thymus barrier using electron-opaque tracers, *J Exp Med* 136:466, 1972.

Regoli D, Barabe J: Pharmacology of bradykinin and related kinins, *Pharmacol Rev* 32:81, 1980.

Renston RH, et al: Evidence for a vesicular transport mechanism in hepatocytes for biliary secretions of immunoglobulin A, *Science* 298:1276, 1980.

Roberts DK, Latta JS: Electron microscopic studies on the red pulp of the mouse spleen, *Anat Rec* 148:81, 1964.

Samuelsson B, Hammarstrom S: Nomenclature of the leukotrienes, *Prostaglandins* 19:645, 1980.

Downloaded From Vet-eBooks.com

Schachter M: Kallikreins (kininogenases): a group of serine proteases with bioregulatory actions, *Pharmacol Rev* 31:1, 1980.

Song SH, Groom AC: A scanning electron microscope study of the splenic red pulp in relation to the sequestration of immature red cells, *J Morphol* 149:437, 1974.

Tehver J, Grahame I: Capsule and trabeculae of spleens of domestic animals, *J Anat* 65:473, 1931.

Theofilopoulos AN, Dixon FJ: The biology and detection of immune complexes, *Adv Immunol* 28:89, 1979.

Tizard IR: *An introduction to veterinary immunology*, ed 3, Philadelphia, 1987, WB Saunders.

Unanue ER: The regulatory role of macrophages in antigenic stimulation, *Adv Immunol* 15:95, 1972.

Weiss L: *The cells and tissues of the immune system: structure, functions, interactions*, Englewood Cliffs NJ, 1972, Prentice-Hall.

Yamori T, Mori Y: Electron microscopic observation of reticuloendothelial system, *Tohoku J Exp Med* 81:330, 1964.

Downloaded From Vet-eBooks.com

CHAPTER 20

Integumentary System

GENERAL CHARACTERISTICS

Form and function. The integument includes the skin and its derivatives. The outermost layer of skin, the **epidermis,** is stratified squamous epithelium (Figs. 5-7 to 5-11 and 20-1). The epidermis has distinct layers, the number of which varies in different regions (Plate I, *1*). The **dermis (corium)** underlies the epidermis and varies from loose to dense collagenous tissue (Fig. 20-2). The **hypodermis (subcutis)** is loose collagenous tissue connecting the dermis to underlying periosteum, perichondrium, or deep fascia. The hypodermis **(superficial fascia)** varies in different regions. Some regions have many adipocytes (footpads); others have few adipocytes (scrotum, eyelids, ears). The dermis and hypodermis contain blood vessels, nerves, and lymphatic vessels.

Many structures are skin derivatives—hair, nails, claws, feathers, horns, antlers, combs, wattles, sweat glands, sebaceous glands, mammary glands, hooves. The skin and its derivatives perform varied functions.

The skin is an effective two-way **barrier** between the internal and external environments. It prevents water, electrolyte, and macromolecule loss. It minimizes the ingress of physical, chemical, and microbial agents. The secretory products of tubular glands (in some animals), the hair coat, and the cutaneous blood supply all mediate **temperature regulation.**

The cutaneous vascular supply also contributes to **blood pressure** alterations. Skin glands have **secretory functions** (sebum, sweat, milk). In some species, skin glands contribute an **excretory function.** The skin assists **calcium homeostasis** through the ultraviolet light conversion of 7-dehydrocholecalciferol to cholecalciferol within the sebaceous glands. Skin pigmentation **protects against ultraviolet radiational damage.** Skin elasticity and strength provide for **motion** and **external form;** highly cornified structures provide for **locomotion.** This system provides for **general behavioral patterns, sexual behavioral displays,** and **mechanical protection.** The skin is an extensive **sensory organ.** The GSA modalities (pain, pressure, temperature) and SSA information from the eyes and ears help integrate the organism with its external environment.

Besides being the largest organ, the skin may reflect various external and internal disease processes (ectoparasitism, autoimmune diseases, endoparasitism, endocrine disorders, nutritional problems). It thus is important clinically.

MAMMALIAN INTEGUMENT

Typical Skin

The epidermis develops from ectoderm whereas the dermis and hypodermis are from mesoderm. Initially a simple cuboidal epithelium forms the epidermis. Basal cell layer proliferation adds to the thickness and stratification of this outer covering. Basal cell proliferation and invagination into the underlying dermis and hypodermis account for hair, feather, and gland formation.

Progressive proliferation and differentiation of mesenchymal cells establish resident cell populations typical of loose and dense collagenous tissues.

Organization of the Skin

Epidermis. The **epidermis** has distinct layers (Figs. 20-1 and 5-7). These were discussed previously. (See "Stratified

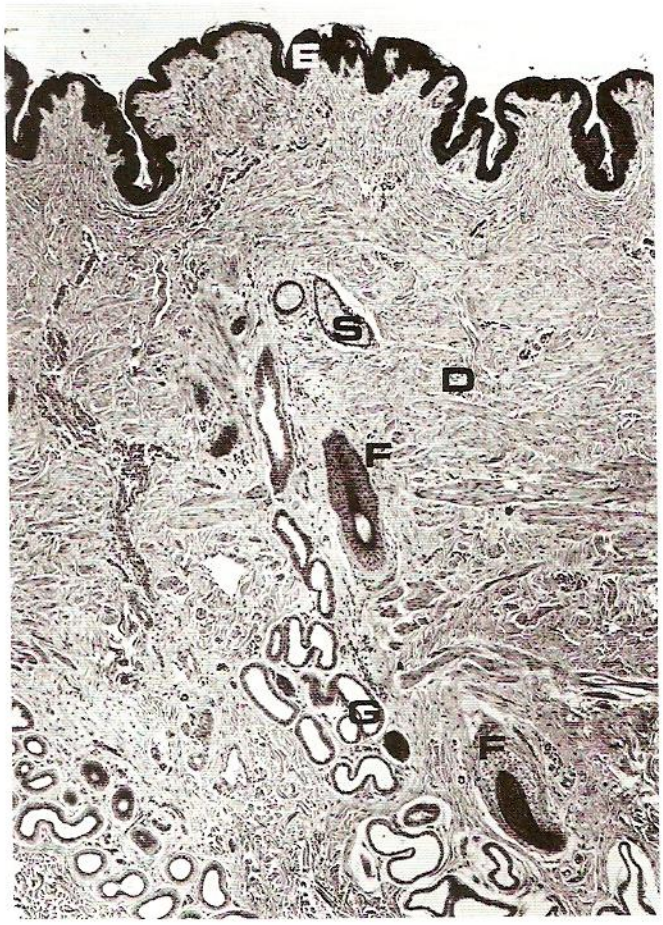

Figure 20-1. Ovine haired skin. The epidermis *(E)* is underlaid by an extensive dermis *(D)* containing hair follicles *(F)*, sebaceous glands *(S)*, and tubular glands *(G)*. (×10.)

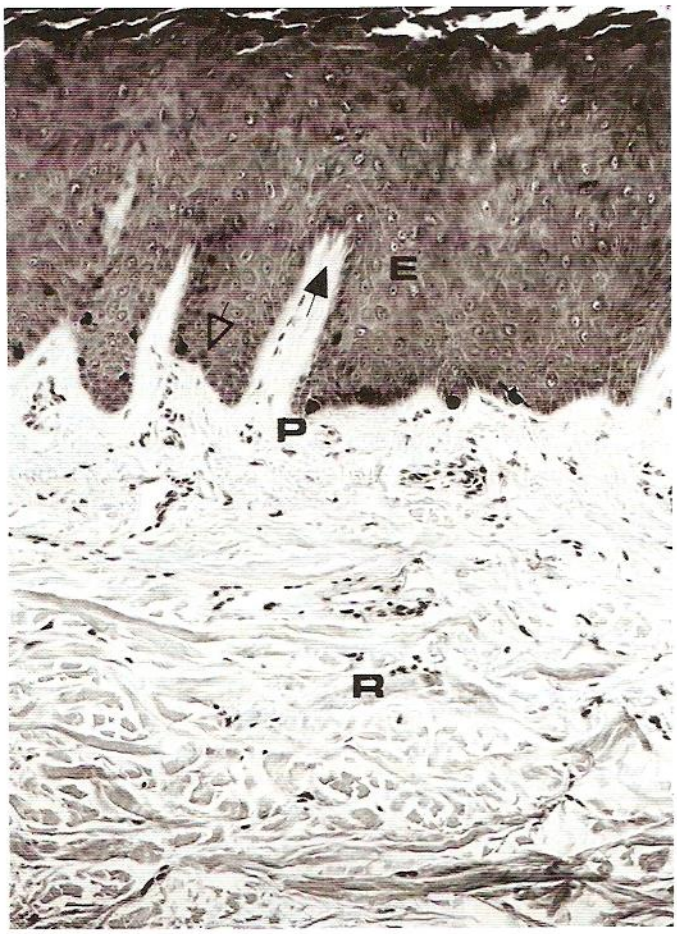

Figure 20-2. Papillary and reticular zones of the dermis. The papillary zone *(P)* is immediately adjacent to the epidermis *(E)* and is continuous with the reticular zone *(R)*. Dermal papillae *(solid arrow)* and epidermal pegs *(open arrow)* are well developed. (×40.)

squamous epithelium," p. 51, and Figs. 5-7 to 5-11.) The number of layers varies from region to region.

The surface covering of the integument, **keratin,** is the transformation product of basal cell differentiation. Once differentiation of these cells occurs, their progeny are considered classic examples of fixed postmitotic cells. This process needs a copious supply of stem cells.

Cells undergoing **keratinization (cornification)** become enucleated, flattened, and filled with a secretory product—keratin. **Keratin** is actually a mixture of low–sulfur content proteins (microfibrils) embedded within an amorphous matrix rich in high–sulfur content protein. Autophagocytosis increases with the accumulation of keratin, resulting in the digestion of all cellular organelles. The cell membranes of contiguous cells are still connected by desmosomes, despite the intracellular alterations. **Soft keratin** characterizes the majority of the epidermis and those cutaneous mucous membranes that are keratinized. **Hard keratin** is typical of the skin appendages—feathers, parts of hair, hooves, etc. Keratohyalin granules are evident during the formation of soft keratin. Desquamation of **keratinocytes** is a continual feature of the process. Hard keratin has high quantities of cystine and many disulfide bonds. This induces great strength and stability to the substance. Keratohyalin granules are not apparent during the formation of hard keratin. Also desquamation is not a feature of the process.

Dermis. The **dermis** is separated from the epidermis by a typical basement membrane. Two zones occur in the dermis—a **papillary** and a **reticular** (Fig. 20-2). The papillary (superficial) zone conforms to the contours of the stratum basale. It contains epidermal structures invaginating into the dermis from the epidermis. The loose collagenous tissue thickness of the region is species variable. The deep (reticular) zone has dense collagenous tissue; the name of this zone refers to the arrangement of collagenous fibers.

Dermal papillae are fingerlike projections extending into the epidermis from the dermis (Fig. 20-2). **Epidermal pegs** are complementary projections of epidermis into the dermis. Confluent epidermal pegs form **epidermal ridges (laminae).** The epidermis and dermis interdigitate through papillae, pegs, and laminae. Dermal papillae increase surface contact with the epidermis. This type of junctional interface is typical in regions subjected to mechanical loading—carnivore footpads and equine hooves. Heavily haired skin usually is not papillated. Dermal papillae also contain many vessels and sensory receptors. Lymphatic tissue, glands, and smooth muscle also occur in the dermis.

Hypodermis. The epidermis and dermis reside upon a **hypodermis** or subcutaneous layer of loose collagenous tissue. The hypodermis attaches the skin to deep structures and permits integumentary motility over these structures. When the hypodermis is infiltrated by many adipocytes, the layer is called the **panniculus adiposus.** The hypodermis blends into the underlying dense collagenous tissue of the deep fascia, periosteum, or perichondrium. Infiltration of adipose tissue is typical in carnivore digital pads and equine digital cushions. They function in mechanical cushioning. Alternating compression and decompression of the equine digital cushion is essential for venous return from the foot.

Vascular, neural, and lymphatic components. The blood supply to typical haired skin is extensive and organized into three vascular plexuses: **superficial** or **subpapillary plexus, middle** or **cutaneous plexus,** and **deep** or **subcutaneous plexus.** The three plexuses communicate with each other. Regional and species-specific variations exist. Haired skin is devoid generally of extensive capillary loops into dermal papillae whereas glabrous skin has extensive capillary loops into the papillary zone.

The cutaneous nerves contain motor and sensory fibers. Sympathetic fibers (GVE) innervate vascular smooth muscle, the arrector pili muscles, and the myoepithelial cells of tubular glands. Most epidermal and dermal nerves are GSA fibers. **The skin is a vast sensory organ.** Various sensory modalities (touch, pain, temperature, itch) are received by afferent endings. Sensory endings occur in the hypodermis, dermis, and epidermis.

Branches of cutaneous nerves innervate hair follicles and form **hair follicle networks.** Sensory nerve endings wrap around the hair follicles and form tactile receptors in mammalian haired skin. This relationship is well-developed in tactile hairs. The sensory nerves of the dermis, **dermal network,** is more extensive in glabrous than in haired skin.

Blind-ended lymphatic capillaries located within dermal papillae drain into papillary lymph vessels.

Downloaded From Vet-eBooks.com

Specialized Skin Regions

The mammalian integument is not uniform. Some skin is haired; some is glabrous. A thick epidermis may characterize some regions; a thin epidermis, others. The dermis also varies in thickness. The dermis is the thickest part of the skin. Regional skin variations relating to amount and type of pelage, distribution and type of glands, and skin thickness are functional adaptations to suit the organism to its environment.

Digital pads. The **foot pads** or **digital pads** of carnivores are highly cornified, thickened, pigmented, and hairless regions. The digital pads resist abrasion and are effective shock absorbers. The heavily cornified epidermis of the digital pads, which is the thickest epidermis of the carnivore skin, consists of all layers. The hypodermis consists of adipose tissue and proper connective tissue, the **digital cushion.** Coiled, tubular sweat glands (merocrine glands) occur in the dermis and hypodermis.

Scrotum. The skin of the scrotum is usually the thinnest skin. The stratum corneum is not well-developed, and the dermis is not extensive. Apocrine tubular and sebaceous glands are present, but species variations exist. Hair follicles are not abundant, and the hairs are short and fine. Smooth muscle fibers of the tunica dartos intersperse among collagenous and elastic fibers. The **tunica dartos** is responsible for the relative position of the testes to the body wall. This is an effective device for regulating scrotal temperature; sperm production is a temperature-dependent phenomenon.

Nose. Integumentary modifications characterize the nose of domestic species. The **planum nasale** of carnivores has a thickened and highly cornified epidermis devoid of sebaceous and tubular glands. The **planum nasolabiale** of the ox and the **planum nasale** of small ruminants (sheep, goats) are devoid of hairs but contain tubular merocrine glands moistening the surface. The epidermis is thickened and highly cornified. The highly cornified porcine **planum rostrale** contains many tubular merocrine glands and is sparsely covered by fine hairs. Fine hairs and sebaceous glands are characteristic of the thin skin also around equine nostrils.

External auditory meatus. The **external ear canal** connects the external auditory opening with the tympanic membrane. Small hair follicles, sebaceous glands and modified, apocrine, tubular glands are present. The glands are **ceruminous glands** of the external auditory meatus. The dermis of this canal blends with the perichondrium and periosteum of the support tissues. The external auditory meatus is moistened by the ceruminous secretions. Despite being moistened, this structure is **not** a mucous membrane.

The external auditory meatus is lined by skin. This structure is subject to many of the typical integumentary disease problems. **Otitis externa** is a common problem of companion animals, especially those with droopy ears.

Mucocutaneous junctions. **Mucocutaneous junctions,** transition points between typical skin and **cutaneous mucous membranes,** occur at all body orifices.

Hairs

Development. Hair follicles are ingrowths of the presumptive epidermis and basement membrane into the underlying dermis. The onset of development is an epidermal thickening becoming a prominent cellular cord. The solid cord of invaginating epidermis undergoes canalization forming a space for the future hair. The remaining, invaginated epider-

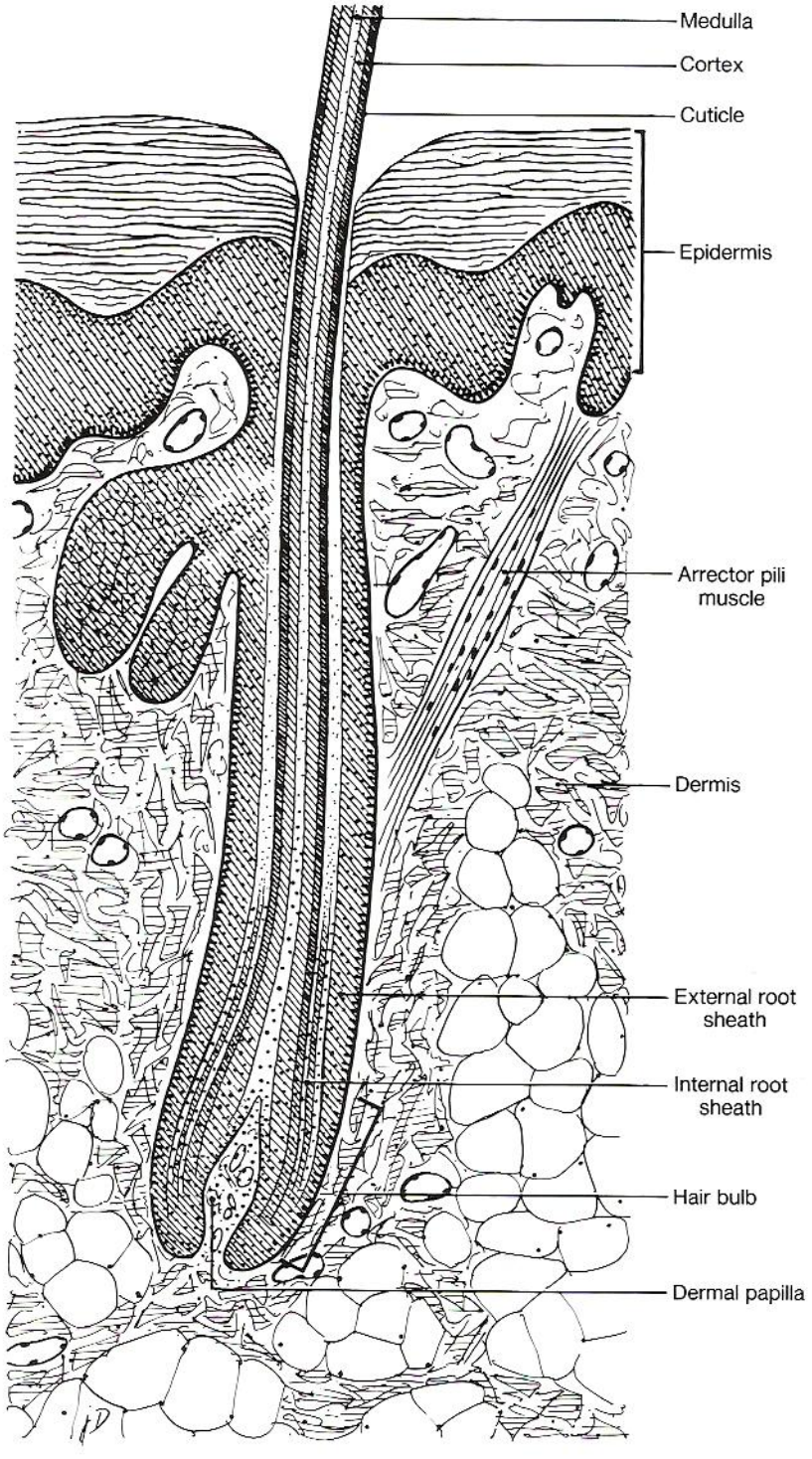

Figure 20-3. Typical hair follicle.

mis continues with the **external root sheath.** This sheath continues as the **germinal matrix** at the base of the developing follicle. The germinal matrix forms the hair and internal root sheath.

Follicular organization. Hairs occur variously in the system and serve various functions—**insulation, protection,** and **sensory reception** (Plate I, 2). Figure 20-3 presents a typical hair in the anagen stage of its growth cycle.

A connective tissue sheath is oriented circumferentially around the **hair follicle** (Fig. 20-4). A basement membrane **(glassy membrane)** separates the connective tissue from follicular epithelium. The **external root sheath** continues to the surface of the skin (Fig. 20-5). An **internal root sheath** has several layers of flattened cells with and without **trichohyalin granules** (Fig. 20-5). The **root sheath cuticle** is a single layer of cornified cells interdigitating with the cornified cells of the hair cuticle. The internal root sheath does not extend beyond the opening of sebaceous glands into the follicle.

The hair has three regions—a cuticle, a cortex, and a medulla (Figs. 20-5 and 20-6). The **cuticle** is a single layer of enucleated, cornified cells. The **cortex** forms the bulk of the hair shaft, consisting of several layers of flattened, cornified cells. Pigment may be present, and many intercellular air spaces occur. The **medulla** may be absent in some hairs. When present, it has cornified cuboidal cells separated by air spaces (Fig. 20-6). Identification of species is possible based on cuticular, cortical, and medullary characteristics.

The hair follicle terminates in a hollow, cone-shaped epidermal peg **(hair bulb)** defining the limits of the **dermal papilla** (Fig. 20-7). Although dermal papillae provide some vascularization, most nutrients are supplied by a circumscribing follicular vascular bed. Dermal papilla may induce growth and regulate differentiation within the germinal matrix.

A smooth muscle mass, the **arrector pili,** extends between the follicular connective tissue and the connective tissue of the papillary region of the skin proper (Fig. 20-3). Its contraction not only erects the hair but may help to express the sebaceous glands located between the muscle and the follicle.

Species characteristics. Hairs typically occur in groups **(hair beds)** of three primary follicles and a variable number of secondary follicles. These groupings may not always be apparent in adults or at the surface.

In dogs, hair beds contain follicles opening separately or through a common opening at the surface. **Compound follicles (clusters)** consist usually of one **principal** or **guard hair** and three to nine **auxiliary (secondary)** or **wool hairs** (Fig. 20-8). A guard hair has a 150 μm diameter as well as a cuticle, cortex, and medulla. The wool hairs have a 70 μm diameter and no medulla. Clustering of hairs may be exaggerated (as in chinchillas, with 75 hairs comprising a cluster and a single surface opening) or minimal (as in horses and cattle, with a single guard hair about 15 μm in diameter). Many wool hairs are maximally 11 μm in diameter.

Hair cycle. Normal hair growth and shedding occur in cycles influenced by

Figure 20-4. Hair follicle. The margins *(arrows)* have been separated partially from the surrounding connective tissue. Note the continuity of the cellular components of the follicle with the surface cells. The intimate association of the dermal papilla to the hair bulb is apparent at the *lowest arrow*. (×25.)

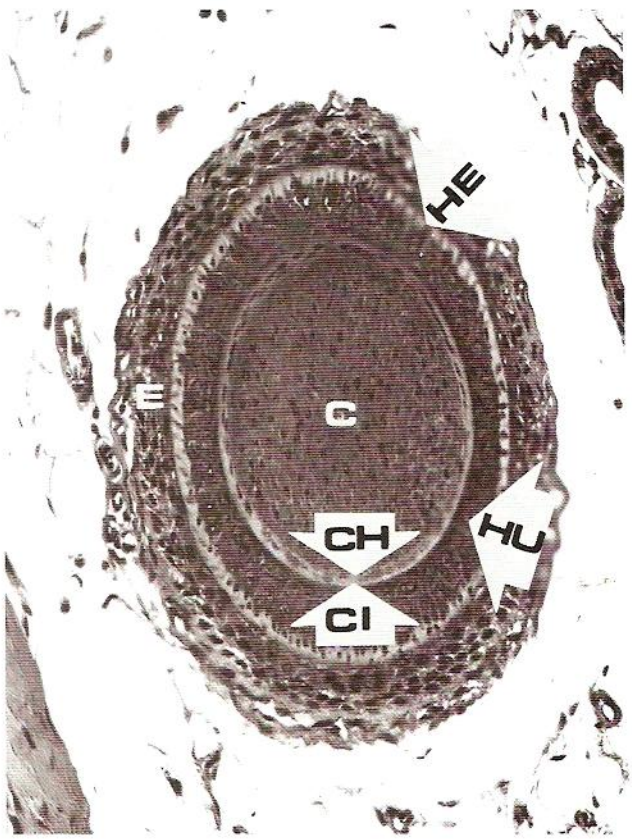

Figure 20-5. Cross-sectioned hair follicle. The external root sheath *(E)* surrounds the hair and is separated from the connective tissue by a glassy membrane (not apparent). The internal root sheath consists of Henle's layer *(HE)*, Huxley's layer *(HU)*, and an inner cuticular layer *(CI)*. The hair consists of a cuticular layer *(CH)* and cortex *(C)*. A medulla is not present. (×63.)

Downloaded From Vet-eBooks.com

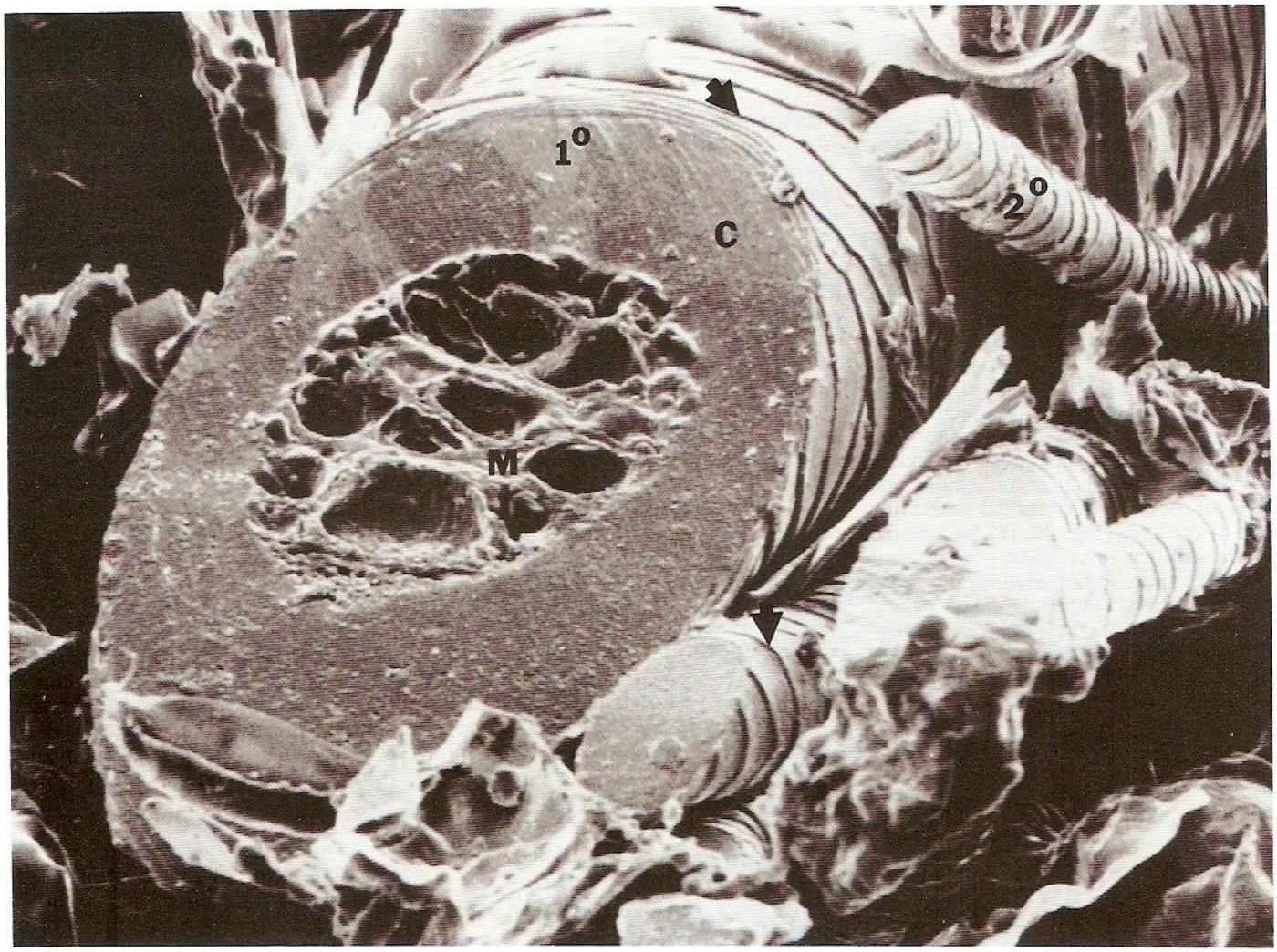

Figure 20-6. Scanning electron micrograph of hairs from the saddle region of a beagle. Cross sections of the main (1°) and secondary (2°) hair shafts are apparent. The main shaft has a cortex *(C)* and a honeycomb-like medulla *(M)*. A medulla is not present in the secondary hairs. The cortices of the primary and secondary hair shafts are protected by organized layers of cuticular cells *(arrows)* overlapping each other in a telescoping pattern. (Courtesy F. Al-Bagdadi.)

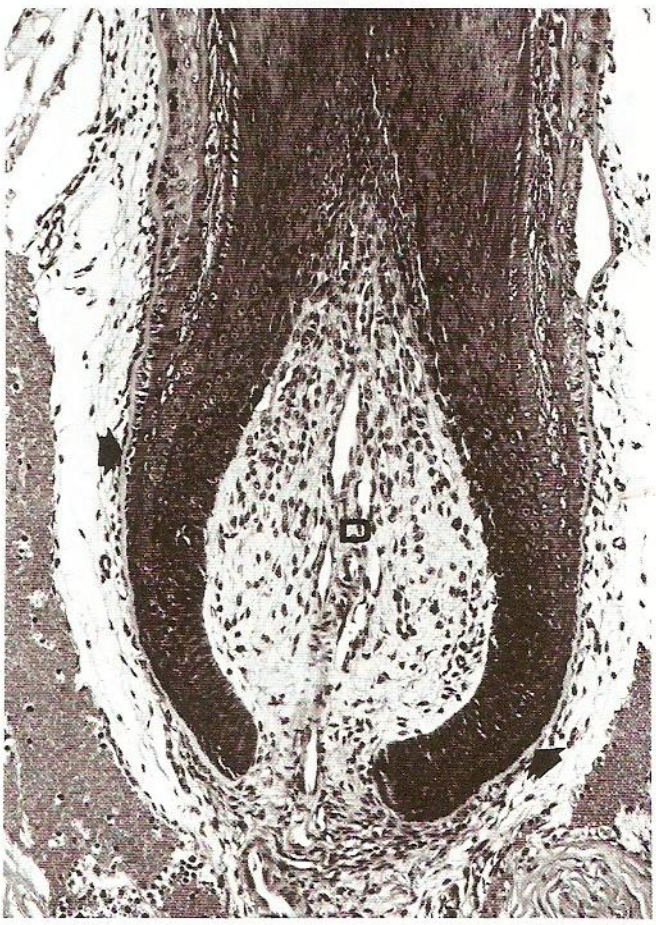

Figure 20-7. Hair bulb and dermal papilla. The cone-shaped hair bulb surrounds the dermal papilla *(D)*. The glassy membrane *(arrows)* is apparent. (×40.)

Downloaded From Vet-eBooks.com

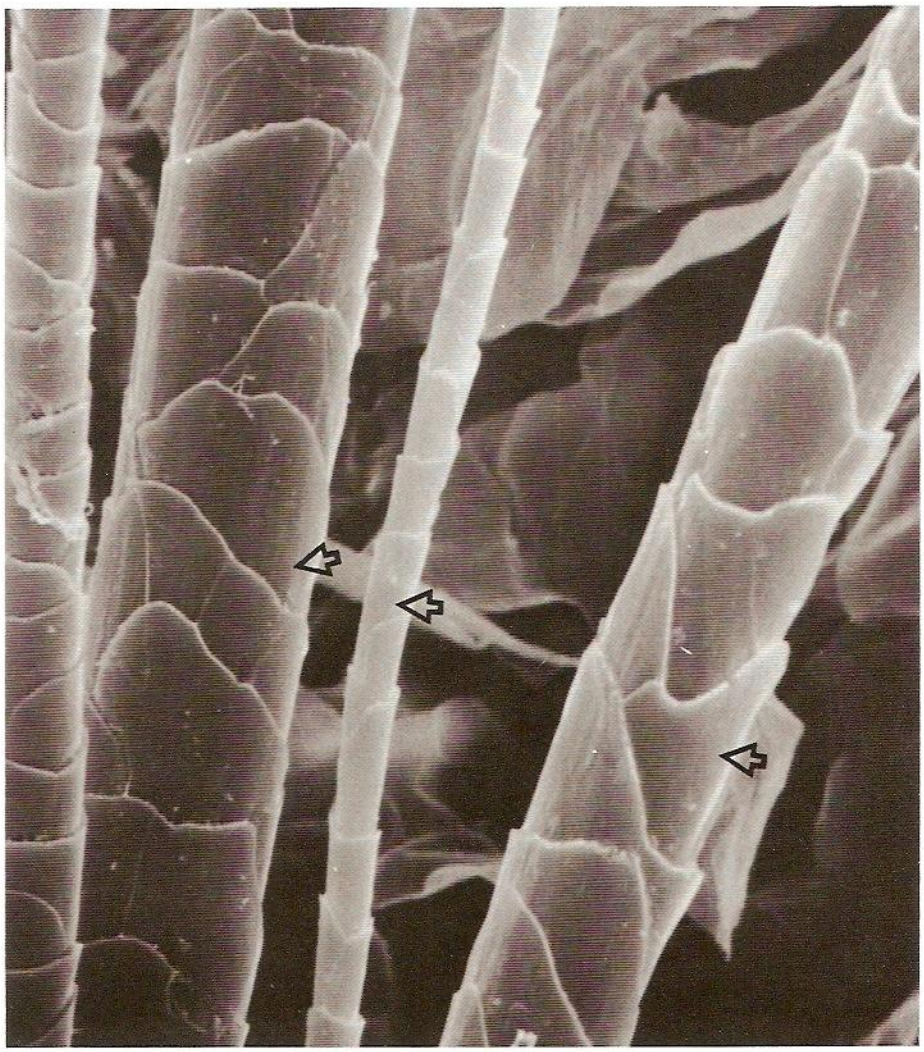

Figure 20-8. A scanning electron micrograph of hair obtained from the saddle region of a beagle. Four hair shafts of different diameters are covered by cuticular cells (*arrows*). The cuticular cells have different shapes. Hair shafts of different sizes form the typical compound hairs of this species. (Courtesy F. Al-Bagdadi.)

the photoperiod. A complete hair cycle has three stages—anagen, catagen, and telogen (Fig. 20-9). **Anagen** is the period when hair growth is accomplished. **Catagen** is a transition stage. **Telogen** is the resting period.

The hair is produced by mitoses of constituent cells of the **germinal matrix** during anagen. The apposition of new cells to the shaft results in hair elongation.

1. During catagen the hair bulb becomes a solid, cornified mass of cells and the distal follicle thins. The forming club-shaped bulb fuses to the hair-shaft and migrates to the level of the sebaceous glands. These hairs, without distinct papillae, are called **club hairs.**
2. A secondary germ develops deep to the club hair. This morphology marks telogen and may be maintained for weeks or months.
3. During early anagen the secondary germ grows deeper, forming a new hair bulb in association with a dermal papilla. Continued mitosis elongates the shaft. New growth eventually displaces the club hair, which is shed, and the cycle continues.

Insights about hair growth and shedding in domestic animals are incomplete. Many laboratory rodents shed their hairs in **synchronized waves** starting ventrally and progressing laterad and dorsad. Carnivores and humans have an **asynchronized mosaic pattern** of growth and shedding, each follicle following its own intrinsic rhythm. Hair cycles are also influenced by the photoperiod.

Many disease conditions are characterized by a dull hair coat in which the cuticular cells are not flattened against the cortex; thus light is not reflected normally. The anagen stage of hair growth may be shortened in some diseases. Accordingly, many hairs in telogen may be shed synchronously.

Sensory hairs. These structures are called **tactile hairs** or **sinus hairs** (Fig. 20-10). Although their distribution is limited, the structure of the hair and follicle is similar to that of normal hairs. The connective tissue sheath adjacent to the glassy membrane is thickened and separated by connective tissue trabeculae from a peripherally located connective tissue sheath. The intertrabecular spaces are filled with blood within venous sinuses. Free nerve endings and Merkel's disks are associated with the epidermal cells and connective tissue fibers.

Special Skin Cells

Melanocytes and intraepidermal macrophages. Melanin-bearing cells in the skin and mucous membranes (conjunctival sac, buccal cavity) impart characteristic pigmentation (Fig. 20-11). Melanin also protects the organism from harmful ultraviolet radiation. Ultraviolet solar ra-

Downloaded From Vet-eBooks.com

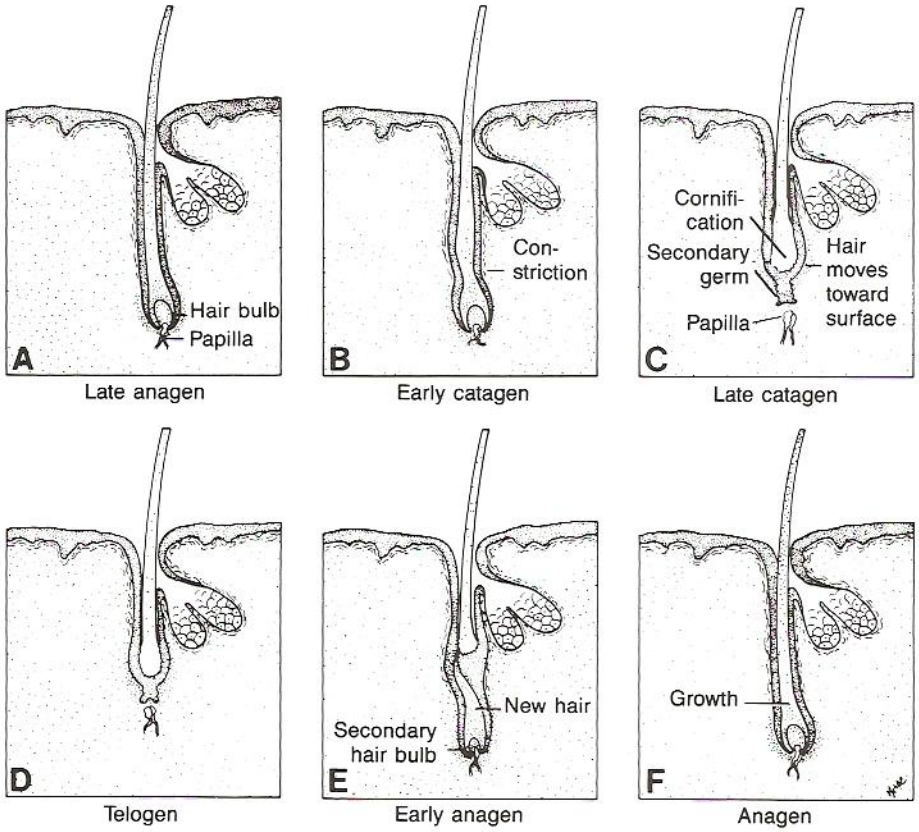

Figure 20-9. Typical hair cycle. **A,** Hair growth begins to slow down. **B,** A club hair starts to form at a constriction in the follicle. **C,** The club hair cornifies, and a secondary germ forms. The club hair moves toward the surface. **D,** Resting stage. **E,** A secondary germ forms a new (secondary) hair bulb, and the club hair is pushed from the follicle as new hair growth progresses. **F,** New hair growth continues, and the cycle is completed.

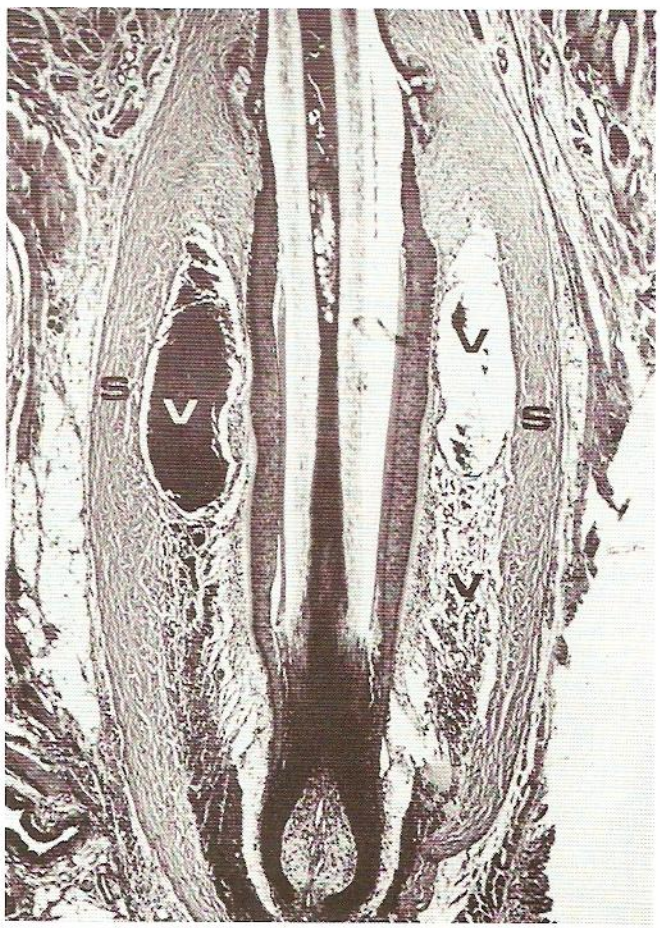

Figure 20-10. Sinus hair from a cat. The hair is surrounded by a well-developed connective tissue sheath *(S)* containing venous sinuses *(V)*. (×10.)

Downloaded From Vet-eBooks.com

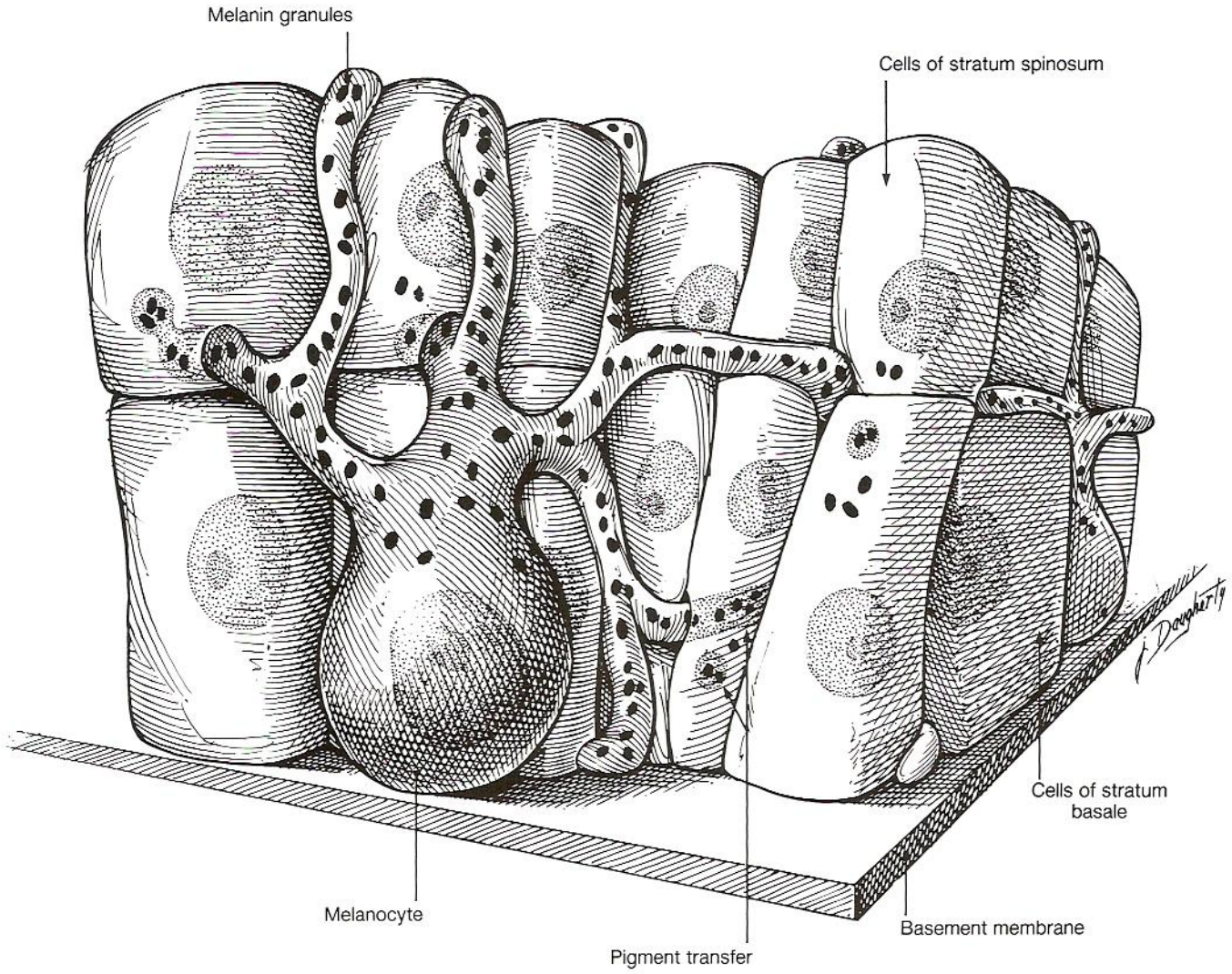

Figure 20-11. Relationship of melanocytes to cells of the epidermis.

diation may contribute to the increased incidence of bovine **ocular squamous cell carcinoma** in the Rocky Mountain West. Despite their protective function, melanoblasts and melanocytes produce a highly malignant tumor, **malignant melanoma.**

Intraepidermal macrophages (formerly called Langerhans cells) are round cells with a clear cytoplasm when stained with H&E. They occur in the peripheral portion of the stratum spinosum. Special staining techniques (gold chloride) demonstrate these cells to have a stellate or dendritic shape.

The intraepidermal macrophages belong to a group of uniquely phagocytic cells that assist with "antigen processing." (See "Histocompatibility," p. 292, and "Antigen presenting cells," p. 293.)

Glands of the Mammalian Skin

Sebaceous and tubular glands

The skin glands, **sebaceous** and **tubular,** are generally associated with hairs. The former typically deposit their product into the follicle; some may empty independently on the skin surface. The latter occur with follicles or open independently on the surface.

Sebaceous glands. Sebaceous glands of hairs evaginate from the root canal lining as simple, branched alveolar glands (Figs. 5-24 and 5-28). (See Chapter 5.) These glands produce **sebum,** consisting of accumulated fatty acids, cholesterol, and vitamin D precursors. Sebum reduces the possible entry of microorganisms through the skin, diminishes water loss, and keeps the hairs and outer skin surface soft and pliable (Fig. 20-12).

Arrector pili muscle contraction may express the glands. The secretory product enters the follicle and then spreads over the surface of the skin.

Some areas of the skin are devoid of sebaceous glands—foot pads, hooves, claws, horns, etc.

Tubular glands. The tubular glands of the skin are simple, coiled, tubular structures. They are extensively developed in the horse and man and are absent in the bird. There are two general types—**merocrine (eccrine)** and **apocrine.** (See Chapter 5.)

Human merocrine tubular glands, the primary sweat glands, open independently of hair follicles. They are restricted to the carnivore foot pads (Fig. 20-13), the ungulate frog, the porcine carpus, and the nasolabial region of ruminants and swine. In humans, sweat glands are usually confined to the mammary, axillary, pubic, and perineal regions.

The apocrine tubular gland is the predominant sweat gland in domestic animals (Figs. 5-21, 5-25, 5-27, and 20-1). They are distributed generally throughout the skin. The canid has extensive tubular glands over the entire body, but they are minimally functional as sweat glands. The equine apocrine tubular glands are active and produce an obvious secretion during physical exertion.

Sweat glands serve both a cooling and an excretory function. The secretory product is watery (serous) and slightly alkaline. In the horse it is strongly alkaline

Downloaded From Vet-eBooks.com

Figure 20-12. Secretory sequence in a sebaceous gland. The stem cells *(S)* migrate from the periphery *(curved arrows)*, mature *(M)*, disintegrate *(D)*, and are propelled to the excretory duct *(straight arrow)*. (×100.)

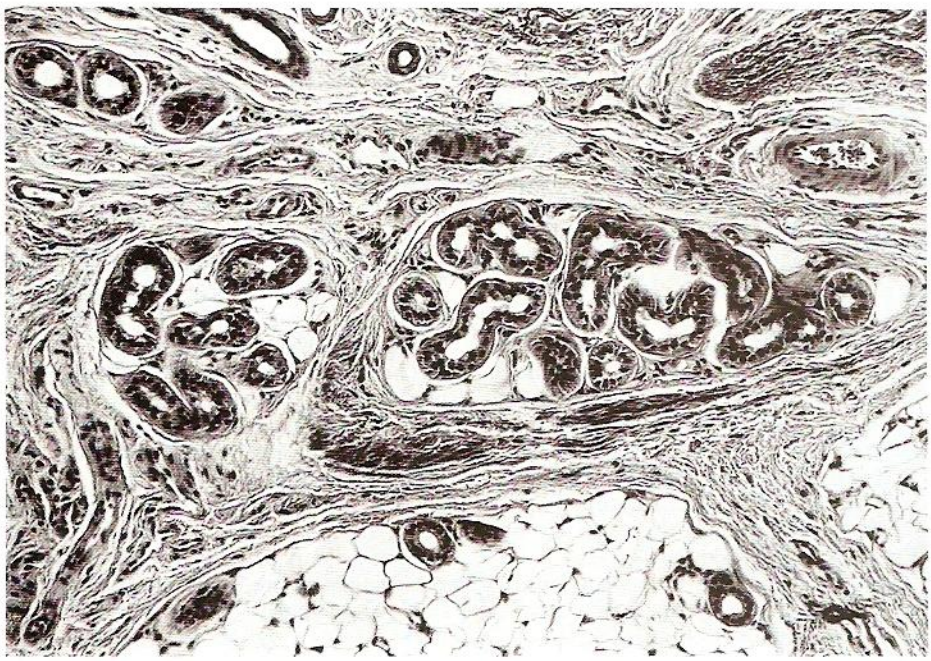

Figure 20-13. Merocrine tubular glands of the feline footpad. These are not the typical tubular glands of domestic animals. (×40.)

and contains albuminoids, serum globulins, and some urea.

Glands of the perianal region

These special skin glands are customarily divided into three types based upon their gross anatomical location—anal, anal sac, and circumanal or perianal.

Anal glands. The **anal glands** are modified tubuloalveolar sweat glands occupying the submucosa of the columnar and intermediate zones of the anal canal (dogs, cats, pigs). They open into the anus (Fig. 20-14). Carnivore anal glands secrete lipids; those of pigs secrete mucoid substances (Fig. 20-15). Lymphatic tissue and venous erectile tissue are present.

Anal sac glands. The **anal sacs or perianal sinuses** are paired, lateral, cutaneous, anal diverticula lined by a cornified stratified squamous epithelium. Each sac has mural glands opening into it (Fig. 20-16). A typical lamina propria is underlaid by a dense fibroelastic connective tissue. Much smooth and skeletal muscle is present in the connective tissue.

The anal sac is present in carnivores and many rodents. In dogs, the anal sac glands are apocrine tubular; in cats, they are apocrine tubular and sebaceous. In both species the glands open into the excretory duct or anal sac neck.

The products of anal sac glands, sloughed cells, and excrement may occlude the opening of the sacs to the anus. The anal sacs may have to be expressed periodically in dogs.

Glands of the circumanal or perianal region. These are the **sebaceous** and the **circumanal glands.** Sebaceous glands are typical but may not be associated with hairs. Canine circumanal glands are nonpatent masses of parenchymal cells described as **hepatocyte-like** (Fig. 20-18). The cells have a finely granular, acidophilic cytoplasm and pale nuclei. Many proteinaceous granules are present. The cells may be polygonal or tall columnar. Because nonpatent ducts from the circumanal glands may connect with the sebaceous glands of the region, these glands may be nonsecretory, abortive sebaceous glands. Circumanal glands are predisposed to neoplasia.

Mammary Gland

General features. The following description generally applies to all species but is especially applicable to cows. The organ is a compound, tubuloalveolar gland considered a modified sweat gland (Fig. 20-19). Lipids are secreted by the apocrine method; proteins and carbohydrates are secreted by the merocrine method.

The mammary gland consists of **teats** and **udder.** Actively lactating glands have

Downloaded From Vet-eBooks.com

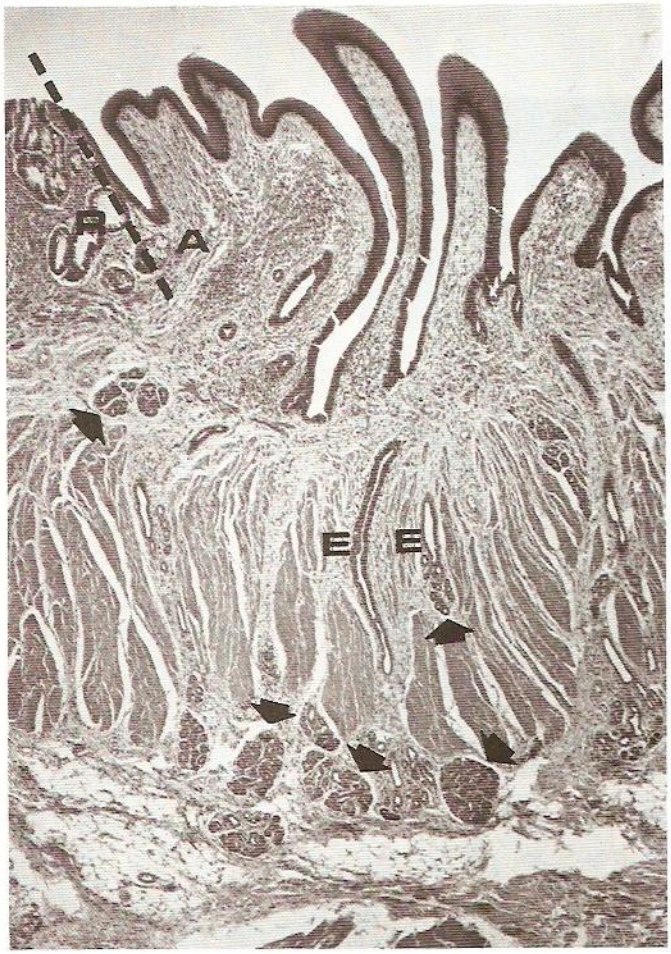

Figure 20-14. Porcine anal glands. The anal glands *(arrows)* are located in the submucosa of the columnar and intermediate zones of the anal canal. *A,* anus; *R,* rectum; *dashed line,* anorectal junction. The excretory ducts *(E)* of these glands open into the anus. (×10.)

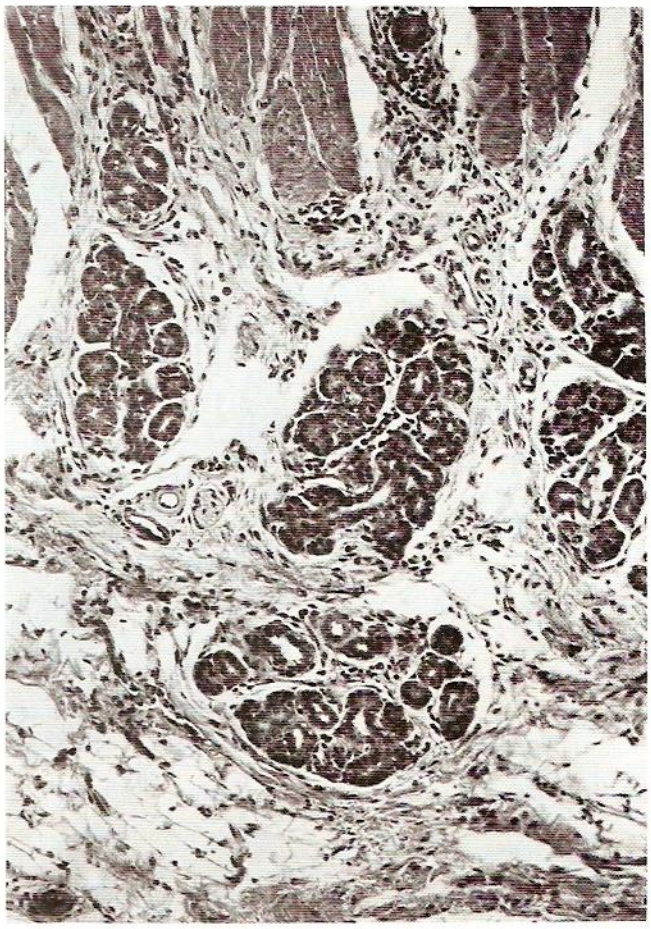

Figure 20-15. Adenomeres of porcine anal glands. These tubuloalveolar glands secrete mucoid substances. (×40.)

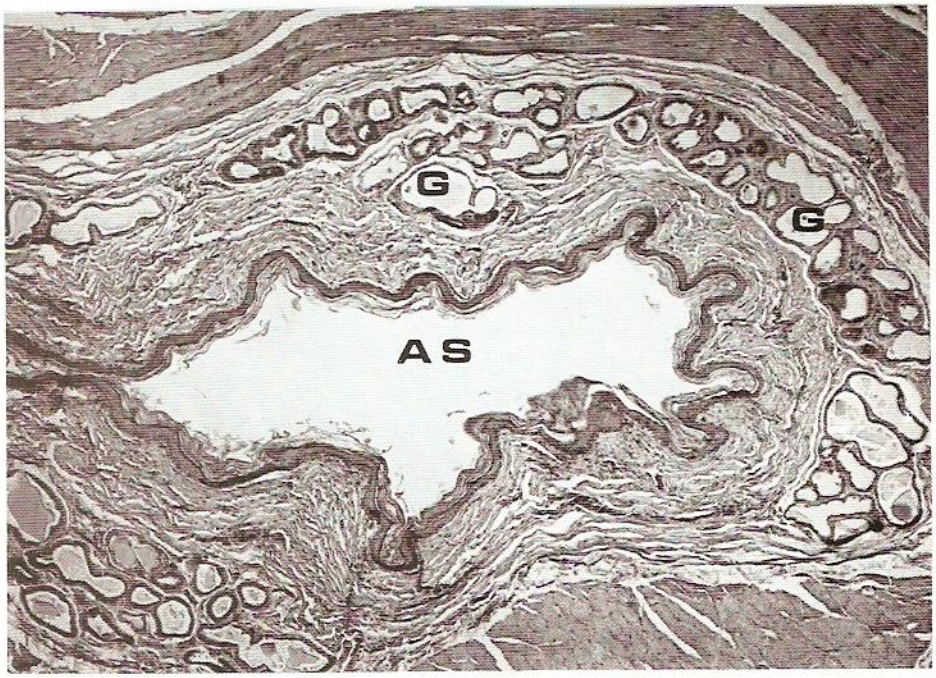

Figure 20-16. Canine perianal sinus. The anal sacs are paired cutaneous diverticula of the anus containing many apocrine tubular glands *(G)* in their walls. *AS,* One of the anal sacs. (×10.)

Downloaded From Vet-eBooks.com

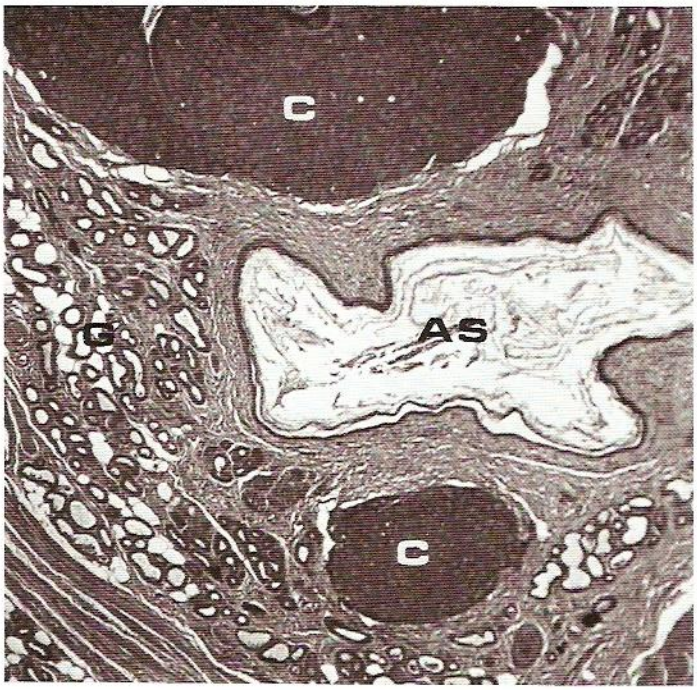

Figure 20-17. Canine circumanal glands *(C)* are solid masses of cells in close association with the anal sacs *(AS)*. *G*, Apocrine tubular glands. (×10.)

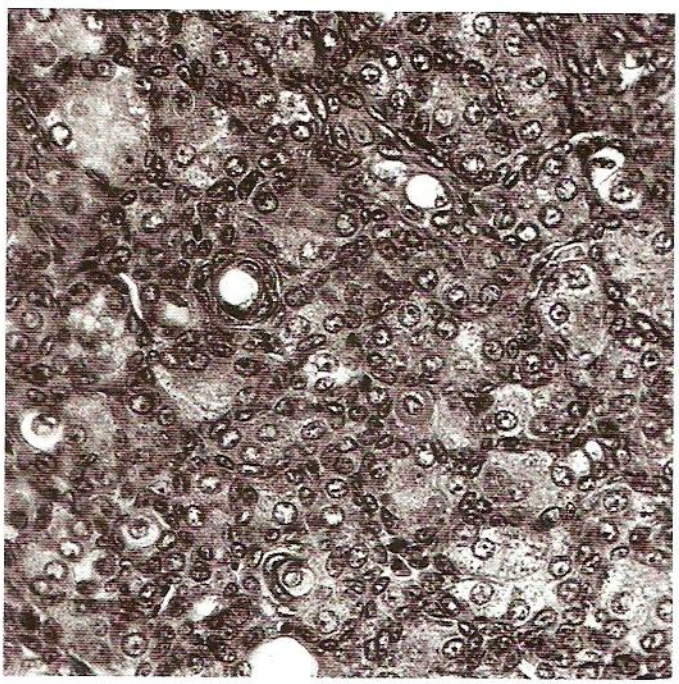

Figure 20-18. Parenchyma of the circumanal glands. The functioning component of these glands consists of a solid mass of acidophilic, polygonal cells. Although ducts are present in this section, they are not patent as they leave the gland. (×100.)

Downloaded From Vet-eBooks.com

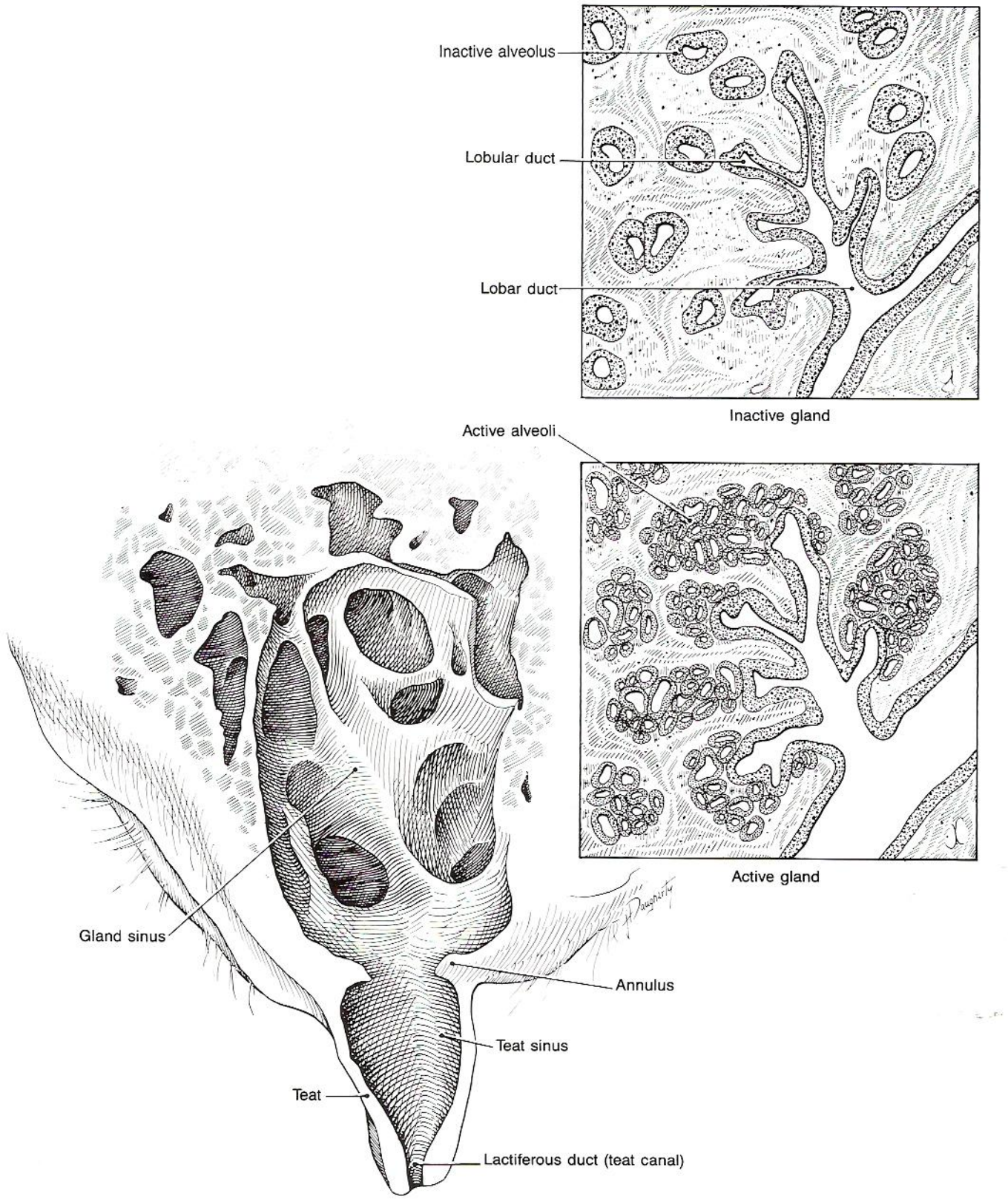

Figure 20-19. Bovine udder. The number of alveoli is reduced in an inactive gland. In an active gland the number increases at the expense of interstitial connective tissue.

Downloaded From Vet-eBooks.com

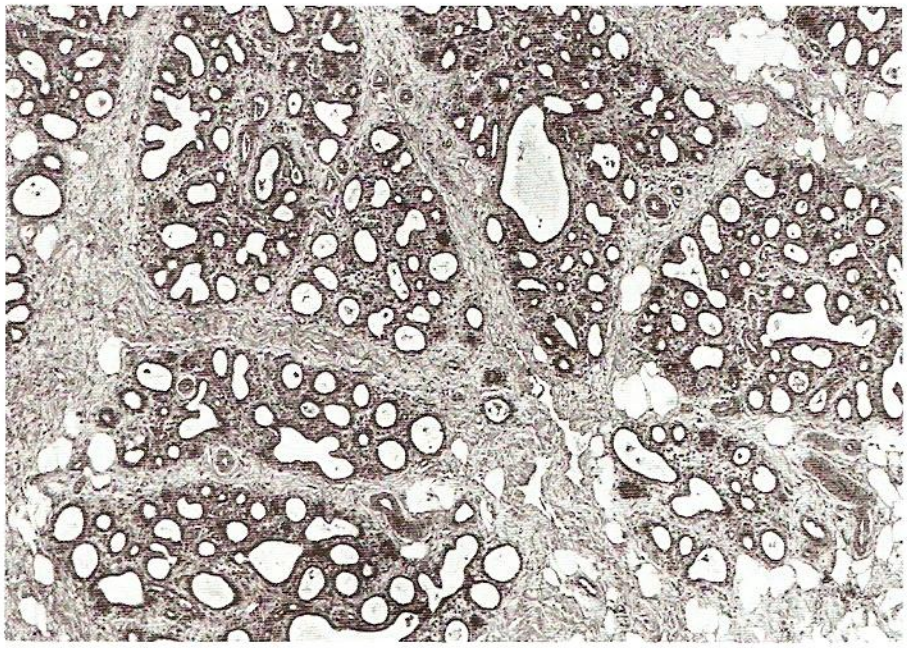

Figure 20-20. Lactating bovine mammary gland. The parenchyma of the organ is predominant. (Compare with Fig. 20-23.) (×16.)

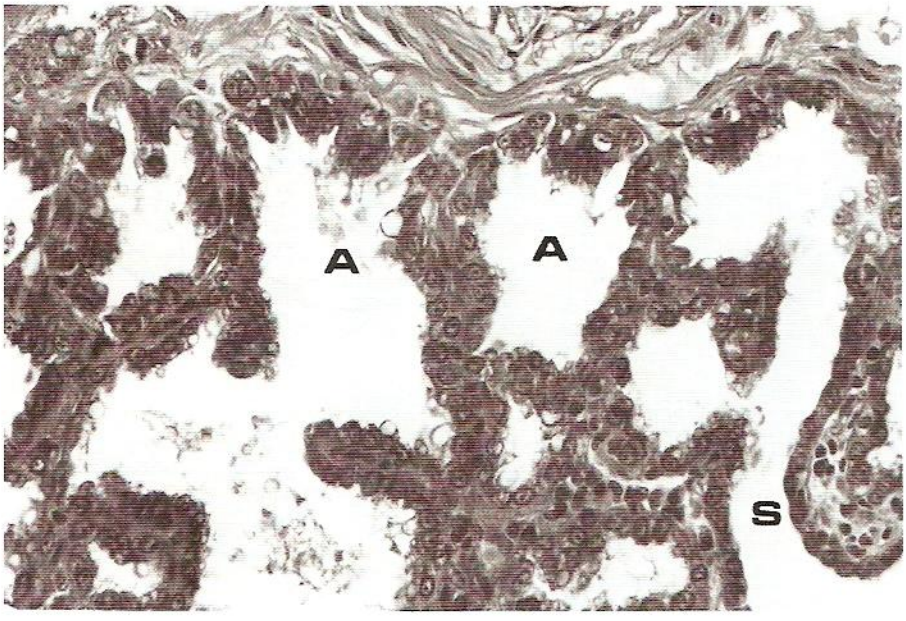

Figure 20-21. Adenomeres of a lactating bovine mammary gland. The alveoli *(A)* are lined by columnar cells with blebs along their apical surfaces. The secretory tubules *(S)* are lined by a cuboidal epithelium. (×100.)

much parenchyma and little connective tissue; the reverse is true of nonlactating glands.

For a cow to produce 40 pounds of milk per day, approximately 8 tons of blood must pass through the udder. This amount of milk is produced, secreted, suspended, and removed from the udder in a short milking period from a sac of tissue weighing about 50 pounds.

Lactating gland. The secretory components are the alveolar epithelial lining cells and the cells of the **intralobular ducts (secretory tubules)** (Figs. 20-19 and 20-20). The active cells are columnar with their apical borders protruding into the lumina (Fig. 20-21). Typical apical blebs indicate apocrine secretion. Fat accumulation is manifested as foamy appearing cells. Small fat droplets may become confluent and form a single large droplet. The lateral cell borders usually are indistinct. The nucleus may be basally displaced or positioned apically during the secretory process. It may even be discharged into the lumen and become part of the secretory product.

Sloughed secretory cells, macrophages, and leukocytes may comprise part of the secretory product throughout lactation (Fig. 20-22). Macrophages and leukocytes are prominent during early lactation as part of the **colostrum.** Colostrum functions as a laxative. In some species it imparts passive immunity to the nursing offspring until they achieve immunological competency.

Inactive secretory cells have a low profile, resulting from a diminished or terminated secretion or from mechanical distortion from the accumulation of luminal secretions. Not all cells, secretory tubules, and alveoli are active at the same time.

One or two **alveoli** drain into a single **secretory tubule** This **(intralobular duct)** is lined by cuboidal cells. The initial part is lined by secretory columnar cells. Intralobular ducts drain into a nonsecretory **lobular duct** lined by cuboidal or columnar cells. The lobular duct, as the primary excretory duct for a lobule, drains into a **lobar duct.** A lobar duct forms from many lobular ducts and is the primary excretory passage for a lobe. Ducts may expand to store milk. Many lobar ducts drain into the **lactiferous sinus,** a common chamber at the base of each quarter of the udder. The volume of this cistern varies. A slight constriction or **annulus** may separate the **glandular part** from the **papillary part** of the sinus. Bistratified columnar epithelium lines the lobar duct and lactiferous sinus. The papillary part of the lactiferous sinus continues with the skin via the **papillary duct.** The internal orifice of this canal is marked by an abrupt change to stratified squamous epithelium (cornified). The epithelium and connective tissue of this region are organized into longitudinal folds. The teat canal epithelium continues through the external orifice as the epidermal teat covering.

The connective tissue varies within the gland. Sparse intralobular, loose collagenous or reticular connective tissue is well vascularized. Many myoepithelial cells are present around adenomeres. Intralobar and interlobar connective tissue is also loose collagenous tissue. Smooth muscle and elastic fibers surround large ducts.

The capsule is a fibroelastic connective tissue, especially rich in elastic fibers, dividing the organ into quarters. The external capsular lamina is dense collagenous tissue comprising the **lateral suspensory ligament.** The **medial suspensory ligament** is especially rich in elastic fibers.

The epithelium and associated connective tissue of the papillary part of the lactiferous sinus and papillary duct are continuous with the dermis and epidermal

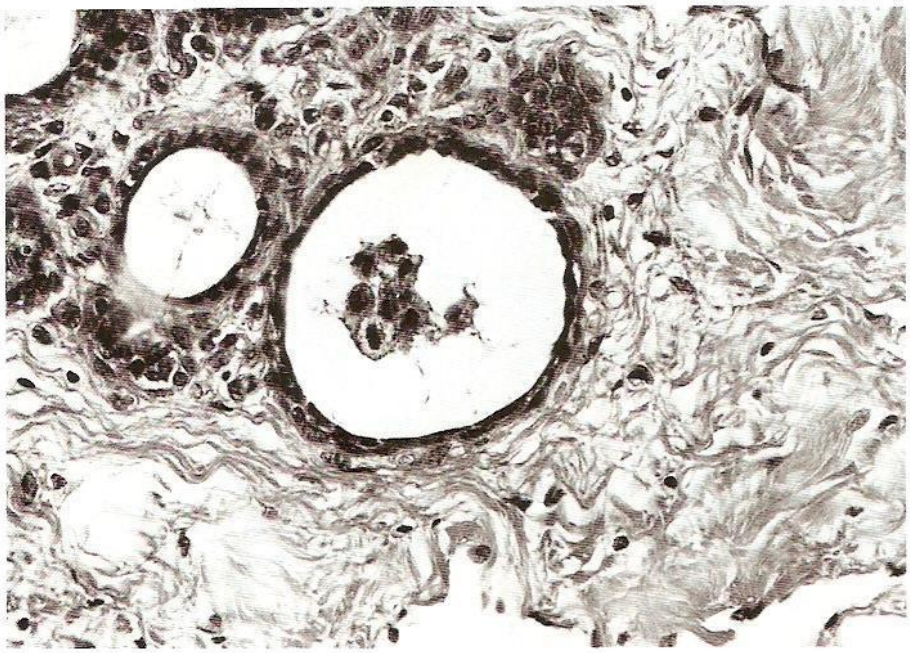

Figure 20-22. Cells within an alveolus. These may be sloughed epithelial cells or migratory cells from the connective tissue. (×100.)

Figure 20-23. Nonlactating bovine mammary gland. The parenchyma is reduced whereas the amount of connective tissue is increased. (Compare with Fig. 20-20.) (×16.)

covering of the teat. The associated dermis is rich in elastic fibers. Smooth muscle fibers in the region of the papillary duct internal orifice are disposed as a sphincter. Extensive longitudinal blood vessels, thick-walled veins, and lymphatic vessels occur with smooth muscle, especially in the regions of the sphincter. The skin of the teat in the cow is hairless and nonglandular.

Nonlactating gland. The parenchyma is reduced and replaced by loose collagenous and adipose tissue (Figs. 20-19 and 20-23). Extensive mononuclear infiltration into the connective tissue and parenchyma is typical. The alveoli and secretory tubules are the predominant deleted components. During activation, the alveoli probably arise from the residual duct system.

During advanced milk production a gradual involution of the udder occurs, leading to a morphology of inactivity. **Corpora amylacea,** concretions of casein and cell detritus, are common in advanced stages of lactation (Fig. 20-24).

Species characteristics. There are many gross and subgross anatomical differences among the mammary glands of domestic species. Although some histological differences exist, they are academic. The number of teats, lactiferous sinuses, and papillary ducts per teat varies; and the number of teat canals per teat likewise ranges widely—ruminants (doe, cow, ewe),1; sow, 2 to 3; mare, 2 to 4; queen, 4 to 7; bitch, 8 to 20; woman, 15 to 24.

Miscellaneous glands

Many glands in specific regions are not unique histologically but do have a unique gross distribution. They are **not** usually hair-associated.

Special sebaceous glands. Ovine **infraorbital glands** form a continuous lining around the infraorbital sinus (Fig. 5-28). The sinus, located rostral and medial to the eye, is lined by thin skin, many sebaceous glands, and a few apocrine tubular glands peripherally. The feline **submental organ** is located within the intermandibular space and consists of accumulations of sebaceous glands. The **supracaudal glands (tail glands)** of dogs and cats are located along the dorsal aspect of the tail. Feline tail glands extend along the entire length of the tail dorsum; excessive secretions of these glands impart a waxy appearance to the tail known as "stud tail." Canine tail glands are confined to a small, raised, oval, and well-circumscribed region at the tail base from which single coarse hairs emanate. Equine **preputial glands** are prominent and active sebaceous glands elaborating sebum **(smegma).** Caprine **scent glands (horn glands)** are hair-associated, modified sebaceous glands located along the caudomedial aspect of the horn base. Their secretion, which includes caproic acid, imparts the typical odor to male goats.

Special tubular glands. The porcine **mental organ** is an accumulation of apocrine tubular glands in the intermandibular space. Porcine **carpal glands,** aggregations of merocrine tubular glands, are located on the medial aspect of the carpus.

Special glands—tubular and sebaceous. Ovine **interdigital glands** occur in the interdigital sinus. Ovine **inguinal glands** occur in the inguinal sinus. Both locations consist of sebaceous and apocrine tubular glands.

HOOVES AND CLAWS

Equine Foot

Structure of the hoof

General features. The hoof consists of epidermis and cornified epidermal deriva-

Downloaded From Vet-eBooks.com

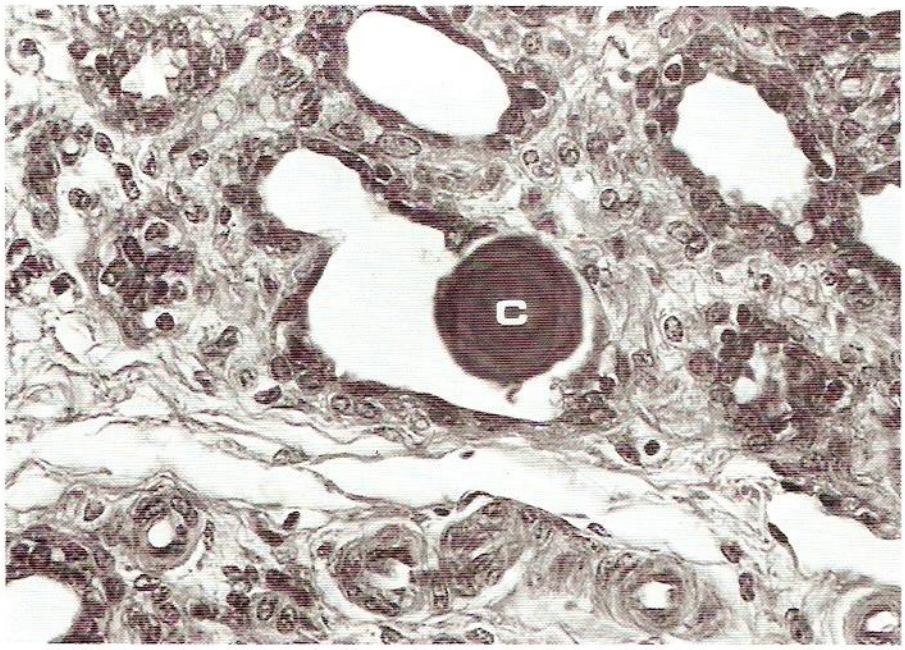

Figure 20-24. Amylaceous corpuscle *(C)* in an alveolus of the bovine mammary gland. This is a concretion of milk protein and cellular debris. (×100.)

Figure 20-25. Equine hoof. *A* (perpendicular to the ground surface) represents the plane of section in Figures 20-26, 20-28, 20-29, 20-31, and 20-32. *B* (parallel to the ground surface) represents the plane of section for Figures 20-27, 20-30, and 20-33.

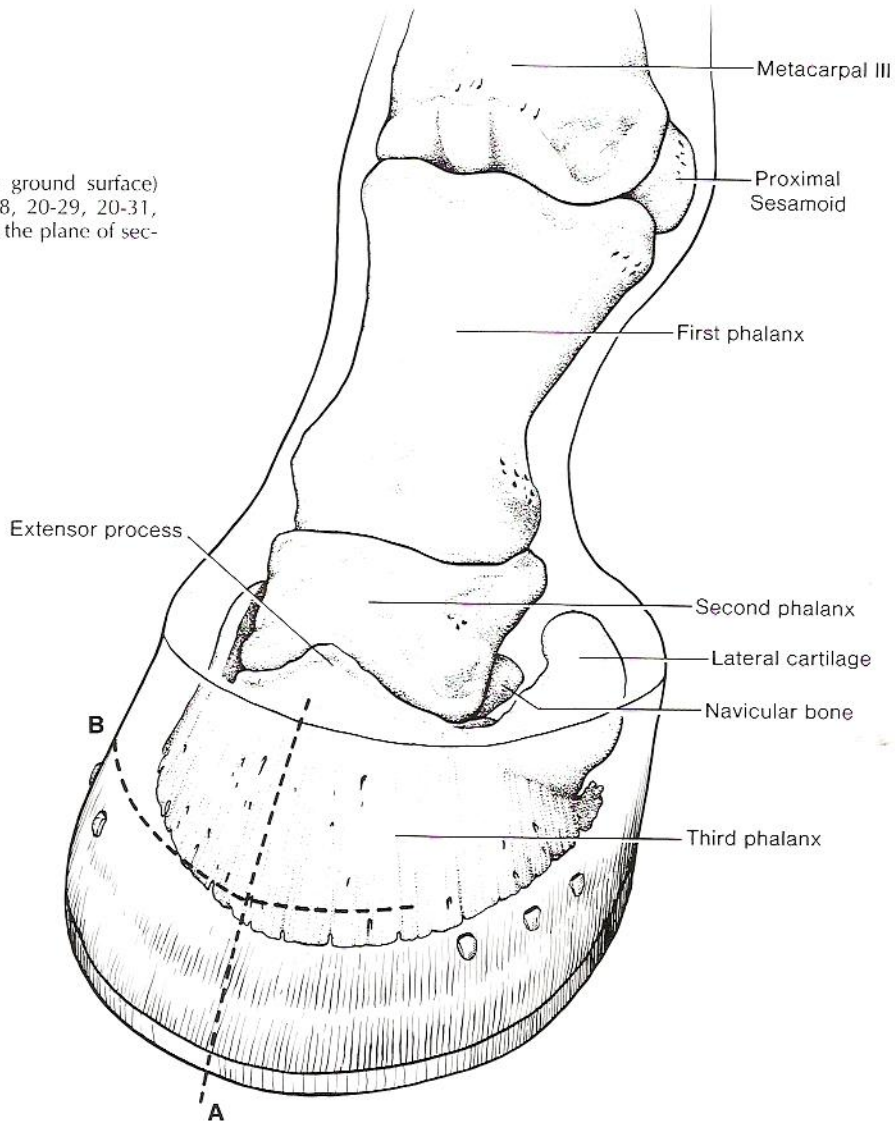

Downloaded From Vet-eBooks.com

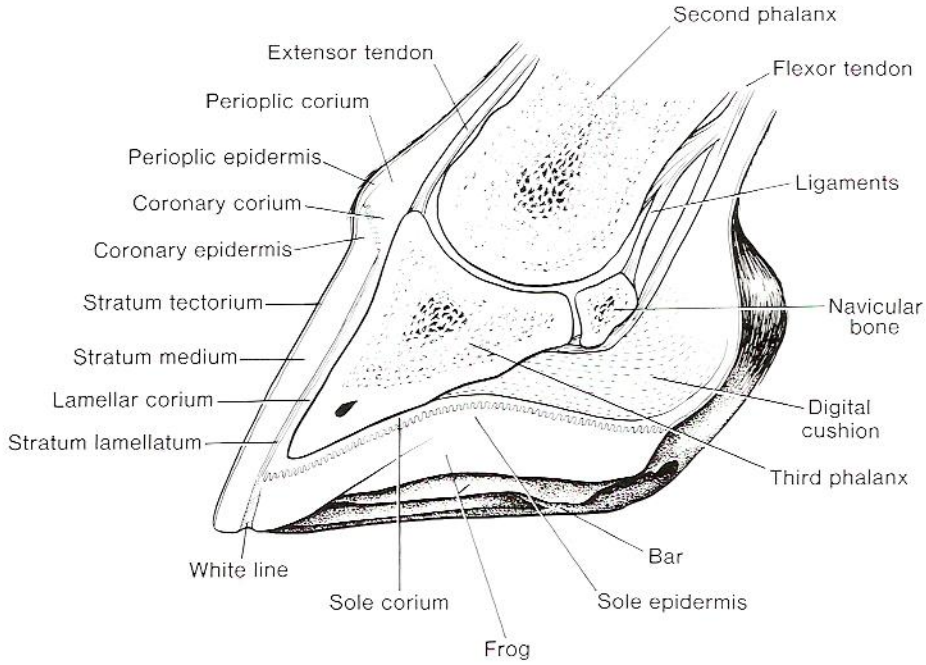

Figure 20-26. Longitudinal section through an equine hoof.

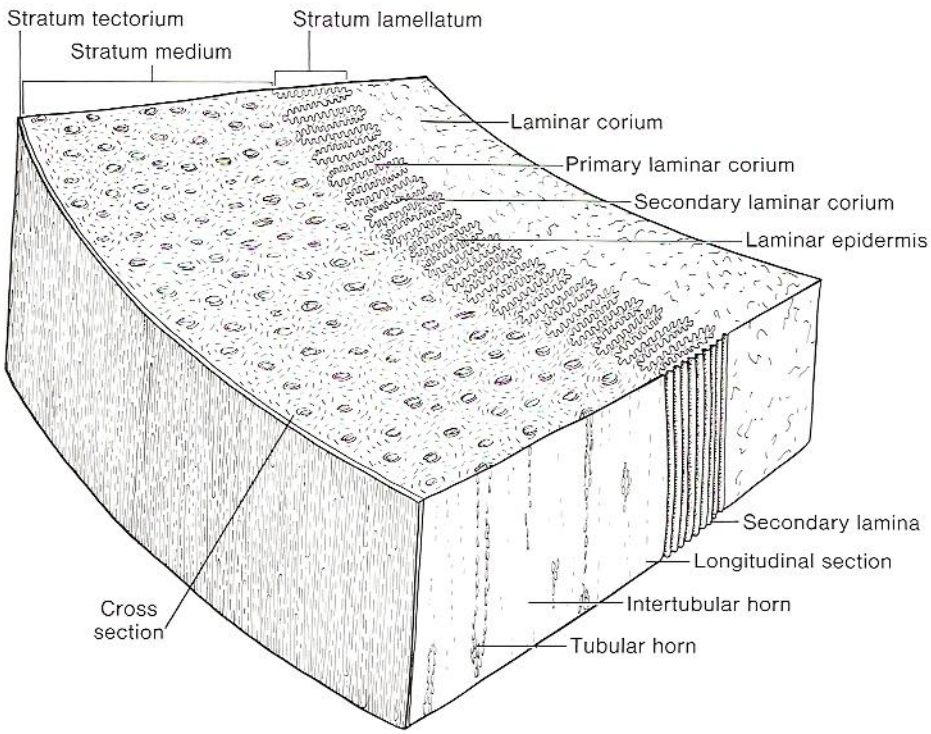

Figure 20-27. Cross section and longitudinal section through the wall of an equine hoof.

tives (Fig. 20-25). Unique geometric relationships exist between the epidermis and related dermis or corium. In some regions the dermis is papillated; in others epidermal pegs are confluent ridges. As a result the interdigitated epidermal and dermal regions are **laminar.**

Most parts of the hoof are formed of cornified material arranged in tubes. Some regions—those between the tubules—are nontubular. One region is laminar.

The histological regions of the hoof are **periople, coronet, laminae, bars, sole,** and **frog** (Fig. 20-26).

The perioplic, coronary, and laminar epidermises form the hoof **wall** (Fig. 20-27). In older horses the coronary and laminar epidermises are primary wall constituents.

Limbic epidermis. The **limbic** or **perioplic epidermis** is also called the **stratum externum** or **stratum tectorium** (Fig. 20-28). It is a shiny, soft, thin, white, cornified material extending over the wall and bulbs, and it may be the means by which water loss from young hooves is diminished. The highly vascular **perioplic (limbic) corium** has papillae oriented "perpendicular" to the ground surface. This orientation produces a downward growth of the perioplic epidermis. **The limbic corium is typical, supporting and nourishing the limbic epidermis.**

Tubular epidermis. The **tubular (coronary) epidermis,** underlaid by the **papillary (coronary) corium,** is also called the **stratum medium** (Fig. 20-29). This part of the wall is typically hard keratin and is devoid of a stratum granulosum and stratum lucidum. The cornified material is disposed as prominent tubular and intertubular horn, constituting the bulk of the hoof wall (Fig. 20-30).

The tubular horn is formed in a manner similar to hair growth (Fig. 20-31). The spaces between tubular horn are filled with intertubular horn. The tubules of horn arise from germinal epithelium covering the lateral and distal parts of the dermal papillae. The intertubular material forms from germinal epithelium in the depths of the epidermal pegs. The papillae of this region are elongated and "perpendicular" to the ground. This orientation results in the cornified cells' forming tubes oriented similarly with respect to the ground. **The tubular epidermis is underlaid by typical dermis (the papillary corium) that nourishes and supports the epidermis.**

Laminar epidermis. The **laminar epidermis (stratum lamellatum)** consists of nontubular horn elaborated at a slow pace "perpendicular" to the stratum medium (Fig. 20-32). It fuses with the stratum medium and holds the wall proper to the underlying dermal structures. The method of fusion is unknown.

The orientation and configuration of the epidermal "pegs" and dermal "papillae" are altered in this region. The dermal papillae and corresponding epidermal pegs are elongated ridges oriented perpendicular to the ground. **Primary** and **secondary laminae** characterize this region (Fig. 20-33). Secondary laminae are oriented at an acute angle to the primary laminae. Primary epidermal laminae are composed of cornified material. Collectively, they are called the **insensitive laminae** (Fig. 20-34). The remaining secondary laminae with associated naked nerve endings, germinal epithelium, and dermal structures are called the **sensitive laminae.** The laminae of the epidermis (stratum lamellatum) interdigitate with

Downloaded From Vet-eBooks.com

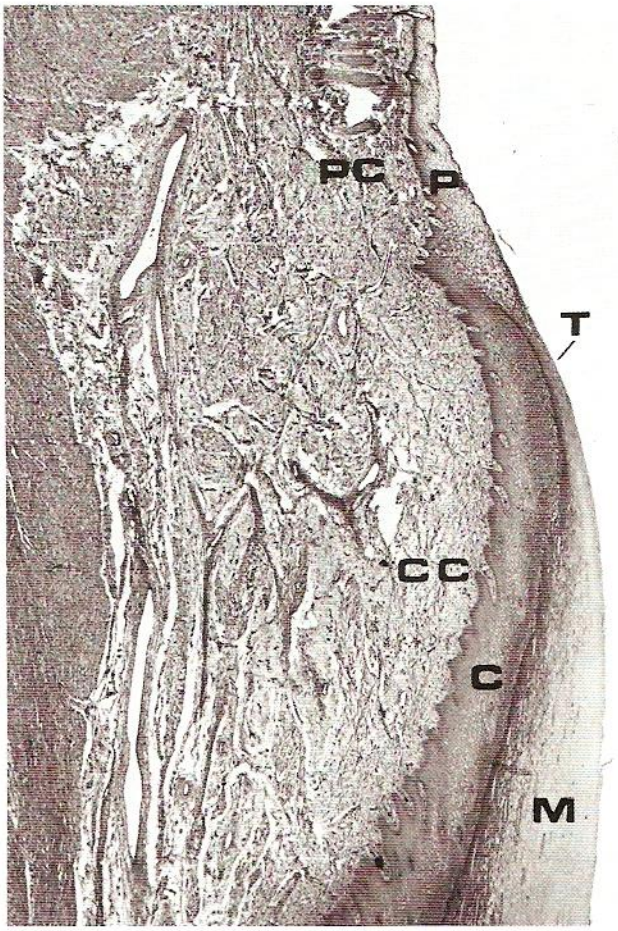

Figure 20-28. A longitudinal section through the perioplic and coronary regions of a fetal equine hoof. *PC*, Perioplic corium; *P*, periople or perioplic epidermis; *T*, stratum tectorium; *CC*, coronary corium; *C*, coronary epidermis; *M*, stratum medium. (×4.)

Figure 20-29. Longitudinal section through the coronary and laminar region of a fetal equine hoof. *CC*, Coronary corium; *C*, coronary epidermis; *M*, stratum medium; *L*, laminar epidermis; *LC*; laminar corium; *3*, third phalanx. The slight obliquity of the section permits visualization of individual laminae. (×40.)

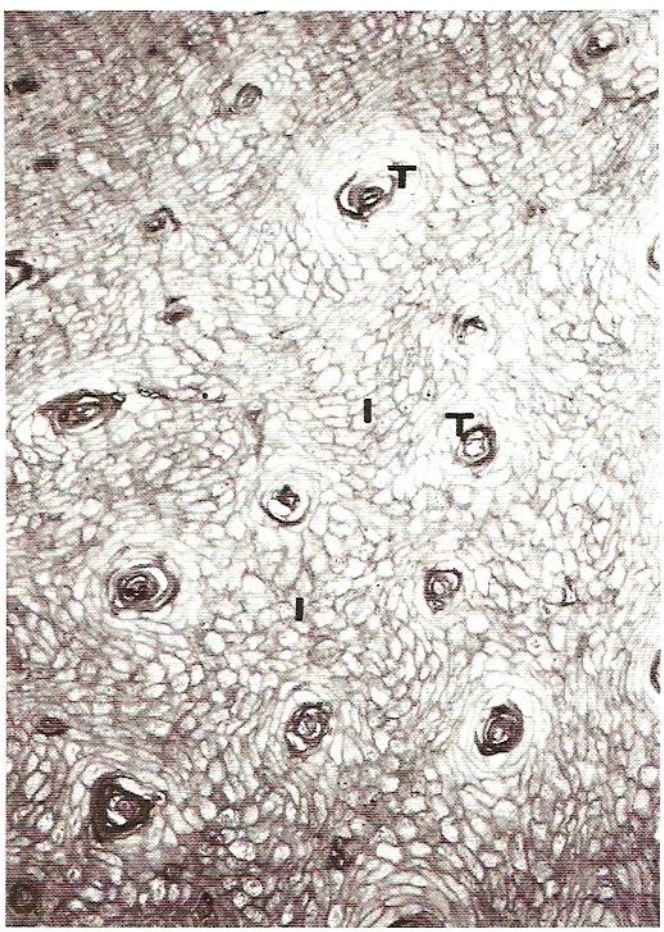

Figure 20-30. Organization of the stratum medium of an equine hoof. The stratum is composed of tubular *(T)* and intertubular *(I)* horn. (×40.)

Downloaded From Vet-eBooks.com

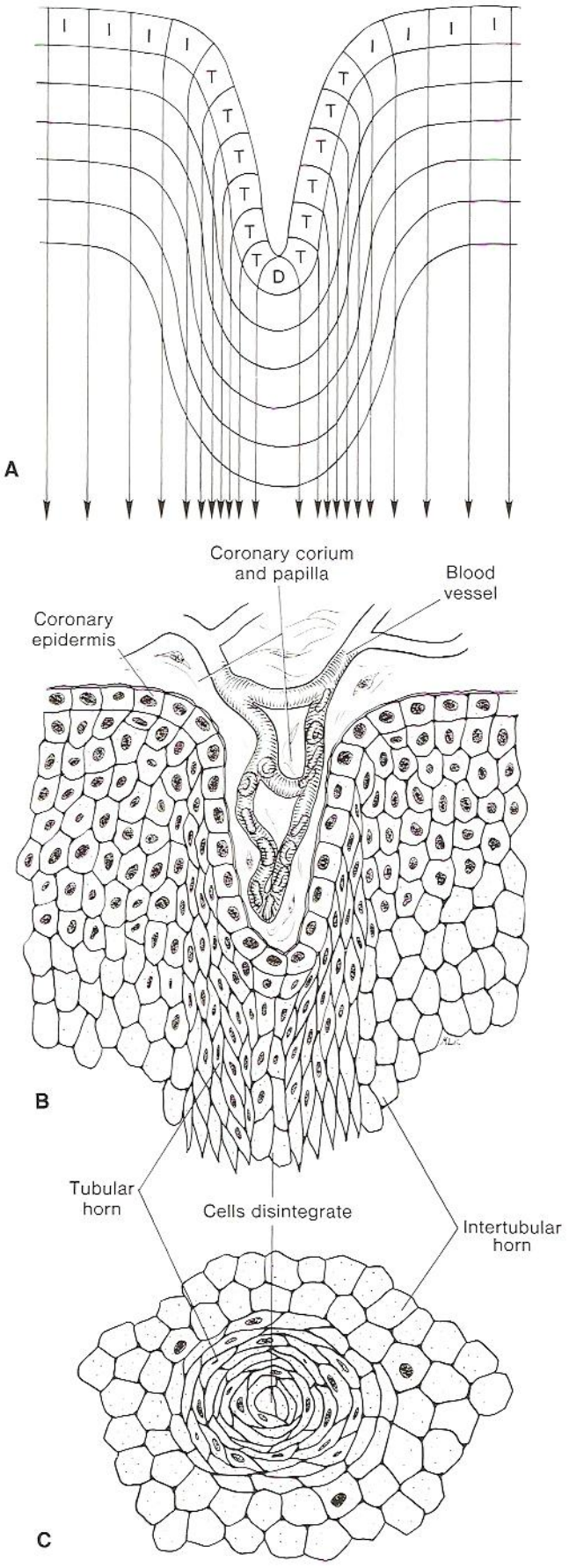

Figure 20-31. Elaboration of tubular and intertubular horn by the coronary epidermis. **A,** This schema represents a longitudinal section through the coronary region. Cells indicated with a *T* line the shoulders of an epidermal peg. They give rise to tubular horn. The cells indicated with an *I* line the apex of an epidermal peg. They give rise to intertubular horn. The cells at *D* disintegrate eventually. **B,** This is the cellular representation of **A. C,** Cross section through the tubular and intertubular horn or the stratum medium. Drawings **A, B,** and **C** are in register with each other.

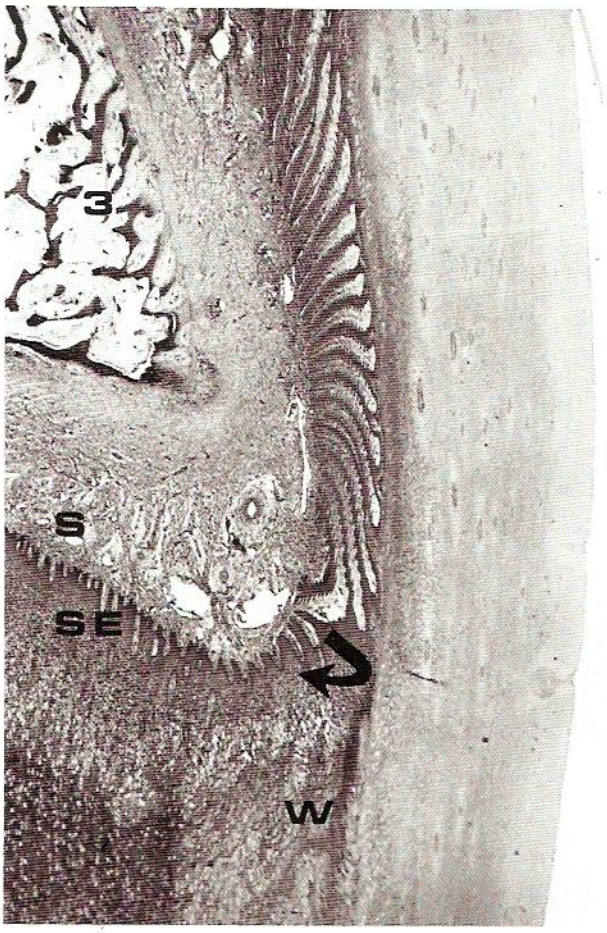

Figure 20-32. Longitudinal section through the laminar and sole region of a fetal equine hoof. The corium and epidermis of the laminar region are continuous *(curved arrow)* with the sole corium *(S)* and sole epidermis *(SE)*. The point of transition or reflection of the epidermis is continued to the ground surface as the white zone *(W)*. *3*, Third phalanx. The change of orientation of cornified material partially accounts for the appearance of the white zone. Primarily, this zone is visible because the degree of cornification or hardness of horn material is different in the stratum medium, white zone, and sole epidermis. The slight obliquity of the section permits visualization of individual laminae. (×4.)

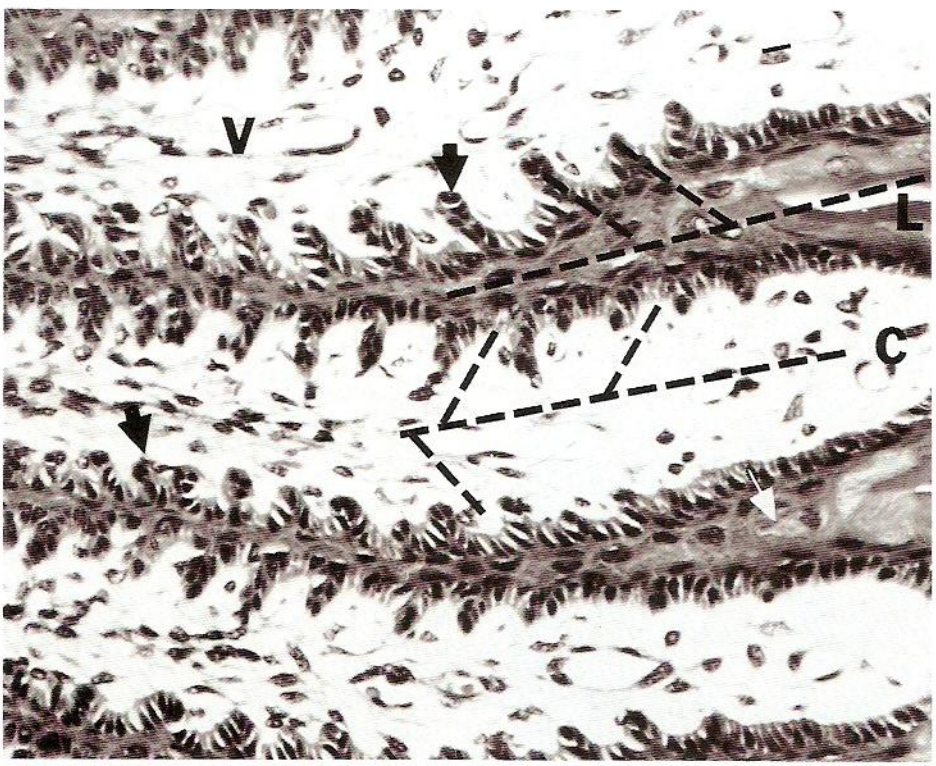

Figure 20-33. Cross section of a fetal equine hoof. The laminar epidermis *(L)* and laminar corium *(C)* are evident. The primary and secondary epidermal laminae are indicated with a *dashed line*. The corresponding laminae of the corium are similarly indicated. Primary epidermal laminae consist of cells *(solid arrows)* comprising the stratum basale. The primary epidermal laminae consist of a few cells *(white arrow)* undergoing rapid cornification. Their dermal constituents are typical. *V*, Blood vessel. Classically, the epidermal laminae are considered the insensitive laminae; the dermal laminae are considered sensitive. Because naked nerve endings probably occur within the secondary epidermal laminae, the sensitive laminae probably also include the secondary epidermal laminae. (×100.)

Downloaded From Vet-eBooks.com

corresponding projections of the **laminar corium.** The insensitive laminae continue to the ground surface as the wall. The junction between the wall laminae and **sole epidermis** is called the **white zone** (Fig. 20-32).

The laminar epidermis and corium are oriented perpendicular to the ground. At the white zone these structures turn around the corner of the wall and become parallel to the ground surface. This point of reflection results in the fusion of horn material oriented differently. Thus the white zone is formed. The white zone is a landmark for shoeing horses. **The stratum lamellatum is epidermis, nourished and supported by a laminar corium.**

Epidermis of the bars, sole, and frog. The **epidermis of the bars, sole,** and **frog** is similar to the tubular regions described previously. The underlying papillae are not long and the horn material is softer than the wall.

Corium of the foot

Corium and digital cushion. The corium and digital cushion constitute the dermis.

Foot corium, a continuation of the skin, contains many elastic fibers and an extensive venous plexus. In most instances, it is intimately associated with the fibrous periosteum of the enclosed osseous structures. These relationships aid in shock absorption and attaching the hoof to the deeper foot structures. The frog corium contains modified sweat glands (merocrine tubular glands).

A **digital cushion** occupies the space between the foot bones and tendons and the hoof ground surface. This fibroelastic connective tissue is an effective shock absorber. Compressive forces transmitted through the digital cushion to the lateral cartilages of the third phalanx are essential features of the venous return mechanism. Inactivity associated with transport results in distal limb edema **(stocking).**

Ruminant and Porcine Claws

Although gross differences exist between the claws of ruminants and porcines and the equine hoof, only a few significant histological differences exist (Fig. 20-34). The claws of these species consist of a **wall, a sole,** and well-developed **bulbs.** The laminar epidermis consists of primary laminae only (Fig. 20-35). These occur with a greater frequency than in horses. Papillary orientation in the sole is more craniad than in horses. Usually more zones of the epidermis are apparent.

Claws of Carnivores

Carnivore claws consist of a wall and sole (Fig. 20-36). The coronary epidermis and associated corium comprise the majority of the wall and consist of long dermal papillae and corresponding epidermal pegs. Laminar epidermis and associated corium are restricted to the dorsolateral wall. The sole corium has thick papillae.

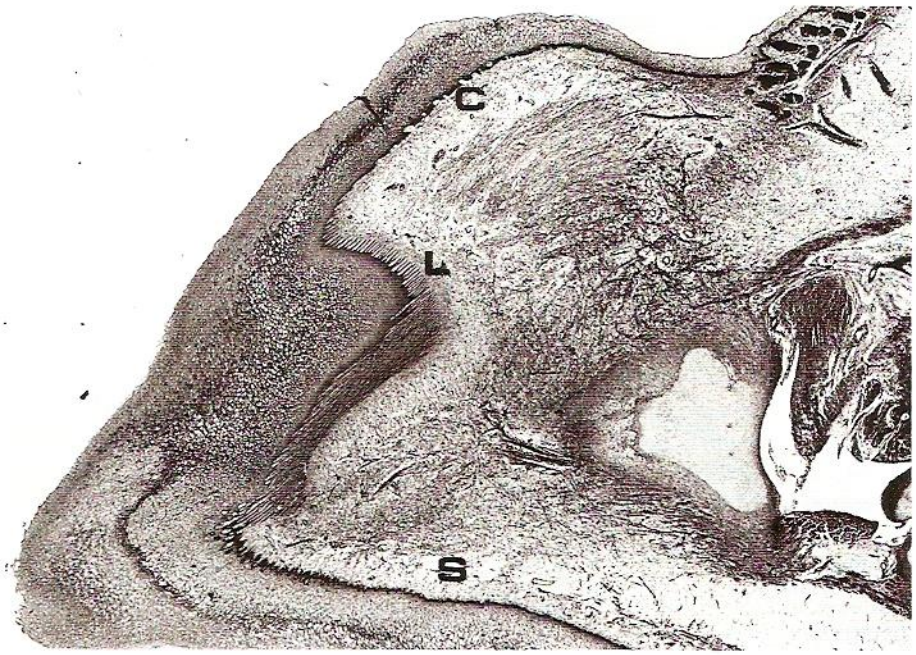

Figure 20-34. Longitudinal section through an ovine fetal claw. The coronary *(C),* laminar *(L),* and sole *(S)* epidermis and corium are indicated. (×4.)

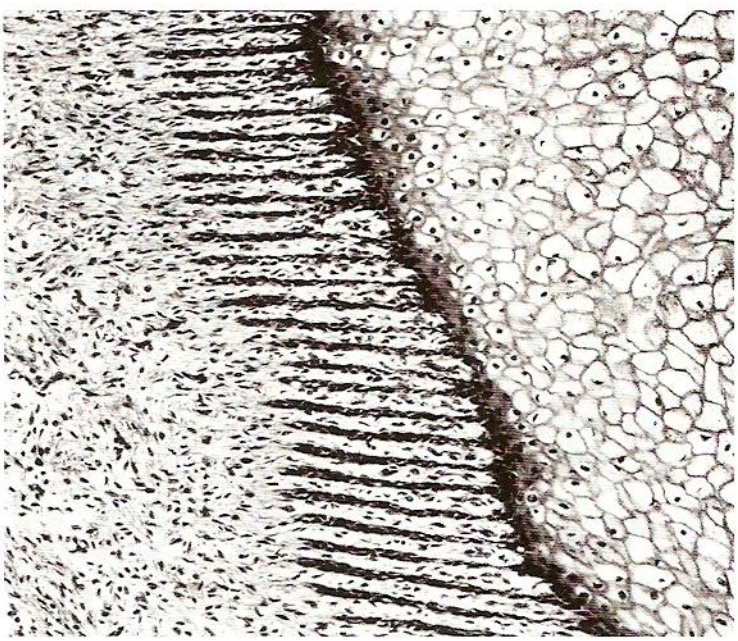

Figure 20-35. Laminae of the fetal bovine claw. Only primary laminae are present. (×40.)

INTEGUMENTARY APPENDAGES

Horns of the ox. The bovine horn consists of three components—os cornua, corium, and epidermis. The **os cornua** or **frontal process** is an outgrowth of the frontal bone. The cornual process is covered by papillated integumentary corium. The associated epidermis gives rise to tubular and intertubular horn. At the base of the horn the epidermis gives rise to soft horn (the **epikeras**), which is similar to the perioplic epidermis of the hoof. Cellular proliferation of epidermal basal cells is slow, and the horn elongates at a slow pace.

Miscellaneous appendages. The antlers of deer and associated species consist

Downloaded From Vet-eBooks.com

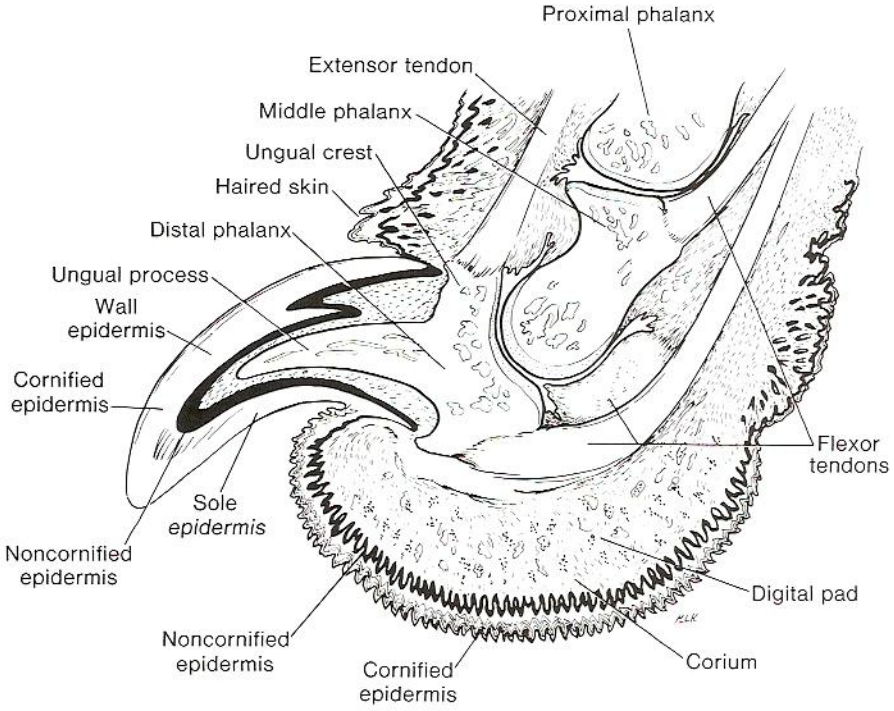

Figure 20-36. Sagittal section through the canine foot.

Figure 20-37. Equine chestnut. The point of transition *(arrow)* from typical epidermis to chestnut *(C)* is marked by an increased epidermal thickness and increased cornification. (×10.)

of bone with, during certain times of the year, a covering of skin (velvet). These structures undergo cyclic growth, maturation, and shedding associated with seasonal breeding habits. The bone develops by a modified endochondral ossification.

Some species grow as much as 25 pounds of bone during the 3-month active growing period at a rate of up to 1 cm per day. No mammalian growth process compares with it. Although antlers are usually confined to males, female caribou and reindeer are antlered.

The **horn** of the pronghorn antelope is very similar to the horn of the ox, but cornified material is shed annually. The frontal process of the giraffe is similar to the antler, but it and the integument are not shed. Rhinoceros horn is matted *hair.*

Dewclaws, chestnut, and ergot. **Dewclaws** of ruminants, swine, and dogs are vestigial digits covered by horn material and dermis. A bony core may or may not be present (limb and species variable). **Chestnuts** and **ergots** are cornified regions of the equine epidermis consisting of tubular and nontubular horn (Fig. 20-37). They are devoid of hairs and glands. Some authorities consider them digital vestiges.

REPAIR OF THE SKIN

The skin is subject to various wounds or disruptions of its anatomical integrity—abrasions, contusions, lacerations, punctures, and incisions. Three types of healing processes are described for **open wounds** (in which tissues underlying the epidermis are exposed to the external environment.) **First-intention healing** occurs when a clean incisional wound is closed immediately. **Second-intention healing** is spontaneous healing without any or with only minimal surgical intervention. **Third-intention healing** is spontaneous healing followed by wound closure.

Minor abrasions to the epidermis without damage to the underlying dermis repair themselves through the mitotic activity of the stratum basale. Although first intention healing may occur faster than second intention healing, all stages of the repair process are integral components of these methods. Excisional wounds in which excessive amounts of tissue are lost are characterized by a marked proliferation of fibrous connective tissue **(granulation tissue).**

Skin repair is a complex activity initiated with injury and continuing through the reorganization of the injured tissues. Skin repair is a continuum divisible into stages—**insult (wounding), induction, inflammation, proliferation,** and **maturation stages.**

The events involved in full-thickness

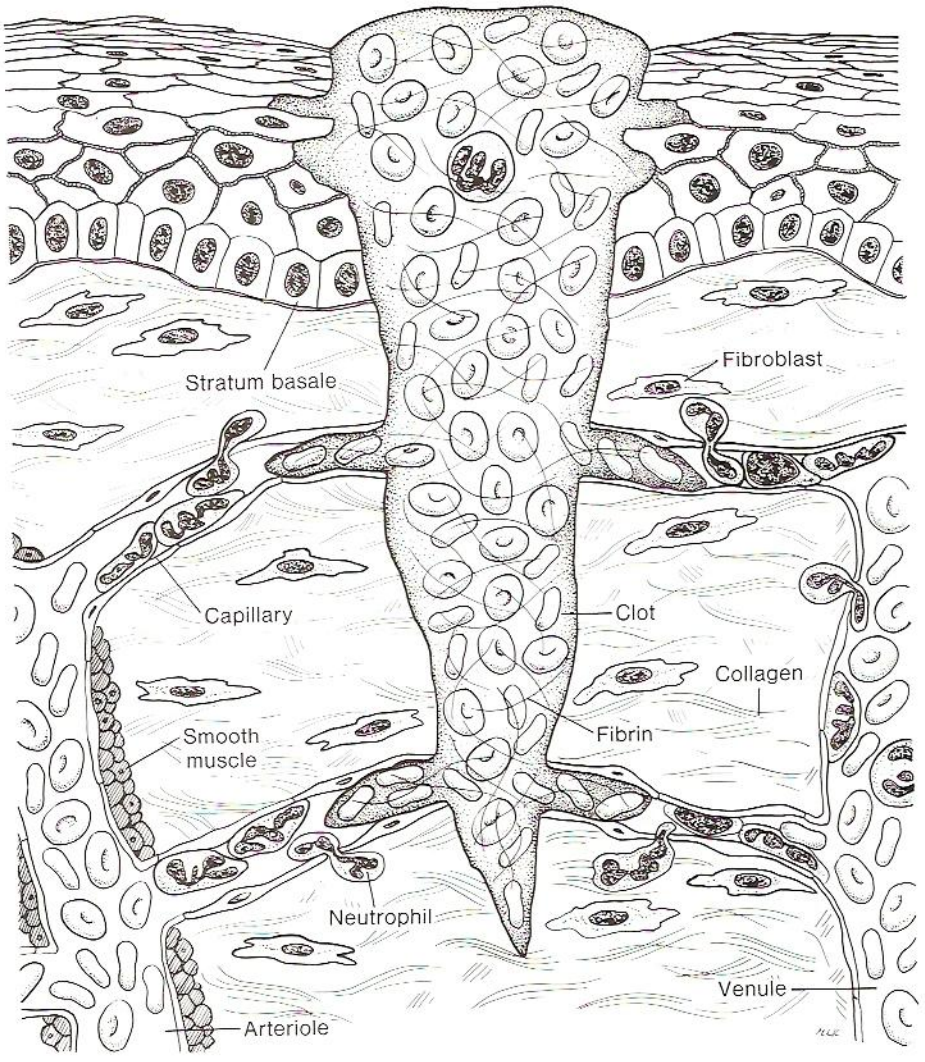

Figure 20-38. Initial events of skin repair. Clot formation has occurred and the defect has been filled. Capillaries have been plugged. Hemostasis has been achieved. The labels on this figure also apply to Figures 20-38 through 20-42.

skin repair, requiring epidermal, dermal, and hypodermal contributions, are similar in most integumentary repair processes.

For simplicity, an incisional wound undergoing second-intention healing is described subsequently (Figs. 20-38 to 20-42).

Insult (wounding) stage. Disruption of skin integrity results in hemorrhage, local cell death, and contamination with microorganisms (Fig. 20-38). Hemostatic mechanisms account for clotting of blood in the wound gap and plugging of severed vessels. The clot minimizes further fluid loss and forms a seal over the injured region. Deprived of their normal vascular supply, the tissues at the injury site undergo desiccation.

Induction stage. Identification of this stage as a distinct entity may be artificial, because new cell induction occurs throughout repair. The precise stimuli for an integrated repair process have not been identified. Initially the resultant localized tissue hypoxia induces neovascularization (Fig. 20-39). Fibroblasts respond to local lactic acid accumulations resulting from macrophage activity, but collagen synthesis cannot occur until essential metabolites are supplied.

Inflammation stage. This stage begins immediately after the injury (Fig. 20-39). Although vasoconstriction is the earliest localized injury response, capillary contraction is followed by capillary dilation with an accompanying increase in vascular permeability. The release of vasoactive substances from endothelial cells, mast cells, and platelets—histamine, serotonin, bradykinin, prostaglandin E_2—initiates a localized vascular response. Chemotactic factors released at the injury site attract neutrophils and fibroblasts. Bradykinin and prostaglandin E_2 may also assist in attracting cells.

Neutrophils are the predominant cells at the injury site for the first 3 days after injury. They are effective phagocytes controlling microbial contamination and removing cellular debris. Macrophages, mast cells, eosinophils, lymphocytes, and plasma cells are also attracted to the injury site.

The duration of inflammation depends upon the amount of contamination, degree of tissue damage, and the presence of infection. A clean wound, one in which no microbes are present, may have a peak inflammatory response in 3 to 4 days. Repair progression is accompanied by a gradual reduction of inflammatory cells.

Proliferation stage. The proliferation stage, involving the mitotic activity of epidermal cells, endothelial cells, and fibroblasts, extends 10 to 14 days postinjury (Fig. 20-40). Stratum basale cells along the margins of the wound migrate across the defect. Similar cells from cut hair follicles within the defect may migrate to cover the wound. This migration is a random process, initiated within the first 24 hours after injury, but it is not visible until keratinization occurs. Following the injury, epidermal cells adjacent to the wound site proliferate to replace the migrating cells. The migrating cells then replace epidermis. The result of these actions (migration and proliferation) is the reestablishment of an epidermal barrier. The barrier overlies the dermis but is beneath the scab, which sloughs in about 7 days.

Endothelial cells proliferate from the ends of severed vessels, initiating the reestablishment of vascularity (Fig. 20-41). Arterial and venous endothelial cell fusion completes neovascularization. Fibroblasts proliferate and synthesize matrix in response to the improved environment. Fibroblasts, moving along fibrin strands that serve as a temporary scaffold, advance with the advancing vascular beds. Some develop the ability to move by contractile mechanisms. These fibroblasts, which contain myofilaments, are termed **myofibroblasts.** They dominate the wound site as inflammation diminishes.

The connective tissue at the wound site **(granulation tissue)** contains many fibroblasts and WBCs but is devoid of nervous tissue cells. It is well-vascularized and the mediator of connective tissue repair—being responsible for **wound contraction,** the movement of full thickness skin toward the center of the defect. Wound contraction is an active process probably dependent upon the myofibroblasts. Although mesenchymal cell differentiation accounts for the fibroblasts of granulation tissue, the determinants for the differentiation of myofibroblasts and fibroblasts is unknown. Granulation tissue, typically, contains both populations of cells.

Downloaded From Vet-eBooks.com

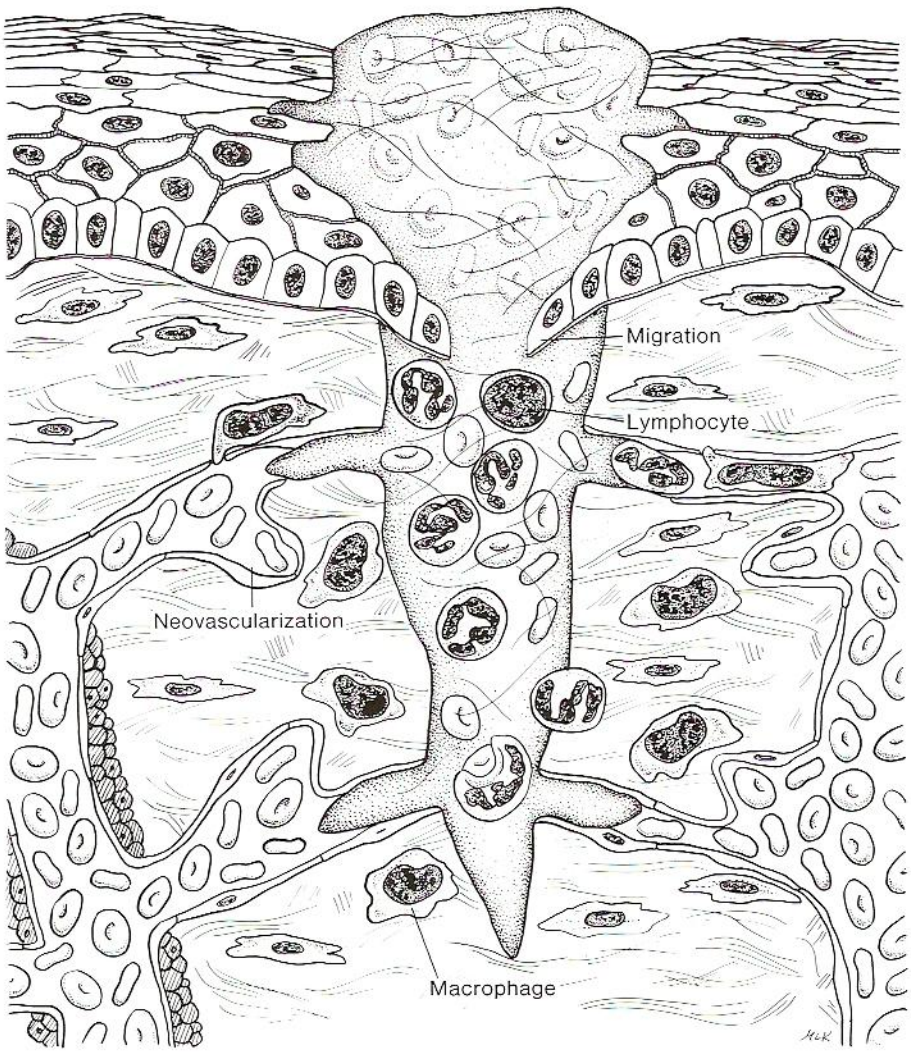

Figure 20-39. Induction and initiation of inflammation. Inflammatory cells have invaded the wound site. Neovascularization and epidermal cell migration are beginning.

Downloaded From Vet-eBooks.com

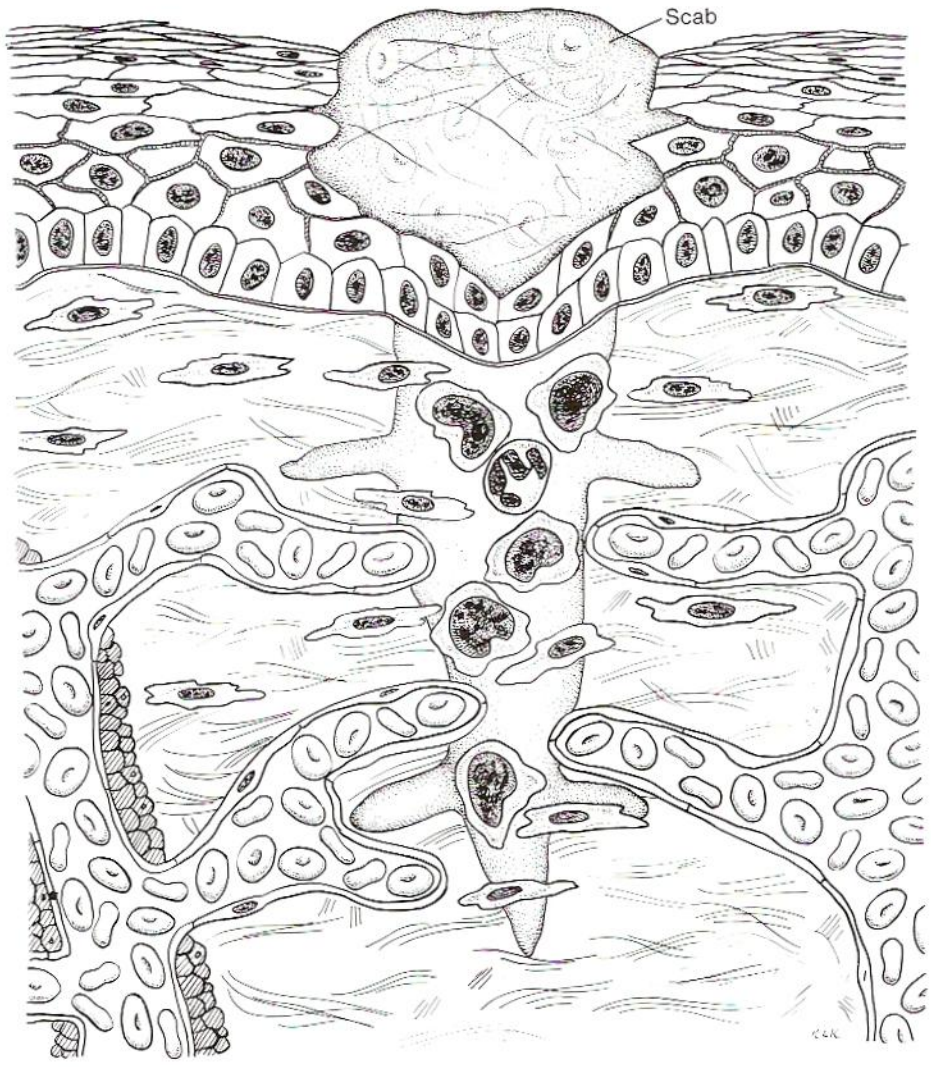

Figure 20-40. Proliferative stage of wound repair. Inflammation has subsided and the epidermal cells have migrated over the wound site beneath the scab. Neovascularization continues, and fibroblasts invade the clot with the new blood vessels.

Downloaded From Vet-eBooks.com

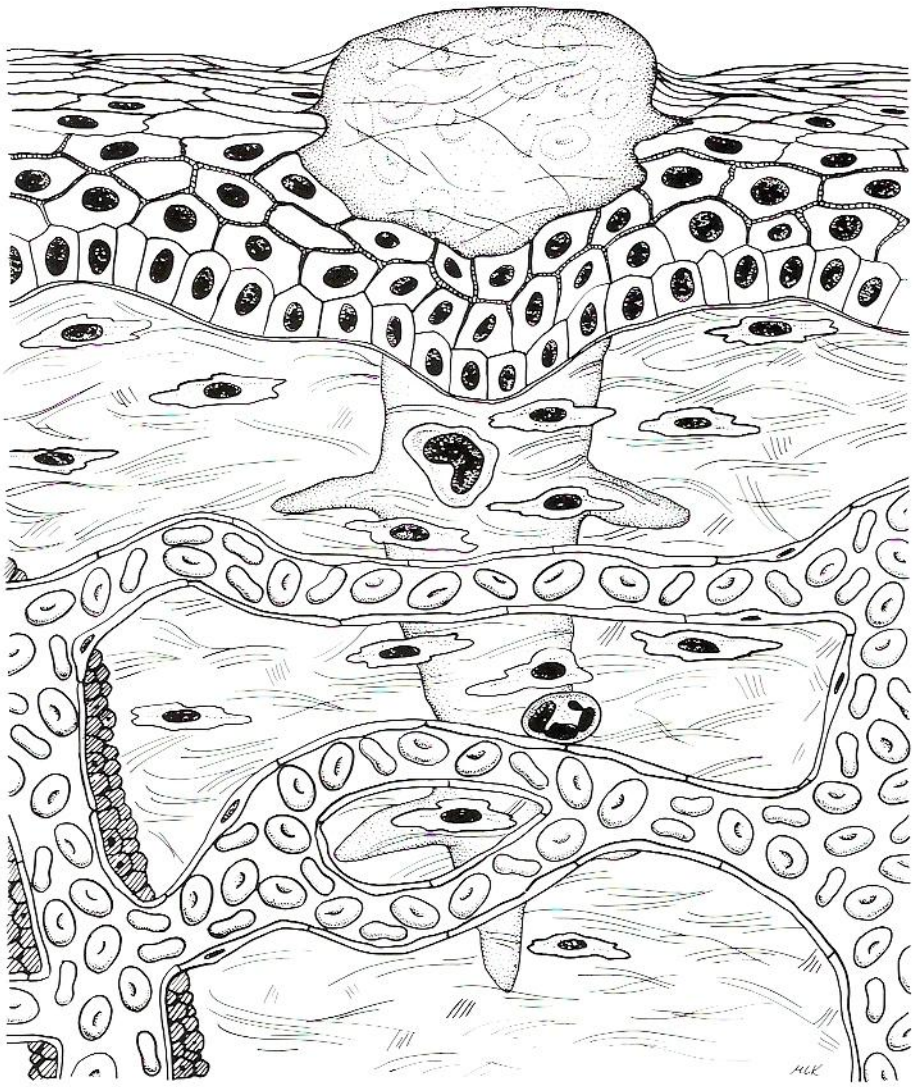

Figure 20-41. Continued proliferation at the wound site. Neovascularization is complete. Fibroblasts continue to proliferate and produce matrix materials.

Maturation stage. The gradual reduction of fibroblasts and a corresponding decrease in capillaries within the wound are the histological features of maturation (Fig. 20-42). The maturation stage is characterized by a balanced synthesis and degradation of connective tissue components. Collagen fibers typically align themselves along stress lines within the wound. A gradual and continual increase in wound strength can be anticipated. Whereas wound strength may approach 25% of preinjury levels by 3 weeks postinjury, some wounds will continue to improve wound strength for 2 years. Innervation of the wound site eventually returns. (See Chapter 17.)

AVIAN INTEGUMENT

Epidermis and dermis. The epidermis of avian skin is thin, loose, and dry (Fig. 20-43). Although it is much thinner than the mammalian counterpart, four strata are defined—**basale, spinosum (stratum intermedium), transitivum,** and **corneum.** The stratum transitivum is probably the avian counterpart of the mammalian stratum granulosum. The dermis and subcutis have been divided into eight strata. The dermis is dense in its depths and abuts on a vast subcutis. Lymphoid tissue is extensive in the corium and subcutis. The corium and epidermis are devoid of glands.

Feathers extend from the epidermis into the corium and assume a configuration similar to that of hairs.

Feathers. Feathers are of epidermal origin and develop within a follicle. The base of the follicle is not continuous over a dermal papilla. Thus the core of the feather contains remnants of vascular connective tissue (**feather pulp**).

The principal parts of a flight feather are the **quill (calamus)** and the **vane (vexillum)** (Fig. 20-44). The quill occurs within the follicle and has two foramina (**proximal umbilicus** and **distal umbilicus**). As the quill grows, the dermal papilla retracts, leaving the desiccated central **pulp.** The **vane** is the feather above the skin surface. It consists of a **rachis,** which is actually the continuation of the quill, and **barbs.** The term vane is actually a collective designation for barbs. The barbs project laterally from the rachis in an oblique and parallel manner. They possess **proximal** and **distal barbules** oriented at right angles to the barbs and parallel to the rachis. The distal barbules have **hooklets** engaging the indentations of the proximal barbules. This relationship establishes a nonporous and flexible sheet that sheds water and facilitates flight.

Down feathers have a small and thin rachis. The barbs are devoid of barbules. Thus, these feathers are loose and fluffy; they serve as good insulation.

Filoplumes are feathers with a hairlike structure. They are scattered over the

Downloaded From Vet-eBooks.com

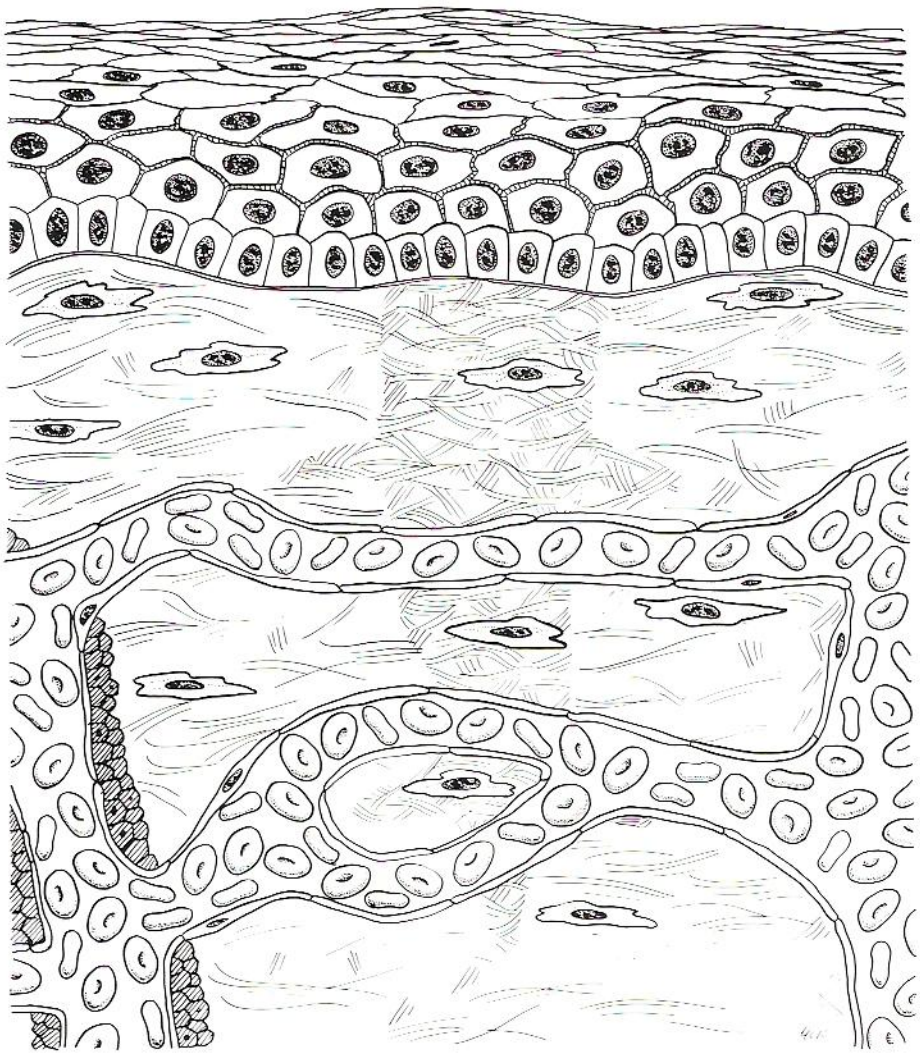

Figure 20-42. Completion of wound repair. Continued remodeling of the wound site will increase wound strength and result in the removal of excess collagen.

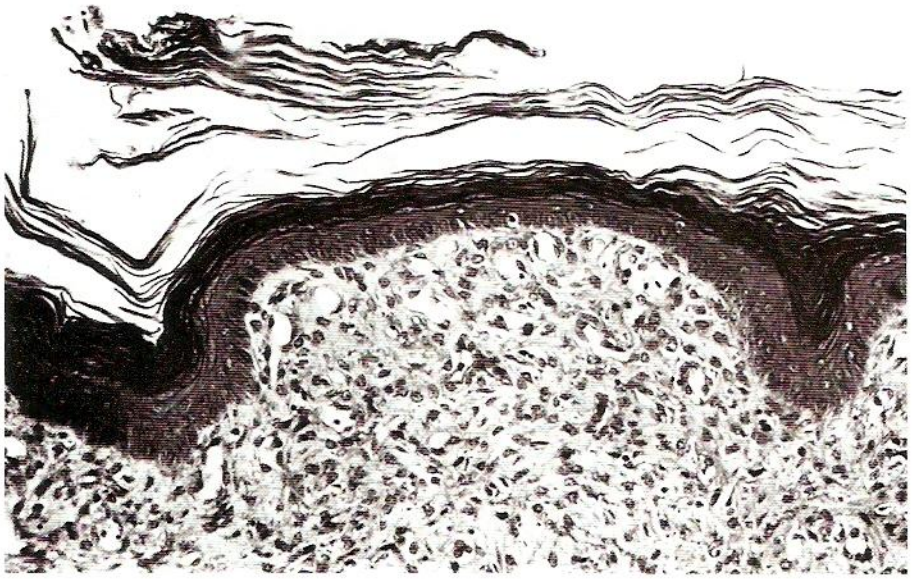

Figure 20-43. Avian skin. The epidermis has a reduced number of layers. (×63.)

Downloaded From Vet-eBooks.com

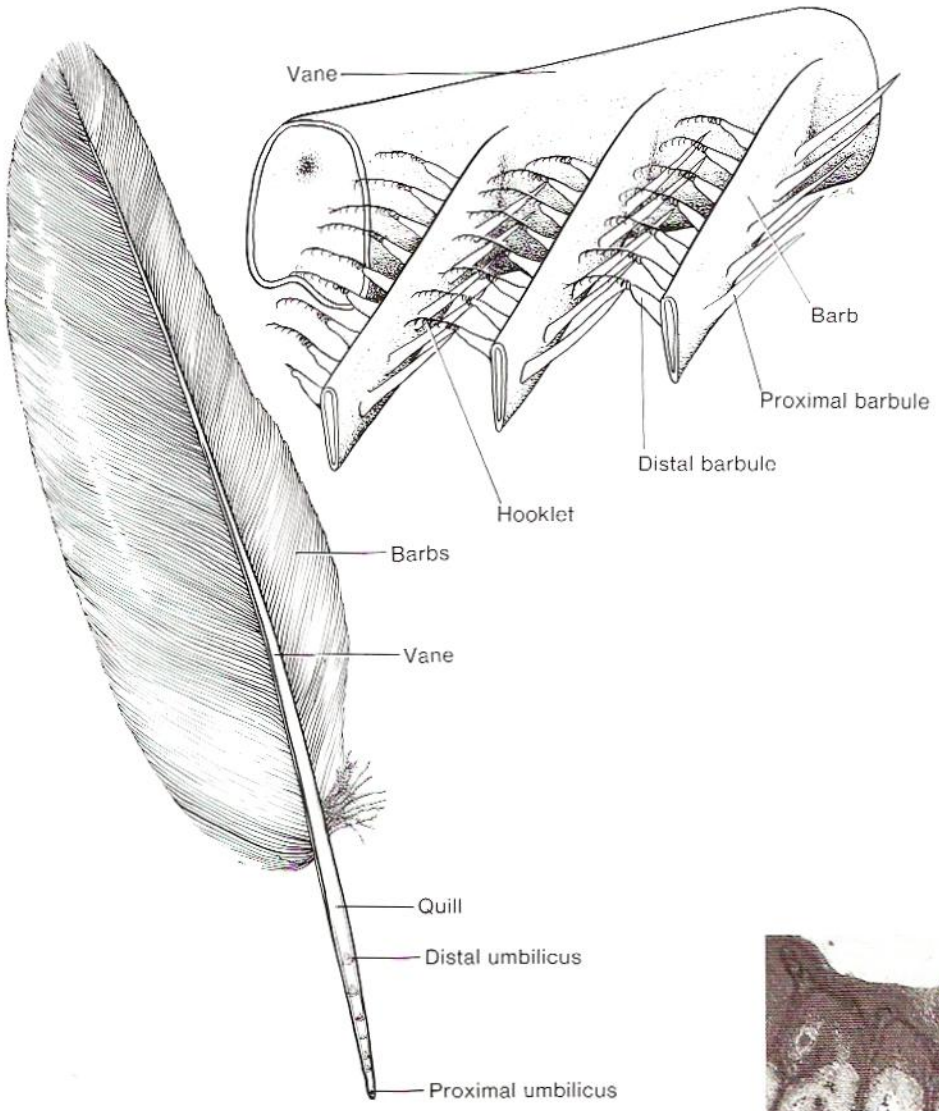

Figure 20-44. Main components of a flight feather.

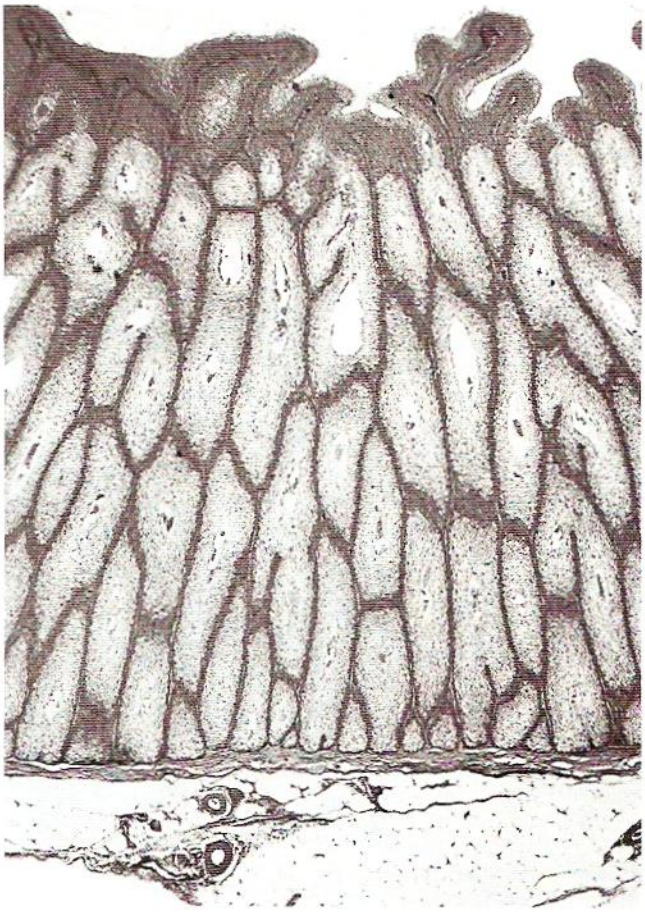

Figure 20-45. Avian uropygial gland. Numerous sebaceous adenomeres are grouped to form this gland. (×10.)

Downloaded From Vet-eBooks.com

body but are especially predominant on the head and neck.

Uropygial gland. The uropygial gland is also called the **oil** or **preen gland.** The only cutaneous gland in birds (Fig. 20-45), it is well-developed in aquatic species and consists of many sebaceous adenomeres opening into a common duct or sinus and emptying onto the surface on a common papilla. The papilla contains smooth muscle fibers extending around the excretory duct. The heavily encapsulated, bilobed duct is situated above the last sacral vertebra.

Specialized structures. There are many epidermal derivatives in birds—scales, toe pads, claws, beaks, wattles, spurs, and combs. Claws, spurs, and beaks are similar to the mammalian claw whereas toe pads may be compared to the pads of carnivores. **Scales** are comparable to those in reptiles and occur on the legs of all birds as well as on the wings of penguins. **Wattles** and **combs** are skin diverticuli containing an extensive vasculature, mucous connective tissue, and fat. In some birds (turkey) erectile tissue is present within these structures.

ADDITIONAL READINGS

Abercrombie M, Flint MH, James DW: collagen formation and wound contraction during repair of small excised wounds in the skin of rats, *J Embryol Exp Morphol* 2:264, 1954.

Adam WS, et al: *Microscopic anatomy of the dog: a photographic atlas,* Springfield Ill, 1970, Charles C Thomas.

Baker BB: Epidermal cell renewal in the dog, *Diss Abst Int* 32B:5526, 1972.

Baker KP: Hair growth and replacement in the cat, *Br Vet J* 130:327, 1974.

Chase HB: Growth of the hair, *Physiol Rev* 34:113, 1954.

Creed RFS: The histology of the mammalian skin with special reference to the dog and cat, *Vet Rec* 70:736, 1958.

Dale BA: Filaggrin, the matrix protein of keratin, *Am J Dermatopathol* 7:65, 1985.

David LT: Histology of the skin of the Mexican hairless swine *(Sus scrofa), Am J Anat* 50:283, 1932.

Edelson RL: The immunologic function of the skin, *Sci Am* 252:46, 1985.

Findlay JD, Yang SH: The sweat glands of Ayrshire cattle, *J Agric Sci* 40:126, 1950.

Godall AM, Yang SH: Myoepithelial cells in bovine sweat glands, *J Agric Sci* 42:159, 1952.

Hausman LA: Structural characteristics of the hair of mammals, *Am Naturalist* 44:496, 1930.

Hibbs RG: The fine structure of human exocrine sweat glands, *Am J Anat* 103:201, 1958.

Hunt TK, Dunphy JE (eds): *Fundamentals of wound management,* New York, 1979, Appleton-Century-Crofts.

Katz SI, Tamaki K, Sachs DH: Epidermal Langerhans cells are derived from cells originating in bone marrow, *Nature* 282:324, 1979.

Lucas AM, Stettenheim PR: *Avian anatomy: integument.* I and II, Washington DC, 1972, Government Printing Office.

Maibach HI, Rovee DT (eds): *Epidermal wound healing,* Chicago, 1972, Year Book Medical Publishers.

Moffat GH: The growth of hair follicles and its relation to the adjacent dermal structures, *J Anat* 102:527, 1968.

Montagna W: *The structure and function of the skin,* ed 9, New York, 1962, Academic Press.

Muller GH (ed): Symposium on the skin and internal disease, *Vet Clin North Am* 9:1, 1979.

Muller GH, Kirk RW: *Small animal dermatology,* Philadelphia, 1976, WB Saunders.

Munger BL: The cytology of apocrine sweat glands. I. Cat and monkey, *Z Zellforsch* 67:373, 1965.

Nielsen SW: Glands of the canine skin, *Am J Vet Res* 14:448, 1953.

Stump JE: Anatomy of the normal equine foot, including microscopic features of the laminar region, *J Am Vet Med Assoc* 151:1588, 1967.

Toker C: Observations on the ultrastructure of a mammary ductule, *J Ultrastruct Res* 21:9, 1967.

Webb AJ, Calhoun ML: The microscopic anatomy of the skin of mongrel dogs, *Am J Vet Res* 15:274, 1954.

Webber AF, Kitchell RL, Sautter JH: Mammary gland studies. I. The identity and characterization of the smallest lobule unit in the udder of the dairy cow, *Am J Vet Res* 16:255, 1955.

Downloaded From Vet-eBooks.com

CHAPTER 21

Digestive System I—Alimentary Canal

GENERAL CHARACTERISTICS

The digestive system includes the alimentary canal and accessory structures—lips, tongue, teeth, and extramural glands. The **alimentary canal (tract)** is a tubular or modified tubular structure extending from mouth to anus. It is divided into organs based on structure and anatomical location. Endoderm gives rise to the epithelial lining of most of the canal. The rostral and caudal epithelium is from stomodeal and proctodeal ectoderm, respectively.

Muscularized lips and the tongue aid in **prehension;** teeth permit **mastication. Deglutition** (swallowing) depends on the muscular activity of the buccal cavity and pharynx. The muscularized esophagus propels the bolus into the stomach, wherein **mechanical** and **chemical digestion** is initiated. The remainder of the tube continues digestion and **absorption.** The tube **propels** the luminal contents toward the anus, culminating in the **elimination** of undigested residue. Some of the less obvious essential functions are the **synthesis and secretion of enzymes, secretion of digestive juices, vitamin production, plasma protein synthesis and secretion, biotransformation of harmful substances,** and **elaboration of essential body metabolites.**

The solid, fluid, and semifluid luminal contents of the digestive system are outside the body until they cross the epithelial barrier.

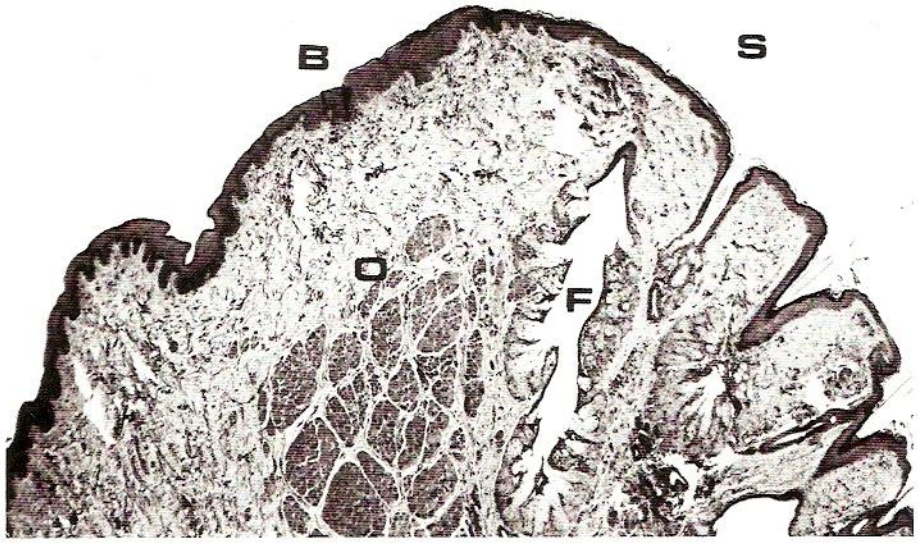

Figure 21-1. Section through a feline lip. The buccal surface *(B)* is a mucous membrane. The skin *(S)* is typical and contains hair follicles *(F)* and associated sebaceous glands. The orbicularis oris muscle *(O)* is in the center of the structure. (×10.)

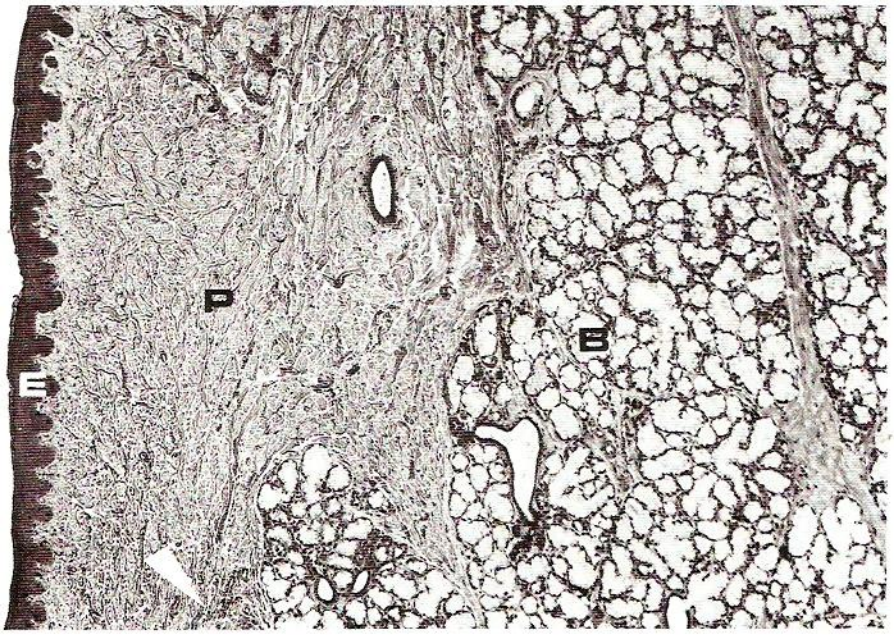

Figure 21-2. Section through a feline cheek. The lamina epithelialis mucosae *(E)* is underlaid by a typical lamina propria mucosae *(P)*. Many mucus-secreting buccal glands *(B)* are present. (×16.)

ORAL STRUCTURES

Buccal cavity proper. The buccal cavity is a modified tube whose lining is a **cutaneous mucous membrane.** The lamina epithelialis mucosae is stratified squamous epithelium with varying degrees of cornification. Large epithelial papillae projecting from the surface epithelium assist in the prehension and mastication of food (ruminants). The lamina propria mucosae blends insensibly with the tela submucosa. The lamina propria mucosae is devoid of glands; it possesses only the excretory ducts of buccal glands. These are either mucous, serous, or mixed glands. The submucosal connective tissue blends with and rests upon the fascia of the underlying skeletal muscle or periosteum, if bone is present.

Lips. The **lips** are folds of fibroelastic tissue at the entrance to the digestive system. A **mucocutaneous junction** occurs on them (Fig. 21-1), and they are cornified in species whose diet contains much roughage (ruminants, horses) but not in

pigs and carnivores.

The lip core has fibroelastic tissue and skeletal muscle. On the integumentary side a dermis and hypodermis are typical, and on the labial side submucosal connective tissue. These tissue layers are not distinct from one another. **Submucosal (labial) glands** are branched, tubuloalveolar types that are mucous in small ruminants and carnivores but mixed in other species. They are serous glands in the bovine planum nasale. The tunica muscularis is skeletal muscle **(orbicularis oris).**

Cheeks. The lamina epithelialis mucosae and submucosal connective tissue are similar to those tissues in the lip (Fig. 21-2). Serous or mucous **buccal glands** occupy the submucosal connective tissue space.

Hard and soft palates. The **hard palate** is covered by a cornified stratified squamous epithelium especially thick and highly cornified on the ruminant **dental pad** (Fig. 21-3). The submucosal connective tissue is typical and continuous with the fibrous periosteum of the buccal cavity roof. Adipose tissue and an extensive vascular bed are present. The caudal region of the hard palate of most species has many branched tubuloalveolar mucous or mixed glands. The **soft palate** is a fibrous and muscular extension of the hard palate. On its dorsal aspect (nasopharynx) is pseudostratified ciliated columnar epithelium. Its ventral surface is covered by typical cutaneous mucous membrane. The connective tissue core may contain glands similar to those in the hard palate. Lymph nodules are common. The porcine palatine tonsil is entirely within the soft palate.



Figure 21-3. Section of a bovine dental pad. This structure replaces the upper incisors of ruminants. It has a highly cornified, thickened lamina epithelialis mucosae (C). (×10.)

Tongue. The tongue is a cranial projection from the buccal cavity floor covered by a cutaneous mucous membrane with a core of skeletal muscle.

The lamina epithelialis mucosae is variously cornified. Many epidermal pegs and dermal papillae are apparent. The mucous membrane projects into the buccal cavity as **lingual papillae** (Fig. 21-4). In horses and ruminants the caudodorsal aspect of the tongue has a thickened and rigid mucous membrane. The lamina propria mucosae and tela submucosa are typical and blend with the epimysium of the intrinsic and extrinsic lingual musculature.

The **lyssa** is characteristic of carnivores.

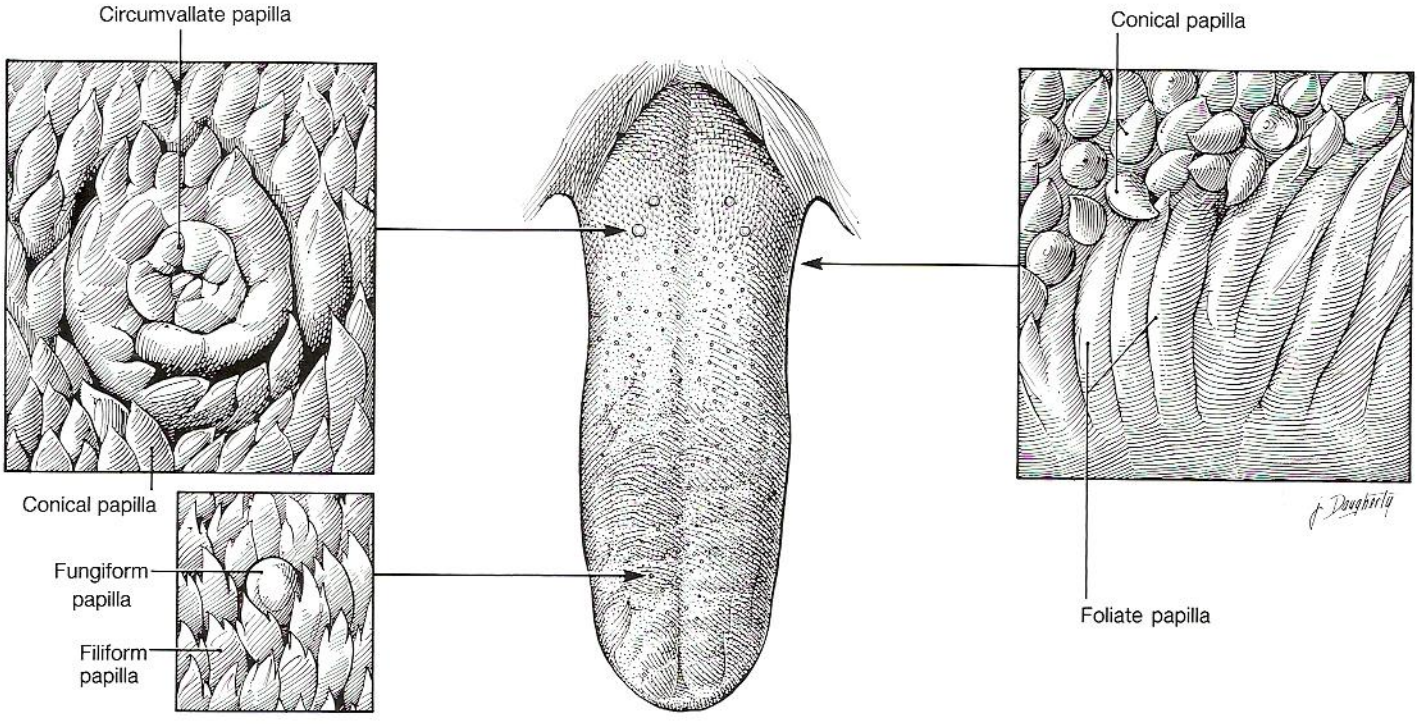

Figure 21-4. Lingual papillae of a canine tongue.

Downloaded From Vet-eBooks.com



Figure 21-5. Scanning electron micrograph of the tongue of a foxhound. The filliform papillae of this portion of the tongue project caudally and are cornified. The configuration is a filliform papilla *(M)* surrounded by four to eight secondary papillae. **Inset:** Enlargement of the papilla marked by an *asterisk*. Note the surrounding secondary papillae. (Courtesy F. Al-Bagdadi.)

It consists of dense collagenous tissue, some adipose tissue, skeletal muscle, and occasionally some cartilage. In the pig it consists primarily of adipose tissue and some connective tissue. It is not well-developed in horses and ruminants.

Lingual papillae are confined to the lingual dorsum. They differ in size, form, number, distribution, and function and are species-variable.

Filiform papillae are numerous and well-developed in cats and ruminants; they serve mechanical functions (Figs. 21-5 and 21-6). They are cornified and shaped like rose thorns with their curvature directed caudad. The core of lamina propria mucosae is typical.

Lenticular or **conical papillae** also serve mechanical functions (Fig. 21-7). They are biconvex and prominent on the dorsum of the caudal third of the tongue.

Fungiform papillae are mushroom-shaped, serving mechanical and gustatory functions (Fig. 21-8). They are not as cornified as the previous types. The primary papillation of the lamina propria mucosae is typical; secondary papillations may also be present.

Foliate papillae are leaf-shaped structures separated by an invagination of mucous membrane (Fig. 21-9). They have taste buds, and the epithelium is nonkeratinized. Fingerlike (secondary) projections from the lamina propria mucosae are present. Branched tubuloalveolar serous glands **(gustatory glands)** of the combined lamina propria-submucosa open into a **papillary sulcus.**

Figure 21-6. Section of a typical feline lingual papilla. Note that it is an entirely epithelial structure. (×10.)

Circumvallate (vallate) papillae are the largest and least encountered papillae (Fig. 21-10). They are not elevated above the lamina epithelialis mucosae but are surrounded by a deep furrow. Numerous taste buds occur in their lateral walls. The lamina propria mucosae is typical. Gustatory glands open into the sulcus and cleanse the region of foodstuffs.

Taste. The **taste buds** are intraepithelial structures located in the walls of foliate, fungiform, and circumvallate papillae (Figs. 21-11 and 21-12). They are ovoid

Downloaded From Vet-eBooks.com

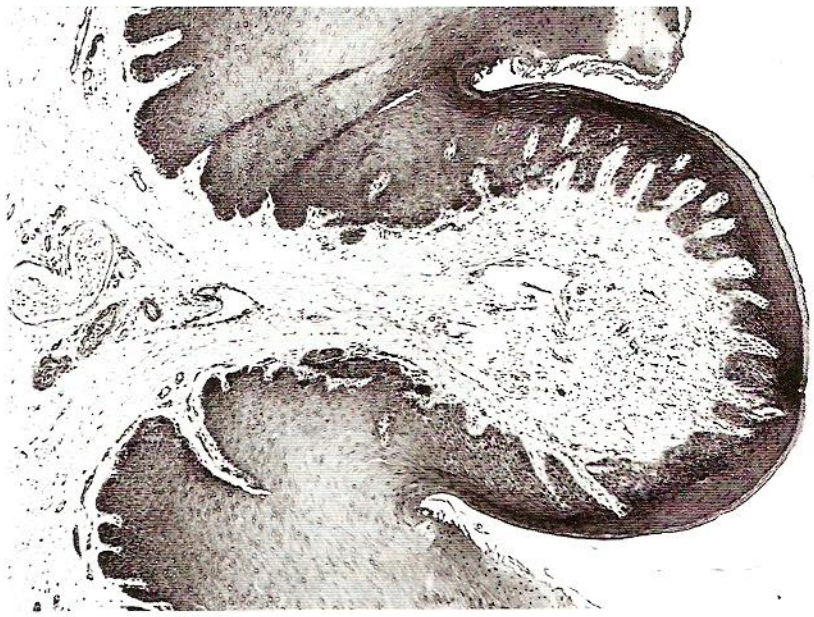

Figure 21-7. Section of a typical lentiform papilla from the dorsal aspect of a bovine tongue. (×16.)

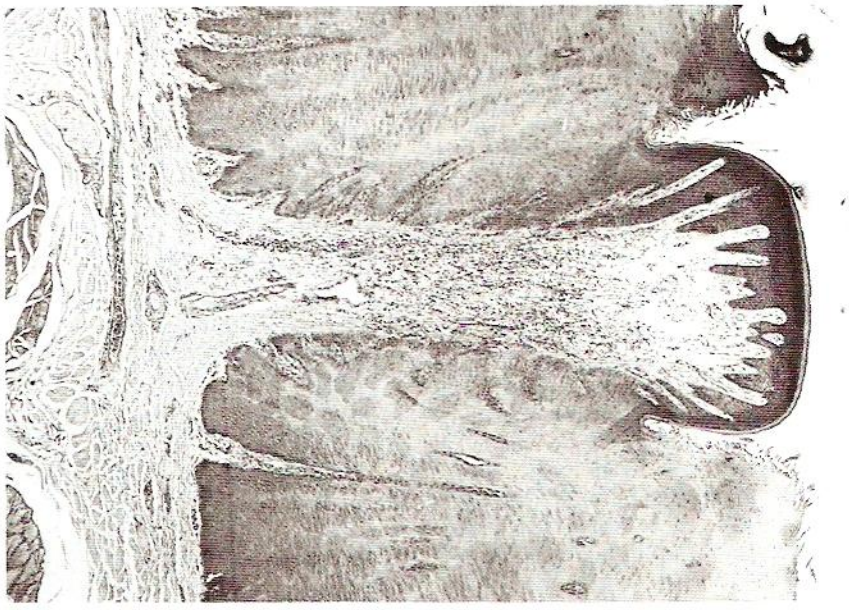

Figure 21-8. Section of a typical fungiform papilla from the tongue of a canine. This structure may be gustatory. (×10.)

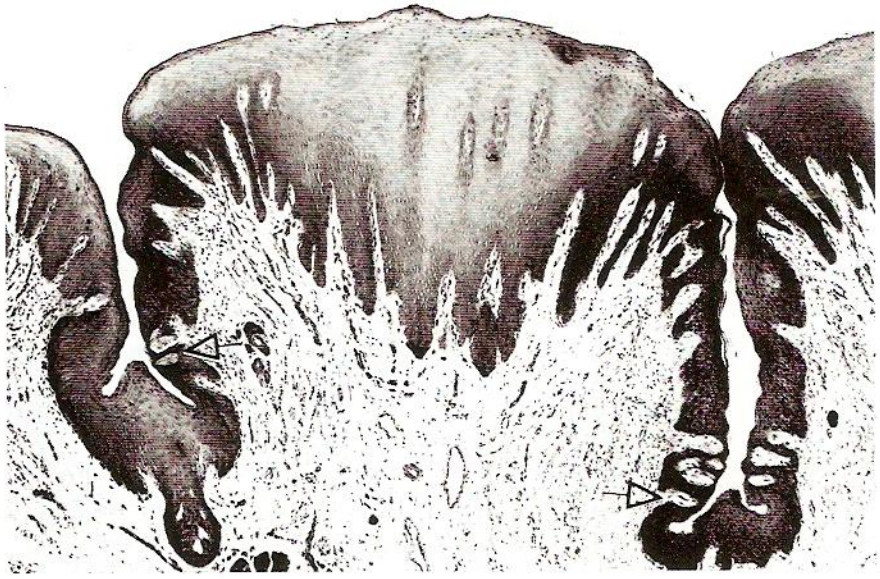

Figure 21-9. Section of a typical foliate papilla from a canine tongue. These papillae are gustatory. *Arrows* point to the taste buds. (×16.)

Downloaded From Vet-eBooks.com

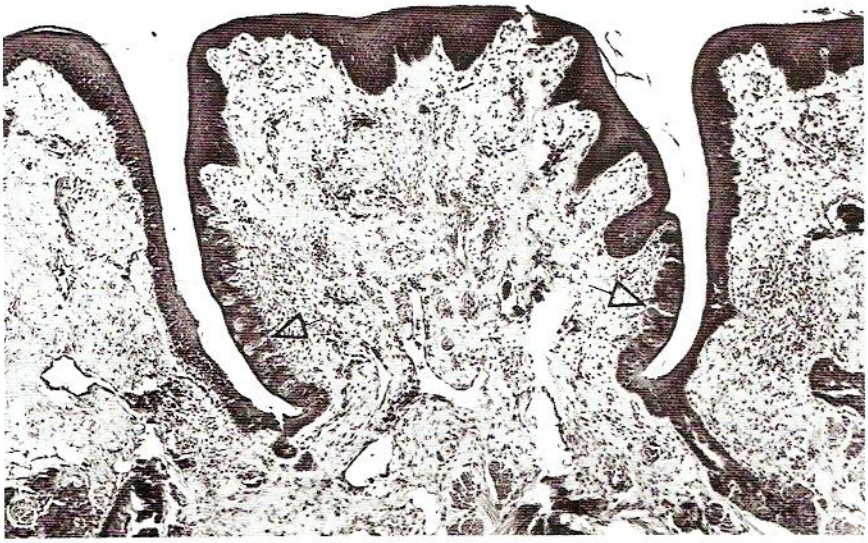

Figure 21-10. Section of a typical circumvallate papilla of the canine tongue. Note the taste buds *(arrows)*. (×16.)

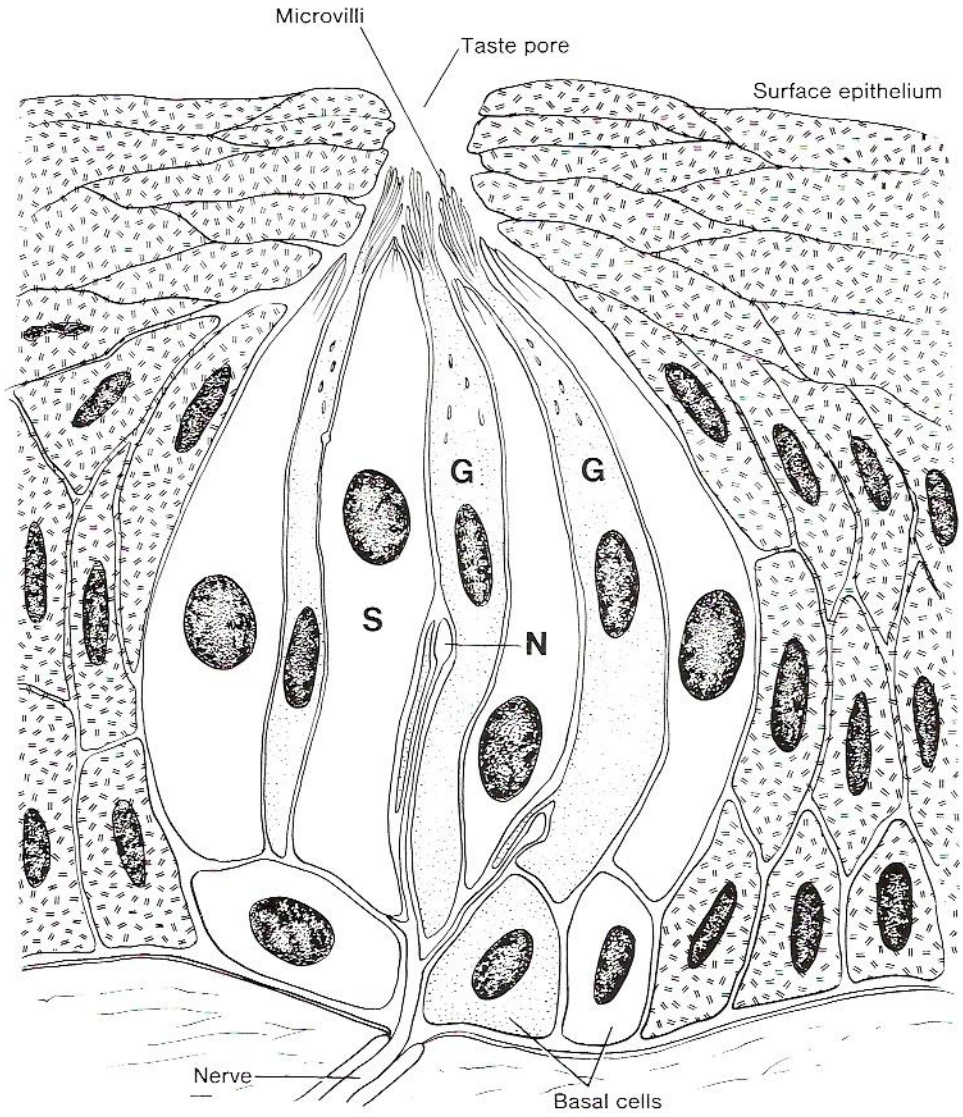

Figure 21-11. The electron microscopic appearance of a taste bud. *G*, Gustatory cells; *S*, sustentacular cell; *N*, nerve ending.

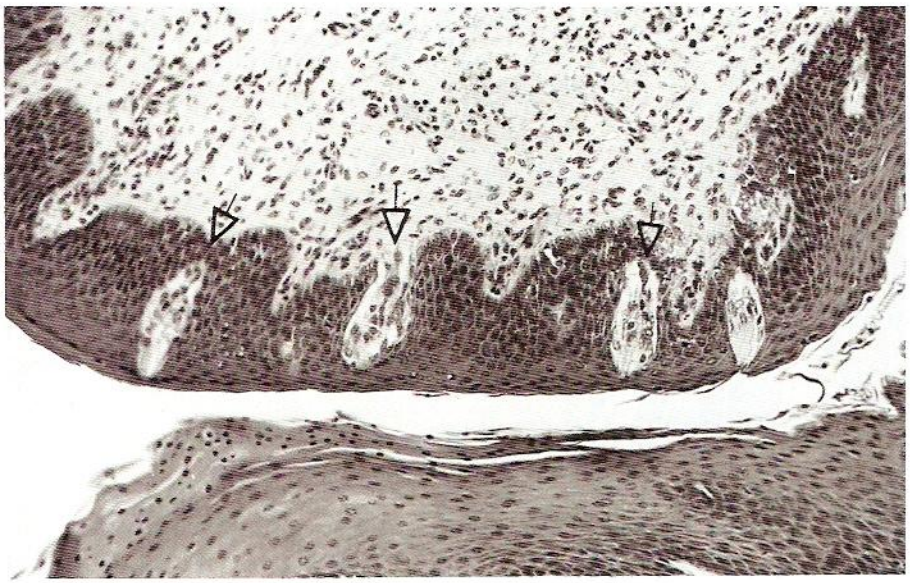

Figure 21-12. Taste buds associated with a circumvallate papilla from a canine tongue. The taste buds *(arrows)* are intraepithelial structures. (×40.)

Figure 21-13. Cells of a taste buds. Both the sustentacular *(open arrow)* and the gustatory *(solid arrow)* cells are spindle-shaped. The taste pore *(bar)* opens on to the epithelial surface. (×160.)

cell masses extending from the basement membrane and opening through a small canal **(taste pore)** at the epithelial surface. Microvilli of constituent cells extend into the taste pore as "taste hairs."

Three cell types visible by light microscopy occur in the taste bud (Fig. 21-13)—**supportive (sustentacular), gustatory (taste receptor),** and **basal.** Supportive (dark) and gustatory (light) cells appear spindle-shaped. Gustatory cells have a dense cytoplasm and a vesicular nucleus; supportive cells, a vacuolated cytoplasm and dense nucleus. Basal cells are small and located along the lateral and basal taste bud borders.

Nerve endings within the taste buds **(intragemmal fibers)** terminate on sensory cells. The gustatory sensations of sour, sweet, salt, and water (neutral) have been described in dogs. The distribution of modalities on the tongue is associated with various types of lingual papillae and has been mapped.

TEETH

Teeth differ in appearance, but they have the same components—**enamel, dentin, cementum,** and **pulp.** Teeth are either simple or complex. **Brachydont (simple)** teeth do not grow after the completion of eruption (Fig. 21-14). They have a **crown, neck,** and **root. Hypsodont (complex)** teeth (ruminants, rodents, horses) are constantly erupting (Fig. 21-15). They do not have a definitive crown, neck, and root but are considered to be composed of root only. They include ruminant cheek teeth, all equine teeth, rodent incisorform teeth, and the canine teeth of pigs.

Development

Dental lamina to cap stage. Tooth development involves the epithelium and underlying connective tissue (Fig. 21-16). An epithelial ridge **(dental lamina)** develops in the **dental arch** of each jaw and grows into the underlying mesenchyme. Cellular proliferation along the lateral border extends the lamina into the mesenchyme. The **enamel organs** of **deciduous (milk) teeth** arise from this lateral extension. At a later period medial or lingual outgrowths of the dental lamina give rise to enamel organs of the **permanent teeth.** Proliferation of epithelium as a solid cell mass continues to the **cap stage** accompanied by a mesenchymal condensation at the base of the cap (Fig. 21-17).

Enamel organ. By complementary growth of the epithelium with **dental papilla mesenchyme,** the cap is converted to a bell during the **bell stage** (Fig. 21-18). The epithelium, now an **enamel organ,** is divisible into distinct regions (Fig. 21-19). The **inner enamel epithelium** has columnar cells **(ameloblasts)** separated from the dental papilla by a basement membrane. It continues with the **outer enamel epithelium** at the lower edges (rim) of the bell. The outer epithelium has small, flattened cells. The center of the enamel organ consists of **stellate reticulum.** The stellate cells, previously tightly packed, are separated by extensive intercellular spaces. The contact region between stellate reticulum and the inner enamel epithelium is occupied by cuboidal cells, the **stratum intermedium** (Fig. 21-19). As development of the tooth progresses, the stellate reticulum **(enamel pulp)** atrophies and the outer enamel epithelium collapses upon the inner.

The dental papilla is trapped within the space delimited by **ameloblasts.** A thin layer of columnar cells **(odontoblasts)** differentiates from the mesenchyme along the inner surface of the ameloblastic basement membrane. The remainder of the papilla becomes the tooth **pulp**—consisting of blood vessels, nerves, and loose collagenous tissue.

Dental sac. A condensed mass of connective tissue, the **dental sac,** surrounds the enamel organ and dental papilla. It

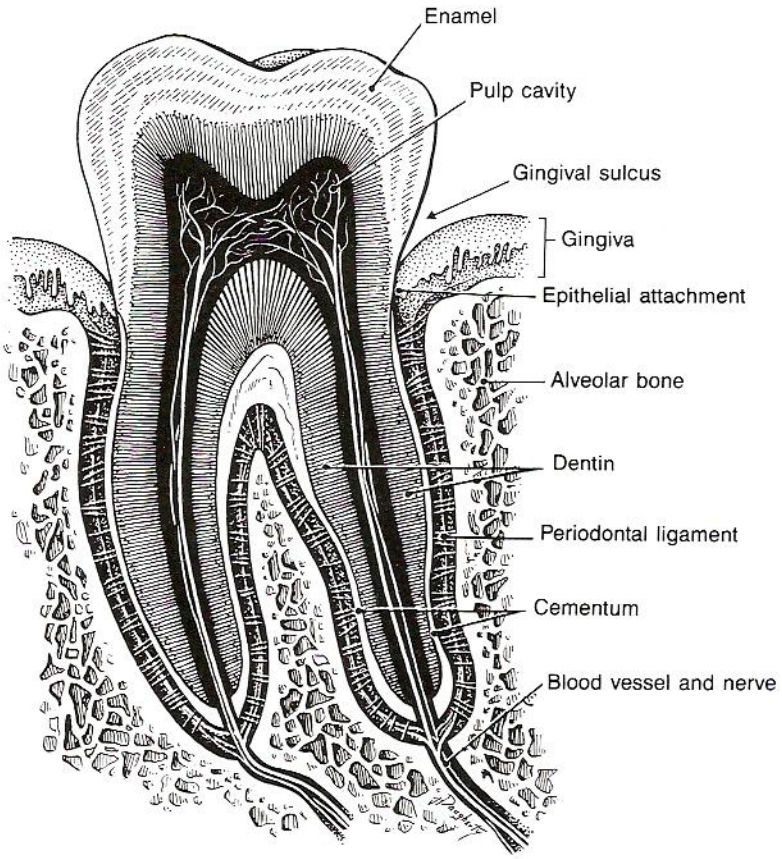

Figure 21-14. Section of a brachydont molariform tooth.

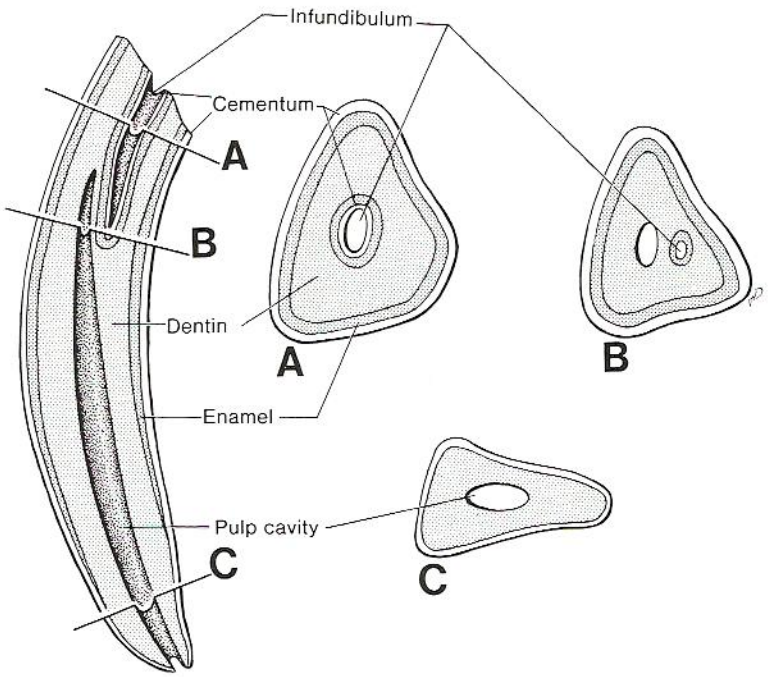

Figure 21-15. Sections (designated by *letters*) through an equine hypsodont incisorform tooth. The entire peripheral surface is covered by cementum.

Downloaded From Vet-eBooks.com

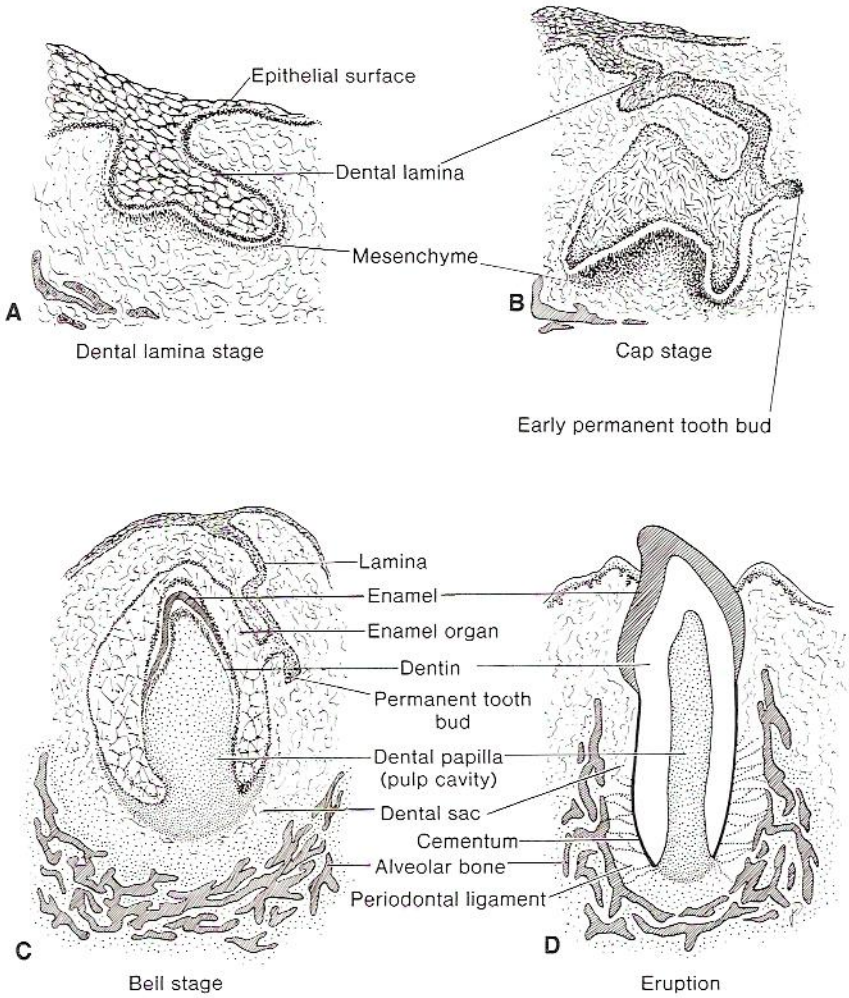

Figure 21-16. Early development of a deciduous brachydont tooth. **A,** The surface epithelium proliferates and invaginates into the underlying mesenchyme as dental lamina. **B,** The attached epithelial mass begins to cavitate adjacent to the mesenchymal condensation. **C,** The enamel organ forms during the bell stage. Enamel and dentin have begun to differentiate. **D,** Eruption has occurred. Dentin and cementum are continuously added until complete eruption is achieved.

Figure 21-17. Cap stage of a secondary tooth bud. The enamel organ is still a condensed mass of epithelial cells *(C)* associated with mesenchyme *(M)*. The mesenchymal condensation indicated is destined to become dental pulp. (×25.)

Downloaded From Vet-eBooks.com

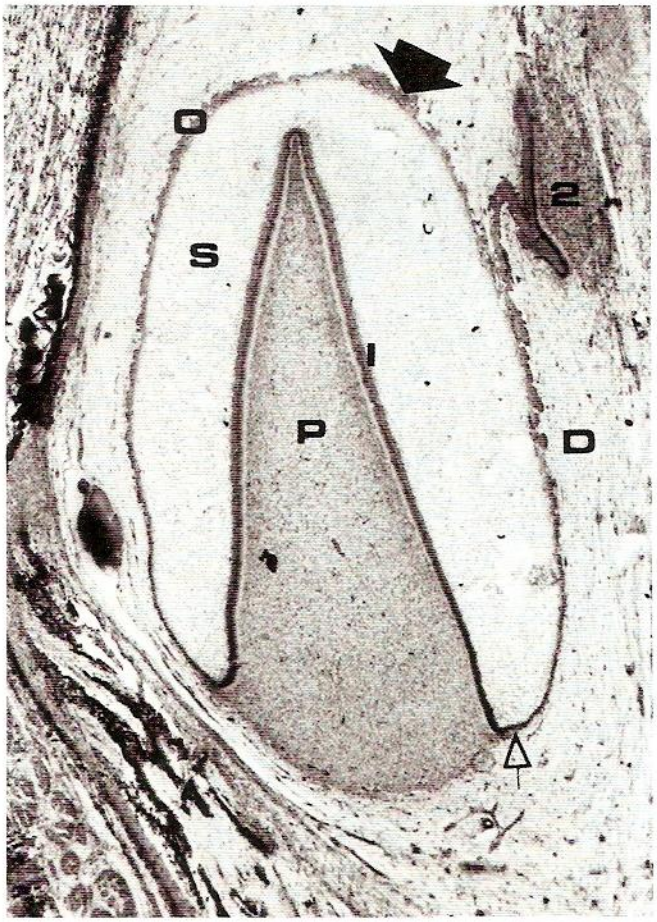

Figure 21-18. Enamel organ in an early bell stage. The organ *(solid arrow)*, which has a permanent tooth bud attached to it *(2)*, consists of an outer enamel epithelium *(O)* that is continuous with the inner enamel epithelium *(I)* at the rim *(open arrow)*. Stellate reticulum *(S)* is between the inner and outer epithelial layers. The enamel organ surrounds a mesenchymal condensation, the dental papilla *(P)*. *D*, is the dental sac. (×6.)

gives rise to

1. The **alveolar bone** and periosteum surrounding the root
2. A layer of **cementum** peripheral to the root dentin
3. The **periodontal membrane** or **ligament**, a network of anchoring fibers that connect the root cementum to alveolar bone

Crown and root formation. The ameloblasts secrete enamel. This appositional process, induced by odontoblastic secretions, starts at the papillary apex and continues toward the gingiva and bell rim. The odontoblasts initiate predentin secretion appositionally at the papillary apex. This process moves laterad toward the rim. When the ameloblastic and odontoblastic secretions meet, they form the tooth **crown.** After the cells have secreted their products and retreated away from the matrix, the ameloblasts migrate outward and the odontoblasts inward.

At the point of continuity between inner and outer enamel epithelia (the future tooth **neck**), an epithelial fold develops and grows downwardly as the **epithelial root sheath.** Dentin continues to develop in this region. The mesenchyme interdigitates itself between the odontoblasts and the root sheath, and cementum develops. The root consists of cementum and dentin. The transition from crown to root is the **tooth neck.**

Eruption. As these processes occur, the dental sac forms alveolar bone. Downward root growth exerts pressure against the stationary alveolar bone. The pressure translates into upward movement or **eruption.** During eruption the tooth crown breaks through the enamel organ and gingiva. Ameloblastic activity ceases at eruption, because the ameloblasts disintegrate. Continued deposition of root substance during eruption forms the definitive tooth position.

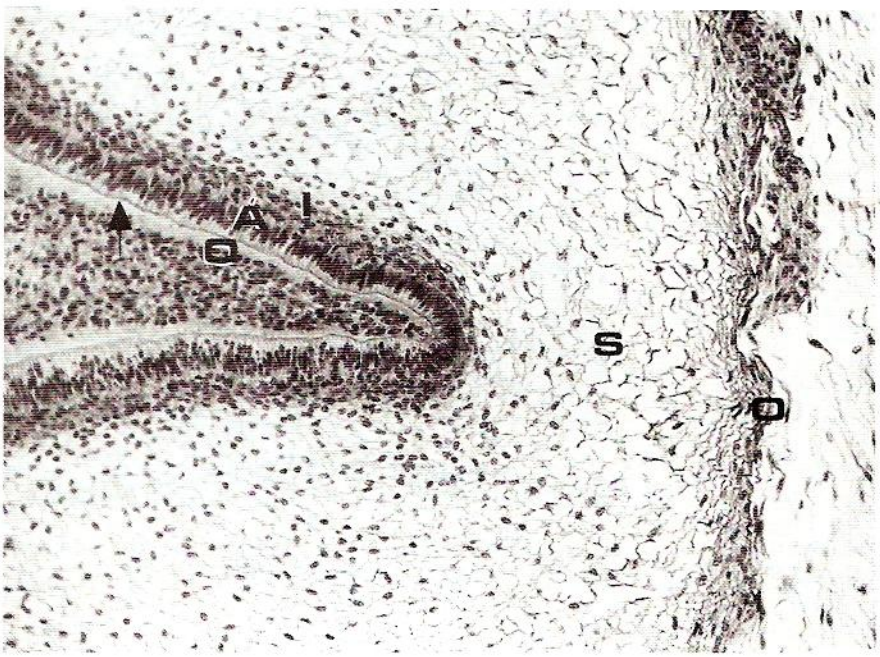

Figure 21-19. Components of the enamel organ. The outer enamel epithelium *(O-right)* is adjacent to the stellate reticulum (S). A layer of cuboidal cells, stratum intermedium *(I)*, underlies the inner enamel epithelium, which is composed of ameloblasts *(A)*. The ameloblasts are separated from the odontoblasts *(O-left)* of the dental papilla by a basement membrane *(arrow)*. (×40.)

Downloaded From Vet-eBooks.com

The enamel organ development of permanent teeth follows the same sequence outlined. As permanent tooth buds develop, their growth exerts pressure against the roots and associated deciduous tooth structures. This induces resorption of the deciduous roots and surrounding alveolar bone. Deciduous tooth loss is followed by replacement with permanent teeth.

Cellular and Matrical Components

Ameloblasts and enamel. **Ameloblasts** are columnar cells that appear hexagonal in cross section (Fig. 21-20). They have an elongated, basally positioned nucleus. The basal part of the cell is rich in mitochondria, the apical portion in RER and Golgi complexes. At the apex of the cell one prismatic extension of ameloblastic apical cytoplasm **(membrane prisms)** is apparent. Material for enamel formation is secreted through this process in the form of slightly mineralized rods. The ameloblasts retreat outwardly before the advancing front of their secretory products. The result is an acellular enamel composed of rods and interrod material. The basic structural unit of enamel is the **enamel rod** (consisting of glycoproteinaceous tubular subunits). Each membrane prism forms a rod; the base of the prism is the **interrod** matrix. Mineralization is progressive and begins in the enamel rods. The mineral content of rods and interrod matrix is the same; the orientations of tubular subunits and crystalline materials differ. During development the most mineralized enamel matrix occurs at the **dentinoenamel junction** whereas the least mineralized occurs at the retreating ameloblastic front.

Enamel, consisting of 95% to 97% apatite crystal, is the hardest body substance. Because ameloblasts disintegrate upon eruption, enamel is incapable of repair.

Odontoblasts and dentin. **Odontoblasts** are loosely packed columnar cells that produce dentin (Fig. 21-21). The predominant organelles are an apically disposed RER and a large supranuclear Golgi complex. The initial secretory product of odontoblasts is **predentin,** which is deposited initially at the dentinoenamel junction and contains **odontoblastic processes (dentinal fibers).** As predentin is secreted, the odontoblasts retreat before the advancing front, but their processes remain and are contained within **dentinal tubules.** Mineralization of predentin results in **dentin.** This method of secretion is similar to the relationship between osteoid seam and mineralizing bone. Dentin contains about 69% inorganic substances.

Unlike ameloblasts, odontoblasts do not disintegrate upon completion of their secretory activity. They remain viable and

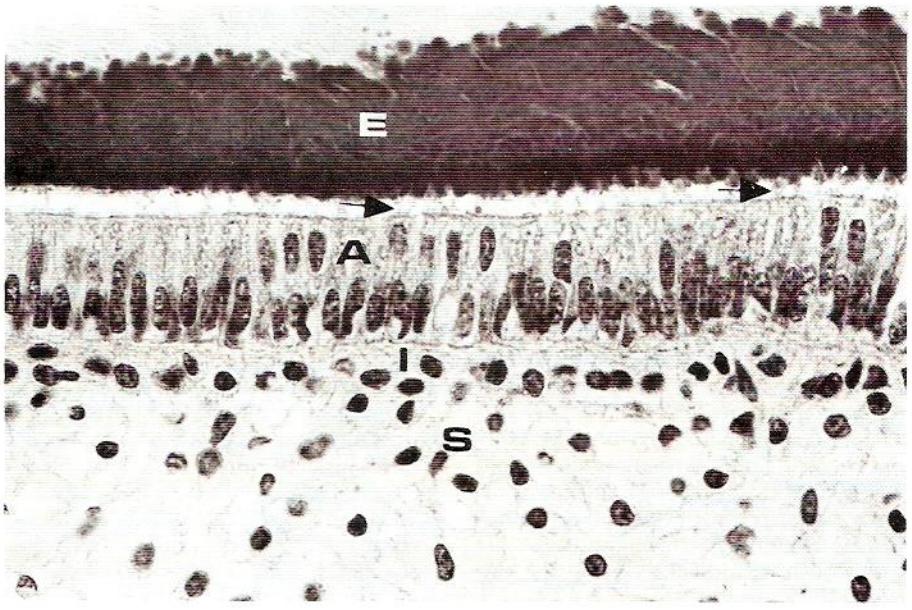

Figure 21-20. Layer of ameloblasts. These cells *(A)* are intimately associated with the stratum intermedium *(I)*, whose cells are continuous with the stellate reticulum *(S)*. Enamel *(E)* has been deposited, and membrane prisms *(arrows)* are apparent. (×160.)

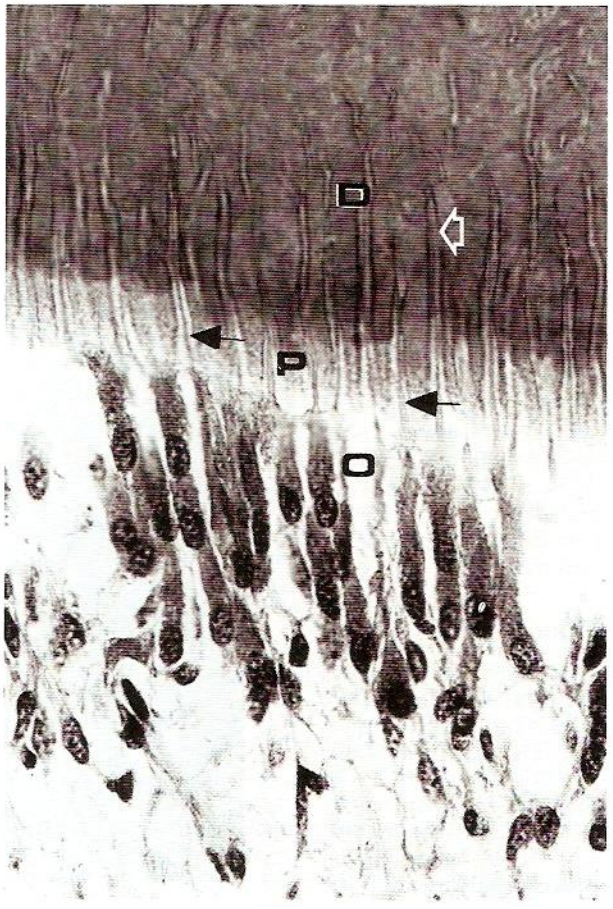

Figure 21-21. Layer of odontoblasts. These cells *(O)* have apical processes, which are dentinal fibers *(solid arrows)* extending into the dentinal tubules *(open arrow)*. Predentin *(P)* is secreted and then mineralized as dentin *(D)*. (×160.)

Downloaded From Vet-eBooks.com

functional cells throughout the life of a tooth.

Cementoblasts and cementum. **Cementoblasts** are differentiated from the dental sac and form **acellular** and **cellular cementum.** This material with or without its contained **cementocytes** is similar to woven bone. Anchoring fibers become embedded in cementum by an appositional growth of cementum around the collagenous fibers, a process similar to the way in which the collagen of tendons is incorporated in and attached to bone.

Dental pulp. The **dental pulp** is connective tissue from the dental papilla lining the pulp cavity. It contains many vessels and nerves within a loose collagenous tissue. These structures enter and exit the pulp cavity through the **apical foramen** of each root. **Secondary dentin** formation continues throughout the life of the tooth, gradually reducing the size of the pulp cavity.

Associated Structures

Periodontal membrane. The **periodontal membrane (ligament)** consists of coarsely bundled collagen fibers and fibroblasts. These fibers are embedded in the cementum and associated alveolar bone, and they anchor the tooth in the **alveolus (socket).** They are ruptured during tooth extraction. Thus the teeth are actually suspended within the alveolus by collagen fibers.

Epithelial attachment. The eruption of teeth through the gingiva creates a break in this mucous membrane. The barrier continuity is maintained, however, through a gingival epithelial attachment to the tooth neck. The **gingival sulcus** is the depression between the tooth and gingiva above the epithelial attachment (Fig. 21-14). It and the epithelial attachment are significant in periodontal disease. **Plaque** commonly accumulates in the sulcus and, with time, hardens to become **tartar.** Breaks in the epithelial attachment provide an entry portal for microbial agents and debris into the vital tissues of the periodontal ligament, resulting in **periodontitis.**

Types of Dentition

Brachydont dentition. The **crown** is covered by enamel and is visible above the **gingiva** (Fig. 21-14). It consists of enamel and dentin. The dentin is visible only on the surface of worn teeth from which the enamel has been removed by abrasion. The tooth **neck** is the area of transition between the crown and root, the point of **epithelial attachment** to the cementum. The root is composed of dentin and cementum adjacent to each other. The periodontal ligament is the suspension device between alveolar bone and root cementum. The dental pulp is a loose collagenous tissue, rich in vessels and nerves, bounded by the dentin of the crown and root (or roots).

Hypsodont dentition. Constantly erupting teeth differ from brachydont teeth (Fig. 21-15), based upon alterations in their development. In brachydont teeth the enamel it organ remains intact until the time of eruption. In hypsodont teeth, the enamel organ ruptures before eruption. This brings the connective tissue of the dental sac into close association with new enamel. As a result cementum is deposited on the enamel. The mature hypsodont tooth structure, especially the **infundibular recess,** requires the enamel organ to be more complex in surface contour than that of simple teeth.

In brachydont teeth, crown eruption is accompanied by the disintegration of ameloblasts. This is not true in hypsodont teeth, they continue their activity beyond eruption. Hypsodont teeth have been described as root teeth without a definitive crown, neck, and root. This is not entirely true. A typical root is confined to the lower portion of the tooth (Fig. 21-15).

PHARYNX

The **oropharynx** extends from the buccal cavity to the esophagus. Its lamina epithelialis mucosae is stratified squamous epithelium. Differing amounts of cornification are species-variable. The lamina propria mucosae—with tonsils, individual lymph nodules, and scattered leukocytes—is typical. Many papillae are obvious and resemble skin dermal papillae. Although the usual lamina muscularis mucosae is not present, a layer of elastic fibers delimits the lamina propria mucosae from the tela submucosa. The latter is typical and contains branched, tubuloalveolar, mucous glands. The tunica muscularis has randomly oriented striated muscle fibers, and the tunica adventitia blends with the deep fascia.

ESOPHAGUS

The esophagus is a muscular tube modified for the voluntary and involuntary movement of foodstuffs to and from the stomach.

Mucosa. Three cellular layers constitute the esophageal mucosa.

The **lamina epithelialis mucosae** is stratified squamous epithelium. Varying degrees of cornification may be apparent, especially in species that ingest hard and dry foods.

The **lamina propria mucosae** is typical and may contain many lymph nodules and scattered lymphatic tissue (humans and pigs). These are prominent at the esophageal/gastric junction.

The **lamina muscularis mucosae** also is typical but of variable occurrence (Fig. 21-22). It is continuous with the elastic fiber layer of the pharynx:

Thick and complete in humans

Consisting of scattered muscle bundles that fuse in the esophagus of horses, ruminants, and cats

Absent in the cervical region of dogs

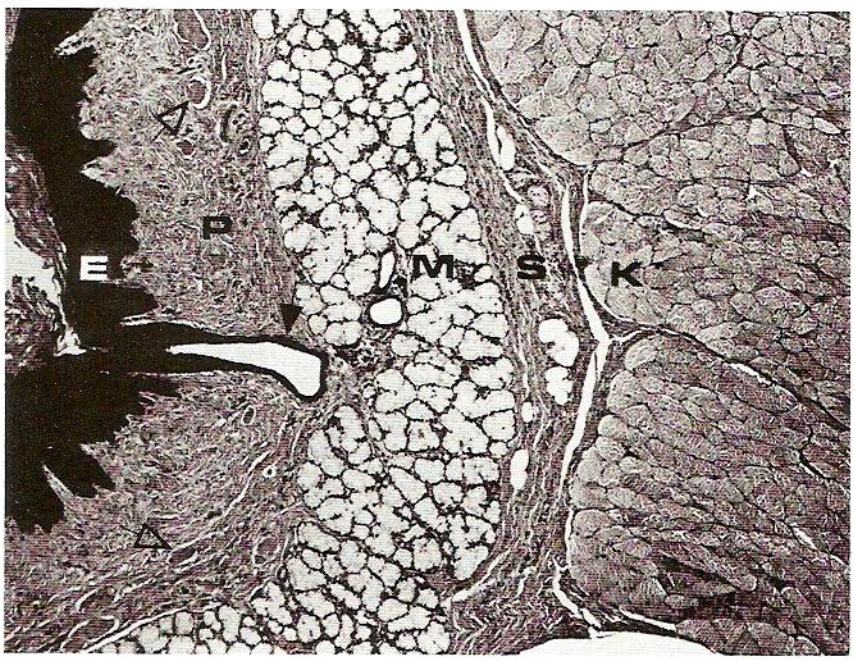

Figure 21-22. Porcine esophagus (lower cervical region). The lamina epithelialis mucosae *(E)* is supported by a lamina propria mucosae *(P)*. The lamina muscularis mucosae consists of scattered bundles of smooth muscle *(open arrows)*. Mucous glands *(M)* are continuous with the epithelial lining via excretory ducts *(solid arrow)*. A tela submucosa *(S)* is adjacent to the skeletal muscle *(K)* of the tunica muscularis. (×12.)

Downloaded From Vet-eBooks.com

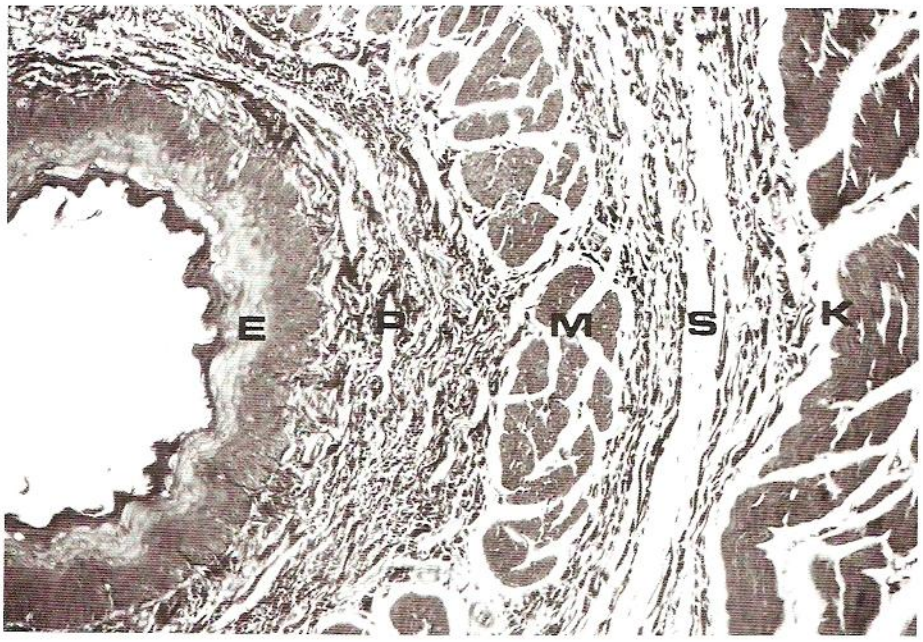

Figure 21-23. Canine esophagus (thoracic region). The lamina epithelialis mucosae *(E)* and lamina propria mucosae *(P)* are typical. The lamina muscularis mucosae *(M)* is extensive. *S*, Tela submucosa; *K*, skeletal muscle of the tunica muscularis. (×40.)

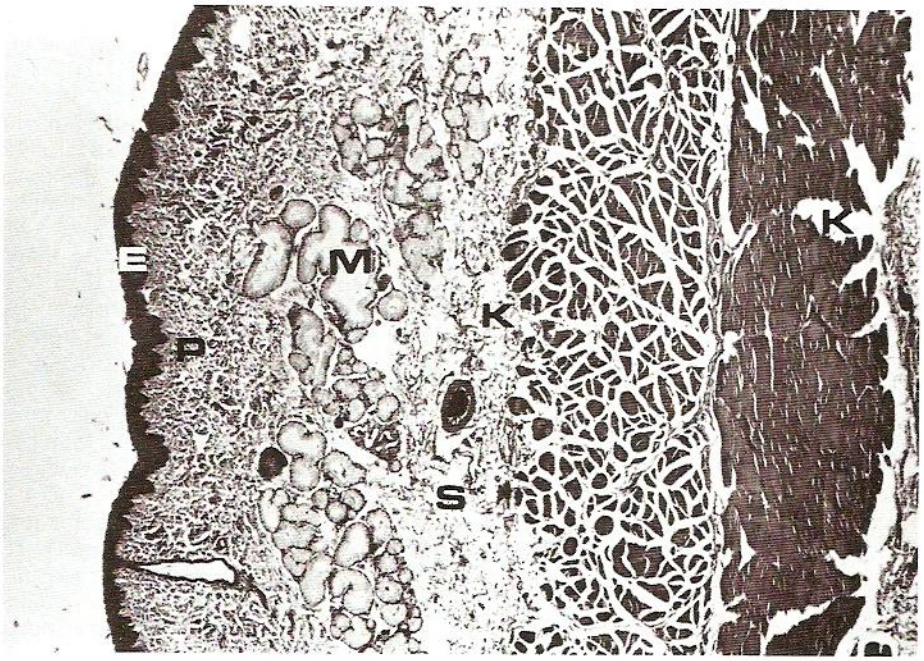

Figure 21-24. Canine esophagus (cervical region). *E*, Lamina epithelialis mucosae; *P*, lamina propria mucosae; *M*, mucous glands; *S*, tela submucosa; *K*, skeletal muscle of the tunica muscularis. A lamina muscularis mucosae is not present. (×10.)

and pigs (though it may become complete near the stomach) (Fig. 21-23).

Submucosa. The tela submucosa is typical, with many branched tubuloalveolar mucous glands. These occur along the entire length of the canine esophagus; along the cervical region (though sparsely in the thoracic portion) of the porcine esophagus; and in the cervical region of the ruminant, equine, and feline esophagi.

The tunica mucosa and tela submucosa have longitudinal folds that permit esophageal expansion.

Muscularis. The tunica muscularis has striated muscle and/or smooth muscle. The inner and outer laminae may be distinct aborally. In ruminants and dogs the tunic is entirely striated (Fig. 21-24); in pigs the cervical region has striated muscle, the thoracic region is mixed, and the caudal region consists of smooth muscle; in horses and cats the tunic consists of striated muscle to the middle region and then of smooth muscle.

Serosa and adventitia. The tunica serosa and tunica adventitia both are typical.

Histophysiology. The esophagus has properties relating to the muscle type comprising its tunica muscularis. The ease of vomiting and/or regurgitation in ruminants and dogs is linked to skeletal muscle distributed throughout its course. Although emesis and regurgitation are abnormal events in dogs, regurgitation is normal in ruminant digestive sequences. Pigs and cats are capable of vomiting in response to irritation within the pharynx and stomach. Despite the presence of skeletal muscle within the cranial two-thirds of the equine esophagus, vomiting is rare in this species.

The pharyngoesophageal and gastroesophageal junctions are physiological sphincters maintaining esophageal pressure higher than gastric pressure. The equine "caudal esophageal sphincter" has enough tone to remain closed during gastric dilation to the point of gastric rupture without the occurrence of vomiting.

During deglutition, food is propelled into the pharynx by the caudal movement of the tongue. Coordinated voluntary and involuntary muscular activities permit the food to pass through the "pharyngoesophageal sphincter" and into the esophagus. Distention of the cranial esophagus initiates a wave of peristalsis moving the bolus aborad. Relaxation of the "gastroesophageal sphincter" permits food to enter the stomach.

General visceral afferent and efferent (GVA, GVE) fibers innervate esophageal smooth muscle and glands. The innervation of these muscle fibers probably originates as somatic visceral efferent (SVE) fibers.

Esophageal dysfunction can result from a number of causes in dogs (foreign body, stricture, perforation). Regurgitation of foodstuffs, not vomiting, is the pathognomonic sign of **obstructive esophageal disease.** Often surgical intervention is considered in such cases. Unfortunately, the esophageal healing potential is less than optimum and leakage is common. Poor tissue strength, coupled with a minimal adventitial or serosal connective tissue, complicates the healing process. A marginal segmental blood supply and the constant movement of thoracic organs (heart, lungs) compound the healing process. The cervical esophagus is devoid of a tunica serosa, and the thoracic esophagus is not intimately associated with one.

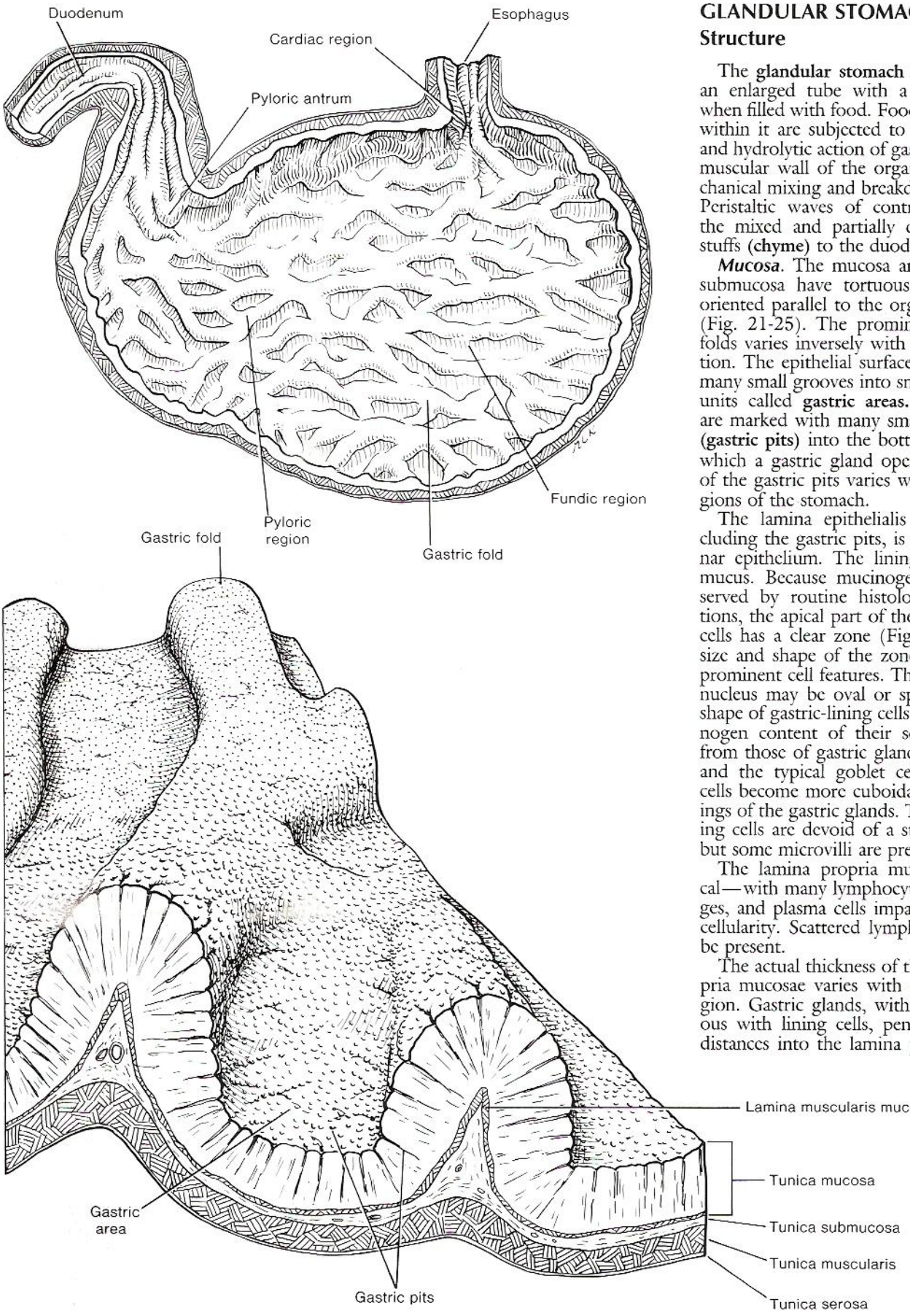

GLANDULAR STOMACH

Structure

The **glandular stomach** is modified as an enlarged tube with a saclike shape when filled with food. Foodstuffs delayed within it are subjected to the enzymatic and hydrolytic action of gastric juice. The muscular wall of the organ induces mechanical mixing and breakdown of foods. Peristaltic waves of contraction propel the mixed and partially digested foodstuffs **(chyme)** to the duodenum.

Mucosa. The mucosa and part of the submucosa have tortuous **gastric folds** oriented parallel to the organ's long axis (Fig. 21-25). The prominence of these folds varies inversely with gastric distention. The epithelial surface is divided by many small grooves into smaller irregular units called **gastric areas.** Gastric areas are marked with many small depressions **(gastric pits)** into the bottom of each of which a gastric gland opens. The depth of the gastric pits varies with specific regions of the stomach.

The lamina epithelialis mucosae, including the gastric pits, is simple columnar epithelium. The lining cells secrete mucus. Because mucinogen is not preserved by routine histological preparations, the apical part of the gastric lining cells has a clear zone (Fig. 21-26). The size and shape of the zone vary but are prominent cell features. The shape of the nucleus may be oval or spheroidal. The shape of gastric-lining cells and the mucinogen content of their secretion differ from those of gastric gland mucous cells and the typical goblet cell. The lining cells become more cuboidal at the openings of the gastric glands. The gastric lining cells are devoid of a striated border, but some microvilli are present.

The lamina propria mucosae is typical—with many lymphocytes, macrophages, and plasma cells imparting a hypercellularity. Scattered lymph follicles may be present.

The actual thickness of the lamina propria mucosae varies with the gastric region. Gastric glands, with cells continuous with lining cells, penetrate variable distances into the lamina propria muco-

Figure 21-25. Note the prominent gastric folds in the *lower* illustration, characteristic of the nondistended canine stomach *(top)*.

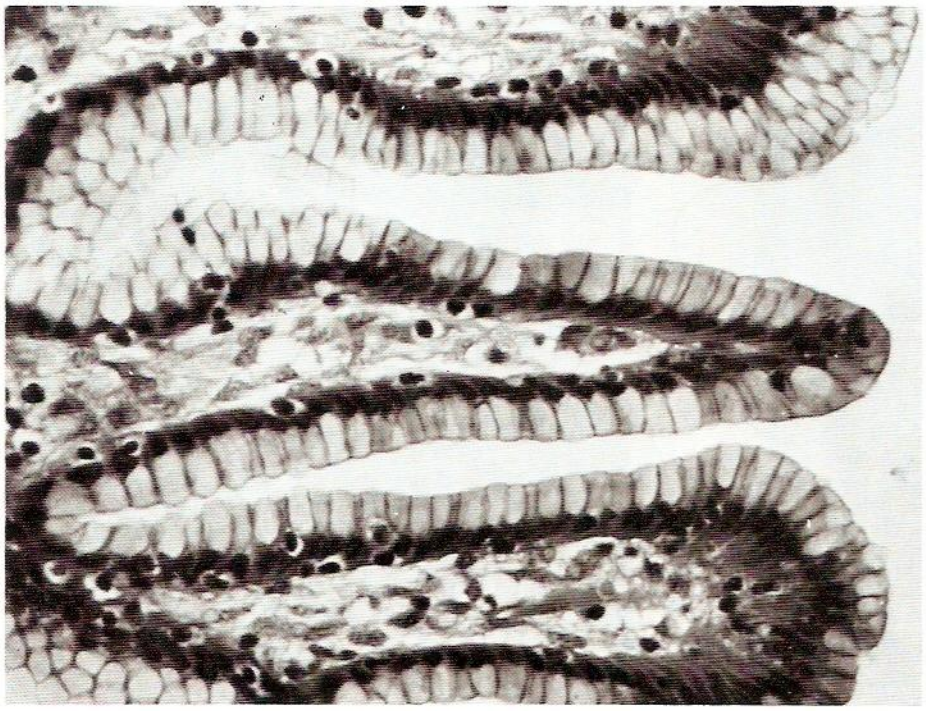

Figure 21-26. Lining cells of an equine stomach. Note the clear zone in the apical portion of each cell. (×160.)

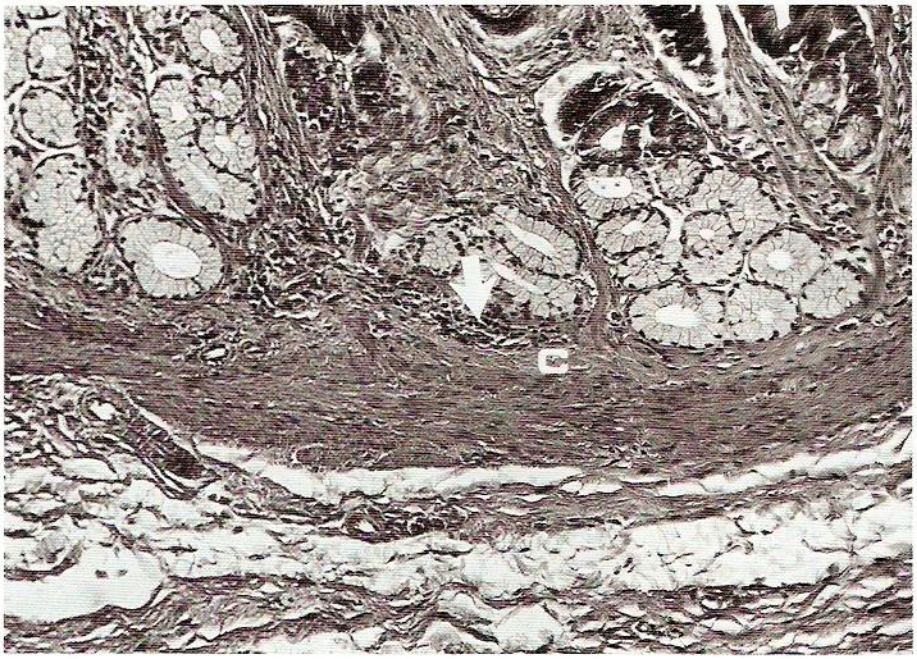

Figure 21-27. Stratum compactum of a canine stomach. The stratum consists of collagenous fibers *(C)*. Note the hypercellularity of the lamina propria mucosae *(arrow)*. (×40.)

sae. Although the lamina propria mucosae may be thick, the actual connective tissue is scant, because it is interdigitated between many gastric glands.

The lamina propria mucosae may contain a distinct **stratum compactum** at the junction of the lamina propria mucosae and the lamina muscularis mucosae (Fig. 21-27). This stratum, consisting of dense collagenous tissue, is well-developed in carnivores. It may protect the stomach from perforation by sharp objects.

A lamina muscularis mucosae is present, but its arrangement varies. The two to four muscle layers comprising this lamina are oriented longitudinally and circularly. Thin strands of smooth muscle extend into the lamina propria mucosae between the glands.

Submucosa. The tela submucosa is typical. Neuronal fibers and ganglion cell cytons form the **submucosal plexus.**

Muscularis. The tunica muscularis mucosae is typical. Its neurons and neuronal processes form the **myenteric plexus** between the inner and outer laminae of smooth muscle (Fig. 17-10).

Serosa. The tunica serosa is typical.

Glandular Regions

Histological differences in the gastric tunica mucosa permit the identification of esophageal, cardiac gland, fundic gland, and pyloric gland regions (Fig. 21-28).

Esophageal region. The esophageal region is the nonglandular portion of the stomach lined by stratified squamous epithelium. Cornification may be present but depends upon species and diet.

Cardiac gland region. The cardiac gland region is not developed equally in all species (Fig. 21-29). Its beginning is marked by a transition from stratified squamous to columnar epithelium.

The **cardiac glands** are branched, tubular, and coiled (Fig. 21-30). The neck of each is nearest the gastric pit opening. The body is the remainder of the adenomere. The neck and upper portion of the body are lined by mucus-secreting, cuboidal cells. The remaining cells are columnar and mucus-secreting. Some **parietal cells** may occur in the canine cardiac gland region, and some **chief cells** in the porcine cardiac gland.

Argentaffin cells are small and pyramid-shaped, with a clear cytoplasm, located between gland lining cells and the basement membrane. Special silver stains demonstrate them (with their silver-containing granules) in an abluminal or infranuclear position. Electron microscopic and immunocytological techniques may reveal as many as ten cell types.

Argentaffin cells secrete material not into the lumen but into the lamina propria mucosae for distribution via blood vessels. They are actually hormone-secreting, **gastrointestinal endocrine cells.** Secretions include **serotonin, motilin, pancreatic glucagon, cholecystokinin, vasoactive intestinal peptide (VIP), somatostatin, gastrin, neurotensin , secretin,** and **enteroglucagon.** The secretory and muscular activities of the gastrointestinal organs, including the pancreas and gallbladder, are controlled by these hormones in response to changing luminal content.

Fundic gland region. The **fundic gland region** is similar to the cardiac gland region (Fig. 21-28). The glands are **proper gastric glands**—branched, tubular, and longer (though less frequently branched) than cardiac region glands (Fig. 21-31). Fundic gland length thickens the lamina propria mucosae (Figs. 21-29 and 21-31), but the amount of connective tissue between the glands is reduced because the glands are tightly packed (Fig. 21-32).

Downloaded From Vet-eBooks.com

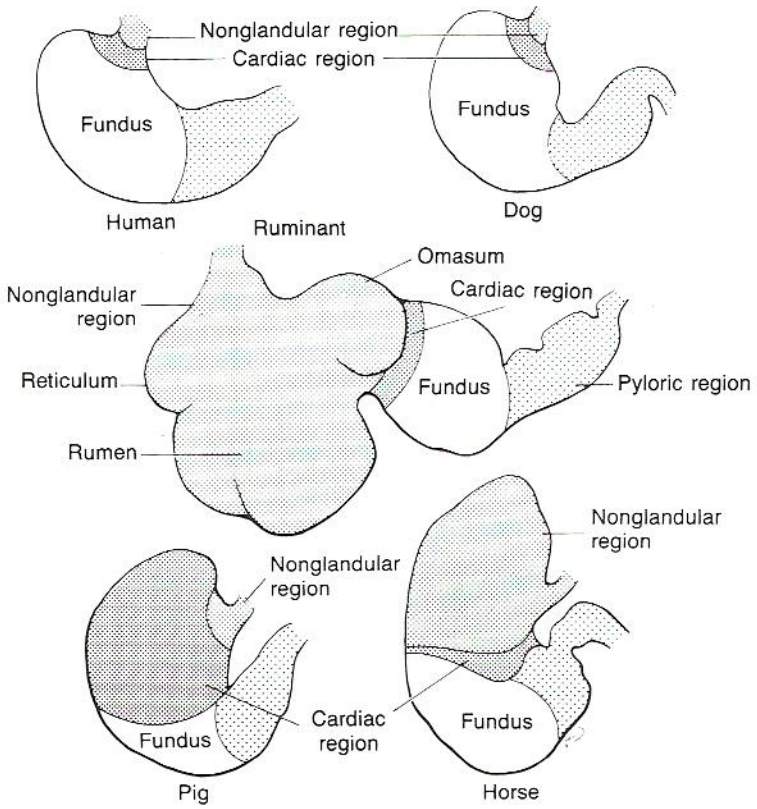

Figure 21-28. Distribution of glandular and nonglandular regions in the stomachs of selected animals. Only glandular regions are indicated. The organs are not drawn to scale.

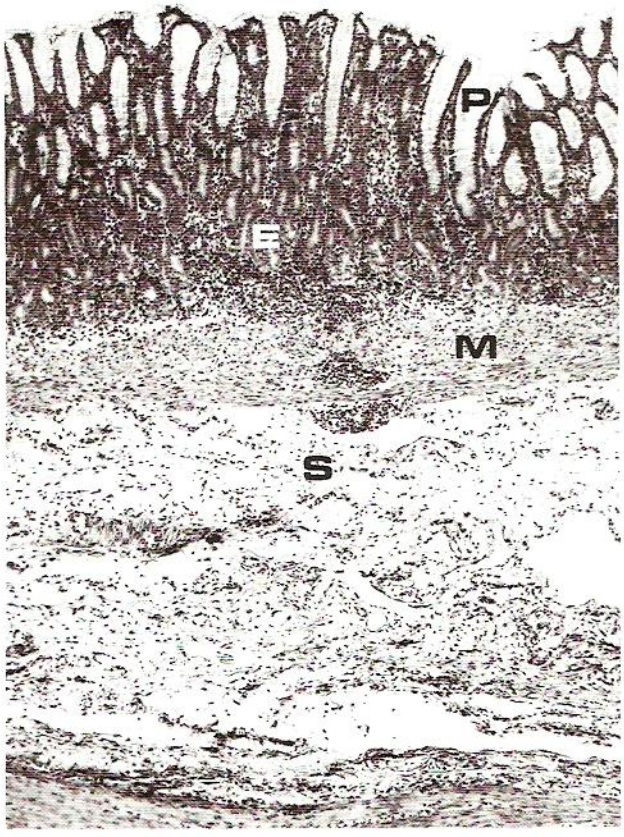

Figure 21-29. Cardiac region of a canine stomach. Simple columnar epithelium *(E)* lines the surface and gastric pits *(P)*. The lamina muscularis mucosae *(M)* and tunica submucosa *(S)* are typical. (×16.)

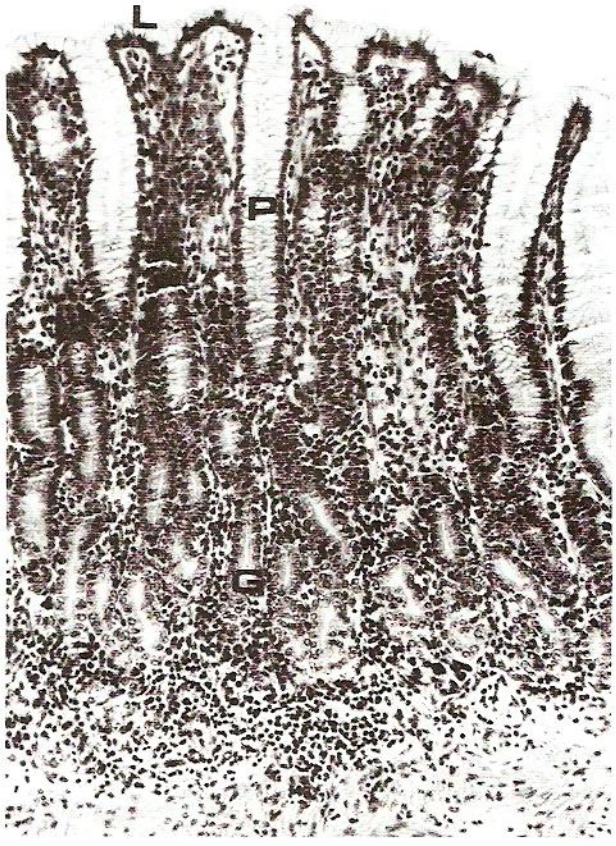

Figure 21-30. Cardiac glands of a canine stomach. The lamina epithelialis mucosae is composed of a simple epithelium, which lines the lumen *(L)*, gastric pits *(P)*, and cardiac glands *(G)*. (×40.)

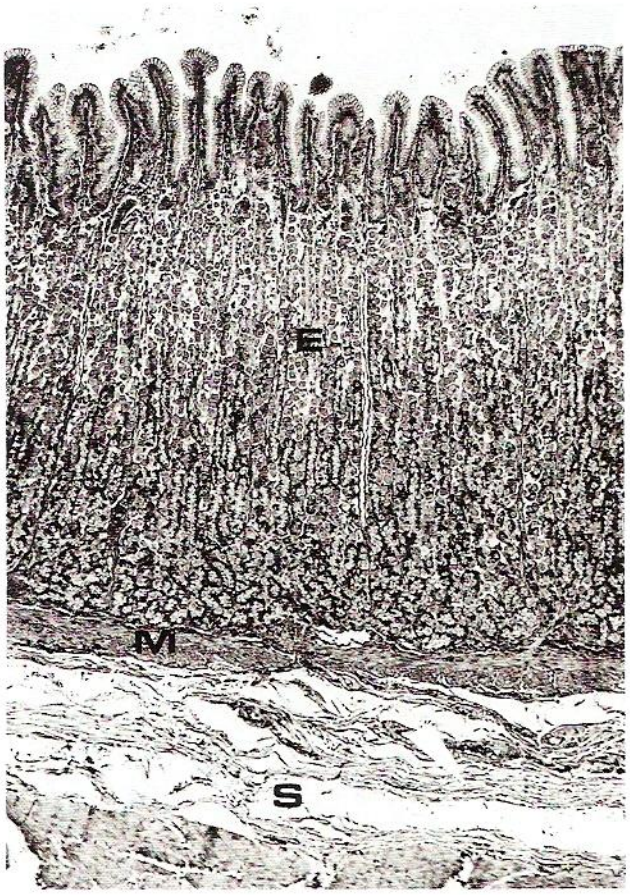

Figure 21-31. Fundic region of a canine stomach. The lamina epithelialis mucosae *(E)* is highly folded. The tunica mucosa is very thick. The lamina muscularis mucosae *(M)* and tunica submucosa *(S)* are typical. (×16.)

Figure 21-32. Gastric pits and fundic glands of a canine stomach. The lining epithelium *(L)*, which consists of columnar cells, extends into the gastric pits and is continuous with the lining cells of fundic glands *(G)*. Note the reduced amount of connective tissue between the fundic glands, as evidenced by the intimate juxtaposition of adenomeres. (×63.)

A fundic gland is divisible into isthmus, neck, body, and base. The **isthmus** (opening) continues into the constricted **neck.** The **body** or main tube continues from the neck and terminates as a dilated and bent adenomere, the **base.**

Three types of cells are apparent in fundic glands—mucous neck, chief, and parietal. Gastrointestinal endocrine cells may also be seen. A **transitional cell** has been described occasionally in the isthmus. Cuboidal transitional cells are responsible for the replacement of lining and glandular epithelial cells.

Mucous neck cells line the neck of the gland and are interspersed among parietal cells. They are cuboidal or low columnar with a pale-staining cytoplasm (Fig. 21-33). Their mucoid product differs from that of the surface lining cells but is similar to the mucoid secretion of cardiac and pyloric gland cells. Neck cell mucus is less viscous than surface lining cell mucus and contains acidic glycosaminoglycans. The secretory product of mucous neck cells may protect the fundic gland from the hydrolytic activity of proteases and hydrochloric acid. Mucous neck cells are thought capable of differentiating into surface and/or glandular lining cells.

Chief cells are the predominant cells of fundic glands (Fig. 21-34). They are pyramid-shaped with a basally positioned, round nucleus. Apically positioned secretory granules **(zymogen granules)** are present in fasted animals. Chief cells are labile to fixation; their secretory granules may be leached from them, imparting an apical foamy appearance (Fig. 21-35). The basal part of the cells contains many RER profiles and free ribosomes, imparting a distinct basophilia. The chief cells synthesize and secrete gastric enzymes—**pepsin, rennin,** and **gastric lipase.**

Parietal cells are distinguished from the other fundic glands cells by their bright-staining, acidophilic cytoplasm (Fig. 21-34). They are large cells scattered throughout the gland from neck to base. Their spheroidal or pyramidal shape with a round nucleus is distinctive (Plate II, *7*). Parietal cells are "wedged" between the chief cells. Although their basal borders contact the basement membrane, not all of them reach the luminal surface directly. Many **intracellular canaliculi** extend from the apical plasmalemma into the cytoplasm proper (Fig. 21-36). The canaliculi appear occluded by many microvilli projecting into these spaces. Apical microvilli also extend between the chief cells and reach the luminal surface. Parietal cells secrete hydrochloric acid. They may also secrete **intrinsic factor,** a substance necessary for the absorption of vitamin B_{12} **(extrinsic factor)** in humans. Carnivores probably do not require intrinsic factor for the absorption of vitamin B_{12}.

Pyloric gland region. The histological organization of the **pyloric gland region** is similar to that of the cardiac gland region (Fig. 21-37). The gastric pits are deeper than in other regions of the stomach, but the pyloric glands are similar to the cardiac glands (Fig. 21-38). The pyloric glands are short, simple, or branched tubes. The predominant cell is mucus-secreting.

The remaining mural elements are typical. A well-developed inner circular lamina of the tunica muscularis is a striking feature. It forms the **pyloric sphincter** at the **gastroduodenal junction** (Fig. 21-39).

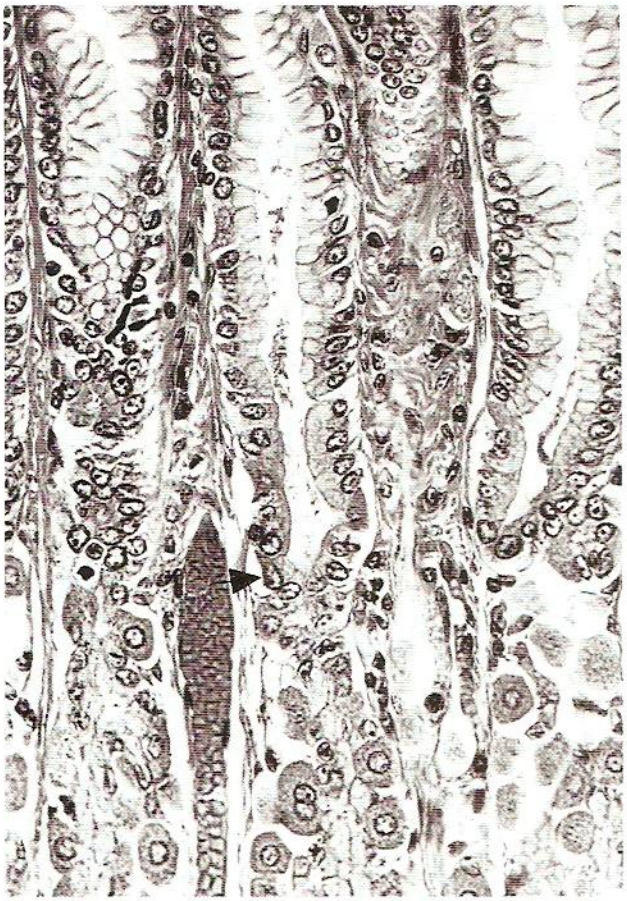

Figure 21-33. Mucous neck cells of a fundic gland in the canine stomach. The neck of the gland is constricted and lined by mucous neck cells *(arrow)*. The secretory product of these cells is mucoid; however, the mucoid product differs from that of surface lining cells. (×100.)

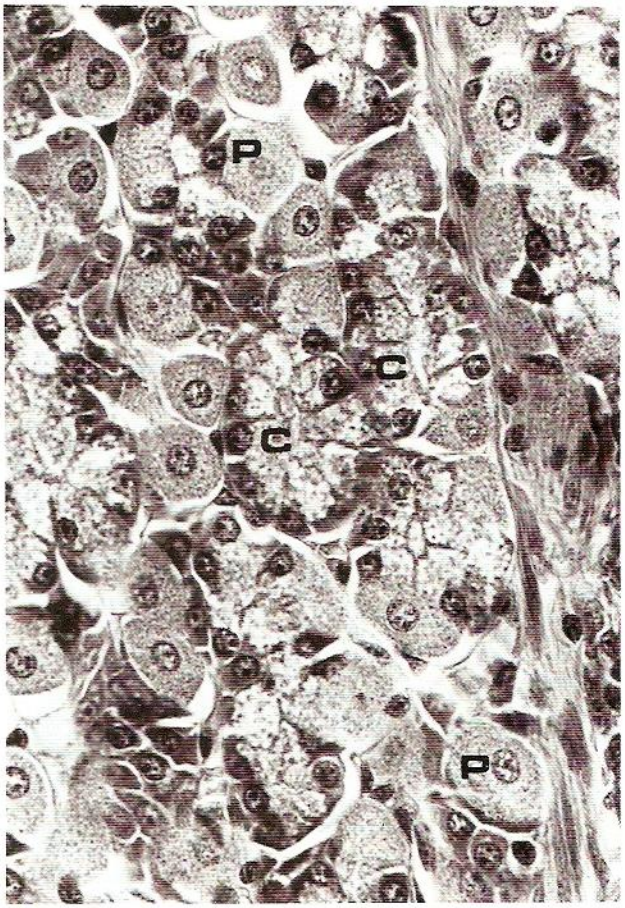

Figure 21-34. Chief cells and parietal cells of a fundic gland in the canine stomach. The chief cells *(C)* have granules along their apical borders. The parietal cells *(P)* are granular and acidophilic. (×160.)

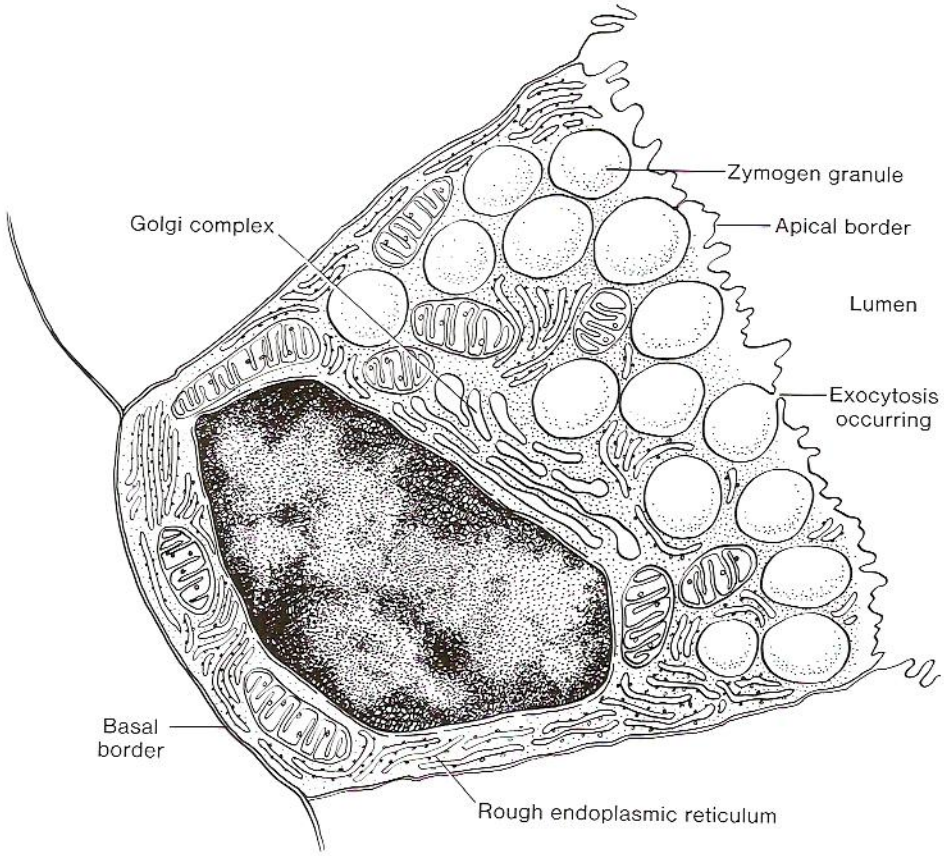

Figure 21-35. Chief cell as seen with the electron microscope. Note its distinct polarity.

Downloaded From Vet-eBooks.com

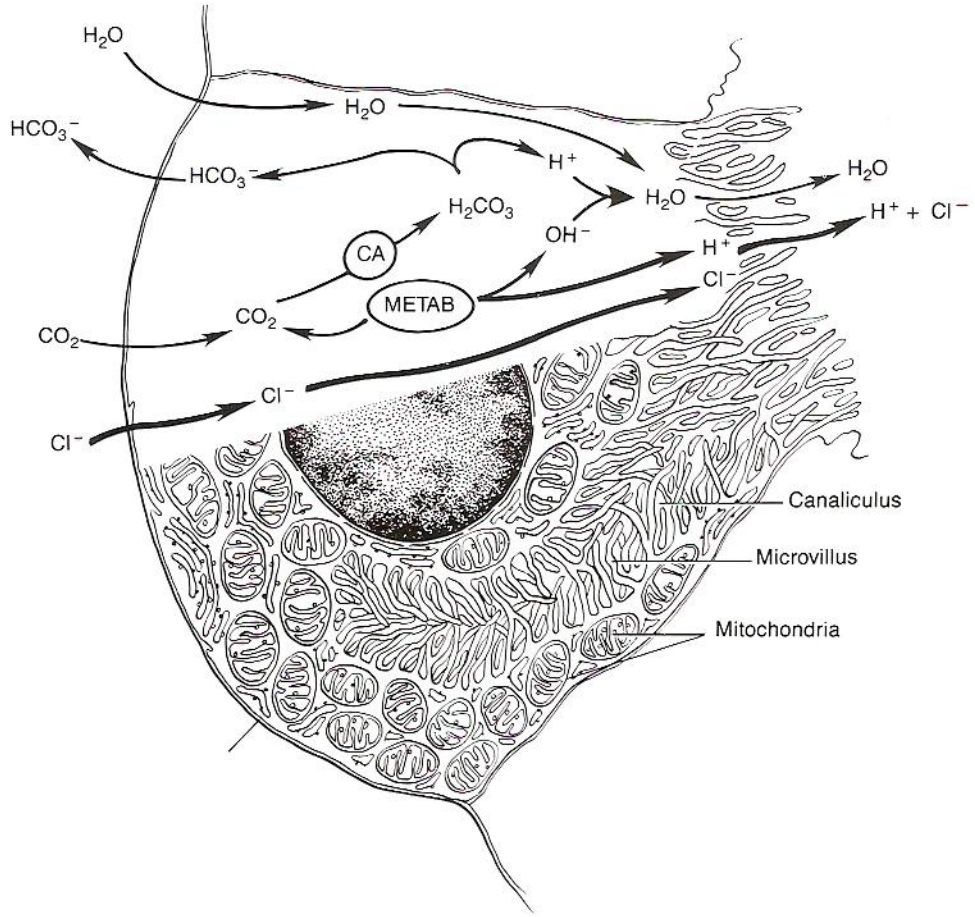

Figure 21-36. Parietal cell as seen with the electron microscope. The upper portion demonstrates the metabolic pathways involved in the synthesis and secretion of hydrochloric acid. Carbon dioxide *(CO_2)* diffuses into the cell and becomes one of the products of metabolism *(METAB)*. It is hydrated to carbonic acid *(H_2CO_3)* under the influence of carbonic anhydrase *(CA)*. Carbonic acid dissociates into hydrogen *(H^+)* and bicarbonate *(HCO_3^-)* ions. The bicarbonate diffuses into the interstitium. Chloride ion *(Cl^-)* diffuses into the cell, becomes coupled with H^+, and is transported into the lumen of the gland as HCl.

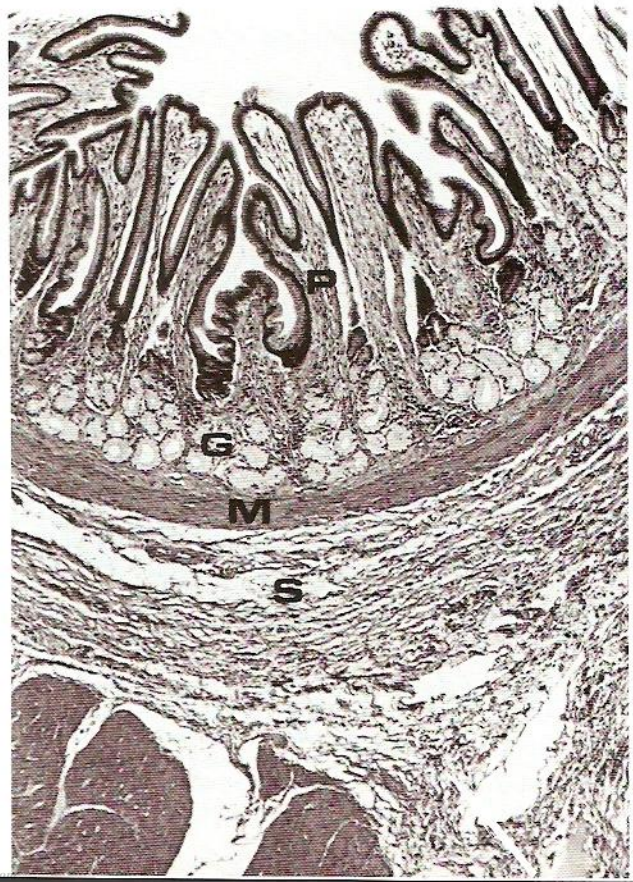

Figure 21-37. Pyloric region of the canine stomach. The surface and gastric pits are typical. Because the tunica mucosa is not as highly folded as in other regions of the stomach, the lamina propria mucosae *(P)* is more visible. Pyloric glands *(G)* are present. The lamina muscularis mucosae *(M)* and tela submucosa are typical *(S)*. (×16.)

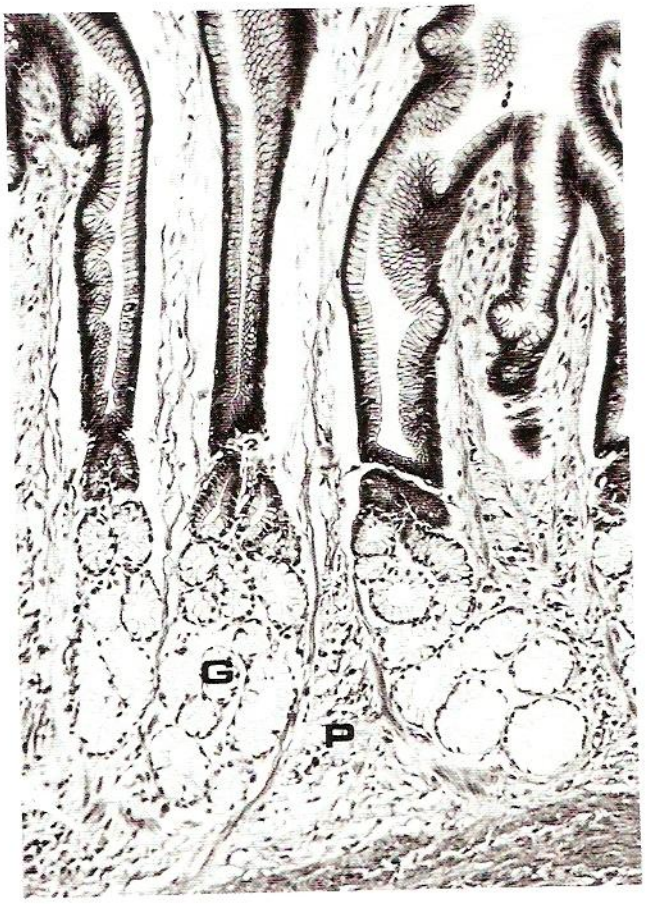

Figure 21-38. Pyloric glands of the canine stomach. The lining of the gastric pit is continuous with that lining of the pyloric glands *(G)*. The lamina propria mucosae *(P)* is extensive and typical. (×40.)

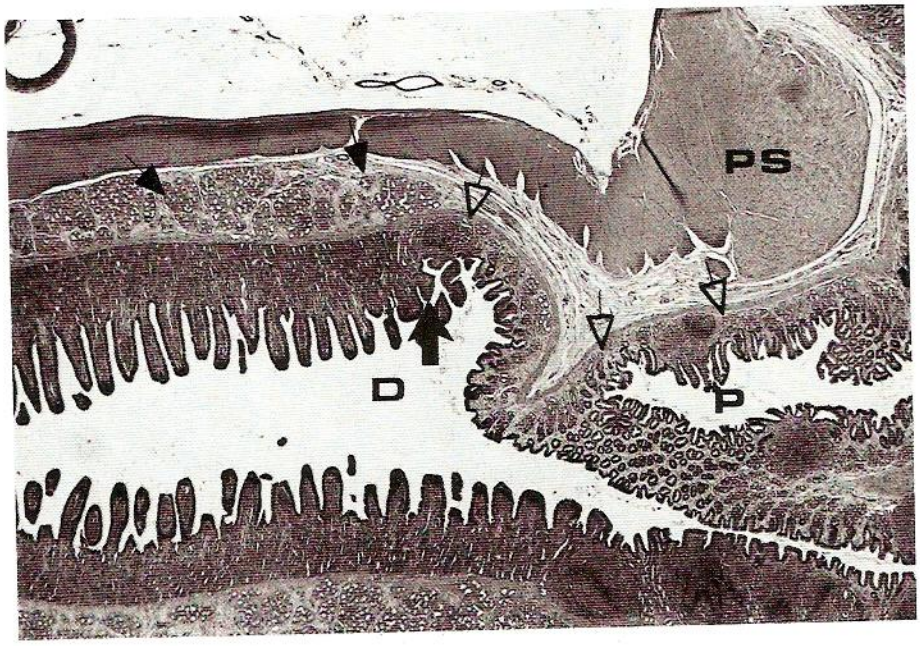

Figure 21-39. Gastroduodenal junction (canine digestive tract). The pyloric region of the stomach *(P)* is continuous with the duodenum *(D)*. The tunica muscularis is modified as the pyloric sphincter *(PS)*. The pyloric glands *(open arrows)* are similar to the submucosal glands of the duodenum *(small solid arrows)*. The latter may be an intestinal continuation of the former. *Large solid arrow,* Actual point of mural reorganization. (×4.)

Histophysiology

Gastric motility. The stomach musculature contracts continually. When emptied, mild peristaltic contractile waves begin and increase in intensity over a period of hours. Food entering the canine stomach causes an initial period of relaxation followed by **gastric slow waves** of contraction. These originate from the longitudinal musculature along the rostral portion of the greater curvature. Food moves toward the pylorus by these propulsive waves. Subsequently, peristaltic waves originating in the antrum propel liquid contents into the duodenum while preventing solid masses of foodstuffs from entering the small intestine. Gastric slow waves are the pacemakers for **antral peristalsis.** Chyme is gradually and continually squirted into the duodenum. The antrum, pylorus, and cranial duodenum probably function as a contractile unit. Regurgitation of chyme from the duodenum back into the stomach does not occur normally, because pyloric contraction persists longer than duodenal contraction.

Gastric emptying occurs when antral contractions overcome the resistance of the pyloric sphincter. The rate at which the stomach empties is influenced by the type of food in the diet. Duodenal distention with chyme, increased acidity, and the products of proteolysis activate a neural reflex that decreases gastric motility, the **enterogastric reflex. Gastric inhibitory peptide** and **vasoactive intestinal peptide** have an inhibitory effect upon gastric motility and secretion. These neural and humoral regulatory mediators permit the small intestine to achieve a more complete digestion of the substances present.

Secretory activity. **Gastric juice** is the combined secretory product of the gastric lining and gland cells. Normal gastric juice consists of Na^+, K^+, Mg^{++}, H^+, Cl^-, $HPO_4^=$, $SO_4^=$, pepsin, rennin (in young animals), lipase, mucus, and water. The function of mucus is to protect the mucosa from being irritated or digested. Gastric juice pH, approximately 1.0, would damage the mucosa were it not for the mucus coating.

Gastric secretion is controlled and influenced by several mechanisms and is divided conveniently into three phases.

The **cephalic phase** is the reflex activation of the stomach (motility and secretion) in response to the thought, sight, smell, or taste of food. Vagal stimulation mediates **gastrin** release from gastrointestinal endocrine cells within the pyloric antrum. Gastric juice secreted during the cephalic phase has a high concentration of H^+ and is rich in pepsin.

The **gastric phase** begins when food enters the stomach and continues until gastric emptying is accomplished. The vagus nerve and gastrin are the influenc-

Downloaded From Vet-eBooks.com

ing factors during this phase. Gastrin release in response to local mechanical and chemical factors is mediated through an intrinsic reflex. Intrinsic stimulation of the stomach seems to be the more important mechanism.

The main effect of gastrin upon the stomach is stimulation of the chief and parietal cells. Hydrochloric acid inhibits gastrin secretion.

The **intestinal phase** has a positive and negative effect upon gastric activity. Food in the small intestine stimulates the **enterogastric reflex** and causes decreased gastric motility. Various luminal substances stimulate the release of **secretin** and **cholecystokinin** from the duodenal mucosa. These hormones antagonize the gastrin effects upon the stomach. **Gastric inhibitory peptide** release inhibits gastric secretion.

The events of the intestinal phase are predominately inhibitory upon the stomach. They ensure a more complete digestion of the chyme and combine to retard the delivery of chyme to a full small intestine.

Gastric acid secretion. Hydrochloric acid secretion by the parietal cells requires energy, because the acid is moved against a concentration gradient. The concentration of H^+ in gastric juice is approximately 3 million times greater than that in plasma. The energy for this process is derived from oxidative metabolism within the parietal cell (Fig. 21-36).

For each H^+ secreted, a OH^- remains. In order for the pH to remain constant within the cell, the OH^- must be neutralized through the **carbonic anhydrase** system. Carbon dioxide, formed within the cell or diffusing into it from the connective tissue, is hydrated to carbonic acid by carbonic anhydrase. Carbonic acid (H_2CO_3) dissociation into H^+ and HCO_3^- provides the buffer for an excess of OH^-. The H^+ reacts with the OH^- to form water and the HCO_3^- diffuses into the connective tissue.

The movement of ions in and out of parietal cells occurs in a predictable manner. Chloride ions diffuse from the blood into the parietal cell. An available H^+ is coupled with a Cl^- and actively transported across the cell membrane into the gastric lumen. This active transport mechanism requires energy derived from oxidative phosphorylation and is linked to the uptake of a Na^+ from the gastric lumen. Sodium ions are pumped actively across the basal cell membrane in exchange for a K^+. The K^+ then diffuses passively out of the cell with the HCO_3^- formed by H_2CO_3 dissociation. Passive and active ion movement associated with HCl secretion maintains cellular electrical balance.

The HCO_3^- leaving the parietal cell enters the general circulation; blood leaving the gastric circulation may be alkaline. The elevated secretion of H^+ associated with a meal is sufficiently high to cause a bicarbonate production capable of raising systemic blood pH and alkalizing the urine. This accounts for the **postprandial alkaline tide.**

The secretion of HCl is influenced by the vagus nerve and gastrin. **Histamine** is also a potent stimulator of hydrochloric acid secretion. The high histamine content of the gastric mucosa has led to the belief that histamine may be requisite for gastric acid secretion. Two types of histamine receptors, **H_1 and H_2,** have been identified. Antihistaminic drugs used commonly for the prophylactic treatment of allergies block the H_1-receptor sites. The H_2-receptor sites, those occurring on parietal cells, are not blocked by H_1-blocking agents. Specific H_2-blocking agents (cimetidine) inhibit gastric acid secretion. Functionally integrated cholinergic, gastrin, and H_2-receptors may modulate parietal cell activity.

Excessive parietal cell secretion with an alteration in the protective mucus coat can erode the gastric mucosa, causing a **gastric (peptic) ulcer.** In humans the constant secretion of HCl by the parietal cells amplifies the problem. In dogs, which secrete HCl when stimulated by food, gastric ulcers with mast cell tumors also are a not uncommon occurrence.

Renewal, replacement, and repair Gastric lining cells are replaced every 3 days, gland cells every 5 to 7 days. Mitotic activity is limited to the lining cells in the depths of gastric pits. As lining cells exfoliate from the surface, they are replaced by cells migrating luminally from the mitotic zone. Undifferentiated cells in the isthmus migrate toward the base of the gland to replace constituent cells. The chief and parietal cells are replaced slowly.

The margins of the stomach are characterized by epithelial cells that appear to be undifferentiated mucus-secreting cells. They divide and migrate over the defect in a manner similar to epidermal healing. Once the lamina propria mucosae has been covered, the lamina epithelialis mucosae invaginates to form new gastric pits and glands. All the epithelium is mitotically active during this stage of healing. Eventually, typical surface lining cells are differentiated and mucous neck cells become identifiable within the glands. Chief cells and parietal cells appear to differentiate from mucous neck cells. The remaining mural elements repair themselves as described previously. The healing properties of the stomach are excellent.

COMPOUND STOMACH

The ruminant stomach consists of a **rumen, reticulum, omasum,** and **abomasum** (Fig. 21-28). The **forestomach,** comprising the first three chambers and derived from the esophageal region of the stomach, is lined by an aglandular stratified squamous epithelium. It breaks down ingesta through mechanical and chemical means. The rumen is a large fermentation vat in which microorganisms (bacteria and protozoa) break down ingested foods and produce **volatile fatty acids** (VFAs), which are absorbed across the lamina epithelialis mucosae into the blood vessels of the lamina propria mucosae. The mechanical action of the reticulum and omasum converts fermented ingesta into fine particulate matter. Absorption of metabolites occurs across the forestomach epithelium. The ingesta then moves into the abomasum, where enzymatic digestion occurs.

Structure

Rumen. The **rumen,** also called the **paunch,** has as its chief identifying features conical papillae that project into the lumen from the cutaneous mucous membrane (Figs. 21-40 and 21-41). The papillae may be 1.5 cm long and contain well-vascularized connective tissue with fine collagen and elastic fibers.

The lamina epithelialis mucosae is cornified stratified squamous epithelium of variable thickness (Fig. 21-42). Its epithelial layers are not well-defined. The cells of the stratum corneum are usually swollen or vesiculated and typically flattened on the papillary apex.

The lamina propria mucosae is typical and blends with the tela submucosa. A condensation of connective tissue fibers in the depths of the lamina propria-submucosa extends into the papillae. The region may be similar to the stratum compactum; it is sometimes mistaken for a lamina muscularis mucosae. The combined lamina propria-submucosa is devoid of lymph nodules and is aglandular.

The tunica muscularis is typical. The **pillars** of the rumen are extensive folds of the entire wall containing a core of muscle from the tunica muscularis. The tunica muscularis and tunica serosa are typical.

Reticulum. The **reticulum** is also called the **honeycomb.** Its morphology is similar to that of the rumen. In the ensuing discussion only distinguishing features are presented.

The mucous membrane has many anastomotic **primary folds** oriented, upon surface view, as a reticulum or honeycomb (Fig. 21-43). From these vertically projecting folds are numerous **secondary** and **tertiary papillae.** An isolated mass of smooth muscle of the lamina muscularis mucosae occurs at the tips of the primary or **reticular folds** (Fig. 21-44) and extends throughout the length of the folds, continuous with the lamina muscularis mucosae of the esophagus. The course of

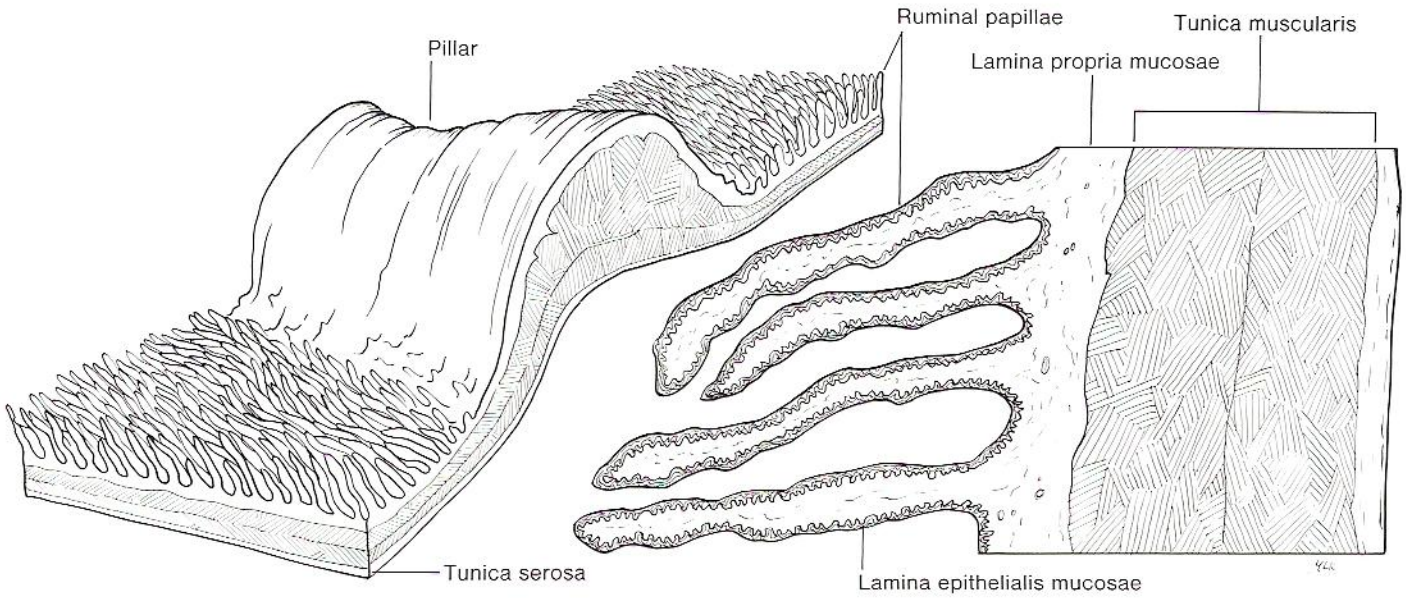

Figure 21-40. Cross section of the ruminal wall. A core of connective tissue is all that is contained within the papillae.



Figure 21-41. Scanning electron micrograph of the ventral sac of a caprine rumen. Leaf-like papillae project into the lumen of the organ. (Courtesy F. Al-Bagdadi.)

Downloaded From Vet-eBooks.com

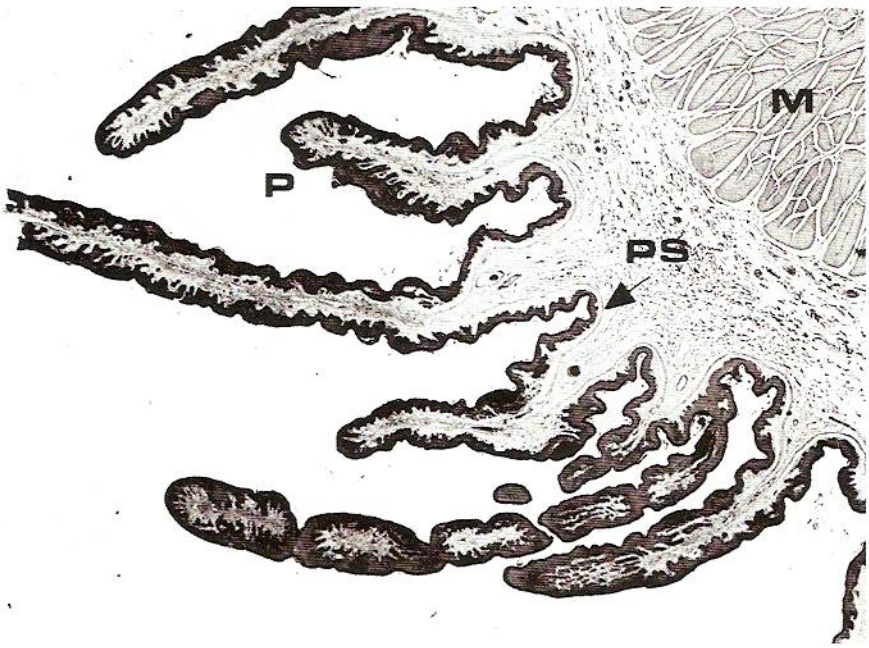

Figure 21-42. Section of a bovine rumen. Conical papillae *(P)* project from the luminal surface of the organ. A lamina muscularis mucosae is not present. The lamina propria-submucosa *(PS)* is typical and adjacent to the tunica muscularis *(M)*. A condensation of connective tissue fibers *(arrow)* should not be mistaken for the lamina muscularis mucosae. (×4.)

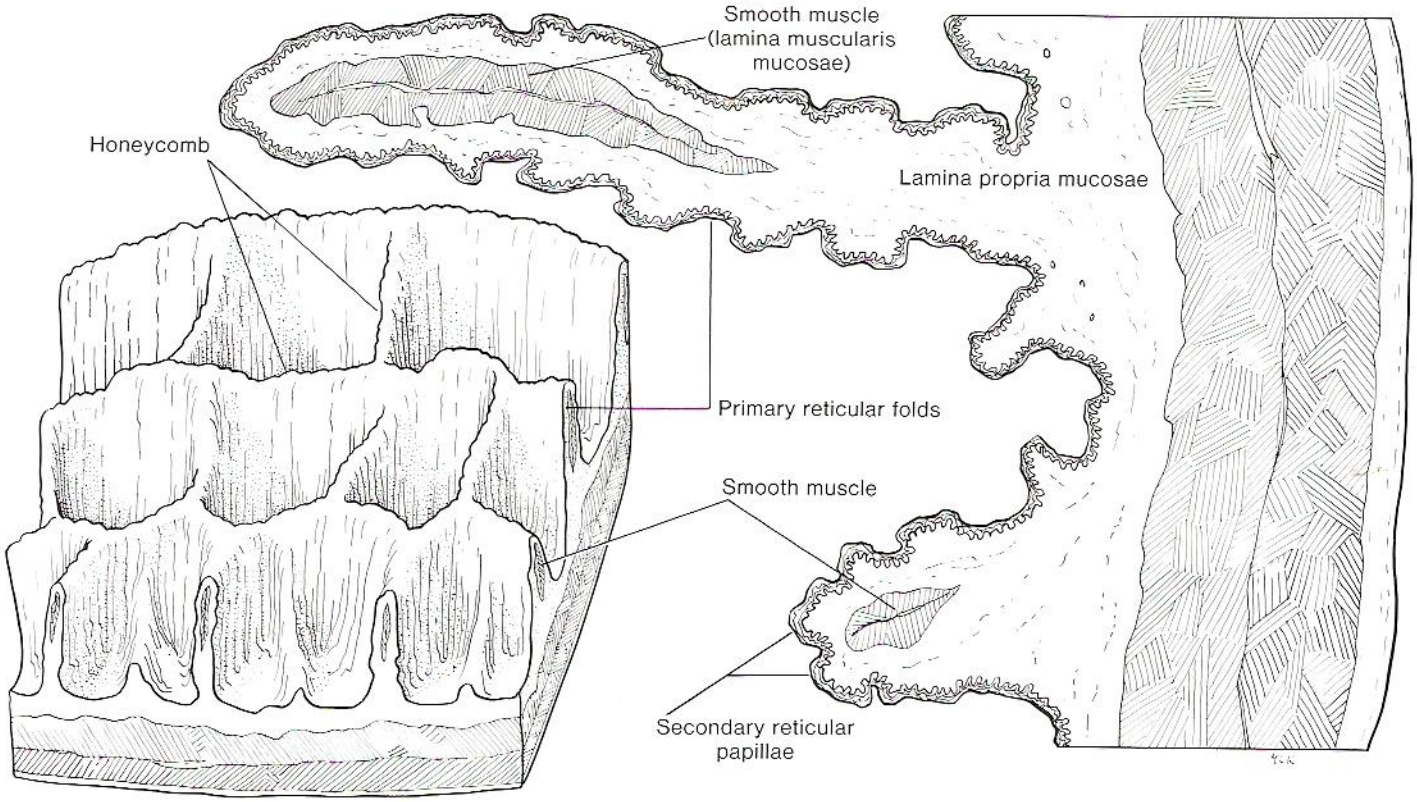

Figure 21-43. Wall of a reticulum. An isolated mass of smooth muscle is located in the tip of the reticular fold.

Downloaded From Vet-eBooks.com

Figure 21-44. Section of a bovine reticulum. Note the primary reticular folds, from which many secondary and tertiary papillae project laterally. The lamina muscularis mucosae *(M)* is present but is confined to the tips of the folds. (×4.)

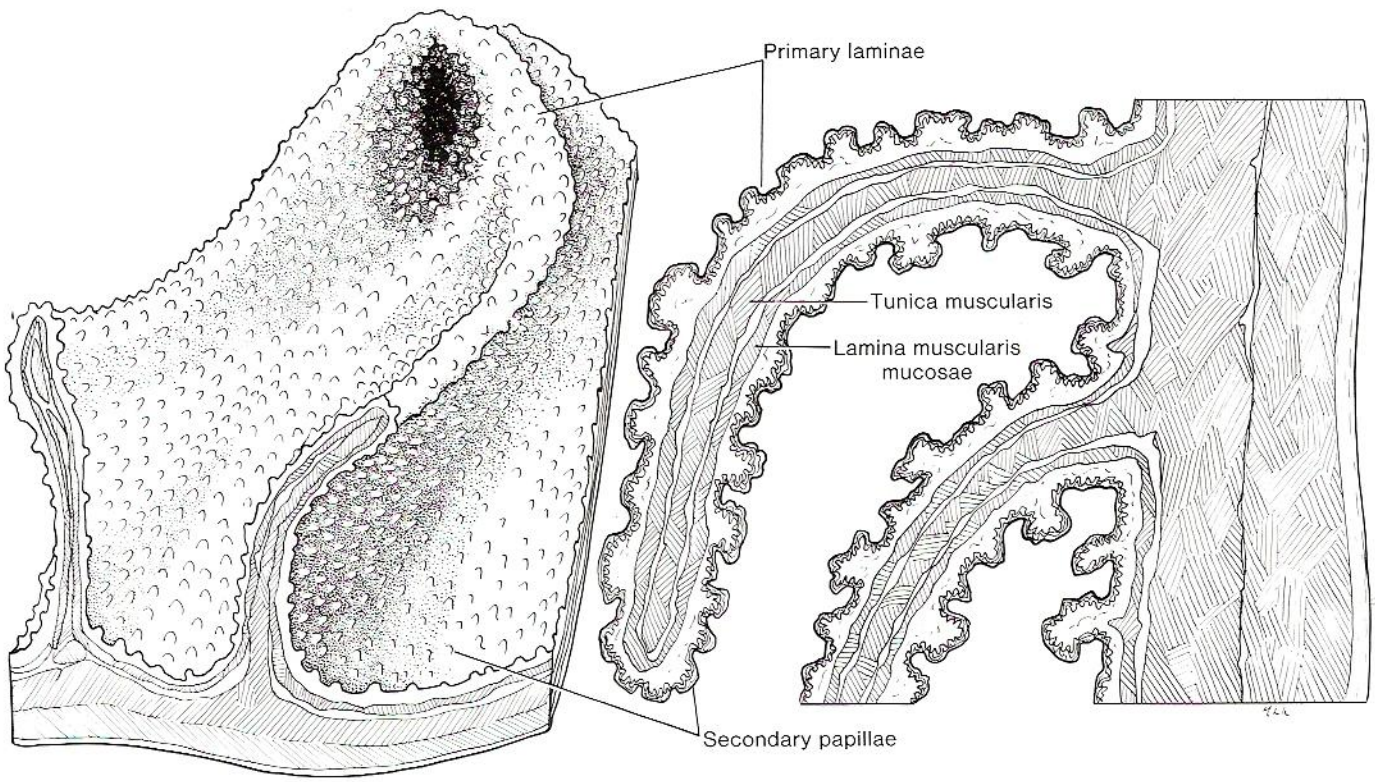

Figure 21-45. Wall of an omasum. The core of each lamina contains elements of the lamina muscularis mucosae and tunica muscularis.

Downloaded From Vet-eBooks.com

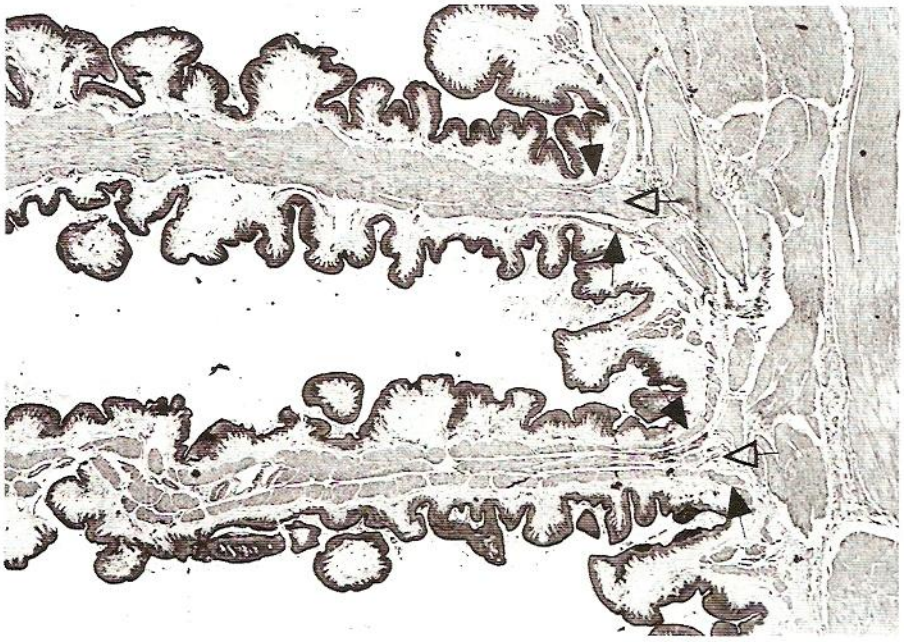

Figure 21-46. Section of a bovine omasum. Note the many laminae from which smaller papillae project. Three layers of smooth muscle occur in the laminae. The two peripheral layers are those of the lamina muscularis mucosae *(solid arrows)*. The central layer is continuous with the smooth muscle of the tunica muscularis *(open arrows)*. (×4.)

the smooth muscle is parallel to, but above, the plane of the surface lining. The lamina muscularis mucosae is confined to this region of the reticulum. The lamina propria-submucosa, tunica muscularis, and tunica serosa are typical. The functions of this chamber are similar to those of the rumen.

Omasum. The terms **many plies** and **book** can be used in connection with the **omasum** (Fig. 21-45). The cornified cutaneous mucous membrane has many, foliate **primary folds (laminae)** as well as smaller papillae. The laminae are covered with short cornified papillae (Fig. 21-46). The lamina muscularis mucosae is continuous and forms a double layer of smooth muscle following the contour of the laminae and the unraised surface lining. The inner layer of the tunica muscularis is interdigitated between the smooth muscle of the lamina muscularis mucosae within the primary folds. At the apices of the laminae the smooth muscle fibers fuse into a thickened muscular mass. The lamina propria mucosae, tunica submucosa, tunica muscularis, and tunica serosa are typical. A mucous connective tissue is present at the apices of the laminae.

Abomasum. The **abomasum** is the glandular portion of the ruminant stomach. The descriptions of the glandular stomach apply to this organ.

Histophysiology of Ruminant Digestion

Development. The rumen, reticulum, and omasum comprise approximately 89% of the total weight of the adult bovine stomach. Whereas the four chambers of the compound stomach are evident within the embryo at approximately 60 days of gestation, the relative proportions of these chambers are not the same as in the adult. The abomasum is the predominant chamber and may be as much as 56% of the organ weight at birth. The adult proportions are achieved gradually and fully attained at about 6 months of age. The speed with which the adult proportions and chamber capacities are attained depends upon the diet. An increase in dietary roughage accelerates development; maintenance on milk or similar diets retards development. The development and growth of ruminal papillae depend upon dietary roughage.

Contractions. Forestomach motility is essential to the accomplishment of mixing, regurgitation, and eructation. As a functional unit the forestomach may be considered two chambers, the rumen-reticulum and the omasum. Neuronal regulation of their movements is achieved through medullary control centers.

The **mixing contractions** of the rumen-reticulum are divided into A-wave and B-wave. The former propel ingesta caudad; the latter occur as forward-moving waves.

Regurgitation contractions, though involuntary, may be regulated by the activity of conscious centers. Reverse peristalsis propels ingesta to the buccal cavity, where it is remasticated and eventually reswallowed. Regurgitation permits more thorough processing of the ingesta.

Eructation contractions expel gas from the rumen. The gas passes into the lungs from the pharynx and it is expired during normal exhalation. As much as 50 liters of gas per hour can be produced in the bovine rumen during fermentation processes. Eructation is essential to preventing the accumulation of gas. Abnormally large accumulations **(bloat)** within the rumen can result in death.

Digestive activities. The relationship between ruminants and the population of microbes (bacteria, protozoa) in their fermentation vat (rumen, reticulum) depends upon a mutual cooperation **(synergism).** The ruminant supplies the ideal anaerobic environment (temperature, pH) and food supply; the microbes degrade plant materials (cellulose), produce VFAs and B vitamins, and synthesize microbial proteins. The ruminal microbes continually move into the aboral components, where they are digested. They thus are direct sources of nutrients; and the anaerobic fermentation that they cause produces carbon dioxide, water, methane, lactic acid, acetic acid, butyric acid, and propionic acid.

The **VFAs—acetic, butyric** and **propionic acids**—contribute approximately 70% of the ruminant's daily energy needs. Although most of their absorption occurs through ruminal papillae, some is accomplished through the reticulum and omasum. The amount and type of VFAs absorbed vary with the diet; the fate of individual VFAs also differs.

Acetic acid, which accounts for about 60% of absorbed VFAs, is the primary source of acetyl–coenzyme A for lipid synthesis. Additionally, acetic acid is metabolized by adipose tissue, muscular tissue, and the mammary gland. **Propionic acid,** which constitutes about 25% of the absorbed VFAs, is the most important source for hepatic glucose production **(gluconeogenesis).** Because minimal quantities of glucose are available to the ruminant from digestion, propionic acid is essential. **Butyric acid,** which constitutes some 15% of the absorbed VFAs, is converted to **β-hydroxybutyric acid** (a **ketone body**) in the lamina epithelialis mucosae of the rumen. β-Hydroxybutyric acid is metabolized in the liver. Ketone bodies **(acetoacetic** and **β-hydroxybutyric acids)** are also oxidized in skeletal muscle. Acetone results from the decarboxylation of acetoacetic acid, and isopropanol from the decarboxylation of β-hydroxybutyric acid.

Although ruminants have essential amino acid requirements, these need not be supplied in the diet. The microbial flora metabolize plant proteins to amino acids and synthesize microbial proteins. The microbes are capable of converting **nonprotein nitrogen** sources to amino acids of microbial proteins. The micro-

bial proteins become available as essential amino acids following their digestion. **Urea,** a common nonprotein nitrogen source, gains access to the rumen through salivary secretions, absorption across the ruminal mucosa from the blood, and dietary supplementation.

The microbes also produce all the B vitamins required by the organism. As long as cobalt is supplied in the diet, it is difficult to induce a vitamin B complex dietary deficiency.

Despite the stratified squamous epithelium lining the forestomach, extensive absorption of nutrients probably occurs in all chambers. VFAs, lactic acid, ammonia, inorganic ions, and water are absorbed through the ruminal lamina epithelialis mucosae. The absorption of materials from the omasum also probably occurs. Materials moving through the omasal interlaminar spaces slowly may be subjected to greater absorption than those moving through the chamber rapidly. VFAs are also likely absorbed by the abomasum.

SMALL INTESTINE

Structure

The small intestine has modifications to increase its absorptive and secretory surfaces—**length, plicae, villi, microvilli.** Although distinctive features characterize various regions of the intestine, the regions share many of these features.

An abrupt change in the mucous membrane occurs at the gastroduodenal junction. Gastric folds are replaced by finger-like projections **(villi)** of the mucous membrane (Fig. 5-22). Permanent **circular folds** are present with villi projecting from them. These folds also contain portions of the tela submucosa. Openings to **intestinal crypts** occur at the base of each villus.

Mucosa. Two cellular layers constitute the intestinal mucosa.

The **lamina epithelialis mucosae** consists of lining cells, goblet cells, and gastrointestinal endocrine cells, and M cells.

1. The lining cells are typical columnar epithelial cells whose apical borders have many microvilli arranged in orderly fashion **(striated border).** The finely granular, acidophilic cytoplasm has a basally displaced, elongated nucleus. These cells actively absorb materials.
2. The goblet cells, which are typical (Plate I, *12*), tend to increase in frequency toward the rectum. Their secretory product protects the lining. In the lower intestine the mucoid layer facilitates movement of the luminal contents toward the anus.
3. The gastrointestinal endocrine cells are typical of all hormonal cells. (See p. 339.)
4. The M cells, modified epithelial cells whose apical surface has microfolds, occur in the lamina epithelialis mucosae covering lymphoid follicles of gut-associated lymphatic tissue (GALT). They endocytose and transport macromolecules in vesicles across their attenuated cytoplasm to their abluminal surface, where the macromolecules are presented to intraepithelial lymphocytes that have infiltrated from the lymphocyte-laden lamina propria mucosae (Fig. 21-47). M cells may provide a mechanism for the immune system to sample luminal antigens.

Intestinal crypts open at the base of each villus as simple, branched, tubular invaginations. The epithelium consists of **columnar lining, goblet, gastrointestinal endocrine,** and **acidophilic granule (Paneth) cells.**

The **acidophilic granule cells** are pyramid-shaped, with supranuclear acidophilic granules and basally displaced nuclei (Fig. 21-48). Their basal portion is basophilic. These cells are present in humans and in ruminants and equids but are absent in other domestic species. Although they cells have many features of protein- or enzyme-secreting cells (suggesting a digestive function), no evidence supports their involvement in digestive processes; rather, the bactericidal enzymes (lysozyme) that are present imply a phagocytic function.

The **lamina propria mucosae** is usually described as loose collagenous tissue with many reticular fibers, granulocytes, and agranulocytes. Intestinal crypts and lymph nodules are also present. The crypts may occupy the bulk of this layer. The frequency of lymph nodules increases caudally, and they may occupy the lamina propria mucosae and tela submucosa as dense nodular aggregations—called GALT. Besides the aforementioned, many lymph vessels **(lacteals)** are present and extend into the villar core. A stratum compactum is present in carnivores, and the lamina muscularis mucosae is typical. Strands of smooth muscle and connective tissue fibers are interdigitated between the crypts into the villar cores.

Submucosa. The tela submucosa is typical. Submucosal glands are simple, branched, tubuloacinar glands opening into crypts (Fig. 21-49). They may be mucous (ruminants, dogs), mixed (cats), or serous (horses, pigs). They are called **intestinal submucosal glands.** In humans,

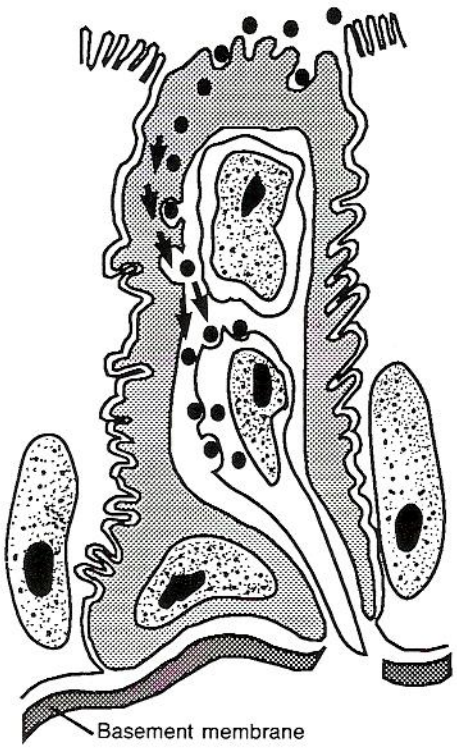

Figure 21-47. M-cell in a follicle of the epithelial lining. These cells *(shaded),* with ridges on their apical surfaces (called macrofolds), are situated among epithelial lining cells whose surfaces have microvilli. Lymphocytes migrate from the associated lymphatic follicles (GALT), traverse the basement membrane, invaginate the basal borders of the M-cells, and become intraepithelial components that move to and from the lining epithelium. They probably leave the epithelium and migrate to the GALT follicles and beyond, wherein specific immune responses are mounted. The M-cells endocytose antigens adhering to their apical surfaces and transport them to the intraepithelial lymphocytes.

Downloaded From Vet-eBooks.com

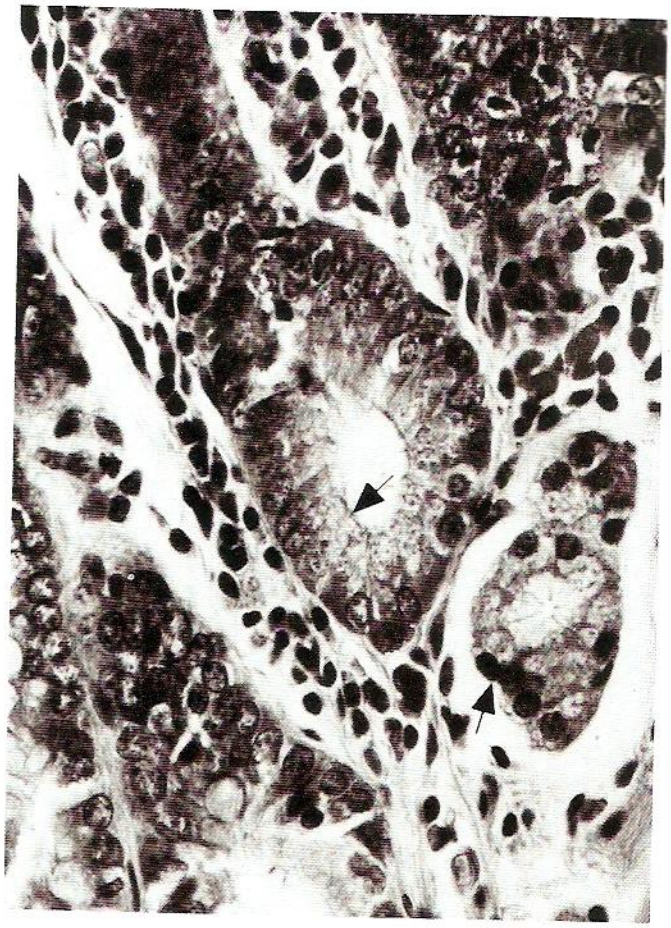

Figure 21-48. Acidophilic granule (Paneth) cells of the intestinal crypts in an equine duodenum. They are pyramid-shaped cells *(arrows)* with apical granules. (×160.)

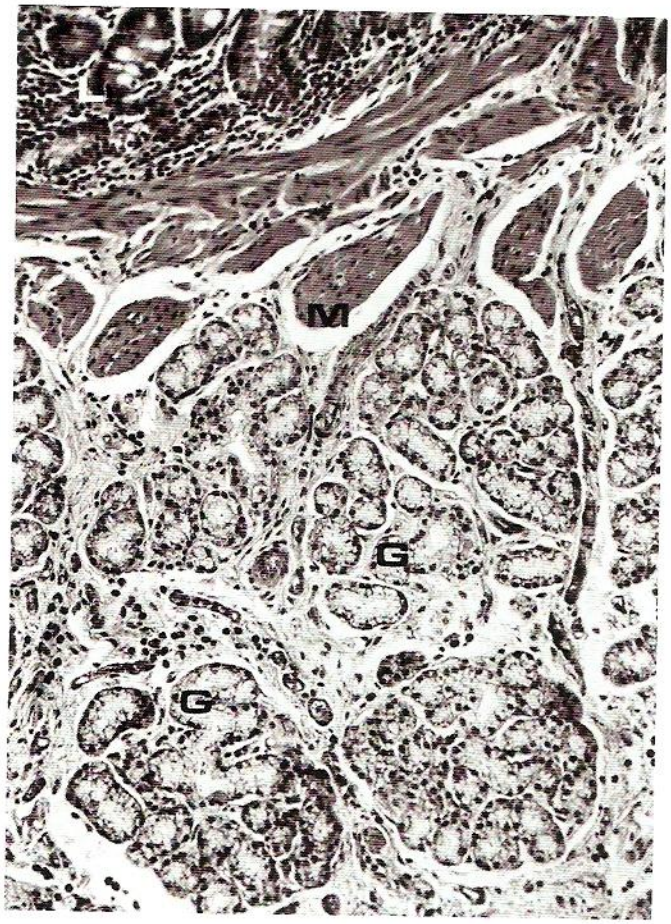

Figure 21-49. Submucosal glands of an equine duodenum. These glands *(G)*, are located peripheral to the tunica mucosa, are continuous with the intestinal crypts.

carnivores, and small ruminants they are confined to the initial or middle portion of the duodenum. In horses, pigs, and large ruminants they extend into the jejunum. These glands may be the aboral continuations of pyloric glands displaced to the submucosa.

Muscularis. The tunica muscularis with myenteric plexus is typical. This smooth muscle contraction produces peristalsis.

Serosa. The tunica serosa is typical.

Regions of the Small Intestine

Duodenum. The duodenal tunica mucosa has many villi and circular folds (Fig. 21-50). Intestinal crypts are prominent. Intestinal submucosal glands may be present. Lymphatic nodules also may be present but are sparse. Although subject to some variations, the villi tend to be regularly shaped, blunt, and wide.

Jejunum. The **jejunum** is similar to the duodenum (Fig. 21-51). Intestinal submucosal glands are confined to the initial region in some species. The villi are thinner, smaller, and fewer than in the duodenum (Fig. 21-52). Mucosal and submucosal lymph nodules are present, especially in pigs. The remaining mural elements are typical (Plate III, *3* and *4*).

Ileum. The **ileum** is similar to the jejunum (Fig. 21-53). Goblet cells are a prominent feature. Aggregated lymph

Downloaded From Vet-eBooks.com

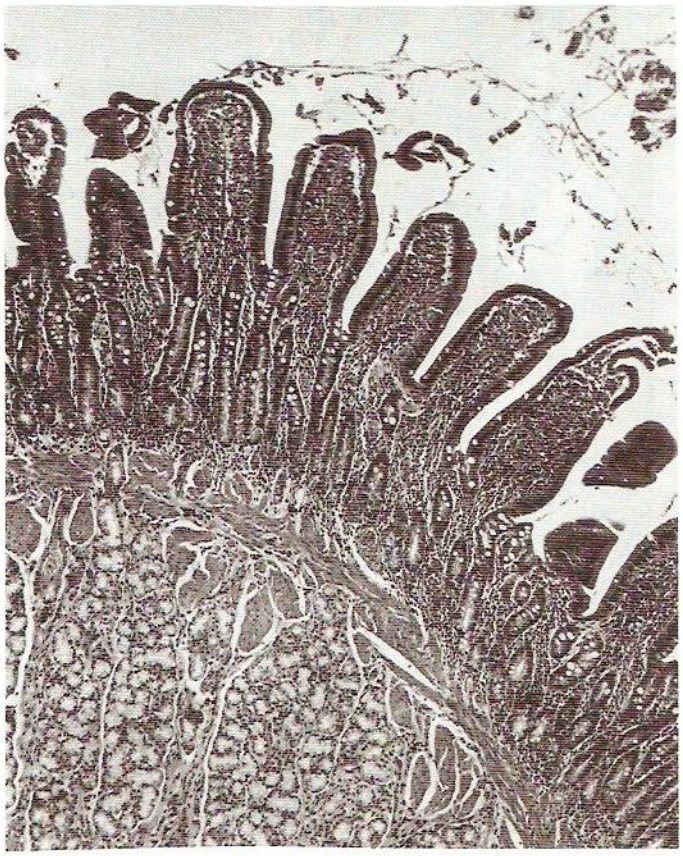

Figure 21-50. Equine duodenum. The villi are blunt and wide. Submucosal glands are present. (×16.)

Figure 21-51. Jejunum of a bushbaby. The villi are long and slender. (×16.)

Figure 21-52. Scanning electron micrograph of villi from the jejunum of a young mouse. Compare with Figure 15-7. (Courtesy D. L. Eisenbrandt.)

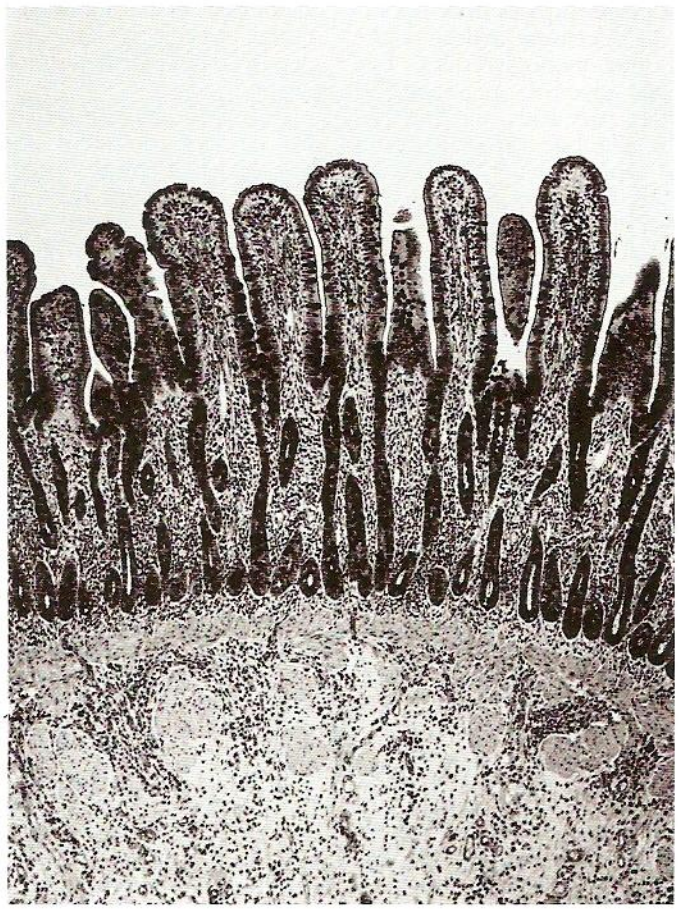

Figure 21-53. Section of an equine ileum. The villi are club-shaped. (×16, Alcian blue–periodic acid Schiff).

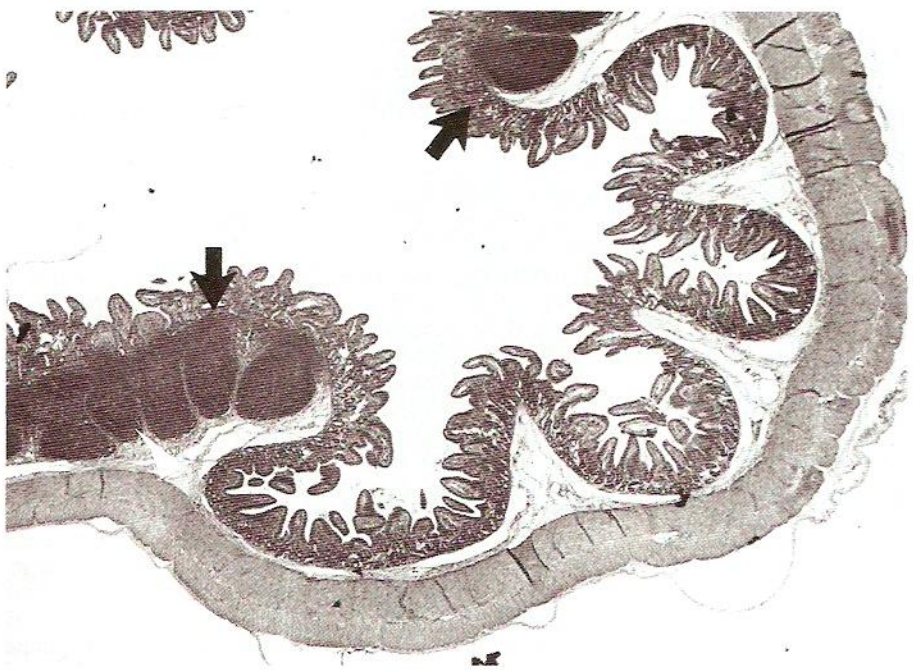

Figure 21-54. Section of a porcine ileum. Peyer's patches *(arrows)* in the antemesenteric portion may be sufficiently large to obliterate the villi. (×4.)

nodules occur frequently in the mucosa-submucosa (Fig. 21-54) and may become sufficiently prominent to fill or obliterate villi. In such instances the mucous membrane is flattened and interrupted by **lymph craters** (especially prominent in swine).

The villi in the ileum are club-shaped. Folds are not present (being more prominent in the jejunum though diminishing in size orad and aborad).

Histophysiology of the Small Intestine

Motility. Intestinal motility mixes, moves, and propels the chyme through the intestine. Ringlike **segmenting contractions** occur in the lamina interna of the tunica muscularis. Denervation does not affect them. Segmenting contractions are not propulsive; they mix the contents and facilitate digestion and absorption. **Peristalsis** propels the luminal contents aborally. Peristalsis involves segmental shortening of the longitudinal layer followed by ringlike contractions of the circular layer. Although peristaltic contractions occur independently of extrinsic innervation, the intrinsic nerve supply (submucosal and myenteric plexuses) must be intact.

Smooth muscle contractions respond to increased intestinal wall stretch **(myenteric reflex).** Normally peristalsis occurs slowly enough to permit absorption of materials. Rapidly propagated muscular contractions **(peristaltic rushes)** may traverse the entire intestine. The resulting decreased transport time may cause diarrhea, malabsorption, or maldigestion.

The extrinsic nerve supply influences the strength and frequency of intrinsic intestinal activity. Vagal stimulation augments intestinal smooth muscle activity; sympathetic stimulation decreases or inhibits it. Sensory stimulation of various regions can inhibit the intestine. Intestinal motility may cease when any part of the intestine is distended **(intestinointestinal inhibitory reflex).** Trauma, peritonitis, obstruction, and surgery can also inhibit the intestine.

Stimulation of the intestine occurs when food enters the stomach or chyme enters the intestine **(gastrointestinal excitatory reflex).** Gastrin and cholecystokinin stimulate intestinal motility, whereas secretin inhibits it.

Digestion and absorption. Goblet cells, lining cells of the intestinal submucosal glands, and lining cells of intestinal crypts in the oral region of the small intestine secrete large quantities of intestinal juice—which contains water, electrolytes, mucins, secretory immunoglobulin A, and enzymes. Many of the enzymes, intracellular in origin, become components of intestinal juice after the disinte-

Downloaded From Vet-eBooks.com

gration of cells that have been shed into the lumen. Localized mechanical and chemical stimulants are effective means of increasing intestinal secretion. Neuronal and humoral stimulation also occurs. Secretin and cholecystokinin stimulate intestinal submucosal glands. A substance contained within an extract of canine small intestine, **enterocrinin,** may stimulate the secretion of intestinal juice.

The complete digestion of foodstuffs and their subsequent absorption into the body are essential functions of the small intestine. Many enzymes, including those from disintegrated cells of the lamina epithelialis mucosae and those from the pancreas, become components of the luminal contents and contribute to digestive processes. Some enzymes (**sucrase, lactase, maltase,** and **aminopeptidase**) are not secreted into the intestinal lumen; they remain integral components of the plasma membrane that constitutes the striated border of intestinal lining cells and are necessary for the complete digestion of nutrients before absorption.

Monosaccharides result from the enzymatic degradation of polysaccharides. Monosaccharide absorption is by **facilitated diffusion.** Proteins and peptides are digested by gastric enzymes, pancreatic enzymes, and hydrochloric acid. **Aminopeptidases** split amino acids from peptides attached to the striated border. Amino acids and sodium are absorbed by the cell in a manner similar to that described for monosaccharides.

Proteins ordinarily must be digested before absorption of them is possible. One unique exception, however, exists. Some animals, ruminants and horses, confer **passive immunity** upon their young exclusively through the immunoglobulins present in **colostrum.** Carnivores utilize **placental** and **colostral transfer** to confer passive immunity upon their young. The transfer of maternal immunity through the colostrum is dependent upon the intact absorption of **immunoglobulins** by intestinal absorptive cells. Although the mechanism of absorption is not well-understood, immunoglobulins are probably subject to endocytosis and may be protected from cellular digestive processes by binding to a receptor molecule within the cell. The immunoglobulins are transported through the cells and released into the general circulation. The ability to absorb immunoglobulins diminishes rapidly in the neonatal animal.

Lipids include **triglycerides, fat-soluble vitamins (A, D, E, K), cholesterol,** and **phospholipids.**

The initial digestion of **neutral fats (triglycerides)** is by the **emulsification** of large fat droplets with bile salts. Progressive emulsification produces small fat droplets subject to the enzymatic activity of pancreatic lipase. Lipases from intestinal lining cells selectively hydrolyze the triglycerides into monoglycerides, free fatty acids, and glycerol. Aggregates of monoglycerides, fatty acids, and bile salts form **micelles.** The bile salts function to transport the constituents of the micelles to cell surfaces. Transcytosis begins with the absorption of these constituents. Bile salts are released to transport more molecules. Monoglycerides and fatty acids diffuse through the plasma membrane, enter the SER, and reconstitute into triglycerides. Small vesicles containing triglycerides pinch off from the SER and migrate directly or through the Golgi complex to the lateral cell margins at the level of the nucleus. The vesicles fuse with the lateral plasma membrane, and the droplets enter the intercellular space. Triglyceride droplets (**chylomicrons**) migrate to the center of the villi. There they enter the lacteals and are carried to the vascular system via the abdominal and thoracic lymph channels. Fatty acids with more than 16 carbons are transported to the blood via the lymph channels; those with less than 16 carbon atoms enter the portal circulation directly.

The entire small intestine is responsible for the absorption of other nutrients—water, bile salts, Na^+, H^+, HCO_3^-, Ca^{++}, Cl^-, $PO_4^=$, $SO_4^=$, and Fe. The duodenum does not absorb bile salts, vitamin B_{12}, or H^+; nor does the ileum absorb sulfates.

Renewal, replacement, and repair. The lining cells of crypts are less differentiated than the lining cells of villi. The striated border is better developed and the microvilli are longer toward the apex of villi than at the base of crypts. Many mitotic figures are present deep within crypts. The lining cells of villi arise from cells deep in the crypts. Stem cells within the crypts divide, differentiate, and migrate toward the tips of the villi; they are then shed into the intestinal lumen. Lining (absorptive) cells of the villi, goblet cells, and acidophilic granule cells differentiate from primitive stem cells. Only the Paneth cells do not migrate onto the villi. Most of the intestinal epithelial cells are replaced about every 3 days. Small intestine repair is similar to stomach repair.

LARGE INTESTINE

Structure

The large intestine is the caudal extension of the alimentary canal. It begins at the ileocecal junction and terminates at the anus. The classical anatomical divisions include the cecum, colon, rectum, and anus. Significant gross modifications characterize the cecum and colon among domestic species. Despite the many gross anatomical modifications of the large intestine, specific regions are difficult to identify based upon histological characteristics.

The organization of the large intestinal wall conforms to the pattern described for the small intestine. Specific features of the large intestine are as follows: villi are absent; intestinal crypts, which are elongated and straight, open to the surface at the luminal margin; goblet cells are conspicuous; acidophilic granule cells are absent; the circular folds of the small intestine are replaced by longitudinally oriented folds; diffuse lymphatic tissue and lymph nodules are conspicuous.

Regions of the Large Intestine

Cecum. The **cecum** is an intestinal modification in herbivores with a simple stomach (horse, rabbit, guinea pig). The features described for the large intestine generally apply to it (Fig. 21-55). Lymph nodules may be prominent at the opening of the cecum (ruminants, swine, dogs) or may be distributed more toward the distal part of the organ (horses, cats). The outer layers of the tunica muscularis of pigs and horses have thickened, flat, longitudinally oriented bands of smooth muscle and elastic fibers (**taeniae ceci**).

Colon. The diameter of the colon is greater than that of the small intestine. The mucous membrane of the colon is smooth and conforms to the general description of the large intestine (Fig. 21-56). The other tunics adhere to the general pattern, except for modifications of the tunica muscularis. The outer layer of the tunica muscularis is thickened into flat, longitudinally oriented bands of smooth muscle and elastic fibers, **taeniae coli** (pigs, horses, humans). A thin layer of longitudinally oriented smooth muscle occurs between the thickenings.

Rectum. This region is similar to other portions of the large intestine. Taeniae coli are absent, but the tunica muscularis is thicker in this region than the colon. The lining and glandular epithelia contain many goblet cells. Also a tunica adventitia replaces the tunica serosa. The tunica mucosa has longitudinally oriented folds in which there is a core of erectile tissue within the lamina propria mucosae. The remaining mural elements are typical.

Anus. This region of the gut, a mucocutaneous junction, is marked by a transition from columnar epithelium to stratified squamous epithelium (the **rectoanal junction**) (Fig. 21-57). The lamina epithelialis mucosae is similar to the lining of the buccal cavity. At the level of the rectoanal junction the lamina muscularis mucosae and the outer layer of the tunica muscularis end. The inner layer of the tunica muscularis continues and terminates

Downloaded From Vet-eBooks.com

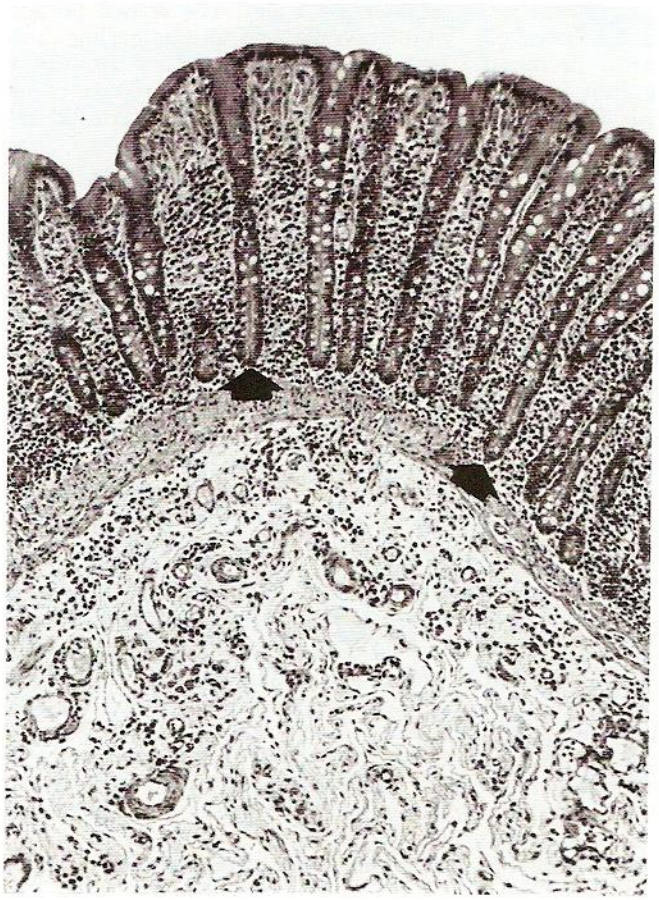

Figure 21-55. Equine cecum. Villi are absent, and intestinal crypts *(arrows)* open at the surface. (×16.)

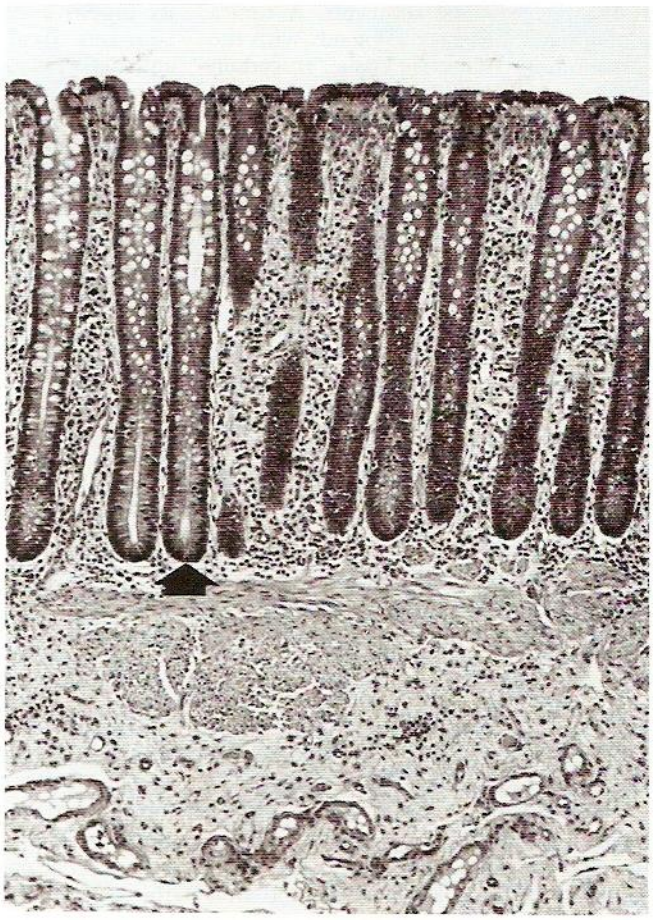

Figure 21-56. Equine colon. Villi are absent, and intestinal crypts *(arrow)* open at the surface. (×16.)

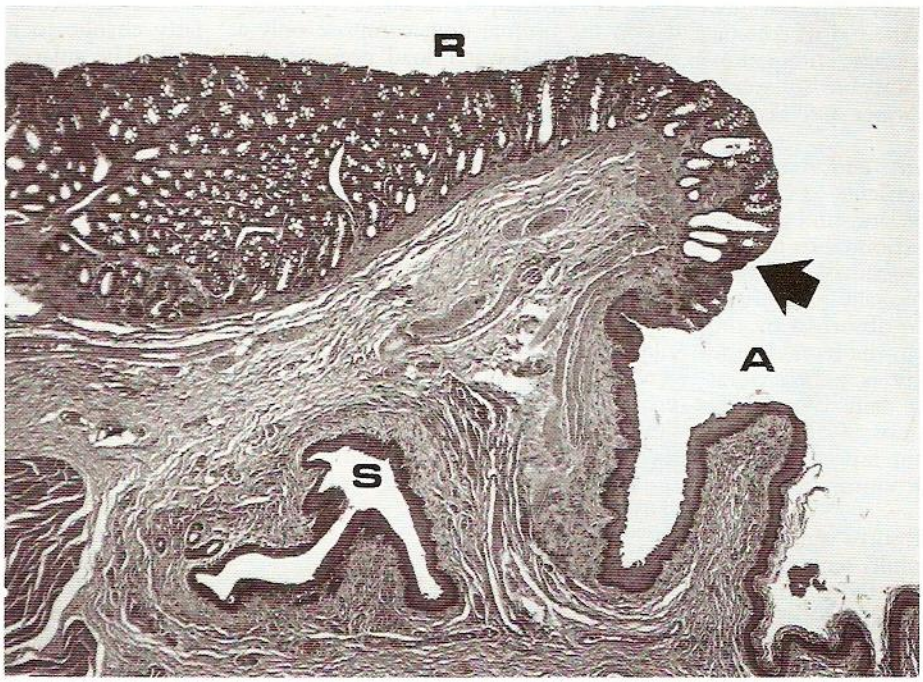

Figure 21-57. Rectoanal junction (feline digestive tract). The columnar epithelium of the rectum *(R)* changes to stratified squamous epithelium of the anus *(A)* at the rectoanal junction *(arrow)*. An anal sac *(S)* is apparent in this section. (×10.)

as the internal anal sphincter. A tunica adventitia is present and blends with the surrounding connective tissue. In certain species, anal glands, anal sacs, and circumanal glands are associated with the anus (Chapter 20).

Histophysiology of the Large Intestine

Motility and secretion. Colonic motility functions in a manner similar to the small intestine. Muscular contractions facilitate the mixing of ingesta and its propulsion to the anus. **Slow wave contractions,** which originate in the intermediate region of the colon, spread toward the cecum or distal colon and account for antiperistaltic and peristaltic movements of ingesta. **Segmenting contractions** ensure the mixing of ingesta. **Mass contractile movements,** originating from the distal segment of the colon, can evacuate the colon or propel the feces toward the anal opening over a long distance.

Colonic movements in the proximal segment of the organ can occur independently of extrinsic nerve supply. Distention of the colon is sufficient to initiate its intrinsic contraction. Food entry into the stomach or duodenum causes a reflex contraction of the colon **(gastrocolic reflex** and **duodenocolic reflex).** The distal segments of the colon, rectum, and anus are more dependent than the proximal segment upon extrinsic innervation.

Mucus lubricates and facilitates the passage of feces and protects the mucosa from mechanical and chemical injury. Acids produced by colonic bacteria, potentially irritating to the mucosa, are neutralized by the alkaline pH of colonic secretions. Upon appropriate stimulation the large intestine is capable of secreting high volumes of water and electrolytes.

Synthesis, absorption, and fermentation. Synthesis of nutrients occurs to varying degrees in the large intestine of most animals and is attributed to the colonic microflora. The synthesis of vitamins B and K is especially significant. These vitamins may be absorbed by the mucosa or eliminated in the feces. In the latter case, **coprophagy** is a behavioral pattern supplementing daily vitamin requirements. The synthesis of many compounds is an important aspect of large-intestinal digestion in nonruminant herbivores.

The large intestine absorbs water, Na^+, Cl^-, and vitamins, while secreting K^+ and HCO_3^-. In humans, the small intestine absorbs 20 times more water daily than the large intestine does.

The large intestine is a fermentation organ in nonruminant herbivores (horses, rabbits, rodents). Cellulose digestion and the subsequent absorption of its digestive products occur in the cecum and colon of the horse and related animals. Volatile fatty acids, produced from the anaerobic metabolism of cellulose by cecal and colonic microflora, are absorbed by the large intestine. Microbial protein production and subsequent utilization by the host organism are similar to those functions described previously.

Renewal, replacement, and repair. These activities in the large intestine are similar to such activities in the small intestine.

Renewal and **replacement** of the lining cells occur independently of dietary intake; and, in fact, dietary intake is not required for the elimination of formed feces. The passage of formed feces occurs during starvation, exfoliated cells from the intestinal tract contributing to the fecal volume

Repair of large intestine lining cells is accomplished in a manner similar to that for small intestine lining cells, Many factors diminish the healing potential. The large intestine is filled with foreign material (feces) and has a high bacterial count. The blood supply, although adequate for normal functioning, is not sufficient to ensure maximal healing. Leakage from the large intestine is a common sequel to repair. That part of the large intestine in the pelvic cavity is devoid of a serosal covering.

Intestinal fluids. The absorptive load to which the gastrointestinal tract is exposed daily far exceeds that from digestive processes alone. Water and electrolytes comprise a major component of this load. Oral fluids, some 20 to 30 ml/lb/day in the normal dog, comprise only a fraction of the water load presented to the intestines and include major contributions from the salivary glands, gastric mucosa, liver, pancreas, and intestinal mucosa. The normal balance requires that absorption exceed secretion. The less differentiated cells of the intestinal crypts, as well as goblet cells of the villi, provide most of the intestinal secretory activity. Absorption is accomplished by the differentiated and older cells lining villi. Although large intestinal absorptive activity is critical for homeostasis, approximately 80% of the absorption of the fluid load is achieved in the small intestine, especially the midjejunum. Disruptions in absorptive/secretory balance can cause diarrhea.

AVIAN DIGESTIVE SYSTEM

Buccal cavity. The buccal cavity and associated structures are generally different from those observed in mammals. A cornified beak is appended to the upper and lower jaw bones. The tongue is narrow and pointed and contains a bone **(entoglossal bone).** The cranial portion of the bone is continued by hyaline cartilage. The stratified squamous epithelium of the tongue, which is variously cornified, continues with the mucous membrane of the buccal cavity.

Teeth are not present although rudimentary tooth buds occur in some birds.

Definitive salivary glands are not present. Instead, the mucosa-submucosa of the buccal cavity has many simple, branched, tubular mucous glands (Fig. 21-58). These glands are lined with large mucous cells.

Crop and esophagus. The lamina epithelialis mucosae of these two structures is a highly cornified stratified squamous epithelium (Fig. 21-59). The lamina propria mucosae consists of loose collagenous tissue with diffuse lymphatic tissue and some lymph nodules.

The accumulation of lymphatic tissue is especially prominent caudal to the crop. The mucous membrane is arranged in longitudinal folds. The lamina muscularis mucosae consists of an undulating mass of longitudinally oriented smooth-muscle fibers. Simple, branched, tubuloalveolar mucous glands are present in the esophagus. The tela submucosa, tunica muscularis, tunica adventitia, and tunica serosa are typical.

The **ingluvies** or **crop** is an esophageal diverticulum. Its lamina epithelialis mucosae is thicker than that of the esophagus. Simple and branched, tubuloalveolar mucous glands are present in anseriform birds (swans, geese) but absent in galliforms (turkeys) and columbiforms (doves). In columbiforms the superficial cells of the lamina epithelialis mucosae undergo a fatty change to a substance called **crop milk.** The enlargement of the esophagus moistens foods through its mucoid secretion and macerates the food through the muscular contractions of its tunica muscularis. The remaining tunics of the wall are similar to those of the esophagus.

Proventriculus. This structure is the glandular stomach of avian species (Fig. 21-60). Its mural organization conforms generally to the pattern typifying most digestive organs. Its glands are different from those in mammalian species.

The tunica mucosa is extensively folded into flattened ridges separated by grooves or sulci. **Mucosal glands** (simple, branched) open into the base of the sulci. Elevations in the tunica mucosa (papillae) contain the opening of the excretory duct of **submucosal glands** (Fig. 21-60). The lamina epithelialis mucosae has columnar cells that extend into the sulci. The lamina epithelialis mucosae continues into the mucosal glands with cuboidal epithelium. The lamina propria mucosae is typical and contains accumulations of diffuse and nodular lymphatic tissue. The lamina muscularis mucosae

Downloaded From Vet-eBooks.com

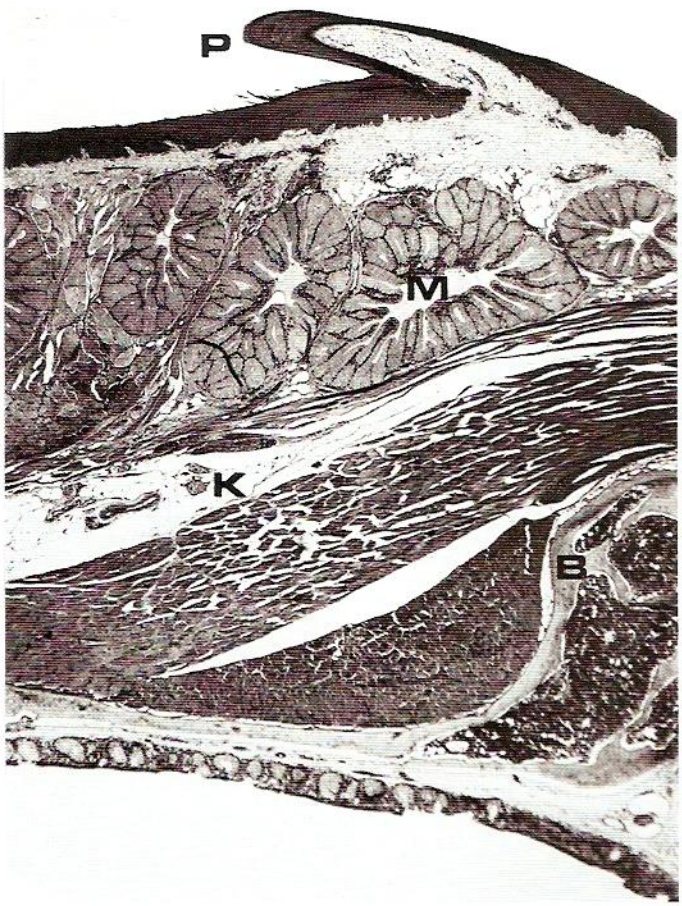

Figure 21-58. Longitudinal section of an avian tongue. A papilla *(P)* protrudes from the dorsal surface. The mass of the tongue consists of mucous glands *(M)*, skeletal muscle *(K)*, and bone *(B)*. (×10.)

Figure 21-59. Avian esophagus. The lamina epithelialis mucosae is stratified squamous epithelium. *M*, Mucous glands. (×10.)

Figure 21-60. Avian proventriculus. Mucosal glands *(M)* are formed by grooves or rugae on the surface of the organ. These are called rugosal glands. Submucosal *(S)* or subrugosal glands consist of adenomeres *(arrows)* radiating from a central excretory duct. The glands open onto papillae *(P)* at the surface. (×4.)

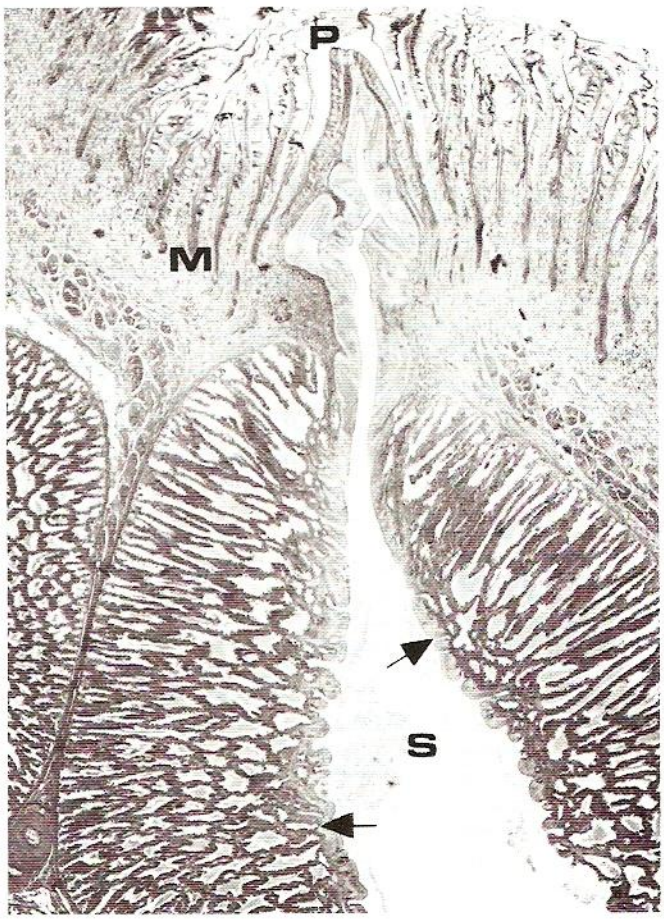

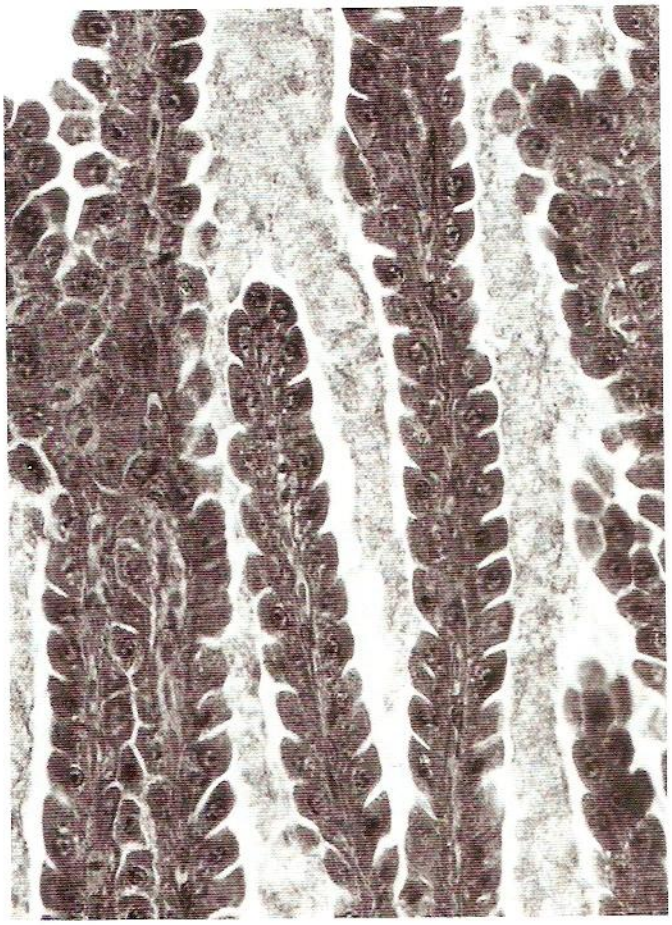

Figure 21-61. Secretory cells of the submucosal glands (proventriculus). These acidophilic cells are not joined at their apical surface and thus impart a serrated appearance to the lining. (×160.)

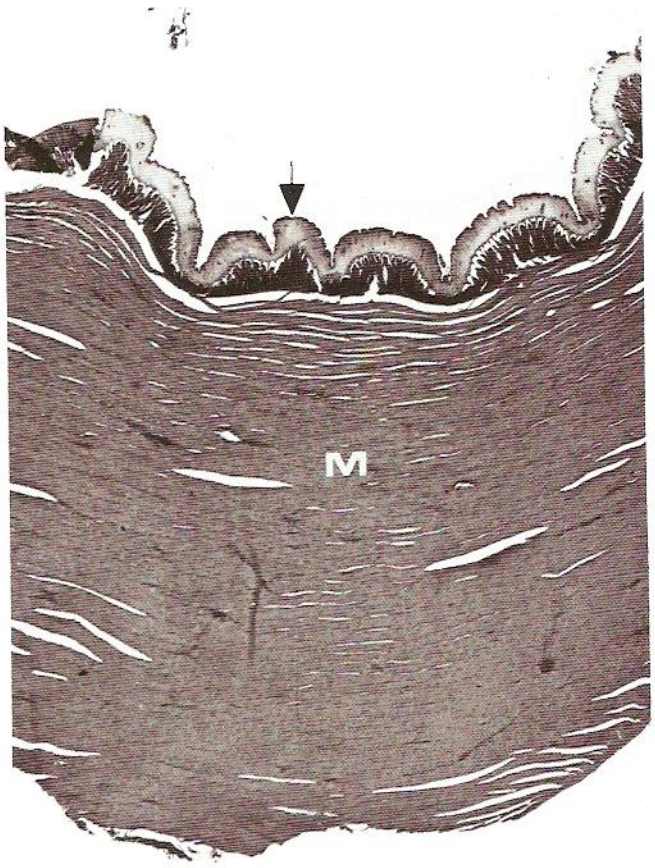

Figure 21-62. Avian ventriculus. The lining *(arrow)* is cornified material secreted by the mucosal glands. The tunica muscularis *(M)* is thick. (×4.)

consists of an interrupted band of longitudinally oriented fibers, strands of which are interdigitated between the mucosal glands.

The tela submucosa is typical but is seemingly displaced by the large and numerous **submucosal glands** (Fig. 21-60). These glands are compound, branched, and tubular. The adenomeres radiate 360 degrees around a central excretory duct lined by a simple or pseudostratified columnar epithelium. The radially oriented glands are lined by secretory cells that may be cuboidal or pyramidal (Fig. 21-61). The apical portions of the secretory cells are not joined together; thus their serrated appearance. These cells have a granular and acidophilic cytoplasm with centrally or paracentrally positioned nuclei. They are the only cell type in the gland. Because avian gastric juice is similar to mammalian gastric juice, it is assumed that this cell must secrete both enzymatic and acidic products.

The tunica muscularis is slightly modified; inner longitudinal, middle circular, and outer longitudinal layers are present. The tunica serosa is typical.

Ventriculus. This portion of the digestive system **(gizzard, muscular stomach)** is connected to the proventriculus by a narrow isthmus devoid of submucosal glands. The luminal surface is lined by a cornified secretion from the mucosal glands (Fig. 21-62). The surface lining of the tunica mucosa consists of low columnar cells with round and basally positioned nuclei. The surface cells continue into the glands and are replaced by gobletlike cells. The mucosal glands are straight and tubular (Fig. 21-63). The lamina propria–submucosa is typical.

A tunica muscularis is present but is not typical. It consists of smooth muscle and dense collagenous tissue. The lateral border of the gizzard consists of regularly arranged dense collagenous tissue. The smooth muscle arises from this connective tissue and spreads throughout the tunic. The tunica serosa is thin.

Lower digestive tract. The **small intestine** is not divisible histologically into distinct regions. Except for the following features, the small intestine is similar to that of mammals:

The **lamina propria** and **tela submucosa** contain large quantities of diffuse and nodular lymphatic tissue. These may become aggregated aborally. A third layer of smooth muscle may comprise the inner portion of the tunica muscularis.

The **ceca** are two blind sacs appended to the junction of the small and large intestines. Villi are present at the orifices but diminish and are lost at the ends of the organs. The lamina propria mucosae and tela submucosa contain many diffuse and aggregated types of lymphatic tissue. The accumulation of nodules at the caecal orifices is called a **caecal tonsil.** The junction of each caecum with other portions of the intestine is circumscribed by a sphincter from the inner circular mass of the tunica muscularis. Water absorption occurs in the cacca, and some believe that cellulose digestion may also occur.

The **rectum** has short, thick villi and an increased number of goblet cells. Except for these differences, it is similar to the small intestine.

The **cloaca,** the common orifice for the digestive, excretory, and reproductive organs, is lined by simple columnar epithelium. The tunica mu-

Downloaded From Vet-eBooks.com

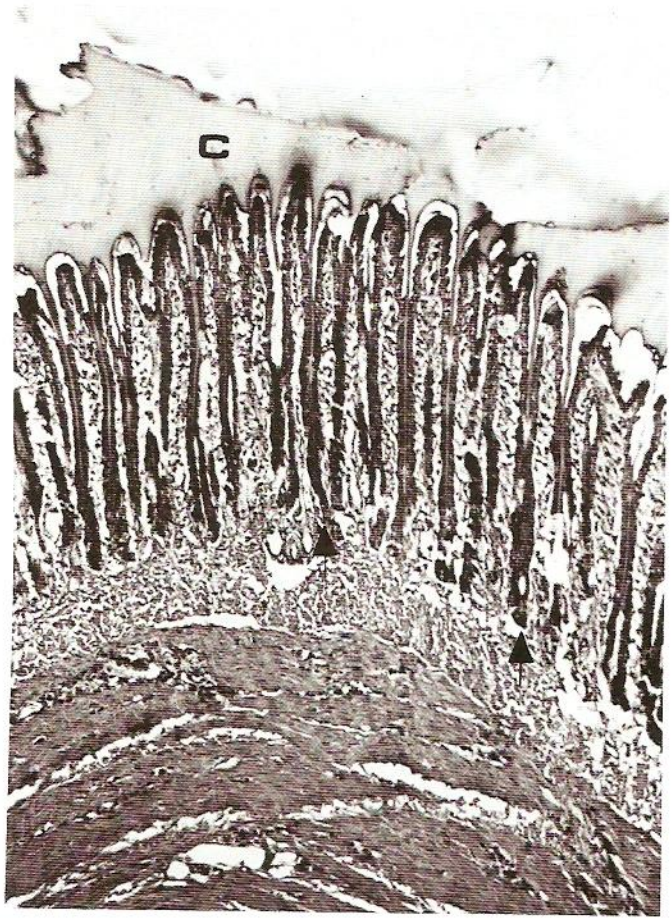

Figure 21-63. Mucosal glands and lining of the avian ventriculus. The cornified material *(C)* is the secretory product of these glands *(arrows)*. (×40.)

cosa is folded extensively and accounts for the compartmentalization of this structure. Lymphatic tissue is present in the associated connective tissue. The bursa of Fabricius is an evagination of the cloaca.

The tunica mucosa of the **anus** is highly folded and lined by keratinized stratified squamous epithelium. A lamina muscularis mucosae is not present, and striated muscle of the tunica muscularis forms the anal sphincter.

ADDITIONAL READINGS

Buccal Cavity

Anderes RL: Canine tooth structure, development, blood and nerve supply, *North Am Vet* 16:37, 1935.

Elwood WK, Bernstein MH: The ultrastructure of the enamel organ related to enamel formation, *Am J Anat* 122:73, 1968.

Garlick NL: The teeth of the ox in clinical diagnosis. I. Developmental anatomy, *Am J Vet Res* 15:226, 1954.

Hand AR: The fine structure of Von Ebner's gland of the rat, *J Cell Biol* 44:340, 1970.

Kallenbach E: Fine structure of rat incisor enamel organ during late pigmentation and regression stages, *J Ultrastruct Res* 30:38, 1970.

Lester KS, Boyde A: Scanning electron microscopy of developing roots of molar teeth of the laboratory rat, *J Ultrastruct Res* 33:80, 1970.

Murray RG, Murray A, Fujimoto S: Fine structure of gustatory cells in rabbit taste buds, *J Ultrastruct Res* 27:444, 1969.

Swenson MJ (ed): *Duke's Physiology of domestic animals*, ed 9, Ithaca NY, 1977, Comstock Publishing.

Weinrab MM, Sharaw Y: Tooth development in sheep, *Am J Vet Res* 25:891, 1964.

Weinstock M: Gap junctions in the odontoblasts of the rat incisor teeth, *Anat Rec* 199:270A, 1981

Tubular Organs

Adkins RB, Ende N, Gobbel WG: A correlation of parietal cell activity with ultrastructural alterations, *Surgery* 62:1059,1967.

Bienenstock J, Befus D: Gut-and-bronchus-associated lymphoid tissue, *Am J Anat* 170:437, 1984.

Bonfanti C: Duodenal glands in the horse, *Rev Med Vet* 4:95, 1952.

Brobeck JR (ed): *Best and Taylor's Physiological basis of medical practice*, ed 10, Baltimore, 1979, Williams & Wilkins.

Brunser O, Luft JH: Fine structure of the apex of absorptive cells from rat small intestine, *J Ultrastruct Res* 31:291, 1970.

Cardell RR, Badenhausen S, Porter KR: Intestinal triglyceride absorption in the rat. An electron microscopical study, *J Cell Biol* 34:123, 1967.

Cooke HJ: Neurobiology of the intestinal mucosa, *Gastroenterology* 90:1057, 1986.

Demke DD: A brief histology of the intestine of the turkey poult, *Am J Vet Res* 15:447, 1952.

Devency CW, Dunphy JE: Wound healing in the gastrointestinal tract. In Hunt TK, Dunphy JE (eds): *Fundamentals of wound management* , New York, 1979, Appleton-Century-Crofts. pp 569-593.

Elias H: Comparison of duodenal glands in domestic animals, *Am J Vet Res* 8:311, 1947.

Freeman BM (ed): *Physiology and biochemistry of the domestic fowl*, New York, 1983, Academic Press.

Hampton JC: An electron microscopic study of mouse colon, *Dis Colon Rectum* 3:423, 1960.

Johnson RR, Young BA: Undifferentiated cells in the gastric mucosa, *J Anat* 101:617, 1967.

Leeson CR, Leeson TS: The fine structue of Brunner's glands in the rabbit, *Anat Rec* 159:409, 1967.

Moon HW: Mechanisms in the pathogenesis of diarrhea: a review, *J Am Vet Med Assoc* 172:443, 1978.

O'Brien TR, et al: *Radiographic diagnosis of abdominal disorders in the dog and cat: radiographic interpretation, clinical signs, pathophysiology*, Philadelphia, 1978, WB Saunders.

Rubin W: Enzyme cytochemistry of gastric parietal cells at a fine structure level, *J Cell Biol* 42:332, 1969.

Sturkie PD: *Avian physiology*, ed 3, New York, 1976, Springer-Verlag.

Titkemeyer CW, Calhoun ML: A comparative study of the structure of the small intestine of domestic animals, *Am J Vet Res* 16:152, 1955.

Trier JS: Structure of the mucosa of the small intestine as it relates to intestinal function, *Fed Proc* 26:1391, 1967.

Watson AG: Structure of the canine esophagus, *NZ Vet J* 21:195, 1973.

Downloaded From Vet-eBooks.com

CHAPTER 22

Digestive System II—Extramural Organs

SALIVARY GLANDS

General features. The salivary glands are evaginations from buccal epithelium into the lamina propria-submucosa. Although the adenomeres of the salivary glands are located at various distances from the buccal lining, their excretory ducts open onto the buccal epithelium. Predicated upon their size, location, and proximity to the buccal cavity, the salivary glands are classified as major or minor. The **major salivary glands**—parotid, mandibular, sublingual, zygomatic, and molar—are large and located some distance from the buccal cavity; their excretory ducts are long. The **minor salivary glands**—labial, lingual, buccal, and palatine—are small and close to the buccal cavity.

The major salivary glands are compound and tubuloalveolar (Chapter 5). Structures unique to them are alveoli, intercalated ducts, and striated ducts. The **striated duct,** also called the **secretory tubule,** is intralobular. **The secretory pathway of the major salivary glands is alveolus** to **intercalated duct** to **intralobular duct** to **lobular duct** to **intralobar duct** to **lobar duct** to **excretory duct.**

Major salivary gland adenomeres have mucous and/or serous cells (Figs. 22-1, 22-2, 22-5, and 22-6). The distribution of serous and mucous cells in mixed salivary glands is also variable. Some adenomeres are exclusively serous or mucous. Others consist of single cells or groups of cells of one type intermingled with predominant cells of the other type. Additionally, **serous demilunes** may cap mucous endpieces. **Myoepithelial cells** are intimately juxtaposed with alveolar secretory cells.

The **intercalated ducts** are small tubules lined by a low cuboidal epithelium (Fig. 22-3). They are nonsecretory ducts connecting alveoli to **striated ducts.** The striated ducts, lined by columnar epithelium, are named for the infranuclear striations that result from accumulations of mitochondria and infoldings of the basal plasmalemma of lining cells (Fig. 22-4). They do not occur in exclusively mucus-secreting salivary glands. In the absence of striated ducts, the intralobular duct is lined by simple columnar epithelium.

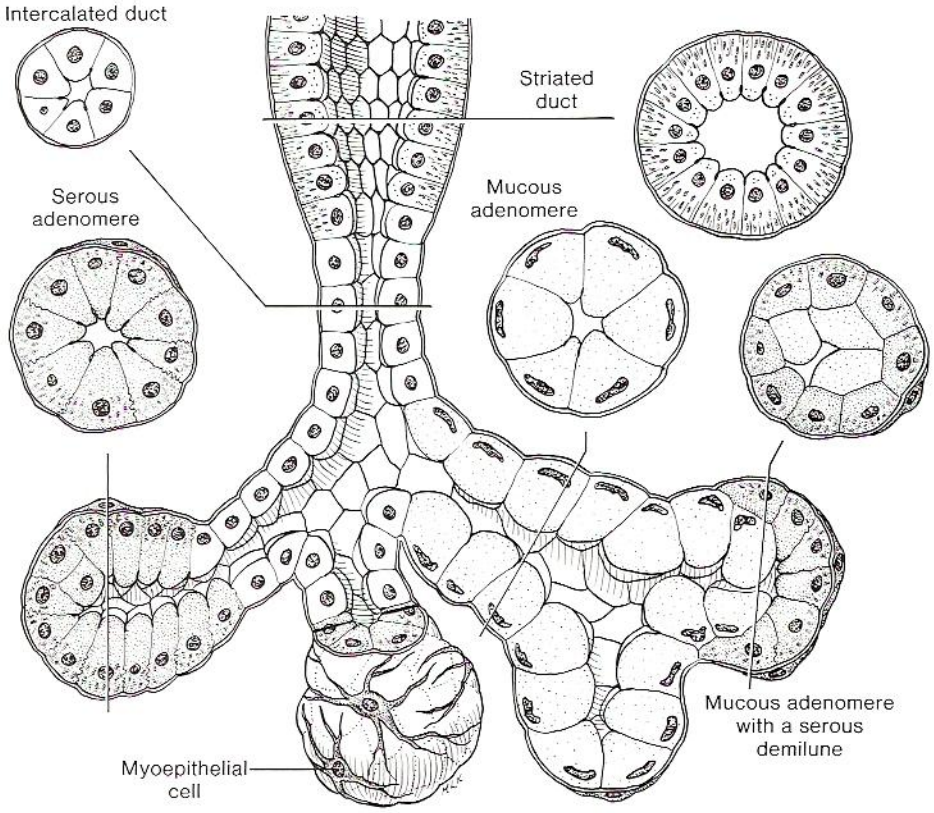

Figure 22-1. Types of adenomeres that characterize the salivary glands.

Bistratified cuboidal or bistratified columnar epithelium may occur at transition points between intralobular and lobular ducts (Figs. 5-14 and 5-15). Larger ducts (both intralobar and lobar) may be lined by pseudostratified columnar epithelium. Stratified squamous epithelium replaces the other lining tissues and becomes the characteristic lining of excretory ducts. It continues with the epithelium lining the buccal cavity.

The salivary gland epithelium (lining and secretory cells) is separated from the surrounding connective tissue by a basement membrane. The intralobular connective tissue consists of reticular connective or loose collagenous tissue. The latter blends with dense collagenous tissue of the capsule.

The organization of minor salivary glands, though not as extensive, is similar to that of the major salivary glands.

Major salivary glands. The major salivary glands conform to the previous description. Their species characteristics are as follows:

Parotid salivary glands: usually serous in domestic animals, humans, and rodents; a few mucous cells or adenomeres present in carnivores (Fig. 22-5); may be mixed in young puppies and lambs

Mandibular salivary glands: usually mucous in dogs and cats (Fig. 22-6); serous in rodents; mixed in horses, humans, and ruminants; the distribution of serous and mucous cells in mixed glands is variable

Sublingual salivary glands: predominant mucous in ruminants, swine, and rodents; mixed in small carnivores, humans, and horses (Fig. 22-7)

Unique salivary glands: the **zygomatic gland** of small carnivores, predominantly mucous with some serous demilunes present; the **molar gland** of felids similar to zygomatic glands

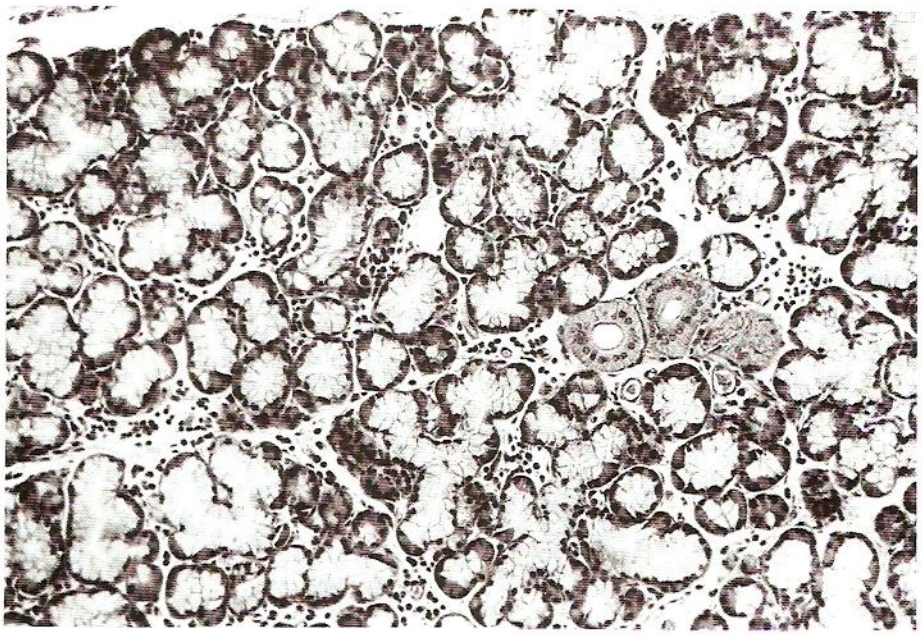

Figure 22-2. Equine sublingual salivary gland. Note the mucous adenomeres and the serous demilunes. This is a mixed salivary gland. (×40).

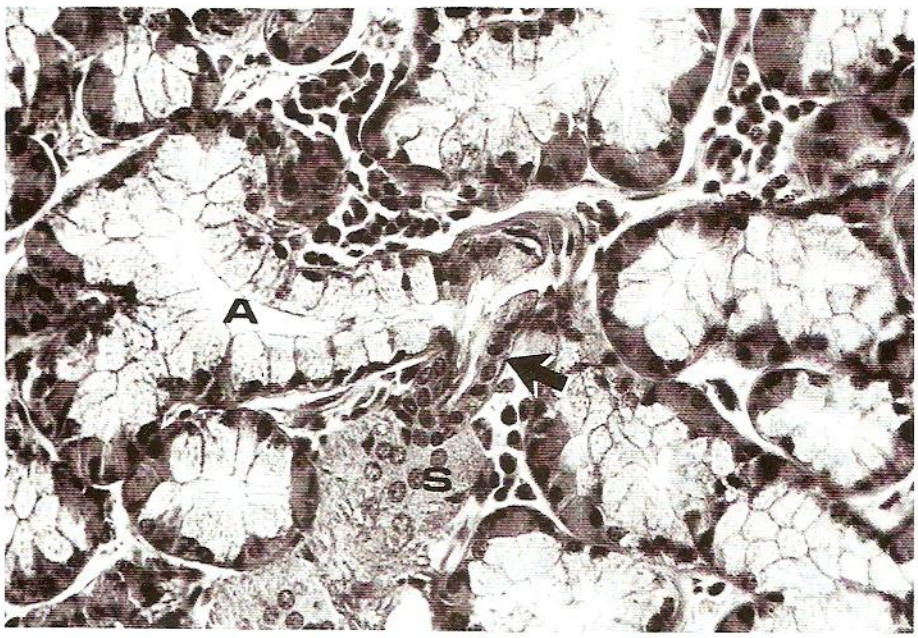

Figure 22-3. Alveolus, intercalated duct, and striated duct of an equine mixed salivary gland. The alveolus *(A)* is lined by mucous cells and serous demilunes. The intercalated duct *(arrow)* connects an alveolus to a striated duct *(S)*. (×100.)

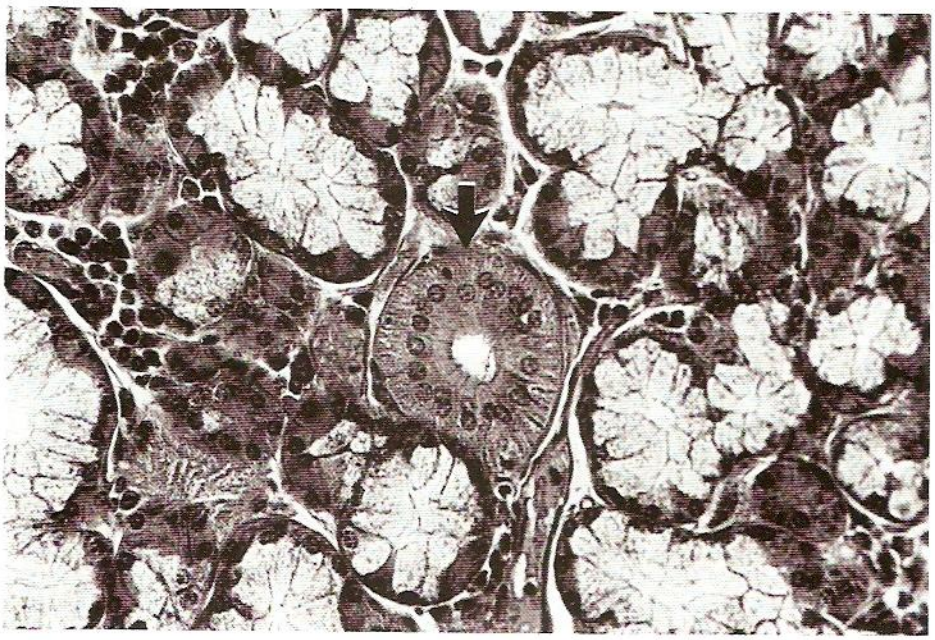

Figure 22-4. Striated duct of an equine mixed salivary gland. The duct *(arrow)* is lined by simple columnar epithelium with basal striations. (×100.)

Downloaded From Vet-eBooks.com

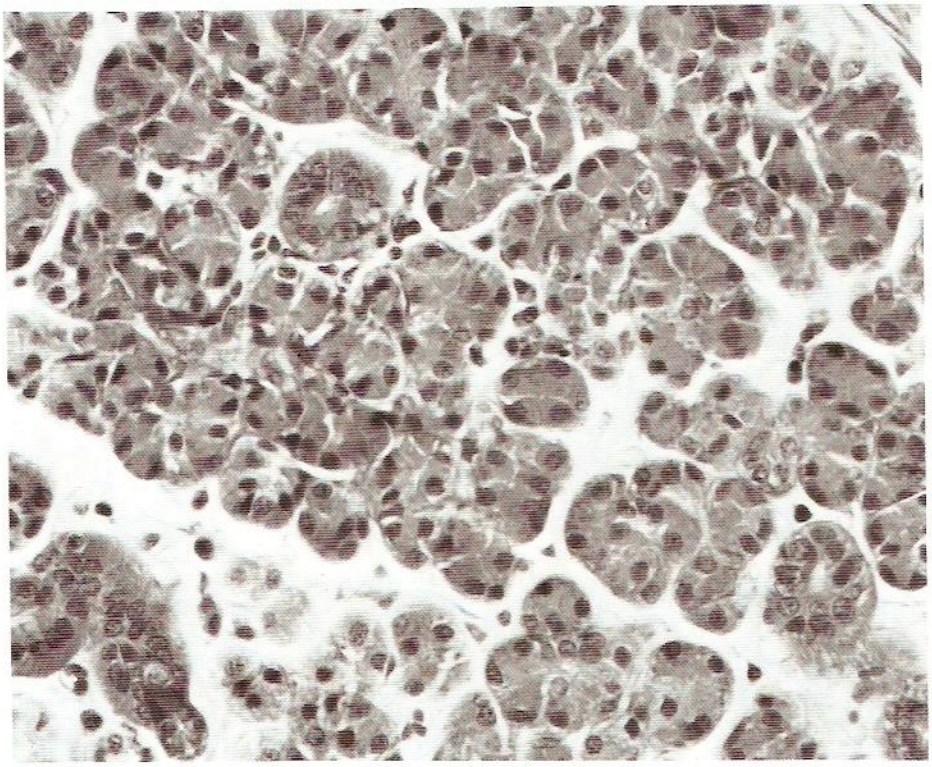

Figure 22-5. Canine parotid salivary gland. The adenomeres are composed of serous cells. (×40)

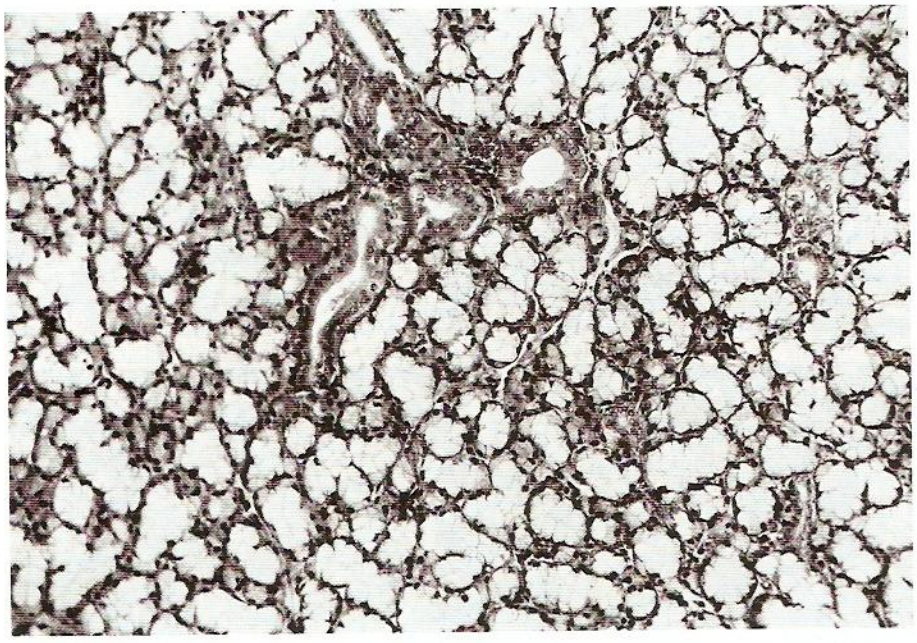

Figure 22-6. Canine mandibular salivary gland. This is a mucous gland. (×40.)

Minor salivary glands. The minor salivary glands comprise a small group scattered throughout the buccal cavity. Located in the lamina propria-submucosa close to the lamina epithelialis mucosae, they include the labial, lingual, buccal, and palatine glands. They are diminutive forms of the major glands and may be mucous, serous, or mixed.

Labial glands: mucous in small ruminants, dogs, and cats; serous in large ruminants, swine, and horses; mixed in humans

Lingual glands: mixed in large ruminants and horses; mucous in carnivores and sheep

Gustatory glands: specialized lingual glands that secrete a serous product in association with large gustatory lingual papillae

Dorsal buccal glands: mucous in large ruminants, carnivores, and horses; the **ventral buccal glands** of these animals are serous; the buccal glands of humans and swine are mixed; palatine glands also mixed

Functional correlates. **Saliva,** the mixed secretory product of all salivary glands, has many functions:

It moistens the cutaneous mucous membrane and foods.

It lubricates and facilitates mastication, deglutition, and phonation.

It aids in adjusting upper digestive tract pH.

It aids in the dissolution and tasting of foods.

It initiates a limited amount of carbohydrate digestion.

The pig, however, seems to be the only domestic animal with sufficient salivary amylase to be of any consequence. The salt content of its saliva may help regulate electrolytes. Lactoperoxidase and immunoglobulin A (IgA) serve as a salivary antimicrobial system.

Saliva consists of proteins, glycoproteins, electrolytes, and water. It is a dilute aqueous fluid; it is not an ultrafiltrate of blood, because the concentrations of H^+, Cl^-, K^+, Na^+, proteins, and glucose differ from those in blood. Saliva production requires energy.

Salivation is under reflex control of the autonomic nervous system. Sensory receptors in the buccal and nasal cavities, pharynx, and stomach respond to the presence, odor, taste, and mastication of foods. Parasympathetic components of cranial nerves VII, IX, and X along with the sympathetic nerves are the motor fibers to the glands. **Both excite salivary secretion.** Parasympathetic stimulation results in a voluminous, dilute, watery saliva. Sympathetic stimulation causes a diminished, viscous, mucous saliva. Antimuscarinic drugs curtail salivation.

The amount of saliva secreted by an animal varies with the species. During a 24-hour period, humans may produce 1 to 2 liters; sheep, 1 to 4 liters; horses, 38 liters; cattle, 90 to 190 liters. The type of diet influences the amount and nature of salivation. In dogs, a fresh meat diet stimulates viscous saliva; a dry food preparation watery saliva. Saliva flow may be influenced by psychic stimulation. The sight or suggestion of food can cause a **conditioned reflex flow** of saliva in dogs and swine. An **unconditioned reflex flow** occurs in response to the presence of food in the mouth of ungulates.

The ion content of saliva depends upon the type and rate of salivation. The striated duct cells influence the ionic and water content. The basal surface of striated duct cells is a large surface area for

Downloaded From Vet-eBooks.com

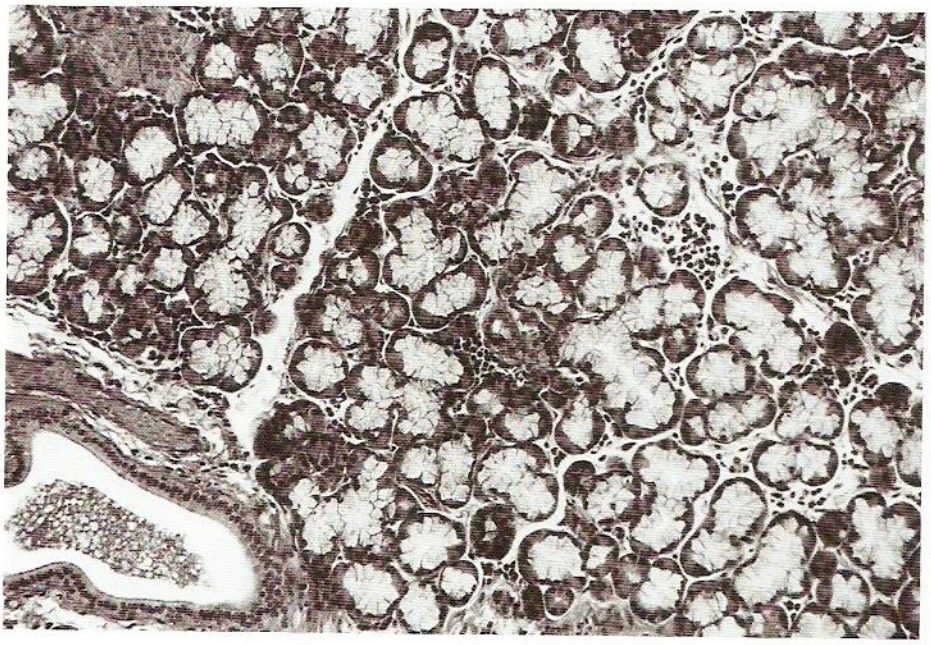

Figure 22-7. Equine sublingual salivary gland. This is a mixed gland. Note the excretory duct in the lower left portion of the micrograph. (×40.)

the rapid transport of fluids and ions. The juxtaposition of mitochondria is a convenient energy source. This morphology resembles that of other epithelial cells (Fig. 5-46).

The juxtaalveolar connective tissue of salivary glands has many plasma cells and small lymphocytes. IgA produced by plasma cells in these loci is transported through the alveolar lining cells, during which time a secretory piece is added. Secretory IgA, which is resistant to proteolysis, protects the mucous membranes of the buccal cavity from pathogenic microorganisms.

LIVER

General characteristics. The liver is the single largest gland, accounting for 2% to 5% of body weight. The ratio of liver weight to body weight is usually constant. The liver is a compound, tubular gland with diverse metabolic functions. These functions are accomplished by two cell types, the hepatocyte and the stellate macrophage. The **hepatocyte** retains a high mitotic potential while performing diverse functions:

1. Synthesis of sugars, plasma proteins, clotting factors, lipids, urea, and ketone bodies
2. Secretion of bile salts and bile acids
3. Excretion of bile pigments
4. Biotransformation of toxic substances, including drugs and hormones
5. Merabolism of lipids, proteins, and carbohydrates

Hematopoiesis is a function during fetal development, and that potential is retained in adults.

The **stellate macrophages** (formerly called von Kupffer cells), members of the macrophage system, line parts of hepatic sinusoids and are associated with hepatocytes.

Development. The liver, although removed from the alimentary canal, opens into that tract. The hepatic parenchyma and ducts arise from endoderm. The extrahepatic bile duct system is a duodenal diverticulum. Hepatocytes develop from endodermal cells secondarily invading the mesenchyme into which the diverticulum has advanced. This dual endodermal development accounts for the unique morphology of liver parenchyma. The plates of hepatocytes, interdigitated with mesenchymally derived sinusoids, continue with the extrahepatic bile ducts opening into the duodenum. Intrahepatic bile ducts develop secondarily from hepatocytes and eventually fuse with the extrahepatic biliary system.

Histological Organization

Connective tissue. The fibrous capsule, consisting of dense collagenous tissue rich in elastic fibers, underlies a serous membrane. The capsular connective tissue continues with the interstitial connective tissue. Although scant in most species, it is prominent in those interlobular regions called **portal areas** and consists of loose collagenous tissue. Porcine liver lobules, however, are invested completely by loose collagenous tissue; thus distinct lobules are evident grossly and histologically (Fig. 22-8). Intralobular connective tissue, scant in all species, is a reticular connective tissue confined to parts of the perisinusoidal space.

Hepatic lobules. **Hepatic lobules** are the morphological units of the liver. These prismatic, polygonal masses have **plates** of hepatocytes placed between anastomotic **hepatic sinusoids** (Fig. 22-9). The plates appear to radiate from a centrally positioned vessel, the **central vein** (Fig. 22-10). The concept of the he-

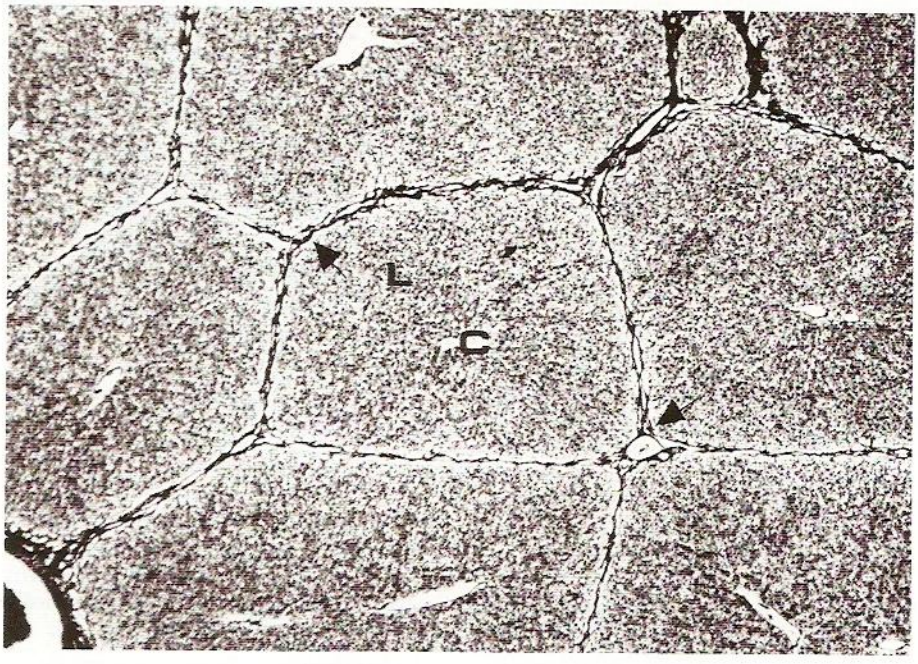

Figure 22-8. Section of a porcine liver. The lobules *(L)* are well-defined by interlobular connective tissue *(arrows)*. A central vein *(C)* is located in the center of each lobule. (×10, reticular stain).

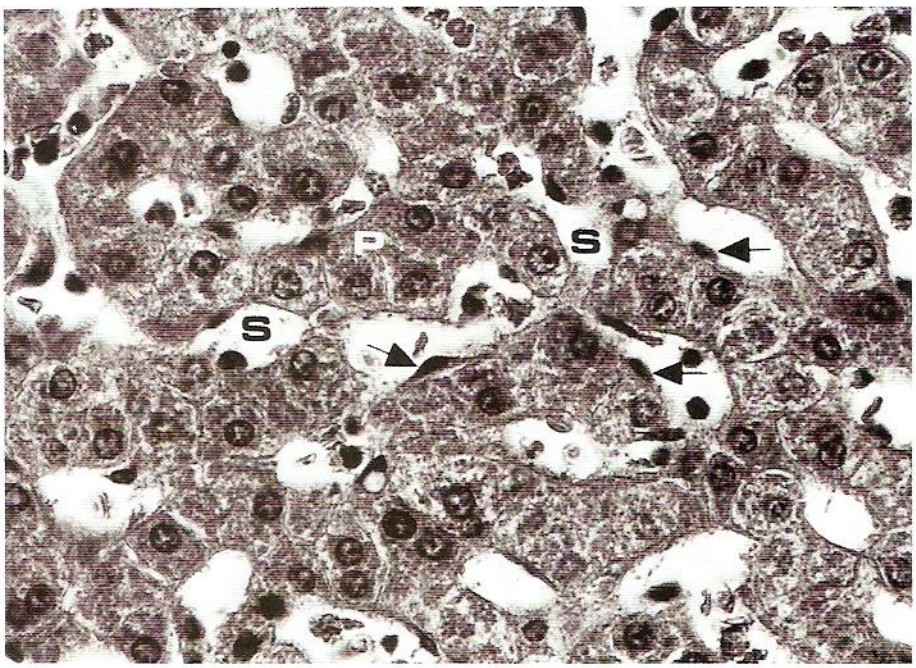

Figure 22-9. Plates and sinusoids of the liver. The plates of hepatocytes *(P)* are separated from each other by sinusoids *(S)*, which are lined by von Kupffer cells *(arrows)* and endothelial cells. (×160.)

Figure 22-10. Hepatic lobule. Whether or not it is lined by connective tissue, the lobule conforms to this general shape.

patic lobule is based upon its structural organization and the blood flow pattern from the periphery through the sinusoids to the central vein.

Hepatocytes. **Hepatocytes** are polyhedral cells with usually distinct boundaries (Fig. 22-11). The vesicular nucleus with prominent nucleoli is centrally positioned and surrounded by an acidophilic cytoplasm containing basophilic material (Plate III, *12*). Binucleated cells may be observed. The appearance of hepatocytes

Downloaded From Vet-eBooks.com

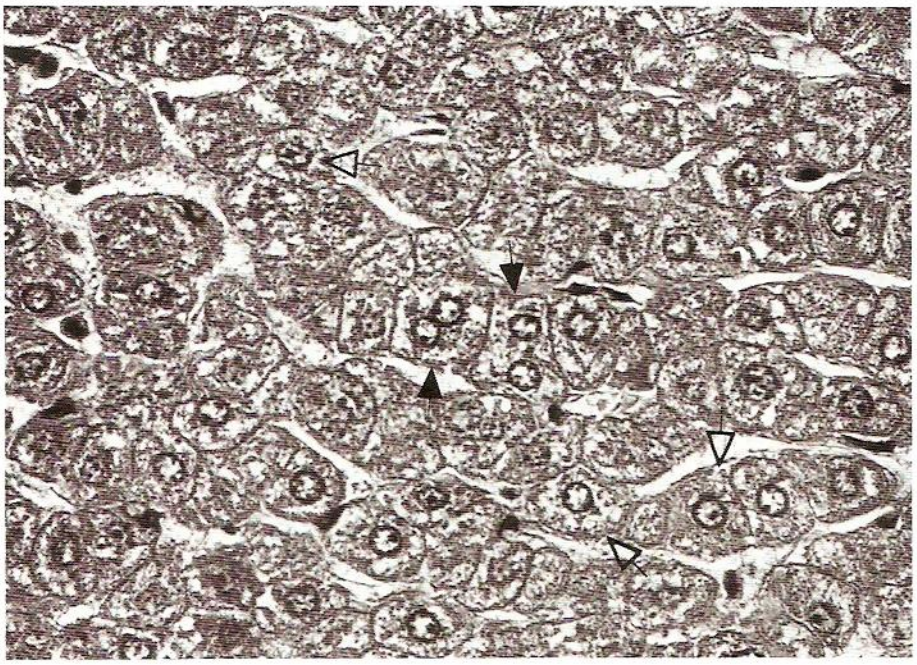

Figure 22-11. Parenchyma of the liver. The hepatocytes may be uninucleated *(open arrows)* or binucleated *(sollid arrows).* (×160.)

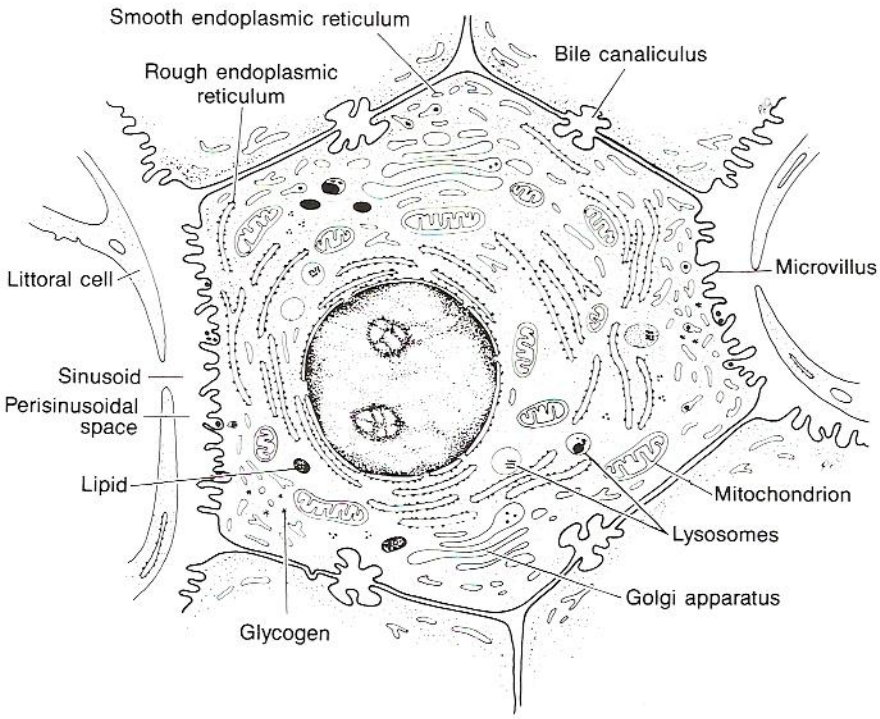

Figure 22-12. Hepatocyte, adjacent cells, perisinusoidal space, and sinusoids as seen on an electron micrograph.

depends upon the physiology at sampling time. Fasted animals have small, turbid, and indistinctly outlined hepatocytes. After feeding, however, the hepatocytes enlarge, become distinctly outlined, and fill with glycogen and lipid inclusions, causing a foamy or honeycombed appearance.

Hepatocyte ultrastructure confirms its functional multiplicity (Fig. 22-12). Many mitochondria are scattered throughout the cell, their shape and distribution depending upon the activity of the cell. An extensive network of clustered RER and free ribosomes corresponds to light microscopic basophilia. The SER extends throughout the cytoplasm and continues with RER profiles. Lysosomes, peroxisomes, lipid droplets, and glycogen are present also. A prominent Golgi complex assumes a juxtanuclear position. The hepatocytic plasma membrane adjacent to the sinusoids have many, short, irregular microvilli. The cell membranes of contiguous hepatocytes have desmosomes and gap junctions. Adjacent cell plasma membranes have indentations in registration with each other. Small microvilli project into the indentations. The small indentations, ramifying between adjacent cells as a system of **bile canaliculi** (Fig. 22-13), are just visible by light microscopy.

Hepatic sinusoids. **Hepatic sinusoids** are the intralobular vascular supply. Blood from interlobular vessels is transported through them to the central veins. The sinusoids comprise a vastly anastomotic network separating hepatic plates from each other (Fig. 22-9). All hepatocytes have at least one surface juxtaposed to a sinusoid.

The predominant sinusoidal lining cell is typically endothelial; the other cell is a member of the macrophage system, a **stellate macrophage.** Stellate macrophages usually reside upon the endothelial cells; however, they may extend across the sinusoidal lumen or even form part of the sinusoidal wall.

The hepatic sinusoids, which are generally devoid of a basal lamina and have many cellular gaps between the lining cells, permit the free movement of materials between the plasma and hepatocytes. Despite the juxtaposition of sinusoids to hepatocytes, a **perisinusoidal space** of varying width separates them. Cells, reticular fibers, and hepatocytic microvilli occupy this space (Figs. 22-12 and 22-14).

Biliary system and portal triads. The **biliary system** of the liver includes **bile canaliculi, intrahepatic ducts,** and **extrahepatic ducts** for the conduction of bile from hepatocytes to the duodenum (Fig. 22-15). The system of secretory cells and conducting tubules comprises the exocrine hepatocytic components. The bile canaliculi are the smallest components of the biliary system and are formed between adjacent hepatocytes (Figs. 22-13 and 22-14). They open into **biliary ductules,** which continue into **interlobular biliary ducts.** The biliary ductules are lined by small, pale-staining cells that may be modified hepatocytes. Interlobular ducts ramify throughout the interlobular connective tissue and anastomose with each other to form larger interlobular bile ducts. Interlobular bile ducts associate with branches of the hepatic artery and hepatic portal vein, forming a **portal triad.**

Interlobular bile ducts are lined by simple cuboidal or columnar epithelium surrounded by loose collagenous tissue. Smooth muscle and elastic fibers may en-

Downloaded from StudentBooks.com

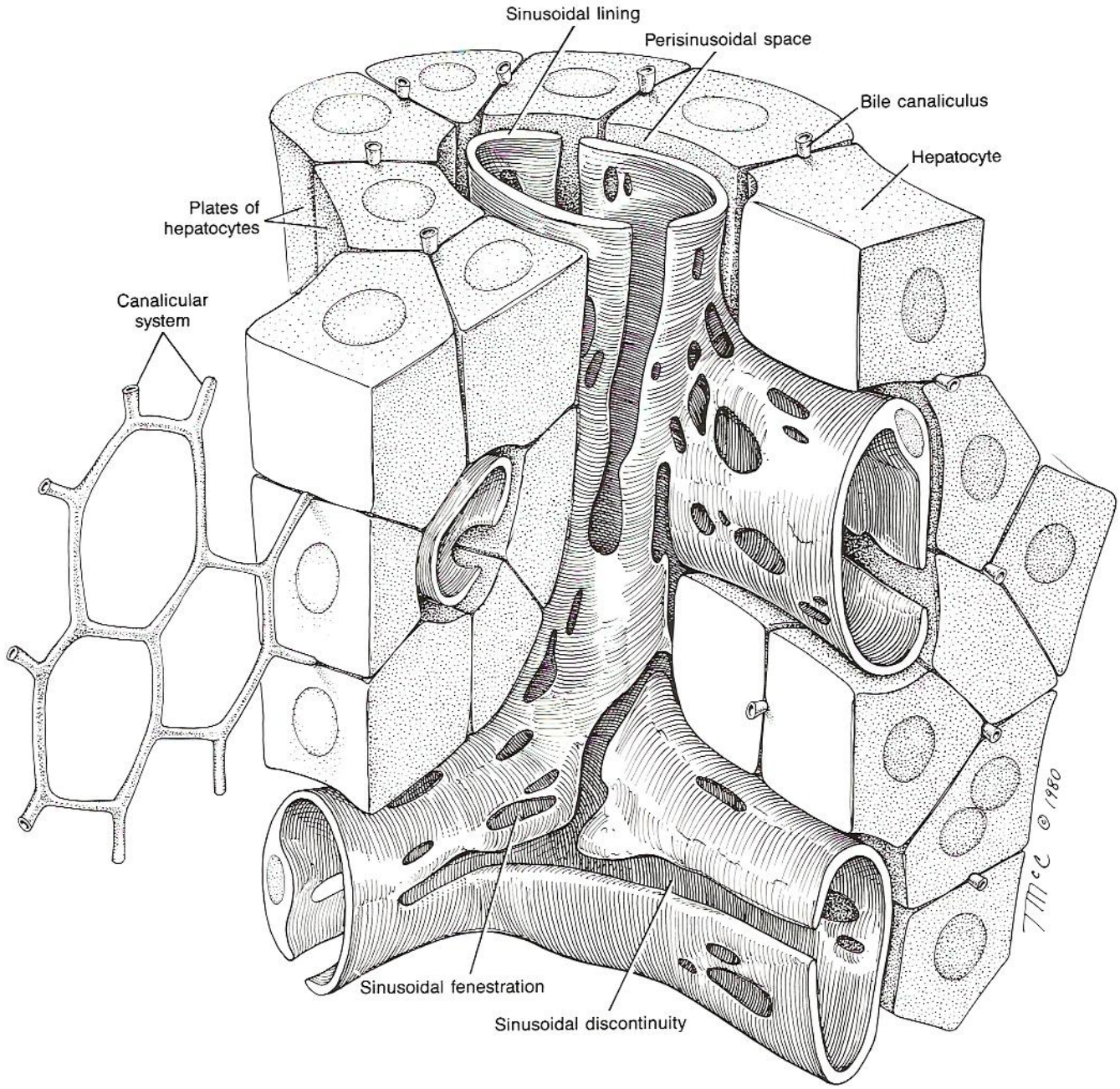

Figure 22-13. Relationships between hepatocytes, sinusoids, and bile canaliculi. The canaliculi are illustrated as tubules for instructional purposes.

velope large interlobular bile ducts. These ducts become confluent and form progressively larger **intrahepatic ducts.** The latter continue as extrahepatic ducts, consisting of **hepatic ducts,** the **cystic duct** from the gallbladder, and the **common bile duct,** which transport bile to the duodenum.

The duct system epithelium blends into and is actually an extension of the duodenal lamina epithelialis mucosae. **The bile canaliculi (located deep in the liver) are spaces "outside the body"** because the space enclosed within them is continuous with the duodenal lumen.

A **portal triad,** consisting of interlobular branches of a bile duct, hepatic artery, and hepatic portal vein, is obvious in regions (between three or more lobules) where there is an accumulation of interlobular connective tissue as a **portal canal.** The portal canal contains a portal triad, nerves, and small lymphatic vessels as well as interlobular connective tissue (Fig. 22-16). The branch of the hepatic portal vein is usually the most prominent structure whereas the lymphatics are usually collapsed and inconspicuous. The portal canal, with its portal triad, is an important landmark in the organization of the liver and the study of normal and abnormal livers.

Vascular, lymphatic, and neural relationships. The liver has a dual vascular circulation: the **nutritional** arterial supply derives from the **hepatic artery;** the **functional** venous vasculature is part of the **hepatic portal vein** (Fig. 22-10).

The hepatic artery divides into branches supplying the individual hepatic lobes. The lobar branches divide into smaller interlobular branches ramifying throughout the interlobular connective tissue space as part of the portal triads. Arterial blood is delivered to the lobules via hepatic sinusoids. The hepatic arterial blood volume accounts for approximately one fifth of the hepatic vascular supply.

Downloaded From Vet-eBooks.com

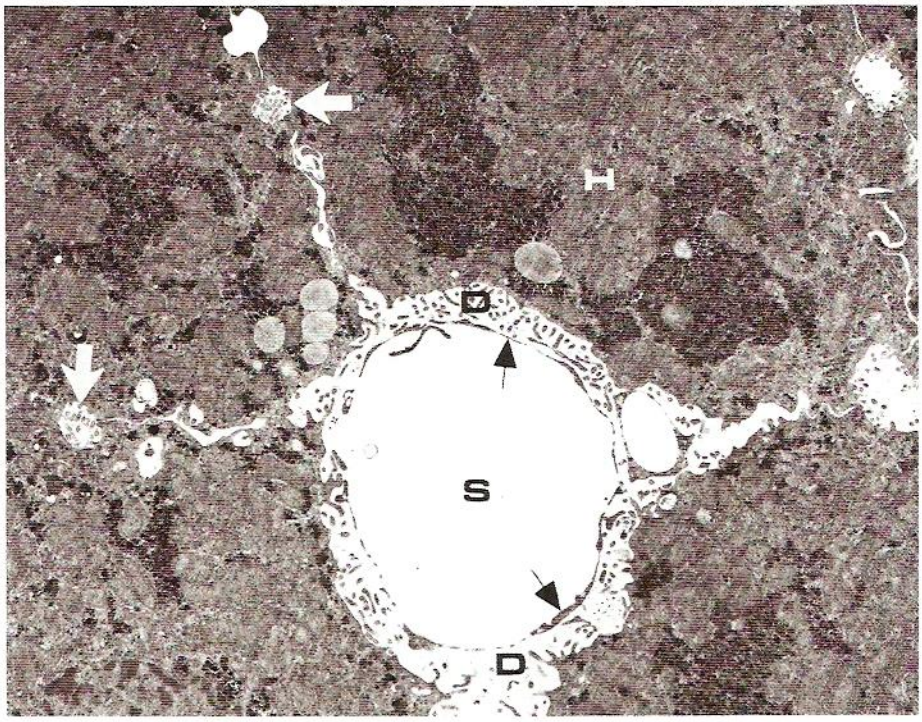

Figure 22-14. Electron micrograph of a liver. Hepatocytes *(H)* form the bulk of the organ. Portions of contiguous borders form bile canaliculi *(white arrows)*. The sinusoids *(S)* are lined by von Kupffer cells and endothelial cells *(black arrows)*. The perisinusoidal space *(D)* separates the sinusoid from hepatocytes. The cell processes within the space are microvillous projections of hepatocytes. (×6000.) (Courtesy W. Todd.)

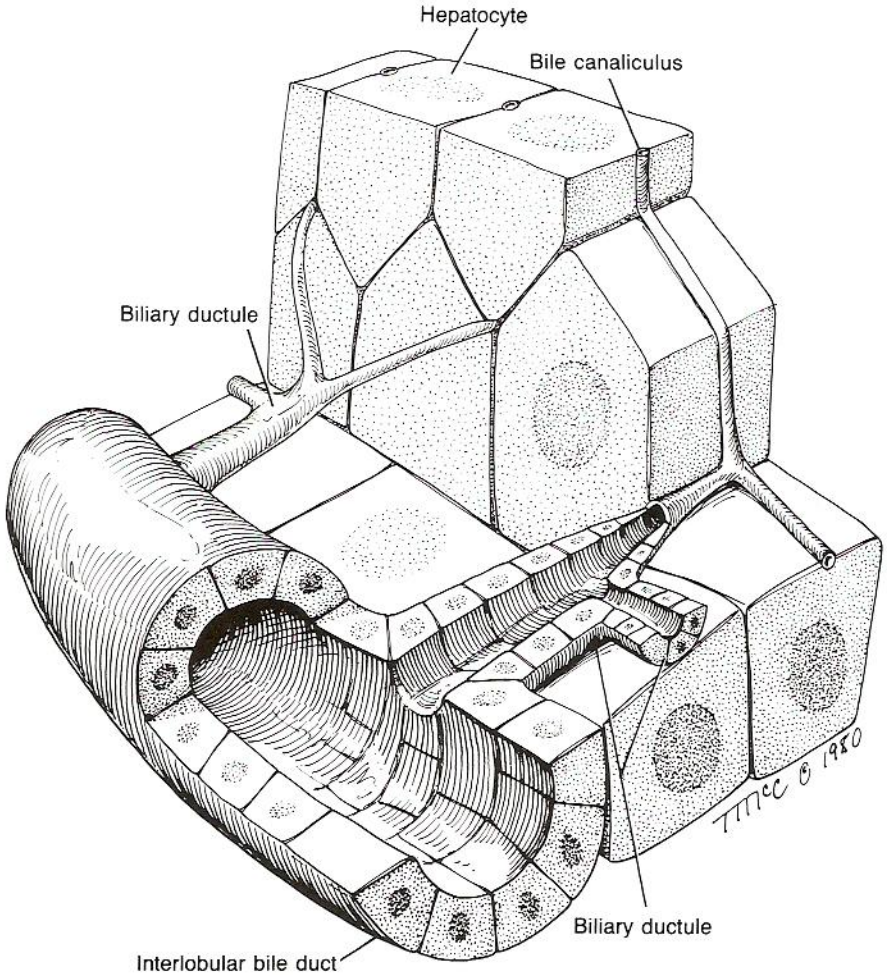

Figure 22-15. Canalicular system and its relationship to intrahepatic bile ducts. The biliary ductules are modified hepatocytes. The bile canaliculi are represented as tubules for instructional purposes.

Downloaded From Vet-eBooks.com

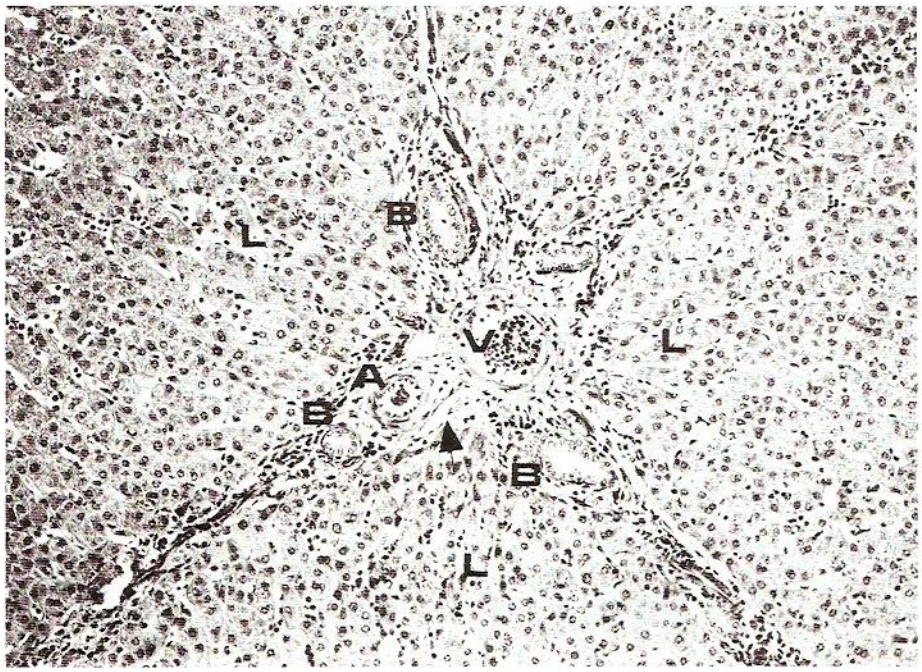

Figure 22-16. Portal area of the liver. This region is located between lobules *(L)*. The region contains branches of the bile duct *(B)*, hepatic vein *(V)*, and hepatic artery *(A)*. Lymphatic vessels *(arrow)* are also present. (×40.)

Figure 22-17. Section of a galline liver. This bird was injected with India ink antemortem. Phagocytic cells of the sinusoids have trapped some of the ink. The sinusoids *(arrows)* are outlined. C, Central vein. (×16.)

Downloaded From Vet-eBooks.com

The hepatic portal vein, originating from capillaries within the small intestine and spleen, supplies approximately four fifths of the hepatic blood volume. It enters the liver and divides into lobar and interlobular branches. The distribution of portal vein branches is similar to that of hepatic artery branches. Venous blood of the hepatic portal venules enters the hepatic sinusoids via inlet venules and mixes with the arterial blood of hepatic arterioles (Fig. 22-17).

Venous drainage is accomplished by a convergent sinusoidal system toward the **central vein.** The central vein, oriented perpendicular to the long axis of the lobule, drains into **sublobular veins.** The larger **hepatic veins** form through the confluence of sublobular venous drainage.

The dual blood supply accomplishes two interrelated functions: the hepatic artery, rich in metabolites and oxygen, supports the liver's metabolic requirements; the hepatic portal vein, laden with substances derived from the intestine and deficient in oxygen, delivers all absorbed substances to the liver. Substances within the portal system, including metabolites and toxic materials, are delivered to the stellate macrophages and hepatocytes for metabolic processing. The venous/arterial mixture (80%:20%) imposes potential restrictions upon hepatocytic function. Any compromise of the arterial blood supply can deprive the hepatocytes in a centrolobular position of required amounts of oxygen and result in their death.

The lymph vessels form an extensive network within both the interlobular and the capsular connective tissue. Despite the observation that more lymph exits the liver than from any other organ, lymphatic vessels do not occur within the lobules. The perisinusoidal space, though not a typical lymphatic channel, is where high volumes of lymph may form. Lymph within the perisinusoidal space probably flows retrograde to the normal flow within the sinusoids and is picked up by the interlobular lymph vessels.

The hepatic nerve supply consists primarily of nonmyelinated fibers of the sympathetic nervous system. Although most of the nerve fibers are vasomotor, some innervate the bile ducts, but none enter the lobules.

Liver units. Hepatic organization may be considered from three perspectives—morphological, secretory, and vascular. The **morphological** perspective makes the hepatic lobule the anatomical unit; the **secretory** perspective makes the hepatic portal lobule the functional unit; the **vascular** perspective makes the hepatic acinus the organizational unit.

The **hepatic lobule** has just been described .

The concept of a **portal lobule** considers the hepatic lobule from the perspective of its exocrine secretory function (Fig. 22-18). All bile canaliculi drain into interlobular bile ducts. A large interlobular bile duct in the portal area, draining the exocrine secretions from adjacent hepatic lobules, then becomes the central focus of a portal lobule.

The concept of a **hepatic acinus** considers the hepatic lobule as the vascular hepatic unit (Fig. 22-18). Hepatic portal venous and hepatic arterial branches radiate from the portal area and extend between hepatic lobules. The end branches of these vessels open into the hepatic sinusoids. Because the axis of the hepatic acinus is perpendicular to the portal area, the sinusoids and parenchyma of adjacent hepatic lobules and the interlobular blood vessels comprise an acinus. (The interlobular bile ducts also follow this pattern.) Three zones—**peripheral, intermediate,** and **centrolobular**—are identifiable based upon their proximity to interlobular vessels.

The insights afforded by this perspective are significant in pathology. Certain hepatic diseases occur in a zonular pattern related to the end branches of interlobular vessels.

Histophysiology of the Liver

Synthesis. Hepatocytes synthesize many substances for export—albumin, fibrinogen, α- and β-globulins, lipoproteins, and cholesterol. Glycogen is synthesized from glucose **(glycogenesis)** and stored in the hepatocytes. The release of glucose from glycogen stores **(glycogenolysis)** occurs upon somatic demand. Lipids and vitamins A, D, K, and B-complex are stored and released similarly. Proteins do not seem to be stored in the liver but are secreted into the blood as they are synthesized.

Excretion—biliary secretions. The liver synthesizes and stores many products eventually secreted into the blood and biliary system. The excretory functions of the liver relate to its synthesis and secretion of substances entering the bile. Bile secretion comprises the exocrine hepatic function. The primary constituents of bile are the **bile salts** (Na^+ and K^+ salts of **glycocholic** and **taurocholic acid**). **Cholic acid,** formed from cholesterol, is conjugated to glycine or taurine to form the bile salts. These salts then emulsify fats in the small intestine, form water-soluble complexes with lipids **(micelles)** in the small intestine to facilitate lipid absorption, and activate intestinal lipases.

Bilirubin, a bile pigment derived from hemoglobin metabolism, is conjugated to a glucuronide by hepatocytic **glucuronyl transferase** (Fig. 12-8). It is the pigmentary part of hepatocytic exocrine secretions, and its conjugation to glucuronic acid is an important hepatic biotransformation function.

Cholesterol, fats, phospholipids, electrolytes, and other organic compounds are components of bile. Selective reabsorption of some of these and their subsequent resecretion by the liver are achieved through the **enterohepatic circulation.**

Biotransformation. Many biologically active and/or toxic compounds are produced by, injected into, or absorbed within the body. Many are altered by the liver to change their toxicity, reduce their activity, or facilitate their elimination. Some hepatic activities cause particular drugs to become more toxic after their metabolism. **Biotransformation** better describes hepatic activities that alter and eliminate these compounds.

Biotransformation of chemical compounds occurs within the SER, mitochondria, and cytosol of hepatocytes. The reactions can be divided into two categories, synthetic and nonsynthetic. **Synthetic (conjugation) reactions** in the cytosol couple substances to endogenous reactive compounds—glucuronide, acetic acid, sulfate, amino acids. **Nonsynthetic reactions** involving the cytosol, SER, and mitochondria include oxidative, reductive, and hydrolytic reactions.

Ethylene glycol is oxidized by **alcohol dehydrogenase** to **oxalic acid,** which chelates calcium. The complex becomes toxic to the kidneys.

Biotransformation reactions essentially increase a compound's water solubility and polarity. Because the compound becomes less lipid-soluble, it is unable to penetrate cell membranes. Its inactivation and elimination are achieved. The phagocytic function of stellate macrophages complements the biotransformation activity of hepatocytes.

General metabolism. The liver is involved in all aspects of carbohydrate, fat, and protein metabolism.

Gluconeogenesis, the synthesis of glucose from **glucogenic amino acids,** citric acid cycle intermediates, and lactic acid, is an aspect of hepatocytic carbohydrate metabolism.

Most of the **β-oxidation** of fat occurs in hepatocytes. **Ketone body formation** also occurs in them.

Protein metabolism includes many diverse functions performed by the liver—deamination, production of keto acids, synthesis of nonessential amino acids, transamination. **Deaminase reactions** and **keto acid production** are important in lipid and carbohydrate synthesis (ketogenic and glucogenic amino acids, respectively): **ketogenic amino acids** yield acetyl–coenzyme A and can form ketone bodies (acetoacetate); **glucogenic amino acids** yield glucose precursors and are integral components of glucose metabo-

Downloaded From Vet-eBooks.com

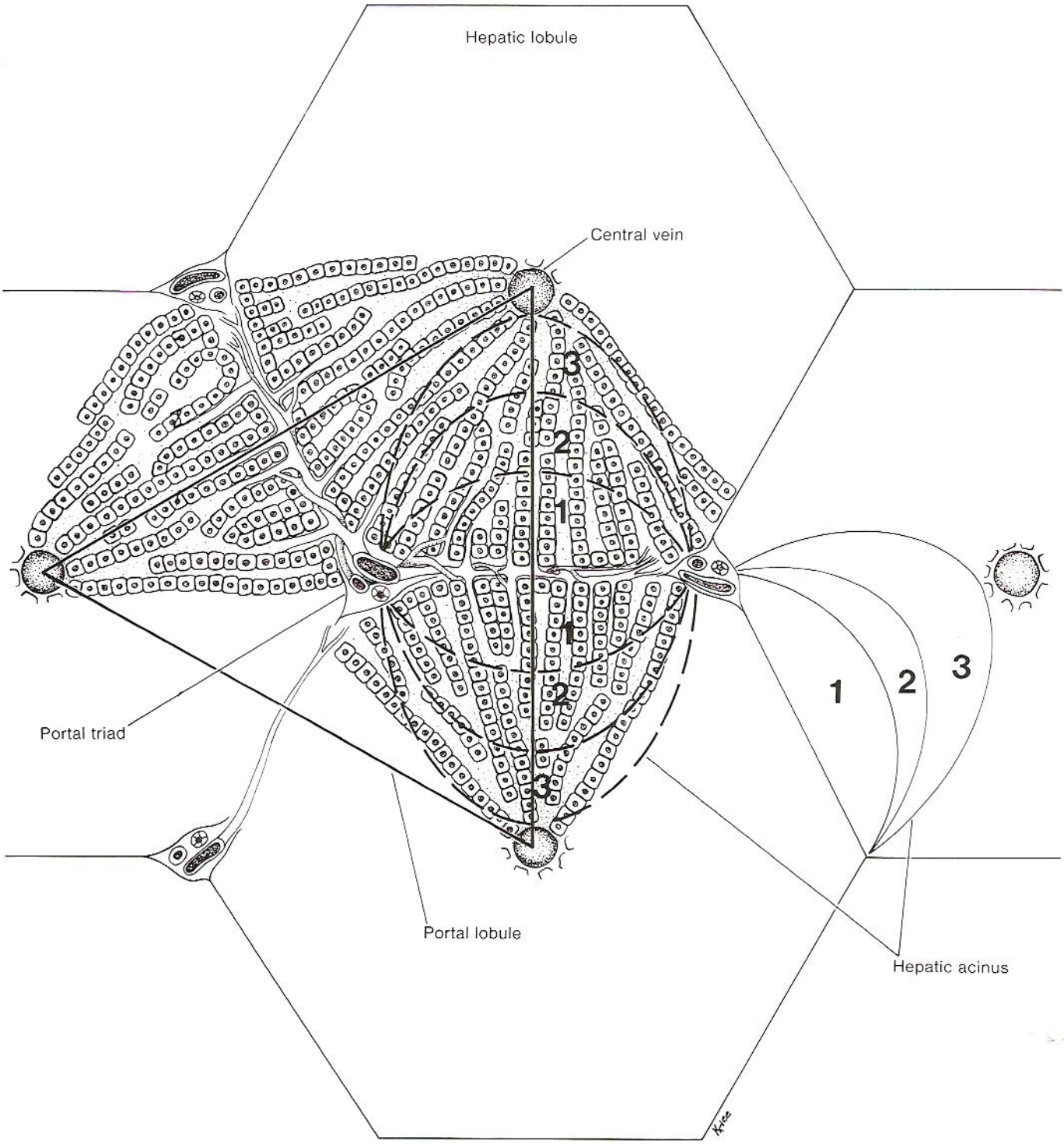

Figure 22-18. Organization of the liver. This may be considered from the standpoint of its structure (hepatic lobule), exocrine activity (portal lobule), or vascular supply (hepatic acinus). The primary landmarks of hepatic lobules are the central veins. The primary landmarks of portal lobules (outlined as a *triangular area*) are the interlobular bile ducts. The primary landmarks of hepatic acini are the zones of contiguous lobules supplied by the same interlobular vessels. The zone closest to the interlobular region *(1)* has the best blood supply, the zone closest to the central vein *(3)* the poorest.

Downloaded From Vet-eBooks.com

lism. In addition, the liver is capable of **nonessential amino acid synthesis,** and it can convert one amino acid to another through **transaminase reactions: alanine aminotransferase (ALT)**, a liver-specific transaminase in carnivores, is used in diagnostics to determine liver function; the enzyme leaks from damaged hepatocytes, and its elevation in the serum can be measured.

The formation of **urea** within hepatocytes is the way the body excretes nitrogenous waste products. Urea, contributing to the renal countercurrent mechanism, influences urine concentration.

The liver plays a passive role in vitamin storage, but its bile secretion is essential for fat-soluble vitamin (A, D, E, K) absorption from the intestinal tract. The liver assumes an active role in vitamin D metabolism.

Regeneration. The mitotic potential of hepatocytes is retained throughout life. Surgical extirpation of part of the liver is followed by a rapid restoration of its original mass. Increased mitosis and cellular hypertrophy account for the restored mass.

Although acute damage from toxic substances may be followed by complete organ recovery, chronic exposure usually results in altered organ function, decreased organ size, and increased intrahepatic fibrous connective tissue **(cirrhosis).**

GALLBLADDER

General characteristics. The **gallbladder** is a diverticulum of the common bile duct. Its lamina epithelialis mucosae is simple columnar epithelium (Fig. 22-19), its lamina propria-submucosa loose collagenous tissue, and its tunica muscularis randomly oriented smooth muscle fibers. Its tunica serosa is typical. In dogs and cats the tunica mucosa is so folded **(mucosal crypts)** that the invaginations are often misinterpreted as simple glands. Glands occur in the bile ducts and gallbladder of certain species, notable the ox.

The **hepatic, cystic,** and **common bile ducts** are structurally similar to the gallbladder, and their mural smooth muscle is disposed in latitudinal and longitudinal layers.

Functional correlates. The gallbladder stores, concentrates, acidifies, and delivers bile to the duodenum upon demand. Bile is prevented from entering the duodenum by a sphincter, a smooth muscle modification surrounding the common bile duct as it passes through the duodenal wall. The sphincter remains closed during fasting and forces bile from the hepatic ducts and common bile duct into the cystic duct and gallbladder. When food enters the mouth, the tone of the sphincter decreases. **Cholecystokinin** is released from intestinal cells by stimulation from fatty acids, acid, protein digestive products, and Ca^{++} in the duodenum. Sphincter relaxation and contraction of the smooth muscle of the gallbladder and associated ducts result from cholecystokinin secretion. Substances causing the gallbladder to contract are called **cholagogues.** The smooth muscle of the gallbladder and ducts is innervated by both divisions of the autonomic nervous system.

Figure 22-19. Bovine gallbladder. The columnar epithelium is underlaid by a typical lamina propria submucosa. (×40.)

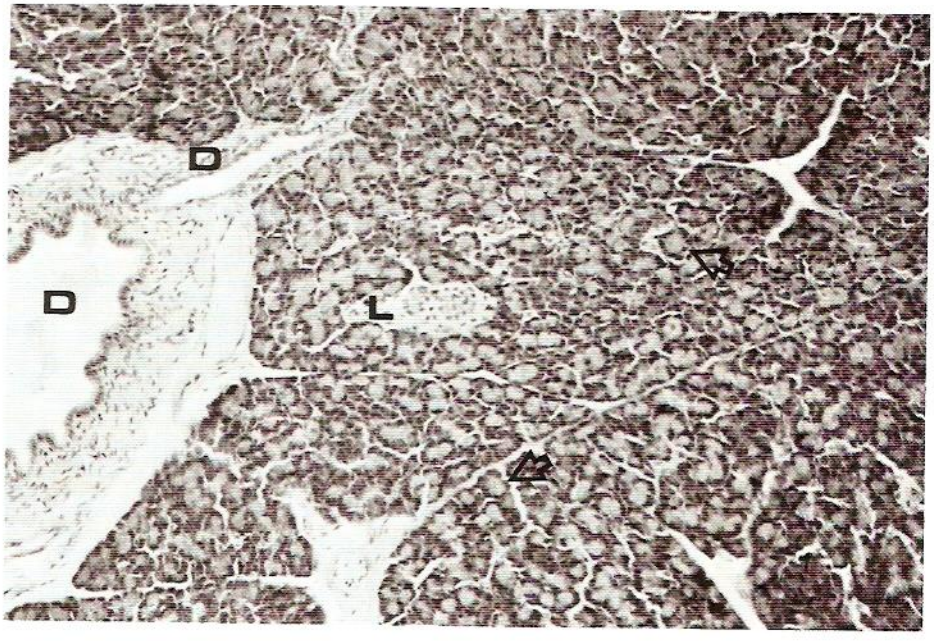

Figure 22-20. Section of a canine pancreas. Most of the gland consists of exocrine adenomeres *(arrows)* and a duct system *(D). L,* Pancreatic islets. (×40.)

EXOCRINE PANCREAS

General characteristics. The pancreas is a compound, tubuloalveolar glandular diverticulum of gut epithelium (Fig. 22-20). It is both an exocrine and an endocrine organ. The exocrine part is similar to the salivary glands (Fig. 22-21)—the main differences being its special glandular epithelium, the absence of striated ducts and basket cells, and the presence of endocrine tissue.

Downloaded From Vet-eBooks.com

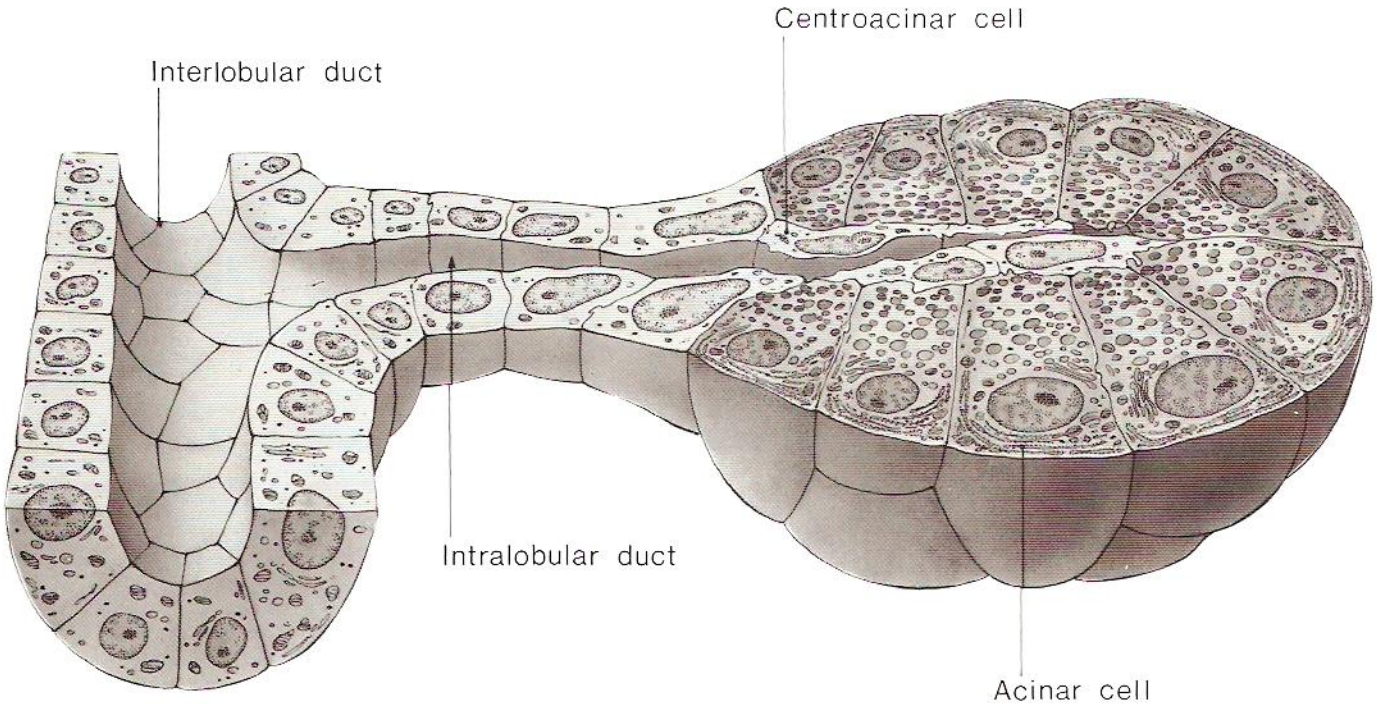

Figure 22-21. Pancreatic adenomere and associated ducts. (From an illustration courtesy R.A. Kainer.)

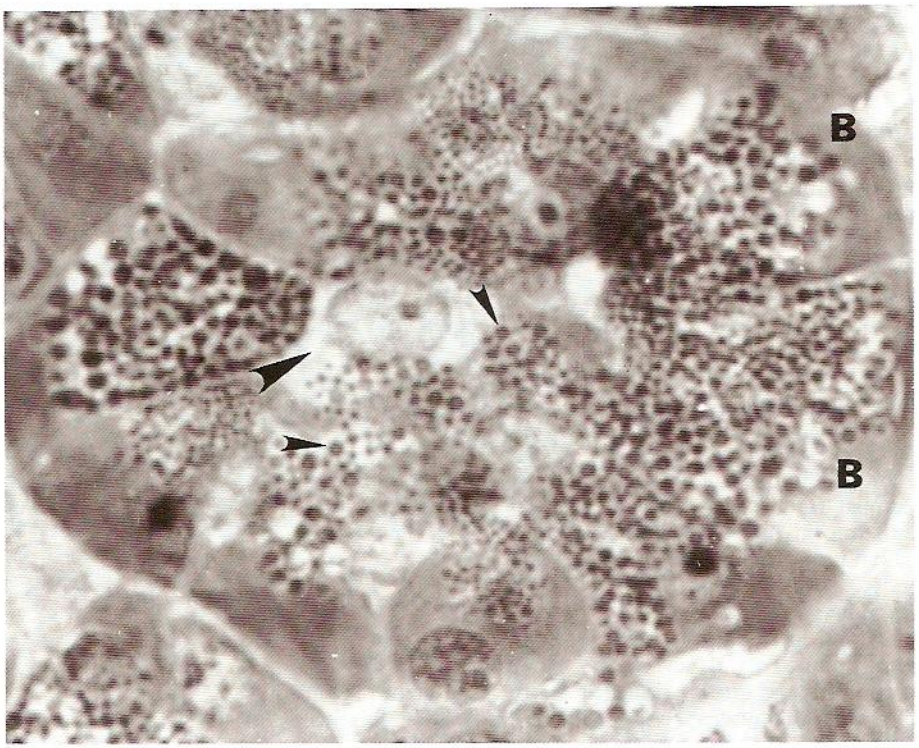

Figure 22-22. Adenomeres of a canine pancreas. This 2 μm plastic-embedded section has excellent detail. Compare it with Figure 22-21. Zymogen granules *(arrowheads)* are well-preserved. The basophilia *(B)* of the basal portion of the cell is obvious. *L*, Lumen of an acinus. (×160, glycol methacrylate–embedded section.)

Downloaded From Vet-eBooks.com

Pancreatic exocrine cells are conical or pyramidal (Fig. 22-21). Although they resemble typical serous cells, they differ basally.

The exocrine region possesses radial striations and is basophilic (Plate II, *10*) due to the accumulation of mitochondria and RER. Cellular nuclei are usually in a parabasal position, and a supranuclear pale-staining region (Golgi zone) may be apparent. The acidophilic lumen usually contains **zymogen granules** (Fig. 22-22), which accumulate during fasting and are extruded during digestion.

The adenomere opens into a small **intercalated duct** lined by squamous or cuboidal epithelium (Fig. 22-21). The ductular epithelium does not, however, begin at the termination of the acinar cells; rather a variable amount of overlap exists. As such, the lining cells of the duct reside, initially, upon the secretory cells of the acinus. The cells lining this surface are called **centroacinar cells.** They do not seem to impair the secretory process, but their significance is not understood.

As the duct system becomes confluent, a change from cuboidal to columnar epithelium occurs. The epithelium of the larger ducts may contain goblet cells as well as simple, branched, tubuloalveolar, mucous glands.

A dense collagenous capsular tissue divides the gland with connective tissue septa. The finest connective tissue is associated with the adenomeres and smaller ducts, and it becomes coarse and continuous with the septal connective tissue.

Functional correlates. **Pancreatic juice** is an alkaline fluid (pH, 8) containing many essential digestive enzymes—**trypsin, chymotrypsin, carboxypeptidases A and B, elastase, ribonuclease, deoxyribonuclease, phospholipase, esterase, collagenase,** and **amylase.** The proteolytic and lipolytic enzymes are secreted as enzyme precursors to prevent digestion of the cells in which they are synthesized. **Trypsinogen,** the inactive form of trypsin, is activated by the proteolytic enzyme **enterokinase** released from the intestinal mucosa. Once activated, trypsin causes other trypsinogen molecules as well as **chymotrypsinogen** (the inactive form of chymotrypsin) to become active. Trypsin also activates **prophospholipase A** into the active form, **phospholipase A.**

The release of activated enzymes into pancreatic tissue, as occurs in **pancreatitis,** can have devastating effects upon the organism. Phospholipase A splits a fatty acid from lecithin, forming **lysolecithin.** Lysolecithin causes damage to cellular membranes. The activation of other pancreatic enzymes can digest cellular components, destroy the pancreas, and damage other visceral organs after leakage into the peritoneal cavity. Serum elevations of lipase and amylase are suggestive of pancreatic disease.

Many electrolytes (Na^+, K^+, Ca^{++}, Mg^{++}, Cl^-, $SO_4^=$, $HPO_4^=$, HCO_3^-) comprise pancreatic juice; however, the major salt secreted by the pancreas is sodium bicarbonate, which produces the alkalinity of pancreatic juice. $NaHCO_3$ neutralizes the acidity of fluids entering the duodenum.

Neural and hormonal mechanisms regulate pancreatic exocrine secretion. Parasympathetic stimulation via the vagus nerve (X) causes the secretion of small amounts of an enzyme-rich pancreatic juice. The mechanisms of the cephalic phase of gastric digestion may also stimulate pancreatic secretion.

The presence of acid in the duodenum causes the release of **secretin** from the intestinal mucosa. Secretin influences the intralobular ducts, causing the release of a thin, watery, bicarbonate-rich, enzyme-poor pancreatic secretion. Neutralization of the acidity reduces secretin release and then reduces pancreatic activity. The release of cholecystokinin from intestinal cells causes the flow of an enzyme-rich pancreatic juice. The hormonal activation of pancreatic activity is the primary mechanism of regulation.

ADDITIONAL READINGS

Bailey CB, Balch CC: Saliva secretion and its relation to feeding in cattle, *Br J Nutr* 15:371, 1961.

Burkel WE, Low FN: The fine structue of rat liver sinusoids, space of Disse and associated tissue space, *Am J Anat* 118:769, 1966.

Caro LG, Palade GE: Protein synthesis, storage, and discharge in the pancreatic exocrine cell. An autoradiographic study, *J Cell Biol* 20:473, 1964.

Elkholm R, Edlund Y: Ultrastructure of the human exocrine pancreas, *J Ultrastruct Res* 2:453, 1959.

Elias H, Sherrick JC: *Morphology of the liver,* New York, 1969, Academic Press.

Farquahr MG: Progress in unraveling pathways of Golgi traffic, *Ann Rev Cell Biol* 1:477, 1985.

Hall RL: Laboratory evaluation of liver disease, *Vet Clin North Am* 15:3, 1985.

Kelly RB: Pathways of protein secretion in eukaryotes, *Science* 230:25, 1985.

Loud AV: A quantitative stereological description of the ultrastructure of normal rat liver parenchymal cells, *J Cell Biol* 37:27, 1968.

Rappaport AM: The structural and functional unit in the human liver (liver acinus), *Anat Rec* 130:673, 1958.

Shackleford JM, Wilborn WH: Ultrastructure of bovine parotid glands, *J Morphol* 127:453, 1969.

Swenson MJ (ed): *Duke's Physiology of domestic animals,* ed 9, Ithaca NY, 1977, Comstock Publishing.

Trotter NL: A fine structure of lipid in mouse liver regenerating after partial hepatectomy, *J Cell Biol* 21:233, 1964.

Wood RL: Evidence of species differences in the ultrastructure of the hepatic sinusoid, *Z Zellforsch* 58:678, 1963.

Yamada E: The fine structure of the gallbladder epithelium of the mouse, *J Biophys Biochem Cytol* 1:444, 1955.

Downloaded From Vet-eBooks.com

CHAPTER 23

Urinary System

KIDNEY

Functional considerations. The kidney and associated urinary passages **filter** blood, **remove** waste products, **recover** useful metabolites, **store** fluid waste, and **transport** that waste to the exterior. The kidney **regulates** fluid volume, acid/base balance, and electrolyte composition. It also functions as an endocrine organ by secreting **renin, renal erythropoietic factor (erythrogen),** and active metabolites of vitamin D.

Organization. The kidney consists of a **cortex** and a **medulla** separated at the **corticomedullary junction.** It is a compound, tubular gland composed of **uniferous tubules.** In some species only one lobe exists; in others the lobes may persist or secondarily fuse.

A lobe has a medullary and a cortical component. The medullary component is the **pyramid,** whose broad base contacts the cortex. One or more pyramids may join to form a **papilla,** the rounded, apical portion of the pyramids projecting into a minor calyx (Gr *kalyx,* shell or pod). The tip of the papilla is fenestrated **(area cribrosa);** the foramina are the openings of uriniferous tubules into the calyces or renal pelvis.

Swine and large ruminants have **multipyramidal** or **multilobar** kidneys (Fig. 23-1). A papilla projects into a **minor calyx;** minor calyces fuse to form **major calyces;** the calyces are continuous with the ureter. **Unipyramidal** or **unilobar** kidneys occur in carnivores, small ruminants, and horses. The kidney has one lobe (cat) or one lobe fusing from several lobes developmentally (sheep, goats, horses). A single, broad-based papilla forms the **renal crest,** which is intimately associated with the expanded portion of the ureter, the **renal pelvis** (Fig. 23-1).

Tubular components. A uriniferous tubule consists of a **nephron** and a **collecting duct system** (Fig. 23-2). The kidneys of a medium-sized dog may contain 800,000 nephrons. The nephron is that part of the uriniferous tubule producing the urine. It consists of a **glomerular capsule, proximal convoluted tubule, nephron loop,** and a **distal convoluted tubule.** A tuft of arterial capillaries (the **glomerulus**) and the **glomerular capsule** comprise a **renal corpuscle.** The duct system, which collects, concentrates, and transports urine, consists of **arched collecting tubules, straight collecting tubules,** and **papillary ducts.**

Two distinct renal cortical regions are visible in histological sections. The **cortex proper** is separated by medullary rays (Fig. 23-3). The **labyrinth** contains renal corpuscles, proximal and distal convoluted tubules, and arched collecting ducts. A medullary ray consists of nephron loops and straight collecting tubules.

The medulla is divisible into an outer and an inner zone. The **outer zone** is juxtaposed to the cortex and contains loops of short nephrons and straight collecting tubules. The **inner zone** contains loops of long nephrons, straight collecting tubules, and papillary ducts.

Development. Renal development progresses through stages in which three systems evolve—**pronephros, mesonephros,** and **metanephros.** The metanephros is the definitive kidney originating from two embryonic anlagen, the metanephric blastema and the metanephric duct. The **metanephric blastema** (a derivative of mesoderm) gives rise to the nephron. The **metanephric duct** (a diverticulum of the mesonephric duct) gives rise to the collecting duct system, renal pelvis, minor and major calyces, and ureter.

Urogenital sinus development from the divided ventral portion of the cloaca accounts for the trigone of the bladder and urethra. The body and apex of the bladder develop from the initial part of the allantoic stalk. Urinary system differentiation is linked to genital system organogenesis. In males the **mesonephric duct** is "discarded" from the urinary system and used as the definitive genital tract. In females new ducts **(paramesonephric)** develop in close association with the mesonephric ducts and form the uterine tubes, uterus, and vagina.

Connective tissue and serosa. The kidney is covered by a loosely adherent capsule of dense collagenous tissue at-

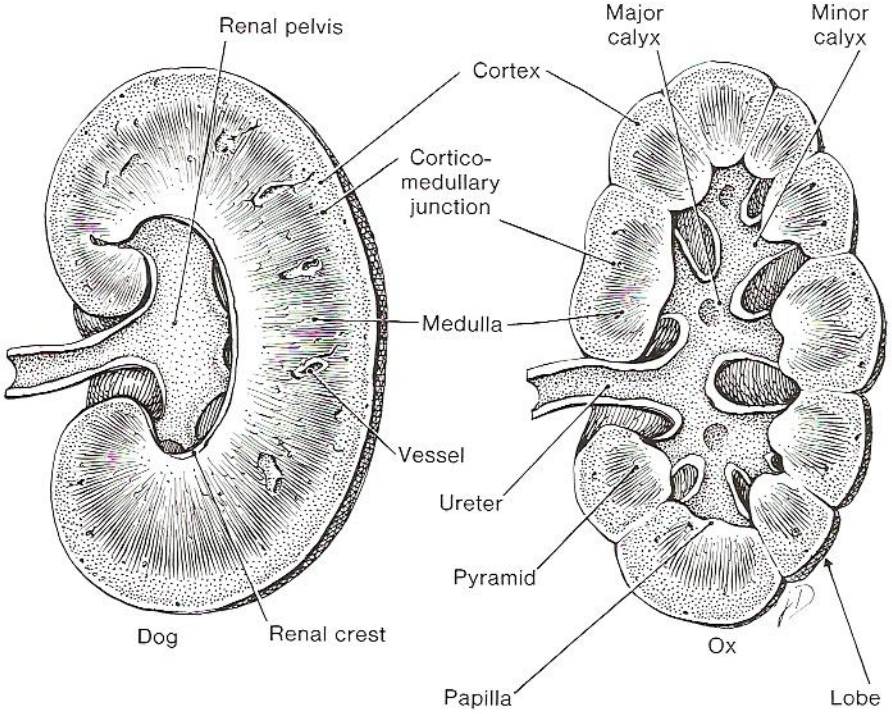

Figure 23-1. Kidney of a dog (unilobar) and an ox (multilobar).

Downloaded From Vet-eBooks.com

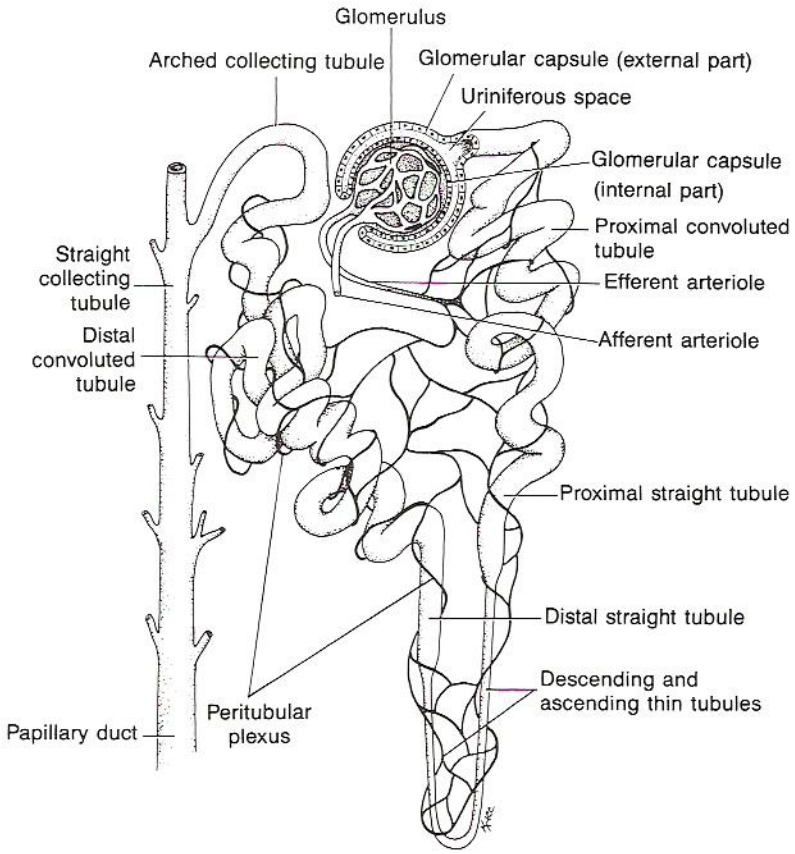

Figure 23-2. Nephron and collecting tubules.

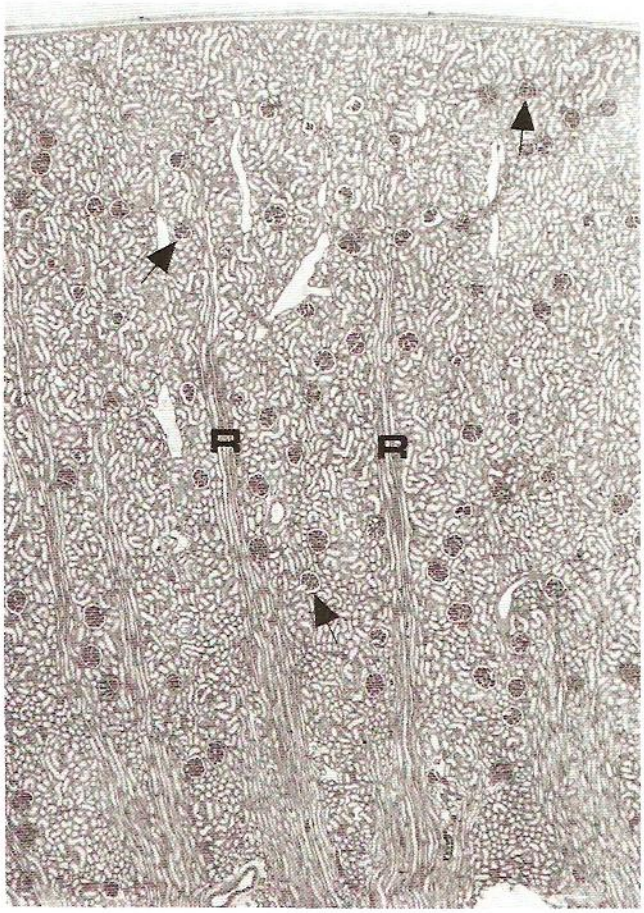

Figure 23-3. Cortex of a canine kidney. Many glomeruli *(arrows)* are scattered among the profiles of tubules. Medullary rays *(R)* are prominent. (×4.)

tached by loose collagenous tissue to the parenchyma. Smooth muscle may be present in the inner capsule. The capsular connective tissue continues with the adventitial coat of the ureter or renal pelvis at the renal hilus.

The connective tissue stroma of the renal parenchyma is scant. Reticular connective tissue forms a delicate meshwork around and between the uriniferous tubules. Adventitial tunics of blood and lymph vessels and nerves form part of the renal interstitium.

NEPHRON

Renal Corpuscle

Renal corpuscles are composed of a tuft of capillaries **(glomerulus)** and the expanded end of a nephron **(glomerular capsule)** (Fig. 23-4). The glomerulus connects the afferent arteriole to the efferent arteriole. The glomerular capsule consists of an **internal** and an **external** part lined by squamous or modified squamous cells. Typical squamous cells

Downloaded From Vet-eBooks.com

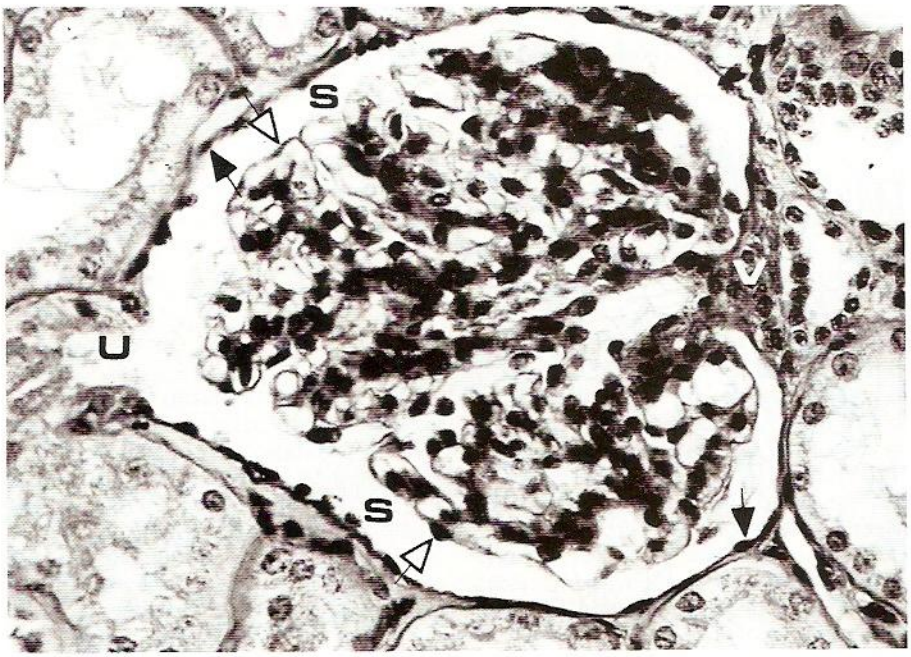

Figure 23-4. Renal corpuscle from a canine kidney. The corpuscle consists of a glomerular capsule and a glomerulus. The glomerular capsule has an external layer (part) *(solid arrows)* and an internal layer (part) *(open arrows)* of cells separated by the uniniferous space *(S)*. Vessels enter and leave the glomerulus at the vascular pole *(V)*. The external part of the glomerular capsule is continuous with the proximal convoluted tubule at the uriniferous pole *(U)*. (×100.)

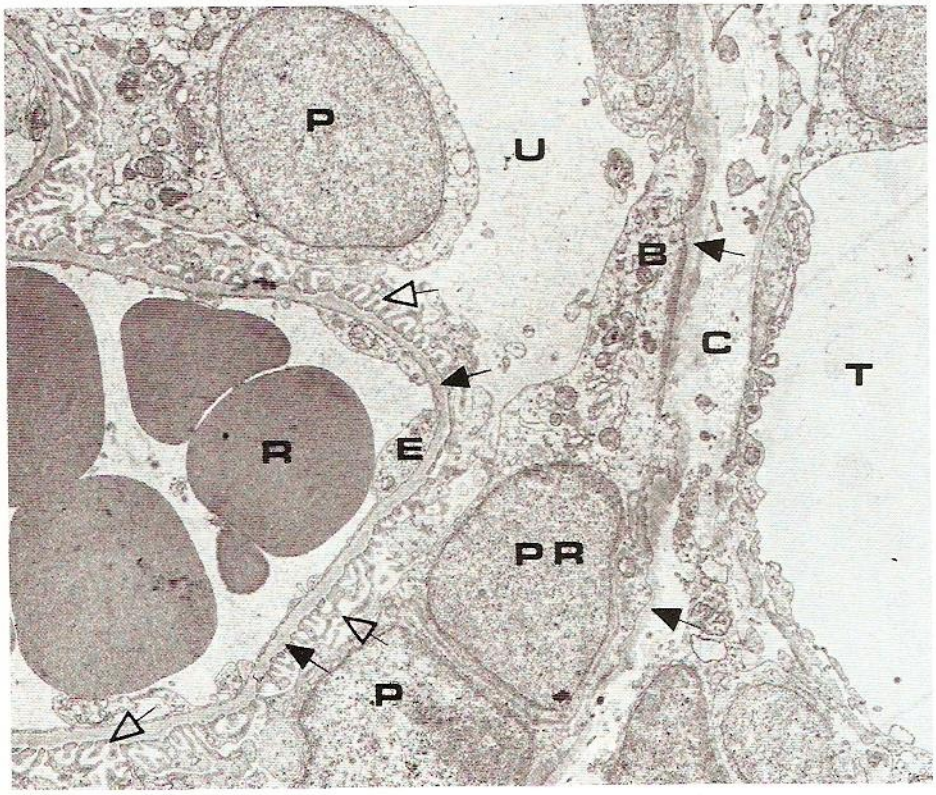

Figure 23-5. Electron micrograph of a portion of a glomerulus. Numerous podocytes *(P)* are close to a capillary laden with erythrocytes *(R)*. The podocytic processes *(open arrows)* are adjacent to the well-developed basal lamina *(solid arrows)*. One podocyte *(PR)* is reflected as the external part of the glomerular capsule *(B)*. The external part is bounded by a basal lamina *(solid arrows)* and connective tissue *(C)*. A portion of a uriniferous tubule *(T)* is adjacent to the renal corpuscle. *(E)*, Endothelium. (×6000.)

comprise the external part. Glomerular capillaries interdigitate with unique internal lining cells.

Internal lining cells—podocytes. The internal lining of the glomerular capsule is a modified simple squamous epithelium that may be difficult to distinguish from the capillary endothelium. The endothelial cells are fenestrated though covered by a complete basement membrane (Fig. 23-5). The internal lining cell bodies do not directly contact the basal lamina (Figs. 23-6 and 23-7) but are elevated from it; however, they do make contact through cytoplasmic processes (Fig. 23-6). Large cytoplasmic processes **(primary foot processes)** extend from the perikaryon of the internal lining cells parallel to the capillary long axis (Fig. 23-7). Minor **(secondary foot) processes** radiate from the primary ones and terminate in orderly feet upon a basal lamina. These secondary processes interdigitate with each other and are separated from adjacent secondary processes by **filtration slits** (Fig. 23-8). A thin **filtration membrane** (or **slit diaphragm**) extends across the filtration slits. Cells with foot processes (internal lining cells) are called **podocytes** (foot cells). The podocytes are aligned along the periphery of the capillaries, their foot processes contributing to the filtration barrier (Fig. 23-9).

Basal lamina and the filtration barrier. These components of the renal corpuscle effectively filter small molecules from the blood.

The **basal lamina,** positioned between the podocytic processes and glomerular endothelial cells (Figs. 23-5, 23-7 to 23-9, and 23-17), is two or three times thicker than most other basal laminae.

The **filtration barrier** has three features—endothelial fenestrations, podocytic slit diaphragms, and a basal lamina—that enable it to limit the passage of small molecules. The endothelial fenestrations (without diaphragms) permit most materials, except cells, to pass from the vascular bed. The podocytic slit diaphragms allow molecules with a diameter of about 9 nm to pass. The basal lamina allows the passage of molecules in the range of 6 nm. The rate of glomerular blood flow, the size and number of molecules, and the types of charges on the molecules all contribute to filtration efficiency.

Basal laminar materials (which include type IV collagen) seem to be formed continually in a laminar fashion by podocytes. Because the basal lamina does not normally thicken through life, new materials are added and removed. The mesangial cells may phagocytize old components of the basal lamina.

Mesangial cells. **Mesangial cells,** located between the glomerular capillary loops and enveloped by the basal lamina,

Downloaded From Vet-eBooks.com

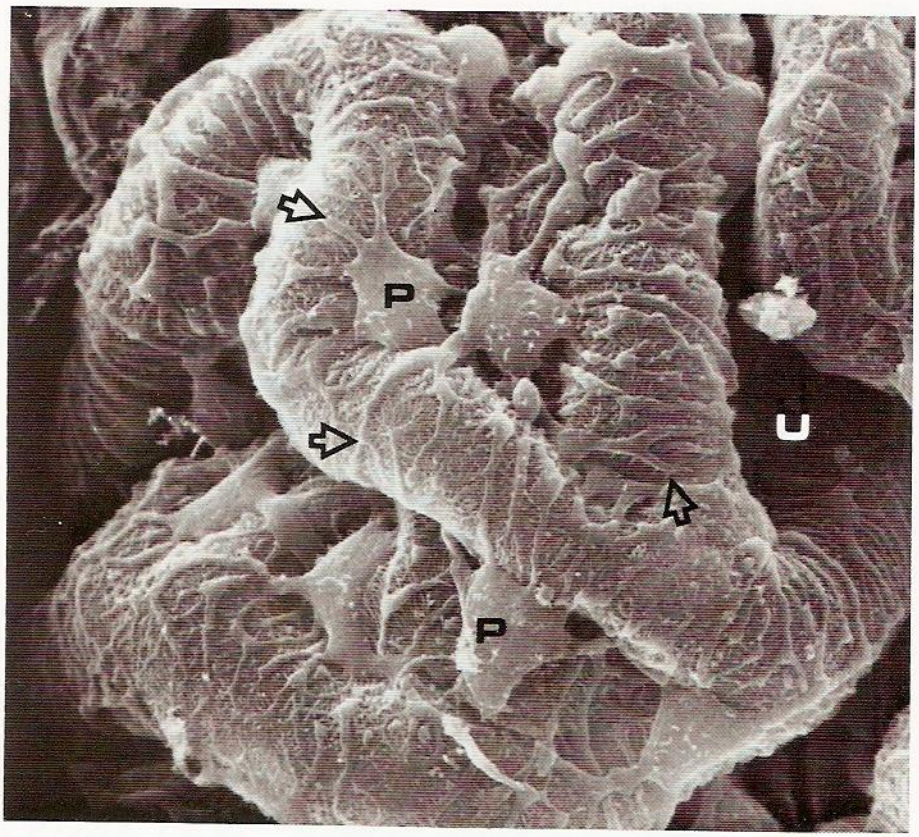

Figure 23-6. Scanning electron micrograph of a freeze fractured renal corpuscle from a canine kidney. Podocytes *(P)* have large or primary foot processes *(open arrows)* associated with the capillaries. Smaller (secondary) foot processes radiate from the primary foot processes and are separated by filtration slits. *U,* Uriniferous space. (×2000.) (Courtesy D.L. Eisenbrandt.)

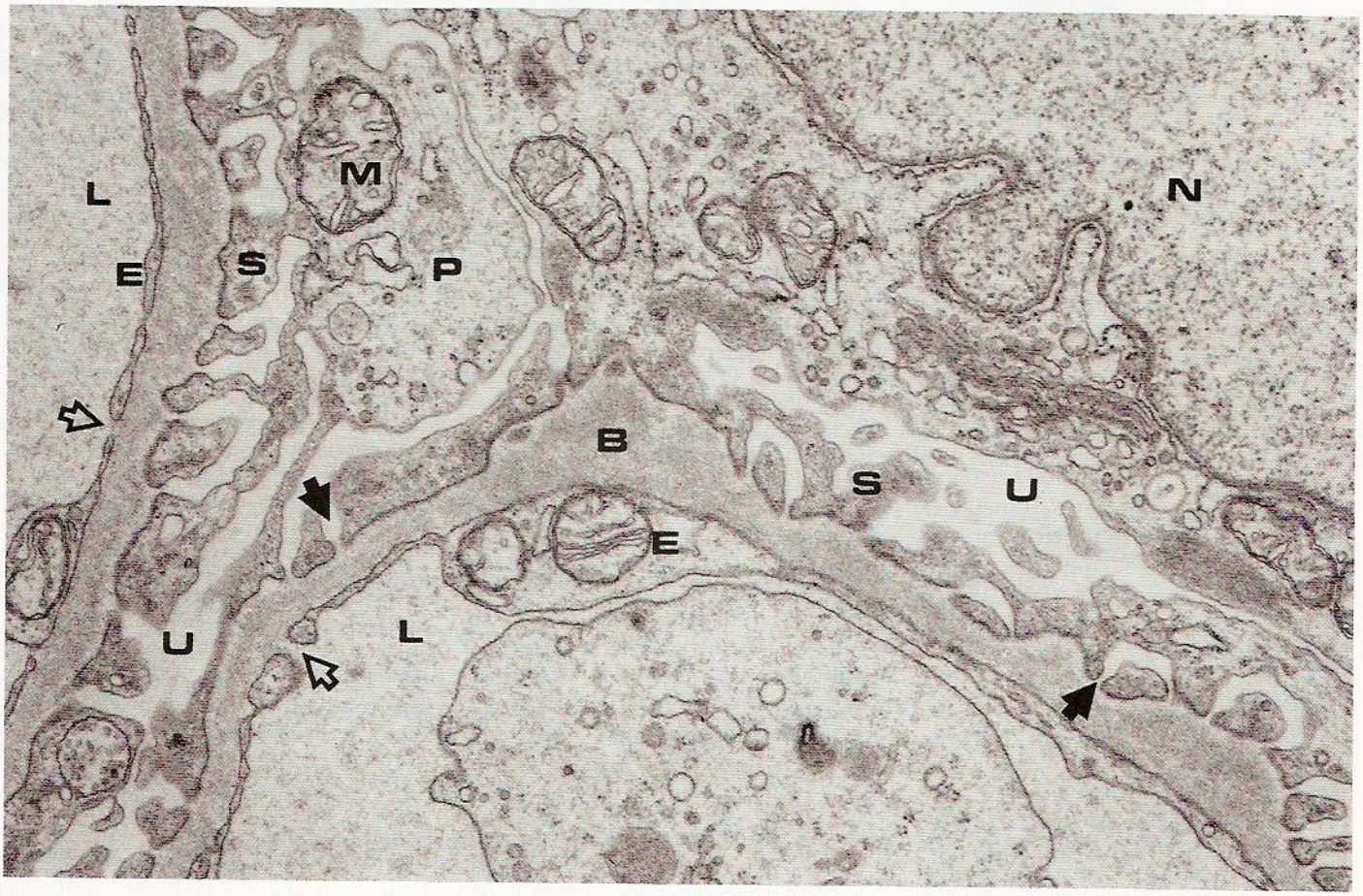

Figure 23-7. Electron micrograph of a podocyte and its processes. Primary foot processes *(P)* have secondary foot processes *(S)* radiating from them. Filtration slits *(solid arrows)* and capillary *(E)* fenestrations *(open arrows)* are apparent. *B,* Basal lamina; *N,* nucleus of podocyte; *M,* mitochondrion; *L,* capillary lumina; *U,* uriniferous space. (×23,000.)

Downloaded From Vet-eBooks.com

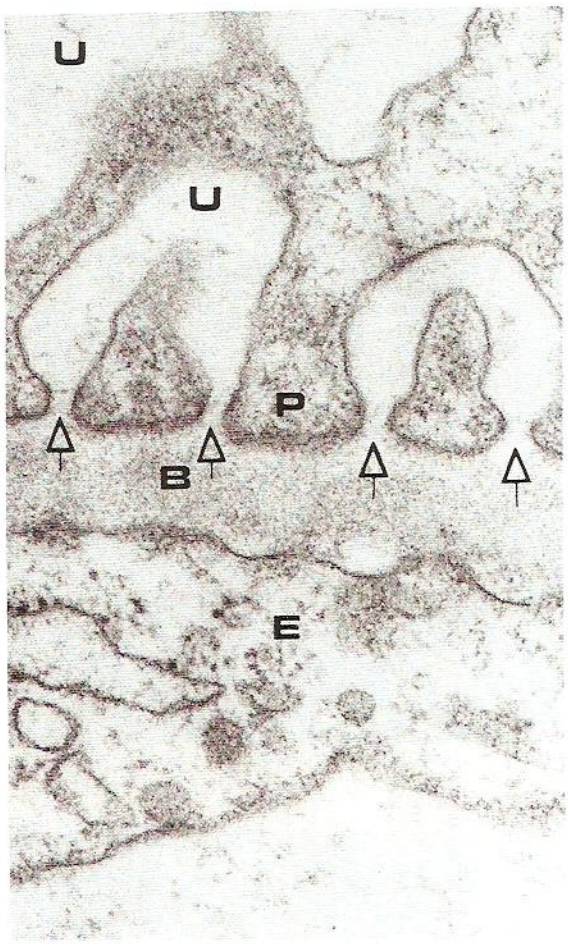

Figure 23-8. Electron micrograph of podocytic processes. Large foot processes have small pedicles *(P)* radiating from them. The pedicles contact the basal lamina *(B)*. Filtration slits *(open arrows)* separate adjacent pedicels. Note the filtration membranes *(left open arrow)*. *E*, Endothelium; *U*, uniniferous space. (×77,000.)

are mesenchymally derived and similar to pericytic cells occurring elsewhere in association with capillaries. Although their precise function has not been defined, they are phagocytic, removing particulate matter from the renal corpuscle. This phagocytosis may include the removal of old elements of the basal lamina as well as general cellular debris.

Mesangial cells also serve a supportive role. The podocytes and their basal lamina do not contact every capillary surface. The basal lamina and foot processes surround groups of capillary tufts. The intervening space is occupied by mesangial cells (Fig. 23-10).

External lining cells. The external layer of the glomerular capsule consists of typical squamous cells. Only their perikarya and nuclei are evident (Fig. 5-44). When PAS is used, a basement membrane is apparent between them and the periglomerular connective tissue (Fig. 5-43). The basement membrane separates external lining cells from surrounding elements. The squamous cells of the external layer continue with proximal convoluted tubule lining cells.

Vascular and urinary poles. Two distinct regions of the renal corpuscle are apparent in ideal sections—a vascular pole and a urinary pole (Fig. 23-4). The **vascular pole** is the region of entry and exit of the arterioles and the region in which the **juxtaglomerular complex** is located. The **urinary pole** is the point of continuity between the glomerular capsule and the proximal convoluted tubule. At this point the squamous epithelium of the parietal layer continues with the cuboidal epithelium of the proximal convoluted tubule.

Tubular Components

Proximal convoluted tubule. The **proximal convoluted tubule** is the longest, widest, and most developed segment of the nephron (Fig. 23-11). It is especially important because of the ease with which it is affected by disease processes and toxic substances. Lined by cuboidal cells with a well-developed brush border (especially obvious with PAS), it is a significant reabsorptive/secretory component of the nephron. Its basal surface resides upon a PAS-positive basement membrane. The basal portion of each of its lining cells is highly folded and contains many mitochondria. The mitochondria contribute to the apparent basal striations. Because their lateral borders are interdigitated, these cells are not easily distinguishable in light microscopic sections. The lateral borders are joined by a shallow belt of tight junctions and a deeper belt of intermediate junctions. The nuclei are spherical, small, and located in a basal or parabasal position. Varying physiology can contribute to an altered morphology of this segment, but generally the lumina are small and the tubules composed of cells with prominent brush borders.

Nephron loop. The proximal convoluted tubule continues into the **nephron.** The length of this segment varies and is indicative of the organism's ability to conserve water. The nephron loop consists of three portions—the **proximal straight tubule,** the **descending** and **ascending thin tubules,** and the **distal straight tubule.**

There are some variations in the nephron loop. Those nephrons in a juxtamedullary position have long thin segments with apices that are deep in the medulla and may extend into the apices of the medullary papillae. Peripherally positioned (subcapsular) nephrons have loops that extend only a short distance into the medullary region. The transition from cuboidal epithelium of the **proximal straight tubule** to squamous epithelium of the **descending thin segment** is abrupt. Because many blood and lymphatic capillaries occupy the medulla, you must look carefully to distinguish the thin segments from other tubules lined by simple squamous epithelium. The thin loop has a large lumen and more nuclei protruding into it than into the capillary lumina. The morphologies of the actual loop (Fig. 23-12) and the ascending and descending thin segments are similar. The transition from squamous epithelium of the **ascending thin segment** to cuboidal epithelium of the **distal straight tubule** is also abrupt. The distal straight tubule ascends to the vascular pole of the renal corpuscle. This portion of the nephron is positioned between the afferent and efferent arterioles. A cell condensation in part of the wall of this tubule at this point is called the **macula densa.** The tubule continues from its juxtacorpuscular position as the **distal convoluted tubule** (Fig. 23-13).

Distal convoluted tubule. Distal convoluted tubules are short and not encountered as frequently in sections as their proximal counterparts. Although they are smaller than proximal convoluted tubules, their luminal diameter/mural thickness ratios are greater than in the

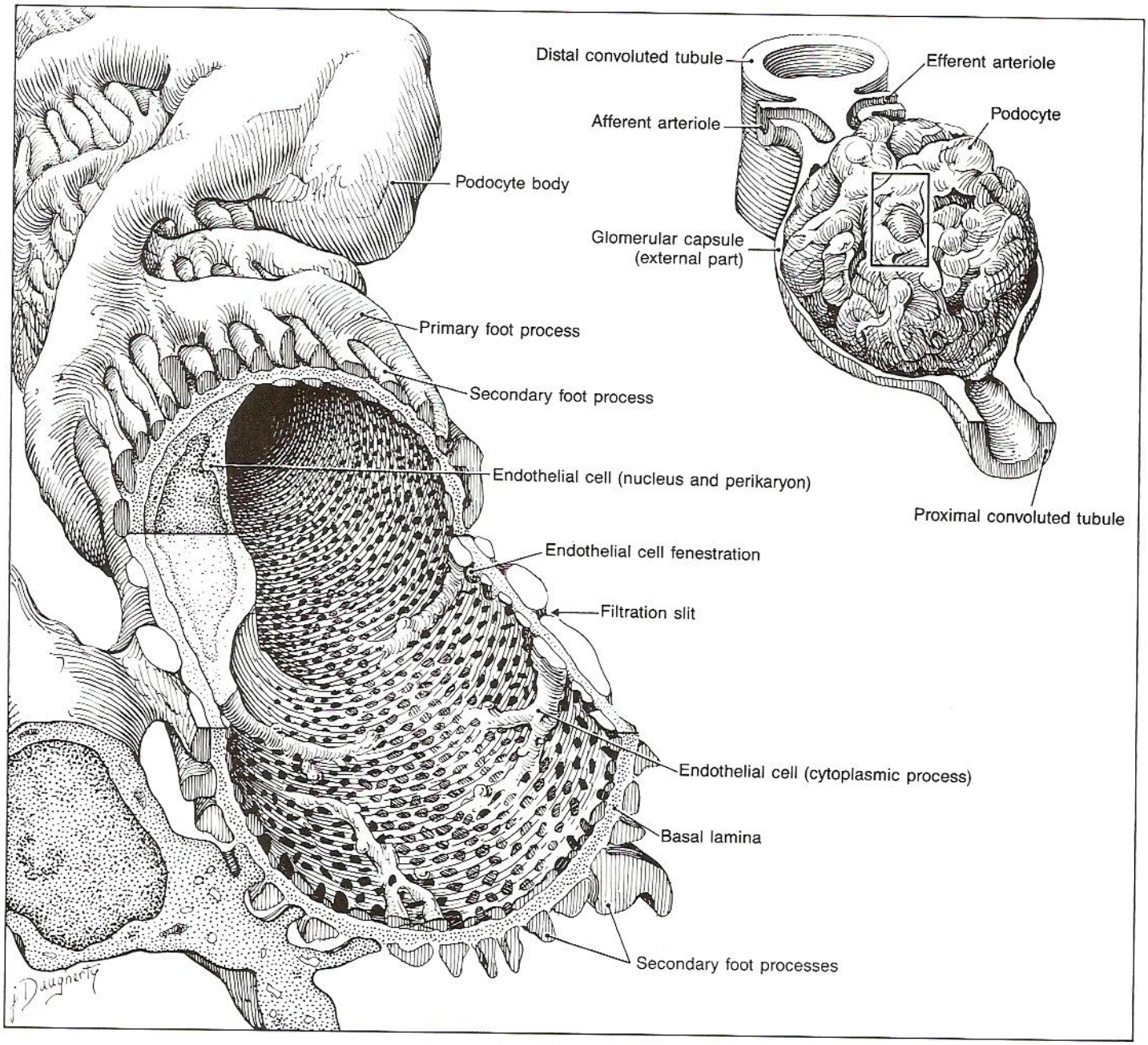

Figure 23-9. Renal corpuscle and podocytes as visualized with the scanning electron microscope.

proximal convoluted tubule. More cells line them, and the lateral cell borders are better defined than the cell borders of their proximal counterparts. The cells of distal convoluted tubules are less acidophilic than those of proximal tubules, and the nuclei are more centrally to parabasally located.

Collecting Duct System

The collecting duct system consists of straight ducts, connecting tubules, arched tubules, and papillary ducts.

Renal organization may be compared to glandular organization: the nephron is the adenomere; the connecting tubules and arched collecting ducts represent intralobular ducts; the straight collecting ducts compare with interlobular ducts; papillary ducts compare with lobar ducts.

Straight collecting ducts occupy medullary rays of the cortex and medulla. They extend from the cortex through the medulla to join with other straight collecting ducts and form large **papillary ducts.** Distal convoluted tubules join collecting ducts in two ways: superficially positioned nephrons empty directly into cortical collecting ducts via **connecting tubules;** midcortical and juxtamedullary nephrons join straight collecting ducts via **arched collecting tubules.** Connecting tubules of several nephrons join to form these arched tubules. The arched tubules course toward the capsule, turn, descend within medullary rays, and join the straight collecting ducts.

The collecting duct system throughout most of its course is lined by cuboidal epithelium. The epithelium of the connecting tubules, arched collecting tubules, and straight collecting ducts consists of cuboidal, pale-staining cells with large, round, dark nuclei. Their lateral cell margins are distinct. These light cells predominate, but dark cells are also observed. Dark cells have more mitochondria and polyribosomes than light cells do, and their number increases as the straight collecting duct continues into

Downloaded From Vet-eBooks.com

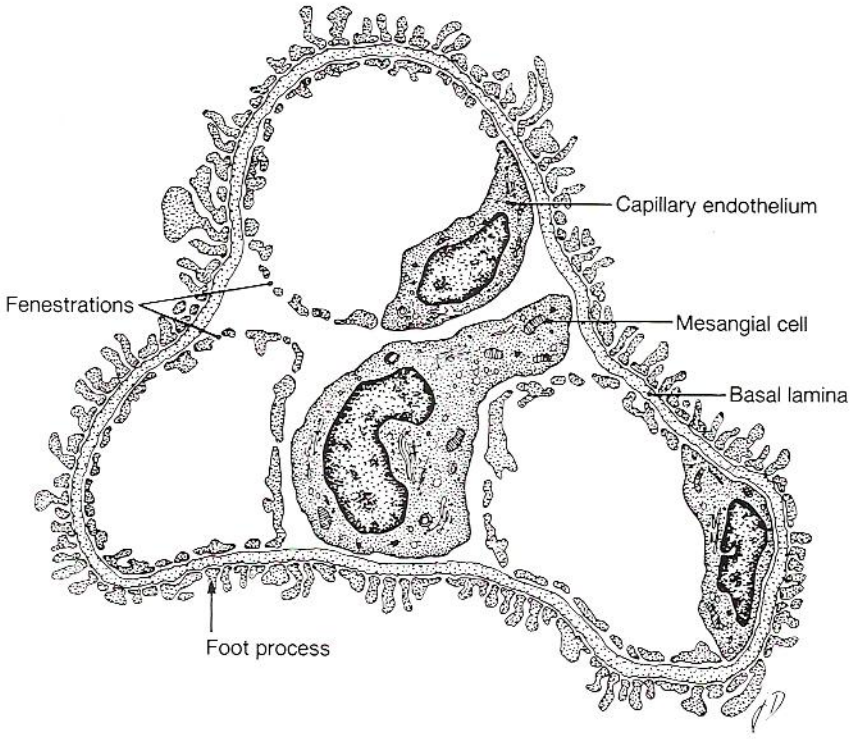

Figure 23-10. Relationship of mesangial cells to capillary endothelium and foot processes of podocytes. The basal lamina does not surround each capillary completely. Mesangial cells comprise the core of any capillary tuft without an intervening basal lamina.

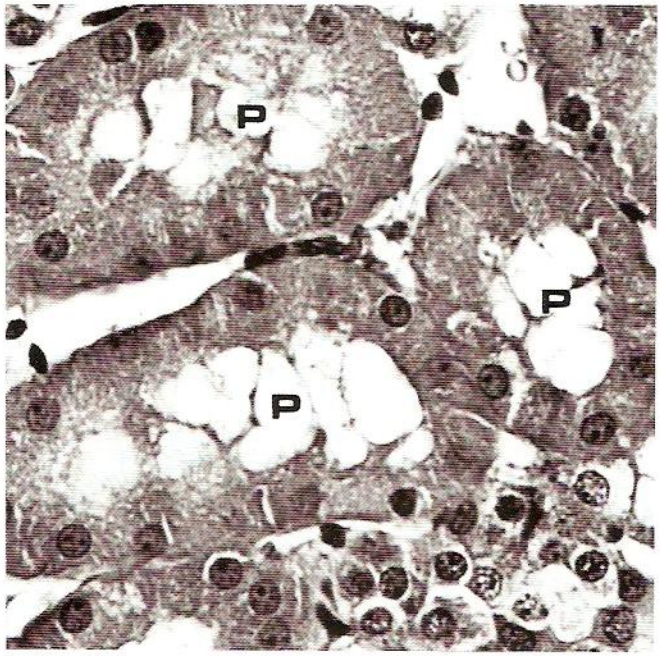

Figure 23-11. Proximal convoluted tubules of a canine kidney. The tubules *(P)* are lined by cuboidal cells. The brush border is not defined clearly. (×160.) (See Fig. 5-51.)

Downloaded From Vet-eBooks.com

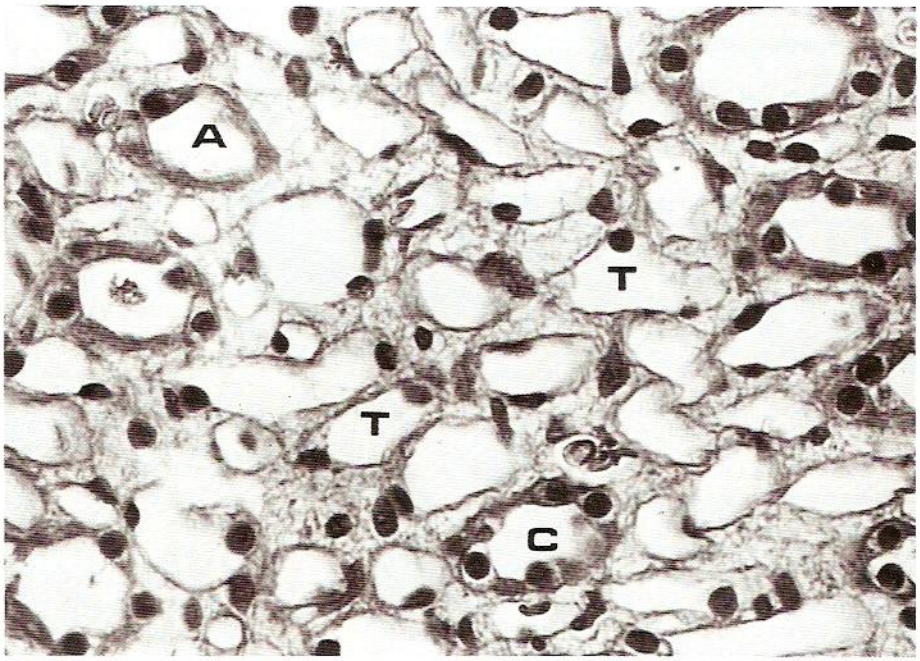

Figure 23-12. Medulla of a canine kidney. Thin segments of nephron loops *(T)*, ascending limbs *(A)* and collecting ducts *(C)* are indicated. (×160.)

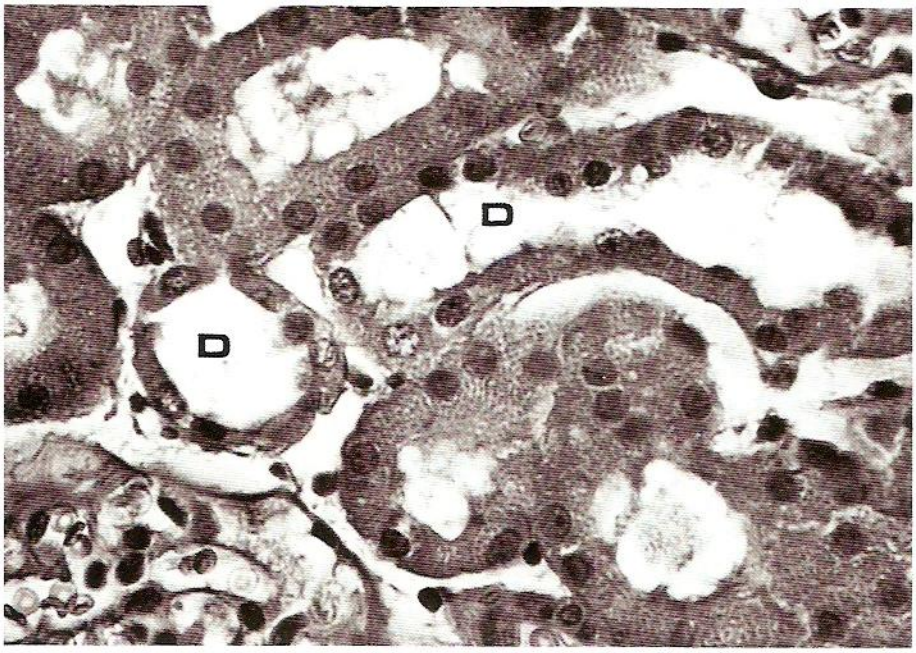

Figure 23-13. Distal convoluted tubules of a canine kidney. The tubules *(D)* are lined by cuboidal epithelium. (×160.)

Downloaded From Vet-eBooks.com

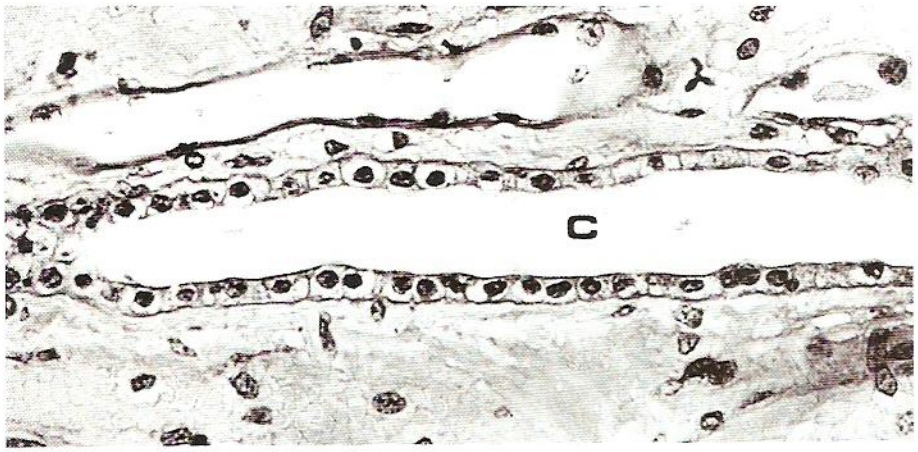

Figure 23-14. Collecting duct from an equine kidney. The duct *(C)* is lined by cuboidal epithelium. Note the clear cytoplasm and distinct lateral cell margins.

Figure 23-15. Area cribrosa of a feline kidney. The collecting ducts are confluent as papillary ducts *(solid arrows)* that open into the renal pelvis *(open arrows)* and form an area cribrosa. (×40.)

the medulla. Also the epithelial height increases within the medullary collecting ducts (Fig. 23-14).

Straight collecting ducts fuse within the inner zone of the medulla to form papillary ducts consisting of columnar epithelium (Fig. 23-15). As the ducts open into the renal pelvis or minor calyces, an **area cribrosa** is formed at the apices of the pyramids or along the renal crest. The ductal epithelium is reflected as the transitional epithelial lining of the intrarenal continuation of the ureter. In ungulates, transitional epithelium may extend a short distance into the papillary ducts.

Stromal Elements

Vasculature, lymphatics, and nerves. Blood is supplied by the **renal artery** (Fig. 23-16). Upon entering the hilus, this artery divides into **interlobar arteries.** The interlobar arteries, coursing parallel to the long axes of the pyramids, turn to follow the long axis of the kidney at the corticomedullary junction. From this point, they continue as the **arcuate arteries.**

The blood supply to the cortex is achieved through ascending or perpendicular branches of the arcuate artery, the **interlobular arteries.** These arteries course through the cortical labyrinth, giving rise to numerous short lateral branches, the **afferent arterioles.** The afferent arterioles enter the vascular pole of the glomerular capsule and divide into large capillary branches, the **glomerulus.** The glomerular capillaries form a loop and reunite as the **efferent arteriole,** which exits the glomerular capsule at the vascular pole (Fig. 23-2). **(Note: The glomerular capillary bed is within the arterial circulation.)** The efferent arteriole then divides into a capillary bed, forming a **peritubular plexus** around cortical uriniferous tubules.

The medullary blood supply originates from efferent arterioles exiting renal corpuscles close to the medulla. Vessels extending from these efferent arterioles descend into the medulla along straight paths and are called **false straight arterioles.** Vessels originating from the arcuate arteries to supply the medulla are called **true straight arterioles.** Capillary branches of the true straight arterioles enmesh and surround medullary uriniferous tubules to form a **peritubular plexus.** The straight arterioles, capillaries, and straight venules form the **vasa recta.**

The interlobular arteries continue to the surface and terminate as a **capsular plexus.** Renal venous drainage occurs through companion vessels to the arteries and their branches.

A superficial set of lymph vessels drains the capsular region; a deep set, distributed similarly to the blood vessels, drains the renal interstitium.

Although there are many unmyelinated sympathetic vasomotor fibers in the nephron, nerves are not demonstrable within the renal corpuscle. Some branches are intimately associated with the tubular epithelial cells, but they do not enter the epithelial lining. General visceral afferent fibers originate in the capsule, pelvis or calyx, and perivascular region. The precise distribution of parasympathetic fibers to and within the kidney has not been determined. Renal transplants demonstrate aptly that the kidney is able to function without extrinsic nerve supply.

Downloaded From Vet-eBooks.com

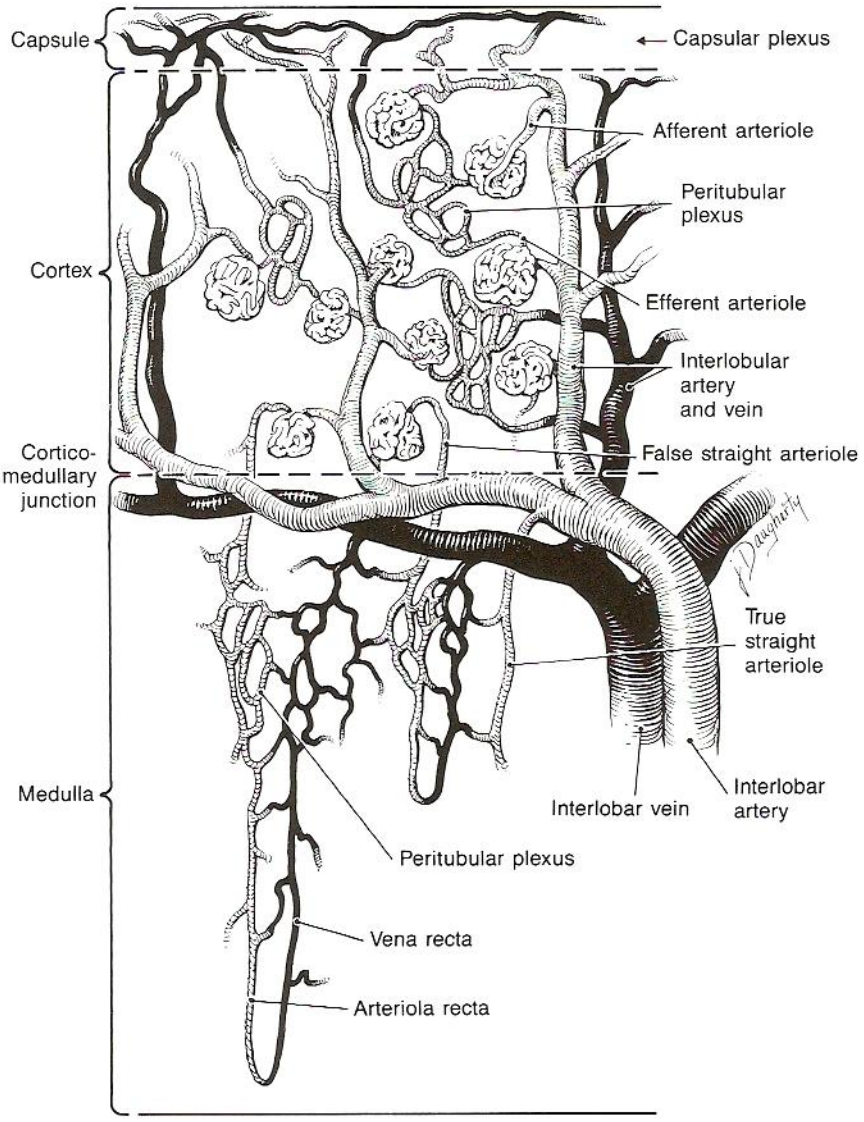

Figure 23-16. Vascular supply of the kidney.

Juxtaglomerular Complex

Histological components. A **juxtaglomerular complex** consists of the following (Fig. 23-17): afferent arteriole, efferent arteriole, macula densa, and extraglomerular mesangium. The smooth muscle of the afferent arteriole is modified as myoepithelial cells, the **juxtaglomerular cells,** that contain secretory granules in various stages of synthesis and storage. Although **granular cells** predominate, some **agranular cells** contribute to the myoepithelioid cuff. One pole of the juxtaglomerular cells contacts the basal lamina of afferent arterial endothelial cells; the other contacts the basal lamina of the macula densa cells in the distal convoluted tubule. **Extraglomerular mesangial (polkissen) cells** occupy the space between the afferent and efferent arterioles adjacent to the glomerulus. They are continuous with intraglomerular mesangium. The precise function of the extraglomerular mesangium is not understood.

The **macula densa** is part of the distal convoluted tubule. It consists of tall epithelial cells that are thinner than cells in other portions of the tubule. As a result the region appears as a dense spot (Fig. 23-18). Because of its strategic location in the distal convoluted tubule and its juxtaposition to the juxtaglomerular cells, the macula could be considered as having a sensory function; however, the precise relationships of its components in the juxtaglomerular complex are not known.

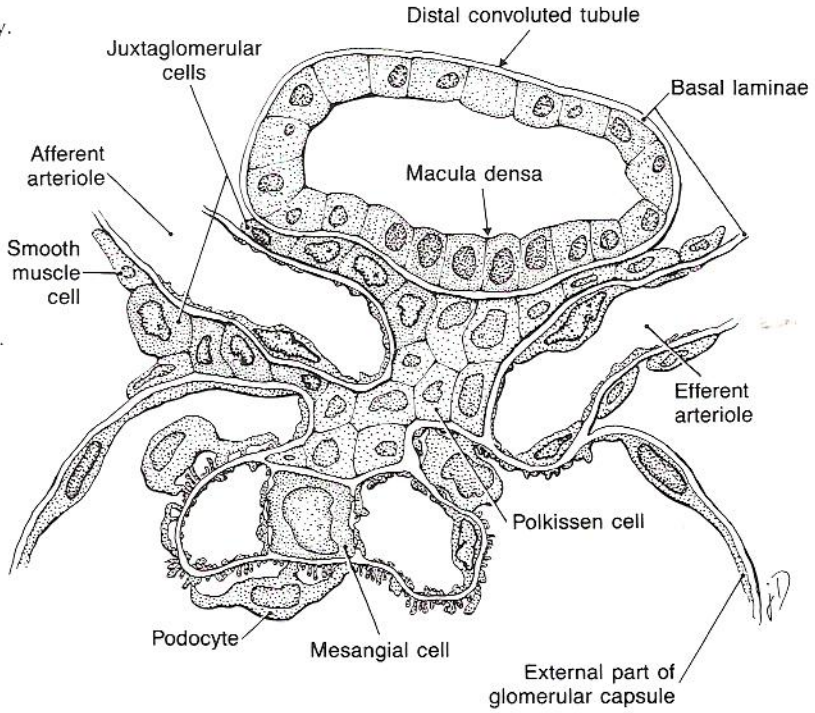

Figure 23-17. The juxtaglomerular apparatus.

Downloaded From Vet-eBooks.com

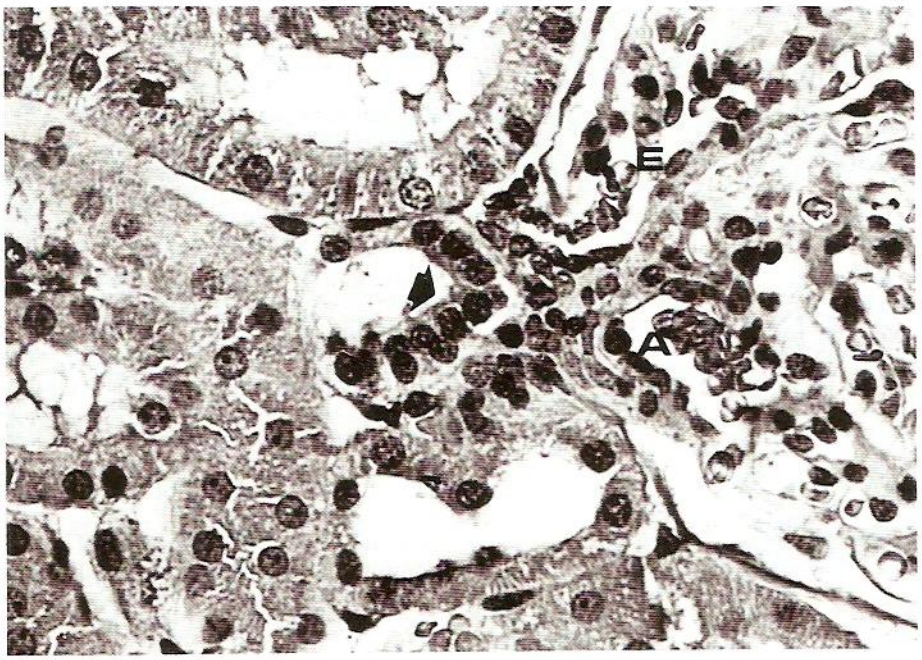

Figure 23-18. Macula densa of a canine kidney. The macula *(arrow)*, which marks the beginning of the distal convoluted tubule, is positioned at the vascular pole close to the afferent *(A)* and efferent *(E)* arterioles. The cells between it and the afferent and efferent arterioles are extraglomerular mesangial (polkissen) cells. (×160.)

Functional correlates. Granular juxtaglomerular cells secrete the proteolytic enzyme **renin.** Renin converts **angiotensinogen,** a plasma protein in the α_2-globulin fraction, to **angiotensin I.** Angiotensin I activation to **angiotensin II** occurs primarily in the lung through a **converting enzyme.** Angiotensin II is the most potent arterial constrictor substance known. It also reduces vascular volume through venous constriction. Its pressor activity increases venous return to the heart, thereby increasing cardiac output and blood pressure. The **renin-angiotensin axis** affects blood volume directly by stimulating the kidneys to retain Na^+ and water. Angiotensin II is also a trophic hormone for the adrenal cortex, causing aldosterone release from the zona glomerulosa. Aldosterone increases renal Na^+ and water retention and thus results in an expanded extracellular fluid volume.

The regulation of renin secretion is probably governed by various mechanisms. Intrarenal baroreceptors (perhaps the juxtaglomerular cells) are sensitive to afferent arteriolar pressure. The release of renin is inversely proportional to this pressure. The macula densa may be a chemoreceptor responsive to Na^+ levels being transported across the distal convoluted tubule, but the precise stimuli have not been determined. Renin release may be inversely proportional to the rate of Na^+ transport. The sympathetic nervous system exerts two effects upon arterial blood pressure—direct and indirect. The direct effect is manifested upon vascular smooth muscle through appropriate adrenergic receptors. The indirect effect is seen when circulating catecholamines stimulate renin release by the activation of β-adrenergic receptors on juxtaglomerular cells. Antidiuretic hormone and angiotensin II inhibit the release of renin. Juxtaglomerular cells also secrete erythrogenin in response to hypoxia and respiratory alkalosis.

Histophysiology of the Kidney

The maintenance of an optimal environment is the primary function of the kidney. This depends upon conserving essential metabolites—ions, sugars, amino acids, water—and secreting metabolic waste products. The proper maintenance of fluid balance is an essential renal function. Three renal mechanisms are used to accomplish these functions—glomerular filtration, tubular reabsorption, and tubular secretion. **The essence of renal function is the filtration of all filterable substances and the reabsorption of essential ones. These mechanisms are complemented by tubular secretion of selected substances.**

The kidney is also an endocrine organ. Its secretion of erythropoietin affects RBC production. Renin, secreted by the juxtaglomerular complex, is essential for the endocrine influence on blood pressure and fluid volume. The renal epithelium is involved in calcium metabolism.

Glomerular filtration. Renal blood flow is about 20% to 25% of the **cardiac output.** Equal to some 5000 ml/gram of tissue/day, it is higher than to other tissues. By comparison, blood flow to the brain is about 1500 ml/gram of tissue/day. Of the total daily renal blood flow, some 60,000 ml of fluid becomes the glomerular filtrate (200 ml/min) in a 30 lb dog. Only 1% or 600 ml (ml/lb/day) of urine are excreted daily. Although the fluid load imposed upon the kidney through glomerular filtration is great, most of the fluid is reabsorbed. A 30 lb dog has an approximate blood volume of 1200 ml. If the pulmonary venous capacity (PVC) is 50, then the plasma volume is 600 ml. Plasma is filtered approximately 100 times a day, and the urine excreted is equal to 1 plasma volume daily.

Blood entering the glomerulus is subject to glomerular filtration. The glomerular filtrate is an **ultrafiltrate** of blood plasma but is devoid of blood cells and contains only trace amounts of albumin. Molecules with molecular weights of 5000 daltons filter through the glomerulus as easily as water. Molecules with a molecular weight of 70,000 daltons—equivalent to that of albumin—have a permeability about 1/200 the permeability of water. Molecules of this size are filtered minimally. Low–molecular weight compounds occur in the filtrate at the same concentration as in the interstitial fluid; the filtrate is **isosmotic** with the interstitial fluid. The barrier, selectively excluding large particles, may be perceived as a molecular sieve: endothelial cells and podocytes exclude the passage of large particles, but their fenestrations and filtration slits do not exclude all substances. The effectiveness of the barrier depends upon endothelial cell, basal lamina, and filtration slit properties.

The formation of the glomerular filtrate **(capsular urine)** uses cardiovascular energy without an energy expenditure by the cells of the renal corpuscle. The principles governing tissue fluid formation (Chapter 6) apply to glomerular filtration.

Various factors influence glomerular filtration rate (GFR)—permeability and filtration surface area, tubular and blood hydrostatic pressure, blood colloid osmotic pressure. The permeability of the basal lamina may be altered in disease processes in which high–molecular weight compounds (immune complexes, mucosubstances, immunoglobulins) are deposited on or within the barrier; the GFR decreases in this circumstance. Failure to develop and/or maintain the number and size of renal corpuscles may decrease the GFR. Increasing tubular hydrostatic pressure (urinary obstruction) or increasing the colloid osmotic pressure of the blood also decreases it. Increasing blood hydrostatic pressure or decreasing blood colloid osmotic pressure increases

Downloaded From Vet-eBooks.com

the net driving force and increases the GFR.

Tubular reabsorption. Substances are reabsorbed selectively in different parts of the uriniferous tubules. Some (glucose, amino acids, Na^+) are reabsorbed by active transport mechanisms; others (water, urea) are reabsorbed passively. Most active transport mechanisms have maximal reabsorption limits, beyond which substances usually absorbed will be excreted. Some hormones (parathormone, aldosterone, antidiuretic hormone [ADH]) also influence the reabsorption process. Passive tubular reabsorption depends upon the same mechanisms that govern the formation of tissue fluid.

Glucose, passing freely through the filtration barrier, is part of the capsular urine; however, 100% of filtered glucose is reabsorbed by an active transport mechanism in the proximal convoluted tubule. Glucose appears in the urine **(glucosuria)** when the capacity of the brush border carrier molecules is exceeded. The **glucose threshold** for tubular reabsorption is not exceeded until blood glucose levels reach twice normal (or 180 to 200 mg/100 ml).

Amino acids are transported actively by three distinct mechanisms for different groups of amino acids. Other substances reabsorbed by the tubular system include Na^+, K^+, $HPO_4^=$, Ca^{++}, ketone bodies (acetoacetate, β-hydroxybutyrate), ascorbic acid, and water. Although most active transport mechanisms occur in the proximal convoluted tubule, other tubular components also participate.

Na^+, the most important extracellular ion for blood volume and osmolality, is 98% reabsorbed in the proximal convoluted tubule and nephron loop. The remainder is reabsorbed in the distal convoluted tubule and collecting duct under the influence of aldosterone. K^+, Mg^{++}, HCO_3^-, and $SO_4^=$ are almost completely reabsorbed in the proximal tubules of the nephron. Ca^{++} and $HPO_4^=$ are filtered and reabsorbed by the proximal convoluted tubule.

Urea passes freely across the diffusion barrier. Its glomerular filtrate is isosmotic with the plasma. Urea is absorbed passively by the proximal uriniferous tubules. The concentration of urea increases in the tubules as water is reabsorbed; thus urea passes down its concentration gradient and out of the tubules into the interstitium and vasa recta. The rate of urine flow and the extent of water reabsorption influence the amount of urea in the urine. Under conditions of low flow rate and concentrated urine formation, most of the urea (about 70%) is reabsorbed. High flow rates and dilute urine formation may reduce urea reabsorption to 10% of that which is filtered.

The amount of urea in the blood is often expressed as **blood urea nitrogen (BUN).** Whereas glomerular filtration is the prime mechanism of urea clearance, because of tubular reabsorption the amount of urea cleared by the kidneys is never equal to the amount filtered. An increased BUN may indicate abnormal kidney function; however, other factors also cause it—increased dietary protein intake, increased protein catabolism, decreased renal perfusion, postrenal obstruction.

Urea tends to concentrate in the renal interstitium, especially at pyramid apices. The graded concentration of urea within the medullary pyramids contributes to the kidney's ability to concentrate other solutes.

Despite the fact that urine is a plasma ultrafiltrate, small amounts of low–molecular weight proteins (albumin) are in it. Most of the filtered protein is reabsorbed by tubular cells. Protein in the urine **(proteinuria)** may result from a decreased capacity of tubular reabsorption or damage, but most proteinuria is a consequence of altered glomerular filtration.

Tubular secretion. Tubular secretory mechanisms complement the clearance of substances filtered. The substances secreted include endogenous (creatinine, histamine, and metabolic products of hormones) and exogenous compounds and their metabolic products (antibiotics, aspirin, various other drugs). Water, various cations (H^+, K^+, Na^+) and anions (HCO_3^-, $HPO_4^=$) pass into the tubular lumen by active or passive mechanisms.

Separate renal mechanisms are used for the reabsorption of various substances, but only two distinct processes are used for the tubular secretion of organic compounds. Both processes are part of active transport mechanisms of the proximal convoluted tubules. One system secretes **organic acids;** the other, **organic bases.** Each system has a maximal capacity, and compounds within each group compete with each other.

The renal role in Ca^{++} and $PO_4^=$ metabolism is discussed in Chapter 9.

The movement of water, NH_3, Na^+, H^+, Cl^-, K^+, HCO_3^-, and urea is essential for countercurrent and/or acid/base mechanisms.

Countercurrent mechanism. The **countercurrent mechanism** is predicated upon the maintenance of an osmolality gradient established from the base to the apex of the pyramid (papilla) (Fig. 23-19). The base of the pyramid (interstitium, tubules, and vasa recta) is **isosmolar** with the blood (300 mOsm) whereas the apex of the pyramid is approximately four times more concentrated **(hyperosmolar)** or 1200 mOsm. The nephron loop, the **countercurrent multiplier,** establishes the gradient through its permeability characteristics, juxtaposition of descending and ascending components, and the direction of the flow of urine within the tubules. Inflow in the descending limb runs parallel and counter to outflow in the ascending limb. The operation of this countercurrent mechanism is explained by various theories; however, the following satisfies many of the observations made. The descending limb of the nephron loop, though relatively impermeable to most solutes, permits the movement of water into the interstitium. The ascending limb is impermeable to water but allows free movement of Na^+ into the interstitium. This relationship, alone, establishes an **increasing** tonicity toward the nephron loop in the descending limb and interstitium and a **decreasing** tonicity from the nephron loop up the ascending limb and interstitium. The transport of Na^+, linked to the active transport of Cl^- in the distal straight tubule, produces a hypotonic tubular fluid in this segment. Sodium may be actively transported out of the distal convoluted tubule and collecting duct, as well as passively transported out of the collecting duct, whereas water is passively transported into the interstitium in the distal convoluted tubule and collecting duct.

Urea also contributes to the concentration gradient. Its concentration increases toward the apex of the nephron loop, both within the tubules and throughout the medullary interstitium. The gradient depends upon urea recirculation from the collecting duct into the interstitium and then into the ascending and descending segments of the nephron loop. The dynamic and constant circulation of urea assures a high urea concentration in the urine and helps increase the Na^+ and Cl^- concentrations of the inner medulla.

The vasa recta contribute to the countercurrent mechanism as **countercurrent exchangers.** Water diffuses out of the arteriolae rectae while Na^+ and urea move down their concentration gradients into the vessels. Conversely, water diffuses into the venae rectae while solutes (Na^+, urea) move into the interstitium. Fluids within the tips of the vasa recta are in equilibrium with the nephron loop and interstitium. The recirculation phenomenon maintains the tubular, vascular, and interstitial gradients. The meager and retarded flow of blood through the medulla assists in maintaining these gradients.

The establishment of a medullary gradient, a tubular function, occurs passively and is attributed to selective permeability of tubular epithelium. Evidence exists that the passive movement of Na^+ occurs with the active transport of Cl^- in the ascending segment of the nephron loop. The maintenance of the gradient, a vas-

Downloaded From Vet-eBooks.com

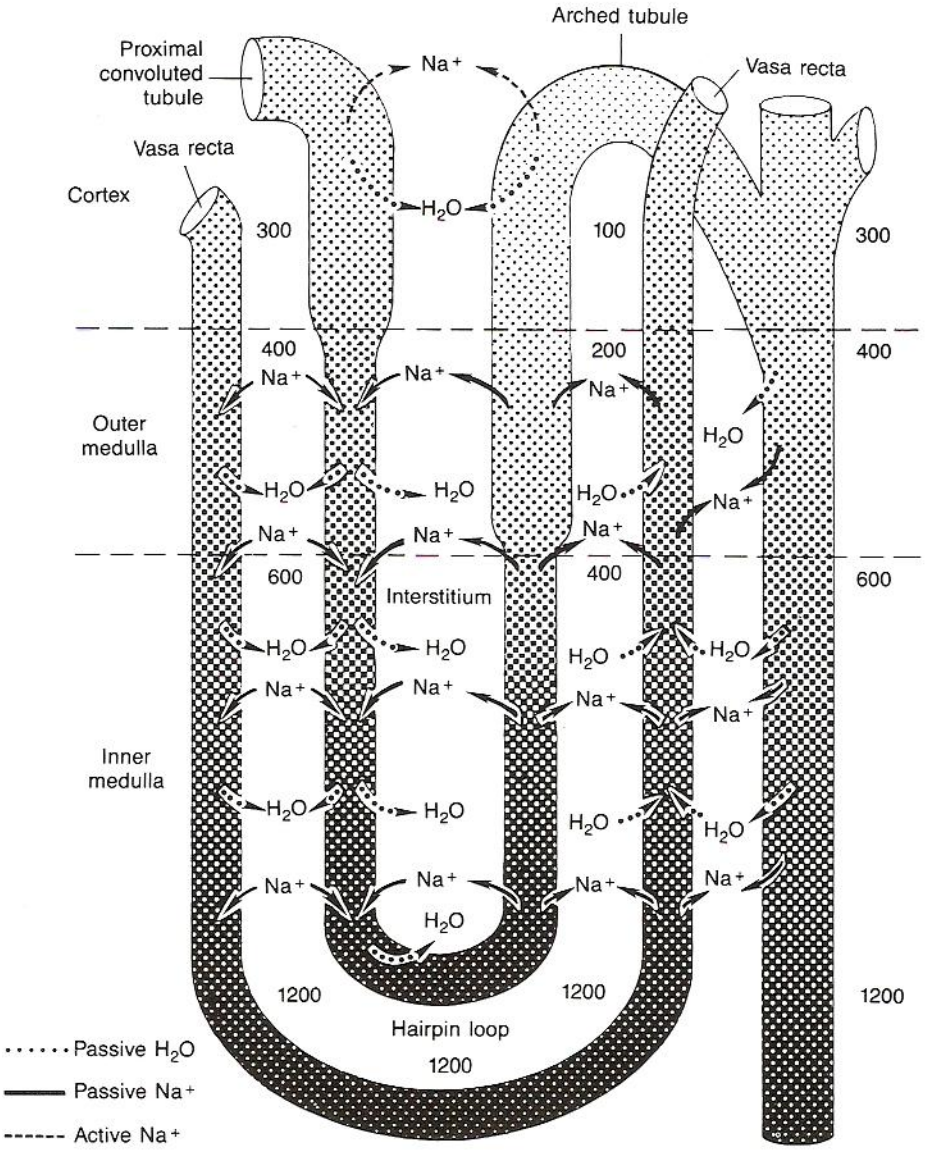

Figure 23-19. Movement of water and sodium through a kidney as related to the countercurrent mechanism. The concentration of urine within the collecting tubules occurs under the influence of ADH. Other solutes, notably urea, contribute to the gradient. As depicted, the gradient (300 to 1200 mOsm) is not the same in all species; however, the relationships are similar. The gradient within the interstitium is similar to that noted for the tubules and vessels. Under the influence of ADH, tubular urine becomes progressively more concentrated toward the hairpin loop, decreases to a hypotonic state in the distal straight tubule, and eventually is hypertonic as it reaches the collecting duct system.

cular function, occurs passively.

The maintenance of proper tissue fluid and blood osmolality is essential for cell function. Hyperosmolar tissue fluid and blood pull fluids from the cells, thereby decreasing cell volume. Hypotonic extracellular fluids cause fluids to move into the cells, increasing cell volume. Both situations impair cell function. The countercurrent multiplier and exchanger mechanisms provide vehicles for the conservation of water and Na^+, both of which are essential for proper fluid volume and tonicity.

The reabsorption of water in the proximal convoluted tubule accounts for about an 80% recovery of filtered fluid volume; the nephron loop reabsorbs another 5% of the filtered fluid. Under the influence of ADH, an additional 14% is reabsorbed in the distal convoluted tubule and collecting ducts. The remaining 1% becomes the fluid volume of excreted urine.

The imbibition of excessive water increases extracellular fluid volume and results in cell swelling. Hypothalamic cells (**osmoreceptor cells**) respond to the increased fluid volume by decreasing ADH secretion. In the absence of ADH, the distal convoluted tubule and collecting duct become impermeable to water, resulting in the excretion of a dilute (hypotonic) urine. Conversely, a decreased fluid volume, resulting in the release of ADH, is characterized by a low volume and hypertonic urine. Animals with **diabetes insipidus** are unable to produce ADH or else they produce insufficient quantities of it and thus characteristically excrete large volumes of dilute urine **(polyuria).** To compensate, they must ingest large volumes of water **(polydipsia).** Polyuria, however, is not always characterized by a hypotonic urine. The retention of osmotically active substances within the tubules also causes water retention. Exceeding the glucose threshold, as in **diabetes mellitus,** results in a hypertonic, high-volume urine. Glucose causes an **osmotic diuresis,** whereas ADH insufficiency results in a **water diuresis.** Polydipsia is a compensatory mechanism for both.

Downloaded From Vet-eBooks.com

Acid/base balance. Deviations from normal pH alter metabolic processes by accelerating or depressing enzymatic activity. Animals are exposed to large quantities of acids daily. Carbon dioxide, the primary metabolic product, results in the formation of acid:

$$CO_2 + H_2O \rightleftarrows H_2CO_3 \rightleftarrows H^+ + HCO_3^-$$

Other acids that are components of the diet or result from metabolism ($SO_4^=$, $PO_4^=$, HCl, lactate, β-hydroxybutyrate) also contribute. The lungs rid the body of excess CO_2. **Buffer systems** (carbonate, phosphate, protein, hemoglobin) neutralize excess acids and bases. The kidneys excrete or conserve acids and bases. The normal pH of the urine varies between species and among individuals of a given species. Carnivore urine is acidic, herbivore alkaline. Omnivore urine (swine, humans) may be acidic or alkaline. Many factors—diet, metabolism, disease—alter urinary pH.

The **proteins** of the body are the most powerful buffers. These amphoteric substances release acids or bases in response to microenvironmental pH changes. The pKs of some proteins are close to the environmental pH (7.4). Thus proteins have a high buffering capacity.

The **phosphate buffer system** is operational close to one of its pKs; it has a high potential for buffering. The extracellular fluid space, however, does not contain high concentrations of phosphates; its role is important within the cells and the renal tubules.

The bicarbonate system is not a powerful buffer, because the interstitial fluid pH is higher (more alkaline) than the effective pK of this system. The efficacy of the bicarbonate buffer system accrues from its ability to regulate the constituents. The lungs regulate CO_2, and the kidneys HCO_3^-.

Deviations from normal blood pH occur under various circumstances. The amount of CO_2 in body fluids affects the pH. **Increased concentrations of CO_2 decrease the pH; decreased concentrations increase it.** Because CO_2 is a continuous product of tissue metabolism, the tendency is for the body fluids to become progressively more acidic. The rate at which CO_2 is removed from the body via expiration must be matched to the rate at which it is produced by the tissues. An increased metabolic rate produces more CO_2 in the tissue fluid, which must be accompanied by an increased respiratory rate. The converse is true with a decreased metabolic rate.

The respiratory rate, independent of the metabolic rate, affects the amount of CO_2 in the tissue fluids. The CO_2 concentration within the tissues is inversely proportional to alveolar ventilation. Under circumstances of a constant metabolic rate, decreased ventilation increases the CO_2 accumulation. Increasing ventilation to twice the normal rate (blowing off CO_2) raises the pH by about 0.2 pH unit. Conversely, decreasing ventilation to one quarter the normal rate (retaining CO_2) depresses the pH by about 0.4 pH unit. **Hyperventilation,** the excessive loss of CO_2 through the lungs, causes a **respiratory alkalosis;** by contrast, **hypoventilation,** the inadequate elimination of CO_2 through the lungs, results in **respiratory acidosis.**

Metabolic acidosis may result from various conditions causing a loss of base—diarrhea, vomiting, or an increased production of acid **(ketoacidosis). Metabolic alkalosis** may result from vomiting in which only gastric contents are lost. Metabolic alkalosis may result from the sequestration of acids in the stomach, as in **abomasal displacement** and other abomasal disorders.

Excursions away from the normal concentration of H^+ are accompanied by renal and pulmonary compensatory mechanisms. Pulmonary compensation of metabolic acidosis is an increased ventilation resulting in CO_2 decreases in tissue fluid. This increases the pH toward normal. The pulmonary compensatory mechanism in metabolic alkalosis is opposite that just described. Metabolic alkalosis induces a decreased pulmonary ventilation, resulting in CO_2 retention and increasing the H^+ concentration in tissue fluid.

The renal compensation of **pulmonary** or **respiratory acidosis** is achieved by the secretion of excess H^+. The is accompanied by movement into the interstitium of HCO_3^- (base conservation). Just the opposite constitutes the renal compensation of **respiratory alkalosis**.

A **paradoxical aciduria** does accompany some metabolic alkalotic conditions (canine vomiting, bovine abomasal displacements). The need to conserve electrolytes (Na^+, K^+, Cl^-) may be a more important renal function than the conservation of H^+ under these circumstances.

The renal secretion of H^+ is achieved by the epithelium of the proximal and distal convoluted tubules in a manner similar to that used by the parietal cell (Fig. 23-20). The active transport of H^+ is associated with the passive uptake of Na^+. The secretion of one H^+ is linked to the movement of a Na^+ into the interstitium and a K^+ into the cell (Na^+-K^+ pump); a HCO_3^- also moves out of the cell into the interstitium for each H^+ secreted.

Although the transport mechanism for H^+ is active, a limiting concentration exists beyond which the transport mechanism does not work. Free H^+ is removed from the urine by reacting with HCO_3^-, $HPO_4^=$, and NH_3 (ammonia). The H^+ reacts with tubular HCO_3^- to form carbonic acid (H_2CO_3). Carbonic anhydrase on the brush borders of the proximal tubule cells catalyzes the conversion of H_2CO_3 to CO_2 and H_2O, effectively removing H^+ from the tubular fluid. CO_2 diffuses into the cells and participates in forming more H_2CO_3 under the influence of carbonic anhydrase. The intracellular H_2CO_3 dissociates into HCO_3^- and H^+, the HCO_3^- diffusing into the extracellular fluid and the H^+ being actively secreted into the tubular lumen. Combination of H^+ with $HPO_4^=$ in the distal convoluted tubules and collecting ducts removes H^+ from the tubular urine. Finally, ammonia (NH_3) is formed within all tubule cells by the activity of enzymes associated with the removal of amines from amino acids. The NH_3, because of its lipid solubility, flows freely across the plasmalemma into the tubular lumina. Once within the tubular fluid, it reacts with H^+ to form NH_4^+ (ammonium ion). Because of its charge, NH_4^+ remains in the tubular urine, the amount depending upon the H^+ secreted. NH_4^+ concentration is high in acidic urine. These mechanisms facilitate the secretion of H^+ by the kidneys.

Although the mechanisms described account for H^+ secretion, the reactivity of H^+ with HCO_3^-, $HPO_4^=$, and NH_3 are important mechanisms for base conservation. During periods of excess H^+ secretion, an increase in detectable (titratable) urinary acids (H^+, $H_2PO_4^-$, NH_4^+) occurs at a time when the body has a need for more HCO_3^- to neutralize the excess acidity. The formation of H_2CO_3 within the tubule, its conversion to CO_2 and H_2O, and the subsequent reabsorption of CO_2 by the tubular cells all return the base (HCO_3^-) to the somatic pool. The formation of titratable urinary acids also serves to conserve Na^+: NH_4^+ replaces the Na^+ exchanged (while a H^+ is secreted).

URINARY PASSAGES

Renal pelvis. The inner surface of the renal pelvis continues with the epithelial lining of the papillary ducts. The epithelium is a thin transitional lining that becomes thicker toward the pelvis. The lamina propria–tunica submucosa is composed of loose collagenous tissue. In equids there are branched, tubuloalveolar, mucous glands here that extend into the ureter. These glands account for the frothy appearance of equine urine. The tunica muscularis may be composed of three, not always distinct, layers of muscle arranged in bundles. The contraction of these muscle bundles tends to "milk" urine from the kidney.

Ureters. The ureters are lined by a

Downloaded From Vet-eBooks.com

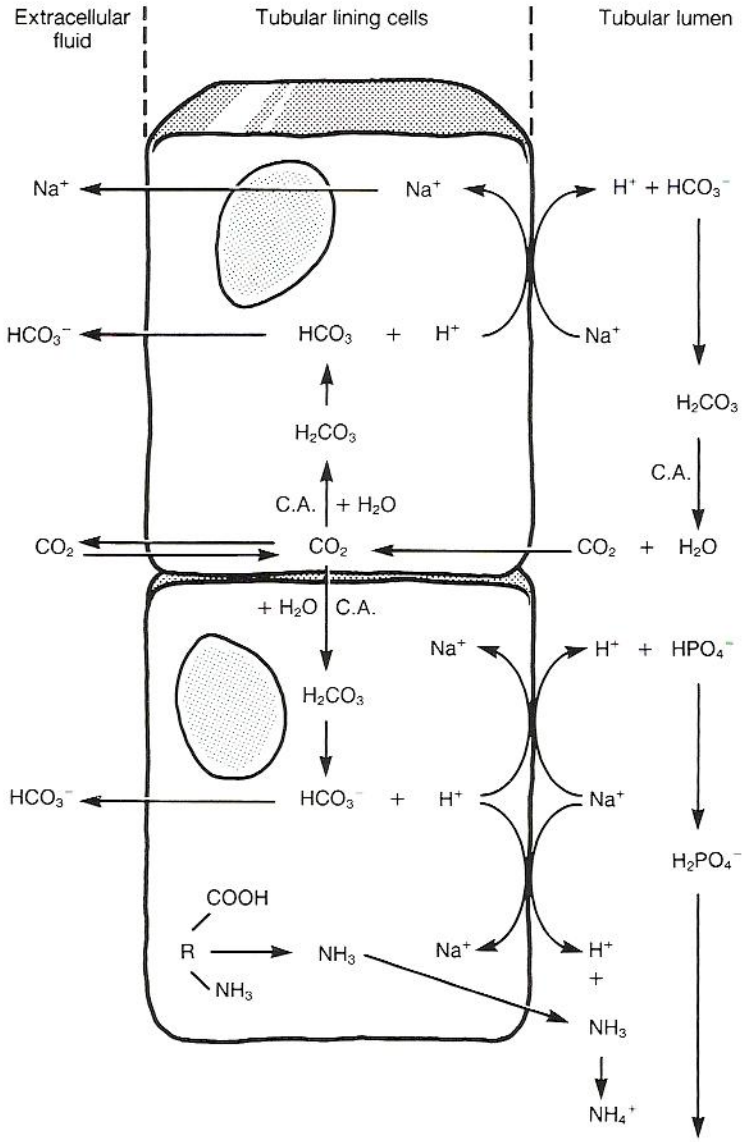

Figure 23-20. Secretory activity of renal tubular lining cells. *C.A.*, Carbonic anhydrase.

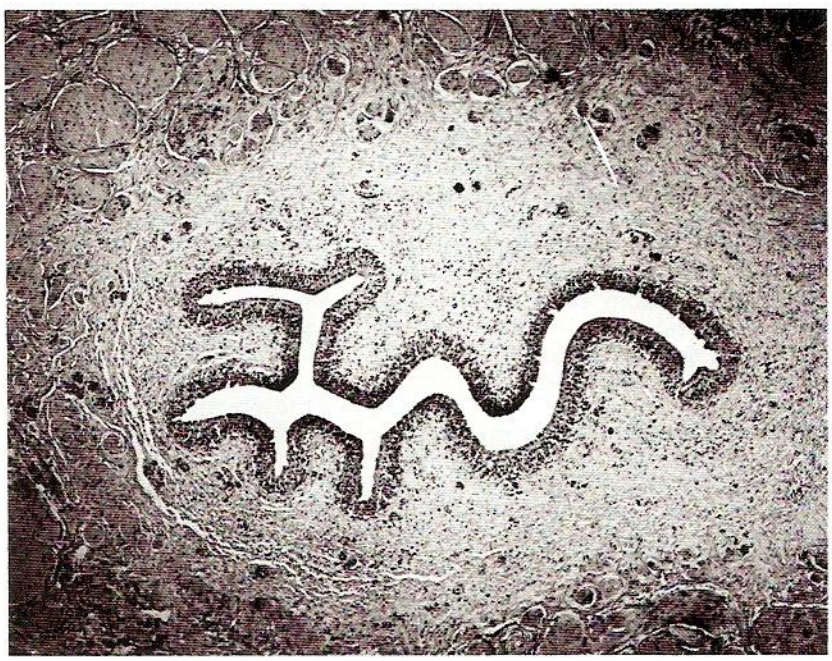

Figure 23-21. Canine ureter. It is lined by transitional epithelium. The lamina propria-submucosa is extensive and surrounded by smooth muscle. (×4.)

Downloaded From Vet-eBooks.com

Figure 23-22. Section of an equine ureter. The lumen *(L)* is lined by transitional epithelium. Note the mucous glands *(G)* in the lamina propria. (×25.)

transitional epithelium (Fig. 23-21). Goblet cells may be present in these structures in horses. The lamina propria–tunica submucosa consists of loose collagenous tissue, and mucous glands are present in some species (Fig. 23-22). The tunica muscularis is typical, with three muscle layers sometimes apparent. The tunica adventitia is also typical. Part of the ureters is covered by a tunica serosa (peritoneum).

Urinary bladder. The ureters open obliquely into the bladder near its neck, and the longitudinal coat of the tunica muscularis of the ureters continues into the bladder wall. There is very little circularly oriented muscle at this junction. Pressure within the bladder tends to close the orifice. Contractions of the ureteral musculature squirts urine into the bladder. The mural elements of the bladder are similar to those of the ureters.

When the bladder is empty, the tunica mucosa of the ureters and bladder is highly folded; at this time the lamina epithelialis mucosae is thick (Fig. 5-15). Upon distention of the bladder, the transitional epithelium becomes thinner and the mucosal folds are effaced (Fig. 5-16).

Urethrae. The urethrae are discussed with their respective reproductive systems.

Micturition. **Micturition (urination),** the passage of urine from the bladder to the exterior, is a spinal reflex facilitated and/or inhibited by higher brain centers. Damage to the sacral segments of the spinal cord may result in an **autonomous bladder** devoid of extrinsic stimulatory innervation and sensation. Voluntary control of bladder function is lost, and urine flow results only from bladder overflow. Residual bladder volume is high in this condition. An **automatic bladder** results from damage to the nervous system cranial to the sacral spinal segments. The reflex arc remains intact, but voluntary control of bladder function is lost. Residual bladder volume is low.

ADDITIONAL READINGS

Andrews PM, Porter KR: A scanning electron microscope study of the nephron, *Am J Anat* 140:81, 1974.

Barajas L: The ultrastructure of the juxtaglomerular apparatus as disclosed by three dimensional reconstructions from serial sections, *J Ultrastruct Res* 33:116, 1970.

Barajas L: The juxtaglomerular apparatus: anatomical considerations in feedback control of glomerular filtration rate, *Fed Proc* 40:78, 1981.

Beeuwkes R, Bonventre JV: Tubular organization and vascular tubular relations in the dog kidney, *Am J Physiol* 229:695, 1975.

Calhoun ML: Comparative histology of the ureters of domestic animals, *Anat Rec* 133:365, 1959.

Christensen GC: Circulation of blood through the canine kidney. *Am J Vet Res* 13:236, 1952.

Dalton AJ, Haguenau F (eds): *Ultrastructure of the kidney,* vol 2, New York, 1967, Academic Press.

Dicker SE: *Mechanisms of urine concentration and dilution in mammals,* London, 1970, Arnold.

Fisher ER: Lysosomal nature of juxtaglomerular granules, *Science* 152:1752, 1966.

Gans JH, Mercer PF: The kidneys. In Swenson MJ (ed): *Duke's Physiology of domestic animals,* ed 9, Ithaca NY, 1977, Comstock Publishing, pp 463-492.

Gingerich DA, Murdick PW: Paradoxic aciduria in bovine metabolic acidosis, *J Am Vet Med Assoc* 166:227, 1975.

Grahame T: The pelvis and calyses of the kidneys of some mammals, *Br Vet J* 109:51, 1953.

Jorgensen F: Electron microscopic studies of normal visceral epithelial cells, *Lab Invest* 17:225, 1967.

Kaneko JJ, Cornelius CW: *Clinical biochemistry of domestic animals,* ed 2, vol 2, New York, 1971, Academic Press.

Latta H: The glomerular capillary wall, *J Ultrastruct Res* 32:526, 1970.

Latta H, Johnson WH, Stanley TM: Sialoglycoproteins and filtration barriers in the glomerular capillary wall, *J Ultrastruct Res* 51:354, 1975.

Monis B, Zambrano D: Transitional epithelium of urinary tract in normal and dehydrated rats, *Z Zellforsch* 85:165, 1968.

Osawa G, Kimmelsteil P, Seiling V: Thickness of glomerular basement membranes, *Am J Clin Pathol* 45:7, 1966.

Osborne CA, Low DG, Finco DR: *Canine and feline urology,* Philadelphia, 1972, WB Saunders.

Pease DC: Electron microscopy of the tubular cells of the kidney cortex, *Anat Rec* 121:723, 1955.

Rhodin J: Anatomy of kidney tubules, *Int Rev Cytol* 7:485, 1958.

Sullivan LP, Grantham JJ: *Physiology of the kidney,* Philadelphia, 1982, Lea & Febiger.

Walker F: The origin, turnover, and removal of glomerular basement membrane, *J Pathol* 110:233, 1973.

Woodburne RT: The sphincter mechanism of the urinary bladder and the urethra, *Anat Rec* 141:11, 1961.

Downloaded From Vet-eBooks.com

CHAPTER 24

Respiratory System

The respiratory system **conducts** and **exchanges** gases. It can be divided into conductive, transitional, and exchange components (Fig. 24-1). The **conductive components** extend from the external nares to the bronchioles. A **transitional component** of respiratory bronchioles—structures that conduct and exchange gases—is present in some animals. The **exchange component** consists of alveolar ducts, alveolar sacs, and alveoli.

Many ancillary functions are also accomplished—**phonation, olfaction, body temperature regulation, excretion, acid/base balance,** and **blood pressure.** Many active substances (histamine, prostaglandins E and F, kallikrein) are produced by the lungs for release into the circulation. Other active substances (prostaglandins E and F, serotonin, bradykinin, norepinephrine) are removed from the pulmonary circulation by the lungs.

The respiratory system also has **protective** functions. Inhaled dry air is humidified by glandular secretions and cooled or warmed by erectile tissue in the upper respiratory tract. Hairs usually trap large foreign particles at the external nares. Those gaining entrance are moved toward the nasopharynx by the **mucociliary apparatus.** Alveolar macrophages are scattered throughout the lung.

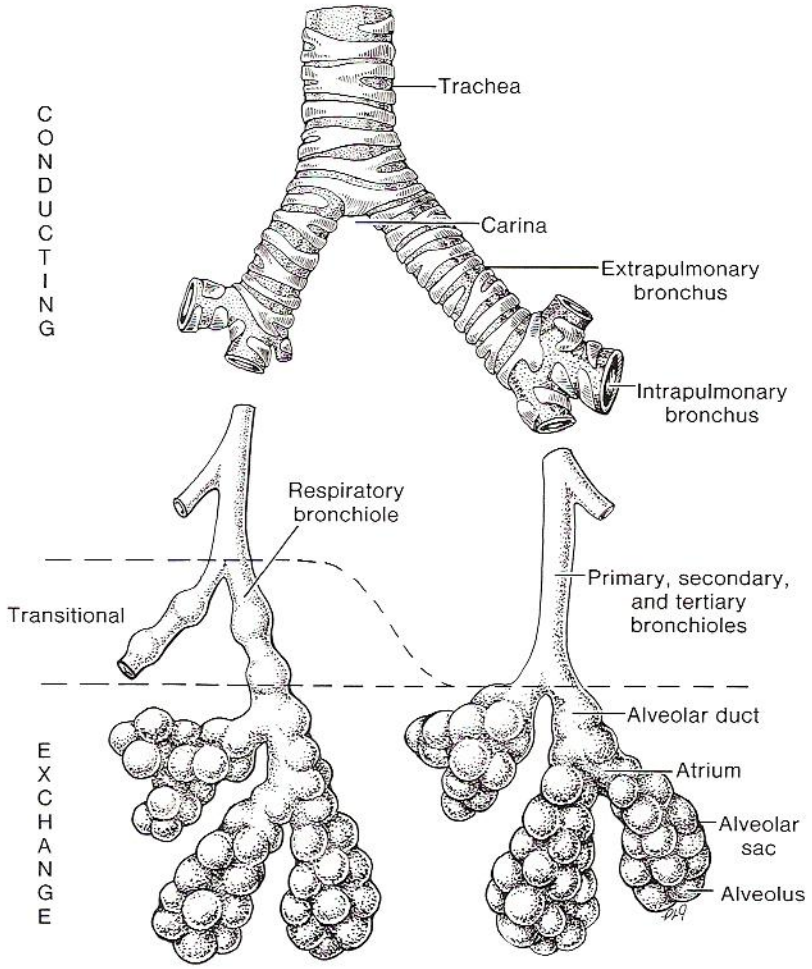

Figure 24-1. Airways from the trachea to the alveoli. The transitional zone is not present or equally developed in all species.

RESPIRATORY TRACT

Conductive Components

The **nasal cavity, paranasal sinuses, nasopharynx, trachea, extra-** and **intrapulmonary bronchi,** and **nonrespiratory bronchioles** cleanse, humidify, and either cool or warm the air as it is conducted to the lungs. Further, these components can influence **olfaction** and **phonation.**

Nasal Cavity

The nasal cavity is divisible into vestibular, respiratory, and olfactory regions.

Vestibular region. The **vestibular region** is the transition point from the integument to the nasal cavity. It is a species-variable cutaneous mucous membrane with a noncornified lamina epithelialis mucosae. Pigment cells may be present. Its typical lamina propria–tela submucosa blends with the underlying fascial covering of muscle or the fibrous layer of bone and cartilage investments. Hairs (vibrissae), sweat glands, and sebaceous glands occur in its cutaneous part. Branched tubuloalveolar glands (serous and mixed) may also be present and assist in humidifying the air.

Respiratory region. The mucous membrane of the **respiratory region** comprises most of the nasal cavity (Fig. 24-2). Its lamina epithelialis mucosae (**respiratory epithelium**), a pseudostratified ciliated columnar epithelium with goblet cells, humidifies and cleanses the air. Its lamina propria–tela submucosa is typical. Many branched, tubuloalveolar, mixed glands **(nasal glands),** which are mostly serous, occur throughout this layer. **Erectile tissue** may also be present. Although the erectile tissue is usually collapsed, it becomes engorged with blood under proper neural stimulation. The glandular tissue humidifies the air, and the engorged erectile tissue cools or warms it by using the mucous membrane as a heat-transfer device. The connective tissue continues with connective tissue of the underlying bone or cartilage.

Olfactory region. The olfactory region is located on the ethmoturbinates, adjacent dorsal turbinates, and nasal septum (Fig. 24-3). Its lamina epithelialis muco-

Downloaded From Vet-eBooks.com

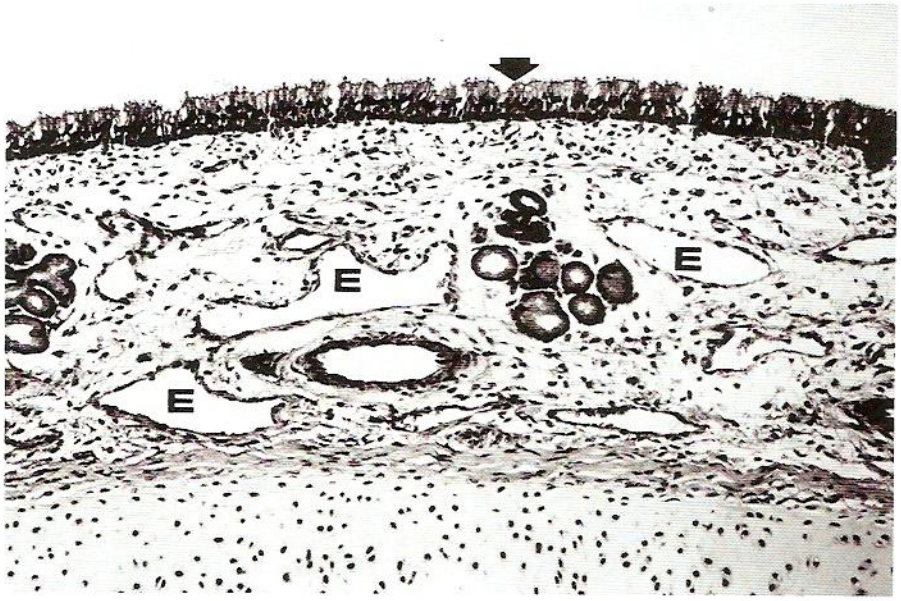

Figure 24-2. Respiratory mucosa. The lamina epithelialis mucosae *(arrow)* is pseudotstratified ciliated columnar epithelium with goblet cells. The lamina propria mucosae contains serous glands and erectile tissue *(E)*. The connective tissue of the lamina propria mucosae is continuous with the fibrous perichondrium of the underlying cartilage. (×40.)

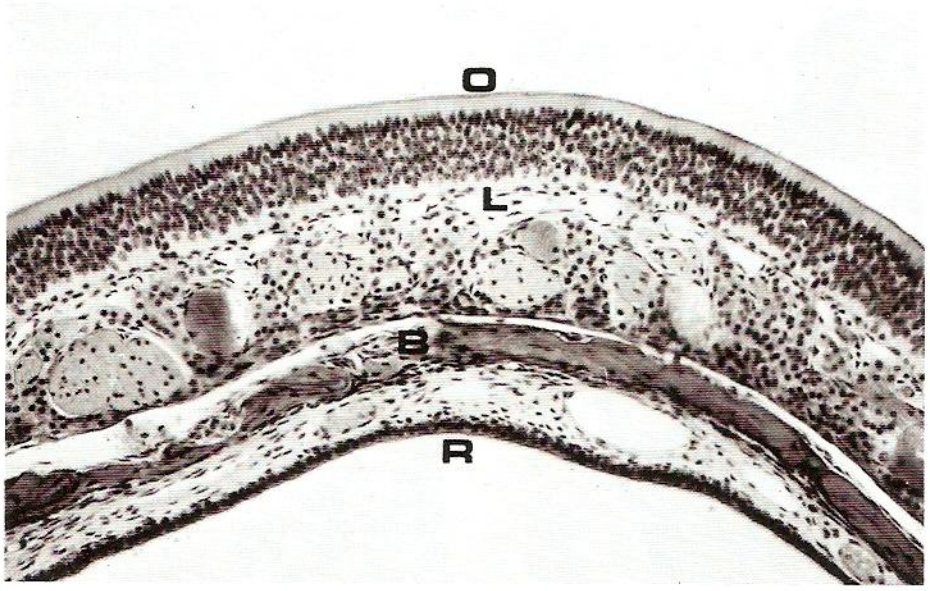

Figure 24-3. Olfactory and respiratory mucosal covering of the osseous portion of a turbinate. The olfactory epithelium *(O)* is a thicker, nonciliated pseudostratified columnar tissue than the respiratory epithelium *(R)*. The lamina propria *(L)* contains many serous glands and bone *(B)*. (×40.)

sae (**olfactory epithelium**) is thick pseudostratified columnar cells, with at times 15 strata apparent in section.

Three cell types are present—sustentacular, basal, and olfactory. The **sustentacular cells** are tall with broad apices and narrow bases; oval vesicular nuclei are positioned toward the apex, and pigment granules responsible for the gross color of the region are present. The **basal cells** are typical of this epithelium. The **olfactory cells** are modified bipolar neurons whose basal processes continue to the brain as axons of the olfactory nerve (I); the apex of each cell is a bulb projection (the **olfactory vesicle**) from which modified cilia (**olfactory hairs** or **receptors**) project, and a round vesicular nucleus is centrally or basally positioned.

The underlying lamina propria mucosae is typical and contains branched tubuloalveolar serous glands (Plate II, *8*). These **olfactory glands** cleanse the olfactory surface and solubilize odor-producing substances.

Paranasal sinuses. The **paranasal sinuses** are spaces within the maxillary, frontal, ethmoid, and sphenoid bones that open into the nasal cavity. Their lining may be cuboidal, squamous, or thin pseudostratified ciliated columnar epithelium. Goblet cells and nasal glands occur less frequently here than in the nasal cavity proper. Erectile tissue is not present. The remaining connective tissue/osseous tissue relationships are similar to those of the nasal cavity proper. The mucosa is called **mucoperiosteum** because of its intimate relationship with the underlying bone.

Vomeronasal organ. The **vomeronasal organ** is a paired, tubular structure parallel to the base of the rostral nasal septum. Partially enclosed by vomeronasal (hyaline) cartilage, it opens into the incisive duct (which connects the nasal and oral cavities).

The rostral part of the vomeronasal organ is lined by respiratory epithelium; the caudal part, by respiratory epithelium along its lateral wall and olfactory epithelium along its medial wall. Although the olfactory epithelium has some unique ultrastructural features, it resembles typical olfactory epithelium. The typical lamina propria-submucosa contains serous, mucous, and seromucoid glands.

The organ samples substances easily volatilized from licking and/or inhalation and may be able to recognize specific pheromones as well as induce mating behavior.

Nasopharynx

The **nasopharynx** is that part of the nasal cavity dorsal to the soft palate connecting the nasal cavity with the oropharynx. Its lamina epithelialis mucosae is pseudostratified ciliated columnar epithelium with goblet cells. Its lamina propria–tela submucosa is typical, with diffuse and nodular lymphatic tissue and prominent elastic fibers. Branched tubuloalveolar glands (mucous, serous, mixed) are present. Its tunica muscularis is composed of skeletal muscle in various orientations, and its tunica adventitia is continuous with the fascia of the region.

Larynx

The **larynx** connects the pharynx with the trachea. It is an irregularly shaped, cartilage-reinforced, muscular tube (Fig. 24-4) whose lamina epithelialis mucosae varies at specific loci within the larynx. Its lining may be stratified squamous or pseudostratified ciliated columnar epithelia. Taste buds are present on the epiglottis of carnivores, swine, ruminants, and humans. The lamina propria–tela submucosa is typical, with some elastic fibers. Diffuse and nodular lymphatic tissue is present. Branched, tubuloalveolar

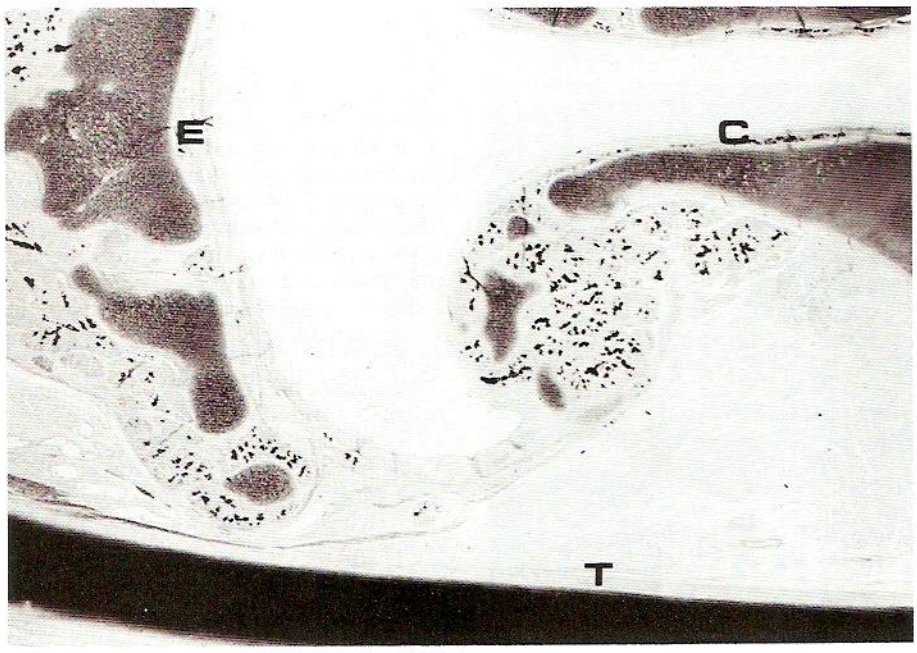

Figure 24-4. Frontal section of a portion of the larynx. Dark-staining tissue is the epiglottic *(E)*, cricoid *(C)*, and thyroid *(T)*, cartilages. (×4, aldehyde fuchsin.)

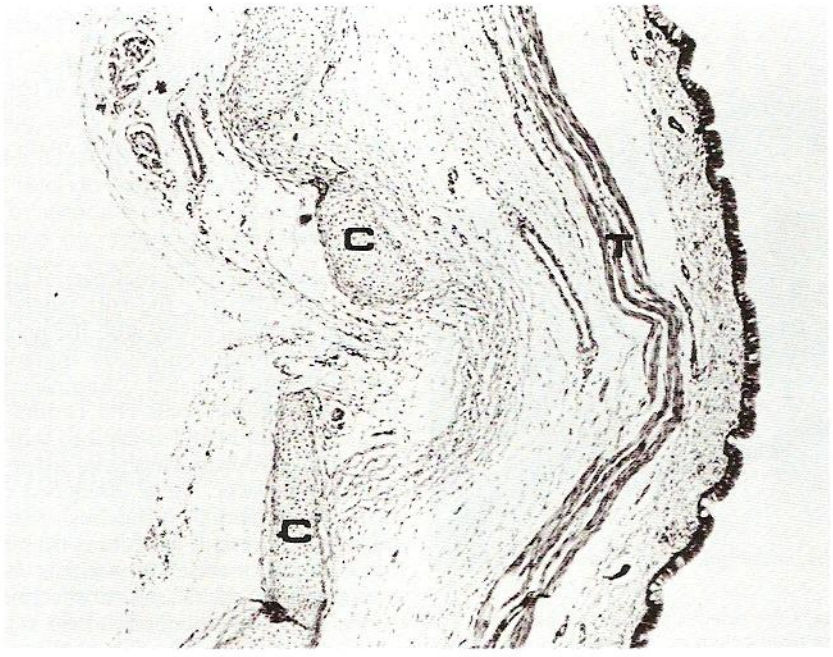

Figure 24-5. Section of a porcine trachea. The cartilage rings *(C)* are incomplete and connected by connective tissue. The trachealis muscle *(T)* is internal to the cartilage. The epithelial lining of the mucosa is typical pseudostratified ciliated columnar epithelium with goblet cells. (×16.)

glands are mostly mucoid, but serous and mixed glands also occur.

The tunica muscularis does not consist exclusively of striated muscle fibers. Hyaline and elastic cartilage replaces some of the muscle mass, accounting for the gross distribution of specific laryngeal cartilages and muscle. The tunica adventitia is typical loose collagenous tissue.

Trachea

The trachea is a tubular organ extending from the larynx to the primary extrapulmonary bronchi (Fig. 24-5). Its lamina epithelialis mucosae is composed of pseudostratified ciliated columnar epithelium with some goblet cells. Its lamina propria–tela submucosa is typical, with prominent elastic fibers that are believed to replace the lamina muscularis mucosae. Branched, coiled, tubuloalveolar mucous glands extend into the submucosal region between the rings of and peripheral to the tracheal cartilage.

The tunica muscularis is reduced to a dorsally positioned, transversely oriented, mass of smooth muscle (the trachealis) extending between the open ends of the horseshoe-shaped cartilage. The muscle may be interrupted by mucosal glands. The tunica adventitia is loose collagenous tissue blending with the cervical fascia or thoracic mediastinal connective tissue.

Extrapulmonary Bronchi

The **extrapulmonary** (or **primary extrapulmonary**) **bronchi** arise from the tracheal bifurcation at the carina and are structurally similar to the trachea.

LUNG

Conductive Components

The lung may be considered a compound tubuloalveolar gland secreting CO_2 in exchange for O_2. This exchange is facilitated by its elasticity. Elastic fibers account for part of the pulmonary compliance in response to an altered thoracic cavity size.

Each half lung, often referred to simply as a **lung,** is divided into **lobes** (species-variable). Lobes are divided into **lobules.** The lobular subdivisions are apparent on the lung surface in ruminants and pigs, present but not readily apparent in horses and humans, and absent in dogs and cats.

The lung is covered by a serous membrane **(visceral pleura)** that follows the surface contours of the lobes. The loose collagenous **subserosal tissue** is rich in elastic fibers (Fig. 24-6). The interlobular connective tissue also is loose and rich in elastic fibers, its intralobular or interstitial space filled with reticular connective tissue and elastic fibers.

Development. Lung development involves contributions from the endoderm and mesoderm. The **endoderm** gives rise to the lung parenchyma as a foregut diverticulum. The parenchyma is the lining epithelium of conductive, transitional, and exchange components of the lung. The **mesoderm** gives rise to all interstitial pulmonary structures.

Lung formation is divided into three stages—glandular, canalicular, and alveolar. The **glandular stage** is characterized by extensive arborization of a single foregut diverticulum from the **laryngotracheal groove.** This stage establishes the basic branching patterns that characterize lung structure. The compound, tubuloalveolar pattern of the airways is obvious.

Downloaded From Vet-eBooks.com

The glandular stage establishes **airways** and **terminal buds.** The terminal buds consist of mitotic cells continually invading the mesenchyme and expanding the pulmonary airways. The **canalicular stage** is characterized by presumptive alveolar lining attenuation and the intimate juxtaposition of capillaries and lung parenchyma. The differentiation of two alveolar lining cells—type I and type II pneumonocytes—also occurs during this stage. The **alveolar stage** establishes the blood-air relationships. Complete lung development extends into the immediate postnatal period.

Intrapulmonary bronchi

Mural organization. The organization of bronchi follows a logical progression from large elements to small ones.

The **extrapulmonary bronchi** continue as **intrapulmonary bronchi,** their elastic fibers becoming integral components of the lamina propria mucosae of intrapulmonary bronchi. The smooth muscle fibers of the tracheal muscle become the lamina muscularis mucosae. The cartilage remains in the position normally occupied by the tunica muscularis.

Based upon their branching, luminal size, and mural elements, the **intrapulmonary bronchi** are subdivided into **primary, secondary,** and **tertiary bronchi.** Intrapulmonary primary bronchi are similar to extrapulmonary primary bronchi (Fig. 24-7). Gradual changes occur from the primary to the tertiary levels. The lamina epithelialis mucosae is pseudostratified ciliated and columnar with goblet cells. The lamina propria mucosae is typical but has elastic fibers. A lamina muscularis mucosae is present and disposed in a helix similar to the elastic fibers, resulting in a highly folded tunica mucosa. The tela submucosa also consists of loose collagenous tissue and contains branched, tubuloalveolar, mucous, or seromucous glands. These glands become scarce toward the tertiary bronchi. In cats they may extend into primary bronchioles. In some species they are present only in the extrapulmonary bronchi or may extend a short distance into the lung. The cartilaginous rings of the large bronchi diminish in size, become plaques, and eventually end at the transition from tertiary bronchi to primary bronchioles (Fig. 24-8).

Bronchial glands. The **bronchial glands** are a mixture of serous and mucous cells. The serous cells are typical and produce watery protein-rich secretory products. The mucoid cells, similar to mucous cells elsewhere, produce different types of mucoid materials. The **mucins** are glycoproteins consisting of more than 50% carbohydrate. The number and types of cells, as well as the nature of the products, is subject to species variation. Many factors—stress, infection, surface irritation—influence the number, distri-

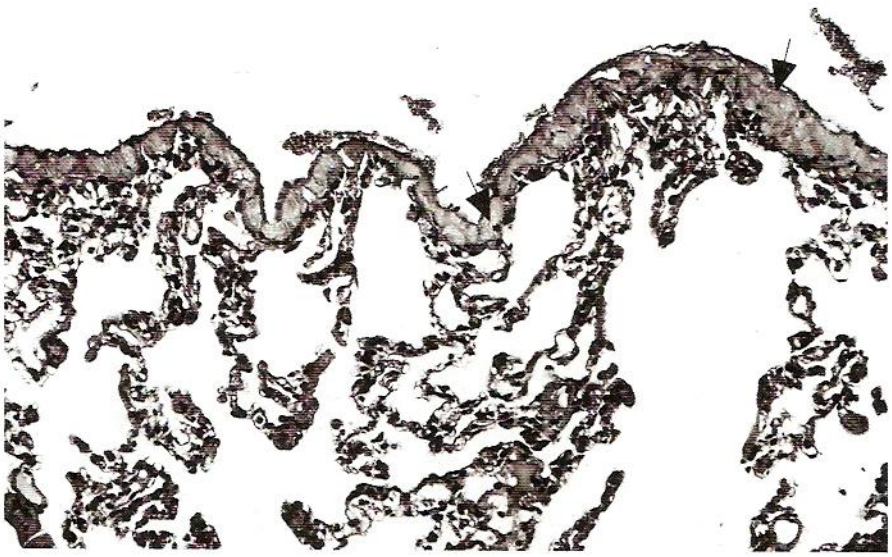

Figure 24-6. Capsule of the feline lung. The capsule *(arrows)* is covered by a layer of mesothelium—visceral pleura. (×40.)

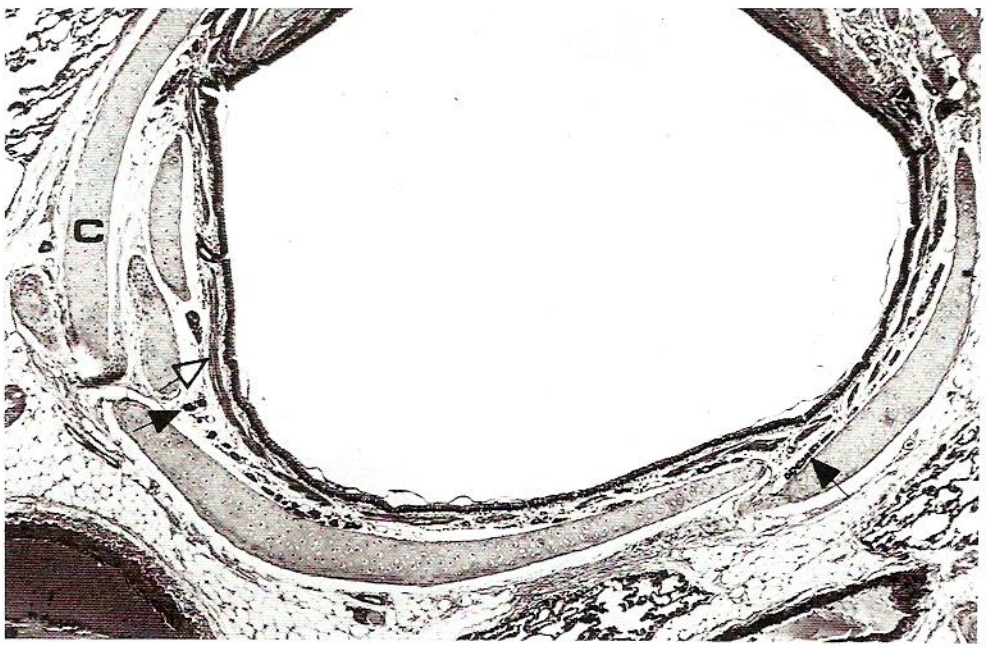

Figure 24-7. Primary bronchus (feline lung). The cartilage *(C)* is disposed as plates. Note the lamina muscularis mucosae *(open arrow)* and mucous glands *(solid arows).* (×10.)

Figure 24-8. Small bronchus (feline lung). Note the cartilage plates *(C)*, mucous glands *(solid arrow)*, and smooth muscle *(open arrow)*. The luminal diameter is reduced. (×16.)

bution, and secretory characteristics of the cells.

Bronchial fluid secretion of all laryngobronchial cells is a mixture of secretory and transudative materials including mucins, serum proteins, lactoferrin, secretory immunoglobulin, immunoglobulin M, and many glycoproteins.

The **mucins** are glycoproteins rich in sulfated amino sugars and uronic acids **(sulfomucins)** or sialic acid **(sialomucins).**

Lactoferrin is an iron-binding protein that contributes to nonspecific immune protection against gram-positive and gram-negative bacteria. Many bacteria need iron for metabolism. Lactoferrin binds the available iron; the growth of iron-requiring bacteria is retarded by this effective bacteriostatic agent.

Secretory immunoglobulins provide surface protection at all mucous membranes (gastrointestinal, urogenital, and respiratory). Immunoglobulin A (IgA) mediates this surface protection. The B cells of the gut-associated lymphatic tissue (GALT) produce IgA. These cells migrate from the GALT to connective tissues of the mucous membranes mentioned previously. The IgA produced by plasma cells diffuses through the epithelial lining and attaches to a proteinaceous **secretory piece** produced by the epithelial cells. The secretory piece and IgA form **secretory IgA (SIgA).** The SIgA seems to prevent bacterial and viral adherence to epithelial surfaces. In the ox, IgA1 is the major secretory immunoglobulin. Immunoglobulin G (IgG) may also occur in bronchial fluid. Antigens gaining access to the mast cells of mucous membranes

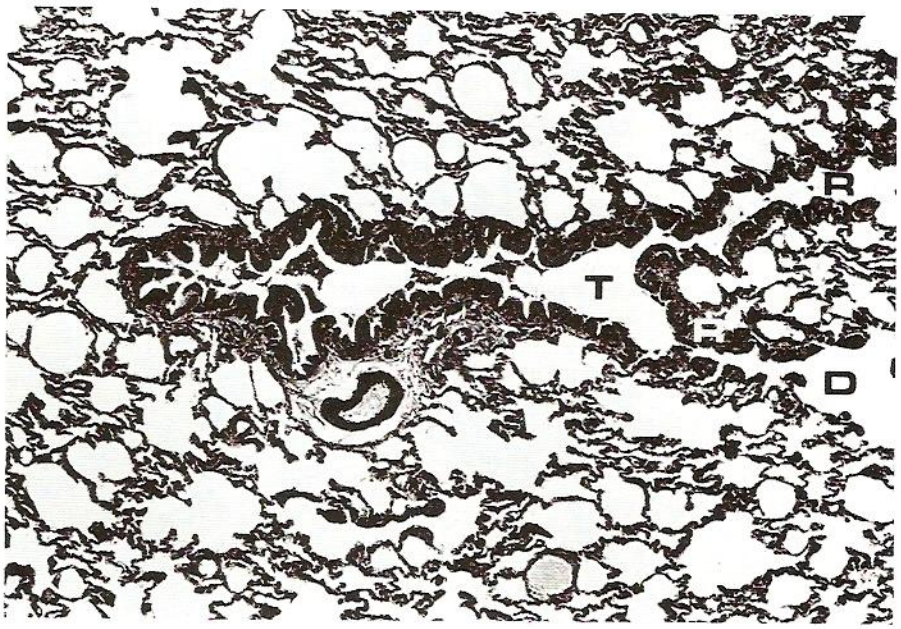

Figure 24-9. Bronchioles of a feline lung. The walls are devoid of cartilage. The terminal bronchiole *(T)* has divided into two respiratory bronchioles *(R)*. Note the alveolar duct *(D)*. (×16.)

can elicit a type I hypersensitivity reaction. The resulting increased vascular permeability can flood the region and mucosal surface with IgG.

Neuroendocrine cells. These cells are discussed subsequently with respiratory bronchioles.

Bronchioles

Mural organization. **Bronchioles** are the smallest conductive components (Fig. 24-9). Their lamina epithelialis mucosae is simple cuboidal or columnar and devoid of goblet cells. Their lining cells are ciliated in the **primary bronchioles.** The cilia diminish in distally positioned bronchioles and do not occur in **tertiary bronchioles. Cilia extend further down the respiratory tree than do glands.** This relationship minimizes the potential for trapping secretions in the transitional and exchange portions of the lung. The glands and cilia comprise the protective **mucociliary apparatus.**

The lamina propria mucosae has fine collagenous and elastic fibers. The lamina muscularis mucosae is continuous. The peripheral connective tissue is similar to

Downloaded From Vet-eBooks.com

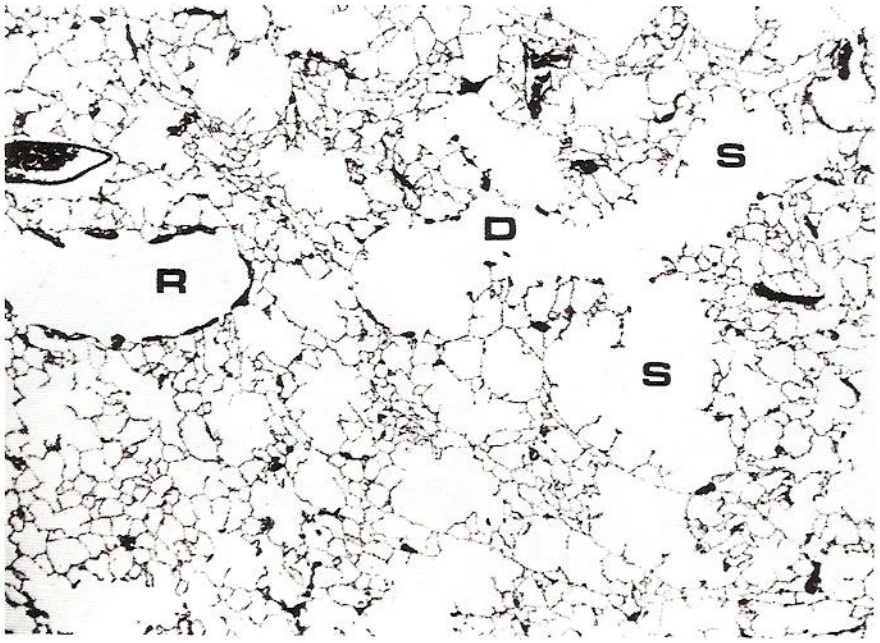

Figure 24-10. Distal airways of a canine lung. A respiratory bronchiole *(R)* continues as an alveolar duct *(D)*, which then continues as two alveolar sacs *(S)*. The atrium is the common opening of the alveolar sacs. (×40.)

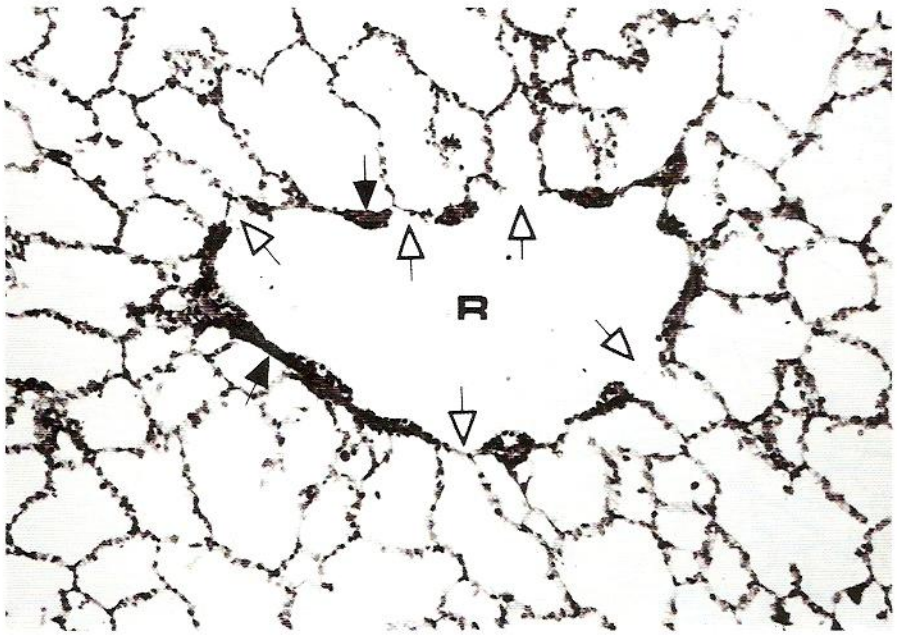

Figure 24-11. Respiratory bronchiole *(R)* of a canine lung. The lamina epithelialis mucosae is underlaid by smooth muscle *(solid arrows)*. The epithelial lining is interrupted by alveoli *(open arrows)*. (×40.)

the lamina propria mucosae but is not extensive. No cartilage is present. The tertiary or **terminal bronchioles** are the primary conducting pathways into a secondary lobule. They divide into several respiratory bronchioles, if the latter are present in the lung.

Bronchiolar and neuroendocrine cells. These cells are discussed subsequently on this page, with the respiratory bronchioles.

Transitional Components

Respiratory bronchioles

Organization. **Respiratory bronchioles** conduct and exchange gases (Fig. 24-10). Their lamina epithelialis mucosae has cuboidal cells, some of which may be ciliated (Fig. 24-11). The cuboidal cells are interrupted by alveoli protruding from the bronchiolar walls (Fig. 24-12). The lamina propria mucosae is indistinct, with fine collagenous and elastic fibers supporting its lining cells. Smooth muscle is present but is loosely organized beneath the cuboidal epithelium.

Species differences. Respiratory bronchioles are absent in small rodents, infrequently observed in ruminants and swine, poorly developed in horses and humans, and well developed in monkeys and carnivores. When they are absent, the terminal bronchioles open into several alveolar ducts (Fig. 24-13).

Bronchiolar lining cells. Two major cell types comprise the lamina epithelialis mucosae of bronchioles—ciliated and nonciliated. The **ciliated cells** predominate in large bronchioles and are typical. The **nonciliated cells** are more frequent in small branches of the bronchioles, becoming the characteristic cell of terminal and respiratory bronchioles (if the latter are present).

Bronchiolar cells are nonciliated and cuboidal with dome-shaped apices protruding into the lumen. Ultrastructural studies indicate that they contain apically positioned, membrane-bound vesicles. Basally, they have much RER, and apically many SER profiles in a supranuclear position. Their morphological features, coupled with the information obtained from studies utilizing tritium-labeled precursors, confirm their ability to secrete proteinaceous, lipid, and carbohydrate products. Based upon the presence of an extensive SER, the role of these cells needs further clarification. Both the synthesis of nonprotein products and the biotransformation of atmospheric contaminants have been ascribed to them. They may secrete proteolytic or mucolytic enzymes that minimize bronchiolar obstruction caused by cell detritus and mucus in the small airways.

Neuroendocrine cells. **Neuroendocrine cells** extend from the larynx to the **bronchioloalveolar portals.** (The latter are the points of transition between cuboidal bronchiolar epithelium and squamous alveolar lining cells.) These small-granule cells are part of the APUD (amine precursor uptake and decarboxylation) series (p. 426). APUD cells of the respiratory system occur singly or as small aggregates **(neuroepithelial bodies)** within the mucosal lining.

The cells are not visible with routine preparation and staining techniques. Fluorescence techniques and special stains are necessary. The presence of dense-core cytoplasmic granules is the identifying feature of electron microscopy.

Some of the cells are innervated. Whether they are innervated by sensory or motor nerves is not clear. Their precise role needs further clarification. Different classes of these cells have been described, based upon staining and ultrastructural features. The cells are intimately juxtaposed with conducting

Downloaded From Vet-eBooks.com

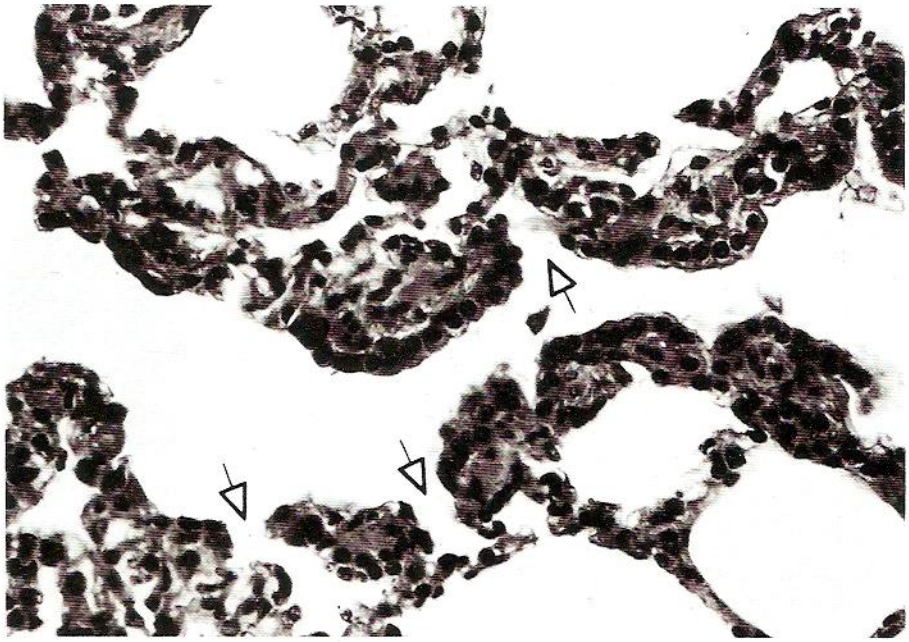

Figure 24-12. Lining of a feline respiratory bronchiole. The cuboidal epithelium is interrupted by alveoli *(arrows)*. (×100.)

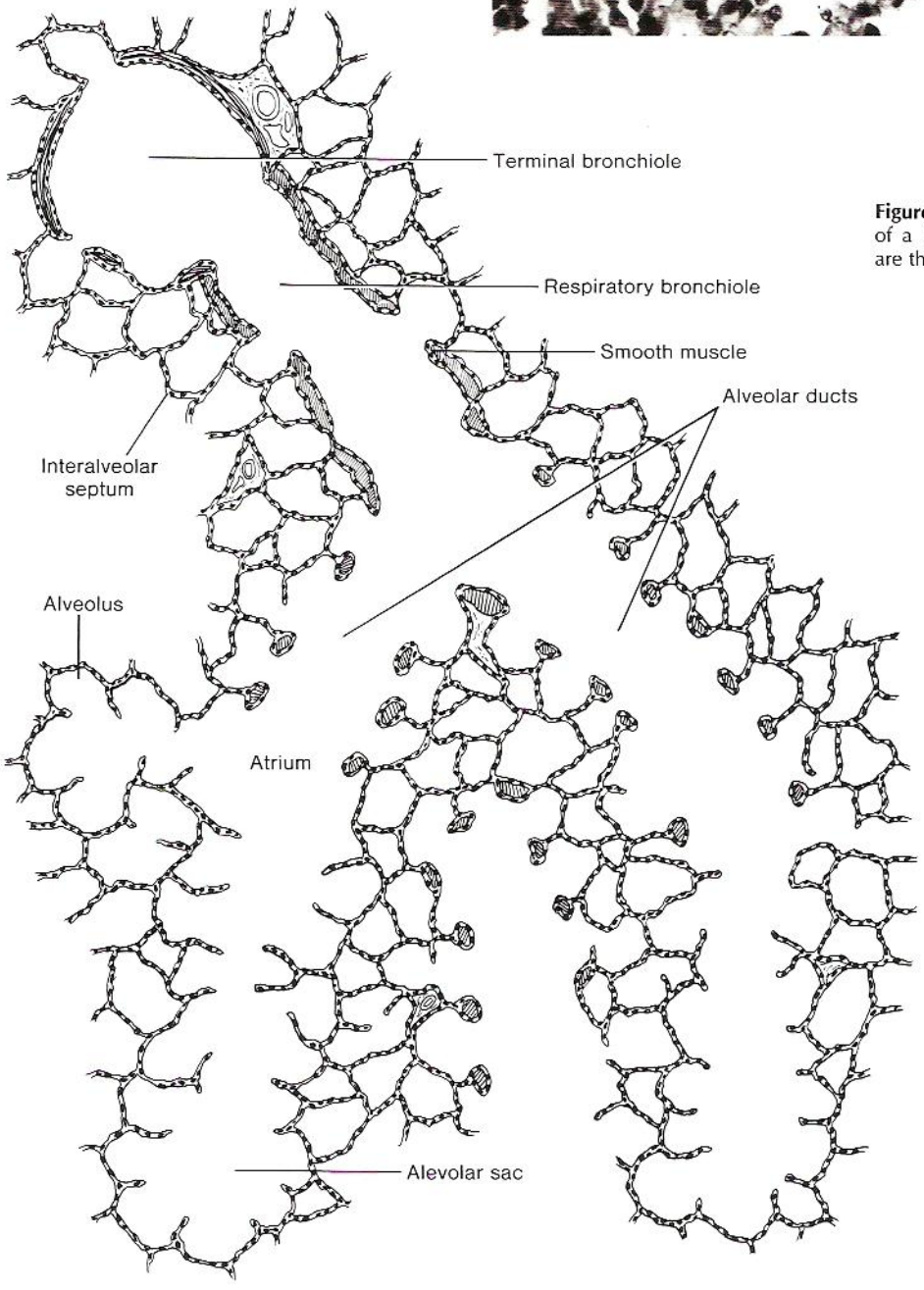

Figure 24-13. Transitional and exchange components of a lung. Respiratory bronchioles do not occur, nor are they equally developed, in all domestic species.

Downloaded From Vet-eBooks.com

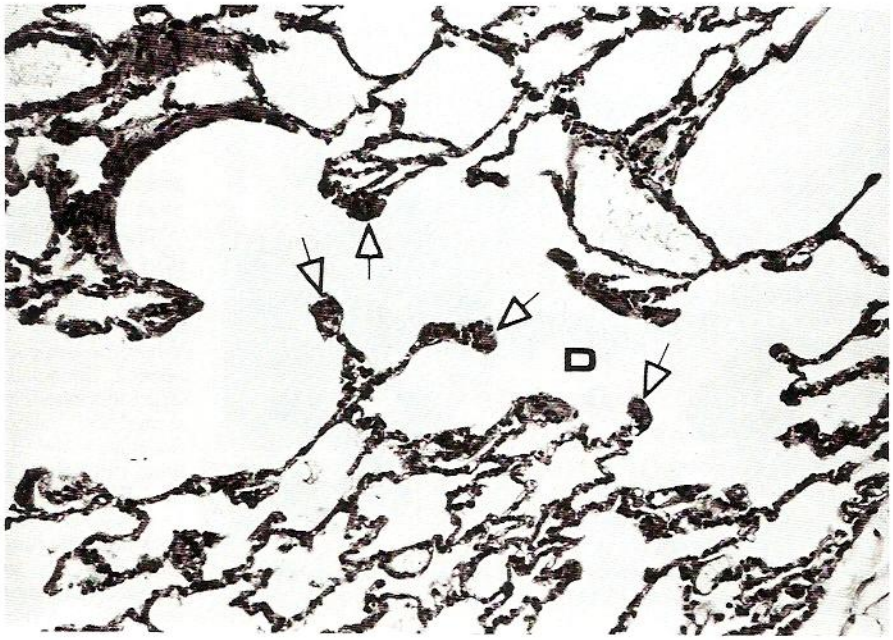

Figure 24-14. Alveolar duct of a feline lung. The duct *(D)* is lined by alveoli. Smooth muscle overlaid with attenuated lining cells *(arrows)* occupies the apices of septa between adjacent alveoli. (×40.)

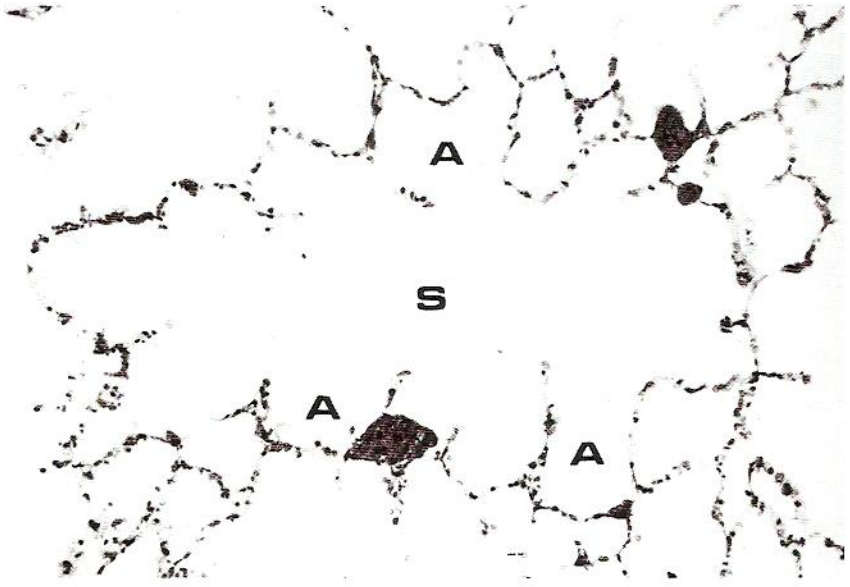

Figure 24-15. Alveolar sac of a canine lung. The walls of the sac *(S)* consist of alveoli *(A)*. The interalveolar septa are devoid of smooth muscle. (×40.)

airway smooth muscle and the pulmonary capillaries of bronchioloalveolar portals. Hypoxia apparently induces their degranulation. It seems inevitable that they will one day be found to have some sort of regulatory function.

Exchange Components

Alveolar ducts, saccules, and alveoli

The lobular respiratory bronchioles or terminal bronchioles divide into numerous **alveolar ducts** (Fig. 24-14).

These ducts (or tubules) are completely lined by **alveoli** (L *alveolus,* small hollow). Smooth muscle may be present along their luminal borders at the apices between adjacent alveoli. Alveolar ducts divide and expand peripherally into **saccules** (sacs) completely lined by alveoli (Fig. 24-15). The common opening of the saccules is called the **atrium.**

The alveolar lining has two types of cells—membranous and granular pneumonocytes.

Membranous pneumonocytes. The **membranous (type I) pneumonocyte** is the primary lining cell of alveoli (Fig. 24-16). It is a squamous cell with a prominent perinuclear region thinning immediately to attenuated processes (Fig. 24-17). Its nucleus protrudes into the alveolar lumen and is the only part of the cell visible by light microscopy.

The ultrastructural features and metabolic activities of type I pneumonocytes do not indicate special metabolic needs. Typical organelles are not conspicuous, and those present are scattered throughout the cells. As the primary lining cells they appear to function in maintaining an interface between the air and blood to

Downloaded From Vet-eBooks.com

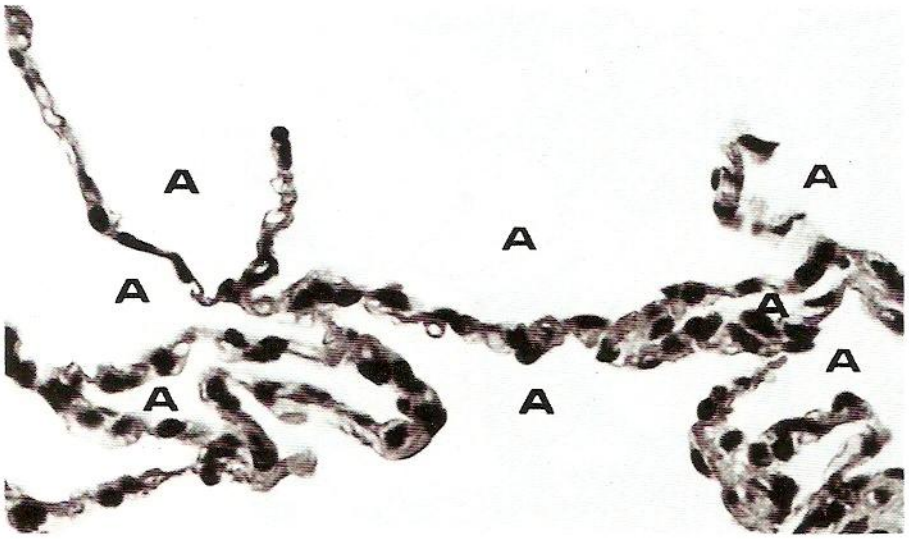

Figure 24-16. Alveolus of a bovine lung. Note that the alveoli *(A)* are separated by capillaries and a minimal amount of connective tissue. Some are collapsed from processing. (×160.)

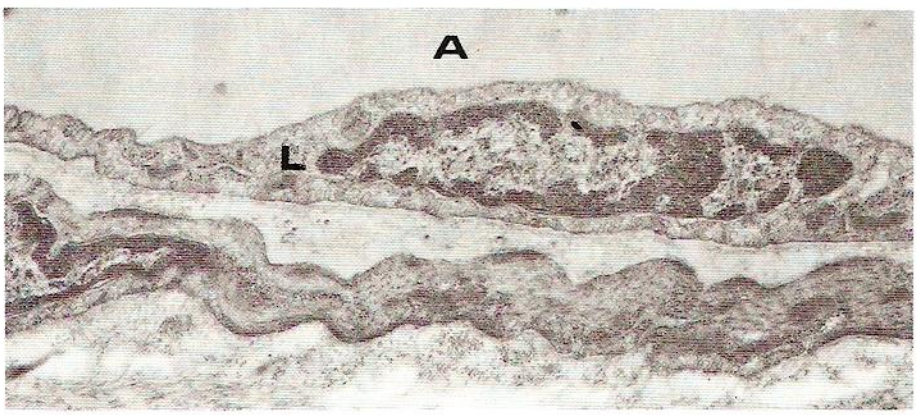

Figure 24-17. Electron micrograph of a membranous (agranular) pneumonocyte from the bovine lung. A squamous cell *(L)* lines the alveolus *(A)*. A fibroblast is subjacent to the lining cell. (×18,000.) (Courtesy G.P. Epling.)

allow the passage of gases.

Granular pneumonocytes. The **granular (type II) pneumonocyte** is the secretory cell of the alveolar lining epithelium. It is visible with the light microscope as a round or cuboidal cell projecting into the alveolar lumen (Fig. 24-18). Although it has a limited occurrence (one to several per alveolus), its foamy cytoplasm makes it a conspicuous feature of the lining.

As part of the alveolar lining, type II pneumonocytes are joined to type I cells by tight junctions. Ultrastructural features confirm their role in secretory functions. Well-developed mitochondria are complemented by RER profiles, an extensive Golgi complex, and **lamellar bodies.** Many multivesicular bodies are also present. The lamellar bodies are an electron microscopic diagnostic feature of these cells (Fig. 24-19), which retain their potential for mitosis and are believed to be the source of both type I and type II pneumonocytes.

Surfactant and surface tension. Pulmonary **surfactant,** the secretory product of type II pneumonocytes, is derived from lamellar bodies. It is a detergent consisting primarily of the surface tension–reducing agent dipalmityl phosphatidylcholine.

Surface tension is the attraction force between molecules at the interface of dissimilar substances. Because alveoli may be considered bubbles attached to tubes (bronchioles), the insights of Laplace concerning surface tension and pressure are applicable. The surface tension (T) in the wall of a spherical bubble tends to contract the bubble; the air pressure (P) inside the bubble tends to expand it. At equilibrium the forces tending toward expansion, *P,* and those tending toward contraction, *T,* are related:

$$P = 2T/r$$

where *r* is the radius of the sphere. If the surface tension is to remain constant, independent of the radius, the pressure required to inflate the sphere must increase as the radius decreases. Conversely, the pressure required to inflate the sphere must decrease as the radius increases.

The following example illustrates this principle:

Two bubbles of unequal size are formed independently as depicted in Figure 24-20. When the stopcock of the connecting tube is opened, the smaller bubble empties into the larger bubble. This system is easily demonstrated with balloons. Importantly, these relationships apply to the pulmonary alveoli. The lung, through its millions of alveoli, is unstable. Based upon Laplace principles, many small alveoli will tend to empty into larger ones until the lung consists of one large alveolus. Similarly, small alveoli require greater pressure (and more work) to overcome surface tension during inspiration.

Surfactant insinuates itself between water molecules in the aqueous phase of the alveolar surface film. This lessens cohesion of the molecules and reduces the surface tension. As the alveoli become smaller and surfactant is more concentrated in the aqueous phase, the surface tension decreases; or as the alveoli become larger and surfactant is spread more thinly, surface tension increases. Surfactant stabilizes the alveoli and ensures that they remain a uniform size. It also lessens the work of inspiration by reducing alveolar surface tension. Alveoli with surfactant are able to fill and expand at lower alveolar pressures than alveoli can without surfactant.

The initial inflation of the lungs at birth is relatively easy because of the presence of surfactant. An absence of surfactant at birth due to a type II pneumonocyte deficiency in humans **(respiratory distress syndrome)** is partially characterized by labored inspiratory efforts.

Alveolar pores. Adjacent alveoli are sometimes connected by pores. These pores seem to distribute the gases and resulting pressure equally among alveoli. They may also facilitate the interalveolar transmission of fluids, particulate matter, bacteria, and alveolar macrophages.

Pulmonary macrophages. The lung is exposed constantly to insult from inspired foreign materials. Various methods are used to cleanse the conductive airways and exchange surfaces. The protective substances within bronchial fluid and the mucociliary apparatus are complemented by pulmonary macrophages.

Two phagocytic cell populations have been identified within the lung—septal cell (macrophage) and alveolar macrophage. The **septal cell,** found mainly in the pulmonary connective tissue space, is a typical macrophage. Materials that

Downloaded From Vet-eBooks.com

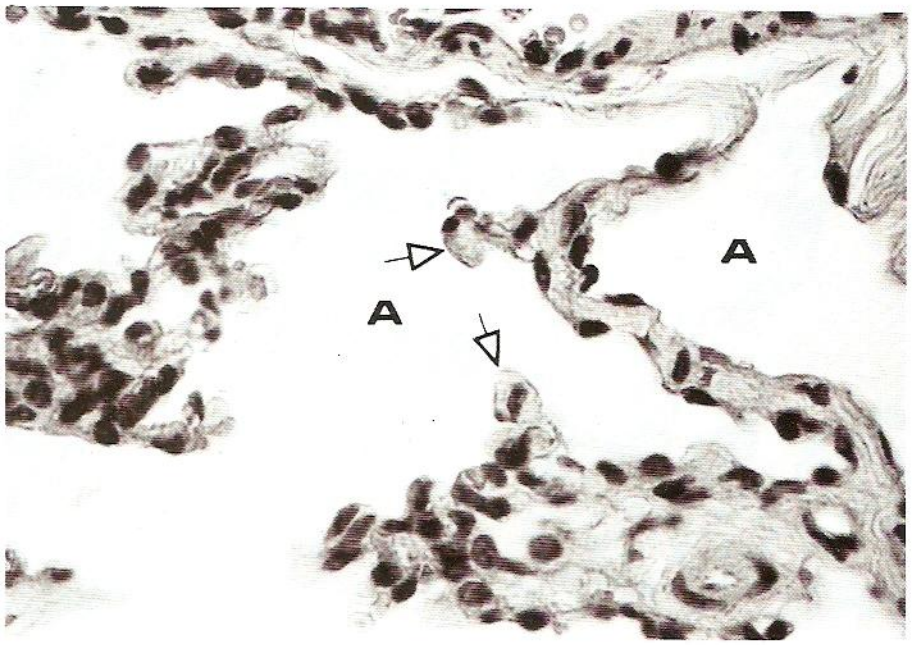

Figure 24-18. Type II lining cells. The predominant cell of the alveoli *(A)* is the membranous pneumonocyte. Type II cells *(arrows)* are scattered along the lining. Although the distinguishing feature of these cells is their vacuolated cytoplasm, they are difficult to identify in light microscopic sections. (×160.)

Figure 24-19. Electron micrograph of a granular pneumonocyte. The cytoplasm protrudes into the alveolus *(A)*. Pale areas *(L)* are lamellar bodies; their dissolution was a result of processing. (×14,000.) (Courtesy G.P. Epling). **Inset:** Typical lamellar body of a granular pneumonocyte. (×17,000.)

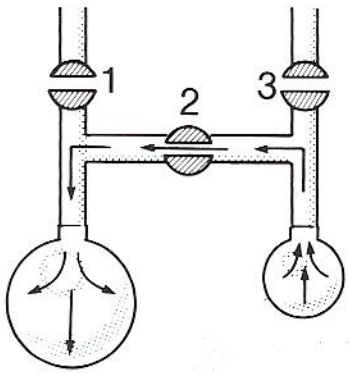

Figure 24-20. Significance of surface tension to luminal diameter. The balloons are filled separately and unevenly while stopcock *2* is closed. With stopcocks *1* and *3* closed, the smaller balloon will empty into the larger balloon when stopcock *2* is opened. Without surfactant, alveoli would react similarly.

reach the alveolar surface and traverse the alveolar wall are subject to clearance by its phagocytic activity. The **alveolar macrophage,** which undergoes transalveolar migration, may protrude into the alveolar lumen between lining cells, reside upon the lining cells, or be free in the lumen (Fig. 24-21). It is rarely a part of the alveolar lining in residence upon the basal lamina.

Upon gaining access to the alveoli, both these macrophages scavenge the surface, ingesting foreign material. Their orad movement is accelerated once they encounter a ciliated surface. Their migration toward the mouth culminates in their being swallowed or expectorated.

Macrophages from the bone marrow are seeded in the lung during early fetal development. This intrapulmonary pool of cells is capable of sustaining itself with appropriate mitotic activity. In adults the bone marrow is the primary extrapulmonary source of cells augmenting the intrapulmonary pool.

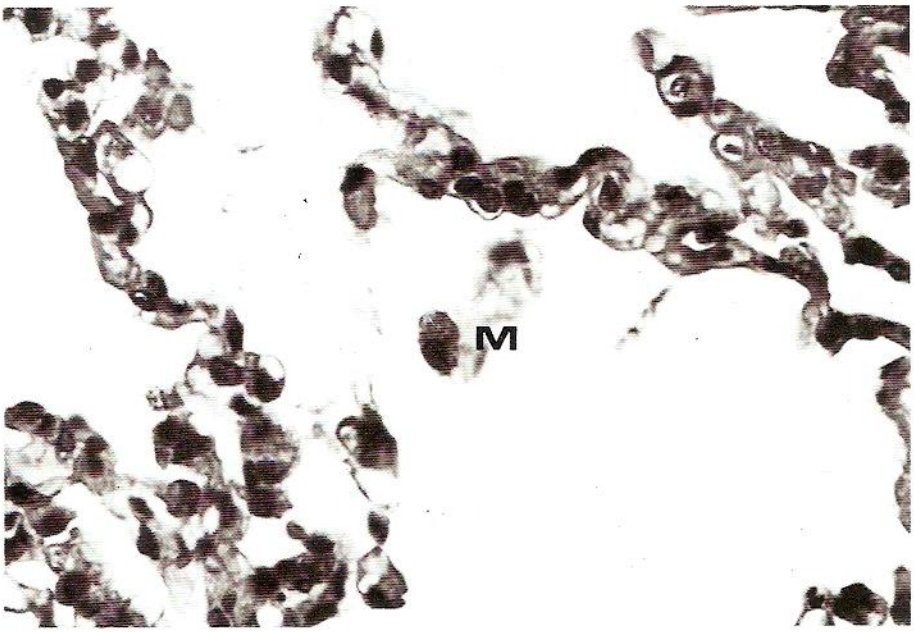

Figure 24-21. Alveolar macrophage *(M)* in the alveolar lumen of a canine lung. The transalveolar migration of these cells is a significant protective mechanism. (×160.)

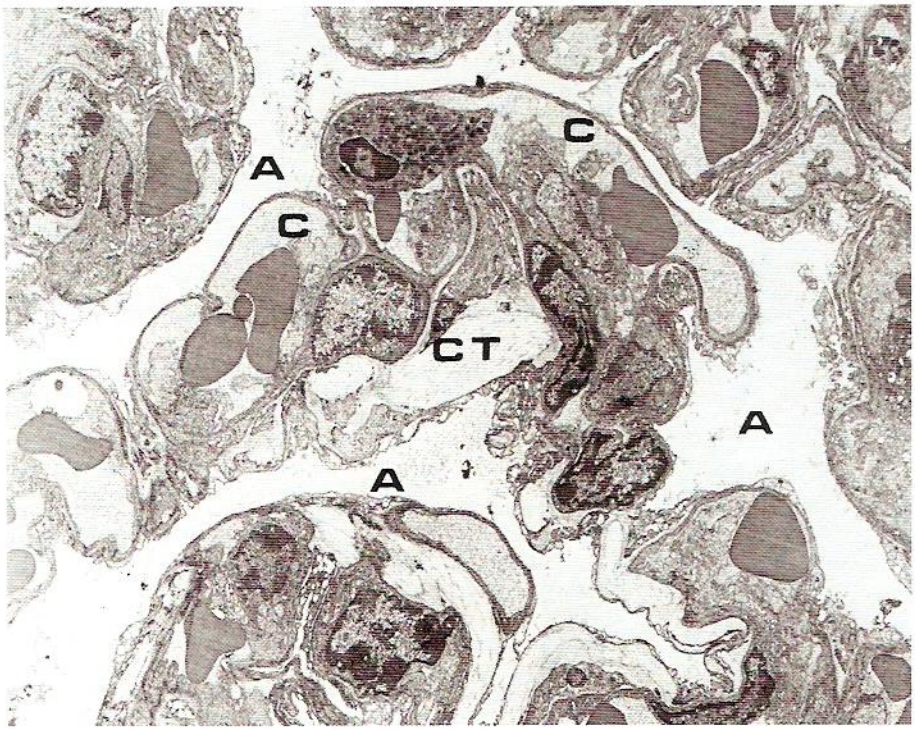

Figure 24-22. Electron micrograph of a bovine lung. Capillaries *(C)* are juxtaposed to alveolar lining cells. These components and the interdigitated basal lamina comprise the blood-air barrier. Alveoli *(A)* are collapsed. Small amounts of connective tissue *(CT)* comprise the septal areas. (×4000.) (Courtesy G.P. Epling.)

Blood/Air Barrier

The lining cells are supported by a basal lamina and fine collagen, reticular, and/or elastic fibers. Adjacent alveoli delimit a clear but reduced interstitial or **septal space** containing the aforementioned fibers, fibroblasts, macrophages, and blood capillaries.

The blood/air barrier consists of **alveolar lining cells, alveolar basal lamina, septal space, endothelium-associated basal lamina,** and **endothelial cells** (Fig. 24-22). Its thickness is variable. Minimally, it is composed of **alveolar lining cells, fused basal laminae,** and **endothelial cells** (Fig. 24-23). It is the thinnest and most efficient diffusion pathway.

Stromal Elements

Vasculature, lymphatics, and nerves. The vascular supply to the lungs is achieved by the pulmonary and bronchial arteries (Fig. 24-24). These vessels provide, respectively, a functional and a nutritional blood supply.

The **pulmonary arteries** and their peripheral divisions follow the distribution of airways to the level of the respiratory bronchioles. At that point they continue as an alveolar capillary bed. In carnivores and monkeys the pulmonary arteries also supply the pleura. In ruminants, swine, horses, and humans the bronchial arteries supply the pleura.

In some species the interlobular pulmonary veins receive blood from adjacent lobules. In others they are intralobular and each lobule has its own pulmonary vein.

The **bronchial arteries** are the primary source of blood to the walls of the bronchi and bronchioles. Although bronchial veins are present, most of the bronchial arterial blood is returned to the heart via the pulmonary veins. The bovine pulmonary vein has a thick and disrupted tunica media, which imparts a sphincterlike appearance to the vessel when cut in cross section.

Two sets of lymphatic vessels drain the lungs—**superficial** and **deep** (Fig. 24-24). The lymphatic capillaries of the superficial drainage originate in the pleural connective tissue and drain toward the hilus in the interlobular septa. The deep vessels originate at the respiratory bronchioles or terminal bronchioles and follow the path of the bronchial tree to the lung hilus. The deep vessels anastomose with the superficial drainage vessels of the interlobular septa. Lymphatic vessels have not been demonstrated in these septa.

General visceral efferent (GVE) fibers from the vagus and thoracic segments of the sympathetic trunk innervate the airway smooth muscle. The parasympathetic nerves stimulate **bronchoconstriction;** the sympathetic nerves, **bronchodilation.** General visceral afferent (GVA) fibers, carried primarily by the vagus nerve, originate from stretch receptors within the lung substance and from nerve endings within the epithelium lining conductive airways.

Histophysiology of the Lung

Exchange of gases

Oxygen delivered to the blood/air barrier traverses the barrier, enters the blood, and is transported to the tissues.

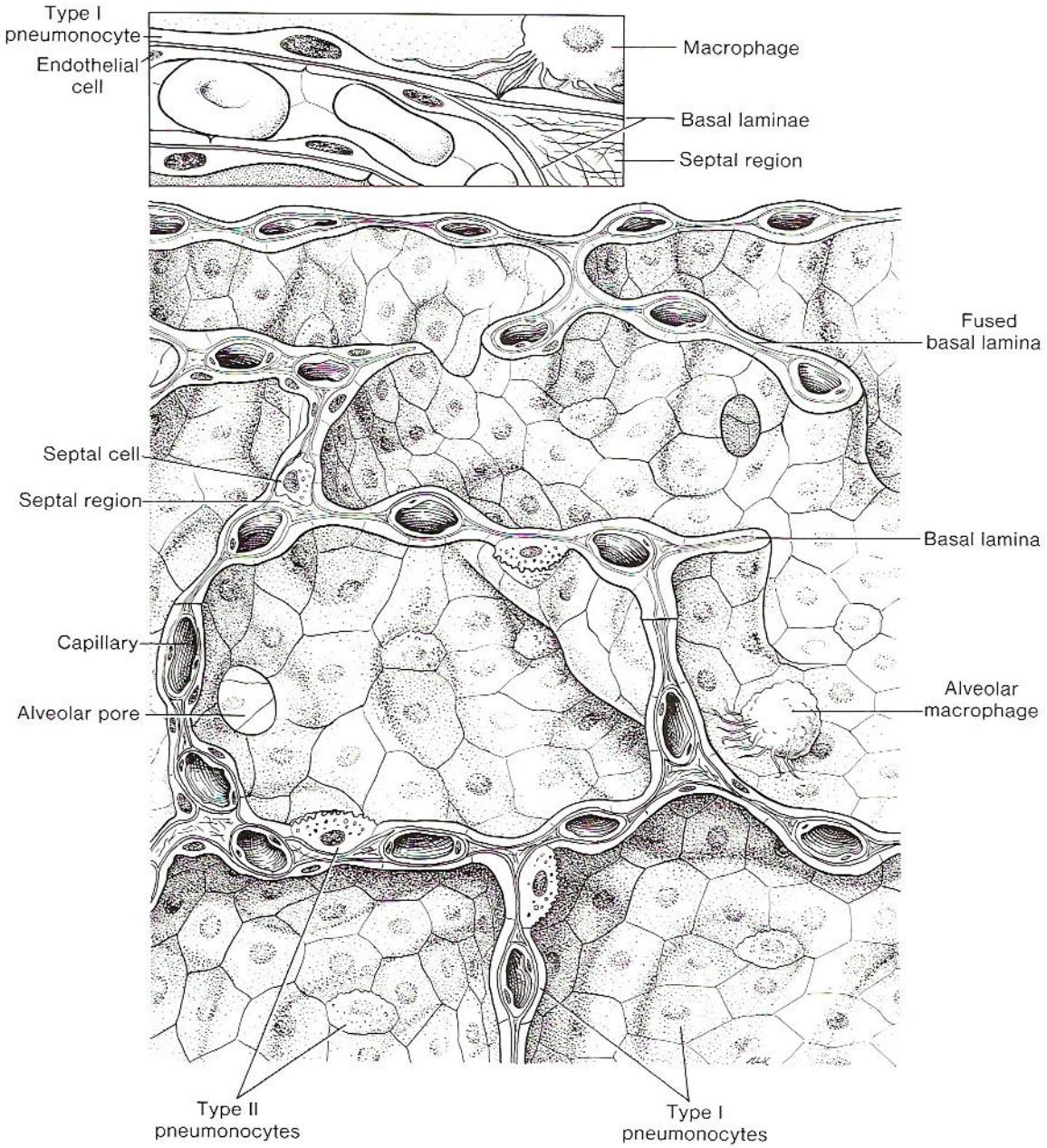

Figure 24-23. Alveoli. **Inset:** The blood-air barrier. The entire lung surface is lined by a continuous layer of epithelial cells.

Blood oxygenation within the pulmonary capillaries depends upon several factors:

1. The amount of O_2 in the inspired air
2. The integrity of the blood/air barrier
3. The amount of blood flowing within the pulmonary circulation
4. The quantity of O_2 dissolved in the blood
5. The amount of hemoglobin in the blood
6. The affinity of the hemoglobin for O_2

Oxygen and hemoglobin. The partial pressure of oxygen (Po_2) in dry air, based upon 20% of 760 mm Hg (sea level), is about 150 mm Hg. After the addition of water, the Po_2 within alveoli is 100 mm Hg. The Po_2 of venous blood (Pvo_2) is approximately 40 mm Hg. Oxygen moves down its pressure gradient, traverses the blood/air barrier, and is carried by the blood. Some oxygen dissolves in the plasma and is carried to the tissues in this form, but the amount of dissolved oxygen within the plasma is about 0.3 ml/100 ml due to solubility limitations. Most of the oxygen is carried by RBC hemoglobin. Hemoglobin increases the oxygen-carrying capacity of blood about 70 times, to some 20 mg/100 ml. Each hemoglobin molecule contains four porphyrins **(heme),** each with a **ferrous iron atom.**

The oxygenation of hemoglobin occurs progressively in four steps and is summarized by the following equation:

$$Hb_4 + 4\ O_2 \leftrightarrows Hb_4(O_2)_4$$

The reversible reaction, which proceeds to the right in the pulmonary capillaries, occurs in less than 10 msec within the lungs. Each of the hemes has a different affinity for O_2. The affinity increases with each oxygenation, so that the last heme has a much greater affinity for O_2 than the first. The oxygen-carrying capacity of the blood is maximal at atmospheric pressure, and most of the oxygen is attached to hemoglobin. **Hemoglobin saturation** or 100% of its oxygen-carrying capacity may be achieved experimentally, but hemoglobin in vivo at an alveolar Po_2 of 100 mm Hg is only 97% saturated. Bronchial venous drainage via the pulmonary veins dilutes the saturation.

Downloaded from Yes-Books.com

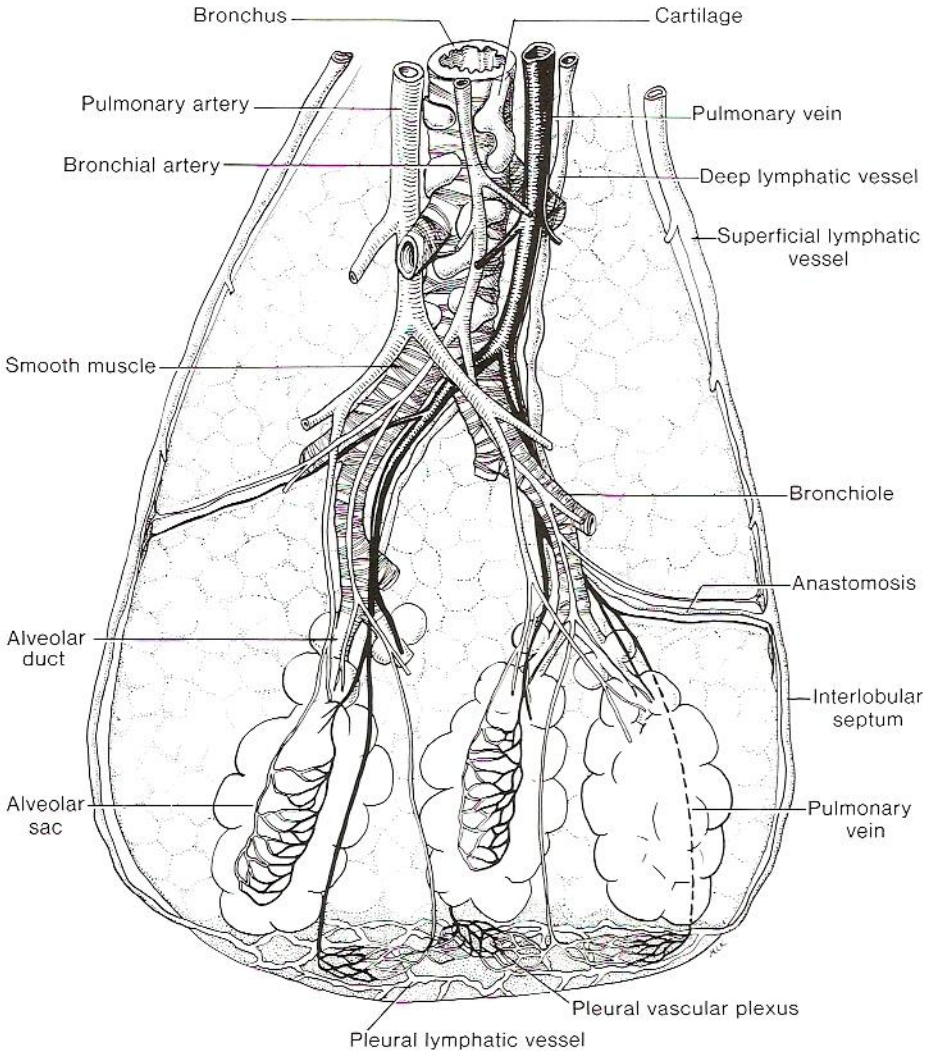

Figure 24-24. Relationships of arteries, veins, and lymphatics to the distal airway in a bovine lung.

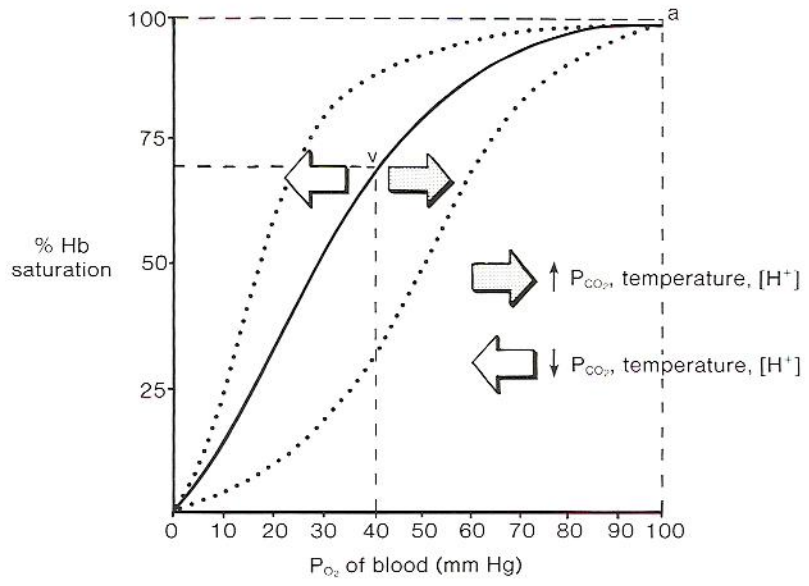

Figure 24-25. Oxygen-hemoglobin dissociation curve. *a*, Arterial blood; *v*, venous blood. An alveolar P_{O_2} of 100 mm Hg results in 97% hemoglobin saturation. Arterial blood varies from 100 to 40 mm Hg P_{O_2}. Venous blood has a P_{O_2} greater than 40 mm Hg. Active tissues cause a shift to the right, inactive tissues a shift to the left.

Oxygen-hemoglobin dissociation. At the tissues, oxygen must dissociate from hemoglobin, move across the capillary wall into the tissue fluid, and diffuse into the cells. The P_{O_2} within the tissues is generally less than 30 mm Hg, and may even be less than 10 mm Hg, whereas the P_{O_2} of arterial blood is between 40 and 100 mm Hg. In these circumstances oxygen dissociates from the hemoglobin, moves into the plasma, and then diffuses into the tissues. The dissociation of oxygen from hemoglobin follows a sigmoid curve (**oxygen-hemoglobin dissociation curve**) relating to the various affinities of the hemes for oxygen (Fig. 24-25). At rest, about 27% of the oxygen is released to the tissues; venous blood contains hemoglobin at 70% saturation. Temperature, pH, and P_{CO_2} influence oxyhemoglobin dissociation. Active tissues produce high quantities of CO_2, elevate local temperature, and increase H^+ concentration ($[H^+]$); more oxygen dissociates from hemoglobin and is available to the tissues. The converse occurs when CO_2, temperature, and $[H^+]$ are decreased.

Oxygen delivery to the tissues. The nature of the oxygen-hemoglobin dissociation curve tells much about hemoglobin and the manner in which O_2 is delivered to the tissues. The P_{O_2} of blood is due to the small amount of dissolved O_2 in the plasma, about 0.3 ml%. However, 70 times this amount is carried by the hemoglobin. As more dissolved O_2 leaves the plasma, more O_2 dissociates from hemoglobin. The dissociation and/or saturation of hemoglobin depends upon the P_{O_2} of dissolved oxygen in the plasma. The shoulder of the curve between a P_{O_2} of 40 and 100 mm Hg, is the normal range of arterial blood. A large change in the P_{O_2} (100 to 40) is accompanied by a small decrease in percent hemoglobin saturation. In the resting organism much more oxygen is carried by the blood than is needed by the tissues. The normal P_{O_2} of venous blood is considered to be 40 mm Hg. Metabolically active tissues have high oxygen requirements. As more oxygen diffuses to them, the P_{O_2} of the blood decreases. Hemoglobin is less able to hold its O_2, and dissociation occurs rapidly below 40 mm Hg. A small drop in P_{O_2} below 40 mm Hg delivers a large quantity of O_2 to the tissues from dissociated hemoglobin. The flat portion of the curve between 100 and 70 mm Hg produces a minor change in hemoglobin saturation, from 97% to 93%. Accordingly, animals are able to live at altitudes higher than sea level (P_{O_2}, 150 mm Hg) without markedly reducing the O_2 carrying capacity of their blood.

Carbon dioxide. The partial pressure of CO_2 (P_{CO_2}) within the tissues is approximately 50 mm Hg whereas that within arterial blood is 40 mm Hg. CO_2

Downloaded From Vet-eBooks.com

moves down its pressure gradient from the tissues into the blood, and its transport is achieved through **dissolution in the plasma** (8%), **binding to the RBC as a carbaminohemogloin** (27%), and **conversion to bicarbonate in the plasma** (65%). Although some reacts chemically with reduced hemoglobin to form carbaminohemoglobin, most entering the RBC is converted to carbonic acid (H_2CO_3) by the enzyme carbonic anhydrase. (Some of the plasma-dissolved CO_2 slowly forms HCO_3^- and H^+.) The subsequent dissociation of H_2CO_3 forms HCO_3^- and H^+ within the RBC. The HCO_3^- diffuses out of the RBC into the plasma, where it is carried for exchange in the pulmonary circulation. The P_{CO_2} of venous blood is approximately 46 mm Hg; that of alveolar air, 40 mm Hg. Within the pulmonary vessels the reverse reactions occur: CO_2 diffuses down its pressure gradient from the plasma, and bicarbonate diffuses into the RBC to become converted back to CO_2 through the action of carbonic anhydrase. More CO_2 leaves the RBC, enters the plasma, and is exchanged. Similarly, the carbamino-CO_2 separates from hemoglobin and is replaced by O_2.

The events of gas exchange are summarized in Figure 24-26.

Acid/base balance. The bicarbonate system has significant buffering capacity. CO_2 produced by the tissues reacts according to the following equation under the catalytic influence of **carbonic anhydrase:**

$$CO_2 + H_2O \rightleftarrows H_2CO_3 \rightleftarrows H^+ + HCO_3^-$$

H_2CO_3, a weak acid, dissociates to H^+ and HCO_3^-, the latter being the conjugate base of that acid. With excess H^+, the equilibrium shifts to the left:

$$H_2CO_3 \leftarrow H^+ + HCO_3^-$$

In the presence of excess base (OH^-), the equilibrium shifts to the right:

$$OH^- + H_2CO_3 \rightarrow H_2O + HCO_3^-$$

The function of the carbonate buffer system is not to prevent pH changes with excess acid or base but to minimize the changes that result.

The amount of blood CO_2 influences these relationships. Increased carbon dioxide shifts the equilibrium to the right:

$$CO_2 + H_2O \rightarrow H_2CO_3 \rightarrow H^+ + HCO_3^-$$

Inability of the lungs to eliminate CO_2, as in **hypoventilation,** causes an increased CO_2 and a decreased pH—**respiratory acidosis.** Renal secretion of excess H^+ and conservation of HCO_3^- are compensatory mechanisms—**compensated respiratory acidosis.**

A decreased amount of CO_2 shifts the equilibrium to the left:

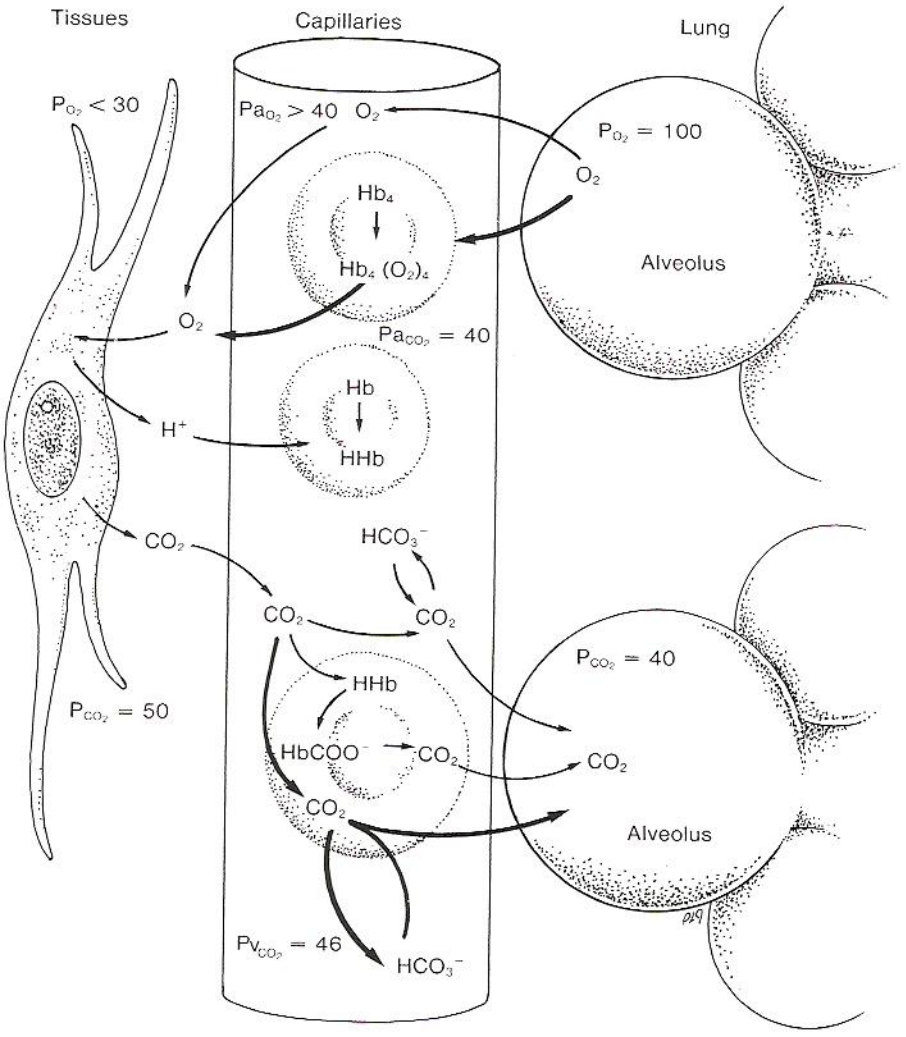

Figure 24-26. Chemical events resulting in the exchange of gases between somatic tissues and capillaries (*left*) and between pulmonary alveoli and capillaries (*right*).

$$CO_2 + H_2O \leftarrow H_2CO_3 \leftarrow H^+ + HCO_3^-$$

Elimination of too much CO_2, as in **hyperventilation,** causes a decreased CO_2 and an increased pH—**respiratory alkalosis.** As the kidneys conserve H^+ and excrete HCO_3^-, **compensated respiratory alkalosis** results. Respiratory acidosis and alkalosis not only are associated with changes in blood CO_2 but result from them.

Ventilation and perfusion. **Ventilation** is the oxygenation of blood within the pulmonary capillaries. **Perfusion** is the movement of blood through the capillaries. The proper exchange of gases occurs at the blood-air barrier when alveolar ventilation ($\dot{V}$) is matched appropriately to pulmonary perfusion ($\dot{Q}$); it is expressed as the $\dot{V}/\dot{Q}$ ratio. Under normal circumstances the $\dot{V}/\dot{Q}$ for an entire lung averages about 1. Not all alveoli, however, have a $\dot{V}/\dot{Q}$ of 1. In quadrupeds dorsally positioned alveoli are usually underperfused and ventrally positioned alveoli overperfused. Underperfused alveoli represent wasted ventilation; overperfused, wasted circulation to the lung.

Changes in the $\dot{V}/\dot{Q}$ affecting an entire lung appreciably alter arterial P_{O_2}. **Anoxia** (reduced P_{O_2}) and **cyanosis** result. Various lung problems (**asthma, bronchitis, pneumonia**) result in a low $\dot{V}/\dot{Q}$ ratio. Vascular problems (**pulmonary stenosis, pulmonary emboli, right-to-left cardiac shunts**) generally account for a high ratio.

Regulation of respiration

Integrated activity. Pulmonary regulation is integrated with cardiovascular regulation. Metabolic demands are accompanied by alterations in respiratory and cardiovascular activity. An increase in metabolic demands, requiring augmented delivery of O_2 to the tissues and a greater ability to remove CO_2, is accompanied by increased ventilation and perfusion. The converse is also true.

Downloaded From Vet-eBooks.com

Neuronal control. Breathing is accomplished through the rhythmic activity of neurons located in the brain stem (pons and medulla). The automatic discharge of specific neuronal pools within the brain stem is modulated by efferent information from conscious centers (cerebrum) and afferent information to respiratory centers from the periphery.

A region within the medulla, called the **respiratory center** and consisting of dorsal and ventral neuronal pools, is responsible for rhythmic inspiratory and expiratory activity. The dorsal neuronal pool controls the phrenic nerve to the diaphragm; the ventral neuronal pool controls the intercostal and accessory respiratory musculature.

Two additional respiratory centers occur within the pons. The **pneumotaxis center,** located in the rostral pontine region, prevents **apnea** (respiratory arrest); the caudally positioned **apneustic center** causes apnea. The pontine centers probably mediate their influence upon respiration through the medullary respiratory center.

Chemical influences. Chemical alterations of the blood influence respiratory activity. Arterial P_{O_2}, P_{CO_2}, and pH are monitored by central and peripheral chemoreceptors (Chapter 18). The peripheral chemoreceptors (carotid and aortic bodies) are sensitive to alterations in these parameters. A decreased arterial P_{O_2}, increased P_{CO_2}, and increased $[H^+]$ result in augmented ventilatory effort. The central chemoreceptors (located within the medulla) are sensitive to P_{CO_2} and $[H^+]$ changes in the cerebrospinal fluid (CSF) or fluid within the brain interstitium. The hydration of CO_2 within the CSF or brain interstitium produces H^+, and the increased $[H^+]$ causes an increased respiratory activity.

Although the chemoreceptors respond to P_{CO_2} and P_{O_2}, an increase in the P_{CO_2} **(hypercapnia)** influences respiration more strongly than does a decrease in the P_{O_2} **(hypoxia).** Arterial P_{O_2} must decrease to about 60 mm Hg before the hypoxic drive becomes evident. Also a decreased P_{O_2} depresses neuronal activity.

AVIAN RESPIRATORY SYSTEM

Upper respiratory tract. The upper respiratory tract of birds includes all mammalian structures plus a syrinx. These organs function in a manner similar to those in mammals.

The **nasal cavity** is lined by the same types of epithelium as described for mammals. The vestibular region is lined by a stratified squamous epithelium that, from a surface view, has a beaded appearance. The basal and intermediate cell layers are oriented vertically and consist of large cells with central nuclei. These rows are covered by a thin double layer of cornified cells. The remaining respiratory and olfactory epithelia are typical. Intraepithelial glands characterize the respiratory epithelium (Fig. 5-20). The lamina propria mucosae is loose collagenous tissue with diffuse and aggregated lymphatic tissue. It is continuous with the underlying connective tissue investments of bone or cartilage.

The avian **trachea** is similar to that of mammals. The typical epithelium contains intraepithelial mucous glands protruding into the lamina propria mucosae. Mucosal and submucosal glands occur variably. The tracheal rings are hyaline cartilage and are complete, presenting an hourglass shape in lateral view. The diameters of these rings vary such that the narrow part of one ring fits into the wide part of an adjacent ring, imparting an overlapping pattern. Ossification of the rings is common in geese and ducks. Longitudinally oriented striated muscle is located at the periphery of the trachea in a lateral position.

The primary bronchi are similar in structure to the trachea. Their hyaline cartilaginous rings are gradually replaced by dense collagenous tissue, and smooth muscle may connect the free surfaces of the cartilage.

The **syrinx,** located at the junction of the trachea and bronchi, is an inverted Y-shaped structure. At the bifurcation a cartilaginous bar with a mucosal-submucosal plication forms the **median vocal fold.** When the bronchi are drawn toward each other, two **lateral vocal folds** are produced at the level of the median vocal fold. These are all responsible for phonation.

The lamina epithelialis mucosae of the syrinx may be either a bistratified squamous or a columnar epithelium. Mucosal glands as well as diffuse and nodular lymphatic tissue are present in the lamina propria mucosae.

Lung. The avian lung is different from the mammalian lung. Compared to the thoracic cavity, it is extremely small and it does not change volume during inhalation and exhalation. The air sacs, which are continuous with the lung duct system, change volume.

The duct system bears no similarity to that of mammals (Fig. 24-27). **Primary bronchi** enter the lung and expand as the **vestibulum.** They continue into the lung as **mesobronchi** and are connected to the **abdominal air sacs. Secondary bronchi** and air sacs arise from the vestibulum and mesobronchi. They may be **dorsal, ventral,** or **lateral,** based on their gross orientation, and they give rise to **tertiary bronchi (parabronchi),** which are continuous with other secondary bronchi. Thus a complete air-conducting loop is formed. The parabronchi are analogous to the alveolar ducts of mammals. **Air vesicles (atria)** project radially from the parabronchi. Atria continue with **air capillaries (air cells).** The air capillaries, continuous loops opening back into the atria, are the structures through which actual gas exchange occurs with the vascular capillaries.

Air sacs. The air sacs associated with the avian lung aid in the movement of air through the lung. These membranous structures do not contribute to gas exchange. Most birds have nine air sacs, which occur free in the body cavities and send diverticula into some bones. **Recurrent bronchi** extend from the air sacs and return air to the parabronchi.

Pulmonary histology. The **intrapulmonary primary bronchi** are similar to their extrapulmonary counterparts. Their lamina epithelialis mucosae has pseudostratified ciliated columnar epithelium with goblet cells and intraepithelial mucous glands. The lamina propria mucosae is loose collagenous tissue with much diffuse and aggregated lymphatic tissue. Lymph nodules are rarely present. The lamina muscularis mucosae is disposed primarily as a circularly or spirally oriented mass of muscle with some longitudinal bundles as well. Hyaline cartilaginous rings present in the initial portions of these bronchi are replaced by cartilaginous plaques. There is no cartilage within the vestibulum. The tunica adventitia blends with the surrounding interstitial connective tissue.

Except for the absence of cartilage, the mural elements of the **vestibulum** are similar to those of the intrapulmonary primary bronchi. The vestibulum is the enlarged portion of the primary conductive pathway, continued caudally by the **mesobronchus,** whose morphology is similar to vestibular morphology. The luminal diameter of this tubule is smaller than the luminal diameters described previously.

Secondary bronchi have a similar morphology (Fig. 24-28). Their lamina epithelialis mucosae is composed of columnar or cuboidal cells, devoid of goblet cells. Their lamina propria mucosae is loose collagenous tissue, usually without lymphatic tissue. The lamina muscularis mucosae is interrupted and multidirectionally oriented. Cartilage is not present. Many interruptions of the wall are encountered due to parabronchi and air vesicles. Because of the latter, portions of the secondary bronchi may be analogous to mammalian respiratory bronchioles.

The mucosal lining of **parabronchi** is interrupted by laterally projecting air vesicles (Fig. 24-29). Between these interruptions the parabronchi are lined by cuboidal or squamous epithelium. The reduced lamina propria mucosae is a fine collagenous tissue. The lamina muscularis

Downloaded From Vet-eBooks.com

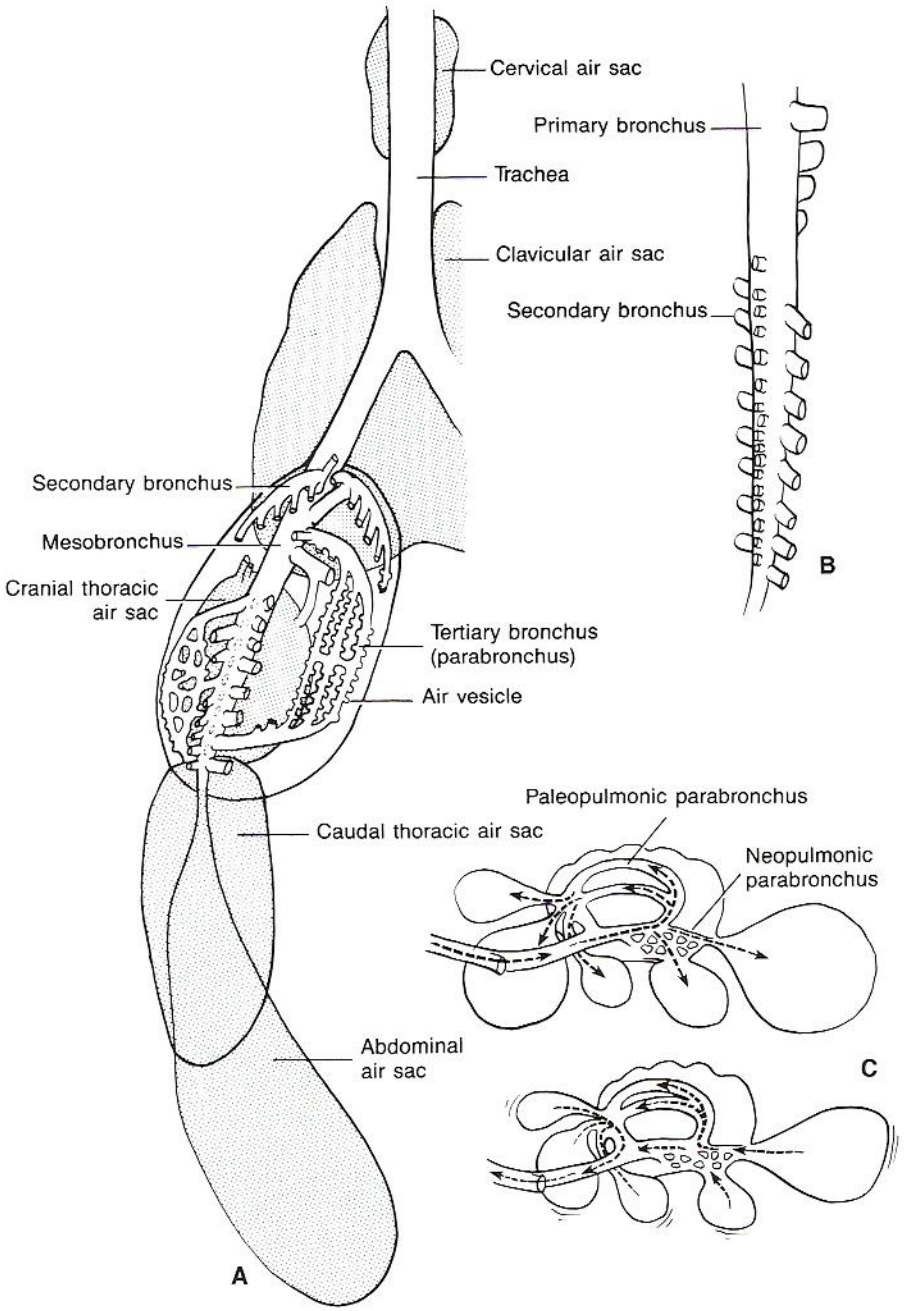

Figure 24-27. Major portion of the avian respiratory system. **A,** Trachea, lung, and air sacs. **B,** Primary and secondary bronchial relationships. **C,** Movement of air through the lung and air sacs.

mucosae is confined to the region beneath the ridges of the lamina epithelialis mucosae as separate bundles of smooth muscle.

The **air vesicles** are lined by a simple squamous epithelium and are supported by a fine interstitial connective tissue (Fig. 24-30). Their epithelium is continuous as a simple squamous lining with that of the **air capillaries.** The air capillary–blood capillary relationship is similar to that described for mammals.

Ventilation of the lung. The avian lung is divided into two phylogenetically distinct units. The **paleopulmon,** well-developed in all birds and especially in domestic fowl, is dorsal and medial to the primary bronchus. A **neopulmon** lies ventral and lateral to the primary bronchus; the degree of its development is species variable. Paleopulmonic parabronchi are highly organized in parallel arrays. Neopulmonic parabronchi form an anastomotic network.

Ventilation of the avian lung occurs by the air sacs' functioning as bellows without any alteration in lung volume. The bird is an abdominal breather. Abdominal muscle movements increase the air sac size, decrease pressure, and cause air to move inwardly. The reverse occurs during expiration. Air movement through the lung is unidirectional and bidirectional during inspiration and expiration (Fig. 24-27)—**unidirectional** through paleopulmonic parabronchi, **bidirectional** through neopulmonic parabronchi to and from the caudal air sacs. This ventilation flow pattern permits birds to extract more oxygen from a specified volume of inspired air than mammals can (Fig. 24-31).

The parabronchial axes are perpendicular to the blood capillary axes within the lung **(cross-current exchanger).** This per-

Downloaded From Vet-eBooks.com

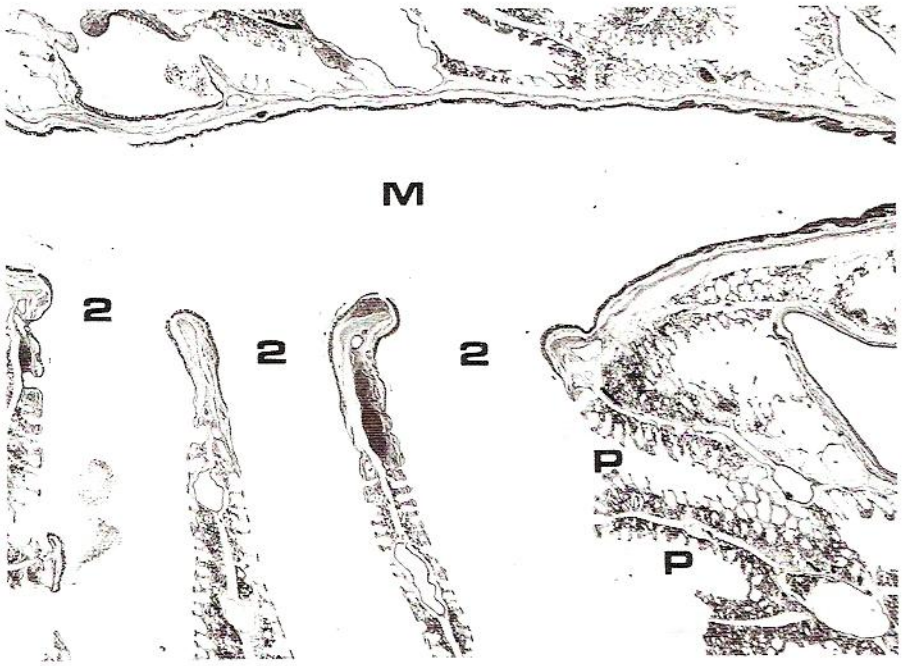

Figure 24-28. Section of an avian lung. *M*, Mesobronchus; *2*, secondary bronchi; *P*, parabronchi (tertiary bronchi). (×4.)

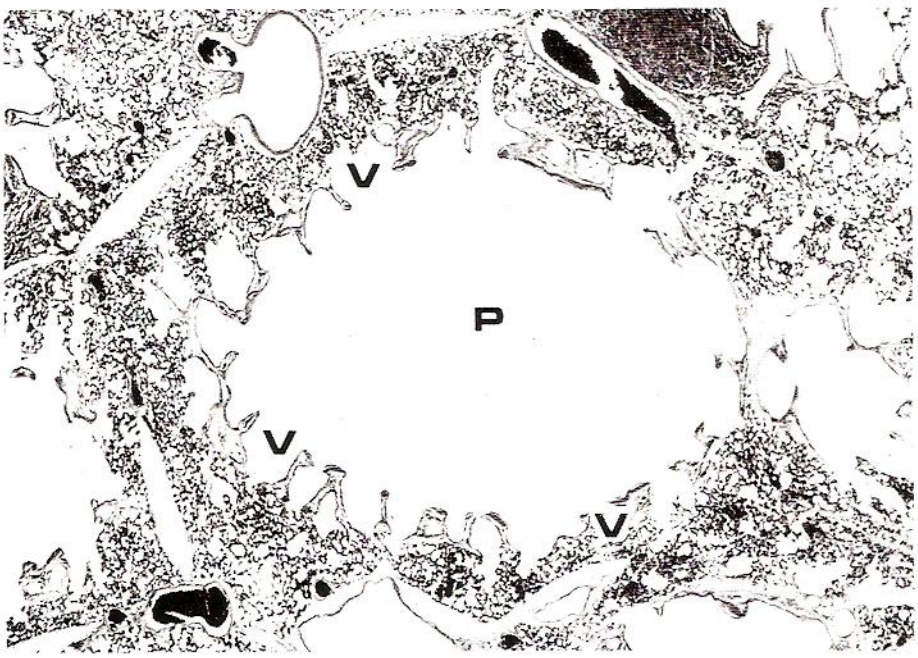

Figure 24-29. Parabronchus of the avian lung. Note that the parabronchus *(P)* has numerous air vesicles *(V)* in its wall. (×16.)

Downloaded From Vet-eBooks.com

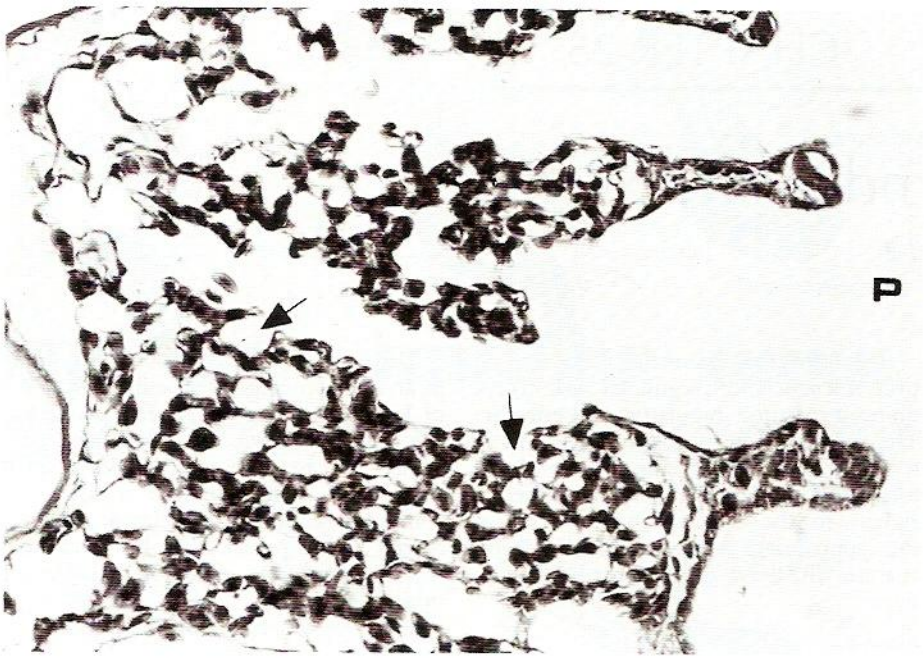

Figure 24-30. Air vesicles of the avian lung. These vesicles, composed of air capillaries *(arrows)* and blood capillaries, are the walls of the parabronchi *(P)*. (×100.)

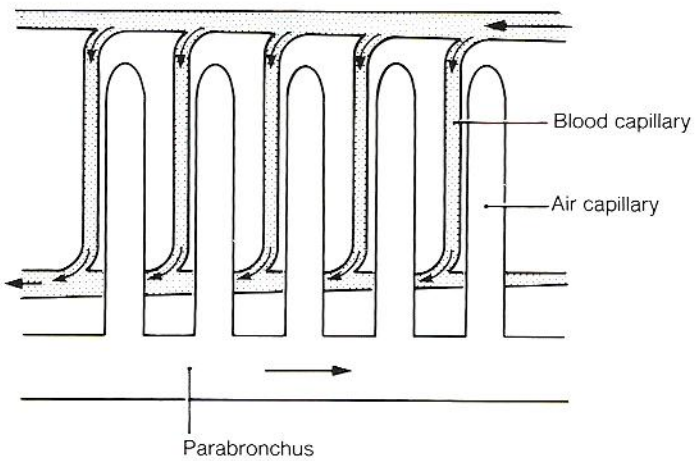

Figure 24-31. Exchange relationships in the avian lung. The orientation of blood and air capillaries establishes a countercurrent relationship.

mits gas exchange independent of flow direction. The relationship between blood capillaries and air capillaries is that of a **countercurrent-type exchanger.** Mixed venous blood enters a blood capillary and flows adjacent to and opposite the flow in an air capillary. The flow in the capillary exits at the point where parabronchial air enters. Thus gaseous exchange and equilibration are enhanced between blood and air capillaries.

ADDITIONAL READINGS

Respiratory Tract—Conductive

Ali MY: Histology of the human nasopharyngeal mucosa. *J Anat* 99:657, 1965.

Amoare JE, Hohnston HW, Rubin M: The stereochemical theory of odor, *Sci Am* 210:43, 1964.

Arstila A, Wersall J: The ultrastructure of the olfactory epithelium of the guinea pig, *Acta Otolaryngol* 64:187, 1967.

Baradi AF, Bourne GH: Gustatory and olfactory epithelia, *Int Rev Cytol* 2:289, 1953.

Bojsen-Moller F: Topography and development of the anterior nasal glands in pigs, *J Anat* 101:321, 1967.

Frisch D: Ultrastructure of mouse olfactory mucosa, *Am J Anat* 121:87, 1967.

Hansell MM, Moretti RL: Ultrastructure of the mouse tracheal epithelium, *J Morphol* 128:159, 1969.

Rhodin J, Dalhamn T: Electron microscopy of the tracheal and ciliated mucosa in the rat, *Z Zellforsch* 44:345, 1956.

Mammalian Lung

Banks WJ Jr, Epling GP: Differentiation and origin of the type II pneumocyte: an ultrastructural study, *Acta Anat* 78:604, 1971.

Bertalanffy FD: Respiratory tissue: structure, histophysiology and cytodynamics. I. Review and basic cytomorphology, *Int Rev Cytol* 16:233, 1964.

Bowden DH, et al: Origin of the lung macrophage: evidence derived from radiation injury, *Arch Pathol* 88:540, 1969.

Comroe JH Jr: *Physiology of respiration: an introductory text,* Chicago, 1965, Year Book Medical Publishers.

Comroe JH, et al: *The lung: clinical physiology and pulmonary function tests,* ed 2, Chicago, 1965, Year Book Medical Publishers.

Epling GP: Electron microscopy of the bovine lungs: lattice and lamellar structures in the alveolar lumina, *Am J Vet Res* 25:1424, 1964.

Engel S: *Lung structure,* Springfield Ill, 1962, Charles C Thomas.

Engel S: *The prenatal lung,* New York, 1966, Pergamon Press.

Karrer HE: The ultrastructure of mouse lung. The alveolar macrophage, *J Biophys Biochem Cytol* 4:693, 1958.

King RJ: The surfactant system of the lung, *Fed Proc* 33:2238, 1974.

Krahl VE: Current concept of the finer structure of the lung, *Arch Intern Med [Chicago]* 96:342, 1955.

Krahl VE: *The human lung* (translation of *Die Menschliche Lunge* by H van Hayek, 1953), New York, 1960, Hafner.

Krahl VE: Anatomy of the mammalian lung. In *Handbook of physiology,* Section 3, *Respiration* (Fenn WO, Rahn H [eds]), vol 1, Chapter 6, Washington DC, 1964, American Physiological Society

Loosle CG, Porter EL: Pre- and postnatal development of the respiratory portion of the human lung, *Am Rev Resp Dis* 80:5, 1959.

Low FN: Electron microscopy of the rat lung. *Anat Rec* 113:437, 1952.

Meyrick B, Reid L: The alveolar brush cell in rat lung—a third pneumocyte, *J Ultrastruct Res* 23:71, 1968.

Miller WS: *The lung,* ed 2, Springfield Ill, 1950, Charles C Thomas.

Plopper CG, Mariassy AT, Hill LH: Ultrastructure of the nonciliated bronchiolar epithelium (Clara) cell of mammalian lung. II. A comparison of horse, steer, sheep, dog, and cat, *Exp Lung Res* 1:155, 1980.

Rooney SA: The surfactant system and lung phospholipid biochemistry, *Ann Rev Resp Dis* 131:439, 1985.

Sorokin SP: A morphologic and cytochemical study of the great alveolar cell, *J Histochem Cytochem* 14:884, 1966.

Tobin CE: Lymphatics of the pulmonary alveoli, *Anat Rec* 120:625, 1954.

Tyler WS, Gillespie JR, Nowell JA: Modern functional morphology of the equine lung, *Equine Vet J* 3:84, 1971.

Avian Lung and Associated Structures

Akester AR: The comparative anatomy of the respiratory pathways in the domestic fowl, pigeon and domestic duck, *J Anat* 94:488, 1960.

Cover MS: The gross and microscopic anatomy of the respiratory system of the turkey. I. The nasal cavity and infraorbital sinus, *Am J Vet Res* 14:113, 1953.

Cover MS: The gross and microscopic anatomy of the respiratory system of the turkey. II. The larynx, trachea, syrinx, bronchi, and lungs, *Am J Vet Res* 14:230, 1953.

Cover MS: Gross and microscopic anatomy of the respiratory system of the turkey. III. The air sacs, *Am J Vet Res* 14:239, 1953.

Freeman BM (ed): *Physiology and biochemistry of the domestic fowl,* vol 4, New York, 1983, Academic Press.

McLeod WM, Wagers RP: The respiratory system of the chicken, *J Am Vet Med Assoc* 95:59, 1939.

Sturkie PD (ed): *Avian physiology,* ed 4, New York, 1986, Springer-Verlag.

CHAPTER 25

Endocrine System

GENERAL CHARACTERISTICS

The endocrine glands are **ductless glands** (or glands of **internal secretion**). Their development is shown in Figure 5-19. They may be distinct organs, parts of organs, or cells of organs. They are sometimes encapsulated without much stroma, generally highly vascularized, and often composed of cells in different forms. They may exist as **single cells, cell clusters, cell cords,** or **cell follicles.** The cells secrete **hormones** into capillaries or sinuses. The hormones are proteins, glycoproteins, polypeptides, steroids, or catecholamines. A gland synthesizes one or several hormones—which it may then secrete or store either temporarily (as presecretory granules) or permanently (as follicular components). Once in the bloodstream, hormones affect the entire organism, a few organs, or a specific organ. Although the entire organism usually be affected, one organ or group of organs usually responds specifically and is termed the **target organ** or **organs;** in other words, some organs have a low threshold, enabling a specific hormonal response to be readily measured.

Nature and function of hormones. Hormones are chemical substances secreted by various cells into the body fluids and exerting an influence upon other cells. Communication between cells is an essential feature of integrated activities.

Various chemical substances are messengers influencing target organ activities. **Neurocrine cells** release neurotransmitters that affect target cells through directed and nondirected synapses. **Paracrine cells** (e.g., neuroendocrine and enteroendocrine) release messengers into tissue fluid and affect adjacent target cells. **Endocrine cells** release blood-borne messengers affecting distant target organs.

Hormones are regulatory substances that function to alter the rates at which existing reactions occur without contributing mass or energy to the reaction. They are contributors to homeostasis in that they influence metabolic reactions and cell differentiation, development, maturation, and aging. They influence cell function by activating cAMP (protein and polypeptide hormones) or specific genes (steroid cells).

Regulatory mechanisms. The regulation of a substance (**regulated system**) requires a receptor, regulator, and effector. The **receptor** perceives alterations in the level of a particular substance and informs the **regulator.** The regulator sends signals to the **effector,** which initiates the appropriate response and thereby changes the level of the regulated substance.

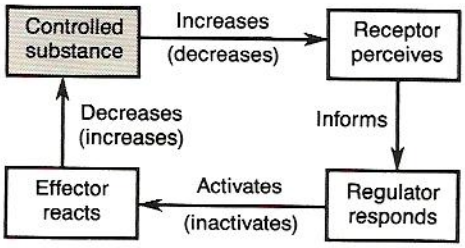

Figure 25-1. Relationships of the components of a regulated system. A negative feedback loop is the common servomechanism. Alterations of a regulated substance or activity lead to a reversal of the initiating event by various effector tissues or organs. If the level of a substance or activity increases, the effectors decrease it. The converse also occurs.

The most important regulated systems in animals are **negative feedback systems** or **loops**—in which the effector reverses the initiating event. If a controlled substance increases, the effector decreases it (Fig. 25-1). The converse is also true. Variations exist in this scheme. The receptor and regulator may be combined, or more than one regulator and effector may be involved.

Positive feedback loops amplify or intensify the initiating event in a regulated system. They are not common in the normal organism, however, but may occur in some disease conditions.

HYPOPHYSIS CEREBRI

Organization and development. The **pars tuberalis** and **pars distalis** form the **anterior pituitary** (adenohypophysis). The **pars intermedia** and the **infundibular process** form the **posterior pituitary** (neurohypophysis). The **pars tuberalis** and **infundibular stalk** form the **hypophyseal base.** In some species the posterior pituitary is actually dorsal to the anterior pituitary whereas in others the anterior pituitary totally surrounds the posterior (Fig. 25-2).

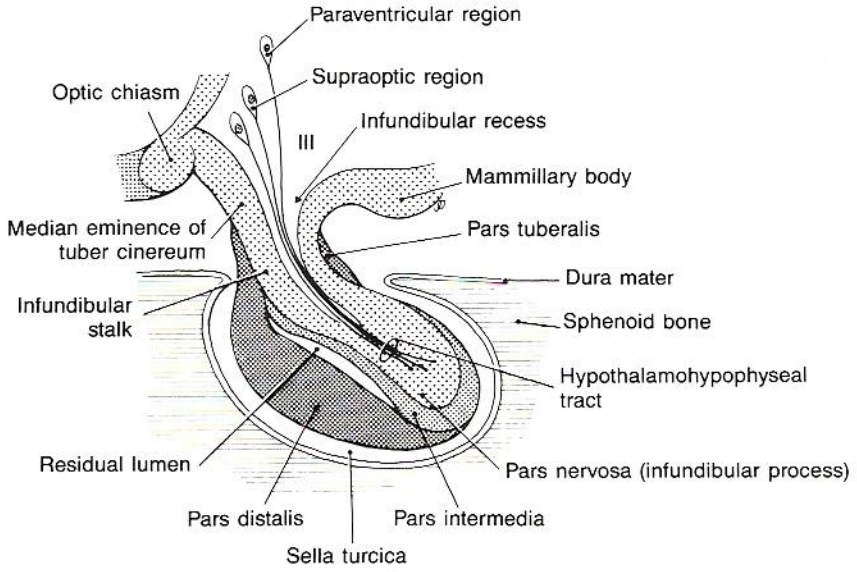

Figure 25-2. Hypophysis cerebri of a pig. The hypophysis is a ventral evagination of the diencephalon that occupies a recess, the sella turcica, within the sphenoid bone.

Downloaded From Vet-eBooks.com

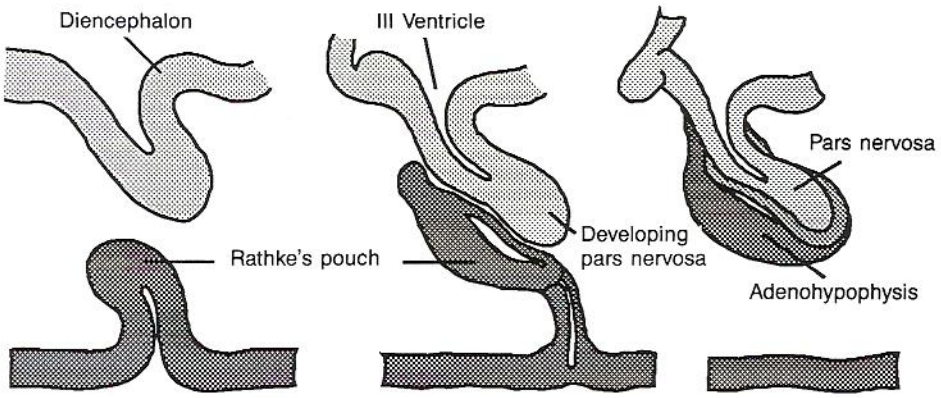

Figure 25-3. Formation of the hypophysis cerebri. The ectoderm of the roof of the mouth evaginates as Rathke's pouch and becomes associated with an evagination of the diencephalon.

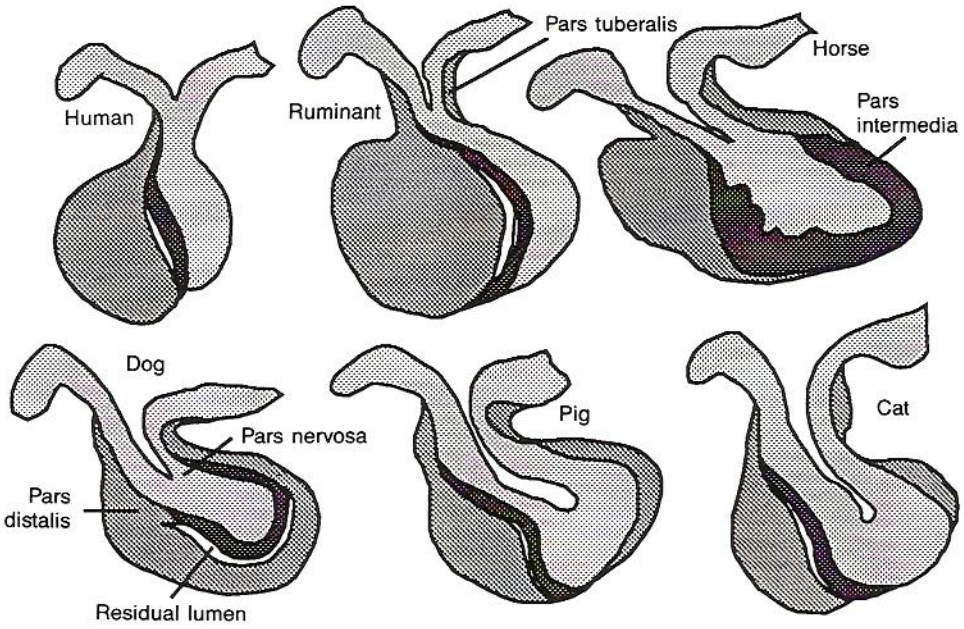

Figure 25-4. Hypophysis cerebri in selected species. These structures are not drawn to scale.

Pituitary gland development depends upon contributions from the buccal cavity (ectoderm) and the diencephalic floor (neuroectoderm). **Rathke's pouch,** an outgrowth of the roof of the oral cavity, grows toward the base of the brain (Fig. 25-3). This pouch differentiates into the **adenohypophysis.** As the pouch grows and contacts the infundibulum from the diencephalic floor, its connection with the oral cavity disintegrates. That portion of Rathke's pouch contacting the neurohypophysis differentiates into the pars intermedia. The rostral part becomes the pars distalis; the dorsal extension of the pars distalis that contacts the infundibular stalk becomes the pars tuberalis. The **residual lumen** of Rathke's pouch may persist as a separation between the anterior and posterior pituitary.

The infundibular stalk is an outgrowth of the median eminence, which is the ventral boundary of the third ventricle in this region. As the infundibular stalk grows, part of the third ventricle is carried with it as the **infundibular recess.** In most species the recess is confined to the infundibular stalk's origin from the median eminence (Fig. 25-4). In some, however (pigs and cats), it extends into the infundibular process.

Adenohypophysis

The adenohypophysis consists of a **pars distalis, pars intermedia,** and **pars tuberalis.**

Pars distalis

The **pars distalis** is the bulk of the adenohypophysis (Fig. 25-5). It is covered by a fibrous capsule of dense collagenous tissue continuous with stromal reticular fibers. Its parenchyma consists of cell cords or clusters intimately associated with sinuses.

Cells. The cells of the pars distalis are divided into chromophobic and chromophilic groups. Chromophilic cells are subdivided into acidophils and basophils.

Chromophobes are small, round cells with a scant cytoplasm and no granules evident by light microscopy (Fig. 25-6). They have little affinity for stains, are usually clustered, and may form the center of cell cords. By electron microscopy, small granules are evident. Chromophobes may actually be chromophilic cells in a state of partial degranulation. They may form a reservoir from which other specific granulated cells arise.

Chromophilic cells are divisible into acidophils and basophils. Classically they have been described based upon complex staining properties with different dyes. Modern immunochemical techniques now allow cell identification based upon the hormone that they contain, precluding the need to describe cells based upon their affinity for certain dyes.

Acidophils are larger than chromophobes, possess a granular acidophilic cytoplasm, and may be polarized (Fig. 25-6). One subset stains immunocytochemically for growth hormone. These cells are called **somatotrops.** Another stains for prolactin. These are called **lactotrops** or **mammotrops.**

Basophils are larger than acidophils and have PAS-positive granules (Fig. 25-6). One subset stains immunocytochemically for thyrotropin; they are called **thyrotrops.** Another stains similarly for follicle-stimulating hormone and luteinizing hormone. These are called **gonadotrops.** The most common subset of basophils stains immunocytochemically for a single precursor molecule, **proopiomelanocortin (POMC),** from which adrenocorticotropin (ACTH), melanocyte-stimulating hormone (MSH), α-endorphin, and β-lipotropic hormone (β-LPH) are derived. These are called **POMC cells.**

The common precursor molecule, POMC, is cleaved into a high–molecular weight form of ACTH and β-LPH. The high–molecular weight form of the ACTH molecule is then cleaved to an N-terminal peptide and normal ACTH. Within the pars intermedia, normal ACTH is cleaved to α-MSH and a corticotropin-like peptide (CLIP). The division of β-LPH yields γ-LPH and β-endorphin within the pars intermedia.

Routine staining characteristics. With routine H&E staining only three cell types are identifiable–**chromophobes** (agranular and unstained), **acidophils** (eosinophilic granules), and **basophils** (hematoxylin-positive granules). The proportion of cell types varies with age, species, sex, and physiology. Generally,

Downloaded From Vet-eBooks.com

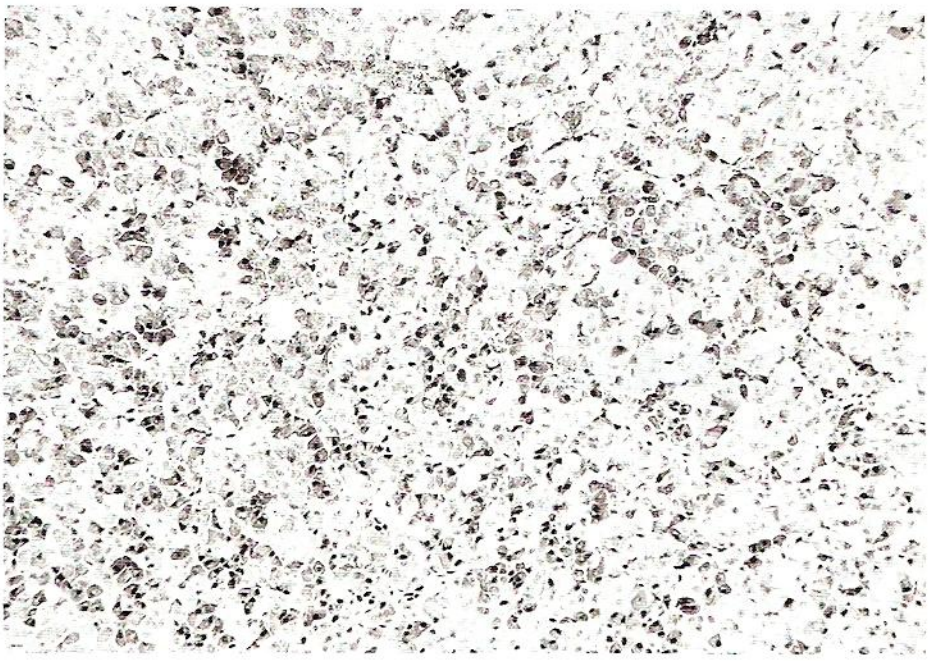

Figure 25-5. Section of the pars distalis of a feline hypophysis cerebri. Cords and clumps of variously stained cells are intimately associated with sinusoids. (×10.)

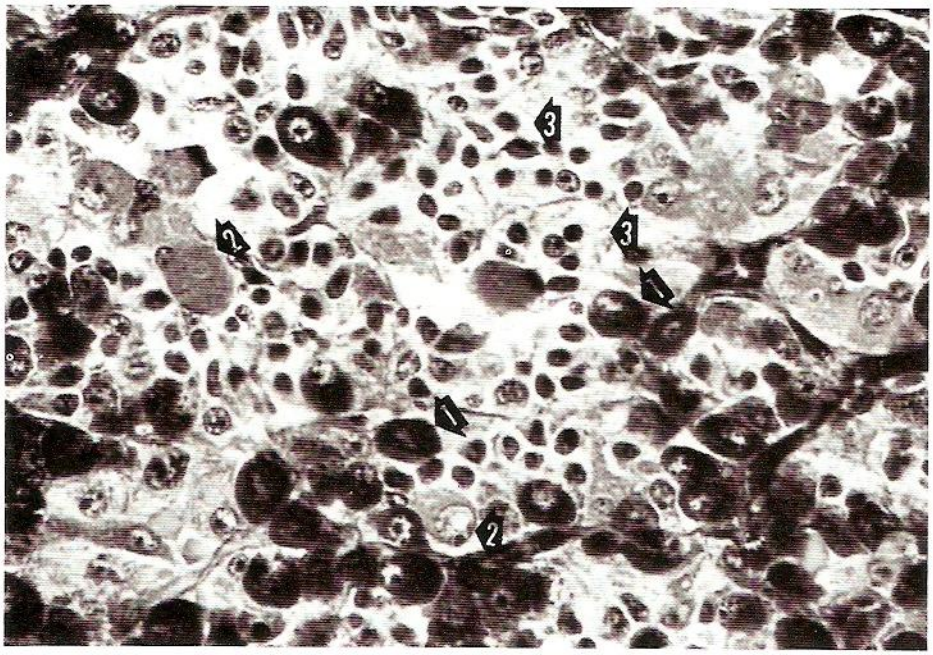

Figure 25-6. Section of an equine pars distalis. Three types of cells are identifiable within this azan-stained specimen—acidophils *(1)*, basophils *(2)*, and chromophobes *(3)*. Fine connective tissue septa delineate clumps of cells. (×160.)

Downloaded From Vet-eBooks.com

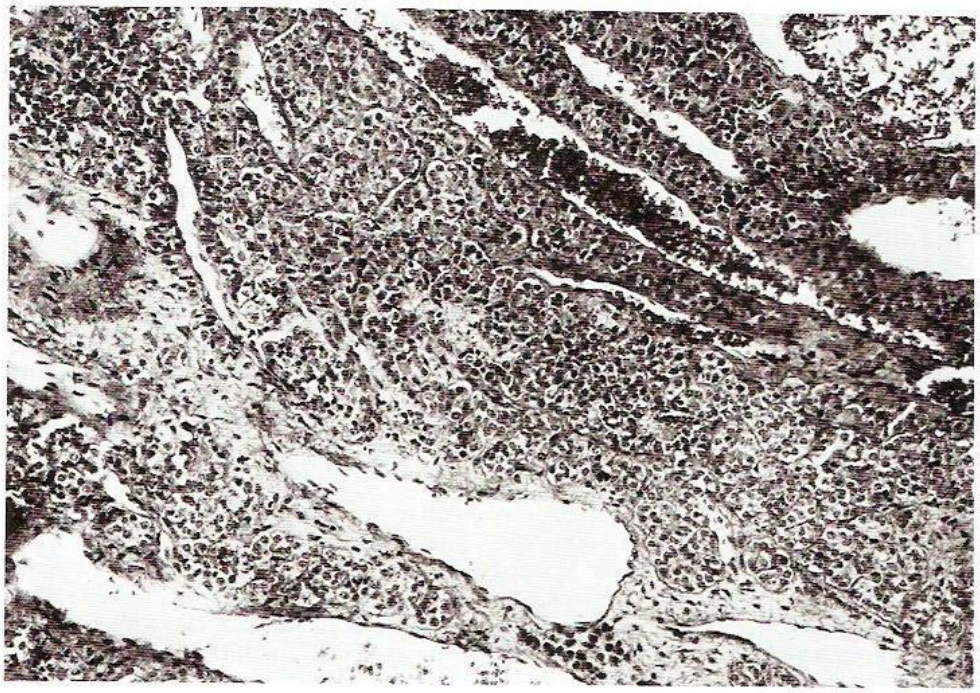

Figure 25-7. Section of a bovine pars tuberalis. The cords of weakly basophilic cells are separated by large vessels. (×40.)

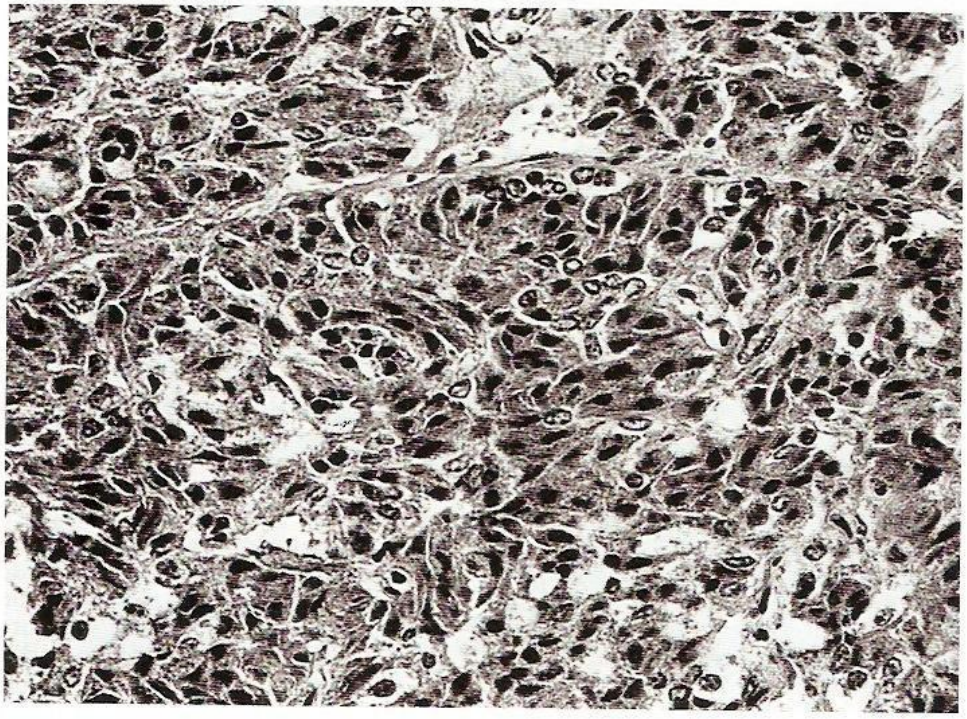

Figure 25-8. Cells of a bovine pars intermedia. The nonspecific basophils are closely clumped. Although not apparent in this section, follicles may be present. (×100.)

50% are chromophobes, 40% are acidophils, and 10% are basophils.

Pars tuberalis

The **pars tuberalis** consists of weakly basophilic cuboidal cells (Fig. 25-7). If present, granules are small. The cells occur in cords or clusters or as follicles. The function of the pars tuberalis has not been established.

Pars intermedia

The **pars intermedia** is well-developed in domestic animals though not in humans (Fig. 25-8). It is adjacent to, but separated from, the neurohypophysis by a discontinuous connective tissue sheath. Cell migration from the pars intermedia into the pars nervosa is common. The predominant cell type of the pars intermedia is a nonspecific basophil (Fig. 25-8). Although these cells are usually disposed in cords or clusters, follicles do occur. The cells secrete **melanocyte-stimulating hormone (MSH).**

Histophysiology of the adenohypophysis

Vascular relationships. The origin and course of vessels supplying the adenohypophysis vary among domestic species, but all form a **hypophyseal portal system (hypothalmohypophyseal portal system). Rostral hypophyseal arteries** form an arterial ring around the median eminence and give rise to arterioles supplying the hypothalamus, including the infundibular stalk. These vessels do not extend into the infundibular process. The pars distalis is supplied indirectly by the rostral hypophyseal arteries. Arteriolar branches terminate as **primary capillary loops** within the median eminence and infundibular stalk. **Short primary capillary loops** supply the external portion of the median eminence, **long primary capillary loops** the internal portion. The primary capillary loops coalesce to form veins that descend into the pars distalis via the pars tuberalis. The veins divide into a second set of capillaries or sinuses throughout the pars distalis. The hypophyseal portal system (formed by primary capillary loops, veins, and secondary capillary plexuses) comprises the major blood supply to the pars distalis.

Somatotrophic hormone. **Somatotrophic hormone (somatotropin, STH, GH, growth hormone)** is produced by **somatotrops** and causes hypertrophy and hyperplasia in somatic cells. Its effects are mediated through a group of polypeptides called **somatomedins.** At least five somatomedins have been isolated, each manifesting slightly different metabolic effects. Somatomedin is derived from liver, kidney, and probably muscle. Without its mediation, the direct effects of GH occur only at high concentrations.

Metabolic processes are altered by the secretion of GH. Protein synthesis is enhanced by the augmented cell uptake of amino acids, the decreased catabolism of proteins, the reduced utilization of amino acids as energy sources, and the increased formation of ribonucleic acid. Glucose utilization is decreased, and glycogen storage enhanced. The increased blood levels of glucose associated with GH secretion are sufficient for the hormone to be considered **diabetogenic.** Under its stimulation, animals mobilize lipid stores and use them as energy sources. Excessive lipid metabolism may result in ketone body formation; it is also **ketogenic.**

Growth hormone release is regulated by two hypothalamic hormones—**growth hormone releasing factor (GHRF) and growth hormone inhibitory factor (GHIF, somatostatin).** Soma-

Downloaded From Vet-eBooks.com

tostatin, also produced by the delta cells of the pancreatic islets, inhibits the secretion of insulin, glucagon, and GH.

More studies are necessary to clarify the stimuli leading to GH release. Acutely, hypoglycemia and increased concentrations of some amino acids stimulate GH release. Chronically, cell protein depletion is a strong stimulus.

The response of skeletal tissues to abnormal STH levels throughout life may be marked by dramatic changes: an oversecretion during adolescence causes **gigantism;** an undersecretion in adolescence causes **dwarfism;** after growth plate closure an oversecretion results in **acromegaly.** GH has an effect on osseous, cartilaginous, and muscular growth.

Prolactin. **Prolactin (luteotrophic hormone, LTH, lactogenic hormone)** is secreted by mammotrops. Mammary gland development occurs under the combined influence of prolactin, estrogen, and progesterone. Prolactin causes the secretion of milk after development of the mammary gland. Murine and ovine prolactin has luteotrophic activity. In columbiform birds, prolactin is responsible for the secretory activity of the crop associated with the formation of "crop milk."

Adrenocorticotrophic hormone. The **adrenocorticotrophic hormone (ACTH, corticotropin)** is secreted by POMC cells, although these cells may still be called **corticotrops** by some authorities. The primary effects of ACTH are upon adrenal gland secretion of **glucocorticoids.** Small amounts of ACTH (permissive effect) induce the secretion of **mineralocorticoids,** but aldosterone secretion is regulated by other mechanisms. As a trophic hormone affecting glucocorticoid release, ACTH exerts effects that are manifested through these substances.

The release of ACTH is regulated by circulating levels of glucocorticoids. These substances manifest a negative feedback influence: corticotropin release and the subsequent increase in circulating glucocorticoids are affected by emotional and physical stress; circulating glucocorticoids levels are subject to the circadian rhythm of hypothalamic and adenohypophyseal secretion, a sine wave–type rhythm (with maximal ACTH and glucocorticoid levels occurring in the morning).

Follicle-stimulating hormone. **Follicle-stimulating hormone (FSH)** is the secretion of gonadotrops. It is responsible for the growth and development of ovarian follicles, and it activates the testes to produce spermatozoa.

Luteinizing hormone. **Luteinizing hormone (LH),** also a secretion of gonadotrops, promotes the conversion of ruptured follicles into corpora lutea. The combined activities of FSH and LH are responsible for the maturation of ova, ovulation, and the development of the corpus luteum. In males LH is also called **ICSH (interstitial cell–stimulating hormone).** It stimulates the secretion of testosterone by **testicular interstitial cells (of Leydig).**

Thyrotrophic hormone. **Thyrotrophic hormone (TSH, thyroid-stimulating hormone)** stimulates and maintains the secretory activity of the thyroid gland.

Melanocyte-stimulating hormone. The dispersion of melanin in melanocytes is mediated by **melanocyte-stimulating hormone (MSH, intermedin),** a secretory product of the pars intermedia. Although this activity has been well-established in lower vertebrates (amphibians), the precise role of MSH in mammals has not been documented.

Lipotropins. Two polypeptide hormones, **β-lipotropin (β-LPH)** and **γ-lipotropin (γ-LPH),** have been isolated from the adenohypophysis. In some species these substances mobilize fats. β-Lipotropin is a precursor of **β-endorphin.**

Regulation of the adenohypophysis

Adenohypophyseal secretions are regulated through **releasing** and **inhibitory factors** secreted by **parvicellular neurons** of the hypothalamus. The primary capillary loops of the hypophyseal portal system and the telodendria of the neurons comprise **neurohemal organs** (Chapter 14). Hypothalamic hormones released into the portal system include **growth hormone–releasing factor (GHRF), growth hormone–inhibitory factor (GHIF), prolactin-releasing factor (PRF), prolactin-inhibitory factor (PIF), ACTH-releasing factor (CRF), FSH-releasing factor (FRF), LH-releasing factor (LRF),** and **TSH-releasing factor (TRF).** Specific excitatory or inhibitory events—body temperature, blood glucose concentration, cellular protein levels, circulating levels of certain general hormones or trophic hormones—exert an influence upon the secretory activity of hypothalamic neurons. The hypothalamic hormones adjust activity of the adenohypophysis. The tropic hormones, besides mediating their influence upon target organs, may function in a short negative feedback loop to affect the secretion of hypothalamic cells. The involvement of more than one regulator generally assures precise regulation of a particular substance or event.

Neurohypophysis

General structure. The **neurohypophysis** is a ventral evagination of the hypothalamus (Fig. 25-4). It includes the **median eminence of the tuber cinereum, the infundibular stalk,** and the **infundibular process** (Fig. 25-9). Numerous unmyelinated neurons comprise the **hypothalamohypophyseal tract,** whose cell bodies are located in the supraoptic and paraventricular nuclei of the hypothalamus. These **magnicellular neurons** are neurosecretory. Their **neurosecretions** move along the axons and accumulate as **neurosecretory bodies** (Fig. 25-10). Many **pituicytes** and neuroglia are scattered among the axons.

Neurohypophyseal hormones and neurophysins. The secretions of magnicellular neurons of the supraoptic and paraventricular nuclei include **oxytocin, vasopressin,** and **neurophysins.** The neurophysins are cystine-rich, proteinaceous, intracellular carrier molecules for the prohormonal forms of the neurosecretory substances. A specific neurophysin for each hormone is packaged into each secretory granule with a prohormone and a converting enzyme. Neurophysins are linked to the prohormones in a 1:1 molar ratio. **Neurophysin I** is associated with antidiuretic hormone (ADH), and **neurophysins II and III** with oxytocin. The specificity of the neurophysins is so precise that they may be used to separate these hormones from pituitary extracts. The secretory granules move by rapid axoplasmic flow to the neurohemal interface. An action potential, triggered by the cell body in response to stimulation, causes a change in cell membrane permeability, an increase in intracellular Ca^{++}, and the exocytotic release of the hormones and neurophysins.

Oxytocin. **Oxytocin,** produced primarily within the paraventricular nucleus, affects the reproductive organs. Milk letdown is mediated by this hormone in response to suckling. The afferent stimulation reaches the hypothalamus and causes the release of the hormone. Oxytocin has a stimulatory effect upon the myometrium. The contractions induced facilitate the ascent of spermatozoa into the oviduct. During pregnancy, oxytocin is secreted by the maternal hypophysis under the influence of fetal and placental estrogens and prostaglandins. The release of oxytocin stimulates myometrial contractions and accelerates parturition. As the fetus passes through the dilated cervix, point pressure of the fetus on the vaginal wall stimulates additional oxytocin release and the marked abdominal contractions that characterize labor. These cascading events are irreversible. Oxytocin can be used to induce parturition in mares.

Antidiuretic hormone. **Antidiuretic hormone (ADH, vasopressin),** produced primarily within the supraoptic nucleus, manifests its properties on the lining cells of the distal convoluted tubules and collecting ducts of the kidneys. Blood osmolality and fluid volume are the stimuli for its secretion. Osmoreceptors within the hypothalamus respond to the osmolality of fluids bathing them and influence the magnocellular neurons responsible for ADH secretion. An increased blood os-

Figure 25-9. Section of a bovine neurohypophysis. It appears as typical nervous tissue. (×40.)

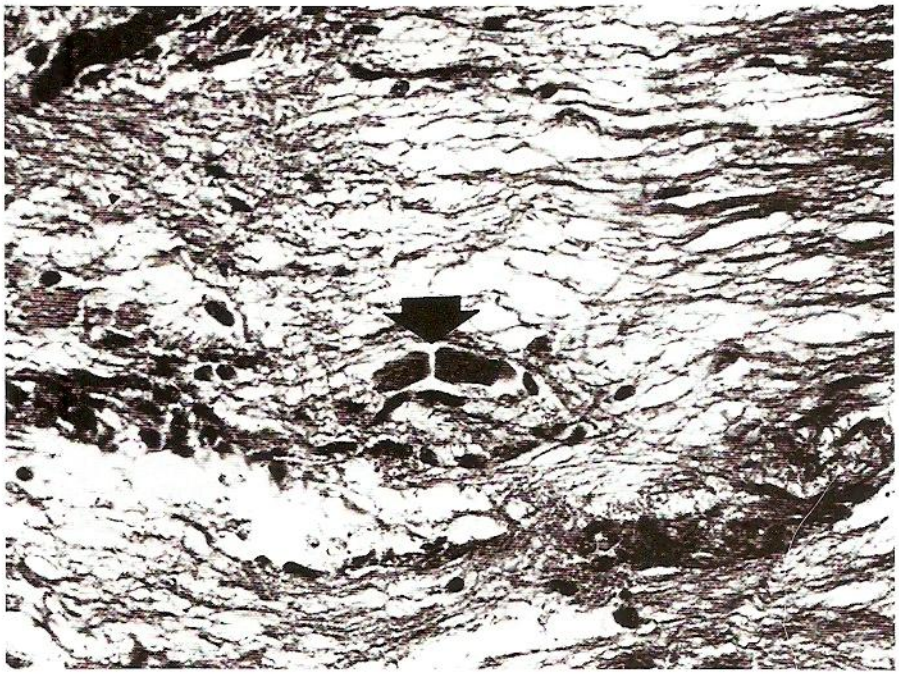

Figure 25-10. Neurosecretory bodies. The neurosecretory products and carrier molecules of specific hypothalamic nuclear regions are transported along axons as neurosecretory bodies *(arrow)*. (×100.)

molality increases the activity of the osmoreceptors and results in the release of ADH. The kidney, responding to ADH by increasing the tubular resorption of water, excretes a low-volume hypertonic urine. The converse is true when blood osmolality decreases.

The extracellular fluid (ECF) volume of the body influences ADH release. An increased ECF volume and the release of atrial natriuretic factor decrease ADH secretion; conversely, a decreased ECF volume increases ADH secretion. Changes in ECF volume effect changes in blood volume. Low-pressure venous baroreceptors in the great veins of the heart, atria, and pulmonary vessels monitor blood volume and influence ADH release. These baroreceptors probably also influence ADH secretion to a greater extent than high-pressure arterial baroreceptors do, because subtle changes in blood volume are not always associated with arterial pressure changes. A marked reduction in blood volume, as from hemorrhage, involves the arterial baroreceptors (carotid and aortic sinuses) in regulating of ADH release. The attendant fall in blood pressure causes an increased release of ADH.

The vasopressive activity of ADH is manifested by exogenous administration of the hormone at dosages exceeding physiological levels. Even after hemorrhage, it is dubious that ADH will manifest sufficient vasopressive activity to alter blood pressure.

EPIPHYSIS CEREBRI

Form and function. This organ (the **pineal body**) is a dorsal evagination of the diencephalic roof. An understanding of its functional significance has been slow to evolve. In lower vertebrates it is a photoreceptor organ, the **third eye** or **pineal eye.** Despite its position in the mammalian cranium, it is a light-sensitive organ. Information from the optic system passes to the midbrain and thence to the thoracic region of the spinal cord, where sympathetic nerves carry it to the apex of the pineal body.

Melatonin and **serotonin** are secretory products of this body. Under continuous light stimulation, the pineal decreases its activity; at the same time melatonin production decreases and gonadal activity increases. Pineal body tumors result in delayed puberty. It is not clear, however, whether the pineal body mediates its influence through the hypothalamus (releasing factors) or pars distalis or whether it acts directly upon the gonads. The gland is probably the biological clock setting circadian rhythms associated with estrous cycles and seasonal breeding characteristics of some species.

Histology. The pineal body is covered by connective tissue of the pia mater (Fig. 25-11). Septation and lobulation are accomplished by connective tissue elements. The primary cellular components are **astrocytes** and **pinealocytes** (epithelioid cells). Typical connective tissue cells (plasma cells, fibroblasts, mast cells, macrophages) may also be present. The **pinealocytes (chief cells)** are large with large, round, open nuclei set in an acidophilic cytoplasm (Fig. 25-11). The **astrocytes** are typical and insinuated between the vascular supply and the pinealocytes. They are often called **interstitial cells.**

The pineal body contains concretions called **corpora arenacea (acervuli, brain sand, psammona bodies)** that appear to be of glial or stromal origin and have the structure of hydroxyapatite crystals. Although they tend to increase with age,

Downloaded From Vet-eBooks.com

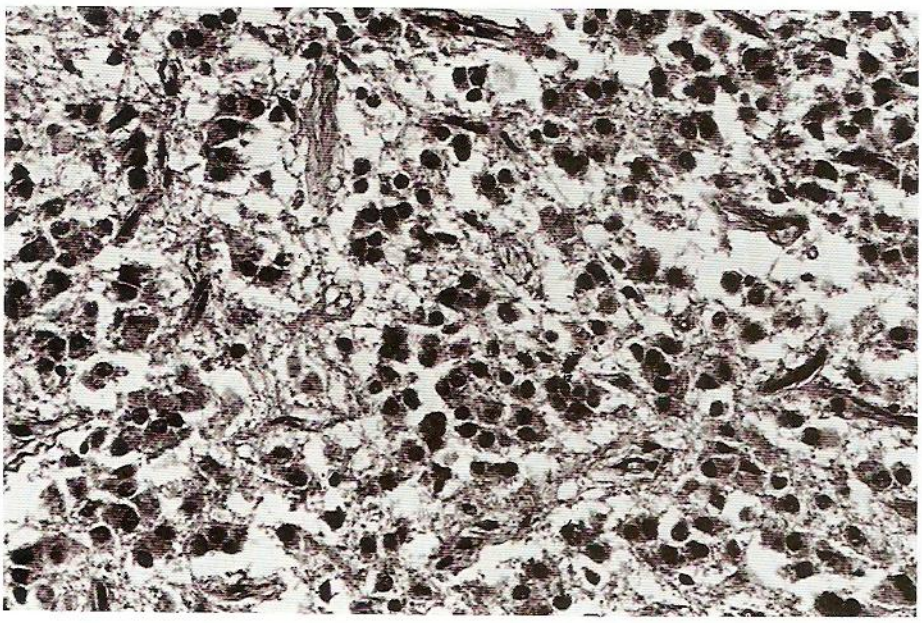

Figure 25-11. Cellular components of an ovine pineal body. (×90.)

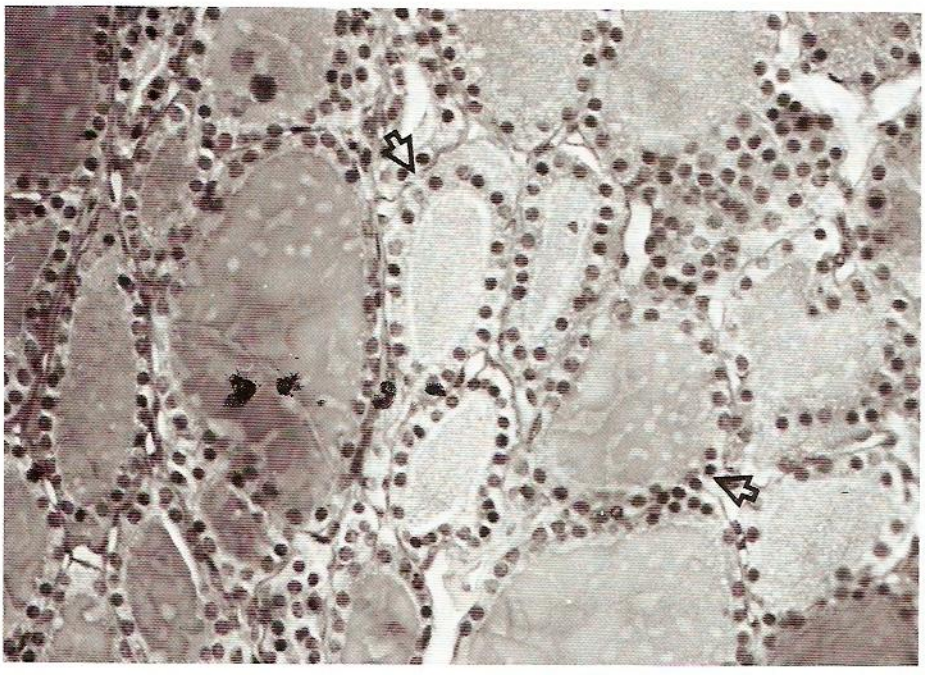

Figure 25-12. Section of a canine thyroid gland. The parenchyma is disposed as follicles *(arrows)* surrounding colloid. (×100, PAS.)

their increased frequency is not associated with a diminished pineal activity.

THYROID GLAND

Development. The thyroid gland is an outgrowth from the floor of the buccal cavity that subsequently loses its cellular connection **(thyroglossal duct)** with the pharyngeal endoderm. It fuses with cellular masses from each fifth pharyngeal pouch **(ultimobranchial body).** Endodermal evaginations from the third and fourth pharyngeal pouches (parathyroid glands) also become intimately associated with or are embedded within the mass of thyroid tissue. The thyroid gland eventually assumes a dorsolateral relationship with the trachea in the region of the larynx.

Histology. The capsule of both thyroid gland lobes consists of loose collagenous tissue. Similar connective tissue septa support the organ. Perifollicular connective tissue consists of extensive quantities of reticular fibers. The structural unit of the thyroid gland is the **thyroid follicle** (Fig. 25-12). Follicles are hollow spheres whose size depends upon the activity of lining cells. The center of each follicle is filled with a gel-like material called **colloid,** the storage form of follicular epithelial secretions. The lining epithelium varies from low cuboidal to high columnar (Fig. 25-13). The height of the cells within a given follicle, however, is uniform.

The thyroid epithelium actually consists of follicular lining cells, comprising at least 90% of the cell population, and light (parafollicular) cells (C cells). The **follicular lining cells** are acidophilic, with basally positioned nuclei (Fig. 25-13). Supranuclear pale-staining Golgi areas may be apparent. There may also be colloid droplets adjacent to the luminal surface. The **parafollicular cells** may, likewise, occur adjacent to or within the lining of the follicle, wherein they occasionally reach the luminal surface (Fig. 25-14). Surrounded by a basal lamina delimiting the follicle from the connective tissue space, they are best identified on the basis of their pale-staining cytoplasm.

Colloid, which contains proteins, glycoproteins, and enzymes, is usually acidophilic. The glycoprotein is PAS-positive. In an active follicle the acidophilic colloid has peripheral irregularities and vacuoles. In an inactive follicle it may be slightly basophilic or acidophilic. The periphery has a smooth profile, and vacuoles are not present. The size of the follicles as well as their epithelial height is also an indicator of follicular activity. Follicular activity is inversely proportional to the diameter of the follicle: small follicles usually have a **high epithelium** (and the appropriate colloid characteristics) and are **active;** large follicles usually have a **low epithelium** and the appropriate colloid characteristics and are **less active.** In follicles that are inactive the epithelium may even be squamous.

Synthesis and storage of thyroid hormones. The simplicity of thyroid follicular morphology does not indicate the complex mechanisms involved in the synthesis, storage, mobilization, and secretion of its hormones—T_4 **(thyroxine** or **tetraiodothyronine)** and T_3 **(triiodothyronine).**

The synthesis of T_4 and T_3 is dependent upon thyroid-stimulating hormone (TSH) and the availability of iodide. Iodide (I^-) is actively transported across the basal cell membrane under the influence of TSH. The iodide pump establishes the concentration of iodide within the thyroid follicular cell. Moving through the epithelial cell to the apical border, iodide is oxidized or activated to its reactive form, iodine (I_2). A **peroxi-**

Downloaded From Vet-eBooks.com

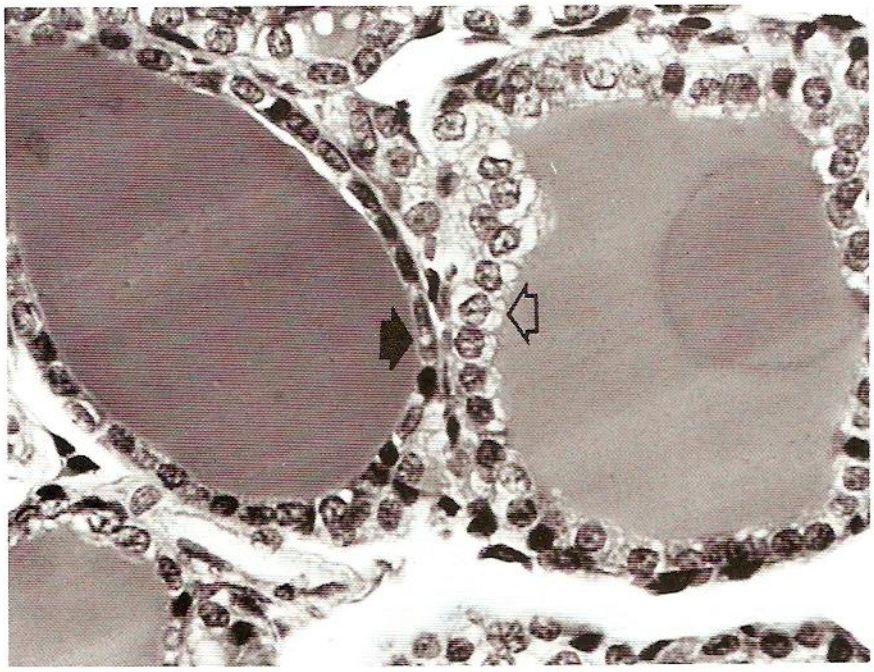

Figure 25-13. Thyroid follicular epithelial cells and follicles. The lining cells may vary from low cuboidal *(solid arrow)* to columnar *(open arrow)* depending upon the level of activity of the gland and individual follicles. (×160.)

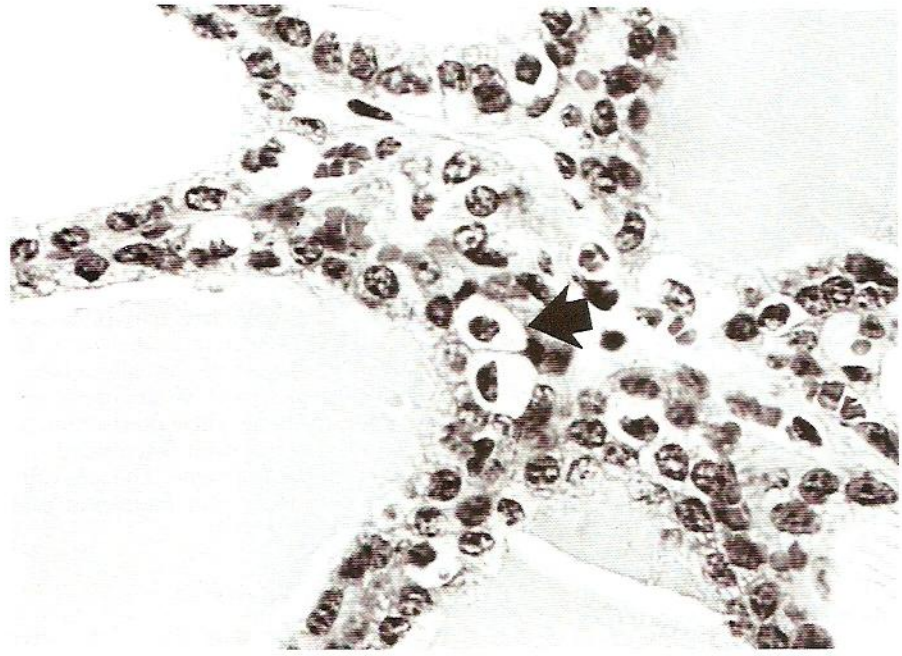

Figure 25-14. Parafollicular cells. These cells *(arrow)* are light-staining and positioned at the edges of the follicles. (×160, PAS.)

dase located in the microvilli of the cell may activate of the halogen. Concomitantly, amino acids entering the cell permit the synthesis of a polypeptide within the RER. Glycosylation of the polypeptide within the Golgi complex results in formation of a **glycoprotein** contained within a secretory vesicle transported across the apical cell border into the colloid. The **iodination** or **organification** of the glycoprotein occurs within or on the apical surface of the cells as the glycoprotein is secreted. Organification results in the formation of **thyroglobulin,** a glycoprotein with a molecular weight in excess of 650,000 daltons. Thyroglobulin contains some carbohydrates (galactose, mannose, N-acetylglucosamine, sialic acid) and **iodoamino acids.** The iodoamino acids are **3-monoiodotyrosine (MIT), 3,5-diiodotyrosine (DIT), 3,5,3′-triiodotyrosine (T_3), and 3,5,3′,5′-tetraiodotyrosine (T_4, thyroxine).**

The iodination of tyrosyl residues attached to thyroglobulin and the formation of MIT and DIT are keys to the formation of T_4 and T_3. The DIT moieties of adjacent thyroglobulin molecules, probably under the influence of a peroxidase, attach to each other to form T_4. Similarly, DIT and MIT on adjacent thyroglobulin molecules attach to each other to form T_3. The coupling of DIT with DIT and DIT with MIT may occur under the influence of TSH.

The synthesis of thyroglobulin conforms to the typical cellular mechanisms utilized to produce a glycoprotein. The organification process is a unique feature of thyroid follicular epithelial cells. Moreover, the storage of the secretory products within the colloidal thyroglobulin is a unique feature of this endocrine gland. The mobilization of thyroglobulin is essential for the secretion of T_4 and T_3. Thyroglobulin must move back into the cell and be digested before the release of T_4 and T_3 is achieved.

Mobilization of thyroid hormones. After stimulation by TSH, follicular epithelial cells undergo morphological changes linked to the transport of thyroglobulin back into the cell. The tall columnar epithelial cells increase in height and acquire many microvilli along their apical borders. The microvilli move in and out of colloid. The foamy and serrated appearance of the colloid at the apical border/colloid interface of active cells indicates colloid mobilization. The endocytotic movement of thyroglobulin into the cells is manifested as many colloid-containing vesicles within the apical margins of the cells. These vesicles, which may be considered phagosomes, migrate toward the basal border and fuse with a primary lysosome. The secondary lysosome, with its activated complement of hydrolases, digests the thyroglobulin molecule. T_4 and T_3 are secreted across the basal cell border whereas MIT and DIT, also released by the protease activity, are recycled within the cell as free tyrosyl and iodide. Under normal conditions thyroglobulin never occurs outside the thyroid follicle.

Effects of thyroid hormones. The thyroid hormones exert many effects upon the cells, tissues, and organs of the body. Although the specific activities are diverse, most involve energy metabolism, growth, and differentiation. The hormones increase O_2 consumption by metabolically active tissues and effect the increased production of energy. Because heat is lost during this process, it is often termed the **calorigenic effect.**

Downloaded From Vet-eBooks.com

The thyroid hormones increase the rates of carbohydrate and lipid metabolism, effects consistent with a generalized increase in basal metabolism. Increased absorption of glucose from the intestine, along with gluconeogenesis and glycogenolysis, occurs under the influence of these hormones. Although the peripheral utilization of glucose is increased, a transitory rise in blood glucose, even to the point of exceeding the renal threshold, can occur in response to T_4 and T_3 secretion. Additionally, the rate of synthesis and secretion of cholesterol rises and there is a total body loss of the substance in response to thyroid hormone stimulation.

The thyroid hormones generally stimulate protein synthesis, but protein catabolism can still occur when metabolic demands require energy supplementation from gluconeogenesis. Similarly, excessive quantities of the thyroid hormones are accompanied by protein catabolic processes. Many other specific effects are manifested by T_4 and T_3 upon other tissues and organs.

The thyroid hormones influence growth and developmental processes. They are essential for the normal development of most organs and systems. The nervous system and skeletal system especially manifest altered development and growth in the absence of these hormones. The mechanisms used by thyroid hormones to influence the normal progression of growth and development are not understood.

Regulation of thyroid hormones. Some iodine occurs free in the plasma, but most occurs as **protein-bound iodine (PBI),** of which the majority is attributable to T_4 and T_3. Protein binding is achieved primarily by a **thyroxine-binding globulin (TBG).** The free hormones, in equilibrium with those bound to TBG, diffuse into the tissues to manifest their varied influences upon metabolic processes. The precise biological relationships between T_4 and T_3 have not been clarified. T_4 has a greater binding affinity for protein, a more prolonged action, and a longer half-life than T_3. Although some investigators believe that both hormones are active, some believe that T_4 is a prohormone deiodinated to the more rapidly active T_3.

Three mechanisms are used to metabolize the iodothyronines (T_4 and T_3)—**conjugation, deamination-transamination,** and **deiodination.** Conjugation with a glucuronide occurs within the liver, followed by excretion of the conjugated hormones in the bile. Hydrolysis of the conjugated product within the intestines may lead to reabsorption of the hormones via the enterohepatic circulation. As amino acids the iodothyronines are subject to deamination-transamination reactions within the liver and kidneys. The most important deactivation process is deiodination of the hormones within the target cells.

The release of T_4 and T_3 by the thyroid gland is regulated through secretion of TSH by the pars distalis. The release of TSH is controlled by hypothalamic secretion of TRF. The thyroid hormones have a negative feedback influence upon the pars distalis and hypothalamus. Exposure to cold ambient temperatures stimulates the hypothalamus to secrete TRF. Emotional stress also has an effect upon TRF release; however, such stress, usually associated with sympathetic discharge and increased metabolic activity, inhibits the release of TRF.

Altered gland activity may result in a decreased (**hypothyroidism**) or increased (**hyperthyroidism**) secretion of T_4 and T_3.

In **primary hypothyroidism** the gland is unable to respond to TSH stimulation and produce appropriate quantities of the thyroid hormones. It may result from various disease processes. Without the appropriate T_4 and T_3 hormones to influence the hypothalamus and pars distalis, the thyroid gland is subjected to constant stimulation by TSH; thyroid enlargement **(goiter)** may result. Iodine-deficient diets manifest this type of glandular change.

In **secondary hypothyroidism,** due to a defect in the hypothalamic or pituitary portion of the control axis, the gland is able to produce T_4 and T_3 but does not have the appropriate stimulation. Thyroglobulin, normally sequestered within the follicles of the gland, may be exposed to immune system components subsequent to damage to the gland. Upon exposure, thyroglobulin functions as an antigen; an immune-mediated (autoimmune) hypothyroid condition may result.

Hyperthyroidism can be due to excessive stimulation of the thyroid gland by TSH or a thyroid tumor.

The role of calcitonin in calcium regulation is discussed in Chapter 9.

PARATHYROID GLANDS

General characteristics. The parathyroid glands are derived from the third **(external parathyroid)** and fourth **(internal parathyroid)** pharyngeal pouches. The position of the external parathyroids may vary from cranial to the thyroids to level with the thoracic inlet. The internal parathyroids either are missing (birds, pigs) or may be embedded within, upon, or close to the thyroid gland (other species).

Histology. The capsule of the external parathyroids is loose collagenous tissue that blends with the surrounding fascia. The internal parathyroids do not have a capsule per se but are surrounded by the loose collagenous tissue of the interstices of the thyroid gland. The parenchyma consists of cords, clusters, strands, sheets, or rosettes of secretory cells. Occasionally, follicles may be present (Fig. 25-15). These cells are supported by a stroma of reticular fibers with numerous capillaries. The primary cell types of the organ include **chief** and **oxyphil cells.** The **chief** (or **principal**) **cells** may be subdivided into **clear** or **light** and **dark chief cells.** They are more abundant than the oxyphilic cells.

The light and dark chief cells represent different physiological states of the same cell. The light (cuboidal) cells are **inactive,** with a light-staining acidophilic cytoplasm and large vesicular nucleus (Fig. 25-16). They predominate in the parathyroid glands of domestic animals and humans. An electron-transparent cytoplasm contains few organelles and few secretory granules. Lipid droplets, lipofuscin inclusions, and glycogen may be present. The dark cells are **active** and occur less frequently than their inactive counterparts in most species. Their small, vesicular nuclei are surrounded by an acidophilic cytoplasm with many secretory granules. Stimulation of the parathyroid gland causes the release of their secretory products and a lightening of their cytoplasm. Constant stimulation converts these cells to light cells that may become vacuolated and eventually clear (water-clear cells). **Water-clear (light)** cells represent exhaustion atrophy of the chief cells.

The **oxyphil cells** occur in oxen, horses, and humans but not regularly in other domestic species. They are large cells with a granular, acidophilic cytoplasm. Their nuclei are small and dark-staining. These cells usually occur in small clusters. Chief cells are presumed to give rise to them. Their precise function, however, has not been determined.

Parathyroid hormone. The role of parathormone in calcium regulation is discussed in Chapter 9.

ADRENAL GLANDS

General characteristics. The **adrenal glands** are small organs situated at or near the cranial poles of the kidneys. Embryologically they are derived from two germ layers, **mesoderm** and **neural crest ectoderm.** The mesenchyme between the root of the mesentery and the developing gonad proliferates and differentiates into the **fetal** or **primitive adrenal cortex.** Neural crest cells develop within the middle of the fetal cortex to form the adrenal medulla. Subsequently, other mesenchymal cells invade the developing gland, proliferate, and evolve into the **definitive** or **adult cortex.** After birth the fetal cor-

Downloaded From Vet-eBooks.com

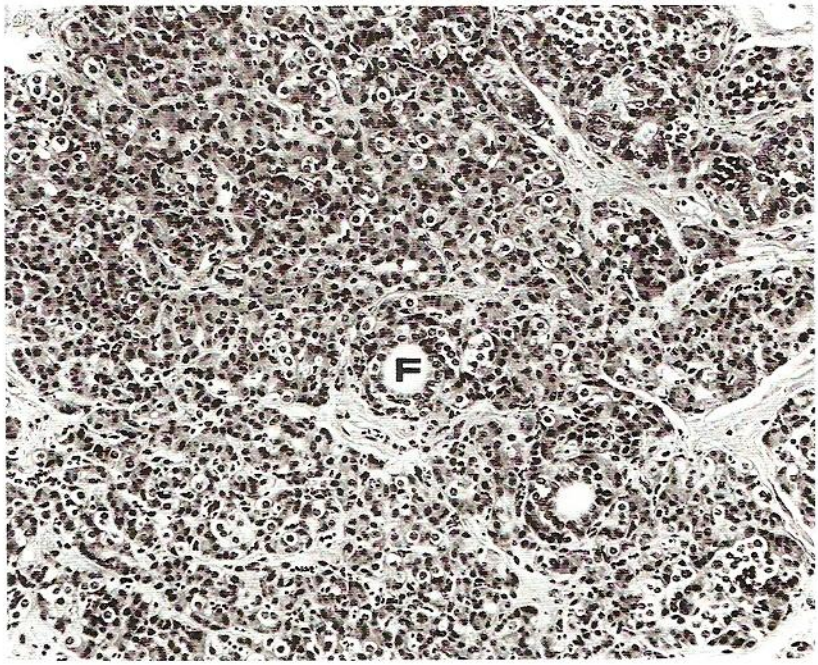

Figure 25-15. Section of a bovine parathyroid gland. Cords or clumps of cells characterize the parenchyma. Follicles *(F)* may occur also. (×40.)

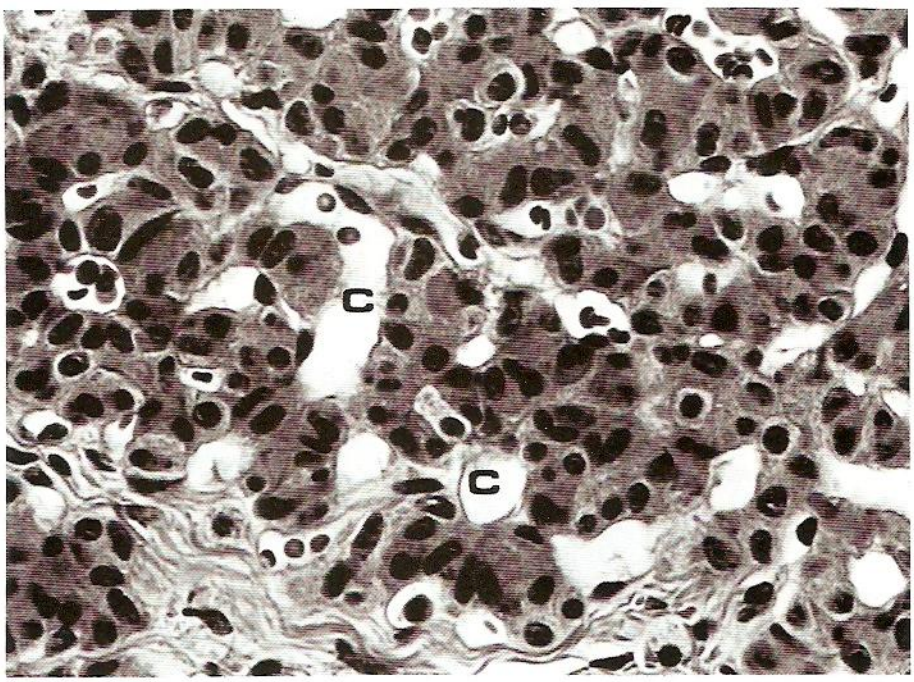

Figure 25-16. Cells of a bovine parathyroid gland. These cords or clumps of cells are closely associated with capillaries *(C)*. (×160.)

tex regresses, except for its innermost region, which becomes the reticular zone. In mammals a distinct cortex and medulla are apparent despite the striking interdigitations that may occur (Fig. 25-17). In birds the cortical and medullary tissue is intermixed (Fig. 25-18). Auxiliary cortical adrenal tissue occurs in some species. In certain rodents, auxiliary adrenal tissue is contained within the epididymis.

The organ is enclosed within a capsule of dense collagenous tissue. Trabeculae of loose collagenous tissue invade the parenchyma to the level of the medulla. The supportive stroma consists of fine collagenous and reticular fibers.

Vascular, lymphatic, and neural relationships. The adrenal glands are highly vascularized organs. The main arteries branch before entry into the gland, giving rise to numerous arterioles. Three primary circulation patterns arise from the arteriolar supply: a **subcapsular** capillary plexus branches throughout the subcapsular region and drains into subcapsular veins; a **cortical** plexus drains through veins into the medulla; and, lastly, **arterioles** traverse the cortex to supply the medulla and drain into medullary veins.

Nerves of the parasympathetic and sympathetic systems innervate the cortex and medulla; however, little information

Downloaded From Vet-eBooks.com

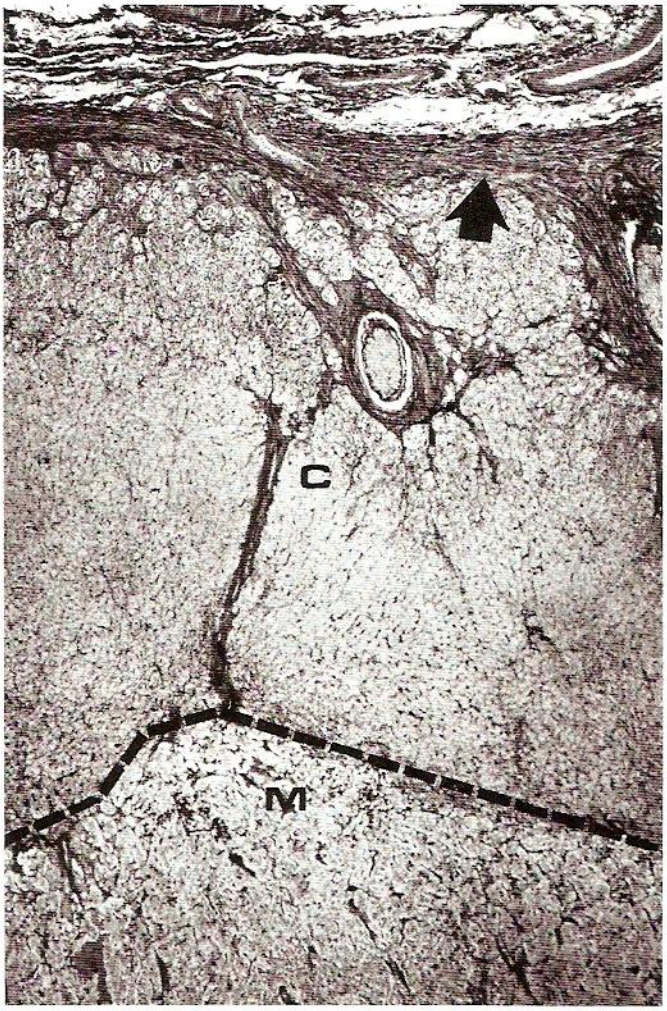

Figure 25-17. Bovine adrenal gland. The gland capsule (*arrow*) continues throughout the organ as connective tissue septa. The gland itself is divided into a cortex (C) and a medulla (*M*), which are clearly denoted by (*dashed line*). (×10, azan stain.)

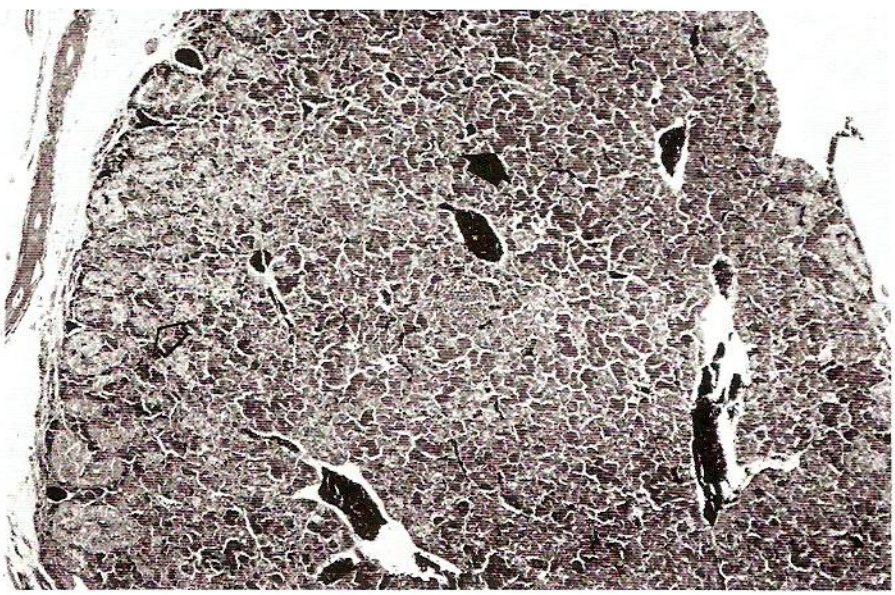

Figure 25-18. Avian adrenal gland. The gland is not divided into a distinct cortex and medulla. The medullary cells *(solid arrow)* are dark-staining and interspersed among the light-staining cortical cells. (×9, azan stain.)

Downloaded From Vet-eBooks.com

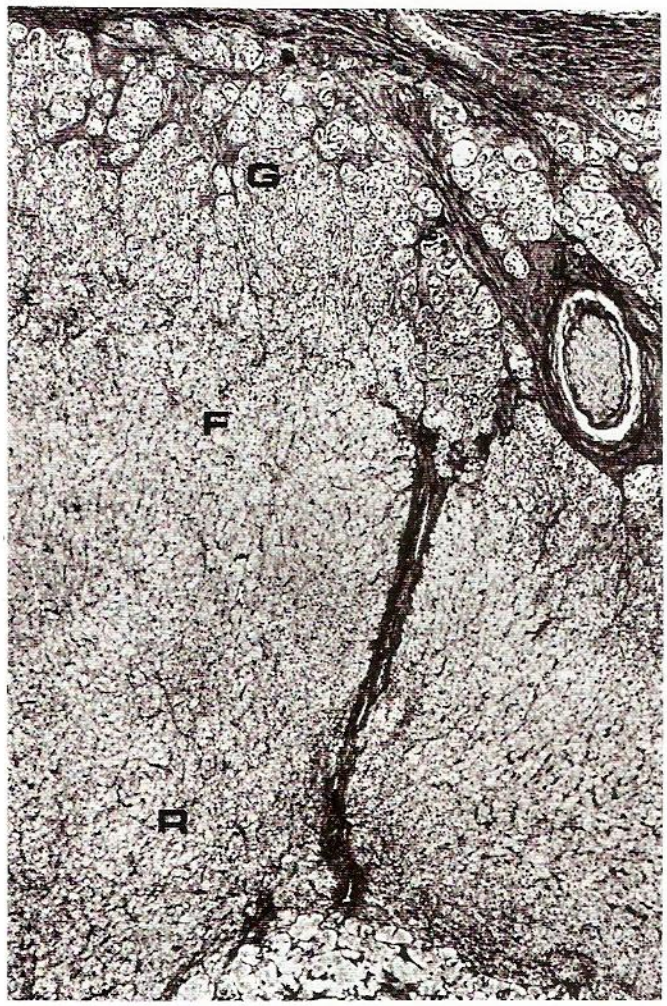

Figure 25-19. Bovine adrenal cortex. *G*, Zona glomerulosa; *F*, zona fasciculata; *R*, zona reticularis. (×16, azan stain.)

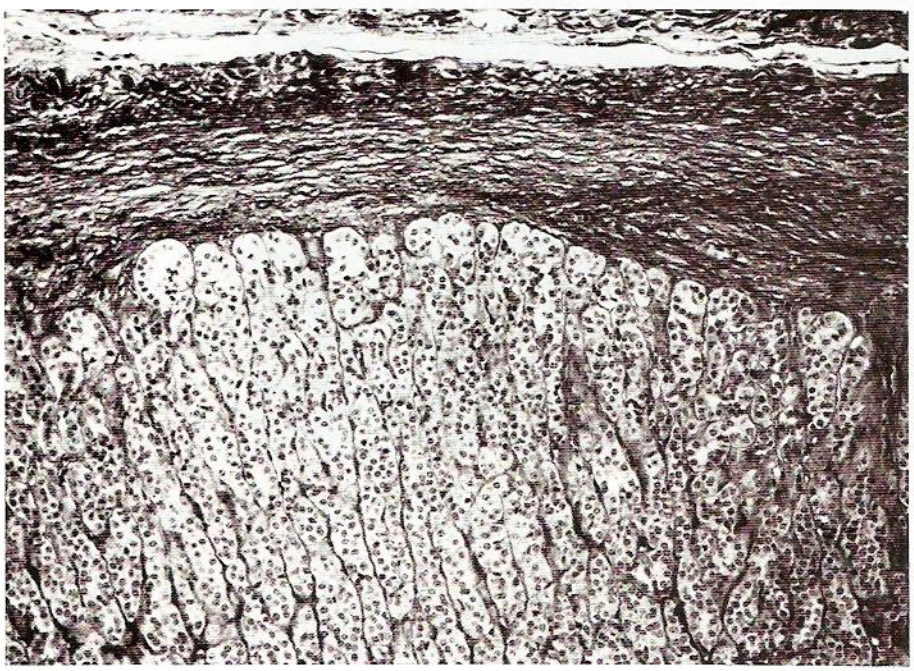

Figure 25-20. Bovine zona glomerulosa. The cells of this zone are clustered as glomeruli. (×40, azan stain.)

is known about the function of the parasympathetic nerves, most fibers being preganglionic and sympathetic to the adrenal medulla.

Lymph vessels occur in the connective tissue of the capsule and interstitial tissue of the gland.

Adrenal Cortex

Zonation and cellular features. The adrenal cortex consists of polyhedral, secretory cells organized into cords, usually two cells thick. The cords are oriented radially from the medullary region (Fig. 25-19). Their orientation and some cytological differences permit the identification of cortical subdivisions—zona glomerulosa, zona fasciculata, and zona reticularis.

The **zona glomerulosa** is also called the **zona arcuata** and the **zona multiformis** (Fig. 25-20). This subcapsular zone (Fig. 25-21) consists of curved cords or arcades (horses, carnivores, pigs) or clustered groups of glomeruli (ruminants, humans). The cells are columnar (humans, horses, carnivores, pigs) or polyhedral (other species) (Fig. 25-22). The parenchyma is closely associated with an extensive vascular network. The cytoplasm is more evenly acidophilic and less foamy than in cells of the adjacent zone. The nuclei are smaller and darker than those of the adjacent zones. The occurrence of fine lipid inclusions is usually linked with an increased cellular activity. In humans and ruminants, basophilic granules may be observed in the cytoplasm.

A **zona intermedia,** consisting of undifferentiated cells, is insinuated between the zona glomerulosa and zona fasciculata of most domestic animals

The **zona fasciculata** is the widest zone of the cortex (Fig. 25-23). It consists of cuboidal or polyhedral cells arranged in radial cords. Each cord consists of one or two cells separated from adjacent cords by an extensive sinus network. The large cells of the outer two thirds of this zone contain large, vesicular nuclei (binucleations are common) within a very foamy cytoplasm (Plate II, *3*). These cells are often called **spongiocytes** (Fig. 25-24). The inner third of the zone contains cells that are free of lipids and have a more basophilic cytoplasm.

The **zona reticularis** consists of cells disposed as freely anastomosing cords (Fig. 25-25). The cells are similar to those of the zona fasciculata, but they contain less lipid and their nuclei and cytoplasm are darker staining. Lipofuscin pigments are commonly encountered.

Form and function. The adrenal cortex is required for life; its hormones influence numerous essential somatic processes. Although many steroid hormones have been isolated from the cortical tissues, they can be readily grouped as **min-**

Downloaded From Vet-eBooks.com

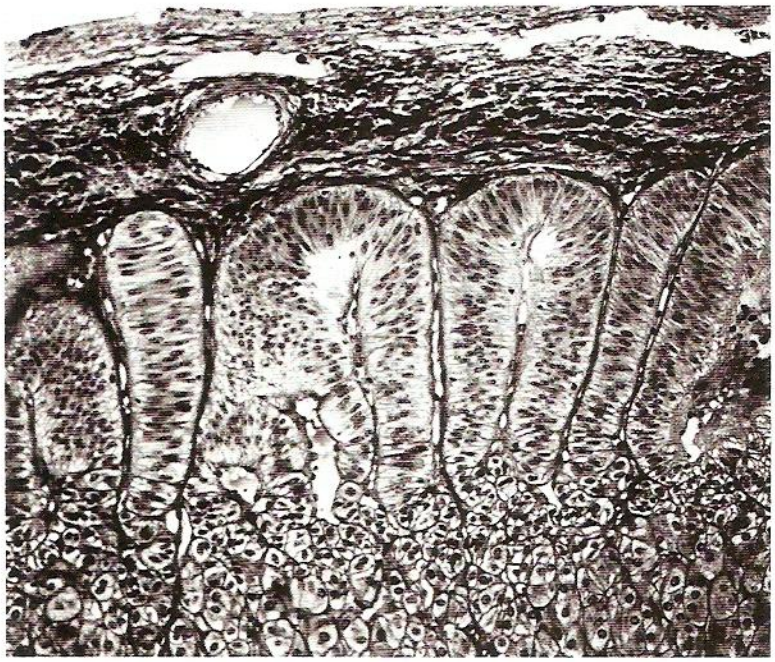

Figure 25-21. Equine zona arcuata. Arcades of cells characterize the outermost zone in this species. (×40, azan stain.)

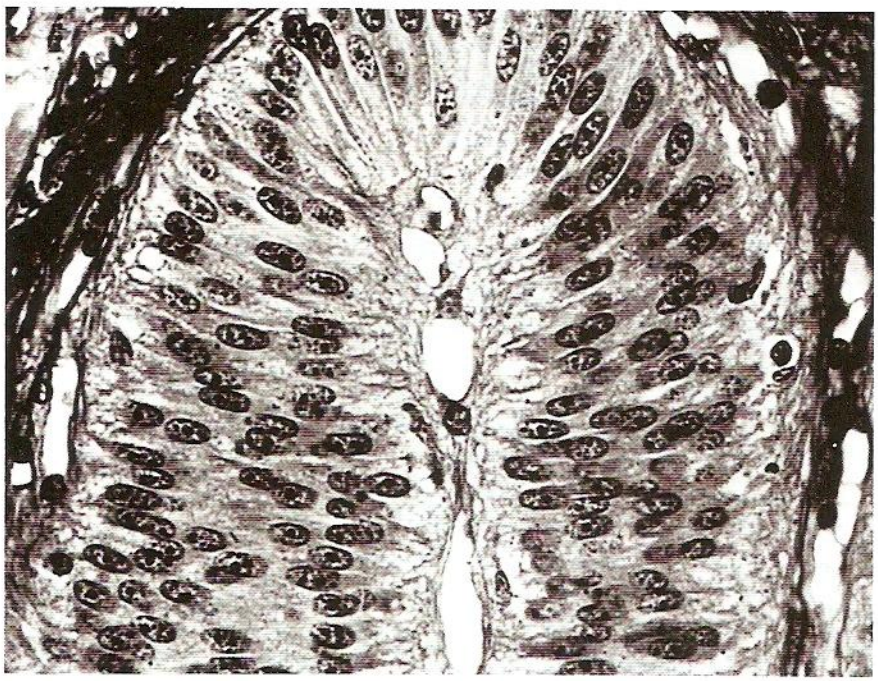

Figure 25-22. Columnar cells of the zona arcuata of an equine adrenal gland. (×160, azan stain.)

Downloaded From Vet-eBooks.com



Figure 25-23. Zona fasciculata of an equine adrenal gland. Polyhedral cells arranged as cords characterize this region. (×40, azan stain.)

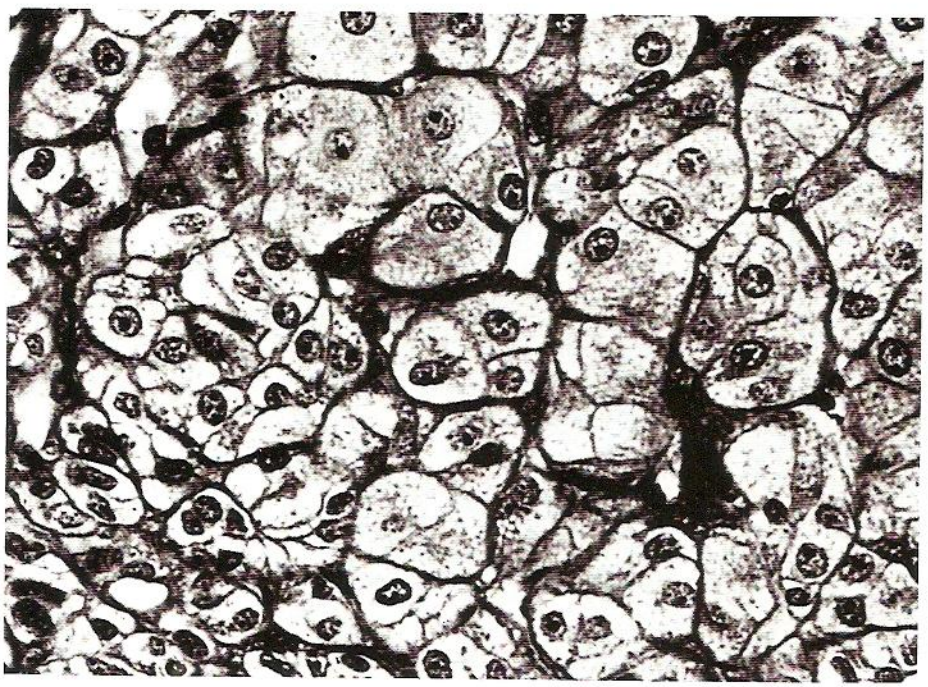

Figure 25-24. Spongiocytes of the outer zona fasciculata of an equine adrenal gland. The large cells have a foamy cytoplasm and vesicular nuclei. (×160, azan stain.)

Downloaded From Vet-eBooks.com



Figure 25-25. Zona reticularis of an equine adrenal gland. The cells are disposed as freely anastomosing cords. (×25, azan stain.)

eralocorticoids, glucocorticoids, and **sex hormones.**

Some evidence exists that the zona glomerulosa may be responsible for the proliferation and differentiation of cells within the cortex. The cells may proliferate within the zona glomerulosa and differentiate into characteristic parenchyma of the zona fasciculata. They appear to move through the cords, eventually degenerating within the zona reticularis.

Histophysiology

Mineralocorticoids. The **mineralocorticoids,** primarily from the activity of the cells of the zona glomerulosa, exert an influence upon ECF electrolytes—especially Na^+ and K^+. The most important mineralocorticoid is **aldosterone;** however, other corticosteroids (corticosterone, cortisol, desoxycorticosterone) have mineralocorticoid activity. The most important activity of aldosterone is the increased tubular reabsorption of Na^+ by the kidneys. Aldosterone exerts a similar effect upon the sweat glands, salivary glands, and intestines.

Many secondary effects relate to this Na^+ conservation mechanism under the influence of aldosterone. The reabsorption of Na^+ is linked to the secretion of K^+ and H^+. Potassium wasting and a slight metabolic alkalosis can result. Decreased K^+ levels lead to muscular weakness, muscular paralysis, and cardiac arrhythmias. The metabolic alkalosis resulting from aldosterone is usually transitory and can be corrected by acid/base regulating mechanisms.

Increased Na^+ retention also increases the retention of water, causing an elevated ECF and blood volume compounded by polydipsia. The elevated fluid volume increases the amount of work accomplished by the heart. Polyuria also occurs as a compensation for the increased fluid volume.

The reverse effects occur in the absence of aldosterone. **Hyponatremia** (decreased Na^+), **hyperkalemia** (increased K^+), and a lower fluid volume can be anticipated without the proper release of aldosterone. The cardiovascular system is unable to function properly because of the reduced fluid volume **(hypovolemia),** and cardiac activity lessens in response to the decreased fluid volume and elevated K^+. **Hypovolemic shock** (insufficient tissue perfusion) and death can result.

The regulated maintenance of Na^+ and K^+ levels within the body is essential to minimize an increase or decrease of these ions. Aldosterone is essential for this balance. The secretion of aldosterone is regulated by the concentration of K^+ and Na^+ in the ECF and the renin-angiotensin system (Chapter 23). **Atrial natriuretic factor (ANF)** inhibits the secretion of aldosterone, renin, and antidiuretic hormone. It also causes a decrease in arterial blood pressure, diuresis, and **natriuresis.** Insufficient adrenocortical secretions of mineralocorticoids (and glucocorticoids) are characteristic of **hypoadrenocorticism (Addison's disease).** Although **Cushing's syndrome (hyperadrenocorticism)** may manifest effects associated with excessive secretions of aldosterone, the primary effects are those manifested by the excess glucocorticoids. The chemotherapeutic approach to Cushing's syndrome, if not monitored carefully, can produce an addisonian animal.

Glucocorticoids. The **glucocorticoids** are secreted primarily by the zona fasciculata of the adrenal cortex. Although other corticosteroids possess glucocorticoid activity (corticosterone, cortisone), the most important glucocorticoid is **cortisol.** Cortisol transported in the blood bound to a plasma globulin, **transcortin** or **cortisosteroid-binding globulin (CBG),** has diverse effects upon the tissues.

Cortisol causes an increased blood glucose **(hyperglycemia)** and a decreased peripheral utilization of glucose. Glycogenesis and gluconeogenesis complement the increased release of hepatic glucose. Cortisol is diabetogenic. Whereas the glucocorticoids stimulate synthesis of hepatic proteins, they inhibit the synthesis of proteins in other tissues. The role of cortisol in lipid metabolism is not well-understood. Although it is lipolytic and causes an increased release of free fatty acids from adipose tissue, excessive quantities of the hormone can lead to excessive lipid deposition. The stimulation of insulin release by cortisol may account for this increased lipid deposition, because insulin promotes lipogenesis and adipose tissue formation.

The antiinflammatory properties of glucocorticoids are significant. These hormones stabilize lysosomal membranes, decrease collagen synthesis, increase collagen degradation, and inhibit the proliferation of fibroblasts. Glucocorticoids also exert many other effects upon the body that are related to the reduction of peripheral protein synthesis—depressed immunocompetency, delayed wound healing, quantitative osteopenia. Gastric ulceration can result from excessive glucocorticoids; the precise mechanism of parietal cell stimulation is not understood.

Glucocorticoids, released in response to stress, help maintain ECF volume and decrease the vasodilation associated with shock. Cortisol and similar drugs exert an influence on mental status. Mental depression associated with glucocorticoid insufficiency can progress to euphoria after the administration of glucocorticoids. Cortisol also complements the functioning of other hormones (GH, glucagon, catecholamines). Finally, glucocorticoirds manifest antiallergic properties by preventing the release of histamine associated with type I hypersensitivity reactions.

The synthesis and release of glucocorticoids from the adrenal cortex are regulated by the secretion of ACTH from the pars distalis. The hypothalamic secretion

Downloaded From Vet-eBooks.com

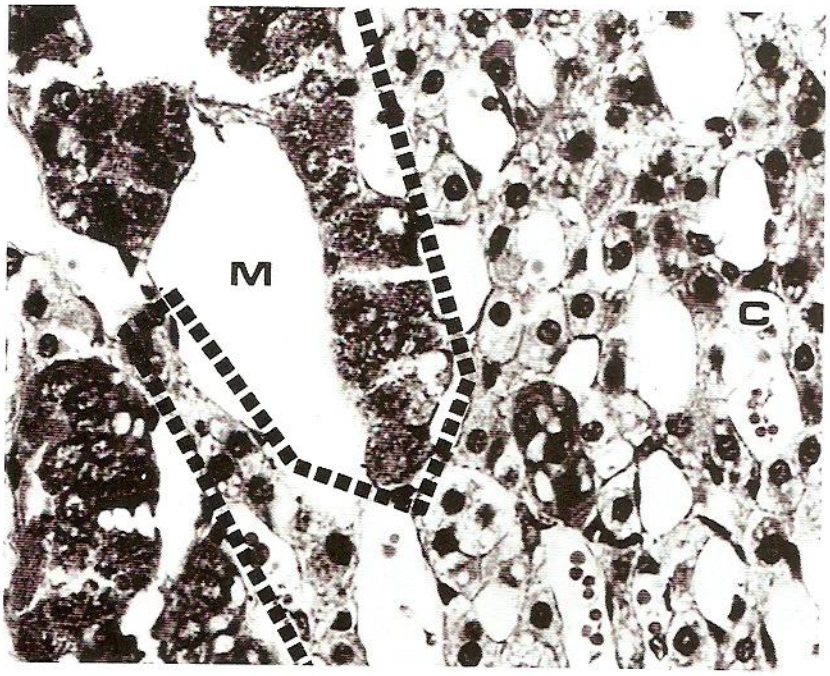

Figure 25-26. Medulla and zona reticularis of a porcine adrenal gland. The corticomedullary junction *(dashed line)* is irregular. The medulla *(M)* consists of *dark*-staining cells; the zona reticularis of the cortex *(C)*, *light*-staining cells. (×160, chromaffin stain.)

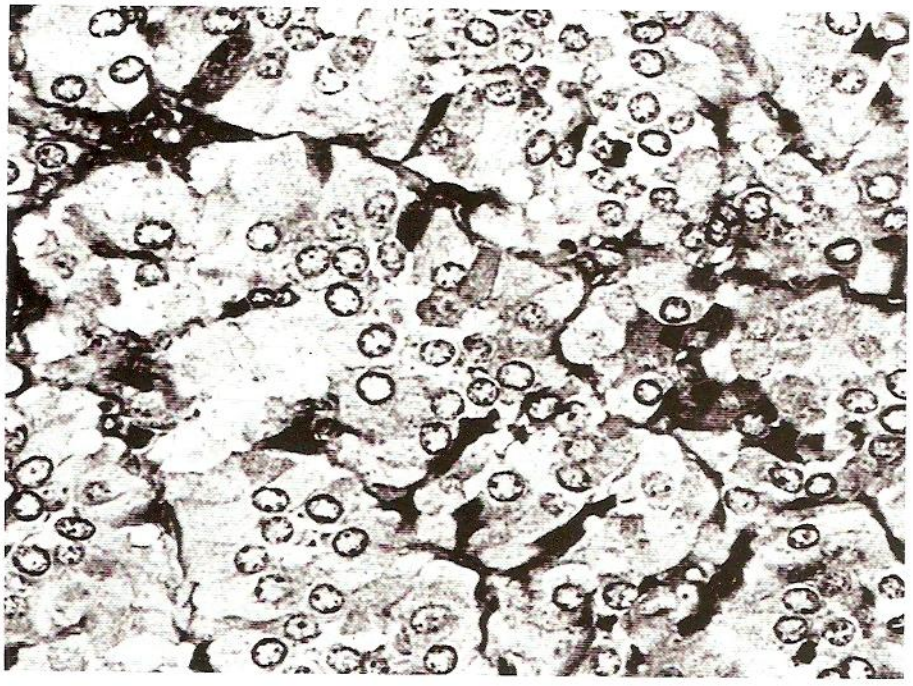

Figure 25-27. Bovine adrenal medulla. The large columnar cells are polarized, their basal borders associated with capillaries. (×160, azan stain.)

of CRF controls the activity of the pars distalis. Circulating levels of glucocorticoids exert a negative feedback influence upon the hypothalamus and pars distalis. Notwithstanding the significance of this servomechanism, other factors influence glucocorticoid release. The circadian rhythmicity of ACTH and glucocorticoid release is probably influenced by cerebral cortical and limbic system activity. Similarly the emotional influence on circulating levels of glucocorticoids is probably mediated through the limbic system. Trauma, perhaps triggering activity in the limbic and reticular-activating systems, stimulates the increased release of glucocorticoids. Stress is a significant stimulus of glucocorticoid secretion.

Adrenal insufficiency **(Addison's disease)** is marked by inability of the adrenal glands to produce mineralocorticoids and glucocorticoids. **Cushing's syndrome** results from the excessive secretion or administration of glucocorticoids.

Sex hormones. The only sex hormone produced in any quantity under normal circumstances is a moderately active adrenal androgen called **dihydroepiandrosterone.** This substance can be metabolized to other sex hormones (testosterone and estradiol).

Adrenal Medulla

Histology. The corticomedullary junction may be either sharply delineated or tightly interdigitated (Fig. 25-26). The primary constituents of the medulla include **glandular cells, ganglion cells, venules,** and **capillaries.** The cells are derived from neural crest ectoderm and are part of the APUD (amine precursor uptake and decarboxylase) system.

The **glandular cells** are large and columnar or polyhedral and possess large vesicular nuclei (Fig. 25-27). They are also polarized, one pole opposing a capillary and the other a venule. The cytoplasm is basophilic and contains fine, chromaffin-positive granules (Fig. 25-28). The resulting pigments are sometimes referred to as **adrenochromes.** As a result of this chromaffin reactivity, the glandular cells are also called **chromaffin cells** or **pheochrome cells.** This reactivity is due to the presence of the **biogenic amines** (catecholamines), **epinephrine,** and **norepinephrine.** The reaction of catecholamines with chromic acid produces a brown substance. The chromaffin cells secrete one or the other catecholamine. In most species these cells are randomly distributed throughout the medulla. In oxen, however, an outer lamina of epinephrine-producing cells is distinct from the inner lamina of norepinephrine-producing cells.

The sympathetic **ganglion cells** are randomly scattered throughout the medulla.

Histophysiology. The function of the adrenal medulla and its relationship to the ANS are discussed in Chapter 17.

Chromaffin system. The chromaffin cells of the adrenal medulla and those outside the adrenal medulla comprise the chromaffin system. Extramedullary chromaffin cells occur in many small bodies, called **paraganglia,** associated with the abdominal aorta. The paraganglia also include two large bodies, the **glands of Zuckerkandl.** Chromaffin cells are all part of the APUD system.

Pheochromocytomas (tumors of the adrenal medullary tissue) commonly involve all of the chromaffin system.

Downloaded From Vet-eBooks.com

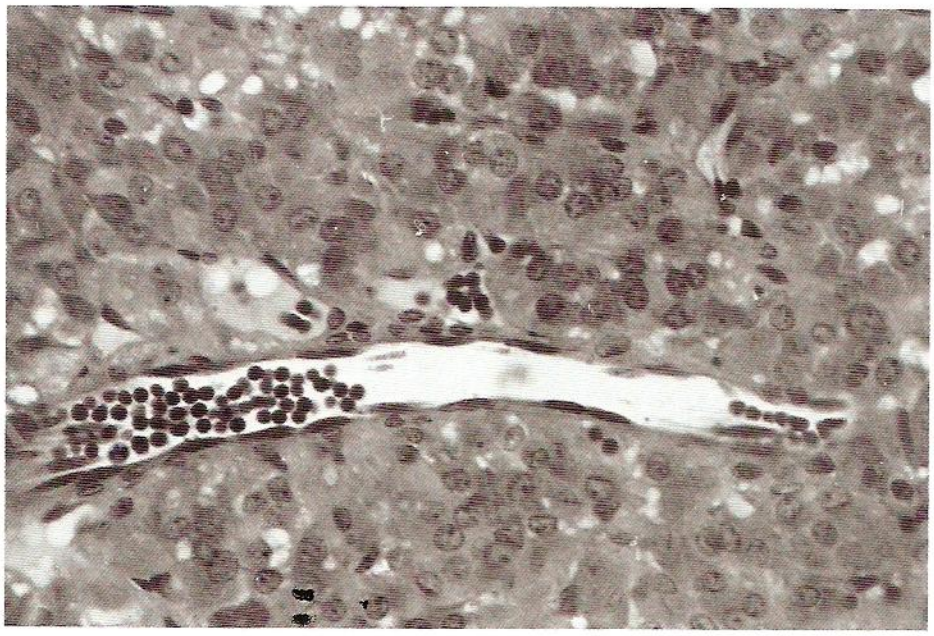

Figure 25-28. Plastic-embedded canine adrenal medulla. The cellular detail is excellent. All the medullary cells in the field are glandular. A sinusoidal capillary traverses the center of the field. (×100, glycol methacrylate–embedded 2 μm section.)

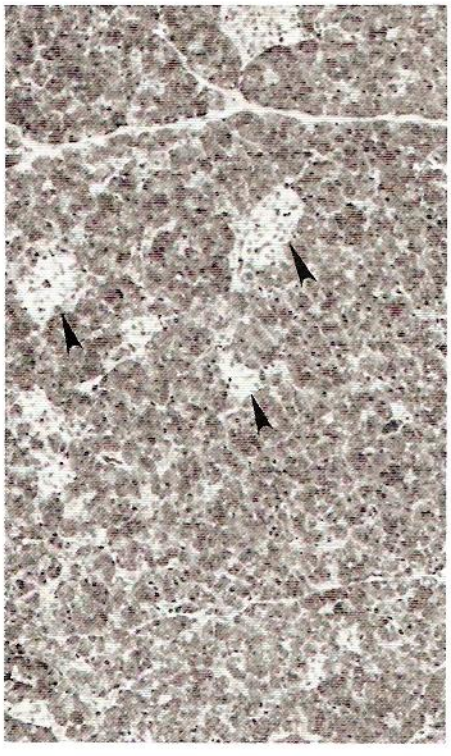

Figure 25-29. Plastic-embedded canine pancreas. Islets are scattered throughout the substance of the gland. (×10, glycol methacrylate–embedded 2 μm section.)

ENDOCRINE PANCREAS

General characteristics. The organization of the pancreas reflects its function as an exocrine and an endocrine organ. The endocrine portions are the **pancreatic islets,** randomly scattered throughout the organ (Fig. 25-29). Developmentally the cells of the islets, as well as those of the acini, are derived from endoderm. The islet cells detach from the developing duct system and are established as endocrine cells.

Histology. The islets are scattered masses of pale-staining cells supported by reticular connective tissue (Fig. 25-30). Large sinuses separate cell cords or clusters. The basic cell types of the islets are alpha cells and beta cells. C cells and delta (D) cells have also been identified.

The **alpha (A, α) cells** are polygonal with nuclei that have a coarse distribution of heterochromatin. The granules are insoluble in alcohol, stain pink or red with Gomori aldehyde fuchsin, and take on a red hue with Mallory-Azan stain.

The **beta (B, β) cells** are structurally similar to α cells. Their granules, however, are soluble in alcohol, stain dark purple with Gomori aldehyde fuchsin, and assume an orange tint with Mallory-Azan stain.

The **C cells** do not contain granules.

The **delta (D, δ) cells** stain blue with the Mallory-Azan technique. Enterochromaffin-like cells also have been identified in the islets.

β Cells are predominant and may comprise more than 75% of the islet cellular population in dogs. They secrete **insulin.** Cells secrete **glucagon, cholecystokinin (CCK), gastric inhibitory peptides,** and **ACTH-endorphin.** The functional significance of C cells, which have been identified in the guinea pig pancreas, has not been clarified. Some investigators believe that the C cell may be a progenitor of the A cell, others that it may be a resting or exhausted A or B cell. It constitutes a small percentage of the cell population. Immunofluorescent studies have shown that the D cell produces **somatostatin** and **vasoactive intestinal peptide (VIP).** Because somatostatin exerts a potent inhibitory influence upon A and B cell activity, it has been postulated that the D cells may serve as local inhibitors of insulin and glucagon secretion. Enterochromaffin cells are believed to secrete **serotonin, motilin,** and **substance P.**

Histophysiology. **Insulin** is the **hypoglycemic factor** secreted by β cells of the pancreatic islets. **Glucagon,** the **hyperglycemic factor,** is secreted by α cells.

Proinsulin, synthesized as an inactive, single polypeptide with a molecular weight of approximately 9000 daltons, is activated within the secretory granules of the cell. During this time it is cleaved by the action of a trypsin-like enzyme into **insulin** and a cleavage fragment (connecting segment). Insulin is a dipeptide with a molecular weight of approximately 6000 daltons.

Glucagon is a single polypeptide with a molecular weight of approximately 3500 daltons. Whereas most of it is produced by the α cells of the pancreatic islets, some **(enteroglucagon)** is secreted by cells of the gastrointestinal mucosa. The functional significance of enteroglucagon is not completely understood.

Insulin and glucagon regulate carbohydrate metabolism. Insulin release occurs in response to increased levels of blood glucose **(hyperglycemia)** whereas glucagon is secreted in response to decreased blood glucose concentrations **(hypoglycemia).** The α and β cells are the receptors and regulators of the servomechanism that responds to blood glucose levels whereas many tissues serve as effectors to maintain homeostatic levels of blood glucose and ensure an ample supply of energy.

Insulin exerts various influences upon cells and tissues:

1. Its generalized effect on carbohydrate metabolism is to facilitate the cellular uptake of glucose. This reduces blood glucose levels while making glucose available for cellular metabolic processes. (It is not required for glucose uptake by the brain, liver, proximal convoluted tubule of the kidney, or RBC.)
2. It increases glucose uptake and enhances glucose metabolism.
3. It increases glycogenesis and glycogenolysis as well as amino acid uptake and protein synthesis.
4. It decreases fatty acid utilization but increases the uptake of glucose by adipocytes and myocytes. This enhances its utilization as an energy source, increases its storage in the form of glycogen, and favors lipogenesis from carbohydrates.

Downloaded From Vet-eBooks.com

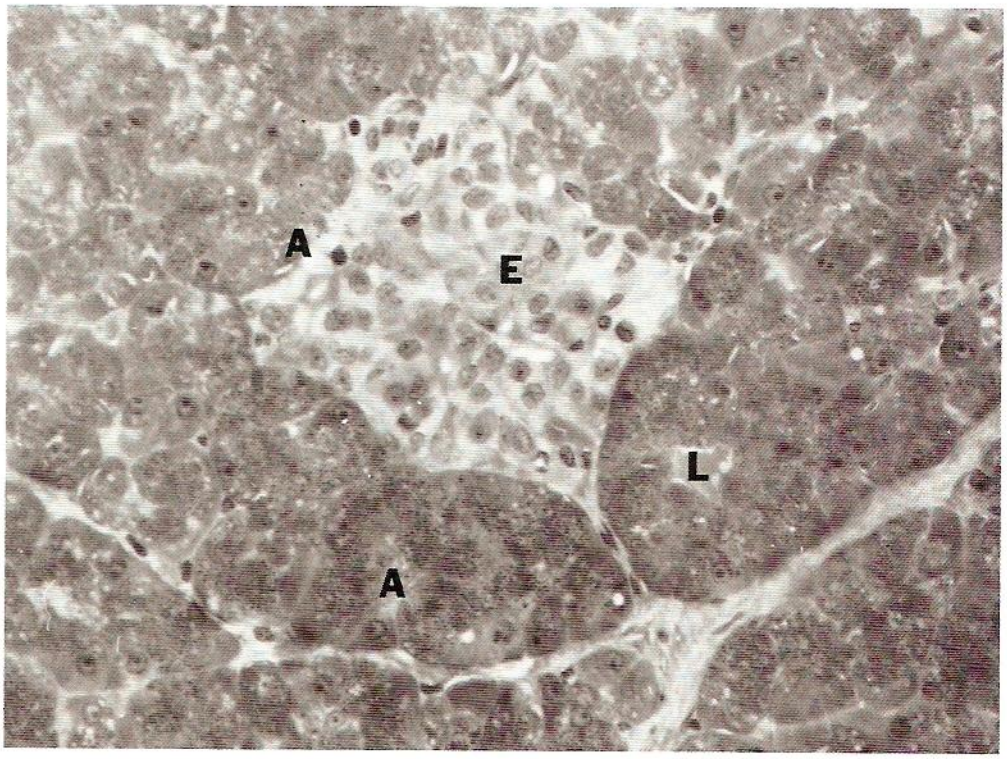

Figure 25-30. Plastic section of a canine pancreas. The endocrine *(E)* portion of the gland—pancreatic islets—are surrounded by pancreatic acini *(A)*. Zymogen granules are evident in the apical cytoplasm. *L*, Lumen. (×100, glycolmethacrylate–embedded 2 μm section.)

5. It decreases blood levels of free fatty acids and triglycerides.

Although insulin does not exert a direct effect upon the uptake of glucose by the liver, it does increase hepatocytic metabolism of glucose. Gluconeogenesis lessens under insulin stimulation. Lipogenesis, amino acid uptake, and protein synthesis all increase within hepatocytes.

Insulin is one of the most important anabolic hormones of the body. It facilitates glucose utilization as an energy source and enhances the storage of glucose as glycogen. It increases the storage of triglycerides and diminishes their use as an energy source. Moreover, amino acids are incorporated into proteins instead of being used as a source of energy. Insulin also has an effect upon intracellular and extracellular K^+. The uptake of glucose is accompanied by the movement of K^+ into cells. Insulin is inactivated by a group of enzymes, collectively called **insulinases,** present in many cells (liver, kidney, skeletal muscle). The rapid turnover of insulin—plasma half-life approximately 10 minutes—requires the continual secretion of insulin to maintain proper metabolic activities.

The absence or insufficient secretion of insulin by the β cells causes **diabetes mellitus.** Glucose levels are high and exceed the renal threshold; therefore **glucosuria** is a significant feature of the disease. The osmotic diuresis from glucose causes a polyuria accompanied by polydipsia. Animals suffering from diabetes mellitus are literally "starving in a sea of plenty." Glucose levels are high, but the animal is unable to utilize glucose as an energy source. **Complicated diabetes mellitus** is characterized by **ketoacidosis.** Excessive mobilization of lipids overwhelms the metabolic capacity of the liver, and ketone bodies form. The release of H^+ from dissociating of ketone bodies causes an acidosis. Diabetic coma and death follow if uncorrected. Hypoglycemia occurs under various circumstances; an islet cell tumor **(insulinoma)** is the main reason for the unregulated release of insulin.

Glucagon, the antagonist of insulin, is glycogenolytic, gluconeogenic, and lipolytic. It thereby ensures the availability of glucose as an energy source. Hepatocytes respond to glucagon stimulation by increasing their release of glucose, the availability of free fatty acids, and the oxidation of amino acids and formation of ketone bodies. Adipocytes release free fatty acids in response to glucagon. Although most of the effects of glucagon are manifested in the liver, the limited effects of this hormone are sufficient to counterbalance the effects of insulin. Glucagon inactivation results from the enzymatic degradation of the polypeptide; however, little is known of the precise mechanism.

MISCELLANEOUS ENDOCRINE GLANDS

Many cells perform endocrine functions as adjunctive activities of the organs with which they are associated. Although the organs of which these cells are a part may not be considered endocrine organs, the functional significance of their contribution to endocrine regulatory mechanisms is no less important than that of the classic endocrine organs.

Secretion of chemical messengers. The maintenance of integrated cellular activity is dependent upon intercellular communication. This communication is achieved through the use of chemical messengers that talk to and influence the behavior of target cells. Classically the nervous and endocrine systems were considered the communication systems. Currently, other cells have been identified as secreting chemical substances that effect intercellular communication. The means by which these chemical messengers are delivered to target cells is the basis for three general categories of cellular communicators—neurocrine, paracrine, and endocrine.

Endocrine cells secrete their chemical messengers into the interstitial space. These messengers move into the bloodstream and are distributed subsequently to target cells some distance from their site of origin. Once called hormones, they are now referred to as **general hormones.** The general hormones are steroids, proteins, and glycoproteins. Based upon its method of delivery to target cells, epinephrine (a catecholamine) may be considered a general hormone.

Neurocrine cells secrete intercellular messengers immediately adjacent to the target cells. The communicating neurons are classical neurocrine cells. Directed synapses are typical examples of this

Downloaded From Vet-eBooks.com

method of communication. The neurotransmitters, then, are the chemical messengers. A nondirected synapse, as exemplified by the postganglionic sympathetic varicosities, could be considered a type of paracrine secretory vehicle.

Paracrine cells secrete their chemical messengers into the interstitial fluid and influence surrounding target cells. Eicosanoids, endogenous polypeptides (angiotensin, kinins), and biologically active amines qualify as **local hormones** or **autacoids.**

APUD system. Certain secretory cells of the mucosal lining of the gastrointestinal tract and respiratory system, thyroid gland, and endocrine pancreas have the ability to secrete polypeptides and biologically active amines as local hormones. These cells are able to concentrate and store biogenic amines as well as synthesize them from requisite precursors. Accordingly, they have high quantities of amino acid decarboxylase—an enzyme essential for the synthesis of biogenic amines. Their ability to incorporate and decarboxylate amine precursors accounts for the name **APUD—amine precursor uptake and decarboxylase.** These cells, believed to arise from neural crest ectoderm, are scattered diffusely or in small groups throughout the body. Over 30 cell types—all capable of polypeptide and amine synthesis and secretion—have been described:

1. Cells secreting gastrointestinal hormones
2. C cells (parafollicular) from the ultimobranchial body secreting calcitonin
3. Pancreatic islets cells
4. Some adenohypophyseal cells
5. Adrenal medullary cells
6. Respiratory tract cells

Neoplasms formed by these cells are called **apudomas** and include gastrin-secreting tumors of the **Zollinger-Ellison syndrome** and calcitonin-producing tumors of the parafollicular cells.

Any attempt to classify biological entities is usually fraught with problems. The classification of chemical messenger–secreting cells is no exception. Neurocrine cells, especially those associated with nondirected synapses, could be easily classified as paracrine cells. Many paracrine cells are actually APUD cells involved in the secretion of local hormones; but some APUD cells produce general hormones. Similarly, postganglionic sympathetic neurons (derived from neural crest ectoderm) secrete biologically active amines (norepinephrine) and are classified as neurocrine cells. Although reasonable justification could be offered for their inclusion as paracrine or APUD cells, a coherent classification scheme will have to await additional insights.

Reproductive hormones. The **ovary** and **testis** are responsible primarily for the production of gametes, but they also synthesize and secrete hormones that affect reproductive as well as other somatic structures and functions.

The ovaries secrete **estrogens** and **progestins** at various stages of the estrous cycle. They also produce **relaxin** in those species requiring functional ovaries throughout gestation. The testes, through their population of interstitial cells, produce **androgens.** The testicular interstitial cells, especially in stallions, also elaborate **estrogens.** The **placenta,** an essential reproductive structure in eutherian mammals, has among its many endocrine functions the secretion of **estrogens, progesterone, placental gonadotropins,** and **prostaglandin $F_{2\alpha}$.**

Gastrointestinal hormones. A variety of cells throughout the gastrointestinal system secrete polypeptides and biogenic amines. These cells have been termed **gastrointestinal endocrine, enteroendocrine, argentaffin, argyrophilic,** and **enterochromaffin.** Since they occur throughout the stomach, intestine, and pancreas, they are also appropriately called **gastroenteropancreatic (GEP) cells.**

They do not comprise a homogeneous cellular population. Twelve ultrastructurally distinct gut endocrine cells are known to secrete more than 20 hormones, suspected hormones, and neurotransmitters. Some have a narrow luminal pole with a tuft of microvilli opening to the surface ("open cells"); others reside upon the basal lamina and do not reach the luminal surface ("closed cells"). The open cells may be sensory and responsive to the dynamic chemical changes occurring within the lumen.

Some GEP cells are appropriately called argentaffin cells, because their secretory granules stain with silver. Others stain with dichromates and are called enterochromaffin cells. These characteristics, however, are not applicable to all GEP cells. Argentaffin and enterochromaffin cells comprise two subsets of the GEP cellular population.

Most GEP cells are APUD cells that permit local modulation of the methods for neurogenically regulating of the gastrointestinal system. Many peptide hormones have been isolated from the gastrointestinal tract and characterized (Table 25-1).

Although the activity and origin of gastrointestinal hormones are confined generally to this system, one hormone (somatostatin) is produced in a number of locations. **Somatostatin (GHIF)** is secreted by the hypothalamus, by δ cells of the pancreatic islets, and by the gastrointestinal mucosa.

Eicosanoids. **Eicosanoids** are a family of compounds derived from **arachidonic acid** (eicosatetraenoic acid) This fatty acid contains 20 (Gr *eikosi*) carbons and 4 (*tetra*) double bonds (*enoic* means having unsaturated bonds.) Subsequent metabolism of arachidonic acid results in the formation of biologically active lipids—including hydroperoxyeicosatetraenoic

Table 25-1. Selected Gastrointestinal Hormones

	Target	Action
Cholecystokinin (CCK)	Stomach, small intestine, pancreas (acini)	↑ Motility
		↑ Motility
		↑ Secretion
Gastrin	Stomach, small intestine	↑ HCl secretion
		↑ Enzyme secretion
		↑ Motility
		↑ Motility
Secretion	Pancreas (ducts), liver, small intestine	↑ HCO_3^- secretion
		↑ HCO_3^- secretion
		↓ Motility
Gastric inhibitory peptide (GIP)		↓ HCl secretion
Serotonin	Stomach	↑ Motility
	Small intestine	↑ Motility
Motilin	Stomach	↑ Motility
Substance P	Stomach	↑ Motility
	Small intestine	↑ Motility
Somatostatin	Pancreas (islets, acini), stomach	↓ Insulin secretion
		↓ Secretion
		↓ Gastrin secretion
Vasoactive intestinal peptide		↓ HCl secretion
	Stomach, pancreas (ducts, acini)	↓ Enzyme secretion
		↓ Motility
		↑ HCO_3^- secretion
		↑ Enzyme secretion
Enteroglucagon	Liver	↑ Glycogenolysis
Pancreatic glucagon	Liver	↑ Glycogenolysis
Histamine	Stomach	↑ HCl secretion

Downloaded From Vet-eBooks.com

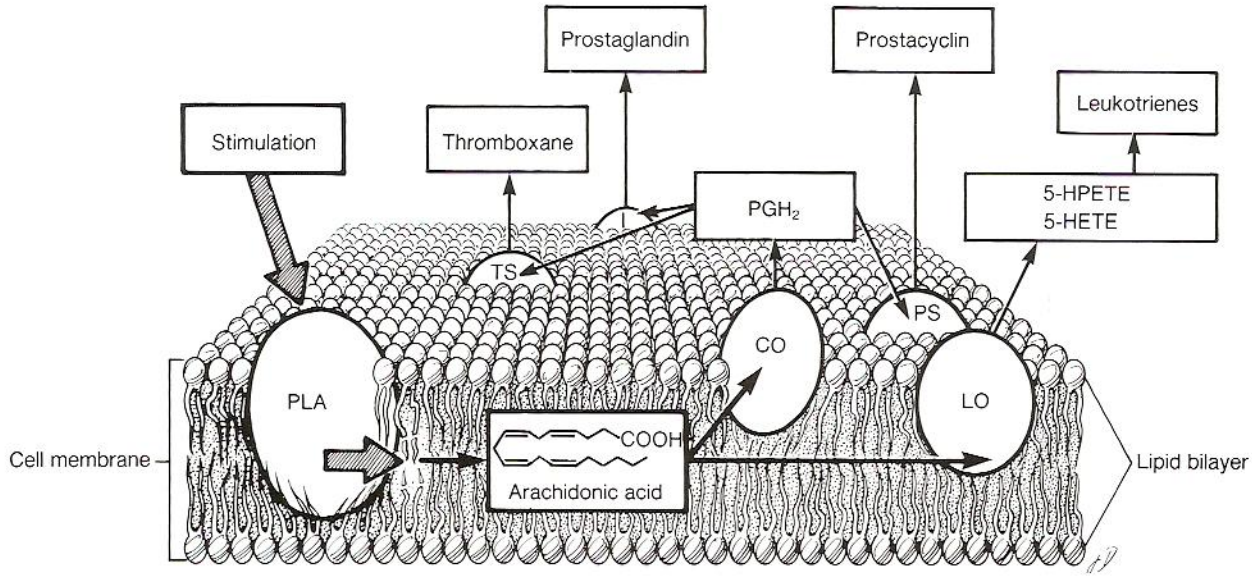

Figure 25-31. Generation of extracellular messengers from arachidonic acid. Minor damage to cell membranes causes the release of arachidonic acid from the fatty acid chains of the lipid bilayer through the action of phospholipase A *(PLA)*. Subsequent enzyme activity converts this substance to various eicosanoids. *CO*, Cyclooxidase; *LO*, lipoxygenases; *PS*, prostacyclin synthase; *I*, isomerase; *TS*, thromboxane synthase; *PGH_2*, prostaglandin H_2; *5-HPETE* and *5-HETE*, hyroxy fatty acid intermediates in the leukotriene pathway.

acid (HPETE), hydroxyeicosatetraenoic acid (HETE), leukotriene (LT), prostaglandin (PG), and thromboxane (TX).

The **eicosanoids** are generated from varying amounts and kinds of perturbation in the plasma membranes of many cells of most organs. After stimulation, arachidonic acid is released from its esterified position in the glycerophospholipids of the lipid bilayer (Fig. 25-31). **Phospholipase A_2,** or a combination of **phospholipase C** and **diglyceride lipase,** mediates the release. Upon release, arachidonic acid activates a **cyclooxygenase**—converting this acid to unstable endoperoxide intermediates, **prostaglandin G_2** and **prostaglandin H_2,** which consist of prostanoic acid (a pentane ring with two aliphatic side chains). Subsequent isomerase and reductase activities produce other prostaglandins. Nine groups of prostaglandins exist and have been designated by the letters A through I. They differ by having various substitutions at the 9 and 11 positions on the pentane ring.

Arachidonic acid is converted by a lipooxygenase to **hydroperoxyeicosatetraenoic acid (HPETE).** The HPETEs are converted to either **hydroxyeicosatetraenoic acid (HETE)** or a **leukotriene (LT).** The HETEs can cause bronchial smooth muscle contraction with a potency comparable to that of histamine.

The LTs are designated A through E. These substances cause the contraction of vascular and respiratory smooth muscle. Also, the activity attributed to slow reacting substance of anaphylaxis (SRS-A) is known to be caused by LTC_4 and LTD_4 (p. 295).

The **prostaglandins** manifest their biological effects locally because the liver and lungs rapidly deactivate these substances. Their influence is upon the organ in which they are produced or (downstream) upon an organ associated with the venous drainage from their organ or tissue of origin. Prostaglandin A_2, PGE_1, and PGE_2 are vasodilators. Bronchodilation, sodium/water diuresis, and increased gastrointestinal motility are mediated by PGE_2. Also PGE_2 may stimulate renin release and inhibit gastric secretion. The vasopressor activity of $PGF_{2\alpha}$ is well documented. It is also a bronchodilator and luteolytic compound. $PGF_{2\alpha}$ is produced in the endometrium and transported to the ovary by a uteroovarian vein. The mechanism of transfer to the ovarian artery has not been determined. Regression of the corpus luteum occurs under the influence of $PGF_{2\alpha}$. The compound's luteolytic activity terminates the luteal phase of estrus and permits the next wave of follicles to mature. This luteolytic function has been documented in mares, ewes, cows, and sows. **Prostacyclin (PGI_2)** is a vasodilator also inhibiting platelet aggregation **(antithrombotic agent).**

The **thromboxanes** are produced from endoperoxide intermediates by the action of **thromboxane synthase.** Thromboxane (TXA_2) is a vasoconstrictor that also stimulates platelet aggregation (i.e., it is **thrombogenic**). The interaction of TXA_2-PGI_2 at the endothelial/blood interface may serve as a mediator in the maintenance of vascular homeostasis in health and disease.

Miscellaneous hormones. Although the primary function of the kidneys is excretion, the organ is involved in endocrine functions also. **Erythrogenin** is essential for the generation of erythropoietin (Chapter 20). Some authorities consider **vitamin D** and its active metabolites to be hormones (p. 124).

ADDITIONAL READINGS

Pituitary Gland

Brahms S: The development of the hypophysis of the cat *(Felis domestica)*, *Am J Anat* 50:251, 1932.

Conklin JL: The identification of acidophilic cells in the human pars distalis, *Anat Rec* 156:347, 1966.

Goldberg RC, Chaikoff IL: On the occurrence of six cell types in the dog anterior pituitary, *Anat Rec* 112:265, 1953.

Harris GW, Donovan BT (eds): *The pituitary gland*, Berkeley, 1966, University of California Press.

Herlant M: The cells of the adenohypophysis and their functional significance, *Int Rev Cytol* 17:299, 1964.

Knigge KM, Scott DE, Weindl A (eds): *Brain endocrine interaction. Median eminence: structure and function*, Basal, 1971, S Karger.

Lederis K: An electron microscopical study of the human neurohypophysis, *Z Zellforsch* 68:847, 1965.

Nakane PK: Classification of anterior pituitary cell types with immunoenzyme histochemistry, *J Histochem Cytochem* 18:9, 1970.

Page RB, Munger BL, Bergland RM: Scanning microscopy of pituitary vascular casts, *Am J Anat* 146:273, 1976.

Pelletier G, Robert F, Hardy J: Identification of human pituitary cell types by immunoelectron microscopy, *J Clin Endocrinol* 46:534, 1978.

Share L, Grosvenor CE: The neurohypophysis. In McCann SM (ed): *Endocrine physiology*. (*Physiology, series 1*, vol 5, *MTP international review of science.*) Baltimore, 1974, University Park Press, pp 1-30

Zambrano D: Ultrastructural changes of the neurohypophysis of the rat after castration. *Z Zellforsch* 86:14, 1968.

Pineal Body

Anderson E: The anatomy of bovine and ovine pineals: Light and electron microscope studies, *J Ultrastruct Res Suppl* 8:1, 1965.

Downloaded From Vet-eBooks.com

Axelrod J: The pineal glands: A neurochemical transducer, *Science* 184:1341, 1974.
Cardinali DP: Melatonin. A mammalian pineal hormone, *Endocrine Rev* 2:327, 1981.
Herbert J: The pineal gland and light-induced oestrus in ferrets, *J Endocrinol* 43:625, 1969.
Jordan HE: The histogenesis of the pineal body of the sheep, *Am J Anat* 12:249, 1911.
Reiter RJ (ed): *The pineal gland,* New York, 1984, Raven Press.
Snyder DL, Cowan RL, Kavanaugh JF: The effect of pineal gland removal on nutrition, antler growth and hormone levels in male white-tailed deer. In Brown RD (ed): *Antler development in cervidae,* Kingsville Tex, 1983, Caesar Kleberg Wildlife Research Institute, p 467.
Wurtman RJ, Axelrod J, Kelly DE: *The pineal.* New York, 1968, Academic Press.

Thyroid Gland

Ekholm R: Thyroglobulin biosynthesis in the rat thyroid, *J Ultrastruct Res* 20:103, 1967.
Ekholm R, Ericson LE: The ultrastructure of the parafollicular cells of the thyroid gland in the rat, *J Ultrastruct Res* 23:378, 1968.
Kingsbury BE: ultimobranchial body and the thyroid gland in the fetal calf, *Am J Anat* 56:445, 1935.
Klinck GH, Oertel JE, Winship I: Ultrastructure of normal human thyroid, *Lab Invest* 22:2, 1970.
Martin JB: Regulation of the pituitary-thyroid axis. In McCann SM (ed): *Endocrine physiology. (Physiology, series 1,* vol 5, *MTP international review of science.)* Baltimore, 1974, University Park Press, pp 67-107.
Sobel HJ: Electron microscopy of I-131–irradiated thyroid, *Arch Pathol* 78:53, 1964.
Welsch U, Flitney E, Pearse AGE: Comparative studies of the ultrastructure of the thyroid parafollicular C cells, *J Microscop* 89:83, 1969.

Parathyroid Glands

Capen CC, Rowland GN: The ultrastructure of the parathyroid glands of young cats, *Anat Rec* 162:327, 1968.
Gaillard PJ, Talmage RV, Budy AM (eds): *The parathyroid glands,* Chicago, 1965, University of Chicago Press.
Godwin MC: The development of the parathyroids in the dog with emphasis upon the origin of accessory glands, *Anat Rec* 68:305, 1937.
Gray TK, Cooper CW, Munson PL: Parathyroid hormone, thyrocalcitonin and the control of mineral metabolism. In McCann SM (ed): *Endocrine physiology. (Physiology, series 1,* vol 5, *MTP international review of science.)* Baltimore, 1974, University Park Press, pp 239-278.
Nakagami K, Yamazaki Y, Tsunoda Y: An electron microscopic study of the human fetal parathyroid gland, *Z Zellforsch* 85:89, 1968.

Adrenal Glands

Axelrod J, Reisine TD: Stress hormones: their interaction and regulation, *Science* 224:452, 1984.
Bloodworth JMB Jr, Powers KL: The ultrastructure of the normal dog adrenal. *J Anat* 102:457, 1968.
Brenner RM: Fine structure of adrenocortical cells in adult male rhesus monkeys, *Am J Anat* 119:429, 1966.
Elfvin LG: The development of the secretory granules in the rat adrenal medulla, *J Ultrastruct Res* 17:45, 1967.
Hopwood D: Adrenal medullary basophilia in ox, pig and sheep: a histochemical, immunohistochemical, and cell fractionation study, *Histochemie* 11:268, 1967.
King RJB: Structure and function of steroid receptors, *J Endocrinol* 114:341, 1987.
Merklin RJ: Suprarenal gland lymphatic drainage, *Am J Anat* 119:359, 1966.
Migally N: The innervation of the mouse adrenal cortex, *Anat Rec* 194:105, 1979.
Morita K, Pollard HB: Chromaffin granule–cytoskeleton interaction, *FEBS Lett* 181:195, 1985.
Mulnix JA: Adrenal cortical disease in dogs, *Vet Scope* 19:12, 1975.
Rhodin JAG: The ultrastructure of the adrenal cortex of the rat under normal and experimental conditions, *J Ultrastruct Res* 34:23, 1971.
Thorn GW (ed): *Steroid therapy: a clinical update for the 1970's,* Kalamazoo Mich, 1974, Upjohn.
Whitehead RH: The histogenesis of the adrenal in the pig, *Am J Anat* 2:349, 1903.
Wood JG: Identification of and observations on epinephrine and norepinephrine containing cells in the adrenal medulla, *Am J Anat* 112:285, 1963.

Endocrine Pancreas

Greider MH, Howell SL, Lacy PE: Isolation and properties of secretory granules from rat islets of Langerhans, *J Cell Biol* 41:162, 1969.
Lacy PE: Electron microscopy of the beta cells of the pancreas, *Am J Med* 31:851, 1961.
Like AA: The ultrastructure of the islets of Langerhans in man, *Lab Invest* 16:937, 1967.
Machino M: On the substructure of secretory granules of the chick beta islet cell, *J Ultrastruct Res* 31:199, 1970.
Unger RH: The pancreas as a regulator of metabolism. In McCann SM (ed): *Endocrine physiology. (Physiology, series 1,* vol 5, *MTP international review of science.)* Baltimore, 1974, University Park Press, pp 179-204.

Miscellaneous Hormones

Bell TG, et al: Biologic interaction of prostaglandins, thromboxane, and prostacyclin: potential nonreproductive veterinary clinical applications, *J Am Vet Med Assoc* 176:1195, 1980.
Goldyne ME: Prostaglandins and other eicosanoids. In Katzung BG (ed): *Basic and clinical pharmacology,* Los Altos Calif, 1982, Lange Medical Publishing, p 196.
Hightower NC, Janowitz HD: Gastrointestinal hormones. In Brobeck JR (ed): *Best and Taylor's Physiological basis of medical practice,* ed 10, Baltimore, 1979, Williams & Wilkins, pp 20-23.
Kindahl H: Prostaglandin biosynthesis and metabolism, *J Am Vet Med Assoc* 176:1173, 1980.
Seguin BE: Role of prostaglandins bovine reproduction, *J Am Vet Med Assoc* 176:1178, 1980.
Welbourn RB, et al: The APUD cells of the alimentary tract in health and disease, *Med Clin North Am* 58:1359, 1974.

Downloaded From Vet-eBooks.com

CHAPTER 26

Male Reproductive System

The male reproductive system consists of the **testes, excretory (genital) ducts, accessory glands,** and **penis.** These organs contribute to the primary function of **reproduction.** The **production** and **transport of spermatozoa, secretion** of fluids, and **placement** of semen in the female tract are complementary functions. The intermittent copulatory organ also **transports urine** to the external environment.

TESTES

General considerations. The testes exist within a specialized pouch of skin, the **scrotum** (Chapter 20). They are combined exocrine and endocrine organs. The exocrine portion is a compound, coiled tubular gland producing spermatozoa as its holocrine product. The endocrine functions relate to the **interstitial** and **sustentacular cells.**

Testicular investments. The testes are enclosed by a capsule, the **tunica albuginea,** composed of dense collagenous tissue (Fig. 26-1). This capsule is covered by a tunica serosa, the connective tissue of which blends with the tunica albuginea.

A vascular layer is present in the tunica albuginea of most species. It is superficial in dogs and rams, deep in stallions and boars. Smooth muscle fibers may be present in the tunica albuginea of horses.

The tunica albuginea is continuous with the loose collagenous tissue of the **mediastinum testis,** in most species at the anterior pole of the testis (Fig. 26-1). It surrounds the **rete testis.** Although the mediastinum of stallions is atypical and inconspicuous, it exists as a true mediastinum. The stallion rete testis is extratesticular and penetrates the tunica albuginea to unite with the efferent ducts.

The tunica albuginea also is continuous with loose collagenous tissue of the **septuli testis** (Fig. 26-1). These septa divide the testis into lobules **(lobuli testis).** The tubules of the lobule **(tubuli contorti** and **tubuli recti)** are surrounded by loose collagenous tissue with many reticular fibers.

Seminiferous tubules. The testicular parenchyma consists of lining cells of the seminiferous tubules and their ducts as well as **interstitial cells.** The **seminiferous tubules (tubuli contorti)** are the exocrine portions of the gland (Fig. 26-2). They radiate from the mediastinum testis as coiled, tubular adenomeres (Fig. 26-3) and are lined by stratified epithelium that consists of basal, intermediate, and superficial zones, dependent upon spermatogenic activity within the tubules. Al-

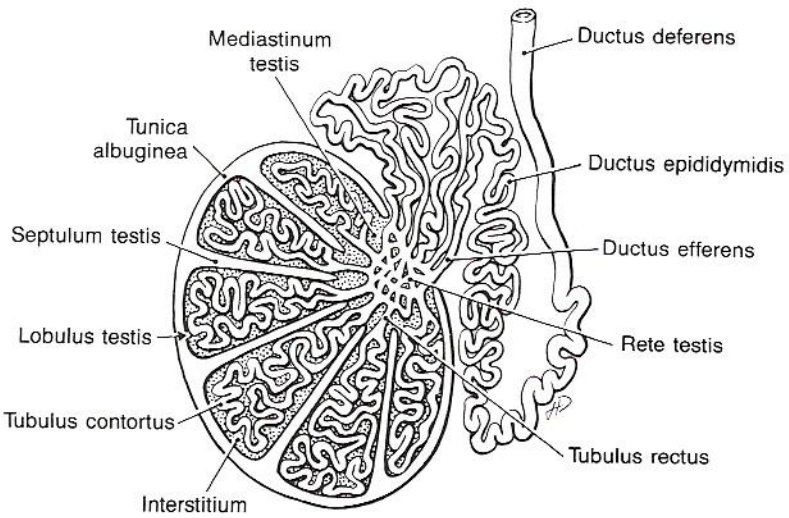

Figure 26-1. Testis and associated structures. The connective tissue investments of extratesticular ducts are not shown.

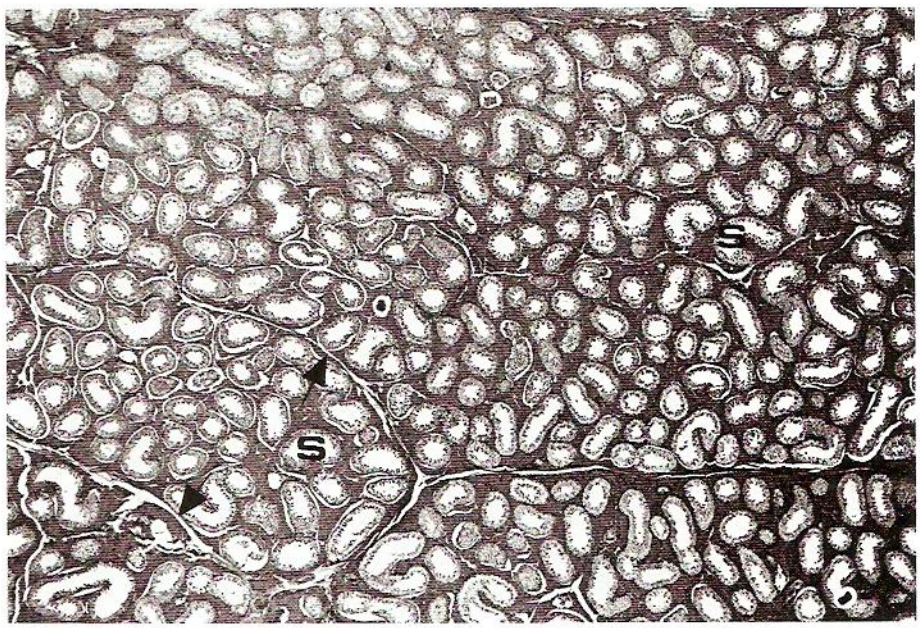

Figure 26-2. Organization of the testis. The seminiferous tubules *(S)* occur within lobules separated by connective tissue septa *(arrows).* (×4.)

Downloaded From Vet-eBooks.com

Figure 26-3. Seminiferous tubules of a cervine testis. The tubules *(S)* are separated by connective tissue and interstitial cells *(I)*. (×40.)

Figure 26-4. Scanning electron micrograph of a freeze fractured sample from a canine seminiferous tubule. Numerous cells comprise the stratified epithelium. The tails of developing spermatozoa protrude into the lumen of the tubule. (×670.) (Courtesy C. J. Connell.)

Downloaded From Vet-eBooks.com

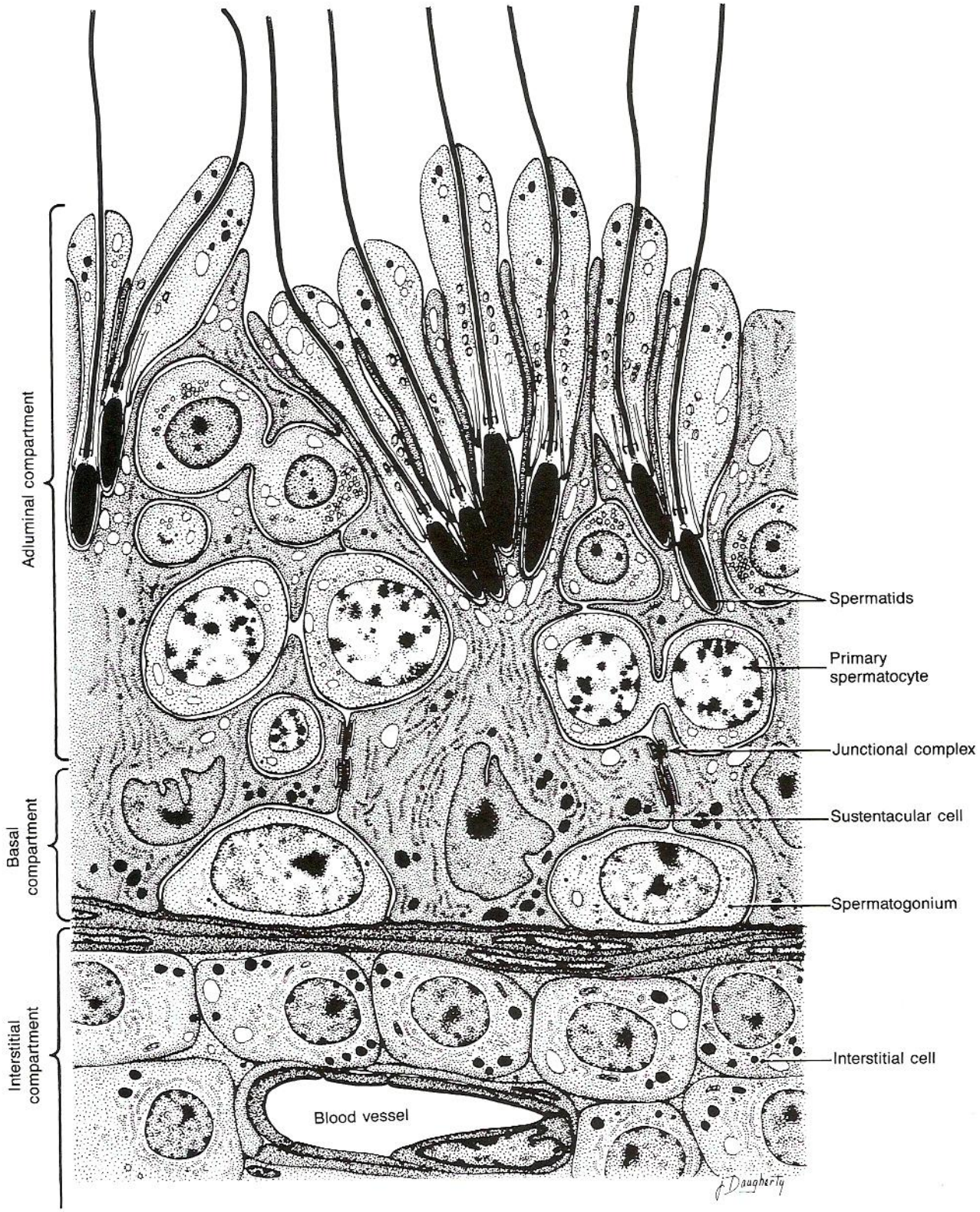

Figure 26-5. Part of an equine seminiferous tubule. Note the relationship of sustentacular (Sertoli) cells to developing spermatozoa. (Courtesy R. P. Amann).

though the epithelium is stratified, it is not typical stratified epithelium (Fig. 26-4). The stratified cells consist of **spermatogonia, primary spermatocytes, secondary spermatocytes, spermatids,** and **spermatozoa** (Fig. 26-5).

Interstitial cells. **Interstitial cells** are the endocrine cells of the testes responsible for **testosterone** secretion (Fig. 26-6). Located in the septal connective tissue, they are polyhedral with large spherical nuclei and distinct nucleoli. Their acidophilic cytoplasm contains many lipid droplets and granules, but these are lost during routine processing (Plate II, *1*). As a result the cells are foamy. They are especially abundant in boars and bulls.

Tubuli recti and rete testis. The semi-

Downloaded From Vet-eBooks.com

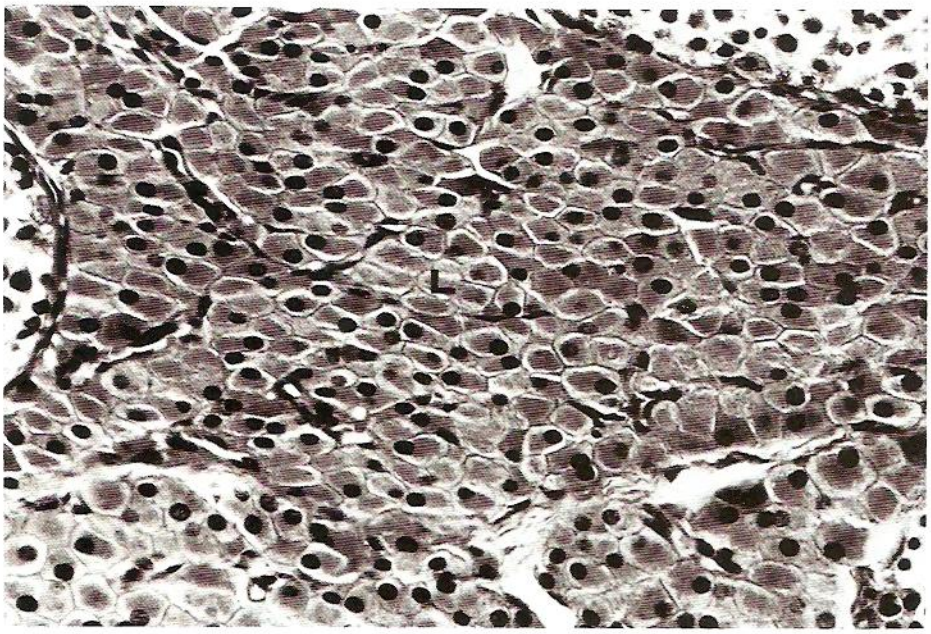

Figure 26-6. Interstitial cells of a porcine testis. These cells (Leydig cells) *(L)* have an acidophilic and foamy cytoplasm. (×100.)

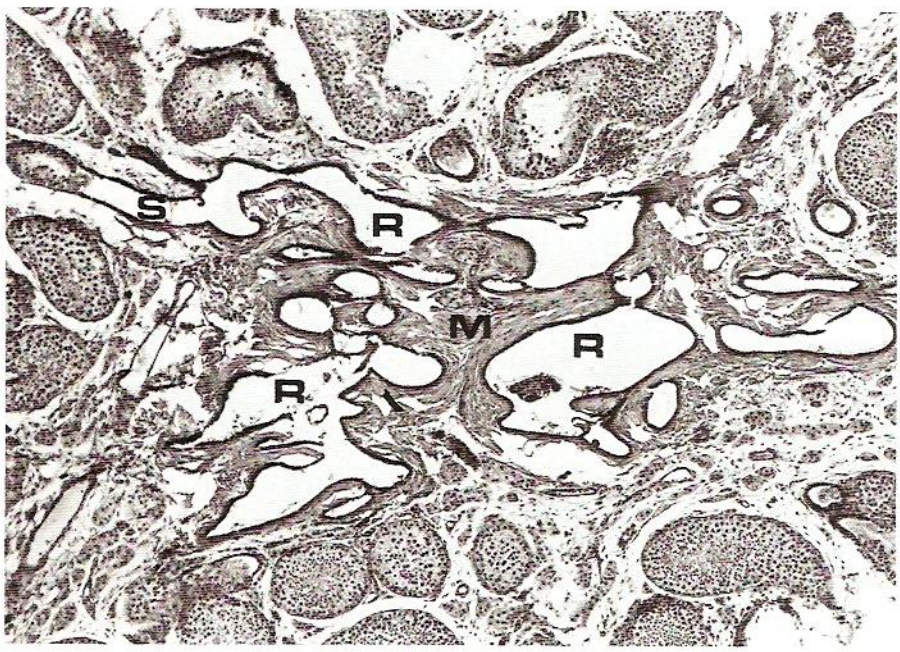

Figure 26-7. Mediastinum of a feline testis. The mediastinum *(M)* contains the rete testis *(R)*. Straight tubules *(S)* connect the rete with seminiferous tubules. (×10.)

niferous tubules are continuous with the **straight tubules (tubuli recti)** and the passages of the **rete testis** (Fig. 26-7). These regions are lined by a squamous, cuboidal, or columnar epithelium. In bulls the rete testis may be lined with a bistratified cuboidal epithelium. The two regions are similar and are best identified by position within the testis. The tubuli recti are straight tubules, but the rete testis consists of randomly anastomotic tubules (Fig. 26-8). In boars the apical borders of the lining cells may possess blebs, signifying apocrine secretory activity. The lining cells of these regions are a continuation of the sustentacular cells that constitute the tubuli contorti.

GENITAL DUCTS

Ductuli efferentes. The **ductuli efferentes** connect the rete testis with the ductus epididymidis (Fig. 26-9). The efferent ductules vary from six to 20 coiled ducts lined by intermittently ciliated columnar epithelium (Fig. 26-10). The current created by ciliary movement helps move spermatozoa toward the larger ducts. Some nonciliated cells are secretory; others are absorptive, their apical surface possessing microvilli. The surrounding lamina propria mucosa blends with the other connective tissue of the region, and some smooth muscle cells are present. The widened and tightly convoluted portions of these tubules connecting with the ductus epididymidis are the head of the organ.

Ductus epididymidis. This is the coiled tube that, with associated connective tissue and muscle, forms the **head, body,** and **tail** of the epididymis (Fig. 26-11). The tail continues as the ductus deferens.

The lamina epithelialis mucosae is pseudostratified stereociliated columnar epithelium (Fig. 26-12). Its basal cells contain lipid droplets; its columnar cells are long and slender, contain lipids, and have apical stereocilia (Fig. 26-13). These nonmotile processes increase the absorptive and secretory surface of the lining and are usually matted together by secretory products. The nature and significance of the products are not known.

The lamina propria mucosae is a highly vascularized loose collagenous tissue. Its lamina muscularis mucosae, arranged in a circular manner, is thicker toward the epididymal tail. The tunica submucosa is loose collagenous tissue centrally and dense collagenous tissue peripherally continuing with the tunica albuginea. Many spermatozoa are stored and mature within the lumen of the ductus epididymidis.

Ductus deferens. The **ductus deferens** is the continuation of the ductus epididymidis (Fig. 26-14). Its lamina epithelialis mucosae is pseudostratified columnar epithelium. A gradual transition occurs from the lining epithelium of the ductus epididymidis to that of the ductus deferens. The lamina propria-submucosa is loose collagenous tissue. The mucosal glands of this duct comprise the ampulla. The tunica muscularis is thick and varies from two distinct inner and outer layers to intermingled fibers. The tunica serosa is present and typical.

SPERMATOGENESIS

Spermatogenesis occurs within the tubuli contorti and ductus epididymidis—the former producing gametes, the latter aiding in their maturation. The sequence is a series of nuclear and cytoplasmic changes that result in highly motile haploid cells suited to survive for short periods outside the body. The progression begins with **spermatogonia** and terminates with **spermatozoa.** These cells, with **sustentacular cells,** comprise the stratified

Downloaded From Vet-eBooks.com

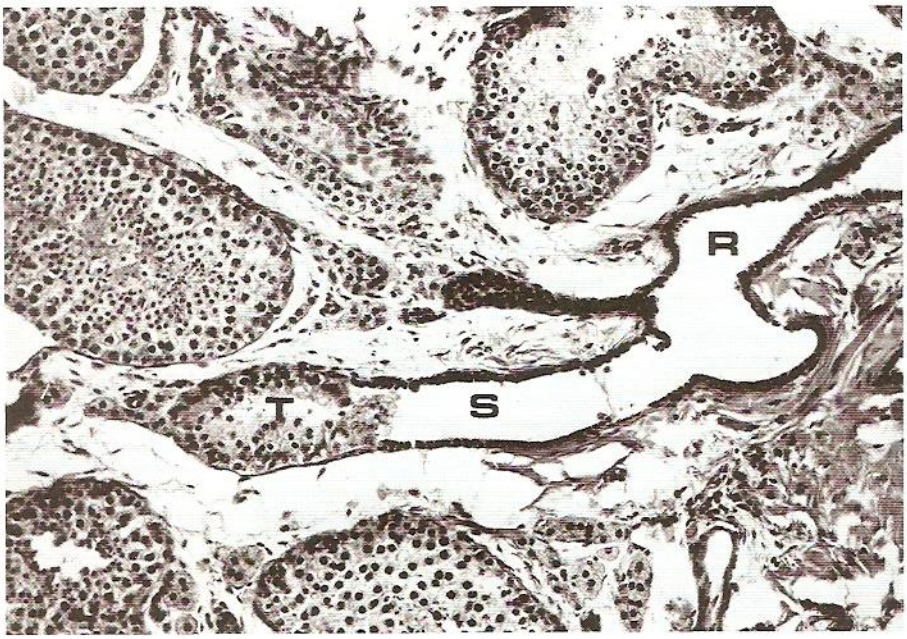

Figure 26-8. Rete testis and tubuli recti of a feline testis. The tubuli contorti *(T)* are connected to the rete testis *(R)* by the tubuli recti *(S)*. (×40.)

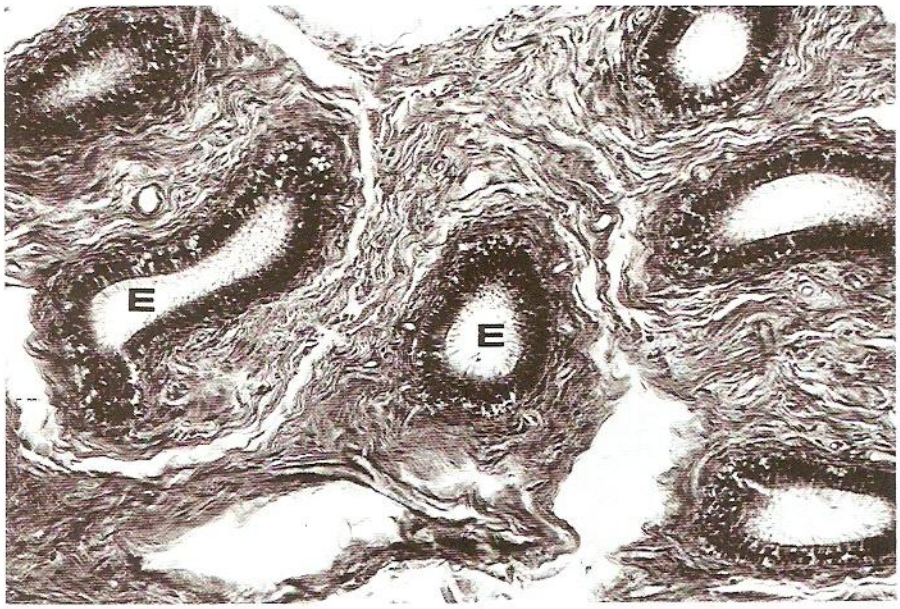

Figure 26-9. Ductuli efferentes. The tubules *(E)* connect the rete testis to the ductus epididymidis. (×40.)

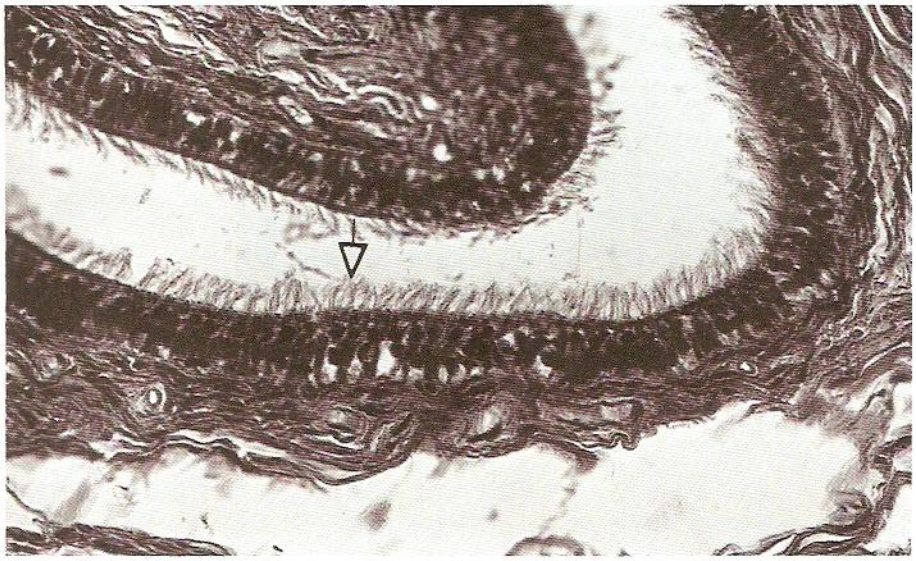

Figure 26-10. Lining cells of the efferent ducts. These cells (columnar epithelial) are kinociliated *(arrow)*. (×100.)

Downloaded From Vet-eBooks.com

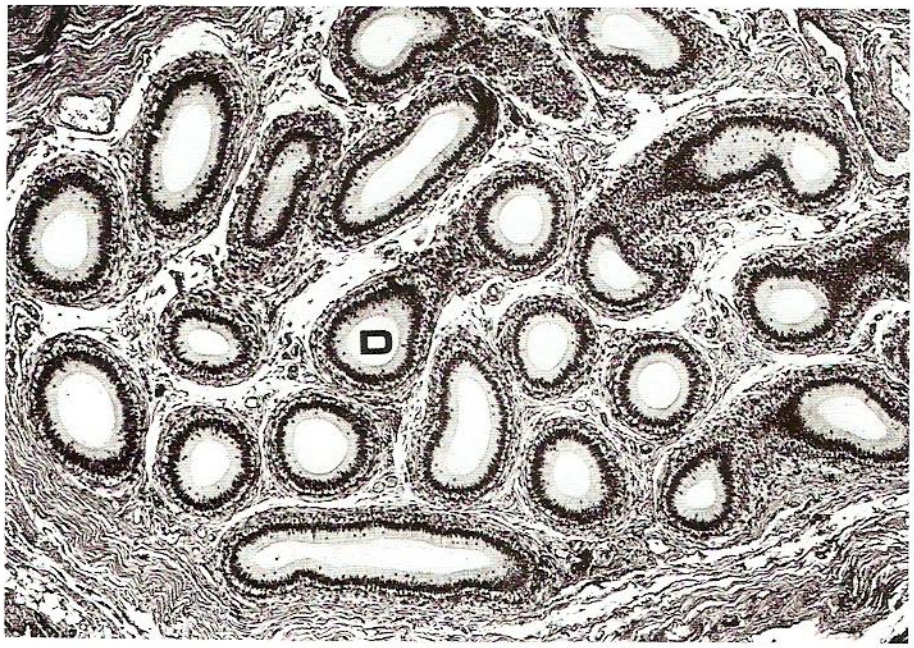

Figure 26-11. Portion of an epididymis. The ductus epididymidis *(D)* is the tubular portion of this organ. (×20.)

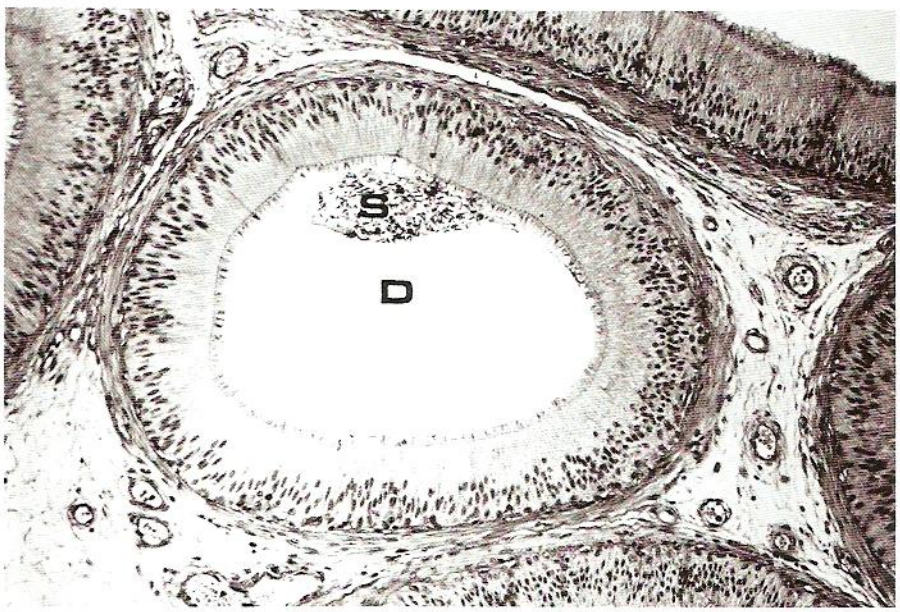

Figure 26-12. Lining cells of the ductus epididymidis. The tubules *(D)* contain spermatozoa *(S)* and are lined by stereociliated epithelium. (×10.)

Downloaded From Vet-eBooks.com

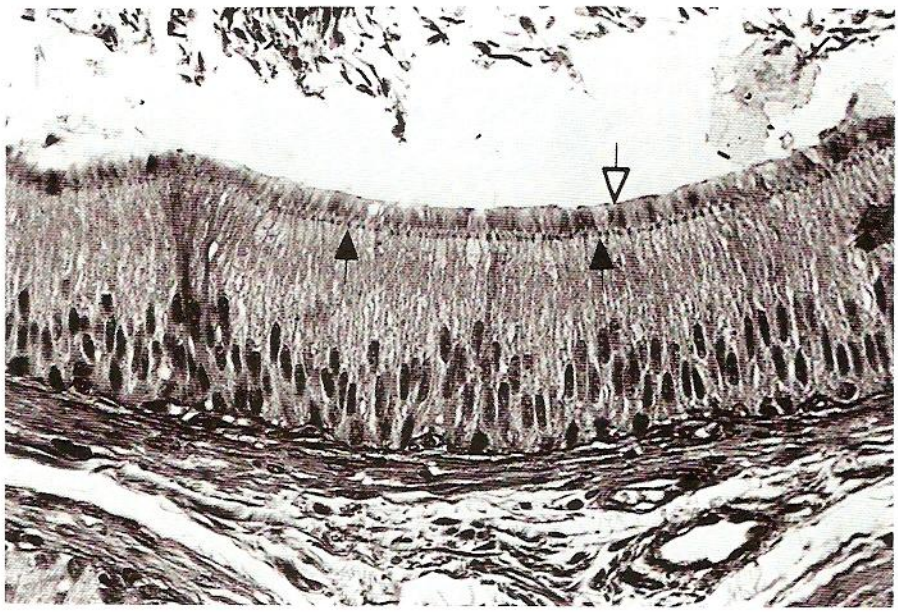

Figure 26-13. Stereocilia of the ductus epididymidis. The lining cells are stereociliated *(open arrow)*. Note the terminal bars *(solid arrows)*. (×100.)

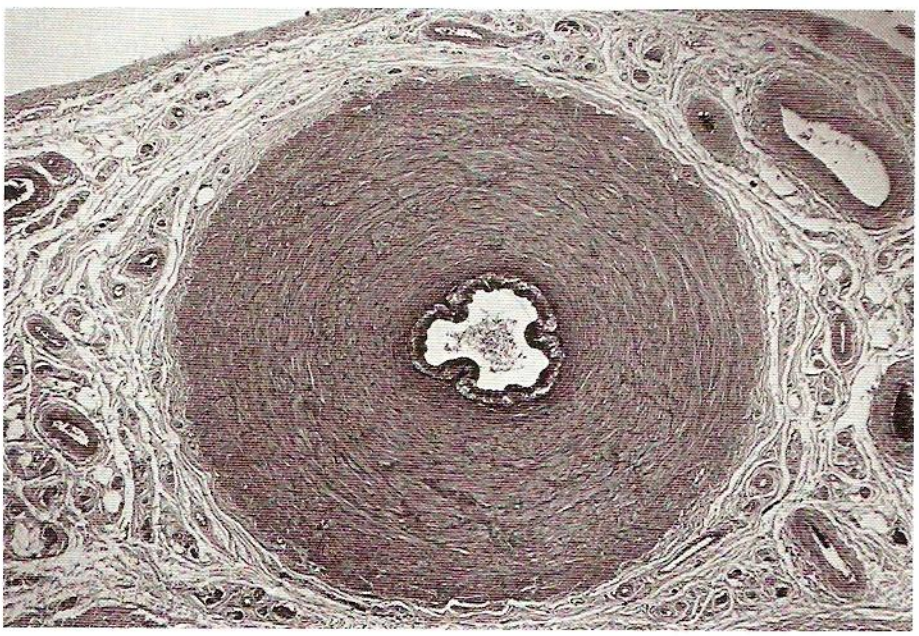

Figure 26-14. Ductus deferens. The duct is a continuation of the ductus epididymidis. Note the extensive amount of smooth muscle peripheral to the lumen of the organ. The ductus deferens is the tubular portion of the vas deferens. (×10.)

Downloaded From Vet-eBooks.com

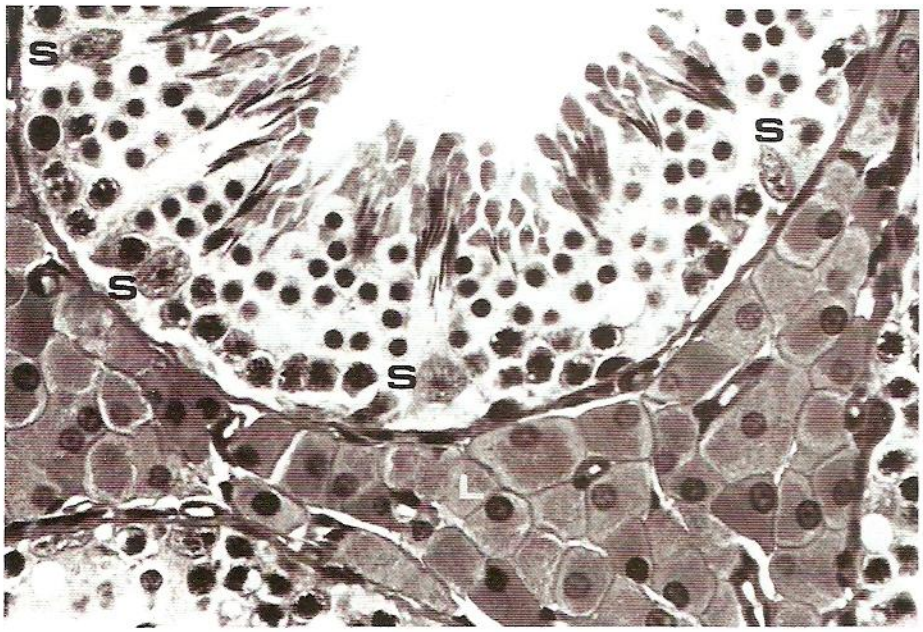

Figure 26-15. Sustentacular (Sertoli) cells of a porcine testis. These cells *(S)* are triangular with triangular nuclei positioned basally. The developing gametes are intimately associated with them. *L*, Interstitial cells. (×160.)

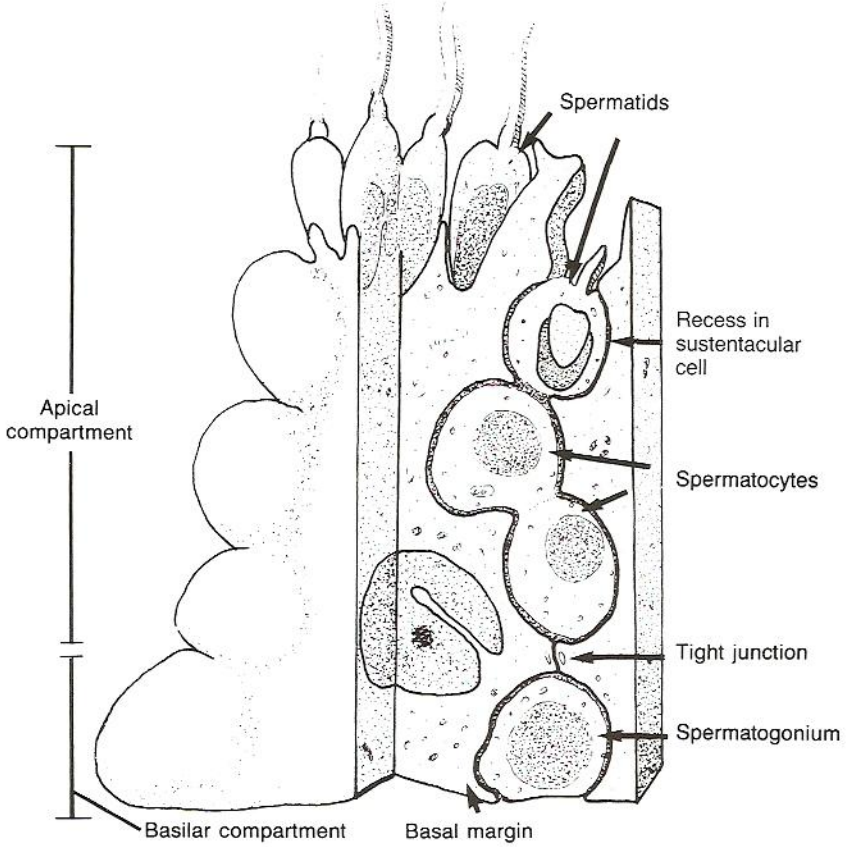

Figure 26-16. The electron microscopic appearance of adjacent sustentacular cells. Spermatogonia occupy the basilar compartment and are directly exposed to influences from the interstitium. Spermatocytes occupy the apical compartment, insulated by the blood-testis barrier.

lining. The most primitive cells reside near the periphery of the tubule; more developmentally advanced cells occur on the luminal border.

Three distinct periods characterize the spermatogenic process—**mitotic, meiotic,** and **metamorphic.** Not all seminiferous tubules are in the same activity period, nor are different portions of one tubule characterized by cells with the same degree of differentiation. Although there are species variations, the spermatocytogenic process occurs in helical waves down the tubuli contorti to the straight tubules.

Sustentacular cells. **Sustentacular (Sertoli) cells** of the seminiferous tubules nurture the developing gametes (Fig. 26-15). They are tall and columnar or triangular, with cytoplasm and cellular margins difficult to distinguish by light microscopy (Plate II, *2*), and are the only cells of the seminiferous tubules extending from the basal lamina to the tubular lumen. Developing gametes are embedded within invaginations of their cytoplasm. Their oval nuclei, usually positioned basally, are vesicular with distinct nucleoli. A characteristic fold in the nuclear membrane may be visible.

Electron microscopy is required to clarify the intimacy between gametes and sustentacular cells. Developing gametes are contained within invaginations along the margins of sustentacular cells that may totally enclose them (Fig. 26-16). Smooth endoplasmic reticular profiles are extensive along the basal cell borders. The presence of this organelle has been interpreted as evidence that this cell synthesizes steroids. Their Golgi complexes are extensive. An **androgen binding protein (ABP),** secreted into the seminiferous tubular lumen, degrades in the ductus epididymidis. Many cytofilaments, occurring throughout these cells, are especially obvious along the lateral cell margins, where they parallel the cells' long axes and aggregate in bundles. The movement of developing gametes from the basal border to the apical margin of a tubule depends upon changes in sustentacular cell cytofilaments. Lysosomes in various stages of activity are conspicuous, their presence correlating with the phagocytosis and removal of residual cytoplasmic droplets from developing spermatozoa.

The abluminal lateral cell membranes of adjacent sustentacular cells are joined by tight junctions, which effectively divide the seminiferous tubule into two compartments—basilar and apical. The **basilar compartment,** located peripherally between the tight junctions and the basal lamina, contains spermatogonia. These cells are influenced by substances moving across the basal lamina from the testicular interstitium, which exchange (between the basal border of the sustentacular cell and the associated capillaries) is facilitated by the relationship. The **apical compartment,** located between the tight junctions and the apical border, contains developing gametes. The sustentacular cells are influenced by their associated capillaries, but the developing gametes are "insulated" from direct influences by the sustentacular cells. The tight junctions

Downloaded From Vet-eBooks.com

and contiguous sustentacular cells form an effective **blood/testis barrier.**

The sustentacular cell provides physical support, protection, and probably nutrition for the gametes. It probably also participates actively in the centripetal movement, development, and release of gametes, because alterations in sustentacular cell morphology correlate with events in the spermatogenic cycle. This intimate relationship implies that sustentacular cells are metabolic regulators. Damaged gametes are phagocytized by the them.

The sustentacular cells also secrete estrogens. **Sertoli cell tumors,** which are common in dogs, may be accompanied by the development of secondary female sex characteristics.

Stage of multiplication. The number of spermatogonia increases during **multiplication** or the **mitotic stage.** Through successive mitotic divisions many spermatogonia undergo changes that transform them into spermatozoa, and their number greatly increases. The number of potential spermatozoa also increases. If all spermatogonia were to differentiate into subsequent cell types at the same time, however, only four haploid gametes would be produced and gamete production would diminish and eventually terminate. As it is, not all spermatogonia differentiate simultaneously; some are retained as stem cells for future differentiation, and the disastrous consequences for the organism are obviated.

Spermatogonia represent many generations of cells—including A cells, intermediate cells (I_1 and I_2), and B cells.

- The **A spermatogonia** are stem cells for this process. They are round, with large round nuclei that contain finely dispersed chromatin and an eccentrically positioned nucleolus. Upon mitotic division, one cell remains a stem cell; the other divides and its progeny differentiate into intermediate (I) spermatogonia.
- The **I spermatogonia** are oval cells with oval nuclei that contain peripheral, coarse chromatin and two or three nucleoli. Subsequent divisions of I spermatogonia give rise to B spermatogonia.
- The **B spermatogonia** are round and small with oval nuclei containing coarse clumped chromatin. Division of these cells leads to the differentiation of primary spermatocytes.

As many as 16 primary spermatocytes result from a single A spermatogonium. Incomplete cytokinesis is characteristic of the mitotic process resulting in B spermatogonia. All spermatogonia occur adjacent to the basement membrane, either singly or in clusters, but they do not form a complete basal layer. They may be difficult to find.

Spermatocytogenesis. **Spermatocytes** are the largest cells of the spermatogenic epithelium comprising the intermediate zone.

Type B spermatogonia differentiate into **primary spermatocytes.** These cells have long lives (approximately 16 days in the bull) and usually are easy to find and identify. Their interphase nuclei contain a fine chromatin network, but they are often observed in the first division of meiosis. They also have a long premeiotic prophase. Thus their nuclei may be coarsely granulated or chromosomes may be visible.

The end of the first division of meiosis marks the differentiation of the **secondary spermatocytes.** These cells are haploid (i.e., the 1N number of chromosomes), smaller than primary spermatocytes, and difficult to find because they enter the second meiotic division almost immediately and form **spermatids.** Their life-span varies from minutes to an hour. Throughout these divisions, cytokinesis is incomplete and the cells are joined by numerous intercellular bridges.

Spermiogenesis. The **spermatids** resulting from division of the secondary spermatocytes remain haploid—comprising the most developed, most numerous, and largest layer of the seminiferous tubular epithelium. The luminal zone in which they are located is known as the **zone of metamorphosis.**

The process converting spermatids to spermatozoa is called **metamorphosis** or **spermiogenesis.** As spermatogenesis ensues, the spermatids move in a centrifugal direction (toward the basement membrane) and then centripetally toward the lumen. The primary organelles involved in spermiogenesis are the nuclei, Golgi apparatus, and centrioles (Fig. 26-17).

- Small granules (**proacrosomal granules**) appear in the vesicles of the Golgi complex, where they coalesce to form a single large **acrosomal vesicle** containing the **acrosome.** The acrosome results from a coalescence of proacrosomal vesicles. The acrosomal vesicle migrates to the nucleus and contacts the outer nuclear membrane at the acrosome.
- The acrosomal vesicle enlarges to cover half the nucleus, collapsing on it and forming the **head cap.** At the same time the centrioles migrate to the cell periphery opposite the acrosome. The residual Golgi complex also migrates here.
- The acrosome becomes indistinguishable from the head cap. Its nucleus increases in density and begins to elongate. At this time the centrioles and developing **flagellum** migrate toward and come in contact with the nuclear membrane. A **caudal sheath** or **manchette** composed of microtubules develops at the caudal edge of the head cap. The spermatid elongates simultaneously.
- A small ring condenses around the proximal centriole. This **annulus** is attached to the inner lamina of the plasmalemma. It slides down the flagellum. At the same time, mitochondria orient themselves in a helical pattern between the proximal centriole and the annulus. Nine longitudi-

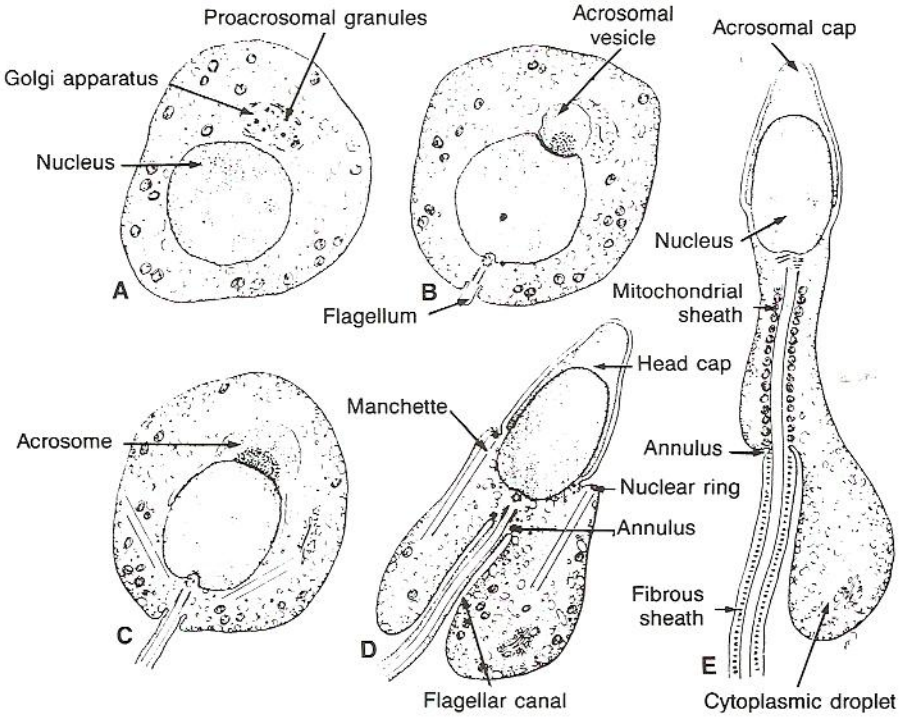

Figure 26-17. Successive stages in the differentiation of a spermatid during spermiogenesis. The sequence of development is **A** → **E.** (Redrawn and modified from Clermont Y, Leblond CP: *Am J Anat* 96:229, 1955.)

Downloaded From Vet-eBooks.com

nal fibers develop between the flagellar doublets and the mitochondria to form the **middle piece.**

The **principal piece** has a flagellar core, dense fibers, and a fibrous sheath.

The irregularly arranged flagellar microtubules comprise the **end piece.**

As the formation of these entities occurs, the remaining cytoplasm is displaced distad along the tail and eventually lost as the **residual body.**

The mature spermatozoon thus has the following: head, neck, middle piece, principal piece, and end piece (Fig. 26-18):

The **head** is covered by the head cap on the rostral and lateral surfaces and by the calyx on the lateral and caudal.

The **neck** has a fossa in which the centriole is located. Longitudinally segmented columns connect the head to the tail.

The **middle piece** consists of a flagellar core in a 9 + 2 axonemic arrangement (Fig. 4-45), fibers continuing with those of the neck, a helical arrangement of mitochondria, and an annulus attached to the plasmalemma.

The **principal piece** has a flagellar core, dense fibers, and a fibrous sheath. The core exists in a 9 + 2 arrangement with fibers of various sizes ending in it and covered by a fibrous sheath.

The **end piece** consists of irregularly arranged flagellar microtubules in a 9 + 2 core arrangement, terminating in random fashion.

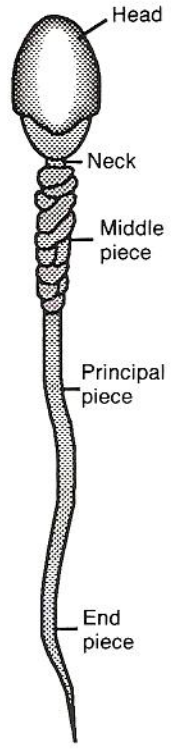

Figure 26-18. Typical spermatozoon.

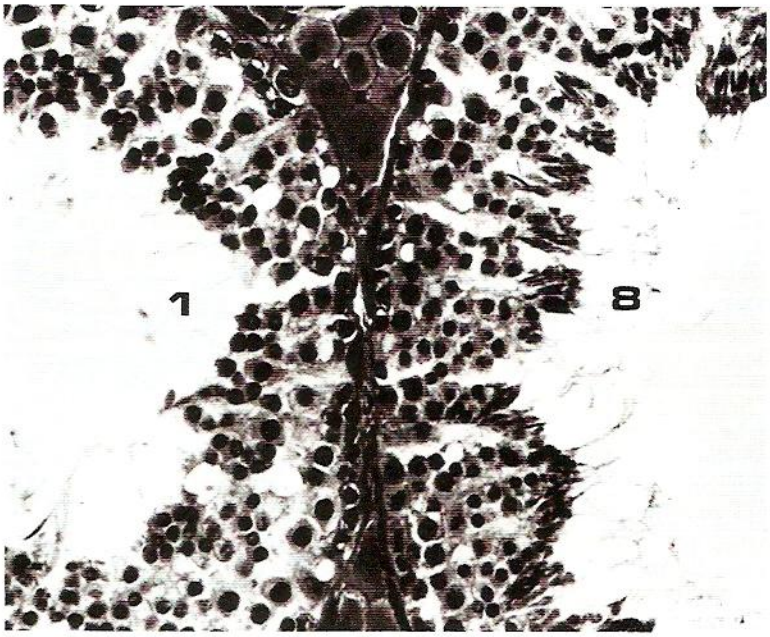

Figure 26-19. Developmental stages in adjacent seminiferous tubules. Stages *1* and *8* represent different degrees of development. (×100.)

The entire spermatozoon is enclosed within a plasmalemma.

Spermatogenic cycle. Not all seminiferous tubules or regions of a tubule are in the same stage of development (Fig. 26-19). The activity is cyclical, may occur in a helical pattern within a seminiferous tubule, and is called a **spermatogenic wave.** Various cell combinations are always associated with each other during this process. In bulls, for example, in which eight stages have been identified, stage 1 (from basal to luminal border) includes **spermatogonia, pachytene primary spermatocytes,** and **round spermatids.** By contrast, stage 8 includes **spermatogonia, zygotene primary spermatocytes, secondary spermatocytes, round spermatids,** and **spermatozoa.** The six remaining stages involve other permutations of the basic cell types. Various stages, the number of stages, and the overall duration of the stages are species-variable. The **spermatogenic cycle** is the sequence of cell events occurring between two successive, identical stages (Fig. 26-20).

In some species the male is always capable of spermiation (i.e., the ejection of viable sperm from the testes). In seasonal breeders the epithelium of the seminiferous tubules is incapable of producing spermatozoa except during specific periods of the year, the breeding season (Fig. 26-3). Examination of tubuli contorti during the nonbreeding season reveals the presence of scattered spermatogonia and sustentacular cells. Few other cells are present, and the tubules are involuted and replaced by connective tissue.

TESTICULAR SECRETIONS

The testes produce gametes and elaborate steroid hormones. Actually, the **seminiferous tubules** produce the gametes and the **interstitial cells** secrete the steroid hormone. Spermatogenesis and testicular steroidogenesis are integrated and associated activities. Testicular regulation occurs through the hypothalamopituitary and gonadal axis. The axis is separated into a hypothalamus–interstitial cell axis and a hypothalamus–tubuli contorti axis. The functions of both axes are related.

Hypothalamus–interstitial cell axis. The hypothalamus is the first regulator, through gonadotropin releasing factors—**luteotropin releasing factor (LRF)** and **follicle-stimulating hormone releasing factor (FRF).** The secretion of LRF and FRF from the hypothalamus is modulated by external influences. Temperature effects on testicular activity may be direct upon the testes or mediated through the hypothalamus. Light is probably the most important factor influencing the axis. The seasonal breeding activity of animals with a rutting season (e.g., deer) responds to decreasing light in the photoperiod. Some domestic animals (goats) increase their breeding activity with **decreasing** daylength; others (horses) increase such activity with **increasing** daylength. Hypothalamic tonus maintains testicular activity, but testicular hormones exert a negative feedback influence on the hypothalamus.

The secretion of LRF and FRF initiates secretory activity by gonadotrops and the release of **luteinizing hormone (LH)** and **follicle-stimulating hormone (FSH).** Luteinizing hormone and **inter-**

Downloaded From Vet-eBooks.com

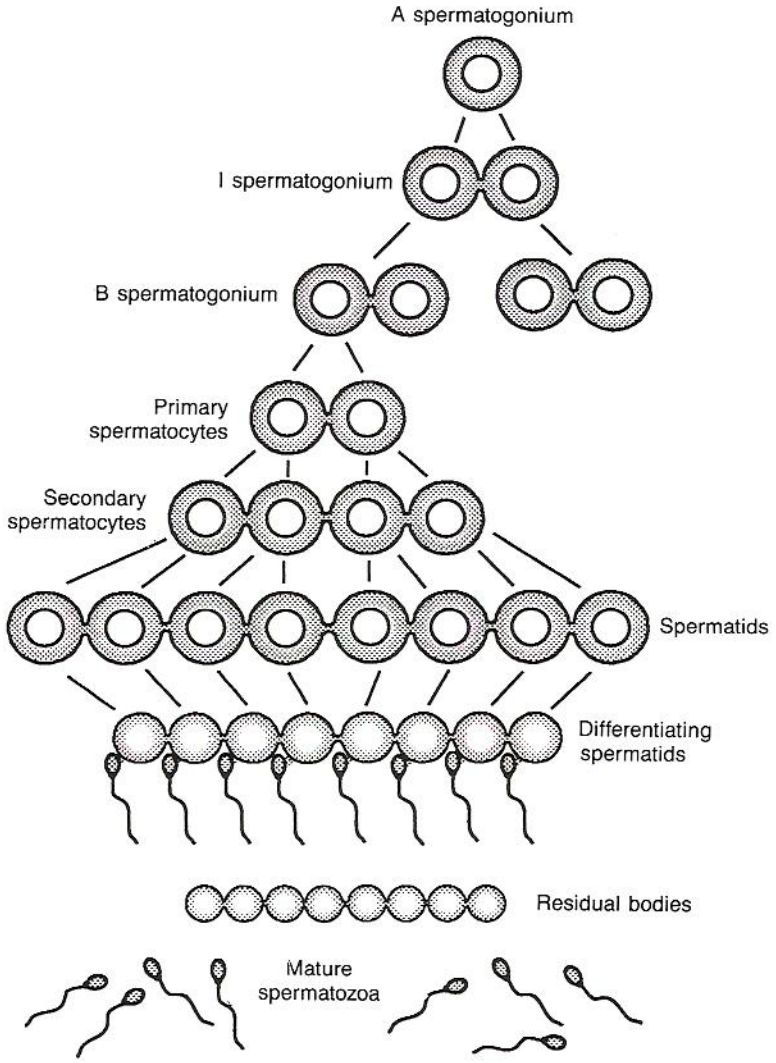

Figure 26-20. Sequential and repetitive stages of spermatogenesis. A single A spermatogonium, as depicted, may give rise to many spermatozoa through successive mitoses and meioses.

stitial cell–stimulating hormone (ICSH) are identical; the term LH is now used in reference to both male and female. LH is the tropic hormone regulating testicular interstitial cells. **Prolactin** potentiates the LH effect upon interstitial cells. Prolactin and testosterone also increase prostate and vesicular gland secretions. Cells responsive to androgens have membrane receptor sites for prolactin.

Testosterone, the steroid hormone of interstitial cells, is synthesized from circulating acetate or cholesterol. Although other androgens occur in males, testosterone is the most important. Small amounts of it occur free and active within the blood; however, most of it is bound to a β-globulin called **testosterone–estradiol binding globulin (TeBG),** which is distinct from that used for cortisol binding. Upon entry into a cell from the active blood pool, testosterone may be converted to its more active form (dihydrotestosterone) or inactivated to metabolites characterized as **17-ketosteroids.** 17-Ketosteroids are the primary excretory products of testosterone. The liver also inactivates testosterone by converting it to sulfates and glucuronides secreted in the bile. Other tissues inactivate testosterone by converting it to **estradiol,** a potent estrogen.

Actions of testosterone. Although testosterone exerts an influence upon the gonads, accessory sex glands, and those organs responsible for secondary male sex characteristics **(androgenic effects),** it also affects almost every cell **(anabolic effects).** The elaboration of testosterone by the forming testes is responsible for development of the external genitalia and accessory sex glands as well as descent of the testes into the scrotum. The external genitalia and accessory sex glands grow under the influence of this hormone.

Testosterone has a positive influence upon basal metabolic rate, electrolyte balance, RBC production, nitrogen retention, skeletal muscle mass, bone development, and bone maintenance.

Hypothalamus–tubuli contorti axis. The seminiferous tubules are regulated by the hypothalamus and pars distalis. The secretion of LH and FSH by the pars distalis, controlled by hypothalamic releasing factors, is essential for development of the tubuli contorti. Although FSH has a direct effect upon the seminiferous tubules, the effects of LH are manifested through testosterone. Testosterone and FSH stimulate the synthesis of androgen-binding protein (ABP) by the sustentacular cells. FSH initiates spermatogenic events, but testosterone is required for the maturation of the spermatozoa. The mechanisms regulating FSH release need further clarification. Testosterone does not influence FSH secretion; rather, **inhibin** secreted by testicular interstitial cells negatively influences the pars distalis and FSH secretion.

ACCESSORY GLANDS

The following are accessory genital glands in males: **ampullary, vesicular, prostate, bulbourethral,** and **urethral glands.** They elaborate serous and mu-

Downloaded From Vet-eBooks.com

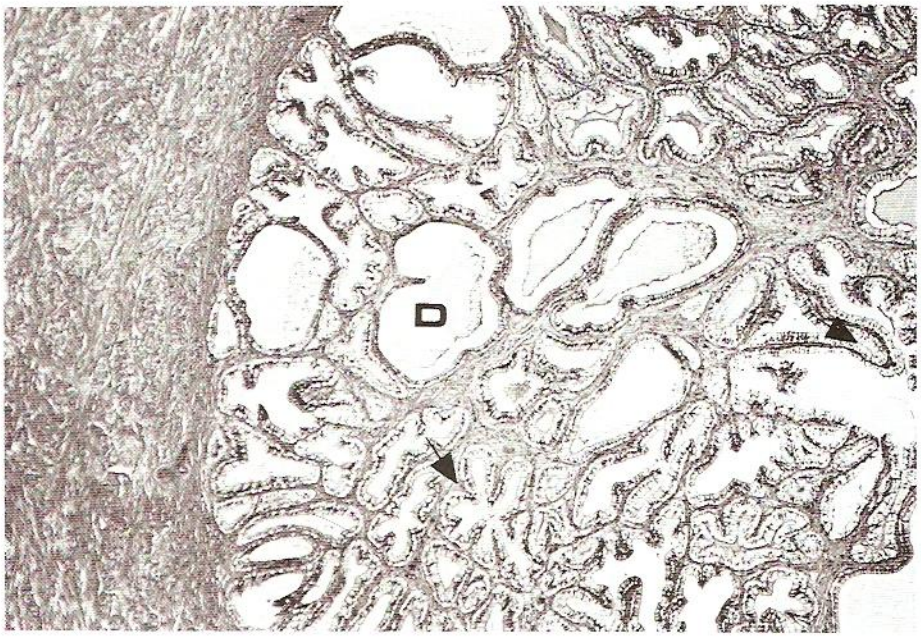

Figure 26-21. Section of a bovine ampullary gland. These glands are branched *(arrows)* and tubular with saclike dilations *(D)*. (×10.)

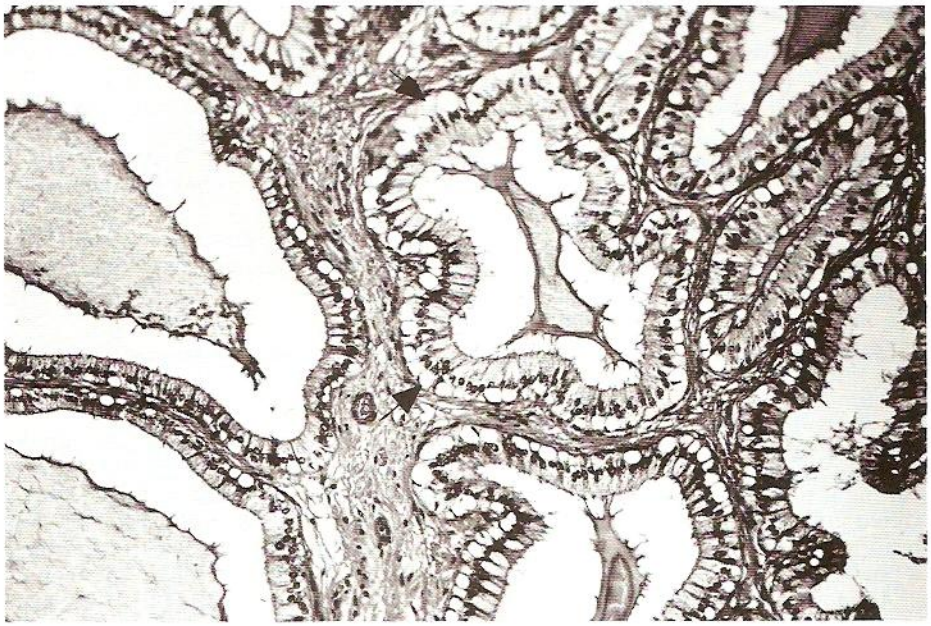

Figure 26-22. Lining cells of a bovine ampullary gland. Columnar epithelial cells contain basal lipid deposits *(arrows)*. (×40.)

cous secretions that nourish and activate the spermatozoa as well as clear the urethral tract before ejaculation. The secretions also transport spermatozoa within the female tract and plug the vagina to help ensure fertilization.

The glands are described as branched tubular or branched tubuloalveolar arranged in lobular units. Each lobular unit may drain into a dilated collecting sinus. These sinuses are not present in all glands of all species; they are also not present in equine vesicular glands and in porcine and ruminant pars disseminata prostatica. The glandular epithelium and epithelium of the collecting sinus (when present) have a simple columnar lining continuous with the pseudostratified or transitional epithelium of the excretory ducts. The glands of a given species are distinguishable, but care must be taken when making interspecies comparisons. Much variation exists.

Ampullary glands. The **ampulla** is an enlargement of the terminal part of the ductus deferens, a branched tubular structure with saclike dilations (Fig. 26-21) that some authors describe as a branched tubuloalveolar gland. It is lined by simple columnar epithelium (Fig. 26-22). In bulls basal accumulations of lipid droplets may occur in the epithelium. There is no special excretory duct system.

The ampulla of ruminants, horses, and dogs contains typical glands in the lamina propria-submucosa. Glands are absent in the ampulla of cats, and they are not well developed in porcine ampullae.

The ampullary glands secrete a white serous fluid whose function is unknown. The secretory product is similar to that of vesicular glands. The large lumina and openings are capable of storing viable spermatozoa.

Vesicular glands. The **vesicular glands,** also called **seminal vesicles** (Fig. 26-23), have a simple columnar glandular epithelium (Fig. 26-24). Infranuclear lipid droplets may be apparent in bulls. The main excretory ducts are lined by stratified columnar epithelium. The overall configuration of the gland is that of a pinnately arranged structure (i.e., a central duct from which radially branching secretory end pieces emanate). Lobular subdivisions are present.

The lamina propria-submucosa is typical. The tunica muscularis may have inner circular and outer longitudinal layers or the layers may be entirely intermingled. When present, a tunica adventitia or tunica serosa is typical.

Vesicular glands are absent in carnivores, true vesicular outpocketings in horses, and compact glandular structures in ruminants and swine.

Seminal fluid, along with the secretions of other accessory sex glands, provides a vehicle for the transport of spermatozoa. The white, gelatinous secretory product aids in formation of the vaginal plug in some rodents. The fructose-rich secretions are used as an energy source by ejaculated spermatozoa.

Prostate gland. The **prostate** consists of two portions—the body and the disseminate part. It is a compound, tubuloalveolar structure lined by low cuboidal or low columnar secretory cells (Figs. 26-25 and 26-26). The cells have apical blebs, indicating their apocrine-type secretory activity. Acidophilic granules and lipid droplets may be present. The duct system is lined by a cuboidal or columnar epithelium that becomes transitional at the urethral entrance.

The **body** of the gland is surrounded by a capsule of dense collagenous tissue continuous with the loose collagenous tissue of the lamina propria-submucosa, in which the adenomeres are located.

The **disseminate part,** surrounded by loose collagenous tissue of the lamina propria-submucosa, is best-de-

Downloaded From Vet-eBooks.com

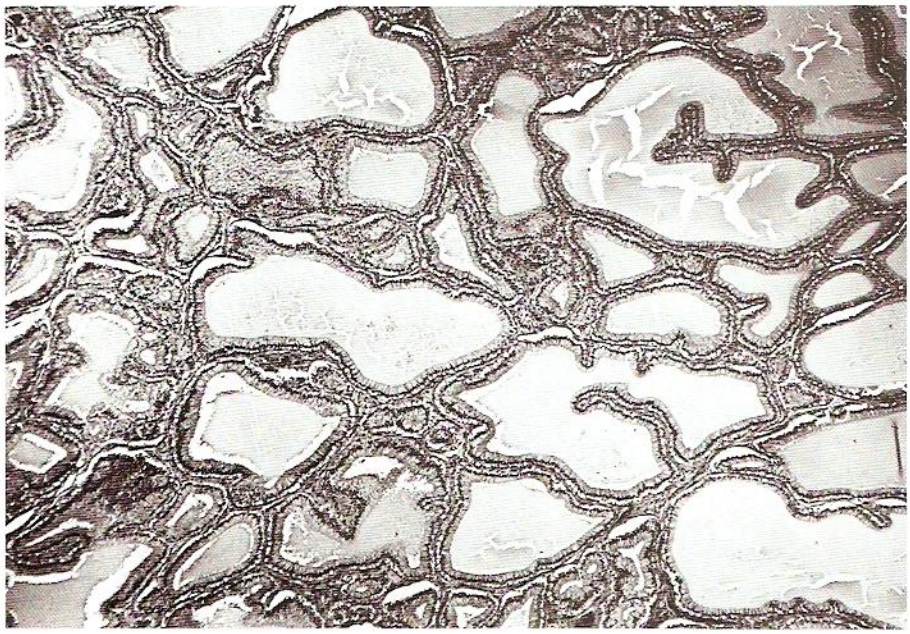

Figure 26-23. Section of a bovine seminal vesicle. (×10.)

Figure 26-24. Lining cells of a bovine seminal vesicle. These columnar cells have infranuclear lipid deposits *(arrows)*. (×40.)

Downloaded From Vet-eBooks.com

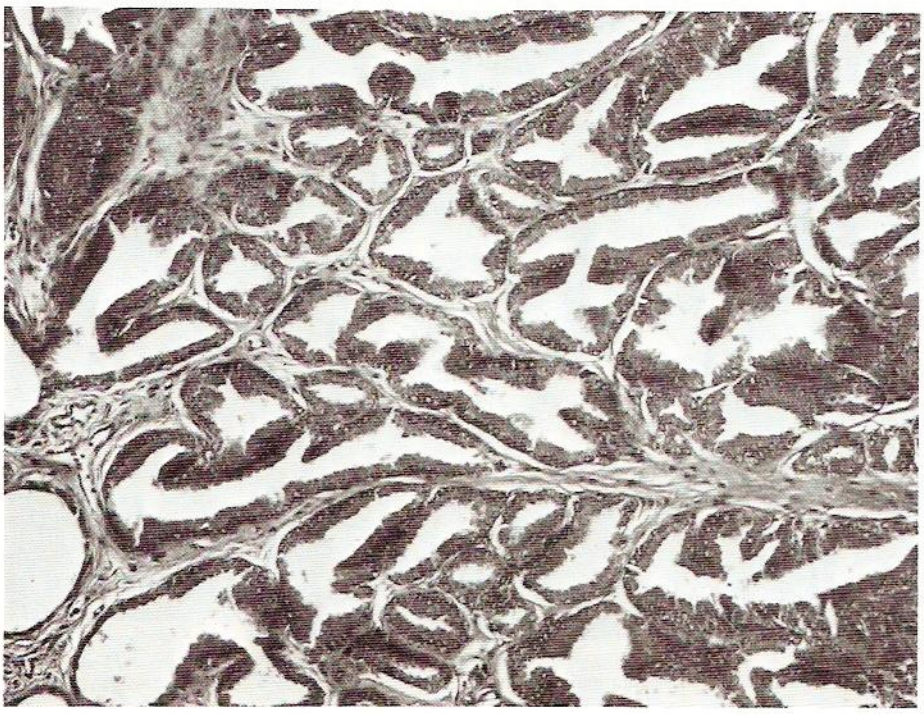

Figure 26-25. Section of a canine prostate gland. (×40.)

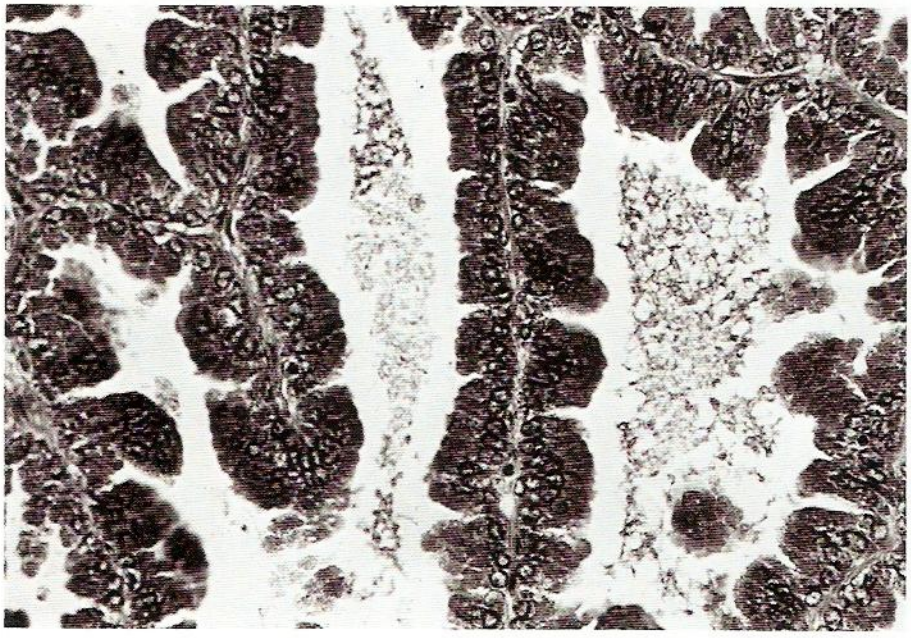

Figure 26-26. Columnar lining cells of a canine prostate gland. (×100.)

veloped along the dorsal urethral surface. It extends laterad and ventrad to encompass the urethra totally and continues with both laterally oriented lobes of the body. Although it is usually confined to the pelvic urethra, isolated portions may be found in the wall of the penile urethra.

The body and disseminate portion of the gland are not equally developed in all domestic species. The body (located peripheral to and surrounds part of the pelvic urethra) is well-developed in carnivores and horses. The disseminate portion is better-developed in bulls and boars. Rams do not have a distinct prostatic body.

The prostate is basically a serous gland with occasional mucous end pieces. It is a seromucoid gland in bulls and a serous gland in dogs. Secretory concretions may be present in the alveoli and duct system. Its secretory activity increases spermatozoan motility and contributes to vaginal plug formation. In bulls, the secretory fluid contains high quantities of fructose and citric acid; however, little else is known regarding its function.

Bulbourethral glands. The **bulbourethral glands** are paired structures located dorsolateral to the pelvic urethra. They are compound, tubuloalveolar glands (Fig. 26-27). The lining cells of the adenomeres are columnar or pyramidal (Fig. 26-28) with a basophilic cytoplasm and basally displaced round or flattened nuclei. The duct system is lined by columnar, pseudostratified, or transitional epithelium.

The capsule of the organ is dense collagenous tissue with some smooth muscle. Striated muscle from the bulbocavernous and urethral muscles occurs with the capsule. The capsular connective tissue is continuous as septal components (loose collagenous tissue) of the lamina propria-submucosa. Diffuse and nodular lymphatic tissue commonly occurs.

Bulbourethral glands occur in all domestic species except dogs. The mucus that they secrete clears the urethra of urine, lubricates the urethra and vagina with a preejaculatory fluid, and may be a source of energy for ejaculated spermatozoa.

URETHRA

General considerations. The urethra is the continuation of the duct system arising at the urinary bladder and opening to the outside. It transports urine, semen, and spermatozoa. Secretory products involved in reproduction gain access to the pelvic urethra at the **colliculus seminalis.** Here the **deferent ducts, vesicular glands,** and some **prostatic ducts** gain access to the urethra. The urethra is divided into **pelvic** and **penile portions** containing erectile tissue along the entire length. It also contains branched, tubular, mucous glands **(urethral glands)** along its length (horses, cats). The occurrence and distribution of these glands are species-variable. They are obliquely oriented and especially numerous along the dorsal surface of the urethra.

Pelvic urethra. The **pelvic urethra** is lined by transitional epithelium. The surrounding lamina propria-submucosa consists of loose collagenous tissue, many glands, and erectile tissue. A tunica muscularis with three muscle layers is present in the neck of the bladder, but these are replaced by a striated **urethral muscle.** An inner and outer layer (superficial and deep to the musculus urethralis) may be present throughout the pelvic urethra. A tunica adventitia is also present. The pelvic urethra generally has more glands but less erectile tissue than the penile urethra.

Downloaded From Vet-eBooks.com

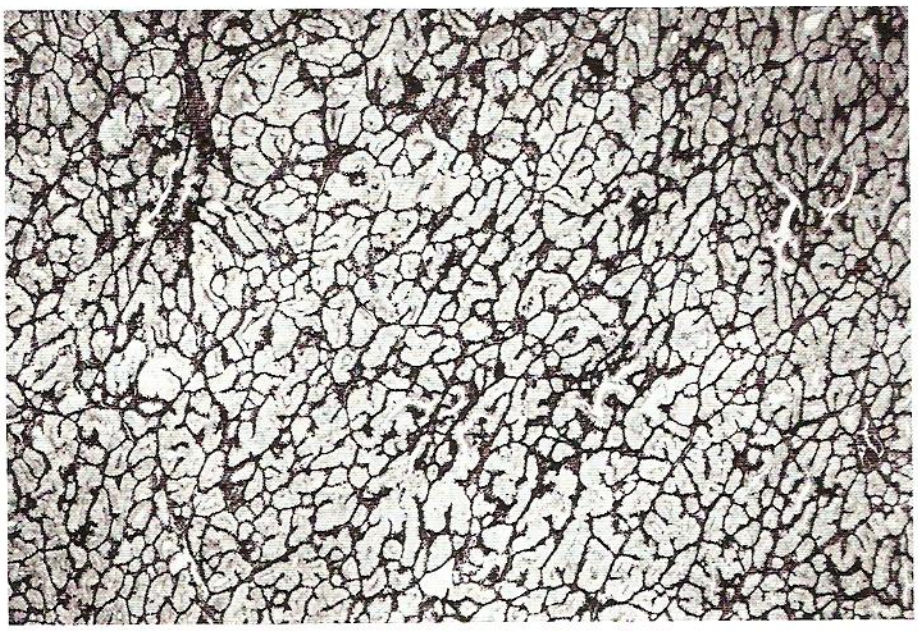

Figure 26-27. Section of a bovine bulbourethral gland. This compound tubuloalveolar gland secretes mucus. (×10.)

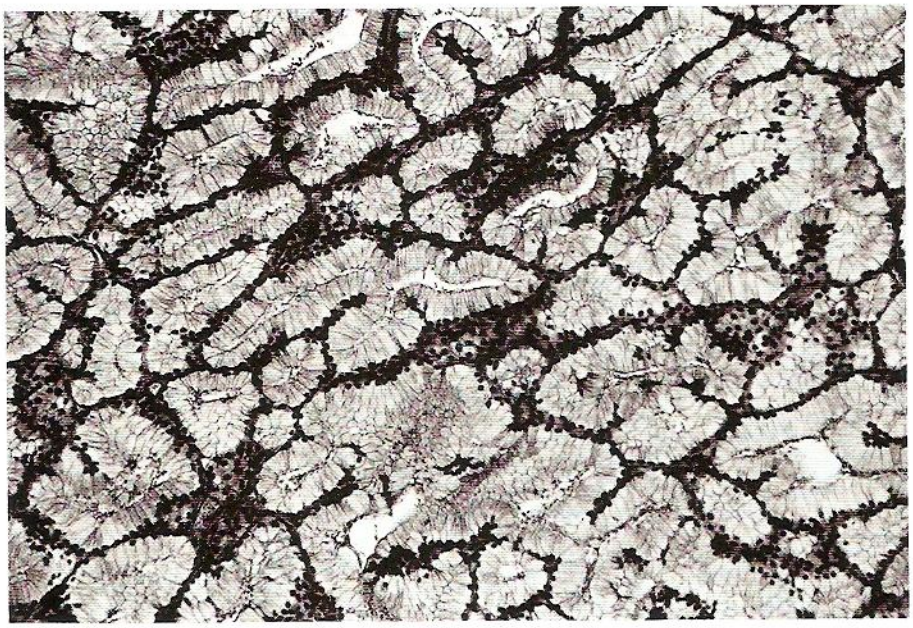

Figure 26-28. Lining cells of a bovine bulbourethral gland. These cells are columnar and basophilic with nuclei that are positioned basally. (×40.)

Downloaded From Vet-eBooks.com

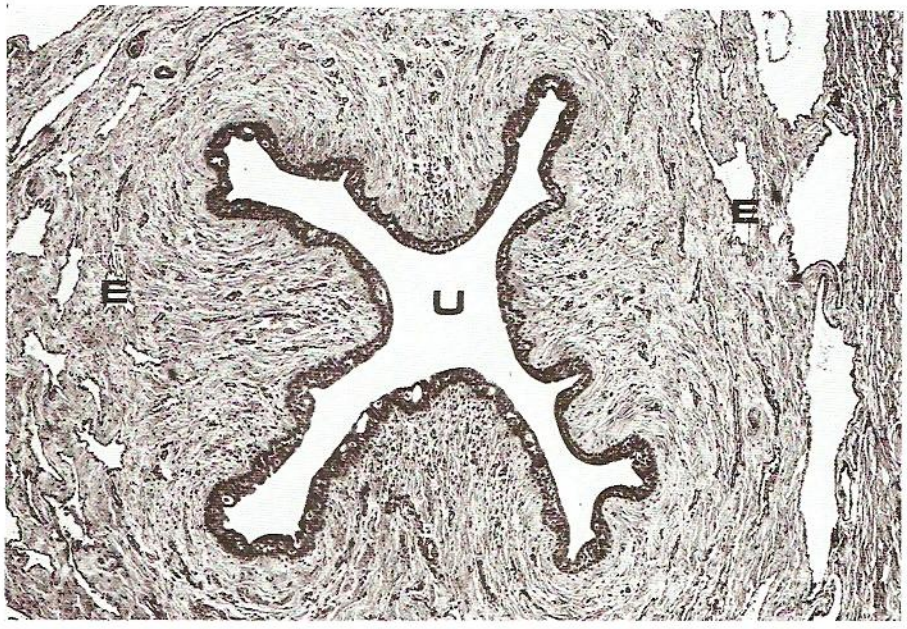

Figure 26-29. Cross section of a canine penile urethra. This structure *(U)* is lined by transitional epithelium. Erectile tissue *(E)* is peripheral to the lumen. (×16.)

Figure 26-30. Cross section through a canine penis. The urethra *(U)* is surrounded by erectile tissue of the corpus spongiosum *(S)*. Dorsally the two corpora cavernosa *(P)* are separated by connective tissue *(C)* continuous with the peripherally positioned tunica albuginea. (×4.)

Penile urethra. The **penile urethra** is lined by a transitional epithelium (Fig. 26-29). Stratified cuboidal, stratified columnar, and simple columnar epithelia also may be observed. This epithelium changes to stratified squamous before or at the urethral opening. Glands may be present in the lamina propria-submucosa (stallions, boars). The tunica muscularis returns to smooth muscle. Erectile tissue is also present in the subepithelial connective tissue space.

COPULATORY ORGAN

Penis. The **penis** is the common outlet for urine and the copulatory ejaculate (semen and spermatozoa). It is part of the urinary and reproductive systems. Although its histological components are similar among most mammalian species, the organizational differences are numerous. A section through one part may differ appreciably from that through a different part due to the differential distribution of some component parts along the length of the organ.

The following description applies to the general configuration and component parts: The penis is divided into roots, body, and glans.

The two **roots** (as well as the body) of the penis are similar in structure.

The **body** consists of a capsule, erectile tissue **(corpora cavernosa penis, corpus cavernosum urethrae,** or **corpus spongiosum)**, smooth muscle **(retractor penis muscle)**, skeletal muscle **(bulbocavernous muscle)**, and urethra (Fig. 26-30). Enclosed by the dense collagenous tissue of the tunica albuginea, which is especially well-developed in those species with a fibrous-type penis (swine, ruminants), it is capable of enlargement when engorged with blood. Connective tissue septa originate from the capsule and continue as the fibrous coverings of the erectile tissue components. These components may include elastic fibers and smooth muscle. Erectile tissue is dense collagenous tissue, rich in elastic fibers and sinuses. It becomes engorged with blood during erection. In species with a vascular-type penis (horses, carnivores, humans) this erectile tissue is well-developed.

The **glans** is well-developed in primates, horses, and dogs. Covered by the penile portion of the prepuce, which is actually a reflection of the integument as a mucous membrane, it may contain erectile tissue (vascular penis), bone (**os penis** of carnivores), cartilage, and dense collagenous tissue (bulls). Its bulk consists of highly vascularized loose collagenous tissue. The free portion is cov-

Downloaded From Vet-eBooks.com

ered by stratified squamous epithelium.

Erectile mechanism. The primary blood supply to the stimulated penis is through the **helicine arteries,** opening into the cavernous tissue. These vessels and the cavernous tissue become engorged with blood. The peripheral, thin-walled veins are occluded against the tunica albuginea. This enhances rigidity. The cavernous tissue of the corpus spongiosum (or corpus cavernosum urethrae) is not as thickly encapsulated as the other cavernous tissue. This permits expansion without occluding the urethra.

During the period of **detumescence** the helicine arteries contract and regain their initial tone. The resulting diminution of blood supply decreases the pressure against the compressed veins. The blood is gradually removed from the erectile tissue and normal circulation through the penis resumes.

ADDITIONAL READINGS

Testes and Associated

Amann RP: A review of anatomy and physiology of the stallion, *J Equine Vet Sci*, May/June, p 83, 1981.

Amann RP, Johnson L, Pickett BW: Connection between the seminiferous tubules and the efferent ducts in the stallion, *Am J Vet Res* 38:1571, 1977.

Bawa SR: The fine structure of the Sertoli cell of the human testis, *J Ultrastruct Res* 9:459, 1963.

Belt WD, Cavazos LF: Fine structure of the interstitial cells of Leydig in the boar, *Anat Rec* 158:333, 1967.

Christensen AK, Fawcett DW: The fine structure of the interstitial cells of the mouse testis, *Am J Anat* 118:551, 1963.

Elftman H: Sertoli cells and testis structure, *Am J Anat* 113:25, 1963.

Fawcett DW, Burgos MH: Studies on the fine structure of the mammalian testes. II. The human interstitial tissue, *Am J Anat* 107:245, 1960.

French FS, Ritzen EM: A high affinity androgen binding protein (ABP) in rat testis: Evidence for secretion into efferent duct fluid and absorption by epididymis, *Endocrinology* 93:88, 1973.

Krestser DMD: The fine structure of the testicular interstitial cells in men of normal androgenic status, *Z Zellforsch* 80:594, 1967.

Ladman AJ: The fine structure of the ductuli efferentes of the opossum, *Anat Rec* 157:559, 1967.

Nagano T, Suzuki F: Freeze-fracture observations on the intercellular junctions of Sertoli cells and of Leydig cells in the human testis, *Cell Tiss Res* 166:37, 1976.

Roberts SJ: *Veterinary obstetrics and genital diseases.* ed 2, Ann Arbor Mich, 1971, Edwards Brothers.

Spermatogenesis

Amann RP: Spermatogenesis in the stallion: a review, *J Equine Vet Sci,* July/Aug, p 131, 1981.

Amann RP: Endocrine changes associated with onset of spermatogenesis in Holstein bulls, *J Dairy Sci* 66:2606, 1983.

Clermont Y: The cycle of the seminiferous epithelium in man, *Am J Anat* 112:35, 1963.

Curtis SK, Amman RP: Testicular development and establishment of spermatogenesis in Holstein bulls, *J Anim Sci* 53:1645, 1981.

Fawcett DW, Ito S: The fine structure of bat spermatozoa, *Am J Anat* 116:567,1965.

Goldvieg SA, Smith AU: The fertility of male rats after moderate and after severe hypothermia, *J Endocr* 14:40, 1956.

Heller CG, Clermont Y: Kinetics of the germinal epithelium in man, *Recent Progr Hormone Res* 20:545, 1964.

Kehlstrom JE: A sex cycle in the male, *Experientia* 22:630, 1966.

Rattner JB, Brinkley BR: Ultrastructure of spermiogenesis, *J Ultrastruct Res* 32:316, 1970.

Roosen-Runge EC: The process of spermatogenesis in mammals, *Biol Rev* 37:343, 1962.

Steinberger E: Hormonal control of mammalian spermatogenesis, *Physiol Rev* 5:1, 1971.

Swiestra EE, Foote RH: Duration of spermatogenesis and spermatozoan transport in the rabbit based on cytological changes, DNA synthesis and labeling with tritiated thymidine, *Am J Anat* 116:401, 1965.

Accessory Glands

Bharadwaj M, Calhoun ML: Histology of the bulbourethral gland of the domestic animals, *Anat Rec* 142:216, 1962.

Brandes D: The fine structure and histochemistry of prostatic glands in relation to sex hormones, *Int Rev Cytol* 20:207, 1966.

Fisher ER, Jeffrey W: Ultrastructure of human normal and neoplastic prostate, *Am J Clin Pathol* 44:119, 1965.

Hirsch EW: Comparative anatomy of prostate gland, *J Urol* 25:669, 1931.

Kainer RA, Faulkner LC, Abdel-Raouf M: Glands associated with the urethra of the bull, *Am J Vet Res* 30:963, 1969.

McDonald LE: *Veterinary endocrinology and reproduction,* Philadelphia, 1969, Lea & Febiger.

Riva A: Fine structure of human seminal vesicle epithelium, *J Anat* 102:71, 1967.

Young WC (ed): *Sex and internal secretions,* Baltimore, 1961, Williams & Wilkins.

Penis and Associated

Bharadwaj M, Calhoun ML: The histology of the urethral epithelium of domestic animals, *Am J Vet Res* 20:841, 1959.

Bharadwaj MG, Calhoun ML: Mode of formation of the preputial cavity in domestic animals, *Am J Vet Res* 22:764, 1961.

Hart BJ, Kitchell RL: External morphology of the erect glans penis of the dog, *Anat Rec* 152:193, 1965.

Downloaded From Vet-eBooks.com

CHAPTER 27

Female Reproductive System

MAMMALS

The mammalian female reproductive system includes various organs contributing directly to or complementing the primary function of **reproduction.** Among the varied functions are **production** of ova, **transport** of male and female gametes for fertilization, **accommodation** and **nourishment** of the developing organism, **parturition** at the appropriate time, and **secretion** of hormones. The organs of the reproductive system include **ovary, oviduct, uterus, vagina,** and **vulva.** The **mammary gland,** included with the integument, is also part of the reproductive system.

Cyclical activity is an integral part of female reproductive organs. The changes are more pronounced and affect more organs in females than in males.

Ovary

General considerations. The paired **ovaries** are homologous to the testes. They perform endocrine and exocrine functions, producing estrogen and progesterone as well as **female gametes (ova).**

Histological organization. The ovary is covered by a **surface epithelium** modified from its visceral peritoneal covering (Fig. 27-1). During early ovarian development and oogenesis the epithelium is cuboidal. It changes with age to a squamous lining. Underlying the surface epithelium is a capsule of dense collagenous tissue, the **tunica albuginea ovarii.**

The ovaries of most animals (mares excepted) consist of two distinct zones—**cortex** and **medulla** (Fig. 27-2). In mares the cortex and medulla are reversed. The cortex is confined to the deep zone of the ovary and reaches the surface only at the **ovulation fossa.** The epithelial covering of the ovulation fossa continues over the rest of the ovary as a typical tunica serosa.

The cortex has many **follicles** in various stages of development and many **corpora lutea,** interstitial cells, and stromal elements. The cortical stroma is a special tissue. Various cells typical of loose collagenous tissue are present, but this is hyperplastic tissue and dense aggregates of fibroblasts are present. The fibroblasts may be parallel to the surface or disposed in an orderly arrangement around the follicles or vessels. They are not ordinary fibroblasts but are adaptive and pleomorphic. They even assume epithelioid characteristics as follicular theca and interstitial gland cells in association with follicles.

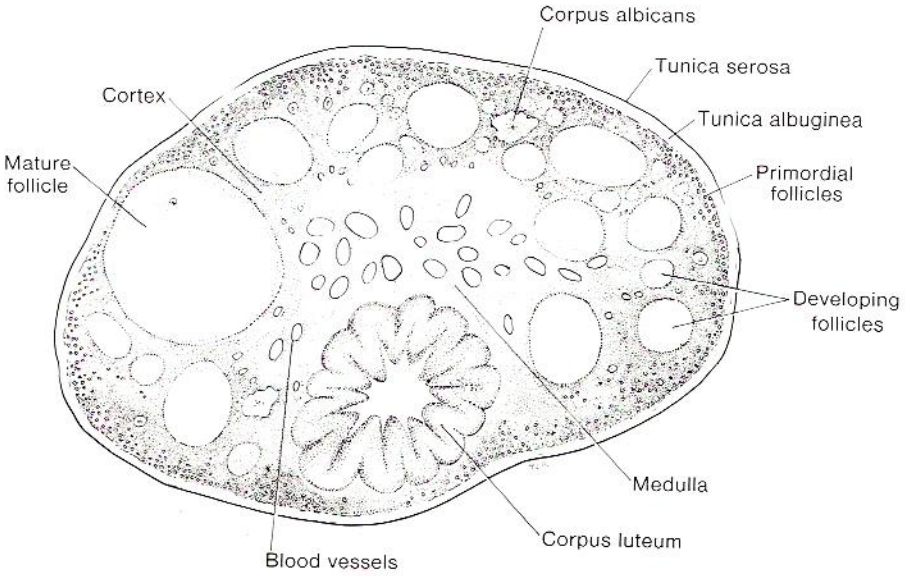

Figure 27.1. A drawing of a canine ovary

Figure 27-1. Canine ovary.

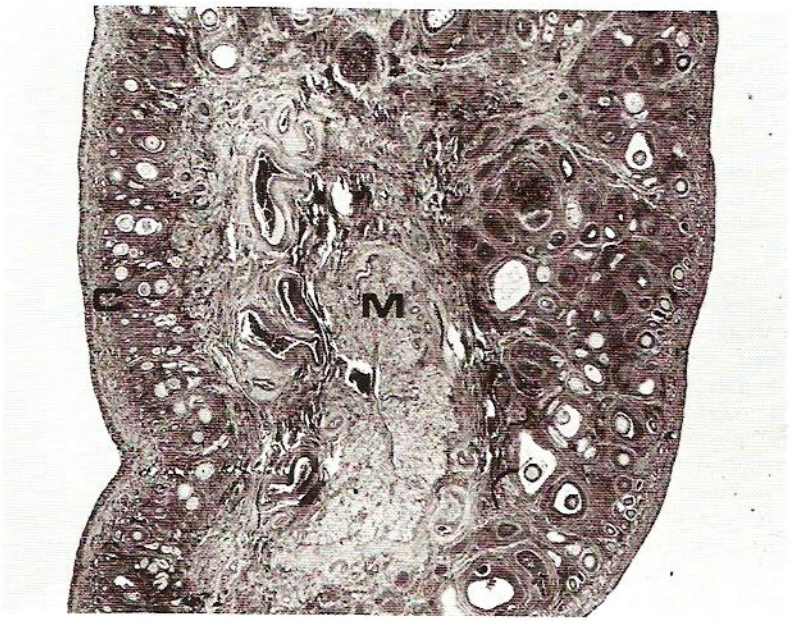

Figure 27-2. Section of a canine ovary. Note the distinct cortex *(C)* and medulla *(M).* (×4.)

Downloaded From Vet-eBooks.com

The **medulla** has large vessels, lymphatics, nerves, and some embryonic remnants. It is a loose collagenous tissue rich in elastic and reticular fibers. The medullary constituents continue with the mesovarian attachment. Embryonic remnants are parts of the **rete ovarii,** the female homologue of the rete testis. They are short, solid cords of epithelial cells.

Vascular, neural, and lymphatic relationships. The ovarian artery enters the organ at the hilus and is distributed to the medulla. Branches continue to the corticomedullary junction and form an extensive plexus from which vessels arise to supply the cortex. The cortical vessels furnish blood to the stromal elements, the thecae of developing and growing follicles, and the corpora lutea. Capillaries form a complete spherical network around developing follicles. As the corpora lutea develop, nascent branches from the peripherally positioned capillary bed form an extensive vascular network within them. Blood is shunted within the cortex whose venous drainage is similar to the arterial supply. An extensive medullary venous plexus may form before the vessels exit at the hilus.

The cortex contains many lymphatic vessels associated with the theca externa of developing follicles. The vessels coalesce, pass radially through the medulla, exit at the hilus, and drain through the lumbar lymph nodes.

Most unmyelinated nerves of the ovary are vasomotor nerves, but some sensory nerves have been observed. Although ganglion cells have been noted within the medulla, their functions are obscure.

Ovarian Cycle

Regulation. The ovary undergoes cyclical changes influenced by the trophic hormones of the pars distalis. Activity of the pars distalis in females, as in males, is regulated by hypothalamic releasing factors—**luteinizing hormone releasing factor (LRF)** and **follicle-stimulating hormone releasing factor (FRF).** Control of hypothalamic activity is subject to regulatory influences similar to those manifested in the male. Optic and olfactory stimuli modulate activity within the **hypothalamic-ovarian axis.** Induced ovulators (cats, minks, lagomorphs) respond to the mechanical stimulation of coitus by ovulating approximately 24 to 48 hours postcoitus. Tonic hypothalamic secretion and negative feedback from ovarian hormones influence the cyclical reproductive activity.

The release of FSH and LH from the pars distalis is the specific regulator of ovarian activity. FSH causes the growth and maturation of ovarian follicles and is responsible for estrogen secretion. Ovarian follicle rupture, ovulation, and the development of corpora lutea occur under the influence of LH. Some LH may be necessary for FSH to manifest its trophic influence upon the follicles. Prolactin manifests luteotrophic properties upon the ovary in rodents and sheep.

The combined influence of FSH and LH (and of prolactin in some species) regulates the cyclical activity of the ovary—**ovum differentiation, follicle development, ovulation, corpus luteum formation, follicle degeneration,** and **corpus luteum degeneration.**

Oogenesis. **Oogenesis** is the formation and development of ova. The differentiation of ova occurs in two stages similar to male gamete development, the **stage of mitosis** and **stage of meiosis.** During mitosis (or multiplication) **oogonia** proliferate from **primordial germ cells,** which have migrated to the germinal ridges from the yolk sac endoderm. They divide and give rise to several generations of identical cells. In some species (ruminants, rodents, swine, humans) the oogonia differentiate and multiply within the developing fetus before parturition occurs. In others (carnivores, lagomorphs) they differentiate in the immediate postnatal period.

Oogonia entering into prophase of the first meiotic division become primary oocytes before or shortly after birth in most species (Fig. 27-3). **Primary oocytes** are arrested in prophase until sexual maturity is achieved. Their further development is synchronized with development and maturation of the follicles. The **first meiotic (reductional) division,** with the consequent conversion of a primary oocyte to a **secondary oocyte,** occurs just before ovulation in most species and is accompanied by formation and expulsion of the **first polar body.** In horses and dogs secondary oocyte formation occurs postovulation (but may be delayed 48 hours in canids). In most other species the **second meiotic (equational) division** occurs when a spermatozoon penetrates the zona pellucida and "activates" the secondary oocyte. The **second polar body** is extruded at this time.

Follicular development. An **ovarian follicle** is a spherical cell aggregation containing the developing gamete. Its growth and development are accompanied by changes in the associated gametes. The continuum of follicular development is characterized by the appearance of specific follicles—**primordial, primary, secondary,** and **mature** (Fig. 27-4). Follicular growth and maturation occur under the influence of gonadotropins (Plate I, *6* and *7*).

As the primary oocyte differentiates, a single layer of flattened mesodermal **(follicular)** cells surrounds it. The complex, now called a **primordial (quiescent) follicle** (Fig. 27-5), contains a primary oocyte. These follicles occur singly or in clusters in the cortical periphery.

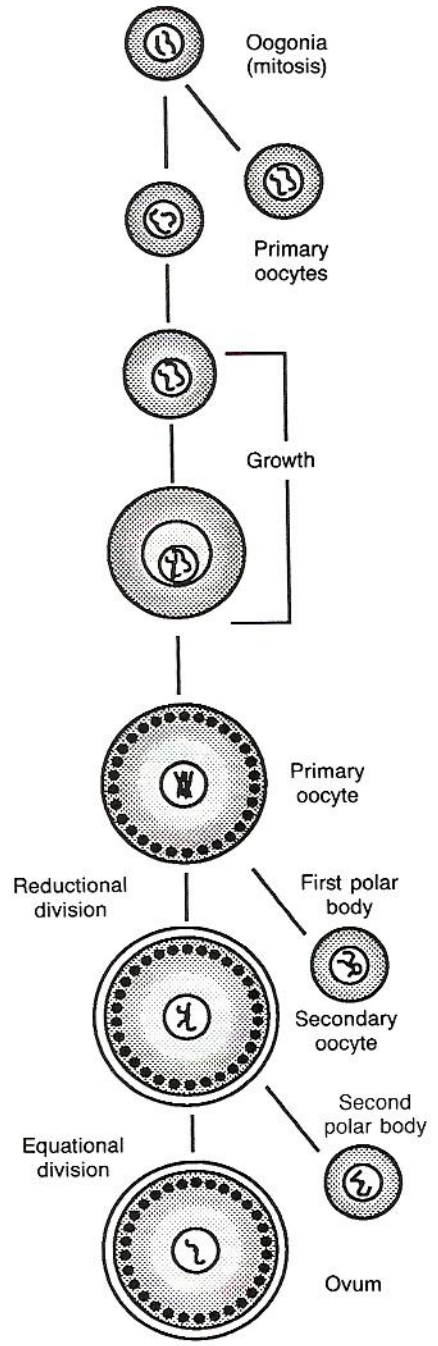

Figure 27-3. Events of oogenesis. Compare this process to that of spermatogenesis in Figure 26-20.

The **primary follicle** (Fig. 27-5) results from a process involving alterations in the primary oocyte, follicular cells, and other stromal elements. Yolk granules accumulate within the primary oocyte and the follicular cells become cuboidal or columnar. The primary follicle still contains a primary oocyte.

The **secondary follicle** results from a process involving the increased population of follicular cells associated with the

Downloaded From Vet-eBooks.com

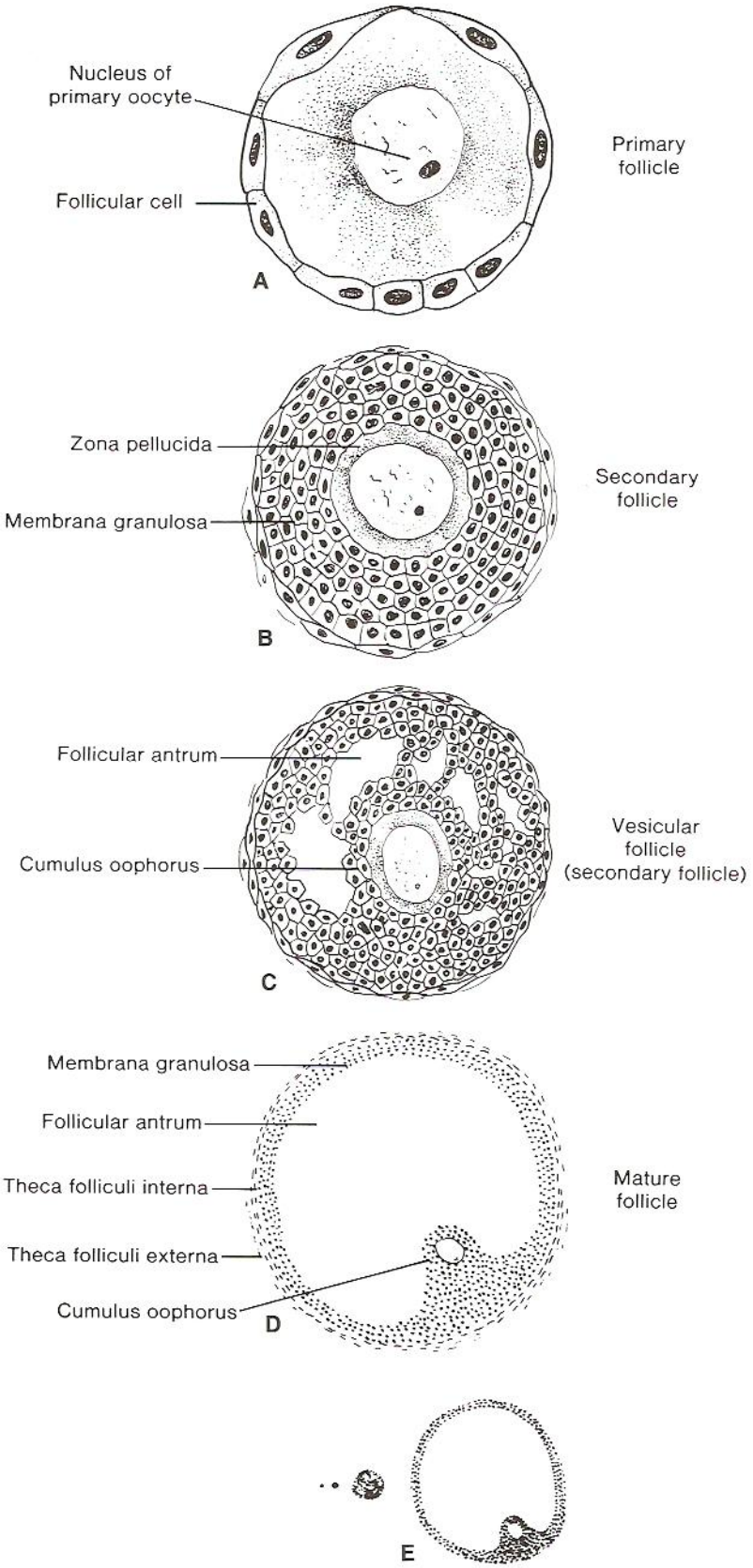

Figure 27-4. Stages of folliculogenesis, from primary to mature follicle. **A, B, C,** and **D** are not to scale. The approximate size relationship is indicated in **E.**

Downloaded From Vet-eBooks.com

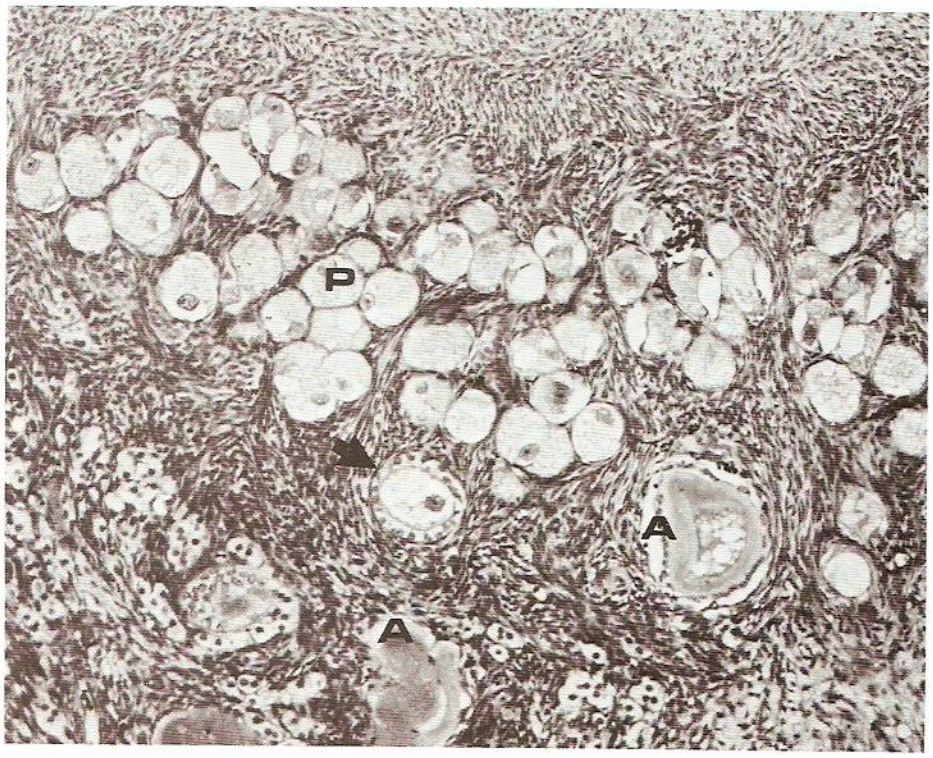

Figure 27-5. Immature follicles of a feline ovary. Primordial *(P)* and primary *(solid arrow)* follicles are present, as are atretic follicles *(A)*. Note the high cellularity of the interstitial connective tissue. (×40.)

primary oocyte. A zona pellucida develops between the primary oocyte and follicular cells (Figs. 27-6 and 27-7). The follicular cells are active mitotically and are now called the **membrana granulosa.** They are separated from the primary oocyte by a PAS-positive, amorphous material (the **zona pellucida**) constituting a thick basement membrane.

Stromal cells differentiate into two layers—**theca folliculi interna** and **theca folliculi externa.** The thecal cells are separated from the membrana granulosa by a basement membrane. The theca folliculi interna consists of large, epithelioid cells and an extensive vascular network. The theca folliculi externa is a layer of fibroblasts. Follicle growth and the development of multilaminar thecal investments are accompanied by movement of the secondary follicle away from the cortical surface. Some of the thecal cells are directed toward the surface as a **thecal cone.** The cone may displace superficially positioned follicles from the deeply positioned, expanding follicle.

The **tertiary (vesicular) follicle** results from granulosa cell secretory activity (Fig. 27-8). Small, fluid-filled, PAS-positive spaces between granulosa cells are apparent during antral development. These small lakes or intercellular clefts filled with **liquor folliculi** become confluent and form the **follicular antrum.** The

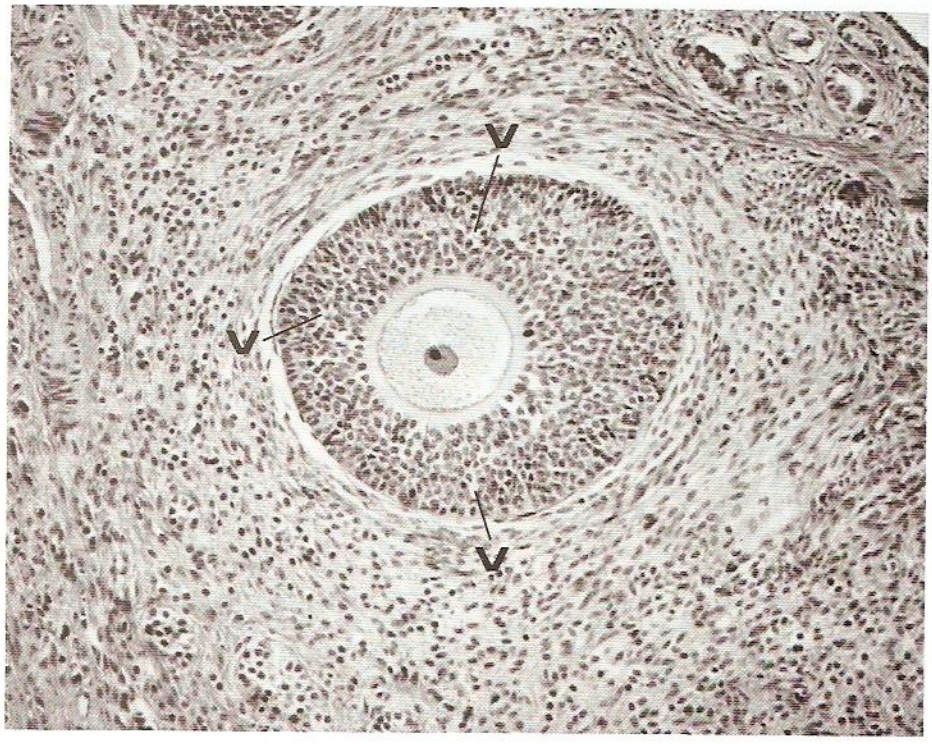

Figure 27-6. Large secondary follicle from a canine ovary. Small intercellular vesiculations *(V)* have begun to form. They will coalesce to form the antrum. (×40.)

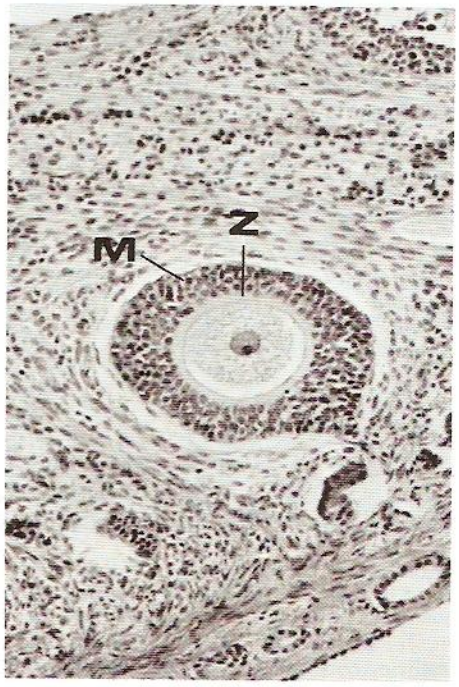

Figure 27-7. Small secondary follicle from a canine ovary. The follicular cells have proliferated and are called the membrana granulosa *(M)* at this stage of development. A zona pellucida *(Z)* separates them from the primary oocyte. Note the development of a thecal cone in the 4 o'clock position of the follicle. (×40.)

Downloaded From Vet-eBooks.com

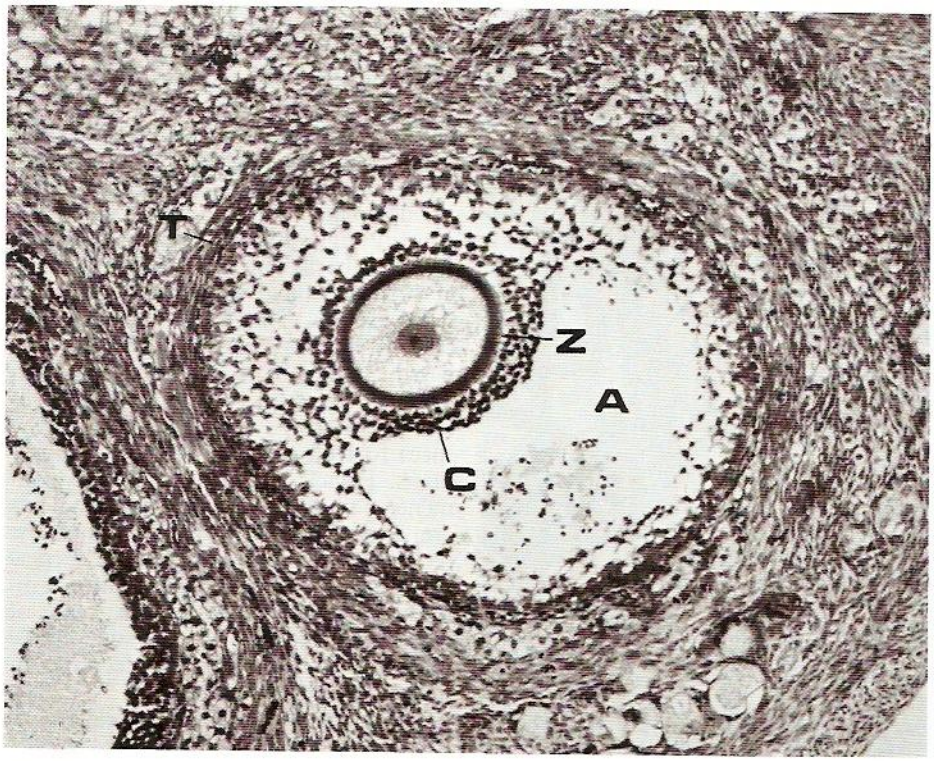

Figure 27-8. Vesicular follicle from a feline ovary. The follicular antrum *(A)* has formed. *C*, Cumulus oophorus; *Z*, zona pellucida; *T*, thecal cells. (×40, Lendrum's phloxine-tartrazine stain.)

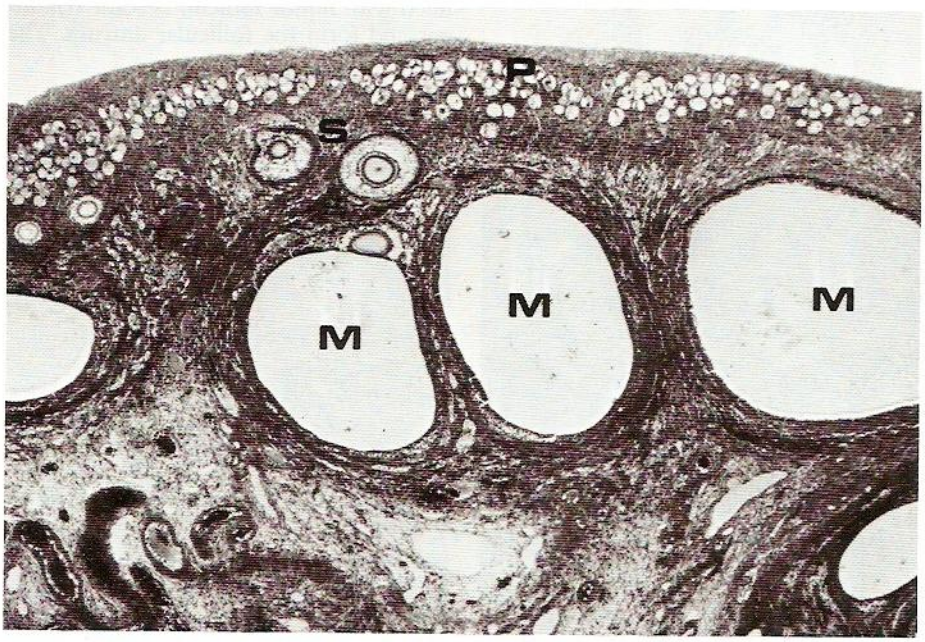

Figure 27-9. Section of a feline ovary. *P*, Primordial follicles; *S*, secondary follicles; *M*, maturing vesicular follicles. Note the size difference. (×10, Lendrum's phloxine-tartrazine.)

follicle continues to grow throughout this period. The primary oocyte is still surrounded by a cluster of granulosa cells continuous with the peripherally displaced membrana granulosa. This mound of cells is called the **cumulus oophorus.** Granulosa cells of the cumulus oophorus immediately adjacent to the primary oocyte become columnar cells oriented radially as the **corona radiata** with cytoplasmic processes that penetrate the zona pellucida and contact microvilli of the ovum. The corona radiata cells probably provide nutritional support for the oocyte. The cells of the cumulus oophorus constitute a visceral layer of granulosa cells separated by the follicular antrum from the parietal layer. The parietal layer forms an aggregation of polyhedral cells called the **stratum granulosum,** whose base resides upon a membrane separating it from cells of the theca folliculi interna. **Despite these developmental changes, the vesicular follicle contains a primary oocyte.**

Preovulatory follicles, also called **mature follicles,** are enlarged structures (Fig. 27-9) extending from protrusions at the surface to the depths of the cortex. Their antra are large with attenuated walls consisting of the previously mentioned cellular and intercellular components.

Ovulation. **Ovulation** is the rupture of a follicle and the release of an oocyte. Its precise mechanism has not been determined. Follicular wall deterioration through enzymatic hydrolysis of connective tissue components by LH-induced **collagenase, protease,** or **plasmins** may be contributory. An increased intrafollicular fluid pressure is not associated with the ovulatory process. The thecal investments of the follicle and the cortical components (tunica albuginea) become thin, and the follicle protrudes from the surface of the ovary. This protrusion, **follicular stigma,** is the site of rupture. The liquor folliculi released upon ovulation probably aids transport of the oocyte from the ovarian surface to the infundibulum.

Upon ovulation the oocyte is surrounded only by the zona pellucida and the **corona radiata.** Together with its associated cells, it provides a mass sufficient to be picked up by the fimbria. In cows the corona radiata is lost at the time of ovulation. In other species it remains intact until spermatozoa are present.

Follicular atresia. Not all developing follicles terminate in ovulation. Many undergo **atresia (degeneration).** Follicular degeneration may occur at any point in the developmental sequence (Fig. 27-10). During the primordial follicular stage, dissolution of the ovum and granulosa cells does not result in scar tissue; the follicle simply disintegrates. Polyoocytic follicles are common and are destined to become atretic.

Follicular atresia during advanced stages of follicular development results in degeneration followed by a scar, the **corpus atreticum.** The degenerative process includes the oocyte and associated cells. The oocyte liquefies, the zona pellucida becomes thickened and folded, and the associated cells degenerate. The walls of the follicle collapse. This is accompanied by connective tissue, phagocytic, and vascular invasion of the follicle. The basement membrane between the granulosa and theca cells thickens. The cells of the theca folliculi interna may hypertrophy

Downloaded From Vet-eBooks.com

Figure 27-10. Atretic follicles from a canine ovary. Not all follicles reach maturity. Many undergo atresia (*A*). (×40.)

Figure 27-11. Section of the corpus luteum of a canine ovary. The cellular mass results from transformation of the membrana granulosa and theca interna cells. (×10.)

and undergo changes similar to their conversion to theca lutein cells. (See "Corpus luteum," below.) The hypertrophic follicular cells are arranged as cords around the degenerating central components. Phagocytic and fibrotic activity completes the transition to a corpus atreticum.

Interstitial gland. The **interstitial gland** of the ovary consists of polyhedral, epithelioid cells within the ovarian stroma that have characteristics of steroid-producing cells. Similar to theca lutein cells of the corpus luteum, they may originate from the theca folliculi interna of atretic follicles. The presence of interstitial glands in prepuberal animals supports this belief.

The complete function of these glands is unknown. They may supply estrogens necessary for the development of secondary sex characteristics in prepuberal animals. After puberty their differentiation is linked to the ovarian cycle and the cyclical atresia of follicles associated therewith. The cells may be a source of estrogens during the postovulatory period.

Hilus cells (located at the hilus of the ovary) have features similar to those of interstitial cells in the testes. Tumors or hyperplasia of these cells results in masculinization in women.

Corpus luteum. After rupture of the ovarian wall and associated follicular mural elements, the ovum is ejected and passes into the oviduct. The remaining portions of the follicle do not degenerate but undergo pronounced changes leading to formation of the **corpus luteum** (Fig. 27-11).

The follicular walls collapse, and granulosa cells protrude into the residual lumen. The hemorrhage accompanying ovulation eventually clots, and the resulting transitory structure is called a **corpus hemorrhagicum.** Granulosa cells proliferate, hypertrophy, and transform into **granulosa lutein cells** (Fig. 27-12). In mares, cows, bitchs, queens, and women the accumulation of a yellow lipid pigment **(lutein)** and other lipids marks the transition to granulosa lutein cells. Although lutein does not accumulate in ewes and sows, other lipids mark the transition from membrana granulosa to granulosa lutein cells.

Invasion of this region by stromal cells and vessels removes the clot, results in reticular fiber deposition, and converts the region to a highly vascularized gland.

Theca folliculi interna cells also convert to lipid-producing, **theca lutein cells.** These are smaller than the granulosa lutein cells and are dispersed peripherally or as septumlike clusters intimately associated with the granulosa lutein cells. In some species (ox) the two types of lutein cells cannot be easily distinguished. The process by which both granulosa and theca cells convert to lutein cells is called **luteinization.** Hypertrophy, hyperplasia, and the accumulation of pigment are essential factors in this process.

Whether lutein is present or absent, the resulting structure is called a **corpus luteum (yellow body).** The fate of the corpus luteum depends upon the reproductive success or failure of the individual.

If fertilization does not occur, the **cylic corpus luteum** slowly degenerates **(regressive corpus luteum)** and is replaced by connective tissue. The corpus luteum, therefore, is converted to a **corpus albicans.**

If fertilization does occur, the **gravid corpus luteum** persists and is active for a variable time during the pregnancy. Retrogressive changes similar to the aforementioned characterize the degeneration of this structure. In some species

Downloaded From Vet-eBooks.com

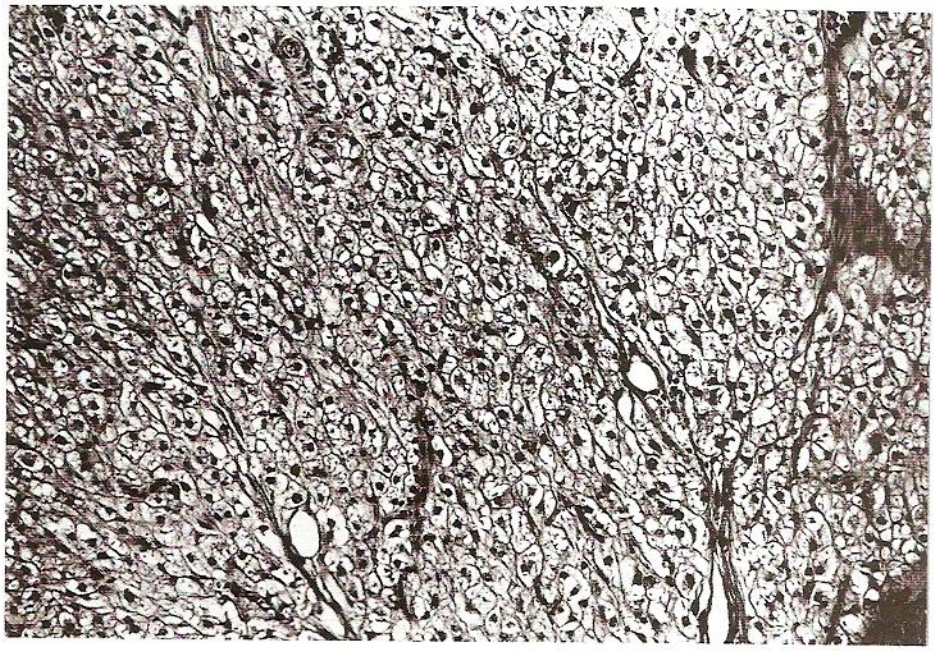

Figure 27-12. Cells of the corpus luteum. These are large and clear, of the granulosa lutein type. (×40.)

the gravid corpus luteum is required throughout the pregnancy. In others it may be removed at various times without detrimental effects upon the gravid uterus.

Ovarian hormones. Ovum production is complemented by the ovary's functioning as an endocrine organ. The ovarian hormones are **estrogens** and **progesterone.** The ovary performs its endocrine functions in response to FSH and LH.

Under the influence of LH, theca interna cells produce two androgens, **androstenedione** and **testosterone.** Under the influence of FSH, the membrana granulosa cells produce estrogens, primarily **estradiol-17β.** Thecal androgens reach the granulosal cells, wherein aromatizing enzymes convert them to estrogens. The estrogens reach the developing antrum and induce proliferation of more granulosa cells and follicle growth. The interstitial gland is also a source of estrogens.

Granulosa cells also produce **folliculostatin,** a protein hormone with negative feedback influence upon FSH production.

Progesterone is produced primarily by the granulosa lutein cells. The corpus luteum also produces a polypeptide hormone, **relaxin**, that functions to relax the ligaments associated with the pubic symphysis before parturition.

The steroidal hormones, responding to the influence of gonadotropins upon the ovary, are synthesized and released to exert a negative feedback influence upon the hypothalamus and pars distalis. Estrogens are responsible for the receptive behavior of females during estrus. The development of female secondary sex characteristics is due partially to estrogens. Mammary gland development is also influenced by this hormone. The normal development and function of the female reproductive tract depends upon estrogens. Estrogens potentiate the effects of oxytocin and prostaglandins on uterine smooth muscle contraction. Additionally, they influence functions other than those of reproduction—skeletal growth, bone maintenance, sebaceous gland activity, electrolyte balance, Ca^{++} and $PO_4^{=}$ retention, and fat deposition. Estrogens are anabolic steroids.

Progesterone, the primary ovarian hormone of the luteal stage of ovarian activity, whose main source is the corpus luteum, assists estrogens in eliciting the characteristic sexual behavior associated with estrus. It also inhibits uterine smooth muscular contraction while promoting uterine gland development; it is required for the maintenance of pregnancy; and it exerts a negative feedback influence on the hypothalamus and pars distalis. Additionally, it enhances development of the secretory and excretory portions of the mammary gland; and it exerts a minor catabolic influence on somatic proteins as well as electrolyte balance.

Uterine Tubes

The **uterine tubes (oviducts)** are extensions of the uterus for transport of the male and female gametes. They are divided into an **infundibulum, ampulla,** and **isthmus.** Fertilization occurs within them.

Histology. In most species the lamina epithelialis mucosae has intermittently ciliated columnar cells (Fig. 27-13). In sows and cows it may be pseudostratified, intermittently ciliated columnar epithelium. Kinocilia are prominent in the cranial portion, where they assist in movement of ova along the highly folded tunica mucosa (Fig. 27-14). Some of the lining cells are devoid of cilia. Ciliogenesis occurs in response to circulating levels of estrogen. The nonciliated, secretory cells become taller under the influence of progesterone and may nourish the ova as well as capacitate the spermatozoa for fertilization.

The lamina propria-submucosa consists of loose collagenous tissue devoid of glands. The tunica mucosa of the ampulla is highly folded. Primary, secondary, and tertiary folds may be apparent in some species. The tunica muscularis is best developed in the isthmus. The smooth muscle is disposed in longitudinal and circular arrays. The tunica serosa is typical, with many blood vessels forming a distinct vascular layer.

Uterus

General considerations. The **uterus** performs functions essential to reproduction. In horses it is the receptacle for semen; in swine, semen is deposited in the uterine cervix. In ruminants, cats, dogs, lagomorphs, and humans insemination is vaginal. Uterine contractions are essential for transport of the spermatozoa. Finally, the uterus is the site for development of the embryo and fetus. It consists of a **body, horns,** and a **neck (cervix).**

Its form is species-variable. Most domestic species have a **bicornuate uterus**—an organ with a body, two large horns, and a single cervix. Primates have a **simple uterus**—an organ with a prominent body, two small horns, and a single cervix. Lagomorphs, monotremes, and marsupials have a **duplex uterus.**

Capacitation, the process by which spermatozoa achieve the ability to penetrate the corona radiata and zona pellucida to accomplish fertilization, occurs after exposure to the female reproductive tract. The uterus and oviducts play a role in the process. The need for capacitation has been determined in a few species and is suspected in others.

The wall of the uterus is divided into **endometrium, myometrium,** and **perimetrium** (Figs. 27-15, 27-16, and 27-24). In spite of this departure from the terminology used in Chapter 15, the uterine mural elements are similar to those of other tubular viscera.

Uterine morphology changes with the estrous cycle. A general description follows; the changes associated with estrus are discussed subsequently.

Downloaded From Vet-eBooks.com

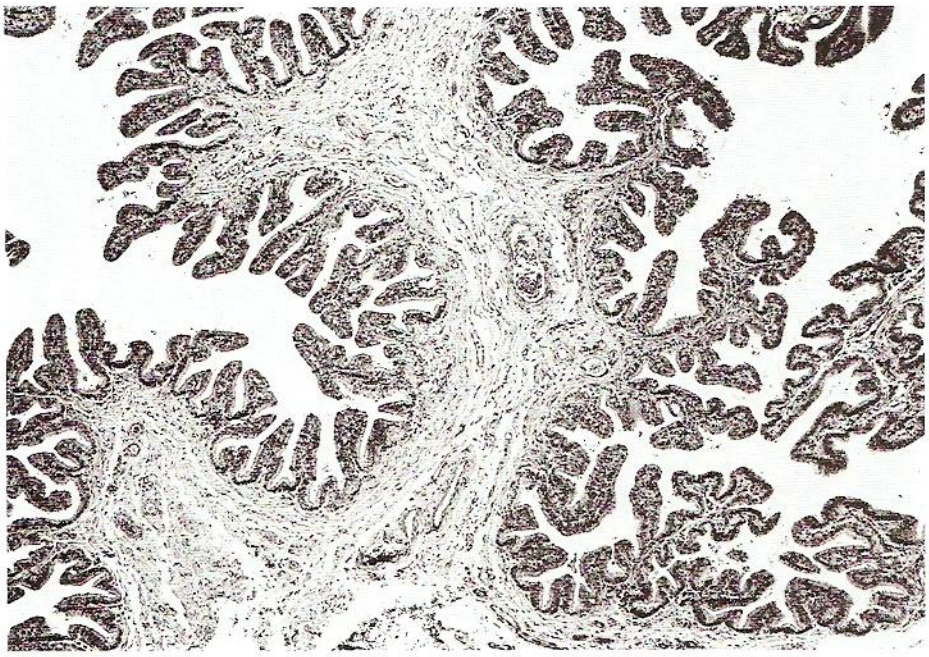

Figure 27-13. Section of an equine oviduct. The lining consists of intermittently ciliated columnar epithelium. (×16.)

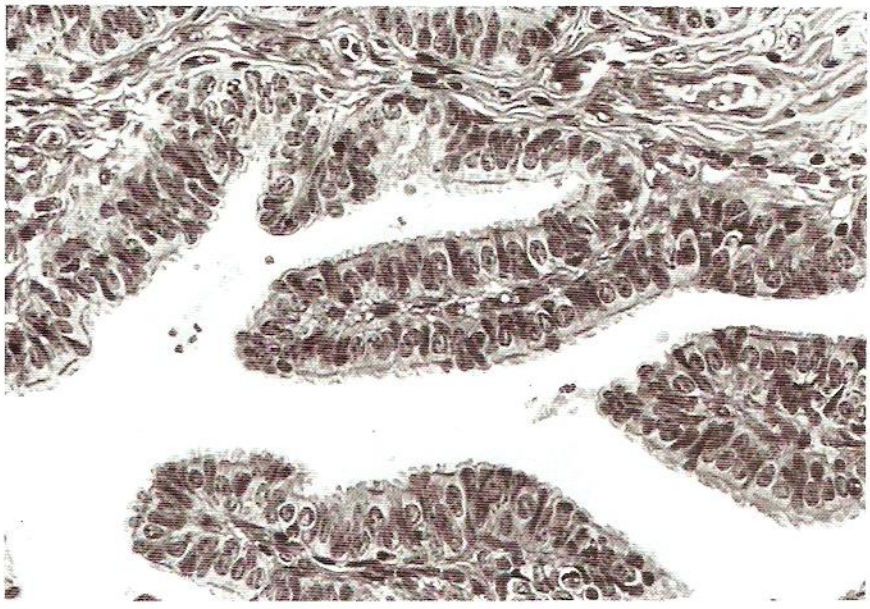

Figure 27-14. Lining cells of the infundibular portion of an equine oviduct. (×100.)

Downloaded From Vet-eBooks.com

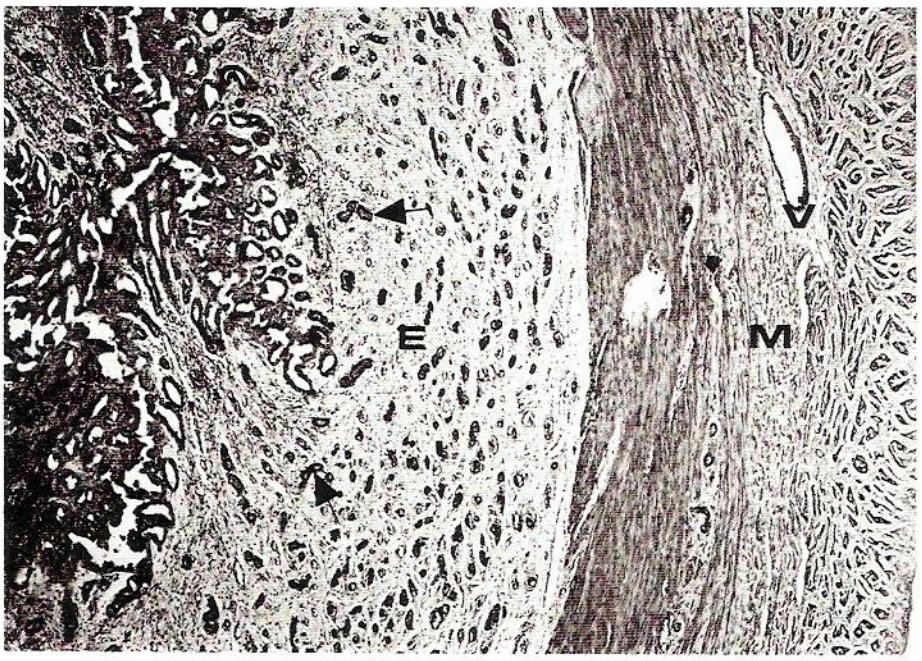

Figure 27-15. Section of a gravid canine uterus. The tubular glands *(arrows)* are branched and coiled. *E,* Endometrium; *M,* myometrium; *V,* vessels of the stratum vasculare. (×40.)

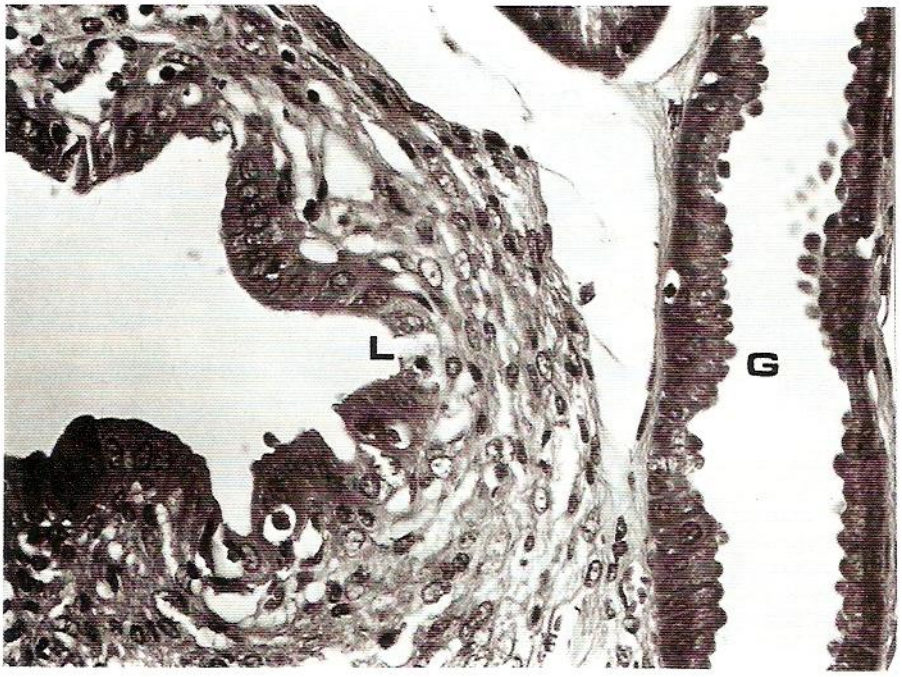

Figure 27-16. Lining and glandular cells of a bovine metestrous uterus. The lining cells *(L)* are columnar. The glandular cells *(G)* also columnar but with apical blebs. (×100.)

Downloaded From Vet-eBooks.com

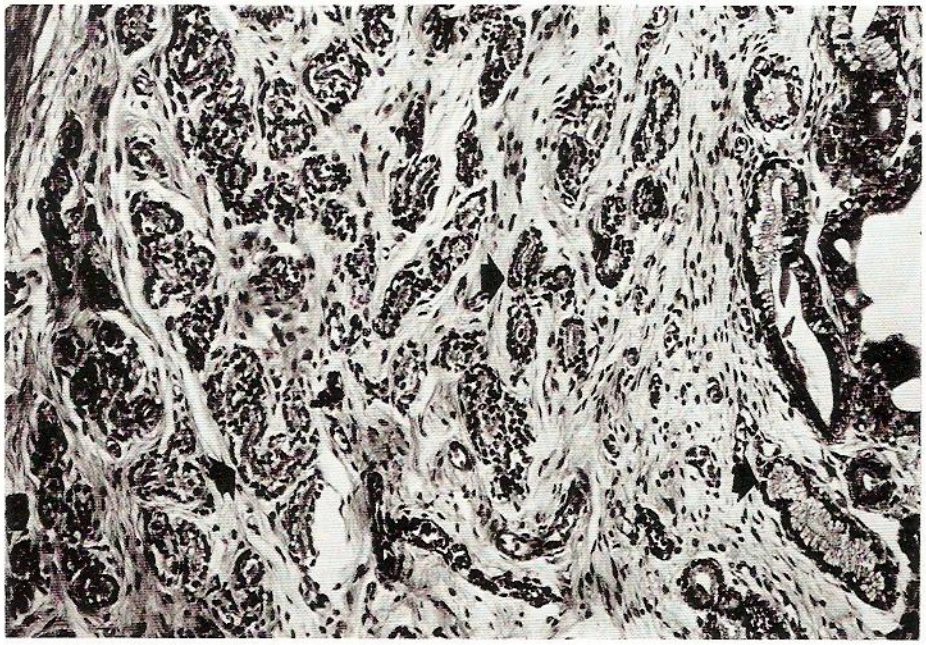

Figure 27-17. Section of the endometrium of a gravid canine uterus. Tubular glands *(arrows)* are branched and coiled. (×40.)

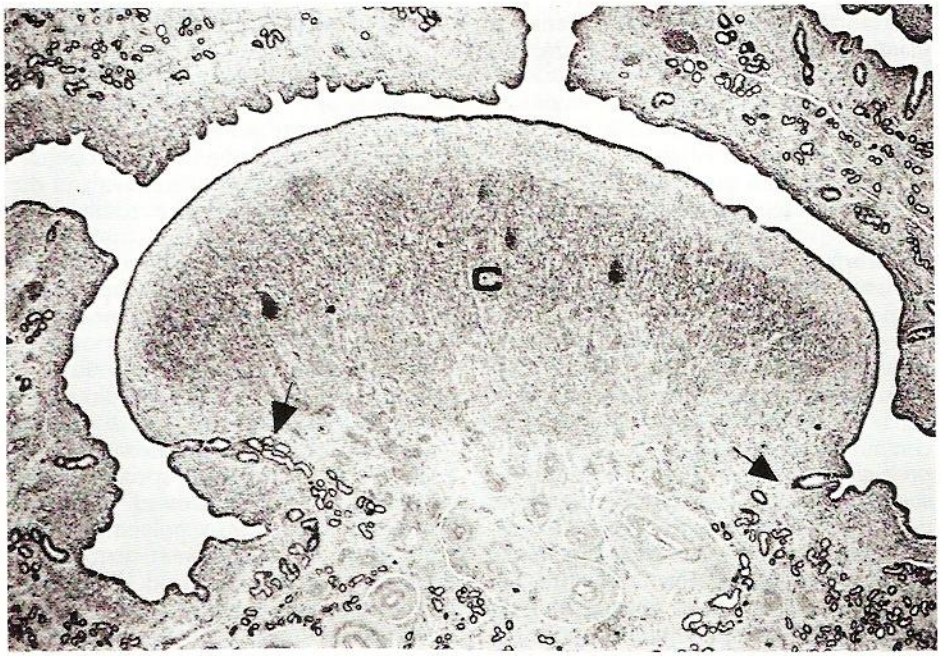

Figure 27-18. Section of a bovine caruncle. This structure *(C)* is devoid of uterine glands *(arrows)*. (×5.)

Endometrium. The **endometrium** is the tunica mucosa (Fig. 27-16). Its lamina epithelialis mucosae is simple columnar epithelium. Patches of pseudostratified columnar epithelium may occur (sows, cows) as well as isolated foci of cuboidal epithelium. **Uterine glands** are simple or branched tubular (Fig. 27-17). Their distal ends have a variable degree of coiling that is species-dependent. The secretory products of the lining and glandular epithelia include mucus, lipids, glycogen, and proteins. These glands extend into the lamina propria-submucosa.

The lamina propria-submucosa is a hyperplastic, loose collagenous tissue superficially with many mononuclears and neutrophils. In ruminants particular regions of the lamina propria-submucosa are highly vascularized and devoid of glands **(caruncles).** Caruncles are sites of contact between maternal tissues and extraembryonic membranes (Fig. 27-18). The peripheral connective tissue of the lamina propria-submucosa is less cellular than the subepithelialconnective tissue. Melanophores occur in the connective tissue of ovine caruncules.

Myometrium. The **myometrium** is the tunica muscularis. It has both a thick inner circular and a thin outer longitudinal coat of smooth muscle that continues into the mesometrium (Fig. 27-16). A vascular layer occurs between the two layers.

Perimetrium. The **perimetrium** or tunica serosa is typical, although a large number of lymphatic vessels may be present (Figs. 27-21 and 27-24).

Cervix. The **cervix uteri** is a valve to close the uterine lumen from the vagina. In sows, it is a thin-walled structure; in cows, it is well-developed. Its lining cells in cows are glandular, their secretory activity varying with the stages of estrus and pregnancy: a clear mucus is secreted during estrus, and a thick cervical seal is produced during pregnancy. Many longitudinal folds give the impression that the cervix is glandular.

The lamina epithelialis mucosae of the **canine** cervix is lined by stratified squamous epithelium underlaid by a glandless lamina propria-submucosa.

The lamina epithelialis mucosae of the **bovine** cervix is composed primarily of gobletlike cells, with some kinociliated columnar cells present in a few species. Simple, tubular glands may also occur.

The lamina propria-submucosa varies from loose to dense collagenous tissue during the estrous cycle. The tunica muscularis is well-developed and rich in elastic fibers.

Vagina

The **vagina** contains a lamina epithelialis mucosae that is usually nonglandular

Downloaded From Vet-eBooks.com

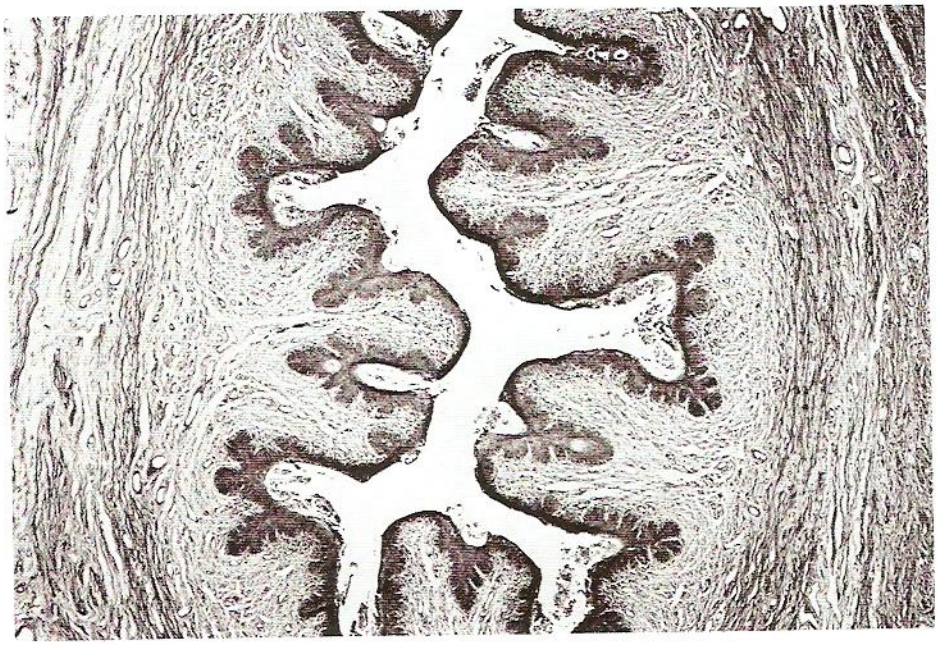

Figure 27-19. Section of a feline vagina. The tunica mucosa is highly folded and lined by stratified squamous epithelium. (×10.)

stratified squamous epithelium (Fig. 27-19). In cows isolated foci of goblet cells are present in the cranial part of the organ. In bitches, intraepithelial glands have been observed during estrus. The tunica mucosa and tunica submucosa are highly folded.

The underlying connective tissue of the lamina propria-submucosa is loose or dense collagenous tissue with scattered lymphatic nodules.

The tunica muscularis consists of two or three layers—an inner longitudinal (variable), a middle circular, and an outer longitudinal. A tunica serosa is present cranially and continues caudad as a tunica adventitia. Some smooth muscle continuing from the broad ligament may also be observed in the subserosal space.

Vulva

The **vulva** consists of **labia** and a **vestibule.** The **clitoris** is part of the vestibule, and the **urethra** opens into the vestibule.

Labia. The **labia** are folds of the integument composed of typical integumentary structures.

Vestibule. The structure of the **vestibule** is similar to that of the caudal vagina. The lamina epithelialis mucosae is noncornified stratified squamous epithelium with an extensive lymphocytic infiltration.

The lamina propria-submucosa consists of loose and dense collagenous tissue rich in elastic fibers. **Vestibular glands** are present. The **major vestibular glands** in ewes, cows, and queens are compound, tubuloalveolar, mucus-producing, and embedded within the constrictor muscle of the vestibulum. The **minor vestibular glands** are branched, tubular, mucus-producing, and scattered throughout the vestibule in most domestic species (in cows they are concentrated near the clitoris). The major vestibular glands are homologous to male bulbourethral glands, the minor vestibular glands homologous to male urethral glands.

The tunica muscularis has an inner longitudinal and an outer circular layer. The outer layer consists of two distinct muscles, the **constrictor vestibuli** and **constrictor vulvae.** The tunica adventitia is typical.

Clitoris. The **clitoris,** homologous to the male penis, has a body, glans, and preputial covering. The body contains cavernous tissue (**corpus cavernosum clitoridis**), adipose tissue, and smooth muscle surrounded by a sheath of dense collagenous tissue. The **glans clitoridis** may contain cavernous tissue (bitches, mares) or highly vascular loose collagenous tissue. The **preputial covering** is an aglandular and hairless reflection of the vestibular cutaneous mucous membrane, rich in sensory nerve endings.

Urethra. The female **urethra** is lined by transitional epithelium continuous with the vestibular cutaneous mucous membrane. The change from transitional to stratified squamous epithelium occurs close to the external orifice. Before the transition, bistratified cuboidal or bistratified columnar epithelium may be apparent.

The lamina propria-submucosa varies from loose to dense collagenous tissue with cavernous sinuses. The distribution and extent of cavernous tissue are subject to species variation.

The tunica muscularis has two or three layers of smooth muscle cranially. The smooth muscle fibers become intermixed with skeletal muscle fibers caudally. The amount, distribution, and relative proportions of these tissues are species-variable.

Cyclical Changes

The female reproductive tract is subject to greater periodical changes than the male tract. Female cyclical activity is manifested microscopically, grossly, and behaviorally. These various states of morphology, function, and appearance relate to the estrous cycle. Estrus, or the period of varying reproductive activity, is influenced by the adenohypophyseal trophic hormones. It is divided into five distinct but continuous stages—proestrus, estrus, metestrus, diestrus, and anestrus.

Proestrus is that part of the cycle noted for follicular growth acceleration under the influence of FSH. The follicle begins to secrete estrogen, which in turn influences the genital organs. The increasing levels of estrogen suppress declining levels of progesterone.

Estrus is marked by the full influence of estrogen on the genital organs. This is the period of **heat,** in which the female will accept the male.

Metestrus is a transitional stage in which declining levels of estrogen are counterbalanced by increasing levels of progesterone.

Diestrus is the period of the cycle under the sole influence of progesterone. Fertilization of the ova and the subsequent pregnancy result in a prolonged diestrus.

If fertilization is not accomplished, **anestrus** may follow. This is a period of variable length in which the reproductive organs are relatively quiescent.

Species differences. The stages of the estrous cycle are of varying lengths in domestic species (Table 27-1).

Animals are either **monestrous** or **polyestrous.** In monestrous species (dogs) one estrous cycle is followed by a long period of anestrus. In polyestrous animals (cows, sows, rodents) one estrous cycle terminates in a period of diestrus, merging into the succeeding estrus cycle as proestrus. In seasonally polyestrous animals (mares, queens, ewes) the terminal diestrus continues as a period of anestrus before the next estrous cycle. The anestrous period in these animals is shorter than that in monestrous animals.

Blood hormone levels vary throughout the estrous cycle. Also hormone levels at various stages of the reproductive cycle are species-variable (Fig. 27-20). Cyclical ovarian, uterine, and vaginal changes synchronize with the secretion of gonadotropins and ovarian hormones.

Downloaded From Vet-eBooks.com

Table 27-1. Characteristics of the Reproductive Cycles of Selected Domestic Animals*

	Type of Cycle	Length of Cycle	Duration of Estrus	Time of Ovulation	Pregnancy Length
Cow	Polyestrous (nonseasonal)	21 days	16 hours	13 hours proestrus	285 days
Ewe	Polyestrous (seasonal)	17 days	1 day	End of estrus	145 days
Mare	Polyestrous (seasonal)	21 days	6 days	Day 5 of estrus	335 days
Sow	Polyestrous (nonseasonal)	21 days	2 to 3 days	Day 2 or 3 of estrus	113 days
Bitch	Monestrous	7 to 8 months	4 to 14 days	Day 2 or 3 of estrus	63 days
Queen	Polyestrous	15 to 21 days	10 to 14 days†	Induced	63 days

*The averages and ranges included are subject to individual and breed variation.
†If mating is achieved, then the duration is reduced to 4 to 6 days.

Ovarian changes. The ovaries undergo changes in accordance with stages of the estrous cycle.

During **proestrus** they respond to FSH, which results in rapid growth of follicles and the initiation of estrogen secretory activity.

During **estrus** the follicles reach maturity and estrogen secretory activity is maximal. FSH secretion decreases, and LH secretion is initiated. This results in ovulation. Ovulation may be considered a transitory period between estrus and metestrus or part of the metestrous stage.

During **metestrus** the corpus luteum develops and progesterone secretion starts.

The **diestrus** is characterized by maximal development of the corpus luteum and maximal progesterone secretion. If pregnancy is not achieved, the corpus luteum involutes and degenerates to a corpus albicans in late diestrus. If pregnancy does occur, the corpus luteum continues its maximal secretion.

In **anestrus,** the ovary is quiescent. The corpus luteum continues its involution and follicular development is arrested.

Uterine changes. The uterus, likewise, undergoes changes in accordance with stages of the estrous cycle.

During **proestrus** the lining epithelium hypertrophies and the uterine glands remain relatively straight (Fig. 27-21). Vascularization and congestion increase in the connective tissue space; hemorrhage may occur. Heterophils begin to invade the epithelial lining.

During **estrus,** epithelial and glandular proliferation continues and becomes more apparent (Fig. 27-22). Cell secretory activity is increased while mononuclear epithelial infiltration continues. The connective tissue space is marked by maximal congestion, edema, and hemorrhage.

In **metestrus,** glandular hyperplasia continues and gland coiling occurs (Fig. 27-23). The high secretory activity continues, while connective tissue edema declines or disappears.

In **diestrus,** maximal glandular hyperplasia is achieved and the glands are extensively coiled. If fertilization occurs, maximal secretory activity is maintained. If fertilization does not occur, the vascularity decreases, secretory activity is arrested, and the lining cells and glands involute.

During **anestrus,** the endometrium is thin and lined by simple cuboidal epithelium (Fig. 27-24). Uterine glands are sparse, assuming a simple or branched tubular shape.

Vaginal changes. The vagina, as the ovaries and uterus, undergoes changes timed to coincide with the stages of estrus. (See Chapter 29.)

Menstrual and estrous cycles compared. The primate menstrual cycle has two phases, follicular and luteal (Fig. 27-25). The **follicular phase** includes those events occurring during proestrus and estrus in other species. It is under the influence of FSH and estrogen and is sometimes called the **proliferative phase.** The **luteal phase** (also called the **progestational** or **secretory phase**) includes events similar to those of metestrus and diestrus.

Changes associated with the endometrium are called the **ischemic** or **premenstrual** and the **menstrual phase.** Necrotic endometrial changes occur under the loosening influence of progesterone and culminate with hemorrhage and loss of part of the endometrium. Endometrial repair is achieved through proliferation of epithelium from the uterine glands and stromal elements of the lamina propria mucosa.

Comparative placentology

The mammalian female reproductive tract facilitates internal fertilization. Subsequent to that, it permits the development of a fertilized egg within the uterus. Complex relationships occur within the uterus between fetal and maternal tissues ensuring nutrition, respiration, removal of waste materials, and protection. The **placenta,** a complex structure resulting from the union of fetal membranes and endometrium, performs these important functions. The placenta is also an endocrine organ responsible for the production of progesterone and relaxin. It is prepared for pregnancy during the metestral and diestral stages of the estrous cycle.

Not all mammals, however, are placental; nor do all mammals bear live young. Mammalian classification is predicated upon the nature of fetal and maternal relationships. **Prototherian mammals** or **monotremes** include the platypus and echidna. These are egg-laying mammals. The **metatherian mammals** or **marsupials** include the kangaroo and opossum. These animals form a transitory **yolk sac placenta.** There is no intimate contact between fetal membranes and the uterine mucosa; they do not form a true placenta.

The remaining extant mammals are the **eutherians.** They are the true **placental mammals.** The fetal membranes (chorion, amnion, yolk sac, and allantois) and the endometrium contribute to the placenta.

Classification. Various means have been devised to classify certain placental characteristics—the distribution of contact, the contribution of extraembryonic membranes, the degree of implantation, the configuration of chorionic attachment, and the combination of fetal and maternal tissues that comprise the placenta. These classifications are used in combination to describe the placenta from different perspectives.

Distribution of chorionic villi

The **chorion** (Gr, afterbirth) is in close contact with the uterine mucosa. Highly vascularized **villi** projecting from this extraembryonic membrane grow into the endometrium. These projections may occur singly or in groups. The subsequent descriptions are of chorioallantoic placentas.

Diffuse placentation. In **diffuse placentas** (mares, sows) the chorionic villi are present over the entire surface. The chorion is wholly attached to the endometrium.

Cotyledonary placentation. The **cotyledonary placenta** (cows, ewes, does) is a multiple structure. The villi are grouped as cotyledons (Gr, *kotyledon,* cup-shaped hollow) and the intercotyledonary space is smooth (devoid of villi). The cotyledons attach to **caruncles** of the endometrium. The **fetal cotyledon** and the **maternal caruncle** form a **placentome.**

Zonary placentation. In the **zonary placenta** (bitches, queens) villi are

Downloaded From Vet-eBooks.com

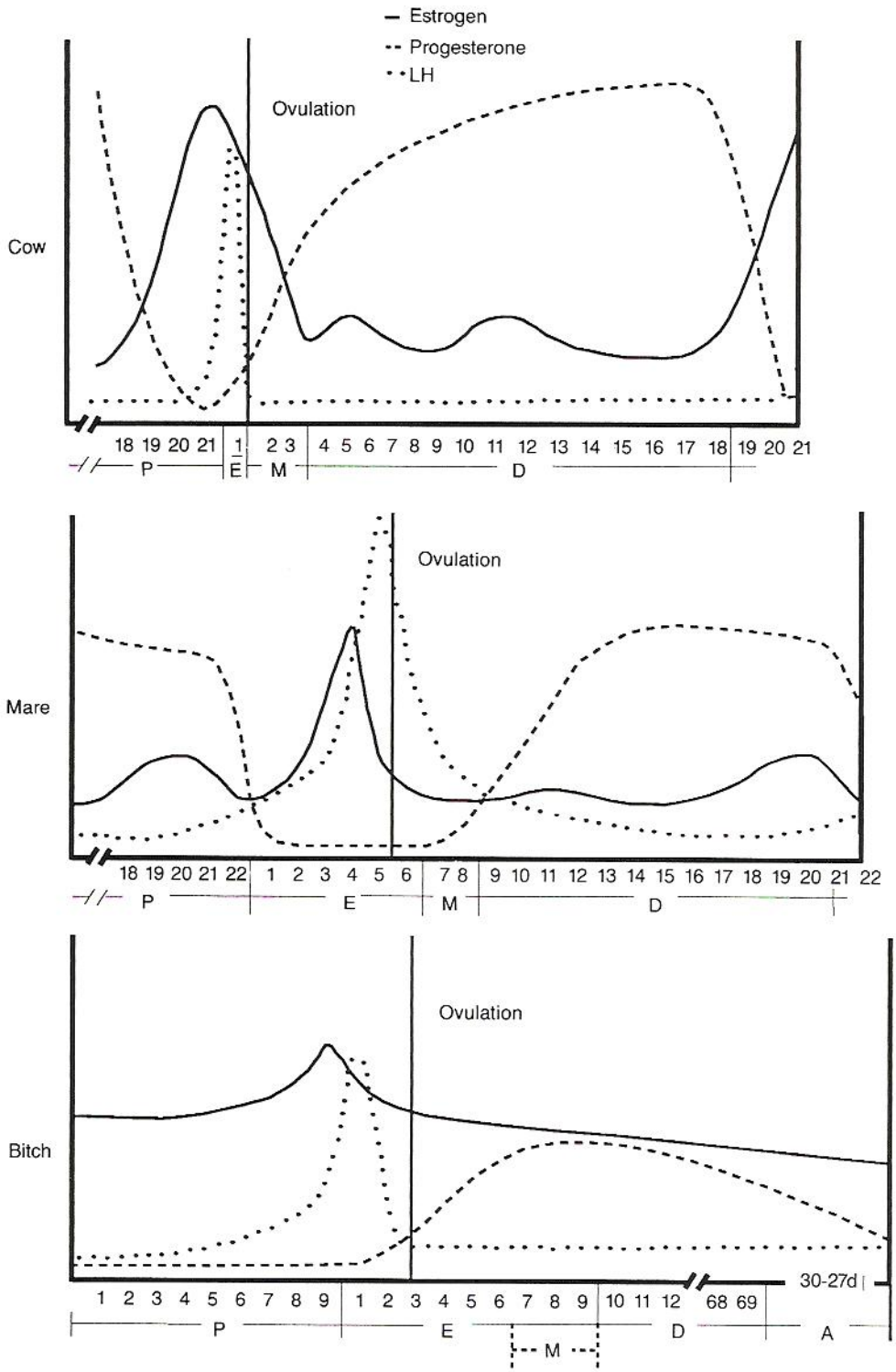

Figure 27-20. Comparative estrous cycles of the cow, mare, and bitch. A prolonged anestrus is unique with canids.

Downloaded From Vet-eBooks.com

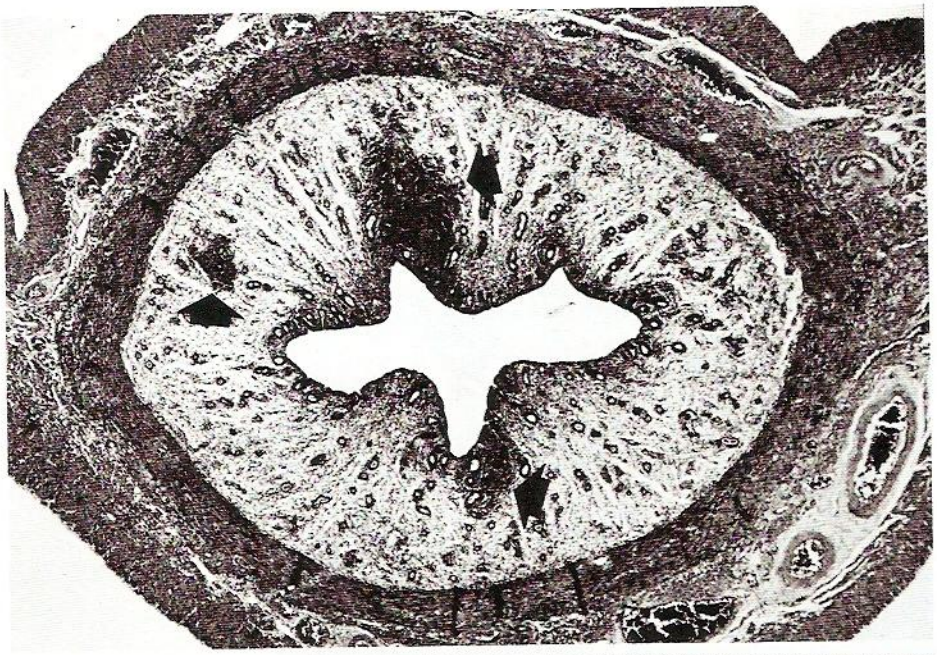

Figure 27-21. Cross section of a canine proestrous uterus. The uterine glands are straight, and hemorrhage is apparent *(arrows)* in the lamina propria mucosae. (×10.) (Note: The magnifications of Figures 27-19 and 27-21 to 27-24 are the same.)

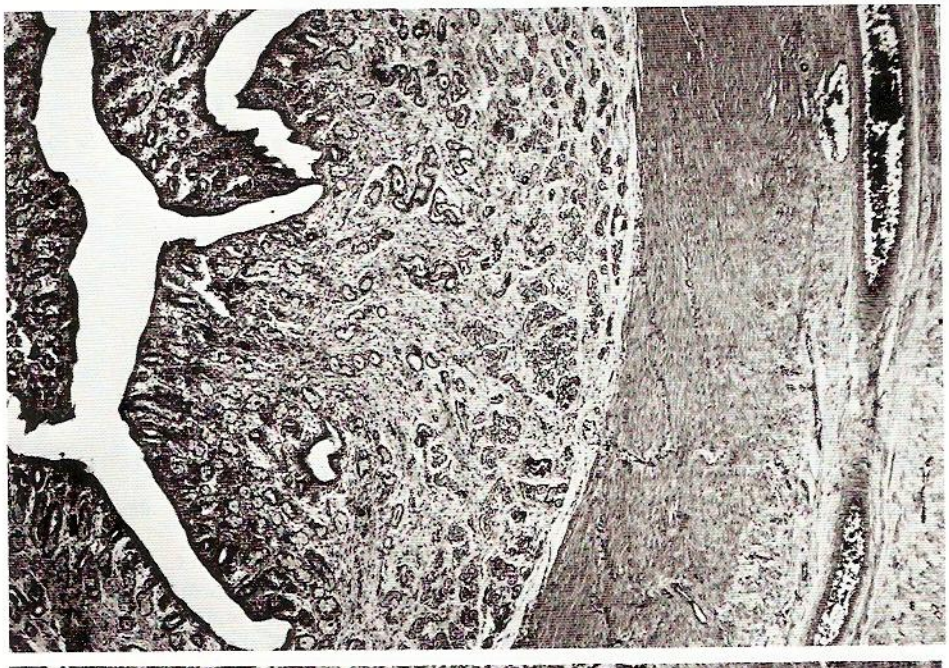

Figure 27-22. Cross section of a canine estrous uterus. Glandular proliferation and general enlargement of the uterus are apparent. (×10.)

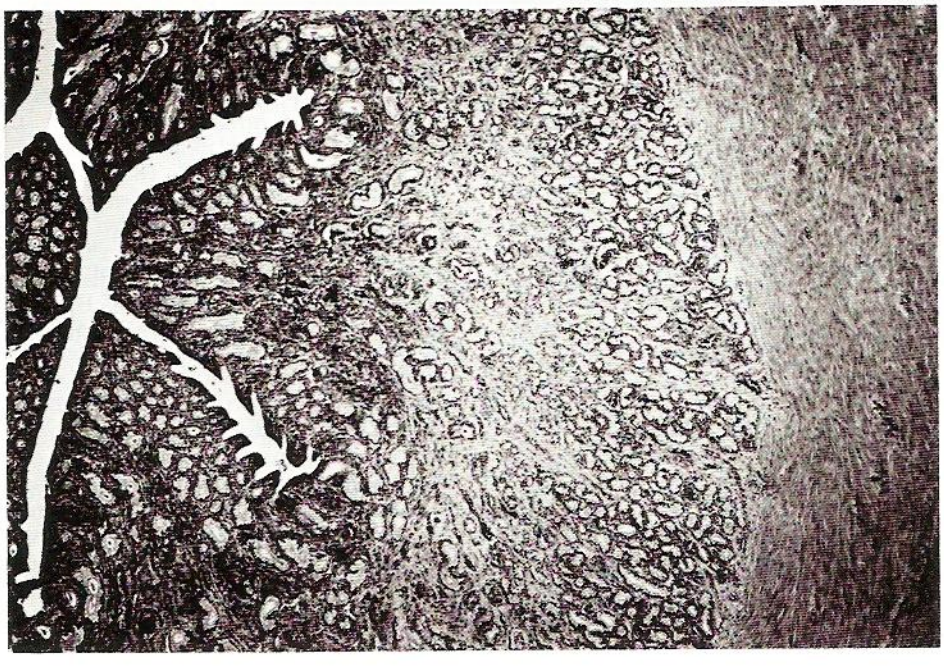

Figure 27-23. A cross section of a canine metestrous uterus. The uterine glands and uterus are larger than in the estrous uterus. (×10.)

Downloaded From Vet-eBooks.com

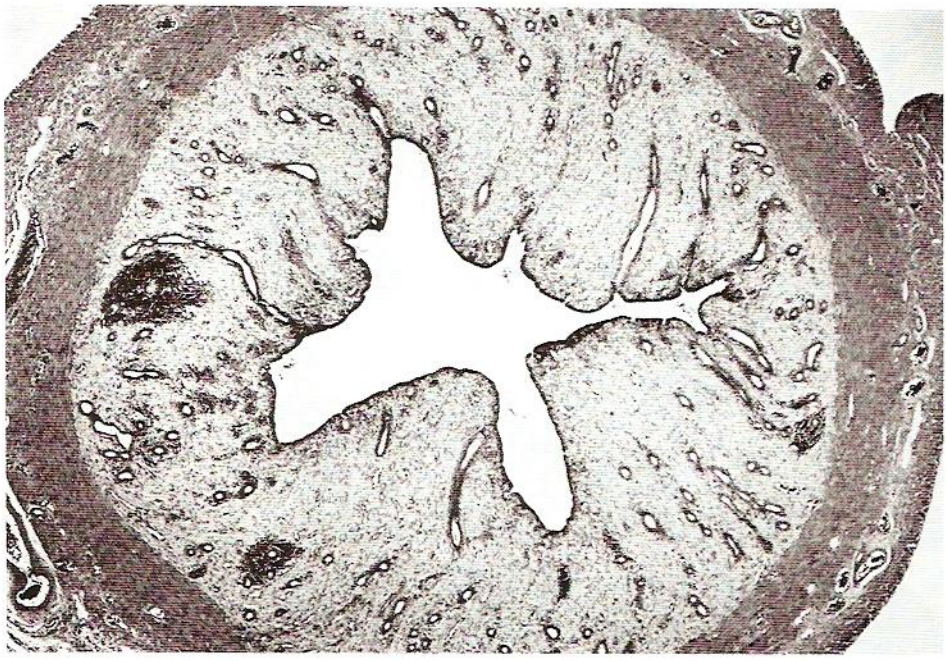

Figure 27-24. Cross section of a canine anestrous uterus. The uterine glands are reduced in number, and the endometrium is reduced in size. (×10.)

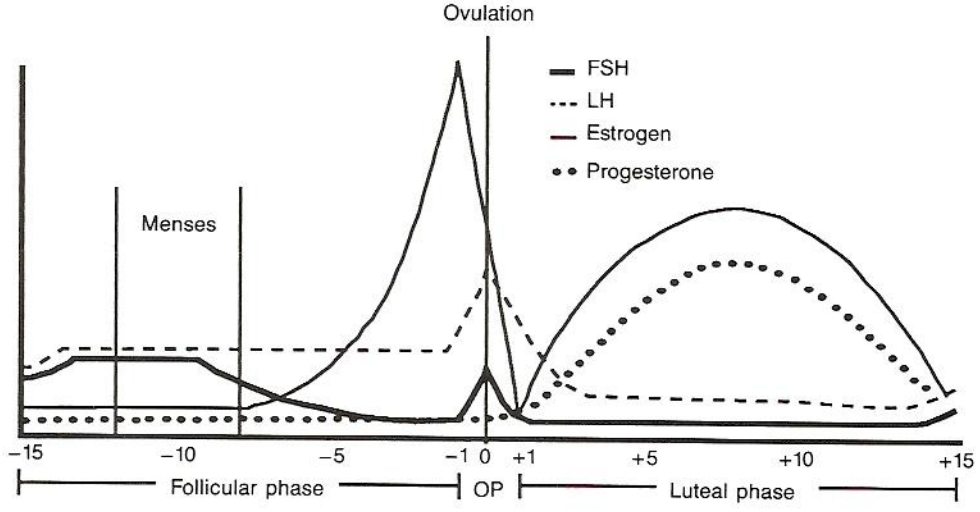

Figure 27-25. Primate menstrual cycle. *OP,* Short ovulatory phase between the two major phases of the cycle.

grouped in a region circumscribing the midportion of the chorion.

Discoidal placentation. **Discoidal placentas** (rodents, primates) are characterized by the grouping of villi in one or two disc-shaped regions.

Extraembryonic membrane contributions

Chorionic placenta. The **trophoblast** is the outer layer of the blastocyst. During **nidation** it invades the uterine mucosa and serves as a nonvascularized attachment point. It nourishes the blastocyst by obtaining nutrients from the uterus until the definitive placenta is formed.

Choriovitelline placenta. There are two types of yolk sac placenta—nonvascularized and vascularized.

In the **nonvascularized** type the differentiated yolk sac endoderm and the trophoderm (the trophoblast following differentiation of the germ layers and chorion) fuse. These layers transport nutrients from the uterine mucosa.

In the **vascularized** type the yolk sac endoderm and trophoderm are separated by a layer of mesoderm containing blood vessels. This is a transitory method of utilizing the embryonic circulation for physiological exchange between fetal and maternal tissues. It is a transitory structure in most eutherian mammals but persists for some time in horses. It is the definitive placenta of metatherian mammals.

Chorioallantoic placenta. The **chorioallantoic placenta** is the definitive or "true" placenta of eutherian mammals, formed by fusion of the **allantoic** (Gr *allas,* sausage) and **chorionic** (afterbirth) **mesoderms.** A vascular invasion enlarges the connective tissue of the allantoic mesoderm. The allantoic vesicle, by contrast, is unaffected by this invasion, though it does vary in size.

Downloaded From Vet-eBooks.com

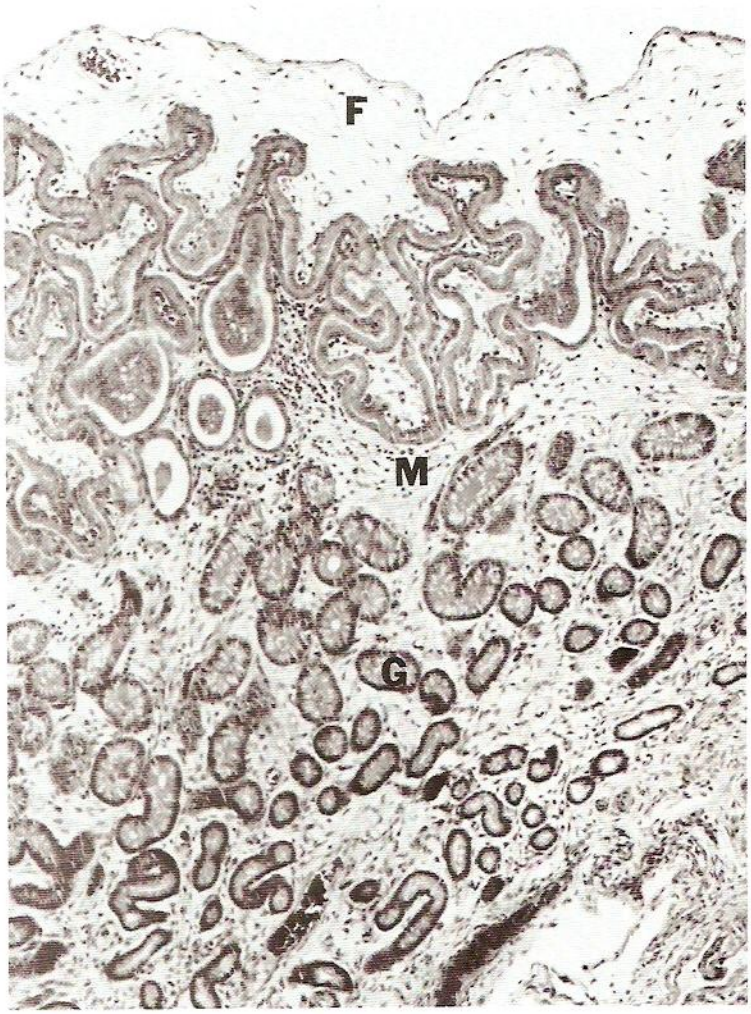

Figure 27-26. Section of the epitheliochorial placenta of a mare. The fetal *(F)* and maternal *(M)* contributions interdigitate. G, Uterine glands. (×10)

Trophoblastic cells from the developing allantochorionic placenta invade the endometrial connective tissue in mares (Fig. 27-26) and form dense aggregations of cells among scattered uterine glands (Fig. 27-27). The large aggregates, **endometrial cups,** may have a 5 cm diameter. The endometrial cup cells are large, often binucleated, and polyhedral (Fig. 27-28). They secrete **equine chorionic gonadotropin (ECG).**

The lymphocytic and eosinophilic infiltration of endometrial cups and the vast lymphatic channels associated with them ensure their ultimate rejection by the maternal immune system. The endometrial cups are maximally developed by the 50th gestational day, begin to regress by the 60th day, and are rejected by the 150th day. After immune rejection they become encapsulated by components of the chorion as pendulous **hippomanes.**

Degree of implantation

The degree of implantation defines the relationship between fetal and maternal tissues and determines the shedding or nonshedding of maternal tissues at parturition. Placentas in which minimal tissue erodes during implantation are nondeciduate. Those in which extensive tissue erosion accompanies implantation are deciduate.

Nondeciduate placenta. In **nondeciduate placentas,** the fetal and maternal tissues may interdigitate, fuse, or be apposed to each other. There is minimal erosion of contributing tissues, and no uterine mucosal elements are lost at parturition.

Deciduate placenta. In **deciduate placentas** the uterine mucosa and chorion are eroded to varying degrees and subsequently fuse. At parturition some maternal tissue is lost.

The **decidual cells** are maternal connective tissue cells with various shapes, sizes, and cytoplasmic inclusions. The cells are similar in dogs, cats, and humans. Their precise function is not known. They may provide nutrition, delineate a cleavage zone at parturition, protect the uterine mucosa against the invading trophoblast, or form placental gonadotrophins. Typical of most eutherian mammals, they occur minimally or not at all in carnivores and ungulates.

Configuration of chorionic attachments

Three types of fetal and maternal contact are defined—folded, villous, and labyrinthine. In the **folded** type undulations of both contributing tissues are interdigitated. In the **villous** type chorionic projections interdigitate with corresponding maternal crypts. In the **labyrinthine** type chorionic villi are fused.

Fetal and maternal contributions

The barriers across which exchange must occur involve all components between fetal and maternal blood. The maximal barrier for exchange includes the following: **uterine endothelium, uterine connective tissue, uterine epithelium, chorionic epithelium, chorioallantoic connective tissue,** and **allantoic endothelium.** Various placentas are formed by the retention and/or deletion of one or more of these components. On this basis,

Downloaded From Vet-eBooks.com

Figure 27-27. Section through the endometrial cups of an equine uterus. The cells of the cups *(E)* are a prominent feature of the lamina propria mucosae. Uterine glands *(G)* are also present. The *solid arrow* points to the advancing front of a mass of infiltrating lymphocytes. (×25.)

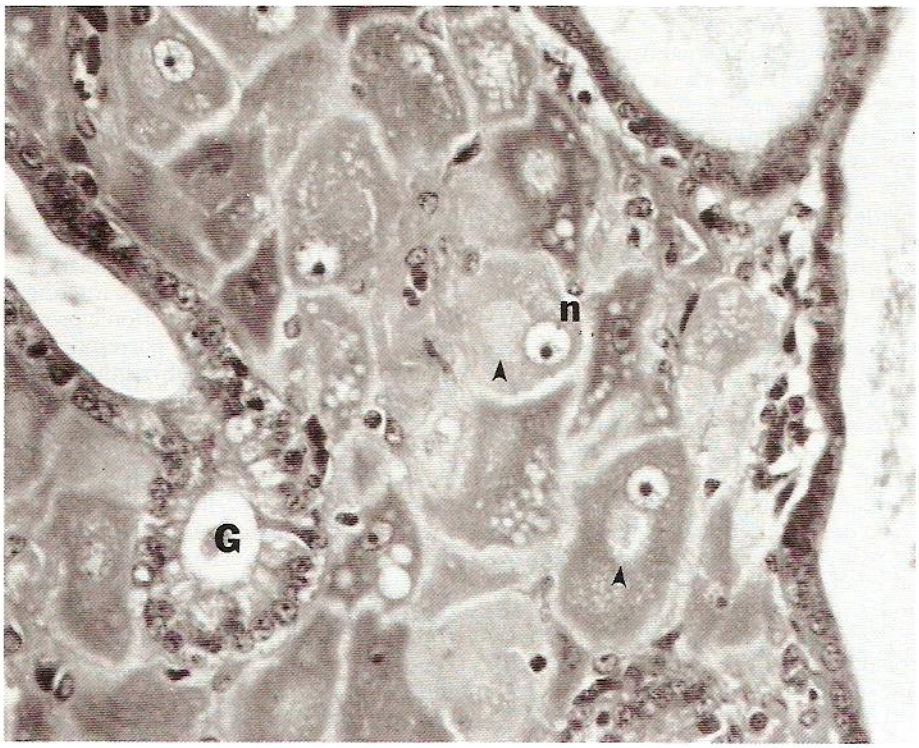

Figure 27-28. Cells of the endometrial cups of an equine uterus. The nuclei *(n)* are vesicular, each with a prominent nucleolus. Note the large negative-staining Golgi region *(arrowheads)*. (×100.)

Downloaded From Vet-eBooks.com

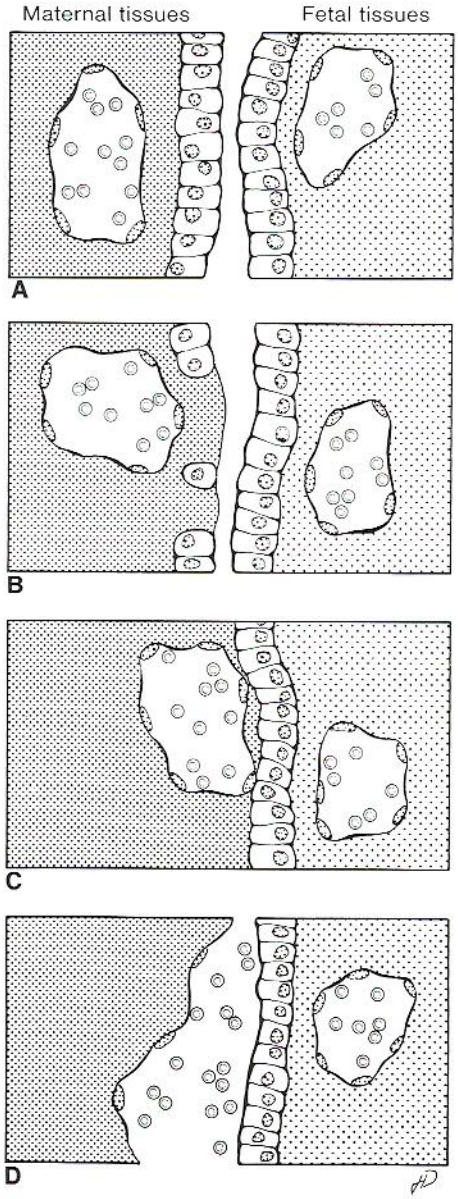

Figure 27-29. Four types of placentation. The fetal tissues remain intact in the placental relationships depicted. **A,** Epitheliochorial; **B,** syndesmochorial; **C,** endotheliochorial; **D,** hemochorial.

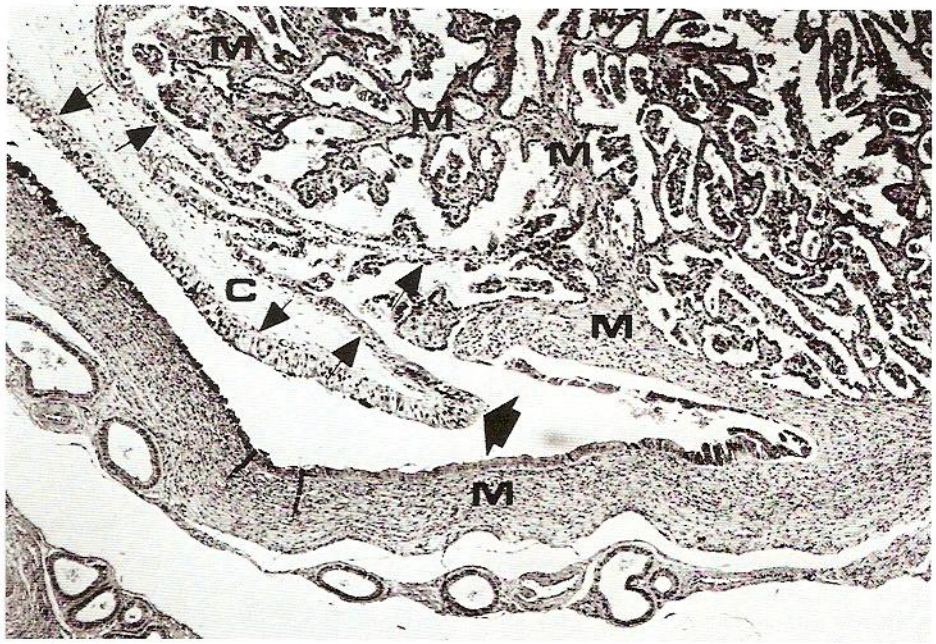

Figure 27-30. Section of a bovine epitheliochorial placenta. The chorioallantois *(C)* of the fetus *(small arrows)* interdigitates with the maternal villi *(M)*. The fetal membrane is reflected away from the placentome *(large arrow)*. (×13.)

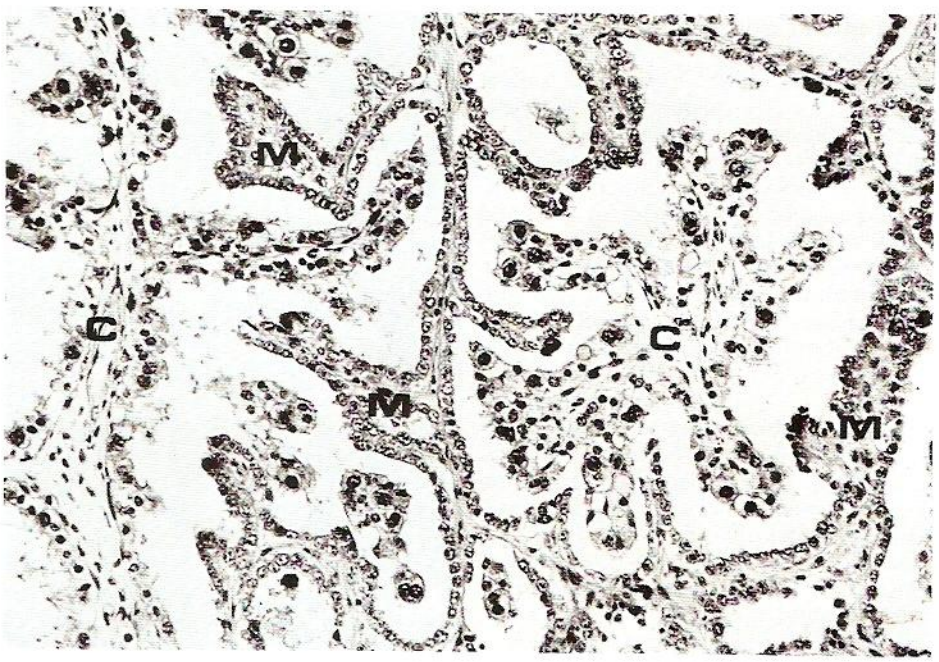

Figure 27-31. Fetal and maternal tissue relationships in a bovine placentome. The maternal tissue *(M)* is lined by uterine epithelium. The chorioallantois *(C)* of the fetus is lined by trophoblastic cells. The separation between these tissues is an artifact. (×50.)

five types of placenta are defined (Fig. 27-29)—epitheliochorial, syndesmochorial, endotheliochorial, hemochorial, and endotheliocndothelial. In the formation of these compound names, the first term refers to the maternal component; the second, to the fetal component.

Epitheliochorial placenta. All six layers are present (Fig. 27-30). The chorionic and uterine epithelia are in contact with one another (Fig. 27-31). This configuration is nondeciduate (sows, mares, cows, ewes, does).

Syndesmochorial placenta. The chorionic epithelium is in direct contact with uterine connective tissue, because the uterine epithelium was eroded. This configuration is also nondeciduate. It occurs focally in ruminants after the establishment of an epitheliochorial placenta and in pathological circumstances.

Endotheliochorial placenta. This type of placentation is characterized by intimate contact of the chorionic epithelium with the uterine capillaries. The uterine epithelium and connective tissue are eroded. This is a deciduate type of pla-

Downloaded From Vet-eBooks.com

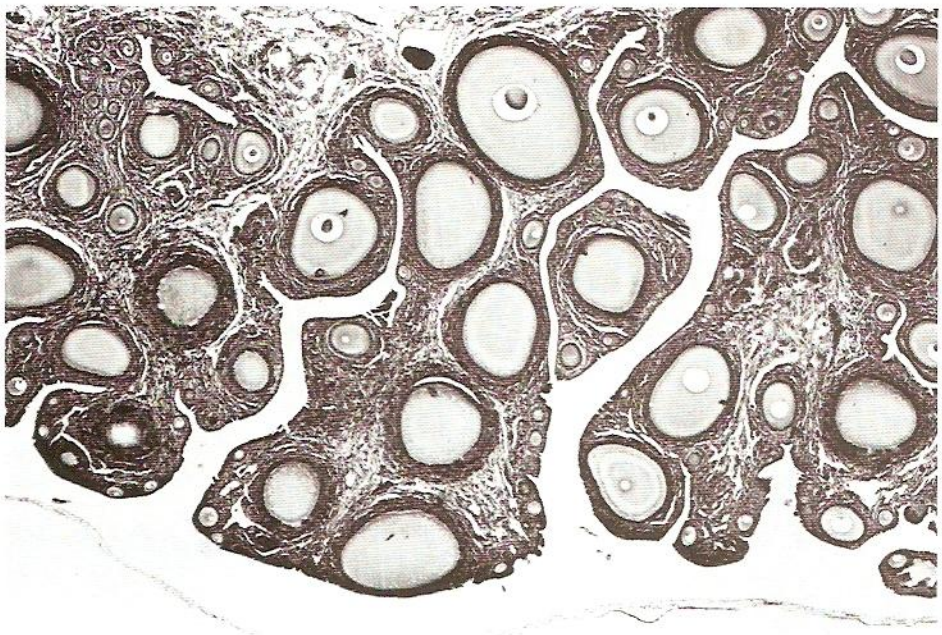

Figure 27-32. Section of an avian ovary. The ovary is a pendulous structure suspended from the abdominal wall. (×10.)

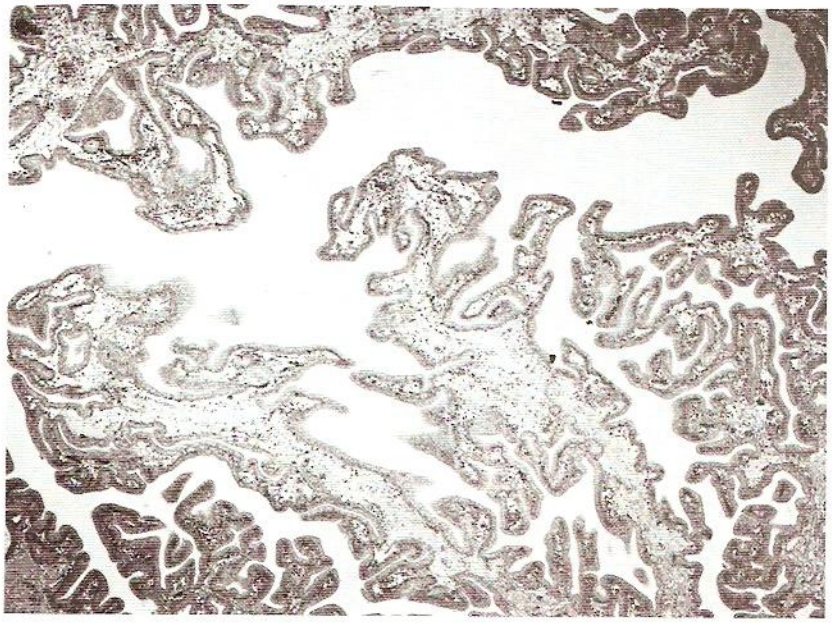

Figure 27-33. Section of the infundibular portion of an avian oviduct. The tunica mucosa is highly folded and devoid of glands. (×10.)

Figure 27-34. Lining epithelium of an avian infundibulum. The lining is pseudostratified ciliated epithelium. Goblet cells may be present, but multicellular glands are absent. (×125.)

Downloaded From Vet-eBooks.com

Figure 27-35. Magnum of the avian oviduct. The tunica mucosa has pronounced folds and many branched tubular glands. (×10.)

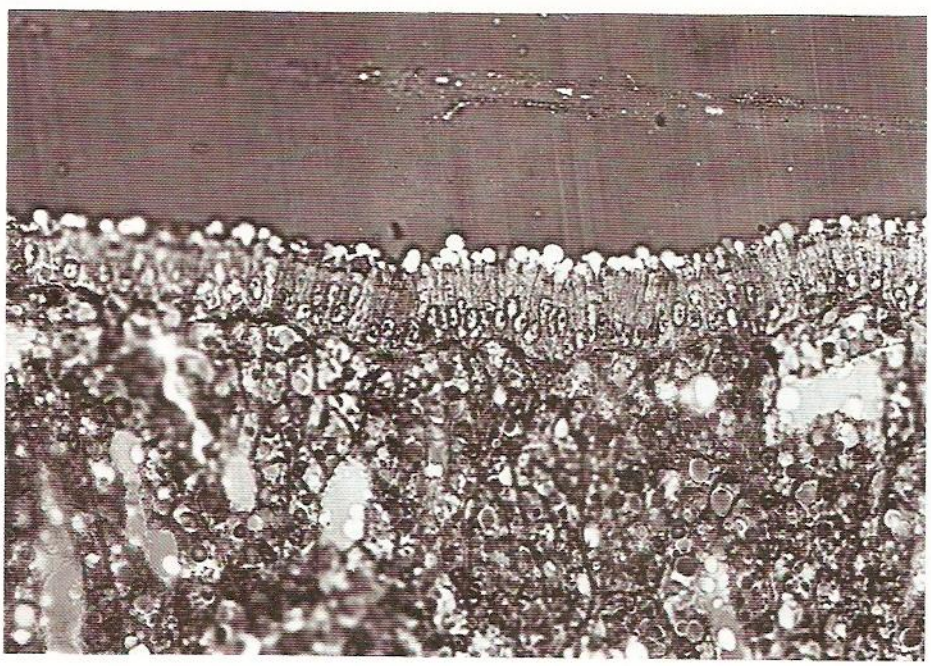

Figure 27-36. Lining cells of the avian magnum. The lumen is filled with a proteinaceous secretory product. The lamina epithelialis consists of ciliated columnar cells. (×125.)

centa (in queens and bitches).

Hemochorial placenta. The chorionic epithelium in this type of placentation contacts maternal blood because the uterine epithelium, connective tissue, and endothelium have been eroded. Further subdivisions of hemochorial placentas consider the number of trophoderm cell layers in contact with the maternal blood. Thus **hemomonochorial, hemodichorial,** and **hemotrichorial** types are recognized. Hemochorial placentation occurs in primates and rodents.

Endothelioendothelial placenta. This type of placentation is characteristic of shrews. The fetal endothelium is separated from the maternal endothelium by a thin layer of discontinuous trophoblast cells. Although functionally the endothelioendothelial placenta has a reduced transport barrier, anatomically it may be considered an endotheliochorial organ.

Species differences. The following unified classification is based upon the previously discussed characteristics:

Swine: diffusely folded, epitheliochorial, nondeciduate placenta
Horses: diffusely villous, epitheliochorial, nondeciduate placenta
Ruminants: cotyledonary villous, epitheliochorial, nondeciduate placenta
Carnivores: zonary labyrinthine, endotheliochorial, deciduate placenta
Humans: discoidal villous, hemochorial, deciduate placenta

BIRDS

General considerations. The avian reproductive system, as the mammalian system, facilitates internal fertilization, but the avian oviduct and uterus are modified to ensure the survival and development of the offspring outside the body. These structures supply the necessary nutrients and enclose the offspring within a protective shell.

Only the left ovary and oviduct are retained in adults as functional entities.

Ovary. Avian **ovaries** are not as compact as mammalian ovaries. They are fingerlike projections suspended pendulously from the abdominal wall by the mesovarium (Fig. 27-32). A cortex and medulla are distinguishable, but the latter is diffuse and not well-developed. The cortex consists of "follicles" in various stages of development.

The term **follicle** is a misnomer, because an antrum does not develop. The follicle contains a primary oocyte, a single layer of membrana granulosa cells, a theca folliculi interna, and a theca folliculi externa. The oocyte and accompanying cells are large. In some domesticated species the primary oocyte reaches a diameter of approximately 30 mm. Ovulation is not followed by the development of a corpus luteum.

Oviduct. The avian **oviduct** is divided into five regions— infundibulum, magnum, isthmus, shell gland (uterus), and vagina. Egg formation involves the elaboration of albumin, formation of shell membranes, "plumping" of the egg, and secretion of materials for the shell. Only the vaginal portion of the oviduct is not involved in these formative processes.

The **infundibulum** is the funnellike cranial extension of the oviduct. Its tunica mucosa is highly folded and caudaly well-vascularized (Fig. 27-33). (Cranially the folds are low.) Its cranial aspects are lined by nonsecretory, ciliated cells. Progressing caudad, the epithelial lining cells are secretory and epithelial grooves of the tunica mucosa are replaced by tubular glands at the junction of the infundibulum and magnum. The infundibular lining epithelium is pseudostratified columnar (Fig. 27-34). The ciliated cells decrease caudally. The secretory lining cells

Downloaded From Vet-eBooks.com

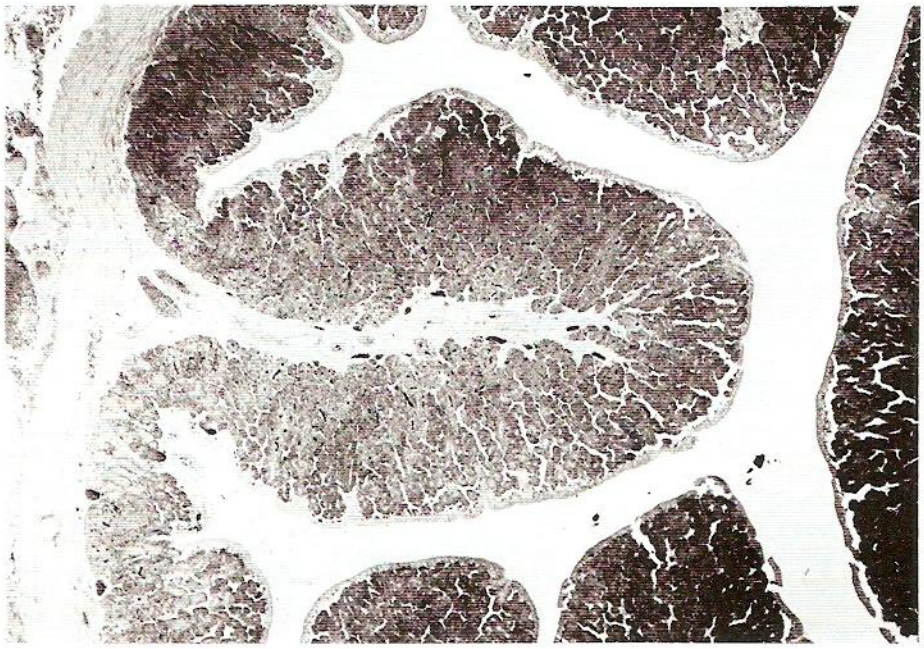

Figure 27-37. Isthmus of the avian oviduct. The tunica mucosa has pronounced folds. Many mucosal glands *(dark areas)* comprise the tunica. (×10.)

Figure 27-38. Lining and glandular epithelium of the avian isthmus. Ciliated columnar epithelial cells line the lumen of the organ. Mucosal glands *(dark areas)* are branched and tubular. (×100.)

and cells of the tubular glands secrete different mucoid materials.

The lamina propria-submucosa is loose collagenous tissue. Diffuse lymphatic tissue is commonly encountered. The tunica muscularis and tunica serosa are typical.

This portion of the oviduct receives the ova and propels them caudad. Fertilization occurs within the infundibulum before the secretion of an enveloping mass of albumen by the magnum. Infundibular glands may store excess spermatozoa.

The **magnum** deposits most of the egg white (Fig. 27-35). Its lamina epithelialis mucosae consists of ciliated and nonciliated columnar cells (Fig. 27-36). Its lamina propria mucosae contains many branched, tubular glands lined by a cuboidal or columnar epithelium. Secretory granules are present along its apical border. The passage of the forming egg through the magnum probably serves as a mechanical stimulation for the release of albumen. The magnum may store enough protein to envelope two eggs.

Although three types of cells (A, B, and C) have been identified within the tubular glands, the A and C cells are probably the same but in different stages of their secretory cycle. Ovalbumin appears to be derived from A cells, whereas B cells seem to be the source of lysozyme. Surface lining cells may be the source of ovomucin and avidin. Goblet cells within the caudal aspect of the magnum stain positively for acidic glycosaminoglycans.

The loose collagenous tissue of the lamina propria-submucosa has much diffuse lymphatic tissue. The tunica muscularis and tunica serosa are typical.

The **isthmus** is lined by ciliated and nonciliated columnar epithelia (Fig.

Downloaded From Vet-eBooks.com

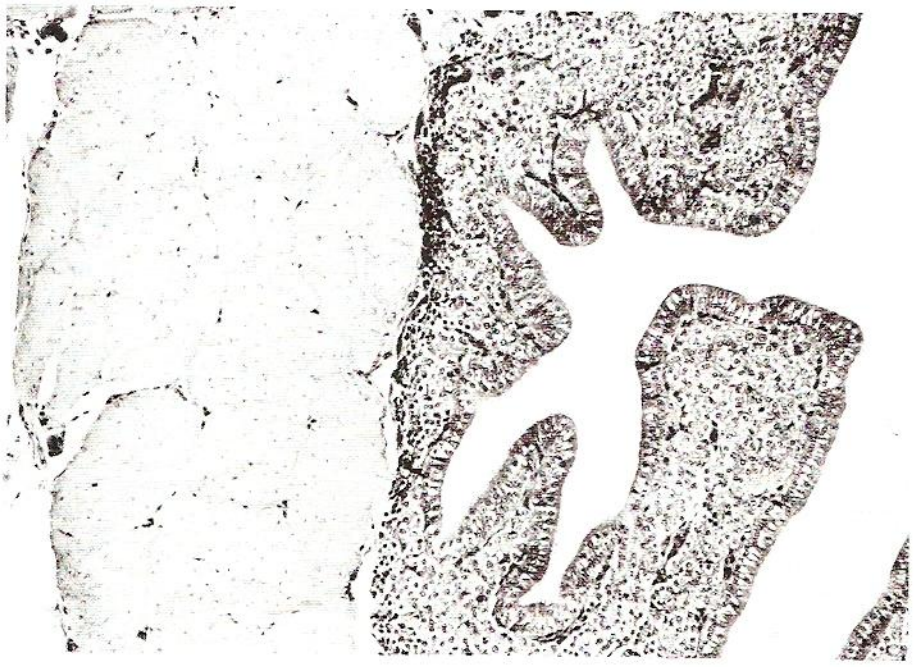

Figure 27-39. Section of the avian uterus. The tunica mucosa is highly folded. This organ produces the shell of the egg. (×50.)

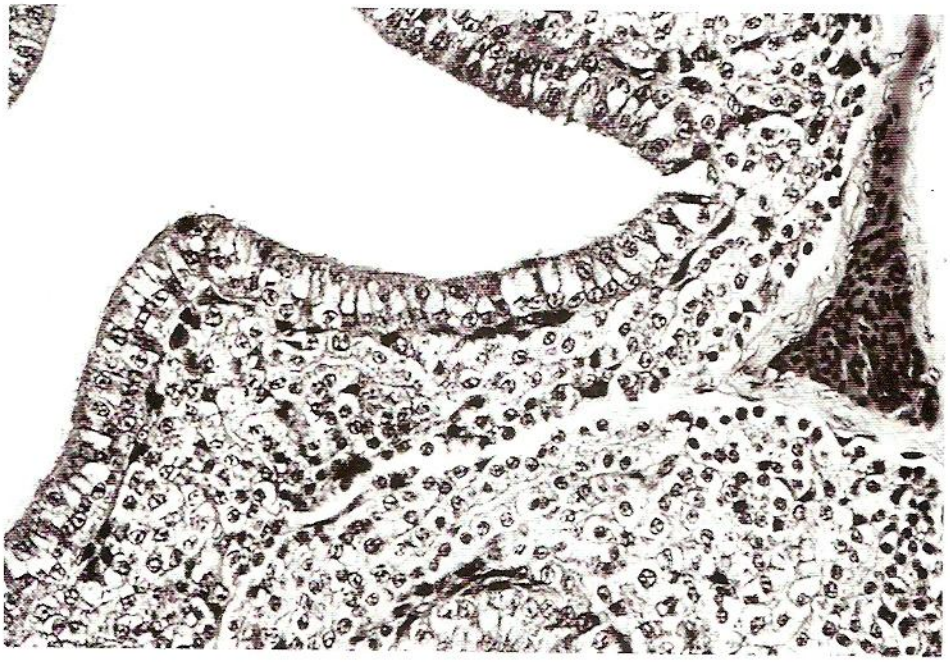

Figure 27-40. Lining cells of the avian uterus. The lamina epithelialis mucosae consists of pseudostratified intermittently ciliated columnar epithelium. (×125.)

27-37). Many branched, tubular glands extend into the lamina propria (Fig. 27-38). The remaining layers are similar to those of the magnum. This portion of the oviduct forms the shell membranes. It may also secrete albuminoids.

The avian **uterus** is not designed for the implantation of the fertilized ova; it is the **shell gland** (Fig. 27-39). Its secretions form the egg shell and dilute the albuminoids. The uterus is divisible into two regions—**tubular shell gland** and **shell gland pouch.** Eggs are "plumped" by the addition of water to thinned albuminoids before shell deposition. Plumping may start in the isthmus and finish in the shell gland pouch.

The lamina epithelialis mucosae consists of intermittently ciliated pseudostratified columnar epithelium (Fig. 27-40). Coiled, tubular glands project into the underlying connective tissue. The gland cells have a centrally placed nucleus; the cytoplasm may contain apically positioned granules or vacuoles. The remaining portions of the wall are similar to the aforementioned structures.

The **vagina** follows the shell gland. Its tunica mucosa is characterized by short mucosal folds. Ciliated and nonciliated lining cells are characteristic of this epithelium, and its surface cells are taller than those of the shell gland. This por-

Downloaded From Vet-eBooks.com

tion of the oviduct is glandless except at the junction with the shell gland pouch. The glands at the pouch-vagina junction are simple, tubular glands lined by columnar epithelial cells containing lipids and PAS-positive material that is not glycogen. These glands, called **sperm host glands,** appear to nourish and store the sperm. The sperm are released upon mucosal distention that accompanies oviposition.

ADDITIONAL READINGS

Ovary

Amsterdam A, Linder H, Groschel-Stewart U: Localization of actin and myosin in the rat oocyte and follicular wall by immunofluorescence, *Anat Rec* 187:311, 1977.

Anderson E, Albertini D: Gap junctions between the oocyte and companion follicle cells in the mammalian ovary, *J Cell Biol* 71:680, 1976.

Baca M, Zamboni L: The fine structure of human follicular oocytes, *J Ultrastruct Res* 19:354, 1967.

Bjersing L: On the ultrastructure of the granulosa lutein cells in porcine corpus luteum, *Z Zellforsch* 82:187, 1967.

Blanchette EJ: Ovarian steroid cells. II. The lutein cell, *J Cell Biol* 31:517, 1966.

Grandy HG, Smith DE (eds): *The ovary,* Baltimore, 1963, Williams & Wilkins.

Hadek R: Morphological and histochemical study on the ovary of the sheep, *Am J Vet Res* 19:873, 1958.

Hodgen GD: The dominant follicle, *Fertil Steril* 38:291, 1982.

Hope J: The fine structure of the developing follicle of the Rhesus ovary, *J Ultrastruct Res* 12:592, 1965.

Phemister RD, et al: Time of ovulation in the Beagle bitch, *Biol Reprod* 8:74, 1973.

Richardson GS: Ovarian physiology, *N Engl J Med* 274:1008, 1966.

Seguin BE: Role of prostaglandins in bovine reproduction, *J Am Vet Med Assoc* 176:1178, 1980.

Weakley BC: Differentiation of the surface epithelium of the hamster ovary. An electron microscopic study, *J Anat* 105:129, 1969.

Uterus and Associated

Abdalla O: Observations on the morphology and histochemistry of the oviducts of the sheep, *J Anat* 102:333, 1968.

Archibald LF, et al: A surgical method for collecting canine embryos after induction of estrus and ovulation with exogenous gonadotropins, *Vet Med Small Anim Clin* 75:228, 1980.

Bal HS, Getty R: Changing morphology of the uterine tubes of the domestic pig *(Sus scrofa domesticus)* with age, *J Gerontol* 25:347, 1970.

Dessouky DA: Electron microscopic studies of the myometrium of the guinea pig, *Am J Obstet Gynecol* 100:30, 1968.

Ferenczy A, et al: Scanning electron microscopy of the human fallopian tube, *Science* 175:783, 1972.

Ginther OJ: Utero-ovarian relationships in cattle. Physiological aspects, *J Am Vet Med Assoc* 153:1656, 1968.

Hook SJ, Hafez ESE: A comparative anatomical study of the mammalian uterotubal junction, *J Morphol* 125:159, 1968.

Huszar G, Roberts JM: Biochemistry and pharmacology of the myometrium and labor: regulation at the cellular and molecular levels, *Am J Obstet Gynecol* 142:25, 1982.

Pineda MH, Kainer RA, Faulkner LC: Dorsal median postcervical fold in the canine vagina, *J Am Vet Med Assoc* 34:1487, 1973.

Schultz RH, Burcalow HB, Fahning ML: A karyometric study of epithelial cells lining the glands of the bovine endometrium, *J Reprod Fertil* 19:169, 1969.

Younes MS, Robertson EM, Bencosme SA: Electron microscope observations on Langerhans cells in the cervix, *Am J Obstet Gynecol* 102:397, 1968.

Cyclic Changes in the System

Adams EC, Hertig AT: Studies on the human corpus luteum. I. Observations on the ultrastructure of development and regression of the luteal cells during the menstrual cycle, *J Cell Biol* 41:696, 1969.

Adams EC, Hertig AT: Studies on the human corpus luteum. II. Observations on the ultrastructure of luteal cells during pregnancy, *J Cell Biol* 41:716, 1969.

Akins EL, Morissette, MC: Gross ovarian changes during estrous cycle of swine, *Am J Vet Res* 29:1953, 1968.

Fowler EH, Feldman MK, Loeb WF: Comparison of histologic features of ovarian and uterine tissues with vaginal smears of the bitch, *Am J Vet Res* 32:327, 1971.

Fowler EH, Loeb WF, Wilson GP: Vaginal cytologic examination of intact and ovariohysterectomized bitches with mammary neoplasia, *Am J Vet Res* 32:51, 1970.

Hatch RD: Anatomic changes in the bovine uterus during pregnancy, *Am J Vet Res* 2:411, 1941.

Holst PA, Phemister RD: Onset of diestrus in the Beagle bitch: definition and significance, *Am J Vet Res* 35:401, 1974.

Johnston SD: Diagnostic and therapeutic approach to infertility in the bitch, *J Am Vet Med Assoc* 176:1335, 1980.

King BF: Ultrastructure of the nonhuman primate vaginal mucosa; epithelial changes during the menstrual cycle and pregnancy, *J Ultrastruct Res* 82:1, 1983.

McDonald LE: *Veterinary endocrinology and reproduction,* Philadelphia, 1969, Lea & Febiger.

Peters H, Levy E: Cell dynamics of the ovarian cycle, *J Reprod Fertil* 11:227, 1966.

Sanger VL, Engle PH, Bell DS: The vaginal cytology of the ewe during the estrous cycle, *Am J Vet Res* 19:283, 1958.

Schutte AP: Canine vaginal cytology. II. Cyclic changes, *J Small Anim Pract* 8:307, 1967.

Wagner W: Bovine parturition, *Compend Contin Educ Pract Vet* 11:517, 1980.

Comparative placentology

Allen WR, Hamilton DW, Moor RM: The origin of equine endometrial cup, *Anat Rec* 177:485, 1973.

Amorosa EC: Histology of the placenta, foetal and neonatal physiology, *Br Med Bull* 17:2, 1961.

Anderson JW: Ultrastructure of the placenta and fetal membranes of the dog. I. The placenta labyrinth, *Anat Rec* 165:5, 1969.

Ashley CA: Study of the human placenta with the electron microscope, *Arch Pathol* 80:377, 1965.

Bjorkman N: The fine structure of the ovine placentome, *J Anat* 99:283, 1965.

Bjorkman N: Fine structure of the fetal-maternal area of exchange in the epitheliochorial and endotheliochorial types of placentation, *Acta Anat Suppl* 1, 86:1, 1973.

Bjorkman NH: Fine structure of cryptal and trophoblastic giant cells in the bovine placentome, *J Ultrastruct Res* 24:249, 1968.

Bjorkman NH: Light and electron microscopic studies on cellular alterations in the normal bovine placentome, *Anat Rec* 163:17, 1969.

Bjorkman NH: *An atlas of placental fine structure,* Baltimore, 1970, Williams & Wilkins.

Davies J, Glasser SR: Histological and fine structural observations on the placenta of the rat, *Acta Anat* 69:542, 1968.

Enders AC: A comparative study of the fine structure of the trophoblast in several hemochorial placentas, *Am J Anat* 116:29, 1965.

Wimsatt WA: Some aspects of the comparative anatomy of mammalian placentome, II, *Am J Obstet* 84:11, 1962.

Avian Reproductive Tract

Brambell RWR: The oogenesis of the fowl *(Gallus bankiva), Philos Trans R Soc (B)* 214:113, 1926.

Fell HF: Histological studies of the gonads of the fowl. II. The histogenesis of the so-called "luteal" cells in the ovary, *Br J Exp Biol* 1:293, 1924.

Fertuck HC, Newstead JD: Fine structural observations on magnum numosa in quail and hen oviducts, *Z Zellforsch* 103:447, 1970.

Freeman BM (ed): *Physiology and biochemistry of the domestic fowl,* vol 4, New York, 1983, Academic Press.

Hewitt EA: The physiology of the reproductive system of the fowl, *J Am Vet Med Assoc* 95:201, 1939.

Kohler PO, Grimley PM, O'Malley BW: Estrogen-induced cytodifferentiation of the ovalbumin-secreting glands of the chick oviduct, *J Cell Biol* 40:8, 1969.

Narbaitz R, DeRobertis RM Jr: Postnatal evolution of steriodogenic cells in the chick ovary, *Histochemie* 15:187, 1968.

Nevalainen TJ: Electron microscope observations on the shell gland mucosa of calcium-deficient hens *(Gallus domesticus), Anat Rec* 164:127, 1969.

Sturkie PD, Mueller WJ: Reproduction in the female and egg production, In: Sturkie PD (ed): *Avian physiology,* ed 4, New York, 1986, Springer-Verlag.

Downloaded From Vet-eBooks.com