MUSCLES OF VERTEBRATES

Comparative Anatomy, Evolution, Homologies and Development

Rui Diogo
Virginia Abdala

Science Publishers

CRC Press
Taylor & Francis Group

MUSCLES OF VERTEBRATES

Comparative Anatomy, Evolution, Homologies and Development

MUSCLES OF VERTEBRATES

Comparative Anatomy, Evolution, Homologies and Development

Rui Diogo
Department of Anthropology
The George Washington University
Washington, DC
USA

Virginia Abdala
Instituto de Herpetologia,
Fundación Miguel Lillo—CONICET,
Tucumán,
Argentina

CRC Press
Taylor & Francis Group
an **informa** business
www.crcpress.com

6000 Broken Sound Parkway, NW
Suite 300, Boca Raton, FL 33487
270 Madison Avenue
New York, NY 10016
2 Park Square, Milton Park
Abingdon, Oxon OX 14 4RN, UK

Science Publishers
Enfield, New Hampshire

Published by Science Publishers, P.O. Box 699, Enfield, NH 03748, USA
An imprint of Edenbridge Ltd., British Channel Islands

E-mail: *info@scipub.net* Website: *www.scipub.net*

Marketed and distributed by:

CRC Press
Taylor & Francis Group
an **informa** business
www.crcpress.com

6000 Broken Sound Parkway, NW
Suite 300, Boca Raton, FL 33487
270 Madison Avenue
New York, NY 10016
2 Park Square, Milton Park
Abingdon, Oxon OX 14 4RN, UK

Copyright reserved © 2010

ISBN 978-1-57808-682-5

Library of Congress Cataloging-in-Publication Data

Diogo, Rui.
Muscles of vertebrates : comparative anatomy, evolution, homologies and development / Rui Diogo, Virginia Abdala.
p. cm.
ISBN 978-1-57808-682-5 (hardcover)
1. Muscles--Anatomy. 2. Muscles--Evolution. 3. Anatomy, Comparative. 4. Vertebrates--Anatomy. I. Diogo, Rui. II. Abdala, Virginia.
QL831 .D56 2010
573.7’ 516--dc22

2010022484

The views expressed in this book are those of the author(s) and the publisher does not assume responsibility for the authenticity of the findings/conclusions drawn by the author(s). Also no responsibility is assumed by the publishers for any damage to the property or persons as a result of operation or use of this publication and/or the information contained herein.

All rights reserved. No part of this publication may be reproduced, stored in a retrieval system, or transmitted in any form or by any means, electronic, mechanical, photocopying or otherwise, without the prior permission of the publisher, in writing. The exception to this is when a reasonable part of the text is quoted for purpose of book review, abstracting etc.

This book is sold subject to the condition that it shall not, by way of trade or otherwise be lent, re-sold, hired out, or otherwise circulated without the publisher’s prior consent in any form of binding or cover other than that in which it is published and without a similar condition including this condition being imposed on the subsequent purchaser.

Printed in the United States of America

Preface

The vertebrates are members of the largest clade of chordates, the Vertebrata, and are characterized for having features such as backbones and spinal columns. More than 58,000 species of vertebrates have been described so far, making up about 5% of all described animal species. Several studies have provided information on the head, neck, pectoral and forelimb musculature of the Vertebrates, but most of them concentrated on a single taxon or a specific subgroup of muscles. The few more inclusive comparative analyses that were actually based on dissections of taxa representing sarcopterygian fish, amphibians, reptiles, monotremes and therian mammals, including modern humans, were published at least half a century ago, and some much earlier than that. Those authors did not have access to information that is now available about, for example, the cephalic and the pectoral muscles of the coelacanth *Latimeria chalumnae*, the role played by neural crest cells in the development and patterning of the vertebrate muscles, or the molecular and other evidence that has accumulated about phylogenetic relationships of Vertebrates. The main aims of the present volume are thus to summarize all the information obtained from our dissections of numerous specimens from vertebrate groups as varied as the Teleostei, Halecomorphi, Ginglymodi, Chondrostei, Cladistia, Dipnoi, Gymnophiona, Anura, Caudata, Testudines, Lepidosauria, Crocodylia, Aves, Monotremata, Marsupialia, Rodentia, Scandentia, Dermoptera and Primates, including *Homo sapiens*, to compare this new information with the data available in the literature, and then to collate and synthesize all of the new and existing data. To our knowledge, this is the most detailed account that has been published so far on the head, neck, pectoral and forelimb musculature of Vertebrates, because it includes information about the mandibular, hyoid, branchial, hypobranchial, epibranchial, pectoral, arm, forearm and hand muscles of each of the major vertebrate taxa. The book also includes hundreds of illustrations (drawings and photographs) of, as well as numerous tables showing the homologies between the muscles of all the major extant vertebrate taxa. It also provides a list of more than a thousand synonyms that have been used by other authors to designate these muscles in the literature, from more then two centuries ago until

the present date. Importantly, it also reviews data obtained in the fields of evolutionary developmental biology, embryology and genetics, and explains how this data helps to understand the evolution and homologies of vertebrate muscles. Chapters 1 and 2 provide an introduction to the main aims of the book and the methodology and material used. Chapter 3 deals with the muscles of non-osteichthyan vertebrates. Chapters 4 and 8 are focused on the head, neck, pectoral and pectoral fin/forelimb muscles of actinopterygians and basal sarcopterygians. Chapters 5 and 9 discuss the evolution and homologies of these muscles, from sarcopterygian fish such as coelacanths to mammals such as modern humans, while Chapters 6, 7 and 10 deal with the muscles of non-mammalian tetrapods. Chapter 11 provides a general discussion of the data presented in Chapters 3 to 10, addressing subjects such as the use of myological characters in phylogenetic reconstructions, the relationship between muscular splittings, fusions, paedomorphism, evolutionary reversions and anatomical complexity, the study of muscles in the context of evolutionary developmental biology, and the proposal of a unifying nomenclature for the head, neck, pectoral and forelimb muscles of the vertebrates as a whole. We thus hope that the information provided in this book will be useful to teachers, students, and researchers working in different fields such as functional morphology, ecomorphology, evolutionary developmental biology, embryology, molecular biology, zoology, evolution, and phylogeny. As the book includes crucial information about the anatomy, development, homologies, evolution and muscular abnormalities of our own species, *Homo sapiens*, it will also be helpful to physicians and medical students.

February 2010 **Rui Diogo and Virginia Abdala**

Acknowledgements

We want to thank the late G. Teugels, as well as J. Snoeks and E. Vreven (Musée Royal de l'Afrique Centrale), P. Laleyé (Université Nationale du Bénin), Z. Peng and S. He (Academy of Sciences of China at Wuhan), T. Grande (Field Museum of Natural History), D. Catania (California Academy of Sciences), M. Stiassny (American Museum of Natural History), M. Sabaj and J. Lundberg (Academy of Natural Sciences of Philadelphia), W. Fink, D. Nelson and H. Ng (Museum of Zoology, University of Michigan), R. Bills and P. Skelton (South African Institute for Aquatic Biodiversity), L. Page and M. Retzer (Illinois Natural History Survey), P. Pruvost and G. Duhamel (Museum National d'Histoire Naturelle), I. Doadrio and J. Fernández (Museo Nacional de Ciencias Naturales de Madrid), J. Joss (Macquarie University), A. Gosztonyi (Centro Nacional Patagónico), J.C. Stazonelli, E. Lavilla, S. Ktretschmar, A. Echavarria, M. Cánepa, D. Baldo, L. Ponssa, C. Abdala and G. Scrocchi (Fundación Miguel Lillo), T. Tedesco and J. Céspedez (Universidad del Nordeste, Argentina), R. Walsh and F. Slaby (Department of Anatomy, GWU), M. Carleton, D. Schmidt, L. Gordon, and R. Vari (National Museum of Natural History), R. Etheridge (San Diego State University), J. Daza (University of Puerto Rico), B. Sacham and Y. Werner (The Hebrew University of Jerusalem), A. Manzano (CCyTTP, Diamante), B. Richmond (Department of Anthropology, GWU), M. Aziz (Department of Anatomy, Howard University), J. Fritz and J. Murphy (Primate Foundation of Arizona), G. Watkins-Colwell (Yale University), D. Flores (Museo Argentino de Ciencias Naturales), R. Barquez (Facultad de Ciencias Naturales, UNT), and R. Montero (Universidad Nacional de Tucumán), among others, for kindly providing a large part of the specimens analyzed for this study. Anthony Herrel (Muséum National d'Histoire Naturelle, Paris) generously permitted the dissection of many specimens of his personal collection. We also want to acknowledge T. Abreu, A. Zanata, F. Meunier, D. Adriaens, F. Wagemans, M. de Pinna, P. Skelton, F. Poyato-Ariza, T. Grande, H. Gebhardt, M. Ebach, A. Wyss, J. Waters, G. Cuny, L. Cavin, F. Santini, J. Briggs, L. Gahagan, M. Gayet, J. Alves-Gomes, G. Lecointre, L. Soares-Porto, P. Bockmann, B. Hall, F. Galis, T. Roberts, G. Arratia, L. Taverne, E. Trajano, C. Ferraris, M. Brito,

R. Reis, R. Winterbottom, C. Borden, B. Richmond, , M. Fabrezi, M.J. Tulli, and A. Russell and many other colleagues for their helpful advice and assistance and for their discussions on vertebrate anatomy, functional morphology, development, phylogeny and evolution in the last years. Also, thanks to all those who have been involved in administering the various grants and other awards that we have received during the last years, without which this work would really not have been possible.

RD wants to thank P. Vandewalle and M. Chardon, for accepting him in the Laboratory of Functional and Evolutionary Morphology in 1998 and for thus giving him the opportunity to begin his research on the anatomy, functional morphology, phylogeny and evolution of Vertebrates. He also wants to thank E. Parmentier, as well as R. Vari and his colleagues S. Weitzman, J. Williams and S. Jewett from the National Museum of Natural History, for accepting him in that amazing museum during two academic years and for providing numerous specimens analyzed in the present work. He also wants to thank I. Doadrio, who received him in the Museo Nacional de Ciencias Naturales de Madrid, and has made available many specimens of the vast fish collection of this museum. Another particularly bright scientist who received RD in his lab for several months was S. Hughes, who RD thanks very, very much. In his lab, at the prestigious MRC Centre for Developmental Neurobiology of the King's College of London, RD took his first steps in Evolutionary Developmental Biology ("Evo-Devo"). He greatly enjoyed the availability, interest, and continuous questioning and curiosity of S. Hughes. RD also wants to take this occasion to thank B. Wood, for inviting him to continue his research at the Anthropology Department of the George Washington University and expand his studies to groups such as the Primates, including modern humans. RD is particularly thankful to all his friends, particularly to Pedro Brito, Claudia Oliveira, Henry Evrard and Diego Alarcon Reina, and, above all, to Alejandrita Pelito Lindo, to the amazing and adorable Tots Pelluda, and to his parents, Valter and Fatima, his brothers, Hugo and Luis, and to his late grandparents Raul and Amélia. He would also like to thank R. Primlani, who kindly invited him and VA to publish this book, as well as other books, with the prestigious Science Publishers (Enfield, USA).

VA wants to thank her husband Julio Calvo for kindly taking care of their children while she was working on this book and for his long-standing patience. She would also like to thank her sister Carolina Abdala, her brother-in-law David Bardavid and friends Cristina Braks, Ana Laura G. Padilla and Tessy Pelejero for their enthusiastic support in January and February 2009, enjoying the beauty of the San Javier mountains in Tucumán and writing parts of various chapters of the book. VA also wishes to thank her children, Agustina, Santiago and Tomás for understanding

her frequent absences and occupations. She is thankful to S. Cintora for her continuous support taking care of her grandsons, to Lucinda Backwell and Fernando Abdala as well as to Esteban Abdala and Connie for their continuous interest and enthusiasm in the achievements of her scientific career, and to her parents Rosa and Ruben Abdala for supporting and loving her along all their lives and beyond.

Thanks to **ALL** of you!!!

Contents

Preface v
Acknowledgements vii

1. Introduction and Aims 1
2. Methodology and Material 6
3. Muscles of Non-Osteichthyan Vertebrates 20
4. Head and Neck Muscles of Actinopterygians and Basal Sarcopterygians 61
5. From Sarcopterygian Fish to Modern Humans: Head Muscles and Neck 108
6. Head and Neck Muscles of Amphibians 205
7. Head and Neck Muscles of Reptiles 228
8. Pectoral and Pectoral Fin Muscles of Actinopterygian and Sarcopterygian Fishes 271
9. From Sarcopterygian Fish to Modern Humans: Pectoral and Forelimb Muscles 287
10. Pectoral and Forelimb Muscles of Limbed Amphibians and Reptiles 359
11. General Comments 421
    - 11.1. Muscular splittings, fusions, paedomorphism, reversions and anatomical complexity 421
    - 11.2. Myological characters and phylogenetic reconstructions 426
    - 11.3. Myology, evolutionary developmental biology, model organisms, and the zebrafish 434
    - 11.4. Proposal of a unifying nomenclature for the muscles of vertebrates 443

References 451
Index 471
About the Authors 477
Color Plate Section 479

Chapter 1

Introduction and Aims

The vertebrates are members of the largest clade of chordates, the Vertebrata, and are characterized for having features such as backbones and spinal columns. More than 58,000 species of vertebrates have been described so far, making up about 5% of all described animal species, and representing over 5000 million years of evolution. Phylogenetically (see Fig. 1.1; see also Figs. 3.1, 4.1., 5.1 and 9.1), extant vertebrates may be divided into cyclostomes (including hagfish and lampreys: see Chapter 3) and Gnathostomes, the latter clade being, in turn, subdivided into chondrichthyans (including holocephalans and elasmobranchs) and osteichthyans. However, according to most authors there is a group of fossil fishes that is more closely related to osteichthyans than are the chondrichthyans: the †Acanthodii, which, together with the Osteichthyes, form a group usually named Teleostomi (e.g., Kardong 2002). In addition, apart from the Teleostomi and Chondrichthyes, there is another group that is usually included in the gnathostomes and that is usually considered the sister-group of teleostomes + chondrichthyans: the †Placodermi (e.g., Kardong 2002).

The Osteichthyes, including bony fishes and tetrapods, is a highly speciose group of animals, comprising more than 42,000 living species. Two main osteichthyan groups are usually recognized: the Sarcopterygii (lobefins and tetrapods), with an estimate of more than 24,000 living species (e.g., Stiassny et al. 2004), and the Actinopterygii (rayfins), including more than 28,000 extant species (e.g., Nelson 2006). The Polypteridae (included in the Cladistia) are commonly considered the most basal extant actinopterygian taxon. The Acipenseridae and Polyodontidae (included in the Chondrostei) are usually considered the sister-group of a clade including the Lepisosteidae (included in the Ginglymodi) and the Amiidae (included in Halecomorphi) plus the Teleostei. Regarding the Teleostei, four main living clades are usually recognized in recent works: the Elopomorpha,

Osteoglossomorpha, Otocephala (Clupeomorpha + Ostariophysi) and Euteleostei. The Sarcopterygii includes two groups of extant fishes, the coelacanths (Actinistia) and lungfishes (Dipnoi), and the Tetrapoda. Within tetrapods, Amphibia is the sister-group of Amniota, which includes the Mammalia and the Reptilia (note: when we use the term 'reptiles' we refer to the group including lepidosaurs, birds, crocodylians and turtles, which, despite some controversy, continues to be considered a monophyletic taxon by most taxonomists: see, e.g., Gauthier et al. 1988; Kardong 2002; Dawkins 2004; Diogo 2007; Conrad 2008). The Amphibia include three main extant groups: caecilians (Gymnophiona or Caecilia), frogs (Anura), and salamanders (Caudata or Urodela), the two latter groups being possibly more closely related to each other than to the caecilians (see, e.g., the recent review of Carroll 2007). The Reptilia include four main extant groups: turtles (Testudines), lepidosaurs (Lepidosauria), crocodylians (Crocodylia) and birds (Aves). The Lepidosauria, Crocodylia and Aves are probably more closely related to each other than to Testudines, being thus usually included in the clade Diapsida; crocodylians are considered to be the closest living relatives of birds, these two groups being included in the clade Archosauria (see, e.g., Gauthier et al. 1988; Dilkes 2000; Kardong 2002; Meers 2003; Dawkins 2004; Conrad 2008). The Lepidosauria comprises the Rhynchocephalia, which includes a single extant genus, *Sphenodon*, and the Squamata, which according to the recent study of Conrad (2008) includes amphisbaenians, mosasaurs, snakes and 'lizards' (as explained by this author, 'lizards' do not form a monophyletic group, because some 'lizards' are more closely related to taxa such as snakes than to other 'lizards': see Conrad 2008 for more details on the interrelationships of squamates). The Mammalia includes the Monotremata and Theria, which comprises marsupials and placentals. Within the latter, the Primates (including modern humans), Dermoptera (including colugos or 'flying lemurs') and Scandentia (including tree-shrews) are included in the clade Euarchonta and are placed in an unresolved trichotomy in Fig. 1.1, because the relationships between these three groups remains mainly unresolved (some authors continue to group colugos with tree-shrews, others group tree-shrews with primates, and yet others group colugos with primates: see, e.g., Sargis 2002ab, 2004; Dawkins 2004; Marivaux et al. 2006; Janecka et al. 2007; Silcox et al. 2007; Diogo 2009).

Several studies have provided information on the head, neck, pectoral and forelimb/pectoral fin musculature of the Vertebrates, but most of them concentrate on a single taxon or a specific subgroup of muscles. The few more inclusive comparative analyses that were actually based on dissections of taxa comprising actinopterygians, sarcopterygian fish, amphibians, reptiles, monotremes and therian mammals, including modern humans, were published at least half a century ago, and some much earlier than

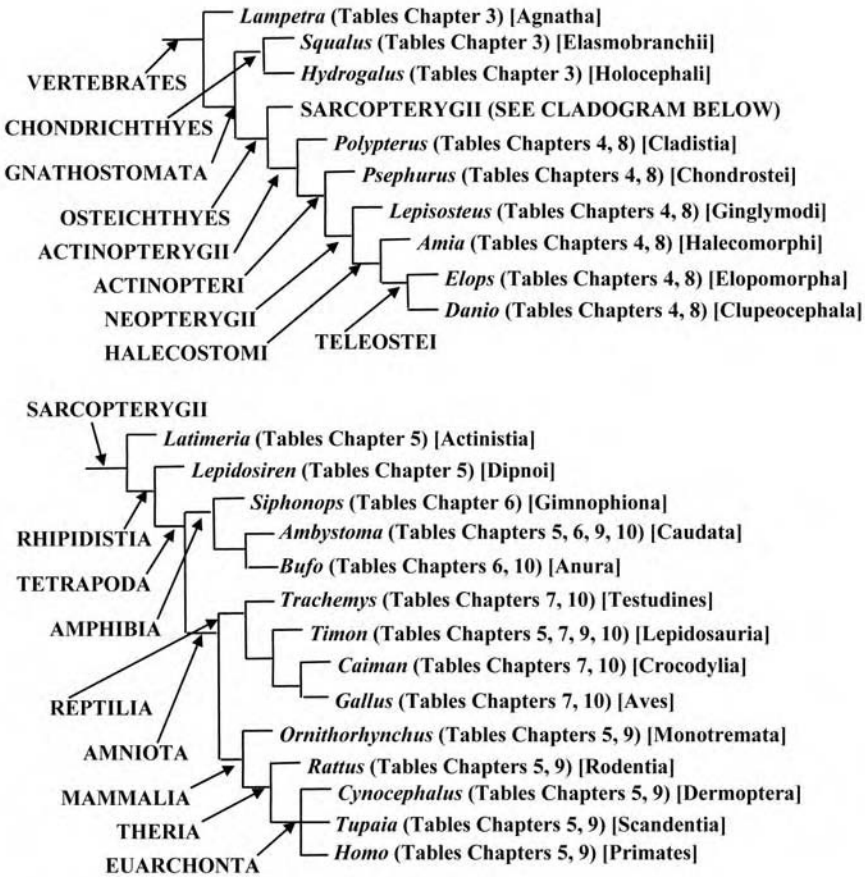

Fig. 1.1 Simplified phylogenetic framework for the discussions provided in this book and the comparison between the muscles of the genera listed in the tables of Chapters 3 to 10 (for more details about the phylogenetic relationships of the main vertebrate clades discussed in Chapters 3 to 10 and the literature from which this phylogenetic scenario is based, see text and Figs. 3.1, 4.1, 5.1, and 9.1).

that (e.g., Humphry 1872ab; Luther 1913–1914; Kesteven 1942–1945; Edgeworth 1902–1935; Huber 1930–1931; Brock 1938). However, none of these works actually covered in detail the whole head, neck, pectoral and forelimb/pectoral fin musculature of all these taxa. Moreover, the authors of these works did not have access to crucial information that is now available about, for example, the cephalic and the pectoral muscles of the coelacanth *Latimeria chalumnae* (discovered only in 1938), the important part played by neural crest cells in the development and patterning of the vertebrate muscles, or the molecular and other evidence that has

accumulated about the phylogenetic interrelationships of vertebrates (e.g., Millot and Anthony 1958; Jarvik 1963, 1980; Alexander 1973; Le Lièvre and Le Douarin 1975; Anthony 1980; Lauder 1980c; Rosen et al. 1981; Noden 1983, 1984, 1986; Hatta et al. 1990, 1991; Adamicka and Ahnelt 1992; Couly et al. 1992; Miyake et al. 1992; Köntges and Lumsden 1996; Pough et al. 1996; Schilling and Kimmel 1997; Kardong and Zalisko 1998; McGonnell 2001; Olsson et al. 2001; Hunter and Prince 2002; Kardong 2002; West-Eberhard 2003; Diogo 2004ab, 2007, 2008; Ericsson and Olsson 2004; Ericsson et al. 2004; Carroll et al. 2005; Thorsen and Hale 2005; Kisia and Onyango 2005; Noden and Schneider 2006; Diogo and Abdala 2007; see Chapters 3–11 and the list of references provided in the end of the book).

The main aims of the present volume are thus to summarize all the information obtained from our dissections of numerous specimens from vertebrate groups as varied as the Teleostei, Halecomorphi, Ginglymodi, Chondrostei, Cladistia, Dipnoi, Gymnophiona, Anura, Caudata, Testudines, Lepidosauria, Crocodylia, Aves, Monotremata, Marsupialia, Rodentia, Scandentia, Dermoptera and Primates, including *Homo sapiens*, to compare this new information with the data available in the literature, and then to collate and synthesize all of the new and existing data. To our knowledge, this is the most detailed account that has been published so far on the head, neck, pectoral and forelimb/pectoral fin musculature of Vertebrates, because it includes information about the mandibular, hyoid, branchial, hypobranchial, epibranchial, pectoral, arm, forearm and hand muscles of each of the major vertebrate taxa. As explained in the Preface, Chapters 1 and 2 provide a short introduction to the main aims of the book and to the methodology and material used. Chapter 3 deals with the muscles of non-osteichthyan vertebrates. Chapters 4 and 8 are focused on the head, neck, pectoral and pectoral fin/forelimb muscles of actinopterygians and basal sarcopterygians. Chapters 5 and 9 discuss the evolution and homologies of these muscles, from sarcopterygian fish such as coelacanths to mammals such as modern humans, while Chapters 6, 7 and 10 deal with the muscles of non-mammalian tetrapods. Chapter 11 provides a general discussion of the data presented in Chapters 1 to 10, addressing subjects such as the use of myological characters in phylogenetic reconstructions, the relationship between muscular splittings, fusions, paedomorphism, evolutionary reversions and anatomical complexity, the study of muscles in the context of evolutionary developmental biology, and the proposal of a unifying nomenclature for the head, neck, pectoral and forelimb/pectoral fin muscles of the vertebrates as a whole. As some readers will probably be particularly interested in a specific clade and/or a specific group of muscles (e.g., the head and neck muscles of amphibians), and, thus, in a specific chapter (e.g., in that case, Chapter 6), we decided that each chapter would follow a consistent organization internally (e.g.,

a short introduction, a main section with the results and discussion, and then some general remarks). So, some results and a few comments may thus be repeated in different chapters, but the book has more consistency of presentation throughout and the readers may quickly obtain the most important information about the taxon and/or group of muscles in which they are interested without having to read all the other parts of the book before that.

As stressed in our previous works (e.g., Diogo et al. 2008ab, 2009ab), one of the major problems researchers face when they compare the muscles of a certain vertebrate taxon with those of other taxa is the use of different names by different authors to designate the same muscle in the members of different clades, and even of the same clade. In order to reconcile the different nomenclatures we use a unifying nomenclature for the head, neck, pectoral and forelimb muscles of the vertebrates as a whole that takes into account the data compiled and discussed in this book. In fact, we are fully aware of the new, ambitious, and clearly needed ontological projects that are now being developed in different biological disciplines. Such ontologies are extremely important and are becoming increasingly popular, because they provide a vocabulary for representing and communicating knowledge about a certain topic and a set of relationships that hold among the terms in that vocabulary. Although we did not have in mind to build an ontology when we began this project, the fact is that we did it, and still do, in each of our works published in the context of comparative vertebrate myology, and particularly in this book. Therefore, we hope that the information provided here will stimulate researchers to develop a detailed ontology of the head, neck, pectoral and forelimb musculature of vertebrates, as well as to undertake future studies about the evolution, homologies, and development of these muscles and of other vertebrate anatomical structures in general. In fact, we sincerely hope that this volume will contribute to the revival of the field of vertebrate comparative myology, which was often neglected in the past few decades but remains crucial to understanding the evolution and phylogeny of vertebrates as a whole, as well as the evolutionary history, anatomical variations, ontogeny and numerous medical problems of modern humans in particular.

Chapter 2

Methodology and Material

Biological Material

The general phylogenetic framework for the comparisons provided in the present work is set out in Fig. 1.1 (see also Figs. 3.1, 4.1, 5.1, and 9.1). In order to facilitate the comparisons between the head, neck, pectoral and forelimb muscles of vertebrates, we carefully chose to include in the tables provided in Chapters 3–10: the lamprey *Lampetra japonica* (Agnatha), the shark *Squalus acanthias* (Elasmobranchii), the ratfish *Hydrolagus colliei* (Holocephali) [non-osteichthyan vertebrates: tables of Chapter 3]; the bichir *Polypterus bichir* (Cladistia), the swordfish *Psephurus gladius* (Chondrostei), the gar *Lepisosteus osseus* (Ginglymodi), the bowfin *Amia calva* (Halecomorphi), the basal teleostean *Elops saurus* and the clupeocephalan teleostean *Danio rerio* (Teleostei) [actinopterygian osteichthyans: tables of Chapters 4 and 8]. Regarding sarcopterygian osteichthyans [tables of Chapters 5, 6, 7, 9 and 10], we include the coelacanth *Latimeria chalumnae* (Actinistia), the lungfish *Lepidosiren paradoxa* (Dipnoi), the salamander *Ambystoma ordinarium* (Caudata or Urodela), the caecilian *Siphonops paulensis* (Gymnophiona), the frog *Bufo* (or *Rhinella*) *arenarum* (Anura), the 'lizard' *Timon lepidus* (Lepidosauria), the turtle *Trachemys scripta* (Testudines), the crocodylian *Caiman latirostris* (Crocodylia) and the bird *Gallus domesticus* (Aves). We also include a member of the phylogenetically most plesiomorphic extant mammal clade, the Monotremata (*Ornithorhynchus anatinus*, or 'platypus'), a member of the Rodentia, the Norwegian rat (*Rattus norvegicus*; because rats are often considered as 'anatomically generalized' therian mammals but at the same time are somewhat closely related to primates), a member of the colugos (or 'flying lemurs') (*Cynocephalus volans*), and a member of the tree-shrews (*Tupaia* sp.). That is, we include in these tables members of the two groups that are usually considered the closest living relatives of primates (colugos and tree-shrews: Fig. 1.1). The latter group is represented in the tables by

our own species, *Homo sapiens*. It is important to explain that, apart from these taxa, we have dissected numerous specimens of other vertebrate taxa. The dissected specimens are from the Colección Mamíferos Lillo of the Universidad Nacional de Tucumán (CML), the Primate Foundation of Arizona (PFA), the Department of Anatomy (GWU-ANA) and the Department of Anthropology (GWU-ANT) of the George Washington University, the Department of Anatomy of Howard University (HU-ANA), the Smithsonian Institution's National Museum of Natural History (USNM), the Cleveland Metroparks Zoo (CMZ), the Yerkes National Primate Research Center (YNPRC), the Duke Lemur Center (DLC), the Museo Nacional de Ciencias Naturales de Madrid (MNCN), the Centro Nacional Patagónico de Argentina (CONICET), the Macquarie University of Australia (MU), the herpetological collection of Diamante-CONICET-Argentina (DIAMR), the Fundación Miguel Lillo of Argentina (FML), the San Diego State University (SDSU), the Laboratory of Functional and Evolutionary Morphology of the University of Liège (LFEM), the American Museum of Natural History (AMNH), the Academy of Natural Sciences of Philadelphia (ANSP), the Chinese Academy of Sciences at Wuhan (CASW), the California Academy of Sciences (CAS), the Field Museum of Natural History (FMNH), the Illinois Natural History Survey (INHS), the Museum National d'Histoire Naturelle de Paris (MNHN), the Musée Royal de l'Afrique Centrale (MRAC), the Université Nationale du Bénin (UNB), the collection of Anthony Herrel (AH), the herpetological collection of the Hebrew University of Jerusalem-Israel (HUJ), the "Museo de Zoologia of the San Pablo University-Brasil" (MZUSP), the Tupinambis Project Tucumán-Argentina (PT), the personal collection of Richard Thomas in Puerto Rico University (RT), and the Peabody Museum of Natural History of Yale University (YPM). The list of specimens examined by us is given below; the number of specimens dissected is followed by an abbreviation that refers to the state of the specimen (alc = alcohol fixed; fre = fresh; for = formalin embalmed; c&s = trypsin-cleared and alizarine-stained). In our dissections, other than their color, there were no notable differences regarding the attachments, overall configuration and general appearance of the muscles of fresh, alcohol fixed, and formalin embalmed specimens.

Specimens dissected

ACTINOPTERYGII—Non-teleostean actinopterygians: *Acipenser sturio*: MNCN 152172, 3 (alc). *Amia calva*: MNCN 35961, 1 (alc), 1 (c&s). *Lepisosteus osseus*: ANSP 107961, 2 (alc); ANSP 172630, 1 (alc); MNCN 246557, 1 (c&s). *Lepisosteus platyrhincus*: AMNH 74789, 2 (alc). *Polypterus bichir*: MNCN 1579, 7 (alc), 1 (c&s). *Psephurus gladius*: CASW, uncatalogued, 1 (alc). **Clupeomorpha:** *Denticeps clupeoides:* MRAC 76-032-P-1, 2 (alc). *Engraulis encrasicolus:* MNCN 68048, 2 (alc); MNCN 65097, 8

(alc); MNCN 1099, 3 (alc). *Engraulis* sp: MNCN 48896, 3 (alc). *Ethmalosa fimbriata:* MNCN 48865, 3 (alc). *Ilisha fuerthii:* MNCN 49338, 8 (alc). *Thryssa setirostris:* MNCN 49294, 2 (alc). **Elopomorpha:** *Albula vulpes*: MNCN 52124, 2 (alc). *Anguilla anguilla*: MNCN 41049, 3 (alc). *Elops lacerta*: LFEM, 2 (alc). *Elops saurus*: MNCN 48752, 2 (alc). *Conger conger*: MNCN 1530, 5 (alc). *Eurypharynx pelecanoides*: AMNH 44315, 1 (alc); AMNH 44344, 1 (alc). *Megalops cyprinoides*: MNCN 48858, 3 (alc). *Notacanthus bonaparte*: MNCN 107324, 3 (alc). **Euteleostei:** *Alepocephalus rostratus:* MNCN 108199, 2 (alc). *Argentina brucei:* USNM 239005, 2 (alc). *Argentina sphyraena:* MNCN 001134, 12 (alc); MNCN 78530, 5 (alc). *Astronesthes niger:* MNCN 1102, 1 (alc). *Aulopus filamentosus:* MNCN 1170, 6 (alc). *Bathylagus euryops:* MNCN 124597, 1 (alc). *Bathylagus longirostris:* USNM 384823, 2 (alc). *Bathylagus tenuis:* MNHN 2005-1978, 2 (alc). *Chlorophthalmus agassizi:* MNCN 1193, 3 (alc); MNCN 1182, 5 (alc). *Coregonus lavaretus:* MNCN 75424, 1 (alc). *Coregonus tugun:* MNCN 75422, 2 (alc). *Esox lucius:* MNCN 197706, 5 (alc). *Galaxias maculatus:* USNM 344889, 2 (alc). *Osmerus eperlanus:* MNCN 193795, 11 (alc). *Osmerus mordax:* USNM 32565, 2 (alc). *Plecoglossus altivelis:* MNCN 192036, 1 (alc). *Retropinna retropinna:* AMNH 30890, 1 (alc). *Salmo trutta:* MNCN 136179, 2 (alc), 1 (c&s); MNCN 16373, 2 (alc); MNCN 40685, 2 (alc). *Salmo* sp: MNCN 48863, 2 (alc). *Searsia koefoedi:* USNM 206896, 2 (alc). *Stokellia anisodon:* AMNH 31037, 1 (alc). *Stomias boa:* MNCN 74444, 8 (alc); MNCN 74456, 4 (alc). *Thymallus thymallus:* MNCN 115147, 1 (alc); MNCN 114992, 1 (alc). *Umbra limi:* MNCN 35672, 2 (alc); 36072, 2 (alc). *Umbra krameri:* MNCN 36659, 3 (alc). *Xenodermichthys copei:* MNCN 78950, 2 (alc); MNCN 1584, 2 (alc); USNM 215527, 2 (alc). **Ostariophysi:** *Bagrus bajad:* LFEM, 1 (alc), 1 (c&s). *Bagrus docmak:* MRAC 86-07-P-512, 1 (alc). *Barbus barbus:* LFEM, 1 (c&s). *Barbus guiraonis:* MNCN 245730, 3 (alc). *Brachyhypopomus brevirostris:* LFEM, 2 (alc). *Brachyhypopomus* sp: INHS 89761, 2 (alc). *Brycon guatemalensis:* MNCN 180536, 3 (alc). *Brycon henni:* CAS 39499, 1 (alc). *Callichthys callichthys:* USNM 226210, 2 (alc). *Catostomus commersonii:* MNCN 36124, 10 (alc). *Citharinus* sp.: 86-016-P-72, 3 (alc). *Cetopsis coecutiens:* USNM 265628, 2 (alc). *Chanos chanos:* USNM 347536, 1 (alc), LFEM, 1 (alc). *Chrysichthys auratus:* UNB, 2 (alc). *Chrysichthys nigrodigitatus:* LFEM, 1 (c&s). *Cobitis paludica:* MNCN 248076, 7 (alc). *Cromeria nilotica:* MRAC P.141098, 2 (alc). *Danio rerio:* MNCN, 10 (alc). *Diplomystes chilensis:* LFEM, 3 (alc). *Distichodus notospilus:* MRAC A0-048-P-2630, 3 (alc). *Gonorynchus gonorynchus:* LFEM, 2 (alc). *Gonorynchus greyi:* FMNH 103977, 1 (alc). *Grasseichthys gabonensis:* MRAC 73-002-P-264, 3 (alc). *Gymnotus carapo:* INHS 35493, 2 (alc). MNCN 115675, 2 (alc). *Kneria wittei:* MRAC P-33512, 2 (alc). *Nematogenys inermis:* USNM 084346, 2 (alc). *Opsariichthys uncirostris:* MNCN 56668, 3 (alc). *Parakneria abbreviata:* MRAC 99-090-P-703, 3 (alc). *Phractolaemus ansorgii:* MRAC P.137982, 3 (alc). *Pimelodus blochii:* LFEM, 2 (alc), 1 (c&s). *Silurus aristotelis:* LFEM, 2 (alc). *Silurus glanis:* LFEM, 2 (alc). *Sternopygus macrurus:* CAS 48241, 1 (alc); INHS 62059, 2 (alc). *Trichomycterus areolatus:* LFEM, 2 (alc). *Xenocharax spilurus:* MRAC A0-048-P-2539, 3 (alc). [†*Chanoides macropoma,* †*Clupavus maroccanus,* †*Lusitanichthys characiformis*, †*Santanichthys diasii,* and †*Sorbininardus apuliensis*, not directly observed by the author, were also included in the cladistic analysis: see above]. **Osteoglossomorpha:** *Hiodon tergisus*: MNCN 36019, 3 (alc). *Mormyrus niloticus*: LFEM, 1 (alc). *Mormyrus tapirus*: MNCN 80593, 3 (alc); MNCN 85283, 1 (alc). *Pantodon buchholzi*: MNCN 73493, 4 (alc). *Xenomystus nigri*: MNCN 227824, 25 (alc).

SARCOPTERYGII—Amphibia: *Ambystoma mexicanum*: MNCN, uncatalogued, 2 (alc). *Ambystoma ordinarium*: MNCN, uncatalogued, 2 (alc). *Ambystoma texanum*:

FML 03402, 1 (alc). *Bufo arenarum*: FML 01352-1, 3 (alc). *Chtonerpethon indistinctum*: JC, uncatalogued, 1 (alc). *Leptodactylus fuscus*: FML, uncatalogued, 2 (alc). *Litoria caerulea*: DIAM 0313, 1 (alc). *Phyllomedusa sauvagi*: FML 04899, 2 (alc), and DIAM 0337, 1 (alc). *Siphonops paulensis*: FML, uncatalogued, 1 (alc); *Siphonops* sp.: DB, uncatalogued, 2 (alc). *Telmatobius laticeps*: FML 3960, 1 (alc). **Aves:** *Cairina moschata*: FML w/d, 1 (alc). *Coturnyx coturnyx*: FML w/d, 2 (alc). *Gallus domesticus*: FML w/d, 3 (alc). *Nothura* (alc). FML w/d 1 (alc). *Pitangus sulphuratus*: FML w/d, 1 (alc). *Thraupis sayaca*: FML w/d, 1 (alc). **Crocodylia:** *Caiman latirostris*: FML w/d, 1 (alc), and CCyTTP w/d, 4 (alc). **Dipnoi:** *Lepidosiren paradoxa*: CONICET, uncatalogued, 1 (alc). *Neoceratodus forsteri*: MU, uncatalogued, 2 (alc). **Lepidosauria:** *Ameiva ameiva*: FML 03637, 4 (alc). *Amphisbaena alba*: FML uncatalogued, 2 (alc). *Anisolepis longicauda*: UNNEC no number, 1 (alc). *Basiliscus vittatus*: SDSU 02097, 1 (alc). *Bogertia lutzae*: MZU(ALC) 54747, 1 (alc). *Briba brasiliana*: MZU(ALC) 73851, 1 (alc). *Callopistes maculatus*: MZU(ALC) 58107, 1 (alc). *Calyptommatus leiolepis*: MZU(ALC) 71339, 1 (alc). *Chalcides chalcides*: FML 03712, 1 (alc). *Cnemidophorus ocellifer*: FML 03389, 2 (alc); FML 03409, 4 (alc), without data, 1 (alc), and FML 17606, 1 (alc). *Cordylus tropidosternon*: AH no number, 1 (alc). *Crocodilurus lacertinus*: MZU(ALC) 12622, 1 (alc). *Dicrodon guttulatum*: FML 02017, 1 (alc). *Diplolaemus bibroni*: MACN 35850, 1 (alc). *Dracaena paraguayensis*: MZU(ALC) 52369, 1 (alc). *Echinosaura horrida*: MZU(ALC) 54452, 1 (alc). *Enyalius iheringii*: MZU(ALC) 74901, 1 (alc). *Garthia gaudichaudii*: MZU(ALC) 45329, 1 (alc). *Garthia penai*: MZU(ALC) 60937, 1 (alc). *Gekko vittatus*: AH no number, 2 (alc). *Gerrohsaurus major*: AH no number, 1 (alc). *Gymnodactylus geckoides*: MZ(ALC) 48128, 1 (alc). *Hemidactylus garnoti*: AH no number, 2 (alc). *Hemidactylus mabouia*: FML 02142, 1 (alc)., and FML 02421, 1 (alc). *Homonota fasciata*: FML 02137, 1 (alc)., and FML 00915, 2 (alc). *Leiosaurus paronae*: MACN 4386, 1 (alc). *Liolaemus cuyanus*: FML 02021, 7 (alc). *Mabuya frenata*: FML 00277, 1 (alc)., and FML 01713, 1 (alc). *Microlophus theresioides*: FML 03674, 1 (alc). *Phelsuma madagascariensis*: AH no number, 2 (alc). *Phyllodactylus gerrophygus*: FML 01563, 2 (alc). *Phyllopezus pollicaris*: FML 02913, 2 (alc). *Phymaturus* (alc).: FML 13834-13844, 3 (alc). *Phymaturus punae*: FML 2942, 4 (alc). *Podarcis sicula*: FML 03714, 1 (alc). *Polychrus acutirostris*: MZU(ALC) 48151, 1 (alc). MZU(ALC) 08605, 1 (alc). *Pristidactylus achalensis*: MACN 32779, 1 (alc). *Proctoporus guentheri*: FML 02010, 1 (alc). *Teius teyous*: FML 00290, 2 (alc). *Stenocercus caducus*: FML 00260, 1 (alc), and FML 00901, 1 (alc). *Thecadactylus rapicauda*: MZU(ALC) 11476, 1 (alc). *Tropidurus etheridgei*: FML 03562, 2 (alc). *Tropidurus hygomi*: FML 08796, 1 (alc). *Tropidurus oreadicus*: FML 08771, 1 (alc). *Tropidurus (alc)inulosus*: FML 00129, 2 (alc)., and FML 03559, 2 (alc). *Tupinambis rufescens*: PT 0084, 1 (alc), PT 0085, 1 (alc)., FML 06412, 1 (alc), FML 06425, 1 (alc), and FML 07420, 1 (alc). *Vanzoia klugei*: MZU(ALC) 59130, 1 (alc). *Varanus* (alc): AH no number, 1 (alc). *Xantusia* (alc).: AH no number 1, 1 (alc). *Zonosaurus* (alc): AH no number, 1 (alc). **Mammalia:** *Cynocephalus volans*: USNM, 144941, 1 (alc); USNM, uncatalogued, 1 (alc). *Didelphis albiventris:* CML 5971, 1 (alc). *Homo sapiens*: GWU-ANA, 1-16, 16 (for). *Hylobates lar*: HU-ANA, H01, 1 (for). *Lepilemur ruficaudatus*: HU-ANA, L01, 1 (for). *Lutreolina crassicaudata:* CML 4114, 1 (alc). *Macaca mulatta*: HU-ANA, M01, 1 (for); YNPRC, M1-9, 9 (for). *Monodelphis dimidiata*: CML 4118, 1 (alc). *Otolemur garnettii*: DLC, OG1-10, 10 (for). *Otolemur crassicaudatus*: DLC, OC1-12, 12 (for). *Ornithorhynchus anatinus*: USNM, 13678, 1 (alc); USNM, uncatalogued, 1 (alc). *Pan troglodytes*: PFA, 1016, 1 (fre); PFA, 1009, 1 (fre); PFA, 1051, 1 (alc.); HU-ANA, C104, 1 (for); GWU-ANT, 01, 1 (for);

GWU-ANT, 02, 1 (for); YNPRC, C1-2, 2 (for); CMZ, C1-2, 2 (for). *Pongo pygmaeus*: HU-ANA, O01, 1 (for); GWU-ANT, 01, 1 (for). *Rattus norvegicus*: USNM, uncatalogued, 2 (alc). *Thylamys venustus*: CML 5586, 1 (alc). *Tupaia sp.*: UNSM, 87244, 1 (alc), USNM, uncatalogued, 1 (alc). **Testudines:** *Cuora amboinensis*: YPM R 14443 1 sp. *Cuora galbinifrons*: YPM R 12735, 1 sp. *Geochelone chilensis*: DIAMR-038, 2 sp., DIAMR-039, 2 sp., DIAMR-040, 1 sp., FML 16879, 1 sp., FML 16880, 1 sp., FML16595, 1 sp., FML 00005, 1 sp., and FML 16978, 1 sp. *Glyptemys insculpta*: YPM R 5952, 1 sp. *Mauremys caspica rivulata*: YPM R 16233-36, 2 sp. *Phrynops hilarii*: DIAMR-044, 1 sp., DIAMR-042, 1 sp., DIAMR-041, 1 sp., DIAMR-043, 1 sp., DIAMR-037, 1 sp., DIAMR-005, 1 sp., DIAMR-006 1 sp., and DIAMR-007, 1 sp. *Podocnemys unifilis*: DIAMR-078, 6 sp. *Rhinoclemmys pulcherrima*: AH uncatalogued, 1 sp. *Sacalia bealei*: YPM R 14670-71 2 sp. *Terrapene carolina*: YPM R 13624 1 sp. YPM R 13622 1 specimen. *Testudo graeca*: HUJ-R 22843; HUJ-R 22845 2 sp. *Trachemys scripta*: RT uncatalogued, 2 sp.

Nomenclature

The myological nomenclature used in the present work essentially follows that of Diogo (2004a, 2007, 2008) and Diogo et al. (2008ab, 2009ab), with a few exceptions, which will be mentioned in the text and tables provided in the following chapters. Regarding the pectoral and forelimb musculature, we recognize five main groups of muscles: the axial muscles of the pectoral girdle, the appendicular muscles of the pectoral girdle and arm, the appendicular muscles of the ventral forearm, the appendicular muscles of the hand, and the appendicular muscles of the dorsal forearm. The appendicular musculature of the pectoral girdle, arm, forearm and hand (see, e.g., Tables 9.2–9.3) derives from the adductor and abductor muscles of the pectoral fin of sarcopterygian fish, and essentially corresponds to the 'abaxial musculature' sensu Shearman and Burke (2009). The axial pectoral girdle musculature (see, e.g., Table 9.2) is derived from the postcranial axial musculature and, together with most of the remaining epaxial and hypaxial muscles of the body (with the exception of, e.g., various muscles of the pectoral girdle and hind limb), form the 'primaxial musculature' sensu Shearman and Burke (2009). As explained by these authors, the muscles of the vertebrate body are classically described as epaxial or hypaxial according to the innervation from either the dorsal or ventral rami of the spinal nerves, respectively, while the terms 'abaxial musculature' and 'primaxial musculature' reflect embryonic criteria that are used to distinguish domains relative to embryonic patterning. The 'primaxial' domain comprises somitic cells that develop within somite-derived connective tissue, and the 'abaxial' domain includes muscle and bone that originates from somites but then mixes with, and develops within, lateral plate-derived connective tissue.

Concerning the head and neck musculature, the main groups of muscles recognized here correspond to those proposed by Edgeworth (1902–1935): external ocular, mandibular, hyoid, branchial, epibranchial, and hypobranchial. Edgeworth (1935) viewed the development of these muscles in the light of developmental pathways leading from presumptive premyogenic condensations to different states in each cranial arch (see Fig. 2.1; the condensations of the first and second arches corresponding respectively to Edgeworth's 'mandibular and hyoid muscle plates', and those of the more posterior, 'branchial' arches corresponding to his 'branchial muscle plates'). According to him these developmental pathways involve migration of premyogenic cells, differentiation of myofibers, directional growth of myofibers and possibly interactions with surrounding structures. These events occur in very specific locations, e.g. dorsal, medial or ventral areas of each cranial arch, as shown in the scheme of Fig. 2.1: for instance, the mandibular muscle plate gives rise dorsally to the premyogenic condensation constrictor dorsalis, medially to the premyogenic condensation adductor mandibulae, and ventrally to the intermandibularis (no description of a ventral mandibular premyogenic condensation was given by Edgeworth); the hyoid condensation usually gives rise to dorso-medial and ventral derivatives; the hypobranchial condensation gives rise to the 'genio-hyoideus' and to the 'rectus cervicus' (as noted by Miyake et al. 1992, it is not clear whether Edgeworth's 'genio-hyoideus' and 'rectus cervicus' represent separate premyogenic condensations or later states of muscle development).

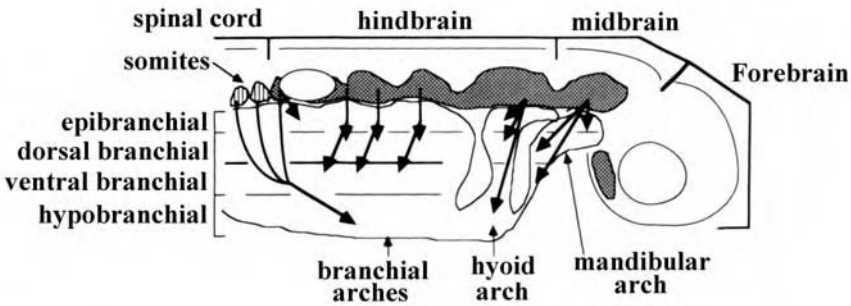

Fig. 2.1 Schematic presentation of embryonic origin of cranial muscles in gnathostomes based on Edgeworth's works (e.g., Edgeworth 1902, 1911, 1923, 1926abc, 1928, 1935); premyogenic cells originate from the paraxial mesoderm (hatched areas) and several somites (areas with vertical bars); large arrows indicate a contribution of cells in segments of the mesoderm to muscle formation of different cranial arches; for more details, see text (modified from Miyake et al. 1992; the nomenclature of the structures illustrated basically follows that of these authors).

According to Edgeworth (1935), although exceptions may occur (see below), the mandibular muscles are generally innervated by the Vth nerve, the hyoid muscles by the VIIth nerve and the branchial muscles by the IXth and Xth nerves. Diogo et al. (2008b) divided the branchial muscles *sensu lato* (that is, all the branchial muscles sensu Edgeworth 1935) into three main groups. The first comprises the 'true' branchial muscles, which are subdivided into: (1) the branchial muscles *sensu stricto* that are directly associated with the movements of the branchial arches and are usually innervated by the glossopharyngeal nerve (CNIX) and (2) the protractor pectoralis and its derivatives, which are instead mainly associated with the pectoral girdle and are primarily innervated by the spinal accessory nerve (CNXI). The second group consists of the pharyngeal muscles, which are only present as independent structures in extant mammals. They are considered to be derived from arches 4–6, and they are usually innervated by the vagus nerve (CNX). As will be seen in Chapter 5, the mammalian stylopharyngeus is considered to be derived from the third arch and is primarily innervated by the glossopharyngeal nerve, being thus grouped with the 'true' branchial muscles, and not with the pharyngeal muscles. The third group is made up of the laryngeal muscles, which are considered to be derived from arches 4–6 and are usually innervated by the vagus nerve (CNX). Regarding the epibranchial and hypobranchial muscles, according to Edgeworth these are "developed from the anterior myotomes of the body" and thus "are intrusive elements of the head"; they "retain a spinal innervation" and "do not receive any branches from the Vth, VIIth, IXth and Xth nerves" (Edgeworth 1935: 189). It is worth mentioning that apart from the mandibular, hyoid, branchial, hypobranchial, and epibranchial musculature, Edgeworth (1935: 5) referred to a primitive "premandibular arch" in "which passed the IIIrd nerve". This IIIrd nerve, together with the IVth and VIth nerves—which according to Edgeworth (1935: 5) are "not segmental nerves; they innervate muscles of varied segmental origin and are, phylogenetically, of later development than are the other cranial nerves"—innervate the external ocular muscles of most extant vertebrates. These external ocular muscles will not be discussed in the present volume.

Some of the hypotheses defended by Edgeworth have been contradicted by recent studies (e.g., certain phylogenetic hypotheses that he used to formulate his theories: see, e.g., Chapters 4 and 5). However, many of his conclusions have actually been corroborated by more recent developmental and genetic studies. For instance, Miyake et al. (1992) published a paper that reexamined, discussed and supported some of the general ideas proposed by Edgeworth (1935). For example, they noted that "Noden (1983, 1984, 1986) elegantly demonstrated with quail-chick chimeras that cranial muscles are embryologically of somitic origin, and

not as commonly thought, of lateral plate origin, and in doing so corroborated the nearly forgotten work of Edgeworth" (Miyake et al. 1992: 214). They also pointed out that molecular developmental studies such as Hatta et al. (1990, 1991) "have corroborated one of Edgeworth's findings: the existence of one premyogenic condensation (the constrictor dorsalis) in the cranial region of teleost fish" (Miyake et al. 1992: 214). Actually, the existence of this and other condensations (e.g., the hyoid condensation) has received further support in developmental studies published more recently (e.g, Knight et al. 2008; Kundrat et al. 2009). For instance, in the zebrafish engrailed immunoreactivity is only detected in the levator arcus palatini + dilatator operculi muscles, i.e., in the two muscles that are derived from the dorsal portion of the mandibular muscle plate (constrictor dorsalis *sensu* Edgeworth 1935) (see Chapter 4). Interestingly, in mammals such as the mouse engrailed immunoreactivity is detected in mandibular muscles that are very likely derived from a more ventral ('adductor mandibulae') portion of that plate, i.e., in the masseter, temporalis, pterygoideus medialis and/or pterygoideus lateralis (see Chapter 5). Also interestingly, Tzahor (2009) and other authors have shown that, among members of a single species, muscles from a particular type of arch (e.g., from the mandibular arch) might originate from different types of cells. For instance, the mandibular 'adductor mandibulae complex' and its derivatives (e.g., masseter) derive from cranial paraxial mesoderm, while the more ventral mandibular muscle intermandibularis and its derivatives (e.g., mylohyoideus) originate from medial splanchnic mesoderm.

As stated by Miyake et al. (1992) and more recently by Diogo et al. (2008b), Edgeworth's (1935) division of the head and neck muscles in external ocular, mandibular, hyoid, branchial, epibranchial, and hypobranchial muscles continues to be widely used by both comparative anatomists and developmental biologists. For instance, Edgeworth's scheme is similar to that proposed in Mallat's anatomical studies (e.g., 1997; the differences between the two schemes are actually mainly nomenclatural ones, for example, the "hyoidean and mandibular superficial constrictors" *sensu* Edgeworth correspond to the "hyoidean and mandibular interbranchial muscles" *sensu* Mallat: see table 2 of Mallat 1997 and Chapter 3 below), as well as to the schemes used in numerous recent developmental and molecular works, such as Holland et al. (1993, 2008), Kuratani et al. (2002, 2004), Trainor et al. (2003), Kuratani (2004, 2005ab, 2008), Kusakabe and Kuratani (2005), Olsson et al. (2005), Kuratani and Ota (2008), and Kuratani and Schilling (2008). However, as expected, some researchers do prefer to catalog the head and neck muscles into groups that do not always correspond to those proposed by Edgeworth (1935). For instance, Noden and Francis-West (2006) refer to three main types of head and neck muscles (Fig. 2.2): the 'extra-ocular' muscles, which

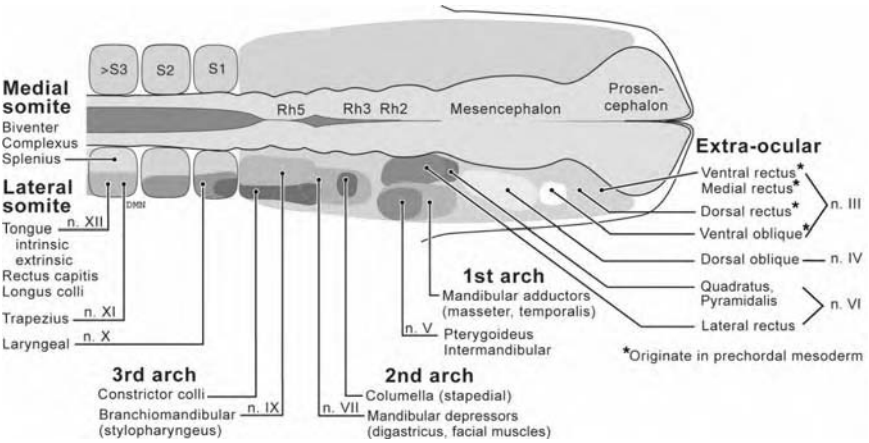

Fig. 2.2 Noden and Francis-West's (2006) scheme showing the locations and main groups of muscle primordia within chick (Reptiles, Aves, Gallus) cephalic paraxial mesoderm, based on their interpretations of the results of recent developmental and molecular studies using techniques such as quail-chick transplants and retroviral injections; names in parentheses indicate some mammalian homologues; the first arch, second arch and third arch muscles shown in the scheme form the 'branchial muscles' sensu Noden and Francis-West 2006, while part of the 'lateral somite' muscles shown in the figure (namely the intrinsic and extrinsic muscles of the tongue, the trapezius, and the laryngeal muscles) form the 'laryngoglossal' musculature sensu these authors (see text) [modified from Noden and Francis-West 2006; the nomenclature of the structures illustrated basically follows that of these authors]. It is remarkable that the use of these new techniques has confirmed a great part of Edgeworth's hypotheses (e.g., Edgeworth 1902, 1911, 1923, 1926abc, 1928, 1935) about the origin and homologies of the vertebrate head and neck muscles, for instance: that the 'adductor mandibulae complex' ('mandibular adductors'), the pterygomandibularis ('pterygoideus') and the intermandibularis derive from the first arch (mandibular muscles sensu Edgeworth 1935); that the masseter and temporalis of mammals correspond to part of the 'adductor mandibulae complex' of non-mammalian groups such as birds; that the levator hyoideus ('columella') and the depressor mandibulae ('mandibular depressors') derive from the second arch (hyoid muscles sensu Edgeworth 1935); that the mammalian stapedius ('stapedial') corresponds to the levator hyoideus of non-mammalian groups such as birds; that part of the 'digastricus' of mammals (i.e., the digastricus posterior) derives from the depressor mandibulae of non-mammalian groups such as birds; that the hyobranchialis ('branchiomandibularis') derives from the third arch, i.e., that it is a branchial muscle sensu Edgeworth 1935; that the intrinsic and extrinsic tongue muscles are derived from somites and they migrate anteriorly during the ontogeny in order to make part of the craniofacial musculature, i.e., that they are hypobranchial muscles sensu Edgeworth (1935). As explained in the text, the main difference between Edgeworth's (1935) and Noden and Francis-West's (2006) schemes is that these latter authors include the laryngeal muscles and the trapezius in their 'laryngoglossal' musculature, which also includes the hypobranchial muscles sensu Edgeworth; that is, they do not consider the trapezius and the laryngeal muscles as part of the 'branchial musculature, as did Edgeworth (see text) [NB: another difference between these schemes is that Noden and Francis-West 2006 consider (probably erroneously in our opinion: see Chapter 4–7) that the 'constrictor colli' (which is part of the interhyoideus sensu the present volume) is not a second arch muscle, i.e., is not a hyoid muscle sensu Edgeworth].

correspond to Edgeworth's extra-ocular muscles, the 'branchial' muscles, which correspond to the mandibular, the hyoid, and most of the branchial mucles sensu Edgeworth, and the 'laryngoglossal' muscles, which include the hypobranchial muscles but also part of the branchial muscles sensu Edgeworth (namely the laryngeal muscles sensu Diogo et al. 2008b). A main advantage of recognizing these three groups is to stress that, in at least vertebrate taxa such as salamanders, chickens and mice, laryngeal muscles such as the dilatator laryngis and constrictor laryngis receive a contribution of somitic myogenic cells (e.g., Noden 1983; Noden et al. 1999; Yamane 2005; Piekarski and Olsson 2007), as do the hypobranchial muscles sensu Edgeworth (see above, and also Chapters 3–7 and 11). That is, the main difference between the 'branchial' and 'laryngoglossal' groups sensu Noden and Francis-West (2006) is that, contrary to the former, the latter receive a contribution of these somitic cells. However, recent developmental studies have shown that some of the 'branchial' muscles sensu Noden and Francis-West (2006), as for instance some 'true' (non-laryngeal) branchial muscles sensu Diogo et al. (2008) such as the protractor pectoralis and the levatores arcuum branchialium of salamanders and the trapezius of chickens and mice, and even some hyoid muscles such as the urodelan interhyoideus, do also receive a contribution of somitic myogenic cells (see, e.g., Piekarski and Olsson 2007; NB: Edgeworth 1935 included the protractor pectoralis and its derivatives—which include the trapezius of amniotes—in the branchial musculature, but he was already aware that these muscles were at least partially originated from somites). Moreover, while it might seem appropriate to designate the laryngeal and hypobranchial muscles of derived vertebrate clades such as birds as 'laryngoglossal' muscles, it would be less suitable to use the name 'laryngoglossal' to designate the hypobranchial muscles of taxa such as lampreys or sharks, because these latter muscles are not functionally associated with a larynx or with a tongue (see Chapter 3). That is why authors who usually work with non-osteichthyan clades often prefer to follow the names that Edgeworth (1935) used to designate the main groups of head and neck muscles, i.e., external ocular, mandibular, hyoid, branchial, hypobranchial, and epibranchial (see, e.g., Holland et al. 1993, Kuratani et al. 2002, 2004, Kuratani 2004, 2005ab, 2008, Kusakabe and Kuratani 2005, Olsson et al. 2005, Kuratani and Ota 2008, Kuratani and Schilling 2008, Holland et al. 2008; see also Chapter 3). As one of the main goals of this volume is precisely to propose a unifying nomenclature for muscles of the Vertebrata as a whole, we will also use these names throughout the book.

In fact, a main advantage and strength of using and expanding the nomenclature proposed by Diogo (2004a, 2007, 2008) and Diogo et al. (2008ab, 2009ab) is that it combines, and thus creates a bridge between, names that are normally used in human anatomy and names that are more

typically used in works dealing with other vertebrate taxa, including bony fishes but also phylogenetically more plesiomorphic vertebrates such as agnathans, elasmobranchs and holocephalans. For instance, coracomandibularis, intermandibularis, and interhyoideus are names that are often used in the literature to designate the muscles of non-osteichthyan vertebrates. As some of these muscles are directly homologous to muscles that are present in osteichthyans and particularly in phylogenetically plesiomorphic sarcopterygian and actinopterygian groups such as cladistians, actinistians and dipnoans, it makes sense to use these names in the descriptions of these latter groups. At the same time, this nomenclature allows us to keep almost all the names that are currently used to designate the muscles of humans (see, e.g., Terminologia Anatomica 1998) and also takes into account major nomenclatural reviews that have been done for other groups of tetrapods (e.g., Nomina Anatomica Avium: Baumel et al. 1979; see Chapter 7). To maintain the stability of the names used in human anatomy is an important aspect of our nomenclature, because these names have been employed for various decades in thousands of publications dealing with human anatomy and medicine and by thousands of teachers, physicians and practitioners. As one of the main goals of using this unifying nomenclature is precisely to avoid the confusion created by the use of different names to designate the same muscles in distinct vertebrate groups, some of the names that we use to designate the muscles of certain taxa do not correspond to the names that are more usually used in the literature for those taxa. So, using the muscles of dipnoans as an example, the adductor mandibulae A3′, the adductor mandibulae A2, the adductor mandibulae A2-PVM, the protractor pectoralis, the coracomandibularis and the sternohyoideus sensu this volume correspond respectively to the ‘adductor mandibulae anterior’, the ‘more anterior/lateral part of the adductor mandibulae posterior’, the ‘more posterior/mesial part of the adductor mandibulae posterior’, the ‘cucullaris’, the ‘geniothoracicus’ and the ‘rectus cervicus’ sensu Miyake et al. (1992) and Bemis and Lauder (1986) (see Chapters 4 and 5). When we cite works that use a nomenclature that differs from that proposed here, the respective synonymy is given in the tables provided throughout the book. It should be noted that the muscles listed in these tables are those that are usually present in adults of the respective taxa; we do not list all the muscles that occasionally appear as variants in the members of these taxa (e.g., although a few adult modern humans may have a platysma cervicale, in the vast majority of cases this muscle is lacking: see Chapter 5). When we use the terms anterior, posterior, dorsal and ventral, we do so in the sense the terms are used for pronograde tetrapods (e.g., in mammals the eye, and thus the muscle orbicularis oculi, is usually anterior to the ear, and thus to the muscle auricularis superior, and dorsal to the mandible, and thus

to the muscle orbicularis oris: see Chapter 5). Although there is obviously some subjectivity concerning the identification of separate muscles, we followed as strictly as possible Edgeworth's (1935) criteria for analyzing the evidence acquired by others and ourselves, including, for instance, the degree of separation of muscular fibers, the differences regarding the function, orientation and insertions of these fibers, and the innervation of the various myological structures being investigated, among others (see Diogo, 2007, 2008; Diogo et al., 2008ab, 2009ab).

Phylogeny and Homology

The definition of homology and its use in systematics and comparative anatomy has been discussed by several authors (e.g., Patterson 1988; de Pinna 1991; Agnarsson and Coddington 2007). The simplest meaning of homology is equivalence of parts (e.g., De Pinna 1991). In the present work we follow the phylogenetic definition of homology, as proposed by Patterson (1988): homology is equal to synapomorphy. Therefore, following De Pinna (1991), we recognize two main types of muscular homology. 'Primary homology' hypotheses are conjectures or hypotheses about common origin of muscular characters that are established after a careful analysis of criteria such as function, topology and ontogeny (i.e., after the so-called test of similarity). In this volume we follow the same methodology that we have employed and carefully explained in previous works (e.g., Diogo, 2007, 2008, and Diogo et al., 2008ab, 2009ab; Abdala and Diogo in press) and thus take into account all the lines of evidence obtained from our dissections and gleaned from the literature in order to formulate such 'primary homology' hypotheses (e.g., the innervation of the muscles; their relationships with other muscular structures; their relationships with hard tissues; the configuration/orientation of their fibers; their development; their function; the configuration or absence/presence of the muscles in embryos of model organisms that were previously the subject of genetic manipulations, e.g., the knock-down of certain hox genes or the induction of C-met mutations; etc.).

This is because, as noted Edgeworth (1935), none of these lines of evidence is infallible. For instance, although the innervation of a muscle generally remains constant and corresponds to its segment of origin (e.g., Luther 1913, 1914; Edgeworth 1935; Kesteven 1942–1945; Köntges and Lumsden, 1996), there are cases in which a single muscle may have different innervations in different taxa. One of the examples provided by Edgeworth (1935: 221) to illustrate this concerns the intermandibularis of extant dipnoans, which "is innervated by the Vth and VII nerves, though wholly of mandibular origin". Also, there are eventually cases in which the same muscle may originate from different regions and/or segments

of the body in different taxa. An example provided by Edgeworth (1935: 221) concerns the branchial muscle protractor pectoralis (his "cucullaris"), which "has diverse origins in *Ornithorhynchus*, *Talusia* and *Sus*; in the first-named it is developed from the 3rd, in the second from the 2nd and in the last from the 1st branchial muscle-plate; these changes are secondary to the non-development of the branchial muscle-plates, from behind forwards; the muscles are homologous and have a constant primary innervation from the Xth nerve". As stressed by Edgeworth (1935: 224), there are also cases in which "an old structure may be lost" (e.g., the branchiomandibularis is lost in extant ginglymodians and teleosts), in which "new muscles may be developed" (e.g., the glossal muscles of tetrapods), and in which "an old structure or group of structures may be transformed" (e.g., the levator hyoideus "may be transformed, either partially or wholly, into a depressor mandibulae"). The occurrence of such phenomena thus raises further difficulties for comparative analyses within different clades. And there are also cases in which "similar secondary developments occur in separate genera or phyla", i.e., cases of convergence and parallelism (see, e.g., Diogo 2004a, 2005 for a recent discussion of these two concepts; see also Chapters 3–10).

Following De Pinna (1991), the 'primary homology' hypotheses have however to pass the second, or "hard", test of homology, i.e., the test of phylogenetic conjunction and congruence (agreement in supporting the same phylogenetic relationships) before they can actually be considered as solid hypotheses of homology, i.e., as 'secondary homology' hypotheses. The important point is, thus, that under the phylogenetic definition of homology it is the test of phylogenetic conjunction and congruence that ultimately determines if a hypothesis can, or cannot, be considered a solid hypothesis of homology. So, if for instance a muscle A of a taxon X and a muscle B of a taxon Y have a similar innervation, function, topology and development but the phylogenetic data available strongly supports the idea that muscles A and B were the result of convergent evolution (i.e., that they were acquired independently in evolution and do not correspond to a structure that was present in the last common ancestor of A and B), then the phylogenetic criterion has preponderance over the other criteria. As explained above, in the specific case of the present work the phylogenetic framework that we use to investigate and discuss the evolution and homologies of the vertebrate muscles of the taxa listed in the tables provided in the book is shown in Fig. 1.1. So, following the methodology explained above, if for example an analysis of the data provided by some lines of evidence (e.g., innervation, function and relationships with other muscular and hard structures) indicates that muscles C and D could be homologous ('primary homology' hypothesis), but within all mammals muscle C is only present in monotremes and muscle D in modern humans, then

we would consider that muscles C and D were likely independently acquired in monotremes and modern humans, respectively, i.e., that these muscles are likely not homologous (i.e., the 'primary homology' hypothesis did not pass the "hard" test of homology, that is the test of phylogenetic conjunction and congruence). So, the hypotheses of homology that are shown in the tables provided in the present work are hypotheses that are phylogenetically congruent with the scenario shown in the cladogram of Fig. 1.1, i.e., they are 'secondary homology' hypotheses sensu De Pinna (1991).

Chapter 3

The Muscles of Non-Osteichthyan Vertebrates

In this chapter, we briefly compare the muscles of living lampreys, living hagfishes, living elasmobranchs, living holocephalans, and basal living osteichthyans and discuss which muscles were probably present in the last common ancestor of the extant vertebrates, in the last common ancestor of the extant gnathostomes, and in the last common ancestor of the extant osteichthyans (Fig. 3.1). This will pave the way for the discussions provided in Chapters 4–10, which are mainly concerned with the muscles of actinopterygian and sarcopterygian osteichthyans. As explained in Chapters 1 and 2, as a base for the data presented in this book, we have literally dissected thousands of specimens of vertebrate taxa as diverse as dipnoans, anurans, caecilians, 'lizards', turtles, birds, monotremes, rodents, tree shrews, flying lemurs, primates, polypteriforms, chondrosteans, lepisosteiforms, amiiforms, and teleosts, but we did not dissect chondrichthyans (including holocephalans and elasmobranchs) nor cyclostomes (including hagfish and lampreys). Therefore, unlike in the remaining chapters, the comparisons and discussions provided in Chapter 3 are essentially based on a review of the data available in the literature. However, as in all chapters, we made an effort to take into account as much information as possible, from classic anatomical descriptions such as those provided by Bischoff (e.g., 1840), Owen (e.g. 1841), Gegenbaur (e.g., 1872), Huxley (e.g., 1876), Cole (e.g., 1896), Allis (e.g., 1897, 1917, 1919, 1922, 1923, 1931), Alcock (e.g., 1898), Edgeworth (e.g., 1902, 1911, 1923, 1926abc, 1928, 1935) and Luther (e.g., 1913, 1914, 1938) to more recent reviews by authors Miyake et al. (1992), Mallat (1996, 1997) Anderson (2008), and others, including, importantly, the developmental and molecular data obtained in evo-devo studies undertaken in the past few decades (e.g., Holland et al. 1993; Kuratani et al. 2002, 2004; Graham 2003; Manzanares and Nieto 2003; Santagati and

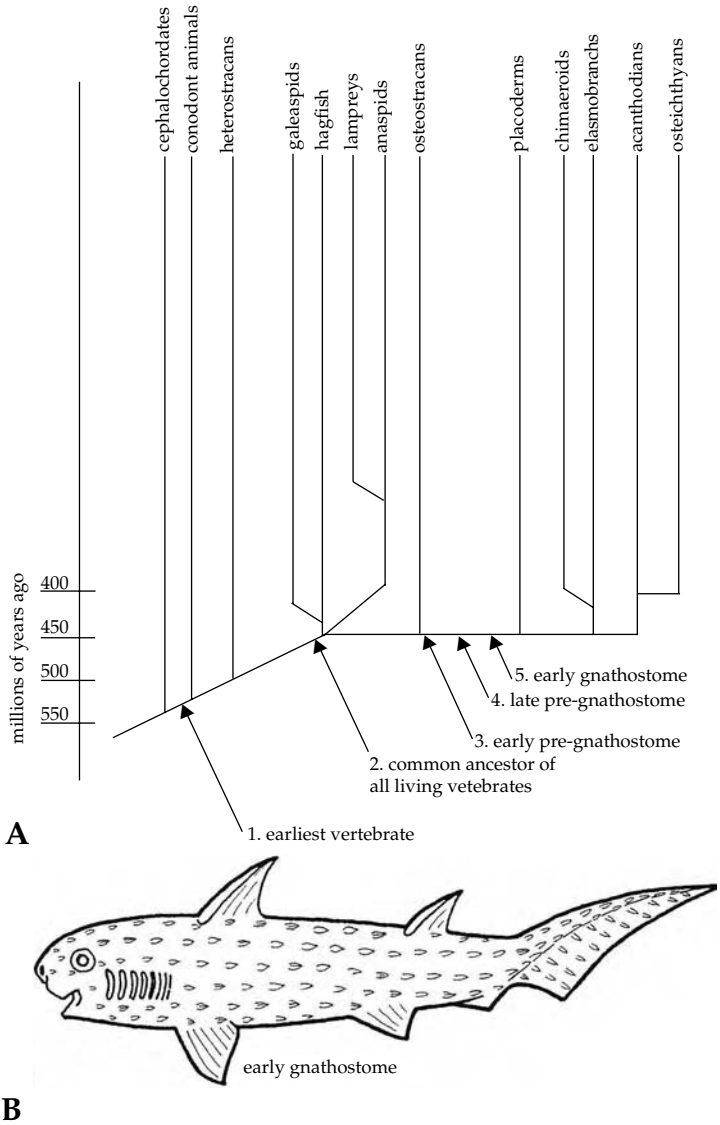

Fig. 3.1 (A) Phylogenetic relationships of non-osteichthyan taxa discussed in Chapter 3, according to Mallat (1996). As explained by Mallat (1996), "the long, almost horizontal line at 450 million years ago indicates a rapid radiation, and is not meant to be interpreted as an unresolved branching scheme". It should be noted that the results of various recent molecular studies indicate that Tunicates (or Urochordates, including ascidians) are actually the closest living relatives of the Vertebrates, and that the Cephalochordates (including amphioxus) are thus the most basal extant Chordates (see, e.g., Garcia-Fernàndez and Benito-Gutiérrez 2009). **(B)** Hypothetical, thelodont-scaled, early gnathostome, based on Mallat's (1996) reconstruction (modified from Mallat 1996).

Rijli 2003; Trainor et al. 2003; Cerny et al. 2004; Kuratani 2004, 2005ab, 2008; Takio et al. 2004; Helms et al. 2005; Kusakabe and Kuratani 2005; Northcutt 2005; Olsson et al. 2005; Shigetani et al. 2005; Kuratani and Ota 2008; Kuratani and Schilling 2008; Holland et al. 2008). However, because we did not dissect chondrichthyan and cyclostome specimens, because osteichthyans, cyclostomes and chondrichthyans have being evolving separately for various hundreds of millions of years (see Fig. 3.1) and also because each of these three lineages has given rise to remarkably peculiar and unique phenotypes, the hypotheses of homology proposed in Chapter 3 are clearly not as solid as those proposed in Chapters 4–10.

In the discussions presented in this chapter, we follow the now commonly accepted phylogenetic hypothesis that living hagfishes and lampreys are more closely related to each other than to other living vertebrates, which has been consistently supported by recent molecular cladistic studies (see, e.g., Kuratani et al. 2002; Fig. 3.1). Therefore, following this phylogenetic framework, when a certain muscle A is absent in non-vertebrate animals and is present in both living lampreys and living gnathostomes, then there are two phylogenetically equally parsimonious solutions: that muscle A was present in the LCA of vertebrates and then secondarily lost in hagfishes, or that the muscle was independently acquired in lampreys and in gnathostomes. We should, however, stress that, in such cases, although these solutions are theoretically equally parsimonious in a cladistic context, if there is detailed information about muscle A of lampreys and of gnathostomes, and if the innervation, topology, blood supply, development, and other features of this muscle in these two groups is actually very similar or identical, we would tend to see the secondary loss in hagfishes as more likely than the independent evolution of a muscle innervated by exactly the same nerves, supplied by exactly the same arteries, surrounded by exactly the same anatomical structures, attached to the same elements, and so on, in lampreys and gnathostomes. If future studies would indicate that hagfishes are in reality phylogenetically closer to gnathostomes than to lampreys, these evolutionary interpretations would not really change so much, because theoretically we would have again the same two equally parsimonious solutions (i.e., a secondary loss of muscle A in hagfishes versus an independent acquisition of muscle A in lampreys and gnathostomes). However, if future studies would instead indicate that lampreys and gnathostomes are phylogenetically more closely related to each other than to hagfishes, as was often defended in the past (see, e.g., Kuratani et al. 2002), the interpretations would be different. That is, in this case we would have a single, most parsimonious solution, i.e., that muscle A was not present in the LCA of vertebrates, and that it was only acquired after the evolutionary split between the hagfishes and the remaining vertebrates (thence

its absence in hagfishes and its presence in lampreys + gnathostomes). Before passing to the discussion of the origin, evolution, ontogeny, functional morphology and homologies of the muscles of non-osteichthyan vertebrates, we would like to clarify that a great part of the functional hypotheses mentioned below, as well as of the figures used in this chapter, are based on Mallat's detailed studies of these vertebrates (e.g., Mallat 1996, 1997). In our opinion, this is one of the best ways to pay a special, and totally deserved, tribute to such a remarkable anatomist.

According to Mallat (1996), the biting, mandibular-arch jaws of gnathostomes evolved primarily through changes in ventilation. In his view, the jawless ancestors of all living vertebrates were benthonektonic predators that ate slow-moving invertebrates, grasping their prey in a ring of oral cartilage that was squeezed by an oral sphincter muscle (Figs. 3.2, 3.3). Initially, the activity level and ventilatory rate of these vertebrates were low. The expiratory phase of their ventilatory cycle resulted from peristaltic contraction of the pharyngeal-wall musculature, whereas inspiration resulted from the passive recoil of unjointed internal and external branchial arches. Then, as 'pre-gnathostomes' (Fig. 3.1) became more active foragers, both expiration and inspiration were strengthened and a capacity for active, forceful inspiration evolved. Correspondingly, many new ventilatory muscles evolved and were attached to the internal arches, which became large, jointed, and highly mobile (Fig. 3.5). The most powerful of these ventilatory muscles closed the mouth during forceful expiration to prevent leakage (the adductor mandibulae: see, e.g., Fig. 3.5 and below), and opened the mouth wide during forceful inspiration (the myotomal hypobranchial muscles: see, e.g., Fig. 3.9 and below), and the branchial arch on which these powerful muscles inserted became the largest, forming the mandibular-arch jaws (Figs. 3.5, 3.8). Now, for the first time, gnathostomes could capture evasive prey, by sucking it in through forceful 'inspiration' and clamping it with biting jaws during 'expiration', the way living gnathostome fish often feed.

Both ammocoetes (lamprey larvae; Fig. 3.4) and sharks (Fig. 3.5) propel ventilatory water through the pharynx unidirectionally, in through the mouth and out through the external gill openings. Each ventilatory cycle consists of an expiratory then an inspiratory phase. Expiration is effected by the branchial superficial constrictor and the interbranchial muscles, the former being a circular sheet that squeezes water through the pharynx by peristalsis (Figs. 3.4, 3.5), the latter running in the gill septa and acting to decrease the height of the pharynx and compress the gill pouches (Fig. 3.6). These expiratory muscles are aided in ammocoetes by a pumping velum and in sharks by muscles to the internal branchial arches. During quiet ventilation, after the expiratory muscles relax, inspiration results from a passive recoil of the pharyngeal skeleton: recoil of

the external arches in ammocoetes versus a recoil of the extrabranchial cartilages, internal arches, and various fibroelastic membranes in sharks. During forceful ventilation, in sharks only, inspiration is aided by the hypobranchial ventilatory muscles, which actively enlarge the pharynx. According to Mallat, lamprey and shark ventilation thus share two main features: (1) expiration through the peristaltic action of branchial superficial constrictor and interbranchial muscles and (2) inspiration through passive recoil of the branchial arches. Consequently, the LCA of verte-

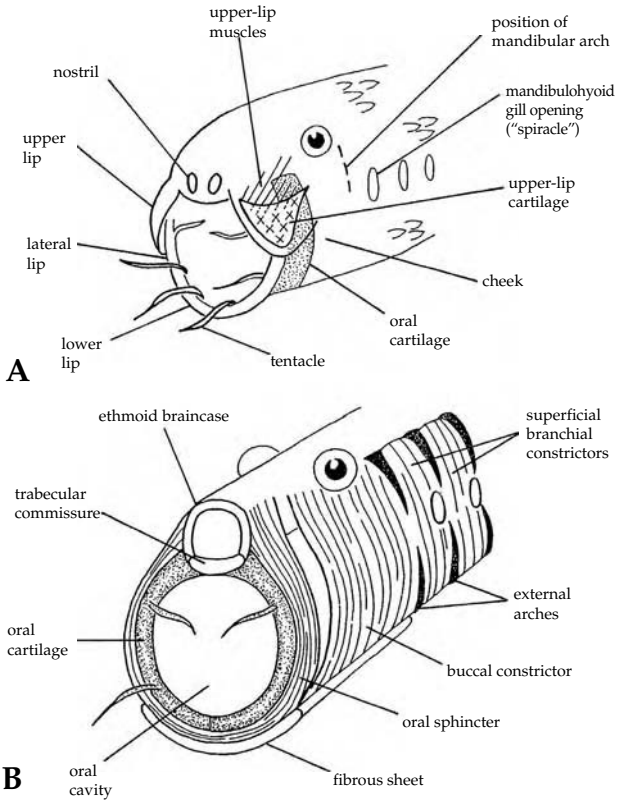

Fig. 3.2 Lips and mouth of the common ancestor of all living vertebrates, according to Mallat (1996). (A) External view, but also showing some cartilages and the muscles in the upper lip. (B) View with the skin and the snout removed, emphasizing the muscles around the oral cavity and pharynx. As stressed in the text, further studies are needed to clarify if the mandibular musculature was already differentiated into 'labial muscles' such as the oral sphincter, buccal constrictor, and the upper-lip muscles sensu Mallat (1996), as proposed by this author, or if the so-called 'labial muscles' of vertebrate groups such as elasmobranchs, holocephalans, cyclostomes, and osteichthyans are instead the result of an independent differentiation of the mandibular mesoderm in these taxa (modified from Mallat 1996; the nomenclature of the structures illustrated basically follows that of this author).

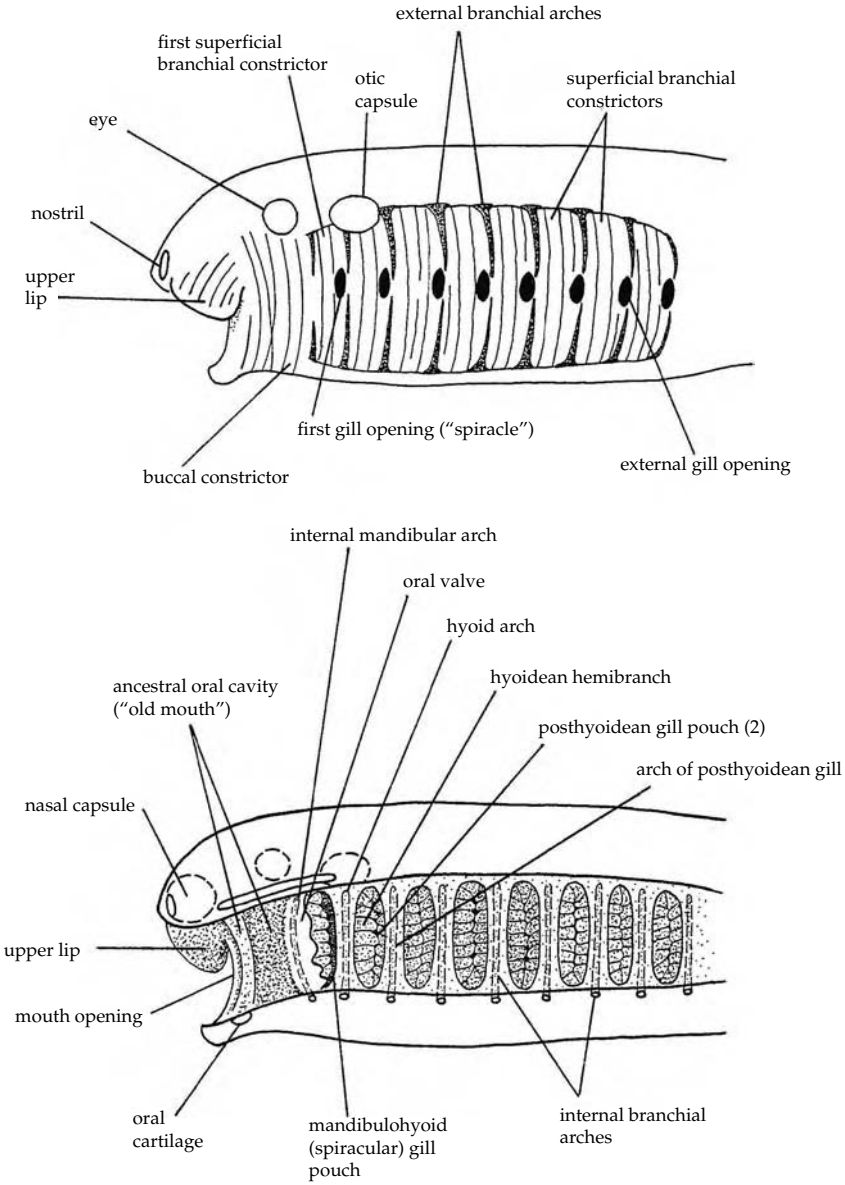

Fig. 3.3 Head and pharynx of the reconstructed common ancestor of all living vertebrates, according to Mallat (1996). External and mid-sagittal views; numbers such as '(1)' and '(2)' are used to identify the ancestral/embryonic gill pouches. According to Mallat (1996) this ancestor may have had more gill pouches than the eight illustrated in this figure (modified from Mallat 1996; the nomenclature of the structures illustrated basically follows that of this author).

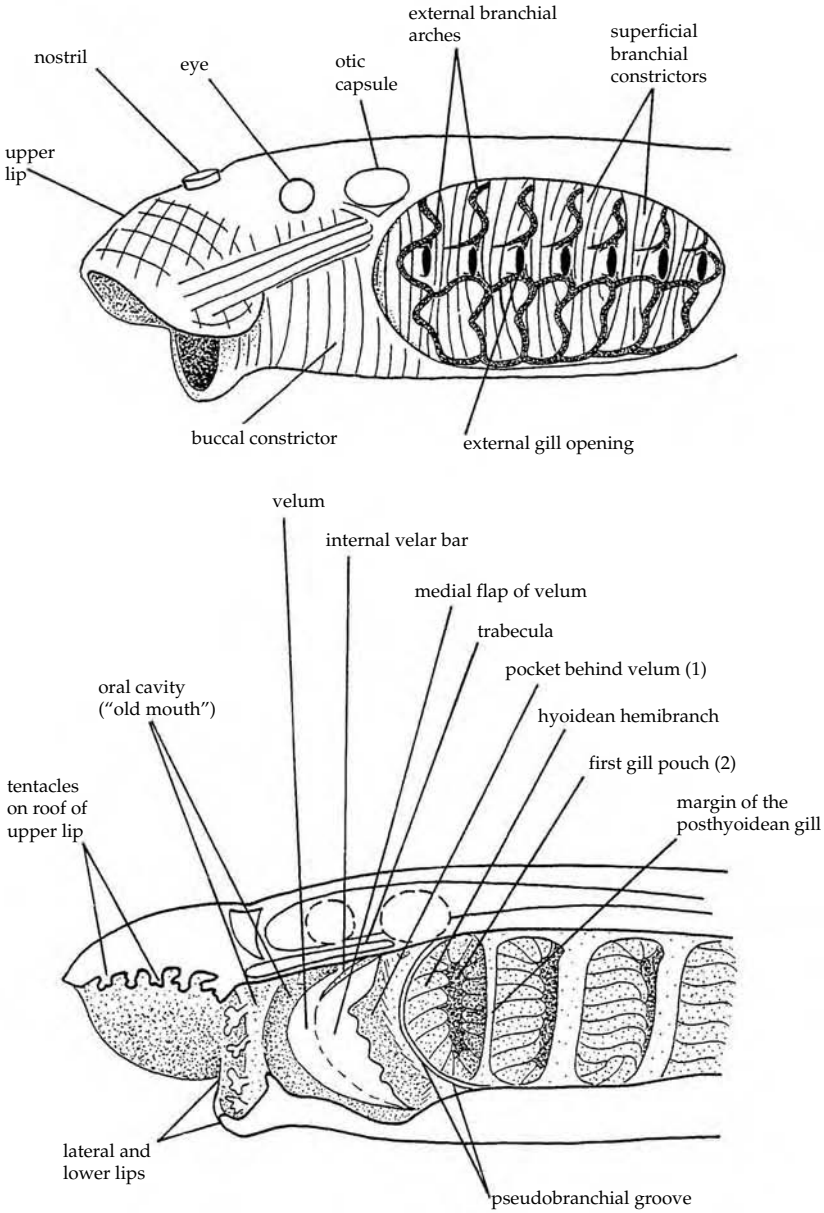

Fig. 3.4 Head and pharynx of ammocoete lampreys (Cyclostomata), according to Mallat (1996); numbers such as '(1)' and '(2)' are used to identify the ancestral/embryonic gill pouches; external and mid-sagittal views. Top: *Lampetra planeri*. Bottom: *Ichthyomyzon fossor* (modified from Mallat 1996; the nomenclature of the structures illustrated basically follows that of this author).

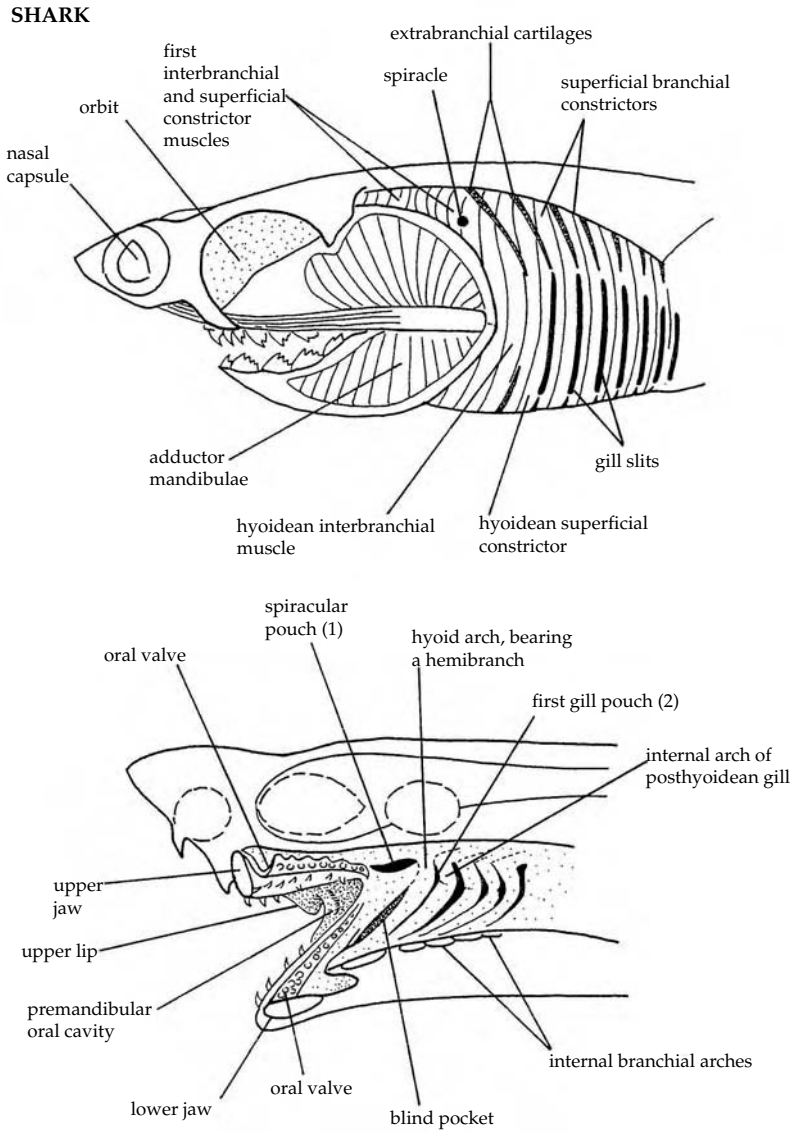

Fig. 3.5 Head and pharynx of sharks (Elasmobranchii), according to Mallat (1996); numbers such as '(1)' and '(2)' are used to identify the ancestral/embryonic gill pouches; external and mid-sagittal views. Top: *Heptanchus maculatus*; this species of shark is shown because, according to Mallat (1996), it has the primitive features of a short snout and a simple type of adductor mandibulae muscle. Bottom: *Triakis semifasciatus* (modified from Mallat 1996; the nomenclature of the structures illustrated basically follows that of this author).

brates must have possessed the superficial constrictor and interbranchial muscles (Figs. 3.2, 3.3).

As also noted by Mallat (1996), the velum of lampreys is a pair of cupped, muscular paddles that push water posteriorly into the pharynx during the expiratory phase of each ventilatory cycle. It is a powerful, piston-like pump that can work against back pressure and force ventilatory water through the sand in which ammocoetes live. Projecting posteriorly from each velar paddle is a 'medial flap', which is supported by the internal velar bar (Fig. 3.4). When the velum starts to contract, its right and left medial flaps come together to form a seal that prevents reflux of water from the pharynx through the mouth. In the embryonic lamprey, the velum develops at the border between the mouth and pharynx, from the buccopharyngeal membrane. Its muscles belong to the mandibular branchial segment, being innervated by the mandibular branch (V3) of the trigeminal nerve. The lateral mouth plates of ammocoetes bear a

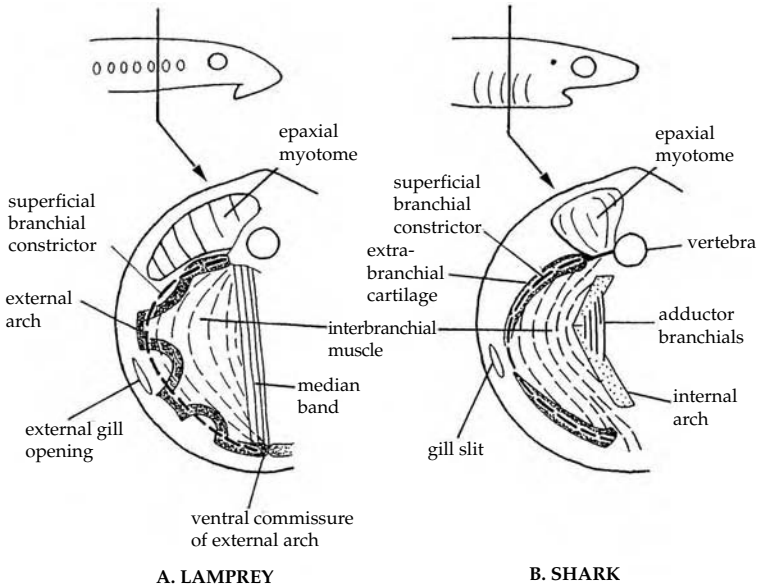

Fig. 3.6 Basic similarities between the gill muscles of lampreys (Cyclostomata) and sharks (Elasmobranchii), according to Mallat (1996): in both animals, the superficial branchial constrictors (broken lines) wrap around the pharynx externally and an interbranchial muscle occupies each gill septum; these two muscles are continuous, separated only by the external branchial arch; a straight band of muscle in the medial part of the lamprey gill ('median band') may correspond to the adductor branchialis of sharks (the adductor branchialis of the first arch corresponding to the adductor mandibulae of Fig. 3.5) (modified from Mallat 1996; the nomenclature of the structures illustrated basically follows that of this author).

superficial resemblance to the branchial arches behind them and have been called a 'premandibular branchial arch' by some authors. However, as stressed by Olsson et al. (2005), "there is no clear fossil evidence that a complete gill arch skeleton ever existed anteriorly to the first gill arch", and most researchers now agree that no such complete 'premandibular' arch was present in the LCA of vertebrates or of gnathostomes. Another idea that was often accepted in the past and that has been contradicted by recent findings is that neural crest cells from the first mandibular arch form a dorsal, 'maxillary' and a ventral, 'mandibular' condensation, which later give rise to the upper jaw cartilage (palatoquadrate) and the lower jaw cartilage (Meckel's cartilage), respectively. In fact, recent developmental studies using vital-dye labeling in both the Mexican axolotl and the chicken embryo have shown that cells which form the ventral or 'mandibular' condensation give rise to both the upper and lower jaw cartilages (e.g. Cerny et al. 2004; Olsson et al. 2005). The dorsal or 'maxillary' condensation contributes to the trabecular cartilage, but not to the jaw joints as previously assumed. Interestingly, Cerny et al.'s (2004) developmental study provides evidence to support the idea that the jaw cartilages of gnathostomes are homologous to the lower lip and velum of lampreys.

It is, however, important to explain that the word 'mandibular' can be used in different contexts and different development stages, including the following: (1) the 'mandibular condensation' is an osteological term that refers to an early stage of development, and that thus seems to be inadequate, as it gives rise to both the upper and lower jaw cartilages, contrary to what was thought in the past; (2) the 'mandible', which is an osteological term that refers to both early and later stages of development, and essentially corresponds to the term 'lower jaw' (note that the 'mandible'/'lower jaw' does not necessarily correspond to 'lower jaw cartilages' and/or to the ossifications of these cartilages, because apart from these cartilages and their ossifications, the 'mandible'/'lower jaw' of adults may include, and often does, other structures, such as dermal bones); (3) the 'mandibular muscular plate' sensu Edgeworth (1935), which, as explained above, is a myological term and refers to an early stage of development (see Fig. 2.1); (4) the 'mandibular muscles' sensu Edgeworth (1935; and sensu this volume), which are myological structures that are found in both early and later stages of development, and that derive from the 'mandibular muscular plate' (see, e.g., Table 3.1); (5) the 'mandibular arch', which is an osteological term, refers to both early and latter stages, and corresponds to the 'first branchial arch', including both the 'palatoquadrate' and the 'lower jaw' (see, e.g., Fig. 3.8). For the reasons explained just above, in this work we avoid the use of the term 'mandibular condensation', but we continue to use the terms 'mandible', 'mandibular muscular plate',

Table 3.1 Mandibular muscles of adults of representative non-osteichthyan extant vertebrate taxa. The nomenclature of the muscles shown in bold follows that of the present work, "ad. mand." meaning adductor mandibulae. In order to facilitate comparisons, in some cases certain names often used by other authors to designate a certain muscle/bundle are given in front of that muscle/bundle, in round brackets; additional comments are given in round brackets (for more details, see text).

Agnatha: *Lampetra japonica* (Japanese lamprey)	Probable plesiomorphic gnathostome condition	Elasmobranchii: *Squalus acanthias* (Spiny dogfish)	Holocephali: *Hydrolagus colliei* (Spotted ratfish)
— [a distinct, independent intermandibularis such as that found in chondrichthyans is seemingly not present in lampreys, but see velothyroideus below and also text]	**Intermandibularis**	**Intermandibularis** [probably corresponds to the intermandibularis (= csv1b″ + csv1a″b″) and possibly to the mandibularis [= csv1c] sensu Lightoller 1939, the latter structure thus corresponding to the intermandibularis posterior of some authors and being at least in some cases innervated by CN7, according to Lightoller 1939; however, it is quite possible that at least part of the intermandibularis sensu Lightoller 1939 corresponds in fact to part of the interhyoideus of osteichthyans, as it is innervated by CN7, and also because, in his table III, Lightoller states that this muscle gives rise to some of the facial muscles of mammals; Miyake et al. 1992 and Anderson 2008 describe a single intermandibularis in elasmobranchs, but they state that at least some elasmobranchs, e.g., electric rays, may have an	**Intermandibularis** [Anderson 2008 describes only one intermandibularis in *Hydrogalus*, but he explains that Kesteven 1942–1945 described this muscle (his 'protractor labii inferioris') as having two parts, and Edgeworth 1935 also states that some holecephalans have both an 'intermandibularis anterior' and an 'intermandibularis posterior'; Edgeworth 1935 interprets the intermandibularis of holocephalans as the anterior-most remnant of the intermandibularis muscle-sheet in elasmobranchs]

		'intermandibularis superficialis' and an 'intermandibularis profundus', as described by Edgeworth 1935 and other authors (see, e.g., his fig. 83)]	
— [a distinct, independent adductor mandibulae A2 such as that found in condrichthyans is seemingly not present in lampreys: see text]	**Ad. Mand. A2**	**Ad. mand. A2** (adductor mandibulae sensu Adams 1919 and Anderson 2008; pars inscriptionalis, musculus quadrato-mandibularis or cs1b' sensu Lightoller 1939; part of adductor mandibulae complex sensu Miyake et al. 1992)	**Ad. mand. A2** (levator mandibulae anterior and posterior sensu Miyake et al. 1992; adductor mandibulae anterior and posterior sensu Anderson 2008)
'Labial muscles' [see text]	**'Labial muscles'**	**'Labial muscles'** [see text]	**'Labial muscles'** [see text]
Velothyroideus [does the velothyroideus sensu Holland et al. 1993 really correspond to the levator arcus palatini of the LCA of gnathostomes? See text]	**Levator arcus palatini**	**Levator arcus palatini** (levator maxillae superioris sensu Adams 1919; levator palatoquadrati sensu Miyake et al. 1992 and Anderson 2008)	— [see text]
Velohyoideus and velocranialis [if the velothyroideus is effectively derived from the constrictor dorsalis, are the other two muscles of the velum, i.e., the velohyoideus and velocranialis, also derived from the constrictor dorsalis, or do they possibly correspond to the intermandibularis and/or the adductor mandibulae of other vertebrates? See text]	—	—	—

Table 3.1 contd...

Table 3.1 contd...

Agnatha: *Lampetra japonica* (Japanese lamprey)	Probable plesiomorphic gnathostome condition	Elasmobranchii: *Squalus acanthias* (Spiny dogfish)	Holocephali: *Hydrolagus colliei* (Spotted ratfish)
—	— [really absent in the LCA of gnathostomes?]	**Spiracularis, depressor palpebrae superioris, levator palpebrae nictitantis and retractor palpebrae superioris** [according to Miyake et al. 1992, all these muscles may be found in sharks, being derived ontogenetically from the constrictor dorsalis anlage; the spiracularis sensu the present work corresponds to the 'constrictor superficialis dorsalis' sensu Adams 1919, and probably corresponds to the 'pars craniomaxillaris' (csd1b'') sensu Lightoller 1939]	—

'mandibular muscles' and 'mandibular arch' as they are often used in the literature.

As described by Mallat (1996), in living Chondrichthyes, the robust internal arches are divided into five segments, connected by movable joints: pharyngo-, epi-, cerato-, hypo-, and basibranchial segments (Fig. 3.8). The segmentation and jointing allow muscles to attach and pull from many different directions. Unlike the extrabranchial cartilages (external branchial arches sensu Mallat 1996), which are embedded firmly in the pharyngeal wall, the internal arches have an extraordinary range of movement within the gnathostome pharynx. During ventilation in sharks, they are proposed to move as shown in Fig. 3.9. During expiration, to decrease pharyngeal volume and expel water, the arch segments are flexed by adductor branchialis and lateral interarcual muscles, and successive arches are pulled closer by dorsal and lateral interarcual muscles (Fig. 3.9A). At the same time, the lateral interarcuals swing the arches posteromedially (Fig. 3.9B), further decreasing pharyngeal volume. During quiet inspiration, the bent arches recoil passively like springs to help enlarge the pharynx and draw in water. On the other hand, active forceful inspiration is effected by the coracobranchial muscles, which rapidly swing the arches anterolaterally and abduct them (Fig. 3.9C). At this time, the mouth is opened wide by the coracomandibular and coracohyoid muscles (along with their common base, the coracoarcualis) (see Figs. 3.8–3.11).

Mallat (1996) stated that "the adductor branchialis, lateral interarcual, and coracobranchial muscles develop from 'branchial muscle plates' in the gill septa, indicating they evolved from the interbranchial muscles". In his opinion, the dorsal interarcuals, coracomandibular, and coracohyoid muscles develop from the anterior myotomes, and thus evolved from epibranchial and hypobranchial myotomes, which overlie much of the pharyngeal musculature in extant cyclostomes. It should, however, be noted that Johanson (2003) and other authors argue that the coracobranchiales of gnathostomes do not correspond to part of the interbranchials of lampreys, because, in their view, the interbranchiales are more likely to be homologous to gnathostome muscles involved in branchial arch constriction rather than expansion (see below). Also, Luther (1938), Lightoller (1939) and others defend the position that the adductor mandibulae of gnathostomes probably derived from a lateral part of the interbranchialis of the first arch (and not from a medial part of this muscle, as defended by Mallat, 1996), or even from the branchial superficial constrictor of this arch, because in gnathostomes the adductor mandibulae lies on the lateral, and not on the medial, surface of its branchial arch.

We agree with Edgeworth (1935), Lightoller (1939) and Lauder (1980ab) in that the 'labial' muscles sensu Anderson (2008) are, at least in some cases, likely related to the 'adductor mandibulae complex'. Mallat (1996)

calls these muscles 'oral muscles', but he recognized that at least some of them (e.g., his 'buccal constrictor') develop from the 'mandibular branchiomere' in lampreys. The 'labial muscles' sensu Anderson (2008) also seem to develop from the mandibular plate in elasmobranchs and osteichthyans (e.g., Edgeworth, 1935). Therefore, whether these muscles are called 'labial' (e.g., Anderson 2008), 'oral' (e.g., Mallat 1996) or 'preorbital/suborbital mandible adductors' (e.g., Edgeworth 1935; Lauder 1980a), the fact is that they do seem to develop from the mandibular mesoderm, as does the 'adductor mandibulae complex'. This idea was supported by the developmental work of Kuratani et al. (2004), who concluded that "experiments labeling the mandibular mesoderm of the early lamprey embryo, before the cheek process has differentiated into the upper lip anlage or the premandibular domain, indicate that a part of the mandibular mesoderm secondarily grows anteriorly and laterally and migrates into the upper lip domain". According to Mallat (1996), the muscles that are derived from this mandibular mesoderm in lampreys, and particularly their 'labial' portion (sensu Anderson 2008), was possibly innervated by both V2 and V3 in the LCA of vertebrates (within living vertebrates, innervation by V2 and V3 is said to occur in lampreys, holocephalans, and possibly hagfishes: see Fig. 3.12), the V2 innervation being secondarily lost in elasmobranchs and osteichthyans. However, it should be noted that according to Kuratani et al. (2004) the nerve that is often called V2 in cyclostomes such as lampreys possibly does not correspond to the V2 of gnathostomes.

Mallat (1996) discussed the homologies between the various 'labial' muscles (sensu Anderson 2008) present in Cephalochordates (Fig. 3.13), in hagfishes (Fig. 3.7), in lampreys (Fig. 3.14), in elasmobranchs (Fig. 3.10) and in holocephalans (Fig. 3.15), and summarized all his hypotheses of homology in a table (see Fig. 3.12). A brief description of these muscles, which is mainly based on Mallat (1996), is given below.

In ammocoetes, the oro-labial musculature is complex. In the upper lip, the largest and most important muscle is the buccalis anterior (Fig. 3.14A), which runs from the superolateral walls of the oral cavity, the superoanterior surface of the lateral mouth plate, the trabecular commissure just below the nasal capsule, and the nasal capsule itself. It forms most of the mass of the upper lip and inserts on to the entire undersurface of the rostro-dorsal plate and on to the lip mucosa. Functionally, the buccalis anterior retracts and constricts the upper lip. Other muscles surround the oral cavity and mouth opening of ammocoetes (Fig. 3.14B): buccal constrictor, elevator labialis ventralis, sublabialis, and basalis tentacularis (sensu Mallat 1996). According to Mallat, the buccal constrictor encircles the oral cavity from the external hyoid bar posteriorly to the front of the eye. It forms the bulk of the 'cheek'. Superiorly, it attaches to the trabeculae and the fibrous braincase. The elevator labialis ventralis surrounds the mouth opening;

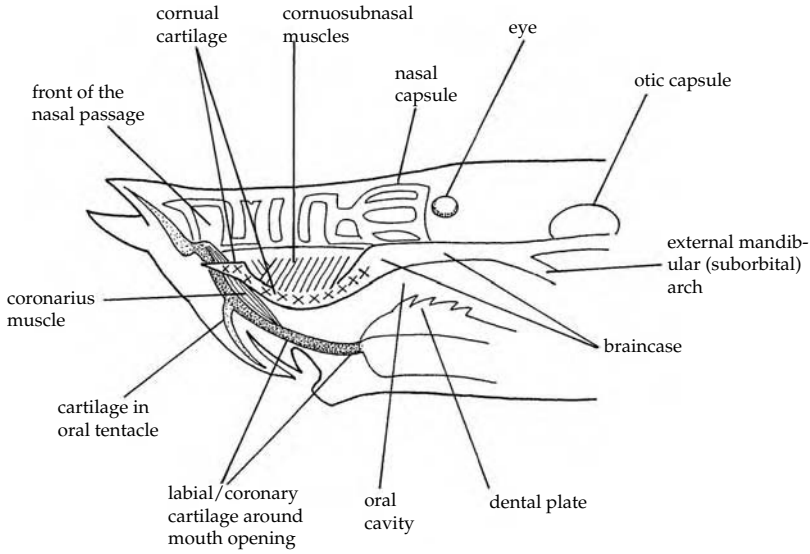

Fig. 3.7 Anterior part of the hagfish *Myxine glutinosa* (Cyclostomata). As explained in the text, according to Mallat (1996) the labeled cartilages and muscles may be homologous to structures in ammocoetes and gnathostomes (modified from Mallat 1996; the nomenclature of the structures illustrated basically follows that of this author).

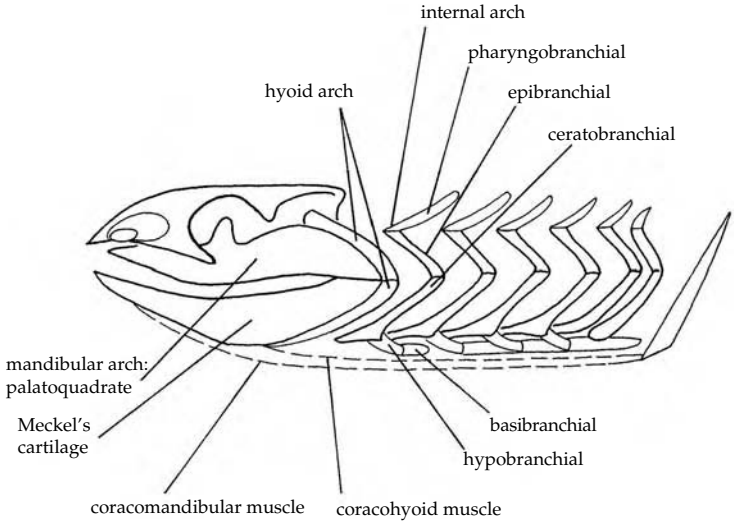

Fig. 3.8 Head and pharyngeal skeleton of the frilled shark *Chlamydoselachus anguineus* (Elasmobranchii); the five segments of an 'internal arch' (sensu Mallat 1996) are labeled; the extrabranchial cartilages are not shown; the coracomandibular and coracohyoid muscles are shown ventrally as broken lines (modified from Mallat 1996; the nomenclature of the structures illustrated basically follows that of this author).

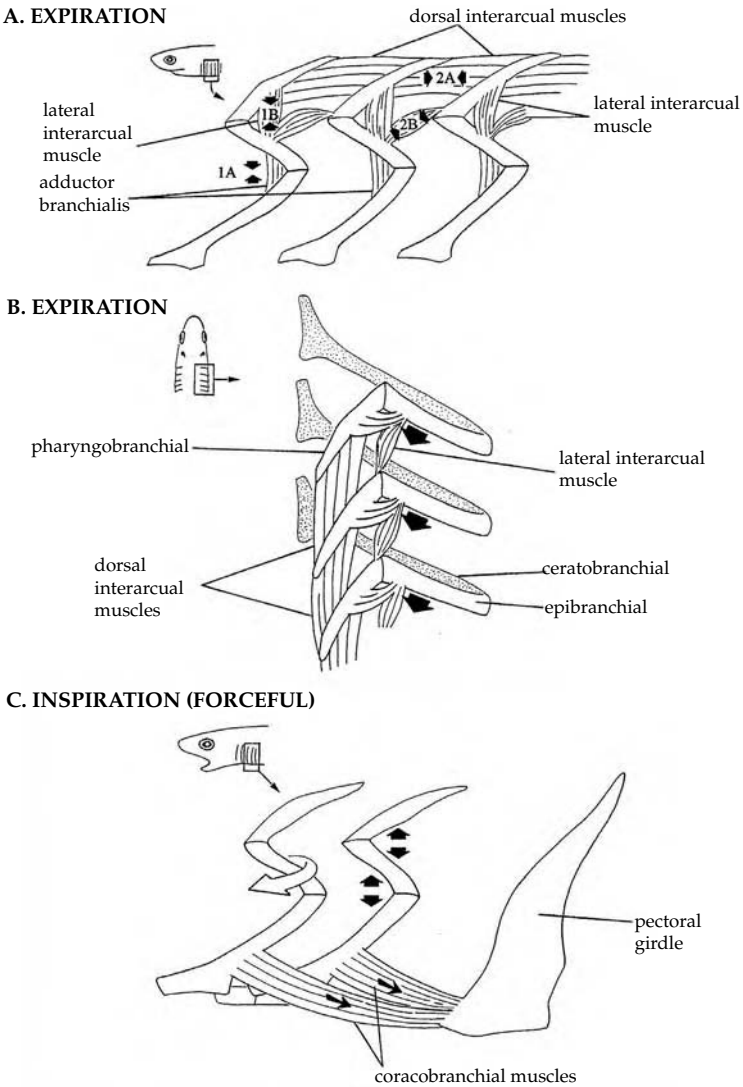

Fig. 3.9 Probable movements of the internal arches during the ventilatory cycle of sharks (Elasmobranchii), according to Mallat (1996). **(A)** expiratory movements, lateral view: the segments are flexed and pulled dorsally by adductor branchialis ('1A') and lateral interarcual muscles ('1B'), while successive arches are pulled closer together by the dorsal and lateral interarcuals ('2A' and '2B') (note: the dorsal interarcuales of sharks are considered to be epibranchial muscles sensu Edgeworth 1935). **(B)** expiratory movements, dorsal view: the lateral interarcual muscles swing the arches posteromedially (arrows). **(C)** forceful inspiration: the coracobranchial muscles swing the arches anterolaterally (large, curved arrow) and abduct the arch segments (dark, diverging arrows) (modified from Mallat 1996; the nomenclature of the structures illustrated basically follows that of this author).

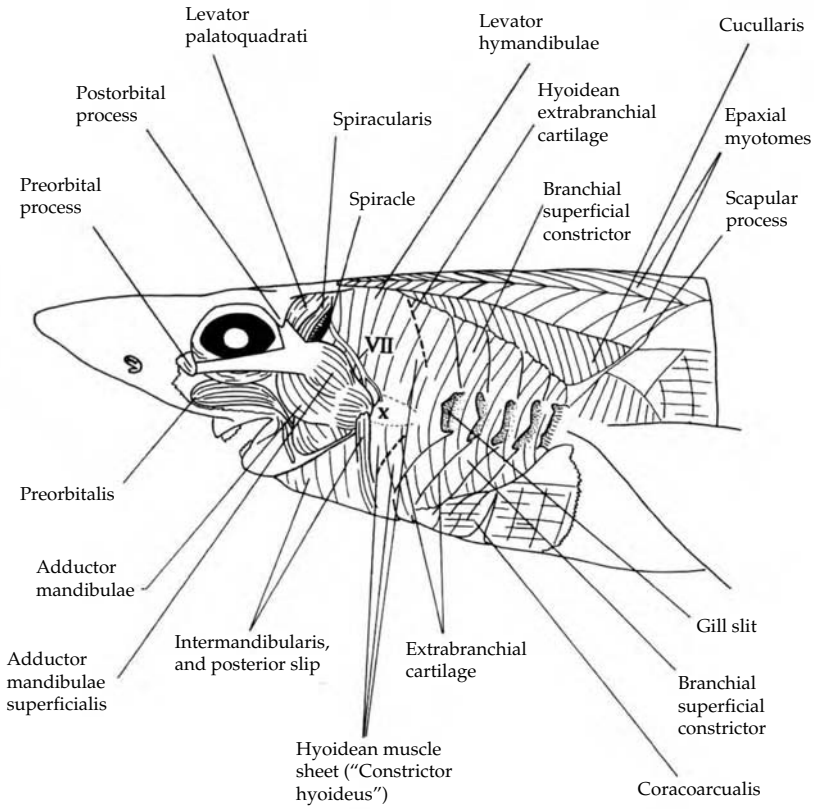

Fig. 3.10 Pharyngeal muscles of the spiny dogfish, *Squalus acanthias* (Elasmobranchii), according to Mallat (1997). 'VII' indicates hyomandibular branch of the facial nerve, while 'X' marks a region behind the jaw from which the expected mandibular musculature is absent and replaced by sheets of dense connective tissue, according to this author (modified from Mallat 1997; the nomenclature of the structures illustrated basically follows that of this author).

ventrally, it blends with the buccal constrictor (Fig. 3.14C). As it ascends, this elevator muscle lies directly anterior to, then directly lateral to, the lateral mouth plate (Fig. 3.14B). Superiorly, it runs along the undersurface of the posterior part and subocular process of the rostro-dorsal plate, then attaches to the fibrous braincase between the eye and nasal capsule. According to Mallat, this muscle raises the lower lip, and probably also acts as an oral sphincter. His description of the sublabialis muscle differs from the literature. Damas (1935), for instance, stated that this muscle originates along a bar of mucocartilage in the ventral longitudinal crest and ascends into the oral tentacles (for this reason, Damas re-named it 'muscle retractor papillaris'). Mallat confirmed its origin, but stated that "the

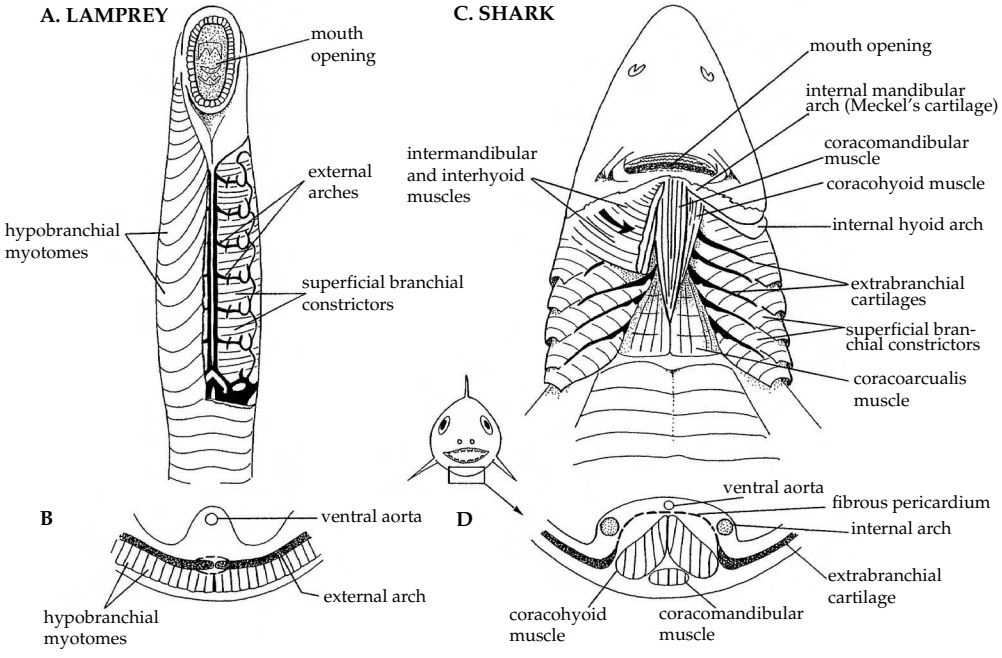

Fig. 3.11 The spinal group of hypobranchial muscles, according to Mallat (1996). These ventilatory muscles of gnathostomes evolved from locomotory myotomes. **(A)** Ventral view of a lamprey, the hypobranchial myotomes have been cut away from the lamprey's left side, exposing the external branchial arches and the superficial branchial constrictors. **(B)** Transverse section through the floor of the lamprey pharynx, showing the relationship between the hypobranchial myotomes and the external arches. **(C)** Ventral view of a shark, the hypobranchial muscles—coracomandibular, coracohyoid, and coracoarcualis—lie much deeper than in lampreys and are concentrated near the ventral midline. **(D)** Transverse section through the floor of the shark pharynx, showing the right/left separation of the extrabranchial cartilages and the deep location of the coracomandibular and coracohyoid muscles (modified from Mallat 1996; the nomenclature of the structures illustrated basically follows that of this author).

Ammocoetes	Sharks (*Squalus*)	*Chimaera*	Vertebrate ancestor	Hagfish	Amphioxus
1. SURFACE STRUCTURE					
lower lip	—	lower lip	lower lip		
lateral lip	labial fold	labial fold	lateral lip		
upper lip	lateral fold of upper lip (and region medial to it that likewise contains the anterior labial cartilage)	nasolabial fold	upper lip	skin over cornual cartilage, and cornuo-subnasal muscel	none
lateral wall of oral (cheek)	buccal membrane (cheek)	lateral wall of oral cavity(cheek)	cheek	lateral wall of oral cavity	oral hood
oral cavity	slit between lip, cheek, and jaw	slit between lip, cheek, and jaw	ancestral oral cavity	oral cavity	oral cavity
mouth opening velum	mouth opening jaws, pseudobranch, and first superficial constrictor	mouth opening jaws	mouth opening mandibular hemibranch, and first superficial constrictor	mouth opening velum	margin of oral hood velum (but no superficial constrictor)
medial flap of velum	oral valve	oral valve	oral valve	?	medial part of velum
2. SKELETON					
rostro-dorsal plate	anterior labial cartilage	prelabial cartilage	upper-lip cartilage	cornual cartilage	
lateral mouth plate, with lateral process	posterior labial cartilages	maxillary labial cartilage, with lateral process	oral cartilage	labial, or coronary, cartilage	hoop formed by bases of tentacular cartilages
ventro-lateral plate	fibrous sheet on Meckel's cartilage	fibrous mass in lower lip	fibrous or cartilaginous sheet		
3. MUSCLES					
buccalis anterior (V_2)	—	levator prelabialis, levator anguli oris ant., labialis anterior (V_2)	upper-lip muscles	cornuosubnasal muscles	
elevator labialis ventralis (V_3)	—	labialis posterior (V_3)	oral sphincter	coronarious basitentacularis	peri-buccal muscles
buccal constrictor (V_3)	levator labii superioris (V_3)	levator anguli oris posterior (V_3)	buccal constrictor	levator cartilaginis basalis, protractor cartilaginis basalis, craniobasialis	—

Fig. 3.12 Proposed homologies in the mouth and lips of ammocoete lampreys and hagfishes (Cyclostomata), sharks (Elasmobranchii), chimaeroids (Holocephala) and amphioxus (Cephalochordata), according to Mallat (1996); see also Figs. 3.7, 3.10, 3.13, 3.14 and 3.15 (modified from Mallat 1996; the nomenclature of the structures illustrated basically follows that of this author).

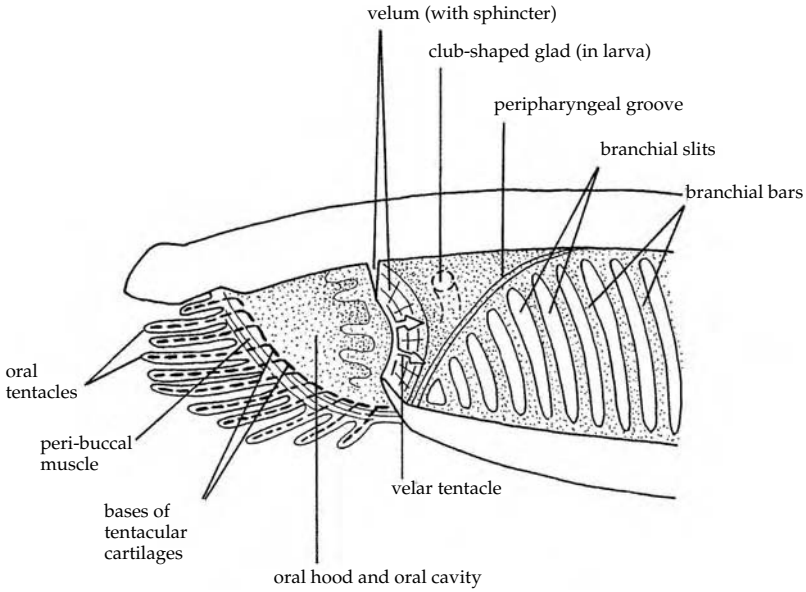

Fig. 3.13 The cephalochordate amphioxus, according to Mallat (1996): as in lampreys, a velum defines the anterior boundary of the pharynx; however, the amphioxus velum is not a ventilatory pump; the club-shaped gland is present only in the larval stage and is included in this adult picture for illustrative purposes only (modified from Mallat 1996; the nomenclature of the structures illustrated basically follows that of this author).

muscle ascended anterior to the lateral mouth plate and inserted on the rostro-dorsal plate lateral to the nasal capsule; it did not send slips to the tentacles; this suggests that the sublabialis does not retract the tentacles, but helps close the mouth by pulling down on the upper lip and pulling up on the floor of the oral cavity; the true retractor of the tentacles was discovered as a distinct, thin-fibered muscle in the anterior part of the oral cavity, along the bases of the tentacles: this new muscle was named basalis tentacularis" (Fig. 3.14B). The maxillary (V2: suboptical) and mandibular (V3) nerves both run through the oro-labial region (Fig. 3.14B). Mostly, V2 innervates the dorsal muscles, V3 the ventral ones. More specifically, V2 innervates the muscles of the upper lip including buccalis anterior, and V3 innervates the circumoral muscles, i.e., buccal constrictor and sublabialis. As for the elevator labialis ventralis, Mallat (1996) considers that this muscle is probably innervated by V3, rather than V2. As explained above, however, one should be careful about using names such as V2 and V3 to designate the nerves of cyclostomes, because according to Kuratani et al. (2004), these nerves possibly do not correspond to the V2 and V3 of gnathostomes.

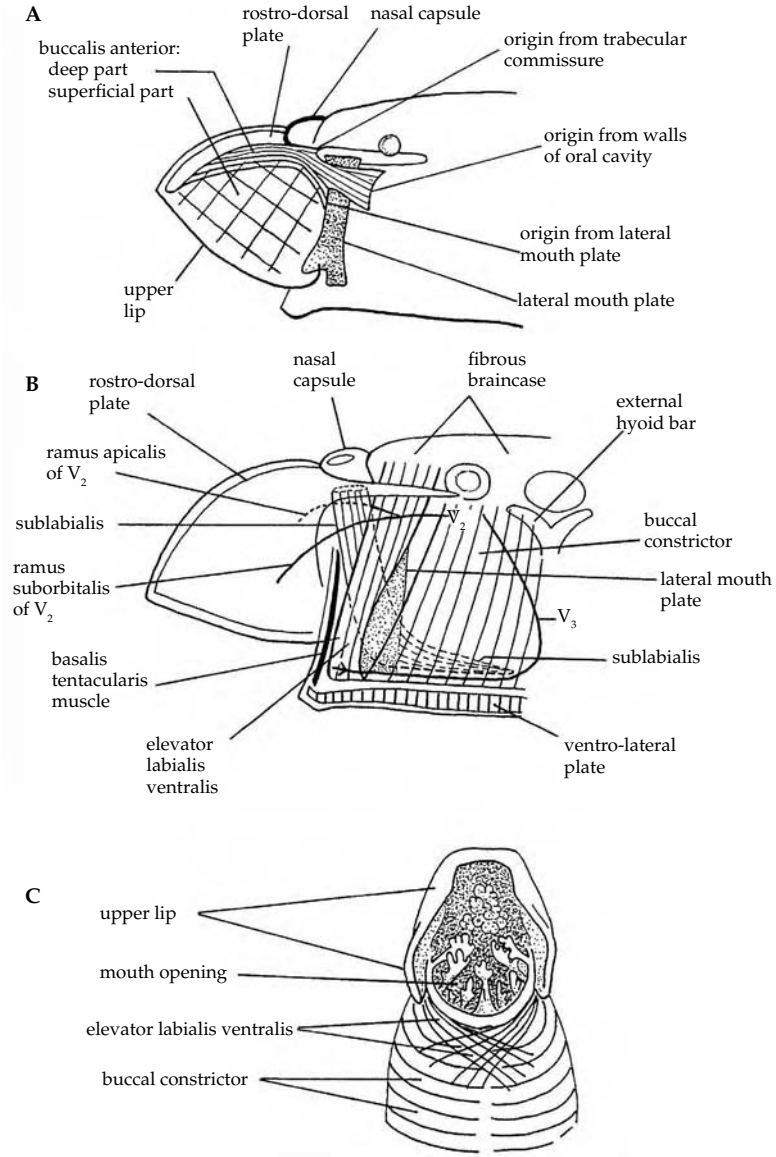

Fig. 3.14 Muscles and nerves of the lips and mouth of ammocoetes (Cyclostomata), according to Mallat (1996). **(A)** Attachments of buccalis anterior, the main muscle of the upper lip. **(B)** Muscles around the oral cavity and mouth opening, and the paths of the maxillary (V2) and mandibular (V3) nerves (note: as explained in the text, the homology between these nerves and the gnathostome nerves V2 and V3 is questioned by some authors). **(C)** Ventral view, showing how the elevator labialis ventralis and buccal constrictor overlap on the floor of the oral cavity (modified from Mallat 1996; the nomenclature of the structures illustrated basically follows that of this author).

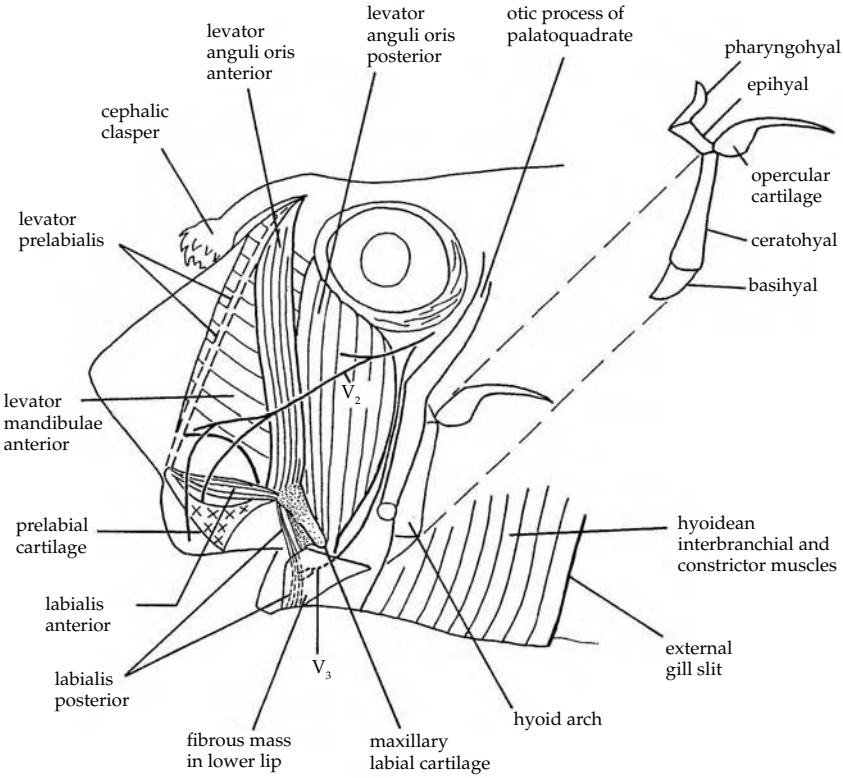

Fig. 3.15 Oro-labial muscles and nerves in *Chimaera monstrosa*, according to Mallat (1996). The V2 innervated muscles to the upper lip are the levator anguli oris anterior, labialis anterior, and levator prelabialis (the latter being rudimentary in *Chimaera* but large in other chimaeroid genera such as *Callorhinchus*). The inset at upper right shows the hyoid arch, including its pharyngohyal segment (modified from Mallat 1996; the nomenclature of the structures illustrated basically follows that of this author).

In sharks, the 'oral' musculature is simpler than in ammocoetes (Fig. 3.10). Whereas the upper lips of ammocoetes are highly muscular, those of sharks lack muscle. That is, no muscles attach to the anterior labial cartilages. Correspondingly, V3 has no motor axons and is strictly a sensory nerve in sharks and in the teleostome gnathostomes. The only muscle around the mouth opening of sharks is the levator labii superioris (often called 'preorbitalis' or 'suborbitalis': see Fig. 3.10). This muscle originates on the ethmoid region of the braincase between the two eyes just rostral to the palatoquadrate (Fig. 3.10). In *Squalus*, it runs back behind the posterior labial cartilages and inserts by a thin tendon on to the adductor mandibulae. In other sharks, however, it extends farther ventrally to insert on Meckel's cartilage. Functionally, the levator labii superioris protrudes the

lips, buccal membrane, and labial cartilages to round the mouth opening during suction feeding. It may also help close the mouth, and in some advanced sharks it protrudes the palatoquadrate. It is innervated by V3.

According to Mallat (1996), "in *Chimaera* (Fig. 3.15) the lip and mouth muscles seem comparable to those of ammocoetes". Three muscles attach to the prelabial cartilage in the nasolabial fold, and can be called 'upper-lip' muscles: levator anguli oris anterior, labialis anterior, and levator prelabialis. They run from the pre-orbital part of the braincase and the maxillary labial cartilage to the prelabial cartilage, much as the buccalis anterior of ammocoetes runs from the anterior braincase and lateral mouth plate to the rostro-dorsal cartilage in the upper lip. Mallat states that "once the chimaera *Hydrolagus colliei* sucks food from the sediment surface, it initiates a series of chewing movements, rapidly protruding then retracting the cheek and lips; the V2-innervated muscles may help to perform these functions". The thin labialis posterior of holocephalans often curves like a sling around the floor of the mouth just posterior to the lips (a similar muscle called labialis inferior is said to lie posterior to this muscle; however, such a labialis inferior was not found in the holocephalan specimens dissected by Mallat 1996). The labialis posterior extends from the superior anterior margin of the maxillary labial cartilage down across the ventral surface of Meckel's cartilage and deep to the fibrous mass in the lower lip (Figs. 3.15). In Mallat's view, "functionally this muscle could weakly lift the lower lip and mandible; it is innervated by V3; in position and innervation, it resembles the similarly sling-like elevator labialis ventralis of ammocoetes". Like the buccal constrictor of ammocoetes and the levator labii superioris of sharks, the levator anguli oris posterior (V3) of holocephalans originates from the suborbital braincase, lies directly posterior to the maxillary labial cartilage, and occupies the cheek anterior to the mandibular arch and jaw joint (Fig. 3.15).

Based on his observations and comparisons and the proposed homologies shown in Fig. 3.12, Mallat (1996) attempted to reconstruct the lips and mouth of the jawless LCA of living vertebrates (Fig. 3.2). According to him, in this LCA the "upper lips were well developed, although the condition in chimaeroids and sharks suggests these lips were not as large as in ammocoetes; muscles ran from the braincase into the upper lips (as in ammocoetes and chimaeroids); the mouth opening was circular and smaller than that of the earliest known sharks (based on ammocoetes and chimaeroids); a ring of oral cartilages lay directly behind the continuous lateral and lower lips, and supported both the anterior margin of the mouth and some sensory tentacles". Also, "these oral cartilages were not serially homologous to the branchial arches (not a premandibular arch: see above); behind this oral ring, in the cheek, a buccal constrictor circled the premandibular oral cavity; this constrictor graded posteriorly into the

branchial superficial constrictors around the pharynx; the anterior part of the buccal constrictor was thickened into a distinct oral sphincter". According to Mallat, the reconstructed oral structures of the LCA of vertebrates (Fig. 3.2) "seem well suited for feeding on semi-sessile soft-bodied invertebrate prey on the ocean floor, where ingestion involved pushing the head against the prey and forcing it into the oral cavity; in this feeding act, the oral sphincter would have squeezed the ring of oral cartilages to grasp the prey animal, then the buccal and branchial constrictor muscles would have squeezed (swallowed) the prey back to the esophagus through peristalsis; no suction was involved in ingesting and swallowing prey; the upper lips and tentacles would have been tactile and gustatory structures, respectively, for detecting prey on the substrate; the mobile upper lips could have draped over the prey, trapping it against the sediment surface directly in front of the mouth, thereby facilitating ingestion; covered with tiny denticles (odontodes), this ancestor would have been more mobile and wide-ranging than the more heavily armored osteostracans and heterostracans". The LCA of vertebrates would thus be a nektobenthonic animal that was "actively swimming along the ocean floor in search of food and stopping to rest only occasionally".

Mallat (1996) argued that the "oro-labial region of ammocoetes (Fig. 3.14) differs from the reconstructed ancestral vertebrate condition (Fig. 3.2) in three ways: first, the upper lip is enlarged, presumably having become so when the ancestors of ammocoetes became burrowers; second, the premandibular oral cavity is enlarged, to hold the velum that projects forward into this cavity; the third derived feature in the oral cavity of ammocoetes is the ventral longitudinal crest, which metamorphoses into the lingual apparatus ('tongue') of adult lampreys". He suggested that "the lingual apparatus evolved in the adult ancestors of extant cyclostomes as an appendage that helped pull worms into the mouth and back through the oral cavity—because that is how hagfish use this apparatus and the associated dental plates; the lingual apparatus of adult lampreys pulls and slices food, and its anatomy suggests it is homologous to that of hagfish". Also, "judging from the many resemblances between the oro-labial structures of ammocoetes and chimaeroids, the evolution of jaws had little effect on the external anatomy of this premandibular region: that is, in the earliest gnathostomes, the cheeks still reached far forward and the mouth opening was not enlarged; however, the mouth opening had attained its lateral corners, reflecting the fact that it now closed in an up-and-down bite, no longer by sphincter action; furthermore, the functions of the oro-labial structures had begun to change: judging from both chimaeroids and sharks, the earliest gnathostomes could protrude and then retract their cheeks during suction feeding, and the upper and lateral

lips now served to round the mouth opening during the expansive phase of the feeding strike".

He considers that "early elasmobranchs began to chase down large, pelagic prey, and the gape of their mouth enlarged to fit this larger prey: to allow this, the lateral corner of the mouth migrated far posteriorly, and the cheek folded into a deep labial pouch as a buccal membrane; simultaneously, the most anterior part of the upper lip flattened to avoid blocking prey entering the mouth (although the posterior part of this lip remained as the lateral fold); in essence, the premandibular mouth structures became smaller to avoid interfering with the capture of large prey by the jaws; incidentally, independent enlargements of the gape must have occurred in the ancestor of acanthodians and Osteichthyes, and in the most highly predacious of the arthrodire placoderms". Lastly, regarding the evolution of the mouth and lips of holocephalans, Mallat (1996) stated that "the relatively small gape and jaws of these animals should be primitive; by this reasoning, chimaeroid feeding must echo a stage after the evolution of jaws but before large, evasive prey were chased down and swallowed whole; indeed, chimaeroids feed mainly on slow invertebrates such as molluscs, crabs, echinoids, polyps, shrimps, and amphipods; although their diets contain many hard items, and their jaws and teeth obviously are modified for forceful shearing or durophagy, chimaeroids otherwise retain the benthic feeding mode of ancestral vertebrates".

Mallat's 1996 ideas are based on a remarkably detailed examination of the configuration of the cartilages, muscles, arteries, nerves, and ligaments of the mouth and lips of living non-osteichthyan vertebrates, and they provide an extremely valuable contribution to understand the evolution and homologies of the mouth and lip structures within basal vertebrates. However, it should be stressed that, contrary to what is shown in Fig. 3.12, in the specific case of the myological structures it is quite possible that there is actually no direct correspondence between any of the individual 'labial' muscles present in living lampreys (i.e., buccalis anterior, elevator labialis ventralis and buccal constrictor in ammocoetes, sensu Mallat 1996), living hagfishes (i.e., coronarious, basitentacularis, levator cartilaginis basalis, protractor cartilaginis basalis, craniobasialis and cornuosubnasalis muscles sensu Mallat 1996), living holocephalans (i.e., levator prelabialis, levator anguli oris anterior, levator anguli oris posterior, labialis anterior and levator posterior sensu Mallat 1996), living elasmobranchs (i.e., preorbitalis/levator labii superioris sensu Mallat 1996 and Anderson 2008), and living osteichthyans (levator maxillae superioris 3 and 4 of *Amia* and palatomandibularis major and minor of *Lepisosteus*—sensu Diogo 2007 and Anderson, 2008—and possibly 'suborbital portion of adductor mandibulae' of acipenseriforms—sensu Lauder 1980a—and/or 'labial muscles' of *Latimeria*—sensu Millot and Anthony

1958 and Anderson 2008). That is, in our opinion one cannot discard the hypothesis that the individual 'labial' muscles present in living lampreys, hagfishes, elasmobranchs, holocephalans and osteichthyans are the result of an independent differentiation (in the lineages that gave rise to these major vertebrate groups) of the mandibular mesoderm. In fact, as stressed above, the developmental work of Kuratani et al. (2004) has not only indicated that at least some of the lamprey 'labial muscles' are the result of a secondary migration of part of the mandibular mesoderm, but also that these muscles are very likely not homologous with the 'labial' muscles of living gnathostomes: "experiments labeling the mandibular mesoderm of the early lamprey embryo, before the cheek process has differentiated into the upper lip anlage or the premandibular domain, indicate that a part of the mandibular mesoderm secondarily grows anteriorly and laterally and migrates into the upper lip domain; no such muscles are known in the gnathostomes, in which all the trigeminal-nerve-innervated muscles are restricted to derivatives of the upper and lower jaws". Further studies, ideally combining dissections and direct comparisons of various lampreys, hagfishes, elasmobranchs, holocephalans, osteichthyans, and non-vertebrate taxa such as Cephalochordates and Tunicates with molecular techniques such as those employed by Kuratani et al. (2004), will, it is hoped, help clarify the evolution and homologies of the 'labial' muscles within these taxa.

Mallat (1997) states that the levator arcus palatini ('levator palatoquadrati' in his terminology) of sharks derives from the interbranchialis 1, and not from the branchial superficial constrictor 1 (has he proposed in 1996). He also states that most fibers of the spiracularis (e.g., Fig. 3.10) and intermandibularis of sharks also derive from the interbranchialis 1, and that only a small portion of these muscles derives from the branchial superficial constrictor 1 (in his 1996 paper, he proposed that these two muscles were mostly derived from the branchial superficial constrictor 1). We tend to agree more with the homologies proposed by Mallat (1996) than with those proposed by Mallat (1997), i.e., that the ventral mandibular muscle intermandibularis (e.g., Fig. 3.11) of the LCA of gnathostomes probably derived from the ventral region of an ancestral branchial superficial constrictor of the first arch, and that the dorsal mandibular muscle levator arcus palatini (= 'levator palatoquadrati': e.g., Fig. 3.10) of this LCA probably derived from the dorsal region of the same constrictor muscle. In fact, the work of various authors (e.g., Marion 1905; Daniel 1928; Luther 1938) has strongly supported the idea that the intermandibularis and the levator arcus palatini sensu this volume effectively derive from the branchial superficial constrictor of the first arch and that the interhyoideus, adductor operculi and adductor arcus palatini sensu this volume derive from the branchial superficial constrictor of the second arch.

Interestingly, according to Holland et al. (1993) the velothyroideus of lampreys may be homologous to the levator arcus palatini + dilatator operculi of teleosts (see Chapter 4), i.e., to the mandibular constrictor dorsalis sensu Edgeworth (1935), and, thus, to the levator arcus palatini of the LCA of gnathostomes. This is because engrailed immunoreactivity has been detected in the lamprey velothyroideus and in the zebrafish levator arcus palatini. Holland et al. stated that the mandibular arch mesoderm of lampreys gives rise to one extrinsic eye muscle, three muscles of the velum (velothyroideus, velohyoideus and velocranialis), and seven muscles of the hood and lip (most, or all, of them probably corresponding to the 'labial' muscles sensu Anderson 2008, and to the muscles shown in the table of Fig. 3.12: see above). If one accepts the homology between the lamprey velothyroideus and the levator arcus palatini of the LCA of gnathostomes, could the two other muscles of the lamprey velum, i.e., the velohyoideus and velocranialis sensu Holland et al. (1993), be homologous to the two other non-'labial' mandibular muscles of this LCA, i.e., the adductor mandibulae and the intermandibularis? Mallat (1996) seems to suggest that this is not the case, because he states that the 'adductor mandibulae complex' sensu Anderson (2008) came from a 'medial band' of the interbranchialis of the first arch (see above), and thus not from the velohyoideus and/or the velocranialis. It should also be stressed that the detection of engrailed immunoreactivity in certain muscles of a taxon A and in certain muscles of a taxon B does not necessarily imply that the former muscles are directly homologous to the latter (Knight et al. 2008). For instance, in the zebrafish engrailed immunoreactivity is only detected in muscles that are derived from the dorsal portion of the mandibular muscle plate (constrictor dorsalis sensu Edgeworth 1935, i.e., the levator arcus palatini + dilatator operculi: see Chapter 4), while in the mouse it is detected in mandibular muscles that are very likely derived from the 'adductor mandibulae' portion of that plate (i.e., masseter, temporalis, pterygoideus medialis and/or pterygoideus lateralis; see Knight et al. 2008 and Chapter 5). That is why detection of immunoreactivity in the lamprey velothyroideus and in the zebrafish levator arcus palatini and dilatator operculi does imply that the latter muscles are homologous to, or derived from, the former muscle. Authors such as Kuratani and Ota (2008) have even suggested that lampreys and probably hagfish lack 'somitomeres', i.e., that cyclostomes probably do not have 'mandibular', 'hyoid' and 'branchial' muscular plates (sensu Edgeworth 1935) such as those present in living gnathostomes (see, e.g., Kuratani and Ota 2008). However, researchers such as Holland et al. (1993), Mallat (1996) and Knight et al. (2008) do consider that at least some of these plates (e.g., the mandibular muscular plate sensu Edgeworth 1935) are present in extant cyclostomes, thus implying that they were present in the LCA of vertebrates.

Regarding the homologies of the branchial muscles sensu Edgeworth, Wiley (1979ab) suggests that the presence of 'ventral branchial musculature in all gill arches' is a synapomorphy of gnathostomes, i.e. that this feature was present in the LCA of gnathostomes but not in the LCA of vertebrates. Johanson (2003) supports this idea. She states that lampreys lack all ventral branchial muscles, including gill arch depressors comparable to the cora cobranchials/pharyngoclaviculares (see Fig. 3.9). According to her, living lampreys do however have various branchial muscles, including: (1) interbranchiales; (2) external branchial constrictors; (3) internal dorsal and ventral diagonal constrictors; (4) median muscle bands; and (5) isolated muscle fibers associated with the interbranchial septum, as well as hypobranchial muscles (see, e.g., Figs. 3.4, 3.6, and also Roberts 1950).

Mallat (1996) argues that the lateral interarcuales and adductores branchiales (see, e.g., Figs. 3.6, 3.9) of sharks derive from the interbranchiales and their 'medial bands', respectively (the 'adductor branchialis' of the first arch corresponding to the adductor mandibulae, and the 'adductor branchialis' of the second arch being absent: see above). He also suggests that the ventral part of the lamprey interbranchial muscles is homologous to the coracobranchiales/pharyngoclaviculares of gnathostomes, but Johanson (2003) does not agree, because the interbranchiales are mainly related to constrictive movements while the coracobranchiales/pharyngoclaviculares are mainly related to expansive movements (see above). In this case, we tend to agree more with Johanson (2003) than with Mallat (1996). We consider that the coracobranchiales/pharyngoclaviculares of gnathostomes probably do not correspond to the ventral part of the interbranchiales of lampreys, because the cyclostome interbranchiales and gnathostome coracobranchiales/pharyngoclaviculares have quite different overall configurations, attachments, and functions. The coracobranchiales/pharyngoclaviculares of gnathostomes thus may (1) be *de novo* structures, (2) correspond to muscular structures that have not been described in detail in hagfishes and/or lampreys, or that were secondarily lost in both these two groups, or (3) derive from the hypobranchial musculature, as defended by some authors (see, e.g., Johansson's 2003 review). The fact that in various gnathostomes the coracobranchiales/pharyngoclaviculares are innervated by nerve XI (see, e.g., Anderson 2008) would perhaps provide support for this latter hypothesis. However, it should be noted that the results obtained from Edgeworth's (1935) detailed comparative study of several vertebrate embryos and adults strongly support the idea that the gnathostome coracobranchiales/pharyngoclaviculares are branchial, and not hypobranchial, muscles. In a recent work, Anderson (2008) has corroborated the view that the coracobranchiales of elasmobranchs are very likely homologous and/or ancestral to the pharyngoclaviculares of osteichthyans (see Figs. 3.17–3.19). The protractor pectoralis (often named

'cucullaris' or 'trapezius', see, e.g., review of Kuratani 2008) is not present as an independent muscle in living non-gnathostome animals, its presence thus constituting a potential synapomorphy of gnathostomes (see, e.g., Fig. 3.16 and below).

According to Mallat (1996), in the LCA of vertebrates the hypobranchial myotomes probably lay superficial to the external branchial arches and pharyngeal musculature (Fig. 3.11A,B), because this is the condition in lampreys and hagfish ('musculus rectus': Marinelli and Strenger, 1956). In hagfish, these hypobranchial muscles run anteriorly to insert on the floor of the oral cavity, so it seems reasonable to propose that in this LCA they pulled posteriorly on this floor to widen the oral cavity or open the mouth. In Mallat's view, these hypobranchial muscles must have shifted,

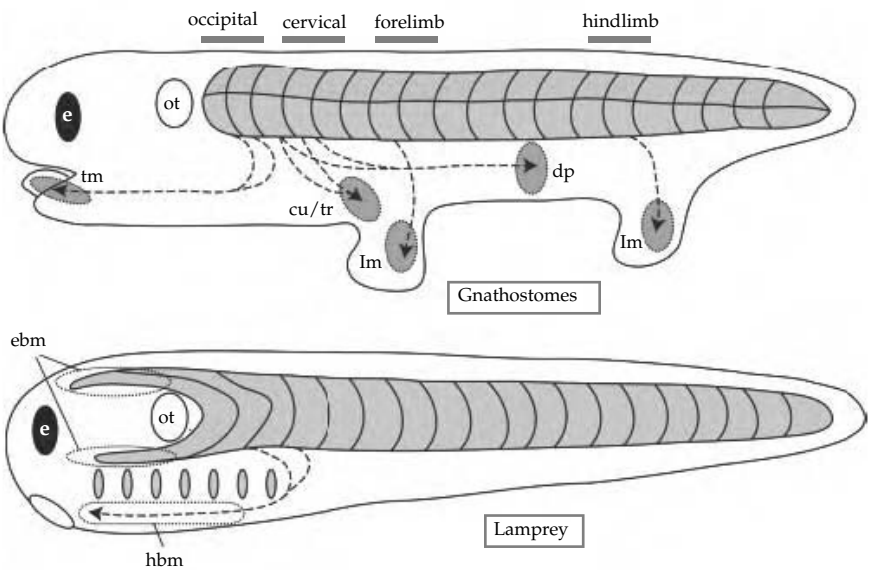

Fig. 3.16 A schematic representation comparing the skeletal muscle patternings between gnathostomes and the lampreys, according to Kusakabe and Kuratani (2005). In gnathostomes (top), some of the hypaxial muscle cells, originating from the four different levels along the anteroposterior axis (indicated by bars at the top), undergo extensive migration (indicated by broken arrows) toward the periphery where they differentiate into the tongue muscle (tm), cucullaris/trapezius muscle (cu/tr), diaphragm (dp), and limb muscles (Im). The cyclostome lamprey (bottom) lacks most of these muscles but possesses a hypobranchial musculature (hbm), which resembles the vertebrate tongue muscles, and an 'epibranchial' musculature, which has a peculiar morphology, extending (from the anterior myotomes) rostrally to the otic vesicle (ot) (modified from Kusakabe and Kuratani 2005; the nomenclature of the structures illustrated follows that of these authors).

in 'pre-gnathostomes', "to a deeper location, in order to insert on the ventrolateral surfaces of the internal mandibular and hyoid arches (Fig. 3.11C); functionally, this would have allowed faster opening of the mouth through a forceful abduction of the jaw and hyoid segments; to allow this shift in depth, however, the right and left rows of external arches (extrabranchial cartilages) must have separated from one another and moved laterally on the pharyngeal floor (Fig. 3.11D)".

Within gnathostomes, an epibranchial musculature is only present in holocephalans and elasmobranchs (e.g., Edgeworth 1935). Mallat (1996) seems to suggest that this musculature may also be present in living non-gnathostome taxa such as lampreys, but Mallat (1997) states that "dorsal interarcuales" (which are considered to be epibranchial muscles sensu Edgeworth 1935: see Fig. 3.9) is "the only group of pharyngeal muscles that is fully unique to condrichthyans". Kusakabe and Kuratani (2005) state that lampreys have 'epibranchial muscles', which "have a peculiar morphology, extending rostrally from the anterior myodomes" (see Fig. 3.16), but Kuratani (2008; pers. comm.) explained that these muscles are likely not homologous with the chondrichthyan epibranchial muscles sensu Edgeworth (1935). In view of the information available at the moment it is thus difficult to discern whether the epibranchial muscles sensu Edgeworth (1935) were only acquired in chondrichthyans or were, instead, present in the LCA of gnathostomes and then secondarily lost in osteichthyans.

General Remarks

In summary, it can be said that the transition from non-vertebrate to vertebrate animals (the latter having numerous cranial ventilatory muscles, contrary to the former) and then the transition from non-gnathostome to gnathostome vertebrates (the latter having many muscles that are not present as independent structures in the former, such as the adductor operculi, interhyoideus, coracomandibularis and sternohyoideus sensu this volume, among others) were crucial events in the evolution and differentiation of the cephalic muscles (see Tables 3.1–3.4, as well as the tables presented in Chapters 4 and 5).

The mandibular musculature of the LCA of gnathostomes was probably divided into the following: the intermandibularis, the levator arcus palatini ('levator palatoquadrati'), the 'adductor mandibulae complex', and, possibly, one or more 'labial muscles' (sensu Anderson, 2008; see above) (see Table 3.1, and also Fig. 3.17). In various holocephalans, various elasmobranchs, and various osteichthyans the intermandibularis is subdivided into an intermandibularis anterior and an intermandibularis posterior (see Chapters 4–7). Such subdivisions were probably acquired

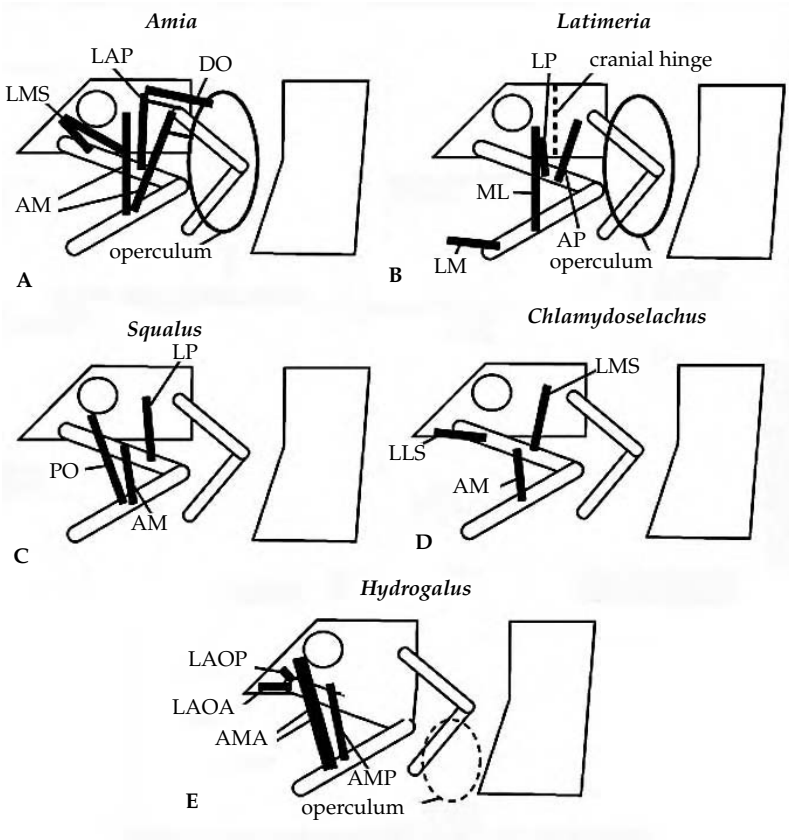

Fig. 3.17 Schematic drawings of the mandibular musculature of the actinopterygian *Amia calva* **(A)** and the sarcopterygian *Latimeria chalumnae* **(B)** (Osteichthyes), the elasmobranchs *Squalus acanthias* **(C)** and *Chlamydoselachus anguineus* **(D),** and the holocephalan *Hydrolagus colliei* **(E),** according to Anderson (2008). The thick black lines represent muscles; the intermandibular muscles are not illustrated. For homologies between the illustrated muscles, see Table 3.1. AM, adductor mandibulae; AMA, adductor mandibulae anterior; AMP, adductor mandibulae posterior; AP, adductor palatoquadrati; DO, dilator operculi; LAOA, labialis anguli oris anterior; LAOA, labialis anguli oris posterior; LAP, levator arcus palatini; LLS, levator labii superioris; LM, labial muscles; LMS, levator maxillae superioris; LP, levator palatoquadrati; ML, mandibular levator; preorbitalis (modified from Anderson 2008; the nomenclature of the structures illustrated follows that of this author).

more than once in gnathostomes (e.g., Edgeworth 1935; Diogo 2007; see also Chapter 7). However, the fact that the LCA of gnathostomes had a divided intermandibularis cannot be discarded. The levator arcus palatini became secondarily lost in holocephalans, probably due to the fusion between the first arch and the mandible in these fishes (see Fig. 3.17; e.g., Miyake et al. 1992; Mallat 1996; Anderson 2008). In elasmobranchs the dorsal part of the mandibular plate gives rise to not only the levator arcus palatini,

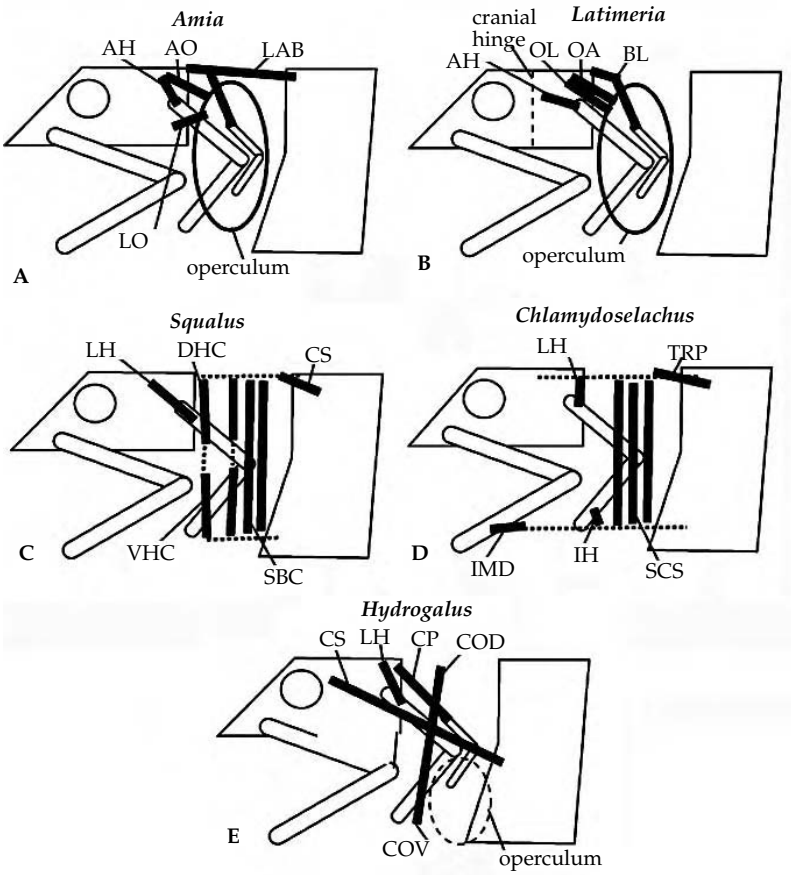

Fig. 3.18 Schematic drawings of the hyoid and branchial musculature of the actinopterygian *Amia calva* **(A)** and the sarcopterygian *Latimeria chalumnae* **(B)** (Osteichthyes), the elasmobranchs *Squalus acanthias* **(C)** and *Chlamydoselachus anguineus* **(D),** and the holocephalan *Hydrolagus colliei* **(E),** according to Anderson (2008). The thick black lines represent muscles; the interhyoid type muscles have not been figured here except in *Chlamydoselachus* to show their relation to the superficial constrictor sheet. For homologies between the illustrated muscles, see Tables 3.2 and 3.3. AM, adductor mandibulae; AMA, adductor mandibulae anterior; AH, adductor hyomandibularis; AO, adductor operculi; BL, branchial levators; COD, constrictor operculis dorsalis; COV, constrictor operculis ventralis; CP, cucullaris profundus; CS, cucullaris; DHC, dorsal hyoid constrictors; IH, interhyoideus; IMD, intermandibularis; LAB, levatores arcuum branchialum; LH, levator hyomandibularis; LO, levator operculi; OA, opercular adductor; OL, opercular levators; SBC, superficial constrictors; SCS, superficial branchial constrictors; TRP, trapezius; VHC, ventral hyoid constrictors (modified from Anderson 2008; the nomenclature of the structures illustrated follows that of this author).

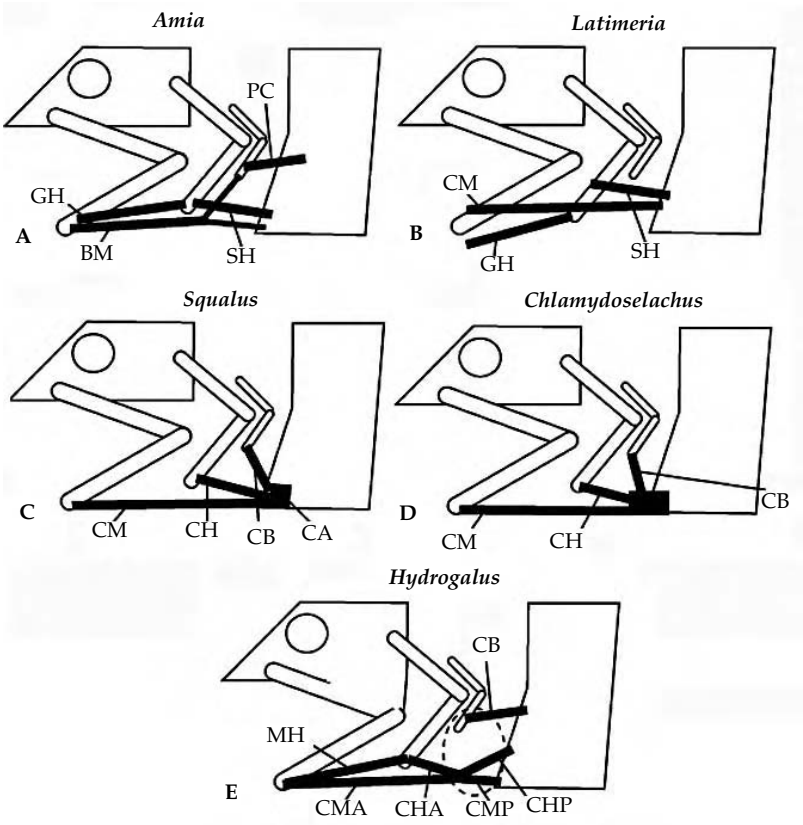

Fig. 3.19 Schematic drawings of the branchial and hypobranchial musculature of the actinopterygian *Amia calva* **(A)** and the sarcopterygian *Latimeria chalumnae* **(B)** (Osteichthyes), the elasmobranchs *Squalus acanthias* **(C)** and *Chlamydoselachus anguineus* **(D),** and the holocephalan *Hydrolagus colliei* **(E),** according to Anderson (2008). The thick black lines represent muscles; the geniohyoideus (GH) muscle in *Latimeria* is drawn without an insertion because it is unclear whether it actually connects to the mandible. For homologies between the illustrated muscles, see Tables 3.3. and 3.4. BM, branchiomandibularis; CA, coracoarcuales; CB, coracobranchials; CH, coracohyoideus; CHA, coracohyoideus anterior; CHP, coracohyoideus posterior; CM, coracomandibularis; CMA, coracomandibularis anterior; CMP, coracomandibularis posterior; GH, geniohyoideus; PC, pharyngo-clavicularis; SH, sternohyoideus (modified from Anderson 2008; the nomenclature of the structures illustrated follows that of this author).

but also to muscles such as the depressor palpebrae superioris, the levator palpebrae nictitantis, the rectractor palpebrae superioris spiracularis, the 'spiracularis' and/or the spiracularis sensu Miyake et al. (1992) (see Fig. 3.10). In gnathostomes the adductor mandibulae is often subdivided (e.g., adductor mandibulae anterior and posterior in holocephalans; A2, A3′, A3′′, A1, A1-OST, Aω, etc. in osteichthyans; see Fig. 3.17 and Chapters 4–7). As

Table 3.2 Hyoid muscles of adults of representative non-osteichthyan extant vertebrate taxa (see caption of Table 3.1).

Agnatha: *Lampetra japonica* (Japanese lamprey)	Probable plesiomorphic gnathostome condition	Elasmobranchii: *Squalus acanthias* (Spiny dogfish)	Holocephali: *Hydrolagus colliei* (Spotted ratfish)
— [a distinct, independent interhyoideus such as that found in gnathostomes does not seem to be present in lampreys: see text and also, e.g., Mallat 1996, 1997]	**Interhyoideus**	**Interhyoideus** (interhyoideus + superficial ventral constrictor of the second arch sensu Allis 1923, Lightoller 1939 and Anderson 2008; constrictor hyoideus ventralis sensu Miyake et al. 1992)	**Interhyoideus** (constrictor operculi ventralis sensu Anderson 2008) [see text]
— [a distinct, independent adductor operculi/constrictor hyoideus dorsalis such as that found in gnathostomes does not seem to be present in lampreys: see text and also, e.g., Mallat 1996, 1997]	**Constrictor hyoideus dorsalis**	**Constrictor hyoideus dorsalis** (part of the constrictor 2 superficialis dorsalis sensu Adams 1919; dorsal hyoid constrictor sensu Anderson 2008; pars inscriptionalis of the dorsal constrictor of the second arch sensu Lightoller 1939 (= csd2b); as can be seen in, e.g., fig. 13 of Lightoller 1939, the pars inscriptionalis of the ventral constrictor of the second arch sensu this author (= csv2b, which corresponds to the ventral superficial constrictor of the second arch sensu Anderson 2008) clearly seems to correspond to part of the interhyoideus sensu this volume, and namely to the interhyoideus posterior of, e.g., *Ambystoma*: see interhyoideus above) [although this muscle clearly seems to correspond to/be modified from the adductor operculi of the LCA of gnathostomes, the name constrictor hyoideus dorsalis is probably more	**Constrictor hyoideus dorsalis** (constrictor operculi dorsalis sensu Anderson 2008: see text) [Miyake et al. 1992 did not describe an adductor operculi/ constrictor hyoideus dorsalis in holocephalans]

		indicated for chondrichthyans, because elasmobranchs, for instance, do not have an opercle]	
— [a distinct, independent adductor arcus palatini such as that found in gnathostomes does not seem to be present in lampreys: see text and also, e.g., Mallat 1996, 1997]	**Adductor arcus palatini**	**Adductor arcus palatini** (part of the constrictor 2 superficialis dorsalis sensu Adams 1919; levator hyomandibulae sensu Miyake et al. 1992 and Lightoller 1939, who divides the levator hyomandibulae in a pars epi-hyoidea (= csd2a) and a levator 2 (= L2); levator hyoideus sensu Anderson 2008)	**Adductor arcus palatini** (levator hyomandibulae sensu Miyake et al. 1992; levator hyomandibularis sensu Anderson 2008)
—	— [really absent in the LCA of gnathostomes? See text]	**Additional hyoid muscles** [according to Miyake et al. 1992, elasmobranchs might have other hyoid muscles such as the 'levator rostri', 'depressor rostri' and 'depressor mandibulae'; this latter muscle should, however, have a different name, because it is very likely not homologous to the depressor mandibulae of dipnoans and tetrapods: see Chapters 4–7]	—

Table 3.3 Branchial muscles of adults of representative non-osteichthyan extant vertebrate taxa (see caption of Table 3.1).

Agnatha: *Lampetra japonica* (Japanese lamprey)	Probable plesiomorphic gnathostome condition	Elasmobranchii: *Squalus acanthias* (Spiny dogfish)	Holocephali: *Hydrolagus colliei* (Spotted ratfish)
Branchial muscles *sensu stricto* [examples of branchial muscles that might be present in lampreys, according to Johanson 2003, are the interbranchiales, external branchial constrictors, internal dorsal and ventral diagonal constrictors, median muscle bands, and isolated muscle fibers associated with the interbranchial septum]	**Branchial muscles *sensu stricto***	**Branchial muscles *sensu stricto*** [examples of branchial muscles that might be present in elasmobranchs, according to Edgeworth 1935, Miyake et al. 1992, and Anderson 2008, are the coracobranchiales, the superficial branchial constrictors, a dorsal branchial muscle complex and an interbranchialis]	**Branchial muscles *sensu stricto*** [examples of branchial muscles that might be present in holocephalans, according to Edgeworth 1935, Miyake et al. 1992, and Anderson 2008, are the coracobranchiales and a dorsal branchial muscle complex]
— [according to Kuratani et al. 2005, Kusakabe and Kuratani 2005 and other authors, the protractor pectoralis is seemingly absent as an independent muscle in living non-gnathostome animals, its presence thus probably constituting a synapomorphy of gnathostomes]	**Protractor pectoralis**	**Protractor pectoralis** (trapezius sensu Allis 1923; part or totality of cucullaris sensu Anderson 2008; probably corresponds to the levator scapulae (= levator 8, or L8) sensu Lightoller 1939; as stated by this latter author, some authors have designated the third to eight levators sensu Lightoller 1939 as 'trapezium system' or as the 'cucullaris complex', which is confusing, because the cucullaris sensu Edgeworth 1935 corresponds only to the levator scapulae sensu Lightoller 1939)	**Protractor pectoralis** [seems to correspond to the cucullaris superficial and probably also to the protractor pectoralis dorsalis sensu Anderson 2008; the cucullaris profundus sensu this author seems to be simply a branchial levator]

Table 3.4 Hypobranchial muscles of adults of representative non-osteichthyan extant vertebrate taxa (see caption of Table 3.1).

Agnatha: *Lampetra japonica* (Japanese lamprey)	Probable plesiomorphic gnathostome condition	Elasmobranchii: *Squalus acanthias* (Spiny dogfish)	Holocephali: *Hydrolagus colliei* (Spotted ratfish)
Undifferentiated hypobranchial musculature (hypoglossal muscle or tongue muscle sensu Goodrich 1958)	**Coraco-mandibularis**	**Coracomandibularis** [Adams 1919 erroneously stated that that the coracomandibularis and coracohyoideus of elasmobranchs are hyoid muscles innervated by cranial nerve 7: see, e.g., his pages 64-66]	**Coracomandibularis** [Anderson 2008 describes a coracomandibularis anterior and posterior in *Hydrolagus* but, as he explains, this is more an artificial division than a real one]
— [see text]	**Sternohyoideus**	**Sternohyoideus** [as explained by Miyake et al. 1992, in some sharks the sternohyoideus (their 'rectus cervicus') remains undivided, while in batoids it is usually subdivided into a coracohyoideus, a coracoarcualis and a coracohyomandibularis, this latter muscle being found only in batoids]	**Sternohyoideus** (rectus cervicus sensu Miyake et al. 1992; coracohyoideus sensu Anderson 2008)
—	—	—	**Mandibulohyoideus?** (part or totality of interhyoideus and/or geniohyoideus sensu Edgeworth 1935 and Kesteven 1942-1945) [Anderson 2008 hypothesizes that the structure he designates as 'mandibulohyoieus' is a hypobranchial muscle that is not homologous to any other cranial muscle found in living gnathostomes; according to him the presence of this peculiar muscle in holocephalans indicates that these fishes have a way of opening the mouth that is somewhat 'intermediate' between that found in living osteichthyans and that found in living elasmobranchs; also according to him, this muscle is innervated by nerves VII and IX; therefore, is this really a hypobranchial muscle, as he suggests, or is it instead part of the hyoid and/or branchial musculature, e.g., part of the interhyoideus, as suggested by Kesteven 1942-1945, Edgeworth 1935 and other authors?]

stated above, it is possible that there is no direct correspondence between any of the individual 'labial' muscles (sensu Anderson 2008) present in living holocephalans (i.e., levator prelabialis, levator anguli oris anterior, levator anguli oris posterior, labialis anterior and levator posterior sensu Mallat 1996), living elasmobranchs (preorbitalis/levator labii superioris sensu Mallat 1996 and Anderson 2008), and living osteichthyans (levator maxillae superioris 3 and 4 of *Amia* and palatomandibularis major and minor of *Lepisosteus*—sensu Diogo 2007 and Anderson 2008—and possibly 'suborbital portion of adductor mandibulae' of acipenseriforms—sensu Lauder 1980a—and/or 'labial muscles' of *Latimeria*—sensu Millot and Anthony 1958 and Anderson 2008). That is, the individual 'labial' muscles present in these three major groups of gnathostomes could well be the result of an independent differentiation of the mandibular mesoderm (see above).

Regarding the hyoid muscles, the LCA of gnathostomes probably had the following: a ventral muscle, the interhyoideus, and two dorsal muscles, the adductor arcus palatini (often called 'levator hyomandibularis' in chondrichthyans, because in these fishes it usually attaches exclusively on the second arch, and not also, or exclusively, on the first arch, as is the case in many osteichthyans), and the adductor operculi (often named 'constrictor hyoideus dorsalis' in chondrichthyans, because living elasmobranchs, for instance, do not have an opercle: see, e.g., Miyake et al. 1992) (see Table 3.2 and also Fig. 3.18). Anderson (2008) suggested that holocephalans do not have an interhyoideus. However, the holocephalan muscle that was named 'constrictor operculi ventralis' by that author (Fig. 3.18E) clearly seems to correspond to the interhyoideus of other living gnathostomes, particularly to that of various elasmobranchs and of basal sarcopterygians such as dipnoans. In fact, the interhyoideus and the adductor operculi of fishes such as dipnoans are remarkably similar to the 'constrictor operculi ventralis' and the 'constrictor operculi dorsalis' of holocephalans (sensu Anderson 2008), respectively: they lie in a superficial position, and together form a structure that resembles the continuous, superficial constrictor of the second arch of non-gnathostome taxa such as lampreys (see Chapters 4 and 5). It should be noted that the hyoid musculature may be differentiated in muscles other than the adductor arcus palatini, the adductor operculi and the interhyoideus in some chondrichthyans (e.g., according to Miyake et al., 1992, batoids may have a 'levator rostri', a 'depressor mandibulae' and/or a 'depressor rostri') and in numerous osteichthyans (e.g., levator operculi, facial muscles of mammals, etc.: see Chapters 4 and 5).

The LCA of gnathostomes probably had several branchial muscles, including various 'ventral branchial muscles' sensu Johanson (2003), 'dorsal branchial muscles' sensu Miyake et al. (1992), 'branchial superficial

constrictors' sensu Mallat (1996) (because these muscles are present in elasmobranchs as well as in non-gnathostome taxa such as lampreys, it is often inferred that they were present in the LCA of vertebrates and of gnathostomes: e.g., Mallat 1996; Anderson 2008), coracobranchiales/ph aryngoclaviculares (if they are effectively seen as branchial, and not as hypobranchial, muscles: see above), and a protractor pectoralis (see Table 3.3 and Figs. 3.18, 3.19). This protractor pectoralis (often named 'trapezius' or 'cucullaris': see above) is a peculiar branchial muscle, because it often runs directly from the neurocranium to the pectoral girdle, being actually related to the protraction of this structure (i.e., it is usually not directly related to the branchial arches). There is in fact some controversy about the primary origin of this muscle, some authors defending that it is exclusively derived from the branchial muscle cells, others arguing that it is derived from hypaxial muscle cells (Fig. 3.16), and still others considering that it derives from branchial and hypaxial muscle cells (see, e.g., the review of Kuratani 2008). According to Kusakabe and Kuratani (2005), the lack of pectoral girdle and of protractor pectoralis muscle in living cyclostomes suggests that these basal vertebrates had "not yet established the 'neck region' comparable to that in gnathostomes" (Fig. 3.16) (it should be noted that according to authors such as Goodrich 1958 the absence of pectoral girdles and fins in extant hagfish and lampreys may be due to a 'degeneration', that is, these structures might have been found in the LCA of vertebrates, but this hypothesis is not commonly accepted nowadays). The protractor pectoralis will be discussed in further detail in Chapter 5.

The LCA of gnathostomes, as well as the LCA of osteichthyans, probably had two hypobranchial muscles, the coracomandibularis and the sternohyoideus (Table 3.4 and Fig. 3.19). As explained by Miyake et al. (1992), although the sternohyoideus ('rectus cervicus' in their terminology) remains undivided in some sharks, in numerous other elasmobranchs it is subdivided into a coracohyoideus, a coracoarcualis and occasionally (e.g., batoids) a coracohyomandibularis (see, e.g., Fig. 3.11). As explained above, in view of the information available at the moment it is difficult to discern whether the epibranchial muscles sensu Edgeworth (1935) were only acquired in chondrichthyans or were, instead, present in the LCA of gnathostomes and then secondarily lost in osteichthyans.

Before finishing this chapter mainly focused on non-osteichthyan vertebrates, we will briefly refer to the body musculature of these animals. In fact, regarding living lampreys and living hagfishes, there is not much to be said, because these taxa lack paired fins, and their body musculature is extremely simple (e.g., in lampreys the body musculature is not divided into epaxial and hypaxial muscles: see, e.g., Fig. 3.16). Living chondrichthyans also have a rather simple and mainly undifferentiated body musculature, but they do have pelvic and pectoral fins. However, as

will be explained in Chapters 8 and 9, in these latter gnathostomes, as well as in plesiomorphic extant osteichthyans, the musculature of the paired fins is also rather simple: the pectoral fin, for instance, is moved by a mainly undifferentiated adductor and a mainly undifferentiated abductor. Such a plesiomorphic configuration was very likely present in the LCA of gnathostomes and also in the LCA of osteichthyans (see Chapters 8 and 9).

Chapter 4

Head and Neck Muscles of Actinopterygians and Basal Sarcopterygians

The discussions provided in this chapter mainly concern the mandibular, hyoid, branchial and hypobranchial muscles of actinopterygians and basal sarcopterygians (see cladogram of Fig. 4.1; as explained in previous chapters, the epibranchial muscles sensu Edgeworth 1935 are absent in extant osteichthyans). Figures 4.3 to 4.8 provide an updated version of the schemes of Miyake et al. (1992), including representatives of some osteichthyan groups that were not considered in Miyake et al.'s paper, such as amphibians and amniotes. The information provided in these figures is complemented with that given in Tables 4.1–4.4.

Mandibular Muscles (Table 4.1; Figs. 4.3, 4.4)

In this section, as well as in the sections regarding the hyoid, branchial and hypobranchial muscles, we first provide a short introductory paragraph explaining Edgeworth hypotheses regarding the respective plate, and then discuss to what extent our own analyses and the works of other authors support, or do not support, those hypotheses. According to Edgeworth (1935), in numerous vertebrates the embryonic mandibular muscle plate gives rise dorsally to the premyogenic condensation constrictor dorsalis, medially to the premyogenic condensation adductor mandibulae, and ventrally to the intermandibularis (no description of a ventral mandibular premyogenic condensation was given by Edgeworth) (Figs. 4.3–4.4). He suggested that a constrictor dorsalis condensation is not found in extant gnathostome taxa such as holocephalan condrichthyans, dipnoans and amphibians. Since he considered that the condrichthyans, actinopterygians and tetrapods were derived from an "early dipnoan stock", he

concluded that the constrictor dorsalis was plesiomorphically absent in the Gnathostomata and independently acquired in some taxa of this clade.

This is one of the few cases in which one of Edgeworth's conclusions is seriously put in question by the evidence now available. In fact, very few researchers would now accept that chondrichthyans, actinopterygians and tetrapods were derived from basal dipnoans (see Figs. 1.1, 3.1, 4.1, 5.1, 9.1, and text). According to the phylogenetic scenario shown in Figs. 1.1 and 4.1, the constrictor dorsalis was either independently lost within dipnoans and amphibians, or lost in the node leading to non-actinistian sarcopterygians and then reacquired in amniotes. Although these options appear equally parsimonious, there are reasons to favor the first one, i.e., that the constrictor dorsalis condensation was independently lost in amphibians and dipnoans. This is because this premyogenic condensation is, in fact, very similar in amniotes and in non-dipnoan sarcopterygian fishes (e.g., Brock 1938). Thus, it makes more sense to consider that such a condensation was lost in dipnoans and in amphibians than to consider that it was lost in non-actinistian sarcopterygians and that a strikingly similar condensation was then independently acquired in amniotes. Actually, it is important to stress that it is not only the condensation that is similar in amniotes and non-dipnoan bony fishes. The adult muscles derived from it in amniotes such as 'lizards', i.e., the levator pterygoidei and protractor pterygoidei, are also strikingly similar to the adult muscle derived from it in sarcopterygians such as *Latimeria*, i.e., the levator arcus palatini (they essentially occupy the same position, running from the neurocranium to the dorsal/dorsolateral margin of the palatoquadrate, and are thus usually related to the elevation of this latter structure: see Chapters 5–7). A detailed analysis of the presence/absence of dorsal mandibular muscles in well-conserved, plesiomorphic dipnoan and amphibian fossils, as well as in other sarcopterygian fossils, is needed to clarify the actual taxonomic distribution of the dorsal mandibular muscles within the Sarcopterygii.

As stated by, e.g., Edgeworth (1935) and Winterbottom (1974), and supported by molecular developmental studies such as Hatta et al. (1990, 1991), in most extant actinopterygians the constrictor dorsalis differentiates into a levator arcus palatini and a dilatator operculi (see Table 4.1 and Figs. 4.3, 4.9–4.11). The former muscle is usually related to the elevation/abduction of the suspensorium (a structural complex formed by the hyomandibula, quadrate and pterygoid bones); the latter is mainly associated with the abduction (opening) of the opercle (see, e.g., Stiassny et al. 2000). However, in extant acipenseriforms the constrictor dorsalis gives rise to a single, peculiar muscle mainly related to the protraction of the hyomandibula, the protractor hyomandibulae (e.g., Danforth 1913; Luther 1913; Sewertzoff 1928; Edgeworth 1935; Kesteven 1942–1945; Miyake et

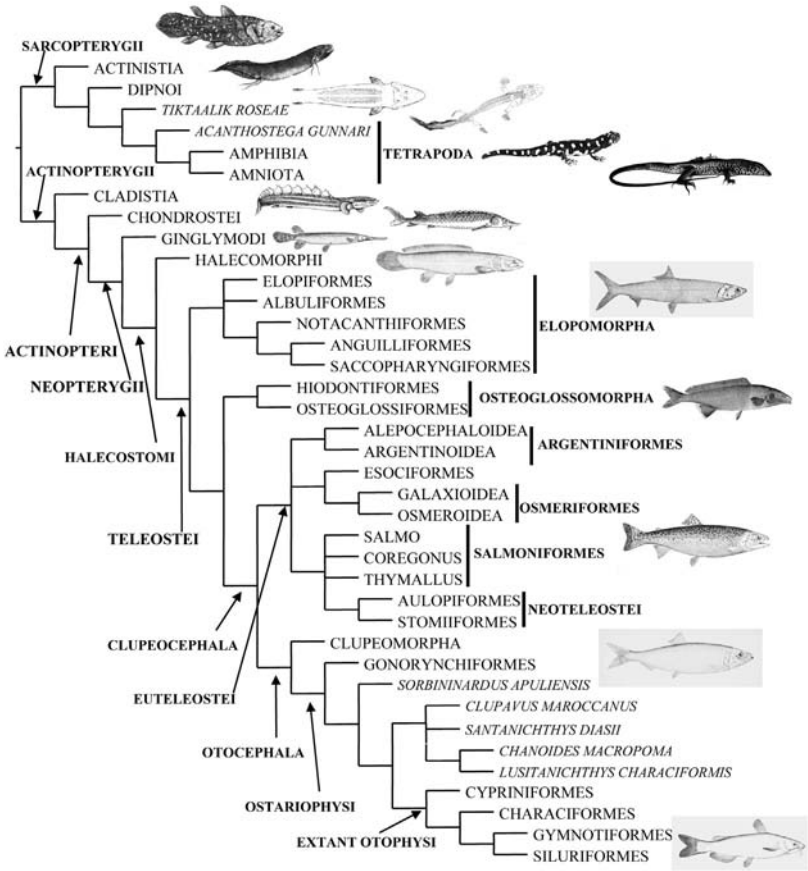

Fig. 4.1 Phylogenetic relationships among the major extant groups of actinopterygians and basal osteichthyan, according to the results of the cladistic analysis of Diogo (2007) (for more details, see text).

al. 1992; Carroll and Wainwright 2003; this work; Table 4.1, Fig. 4.3). The presence of a separate dilatator operculi in adults could thus be seen as a feature acquired in the node leading to all extant actinopterygians and then reverted in a node leading to extant acipenseriforms or, instead, as a feature independently acquired in cladistians and in neopterygians (see Fig. 4.1). We agree with Lauder (1980a), Lauder and Liem (1983) and others that there are strong reasons to suggest that a separate dilatator operculi was present in the ancestor of extant actinopterygians. In fact, the dilatator operculi of *Polypterus* and the dilatator operculi of neopterygians have a similar developmental origin (the dorsal part of the mandibular muscle plate), a similar innervation (the Vth nerve), a similar function (essentially related to opercle abduction), and

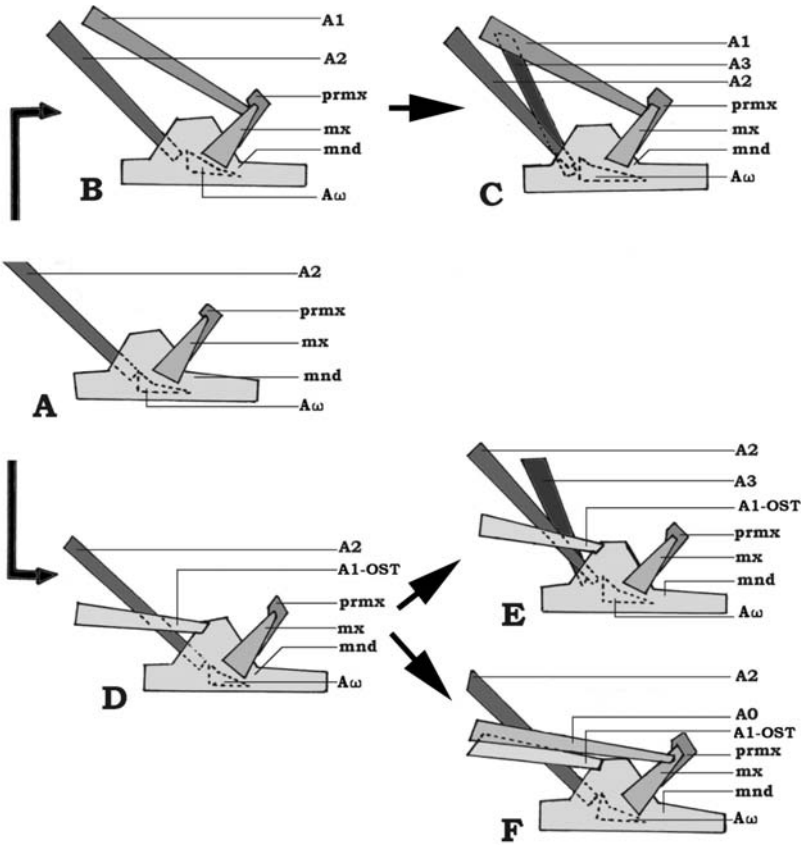

Fig. 4.2 Scheme illustrating the two patterns of adductor mandibulae differentiation of teleostean fishes, based on Gosline (1989), and following the nomenclature of Diogo and Chardon (2000a) (modified from Diogo and Chardon 2000a). **(A)** Basal type in which the cheek muscle is undivided. **(B)** The neoteleostean pattern in which an upper part of the cheek muscle (A1) has become attached to the maxilla. **(C)** Secondary differentiation in neoteleostean fishes in which a mesial part of the cheek muscle (A3) is present. **(D)** Initial differentiation in the ostariophysan pattern in which a lower part of the cheek muscle (A1-OST) has developed a separate attachment to the back of the mandible. **(E)** Differentiation in some ostariophysan fishes in which a mesial part of the cheek muscle (A3) is present. **(F)** Differentiation in some ostariophysan fishes in which an adductor mandibulae section (A0) has developed, via the primordial ligament, an attachment to the maxilla. A0, A1, A1-OST, A2, A3, Aω, sections of the adductor mandibulae; mnd, mandible; mx, maxilla; prmx, premaxilla.

a similar overall configuration (e.g., Pollard 1892; Allis 1897, 1922; Edgeworth 1935; Winterbottom 1974; Lauder 1980a; Lauder and Liem 1983; Miyake et al. 1992; this work). The absence of a distinct dilatator operculi in adult extant acipenseriforms may well be related to the fact that these fishes peculiarly lack an opercular bone and/or to the fact that they seemingly are paedomorphic

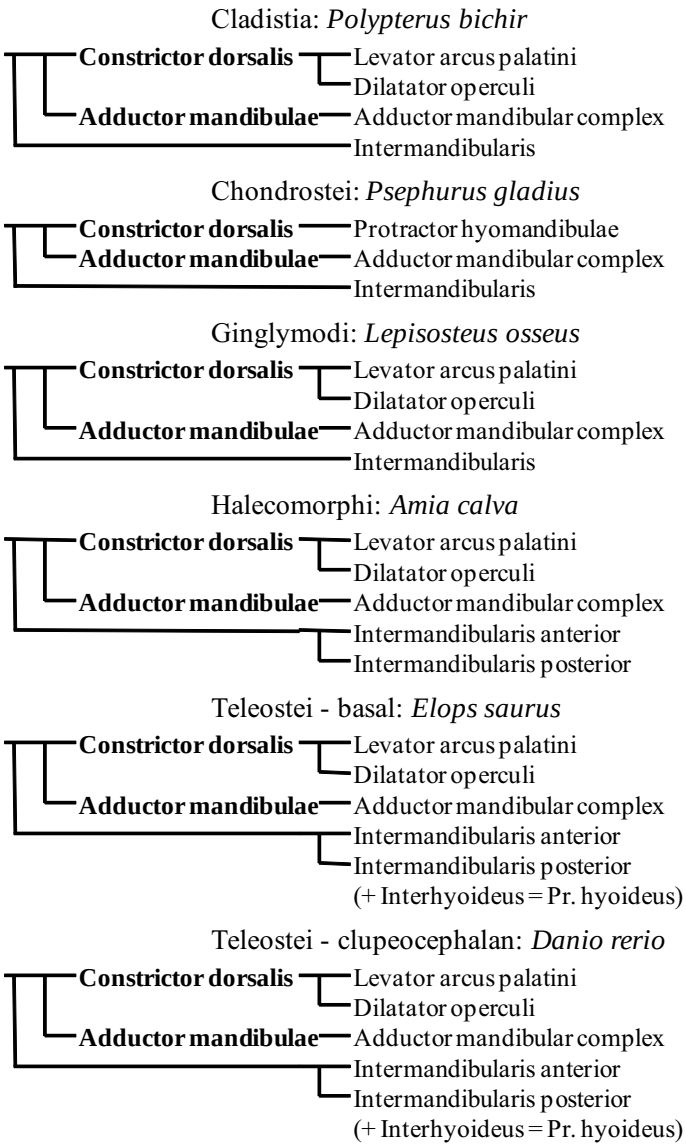

Fig. 4.3 Developmental lineages of mandibular muscles in actinopterygians; Edgeworth's presumptive premyogenic condensations are in a bold face (modified from Miyake et al. 1992); the nomenclature of the muscles listed on the right of the figure follows that of the present work, "Pr. hyoideus" meaning protractor hyoideus. Data compiled from evidence provided by developmental biology, comparative anatomy, experimental embryology and molecular biology, innervation and phylogeny (in studies of the authors and of other researchers). For more details, see text.

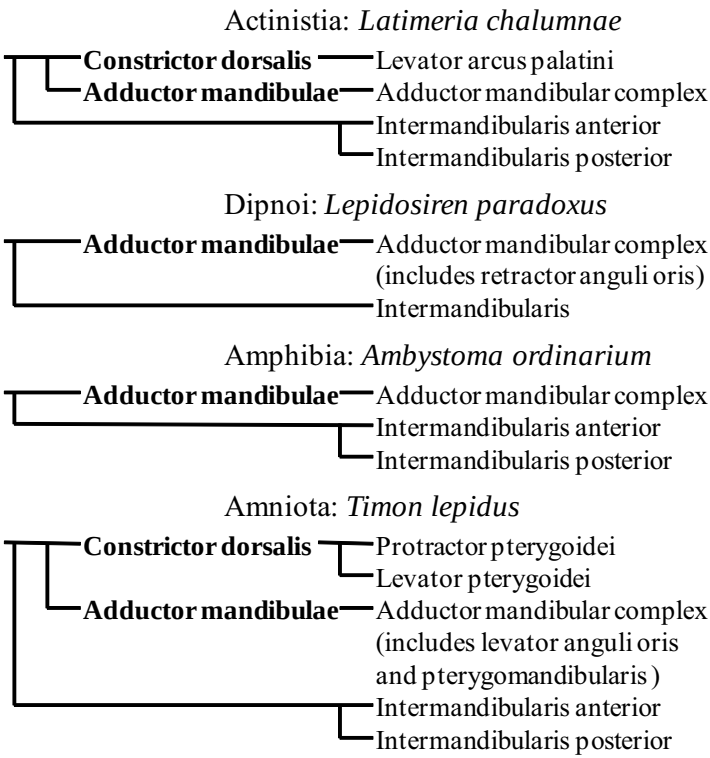

Fig. 4.4 Developmental lineages of mandibular muscles in sarcopterygians (modified from Miyake et al. 1992; see caption of Fig. 4.3).

(e.g., Bemis et al. 1997; Findeis 1997; see Chapter 11). This latter point could effectively help explain why, unlike most other living actinopterygians in which the constrictor dorsalis becomes ontogenetically differentiated into two muscles, adult acipenseriforms retain a single, undivided dorsal mandibular muscle, the protractor hyomandibulae (see Chapter 11). Miyake et al (1992: 221) stated: a "spiracularis was described in *Polypterus* by Edgeworth (1935), but confirmation of its actual existence in *Polypterus* is needed". No spiracularis was found in the specimens of this taxon or of any other osteichthyan group that we have dissected.

In all major osteichthyan groups listed in Table 4.1 and Figs. 4.3 and 4.4, the ventral portion of the mandibular muscle plate gives rise to the intermandibularis. In adult extant members of the Actinistia, Chondrostei, Ginglymodi and Dipnoi, the intermandibularis is mainly undivided (Fig. 4.9). In adult specimens of *Amia*, of *Latimeria*, and of numerous amphibian, amniote and teleostean genera, this structure is divided into an intermandibularis anterior and an intermandibularis posterior (Fig. 4.10). It

is rather difficult to discern whether or not the intermandibularis was divided in adult members of the LCA of osteichthyans (Table 4.1). We tentatively hypothesize that it was (Table 4.1), because a divided intermandibularis is found in numerous chondrichthyans, actinopterygians and sarcopterygians (see also Chapter 3). However, a detailed analysis of the taxonomic distribution of this feature in Chondrichthyes, and, if possible, in key osteichthyan and non-osteichthyan gnathostome fossils such as the Acanthodii, is needed to clarify this issue. As its name indicates, the intermandibularis is usually a transversal muscle connecting the two mandibles. In most teleosts the intermandibularis posterior forms, together with the interhyoideus (see below), the protractor hyoideus (Fig. 4.15), which is thus derived from both the mandibular and hyoid muscle plates (e.g., Edgeworth 1935; Winterbottom 1974; Schilling and Kimmel 1997; Hernandez et al. 2002, 2005; this study). The protractor hyoideus is innervated by both the Vth and the VIIth nerves and functionally is a complex muscle: Osse (1969) and other authors demonstrated that its anterior and posterior portions may contract differently during different phases of respiration. Nonetheless, as stated by Stiassny (2000), as a broad generality it can be said that the protractor hyoideus plays a primary role in the elevation (protraction) of the hyoid bars and in the depression of the mandible. According to the phylogenetic scenario shown in Fig. 4.1, although a protractor hyoideus is not found in a few teleost taxa such as *Albula* and *Mormyrus* (e.g., Greenwood 1971, 1977; Winterbottom 1974; this work), the ancestors of extant teleosts did probably have a protractor hyoideus. Based on the altered morphology of the protractor hyoideus in morpholino-mediated Hox PG2 (*hoxa2b* and *hoxa2a*) knock-down larvae, Hunter and Prince (2002: 378) suggested that in the zebrafish "the basihyal (cartilage) may be important for the proper ontogenetic organization" of the intermandibularis posterior and the interhyoideus, and, thus, for the association of their fibers and the formation of the protractor hyoideus. Further studies are needed to check if this is so and if it is a general feature within the Teleostei.

The adductor mandibulae condensation is found in members of all major osteichthyan groups (Table 4.1, Figs. 4.3, 4.4). The number of structures originated from this condensation is highly variable within these groups. The adductor mandibulae A3′ and A3″ sensu this volume (which correspond to the "mesial adductor mandibulae divisions" sensu Lauder 1980a) are seemingly plesiomorphically present in osteichthyans (Lauder 1980a; Table 4.1, Figs. 4.9–4.10). One of these bundles or both may, however, be missing in osteichthyan taxa such as dipnoans, acipenseriforms and various teleosts (Table 4.1). The adductores mandibulae A2 and A_{ω} were seemingly also found in basal osteichthyans (e.g., Lauder 1980ab; Table 4.1, Figs. 4.17, 4.19). The A_{ω} may be missing in extant osteichthyans such as

Table 4.1 Mandibular muscles of adults of representative actinopterygian taxa; the nomenclature of the muscles shown in bold follows that of the present work, "ad. mand." meaning adductor mandibulae (in order to facilitate comparisons, certain names used by other authors are shown in parentheses; additional comments are given in square brackets); data compiled from evidence provided by developmental biology, comparative anatomy, functional morphology, paleontology, experimental embryology and molecular biology, innervation and phylogeny (in studies of the author and of other researchers). For more details, see text (see also Figs. 4.2 and 4.3).

Probable plesiomorphic osteichthyan condition	Cladistia: *Polypterus bichir* (Bichir)	Chondrostei: *Psephurus gladius* (Chinese swordfish)	Ginglymodi: *Lepisosteus osseus* (Longnose gar)	Halecomorphi: *Amia calva* (Bowfin)	Teleostei - basal: *Elops saurus* (Ladyfish)	Teleostei-clupeocephalan: *Danio rerio* (Zebrafish)
Intermandibularis anterior [intermandibularis anterior and posterior plesiomorphically present in osteichthyans? See text]	**Intermandibularis**	**Intermandibularis**	**Intermandibularis**	**Intermandibularis anterior**	**Intermandibularis anterior**	**Intermandibularis anterior**
Intermandibularis posterior [see above]	—	—	—	**Intermandibularis posterior**	**Intermandibularis posterior** [forming, together with interhyoideus, the protractor hyoideus]	**Intermandibularis posterior** [see on the left]
—	—	—	—	—	**Protractor hyoideus** [including intermandibularis posterior and interhyoideus; it is thus derived from both the mandibular and hyoid muscle plates]	**Protractor hyoideus** [see on the left]

Ad. mand. A3′	**Ad. mand. A3′** (ad. mand. temporalis sensu Lauder 1980a)	—	**Ad. mand. A3′** (preorbitalis superficialis sensu Lauder 1980a; the A3′ and A3″ mainly correspond to the adductor 2 sensu Adams 1919)	**Ad. mand. A3′**	—	—
Ad. mand. A3″	**Ad. mand .A3″** (ad. mand. pterygoideus sensu Lauder 1980a)	—	**Ad. mand. A3″** (preorbitalis profundus sensu Lauder 1980a)	**Ad. mand. A3″**	—	—
Ad. mand. A2	**Ad. mand. A2** (ad. mand. posterolateral sensu Lauder 1980a)	**Ad. mand. A2** (ad. mand. sensu Carroll and Wainwright 2003) [Adams 1919 described both an A2 and an A3′ in *Polyodon*, but only an A2 in *Acipenser*; in the *Psephurus* specimens dissected by us we did not find a separate, distinct A3′ as found in other osteichthyans]	**Ad. mand. A2** (ad. mand. posterolateral sensu Lauder 1980a; it mainly corresponds to the adductor 1 sensu Adams 1919)	**Ad. mand. A2**	**Ad. mand. A2**	**Ad. mand. A2**

Table 4.1 contd...

Table 4.1 contd...

Probable plesiomorphic osteichthyan condition	Cladistia: *Polypterus bichir* (Bichir)	Chondrostei: *Psephurus gladius* (Chinese swordfish)	Ginglymodi: *Lepisosteus osseus* (Longnose gar)	Halecomorphi: *Amia calva* (Bowfin)	Teleostei - basal: *Elops saurus* (Ladyfish)	Teleostei-clupeocephalan: *Danio rerio* (Zebrafish)
'Labial muscles' plesiomorphically present in osteichthyans? See text	—	—	-- [palato-mandibularis minor and major of *Lepisosteus* correspond to/derive from the 'labial muscles' of non-osteichthyan vertebrates? See text]	—[levator maxillae superioris 3 and 4 of *Amia* correspond to/derive from the 'labial muscles' of non-osteichthyan vertebrates? See text]	—	—
—	—	—	**Palato-mandibularis minor and major** (these structures mainly correspond to the adductor 3 sensu Adams 1919)	—	—	—
—	—	—	—	**Levator maxillae superioris 3 and 4**	—	—
—	—	—	—	—	—	**Ad. mand. A1-OST**
—	—	—	—	—	—	**Ad. mand. A0**
Ad. mand. Aω	**Ad. mand. Aω** [contrary to what is shown in Adams' 1919 table I, *Polypterus* does have an Aω]	—	—	**Ad. mand. Aω**	**Ad. mand. Aω**	**Ad. mand. Aω**

Levator arcus palatini	**Levator arcus palatini** (levator maxillae superioris sensu Adams 1919)	**Protractor hyomandibulae** [seemingly originated from the portion of the hyoid muscle plate from which originate the adductor arcus palatini and dilatator operculi of other actinopterygians]	**Levator arcus palatini** (protractor hyomandibularis sensu Adams 1919)	**Levator arcus palatini** (includes the levator arcus palatini + protractor hyomandibularis sensu Adams 1919)	**Levator arcus palatini**	**Levator arcus palatini**
—	**Dilatator operculi** (protractor hyomandibularis sensu Adams 1919)	— [dilatator operculi absent as a separate element, but see above]	**Dilatator operculi** (adductor operculi sensu Adams 1919)	**Dilatator operculi**	**Dilatator operculi**	**Dilatator operculi**

chondrosteans, ginglymodians, various teleosts and most tetrapods (Table 4.1, Fig. 4.18). In the adult specimens of the 'lizard' *Timon* analyzed by us the adductor mandibulae has a large anteroventral portion lodged in the 'adductor fossa' (sensu, e.g., Lauder, 1980b), which is remarkably similar to the Aω of bony fishes. Such an anteroventral portion of the adductor mandibulae was also described in other extant reptiles (see Chapter 7). In view of the data available, it is difficult to discern whether this anteroventral portion of the adductor mandibulae is effectively homologous to the Aω of bony fishes.

In Lauder's (1980a) table II it is suggested that the palatomandibularis minor and major of extant ginglymodians (Fig. 4.18) are likely homologous to the levator maxillae superioris 3 and 4 of living halecomorphs (Fig. 4.10), since these structures represent an 'anterior division' of the adductor mandibulae. However, the overall configuration, position and attachments of the ginglymodian palatomandibularis minor and major are markedly different from those of the halecomorph levator maxillae superioris 3 and 4. For instance, the *Lepisosteus* palatomandibularis minor and major of *Lepisosteus* insert dorsally on the ectopterygoid/entopterygoid and ventrally on the mandible (Fig. 4.18), while section 3 of the levator maxillae superioris of *Amia* inserts dorsally on the neurocranium and orbital bones and ventrally mainly on the autopalatine (Fig. 4.10). The phylogenetic scenario shown in Fig. 4.1 supports a close relationship between the Halecomorphi and the Teleostei, contradicting that ginglymodians and halecomorphs are sister-groups. This indicates that the ginglymodian palatomandibularis minor and the halecomorph levator maxillae 3 and 4 may well be non-homologous (Table 4.1; see also Chapter 3).

Apart from the divisions of the adductor mandibulae condensation that were mentioned above, other divisions may eventually be found in adult osteichthyans, e.g., the A1-OST and A0 (sensu Diogo and Chardon 2000; e.g., Figs. 4.2, 4.11), and the A2-PVM, the pseudotemporalis, retractor anguli oris, the levator anguli oris mandibularis and the pterygomandibularis (see Chapter 5). It is important to stress that we found, in the adult dipnoan specimens we dissected, a peculiar section of the adductor mandibulae that has some fibers associated with those of the A2 but is well-differentiated from it. As this section is somewhat posterior, ventral, and medial to the main body of the A2, we call it adductor mandibulae A2-PVM (the PVM thus meaning posteroventromesial). Edgeworth (1935), Bemis (1986), Bemis and Lauder (1986), Miyake et al. (1992) and others did not mention the presence of such an adductor mandibulae section in extant dipnoans (the A2-PVM should not be confused with the retractor anguli oris of these fishes or to the 'retractor anguli oris' of reptiles such as *Sphenodon*, which is usually situated posteroventrolaterally to the A2, being mainly superficial, and not mesial, to the A2; in fact, both the

A2-PVM and the retractor anguli oris can be found in the same taxon, e.g., in *Lepidosiren*). The A2-PVM of dipnoans seemingly corresponds to the structure that is often named 'adductor mandibulae posterior' by researchers working with amphibian and amniote tetrapods (e.g., Brock, 1938; Carroll and Holmes, 1980; Iordansky 1992; Moro and Abdala, 2000; Montero et al. 2002; Abdala and Moro 2003; see Chapters 5–7). However, it is important to note that it is possible that some of the structures that have been, and continue to be, named 'adductor mandibulae posterior' in clades such as turtles are not homologous to the structures that have been designated by the same name in other non-mammalian tetrapod groups, and, thus, to the A2-PVM sensu the present work (see Chapters 6 and 7 for more details on this subject). All extant non-dipnoan bony fishes dissected by us lack an A2-PVM. The textual descriptions and illustrations of the 'adductor mandibulae complex' of *Latimeria* provided by Millot and Anthony (1958) and Adamicka and Ahnelt (1992) indicate that such an A2-PVM is also missing in that taxon.

Although the adductor mandibulae divisions are usually related with the adduction of the mandible, this is not always the case. For instance, some of them may attach to structures other than the mandible, such as the maxilla (e.g., the adductor mandibulae A0: Fig. 4.11) and thus not be directly related to lower jaw adduction (see, e.g., Winterbottom 1974; Stiassny 2000). Certain divisions of the adductor mandibulae may inclusively be related with the opening, and not the closing, of the mouth, as is the case of the 'abductor mandibulae' of saccopharyngiform teleosts (e.g., Tchernavin, 1947ab, 1953; this work).

Hyoid Muscles (Table 4.2; Figs. 4.5, 4.6)

According to Edgeworth (1935) the constrictor hyoideus condensation usually gives rise to dorso-medial and ventral derivatives throughout the major groups of gnathostomes. As shown in Table 4.2, two dorso-medial hyoid muscles were seemingly found in plesiomorphic osteichthyans: the adductor arcus palatini and the adductor operculi (Fig. 4.11). These two muscles, which as their name indicates are usually related to the adduction of the suspensorium/palatoquadrate and of the opercle, are found in *Latimeria* and in most living actinopterygians (Table 4.2, Figs. 4.5, 4.6). Some actinopterygians may, however, lack an adductor operculi (e.g., saccopharyngiform teleosts: Tchernavin 1947ab, 1953; this work). In living chondrosteans the dorso-medial portion of the hyoid muscle plate gives rise to a peculiar retractor hyomandibulae, and not to an adductor arcus palatini similar to that found in most other actinopterygians (e.g., Danforth

Table 4.2 Hyoid muscles of adults of representative actinopterygian taxa (see caption of Table 4.1, and also Figs. 4.4 and 4.5).

Probable plesiomorphic osteichthyan condition	Cladistia: *Polypterus bichir* (Bichir)	Chondrostei: *Psephurus gladius* (Chinese swordfish)	Ginglymodi: *Lepisosteus osseus* (Longnose gar)	Halecomorphi: *Amia calva* (Bowfin)	Teleostei - basal: *Elops saurus* (Ladyfish)	Teleostei - clupeocephalan: *Danio rerio* (Zebrafish)
Interhyoideus	**Interhyoideus**	**Interhyoideus**	**Interhyoideus**	**Interhyoideus**	**Interhyoideus** [forming, together with intermandibularis posterior, the protractor hyoideus: see Table 4.1]	**Interhyoideus** [see on the left]
—	**Hyohyoideus**	**Hyohyoideus**	**Hyohyoideus**	**Hyohyoideus inferior**	**Hyohyoideus inferior**	**Hyohyoideus inferior**
—	—	—	—	**Hyohyoideus abductor** [often considered as part of a hyohyoideus superior]	**Hyohyoideus abductor** [see on the left]	**Hyohyoideus abductor** [see on the left]
—	—	—	—	**Hyohyoidei adductores** [often considered as part of a hyohyoideus superior]	**Hyohyoidei adductores** [see on the left]	**Hyohyoidei adductores** [see on the left]
Adductor operculi (or constrictor hyoideus dorsalis?) [it is perhaps more appropriate to designate the muscle of non-holostean actinopterygians as constrictor hyoideus	**Adductor operculi (or constrictor hyoideus dorsalis?)** (part of adductor hyomandibularis sensu Adams 1919) [see on the left]	**Adductor operculi (or constrictor hyoideus dorsalis?)** (opercularis sensu Carroll and Wainwright 2003) [see on the left]	**Adductor operculi (or constrictor hyoideus dorsalis?)** (levator operculi sensu Adams 1919)	**Adductor operculi** [here it is more appropriate to use the name adductor operculi, because the constrictor hyoideus dorsalis	**Adductor operculi**	**Adductor operculi**

dorsalis, and not as adductor operculi, because: 1) it corresponds directly to the constrictor hyoideus dorsalis of non-actinopterygian vertebrates (see Chapter 3); 2) it does not correspond directly to the adductor operculi of holosteans, i.e. this latter muscle corresponds only to part of the constrictor hyoideus dorsalis, because this constrictor actually corresponds to the adductor operculi + levator operculi (and occasionaly to part or the totality of the 'adductor hyomandibulae' of some teleosts, see below) of holosteans]				is really divided into an adductor operculi and a levator operculi; this is also a way of differentiating the adductor operculi of *Amia* + teleosts from the 'adductor operculi' of *Latimeria*, which was seemingly acquired via an independent differentiation of the constrictor hyoideus dorsalis into an 'adductor operculi', an 'adductor hyomandibulae', and a 'levator operculi']		
Adductor arcus palatini	**Adductor arcus palatini** (part of adductor hyomandibularis sensu Adams 1919)	**Retractor hyomandibulae** [seemingly originated from the portion of the hyoid muscle plate from which originates the adductor arcus palatini of other actinopterygians]	**Adductor arcus palatini** [Adams 1919 failed to describe an adductor arcus palatini ('adductor hyomandibularis') in *Lepisosteus*, but in his table I he did recognize that this muscle is probably present in this taxon]	**Adductor arcus palatini** (adductor hyomandibularis sensu Adams 1919)	**Adductor arcus palatini** (adductor hyomandibularis sensu Adams 1919)	**Adductor arcus palatini**

Table 4.2 contd...

Table 4.2 contd...

Probable plesiomorphic osteichthyan condition	Cladistia: *Polypterus bichir* (Bichir)	Chondrostei: *Psephurus gladius* (Chinese swordfish)	Ginglymodi: *Lepisosteus osseus* (Longnose gar)	Halecomorphi: *Amia calva* (Bowfin)	Teleostei - basal: *Elops saurus* (Ladyfish)	Teleostei - clupeocephalan: *Danio rerio* (Zebrafish)
—	—	—	—	—	—	**'Adductor hyomandibulae X'** [seemingly not homologous to the 'adductor hyomandibulae Y' of *Latimeria*]
—	—	— [Adams 1919 stated that chondrosteans and *Lepisosteus* have a separate 'levator operculi', but the structure he designated under that name actually corresponds to the adductor operculi sensu the present work: compare, e.g., his plate II with Figs. 4.22 and 4.23]	— [see on the left]	**Levator operculi** [seemingly not homologous to the 'levator operculi' of *Latimeria*]	**Levator operculi** [see on the left]	**Levator operculi** [see on the left]

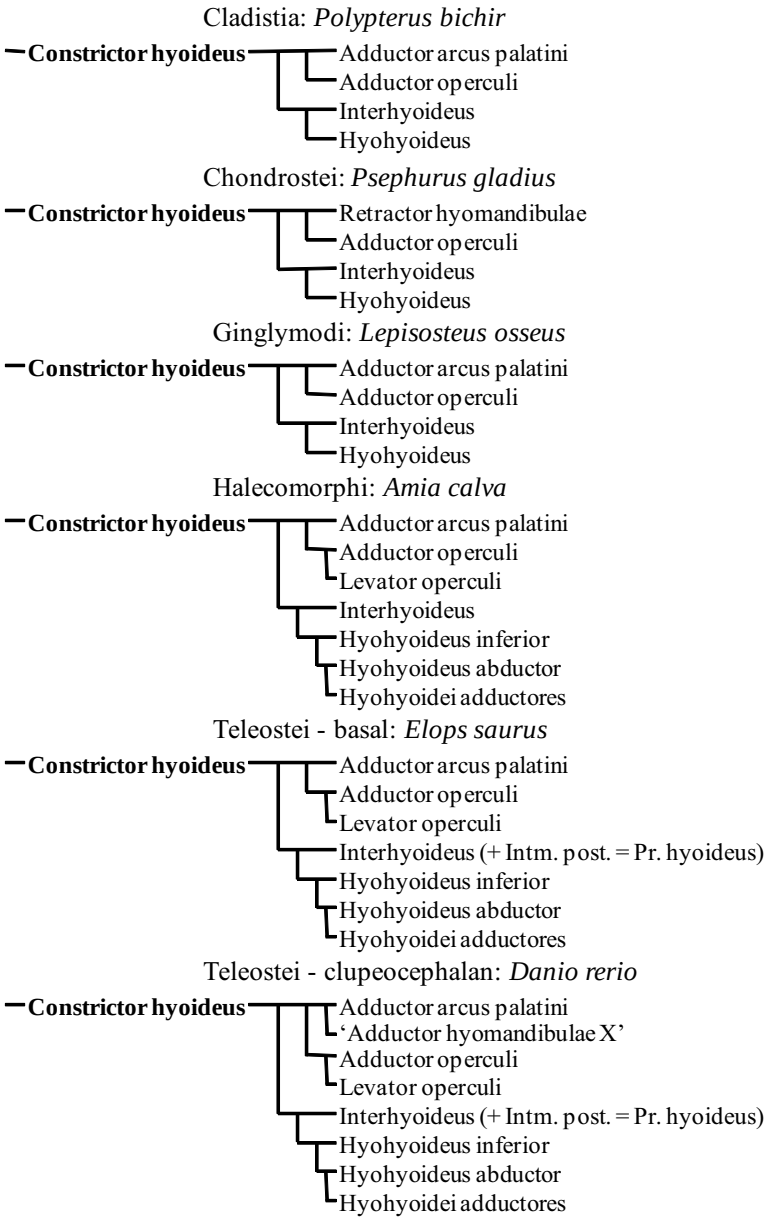

Fig. 4.5 Developmental lineages of hyoid muscles in actinopterygians, "Pr. hyoideus" meaning protractor hyoideus and "Intm. post." meaning intermandibularis posterior (modified from Miyake et al. 1992; see caption of Fig. 4.3).

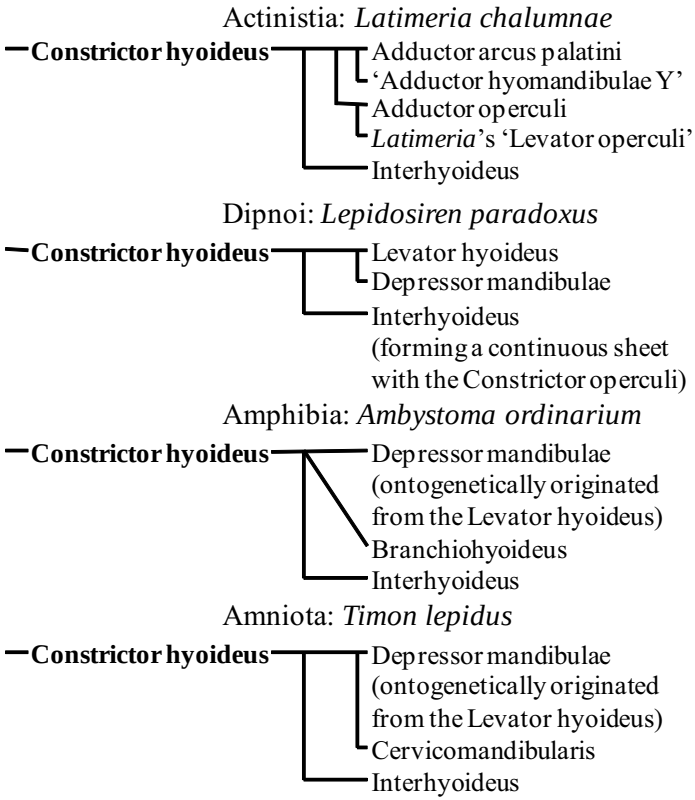

Fig. 4.6 Developmental lineages of hyoid muscles in sarcopterygians (modified from Miyake et al. 1992; see caption of Fig. 4.3).

1913; Luther 1913; Edgeworth 1935; Kesteven 1942–1945; Miyake et al. 1992; Carroll and Wainwright 2003; this work; Table 4.2, Fig. 4.5).

As stressed by Winterbottom (1974: 239), apart from the adductor arcus palatini, some osteichthyans have other muscles connecting the neurocranium to the palatoquadrate/suspensorium and promoting the adduction of these latter structures. Examples of this are the muscles described by him under the name "adductor hyomandibulae". We have found well-differentiated muscles "adductor hyomandibulae" sensu Winterbottom in various teleosts (Table III; Fig. 5); an "adductor hyomandibulae" is seemingly also found in *Latimeria* (see Millot and Anthony 1958 and Chapter 5). As stressed by Winterbottom (1974: 239), at least some of these "adductor hyomandibulae" muscles were seemingly acquired independently (i.e., they are non-homologous), since they may be originated "(1) either from the posterior region of the adductor arcus palatini or (2) from the anterior fibers of the adductor operculi". This is,

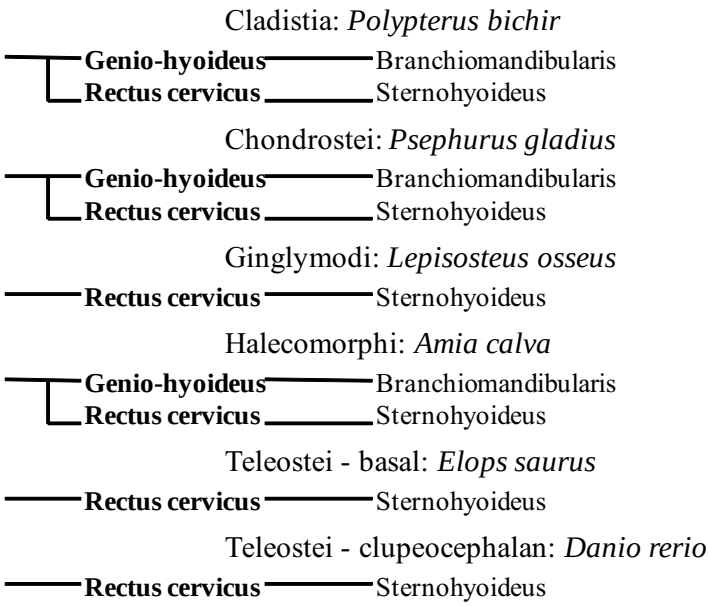

Fig. 4.7 Developmental lineages of hypobranchial muscles in actinopterygians (modified from Miyake et al. 1992; see caption of Fig. 4.3).

for example, the case of the "adductor hyomandibulae" found in *Latimeria* and in teleosts such as *Danio*, which are designated in the present book as "adductor hyomandibulae Y" and "adductor hyomandibulae X", respectively. Miyake et al. (1992) suggested that, apart from these taxa, other key osteichthyan genera listed in the tables of this chapter, e.g., *Amia* and *Lepisosteus*, also have an "adductor hyomandibulae" sensu Winterbottom (note: the muscles named "adductor hyomandibulae" and "adductor arcus palatini" in Winterbottom's work and in the present study correspond respectively to the muscles named "adductor arcus palatini" and "adductor hyomandibulae" in Miyake et al.'s paper). However, in the *Amia* and *Lepisosteus* specimens dissected by us there is no separate, well-differentiated "adductor hyomandibulae" sensu Winterbottom. This is also the case in the specimens of these genera that were analyzed by, e.g., Lauder (1980a), who stated that "in *Lepisosteus* the adductor arcus palatini (= Winterbottom's "adductor hyomandibulae") and the adductor hyomandibulae (= Winterbottom's "adductor arcus palatini") form a continuous sheet of parallel-fibered muscle" and that "the adductor arcus palatini (= Winterbottom's "adductor hyomandibulae") is absent in *Amia*" (Lauder 1980a: 289). [As explained by Winterbottom (1974), the reason why some authors use the name "adductor hyomandibulae" to designate his "adductor arcus palatini" is that in various osteichthyans the mesial

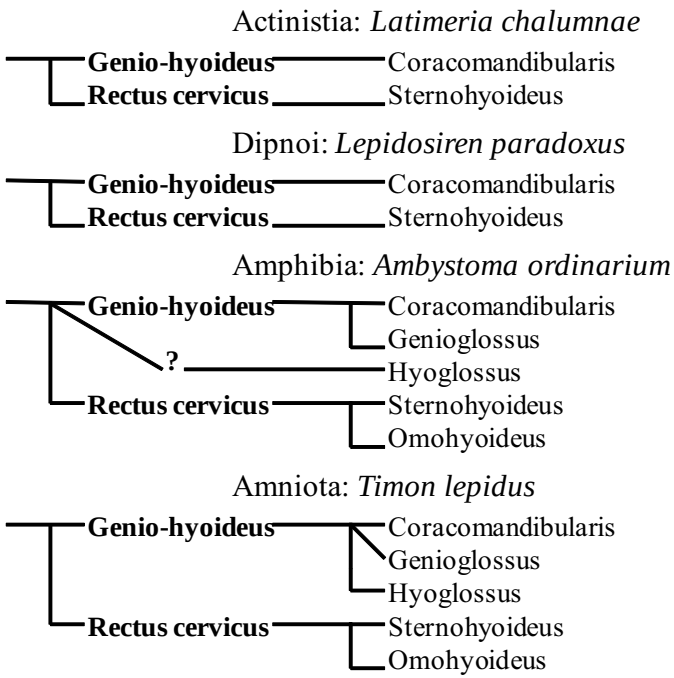

Fig. 4.8 Developmental lineages of hypobranchial muscles in sarcopterygians (modified from Miyake et al. 1992; see caption of Fig. 4.3).

insertion of this muscle is exclusively on the hyomandibula. However, as he pointed out, the name "adductor hyomandibulae" becomes clearly inappropriate in the numerous cases in which the muscle is expanded anteriorly along the floor of the orbit and attaches on more anterior elements of the suspensorium such as the metapterygoid and/or entopterygoid.]

Apart from the levator operculi, the adductor operculi and the muscles "adductor hyomandibulae", other dorso-medial hyoid muscles may be found in living osteichthyans (e.g., Figs. 4.5, 4.6). For instance, *Amia* and most extant teleosts have a levator operculi (Figs. 4.10, 4.11). The levator operculi of these fishes is usually related to a peculiar mechanism mediating lower jaw depression via the so-called 'four-bar linkage system' in which the force of contraction of this muscle is transmitted through the opercular series and the interoperculo-mandibular ligament to the lower jaw (e.g., Stiassny 2000). A levator operculi may be missing in certain teleosts, such as saccopharyngiforms (e.g., Tchernavin 1947ab, 1953; this work). Millot and Anthony (1958) stated that *Latimeria* has a "levator operculi". As can be seen in the descriptions and the figures provided by these authors (see, e.g., their plate VII), and as recognized in

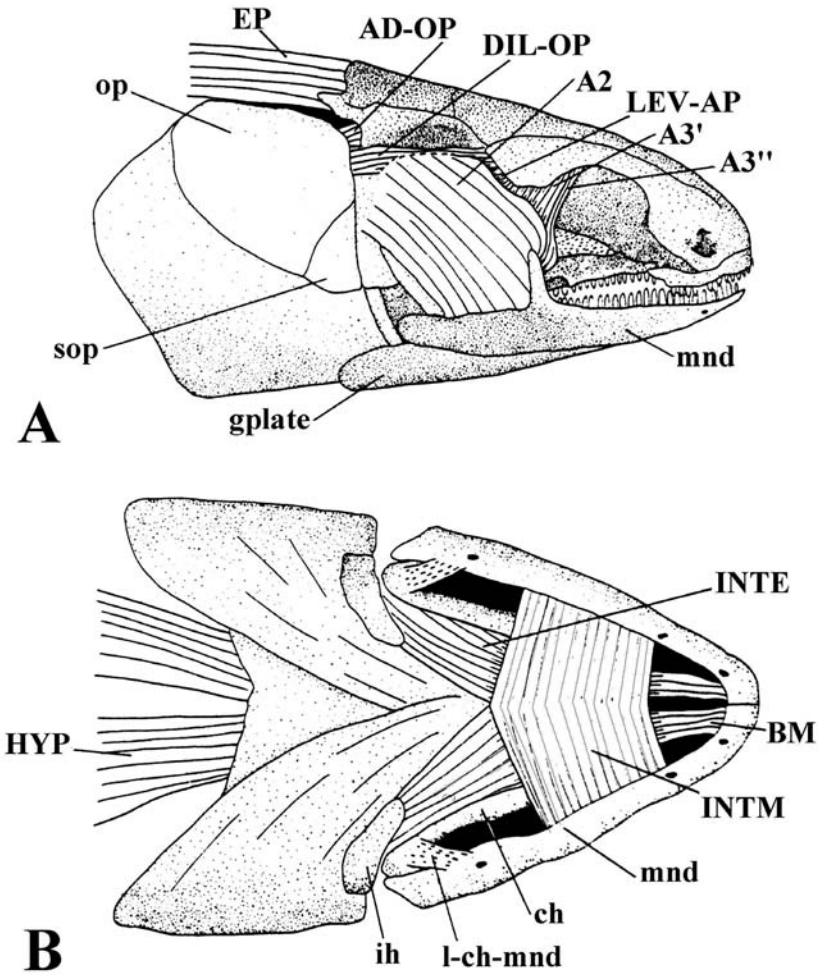

Fig. 4.9 *Polypterus senegalus* (Cladistia): lateral **(A)** and ventral **(B)** views of the head after removal of the eye, suborbital bones, gular plates, and maxilla; in the ventral view the muscle hyohyoideus is not shown (modified from Lauder 1980a; the nomenclature of the structures illustrated follows that used in the present work). A2, A3′, A3″, adductor mandibulae A2, A3′ and A3″; AD-OP, adductor operculi; BM, branchiomandibularis; ch, ceratohyal; DIL-OP, dilatator operculi; EP, epaxialis; gplate, gular plate; HYP, hypoaxialis; ih, interhyal; INTE, interhyoideus; INTM, intermandibularis; l-ch-mand, ligament between ceratohyal and mandible; LEV-AP, levator arcus palatini; mnd, mandible; op, opercle; sop, subopercle.

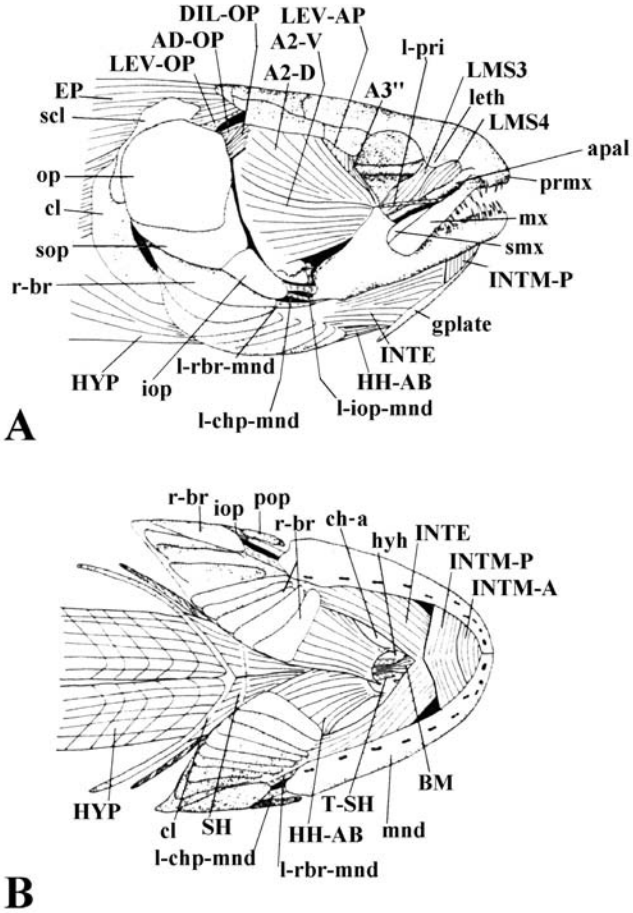

Fig. 4.10 *Amia calva* (Halecomorphi): lateral **(A)** and ventral **(B)** views of the cephalic musculature after removal of the eye, dorsal aspect of the preopercle, and gular plate; in the lateral view the A3′ is nor shown; in the ventral view the hyohyoideus inferior and the hyohyoidei adductores are not shown (modified from Lauder 1980a; the nomenclature of the structures illustrated follows that used in the present work). A2-V, A2-D, A3′′, adductor mandibulae A2-V, A2-D and A3′′; AD-OP, adductor operculi; AD-SUP, adductor superficialis; apal, autopalatine; BM, branchiomandibularis; ch-a, anterior ceratohyal; cl, cleithrum; DIL-OP, dilatator operculi; EP, epaxialis; gplate, gular plate; HH-AB, hyohyoideus abductor; hyh, hypohyal; HYP, hypoaxialis; INTE, interhyoideus; INTM-A, INTM-P, intermandibularis anterior and posterior; iop, interopercle; l-chp-mand, ligament between posterior ceratohyal and mandible; l-iop-mand, ligament between interopercle and mandible; l-pri, primordial ligament; l-rbr-mand, ligament between branchiostegal rays and mandible; leth, lateral-ethmoid; LEV-AP, levator arcus palatini; LEV-OP, levator operculi; LMS3, LMS4, levator maxillae superioris 3 and 4; branchiomandibularis; mnd, mandible; mx, maxilla; op, opercle; pop, preopercle; prmx, premaxilla; r-br, branchiostegal rays; scl, supracleithrum; SH, sternohyoideus; smx, supramaxilla; sop, subopercle; T-SH, tendon of sternohyoideus.

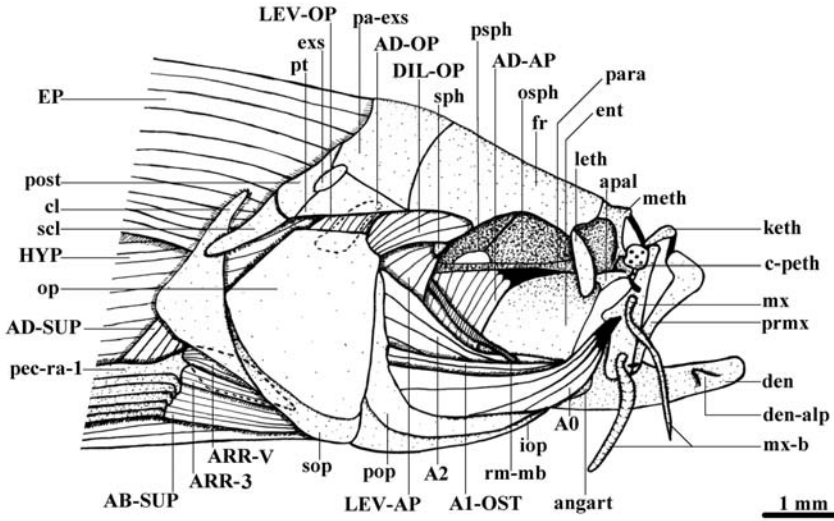

Fig. 4.11 *Danio rerio* (Teleostei, Cypriniformes): lateral view of the cephalic musculature; all muscles are exposed, the maxillary barbels and the mesial branch of the ramus mandibularis are also illustrated; the nasals, infraorbitals and postcleithra were removed. A0, A1-OST, A2, adductor mandibulae A0, A1-OST and A2; AB-SUP, abductor superficialis; AD-AP, adductor arcus palatini; AD-OP, adductor operculi; AD-SUP, adductor superficialis; angart, angulo-articular; apal, autopalatine; ARR-3, arrector 3; ARR-V, arrector ventralis; c-peth, pre-ethmoid cartilage; cl, cleithrum; den, dentary bone; den-alp, anterolateral process of dentary bone; DIL-OP, dilatator operculi; ent, entopterygoid; EP, epaxialis; exs, extrascapular; fr, frontal; HYP, hypoaxialis; iop, interopercle; keth, kinethmoid; leth, lateral-ethmoid; LEV-AP, levator arcus palatini; LEV-OP, levator operculi; meth, mesethmoid; mx, maxilla; mx-b, maxillary barbel; op, opercle; osph, orbitosphenoid; pa-exs, parieto-extrascapular; para, parasphenoid; pec-ra-1, pectoral ray 1; pop, preopercle; post, posttemporal; prmx, premaxilla; psph, pterosphenoid; pt, pterotic; rm-mb, mesial branch of ramus mandibularis; scl, supracleithrum; sop, subopercle; sph, sphenotic.

their page 61, the fibers of this 'levator operculi' are deeply blended with those of the adductor operculi. This has made Lauder (1980c) and others very skeptical about the presence, in *Latimeria*, of a distinct, well-differentiated muscle levator operculi such as that found in *Amia* and teleosts. However, Adamicka and Ahnelt (1992: 108) reaffirmed, seemingly based on their own observations of *Latimeria*, that this taxon "does have a levator operculi muscle differentiated out of the adductor (operculi)". According to the results of Diogo's (2007) cladistic analysis, the 'levator operculi' of *Latimeria* is probably non-homologous to the levator operculi of *Amia* and teleosts (see tables of Chapters 4 and 5; Fig. 4.1). It is important to stress that the function of the *Latimeria*'s 'levator operculi' is, in fact, not similar to that of the levator operculi of *Amia* and teleosts. This is because, contrary to these latter fishes, *Latimeria* has no interoperculo-mandibular ligament

and, consequently, has no opercular mechanism mediating mandible depression (e.g., Millot and Anthony 1958; Alexander 1973; Anthony 1980; Lauder 1980c). In order to distinguish the 'levator operculi' of *Latimeria* and the levator operculi of *Amia* and teleosts the former muscle is named '*Latimeria*'s levator operculi' in the present work (see Tables 5.3–5.4).

A muscle named 'levator operculi' is shown in an illustration of the dipnoan *Neoceratodus* by Kardong (2002; see his fig. 10.39B). However, in the dipnoan specimens dissected by us, as well as in those described by, e.g., Bischoff (1840), Owen (1841), Luther (1913–1914), Edgeworth (1935), Kesteven (1942–1945), Bemis (1986), Bemis and Lauder (1986), and Bartsch (1992, 1993, 1994), there is no structure resembling the 'levator operculi' of *Latimeria* or the levator operculi of *Amia* and teleosts. In fact, the 'levator operculi' of Kardong (2002: fig. 10.39B) seemingly corresponds to the constrictor operculi of Bemis and Lauder (1986), which may correspond to the adductor operculi of other bony fishes but forms, in extant adult dipnoans, a continuous sheet of fibers together with other cranial muscles.

Examples of other dorso-medial hyoid muscles found in osteichthyans are, e.g., the levator hyoideus and the depressor mandibulae (Fig. 4.6; see also Chapter 5). The levator hyoideus is usually related with the elevation of the posterodorsal portion of the ceratohyal (Fig. 4.21), whereas the depressor mandibulae is often related with the opening of the mouth (see Chapter 5). These muscles are found in at least some developmental stages of extant dipnoans and of numerous extant tetrapods. Contrarily to what is suggested in Chapter 5, Edgeworth (1935) stated that the depressor mandibulae of adult dipnoans such as *Protopterus* and *Lepidosiren* is not homologous with part or totality of the depressor mandibulae of adult tetrapods. This is because in the dipnoan developmental series observed by him the levator hyoideus and the depressor mandibulae seemingly appear at the same time, while in tetrapods the depressor mandibulae appears as a modification of part, or the totality, of the levator hyoideus. Forey (1986) and others, however, have suggested that the depressor mandibulae/levator hyoideus of adult *Protopterus* and *Lepidosiren* are homologous with the depressor mandibulae/levator hyoideus of adult tetrapods, and that this actually provides support for a close relationship between dipnoans and tetrapods. Our observations, comparisons and phylogenetic results strongly corroborate Forey's hypothesis: the innervation, position, relationships with other structures, and function of the depressor mandibulae/levator hyoideus of adult dipnoans are strikingly similar to those of the depressor mandibulae/levator hyoideus of adult tetrapods, and the results of Diogo's (2007) cladistic analysis do strongly support that dipnoans are effectively the closest living relatives of tetrapods (Fig. 4.1). Even authors who have adhered to Edgeworth's (1935)

view do in fact admit that the depressor mandibulae of adult dipnoans is "functionally and topographically comparable" to the depressor mandibulae of adult tetrapods such as salamanders (e.g., Bauer 1997: 79).

The following hypothesis concerning the evolution of the levator hyoideus and depressor mandibulae may therefore be tentatively proposed. The first evolutionary step was probably the differentiation of the levator hyoideus (possibly from the portion of the hyoid muscle plate that gives rise to the adductor arcus palatini in other osteichthyans, but this is far from clear: Chapter 5; see below). A configuration such as this, i.e., in which there is no depressor mandibulae and in which the levator hyoideus consists of a single mass of fibers attaching to the hyoid arch, is found, for example, in early development stages of the dipnoan *Neoceratodus* and of various tetrapods (e.g., Edgeworth 1935: fig. 313; Bartsch 1994: fig. 2B). The second evolutionary step may have been the attachment of some fibers of the levator hyoideus to the mandible and the ulterior differentiation of these fibers into a depressor mandibulae. A configuration such as this, i.e., in which the levator hyoideus and the depressor mandibulae inserting respectively to the hyoid arch and to the mandible, is found in early development stages of various tetrapods and of the dipnoans *Lepidosiren* and *Protopterus*, as well as in juveniles and adults of these two dipnoan genera and of amphibians such as *Siren* (Edgeworth 1935: see his fig. 327; Chapter 5). These two evolutionary steps seemingly occurred before the phylogenetic splitting between dipnoans and tetrapods, since at least some members of these groups have depressor mandibulae fibers attaching on the mandible. In other words, the last common ancestors of dipnoans and tetrapods probably had, in at least some stages of their development, both a levator hyoideus and a depressor mandibulae. After that phylogenetic splitting, the evolution of these muscles has seemingly been rather diverse and complex. For instance, in the dipnoan *Neoceratodus*, the levator hyoideus becomes ontogenetically blended with other hyoid muscles, being absent as a separate element in adults; a separate depressor mandibulae is missing in early and late developmental stages of this taxon. In the dipnoans *Lepidosiren* and *Protopterus* and in tetrapods such as *Siren*, these two muscles remain as separate elements until the adult stages (see Chapter 5). As in *Neoceratodus*, the levator hyoideus is also absent as a separate element in numerous adult tetrapods, but for a different reason: because, as shown by, e.g., Edgeworth (1935), in the course of their development all the fibers of this muscle become ontogenetically attached to the mandible, thus constituting the depressor mandibulae (see Chapter 5).

Therefore, the levator hyoideus of adult dipnoans such as *Protopterus* and *Lepidosiren* (Fig. 4.21), as well as of adult tetrapods such as *Siren*, seemingly corresponds to the levator hyoideus of adult amphibians such as *Ambystoma* and to part of the depressor mandibulae of adult amniotes such

as *Timon* (see Chapter 5). The depressor mandibulae of *Protopterus* and *Lepidosiren* and of *Siren* seemingly corresponds to the depressor mandibulae of adult amphibians such as *Ambystoma* and to part of the depressor mandibulae of adult amniotes such as *Timon* (see Chapters 5–7). The statements of Edgeworth regarding the ontogenetic differences between the dipnoan depressor mandibulae and the depressor mandibulae of tetrapods such as *Ambystoma* may thus be due to two main factors: (1) the mode of appearance of these structures may effectively be somewhat different in dipnoans and in tetrapods (which, in view of the recent discoveries in the field of evolutionary developmental biology, does not completely invalidate the hypothesis that they are homologous: see, e.g., Gould 2002; West-Eberhard 2003; Carroll et al. 2005; Kirschner and Gerhart 2005; see also below); (2) the mode of appearance of the depressor mandibulae of dipnoans is, in reality, similar to that of that of the depressor mandibulae of urodeles (i.e., it appears ontogenetically after the levator hyoideus, resulting from the differentiation of part of its fibers), but the youngest dipnoan specimens observed by Edgeworth 1935 were too old to detect such a differentiation (i.e., the differentiation had already occurred and thus both the levator hyoideus and the depressor mandibulae were already present in those specimens, giving the idea that these structures were ontogenetically originated at the same time). Further detailed comparative analyses on the development of the hyoid muscles of dipnoans and of other osteichthyans are needed to clarify this issue.

Such detailed analyses are also needed to clarify whether the portions of the constrictor hyoideus from which originate the levator hyoideus/depressor mandibulae and the constrictor operculi of extant dipnoans may eventually correspond to the portions that give rise to the adductor arcus palatini and the adductor operculi of other bony fishes, as suggested by, e.g., Edgeworth (1935) and Diogo (2007). Edgeworth (1935: 102) stated that the levator hyoideus of dipnoans is derived from the portion of the constrictor hyoideus that gives rise to the retractor hyomandibulae in extant acipenseriforms, which seemingly corresponds to the adductor arcus palatini of other bony fishes (Table 4.2; see above). It should be noted that in living dipnoans the hyomandibula is very reduced or even missing and the palatoquadrate is fused to the neurocranium, being thus much less mobile than that of most other bony fishes. Therefore, the portion of the hyoid muscle plate that gives rise to the adductor arcus palatini of other bony fishes may have lost its usual attachments to the hyomandibula and/or palatoquadrate and became attached to the ceratohyal. The dorsal surface of the ceratohyal actually is more dorsal in dipnoans than in most other bony fishes, occupying a position somewhat similar to that of the hyomandibula of these latter fishes (Fig. 4.21; e.g., Rosen et al. 1981; Forey 1986; Bauer 1997; this work). Our observations of juvenile and adult

specimens of *Lepidosiren* pointed out that in these specimens the levator hyoideus attaches not only to the dorsal surface of the ceratohyal, but also to part of its dorsomesial margin (Fig. 4.21). Thus, as the adductor arcus palatini of other bony fishes usually attaches on the dorsomesial margin of the hyomandibula/palatoquadrate in order to promote their adduction, it seems that the dipnoan levator hyoideus might promote not only an elevation, but also an adduction, of the dorsal portion of the ceratohyal. Regarding the dipnoan constrictor operculi (Fig. 12), it could effectively be originated from the same portion of the constrictor hyoideus

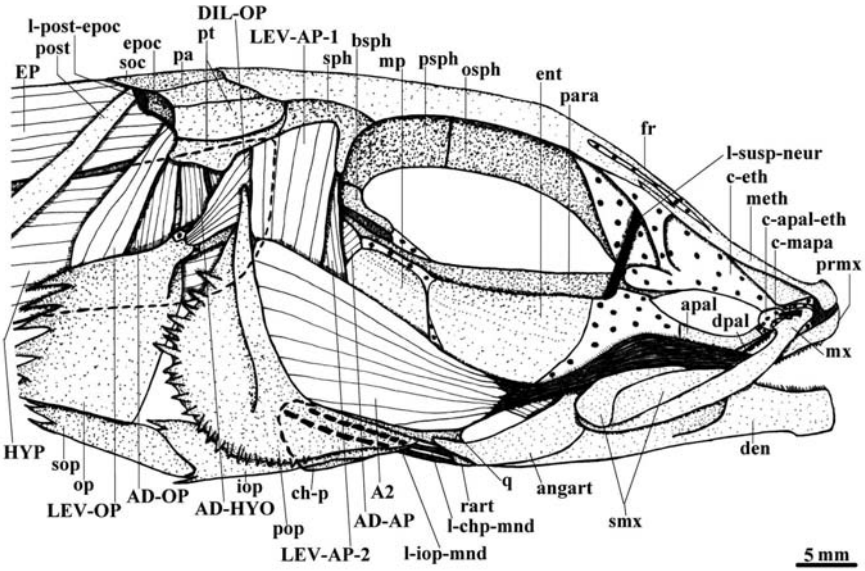

Fig. 4.12 *Alepocephalus rostratus* (Teleostei, Alepocephaloidea): lateral view of the cephalic musculature; the pectoral girdle muscles are not illustrated; most elements of the pectoral girdle, as well as the nasals and infraorbitals, were removed. A2, adductor mandibulae A2; AD-AP, adductor arcus palatini; AD-HYO, adductor hyomandibulae; AD-OP, adductor operculi; angart, angulo-articular; apal, autopalatine; bsph, basisphenoid; c-apal-eth, cartilage between autopalatine and ethmoid region; c-eth, ethmoid cartilage; c-mapa, small cartilage between maxilla and autopalatine; ch-p, posterior ceratohyal; den, dentary bone; dpal, dermopalatine; DIL-OP, dilatator operculi; ent, entopterygoid; EP, epaxialis; epoc, epioccipital; fr, frontal; HYP, hypoaxialis; iop, interopercle; l-chp-mnd, ligament between posterior ceratohyal and mandible; l-iop-mnd, ligament between interopercle and mandible; l-pri, primordial ligament; l-post-epoc, ligament between posttemporal and epioccipital; l-susp-neur, ligament between suspensorium and neurocranium; leth, lateral-ethmoid; LEV-AP-1, 2, sections of levator arcus palatini; LEV-OP, levator operculi; meth, mesethmoid; mp, metapterygoid; mx, maxilla; op, opercle; osph, orbitosphenoid; pa, parietal; para, parasphenoid; pop, preopercle; post, posttemporal; prmx, premaxilla; psph, pterosphenoid; pt, pterotic; q, quadrate; rtart, retroarticular; smx, supramaxillae; soc, supraoccipital; sop, subopercle; sph, sphenotic.

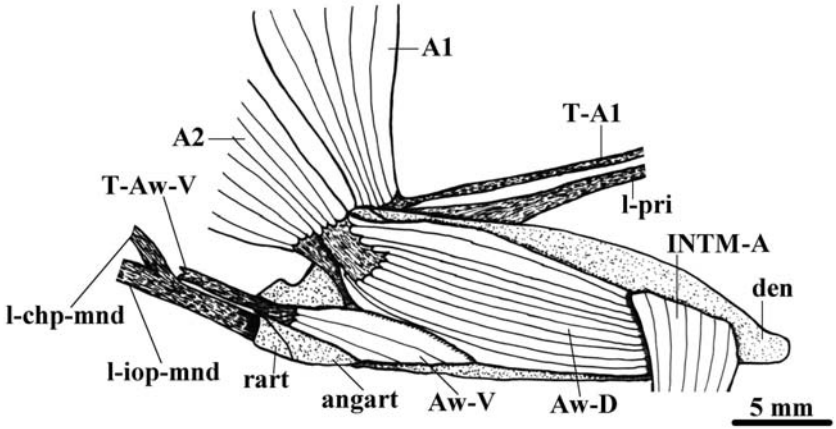

Fig. 4.13 *Aulopus filamentosus* (Teleostei, Aulopiformes): mesial view of the left mandible and adductor mandibulae; the anterior intermandibularis and the primordial ligament, as well as the ligaments between the mandible, posterior ceratohyal and interopercle, are also shown; mandibular teeth were removed. A1, A2, Aω-D, Aω-V, sections of adductor mandibulae; angart, angulo-articular; den, dentary bone; l-chp-mnd, ligament between posterior ceratohyal and mandible; l-iop-mnd, ligament between interopercle and mandible; l-pri, primordial ligament; T-A1, tendon of A1; T- Aω-V, tendon of Aω-V; rtart, retroarticular.

that gives rise to the adductor operculi in other bony fishes. This seems to be supported by the fact that some plesiomorphic fossil dipnoans exhibit well-defined scars on the mesial margin of the opercle for the attachment of a muscular structure that seemingly corresponds to the adductor operculi of other fishes (e.g., Campbell and Barwick 1986). Be that as it may, in adult extant dipnoans the constrictor operculi forms a sheet of fibers that is continuous with other muscles such as the interhyoideus. Therefore, even if the constrictor operculi of dipnoans is eventually derived from the portion of the constrictor hyoideus that gives rise to the adductor operculi in other bony fishes, in adult extant dipnoans there is no separate, distinct adductor operculi as found in adult members of, e.g., *Latimeria* and most actinopterygians (see Chapter 5).

Regarding the ventral portion of the hyoid muscle plate, the plesiomorphic condition for osteichthyans is seemingly that in which that portion gave rise to a single division, which is designated here as interhyoideus (Table 4.2). In most extant actinopterygians, part of the interhyoideus becomes ontogenetically differentiated into a distinct, separate muscle, the hyohyoideus (Table 4.2; Fig. 4.5). In *Amia* and most teleosts, the hyohyoideus is subdivided into hyohyoideus inferior, hyohyoideus abductor and hyohyoidei adductores (Fig. 4.15). The hyoideus abductor and hyohyoidei adductores are often considered parts of a hyohyoideus superior (Table 4.2; Fig. 4.5). As stated by Stiassny's (2000: 122), "there is

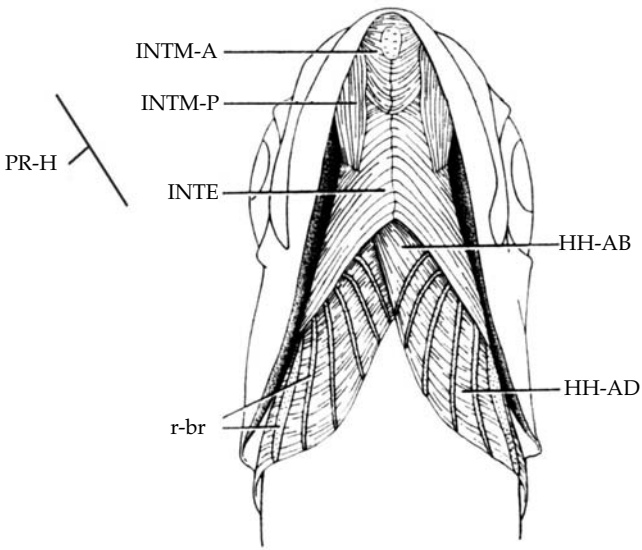

Fig. 4.14 *Hiodon alosoides* (Teleostei, Hiodontiformes): ventral view of the cephalic musculature (modified from Greenwood 1971). HH-AB, hyohyoideus abductor; HH-AD, hyohyoidei adductores; INTE, interhyoideus; INTM-A, INTM-P, anterior and posterior sections of intermandibularis; PR-H, protractor hyoideus; r-br, branchiostegal rays.

little commentary in the literature regarding the function of HhI (hyohyoideus inferior) but adduction of the hyoid bar is suggested by its position and presumed line of action". Regarding the hyohyoideus abductor and the hyohyoidei adductores, they are usually related with the expansion and the constriction of the branchiostegal membranes, respectively (Fig. 4.15). The interhyoideus, which as its name indicates usually connects the two hyoid bars, has become associated with the intermandibularis posterior in teleosts, forming the peculiar protractor hyoideus (Tables 4.1, 4.2; see above).

Miyake et al.'s (1992) table I suggests that in extant cladistians, chondrosteans and ginglymodians the hyohyoideus is differentiated into two well-differentiated divisions, namely a hyohyoideus inferior and a hyohyoideus superior. However, in the adult specimens of these three groups that we have dissected the hyohyoideus is not divided into well-differentiated parts as is the case in *Amia* and teleosts. It is instead essentially constituted by a continuous sheet of fibers. These observations seem to be supported by those of other authors. For instance, Lauder (1980a: 293) wrote that "in *Lepisosteus* the hyohyoideus superioris (…) also (as in *Polypterus*) is continuous with the fibers of the hyohyoideus inferioris"

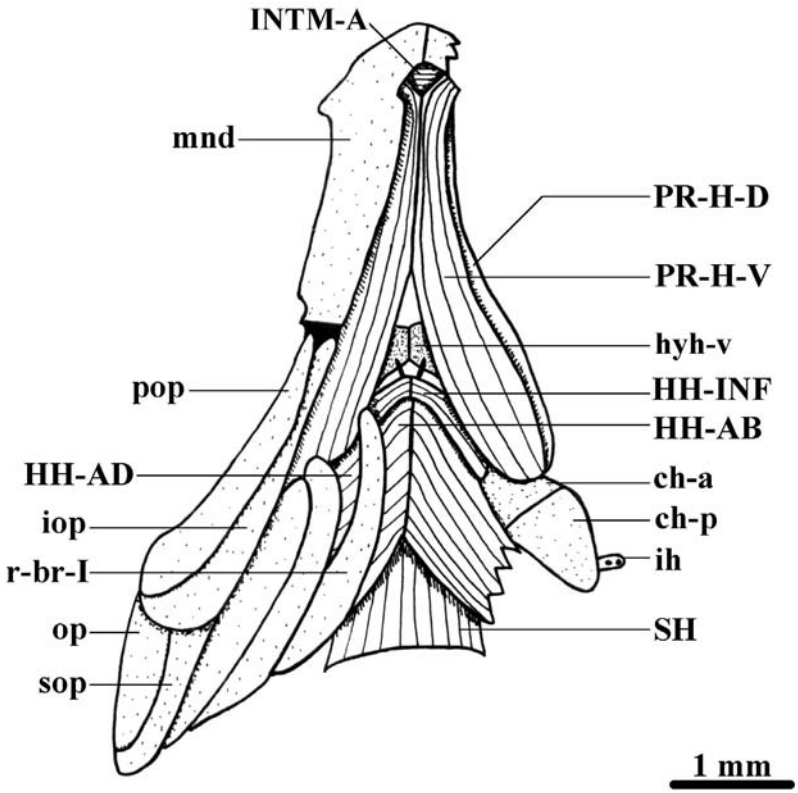

Fig. 4.15 *Danio rerio* (Teleostei, Cypriniformes): ventral view of the ventral cephalic musculature; on the right side a portion of the hyohyoidei adductores, as well as of the mandible, was cut, and the opercle, interopercle, subopercle and preopercle are not represented. ch-a, ch-p, anterior and posterior ceratohyals; HH-AB, hyohyoideus abductor; HH-AD, hyohyoidei adductores; HH-INF, hyohyoideus inferior; hyh-v, ventral hypohyal; ih, interhyal; INTM-A, anterior intermandibularis; iop, interopercle; mnd, mandible; op, opercle; pop, preopercle; PR-H-D, PR-H-V, sections of protractor hyoideus; r-br-I, branchiostegal ray I; SH, sternohyoideus; sop, subopercle.

(i.e., the fibers of the hyohyoideus form a continuous sheet, as is the case in the *Lepisosteus* and *Polypterus* specimens dissected by us). The hyohyoideus of the chondrosteans described by, e.g., Danforth (1913: *Polyodon*) and Carroll and Wainwright (2003: *Scaphirhynchus*) is also constituted by a continuous sheet of fibers, as is the case in the *Psephurus* and *Acipenser* specimens we analyzed (note: the interhyoideus of this work corresponds to the "geniohyoideus posterior" and the "constrictor ventralis posterior" sensu Danforth 1913 and of Carroll and Wainwright 2003, respectively).

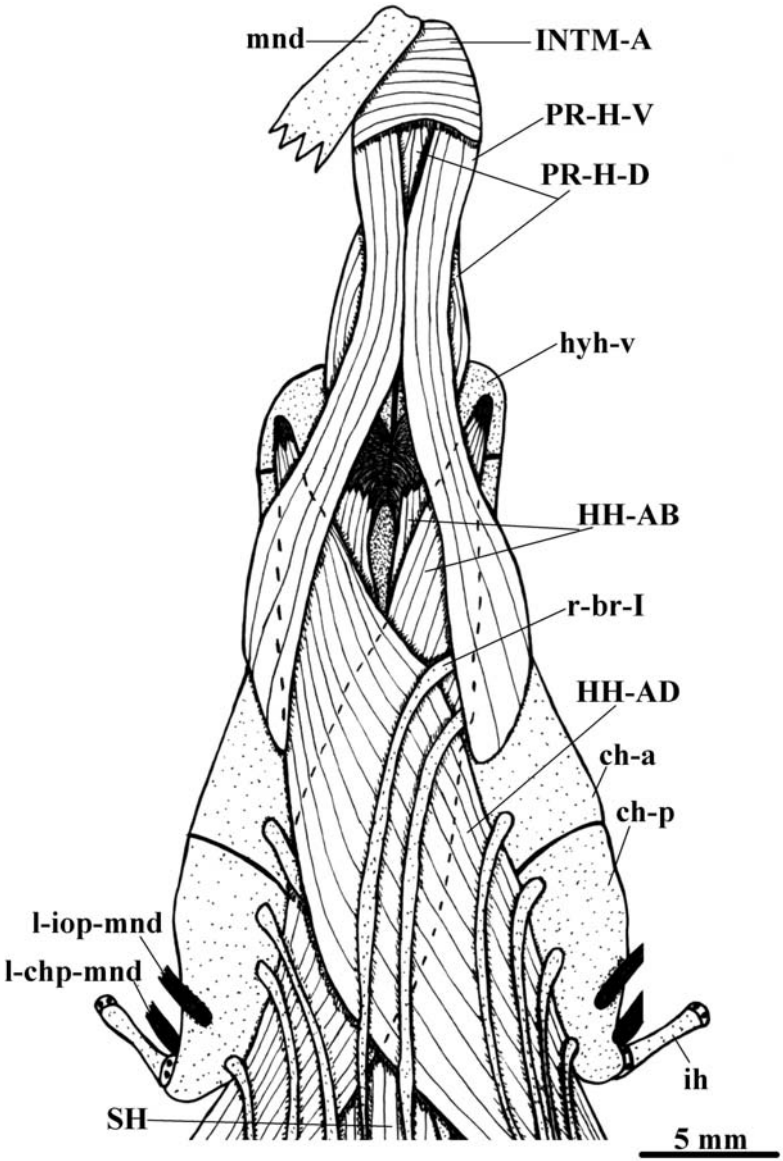

Fig. 4.16 *Alepocephalus rostratus* (Teleostei, Alepocephaloidea): ventral view of the cephalic musculature; on the right side, the mandible was removed; on the left side, the mandible was cut. ch-a, ch-p, anterior and posterior ceratohyals; HH-AB, hyohyoideus abductor; HH-AD, hyohyoidei adductores; hyh-v, ventral hypohyal; ih, interhyal; INTM-A, anterior intermandibularis; l-chp-mnd, ligament between posterior ceratohyal and mandible; l-iop-mnd, ligament between interopercle and mandible; mnd, mandible; PR-H-D, PR-H-V, sections of protractor hyoideus; r-br-I, branchiostegal ray I; SH, sternohyoideus.

There is seemingly no well-differentiated, separate hyohyoideus in extant Sarcopterygii (see Chapter 5). That is, there are some sarcopterygians in which the portion of the hyoid muscle plate that gives rise to the interhyoideus and hyohyoideus in actinopterygians might eventually be somewhat differentiated into bundles that may resemble those two structures, but these bundles remain deeply blended throughout all their lives. This is, e.g., the case of the interhyoideus anterior and the interhyoideus posterior of various salamanders (see Chapters 5 and 6, and also, e.g., Lubosch 1914; Luther 1913-1914; Edgeworth 1935; Kesteven 1942–1945; Jarvik 1963; Larsen and Guthrie 1975; Carroll and Holmes 1980; Bauer 1992; Haas 2001). This is seemingly also the case of the 'géniohyoïdien' and the 'hyohyoïdien' described by Millot and Anthony (1958) in *Latimeria*, which are deeply blended in the adult members of this genus and which, thus, seem to correspond to the interhyoideus of the present work (see Chapter 5).

Apart from the muscles mentioned in the paragraphs above, osteichthyans may exhibit other hyoid muscles (Table 4.2 and Chapters 5–7). For instance, in at least some developmental stages of various urodeles there is a peculiar muscle branchiohyoideus connecting the hyoid and branchial arches. Ontogenetically, this muscle appears between the interhyoideus and the levator hyoideus/depressor mandibulae, a position that "makes it difficult to determine if it belongs to the dorsal or ventral (hyoid) muscles" (Ericsson and Olsson 2004: 136) (see Fig. 4.6). According to Lauder and Shaffer (1985: 308) the function of the branchiohyoideus is to "mediate hyoid retraction and possibly also produce ceratobranchial abduction in the absence of antagonistic activity". Edgeworth (1935) and Lauder and Shaffer (1988) stated that the branchiohyoideus becomes lost after metamorphosis in most urodeles. However, the metamorphosed specimens of *Ambystoma ordinarium* examined by us do have a distinct muscle branchiohyoideus (see Chapter 5). As explained by Edgeworth (1935), the structure that is often named 'branchiohyoideus' in amniotes is seemingly homologous to the branchial muscle subarcualis rectus 1 of amphibians, and not to the hyoid muscle branchiohyoideus of the present work (which Edgeworth designated as 'branchiohyoideus externus') (see Chapters 5–7). Jarvik (1963) suggested that a branchiohyoideus similar to that of urodeles may have been present in at least some of the sarcopterygian fossil fishes placed in his "porolepiform-stock". However, as stressed by, e.g., Rosen et al. (1981), some of Jarvik's interpretations of fossils, principally those concerning soft structures, should be viewed with much caution, since they were profoundly influenced by certain strong, and rather heterodox, beliefs of this author. For instance, in this specific case regarding the eventual presence of a branchiohyoideus in his "porolepiforms", this has much to do with his profound conviction that these latter fishes were the

sister-group of urodeles and, thus, that amphibians are not monophyletic, a view to which almost no authors would adhere nowadays ("these great resemblances … cannot possibly be due to parallel evolution and they prove definitively that the urodeles are closely related to and descendants of porolepiforms": Jarvik 1963: 61). Therefore, a detailed, updated, and if possible less biased, comparative analysis is needed in order to clarify whether or not a branchiohyoideus is present in sarcopterygian fish fossils.

Branchial Muscles (Table 4.3)

The muscles listed in Tables 4.3 and 5.5–5.6 correspond to the branchial muscles *sensu lato* of Edgeworth (1935). They can be divided into three groups. The first comprises the 'true' branchial muscles, which are subdivided into: (A) the branchial muscles *sensu stricto* that are directly associated with the movements of the branchial arches and that in mammals are usually innervated by the glossopharyngeal nerve (CNIX); (B) the protractor pectoralis and its derivatives, which are instead mainly associated with the pectoral girdle and are primarily innervated by the spinal accessory nerve (CNXI). The second group consists of the pharyngeal muscles, which are only present as independent structures in extant mammals. They are considered to be derived from arches 4–6, and they are usually innervated by the vagus nerve (CNX). As will be seen in Chapter 5, the mammalian stylopharyngeus is considered to be derived from the third arch and is primarily innervated by the glossopharyngeal nerve, being thus grouped with the 'true' branchial muscles, and not with the pharyngeal muscles. The third group is made up of the laryngeal muscles, which are considered to be derived from arches 4–6 and are usually innervated by the vagus nerve (CNX).

Most adult vertebrates retain various branchial muscles *sensu stricto* (e.g., Bischoff 1840; Owen 1841; Allis 1923; Edgeworth 1935; Millot and Anthony 1958; Wiley 1979ab; Jollie 1982; Bemis 1986; Miyake et al. 1992; Wilga et al. 2000; Kardong 2002; Carroll and Wainwright 2003; Johanson 2003; this study) (Tables 4.3 and 5.5–5.6). However, the branchial muscles *sensu stricto* are not present as a group in extant reptiles and extant mammals (see Chapter 5). For instance, many adult reptiles have only one branchial muscle *sensu stricto*, the subarcualis rectus I (see above). The two branchial muscles *sensu stricto* found in adult reptiles such as 'lizards', i.e., the hyobranchialis and 'ceratohyoideus', seem to be the result of a subdivision of the subarcualis rectus I (see Chapters 5 and 7). Adult extant mammals lack all the branchial muscles *sensu stricto* except the subarcualis rectus I (which in most adult mammals gives rise to the ceratohyoideus and stylopharyngeus), the subarcualis rectus II (usually present only in

Table 4.3 Branchial muscles of adults of representative extant actinopterygian taxa (see caption of Table 4.1).

Probable plesiomorphic osteichthyan condition	Cladistia: *Polypterus bichir* (Bichir)	Chondrostei: *Psephurus gladius* (Chinese swordfish)	Ginglymodi: *Lepisosteus osseus* (Longnose gar)	Halecomorphi: *Amia calva* (Bowfin)	Teleostei - basal: *Elops saurus* (Ladyfish)	Teleostei - clupeoce-phalan: *Danio rerio* (Zebrafish)
Branchial muscles *sensu stricto*	**Branchial muscles *sensu stricto*** [according to Miyake et al. 1992, *Polypterus* might have a dorsal branchial muscle complex, transversi ventrales 2–4, a pharyngoclavicularis, a rectus communis and possibly an interarcualis ventralis 1]	**Branchial muscles *sensu stricto*** [according to Miyake et al. 1992, chondrosteans may have a dorsal branchial muscle complex, transversi ventrales 4–5, a pharyngoclavicularis, obliqui ventrales 2–3 and possibly an interarcualis ventralis 1]	**Branchial muscles *sensu stricto*** [according to Miyake et al. 1992, ginglymodians may have a dorsal branchial muscle complex, a transversus ventralis 5, a pharyngo-clavicularis, obliqui ventrales 1–4 and a possibly transversi ventralis 4–5]	**Branchial muscles *sensu stricto*** [according to Miyake et al. 1992, *Amia* might have a dorsal branchial muscle complex, obliqui ventrales 1–4, a transversus ventralis 5,a rectus ventralis 4, pharyngo-clavicularis internus and externus, and possibly transversi ventralis 3–4]	**Branchial muscles *sensu stricto*** [according to Miyake et al. 1992, teleosts may have a dorsal branchial muscle complex, an interbranchialis adductoris, obliqui ventrales 1–4, transversi ventrales 1–4, recti ventrales 2–4, pharyngo-clavicularis internus and externus, a rectus communis, and possibly an interarculalis ventralis 1 and/or a rectus ventralis 1]	**Branchial muscles sensu stricto** [see on the left]

Protractor pectoralis	**Protractor pectoralis** (cucullaris sensu Edgeworth 1935)	**Protractor pectoralis** (cucullaris sensu Edgeworth 1935)	—	**Protractor pectoralis** (cucullaris sensu Edgeworth 1935)	—	— [with in the zebrafish specimens dissected by us, a distinct, independent protractor pectoralis was usually absent in adults, but was found in some old larvae]
Constrictor laryngis present in LCA of osteichthyans? See text and below	'Constrictor laryngis' and 'dilatator laryngis' of *Polypterus* are homologous to the constrictor laryngis and dilatator laryngis of sarcopterygians? See text and below	—	—	—	—	—
Dilatator laryngis present in LCA of osteichthyans? See text and below	See above	—	—	—	—	—
See on the right	**'Dilatator laryngis'** [according to Edgeworth 1935, this muscle is not homologous with the 'dilatator laryngis' of *Amia* and *Lepisosteus* nor with the dilatator laryngis of sarcopterygians]	—	—	—	—	—

Table 4.3 contd...

Table 4.3 contd...

Probable plesiomorphic osteichthyan condition	Cladistia: *Polypterus bichir* (Bichir)	Chondrostei: *Psephurus gladius* (Chinese swordfish)	Ginglymodi: *Lepisosteus osseus* (Longnose gar)	Halecomorphi: *Amia calva* (Bowfin)	Teleostei - basal: *Elops saurus* (Ladyfish)	Teleostei - clupeoce-phalan: *Danio rerio* (Zebrafish)
See on the right	—	—	**'Dilatator laryngis'** [according to Edgeworth 1935, the 'dilatator laryngis' of *Lepisosteus* and *Amia* is not homologous with the 'dilatator laryngis' of *Polypterus* nor with the dilatator laryngis of sarcopterygians]	**'Dilatator laryngis'** [see on the left]	—	—
See on the right	**'Constrictor laryngis'** [according to Edgeworth 1935, this muscle might well be homologous with the constrictor laryngis of sarcopterygians; if this is the case, the presence of this muscle would be plesiomorphic for osteichthyans]	— [seemingly absent, according to Edgeworth 1935]	— [seemingly absent, according to Edgeworth 1935]	—	—	—

adult marsupials) and the subarcualis rectus III (usually present only in adult monotremes) (e.g., Edgeworth 1935; Chapter 5).

As will also be explained in Chapter 5, the mammalian acromiotrapezius, spinotrapezius, cleido-occipitalis, sternocleidomastoideus, cleidomastoideus and sternomastoideus correspond to the reptilian trapezius and sternocleidomastoideus and thus to the protractor pectoralis of dipnoans, amphibians, and other vertebrates. The protractor pectoralis is not a branchial muscle *sensu stricto* because it is mainly involved in the movements of the pectoral girdle and not of the branchial arches (e.g., Edgeworth 1935; see Chapter 5 for more details on the development and homologies of this muscle).

The mammalian laryngeal muscles thyroarytenoideus, vocalis, cricoarytenoideus lateralis and arytenoideus seemingly derive from the laryngeus of non-mammalian tetrapods such as salamanders, which in turn derives from the constrictor laryngis of dipnoans such as *Lepidosiren*; the mammalian cricoarytenoideus posterior corresponds to the dilator laryngis of other tetrapods and of dipnoans (Chapter 5). Some non-sarcopterygian vertebrates such as *Polypterus*, *Lepisosteus* and *Amia* have a 'constrictor laryngis' and/or a 'dilatator laryngis', but it is not clear whether these muscles do actually correspond to the constrictor laryngis and dilatator laryngis of sarcopterygians and thus whether or not these latter muscles are plesiomorphically present in osteichthyans (e.g., Edgeworth 1935; Chapter 5). The few descriptions of the laryngeal region of *Latimeria* do not allow us to appropriately discern whether or not these laryngeal muscles are present in this taxon (e.g., Millot and Anthony 1958). The laryngeus of tetrapods does not seem to be plesiomorphically found in sarcopterygians, because it is seemingly absent in sarcopterygian fish as dipnoans; a detailed study of the laryngeal region of *Latimeria* is, however, needed in order to support, or to contradict, this hypothesis.

Hypobranchial Muscles (Table 4.4; Figs. 4.7, 4.8)

According to Edgeworth (1935), there are two major lineages of muscles that originate from the hypobranchial muscle plate: his 'genio-hyoideus' and his 'rectus cervicus' (Figs. 4.5, 4.6). As noted Miyake et al. (1992), it is not very clear if Edgeworth's 'genio-hyoideus' and 'rectus cervicus' represent separate premyogenic condensations or later states of muscle development.

The plesiomorphic condition for osteichthyans is seemingly that found in adult members of Actinistia and Dipnoi, in which there is a coracomandibularis and a sternohyoideus (sensu this volume: see Chapter 5). According to, e.g., Edgeworth (1935), Kesteven (1942–1945), Wiley (1979ab), Jollie (1982), Mallat (1997), Wilga et al. (2000) and Johanson (2003), these muscles were originally mainly related with the opening

of the mouth. Extant tetrapods exhibit various hypobranchial muscles that are not found in other living osteichthyans, such as the omohyoideus and the specialized glossal muscles related with tongue movements (Chapter 5). The omohyoideus and the genioglossus are seemingly derived from the sternohyoideus and the coracomandibularis, respectively (Edgeworth, 1935; Chapter 5). However, the statements of Edgeworth (1935) regarding the origin of the hyoglossus are somewhat confused: in his page 196 it is stated that in amphibians such as salamanders this muscle originates from the sternohyoideus, but in his page 211 he affirmed that "the hypobranchial muscles of Amphibia, Sauropsida and Mammalia are essentially similar (...), a genioglossus and a hyoglossus are developed from the genio-hyoideus (= coracomandibularis)". Jarvik (1963: 41) reanalyzed this issue and stated that the hyoglossus of salamanders "seems to be an anterior portion of the rectus cervicus" (sternohyoideus sensu the present work). Larsen and Guthrie (1975) suggested that the hyoglossus of salamanders may eventually originate from "part of the genioglossus complex" (and, thus, from the coracomandibularis of sarcopterygian fish), but stated that it was not possible to confirm this hypothesis "without examining early ontogenetic stages". The information provided in more recent publications referring to the cranial musculature of salamanders, e.g., Carroll and Holmes (1980), Lauder and Shaffer (1985, 1988), Reilly and Lauder (1989, 1990, 1991), Iordansky (1992), Bauer (1992, 1997), Kardong and Zalisko (1998), Haas (2001), Kardong (2002), Ericsson and Olsson (2004) and Ericsson et al. (2004), does not make it possible to completely clarify whether the hyoglossus of these amphibians is derived from the sternohyoideus or from the coracomandibularis (or eventually from both). The analysis of the salamander specimens examined in the present work does also not help clarify this issue; minute comparative analyses of the development of the hyoglossus in salamanders and in other tetrapods are thus needed.

In extant cladistians, chondrosteans and halecomorphs, the coracomandibularis is modified into a peculiar muscle branchiomandibularis connecting the branchial arches and the mandible (Figs. 4.9, 4.10), which is missing in living ginglymodians and teleosts (Fig. 4.15). Wiley (1979ab) and Lauder and Liem (1983) defended that the ancestors of extant actinopterygians probably had a branchiomandibularis, and that the absence of this muscle in living ginglymodians and teleosts is due to a secondary loss. The phylogenetic results of Diogo (2007) strongly support this hypothesis (see Fig. 4.1).

Table 4.4 Hypobranchial muscles of adults of representative actinopterygian taxa (see caption of Table 4.1, and also Figs. 4.6 and 4.7).

Probable plesiomorphic osteichthyan condition	Cladistia: *Polypterus bichir* (Bichir)	Chondrostei: *Psephurus gladius* (Chinese swordfish)	Ginglymodi: *Lepisosteus osseus* (Longnose gar)	Halecomorphi: *Amia calva* (Bowfin)	Teleostei - basal: *Elops saurus* (Ladyfish)	Teleostei - clupeocephalan: *Danio rerio* (Zebrafish)
Coracomandibularis	**Branchiomandibularis** [modified/ derived from coracomandibularis]	**Branchiomandibularis** [see on the left]	—	**Branchiomandibularis** [see on the left]	—	—
Sternohyoideus	**Sternohyoideus**	**Sternohyoideus**	**Sternohyoideus**	**Sternohyoideus**	**Sternohyoideus**	**Sternohyoideus**

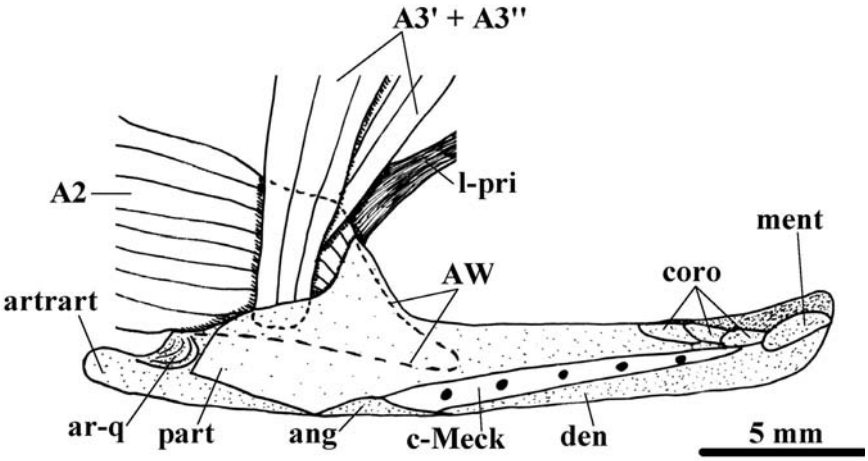

Fig. 4.17 *Polypterus bichir* (Cladistia): mesial view of adductor mandibulae and mandible; mandibular teeth are not illustrated. A2, A3′, A3′′, AW, adductor mandibulae A2, A3′, A3′′ and Aω; ang, angular; ar-q, articulatory facet for quadrate; artrart, articulo-retroarticular; c-Meck, Meckelian cartilage; coro, coronoids; den, dentary bone; l-pri, primordial ligament; ment, mentomeckelian bone; part, prearticular.

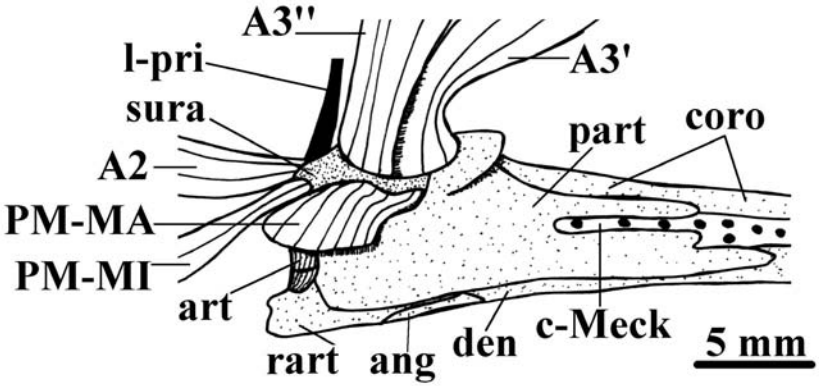

Fig. 4.18 *Lepisosteus osseus* (Ginglymodi): mesial view of adductor mandibulae and mandible; mandibular teeth are not illustrated. A2, A3′, A3′′, adductor mandibulae A2, A3′, A3′′; ang, angular; art, articular; c-Meck, Meckelian cartilage; coro, coronoids; den, dentary bone; l-pri, primordial ligament; part, prearticular; PM-MA, PM-MI, palatomandibularis major and minor; rart, retroarticular; sura, surangular.

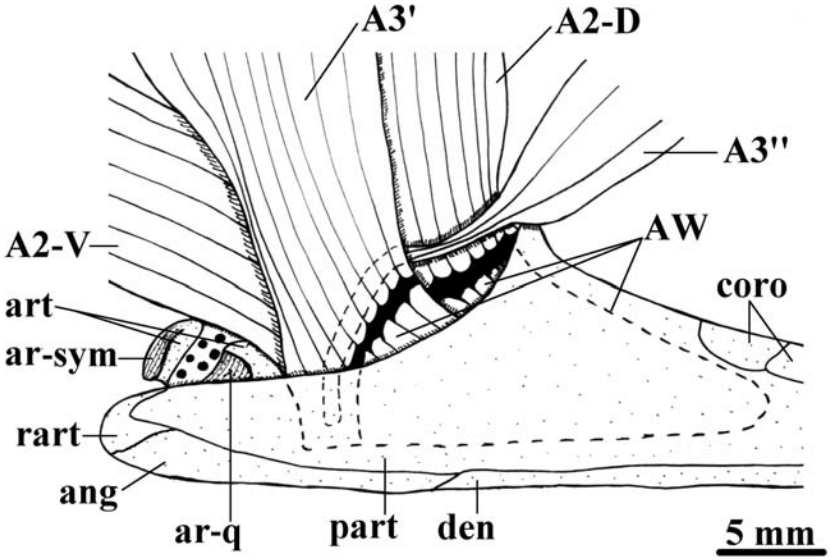

Fig. 4.19 *Amia calva* (Halecomorphi): mesial view of mandible and of adductor mandibulae sections A2, A3′, A3′′ and Aω; the levator maxillae superioris 3 and 4 and the mandibular teeth are not illustrated. A2-D, A2-V, A3′, A3′′, AW, adductor mandibulae A2-D, A2-V, A3′, A3′′ and Aω; ang, angular; ar-q, ar-sym, articulatory facets for quadrate and for symplectic; art, articular; coro, coronoids; den, dentary bone; part, prearticular; rart, retroarticular.

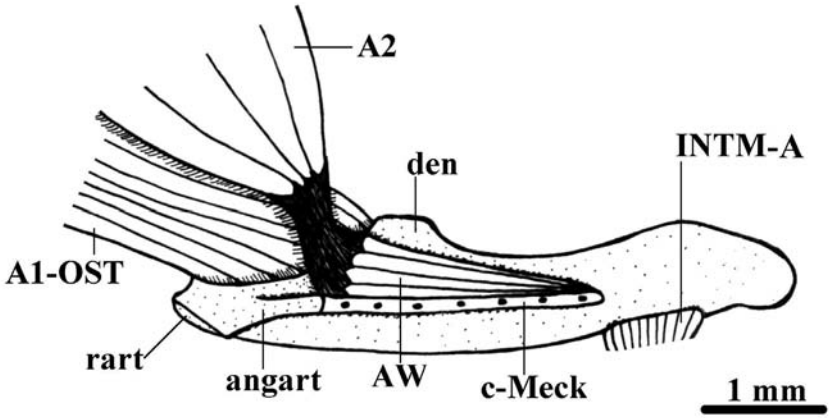

Fig. 4.20 *Danio rerio* (Teleostei, Cypriniformes): mesial view of the left mandible and adductor mandibulae, the anterior intermandibularis is also shown; the adductor mandibulae A0 was removed. A1-OST, A2, adductor mandibulae A1-OST, A2 and Aω; angart, angulo-articular; c-Meck, Meckelian cartilage; coro, coronoids; den, dentary bone; INTM-A, intermandibularis anterior; rart, retroarticular.

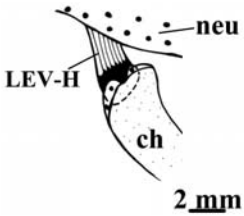

Fig. 4.21 *Lepidosiren paradoxa* (Dipnoi): lateral view of levator hyoideus; the ventral portion of the ceratohyal was cut. LEV-H, levator hyoideus; neu, neurocranium.

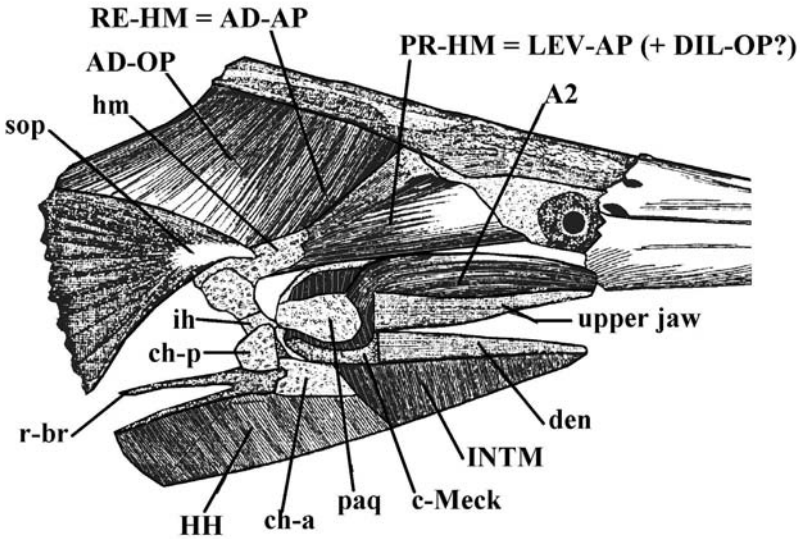

Fig. 4.22 *Polyodon spathula* (Chondrostei): lateral view of the cephalic muscles (modified from Danforth 1913; the nomenclature of the structures illustrated follows that used in the present work). A2, adductor mandibulae A2; AD-AP, adductor arcus palatini; AD-OP, adductor operculi; ch-a, ch-p, anterior and posterior ceratohyals; c-Meck, Meckelian cartilage; den, dentary bone; DIL-OP, dilatator operculi; hm, hyomandibula; ih, interhyal; INTM, intermandibularis; LEV-AP, levator arcus palatini; paq, palatoquadrate; PR-HM, protractor hyomandibulae; r-br, branchiostegal rays; RE-HM, retractor hyomandibulae; sop, subopercle.

General Remarks

In view of the information summarized above, it thus seems that plesiomorphically in osteichthyans the mandibular muscle plate gave rise to the levator arcus palatini, dorsally, to the adductor mandibulae A2, A3′, A3″ and A_{ω}, medially, and to a divided intermandibularis, ventrally. Within osteichthyan evolution, the posterior part of the intermandibularis becomes associated with the interhyoideus in teleosts, forming the peculiar muscle protractor hyoideus. The number of divisions of the ‘adductor

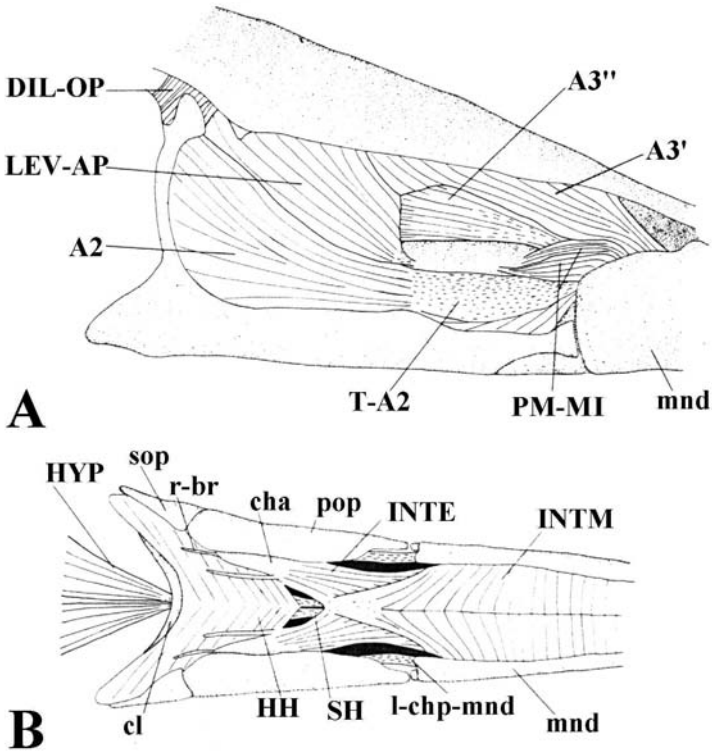

Fig. 4.23 *Lepisosteus oculatus* (Ginglymodi): lateral **(A)** and ventral **(B)** views of the cephalic musculature after removal of the eye (modified from Lauder 1980a; the nomenclature of the structures illustrated basically follows that of this author). A2, A3′, A3′′, adductor mandibulae A2, A3′ and A3′′; cha, anterior ceratohyal; cl, cleithrum; DIL-OP, dilatator operculi; HH, hyohyoideus; HYP, hypoaxialis; INTE, interhyoideus; INTM, intermandibularis; l-chp-mnd, ligamentum between posterior ceratohyal and mandible; LEV-AP, levator arcus palatini; mnd, mandible; PM-MI, palatomandibularis minor; pop, preopercle; r-br, branchiostegal rays; SH, sternohyoideus; sop, subopercle; T-A2, tendon of adductor mandibulae A2.

mandibulae complex′ has changed during the evolutionary history of osteichthyans, some peculiar divisions being exclusively found in extant members of certain groups, e.g., the A1-OST (ostariophysans), A0 (cypriniforms), palatomandibularis minor and major (ginglymodians), levator maxillae superioris 3 and 4 (halecomorphs), A2-PVM (non-actinistian sarcopterygians) and pterygomandibularis (tetrapods). The number of dorsal mandibular muscles is also variable within adult osteichthyans: some taxa have a single muscle (e.g., *Latimeria*, in which there is only a levator arcus palatini and which seems to represent the plesiomorphic condition for osteichthyans: see above); some have more than one muscle (e.g., the numerous actinopterygians exhibiting a levator arcus palatini

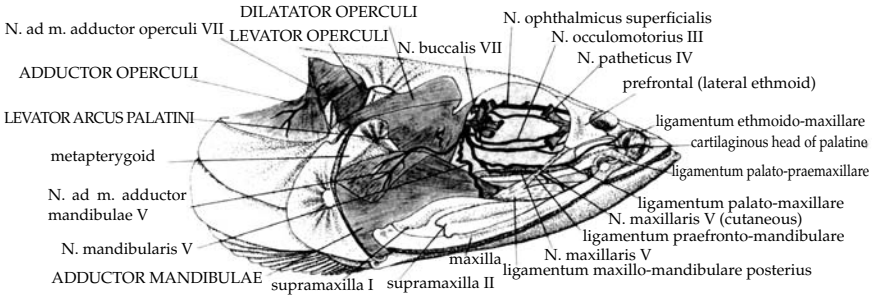

Fig. 4.24 *Elops saurus* (Teleostei, Elopiformes): lateral view of the cephalic muscles; the dorsal edge of the opercular bone has been folded over to expose the muscle adductor operculi (modified from Vrba 1968; the nomenclature of the structures illustrated follows that of this author).

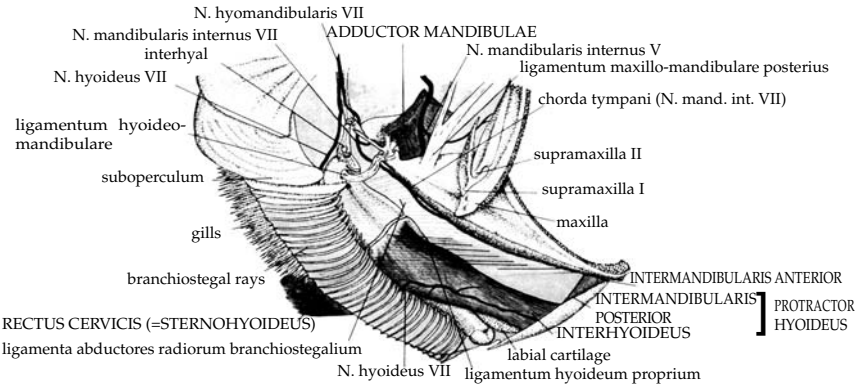

Fig. 4.25 *Elops saurus* (Teleostei, Elopiformes): ventral head region; right lateral view of fully extended jaw apparatus, the interopercle has been removed (modified from Vrba 1968; the nomenclature of the structures illustrated follows that of this author).

and a dilatator operculi or the numerous amniotes exhibiting a levator pterygoidei and a protractor pterygoidei); and some have none (e.g., living dipnoans and amphibians).

Regarding the hyoid muscle plate, the plesiomorphic condition for osteichthyans is seemingly that in which this plate gave rise to a single ventral division, which is designated here as interhyoideus, and to two dorsomedial divisions, the adductor arcus palatini and the adductor operculi. In actinopterygians a portion of the interhyoideus became differentiated into a separate muscle, the hyohyoideus, which then became divided into three separate, well-recognizable divisions in halecostomes, the hyohyoideus inferior, the hyohyoideus abductor and the hyohyoidei adductores. Other hyoid muscles may be found in osteichthyans, e.g., the branchiohyoideus of urodeles and the levator operculi of halecostomes.

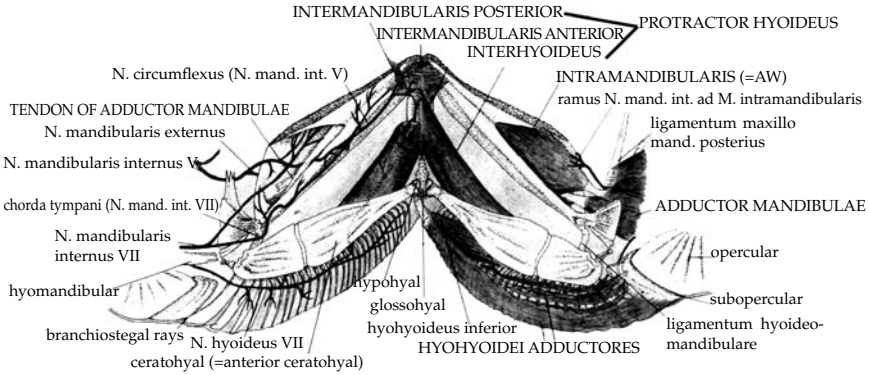

Fig. 4.26 *Elops saurus* (Teleostei, Elopiformes): dorsal view of the nerves and muscles of the lower jaw; on the left side the adductor mandibulae, intermandibularis and hyohyoidei have been removed and the posterior gular plate insertion of the intermandibularis posterior and anterior gular plate origin of the interhyoideus have been turned up (modified from Vrba 1968; the nomenclature of the structures illustrated follows that of this author).

Latimeria has a muscle 'levator operculi' that in certain aspects resembles, but is seemingly not homologous to, that of halecostomes. *Latimeria* also has an 'adductor hyomandibulae' that somewhat resembles, but is seemingly also not homologous to, the muscles 'adductor hyomandibulae' found in certain other osteichthyans such as actinopterygians. As explained above, there are many uncertainties concerning the homologies and evolution of the levator hyoideus/depressor mandibulae of dipnoans and tetrapods. According to the hypothesis proposed in the present work, both these muscles seem to have been found in at least some ontogenetic stages of the ancestors that later gave rise to dipnoans and tetrapods (see above). Interestingly, Köntges and Lumsden (1996) and others have shown that in tetrapods such as birds the posterior region of the mandible in which the depressor mandibulae attaches is constituted by neural crest derivatives of the hyoid arch, and not of the mandibular arch. This is, in fact, one of the various examples given by these authors to illustrate the highly constrained pattern of cranial skeletomuscular connectivity they found in these tetrapods, in which each rhombomeric neural crest population remains coherent throughout ontogeny, forming both the connective tissues of specific muscles and their respective attachment sites on to the neuro- and viscerocranium (see Chapter 11). It would thus be interesting to investigate whether the depressor mandibulae of dipnoans such as *Protopterus* and *Lepidosiren* also attaches in a region of the mandible constituted by neural crest derivatives of the hyoid arch. If that is the case, and if further investigation eventually support that the mandible of extant non-dipnoan bony fishes is exclusively formed by mandibular neural crest derivatives, this would indicate that the presence

of a depressor mandibulae in tetrapods and dipnoans might be related to an evolutionary change in which hyoid neural crest derivatives have become incorporated in the formation of the lower jaw.

Regarding the branchial muscles, these can be divided into three groups, i.e., the 'true' branchial muscles (comprising the branchial muscles *sensu stricto* and the protractor pectoralis and its derivatives), the pharyngeal muscles, which are only present as independent structures in extant mammals, and the laryngeal muscles. Most adult vertebrates retain various branchial muscles *sensu stricto*, but these muscles are not present as a group in extant amniotes. As explained above, some non-sarcopterygian vertebrates have a 'constrictor laryngis' and/or a 'dilatator laryngis', but it is not clear whether these muscles do actually correspond to the constrictor laryngis and dilatator laryngis of sarcopterygians and thus whether or not these latter muscles are plesiomorphically present in osteichthyans.

Concerning the hypobranchial muscles, the plesiomorphic condition for osteichthyans seemingly corresponds to that found in extant actinistians and dipnoans, in which there is a coracomandibularis and a sternohyoideus. Changes to this plesiomorphic condition occurred within osteichthyan evolution. For instance, in actinopterygians the coracomandibularis became modified into a peculiar branchiomandibularis, while in sarcopterygians such as tetrapods the hypobranchial muscle plate became differentiated into various muscles that are absent in other extant osteichthyans, such as the omohyoideus and the glossal muscles of the tongue. In mammals, the hypobranchial muscle plate has become divided into an even greater number of muscles; this is also the case of the mandibular and hyoid muscle plates, which in mammals usually give rise to more muscles than in other tetrapods (e.g., Edgeworth 1935; Brock 1938; Jarvik 1963, 1980; Gorniak, 1985; Pough et al. 1996; Kardong and Zalisko 1998; Kardong 2002; Kisia and Onyango 2005; see Chapters 5–7).

It should be emphasized that, as mentioned above, the discussions and the hypotheses advanced in this chapter are based on data compiled from evidence provided by developmental biology, comparative anatomy, functional morphology, paleontology, experimental embryology and molecular biology, innervation and phylogeny. In fact, as stressed by, e.g., Edgeworth (1935: 222), in order to provide a well-grounded analysis on the homologies and evolution of a certain muscle within different taxa it is imperative to take in consideration all the available lines of evidence, since "no one criterion is sufficient, not even two" (see Chapter 2). This is one of the reasons why we mentioned above that even if the development of the depressor mandibulae of dipnoans is not completely similar to the development of the anterior part of the depressor mandibulae of tetrapods such as salamanders, this does not necessarily mean that these structures are

not homologous. This is because, in this specific case, there are actually several different lines of evidence supporting their homology: (1) innervation (e.g., they are innervated by the VIIth nerve); (2) adult anatomy (e.g., they occupy a similar position and have similar relationships to other structures); (3) functional morphology (e.g., they have a similar function, being mainly related to the depression of the lower jaw); (4) ontogeny (even if their development is eventually not completely similar, as suggested by Edgeworth, most aspects concerning this development are actually similar, e.g., they originate from the dorso-medial portion of the hyoid muscle plate); and (5) phylogeny (e.g., the phylogenetic results of the present work support that dipnoans are effectively the closest living relatives of tetrapods).

The examples provided in this chapter thus illustrate the risks of discussing the homologies of structures such as muscles on the basis of a single line of evidence, even if it concerns innervation or development. But they also illustrate that when various lines of evidence are available (e.g., developmental biology, comparative anatomy, functional morphology, paleontology, experimental embryology, innervation and/or phylogeny) and when all these are taken into consideration, it is effectively possible to establish well-grounded hypotheses of homology. In other words, the hard work, in this case, does seem to be rewarding. In fact, one of the points that we want to stress in this book is precisely that a better understanding of the muscles of a certain taxon does allow a much more detailed, integrative analysis of the comparative anatomy, functional morphology, ecomorphology and evolution of that taxon.

Chapter 5

From Sarcopterygian Fish to Modern Humans—Head and Neck Muscles

Chapter 4 concentrated mainly on the results relevant to the actinopterygians (the group that includes extant cladistians, chondrosteans, ginglymods, halecomorphs and teleosts), but it also compared the head and neck muscles of those fish with the musculature of some sarcopterygians. Chapter 5 focuses mainly on sarcopterygians (the group that includes extant actinistians, dipnoans and tetrapods: see Fig. 5.1) and particularly on how the head and neck muscles evolved during the transitions from sarcopterygian fish and non-mammalian tetrapods to monotreme and therian mammals, including modern humans. Tables 5.1–5.8 summarize the best-supported hypotheses of homology for the head and neck muscles of the sarcopterygian taxa listed in those tables. Importantly, Tables 5.1, 5.3, 5.5 and 5.7 also include comments about the development and muscular variations/abnormalities of our own species, *Homo sapiens*, which are presented mainly, but not exclusively, in the right-hand columns of these tables.

Mandibular Muscles (Tables 5.1–5.2)

The plesiomorphic condition for sarcopterygians is that two ventral mandibular muscles, the intermandibularis anterior and intermandibularis posterior, connect the hemimandibles (Figs. 5.2, 5.3, 5.5). The mylohyoideus and digastricus anterior of mammals (Figs. 5.9, 5.16) correspond to the intermandibularis posterior of other sarcopterygians (e.g., Bryant 1945; Jarvik 1963, 1980; Saban 1971; this work). Contrary to the condition in monotremes (Fig. 5.9), in most marsupials and placentals, including

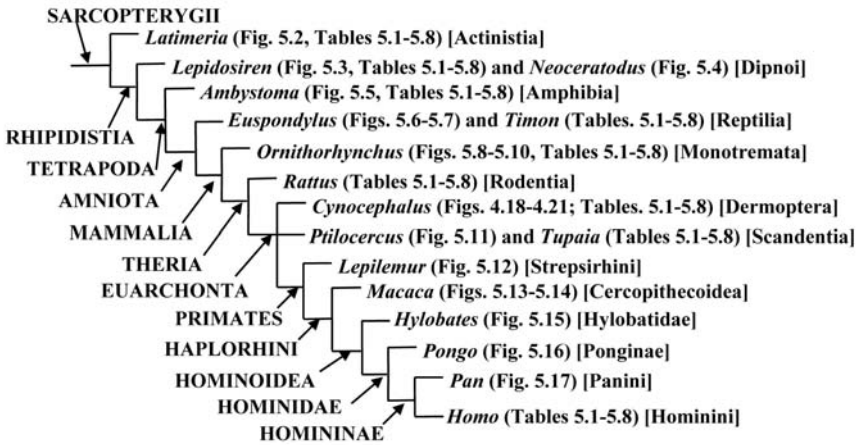

Fig. 5.1 Phylogenetic framework for the discussion provided in the present paper and the comparison between the head and neck muscles of the genera listed in Tables 5.1–5.8 and shown in Figs. 5.2–5.21, based on Shoshani et al. (1996), Kardong (2002), Sargis (2002ab, 2004), Dawkins (2004), Kemp (2005), Marivaux et al. (2006), Diogo (2007), Janecka et al. (2007), and Silcox et al. (2007) (see Chapters 1 and 2).

modern humans, the digastricus anterior and the digastricus posterior (a dorso-medial hyoid muscle: see below) form a compound structure (the 'digastricus') that is often related to the depression of the mandible. Interestingly, in teleostean fish (which are actinopterygians, not sarcopterygians), the intermandibularis posterior and a ventral hyoid muscle (the interhyoideus) combine to form the protractor hyoideus, which is also often related to the opening of the mouth (see Chapter 4). According to Edgeworth (1935) various tetrapod groups have independently acquired different mechanisms for depressing the mandible (i.e., to open the mouth) that use muscles other than the hypobranchial ones: amphibians and reptiles usually have a depressor mandibulae (which is a modified dorso-medial hyoid muscle: Tables 5.3, 5.4 and Figs. 5.3, 5.5, 5.6; see below), monotremes have a detrahens mandibulae (which is a new division of the adductor mandibulae: Tables 5.1, 5.2, and Fig. 5.9; see below), and marsupial and placental mammals usually have the 'digastricus', i.e., the compound structure formed from the digastricus anterior and digastricus posterior.

The plesiomorphic condition for the sarcopterygian adductor mandibular muscles is seemingly that in which there is an adductor mandibulae A2, an adductor mandibulae Aω, an adductor mandibulae A3′, and possibly an adductor mandibulae A3″. The adductor mandibulae Aω was not present as an independent muscle in any of the mammals we dissected, and to our knowledge it has also not been found in any extant

Table 5.1 Mandibular muscles of adults of representative sarcopterygian taxa. The nomenclature of the muscles shown in bold follows that of text; in order to facilitate comparisons, in some cases names often used by other authors to designate a certain muscle/bundle are given in parentheses; additional comments are given in square brackets. Data from evidence provided by our own dissections and comparisons and by a review of the literature (see text and also Table 5.2 and Figs. 5.1–5.27).

Actinistia: *Latimeria chalumnae* (Coelacanth)	Dipnoi: *Lepidosiren paradoxa* (South American lungfish)	Amphibia: *Ambystoma ordinarium* (Michoacan stream salamander)	Reptilia: *Timon lepidus* (Ocellated 'lizard')	Mammalia (Monotremata): *Ornithorhynchus anatinus* (Platypus)	Mammalia (Rodentia): *Rattus norvegicus* (Norwegian rat)	Mammalia (Dermoptera): *Cynocephalus volans* (Philippine colugo)	Mammalia (Scandentia): *Tupaia* sp. (Tree-shrew)	Mammalia (Primates): *Homo sapiens* (Modern human)
Inter-mandibularis posterior	**Inter-mandibularis**	**Inter-mandibularis posterior**	**Inter-mandibularis posterior**	**Mylohyoideus** [as described by, e.g., Lightoller 1942, there is a mylohyoideus profundus, a mylo-hyoideus superficialis and, superficially to the latter, a digastricus anterior; Saban 1971 states that these three structures come from the same embryological structure, i.e., that they seem to correspond to the intermandibularis posterior of other vertebrates: this is also supported by, e.g., Jarvik 1963, 1980]	**Mylohyoideus** [the mylohyoideus and digastricus anterior of rats clearly seem to correspond to the posterior, not the anterior, intermandibularis of other sarcopterygians, because the transversus mandibularis of rats corresponds to the intermandibularis anterior of other sarcopterygians; this is also supported by, e.g., Bryant 1945]	**Mylohyoideus**	**Mylohyoideus** (posterior part of mylohyoid sensu Le Gros Clark 1924)	**Mylohyoideus**
—	—	—	—	**Digastricus anterior** [the correspondence between the mammalian digastricus anterior and part of the intermandibularis of other sarcopterygians is	**Digastricus anterior** (anterior belly of digastricus sensu Greene 1935)	**Digastricus anterior** (part of biventer sensu Leche 1886)	**Digastricus anterior**	**Digastricus anterior** (anterior belly of biventer mandibulae sensu Huber 1930a)

				strongly supported by, e.g., innervation (the intermandibularis and digastricus anterior are usually innervated by the ramus ventralis of CN5), ontogeny (e.g., the development of the marsupial *Dasyrurus*), and comparative anatomy of adults: see, e.g., Edgeworth 1935]				
Inter-mandibularis anterior	—	**Inter-mandibularis anterior** (submentalis sensu Iordansky 1992)	**Inter-mandibularis anterior**	—	**Inter-mandibularis anterior** (transversus mandibularis sensu Greene 1935)	—	**Inter-mandibularis anterior** (anterior part of mylohyoid sensu Le Gros Clark 1924 and Sprague 1944a)	—
Adductor mandibulae A2 (adductor mandidulae "superficiel" sensu Millot and Anthony 1958)	**Adductor mandibulae A2** (part of adductor mandidulae posterior sensu Bemis and Lauder 1986)	**Adductor mandibulae A2** (adductor mandibulae externus sensu Iordansky 1992)	**Adductor mandibulae A2** (adductor mandibulae externus sensu Abdala and Moro 2003)	**Masseter** (corresponds to the masseter + zygomatico-mandibularis, and possibly to the maxillo-mandibularis, sensu Saban 1971) [as shown in, e.g., Saban's 1971 fig. 569, in the platypus specimens dissected by us the masseter is mainly divided into a deep part with anterior and posterior bundles and a superficial part with anterior and posterior bundles]	**Masseter** [as described by Greene 1935, in the Norwegian rats dissected by us the masseter is mainly divided into a deep part with anterior and posterior bundles and a superficial part with anterior and posterior bundles]	**Masseter** (masseter + zygomatico-mandibularis sensu Stafford and Szalay 2000) [in the colugo specimens dissected by us the masseter is subdivided into a superficial bundle, a deep bundle, and a zygomatico-mandibular bundle; the latter	**Masseter** [as described by, e.g., Le Gros Clark, 1924, in the *Tupaia* specimens dissected by us the masseter is mainly divided into deep, intermediate and superficial bundles]	**Masseter** [in modern humans the masseter is usually mainly divided into deep and superficial bundles]

Table 5.1 contd...

Table 5.1 contd...

Actinistia: *Latimeria chalumnae* (Coelacanth)	Dipnoi: *Lepidosiren paradoxa* (South American lungfish)	Amphibia: *Ambystoma ordinarium* (Michoacan stream salamander)	Reptilia: *Timon lepidus* (Ocellated 'lizard')	Mammalia (Monotremata): *Ornithorhynchus anatinus* (Platypus)	Mammalia (Rodentia): *Rattus norvegicus* (Norwegian rat)	Mammalia (Dermoptera): *Cynocephalus volans* (Philippine colugo)	Mammalia (Scandentia): *Tupaia* sp. (Tree-shrew)	Mammalia (Primates): *Homo sapiens* (Modern human)
				is sometimes considered as an independent muscle, but at least in the case of *Cynocephalus*, it is closely blended with the other masseter bundles]				
—	—	—	—	**Detrahens mandibulae** [some authors consider that the detrahens mandibulae is homologous to the digastricus anterior of other mammals, but this does not seem to be the case: see Saban 1968, p. 264; as stressed by, e.g., Saban 1971, the detrahens mandibulae clearly seems to correspond to part of the adductor mandibulae A2 of non-mammalian tetrapods]	—	—	—	—
—	—	—	—	**Temporalis** [corresponds to part of the A2 of non-mammalian tetrapods but may possibly also include part of other adductor mandibulae structures such as the pseudotemporalis: see Barghusen 1968]	**Temporalis** [Greene 1935, describes the temporalis of rats as an undivided muscle, but as stated by Walker and Homberger 1997, in the specimens	**Temporalis** [in the *Cynocephalus* specimens dissected by us the temporalis is not clearly divided into superficial and	**Temporalis** [in the *Tupaia* specimens dissected by us the temporalis is mainly divided into a superficial bundle, a deep	**Temporalis** [the temporalis of modern humans is usually described as an undivided

					dissected by us this muscle is divided into two bundles, one more superficial and anterior and the other more deep and posterior]	deep bundles, and there is no distinct pars supra-zygomatica such as that found in *Tupaia*]	bundle, and a pars supra-zygomatica sensu Saban 1971]	muscle, but various authors, e.g., Gorniak 1985, consider that it is in fact often divided into superficial and deep bundles]
—	—	—	—	**Pterygoideus lateralis** [in some parts of Edgeworth' 1935 work he seems to suggest that the pterygoideus lateralis and medialis are both included in the 'pterygoideus medialis' of monotremes and that the pterygoideus lateralis only becomes separated in other extant mammals; however, in other parts of Edgeworth's 1935 work he clearly states that the pterygoideus lateralis corresponds to part of the adductor mandibulae externus (= A2) of reptiles; more recent works, e.g., Barghusen 1968 and Jouffroy 1971, support this latter hypothesis; developmental data also indicate that the pterygoideus lateralis and pterygoideus	**Pterygoideus lateralis** (pterygoideus externus sensu Greene 1935) [in the Norwegian rats dissected by us the pterygoideus lateralis is constituted by a single bundle]	**Pterygoideus lateralis** [in the *Cynocephalus* specimens dissected by us the pterygoideus lateralis is constituted by a single bundle]	**Pterygoideus lateralis** (pterygoideus externus sensu Le Gros Clark 1924, 1926) [as described by, e.g., Le Gros Clark 1924, in the *Tupaia* specimens dissected by us the pterygoideus lateralis is constituted by a single bundle]	**Pterygoideus lateralis** [in modern humans the pterygoideus lateralis is usually divided into superior and inferior heads: see, e.g., Birou et al 1991; Aziz et al. 1998; El Haddioui et al. 2005]

Table 5.1 contd...

Table 5.1 contd...

Actinistia: *Latimeria chalumnae* (Coelacanth)	Dipnoi: *Lepidosiren paradoxa* (South American lungfish)	Amphibia: *Ambystoma ordinarium* (Michoacan stream salamander)	Reptilia: *Timon lepidus* (Ocellated 'lizard')	Mammalia (Monotremata): *Ornithorhynchus anatinus* (Platypus)	Mammalia (Rodentia): *Rattus norvegicus* (Norwegian rat)	Mammalia (Dermoptera): *Cynocephalus volans* (Philippine colugo)	Mammalia (Scandentia): *Tupaia* sp. (Tree-shrew)	Mammalia (Primates): *Homo sapiens* (Modern human)
				medialis do not develop from the same anlage (e.g., Smith 1994); the platypus specimens dissected by us have both a pterygoideus lateralis and a pterygoideus medialis]				
—	**Adductor mandibulae A2-PVM** (part of adductor mandidulae posterior sensu Bemis and Lauder 1986)	**Adductor mandibulae A2-PVM** (adductor mandibulae posterior sensu Iordansky 1992; levator mandibulae posterior sensu Edgeworth 1935 and Piatt 1938) [Piatt 1938 and other authors suggest that the A2-PVM of tetrapods such as urodeles derives ontogenetically from the A3′ and/or A3″, but the developmental	**Adductor mandibulae A2-PVM** (adductor mandibulae posterior sensu Abdala and Moro 2003 and Holliday and Witmer 2007)	— [the A2-PVM is probably absent as a separated, independent structure in mammals, although it cannot be completely discarded that it was this muscle that actually gave rise to the mammalian tensor tympani and/or tensor veli palatini: see text and Table 5.2]	—	—	—	—

		work of Ericsson and Olsson 2004 strongly supports that it derives instead from the A2: see Chapters 6 and 7 for more details on the homologies of the A2-PVM within non-mammalian tetrapods]						
—	**Retractor anguli oris** [seemingly derived from lateral portion of adductor mandibulae]	—	— [but see levator anguli oris mandibularis below]	—	—	—	—	—
—	—	—	**Levator anguli oris mandibularis** (levator anguli oris sensu Diogo 2007, 2008) [present, somewhat blended with A2; we use the name "mandibularis" to distinguish this muscle from the levator anguli oris facialis of certain mammals,	—	—	—	—	—

Table 5.1 contd...

Table 5.1 contd...

Actinistia: *Latimeria chalumnae* (Coelacanth)	Dipnoi: *Lepidosiren paradoxa* (South American lungfish)	Amphibia: *Ambystoma ordinarium* (Michoacan stream salamander)	Reptilia: *Timon lepidus* (Ocellated 'lizard')	Mammalia (Monotremata): *Ornithorhynchus anatinus* (Platypus)	Mammalia (Rodentia): *Rattus norvegicus* (Norwegian rat)	Mammalia (Dermoptera): *Cynocephalus volans* (Philippine colugo)	Mammalia (Scandentia): *Tupaia* sp. (Tree-shrew)	Mammalia (Primates): *Homo sapiens* (Modern human)
			which is a facial (hyoid), and not a mandibular, muscle; as explained by, e.g., Abdala and Moro 2003 and Wu 2003, some 'lizards' such as *Lanthanotus*, as well as some other lepidosaurs such as *Sphenodon*, have a levator anguli oris mandibularis but also a 'retractor anguli oris' that occupies the postero-ventro-lateral region of the 'adductor mandibulae complex' and that is, thus, similar (although it is probably not homologous) to the retractor anguli oris of dipnoans: see Chapter 7]					

Adductor mandibulae A3′ (adductor mandidulae "moyen" sensu Millot and Anthony 1958)	**Adductor mandibulae A3′** (adductor mandidulae anterior sensu Bemis and Lauder 1986)	**Pseudo-temporalis** (pseudo-temporalis posterior and anterior sensu Iordansky 1992; superficial and deep levator mandibulae anterior sensu Edgeworth 1935 and Piatt 1938; adductor mandibulae A3′ and A3″ sensu Diogo 2007, 2008)	**Pseudo-temporalis** (pseudo-temporalis superficialis and profundus sensu Abdala and Moro, 2003 and Holliday and Witmer, 2007; adductor mandibulae A3′ and A3″ sensu Diogo, 2007, 2008)	— [the pseudotemporalis of non-mammalian tetrapods seems to correspond to part of the pterygoideus medialis, and possibly also to part of the masseter, of extant mammals: see above]	—	—	—	—
Adductor mandibulae A3″ (adductor mandidulae "profond" sensu Millot and Anthony 1958)	—	— [both the adductor A3′ and A3″ seem to be included in the pseudo-temporalis of extant amphibians and reptiles: see text]	—[see on the left]	—	—	—	—	—
—	—	—	—	**Pterygoideus medialis** [the pterygoideus medialis seems to correspond to/ derive from the pseudotemporalis of amphibians such as *Ambystoma*, and, thus, both the pseudotemporalis and	**Pterygoideus medialis** (pterygoideus internus sensu Greene 1935)	**Pterygoideus medialis**	**Pterygoideus medialis** (pterygoideus internus sensu Le Gros Clark 1924, 1926)	**Pterygoideus medialis**

Table 5.1 contd...

Table 5.1 contd...

Actinistia: *Latimeria chalumnae* (Coelacanth)	Dipnoi: *Lepidosiren paradoxa* (South American lungfish)	Amphibia: *Ambystoma ordinarium* (Michoacan stream salamander)	Reptilia: *Timon lepidus* (Ocellated 'lizard')	Mammalia (Monotremata): *Ornithorhynchus anatinus* (Platypus)	Mammalia (Rodentia): *Rattus norvegicus* (Norwegian rat)	Mammalia (Dermoptera): *Cynocephalus volans* (Philippine colugo)	Mammalia (Scandentia): *Tupaia* sp. (Tree-shrew)	Mammalia (Primates): *Homo sapiens* (Modern human)
				pterygomandibularis of reptiles such as *Timon*: see Table 5.2, cells above and cell below; Adams 1919 stated that monotremes do not have a pterygoideus medialis, and according to Saban 1968 this muscle appears in early embryos of monotremes but then disappears during ontogeny; however, our dissections indicate that, although somewhat mixed, both the pterygoideus lateralis and the pterygoideus medialis are present in *Ornothorhynchus*; Murray 1981 also described a pterygoideus lateralis and a pterygoideus medialis in the Echidna)				

—	—	**Pterygo-mandibularis** [at least some caecilian amphibians have a 'pterygoideus', which seems to correspond to the ptery-gomandibularis of reptiles: see Chapter 6]	**Pterygo-mandibularis** (pterygoideus sensu Holliday and Witmer 2007) [seemingly derived from mesial portion of adductor mandibulae; the ptery-gomandibularis of reptiles such as *Timon* seems to correspond to part of the pterygoideus medialis, and probably also to part or all of the tensor tympani and/or tensor veli palatini, of extant mammals: see text]	**Tensor tympani** [Maier 2008 confirms that the tensor tympani is present in *Ornithorynchus*: the chorda tympani passes below the insertion of the muscle (hypotensoric configuration, which, according to this author, probably represents the plesiomorphic configuration for mammals)]	**Tensor tympani** [Maier 2008 confirms that the tensor tympani is present in *Rattus norvegicus*: the chorda tympani passes below the insertion of the muscle (hypotensoric) but in some other rodents it passes above the muscle (epitensoric): see on the left]	**Tensor tympani** [Maier 2008 confirms that the tensor tympani is present in *Cynocephalus volans*: the chorda tympani passes below the insertion of the muscle (hypotensoric): see on the left]	**Tensor tympani** [really present in *Tupaia*? Maier 2008 states that the tensor tympani is not present in *Tupaia* nor in *Ptilocercus*; he examined numerous *Tupaia* specimens and did not find the muscle, and he cites some other authors who also did not find it in this taxon; but he recognizes that the muscle was described in *Tupaia* by some authors, and particularly in the detailed works of Saban (see, e.g., Saban 1968), although he considers that Saban and other authors were mistaken and that the tensor tympani is autapo-morphically absent in the Scadentia; as	**Tensor tympani**

Table 5.1 contd...

Table 5.1 contd...

Actinistia: *Latimeria chalumnae* (Coelacanth)	Dipnoi: *Lepidosiren paradoxa* (South American lungfish)	Amphibia: *Ambystoma ordinarium* (Michoacan stream salamander)	Reptilia: *Timon lepidus* (Ocellated 'lizard')	Mammalia (Monotremata): *Ornithorhynchus anatinus* (Platypus)	Mammalia (Rodentia): *Rattus norvegicus* (Norwegian rat)	Mammalia (Dermoptera): *Cynocephalus volans* (Philippine colugo)	Mammalia (Scandentia): *Tupaia* sp. (Tree-shrew)	Mammalia (Primates): *Homo sapiens* (Modern human)
							stressed by Wible 2009, detailed studies on the ear region of tree-shrews are thus needed to clarify whether or not this muscle is present in these mammals]	
—	—	—	—	**Tensor veli palatini** [as described by, e.g., Saban 1971, in the platypus specimens dissected by us the tensor veli palatini is present as an independent muscle: see text]	**Tensor veli palatini**	**Tensor veli palatini**	**Tensor veli palatini**	**Tensor veli palatini**
Adductor mandibulae Aω (intra-mandibular adductor sensu Lauder 1980b)	—	—	**Adductor mandibulae Aω** [in *Timon* and other reptiles the adductor mandibulae has a large and distinct anteroventral division that is lodged in the "adductor	—	—	—	—	—

			fossa" of Lauder 1980b, and that is very similar to the Aω of other osteichthyans: see Chapter 7]					
Levator arcus palatini [Edgeworth 1935 suggested that the dorsal mandibular musculature was probably acquired independently within gnathostomes, but the presence of this musculature is very likely plesiomorphic for this group, and perhaps for vertebrates as a whole: see Chapters 3 and 4]	—	— [the only dorsal mandibular muscle present in urodeles such as *Ambystoma* is the levator bulbi; amphibians such as caecilians have a 'levator quadrati': see, e.g., Kleinteich and Haas 2007; according to Edgeworth 1935 and others, this latter muscle is derived from the adductor mandibulae, but Brocks 1938 and others argue that it is a dorsal mandibular muscle; see Chapter 6]	**Levator pterygoidei** [it is derived from the constrictor dorsalis, so it probably corresponds to part of the levator arcus palatini of *Latimeria*: e.g., Brocks 1938; Holliday and Witmer 2007; this study]	—	—	—	—	—

Table 5.1 contd...

Table 5.1 contd...

Actinistia: *Latimeria chalumnae* (Coelacanth)	Dipnoi: *Lepidosiren paradoxa* (South American lungfish)	Amphibia: *Ambystoma ordinarium* (Michoacan stream salamander)	Reptilia: *Timon lepidus* (Ocellated 'lizard')	Mammalia (Monotremata): *Ornithorhynchus anatinus* (Platypus)	Mammalia (Rodentia): *Rattus norvegicus* (Norwegian rat)	Mammalia (Dermoptera): *Cynocephalus volans* (Philippine colugo)	Mammalia (Scandentia): *Tupaia* sp. (Tree-shrew)	Mammalia (Primates): *Homo sapiens* (Modern human)
—	—	—	**Protractor pterygoidei** [it is derived from the constrictor dorsalis, so it probably corresponds to part of the levator arcus palatini or of, e.g., *Latimeria*: Brocks 1938; Holliday and Witmer 2007; this study]	—	—	—	—	—
—	—	**Levator bulbi** [according to, e.g., Edgeworth 1935 this muscle is derived from the adductor mandibulae; however, our dissections and comparisons support Brocks' 1938 hypothesis, i.e., that the levator bulbi, as well as the 'levator	**Levator bulbi** (the levator bulbi sensu Frazzeta 1962, Haas 1997, and Schumacher 1973 seemingly corresponds to the tensor periorbitae sensu Holliday and Witmer 2007; see Chapter 7)	—	—	—	—	—

		quadrati' of caecilians, are the remains of the constrictor dorsalis group in amphibians; according to Brocks 1938 the constrictor dorsalis group is conserved in many reptiles because of their kinetic skull: see Chapters 6 and 7]						

Table 5.2 Scheme illustrating the authors' hypotheses regarding the homologies of the mandibular muscles of adults of representative sarcopterygian taxa. The nomenclature of the muscles follows that used in the text. Data from evidence provided by our own dissections and comparisons and by a review of the literature. The black arrows indicate the hypotheses that are most strongly supported by the evidence available; the grey arrows indicate alternative hypotheses that are supported by some of the data, but overall they are not as strongly supported by the evidence available as are the hypotheses indicated by black arrows (e.g., the overall analysis of the data available indicates that the urodele levator bulbi is a dorsal mandibular muscle, but the possibility that it derives from the adductor mandibulae cannot be completely ruled out: see text, Table 5.1, and Figs. 5.1–5.27). VENTRAL, DORSAL = Ventral musculature and dorsal constrictor musculature sensu Edgeworth, 1935; ad. = adductor; interm. = intermandibularis; le. = levator; man. = mandibulae.

	Latimeria (7 muscles)	*Lepidosiren* (5 muscles)	*Ambystoma* (6 muscles)	*Timon* (11 muscles)	*Ornithorhynchus* (9 muscles)	*Rattus* (9 muscles)	*Cynocephalus* (8 muscles)	*Tupaia* (9 muscles)	*Homo* (8 muscles)
VENTRAL	Interm. posterior	Interm.	Interm. posterior	Interm. posterior	Mylohyoideus	Mylohyoideus	Mylohyoideus	Mylohyoideus	Mylohyoideus
	---	---	---	---	Digastricus anterior	Digastricus anterior	Digastricus anterior	Digastricus anterior	Digastricus anterior
	Interm. anterior	---	Interm. anterior	Interm. anterior	---	Interm. anterior	---	Interm. anterior	---
ADDUCTOR MANDIBULAE	Ad. man. A2	Ad. man. A2	Ad. man. A2	Ad. man. A2	Masseter	Masseter	Masseter	Masseter	Masseter
	---	---	---	---	Detrahens man.	---	---	---	---
	---	---	---	---	Temporalis	Temporalis	Temporalis	Temporalis	Temporalis
	---	---	---	---	Pterygoideus lateralis	Pterygoideus lateralis	Pterygoideus lateralis	Pterygoideus lateralis	Pterygoideus lateralis
	---	Ad. man. A2-PVM	Ad. man. A2-PVM	Ad. man. A2-PVM	---	---	---	---	---
	---	Retractor ang. oris	---	---	---	---	---	---	---
	---	---	---	Le. anguli oris mandibularis	---	---	---	---	---
	Ad. mand. A3'	Ad. man. A3'	Pseudotemporalis	Pseudotemporalis	---	---	---	---	---
	---	---	---	---	Pterygoideus medialis	Pterygoideus medialis	Pterygoideus medialis	Pterygoideus medialis	Pterygoideus medialis
	Ad. mand. A3"	---	Pterygomandibularis	Pterygomandibularis	Tensor tympani	Tensor tympani	Tensor tympani	Tensor tympani	Tensor tympani
					Tensor veli palatini	Tensor veli palatini	Tensor veli palatini	Tensor veli palatini	Tensor veli palatini
	Ad. mand. Aω	---	---	Ad. man. Aω	---	---	---	---	---
DORSAL	Le. arcus palatini			Le. pterygoidei	---	---	---	---	---
	---		---	Protractor pterygoidei	---	---	---	---	---
	---	---	Le. bulbi	Le. bulbi	---	---	---	---	---

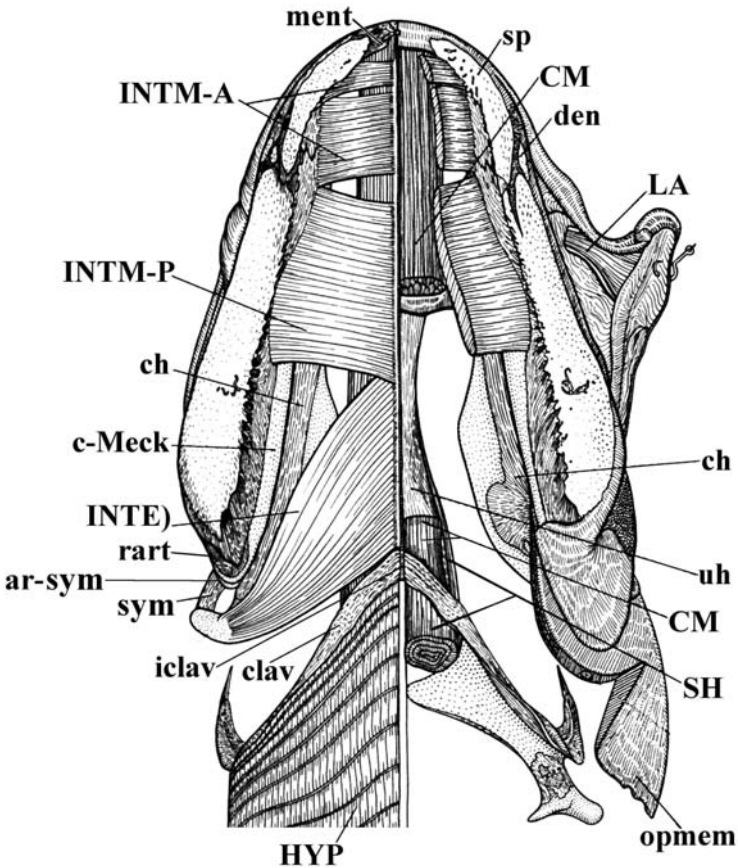

Fig. 5.2 *Latimeria chalumnae* (Cladistia): ventral view of the cephalic musculature; on the left side are shown the most superficial cephalic muscles, after removal of the gular plate; on the right side are shown these most muscles were removed or cut in order to shown muscles that are situated more dorsally (modified from Millot and Anthony 1958; the nomenclature of the structures illustrated follows that used in the present work). ar-sym, articulatory facet for symplectic; c-Meck, Meckelian cartilage; ch, ceratohyal; clav, clavicle; CM, coracomandibularis; dent, dentary bone; HYP, hypoaxialis; iclav, interclavicle; INTE, interhyoideus; INTM-A, INTM-P, intermandibularis anterior and posterior; LA, labialis; ment, mentomeckelian bone; opmem, opercular membrane; rart, retroarticular; SH, sternohyoideus; sp, splenial bone; sym, symplectic, uh, urohyal.

mammals described in the literature. The adductor mandibulae A2-PVM, retractor anguli oris and levator anguli oris mandibularis of extant dipnoans and non-mammalian tetrapods correspond to part of the A2 of bony fishes such as *Latimeria* (see Chapter 4 and Figs. 5.3, 5.4, 5.6; but see comments on the homology of the A2-PVM in non-mammalian tetrapods, in Chapters 6 and 7). The masseter, temporalis, pterygoideus lateralis and

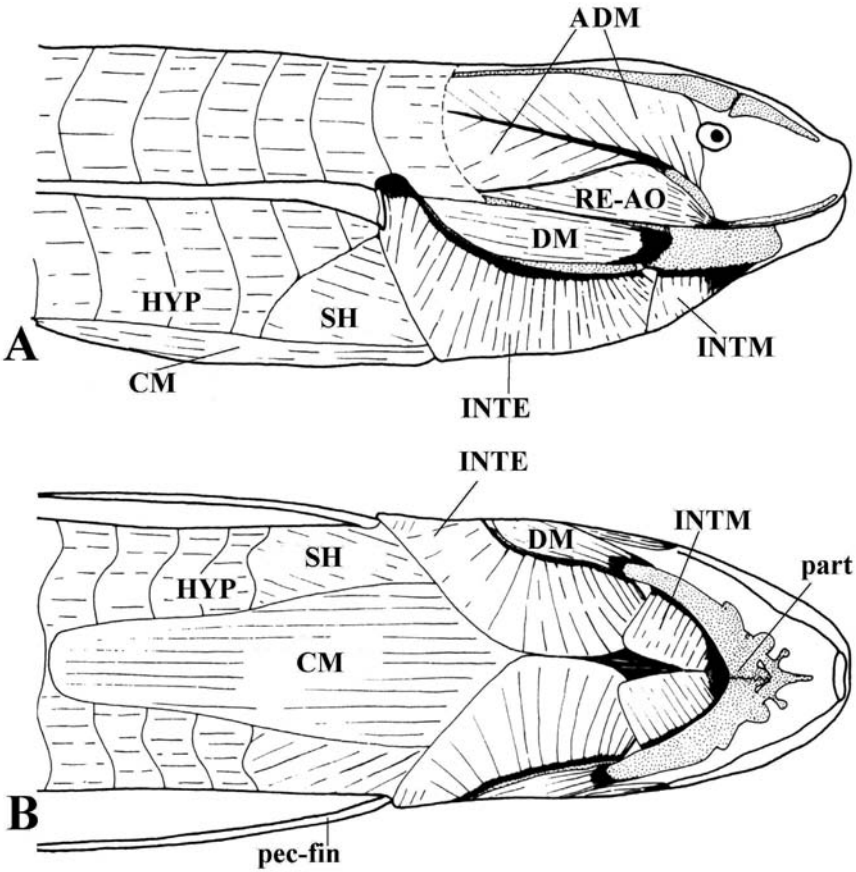

Fig. 5.3 *Lepidosiren paradoxa* (Dipnoi): **(A)** lateral view of the cephalic musculature; **(B)** ventral view of the cephalic musculature [modified from Bemis and Lauder 1986 and Diogo 2008; the nomenclature of the structures illustrated follows that used in the present work; anterior is to the right]. ADM, 'adductor mandibulae complex'; CM, coracomandibularis; DM, depressor mandibulae; HYP, hypaxialis; INTE, interhyoideus; INTM, intermandibularis; part, prearticular; RE-AO, retractor anguli oris; SH, sternohyoideus.

detrahens mandibulae of monotremes and the masseter, temporalis and pterygoideus lateralis of other extant mammals apparently correspond to the A2 of reptiles such as *Timon* (Figs. 5.4, 5.6, 5.9, 5.13, 5.16). However, it should be noted that although the mammalian temporalis seemingly corresponds to part of the A2 of other tetrapods, it may also include part of other adductor mandibulae structures such as the pseudotemporalis (see, e.g., Barghusen 1968). In two previous papers (Diogo et al. 2008ab) we stated that the tensor tympani and tensor veli palatini of mammals were probably derived from the adductor mandibulae A2-PVM, as proposed by

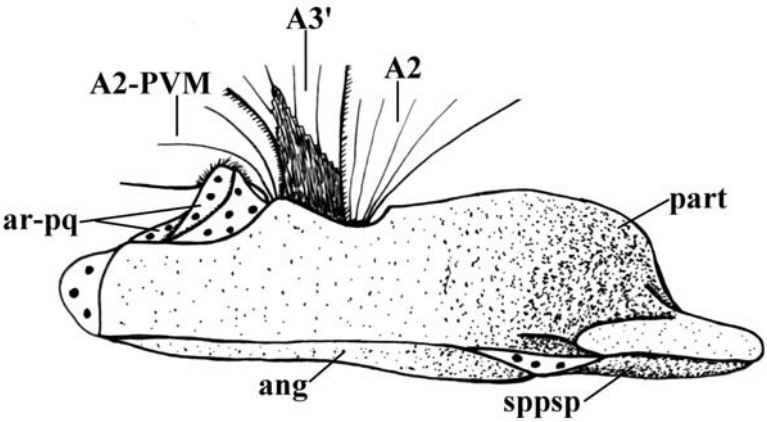

Fig. 5.4 *Neoceratodus forsteri* (Dipnoi): mesial view of adductor mandibulae and mandible; the mandibular tooth-plates are not illustrated [anterior is to the right, dorsal is to the top]. A2, A2-PVM, A3′, adductor mandibulae A2, A2-PVM and A3′; ang, angular; ar-pq, articulatory facet for palatoquadrate; part, prearticular; sppsp, splenio-postsplenial bone.

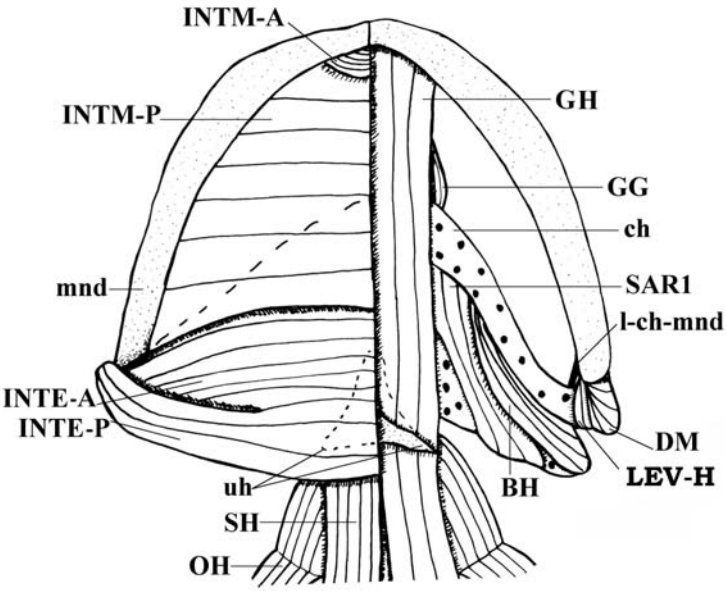

Fig. 5.5 *Ambystoma ordinarium* (Amphibia, Caudata): ventral view of the cephalic musculature; on the right side the most ventral muscles were removed (anterior is to the top). BH, branchiohyoideus; ch, ceratohyal; DM, depressor mandibulae; GG, genioglossus; GH, geniohyoideus; INTE-A, INTE-P, anterior and posterior bundles of interhyoideus; INTM-A, INTM-P, intermandibularis anterior and posterior; l-ch-mand, ligament between ceratohyal and mandible; LEV-H, levator hyoideus; mnd, mandible; OH, omohyoideus; SAR1, subarcualis rectus 1; SH, sternohyoideus; uh, urohyal.

Edgeworth (1935), Saban (1971) and others, but that they could also have been derived from the pterygomandibularis instead (see, e.g., table 1 of Diogo et al. 2008b). However, the dissections, comparisons and review of the literature available on this subject that we carried out after writing those papers had indicated that the most likely hypothesis is actually that the tensor tympani and tensor veli palatini correspond to part of or are derived from the pterygomandibularis, as is in fact accepted by most anatomists (e.g., Adams 1919; Brocks 1938; Goodrich 1958; Barghusen 1986; Smith 1992; Witmer 1995b), although the idea that these two muscles derive instead from the A2-PVM cannot be completely discarded (Table 5.2). The main arguments supporting the differentiation of the tensor tympani and tensor veli palatini from the pterygomandibularis have been clearly summarized in works by Barghusen (1986), among others. As recently stressed by a colleague (Peter Johnson, pers. comm.), apart from the arguments summarized in such works, there is also new developmental data supporting this hypothesis. For instance, in Smith's (1994) detailed work on the development of the craniofacial musculature of marsupials, she found that the pterygoideus medialis, the tensor tympani and the tensor veli palatini of these mammals develop ontogenetically from the same medial anlage, which seems to correspond to the anlage that forms the pterygomandibularis + pseudotemporalis in reptiles. Interestingly, in fig. 3B of Smith's paper, there appears to be a thin, small muscle connecting the malleus and the incus, which could possibly be a 'remnant of the PVM' according to Peter Johnson (pers. comm.), but this latter hypothesis clearly needs to be investigated in much more detail, obviously. Actually, one of the main arguments that Saban (1961) and other authors provided in favor of a derivation of the mammalian tensor veli palatini and tensor tympani from the A2-PVM was that Edgeworth (1935) stated that his development work has clearly shown that the two former muscles were derived ontogenetically from the 'levator mandibulae posterior', which is the name that is often used in the literature to designate the A2-PVM sensu the present work (see Table 5.1 and Chapters 4, 6 and 7). However, as explained in Chapters 6 and 7, there is actually much confusion in the literature about the identity and homologies of the components of the 'adductor mandibulae complex' of tetrapods, and particularly of the structures that are often named 'adductor mandibulae posterior' in different non-mammalian tetrapod clades. It is thus possible that in this specific case Edgeworth (1935) used the name 'levator mandibulae posterior' to designate the pterygomandibularis (and not the A2-PVM) sensu the present work, as suggested by Goodrich (1958) and other authors. Goodrich (1958) stated that a correct interpretation of Edgeworth's data actually supports the idea that the tensor tympani and tensor veli palatini are derived from the pterygomandibularis because the that data shows that the mammalian tensor tympani, tensor veli palatini and pterygoideus medialis derive from the same anlage, as was

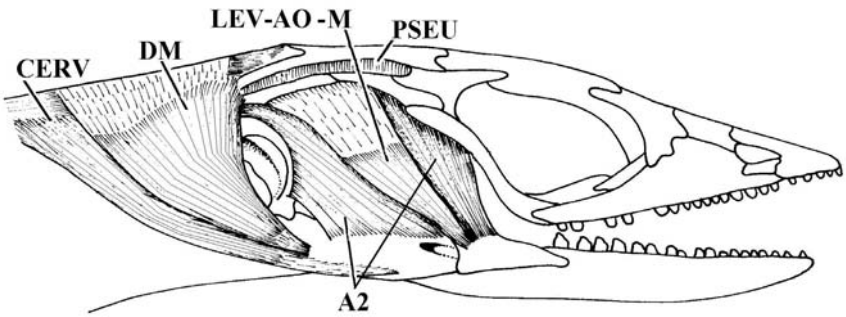

Fig. 5.6 *Euspondylus acutirostris* (Reptilia, Lepidosauria): lateral view of the cephalic musculature; the adductor mandibulae A2-PVM is not shown (modified from Montero et al. 2002 and Diogo 2008; the nomenclature of the structures illustrated follows that used in the present work; anterior is to the right). A2, adductor mandibulae A2; CERV, cervicomandibularis; DM, depressor mandibulae; LEV-AO-M, levator anguli oris mandibularis; PSEU, pseudotemporalis.

precisely found in more recent works such as Smith (1994) (see above; see also Tables 5.1–5.2).

Regarding the mammalian pterygoideus medialis, this seems to derive from the pseudotemporalis, and possibly also from part of the pterygomandibularis, of non-mammalian tetrapods (Figs. 5.6, 5.7, 5.16; see also, e.g., Edgeworth 1935; Saban 1986, 1971). Unusually among vertebrates, extant mammals lack any dorsal mandibular muscles sensu Edgeworth (1935) (e.g., Saban 1968, 1971; Kardong 2002; this work). Interestingly, engrailed immunoreactivity has been detected in tetrapod mandibular muscles that are derived from the 'adductor mandibulae' plate sensu Edgeworth, such as the masseter, temporalis, pterygoideus medialis and pterygoideus lateralis of mice (Knight et al. 2008). As explained in Chapters 3 and 4, within teleost fish such as the zebrafish, engrailed immunoreactivity has only been detected in dorsal mandibular muscles sensu Edgeworth, i.e., in the levator arcus palatini and dilatator operculi. This means that the muscles that arise from cells expressing the same gene in two different vertebrate taxa are not necessarily homologous among those taxa, thus supporting the idea that no single criterion (including the expression of genes such as engrailed) is enough to establish myological homologies (for more details on this subject, see Chapters 2, 3 and 4).

Hyoid Muscles (Tables 5.3–5.4)

Edgeworth (1935) and Huber (1930ab, 1931) divided the hyoid muscles into two main groups: dorso-medial and ventral (Table 5.4). The plesiomorphic configuration for sarcopterygians is a single ventral hyoid muscle, the

Table 5.3 Hyoid muscles of adults of representative sarcopterygian taxa (see caption of Table 5.1, text and also Table 5.4 and Figs. 5.1–5.27).

Actinistia: *Latimeria chalumnae* (Coelacanth)	Dipnoi: *Lepidosiren paradoxa* (South American lungfish)	Amphibia: *Ambystoma ordinarium* (Michoacan stream salamander)	Reptilia: *Timon lepidus* (Ocellated 'lizard')	Mammalia (Monotremata): *Ornithorhynchus anatinus* (Platypus)	Mammalia (Rodentia): *Rattus norvegicus* (Norwegian rat)	Mammalia (Dermoptera): *Cynocephalus volans* (Philippine colugo)	Mammalia (Scandentia): *Tupaia* sp. (Tree-shrew)	Mammalia (Primates): *Homo sapiens* (Modern human)
Adductor arcus palatini	— [the portion of the hyoid muscle anlage that gives rise to the levator hyoideus/ depressor mandibulae of non-actinistian sarco-pterygians probably corresponds to that giving rise to the adductor arcus palatini in other osteichthyans: see text]	—	—	—	—	—	—	—
'Adductor hyomandibulae Y' [seemingly not homologous with the adductor hyomandibulae of actinoptery-gians such as teleosts: see text]	— [seemingly absent in dipnoans and tetrapods, although it may possibly be included in the levator hyoideus/ depressor mandi-bulae: see text]	—	—	—	—	—	—	—

Adductor operculi [its fibers are seemingly deeply blended with those of the adductor arcus palatini: see text]	—	—	—	—	—	—	—	—
***Latimeria*'s 'levator operculi'** [seemingly not homologous with the levator operculi of halecomorph and teleostean actinoptery-gians: see text]	—	—	—	—	—	—	—	—
—	**Depressor mandibulae** [according to Forey 1986 the depressor mandibulae and levator hyoideus of extant dipnoans develop from the same ontogenetic anlage]	**Depressor mandibulae** [depressor mandibulae anterior sensu Diogo 2007, 2008 and Diogo et al. 2008ab] [seems to correspond to the 'pars noto-gnathica' sensu Lightoller 1939, which, contrary to what was suggested by this author, does not seem to directly correspond	**Depressor mandibulae** [Haas 1973 described both a depressor mandibulae and a 'stylohyoideus' in *Sphenodon*, and states that such a muscle is "found elsewhere in reptiles only in Gekkota": see Chapter 7]	**Styloideus** (the styloideus sensu Huber 1930a corresponds to the interhyoideus sensu Edgeworth 1935 and to the posterior digastric sensu Parsons 1898) [Edgeworth 1935 suggested that the styloideus of monotremes and the stylohyoideus of other mammals derive from the interhyoideus; our observations and comparisons strongly support the interpretations of, e.g., Huber 1930a and Saban 1968, 1971, i.e., that the monotreme styloideus and stapedius and the	**Stylohyoideus** [see on the left]	— [Saban 1968 states that the stylohyoideus is present in *Cynocephalus* but Gunnell and Simmons 2005 consider that this muscle is missing in this taxon; our dissections clearly indicate that the stylohyoideus is not present as an independent structure in adult colugos]	**Stylohyoideus** [Sprague 1944a states that the styloglossus of certain tree-shrews is innervated by the hypoglossal nerve, but Le Gros Clark 1926 and Lightoller 1934 claim that this muscle is innervated by the facial nerve, as in other mammals]	**Stylo-hyoideus** [Gasser's 1967 devel-opmental study indicates that in modern humans the digastricus posterior, stapedius and stylo-hyoideus derive from the same anlage]

Table 5.3 contd...

Table 5.3 contd...

Actinistia: *Latimeria chalumnae* (Coelacanth)	Dipnoi: *Lepidosiren paradoxa* (South American lungfish)	Amphibia: *Ambystoma ordinarium* (Michoacan stream salamander)	Reptilia: *Timon lepidus* (Ocellated 'lizard')	Mammalia (Monotremata): *Ornithorhynchus anatinus* (Platypus)	Mammalia (Rodentia): *Rattus norvegicus* (Norwegian rat)	Mammalia (Dermoptera): *Cynocephalus volans* (Philippine colugo)	Mammalia (Scandentia): *Tupaia* sp. (Tree-shrew)	Mammalia (Primates): *Homo sapiens* (Modern human)
		to the 'nucho-maxillaris' of sharks, because such a 'nucho-maxillaris' is not present in any of the bony fishes dissected by us, i.e., it was very likely not present in the LCA of osteichthyans]		therian stylohyoideus, digastricus posterior, jugulohyoideus, stapedius and possibly mandibulo-auricularis correspond to the depressor mandibulae of reptiles such as *Timon*]				
—	—	—	—	—	**Digastricus posterior** [see above]	**Digastricus posterior** (part of biventer sensu Leche 1886) [our dissections indicate that the digastricus posterior and digastricus anterior of colugos are joined by a tendinous intersection, as described by Saban 1968]	**Digastricus posterior** [our dissections indicate that the digastricus posterior and digastricus anterior of *Tupaia* are joined by a well-developed tendon, as described by, e.g., Sprague 1944a]	**Digastricus posterior** [the digastricus posterior and digastricus anterior of modern humans are usually joined by a well-developed tendon]

—	—	—	—	—	—	**Jugulohyoideus** (mastoideo-styloideus sensu Saban 1968) [seemingly corresponds to part of the stylohyoideus and/or possibly of the digastricus posterior of mammals such as rats: Table 5.3; see, e.g., Huber 1930a, 1931; Saban 1968]	**Jugulo-hyoideus** [see on the left]	—
—	—	**Branchio-hyoideus** [according to Edgeworth 1935 and Ericsson and Olsson 2004 the branchio-hyoideus, interhyoideus and levator hyoideus appear at about the same time in urodele embryos, and it is thus difficult to infer whether the branchio-hyoideus is ontogenetically derived from the ventral or f	— [the 'branchio-hyoideus' of reptiles is a branchial muscle that seemingly corresponds to the subarcualis rectus 1, and not to the hyoid muscle branchio-hyoideus, of amphibians: see text]	—	—	—	—	—

Table 5.3 contd...

Table 5.3 contd...

Actinistia: *Latimeria chalumnae* (Coelacanth)	Dipnoi: *Lepidosiren paradoxa* (South American lungfish)	Amphibia: *Ambystoma ordinarium* (Michoacan stream salamander)	Reptilia: *Timon lepidus* (Ocellated 'lizard')	Mammalia (Monotremata): *Ornithorhynchus anatinus* (Platypus)	Mammalia (Rodentia): *Rattus norvegicus* (Norwegian rat)	Mammalia (Dermoptera): *Cynocephalus volans* (Philippine colugo)	Mammalia (Scandentia): *Tupaia* sp. (Tree-shrew)	Mammalia (Primates): *Homo sapiens* (Modern human)
		rom the dorso-medial hyoid musculature; however, the developmental study of Piatt 1938 indicates that this muscle is in fact part of the dorso-medial hyoid musculature]						
—	**Levator hyoideus** [see depressor mandibulae above]	**Levator hyoideus** (depressor mandibulae posterior sensu Diogo 2007, 2008 and Diogo et al. 2008ab) [seems to correspond to the pars cephalo-gnathica sensu Lightoller 1939]	**—** [the adult *Timon* specimens dissected do not have an independent levator hyoideus but, as explained by Edgeworth 1935 and other authors, some adult reptiles do have this muscle, and it is very likely that the LCA of reptiles also did also have this muscle: see Chapter 7]	**Stapedius** (levator hyoideus sensu Edgeworth 1935) [the mammalian stapedius clearly derives from the levator hyoideus of other tetrapods: e.g., Huber 1930ab, 1931; Edgeworth 1935; Brocks 1938; Saban 1968, 1971; Kardong 2002; in fact it should be noted that, as stressed by Edgeworth 1935 and explained in Chapter 7, it is possible, and even likely, that the muscle levator hyoideus that is present in some reptiles is directly homologous to the	**Stapedius**	**Stapedius**	**Stapedius**	**Stapedius**

				mammalian stapedius: if this is actually the case, then it would be probably more appropriate to designate the muscle of those non-mammalian tetrapods as stapedius, as proposed by Schumacher 1973 and other authors, or, even better, to designate the muscle of mammals as levator hyoideus, as proposed by Edgeworth 1935 and other authors; see Chapter 7]				
—	—	—	**Cervico-mandibularis** (cervico-mandibularis posterior sensu Edgeworth 1935) [our dissections and comparisons support the view of, e.g., Huber 1930a and Edgeworth 1935, i.e. that this muscle corresponds to part of the depressor mandibulae/ levator hyoideus of sarcopterygian fish such as *Lepidosiren*; see text]	**Platysma cervicale** (the platysma cervicale sensu Jouffroy and Saban 1971 corresponds to the pars nuchalis of the platysma sensu Saban 1971 and to part of the platysma sensu Lightoller 1942) [see text]	**Platysma cervicale** [the cranial panniculus of Greene 1935 corresponds to the platysma cervicale + auriculolabialis inferior (= zygomaticus major) sensu this volume; the superficial portion of the cervical panniculus sensu Greene 1935 corresponds to the sphincter colli profundus + superficialis sensu this volume; the deep cervical panniculus sensu Greene 1935 corresponds to the sternofacialis sensu this volume, which he describes as an upper limb muscle but, as	**Platysma cervicale** (part of platysma sensu Leche 1886)	**Platysma cervicale** (part of platysma sensu Le Gros Clark 1924 and of notoplatysma sensu Lightoller 1934)	**—** [according to, e.g., Gasser 1967 the platysma cervicale (= his nuchal platysma) is present in early devel-opmental stages of modern humans, disappearing in later stages; Aziz 1981 considers that the transversus nuchae found in some humans is a remnant of the platysma cervicale, but Gasser 1967 describes both

Table 5.3 contd...

Table 5.3 contd...

Actinistia: *Latimeria chalumnae* (Coelacanth)	Dipnoi: *Lepidosiren paradoxa* (South American lungfish)	Amphibia: *Ambystoma ordinarium* (Michoacan stream salamander)	Reptilia: *Timon lepidus* (Ocellated 'lizard')	Mammalia (Monotremata): *Ornithorhynchus anatinus* (Platypus)	Mammalia (Rodentia): *Rattus norvegicus* (Norwegian rat)	Mammalia (Dermoptera): *Cynocephalus volans* (Philippine colugo)	Mammalia (Scandentia): *Tupaia* sp. (Tree-shrew)	Mammalia (Primates): *Homo sapiens* (Modern human)
					noted by Jouffroy and Saban 1971, is in fact a facial muscle that is probably derived from the sphincter colli profundus: e.g., Jouffroy and Saban 1971; Ryan, 1986, 1989; this work]			a platysma cervicale and a transversus nuchae in early human embryos]
				Platysma myoides (seemingly corresponds to pars omoidea sensu Saban 1971)	**Platysma myoides** (blended with platysma cervicale)	**Platysma myoides** (platysma myoides superior + 'jugalis propatagii' sensu Leche 1886; dorsal sheet of propatagial complex sensu Thewissen and Babcock 1991, 1993) [blended with platysma cervicale; Leche 1886 stated that the propatagial complex of dermopterans has a dorsal	**Platysma myoides** [blended with platysma cervicale]	**Platysmamyoides** (platysma sensu Netter 2006; tracheo-platysma sensu Lightoller 1940a)

						muscle formed by the platysma myoides and the "jugalis propatagii" and a ventral muscle; Thewissen and Babcock 1991, 1993, studied the configuration and innervation of these muscles and concluded that the dorsal one is innervated by the facial nerve and the ventral one by cervical spinal nerves; the dorsal and ventral muscles therefore seem to correspond respectively to the platysma myoides and to part of the panniculus carnosus of other mammals]		

Table 5.3 contd...

Table 5.3 contd...

Actinistia: *Latimeria chalumnae* (Coelacanth)	Dipnoi: *Lepidosiren paradoxa* (South American lungfish)	Amphibia: *Ambystoma ordinarium* (Michoacan stream salamander)	Reptilia: *Timon lepidus* (Ocellated 'lizard')	Mammalia (Monotremata): *Ornithorhynchus anatinus* (Platypus)	Mammalia (Rodentia): *Rattus norvegicus* (Norwegian rat)	Mammalia (Dermoptera): *Cynocephalus volans* (Philippine colugo)	Mammalia (Scandentia): *Tupaia* sp. (Tree-shrew)	Mammalia (Primates): *Homo sapiens* (Modern human)
—	—	—	—	— [as described by, e.g., Lightoller 1942 in the platypus specimens dissected by us there is a bundle of the platysma that is somewhat similar to the occipitalis of the mammals listed on the right, but this bundle is clearly part of the platysma, i.e., it does not constitute an independent muscle]	**Occipitalis** (cranial part of levator auris longus sensu Greene 1935) [the occipitalis of *Rattus* is similar to that of *Tupaia* and *Cynocephalus*, i.e., it has a medial portion (= occipitalis sensu Lightoller 1934) that extends anteriorly to blend with the frontalis and a lateral portion (= cervico-auriculo-occipitalis sensu Lightoller 1934) that runs antero-ventrolaterally to attach on the posterior surface of the ear; these two portions are deeply blended posteriorly, attaching to the dorsal region of the neck, just medially to the posterior attachment of the auricularis posterior]	**Occipitalis** [see on the left]	**Occipitalis** (occipitalis + cervico-auriculo-occipitalis sensu Lightoller 1934: see on the left)	**Occipitalis** [Gasser's 1967 devel-opmental study in modern humans indicates that the occipitalis, auricularis posterior and transversus nuchae develop from the same anlage]
—	—	—	—	—	**Auricularis posterior** (caudal part of levator auris longus sensu Greene 1935: see above)	**Auricularis posterior** [see above]	**Auricularis posterior** [see above]	**Auricularis posterior** [see above]

—	—	—	—	**Extrinsic muscles of the ear** [our dissections and comparisons indicate that the platypus has at least some extrinsic muscles of the ear, as suggested by Lightoller 1942; according to Huber 1930ab, 1931, and Jouffroy and Saban 1971, some of the extrinsic muscles of the ear derive from the platysma while others derive from the sphincter colli profundus]	**Extrinsic muscles of the ear** [examples of extrinsic, facial muscles of the ear present in therian mammals are the obliquus auriculae, transversus auriculae, helicis, tragicus and/or antitragicus: see, e.g., Jouffroy and Saban 1971]	**Extrinsic muscles of the ear** [see on the left]	**Extrinsic muscles of the ear** [see on the left]	**Extrinsic muscles of the ear** [see on the left]
—	—	—	—	— [although Adams et al. 1929 and others suggest that the therian mandibulo-auricularis is a 'preauricular' muscle and thus derives from the sphincter colli profundus, most researchers consider that it is instead a 'post-auricular' muscle derived from the platysma (e.g., Huber 1930ab, 1931; Ryan 1986, 1989); however, a few authors, such as Lightoller 1934 and Jouffroy and Saban 1971, have suggested that the mandibulo-auricularis may in fact be ontogenetically and phylogenetically more related to deeper dorso-median muscles such as the stylohyoideus, digastricus	**Mandibulo-auricularis** [see on the left]	**—** [as stated by Lightoller 1934, contrary to lemurs and, e.g., *Tupaia*, in primates such as *Tarsius* and marmosets the mandibulo-auricularis probably corresponds to a strong sheet connecting the posterior edge of the mandible to the bony external auditory meatus, which might well correspond to the stylo-mandibular ligament	**Mandibulo-auricularis** (auriculo-mandibularis sensu Lightoller 1934) [see on the left]	— [seemingly corresponds to the stylo-mandibular ligament, which is usually present in modern humans: see on the left; according to Jouffroy and Saban 1971 it may also correspond to the stylo-auricularis muscle abnormally present in a few modern humans]

Table 5.3 contd...

Table 5.3 contd...

Actinistia: *Latimeria chalumnae* (Coelacanth)	Dipnoi: *Lepidosiren paradoxa* (South American lungfish)	Amphibia: *Ambystoma ordinarium* (Michoacan stream salamander)	Reptilia: *Timon lepidus* (Ocellated 'lizard')	Mammalia (Monotremata): *Ornithorhynchus anatinus* (Platypus)	Mammalia (Rodentia): *Rattus norvegicus* (Norwegian rat)	Mammalia (Dermoptera): *Cynocephalus volans* (Philippine colugo)	Mammalia (Scandentia): *Tupaia* sp. (Tree-shrew)	Mammalia (Primates): *Homo sapiens* (Modern human)
				posterior, stapedius and/or jugulohyoideus than to the facial muscles; although we tentatively follow here the most consensual view, we consider that Lightoller's hypothesis should not be completely ruled out, because the mandibulo-auricularis usually does lie deeper than all the other facial muscles and also because its topology, the orientation of its fibers, and its attachments (e.g., on the mandible and/or near the ear region) are in fact similar to those of the deeper dorsomedial hyoid muscles of mammals and to the depressor mandibul ae/ levator hyoideus of other tetrapods; also, Seiler's 1980 developmental studies of tree-shrews and primates seem to suggest that the mandibulo-auricularis does not develop from the anlages that give rise to most other facial muscle, but instead from a different, deeper anlage]		of modern humans; such a configuration is found in the colugos dissected, i.e., there is no fleshy muscle mandibulo-auricularis, but instead a strong fascia running from the posterior edge of the mandible to the bony external auditory meatus]		

—	—	—	—	—	—	—	—	**Risorius** [Huber 1930ab, 1931, and others suggest that the risorius derives from the sphincter colli profundus; our dissections and comparisons support the conclusions of Jouffroy and Saban's 1971 review, i.e., that the risorius derives instead from the platysma myoides; this latter hypothesis is also supported by the developmental data of Gasser 1937: see, e.g., his fig. 10]
Interhyoideus ('génio-hyoïdien' + 'hyohyoïdien sensu Millot and Anthony 1958, which, as is shown in the illustrations of these authors, are effectively deeply blended: see text]	**Interhyoideus** [see on the left]	**Interhyoideus** (interhyoideus anterior + interhyoideus posterior sensu Piatt 1938, Bauer 1992, 1997, and Ericsson and Olsson 2004, which probably correspond	**Interhyoideus** (constrictor colli sensu Herrel et al. 2005)	**Interhyoideus profundus** (sphincter colli profundus sensu Lightoller 1942; hyomandibularis sensu Edgeworth, 1935) [Edgeworth 1935, claimed that none of the mammalian facial muscles are derived from the interhyoideus because all of them are *de novo* structures;	—	—	—	—

Table 5.3 contd...

Table 5.3 contd...

Actinistia: *Latimeria chalumnae* (Coelacanth)	Dipnoi: *Lepidosiren paradoxa* (South American lungfish)	Amphibia: *Ambystoma ordinarium* (Michoacan stream salamander)	Reptilia: *Timon lepidus* (Ocellated 'lizard')	Mammalia (Monotremata): *Ornithorhynchus anatinus* (Platypus)	Mammalia (Rodentia): *Rattus norvegicus* (Norwegian rat)	Mammalia (Dermoptera): *Cynocephalus volans* (Philippine colugo)	Mammalia (Scandentia): *Tupaia* sp. (Tree-shrew)	Mammalia (Primates): *Homo sapiens* (Modern human)
		respectively to the pars inter-hyoidea + pars inscriptionalis of the ventral superficial constrictor of the second arch sensu Lightoller 1939) [as stated by Piekarski and Olsson 2007, recent developmental works indicate that the interhyoideus of sarcopterygians such as *Ambystoma* might be derived ontogenetically not only from the hyoid region but also possibly from anterior somites: see text]		however, this view has been abandoned and it is now commonly accepted that the mammalian muscles correspond to the interhyoideus and possibly dorso-medial muscles such as the cervicomandibularis of reptiles such as the 'lizard' *Timon*: see above and also text]				

—	—	—	—	**Sphincter colli superficialis** (corresponds to the sphincter colli externus of platypus and sphincter colli of echidna, sensu Huber 1930a) [corresponds to part of the inter-hyoideus of non-mammalian tetrapods: e.g., Huber 1930a; Jouffroy and Saban 1971; Lightoller 1940a states that Huber's 1930a sphincter colli superficialis (of, e.g., marsupials and rodents) corresponds to muscle he named 'transitus', i.e., to a part of the sphincter colli profundus that passes superficial to the platysma but that originally was deep to it: Lightoller claims that the rest of the sphincter colli profundus (i.e., everything except the 'transitus') is absent in all primates, and that it is thus this 'transitus' that gives the tracheo-platysma of primates; however, our dissections and comparisons strongly indicate that the configuration of the platysma of primates such as lemurs is in fact similar to that found in, e.g., colugos and tree-shrews, i.e., these latter mammals have both a platysma cervicale and a	**Sphincter colli superficialis** (transitus sensu Lightoller 1942) [as explained by, e.g., Lightoller 1940a, 1942, although much reduced, in rodents such as rats the sphincter colli does have a component that is superficial to the platysma - i.e., a sphincter colli superficialis]	**—** [Jouffroy and Saban 1971, p. 484, state that colugos have a sphincter colli superficialis, but as they explain in their p. 496, this is because they consider that the ventral sheet of the propatagial muscle complex of colugos probably corresponds to the sphincter colli superficialis of other mammals; Thewissen and Badcock 1991, 1993, have, however, shown that this ventral sheet is in fact innervated by cervical spinal nerves and not by the facial nerve, as is the sphincter colli superficialis; moreover, as shown in fig. 1 of these latter authors, the position and the orientation of	**Sphincter colli superficialis** (seems to correspond to the occipito-cervicalis sensu Lightoller 1934, and might correspond to the cervico-mandibularis sensu Le Gros Clark 1926, which was originally described as part of the platysma of *Ptilocercus* but seems rather to correspond to the sphincter colli superficialis of *Tupaia* and other mammals)	**—** [it is commonly accepted that primates such as modern humans and chimpan-zees do not have a sphincter colli superfi-cialis, but according to Burrows et al. 2006 this muscle may be found in some chimpan-zees and perhaps even in some modern humans; in the modern human cadavers we dissected the sphincter colli superficialis was not present as an indepen-dent muscle]

Table 5.3 contd...

Table 5.3 contd...

Actinistia: *Latimeria chalumnae* (Coelacanth)	Dipnoi: *Lepidosiren paradoxa* (South American lungfish)	Amphibia: *Ambystoma ordinarium* (Michoacan stream salamander)	Reptilia: *Timon lepidus* (Ocellated 'lizard')	Mammalia (Monotremata): *Ornithorhynchus anatinus* (Platypus)	Mammalia (Rodentia): *Rattus norvegicus* (Norwegian rat)	Mammalia (Dermoptera): *Cynocephalus volans* (Philippine colugo)	Mammalia (Scandentia): *Tupaia* sp. (Tree-shrew)	Mammalia (Primates): *Homo sapiens* (Modern human)
				platysma myoides, although these two latter muscles are blended; in primates such as modern humans the platysma cervicale is usually missing, i.e., the platysma sensu Netter 2006 corresponds to the platysma myoides of other mammals: see above; if we accept, as it is nowadays commonly accepted, that the sphincter colli of mammals derives from the interhyoideus of other tetrapods, it makes sense to suppose that plesiomorphically the sphincter colli was a superficial muscle, as is the non-mammalian interhyoideus, and not a deep muscle: see text]		the fibers of that ventral sheet are not similar to those of the sphincter colli superficialis of other mammals (e.g., in a lateral view it appears deep, not superficial, to the platysma); our dissections indicate that colugos do not have a fleshy, distinct muscle sphincter colli superficialis]		

—	—	—	—	— [absent as an independent muscle in the platypus, although part of it might have given rise to deep facial muscles such as the orbicularis oris, orbicularis oculi, mentalis and/or naso-maxillo-labialis (which clearly seem to correspond to the muscles that are designated under the same names in other mammals) and possibly to the 'sphincter bursae buccalis' sensu Huber 1930a (which, contrary to what was stated by this latter author, seems to correspond to the 'buccinatorius' of the echidna and to the buccinatorius of other mammals); in the echidna part of the sphincter colli passes deep to other facial muscles, forming the sphincter colli profundus: e.g., Lightoller 1942; Jouffroy and Saban 1971]	**Sphincter colli profundus** (superficial portion of cervical platysma sensu Greene 1935; sphincter colli profundus + 'primitive sphincter colli' of fig. 6 of Huber 1930; transitus sensu Lightoller 1940a) [deeply blended with the sphincter colli superficialis]	**Sphincter colli profundus** [absent according to Jouffroy and Saban 1971, but this muscle is clearly present in the specimens dissected: dorsally it runs deep to the platysma myoides while ventrally it meets its counterpart in the ventral midline of the head]	**Sphincter colli profundus**	—
—	—	—	—	—	**Sternofacialis** (deep cervical panniculus sensu Greene 1935: see platysma cervicale above)	—	—	—

Table 5.3 contd...

Table 5.3 contd...

Actinistia: *Latimeria chalumnae* (Coelacanth)	Dipnoi: *Lepidosiren paradoxa* (South American lungfish)	Amphibia: *Ambystoma ordinarium* (Michoacan stream salamander)	Reptilia: *Timon lepidus* (Ocellated 'lizard')	Mammalia (Monotremata): *Ornithorhynchus anatinus* (Platypus)	Mammalia (Rodentia): *Rattus norvegicus* (Norwegian rat)	Mammalia (Dermoptera): *Cynocephalus volans* (Philippine colugo)	Mammalia (Scandentia): *Tupaia* sp. (Tree-shrew)	Mammalia (Primates): *Homo sapiens* (Modern human)
—	—	—	—	**Cervicalis transversus** [its position and the orientation of its fibers are similar to those of the interscutularis of non-monotreme mammals such as rats; Lightoller 1940a seems to support the homology of these muscles, because he states that there is a cervicalis transversus in rodents; however, according to Jouffroy and Saban 1971 the interscutularis is derived from the pars intermedia of the sphincter colli profundus, while the cervicalis transversus is derived from the pars cervicalis of this latter muscle]	— [see on the left]	—	—	—
—	—	—	—	— [see above]	**Interscutularis** [see cervicalis transversus above]	—	—	—

—	—	—	—	— [our dissections and comparisons support Jouffroy and Saban's 1971 hypothesis: (1) the zygomaticus major and minor are absent in mammals such as monotremes; (2) in placentals, the zygomaticus is plesiomorphically attached to the zygomatic arch, but in some cases it extends posteriorly to attach to the ear (that is why it is sometimes named auriculolabialis); (3) in a few mammals, such as some ungulates, pinnipedes, bats, rodents, tree-shrews and primates, the zygomaticus is divided into superficial (= auriculolabialis inferior and zygomaticus major sensu Jouffroy and Saban 1971) and deep (= auriculolabialis superior and zygomaticus minor sensu Jouffroy and Saban 1971) portions, the former originating ventrally and/or posteriorly to the latter, thus usually lying nearer the ear and	**Zygomaticus major** (part or all of auriculolabialis sensu Greene 1935; zygomatico-labialis superficialis and or auriculolabialis inferior sensu Jouffroy and Saban 1971) [our dissections indicate that the 'auriculolabialis' of Norwegian rats is deeply blended with the platysma; does this mean that it is really part of and/or derived from the platysma (see on the left)? Probably not, because as stated by Greene 1935 in other rats and other rodents this 'auriculolabialis' is much more distinct from the platysma, being seemingly a derivative of the sphincter colli profundus; however, it is possible that some of the mammalian structures that are designated as 'zygomaticus major and minor' and/or 'auriculolabialis inferior and superior' in the	**Zygomaticus major** [in Huber's 1930a fig. 27 of the 'primate ground plan of superficial facial musculature', he suggests that the auriculabialis inferior (= zygomaticus major) derives from the platysma (see on the left), but at least in the case of colugos the former muscle is well distinguished from the latter, because these muscles are in fact perpendicular to each other; there is a significant difference between *Cynocephalus*, *Lemur* and *Tupaia*: in *Cynocephalus* the auriculolabialis inferior (=	**Zygomaticus major** (auriculo-labialis inferior or zygomatico-labialis sensu Jouffroy and Saban 1971, Le Gros Clark 1926, and Lightoller 1934) [see on the left]	**Zygomaticus major** [Gasser's 1967 developmental study indicate that the zygomaticus major and zygomaticus minor of modern humans derive from his 'infraorbital lamina', and not from his 'mandibular lamina', i.e., they seem to be onto-genetically more related with the facial muscles of the orbit region than with those of the mouth region; interestingly, in earlier stages of human development these two muscles are more separated from each other than in later stages, i.e., in this respect the

Table 5.3 contd...

Table 5.3 contd...

Actinistia: *Latimeria chalumnae* (Coelacanth)	Dipnoi: *Lepidosiren paradoxa* (South American lungfish)	Amphibia: *Ambystoma ordinarium* (Michoacan stream salamander)	Reptilia: *Timon lepidus* (Ocellated 'lizard')	Mammalia (Monotremata): *Ornithorhynchus anatinus* (Platypus)	Mammalia (Rodentia): *Rattus norvegicus* (Norwegian rat)	Mammalia (Dermoptera): *Cynocephalus volans* (Philippine colugo)	Mammalia (Scandentia): *Tupaia* sp. (Tree-shrew)	Mammalia (Primates): *Homo sapiens* (Modern human)
				being more associated with the platysma (that is why some authors argue that it might derive from the platysma, although its innervation seems to indicate the contrary); Jouffroy and Saban 1971 explicitly state that these superficial and deep portions correspond very likely to the zygomaticus major and minor of modern humans, respectively; (4) according to them, in mammals such as tree-shrews and primates such as lemurs the zygomatic muscles, and particularly the zygomaticus major, often extends posteriorly in order to attach to the ear (Fig. 12), but this 'trend' is reversed in 'higher' primates: for example, in modern humans both the zygomaticus major and zygomaticus minor usually originate relatively far from the ear, although in a few cases at least one of these muscles might originate in the ear region]	literature are really part of and/or derive from the platysma, i.e., that they are not really homologous to the zygomaticus major and minor sensu this volume: e.g., Boas and Paulli 1908; Huber 1930a; Edgeworth 1935; Jouffroy and Saban 1971; it cannot be completely ruled out, however, that at least in some cases the 'zygomaticus major' and/or 'auriculolabialis inferior' derive from the platysma, while the 'zygomaticus minor' and/or 'auriculolabialis superior' derive from, e.g., the orbicularis oculi]	zygomaticus major) is superficial to the platysma cervicale; in *Lemur* these two muscles lie in the same plane; in *Tupaia* the auricularis inferior is deep to the platysma cervicale: e.g., Lightoller 1934; this work]		configuration seen in those early stages is more similar to that seen in adult mammals such as colugos, tree-shrews and 'lower' primates: see, e.g., Fig. 5.12]

—	—	—	—	—	**Zygomaticus minor** (zygomaticus sensu Greene 1935; zygomatico-labialis profundus and or auriculolabialis superior sensu Jouffroy and Saban 1971)	**Zygomaticus minor**	**Zygomaticus minor** (auriculolabialis superior sensu Jouffroy and Saban 1971, Le Gros Clark 1926, and Lightoller 1934)	**Zygomaticus minor**
—	—	—	—	—	**Orbito-temporo-auricularis** (the frontalis sensu Greene 1935 corresponds to the orbito-temporo-auricularis sensu Edgeworth 1935)	**Frontalis** [our dissections and comparisons indicate that the frontalis and auriculo-orbitalis of *Cynocephalus* and *Tupaia* and the frontalis, temporo-parietalis and auricularis anterior of modern humans, correspond to the orbito-temporo-auricularis of mammals such as rats: see Table 5.4]	**Frontalis**	**Frontalis**

Table 5.3 contd...

Table 5.3 contd...

Actinistia: *Latimeria chalumnae* (Coelacanth)	Actinistia: *Latimeria chalumnae* (Coelacanth)	Actinistia: *Latimeria chalumnae* (Coelacanth)	Actinistia: *Latimeria chalumnae* (Coelacanth)	Mammalia (Monotremata): *Ornithorhynchus anatinus* (Platypus)	Mammalia (Rodentia): *Rattus norvegicus* (Norwegian rat)	Mammalia (Dermoptera): *Cynocephalus volans* (Philippine colugo)	Mammalia (Scandentia): *Tupaia* sp. (Tree-shrew)	Mammalia (Primates): *Homo sapiens* (Modern human)
—	—	—	—	—	—	**Auriculo-orbitalis** [see above; this muscle usually runs from the auricular region to the orbital region, being inferior and/or deep to the frontalis: e.g., Fig. 5.12]	**Auriculo-orbitalis** (auriculo-orbitalis or orbito-auricularis sensu Lightoller 1934; it might correspond to *Tupaia*'s attrahens aurem sensu Le Gros Clark 1924, and/or to the *Ptilocercus*' scutularis + portio transiens sensu Le Gros Clark 1926)	**Temporo-parietalis** [see above; according to Jouffroy and Saban 1971, this muscle is related to, but different from, the auricularis superior; they state that it corresponds to the temporal part of the frontalis, which is also named epicranio-temporal or orbito-temporalis, and which has a longitudinal orientation and covers the temporal aponeurosis, being often fused in primates with the auriculares anterior and superior and also to part of the galea aponeurotica]

—	—	—	—	—	—	—	— [contrary to *Ptilocercus*, *Tupaia* seems to only have an auriculo-orbitalis sensu Lightoller 1934, i.e., it does not have a separate temporo-parietalis and a separate auricularis anterior: see above]	**Auricularis anterior**
—	—	—	—	—	—	**Auricularis superior** (auricularis anterior superior of fig. 409 of Jouffroy and Saban 1971)	**Auricularis superior**	**Auricularis superior**
—	—	—	—	**Orbicularis oculi**	**Orbicularis oculi**	**Orbicularis oculi**	**Orbicularis oculi**	**Orbicularis oculi**
—	—	—	—	—	—	**Zygomatico-orbicularis** [there is a very thin group of fibers attaching to the medial margin of the posterior portion of the orbicularis oculi, anteriorly, and to the dorsal surface of the	**Zygomatico-orbicularis** [Lightoller 1934 states that in *Tupaia javanica* there is a group of fibers running from the region lying posterodorsally to the eye to the dorsal margin of	—

Table 5.3 contd...

Table 5.3 contd...

Actinistia: *Latimeria chalumnae* (Coelacanth)	Actinistia: *Latimeria chalumnae* (Coelacanth)	Actinistia: *Latimeria chalumnae* (Coelacanth)	Actinistia: *Latimeria chalumnae* (Coelacanth)	Mammalia (Monotremata): *Ornithorhynchus anatinus* (Platypus)	Mammalia (Rodentia): *Rattus norvegicus* (Norwegian rat)	Mammalia (Dermoptera): *Cynocephalus volans* (Philippine colugo)	Mammalia (Scandentia): *Tupaia* sp. (Tree-shrew)	Mammalia (Primates): *Homo sapiens* (Modern human)
						zygomatic arch, posteriorly; this thin group of fibers lies deep to most fibers of the orbicularis oculi and auriculo-orbitalis, being in fact deeply blended with the temporal fascia covering the temporalis in lateral view; however, our dissections indicate that there are in fact some fleshy fibers, which thus should be considered a zygomatico-orbicularis sensu Le Gros Clark 1924, 1926, even if this is a poorly developed muscle; the lemur shown in fig. 4 of Lightoller 1934 also seems to have such a group of fleshy fibers]	the zygomatic arch, but that it cannot correspond to the zygomatico-orbicularis sensu Le Gros Clark 1924 because it lies deep to the orbicularis oculi; however, Le Gros Clark 1924 stated that his zygomatico-orbicularis lies deep to at least some fibers of the orbicularis oculi; the group of fibers described by Lightoller thus seems to correspond to the zygomatico-orbicularis sensu Le Gros Clark]	

—	—	—	—	—	—	—	—	**Depressor supercilii** [the depressor supercilii and corrugator supercilii are seemingly derived from the orbicularis oris: see Table 5.4]
—	—	—	—	—	—	**Corrugator supercilii** [see above]	**Corrugator supercilii** (superciliaris sensu Jouffroy and Saban 1971)	**Corrugator supercilii**
—	—	—	—	**Naso-labialis** [Lightoller 1942 and Saban 1971 state that deep to the cranial (anterior) portion of the orbicularis oculi of the echidna lies a small naso-labialis; according to Lightoller 1942 in the platy-pus there is a somewhat similar structure, but it is not as differentiated from the other facial musculature as in the echidna; in the platypus dissected by us the naso-labialis does seem to be an independent muscle, being in fact very similar to the naso-labialis of the echidna – see, e.g., fig. 4 of Lightoller 1942, which suggests that the naso-labialis derives from a part of the sphincter colli superficialis ('transitus' sensu Lightoller): Huber 1930a; Jouffroy and Saban 1971]	**Naso-labialis** (levator labii superioris sensu Parsons 1898 and Greene 1935; pars jugularis of superficial maxillo-naso-labialis sensu Lightoller 1940b)	**Naso-labialis**	**Naso-labialis** (levator labii superioris sensu Le Gros Clark 1924) [not described by Le Gros Clark, 1926 but his fig. 49 seems to suggest that it may also be present in *Ptilocercus*]	**Levator labii superioris** [the levator labii superioris and levator labii superioris alaeque nasi clearly seem to correspond to the naso-labialis of the other therian mammals listed on the left: Table 5.4; Gasser's 1967 developmental study suggests that at least in modern humans these two muscles appear ontogenetically in the orbital region]

Table 5.3 contd...

Table 5.3 contd...

Actinistia: *Latimeria chalumnae* (Coelacanth)	Dipnoi: *Lepidosiren paradoxa* (South American lungfish)	Amphibia: *Ambystoma ordinarium* (Michoacan stream salamander)	Reptilia: *Timon lepidus* (Ocellated 'lizard')	Mammalia (Monotremata): *Ornithorhynchus anatinus* (Platypus)	Mammalia (Rodentia): *Rattus norvegicus* (Norwegian rat)	Mammalia (Dermoptera): *Cynocephalus volans* (Philippine colugo)	Mammalia (Scandentia): *Tupaia* sp. (Tree-shrew)	Mammalia (Primates): *Homo sapiens* (Modern human)
—	—	—	—	—	—	—	—	**Levator labii superioris alaeque nasi** [see above]
—	—	—	—	—	**Procerus** (nasolabialis superficialis sensu Ryan 1989) [not described by Greene 1935 but seems to be present in the rats dissected by us; see also, e.g., Ryan 1989]	—	—	**Procerus**
—	—	—	—	**Buccinatorius** (the buccinatorius sensu Lightoller 1942 corresponds to the sphincter bursae buccalis sensu Huber 1930a) [according to Huber 1930a there is no buccinatorius in the platypus, and the "buccinatorius" of echidna may well not be homologous with that of other mammals, because it may well be derived from the platysma and not from the sphincter colli profundus; however, as noted in later works, e.g., Lightoller 1942 and Jouffroy and Saban 1971,	**Buccinatorius** [not described by Greene 1935 but clearly present in the rats dissected by us, being in fact subdivided into various sections; see also, e.g., Ryan 1989]	**Buccinatorius**	**Buccinatorius** [not described by Le Gros Clark 1924, but clearly present in the *Tupaia* specimens we dissected; it is also present in *Ptilocercus*, see, e.g., Le Gros Clark 1926]	**Buccinatorius**

				the "sphincter bursae buccalis" of platypus might well correspond to the "buccinatorius" of echidna and/or to the buccinatorius of other mammals]				
—	—	—	—	—	**Dilatator nasi** (dilatator naris sensu Greene 1935 and Peterka 1936) [we prefer to use the name dilatator nasi because the name dilatator naris is often used to designate the pars alaris of the nasalis: see, e.g., Jouffroy and Saban 1971]	—	—	—
—	—	—	—	—	**Maxillo-naso-labialis** (seemingly incorporates the maxillo-labialis and naso-labiais profundus sensu Jouffroy and Saban 1971 and Ryan 1989) [not described by Greene 1935, but clearly present in the rats dissected by us; see also, e.g., Ryan 1989]	**Maxillo-naso-labialis**	**Maxillo-naso-labialis** (maxillo-nasalis sensu Jouffroy and Saban 1971; it might correspond to the dilator naris, zygomatici and/or erector vibrissae sensu Le Gros Clark 1924, and thus might possibly be included in the orbicularis oculi (sensu Le Gros Clark 1926) of *Ptilocercus*)	**Nasalis** [the nasalis and depressor septi nasi of modern humans seem to correspond to the maxillo-naso-labialis of e.g. rats, colugos and tree-shrews: see, e.g., Jouffroy and Saban 1971]

Table 5.3 contd...

Table 5.3 contd...

Actinistia: *Latimeria chalumnae* (Coelacanth)	Dipnoi: *Lepidosiren paradoxa* (South American lungfish)	Amphibia: *Ambystoma ordinarium* (Michoacan stream salamander)	Reptilia: *Timon lepidus* (Ocellated 'lizard')	Mammalia (Monotremata): *Ornithorhynchus anatinus* (Platypus)	Mammalia (Rodentia): *Rattus norvegicus* (Norwegian rat)	Mammalia (Dermoptera): *Cynocephalus volans* (Philippine colugo)	Mammalia (Scandentia): *Tupaia* sp. (Tree-shrew)	Mammalia (Primates): *Homo sapiens* (Modern human)
—	—	—	—	—	—	—	—	**Depressor septi nasi** [see above]
—	—	—	—	—	**Levator anguli oris facialis** (levator anguli oris or caninus sensu Lightoller 1934; bucco-naso-labialis sensu Ryan 1986; buccinatorius sensu Greene 1935 and Bryant 1945; pars profunda of maxillo-naso-labialis sensu Lightoller 1940b) [we use the name levator anguli facialis in order to distinguish this muscle from the levator anguli oris mandibularis of some non-mammalian tetrapods, which is a mandibular, and not a hyoid, muscle: see Chapter 4,]	**Levator anguli oris facialis**	**Levator anguli oris facialis** (levator anguli oris sensu Le Gros Clark 1926; incisivus superior + caninus sensu Lightoller 1934) [as noted by Lightoller 1934, this muscle is deeply blended with the orbicularis oris]	**Levator anguli oris facialis** [Gasser's 1967 study of human development supports the claim that the levator anguli oris facialis, orbicularis oris, depressor labii inferioris, depressor anguli oris and mentalis have a common ontogenetic origin, being derived from his 'mandibular lamina'; see also, e.g., Sullivan and Osgood 1927 and Jouffroy and Saban 1971]
—	—	—	—	**Orbicularis oris** (plicae anguli oris sensu Huber 1930a)	**Orbicularis oris**	**Orbicularis oris**	**Orbicularis oris** [see maxilo-naso-labialis above]	**Orbicularis oris**

—	—	—	—	—	—	—	—	**Depressor labii inferioris** [see levator anguli oris facialis above]
—	—	—	—	—	—	—	—	**Depressor anguli oris** [see levator anguli oris facialis above]
—	—	—	—	**Mentalis** [present in the platypus, but seemingly not in echidna, according to, e.g., Lightoller 1942 and Saban 1971]	—	**Mentalis**	**Mentalis** (labiorum profundi inferioris sensu Lightoller 1934)	**Mentalis** [see levator anguli oris facialis above]

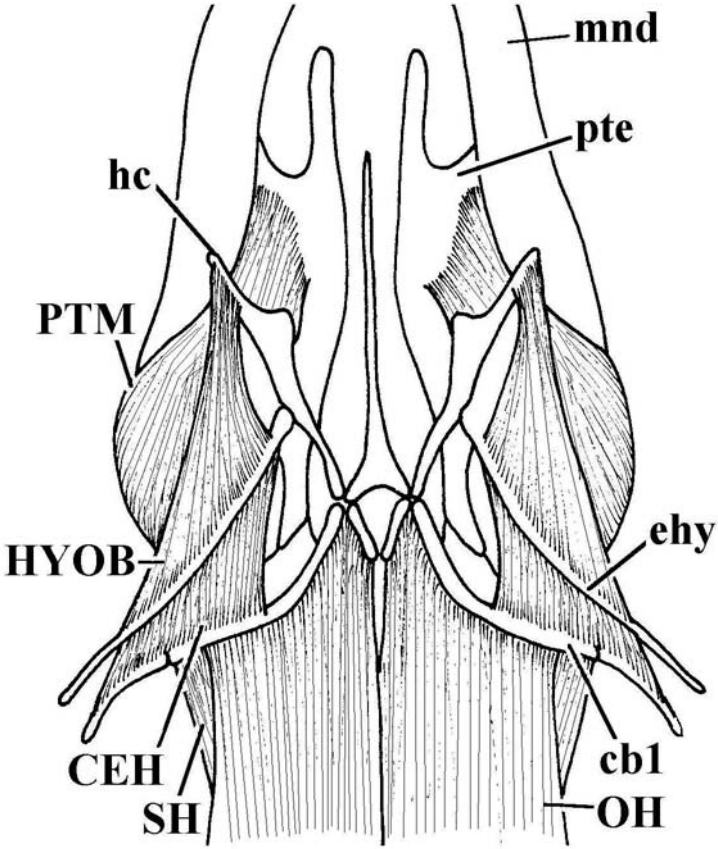

Fig. 5.7 *Euspondylus acutirostris* (Reptilia, Lepidosauria): ventral view of the deep ventral cephalic musculature; muscles such as the intermandibularis, interhyoideus, geniohyoideus, genioglossus and hyoglossus are not shown (modified from Montero et al. 2002 and Diogo 2008; the nomenclature of the structures illustrated follows that used in the present work; anterior is to the top). cb1, ceratobranchial 1; CEH, ceratohyoideus; ehy, epihyal; hc, hyoid cornu; HYOB, hyobranchilais; mnd, mandible; OH, omohyoideus; pte, pterygoid; PTM, pterygomandibularis; SH, sternohyoideus.

interhyoideus, and two dorso-medial hyoid muscles, the adductor arcus palatini and the adductor operculi (note that the 'adductor hyomandibulae Y' and 'levator operculi' of *Latimeria* are not homologues of the adductor hyomandibulae and levator operculi of actinopterygians such as teleosts: see Chapter 4). The depressor mandibulae, levator hyoidei, branchiohyoideus and cervicomandibularis of extant dipnoans, amphibians and reptiles seem to develop from the anlage that give rise to the adductor arcus palatini in other osteichthyans (see Chapter 4 and Figs. 5.3, 5.5, 5.6). The adductor operculi is not present as an independent muscle in extant dipnoans, amphibians and reptiles;

Table 5.4 Scheme illustrating the authors' hypotheses regarding the homologies of the hyoid muscles of adults of representative sarcopterygia taxa (see caption of Table 5.2, text, Table 5.3 and Figs. 5.1–5.27). ad. = adductor; al. = alaeque; branchio. + cerat. = branchiohyoideus ceratomandibularis; de. man. = depressor mandibulae; ex. = extrinsic; inf. = inferioris; le. = levator; mus. = muscles; poar. = present in other adu reptiles; prof. = profundus; sup. = superioris; supe. = superficialis; tra. = transversus.

	Latimeria (5 mus.)	*Lepidosiren* (3 mus.)	*Ambystoma* (4 mus.)	*Timon* (3 mus.)	*Ornithorhynchus* (12 mus. - not ex. ear*)	*Rattus* (23 mus. - not ex. ear*)	*Cynocephalus* (22 mus. - not ex. ear*)	*Tupaia* (25 mus. - not ex. ear*)	*Homo* (27 mus.- not ex. ear*
DORSO-MEDIAL HYOID MUS.	'Ad.hyomandibulae Y'	---	---	---	---	---	---	---	---
	Ad. arcus palatini	---	---	---	---	---	---	---	---
	---	De. man.	De. man.	De. man.	Styloideus	Stylohyoideus	---	Stylohyoideus	Stylohyoideus
	---	---	---	---	---	---	Jugulohyoideus	Jugulohyoideus	---
	---	---	---	---	---	Digastricus posterior	Digastricus posterior	Digastricus posterior	Digastricus posterior
	Latimeridis 'le.operculi'	---	---	---	---	---	---	---	---
	Ad. operculi	---	---	---	---	---	---	---	---
	---	---	Branchio+Cerat.	---	---	---	---	---	---
	---	Le. hyoideus'	Le. hyoideus*	— (Le.hyoideus poar.)	Stapedius	Stapedius	Stapedius	Stapedius	Stapedius
	---	---	---	Cervicomandibularis	Platysma cervicale	Platysma cervicale	Platysma cervicale	Platysma cervicale	---
	---	---	---	---	Platysma myoides	Platysma myoides	Platysma myoides	Platysma myoides	Platysma myoides
	---	---	---	---	---	Occipitalis	Occipitalis	Occipitalis	Occipitalis
	---	---	---	---	---	Auricularis posterior	Auricularis posterior	Auricularis posterior	Auricularis posterior
	---	---	---	---	Ex. ear mus.*	Ex. ear mus.*	Ex. ear mus.*	Ex. ear mus.*	Ex. ear mus.*
	---	---	---	---	---	Mandibulo-auricularis	---	Mandibulo-auricularis	---
	---	---	---	---	---	---	---	---	Risorius
VENTRAL HYOID MUS.	Interhyoideus	Interhyoideus	Interhyoideus	Interhyoideus	Interhyoideus prof.	---	---	---	---
	---	---	---	---	Sphincter colli supe.	Sphincter colli supe.	—	Sphincter colli supe.	---
	---	---	---	---	—(colli prof. in Echidna)	Sphincter colli prof.	Sphincter colli prof.	Sphincter colli prof.	---
	---	---	---	---	---	Sternofacialis	---	---	---
	---	---	---	---	Cervicalis tra.	---	---	---	---
	---	---	---	---	---	Interscutularis	---	---	---
	---	---	---	---	---	Zygomaticus major	Zygomaticus major	Zygomaticus major	Zygomaticus major
	---	---	---	---	---	Zygomaticus minor	Zygomaticus minor	Zygomaticus minor	Zygomaticus minor
	---	---	---	---	---	Orbito-temporo-auricularis	Frontalis	Frontalis	Frontalis
	---	---	---	---	---	---	Auriculo-orbitalis	Auriculo-orbitalis	Temporoparietalis
	---	---	---	---	---	---	---	---	Auricularis anterior
	---	---	---	---	---	---	Auricularis superior	Auricularis superior	Auricularis superior
	---	---	---	---	Orbicularis oculi	Orbicularis oculi	Orbicularis oculi	Orbicularis oculi	Orbicularis oculi
	---	---	---	---	---	---	Zygomatico-orbicularis	Zygomatico-orbicularis	---
	---	---	---	---	---	---	---	---	Depressor supercilii
	---	---	---	---	---	---	Corrugator supercilii	Corrugator supercilii	Corrugator supercilii
	---	---	---	---	Naso-labialis	Naso-labialis	Naso-labialis	Naso-labialis	Le. labii sup.
	---	---	---	---	---	---	---	---	Le. labii sup. al. nasi
	---	---	---	---	---	Procerus	---	---	Procerus
					Buccinatorius	Buccinatorius	Buccinatorius	Buccinatorius	Buccinatorius
	---	---	---	---	---	Dilatator nasi	---	---	---
	---	---	---	---	---	Maxillo-naso-labialis	Maxillo-naso-labialis	Maxillo-naso-labialis	Nasalis
	---	---	---	---	---	---	---	---	Depressor septi nasi
	---	---	---	---	---	Le. anguli oris facialis	Le. anguli oris facialis	Le. anguli oris facialis	Le. anguli oris facialis
	---	---	---	---	Orbicularis oris	Orbicularis oris	Orbicularis oris	Orbicularis oris	Orbicularis oris
	---	---	---	---	---	---	---	---	Depressor labii inf.
	---	---	---	---	---	---	---	---	Depressor anguli oris
	---	---	---	---	Mentalis	---	Mentalis	Mentalis	Mentalis

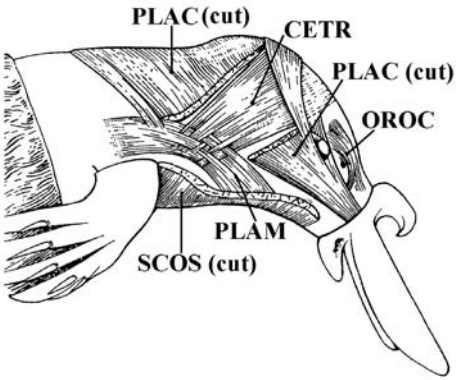

Fig. 5.8 *Ornithorhynchus anatinus* (Mammalia, Monotremata): lateral view of the deep facial musculature; muscles such as the interhyoideus profundus, buccinatorius, orbicularis oris and mentalis are not shown (modified from Lightoller 1942 and Saban 1971; the nomenclature of the structures illustrated basically follows that used in the present work; anterior is to the right). CETR, cervicalis transversus; OROC, orbicularis oculi; PLAC, PLAM, platysma cervicale and platysma myoides; SCOS, sphincter colli superficialis.

at least in dipnoans it is most likely fused with the ventral hyoid muscle interhyoideus (Fig. 5.3; see Chapter 4). The number of hyoid muscles found in extant mammals, and particularly in therians (placentals + marsupials), is much greater than that found in extant non-mammalian tetrapods (Tables 5.3, 5.4). Also, in non-mammalian vertebrates the hyoid muscles are mainly restricted to the region of the second branchial arch and occasionally to the mandibular and/or neck regions (Figs. 5.3, 5.5, 5.6), whereas in extant mammals these muscles extend more anteriorly, covering much of the anterior region of the head (Figs. 5.8, 5.12, 5.14). With the exception of styloideus, stylohyoideus, digastricus posterior, jugulohyoideus and stapedius, all the mammalian hyoid muscles listed in Tables 5.3–5.4 are usually designated as facial muscles because they attach to freely movable skin and are associated with the display of facial expressions (Figs. 5. 8, 5.12, 5.14, 5.18, 5.22–5.27; e.g., Ruge 1885–1910; Boas and Paulli, 1908; Lightoller 1928–1942; Huber 1930-1931; Edgeworth 1935; Andrew 1963; Gasser 1967; Jouffroy and Saban 1971; Saban 1971; Seiler 1971–1980; Minkoff 1979; Preuschoft 2000; Schmidt and Cohn 2001; Burrows and Smith 2003; Burrows et al. 2006; Burrows 2008; Diogo et al. 2009b). Some researchers have suggested that the mammalian facial muscles derive exclusively from the interhyoideus of non-mammalian tetrapods (e.g., Huber 1930ab, 1931), but our dissections and comparisons support Lightoller (1942), Jouffroy and Saban (1971) and others, who claim that at least some of these muscles (e.g., platysma cervicale, platysma myoides, mandibulo-auricularis) correspond to part of the dorso-medial hyoid musculature (e.g., cervicomandibularis) of other tetrapods (Tables 5.3–5.4 and Figs. 5.6, 5.8, 5.12, 5.14, 5.18, 5.22–5.27). The evolution

and homologies of the mammalian facial muscles have been, and continue to be, controversial. In light of the overall analysis of the data obtained by our dissections and comparisons and by a review of the literature, it can be said that some of the hypotheses proposed in Table 5.3 and shown in Table 5.4 (black arrows) are in fact well supported by the data that are now available. For instance, the data available on topology, functional morphology, development and innervation strongly suggest that the platysma cervicale, platysma myoides, occipitalis, auricularis posterior and some of the extrinsic muscles of the ear (e.g., antitragicus, helicis and/or transversus and obliquus auriculae) of mammals have a common phylogenetic and ontogenetic origin (e.g., Boas and Paulli 1908; Huber 1930ab, 1931; Gasser 1967; Jouffroy and Saban 1971; Saban 1971; Diogo et al. 2009b; this work) (Figs. 5.8, 5.12, 5.14, 5.18, 5.22–5.27 and Tables 5.3–54). These same lines of evidence also suggest that the interhyoideus profundus, sphincter colli superficialis, sphincter colli profundus, naso-labialis, levator labii superioris, levator labii superioris alaeque nasi, buccinatorius, dilatator nasi, maxillo-naso-labialis, nasalis, depressor septi nasi, levator anguli oris facialis, orbicularis oris, depressor labii inferioris, depressor anguli oris and/or mentalis of mammals derive from the interhyoideus (Figs. 5.8, 5.12, 5.14, 5.18, 5.22–5.27 and Tables 5.3–5.4; see also, e.g., Gasser 1967; Jouffroy and Saban 1971; Saban 1971; Seiler 1971–1980). However, it is still not clear, for instance, if the therian mandibulo-auricularis (a muscle that is usually deep to all the other mammalian facial muscles) is phylogenetically more closely related to the other facial muscles than to deeper dorso-median muscles such as the stylohyoideus, digastricus posterior, jugulohyoideus and stapedius (e.g., Lightoller 1934; Jouffroy and Saban 1971; Seiler 1971–1980; this work) (Tables 5.3–5.4 and Fig. 5.12). Also, it is commonly accepted that muscles such as the zygomaticus major, zygomaticus minor, orbito-temporo-auricularis, frontalis, auriculo-orbitalis, temporoparietalis, auricularis anterior and auricularis superior derive from the sphincter colli profundus and/or superficialis, but Seiler (1971–1980), based on his comparative and developmental studies, argues that at least some of these muscles may derive from the platysma cervicale and/or myoides (Tables 5.3–5.4). Seiler carried out an impressive series of studies on the facial muscles of mammals, which are, unfortunately, often neglected by non-German-speaking authors. However, some of Seiler's methods and interpretations are questionable. For example, in his 1980 developmental study of primates and tree-shrews, he argues that the facial muscles that are more superficial in early developmental stages are necessarily part of a 'platysma anlage' and thus derived phylogenetically from an 'ancestral platysma', whereas the majority of the other facial muscles are part of a 'sphincter colli profundus' anlage and thus are derived phylogenetically from a 'primitive sphincter colli profundus'. This contrasts with Gasser's (1967) study of the ontogeny of the facial muscles of modern humans, in which various other anlages are recognized in early developmental stages. Also, it should be

stressed that in adult mammals, including monotremes, at least some portions of the platysma (cervicale and/or myoides) lie deep to facial muscles such as the sphincter colli superficialis and even to facial muscles that Seiler categorizes as 'sphincter colli profundus derivatives' (e.g., part of the orbicularis oris and/or levator labii superioris) (e.g., Boas and Paulli 1908; Lightoller 1928–1942; Huber 1930–1931; Andrew 1963; Jouffroy and Saban 1971; Saban 1971; Minkoff 1979; Preuschoft 2000; Schmidt and Cohn 2001; Burrows and Smith 2003; Burrows et al. 2006; this work) (Tables 5.3–5.4 and Fig. 5.8). The majority of researchers consider that the sphincter colli of mammals derives from the interhyoideus of other tetrapods, so it is likely that the mammalian sphincter colli was plesiomorphically mainly superficial, and not deep, to the other hyoid muscles (the interhyoideus of other tetrapods is usually superficial not only to the other hyoid muscles, but to all the other muscles of the head). Monotremes are plesiomorphic mammals, and both the platypus and the echidna have a well-developed, broad sphincter colli superficialis that is superficial to most of the other facial muscles (the platypus actually lacks a sphincter colli profundus, although it has an interhyoideus profundus that seems to be derived from the deeper part of the interhyoideus; in the echidna most of the sphincter colli is superficial to the other facial muscles, but part of it passes deep to these muscles, forming a sphincter colli profundus: e.g., Huber 1930a; Lightoller 1942; Jouffroy and Saban 1971; this work) (Tables 5.3–5.4 and Fig. 5.8). A more detailed comparative analysis of the development and innervation of the hyoid group of muscles in vertebrates, including various key mammalian groups such as monotremes, is needed to clarify these and other controversial issues regarding the origin, homologies and evolution of the mammalian facial muscles and to test the hypotheses proposed in Tables 5.3–5.4.

Branchial, Pharyngeal and Laryngeal Muscles (Tables 5.5–5.6)

The muscles listed in Tables 5.5 and 5.6 correspond to the branchial muscles *sensu lato* of Edgeworth (1935). As explained in Chapter 4, they can be divided into three groups: the first comprises the 'true' branchial muscles, which are subdivided into the branchial muscles *sensu stricto* and the protractor pectoralis and its derivatives; the second includes the pharyngeal muscles, which are only present as independent structures in extant mammals; and the third group is made up of the laryngeal muscles (see Chapter 4 for more details on these groups of muscles and their innervation).

Sarcopterygians such as coelacanths, dipnoans and many amphibians retain various branchial muscles *sensu stricto* (e.g., Bischoff 1840; Owen 1841; Cuvier and Laurillard 1849; Pollard 1892; Gaupp 1896; Allis 1897, 1922; Danforth 1913; Lubosch 1914; Sewertzoff 1928; Edgeworth 1935;

Brock 1938; Piatt 1938; Millot and Anthony 1958; Osse 1969; Larsen and Guthrie, 1975; Greenwood 1977; Wiley 1979ab; Jollie 1982; Bemis et al. 1983, 1997; Lauder and Shaffer 1985, 1988; Bemis 1986; Reilly and Lauder 1989, 1990, 1991; Miyake et al. 1992; Wilga et al. 2000; Kardong 2002; Carroll and Wainwright 2003; Johanson 2003; Kleinteich and Haas 2007; this work) (Tables 5.5–5.6). Most authors agree that the branchial muscles *sensu stricto* are not present as a group in extant reptiles and extant mammals (Tables 5.5–5.6). For instance, many adult reptiles have only one branchial muscle *sensu stricto*, the hyobranchialis (which is often named 'branchiohyoideus' or 'branchiomandibularis' in the literature; see Tables 5.3–5.4 and Chapter 7). The two branchial muscles *sensu stricto* seen in adult reptiles such as the 'lizard' *Euspondylus*, the hyobranchialis and 'ceratohyoideus', seem to be the result of a subdivision of the subarcualis rectus I sensu Edgeworth (1935). That is, the 'ceratohyoideus' found in these reptiles seems to correspond to/derive from part of the hyobranchialis of other reptiles (Tables 5.5–5.6 and Fig. 5.7; see Chapter 7). Adult extant mammals lack all the branchial muscles *sensu stricto* except the subarcualis rectus I sensu Edgeworth (1935) (present in most adult mammals, being often divided into a ceratohyoideus and a stylopharyngeus: see below), the subarcualis rectus II (usually present only in adult marsupials) and the subarcualis rectus III (usually present only in adult monotremes) (e.g., Edgeworth 1935; Smith 1992).

Edgeworth (1935) claimed that the pharyngeal muscles of mammals are not derived from branchial muscle plates, but from a separate *de novo* condensation of myoblasts surrounding the pharyngeal epithelium. He did not consider the mammalian pharyngeal muscles to be homologous with the 'pharyngeal muscles' of some amphibians (which probably correspond to branchial muscles *sensu stricto*, such as the levatores arcuum branchialum and/or the transversus ventralis: see Chapter 6) and some reptiles (which are seemingly derived from the hyoid musculature: see Chapter 7) (e.g., Piatt 1938; Schumacher 1973; Smith 1992). However, our dissections and literature research support Smith's (1992) and Noden and Francis-West's (2006) claims that one of the mammalian muscles included in Edgeworth's pharyngeal group, the stylopharyngeus, is not a *de novo* structure, but is instead a derivative of the branchial musculature *sensu stricto* and namely of the subarcualis rectus I (Tables 5.5–5.6). The mammalian stylopharyngeus and the reptilian 'subarcualis rectus I' (see below) are among the few muscles in either taxon innervated by the glossopharyngeal nerve (CNIX): most of the mammalian pharyngeal muscles are innervated, instead, by the vagus nerve (CNX). In fact, in many mammals, including primates such as *Macaca*, the ceratohyoideus and stylopharyngeus are closely related and are innervated by the same ramus of the glossopharyngeal nerve (buccal ramus sensu Sprague 1944ab; see also Saban 1968).

Table 5.5 Branchial, pharyngeal and laryngeal muscles of adults of representative sarcopterygian taxa (see caption of Table 5.1, text and also Table 5.6 and Figs. 5.1–5.27).

Actinistia: *Latimeria chalumnae* (Coelacanth)	Dipnoi: *Lepidosiren paradoxa* (South American lungfish)	Amphibia: *Ambystoma ordinarium* (Michoacan stream salamander)	Reptilia: *Timon lepidus* (Ocellated 'lizard')	Mammalia (Monotremata): *Ornithorhynchus anatinus* (Platypus)	Mammalia (Rodentia): *Rattus norvegicus* (Norwegian rat)	Mammalia (Dermoptera): *Cynocephalus volans* (Philippine colugo)	Mammalia (Scandentia): *Tupaia* sp. (Tree-shrew)	Mammalia (Primates): *Homo sapiens* (Modern human)
Branchial muscles *sensu stricto* [adult bony fish and amphibians often have various branchial muscles sensu stricto, e.g. the constrictores branchiales, levatores arcuum branchialium, transversi ventrales and/or subarcuales recti, among others: e.g., Edgeworth 1935; Kesteven 1942–1945]	**Branchial muscles *sensu stricto*** [see on the left]	**Branchial muscles *sensu stricto*** [see on the left]	— [absent as a group; adult 'lizards' such as *Timon* lack all the branchial muscles *sensu stricto*, except the derivatives of the 'subarcualis 1', e.g., the hyobranchialis and 'ceratohyoideus': see text]	— [absent as a group; the only branchial muscles *sensu stricto* that are present as independent structures in adult monotremes such as the platypus are the subarcualis rectus III, the ceratohyoideus, and seemingly the stylopharyngeus, the two latter muscles being probably the result of a subdivision of the subarcualis rectus I; it should be noted that a subarcualis rectus II is present in extant mammals such as marsupials: e.g., Edgeworth 1935; see text]	— [absent as a group; the only branchial muscles *sensu stricto* that are present as independent structures in adult rodents such as the Norwegian rat are the ceratohyoideus and seemingly the stylopharyngeus: see text]	— [absent as a group; the only branchial muscles *sensu stricto* that are present as independent structures in adult colugos are the ceratohyoideus and seemingly the stylopharyngeus: see text]	— [absent as a group; the only branchial muscles *sensu stricto* that are present as independent structures in adult tree-shrews as *Tupaia* are the ceratohyoideus and seemingly the stylopharyngeus: see text]	— [absent as a group; the only branchial muscle *sensu stricto* that is present as an independent structure in adult modern humans is seemingly the stylopharyngeus: see text]

— [see above]	— [see above]	— [see above]	**Hyobranchialis** (part or totality of subarcualis rectus I or of branchiohyoideus sensu Edgeworth 1935 and Herrel et al. 2005) [see text and Chapter 7]	**Stylopharyngeus** [the data now available on innervation, development, topology and comparative anatomy indicate that the mammalian stylopharyngeus is probably not a *de novo* pharyngeal muscle sensu Edgeworth, but instead a derivative of the branchial muscles *sensu stricto*: see text and above]	**Stylopharyngeus** [see text and above]	**Stylopharyngeus** [see text and above]	**Stylopharyngeus** [see text and above]	**Stylopharyngeus** [see text and above]
— [see above]	— [see above]	— [see above]	**'Ceratohyoideus'** (probably corresponds to the ceratohyoideus sensu Abdala and Moro 2003) [see text and Chapter 7]	**Ceratohyoideus** [see text and above]	**Ceratohyoideus** (the ceratohyoideus sensu House 1953 corresponds to the branchiohyoideus sensu Sprague 1943 and to the hyoideus latus, keratohyoideus brevis and intercornualis sensu Saban 1968) [see text and above]	**Ceratohyoideus** [see text and above]	**Ceratohyoideus** (interhyoideus sensu Le Gros Clark 1926) [see text and above]	**—** [absent as an independent muscle in modern humans, but present in other primates: e.g., Sprague 1944b; Saban 1968; this work]
—	—	—	—	**Subarcualis rectus III** [see text and above]	—	—	—	—

Table 5.5 contd...

Table 5.5 contd...

Actinistia: *Latimeria chalumnae* (Coelacanth)	Dipnoi: *Lepidosiren paradoxa* (South American lungfish)	Amphibia: *Ambystoma ordinarium* (Michoacan stream salamander)	Reptilia: *Timon lepidus* (Ocellated 'lizard')	Mammalia (Monotremata): *Ornithorhynchus anatinus* (Platypus)	Mammalia (Rodentia): *Rattus norvegicus* (Norwegian rat)	Mammalia (Dermoptera): *Cynocephalus volans* (Philippine colugo)	Mammalia (Scandentia): *Tupaia* sp. (Tree-shrew)	Mammalia (Primates): *Homo sapiens* (Modern human)
— [the protractor pectoralis is not present as an independent structure in *Latimeria*, but it is present in numerous sarco-pterygians and actino-pterygians and was very likely present in the common ancestor of these two groups: e.g., Edgeworth 1935; Straus and Howell 1936; this work]	**Protractor pectoralis** (cucullaris sensu Edgeworth 1935)	**Protractor pectoralis** (cucullaris sensu Edgeworth 1935)	**Trapezius** (capitodorsoclavicularis sensu Tsuihiji 2007)	**Acromiotrapezius** (anterior trapezius sensu Saban 1971) [the anterior and posterior trapezius sensu Saban 1971, are well separate in platypus and clearly correspond to the acromiotrapezius and spinotrapezius of other mammals; according to Edgeworth 1935 in monotremes the subarcualis I derives from the branchial arch 1, while the subarcualis III, trapezius and sternocleidomastoideus derive from the branchial arch 3; but see text]	**Acromiotrapezius** (dorsoscapularis superior, anterior trapezius or trapezius superior sensu Greene 1935) [it is somewhat blended with the spinotrapezius, but is considered as a separate muscle by many authors, see, e.g., Greene 1935; according to Edgeworth 1935 in placental mammals the subarcualis I usually derives from the branchial arch 1 (in some cases it may atrophy during development as, e.g., in *Manis* and seemingly in most anthropoids, including modern humans), while the acromiotrapezius, spinotrapezius, cleido-occipitalis, cleidomastoideus, sternomastoideus	**Acromiotrapezius** [contrary to what is stated by Macalister 1872 and Gunnell and Simmons 2005 in the colugos dissected by us both the spinotrapezius and the acromiotrapezius are present as independent structures: the former mainly inserts on the scapular spine, while the latter mainly inserts on the acromion; this is also the case in the specimens examined by, e.g., Leche 1886: see his fig. 8; as stated by Macalister 1872 in colugos the trapezius complex (= acromiotrapezius	**Trapezius** [in both *Tupaia* and *Ptilocercus*, it is a single, continuous muscle, which seems to correspond to the acromiotrapezius + spinotrapezius of other mammals: e.g., Le Gros Clark 1924, 1926; George 1977; this work]	**Trapezius** [it has 3 parts, i.e., the acromiotrapezius, claviculotrapezius and spinotrapezius sensu Kardong 2002, which are not differentiated into separate muscles, as is the case in various other mammals; the human 'claviculo-trapezius' probably corresponds to part of the trapezius of, e.g., *Tupaia*, although it may possibly correspond to the cleido-occipitalis of this latter taxon: e.g., Jouffroy 1971; Table 5.6]

					and sterno-cleidomastoideus derive from the branchial arch 2; also according to Edgeworth 1935 in certain adult placentals, e.g., *Sus*, there is a single branchial arch, which gives rise to all the muscles listed above; but see text]	+ spinotrapezius sensu this volume) does not reach the cranium anteriorly and does not attach on the clavicle posteriorly; i.e. this trapezius complex does not include a 'cleido-trapezius' sensu Kardong 2002 and does not seem to include the cleido-occipitalis sensu this volume]		
—	—	— [but see Chapter 6]	— [but see Chapter 7]	**Spinotrapezius** (posterior trapezius sensu Saban 1971: see above)	**Spinotrapezius** (dorsoscapularis, inferior posterior trapezius or trapezius inferior superior sensu Greene 1935) [see above]	**Spinotrapezius** [see above]	— [see above]	— [see above]
—	—	—	—	**Dorso-cutaneous** [present in monotremes as well as in some other extant mammals; seemingly corresponds to part of the trapezius of tetrapods such as 'lizards': e.g., Jouffroy 1971; Jouffroy and Lessertisseur 1971]	—	—	—	—

Table 5.5 contd...

Table 5.5 contd...

Actinistia: *Latimeria chalumnae* (Coelacanth)	Dipnoi: *Lepidosiren paradoxa* (South American lungfish)	Amphibia: *Ambystoma ordinarium* (Michoacan stream salamander)	Reptilia: *Timon lepidus* (Ocellated 'lizard')	Mammalia (Monotremata): *Ornithorhynchus anatinus* (Platypus)	Mammalia (Rodentia): *Rattus norvegicus* (Norwegian rat)	Mammalia (Dermoptera): *Cynocephalus volans* (Philippine colugo)	Mammalia (Scandentia): *Tupaia* sp. (Tree-shrew)	Mammalia (Primates): *Homo sapiens* (Modern human)
—	—	—	—	— [according to Edgeworth 1935 the cleido-occipitalis of mammals, e.g., *Tatusia* seems to correspond to part of the reptilian trapezius, but the 'cleido-occipitalis' of, e.g., the placental carnivores may well correspond to the part of the reptilian sternocleidomastoideus]	**Cleido-occipitalis** (the cleido-occipitalis sensu Wood 1870 and Edgeworth 1935 corresponds to the clavotrapezius and cleido-occipitalis cervicalis sensu Greene 1935) [the position and orientation of the fibers of the cleido-occipitalis of, e.g., *Rattus* and *Tupaia* are more similar to those of the monotreme sterno-cleidomastoideus than to those of the monotreme trapezius; also, according to Greene 1935 in, e.g., rats the cleido-occipitalis, sternomastoideus and cleidomastoideus are all innervated by the "spinal accessory and *third* and *fourth* cervical nerves through the subtrapezial	— [see acromiotrapezius above]	**Cleido-occipitalis** [see on the left]	— [usually absent as an independent muscle, but may be found in a few modern humans: e.g., Wood 1870]

					plexus", while the spinotrapezius and acromiotrapezius are innervated by the "spinal accessory and *second* and *third* cervical nerves through the subtrapezial plexus"]			
—	—	— [but see Chapter 6]	**Sternocleidomastoideus** (episternocleido-mastoideus sensu Herrel et al. 2005; capiticleidoepisternalis sensu Tsuihiji 2007) [see on the left]	**Cleidomastoideus** [as suggested by Howell 1937a and Saban 1971, in the platypus specimens dissected by us both the sternomastoideus and cleidomastoideus are present as independent structures]	**Cleidomastoideus**	**Cleidomastoideus** [contrary to what is suggested in Leche's 1986 fig. 4, the colugos dissected have both a sternomastoideus and a cleidomastoideus, which are well separated; each of these muscles attaches anteriorly on the mastoid process by a thin and long tendon]	**Cleido-mastoideus**	**Sternocleido-mastoideus** [including sternal and clavicular heads, which clearly seem to correspond to the sterno-mastoideus and cleido-mastoideus of other mammals, but are not really differentiated into independent muscles]
—	—	—	—	**Sternomastoideus**	**Sternomastoideus**	**Sternomastoideus**	**Sterno-mastoideus**	—

Table 5.5 contd...

Table 5.5 contd...

Actinistia: *Latimeria chalumnae* (Coelacanth)	Dipnoi: *Lepidosiren paradoxa* (South American lungfish)	Amphibia: *Ambystoma ordinarium* (Michoacan stream salamander)	Reptilia: *Timon lepidus* (Ocellated 'lizard')	Mammalia (Monotremata): *Ornithorhynchus anatinus* (Platypus)	Mammalia (Rodentia): *Rattus norvegicus* (Norwegian rat)	Mammalia (Dermoptera): *Cynocephalus volans* (Philippine colugo)	Mammalia (Scandentia): *Tupaia* sp. (Tree-shrew)	Mammalia (Primates): *Homo sapiens* (Modern human)
—	—	— [see on the right]	— [plesiomorphically reptiles have no muscular pharynx; reptiles such as crocodylians do possess a secondary palate and a means to constrict the pharynx, but this constrictor is a derivative of an hyoid muscle, the interhyoideus: see Chapter 7]	**Constrictor pharyngis** [there is only one constrictor of the pharynx in monotremes, but the cricothyroideus and the palatopharyngeus are already differentiated in these mammals; some authors consider that amphibians may have 'pharyngeal muscles' lying between the hyoid apparatus and the pharyngeal wall: e.g., Piatt 1938; Smith 1992; however, these 'pharyngeal muscles' seem in fact to be branchial muscles *sensu stricto*, e.g., the levatores arcuum branchialium and/or the transversi ventrales sensu Edgeworth 1935: see, e.g., Saban, 1971, p. 708]	**Constrictor pharyngis medius** (ceratopharyngeus and/or hyopharyngeus sensu House 1953)	**Constrictor pharyngis medius**	**Constrictor pharyngis medius**	**Constrictor pharyngis medius** [including the pars ceratopharyngea and the pars chondro-pharyngea sensu Terminologia Anatomica 1998, which insert on the hyoid bone and on the thyroid cartilage, respectively]

—	—	—	—	—	**Constrictor pharyngis inferior** [as described by Saban 1968, the constrictor pharyngis inferior of therian mammals is often divided into a pars thryropharyngea attaching on the thyroid cartilage, a pars cricopharyngea attaching on the cricoid cartilage, and a pars intermedia lying between these two myological structures; the pars intermedia is often reduced in mammals such as primates and is often absent in mammals such as rodents]	**Constrictor pharyngis inferior** [see on the left]	**Constrictor pharyngis inferior** [see on the left]	**Constrictor pharyngis inferior** [see on the left]
—	—	—	—	**Cricothyroideus** [in the platypus specimens dissected by us the cricothyroideus is seemingly not divided into a pars obliqua and a pars recta; it should be noted that in terms of both its ontogeny and phylogeny the mammalian cricothyroideus is clearly a pharyngeal muscle, and not a	**Cricothyroideus** [including a pars obliqua and a pars recta: see on the right]	**Cricothyroideus** [including a pars obliqua and a pars recta, which are more separated than in *Rattus* and *Tupaia* but are not as separated as in modern humans]	**Cricothyroideus** [including a pars obliqua and a pars recta: see on the left]	**Cricothyroideus** [including a pars obliqua and a pars recta: see on the left]

Table 5.5 contd...

Table 5.5 contd...

Actinistia: *Latimeria chalumnae* (Coelacanth)	Dipnoi: *Lepidosiren paradoxa* (South American lungfish)	Amphibia: *Ambystoma ordinarium* (Michoacan stream salamander)	Reptilia: *Timon lepidus* (Ocellated 'lizard')	Mammalia (Monotremata): *Ornithorhynchus anatinus* (Platypus)	Mammalia (Rodentia): *Rattus norvegicus* (Norwegian rat)	Mammalia (Dermoptera): *Cynocephalus volans* (Philippine colugo)	Mammalia (Scandentia): *Tupaia* sp. (Tree-shrew)	Mammalia (Primates): *Homo sapiens* (Modern human)
				laryngeal muscle as it is sometimes suggested in the literature: e.g., Edgeworth 1935; Negus 1949; DuBrul 1958; Starck and Schneider 1960; Saban 1968; Wind 1970; Crelin 1987; Harrison 1995; this work]				
—	—	—	—	**—** [according to Edgeworth 1935 the constrictor pharyngis superior is missing in monotremes and was very likely poorly developed in the first placentals, being probably similar to the 'glossopharyngeus 'of, e.g., rats (see on the right); according to that author the constrictor pharyngis superior only became a broad muscle as that found in, e.g., modern humans later in evolution; House 1953 and Smith 1992 suggest that the pterygopharyngeus	**Constrictor pharyngis superior** (glossopharyngeus sensu House 1953) [the constrictor pharyngis superior of rats seemingly includes only a pars glossopharyngea: see on the left]	**Constrictor pharyngis superior** [our dissections indicate that it includes a pars glossopharyngea and possibly a pars buccopharyngea]	**Constrictor pharyngis superior** [seemingly includes a pars buccopharyngea, a pars pterygo-pharyngea (corresponding to the pterygo-pharyngeus of, e.g., rats and colugos? see on the left), and possibly a pars glosso-pharyngea: e.g., Sprague 1944a; this work]	**Constrictor pharyngis superior** [includes a pars buccopharyngea, a pars pterygo-pharyngea (corresponding to the pterygo-pharyngeus of, e.g., rats and colugos? see on the left), a pars mylopharyngea, and a pars glossopharyngea]

				of, e.g., rats probably correspond to part of the constrictor pharyngis superior of modern humans; in our opinion it is more plausible to assume that the pterygopharyngeus became part of the human constrictor pharyngis superior (see, e.g., Fig. 15) than to assume that a muscle such as the 'glossopharyngeus' of rats migrated superiorly in order to attach on the hard palate; however, until more data are available, one cannot completely discard the hypothesis that the pterygopharyngeus of, e.g., rats and colugos might be simply missing or deeply blended with the palatopharyngeus in mammals such as *Tupaia* and *Homo*: Table 5.6]				
—	—	—	—	—	**Pterygopharyngeus** [see above]	**Pterygo-pharyngeus** [see above]	— [see above]	— [see above]
—	—	—	—	**Palatopharyngeus**	**Palatopharyngeus** [more blended with the salpingo-pharyngeus than in modern humans]	**Palato-pharyngeus** [more blended with the salpingo-pharyngeus than in modern humans]	**Palato-pharyngeus** [more blended with the salpingo-pharyngeus than in modern humans]	**Palato-pharyngeus**

Table 5.5 contd...

Table 5.5 contd...

Actinistia: *Latimeria chalumnae* (Coelacanth)	Dipnoi: *Lepidosiren paradoxa* (South American lungfish)	Amphibia: *Ambystoma ordinarium* (Michoacan stream salamander)	Reptilia: *Timon lepidus* (Ocellated 'lizard')	Mammalia (Monotremata): *Ornithorhynchus anatinus* (Platypus)	Mammalia (Rodentia): *Rattus norvegicus* (Norwegian rat)	Mammalia (Dermoptera): *Cynocephalus volans* (Philippine colugo)	Mammalia (Scandentia): *Tupaia* sp. (Tree-shrew)	Mammalia (Primates): *Homo sapiens* (Modern human)
—	—	—	—	—	—	—	—	**Musculus uvulae** [according to Edgeworth 1935 this muscle is only found in a few mammals such as primates, corresponding to part of the palato-pharyngeus of other mammals]
—	—	—	—	—	**Levator veli palatini** [corresponds to part of the palatopharyngeus of monotremes: e.g., Edgeworth 1935; Saban 1968; this work]	**Levator veli palatini**	**Levator veli palatini**	**Levator veli palatini**
—	—	—	—	—	**Salpingopharyngeus** [corresponds to part of the palatopharyngeus of monotremes: e.g., Edgeworth 1935; Saban 1968; this work]	**Salpingo-pharyngeus**	**Salpingo-pharyngeus**	**Salpingo-pharyngeus**

Present? Some non-sarcopterygian vertebrates, e.g., *Polypterus* have a 'constrictor laryngis' and/or a 'dilatator laryngis', but it is not clear if these muscles actually correspond to the constrictor laryngis and dilatator laryngis of sarco-pterygians and thus if these latter muscles are plesio-morphically present in osteichthyans: e.g., Edgeworth 1935; the few descriptions of the laryngeal region of *Latimeria chalumnae* do not allow us to appropriately discern if these muscles are, or are not, present in this taxon: e.g., Millot and Anthony 1958]	**Constrictor laryngis**	**Constrictor laryngis** [see on the right]	**Constrictor laryngis** [see on the right]	— [recent developmental works indicate that in amphibians, e.g., salamanders and reptiles, e.g., chickens laryngeal muscles such as the dilatator laryngis are at least partially derived ontogenetically from somites and possibly also from branchial mesoderm: e.g., Piekarski and Olsson 2007; the ontogenetic derivation of these muscles is thus actually similar to that of muscles such as the protractor pectoralis of amphibians and the trapezius/sternocleidomastoideus of reptiles: see text; according to Piekarski and Olsson, 2007 in some cases the constrictor oesophagus might also be at least partially derived ontogenetically from somites: see text]	—	—	—	—

Table 5.5 contd...

Table 5.5 contd...

Actinistia: *Latimeria chalumnae* (Coelacanth)	Dipnoi: *Lepidosiren paradoxa* (South American lungfish)	Amphibia: *Ambystoma ordinarium* (Michoacan stream salamander)	Reptilia: *Timon lepidus* (Ocellated 'lizard')	Mammalia (Monotremata): *Ornithorhynchus anatinus* (Platypus)	Mammalia (Rodentia): *Rattus norvegicus* (Norwegian rat)	Mammalia (Dermoptera): *Cynocephalus volans* (Philippine colugo)	Mammalia (Scandentia): *Tupaia* sp. (Tree-shrew)	Mammalia (Primates): *Homo sapiens* (Modern human)
— [the laryngeus of tetrapods does not seem to be plesio-morphically found in sarcop-terygians, because it is absent in sarcopterygian fish as dipnoans; a detailed study of the laryngeal region of *Latimeria* is however needed in order to support, or to contradict, this hypothesis: see above]	— [see on the left]	**Laryngeus** [the laryngeus and constrictor laryngis of amphibians derive onto-genetically from the same anlage: e.g., Edgeworth 1935]	— [see on the right]	**Thyrocricoarytenoideus** (the thyrocricoarytenoideus sensu Saban 1968 corresponds to the thyroarytenoideus sensu Edgeworth 1935; it has two bundles, which seemingly correspond to the thyroarytenoideus and cricoarytenoideus lateralis of other mammals: that is why we prefer to use the name thyrocricoarytenoideus for the monotreme muscle) [Smith 1992, p. 340, states, that "the laryngeal muscles of mammals and amphibians are innervated by two homologous branches of cranial nerve X, the superior and inferior (or recurrent) laryngeal nerves; in contrast in reptiles (except in Aves) the innervation of the larynx is via a	**Thyroarytenoideus** [mainly divided into superficial and deep bundles]	**Thyroary-tenoideus** [divided into a posterior, medial bundle, and an anterior, lateral part, which seem to correspond respectively to the pars intermedia and pars superioris of fig. 69 of Starck and Schneider 1960; the latter bundle is in turn subdivided into a medial bundle and a lateral bundle, the latter being fused with the cricoarytenoideus posterior and thus seemingly corresponding to the ceratoary-tenoideus lateralis sensu Harrison 1995]	**Thyroary-tenoideus** [mainly divided into superficial and deep bundles]	**Thyroary-tenoideus** [often includes a pars thyroepiglottica, a pars aryepiglottica, a pars superioris, a pars ventricularis and/or a ceratoary-tenoideus lateralis sensu Saban 1968 and Harrison 1995]

				single laryngeal nerve that is a branch of cranial nerve IX"; this supports Edgeworth's 1935 view that the 'laryngei' of reptiles is not homologous to the laryngeus of amphibians and thus to the thyrocricoarytenoideus + arytenoideus of monotremes: Table 5.6]				
—	—	—	—	—	—	—	—	**Vocalis** (thyroary-tenoideus inferior sensu Saban 1968) [according to, e.g., Edgeworth 1935 the vocalis is only found in a few taxa such as some primates, and corresponds to the medial portion of the thyroary-tenoideus of other mammals]
—	—	—	—	—	**Cricoarytenoideus lateralis** (cricoarytenoideus ventralis sensu Whidden 2000) [see thyrocricoary-tenoideus above]	**Cricoarytenoideus lateralis**	**Cricoary-tenoideus lateralis**	**Cricoary-tenoideus lateralis**
—	—	—	—	**Arytenoideus** (interarytenoideus sensu Saban 1971 which is divided into crico-pro-arytenoideus and ary-pro-arytenoideus)	**Arytenoideus** (interarytenoideus sensu Edgeworth 1935)	**Arytenoideus**	**Arytenoideus**	**Arytenoideus transversus**

Table 5.5 contd...

Table 5.5 contd...

Actinistia: *Latimeria chalumnae* (Coelacanth)	Dipnoi: *Lepidosiren paradoxa* (South American lungfish)	Amphibia: *Ambystoma ordinarium* (Michoacan stream salamander)	Reptilia: *Timon lepidus* (Ocellated 'lizard')	Mammalia (Monotremata): *Ornithorhynchus anatinus* (Platypus)	Mammalia (Rodentia): *Rattus norvegicus* (Norwegian rat)	Mammalia (Dermoptera): *Cynocephalus volans* (Philippine colugo)	Mammalia (Scandentia): *Tupaia* sp. (Tree-shrew)	Mammalia (Primates): *Homo sapiens* (Modern human)
—	—	—	—	—	—	—	—	**Arytenoideus obliquus** [it is commonly accepted that the arytenoideus transversus and arytenoideus obliquus derive from the arytenoideus of other mammals; however, as the pars aryepiglottica is seemingly derived from the thyroary-tenoideus, the possibility that the arytenoideus obliquus also derives from this latter muscle, and not from the arytenoideus, cannot be ruled out: e.g., Saban 1968; Table 5.6]

Present? See constrictor laryngis above	**Dilatator laryngis** [see on the right]	**Dilatator laryngis** [see on the right]	**Dilatator laryngis** [see on the right]	**Cricoarytenoideus posterior** (cerato-crico-arytenoideus sensu Saban 1971) [the cricoarytenoideus posterior of mammals corresponds to the dilatator laryngis of reptiles, amphibians and dipnoans, which is not homologous to the 'dilatator laryngis' of the actinopterygians *Amia* and *Lepisosteus* nor to the 'dilatator laryngis' of the actinopterygian *Polypterus*, according to Edgeworth 1935]	**Cricoarytenoideus posterior** (cricoarytenoideus dorsalis sensu Whidden 2000)	**Cricoarytenoideus posterior**	**Cricoary-tenoideus posterior**	**Cricoary-tenoideus posterior** [including the ceratocricoideus sensu Harrison 1995, which, according to this author, is found in about 63% of modern humans]

Table 5.6 Scheme illustrating the authors' hypotheses regarding the homologies of the branchial, pharyngeal and laryngeal muscles of adults of representative sarcopterygian taxa (see caption of Table 5.2, text, and also Table 5.5 and Figs. 5.1–5.27). ab. = absent; ap. = apparatus; br. = branchial; co. = constrictor; fu. = functional; le. = levator; mus. = muscles; post. = posterior; pre. = present; pro. = protractor; st. = *sensu stricto*.

		Latimeria (4 mus.-not st.*)	*Lepidosiren* (3 mus.-not st.*)	*Ambystoma* (4 mus.-not str.*)	*Timon* (4 mus.-not br. st.*)	*Ornithorhynchus* (11 mus.-not br. st.*)	*Rattus* (17 mus.-not br. st.*)	*Cynocephalus* (16 mus.-not br. st.*)	*Tupaia* (15 mus.-not br. st.*)	*Homo* (16 mus.-not br. st.*)
TRUE BRANCHIAL MUS.	STRICTO*	Fu. mus.br. ap.*	Fu. mus. br. ap.*	Fu. mus.br. ap*	— (ab. as group, see text)	— (ab. as group, see text)	— (ab. as group, see text)	— (ab. as group, see text)	— (abs. as group, see text)	— (abs. as group, see text)
		---	---	---	Hyobranchialis*	Stylopharyngeus*	Stylopharyngeus*	Stylopharyngeus*	Stylopharyngeus*	Stylopharyngeus*
		---	---	---	'Ceratohyoideus' *	Ceratohyoideus*	Ceratohyoideus*	Ceratohyoideus*	Ceratohyoideus*	---
		---	---	---	---	Subarcualis rectus III*	---	---	---	---
	OTHER	---	Pro. pectoralis	Pro. pectoralis	Trapezius	Acromiotrapezius	Acromiotrapezius	Acromiotrapezius	Trapezius	Trapezius
		---	---	---	---	Spinotrapezius	Spinotrapezius	Spinotrapezius	---	---
		---	---	---	---	Dorsocutaneous	---	---	---	---
		---	---	---	---	---	Cleido-occipitalis	---	Cleido-occipitalis	---
		---	---	---	Sternocleidomastoideus	Cleidomastoideus	Cleidomastoideus	Cleidomastoideus	Cleidomastoideus	Sternocleidomastoideus
		---	---	---	---	Sternomastoideus	Sternomastoideus	Sternomastoideus	Sternomastoideus	---
PHARYNGEAL MUS.		---	---	---	---	Co. pharyngis	Co.pharyngis medius	Co. pharyngis medius	Co. pharyngis medius	Co. pharyngis medius
		---	---	---	---	---	Co.pharyngis inferior	Co. pharyngis inferior	Co. pharyngis inferior	Co. pharyngis inferior
		---	---	---	---	Cricothyroid	Cricothyroideus	Cricothyroideus	Cricothyroideus	Cricothyroideus
		---	---	---	---	---	Co.pharyngis superior	Co. pharyngis superior	Co. pharyngis superior	Co. pharyngis superior
		---	---	---	---	---	Pterygopharyngeus	Pterygopharyngeus	---	---
		---	---	---	---	Palatopharyngeus	Palatopharyngeus	Palatopharyngeus	Palatopharyngeus	Palatopharyngeus
		---	---	---	---	---	---	---	---	Musculus uvulae
		---	---	---	---	---	Le. veli palatini	Le. veli palatini	Le. veli palatini	Le. veli palatini
		---	---	---	---	---	Salpingopharyngeus	Salpingopharyngeus	Salpingopharyngeus	Salpingopharyngeus
LARYNGEAL MUS.		?see Table 5.5?	Co. laryngis	Co. laryngis	Co. laryngis	---	---	---	---	---
		---	---	Laryngeus	---	Thyrocricoarytenoideus	Thyroarytenoideus	Thyroarytenoideus	Thyroarytenoideus	Thyroarytenoideus
		---	---	---	---	---	---	---	---	Vocalis
		---	---	---	---	---	Cricoarytenoideus lateralis	Cricoarytenoideus lateralis	Cricoarytenoideus lateralis	Cricoarytenoideus lateralis
		---	---	---	---	Arytenoideus	Arytenoideus	Arytenoideus	Arytenoideus	Arytenoideus transversus
		---	---	---	---	---	---	---	---	Arytenoideus obliquus
		?see Table 5.5?	Dilator laryngis	Dilator laryngis	Dilator laryngis	Cricoarytenoideus post.	Cricoarytenoideus post.	Cricoarytenoideus post.	Cricoarytenoideus post.	Cricoarytenoideus post.

Developmental data from monotremes and marsupials show that early in development the stylopharyngeus is similar to the non-mammalian 'subarcualis rectus I' in position, function, and connections. As stressed by Smith (1992), although Edgeworth (1935) did not accept that the stylopharyngeus was derived from the branchial musculature *sensu stricto*, he did state that it develops from a muscle primordium that differs from the one that gives rise to the other pharyngeal muscles. The homology between the mammalian stylopharyngeus and part of the 'subarcualis rectus I' of other tetrapods is further supported by the results of a comparison between adult mammals and adult non-mammalian tetrapods. The stylopharyngeus of mammals usually originates from the styloid process, which is derived from a portion of the second (hyoid) arch; the 'subarcualis rectus I' of non-mammalian taxa is usually associated with this arch (Saban 1971; Smith 1992). Also, as explained above, some reptiles, e.g., 'lizards', have two branchial muscles *sensu stricto*, which apparently are the result of a subdivision of the 'subarcualis rectus I' sensu Edgeworth 1935 (Tables 5.5–5.6 and Fig. 5.7). The more anterior of these muscles, the hyobranchialis (often called 'branchiohyoideus' or 'branchiomandibularis'), usually originates from the hyoid arch (as does the mammalian stylopharyngeus, see above), and connects the hyoid cornu to the epihyal (Fig. 5.7), although in various reptilian groups it extends anterolaterally to attach on the lower jaw (Figs. 7.8, 7.9: that is why it is usually named 'branchiomandibularis' in these groups). We refer to this muscle as the hyobranchialis, because it is not homologous with the hyoid muscle branchiohyoideus of amphibians (Chapter 6) or with the hypobranchial muscle branchiomandibularis of actinopterygian fish such as cladistians, chondrosteans and *Amia* (see above). The most posteriorly situated muscle in 'lizards', often named the 'ceratohyoideus', usually connects the hyoid arch to other (more posterior) branchial arches, as does the mammalian ceratohyoideus (Tables 5.5–5.6 and Figs. 5.7 and 5.11). It should be noted that in various mammals, such as colugos and tree-shrews, the stylopharyngeus does not reach the styloid process, i.e., it may originate from more distal hyoid structures such as the epihyal (as does the reptilian hyobranchialis; e.g., Sprague 1942, 1943, 1944ab; Saban 1968; this work) (Fig. 5.7). This observation, together with the other data available (see above), suggests that the combination of stylopharyngeus and the ceratohyoideus in mammals, and the combination of hyobranchialis and the 'ceratohyoideus' in reptiles, are both the result of the subdivision of the 'subarcualis rectus I' sensu Edgeworth 1935 (Tables 5.5–5.6). However, this does not mean that the stylopharyngeus of mammals is necessarily the homologue of the reptilian hyobranchialis, for one cannot refute the hypothesis that the subdivision of the 'subarcualis rectus I' into two muscles occurred more than once within the amniotes

resulting in the hyobranchialis and 'ceratohyoideus' of 'lizards' and in the stylopharyngeus and ceratohyoideus of mammals (see Chapter 7).

The mammalian acromiotrapezius, spinotrapezius, dorsocutaneous, cleido-occipitalis, sternocleidomastoideus, cleidomastoideus and sternomastoideus correspond to the reptilian trapezius and sternocleidomastoideus and thus to the protractor pectoralis of amphibians, dipnoans and other osteichthyans. The protractor pectoralis is not a branchial muscle *sensu stricto* because it is mainly involved in the movements of the pectoral girdle and not of the branchial arches (Tables 5.5–5.6 and Fig. 5.9; see above). Interestingly, the results of recent developmental and molecular studies indicate that the protractor pectoralis of *Ambystoma* and the trapezius of chickens and mice are at least partially derived from somites (e.g., Köntges and Lumsden 1996; Matsuouka et al. 2005; Noden and Francis-West 2006; Piekarski and Olsson 2007; Shearman and Burke 2009). These

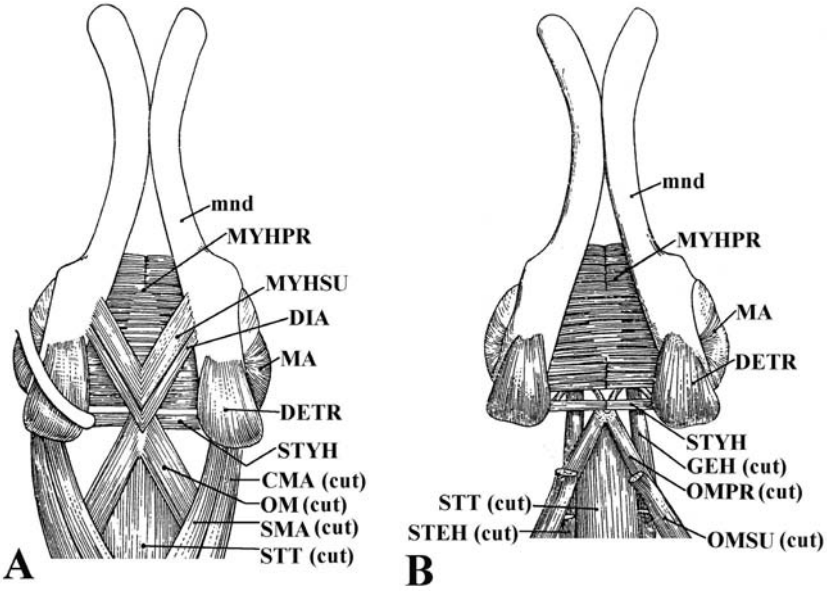

Fig. 5.9 *Ornithorhynchus anatinus* (Mammalia, Monotremata): (A) ventral view of the head and neck musculature, muscles such as the geniohyoideus and sternohyoideus are not shown; (B) same view, but the digastricus anterior, superficial part of the mylohyoideus, sternomastoideus, and cleidomastoideus were removed and the anterior portion of the sternohyoideus and of the superficial part of the omohyoideus were partially cut [modified from Edgeworth 1935 and Saban 1971; the nomenclature of the structures illustrated basically follows that used in the present work; anterior is to the top]. CMA, cleidomastoideus; DETR, detrahens mandibulae; DIA, digastricus anterior; GEH, geniohyoideus; MA, masseter; mnd, mandible; MYHPR, MYHSU, pars profunda and pars superficialis of mylohyoideus; OM, omohyoideus; OMPR, OMSU, pars profunda and pars superficialis of omohyoideus; SMA, sternomastoideus; STEH, sternohyoideus; STT, sternothyroideus; STYH, styloideus.

studies have also shown that during the ontogeny of mice some of the cells of the trapezius that originated from the somites pass the lateral somitic frontier in order to develop within lateral plate-derived connective tissue of the forelimb (e.g., Shearman and Burke 2009). That is, the trapezius is a rather peculiar muscle that is directly associated with three different types of connective tissue: connective tissue derived from branchial arch crest cells, somite-derived connective tissue, and lateral plate-derived (forelimb) connective tissue. Therefore, it is actually not clear whether the protractor pectoralis was primarily derived from the paraxial mesoderm, as suggested by Edgeworth (1935), and only later became ontogenetically associated with the cranialmost somites and even with lateral plate-derived connective tissue of the forelimb, or whether it was instead primarily derived from somites. Also interestingly, recent works have shown that apart from branchial muscles (sensu Edgeworth 1935, Diogo et al. 2008b, and the present work) such as the protractor pectoralis and the laryngeal muscles constrictor laryngis and dilatator laryngis, even branchial muscles *sensu stricto* such as the levatores arcuum branchialium and hyoid muscles such as the interhyoideus are also partially derived from somites in tetrapods such as amphibians (e.g., Piekarski and Olsson 2007). Thus, the fact that muscles such as the protractor pectoralis have a partial somitic origin does not necessarily mean that they cannot be considered to be part of the branchial musculature. Matsuoka et al. (2005) recognize that the amniote trapezius is partially derived from somites but also argue that the sum of the data available (i.e., innervation, topology, development and phylogeny) provides more support for grouping this muscle with the 'true' branchial musculature than for including it in the hypobranchial musculature or in the postcranial axial musculature sensu Jouffroy (1971). In fact, it is important to stress that recent lineage-tracing analyses in transgenic mice provide some support for the idea that the trapezius is a branchial muscle: these analyses reveal that neural crest cells from a caudal pharyngeal arch travel with the trapezius myoblasts and form tendinous and skeletal cells within the spine of the scapula (see, e.g., Noden and Schneider 2006). According to Noden and Schneider (2006: 14), "this excursion seemingly recapitulates movements established ancestrally, when parts of the pectoral girdle abutted caudal portions of the skull". The innervation of the trapezius by the accessory nerve (CNXI) and, in many cases, by C3 and C4 spinal cord segments adds weight to the argument that the muscle is derived from both the paraxial mesoderm and somites. Support for a branchial component also comes from the position of the accessory nucleus in the ventral horn of the spinal cord, which is in line with the more cranial branchiomotor nuclei (see, e.g., Wilson-Pauwels et al. 2002; Butler and Hodos 2005).

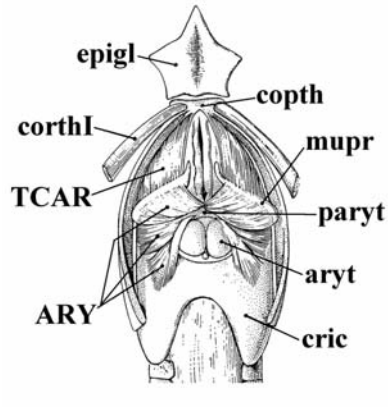

Fig. 5.10 *Ornithorhynchus anatinus* (Mammalia, Monotremata): dorsal view of the laryngeal musculature; the cricoarytenoideus posterior is not shown [modified from Göppert 1937 and Saban 1971; the nomenclature of the structures illustrated basically follows that used in the present work; anterior is to the top]. ARY, arytenoideus; aryt, arytenoid cartilage; copth, copula thyroidea; corthI, cornua thyroidea I; cric, cricoid cartilage; epigl, epiglottis; mupr, muscular process; paryt, proarytenoid cartilage; TCAR, thyrocricoarytenoideus.

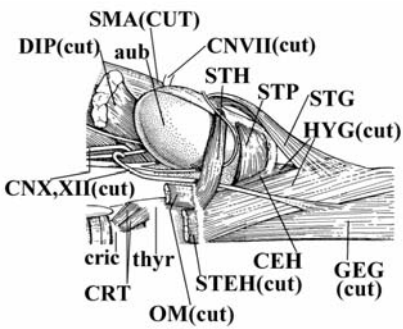

Fig. 5.11 *Ptilocercus lowii* (Mammalia, Scandentia): ventral view of the musculature of the hyoid region of the right side of the body; muscles such as the geniohyoideus, sternothyroideus and thyrohyoideus are not shown [modified from Le Gros Clark 1926 and Saban 1968; the nomenclature of the structures illustrated basically follows that used in the present work; anterior is to the right]. aub, auditory bulla; CEH, ceratohyoideus; CNVII,X,XII, cranial nerves VII, X and XII; cric, cricoid cartilage; CRT, cricothyroideus; DIP, digastricus posterior; GEG, genioglossus; HYG, hyoglossus; OM, omohyoideus; SMA, sternomastoideus; STEH, sternohyoideus; STG, styloglossus; STH, stylohyoideus; STP, stylopharyngeus; thyr, thyroid cartilage.

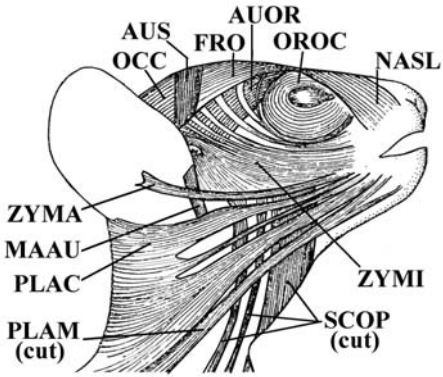

Fig. 5.12 *Lepilemur* sp. (Mammalia, Primates): lateral view of the facial musculature; muscles such as the buccinatorius, orbicularis oris and mentalis are not shown (modified from Jouffroy and Saban 1971; the nomenclature of the structures illustrated basically follows that used in the present work; anterior is to the right). AUOR, auriculo-orbitalis; AUS, auricularis superior; FRO, frontalis; MAAU, mandibulo-auricularis; NASL, nasolabialis; OCC, occipitalis; OROC, orbicularis oculi; PLAC, PLAM, platysma cervicale and platysma myoides; SCOP, sphincter colli profundus; ZYMA, ZYMI, zygomaticus major and zygomaticus minor.

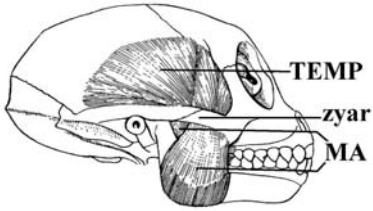

Fig. 5.13 *Macaca mullata* (Mammalia, Primates): lateral view of the masseter and temporalis (modified from Schumacher 1961 and Saban 1968; the nomenclature of the structures illustrated basically follows that used in the present work; anterior is to the right). MA, masseter; TEMP, temporalis; zyar, zygomatic arch.

Detailed analysis of the data obtained from our dissections, combined with the information provided in the literature, have allowed us to develop robust hypotheses of homology for most of the pharyngeal and laryngeal muscles (Tables 5.5–5.6). The monotreme pharyngeal muscle constrictor pharyngis corresponds to the constrictor pharyngis medius + constrictor pharyngis inferior + constrictor pharyngis superior + pterygopharyngeus of therian mammals, although it is possible that at least part of this latter muscle is derived from the palatopharyngeus (Tables 5.5–5.6 and Fig. 5.15). The pharyngeal muscles salpingopharyngeus + levator veli palatini + musculus uvulae + palatopharyngeus of therian mammals clearly seem to correspond to the palatopharyngeus of monotremes (Tables 5.5–5.6 and Fig. 5.15). With respect to the laryngeal muscles, the thyroarytenoideus,

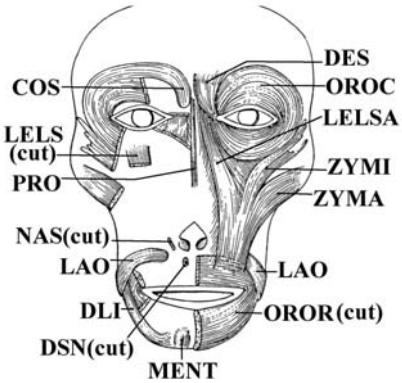

Fig. 5.14 *Macaca cyclopis* (Mammalia, Primates): anterior view of the facial musculature; muscles such as the buccinatorius, platysma, frontalis, and occipitalis are not shown; on the left side the depressor supercilii was removed and the orbicularis oculi, zygomaticus minor, zygomaticus major, levator labii superioris, levator labii superioris alaeque nasi were partially cut (modified from Shibata 1959 and Jouffroy and Saban 1971; the nomenclature of the structures illustrated basically follows that used in the present work). COS, corrugator supercilii; DES, depressor supercilii; DLI, depressor labii inferioris; DSN, depressor septi nasi; LAO, levator anguli oris facialis; LELS, levator labii superioris; LELSA, levator labii superioris alaeque nasi; MENT, mentalis; NAS, nasalis; OROC, orbicularis oculi; OROR, orbicularis oris; PRO, procerus; ZYMA, ZYMI, zygomaticus major and zygomaticus minor.

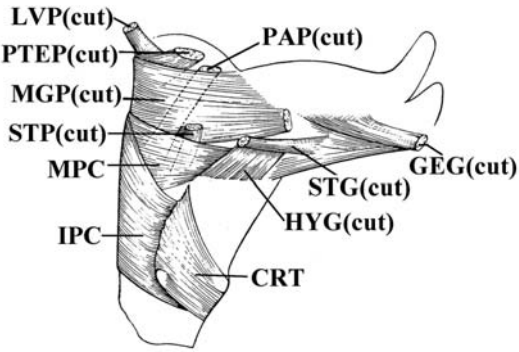

Fig. 5.15 *Hylobates hoolock* (Mammalia, Primates): lateral view of the pharyngeal musculature [modified from Kanagasuntheram 1952–1954 and Saban 1968; the nomenclature of the structures illustrated basically follows that used in the present work; anterior is to the top, dorsal is to the left: see text]. CRT, cricothyroideus; GEG, genioglossus; HYG, hyoglossus; IPC, constrictor pharyngis inferiori; LVP, levator veli palatini; MGP, mylo-glossopharyngeus; MPC, constrictor pharyngis medius; PAP, palatopharyngeus; PTEP, pterygopharyngeus; STG, styloglossus; STP, stylopharyngeus.

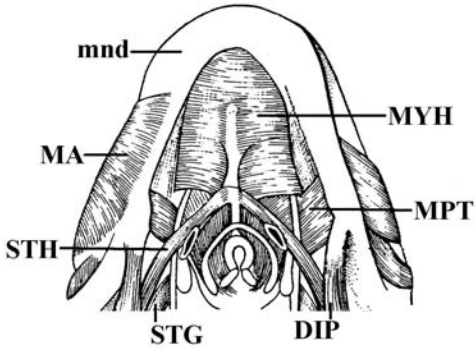

Fig. 5.16 *Pongo pygmaeus* (Mammalia, Primates): ventral view of the head musculature; on the right side the superficial portion of the masseter was removed (modified from Edgeworth 1935 and Saban 1968; the nomenclature of the structures illustrated basically follows that used in the present work; anterior is to the top). DIP, digastricus posterior; mnd, mandible; MA, masseter; MPT, pterygoideus medialis; MYH, mylohyoideus; STG, styloglossus; STH, stylohyoideus.

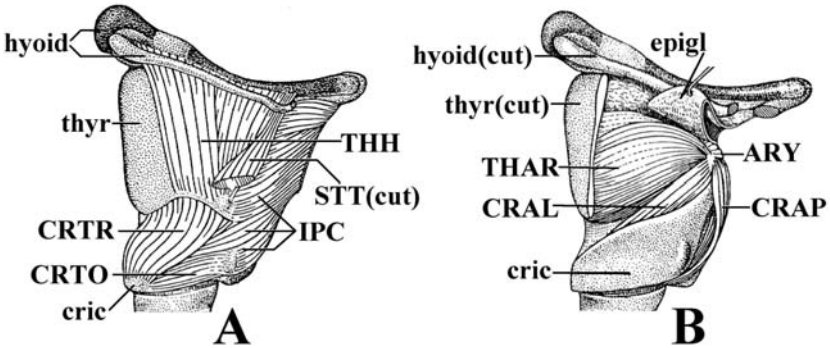

Fig. 5.17 *Pan troglodytes* (Mammalia, Primates): **(A)** lateral view of the laryngeal musculature; **(B)** same view, but the thyrohyoideus, sternothyroideus, constrictor pharyngis inferior and cricothyroideus were removed and the lateral portions of the thyroid cartilage and hyoid bone were partially cut (modified from Starck and Schneider 1960 and Saban 1968; the nomenclature of the structures illustrated basically follows that used in the present work; anterior is to the top, dorsal is to the right: see text). ARY, arytenoideus; CRAL, cricoarytenoideus lateralis; CRAP, cricoarytenoideus posterior; cric, cricoid cartilage; CRTO, CRTR, pars obliqua and pars recta of cricothyroideus; epigl, epiglottis; IPC, constrictor pharyngis inferior; STT, sternothyroideus; THAR, thyroarytenoideus; THH, thyrohyoideus; thyr, thyroid cartilage.

vocalis, cricoarytenoideus lateralis and arytenoideus of therian mammals correspond to the thyrocricoarytenoideus and arytenoideus of monotremes and to the laryngeus of non-mammalian tetrapods such as salamanders. The mammalian cricoarytenoideus posterior corresponds to the dilator laryngis of other tetrapods (Tables 5.5–5.6 and Figs. 5.10, 5.17). It should be noted that in terms of both its ontogeny and phylogeny the mammalian cricothyroideus is clearly a pharyngeal, and not a laryngeal, muscle as is sometimes suggested in the literature (e.g. Terminologia Anatomica 1998) (Tables 5.5–5.6 and Figs. 5.11, 5.15, 5.17). It should also be noted that according to Smith (1994) and other authors marsupials have no levator veli palatini. Their 'functional superior constrictor' is formed by an expansion of the stylopharyngeus, and not from the same mass of muscles that give rise to the middle and inferior constrictors, as is the case in placental mammals.

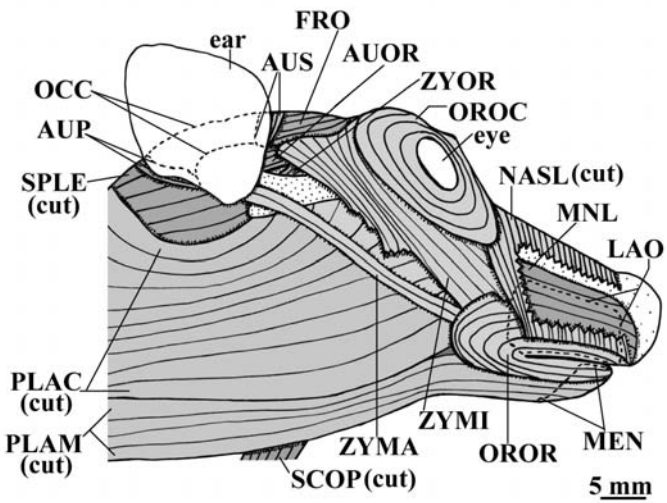

Fig. 5.18 *Cynocephalus volans* (Mammalia, Dermoptera): lateral view of the facial muscles, the splenius capitis is also shown; anteriorly, the nasolabialis was partially cut in order to show the maxillo-naso-labialis (anterior is to the right; muscles shown in darker grey are deeper than [medial to] those shown in lighter grey). AUOR, auriculo-orbitalis; AUP, auricularis posterior; AUS; auricularis superior; FRO, frontalis; LAO, levator anguli oris facialis; MEN, mentalis; MNL, maxillo-naso-labialis; NASL, naso-labialis; OCC, occipitalis; OROC, orbicularis occuli; OROR, orbicularis oris; PLAC, platysma cervicale; PLAM, platysma myoides; SCOP, sphincter colli profundus; SPLE, splenius capitis; ZYMA, zygomaticus major; ZYMI, zygomaticus minor; ZYOR, zygomatico-orbitalis.

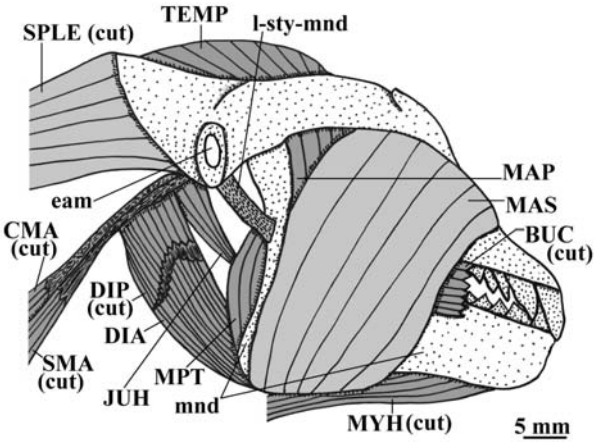

Fig. 5.19 *Cynocephalus volans* (Mammalia, Dermoptera): postero-ventro-lateral view of the masseter, buccinatorius, pterygoideus medialis, temporalis, digastricus anterior, digastricus posterior, jugulohyoideus, sternomastoideus, cleidomastoideus, mylohyoideus and splenius capitis (anterior is to the right; muscles shown in darker grey are deeper than [medial to] those shown in lighter grey). BUC, buccinatorius; CMA, cleidomastoideus; DIA, DIP, digastricus anterior and digastricus posterior; eam, external auditory meatus; JUH, jugulohyoideus; l-sty-mnd, stylomandibular ligament; MAP, MAS, pars profunda and pars superficialis of masseter; mnd, mandible; MPT, pterygoideus medialis; MYH, mylohyoideus; SMA, sternomastoideus; SPLE, splenius capitis; TEMP, temporalis.

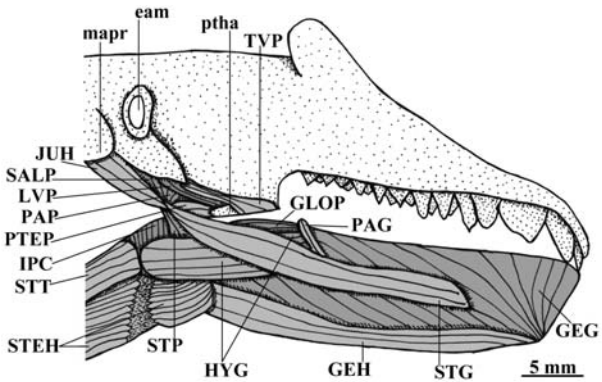

Fig. 5.20 *Cynocephalus volans* (Mammalia, Dermoptera): ventro-lateral view of the genioglossus, geniohyoid, styloglossus, hyoglossus, sternothyroid, sternohyoid, palatoglossus, tensor veli palatini, levator veli palatini, pterygopharyngeus, salpingopharyngeus, stylopharyngeus, jugulohyoideus and constrictor pharyngis inferior; the mandible, zygomaticus arch and part of the orbit were removed (anterior is to the right; muscles shown in darker grey are deeper than [medial to] those shown in lighter grey). eam, external auditory meatus; GEG, genioglossus; GEH, geniohyoideus; GLOP, glossopharyngeus; HYG, hyoglossus; IPC, constrictor pharyngis inferior; JUH, jugulohyoideus; LVP, levator veli palatini; mapr, mastoid process; PAG, palatoglossus; PAP, palatopharyngeus; PTEP, pterygopharyngeus; ptha, pterygoid hamulus; SALP, salpingopharyngeus; STEH, sternohyoideus; STG, styloglossus; STP, stylopharyngeus; STT, sternothyroideus; TVP, tensor veli palatini.

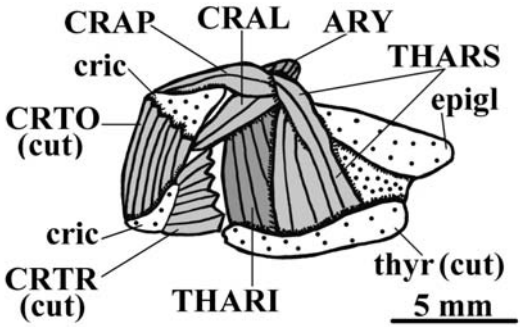

Fig. 5.21 *Cynocephalus volans* (Mammalia, Dermoptera): lateral view of the laryngeal muscles and of the pharyngeal muscle cricothyroideus; this latter muscle and the lateral surface of the thyroid cartilage were partially cut in order to show the deeper (more medial) muscles (anterior is to the left, dorsal to the top; muscles shown in darker grey are deeper than [medial to] those shown in lighter grey). ARY, arytenoideus; CRAL, cricoarytenoideus lateralis; CRAP, cricoarytenoideus posterior; cric, cricoid cartilage; CRTO, CRTR, pars obliqua and pars recta of cricothyroideus; epigl, epiglottis; THARI, THARS, pars intermedia and pars superioris of thyroarytenoideus; thyr, thyroid cartilage.

Fig. 5.22 *Macaca mulatta* (Mammalia, Primates): lateral view of the facial muscles of an adult specimen, the temporalis is also shown [anterior is to the right; the scale bar that is shown on the right, at the bottom, corresponds to 1 cm]. DAO, depressor anguli oris; DLI, depressor labii inferioris; FRO, frontalis; LAO, levator anguli oris facialis; LELS, levator labii superioris; LELSA, levator labii superioris alaeque nasi; OROC, orbicularis occuli; OROR, orbicularis oris; PLAC, platysma cervicale; PLAM, platysma myoides; PLAMD, decussating fibers of platysma myoides; TEMP, temporalis; ZYMA, zygomaticus major; ZYMI, zygomaticus minor.

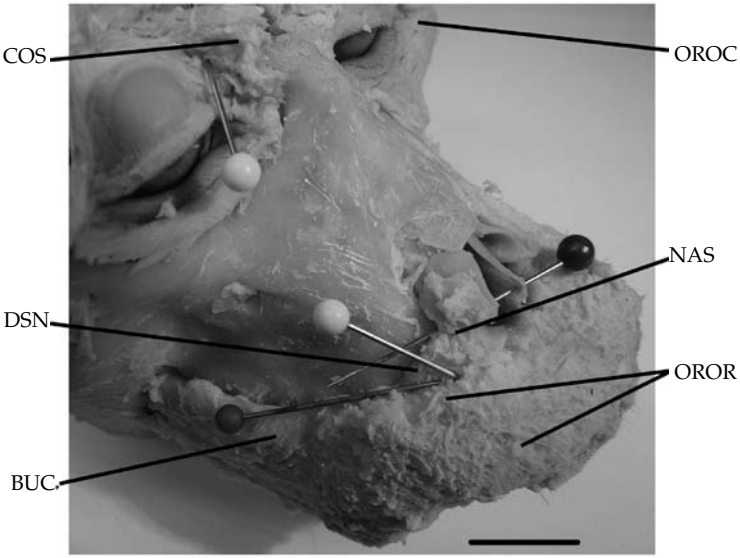

Fig. 5.23 *Macaca mulatta* (Mammalia, Primates): anterolateral view of the facial muscles of an adult specimen [anterior is to the right; the scale bar that is shown on the right, at the bottom, corresponds to 1 cm]. BUC, buccinatorius; COS, corrugator supercilii; DSN, depressor septi nasi; NAS, nasalis; OROC, orbicularis occuli; OROR, orbicularis oris.

Fig. 5.24 *Hylobates lar* (Mammalia, Primates): lateral view of the facial muscles of an adult specimen [anterior is to the right; the scale bar that is shown on the right, at the bottom, corresponds to 1 cm]. AUOR, auriculo-orbitalis; AUP, auricularis posterior; AUS, auricularis superior; DAO, depressor anguli oris; DES, depressor supercilii; DLI, depressor labii inferioris; LELS, levator labii superioris; LELSA, levator labii superioris alaeque nasi; OROC, orbicularis occuli; OROR, orbicularis oris; PLAC, platysma cervicale; PLAM, platysma myoides; ZYMA, zygomaticus major; ZYMI, zygomaticus minor.

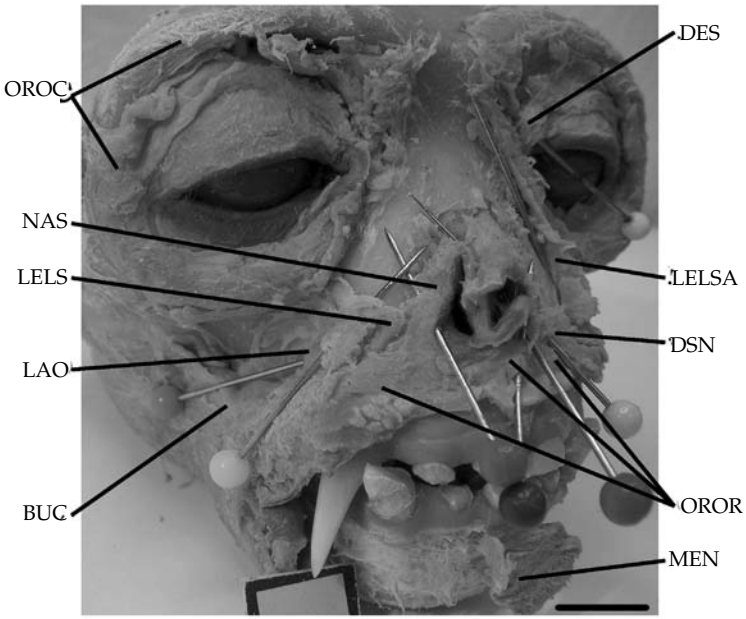

Fig. 5.25 *Hylobates lar* (Mammalia, Primates): anterolateral view of the facial muscles of an adult specimen [anterior is to the right; the scale bar that is shown on the right, at the bottom, corresponds to 1 cm]. BUC, buccinatorius; DES, depressor supercilii; DSN, depressor septi nasi; LAO, levator anguli oris facialis; LELS, levator labii superioris; LELSA, levator labii superioris alaeque nasi; MEN, mentalis; NAS, nasalis; OROC, orbicularis occuli; OROR, orbicularis oris.

Hypobranchial Muscles (Tables 5.7–5.8)

According to Edgeworth (1935), the hypobranchial muscles are divided into a 'geniohyoideus' group and a 'rectus cervicus' group (Tables 5.7–5.8). However, as explained in Chapters 3 and 4, it is not clear whether Edgeworth's groups represent separate premyogenic condensations or become apparent only at the later stages of muscle development. The plesiomorphic condition for sarcopterygians is seemingly that found in extant actinistians and dipnoans: there are two hypobranchial muscles that are mainly related to the opening of the mouth, the coracomandibularis and the sternohyoideus (Edgeworth 1935; Kesteven 1942–1945; Wiley 1979ab; Jollie 1982; Mallat 1997; Wilga et al. 2000; Johanson 2003; this work) (Tables 5.7–5.8 and Fig. 5.3). Amphibians and reptiles have various hypobranchial muscles (e.g., the omohyoideus and the specialized glossal muscles related to tongue movements) that are not present in sarcopterygian fish (Tables 5.7–5.8 and Figs. 5.5, 5.7). The geniohyoideus, genioglossus, hyoglossus and intrinsic muscles of the tongue of



Fig. 5.26 *Pongo pygmaeus* (Mammalia, Primates): lateral view of the facial muscles of a neonatal specimen, the masseter is also shown [anterior is to the right; the scale bar that is shown on the right, at the bottom, corresponds to 1 cm]. AUOR, auriculo-orbitalis; AUS, auricularis superior; COS, corrugator supercilii; DAO, depressor anguli oris; DES, depressor supercilii; DSN, depressor septi nasi; DLI, depressor labii inferioris; FRO, frontalis; LELS, levator labii superioris; LELSA, levator labii superioris alaeque nasi; MAS, masseter; NAS, nasalis; OCC, occipitalis; OROC, orbicularis occuli; OROR, orbicularis oris; PLAM, platysma myoides; PRO, procerus; ZYMA, zygomaticus major; ZYMI, zygomaticus minor.

non-mammalian tetrapods very likely correspond to the coracomandibularis of sarcopterygian fish, although it is possible that the 'hyoglossus' of, e.g., salamanders is at least partially derived from the sternohyoideus (e.g., Edgeworth 1935; Jarvik 1963; this work) (Tables 5.7–5.8 and Fig. 5.5). The styloglossus and palatoglossus of therian mammals seem to correspond to part of the hyoglossus of monotremes (Tables 5.7–5.8 and Figs. 11, 15, 16). The mammalian thyrohyoideus and sternothyroideus correspond to part of the sternohyoideus of reptiles such as *Timon* (Tables 5.7–5.8 and Fig. 5.9; it should be noted that some authors described a 'sternothyroideus' in a few reptilian taxa, but that this muscle is probably not homologous to the mammalian sternothyroideus: see Table 5.2 and Chapter 7).



Fig. 5.27 *Pan troglodytes* (Primates): lateral view of the facial muscles of an infant specimen [anterior is to the right; the scale bar that is shown on the right, at the bottom, corresponds to 1 cm]. DAO, depressor anguli oris; DES, depressor supercilii; DLI, depressor labii inferioris; FRO, frontalis; LELS, levator labii superioris; LELSA, levator labii superioris alaeque nasi; OROC, orbicularis occuli; OROR, orbicularis oris; PLAM, platysma myoides; ZYMA, zygomaticus major; ZYMI, zygomaticus minor.

General Remarks

As can be seen in Tables 5.2, 5.4, 5.6 and 5.8, the evolution of the sarcopterygian head and neck muscles apparently involved more events during which a muscle became subdivided (diverging arrows) than events that involve the fusion of muscles (shown as converging arrows in those tables, although it should be noted that not all the converging arrows shown in these tables actually refer to a true fusion of the muscles during ontogeny: see Chapter 11). However, contrary to what is often stated in general textbooks (e.g., Kisia and Onyango 2005), this does not mean that 'higher' primates, and namely modern humans, have more muscles than other mammals. For example, modern humans have fewer mandibular muscles than reptiles such as 'lizards', and fewer than mammals such as tree-shrews, rats and monotremes (Table 5.2). The number of true branchial muscles (Table 5.6) found in modern humans is also smaller than that found in most other mammals. Actually, in the case of these muscles if there is a 'trend'

at the time of the evolutionary transitions that led to the origin of primates and subsequently to modern humans, then it is to reduce, and not increase, the total number of muscles (e.g., monotremes such as the platypus usually have 8 muscles, rodents such as rats 7, colugos 6, tree-shrews such as *Tupaia* 6, and modern humans 3: Table 5.6). With respect to the pharyngeal musculature, there is a clear increase in the number of muscles at the time of the evolutionary transition leading to therian mammals, but then no increase at the time of the transition leading to the emergence of 'higher' primates and modern humans (e.g., monotremes such as the platypus usually have 3 muscles, rodents such as rats 8, colugos 8, tree-shrews such as *Tupaia* 7, and modern humans 8: Table 5.6). The number of hypobranchial muscles (not including the intrinsic muscles of the tongue) is relatively constant within the therian mammals listed in Table 5.8, although in this case modern humans do have more muscles than the other taxa (e.g., rodents such as rats usually have 8 muscles, colugos 7, tree-shrews such as *Tupaia* 8, and modern humans 9).

Interestingly, the number of facial and laryngeal muscles found in modern humans is clearly greater than that found in most other mammalian taxa. Modern humans usually have 24 facial muscles (not including the extrinsic muscles of the ear); monotremes such as the platypus usually have 10, rodents such as rats 20, colugos 19, and tree-shrews such as *Tupaia* 21 (Tables 5.3–5.4). Examples of facial muscles present in modern humans and lacking in most other mammals are the risorius, depressor supercilii, levator labii superioris alaeque nasi, depressor septi nasi, depressor labii inferioris and depressor anguli oris (e.g., Ruge 1885–1910; Boas and Paulli,1908; Lightoller 1928–1942; Huber 1930–1931; Edgeworth 1935; Andrew 1963; Gasser 1967; Jouffroy and Saban 1971; Saban 1971; Seiler 1971–1980; Minkoff 1979; Preuschoft 2000; Schmidt and Cohn 2001; Burrows and Smith 2003; Burrows et al. 2006; Burrows 2008; Diogo et al. 2009b; this work) (Tables 5.3–5.4). With respect to the laryngeal muscles, there are usually 6 present in modern humans, while there are 4 in, e.g., *Tupaia*, colugos and rats, and 3 in monotremes (Table 5.6). The vocalis and arytenoideus obliquus are examples of laryngeal muscles that are usually present in modern humans but lacking in most other mammalian and non-mammalian taxa (e.g., Edgeworth 1935; Negus 1949; DuBrul 1958; Starck and Schneider 1960; Saban 1968; Wind 1970; Crelin 1987; Harrison 1995; this work) (Tables 5.5–5.6). These data are consistent with the important role played by facial expression and by vocal communication in primates in general, and in modern humans in particular. The relationship between muscular splittings or fusions and the evolution of anatomical complexity will be discussed in greater detail in Chapter 11.

Table 5.7 Hypobranchial muscles of adults of representative sarcopterygian taxa (see caption of Table 5.1, text and also Table 5.8 and Figs. 5.1–5.27).

Actinistia: *Latimeria chalumnae* (Coelacanth)	Dipnoi: *Lepidosiren paradoxa* (South American lungfish)	Amphibia: *Ambystoma ordinarium* (Michoacan stream salamander)	Reptilia: *Timon lepidus* (Ocellated 'lizard')	Mammalia (Monotremata): *Ornithorhynchus anatinus* (Platypus)	Mammalia (Rodentia): *Rattus norvegicus* (Norwegian rat)	Mammalia (Dermoptera): *Cynocephalus volans* (Philippine colugo)	Mammalia (Scandentia): *Tupaia* sp. (Tree-shrew)	Mammalia (Primates): *Homo sapiens* (Modern human)
Coraco-mandibularis	**Coraco-mandibularis** (geniothoracis sensu Bemis and Lauder 1986)	**Geniohyoideus** (coraco-mandibularis sensu Diogo 2007, 2008)	**Geniohyoideus** (coraco-mandibularis sensu Diogo 2007, 2008)	**Geniohyoideus** [according to Edgeworth 1935 the geniohyoideus, genioglossus and hyoglossus of mammals develop ontogenetically at the same time; according to him, the two former muscles develop internally (more medially), while the latter develops externally (more laterally)]	**Geniohyoideus**	**Geniohyoideus**	**Geniohyoideus**	**Geniohyoideus**
—	—	**Genioglossus** [as explained by, e.g., Edgeworth 1935 and Piatt 1938 the genioglossus of salamanders such as *Ambystoma* and of reptiles such as 'lizards' corresponds to part of the	**Genioglossus** [see on the left]	**Genioglossus** [as explained by, e.g., Piekarski and Olsson 2007 in mammals such as dogs the tongue muscles are sometimes innervated by both the hypoglossal (CNXII) and the facial (VII) nerves, thus	**Genioglossus** [not described by, e.g., Greene 1935, but present as an independent structure in the rats dissected by us; Bryant 1945 and other authors support	**Genioglossus**	**Genioglossus** (geniohyoglossus sensu Le Gros Clark 1924, 1926)	**Genioglossus**

		coracomandibularis of sarcopterygian fish]		indicating that at least in some cases these muscles may have a dual origin]	the claim that this muscle is effectively often present in rodents]			
—	—	— [according to, e.g., Piatt 1938 and Saban 1968, 1971, extant amphibians such as salamanders do not have well-developed, well-differentiated intrinsic muscles of the tongue like those found in extant amniotes]	**Intrinsic muscles of the tongue** [according to Saban 1971, Jouffroy and Lessertisseur 1971, Smith 1988, 1992, Meyers and Nishikawa 2000 and Herrel et al. 2005, examples of reptilian intrinsic tongue are the 'longitudinalis', the 'transversus linguae ventralis', the 'transversus linguae dorsalis', the 'verticalis linguae' and the 'annularis': see on the right and Chapter 7]	**Intrinsic muscles of the tongue** [according to Saban 1968 the intrinsic muscles of the tongue of amniotes derive from both the genioglossus and hyoglossus: Table VIII; examples of these muscles are, e.g., the longitudinalis superior, longitudinalis inferior, transversus linguae and/or verticalis linguae: e.g., Anderson 1881; Edgeworth 1935; Jarvik 1963; Saban 1968, 1971; Smith 1988, 1992; Sokoloff 2000; Herrel et al. 2005; this work; according to Herrel (Anthony Herrel, pers. comm.), the 'longitudinalis', 'transversus linguae', 'verticalis linguae' and	**Intrinsic muscles of the tongue** [see on the left]	**Intrinsic muscles of the tongue** [see on the left]	**Intrinsic muscles of the tongue** [see on the left]	**Intrinsic muscles of the tongue** [see on the left]

Table 5.7 contd...

Table 5.7 contd...

Actinistia: *Latimeria chalumnae* (Coelacanth)	Dipnoi: *Lepidosiren paradoxa* (South American lungfish)	Amphibia: *Ambystoma ordinarium* (Michoacan stream salamander)	Reptilia: *Timon lepidus* (Ocellated 'lizard')	Mammalia (Monotremata): *Ornithorhynchus anatinus* (Platypus)	Mammalia (Rodentia): *Rattus norvegicus* (Norwegian rat)	Mammalia (Dermoptera): *Cynocephalus volans* (Philippine colugo)	Mammalia (Scandentia): *Tupaia* sp. (Tree-shrew)	Mammalia (Primates): *Homo sapiens* (Modern human)
				'annularis' of reptiles are very likely homologous to the longitudinalis, transversus linguae, verticalis linguae and annularis of mammals, respectively: see on the left and Chapter 7]				
—	—	**Hyoglossus** [the statements of Edgeworth 1935 concerning the hyoglossus of salamanders such as *Ambystoma* are confusing: on page 196 he states that it derives from the sternohyoideus (= his 'rectus cervicus') but on page 211 he suggests that as in other amphibians, as well as in reptiles and mammals, it	**Hyoglossus** [according to Edgeworth 1935 the hyoglossus of 'lizards' such as *Timon* corresponds to part of the coracomandibularis of other amphibians and sarcopterygian fish]	**Hyoglossus**	**Hyoglossus**	**Hyoglossus** [as described by e.g. Edgeworth 1935, in colugos the hyoglossus and thyrohyoideus are seemingly fused]	**Hyoglossus** (hyoglossus + chondroglossus sensu Le Gros Clark 1926) [according to Saban 1968, in primates and tree-shrews the hyoglossus is divided into a chondroglossus and a ceratoglossus; this is supported by, e.g., Le Gros Clark 1926, and	**Hyoglossus** [see on the left]

		derives from the coracomandibularis (= his 'geniohyoideus'); the results of the developmental work of Piatt 1938 support this latter hypothesis]					Sprague 1944a, although this latter author erroneously states that the chondroglossus is part of the genioglossus and not of the hyoglossus]	
—	—	—	—	—	**Styloglossus** [our dissections and comparisons support Edgeworth's 1935 suggestion that the styloglossus and palatoglossus of therian mammals likely correspond to part of the hyoglossus of monotremes]	**Styloglossus**	**Styloglossus**	**Styloglossus**
—	—	—	—	—	— (seemingly not present as an independent muscle in the rats dissected; this is supported by Barrow and Capecchi 1999 and others)	**Palatoglossus** [seemingly present as an independent muscle in the colugos dissected by us, being formed by a group of fibers running from	— [seemingly not present as a separate muscle in the *Tupaia* specimens dissected by us; it is also not described by Le Gros Clark 1924, 1926 and others]	**Palatoglossus**

Table 5.7 contd...

Table 5.7 contd...

Actinistia: *Latimeria chalumnae* (Coelacanth)	Dipnoi: *Lepidosiren paradoxa* (South American lungfish)	Amphibia: *Ambystoma ordinarium* (Michoacan stream salamander)	Reptilia: *Timon lepidus* (Ocellated 'lizard')	Mammalia (Monotremata): *Ornithorhynchus anatinus* (Platypus)	Mammalia (Rodentia): *Rattus norvegicus* (Norwegian rat)	Mammalia (Dermoptera): *Cynocephalus volans* (Philippine colugo)	Mammalia (Scandentia): *Tupaia* sp. (Tree-shrew)	Mammalia (Primates): *Homo sapiens* (Modern human)
						the soft palate and/or the lateral wall of the oropharynx to the posterolateral surface of the tongue]		
—	—	**Interradialis** [according to Piatt 1938 in at least some adult *Ambystoma* there is a hypobranchial muscle interradialis, which derives ontogenetically from the genioglossus]	—	—	—	—	—	—
Sternohyoideus	**Sternohyoideus** (rectus cervicus sensu Bemis and Lauder 1986)	**Sternohyoideus** (rectus cervicus sensu Lauder and Shaffer 1988)	**Sternohyoideus** (rectus cervicus sensu Kardong 2002; episternohyoideus sensu Edgeworth 1935)	**Sternohyoideus** [in the platypus specimens examined by us this muscle is deeply blended posteriorly with the sternothryroideus, as stated by Saban 1971]	**Sternohyoideus**	**Sternohyoideus** [as described by, e.g., Leche 1886, and Saban 1968, in *Cynocephalus* the sternohyoideus has two bundles: the posterior one extends	**Sternohyoideus** [deeply blended with the sternothyroideus]	**Sternohyoideus**

						anteriorly in order to reach the posterior region of the thyroid cartilage and then contacts, via a broad but thin tendon, the anterior one that extends anteriorly to attach to the lesser cornu of the hyoid]		
—	—	**Omohyoideus** [the omohyoideus, sternothyroideus and thyrohyoideus of tetrapods clearly correspond to part of the sternohyoideus of sarcopterygian fish: e.g., Edgeworth 1935; Saban 1968, 1971; Diogo 2007, 2008; this work]	**Omohyoideus**	**Omohyoideus** [as stated by, e.g., Saban 1971 in the platypus specimens dissected by us the omohyoideus is anteriorly divided into superficial and deep bundles]	**Omohyoideus**	— [not present as an independent structure in the colugos dissected by us as well as by Gunnell and Simmons 2005 and others]	**Omohyoideus** [George 1977 states that this muscle has no distinct tendinous intersection, but Le Gros Clark 1924, 1926, and Sprague 1944a, describe such an intersection in tree-shrews such as *Tupaia* and *Ptilocercus*]	**Omohyoideus** [it has superior and inferior bellies, which are separated by a distinct tendon]

Table 5.7 contd...

Table 5.7 contd...

Actinistia: *Latimeria chalumnae* (Coelacanth)	Dipnoi: *Lepidosiren paradoxa* (South American lungfish)	Amphibia: *Ambystoma ordinarium* (Michoacan stream salamander)	Reptilia: *Timon lepidus* (Ocellated 'lizard')	Mammalia (Monotremata): *Ornithorhynchus anatinus* (Platypus)	Mammalia (Rodentia): *Rattus norvegicus* (Norwegian rat)	Mammalia (Dermoptera): *Cynocephalus volans* (Philippine colugo)	Mammalia (Scandentia): *Tupaia* sp. (Tree-shrew)	Mammalia (Primates): *Homo sapiens* (Modern human)
—	—	—	— [some authors have described a 'sternothyroideus' in a few reptilian taxa, but this muscle is probably not homologous to the mammalian sternothyroideus: see Chapter 7]	**Sternothyroideus** [see above]	**Sterno-thyroideus**	**Sterno-thyroideus**	**Sternothyroideus**	**Sternothyroideus**
—	—	—	—	—	**Thyrohyoideus** [as explained above, the thyrohyoideus of therian mammals clearly corresponds to part of the sternohyoideus of non-mammalian tetrapods; however, it is not clear if it corresponds to part of the monotreme sternohyoideus	— [not present as an independent structure in the colugos dissected by us; it is seemingly fused with the hyoglossus: see above]	**Thyrohyoideus**	**Thyrohyoideus**

					or, instead, to part of the monotreme sterno-thyroideus: e.g., Edgeworth 1935; Saban 1968; Table VIII]			

Table 5.8 Scheme illustrating the authors' hypotheses regarding the homologies of the hypobranchial muscles of adults of representative sarcopterygian taxa (see caption of Table 5.2, text, and also Table 5.7 and Figs. 5.1–5.27). 'GENIOHYOIDEUS', 'RECTUS CERVICIS' = 'geniohyoideus' and 'rectus cervicus' groups sensu Edgeworth, 1935; in. to. = intrinsic muscles of the tongue; mus. = muscles.

	Latimeria (2 mus.)	*Lepidosiren* (2 mus)	*Ambystoma* (6 mus. - not in.to.*)	*Timon* (5 mus. - not in. to.*)	*Ornithorhynchus* (6 mus. - not in. to.*)	*Rattus* (8 mus. - not in. to.*)	*Cynocephalus* (7 mus. - not in. to.*)	*Tupaia* (8 mus. - not in. to.*)	*Homo* (9 mus. - not in. to.*)
'GENIOHYOIDEUS'	Coracomandibularis	Coracomandibularis	Geniohyoideus	Geniohyoideus	Geniohyoideus	Geniohyoideus	Geniohyoideus	Geniohyoideus	Geniohyoideus
	---	---	Genioglossus	Genioglossus	Genioglossus	Genioglossus	Genioglossus	Genioglossus	Genioglossus
	---	---	---	Intrinsic.mus. tongue*	Intrinsic mus. tongue*	Intrinsic mus. tongue*	Intrinsic mus. tongue*	Intrinsic mus. tongue*	Intrinsic mus. tongue*
	---	---	Hyoglossus	Hyoglossus	Hyoglossus	Hyoglossus	Hyoglossus	Hyoglossus	Hyoglossus
	---	---	---	---	---	Styloglossus	Styloglossus	Styloglossus	Styloglossus
	---	---	---	---	---	---	Palatoglossus	---	Palatoglossus
	---	---	Interradialis	---	---	---	---	---	---
'RECTUS-CERVICIS'	Sternohyoideus	Sternohyoideus	Sternohyoideus	Sternohyoideus	Sternohyoideus	Sternohyoideus	Sternohyoideus	Sternohyoideus	Sternohyoideus
	---	---	Omohyoideus	Omohyoideus	Omohyoideus	Omohyoideus	---	Omohyoideus	Omohyoideus
	---	---	---	---	Sternothryroideus	Sternothryroideus	Sternothryroideus	Sternothryroideus	Sternothryroideus
	---	---	---	---	---	Thyrohyoideus	---	Thyrohyoideus	Thyrohyoideus

Chapter 6

Head and Neck Muscles of Amphibians

The main goal of Chapter 5 was to discuss the homologies and evolution of the muscles within the Sarcopterygii as a whole, and, thus, to provide a basis for works that would be more specifically concerned with each of the major sarcopterygian groups. The main goal of Chapter 6 is thus to use the information provided in Chapter 5 as a basis for a more detailed, specific analysis of the mandibular, hyoid, branchial and hypobranchial muscles of the three extant amphibian taxa, i.e., salamanders (Caudata, or Urodela), frogs (Anura), and caecilians (Gymnophiona). This is an opportune moment to undertake a review of the comparative anatomy, homologies and evolution of these muscles within amphibians because studies published in this past decade have provided new information about the ontogeny of the cephalic muscles in representatives of each of these amphibian groups, which is particularly useful in analyzing the homologies of these muscles within these groups (e.g., Olsson et al. 2000, 2001; Palavecino 2000; Chanoine and Hardy 2003; Ericsson and Olsson 2004; Ericsson et al. 2004; Kleinteich and Haas 2007; Piekarski and Olsson 2007; Zierman and Olsson 2007). In addition, Carroll has (2007) published an excellent, extensive review on the phylogeny and evolution of caecilians, urodeles and anurans, which provides the phylogenetic background for our discussions about plesiomorphic versus derived traits within the amphibians. As explained by this latter author, the extant amphibians are included in three main groups: caecilians (Gymnophiona or Caecilia sensu Carroll 2007), frogs (Anura), and salamanders (Caudata, or Urodela), the two latter groups being possibly more closely related to each other than to the caecilians (see Fig. 1.1, Chapters 1 and 2, and text below).

Mandibular Muscles (Table 6.1)

The adductor mandibulae A2 (Figs. 6.1, 6.2, 6.3, 6.6, 6.7), the adductor mandibulae A2-PVM (Figs. 6.1, 6.3, 6.6, 6.7) and the pseudotemporalis (Figs. 6.1, 6.2, 6.3, 6.6) are included in the so-called 'adductor mandibulae complex' of amphibians, which is often named 'levator mandibulae complex' (see, e.g., Carroll 2007). In the urodeles dissected by us the adductor mandibulae A2 is a large muscle lying laterally and anteriorly to the A2-PVM. In the caecilians we dissected, the A2 is covered by the skull bones, which form an adductor chamber: in *Siphonops* and *Chthonerpeton* this muscle is well developed (see Figs. 6.6, 6.7). The A2 of the anurans dissected by us corresponds to the 'levator mandibulae externus', but possibly also to the 'levator mandibulae longus', sensu

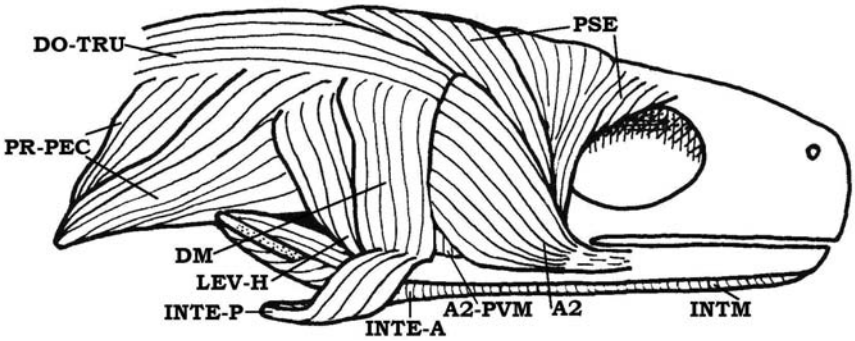

Fig. 6.1 *Ambystoma tigrinum* (Amphibia, Caudata): lateral view of cephalic musculature (modified from Larsen and Guthrie 1975; the nomenclature of the myological structures illustrated follows that of the present work; for more details about the osteological structures illustrated, see Larsen and Guthrie 1975). A2, A2-PVM, adductor mandibulae A2 and A2-PVM; DM, depressor mandibulae; DO-TRU, dorsalis trunci; INTE-A, INTE-P, interhyoideus anterior and posterior; INTM, intermandibularis; LEV-H, levator hyoideus; PR-PEC, protractor pectoralis; PSE, pseudotemporalis.

Ziermann and Olsson (2007) and others, the A2-PVM and pseudotemporalis thus possibly corresponding respectively to the 'levator mandibulae articularis' and 'levator mandibulae internus' sensu these authors (Table 6.1 and Fig. 6.3). The idea that the 'levator mandibulae longus' of anurans corresponds to part of the A2 sensu this volume is supported by the fact that, in these amphibians, the 'levator mandibulae longus' is often the first element of the 'adductor mandibulae complex' to become differentiated during ontogeny (e.g., Ziermann and Olsson 2007). During the development of bony fish and tetrapods, the first adductor mandibulae muscle to become differentiated is generally the A2 (see Chapters 3–5). However, the hypothesis proposed by Carroll and Holmes (1980), Iordansky (1992)

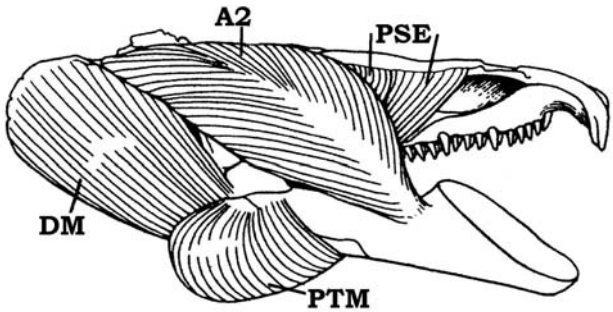

Fig. 6.2 *Siren lacertina* (Amphibia, Caudata): lateral view of the cephalic musculature (modified from Carroll and Holmes 1980; the nomenclature of the myological structures illustrated follows that of the present work; for more details about the osteological structures illustrated, see Carroll and Holmes 1980). A2, adductor mandibulae A2; DM, depressor mandibulae; PSE, pseudotemporalis; PTM, pterygomandibularis.

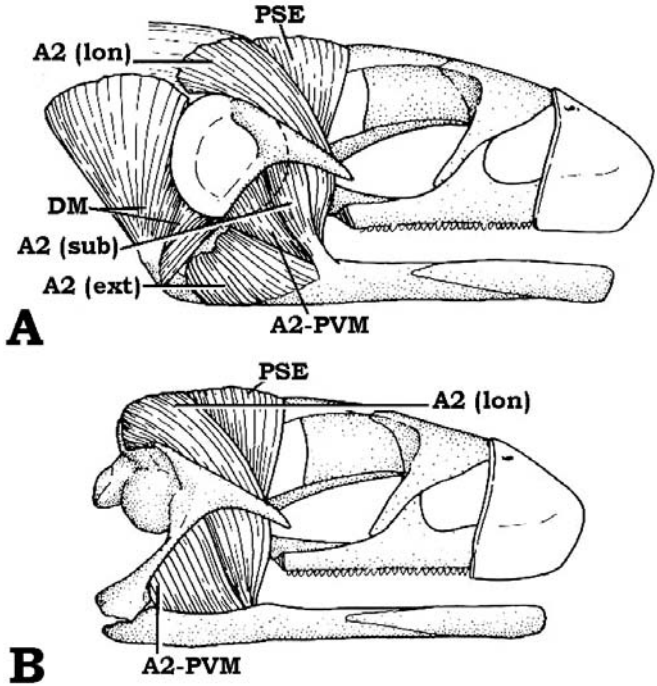

Fig. 6.3 *Rana temporaria* (Amphibia, Anura): **(A)** Lateral view of the cephalic musculature; **(B)** same view, but (modified from Duellman and Trueb 1986; the nomenclature of the myological structures illustrated follows that of the present work; for more details about the osteological structures illustrated, see Duellman and Trueb 1986). A2 (sub), A2 (ext), A2 (lon), 'subexternus', 'externus' and 'longus' portions of adductor mandibulae, which probably correspond to the A2 sensu the present work; A2-PVM, adductor mandibulae A2-PVM; DM, depressor mandibulae; PSE, pseudotemporalis.

Table 6.1 Mandibular muscles of adults of representative urodele, anuran and caecilian taxa. The nomenclature of the muscles shown in bold follows that of text; in order to facilitate comparisons, in some cases names often used by other authors to designate a certain muscle/bundle are given in front of that muscle/bundle, in parentheses; additional comments are given in square brackets. Data compiled from evidence provided by our own dissections and comparisons and by a review of the literature (see text and Figs. 6.1–6.7).

Amphibia.(Caudata): ***Ambystoma ordinarium*** (Michoacan stream salamander)	Amphibia (Anura): ***Rhinella arenarum*** (Argentine common toad)	Amphibia (Gymnophiona): ***Siphonops paulensis*** (Catuchi caecilian)
Intermandibularis posterior	**Intermandibularis posterior**	**Intermandibularis**
Intermandibularis anterior (submentalis sensu Iordansky 1992 and Carroll 2007)	**Intermandibularis anterior** (submentalis sensu Iordansky 1992 and Carroll 2007) [in at least some tadpoles of anurans the intermandibularis is divided into three portions, i.e., an intermandibularis anterior, an intermandibularis posterior, and a 'mandibulolabialis': see, e.g., Olsson et al. 2002; Carroll 2007]	— [in this species the intermandibularis is not divided into intermandibularis anterior and intermandibularis posterior, but see text]
Adductor mandibulae A2 (adductor mandibulae externus sensu Carroll and Holmes 1980, Iordansky 1992 and Carroll 2007)	**Adductor mandibulae A2** (seem to correspond to the levator mandibulae externus, and possibly also to the levator mandibulae longus, sensu Haas 2001 and Ziermann and Olsson 2007: see text)	**Adductor mandibulae A2** (adductor mandibulae externus sensu Carroll 2007, which, according to this author, corresponds to the levator mandibulae anterior sensu Bemis et al. 1983: see his fig. 14G) [seems to correspond to both the levator mandibulae longus and levator mandibulae externus of the caecilian larvae described by Kleinteich and Haas 2007; see text]
Adductor mandibulae A2-PVM (adductor mandibulae posterior sensu Carroll and Holmes 1980, Iordansky 1992 and Carroll 2007; levator mandibulae posterior sensu Edgeworth 1935 and Piatt 1938; levator mandibulae articularis sensu Ericsson and Olsson 2004)	**Adductor mandibulae A2-PVM** (adductor mandibulae articularis sensu Iordansky 1992; levator mandibulae articularis sensu Ziermann and Olsson 2007; levator mandibularis posterior sensu Sedra and Michel 1957)	**Adductor mandibulae A2-PVM** (levator mandibulae articularis sensu Kleinteich and Haas 2007)

Pseudotemporalis (superficial and deep portions of levator mandibulae anterior sensu Edgeworth 1935 and Piatt 1938; pseudotemporalis anterior and posterior sensu Iordansky 1992; adductor mandibulae internus sensu Carrol and Holmes 1980 and Carroll 2007, which includes a pseudotemporalis superficialis and a pseudotemporalis profundus) [both the adductor A3′ and A3″ of osteichthyan fishes seem to be included in the pseudotemporalis of extant amphibians and reptiles]	**Pseudotemporalis** (levator mandibulae internus sensu Haas 2001 and Ziermann and Olsson 2007, although it can possibly also include the levator mandibulae longus sensu these authors: see text)	**Pseudotemporalis** (levator mandibulae internus sensu Kleinteich and Haas 2007)
Pterygomandibularis [the urodele muscle 'pterygoideus' sensu Carroll and Holmes 1980 and Haas 2001 seems to correspond to the muscle 'pterygoideus' of caecilians and, thus, to the pterygomandibularis of reptiles; see text and also Chapters 5 and 7]	— [see text]	**Pterygomandibularis** [the caecilian muscle 'pterygoideus' sensu Iordansky 1996, Kleinteich and Haas 2007 and Carroll 2007 and 'levator mandibulae posterior' sensu Bemis et al. 1983 seems to correspond to the pterygomandibularis of reptiles such as the 'lizard' *Timon*: see text and also Chapters 5 and 7]
—	—	**Levator quadrati** (sensu Iordansky 1996 and Bemis et al. 1983) [Iordansky 1996 suggested that the levator quadrati of caecilians corresponds to the levator pterygoidei + protractor pterygoidei of reptiles]
Levator bulbi [it probably corresponds to part of the levator arcus palatini of *Latimeria*: see Chapter 5]	**Levator bulbi**	— [see text]

and others, i.e., that the anuran 'levator mandibulae longus' corresponds to part of the pseudotemporalis, and not of the A2, of urodeles, cannot be completely discarded. In anuran larvae and adults the 'levator mandibulae externus' sensu Ziermann and Olsson (2007) is often poorly developed; in caecilian larvae the 'levator mandibulae externus' sensu Kleinteich and Haas (2007) is often also a small bundle, which becomes absent as an independent structure in adults, being possibly fused with the 'levator mandibulae longus' sensu these authors (e.g., Kleinteich and Haas 2007; Ziermann and Olsson 2007; see Figs. 6.3, 6.6, 6.7 and Table 6.1).

In the urodeles and anurans dissected by us the pseudotemporalis is often divided into a superficial bundle (which probably corresponds to the 'adductor mandibulae A3' sensu Diogo and Chardon 2000 and Diogo 2007, 2008, to the 'pseudotemporalis posterior' sensu Iordansky 1992, and to the 'levator mandibulae anterior superficialis' sensu Edgeworth 1935 and Piatt 1938), and a deep bundle (which probably corresponds to the adductor mandibulae A3'' sensu Diogo and Chardon 2000 and Diogo 2007, 2008, to the 'pseudotemporalis anterior' sensu Iordansky 1992, and to the 'levator mandibulae anterior profundus' sensu Edgeworth 1935 and Piatt 1938) (see Figs. 6.1, 6.2, 6.3). In the caecilians we dissected, as well as in those caecilians described by Bemis et al. (1983), Carroll (2007) and other authors, the pseudotemporalis is mainly undivided (see Fig. 6.6).

The pterygomandibularis is a muscle that is often found in reptiles and that, as its name indicates, usually connects the pterygoid region to the retroarticular process of the mandible (e.g., Oelrich 1956; Abdala and Moro 1996; Herrel et al. 2005; Chapters 4–5, 7). Confusingly, Versluys (1904), based on the erroneous (see Chapter 5) supposition that the pterygomandibularis of reptiles corresponds to the pterygoideus medialis and pterygoideus lateralis of mammals, decided to name the pterygomandibularis as 'pterygoideus'. Since then, both the names 'pterygoideus' and pterygomandibularis have been used to designate the reptilian muscle (see, e.g., Abdala and Moro 1996 and Tables 5.1 and 7.1). This is particularly problematic because many reptiles have two other mandibular muscles that are named levator pterygoideus and protractor pterygoideus, but that, contrary to the pterygomandibularis, are dorsal mandibular muscles, i.e., are derived from the constrictor dorsalis anlage sensu Edgeworth (1935) (see Chapters 2–5 and 7). In the caecilians we dissected, as well as those described by Iordansky (1996), Kleinteich and Haas (2007), Carroll (2007) and others, there is a muscle that is often named 'pterygoideus' and that does seem to correspond to the pterygomandibularis of reptiles, as proposed by Iordansky (1996) and Kleinteich and Haas (2007) (Fig. 6.7). In fact, it is generally agreed that this muscle 'pterygoideus' of caecilians is derived ontogenetically from the pseudotemporalis (Carroll 2007), as is the pterygomandibularis of reptiles (see Chapters 5 and 7). In caecilians

the 'pterygoideus' is functionally related to the opening of the mouth, and to the holding of the lower jaw against the quadrate (Carroll 2007). As described by Carroll and Holmes (1980) and others, urodeles, but not anurans, often have a muscle 'pterygoideus' that seems to be homologous to that of caecilians and, thus, to the pterygomandibularis of reptiles (Fig. 6.2), although in taxa such as *Ambystoma* this muscle is usually deeply mixed with the pseudotemporalis profundus (Table 6.1; see also, e.g., Luther 1914 and Haas 2001).

The intermandibularis is derived ontogenetically from the ventral portion of the mandibular muscle plate (sensu Edgeworth 1935: see Chapters 2–5), and not from the central portion of this plate, as are the adductor mandibulae A2, adductor mandibulae A2-PVM, pseudotemporalis and pterygomandibularis. In all extant amphibians the intermandibularis is a large muscle that connects the two hemimandibles (Figs. 6.1, 6.4, 6.6, 6.7). In anurans and urodeles, it is often divided into an intermandibularis anterior (which is often named submentalis) and an intermandibularis posterior (Fig. 6.4), and in at least some anuran tadpodes it is also divided into a 'mandibulolabialis' sensu Carroll (2007). In the caecilians dissected by us, as well as in those described by Kesteven (1942–1945), Bemis et al. (1983), Kleinteich and Haas (2007), Carroll (2007) and others, the intermandibularis is constituted by a single mass of fibers (see Figs. 6.6, 6.7 and Table 6.1).

Edgeworth (1935) suggested that adult amphibians do not have muscles derived from the 'dorsal portion of the mandibular muscle plate', i.e., from the constrictor dorsalis anlage. However, as explained by Brock (1938), Iordansky (1996) and others, the levator quadrati and levator bulbi of adult amphibians do seem to derive from this anlage (see Chapter 5). Brock (1938) defended that the levator quadrati of caecilians and the levator bulbi of urodeles and anurans are the remains of the 'constrictor dorsalis group' in amphibians. According to this author, the 'constrictor dorsalis group' is usually more fully conserved in extant reptiles because of their kinetic skull (as is the case in the 'lizard' *Timon*, many extant reptiles have three dorsal mandibular muscles, the levator pterygoidei, the protractor pterygoidei and the levator bulbi: see Chapters 5 and 7). Iordansky (1996) stated that the levator quadrati of caecilians corresponds to the levator pterygoideus + protractor pterygoidei of reptiles. Some authors, including Edgeworth (1935), have suggested that the levator bulbi of urodeles and anurans corresponds to the compressor glandulae orbitalis of caecilians. However, this homology was questioned by Duellman and Trueb (1986) and others. Carroll (2007: 25) stated that "caecilians have a muscle (the compressor tentaculi) that is homologous with the levator bulbi, but its function has shifted to manipulation of the tentacle (Duellman and Trueb 1986: 385)". However, the caecilian muscle to which Duellman and Trueb

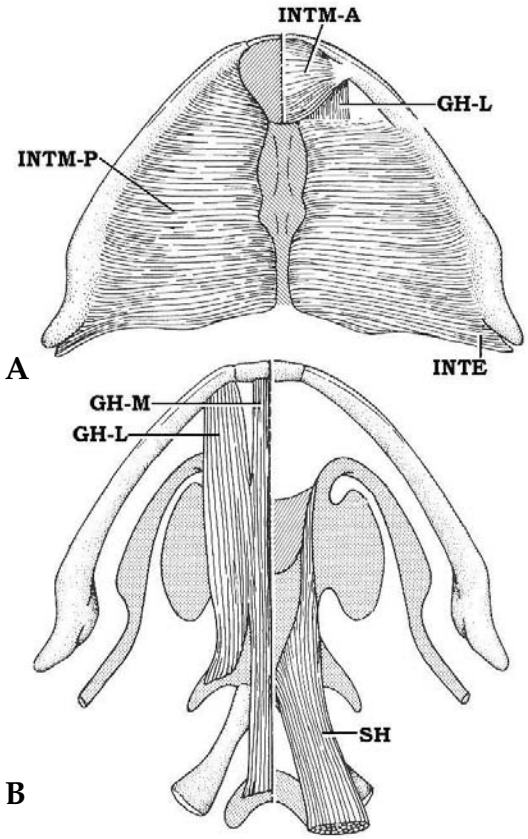

Fig. 6.4 *Bufo marinus* (Amphibia, Anura): (A) Ventral view of the cephalic musculature; (B) same view, but the superficial muscles were removed in order to show the hypobranchial muscles geniohyoideus (on the left) and sternohyoideus (on the right) (modified from Duellman and Trueb 1986; the nomenclature of the myological structures illustrated follows that of the present work; for more details about the osteological structures illustrated, see Duellman and Trueb 1986). GH-L, GH-M, geniohyoideus lateralis and geniohyoideus medialis; INTE, interhyoideus; INTM-A, INTM-P, intermandibularis anterior and intermandibularis posterior; SH, sternohyoideus.

(1986) are referring in their page 385 is an ocular muscle innervated by nerve VI (abducens), and not a mandibular muscle innervated by nerve V, as is the levator bulbi of anurans and urodeles (see also Ramaswami 1942).

In fact, within the amphibians dissected by us, a distinct levator bulbi was effectively only found in urodeles and anurans, and a distinct levator quadrati was only found in caecilians. As the levator bulbi of urodeles and anurans is indeed similar to that of reptiles (see Chapters 5 and 7), it is very

likely that in the last common ancestor (LCA) of amphibians + amniotes the dorsal mandibular muscles were already divided into: (1) an undivided 'levator palatini', which was probably similar to, and derived from part of, the levator arcus palatini of sarcopterygian fish such as *Latimeria*; and (2) a levator bulbi, which was probably similar to that of extant urodeles, anurans and reptiles, and also derived from part of the levator arcus palatini (Table 6.1). Then, during the evolutionary events leading to the origin of urodeles and anurans, the 'levator palatini' was secondarily lost, probably because these taxa lack a cranial kinesis such as that found in fish such as coelacanths and in many reptiles (Brock 1938), leaving only the levator bulbi (Table 6.1). As proposed by Iordansky (1996), the levator quadrati of caecilians thus probably corresponds to the levator pterygoidei + protractor pterygoidei of reptiles such as *Timon*, which are derived from the 'levator palatini' of the LCA of amphibians + amniotes (Table 6.1; see Chapter 7). That is, the levator bulbi was probably secondarily lost during the evolutionary events that led to the origin of caecilians. An alternative, less likely hypothesis is that the levator quadrati of caecilians is an undifferentiated muscle corresponding to both the 'levator palatini' and levator bulbi of the LCA of amphibians + amniotes, i.e., to the levator arcus palatini of sarcopterygian fish such as *Latimeria*.

Hyoid Muscles (Table 6.2)

The interhyoideus (Figs. 6.1, 6.2, 6.4, 6.6) is a hyoid muscle that primarily passes from the hyoid bar to the ventral middle line, behind the intermandibularis (see Chapters 3–5). Several urodele and some anuran and caecilian amphibians have an interhyoideus anterior and an interhyoideus posterior, which is often named 'interbranchialis' or 'sphincter colli' (Figs. 6.1, 6.6; see also, e.g., Edgeworth 1935; Piatt 1938; Nussbaum 1983; Duellman and Trueb 1986; Bauer 1992, 1997; Carroll 2007; Kleinteich and Haas 2007). Interestingly, the developmental study of Ericsson and Olsson (2004) suggested that the interhyoideus anterior and interhyoideus posterior of *Ambystoma mexicanum* might derive from distinct, separate anlages, while the developmental work of Piekarski and Olsson 2007 indicated that in this species at least part of the interhyoideus derives ontogenetically from anterior somites. In the adult caecilian specimens we dissected, the interhyoideus seems to be constituted by a single, continuous mass of fibers. However, Nussbaum (1983), Duellman and Trueb (1986), Carroll (2007), Kleinteich and Haas (2007) and others did describe an interhyoideus anterior and an interhyoideus posterior in some caecilians (see Fig. 6.6). Bemis et al. (1983: 85) stated that "due to its position directly behind the retroarticular process", the action of the interhyoideus of caecilians "is

Table 6.2 Hyoid muscles of adults of representative urodele, anuran and caecilian taxa (see caption of Table 6.1, text and Figs. 6.1–6.7).

Amphibia.(Caudata): ***Ambystoma ordinarium*** (Michoacan stream salamander)	Amphibia (Anura): ***Rhinella arenarum*** (Argentine common toad)	Amphibia (Gymnophiona): ***Siphonops paulensis*** (Catuchi caecilian)
Depressor mandibulae (depressor mandibulae anterior sensu Diogo 2007, 2008, and Diogo et al. 2008b)	**Depressor mandibulae** [see text]	**Depressor mandibulae** [see text]
Ceratomandibularis ('branchiomandibularis' sensu Edgeworth 1935) [the 'hyomandibularis' of caecilians seems to correspond to the ceratomandibularis, or possibly to the ceratomandibularis + branchiohyoideus, of urodeles, which probably correspond to part of the depressor mandibulae/levator hyoideus of dipnoans: see Chapter 5]	— [see text]	— ('subhyoideus' or 'hyomandibularis' sensu Lawson 1965, Wikinson and Nussbaum 1997, Carroll 2007 and Kleinteich and Haas 2007) [the 'hyomandibularis' is found in larvae, but also in some adults, of caecilians: see, e.g., Edgeworth 1935; Lawson 1965; Kleinteich and Haas 2007]
Branchiohyoideus (ceratohyoideus externus or branchiohyoideus externus sensu Edgeworth 1935, Piatt 1938, Lightoller 1939, Bauer 1997 and Ericsson and Olsson 2004; subhyoideus sensu Carroll 2007)	— [see text]	— [see text]
Levator hyoideus (depressor mandibulae posterior sensu Diogo 2007, 2008, and Diogo et al. 2008b) [contrary to the levator hyoideus of some neotenic urodeles such as *Siren*, the levator hyoideus of adults of *Ambystoma*, as well as of various other urodele taxa, inserts on the mandible, and not on the hyoid bar: see text]	— [see text]	— [see text]
Interhyoideus [urodeles often have an interhyoideus anterior and an interhyoideus posterior, which is often named 'interbranchialis' or 'sphincter colli': see, e.g., Piatt 1938; Bauer 1992, 1997; Ericsson and Olsson 2004; Carroll 2007]	**Interhyoideus** [anurans may also have an interhyoideus anterior and an interhyoideus posterior: see, e.g., Carroll 2007]	**Interhyoideus** [caecilians may also have an interhyoideus anterior and an interhyoideus posterior: see, e.g., Nussbaum 1983; Duellman and Trueb 1986; Kleinteich and Haas 2007; Carroll 2007]

to close the lower jaw", stressing that "this function of the interhyoideus in caecilians is unique among tetrapods".

In the adult urodele, anuran and caecilian amphibians we dissected, as well as in those described by other authors, the depressor mandibulae (Figs. 6.1, 6.2, 6.3, 6.6) usually originates from the posterolateral surface of the skull and passes to the retroarticular process of the mandible, being mainly a jaw opener (e.g., Ecker 1889; Gaupp 1896; Luther 1914; Lubosch 1938; Duellman and Trueb 1986; Bauer 1992, 1997; Luther 1914; Wilkinson and Nussbaum 1997; Carroll 2007). In various urodeles, including *Ambystoma* (Fig. 6.1 and Table 6.2), the fibers corresponding to those of the levator hyoideus of dipnoans become attached on to the mandible, forming a muscle that is often named 'depressor mandibulae posterior' (see Chapters 4–5). As this muscle is clearly homologous to the muscle levator hyoideus that inserts on the hyoid bar in numerous dipnoan and tetrapod larvae as well as in adult dipnoans and in some adult tetrapods, including some neotenic urodeles such as *Siren*, we prefer to designate it, throughout this volume, as levator hyoideus, as proposed by Edgeworth (1935) (Fig. 6.1 and Table 6.2; see also Chapters 4 and 5).

The levator hyoideus is usually present as an independent muscle in caecilian larvae (Fig. 6.6), but not in caecilian adults (e.g., Edgeworth 1935; Kleinteich and Haas 2007). According to Edgeworth (1935), in at least some caecilian adults this muscle is fused with the depressor mandibulae. In anuran larvae the depressor mandibulae and the levator hyoideus are often separated: the depressor mandibulae may be subdivided into a suspensorioangularis, a quadratoangularis, and a hyoangularis, which, as their names indicate, insert on the mandible; the levator hyoideus may be subdivided into an orbitohyoideus and a suspensoriohyoideus, which, as their names indicate, insert on the hyoid bar (e.g., Edgeworth 1935; Paterson 1939; Weisz 1945ab; Sedra 1949; Sedra and Michael 1957; Sokol 1977; Palavecino 2000; Olsson et al. 2001; Kleinteich and Haas 2007; Carroll 2007). However, in post-metamorphic anurans, the orbitohyoideus and suspensoriohyoideus often become inserted on the mandible and fused with the depressor mandibulae, the levator hyoideus thus being often not present as an independent muscle, although it possibly corresponds to the posterior bundle of the depressor mandibulae of some adult anurans (Fig. 6.4A) (e.g., Edgeworth 1935; Sedra 1949; Palavecino 2000; Kleinteich and Haas 2007; Carroll 2007; for further considerations about the depressor mandibulae of adult anurans, see, e.g., Starret 1968; Hoyos 1999; Manzano et al. 2003).

The branchiohyoideus (Fig. 5.5) is a muscle that usually originates on the dorsal margin of the ceratohyal and runs anteroventrally, below the hyoid bar and internal to the interhyoideus, to insert on the mesial surface of the ceratohyal and/or the epihyal (e.g., Edgeworth 1935; see Chapter 5).

It is found in urodele larvae and some urodele obligate neotenes such as *Ambystoma ordinarium* (Fig. 5.5 and Table 6.2), and is usually absent as an independent structure in fully metamorphosed adult urodeles. However, as stressed by Piatt (1938: 542) and others, in some metamorphosed urodeles the branchiohyoideus "may persist as late as the sixth week following the advent of terrestrial life". The branchiohyoideus should not be confused with the ceratomandibularis ('branchiomandibularis' sensu Carroll 2007), which is a muscle that usually runs from the ceratohyal to the mandible (Fig. 6.6B). The ceratomandibularis and the branchiohyoideus seem to derive ontogenetically from the same anlage (e.g., Piatt 1938; Bauer 1997). The ceratomandibularis is often absent as an independent structure in fully metamorphosed adult urodeles, but, as described by Bauer (1997), may persist in some obligate neotenes (e.g., *Ambystoma originarium*: Table 6.2). In his figure 31B, Carroll (2007) seems to suggest that the branchiohyoideus of urodeles is homologous to the 'hyomandibularis' (or 'subhyoideus') muscle that is present in larvae and in some adults of caecilians. However, Edgeworth (1935), Kleinteich and Haas (2007) and others stated that the 'hyomandibularis' of caecilians corresponds to the ceratomandibularis, and not the branchiohyoideus, of urodeles (Fig. 6.6). This idea is supported by the fact that, as its name indicates, the caecilian 'hyomandibularis' often attaches anteriorly on the mandible, as does the urodele ceratomandibularis, and not on the hyoid bar, as does the urodele branchiohyoideus. An alternative hypothesis is that the 'hyomandibularis' of caecilians is an undifferentiated muscle corresponding to both the ceratomandibularis and branchiohyoideus of urodeles (Table 6.2). In the adult anurans we dissected, neither the ceratomandibularis nor the branchiohyoideus seems to be present as an independent structure. Edgeworth (1935), Jarvik (1963, 1980) and others stated that these two muscles are effectively missing in anuran adults (Table 6.2).

Branchial Muscles (Table 6.3)

InTable 6.3, we follow the nomenclature used in Chapters 2–5 and thus consider the 'true' branchial muscles sensu stricto as a group. Examples of 'true' branchial muscles sensu stricto that are present in urodele larvae and/or adults are the levatores arcuum branchialum, transversi ventrales and subarcuales recti; examples of these muscles in anuran larvae and/or adults are the levatores arcuum branchialum, subarcuales obliqui, subarcuales recti and petrohyoideus; examples of these muscles in caecilian larvae and/or adults are the levatores arcuum branchialum, transversi ventrales, subarcuales obliqui and subarcuales recti (Figs. 6.4, 6.6; for more details on the amphibian 'true' branchial muscles sensu stricto, see, e.g., Humphry 1871; Gaupp 1986; Ecker 1889; Edgeworth 1935; Piatt 1938;

Kesteven 1942–1945; Fox 1959; Bemis et al. 1983; Duellman and Trueb 1986; Haas 1996; Kleinteich and Haas 2007; Carroll 2007; Ziermann and Olsson 2007).

The protractor pectoralis (Fig. 6.1) corresponds to the 'cucullaris' sensu Edgeworth (1935), which, according to that author, is a muscle that derives from a caudal levator arcus branchialis of plesiomorphic vertebrates and that became secondarily attached to the pectoral girdle, thus connecting this structure to the skull. Interestingly, recent developmental works suggest that in amphibians such as *Ambystoma mexicanum* the protractor pectoralis, as well as laryngeal muscles such as the dilatator laryngis, derive ontogenetically not only from the branchial mesoderm but possibly also from anterior somites (see, e.g., Piekarski and Olsson 2007; see also Chapter 5). More details about the development and evolution of the protractor pectoralis are given in Chapter 3 and particularly in Chapter 5. As described by Edgeworth (1935), the protractor pectoralis is often a large muscle in metamorphosed anurans and in both larvae and adults of urodeles (Fig. 6.1), being absent in the adult caecilians dissected by us. This is very likely related to the fact that extant caecilians do not have a pectoral girdle (see the recent review of Carroll 2007), which is the structure to which this muscle usually attaches.

As their name indicates, the dilatator laryngis and constrictor laryngis (Fig. 6.6) are antagonistic muscles (e.g., Duellman and Trueb 1986). They are often present in larvae and adults of urodeles, anurans and caecilians and form, together with the laryngeus, the laryngeal muscles sensu this volume (Fig. 6.1; Table 6.3). As described by Edgeworth (1935), the laryngeus is present in larvae and adults of urodele and caecilian taxa such as *Ichthyophis*, *Caecilia*, *Hypogeophis*, *Amphiuma*, *Menopoma*, and *Ambystoma* (Table 6.3), but in taxa such as *Salamandra*, *Triton* and *Siphonops* (Table 6.3) it atrophies during ontogeny, being absent as an independent muscle in adults. As also described by this author, the laryngeus does not seem to be present as a separate muscle in anuran adults (Table 6.3); according to him this muscle is also missing in anuran larvae.

Hypobranchial Muscles (Table 6.4)

According to Edgeworth (1935), the hypobranchial muscles are divided into a 'geniohyoideus' group and a 'rectus cervicus' group (Table 6.4; Chapter 2). Extant sarcopterygian fish have two hypobranchial muscles, the coracomandibularis and the sternohyoideus, which are included in the 'geniohyoideus' and 'rectus cervicus' groups sensu Edgeworth, respectively (e.g., Edgeworth 1935; Kesteven 1942–1945; Wiley 1979ab; Wilga et al. 2000; this work) (Chapters 4–5). These muscles connect the pectoral girdle to the mandible and the hyoid bar and are mainly related to the

Table 6.3 Branchial muscles of adults of urodele, anuran and caecilian taxa (see caption of Table 6.1, text and Figs. 6.1–6.7).

Amphibia.(Caudata): ***Ambystoma ordinarium*** (Michoacan stream salamander)	Amphibia (Anura): ***Rhinella arenarum*** (Argentine common toad)	Amphibia (Gymnophiona): ***Siphonops paulensis*** (Catuchi caecilian)
'True' branchial muscles sensu stricto [see text]	**'True' branchial muscles sensu stricto** [see text]	**'True' branchial muscles sensu stricto** [see text]
Protractor pectoralis (cucullaris or cucullaris major sensu Edgeworth 1935 and Carroll 2007; trapezius sensu Jollie 1962) [in his fig. 14.16, Jollie 1962 shows a *Cryptobranchus* specimen with a 'sternomastoideus' and a 'trapezius' divided into at least two parts, i.e., a 'pars spinotrapezius' and a 'pars clavotrapezius'; however, both his illustration and his captions suggest that at least part of the 'trapezius' is deeply blended with the 'sternomastoideus', so it is not clear if in this taxon the protractor pectoralis is really differentiated into a separate, distinct trapezius and a separate, distinct sternocleidomastoideus sensu the present work, as is the case in many extant amniotes; according to Howell 1933-1937, the sternocleidomastoideus is actually only present as a separate muscle in reptiles and mammals; see Chapter 5]	**Protractor pectoralis** (cucullaris sensu Edgeworth 1935)	— [see text]
—	**Interscapularis** [according to Howell 1935, contrary to other tetrapods, anurans have a peculiar muscle interscapularis, which clearly seems to be a branchial muscle, and which, according to him, is probably derived from the protractor pectoralis]	—
Constrictor laryngis	**Constrictor laryngis**	**Constrictor laryngis**

Laryngeus [the laryngeus and constrictor laryngis of amphibians are derived ontogenetically from the same anlage; contrary to other urodeles, in which the laryngeus is divided into laryngeus dorsalis and laryngeus ventralis sensu Piatt 1938, in *Ambystoma* the laryngeus is often constituted by a single mass of fibers, which corresponds to the laryngeus ventralis, according to Edgeworth 1935]	— [see text]	— [but present in some caecilian adults: see text]
Dilatator laryngis	**Dilatator laryngis**	**Dilatator laryngis**

Table 6.4 Hypobranchial muscles of adults of urodele, anuran and caecilian taxa (see caption of Table 6.1, text and Figs. 6.1–6.7).

Amphibia.(Caudata): ***Ambystoma ordinarium*** (Michoacan stream salamander)	Amphibia (Anura): ***Rhinella arenarum*** (Argentine common toad)	Amphibia (Gymnophiona): ***Siphonops paulensis*** (Catuchi caecilian)
Geniohyoideus (sensu Lauder andShaffer 1988)	**Geniohyoideus** (geniobranchialis sensu Haas 1996; includes the geniohyoideus lateralis and geniohyoideus mesialis sensu Carroll 2007)	**Geniohyoideus**
Genioglossus [according to Edgeworth 1935 and Piatt 1938 the genioglossus of salamanders such as *Ambystoma* is derived from the coracomandibularis; it may be missing in urodele taxa such as *Siren* and *Spelerpes*]	**Genioglossus**	**Genioglossus**
— [as explained in Chapter 5, extant amphibians seemingly not have well-developed, independent 'intrinsic muscles of the tongue' like those found in extant amniotes; it should, however, be noted that Schwenk 2001 and others do not agree with the definition of 'extrinsic' and 'intrinsic' muscles of the tongue, and consider that the latter should actually not be considered as independent muscles]	— [see on the left]	— [see on the left]
Hyoglossus [the statements of Edgeworth 1935, concerning the hyoglossus of urodeles such as *Ambystoma*, are confusing: on page 196 he states that it derives from the sternohyoideus but on page 211 he suggests that, as in other amphibians and in reptiles and mammals, it derives from the coracomandibularis; the results of the developmental work of Piatt 1938 support this latter hypothesis]	**Hyloglossus**	— [as described by Edgeworth 1935, the hyoglossus does not seem to be present as a separate muscle in *Siphonops*]
Interradialis [see text]	—	—
Sternohyoideus (rectus cervicus sensu Lauder and Shaffer 1988, Kardong 2002 and Carroll 2007)	**Sternohyoideus** (rectus cervicus sensu Carroll 2007)	**Sternohyoideus** (rectus cervicus sensu Kleinteich and Haas 2007 and Carroll 2007)

Omohyoideus (pectoriscapularis sensu Edgeworth 1935, Walker 1954 and Kardong 2002) [according to Edgeworth 1935, the omohyoideus is derived from the sternohyoideus; the abdomino-hyoideus sensu Piatt 1938 probably corresponds to the omohyoideus sensu this volume]	**Omohyoideus**	—

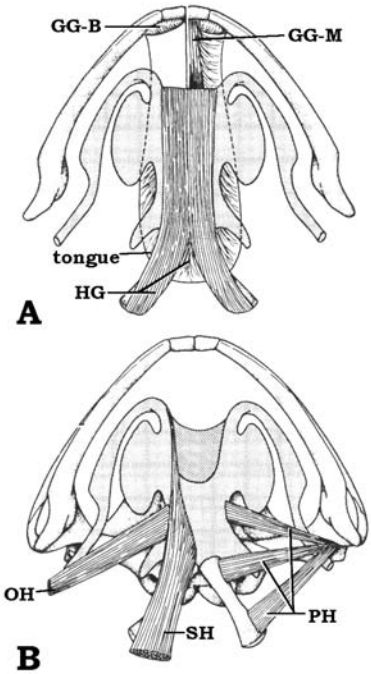

Fig. 6.5 *Bufo marinus* (Amphibia, Anura): **(A)** Ventral view showing the hypobranchial tongue muscles genioglossus and hyoglossus; **(B)** same view showing the hypobranchial muscles sternohyoideus and omohyoideus (on the left) and the branchial muscles petrohyoideus (on the right) (modified from Duellman and Trueb 1986; the nomenclature of the myological structures illustrated follows that of the present work; for more details about the osteological structures illustrated, see Duellman and Trueb 1986). GG-B, GG-M, genioglossus basilis and genioglossus medialis; HG, hyoglossus; OH, omohyoideus; PH, petrohyoideus; SH, sternohyoideus.

opening of the mouth. Amphibians and amniotes have various hypobranchial muscles (Table 6.4). The amphibian muscles geniohyoideus (Figs. 6.4, 6.6, 6.7), genioglossus (Figs. 6.5, 6.7), and hyoglossus (Fig. 6.5) derive very likely from the coracomandibularis of sarcopterygian fish, the sternohyoideus (Figs. 6.4, 6.6, 6.7) and omohyoideus (Fig. 6.5) deriving from the sternohyoideus of these fish (see Chapter 5). It is, however, possible that the 'hyoglossus' of some urodeles is at least partially derived from the sternohyoideus (e.g., Edgeworth 1935; Jarvik 1963; Chapter 5).

Ecker (1889) and other authors stated that the geniohyoideus of adult anurans is often divided into a geniohyoideus lateralis and a geniohyoideus medialis, which run from different regions of the hyoid bar to different regions of the mandible. Our observations of adult anurans match with this description of the spatial arrangement of the geniohyoideus (Fig. 6.4). However, because in some amphibians this muscle does not originate from

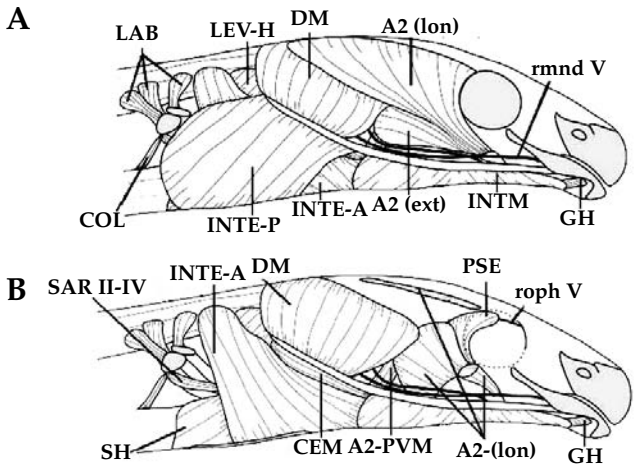

Fig. 6.6 *Ichthyophis kohtaoensis* (Amphibia, Gimnophiona): **(A)** Lateral view of the cephalic musculature of a larva; **(B)** same view, but the eye, the interhyoideus posterior, as well as the adductor mandibulae 'externus' and part of the lateral layer of the adductor mandibulae 'longus' sensu Kleinteich and Haas (2007) were removed (modified from Kleinteich and Haas 2007; the nomenclature of the myological structures illustrated follows that of the present work; for more details about the osteological structures illustrated, see Kleinteich and Haas 2007). A2 (ext), A2 (lon), 'externus' and 'longus' portions of adductor mandibulae, which probably correspond to the A2 sensu the present work; A2-PVM, adductor mandibulae A2-PVM; CEM, ceratomandibularis; COL, constrictor laryngis; DM, depressor mandibulae; GH, geniohyoideus; INTE-A, INTE-P, interhyoideus anterior and interhyoideus posterior; INTM, intermandibularis; LAB, levatores arcuum branchialium; LEV-H, levator hyoideus; PSE, pseudomandibularis; rmnd V, roph V, ramus ophthalmicus and ramus mandibularis V; SAR II-IV, subarcualis rectus II-IV; SH, sternohyoideus.

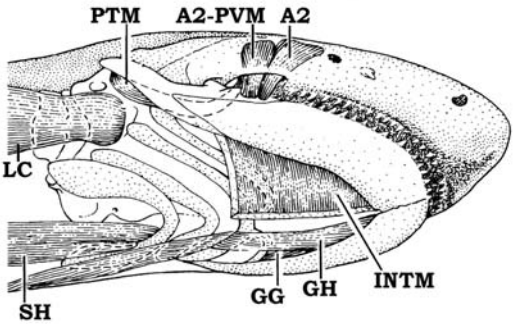

Fig. 6.7 *Dermophis mexicanus* (Amphibia, Gimnophiona): ventral view of the cephalic musculature, on the right of the animal the A2, A2-PVM, pterygomandibularis and intermandibularis were removed (modified from Bemis et al. 1983; the nomenclature of the myological structures illustrated follows that of the present work; for more details about the osteological structures illustrated, see Bemis et al. 1983). A2, A2-PVM, adductor mandibulae A2 and A2-PVM; GG, genioglossus; GH, geniohyoideus; INTM, intermandibularis; LC, longus capitis; PTM, pterygomandibularis; SH, sternohyoideus.

the hyoid bar, but on more posterior branchial arches, Haas (1996) and others proposed to use the name 'geniobranchialis', and not geniohyoideus. But most authors prefer to continue using the name geniohyoideus, because the muscle is clearly homologous to the geniohyoideus of other tetrapods (see Chapter 5; Table 6.4).

The 'tongue' muscles genioglossus and hyoglossus are often present in urodeles and anurans, although the first muscle may be absent in urodeles such as *Siren* and *Pseudotriton* (see Figs. 6.5, 6.7, and also, e.g., Ecker 1998; Edgeworth 1935; Duellman and Trueb 1986). According to Duellman and Trueb (1986), in caecilians the hyoglossus is not present as an independent structure. We were also unable to find this muscle in the adult caecilians we dissected. In fact, the tongue in *Siphonops* and *Chthonerpeton* is very much like that described in *Dermophis* by Bemis et al. (1983), being large but only slightly free at its margins, and being associated with a single glossal muscle, the genioglossus (Fig. 6.7; see also Carroll 2007). As described by Piatt (1938), in at least some adult *Ambystoma* there is a hypobranchial muscle interradialis, which probably derives from the genioglossus (Table 6.4).

The sternohyoideus and omohyoideus usually connect the pectoral girdle to the hyobranchial apparatus (Figs. 6.4, 6.5, 6.6, 6.7). Carroll (2007: 40) stated that "the omohyoideus (of anurans) cannot be compared to any muscle in salamanders". However, urodeles do have a muscle omohyoideus (Fig. 6.2), which clearly seems to be homologous to that of anurans (e.g., Albrecht 1876; Edgeworth 1935; this work). Caecilians do not have a pectoral girdle, and in the specimens dissected by us, as well as in those described by other authors, the omohyoideus is not present as an independent structure (Table 6.4). However, these amphibians do have a muscle sternohyoideus, which usually arises directly from the fascia of the muscle rectus abdominis (Figs. 6.6, 6.7 and Table 6.4; e.g., Edgeworth, 1935; Kleinteich and Haas 2007; this work).

General Remarks

Based on the information mentioned above and given in Tables 6.1–6.4 about the mandibular, hyoid, branchial and hypobranchial muscles of caecilians, urodeles and anurans, as well on the data provided in the other chapters of this book, it is possible to briefly summarize here those muscles that might have been present in the LCA of these three amphibian groups.

Regarding the mandibular muscles, this LCA probably had an adductor mandibulae A2, an adductor mandibulae A2-PVM, a pseudotemporalis, a pterygomandibularis, an intermandibularis anterior, an intermandibularis posterior, a 'levator palatini', and a levator bulbi. Caecilians usually have

a single intermandibularis, either because one of the intermandibularis muscles was secondarily lost or, more likely, because their intermandibularis is an undifferentiated muscle that does not become subdivided into anterior and posterior portions during ontogeny. As explained above, the 'levator palatini' was probably secondarily lost in urodeles and anurans, and the levator bulbi was probably secondarily lost in caecilians, although it cannot be discarded that the levator quadrati of caecilians is in fact an undifferentiated muscle corresponding to both the 'levator palatini' and levator bulbi of the LCA of amphibians + amniotes, i.e., to the levator arcus palatini of sarcopterygian fish such as *Latimeria*. The secondary loss of a 'levator palatini' in anurans and urodeles might constitute a potential synapomorphy of the clade including these two amphibian groups, if it is accepted that these two groups are more closely related to each other than to caecilians (see the recent overview of Carroll 2007). Iordansky (1996) and Kleinteich and Haas (2007) suggested that the caecilian muscle that they call 'pterygoideus' probably corresponds to the pterygomandibularis of reptiles, and, thus, that the pterygomandibularis was probably present in the LCA of tetrapods and in the LCA of amphibians. As noted above, this idea is supported by the fact that some urodeles do have a muscle 'pterygoideus' that seems to be homologous to the 'pterygoideus' of caecilians. That is, following this interpretation it would be effectively more parsimonious to assume that the pterygomandibularis was present in the LCA of tetrapods and then secondarily lost (i.e., probably not differentiated from the pseudotemporalis) in anurans than to assume that it was independently acquired in caecilians, in urodeles, and in amniotes. Future detailed studies, ideally including information about the development of these muscles in various representatives of amphibians and amniotes and data about plesiomorphic, fossil members of these two tetrapod groups, are clearly needed to clarify whether or not the 'pterygoideus' of caecilians, the 'pterygoideus' of urodeles, and the pterygomandibularis of amniotes are homologous structures.

Concerning the hyoid muscles, the LCA of urodeles, anurans and caecilians probably had an interhyoideus, a depressor mandibulae, a levator hyoideus, and possibly a ceratomandibularis, if one accepts the idea, defended by Edgeworth (1935) and others, that the 'hyomandibularis' of caecilians is effectively homologous to the ceratomandibularis of urodeles (i.e., that this muscle was present in the LCA of these two groups) and that anurans and urodeles are sister-groups. That is, under this scenario one would consider that the ceratomandibularis was present in the LCA of extant amphibians and secondarily lost in anurans. However, as explained above, one cannot discard the hypothesis that the 'hyomandibularis' corresponds to both the ceratomandibularis and branchiohyoideus of urodeles (i.e., that the LCA of extant amphibians had a

'hyomandibularis' similar to those of caecilians, and that only in urodeles this 'hyomandibularis' became differentiated into ceratomandibularis and branchiohyoideus). The levator hyoideus is present as an independent structure in the closest living relatives of tetrapods, i.e., the dipnoans, as well as in at least some adult members of the three main extant tetrapod groups, i.e., the amphibians, reptiles and mammals (e.g., Edgeworth 1935; this work). Therefore, it is in fact likely that this muscle was present as an independent structure in the LCA of extant tetrapods and in the LCA of extant amphibians. The interhyoideus of the LCA of caecilians, urodeles and anurans possibly included an interhyoideus anterior and an interhyoideus posterior, because both these latter structures are present in at least some members of these three amphibian groups (see above).

With respect to the branchial muscles, the following muscles were probably present in the LCA of extant amphibians: a protractor pectoralis, a constrictor laryngis, a dilatator laryngis, a laryngeus, and various 'true' branchial muscles sensu stricto (see above). As explained in Chapter 5, the laryngeus was probably present in the LCA of extant tetrapods (Table 6.3). As this muscle is present in some urodeles and caecilians, it was very likely also present in the LCA of extant amphibians, its absence in anurans being probably due to a secondary loss. The absence, in extant caecilians, of a muscle protractor pectoralis such as that found in other amphibian and non-amphibian sarcopterygians is very likely related to the fact that these amphibians lack a pectoral girdle, which is the usual site of insertion of this muscle (see above).

Regarding the hypobranchial muscles, the LCA of urodeles, anurans and caecilians probably had a geniohyoideus, a genioglossus, a hyoglossus, a sternohyoideus, and an omohyoideus. Within extant sarcopterygians a hypobranchial muscle interradialis has only been described in some urodeles; therefore, this muscle was very likely absent in the LCA of extant amphibians (see above).

Before ending this chapter, we would like to stress that the suggested homologies summarized in Tables 6.1–6.4 are simply scientific hypotheses that need to be and, it is hoped, will be tested by data obtained in the future. Detailed comparative ontogenetic studies of key caecilian taxa as well as of a range of other amphibian and non-amphibian tetrapods, for example, are clearly needed to address controversial questions such as the following: Is the 'hyomandibularis' of caecilians effectively homologous to the ceratomandibularis of urodeles? And is the 'pterygoideus' of caecilians homologous to the 'pterygoideus' of urodeles and to the pterygomandibularis of amniotes? Or does the caecilian 'hyomandibularis' correspond to both ceratomandibularis + branchiohyoideus of urodeles? Is the intermandibularis of caecilian adults an undifferentiated muscle corresponding to the intermandibularis anterior + intermandibularis posterior

of other amphibians, which does not become subdivided into these two structures during the ontogeny of caecilians? Could the levator quadrati of adult caecilians be also an undifferentiated muscle corresponding not only to the levator pterygoidei + protractor pterygoidei, but also to the levator bulbi, of reptiles such as the 'lizard' *Timon*? It is hoped that the present work will stimulate, and pave the way for, future studies on the comparative anatomy, development, functional morphology, and evolution of the amphibian muscles.

Chapter 7

Head and Neck Muscles of Reptiles

In this chapter we focus on the comparative anatomy, evolution and homologies of the head and neck muscles of the major extant clades of reptiles, that is, Testudines (turtles), Lepidosauria (including *Sphenodon*, 'lizards', mosasaurs, snakes and amphisbaenians sensu Conrad 2008: see below), Crocodylia (crocodylians), and Aves (birds). Many anatomical works have provided information about the head and neck musculature of reptiles (e.g., Fürbringer 1874, 1876; Albrecht 1876; Versluys 1898, 1904; Edgeworth 1911, 1935; Phisalix 1914; Adams 1919; Camp 1923; Lakjer 1926; Brock 1938; Engels 1938; Lightoller 1939; Walker 1954; Oelrich 1956; Schumacher 1961, 1973; Frazzetta 1962; Jollie 1962; Jarvik 1963, 1980; Iordansky 1964, 2000, 2004, 2008; Barghusen 1968, 1986; Gaunt and Gans 1969; Haas 1973; Vanden Berge 1975; Rieppel 1980, 1981, 1984, 1990; Ghetie et al. 1981; Busbey 1989; Elzanowski 1987; Smith 1988; Witmer 1995ab, 1997; Abdala and Moro 1996, 2003; Moro and Abdala 1998, 2000; Herrel et al. 1999, 2005; Wyneken 2001; Montero et al. 2002; Sedlmayr 2002; Holliday and Witmer 2007; Tsuihiji 2007; Conrad 2008; Tsukahara et al. 2009; Abdala et al. in press). However, as is the case with other vertebrate groups, most of these works focused on a specific reptilian taxon and/or a specific head and neck region, and none of them has actually provided detailed information about the homologies of the whole head and neck musculature of turtles, lepidosaurs, crocodylians and birds. The present account of the comparative anatomy, homologies and evolution of the head and neck muscles of these latter groups is based on the results of our own dissections of numerous members of each of these groups, combined with an exhaustive literature review. In fact, we made an effort to take into account as much bibliographical information as possible, from classic anatomical descriptions (e.g., Fürbringer 1874, 1876; Albrecht 1876; Versluys 1898, 1904; Edgeworth

1911, 1935; Phisalix 1914; Adams 1919; Lakjer 1926; Engels 1938; Lightoller 1939) to more recent reviews (e.g., Haas 1973; Schumacher 1973; Vanden Berge 1975; Gethie et al. 1981; Müller and Weber 1998; Noden et al. 1999; Iordansky 2000, 2008; Abdala and Moro 2003; Holliday and Witmer 2007; Conrad 2008; Holliday 2009; Abdala et al. in press), including, importantly, the developmental and molecular data obtained in the numerous evo-devo studies that have been undertaken in the past few decades with both reptilian and non-reptiles tetrapods such as chickens, quails, salamanders, frogs and mice (e.g., Noden 1983, 1984, 1986; McClearn and Noden 1988; Davis et al. 1991; Couly et al. 1992; Gardner and Barald 1992; Köntges and Lumsden 1996; Huang et al. 1999; Marcucio and Noden 1999; Olsson et al. 2000, 2001, 2005; Ellies and Tucker 2002; Mootoosamy and Dietrich 2002; Borue and Noden 2004; Ericsson and Olsson 2004; Ericsson et al. 2004; Le Douarin et al. 2004; Prunotto et al. 2004; O'Gorman 2005; Yamane 2005; Noden and Francis-West 2006; Noden and Schneider 2006; Piekarski and Olsson 2007; Ziermann and Olsson 2007; Knight et al. 2008; Kundrát et al. 2009; Shearman and Burke 2009; Tzahor 2009). The results of our observations and comparisons are summarized in Tables 7.1–7.4, which present the best-supported hypotheses of homology for the muscles discussed in this chapter.

As stressed in previous chapters, one of the major problems researchers face when they compare the muscles of a certain tetrapod taxon with those of other taxa is the use of different names by different authors to designate the same muscle in the members of different clades, and even of the same clade. In this respect, some of the names that are often used to designate the avian muscles in the literature (e.g., *Nomina Anatomica Avium*: Baumel et al. 1979) are particularly problematic, because they are different from the names used to designate homologous muscles in other reptiles and/or similar to the names that are used to designate non-homologous muscles in mammals (e.g., 'masseter', 'mylohyoideus', 'stylohyoideus', 'ceratoglossus', 'thyrohyoideus': see Tables 1–4 and text below). In order to reconcile the nomenclatures used for turtles, lepidosaurs, crocodylians, birds and mammals, as well as for other extant sarcopterygian groups such as caecilians, anurans, urodeles, dipnoans and coelacanths, we thus use a unifying nomenclature for the head and neck muscles of the Vertebrata as a whole (see Chapters 1, 2 and 11). The muscle names that we propose are shown in bold letters in these tables, which also provide a list of more than one hundred synonyms that have been used by other authors to designate these reptilian muscles in the literature.

Mandibular Muscles (Table 7.1)

The intermandibularis is a ventral mandibular muscle (e.g., Edgeworth 1935; Diogo 2007, 2008; Diogo et al. 2008ab) that usually connects the two hemimandibles (e.g., Figs. 7.1, 7.2). In numerous lepidosaurs, including *Timon*, the anlage that gives rise to the intermandibularis becomes differentiated into two separated muscles, the intermandibularis anterior and intermandibularis posterior (Table 7.1; Fig. 7.2). In turtles, including *Trachemys scripta* (Table 7.1), the intermandibularis is often not clearly divided into an intermandibularis anterior and an intermandibularis posterior, although some authors stated that both these muscles might be present in a few turtles (see, e.g., Schumacher 1973; Wyneken 2001). As explained by Schumacher (1973), in crocodylians the intermandibularis might be slightly differentiated into bundles, but these reptiles usually do not have distinct, well-differentiated muscles intermandibularis anterior and intermandibularis posterior such as those found in lepidosaurs such as *Timon* (Table 7.1; Figs. 7.1 and 7.9, compare with Fig. 7.2). Most birds, including *Gallus*, also have a mainly undivided intermandibularis (Table 7.1; Fig. 7.8). Some authors described a 'caudal mylohyoieus' (often also named 'pars intermandibularis of the constrictor colli') in birds such as chickens, but this structure is actually part of the hyoid muscle interhyoideus, and not of the mandibular musculature (e.g., Baumel et al. 1979; McClearn and Noden 1988; this work; see Fig. 7.8, Table 7.2, and text below). As explained in Chapter 5, the last common ancestor (LCA) of sarcopterygians, the LCA of tetrapods, and the LCA of amniotes likely had

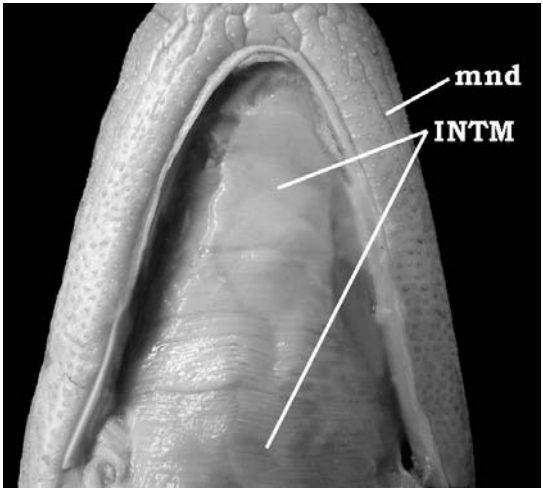

Fig. 7.1 *Caiman latirostris* (Reptilia, Crocodylia): ventral view of the adult cephalic musculature showing the intermandibularis muscle (anterior is to the top). INTM, intermandibularis; mnd, mandible.

both an intermandibularis anterior and an intermandibularis posterior, because these two muscles are present in at least some members of most of the major extant sarcopterygian clades, i.e., of coelacanths, amphibians, reptiles, and mammals. According to this hypothesis, the fact that turtles, crocodylians and birds often have a single intermandibularis could therefore be the result of a secondary loss of one of the two muscles that were plesiomorphically present in the LCA of amniotes. Or, more likely, the single intermandibularis of these reptiles could be an undifferentiated muscle that corresponds to the intermandibularis anterior + intermandibularis posterior of lepidosaurs such as *Timon*, but that does not become subdivided into two separate muscles during ontogeny. However, as also noted in previous chapters, one cannot completely discard the hypothesis that at least some of the structures that are designated as 'intermandibularis anterior' and 'intermandibularis posterior' in sarcopterygians such as coelacanths, salamanders, anurans, lepidosaurs and various mammals

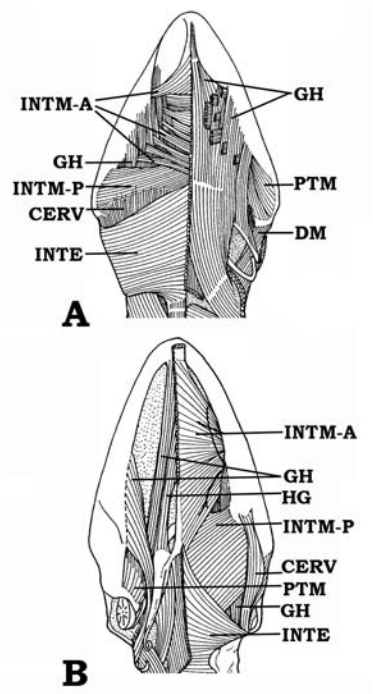

Fig. 7.2 *Coleonyx variegatus* and *Uroplatus fimbriatus* (Reptilia, Lepidosauria): ventral view of the adult cephalic musculature of *Coleonyx variegatus* **(A)** and *Uroplatus fimbriatus* **(B)** (modified from Camp 1923 and Haas 1973; the nomenclature of the myological structures illustrated follows that of the present work; anterior is to the top). CERV, cervicomandibularis; DM, depressor mandibulae; GH, geniohyoideus; HG, hyoglossus; INTE, interhyoideus; INTM-A, INTM-P, anterior and posterior bundles of intermandibularis; PTM, pterygomandibularis.

Table 7.1 Mandibular muscles of adults of representative reptilian taxa. The nomenclature of the muscles shown in bold follows that of text; in order to facilitate comparisons, in some cases names often used by other authors to designate a certain muscle/bundle are given in front of that muscle/bundle, in parentheses; additional comments are given in square brackets. Data compiled from evidence provided by our own dissections and comparisons and by an extensive review of the literature (see text).

Reptilia, Testudines: *Trachemys scripta* (Red-eared slider turtle)	Reptilia, Lepidosauria: *Timon lepidus* (Ocellated lizard)	Reptilia, Crocodylia: *Caiman latirostris* (Brown-snouted caiman)	Reptilia, Aves: *Gallus domesticus* (Domestic chicken)
Intermandibularis [see text]	**Intermandibularis posterior**	**Intermandibularis** [see text]	**Intermandibularis** (mylohyoideus or mylohyoideus anterior sensu Engels 1938) [see text]
— [see text]	**Intermandibularis anterior**	— [see text]	— [see text]
Adductor mandibulae A2-PVM (adductor mandibulae posterior sensu Schumacher 1973, Rieppel 1990 and Holliday and Witmer 2007) [Adams 1919 stated that the 'adductor mandibulae complex' of turtles is mainly undivided, but Edgeworth 1935, Schumacher 1973, Rieppel 1990, Holliday and Witmer 2007 and others have shown that in turtles this complex does comprise various separate muscles, including the adductor mandibulae A2-PVM]	**Adductor mandibulae A2-PVM** (adductor mandibulae posterior sensu Haas 1973, Abdala and Moro 2003, Wu 2003 and Holliday and Witmer 2007; part of the adductor mandibulae externus sensu Iordansky 2004, which also includes the A2)	**Adductor mandibulae A2-PVM** (adductor mandibulae posterior sensu Busbey 1989 and Holliday and Witmer 2007)	**Adductor mandibulae A2-PVM** (adductor mandibulae posterior sensu Elzanowski 1987; adductor caudalis sensu Baumel et al. 1979 and McClearn and Noden 1988; seemingly corresponds to the adductor mandibulae posterior, adductor mandibulae ossis quadrati or adductor mandibulae caudalis sensu Holliday and Witmer 2007) [the A2-PVM is not always considered to be a separate muscle in galliforms (the avian order that includes *Gallus domesticus*), but this muscle was in fact described in the specimens described by Vanden Berge 1975 and is present in the specimens dissected by us; see also, e.g., McClearn and Noden 1988]

Adductor mandibulae A2 (adductor mandibulae externus sensu Schumacher 1973, Rieppel 1990 and Holliday and Witmer 2007) [in turtles the A2 is often divided into three sections: 'profundus', 'medialis' and 'superficialis': e.g., Schumacher 1973, Rieppel 1990 and Holliday and Witmer 2007; Schumacher 1973 stated that trionychid turtles have both an A2 ('musculus adductor mandibulae externus') and a 'musculus zygomaticomandibularis', the latter structure being a 'separate division' of the A2 according to this author]	**Adductor mandibulae A2** (adductor mandibulae externus sensu Abdala and Moro 1996, 2003; part of the adductor mandibulae externus sensu Haas 1973 and Wu 2003, which also includes the levator anguli oris mandibularis and the 'retractor anguli oris'; part of the adductor mandibulae externus sensu Iordansky 2004, which also includes the A2-PVM) [as explained by Wu 2003, Holliday and Witmer, 2007 and others, in lepidosaurs the A2 ('adductor mandibulae externus') is often divided into three sections: 'profundus', 'medialis' and 'superficialis']	**Adductor mandibulae A2** [according to Busbey 1989, Holliday and Witmer 2007 and others, in crocodylians the A2 ('adductor mandibulae externus') is often divided into three sections: 'profundus', 'medialis' and 'superficialis']	**Adductor mandibulae A2** (adductor externus sensu Baumel et al. 1979, Elzanowski 1987, McClearn and Noden 1988 and Köntges and Lumsden 1996; masseter and quadratomandibularis complex of, e.g., Ghetie et al. 1981) [Adams 1919 stated that birds such as chickens have a small muscle entotympanicus that is a 'remnant' of the 'adductor mandibulae complex': see, e.g., his plate VIII; however, this small muscle is not reported in more recent works: see, e.g., Vanden Berge 1975, Noden 1983; McClearn and Noden 1988; Noden and Francis-West 2006]
— [not present in turtles, according to, e.g., Adams 1919 and Schumacher 1973; Rieppel's 1990 study corroborated the idea that, contrary to lepidosaurs, turtles such as *Chelydra* do not form a levator anguli oris mandibularis at any developmental stage]	**Levator anguli oris mandibularis** (levator anguli oris sensu Diogo 2007, 2008) [present, somewhat blended with A2; we use the name "mandibularis" to distinguish this muscle from the levator anguli oris facialis of certain mammals, which is a facial (hyoid), and not a mandibular, muscle; according to Wu 2003, Holliday and Witmer 2007 and others, the levator angulis oris mandibularis of reptiles is derived from the A2 ('adductor mandibulae externus'), as proposed in Chapters 4 and 5; see text]	— [as explained by, e.g., Haas 1973, the levator anguli oris mandibularis is not present in adult crocodylians and adult birds]	— [see on the left]

Table 7.1 contd...

Table 7.1 contd...

Reptilia, Testudines: *Trachemys scripta* (Red-eared slider turtle)	Reptilia, Lepidosauria: *Timon lepidus* (Ocellated lizard)	Reptilia, Crocodylia: *Caiman latirostris* (Brown-snouted caiman)	Reptilia, Aves: *Gallus domesticus* (Domestic chicken)
Pseudotemporalis [not present in turtles according to Adams 1919, but present in the specimens dissected by us and described by Schumacher 1973, Rieppel 1990, Holliday and Witmer 2007 and others]	**Pseudotemporalis** [see text]	**Pseudotemporalis** [according to Holliday and Witmer 2007 crocodylians and birds have a 'pseudotemporalis profundus' (which corresponds to the 'adductor mandibulae intermedius' sensu Iordansky 1964, 2000, and to the 'quadratomandibularis' or 'adductor mandibulae caudalis' of avian literature, and may correspond to the A3″ of at least some bony fish) and a 'pseudotemporalis superficialis' (which may thus correspond to the A3′ of at least some bony fish, and which, in some birds, includes a small belly that is sometimes named 'musculus caput absconditum' in avian literature)]	**Pseudotemporalis** (probably includes the quadratomandibularis sensu Elzanowski 1987: see text and on the left)
Pterygomandibularis ventralis (pterygoideus ventralis sensu Schumacher 1973; pterygoideus typicus sensu Wu 2003) [Adams 1919, Haas 1973, Rieppel 1990 and others suggested that the pterygomandibularis ('pterygoideus' in their nomenclature) of turtles is mainly undivided; however, it is now commonly accepted that turtles do have a pterygomandibularis ventralis and a pterygomandibularis dorsalis such as those of other	**Pterygomandibularis** (pterygoideus anterior sensu Adams 1919; pterygoideus sensu Lightoller 1939, Goodrich 1958, Iordansky 2004, Holliday and Witmer 2007) [according to Adams 1919, in lepidosaurs such as *Sphenodon* and *Iguana* there is a single pterygomandibularis, but in other lepidosaurs, such as *Varanus*, there is a pterygomandibularis ventralis and a pterygomandibularis dorsalis; contrary to the statements of Adams 1919, it is now commonly accepted that *Sphenodon*, as well	**Pterygomandibularis ventralis** (pterygoideus posterior sensu Adams 1919, Busbey 1989 and Iordansky 2000; pterygoideus typicus or pterygoideus superficialis sensu Haas 1973 and Wu 2003)	**Pterygomandibularis ventralis** (pterygoideus posterior sensu Adams 1919 and Iordansky 2000; probably corresponds to the pars ventromedialis of the pterygoideus sensu Baumel et al. 1979 and McClearn and Noden 1988; part of pterygoideus sensu Köntges and Lumsden 1996) [in various birds the pterygomandibularis ventralis sensu this volume includes a small section that is sometimes designated as 'muscle retractor palatini' in the literature: see, e.g., Holliday and Witmer 2007]

reptiles: see, e.g., Schumacher 1973, Witmer 1995b and Holliday and Witmer 2007]	as some other lepidosaurian taxa (e.g., Haas 1973), have both a pterygomandibularis dorsalis and a pterygomandibularis ventralis: see, e.g., Haas 1973, Witmer 1995b, Wu 2003, Holliday and Witmer 2007]		
Pterygomandibularis dorsalis (pterygoideus dorsalis sensu Schumacher 1973; pterygoideus atypicus sensu Wu 2003) [based on his own interpretation of Edgeworth's 1935 developmental study, Wu 2003 suggested that the pterygomandibularis dorsalis ('anterior' or 'atypicus' in his terminology) actually differentiates earlier than the pterygomandibularis ventralis during the ontogeny of reptiles and, thus, that the pterygomandibularis ventralis may be a more 'primitive' subdivision of the adductor mandibular complex']	— [but present in lepidosaurs such as *Sphenodon* and seemingly also in some squamates: see pterygomandibularis above and text]	**Pterygomandibularis dorsalis** (pterygoideus anterior sensu Adams 1919, Schumacher 1973, Busbey 1989 and Iordansky 2000; pterygoideus atypicus or pterygoideus profundus sensu Haas 1973 and Wu 2003)	**Pterygomandibularis dorsalis** (pterygoideus anterior sensu Adams 1919 and Iordansky 2000; probably corresponds to the pars dorsolateralis of the pterygoideus sensu Baumel et al. 1979 and McClearn and Noden 1988; part of pterygoideus sensu Köntges and Lumsden 1996)
Adductor mandibulae Aω (intramandibularis sensu Schumacher 1973, Rieppel 1990 and Iordansky 2008: see on the right) [see on the right]	**Adductor mandibulae Aω** (intramandibular sensu Iordansky 2008) [in *Timon* the adductor mandibulae has a large and distinct anteroventral portion that is lodged in the "adductor fossa" sensu Lauder 1980ab, and	**Adductor mandibulae Aω** (intramandibular sensu Schumacher 1973, Busbey 1989, Holliday and Witmer 2007, and Iordansky 2008: see on the left)	— [absent as a distinct structure in *Gallus*, but present in other birds, such as Palaeognathae, Sphenisciformes, Pelicaniformes and Procelariformes, according to Holliday and Witmer 2007 and Iordansky 2008: see on the left]

Table 7.1 contd...

Table 7.1 contd...

Reptilia, Testudines: *Trachemys scripta* (Red-eared slider turtle)	Reptilia, Lepidosauria: *Timon lepidus* (Ocellated lizard)	Reptilia, Crocodylia: *Caiman latirostris* (Brown-snouted caiman)	Reptilia, Aves: *Gallus domesticus* (Domestic chicken)
	that seems very similar to the Aω of other osteichthyans; Iordansky 2008 reviewed this subject, and stated that crocodilians, some turtles, some lepidosaurs and charadriiform and procellariiform birds do have 'intramandibular' muscles; he defended that there are two main types of these muscles in reptiles (the 'lacertiloidan' and 'crocodiloidan' types), that some turtles have rudiments of both muscle types, and that probably these two types of muscles "originated from different parts of primitive fish jaw adductors; they are not homologues to each other"]		
— [see text]	**Levator bulbi** (retractor pterygoidei sensu Moro and Abdala 2000 and Abdala and Moro 2003; part or totality of depressor palpebrae sensu Edgeworth 1935; tensor periorbitae or periorbitalis sensu Holliday and Witmer 2007)	**Levator bulbi** (part or totality of depressor palpebrae sensu Edgeworth 1935; tensor periorbitae or periorbitalis sensu Holliday and Witmer 2007)	**Levator bulbi** (part or totality of depressor palpebrae sensu Edgeworth 1935 and Elzanowski 1987; palpebral depressor sensu Noden et al. 1999 and Noden and Francis-West 2006; tensor periorbitae or periorbitalis sensu Holliday and Witmer 2007)
— [see text]	**Levator pterygoidei** (part or totality of pterygo-parietalis sensu Adam 1919)	— [but see text]	— [but see text]

--- [see text]	**Protractor pterygoidei** (part or totality of pterygo-sphenoidalis sensu Adam 1919)	— [really absent in adults of *Caiman latirostris*? See text]	**Protractor pterygoidei** (part of protractor pteryoidei et quadrati sensu Elzanowski 1987; part of protractor pterygoquadrati sensu Köntges and Lumsden 1996 and seemingly of quadrate protractor sensu Noden et al. 1999 and Noden and Francis-West 2006) [see text]
---	—	—	**'Protractor quadratus'** (part of protractor pteryoidei et quadrati sensu Elzanowski 1987; part of protractor pterygoquadrati sensu Köntges and Lumsden 1996 and seemingly of quadrate protractor sensu Noden et al. 1999 and Noden and Francis-West 2006)

are, instead, the result of an independent (convergent/parallel) division of a mainly undivided muscle intermandibularis into two separate muscles.

The 'adductor mandibulae complex' of reptiles includes mandibular muscles such as the adductor mandibulae A2-PVM, the adductor mandibulae A2, the levator anguli oris mandibularis, the 'retractor anguli oris', the pseudotemporalis, the pterygomandibularis ventralis, the pterygomandibularis dorsalis and the adductor mandibulae Aω. The A2 is well developed in extant reptiles, being usually situated laterally and rostrally to the maxillary and mandibular nerves, respectively (e.g., Holliday and Witmer 2007; this work; Figs. 7.3, 7.8, 7.12). This muscle is often subdivided into three sections: 'profundus', 'medialis' and 'superficialis'

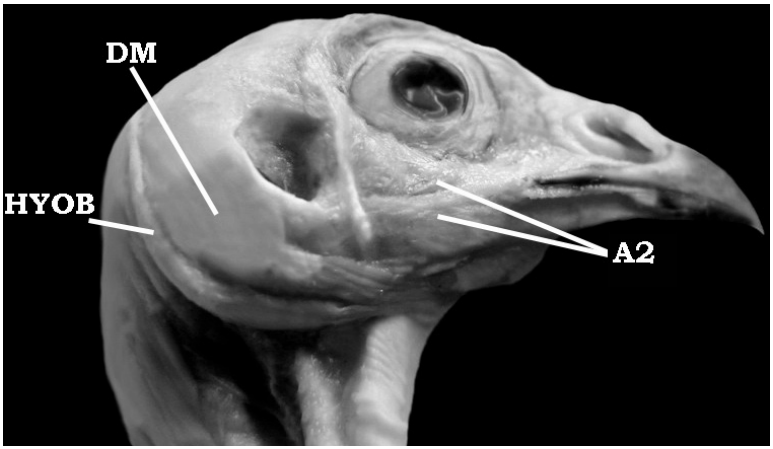

Fig. 7.3 *Coturnix coturnix* (Reptilia, Aves): lateral view of the adult cephalic musculature showing the superficial section of the adductor mandibulae A2; see configuration of this musculature in a 15-day embryo of this species in Fig. 3 (anterior is to the right). A2, adductor mandibulae A2; DM, depressor mandibulae; HYOB, hyobranchialis.

(Table 7.1; Fig. 7.4). Holliday and Witmer (2007) stated that in birds the A2 ('adductor mandibulae externus') is often only divided into two main sections: 'profundus' (which includes the 'adductor mandibulae externus coronoideus' and 'adductor mandibulae externus zygomaticus' sensu some authors) and 'superficialis' (which includes a muscle slip that is often designated as 'adductor externus pars profundus' or 'articularis externus'). According to these authors, the 'medialis' section of the A2 is not sufficiently distinct to be reliably identified in birds. However, this latter section is clearly recognizable in the *Gallus* specimens dissected by us and also in the specimens described by other authors (see, e.g., Lakjer 1926). In the turtles that we dissected, the 'profundus' section is the more developed portion of the A2 (Fig. 7.4).

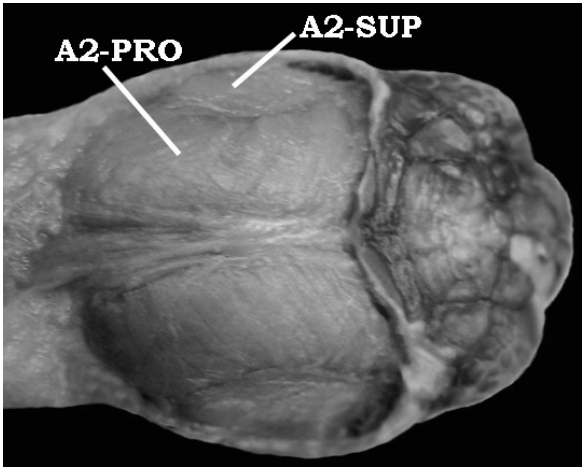

Fig. 7.4 *Geochelone chilensis* (Reptilia, Testudines): dorsal view of the adult cephalic musculature showing the superficial and deep sections of the adductor mandibulae A2 (anterior is to the right). A2-PRO, A2-SUP, pars profunda and pars superficialis of the adductor mandibulae A2.

There is much confusion and controversy in the literature regarding the homology of the structures that are often named 'adductor mandibulae posterior' in non-mammalian tetrapod groups such as caecilians, urodeles, anurans, turtles, lepidosaurs, crocodylians and birds. As explained by Rieppel (1990), the 'adductor mandibulae posterior' seems to derive ontogenetically from the 'adductor mandibulae internus' (which corresponds to the A3′/A3″ of bony fish) in turtles and from the 'adductor mandibulae externus' (which corresponds to the A2 of bony fish) in other reptilian groups such as lepidosaurs. Therefore, this could indicate that the 'adductor mandibulae posterior' of turtles is not homologous to the A2-PVM sensu the present work, because evolutionarily this latter muscle is supposedly derived from the A2 (see Chapters 4 and 5). However, according to Rieppel (1990), the posterior (but not the anterior) head of the 'adductor mandibulae posterior' of adult turtles does seem to be the topological counterpart of the 'adductor mandibulae posterior' of adult lepidosaurs. So, for Rieppel (1990: 52), this could actually provide "another example for the well known phenomenon that structures judged to be homologous by their topological relationship in the adult may develop (ontogenetically) along different pathways; the problem then is to decide whether the relationship of homology should be based on the static adult topography or rather on the dynamic developmental patterns". But it should also be stressed that ontogenetic studies have their own problems, and it is not always easy to actually determine the specific anlage from which a certain

muscle develops. For instance, some developmental studies indicated that the 'adductor mandibulae posterior' of non-testudine reptiles such as birds also develops ontogenetically from the 'adductor mandibulae internus' (A3′/A3″) (e.g., McClearn and Noden 1988). That is, these studies contradict the statements of Rieppel (1990), who suggested that, within extant reptiles, this only happens in turtles. To add to the confusion, the studies of Piatt (e.g., 1938) also suggested that the 'adductor mandibulae posterior' of the urodele *Ambystoma* develops from the 'adductor mandibulae internus' (A3′/A3″), but the work of Ericsson and Olsson (2004), using more recent techniques, indicated that it actually develops from the 'adductor mandibulae externus' (A2), thus supporting the idea that the urodele 'adductor mandibulae posterior' is effectively homologous to the A2-PVM sensu Diogo et al. (2008ab) and sensu the present work. In fact, a related problem concerns the homology of the 'intramandibularis' (Aω sensu the present work: see Table 7.1) in reptiles, because this latter muscle seems to derive from the 'adductor mandibulae externus' (A2) in lepidosaurs and from the 'adductor mandibulae internus' (A3′/A3″) in turtles, as explained by Rieppel (1990). To further complicate this subject, the 'adductor mandibulae posterior' and the 'intramandibularis' of turtles are partially blended to each other, as are the 'adductor mandibulae posterior' and the 'intramandibularis' of lepidosaurs. This similarity between the connection of these two muscles in turtles and in lepidosaurs could be used as an argument to favor the hypothesis that, despite the apparent (real, or erroneously suggested by the developmental studies that have addressed this subject so far) differences regarding the developmental pathways leading to the formation of both the 'adductor mandibulae posterior' and 'intramandibularis' in turtles and in other reptilian groups such as lepidosaurs, these structures are actually homologous within extant reptiles. It should be noted that in the recent, detailed study of Holliday and Witmer (2007), these authors have effectively supported the idea that at least part of the 'adductor mandibulae posterior' of turtles is homologous to the 'adductor mandibulae posterior' of lepidosaurs, crocodylians and birds, and, thus, to the A2-PVM sensu Diogo et al. (2008ab) and sensu this paper. This idea is also strongly supported by our dissections of various members of these four major extant reptilian clades (see Table 7.1).

Contrary to birds, turtles and crocodylians, some 'lizards' and some other lepidosaurs such as amphisbaenians and *Sphenodon* have a levator anguli oris mandibularis (Fig. 5.6) and also a 'retractor anguli oris' (e.g., Haas 1973; Rieppel 1980; Moro and Abdala 2000; Abdala and Moro 2003; Wu 2003; this work; see Table 7.1). This latter muscle occupies the posteroventrolateral region of the 'adductor mandibulae complex' and, thus, is topologically similar to the retractor anguli oris of dipnoans (see Chapters 4 and 5). According to Wu (2003), the levator anguli oris mandibularis of

lizards such as *Timon* corresponds to the 'retractor anguli oris' + levator anguli oris mandibularis of taxa such as *Sphenodon*. Although phylogenetically it is more parsimonious to assume two independent acquisitions (i.e., within the evolution of dipnoans and the evolution of reptiles) than one acquisition (i.e., in the LCA of dipnoans + tetrapods) plus numerous secondary losses (i.e., in amphibians, in mammals, and in various reptilian groups), future studies are needed to investigate whether or not the 'retractor anguli oris' and/or possibly the levator anguli oris mandibularis of reptiles such as *Sphenodon* are homologous to the retractor anguli oris of dipnoans.

The pseudotemporalis (Fig. 5.7) is divided into superficialis and profundus layers in at least some members of the four major extant reptilian clades. In turtles, the pseudotemporalis is visible only after resection of the temporal roof. Elzanowski (1987) described a 'musculus quadratomandibularis' in birds but, based on its topology, we consider that this structure is very likely homologous to/derived from the profundus layer of the pseudotemporalis of other extant reptiles. Both a pterygomandibularis ventralis and a pterygomandibularis dorsalis are found in at least some members of the four major extant reptilian clades, including the phylogenetically basal lepidosaur *Sphenodon* (Table 7.1; Figs. 7.5, 7.6). However, most other lepidosaurs have a single pterygomandibularis (Table 7.1; Figs. 7.2, 7.7, 7.13). As explained in Chapter 6, early authors,

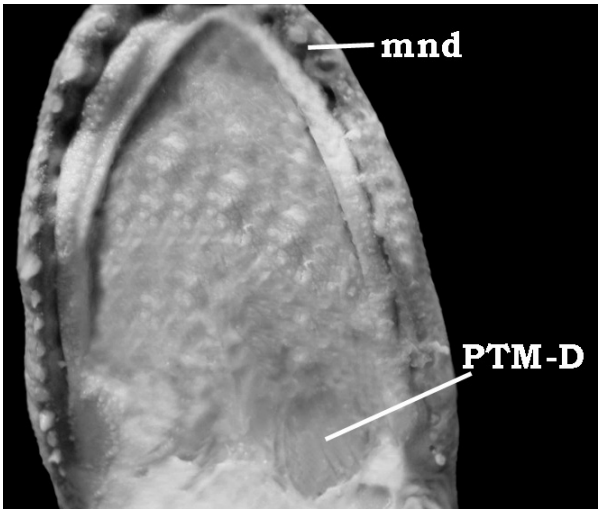

Fig. 7.5 *Caiman latirotris* (Reptilia, Crocodylia): ventral view of the adult cephalic musculature with a portion of the thick aponeurosis cover reflected to show the pterygomandibularis dorsalis muscle (anterior is to the top). Mnd, mandible; PTM-D, pterygomandibularis dorsalis.

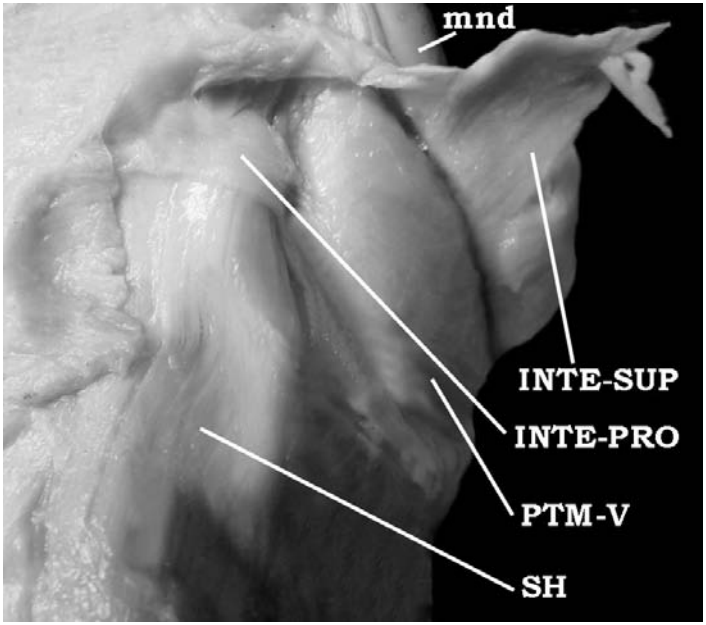

Fig. 7.6 *Caiman latirostris* (Reptilia, Crocodylia): ventral view of the adult ventral cephalic musculature; on the left side of the body (right side of the figure) superficial structures such as the pars superficialis of the interhyoideus were reflected to show the deeper musculature (anterior is to the top). INTE-PRO, INTE-SUP, pars profunda and pars superficialis of interhyoideus; mnd, mandible; PTM-V, pterygomandibularis ventralis; SH, sternohyoideus.

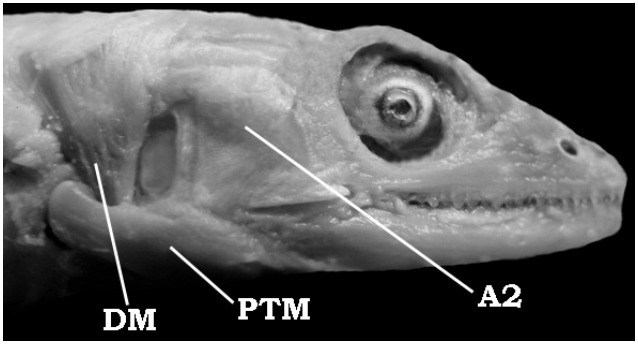

Fig. 7.7 *Polychrus acutirostris* (Reptilia, Lepidosauria): lateral view of the adult cephalic musculature showing the posterior process of the jaw covered by the pterygomandibularis and the depressor mandibulae (anterior is to the right). A2, adductor mandibulae A2; DM, depressor mandibulae; PTM, pterygomandibularis.

including Versluys (1904), based on the erroneous (see Diogo et al. 2008b) supposition that the pterygomandibularis of reptiles corresponds to the pterygoideus medialis and pterygoideus lateralis of mammals, decided to name the reptilian pterygomandibularis as 'pterygoideus'. Since then, both the names 'pterygoideus' and pterygomandibularis have been used to designate the reptilian muscle (see Table 7.1). This is particularly problematic because many reptiles have two other mandibular muscles that are named levator pterygoideus and protractor pterygoideus, but that, contrary to the pterygomandibularis, are dorsal mandibular muscles, i.e., are derived from the constrictor dorsalis anlage sensu Edgeworth (1935) (see Table 7.1 and text below).

Because turtles, birds, crocodylians, and lepidosaurs such as *Sphenodon* and some squamates (e.g., Haas 1973) have a pterygomandibularis ventralis and a pterygomandibularis dorsalis, the LCA of extant reptiles very likely had both these muscles (Witmer 1995b; Wu 2003; Holliday and Witmer 2007; this work). This plesiomorphic condition implies not only more muscular divisions, but also more complex relationships between them. Thus, in turtles these two muscles are further subdivided into smaller bundles and some of these bundles lie in a more rostral position than do the pterygomandibularis derivatives in other reptiles. Elzanowski (1987) also described a particularly complex configuration of the pterygomandibularis derivatives in birds, with different grades of pennation. The descriptions of this author were corroborated by our dissections. Interestingly, the relationships among the pterygomandibularis derivatives, the depressor mandibulae and the posterior process of the mandible are quite distinct within different reptilian groups. So, for instance, in 'lizards' the posterior process of the mandible is mainly covered laterally by the pterygomandibularis (Figs. 5.7, 7.7), and the depressor mandibulae lies in a more dorsal location (Figs. 5.6, 7.7, 7.10). In turtles, the depressor mandibular usually lies in a more ventral position and often covers the posterior mandibular process. In crocodylians the pterygomandibularis ventralis and the depressor mandibulae meet at the midline of the posterior portion of the mandible. In birds (Figs. 7.3, 7.8), as in turtles, the depressor mandibulae covers almost all the posterior mandibular process, and the pterygomandibularis ventralis and pterygomandibularis dorsalis lie in a more rostral position. Haas (1973), Wu (2003), Holliday and Witmer (2007) and others suggested that the pterygomandibularis of squamates such as *Timon* corresponds to the pterygomandibularis ventralis of other reptiles. However, more detailed ontogenetic and comparative studies are needed to clarify whether the pterygomandibularis dorsalis is effectively completely missing in these squamates or, instead, whether the pterygomandibularis of these taxa actually corresponds to both the pterygomandibularis ventralis + pterygomandibularis dorsalis of other reptiles.

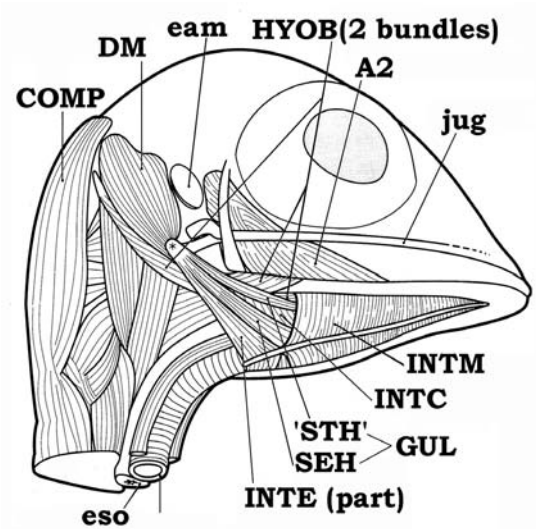

Fig. 7.8 *Coturnix coturnix* (Reptilia, Aves): ventrolateral view of the superficial head musculature of a 15-day embryo; see configuration of this musculature in an adult member of this species in Fig. 3 (modified from McClearn and Noden 1988; the nomenclature of the myological structures illustrated follows that of the present work, while that of the skeletal structures follows McClearn and Noden 1988; anterior is to the right). A2, adductor mandibulae A2; COMP, complexus (not a mandibular, hyoid, branchial or hypobranchial muscle); DM, depressor mandibulae; eam, external auditory meatus; eso, esophagus; HYOB, hyobranchialis; INTC, interceratobranchialis; jug, jugal bar; SEH, serpihyoideus (bundle of gularis); 'STH', 'stylohyoideus' (bundle of gularis); tra, trachea.

Examples of dorsal mandibular muscles (i.e., muscles derived from the constrictor dorsalis anlage sensu Edgeworth 1935; see Chapters 2–5) that are present in extant reptiles are the levator bulbi, protractor pterygoidei, levator pterygoidei, 'protractor quadrati' and 'protractor quadratus' (Table 7.1). According to researchers such as Edgeworth (1935), Brock (1938) and Schumacher (1973), the constrictor dorsalis is formed in early ontogenetic stages of turtles but then atrophies, and none of these dorsal mandibular muscles is thus present in adult turtles. Interestingly, in his developmental study of the turtle *Chelydra serpentina*, Rieppel (1990) stated that no constrictor dorsalis rudiment could be identified unequivocally during any developmental stage of this species. The adult turtle specimens dissected by us and described by others (e.g., Schumacher 1973) do effectively lack dorsal mandibular muscles (Table 7.1). Edgeworth (1935) suggested that in *Sphenodon* the constrictor dorsalis persists until the adult stage as a single mass, which he called 'spheno-pterygo-quadratus'. However, as explained in more recent works, this taxon often has a protractor pterygoidei, a levator pterygoidei and a levator bulbi, as have

most other non-ophidian lepidosaurs (see, e.g., Wu 2003). In ophidians (snakes) the dorsal mandibular musculature is well developed and is often divided into a levator pterygoidei, a protractor pterygoidei plus a 'protractor quadrati' (according to Haas 1973, these two muscles derive from the protractor pterygoidei of other reptiles), and a retractor pterygoidei plus a retractor vomeris (according to Haas 1973, these two muscles derive from the levator bulbi of other reptiles). Abdala and Moro (2003) and others stated that *Sphenodon* also has a 'retractor pterygoidei', but this latter muscle actually corresponds to the levator bulbi sensu the present work, as explained by Moro and Abdala (2000).

According to Brock (1938), the constrictor dorsalis is formed in early ontogenetic stages of crocodylians but then atrophies, and the only dorsal mandibular muscle that is present in crocodylian adults is the levator bulbi. In the adult specimens of *Caiman latirostris* we dissected, we were unable to find a separate protractor pterygoidei or a separate levator pterygoidei such as those seen in lepidosaur taxa such as *Timon* (Table 7.1). However, in their figs. 4 and 5, Holliday and Witmer (2007) show not only a levator bulbi ('periorbitalis' or 'tensor periorbitae' in their terminology), but also a protractor pterygoidei in crocodylians such as *Alligator*, although in a later paper Holliday (2009: 1256) stated that, contrary to birds, "crocodyliforms lost m. protractor pterygoideus". More studies are clearly needed to clarify the taxonomic distribution and homologies of the dorsal mandibular muscles in crocodylians. In their figs. 4 and 6, Holliday and Witmer (2007) also show three dorsal mandibular muscles, i.e., a protractor pterygoidei, a levator bulbi ('periorbitalis' or 'tensor periorbitae') and a 'protractor quadratus' in birds such as *Struthio*. These three muscles are present in various other birds, including *Gallus* (e.g., Noden 1983; Elzanowski 1987; McClearn and Noden 1988; Holliday and Witmer 2007; Knight et al. 2008; this work; Table 7.1).

As mentioned above, adult turtles do not have dorsal mandibular muscles. If one accepts that turtles are the sister-group of the clade including the other extant reptiles (see Chapters 1 and 2), one could argue that these muscles were plesiomorphically absent in the LCA of reptiles and then acquired in the clade including birds, crocodylians and lepidosaurs. However, Brock (1938) and others defended that the plesiomorphic condition for tetrapods, and for reptiles, is to have one or more dorsal mandibular muscles. This idea is supported by the studies of Edgeworth (1935) and Schumacher (1973), which indicated that the constrictor dorsalis anlage is formed in early ontogenetic stages of turtles but then atrophies in later stages (see above). Moreover, extant amphibians also have dorsal mandibular muscles: our dissections of numerous amphibian specimens confirmed that a levator bulbi is present in urodeles and anurans, and that a levator quadrati is present in caecilians (Chapter 6). According to Brock

(1938), the 'constrictor dorsalis group' is usually more fully conserved in extant reptiles such as lepidosaurs because of their kinetic skull, and tends to be secondarily reduced in taxa with a less kinetic skull, such as turtles, crocodylians, birds and amphibians. Iordansky (1996) stated that the levator quadrati of caecilians corresponds to the levator pterygoideus + protractor pterygoidei of reptiles. As the levator bulbi of urodeles and anurans is indeed similar to that of reptiles, it is very likely that in the LCA of tetrapods the dorsal mandibular muscles were already divided into: (1) a levator bulbi and (2) an undivided 'levator palatini', which was probably similar to, and derived from part of, the levator arcus palatini of sarcopterygian fish such as *Latimeria* (see Chapters 5 and 6). Then, during the evolutionary events leading to the origin of urodeles and anurans, the 'levator palatini' was secondarily lost, probably because these taxa lack a cranial kinesis such as that found in fish such as coelacanths and in reptiles such as lepidosaurs (Brock 1938), leaving only the levator bulbi. As proposed by Iordansky (1996), the levator quadrati of caecilians thus probably corresponds to the structure that gave rise to reptilian muscles such as the levator pterygoidei, the protractor pterygoidei, the 'protractor quadrati' (of snakes) and the 'protractor quadratus' (of birds) (see Table 7.1). The levator bulbi was probably secondarily lost during the evolutionary events that lead to the origin of caecilians. An alternative, less likely hypothesis is that the levator quadrati of caecilians is an undifferentiated muscle corresponding to both the 'levator palatini' and levator bulbi of the LCA of amphibians + amniotes. Be that as it may, the 'protractor quadratus' of birds and the 'protractor quadrati' of snakes are not homologues to the levator quadrati of caecilians (Table 1; see also Chapter 6). As the 'protractor quadrati' of snakes and the 'protractor quadratus' of birds are derived from the protractor pterygoidei, one could hypothesize that these structures might be homologous to each other. However, it is phylogenetically more parsimonious to accept that they structures were acquired independently in each of these groups (two evolutionary steps) than to assume that a 'protractor quadratus'/'protractor quadrati' was present in the LCA of lepidosaurs, birds and crocodylians, and then secondarily lost in crocodylians and particularly in numerous lepidosaurian clades (see Conrad 2008, for a recent review of the phylogenetic position of snakes within lepidosaurs). In a recent paper, Holliday (2009) argues that, although the levator pterygoidei is missing in extant crocodylians and birds, there is evidence supporting the idea that this muscle was present in archosaurs such as dinosaurs, thus indicating that both the levator pterygoidei and the levator pterygoidei were present in the LCA of lepidosaurs, crocodylians and birds. A major question that remains open, however, is whether in the LCA of all extant reptiles (i.e., also including turtles) the 'levator palatini' sensu Abdala and Diogo (in press) was still

mainly undivided (as was very likely that of the LCA of tetrapods: see above) or was, instead, already divided into different muscles, such as the levator pterygoidei and the protractor pterygoidei.

Hyoid Muscles (Table 7. 2)

According to Edgeworth (1935) the hyoid musculature comprises dorso-medial and ventral muscles. The LCA of tetrapods probably had two dorso-medial hyoid muscles, the depressor mandibulae and levator hyoideus, and a ventral hyoid muscle, the interhyoideus (Chapters 4, 5). Apart from these three muscles (Figs. 7.2, 7.3, 7.6–7.10), extant reptiles might have other muscles such as the cervicomandibularis (Figs. 5.6, 7.2), which is a dorso-medial hyoid muscle that probably derived from the depressor mandibulae, and the gularis (Fig. 7.8) and interceratobranchialis (Fig. 7.8), which are likely ventral hyoid muscles derived from the interhyoideus (Table 7.2). As explained by Schumacher (1973), Smith (1992) and others, plesiomorphically in reptiles there is no muscular pharynx, but crocodilians do possess a secondary palate and a means to constrict the pharynx by using a deep bundle (Fig. 7.6) of the interhyoideus ('constrictor colli profundus' or 'constrictor pharyngis' in Schumacher's 1973 terminology), which, interestingly, is topologically similar to the muscle interhyoideus profundus of monotreme mammals (which is also often designated in the literature as 'constrictor colli profundus') (see Chapter 5). The remaining, more superficial part of the interhyoideus of crocodylians is blended with the mandibular muscle intermandibularis, as can be seen in *Caiman latirotris* (Fig. 7.9). The avian interceratobranchialis is a small muscle that usually connects the medial and ventromedial surfaces of the ceratobranchial cartilages to the ventral midline raphe (Fig. 7.8), and that, as stated above, is probably derived from the interhyoideus (see *Hypobranchial Muscles* below for more details on this subject).

As noted by Edgeworth (1935), numerous birds, including *Gallus*, have a muscle gularis (Fig. 7.8), which is often described as part of the 'tongue musculature' but is actually innervated by cranial nerve VII and very likely derived from the anterior part of the interhyoideus. The gularis sensu Edgeworth (1935) and sensu the present work corresponds to the 'serpihyoideus' plus 'stylohyoideus' sensu, e.g., Huang et al. (1999) and McClearn and Noden (1988). Interestingly, Versluys (1904) and Haas (1973) also described a 'stylohyoideus' in the lepidosaur *Sphenodon* (Fig. 7.10), which is somewhat similar to the stylohyoideus of therian mammals, running from the dorsal end of the hyoid arch to the basal part of the 'cornu branchiale I' and/or the interhyoideus. As the 'stylohyoideus' of birds (Fig. 7.8), this muscle 'stylohyoideus' also seems to be derived from the interhyoideus (Fig. 7.10). However, Haas (1973) stated that this muscle is only

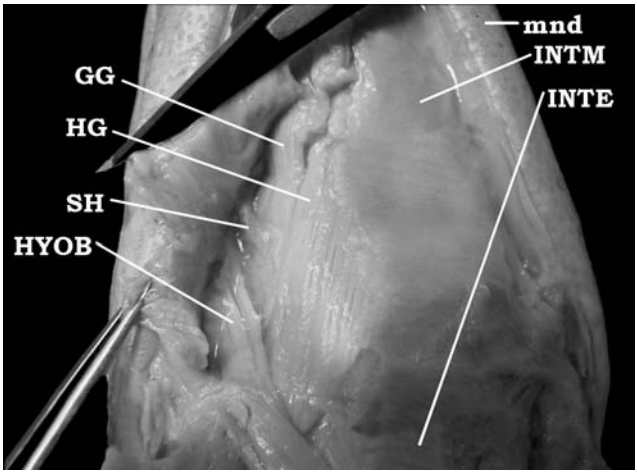

Fig. 7.9 *Caiman latirostris* (Reptilia, Crocodylia): ventral view of the adult cephalic musculature; on the right side of the body (left side of the picture) superficial structures such as the intermandibularis and the interhyoideus were reflected to show the deeper musculature (anterior is to the top). GG, genioglossus; HG, hyoglossus; HYOB, hyobranchialis; INTE, interhyoideus; INTM, intermandibularis; mnd, mandible; SH, sternohyoideus.

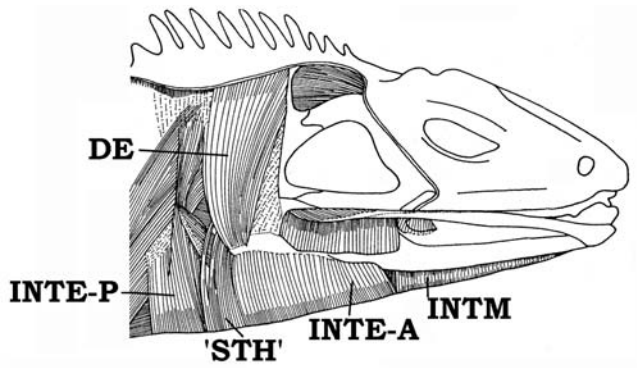

Fig. 7.10 *Sphenodon punctatus* (Reptilia, Lepidosauria): lateral view of the adult cephalic musculature (modified from Versluys 1898 and Haas 1973; the nomenclature of the myological structures illustrated follows that of the present work; anterior is to the right). DM, depressor mandibulae; INTE-A, INTE-P, anterior and posterior bundles of interhyoideus; INTM, intermandibularis; 'STH', 'stylohyoideus'.

found in *Sphenodon* and in the squamate clade Gekkota, thus suggesting that the muscle is not homologous to the avian 'stylohyoideus'.

Köntges and Lumsden (1996: 3241) stated that the 'reptilian stylohyoideus' "shifted its attachment point from the lower jaw to the styloid process of the otic capsule" in order to form the mammalian stylohyoideus, and that "the 2nd arch derived retroarticular process and attached depressor mandibulae were lost" in mammals. However, phylogenetically basal mammals such as monotremes do not have a separate stylohyoideus, and the therian stylohyoideus derives most likely from the depressor mandibulae (Chapter 5), and not from the interhyoideus, as does the avian 'stylohyoideus' (Fig. 7.8) and the 'stylohyoideus' of *Sphenodon* and the Gekkota (Fig. 7.10). Moreover, extant reptiles such as crocodylians, turtles and the vast majority of lepidosaurs do not have a 'stylohyoideus' such as that found in birds nor a 'stylohyoideus' such as that found in *Sphenodon* and Gekkota (Table 7.1). Therefore, it seems unlikely that a muscle 'stylohyoideus' was present in the LCA of reptiles (as this would oblige us to assume a great number of secondary losses, e.g., in turtles, crocodylians, and numerous squamate groups) and, even more so, in the LCA of the amniotes as a whole (as this would oblige us to assume even more secondary losses, e.g., in groups such as the monotremes). However, further studies on a wide range of taxa from all the major extant reptilian groups, and particularly of birds and lepidosaurs, are needed to clarify the taxonomic distribution of the 'stylohyoideus' muscles within reptiles.

The dorso-medial hyoid muscle depressor mandibulae is mainly a jaw opener that is present in birds, turtles, crocodylians and lepidosaurs and that usually runs from the posterolateral surface of the skull to the retroarticular process of the mandible (Figs. 7.2, 7.3, 7.7, 7.8, 7.10; Table 7.2). In some turtles, e.g., *Dermochelys* and *Testudo*, the depressor mandibulae has a small bundle that is attached to the auditory tube and that is sometimes designated as 'musculus dilatator tubae' in the literature (e.g., Edgeworth 1935; Schumacher 1973; Wyneken 2001). This supports the hypothesis, defended in Chapter 5, that mammalian hyoid muscles that are associated with the ear/auditory region, such as the stylohyoideus, the stapedius and/or the mandibulo-auricularis, are probably derived from the anlage that gives rise to the depressor mandibulae/levator hyoideus of sarcopterygian fish such as *Lepidosiren* (see Table 5.4 and also below).

Anatomists such as Saban (1968, 1971) suggested that the cervicomandibularis (Fig. 5.6) derives from the interhyoideus. However, our dissections, comparisons and review of the literature support the view defended by, e.g., Huber (1930ab, 1931) and Edgeworth (1935), i.e., that the cervicomandibularis corresponds instead to part of the depressor mandibulae/levator hyoideus of sarcopterygian fish such as *Lepidosiren*. Table 2 of Diogo et al. (2008ab) suggested that the cervicomandibularis

Table 7.2 Hyoid muscles of adults of representative reptilian taxa (see caption of Table 7.1 and text).

Reptilia, Testudines: *Trachemys scripta* (Red-eared slider turtle)	Reptilia, Lepidosauria: *Timon lepidus* (Ocellated lizard)	Reptilia, Crocodylia: *Caiman latirostris* (Brown-snouted caiman)	Reptilia, Aves: *Gallus domesticus* (Domestic chicken)
Depressor mandibulae [see text]	**Depressor mandibulae** (pars noto-gnathica sensu Lightoller 1939, which, contrary to what was suggested by this author, does not seem to correspond directly to the nucho-maxillaris of sharks, because such a 'nucho-maxillaris' is not present in any of the bony fishes dissected by us, i.e., it was very likely not present in the LCA of osteichthyans, in the LCA of sarcopterygians, nor in the LCA of tetrapods: see Chapter 5) [according to Edgeworth 1935, the anlage that gives rise to the depressor mandibulae and cervicomandibularis in lizards such as *Timon* gives rise to three muscles in snakes, which he named as 'occipito-quadrato-mandibularis', 'cervico-mandibularis' and 'neuro-costo-mandibularis']	**Depressor mandibulae**	**Depressor mandibulae** [according to Adams 1919, *Gallus* have a small muscle parietomandibularis that is probably derived from the depressor mandibulae: see, e.g., his plate VIII; however, this muscle is not mentioned in more recent descriptions of this taxon: see, e.g., Köntges and Lumsden 1996; Noden and Francis-West 2006]
— [but see text]	**Cervicomandibularis** (cervicomandibularis posterior sensu Edgeworth 1935; seems to correspond to the pars cephalo-gnathica sensu Lightoller 1939) [see text]	— [but see text]	— [but see text]
— [as explained by Edgeworth 1935, Schumacher 1973 and others, the levator hyoideus is not present as a separate muscle in adult turtles; according to Edgeworth 1935, in turtles such as *Chrysemys* the	— [see text]	**Levator hyoideus** [according to Edgeworth 1935, Lightoller 1939, Schumacher 1973 and others, the levator hyoideus is usually present as a separate muscle in adult crocodylians]	**Levator hyoideus** (muscle of the columella sensu Baumel et al. 1979 and McCleark and Noden 1988; stapedius sensu Köntges and Lumsden 1996) [the levator hyoideus (often named 'laxator tympani', 'occipito-tympanicus', 'stapedius', 'extracolumellaris', 'columellae', 'muscle

levator hyoidei is not formed even as a temporary structure during ontogeny: see text]			of the columella' or 'extra-stapedial muscle' in the literature) is often present in adult birds, including galliforms (which include *Gallus*): see, e.g., Edgeworth 1935 and McCleark and Noden 1988]
Interhyoideus (constrictor colli sensu Schumacher 1973 and Wyneken 2001)	**Interhyoideus** [Lightoller 1939 states that in numerous lepidosaurs, including *Sphenodon*, the interhyoideus is mainly constituted by a single mass, that is, the structure that he designates as 'pars interhyoideia' and that corresponds to the interhyoideus anterior of amphibians such as *Ambystoma* is not differentiated in these reptiles]	**Interhyoideus** (constrictor colli sensu Schumacher 1973) [see text]	**Interhyoideus** (constrictor colli sensu Edgeworth 1935; part or totality of cutaneous colli sensu Ghetie et al. 1981; includes the pars intermandibularis as well as the other parts of the constrictor colli sensu Baumel et al. 1979, the caudal mylohyoideus and the constrictor colli sensu McClearn and Noden 1988, and the mylohyoideus posterior and constrictor colli sensu Köntges and Lumsden 1996)
—	—	—	**Gularis** (serpihyoideus plus stylohyoideus sensu Baumel et al. 1979, McClearn and Noden 1988, Köntges and Lumsden 1996 and Huang et al. 1999: see interhyoideus above) [see text]
—	—	—	**Interceratobranchialis** (interkeratoideus sensu Edgeworth 1935; ceratohyoideus sensu Engels 1938) [see text]

probably corresponds specifically to part of the levator hyoideus ('depressor mandibulae posterior' in their terminology) of amphibians, but the cervicomandibularis actually seems to derive from the depressor mandibulae (Fig. 5.6; Table 5.4). In his recent study, Tsuihiji (2007) corroborated this latter idea and stated that in lepidosaurs such as *Sphenodon* the depressor mandibulae and the cervicomandibularis are completely blended to each other, as previously described by Haas (1973), who suggested that the condition present in this genus represents the plesiomorphic condition for the Lepidosauria and for the Reptilia as a whole. According to Tsuihiji (2007), the avian depressor mandibulae is usually mainly undivided. However, three bundles of this muscle have been reported in some birds (e.g., tinamiforms: Elzanowski 1987), and we found two branches of this muscle in birds such as *Gallus*, *Nothura* and *Pitangus*. Edgeworth (1935) and Schumacher (1973) stated that the cervicomandibularis is usually not present as a separate muscle in turtles. However, Schumacher's (1973) illustrations do show a 'cervicomandibularis' is some turtles (see, e.g., his fig. 39). Wyneken (2001) reported that in sea turtles the depressor mandibulae is often divided into different bundles, but he did not describe a separate muscle cervicomandibularis in these reptiles. Edgeworth (1935), Schumacher (1973), Noden (1983), McClearn and Noden (1988) and others also stated that in crocodylians and birds the depressor mandibulae is often divided into bundles, but that these reptiles do not have a separate muscle cervicomandibularis as found in lepidosaurs such as *Timon* (see Fig. 5.6).

In our opinion, the more posterior bundles of at least some of the depressor mandibulae muscles described in turtles, crocodylians and birds by the authors mentioned just above might well correspond to the cervicomandibularis of taxa such as *Timon*. This is because these bundles clearly derive from the same anlage that gives rise to the cervicomandibularis (i.e., they derive from the depressor mandibulae anlage, and namely from its posterior portion, as does the cervicomandibularis: see above), and their overall configuration and function is very similar to that of this latter muscle. For instance, the topology of the posterior bundle of the depressor mandibulae that we found in our dissections of the turtle *Trachemys* is effectively very similar to that of the cervicomandibularis of 'lizards' such as *Timon*. The reason the vast majority of anatomists described, and continue to describe, this structure in turtles, crocodylians and birds as a posterior bundle of the depressor mandibulae (as we are doing in the present work), and not as a distinct muscle cervicomandibularis, is that in numerous, if not most, of the taxa of these three groups this structure does not seem to be as differentiated from the main body of the depressor mandibulae as is the cervicomandibularis of most 'lizards' (e.g., Edgeworth 1935; Schumacher 1973; Wyneken 2001; Tsuihiji 2007; this work). What needs to be clarified in

future studies including a wider range of reptilian taxa is, thus, whether in the LCA of extant reptiles the posterior fibers of the depressor mandibulae were still deeply blended to the main body of this muscle, as suggested by Haas (1973), or whether these fibers were already somewhat differentiated from the anterior portion of the muscle, forming a posterior bundle of the depressor mandibulae such as that found in various turtles, crocodylians and birds (which then became, apomorphically, further differentiated in order to form the cervicomandibularis of squamates such as *Timon*: Fig. 5.6; Table 7.2).

As noted by Edgeworth (1935) and others, the levator hyoideus is present as a separate muscle in early ontogenetic stages of most reptilian taxa (but not all, e.g., not in turtles such as *Chrysemys*), but then, in later stages, it fuses with the depressor mandibulae in taxa such as *Sphenodon* and many squamates (Table 7.1). However, in squamate taxa such as the Gekkota, as well as in crocodylians and birds, the muscle usually persists as a separate structure until the adult stage, being usually named 'laxator tympani' (e.g., Brock 1938), 'occipito-tympanicus' (e.g., Edgeworth 1935), 'stapedius' (e.g., Lightoller 1939; Schumacher 1973), 'extracolumellaris' (e.g., Lee 2000; Conrad 2008), 'columellae' (e.g., Witmer 1995b), 'muscle of the columella' (e.g., Baumel et al. 1979; McCleark and Noden 1988) or 'extra-stapedial muscle' (e.g., Goodrich 1958). The developmental work of McCleark and Noden (1988), with quails, strongly supports the idea that the 'muscle of the columella' of reptiles corresponds to the levator hyoideus of sarcopterygian fish such as *Lepidosiren*, because this reptilian muscle differentiates from the very same anlage that gives rise to the depressor mandibulae, as does the dipnoan levator hyoideus (see Diogo 2007, 2008; Diogo et al. 2008b). In fact, as stressed by Edgeworth (1935), it is very likely that the muscle levator hyoideus that is present in adult non-mammalian tetrapods such as these reptiles is directly homologous to the mammalian stapedius (see Chapter 5). If this is actually the case, then it would be probably more appropriate to designate the muscle of these non-mammalian tetrapods as stapedius, as proposed by Schumacher (1973), or, even better, to designate the muscle of mammals as levator hyoideus, as proposed by Edgeworth (1935).

Branchial Muscles (Table 7.3)

As explained in Chapters 4 and 5, in this volume we divide the branchial muscles into three main groups, i.e., the 'true' branchial muscles, the pharyngeal muscles, and the laryngeal muscles, the second group being present only in mammals (as stated above, crocodilians do possess a secondary palate and a means to constrict the pharynx, but they do that by using a deep bundle of the interhyoideus, which is a hyoid, and

Table 7.3 Branchial muscles of adults of representative reptilian taxa (see caption of Table 7.1 and text).

Reptilia, Testudines: *Trachemys scripta* (Red-eared slider turtle)	Reptilia, Lepidosauria: *Timon lepidus* (Ocellated lizard)	Reptilia, Crocodylia: *Caiman latirostris* (Brown-snouted caiman)	Reptilia, Aves: *Gallus domesticus* (Domestic chicken)
Hyobranchialis (corresponds to the branchiohyoideus plus branchiomandibularis visceralis sensu Schumacher 1973) [see text]	**Hyobranchialis** (corresponds to part of the subarcualis rectus 1 and to the branchiohyoideus sensu Edgeworth 1935 and Herrel et al. 2005) [according to Edgeworth 1935, snakes do not have branchial muscles *sensu stricto*, i.e., contrary to lepidosaurs such as *Timon*, they do not have a hyobranchialis or a 'ceratohyoideus']	**Hyobranchialis** (corresponds to the branchiomandibularis visceralis, and probably also to the branchiomandibularis spinalis, sensu Schumacher 1973) [see text]	**Hyobranchialis** (corresponds to the branchiomandibularis visceralis, and probably also to the branchiomandibularis spinalis, sensu Schumacher 1973; branchiomandibularis sensu Engels 1938, McClearn and Noden 1988 and Köntges and Lumsden 1996; geniohyoideus sensu Gethie et al. 1981)
— [seems to be absent as a separate muscle in turtles: see hyobranchialis above]	**'Ceratohyoideus'** [Haas 1973 stated that the lepidosaurian 'ceratohyoideus' is a hyoid muscle (innervated by the cranial nerve VII), but this muscle clearly seems to be part of the branchial musculature: see text and Chapter 5]	— [seems to be absent as a separate muscle in crocodylians: see hyobranchialis above]	— [seems to be absent as a separate muscle in birds: see hyobranchialis above]
Trapezius (cucullaris or capiti-plastralis sensu Fürbringer 1874 and Edgeworth 1935; plastrosquamosus sensu Schumacher 1973) [see text]	**Trapezius** (capitidorsoclavicularis or dorsoscapularis sensu Fürbringer 1876, 1900, Edgeworth 1935, Holmes 1977 and Tsuihiji 2007) [Edgeworth 1935, Tsuihiji 2007 and others stated that in *Sphenodon* and some other lepidosaurs	**Trapezius** (dorsoscapularis sensu Fürbringer and Tsuihiji 2007) [as described by Meers 2003, Tsuihiji 2007 and others, in birds and crocodylians, including *Caiman*, the trapezius is not directly originated from the skull; according to Tsuihiji 2007, this feature might constitute	**Trapezius** (cervical part of cranio-cervicalis sensu Edgeworth 1935; part or totality of cucullaris sensu Elzanowski 1987; cucullaris cervicus sensu Dilkes 2000 and Tsuihiji 2007) [Edgeworth 1935 suggested that in birds the muscles that perform the functions that are usually undertaken by the trapezius and the sternocleidomastoideus are not homologous

	there is no differentiation between the trapezius and the sternocleidomastoideus, but that most other lepidosaurs have these two muscles; fig. 14.13 of Jollie 1962 shows an *Iguana* specimen with the trapezius divided into, at least, a 'pars clavotrapezius' and a 'pars spinotrapezius' (see Fig. 10.11); the names used by Jollie 1962 thus suggest that these are simply bundles of the trapezius, and not really separate muscles such as the acromiotrapezius and the spinotrapezius of some mammals: this idea is also supported by Kardong 2002 and others]	a synapomorphy of birds + crocodylians]	to these two latter muscles, because they "are developed from occipital myotomes"; however, although recent studies have confirmed that muscles such as the trapezius are effectively partially originated from somites in birds such as chickens as well as in other taxa such as mice, the avian sternocleidomastoideus and trapezius clearly seem to correspond to sternocleidomastoideus and trapezius of other amniotes: see text and, e.g., Dilkes 2000, Tsuihiji 2007, Noden and Francis-West 2007 and Shearman and Burke 2009]
— [see text]	**Sternocleidomastoideus** (capiticleidoepisternalis or episternocleidomastoideus sensu Fürbringer 1876, Edgeworth 1935, Holmes 1977, Herrel et al. 2005 and Tsuihiji 2007) [see trapezius above and text]	**Sternocleidomastoideus** (capitisternalis sensu Fürbringer 1876, 1900 and capitiepisternalis sensu Tsuihiji 2007) [Tsuihiji 2007 states that in Crocodylia this muscle is divided into an anterior part, atlantimastoideus (iliocostalis capitis sensu Seidel 1978), running from the atlas to the mastoid process, and a posterior part, sternoatlanticus, running from the atlas to the episternum; these divisions do not seem to correspond with divisions of the muscle found in humans and other mammals, they seem to be characteristic of Crocodylia]	**Sternocleidomastoideus** (cranial part of cranio-cervicalis sensu Edgeworth 1935; cucullaris capitis or dermotemporalis sensu Dilkes 2000 and Tsuihiji 2007) [Tsuihiji 2007 states that in Aves this muscle may be divided into as many as three slips depending on the species, e.g., pars interscapularis, pars propatagialis and pars clavicularis; these three divisions do not seem to correspond with divisions of the muscle found in humans and other mammals, they seem to be characteristic of Aves]

Table 7.3 contd...

Table 7.3 contd...

Reptilia, Testudines: *Trachemys scripta* (Red-eared slider turtle)	Reptilia, Lepidosauria: *Timon lepidus* (Ocellated lizard)	Reptilia, Crocodylia: *Caiman latirostris* (Brown-snouted caiman)	Reptilia, Aves: *Gallus domesticus* (Domestic chicken)
Constrictor laryngis (probably corresponds to the cricohyoideus sensu Gaunt and Gans 1968: see, e.g., Schumacher 1973)	**Constrictor laryngis** [see text and, e.g., Diogo et al. 2008b]	**Constrictor laryngis** [see text and, e.g., Edgeworth 1935 and Schumacher 1973]	**Constrictor laryngis** [see text and, e.g., Edgeworth 1935]
Dilatator laryngis (probably corresponds to the cricoarytenoideus sensu Gaunt and Gans 1968)	**Dilatator laryngis** [see text and, e.g., Diogo et al. 2008b]	**Dilatator laryngis** [see text and, e.g., Edgeworth 1935 and Schumacher 1973]	**Dilatator laryngis** [see text and, e.g., Edgeworth 1935]

not a branchial, muscle). Following this nomenclature, two groups can be recognized in reptiles: the 'true' branchial muscles and the laryngeal muscles. The 'true' branchial muscles are subdivided into (A) the 'true' branchial muscles *sensu stricto* (e.g., hyobranchialis and 'ceratohyoideus'), which are directly associated with the movements of the branchial arches and are often innervated by the glossopharyngeal nerve (CNIX); and (B) the derivatives of the protractor pectoralis ('cucullaris') of bony fish and amphibians (e.g., trapezius, sternocleidomastoideus), which are instead mainly associated with the movement of postcranial structures such as the pectoral girdle and are primarily innervated by the spinal accessory nerve (CNXI). The laryngeal muscles (e.g., constrictor laryngis, dilatator laryngis) are usually innervated by the vagus nerve (CNX).

According to Edgeworth (1935), the only element of the 'true' branchial musculature *sensu stricto* that is present in adult reptiles is the 'subarcualis rectus I', which corresponds to the hyobranchialis of most reptiles and which is differentiated into an additional muscle in *Sphenodon* and various squamates, the 'ceratohyoideus' (Fig. 5.6 and Table 7.3; e.g., Haas 1973; Montero et al. 2002; Abdala and Moro 2003; this work). As mentioned in Chapter 5, we prefer to use the name hyobranchialis instead of 'branchiohyoideus' or 'branchiomandibularis', because this reptilian branchial muscle is clearly not homologous to the hyoid muscle branchiohyoideus that is often found in urodelan amphibians nor to the hypobranchial muscle branchiomandibularis that is often found in cladistians, chondrosteans and *Amia* (see Chapters 4 and 6). Schumacher (1973) described two 'true' branchial muscles *sensu stricto* in turtles, the 'branchiomandibularis pars visceralis' and 'branchiohyoideus', and stated that the 'branchiohyoideus' is often designated in the literature as 'ceratohyoideus'. However, this structure attaches anteriorly on the cornu hyale, i.e., on the typical anterior insertion of the hyobranchialis, and not of the 'ceratohyoideus', of lepidosaurs (see Fig. 5.6). In fact, the testudine 'branchiohyoideus' and 'branchiomandibularis pars visceralis' sensu Schumacher (1973) clearly seem to correspond to the 'branchiomandibularis pars visceralis' and 'branchiomandibularis pars spinalis' of crocodylians and to the two bundles of the muscle 'branchiomandibularis' of birds, and, thus, of the muscle hyobranchialis sensu the present work (Fig. 7.8; Table 7.3). That is, the turtles described by Schumacher (1973) and by other authors (e.g., Lakjer 1926; Edgeworth 1935; Wyneken 2001) and dissected by us do not seem to have a separate muscle 'ceratohyoideus' such as that found in lepidosaurs (Fig. 5.6; Table 7.3).

Schumacher (1973) used the names 'branchiomandibularis pars visceralis' and 'branchiomandibularis pars spinalis' to describe the two bundles of the hyobranchialis in crocodylians, because he considered that these two structures have a different origin and a different innervation. According to

him, the 'branchiomandibularis pars visceralis' is derived from the branchial musculature and innervated by the glossopharyngeal nerve (CNIX), while the 'branchiomandibularis pars spinalis' is derived from the hypobranchial musculature and innervated by the hypoglossal nerve (CNXII). However, these two structures were considered to be bundles of the same muscle by Edgeworth (1935) and, topologically, they are effectively similar to each other and are effectively often deeply blended posteriorly. Moreover, recent developmental studies have reported that, at least in birds (Fig. 7.8), the two bundles of the 'branchiomandibularis' (which clearly seem to correspond to the 'branchiomandibularis pars spinalis' and 'branchiomandibularis pars visceralis' sensu Schumacher 1973: see above) are actually innervated by the same nerve (the glossopharyngeal nerve) and differentiated from the very same anlage (which derives from the third branchial arch; in quails, these two structures actually become partially separated only by day 8: see, e.g., McCleark and Noden 1988; Noden and Francis-West 2006). These recent studies thus strongly support the idea that the 'branchiomandibularis pars spinalis' and 'branchiomandibularis pars visceralis' sensu Schumacher (1973) are, in fact, part of the same muscle, as is now often accepted in the literature, and, thus, that each of these two structures does correspond to part of the hyobranchialis sensu the present work. Further studies, ideally including new techniques in conjunction with motoneuron axon labeling data, are, however, needed to settle whether or not the hyobranchialis is at least partially innervated by the hypoglossal nerve in some reptilian taxa such as crocodylians, as suggested by Schumacher (1973).

As mentioned by Edgeworth (1935) and Straus and Howell (1936), the topology (e.g., running from the postcranial region of the body to the squamosal bone) and innervation (e.g., innervated by the 'ramus accessorius of the vagus nerve' and by the 'branches of the cervical nerve III') of the testudine muscle 'plastrosquamosus' are remarkably similar to those of the trapezius + sternocleidomastoideus of other reptiles. This testudine muscle thus probably corresponds to an undivided 'cucullaris', i.e., to the trapezius + sternocleidomastoideus of taxa such as *Timon* (Table 7.3). This idea is corroborated by Holmes (1977) and Dilkes (2000), who stated that all major groups of living reptiles have a sternocleidomastoideus, except snakes, which also lack the trapezius, and turtles, which do have a trapezius. Holmes (1977) suggested that plesiomorphically in reptiles the sternocleidomastoideus was not present as a separate muscle. However, this seems unlikely, because this muscle is present in lepidosaurs, crocodylians, birds and mammals, so it was very likely present in the LCA of amniotes and in the LCA of reptiles. It should be noted that Fürbringer (1874) described a 'testoscapuloprocoracoideus' and a 'capitiplastris' in turtles and considered that these muscles are homologous to the trapezius

and sternocleidomastoideus of other reptiles, respectively (if this were the case, then the 'capitiplastralis' sensu Edgeworth 1935, i.e., the 'plastrosquamosus' sensu Schumacher 1973, would not correspond to an undivided 'cucullaris' (trapezius + sternocleidomastoideus) but to the sternocleidomastoideus sensu the present work: see above). We also found these two muscles in the turtles we dissected. However, it is now commonly accepted that the muscles 'testoscapularis' and 'testocoracoideus' of turtles are actually postcranial (pectoral) muscles, and not head and neck muscles sensu the present work, although it is not completely clear whether or not the 'testoscapuloprocoracoideus' described by Fürbringer (1874) effectively corresponds to one or both of these muscles (e.g., Wyneken 2001). Further studies are thus needed to clarify the identity/homology of the 'testoscapuloprocoracoideus' sensu Fürbringer (1874).

As their name indicates, the dilatator laryngis and constrictor laryngis are antagonistic laryngeal muscles that are present in members of all the four major extant reptilian clades (Fig. 7.11; Table 7.3). According to Edgeworth (1935), in birds such as *Gallus* the constrictor laryngis has a

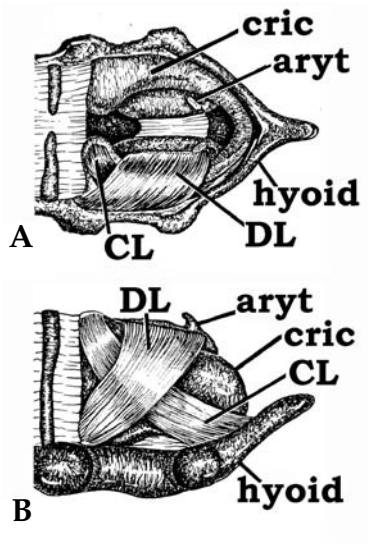

Fig. 7.11 *Chelydra serpentina* (Reptilia, Testudines): **(A)** Dorsal view of the adult laryngeal musculature, the muscles of the left side of the body were removed; **(B)** Lateral view showing the adult laryngeal muscles on the sagitally dissected hyoid bone (modified from Gaunt and Gans 1968; the nomenclature of the myological structures illustrated follows that used in the present work, while that of the skeletal structures follows Gaunt and Gans 1969; anterior is to the right). aryt, arytenoid cartilage; CL, constrictor laryngis; cric, cricoid cartilage; DL, dilatator laryngis.

pars ventralis and a pars dorsalis early in ontogeny, but in later stages the pars ventralis atrophies and only the pars dorsalis persists until the adult stage. Also according to this author, some birds have 'laryngei' muscles (which in his view are not homologous to the laryngei muscles of amphibians: see Chapters 5 and 6), but these muscles are not present as separate structures in adults of the genus *Gallus*. We effectively did not find such muscles in the chickens we dissected. Such muscles are also seemingly not present in adults of crocodylians such as *Caiman*, of lepidosaurs such as *Timon*, and of turtles such as *Trachemys* (Fig. 7.11; Table 7.3; e.g., Edgeworth 1935; Gaunt and Gans 1969; Schumacher 1973; this work).

Hypobranchial Muscles (Table 7.4)

As explained in the previous chapters, according to Edgeworth (1935), there are two major lineages of muscles originated from the hypobranchial muscle plate: the 'genio-hyoideus', which in tetrapods gives rise to structures such as the tongue muscles (e.g., geniohyoideus, genioglossus, hyoglossus and intrinsic muscles of the tongue), and the 'rectus cervicus', which gives rise to structures such as the infrahyoid muscles (e.g., sternohyoideus, omohyoideus) (Table 7.4; as noted by Miyake et al. 1992, it is not clear whether Edgeworth's 'genio-hyoideus' and 'rectus cervicus' represent separate premyogenic condensations or later states of muscle development). It should be stressed that the musculature that is often designated as 'tongue musculature' of birds includes not only hypobranchial muscles, as is often the case in other amniotes, but also mandibular (the intermandibularis), hyoid (the gularis, which includes the 'stylohyoideus' and 'serpihyoideus' sensu Huang et al. 1999, and also the interceratobranchialis, although some authors have argued that this latter muscle could actually be a mandibular muscle or a branchial muscle: see below), and branchial (the hyobranchialis, i.e., the 'branchiomandibularis' sensu Huang et al. 1999) muscles (see Fig. 7.8 and Table 7.4). The developmental work of Huang et al. (1999) has shown that somites 2–6 participate in the formation of the hypobranchial muscles of chickens, but not of the other, non-hypobranchial 'tongue muscles' listed above, with exception to the interceratobranchialis (Fig. 7.8), which included a few somite myogenic cells. As explained by these authors, since myoblasts from more cranially located somites and those from more caudally located somites are not different in the extent of their contribution to the individual avian 'tongue muscles', it seems that myoblasts from different somites have the same ability to invade the 'tongue primordia' and contribute to the 'tongue muscles'. This means that myoblasts from different somites intermingle during their migration to the 'tongue anlagen'. Huang et al.'s (1999) results have actually shown that cells from multiple somites stream

to a focal point and then migrate as a single location. In this context, the mechanisms of myogenic cell migration of the tongue differ from those in the limb bud. In the limb bud, myoblasts initially appear to emigrate from the somites strictly laterally along projections of the original segmental borders into limb bud mesoderm. The obvious mixing of myoblasts from different somites takes place much later at the central part of the forearm and hand. According to Huang et al. (1999), the reason for this difference between tongue and limb could be that the distances between the source and destination of muscle precursor cells are longer for the tongue, and also that the cells that migrate to the tongue are restricted to a narrow band that is often named 'hypoglossal cord' in the literature.

One interesting result of Huang et al.'s (1999) developmental work, mentioned above, is that it has shown that the avian muscle interceratobranchialis (Fig. 7.8; Table 7.2) included a few somitic myogenic cells. Edgeworth (1935) stated that this avian muscle ('interkeratoideus' in his terminology) is a mandibular muscle innervated by cranial nerve V and, very likely, derived from the intermandibularis. However, this muscle has also been reported to have a hypoglossal nerve innervation (e.g., Vanden Berge 1975), and some authors thus consider that it is a branchial muscle derived from the third and/or fourth branchial arches (see, e.g., table 1 of Marcucio and Noden 1999). But more recent developmental studies indicated that the interceratobranchialis is actually derived ontogenetically from the same axial level as the hyoid muscles depressor mandibulae and gularis ('serpihyoideus' + 'stylohyoideus'), and, because of this, this muscle is now often commonly considered to be a hyoid muscle (see, e.g., Noden and Francis-West 2006). A careful analysis of the topology of the interceratobranchialis in adult birds such as chickens also indicates that this structure is derived from the hyoid musculature and probably from the interhyoideus, because it lies just dorsal to, and is associated with, the anteroventral portion of the interhyoideus ('constrictor colli, pars intermandibularis' sensu Baumel et al. 1979) and its derivatives (e.g., gularis, i.e., 'serpihyoideus' + 'stylohyoideus' sensu Baumel et al. 1979) (see *Hyoid Muscles* above, Table 7.2, and Fig. 7.8). The data obtained in Huang et al.'s (1999) work, showing that the interceratobranchialis receives some (although very few) contribution from somitic myogenic cells, does also support the idea that this muscle is more likely part of the hyoid musculature than of the mandibular musculature. This is because in other tetrapod taxa such as amphibians, some hyoid muscles (e.g., the interhyoideus) also receive a contribution of somitic myogenic cells (some branchial muscles might also include such cells, and hypobranchial muscles almost always do), while mandibular muscles almost never do (see, e.g., the recent work of Piekarski and Olsson 2007, for more details on this subject; see also Chapter 5). The most convincing argument supporting this idea

Table 7.4 Hypobranchial muscles of adults of representative reptilian taxa (see caption of Table 7.1 and text).

Reptilia, Testudines: *Trachemys scripta* (Red-eared slider turtle)	Reptilia, Lepidosauria: *Timon lepidus* (Ocellated lizard)	Reptilia, Crocodylia: *Caiman latirostris* (Brown-snouted caiman)	Reptilia, Aves: *Gallus domesticus* (Domestic chicken)
Geniohyoideus	**Geniohyoideus** (geniohyoideus and/or mandibulohyoideus sensu Edgeworth 1935 and Herrel et al. 2005)	**Geniohyoideus** [see text]	— [see text]
Genioglossus	**Genioglossus** [see text]	**Genioglossus** [see text]	— [see text]
Hypoglossoglossus [as explained by Schumacher 1973, this muscle is often present in turtles and is probably derived from the genioglossus; it often originates from the dorsal side and lateral margin of the hypoglossum and inserts onto the lingual process and the anterior part of the tongue]	—	—	—
Entoglossoglossus [as explained by Schumacher 1973, this muscle is also often present in turtles and is also probably derived from the genioglossus; it corresponds to the 'protrusor linguae' or to the 'hyoentoglossus' of some authors and often runs posteriorly from the apex of the lingual process to the lateral margins of the hypoglossum]	—	—	—

— [see on the right]	**Intrinsic muscles of the tongue** [according to Saban 1971, Smith 1988, 1992, and Herrel et al. 2005, examples of reptilian intrinsic tongue are the 'longitudinalis' (which seemingly derives from the hyoglossus; note that some reptilian taxa have both a dorsal longitudinal layer and a ventral longitudinal layer, which are similar to the longitudinalis dorsalis and longitudinalis ventralis of mammals such as humans, respectively), the 'transversus linguae ventralis', the 'transversus linguae dorsalis', the 'verticalis linguae' and the 'annularis' (the 'verticalis linguae' corresponds to the 'accelerator' sensu Herrel et al. 2005); Edgeworth 1935 suggested that the 'accelerator' corresponds to part or the totality of the 'annulus of the lingual process of the basihyobranchiale' and, thus, seemingly to the 'annularis'/'ring muscle' sensu Smith 1988, 1992; however, the works of Saban 1968, 1971 and others seem to indicate that the 'verticalis linguae' and 'annularis' may be present at the same time in the same taxon; at least part of the 'verticalis linguae' derives from the genioglossus according to Saban 1971]	— [according to Edgeworth 1935, crocodylians do not have a longitudinalis linguae nor a transversus l inguae, but Schumacher 1973 stated that crocodylians do often have a transversalis linguae; see on the left]	— [according to Noden and Francis-West 2006 and others, birds lack intrinsic tongue muscles; see on the left]

Table 7.4 contd...

Table 7.4 contd...

Reptilia, Testudines: *Trachemys scripta* (Red-eared slider turtle)	Reptilia, Lepidosauria: *Timon lepidus* (Ocellated lizard)	Reptilia, Crocodylia: *Caiman latirostris* (Brown-snouted caiman)	Reptilia, Aves: *Gallus domesticus* (Domestic chicken)
Hyoglossus	**Hyoglossus**	**Hyoglossus**	**Hyoglossus** [corresponds to the 'ceratoglossus' sensu Engels 1938, Köntges and Lumsden 1996 and Huang et al. 1999, which is thus not homologous to the ceratoglossus of some mammals because this latter structure corresponds to a bundle of the hyoglossus, and not to the hyoglossus as a whole, as does the 'ceratoglossus' of birds: see Chapter 5]
—	—	—	**Hypoglossus** [as described by Edgeworth 1935, Huang et al. 1999 and others, birds often have a muscle hypoglossus, which derives, together with the hyoglossus, from the posterior part of the 'geniohyoideus anlage', the anterior part of this anlage thus giving rise to the geniohyoideus and the genioglossus (as explained in the text, both these two latter muscles are often absent in adults of the genus *Gallus*)]
Sternohyoideus (rectus cervicus sensu Edgeworth 1935; coracohyoideus sensu Schumacher 1973 and Wyneken 2001)	**Sternohyoideus** (episternohyoideus sensu Edgeworth 1935 and Holmes 1977; rectus cervicus sensu Kardong 2002) [see text]	**Sternohyoideus** (episternohyoideus sensu Edgeworth 1935 and Holmes 1977; probably corresponds to the episternobranchiotendineus and/or episternobranchialis	**Sternohyoideus** [see text]

		sensu Schumacher 1973: see, e.g., Sedlmayr 2002) [according to Sedlmayr 2002 and others, in some crocodylians the rectus cervicus gives rise to the sternohyoideus, to the omohyoideus, and to a structure that is often named musculus sternomandibularis in the literature; according to Edgeworth 1935 this sternomandibularis' is effectively mainly derived from the rectus cervicus, and namely from the sternohyoideus, but its anterior portion 'is formed by a part or the whole genio-hyoideus]	
—	—	—	**Cricohyoideus** [this muscle is present in various birds, including *Gallus*, corresponding to, or including, the structure that is often designated as 'thyrohyoideus' in the literature (see text), although this latter structure is very likely not homologous to the mammalian thyrohyoideus because it is not present as a separate muscle in turtles, lepidosaurs and crocodylians and, thus, was probably not present in the LCA of reptiles]

Table 7.4 contd...

Table 7.4 contd...

Reptilia, Testudines: *Trachemys scripta* (Red-eared slider turtle)	Reptilia, Lepidosauria: *Timon lepidus* (Ocellated lizard)	Reptilia, Crocodylia: *Caiman latirostris* (Brown-snouted caiman)	Reptilia, Aves: *Gallus domesticus* (Domestic chicken)
—	—	—	**Tracheohyoideus** (possibly corresponds to the tracheolateralis sensu Huang et al. 1999 and/ or to the trachealis laterali sensu Tsukahara et al. 2009) [see text]
—	—	—	**Sternotrachealis** [see text]
— [the descriptions of Edgeworth 1935, Schumacher 1973 and Wyneken 2001 indicate that in turtles the omohyoideus is missing, or, more likely, is not differentiated from the sternohyoideus; in the turtles we dissected we were effectively unable to find a separate omohyoideus such as that found in other extant reptiles]	**Omohyoideus** [present in most lepidosaurs, including *Iguana* and *Sphenodon*: see, e.g., Haas 1973 and Holmes 1977]	**Omohyoideus** [as explained by Edgeworth 1935, Holmes 1977 and others, the omohyoideus is often present as a separate muscle in crocodylians; it probably corresponds to the coracohyoideus sensu Schumacher 1973: see, e.g., Sedlmayr 2002]	**Omohyoideus** [according to Sedlmayr 2002 the omohyoideus corresponds to the structure that is often named 'cleidohyoideus' in the avian literature, although it might actually include both the 'cleidohyoideus' and the 'cleidotrachealis' sensu Huang et al. 1999, and, thus, the 'cleidolaryngeal' sensu Noden et al. 1999: see text]

has, however, been provided in works such as Köntges and Lumsden (1996), because these works have conclusively shown that: (1) the connective tissues/fasciae associated with the interceratobranchialis are derived from hyoid crest cells and (2) that this muscle attaches exclusively to hyoid crest-derived skeletal domains. Further studies are, however, still needed to clarify if this muscle is innervated by CNV (as proposed by, e.g., Edgeworth 1935), or CNXII (as proposed by, e.g., Vanden Berge 1975), and/or by CNVII (as are, almost always, the hyoid muscles).

Schumacher (1973) suggested that crocodylians do not have a separate, independent muscle geniohyoideus. However, Edgeworth (1935) clearly described this muscle in various crocodylian taxa, and his descriptions were corroborated by the recent study of Sedlmayr (2002) (who stated that the geniohyoideus of crocodylians includes, or is deeply associated with, the 'branchiomandibularis pars spinalis' sensu Schumacher 1973, i.e., to part of the hyobranchialis sensu the present work: see above) (Table 7.4). Regarding birds, as explained by Edgeworth (1935) in earlier ontogenetic stages *Gallus* has a muscle that corresponds to the geniohyoideus + genioglossus of other reptiles but then this muscle disappears later in ontogeny, so both the geniohyoideus and genioglossus are absent in adults of this genus and of most other avian taxa (see Fig. 7.8 and Table 7.4; it is important to note that, particularly in the older literature, the name 'geniohyoideus' has been erroneously used for avian structures such as the hyobranchialis: see, e.g., Müller and Weber 1998). Recent developmental studies confirmed that the 'genioglossus' (which probably corresponds to the geniohyoideus - genioglossus sensu Edgeworth 1935 and Engels 1938 and sensu the present work) is absent in adult chickens but persists through at least 18 days of development in passeriform birds such as quails (see, e.g., Köntges and Lumsden 1996; Huang et al. 1999; Marcucio and Noden 1999). Müller and Weber (1998) reported both a geniohyoideus and a genioglossus in some adult palaeognathous birds, and, although they stated that these structures are often deeply blended, they argued that both were probably present in the LCA of extant birds, and then were secondarily lost, being absent in most adult neognathous birds. Interestingly, Engels (1938) and others have described a 'vestigial geniohyoideus-genioglossus muscle' in a few adult neognathous passeriform birds, e.g., *Corvus* and *Toxostoma*. It should be noted that some reptiles have glossal muscles other than the genioglossus (Fig. 7.9), the intrinsic muscles of the tongue, and the hyoglossus (Fig. 7.9). For instance, turtles often have a hypoglossoglossus and an entoglossoglossus, and birds often have a hypoglossus (Table 7.4; e.g., Edgeworth 1935; Engels 1938; Schumacher 1973; Müller and Weber 1998; Huang et al. 1999; this work).

According to Diogo (2008b) the LCA of amniotes very likely had two derivatives of the 'rectus cervicus' sensu Edgeworth (1935): the

sternohyoideus and the omohyoideus (see, e.g., Fig. 5.7). Jollie (1962), Abdala and Moro (2003) and others described and illustrated a 'sternothyroideus' in some lepidosaurian taxa, including *Iguana* (see, e.g., Fig. 10.11). However, it is commonly accepted in the literature that most, if not all, turtles, crocodylians and birds do not have a separate, well-defined muscle sternothyroideus such as that found in mammals (see, e.g., Saban 1968, 1971; Schumacher 1973; Wyneken 2001; Sedlmayr 2002). In our dissections, we were effectively unable to find such a muscle in a member of these three groups. This thus supports the idea that the sternothyroideus was not present in the LCA of reptiles and, therefore, in the LCA of amniotes, i.e., that the structure that is designated as 'sternothyroideus' in some lepidosaurs is not homologous to the mammalian sternothyroideus. Further studies are needed to clarify the exact taxonomic distribution and homologies of the former structure within reptiles.

The peculiar syringeal muscles of birds are usually innervated by the hypoglossal nerve (XII), and are part of the hypobranchial musculature, and namely of the 'rectus cervicus' group sensu Edgeworth (1935) (see, e.g., the recent work of Tsukahara et al. 2009). According to Sedlmayr (2002) and others, in these reptiles the 'rectus cervicus' (which is often named 'tracheo-laryngo-hyoideus' in the literature) gives rise to the sternohyoideus (which might correspond to, or include the, 'tracheolaryngealis' sensu Noden et al. 1999), to the omohyoideus (which is often designated as 'cleidohyoideus' in the literature but might include both the 'cleidohyoideus' and the 'cleidotrachealis' sensu Huang et al. 1999), and to a structure that is often named 'musculus cricohyoideus' (often also designated as 'musculus thyrohyoideus' in the literature), which in turn gives rise to a 'sternotrachealis' and a 'tracheohyoideus' (this latter muscle probably corresponds to the 'tracheolateralis' sensu Huang et al. 1999 and/or to the 'trachealis laterali' sensu Tsukahara et al. 2009). However, Engels (1938) and others suggested that the 'cricohyoideus' sensu Edgeworth (1935) actually corresponds to both the structures that are often named 'thyrohyoideus' and 'tracheohyoideus' in the avian literature. Tsukahara et al. (2009) used names such as 'tracheobronchialis ventralis', 'syringeus ventromesialis', 'syringeus ventrolateralis' and 'syringeus dorsolateralis' to describe some of the components of the complex syringeal musculature of birds such as *Corvus*. Detailed studies on the development and innervation of the 'tongue' and syringeal muscles of numerous representatives of each of the major avian clades are clearly needed to clarify the exact taxonomic distribution and homologies of the derivatives of the 'rectus cervicus' (sensu Edgeworth 1935) within these clades.

General Remarks

In terms of number of muscles, the cranial musculature of reptiles varies within narrow limits, being, in general, somewhat conservative. A significant part of the anatomical variation that is seen between the major extant clades seems to be linked to the general skull shape; for instance, some of the cephalic muscles tend to be more vertically oriented as the skull becomes more globe-like (e.g., Fig. 7.8, compare with Fig. 7.13). Based on the information given in Tables 7.1–7.4 and discussed above about the mandibular, hyoid, branchial and hypobranchial muscles of turtles, lepidosaurs, crocodylians and birds, as well on the data provided by Diogo et al. (2008b) about the muscles of other sarcopterygian groups, it is thus possible to briefly summarize below which muscles were probably present in the LCA of these four reptilian groups.

Regarding the mandibular muscles, this LCA likely had an adductor mandibulae A2, an adductor mandibulae A2-PVM, a pseudotemporalis, a pterygomandibularis ventralis, a pterygomandibularis dorsalis, a levator bulbi, and, possibly, an adductor mandibulae Aω, an intermandibularis anterior and an intermandibularis posterior, and a protractor pterygoidei and/or other dorsal mandibular muscles. As explained above, one cannot completely discard the hypothesis that the levator anguli oris mandibularis and/or 'retractor anguli oris' of reptiles such as lepidosaurs correspond to/derive from the retractor anguli oris of sarcopterygian fish such as dipnoans. If this were the case, this would mean that the LCA of tetrapods and the LCA of reptiles had at least one of these structures. However, phylogenetic parsimony indicates that this hypothesis is rather unlikely because these structures are missing in extant amphibians, turtles, crocodylians, birds and mammals (see above). Regarding the hyoid muscles, the LCA of extant reptiles probably had an interhyoideus and a depressor mandibulae. As noted above, the presence of a 'stylohyoideus' in lepidosaurs such *Sphenodon* and *Gekkota*, of a gularis and a interceratobranchialis in birds, and of a separate, well-differentiated muscle cervicomandibularis such as that found in numerous lepidosaurs, represent very likely apomorphic, and not plesiomorphic, features within reptiles. With respect to the branchial muscles, this LCA likely had a hyobranchialis, a trapezius, a sternocleidomastoideus, a constrictor laryngis, and a dilatator laryngis. Lastly, the hypobranchial musculature of this LCA probably included a sternohyoideus, an omohyoideus, a geniohyoideus, a genioglossus, a hyoglossus, and at least some intrinsic muscles of the tongue.

Before ending this chapter, we would like to emphasize that detailed comparative studies on the development, innervation, and adult configuration of the head and neck muscles of an even wider range of not only reptilian, but also of numerous other tetrapod and non-tetrapod

sarcopterygian taxa are clearly needed to help address controversial questions such as the following: Do the levator anguli oris mandibularis and/or 'retractor anguli oris' of reptiles such as lepidosaurs correspond to/derive from the retractor anguli oris of dipnoans? Is the intermandibularis of most adult birds, crocodylians and turtles an undifferentiated muscle that corresponds to the intermandibularis anterior + intermandibularis posterior of lepidosaurs such as *Timon* and that does not become subdivided during ontogeny? Or are the intermandibularis anterior and the intermandibularis posterior of tetrapods such as salamanders, anurans, lepidosaurs and various mammals instead the result of an independent (convergent/parallel) division of a plesiomorphically undivided muscle intermandibularis into two separate muscles? What is the exact innervation of the interceratobranchialis within the different clades of extant birds? Was the 'levator palatini' of the LCA of reptiles still mainly undivided as was very likely that of the LCA of tetrapods and of the LCA of amphibians, or was it instead already divided into different muscles, such as the levator pterygoidei and protractor pterygoidei? Is the pterygomandibularis dorsalis really completely missing in squamates such as *Timon* or does the pterygomandibularis of these reptiles actually correspond to both the pterygomandibularis ventralis + pterygomandibularis dorsalis of other reptiles? What is the exact taxonomic distribution of the structures that are often named 'stylohyoideus' and 'sternothyroideus' in reptiles? Were the posterior fibers of the depressor mandibulae of the LCA of extant reptiles still deeply blended to the main body of this muscle, or were these fibers already somewhat differentiated from the anterior portion of the muscle, forming a posterior bundle of the depressor mandibulae such as that found in various turtles, crocodylians and birds? Is the turtle muscle 'testoscapuloprocoracoideus' sensu Fürbringer (1874) effectively a pectoral muscle, or does it correspond to the sternocleidomastoideus sensu the present work, as suggested by this author? It is hoped that the present work will stimulate, and pave the way for, future studies on the comparative anatomy, development, functional morphology, and evolution of the head and neck muscles of turtles, lepidosaurs, crocodylians and birds.

Chapter 8

Pectoral and Pectoral Fin Muscles of Actinopterygian and Sarcopterygian Fishes

As is the case with the cranial muscles (see Chapters 3–7), the most comprehensive comparative analyses of osteichthyan pectoral muscles and pectoral fin/forelimb muscles of vertebrates that were actually based on a direct observation of taxa as varied as, e.g., the Teleostei, Halecomorphi, Ginglymodi, Chondrostei, Cladistia, Dipnoi, Amphibia and Amniotes, and not mainly on a recompilation from the literature, were provided long ago, by authors Humphry (1872ab), Brooks (1886–1889), Ribbing (1907), Romer (1922–1944), Howell (1933–1937), Haines (1939–1958), and Straus (1942), among others. Thus, despite the quality of these works, their authors could not access information now available concerning, for example, the pectoral and pectoral fin musculature of *Latimeria chalumnae* and the essential role of neural crest cells in the development and patterning of the cephalic (see Chapters 3–7) and also the pectoral and pectoral fin/pectoral limb muscles (e.g., McGonnell 2001) of vertebrates. Also, some of hypotheses proposed in those works regarding the homologies and evolution of osteichthyan pectoral muscles were based on phylogenetic hypotheses that have been contradicted by numerous studies. For instance, Romer (1944) defended that the cladistian *Polypterus* is more closely related to tetrapods than are the extant dipnoans, a view to which very few authors would adhere nowadays (see Chapters 1 and 2, and also Chapter 9). Chapter 8 provides an updated discussion on the homologies and evolution of the pectoral and pectoral fin muscles of actinopterygian and sarcopterygian fishes; the pectoral and forelimb muscles of tetrapods are discussed in Chapters 9 and 10.

Actinopterygian Fishes (Table 8.1)

The plesiomorphic condition for actinopterygians clearly seems to be that in which there are only two pectoral muscles related to the movements of the pectoral fins, the abductor and the adductor, which may be subdivided into different bundles. Such a condition is found, for example, in extant chondrosteans and in extant cladistians (Fig. 8.1). In fact, this condition seems to be plesiomorphic for the osteichthyans and for the gnathostomes as a whole (see Table 8.1), because it is also found in extant actinistian and dipnoan sarcopterygians (see below) as well as in non-osteichthyan gnathostomes such as extant chondrichthyans (e.g., Romer 1924; Jarvik 1963, 1980; Kardong and Zalisko 1998; Kardong 2002; see also Chapter 3). In both actinopterygian fishes (e.g., Fig. 8.11) and sarcopterygian fishes (e.g., Fig. 8.14) the adductor and abductor of the pectoral fin are often subdivided into an adductor superficialis and adductor profundus (which correspond to the adductores superficiales 1 and 2 sensu Diogo et al. 2001 and Diogo 2004a) and into abductor superficialis and abductor profundus (which correspond to the abductores superficiales 1 and 2 sensu Diogo et al. 2001 and Diogo 2004a), respectively. In the present chapter, the adductor superficialis and adductor profundus are considered as bundles of the adductor of the pectoral fin, and not as separate muscles; the abductor superficialis and abductor profundus are considered as bundles of the abductor of the fin, and also not as individual muscles (Table 8.1). As their names indicate, in non-tetrapod vertebrates the adductor and the abductor are mainly related to the adduction and with the abduction of the pectoral fin, respectively (e.g., Bischoff 1840; Owen 1841; Pollard 1892; Romer 1924; Millot and Anthony 1958; Greenwood and Thomson 1960; Jessen 1972; Winterbottom 1974; Brosseau 1978ab; Lauder and Liem 1983; Adriaens et al. 1993; Kardong and Zalisko 1998; Diogo et al. 2001; Kardong 2002; Westneat et al. 2004; Thorsen and Westneat 2005; Thorsen and Hale 2005).

Contrary to extant cladistians and chondrosteans, as well as to extant sarcopterygian fishes, the living ginglymodians, the living halecomorphs, and the vast majority of the living teleosts exhibit a separate, well-distinguished muscle arrector dorsalis, which may be subdivided into different bundles (e.g., Fig. 8.13). This arrector dorsalis usually originates on the mesial surface of the pectoral girdle, laterally to the adductor of the fin and to the mesocoracoid arch (when this structure is present) and inserts on the proximal head of the first and eventually of the second pectoral fin rays (e.g., Figs. 8.2, 8.4, 8.5B, 8.11, 8.13). The arrector dorsalis is ontogenetically derived from the adductor of the pectoral fin (e.g., Jessen 1972; Winterbottom 1974; Thorsen and Hale 2005). The arrector dorsalis

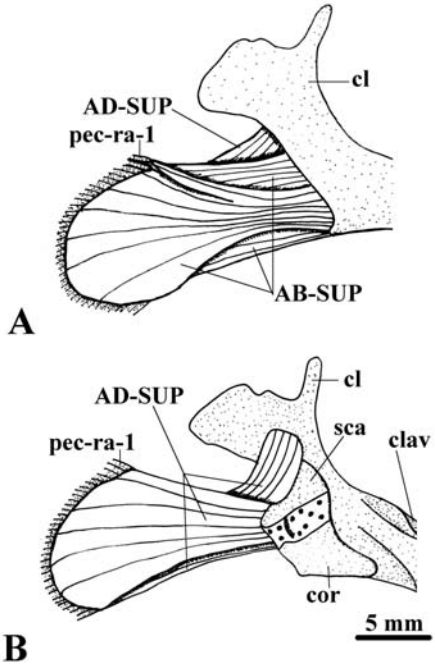

Fig. 8.1 *Polypterus bichir* (Cladistia): lateral **(A)** and mesial **(B)** views of the pectoral musculature; in the lateral view the adductor of the pectoral fin is also illustrated. AB-SUP, abductor superficialis; AD-SUP, adductor superficialis; cl, cleithrum; clav, clavicle; cor, coracoid; pec-ra-1, pectoral ray 1; sca, scapula.

was seemingly phylogenetically acquired in the node leading to the Neopterygii (see Fig. 4.1; Table 8.1).

Apart from the arrector dorsalis, other separate, well-distinguished arrector muscles may be present in neopterygians (Table 8.1). One of these muscles is the arrector ventralis, which is found in the great majority of extant teleosts and was seemingly phylogenetically acquired in the node leading to the Teleostei (Fig. 4.1; Table 8.1). The arrector ventralis usually originates lateral to the abductor and inserts on the first pectoral ray (e.g., Fig. 8.5A). It is ontogenetically derived from the abductor of the pectoral fin (e.g., Jessen, 1972; Winterbottom 1974; Thorsen and Hale 2005). The other muscle is the small muscle arrector 3, which usually connects the pectoral girdle to the ventrolateral surface of the first pectoral ray (e.g., Figs. 8.7, 8.8). This small muscle has been frequently neglected in the literature; that is, it has frequently been overlooked or considered as a bundle of the arrector ventralis or of the abductor of the fin (e.g., by Brosseau 1978ab). However, as explained by Diogo (2007), the arrector 3 is found in

Table 8.1 Pectoral and pectoral fin muscles of adults of representative actinopterygian taxa. The nomenclature of the muscles shown in bold follows that of the text; in order to facilitate comparisons, in some cases names often used by other authors to designate a certain muscle/bundle are given in front of that muscle/bundle, in parentheses. Data compiled from evidence provided by our own dissections and comparisons and by an overview of the literature (see text and Figs. 8.1 to 8.17).

Probable plesiomorphic osteichthyan condition	Cladistia: *Polypterus bichir* (Bichir)	Chondrostei: *Psephurus gladius* (Chinese swordfish)	Ginglymodi: *Lepisosteus osseus* (Longnose gar)	Halecomorphi: *Amia calva* (Bowfin)	Teleostei—basal: *Elops saurus* (Ladyfish)	Teleostei—clupeocephalan: *Danio rerio* (Zebrafish)
Abductor (of pectoral fin)	**Abductor (of pectoral fin)**	**Abductor (of pectoral fin)**	**Abductor (of pectoral fin)**	**Abductor (of pectoral fin)**	**Abductor (of pectoral fin)**	**Abductor (of pectoral fin)** (abductores superficiales 1 and 2 sensu Diogo et al. 2001 and Diogo 2004a)
Adductor (of pectoral fin)	**Adductor (of pectoral fin)**	**Adductor (of pectoral fin)**	**Adductor (of pectoral fin)**	**Adductor (of pectoral fin)**	**Adductor (of pectoral fin)**	**Adductor (of pectoral fin)** (adductores superficiales 1 and 2 sensu Diogo et al. 2001 and Diogo 2004a)
—	—	—	**Arrector dorsalis**	**Arrector dorsalis**	**Arrector dorsalis**	**Arrector dorsalis** (adductor profundus sensu Diogo et al. 2001 and Diogo 2004a) [according to authors such as Jessen 1972, Winterbottom 1974 and Thorsen and Hale 2005, the arrector dorsalis is ontogenetically derived from the adductor of the pectoral fin]
—	—	—	—	—	**Arrector ventralis**	(arrector dorsalis sensu Diogo et al. 2001 and Diogo 2004a) [according to Jessen 1972, Winterbottom 1974, Thorsen and Hale 2005 and other authors, the arrector ventralis is ontogenetically derived from the abductor of the pectoral fin]

—	—	—	—	—	—	**Arrector 3** (large external bundle of superficial abductor sensu Brosseau 1978ab; arrector ventralis sensu Diogo et al. 2001 and Diogo 2004a) [this small muscle has frequently been overlooked or considered as a bundle of the arrector ventralis or of the abductor of the pectoral fin; it is thus more likely that the arrector 3 derives from the abductor, and not from the adductor, of the pectoral fin]

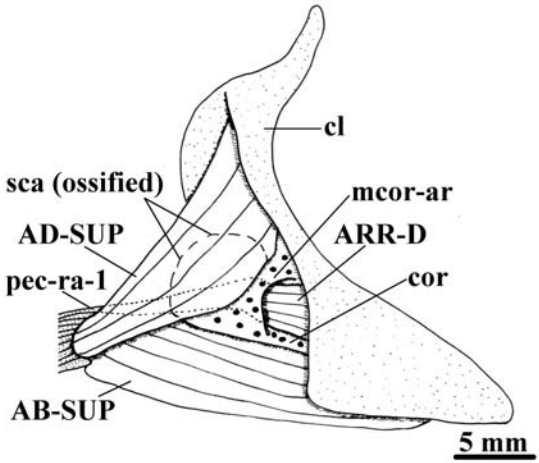

Fig. 8.2 *Lepisosteus osseus* (Ginglymodi): mesial view of the pectoral musculature; despite being a lateral structure, the abductor superficialis is also shown. AB-SUP, abductor superficialis; AD-SUP, adductor superficialis; ARR-D, arrector dorsalis; cl, cleithrum; cor, coracoid; mcor-ar, mesocoracoid arch; pec-ra-1, pectoral ray 1; sca, scapula.

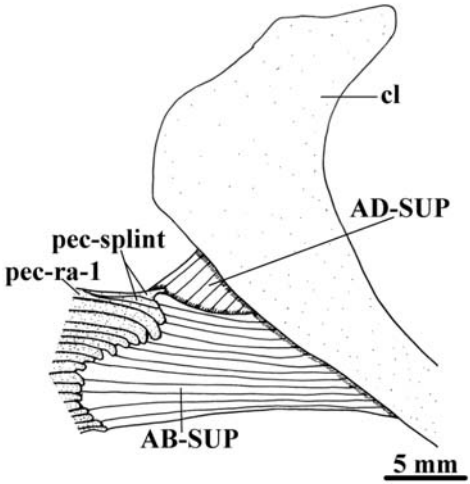

Fig. 8.3 *Amia calva* (Halecomorphi): lateral view of the pectoral musculature; despite being a mesial structure, the adductor superficialis is also shown. AB-SUP, abductor superficialis; cl, cleithrum; pec-ra-1, pectoral ray 1; pec-splint, pectoral splint.

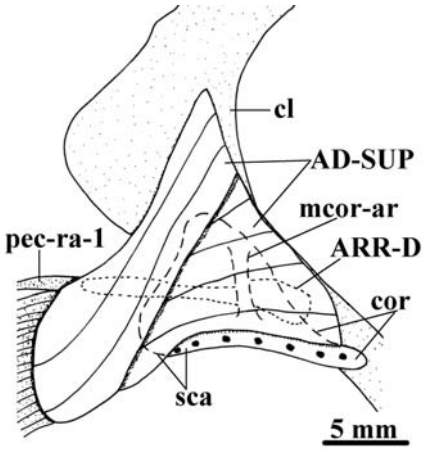

Fig. 8.4 *Amia calva* (Halecomorphi): mesial view of the pectoral musculature. AD-SUP, adductor superficialis; ARR-D, arrector dorsalis; cl, cleithrum; cor, coracoid; mcor-ar, meso-coracoid arch; pec-ra-1, pectoral ray 1; sca, scapula.

numerous otocephalans, and apparently in at least some euteleosts, thus constituting a potential synapomorphy of the Clupeocephala (see Fig. 4.1; Table 8.1).

In previous works by one of us (RD) and colleagues (e.g., Diogo et al. 2001; Diogo 2004a) the arrector 3 (sensu this volume) was named "arrector ventralis". One of the main reasons for this confusion was precisely the fact that the small muscle arrector 3 was not described by Winterbottom (1974) and other authors. Because of this confusion, the names attributed to the teleostean pectoral muscles by Diogo et al. (2001a) and Diogo (2004a) were substantially different from those proposed by Winterbottom (1974). In order to solve this problem, Diogo (2007) and Diogo and Abdala (2007) opted to designate this small muscle as arrector 3, and to use the nomenclature proposed by Winterbottom (1974) to designate the other teleostean pectoral muscles. Here we thus follow the nomenclature proposed by Diogo (2007) and Diogo and Abdala (2007). Therefore, in order to facilitate comparisons between the nomenclature used in previous works such as Diogo et al. (2001) and Diogo (2004a) and more recent publications such as Diogo (2007), Diogo and Abdala (2007), and the present book, it should be emphasized that the "arrector ventralis", "arrector dorsalis", "abductor superficialis 1", "abductor superficialis 2", "adductor superficialis 1", "adductor superficialis 2" and "abductor profundus" sensu the former (older) works correspond respectively to the arrector 3, arrector ventralis, abductor superficialis, abductor profundus, adductor superficialis, adductor profundus and arrector dorsalis sensu the latter (more recent) publications (including this volume).

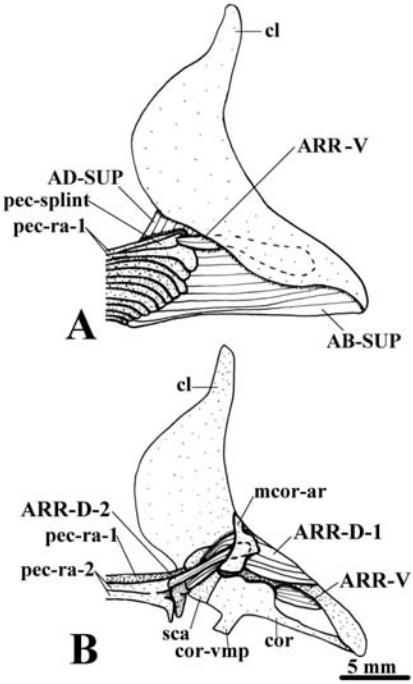

Fig. 8.5 *Elops saurus* (Teleostei, Elopiformes): lateral (A) and mesial (B) view of the pectoral musculature; in the mesial view the adductor superficialis and abductor superficialis are not shown. AB-SUP, abductor superficialis; AD-SUP, adductor superficialis; ARR-D-1, 2, arrector dorsalis 1 and 2; ARR-V, arrector ventralis; cl, cleithrum; cor, coracoid; cor-vmp, ventromesial process of coracoid; mcor-ar, mesocoracoid arch; pec-ra-1, 2, pectoral rays 1 and 2; pec-slint, pectoral splint; sca, scapula.

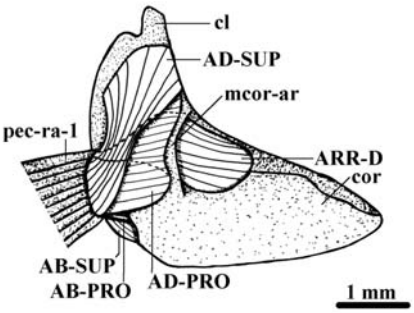

Fig. 8.6 *Denticeps clupeoides* (Teleostei, Clupeiformes): mesial view of the pectoral girdle musculature; the lateral muscles abductor superficialis and abductor profundus are also shown. AB-PRO, abductor profundus; AB-SUP, abductor superficialis; AD-PRO, adductor profundus; AD-SUP, adductor superficialis; ARR-D, arrector dorsalis; cl, cleithrum; cor, coracoid; mcor-ar, mesocoracoid arch; pec-ra-1, pectoral ray 1.

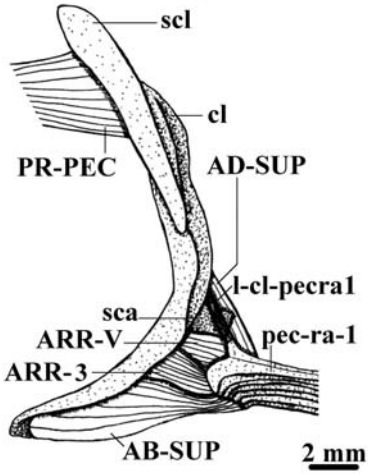

Fig. 8.7 *Chanos chanos* (Teleostei, Gonorynchiformes): lateral view of the pectoral girdle musculature. AB-SUP, abductor superficialis; AD-SUP, adductor superficialis; ARR-3, arrector 3; ARR-V, arrector ventralis; cl, cleithrum; l-cl-pecra1, ligament between cleithrum and pectoral ray 1; pec-ra-1, pectoral ray 1; PR-PEC, protractor pectoralis; sca, scapula; scl, supracleithrum.

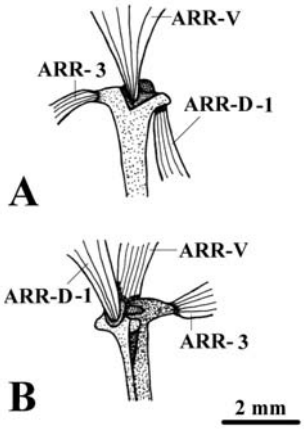

Fig. 8.8 *Chanos chanos* (Teleostei, Gonorynchiformes): lateral **(A)** and mesial **(B)** views of the anterior portion of the first pectoral ray and the insertions of the section 1 of the arrector dorsalis, of the arrector 3 and of the arrector ventralis. ARR-3, arrector 3; ARR-D-1, section 1 of arrector dorsalis; ARR-V, arrector ventralis.

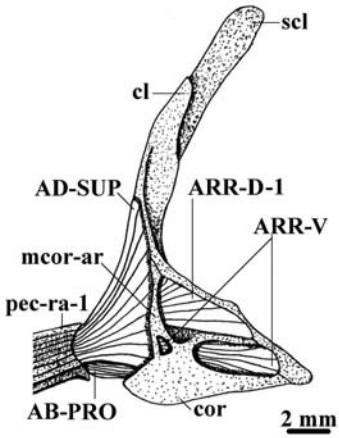

Fig. 8.9 *Chanos chanos* (Teleostei, Gonorynchiformes): mesial view of the pectoral girdle musculature, the lateral muscle abductor profundus is also shown. AB-PRO, abductor profundus; AD-SUP, adductor superficialis; ARR-D-1, arrector dorsalis 1; ARR-V, arrector ventralis; cl, cleithrum; cor, coracoid; mcor-ar, mesocoracoid arch; pec-ra-1, pectoral ray 1; scl, supracleithrum.

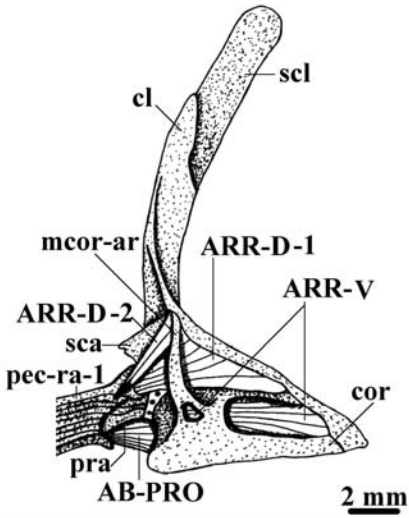

Fig. 8.10 *Chanos chanos* (Teleostei, Gonorynchiformes): mesial view of the pectoral girdle musculature, the lateral muscle abductor profundus is also shown; the adductor superficialis was removed. AB-PRO, abductor superficialis, ARR-D-1, 2, arrector dorsalis 1 and 2; ARR-V, arrector ventralis; cl, cleithrum; cor, coracoid; mcor-ar, mesocoracoid arch; pec-ra-1, pectoral ray 1; pra, proximal radials; sca, scapula; scl, supracleithrum.

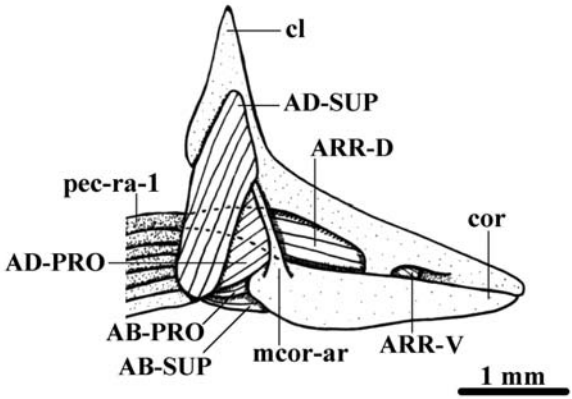

Fig. 8.11 *Danio rerio* (Teleostei, Cypriniformes): mesial view of the pectoral musculature; despite being lateral structures, the abductor superficialis and abductor profundus are also shown. AB-PRO, abductor profundus; AB-SUP, abductor superficialis; AD-PRO, adductor profundus; AD-SUP, adductor superficialis; ARR-D, arrector dorsalis; ARR-V, arrector ventralis; cl, cleithrum; cor, coracoid; mcor-ar, mesocoracoid arch; pec-ra-1, pectoral ray 1.

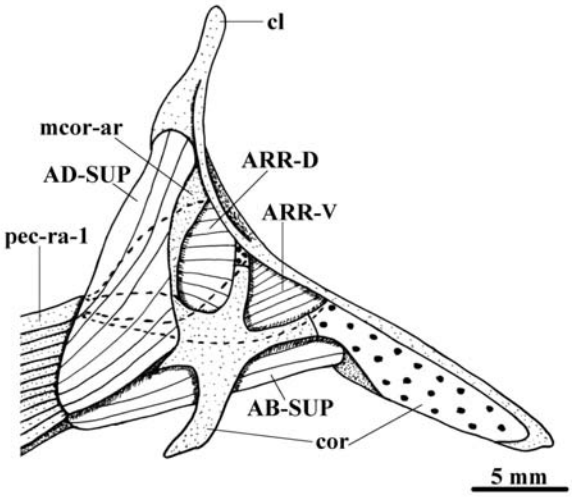

Fig. 8.12 *Alepocephalus rostratus* (Teleostei, Alepocephaloidea): mesial view of the pectoral girdle musculature, the lateral muscle abductor superficialis is also shown. AB-SUP, abductor superficialis; AD-SUP, adductor superficialis; ARR-D, arrector dorsalis; ARR-V, arrector dorsalis; cl, cleithrum; cor, coracoid; mcor-ar, mesocoracoid arch; pec-ra-1, pectoral ray 1.

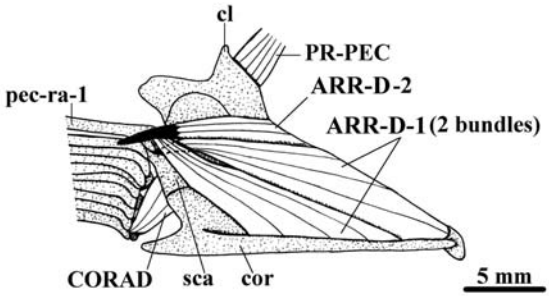

Fig. 8.13 *Aulopus filamentosus* (Teleostei, Aulopiformes): mesial view of the pectoral girdle musculature. ARR-D-1, 2, arrector dorsalis 1 and 2; cl, cleithrum; cor, coracoid; CORAD, coracoradialis; PR-PEC, protractor pectoralis; pec-ra-1, pectoral ray 1; sca, scapula.

As explained by Thorsen and Hale (2005: 149) the arrectors of the pectoral fin "initiate the movement of the fin at the leading edge" while the adductor and the abductor "power the upstroke and downstroke." Besides the abductor, the adductor and the arrector muscles, some derived teleosts (e.g., certain neoteleosts) may eventually exhibit other pectoral muscles, such as the coracoradialis, adductor radialis, interradialis pectoralis and adductor medialis (e.g., Fig. 8.13; see also, e.g., Winterbottom 1974).

Sarcopterygian Fishes

The plesiomorphic condition for sarcopterygians seems also to be that in which there are only two distinct muscles associated with the movements of the pectoral fins, the abductor and the adductor; this condition is found in extant dipnoans (Figs. 8.15, 8.16) and seemingly also in extant actinistians (Fig. 8.14; see below). However, contrary to the configuration found in actinopterygians and in non-osteichthyan gnathostomes such as living chondrichthyans, in these two sarcopterygian groups the adductor and the abductor extend far into the pectoral fin, thus giving to this fin its characteristic 'lobed' or 'fleshy' appearance (e.g., Figs. 8.14, 8.15, 8.16; see also, e.g., Bischoff, 1840; Owen, 1841; Romer, 1924; Howell 1933b; Millot and Anthony 1958; Jessen 1972; Kardong and Zalisko 1998; Kardong 2002).

Millot and Anthony (1958) suggested that apart from the adductor and the abductor of the pectoral fin, *Latimeria* exhibits various 'pronator' and 'supinator' muscles (see Fig. 8.14). We were not able to dissect *Latimeria* specimens due to the difficulty of finding specimens of this genus that are available for muscular examination. However, from the textual descriptions and the illustrations provided by Millot and Anthony (1958), it seems that their 'pronator' and 'supinator' muscles are not well-separated, functionally independent muscles, but are, instead, bundles

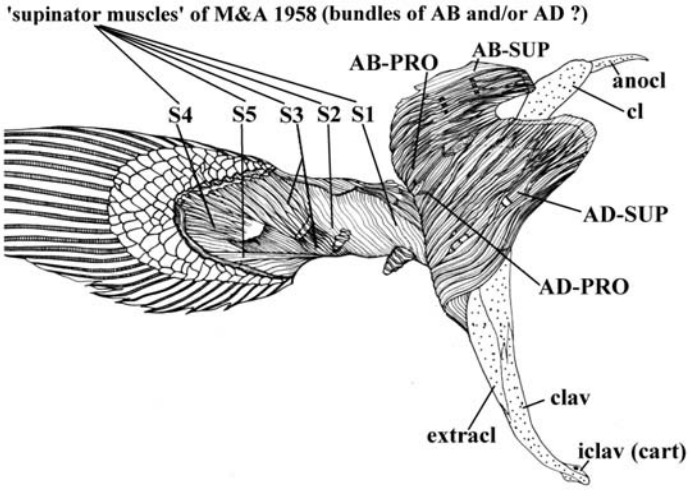

Fig. 8.14 *Latimeria chalumnae* (Cladistia): lateral view of pectoral musculature (modified from Millot and Anthony 1958: the nomenclature of the structures illustrated follows that of the present work). AB-PRO, abductor profundus; AB-SUP, abductor superficialis; AB-PRO, abductor profundus; AD-SUP, adductor superficialis; anocl, anocleithrum; cl, cleithrum; clav, clavicle; extracl, extracleithrum; S1, S2, S3, S4, S5, 'supinator muscles' of Millot and Anthony 1958 (bundles of the abductor and/or adductor of the fin sensu the present work).

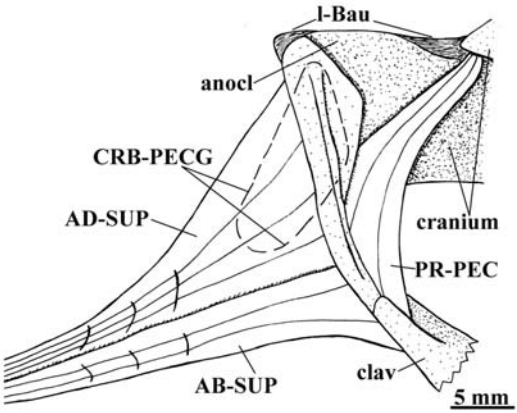

Fig. 8.15 *Neoceratodus forsteri* (Dipnoi): lateral view of pectoral musculature. AB-SUP, abductor superficialis; AD-SUP, adductor superficialis; anocl, anocleithrum; cl, cleithrum; clav, clavicle; CRB-PECG, muscle between cranial rib and pectoral girdle; l-Bau, Baudelot's ligament; PR-PEC, protractor pectoralis.

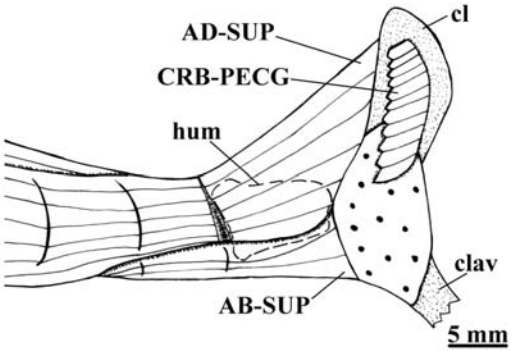

Fig. 8.16 *Neoceratodus forsteri* (Dipnoi): mesial view of pectoral musculature; despite being a lateral structure, the abductor superficialis is also shown; in relation to the lateral view illustrated in Fig. 8.15 the anocleithrum, the Baudelot's ligament and the protractor pectoralis were removed and the muscle between the cranial rib and the pectoral girdle was cut. AB-SUP, abductor superficialis; AD-SUP, adductor superficialis; cl, cleithrum; clav, clavicle; CRB-PECG, muscle between cranial rib and pectoral girdle; hum, humerus.

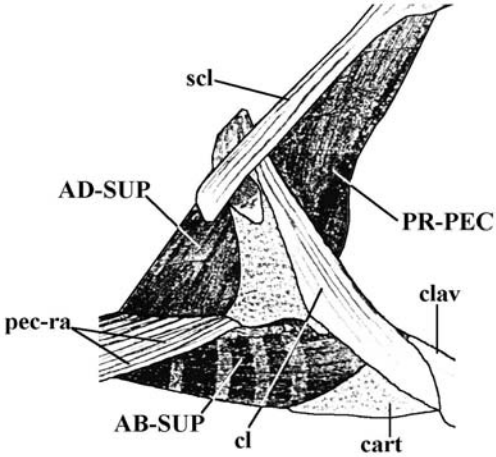

Fig. 8.17 *Polyodon spathula* (Chondrostei): lateral view of the pectoral girdle muscles (modified from Danforth 1913; the nomenclature of the structures illustrated follows that used in the present work). AB-SUP, abductor superficialis; AD-SUP, adductor superficialis; cart, cartilage; cl, cleithrum; clav, clavicle; pec-ra, pectoral rays; PR-PEC, protractor pectoralis; sca, scapula; scl, supracleithrum.

of the adductor and of the abductor of the fins sensu this volume (see, e.g., in Fig. 8.14 the seemingly poor differentiation between Millot and Anthony's 'supinators' 1 and 2). As in extant dipnoans (see, e.g., Figs. 8.15, 8.16), these adductor and abductor bundles of *Latimeria* may eventually resemble certain tetrapod pectoral and forelimb muscles, but are not as distinct and as functionally independent as are these latter muscles (e.g., Romer 1924; see Chapter 9). This view is indirectly supported by the results of the cladistic analysis of Diogo (2007), which strongly support that tetrapods are more closely related to dipnoans than to actinistians (see Fig. 4.1). Thus, according to these results it would seem rather unsound that *Latimeria* may effectively exhibit several distinct muscles like those found in extant tetrapods, since this would imply (1) that such muscles were independently acquired twice in evolution or (2) that such muscles were acquired only once and were present in the last common ancestor of actinistians, dipnoans and tetrapods, but were secondarily lost within the Dipnoi (see Fig. 4.1). An apparently more plausible scenario would be to consider that in this last common ancestor of actinistians, dipnoans and tetrapods the abductor and the adductor of the fins were eventually already differentiated in certain subdivisions, but that these subdivisions, as well as other subdivisions acquired later in evolution, only became well-separated, independent muscles during the subsequent evolutionary transitions leading to the origin of tetrapods. However, only a detailed, updated analysis of the pectoral muscles of *Latimeria* may clarify whether the members of this genus exhibit (as suggested by Millot and Anthony 1958) or do not exhibit (as suggested here) well-differentiated pectoral/pectoral fin muscles other than the abductor and the adductor of the fin.

General Remarks

From a similar plesiomorphic overall configuration (i.e., the presence of only two muscles, the abductor and the adductor of the fin), the evolution of the pectoral and pectoral fin/forelimb musculature has been rather different within the actinopterygian and the sarcopterygian clades. Within the Actinopterygii, different arrector muscles were acquired at different evolutionary stages: an arrector dorsalis is present only in extant neopterygians, an arrector ventralis is present only in extant teleosts, and an arrector 3 is present only in extant clupeocephalans. These three arrector muscles, together with the adductor and the abductor, for example, are present in one of the model organisms that is most studied among actinopterygians as well as among osteichthyan fishes in general, the zebrafish *Danio rerio* (Table 8.1). As explained above, apart from these five muscles, other pectoral/pectoral fin muscles may eventually be found in some derived actinopterygians, e.g., in certain neoteleosts. Within sarcopterygians, the

most significant evolutionary transformations concerning the appendicular musculature occurred in the transitions that had led to the origin of the tetrapods: the configuration of the pectoral and forelimb musculature of all living tetrapods is markedly different from the pectoral/pectoral fin musculature found in living sarcopterygian fishes (see Chapters 9 and 10).

As a result of the different evolutionary routes followed within the actinopterygian and the sarcopterygian clades, none of the individual muscles found, for example, in derived actinopterygians such as teleosts is found in derived sarcopterygians such as tetrapods (see Table 8.1 and Chapters 9 and 10). Thus, concerning the pectoral and pectoral fin/forelimb musculature, much caution should be observed when, for instance, one takes a model actinopterygian organism such as the teleostean zebrafish to be representative of osteichthyan (bony) fishes as a whole or to be representative of the plesiomorphic condition found in these fishes, as is unfortunately done in some recent developmental and molecular studies (see also Chapter 11). Also, much caution should be taken when the results obtained in developmental and molecular studies concerning the pectoral and pectoral fin muscles of a model actinopterygian such as the zebrafish are compared with those concerning the pectoral and forelimb muscles of model tetrapods such as salamanders, chickens or rats. A proper knowledge of the osteichthyan pectoral musculature is thus important not only to increase our general understanding of the comparative anatomy, functional morphology, and evolution of this group, but also to provide a solid basis for the comparisons and extrapolations made in such developmental and molecular studies. It is hoped that the information provided in this chapter will contribute to a better knowledge of the pectoral and forelimb muscles of actinopterygian and sarcopterygian fishes, as well as help pave the way for future comparative, functional, evolutionary, molecular and/or developmental works concerning this group and the vertebrates as a whole.

Chapter 9

From Sarcopterygian Fish to Modern Humans—Pectoral and Forelimb Muscles

Chapter 8 mainly focused on actinopterygian and sarcopterygian fishes. The present chapter focuses mainly on the Sarcopterygii as a whole (including extant actinistians, dipnoans and tetrapods) and particularly on the way in which the pectoral and pectoral fin/forelimb muscles have evolved during the transitions from sarcopterygian fish and non-mammalian tetrapods to monotreme and therian mammals and to modern humans (Fig. 9.1).

Several studies have provided information on the pectoral and/or forelimb musculature of sarcopterygians, but most of these focused on a single taxon (Diogo and Abdala 2007; Diogo 2007; Diogo et al. 2009a). The few comparative analyses that were actually based on a direct dissection of members of taxa as diverse as, e.g., sarcopterygian fish, amphibians, reptiles, monotremes and therian mammals, including humans, were published decades ago by Humphry (1872ab), Brooks (1886–1889), Ribbing (1907), Romer (1922–1944), Howell (1933–1937), Haines (1939–1958), and Straus (1942), among others. Thus, these authors did not have access to the information that is now available concerning the development of the pectoral and forelimb muscles of taxa such as marsupials, chickens, and humans (e.g., Cheng 1955; Cihak 1972; Shellswell and Wolpert 1977), the essential role of neural crest cells in the development and patterning of not only the axial but also the appendicular muscles in vertebrates (e.g., McGonnell 2001; Thorsen and Hale 2005), or the molecular and other evidence that has accrued about the phylogenetic relationships of some groups. Moreover, although the authors mentioned above did compare a wide range of sarcopterygian taxa, the results of their comparisons

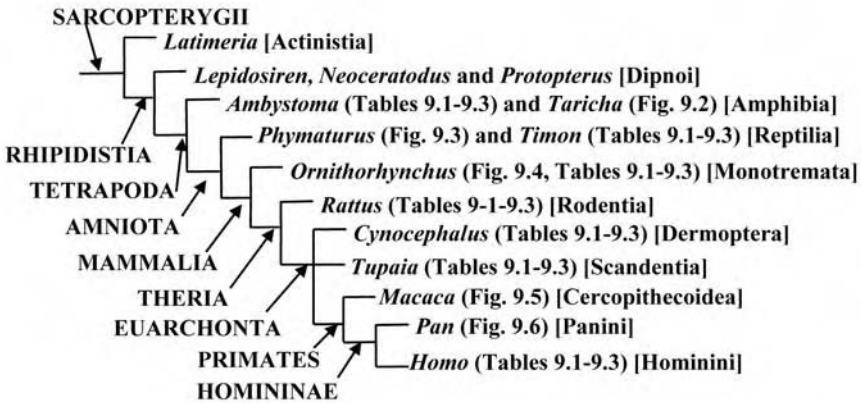

Fig. 9.1 Phylogenetic framework for the discussion provided in the present paper and the comparison between the head and neck muscles of the genera listed in Tables 9.1–9.3 and shown in Figs. 9.2–9.6, based on Shoshani et al. (1996), Kardong (2002), Sargis (2002ab, 2004), Dawkins (2004), Kemp (2005), Marivaux et al. (2006), Diogo (2007), Janecka et al. (2007), and Silcox et al. (2007) (see Chapters 1 and 2).

were usually published in papers that were mainly focused on a regionally localized group of muscles (e.g., forearm extensors, Haines 1939; forearm flexors, Straus 1942; Haines 1950; muscles of pectoral girdle and arm, Howell 1935, 1936a, 1937a; Romer 1924, 1944; muscles of forearm and hand, Howell 1936b, 1937d), or on a specific subgroup of sarcopterygians (e.g., amphibians, Howell 1935; reptiles, Howell 1936; monotremes, Howell 1937acd).

For the present chapter, we dissected the pectoral and forelimb muscles of representative members of groups as diverse as sarcopterygian fish, amphibians, reptiles, monotremes and therian mammals, including modern humans, compared our data with the information available in the literature, and then collated and synthesized all of the new and existing data in Tables 9.1–9.3. Importantly, Table 9.1 includes comments about the development and muscular variations/abnormalities of our own species, *Homo sapiens*, which are presented mainly, but not exclusively, in the right column of the table.

Pectoral Muscles Derived from Postcranial Axial Musculature (Tables 9.1–9.2)

As explained in Chapters 3 and 8, the plesiomorphic condition for gnathostomes, for osteichthyans, and very likely also for sarcopterygians is that in which there are only two distinct pectoral muscles associated with the movements of the pectoral fins, one abductor and one adductor. This

condition is found in extant dipnoans and is also likely present in extant actinistians (see Chapter 8). However, contrary to the configuration found in actinopterygians and in non-osteichthyan gnathostomes such as living chondrichthyans, in sarcopterygian fish these two muscles extend far into the pectoral fin, thus giving to this fin its characteristic 'lobed' or 'fleshy' appearance (e.g., Bischoff 1840; Owen 1841; Romer 1924; Howell 1933b; Millot and Anthony 1958; Jessen 1972; Kardong 2002; Diogo 2007; Diogo and Abdala 2007). The majority of the pectoral and forelimb muscles of tetrapods derives from the adductor and abductor muscles of basal sarcopterygians. However, a few of these muscles derive instead from the postcranial axial (epaxial and hypaxial) musculature, which is mainly undivided in sarcopterygian fish, but it is highly specialized in tetrapods (e.g., Jouffroy 1971). As explained in Chapter 2, the appendicular musculature of the pectoral girdle, arm, forearm and hand that derives from the adductor and abductor muscles (see Tables 9.2, 9.3) essentially corresponds to the 'abaxial musculature' sensu Shearman and Burke (2009) and other authors, while the axial pectoral girdle musculature (see Table 9.2) that is derived from the postcranial axial musculature, as well as most of the remaining epaxial and hypaxial muscles of the body (with the exception of, e.g., the muscles of the pectoral girdle and of the hind limb), correspond to the 'primaxial musculature' sensu these authors. As they explain, the muscles of the vertebrate body are classically described as epaxial or hypaxial according to the innervation from either the dorsal or ventral rami of the spinal nerves, respectively, while the terms 'abaxial musculature' and 'primaxial musculature' reflect embryonic criteria that are used to distinguish domains relative to embryonic patterning. The 'primaxial' domain comprises somitic cells that develop within somite-derived connective tissue, and the 'abaxial' domain includes muscle and bone that originates from somites but then mixes with, and develops within, lateral plate-derived connective tissue. Interestingly, recent developmental and molecular studies have shown that most of the cells contributing to the latissimus dorsi (which clearly seems to have derived, in evolution, from the adductor/abductor of the pectoral fin of sarcopterygian fish and should, therefore, at least in theory, be considered an appendicular muscle and, thus, an 'abaxial' muscle sensu Shearman and Burke 2009: see Table 9.2 and below), as well as to the trapezius (which, in the present work, is considered to be a branchial muscle of the head and neck musculature: see Chapters 3–7), of mice are primaxial, and that only a small part of these cells are actually abaxial (e.g., Shearman and Burke 2009). According to Shearman and Burke (2009: 609–610), this might indicate that "primitively these muscles were entirely primaxial and associated with the axial musculoskeletal system; during the expansion of the lateral plate and the evolution of the appendicular system, the lateral plate may

Table 9.1 Pectoral and forelimb muscles of adults of representative tetrapod taxa. The nomenclature of the muscles shown in bold follows that of the text; in order to facilitate comparisons, in some cases names often used by other authors to designate a certain muscle/bundle are given in front of that muscle/bundle, in paretheses; additional comments are given in square brackets. Data compiled from evidence provided by our own dissections and comparisons and by an overview of the literature (see text, Tables 9.2 and 9.3, and Figs. 9.1–9.6).

Amphibia (Caudata): *Ambystoma ordinarium* (Michoacan stream salamander)	Reptilia (Lepidosauria): *Timon lepidus* (Ocellated 'lizard')	Mammalia (Monotremata): *Ornithorhynchus anatinus* (Platypus)	Mammalia (Rodentia): *Rattus norvegicus* (Norwegian rat)	Mammalia (Dermoptera): *Cynocephalus volans* (Philippine colugo)	Mammalia (Scandentia): *Tupaia* sp. (Tree-shrew)	Mammalia (Primates): *Homo sapiens* (Human)
Serratus anterior (part of serrati sensu Howell 1937b)	**Serratus anterior** (serratus ventralis sensu Kardong and Zalisko 1998, and Kardong 2002)	**Serratus anterior** (serrati scapulae sensu Howell 1937a)	**Serratus anterior** (serratus magnus sensu Greene 1935, and cervical part of serratus ventralis sensu Walker and Homberger 1998)	**Serratus anterior** (serratus anticus major sensu Leche 1886)	**Serratus anterior** (serratus anticus sensu Le Gros Clark 1926; ventral portion of serratus anticus and of serratus magnus sensu Le Gros Clark 1924, and George 1977)	**Serratus anterior**
— [but see text and Chapter 10]	— [but see text and Chapter 10]	**Rhomboideus** [as noted by Howell 1937a, there is a single rhomboideus muscle in monotremes; our dissections indicate that this muscle is poorly differentiated into dorsal and ventral portions, the former being somewhat posterior to the latter; Jouffroy and Lessertisseur	**Rhomboideus major** (rhomboideus thoracis sensu Walker and Homberger 1998; rhomboideus posticus sensu Peterka 1936) [posterior and somewhat dorsal to rhomboideus minor]	**Rhomboideus** [as described by Macalister 1872, the rhomboideus is undivided; it seems to correspond to the rhomboideus minor + major of humans, because none of its fibers	**Rhomboideus major** (part of rhomboideus cervicus sensu Le Gros Clark 1924, 1926, and George 1977)	**Rhomboideus major**

		1971 use the terms rhomboideus cervicus and capitis to designate these bundles, but their configurations are in fact more similar to those of the rhomboideus major and minor of, e.g., humans]		extends anteriorly to the anterior margin of the medial side of the scapula: see fig. 8 of Leche 1886]		
—	—	— [see above]	**Rhomboideus minor** (rhomboideus cervicus sensu Walker and Homberger 1998; rhomboideus anticus sensu Peterka 1936)	— [see above]	**Rhomboideus major** (part of rhomboideus cervicus sensu Le Gros Clark 1924, 1926, and George 1977)	**Rhomboideus minor**
—	—	— [see above]	**Rhomboideus occipitalis** (occipitosc-apularis plus levator scapulae dorsalis sensu Greene 1935)	—	**Rhomboideus occipitalis** (rhomboideus capitis sensu Le Gros Clark 1924, 1926, and George 1977)	— [found in various primates and occasionally in humans, being the rhombo-atlantoid sensu Wood 1867ab, 1870; see also Aziz 1981)
Levator scapulae	**Levator scapulae**	**Levator scapulae** (levator scapulae dorsalis sensu Howell 1937ab, and Jouffroy and Lessertisseur 1971) [as described	**Levator scapulae** (levator anguli scapulae sensu Greene 1935)	**Levator scapulae** [in *Tupaia* and *Cynocephalus* this muscle is deeply	**Levator scapulae** (levator anguli scapulae sensu Le Gros Clark 1926; dorsal part of serratus anticus	**Levator scapulae**

Table 9.1 contd...

Table 9.1 contd...

Amphibia (Caudata): *Ambystoma ordinarium* (Michoacan stream salamander)	Reptilia (Lepidosauria): *Timon lepidus* (Ocellated 'lizard')	Mammalia (Monotremata): *Ornithorhynchus anatinus* (Platypus)	Mammalia (Rodentia): *Rattus norvegicus* (Norwegian rat)	Mammalia (Dermoptera): *Cynocephalus volans* (Philippine colugo)	Mammalia (Scandentia): *Tupaia* sp. (Tree-shrew)	Mammalia (Primates): *Homo sapiens* (Human)
		by Jouffroy and Lessertisseur 1971, the levator scapulae and the levator claviculae are somewhat mixed in the Platypus, thus supporting the idea that these muscles derive from the same structure, which seems to be an anterior (cranial) part of the serratus anterior; in fact, Jouffroy and Lessertisseur 1971 explain that the innervation of the levator claviculae is similar to that of the rhomboideus while that of the levator scapulae is similar to that of the serratus anterior, but that there is still more evidence supporting that the levator claviculae derives from the levator scapulae, and not from the rhomboideus]		mixed with the serratus anterior]	sensu Le Gros Clark 1924, and of serratus magnus sensu George 1977)	

—	— [fig. 56A of Jouffroy 1971, shows a levator scapulae ventralis (= levator claviculae) in *Iguana*; however, most descriptions of this taxon indicate that it does not have an independent, distinct levator claviculae as found in the vast majority of mammals: see, e.g., Howell 1935, 1937b, and also Chapter 10]	**Levator claviculae** (atlantoscapularis inferior, omotrachelien, omoatlantic, atlanto-acromialis, cervico-humeralis, trachelo-acromial, acromio-atlantal, occipito-acromial and levator scapulae ventralis sensu Howell 1937b and Jouffroy and Lessertisseur 1971) [our dissections of *Ornithorhynchus* support the descriptions of Jouffroy and Lessertisseur 1971: the levator scapulae and the levator claviculae are somewhat mixed in this taxon; this seems to indicate that the levator claviculae does not derive from part of the rhomboideus, as suggested by Cheng's 1955 developmental study of *Didelphis*, but instead from the levator scapulae, as defended by most anatomists:	**Levator claviculae** (levator scapulae ventralis sensu Greene 1935; omotransversalis sensu Walker and Homberger 1998)	**Levator claviculae** (omocervicalis sensu Gunnell and Simmons 2005)	**Atlantoscapularis anticus** (levator scapulae sensu Le Gros Clark 1924; levator scapulae anticus sensu Le Gros Clark 1926; atlantoscapularis ventralis sensu George 1977)	— [found in various primates and occasionally in humans, see Wood 1970]

Table 9.1 contd...

Table 9.1 contd...

Amphibia (Caudata): *Ambystoma ordinarium* (Michoacan stream salamander)	Reptilia (Lepidosauria): *Timon lepidus* (Ocellated 'lizard')	Mammalia (Monotremata): *Ornithorhynchus anatinus* (Platypus)	Mammalia (Rodentia): *Rattus norvegicus* (Norwegian rat)	Mammalia (Dermoptera): *Cynocephalus volans* (Philippine colugo)	Mammalia (Scandentia): *Tupaia* sp. (Tree-shrew)	Mammalia (Primates): *Homo sapiens* (Human)
		see, e.g., Howell 1937ab, Jouffroy and Lessertisseur 1971, and Jouffroy 1971; further studies are, however, needed to clarify this issue]				
—	—	**---** [absent in extant monotremes, but found in several marsupial and placental mammals, including many primates: see Jouffroy 1971 and Warburton 2003]	— [see on the left]	**---** [see on the left]	**Atlantoscapularis posticus** (part of rhomboideus capitis sensu Le Gros Clark 1924; levator scapulae posticus sensu Le Gros Clark 1926; atlantoscapularis dorsalis sensu George 1977) [as suggested by Jouffroy 1971, the atlantoscapularis posticus seems to derive from the levator claviculae and not from the levator scapulae; this is supported by, e.g., the configuration found in gorillas, in which the atlantoscapularis anticus and posticus are deeply mixed: see, e.g., fig. 36 of Jouffroy 1961]	— [see on the left]

—	**Sternocoracoideus**	**Sternocoracoideus** (sensu Howell 1937ab, and Jouffroy and Lessertisseur 1971; sterno-epicoracoideus sensu Lander 1918)	**Subclavius** [there is some confusion regarding the homologies of the therian subclavius; Jouffroy and Lessertisseur 1971 suggest that it possibly corresponds to both the sternocor-acoideus and costocora-coideus of non-therian tetrapods such as *Ornithorhynchus*; as the therian subclavius may originate on the sternum, the ribs, or both, and may insert on the clavicle, the scapula, or both, one may accept that it eventually corresponds to both the sternocor-acoideus and costocora-coideus; however, the fact that humans have	**Subclavius**	**Subclavius**	**Subclavius**

Table 9.1 contd...

Table 9.1 contd...

Amphibia (Caudata): *Ambystoma ordinarium* (Michoacan stream salamander)	Reptilia (Lepidosauria): *Timon lepidus* (Ocellated 'lizard')	Mammalia (Monotremata): *Ornithorhynchus anatinus* (Platypus)	Mammalia (Rodentia): *Rattus norvegicus* (Norwegian rat)	Mammalia (Dermoptera): *Cynocephalus volans* (Philippine colugo)	Mammalia (Scandentia): *Tupaia* sp. (Tree-shrew)	Mammalia (Primates): *Homo sapiens* (Human)
			a subclavius and a costocoracoid ligament, together with the fact that the configuration of the latter is somewhat similar to that of the muscle costocoracoideus of non-therian tetrapods, could indicate that the subclavius corresponds exclusively to the sternocoracoideus of these latter tetrapods; Cheng's 1955 developmental study supports the idea that the 'costoscapularis' (which seemingly corresponds to the costocoracoideus sensu this volume) and the subclavius derive from the same anlage]			

—	**Costoscoracoideus**	**Costoscoracoideus**	— [seems to be absent in the rat specimens dissected by us: see above; however, Wood 1870, p. 108, states that the Norwegian rat has a 'sternoscapular' muscle: does this muscle correspond to the 'costoscapularis' (which, as explained above, seemingly corresponds to the costocoracoideus sensu this volume)?]	—	—	— (corresponds to the costocoracoid ligament of most humans? See above) [might be eventually present as an anomaly in humans, if it is eventually homologous with part or all of the 'sternoclavicularis', 'sternocostalis', 'scapuloclavicularis' and/or 'sternoscapularis' of Wood 1870, although it might well not correspond to part or the totality of any of these muscles; the observation of the human specimen shown in Huntington's 1904 plate 8, which has both a 'sterno-clavicularis' and a 'sternoscapularis', clearly seems to indicate that the 'sternoclavicularis', often running from the sternum and/or first rib to the clavicle, corresponds to the subclavius and thus to the

Table 9.1 contd...

Table 9.1 contd...

Amphibia (Caudata): *Ambystoma ordinarium* (Michoacan stream salamander)	Reptilia (Lepidosauria): *Timon lepidus* (Ocellated 'lizard')	Mammalia (Monotremata): *Ornithorhynchus anatinus* (Platypus)	Mammalia (Rodentia): *Rattus norvegicus* (Norwegian rat)	Mammalia (Dermoptera): *Cynocephalus volans* (Philippine colugo)	Mammalia (Scandentia): *Tupaia* sp. (Tree-shrew)	Mammalia (Primates): *Homo sapiens* (Human)
						sternocoracoideus of monotremes, and that the 'sternoscapularis', often running from the first and/ or second ribs to the scapula, corresponds to the costocoracoideus of monotremes]
Pectoralis	**Pectoralis**	**Pectoralis major** (anterior portion of pectoralis sensu Jouffroy and Lessertisseur 1971) [the pectoralis major of monotremes is not subdivided into clavicular, sternocostal and abdominal heads: see text]	**Pectoralis major** (ectopectoralis sensu Lander 1918) [our dissections indicate that it is divided into three heads, and not two as stated by Greene 1935: these three heads clearly correspond to the clavicular, sternocostal and abdominal heads of the pectoralis major of humans; contrary to the descriptions of	**Pectoralis major** (ectopectoralis sensu Lander 1918) [this author describes a single head of the pectoralis major in colugos, while Leche 1886, describes two; our dissections indicate that it is divided into clavicular, sternocostal and abdominal heads]	**Pectoralis major** (ectopectoralis sensu Lander 1918) [the sternocostal and abdominal heads are present as independent structures, but as noted by Jouffroy 1971, the clavicular head is seemingly fused with the deltoideus clavicularis]	**Pectoralis major** [divided into clavicular, sternocostal and abdominal heads; it should be noted that about 3-5% of humans have a muscle sternalis, which should not be confused with the 'sternocostalis' or 'supracostalis' muscles, because these two latter muscles are deep (dorsal) to the pectoralis, while

			Greene 1935, in the rats dissected by us the pectoralis major did originate from the clavicle; the figures of Greene 1935 and Walker and Homberger 1997 suggest that the pectoralis major contacts its counterpart at the midline]			the 'true' sternalis sensu Jouffroy 1971 is completely superficial (ventral) to the pectoralis; Jouffroy 1971 states that some of the structures that are often named 'supracostalis' in the literature may derive from the rectus thoracis, others from the scaleni, and still others from the external oblique of the thoracic region, but not from the pectoralis, thus contradicting Lander's 1918 hypothesis; Parsons 1898, Huntington 1904 and Jouffroy 1971 suggest that the 'true' sternalis probably derives from the pectoralis, and specifically from the pectoralis major, because it is superficial (ventral) to this latter structure and it is usually innervated

Table 9.1 contd...

Table 9.1 contd...

Amphibia (Caudata): *Ambystoma ordinarium* (Michoacan stream salamander)	Reptilia (Lepidosauria): *Timon lepidus* (Ocellated 'lizard')	Mammalia (Monotremata): *Ornithorhynchus anatinus* (Platypus)	Mammalia (Rodentia): *Rattus norvegicus* (Norwegian rat)	Mammalia (Dermoptera): *Cynocephalus volans* (Philippine colugo)	Mammalia (Scandentia): *Tupaia* sp. (Tree-shrew)	Mammalia (Primates): *Homo sapiens* (Human)
						by nerves of the brachial plexus, and namely by 'pectoral nerves', according to Huntington 1904]
—	—	**Pectoralis minor** (posterior portion of pectoralis sensu Jouffroy and Lessertisseur 1971) [our dissections indicate that, as suggested by Jouffroy and Lessertisseur 1971, the pectoralis of *Ornithorhynchus* is differentiated into an anterior, ventral portion, i.e., the pectoralis major, and a posterior, dorsal portion, i.e., the pectoralis minor]	**Pectoralis minor** (entopectoralis sensu Lander 1918) [as described by Greene 1935, it is divided into three sections corresponding to the cephalic part of the entopectoralis (= 'pectoralis minor), the caudal part of the entopectoralis (= 'pectoralis abdominalis') and the xiphihumeralis (= 'pectoralis tertius') sensu Lander 1918]	**Pectoralis minor** (entopectoralis sensu Lander 1918) [as described by this author and by Leche 1886, it includes a single section]	**Pectoralis minor** (entopectoralis sensu Lander 1918) [divided into two heads corresponding to the pectoralis minor and abdomino-humeralis sensu Le Gros Clark 1924, 1926, to the pectoralis minor and the pectoralis abdominalis sensu George 1977, and to the pectoralis minor and the pars abdominalis of the pectoralis sensu Kladetzky and Kobold 1966]	**Pectoralis minor** [includes a single section]

— [as noted by Jollie 1962 and other authors, the panniculus carnosus is not present as a distinct muscle in amphibians and reptiles]	— [see on the left]	**Panniculus carnosus (part?)** [some authors consider that the panniculus carnosus is the muscle that gave rise to many of the facial muscles of humans, as well as to muscles such as the palmaris brevis; however, Huber 1930a, Howell 1936bc, Cheng 1955 and Jouffroy 1971 contradict this idea and defend that the panniculus carnosus is actually a muscle that is at least partially derived from the pectoralis (being often at least partially innervated by 'thoracic nerves') and that, in some mammals such as rats, extended cranially to reach the head region; Prunotto et al.'s 2004 study of Met mutants shows that the panniculus carnosus (which includes the structure that they designate as 'cutaneous maximus') is derived from	**Panniculus carnosus (part?)** (cutaneous maximus, but not platysma nor superficial and deep portions of cervical panniculus—which are hyoid muscles—sensu Greene 1935) [Greene 1935 states that the structure that he designated as 'cervical panniculus', which includes the 'tracheoplatysma' and the sternofacialis, is innervated by facial + 'superficial cervical' nerves; Jouffroy and Saban 1971 state that the sternofacialis corresponds to the 'cervical portion of the sphincter colli profundus']	**Panniculus carnosus (part?)** [dermopterans have a panniculus carnosus, which makes part of their 'flying membrane', which includes the 'ventral sheet of the propatagial complex', the 'humero-patagialis' and the 'coraco-patagialis' (these 3 structures might be considered part of the 'panniculus carnosus pectoralis', i.e., they are seemingly derived from the pectoralis), as well as other structures such as the 'plagiopatagialis dorsalis' and the 'plagiopatagialis ventralis': see Jouffroy and Saban 1971]	**Panniculus carnosus (part?)** [the pectoralis abdominalis corresponds to the 'abdomino-humeralis' sensu Le Gros Clark 1924, 1926, so only the 'dorso-humeralis' sensu this latter author is considered to be part of the panniculus carnosus by Jouffroy 1971; the panniculus carnosus of *Tupaia* is deeply blended with the pectoralis abdominalis, thus supporting the idea that at least part of the panniculus carnosus does derive from the pectoralis: see on the left]	**---** [but present in some primates and present as an anomaly in a few humans]

Table 9.1 contd...

Table 9.1 contd...

Amphibia (Caudata): *Ambystoma ordinarium* (Michoacan stream salamander)	Reptilia (Lepidosauria): *Timon lepidus* (Ocellated 'lizard')	Mammalia (Monotremata): *Ornithorhynchus anatinus* (Platypus)	Mammalia (Rodentia): *Rattus norvegicus* (Norwegian rat)	Mammalia (Dermoptera): *Cynocephalus volans* (Philippine colugo)	Mammalia (Scandentia): *Tupaia* sp. (Tree-shrew)	Mammalia (Primates): *Homo sapiens* (Human)
		'migratory hypaxial muscles' (i.e., from 'true appendicular muscles', in this case), and not from 'non-migratory' (body) hypaxial muscles]				
Supracoracoideus	**Supracoracoideus**	**Infraspinatus** (supracoracoideus sensu Jouffroy and Lessertisseur 1971; coracohumeralis intermedius sensu Howell 1937ab) [according to most authors, including Romer 1924, 1944, and Kardong 2002, the supraspinatus and infraspinatus of mammals are derived from the supracoracoideus of reptiles and amphibians; it is thus interesting to note that in non-mammalian tetrapods the supracoracoideus	**Infraspinatus** [Warburton 2003 states that marsupials such as *Didelphis* have a muscle cleidoacromialis, which is not homologous with the subclavius but is, instead, a 'true' appendicular muscle derived from the supracoracoideus; this muscle seems to be often absent in placentals, including rats, although Wood 1870 stated that rats have	**Infraspinatus**	**Infraspinatus**	**Infraspinatus** [see cells on the left]

		is a ventral, and not a dorsal, muscle, which is often related with the adduction of the humerus, a function that is the opposite of the function that is often carried out by the supraspinatus of mammalian taxa such as humans]	a 'scapulo-clavicularis', which might correspond to the cleidoacromialis sensu Warburton 2003; Wood 1870 also stated that a few humans may have a 'scapulo-clavicularis']			
—	—	**Supraspinatus** (suprascapularis sensu Jouffroy and Lessertisseur 1971; coracohumeralis profundus sensu Howell 1937ab) [the infraspinatus and supraspinatus are derived from the supracoracoideus; as in a few reptiles such as chameleons the supracoracoideus occupies a more dorsal position than it usually does in non-mammalian tetrapods, some authors consider that it is transformed into an infraspinatus and a supraspinatus as in mammals (these two muscles	**Supraspinatus**	**Supraspinatus**	**Supraspinatus**	**Supraspinatus**

Table 9.1 contd...

Table 9.1 contd...

Amphibia (Caudata): *Ambystoma ordinarium* (Michoacan stream salamander)	Reptilia (Lepidosauria): *Timon lepidus* (Ocellated 'lizard')	Mammalia (Monotremata): *Ornithorhynchus anatinus* (Platypus)	Mammalia (Rodentia): *Rattus norvegicus* (Norwegian rat)	Mammalia (Dermoptera): *Cynocephalus volans* (Philippine colugo)	Mammalia (Scandentia): *Tupaia* sp. (Tree-shrew)	Mammalia (Primates): *Homo sapiens* (Human)
		are usually dorsal to the pectoral girdle in mammals), but this is not accepted by, e.g., Jouffroy and Lessertisseur 1971; see infraspinatus above]				
Deltoideus scapularis [the deltoideus scapularis sensu Jouffroy 1971 corresponds to the dorsalis scapulae sensu Howell 1937b, Romer 1944, Walthall and Ashley-Ross 2006, Diogo and Abdala 2007, and Diogo 2007]	**Deltoideus scapularis** (dorsalis scapulae sensu Diogo and Abdala 2007, and Diogo 2007)	**Deltoideus scapularis** (scapulodeltoideus sensu Jollie 1962)	**Deltoideus scapularis** [Greene 1935 describes only an acromiodeltoid and a spinodeltoid in *Rattus*; in the rats dissected by us there are three distinct deltoid muscles: a deltoideus scapularis, a deltoideus acromialis, and a deltoideus clavicularis; this is also supported by, e.g., Peterka 1936]	**Deltoideus scapularis**	**Deltoideus scapularis** (teres minor sensu Le Gros Clark 1924, 1926)	**Deltoideus, part** [scapular portion of deltoideus; as noted by, e.g., Parsons 1898 and Jouffroy 1971, humans, various other primates and a few other mammals have a single deltoideus, which corresponds to the deltoideus scapularis + deltoideus clavicularis + deltoideus acromialis of most mammals]

Procoracohumeralis [according to Romer 1944, the procoracohumeralis longus of urodeles corresponds to the deltoideus clavicularis + humeroradialis of reptiles (see Fig. 10.13) and to the deltoideus clavicularis + deltoideus acromialis of mammals; according to him the procoracohumeralis brevis of urodeles corresponds to the scapulo-humeralis anterior of reptiles and to the teres minor of mammals; however, this latter muscle seems instead to correspond to part of the deltoideus scapularis on non-mammalian tetrapods, the scapulo-humeralis anterior being absent in extant mammals: see scapulo-humeralis anterior below and also Chapter 10]	**Deltoideus clavicularis** (procoracohumeralis sensu Diogo and Abdala, 2007, and Diogo 2007) [in this case using the name deltoideus clavicularis, which is used by most authors working with amniotes, is justified because this muscle does not correspond directly to the procoracohumeralis of *Ambystoma*: it corresponds only to part of it, the other part corresponding to the scapulo-humeralis anterior of *Timon*: see on the left and also Chapter 10]	**Deltoideus clavicularis** (epicoracohumeralis sensu Lander 1918; deltoideus clavicularis + coracohumeralis superficialis sensu Howell 1937a) [our dissections clearly suggest that as proposed by Jouffroy and Lessertisseur 1971, the deltoideus clavicularis of *Ornithorhynchus* corresponds to the deltoideus clavicularis + coracohumeralis superficialis sensu Howell 1937a; this latter author stated that the coracohumeralis superficialis corresponds to part of the pectoralis of other mammals, but in the *Ornithorhynchus* dissected by us it clearly corresponds to the deltoideus clavicularis of other mammals, which is effectively often mixed with, but not part of, the pectoralis]	**Deltoideus clavicularis** (part of acromiod-eltoideus sensu Greene 1935, and part or all of cleidobrachialis sensu Walker and Homberger 1998)	**Deltoideus clavicularis**	**Deltoideus clavicularis** [fused with clavicular head of pectoralis major]	**Deltoideus, part** [clavicular head of deltoideus]

Table 9.1 contd...

Table 9.1 contd...

Amphibia (Caudata): *Ambystoma ordinarium* (Michoacan stream salamander)	Reptilia (Lepidosauria): *Timon lepidus* (Ocellated 'lizard')	Mammalia (Monotremata): *Ornithorhynchus anatinus* (Platypus)	Mammalia (Rodentia): *Rattus norvegicus* (Norwegian rat)	Mammalia (Dermoptera): *Cynocephalus volans* (Philippine colugo)	Mammalia (Scandentia): *Tupaia* sp. (Tree-shrew)	Mammalia (Primates): *Homo sapiens* (Human)
—	—	—	**Deltoideus acromialis** [as stated by Jouffroy and Lessertisseur 1971 and Jouffroy 1971, the deltoideus acromialis of eutherian mammals corresponds to part of the deltoideus clavicularis of monotremes]	**Deltoideus acromialis**	**Deltoideus acromialis**	**Deltoideus, part** [acromial portion of the deltoideus]
—	— [but see Chapter 10]	**Teres minor** [seemingly corresponds to part of the deltoideus scapularis of non-mammalian tetrapods, being possibly directly homologous to the reptilian scapulo-humeralis posterior: see cell on the left; as explained by Jouffroy 1971, the supposed homology between the mammalian	**Teres minor**	**Teres minor**	**---** [as noted by Kladetsky and Kobold 1966 and George 1977, in *Tupaia* the teres minor might eventually be present as an independent muscle, but in the vast majority of cases it is completely fused to the infraspinatus and/or possibly with the deltoideus scapularis]	**Teres minor**

		teres minor and the scapulo-humeralis anterior proposed by, e.g., Romer 1944 and Cheng 1955, has two main problems: (1) both the scapulo-humeralis anterior and teres minor are present in monotremes; (2) in reptiles such as 'lizards' the nerve innervating the scapulo-humeralis anterior is related with the radial nerve, and not with the axillary nerve, which is the nerve that usually innervates the teres minor in mammals (and the deltoideus scapularis in mammals and in reptiles)]				
— [see cell on the right]	**Scapulo-humeralis anterior** (proscapulo-humeralis brevis sensu Romer 1924, 1944) [the scapulo-humeralis anterior of *Timon* seemingly corresponds to part of the procoracohumeralis of *Ambystoma*: see above]	**Scapulo-humeralis anterior** (proscapulo-humeralis sensu Howell 1937ab and Jouffroy and Lessertisseur 1971)	— [the scapulo-humeralis anterior seems to be absent as an independent muscle in extant placental mammals: see above]	—	—	—

Table 9.1 contd...

Table 9.1 contd...

Amphibia (Caudata): *Ambystoma ordinarium* (Michoacan stream salamander)	Reptilia (Lepidosauria): *Timon lepidus* (Ocellated 'lizard')	Mammalia (Monotremata): *Ornithorhynchus anatinus* (Platypus)	Mammalia (Rodentia): *Rattus norvegicus* (Norwegian rat)	Mammalia (Dermoptera): *Cynocephalus volans* (Philippine colugo)	Mammalia (Scandentia): *Tupaia* sp. (Tree-shrew)	Mammalia (Primates): *Homo sapiens* (Human)
Subcoracoscapularis [see Chapter 10]	**Subcoracoscapularis**	**Subscapularis** [although some non-mammalian tetrapods do have both a subcoraco-scapularis and a muscle 'teres major' that is probably homologous to the mammalian teres major, their muscle subcoraco-scapularis is often divided into a 'subscapularis' head and a 'subcoracoideus' head; therefore, we prefer to keep the term subscapularis for mammals, instead of using the term subcoracoscapularis, because the mammalian subscapularis might well correspond only to the 'subscapularis' head, and not to both this head and the 'subcoracoideus' head, of the non-mammalian subcoraco-scapularis	**Subscapularis**	**Subsc-apularis** [the configuration of the teres major and of the subscapularis in colugos clearly indicates that these muscles are derived from the same anlage, because they are deeply blended at their origins on the scapula]	**Subscapularis**	**Subscapularis**

		of non-mammalian tetrapods: see Chapter 10]				
— [but see Chapter 10]	**---** [but see Chapter 10]	**Teres major** [see text]	**Teres major**	**Teres major**	**Teres major** [one of the proximal heads (medial) of the dorsoepitr-ochlearis is associated with the teres major while the other (lateral) is associated with the latissimus dorsi]	**Teres major**
Latissimus dorsi	**Latissimus dorsi**	**Latissimus dorsi**	**Latissimus dorsi**	**Latissimus dorsi**	**Latissimus dorsi** (latissimus dorsi + spinohumeralis sensu Le Gros Clark 1924)	**Latissimus dorsi**
Triceps brachii [includes coracoideus, scapularis medialis, humeralis lateralis and humeralis medialis sections, which correspond respectively to the 'anconeus coracoideus', 'anconeus scapularis medialis', 'anconeus humeralis lateralis' and 'anconeus humeralis medialis' sensu Walthall and Ashley-Ross 2006, Diogo and Abdala 2007, and Diogo 2007: see Chapter 10]	**Triceps brachii** [see on the left]	**Triceps brachii** [as in the other mammals included in this table, it includes long, lateral and medial heads, which seem to correspond respectively to the 'anconeus scapularis medialis', 'anconeus humeralis lateralis' and 'anconeus humeralis medialis' of non-mammalian tetrapods: see on the left]	**Triceps brachii** [see cells on the left]	**Triceps brachii** (the 'anconeus longus, externus and internus' sensu Leche 1886 correspond respectively to the long, lateral and medial heads of the triceps brachii sensu this volume) [see on the left]	**Triceps brachii** [see cells on the left]	**Triceps brachii** [see cells on the left; the triceps brachii sensu this volume includes the 'articularis cubiti', which is listed in Terminologia Anatomica 1998 as a distinct muscle, but which is clearly part of the triceps brachii, being a small bundle that connects the main body of the triceps brachii to the posterior capsule of the elbow joint, and

Table 9.1 contd...

Table 9.1 contd...

Amphibia (Caudata): *Ambystoma ordinarium* (Michoacan stream salamander)	Reptilia (Lepidosauria): *Timon lepidus* (Ocellated 'lizard')	Mammalia (Monotremata): *Ornithorhynchus anatinus* (Platypus)	Mammalia (Rodentia): *Rattus norvegicus* (Norwegian rat)	Mammalia (Dermoptera): *Cynocephalus volans* (Philippine colugo)	Mammalia (Scandentia): *Tupaia* sp. (Tree-shrew)	Mammalia (Primates): *Homo sapiens* (Human)
						that is often related with the lifting of the capsule away from the joint]
— [but see text and Table 10.1]	**---** [but see text and Table 10.1]	**Dorsoepitrochlearis** (dermo-flexor antebrachii or dorso-antebrachialis sensu Jouffroy and Lessertisseur 1971) [see text; further lines of evidence that support the idea that the dorsoepitrochlearis effectively derives from the triceps brachii are that (1) plesiomorphically in therian mammals the dorsoepitrochlearis often inserts on the olecranon process of the ulna, as usually does the triceps brachii, and (2) in some mammals, including primates such as new world monkeys and non-human hominoids, the	**Dorsoepitr-ochlearis** (epitrochleo-anconeus, extensor antibrachii longus and extensor parvus antibrachii sensu Greene 1935) [according to Greene 1935 the dorsoepitrochlearis is innervated by the ulnar nerve, but this may be a confusion of Greene's, because at least in mammals such as primates this muscle is usually innervated by the radial nerve, and because Greene confuses (see, e.g., his list of synonyms) the	**Dorsoepitr-ochlearis** (part of dorsoepitr-ochlearis sensu Macalister 1872, which also included the dorso-brachialis sensu Leche 1886)	**Dorsoepitrochlearis**	**---** [probably corresponds to the tensor fasciae antebrachii of humans]

		dorsoepitrochlearis is often partially originated from the scapula, as the triceps brachii often is]	dorsoepitrochlearis with the epitrochleo-anconeus, which is a different muscle that is effectively usually innervated by the ulnar nerve: see epitrochleo-anconeus below]			
Humeroante-brachialis (part of biceps sensu Romer 1944, and of brachialis sensu Howell 1937b) [Howell and Straus 1932 state that the plesiomorphic condition of the biceps brachii was probably that in which only the coracoid (or short) head to the biceps was present (corresponding to the coracoradialis of amphibians such as anurans), and that the long head going to the glenoid is only present in "vertebrates higher than the reptiles", so it is possible that the plesiomorphic condition for tetrapods is to have a coracoradialis (as anurans often have), which gave	**Brachialis** (brachialis inferior sensu Diogo and Abdala 2007 and Diogo 2007) [see below]	**Brachialis** (brachialis anticus sensu Shrivastava 1962ab)	**Brachialis** (brachialis anticus sensu Greene 1935)	**Brachialis** (brachialis anticus sensu Macalister 1872; brachialis internus sensu Leche 1886)	**Brachialis** (brachialis anticus sensu Le Gros Clark 1924, 1926)	**Brachialis** (brachialis anticus and flexor brachii brevis sensu Parsons 1898)

Table 9.1 contd...

Table 9.1 contd...

Amphibia (Caudata): *Ambystoma ordinarium* (Michoacan stream salamander)	Reptilia (Lepidosauria): *Timon lepidus* (Ocellated 'lizard')	Mammalia (Monotremata): *Ornithorhynchus anatinus* (Platypus)	Mammalia (Rodentia): *Rattus norvegicus* (Norwegian rat)	Mammalia (Dermoptera): *Cynocephalus volans* (Philippine colugo)	Mammalia (Scandentia): *Tupaia* sp. (Tree-shrew)	Mammalia (Primates): *Homo sapiens* (Human)
rise to the short head of the biceps brachii, a humeroante-brachialis, which gave rise, in turn, to the brachialis and likely to the long head of the biceps brachii, and a coracobrachialis, which gave rise to the coracobrachialis; this hypothesis is also supported by the fact that, as stressed by Howell and Straus 1933, in mammals such as marsupials the long head of the biceps usually goes to the ulna (as the brachialis usually does, thus supporting that this head comes from the 'primitive' brachialis or humeroante-brachialis) and the short head of the biceps usually goes to the radius (thus supporting that this head derives from/corresponds to the 'primitive' coracoradialis); then, in mammals such as colugos and tree-shrews						

the two heads of the biceps are usually blended distally, inserting on the radius + ulna; and then, in primates, the biceps brachii usually goes only to the radius; see also Chapter 10]						
— [as noted by Romer 1944, Kardong 2002 and other authors, the long head of the biceps brachii of amniotes clearly seems to correspond to part of the humeroantebrachialis of amphibians; however, it remains unclear if the short head of the biceps brachii of amniotes corresponds to part of the humeroantebrachialis (as proposed by Jouffroy 1971), to part or all of the coracoradialis (as proposed by Romer 1944) and/or to part of the coracobrachialis of amphibians such as anurans (as proposed by Jouffroy and Lessertisseur 1971): see brachialis above and Chapter 10]	**Biceps brachii** (humeroante-brachialis sensu Diogo and Abdala 2007 and Diogo 2007; short and long heads of biceps brachii sensu Jouffroy 1971)	**Biceps brachii** [both short and long heads are present, corresponding to the coracoid and procoracoid heads sensu Jouffroy and Lessertisseur 1971]	**Biceps brachii** [both short and long heads are present]	**Biceps brachii** [both short and long heads are present]	**Biceps brachii** [both short and long heads are present]	**Biceps brachii** [both short and long heads are present]

Table 9.1 contd...

Table 9.1 contd...

Amphibia (Caudata): *Ambystoma ordinarium* (Michoacan stream salamander)	Reptilia (Lepidosauria): *Timon lepidus* (Ocellated 'lizard')	Mammalia (Monotremata): *Ornithorhynchus anatinus* (Platypus)	Mammalia (Rodentia): *Rattus norvegicus* (Norwegian rat)	Mammalia (Dermoptera): *Cynocephalus volans* (Philippine colugo)	Mammalia (Scandentia): *Tupaia* sp. (Tree-shrew)	Mammalia (Primates): *Homo sapiens* (Human)
Coracobrachialis [corresponds to the coracobrachialis longus/superficialis sensu Walthall and Ashley-Ross 2006, Diogo and Abdala 2007, and Diogo 2007; the coracobrachialis medius/proprius and coracobrachialis profundus/brevis seem to be missing in urodeles, e.g., *Taricha*, but are present in various other amphibians according to, e.g., Howell 1935 and Romer 1944; see Chapter 10]	**Coracobrachialis** [corresponds to the coracobrachialis longus sensu Diogo and Abdala 2007 and Diogo 2007; as in many other reptiles, the coracobrachialis is divided into two bundles that seem to correspond to the coracobrachialis longus/superficialis and coracobrachialis profundus/brevis sensu Parsons 1898 and George 1977: see Fig. 10.12]	**Coracobrachialis** [Parsons 1898 states that monotremes have a coracobrachialis longus/superficialis, a coracobrachialis medius/proprius and a coracobrachialis brevis/profundus; however, our dissections support the descriptions of Howell 1937b, Jollie 1962 and Jouffroy and Lessertisseur 1971: i.e., the brevis/profundus section does not seem to be present as an independent muscle in *Ornithorhynchus*]	**Coracobrachialis** [has a single section, which seemingly corresponds to the coracobr-achialis medius/proprius of other mammals]	**Coracobra-chialis** [has two sections, which seemingly correspond to the coracobr-achialis medius/proprius and coracobr-achialis brevis/profundus of other mammals]	**Coracobra-chialis** [has two sections, which seemingly correspond to the coracobrachialis medius/proprius and coracobrachialis brevis/profundus of other mammals: see, e.g., George 1977]	**Coracobrachialis** [has a single section, which seemingly correspond to the coracobrachialis medius/proprius of other mammals: see, e.g., Parsons 1898, and Jouffroy 1971]
Pronator quadratus (pronator profundus sensu Walthall and Ashley-Ross 2006, Diogo and Abdala 2007, and Diogo 2007)	**Pronator quadratus** (pronator profundus sensu Moro and Abdala 2004, Abdala and Moro 2006, Diogo and Abdala 2007, and Diogo 2007)	—	**Pronator quadratus**	**---** [Leche 1886, describes a few fibers running from the ulna to the radius in the colugos he dissected; he stated that they could correspond to a	**Pronator quadratus**	**Pronator quadratus**

				vestigial pronator quadratus; in the colugo specimens we dissected there is no well-defined, distinct pronator quadratus as found in most other mammals]		
—	**Pronator accessorius** [our dissections and comparisons support that the pronator accessorius of reptiles corresponds to part of the pronator quadratus of, e.g., *Ambystoma*, as proposed by Straus 1942 and other authors]	**---** [as noted by, e.g., Howell 1936b, Straus 1942, and Lewis 1989, the pronator accessorius is seemingly absent as an independent muscle in mammals]	—	—	—	—
Contrahentium caput longum (ulnocarpalis sensu Straus 1942 and Bunnell 1942) [Ribbing 1907 states that the contrahentium caput longum and the contrahentes digitorum may originally form a primitive, continuous unit running from the ulna to the digits;	— [see on the left; according to Diogo and Abdala 2007, a few 'lizards' may eventually have a small muscle that somewhat resembles the contrahentium caput longum of *Ambystoma*]	— [see on the left]	—	—	—	**-** [some authors, including McMurrich 1903ab, consider that the contrahentium caput longum might appear as an anomalous muscle in some humans, which is often designated as the 'ulnocarpeus', but this scenario

Table 9.1 contd...

Table 9.1 contd...

Amphibia (Caudata): *Ambystoma ordinarium* (Michoacan stream salamander)	Reptilia (Lepidosauria): *Timon lepidus* (Ocellated 'lizard')	Mammalia (Monotremata): *Ornithorhynchus anatinus* (Platypus)	Mammalia (Rodentia): *Rattus norvegicus* (Norwegian rat)	Mammalia (Dermoptera): *Cynocephalus volans* (Philippine colugo)	Mammalia (Scandentia): *Tupaia* sp. (Tree-shrew)	Mammalia (Primates): *Homo sapiens* (Human)
Howell 1936b, however, considers that the contrahentium caput longum is simply a contrahentes digitorum that has migrated proximally; Straus 1942 states that none of these theories are satisfactory and that the contrahentium caput longum derives from his 'flexor palmaris profundus' layer, which also included the flexor accessorius lateralis and medialis of the present volume (see below); according to him the contrahentium caput longum is possibly not separated from his 'flexor palmaris profundus' in extant amniotes, thus forming part of the flexor digitorum longus/ profundus sensu this volume]						is considered "exceedingly doubtful" by Straus 1942, because the contrahentium caput longum is only consistently found as a separate, distinct muscle in amphibians: see on the left]

Flexor accessorius lateralis (caput dorsale of flexor palmaris profundus sensu Straus 1942) [as stated by Diogo and Abdala 2007, this muscle is absent as an independent structure in extant amniotes; these authors hypothesized that it could eventually correspond to part of the pronator accessorius of reptiles, but it is very likely that the flexor accessorius medialis and lateralis correspond instead to part of the flexor digitorum longus of reptiles and monotremes and of the flexor digitorum profundus of therian mammals: see, e.g., Straus 1942, Lewis 1989, and Chapter 10]	— [absent as an independent muscle in extant amniotes, but see on the left and also Chapter 10]	—	—	—	—	—
Flexor accessorius medialis (caput volare of flexor palmaris profundus sensu Straus 1942) [see flexor accessorius laterali above and Chapter 10]	—	—	—	—	—	—

Table 9.1 contd...

Table 9.1 contd...

Amphibia (Caudata): *Ambystoma ordinarium* (Michoacan stream salamander)	Reptilia (Lepidosauria): *Timon lepidus* (Ocellated 'lizard')	Mammalia (Monotremata): *Ornithorhynchus anatinus* (Platypus)	Mammalia (Rodentia): *Rattus norvegicus* (Norwegian rat)	Mammalia (Dermoptera): *Cynocephalus volans* (Philippine colugo)	Mammalia (Scandentia): *Tupaia* sp. (Tree-shrew)	Mammalia (Primates): *Homo sapiens* (Human)
Flexor digitorum communis	**Flexor digitorum longus** (flexor digitorum communis sensu Diogo and Abdala 2007, and Diogo 2007) [we prefer to use here the name flexor digitorum longus, because this muscle does not seem to correspond directly to the flexor digitorum communis of *Ambystoma*; i.e., it probably also includes part or all of the flexor accessorius lateralis and medialis and/or eventually of the contrahentium caput longum of this latter taxon: see above]	**Flexor digitorum longus + part of flexores breves superficiales** [in the *Ornithorhynchus* specimens dissected the flexor digitorum longus seems to be fused to tendons of the flexores breves superficiales; this is supported by Jouffroy and Lessertisseur 1971, who state that the compound formed by these structures corresponds to the flexor digitorum profundus, flexor digitorum superficiales and likely the palmaris longus of most other mammals]	**Flexor digitorum profundus** [as stated by, e.g., Lewis 1989, much of the confusion regarding the homologies of the flexor digitorum profundus and superficialis of mammals is that these names derive from the human anatomy; for instance, in the rats, colugos and tree-shrews we dissected the flexor digitorum superficialis is less developed than in humans, being deeply mixed with and/or having a significant part deep to the flexor digitorum profundus: see also, e.g., Leche 1886; Le Gros Clark 1924, 1926; Greene 1935; Haines 1950, 1955]	**Flexor digitorum profundus** [see on the left]	**Flexor digitorum profundus** [see on the left]	**Flexor digitorum profundus** [see on the left]

—	—	—	—	—	—	**Flexor pollicis longus** [in most mammals, including rats, tree-shrews and colugos, the flexor digitorum profundus often attaches to digit 1; however, the differentiation of this muscle in a well-developed, distinct flexor pollicis longus is very rare; according to McMurrich 1903ab this occurs in humans, *Hylobates*, and a few other mammals such as dogs and hyenas]
—	—	—	**Flexor digitorum superficialis** [see flexor digitorum profundus above]	**Flexor digitorum superficialis**	**Flexor digitorum superficialis**	**Flexor digitorum superficialis** (flexor sublimis sensu Windle 1889)
—	— [there is a 'palmaris longus' in other 'lizards', as well as in other reptiles, e.g., turtles (see, e.g.,	—	**Palmaris longus** [Straus 1942 states that the 'palmaris longus' muscles of placentals + marsupials may	**Palmaris longus** [see cell on the left and also text]	**Palmaris longus** [see cell on the left and also text]	**Palmaris longus** [see cell on the left and also text]

Table 9.1 contd...

Table 9.1 contd...

Amphibia (Caudata): *Ambystoma ordinarium* (Michoacan stream salamander)	Reptilia (Lepidosauria): *Timon lepidus* (Ocellated 'lizard')	Mammalia (Monotremata): *Ornithorhynchus anatinus* (Platypus)	Mammalia (Rodentia): *Rattus norvegicus* (Norwegian rat)	Mammalia (Dermoptera): *Cynocephalus volans* (Philippine colugo)	Mammalia (Scandentia): *Tupaia* sp. (Tree-shrew)	Mammalia (Primates): *Homo sapiens* (Human)
	Fig. 10.12); Howell 1936b and others suggest that this muscle is probably not homologous with the palmaris longus of mammals; however, Haines 1950 and other authors suggested that the 'palmaris longus' of at least some reptiles and the palmaris longus of at least some mammals are in fact probably homologous, i.e., that the last common ancestor of mammals and reptiles probably had a palmaris longus: see text and Chapter 10]		eventually be derived from the flexor carpi radialis (this would be an exception), from the flexor digitorum superficialis (this is the most frequent case) and/or from the flexor carpi ulnaris (this is somewhat frequent), and that in certain mammals, such as some marsupials and some Carnivora, there are two 'palmaris longus', probably derided from the flexor carpi ulnaris and/or flexor digitorum superficialis; see also text; McMurrich 1903a considers that the palmaris longus			

			of mammals corresponds to part of the flexor digitorum longus of reptiles]			
Flexor carpi ulnaris (flexor antebrachii et carpi ulnaris sensu Diogo and Abdala 2007, and Diogo 2007)	**Flexor carpi ulnaris** (flexor antebrachii et carpi ulnaris sensu Diogo and Abdala 2007 and Diogo 2007)	**Flexor carpi ulnaris**	**Flexor carpi ulnaris**	**Flexor carpi ulnaris**	**Flexor carpi ulnaris**	**Flexor carpi ulnaris**
Epitrochleoanconeus [see Chapter 10]	**Epitrochleo-anconeus** (flexor antebrachii ulnaris sensu Jouffroy and Lessertisseur, 1971)	**Epitrochleoanconeus** [Straus 1942 states that the epitrochleoanconeus is much more developed in monotremes than in other mammals, i.e., that in monotremes it is more similar to that of non-mammalian tetrapods than to that of therian mammals]	**Epitrochleo-anconeus** [Greene's 1935 work suggests that this muscle is not present in *Rattus*, but this may well be due to Greene's confusion between the dorsoepitr-ochlearis and the epitrochle-oanconeus; this latter muscle seems to be present in the *Rattus norvegicus* specimens dissected by us]	**Epitrochleo-anconeus**	**Epitrochleoanconeus** (condylo-olecranonis sensu Le Gros Clark 1924, 1926)	**—** [as noted by Straus 1942 and other authors, this muscle may be occasionaly found in humans; when it is not present as an independent muscle it likely corresponds to the fibrous arcade spanning the interval between the epicondylar and olecranon heads of the flexor carpi ulnaris]
Flexor antebrachii et carpi radialis [as explained by Straus 1942 and other authors, in most urodeles the flexor antebrachii et carpi radialis is usually	**Flexor carpi radialis** (flexor antebrachii et carpi radialis sensu Diogo and Abdala 2007 and Diogo 2007)	**Flexor carpi radialis**	**Flexor carpi radialis**	**Flexor carpi radialis**	**Flexor carpi radialis**	**Flexor carpi radialis** [as noted by Lewis 1989, occasionally in humans the flexor carpi radialis may be divided into a

Table 9.1 contd...

Table 9.1 contd...

Amphibia (Caudata): *Ambystoma ordinarium* (Michoacan stream salamander)	Reptilia (Lepidosauria): *Timon lepidus* (Ocellated 'lizard')	Mammalia (Monotremata): *Ornithorhynchus anatinus* (Platypus)	Mammalia (Rodentia): *Rattus norvegicus* (Norwegian rat)	Mammalia (Dermoptera): *Cynocephalus volans* (Philippine colugo)	Mammalia (Scandentia): *Tupaia* sp. (Tree-shrew)	Mammalia (Primates): *Homo sapiens* (Human)
not differentiated into a pronator teres ('flexor antebrachii radialis') and a flexor carpi radialis: see Chapter 10]						flexor carpi radialis longus and a flexor carpi radialis brevis]
— [see flexor antebrachii et carpi radialis above]	**Pronator teres** [corresponds to part of the flexor antebrachii et carpi radialis of *Ambystoma*: see flexor antebrachii et carpi radialis above]	**Pronator teres** [as explained by Straus 1942, Haines 1950, and Lewis 1989, the pronator teres of mammals corresponds to the flexor antebrachii radialis/pronator teres of taxa such as *Timon*, i.e., it is not partially derived from the pronator quadratus as suggested by Howell 1936b and other authors]	**Pronator teres**	**Pronator teres** [as in some bats, in colugos this muscle does not pronate the forearm, but mainly flexes it, together with the supinator and the brachioradialis: see, e.g., Leche 1886]	**Pronator teres** (pronator radii teres sensu Le Gros Clark 1924, 1926)	**Pronator teres**
Flexores breves superficiales	**Flexores breves superficiales** (flexores digiti brevis superficialis sensu Abdala and Moro 2006)	— [the flexores breves superficiales are absent as a group in mammals, but some of them seemingly correspond to mammalian structures such as the flexor	—	—	—	—

		brevis digitorum manus and/or the palmaris brevis, as well as part of the flexor digitorum superficialis of most mammals: see flexor digitorum superficialis above]				
—	— [see Chapter 10]	—	**Palmaris brevis** [it is difficult to discern whether this small muscle is present in the specimens we dissected, but Peterka 1936 and other authors state that rats do have this muscle, and Jouffroy 1971 also states that rodents usually have this muscle]	**Palmaris brevis** [not described by Leche 1886, but present and well developed in the colugos we dissected]	**Palmaris brevis** (muscle of hypothenar pad sensu Haines 1955) [some authors describe a distinct muscle 'palmaris superficialis' in tree-shrews such as *Tupaia*, but in the most recent detailed descriptions, such as those of George 1977, the 'palmaris superficialis' is considered to be a 'simple fibrous plate']	**Palmaris brevis** [as explained by, e.g., Howell 1936b and Lewis 1989, the palmaris brevis is seemingly not present as an independent muscle in non-mammalian tetrapods such as 'lizards' and salamanders; it likely corresponds to part of their flexores breves superficiales]
—	—	—	— [contrary to the 'opponens digiti V' of colugos (see on the right), the 'opponens digiti quinti' (sensu Greene 1935) of rats does seem	**Flexor brevis digitorum manus** (opponens digiti V sensu Leche 1886) [the opponens digiti V sensu this author is very similar	**Flexor brevis digitorum manus** (primitive flexor brevis manus sensu Howell 1936b and Straus 1942; flexor brevis manus sensu Le Gros Clark 1924, 1926, and George 1977)	—

Table 9.1 contd...

Table 9.1 contd...

Amphibia (Caudata): *Ambystoma ordinarium* (Michoacan stream salamander)	Reptilia (Lepidosauria): *Timon lepidus* (Ocellated 'lizard')	Mammalia (Monotremata): *Ornithorhynchus anatinus* (Platypus)	Mammalia (Rodentia): *Rattus norvegicus* (Norwegian rat)	Mammalia (Dermoptera): *Cynocephalus volans* (Philippine colugo)	Mammalia (Scandentia): *Tupaia* sp. (Tree-shrew)	Mammalia (Primates): *Homo sapiens* (Human)
			to correspond to the opponens digiti minimi of the present work, because it is deep, and not superficial, to the flexor digiti minimi brevis]	and seems to correspond to the flexor brevis digitorum manus of, e.g., *Tupaia*, being superficial, and not deep, to the flexor digiti minimi brevis]		
— [but see Chapter 10]	**Lumbricales**	**Lumbricales** [according to Jouffroy and Lessertisseur 1971, the Platypus usually has 3 lumbricales, to digits 3, 4 and 5, and the Echidna often has 4 or 5 lumbricales, to digits 2, 3, 4 and 5, or to digits 1, 2, 3, 4, and 5]	**Lumbricales** [as described by Greene 1935, *Rattus* usually has 4 lumbricales, to digits 2, 3, 4, and 5]	**Lumbricales** [as described by Leche, Cynocephalus usually has 7 lumbricales, to the radial sides of digits 2, 3, 4, and 5, and to the ulnar sides of digits 2, 3 and 4]	**Lumbricales** [as described by Le Gros Clark 1924 and George 1977, *Tupaia* usually has 4 lumbricales, to digits 2, 3, 4, and 5]	**Lumbricales** [as described by Netter 2006, humans usually have 4 lumbricales, to digits 2, 3, 4, and 5]
Contrahentes digitorum [see Chapter 10]	**Contrahentes digitorum** (include the flexor digitorum V transversus I and flexor digitorum V transversus II sensu Abdala and Moro 2006, Diogo and Abdala 2007,	— [according to Jouffroy and Lessertisseur 1971, the contrahens to digit 1 (= adductor pollicis) is seemingly present but there are no other contrahentes digitorum in	**Contrahentes digitorum** [the contrahentes digitorum, other than the adductor pollicis, are really present in *Rattus norvegicus*? It was not possible	**Contrahentes digitorum** (adductor indicis and adductor digiti V sensu Leche 1886) [as described by Leche 1886, colugos	**Contrahentes digitorum** (part of the contrahentes manus sensu George 1977, which also include the adductor pollicis) [Le Gros Clark 1924 does not describe the contrahentes digitorum	— [humans usually only have a contrahens, which goes to digit 1 and thus corresponds to the adductor pollicis sensu this volume: see adductor pollicis

	and Diogo 2007: see Chapter 10)	monotremes, with the exception of an eventual contrahentes going to digit 5; according to Howell 1937d, even the adductor pollicis is absent in monotremes]	to appropriately discern whether or not these muscles are present in the rats we dissected; Greene 1935 does not describe contrahentes other than the adductor pollicis in this taxon, but Peterka 1936 and others seem to suggest that they may be present in at least some rats; this is in fact supported by Cihak 1972, who states that rats actually have three well-developed contrahentes, i.e., an adductor pollicis to digit 1 and two other contrahentes, which thus probably correspond to the contrahentes to digits 2 and 5, as suggested by Peterka 1936; this idea is also supported by McMurrich	usually have contrahentes to digits 1 (adductor pollicis), 2 and 5]	to digits 2 and 5 in *Tupaia minor*, but they are very likely present: they were found in all the *Tupaia* specimens analyzed by us and by, e.g., Haines 1955 and George 1977]	below, and also text]

Table 9.1 contd...

Table 9.1 contd...

Amphibia (Caudata): *Ambystoma ordinarium* (Michoacan stream salamander)	Reptilia (Lepidosauria): *Timon lepidus* (Ocellated 'lizard')	Mammalia (Monotremata): *Ornithorhynchus anatinus* (Platypus)	Mammalia (Rodentia): *Rattus norvegicus* (Norwegian rat)	Mammalia (Dermoptera): *Cynocephalus volans* (Philippine colugo)	Mammalia (Scandentia): *Tupaia* sp. (Tree-shrew)	Mammalia (Primates): *Homo sapiens* (Human)
			1903ab, who states that mice have contrahentes to digits 1, 2 and 5]			
—	— [see cell above]	**Adductor pollicis** [the adductor pollicis of mammals clearly corresponds to part of the contrahentes digitorum of other tetrapods, but most anatomists working with mammals describe it as a muscle that is somewhat independent from the other contrahentes, thus deserving a distinct name]	**Adductor pollicis**	**Adductor pollicis** (adductor pollicis or part of the contrahentes sensu Leche 1886, which also include the contrahentes digitorum described above)	**Adductor pollicis** (part of the contrahentes manus sensu George 1977, which also include the contrahentes digitorum described above)	**Adductor pollicis**
—	—	—	—	—	—	**'Volaris primus of Henle'** [see text and Table 10.3]
Flexores breves profundi [see Chapter 10]	**Flexores breves profundi** (flexores digiti brevis profundus sensu Abdala and Moro 2006) [see Chapter 10]	**Flexores breves profundi** (interossei sensu Jouffroy and Lessertisseur 1971) [the Platypus often has 8 to 10 flexores breves	**Flexores breves profundi** (palmar interossei sensu Greene 1935) [*Rattus* usually has the full series of flexores	**Interossei** (interossei externi and interni sensu Leche 1886) [apart from the flexor pollicis brevis and the flexor	**Interossei** [see text; see also on the left] [apart from the flexor pollicis brevis and the flexor digiti minimi brevis (which correspond	**Interossei palmares** [see text; see also cells on the left]

		profundi, inserting on digits 1, 2, 3, 4 and 5 ; see also text]	breves profundi, i.e., it has flexores breves profundi going to the radial sides of digit 1 (this muscle corresponds to the flexor pollicis brevis sensu this volume: see below), 2, 3, 4, and 5, and to the ulnar sides of digits 5 (this muscle corresponds to the flexor digiti minimi brevis plus the opponens digiti minimi sensu this volume), 4, 3, 2 and 1; we use the name interossei for *Cynocephalus* and *Tupaia* because in these taxa, unlike in rats, the flexores breves are deeply mixed with the intermetacarpales, forming the 'interossei externi' sensu Leche 1886, and the dorsal interossei sensu Le Gros Clark 1924; as noted by, e.g., Haines 1955, in *Tupaia* the three interossei attaching on the ulnar side of digit 2 and radial sides of digits 4	digiti minimi brevis (which correspond to the flexores breves profundi 1 and 5 sensu this volume), colugos seemingly have 3 (to digits 2, 4 and 5) or possibly 4 (to digits 1, 2, 4 and 5) flexores breves profundi, that is, they seemingly have a total of 5, or possibly 6, flexores breves profundi; see cells on the left, and also text]	to the flexores breves profundi 1 and 5 sensu this volume), *Tupaia* seemingly has 3 (to digits 2, 4 and 5) or possibly 4 (to digits 1, 2, 4 and 5) flexores breves profundi, that is, it seemingly has a total of 5, or possibly 6, flexores breves profundi; see cells on the left, and also text]	

Table 9.1 contd...

Table 9.1 contd...

Amphibia (Caudata): *Ambystoma ordinarium* (Michoacan stream salamander)	Reptilia (Lepidosauria): *Timon lepidus* (Ocellated 'lizard')	Mammalia (Monotremata): *Ornithorhynchus anatinus* (Platypus)	Mammalia (Rodentia): *Rattus norvegicus* (Norwegian rat)	Mammalia (Dermoptera): *Cynocephalus volans* (Philippine colugo)	Mammalia (Scandentia): *Tupaia* sp. (Tree-shrew)	Mammalia (Primates): *Homo sapiens* (Human)
			on the right]and 5 are somewhat ventral to, but not really separated from, the four interossei attaching on the radial sides of digits 2 and 3 and ulnar sides of digits 3 and 4; that is why we prefer to refer here to interossei [= flexores breves profundi + intermetacarpales), and to not subdivide these latter muscles into interossei palmares and interossei dorsales, as we do in humans: see cells on the right			
—	—	—	—	—	—	**Interossei dorsales** [see interossei palmares]
—	—	— [our dissections of support that, as described by Howell 1937d and Jouffroy and Lessertisseur	**Flexor brevis pollicis** [contrary to the platypus, in *Rattus*, as well as in the other therian	**Flexor pollicis brevis**	**Flexor pollicis brevis** (radial head of flexor brevis profundus 1 sensu Haines 1955)	**Flexor pollicis brevis** [the results of Cihak's 1972 developmental studies of human

		1971, there is are no independent, distinct flexor brevis pollicis nor digiti minimi brevis in the platypus; that is, the radial head of the biccipital flexor brevis profundus of digit 1 and the ulnar head of the biccipital flexor brevis profundus of digit 5, which corresponds respectively to the flexor pollicis brevis and the flexor digiti minimi brevis of other mammals, are not really independent and distinct from the remaining flexores breves profundi]	mammals included in this table, the radial head of the biccipital flexor brevis profundus of digit 1 and the ulnar head of the biccipital flexor brevis profundus of digit 5 are clearly distinct from the remaining flexores breves profundi, being named respectively flexor pollicis brevis and flexor digiti minimi brevis by most anatomists]			fetuses suggest that both the superficial and deep heads of the flexor pollicis brevis of humans are derived from the flexores breves profundi]
—	—	—	**---** [seemingly absent as an independent muscle in *Rattus*, *Tupaia* and *Cynocephalus*, but found in other non-primate therian mammals: see, e.g., Jouffroy 1971]	**—** [see on the left]	**—** [see on the left]	**Opponens pollicis** [Howell 1936b and other authors stated that the opponens pollicis and opponens digiti minimi probably derive from part of the flexores breves

Table 9.1 contd...

Table 9.1 contd...

Amphibia (Caudata): *Ambystoma ordinarium* (Michoacan stream salamander)	Reptilia (Lepidosauria): *Timon lepidus* (Ocellated 'lizard')	Mammalia (Monotremata): *Ornithorhynchus anatinus* (Platypus)	Mammalia (Rodentia): *Rattus norvegicus* (Norwegian rat)	Mammalia (Dermoptera): *Cynocephalus volans* (Philippine colugo)	Mammalia (Scandentia): *Tupaia* sp. (Tree-shrew)	Mammalia (Primates): *Homo sapiens* (Human)
						superficiales; however, it is now commonly accepted that these two muscles derive respectively from the flexor brevis pollicis and the flexor digiti minimi brevis, as stated by Lewis 1989, and supported by Cihak's 1972 ontogenetic studies of human fetuses]
—	—	— [see above]	**Flexor digiti minimi brevis** (flexor digiti quinti brevis sensu Greene 1935) [see above]	**Flexor digiti minimi brevis** (flexor brevis digiti V sensu Leche 1886)	**Flexor digiti minimi brevis** (flexor digiti quinti manus sensu George 1977; ulnar head of flexor brevis profundus 5 sensu Haines 1944)	**Flexor digiti minimi brevis**
—	—	—	**Opponens digiti minimi** (opponens digiti quinti sensu Greene 1935)	—	—	**Opponens digiti minimi** [see above]
— [see Chapter 10]	**Abductor pollicis brevis** (abductor brevis pollici sensu	**Abductor pollicis brevis**	**Abductor pollicis brevis** (abductor	**Abductor pollicis brevis**	**Abductor pollicis brevis**	**Abductor pollicis brevis**

	Abdala and Moro 2006)		pollicis sensu Greene 1935)			
Abductor digiti minimi (extensor lateralis digiti IV sensu Walthall and Ashley-Ross 2006, Diogo 2007, Diogo and Abdala 2007 and Diogo et al. 2009a) [see Chapter 10]	**Abductor digiti minimi** (abductor digitorum V sensu Abdala and Moro 2006, Diogo and Abdala 2007, and Diogo 2007) [see Chapter 10]	**Abductor digiti minimi**	**Abductor digiti minimi** (abductor digiti quinti sensu Greene 1935; abductor digiti V sensu Rocha-Barbosa et al. 2007)	**Abductor digiti minimi**	**Abductor digiti minimi** (abductor digiti quinti manus sensu George 1977; abductor minimi digiti sensu Le Gros Clark 1924, 1926)	**Abductor digiti minimi**
Intermetacarpales [see Chapter 10]	**Intermetacarpales** (intermetacarpales I and II sensu Abdala and Moro 2006, Diogo and Abdala 2007, and Diogo 2007) [see Chapter 10]	— [see text]	**Intermetacarpales** [our dissections of *Rattus norvegicus* indicate that this taxon has four intermetacarpales, the first inserting on the radial side of digit 2, the second on the radial side of digit 3, the third on the medial side of digit 3, and the fourth on the medial side of digit 4; see also text]	— [see text]	— [see text]	— [see text]
— [see Chapter 10]	**Dorsometacarpales** [see Chapter 10]	**---** [not present as a group in extant mammals, but part or all of some of them may be eventually fused to the dorsal interossei, intermetacarpales	—	—	—	—

Table 9.1 contd...

Table 9.1 contd...

Amphibia (Caudata): *Ambystoma ordinarium* (Michoacan stream salamander)	Reptilia (Lepidosauria): *Timon lepidus* (Ocellated 'lizard')	Mammalia (Monotremata): *Ornithorhynchus anatinus* (Platypus)	Mammalia (Rodentia): *Rattus norvegicus* (Norwegian rat)	Mammalia (Dermoptera): *Cynocephalus volans* (Philippine colugo)	Mammalia (Scandentia): *Tupaia* sp. (Tree-shrew)	Mammalia (Primates): *Homo sapiens* (Human)
		and/or flexores breves profundi of mammals: see, e.g., Cihak 1972 and Lewis 1989]				
Extensor antebrachii et carpi radialis [see Chapter 10]	**Extensor antebrachii et carpi radialis** (extensor carpi radialis sensu Abdala and Moro 2006) [see Chapter 10]	**Extensor carpi radialis**	**Extensor carpi radialis longus** [this muscle and the extensor carpi radialis brevis, are derived from the extensor carpi radialis]	**Extensor carpi radialis longus**	**Extensor carpi radialis longus**	**Extensor carpi radialis longus**
— [see Chapter 10]	— [see Chapter 10]	—	**Extensor carpi radialis brevis** [see extensor carpi radialis above]	**Extensor carpi radialis brevis**	**Extensor carpi radialis brevis**	**Extensor carpi radialis brevis**
— [see Chapter 10]	— [see Chapter 10]	**Brachioradialis**	— [not present as an independent muscle in rats]	**Brachioradialis** (supinator longus sensu Macalister 1872, and Leche 1886) [Gunnell and Simmons 2005 stated that *Cynocephalus* lacks a brachior-adialis but this clearly seems to be due to an error: this muscle	**Brachioradialis** [seemingly absent as an independent structure in tree-shrews such as *Ptilocercus* and eventually even in some specimens of *Tupaia javanica*: see Le Gros Clark 1926 and George 1977]	**Brachioradialis**

				is present and well developed in the specimens dissected by Macalister 1872, by Leche 1886, and by us]		
— [see Chapter 10]	— [see Chapter 10]	**Supinator** [as noted by Jouffroy and Lessertisseur 1971 and Lewis 1989, the supinator of mammals corresponds to part of the extensor antebrachii et carpi radialis of reptiles such as *Timon*, and not of the abductor pollicis longus ('supinator manus'), as suggested by Howell 1936b]	**Supinator**	**Supinator** (supinator brevis sensu Leche 1886)	**Supinator**	**Supinator** (supinator brevis sensu Parsons 1898)
Extensor antebrachii et carpi ulnaris	**Extensor antebrachii et carpi ulnaris**	**Extensor carpi ulnaris**	**Extensor carpi ulnaris**	**Extensor carpi ulnaris**	**Extensor carpi ulnaris**	**Extensor carpi ulnaris**
— [see Chapter 10]	— [see Chapter 10]	**Anconeus** [see text]	**Anconeus**	**Anconeus** (anconeus quartus sensu Leche 1886)	**Anconeus**	**Anconeus**
Extensor digitorum [see Chapter 10]	**Extensor digitorum** [see Chapter 10]	**Extensor digitorum** (extensor digitorum communis sensu Jouffroy and Lessertisseur 1971, Stein 1981, and Warburton 2003) [contrary to Ribbing	**Extensor digitorum** (extensor digitorum communis sensu Greene 1935) [according to	**Extensor digitorum** (extensor digitorum communis sensu Leche 1886) [as described	**Extensor digitorum** (extensor digitorum communis sensu George 1977; extensor communis digitorum sensu Le Gros Clark 1924, 1926) [as	**Extensor digitorum** [as described by Lewis 1989 and other authors, in humans this muscle usually sends

Table 9.1 contd...

Table 9.1 contd...

Amphibia (Caudata): *Ambystoma ordinarium* (Michoacan stream salamander)	Reptilia (Lepidosauria): *Timon lepidus* (Ocellated 'lizard')	Mammalia (Monotremata): *Ornithorhynchus anatinus* (Platypus)	Mammalia (Rodentia): *Rattus norvegicus* (Norwegian rat)	Mammalia (Dermoptera): *Cynocephalus volans* (Philippine colugo)	Mammalia (Scandentia): *Tupaia* sp. (Tree-shrew)	Mammalia (Primates): *Homo sapiens* (Human)
		1907 and others, Straus 1941ab and other authors consider that plesiomorphically in tetrapods the extensor digitorum did not reach the phalanges of the digits and, thus, that the extensor digitorum of mammals, which does insert on the phalanges, includes part of the extensores digitorum breves; according to Jouffroy and Lessertisseur 1971, in the Platypus the extensor digitorum usually sends tendons to the five digits]	Greene 1935, in *Rattus* the extensor digitorum usually sends tendons to digits 2, 3, 4 and 5]	by Leche 1886, in colugos the extensor digitorum usually sends tendons to digits 2, 3, 4 and 5]	described by Le Gros Clark 1924 and George 1977, in *Tupaia* the extensor digitorum usually sends tendons to digits 2, 3, 4 and 5; see Kaneff 1979, 1980ab for variations of this muscle in this genus]	tendons to digits 2, 3, 4 and 5, although occasionally it can also send a tendon to digit 1]
Extensores digitorum breves [see Chapter 10]	**Extensores digitorum breves** [see Chapter 10]	— [it is commonly accepted that the extensores digitorum breves are absent as a group in extant mammals; they gave rise to independent, distinct muscles such as the extensor pollicis	—	—	—	—

		longus, extensor indicis, extensor digit III proprius, extensor digiti quarti and extensor digiti minimi: see text and also below]				
—	—	**Extensor digiti minimi** (extensor lateralis sensu Jouffroy and Lessertisseur 1971) [according to Jouffroy and Lessertisseur 1971, in the Platypus the extensor digiti minimi has a single tendon, inserting on digit 5, but in the Echidna it has two tendons inserting on digits 4 and 5; some develo-mental studies, e.g., Cihak 1972, indicate that this muscle derives from the extensor digitorum, while others, e.g., Gräfenberg 1906, indicate that it corresponds to part of the extensores digitorum breves; the analysis of other lines of evidence strongly	**Extensor digiti minimi** (extensor digiti quinti proprius sensu Greene 1935, and Howell 1936b; extensor digiti quinti sensu Peterka 1936) [as described by Greene 1935, in *Rattus* this muscle usually inserts on digit 5; see cell on the left and text]	**Extensor digiti minimi** (extensor digitorum secundus sensu Leche 1886) [as described by Leche 1886, in colugos this muscle usually inserts on digits 3, 4 and 5; see cells on the left and text]	**Extensor digiti minimi** (extensor digitorum ulnaris sensu George 1977; extensor digitorum lateralis sensu Le Gros Clark 1924, 1926) [as described by Le Gros Clark 1924 and George 1977, in *Tupaia* this muscle usually inserts on digits 4 and 5; see cells on the left and text, and see also Kaneff 1979, 1980ab for variations of this muscle in *Tupaia*]	**Extensor digiti minimi** [as described by Netter 2006 and others, in humans this muscle usually inserts on digit 5; see on the left and text]

Table 9.1 cond...

Table 9.1 contd...

Amphibia (Caudata): *Ambystoma ordinarium* (Michoacan stream salamander)	Reptilia (Lepidosauria): *Timon lepidus* (Ocellated 'lizard')	Mammalia (Monotremata): *Ornithorhynchus anatinus* (Platypus)	Mammalia (Rodentia): *Rattus norvegicus* (Norwegian rat)	Mammalia (Dermoptera): *Cynocephalus volans* (Philippine colugo)	Mammalia (Scandentia): *Tupaia* sp. (Tree-shrew)	Mammalia (Primates): *Homo sapiens* (Human)
		supports this latter hypothesis: (1) both the extensor digitorum and extensor digiti minimi usually have tendons to digits 4 and 5 in mammals: as the extensor digitorum of other tetrapods usually has a single tendon to each digit, it is unlikely that it corresponds to both the former muscles; (2) there are known homologies for the mammalian extensores digitorum breves 1 (ext pollicis longus), 2 (extensor indicis proprius), and 3 (extensor digiti III proprius), but not for those of digits 4 and 5: the extensor digiti minimi precisely goes to digits 4 and 5 in many mammals; (3) as noted by Lewis 1989, the				

		tendons of the mammalian extensor digiti minimi often occupy the deep plane on the dorsum of the hand, i.e., they are usually deep to the tendons of the extensor digitorum; see text]				
—	—	—	**Extensor digiti quarti** (extensor digiti quarti proprius sensu Howell 1936b) [as its name indicates, in *Rattus* this muscle usually inserts on digit 4; see extensores digitorum breves above and also text]	—	—	—
—	—	**Extensor digitus III proprius** (part of extensor profundus sensu Jouffroy and Lessertisseur 1961) [as its name indicates, in the Platypus and the Echidna this muscle usually inserts on digit 3; see extensores digitorum breves above and also text]	**---** [not described by Greene 1935; this muscle is seemingly missing in the *Rattus norvegicus* specimens we dissected; see extensores digitorum breves above and also text]	—	—	—

Table 9.1 contd...

Table 9.1 contd...

Amphibia (Caudata): *Ambystoma ordinarium* (Michoacan stream salamander)	Reptilia (Lepidosauria): *Timon lepidus* (Ocellated 'lizard')	Mammalia (Monotremata): *Ornithorhynchus anatinus* (Platypus)	Mammalia (Rodentia): *Rattus norvegicus* (Norwegian rat)	Mammalia (Dermoptera): *Cynocephalus volans* (Philippine colugo)	Mammalia (Scandentia): *Tupaia* sp. (Tree-shrew)	Mammalia (Primates): *Homo sapiens* (Human)
—	—	**Extensor indicis** [in the Platypus this muscle usually inserts on digit 2; see extensores digitorum breves above and also text]	**Extensor indicis** (extensor indicis proprius sensu Greene 1935) [as described by Greene 1935, in *Rattus* this muscle usually inserts on digits 2 and 3; see extensores digitorum breves above and also text]	**Extensor indicis** [as described by Leche 1886, in colugos this muscle usually inserts on digits 1, 2 and 3; see extensores digitorum breves above and also text]	**Extensor indicis** [as described by Le Gros Clark 1924, George 1977 and Kaneff 1979, 1980ab, Leche 1886, in *Tupaia* this muscle usually inserts on digits 2 and 3, although sometimes it also attaches to digits 1 and/or 4; see extensores digitorum breves above and also text]	**Extensor indicis** [as described by Netter 2006 and others, in humans this muscle usually inserts on digit 2; see extensores digitorum breves above and also text]
—	—	**Extensor pollicis longus** [in the Platypus this muscle usually inserts on digit 1; see extensores digitorum breves above and also text]	**Extensor pollicis longus** [as described by Greene 1935, in *Rattus* this muscle usually inserts on digits 2 and 3; see extensores digitorum breves above and also text]	**Extensor pollicis longus** (extensores pollicis longus et brevis sensu Leche 1886) [as described by Leche 1886, in colugos this muscle usually inserts on digit 1; see extensores digitorum breves above and also text]	**Extensor pollicis longus** (part of extensor digitorum radialis sensu George 1977, and of extensor profundus digitorum sensu Le Gros Clark 1924, 1926, which also include the extensor indicis) [as described by George 1977 and Kaneff 1979, 1980ab, in *Tupaia* this muscle usually inserts on digit 1; see extensores digitorum breves above and also text]	**Extensor pollicis longus** [as described by Netter 2006 and others, in humans this muscle usually inserts on digit 1; see extensores digitorum breves above and also text]

Abductor et extensor digiti I [see Chapter 10]	**Abductor pollicis longus** [see Chapter 10]	**Abductor pollicis longus** [Jouffroy and Lessertisseur 1971 seem to suggest that the plesiomorphic condition for mammals is that in which the abductor pollicis longus has a single tendon to digit 1, as is usually the case in monotremes, although the muscle of the Platypus sometimes has two tendons to this digit]	**Abductor pollicis longus** (extensor pollicis brevis sensu Greene 1935) [in rats there is seemingly no sign of a differentiation of the abductor pollicis longus into two bundles corresponding to the abductor pollicis longus and extensor pollicis brevis of humans; in fact, in rats the abductor pollicis longus is often deeply mixed with the extensor pollicis longus, although but for Greene 1935 it is clear that the tendon of the extensor pollicis longus goes to the distal phalanx of the thumb and that the tendon of the abductor pollicis longus goes only to the proximal phalanx of this digit]	**Abductor pollicis longus** (extensor pollicis brevis plus abductor pollicis longus of Leche 1886; extensor pollicis brevis of Chapman 1902)	**Abductor pollicis longus** (abductor pollicis sensu Le Gros Clark 1924, 1926) [the *Tupaia* specimens we dissected lack an extensor pollicis brevis; George 1977, stated that an 'extensor pollicis brevis' was reported in *Tupaia picta*, but this muscle may not be homologous to that of humans, because the latter is said to be plesiomorphically missing in primates: see, e.g., Lewis 1989; Gibbs 1999; Gibbs et al. 2000, 2002]	**Abductor pollicis longus**

Table 9.1 contd...

Amphibia (Caudata): *Ambystoma ordinarium* (Michoacan stream salamander)	Reptilia (Lepidosauria): *Timon lepidus* (Ocellated 'lizard')	Mammalia (Monotremata): *Ornithorhynchus anatinus* (Platypus)	Mammalia (Rodentia): *Rattus norvegicus* (Norwegian rat)	Mammalia (Dermoptera): *Cynocephalus volans* (Philippine colugo)	Mammalia (Scandentia): *Tupaia* sp. (Tree-shrew)	Mammalia (Primates): *Homo sapiens* (Human)
—	—	—	—	—	— [see above]	**Extensor pollicis brevis** [derived from part of the abductor pollicis longus: see, e.g., Jouffroy 1971; Kaneff 1979, 1980ab; Lewis 1989]

have recruited putative latissimus and spinotrapezius cells to the limb, thereby altering the insertion points and functions of these muscles". Further developmental, molecular, and comparative studies are needed to test this interesting evolutionary hypothesis.

Within the non-mammalian taxa muscles listed in Tables 9.1–9.3, four derive from this axial musculature: serratus anterior, levator scapulae, sternocoracoideus and costocoracoideus. These four muscles connect the axial skeleton to the pectoral girdle, and thus are associated with the movements of the pectoral girdle. Most textbooks state that the rhomboideus (Figs. 9.4, 9.5), a muscle derived from the postcranial axial musculature that also connects the axial skeleton to the pectoral girdle, is only consistently found in mammals (e.g., Kardong 2002). In reptiles such as *Timon* and amphibians such as *Ambystoma* the rhomboideus does not seem to be present as an independent muscle (Tables 9.1–9.3). However, Dilkes (2000) stated that a 'rhomboideus' is found in numerous reptiles, and that what is not resolved is whether the plesiomorphic reptilian condition is to have one rhomboideus muscle or both a rhomboideus superficialis and a rhomboideus profundus. According to some authors, a 'rhomboideus' is also found in some anurans (e.g., Howell 1937b). We did find a 'rhomboideus' in certain non-mammalian tetrapods we dissected, such as anurans, crocodylians and birds, as shown in Tables 10.1 and 10.2: this subject is thus discussed in more detail in Chapter 10.

Other examples of mammalian pectoral muscles that are derived from the postcranial axial musculature and connect the pectoral girdle to the axial skeleton are the levator claviculae, atlantoscapularis anticus, atlantoscapularis posticus and subclavius (see Fig. 9.5). The former three muscles very likely correspond to parts of the levator scapulae of non-mammalian tetrapods such as *Timon*; the latter muscle corresponds to the sternocoracoideus and/or costocoracoideus of those tetrapods (Tables 9.1–9.3). It should be noted that the hypaxial musculature sensu the present volume corresponds to the 'non-migratory hypaxial musculature' sensu Yamane (2005), while the appendicular musculature sensu the present is included in the 'migratory hypaxial musculature' sensu this latter author. That is, according to Yamame the appendicular muscles are 'hypaxial migratory muscles' that migrated to the limbs. Also according to him, the hypobranchial muscles sensu this volume, as well as the tongue muscles, the diaphragm and possibly the protractor pectoralis, are also 'hypaxial migratory muscles' (see discussion about protractor pectoralis in Chapter 5).

Table 9.2 Scheme illustrating the authors' hypotheses regarding the homologies of the pectoral and arm muscles of adults of representative tetrapod taxa. The nomenclature of the muscles follows that used in the text. Data compiled from evidence provided by our own dissections and comparisons, and from a review of the literature. The black arrows indicate the hypotheses that are most strongly supported by the evidence available; the grey arrows indicate alternative hypotheses that are supported by some data, but that overall are not as strongly supported by the evidence as are the hypotheses indicated by the black arrows (e.g., the overall analysis of the data available indicates that the dorsoepitrochlearis corresponds to part of the triceps brachii of non-mammalian tetrapods, but the possibility that it corresponds instead to part of the latissimus dorsi of these latter animals cannot be discarded: see text, Tables 9.1 and 9.3, and Figs. 9.1–9.6).

	Ambystoma	*Timon*	*Ornithorhynchus*	*Rattus*	*Cynocephalus*	*Tupaia*	*Homo*
AXIAL: PECTORAL GIRDLE	Serratus anterior	Serratus anterior	Serratus anterior	Serratus anterior	Serratus anterior	Serratus anterior	Serratus anterior
	---	---	Rhomboideus	Rhomboideus major	Rhomboideus	Rhomboideus major	Rhomboideus major
	---	---	---	Rhomboideus minor	---	Rhomboideus minor	Rhomboideus minor
	---	---	---	Rhomboideus occipitalis	---	Rhomboideus occipitalis	---
	Levator scapulae	Levator scapulae	Levator scapulae	Levator scapulae	Levator scapulae	Levator scapulae	Levator scapulae
	---	---	Levator claviculae	Levator claviculae	Levator claviculae	Atlantoscapularis anticus	---
	---	---	---	---	---	Atlantoscapularis posticus	---
	---	Sternocoracoideus	Sternocoracoideus	Subclavius	Subclavius	Subclavius	Subclavius
	---	Costocoracoideus	Costocoracoideus	---	---	---	---
APPENDICULAR: PECTORAL GIRDLE AND ARM	Pectoralis	Pectoralis	Pectoralis major	Pectoralis major	Pectoralis major	Pectoralis major	Pectoralis major
	---	---	Pectoralis minor	Pectoralis minor	Pectoralis minor	Pectoralis minor	Pectoralis minor
	---	---	Panniculus carnosus (part)	Panniculus carnosus (part)	Panniculus carnosus (part)	Panniculus carnosus (part)	Panniculus carnosus (part)
	Supracoracoideus	Supracoracoideus	Infraspinatus	Infraspinatus	Infraspinatus	Infraspinatus	Infraspinatus
	---	---	Supraspinatus	Supraspinatus	Supraspinatus	Supraspinatus	Supraspinatus
	Deltoideus scapularis	Deltoideus scapularis	Deltoideus scapularis	Deltoideus scapularis	Deltoideus scapularis	Deltoideus scapularis	Part of deltoideus
	Procoracohumeralis	Deltoideus clavicularis	Deltoideus clavicularis	Deltoideus clavicularis	Deltoideus clavicularis	Deltoideus clavicularis	Part of deltoideus
	---	---	---	Deltoideus acromialis	Deltoideus acromialis	Deltoideus acromialis	Part of deltoideus
	---	---	Teres minor	Teres minor	Teres minor	---	Teres minor
	---	Scapulo-humeralis anterior	Scapulo-humeralis anterior	---	---	---	---
	Subcoracoscapularis	Subcoracoscapularis	Subscapularis	Subscapularis	Subscapularis	Subscapularis	Subscapularis
	---	---	Teres major	Teres major	Teres major	Teres major	Teres major
	Latissimus dorsi	Latissimus dorsi	Latissimus dorsi	Latissimus dorsi	Latissimus dorsi	Latissimus dorsi	Latissimus dorsi
	Triceps brachii	Triceps brachii	Triceps brachii	Triceps brachii	Triceps brachii	Triceps brachii	Triceps brachii
	---	---	Dorsoepitrochlearis	Dorsoepitrochlearis	Dorsoepitrochlearis	Dorsoepitrochlearis	---
	Humeroantebrachialis	Brachialis	Brachialis	Brachialis	Brachialis	Brachialis	Brachialis
	---	Biceps brachii	Biceps brachii	Biceps brachii	Biceps brachii	Biceps brachii	Biceps brachii
	Coracobrachialis	Coracobrachialis	Coracobrachialis	Coracobrachialis	Coracobrachialis	Coracobrachialis	Coracobrachialis

Appendicular Muscles of the Pectoral Girdle and Arm (Tables 9.1–9.2)

As explained above, all the tetrapod muscles discussed in this and the next section are derived from the abductor and adductor muscles of the pectoral fin of basal sarcopterygians. With a few exceptions, all these muscles insert directly on the forelimb (arm, forearm, and/or hand). One of the exceptions is the pectoralis minor, which in many mammals inserts on both the humerus and the pectoral girdle, but in others, including modern humans, inserts exclusively on the pectoral girdle (usually on the coracoid process). The homologies of the pectoralis minor and pectoralis major of mammals (Fig. 9.5) have been the subject of much controversy in the past. Some authors suggested that the mammalian pectoralis major corresponds to the pectoralis of other tetrapods (Fig. 9.2), the pectoralis

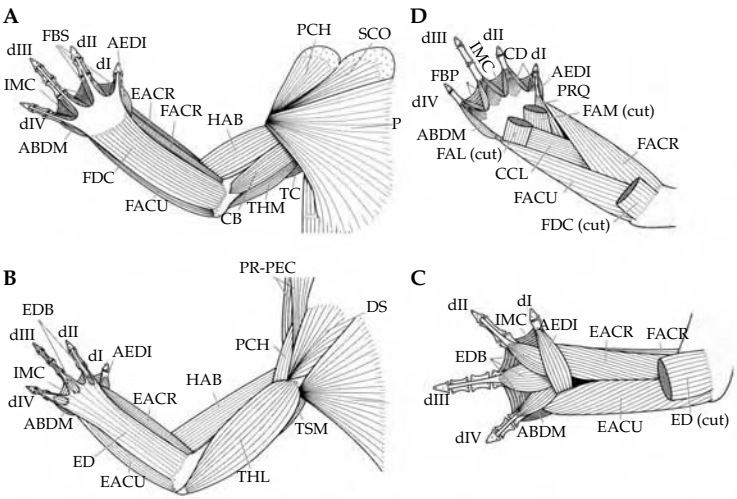

Fig. 9.2 *Taricha torosa* (Amphibia): **(A)** Ventral view of the superficial musculature of the pectoral girdle and forelimb; **(B)** Dorsal view of the superficial musculature of the pectoral girdle and forelimb; **(C)** Ventral view of the deep musculature of the forearm; **(D)** Dorsal view of the deep musculature of the forearm (anterior is towards the top of the figure; modified from Walthall and Ashley-Ross 2006: the nomenclature of the structures illustrated follows that of the present work). ABDM, abductor digiti minimi; AC, anconaeus coracoideus; AED1, abductor et extensor digiti I; CB, coracobrachialis; CCL, contrahentium caput longum; CD, contrahentes digitorum; dI, dII, dIII, dIV, digits I, II, III and IV; DS, deltoideus scapularis; EACR, extensor antebrachii et carpi radialis; EACU, extensor antebrachii et carpi ulnaris; ED, extensor digitorum; EDB, extensores digitorum breves; FACR, flexor antebrachii et carpi radialis; FACU, flexor antebrachii et carpi ulnaris; FAL, flexor accessorius lateralis; FAM, flexor accessorius medialis; FBP, flexores breves profundi; FBS, flexores breves superficiales; FDC, flexor digitorum communis; HAB, humeroantebrachialis; IMC, intermetacarpales; LD, latissimus dorsi; P, pectoralis; PCH, procoracohumeralis; PR-PEC, protractor pectoralis; PRQ, pronator quadratus; SCO, supracoracoideus; TC, THL, THM, TSM, coracoideus, humeralis lateralis, humeralis medialis and scapularis medialis sections of triceps brachii.

Table 9.3 Scheme illustrating the authors' hypotheses regarding the homologies of the forearm and hand muscles of adults of representative tetrapod taxa (see caption of Table 9.2, and also text, Tables 9.1 and 9.3, and Figs. 9.1–9.6). dor = dorsales, fbp = flexores breves profundi, int = intermetacarpales, t.fbs = tendons of flexores breves superficiales.

Ambystoma	*Timon*	*Ornithorhynchus*	*Rattus*	*Cynocephalus*	*Tupaia*	*Homo*
Pronator quadratus	Pronator quadratus	---	Pronator quadratus	---	Pronator quadratus	Pronator quadratus
---	Pronator accessorius	---	---	---	---	---
Contrahentium caput longum	---	---	---	---	---	---
Flexor accessorius lateralis	---	---	---	---	---	---
Flexor accessorius medialis	---	---	---	---	---	---
Flexor digitorum communis	Flexor digitorum longus	Flexor digitorum longus+ t. fbs	Flexor digitorum profundus	Flexor digitorum profundus	Flexor digitorum profundus	Flexor digitorum profundus
---	---	---	---	---	---	Flexor pollicis longus
---	---	---	Flexor digitorum superficialis	Flexor digitorum superficialis	Flexor digitorum superficialis	Flexor digitorum superficialis
---	---	---	Palmaris longus	Palmaris longus	Palmaris longus	Palmaris longus
Flexor carpi ulnaris	Flexor carpi ulnaris	Flexor carpi ulnaris	Flexor carpi ulnaris	Flexor carpi ulnaris	Flexor carpi ulnaris	Flexor carpi ulnaris
Epitrochleoanconeus	Epitrochleoanconeus	Epitrochleoanconeus	Epitrochleoanconeus	Epitrochleoanconeus	Epitrochleoanconeus	---
Flexor antebrachii et carpi radialis	Flexor carpi radialis	Flexor carpi radialis	Flexor carpi radialis	Flexor carpi radialis	Flexor carpi radialis	Flexor carpi radialis
---	Pronator teres	Pronator teres	Pronator teres	Pronator teres	Pronator teres	Pronator teres
Flexores breves superficiales	Flexores breves superficiales	--- (absent as a group, but see text)	--- (see text)	--- (see text)	--- (see text)	--- (see text)
---	---	---	Palmaris brevis	Palmaris brevis	Palmaris brevis	Palmaris brevis
---	---	---	---	Flexor brevis digitorum manus	Flexor brevis digitorum manus	---
---	Lumbricales	Lumbricales	Lumbricales	Lumbricales	Lumbricales	Lumbricales
Contrahentes digitorum	Contrahentes digitorum	--- (but see text)	Contrahentes digitorum	Contrahentes digitorum	Contrahentes digitorum	---
---	---	Adductor pollicis	Adductor pollicis	Adductor pollicis	Adductor pollicis	Adductor pollicis
---	---	---	---	---	---	Volaris primus of Henle'
Flexores breves profundi	Flexores breves profundi	Flexores breves profundi	Flexores breves profundi	Flexor brevis profundis 2	Flexor brevis profundis 2+	Flexor brevis profundis 2
				Interossei (fbp 3-9 + int 1-4)	Interossei (fbp 3-9 + int 1-4)	Interossei pal.1-3 (fbp 4,7,9)
---	---	---	---	---	---	Interossei dor. 1-4
---	---	---	Flexor pollicis brevis	Flexor pollicis brevis	Flexor pollicis brevis	Flexor pollicis brevis
---	---	---	---	---	---	Opponens pollicis
---	---	---	Flexor digiti minimi brevis	Flexor digiti minimi brevis	Flexor digiti minimi brevis	Flexor digiti minimi brevis
---	---	---	Opponens digiti minimi	---	---	Opponens digiti minimi
---	Abductor pollicis brevis	Abductor pollicis brevis	Abductor pollicis brevis	Abductor pollicis brevis	Abductor pollicis brevis	Abductor pollicis brevis
Abductor digiti minimi	Abductor digiti minimi	Abductor digiti minimi	Abductor digiti minimi	Abductor digiti minimi	Abductor digiti minimi	Abductor digiti minimi
Intermetacarpales	Intermetacarpales	--- (but see text)	Intermetacarpales	--- (see text)	--- (see text)	--- (see text)
---	Dorsometacarpales	--- (absent as a group, but see text)	--- (see text)	--- (see text)	--- (see text)	--- (see text)
Extensor antebrachii et carpi radialis	Extensor antebrachii et carpi radialis	Extensor carpi radialis	Extensor carpi radialis longus	Extensor carpi radialis longus	Extensor carpi radialis longus	Extensor carpi radialis longus
---	---	---	Extensor carpi radialis brevis	Extensor carpi radialis brevis	Extensor carpi radialis brevis	Extensor carpi radialis brevis
---	---	Brachioradialis	---	Brachioradialis	Brachioradialis	Brachioradialis
---	---	Supinator	Supinator	Supinator	Supinator	Supinator
Extensor antebrachii et carpi ulnaris	Extensor antebrachii et carpi ulnaris	Extensor carpi ulnaris	Extensor carpi ulnaris	Extensor carpi ulnaris	Extensor carpi ulnaris	Extensor carpi ulnaris
---	---	Anconeus	Anconeus	Anconeus	Anconeus	Anconeus
Extensor digitorum	Extensor digitorum	Extensor digitorum	Extensor digitorum	Extensor digitorum	Extensor digitorum	Extensor digitorum
Extensores digitorum breves	Extensores digitorum breves	--- (absent as a group, but see text)	--- (see text)	--- (see text)	--- (see text)	--- (see text)
---	---	Extensor digit minimi	Extensor digiti minimi	Extensor digiti minimi	Extensor digiti minimi	Extensor digiti minimi
---	---	---	Extensor digiti quarti	---	---	---
---	---	Extensor digiti III proprius	---	---	---	---
---	---	Extensor indicis	Extensor indicis	Extensor indicis	Extensor indicis	Extensor indicis
--- (edbI included in muscle below?)	---	Extensor pollicis longus	Extensor pollicis longus	Extensor pollicis longus	Extensor pollicis longus	Extensor pollicis longus
Abductor et extensor digiti 1	Abductor pollicis longus	Abductor pollicis longus	Abductor pollicis longus	Abductor pollicis longus	Abductor pollicis longus	Abductor pollicis longus
---	---	---	---	---	---	Extensor pollicis brevis

minor being derived from axial musculature (e.g., from the rectus abdominis) and being plesiomorphically attached to the pectoral girdle, not to the humerus (e.g., Lander 1918). Other authors suggested that it is in fact the pectoralis minor that corresponds to the pectoralis of other tetrapods, the pectoralis major being derived from other appendicular muscles (e.g., from the 'supracoracoideus' and/or 'axillary' groups sensu Jouffroy 1971; e.g., Howell 1937ab). However, most authors now accept that both the pectoralis major and pectoralis minor derive from the pectoralis of non-mammalian tetrapods (e.g., Kardong 2002; Warburton 2003; see also Chapter 10). In fact, the data now available on the innervation and development of the pectoralis major and pectoralis minor clearly supports this latter view (e.g., in the vast majority of mammals both these muscles are innervated by pectoral nerves, and they derive from the same anlage during the development of, e.g., the marsupial *Didelphis*: Romer 1944; Cheng 1955; Jouffroy 1971; Warburton 2003). This view is also supported by our own dissections (Tables 9.1–9.3). In monotremes such as *Ornithorhynchus*, the pectoralis is similar to that of non-mammalian tetrapods such as *Ambystoma* (Fig. 9.2). However, it is differentiated into an anterior, superficial component (pectoralis major) that is undivided and inserts on the humerus, and a posterior, deeper component (pectoralis minor) that is also undivided and that also attaches on the humerus, not to the pectoral girdle. In therian mammals such as the Norwegian rat, the pectoralis major attaches on the humerus and is divided into three sections, which seemingly correspond to the clavicular, sternocostal, and abdominal components of the pectoralis major of modern humans (Table 9.1). The pectoralis minor is also divided into three components corresponding to the 'cephalic' (attaching on the pectoral girdle and humerus, and equivalent to the 'pectoralis minor' of some authors), 'caudal' (attaching on the humerus, and equivalent to the 'pectoralis abdominis' of some authors), and 'tertius' (attaching on the pectoral girdle, and equivalent to the 'xiphiohumeralis' of some authors) components of the 'entopectoralis' sensu Lander (1918) (Table 9.1). In the tree-shrew *Tupaia*, the pectoralis major attaches to the humerus and is divided into two sections that seemingly correspond to the sternocostal and abdominal sections of the modern human pectoralis minor (the clavicular component being seemingly fused with the deltoideus clavicularis: Table 9.1). The pectoralis minor in *Tupaia* is divided into a 'cephalic' and a 'caudal' component sensu Lander (1918). The former attaches to the humerus and shoulder capsule; the latter attaches exclusively on the humerus. Contrary to the descriptions of Lander (1918), in the *Tupaia* specimens dissected by us neither of these two sections attaches directly on to the coracoid process (see also Le Gros Clark 1924; George 1977). The major subdivisions and distal attachments of the pectoralis major and pectoralis minor of colugos and modern humans are essentially similar:

the pectoralis major attaches to the humerus and is subdivided into clavicular, sternocostal and abdominal components; the undivided pectoralis minor attaches on the coracoid process of the scapula (Table 9.1). The data obtained from our dissections, comparisons and review of the literature therefore indicates that the plesiomorphic condition for extant mammals is to have a pectoralis minor inserting on the humerus, and not on the pectoral girdle as suggested by Lander (1918).

It is now accepted that the mammalian supraspinatus and infraspinatus, which usually connect the dorsal region of the pectoral girdle to the proximal region of the arm (Fig. 9.5), correspond to the supracoracoideus, a muscle that lies ventral, and not dorsal, to the pectoral girdle in most other extant tetrapods (Figs. 9.2, 9.5; Tables 9.1–9.3; e.g., Kardong 2002). It is also accepted that the coracobrachialis, brachialis and biceps brachii of mammals correspond to/derive from the coracobrachialis, humeroantebrachialis, and coracoradialis (a coracoradialis is found in, e.g., anurans: see Chapter 10) of non-mammalian tetrapods such as amphibians, and that the deltoideus scapularis, deltoideus clavicularis, deltoideus acromialis, teres minor and scapulo-humeralis anterior of the former correspond to the deltoideus scapularis and procoracohumeralis of the latter (Figs. 9.2, 9.4, 9.5; Tables 9.1–9.3; see also Chapter 10). The deltoideus scapularis, clavicularis and acromialis are fused into a single muscle in mammals such as modern humans (Tables 9.1–9.3).

There is still controversy regarding the origin of the mammalian dorsoepitrochlearis (Fig. 9.5). This is one of the examples where different lines of evidence apparently support different hypotheses of homology, thus stressing the importance of taking into account all the data available (see above). Some authors, mainly influenced by Cheng's (1955) study of the ontogeny of the muscles of the marsupial *Didelphis*, argue that the mammalian dorsoepitrochlearis corresponds to part of the latissimus dorsi of other tetrapods, because both these muscles seem to originate from the same developmental anlage (Jouffroy 1971; Jouffroy and Lessertisseur 1971; Warburton 2003). Regarding innervation, the situation found in the phylogenetically plesiomorphic monotremes is ambiguous; the dorsoepitrochlearis is apparently innervated by branches of the nerves innervating both the triceps brachii (radial nerve) and the latissimus dorsi (subscapular nerves) (Jouffroy and Lessertisseur 1971). In the vast majority of other mammals, however, including marsupials, the dorsoepitrochlearis is innervated solely by the radial nerve (Jouffroy 1971). This has led some authors to argue that the mammalian dorsoepitrochlearis corresponds to part of the triceps brachii, and not of the latissimus dorsi, of other tetrapods (e.g., Howell 1937b; Gibbs 1999). Our dissections and comparisons indicate that when all the lines of evidence are taken into account there is more support for an origin of the dorsoepitrochlearis from the triceps brachii.

In most mammals the dorsoepitrochlearis is effectively deeply mixed with the latissimus dorsi proximally and the triceps brachii distally (Fig. 9.5B). However, regarding its overall configuration and the direction of its fibers, the dorsoepitrochlearis is in general more similar to the triceps brachii than to the latissimus dorsi. As shown in, e.g., Fig. 9.5B, the dorsoepitrochlearis usually runs parallel to the triceps brachii, being almost, or completely, perpendicular to the proximal fibers of the latissimus dorsi with which it is associated. Its overall configuration, the direction of its fibers, and its relationship with other soft as well as hard tissues all suggest that the dorsoepitrochlearis is a medial, superficial component of the triceps brachii that instead of attaching proximally on the pectoral girdle attaches on the latissimus dorsi (Fig. 9.5B). Actually, it should be noted that in phylogenetically plesiomorphic therian mammals the dorsoepitrochlearis often inserts on the olecranon process of the ulna (as usually does the triceps brachii). Moreover, in various mammalian taxa, including primates such as new world monkeys and apes, the dorsoepitrochlearis is often partially originated from the scapula (the 'triceps coracoideus' of non-mammalian tetrapods usually has a scapular origin: see below).

The hypothesis that the dorsoepitrochlearis derives from the triceps brachii is also supported by phylogenetic parsimony. This is because, as shown in Table 9.1 and explained in Chapter 10, in various non-extant mammalian tetrapods the triceps brachii has actually four distinct components, or heads, and not three as in most extant mammals. According to various authors the long, medial and lateral heads of the triceps brachii of mammals correspond respectively to the 'scapularis', 'humeralis medialis' and 'humeralis lateralis' components of the triceps brachii of other tetrapods (e.g., Howell 1937b). That is, the component that is missing in extant mammals, the 'triceps coracoideus', is precisely a medial, superficial head of the triceps brachii that runs from the elbow to the pectoral girdle in most non-mammalian tetrapods (see, e.g., the descriptions of Walthall and Ashley-Ross 2006 and Fig. 9.2C). Thus, it is phylogenetically more parsimonious to assume that during the evolutionary transition leading to mammals the 'triceps coracoideus' was simply modified into a dorsoepitrochlearis, than to assume that it was completely lost and that in the course of the same evolutionary transition, a new muscle (that in many ways is very similar to the triceps coracoideus) was acquired through the differentiation of the latissimus dorsi. The former hypothesis does not force us to assume the loss of a certain structure, nor the emergence of a new one, whereas the latter hypothesis forces us to assume both. The fact that in various mammals the dorsoepitrochlearis is proximally attached to muscles other than the latissimus dorsi (e.g., teres major in tree-shrews: Table 9.1), also indicates that the association between these muscles was acquired secondarily. That is, originally the structure that became the

mammalian dorsoepitrochlearis was very likely not attached to the latissimus dorsi. In summary, we consider that all the available evidence supports this latter hypothesis, although the possibility that the dorsoepitrochlearis originated from the latissimus dorsi cannot be completely rejected (Table 9.2). We plan to address this issue in a future study.

Probably due in part to the fact that in various mammals the distal portion of the latissimus dorsi blends with the distal portion of the teres major and/or that the latter is attached to the proximal portion of the dorsoepitrochlearis, some authors have suggested that the teres major (Fig. 9.5) corresponds to part of the latissimus dorsi of non-mammalian tetrapods such as *Ambystoma* (e.g., Romer 1924, 1944; Howell 1935, 1937ab) (Table 9.1). Some textbooks continue to follow this view (e.g., Kardong 2002). However, most researchers now agree that the mammalian teres major corresponds to part of the subcoracoscapularis (Tables 9.1–9.3). In fact, the data now available regarding various lines of evidence, including development, innervation and topology, strongly supports this hypothesis (for instance, the subscapularis and teres major develop from the same anlage in mammals such as *Didelphis*; these two muscles are innervated by similar subscapular nerves in most mammals; they are also intimately related or even fused in various mammals: e.g., Cheng 1955; Jouffroy 1971; Jouffroy and Lessertisseur 1971; Warburton 2003; this work).

Appendicular Muscles of the Forearm and Hand (Tables 9.1, 9.3)

The muscles of the forearm and hand of tetrapods may be divided into three main groups: the ventral muscles of the forearm (usually flexors of the hand/digits and/or pronators of the forearm), the muscles of the hand (which are mainly ventral muscles and are often associated with the flexors of the hand/digits) and the dorsal muscles of the forearm (usually extensors of the hand/digits and/or supinators of the forearm) (Table 9.3).

As explained in Table 9.1 and shown in Table 9.3, the overall analysis of the data obtained from our dissections, comparisons and review of the literature allow well-supported hypotheses of homology to be established for most of the ventral forearm muscles. The mammalian pronator quadratus corresponds to the pronator quadratus of non-mammalian taxa such as *Ambystoma* (Fig. 9.2C), and the pronator accessorius found in 'lizards' and some other reptiles (Fig. 9.3C; see Chapter 10) is the result of the differentiation of part of this muscle (Tables 9.1–9.3). The flexor digitorum longus of 'lizards' such as *Timon* (Fig. 9.3C) corresponds to the flexor digitorum communis, flexor accessorius lateralis, flexor accessorius medialis and possibly contrahentium caput longum of urodeles such as *Ambystoma* (Fig. 9.2A, C; Tables 9.1–9.3). In monotremes the flexor digitorum longus blends with the tendons of the flexores breves superficiales,

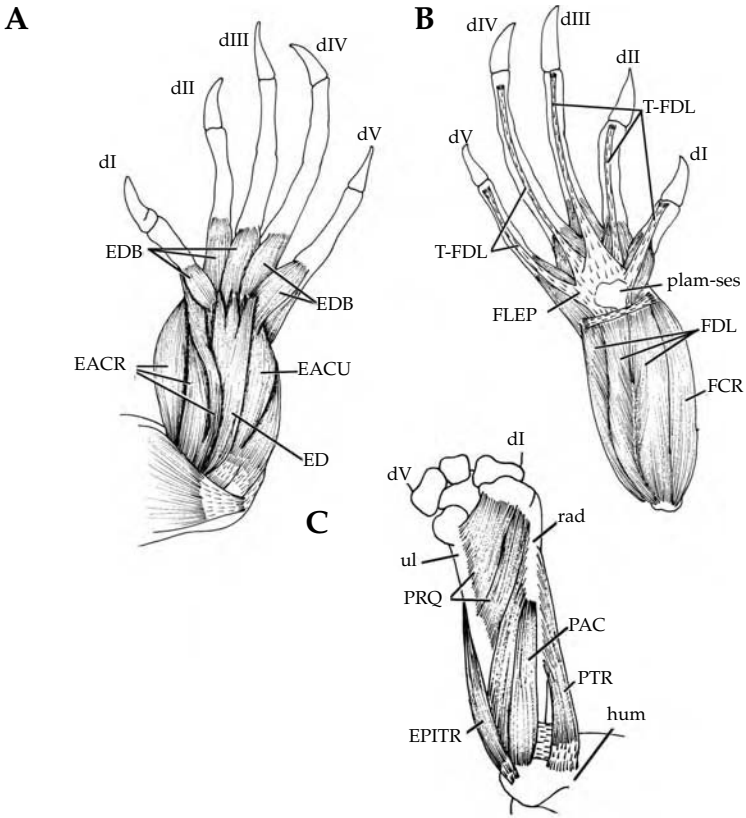

Fig. 9.3 *Phymaturus* sp. (Reptilia): **(A)** Dorsal view of the superficial musculature of the forearm; **(B)** Ventral view of the superficial musculature of the forearm; **(C)** Ventral view of the deep musculature of the forearm (anterior is towards the top of the figure; modified from Abdala and Moro 2006: the nomenclature of the structures illustrated follows that of the present work). dI, dII, dIII, dIV, dV, digits I, II, III, IV and V; EACR, extensor antebrachii et carpi radialis; EACU, extensor antebrachii et carpi ulnaris; ED, extensor digitorum; EDB, extensores digitorum breves; EPITR, epitrochleoanconeus; FCR, flexor carpi radialis; FDL, flexor digitorum longus; FLEP, flexor plate; hum, humerus; PAC, pronator accessorius; palm-ses, palmar sesamoid; PRQ, pronator quadratus; PTR, pronator teres; rad, radius; T-FDL, tendons of flexor digitorum longus; ul, ulna.

which are in fact ventral muscles of the hand (Fig. 9.4; Tables 9.1–9.3). In most other extant mammals the compound structure formed by the former muscle and the latter tendons is subdivided into a flexor digitorum profundus, a palmaris longus and a flexor digitorum superficialis. The flexor digitorum superficialis does not comprise exclusively the tendons of the flexores breves superficiales, for it also incorporates part of the fleshy belly of the flexor digitorum longus of, e.g., monotremes (Fig. 9.5; Tables

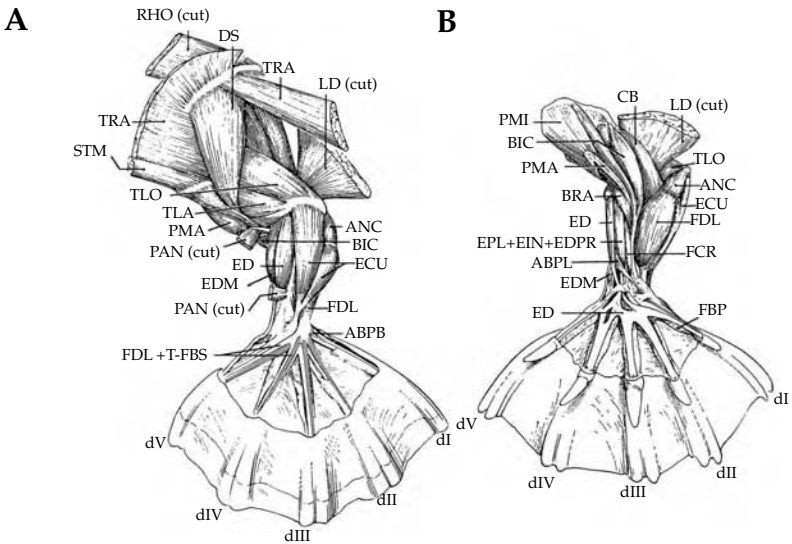

Fig. 9.4 *Ornithorhynchus anatinus* (Mammalia, Monotremata): **(A)** Showing dorsal musculature of the pectoral girdle, arm, forearm and ventral (palmar) musculature of hand; **(B)** Showing ventral musculature of the pectoral girdle, arm, forearm and dorsal musculature of hand (anterior is towards the top and the left of the figure; modified from Cuvier and Laurillard 1849 and Jouffroy and Lessertisseur 1971: the nomenclature of the structures illustrated follows that of the present work). ABPB, abductor pollicis brevis; ABPL, abductor pollicis longus; ANC, anconeus; BIC, biceps brachii; BRA, brachialis; CB, coracobrachialis; dI, dII, dIII, dIV, dV, digits I, II, III, IV and V; DS, deltoideus scapularis; ECU, extensor carpi ulnaris; ED, extensor digitorum; EDM, extensor digiti minimi; EDPR, extensor digiti III proprius; EIN, extensor indicis; EPL, extensor pollicis longus; FBP, flexores breves profundi; FCR, flexor carpi radialis; FDL, flexor digitorum longus; LD, latissimus dorsi; PAN, panniculus carnosus (cutaneous muscle); PMA, pectoralis major; PMI, pectoralis minor; RHO, rhomboideus; STM, sterno-mastoideus (branchial muscle); T-FBS, tendons of flexores breves superficiales; TLA, TLO, lateralis and longus sections of triceps brachii; TRA, trapezius (branchial muscle).

9.1–9.3). In a few mammals, including modern humans, there is a flexor pollicis longus, which is derived from the part of the flexor digitorum profundus that attaches to the first digit, or pollex (Lewis 1989; this work) (Tables 9.1–9.3). The flexor carpi radialis, pronator teres ('flexor antebrachii radialis'), flexor carpi ulnaris and epitrochleoanconeus ('flexor antebrachii ulnaris') of mammals correspond to the same muscles in other tetrapods. Urodeles such as *Ambystoma* have an undivided flexor antebrachii et carpi radialis, but a distinct pronator teres is found in amphibians such as anurans (Tables 9.1–9.3 and Figs. 9.2–9.5; see Chapter 10).

There is empirical evidence supporting the contention that at least some of the 'palmaris longus' muscles of tetrapods are not homologous. For instance, some mammalian taxa have two 'palmaris longus' muscles,

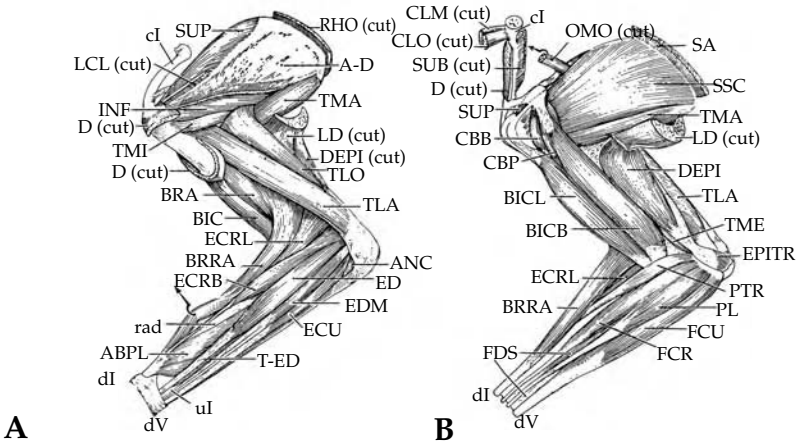

Fig. 9.5 *Macaca mulatta* (Mammalia, Primates): **(A)** Dorsal view of the musculature of the pectoral girdle, arm and forearm; **(B)** Ventral view of the musculature of the pectoral girdle, arm and forearm (anterior is towards the top and the left of the figure; modified from Howell and Straus 1933, and Jouffroy 1971: the nomenclature of the structures illustrated follows that of the present work). ABPL, abductor pollicis longus; A-D, aponeurosis of deltoideus; ANC, anconeus; BIC, biceps brachii; BICL, BICB, longus and brevis (short) sections of biceps brachii; BRA, brachialis; BRRA, brachioradialis; CBB, CBP, brevis and proprius sections of the coracobrachialis; cl, clavicle; CLM, cleido-mastoideus (branchial muscle); CLO, cleido-occipitalis (branchial muscle); D, deltoideus; dI, dV, digits I and V; DEPI, dorsoepitrochlearis; ECRB, extensor carpi radialis brevis; ECRL, extensor carpi radialis longus; ECU, extensor carpi ulnaris; ED, extensor digitorum; EDM, extensor digiti minimi; EPITR, epitrochleoanconeus; FCR, flexor carpi radialis; FCU, flexor carpi ulnaris; FDS, flexor digitorum superficialis; INF, infraspinatus; LCL, levator claviculae; LD, latissimus dorsi; OMO, omohyoideus (hypobranchial muscle); PL, palmaris longus; PTR, pronator teres; rad, radius; RHO, rhomboideus; SA, serratus anterior; SSC, subscapularis; SUB, subclavius; SUP, supraspinatus; T-ED, tendon of extensor digitorum; TLA, TLO, TME, lateralis, longus and medialis sections of triceps brachii; TMA, teres major; TMI, teres minor; ul, ulna.

one being derived from the flexor digitorum superficialis and innervated by the median nerve, the other derived from the flexor carpi ulnaris and innervated by the ulnar nerve (e.g., Straus 1942; Jouffroy 1971). According to Straus (1942), most of the 'palmaris longus' muscles of mammals are derived from the flexor digitorum superficialis; some are derived from the flexor carpi ulnaris, and a few from the flexor carpi radialis (in his view, this is the case in primates). Jouffroy (1971) states that when the mammalian 'palmaris longus' is derived from either the flexor digitorum superficialis or the flexor carpi radialis, it is always innervated by the median nerve. Only when it is derived from the flexor carpi ulnaris is it at least partially innervated by the ulnar nerve. Our dissections suggest that the 'palmaris longus' muscles of the therian mammals listed in Tables 9.1–9.3 are very likely homologous and are derived from neither the flexor carpi ulnaris nor the flexor carpi radialis, although this latter hypothesis cannot be

completely discarded in the case of modern humans. The 'palmaris longus' of rats blends with the proximal portion of the flexor carpi ulnaris, but it is innervated by the median nerve so it is very likely not derived from the latter muscle (e.g., Greene 1935; this work). The 'palmaris longus' of tree-shrews and colugos are also innervated by the median nerve, and their configuration suggests they derive from the flexor digitorum superficialis (e.g., Le Gros Clark, 1924, 1926; George 1977; this work). It is therefore not parsimonious to assume that the common ancestor of colugos, tree-shrews and primates had a 'palmaris longus' muscle derived from the flexor brevis superficialis, and that during the course of the transition to primates that muscle was lost, and a new 'palmaris longus', morphologically similar to the former, but derived from the flexor carpi radialis, was acquired.

The homologies of the hand muscles have been the subject of numerous discussions and remain controversial. Examples of mammalian hand muscles include the following: the palmaris brevis and flexor brevis digitorum manus, which are ventral (palmar, superficial) to the other muscles and are often poorly developed or absent; the abductor pollicis brevis and abductor digiti minimi, which usually lie on the ventrolateral (radial) and ventromesial (ulnar) surface of the hand and abduct the most lateral and most medial digits, respectively; the lumbricales, which are deeper and are usually associated with the tendons of the flexor digitorum profundus, being often related to the extension and/or flexion of different parts of the digits; the contrahentes digitorum, which are deep to the lumbricales and often adduct the digits; the flexores breves profundi, which usually are deep to the contrahentes digitorum and which are biccipital, inserting, respectively, on the radial (lateral) and ulnar (medial) sides of the digits, and being mainly associated with the abduction, adduction, flexion and/or extension of different parts of the digits; and the intermetacarpales, which are the deepest (most dorsal) muscles of the hand and are usually related to the abduction of the digits. The dorsometacarpales are not present as independent muscles in extant mammals (Tables 9.1–9.3 and Figs. 9.4, 9.5).

As shown in Tables 9.1 and 9.3 and explained above, in extant mammals the flexores breves superficiales are not present as a group, but some of the mammalian muscles do include/correspond to part of these muscles. This is precisely the case with the palmaris brevis and flexor brevis digitorum manus. This is also the case with the tendons that are fused with the monotreme flexor digitorum longus and incorporated into the therian flexor digitorum superficialis (Tables 9.1–9.3 and Fig. 9.4A; see above and, e.g., Howell 1936a; Straus 1942; Jouffroy 1971; Lewis 1989). As convincingly argued by Lewis (1989), the abductor pollicis brevis and abductor digiti minimi of mammals (Fig. 9.6) do not correspond to part of the flexores breves superficiales of other tetrapods. In fact, our dissections confirm the observations in the literature that the flexores breves superficiales, abductor pollicis

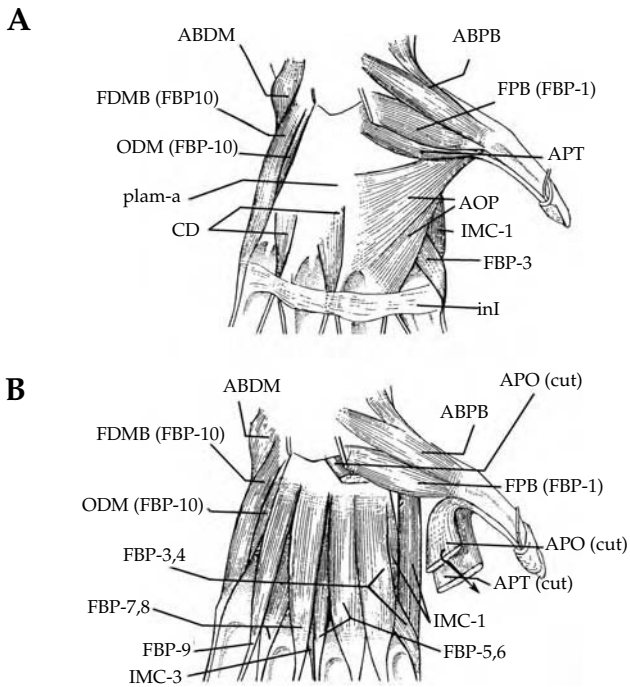

Fig. 9.6 *Pan troglodytes* (Mammalia, Primates): **(A)** Ventral (palmar) view, contrahentes layer; **(B)** Ventral (palmar) view, the contrahentes to digits IV and V were removed, and that to digit 1 was cut (the proximal region of the hand is towards the top of the figure; modified from Forster 1917 and Jouffroy, 1971: the nomenclature of the structures illustrated follows that of the present work). ABDM, abductor digiti minimi; ABPB, abductor pollicis brevis; APO, APT, obliquus and transversus sections of adductor pollicis; CD, vestigial, aponeurotic contrahentes digitorum to digits IV and V; FBP-1,3,4,5,6,7,8,9,10, flexores breves profundi 1, 3, 4, 5, 6, 7, 8, 9, and 10; FDMB, flexor digiti minimi brevis; FPB, flexor pollicis brevis; inl, intercapitular ligaments; IMC-1,3, intermetacarpales 1 and 3; ODM, opponens digiti minimi; palm-a, palmar aponeurosis.

brevis, and abductor digiti minimi may coexist in various non-mammalian tetrapods (Tables 9.1–9.3). The lumbricales, contrahentes digitorum, flexores breves profundi and intermetacarpales are also found in tetrapods other than mammals (Tables 9.1–9.3; see also Chapter 10).

The first contrahens digitorum (to digit 1) is highly developed in many mammals, and is sometimes divided into transverse and oblique heads; many researchers use the name adductor pollicis to designate this muscle (Tables 9.1–9.3 and Fig. 9.5). In various mammals, including modern humans, the other contrahentes digitorum are aponeurotic (Fig. 9.6) or absent as independent structures. Interestingly, early in their ontogeny modern humans have four contrahentes digitorum. That of digit 1 gives

rise to the well-developed adductor pollicis, with perhaps some contribution of that of digit 2; those of digits 4 and 5, as well as part of that of digit 2, apparently become incorporated into the dorsal interossei (e.g., Cihak 1972). Therefore, the main difference between adult mammals such as chimpanzees (Fig. 9.6) and modern humans may be that in the former the contrahentes digitorum to digits 4 and 5 do not become completely incorporated ontogenetically into the interossei muscles, persisting as independent, although highly reduced and aponeurotic, structures in later developmental stages.

According to Lewis (1989) the plesiomorphic condition for mammals, and probably also for primates, is to have 10 flexores breves profundi inserting on the lateral (radial) and medial (ulnar) sides of the five digits. It should be noted that each of the 10 flexores breves profundi sensu Lewis corresponds to one of the two heads of each of the five biccipital flexores breves profundi sensu Haines (1950, 1955) and other authors. That is, the flexores breves profundi 1 and 2 sensu Lewis correspond respectively to the radial and ulnar head of the flexor brevis profundus 1 (to digit 1) sensu Haines, the flexores breves profundi 3 and 4 of Lewis correspond to the radial and ulnar head of the flexor brevis profundus 2 (to digit 2) sensu Haines, and so on. According to Lewis (1989) each of the palmar interossei of primates such as chimpanzees corresponds directly to one of the flexores breves profundi of non-mammalian tetrapods. In his view, mammals such as chimpanzees therefore have 9 flexores breves profundi (Fig. 9.6): the flexor pollicis brevis + opponens pollicis inserting on digit 1 and metacarpal I (= 'flexor brevis profundus 1'), a first palmar interosseous inserting on the lateral side of digit 2 (= 'flexor brevis profundus 3'), a second palmar interosseous inserting on the medial side of digit 2 (= 'flexor brevis profundus 4'), a third palmar interosseous inserting on the lateral side of digit 3 (= 'flexor brevis profundus 5'), a fourth palmar interosseous inserting on the medial side of digit 3 (= 'flexor brevis profundus 6'), a fifth palmar interosseous inserting on the lateral side of digit 4 (= 'flexor brevis profundus 7'), a sixth palmar interosseous inserting on the medial side of digit 4 (= 'flexor brevis profundus 8'), a seventh palmar interosseous inserting on the lateral side of digit 5 (= 'flexor brevis profundus 9'), and the flexor digiti minimi brevis + opponens digiti minimi inserting on the medial side of digit 5 and of metacarpal V (= 'flexor brevis profundus 10'). A palmar interosseous inserting on the medial side of digit 1 (= 'flexor brevis profundus 2') may be found in a few *Pan* specimens: these specimens thus exhibit all the ten flexores breves profundi (Lewis 1989; this work). According to this scenario, the three palmar interossei inserting respectively on the medial side of digit 2, the lateral side of digit 4 and the lateral side of digit 5 in modern humans correspond to the flexores breves profundi 4, 7 and 9 (i.e., to the second, fifth and seventh of the

seven palmar interossei found in most chimpanzees). The flexores breves profundi 3, 5, 6 and 8 of modern humans (which correspond to the first, third, fourth and sixth of the seven palmar interossei found in most chimpanzees) fuse with the intermetacarpales (and eventually also with some contrahentes digitorum and/or some dorsometacarpales) to form the four dorsal interossei (Cihak 1972; Lewis 1989) (Tables 9.1–9.3). As a consequence the 'dorsal interossei' of mammals are not necessarily equivalent. For example, the four 'dorsal interossei' of chimpanzees are not equivalent to the four dorsal interossei of modern humans, because they receive little or no contribution from the flexores breves profundi. That is, they essentially correspond to the intermetacarpales of non-mammalian tetrapods, although they may eventually also include part of the contrahentes digitorum and/or of the dorsometacarpales, as explained above (Tables 9.1–9.3 and Fig. 9.6). It should be noted that adult modern humans often have a small muscle inserting on the ulnar side of digit I, which is often named 'interosseous volaris primus of Henle' (Tables 9.1–9.3). According to some authors, this small muscle probably corresponds to the 'flexor brevis profundus 2' of other tetrapods (see, e.g., Abramowitz 1955; Lewis 1989; Susman et al. 1999); however, our dissections, comparisons and review of the literature indicate that it is more likely derived from the adductor pollicis (Diogo et al., in preparation; see Table 10.3). In the studies of Abramowitz (1955), Lewis (1989), Susman et al. (1999) and Henkel-Kopleck and Schmidt (2000), the 'interosseous volaris primus of Henle' was found in 100%, in 92%, in 86%, and in 69% of the adult human bodies examined, respectively. That is, this muscle does seem to be present in the majority of adult modern humans; that is why it is listed in Tables 9.1 and 9.3.

Some authors consider that the intermetacarpales, contrahentes digitorum (excluding the adductor pollicis) and dorsometacarpales are missing in monotremes (e.g., Howell 1937d; Jouffroy and Lessertisseur 1971). Our dissections of *Ornithorhynchus* confirm that these muscles are effectively not present as independent structures in this taxon. However, as in mammals such as modern humans at least some of these muscles fuse with the flexores breves profundi (e.g., to form the dorsal interossei: see above), the possibility that in monotremes at least parts of them are incorporated into the flexores breves profundi cannot be ruled out (Tables 9.1–9.3). A detailed ontogenetic study of the hand muscles in monotremes, such as the one undertaken by Cihak (1972) in modern humans, is needed to clarify this issue.

The detailed analysis of the data obtained from our dissections, combined with the information provided in the literature, have allowed us to develop robust hypotheses of homology for most of the dorsal muscles of the forearm. The extensor carpi radialis longus, extensor carpi radialis brevis, brachioradialis and supinator of mammals (Fig. 9.5) clearly

correspond to the extensor antebrachii et carpi radialis of tetrapods such as *Ambystoma* (Fig. 9.2) (Tables 9.1–9.3; note that some reptiles do have a 'brachioradialis' muscle that seems to be homologous to the mammalian brachioradialis: see Fig. 10.12 and Chapter 10). In fact, according to some authors, in some urodeles, e.g. *Necturus*, part of the extensor antebrachii et carpi radialis is differentiated into at least one of the four former muscles (e.g., Haines 1939; Jouffroy 1971; Jouffroy and Lessertisseur 1971; Lewis 1989; Meers 2003) (see Table 9.1 and Chapter 10). In mammals such as modern humans part of the abductor pollicis longus forms the extensor pollicis brevis (e.g., Jouffroy 1971; Kaneff 1980a; Lewis 1989; this work) (Tables 9.1–9.3). Most authors consider that, contrary to the condition in other tetrapods, in extant mammals the extensores digitorum breves are not present as a group. This is because mammals often lack some of these muscles, and the ones that remain are usually considered to be functionally independent from each other (e.g., modern humans usually lack short extensors to digits 3 and 4; Tables 9.1–9.3; see also, e.g., Howell 1936b; Haines 1939; Jouffroy 1971; Jouffroy and Lessertisseur 1971; Lewis 1989). However, it should be noted that the outcome of our dissections, comparisons and review of the literature suggest that the first mammals may well have had four, or even five, muscles corresponding to the extensores digitorum breves of other tetrapods. In fact, the phylogenetically most plesiomorphic extant mammals, the monotremes, have four muscles that seemingly correspond to the extensores digitorum breves of other tetrapods (the extensor pollicis longus, extensor indicis, extensor digiti III proprius, and extensor digiti minimi: Tables 9.1–9.3). Moreover, a fifth short extensor, the extensor digiti quarti, is found in some therian mammals such as rats (Tables 9.1–9.3). The extensor digiti minimi of mammals such as tree-shrews (which usually inserts on digits 4 and 5) seems to correspond to the extensores digitorum breves of digits 4 and 5 of other tetrapods and, thus, to the extensor digiti minimi and extensor digiti quarti of rats (Tables 9.1–9.3). The extensor indicis of mammals such as rats and tree-shrews (which usually inserts on digits 2 and 3) seems to correspond to the extensores digitorum breves of digits 2 and 3 of other tetrapods and, thus, to the extensor digiti III proprius and extensor indicis of monotremes (Tables 9.1–9.3). A detailed comparative investigation of the development and innervation of the short extensors in tetrapods is, however, needed to clarify the exact homologies between the muscles of amphibians, reptiles, monotremes, marsupials and placentals.

Some authors have stated that the anconeus, a small muscle situated on the dorsal region of the elbow (Figs. 9.4, 9.5), is derived from the triceps brachii (e.g., Howell 1936b, 1937b). However, it is now commonly accepted that this small muscle corresponds to part of the extensor antebrachii et carpi ulnaris of taxa such as *Ambystoma* and *Timon* (e.g., Haines 1939;

Jouffroy 1971; Jouffroy and Lessertisseur 1971; Lewis 1989) (Tables 9.1–9.3 and Figs. 9.2, 9.3). In fact, in some non-mammalian tetrapods this latter muscle is also divided into an extensor carpi radialis and an anconeus (this latter muscle is also referred to as 'extensor antebrachii ulnaris'; Haines 1939; Jouffroy 1971; Jouffroy and Lessertisseur 1971; see Chapter 10). According to Lewis (1989: 133), the intimate relationship between the anconeus and the triceps brachii is "clearly a secondary feature" because in reptiles such as *Sphenodon* the anconeus and the triceps brachii are clearly distinct. Lewis exposes the flaw in the argument that the mammalian anconeus is derived from the triceps brachii because it is innervated by the radial nerve, by pointing out that "the nerve that supplies the anconeus of mammals is merely the attenuated remnant of a branch (sometimes called nerve extensorius caudalis) which enters the forearm to join the posterior interosseous nerve (nerve extensorius caudalis) in more primitive tetrapods and participate in the nerve supply of the forearm extensor musculature". Shellswell and Wolpert's (1977) elegant study of the development of the chicken forelimb muscles strongly supports the proposal that, at least in this tetrapod taxon, the anconeus is effectively derived from the extensor antebrachii et carpi ulnaris, and not from the triceps brachii (see also Chapter 10).

General Remarks

With respect to changes in the number of pectoral and forelimb muscles, the most striking transition within sarcopterygian evolutionary history was that leading to the origin of tetrapods (Tables 9.1–9.3). While extant sarcopterygian fish have an abductor and an adductor of the fin and mainly undifferentiated hypaxial and epaxial musculature, extant salamanders such as *Ambystoma* and *Taricha* have more than 40 pectoral and forelimb muscles (including all the intrinsic muscles of the hand, such as the flexores breves superficiales and flexores breves profundi; Walthall and Ashley-Ross 2006; this work). Contrary to what is often stated in general textbooks (e.g., Kisia and Onyango 2005), there is no clear increase in the number of pectoral and forelimb muscles at the time of the evolutionary transition leading to mammals, and there is certainly no increase at the time of the transition leading to the emergence of 'higher' primates and modern humans. In fact, within the amniotes listed in Tables 9.1–9.3, humans are those with a smaller number of pectoral and forelimb muscles (about 60 muscles in total). One of the regions where modern humans clearly have a smaller number of muscles than many other tetrapods is precisely the one that supposedly make us so special: our hand. For example, whereas modern humans usually have 20 intrinsic muscles of the hand (1 palmaris brevis + 4 lumbricales + 1 adductor pollicis + 3 palmares interossei + 4 dorsales

interossei + 1 flexor pollicis brevis + 1 opponens pollicis + 1 flexor digiti minimi brevis + 1 opponens digiti minimi + 1 abductor digiti minimi + 1 abductor pollicis brevis + 1 'interosseous volaris primus of Henle'), 'lizards' such as *Polychrus* may have more than 35 (see, e.g., Moro and Abdala 2004). The mobility of the hand and its digits is, of course, only partly related to the number of hand muscles, and what does make humans special in terms of hand manipulation is actually the mobility of, and the differentiation of peculiar muscles (e.g., extensor pollicis brevis) associated with, the thumb (e.g., Lewis 1989; see Chapter 10). The relationship between the number of muscles, muscular evolution, and anatomical complexity will be discussed in more detail in Chapter 11.

Chapter 10

Pectoral and Forelimb Muscles of Limbed Amphibians and Reptiles

Chapter 9 mainly focused on the Sarcopterygii as a whole (including extant actinistians, dipnoans and tetrapods), and particularly on how the pectoral and pectoral fin/forelimb muscles have evolved during the transitions from sarcopterygian fish and non-mammalian tetrapods to monotreme and therian mammals and namely to modern humans. Within the seven taxa included in the tables provided in that chapter, five were mammals. The two other taxa, *Ambystoma* and *Timon*, were included in those tables to show the general hypotheses of homology between the muscles of these five mammalian taxa and the muscles of amphibians such as urodeles and reptiles such as lepidosaurs. In Chapter 10, we turn our focus to the major groups of limbed amphibians and reptiles, that is, urodeles, anurans, lepidosaurs, crocodylians, birds, and turtles. The tables in this chapter thus include *Ambystoma* and *Timon* as representative members of urodelan amphibians and of lepidosaurian reptiles, but they also include *Bufo*, *Caiman*, *Gallus* and *Trachemys* as representative members of anuran amphibians and of crocodylians, birds and turtles, respectively (adult extant caecilian amphibians lack a pectoral girdle and also lack limbs and, thus, their pectoral and forelimb musculature is extremely reduced: these amphibians are therefore not discussed in the present chapter; see, e.g., Carroll 2007).

Many anatomical works have provided information about the pectoral and forelimb muscles of amphibians and reptiles (e.g., Mivart 1869; Humphry 1872ab; Fürbringer 1876; Ecker 1889; Gaupp 1896; McMurrich 1903ab; Ribbing 1907, 1938; Romer 1922, 1924, 1944; Howell 1935, 1936ab;

Haines 1939, 1950; Straus 1942; Sullivan 1962, 1967; Grim 1971; Hudson et al. 1972; Walker 1973; Holmes 1977; Ghetie et al. 1981; Duellman and Trueb 1986; Russell 1988; Manzano 1996; Burton 1998; Dilkes 2000; Wyneken 2001; Meers 2003; Walthall and Ahsley-Ross 2006; Maxwell and Larsson 2007; Russell and Bauer 2008). However, most of these works have focused on a specific taxon and/or a specific pectoral or forelimb region, and none of them has actually provided detailed information about the homologies of all the pectoral and forelimb muscles of urodeles, anurans, lepidosaurs, crocodylians, birds, and turtles. The present account of the comparative anatomy, homologies and evolution of the forelimb and pectoral muscles of these groups is based on the results of our own recent dissections of various members of each of these groups, combined with an exhaustive literature review. As the results of our observations and comparisons are summarized in Tables 10.1–10.3, we will briefly summarize, below, the information presented in these tables and pay special attention to issues that remain particularly controversial among morphologists. We should note that in this book we follow the interpretation that has been commonly supported in the studies of fossils and of hox genes, and thus consider that the three digits that are usually present in adult birds are digits 1, 2 and 3, and not digits 2, 3 and 4, as is often suggested by the authors of embryological studies (for recent reviews on this subject, see, e.g., Burke and Feduccia 1997; Galis et al. 2003, 2005; Vargas and Fallon 2005ab; Vargas et al. 2008; Kundrát 2009). However, to make this clear, we always also state, in parentheses, which is the number of the digit according to most embryologists. So, for instance, if we refer to the most radial digit of adult chickens, we state "digit 1 (i.e., digit 2 according to most embryologists)". We consider that this is a clear, simple, and also neutral way of referring to the avian digits.

Pectoral Muscles Derived from the Postcranial Axial Musculature (Tables 10.1–10.2)

Amphibian and reptilian taxa have six pectoral muscles derived from the postcranial axial musculature: serratus anterior, rhomboideus, levator scapulae, opercularis, sternocoracoideus and costocoracoideus. These six muscles mainly connect the axial skeleton to the pectoral girdle and are thus associated with the movements of this girdle (see Chapter 9). Authors such as Kardong (2002) suggested that reptiles do not have a rhomboideus, but Howell (1935, 1936a, 1937b), Sullivan (1962, 1967), Hudson et al. (1972), Duellman and Trueb (1986) and Dilkes (2000), among others, argued that crocodylians, birds, and at least some anurans do have a 'rhomboideus'. For instance, Howell (1935, 1937b) and Duellman and Trueb (1986) described a 'rhomboideus anterior' and a 'rhomboideus posterior' in anurans such

as *Rana*. Our dissections confirmed the presence of these two structures in frogs such as *Bufo* (Tables 10.1–10.2). Howell (1936a), Dilkes (2000) and Meers (2003) also described a 'rhomboideus' in crocodylians, and Howell (1937b), Sullivan (1962, 1967), Hudson et al. (1972), and Dilkes (2000) reported a 'rhomboideus superficialis' and a 'rhomboideus profundus' in birds. These descriptions are also confirmed by our dissections (Tables 10.1–10.2). To our knowledge, a 'rhomboideus' has never been described in lepidosaurs or turtles, and we were effectively unable to find this structure in the turtles and lepidosaurs we dissected (Tables 10.1–10.2). In one of the most detailed reviews of mammalian pectoral and forelimb muscles, Jouffroy (1971) stated that the mammalian rhomboideus is homologous to the 'basiscapularis' of 'lower tetrapods', thus supporting the idea that at least some extant non-mammalian tetrapods do have a muscle that is homologous to the rhomboideus of mammals. Our dissections and comparisons also corroborate that the overall configuration and the proximal and distal attachments of the 'rhomboideus' of anurans, crocodylians and birds are effectively similar to those of the rhomboideus of mammals, and, thus, that these structures are probably homologous (see Tables 10.1–10.2). However, further studies, ideally including a detailed analysis of the innervation and development of the 'rhomboideus' of numerous amphibians and reptiles, are needed to investigate whether or not the 'rhomboideus' of these taxa is homologous to the mammalian rhomboideus.

The levator scapulae is not present as a distinct muscle in birds (Tables 10.1–10.2). As noted by Hetherington and Tugaoen (1990), in urodeles such as *Ambystoma* the muscle that is often named 'opercularis' clearly corresponds to part of the levator scapulae sensu this volume, which, in anurans such as *Rana*, is completely differentiated into two distinct muscles, the levator scapulae superioris and the opercularis sensu this volume (Tables 10.1–10.2). Therefore, the name opercularis should only be used for anurans (according to Carroll 2007, it is possible that the last common ancestor of all caecilians had a levator scapulae extending from the margin of an 'operculum'-like structure to the suprascapula, but this muscle is missing in extant caecilians). Piatt (1938), based on his developmental study of *Ambystoma*, suggested that the levator scapulae of this taxon derives from somites 2–4, together with the hypobranchial muscles. The recent ontogenetic work of Piekaski and Olsson (2007) indicated, in turn, that in *Ambystoma* the levator scapulae derives mainly from somite 3, being innervated by the first spinal nerve and also by the nerve hypoglossus, which is somewhat unexpected because this latter nerve is effectively usually associated with the hypobranchial muscles (see, e.g., Chapters 2–7). However, Piekaski and Olsson (2007) did show that the development and innervation of the levator scapulae are different from the innervation and development of the branchial muscle protractor pectoralis ('cucullaris'), thus contradicting that the levator scapulae of urodeles derives from the protractor pectoralis, as was

Table 10.1 Pectoral and forelimb muscles of adults of representative amphibians and reptilian taxa. The nomenclature of the muscles shown in bold follows that of the text; in order to facilitate comparisons, in some cases names often used by other authors to designate a certain muscle/bundle are given in front of that muscle/bundle, in parentheses; additional comments are given in square brackets. Data compiled from evidence provided by our own dissections and comparisons and by an overview of the literature (see text, Tables 10.2 and 10.3, and Figs. 10.1–10.13).

Amphibia (Caudata): *Ambystoma ordinarium* (Michoacan stream salamander)	Amphibia (Anura): *Bufo arenarum* (Argentine common toad)	Reptilia (Testudines): *Trachemys scripta* (Red-eared slider turtle)	Reptilia (Lepidosauria): *Timon lepidus* (Ocellated 'lizard')	Reptilia (Crocodylia): *Caiman latirostris* (Brown-snouted caiman)	Reptilia (Aves): *Gallus domesticus* (Chicken)
Serratus anterior (part of serrati sensu Howell 1937a)	**Serratus anterior** (part of serrati sensu Howell 1935, 1937b)	**Serratus anterior** [the 'testocoracoideus' sensu Gaunt and Gans 1968 and others probably corresponds to part or all of the serratus anterior sensu this volume: see, e.g., Wyneken 2001]	**Serratus anterior** (serratus ventralis sensu Kardong and Zalisko 1998 and Kardong 2002) [according to Holmes 1977, Dilkes 2000, Tsuihiji 2007 and others, lepidosaurs, crocodylians and birds have a 'serratus superficialis' and a 'serratus profundus'; according to Holmes 1977, the 'serratus profundus' corresponds to the serratus anterior]	**Serratus anterior** (serratus ventralis sensu Meers 2003)	**Serratus anterior**
—	**Rhomboideus** [according to Howell 1935, 1937b there is a 'rhomboideus' in anurans such as *Rana*, but not in urodeles; see text]	— [seemingly not present as a distinct muscle in turtles; see text]	— [see text]	**Rhomboideus** ['rhomboideus' is present in crocodylians according to Howell 1936a, Dilkes 2000 and Meers 2003; see text]	**Rhomboideus** ['rhomboideus' is present in birds according to Howell 1937b, Sullivan 1962, 1967 and Dilkes 2000, see on the left; Sullivan 1962, 1967 describes a 'rhomboideus superficialis' and

					a 'rhomboideus profundus' in chickens; see text]
Levator scapulae (thoracico-scapularis sensu Jouffroy 1971; levator scapulae superioris sensu Hetherington and Tugaoen 1990; opercularis sensu Walthall and Ashley-Ross 2006 and Piekarski and Olsson 2007; includes the collumellaris and the opercularis sensu Duellman and Trueb 1986 and Carroll 2007) [see text]	**Levator scapulae superioris** (levator scapulae sensu Howell 1935, 1937b) [see text]	**Levator scapulae**	**Levator scapulae** [according to Holmes 1977, Dilkes 2000 and others, in lepidosaurs, including *Sphenodon*, the levator scapulae is usually divided into superficial and deep heads]	**Levator scapulae** [according to Holmes 1977, Dilkes 2000, Meers 2003, Tsuihiji 2007 and others, all the Crocodylia have a mainly undivided levator scapulae; according to Holmes 1977, the 'levator scapulae profundus' portion of the 'collothoraciscapularis profundus' sensu Fürbringer 1876 appears to be part of the serratus musculature, and not of the levator scapulae sensu this volume]	— [according to Dilkes 2000 and others, in birds the levator scapulae is not present as an independent muscle]
— [absent as an independent muscle, see text]	**Opercularis** (colummelaris sensu Carroll 2007) [seemingly only found as an independent muscle in anurans, see text]	—	—	—	—
— [Mivart 1869 suggested that the subclavius could be part of the procoracohumeralis of amphibians, but according to Romer 1924	— [see on the left]	— [see on the left]	**Sternocoracoideus** (sternocoracoid superior and inferior sensu Howell 1937b) [Holmes 1977 and Dilkes 2000 state that in lepidosaurs, including *Iguana* and *Sphenodon*,	— [according to Fürbringer 1876, Walker 1973, Holmes 1977, Dilkes 2000 and others, the sternocoracoideus is not present as an independent muscle	**Sternocoracoideus** [according to Dilkes 2000 and others, the sternocoracoideus is present in birds]

Table 10.1 contd...

Table 10.1 contd...

Amphibia (Caudata): *Ambystoma ordinarium* (Michoacan stream salamander)	Amphibia (Anura): *Bufo arenarum* (Argentine common toad)	Reptilia (Testudines): *Trachemys scripta* (Red-eared slider turtle)	Reptilia (Lepidosauria): *Timon lepidus* (Ocellated 'lizard')	Reptilia (Crocodylia): *Caiman latirostris* (Brown-snouted caiman)	Reptilia (Aves): *Gallus domesticus* (Chicken)
this latter muscle gives rise to mammalian muscles such as the teres minor and the deltoideus clavicularis instead; according to Howell 1937b, the sternocoracoideus and costocoracoideus are not present as distinct muscles in urodeles and anurans, then, reptiles such as *Iguana* have a costocoracoideus and a sternocoracoideus superior and inferior, then mammals such as *Ornithorynchus* have a costocoracoideus and a sternocoracoideus and then placental mammals have a 'costoscapularis' and a subclavius, which thus seems to correspond to the sternocoracoideus of other tetrapods]			the sternocoracoideus is present and is divided into superficial and deep heads]	in turtles and in crocodylians]	
— [see above]	— [see above]	— [according to Walker 1973, the costocoracoideus is not present as a distinct muscle in turtles]	**Costoscoracoideus** (costoscapularis sensu Howell 1936a, 1937b and Holmes 1977; costosternocoracoideus	**Costoscoracoideus** (costosternocoracoideus sensu Holmes 1977 and Dilkes 2000) [according to Meers	— [according to Dilkes 2000 and others, the costocoracoideus is not present as an independent muscle in birds]

			sensu Holmes 1977 and Dilkes 2000) [Howell 1937b, Homes 1977, Dilkes 2000 and others state that in lepidosaurs, including *Sphenodon* and *Iguana*, the costocoracoideus is present and is subdivided into 'pars superficialis' and 'pars profundus']	2003, in crocodylians the costocoracoideus is divided into 'pars superficialis' and 'pars profundus']	
Pectoralis	**Pectoralis**	**Pectoralis** (pectoralis major sensu Wyneken 2001)	**Pectoralis** [according to Fürbringer 1876, Walker 1983, Holmes 1977, Dilkes 2000 and others, the pectoralis is present in all the major extant reptilian clades; according to Romer 1944, Kardong 2002 and others, the plesiomorphic condition for reptiles is that in which this muscle was mainly undivided]	**Pectoralis** [see text]	**Pectoralis** (includes pectoralis pars thoracica sensu Maxwell and Larsson 2007) [see text]
Supracoracoideus (coracohumeralis sensu Howell 1935, 1937b)	**Supracoracoideus** (coracohumeralis sensu Howell 1935, 1937b)	**Supracoracoideus** [according to Walker 1973, in turtles the supracoracoideus often consists of 'anterior' and 'posterior' parts]	**Supracoracoideus** (coracohumeralis sensu Howell 1936a)	**Supracoracoideus** [according to Meers 2003, in crocodylians the supracoracoideus is often divided into three heads: 'longus', 'intermedius' and 'brevis']	**Supracoracoideus** (pectoralis secundus sensu Jollie 1962)

Table 10.1 contd...

Table 10.1 contd...

Amphibia (Caudata): *Ambystoma ordinarium* (Michoacan stream salamander)	Amphibia (Anura): *Bufo arenarum* (Argentine common toad)	Reptilia (Testudines): *Trachemys scripta* (Red-eared slider turtle)	Reptilia (Lepidosauria): *Timon lepidus* (Ocellated 'lizard')	Reptilia (Crocodylia): *Caiman latirostris* (Brown-snouted caiman)	Reptilia (Aves): *Gallus domesticus* (Chicken)
Deltoideus scapularis [the deltoideus scapularis sensu Jouffroy 1971 corresponds to the dorsalis scapulae sensu Howell 1937b, Romer 1944, Walthall and Ashley-Ross 2006, Diogo and Abdala 2007, and Diogo 2007]	**Deltoideus scapularis** (dorsalis scapulae sensu Howell 1935, 1937b)	**Deltoideus scapularis** (dorsal, or scapular, part of deltoideus sensu Walker 1973 and Wyneken 2001)	**Deltoideus scapularis** (dorsalis scapulae sensu Howell 1936a, Diogo and Abdala 2007, and Diogo 2007) [according to Holmes 1977 and Dilkes 2000, the deltoideus scapularis is present in turtles, crocodylians, birds and lepidosaurs]	**Deltoideus scapularis** (dorsalis scapulae sensu Fürbringer 1876)	**Deltoideus scapularis** (part of acromialis sensu Ribbing 1938; part of deltoideus sensu Jollie 1962) [according to Dilkes 2000, the deltoideus scapularis probably corresponds to the muscle that is often designated, in birds, as 'deltoideus major', and not to both the 'deltoideus major' and 'deltoideus minor', as suggested by Romer 1944; as explained by Sullivan 1962, 1967, the avian muscles that he designates as 'deltoideus' and 'coracobrachialis anterior' correspond to the muscles that are often named as 'deltoideus major' and 'deltoideus minor' by other authors, respectively]

—	—	— [see on the left]	— [according to Romer 1944, Jollie 1962, Jouffroy 1971 and Holmes 1977 the scapulo-humeralis posterior is present in *Sphenodon*, crocodylians and birds and absent in turtles and all 'lizards' except *Agama*; according to Dilkes 2000 this muscle is also present in squamates; see text]	**Scapulo-humeralis posterior** (scapulo-humeralis caudalis sensu Meers 2003) [see on the left and text]	**Scapulo-humeralis posterior** (scapulo-humeralis caudalis sensu Dilkes 2000 and Maxwell and Larsson 2007) [see on the left and text]
Procoracohumeralis [see text]	**Procoracohumeralis**	**Deltoideus clavicularis** (ventral, or clavicular, part of deltoideus sensu Walker 1973 and Wyneken 2001) [Dilkes 2000 states that in turtles the deltoideus clavicularis is partially fused with the deltoideus scapularis; these two structures are described as 'part of the deltoideus' by Walker 1973 and Wyneken 2001, and Walker 1973 states that in some turtles, such as trionychids, the 'deltoideus' is undivided, i.e., that the 'dorsal, or scapular, head' is not differentiated in these turtles]	**Deltoideus clavicularis** (procoracohumeralis sensu Diogo and Abdala 2007 and Diogo 2007) [in the case of reptiles, using the name deltoideus clavicularis, which is used by most authors working with amniotes, is justified because this muscle does not correspond directly to the procoracohumeralis of amphibians such as *Ambystoma*: it corresponds only to part of it, the other part corresponding to the scapulo-humeralis anterior of *Timon*: see on the left; according to Holmes 1977 and Dilkes 2000, the deltoideus clavicularis is present in turtles, crocodylians, lepidosaurs and birds]	**Deltoideus clavicularis** (scapularis inferior sensu Fürbringer 1876)	**Deltoideus clavicularis** (part of acromialis sensu Ribbing 1938] [according to Dilkes 2000, in birds the deltoideus clavicularis is sometimes divided into a 'pars cranialis' and a 'pars caudalis'; as stated by Dilkes 2000, the 'deltoideus minor' of birds probably corresponds to part or all of the deltoideus clavicularis of other tetrapods, and not to part of the deltoideus scapularis, as suggested by Romer 1944: see deltoideus scapularis above]

Table 10.1 contd...

Table 10.1 contd...

Amphibia (Caudata): *Ambystoma ordinarium* (Michoacan stream salamander)	Amphibia (Anura): *Bufo arenarum* (Argentine common toad)	Reptilia (Testudines): *Trachemys scripta* (Red-eared slider turtle)	Reptilia (Lepidosauria): *Timon lepidus* (Ocellated 'lizard')	Reptilia (Crocodylia): *Caiman latirostris* (Brown-snouted caiman)	Reptilia (Aves): *Gallus domesticus* (Chicken)
—	—	— [see on the left]	— [the humeroradialis does not seem to be present as a distinct muscle in *Timon*, but contrary to the statements of Meers 2003, Romer 1944 and Jollie 1962 defended that, apart from birds and crocodylians, the humeroradialis is also present in *Sphenodon*]	**Humeroradialis** [according to Meers 2003, the humeroradialis (Fig. 10.13) is mainly a flexor of the antebrachium that is only present in living archosaurs, i.e., in birds and crocodylians and that was probably derived from the dorsal musculature, being perhaps developmentally related with the deltoid muscles (e.g., it is innervated by the axillary nerve: see brachioradialis); Romer 1944, Jollie 1962, Sullivan 1962, 1967 and others do support the idea that the humeroradialis is related to the deltoid group (see Fig. 10.13), and specifically to the deltoideus clavicularis, thus corresponding to part of the procoracohumeralis longus of amphibians]	**Humeroradialis** (deltoides propatagialis sensu Romer 1944; tensor patagii sensu Jollie 1962; tensor propatagii sensu Sullivan 1962, 1967; tensor propatagialis sensu Meers 2003) [see on the left]

—	—	— [according to Holmes 1977 and Dilkes 2000, the scapulo-humeralis anterior is not present as a separate muscle in turtles]	**Scapulo-humeralis anterior** [according to Romer 1944, Jollie 1972, Holmes 1977 and Dilkes 2000, the scapulo-humeralis anterior is present in *Sphenodon*, 'lizards' and birds]	— [as explained by Fürbringer 1876, Romer 1944, Holmes 1977, Dilkes 2000, Meers 2003 and others, in crocodylians the scapulo-humeralis anterior is not present as an independent muscle, i.e., it is not differentiated from the deltoideus clavicularis]	**Scapulo-humeralis anterior** (scapulohumeralis cranialis sensu Dilkes 2000 and Maxwell and Larsson 2007)
Subcoracoscapularis [really present in *Ambystoma*? See text]	**Subcoracoscapularis** (subscapularis sensu Ecker1889)	**Subcoraco-scapularis** (subscapularis sensu Walker 1973, Holmes 1977, Dilkes 2000 and Wyneken 2001) [according to Walker 1973, the subcoracoscapularis is usually undivided in turtles, but may be divided into a shorter, 'medial head' and a longer, 'lateral head' in taxa such as sea turtles, *Testudo* and *Hydromedusa*]	**Subcoracoscapularis** (subscapularis plus subcoracoideus sensu Holmes 1977 and Dilkes 2000) [according to Holmes 1977 and Dilkes 2000, the subcoracoscapularis is mainly undivided in turtles and crocodylians, corresponding to the muscle that is often designated, in these two groups, as 'subscapularis'; in *Sphenodon*, squamates and birds, the subcoracoscapularis is divided into a 'subscapularis' and a 'subcoracoideus', each of these two structures being in turn often subdivided into two heads in various birds]	**Subcoracoscapularis** (subscapularis sensu Dilkes and Meers 2003) [see on the left]	**Subcoracoscapularis** (subscapularis plus subcoracoideus sensu Sullivan 1962, 1967, Dilkes 2000 and Maxwell and Larsson 2007) [see on the left]

Table 10.1 contd...

Table 10.1 contd...

Amphibia (Caudata): *Ambystoma ordinarium* (Michoacan stream salamander)	Amphibia (Anura): *Bufo arenarum* (Argentine common toad)	Reptilia (Testudines): *Trachemys scripta* (Red-eared slider turtle)	Reptilia (Lepidosauria): *Timon lepidus* (Ocellated 'lizard')	Reptilia (Crocodylia): *Caiman latirostris* (Brown-snouted caiman)	Reptilia (Aves): *Gallus domesticus* (Chicken)
— [see text]	—	**Teres major** [see text]	— [see text]	**Teres major** [see text]	— [see text]
Latissimus dorsi	**Latissimus dorsi**	**Latissimus dorsi** [see on the left]	**Latissimus dorsi** [the latissimus dorsi is present in all living reptiles, being mainly undivided in crocodylians, lepidosaurs and turtles, as described by Holmes 1977, Dilkes 2000, Meers 2003 and others]	**Latissimus dorsi** [see on the left]	**Latissimus dorsi** [according to Dilkes 2000 and others, in birds the latissimus dorsi is often divided into a 'pars cranialis' and a 'pars caudalis']
Triceps brachii [the triceps brachii of urodeles usually includes coracoideus ('coracotriceps'), scapularis medialis ('dorsitriceps'), humeralis lateralis ('humerotriceps lateralis') and humeralis medialis ('humerotriceps lateralis') sections, which correspond respectively to the 'anconeus coracoideus', 'anconeus scapularis medialis', 'anconeus humeralis lateralis' and 'anconeus humeralis medialis' sensu Walthall and Ashley-Ross 2006, Diogo and Abdala 2007, and Diogo 2007; Howell 1935, 1937b	**Triceps brachii** [according to Howell 1935, 1937b, in anurans such as *Rana* the 'coracotriceps' is not present as a distinct structure, but the 'dorsitriceps' (or 'anconeus scapularis') is present, and the 'humerotriceps' is divided into three divisions comprising 'laterale', 'mediale', and 'profundum', the 'profundus' division being merely a separable part of the 'mediale' division]	**Triceps brachii** [according to Walker 1973, Holmes 1977, Dilkes 2000 and Wyneken 2001, in turtles the triceps brachii usually has a 'scapular' head and a 'humeral' head (which are designated as 'long lateral head and short lateral head' by Holmes 1977), and in some taxa, such as *Dermochelys*, only one head (the 'humeral' head according to Wyneken 2001) is present]	**Triceps brachii** [according to Holmes 1977 and Dilkes 2000, the number of heads of the triceps brachii is usually four ('scapular', 'coracoid', 'lateral humeral', and 'medial humeral') in lepidosaurs, including *Sphenodon*; Holmes 1977 argues that having four heads is the plesiomorphic condition for reptiles, and Chapter 9 supports the idea that this is also the plesiomorphic condition for amniotes and for living tetrapods as a whole, because extant amphibians often have four heads of the triceps, and mammals usually have three heads of the triceps plus a	**Triceps brachii** [according to Dilkes 2000, the number of heads of the triceps brachii is usually five ('scapular', 'coracoid', 'lateral humeral', 'medial humeral', and an 'extra humeral' head known as the 'posticum') in crocodylians; Holmes 1977 suggests that crocodylians usually only have four heads, but Meers 2003 does describe five heads (which he designated as 'triceps longus lateralis', 'triceps longus caudalis', 'triceps brevis cranialis', 'triceps brevis intermedius' and 'triceps	**Triceps brachii** [according to Dilkes 2000, the number of heads of the triceps brachii is usually two or three ('scapulotriceps', 'humerotriceps', and occasionally a greatly reduced 'coracotriceps') in Aves; Grim 1971, Haninec et al. 2009 and others state that Aves such as chickens have a 'dorsoepitrochlearis', which is usually named 'metapatagial latissimus dorsi', and which would correspond to the triceps coracoideus sensu this volume and thus to the 'coracotriceps' sensu Dilkes 2000;

seems to suggest that the 'coracotriceps' of urodeles such as *Necturus* might correspond to triceps coracoideus of reptiles such as *Iguana* and thus to the dorso-epitrochlearis of mammals]			dorsoepitrochlearis, which clearly seems to derive from/correspond to the coracoid head of the triceps of other tetrapods]	brevis caudalis'), as did Dilkes 2000]	however, Sullivan 1962, 1967 only describes a 'humerotriceps' and a 'scapulotriceps' in chickens]
Humeroantebrachialis (part of biceps sensu Romer 1944 and of brachialis sensu Howell 1937b) [according to Romer 1944, Kardong 2002 and others, the humeroantebrachialis of urodeles such as *Ambystoma* corresponds to the brachialis inferior and to part of the biceps (the long head) of other tetrapods; according to these authors, in many anuran amphibians (but not in urodeles) there is also a coracoradialis, which seemingly corresponds to the short head of the biceps brachii of tetrapods such as mammals: see Chapter 9]	**Humeroantebrachialis** [see on the left]	**Brachialis** (brachialis inferior sensu Romer 1944, Walker 1973, Holmes 1977, Dilkes 2000 and Wineken 2001)	**Brachialis** (brachialis inferior sensu Romer 1944, Holmes 1977 and Dilkes 2000)	**Brachialis** (brachialis inferior sensu Romer 1944, Holmes 1977 and Dilkes 2000)	**Brachialis** (brachialis inferior sensu Holmes 1977 and Dilkes 2000)

Table 10.1 contd...

Table 10.1 contd...

Amphibia (Caudata): *Ambystoma ordinarium* (Michoacan stream salamander)	Amphibia (Anura): *Bufo arenarum* (Argentine common toad)	Reptilia (Testudines): *Trachemys scripta* (Red-eared slider turtle)	Reptilia (Lepidosauria): *Timon lepidus* (Ocellated 'lizard')	Reptilia (Crocodylia): *Caiman latirostris* (Brown-snouted caiman)	Reptilia (Aves): *Gallus domesticus* (Chicken)
---	**Coracoradialis** [the coracoradialis is often designated as 'biceps' in the literature about anurans, but it likely corresponds only to the short head of the biceps brachii of reptiles and mammals: see humeroantebrachialis/ brachialis above; see also Chapter 9]	**Biceps brachii** [Walker 1973 states that turtles often have a 'superficial' head and a 'deep' head of the biceps brachii, which usually originate from the coracoid; he states that in testudinines and sea turtles the biceps brachii is mainly undivided or only partially divided, but Wyneken 2001 states that in most sea turtles the biceps is actually clearly divided into 'superficial' and 'deep' heads]	**Biceps brachii** (humeroantebrachialis sensu Diogo and Abdala 2007, and Diogo 2007; short and long heads of biceps brachii sensu Jouffroy 1971) [Holmes 1977 and Dilkes 2000 state that apart from some birds, in which there is usually an origin from the humerus and the coracoid, the biceps brachii of reptiles normally originates from the coracoid only; as described by these authors, the biceps brachii has more than one belly in non-avian reptiles such as some lepidosaurs and some turtles: see also cells on the right]	**Biceps brachii** [Meers 2003 states that occasionally in some crocodylians a poorly developed 'short head' of the biceps may originate from the shoulder joint capsule]	**Biceps brachii** [see on the left]
Coracobrachialis (corresponds to the coracobrachialis longus/ superficialis sensu Walthall and Ashley-Ross 2006, Diogo and Abdala 2007, and Diogo 2007) [the coracobrachialis medius/proprius and coracobrachialis profundus/brevis seem	**Coracobrachialis**	**Coracobrachialis** (coracobrachialis magnus plus coracobrachialis brevis sensu Walker 1973 and Wyneken 2001, which correspond respectively to the coracobrachialis longus plus coracobrachialis brevis sensu Holmes 1977 and Dilkes 2000)	**Coracobrachialis** (coracobrachialis superficialis/longus plus coracobrachialis profundus/ brevis sensu Howell 1936a, Romer 1944, Jollie 1962, Holmes 1977 and Dilkes 2000) [according to Jollie 1962, Holmes 1977 and Dilkes 2000, turtles, *Sphenodon*,	**Coracobrachialis** (coracobrachialis brevis sensu Holmes 1977 and Dilkes 2000) [according to Romer 1944, Holmes 1977 and Dilkes 2000 crocodylians have only a 'coracobrachialis brevis'; Meers 2003 describes a 'coracobrachialis brevis ventralis' and a	**Coracobrachialis** (coracobrachialis longus plus coracobrachialis brevis, or coracobrachialis cranialis plus coracobrachialis caudalis, or coracobrachialis anterior plus coracobrachialis posterior, sensu Jollie 1972, Holmes 1977

to be missing in urodeles such as *Taricha*, but are present in various other urodeles according to Howell 1935, Romer 1944, Jollie 1962 and other authors]			'lizards', and birds have a 'coracobrachialis brevis' and a 'coracobrachialis longus' (see, e.g., Fig. 10.12) – in birds, these two structures are usually designated as 'coracobrachialis cranialis' (or 'anterior') and 'coracobrachialis caudalis' (or 'posterior', respectively]		and Dilkes 2000) [as explained by Sullivan 1962, 1967, the avian muscles that he designates as 'coracobrachialis anterior' and 'coracobrachialis' correspond to the muscles that are often named as 'deltoideus minor' and 'coracobrachialis anterior' by other authors, respectively; also according to that author, the avian muscle that he designates as 'coracobrachialis posterior' has no separate homologue in other, non-avian reptiles; see on the left and also text]
Pronator quadratus (pronator profundus sensu Ribbing 1907, Walthall and Ashley-Ross 2006, Diogo and Abdala 2007, and Diogo 2007) [we prefer to use here the name pronator quadratus because this name is used by a great number of authors	**Pronator quadratus** (pronator profundus sensu Ribbing 1907) [Ribbing 1907 states that the 'abductor pollicis' sensu Gaupp 1896 corresponds to the pronator quadratus sensu this volume, and not to the abductor pollicis brevis sensu this volume]	**Pronator quadratus** (probably corresponds to part of the pronator profundus sensu Walker 1973, the other part corresponding to the pronator accessorius sensu this volume; pronator profundus sensu Abdala et al. 2008) [according to Walker	**Pronator quadratus** (pronator profundus sensu Moro and Abdala 2004, Abdala and Moro 2006, Diogo and Abdala 2007, and Diogo 2007)	**Pronator quadratus** (pronator profundus sensu Straus 1942)	**Pronator quadratus** [see text, and also pronator accessorius below]

Table 10.1 contd...

Table 10.1 contd...

Amphibia (Caudata): *Ambystoma ordinarium* (Michoacan stream salamander)	Amphibia (Anura): *Bufo arenarum* (Argentine common toad)	Reptilia (Testudines): *Trachemys scripta* (Red-eared slider turtle)	Reptilia (Lepidosauria): *Timon lepidus* (Ocellated 'lizard')	Reptilia (Crocodylia): *Caiman latirostris* (Brown-snouted caiman)	Reptilia (Aves): *Gallus domesticus* (Chicken)
working with both non-mammalian and mammalian tetrapods: see, e.g., Jouffroy 1971, and Jouffroy and Lessertisseur 1971]		1973 and Holmes 1977, the pronator quadratus is missing in some turtles]			
—	—	**Pronator accessorius** (probably corresponds to part of the pronator profundus sensu Walker 1973, the other part corresponding to the pronator quadratus sensu this volume [according to Abdala et al. 2008, turtles often have a pronator accessorius]	**Pronator accessorius** [as explained by Straus 1942 and others and in Chapter 9, the pronator accessorius is a peculiar reptilian muscle that very likely corresponds to part of the pronator quadratus of tetrapods such as amphibians]	— [Straus 1942 states that the only major group of living reptiles in which the pronator accessorius is missing is the Crocodylia; Meers 2003 corroborates that this muscle is missing in crocodylians, and this muscle is effectively seemingly missing in the *Caiman* specimens that we have dissected]	— [really absent? In the chickens we dissected the pronator accessorius did not seem to be present as a distinct muscle, and this muscle was also not described in the chickens and the other birds analyzed by Meyers 1996, Shellswell and Wolpert 1977, Maxwell and Larsson 2007 and others; however, according to Straus 1942, the only major group of living reptiles in which the pronator accessorius is missing is the Crocodylia: see on the left, and also pronator quadratus above]

Contrahentium caput longum (ulnocarpalis sensu McMurrich 1903ab, Straus 1942, and Bunnell 1942) [McMurrich 1903a and Ribbing 1907 support the idea that the flexor accessorius lateralis and medialis of urodeles correspond to part of the flexor digitorum longus of reptiles and, although they state that the contrahentium caput longum of urodeles may also correspond to part of the flexor digitorum longus of reptiles, they consider that it is more likely, based on topology and innervation, that the former muscle is completely missing in reptiles; see also Chapter 9]	**Contrahentium caput longum** (ulnocarpalis plus intercarpalis sensu Gaupp 1896)	—	— [see on the left; according to Diogo and Abdala 2007, a few 'lizards' may eventually have a small muscle that somewhat resembles the contrahentium caput longum of *Ambystoma*]	—	—
Flexor accessorius lateralis (caput dorsale of flexor palmaris profundus sensu Straus 1942; seemingly corresponds to the palmaris profundus III sensu McMurrich 1903a: see pronator quadratus)	**Flexor accessorius** (sensu Ribbing 1907; palmaris profundus sensu Gaupp 1896, Straus 1942 and Manzano et al. 2008) [as explained by Ribbing 1907 and others, anurans have a single	—	— [absent as an independent muscle in extant amniotes, but see on the left]	—	—

Table 10.1 contd...

Table 10.1 contd...

Amphibia (Caudata): *Ambystoma ordinarium* (Michoacan stream salamander)	Amphibia (Anura): *Bufo arenarum* (Argentine common toad)	Reptilia (Testudines): *Trachemys scripta* (Red-eared slider turtle)	Reptilia (Lepidosauria): *Timon lepidus* (Ocellated 'lizard')	Reptilia (Crocodylia): *Caiman latirostris* (Brown-snouted caiman)	Reptilia (Aves): *Gallus domesticus* (Chicken)
[the flexor accessorius medialis and lateralis correspond very likely to part of the flexor digitorum longus of reptiles and monotremes and of the flexor digitorum profundus of therian mammals: see, e.g., Straus 1942 and Lewis 1989; see also Chapter 9]	flexor accessorius, which corresponds to the flexor accessorius lateralis plus flexor accessorius medialis of urodeles]				
Flexor accessorius medialis (caput volare of flexor palmaris profundus sensu Straus 1942) [see flexor accessorius lateralis above]	— [see flexor accessorius above]	—	—	—	—
Flexor digitorum communis (palmaris superficialis sensu McMurrich 1903a; flexor primordialis communis sensu Ribbing 1907)	**Flexor digitorum communis** (flexor primordialis communis sensu Ribbing 1907; flexor digitorum communis longus sensu Manzano 1996 and Manzano et al. 2008)	**Flexor digitorum longus** (flexor primordialis communis plus flexor accessorius communis sensu Ribbing 1907) [according to Ribbing 1907, Abdala et al. 2008 and others, in turtles the flexor digitorum longus (not including the 'palmaris longus': see 'palmaris longus' below)	**Flexor digitorum longus** (palmaris communis sensu Holmes 1977 and Dilkes 2000; flexor digitorum communis sensu Diogo and Abdala 2007, and Diogo 2007; it probably also includes the 'pronator radii teres' sensu McMurrich 1903a and Holmes 1977, at least in taxa such as *Sphenodon* and 'lizards': see	**Flexor digitorum longus** (palmaris communis sensu Holmes 1977 and Dilkes 2000) [according to Meers 2003, in crocodylians the flexor digitorum longus has humeral, ulnar and carpal heads (the humeral head clearly corresponds to the superficial head sensu	**Flexor digitorum longus** (flexor accessorius communis sensu Ribbing 1938; palmaris communis sensu Holmes 1977 and Dilkes 2000) [according to Sullivan 1962, Shellswell and Wolpert 1977, Meyers 1996, Dilkes 2000 and others, Aves usually

		is often divided into a superficial bundle and a deep bundle]	flexor carpi radialis) [see text]	Holmes 1977, while the two other heads seem to correspond to the deep humeral and deep ulnar heads sensu Holmes 1977, see text) and inserts on the penultimate phalanx of digits 1, 2 and 3 (and not digits 2, 3 and 4 as stated by Dilkes 2000); contrary to Meers 2003, Holmes 1977 and Dilkes 2000 state that in lepidosaurs, turtles and crocodylians the flexor pollicis longus usually inserts on the distal phalanges of the digits, and in the crocodylian shown in fig. 16 of Meers 2003 this muscle does seem to insert on the distal phalanges]	have a superficial head and a deep head of the flexor digitorum longus, which, in neognath birds, are usually inserted on the two phalanges of digit 2 (i.e., digit 3 according to embryology) and on the distal phalanx of the same digit, respectively; also according to Dilkes 2000, the kiwi *Apteryx* lacks the superficial head and has a mostly tendinous deep head that inserts on the terminal phalanx of digit 2; see text]
—	— [does the 'palmaris longus' of anurans (sensu Gaupp 1896 and others) really correspond to the palmaris longus sensu this volume, or does it correspond to the flexor digitorum communis of urodeles? See text and cells on the right]	**'Palmaris longus'** [as described by Walker 1973, Abdala et al. 2008 and others, turtles often have a broad muscle 'palmaris longus', which is possibly homologous to the palmaris longus of mammals: see on the left]	— [see text]	— [Meers 2003 does not describe a palmaris longus in crocodylians; Haines 1950 stated that crocodylians do not have a palmaris longus; see text]	—

Table 10.1 contd...

Table 10.1 contd...

Amphibia (Caudata): *Ambystoma ordinarium* (Michoacan stream salamander)	Amphibia (Anura): *Bufo arenarum* (Argentine common toad)	Reptilia (Testudines): *Trachemys scripta* (Red-eared slider turtle)	Reptilia (Lepidosauria): *Timon lepidus* (Ocellated 'lizard')	Reptilia (Crocodylia): *Caiman latirostris* (Brown-snouted caiman)	Reptilia (Aves): *Gallus domesticus* (Chicken)
Flexor carpi ulnaris (part of flexor antebrachii et carpi ulnaris sensu Diogo and Abdala 2007, and Diogo 2007) [see text]	**Flexor carpi ulnaris**	**Flexor carpi ulnaris** (part of the flexor carpi ulnaris sensu Walker 1973 and Abdala et al. 2008: see epitrochleoanconeus below)	**Flexor carpi ulnaris** (part of flexor antebrachii et carpi ulnaris sensu Diogo and Abdala 2007 and Diogo 2007) [according to Dilkes 2000, the flexor carpi ulnaris is present in all major extant groups of reptiles]	**Flexor carpi ulnaris**	**Flexor carpi ulnaris**
Epitrochleoanconeus (flexor antebrachii ulnaris sensu McMurrich 1903a and Ribbing 1907) [see flexor carpi ulnaris above]	**Epitrochleoanconeus** (epitrochleo-cubitalis sensu Gaupp 1896 and Manzano et al. 2008; flexor antebrachii ulnaris sensu McMurrich 1903a and Ribbing 1907)	**Epitrochleoanconeus** (flexor antebrachii ulnaris sensu Ribbing 1907, 1938; part of the flexor carpi ulnaris sensu Walker 1973 and Abdala et al. 2008) [see text]	**Epitrochleoanconeus** [Holmes 1977 stated that the epitrochleoanconeus is differentiated in lepidosaurs, including *Sphenodon*, and argues that the epitrochleoanconeus was probably plesiomorphically present as a distinct muscle in reptiles]	**Epitrochleoanconeus** (really present in Caiman? See text)	**Epitrochleoanconeus** (flexor antebrachii ulnaris sensu Ribbing 1938; entepicondylo-ulnaris sensu Maxwell and Larsson 2007) [Ribbing 1938 described a flexor carpi ulnaris and a 'flexor antebrachii ulnaris' in birds, the latter muscle being very likely homologous to the epitrochleoanconeus sensu this volume]
Flexor antebrachii et carpi radialis (flexor carpi radialis sensu McMurrich 1903) [see text]	**Flexor carpi radialis**	**Flexor carpi radialis** [as described by Walker 1973, Holmes 1977 and Abdala et al. 2008, in turtles the pronator teres (which Holmes designates as a 'head of the flexor carpi radialis') and the flexor carpi r	**Flexor carpi radialis** (part of flexor carpi radialis sensu Holmes 1977 and Dikes 2000) [see text]	**Flexor carpi radialis** (part of flexor carpi radialis sensu Holmes 1977 and Dilkes 2000 and of pronator teres sensu Meers 2003) [see text]	**Flexor carpi radialis** (part of flexor carpi radialis sensu Holmes 1977 and Dilkes 2000; seems to correspond to the pronator superficialis sensu Sullivan 1962, Shellswell and Wolpert 1977,

		adialis are usually present as distinct muscles]			Meyers 1996 and Dilkes 2000) [see text]
—	**Pronator teres** (flexor antibrachii radialis sensu Ribbing 1907; seems to correspond to the flexor antebrachii lateralis superficialis and profundus sensu Gaupp 1896, although Ribbing 1907 stated that it actually corresponds to the flexor antibrachii medialis sensu Gaupp 1896)	**Pronator teres** (pronator radii teres Holmes 1977)	**Pronator teres** (flexor antibrachii radialis sensu Ribbing 1907; part of flexor carpi radialis sensu Holmes 1977 and Dikes 2000)	**Pronator teres** (part of flexor carpi radialis sensu Holmes 1977 and Dilkes 2000 and of pronator teres sensu Meers 2003)	**Pronator teres** (part of flexor carpi radialis sensu Holmes 1977 and Dilkes 2000; seems to correspond to the pronator profundus sensu Sullivan 1962, Shellswell and Wolpert 1977, Meyers 1996 and Dilkes 2000)
Flexores breves superficiales (flexores digitorum breves superficiales sensu McMurrich 1903ab) [as described by McMurrich 1903ab and others, amphibians such as *Ambystoma* usually have four flexores breves superficiales, each inserting on each of the four digits]	**Flexores breves superficiales** [see on the left]	**Flexores breves superficiales** (flexor brevis superficialis sensu Walker 1973; flexores digiti brevis superficiales sensu Abdala et al. 2008) [according to Walker 1973, in turtles, including *Trachemys*, the flexores breves superficiales often include eight slips, there being two slips to each of the three middle digits and one to the first and fifth digits; however, as explained by Abdala et al. 2008, turtles such as *Trachemys*	**Flexores breves superficiales** (part of flexores digitorum breves superficiales sensu McMurrich 1903ab; flexores breves sublimes sensu Holmes 1977; flexores digiti brevis superficialis sensu Abdala and Moro 2006) [as described by McMurrich 1903ab and others, lepidosaurs such as 'lizards' often have five flexores breves superficiales, inserting on digits 1, 2, 3, 4 and 5]	**Flexores breves superficiales** (part of flexores breves sublimes sensu Holmes 1977; flexores digitorum breves superficiales and probably also flexor digiti quinti and/or transversus palmaris sensu Meers 2003) [see text]	**Flexores breves superficiales** [really present in birds? See text]

Table 10.1 contd...

Table 10.1 contd...

Amphibia (Caudata): *Ambystoma ordinarium* (Michoacan stream salamander)	Amphibia (Anura): *Bufo arenarum* (Argentine common toad)	Reptilia (Testudines): *Trachemys scripta* (Red-eared slider turtle)	Reptilia (Lepidosauria): *Timon lepidus* (Ocellated 'lizard')	Reptilia (Crocodylia): *Caiman latirostris* (Brown-snouted caiman)	Reptilia (Aves): *Gallus domesticus* (Chicken)
		only have five flexores breves superficiales sensu this volume, one to each digit; according to Walker 1973, the insertion of the flexores breves superficiales is variable in turtles, i.e., it may be on the proximal phalanges (as is the case in *Trachemys*; this is corroborated by Abdala et al. 2008), the sheaths of the long flexor tendon, or the 'penultimate' phalanges]			
--- [really absent in *Ambystoma ordinarium*? In the *Ambystoma ordinarium* specimens dissected by us the lumbricales were seemingly not present as distinct, separate muscles, and these muscles were also not described in other urodeles such as *Taricha* by Walthall and Ashley-Ross 2006 and others; however, McMurrich 1903a shows	**Lumbricales** [our dissections of anurans such as *Phyllomedusa bicolor* show that these anurans have both 'lumbricales breves' and 'lumbricales longi': see also, e.g., Gaupp 1896 and Manzano 1996]	**Lumbricales** (lumbricalis sensu Abdala et al. 2008) [according to Walker 1973, in *Trachemys* there are two lumbricales to the 'penultimate' phalanx of each of the three middle digits and one to the penultimate phalanx of the first and fifth digits; however, as explained by Abdala et al. 2008, turtles such as *Trachemys* have only five lumbricales sensu this	**Lumbricales** [according to McMurrich 1903ab and others, 'lizards' often have five lumbricales inserting on digits 1, 2, 3, 4 and 5, but some 'lizards' have fewer lumbricales; note that Russell and Bauer 2008 designate the lumbricales sensu this volume as 'the palmar head of the flexor digitorum longus', and the flexores breves profundi sensu this volume as the lumbricales]	**Lumbricales** [according to Meers 2003, crocodylians have five lumbricales, the first attaching to digit 2, the second to digit 2, the third to digit 3, the fourth to digit 3, and the fifth to digit 5]	**---** [really absent in *Gallus domesticus*? See text]

an *Ambystoma tigrinum* specimen where the lumbricales are present as distinct muscles, and these muscles are present in other amphibians, such as anurans: see on the right and text]		volume, each attaching to the 'ungual' phalanx of each digit]			
Contrahentes digitorum (part of flexores digitorum breves medii sensu McMurrich 1903ab) [as described by McMurrich 1903ab and others, urodeles such as *Ambystoma* often have four contrahentes, each inserting on each of the four digits]	**Contrahentes digitorum** (part of flexores digitorum breves medii sensu McMurrich 1903ab; probably includes the adductor pollicis sensu Manzano et al. 2008) [according to Ribbing 1907, anurans such as *Discoglossus* have four contrahentes digitorum sensu this volume, which probably include the 'flexor teres indicis', the 'caput volare des m. flexor teres digiti V' and the 'adductor proprius digiti V' sensu Gaupp 1896]	**Contrahentes digitorum** (includes adductor digiti minimi sensu Walker 1973) [Walker 1973 describes a single contrahens in turtles such as *Trachemys*, which he designates as 'adductor digiti minimi' and goes to digit 5; according to him, some turtles have contrahentes to digits 4 and 5, and some other turtles lack contrahentes; Abdala et al. 2008 stated that turtles such as *Trachemys* have 'contrahentes' to the proximal phalanx of each digit, but they stated that these 'contrahentes' are the deepest ventral (palmar) muscles of the hand, so these 'contrahentes' probably do not correspond to the contrahentes	**Contrahentes digitorum** (part of flexores digitorum breves medii sensu McMurrich 1903ab and Lewis 1989; include the flexor digitorum V transversus I and II of e.g., Abdala and Moro 2006) [as explained by Lewis 1989, the 'flexores digitorum intermedii' sensu Holmes 1977, Meers 2003 and others, or 'flexores digitorum breves medii' sensu McMurrich 1903ab and others, clearly seem to correspond to the contrahentes digitorum sensu this volume because, as indicated by the names used by these authors, these muscles are ventral to the flexores breves superficiales and dorsal to the flexores breves profundi; this idea is also supported by Howell 1936ab and others, who explicitly designate the	**Contrahentes digitorum** (part of flexores digitorum breves medii sensu McMurrich 1903ab and others; flexores digitorum intermedii sensu Holmes 1977 and Meers 2003) [according to Meers 2003, crocodylians usually have a 'flexor digitorum intermedius digiti IV et V' (that is, a contrahens sensu this volume, see on the left), which is commonly inserted on the distal end of the proximal phalanx of digit 4 and, sometimes, also on the distal metacarpal of digit 5; Meers 2003 describes an additional muscle in *Alligator mississippiensis*, the 'flexor digitorum intermedius digiti V', which was absent in all	**Contrahentes digitorum** [Holmes 1977 seems to suggest that the contrahentes digitorum are present in all major extant groups of reptiles; the 'adductor indicis' sensu Sullivan 1962 and Shellswell and Wolpert 1977 (which goes to digit 1, i.e., digit 2 according to embryology, and corresponds to the 'adductor alulae' sensu Meyers 1996) is possibly part of the contrahentes digitorum sensu this volume]

Table 10.1 contd...

Table 10.1 contd...

Amphibia (Caudata): *Ambystoma ordinarium* (Michoacan stream salamander)	Amphibia (Anura): *Bufo arenarum* (Argentine common toad)	Reptilia (Testudines): *Trachemys scripta* (Red-eared slider turtle)	Reptilia (Lepidosauria): *Timon lepidus* (Ocellated 'lizard')	Reptilia (Crocodylia): *Caiman latirostris* (Brown-snouted caiman)	Reptilia (Aves): *Gallus domesticus* (Chicken)
		sensu this volume, which usually are deep (dorsal) to the flexores breves superficiales, but superficial (ventral) to the flexores breves profundi and to the intermetacarpales]	'flexores digitorum breves intermedii/medii' of reptiles as contrahentes]	the other crocodylian species examined by him and which, according to him, possibly derives from the flexores breves profundi, and not from the contrahentes layer]	
Flexores breves profundi (flexores digitorum breves profundi sensu McMurrich 1903ab) [as described by McMurrich 1903ab and other authors, urodeles such as *Ambystoma* usually have eight flexores breves profundi sensu this volume, inserting on the ulnar and radial sides of each of the four digits (the muscles that insert on the ulnar and radial side of each digit are often considered as 'heads' of a single, 'biccipital' muscle, so McMurrich and others actually often refer to four 'biccipital' muscles, which thus correspond to	**Flexores breves profundi** [according to Ribbing 1907 there are eight flexores breves profundi sensu this volume (often described as '4 biccipital muscles': see on the left) in anurans such as *Rana*, which include the 'opponens indicis', 'flexor ossis metacarpi III', 'flexor ossis metacarpi IV' and 'opponens digiti V' and possibly the 'abductor secundus digiti V' sensu Gaupp 1896; the anuran 'flexores digitorum minimi' sensu Ribbing 1907, which are flexors of the digits and are often, but not always,	**Flexores breves profundi** [the flexores breves profundi sensu this volume possibly correspond to part or all of the 'interossei volares' sensu Walker 1973 and/or of the 'flexores digiti brevis profundus' sensu Abdala et al. 2008 (the 'interossei dorsales' sensu Walker 1973 possibly corresponding to the intermetacarpales + dorsometacarpales sensu this volume); however, Walker 1973 states that the 'interossei volaris' insert on the proximal phalanges in *Trachemys*, while Abdala et al. 2008 state that the 'flexores digiti brevis profundi'	**Flexores breves profundi** (flexores digitorum breves profundi sensu McMurrich 1903ab; flexores digiti brevis profundus sensu Abdala and Moro, 2006) [as described by McMurrich 1903ab and others, 'lizards' usually have 10 flexores breves profundi sensu this volume (often described as '5 biccipital muscles': see on the left)]	**Flexores breves profundi** (flexores digitorum profundus, and possibly also flexor digitorum intermedius digiti V, sensu Meers 2003: see contrahentes digitorum) [Meers 2003 described five 'flexores breves profundi' (or six, if the muscle that he named as 'flexor digitorum intermedius digiti V' is also part of the deep flexor layer: see contrahentes digitorum above), so crocodylians clearly seem to have the full series of deep flexors, i.e., to have 10 flexores breves profundi sensu this volume, each digit receiving two of	**Flexores breves profundi** (flexores digitorum breves profundi sensu Ribbing 1938 and Holmes 1977) [according to Ribbing 1938, Holmes 1977 and others, birds do have flexores breves profundi; it is possible that the 'flexor indicis' and/or 'flexor digiti quarti' sensu Sullivan 1962 and Shellswell and Wolpert 1977 correspond to part of the flexores breves profundi sensu this volume, although they might actually correspond to the flexores breves superficiales sensu this volume; in this latter

the eight flexores breves profundi sensu this volume: see Chapter 9]	superficial (ventral) to the intermetacarpales according to Burton 1998 and correspond to the 'flexor teres digitorum III, IV, and V' sensu Gaupp 1896 and to the 'flexores teretes I, II, III and IV' sensu Burton 1998, and the 'interphalangei' sensu Ribbing 1907, which correspond to the 'interphalangeus digiti IV and interphalangeus digiti V' sensu Gaupp 1896', probably correspond to or are derived from muscles such as the flexores breves profundi sensu this volume (the 'flexores digitorum minimi', at least, clearly seem to correspond to/derive from the flexores breves profundi); according to Ribbing 1907 and Burton 1998, these two groups of muscles are also present in at least some urodeles]	insert on the metacarpals of this taxon]		these muscles (i.e., each of the five 'muscles' described by Meers 2003 corresponds to two of the flexores breves profundi sensu this volume: see on the left)]	case, the flexores breves profundi sensu this volume might instead correspond to part/all of the interossei ventralis sensu Sullivan 1962 and Shellswell and Wolpert 1977: see flexores breves superficiales above]

Table 10.1 contd...

Table 10.1 contd...

Amphibia (Caudata): *Ambystoma ordinarium* (Michoacan stream salamander)	Amphibia (Anura): *Bufo arenarum* (Argentine common toad)	Reptilia (Testudines): *Trachemys scripta* (Red-eared slider turtle)	Reptilia (Lepidosauria): *Timon lepidus* (Ocellated 'lizard')	Reptilia (Crocodylia): *Caiman latirostris* (Brown-snouted caiman)	Reptilia (Aves): *Gallus domesticus* (Chicken)
— [seemingly absent in *Ambystoma ordinarium*]	**Abductor pollicis brevis** [really present as a distinct muscle in anurans, corresponding to the abductor pollicis sensu Gaupp 1896 and Manzano et al. 2008? See text, and pronator quadratus above]	**Abductor pollicis brevis**	**Abductor pollicis brevis** (abductor brevis pollici sensu Abdala and Moro 2006)	**Abductor pollicis brevis** (abductor metacarpi I sensu Meers 2003)	**Abductor pollicis brevis** [the 'abductor alulae' sensu Meyers 1996 corresponds to the 'abductor indicis' sensu Sullivan 1962 and Shellswell and Wolpert 1977 and goes to digit 1 (i.e., digit 2 according to embryology), thus seemingly corresponding to the abductor pollicis brevis sensu this volume]
Abductor digiti minimi (extensor lateralis digiti IV sensu Walthall and Ashley-Ross 2006 and Chapter 9) [see text]	**Abductor digiti minimi** (abductor primus digiti V sensu Gaupp 1896)	**Abductor digiti minimi** (abductor digitorum V sensu Abdala et al. 2008)	**Abductor digiti minimi** (abductor digitorum V sensu Abdala and Moro 2006)	**Abductor digiti minimi** (abductor metacarpi V sensu Meers 2003)	--- [see text]
Intermetacarpales [as described by McMurrich 1903ab and others, urodeles such as *Ambystoma* usually have three intermetacarpales connecting the metacarpals of the four digits]	**Intermetacarpales** (transversi metacarpi sensu Gaupp 1896; transversi metacarporum sensu Burton 1998; transversus metacarpi superficialis plus transversus metacarpi profundus sensu Manzano 1996) [as described by Ribbing 1907, Burton 1998	**Intermetacarpales** [Abdala et al. 2008 state that turtles such as *Trachemys* have 4 intermetacarpales, which connect the metacarpals of digits 1 and 2, of digits 2 and 3, of digits 3 and 4, and of digits 4 and 5; Walker 1973 did not describe intermetacarpales in	**Intermetacarpales** (intermetacarpales I and II sensu Abdala and Moro 2006, Diogo and Abdala 2007, and Diogo 2007) [as described by Abdala and Moro 2006 and others, 'lizards' often have four 'intermetacarpales I' connecting the metacarpals of the five digits and four 'intermetacarpales 2', also	**Intermetacarpales** (part of interossei dorsalae sensu Meers 2003) [Meers 2003 describes various 'dorsal interossei' and various 'ventral interossei' in crocodylians, but these muscles are not homologous to the dorsal and ventral interossei of	**Intermetacarpales** [the intermetacarpales sensu this volume probably correspond to part of the 'interossei dorsales' and/or 'interossei ventrales' sensu Sullivan 1962, Shellswell and Wolpert 1977, Meyers 1996 and others, although they might also/instead include

	and others, anurans usually have three intermetacarpales connecting the metacarpals of the four digits]	turtles, but it is possible that the muscles that he described under the name 'interossei dorsales' include the intermetacarpales sensu this volume; see also on the left]	connecting the metacarpals of these five digits]	mammals such as humans; they clearly seem to correspond, instead, to the intermetacarpales and to the dorsometacarpales of other reptiles: see Chapter 9]	the 'abductor medius' sensu Sullivan 1962 and Shellswell and Wolpert 1977, which corresponds to the 'abductor digiti majoris' sensu Meyers 1996: see lumbricales above]
— [see text]	**Dorsometacarpales** [probably correspond to the 'extensores breves profundi' sensu Gaupp 1896; according to Haines 1939, the dorsometacarpales are highly developed in anurans such as *Rana*: see text]	**Dorsometacarpales** (possibly correspond to part of interossei dorsales sensu Walker 1973; see intermetacarpales above) [according to Abdala et al. 2008, turtles such as *Trachemys* have five dorsometacarpales, each covering the dorsal surface of each of the five digits and sending a tendon that attaches from the second phalanx to the ungual phalanx of each digit]	**Dorsometacarpales** [according to Holmes 1977, the dorsometacarpales are usually found in the major extant reptilian groups] [our dissections indicate that 'lizards' usually have five dorsometacarpales inserting on digits 1, 2, 3, 4 and 5]	**Dorsometacarpales** (part of interossei dorsalae sensu Meers 2003) [see intermetacarpales above]	**Dorsometacarpales** [in birds, the dorsometacarpales sensu this volume correspond very likely to part, or all, of the 'interossei dorsalis' sensu Sullivan 1962, Shellswell and Wolpert 1977, Meyers 1996 and others; see on the left and on the right and also intermetacarpales above]
Extensor antebrachii et carpi radialis (including extensor radialis longus + extensor radialis brevis sensu Straus 1941ab) [the extensor carpi radialis longus and brevis are not present as independent muscles in *Ambystoma*; according to Howell	**Extensor antebrachii et carpi radialis** [according to Haines 1939, the extensor antebrachii et carpi radialis sensu this volume is divided into five divisions in anurans such as *Rana*, which he designates as 'extensor radialis	**Extensor antebrachii et carpi radialis** (extensor radialis superficialis, extensor carpi intermedius and extensor radialis profundus sensu Haines 1939 and Walker 1973; extensor carpi radialis sensu Abdala et al. 2008) [see on the	**Extensor antebrachii et carpi radialis** (including extensor radialis longus + extensor radialis brevis sensu Straus 1941ab; extensor carpi radialis sensu Abdala and Moro, 2006) [see on the left, and also text and brachioradialis below]	**Extensor antebrachii et carpi radialis** (extensor radialis superficialis, extensor carpi intermedius and extensor radialis profundus sensu Haines 1939 [see on the left, and also text and brachioradialis below]	**Extensor antebrachii et carpi radialis** (including extensor carpi radialis sensu Ribbing 1938) [the extensor antebrachii et carpi radialis sensu this volume includes,

Table 10.1 contd...

Table 10.1 contd...

Amphibia (Caudata): *Ambystoma ordinarium* (Michoacan stream salamander)	Amphibia (Anura): *Bufo arenarum* (Argentine common toad)	Reptilia (Testudines): *Trachemys scripta* (Red-eared slider turtle)	Reptilia (Lepidosauria): *Timon lepidus* (Ocellated 'lizard')	Reptilia (Crocodylia): *Caiman latirostris* (Brown-snouted caiman)	Reptilia (Aves): *Gallus domesticus* (Chicken)
1936b, these two muscles may be found in at least some other amphibians such as *Necturus*, but see on the right; Haines 1939 describes three heads of the extensor antebrachii et carpi radialis in urodeles such as *Salamandra*: 'superficialis', 'intermedius' and 'profundus'; these three heads possibly correspond to the three heads that are often designated by the same names in reptiles such as 'lizards', but see text]	profundus' ('flexor antibrachii lateralis profundus' sensu Gaupp 1896), 'extensor radialis intermedius', or 'brachioradialis' ('flexor antibrachii lateralis superficialis, caput inferius' sensu Gaupp 1896), 'extensor radialis superficialis' ('extensor carpi radialis, caput inferius' sensu Gaupp 1896), and two 'small accessory slips' ('extensor carpi radialis caput superius' and 'flexor antibrachii lateralis superficialis caput superius' sensu Gaupp 1896); see on the right and on the left]	left, and also text and brachioradialis below]			very likely, the 'extensor metacarpi radialis' and the 'supinator' sensu Meyers 1996: see on the left, and also text and brachioradialis below]
— [not present as an independent muscle in *Ambystoma*; see text]	— [see text, and also extensor antebrachii et carpi radialis above]	**Brachioradialis** (tractor radii sensu Haines 1939, Walker 1973, Wyneken 2001, and Abdala et al. 2008) [see text]	— [our dissections indicate that *Timon* does not have a distinct, separate brachioradialis muscle such as that found in mammals, but Holmes 1977 suggests that the 'supinator longus' (which clearly seems to correspond to the	**Brachioradialis** (seems to correspond to the supinator sensu Meers 2003) [see text]	— [is the brachioradialis really absent as a distinct muscle in chickens? None of the muscles described in chickens and other birds by Sullivan 1962, Shellswell and Wolpert 1977, Meyers 1996 and others

			mammalian brachioradialis: see on the right) is usually present in extant reptiles and was probably already differentiated in the last common ancestor of all extant reptiles; Haines 1939 states that the 'supinator longus'/'tractor radii' is present as a distinct muscle in *Sphenodon*; see text and Fig. 10.12]		seem to correspond to the brachioradialis sensu this volume, unless the humeroradialis/'tensor propatagii' of birds does correspond to the brachioradialis sensu this volume: see text]
Extensor antebrachii et carpi ulnaris (extensor ulnaris sensu Straus 1941ab) [see text]	**Extensor carpi ulnaris** [Ribbing 1907 states that, contrary to urodeles, in anurans the extensor carpi ulnaris' and 'extensor antebrachii carpi ulnaris' (anconeus sensu this volume) are often present as distinct muscles; see on the left]	**Extensor antebrachii et carpi ulnaris** (extensor ulnaris sensu Haines 1939; extensor carpi ulnaris sensu Walker 1973 and Abdala et al. 2008) [as described by Ribbing 1907, Walker 1973 and Abdala et al. 2008, in *Trachemys* the extensor antebrachii et carpi ulnaris is mainly undivided, but in some turtles such as *Testudo*, *Pelomedusa*, *Chelodina* and *Emys*, it is divided into an 'extensor carpi ulnaris' connecting the humerus and ulna and an 'extensor carpi ulnaris accessorius' connecting the ulna and carpus, which	**Extensor antebrachii et carpi ulnaris** (extensor carpi ulnaris plus extensor antibrachii ulnaris sensu Haines 1939; extensor ulnaris sensu Straus 1941ab; extensor carpi ulnaris + anconeus quartus sensu Holmes 1977) [see on the left and on the right]	**Extensor antebrachii et carpi ulnaris** (flexor ulnaris sensu Meers 2003; extensor carpi ulnaris + anconeus quartus sensu Holmes 1977) [the extensor antebrachii et carpi ulnaris sensu this volume clearly corresponds to the 'flexor ulnaris' sensu Meers 2003; as described by Holmes 1977, Dilkes 2000 and others and corroborated by our dissections, in crocodylians this muscle clearly seems to extend the antebrachium, and not to flex it, as proposed by Meers 2003]	**Extensor carpi ulnaris** (seemingly corresponds to the extensor metacarpi ulnaris sensu Shellswell and Wolpert 1977 and Meyers 1996) [are the 'extensor carpi ulnaris' and the 'anconeus' of birds really homologous with the extensor carpi ulnaris and the anconeus of mammals? See text]

Table 10.1 contd...

Table 10.1 contd...

Amphibia (Caudata): *Ambystoma ordinarium* (Michoacan stream salamander)	Amphibia (Anura): *Bufo arenarum* (Argentine common toad)	Reptilia (Testudines): *Trachemys scripta* (Red-eared slider turtle)	Reptilia (Lepidosauria): *Timon lepidus* (Ocellated 'lizard')	Reptilia (Crocodylia): *Caiman latirostris* (Brown-snouted caiman)	Reptilia (Aves): *Gallus domesticus* (Chicken)
		probably correspond to the 'anconeus' and 'extensor carpi radialis' sensu Holmes 1977, respectively; see on the left]			
— [see extensor antebrachii et carpi ulnaris]	**Anconeus** (epicondylo-cubitalis sensu Gaupp 1896; extensor antebrachii ulnaris sensu Ribbing 1907) [see extensor carpi ulnaris]	— [see extensor antebrachii et carpi ulnaris]	— [see extensor antebrachii et carpi ulnaris]	— [see extensor antebrachii et carpi ulnaris]	**Anconeus** (anconeus quartus sensu Holmes 1977; seemingly corresponds to the ectepicondylo-ulnaris sensu Meyers 1996 and Maxwell and Larsson 2007) [see extensor carpi ulnaris]
Extensor digitorum (extensor digitorum communis sensu Ribbing 1907 and Walthall and Ashley-Ross 2006, Diogo and Abdala 2007, and Diogo 2007; humerodorsalis sensu Haines 1939)	**Extensor digitorum** (extensor digitorum communis longus sensu Gaupp 1896 and Manzano et al. 2008; extensor digitorum communis sensu Ribbing 1907; humerodorsalis sensu Haines 1939)	**Extensor digitorum** (humerodorsalis sensu Haines 1939; extensor digitorum communis sensu Walker 1973; extensor digitorum longus sensu Abdala et al. 2008) [as described by Walker 1973 and Abdala et al. 2008, in turtles such as *Trachemys* the extensor digitorum has eight tendons attaching on the ulnar and radial sides of the distal end of each metacarpal, except	**Extensor digitorum** (humerodorsalis sensu Haines 1939; extensor digitorum longus sensu Abdala and Moro 2006; extensor digitorum communis sensu Diogo and Abdala 2007, and Diogo 2007) [as explained by Howell 1936ab, Haines 1939, Straus 1941ab, Holmes 1977 and Dilkes 2000, lepidosaurs, turtles, crocodylians and birds have an extensor digitorum, which usually inserts on the	**Extensor digitorum** (extensor digitorum longus sensu Holmes 1977 and Dilkes 1977; extensor carpi ulnaris longus sensu Meers 2003) [as described by Holmes 1977 and Dilkes 2000, crocodylians have an extensorum digitorum ('longus'), which originates on the distal portion of the humerus and usually inserts variably on the metacarpals of digits II,	**Extensor digitorum** (extensor digitorum longus sensu Ribbing 1938, Holmes 1977 and Dilkes 2000; extensor longus communis sensu Dilkes 2000) [probably includes the 'extensor digitorum communis' sensu Sullivan 1962, Shellswell and Wolpert 1977, and Meyers 1996, which goes to digits 1 and 2 (i.e., 2 and 3 according to embryology), but

		for digit 1 and 5, which lack tendons to their radial and ulnar sides, respectively]	metacarpals but, in some taxa such as birds, extends distally to insert on the phalanges]	III and/or IV, and clearly seems to correspond to the extensor carpi ulnaris longus sensu Meers 2003]	usually does not extend distally to the proximal phalanges of these digits; in chickens, the 'extensor metacarpi longus digiti majoris' sensu Meyers 1996 ('extensor medius longus' sensu Sullivan 1962 and Shellswell and Wolpert 1977) often goes from the proximal portion of the radius and/or ulna to the distal phalanx of digit 2 (i.e., digit 3 according to embryology); according to Sullivan 1962 and Shellswell and Wolpert 1977, their 'extensor indicis longus' corresponds to part of the long extensors of the hand, i.e., of the extensor digitorum sensu this volume, because these authors also describe an 'extensor medius brevis' connecting the metacarpal region to digit 2 (i.e., digit 3 according to embryology), which would thus correspond to part of the extensores digitorum breves sensu this volume]

Table 10.1 contd...

Table 10.1 contd...

Amphibia (Caudata): *Ambystoma ordinarium* (Michoacan stream salamander)	Amphibia (Anura): *Bufo arenarum* (Argentine common toad)	Reptilia (Testudines): *Trachemys scripta* (Red-eared slider turtle)	Reptilia (Lepidosauria): *Timon lepidus* (Ocellated 'lizard')	Reptilia (Crocodylia): *Caiman latirostris* (Brown-snouted caiman)	Reptilia (Aves): *Gallus domesticus* (Chicken)
Extensores digitorum breves [urodeles such as *Ambystoma* often have three extensores digitorum breves, going to digits 2, 3 and 4; it is possible that the short extensor going to digit 1 is included in the 'abductor et extensor digit 1' sensu Walthall and Ashley-Ross 2006, that is, that in urodeles such as *Ambystoma* and *Taricha* this short extensor is fused to/deeply blended with the abductor pollicis longus sensu this volume; that is why we prefer to keep the name 'abductor et extensor digit 1' for *Ambystoma*, below; Haines 1939 argues that, apart from the abductor pollicis longus, there is also a short extensor to digit 1 in urodeles such as *Salamandra*: if this is the case, this latter extensor is thus directly homologous to the extensor pollicis longus of mammals]	**Extensores digitorum breves** [probably correspond to the extensores breves superficiales, and, possibly, also to the extensores breves medii, sensu Gaupp 1896; according to Haines 1939 and others, anurans such as *Rana* usually have eight extensores digitorum breves, i.e., they have two muscles inserting on each of the four digits]	**Extensores digitorum breves** (extensores digiti brevis sensu Abdala et al. 2008) [according to Walker 1973 and Abdala et al. 2008, turtles such as *Trachemys* have five extensores digitorum breves, each going to each digit; Walker 1973 stated that the insertion of these muscles is on the 'penultimate phalanges' of the digits, while Abdala et al. 2008 stated it is on the 'first phalanx' of the digits]	**Extensores digitorum breves** (extensor digitorum brevis communis sensu Holmes 1977; extensores digiti brevis sensu Abdala and Moro, 2006) [according to Holmes 1977, in *Sphenodon* and 'lizards' the extensores digitorum breves insert on the distal phalanges of the digits; Haines 1939 argues that the plesiomorphic condition for reptiles, found for instance in turtles and in lepidosaurs such as *Sphenodon* and numerous 'lizards', is to have five extensores digitorum breves to the five digits; see text]	**Extensores digitorum breves** (extensor digitorum brevis communis sensu Holmes 1977) [see text]	**Extensores digitorum breves** (extensores breves digitorum superficiales and seemingly also extensores breves digitorum profundi sensu Ribbing 1938; extensor digitorum brevis communis sensu Holmes 1977) [in chickens the extensores digitorum breves include the 'extensor indicis brevis' sensu Sullivan 1962 and Shellswell and Wolpert 1977 (which corresponds to the 'extensor brevis alulae' sensu Meyers 1996 and goes to digit 1, i.e., to digit 2 according to embryology), and also the 'extensor medius brevis' sensu Sullivan 1962 and Shellswell and Wolpert 1977 (which goes to digit 2, i.e., to digit 3 according to embryology); as explained above, the

					'ulnimetacarpalis dorsalis' sensu Sullivan 1962, Shellswell and Wolpert 1977 and Meyers 1996 might correspond to a reduced short extensor ('extensor digiti brevis') of digit 3, i.e., of digit 4 according to embryology, although it cannot be discarded that it actually corresponds to a reduced abductor digiti minimi sensu this volume: see, e.g, fig. 1 of Shellswell and Wolpert 1977, and abductor digiti minimi above]
Abductor et extensor digiti I (supinator manus sensu Brooks 1889, Ribbing 1907, Haines 1939, Howell 1936ab and Straus 1941ab) [see extensores digitorum breves above]	**Abductor pollicis longus** (abductor indicis longus sensu Gaupp 1896 and Manzano et al. 2008; supinator manus sensu Haines 1939) [see text]	**Abductor pollicis longus** (supinator manus sensu Haines 1939 and Walker 1973) [according to Haines 1939, Walker 1973 and Abdala et al. 2008, turtles usually have an abductor pollicis longus running from the ulna to the metacarpal I]	**Abductor pollicis longus** (supinator manus sensu Haines 1939 and Holmes 1977; abductor longus pollicis sensu Abdala and Moro 2006; abductor et extensor digiti I sensu Diogo and Abdala 2007 and Diogo 2007) [according to Holmes 1977, all major groups of living reptiles have an abductor pollicis longus, which usually originates from the distal end of the ulna and often inserts on	**Abductor pollicis longus** (supinator manus sensu Holmes 1977) [see on the left, and also extensores digitorum breves above]	**Abductor pollicis longus** (abductor digit 1 sensu Ribbing 1938; supinator manus sensu Holmes 1977) [this muscle goes to digit 1 (i.e., digit 2 according to embryology) and probably corresponds to the 'extensor indicis longus' sensu Sullivan 1962 and Shellswell and Wolpert 1977 and thus to the 'extensor longus alulae' sensu Meyers

Table 10.1 contd...

Table 10.1 contd...

Amphibia (Caudata): *Ambystoma ordinarium* (Michoacan stream salamander)	Amphibia (Anura): *Bufo arenarum* (Argentine common toad)	Reptilia (Testudines): *Trachemys scripta* (Red-eared slider turtle)	Reptilia (Lepidosauria): *Timon lepidus* (Ocellated 'lizard')	Reptilia (Crocodylia): *Caiman latirostris* (Brown-snouted caiman)	Reptilia (Aves): *Gallus domesticus* (Chicken)
			the radial side of the carpus and the metacarpal I (in crocodylians, turtles and *Sphenodon*) and also to the distal end of the radius (in 'lizards')]		1996, which, as noted by this latter author, has often been designated as 'extensor pollicis longus', 'extensor longus pollicis' or 'extensor ossis metacarpi pollicis' by other authors]

often suggested in the older literature (for more details about this subject, see Piekaski and Olsson 2007).

Regarding the sternocoracoideus and costocoracoideus, the former muscle is present in various lepidosaurs and birds, while the latter is found in various lepidosaurs and crocodylians, being often subdivided into a 'pars superficialis' and a 'pars profundus' (Tables 10.1–10.2). The evolution and homologies of these muscles and of the mammalian subclavius are discussed in Chapter 9.

Appendicular Muscles of the Pectoral Girdle and Arm (Tables 10.1–10.2)

The pectoralis muscle of amphibians and reptiles is an intrinsic muscle of the forelimb (i.e., an appendicular muscle: see, e.g., Romer 1944, Russell and Bauer 2008, and Chapter 9) that is differentiated, in mammals, into the pectoralis major, the pectoralis minor, and at least part of the panniculus carnosus (Chapter 9). The pectoralis muscle in amphibians and reptiles is usually divided into superficial and deep heads (e.g., Russell and Bauer 2008). Our dissections show three heads of the pectoralis in anurans such as *Bufo*. Manzano (1996) also described three heads of this muscle in pseudid frogs, which she designated as 'epicoracoideus', 'esternalis' and 'abdominalis'. Interestingly, in *Ambystoma*, as well as in other urodeles such as *Taricha* (Walthall and Ashley-Ross 2006), the pectoralis is mainly undivided. According to Romer (1944), Kardong (2002) and others, the plesiomorphic condition for reptiles is that in which the pectoralis is also mainly undivided, as is often the case in lepidosaurs. In crocodylians, the pectoralis is, however, usually subdivided into two or three heads: 'cranial' and 'caudal', or 'cranial', 'caudal' and 'deep', sensu Meers (2003). In birds the pectoralis is often divided into a 'pectoralis superficialis' and a 'pectoralis profundus' (e.g., Dilkes 2000), although Hudson et al. (1972) and other authors refer to a 'pars thoracica', a 'pars propatagialis' and a 'pars abdominalis'. The avian 'pectoralis profundus' seemingly does not correspond to the 'entopectoralis' of mammals. It seems to correspond instead to part of the mammalian 'ectopectoralis', i.e., of the pectoralis major sensu this volume, which is also often divided, in the mammalian literature, into 'profundus' (abdominal head sensu this volume) and 'superficialis' (sternocostal and/or clavicular head sensu this volume). The three divisions of the mammalian 'entopectoralis', i.e., the pectoralis abdominalis, pectoralis minor and 'pectoralis tertius' sensu this volume, thus seem to be absent as distinct structures in birds and in most, if not all, non-mammalian tetrapods (Tables 10.1–10.2; see also Chapter 9).

It is now accepted that the mammalian supraspinatus and infraspinatus, which usually connect the dorsal region of the pectoral girdle to the proximal region of the arm, derive from the supracoracoideus (Tables

Table 10.2 Scheme illustrating the authors' hypotheses regarding the homologies of the pectoral and arm muscles of adults of representative amphibian and reptilian taxa. The nomenclature of the muscles follows that used in the text. Data compiled from evidence provided by our own dissections and comparisons, and from a review of the literature. The black arrows indicate the hypotheses that are most strongly supported by the evidence available; the grey arrows indicate alternative hypotheses that are supported by some data, but that overall are not as strongly supported by the evidence as are the hypotheses indicated by the black arrows (see text, Tables 10.1 and 10.3, and Figs. 10.1–10.13). sup, superioris.

	Ambystoma	*Bufo*	*Trachemys*	*Timon*	*Caiman*	*Gallus*
AXIAL: PECTORAL GIRDLE	Serratus anterior	Serratus anterior	Serratus anterior	Serratus anterior	Serratus anterior	Serratus anterior
	—	Rhomboideus	—	—	Rhomboideus	Rhomboideus
	Levator scapulae	Levator scapulae sup.	Levator scapulae	Levator scapulae	Levator scapulae	—
	—	Opercularis	—	—	—	—
	—	—	—	Sternocoracoideus	—	Sternocoracoideus
	—	—	—	Costocoracoideus	Costocoracoideus	—
APPEMDICULAR: PECTORAL GIRDLE AND ARM	Pectoralis	Pectoralis	Pectoralis	Pectoralis	Pectoralis	Pectoralis
	Supracoracoideus	Supracoracoideus	Supracoracoideus	Supracoracoideus	Supracoracoideus	Supracoracoideus
	Deltoideus scapularis	Deltoideus scapularis	Deltoideus scapularis	Deltoideus scapularis	Deltoideus scapularis	Deltoideus scapularis
	—	—	—	—	Scapulo-humeralis posterior	Scapulo-humeralis posterior
	Procoracohumeralis	Procoracohumeralis	Deltoideus clavicularis	Deltoideus clavicularis	Deltoideus clavicularis	Deltoideus clavicularis
	—	—	—	—	Humeroradialis	Humeroradialis
	—	—	—	Scapulo-humeralis anterior	—	Scapulo-humeralis anterior

APPEMDICULAR: PECTORAL GIRDLE AND ARM					
Subcoracoscapularis	Subcoracoscapularis	Subcoraco-scapularis	Subcoracoscapularis	Subcoracoscapularis	Subcoracoscapularis
—	—	Teres major	—	Teres major	—
Latissimus dorsi	Latissimus dorsi	Latissimus dorsi	Latissimus dorsi	Latissimus dorsi	Latissimus dorsi
Triceps brachii	Triceps brachii	Triceps brachii	Triceps brachii	Triceps brachii	Triceps brachii
Humeroantebrachialis	Humeroantebrachialis	Brachialis	Brachialis	Brachialis	Brachialis
—	Coracoradialis	Biceps brachii	Biceps brachii	Biceps brachii	Biceps brachii
Coracobrachialis	Coracobrachialis	Coracobrachialis	Coracobrachialis	Coracobrachialis	Coracobrachialis

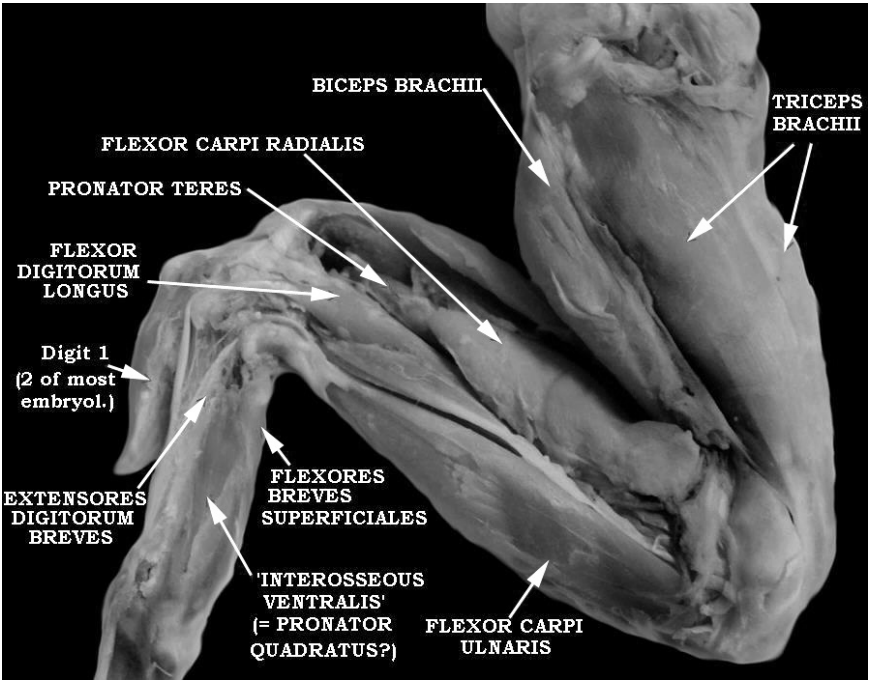

Fig. 10.1 *Gallus domesticus* (Reptilia, Aves): ventral view of the superficial musculature of the wing. embryol., embryologists.

10.1–10.2), a muscle that lies ventral, and not dorsal, to the pectoral girdle in most other extant tetrapods (e.g., Kardong 2002; Chapter 9). In a few non-mammalian taxa, such as chameleons, the supracoracoideus does also occupy a more dorsal space, as in mammals, thus leading some authors to propose that these reptiles do have an 'infraspinatus' and a 'supraspinatus' (see, e.g., Jouffroy 1971). However, this idea is not accepted by Romer (1922, 1924, 1944), Jouffroy (1971) and others, who argue that the dorsal position of the supracoracoideus of chameleons was acquired inside the reptilian clade, while the change from a ventral supracoracoideus to a dorsal infraspinatus and a dorsal supraspinatus was acquired during the evolutionary transitions that led to the origin of extant mammals.

The deltoideus scapularis is consistently present in amphibians and reptiles. In turtles, the deltoid musculature has been described as one of the most variable of the shoulder muscles (Walker 1973). The scapulo-humeralis posterior is present as a distinct muscle only in birds, crocodylians, and possibly a few lepidosaurs such as *Agama* (Tables 10.1–10.2; see also Chapter 9). As explained by Romer (1944), the 'longus' head of the amphibian procoracohumeralis corresponds to the deltoideus clavicularis plus humero-radialis of reptiles such as *Sphenodon*, birds and crocodylians (see Fig. 10.13),

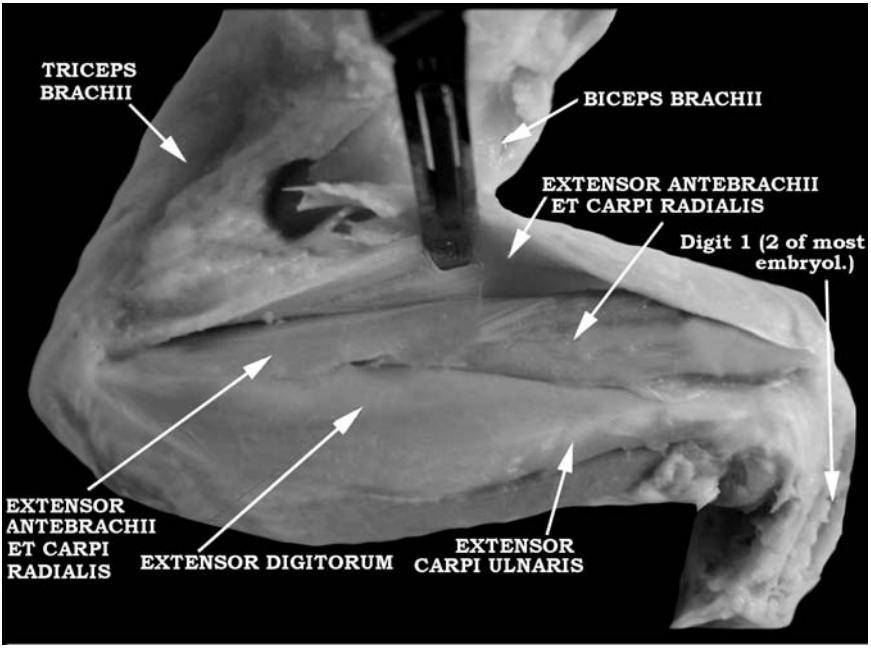

Fig. 10.2 *Gallus domesticus* (Reptilia, Aves): dorsal view of the deep musculature of the wing. embryol., embryologists.

and the 'brevis' head of the amphibian procoracohumeralis corresponds to the scapulo-humeralis anterior of reptiles such as lepidosaurs and birds (Tables 10.1–10.2; see also Chapter 9). According to Jouffroy (1971), the reptilian scapulo-humeralis posterior might be homologous to the mammalian teres minor, because both these muscles derive from the deltoideus scapularis (see Table 10.2). However, Holmes (1977) and others argued that the scapulo-humeralis anterior and scapulo-humeralis posterior were acquired during the evolution of reptiles, i.e., that these muscles were not differentiated in the last common ancestor (LCA) of extant reptiles, and, thus, that the mammalian teres minor cannot be directly homologous to the scapulo-humeralis posterior of some reptilian taxa.

The subcoracoscapularis is consistently present in amphibians and reptiles. This muscle was not described in *Taricha torosa* by Walthall and Ashley-Ross (2006), and our dissections did not allow us to appropriately discern if it is present in urodeles such as *Ambystoma ordinarium* (Table 10.1). However, according to Romer (1944), Kardong (2002), and other authors, the subcoracoscapularis is found in various urodeles. As explained in Chapter 9, the mammalian teres major is probably derived from the subcoracoscapularis (Tables 10.1–10.2). According to Dilkes (2000), there is a 'teres major' in turtles, crocodiles and many 'lizards', but not in lepidosaurs such as *Sphenodon* and

Iguana and in birds. Jouffroy (1971) and Meers (2003) confirm that crocodylians have a 'teres major'. Romer (1944) also states that there is a 'teres major' in crocodylians and that this muscle is absent in *Sphenodon* and Aves, but, contrary to (Dilkes 2000), he argues that the 'teres major' is also missing in the whole Lacertilia. In our dissections, we were effectively unable to find a distinct 'teres major' in 'lizards' such as *Timon*. Walker (1973) and Wyneken (2001) state that turtles often have a 'teres major', although this structure is often blended with the latissimus dorsi. Howell (1937b) defends that only mammals have a 'true' teres major, thus suggesting that the 'teres major' of reptiles such as crocodylians and turtles is not homologous to the mammalian teres major. In view of our dissections, comparisons and review of the literature, however, we see no reasons to completely discard, *a priori*, the hypothesis that the 'teres major' of reptiles such as crocodylians and turtles might be homologous to the teres major of mammals. Actually, if future studies do reveal that a 'teres major' is effectively present in at least some lepidosaurs, as stated by Dilkes (2000), it would be phylogenetically more parsimonious to assume that the LCA of amniotes had a teres major and that this muscle was secondarily lost in the node leading to Crocodylia, than to assume that a 'teres major' was independently acquired in lepidosaurs, turtles and birds and that, in addition, a remarkably similar muscle, the mammalian teres major, was independently acquired in mammals.

The latissimus dorsi is a dorsal muscle of the pectoral girdle and the triceps brachii is mainly an extensor of the forearm; both these muscles are consistently present in urodeles, anurans, turtles, lepidosaurs, crocodylians and birds (Tables 10.1–10.2). As explained in Chapter 9, the mammalian dorsoepitrochlearis was very likely derived from the coracoid head of the triceps brachii of non-mammalian tetrapods. The details about the specific subdivisions of the triceps brachii in urodeles, anurans, turtles, lepidosaurs, crocodylians and birds are given in Table 10.1. The humeroantebrachialis of urodeles such as *Ambystoma* very likely corresponds to the brachialis and to part (the long head) of the biceps brachii of amniotes; in many anuran amphibians (but usually not in urodeles) there is also a coracoradialis, which probably corresponds to the short head of the biceps brachii of amniotes, although it is possible that this short head derives instead/also from the coracobrachialis (see Tables 10.1–10.2 and Chapter 5). Our dissections of anurans confirmed that, contrary to urodeles such as *Ambystoma*, which only have a humeroantebrachialis and a coracobrachialis, anurans such as *Bufo* do have a humeroantebrachialis, a coracobrachialis, and a coracoradialis (Tables 10.1–10.2). Romer (1944) suggested that the 'coracobrachialis externus' plus 'coracobrachialis internus' of birds correspond to the coracobrachialis brevis of crocodylians, and, thus, that the coracobrachialis longus is absent in birds. However, as explained by Jollie (1962), Holmes (1977), Dilkes (2000) and other authors, and corroborated by our dissections, birds do seem to have both a

coracobrachialis brevis and a coracobrachialis longus sensu this volume (see Tables 10.1, 10.3).

Appendicular Muscles of the Forearm and Hand (Tables 10.1, 10.3)

As explained in Chapter 9, the muscles of the forearm and hand of tetrapods may be divided into three main groups: the ventral muscles of the forearm (usually flexors of the hand/digits and/or pronators of the forearm), the muscles of the hand, and the dorsal muscles of the forearm (usually extensors of the hand/digits and/or supinators of the forearm). In both amphibian and reptiles, the extensor (dorsal) and flexor (ventral) layers of the forearm have the same basic structure, being both composed superficially by three muscular complexes: the 'ulnar extensors/flexors', the 'radial extensors/flexors' and the 'extensor/flexor digitorum communis/longus'. These muscular complexes usually arise from the humerus and insert on the distal portion of the radius, the distal portion of the ulna, and the hand (carpal, metacarpal and/or phalangeal) bones, respectively. These six muscular complexes are present in all major extant clades of limbed amphibians and reptiles. We prefer to use the name muscular complexes, because all these six complexes actually include more than one muscle in at least one of these clades (see Tables 10.1, 10.3, and also below). Contrary to most other non-mammalian tetrapods, crocodylians have a more distal insertion of the 'radial extensors/flexors' and the 'ulnar extensors/flexors'. For instance, the 'pars superficialis' and 'pars intermedia' (sensu Holmes 1977) of the extensor antebrachii et carpi radialis of crocodylians insert on the radial bone (i.e., a carpal bone), and not on the radius (see Table 10.1). In birds this tendency is still more acute, e.g., part of the extensor antebrachii et carpi radialis extends distally to insert on the proximal end of metacarpus I (e.g., Hudson et al. 1972; this work). In mammals, the insertion of the muscles of the forearm on hand bones is common (e.g., Jouffroy 1971; see Chapter 9). Interestingly, a similar trend is also found in some anurans (e.g., *Phyllomedusa*: Manzano 1996; this work; see below).

Concerning the 'flexor digitorum communis/longus' muscular complex, the flexor accessorius lateralis and flexor accessorius medialis of urodeles are fused with the flexor digitorum communis to form the flexor digitorum longus of reptiles and monotremes, which in therian mammals is usually divided into a flexor digitorum profundus and a flexor digitorum superficialis (note, however, that this latter muscle also includes part of the flexores breves superficiales of non-mammalian tetrapods) (Tables 10.1, 10.3; Chapter 9). According to Holmes (1977) and Dilkes (2000), in reptiles such as 'lizards', *Sphenodon* and crocodylians the flexor digitorum longus usually has 'superficial', 'deep ulnar' and 'deep humeral' heads, the

Table 10.3 Scheme illustrating the authors' hypotheses regarding the homologies of the forearm and hand muscles of adults of representative amphibian and reptilian taxa (see caption of Table 10.2, and also Tables 10.1 and 10.2 and Figs. 10.1–10.13). an., antebrachii.

	Ambystoma	*Bufo*	*Trachemys*	*Timon*	*Caiman*	*Gallus*
APPENDICULAR: VENTRAL FOREARM	Pronator quadratus	Pronator quadratus	Pronator quadratus	Pronator quadratus	Pronator quadratus	Pronator quadratus
	—	—	Pronator acessorius	Pronator acessorius	—	—
	Contrahentium caput longum	Contrahentium caput longum	—	—	—	—
	Flexor accessorius lateralis	Flexor accessorius	—	—	—	—
	Flexor accessorius medialis	—	—	—	—	—
	Flexor digitorum communis	Flexor digitorum communis	Flexor digitorum longus	Flexor digitorum longus	Flexor digitorum longus	Flexor digitorum longus
	—	—	Palmaris longus'	—	—	—
	Flexor carpi ulnaris	Flexor carpi ulnaris	Flexor carpi ulnaris	Flexor carpi ulnaris	Flexor carpi ulnaris	Flexor carpi ulnaris
	Epitrochleoanconeus	Epitrochleoanconeus	Epitrochleoanconeus	Epitrochleoanconeus	Epitrochleoanconeus	Epitrochleoanconeus
	Flexor an. et carpi radialis	Flexor carpi radialis	Flexor carpi radialis	Flexor carpi radialis	Flexor carpi radialis	Flexor carpi radialis
	—	Pronator teres	Pronator teres	Pronator teres	Pronator teres	Pronator teres
APPENDICULAR: VENTRAL AND DORSAL HAND	Flexores breves superficiales	Flexores breves superficiales	Flexores breves superficiales	Flexores breves superficiales	Flexores breves superficiales	Flexores breves superficiales
	—	Lumbricales	Lumbricales	Lumbricales	Lumbricales	—
	Contrahentes digitorum	Contrahentes digitorum	Contrahentes digitorum	Contrahentes digitorum	Contrahentes digitorum	Contrahentes digitorum
	Flexores breves profundi	Flexores breves profundi	Flexores breves profundi	Flexores breves profundi	Flexores breves profundi	Flexores breves profundi

APPENDICULAR: VENTRAL AND DORSAL HAND	—	Abductor pollicis brevis	Abductor pollicis brevis	Abductor pollicis brevis	Abductor pollicis brevis	Abductor pollicis brevis
	Abductor digiti minimi	Abductor digiti minimi	Abductor digiti minimi	Abductor digiti minimi	—	Abductor digiti minimi
	Intermetacarpales	Intermetacarpales	Intermetacarpales	Intermetacarpales	Intermetacarpales	Intermetacarpales
	—	Dorsometacarpales	Dorsometacarpales	Dorsometacarpales	Dorsometacarpales	Dorsometacarpales
APPENDICULAR: DORSAL FOREARM	Extensor an. et carpi radialis	Extensor an. et carpi radialis	Extensor an. et carpi radialis	Extensor an. et carpi radialis	Extensor an. et carpi radialis	Extensor an. et carpi radialis
	—	—	Brachioradialis	—	Brachioradialis	—
	Extensor an. et carpi ulnaris	Extensor carpi ulnaris	Extensor an. et carpi ulnaris	Extensor an. et carpi ulnaris	Extensor an. et carpi ulnaris	Extensor carpi ulnaris
	—	Anconeus	—	—	—	Anconeus
	Extensor digitorum	Extensor digitorum	Extensor digitorum	Extensor digitorum	Extensor digitorum	Extensor digitorum
	Extensores digitorum breves	Extensores digitorum breves	Extensores digitorum breves	Extensores digitorum breves	Extensores digitorum breves	Extensores digitorum breves
	Abductor et extensor digiti 1	Abductor pollicis longus	Abductor pollicis longus	Abductor pollicis longus	Abductor pollicis longus	Abductor pollicis longus

last being very likely fused with the structure that Holmes (1977) designated as 'pronator radii teres' (see Tables 10.1, 10.3, and below). Therefore, it is possible that the 'superficial' head derives from or corresponds to the amphibian flexor digitorum communis, and that the two reptilian 'deep' heads derive from or correspond to the amphibian flexor accessorius lateralis and flexor accessorius medialis. Also according to Holmes (1977) and Dilkes (2000), the plesiomorphic condition for reptiles is to have a flexor digitorum longus inserted on the distal phalanges of digits 1, 2, 3, 4 and 5, although in some taxa such as birds and crocodylians the muscle inserts only on some of these digits. For instance, the flexor digitorum longus of birds usually inserts exclusively on digit 2 (i.e., digit 3 according to most embryologists) (see Tables 10.1, 10.3, and below). Ribbing (1938) and other authors described a 'flexor digitorum sublimis' in birds, but this structure clearly seems to correspond to the 'superficial' head of the flexor digitorum longus sensu Holmes (1977) and Dilkes (2000), and not to the flexor digitorum superficialis (often called 'sublimis') of marsupial and placental mammals (see Chapter 9). The contrahentium caput longum of amphibians may also correspond to part of the flexor digitorum longus of reptiles and monotremes, but it is more likely that the former muscle is completely missing in amniotes (Tables 10.1, 10.3; Chapter 9). The flexor accessorius of anurans such as *Bufo* corresponds to the flexor accessorius medialis plus flexor accessorius lateralis of urodeles such as *Ambystoma* (e.g., Ribbing 1907; see Tables 10.1, 10.3).

One muscle that also makes part of the 'flexor digitorum communis/longus' complex is the palmaris longus, which is variable among tetrapods and is often the most superficial ventral muscle of the forearm. As explained in Chapter 9, some of the structures that are designated as 'palmaris longus' in different tetrapod groups are probably not homologous to each other. For instance, Gaupp (1896) described a 'palmaris longus' in anurans. However, Howell (1935, 1936ab) and Straus (1942) stated that a 'true palmaris longus' is only seen as a variant in some reptiles such as *Iguana* (see Fig. 10.12), and is only consistently present in mammals. In fact, it should be noted that the flexor digitorum communis of amphibians is often designated, in the old literature, as 'palmaris communis' and/or as 'flexor digitorum longus'. Therefore, it would actually not be surprising if Gaupp (1896) had simply combined these names and thus used the name 'palmaris longus' to designate the flexor digitorum communis sensu this volume (Tables 10.1, 10.3). Regarding reptiles, there is no 'palmaris longus' in *Timon* (Tables 10.1, 10.3), but there is a 'palmaris longus' in other 'lizards', as well as in other clades such as turtles, according to Howell (1936ab), Haines (1939, 1950), Walker (1973), Russell and Bauer (2008), Abdala et al. (2008) and other authors, and according,to our dissections (see also Fig. 10.12). Howell (1936b) argued that the 'palmaris longus' found in some reptiles is probably derived from part of the flexor carpi radialis, although he also stated that some

reptiles may have a 'palmaris longus' derived from the flexor carpi ulnaris, thus supporting the idea that at least some of these 'palmaris longus' muscles are not homologous to each other. Straus (1942) also states that the structures that are designated as 'palmaris longus' in therian mammals may eventually be derived from the flexor carpi radialis, from the flexor digitorum superficialis and/or from the flexor carpi ulnaris (see Chapter 9). In a recent review, Russell and Bauer (2008) considered the 'palmaris longus' of 'lizards' as an additional 'humeral' head of the flexor digitorum longus. According to our dissection, the 'palmaris longus' is a muscle occasionally present in 'lizards' such as *Tupinambis* (Fig. 10.3), *Teyus*, *Ameiva*, and varanids but tends to be absent in iguanids (but see Fig. 10.12 and text above). In the lepidosaurian specimens we dissected, the 'palmaris longus' often inserts superficially to the distal insertion of the common tendon of the flexor digitorum longus and to the flexor plate, being the only ventral forearm muscle that has some connection with the most superficial muscles of the hand. As can be seen in Fig. 10.3, this 'palmaris longus' forms a continuum with the layer of the flexores breves superficiales. Taking this into consideration, we do support the statements of Howell (1935, 1936ab), Straus (1942) and others according to which anurans do not have a 'palmaris longus'. This is because the only forearm muscle that connects the forearm to the most superficial layer of the hand muscles in anurans is the flexor digitorum communis (Fig. 10.4). In the 'lizards' that we have dissected, the 'palmaris longus' tends to have a more ulnar topology

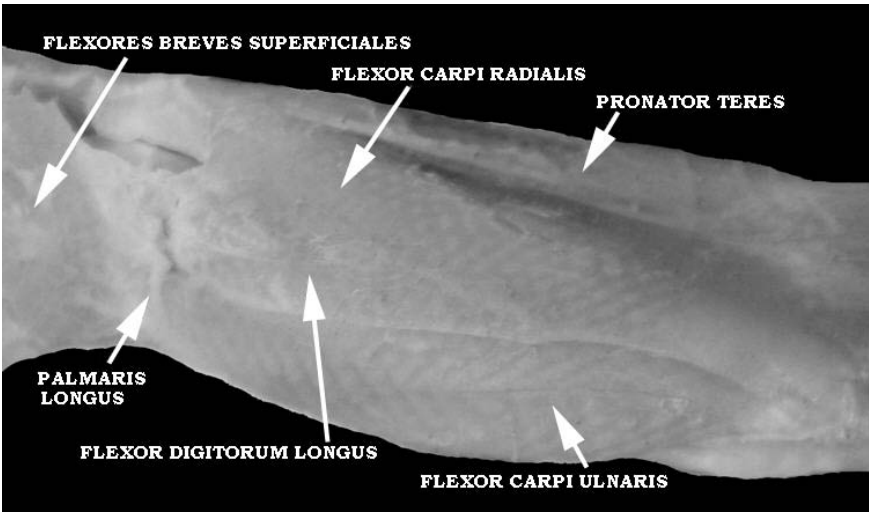

Fig. 10.3 *Tupinambis meriane* (Reptilia, Lepidosauria): ventral view of the superficial musculature of the forelimb, showing the continuous layer between the flexores digitorum breves and the 'palmaris longus'.

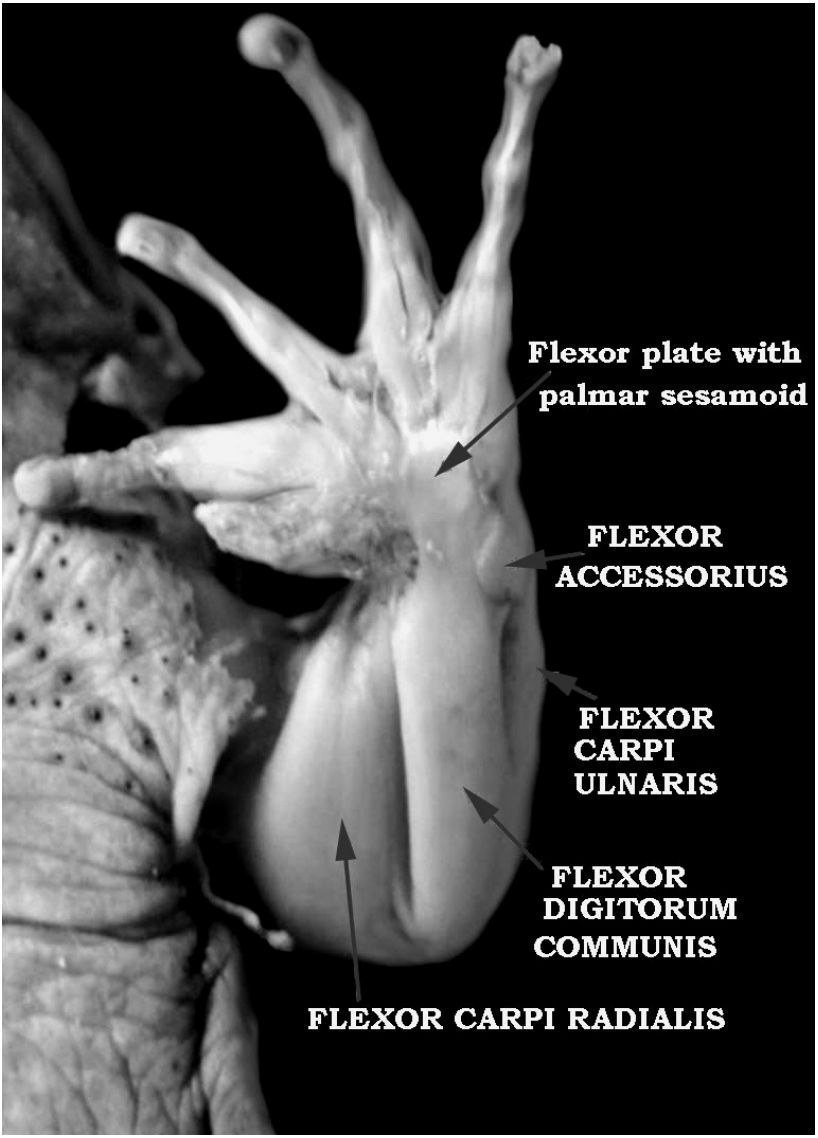

Fig. 10.4 *Telmatobius laticeps* (Amphibia, Anura): ventral view of the superficial musculature of the forelimb and hand showing the flexor plate with the embedded sesamoid.

(Fig. 10.3). According to Walker (1973) and Abdala et al. (2008), as well as our dissections, a 'palmaris longus' with the same overall configuration as that found in lepidosaurs is present in turtles such as *Trachemys* and *Chelonoidis* (Tables 10.1, 10.3). Haines (1950) and Lewis (1989) stated that the palmaris longus might have been part of the muscular equipment of the LCA

of amniotes, thus suggesting that at least some of the structures designated as 'palmaris longus' in reptiles such as lepidosaurs and turtles are homologous to at least some of the structures designated as palmaris longus in mammals (see Chapter 9, and also Tables 10.1, 10.3).

Regarding the ulnar ventral (flexor) muscular complex of the forearm, in amphibians, reptiles and mammals this usually includes a flexor carpi ulnaris and an epitrochleoanconeus (Tables 10.1, 10.3). This latter muscle, which is often also designated as 'flexor antebrachii ulnaris', usually runs from the medial epicondyle of the humerus to the proximal portion of the ulna, being very thin proximally and being very easily not detected or confused with the flexor carpi ulnaris in dissections of the forearm. According to Walthall and Ashley-Ross (2006), there is a 'flexor antebrachii et carpi ulnaris' in the urodele *Taricha*. However, our dissections indicate that a distinct flexor carpi ulnaris and a distinct epitrochleoanconeus may be present in at least some members of the genus *Ambystoma*, and McMurrich (1903ab), Ribbing (1907) and Straus (1942) confirm that these two muscles are effectively differentiated in at least some urodeles. The epitrochleoanconeus is commonly present in reptiles. Walker (1973), Abdala et al. (2008) and other authors did not recognize a distinct epitrochleoanconeus in the turtle *Trachemys*, but Holmes (1977) stated that he did find this muscle in a specimen of this genus dissected by him. Straus (1942) and Meers (2003) suggested that the epitrochleoanconeus is absent in crocodylians, but we did find it in the specimens of *Caiman latirostris* we dissected (Tables 10.1, 10.3).

Regarding the radial ventral (flexor) muscular complex, Macalister (1869) stated that in most amphibians, including urodeles, the flexor antebrachii et carpi radialis is usually differentiated into a 'flexor antebrachii radialis' (pronator teres sensu this volume) and a flexor carpi radialis. However, according to McMurrich (1903ab), Straus (1942) and other authors, these structures are usually not present as separate, distinct muscles in urodeles, and this seems effectively to be the case in the *Ambystoma* specimens we dissected (Tables 10.1, 10.3). Ribbing (1907) also supported this idea, stating that the flexor carpi radialis and the pronator teres are present as distinct muscles in anurans, but not in urodeles (Tables 10.1, 10.3). According to Walthall and Ashley-Ross (2006), the flexor antebrachii et carpi radialis of urodeles such as *Taricha* flexes, but also helps to pronate, the hand, i.e., it does the function of the flexor carpi radialis and of the pronator teres of other tetrapods. There is some confusion regarding the identity of the flexor carpi radialis and of the pronator teres in reptiles. The 'two heads of the flexor carpi radialis' sensu Holmes (1977), Dilkes (2000) and others and of the 'pronator teres' sensu Meers (2003), which are usually present in lepidosaurs, including *Sphenodon* and *Iguana* and other taxa such as *Timon*, as well as in some crocodylians, in turtles, and in birds (according to Dilkes 2000 these 'two heads' are often designated as 'pronator superficialis and pronator profundus' in birds), clearly

seem to correspond to the flexor carpi radialis and pronator teres of mammals. However, the structure that McMurrich (1903a) and Holmes (1977) described as 'pronator radii teres' in taxa such as *Sphenodon* and 'lizards' clearly seems to derive from the flexor digitorum longus, as recognized by these two latter authors. That is, this 'pronator radii teres' probably does not correspond to the pronator teres sensu this volume, which derives from the flexor antebrachii et carpi radialis (Tables 10.1, 10.3; Chapter 9). As described by Straus (1942) and Meers (2003), and corroborated by our dissections of *Caiman latirostris*, in some crocodylians the pronator teres and the flexor carpi radialis are deeply blended, while in other crocodylians these two muscles are well separated, corresponding to the 'two heads of the flexor carpi radialis' sensu Holmes (1977) and Dilkes (2000).

The remaining ventral muscles of the forearm are the pronator quadratus and pronator accessorius (Tables 10.1, 10.3). The pronator quadratus is present in urodeles, anurans, turtles, lepidosaurs, crocodylians, birds and mammals. However, a fully differentiated pronator accessorius is found only in reptiles (Tables 10.1, 10.3). As explained above, the structure that is often designated as 'pronator profundus' in birds corresponds to the pronator teres, and not to the pronator quadratus, sensu this volume (see also Table 10.1). However, birds have a ventral forearm muscle that is often designated as 'ulnimetacarpalis ventralis' (e.g., Sullivan 1962; Shellswell and Wolpert 1977; Meyers 1996) and that usually connects the distal portion of the ulna to the metacarpal region, which probably corresponds to the pronator quadratus and/or possibly (less likely) to the pronator accessorius sensu this volume (Tables 10.1, 10.3). This idea is supported by Straus (1942), Holmes (1977) and others, who state that the pronator quadratus is present as a distinct muscle in all major extant groups of reptiles.

Regarding the dorsal muscles of the forearm, one issue that has been the subject of much confusion in the literature concerns the homologies of the extensor antebrachii et carpi radialis and its derivatives in non-mammalian tetrapods and the mammalian extensor carpi radialis longus, extensor carpi radialis brevis, brachioradialis, and supinator (Tables 10.1, 10.3). Howell (1936b), Meers (2003) and other authors described an 'extensor carpi radialis longus' and an 'extensor carpi radialis brevis' in reptiles such as *Iguana* and crocodylians. However, most authors argue that reptiles have a single 'extensor carpi radialis', which corresponds to the extensor antebrachii et carpi radialis sensu this volume and is usually subdivided into three bundles in amphibians such as urodeles and reptiles such as turtles, crocodylians and lepidosaurs, i.e., 'superficialis', 'profundus', and 'intermedius' (e.g., Humphry 1872ab; Walker 1973; Holmes 1977; Lewis 1989; Dilkes 2000; Abdala et al. 2008; this work; see Tables 10.1, 10.3). Humphry (1872ab), Lewis (1989) and other authors suggested that these three bundles might have given rise to the extensor carpi radialis (brevis + longus), brachioradialis and supinator of

mammals, respectively. However, it is important to note that, apart from these three bundles of the extensor antebrachii et carpi radialis, reptiles usually also have a muscle 'supinator longus'/'tractor radii' sensu Holmes (1977), which is actually the probable homologue of the mammalian brachioradialis (see Tables 10.1, 10.3, and below). Therefore, the muscle mass formed by the extensor antebrachii et carpi radialis of reptiles such as crocodylians and turtles seems to correspond to the structure that has given rise to the mammalian extensor carpi radialis longus, extensor carpi radialis brevis and supinator, but not to the mammalian brachioradialis (see Fig. 10.12). It is, however, possible that the structure that has been often designated as the 'intermedius' head of the extensor antebrachii et carpi radialis in other non-mammalian tetrapods such as urodeles, for instance, actually corresponds to the structure that has given rise to the mammalian brachioradialis, as suggested by Humphry (1872ab) and Lewis (1989). That is, it is possible, and even likely, that the 'intermedius' head of taxa such as urodeles is actually not homologous to the 'intermedius' head of reptiles such a crocodylians and turtles. In crocodylians, the extensor antebrachii et carpi radialis sensu this volume seems to include the 'extensor carpi radialis longus', the 'extensor carpi radialis brevis', and the 'abductor radialis' sensu Meers (2003), although part of the 'extensor carpi radialis brevis' sensu Meers (2003) (his 'pars ulnaris') might actually correspond to the abductor pollicis longus sensu this volume (see Tables 10.1, 10.3, and below). The crocodylian 'extensor carpi radialis longus', 'extensor carpi radialis brevis' (or at least its 'pars radialis'), and the 'abductor radialis' sensu Meers (2003) might well correspond to the 'pars superficialis, pars intermedia and pars profunda of the extensor carpi radialis' sensu Holmes (1977) and, thus, to the structures that have differentiated, in mammals, to give rise to the distinct extensor carpi radialis longus, extensor carpi radialis brevis and supinator muscles. This is because the two former crocodylian structures insert on hand bones, as usually do the mammalian extensor carpi radialis longus and extensor carpi radialis brevis, while the latter, third structure does not reach the hand bones, inserting, distally, exclusively on the forearm bones, as usually does the mammalian supinator. This hypothesis is supported by the fact that some authors have precisely designated the 'extensor carpi radialis profundus' sensu Holmes (1977) as 'supinator' or 'supinator brevis' (see, e.g., Walker 1973; see also Tables 10.1, 10.3, and below).

The 'supinator longus' ('tractor radii') sensu Holmes (1977), which in reptiles such as turtles is innervated by the 'inferior brachial nerve' and the radial nerve (e.g., Haines 1939), clearly seems to correspond to the brachioradialis of mammals, because its origin on the humerus is more lateral and more proximal than that of the other derivatives of the 'extensor antebrachii et carpi radialis anlage' (see, e.g., fig. 19 of Holmes 1977). This idea is supported by the fact that in the old literature the mammalian brachioradialis was precisely often designated as 'supinator longus' and the reptilian 'tractor radii' was

precisely often designated as brachioradialis (see, e.g., Walker 1973; Chapter 9). Jollie (1962) suggested that the humeroradialis is present in crocodylians and *Sphenodon* and corresponds to the 'tensor patagii' of birds and to the brachioradialis of mammals. Meers (2003) stated that the humeroradialis of crocodylians (Fig. 10.13) is homologous to the 'tensor propatagialis' of birds, but that this muscle is missing in other living reptiles, thus suggesting that the mammalian brachioradialis is effectively homologous to the crocodylian muscle that he designated as 'supinator'. It is important to note that the overall configuration and function of the humeroradialis sensu Meers (2003) are in fact somewhat similar to those of the mammalian brachioradialis, because the humeroradialis is derived ontogenetically from the dorsal (extensor) anlage but acts mainly as a flexor of the antebrachium (see, e.g., Meers 2003, Table 10.1, and Fig. 10.13). However, regarding its innervation, the humeroradialis sensu Meers (2003) does not seem to be homologous to the mammalian brachioradialis, because it is innervated by the axillary nerve, and not by the radial nerve. Moreover, the 'supinator' sensu Meers (2003) also has an overall configuration and function that are similar to those of the mammalian brachioradialis (i.e., it is part of the extensor musculature but also acts mainly as a flexor of the antebrachium) and, contrary to the humeroradialis, is mainly innervated by the radial nerve, as is the mammalian brachioradialis (see, e.g., Meers 2003). Therefore, the mammalian brachioradialis does seem to be homologous to the 'supinator', and not to the humeroradialis, sensu Meers (2003) (Tables 10.1, 10.3).

Haines (1939) correctly stated that the 'tractor radii' (which, as explained above, very likely corresponds to the brachioradialis sensu this volume) is not present as a separate muscle in amphibians such as *Salamandra*; but, at the same time, he designated the 'intermedius' head of the extensor antebrachii et carpi radialis of *Salamandra* as a 'brachioradialis'. This seems to support the hypothesis, proposed above, that the structure that is often designated as the 'intermedius' head of the extensor antebrachii et carpi radialis in taxa such as urodeles is actually not directly homologous to the 'intermedius' head of reptiles such as turtles and crocodylians. In any case, most authors argue that, even if the 'intermedius' head of taxa such as urodeles effectively corresponds to the structure that has given rise to the mammalian brachioradialis, this 'intermedius' head is just a poorly differentiated part of the extensor antebrachii et carpi radialis, and not a distinct, separate muscle, as is the mammalian brachioradialis (see, e.g., Humphry 1872ab; Howell 1936b; Straus 1941ab; Lewis 1989; see also Tables 10.1, 10.3 and Chapter 9).

Regarding the ulnar dorsal (extensor) muscular complex, the anconeus (often designated as 'extensor antebrachii ulnaris') and the extensor carpi ulnaris are seemingly not present as independent muscles in *Ambystoma* and *Timon*. But Haines (1939), Sullivan (1962), Jouffroy (1971), Jouffroy and Lessertisseur (1971), Holmes (1977), Shellswell and Wolpert (1977) and others do describe an 'anconeus' in amphibians such as *Salamandra* and various

reptiles, such as *Sphenodon* and some birds. However, it is important to note that we did not find a distinct, separate anconeus such as that found in mammals in the turtles and in the numerous 'lizards' we dissected, that Howell (1936ab) does not describe an 'anconeus' in urodeles such as *Necturus* and 'lizards' such as *Iguana*, and that Meers (2003) does not describe a distinct 'anconeus' in crocodylians. Moreover, Haines (1939), who did describe an 'anconeus' in *Salamandra*, *Triton*, and *Rana*, argued that the 'anconeus' is rarely present as a separate, distinct muscle in urodeles and apparently also in anurans, thus suggesting that the 'anconeus' of reptiles, the 'anconeus' of amphibians and the anconeus of mammals were acquired independently in the evolution of these clades, i.e., that they are not homologous to each other. As the 'anconeus' that Haines (1939), Sullivan (1962), Jouffroy (1971), Jouffroy and Lessertisseur (1971), Holmes (1977), Shellswell and Wolpert (1977) and other authors describe in some amphibians and reptiles and the anconeus of mammals have a similar overall configuration and a similar innervation, and derive from the same anlage (i.e., derive from the 'extensor antebrachii et carpi ulnaris' anlage), this would be a clear illustration of convergent/parallel evolution. For instance, Sullivan (1962), Shellswell and Wolpert (1977), Meyers (1996), and Maxwell and Larsson (2007) described a muscle 'anconeus' (or 'ectepicondylo-ulnaris') in birds such as chickens, which connects the distal dorsal margin of the humerus to the proximal dorsal margin and derives ontogenetically from the extensor antebrachii et carpi ulnaris sensu this volume, as does the anconeus of mammals. If further studies, including a broader sampling of amphibian and reptilian taxa, do show that an 'anconeus' is effectively present in at least some members of all, or at least most of, the major extant clades of limbed amphibians and reptiles, this would probably indicate that in the LCA of tetrapods the extensor antebrachii et carpi ulnaris was at least already partially differentiated into an antebrachial, proximal portion and a carpal, distal portion, which then gave rise to the anconeus and extensor carpi ulnaris sensu this volume, respectively.

The remaining muscles of the dorsal (extensor) layer of the forearm are the extensor digitorum, the extensores digitorum breves (often designated as 'short extensors of the digits'), and the abductor pollicis longus, which in urodeles such as *Ambystoma* and *Taricha* is possibly fused with the short extensor of digit 1, forming the abductor et extensor digit 1 (see Tables 10.1, 10.3). Within crocodylians, Meers (2003) included the following, in the 'intrinsic extensors of the manus': five 'extensores digitorum superficiales' that often attach to the distal phalanges of digits 1, 2, 3, 4 and 5; six 'extensores digitorum profundi' that often attach to the distal phalanges of these five digits; one 'extensor pollicis superficialis et indicis proprius' attaching to the distal portions of digits 1 and 2; one 'extensor metacarpi I' attaching to metacarpal I; and one 'extensor metacarpi IV' attaching to metacarpal IV. All these 14 muscles seem to correspond to/derive from the extensores digitorum breves sensu this volume, except the

'extensor metacarpi I' or possibly the 'extensor digiti I superficialis', as one of these two latter structures might well correspond to the abductor pollicis longus sensu this volume (Tables 10.1, 10.3). The 'extensor digiti I superficialis' could correspond to the abductor pollicis longus because, as is often the case with this latter muscle, it is the largest and most lateral dorsal (extensor) muscle of the hand (compare, e.g., fig. 13 of Meers 2003 with fig. 2 of Moro and Abdala 2006). However, this 'extensor digiti I superficialis' inserts on the distal phalanx of digit 1, and not on the metacarpal I, as often does the abductor pollicis longus of other reptiles. This might indicate that, if the abductor pollicis longus sensu this volume is actually present in crocodylians, it might perhaps correspond to the 'extensor metacarpi I' sensu Meers (2003), because this latter structure precisely inserts on metacarpal I, and not on the distal phalanx of digit I. However, the most likely hypothesis, in view of our dissections, comparisons, and review of the literature, is that all these 14 muscles described by Meers (2003) are actually part of the extensores digitorum breves sensu this volume, and that this author failed to describe the abductor pollicis longus. This is because Holmes (1977) and others clearly stated that this latter muscle is present in crocodylians and is similar to the abductor pollicis longus of other reptiles, going mainly from the ulna to the carpal/metacarpal region. Meers (2003) did not describe a muscle with such a configuration in crocodylians, because his 'extensor metacarpi I' runs from the radial bone to the metacarpal I, and his 'extensor digiti I superficialis' runs from the radial bone to the distal phalanx of digit I. Another plausible hypothesis is that the abductor pollicis longus sensu this volume corresponds to the 'extensor carpi radialis brevis pars ulnaris' sensu Meers (2003), because this latter structure is well developed, originates from the ulna, and inserts on the carpal/metacarpal region (on the radial bone according to Meers 2003), as usually does the abductor pollicis longus of other reptiles. It should be noted that Russell and Bauer (2008) described, in lepidosaurs, a 'superficial extensores digitores brevis complex' and an 'interossei dorsales' complex. According to them, the former complex is subdivided into superficial and deep components (see Fig. 10.5). In view of our dissections, observations and review of the literature, we consider that the structures that these authors designated as 'extensores digitores brevis profundus' correspond to the dorsometacarpales sensu this volume (see Tables 10.1, 10.3).

The homologies of the hand muscles of tetrapods have been the subject of numerous discussions and were discussed in Chapter 9. Examples of amphibian and reptilian hand muscles include the following: the flexores breves superficiales, which are ventral (palmar, superficial) to the other muscles; the abductor pollicis brevis and abductor digiti minimi, which usually lie on the ventrolateral (radial) and ventromesial (ulnar) surface of the hand and abduct the most lateral (radial) and most medial (ulnar) digits, respectively; the lumbricales, which are deeper and are usually associated

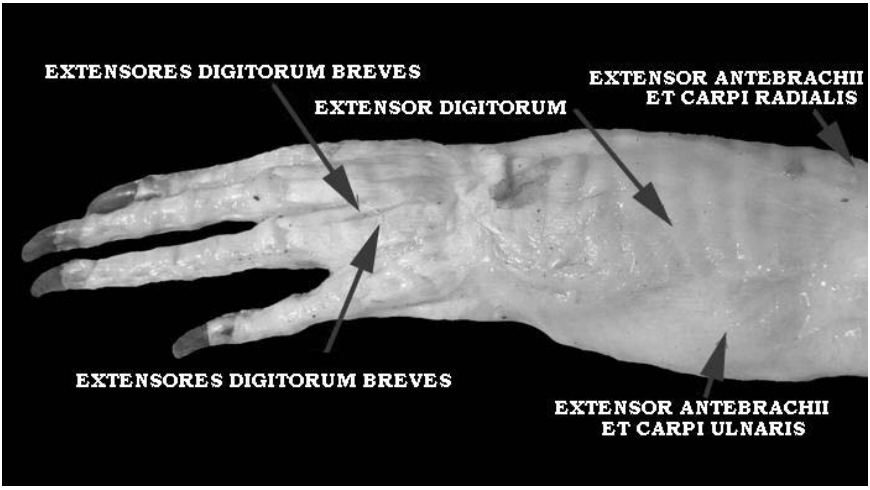

Fig. 10.5 *Tupinambis meriane* (Reptilia, Lepidosauria): dorsal view of the dorsal (extensor) muscles of the forearm and hand.

with the tendons of the flexor digitorum communis/longus, being often related to the extension and/or flexion of different parts of the digits; the contrahentes digitorum, which are deep to the lumbricales; the flexores breves profundi, which are usually deep to the contrahentes digitorum and which often insert on both the radial and ulnar sides of the digits (note that in the present volume each of the 'biccipital muscles' that are often described in the literature as going to both sides of a single digit are considered to be two distinct flexores breves profundi muscles: see Chapter 9); the intermetacarpales, which are the deepest (most dorsal) muscles of the ventral (palmar); and the dorsometacarpales, which are part of the dorsal layer of the hand and, thus, are the most dorsal intrinsic muscles of the hand (the dorsometacarpales are not present as distinct muscles in mammals) (Tables 10.1, 10.3).

The flexores breves superficiales are consistently present in limbed amphibians and reptiles (Tables 10.1, 10.3). However, there is some confusion, in the literature, about the presence of these muscles in birds. Holmes (1977) suggested that the flexores breves superficiales are present in all major extant groups of reptiles, but Ribbing (1938) argued that these muscles are not present as a group in birds. We could not identify, in the chickens we dissected, muscles that clearly correspond to the flexores breves superficiales of other reptiles. But it is possible, and even likely, that the 'flexor indicis' sensu Sullivan (1962) and Shellswell and Wolpert (1977) (which goes to digit 1, i.e., to digit 2 according to most embryologists, and corresponds to the 'flexor alulae' or 'flexor pollicis' or 'flexor digiti II' or 'flexor digiti secundi manus' or 'adductor indicis' sensu Meyers 1996) and/or the 'flexor digiti quarti' sensu Sullivan

(1962) and Shellswell and Wolpert (1977) (which goes to digit 3, i.e., digit 4 according to most embryologists, and corresponds to the 'flexor digiti minoris' or 'flexor minimi digiti' or 'flexor minimi digiti + flexor minimi digiti brevis' or 'flexor digiti III' or 'flexor digiti IV' or 'flexor digiti quarti brevis + abductor digiti quarti proprius' or 'flexor digiti quarti manus longus' or 'flexor longus muscle of the fourth digit' sensu Meyers 1996) are part of the flexores breves superficiales sensu this volume. However, we cannot completely discard the hypothesis that at least some of these latter muscles correspond, instead, to part of the flexores breves profundi, if the 'interossei ventralis' and 'interossei dorsalis' sensu Sullivan (1962), Shellswell and Wolpert (1977) and Meyers (1996) actually correspond to the intermetacarpales and dorsometacarpales sensu this volume, respectively (see Tables 10.1, 10.3). In amphibians the flexores breves superficiales have a particular conformation, because they are often markedly reduced and mainly associated with the structure that is often designated as 'palmar aponeurosis' in the literature (e.g., Ecker 1889; Walthall and Ashley Ross 2006). It should be taken into account, however, that the name 'palmar aponeurosis' is misleading, as this structure is actually not an aponeurosis, but a strong tendon with a palmar sesamoid embedded in it. We found this structure in anurans such as *Bufo* and *Telmatobius* and called it flexor plate (Fig. 10.4; see also Figs. 10.5–10.10). However, in some anurans this flexor plate might be very small (e.g., *Pseudis minutus*) or even completely missing (e.g., *Pseudis paradoxa*) (see, e.g., Manzano 1996). Some reptiles do have a 'true palmar aponeurosis', that is, a superficial (ventral) structure that has a typical aponeurotic configuration, and that is often related to the flexores breves superficiales (see, e.g., Haines, 1950; Meers, 2003; Abdala et al. 2008).

The lumbricales are usually present in anurans, turtles, lepidosaurs and crocodylians, but absent in most urodeles and seemingly also in birds. In fact, our dissections indicate that birds such as chickens have no distinct lumbricales muscles such as those seen in other tetrapods. Sullivan (1962), Shellswell and Wolpert (1977), Meyers (1996) and others have not used the name 'lumbricales' to describe any of the hand muscles of chickens and of other groups of Aves. However, they do describe a muscle ('abductor medius' sensu Sullivan 1962 and Shellswell and Wolpert 1977, which goes to digit 2, i.e., digit 3 according to most embryologists, and corresponds to the 'abductor digiti majoris' sensu Meyers 1996) that is 'applied to' the tendons of the flexor pollicis longus according to Sullivan (1962) and Shellswell and Wolpert (1977) and 'covered by' these tendons according to Meyers (1996), and that could thus correspond to part of the lumbricales sensu this volume. If this muscle is actually not part of the lumbricales, it would probably correspond to part of the intermetacarpales sensu this volume, because it seems to mainly abduct digit 2 (i.e., digit 3 according to most embryologists). Regarding the contrahentes digitorum, the flexores breves profundi, the intermetacarpales and

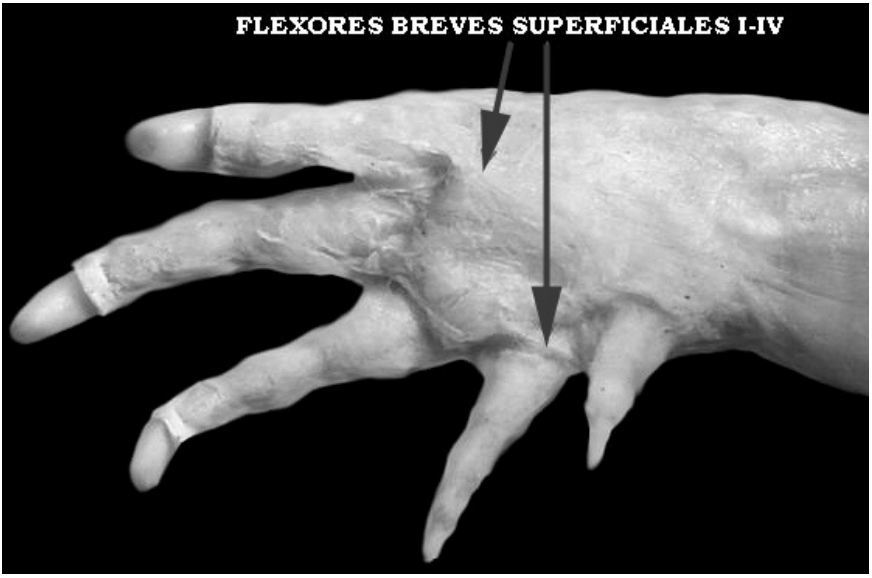

Fig. 10.6 *Caiman latirostris* (Reptilia, Crocodylia): ventral view of the most superficial (ventral, or palmar) layer of the hand muscles.

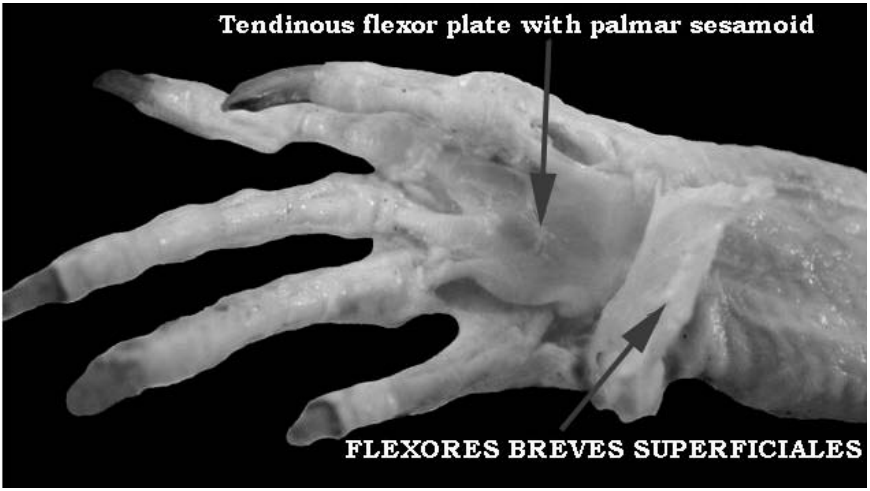

Fig. 10.7 *Tupinambis meriane* (Reptilia, Lepidosauria): ventral view of the flexor plate after resection of the superficial layer of flexores breves superficiales.

Fig. 10.8 *Caiman latirostris* (Reptilia, Crocodylia): ventral view of the palm of the hand after resection of part of the aponeurotic tissues covering it.

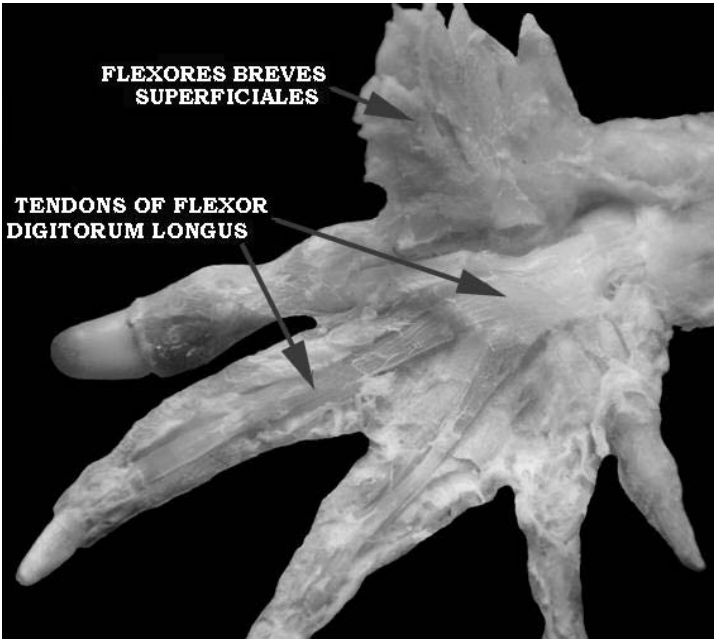

Fig. 10.9 *Caiman latirostris* (Reptilia, Crocodylia): ventral view of the palm of the hand after resection of the layer of the flexores breves superficiales, showing that the expanded tendon of the flexor digitorum longus does not form a flexor plate.

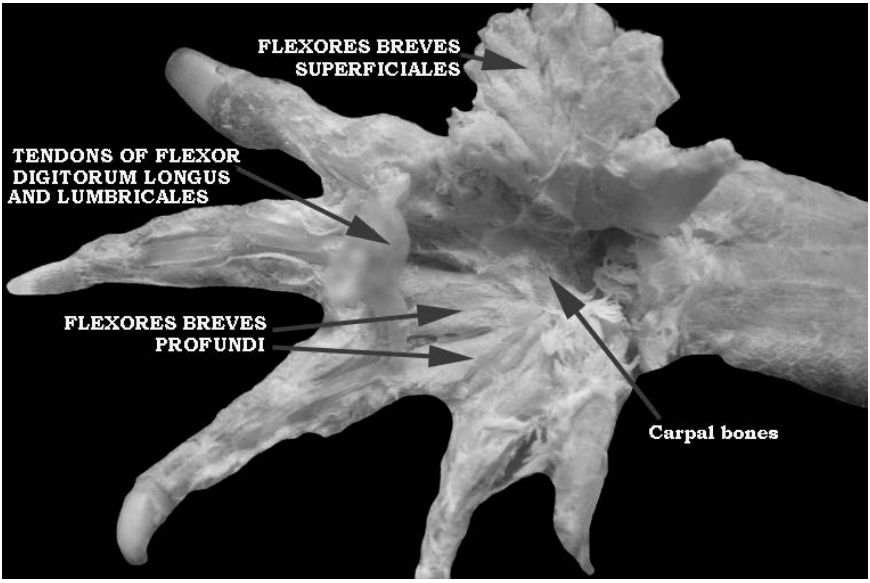

Fig. 10.10 *Caiman latirostris* (Reptilia, Crocodylia): ventral view of the deep (dorsal) musculature of the palm of the hand after resection of the more superficial (ventral, or palmar) layers.

the dorsometacarpales, one or more muscles of each of these four muscular groups is always present in at least some urodeles, anurans, lepidosaurs, turtles, crocodylians and birds (Tables 10.1, 10.3). In fact, it should be noted that although the dorsometacarpales are seemingly not present as distinct muscles in the *Ambystoma* specimens we dissected, and are also not described in urodeles such as *Taricha* by Walthall and Ashley-Ross (2006) and other authors, these muscles have been described in other urodeles. For instance, Straus (1941ab) stated that urodeles such as *Salamandra* and *Cryptobranchus* do have dorsometacarpales (see his table 1), and illustrated a *Necturus* specimen with 'dorsometacarpales' in his fig. 1, although he explains that, in this specific case, the 'dorsometacarpales' of *Necturus* probably correspond to the 'extensores digitorum breves' sensu other authors. Haines (1939) argued that anurans such as *Rana* and urodeles such as *Salamandra* clearly have both extensores digitorum breves and dorsometacarpales, so at least some urodeles and anurans do seem to have dorsometacarpales sensu this volume (see Tables 10.1, 10.3). Lastly, the abductor pollicis brevis and abductor digiti minimi are also consistently present in most major extant clades of limbed amphibians and reptiles, the exceptions being urodeles, which lack an abductor pollicis brevis, and birds, which seemingly lack an abductor digiti minimi, as will be discussed below (Tables 10.1, 10.3).

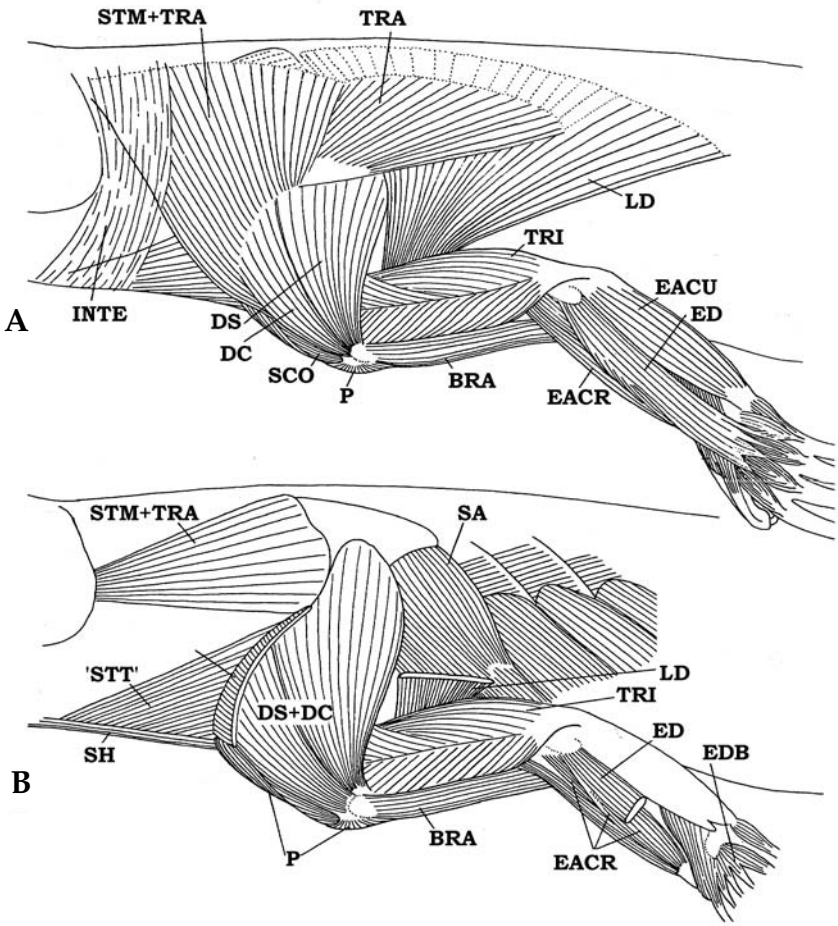

Fig. 10.11 *Iguana* sp. (Reptilia, Lepidosauria): **(A)** Lateral view of the musculature of the pectoral girdle, arm, forearm and hand; **(B)** Same view, the trapezius, the latissimus dorsi and the superficial layer of the forearm muscles were cut to show the deeper muscles (anterior is towards the left of the figure; modified from Jollie 1962: the nomenclature of the structures illustrated follows that of the present work). BRA, brachialis; DC, deltoideus clavicularis; DS, deltoideus scapularis; EACR, extensor antebrachii et carpi radialis; EACU, extensor antebrachii et carpi ulnaris; ED, extensor digitorum; EDB, extensores digitorum breves; INTE, interhyoideus (hyoid muscle); LS, levator scapulae; LD, latissimus dorsi; P, pectoralis; SA, serratus anterior; SCO, supracoracoideus; SH, sternohyoideus (hypobranchial muscle); STM, sternocleidomastoideus (branchial muscle); 'STT', sternothyroideus (hypobranchial muscle); TRA, trapezius (branchial muscle); TRI, triceps brachii.

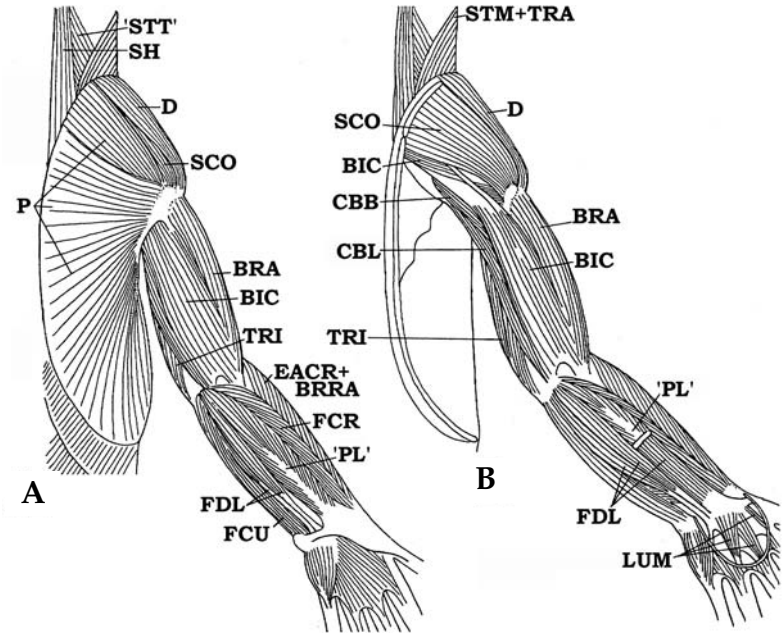

Fig. 10.12 *Iguana* sp. (Reptilia, Lepidosauria): **(A)** Ventral view of the musculature of the pectoral girdle, arm, forearm and hand; **(B)** Same view, but some superficial muscles (e.g., pectoralis, 'palmaris longus') were cut to show the deeper muscles (anterior is towards the top of the figure; modified from Jollie 1962: the nomenclature of the structures illustrated follows that of the present work). BIC, biceps brachii; BRA, brachialis; BRRA, brachioradialis; CBB, CBL, brevis and longus sections of the coracobrachialis; D, deltoideus; EACR, extensor antebrachii et carpi radialis; FCR, flexor carpi radialis; FCU, flexor carpi ulnaris; FDL, flexor digitorum longus; LUM, lumbricales; P, pectoralis; PL, 'palmaris longus'; SCO, supracoracoideus; SH, sternohyoideus (hypobranchial muscle); STM, sternocleidomastoideus (branchial muscle); 'STT', sternothyroideus (hypobranchial muscle); TRA, trapezius (branchial muscle); TRI, triceps brachii.

General Remarks

Our dissections, comparisons and review of the literature indicate that the pectoral and forelimb musculature of limbed amphibians and reptiles does conform to a general pattern that seems to have been acquired very early in the evolutionary history of tetrapods. Regarding the total number of pectoral and forelimb muscles, there is actually not a great difference between the condition found in amphibians such as urodeles and in amniotes such as 'lizards' (see also Chapter 9). Therefore, although some muscles can be reduced or missing in some amphibian and reptilian clades, and a clear departure of this general pattern is obviously present in birds, the same general muscular 'architecture' is easily distinguishable in all major extant clades of limbed amphibians and reptiles.

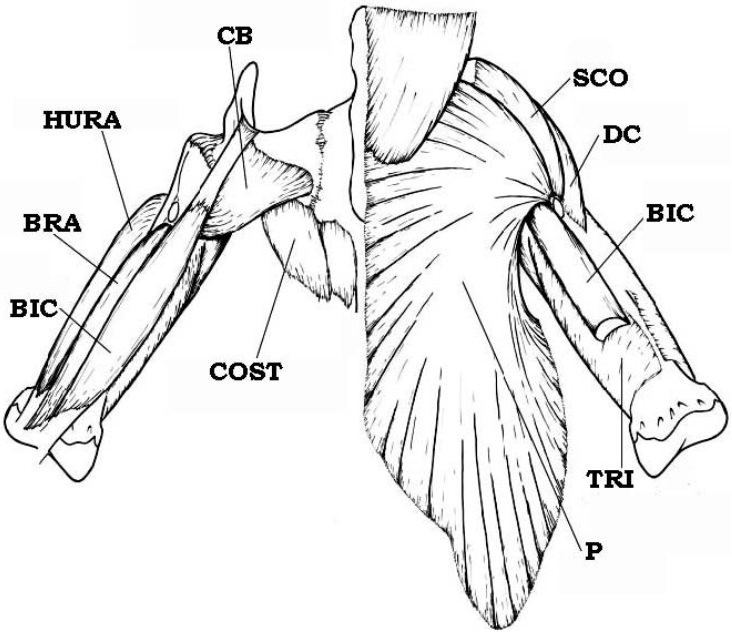

Fig. 10.13 *Alligator mississippiensis* (Reptilia, Crocodylia): ventral view of the musculature of the pectoral girdle and arm, with several muscles removed on each side to facilitate viewing the deeper musculature: the muscles removed were the brachioradialis and humeroradialis, on the left side, and the deltoideus, the pectoralis and the supracoracoideus, on the right side (anterior is towards the top of the figure; modified from Meers 2003: the nomenclature of the structures illustrated follows that of the present work). BIC, biceps brachii; BRA, brachialis; COST, costocoracoideus; CB, coracobrachialis; DC, deltoideus clavicularis; HUA, humeroradialis; P, pectoralis; SCO, supracoracoideus; TRI, triceps brachii.

Among the most notable anatomical differences between groups, one that seems to have relevant evolutionary and functional implications concerns the distal insertion points of the forearm musculature. As explained above, contrary to most other non-mammalian tetrapods, crocodylians and birds have a more distal insertion of the 'radial extensors/flexors' and the 'ulnar extensors/flexors' muscular complexes. The 'pars superficialis' and 'pars intermedia' (sensu Holmes 1977) of the extensor antebrachii et carpi radialis of crocodylians insert on the radial bone, and not on the radius, and in birds part of this muscle extends distally to insert on the proximal end of metacarpal I. As also explained above, the insertion of the muscles of the forearm on hand bones is common in mammals, and, interestingly, a similar trend is found in some anurans with peculiarly subtle digital movement abilities, such as *Phyllomedusa* (see Manzano et al. 2008; Chapter 9). One can thus argue that the complexity of the 'extrinsic'

musculature of the hand (i.e., of the forearm musculature), as well as the more distal insertion of at least some of its components, evolved in a few, derived tetrapod taxa in correlation with the acquisition of these more subtle digital movement abilities. This hypothesis could seem to be counterintuitive, because one tends to think that these abilities are necessarily related with a greater number and/or a more complex configuration of the intrinsic hand muscles. However, this hypothesis is strongly supported by the configuration found in taxa such as modern humans, which have the capacity to make and manipulate complex tools using a remarkably wide range of digital movements, particularly with the help of the thumb. In our species, the number of intrinsic muscles of the hand is actually smaller than that found in chimpanzees and numerous other primates, as well as in other tetrapods such as 'lizards' and urodeles; what is actually peculiar in modern humans is the great number of forearm muscles that attach directly on the digits, including muscles that are not differentiated in most other tetrapods and even in most other primates, such as the extensor pollicis brevis and the flexor pollicis longus (e.g., Chapter 9; Lewis 1989; Diogo and Wood 2009).

Regarding the similarities of the general 'architecture' of the pectoral and forelimb muscles of the major extant groups of limbed tetrapods, it is actually interesting to note that in at least some cases even the reduction of the number of digits in some groups has provoked no profound modification in the corresponding musculature, indicating that muscles probably form and insert where needed to be capable of moving the most extreme (i.e., radial and ulnar) digits. For instance, the anuran muscle that is commonly accepted (see, e.g., Haines 1939) to be the homologue of the abductor pollicis longus of reptiles is often designated in the literature as 'abductor indicis longus' (see, e.g., Gaupp 1896; see also Tables 10.1, 10.3). This is because it is commonly accepted that the most radial digit of adult anurans corresponds to digit 2 of tetrapods with five digits, i.e., in anurans the probable homologue of the abductor pollicis longus goes to digit 2, and not to digit 1, as is often the case in other tetrapods. So, interestingly, in this specific case, what seems to be important, for the formation and attachments of the abductor pollicis longus, is mainly the position, and not the 'specific identity', of the digit to which the muscle attaches (i.e., the muscle does not insert on digit 1, as is the case in most tetrapods, because this digit is lacking in adult anurans, but instead inserts on digit 2, which is the most radial digit of adult anurans). This idea is also supported by some other examples. For instance, in anurans the probable homologue of the abductor pollicis brevis (see Table 10.1) also attaches on digit 2 of adults, and not digit 1 as is the case in most tetrapods. Also, in urodeles such as *Taricha* and *Ambystoma*, the probable homologue of the abductor digiti minimi of other tetrapods (i.e., the 'extensor lateralis digiti IV' sensu Walthall and Ashley-Ross 2006 and others) goes to digit 4 and not to digit 5 (which is

commonly accepted to be missing in adult urodeles such as *Ambystoma*, i.e., these adult urodeles have only digits 1, 2, 3 and 4). However, within the muscles analyzed in the present chapter, there are seemingly some exceptions to this rule. For instance, Sullivan (1962), Shellswell and Wolpert (1977), Meyers (1996) and others did not describe an abductor of the most medial/ulnar digit of birds such as chickens, thus suggesting that the abductor digiti minimi is lacking in these reptiles. We were also unable to find a distinct abductor digiti minimi in the chickens we dissected (Tables 10.1, 10.3). The evidence available strongly indicates that digit 5 is missing in adult chickens, i.e., the most ulnar digit of adult chickens is digit 3 according to most studies of fossils and hox genes and digit 4 according to most embryological studies (see above). So, in this case, it seems that the 'specific identity' of the digit is actually important, that is, there is no abductor digiti minimi to digit 3 (i.e., 4 according to most embryologists), even if this is the most ulnar digit of adult chickens. However, it should be noted that some authors have designated the 'ulnimetacarpalis dorsalis' sensu Sullivan (1962), Shellswell and Wolpert (1977) and Meyers (1996) as 'flexor and abductor of the fourth digit', thus suggesting that this muscle, which in chickens usually goes from the distal portion of the ulna to the ulnar/medial portion of the carpometacarpal region, might actually correspond to a reduced abductor digiti minimi sensu this volume. Another plausible hypothesis is that this 'ulnimetacarpalis dorsalis' corresponds instead to a reduced short extensor (i.e., part of the extensores digitorum breves) to digit 3 (i.e., to digit 4 according to most embryologists) (see, e.g., fig. 1 of Shellswell and Wolpert 1977; see also Table 10.1). In our opinion, it would thus be interesting to carefully address, in future developmental and/or genetic studies, this puzzling issue about the relationship between the formation and attachments of a muscle and the position versus the 'specific identity' of the digit(s) to which it attaches. As stressed above, future works are also needed to address some other crucial questions that need to be clarified. For instance, further studies, ideally including a detailed analysis of the innervation and development of the 'rhomboideus' and 'anconeus' of a broader sampling of amphibian and reptilian taxa, are needed to investigate whether or not these structures are homologous to the mammalian rhomboideus and anconeus, respectively.

Chapter 11

General Comments

11.1 Muscular Splittings, Fusions, Paedomorphism, Reversions and Anatomical Complexity

As can be seen in the tables provided throughout this book, and discussed in more detail in Chapters 5 and 9, the evolution of the vertebrate head, neck, pectoral and forelimb muscles seemed to have involved more events during which a muscle became subdivided (splitting: e.g., diverging arrows in Tables 5.2, 5.4, 5.6, 5.8, 9.2, 9.3, 10.2 and 10.3) than events that involve the fusion of muscles (e.g., shown as converging arrows in these latter tables, although it should be noted that not all the converging arrows shown in these tables actually refer to a true fusion of the muscles during evolution and/or ontogeny: see below). However, contrary to what is often stated in general textbooks (e.g., Kisia and Onyango, 2005), this does not mean that 'higher' primates, and namely modern humans, have more muscles than, for instance, other mammals and, to some extent (e.g., hand muscles and mandibular muscles), even than non-mammalian taxa such as reptiles or amphibians.

For example, modern humans have fewer mandibular muscles than reptiles such as 'lizards' and mammals such as tree-shrews, rats and monotremes (Table 5.2). The number of true branchial muscles found in modern humans is also smaller than that found in most other mammals (Table 5.6). Actually, as explained in Chapter 5, in the case of the true branchial musculature, if there is a 'trend' at the time of the evolutionary transitions that led to the origin of primates and subsequently to modern humans, then it is to reduce, and not increase, the total number of muscles. With respect to the pharyngeal musculature, there is a clear increase in the number of muscles at the time of the evolutionary transition leading to therian mammals, but then no increase at the time of the transition leading to the emergence of 'higher' primates and modern humans (Table 5.6). The number of hypobranchial muscles (not including the intrinsic muscles of

the tongue) is relatively constant within the therian mammals listed in Table 5.8, although in this case modern humans do have more muscles than the other taxa listed in that table. As also explained in Chapter 5, it is thus interesting to note that the number of facial and laryngeal muscles found in modern humans is clearly greater than that found in most other mammalian taxa. Modern humans usually have 24 facial muscles (not including the extrinsic muscles of the ear), while monotremes such as the platypus usually have 10, rodents such as rats 20, colugos 19, and tree-shrews such as *Tupaia* 21 (Table 5.4). With respect to the laryngeal muscles, there are usually 6 present in modern humans, while there are 4 in, e.g., *Tupaia*, colugos and rats, and 3 in monotremes (Table 5.6). These data are thus consistent with the important role played by facial expression and by vocal communication in primates in general, and in modern humans in particular (see, e.g., Ruge 1885–1910; Boas and Paulli, 1908; Lightoller 1928–1942; Huber 1930–1931; Edgeworth 1935; Andrew 1963; Gasser 1967; Jouffroy and Saban 1971; Saban 1971; Seiler 1971–1980; Minkoff 1979; Preuschoft 2000; Schmidt and Cohn 2001; Burrows and Smith 2003; Burrows et al. 2006; Burrows 2008; Diogo et al. 2009b).

With respect to the changes in the number of pectoral and pectoral fin/forelimb muscles during vertebrate evolution, the most striking transition was clearly that leading to the origin of tetrapods (Chapter 9). While extant sarcopterygian fish have an abductor and an adductor of the fin and a mainly undifferentiated hypaxial and epaxial musculature, extant salamanders such as *Ambystoma* and *Taricha* have more than 40 pectoral and forelimb muscles (Tables 9.1–9.3). Interestingly, there is no clear increase in the number of pectoral and forelimb muscles at the time of the evolutionary transition leading to mammals, and there is certainly no increase at the time of the transition leading to the emergence of 'higher' primates and modern humans. In fact, as explained in Chapter 9, within the amniotes listed in Tables 9.1–9.3, humans are those with a smaller number of pectoral and forelimb muscles (60 muscles in total, including the small 'interosseous volaris primus of Henle', which seems to be present in more than 50% of adult modern humans: see Chapter 9). One region in which humans clearly have a smaller number of muscles than many other tetrapods is precisely one that supposedly make us so special: our hand. For example, whereas modern humans usually have 20 intrinsic muscles of the hand, 'lizards' such as *Polychrus* may have more than 35 (Chapter 9).

The mobility of the hand and its digits is, of course, only partly related to the number of hand muscles, and what does make modern humans special in terms of hand manipulation is actually the remarkable mobility of, and the differentiation of peculiar muscles (e.g., extensor pollicis brevis and flexor pollicis longus) associated with, the thumb (e.g., Lewis 1989; see Chapters 9 and 10). However, returning to the subject of muscle splittings

and fusions, if the evolution of vertebrate muscles has involved more events during which a muscle became subdivided (splitting) than events that involve the fusion of muscles, why does this not necessarily mean that 'higher' primates, and namely modern humans, have more muscles than mammals such as rats or tree-shrews and non-mammalian taxa such as reptiles or amphibians? In our opinion, there are four main possible reasons for this.

First, in some cases (e.g., pectoral and pectoral fin/forelimb muscles), the greater number of evolutionary splittings occurred during the transitions that led to the origin of groups such as the tetrapods, and not during the transitions that have subsequently led to the emergence of mammals and then of primates, including modern humans (see Chapter 9).

Second, some of the muscles present in at least some of our ancestors were seemingly completely lost at various stages in our evolution (e.g., the intermandibularis anterior was probably present in the common ancestor of sarcopterygians and/or of tetrapods, but it is missing in modern humans) (see Chapter 5).

Third, some of the muscles that are found in other vertebrate taxa (e.g., the detrahens mandibulae of monotremes) are peculiar, apomorphic, features of those taxa (see Chapter 5). This stresses that, as is now well known in theory, but unfortunately often neglected in general textbooks and even in specialized papers, evolution is not directed 'towards' a goal, and surely not 'towards' modern humans. Each taxon has its own particular mix of primitive and derived anatomical structures, which is the result of its unique evolutionary history. That is why monotremes, for instance, have peculiar muscles such as detrahens mandibulae, which are not found in any other extant vertebrates. And that is why throughout this book we prefer to use the term *correspond*, because muscles such as the detrahens mandibulae are not *'ancestral'* to the muscles of therian mammals. The monotreme detrahens mandibulae simply *corresponds* to a part of the 'adductor mandibulae complex' of non-mammalian tetrapods that, in monotremes, became sufficiently differentiated to deserve being recognized as a separate muscle.

The fourth reason, which is related to the second reason mentioned above (i.e., to the 'loss' of certain muscles during evolution), is that some extant vertebrate taxa are extremely paedomorphic, and it is likely that some of our direct ancestors were paedomorphic too. Paedomorphism (also called juvenification) is a phenotypic and/or genetic change in which the adults of a taxon retain traits previously seen only in earlier developmental stages of ancestor/related taxa. The underlying mechanisms for this comprise heterochrony, but there are several types of paedomorphism, including neoteny (e.g., somatic, or physical, development is slowed, resulting in a sexually mature juvenile or larval form), progenesis (e.g.,

development is halted before full maturity) and postdisplacement (e.g., start of development is delayed). Paedomorphism is common in many animal species, including domestic animals such as dogs; among the taxa listed in the tables provided in this book, two are particularly famous for having a great number of paedomorphic features: extant chondrosteans and extant dipnoans (see, e.g., Bemis 1984; Bemis et al. 1997; Findeis 1997; Diogo 2007). Within the context of the evolution of vertebrate muscles, paedomorphism is important because it is usually associated with an evolutionary decreasing of the number of muscles, but is actually not the product of a *true fusion* of two or more muscles. In other words, an example of paedomorphism would be as follows: (1) in the beginning, a muscle X is found in all the phylogenetically basal members of a clade A as well as in the last common ancestor (LCA) of this clade (e.g., in all the phylogenetically basal members and the LCA of gnathostomes); (2) then, in the evolutionary transitions leading to a phylogenetically more derived, less inclusive group B within that clade A (e.g., the group Osteichthyes), muscle X differentiates into muscles Y and Z, so that all the adults of group B now have muscles Y and Z (because, during the ontogeny of the members of group A, there are now two developmental stages, instead of one: in the earliest, muscle X appears and then, in the oldest, it becomes differentiated into muscles Y and Z); (3) then, when a certain, new paedomorphic species C of that group B is formed, the adult organisms of this new species will only have one muscle, muscle X, but this is not because there is a true fusion, during the ontogeny of these organisms, between muscles Y and Z, but instead because these organisms lost the oldest of the two ontogenetic stages described above (i.e., because of paedomorphism, they retained only the earliest ontogenetic stage, i.e., the formation of muscle X, and develop until the adult stage without passing by the oldest ontogenetic stage described above, that is, the differentiation of muscle X into muscles Y and Z). That is, in this case paedomorphism leads to an evolutionary reversion to the plesiomorphic state found in the phylogenetically basal members of clade A: as in these latter organisms, muscle X of the members of the paedomorphic species C never becomes differentiated, during ontogeny, into muscles Y and Z. This is thus in contrast with cases in which there is a true fusion of muscles Y and Z to form a single muscle, because when there is such a true fusion there are three (and not only one, as in the ontogeny of the paedomorphic organisms) ontogenetic stages, i.e., a first stage in which muscle X is formed, a second stage in which it is then differentiated into muscles Y and Z, and a third stage in which muscles Y and Z become completely fused, forming a single muscle. Thus, in summary, while the end product of a true fusion and of an evolution towards a paedomorphic species would be similar (i.e., adults having only a single muscle), the developmental sequences leading to the presence of

this single muscle in the two cases would actually be quite different, i.e., three ontogenetic stages (formation, split, fusion) versus a single ontogenetic stage (formation).

It is important to note that in some of the cases in which we use converging arrows in the tables of Chapters 5, 9 and 10, we are actually including at least a few cases related with paedomorphism, and not with a true fusion of the muscles. For example, in Table 5.4 the adductor operculi and interhyoideus of *Latimeria* have converging arrows leading to the interhyoideus of *Lepidosiren*, because the interhyoideus of *Lepidosiren* corresponds to the interhyoideus + adductor operculi of *Latimeria* (i.e., the anlage that ontogenetically gives rise to the interhyoideus + adductor operculi of the latter taxon corresponds to the anlage that ontogenetically gives rise to the interhyoideus of the former taxon). However, in this specific case, the data available in the literature indicates that there is no true fusion between the interhyoideus and adductor operculi during the ontogeny of *Lepidosiren* and of other extant dipnoans: what seems to happen is that during the ontogeny of these fishes the anlage that gives rise to the interhyoideus never becomes really differentiated into an adductor operculi, as it does in most other bony fish (see Chapters 4 and 5). In fact, as stated above, extant dipnoans and extant acipenseriforms are usually famous for being particularly paedomorphic. And, as predicted, the number of muscles seen in adults of groups such as the dipnoans, for instance, is usually smaller than the number of muscles seen in adults of the other sarcopterygian taxa. So, for instance, *Lepidosiren* adults have only 5 mandibular muscles, 3 hyoid muscles, 3 branchial muscles except the branchial muscles *sensu stricto*, and 2 hypobranchial muscles, the total number of head and neck muscles of these adults being thus smaller than the total number of head and neck muscles found in the adults of any other taxon shown in Tables 5.2, 5.4, 5.6 and 5.8. And, as explained in Chapters 4 and 5, one muscular peculiarity that clearly seems to illustrate an example of paedomorphic trait in living dipnoans precisely concerns the absence, in the adult members of this species, of an independent adductor operculi, i.e., contrary to most other bony fish, during the ontogeny of extant dipnoans this muscle never seems to become differentiated from the interhyoideus (see Table 5.2). Regarding the chondrosteans, the absence of a dilatator operculi in adult extant acipenseriforms may also be related to the fact that, contrary to most other actinopterygians, in which the constrictor dorsalis becomes ontogenetically differentiated into two muscles (the levator arcus palatini and dilatator operculi), acipenseriforms remain during their whole ontogeny with a single constrictor dorsalis muscle (the protractor hyomandibulae), as explained in Chapter 4 (see Table 4.1).

Paedomorphism is an important topic in evolutionary biology, because paedomorphic events are an example of macroevolutionary changes that

are not necessarily 'Darwinian' (Boto et al. 2009). For instance, Bemis (1984) reviewed some seemingly paedomorphic morphological transformations occurring from the most basal lungfish forms to extant dipnoans (e.g., the loss of heterocercal tail, the fusion of medial fins, the reduction of fin rays, the loss of cosmine, the changes in scale shape, the reductions in ossification and the increase of cell size), and suggested that all these features are very likely related to a paedomorphic event, which may well be due to selection of one of these features, or may even be related to any other, different reason (e.g., genetic, physiological). Therefore, the evolutionary transformations leading to many of the features listed above was not necessarily 'Darwinian' in the sense that these transformations were probably not related to the direct adaptive value of, or to a direct selection towards, those features. In other words, if for example a feature A resulting from paedomorphism proves to be adaptive, selection will favor that feature, and, thus paedomorphism will be selected, with the paedomorphic features B, C, D, for example, being present in the selected organism but not because they were directly selected. It is important to emphasize that paedomorphism has seemingly played an important role not only in lungfish and chondrostean evolution, but also in the evolution of several other vertebrate groups and seems in fact to be a rather common macroevolutionary event (e.g., Boto et al. 2009). If this is so, the number of evolutionary transitions in which a decrease of the number of muscles is directly related to a process of 'juvenification' may actually be much higher than previously thought; moreover, as these evolutionary transitions are related to paedomorphism, it is probable, and even likely, that a great part of them are in fact not associated by a direct 'Darwinian' selection towards those transitions. We therefore consider that paedomorphism should be seriously taken into account in evolutionary and comparative studies concerning not only osteological, but also myological, features.

11.2 Myological Characters and Phylogenetic Reconstructions

An interesting issue that is also often neglected in phylogenetic and evolutionary studies of vertebrates concerns the use of myological characters for phylogenetic reconstructions. This issue has been recently analyzed by Diogo (2004ab, 2007), and we consider that it is appropriate, in the context of the present book, to briefly summarize here the main ideas, results, and conclusions provided in those works.

One example of the few works available in the literature discussing the utility of myological data for phylogenetic reconstructions was a study by Borden (1999). In that paper, Borden described in detail the configuration and variation of 93 muscles in 15 species of the genus *Naso,* or unicornfishes, of the Acanthuridae (Teleostei: Percomorpha), and discussed the

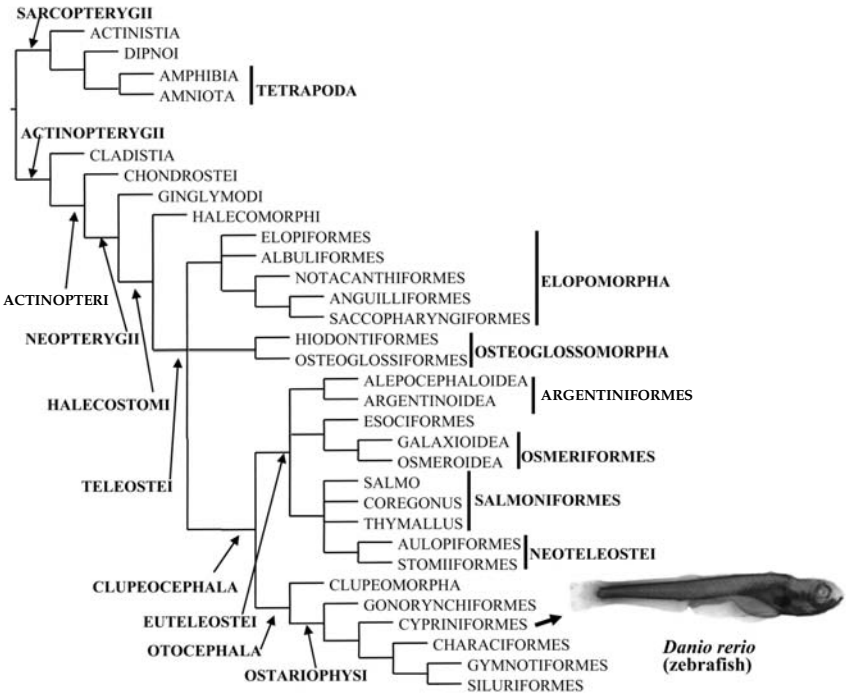

Fig. 11.1 Phylogenetic position of the zebrafish (Teleostei, Cypriniformes) among the major extant osteichthyan groups, based on the results of the cladistic analysis of Diogo 2007, but with the Elopomorpha, Osteoglossomorpha and Clupeocephala placed in a trichotomy (compare with Fig. 4.1) (modified from Diogo et al. 2008a).

Color image of this figure appears in the color plate section at the end of the book.

phylogenetic implication of the myological results obtained. As noted by Borden (1999: 191), very few phylogenetic studies have focused on myology for a variety of reasons: "investigators may be reluctant to use myology due, for example, to the plethora of names that have been used to describe the same muscles, to the realization that osteological proficiency is mandatory in order to identify muscle, leading them to concentrate only on osteology, or to the requirement of potentially finer dissection to preserve muscle bundles and nerves; furthermore, fossil fishes leave few if any myological clues, complicating hypotheses between extinct and extant fishes." In consequence, "of those studies using myology as a basis of information, most are functional works often analyzing the role of various muscles in feeding or locomotion or comparing a muscle or specific group across a number of taxa systematically and/or ecologically related" (Borden 1999: 191). Explicit cladistic analyses based on myological data are, thus, rather rare. Within bony fishes, for instance, some of

the most relevant examples of such analyses listed by Borden (1999) are that of Winterbottom (1974) using 74 myological characters to investigate the relationships of the tetraodontiforms, that of Winterbottom (1993) using 46 myological characters to reconstruct the relationships among the acanthurid genera, and that of Borden (1998) using about 10 myological characters to investigate the phylogeny inside the acanthurid genus *Naso*. However, as these studies are essentially restricted to myology, they do not allow a direct comparison between the homoplasy and phylogenetic relevance of myological versus osteological data. Some works by other authors did include certain myological characters together with various osteological ones, e.g., Howes (1983a) and Schaefer (1990). But the number of myological characters included in those works is rather small; moreover, those works do not provide a direct comparison between the homoplasy and retention levels found in the osteological and myological characters examined.

In order to provide such a comparison, Diogo (2004ab) compared the homoplasy levels and phylogenetic relevance of 91 myological and 303 osteological characters in the reconstruction of the higher-level phylogeny of a diverse and representative group of teleosts, the Siluriformes (or catfish). As explained by Diogo (2004ab), such a direct comparison of the relative contribution of these two types of data sets for phylogenetic reconstructions has the advantage that the homoplasy levels and the phylogenetic trees being compared refer to the same clade and, more importantly, to the very same terminal taxa. In major lines, the overall analysis of the results presented by Diogo (2004ab) indicated the following: (1) osteological structures display a greater morphological variation than myological ones; (2) this difference (which is very likely over-enhanced by the fact that the phylogenetic variation of osteological structures has historically been the subject of more studies and descriptions than that concerning the myological ones) is particularly notable regarding lower taxa, such as genera or species; (3) myological characters provide, however, a high proportion of informative characters for disclosing the relationships between higher taxa and, thus, for disclosing the phylogeny of the clades in which these taxa are included.

In 2007, Diogo published an extensive cladistic analysis of osteichthyan higher-level interrelationships based on a phylogenetic study of 356 characters in 80 extant and fossil terminal taxa (see Fig. 4.1). He decided to investigate whether or not the conclusions of Diogo (2004ab), based on a phylogenetic study of the Siluriformes, were supported by a comparison of the myological and osteological characters included in his new cladistic analysis of the higher-level phylogeny of osteichthyans. As in the case study provided by siluriforms (Diogo 2004ab), the osteological components included in the cladistic analysis of Diogo (2007) did exhibit

a greater morphological variation than the myological ones. For instance, the 81 osteological components examined for Diogo's (2007) cladistic analysis provided 198 phylogenetic characters (in an arithmetical mean of about *2.4 phylogenetic characters* for *each osteological component* examined), while the 63 muscles examined for that same analysis provided 122 phylogenetic characters (in an arithmetical mean of about *1.9 phylogenetic characters for each muscle* examined). This thus seems to corroborate the opinion of Borden (1999), who pointed out that muscular characters are somewhat more 'conservative' than osteological ones, these latter thus demonstrating a higher variability. However, contrary to what was suggested by Borden (1999) and supported by the data of Diogo (2004ab), the proportion of autapomorphic characters within the osteological characters examined by Diogo (2007) (49 in a total of 198, i.e., about 25%) was not higher than that within the myological characters analyzed by him in the same work (33 in a total of 122, i.e., about 27%).

All things being counted, it can thus be said that each osteological component examined by Diogo (2007) provided, on average, more informative characters: the 81 osteological components examined for that analysis provided 198 phylogenetic characters, of which 149 are informative (i.e., *1.8* informative characters per osteological component examined); the 63 muscles examined for the analysis provided 122 phylogenetic characters, of which 89 are informative (i.e., *1.4* informative characters per muscle examined). However, it is important to stress that although very likely indicating a true higher osteological variation, as suggested by Borden (1999), these numbers are probably also related with the fact that in the literature there are much fewer phylogenetic works based on myology than works based on osteology. In fact, a significant number of the osteological characters included in the cladistic analysis of Diogo (2007) were inspired, in some way, by characters previously pointed out in phylogenetic studies of other authors. These latter studies thus called Diogo's attention to the variability exhibited by certain osteological features within the groups included in the cladistic analysis of the present work. This historical bias should therefore be kept in mind when one discusses the 'variability' of, and the consequent number of informative phylogenetic characters provided by, osteological versus myological structures.

Regarding the arithmetical mean of the Retention Index (RI) of the informative muscular characters examined by Diogo (2007) (= 0.82), it was considerably higher than that of the informative osteological ones examined in the same work (= 0.71). It should be explained that the Consistency Index (CI) of a character is simply related with the level of homoplasy exhibited by that character, while the Retention Index also takes into account whether the character helps to retain a certain clade in the obtained cladogram of the group being studied. So, to give a simple

example, if, a certain feature X is found in the actinopterygian *Pimelodus* (Teleostei: Siluriformes) and in the distantly related sarcopterygian *Timon* (Reptilia: Lepidosauria), that character will have, according to the phylogenetic scenario shown in Fig. 4.1, a CI of 0.5 (it was independently acquired two times) and an RI of 0.0 (it does not help to retain any of the clades shown in that figure). However, if a certain feature Z is found, for instance, in *Pimelodus* and *Timon*, but also in all the elopomorph (Teleostei: Elopomorpha) genera examined, this feature Z will have, according to the scenario shown in Fig. 4.1, a CI of 0.33 and an RI of 0.75 (since it was independently acquired in three different, non-related groups, i.e., *Pimelodus*, *Timon*, and the Elopomorpha, but, contrary to feature X, it helps to retain one of the clades shown in the cladogram of Fig. 4.1, i.e., the Elopomorpha).

Taking this into account, it can thus be said that each of the 89 informative myological characters used by Diogo (2007) is on average more useful for the retention of the clades shown in Fig. 4.1 than each of the 149 osteological informative characters listed used in the same work. In the case study provided by catfishes (Diogo 2004ab), the arithmetical mean of the RI of the informative muscular characters was also higher than that of the informative osteological ones, but the difference was less pronounced (0.80 and 0.77, respectively). The arithmetical mean of the CI of the informative muscular characters used by Diogo (2007) was also considerably higher than that of the informative osteological characters used in the same work (0.71 and 0.52, respectively). These results are different from those obtained in the case study provided by catfishes (Diogo 2004ab), in which the arithmetical mean of the CI of the informative osteological characters was a little higher than that of the informative myological characters (0.66 and 0.64, respectively).

As stressed by Diogo (2004ab, 2007), another interesting way to analyze the phylogenetic contribution of myological versus osteological features is to simply compare the phylogenetic trees generated from these two different kinds of data. Interestingly, the CI of the 'myological' cladogram obtained by Diogo (2007) was higher than the CI of the 'osteological' cladogram obtained by him in the same work (0.48 and 0.37, respectively). The RI of the 'myological' cladogram is also higher than the RI of the 'osteological' cladogram obtained in that work, but the difference between these indexes is less pronounced (0.77 and 0.76, respectively).

In summary, the overall examination of the data provided by Diogo (2004ab) and Diogo (2007) indicated that osteological structures seemingly display a greater morphological variation than the myological ones, providing more characters to phylogenetic analyses (this being very likely over-enhanced by a historical bias: see above). But this difference refers particularly to lower clades; myological characters are seemingly highly

useful in providing informative characters to disclose the relationships between higher clades, and, thus, to help in inferring the higher-level phylogeny of the groups being studied. As stressed by Diogo (2004ab, 2007), other authors have defended the reliability of muscular characters to disclose the higher-level phylogeny of major tetrapod groups such as birds (McKitrick 1991), hadrosaurian dinosaurs (Dilkes 2000), and primates (Shoshani et al. 1996; Collard and Wood 2000; Gibbs et al. 2000, 2002). For instance, contrary to some works that are mainly based on osteological characters, phylogenetic analyses of the primate superfamily Hominoidea mainly based on myological data support the nowadays commonly accepted molecular cladograms indicating a sister-group relationship between the hominin tribes Panini (chimpanzees and bonobos) and Hominini (fossil and modern humans) and between the clade formed by these two tribes and the gorillas (see Gibbs et al. 2002). We would also like to emphasize that one of us (VA) has been participating in a long-term project with reptiles designed to investigate the use of myological features in cladistic analyses, which has already revealed more than 90 useful muscular characters to study the phylogeny of various squamate groups (e.g., Abdala and Moro 1996, 2003, 2006; Moro and Abdala 1998, 2000; Abdala et al. in press). We would also like to mention the work of Witmer and colleagues (see, e.g., Witmer 1995ab, 1997), among others, who have stressed the importance of carefully investigating the soft tissues of fossil taxa and of including the information obtained in such investigations in phylogenetic reconstructions.

The points discussed above thus raise interesting questions. For instance, what explains the seemingly greater morphological variation of osteological structures? Does natural selection eventually act, in certain cases, more on bones than on muscles? Is the development of myological structures more constrained than that of osteological features? Why do muscular structures seem to be particularly reliable in revealing the higher-level phylogeny of major clades? According to Gibbs et al. (2002), for example, one reason for the apparently high reliability of muscular characters in revealing the phylogeny of higher taxa may be related to the results of the experiments that used rhombomeric quail-to-chick grafts to investigate the influence of hindbrain segmentation on craniofacial patterning (Köntges and Lumsden 1996). Those experiments showed that each rhombomeric population remains coherent throughout ontogeny, with rhombomere-specific matching of muscle connective tissue and their attachment sites for all branchial and tongue muscles. One point that is not always well understood and that is important to emphasize is that the specificity of muscle attachments to which Köntges and Lumsden 1996 are referring is effectively related to the *connective tissue/fasciae* associated with the muscles, and not with the *ontogenetic and/or phylogenetic origin*

of these muscles. So, for instance, the avian hyobranchialis ('branchiomandibularis' sensu Köntges and Lumsden 1996) is a branchial muscle (see text and Table 7.3 of Chapter 7), but it is anteriorly attached to hyoid (2nd arch) crest-derived skeletal domains (i.e., the retroarticular process of the mandible). This is because the anterior part of this muscle is associated with connective tissue/fasciae that is precisely derived from hyoid crest cells. This hyobranchialis was actually the only muscle studied by Köntges and Lumsden (1996) that derives its connective tissue from more than one branchial arch, because contrary to its anterior portion, its posterior portion is associated with connective tissue/fascia derived from the 3rd and 4th arches and, accordingly, inserted on the 3rd and 4rth arch crest-derived skeletal domains. Other examples that illustrate the model proposed by Köntges and Lumsden 1996 concern the hypobranchial muscles hyoglossus, hypoglossus and genioglossus. As explained in Chapter 7, previous mapping studies have shown that the myocytes and the innervation of these three muscles are derived from the much more posterior axial levels of the first somites (the fist six somites according to, e.g., Haung et al. 1999). However, as explained by Köntges and Lumsden (1996: 3240–3241), their "skeletal attachment fascia are derived from the more anterior axial levels of cranial neural crests". That is why the genioglossus and hypoglossus, for instance, are attached to skeletal elements such as the paraglossals and the ventral basihyoid sensu Köntges and Lumsden (1996), which are derived from mandibular arch crest from the posterior midbrain. And that is why the hyoglossus ('ceratoglossus' sensu Köntges and Lumsden 1996), which is also ontogenetically and phylogenetically derived from the geniohyoideus (as are the genioglossus and hypoglossus: see text and Table 7.4 of Chapter 7), is instead attached to hyoid (2nd arch) crest-derived skeletal elements. That is, the attachments of these three hypobranchial muscles are primarily determined by the origin of the connective tissues/fasciae to which they are associated, and not by their ontogenetic and phylogenetic origin. It should be noted that there are a few exceptions to the model proposed by Köntges and Lumsden (1996). For instance, at least some facial muscles of mammals, which are derived from the second (hyoid) arch and are apparently associated with connective tissue/fascia also derived from this arch, move into midfacial and jaw territories populated only by frontonasal and first arch crest cells (see, e.g., O'Gorman 2005; Noden and Francis-West 2006). Interestingly, and probably in relation with this, Prunotto et al. (2004) have shown that the facial muscles behave, in terms of C-met mutations, as hypaxial migratory muscles. That is, contrary to most other head muscles, with exception to the hypobranchial muscles (e.g., Huang et al. 1999: see Chapter 7), the facial muscles are absent in organisms with C-met muta-

tions, thus suggesting that these mammalian muscles migrate far away from their primary origin.

As hypothesized by Gibbs et al. (2002: 13), if "a similar system (as the model proposed by Köntges and Lumsden 1996 for the cephalic muscles) operates elsewhere in the body, it would help explain how muscle gross morphology is conserved, whereas the shapes of the skeletal elements to which the muscles are attached are susceptible to changes that contrive to obscure phylogeny". In fact, at least with respect to vertebrate major groups such as teleost fishes, for instance, the principal points of muscular origin and insertion do seem to be rather stable Diogo (2004ab, 2007; this work). Another contributory factor suggested by Gibbs et al. (2002: 13) to explain the seemingly high reliability of muscular structures in phylogenetic reconstructions of higher taxa is that these structures "are not as prone to homolology as skeletal characters". The term *homolology* refers to shared character states that are phylogenetically misleading and that result from similarities in the way that genotypes interact with the environment. Thus, because bone is a dynamic tissue, "many osseous morphologies would be homolologous", with "homolology playing a minor role in the generation of the phenotypes" referring to muscular and soft tissues, since "whereas the mass of a muscle may be affected by activity or inactivity, its attachments are unlikely to be" (Gibbs et al. 2002: 13). However, homolology cannot be the whole explanation for the difference in phylogenetic reliability between osteological and myological structures, since dental enamel, for example, does not remodel and, thus, is not prone to homolology, at least in theory (Gibbs et al. 2002). But some authors have suggested that function or developmental constraints may make tooth morphology particularly prone to homoplasy and, therefore, a poor guide to phylogenetic reconstructions (e.g., Hartman 1988; Hunter and Jernvall 1995; Jernvall, 2000).

More direct comparisons of the homoplasy levels and the reliability of muscular and osteological data for phylogenetic reconstructions, such as those provided by Diogo (2004ab, 2007), are clearly needed to infer whether the patterns found in those studies are supported by other works done with other taxa, or with the same taxa, and, thus, to help clarify some of the general questions formulated above. Anyway, Diogo's (2004ab, 2007) studies stress that the inclusion of muscular characters, and particularly the conjugation of the complementary information provided by these and other types of morphological characters, allows more comprehensive and, very likely, more resolved, phylogenetic reconstructions. The inclusion of myological data on phylogenetic and evolutionary analyses also allows a more embracing, integrative discussion on the evolution and function of the structural complexes being examined, and, thus, on the origin and macroevolution of the higher clades being studied. It is

particularly remarkable that many of the synapomorphies characterizing higher clades such as the vertebrates, the chondrichthyans, the gnathostomes, the Actinopterygii, the teleosts, the sarcopterygians, the tetrapods, the amphibians, the reptiles, and the mammals refer to myological features (see Chapters 3–10; see also, e.g., Diogo 2007). The analysis of these features may, thus, effectively play a crucial role in the understanding of the origin and macroevolution of these and other higher clades. Therefore, despite the intrinsic difficulties in doing so, such as those related with museum availability or the arduousness of muscular dissections, it is hoped that the present volume will stimulate zoologists to take into account myological features in their phylogenetic reconstructions and in their evolutionary and functional analyses.

11.3 Myology, Evolutionary Developmental Biology, Model Organisms, and the Zebrafish

As explained in a work by Carroll (2005), the intimate connection between development and evolution has long been appreciated in biology. For instance, Darwin and Huxley "leaned heavily on the facts of embryology (as they were in the mid-nineteenth century) to connect man to animal kingdom and for indisputable evidence of evolution" (Carroll 2005: 5). But "while Darwin and Huxley were right about development as a key to evolution, for more than one hundred years after their chief works, virtually no progress was made in understanding the mysteries of development" (Carroll 2005: 6). Thus, during that time different kinds of biologists were approaching evolution at dramatically different scales. Embryologists "were preoccupied with phenomena that could be studied by manipulating the eggs and the embryos of a few species, and the evolutionary framework faded from embryology's view"; evolutionary biologists were "studying genetic variation in populations, ignorant of the relationship between genes and form" (Carroll 2005: 7). However, this began to change in the 1970s, when "voices for the reunion of embryology and evolutionary biology made themselves heard" (Carroll 2005: 7). As stressed by Carroll (2005), one illustrative example of this is Gould, whose book *Ontogeny and Phylogeny* (1977) revived discussion of the ways in which the modification of development may influence evolution. From this reunion between developmental biology and evolutionary biology resulted the so-called evolutionary developmental biology, or Evo-Devo. Since then, we have assisted in a real "Evo-Devo Revolution". Among the numerous important contributions of this Evo-Devo Revolution, one of the most remarkable was to reveal that despite their great differences in appearance and physiology, all complex animals share a common "tool kit" or "master" genes that govern the formation and patterning of their

bodies and body parts (e.g., Gould 2002; West-Eberhard 2003; Carroll 2005; Carroll et al. 2005; Kirschner and Gerhart 2005).

The discovery of this "tool kit", like most of the first discoveries associated with the Evo-Devo Revolution, resulted from experiments on fruit flies. However, many other organisms are now the subject of study by evolutionary developmental biologists. Of these organisms, one of the most studied is the zebrafish (*Danio rerio*), a freshwater teleostean fish of the order Cypriniformes (see Fig. 11.1; see also Figs. 1.1 and 4.1 and Chapters 4 and 8). This is due to a combination of advantages making this fish an ideal organism for researchers interested in embryonic development, comparative anatomy, physiology and disease, such as its small size, its large number of offspring, its short generation time, or its very rapid and synchronous embryonic development (e.g., Cubbage and Mabee 1996; Schilling and Kimmel 1997; Schilling 2002). As stated by Cubbage and Mabee (1996), comparisons between zebrafish and other vertebrates are usually done in developmental studies, the zebrafish being often taken as a 'good representative' of teleosts, of actinopterygians and/or even of bony fishes (i.e., of non-tetrapod osteichthyans) as a whole (see Fig. 1.1). Several of those developmental studies deal with zebrafish myology, but only a few of them focus on cranial muscles, and these latter mainly concern larval stages (see Diogo et al. 2008a). In fact, as stressed by (Schilling 2002: 73), until 2002 "no study has (had) carefully described the anatomy of the musculature of the adult zebrafish". Schilling (2002) provided a short summary of the myology of the adult zebrafish. But, as he recognized, this was mainly based on an extrapolation from his "own observations of larval cranial muscles" and from "studies in other teleosts", and not from direct dissection of adult specimens of *Danio rerio* (Schilling 2002: 73).

Apart from the poor knowledge of the late stages of development of the zebrafish cranial muscles there were also problems with the homologation between some of these muscles and those of other vertebrates. To give just an example, in a relatively recent paper it is stated that "while the rat geniohyoideus is composed predominantly of fast fibers, a trait shared by the homologous intermandibularis posterior of the zebrafish, the pattern of fiber type distribution is quite different; slow fibers in the rat geniohyoideus are not regionalized but rather mixed in among fast fibers; such a mosaic distribution characterizes mammalian muscles" (Hernandez et al. 2005: 332). However, the muscle that is often called geniohyoideus in mammals and, thus, in the rat, does not correspond to the intermandibularis posterior of the zebrafish but, instead, to part of the coracomandibularis, a muscle that is missing in the zebrafish (see Chapters 4 and 5). This example illustrates how an insufficient knowledge of the muscles of model organisms such as the zebrafish and of their homologies with other vertebrates may effectively weaken the discussions

and evolutionary hypotheses advanced in Evo-Devo studies. In fact, one of the main aims of Evo-Devo is to compare the development of different organisms and to discuss the implications of the data obtained in an evolutionary context. Without a proper knowledge of the structures being examined and without well-grounded hypotheses of homology between these structures and those of other organisms, it is thus difficult to attain this aim. As stressed by, e.g., Hunter and Prince (2002), one of the main problems of interpreting and comparing the data obtained in studies of model organisms such as the zebrafish relates to the insufficient knowledge of its vertebrate muscles and their homologies. For instance, these authors recognized that it was rather difficult to compare the effect of Hox PG2 loss of function on the development of the individual cranial muscles of zebrafish and of tetrapods, as "the precise homologies between individual pharyngeal arch muscles are difficult to determine, because of the differing organization and number of muscles" (Hunter and Prince 2002: 383).

As explained in Chapters 1 and 2, one of the main aims of this book was thus to solve this problem, by carefully analyzing the homologies of the muscles of model organisms such as rats, salamanders, chickens and the zebrafish and the muscles of other vertebrates, and by applying a unifying nomenclature to the vertebrate muscles as a whole (see below). It should be noted that, in a recent work by one of us (RD) together with S. Hughes and Y. Hinits (Diogo et al. 2008a), we precisely examined in detail the development of the cephalic muscles of the zebrafish and compared those muscles with those of other vertebrates in order to provide, for the first time, a solid basis for future molecular, developmental and Evo-Devo works concerning the muscles of this fish and other model organisms. Four main questions were addressed in that work: (1) How are the mandibular, hyoid and hypobranchial muscles of zebrafish developed until they reach their adult form? (2) To which muscles of other osteichthyans do these muscles correspond? (3) Is there a correspondence between the ontogeny of these muscles in the zebrafish and their evolutionary history within the Osteichthyes? (4) Regarding these muscles, is it appropriate to consider the zebrafish as a "good representative" of teleosts, of actinopterygians and/or of bony fishes? As that work was done with S. Hughes and Y. Hinits and has been published elsewhere (Diogo et al. 2008a), we will only briefly summarize its main results here (which, in our opinion, provide interesting insights for the overall context of this book, i.e., the comparative myology and evolution of vertebrates). Thus, Figs. 11.2–11.5 show the development of the zebrafish cephalic muscles, from 4-day larvae to adults, while Table 11.1 provides a brief summary of all the mandibular (man), hyoid (hyo) and hypobranchial (hyp) muscles found in the adult zebrafish, their attachments and their main functions.

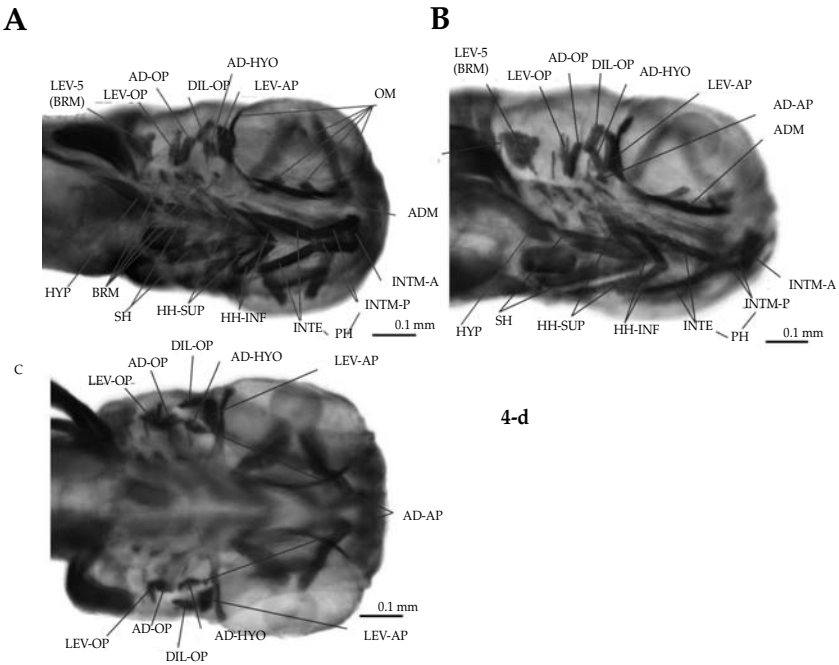

Fig. 11.2 Larval musculature of the zebrafish (Teleostei, Cypriniformes; 4-day-larvae: 3.0 mm Total Length): ventrolateral (**A,B**, showing different angles and certain distinct structures) and dorsal **(C)** views of immunohistochemical detection of myosin heavy chain in the cephalic muscles; anterior to right (modified from Diogo et al. 2008a). AD-AP, adductor arcus palatini; AD-HYO, adductor hyomandibulae; AD-OP, adductor operculi; ADM, adductor mandibulae; BRM, branchial muscles; DIL-OP, dilatator operculi; HH-INF, hyoideus inferior; HH-SUP, hyoideus superior; HYP, hypaxialis; INTE, interhyoideus; INTM-A, INTM-P, intermandibularis anterior and posterior; LEV-AP, levator arcus palatini; LEV-OP, levator operculi; LEV-5, levator arcus branchialis 5; OM, ocular muscles; PR-H, protractor hyoideus; PR-PEC, protractor pectoralis; SH, sternohyoideus.

Color image of this figure appears in the color plate section at the end of the book.

One of the subjects that we briefly discuss here concerns the third question above: is there a correspondence between the development of the mandibular, hyoid and hypobranchial muscles in the zebrafish and the evolution of these muscles within the vertebrates? As explained in Chapters 3–5, within vertebrate evolutionary history the mandibular muscles intermandibularis anterior, intermandibularis posterior, adductor mandibulae and levator arcus palatini were seemingly found in basal osteichthyans; the dilatator operculi was only acquired later in evolution, being exclusively found in actinopterygians. Interestingly, however, according to the times of appearance provided by Schilling and Kimmel's (1997: see their table 3), ontogenetically the dilatator operculi, the levator arcus palatini, the intermandibularis anterior and the intermandibularis

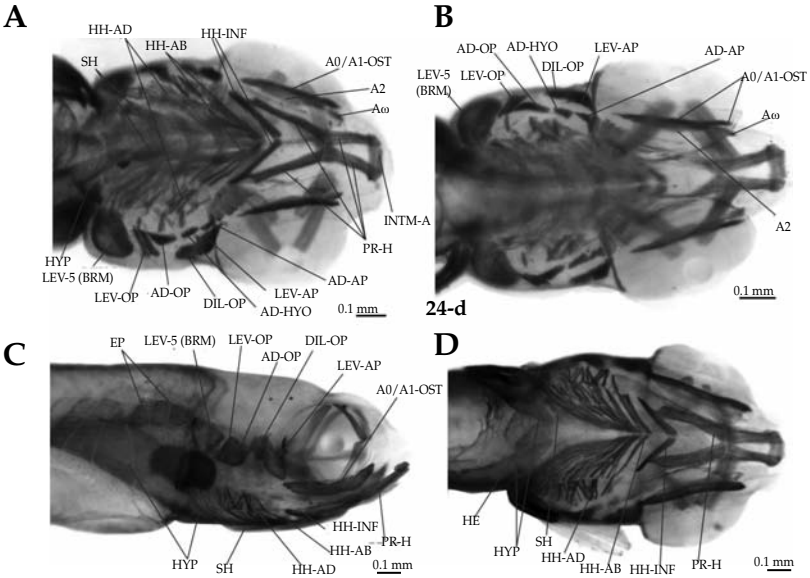

Fig. 11.3 Late larval musculature of the zebrafish (Teleostei, Cypriniformes; 24-day larvae): ventral **(A)** and dorsal **(B)** views of the cephalic muscles of 24-day zebrafish larvae with a Total Length of 6.0 mm; lateral **(C)** and ventral **(D)** views of the cephalic muscles and of the anterior portion of the body musculature of 24-day zebrafish larvae with a Total Length of 6.9 mm; anterior to right (modified from Diogo et al. 2008a). A0, A1-OST, A2, A0, AW, sections A0, A1-OST, A2, A0 and Aω of 'adductor mandibulae complex'; AD-AP, adductor arcus palatini; AD-HYO, adductor hyomandibulae; AD-OP, adductor operculi; BRM, branchial muscle; DIL-OP, dilatator operculi; EP, epaxialis; HE, heart; HH-AB, hyoideus abductor; HH-AD, hyoidei adductores; HH-INF, hyoideus inferior; HYP, hypaxialis; INTM-A, intermandibularis anterior; LEV-AP, levator arcus palatini; LEV-OP, levator operculi; LEV-5, levator arcus branchialis 5; PR-H, protractor hyoideus; PR-H-D, PR-H-D, dorsal and ventral parts of protractor hyoideus; SH, sternohyoideus.

Color image of this figure appears in the color plate section at the end of the book.

posterior appear at about the same time in the zebrafish, i.e., at 62 hours (the adductor mandibulae appears at 53 hours). In contrast, the development of the zebrafish adductor mandibulae divisions does seem to follow the order in which these divisions were acquired in evolution. In fact, the A2 and Aω were acquired earlier in evolution, being plesiomorphically found in osteichthyans; the A1-OST and A0 were acquired later, namely in the nodes leading to ostariophysans and to cypriniforms, respectively (see Chapters 3–5). During zebrafish development, the A2 and Aω also form earlier, being already separated in the 9-day-old larvae examined; the A1-OST and A0 can be recognized only in the 35-day-old juveniles and the adults studied by Diogo et al. (2008a) (see Figs. 11.2–11.5).

The order in which the hyoid muscles were acquired in evolution is: first, the interhyoideus, adductor operculi and adductor arcus palatini

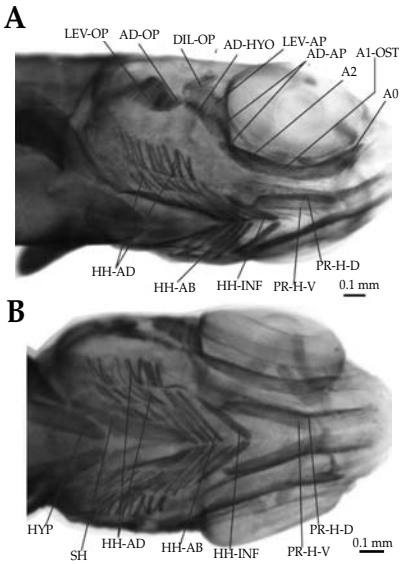

Fig. 11.4 Juvenile musculature of the zebrafish (Teleostei, Cypriniformes; 35-day juveniles: 7.4 mm Total Length): ventrolateral **(A)** and ventral **(B)** views of the cephalic muscles; anterior to right (modified from Diogo et al. 2008a). A0, A1-OST, A2, sections A0, A1-OST, and A2 of 'adductor mandibulae complex'; AD-AP, adductor arcus palatini; AD-HYO, adductor hyomandibulae; AD-OP, adductor operculi; DIL-OP, dilatator operculi; HH-AB, hyoideus abductor; HH-AD, hyoidei adductores; HH-INF, hyoideus inferior; HYP, hypaxialis; LEV-AP, levator arcus palatini; LEV-OP, levator operculi; PR-H-D, PR-H-D, dorsal and ventral parts of protractor hyoideus; SH, sternohyoideus.

Color image of this figure appears in the color plate section at the end of the book.

(plesiomorphically found in osteichthyans); then, the hyohyoideus (found only in extant actinopterygians); then, the levator operculi (found only in extant halecomorphs and teleosts); and, lastly, the "adductor hyomandibulae" (found in some teleosts, seemingly not homologous with the "adductor hyomandibulae" of osteichthyans such as *Latimeria*) (see Chapters 3–5). According to Schilling and Kimmel (1997: see their table 3), in the zebrafish the interhyoideus and the hyohyoideus appear at 58 hours, the adductor operculi and adductor hyomandibulae at 68 hours, and the levator operculi at 85 hours (note that Schilling and Kimmel 1997 listed only one adductor of the suspensorium in their table 3, which they named 'adductor hyomandibulae', and thus did not refer to an adductor arcus palatini in that table). Thus, as in vertebrate evolution, in zebrafish ontogeny the levator operculi forms later than the interhyoideus, the hyohyoideus and the adductor operculi. However, contrary to evolution, the zebrafish hyohyoideus seemingly develops earlier than the adductor operculi.

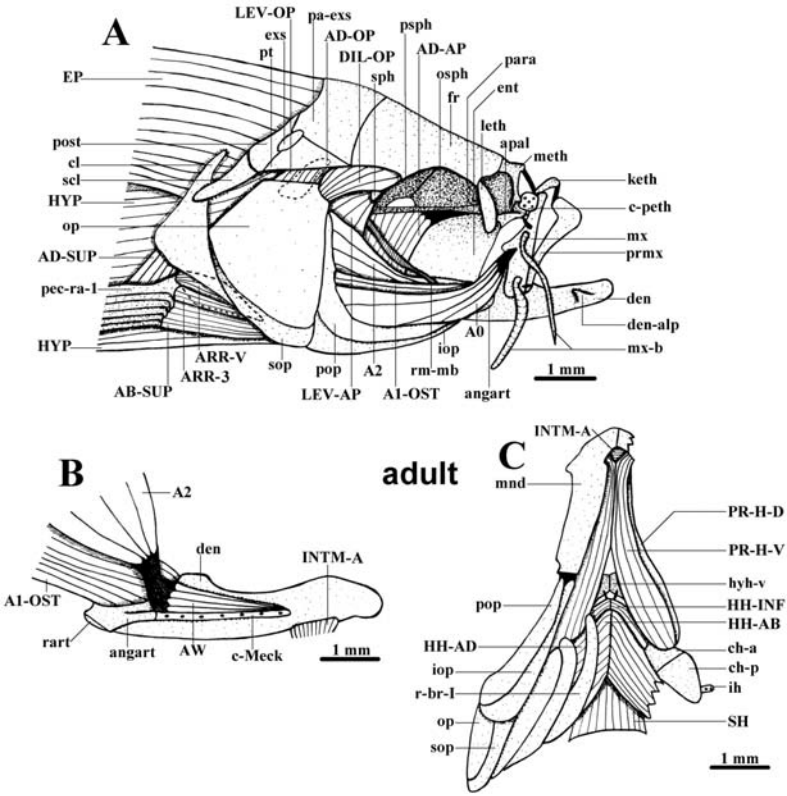

Fig. 11.5 Adult musculature of the zebrafish (Teleostei, Cypriniformes; adults: 45.1 mm Total Length): **(A)** Lateral view of the cranial cephalic muscles and surrounding skeletal structures. **(B)** Mesial view of the left mandible and adductor mandibulae, part of the anterior intermandibularis is also shown, the adductor mandibulae A0 was removed. **(C)** Ventral view of the cephalic muscles and surrounding skeletal structures, on the right side a portion of the hyohyoidei adductores, as well as of the mandible, was cut, and the opercle, interopercle, subopercle and preopercle are not represented. A0, A1-OST, A2, AW, sections A0, A1-OST, A2 and Aω of the adductor mandibulae; AB-SUP, abductor superficialis; AD-AP, adductor arcus palatini; AD-OP, adductor operculi; AD-SUP, adductor superficialis; angart, angulo-articular; apal, autopalatine; ARR-3, arrector 3; ARR-V, arrector ventralis; c-Meck, Meckelian cartilage; c-peth, pre-ethmoid cartilage; ch-a, ch-p, anterior and posterior ceratohyals; cl, cleithrum; den, dentary bone; den-alp, anterolateral process of dentary bone; DIL-OP, dilatator operculi; ent, entopterygoid; EP, epaxialis; exs, extrascapular; fr, frontal; HH-AB, hyohyoideus abductor; HH-AD, hyohyoidei adductores; HH-INF, hyohyoideus inferior; hyh-v, ventral hypohyal; HYP, hypaxialis; ih, interhyal; INTM-A, intermandibularis anterior; iop, interopercle; keth, kinethmoid; leth, lateral-ethmoid; LEV-AP, levator arcus palatini; LEV-OP, levator operculi; meth, mesethmoid; mnd, mandible; mx, maxilla; mx-b, maxillary barbel; op, opercle; osph, orbitosphenoid; pa-exs, parieto-extrascapular; para, parasphenoid; pec-ra-1, pectoral ray 1; pop, preopercle; post, posttemporal; prmx, premaxilla; PR-H-D, PR-H-V, dorsal and ventral sections of protractor hyoideus; psph, pterosphenoid; pt, pterotic; r-br-I, branchiostegal ray I; rart, retroarticular; rm-mb, mesial branch of ramus mandibularis; scl, supracleithrum; SH, sternohyoideus; sop, subopercle; sph, sphenotic.

As explained in Chapters 4 and 5, there is a single hypobranchial muscle in the zebrafish, the sternohyoideus, which appeared at 53 hours in the study of Schilling and Kimmel (1997). Interestingly, during zebrafish development the overall configuration of this muscle is changed in a manner that resembles the changes occurred in actinopterygian evolution. In fact, in basal adult actinopterygians the sternohyoideus is longitudinally divided in left and right parts that are easily distinguished from each other (see Chapter 4). This plesiomorphic overall configuration was, however, changed in the node leading to the Teleostei: in adult teleosts, including the zebrafish, the sternohyoideus is a cone-shaped structure in which the left and right parts are hardly distinguished from each other. In early zebrafish larvae the sternohyoideus is longitudinally divided in left and right parts that are easily distinguished from each other, thus resembling the configuration found in basal adult actinopterygians (see Figs. 11.2–11.5). Thus, regarding its overall configuration, there is some correspondence between the development of the sternohyoideus in the zebrafish and the evolution of this muscle within the actinopterygian osteichthyans.

The examples provided above thus illustrate that although in certain cases there is a correspondence between the ontogeny of the mandibular, hyoid and hypobranchial muscles in model organisms such as the zebrafish and the evolution of these muscles within vertebrates, this is clearly not always the case. This seems also to apply to other zebrafish cranial muscles, as well as to other cranial structures such as cartilages and bones. For instance, in 4-day-old zebrafish larvae the branchial muscle levator arcus branchialis 5 is already much broader than the other branchial muscles (see Figs. 11.2–11.5). Thus, the broadening of this muscle occurs earlier in development than, e.g., the differentiation of the adductor mandibulae in different sections. However, in evolution the hypertrophy of the levator arcus branchialis 5 occurred only in the node leading to cypriniforms, thus much later than the division of the adductor mandibulae in different sections (see Chapters 3–5). The modification of the muscle levator arcus branchialis 5, as well as of the skeletal structure that is moved by this muscle, the ceratobranchial 5, is related to the specialized peculiar feeding mechanisms of cypriniforms (e.g., Edgeworth 1935; Winterbottom 1974; Schilling and Kimmel 1997). In fact, in cypriniforms the ceratobranchial 5 bears teeth and ossifies earlier than other ceratobranchials (e.g., Cubbage and Mabee, 1996). Schilling and Kimmel (1997: 2958–2959) considered the early ossification of the ceratobranchial 5 in cypriniforms as a case of 'acceleration' of development. According to these authors, "the control of size of a particular element might be accomplished by acceleration or retarding when differentiation begins; the same hold for muscles since cartilages and their muscles develop together, and

larger cartilages tend to be associated with larger muscles". Therefore, coordinated ontogenetic timing changes might ensure proper size relationships between skeletal and myological structures. Such changes are also seen in the development of the muscles of other vertebrate taxa. For instance, in evolution the order of appearance was (1) 'adductor mandibulae complex' (A2, plesiomorphically present in vertebrates), (2) Aω (differentiated only in osteichthyans), (3) A3′/A3″ (also differentiated only in osteichthyans, and seemingly differentiated, in evolutionary time, after the differentiation of the Aω: see, e.g., Lauder 1980ab), (4) A2-PVM (differentiated only in the clade including dipnoans + tetrapods) and (5) pterygomandibularis (differentiated only in the tetrapods) (see Chapters 3–7 and Table 5.2). However, the developmental works of Rieppel (1990) and other authors have indicated that in the ontogeny of turtles the order of appearance is (1) 'adductor mandibulae complex', (2) Aω ('intramandibularis' sensu Rieppel), (3) A3′/A3″ ('adductor mandibulae internus' sensu Rieppel), (4) pterygomandibularis ('pterygoideus' sensu Rieppel) and (5) A2-PVM ('adductor mandibulae posterior' sensu Rieppel). That is, as with the zebrafish, there seems to be a general correspondence between the ontogeny of the mandibular muscles of turtles and the evolution of these muscles within vertebrates, but with some exceptions: in this specific case, contrary to evolution, the pterygomandibularis differentiates earlier than the A2-PVM (but see comments on Chapter 7 about the problems of establishing homologies between the muscles of turtles and the muscles of other reptiles and, thus, of other vertebrates). We plan to address this fascinating subject in more detail in a future work.

Another related subject that, in our opinion, is worth discussing here concerns the use of model organisms such as the zebrafish to investigate the development and/or evolution of vertebrates or of certain specific vertebrate subgroups. As explained above, because the zebrafish is the most studied model organism among osteichthyan fishes, it is often taken as a "good representative" of teleosts, of actinopterygians, and even of bony fishes in developmental and molecular studies. But, regarding its mandibular, hyoid and hypobranchial muscles, to what extent is it appropriate to consider the zebrafish as a "good representative" of these clades? As can be seen in the tables of Chapters 4 and 5, of the 13 mandibular, hyoid and hypobranchial muscles found in the adult zebrafish (intermandibularis anterior, protractor hyoideus, adductor mandibulae, levator arcus palatini, dilatator operculi, hyohyoideus inferior, hyohyoideus abductor, hyohyoidei adductores, adductor arcus palatini, adductor hyomandibulae, adductor operculi, levator operculi, and sternohyoideus; see also Table 11.1 and Fig. 11.5), all 13 are found in at least some other living teleosts, and 12 are found in at least some other extant actinopterygians (the protractor hyoideus being the exception). Therefore, although

the zebrafish occupies a rather derived phylogenetic position within the Actinopterygii and even within the Teleostei (see Figs. 1.1. and 4.1), with respect to these muscles, it seems justified to consider the zebrafish as a potential representative of these two groups. However, of these 13 muscles only 6 are found in at least some extant sarcopterygian fishes (intermandibularis anterior, adductor mandibulae, levator arcus palatini, adductor arcus palatini, adductor operculi, and sternohyoideus). Therefore, with respect to the mandibular, hyoid and hypobranchial muscles, caution is required if the zebrafish is taken as an representative of bony fishes as a whole. Lastly, it should be stressed that of these 13 muscles only 3 are found in at least some extant adult tetrapods (intermandibularis anterior, adductor mandibulae, and sternohyoideus). Therefore, one should be extremely careful to extrapolate the results obtained in molecular and developmental studies of model organisms such as the zebrafish to other taxa and particularly to tetrapod taxa and to our own species, *Homo sapiens*. However, one should also notice that the muscles of other model organisms, such as rats, are in reality essentially the same muscles (with, of course, some exceptions) that are present in phylogenetically basal members of our own biological order, the Primates, such as lemurs (see, e.g., Diogo et al. 2009b). This subject is further discussed in the next section.

11.4 Proposal of a Unifying Nomenclature for the Muscles of Vertebrates

As stressed in the first chapters of this book, one of the major problems researchers face when they compare the muscles of modern humans with those of other primates and non-primate vertebrates is the use of different names by different authors to designate the same muscle in the members of different clades, and even of the same clade. In order to reconcile these different nomenclatures we propose, in this book, a unifying nomenclature for the head, neck, pectoral and pectoral fin/forelimb muscles of the vertebrates as a whole that takes into account all the data obtained from our dissections, comparisons, and review of the literature. The muscle names that we propose are shown in bold letters in the tables provided throughout the book, which also provide a list of more than a thousand synonyms that have been used by other authors to designate these muscles in the literature, from more than two centuries ago until the present date. To our knowledge, this is the first time that such a detailed list of synonyms of the head, neck, pectoral and pectoral fin/forelimb muscles, of all the major vertebrate clades, is compiled in a single book. The fact that more than a thousand synonyms have been, and continue to be, used in the literature to describe the muscles listed in the tables

Table 11.1 Brief summary of the mandibular (man), hyoid (hyo) and hypobranchial (hyp) muscles found in the adult zebrafish, their attachments and main functions.

Name	Origin	Insertion	Function
Intermandibularis anterior (man)	dentary bone (mandible)	dentary bone of other side of body (mandible)	joins the two mandibles
Protractor hyoideus (man + hyo: intermandibularis posterior + interhyoideus)	ventral and dorsal portions: ventromesial surface of dentary bone (mandible)	ventral portion: anterior ceratohyal and ventral hypohyal; dorsal portion: anterior ceratohyal (hyoid arch)	mainly elevation of hyoid bars, as well as depression of mandible (mouth opening)
Adductor mandibulae A2 (man)	- preopercle, hyomandibula and metapterygoid (suspensorium)	- coronomeckelian bone (mandible)	the 'adductor mandibulae complex' is mainly related with mouth closure, but the maxillary component A0 can also play a central role in the mouth protrusion mechanisms of the zebrafish (see text)
Adductor mandibulae A1-OST (man)	- preopercle and quadrate (suspensorium)	- angulo-articular and dentary bone (mandible)	
Adductor mandibulae A0 (man)	- preopercle and quadrate (suspensorium)	- maxilla (upper jaw)	
Adductor mandibulae Aω (man)	- mesial surface of angulo-articular and dentary bone (mandible)	- tendon of adductor mandibulae A2	
Levator arcus palatini (man)	sphenotic (neurocranium)	metapterygoid and hyomandibula (suspensorium)	suspensorial elevation/ abduction
Dilatator operculi (man)	frontal and pterotic (neurocranium) and hyomandibula (suspensorium)	anterodorsal surface of opercle	opercular abduction (opening)
Hyohyoideus inferior (hyo)	anterior ceratohyals (hyoid arch)	mesial aponeurosis, meeting its contralateral counterpart	adduction of the hyoid arch (see text)
Hyohyoideus abductor (hyo)	first branchiostegal ray	mesial aponeurosis, meeting its contralateral counterpart	expansion of branchiostegal membrane

Hyohyoidei adductores (hyo)	opercle and subopercle	branchiostegal rays	constriction of branchiostegal membrane
Adductor operculi (hyo)	pterotic (neurocranium)	posterodorsal surface of opercle	opercular adduction (closure)
Adductor arcus palatini (hyo)	parasphenoid (neurocranium)	mesial sides of hyomandibula, metapterygoid and entopterygoid (suspensorium)	suspensorial adduction
Adductor hyomandibulae X (hyo)	parasphenoid (neurocranium)	mesial side of hyomandibula (suspensorium)	hyomandibular adduction
Levator operculi (hyo)	ventrolateral margin of pterotic (neurocranium)	dorsomesial edge of opercle	jaw depression (its force of contraction is transmitted through the opercular series and the interoperculo-mandibular ligament to the lower jaw: see text)
Sternohyoideus (hyp)	anterior region of cleithrum (pectoral girdle)	urohyal (associated with hyoid arch)	plays a major role in hyoid depression and, through a series of mechanical linkages, in mouth opening and suspensorial abduction

provided in this volume stresses the problem that researchers face when trying to compare the structures of the taxa they are studying with those described by other authors in other taxa, or even in the same taxa. This is particularly problematic for researchers who work in fields other than comparative anatomy (e.g., psychologists or neurobiologists interested in the evolution of facial expressions, such as Sherwood et al., 2003; Parr and Waller, 2006; Waller et al., 2006, 2008ab).

One of the main goals of this book is therefore to provide researchers with tools to compare the muscles in their study animal with muscles previously described in the literature. A main advantage and strength of our nomenclature is that it combines, and thus creates a bridge between, the names used by human anatomists and by researchers working with non-human primates and non-primate vertebrates. To give an example, the terms platysma myoides, platysma cervicale, sphincter colli superficialis, sphincter colli profundus, cervicalis transversus, naso-labialis, sternofacialis, interscutularis, orbito-temporo-auricularis, auriculo-orbitalis and maxillo-naso-labialis are often used to designate the muscles of non-primate mammals (e.g., Jouffroy and Saban 1971). As some of the muscles that are present in these mammals are directly homologous with muscles that are seen in primates and particularly in strepsirhines (e.g., platysma cervicale, platysma myoides, sphincter colli profundus, auriculo-orbitalis, naso-labialis, and maxillo-naso-labialis; see Diogo et al., 2009b), it is reasonable to use these names in the descriptions of these primates (and not to use, as it is often done in the literature, different names to designate these muscles in primates, e.g., 'notoplatysma', 'tracheoplatysma', 'sphincter colli', 'auricularis anterior', 'levator labii inferioris', and 'nasalis', respectively: see Chapter 5). At the same time, our nomenclature takes into account major nomenclatural reviews that have been done for non-human tetrapod taxa (e.g., Nomina Anatomica Avium: Baumel et al. 1979) and, importantly, retains most of the names used for the muscles of modern humans as set out in, e.g., the Terminologia Anatomica (1998), for it is also important to maintain the stability of a nomenclature that has been consistently used during various decades in thousands of publications dealing with human anatomy, evolution, psychology and medicine. In fact, continuing with the example of the facial muscles, there are only two differences between the names we use for the muscles of modern humans and the names used in Terminologia Anatomica (1998): (1) instead of 'platysma' we use the name platysma myoides (because the muscle of modern humans corresponds to the platysma myoides, and not to the whole 'platysma' i.e., platysma myoides + platysma cervicale, of other mammals) and (2) in place of 'levator anguli oris' we use the name levator anguli oris facialis (as explained in Chapters 4–7, in order to distinguish this facial muscle from the reptilian mandibular muscle that is also designated as

'levator anguli oris', we propose to name the mammalian facial muscle levator anguli oris facialis and the reptilian mandibular muscle levator anguli oris mandibularis) (see Tables 5.3–5.4).

An important consequence of using this unifying nomenclature is that it clearly stresses that the muscles that are present in distinct vertebrate taxa are, in general, not as different as the incongruous nomenclatures that are often applied to those vertebrate taxa might suggest. It is true that, as explained in the above sections, of all the muscles that are usually present in adults of model organisms such as the zebrafish, very few are actually present as independent muscles in extant adult members of *other* major vertebrate clades. However, one of the crucial conclusions of the research that we have been doing in the past few years, after dissecting more than a thousand vertebrate specimens and doing an extensive review of the literature, is that *within each* of the major vertebrate clades we studied, the number and overall configuration of muscles are actually rather constant (see Chapters 3–10). That is, what is really remarkable in the evolution of the taxa within these major clades is actually the tendency to maintain the same structures rather than to acquire new muscles or to completely lose existing muscles. In other words, after many years of experience, we began to understand that, as a general rule, when a researcher working exclusively with a taxon A of a clade B states how peculiar are the muscles of that taxon and how for instance that taxon has completely lost a muscle C that is usually found in other members of clade B and has acquired a completely new, unique muscle D, a careful myological analysis often leads to the conclusion that muscles C and D are in fact homologous. The problem is that, when the homology between muscles C and D is actually recognized, it is often too late: the anxious researcher has probably already published his work, revealing how strange and peculiar is the taxon A and particularly its unique muscle D, which he very likely described under a name that is new to science, thus making future myological comparisons between distinct vertebrate taxa even more difficult then they already are. To some extent, one could say that some of the supposed anatomical differences that are described in the literature between certain vertebrate taxa are more the product of the descriptions made and nomenclatures used by the researchers, than the actual product of morphological evolution.

To come back to the example regarding the facial muscles, the use of the unifying nomenclature presented in this book actually stressed that, contrary to what has often been suggested in the literature, the muscles that are present in phylogenetically basal primates such as the strepsirhines (e.g., lemurs) are in reality essentially the same muscles that are present in non-primate mammals such as tree-shrews and colugos (Diogo et al. 2009b; see Chapter 5 and Fig. 5.18). The main difference between tree-shrews and strepsirhines is that the latter usually have a muscle,

the depressor supercilii, that is usually not differentiated in tree-shrews, and that strepsirhines lack two muscles that are often present in tree shrews, the sphincter colli superficialis and the peculiar, small zygomatico-orbicularis. Also, the muscles present in macaques are essentially the same muscles that are seen in hominoids, with a few exceptions (Figs. 5.22–5.27). These monkeys do not have distinct risorius, auricularis anterior and temporoparietalis muscles like those found in hominoids such as humans, but have muscles that are usually not differentiated in some hominoid taxa, e.g., the platysma cervicale (usually not differentiated in orangutans, panins—i.e., chimpanzees and bonobos—and hominins) and the auricularis posterior (usually not differentiated in orangutans) (Figs. 5.22–5.27). Overall, monkeys and hominoids have more facial muscles than strepsirhines and, among the taxa dissected by us, modern humans, together with gorillas, have the greatest number of facial muscles, and this is consistent with the important role played by facial expression in anthropoids in general, and in modern humans in particular (e.g., Burrows 2008; Diogo et al. 2009b; see Chapter 5). But the data obtained in our research, as well as the works of Burrows and Smith (2003) and Burrows et al. (2006), show that the difference between the number of facial muscles present in modern humans and in hominoids such as hylobatids, chimpanzees and orangutans, and between the number of muscles seen in these latter hominoids and in strepsirhines, is not as marked as previously thought (see, e.g., Huber 1930b, 1931).

Another interesting example related to this subject concerns the similarities of the general 'architecture' of the pectoral and forelimb muscles of the major extant groups of limbed tetrapods. Within these extant groups turtles, for instance, are often used to illustrate a remarkable case of evolutionary novelty, because their ribs contribute to the carapace and are superficial to the pectoral girdle (e.g., Shearman and Burke 2009). In most vertebrates, the pectoral girdle does not articulate with the vertebrate, and it sits in a muscular sling lateral to the ribs; the inverted relationship of the ribs and pectoral girdle in turtles results from the lateral, rather than ventral, trajectory of the growing ribs (e.g., Shearman and Burke 2009). However, as stressed by Walker (1947) and other authors and explained in Chapter 10, the development of the testudine shoulder and forelimb muscles remains essentially similar to that of other amniotes. As noted in Chapter 10, it is also interesting to note that, among some tetrapod groups, other dramatic evolutionary events, such as the reduction of the number of digits, have also not provoked a profound modification in the overall configuration of the corresponding musculature, indicating that muscles probably form and insert where needed to be capable of moving the most extreme (i.e., radial and ulnar) hand digits. So, at least in this specific example, what seems to be important for the formation and attachments

of some forelimb muscles is mainly the position, and not the 'specific identity', of the digit to which the muscle attaches (for more details on this subject, see Chapter 10). However, as also explained in Chapter 10, there are seemingly some exceptions to this rule. For instance, the abductor digiti minimi seems to be lacking in birds such as chickens. The evidence available strongly indicates that digit 5 is missing in adult chickens, i.e., the most ulnar digit of adult chickens is digit 3 according to most studies of fossils and hox genes and digit 4 according to most embryological studies (see Chapter 10). So, in this case, it seems that the 'specific identity' of the digits is actually important, that is, there is no abductor digiti minimi to digit 3 (i.e., 4 according to most embryologists), even if this is the most ulnar digit of adult chickens. However, again, these latter examples seem to constitute an exception, rather than the rule, although this puzzling topic about the relationship between the formation and attachments of a muscle and the position versus the 'specific identity' of the structures to which it attaches clearly needs to be studied in a more careful and integrative way in future developmental and/or genetic studies. We hope that the present work will pave the way and stimulate researchers to undertake studies addressing this subject and other questions that were raised throughout this book about the comparative anatomy, homologies, development and evolution of the head, pectoral and pectoral fin/forelimb muscles of vertebrates. There are, of course, endless directions for future research. But if we would have to chose only some of them, i.e., those that we think could be particularly interesting and/or engaging, these would perhaps be (1) to carefully analyze the muscles of non-vertebrate animals such as amphioxus and 'urochordates', in order to investigate the origin of the vertebrate muscles, (2) at the other extreme, to focus on primates in more detail, and particularly on the evolution of their facial muscles and facial expressions, of their larygeal muscles and vocal communication, and of their limb muscles and locomotion, among others, and (3) a broad comparison of primates and modern humans with other vertebrate groups that would lead to a more careful and integrative discussion of aspects that are more directly related with human anatomy and medicine, including the presence of muscular abnormalities and their evolutionary and phylogenetic relevance for understanding human diseases and for undertaking muscular surgeries, as well as the relationship between ontogeny, genetics, and myological abnormalities, including the so-called (somewhat controversially) 'atavisms' (e.g., Hall 1984; Miller 2009).

For us, this is the end of a long journey through dissection rooms, natural history museums, and libraries. But it is also a new beginning and an opportunity to explore new ideas and new lines of research that, explored either inside or outside dissecting rooms, museums and libraries, will surely continue to be related with the study of one of the most

puzzling, charming and fascinating subjects within natural sciences and, in our opinion, within sciences as a whole: the evolution and phylogeny of biological organisms.

References

Abdala V, Moro S (1996) Cranial musculature of South American Gekkonidae. *J Morphol* 229, 59–70.

Abdala V, Moro S (2003) A cladistic analysis of ten lizard families (Reptilia: Squamata) based on cranial musculature. *Russ J Herpetol* 10, 53–78.

Abdala V, Moro S (2006) Comparative myology of the forelimb of *Liolaemus* sand lizards (Liolaemidae). *Acta Zool* 87, 1–12.

Abdala V, Diogo R (in press) Comparative anatomy, homologies and evolution of the head and neck musculature of frogs (Anura), salamanders (Urodela) and caecilians (Gimnophiona) (Tetrapoda: Amphibia). *Int J Morphol.*

Abdala V, Manzano AS, Herrel A (2008) The distal forelimb musculature in aquatic and terrestrial turtles: phylogeny or environmental constraints? *J Anat* 213, 159–172.

Abdala V, Manzano AS, Nieto L, Diogo R (in press) Comparative myology of Leiosauridae (Squamata) and its bearing on their phylogenetic relationships. *Belg J Zool.*

Abramowitz I (1955) On the existence of a palmar interosseous muscle in the thumb with particular reference to the Bantle-speaking Negro. *South African J Sci* 51, 270–276.

Adamicka P, Ahnelt H (1992) Two jaw articulations in *Latimeria chalumnae* (Actinistia, Coelacanthidae). *Zool Jb Anat* 122, 107–112.

Adams LA (1919) A memoir on the phylogeny of the jaw muscles in recent and fossils vertebrates. *Annals NY Acad Sci* 28, 51–166.

Adams SB, Wheeler JFG, Edgeworth FH (1929) On the innervation of the platysma and the mandibulo-auricularis. *J Anat* 63, 242–252.

Adriaens D, Decleyre D, Verraes W (1993) Morphology of the pectoral girdle in *Pomatoschistus lozanoi* De Buen, 1923 (Gobiidae), in relation to pectoral fin adduction. *Belg J Zool* 123, 135–157.

Agnarsson I, Coddington JA (2007) Quantitative tests of primary homology. *Cladistics* 23, 1–11.

Albrecht P (1876) *Beitrag zur Morphologie des M. omo-hyoides und der ventralen inneren Interbranchialmusculatur in der Reihe der Wirbelthiere*. Unpublished PhD Dissertation, Universität zu Kiel, Kiel.

Alcock R (1898) The peripheral distribution of the cranial nerves of ammocoetes. *J Anat Physiol* 33, 131–154.

Alexander RMcN (1973) Jaw mechanisms of the coelacanth *Latimeria*. *Copeia* 1973, 156–158.

Allis EP (1897) The cranial muscles and cranial nerves of *Amia calva*. *J Morphol* 12, 487–737.

Allis EP (1917) The prechordal portion of the chondrocranium of *Chimaera colliei. Proc Zool Soc Lond* 1917, 105–143.

Allis EP (1919) The lips and the nasal apertures in the gnathostome fishes. *J Morphol* 32, 123–221.

Allis EP (1922) The cranial anatomy of *Polypterus*, with special reference to *Polypterus bichir*. *J Anat* 56, 180–294.

Allis EP (1923) The cranial anatomy of *Chlamydoselachus anguineus. Acta Zool* 4, 162–219.

Allis EP (1931) Concerning the mouth opening and certain features of the visceral endoskeleton of *Cephalaspis. J Anat* 65, 509–527.

Anderson PSL (2008) Cranial muscle homology across modern gnathostomes. *Biol J Linn Soc* 94, 195–216.

Anderson RJ (1880) A variety of the mylopharyngeus and other unusual muscular abnormalities. *J Anat Physiol* 14, 357–359.

Anderson RJ (1881) The morphology of the muscles of the tongue and pharynx. *J Anat Physiol* 15, 382–391.

Andrew RJ (1963) Evolution of facial expression. *Science* 142, 1034–1041.

Anthony J (1980) Évocation des travaux français sur *Latimeria* notamment depuis 1972. *Proc R Soc Lond B* 208, 349–367.

Aziz MA (1981) Possible "atavistic" structures in human aneuploids. *Am J Phys Anthropol* 54, 347–353.

Aziz MA, Cowie RJ, Skinner CE, Abdi TS, Orzame G (1998) Are the two heads of the human lateral pterygoid separate muscles? A perspective based on their nerve supply. *J Orofac Pain* 2, 226–239.

Barghusen HR (1968) The lower jaw of cynodonts (Reptilia, Therapsida) and the evolutionary origin of mammal-like adductor jaw musculature. *Postilla* 116, 1–49.

Barghusen HR (1986) On the evolutionary origin of the therian tensor veli palatini and tensor tympani muscles. In *The Ecology and Biology of Mammal-like Reptiles* (eds. Hotton N, MacLean PD, Roth JJ, Roth EC), pp. 253–262. Washington DC: Smithsonian Institution Press.

Barrow JR, Capecchi MR (1999) Compensatory defects associated with mutations in *Hoxa1* restore normal palatogenesis to *Hoxa2* mutants. *Development* 126, 5011–5026.

Bartsch P (1992) On the constructional anatomy of the jaw suspension and the cranial base in the larva of *Neoceratodus forsteri* (Krefft 1870). *Zool Jb Anat* 122, 113–127.

Bartsch P (1993) Development of the snout in the Australian lungfish *Neoceratodus forsteri* (Krefft, 1870), with special reference to cranial nerves. *Acta Zool (Stockh)* 74, 15–29.

Bartsch P (1994) Development of the cranium of *Neoceratodus forsteri*, with a discussion of the suspensorium and the opercular apparatus in Dipnoi. *Zoomorphology* 114, 1–31.

Bauer WJ (1992) A contribution to the morphology of the m. interhyoideus posterior (VII) of urodele Amphibia. *Zool Jb Anat* 122, 129–139.

Bauer WJ (1997) A contribution to the morphology of visceral jaw–opening muscles of urodeles (Amphibia: Caudata). *J Morphol* 233, 77– 97.

Baumel JJ, King AS, Lucas AM, Breazile JE, Evans HE (1979) *Nomina Anatomica Avium*. New York: Academic Press.

Bemis WE (1986) Feeding mechanisms of living Dipnoi: anatomy and function. *J Morphol, suppl.* 1, 249–275.

Bemis WE (1984) Paedomorphosis and the evolution of Dipnoi. *Paleobiology* 10, 293–307.

Bemis WE, Lauder CV (1986) Morphology and function of the feeding apparatus of the lungfish, *Lepidosiren paradoxa* (Dipnoi). *J Morphol* 187, 81–108.

Bemis WE, Schwenk K, Wake MH (1983) Morphology and function of the feeding apparatus in *Dermophis mexicanus*. *Zool J Linn Soc* 77, 75–96.

Bemis WE, Findeis EK, Grande L (1997) An overview of Acipenseriformes. *Environ Biol Fish* 48, 25–71.

Birou G, Garcier JM, Guillot M, Vanneuville G, Chazal J (1991) A study of the lateral pterygoid muscle: anatomic sections and CT appearances. *Surg Radiol Anat* 13, 307–311.

Bischoff TLW (1840) Description anatomique du *Lepidosiren paradoxa*. *Ann Sci Nat* 14, Ser 2, 116–159.

Boas JEV, Paulli S (1908) *The elephant head—Studies in the comparative anatomy of the organs of the head of the Indian elephant and other mammals, 1: The facial muscles and the proboscis*. Jena: Gustav Fischer.

Borden WC (1998) Phylogeny of the unicornfishes (*Naso*, Acanthuridae) based on soft anatomy. *Copeia* 1998, 104–113.

Borden WC (1999) Comparative myology of the unicornfishes, *Naso* (Acanthuridae, Percomorpha), with implications for phylogenetic analysis. *J Morphol* 239, 191–224.

Borue X, Noden DM (2004) Normal and aberrant craniofacial myogenesis by grafted trunk somitic and segmental plate mesoderm. *Development* 131, 3967–3980.

Boto L, Doadrio I, Diogo R (2009) Prebiotic world, macroevolution, and Darwin's theory: a new insight. *Biol & Philos* 24, 119–128.

Brock GT (1938) The cranial muscles of the *Gecko*—a general account with a comparison of muscles in other gnathostomes. *Proc Zool Soc Lond (Ser B)* 108, 735–761.

Brooks HSJ (1886a) On the morphology of the intrinsic muscles of the little finger, with some observations on the ulnar head of the short flexor of the thumb. *J Anat Physiol* 20, 644–661.

Brooks HSJ (1886b) Variations in the nerve supply of the flexor brevis pollicis muscle. *J Anat Physiol*, 20, 641–644.

Brooks HSJ (1887) On the short muscles of the pollex and hallux of the anthropoid apes, with special reference to the opponens hallucis. *J Anat Physiol* 22, 78–95.

Brooks HSJ (1889) Morphology of the muscles on the extensor aspect of the middle and distal segments of the limbs: with an account of the various paths which are adopted by the nerve-trunks in these segments. *Stud Mus Zool Univ Coll Dundee* 1, 1–17.

Brosseau AR (1978a) The pectoral anatomy of selected Ostariophysi, II—the Characiformes. *J Morphol* 148, 89–136.

Brosseau AR (1978b) The pectoral anatomy of selected Ostariophysi, I—the Cypriniformes and Siluriformes. *J Morphol* 150, 79–115.

Bryant MD (1945) Phylogeny of Nearctic Sciuridae. *Am Midland Nat* 33, 257–390.

Bunnell S (1942) Surgery of the intrinsic muscles of the hand other than those producing opposition of the thumb. *J Bone Joint Surg Am* 24, 1–31.

Burke AC, Feduccia A (1997) Developmental patterns and the identification of homologies in the avian hand. *Science* 278, 666–668.

Burrows AM (2008) The facial expression musculature in primates and its evolutionary significance. *Bioessays*, 30, 212–225.

Burrows AM, Smith TD (2003) Muscles of facial expression in *Otolemur* with a comparison to Lemuroidea. *Anat Rec* 274, 827–836.

Burrows AM, Waller BM, Parr LA, Bonar CJ (2006) Muscles of facial expression in the chimpanzee (*Pan troglodytes*): descriptive, comparative and phylogenetic contexts. *J Anat* 208, 153–167.

Busbey AB (1989) Form and function of the feeding apparatus of *Alligator mississippiensis*. *J Morphol* 202, 99–127

Burton TC (1998) Pointing the way: the distribution and evolution of some characters of the finger muscles of frogs. *Am Mus Nov* 3229, 1–13.

Butler AB, Hodos W (2005) *Comparative Vertebrate Neuroanatomy: Evolution and Adaptation*. Hoboken: Wiley Interscience.

Camp CL (1923) Classification of the lizards. *Bull Amer Mus Nat Hist* 48, 289–481.

Campbell KSW, Barwick RE (1986) Paleozoic lungfishes—a review. *J Morphol*, suppl 1, 93–131.

Carroll AM, Wainwright PC (2003) Functional morphology of feeding in the sturgeon, *Scaphirhyncus albus*. *J Morphol* 256, 270–284.

Carroll RL (2007) The Paleozoic ancestry of salamanders, frogs and caecilians. *Zool J Linn Soc* 150, 1–140.

Carroll RL, Holmes R (1980) The skull and jaw musculature as guides to the ancestry of salamanders. *Zool J Linn Soc Lond* 68, 1–40.

Carroll SB (2005) *The New Science of Evo-Devo: Endless Forms Most Beautiful*. New York: WW Norton & Company.

Carroll SB, Grenier JK, Weathrbee SD (2005) *From DNA to Diversity—Molecular Genetics and the Evolution of Animal Design (2nd Ed.)*. Malden: Blackwell Science.

Cerny R, Lwigale P, Ericsson R, Meulemans D, Epperlein HH, Bronner-Fraser M (2004) Developmental origins and evolution of jaws: new interpretation of "maxillary" and "mandibular". *Dev Biol* 276, 225–36.

Chanoine C, Hardy S (2003) *Xenopus* muscle development: from primary to secondary myogenesis. *Dev Dyn* 226, 12–23.

Chapman HC (1902) Observations upon *Galeopithecus volans*. *Proc Acad Nat Sci Philad* 54, 241–254.

Cheng C-C (1955) The development of the shoulder region of the opossum, *Didelphis virginiana*, with special reference to musculature. *J Morphol* 97, 415–471.

Chi TK (1937) An unusual variation of the pharyngeal muscles. *J Anat* 72, 134–135.

Cihak R (1972) Ontogenesis of the skeleton and intrinsic muscles of the human hand and foot. *Adv Anat Embryol Cell Biol* 46, 1–194.

Collard M, Wood B (2000) How reliable are human phylogenetic hypotheses? *Proc Natl Acad Sci US* 97, 5003–5006.

Cole FJ (1896) On the cranial nerves of *Chimaera monstrosa* (Linn. 1754); with a discussion of the lateral line system and the morphology of the chorda tympani. *Trans R Soc Edinb* 38, 631–680.

Conrad JL (2008) Phylogeny and systematics of Squamata (Reptilia) based on morphology. *Bull Am Mus Nat Hist* 310, 1–182.

Couly GF, Coltey PM, LeDouarin NM (1992) The developmental fate of the cephalic mesoderm in quail-chick chimeras. *Development* 114, 1–15.

Crelin ES (1987) *The Human Vocal Tract: Anatomy, Function, Development, and Evolution*. New York: Vantage Press Inc.

Cubbage CC, Mabee PM (1996) Development of the cranium and paired fins in the zebrafish *Danio rerio* (Ostariophysi, Cyprinidae). *J Morphol* 229, 121–160.

Cuvier G, Laurillard L (1849) *Recueil de planches de myologie*. Anatomie comparée, 3, Paris.

Damas H (1935) Contribution a l'etude de la metamorphose de la tete de la lamproie. *Arch Biol* 46, 171–227.

Danforth CH (1913) The myology of *Polyodon*. *J Morphol* 24, 107–146.

Daniel JF (1928) *The Elasmobranch Fishes (2nd. Ed.)*. Berkeley: University of California Press.

Davis CA, Holmyard DP, Millen KJ, Joyner AL. 1991. Examining pattern formation in mouse, chicken and frog embryos with an En-specific antiserum. *Development* 111, 287–298.

Dawkins R (2004) *The Ancestor's Tale—a Pilgrimage to the Dawn of Life*. Boston: Houghton Mifflin.

De Pinna MCC (1991) Concepts and tests of homology in the cladistic paradigm. *Cladistics* 7, 367–394.

Dilkes DW (2000) Appendicular myology of the hadrosaurian dinosaur *Maiasaura peeblesorum* from the Late Cretaceous (Campanian) of Montana. *Trans R Soc Edin (Earth Sci)* 90, 87–125.

Diogo R (2004a) *Morphological Evolution, Aptations, Homoplasies, Constraints, and Evolutionary Trends: catfishes as a case study on general phylogeny and macroevolution*. Enfield: Science Publishers.

Diogo R (2004b) Muscles versus bones: catfishes as a case study for an analysis on the contribution of myological and osteological structures in phylogenetic reconstructions. *Anim Biol* 54, 373–391.

Diogo R (2005) Evolutionary convergences and parallelisms: their theoretical differences and the difficulty of discriminating them in a practical phylogenetic context. *Biol Philos* 20, 735–744.

Diogo R (2007) *On the Origin and Evolution of Higher Clades: osteology, myology, phylogeny and macroevolution of bony fishes and the rise of tetrapods*. Enfield: Science Publishers.

Diogo R (2008) Comparative anatomy, homologies and evolution of the mandibular, hyoid and hypobranchial muscles of bony fish and tetrapods: a new insight. *Anim Biol* 58, 123–172.

Diogo R (2009). The head musculature of the Philippine colugo (Dermoptera: *Cynocephalus volans*), with a comparison to tree-shrews, primates and other mammals. *J Morphol* 270, 14–51.

Diogo R, Chardon M (2000) Homologies between different adductor mandibulae sections of teleostean fishes, with a special regard to catfishes (Teleostei: Siluriformes). *J Morphol* 243, 193–208.

Diogo R, Abdala V (2007). Comparative anatomy, homologies and evolution of the pectoral muscles of bony fish and tetrapods: a new insight. *J Morphol* 268, 504–517.

Diogo R, Wood BA (2009) Comparative anatomy and evolution of the pectoral and forelimb musculature of primates: a new insight. *Am J Phys Anthropol, Meeting Suppl* 48, 119.

Diogo R, Oliveira C, Chardon M (2001) On the osteology and myology of catfish pectoral girdle, with a reflection on catfish (Teleostei: Siluriformes) plesiomorphies. *J Morphol* 249, 100–125.

Diogo R, Hinits Y, Hughes SM (2008a) Development of mandibular, hyoid and hypobranchial muscles in the zebrafish: homologies and evolution of these muscles within bony fishes and tetrapods. *BMC Dev Biol* 8, 24–46.

Diogo R, Abdala V, Lonergan N, Wood BA (2008b). From fish to modern humans—comparative anatomy, homologies and evolution of the head and neck musculature. *J Anat* 213, 391–424.

Diogo R, Abdala V, Aziz MA, Lonergan N, Wood BA (2009a). From fish to modern humans—comparative anatomy, homologies and evolution of the pectoral and forelimb musculature. *J Anat* 214, 694–716.

Diogo R, Wood BA, Aziz MA, Burrows A (2009b). On the origin, homologies and evolution of primate facial muscles, with a particular focus on hominoids and a suggested unifying nomenclature for the facial muscles of the Mammalia. *J Anat* 215, 300–319.

DuBrul EL (1958) *Evolution of the Speech Apparatus*. Springfield: Thomas.

Duellman WE, Trueb L (1986) *The Biology of Amphibians*. New York: McGraw-Hill Book Company.

Ecker A (1889) *Anatomy of the Frog*. Oxford: Clarendon Press.

Edgeworth FH (1902) The development of the head muscles in *Scyllium canicula*. *J Anat Physiol* 37, 73–88.

Edgeworth FH (1911) On the morphology of the cranial muscles in some vertebrates. *Q J Micr Sci N S* 56, 167–316.

Edgeworth FH (1923) On the development of the hypobranchial, branchial and laryngeal muscles of *Ceratodus*, with a note on the development of the quadrate and epihyal. *Q J Micr Sci N S* 67, 325–368.

Edgeworth FH (1926a) On the hyomandibula of Selachii, Teleostomi and *Ceratodus*. *J Anat Physiol* 60, 173–193.

Edgeworth FH (1926b) On the development of the coraco-branchialis and cucullaris in *Scyllium canicula*. *J Anat Physiol* 60, 298–308.

Edgeworth FH (1926c) On the development of the cranial muscles in *Protopterus* and *Lepidosiren*. *Trans R Soc Edinb* 54, 719–734.

Edgeworth FH (1928) The development of some of the cranial muscles of ganoid fishes. *Philos Trans R Soc Lond (Biol)* 217, 39–89.

Edgeworth FH (1935) *The Cranial Muscles of Vertebrates*. Cambridge: Cambridge University Press.

El Haddioui AL, Zouaoui A, Bravetti P, Gaudy JF (2005) Functional anatomy of the human lateral pterygoid muscle. *Surg Radiol Anat* 27, 271–286.

Ellies DL, Tucker AS, Lumsden A (2002) Apoptosis of premigratory neural crest cells in rhombomeres 3 and 5: consequences for patterning of the branchial region. *Dev Biol* 251, 118–128.

Elzanowski A (1987) Cranial and eyelid muscles and ligaments of the tinamous (Aves: Tinamiformes). *Zool Jb Anat* 116, 63–118.

Engels WL (1938) Tongue musculature of passerine birds. *Auk* 55, 642–650.

Ericsson R, Olsson L (2004) Patterns of spatial and temporal visceral arch muscle development in the Mexican axolotl (*Ambystoma mexicanum*). *J Morphol* 261, 131–140.

Ericsson R, Cerny R, Falck P, Olsson L (2004) Role of cranial neural crest cells in visceral arch muscle positioning and morphogenesis in the Mexican axolotl (*Ambystoma mexicanum*). *Dev Dynam* 231, 237–247.
Findeis EK (1997) Osteology and phylogenetic relationships of recent sturgeons. *Environ Biol Fish* 48, 73–126.
Forey PL (1986) Relationships of lungfishes. *J Morphol, suppl.* 1, 75–91.
Forster A (1917) Die mm. contrahentes und interossei manus in der Säugetierreihe und beim Menschen. *Arch Anat Physiol Anat Abt* 1916, 101–378.
Fox H (1959) A study of the development of the head and pharynx of the larval urodele *Hynobius* and its bearing on the evolution of the vertebrate head. *Philos Trans R Soc Lond B Biol Sci 242*, 151–204.
Frazzetta TH (1962) A functional consideration of cranial kinesis in lizards. *J Morphol* 111, 287–320.
Fürbringer M (1874) Zur vergleichenden Anatomie der Schultermuskeln—2-teil. *Jena Zeitschr Naturwiss* 8, 175–280.
Fürbringer M (1876) Zur vergleichenden Anatomie der Schultermuskeln—3-teil, capitel IV, Saurier und Crocodile. *Gegenbaurs Morphol Jahrb* 1, 636–816.
Galis F, Kundrát M, Sinervo B (2003). An old controversy solved: bird embryos have five fingers. *Trends Ecol Evol* 18, 7–9.
Galis F, Kundrát M, Metz JAJ (2005). Hox genes, digiti identities and the theropod/bird transition. *J Exp Zool B Mol Dev Evol* 304, 198–205.
Garcia-Fernàndez J, Benito-Gutiérrez É (2009) It's a long way from amphioxus: descendants of the earliest chordate. *Bioessays* 31, 665–675.
Gardner CA, Barald KF (1992) Expression patterns of engrailed–like proteins in the chick embryo. *Dev Dyn* 193, 370–388.
Gasser RF (1967) The development of the facial muscles in man. *Am J Anat* 120, 357–376.
Gaunt AS, Gans C (1969) Mechanisms of respiration in the snapping turtle, *Chelydra serpentina* (Linné). *J Morphol* 128, 195–228.
Gauthier J, Kluge AG, Rowe T (1988) Amniote phylogeny and the importance of fossils. *Cladistics* 4, 105–209.
Gaupp E (1896) *A. Ecker's und R. Wiedersheim's Anatomie des Frosches, part 1*. Braunschweig: Friedrich Vieweg und Sohn.
Gegenbaur C (1872) *Untersuchungen zur Vergleichenden Anatomie der Wirbelthiere. III. Das Kopfskelet der Selachier*. Leipzig: Engelmann.
George RM (1977) The limb musculature of the Tupaiidae. *Primates* 18, 1–34.
Ghetie V, Chitescu ST, Cotofan V, Hillebrand A (1981) *Atlas de anatomía de las aves domésticas*. Madrid: Editorial Acribia.
Gibbs S (1999) *Comparative soft tissue morphology of the extant Hominoidea, including man*. Unpublished PhD thesis, The University of Liverpool.
Gibbs S, Collard M, Wood BA (2000) Soft-tissue characters in higher primate phylogenetics. *Proc Natl Acad Sci* US 97, 11130–11132.
Gibbs S, Collard M, Wood BA (2002) Soft-tissue anatomy of the extant hominoids: a review and phylogenetic analysis. *J Anat* 200, 3–49.
Goodrich ES (1958) *Studies on the Structure and Development of Vertebrates*. New York: Dover Publications.
Göppert E (1937) Kehlkopf und Trachea. In *Handbuch der Vergleichenden, Anatomie der Wirbeltiere, Vol. 3* (eds. Bolk L, Göppert E, Kallius E, Lubosch W), pp. 797–866. Berlin: Urban & Schwarzenberg.
Gorniak GC (1985) Trends in the action of mammalian masticatory muscles. *Am Zool* 25, 331–337.
Gosline WA (1989) Two patterns of differentiation in the jaw musculature of teleostean fishes. *J Zool (Lond)* 218, 649–661.
Gould SJ (1977) *Ontogeny and Phylogeny*. Cambridge: Harvard University Press.
Gould SJ (2002) *The Structure of Evolutionary Theory*. Harvard: Belknap.

Gräfenberg E (1906) Die enntwicklung der Knochen, Muskeln und Nerven der Hand und der für die Bewegungen der Hand bestimmten Muskeln des Unterarmes. *Anat H* 30, 7–154.

Graham A (2003) Development of the pharyngeal arches. *Am J Med Genet* 119A, 251–256.

Greene EC (1935) *Anatomy of the Rat*. New York: Hafner Publishing Co.

Greenwood PH (1971) Hyoid and ventral gill arch musculature in osteoglossomorph fishes. *Bull Brit Mus Nat Hist (Zool.)* 22, 1–55.

Greenwood PH (1977) Notes on the anatomy and classification of elopomorph fishes. *Bull Br Mus Nat Hist (Zool.)* 32, 65–103.

Greenwood PH, Thomson KS (1960) The pectoral anatomy of *Pantodon buchholzi* Peters (a freshwater flying fish) and the related Osteoglossidae. *Proc Zool Soc Lond* 135, 283–301.

Grim M (1971) Development of the primordia of the latissimus dorsi muscle of chicken. *Folia Morphol (Prague)* 19, 252–258.

Gunnell GF, Simmons NB (2005) Fossil evidence and the origin of bats. *J Mammal Evol* 12, 209–246.

Haas G (1973) Muscles of the jaws and associated structures in the Rhynchocephalia and Squamata. In *Biology of the Reptilia, Vol. 14* (eds. Gans C, Parsons TS), pp. 285–490. New York: Academic Press.

Haas A (1996) The larval hyobranchial apparatus of discoglossoid frogs: its structure and bearing on the systematics of the Anura (Amphibia: Anura). *J Zool Syst Evol Res* 35, 179–197.

Haas A (2001) The mandibular arch musculature of anuran tadpoles with comments on the homologies of amphibian jaw muscles. *J Morphol* 247, 1–33.

Haines RW (1939) A revision of the extensor muscles of the forearm in tetrapods. *J Anat* 73, 211–233.

Haines RW (1946) A revision of the movements of the forearm in tetrapods. *J Anat* 80, 1–11.

Haines RW (1950) The flexor muscles of the forearm and hand in lizards and mammals. *J Anat* 84, 13–29.

Haines RW (1951) The extensor apparatus of the finger. *J Anat* 85, 251–259.

Haines RW (1952) The shoulder joint of lizards and the primitive reptilian shoulder mechanism. *J Anat* 86, 412–422.

Haines RW (1955) The anatomy of the hand of certain insectivores. *Proc Zool Soc Lond* 125, 761–777.

Haines RW (1958) Arboreal or terrestrial ancestry of placental mammals. *Q Rev Biol* 33, 1–23.

Hall BK (1984) Developmental mechanisms underlying the formation of atavisms. *Biol Rev* 59, 89–124.

Haninec P, Tomás R, Kaiser R, Cihak R (2009) Development and clinical significance of the musculus dorsoepitrochlearis in men. *Clin Anat* 22, 481–488.

Harrison DFN (1995) *The Anatomy and Physiology of the Mammalian Larynx*. Cambridge: University Press.

Hartman SE (1988) A cladistic analysis of hominoid molars. *J Human Evol* 17, 489–502.

Hatta K, Schilling TF, Bremiller R, Kimmel CB (1990) Specification of jaw muscle identity in zebrafish: correlation with engrailed-homeoprotein expression. *Science* 250, 802–805.

Hatta K, Bremiller R, Westerfield M, Kimmel CB (1991) Diversity of expression of engrailed-like antigens in zebrafish. *Development* 112, 821–832.

Helms JA, Cordero D, Tapadia MD (2005) New insights into craniofacial morphogenesis. *Development* 132, 851–861.

Henkel-Kopleck A, Schmidt HM (2000) Das Ligamentum metacarpale pollicis. *Handchir Mikrochir Plast Chir* 32, 1–8.

Hernandez LP, Barresi MJF, Devoto SH (2002) Functional morphology and developmental biology of zebrafish: reciprocal illumination from an unlikely couple. *Integr Comp Biol* 42, 222–231.

Hernandez LP, Patterson SE, Devoto SH (2005) The development of muscle fiber type identity in zebrafish cranial muscles. *Anat Embryol* 209, 323–334.
Herrel A, Aerts P, Fret J, De Vree F (1999) Morphology of the feeding system in agamid lizards: ecological correlates. *Anat Rec* 254, 496–507.
Herrel A, Canbek M, Özelmas Ü, Uyanoglu M, Karakaya M (2005) Comparative functional analysis of the hyolingual anatomy in lacertid lizards. *Anat Rec A* 284, 561–573.
Hetherington TE, Tugaoen JR (1990) Histochemical studies on the amphibian opercularis muscle (Amphibia). *Zoomorphology* 109, 273–279.
Holland ND, Holland LZ, Honma Y, Fudjii T (1993) Engrailed expression during development of a lamprey, *Lampetra japonica*: a possible clue to homologies between agnathan and gnathostome muscles of the mandibular arch. *Dev Growth Diff* 35, 153–160.
Holland LZ, Holland ND, Gilland E (2008) *Amphioxus* and the evolution of head segmentation. *Integr Comp Biol* 48, 630–646.
Holliday CM (2009) New insights into dinosaur jaw muscle anatomy. *Anat Rec* 292, 1246–1265.
Holliday CM, Witmer LM (2007) Archosaur adductor chamber evolution: integration of musculoskeletal and topological criteria in jaw muscle homology. *J Morphol* 268, 457–484.
Holmes R (1977) The osteology and musculature of the pectoral limb of small captorhinids. *J Morphol* 152, 101–140.
House EL (1953) A myology of the pharyngeal region of the albino rat. *Anat Rec* 116, 363–381.
Howell AB (1933a) Morphogenesis of the shoulder architecture, Part I—General considerations. *Q Rev Biol* 8, 247–259.
Howell AB (1933b) Morphogenesis of the shoulder architecture, Part II—Pisces. *Q Rev Biol* 8, 434–456.
Howell AB (1935) Morphogenesis of the shoulder architecture, Part III—Amphibia. *Q Rev Biol* 10, 397–431.
Howell AB (1936a) Morphogenesis of the shoulder architecture, Part IV—Reptilia. *Q Rev Biol* 11, 183–208.
Howell AB (1936b) Phylogeny of the distal musculature of the pectoral appendage. *J Morphol* 60, 287–315.
Howell AB (1936c) The phylogenetic arrangement of the muscular system. *Anat Rec* 66, 295–316.
Howell AB (1937a) Morphogenesis of the shoulder architecture, Part V—Monotremata. *Q Rev Biol* 12, 191–205.
Howell AB (1937b) Morphogenesis of the shoulder architecture, Part IV—Therian Mammalia. *Q Rev Biol* 12, 440–463.
Howell AB (1937c) The swimming mechanism of the platypus. *J Mammal* 18, 217–222.
Howell AB (1937d) The musculature of antebrachium and manus in the platypus. *Amer J Anat* 59, 425–432.
Howell AB, Straus WL (1933) The muscular system. In *The Anatomy of the Rhesus Monkey* (eds. Hartman CG, Straus WL), pp. 89–175. Baltimore: Williams and Wilkins Co.
Hoyos JM (1999) The musculus depressor mandibulae complex in frogs, with special remarks on ranids. *Amphibia-Reptilia* 20, 265–278.
Huang R, Zhi Q, Izpisua-Belmonte J-C, Christ B, Patel K (1999) Origin and development of the avian tongue muscles. *Anat Embryol* 200, 137–152.
Huber E (1930a) Evolution of facial musculature and cutaneous field of trigeminus—Part I. *Q Rev Biol* 5, 133–188.
Huber E (1930b) Evolution of facial musculature and cutaneous field of trigeminus—Part II. *Q Rev Biol* 5, 389–437.
Huber E (1931) *Evolution of Facial Musculature and Expression*. Baltimore: The Johns Hopkins University Press.

Hudson GE, Schreiweis DO, Wang SYC (1972) A numerical study of the wing and leg muscles of *Tinamous* (Tinamidae). Northwest Sci 46, 207–255.

Humphry GM (1871) The muscles and nerves of the *Cryptobranchus japonicus*. *J Anat Physiol* 6, 1–61.

Humphry GM (1872a) Observations in myology—the myology of Cryptobranch, *Lepidosiren*, dog-fish, *Ceratodus*, and *Pseudopus palasii*, with the nerves of Cryptobranch and *Lepidosiren* and the disposition of muscles in vertebrate animals. Cambridge: Macmillan & Co.

Humphry GM (1872b) The disposition of muscles in Vertebrate animals. *J Anat Physiol* 6, 293–376.

Hunter JP, Jernvall J (1995) The hypocone as a key innovation in mammalian evolution. *Proc Natl Acad Sci US* 92, 10718–10722.

Hunter MP, Prince VE (2002) Zebrafish Hox Paralogue group 2 genes function redundantly as selector genes to pattern the second pharyngeal arch. *Dev Biol* 247, 367–389.

Huntington GS (1904) The derivation and significance of certain supernumerary muscles of the pectoral region. *J Anat Physiol* 39, 1–54.

Huxley TH (1876) Contributions to morphology: Ichthyopsida No. 1—on *Ceratodus Forsteri*, with observations on the classification of fishes. *Proc Zool Soc (Lond)* 1876, 24–59.

Iordansky NN (1964) The jaw muscles of the crocodiles and some relating structures of the crocodylian skull. *Anat Anz* 115, 256–280.

Iordansky NN (1992) Jaw muscles of the Urodela and Anura: some features of development, functions, and homology. *Zool Jb Anat* 122, 225–232.

Iordansky NN (1996) Evolution of the musculature of the jaw apparatus in the Amphibia. *Adv Amph Res* 1, 3–26.

Iordansky NN (2000) Jaw muscles of the crocodiles: structure, synonymy, and some implications on homology and functions. *Russ J Herpetol* 7, 41–50.

Iordansky NN (2004) The jaw apparatus of *Lialis* (Lacertilia, Pygopodidae): patterns of intensification of cranial kinesis and the problem of the origin of snakes. *Entomol Rev (Suppl. 1)* 84, 99–109.

Iordansky NN (2008) Intramandibular muscles and some problems of evolution of the jaw apparatus in vertebrates. *Zool Zhurnal* 87, 49–61.

Janeka JE, Miller W, Pringle TH, Wiens F, Zitzmann A, Helgen KM, Springer MS, Murphy WJ (2007) Molecular and genomic data identify the closest living relative of Primates. *Science* 318, 792–794.

Jarvik E (1963) The composition of the intermandibular division of the head in fishes and tetrapods and the diphyletic origin of the tetrapod tongue. *Kungl Sven Veten Handl* 9, 1–74.

Jarvik E (1980) *Basic Structure and Evolution of Vertebrates*. London: Academic Press.

Jernvall J (2000) Linking development with generation of novelty in mammalian teeth. *Proc Natl Acad Sci US* 97, 2641–2645.

Jessen H (1972) Schultergürtel und Pectoralflosse bei Actinopterygiern. *Fossils and Strata* 1, 1–101.

Johanson Z (2003) Placoderm branchial and hypobranchial muscles and origins in jawed vertebrates. *J Vert Paleont* 23, 735–749.

Jollie M (1962) *Chordate Morphology*. New York: Reinhold.

Jollie M (1982) Ventral branchial musculature and synapomorphies questioned. *Zool J Linn Soc* 75, 35–47.

Jouffroy FK (1971) Musculature des membres. In *Traité de Zoologie, XVI: 3 (Mammifères)* (ed. Grassé PP), pp. 1–475. Paris: Masson et Cie.

Jouffroy FK, Lessertisseur J (1971) Particularités musculaires des Monotrémes—musculature post-craniénne. In *Traité de Zoologie, XVI: 3 (Mammifères)* (ed. Grassé PP), pp. 679–836. Paris: Masson et Cie.

Jouffroy FK, Saban R (1971) Musculature peaucière. In *Traité de Zoologie, XVI: 3 (Mammifères)* (ed. Grassé PP), pp. 477–611. Paris: Masson et Cie.

Kanagasuntheram R (1952–1954) Observations on the anatomy of the hoolock gibbon. *Ceylon J Sci Stect G* 5, 11-64+69-122.

Kaneff A (1979) Évolution morphologique des musculi extensores digitorum et abductor pollicis longus chez l'Homme. I. Introduction, méthodologie, M. extensor digitorum. *Gegenbaurs Morphol Jahrb* 125, 818–873.

Kaneff A (1980a) Évolution morphologique des musculi extensores digitorum et abductor pollicis longus chez l'Homme. II. Évolution morphologique des m. extensor digiti minimi, abductor pollicis longus, extensor pollicis brevis et extensor pollicis longus chez l'homme. *Gegenbaurs Morphol Jahrb* 126, 594–630.

Kaneff A (1980b) Évolution morphologique des musculi extensores digitorum et abductor pollicis longus chez l'Homme. III. Évolution morphologique du m. extensor indicis chez l'homme, conclusion générale sur l 'évolution morphologique des musculi extensores digitorum et abductor pollicis longus chez l'homme. *Gegenbaurs Morphol Jahrb* 126, 774–815.

Kardong KV (2002) *Vertebrates: Comparative Anatomy, Function, Evolution (3rd Ed.)*. New York: McGraw-Hill.

Kardong KV, Zalisko EJ (1998) *Comparative Vertebrate Anatomy—a Laboratory Dissection Guide*. New York: McGraw-Hill.

Kemp TS (2005) *The Origin and Evolution of Mammals*. New York: Oxford University Press.

Kesteven HL (1942–1945) The evolution of the skull and the cephalic muscles. *Mem Austr Mus* 8, 1–361.

Kirschner MW, Gerhart JC (2005) *The Plausibility of Life—Resolving Darwin's Dilemma*. London: Yale University Press.

Kisia SM, Onyango DW (2005) *Muscular system of vertebrates*. Enfield: Science Publishers.

Kladetsky J, Kobold H (1966) Das teres-minor problem, der nervus auxilliaris und die Hautrumpftmuskulatur bei *Tupaia glis* (Diard 1820). *Anat Anz* 119, 1–29.

Kleinteich T, Haas A (2007) Cranial musculature in the larva of the caecilian, *Ichthyophis kohtaoensis* (Lissamphibia: Gymnophiona). *J Morphol* 268, 74–88.

Knight RD, Mebus K, Roehl HH (2008) Mandibular arch muscle identity is regulated by a conserved molecular process during vertebrate development. *J Exp Zool (Mol Dev Evol)* 310B, 355–369.

Köntges G, Lumsden A (1996) Rhombencephalic neural crest segmentation is preserved throughout craniofacial ontogeny. *Development* 122, 3229–3242.

Kundrát M (2009). Primary chondrification foci in the wing basipodium of *Struthio camelus* with comments on interpretation of autopodial elements in Crocodilia and Aves. *J Exp Zool B Mol Dev Evol* 312, 30–41.

Kundrát M, Janacek J, Martin M (2009) Development of transient head cavities during early organogenesis of the Nile Crocodile (*Crocodylus niloticus*). *J Morphol* 270, 1069–1083.

Kuratani S (2004) Evolution of the vertebrate jaw: comparative embryology and molecular developmental biology reveal the factors behind evolutionary novelty. *J Anat* 205, 335–347.

Kuratani S (2005a) Craniofacial development and the evolution of the vertebrates: the old problems on a new background. *Zoolog Sci* 22, 1–19.

Kuratani S (2005b) Cephalic neural crest cells and the evolution of craniofacial structures in vertebrates: morphological and embryological significance of the premandibular-mandibular boundary. *Zoology* 108, 13–25.

Kuratani S (2008) Evolutionary developmental studies of cyclostomes and the origin of the vertebrate neck. *Develop Growth Differ* 50, 189–194.

Kuratani S, Ota KG (2008) Primitive versus derived traits in the developmental program of the vertebrate head: views from cyclostome developmental studies. *J Exp Zool (Mol Dev Evol)* 310B, 294–314.

Kuratani S, Schilling T (2008) Head segmentation in vertebrates. *Integr Comp Biol* 48, 604–610.

Kuratani S, Kuraku S, Murakami Y (2002) Lamprey as an evo-devo model: lessons from comparative embryology and molecular phylogenetics. *Genesis* 34, 175–183.

Kuratani S, Murakami Y, Nobusada Y, Kusakabe R, Hirano S (2004) Developmental fate of the mandibular mesoderm in the lamprey, *Lethenteron japonicum*: comparative morphology and development of the gnathostome jaw with special reference to the nature of the trabecula cranii. *J Exp Zool (Mol Dev Evol)* 302B, 458–468.

Kusakabe R, Kuratani S (2005) Evolution and developmental patterning of the vertebrate skeletal muscles: perspectives from the lamprey. *Dev Dyn* 234, 824–834.

Johanson Z (2003) Placoderm branchial and hypobranchial muscles and origins in jawed vertebrates. *J Vert Paleont* 23, 735–749.

Lander KF (1918) The pectoralis minor: a morphological study. *J Anat* 52, 292–318.

Lakjer T (1926) *Die Trigeminus-versorgte Kaumuskulatur der Sauropsiden*. Kopenhagen: CA Reitzel.

Larsen JH, Guthrie DJ (1975) The feeding system of terrestrial tiger salamanders (*Ambystoma tigrinum melanostictum* Baird). *J Morphol* 147, 137–154.

Lauder GV (1980a) Evolution of the feeding mechanisms in primitive actinopterygian fishes: a functional anatomical analysis of *Polypterus*, *Lepisosteus*, and *Amia*. *J Morphol* 163, 283–317.

Lauder GV (1980b) On the evolution of the jaw adductor musculature in primitive gnathostome fishes. *Breviora* 460, 1–10.

Lauder GV (1980c) The role of the hyoid apparatus in the feeding mechanism of the coelacanth *Latimeria chalumnae*. *Copeia* 1980, 1–9.

Lauder GV, Liem KF (1983) The evolution and interrelationships of the actinopterygian fishes. *Bull Mus Comp Zool* 150, 95–197.

Lauder GV, Shaffer HB (1985) Functional morphology of the feeding mechanism in aquatic ambystomatid salamanders. *J Morphol* 185, 297–326.

Lauder GV, Shaffer HB (1988) Ontogeny of functional design in tiger salamanders (*Ambystoma tigrinum*): are motor patterns conserved during major morphological transformations? *J Morphol* 197, 249–268.

Lawson R (1965) The anatomy of *Hypogeophis rostratus* Cuvier (Amphibia: Apoda or Gymnophiona), II, the musculature. *Proc Univ Newcastle Phil Soc* 1, 52–63.

Leche W (1886) Über die Säugethiergattung *Galeopithecus*: eine morphologische untersuchung. *Kungl Svenska Vetenskap Akad Stockholm* 21, 3–92.

Le Douarin NM, Creuzet S, Couly G, Dupin E (2004) Neural crest plasticity and its limits. *Development* 131, 4637–4650.

Lee MS (2000) Soft anatomy, diffuse homoplasy, and the relationships of lizards and snakes. Zool Scripta 29, 101–130.

Le Gros Clark WE (1924) The myology of the tree-shrew (*Tupaia minor*). *Proc Zool Soc Lond* 1924, 461–497.

Le Gros Clark WE (1926) On the anatomy of the pen-tailed tree-shrew (*Ptilocercus lowii*). *Proc Zool Soc Lond* 1926, 1178–1309.

Le Lièvre C, Le Douarin NM (1975) Mesenchymal derivatives of the neural crest: analysis of chimaeric quail and chick embryos. *J Embryol Exp Morphol* 34, 125–154.

Lewis OJ (1989) *Functional Morphology of the Evolving Hand and Foot*. Oxford: Clarendon Press.

Lightoller GS (1928a) The action of the m. mentalis in the expression of the emotion of distress. *J Anat* 62, 319–332.

Lightoller GS (1928b) The facial muscles of three orangutans and two cercopithecidae. *J Anat* 63, 19–81.

Lightoller GS (1934) The facial musculature of some lesser primates and a *Tupaia*. *Proc Zool Soc Lond* 1934, 259–309.

Lightoller GS (1939) V. Probable homologues. A study of the comparative anatomy of the mandibular and hyoid arches and their musculature—Part I. Comparative myology. *Trans Zool Soc Lond* 24, 349–382.

Lightoller GS (1940a) The comparative morphology of the platysma: a comparative study of the sphincter colli profundus and the trachelo-platysma. *J Anat* 74, 390–396.
Lightoller GS (1940b) The comparative morphology of the m. caninus. *J Anat* 74, 397–402.
Lightoller GS (1942) Matrices of the facialis musculature: homologization of the musculature in monotremes with that of marsupials and placentals. *J Anat* 76, 258–269.
Lubosch W (1914) Vergleischende anatomie der kaumusculatur der Wirbeltiere, in fünf teilen: 1—die kausmuskulatur der Amphibien. *Jen Z Naturwiss* 53, 51–188.
Luther A (1913) Über die vom N trigeminus versorgte Muskulatur des Ganoiden and Dipneusten. *Acta Soc Scient Fenn* 41, 1–72.
Luther A (1914) Über die vom N trigeminus versorgte Muskulatur der Amphibien, mit einem vergleichenden Aublick über deu Adductor mandibulae der Gnathostomen, und cinem Beitrag zum Verständnis der Organisation der Anurenlarven. *Acta Soc Scient Fenn* 44, 1–151.
Luther A (1938) Die Visceralmuskulatur der Acranier, Cyclostomen, und Fische. A. Acranier, Cyclostomen, Selachier, Holocephalen, Ganoiden und Dipnoer. In *Handbuch der vergleichenden Anatomie der Wirbeltiere, Vol. 5* (eds. Bolk L, Goppert E, Kallius E, Lubosch W), pp. 468–542. Berlin: Urban & Schwarzenberg.
Macalister A (1869) On the arrangement of the pronator muscles in the limbs of vertebrate animals. J Anat Physiol 3, 335–340.
Macalister A (1872) The myology of the Cheiroptera. *Phil Trans R Soc Lond* 162, 125–171.
Maier W (2008) Epitensoric position of the chorda tympani in Anthropoidea: a new synapomorphic character, with remarks on the fissura glaseri in Primates. In *Mammalian Evolutionary Morphology: a Tribute to Frederick S. Szalay* (eds. Sargis EJ, Dagosto M), pp. 339–352. Springer: Dordrecht.
Mallat J (1996) Ventilation and the origin of jawed vertebrates: a new mouth. *Zool J Linn Soc* 117, 329–404.
Mallat J (1997) Shark pharyngeal muscles and early vertebrate evolution. *Acta Zool* 78, 279–294.
Manzanares M, Nieto MA (2003) A celebration of the new head and an evaluation of the new mouth. *Neuron* 37, 895–898.
Manzano AS (1996) *Análisis de la musculatura de la familia Pseudidae (Amphibia: Anura)*. Unpublished PhD thesis, Universidad Nacional de Tucumán, Argentina.
Manzano A, Moro S, Abdala V (2003) The depressor mandibulae muscle in Anura. *Alytes* 20, 93–131.
Manzano AS, Abdala V, Herrel A (2008b) Morphology and function of the forelimb in arboreal frogs: specializations for grasping ability? *J Anat* 213, 296–307.
Marcucio RS, Noden DM (1999) Myotube heterogeneity in developing chick craniofacial skeletal muscles. *Dev Dyn* 214, 178–194.
Marion E (1905) Mandibular and pharyngeal muscles of *Acanthias* and *Raia*. *Am Nat* 39, 891–924.
Marivaux L, Bocat L, Chaimanee Y, Jaeger J-J, Marandat B, Srisuk P, Tafforeau P, Yamee C, Welcomme J-L (2006) Cynocephalid dermopterans from the Palaeogene of South Asia (Thailand, Myanmar and Pakistan): systematic, evolutionary and palaeobiogeographic implications. *Zool Scripta* 35, 395–420.
Matsuoka T, Ahlberg PE, Kessaris N, Iannarelli P, Dennehy U, Richardson WD, McMahon AP, Koentges G (2005). Neural crest origins of the neck and shoulder. *Nature* 436, 347–355.
Maxwell EE, Larsson HCE (2007) Osteology and myology of the wing of the Emu (*Dromarius novaehollandiae*), and its bearing on the evolution of vestigial structures. *J Morphol* 268, 423–441.
McClearn D, Noden DM (1988) Ontogeny of architectural complexity in embryonic quail visceral arch muscles. *Amer J Anat* 183, 277–293.
McGonnell IM (2001) The evolution of the pectoral girdle. *J Anat* 199, 189–194.
McKitrick MC (1991) Phylogenetic analysis of avian hindlimb musculature. *Misc Publ Mus Zool Univ Mich* 179, 1–85.

McMurrich JP (1903a) The phylogeny of the forearm flexors. *Amer J Anat* 2, 177–209.
McMurrich JP (1903b) The phylogeny of the palmar musculature. *Amer J Anat* 2, 463–500.
Meers MB (2003) Crocodylian forelimb musculature and its relevance to Archosauria. *Anat Rec* 274A, 891–916.
Meyers RA (1996) Morphology of the antebrachial musculature in the American Kestrel, *Falco sparverius* (Aves). *Ann Anat* 178, 49–60.
Miller GB (2009) Ancestral patterns in bird limb development: a new look at Hampe's experiment. *J Evol Biol* 2, 31–47.
Millot J, Anthony J (1958) Anatomie de *Latimeria chalumnae*—I, squelette, muscles, et formation de soutiens. Paris: CNRS.
Minkoff EC, Mikkelsen P, Cunningham WA, Taylor KW (1979) The facial musculature of the opossum (*Didelphis virginiana*). *J Mammal* 60, 46–57.
Mivart SG (1869). Notes on the myology of *Menopoma alleghaniense*. *Proc Zool Soc Lond* 1869, 254–261.
Miyake T, McEachran JD, Hall BK (1992) Edgeworth's legacy of cranial muscle development with an analysis of muscles in the ventral gill arch region of batoid fishes (Chondrichthyes: Batoidea). *J Morphol* 212, 213–256.
Montero R, Moro SA, Abdala V (2002) Cranial anatomy of *Euspondylus acutirostris* (Squamata: Gymnophthalmidae) and its placement in a modern phylogenetic hypothesis. *Russ J Herpetol* 9, 215–228.
Mootoosamy RC, Dietrich S (2002) Distinct regulatory cascades for head and trunk myogenesis *Development* 129, 573–583.
Moro SA, Abdala V (1998) Cranial myology of some species of *Liolaemus* and *Phymaturus* (Squamata: Tropiduridae: Liolaeminae). *Amphibia–Reptilia* 19, 171–192.
Moro SA, Abdala V (2000) Cladistic analysis of Teiidae (Squamata) based on myological characters. *Russ J Herpetol* 7, 87–102.
Moro S, Abdala V (2004) Análisis descriptivo de la miología flexora y extensora del miembro anterior de *Polychrus acutirostris* (Squamata, Polychrotidae). *Pap Avulsos Zool (São Paulo)* 44, 81–89.
Müller W, Weber E (1998) Re-discovery of a supposedly lost muscle in palaeognathous birds and its phylogenetic implications. *Mitt Mus Nat Berl (Zool Reihe)* 74, 11–18.
Murray PF (1981) A unique jaw mechanism in the echidna, *Tachglossus aculeatus* (Monotremata). Austral J Zool 29, 1–5.
Negus VE (1949) *The Comparative Anatomy and Physiology of the Larynx*. New York: Hafner Publishing Company.
Nelson JS (2006) *Fishes of the World (4th ed)*. New York: John Wiley & Sons.
Netter FH (2006) *Atlas of Human Anatomy (4th ed.)*. Philadelphia: Saunders.
Noden DM (1983) The embryonic origins of avian cephalic and cervical muscles and associated connective tissues. *Am J Anat* 168, 257–276.
Noden DM (1984) Craniofacial development: new views on old problems. *Anat Rec* 208, 1–13.
Noden DM (1986) Patterning of avian craniofacial muscles. *Dev Biol* 116, 347–356.
Noden DM, Francis-West P (2006) The differentiation and morphogenesis of craniofacial muscles. *Dev Dyn* 235, 1194–1218.
Noden DM, Schneider RA (2006) Neural crest cells and the community of plan for craniofacial development: historical debates and current perspectives. In *Neural Crest Induction & Differentiation—Advances in experimental medicine and biology*, Vol. 589 (ed. Saint-Jeannet J), pp. 1–31. Georgetown: Landes Bioscience.
Noden DM, Marcucio R, Borycki AG, Emerson CP (1999) Differentiation of avian craniofacial muscles, I, Patterns of early regulatory gene expression and myosin heavy chain synthesis. *Dev Dyn* 216, 96–112.
Northcutt RG (2005) The new head hypothesis revisited. *J Exp Zool (Mol Dev Evol)* 304B, 274–97.

Oelrich TM (1956) The anatomy of the head of *Ctenosaura pectinata*. *Misc Pub Mus Zool Univ Michigan* 94, 1–122.

O'Gorman S (2005) Second branchial arch lineages of the middle ear of wild-type and Hoxa2 mutant mice. *Dev Dyn* 234, 124–131.

Olsson L, Ericsson R, Falck P (2000) Neural crest contributions to cranial muscle fate and patterning in the Mexican axolotl (*Ambystoma mexicanum*). In *Regulatory Processes in Development: the Legacy of Sven Hörstadius* (eds. Olsson L, Jacobson C-O), pp. 159–166. London: Portland Press.

Olsson L, Falck P, Lopez K, Cobb J, Hanken J (2001) Cranial neural crest cells contribute to connective tissue in cranial muscles in the anuran amphibian, *Bombina orientalis*. *Dev Biol* 237, 354–367.

Olsson L, Ericsson R, Cerny R (2005) Vertebrate head development: segmentation, novelties, and homology. *Theory Biosci* 124, 145–63.

Osse JWM (1969) Functional morphology of the head of the perch (*Perca fluviatis* L.): an electromyographic study. *Neth J Zool* 19, 289–392.

Owen R (1841) Description of the *Lepidosiren annectens*. *Trans Linn Soc Lond* 18, 327–361.

Palavecino P (2001) *Desarrollo de la musculatura mandibular e hioidea en Leptodactylinae del noroeste argentino.* Unpublished PhD thesis, Universidad Nacional de Tucumán, Tucumán.

Parsons FG (1898) The muscles of mammals, with special relation to human myology: a course of lectures delivered at the Royal College of Surgeons of England—lecture I, the muscles of the head and neck. *J Anat Physiol* 32, 428–450.

Paterson NF (1939) The head of *Xenopus laevis*. *Q J Microsc Sci* 81, 161–234.

Patterson C (1988) Homology in classical and molecular biology. *Mol Biol Evol* 5, 603–625.

Peterka HE (1936) A study of the myology and osteology of tree sciurids with regard to adaptation to arboreal, glissant and fossorial habits. *Trans Kansas Acad Sci* 39, 313–332.

Pettersen GC, Koltis GG, White MJ (1979) An examination of the spectrum of anatomic defects and variations found in eight cases of trisomy 13. *Amer J Med Genet* 3, 183–210.

Phisalix M (1914) Anatomie comparée de la tête et de l'appareil venimeux chez les serpents. *Ann Sci Nat (Ser 9)* 19, 1–114.

Piatt J (1938) Morphogenesis of the cranial muscles of *Ambystoma punctatum*. *J Morphol* 63, 531–587.

Piekarski N, Olsson L (2007) Muscular derivatives of the cranialmost somites revealed by long-term fate mapping in the Mexican axolotl (*Ambystoma mexicanum*). *Evol & Dev* 9, 566–578.

Pollard HB (1892) On the anatomy and phylogenetic position of *Polypterus*. *Zool Jb* 5, 387–428.

Pough FH, Heiser JB, McFarland WN (1996) *Vertebrate Life (4th Ed.)*. New Jersey: Prentice-Hall.

Preuschoft S (2000) Primate faces and facial expressions. *Soc Res* 67, 245–271.

Prunotto C, Crepaldi T, Forni PE, Leraci A, Kelly RG, Tajbakhsh S, Buckingham M, Ponzetto C (2004) Analysis of Mlc-lacZ Met mutants highlights the essential function of Met for migratory precursors of hypaxial muscles and reveals a role for Met in the development of hyoid arch-derived facial muscles. *Dev Dyn* 231, 582–591.

Ramaswami LS (1942) The segmentation of the head of *Ichthyophius glutinosus* (Linné). *Proc Zool Soc Lond* 112, 105–112.

Reilly S, Lauder GV (1989) Kinetics of tongue projection in *Ambystoma tigrinum*: quantitative kinematics, muscle function and evolutionary hypotheses. *J Morphol* 199, 223–243.

Reilly S, Lauder GV (1990) The evolution of tetrapod feeding behavior: kinematic homologies in prey transport. *Evolution* 44, 1542–1557.

Reilly S, Lauder GV (1991) Prey transport in the tiger salamander: quantitative electromyography and muscle function in tetrapods. *J Exp Zool* 260, 1–17.

Ribbing L (1907) Die distale Armmuskulatur der Amphibien, Reptilien und Säugetiere. *Zool Jb* 23, 587–680.

Ribbing L (1938) Die muskeln und nerven der extremitäten. In *Handbuch der Vergleichenden Anatomie der Wirbeltiere Urban & Schwarzenberg* (eds. Bolk L, Göppert E, Kallius E, Lubosch W), pp. 543–656. Amsterdam: Asher & Co.

Rieppel O (1980) The trigeminal jaw adductor musculature of *Tupinambis*, with comments on the phylogenetic relationships of the Teiidae (Reptilia: Lacertilia). *Zool J Linn Soc* 69, 1–29.

Rieppel O (1981) The skull and jaw adductor musculature in chameleons. *Rev Suisse Zool* 88, 433–445.

Rieppel O (1984) The structure of the skull and jaw adductor musculature in the Gekkota, with comments on the phylogenetic relationships of the Xantusiidae (Reptilia: Lacertilia). *Zool J Linn Soc* 82, 291–318.

Rieppel O (1990) The development of the jaw adductor musculature in the turtle *Chelydra serpentina*. *Zool J Linn Soc* 98, 27–62.

Roberts TDM (1950) The respiratory movements of the lamprey (*Lampetra fluviatilis*). *Proc R Soc Edinb (Biol)* 64, 235–252.

Rocha-Barbosa O, Loguercio MFC, Renous S, Gasc J-P (2007) Comparative study on the forefoot and hindfoot intrinsic muscles of some Cavioidea rodents (Mammalia, Rodentia). *Zoology* 110, 58–65.

Romer AS (1922) The locomotor apparatus of certain primitive and mammal-like reptiles. *Bull Am Mus Nat Hist* 46, 517–606.

Romer AS (1924) Pectoral limb musculature and shoulder-girdle structure in fish and tetrapods. *Anat Rec* 27, 119–143.

Romer AS (1944) The development of tetrapod limb musculature—the shoulder region of *Lacerta*. *J Morphol* 74, 1–41.

Rosen DE, Forey PL, Gardiner BG, Patterson C (1981) Lungfishes, tetrapods, paleontology and plesiomorphy. *Bull Am Mus Nat Hist* 167, 159–276.

Ruge G (1885) Über die Gesichtsmuskulatur der Halbaffen. *Morph Jb* 11, 243–315.

Ruge G (1897) *Über das peripherische Gebiet des nervus facialis boi Wirbelthieren*. Festschr f Gegenbaur, 3, Leipzig.

Ruge G (1910) Verbindungen des Platysma mit der tiefen Muskulatur des Halses beim Menschen. *Morph Jb* 41, 708–724.

Russell AP (1988) Limb muscles in relation to lizard systematics: a reappraisal. In *Phylogenetic Relationships of Lizard Families: Essays Commemorating Charles L. Camp* (eds. Estes R, Pregill G), pp. 119–281. Stanford: Stanford University Press.

Russell AP, Bauer AM (2008) The appendicular locomotor apparatus of *Sphenodon* and normal-limbed squamates. In *Biology of Reptilia, vol. 21, The Skull and Appendicular Locomotor Apparatus of Lepidosauria* (eds. Gans C, Gaunt AS, Adler K), pp. 1–465. New York: Society for the Study of Amphibians and Reptiles.

Ryan JM (1986) Comparative morphology and evolution of cheek pouches in rodents. *J Morphol* 190, 27–42.

Ryan JM (1989) Evolution of cheek pouches in African pouched rats (Rodentia: Cricetomyinae). *J Mammal* 70, 267–274.

Saban R (1968) Musculature de la tête. In *Traité de Zoologie*, XVI: 3 (Mammifères) (ed. Grassé PP), pp. 229–472. Paris: Masson et Cie.

Saban R (1971) Particularités musculaires des Monotrémes—musculature de la tête. In *Traité de Zoologie*, XVI: 3 (Mammifères) (ed. Grassé PP), pp. 681–732. Paris: Masson et Cie.

Santagati F, Rijli FM (2003) Cranial neural crest and the building of the vertebrate head. *Nat Rev Neurosci* 4, 806–18.

Sargis EJ (2002a) The postcranial morphology of *Ptilocercus lowii* (Scandentia, Tupaiidae): an analysis of primatomorphan and volitantian characters. *J Mammal Evol* 9, 137–160.

Sargis EJ (2002b) Functional morphology of the forelimb of tupaiids (Mammalia, Scandentia) and its phylogenetic implications. *J Morphol* 253, 10–42.

Sargis EJ (2004) New views on tree shrews: the role of tupaiids in primate supraordinal relationships. *Evol Anthropol* 13, 56–66.

Schwenk K (2001) Extrinsic vs. intrinsic lingual muscles: a false dichotomy? *Bull Mus Comp Zool (Harvard Univ)* 156, 219–235.

Sedra SN (1949) The metamorphosis of the jaws and their muscles in the toad, *Bufo regularis* Reuss, correlated with the changes in the animal's feeding habits. *Proc Zool Soc Lond* 120, 405–449.

Sedra SN, Michael MI (1957) The development of the skull, visceral arches, larynx and visceral muscles of the South African Clawed Toad, *Xenopus laevis* (Daudin) during the process of metamorphosis (from Stage 55 to Stage 66). *Verh Koninklijke Nederlandse Akad Wetenschappen Afd Natuurkunde* 51, 3–80.

Shellswell GB, Wolpert L (1977) The pattern of muscle and tendon development in the chick wing. In *Vertebrate Limb and Somite Morphogenesis* (eds. Ede D, Hinchcliffe R, Balls M), pp. 71–86. Cambridge: Cambridge University Press.

Schilling TF (2002) The morphology of larval and adult zebrafish. In *Zebrafish: a Practical Approach* (eds. Nüsslein-Volhard C, Dahm R), pp. 59–94. New York: Oxford University Press.

Schilling TF, Kimmel CB (1997) Musculoskeletal patterning in the pharyngeal segments of the zebrafish. *Development* 124, 2945–2960.

Schmidt KL, Cohn JF (2001) Human facial expressions as adaptations: evolutionary questions in facial expression research. *Yearb Phys Anthropol* 44, 3–24.

Schumacher GH (1961) *Funktionelle morphologie der kaumuskulatur*. Jena: VEB Gustav Fischer Verlag.

Schumacher GH (1973) The head muscles and hyolaryngeal skeleton of turtles and crocodilians. In *Biology of the Reptilia, Vol. 14* (eds. Gans C, Parsons TS), pp. 101–199. New York, Academic Press.

Sedlmayr JC (2002) *Anatomy, evolution and functional significance of the cephalic vasculature in Archosauria*. Unpublished PhD thesis, Ohio University, Ohio.

Seiler R (1971a) A comparison between the facial muscles of Catarrhini with long and short muzzles. *Proc. 3rd Int. Congr. Primat., Zürich 1970, vol. 1.*, pp. 157–162. Basel: Karger.

Seiler R (1971b) Facial musculature and its influence on the facial bones of catarrhinous Primates. I. *Morphol Jb* 116, 122–142.

Seiler R (1971c) Facial musculature and its influence on the facial bones of catarrhine Primates. II. *Morphol Jb* 116, 147–185.

Seiler R (1971d) Facial musculature and its influence on the facial bones of catarrhine Primates. III. *Morphol Jb* 116, 347–376.

Seiler R (1971e) Facial musculature and its influence on the facial bones of catarrhine Primates. IV. *Morphol Jb* 116, 456–481.

Seiler R (1974a) Muscles of the external ear and their function in man, chimpanzees and *Macaca*. *Morphol Jb* 120, 78–122.

Seiler R (1974b) Particularities in facial muscles of *Daubentonia madagascariensis* (Gmelin 1788). *Folia Primatol* 22, 81–96.

Seiler R (1975) On the facial muscles in *Perodicticus potto* and *Nycticebus coucang*. *Folia Primatol* 23, 275–289.

Seiler R (1979) Criteria of the homology and phylogeny of facial muscles in primates including man. I. Prosimia and Platyrrhina. *Morphol Jb* 125, 191–217.

Seiler R (1980) Ontogenesis of facial muscles in primates. *Morphol Jb* 126, 841–864.

Sewertzoff AN (1928) The head skeleton and muscles of *Acipenser ruthenus*. *Acta Zool-Stockholm* 9, 193–319.

Shattock SG (1882) A Kerato-thyro-hyoid muscle as a variation in human anatomy. *J Anat Physiol* 171, 124–125.

Shearman RM, Burke AC (2009) The lateral somitic frontier in ontogeny and phylogeny. *J Exp Biol (Mol Dev Evol)* 312B, 602–613.

Shibata S (1959) On the facial musculature of *Macacus cyclopsis*. *OFAJ* 34, 159–176.

Shigetani Y, Sugahara F, Kuratani S (2005) A new evolutionary scenario for the vertebrate jaw. *Bioessays* 27, 331–338.

Shoshani J, Groves CP, Simons EL, Gunnell GF (1996) Primate phylogeny: morphological vs molecular results. *Mol Phylogenet Evol* 5, 102–154.

Shrivastava RK (1962a) The deltoid musculature of the Marsupialia. *Amer Midland Nat* 67, 305–320.

Shrivastava RK (1962b) The deltoid musculature of the Monotremata. *Amer Midland Nat* 67, 434–440.

Silcox MT, Sargis EJ, Bloch JI, Boyer DM (2007) Primate origins and supraordinal relationships: morphological evidence. In *Handbook of Palaeoanthropology, Vol. 2: Primate Evolution and Human Origins* (eds. Henke W, Tattersall I), pp. 831–859. Springer Verlag: Heidelberg.

Smith KK (1988) Form and function of the tongue in agamid lizards with comments on its phylogenetic significance. *J Morphol* 196, 157–171.

Smith KK (1992) The evolution of the mammalian pharynx. *Zool J Linn Soc* 104, 313–349.

Smith KK (1994) Development of craniofacial musculature in *Monodelphis domestica* (Marsupialia: Didelphidae). *J Morphol* 222, 149–173.

Sokol OT (1977) The free swimming *Pipa* larvae, with a review of pipoid larvae and pipid phylogeny (Anura: Pipidae). *J Morphol* 154, 357–425.

Sokoloff AJ (2000) Localization and contractile properties of intrinsic longitudinal motor units of the rat tongue. *J Neurophysiol* 84, 827–835.

Sprague JM (1942) The hyoid apparatus of *Neotoma*. *J Mammal* 23, 405–411.

Sprague JA (1943) The hyoid region of placental mammals with special reference to the bats. *Am J Anat* 72, 385–472.

Sprague JA (1944a) The hyoid region in the insectivora. *Am J Anat* 74, 175–216.

Sprague JA (1944b) The innervation of the pharynx in the rhesus monkey, and the formation of the pharyngeal plexus in primates. *Anat Rec* 90, 197–208.

Stafford BJ, Szalay FS (2000) Craniodental functional morphology and taxonomy of dermopterans. *J Mammal* 81, 360–385.

Starck D, Schneider R (1960) Respirationsorgane. In *Primatologia III/2* (eds. Hofer H, Schultz AH, Starck D), pp- 423, 587. Basel: S. Karger.

Starret P (1968) *The phylogenetic significance of the jaw musculature in anuran amphibians.* Unpublished PhD thesis, University of Michigan, Ann Arbor.

Stein B (1981) Comparative limb myology of two opossums, *Didelphis* and *Chironectes*. *J Morphol* 169, 113–140.

Stiassny MLJ (2000) Gross functional anatomy: muscular system. In *The Handbook of Experimental Animals* (eds. Bullock G, Bunton TE), pp. 119–128. London: Academic Press.

Stiassny MLJ, Wiley EO, Johnson GD, De Carvalho MR (2004). Gnathostome fishes. In *Assembling the Tree of Life* (eds. Donaghue MJ, Cracraft J), pp. 410–429. New York: Oxford University Press.

Straus WL (1941a) The phylogeny of the human forearm extensors. *Hum Biol* 13, 23–50.

Straus WL (1941b) The phylogeny of the human forearm extensors (concluded). *Hum Biol* 13, 203–238.

Straus WL (1942) The homologies of the forearm flexors: urodeles, lizards, mammals. *Am J Anat* 70, 281–316.

Straus WL, Howell AB (1936) The spinal accessory nerve and its musculature. *Q Rev Biol* 11, 387–405.

Sullivan GE (1962) Anatomy and embryology of the wing musculature of the domestic fowl (*Gallus*). Aust J Zool 10, 458–518.

Sullivan GE (1967) Abnormalities of the muscular anatomy in the shoulder region of paralysed chick embryos. Aust J Zool 15, 911–940.

Sullivan WE, Osgood CW (1927) The musculature of the superior extremity of the orang-utan, *Simia satyrus*. *Anat Rec* 35, 193–239.

Susman RL, Nyati L, Jassal MS (1999) Observations on the pollical palmar interosseus muscle (of Henle). *Anat Rec* 254, 159–165.

Takio Y, Pasqualetti M, Kuraku S, Hirano S, Rijli FM, Kuratani S (2004) Comment on: Lamprey Hox genes and the evolution of jaws. *Nature* 429, 1–2.
Taylor J (1925) An unusual variation of the omo-hyoid muscle. *J Anat* 59, 331–332.
Tchernavin VV (1947a) Six specimens of Lyomeri in the British Museum (with notes on the skeleton of the Lyomeri). *J Linn Soc Lond (Zool)* 41, 287–350.
Tchernavin VV (1947b) Further notes on the structure of the bony fishes of the order Lyomeri (Eurypharynx). *J Linn Soc Lond (Zool)* 41, 387–393.
Tchernavin VV (1953) The feeding mechanisms of a deep-sea fish, *Chauliodus sloani* Schneider. *Br Mus Nat Hist (Zool)* 1953, 1–101.
Terminologia Anatomica (1998). Federative Committee on Anatomical Terminology. Stuttgart: Georg Thieme.
Thewissen JGM, Babcock SK (1991) Distinctive cranial and cervical innervation of wing muscles: new evidence for bat Monophyly. *Science* 251, 934–936.
Thewissen JGM, Babcock SK (1993) The implications of the propatagial muscles of flying and gliding mammals for archontan systematics. In *Primates and Their Relatives in Phylogenetic Perspective* (ed. MacPhee RDE), pp. 91–107. New York: Plenum Press.
Thorsen DH, Hale ME (2005) Development of zebrafish (*Danio rerio*) pectoral fin musculature. *J Morphol* 266, 241–55.
Thorsen DH, Westneat MW (2005) Diversity of pectoral fin structure and function in fishes with labriform propulsion. *J Morphol* 263, 133–150.
Trainor PA, Melton KR, Manzanares M (2003) Origins and plasticity of neural crest cells and their roles in jaw and craniofacial evolution. *Int J Dev Biol* 47, 541–453.
Tretjakoff D (1929) Die schleimknorpeligen Bestandteile im Kopfskelett von Ammocoetes. *Zeitschrift Wissen Zool* 133, 470–516.
Tsuihiji T (2007) Homologies of the longissimus, iliocostalis, and hypaxial muscles in the anterior presacral region of extant diapsida. *J Morphol* 268, 986–1020.
Tsukahara N, Kamata N, Nagasawa M, Sugita S. 2009. Bilateral innervation of syringeal muscles by the hypoglossal nucleus in the jungle crow (*Corvus macrorhynchos*). *J Anat* 215, 141–149.
Tzahor E (2009) Heart and craniofacial muscle development: a new developmental theme of distinct myogenic fields. *Dev Biol* 327, 273–279.
Vanden Berge JC (1975) Aves myology. In *The Anatomy of the Domestic Animals (Vol. I)* (ed. Getty R), pp. 1802–1843. Philadelphia: W.B. Saunders.
Vargas AO, Fallon JF (2005a). Birds have dinosaur wings, the molecular evidence. *J Exp Zool B Mol Dev Evol* 304, 86–90.
Vargas AO, Fallon JF (2005b). The digits of the wing of birds are 1, 2, and 3, a review. *J Exp Zool B Mol Dev Evol* 304, 206–219.
Vargas AO, Kohlsdorf T, Fallon JF, Vandenbrooks J, Wagner GP (2008) The evolution of HoxD-11 expression in the bird wing: insights from *Alligator mississippiensis*. *PLoS ONE* 3, e3325.
Versluys J (1904) Entwicklung der Columella auris bei den Lacertiliern. *Zool Jahrb Abt Anat Ontog Tiere* 19, 108–188.
Vrba ES (1968) Contributions to the functional morphology of fishes—part V, the feeding mechanism of *Elops saurus* Linnaeus. *Zool Afr* 3, 211–236.
Walker WF (1954) *Vertebrate Dissection*. London: W. B. Saunders Company.
Walker WF (1973) The locomotor apparatus of testudines. In *Biology of the Reptilia, Vol. 14* (eds. Gans C, Parsons TS), pp. 1–100. New York: Academic Press.
Walker WF, Homberger DG (1998). *Anatomy and Dissection of the Rat (3rd Edition)*. New York: Freeman Company.
Walthall JC, Ashley–Ross MA (2006) Postcranial myology of the California newt, *Taricha torosa*. *Anat Rec A* 288, 46–57.
Walther WG (1922) *Die Neu-Guinea-Schieldkröte Carettochelys insculpta Ramsay*. Unpublished PhD thesis, The University of Leiden.

Warburton NM (2003) *Functional morphology and evolution of marsupial moles (Marsupialia: Notoryctemorphia)*. Unpublished PhD thesis, The University of Western Australia.

Weisz PB (1945a) The development and morphology of the larva of the South African clawed toad, *Xenopus laevis*, I, the third-form tadpole. *J Morphol* 77, 163–192.

Weisz PB (1945b) The development and morphology of the larva of the South African clawed toad, *Xenopus laevis*, II, the hatching and the first- and second-form tadpoles. *J Morphol* 77, 193–217, 1945b.

Wells LH, Thomas EA (1927) A note on two abnormal laryngeal muscles in a Zulu. *J Anat* 61, 340–343.

West-Eberhard MJ (2003) *Developmental Plasticity and Evolution*. New York: Oxford University Press.

Westneat MW, Thorsen DH, Walker JA, Hale ME (2004) Structure, function, and neural control of pectoral fins in fishes. *IEEE J Oceanic Engen* 29, 674–683.

Whidden HP (2000) Comparative myology of moles and the phylogeny of the Talpidae (Mammalia, Lipotyphla). *Am Museum Novitates* 3294, 1–53.

Wible JR (2009) The ear region of the pen-tailed treeshrew, *Ptilocercus lowii* Gray, 1848 (Placentalia, Scandentia, Ptilocercidae). *J Mammal Evol* 16, 199–233.

Windle BCA (1889) The flexors of the digits of the hand, I, The muscular masses in the forearm. *J Anat Physiol* 24, 72–84.

Wiley EO (1979a) Ventral gill arch muscles and the interrelationships of gnathostomes, with a new classification of the Vertebrata. *J Linn Soc Lond (Zool)* 67, 149–179.

Wiley EO (1979b) Ventral gill arch muscles and the phylogenetic interrelationships of *Latimeria*. *Occ Pap Calif Acad Sci* 134, 56–67.

Wilga CD, Wainwright PC, Motta PJ (2000) Evolution of jaw depression mechanisms in aquatic vertebrates: insights from Chondrichthyes. *Biol J Linn Soc* 71, 165–185.

Wilkinson M, Nussbaum RA (1997) Comparative morphology and evolution of the lungless caecilian *Atretochoana eiselti* (Taylor) (Amphibia: Gymnophiona: Typhlonectidae). Biol J Linn Soc 62, 39–109.

Wilson-Pauwels L, Akesson EJ, Stewart PA, Spacey SD (2002) *Cranial Nerves in Health and Disease*. Hamilton: B.C. Decker Inc.

Wind J (1970) *On the Phylogeny and Ontogeny of the Human Larynx*. Groningen: Wolters-Noordhoff.

Winterbottom R (1974) A descriptive synonymy of the striated muscles of the Teleostei. *Proc Acad Nat Sci (Phil)* 125, 225–317.

Winterbottom R (1993) Myological evidence for the phylogeny of recent genera of surgeonfishes (Percomorpha, Acanthuridae), with comments on Acanthuroidei. *Copeia* 1993, 21–39.

Witmer LM (1995a) The extant phylogenetic bracket and the importance of reconstructing soft tissues in fossils. In *Functional Morphology in Vertebrate Paleontology* (ed. Thomason JJ), pp. 19–33. New York: Cambridge University Press.

Witmer LM (1995b) Homology of facial structures in extant archosaurs (birds and crocodilians), with special reference to paranasal pneumaticity and nasal conchae. *J Morphol* 225, 269–327.

Witmer LM (1997) The evolution of the antorbital cavity of archosaurs: a study in soft-tissue reconstruction in the fossil record with an analysis of the function of pneumaticity. *J Ver Paleontol* 17 (suppl. 1), 1–73.

Wood J (1866) Variations in human myology observed during the Winter Session of 1865–6 at King's College, London. *Proc R Soc Lond* 15, 229–244.

Wood J (1867a) On human muscular variations and their relation to comparative anatomy. *J Anat Physiol* 1867, 44–59.

Wood J (1867b) Variations in human myology observed during the Winter Session of 1866–7 at King's College London. *Proc R Soc Lond* 15, 518–545.

Wood J (1868) Variations in human myology observed during the winter session of 1867–68 at King's College, London. *R Soc Lond* 16, 483–525.

Wood J (1870) On a group of varieties of the muscles of the human neck, shoulder, and chest, with their transitional forms and homologies in the Mammalia. *Philos Trans R Soc Lond* 160, 83–116.

Wu X–C (2003) Functional morphology of the temporal region in Rhyncocephalia. *Can J Earth Sci* 40, 589–607.

Wyneken J (2001) *The Anatomy of Sea Turtles*. Miami: U.S. Department of Commerce NOAA Technical Memorandum NMFS-SEFSC-470.

Yamane A (2005) Embryonic and postnatal development of masticatory and tongue muscles. Cell Tissue Res 322, 183–189.

Ziermann JM, Olsson L (2007) Patterns of spatial and temporal cranial muscle development in the African clawed frog, *Xenopus laevis* (Anura: Pipidae). *J Morphol* 268, 791–804.

About the Authors

Rui Diogo is a biologist and anthropologist graduated from the University of Aveiro (Portugal). He undertook his PhD at the University of Liège (Belgium) and is now carrying out research at the Anthropology Department of the George Washington University (USA). He has contributed to numerous publications, including *Catfishes*, edited together with G. Arratia, B.G. Kapoor and M. Chardon, and *Gonorynchiformes and Ostariophysan Interrelationships—A Comprehensive Review*, edited with T. Grande and F. Poyato-Ariza. He is the author of the books *Morphological Evolution, Aptations, Homoplasies, Constraints and Evolutionary Trends—Catfishes as a Case Study on General Phylogeny and Macroevolution* and *The Origin of Higher Clades—Osteology, Myology, Phylogeny and Evolution of Bony Fishes and the Rise of Tetrapods*. His current projects include works on the comparative anatomy, development, functional morphology, phylogeny and macroevolution of vertebrates.

Virginia Abdala is Professor at the Universidad Nacional de Tucumán (Argentina) and researcher at the National Council of Research (CONICET-Argentina). She has contributed to many publications in the fields of Vertebrate Comparative Anatomy and Ecomorphology. Her current projects include works on the comparative anatomy and evolution of muscles, sesamoid bones and tendons in tetrapods.