Venomous Snakes-Envenoming, Therapy

Jiri Valenta

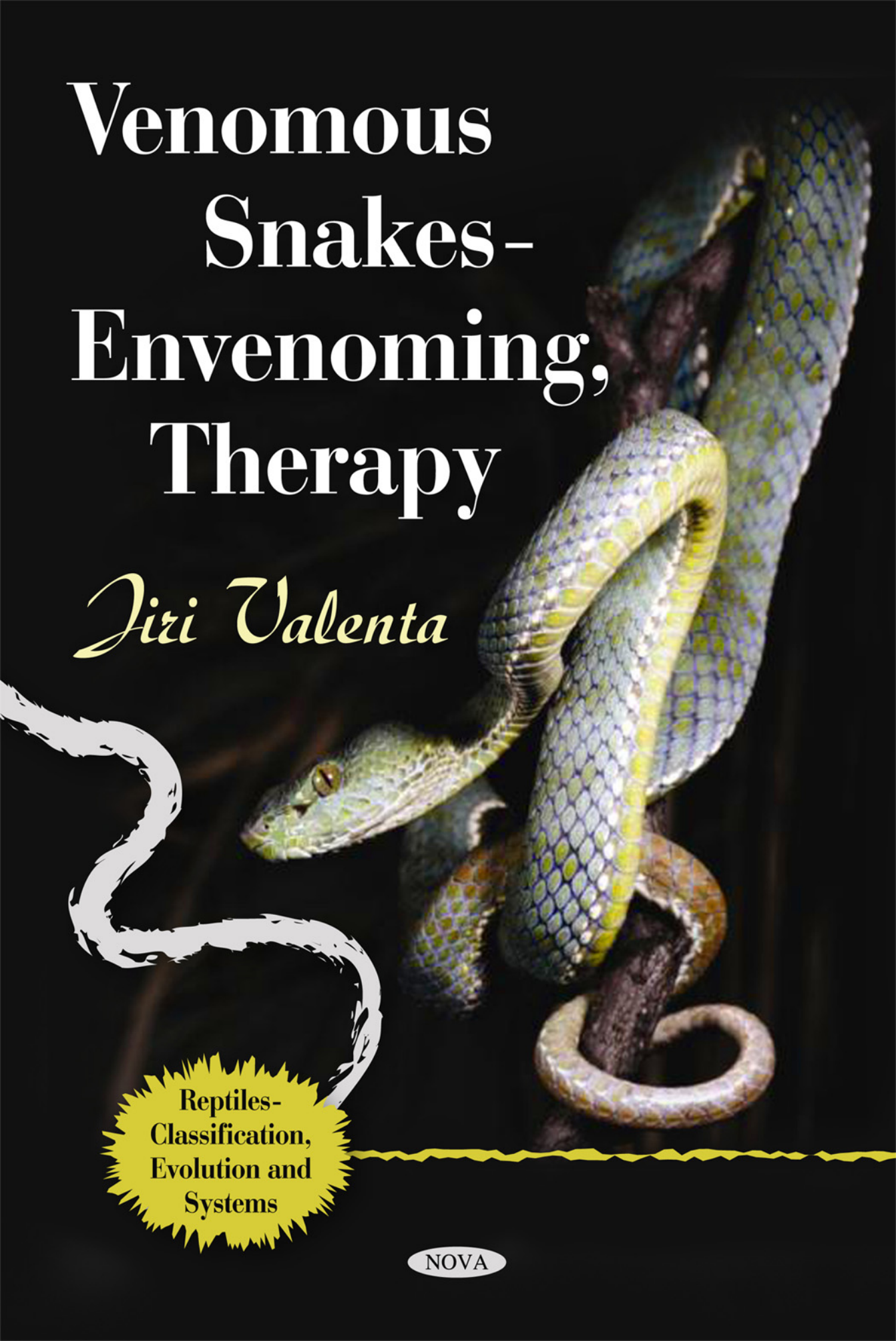

Reptiles-Classification, Evolution and Systems

NOVA

VENOMOUS SNAKES - ENVENOMING, THERAPY

No part of this digital document may be reproduced, stored in a retrieval system or transmitted in any form or by any means. The publisher has taken reasonable care in the preparation of this digital document, but makes no expressed or implied warranty of any kind and assumes no responsibility for any errors or omissions. No liability is assumed for incidental or consequential damages in connection with or arising out of information contained herein. This digital document is sold with the clear understanding that the publisher is not engaged in rendering legal, medical or any other professional services.

REPTILES – CLASSIFICATION, EVOLUTION AND SYSTEMS

Additional books in this series can be found on Nova's website at:

https://www.novapublishers.com/catalog/index.php?cPath=23_29&seriesp=Reptiles+-+Classification%2C+Evolution+and+Systems

REPTILES – CLASSIFICATION, EVOLUTION AND SYSTEMS

VENOMOUS SNAKES - ENVENOMING, THERAPY

JIRI VALENTA

Nova Science Publishers, Inc.
New York

2nd revised edition (1st edition in Czech: Galen Publishing, Prague 2008)
Photos: Ing Vladislav T. Jirousek - www.zoo-foto.cz, Petr Velensky, Dr Jiri Valenta
Figures: Karel Vavra
List of venomous snakes, zoological cooperation: Dr Ivan Rehak, CSc.

Copyright © 2010 by Nova Science Publishers, Inc.

All rights reserved. No part of this book may be reproduced, stored in a retrieval system or transmitted in any form or by any means: electronic, electrostatic, magnetic, tape, mechanical photocopying, recording or otherwise without the written permission of the Publisher.

For permission to use material from this book please contact us:
Telephone 631-231-7269; Fax 631-231-8175
Web Site: http://www.novapublishers.com

NOTICE TO THE READER

The Publisher has taken reasonable care in the preparation of this book, but makes no expressed or implied warranty of any kind and assumes no responsibility for any errors or omissions. No liability is assumed for incidental or consequential damages in connection with or arising out of information contained in this book. The Publisher shall not be liable for any special, consequential, or exemplary damages resulting, in whole or in part, from the readers' use of, or reliance upon, this material.

Independent verification should be sought for any data, advice or recommendations contained in this book. In addition, no responsibility is assumed by the publisher for any injury and/or damage to persons or property arising from any methods, products, instructions, ideas or otherwise contained in this publication.

This publication is designed to provide accurate and authoritative information with regard to the subject matter covered herein. It is sold with the clear understanding that the Publisher is not engaged in rendering legal or any other professional services. If legal or any other expert assistance is required, the services of a competent person should be sought. FROM A DECLARATION OF PARTICIPANTS JOINTLY ADOPTED BY A COMMITTEE OF THE AMERICAN BAR ASSOCIATION AND A COMMITTEE OF PUBLISHERS.

LIBRARY OF CONGRESS CATALOGING-IN-PUBLICATION DATA

Valenta, Jiri, 1960- Venomous snakes : envenoming, therapy / Jiri Valenta. -- 2nd rev. ed.
p. cm.
Includes bibliographical references and index.
ISBN 978-1-61209-217-1 (eBook)

Published by Nova Science Publishers, Inc. ✠ New York

CONTENTS

Preface		**vii**
Introduction		**ix**
List of Abbreviations		**xiii**
Chapter 1	Zoological Basis	**1**
Chapter 2	Epidemiology of Snakebites	**17**
Chapter 3	Snake Venoms	**27**
Chapter 4	Snake Antivenoms	**51**
Chapter 5	Snakebite: Therapy and Prevention	**59**
Chapter 6	Envenoming and Snakebite Treatment in Specific Snake Groups	**85**
Chapter 7	List of Venomous Snakes	**235**
Glossary		**289**
Author's Affiliation		**301**
Index		**303**
Pictures		**323**

PREFACE

This is a comprehensive monograph on the problems of intoxication incurred by snake venom. This publication is primarily intended for those at all levels of health care, for members of rescue teams, surgeries and emergency hospitals, as well as specialized workplaces and intensive care units. Providing didactic instructions for first aid and treatment procedures, information is also presented on venomous snakes, the fundaments of their morphology and behavior, snakebite prevention, the composition of snake venom, symptoms of envenoming, plus first aid in the event of snakebite for non-professionals, travelers, terrain biologists, and breeders. This book features an updated alphabetical list of types and sub-types of all venomous snakes, including their home ranges, as well as a comprehensive index, list of abbreviations, glossary, and color picture insert with one hundred photographs of venomous snakes.

INTRODUCTION

Few creatures in the history of man have attracted more attention than snakes. One of the first attempts to describe a snake in literature can be found in the Bible, where it is described in the Old Testament as *''more shrewd than any of the wild animals that the Lord God had made''* (Gn 3:1). The serpent is shown as a deceiver, luring Man to fall by eating from the Tree of Life, for which Adam and Eve were banished from the Garden of Eden. For doing so, the snake is castigated by God with punishments it bears still. *'The Lord God said to the serpent, "Because you have done this, cursed are you above all the wild beasts and all the living creatures of the field! On your belly you will crawl and dust you will eat all the days of your life. And I will put hostility between you and the woman and between your offspring and her offspring; her offspring will attack your head, and you will attack her offspring's heel."* (Gn 3:14-15). As is evident from the Old Testament, the snake acts neither as Satan nor for him at this point. Indeed, it does so on its own behalf, saying to Eve, *''Surely you will not die, for God knows that when you eat from it your eyes will open and you will be like divine beings who know good and evil.''* (Gn 3:4-5) In no case should this be viewed as temptation or a satanic notion, but rather as a step towards another stage of evolution for mankind. In fact, let this be the start of the biblical serpent's reformation. After all, it was only an enticer, for did not Woman perform what was forbidden?

The cult of the snake has played a part or is visible in many cultures, religions, and traditions. Examples not only include cave paintings in Spain and France, but also others by the Bushmen of South Africa and Australian aborigines, as well as in prehistory and more recent times.

Mention should be made of the vital role played by the cobra in the history of Egypt. Its intrinsic link to the cult of Imhotep - the builder and healer - was in the form of Ureus. This sacred serpent became a potent symbol of the divinity and power of Egyptian pharaohs, indeed it was the insignia of the kings - the headband shaped as an upright cobra with an outstretched hood. Furthermore, snakes were important as ritual animals in antiquity: be it in the Greek rooms of healing known as asclepieions, or Roman temples to Vesta, where snakes were kept by the Vestal Virgins. The serpent symbolized fruitfulness and wisdom both for the antique world and ancient Egypt.

Greek myths attribute the origin, or at least the occurrence of snakes in North Africa, to the hideous and deadly creature of Medusa as a result of her death at the hand of Perseus, poetically described by Ovid as: *''For the one achieved high heaven, and the other, (as he bore the viperous monster-head) on sounding wings hovered a conqueror in the fluent air, over sands, Libyan, where the Gorgon-head dropped clots of gore, that, quickening on the*

ground, became unnumbered serpents; fitting cause to curse with vipers that infested land.'' (Metamorphoses, Book IV, Ovidius Naso, Brooks More edition, Cornhill Publishing Co., 1922)

Elsewhere, the role of god was assigned to the serpent in Aztec culture, thereby transformed into the feathered serpent known as Quetzalcoatl. Moreover, snakes proliferate in Asian religions. According to myth, it was a snake - probably the king cobra - that revealed the meaning of life and faith to Buddha. Other examples include the Indian god Vishnu, who rested upon the body of a multiheaded cobra in the sea of milk, whilst Shiva wears a cobra wrapped around his neck. Some temples in Kangra Valley, North India, are dedicated to nāgas, deities in the form of great snakes, which are depicted with cobra fans on their heads. Moreover, many places in India celebrate certain days of the year that are consecrated to cobras. One fable tells that killing a snake, especially a cobra, will bring trouble that must be redressed via a ritual, something which rural Indians still abide by today.

Therefore, the role of snakes in the history of mankind is evident, much like their influence on the state of the human mind. The fear of snakes is incomparable to anything posed by other animals. Beside arachnophobia - the fear of spiders, ophidiophobia, which refers to the fear of snakes, is the widest form of pathological reaction to animals. In heavily affected persons, it is not restricted to exclusion of a real threat; feelings can also be associated with just seeing an animal or merely a depiction of one. Sometimes fear is amplified by a physical experience, as in a vegetative response. Whether such extreme reactions are determined by evolution (phylogeny) or are genetic in nature remains unclear. It might even be stated that snakes create feelings of fear in zoo-based primates, including apes. Nevertheless, the epidemiology of snakebites in children reveals a certain lack of fear and respect for venomous snakes, which is probably due to unfamiliarity or assurance. Whatever the case, attempts at physical exposure to snakes, as observed in certain children, did not reveal any connection with atavism or a satisfactory educational influence. However, indigenous peoples, such as in Africa, commonly associate fear with snakes and usually consider any such creature as highly venomous. Responses like these are easily substantiated; in addition to a lack of education and information, it is natural that any tribesperson attempting to be heroic by belittling the danger of venomous snakes would not survive long in the wild.

Why is that snakes are so mythologized? Answering this question is not simple. There may be several factors involved: their venomousness, the imminent mortal danger, and potential loss of life or impact on health even following a minor bite; these are sure to be amongst the most important to humans. In fact, it is these which distinguish snakes from other much larger animals that pose a threat to Man, creatures whose attack would result in visible physical devastation to tissue, unlike the 'godlike' bite of a venomous snake, and explaining this is far from easy. Consequently, a number of other points must have contributed to placing snakes in this most lofty of positions. Returning to one of the factors listed earlier, venom causes prey to be killed by a single rapid bite, added to which snakes are able to devour catch many times bigger than their mouths, plus they move without legs, even in trees and underground. However, such explanations are insufficient when investigating the extraordinary interest snakes possess for humans, which can but underline their truly mythical nature.

A host of folk tales are associated with snakes. For example, the Czech version of Goldilocks, by K J Erben, boasts a hero with the magic ability to understand animal speech

after eating some snake meat. In the 19th and early 20th centuries, notions abounded in rural communities of snakes biting their tails and rolling down hills, and of a snake wedding complete with the crowning of a queen. The superstition of snakes sipping milk from cows is also widespread, although it is plain that snakes do not actually drink milk and visit cowsheds only to get warm and catch rodents. Another falsehood is that snakes are slimy and clammy, but this is true of eels and yet they are not generally despised by people. Moreover, the myth of snakes hypnotizing prey is just that - only a myth. If a snake's prey were to be paralyzed via hypnosis, the snake's ability to see their potential catch would weaken. Nevertheless, rumors and misconceptions like these continue to shape how snakes are perceived.

Despite the reverence held for snakes by some ethnic groups, the eating of their meat does occur amongst the indigenous peoples of a number of African, Asian, and South American countries, as well as being served as a delicacy in local restaurants. This trade in meat - catching, selling, and consuming it - relates mostly to larger non-venomous snakes like pythons and boas, but even venomous snakes such as cobras are not immune to such treatment. Snake meat itself is said to be delicious and reminiscent of fine game or chicken. The entrails of creatures are used in soup, including a Chinese immunity-boosting variety made of snake gall bladders. Other uses of venomous snakes in gastronomy include special alcoholic beverages called snake liquor and health potions, which are produced by pickling venomous snakes in spirit, an example being Japanese mamushi saké.

Alongside all manner of myths, cults and superstitions, a real interest in venoms has developed, be it causes, duration and possible therapy. Notes on the effects and treatment of snakebites, in addition to the use of venom as medicine, appear in Egyptian papyruses, as well as in works by Aristotle, Nicandros of Colophon, Plinius, Hippocrates, Celsus, Pedanius Dioscorides, Galenus, and Avicenna. In the Renaissance period, snakebites were investigated by the French scientists Ambroise Paré and Jacques Grévin. The first ever work of methodology conducted on venomous snakes was produced by a Florence physician, Francesco Redi (1621-1697), which outlined the venom apparatus of snakes. This served as the foundation for a later study on animal toxinology by Italian Felice Fontana (1720-1805). At the cusp of the 20th century and in the years that followed, interest in such work rose dramatically, accompanied by an increasing number of studies dedicated to toxins, toxinology and the therapy of envenoming-related cases. However, not every scientific paper was wholly based on reality. The threats associated with the venomous nature of snakes, which in Central Europe relates to the rather less venomous common viper, used to be largely overestimated in the otherwise reliable literature of the day, and still is to a point at the present. A venerable Czech journal, Vesmir, published the following in 1895: *''To prevent the terrible consequences of snakebite, the aid given below shall be used. First, venom should be eliminated from the wound, which is done by cutting off the place so affected and dripping ammonia, chromic acid, fuming nitric acid, or tincture of iodine into the wound; alternatively the wound may be burnt using a hot iron ...'* Using such a therapeutic procedure, no one would wonder at such 'terrible consequences'.

To some extent, the special position reserved for snakes in the human psyche may also have a bearing on the attraction of capturing and keeping snakes. It cannot be ignored that the act of owning snakes possesses vague phallic connotations, or at least lends their owners some kudos based on their reptiles' alleged or very real risk. Some might even acquire a snake based on the single fact it is highly perilous or mortally so.

However, reflecting on the various qualities of breeders and owners should not serve as a distraction. In general, such people are well-informed enthusiasts and lovers of nature in all its bounty, which certainly includes snakes. They expand our horizons by building upon present knowledge on snake behavior and reproduction, requirements and habits, as well as via regrettable cases of bites caused by misfortune or careless handling.

''Within the period of six months, I was bitten by a number of reptiles including the black mamba, the African boomslang, the cobra, and the rattlesnake. I found myself at ICU four times. Several times, venom was sprayed into my eyes. Nevertheless, I always pulled through without any lasting effects'' (Marais, 1995). J. Marais is surely one of the foremost snake experts and keepers, although such incomprehension of the danger posed by a snakebite is by no means recommended. In stark contrast, the following comment by Czech herpetologist Zdenek Vogel is full of wisdom, *''Keepers of this kind of reptile should never get used to their snakes more than the snakes can get used to them. Any bravura or snake charming are unacceptable in the husbandry of snakes... All sorts of such intimacies with cobras, rattlesnakes and other dangerous reptiles will eventually lead to the cemetery.'* Which is in my particular case, speaking from personal experience, '...or at least intensive care.'

LIST OF ABBREVIATIONS

AAPCC	American Association of Poison Control Center
ACE	angiotensin-converting enzyme
ACh	acetylcholine
AChE	acetylcholinesterase
ADPase	adenosine diphosphatase
AF	Afrikaans
ALI/ARDS	acute lung injury / acute respiratory distress syndrome
ALT	alanine aminotransferase
APC	activated protein C
APTT	activated partial thrombin time
ASA	acetyl salicylic acid, e.g. Acylpyrin
AST	aspartate aminotransferase
AT	antithrombin III
AV-block	atrioventricular block. Failure of conduction from atria to ventricles.
app.	approximately
BP	blood pressure
CC	creatine cinase
CLD	certain lethal dose, see also LD_{100}
CNS	central nervous system
CPAP	continuous positive airway pressure
CRP	C-reactive protein
CRRT	continual renal replacement therapy: hemofiltration, hemodialysis
CVF	cobra venom factor
D-dim	D-dimer, fibrin degradation product
Da	Dalton, atomic mass unit
DIC	disseminated intravascular coagulation
DRC	Democratic Republic Congo
DTX	dendrotoxins
ECG	electrocardiograph
EEG	electroencephalograph
EN	English
ES	Spanish
EVLW	extravascular lung water
Fab	Fab (fragment antigen binding) fragments

FBG	fibrinogen
FDP	fibrin degradation products
FF (FV, FVII,…)	coagulation factors
FPA	fibrinopeptide A
FPB	fibrinopeptide B
FR	French
FTL	fatal time limit
GIT	GI tract, gastrointestinal tract
GMT	glutamyl transpeptidase
Hb	hemoglobin
Hct	hematocrit; the *ratio* of blood volume that is red blood cells
HE	Hebrew
HF	hemorrhagic factors
ICU	intensive care unit
IM	intra musculum, within a muscle
INR	international normalized ratio, a method for reporting PT results
IP	intra peritoneam, within the peritoneal cavity
IV	intra venam, within a vein
in part.	partially
in vivo	experimentation using a whole, living organism
JA	Japanese
kat	katal, SI unit of catalytic activity
kDa	kilodalton, atomic mass unit
LD	lactate dehydrogenase
LD_0	median or average dose at which no mortality occurs, see also MLD
LD_{50}	lethal dose 50%
LD_{100}	lethal dose 100%, see also CLD
LMT	last mortality time
LMWH	low molecular weight heparin
MB fraction	muscle brain fraction of CC
MLD	minimal lethal dose: a maximum quantity that will kill no animal
MODS	multiple organ dysfunction syndrome
nACh	Nicotinic acetylcholine receptors
ng	nanogram, SI unit of mass
p.o.	per os, orally
PAF	platelet-activating factor
PAI	plasminogen activator inhibitor
PAWP	pulmonary artery wedge pressure
PF1.2	prothrombin fragment 1.2
PGI_2	prostaglandin I_2
PI	pressure immobilization bandage
PKS	plasmatic coagulation system
PLA_2	phospholipase A2
PLT	platelets
PT	Portuguese
PT	prothrombin time

RSA	The Republic of South Africa
RT	reptilase time
RU	Russian
SC	sub cutam, subcutaneous
sp.	singular abbreviation for species, used when the actual specific name cannot or need not be specified
ssp.	subspecies
syn.	synonym
TAT	thrombin-antithrombin complex
TEG	thromboelastography; a method of testing the efficiency of blood coagulation
TESS	Toxic Exposure Surveillance System
TNF	tumor necrosis factor
tPA	tissue plasminogen activator
TT	thrombin time
U	urea
UFH	unfractionated heparin
VFN 1.	LF UKVseobecna fakultni nemocnice 1. lekarske fakulty Univerzity Karlovy v Praze (General Teaching Hospital of the First Medical Faculty, Charles University, Prague)
vs.	versus
vWF	von Willebrand factor
WHO	World Health Organization

Chapter 1

ZOOLOGICAL BASIS

1.1. EVOLUTION AND PHYLOGENY OF SNAKES

Where snakes actually originate from still is unclear. Unquestionably, they belong to the squamates order of scaled reptiles; their relationship to lizards is also beyond dispute. The rise of snakes' specific physical configuration is usually linked to hypothetical predecessors that led a subterranean life or inhabited cracks. However, alternative hypotheses concerning the aquatic ancestors of snakes also exist, winning increasing support from experts. Snakes are presumed to have evolved from anguimorphous, most probably varanid-like lizards within the process of diversification of ancestral scaled reptiles, in the Late Jurassic period about 150 million years ago. The oldest known fossil relics believed to be most likely related to snakes are highly fragmentary and come from the Early Cretaceous, which are over 120 million years old. The merging of the Lower and Middle Cretaceous produced *Pachyrhachis problematicus* in Israel, a very intriguing marine squamate reptile. Ranked as a member of the mosasaur family by some experts, this reptile is assumed to be an early snake with the remnants of rear legs. Thus, *Pachyrhachis* may support the idea of snakes originating from marine varanid-like lizards.

Described from the Algerian Middle Cretaceous from strata nearly 100 million years old, *Lapparentophis defrennei* can be indisputably considered a snake - most probably one of terrestrial form. In addition, other species appeared, for instance *Simoliophis,* supposedly a water snake. Any exact phylogenetic ranking of these prehistoric examples referred to as *Cholophidia* remains unclear for the moment. Shortly afterwards, the first family appeared: false coral snakes, *Aniliidae*; this monotypic group of a single species has survived until today. From the Upper Cretaceous, when apparently an important adaptive radiation of primeval snakes occurred, fossil documentation shows that snakes increased in diversity, although interpretation of their phyletic relationships greatly varies. A higher number of lineages may have originated, from which many more recently became extinct without any evolutionary successors. Genera that appeared at that time include *Madtsoia* and *Gigantophis*, members of a highly successful and widespread snake group that in some places (*Wonambi* genus in Australia) survived until the Pleistocene. These reptiles resemble later large boid snakes in the size and shape of their body. Sometimes considered an important phylogenetic node, *Dinilysia,* a reptile similar to a boa, is another Late Cretaceous form to emerge from Patagonia.

It was at the beginning of the Tertiary period when monumental forms resembling pythons or boas proliferated, while in the later Eocene the family of boas (*Boidae*) appeared, including genera that were either very close to recent members or still survive today (such as *Charina*). Evidence has been produced as regards members of the recent *Tropidophiidae* family as well. The earliest documented blind snakes (*Scolecophidi*) also come from the Eocene. In addition, the most archaic forms of so-called modern snakes *Caenophidia* appeared for the first time, from an ancestral relationship of extant wart snakes (*Acrochordoidea*) and ancient *Colubroidea* snakes, and maybe even the first colubrid snakes, *Colubridae*.

However, climatic changes at the meeting of the Eocene and Oligocene periods, along with less favorable conditions in the course of the Oligocene, brought about a vast reduction in prehistoric Eocene snake fauna, resulting in fundamental changes in its taxonomical structure. While some of the archaic lineages died out and *Booidea* and related forms shrank to some extent, *Caenophidia* took the lead and later developed at an enormous rate in the Miocene, which lasted until modern times. It is clear the evolution of snakes as such did not proceed independently, but in accord with the general transformation of the natural world at a time of climatic change, and in close correlation with alterations in other fauna as well, reflecting the changing pressure of rivalry in predators and their adversaries, and responding to diverse availability of diet. Even in the Oligocene, over 30 million years ago, colubrid snakes (*Colubridae*) were expanding throughout Asia, Europe, and North America. The oldest elapid snakes (*Elapidae*) in fossil records appeared in the Lower Miocene in Europe over 20 million years ago (*Palaeonaja*); more recent Miocene findings also show them inhabiting a number of places around North America, Europe, and Asia. Moreover, it is the Miocene period when vipers (*Viperidae*) first appear in fossil records over 20 million years old, these being snakes that soon proliferated as well. For instance, *Vipera antiqua*, a smaller close relative of the recent *V. ammodytes*, ranged throughout Europe as long ago as the lower Miocene together with *V. platyspondyla,* a snake closely related to the recent *V. xanthina*. Throughout the Miocene adaptive radiation of modern snakes, numerous extant colubrid, elapid and viperid genera or species evolved. In Europe, not only were there colubrid and viperid species as more recently, but even elapids and boids could be found.

Pliocene snake fauna already featured high diversity and taxonomic similarity to that of recent times, developments which were further affected by Pleistocene glaciations as well as marine transgressions and shrinkage. All of the above was accompanied by changes in snake fauna populations in different parts of the world, resulting in the map of zoogeographical distribution of snakes and their taxonomical structure as it is known today. Currently, snakes are present on every continent except Antarctica, including a number of islands. Approximately 3,000 species have been described to date, mostly colubroids (*Colubroidea*), in addition to the most abundant family in terms of species, *Colubridae*, which covers elapids (*Elapidae*), viperids (*Viperidae*), and the less-numerous *Atractaspididae* family including burrowing asps and other snakes.

The exact time when snakes became venomous is not known. However, indications of venomousness existed as long ago as the Cretaceous Period in the *Pachyrhachis* genus that can be considered a sister taxon linked to all extant snakes. This is noteworthy as it suggests in some snake lineages venomousness could have present in their earliest evolutionary phases. After all, laboratory experiments with saliva from recent non-venomous snakes with archaic origins indicate a certain level of toxicity. Nevertheless, venomousness, as is

understand from a practical aspect, only exists in colubroids (*Colubroidea*) within the variety of contemporary snakes. The presence of venom secretion from modified salivary glands in the upper jaw may even have been a common trait from the very start, being apparently one of the reasons for the extraordinary evolutionary success of these snakes. The non-existence of venom secretion in some colubrids might obviously be only a secondary feature. In colubroid snakes, the process of evolution was accompanied by extensive modifications to the venomous gland, as well as the growth and development of specialized venom-delivering apparatus. The wonderful adaptive radiation of these snakes brought about venom-specialist families, namely in two basic parallel lineages: the solenoglyphous (viperids, *Viperidae*) and proteroglyphous (elapid snakes, *Elapidae*). Since the Miocene period, these two families have presented two successful alternative approaches in maximizing the potential of snake venom.

1.2. TAXONOMY OF SNAKES

Snake taxonomy is far from being completed and stable. Views of the mutual relationships of taxonomy groups as well as particular genera are still being developed and altered. Even today, further species are still being discovered, a number of which await detailed scientific description, and some former species have been newly classified amongst subspecies as a result of greater insight on their morphology. Increased knowledge and these new findings on the classification of such snakes have also brought about changes to the scientific names of genera and species.

Moreover, splits in high-level taxonomy groups like families and subfamilies are not always apparent and delineating them is an unfinished chapter. For example, true sea snakes are either placed within the elapid family (*Elapidae*) or under the separate *Hydrophiidae* family, the sea krait subfamily (*Laticaudinae*) is also placed under a separate family; the crotalids (*Crotalidae*) are still maintained as forming a separate group by some authors, whilst elapid subfamilies are sometimes not listed at all due to their ambiguity. Similar problems exist in the vast colubrid family (*Colubridae*), which will most probably be segregated and rearranged at some point. Creating permanent and clear classification within such diversity as has evolved on the Earth through the ages is definitely not an easy task, and may prove nigh on impossible.

Furthermore, according to new findings from animal genome research, the Darwinist understanding of a relationship based on morphology resemblance probably does not reflect reality in terms of development and genetics. It cannot be predicted that future generations will see an entirely altered taxonomy based on new rules respecting evolution and relationships in a superior way.

The brief overview of venomous snake classification given below shows the recent position of snakes in the animal system in addition to their general mutual relationships. It should be born in mind that contemporary taxonomy knowledge indicates a monophyletic status of many of the taxa listed, namely *Colubrinae*, *Lamprophiinae*, *Natricinae*, and *Elapinae*. They greatly resemble polyphyletic or paraphyletic taxa instead, meaning their nature is collective and merely temporary. Therefore, they will have to be re-classified, although existing knowledge on the relevant phyletic relationships still does not allow for taking such a step with the necessary responsibility.

From a practical point of view, certain problems have arisen caused by dramatic recent development in the field of snake taxonomy. This is reflected in a large number of changes in nomenclature published in parallel (e.g. segregating genera, shifting taxa between subspecies and species levels, creating synonyms for previously described taxa and relocating species under different genera), as traced by a small number of specialists. Naturally, publications in toxicology define subjects under study following recent systematics, and on many occasions they are err on the conservative side by employing names long established. The persistence of the nomenclature is relatively high in relevant statistics, as well as amongst manufacturers of antivenoms and, more generally, in the awareness of the public, including snake owners. Any vehement acceptance of alterations in taxonomy would actually be counterproductive. Therefore, a certain conservative approach has been maintained in the snake nomenclature used herein; notes on the possible occurrence of older or more recent synonyms are given where important.

Position of Snakes within the Zoological System and Overview of Families Containing Species of Venomous Species

Class: *Reptilia* - Reptiles

Subclass: *Lepidosauria*

Order: *Squamata* - Scaled reptiles

Suborder: *Ophidia, Serpentes* - Snakes

There are 14 families under the title of non-venomous snakes, and 4 families of a venomous type are listed below under the *Colubroidea* superfamily:

Superfamily: *Colubroidea* - Colubroid snakes

Family: *Colubridae* - Colubrid snakes
Venomous species are found in five colubrid subfamilies out of total of seven:
Colubrinae (about 650 species), *Homalopsinae* (35+ species), *Lamprophiinae* (205+ species), *Natricinae* (195+ species), and *Xenodontinae* (540+ species).

Family: *Atractaspididae* - Burrowing asps
Subfamily: *Atractaspidinae* - Burrowing asps (17 species)
Subfamily: *Aparallactinae* (40+ species)

Family: *Elapidae* - Elapids
Subfamily: *Elapinae* (130+ species)
Subfamily: *Hydrophiinae* (165+ species)

Family: *Viperidae* - Viperids
Subfamily: *Azemiopinae* (1 species)

Subfamily: *Viperinae* (65+ species)
Subfamily: *Crotalinae* (about 155 species)

+ stands for 'or more' (e.g. if any subspecies are considered species by other authors)

1.3. MORPHOLOGY OF SNAKES

Anatomically, the skeletons of snakes (*Ophidia* or *Serpentes*) lack limbs, with vestiges of such retained in more primitive groups like boids. The kinetic and extendable skull of the snake features a large number of articulations, the facial part joined flexibly with the lower section of the braincase and loose ligaments on the left and right of the lower jaw. The skull configuration allows for ingestion of large prey by dilating the jaws and pushing via alternate movements of their right and left sides. The backbone may consist of over 300 vertebrae with ribs that articulate with the same.

Snakes are variable in length, ranging from 15 cm up to 10 m. The largest snake ever found was an Asian reticulated python (*Python reticulatus*) caught in 1912, with a length of 32 feet and 9.5 inches (999.49 cm.) Nevertheless, the South American forests are believed to host much longer specimens of large anacondas, which are non-venomous snakes. Among venomous examples, the king cobra (*Ophiophagus hannah*) reigns when it comes to length, with a documented size of 560 cm, followed by the black mamba (*Dendroaspis polylepis*) at 430 cm, and the coastal taipan (*Oxyuranus scutellatus*) at 380 cm. The heaviest venomous snake is the large eastern diamond-backed rattlesnake (*Crotalus adamanteus*) that weighs 10 kg and inhabits North America.

The western blackhead snake (*Tantilla planiceps*), a member of the colubrid family (*Colubridae*), which has rear fangs and is found in the southwest of America, seems to be the least venomous snake. It can grow up to 15 cm in length and feeds on worms, centipedes and insects.

A well-muscled body, flexible skeleton and moving ribs enable snakes to move forward using variations of motion of lateral undulation, rectilinear movement, and that resembling a concertina, as well as side-winding on loose ground. The actual speed of movement snakes can achieve is often overstated. The fastest snake, which is the mamba, can move at around 12 to 15 kph, i.e. equivalent to a slight jog. It is true that some places exist in the African bush so dense with shrubs that people cannot reach such a speed. However, the notion of a mamba chasing a man is completely absurd. The brisk attack of this snake, much like that of the cobra, would be performed over a shorter distance, 1 to 3 m at the most, with mans' inattention the reason for being bitten rather than impeded motion. A snake capable of such speed is most likely to escape before being seen. Nevertheless, the motion of large vipers, especially those with a robust body like the *Bitis* genus, is slow and hesitant. Therefore, a person could stumble across one at close range, meaning a higher probability of attack due to the snake sensing an imminent threat.

Again, the speed of a snake attacking its prey or defending itself is often exaggerated. The measured speed of charge of the European viper after forming an 'S-coil' in the frontal part of its body lasts about 0.1 s, which equals the speed of attack of 2 mps at a maximum

distance of 20 cm. However, during such a period the viper has to open its mouth, erect its fangs, bite, and discharge its venom all at the same time. In fact, there is often a double strike. The process described above may not be fully maintained when acting in defense, in which an assault is only hinted at by the snake but not fully performed, including the bite and discharge of venom; this chiefly applies to the Viperid family (*Viperidae*).

Snakeskin is entirely covered in scales of different shapes and is dry to the touch, with a texture resembling slightly rough upholstery. Some snakes, saw-scaled vipers listed under the *Echis* genus for example, can rub their sharp lateral scales against each other, employing such behavior to warn a disturbing presence by creating sound. The same goes for the bony rattle at the tips of tails of rattlesnakes belonging to the *Crotalus* and *Sistrurus* genera. The rattle consists of free moving ossified segments, which are added to continuously each time the snake sheds its skin. The shape, size, and number of scales are often used to identify a genus or species. The outer horny layer of snakeskin called slough or exuvia is removed and replaced by a new one on a periodical basis.

The eyelids of snakes are transparent and fused, hence they have a fixed stare. The pupil is either in the shape of a ring or an upright slot, and only in extraordinary cases is it slotted horizontally. The ring and larger pupils are usually seen in snakes with diurnal activity, while slotted and small ring pupils tend to be features of nocturnal snakes. In some tree colubrids, a horizontally slotted pupil serves to enhance panoramic binocular sight, essential when it comes to properly focusing on prey. In fact, snakes perceive stationary items very badly, which is the reason for the swinging motion that can sometimes be observed: they are attempting to move their eyes towards their prey. This is also why an animal being hunted stiffens instinctively.

The tongues of snakes are forked, allowing for chemosensory sensual recognition by the creatures. The tongue can transmit chemical olfactory perceptions via a microscopic quantity of matter, or even merely molecules, into the highly developed vomeronasal or Jacobson's organ, these being palate cavities equipped with sensory epithelium. Furthermore, the olfactory organ is used to perceive smells.

The snakes of the *Crotalinae* subfamily possess a special auxiliary organ that cannot be found in any other animal: thermal receptors formed by a pair of small cup-shaped cavities placed in the upper jaw and covered with a thermo-sensitive membrane. This organ provides exact stereotactic information for detecting a source of heat at temperatures of only 0.2 - 0.5 ^{o}C above that of the ambient atmosphere, facilitating a snake to detect prey in even complete darkness. A blinded rattlesnake will strike its prey in 98% of cases, whilst only 27% of strikes are successful after the thermal receptors have been covered. A similar sensory organ is found in non-venomous boid snakes as well. In addition, it seems it is even possessed by some venomous colubrids like *Dromophis, Malpolon, Psammophis*, and *Rhamphiophis*; however, the pits are placed on the vertex in such snakes.

The auditory organ has changed in order to capture vibrations from the ground instead of analyzing sound waves. These vibrations are sensed by scales on the belly, intercostal space structures and lower jaw, the latter which vibrates the quadrate bone, with all such impulses being transmitted to stapes and nerve endings. Consequently, snakes are deaf in the human sense, and any attempts at driving away venomous snakes by noisy behavior while on a family trip out is senseless but commonplace. Research made on this organ has revealed that coughing or gunshots do not disturb snakes, although a cat walking or even a piece of paper falling onto a writing pad is registered immediately.

One general misconception is that snakes bathe in blinding summer sunshine. Despite the fact that sunbathing is a normal form of thermoregulatory behavior among many snakes, namely those from colder regions, snakes are mostly unable to tolerate harsh sunlight and high temperatures. For the majority, ideal temperatures lie between 25°C and 30°C, and they cannot cope with anything exceeding 40°C. Any exposure to hot sun is acceptable only for a few minutes. Indeed, if left for several dozen minutes in the sun, a snake will die even at lower temperatures. In hot climates, in the rocks, desert, and savannah, snakes hide during the day and come out to hunt at night. The same goes for South and Central European vipers in extremely hot summer months, hence spending a night out under the stars and unprotected by a tent in such a season can pose a threat in certain localities. If temperatures permanently fall below 20°C, snakes become torpid and slow down their motions. As a result, it is common practice to artificially cool large or dangerous snakes in order to handle them better, e.g. by using a refrigerator.

1.4. THE VENOM APPARATUS IN SNAKES

Depending on venom production and use, venomous animals can be referred to as cryptotoxic, i.e. not possessing any specific venom producing apparatus, and phanerotoxic, those with the presence of a specific organ, i.e. a venomous gland.

The cryptotoxic group features beetles, such as soldier beetles termed cantharids, molluscs, e.g. natural oysters in the summer, certain fish species in their reproductive period or if their diet includes venomous plankton, and other creatures.

In the animals deemed phanerotoxic a venom-delivering apparatus may be absent or present. This trait is used to classify them as passive toxic animals possessing no delivery mechanism, or active toxic animals with a venom-delivering apparatus.

Those that are passive toxic feature an open duct of venom glands on the surface of the skin, examples being frogs and toads, newts and salamanders.

Venomous snakes are active phanerotoxic animals. They have a specialized venom-producing organ, a venomous gland and, with some rare exceptions, a delivery mechanism in form of venomous fangs.

In snakes, venom is produced in a venom gland - *glandula venenosa* - that has developed from the salivary gland (*glandula maxillaris*) in the upper jaw; it is placed behind the salivary gland but deeper under the surface. It forms part of the digestive tract of snakes. The role of venom is not only to kill or immobilize prey, but also to facilitate digestion. In the majority of snakes, the size of the venomous gland largely exceeds that of the saliva gland. Indeed, it can extend from the eye up to the end of a snake's skull and, in some viperid snakes, it can even stretch up to the neck. In the front section of the venomous gland, there is a slime gland containing secretion probably designed to prevent spontaneous discharge of venom in combination with a flap in its channel. The system opens through a duct placed in a mucous fold near the fang channel on the base of a fang.

Fangs have developed from non-grooved teeth of the upper jaw. Snakes can be differentiated on the basis of teeth morphology, stage of development, and location in the upper jaw to *Aglypha*, which comes from the Greece glyphé, i.e. the groove, featuring non-differentiated teeth of the same length without longitudinal grooves or hollows, and

Glyphodonta with certain teeth furnished with grooves or hollows connected with the venom gland. (Figure 1.)

Aglyphous snakes cover so-called non-venomous varieties like pythons, boas and many elapid snakes.

Nevertheless, as many as two thirds of *Colubridae* seem to have developed the venomous gland, referred to as Duvernoy's gland, or a rudimentary form of it along the sides of the upper jaw. Even though these snakes have not evolved any injection mechanism, bites from such a ''non-venomous snake'' may very occasionally cause a limited response due to the small amount of the gland content that is spontaneously discharged to the snake's oral cavity.

Glyphodont snakes are venomous snakes with a venom-injecting mechanism. They can be placed into one of three groups depending on the shape and location of their fangs.

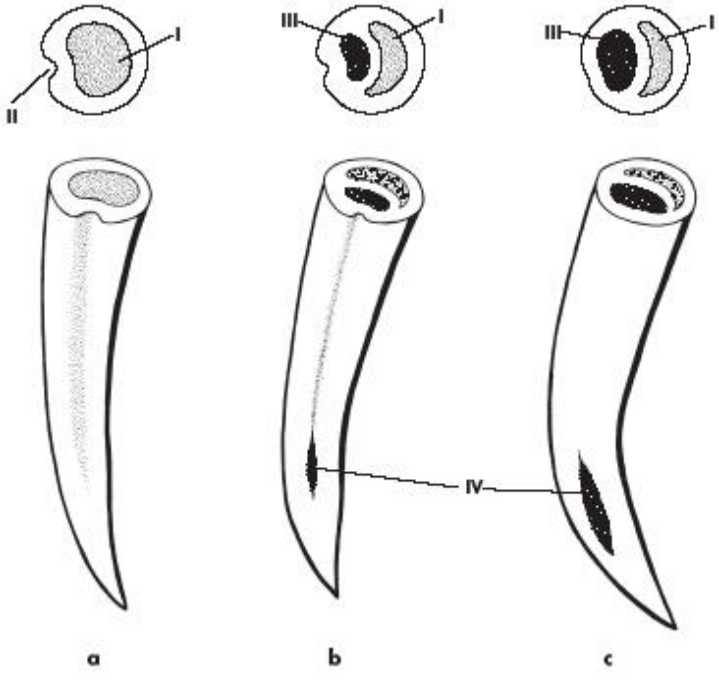

Figure 1. Types of fangs (edited according to Kurka et al., 1984),a - Opisthoglyphous, b - Proteroglyphous, c – Solenoglyphous, I - Pulp cavity, II - Venom groove, III - Venom duct, IV - Orifice of venom duct

Opistoglypha. These are snakes with rear fangs featuring a rather shallow groove in the front of their fangs, these being larger than the rest of their teeth. They are placed at the end of the upper jaw, mostly behind the eyes, although they can be even located closer in some snakes, generally in the middle of the jaw. The snakes of this group are members of venomous genera belonging to the *Colubridae* family. Although the venom mechanism is rather primitive, Duvernoy's gland opens above the venom teeth, thus ensuring the transfer of venom to the body of prey. Their venom is quite effective. It is most necessary for tree dwelling and bird hunting snake species to make sure they immediately kill or immobilize

their prey. Any further pursuit would be impossible in this type of habitat. Nevertheless, there are still some opisthoglyphous colubrid genera, such as *Rhabdophis*, that are neither bound to trees nor can be termed ornithophagous snakes. Biting humans is, however, rare. Penetrating the human skin with rear fangs would require the jaws to open at a very wide angle, and the application of any significant amount of venom via a shallow channel is improbable from such a brief and shallow bite. From this point of view, boigas are more dangerous snakes with their fangs placed towards to the centre of the jaw.

Proteroglypha. These snakes feature relatively small fangs placed at the front of the upper jaw along its sides in front of other maxillary teeth. The fangs have a deep groove at the front, which in some snake genera are encased in the form of channel. As Proteroglyphous snakes are unable to fully control venom application using special muscles, they mostly hold onto their prey in their jaws following a bite, injecting venom by repeatedly manipulating the jaws. A similar situation may occur if a human is bitten due to a defensive action. There have even been reports of snake fangs remaining in a wound after the creature itself has been removed following an attack. The Proteroglypha group covers elapid snakes (*Elapidae*), examples including cobras, mambas, kraits, taipans, sea snakes and sea kraits.

Certain cobra species can defend themselves by spraying venom, which is called spitting; by opening its mouth, a snake reveals short fangs with openings at the front and discharges the venom through these slots under high pressure. In fact, the droplets produced might carry as far as a distance of several meters. Thus, the term spitting is rather inadequate to express this kind of action. In addition, it is uncertain as to the target of the snake - the face or, more precisely, the eyes of the individual that caused disturbance. The conical shape of the droplets of venom might hit the eyes, just as they would any other part of the body within range.

Solenoglypha. These snakes comprise advanced groups possessing large folded fangs along the sides of the front part of the upper jaw. The fangs include a fully closed channel which forms a cavity. Venom is injected very promptly and in a manner well controlled by muscles of the venomous gland. Snakes like these mostly attack by means of a rapid strike immediately after forming an 'S-coil' from the front part of their bodies. Afterwards, the mouth opens, and with fangs erect, venom is injected into the resultant wound. Then the snake retreats swiftly, without further gripping the prey in its jaws. However, such an attack may be repeated, and any prey that does not die on the spot or is immobilized and unmoving is pursued. A defensive attack from these snakes may not always be complete, i.e. involving a perfect bite and application of sufficient venom, although the manner in which it is conducted is similar. Snakes can very probably distinguish between their hunting and defending behavior: in over a half of bites made upon defense, either zero or a minimal quantity of venom is discharged. The *Solenoglypha* include viperid snakes (*Viperidae*): night adders, vipers, and rattlesnakes. (Figure 2)

Special fangs have evolved in the *Atractaspididae* family which are used to hunting in narrow corridors and dens. To be able to hit their prey, they can turn and eject their front fangs to one side and perform an attack by a swift side stab without opening their mouths. A similar action proceeds when a snake is grasped some distance below its head and defends itself, it can stab the hand grasping it by rapidly shaking its head to either side.

The fangs are covered by a mucous fold pulled over them. In the course of time, fangs are renewed in most snakes, with new pairs growing behind the older and larger ones. Indeed, it is no exception to find several fangs in a row, for instance in the *Bitis* genus of vipers, where

up to six successive fangs can be found in *Bitis gabonica*, also visible in bite marks on humans.

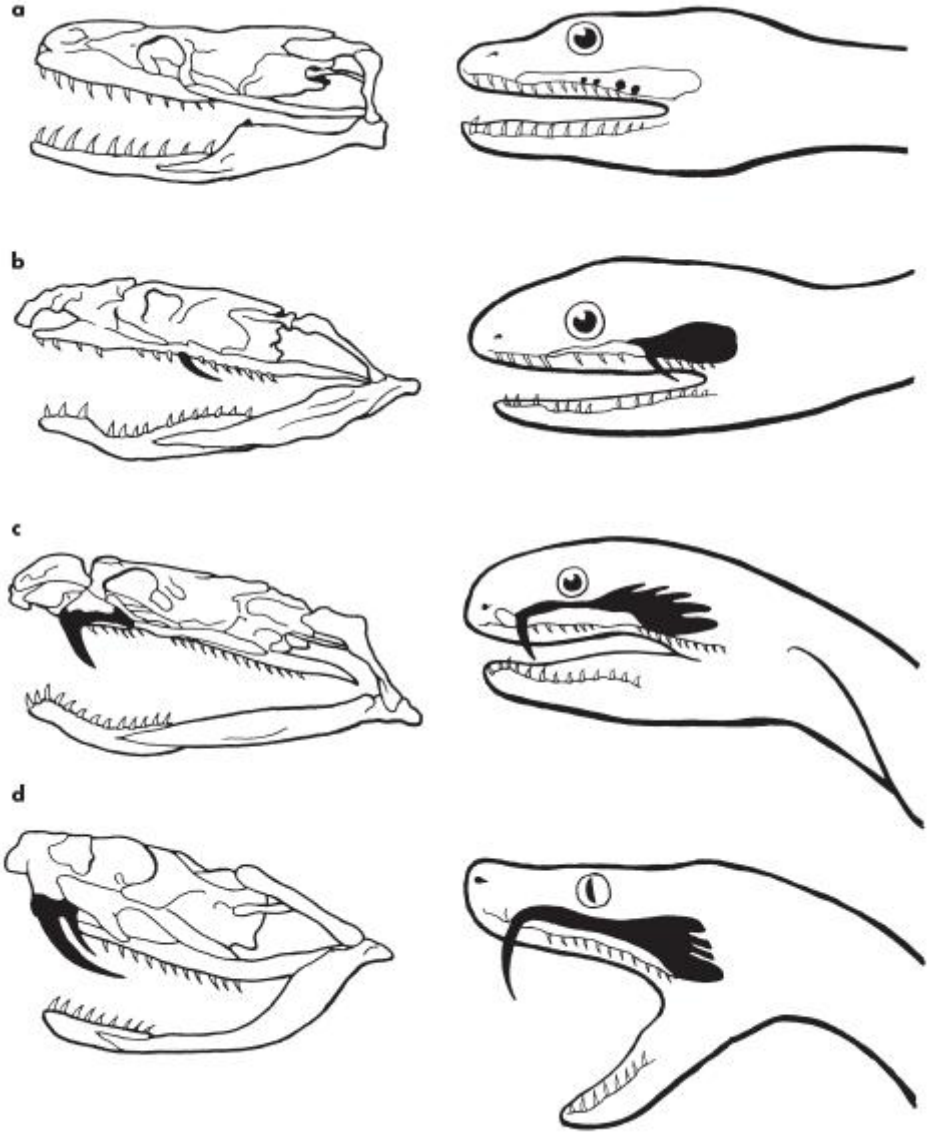

Figure 2. Types of venom apparatus and fangs in snakes a - Aglyphous, b - Opisthoglyphous, c - Proteroglyphous, d – Solenoglyphous.

Fang size may greatly vary; in smaller proteroglyphous snakes, they can grow to a mere 2 or 3 mm. In sea snakes and sea kraits, fangs are usually unable to penetrate neoprene diving suits. However, the erectile fangs of larger vipers and rattlesnakes can reach several

centimeters in length, the record holder being the Gabon viper (*Bitis gabonica*) which boasts fangs 4-5 cm long.

1.5. DISTRIBUTION OF VENOMOUS SNAKES

Venomous snakes inhabit a major part of the Earth's surface, be it dry land or sea. Nevertheless, places without snakes do actually exist as well. In general, they involve cold regions with an adverse climate, or islands that snakes could not reach by migrating through evolution or via the intervention of humans.

In the southern hemisphere, snakes do not inhabit Antarctica, the entire territory of Chile, which was blocked to them from the east due to the Andes Mountains causing a barrier; then there are the Galápagos Islands, New Zealand and Madagascar. As regards Oceania, they live in Polynesia, Micronesia, the New Hebrides, the Loyalty Islands and the Hawaiian Islands. Nonetheless, sea snakes are found in the territory of the Pacific Ocean, but they do not extend to the Atlantic Ocean. The most southerly venomous snake is one of the lanceheads (*Bothrops*), with its territory extending as far as Tierra del Fuego.

In the northern hemisphere, the situation is more complicated from a geographical point of view. The northerly limitation on territory in Europe and Asia, which affects the common viper (*Vipera berus*), is defined by the Arctic Circle. The creature also does not live in the far northern regions of Norway, Sweden, Finland and Russia, but can occasionally appear in the polar circle. Its home range continues throughout Asia, and ends below the 60th parallel north of Sakhalin Island. To the west, this species does not inhabit Ireland, Iceland and Greenland. In North America, the territory of venomous snakes approximately follows the 50th parallel, which is the US and Canadian border, where they can be found practically only in the vicinity of the Great Lakes and on certain islands around eastern Canada.

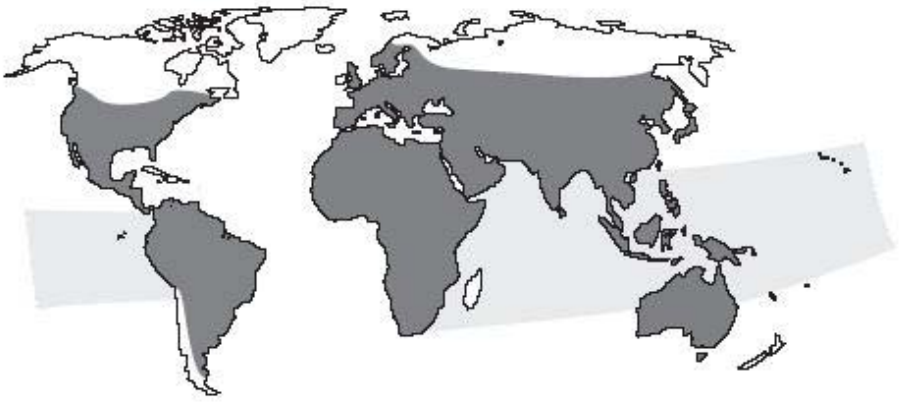

Figure 3. Global distribution of venomous snakes (freely edited according to Kornalik, 1967). The light gray sections indicate the approximated home ranges of marine snakes The white areas are territories estimated to be free of venomous snakes.

Within the colder parts of the territory, venomous snakes cannot be found on the Cape Verde Islands, the Canary Islands, the Balearic Islands, or in Corsica, Sardinia, Malta, Crete and on other Greek islands. In terms of Central America, they do not occur on any Caribbean island except Tobago, Trinidad, Saint Lucia and Martinique, where venomous snakes do reside; see Figure 3.

As already mentioned, sea snakes inhabit neither the Atlantic Ocean nor the Mediterranean Sea, but occur in the Indian and Pacific Ocean. Most of them dwell in the waters that stretch between the Gulf of Persia and Indo-Chinese and Australian regions. Some extend over the Pacific Ocean as far as the US coast.

Regarding elevation, most snakes inhabit localities below 2,000-2,500 meters above sea level; but even here there are some exceptions. For example, the common viper (*Vipera berus*) may ascend to 3,000 meters above sea level in the Alps and Scandinavian mountains, and the central plateau dusky rattlesnake (*Crotalus triseriatus*) of Central America is able to live as high up as 4,400 meters above sea level. The Himalayan pit viper (*Gloydius himalayanus*), a dweller of forests, holds the record for altitude, as 3,000 - 4,000 meters is usual for it, but this snake has even been discovered at a height of 5,300 meters, at the very edge of a glacial zone.

Although venomous snakes have adapted to living in nearly any habitat globally, particular groups of these snakes prefer specific types of landscapes. For example, *Viperinae* snakes favor quite dry and open ground, often wooded areas in sub-mountainous and mountainous ranges with sand or stony substrates. With some exceptions, the Gabon and rhinoceros vipers avoid dense forested enclaves with restricted sunlight. However, *Atheris*, one of the *Viperinae* genera, has specialized in hunting and dwelling in trees and bushes.

Crotalinae snakes have similar requirements concerning landscape: they reside in savannahs, sparse woodland and thickets in the sub-mountains and mountains of America and Asia. However, there are exceptions to the rule in this group as well. Several lancehead (*Bothrops*) and Asian pit viper (*Trimeresurus*) species are frequent inhabitants of forests and their surroundings, while some species of the *Agkistrodon* genus prefer proximity to water.

Unlike the viperids (*Viperidae*), most elapid (*Elapidae*) species seem to consider ideal habitats to be damp or dense tropical forests, or at the very least the environs of such, as do a number of Asian cobra species of *Naja* and *Ophiophagus* genera, as well as coral snakes of the *Micrurus* genus.

However, African cobras and mambas largely inhabit localities of grass savannahs in addition to shrubby and sparse bush environments, with cobras living a terrestrial life and mambas as tree dwellers. Similar dry or even partial desert locations are resided in by some Australian coral snakes, too.

Sea snakes that once again belong to the group of elapid snakes (*Elapidae*) largely prefer salt water; they are less common in brackish waters and rare in fresh waters.

The *Atractaspididae* snakes family members lead an intriguing way of life - they inhabit tunnels and dens underground, where they also hunt.

Boigas, venomous colubrids, are chiefly tree or shrub dwellers, while damp and forested enclaves prevail as far as *Natricinae* snakes are concerned.

1.6. ETHOLOGY BASIS, HUNTING, ATTACKS AND DEFENSE

When hunting, venomous snakes use solely their venom apparatus. A snakebite thereby means immediate or delayed paralysis, immobilization and eventual death to prey. Therefore, the venom mechanism and toxins are tailored to the type of hunting and intended prey.

Some of the *Atractaspididae* snakes, more specifically, burrowing asps (*Atractaspis*), which hunt for rodents in narrow tunnels underground, can slightly open their mouths by releasing the lower jaw and lash out with their long fangs by shifting the head aside and moving backward. A similar method is also used in defense; when gripped behind its head, the snake can stab with its fangs, employing side movements of its head and jaws.

The venomous arboreal colubrids *Thelotornis* and *Dispholidus*, which principally hunt birds and chameleons, possess rear fangs and toxins effective enough for birds. The rear position of their fangs poses some limitation for these snakes in that their prey has to be rather small, as the angle of the open mouth does not always allow for larger animals to be bitten successfully. Nonetheless, they are efficient predators with good motional skills and eyesight, essential qualities for this style of hunting. The effective toxins kill prey in a very short time due to hunted animals being held in the snake's mouth, this is in addition to frequently being grasped by the creature's coiled body. If prey is let go of too soon, it could escape to beyond the snake's reach. Considering the position of the fangs in the rear part of the upper jaw, envenoming a human via a defensive bite would be technically too complicated for most representatives of the *Colubridae* family. With this in mind, boigas are the most dangerous snakes, with their fangs placed in the middle of their upper jaw.

Elapid snakes (*Elapidae*) are mostly terrestrial animals that hunt small mammals, frogs, lizards and other reptiles, although this family does includes marine piscivorous snakes. These representatives excel in terms of motional skills and are able to paralyze prey very swiftly owing to their venom, which contains effective neurotoxins. Most of them hold their prey in their mouths, pumping venom into the animal by repeatedly clasping their jaws - much like chewing - as venom discharge is not controlled by the muscles of the venomous gland. In coral snakes, cobras for instance, the speed of movement over solid surfaces and that of potential attack should be paid heed to by snake keepers and hunters. When in danger, a large cobra is capable of performing an assault over a distance of several meters in just fractions of a second. However, the speed and aggressiveness of the mamba (*Dendroaspis*) is often overstated. Even though mambas are probably the quickest snakes - the velocity and level of threat involved is described in the snake morphology chapter - popular belief of their pace is based on myth. While it is true that a bite from a mamba proves mortal without treatment due to the content of neurotoxins, it is still not ranked highly in snake envenoming epidemiology in its home territories. When snake collecting in south-east Senegal, only four black mamba (*Dendroaspis polylepis*) individuals were captured out of total 1,280 snakes. Considering the fact this snake is not very rare, a possible explanation may be timely escape from the area under survey. Much like other snakes, mambas are not keen on making contact with humans, and intentional attacks on people are not listed amongst their behavioral traits. Any possible case of a mamba approaching a man might be explained as inquisitive behavior. They will attack only if sensing a threat, just like any other snake, although the swiftness of this action can exceed the response of humans.

Marine coral snakes - sea snakes and sea kraits - are hunters of small fish largely in the vicinity of coral reefs. They may often follow or pursue divers, occasionally with even close physical contact taking place in form of twining around legs. Nonetheless, occurrences of snakebite are rare, in fact, their fangs are so small they are incapable of penetrating a neoprene diving suit, and defensive biting is not typical of these snakes. Moreover, there are instances on record of children playing with sea snakes washed up on beaches, but no child has been bitten. It is more usual for fishermen to come into contact with sea snakes, although such individuals are at risk of snakebite to some extent anyway.

The viperid family (*Viperidae*), an advanced snake taxon in terms of evolution, can hunt prey by swift and sometimes repeated bites using erected fangs. They do not hold prey in their mouths as the bitten animal is subsequently pursued. Viperids' venom is a complex of toxins and enzymes affecting a number of vital systems, meaning death to their prey even if the attack is rather unsuccessful. The biting of humans by viperids, namely vipers (*Viperinae*) is nothing rare in the wild. The higher rate of incidence is caused by the lesser speed of the viper. While elapid snakes (*Elapidae*) can mostly escape from humans very quickly, vipers do so much slower, whilst some species, like the *Bitis* genus, show little enthusiasm to get away. This can expose such snakes to direct contact with humans much more often. Attacking prey and defensive attacks in viperids follow certain rules and procedures, see chapter 1.3 Morphology of snakes. The anatomical configuration of the venom mechanism, as well as the ability to differentiate between predation and defense is discernable in viperids by a high rate of so-called dry bites - those where venom is not released - and mere warnings of a strike as a deterrent.

To put off an enemy, snakes employ the most basic sound they can emit - a hiss - despite not being able to hear. In addition, saw-scaled vipers (*Echis)* and rattlesnakes (*Crotalus)* have another method of warning by sound. When threatened, the *Echis* viper emits a crisp or strident (sharp) sound by rubbing together coils of its body, which is covered in thick ridged scales. The use of the rattle on the tail of rattlesnakes (*Crotalus)* serves the same purpose. The speculation that this is a passive form of audible defense to deter herds of running animals in an open plain should not be ruled out. Other forms of deterrence include visibly enlarging the body. This is performed by cobras by erecting and typically extending the ribs in the front part of the body to form a hood, whereas the Gabon viper (*Bitis gabonica*) inflates its neck. Another example is the opening of the mouth to display the different color inside, which could function so as to make the creature more visible and simulate an attack. For instance, as the names suggest, the inner part of mouth of the western cottonmouth (*Agkistrodon piscivorus leucostoma*) is white, and in the black mamba (*Dendroaspis polylepis*) it is black.

The speed and behavior of venomous snakes relates to the safe distance one can stand from them as well as estimating the potential of attack. The swifter the snake is when moving and performing an attack, added to which the physically larger the creature, the greater the distance that must be kept for safety's sake. In cobras and mambas, this can be up to several meters depending on the size of the snake. Considering the 4-meter black mamba (*Dendroaspis polylepis*) or the king cobra (*Ophiophagus hannah*) of 5 meters, these snakes, if ideally positioned, are able to carry out a surprise attack over a distance of nearly two meters without any prior movement. Compared to the species above, the lesser *Vipera* and *Cerastes* genera, or even the rapid saw-scaled vipers (*Echis*), prove incapable of placing a bite at a distance of over 50 cm. Such a short distance can be considered safe with the 'lazy' Gabon viper as well, in spite of its size, unless it is poised in a threatening position. However, the

information above definitely cannot not be applied to the large and short-tempered *Crotalus* and *Bothrops* genera, which are capable of a flying attack of over 1 meter from a point of attack, despite their mighty bodies.

When determining a distance to be kept from a snake, the poise of the creature is crucial. A safe distance from a snake that is lying outstretched, escaping or quietly resting is sure to be reduced and any attack is less probable, unlike in the case of a viper coiled up with its head elevated and ready to strike, a rattlesnake that has formed the typical coil at the front part of its body or an erect cobra threatening to attack.

When kept in a terrarium, an attacking snake protects itself and its limited territory. In fact, keeping any form of safe distance is practically impossible. The apparent calm of the hidden snake should not be mistakenly relied upon, and placing one's hands inside the terrarium in the presence of the snake is likely to wind up in a bite.

Another form of defense employed by snakes and animals alike is that of protective coloring. Spotting the black mamba or a *Trimeresurus* snake in tree branches, the Gabon viper in fallen leaves or the Levantine viper (*Vipera lebetina*) in stony and sandy environments is sure to require a lot of attention.

In addition, certain snakes, the ringhals (*Hemachatus hemachatus*) for instance, feature an ability to play dead, known as *thanatosis*, when the snake lies on its back, exposing its lighter underside, coiling up and opening its mouth. The snake's mouth hangs free in order to resemble bleeding. This puts potential aggressors off due to gathering carrion, although even snakes in this position can prove dangerous to hunters or curious individuals, as they can, nevertheless, bite.

Naturally, escape is the snake's principal and initial form of defense and, as mentioned earlier, when walking around normally, one would hard pushed to actually see a snake even if the area is rife with them. After all, snakes do not crave attention.

REFERENCES

FELIX, J., et al. *Hadi.* 2. vyd. Praha : Statni zemedelske nakladatelstvi, 1981, 155 pp. (in Czech)

GAISLER, J. *Zoologie obratlovcu.* Praha : Academia, 1983, pp. 307-314. (in Czech)

HAYES, WK., LAVIN-MURCIO, P., KARDONG, KV. Delivery of Duvernoy´s secretion into prey by the brown tree snake, *Boiga irregularis* (Serpentes: *Colubridae*). *Toxicon*, 1993, 31, No. 7, pp. 881-887.

HEGNER, D. *Jedovai hadi v prirode a terariich.* Uvaly : Ratio, 1999, 188 pp. (in Czech)

MATTISON, CH. *Hadi.* Praha : Ottovo nakladatelstvi, 2001, 192 pp. (in Czech)

KORNALIK, F. *Zivocisne toxiny.* Praha : SZN, 1967, 288 pp. (in Czech)

KURKA, A., PFLEGER, V. *Jedovatí živočichové.* Praha : Academia, 1984, 165 pp. (in Czech)

MARAIS, J. *Fascinujici svet hadu.* Praha : Rebo Productions, 1995, 143 pp. (in Czech)

MEIER, J., STOCKER, KF. Biology and distribution of venomous snakes of medical importance and the composition of snake venoms. In MEIER, J., WHITE, J. (Eds), *Handbook of clinical toxicology of animal venoms and poisons.* Boca Raton: CRC Press, 1995, pp. 364-412.

REHAK, I. O jedovatosti »nejedovatych« uzovek. *Ziva*, 1990, 38, No. 3, pp. 130-131. (in Czech)

REHAK, I. Evoluce, fylogeneze a taxonomie hadu. *Terarista*, 1991, 2, No. 3-4, p. 18. (in Czech)

REHAK, I. Soucasne nazory na klasifikaci hadu. *Terarista*, 1991, 2, No. 3-4, pp. 18-20. (in Czech)

REHAK, I. Distribution, ecology and variability of snakes in Czechoslovakia. In KORSOS, Z., KISS I. (Eds), *Proc. Sixth Ord. Gen. Meet.* S.E.H. Budapest 1991, 1992, pp. 383-388.

REHAK, I. Serpentes - Hadi, Hady. In BARUS, V., OLIVA, O. (Eds.), *Plazi - Reptilia.* Praha : Academia, 1992, pp. 106-172. (in Czech)

STÖCKLIN, R., CRETTON, G. *The ultimate database on venomous animals, snakes.* CD-rom, Geneva : Atheris Laboratories, 1998.

TRAPE, JF., PISON, G., GUYAVARCH, E., et al. High mortality from snakebite in south-eastern Senegal. *Trans R Soc Trop Med Hyg*, 2001, 95, No. 4, pp. 420-423.

VALENTA, J., SIMAK, J. Intoxikace zivocisnymi jedy. In Pokorny, J. (Ed.), *Urgentni medicina.* Praha : Galen, 2004, pp. 258-264. (in Czech)

VOGEL, Z. *Zezivota plazu prazske zoologicke zahrady*. Praha : Orbis, 1953, 84 pp. (in Czech)

Chapter 2

EPIDEMIOLOGY OF SNAKEBITES

2.1. EPIDEMIOLOGICAL NOTES

Information on epidemiological indicators, incidence, mortality, and morbidity of snakebites is not comprehensive both within particular countries and globally. There are several reasons for this. Due to the limited numbers of venomous snakes, there is such a low incidence of snakebites and subsequent morbidity in European countries that neither sparks statistical concern nor interest from medical circles. Information on the total number of envenomed individuals cannot be obtained, and actually tracing such people within health institutions is practically impossible. The only data available is on patients dealt with by toxinology centers or hospitalized at particular institutions. Thus, the numbers obtained officially that relate to incidence and morbidity are probably highly understated.

The situation in developing Asian and African rural countries where dangerous snakes frequently occur is of a completely different nature. The effects of snakebites are significant in terms of epidemiology; however, the reporting and screening systems are either not uniform in style, are not adhered to or do not exist at all. Moreover, a number of affected persons are not subject to therapy in health institutions, as they seek assistance from traditional indigenous healers, which may be true in up to 80% of cases, or, worst of all, cannot make it to a distant hospital before the severe venom deals them a fatal blow. It is estimated that in developing nations where distances from hospitals are very large, only 50% of all envenomed individuals are within reach of medical care. Therefore, the incidence, morbidity and mortality figures obtained in such regions are substantially lower than the estimated and exact amounts.

Even in countries with well-developed systems of medical services and those governing the reporting of statistics, such as the USA, epidemiological data is not uniform, and the numbers of snakebites unreported and untreated in official medical institutions is assumed to be high as well. Again, official incidence and morbidity figures are certainly lower than those of reality.

With this in mind, epidemiological works from most countries are often elaborated and subject to estimates largely produced on evidence from health institutions and consultation centers, in addition to surveys on families from randomized areas.

In most cases, snakebites by venomous snakes are associated with farming; less frequently, trips in the wild, either temporary or permanent, are involved. In these cases,

lower limbs are the most frequent localization of the bite compared to upper limbs. The numbers of attacks vary according to season.

In industrially developed nations, a certain quantity of snakebites and envenomings are consequences of exotic venomous snakes being kept captive. In the 1990s, exotic snakes were responsible for 21% of snakebites in Utah, the USA. In the Czech Republic, the percentage of attack by exotic venomous snakes accounted for over 40% of the total number, according to consultations at the Toxinology Center of Prague. However, while the numbers of visitations following snakebites by the common viper probably do not match the incidence of actual snakebites, the figures obtained for snakebites by exotic varieties are very close to those of incidence. Therefore, the real percentage of envenoming cases by snakes kept in captivity is likely to be lower. Substantially lower numbers of envenomings by exotic snakes - a mere 4% - are provided in reports by the American Association of Poison Control Centers (AAPCC), within the Toxic Exposure Surveillance System (TESS), for the periods of 1999 and 2000.

Amongst snake holders, the upper limbs are typical areas affected by bites, the usual reasons including work in terrariums in the presence of snakes, the feeding of young snakes and inadequate handling of a snake itself.

2.2. EUROPE

Generally, the importance of the snakebite in terms of epidemiology is minimal for Europe, which also is implied by the statistics available. Envenomings are chiefly caused by vipers of the *Vipera* genus: the common viper (*V. berus*), the nose-horned viper (*V. ammodytes*) and the asp viper (*V. aspis*). Except for the European portion of Turkey (the rock viper *V. xanthina*), snakebites by other European dwelling vipers of the same genus, as well as those carried out by venomous colubrids like *Malpolon monspessulanus*, are rather rare.

A relatively high snakebite incidence has been recorded in *Sweden*, which might have been influenced by the system of reporting to the Swedish Toxinology Center. The territories of the common viper (*V. berus*), are inhabited by 5.3 million people, i.e. 63% of the Swedish population. In 1985-1989, 4,269 incidents resulted in consultation around Sweden. According to other data sources, occurrence is around 1,300 cases a year, with about 12% of those affected being hospitalized; which is equal to the number of 136 patients with zero mortality that were hospitalized in 1975 and that of morbidity: 2.6 per 100,000 inhabitants a year, as reported. However, in 1911-1978, a total of 44 cases of death as a consequence of being bitten by a common viper were recorded.

For *Finland***,** the numbers reported are much higher: morbidity of 4.1 per 100,000 inhabitants and mortality of 0.02 per 100,000 inhabitants a year; which means 0.5% of fatal cases.

In *Italy***,** 2,329 cases of envenomings were recorded in 1980-1984, out of which 62% were asymptomatic cases and 885 persons showed symptoms of envenoming; 3 patients died.

The estimated total numbers are as follows: incidence of snakebites 5 per 100,000 persons, morbidity of 1 per 100,000 and mortality of 0.01-0.04 per 100,000 inhabitants a year. In terms of fatal cases, the figure is 0.1-0.6%.

Spain's data shows a morbidity of 1.4-4 per 100,000 inhabitants and mortality of 0.006-0.02 per 100,000 inhabitants a year; which means some 0.6-1.8% of *fatalities via envenoming.*

In *France***,** the approximate annual incidence of snakebites is 2.5 per 100,000 people, morbidity is below 0.5 per 100,000 people; about 0.3% of those affected die.

The *United Kingdom* reports 200 hospitalizations a year, with a current mortality rate of zero. Morbidity is currently a mere 0.1 per 100,000 inhabitants a year. In 1950-1972, England and Wales recorded only a single fatal case; within the UK, only 14 cases of death as a result of envenoming by the common viper were reported in the last 100 years.

A very low morbidity rate and zero mortality is reported by *Switzerland.*

In *Poland*, there is relatively high percentage of deaths: 1.1%, which is equal to that of Israel, where they report l.3%; however, attacks were performed by much more serious snakes in terms of toxinology. The Polish information might be, and probably is, greatly affected by incomplete or understated morbidity data.

In the *Czech Republic***,** several dozens of snakebites by the common viper are reported annually. The cases of snakebites by exotic venomous snakes are decreasing compared to the past, with several incidents registered a year. However, some of them involve life-threatening envenomings that require therapy utilizing severe medication. No fatal case in connection with a snakebite by the viper or any other species has been recorded by the Toxinology Center within 15 years.

For the *European* population of 730 million people, estimated total numbers involve 25,000 snakebites, 8,000 cases with symptoms of envenoming, and 30-50 fatal cases a year, i.e. 0.37 to 0.62% of those envenomed, which equals the incidence of 3.24 bites per 100,000 inhabitants a year, a morbidity of 1.1 per 100,000 inhabitants a year, and mortality of 0.004-0.006 per 100,000 European inhabitants a year.

2.3. THE MIDDLE EAST

As in North America, the cases of scorpion bites prevail over those by snakes in this region, with dangerous venomous snakes including the *Vipera* and *Macrovipera* genera, such as the Palestine viper (*V. palestinae*), rock viper (*V. xanthina*) and Levantine viper (*M. lebetina*). These snakes take the greatest share of the reported envenomings. Other vipers of the *Cerastes, Pseudocerastes* and *Vipera* genus are insignificant due to their lower toxicity.

In this region, the estimated total quantity of snakebites amounts to 20,000 per 160 million inhabitants, of which there are 15,000 envenomings and a mortality rate of approximately 100 cases a year. The numbers above correspond to this high incidence and morbidity; however, they are not quite in correlation with the data provided for *Israel*, where morbidity is 3-5 cases per 100,000 inhabitants, while mortality reaches 0.3 per 100,000 inhabitants, which means 1.3% of fatal cases. Estimated total incidence amounts to 12.5 cases per 100,000 inhabitants a year, a morbidity rate of 9.4 patients per 100,000 inhabitants a year, and mortality of 0.06 per 100,000 inhabitants a year, which makes for 0.6% of lethal cases from the total number of envenomed patients.

2.4. AFRICA

The African countries are considered among those assumed to have much understated prevalence of statuses associated with snakebites for the reasons listed above. The major representatives of Africa's epidemiologically most serious snakes involve the saw-scaled vipers of the *Echis* genus, i.e. *E. ocellatus* and *E. leucogaster*, the African puff adder (*Bitis arietans*); the black and white cobra (*Naja melanoleuca*) and the black-necked spitting cobra (*N. nigricollis*), mambas (*Dendroaspis* sp.) and the West-African night adder (*Causus maculatus*). As for the north-eastern part of the continent, similarly as in the Middle East, there is the Levantine viper (*Macrovipera lebetina*).

The factors responsible for the high morbidity and mortality values in the developing agricultural countries involve abundance of toxinologically dangerous snakes, a long time of delay due to the poor availability and quality of health facilities, lacking medicaments and antivenoms, and also erudition of the personnel, which is not always satisfactory.

Nigeria reports the incidence of 497-600 snakebites per 100,000 inhabitants a year with 12% of fatal cases, which means mortality of nearly 60 cases per 100,000 inhabitants a year. Up to 10% of beds in hospitals occupied in the country involve cases of snake envenoming. The type of envenoming by *Echis* snakes with its severe symptoms of hemocoagulation failure requiring an intensive and highly-specialized approach is by no means co-responsible for the high rate of mortality in certain regions of Nigeria - especially that related to children - that reaches up to 16%.

A similar situation exists in *Benin*, where the estimated incidence is 450 snakebites per 100,000 inhabitants a year with a lethality rate of 5.6%. Nonetheless, official reports provide only unreal rates of 70 snakebites per 100,000 inhabitants a year, with a lethality rate of 1%.

In *Senegal,* they report mortality following a snakebite 11.7-14 cases per 100,000 inhabitants a year. In *Ghana,* 86 snakebites per 100,000 inhabitants a year occur, with bites largely caused by *Echis* snakes, with a lethality rate reaching up to unbelievable 28%.

Kenya reports the incidence of 150 snakebites per 100,000 inhabitants a year with the mortality rate of 6.7 per 100,000 inhabitants a year; nevertheless, it is assumed that 70% of those affected will not visit any health institution at all, which modifies the provided data to a great extent.

Higher morbidity and lethality rates exist in Côte d'Ivoire: 130-400 cases of envenoming per 100,000 inhabitants a year, with 2% to 28% of fatalities.

Generally, estimated total numbers involve 1 million bites by venomous snakes a year for the *African* population counting 760 million people, with one half, i.e. about 500,000 people, that showed symptoms of envenoming, of which 20,000 people a year die. Such numbers correspond to the incidence of 131 bites per 100,000 inhabitants a year, a morbidity of 65 patients per 100,000 inhabitants a year, and mortality of 2.6 victims per 100,000 inhabitants a year. Fatalities involve about 2% from the number of bitten and 4% from envenomed patients.

2.5. ASIA

A number of Asian countries including India share a similar situation as those of Africa, with resulting high morbidity and mortality of snakebites. The number of deaths, which is 25,000 to 30,000 annually as provided by some authors, seems to be understated.

In Asia, especially in India, snakes co-responsible for the cases of dangerous envenoming involve the Russell's viper (*Daboia russelli*), saw-scaled viper (*Echis carinatus*), Indian cobra (*Naja naja*) for the Asian cobras, Indian krait (*Bungarus caeruleus*) and banded krait (*B. fasciatus*) for kraits, and Malayan pit viper (*Calloselasma rhodostoma*).

Certain *Indian* and *Pakistan* localities report the incidence of 163 snakebites - largely by *E. carinatus* and *D. russelli* - per 100,000 inhabitants a year with a morbidity of 70 cases per 100,000 inhabitants a year and mortality of 2.4 cases per 100,000 inhabitants a year, where lethality ranges from 1.7% to 20% of cases. In the Indian State of Maharashtra, snakebites kill over 1,000 people per year.

In *Sri Lanka*, they estimate 60,000 bites with 900 fatal cases a year. Provided rates of mortality make 5.6, and even 18 cases in some places per 100,000 inhabitants a year. 40% of the envenomings involve snakebites from the Russel's viper (*D. russelli*), while 35% cases goes on the account of the Indian cobra (*N. naja*).

With 2,000 fatal cases a year, death following a bite from *D. russelli* occupies the place 5 on the list of causes of death in *Burma* (Myanmar). The mortality in this country seems to be the highest throughout Asia, thus probably around the globe; nevertheless, such high numbers might be influenced by the higher quality of reporting system compared to that of other Asian regions. The 70% of fatalities in this country is caused by the Russel's viper (*D. russelli*), largely at work in rice fields.

In *Japan,* the incidence varies from 10 to 500 snakebites per 100,000 inhabitants a year depending on the region, with Asian pit vipers of the *Trimeresurus* genus responsible for the most of cases, with morbidity of 0.2 to 120 cases per 100,000 inhabitants a year, and 0.8% to 1% of fatalities. The variance in the figures is determined by the climatic differences between the northern and the southern part of the country, with increased incidence of snakebites and morbidity southwards.

In general, some 4 million snakebites from venomous snakes a year are estimated for the *Asian* population of 3.5 billion people, where symptoms of envenoming are present in one half of the cases, i.e. 2 million, and a total number of deaths is 100,000, which involves the incidence of 114 snakebites per 100,000 inhabitants a year, morbidity of 57 cases per 100,000 inhabitants a year, and mortality of 2.9 victims per 100,000 inhabitants a year. Fatalities involve 2.5% of the bitten persons and 5% of the envenomed patients.

2.6. NORTH AMERICA

Even though the territory of Canada and the USA is inhabited by a number of highly dangerous venomous snakes, incidence and morbidity and mainly mortality figures are very low. The reason is that the situation is 180 degrees different from that of Africa and Asia: snake localities are limited and less-inhabited, good health services are promptly available,

and the quality level of final treatment of envenoming is very high. Deaths in this area are largely caused by delays or cases of refused therapy by patients.

The North America's dangerous snakes are largely the rattlesnakes (*Crotalus*), which for the USA namely involves the western diamond-backed rattlesnake (*C. atrox*) and eastern diamond-backed rattlesnake (*C. adamanteus*).

Within the USA and Canada, they estimate about 45,000 bites from venomous snakes a year, which includes 10,000 cases of envenoming and 6,500 to 7,000 cases of people seeking medical help. Approximately 5 to 15 people a year die from snake envenoming. The snakebite incidence is variable depending on the region from 0.7 to 15 per 100,000 inhabitants a year, morbidity ranges from 0.5 to 5 patients per 100,000 inhabitants a year, and mortality is 0.005 to 0.01 victims per 100,000 inhabitants a year. There are about 0.1-1.6% fatalities a year. However, numbers of envenomings reported by the American Association of Poison Control Centers (AAPCC) in the framework of the Toxic Exposure Surveillance System (TESS) are substantially lower: only 1,729 cases in the wild and 80 cases by exotic snakes held in captivity are provided for 1999; in 2000, there were 1,918 cases of envenoming caused by local snakes and 83 envenomings by exotic snakes.

2.7. CENTRAL AND SOUTH AMERICA

This vast region with diverse habitats is ranged by venomous snakes throughout the most of its territory. Mexican savannahs that involve sandy and rocky habitats are rich in rattlesnakes (*Crotalus*): *C. atrox* and *C. durissus durissus*. For South America, the snakes of the highest concern in terms of epidemiology include the South American rattlesnake (*Crotalus durissus terrificus*), *Micrurus* snakes, and lanceheads like the common lancehead (*Bothrops atrox*), jararaca (*B. jararaca*), jararacussu (*B. jararacussu*) and South American bushmaster (*Lachesis muta*). In *Mexico*, the indicators are supposed to be higher than those of North America, with about 100 mortal cases alone.

In *Brazil*, the incidence of snakebites is 350 to 450 per 100,000 inhabitants a year. Morbidity ranges from 6.8 to 192 cases per 100,000 inhabitants a year, and mortality is 0.4-5 deaths per 100,000 inhabitants a year; fatal cases number 0.4% - 6.5%. The wide ranges above are determined by specific localities; figures for the forest will naturally increase.

In the Brazilian epidemiological analysis of cases in the last 100 years (1901 to 2000), Bochner and Struchiner (2003) provide lanceheads (*Bothrops*) as snakes mainly responsible for snakebites and overall lethality of 0.45%, where 1.87% of snakebites were caused by rattlesnakes (*Crotalus*), 0.95% by bushmasters (*Lachesis*), 0.52% by coral snakes of the *Micrurus* genus and 0.31% by lanceheads (*Bothrops*).

In *Costa Rica*, the morbidity is estimated to 20-35 cases per 100,000 inhabitants a year, and mortality to 0.2-1.2 per 100,000 inhabitants a year. Lethality ranges from 2.3% to 3.3% of the cases. Nevertheless, a survey carried out in the populations of indigenous people showed that the epidemiology indicators in the region would be possibly much higher.

The *Ecuador* situation can be outlined as that of high lethality of the cases - as much as 5.4% of patients treated in hospitals and 6.3% of people treated at home will die. In forest localities, the incidence can reach up to 1,000 snakebites per 100,000 inhabitants a year. Morbidity within country is 16-30 cases per 100,000 inhabitants a year, and mortality is 1.8

per 100,000 inhabitants a year. The highest fatality is reported from *Venezuela:* 6.5% of cases.

The estimated total numbers for the population of 400 million inhabitants in *Central and Southern America* are 300,000 snakebites, 150,000 cases of envenomings, and 5,000 mortal cases per year, which involves the incidence of 75 snakebites per 100,000 inhabitants a year, morbidity of 37 cases per 100,000 inhabitants a year, and mortality of 1.25 deaths per 100,000 inhabitants a year. Overall lethality is 1.6% of the bitten persons and 3.2% of the envenomed patients.

2.8. AUSTRALIA AND OCEANIA

Within the Australian and Oceanian territory, terrestrial venomous snakes are in fact limited only to Australia including Tasmania and the islands located in the north of the continent. New Zealand and most of other Pacific islands are not inhabited by venomous snakes at all. Naturally, the Pacific and Indian Ocean are home ranges of marine venomous snakes. Even though venoms in these animals are highly effective, the epidemiological relevance is quite low: snakebites are not very frequent, concerning mostly local fishermen.

The snakebite incidence specified by *Australian* reports is 3-18 cases of snakebite per 100,000 inhabitants a year, a mean morbidity of 4 envenomings per 100,000 inhabitants a year, and mortality in connection with a snakebite of 0.03 deaths per 100,000 inhabitants a year. Thus, several envenomings per year present mortal cases. In the period from 1981 to 1991, total 18 envenomed persons died in Australia, with 11 deaths caused by brown snakes, *Pseudonaja* and 4 deaths caused by tiger snakes, *Notechis*; 2 affected persons succumbed to snakebites of taipans (*Oxyuranus*) and a single person died from the snakebite caused by a death adder (*Acanthophis*). However, not every death is recorded. The snakes of the *Pseudonaja* genus are considered the most dangerous as their venoms can cause immediate collapse and sudden death.

In *Papua-New Guinea***,** the incidence is much higher with 215-526 bites per 100,000 inhabitants a year, the recorded morbidity relatively lower with 3-82 cases per 100,000 inhabitants, and the mean mortality high with 7.9 deaths per 100,000 inhabitants a year.

In general, 10,000 snakebites, 3,000 envenomings and 200 deaths a year are estimated for the *Australian and Oceanian* population of 20 million people, which involves the incidence of 50 snakebites, 15 envenomings and 1 death per 100,000 inhabitants a year.

2.9. WORLD-WIDE FIGURES

A total of strikes by venomous snakes for the *global population* of 5.85 billion people are estimated to 5.4 million, of which the number of envenomings is approximately 2.7 million of cases (see Fig 4). Reported numbers of deaths as a result of snakebites range from 20,000 (Warrell, 1993) to 50,000 (Swaroop et Grab, 1954) or even up to 125,000 (Chippaux, 1998) cases per year. However, the lower estimations seem to be understated based on the reasons mentioned above, i.e. the high number of untreated and unreported cases world-wide. The WHO (World Health Organization) Report from 1979 is in accord with the calculation above,

stating 250,000 deaths a year as a result of strikes by venomous animals, namely snakes and scorpions. Provided that 50% of the cases were caused by venomous snakes, the numbers approximately match Chippaux's estimations.

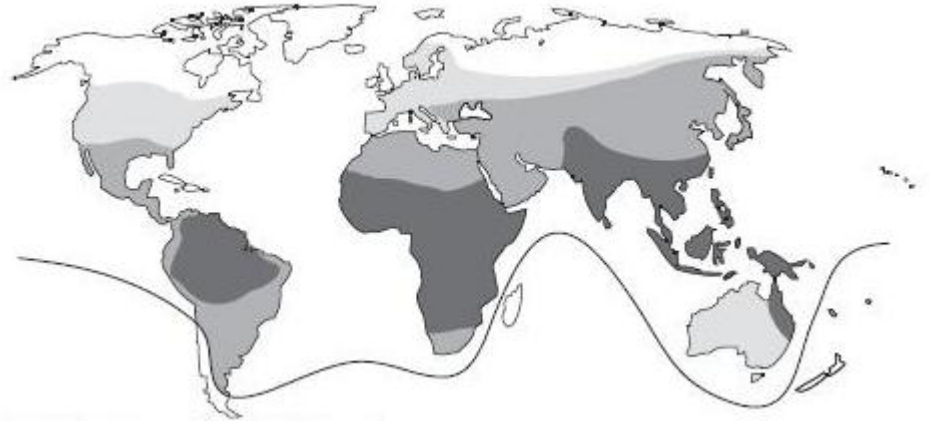

Figure 4. Global incidence of envenomings following snakebites (freely edited according to Chippaux, 1998) (Dark: more than 100 envenomings; midle: 25-100 envenomings; mild: less than 25 envenomings per 100,000 inhabitants a year).

REFERENCES

BOCHNER, R., STUCHINER, CJ. Snake bite epidemiology in the last 100 years in Brazil: a rewiew. *Cad Saude Publica*, Rio de Janeiro 2003, 19, No. 1, pp. 7-16.

HABIB, AG., GEBI, UI., ONYEMELUKWE, GC. Snake bite in Nigeria. *Afr J Med Sci*, 2001, 30, pp. 171-178.

CHIPPAUX, JP. Snake-bites: appraisal of the global situation. *Bulletin of the World Health Organization*, 1998, 76, No. 5, pp. 515-524.

ISMAIL, M., MEMISH, ZA. Venomous snakes of Saudi Arabia and the Middle East: a keynote for travellers. *Int J of Antimikrob Agents*, 2003, 21, pp. 164-169.

KARLSON-STIBER, C., PERSSON, H. Antivenom treatment in Vipera berus envenoming - report of 30 cases. *J Intern Med*, 1994, 235, pp. 57-61.

KURKA, A, PFLEGER, V. *Jedovati izivocichove*, Praha : Academia, 1984, 165 s. (in Czech)

MARAIS, J. *Fascinujici svet hadu*. Praha : Rebo Productions, 1995, 143 s. (in Czech)

MEIER, J., WHITE, J. (Eds.). *Handbook of clinical toxicology of animal venoms and poisons. Boca Raton* : CRC Press, 1995, 752 p.

PERSSON, H., IRESTEDT, B. A study of 136 cases of adder bite treated in Swedish hospitals during one year. *Acta Med Scand*, 1981, 210, No. 6, pp. 433-439.

POZIO, E. Venomous snake bites in Italy: epidemiological and clinical aspects. *Trop Med Parasit*, 1988, 39, pp. 62-66.

REID, HA. Adder bites in Britain. *Br Med J*, 1976, 2, No. 6028, pp. 153-156.

SEKOGUCHI, S., NIKAI, T., SUZUKI, Y., et al. Kinin-releasing enzyme from the venom of Bitis arietans (Puff Adder). *Biochim Biophys Acta*, 1986, 884, No. 3, p. 502-509.

SUTHERLAND, SK. Death from snake bite in Australia 1981-1991. *Med J Aust*, 1992, 157, No. 11-12, pp. 740-746.

SWAROOP, S., GRAB, B. Snakebite mortality in the world. *Bull World Health Organ*, 1954, 10, pp. 35-76.

WARRELL, DA. Venomous bites and stings in the tropical world. *Med J Aust*, 1993, 159, No. 11-12, pp. 773-779.

Chapter 3

SNAKE VENOMS

3.1. SNAKE VENOMS - PHYSICAL TRAITS AND COMPOSITION

Snake venom produced and stored in venom glands is a viscous liquid of either a white, yellow color, or of a dark orange hue depending on the species, age, and condition of the snake. Fresh native venom can be clear, or polluted with the epithelia of ducts and mucin floccules. The operation and effectiveness of a liquid venom has certain time limits. Under normal temperatures, the destruction of toxins takes place outside the venom apparatus, which in part is caused by proteolytic enzymes of the animal and by bacterial activity. On average, fresh venom accounts for only one third of the weight of the same as dry matter.

For laboratory and pharmaceutical purposes, some venomous snake species are kept on farms, where their venom is collected artificially on a routine basis. The fangs of a snake, which is held behind the head, are made to bite through a cellophane cover on a beaker, into which the venom is drained. The venom draining process is accelerated by gently manipulating the venom gland or by soft electrical impulses. Alternatively, venom can be collected without the need for piercing the cover of a vessel but by opening a snake's mouth and carrying out pressure maneuvers. After completing the collecting process, the venom must be immediately modified, which is usually done by centrifugation and subsequent drying. Lyophilized venom may then be stored over longer periods, such as in the order of years or decades. However, some components lose some partial effectiveness during the process of preparing the dry matter, while the activity of others diminishes during storage.

Nevertheless, any loss of effectiveness in fresh venom is something which should not be relied upon, as some components maintain their function even up to a certain level of destruction. For example, cases of envenoming have been recorded during post mortem examinations on dead snakes or via other types of handling of the same, even a long time after death.

3.2. EFFECTIVENESS OF SNAKE VENOMS

Only about 10-20% of snake species are venomous. However, this does not mean that all of them are actually dangerous in every circumstance, as some of them are unable to inject venom via a defensive bite due to their jaws being small or the fangs being inadequately located. Meanwhile, others can only cause nausea or slight symptoms of envenoming as a

result of the quantity of venom and its properties, and only a few of the remainder cause serious envenoming with potentially fatal consequences.

Snake venoms combine dozens of biologically active components, protein-based toxins and enzymes, polypeptide and peptide toxins, polysaccharides, low molecular substances, and ions. The active substances of venoms may be classified subject to their chemical make-up, thus forming two groups: toxins and enzymes.

Toxins consist of peptides, polypeptides and proteins lacking enzymatic activity with molecular weights usually below the range of 3 to 30 kDa. They attack specific targets; most frequently, these involve membrane receptors of target cells in particular systems. The effect of the toxins is determined by the quantity of the toxin and target receptors, and is fully dose-specific. Venoms rich in toxins are found in elapids (*Elapidae*).

Enzymes are substances based on proteins too, but their molecular weight is frequently higher than 30 kDa. Some enzymes feature a lower level of immunogenicity, which is often combined with low molecular glycosylation. The intensity of an enzyme effects is significantly influenced by the time of action, in addition to concentration. Enzymes form the key elements of venoms in viperids (*Viperidae*).

The severity of a snakebite will depend on the toxicity of the venom, type of systemic effect, quantity ingested, and the speed of its release into tissues and systems, i.e. penetration into the hypodermis and muscular matter, as well as the organs via vascular or lymphatic systems.

For snake venom effectiveness, the main parameters include the toxicity of the venom. To facilitate comparison of toxicity, venom quantity related to the weight of the victim needs to be provided. A dose is determined *in vivo* to kill 50% of the group of animals envenomed, which mostly comprise mice; this quantity is referred to as LD_{50}. In the past, other labels existed: the so-called LD_0 (MLD - minimal lethal dose) - the maximum dose that would kill no animals; and LD_{100} (CLD - certain lethal dose), the minimum dose with 100% lethality (see chart 1). The velocity of effect together with a venom's potency can be represented by two values: FTL (Fatal Time Limit) - the duration to the death of the first animal; and LMT (Last Mortality Time) - the duration to the death of the last animal. According to WHO's recommendations from 1981, hemorrhagic and necrotizing venoms are tested by the size of the zone affected on day 1 and day 3 following intradermal application.

The greatest toxicity, defined as LD_{100} for mice, belongs to certain sea snakes, e.g. the common sea snake (*Enhydrina schistosa*) and other elapids, the coastal taipan (*Oxyuranus scutellatus*), the mainland tiger snake (*Notechis scutatus*), and the Indian cobra (*Naja naja*). Probably the highest toxic potency can be assigned to the venom of other taipans - the inland taipan (*Oxyuranus microlepidotus*), a snake also known under a synonym - *Parademansia microlepidota*, which is capable of creating toxicity four times greater than that of the coastal taipan.

The complex nature of snake venoms pre-determines the variability of some traits of the same to some extent.

In addition to the primary or standard type of effect, which is specific to genus or species, variability exists in the composition of particular components, therefore, many times in immunogenicity of venom as a complex. A certain level of variation in toxin composition can be recorded within the particular species inhabiting different regions and, in fact, a single region. The actual make-up of snake venom changes within ontogenesis as well, and variations might possibly depend on the season. Contrary to expectation, a bite by a young

snake is dangerous, as toxins in young snakes can be more effective than those of adults. The possible reasons for this include compensation for their lower speed or poor hunting skills. Another similar factor relates to the greater probable effectiveness of snake venom in early spring following winter hibernation, for instance, in the common viper.

Just like the exact composition of venom within a species, the quantity produced also varies. In large species, the amount is naturally higher (see chart 2). It also depends on the condition of the snake, and the addition of saliva to venom, which may differ.

The action of the venom that occurs following a snakebite depends upon its quantity and composition. Aside from venom toxin potency and venom quantity in venomous apparatus, the factors responsible for the severity of snakebite envenoming in humans include the quantity of venom injected into a wound (see chart 3). In terms of the amount of venom, envenoming by large *Crotalus* species and certain cobras, such as *Naja haje*, can be highly dangerous and might prove even lethal, although these snakes do not compare to the common viper (*Vipera berus*) when it comes to effectiveness in relation to quantity, the latter giving bites resulting in very low morbidity and mortality. Finally, bites by snakes boasting a high number of effective venom components are the most dangerous. The lethality rate for envenoming without any subsequent treatment is 50% for the common death adder (*Acanthophis antarcticus*), 73% for the South American rattlesnake (*Crotalus durissus terrificus*), and even 100% for the coastal taipan (*Oxyuranus scutellatus*).

Chart 1. LD_{100} for 100 g of mice SC

Common seasnake (*Enhydrina schistosa*	0.015 mg	
Coastal taipan *Oxyuranus scutellatus*		0.017
Indian cobra *Naja naja*		0.020
Mainland tiger snake *Notechis scutatus*	0.024	
Black mamba *Dendroaspis polylepis*		0.060
Common death adder *Acanthophis antarcticus*	0.070	
Eastern green mamba *Dendroaspis angusticeps*	0.080	
South American rattlesnake *Crotalus durissus*		0.110
Southern coral snake *Micrurus frontalis*	0.250	
Common viper *Vipera berus*		0.250
Red-bellied black snake *Pseudechis porphyriacus*	0.280	
Egyptian cobra *Naja haje*		0.400
African puff adder *Bitis arietans*		0.600
Jararaca *Bothrops jararaca*		0.700
Southern copperhead *Agkistrodon contortrix*		1.100
Jararacussu *Bothrops jararacusu*		1.750
Western diamond-backed rattlesnake *Crotalus atrox*		1.900
Common lancehead *Bothrops atrox*		3.100

Chart 2. Quantity of dry venom in one collection from an adult snake

Western diamond-backed rattlesnake *Crotalus atrox*		1,500 mg
Western cottonmouth *Agkistrodon piscivorus*		1,100
Gabon viper *Bitis gabonica*		1,000
Red diamond rattlesnake *Crotalus ruber*	700	
Coastal taipan *Oxyuranus scutellatus*		400

Chart 2. (Continued)

South American rattlesnake *Crotalus durissus*		300
Common death adder *Acanthophis antarcticus*	230	
Russell's viper *Daboia russelli*	200	

Chart 3. Lethal doses for a human and a maximum quantity of venom in mg of dry matter

	Human lethal dose	Max. quantity of venom	No. of doses
Coastal taipan *Oxyuranus scutellatus*	5	400	80
Indian cobra *Naja naja*	10-17	230	20
Eastern diamond-backed rattlesnake *Crotalus adamanteus*	60	1,000	16
South American rattlesnake *Crotalus durissus*	24	300	13
Southern coral snake *Micrurus frontalis*	15	60	4
Common seasnake *Enhydrina schistosa*	3.5	15	4
Common viper *Vipera berus*	15	10	0

Viperidae, which are solenoglyphous snakes, regulate to some degree the quantity of venom released. Therefore, a snakebite may not be always accompanied by envenoming, even when delivering a perfect defense bite. Within a single species, a fluent transition exists from warning bites without envenoming, known as dry bites, up to serious or even lethal snakebites, all being determined by the amount of venom injected.

In proteroglyphous elapids (*Elapidae*), which boost venom discharge following a bite by 'chewing', the quantity of venom injected may be reduced. Therefore, the process of envenoming is weakened due to the short duration of a bite in instances of brief attack or immediate separation of the snake.

The minimum incidence of envenoming following a bite by venomous colubrids (*Colubridae*) cannot be put down to a low rate of toxin effectiveness, as it is rather high in certain groups. However, opistoglyphous colubrids have a very small quantity of venom available, in addition to which they hardly ever achieve a full bite and do not discharge a significant amount of venom through their rear fangs, thereby lacking the capacity of delivering a defensive bite.

Generally, envenomation numbers are estimated to be approximately fewer than one half of actual bites. Snakebites by *Pseudonaja* snakes feature the highest incidence of envenomation (80%); the lowest seeming to be that of *Echis* species - a mere 10% (Theakston et al., 2003).

Injecting venom into well-perfused tissue, or even directly into the vascular system, is hazardous. In this respect, rapid death has been described in humans following attacks by the Indian cobra (*Naja naja*), within 15 minutes, and the South American rattlesnake (*Crotalus durissus*) within 10 minutes. Another essential element in cases of venom injection into well-perfused tissue or the vascular system is the composition of venom. When neurotoxins prevail, the resultant effect does not depend on differences in toxicity according to the route

of penetration. The venom of the Indian cobra (*Naja naja*) will act on a mouse in virtually the same quantity whether applied subcutaneously or intravenously. Conversely, venoms of lanceheads, such as the jararaca (*Bothrops jararaca*) and common lancehead (*B. atrox*) with their hemocoagulation and hemorrhagic activities, are frequently more effective when spread within the circulation system if applied intravenously compared to subcutaneous application.

Furthermore, a toxin's effectiveness does not prove identical for all victims. The relative non-susceptibility or, more precisely, a decreased susceptibility to venom exists within related groups of snakes. Conversely, snake venom is phylogenetically formed for maximum effect in relation to potential prey and hunting methods. For example, venom toxins of tree-dwelling colubrids are highly effective on birds, whereas a viper's venom works well on small rodents, etc. The venom of the African boomslang (*Dispholidus typus*) is lethal to a pigeon, starting from a dose of 0.0002 mg, while the equivalent dose for a mouse weighing 100 g is 0.8 mg.

The role of venom does not only involve safe and fast paralyzation, immobilization, or killing of prey, the proteolytic components within the venom also ensure enzymatic destruction of tissue shortly following injection, thus facilitating the subsequent process of digestion.

In general, the effect of venom is identical in both animals and humans. Neurotoxicity is displayed by muscular paralysis, kallikrein enzymes and other vasodilation components produce hypotension, and hemocoagulation affecting substances by hemocoagulation dysfunction. Nevertheless, dissimilarities in action exist, determined by the quantity of toxins in relation to the weight of the victim. The most potent neurotoxins present in the venom of mambas (*Dendroaspis*) are capable of paralyzing small prey practically immediately, while for humans the process of envenoming proceeds successively from the dysfunction of cranial nerves to the main effect on respiratory muscles in the order of several dozen minutes.

Neurotoxins of some viperids (*Viperidae*), for example the Russel's viper (*Daboia russelli*) or the South American rattlesnake (*Crotalus durissus terrificus*), which are partly responsible for killing prey and immobilization, are usually displayed in humans by insignificant dysfunction in the area of cranial nerves, and any such effect may not be at all apparent. The most distinct difference in action of a dose of toxin, depending on weight of the victim, can be seen in venoms with an effect on hemocoagulation. The majority of them cause prey to die immediately from hemocoagulation due to their remarkable prothrombotic potency. However, some of the essentially prothrombotic enzymes in venom stimulate pathophysiological processes, which will, on the contrary, result in either eventual increased hemorrhage or death by exsanguination. This mechanism of action presents one of the main causes for morbidity and mortality in humans when envenomed by snakes, for example, following a snakebite by the *Echis* viper, which practically never happens when hunting in the wild.

3.3. Classification Of Snake Venoms And Their Effects

3.3.1. Classification by Type, Site, and Severity of Envenoming

The type of effects of toxin and human envenoming can be outlined depending on localized or the systemic level of symptoms and their severity. This way, results in terms of

the general destructive effect of venom components on tissues can be differentiated from specific effects on particular systems. The destruction caused by enzymes and toxins will be expressed by damage at either a localized (i.e. necrosis) or systemic level, such as myonecrosis, damage to the capillary system with subsequent extravasation, hypotension, and shock. Systemic specific damage then principally involves neural tissue, neuromuscular junctions, conductive apparatus of the heart and myocardium, platelets, the plasma coagulation system, effects on renal structures, etc.

With this in mind, the three basic types of envenoming that follow can be identified:

Type 1: Enzymatic type. Largely with local symptoms, tissue damage, extra vascular transfers of water, and the development of edema, as well as hypotension, even shock. Symptoms are largely subject to the actions of enzymes.

Type 2: Toxin type. This brings about a systemic effect, which is predominantly more serious, with minor local traces. Symptoms are largely subject to actions of toxins.

Type 3: Combined type. Both localized and systemic effects are distinguishable, with either the former or latter dominating depending on the case in question. Symptoms are determined by the action of both enzymes and toxins. Unfortunately, neither the severity of envenoming nor the nature of the damage, i.e. toxin effect, can be evident from this classification method.

3.3.2. Classification by Systemic Effect and Symptoms of Envenoming

In most cases, toxins and, consequently, in part the clinical symptoms of envenoming can be differentiated according to the system they affect. The severity of envenoming is determined by the level of influence, damage to failure of organs or systems. In addition, using this key to categorize toxins has its advantages. One type of a toxin can often contribute towards damage to several systems. Phospholipase A_2 (PLA_2), the isoenzymes which damage various tissues, systems, and organs, serves as an example. Due to its enzymes that can act, for instance, as presynaptic neurotoxins, results show locally destructive activities, damage to endothelium, and the exertion of a number of other activities.

However, a single clinical system or organ can be affected and caused detriment to by a number of types of toxins of a different nature and method of effect; examples include venom components that affect the cardiovascular apparatus by acting on the conductive apparatus of the heart, myocardium, vessel resistance, and vessel wall integrity. They do so via totally diverse biochemical and pathophysiological mechanisms, starting with dysrhythmia and extending to extravascular hypotension.

3.3.2.1. Venom Components with Localized Effects

The snake venom substances that act locally are principally of enzymatic type. Their destructive action does not specifically target certain types of tissues, but it tends to focus on molecules forming such tissues. Protein-degrading enzymes, i.e. proteolytic enzymes, are referred to as proteinases (proteases), with representatives classified depending on the nature of the active centre of the enzyme: aspartate, cysteine and serine proteinases, and metalloproteinases. Endopeptidases destruct proteins by lysis of inner peptide chains, while exopeptidases degrade the ends of the peptidic chains. Other hydrolytic enzymes in snake

venom include those that cleave lipids, phospholipids, saccharides, polysaccharides, and nucleic acids. Hyaluronidases (hyases) are enzymes that contribute towards destroying mucopolysaccharide components of tissues through hydrolysis.

Other components with a localized effect include a number of PLA_2 forms, hemorrhagins of variable enzymatic and non-enzymatic contents, and myotoxins. However, the action of such components involved in effects of the most severe localized type often becomes widespread, resulting in the development of primary intravascular hemolysis via the destruction of erythrocyte walls, damage to endothelium, including extravasation, and deep myolysis.

Locally acting enzymes chiefly cause intradermal bleeding, damage to tissue and necrosis within the bitten site, just like necrotoxins do, but they impact in a general way too, i.e. myodestruction, myoglobinuria, renal failure, extravasation and hemorrhaging . A varying quantity of these enzymes is present in virtually any venomous snake, with a clinically significant concentration in venoms of viperid snakes (*Viperidae*), i.e. members of *Bitis*, *Daboia*, *Echis,* and *Macrovipera* genera, and also the *Crotalinae* subfamily, namely the *Crotalus* genus. In addition, localized effects of venoms are caused by some elapid snakes (*Elapidae*), for instance several cobras of the *Naja* genus. Furthermore, localized detriment can be also caused by cytotoxic polypeptides without enzymatic activity.

Types of Enzymes with Localized Effects - Examples:

* *Alanin aminotransferase*, L-alanin molecule degradation.
* *Phospholipases*, phospholipid-destructing hydrolases, e.g. phospholipase A_2 *(PLA_2)*.
* *Acetylcholinestherase*, acetylcholine-degrading hydrolytic enzymes.
* *Alcalic* and *acid phosphatase*, phosphoester decomposition.
* *5´-nucleotidase*, 5´-ribonucleotide destruction.
* *Phosphodiesterase*, 5´-nucleotide elimination from oligonucleotide molecules.
* *Desoxyribonuclease* and *ribonuclease*, cleavage of DNA and RNA.
* *Hyaluronidase*, cleavage of hyaluron acid and its salts contained in tissues.
* *Non-specific proteases*, hydrolysis of casein, hemoglobin, and gelatine molecules.
* *Elastase*, hydrolysis of elastin.
* *Hemorrhagic proteases*, collagen destruction.
* *Collagenases*, collagen proteolytic degradation.

3.3.2.2. Venom Components with Neurotoxic Activities

In most cases, neurotoxins cause a reversible effect on neuromuscular transmission, which is exhibited by progressive muscular paralysis. The symptoms of muscular paralysis primarily start in the region of the cranial nerves with ptosis, ophtalmophlegia, hazy or double vision, dysarthria, dysphagia featuring increased salivation, and facial muscle weakness.

In more serious cases, a weakness in limbs and loss of deep tendon reflexes spread, most severely resulting in paralysis of respiratory muscles. In some cases, the onset of neurotoxic symptoms has been recorded after just several minutes, but in others 6-10 hours following a bite. Death caused by suffocation under full consciousness will ensue unless respiratory support is offered. Several neurotoxins may also have a local anesthetic effect, revealed through paralysis of sensitive nerves at the wound.

Neurotoxins form a significant portion of venom in elapids (*Elapidae*). In that of other families, these components are present in a lesser quantity and have a considerably reduced

effect. In vipers (*Viperinae*), neurotoxins bearing a clinically apparent effect are found in the Russel's viper (*Daboia russelli*), common viper (the *Vipera berus bosniensis* subspecies), asp viper (*Vipera aspis*), and others. As for *Crotalinae* members, a significant neurotoxic activity has been reported from the South American rattlesnake (*Crotalus durissus terrificus*).

Generally, two basic types of neurotoxins - presynaptic and postsynaptic - are recognized. The majority of neurotrophic components in snake venom are grouped under one of these.

Presynaptic Neurotoxins

Presynaptic neurotoxins may partially be responsible for the disorder of conduction, or transmission of impulses on neuromuscular end-plates in particular, but presumably on other types of neural connections as well.

PLA_2 are the main type of presynaptic neurotoxins. The mechanisms of all presynaptic effects of neurotoxins still have not been fully explained. They include blocking potassium, sodium, and calcium channels of the terminal axon, as well as damage to or destruction of the axon, with the resultant release of acetylcholine (ACh) from neural endings and its subsequent absence, including disorder or complete blocking of transmission, which might even be irreversible.

In most cases, the onset of symptoms will be delayed; they rarely occur sooner than 1 to 2 hours after a snakebite. The developing symptoms of the effect of toxins cannot be influenced by an antivenom; they will only abate after some time based on the repair of relevant terminal axons. Considering the possible irreversibility of damage to these structures, it is important that antivenom is administered promptly, before any clinical manifestation of the symptoms.

Typical presynaptic neurotoxins will not cause fatal muscular paralysis with subsequent elimination of respiratory muscles, but only affect cranial nerve muscles, triggering the relevant symptoms and general muscle weakness. It is possible that the effect of these toxins is also a factor in certain vegetative symptoms from envenoming by viperid snake (*Viperidae*) venom.

Presynaptic neurotoxins do not form any major component of neurotoxins in the venoms of coral and sea snakes, whilst in viperids these neurotoxins mostly present a single venom component of neurotoxic importance. Certain exceptions exist, involving the Russel's viper (*Daboia russelli*), South African mountain adder (*Bitis atropos*), South American rattlesnake (*Crotalus durissus terrificus*), and some of the Asian moccasins (*Gloydius*), as a certain amount of postsynaptic α-neurotoxin has been isolated from the venoms of these snakes as well.

Fasciculins can be ranked among the neurotoxic components of snake venom that also act presynaptically. These are acetylcholinesterase (AChE) inhibitors, thus increasing the quantity of available ACh on a neuromuscular end-plate, which results in muscular fasciculations; contractions like these do not seem to possess any paralyzing effect, although they can potentiate the effect of certain presynaptic neurotoxins. These components are contained in the venoms of some coral and sea snakes, including the black and green mamba (*Dendroaspis polylepis*, *D. viridis*), but not the Jameson's mamba (*D. jamesoni*).

Presynaptic effects can be observed in *dendrotoxins* of the mamba (*Dendroaspis sp*), although with use of a different kind of mechanism. By blocking potassium channels, these substances cause a surplus of available ACh, permanent depolarization, elimination of a neuromuscular end-plate and muscular paralysis. Their effect is boosted by the anticholinesterase action of fasciculins.

Enzymes with a Presynaptic Effect or Enzymes where Such Effect is Predominant - Examples:

* *Acanthoxin* (AcTX), neurotoxic PLA_2 isolated from the venom of the common death adder (*Acanthophis antarcticus*).

* *Agkistrodotoxin* (AgkTX), neurotoxic PLA_2 isolated from the venom of the Halys pit viper (*Agkistrodon halys*).

* *Ammodytin*, neurotoxic PLA_2 from the venom of the nose-horned viper (*Vipera ammodytes*).

* *Ammodytoxin* (AmTX), neurotoxic and myotoxic PLA_2 isolated from the venom of the nose-horned viper (*Vipera ammodytes*) and Russel's viper (*Daboia russelli*).

* *Bungarotoxin β* (BgTX-β), neurotoxic PLA_2 from venoms of kraits (*Bungarus* sp.). The toxin causes a presynaptic block of neuromuscular end-plates by inhibiting the release of ACh on the neuromuscular end-plate.

* *Caudoxin* (*Caudotoxin*, CDX), neurotoxic PLA_2 isolated from venoms of the Russel's viper (*D. russelli*) and Africa's horned puff adder (*Bitis caudalis*).

* *Crotoxin*, a PLA_2-containing protein complex; a substance with neurotoxic, hemolytic, and necrotizing effects, affecting the release of ACh on the neuromuscular end-plate. Isolated from the venom of the South American rattlesnake (*Crotalus durissus terrificus*).

* *Daboiatoxin* (DbTX), neurotoxic PLA_2 isolated from the venom of the Russel's viper (*Daboia russelli*).

* *Dendrotoxins* (DTX), a series of toxins isolated from mamba (*Dendroaspis* sp.) venoms in form of small protein molecules blocking voltage-controlled potassium channels in neurons. The DTX I subtype of the black mamba (*D. polylepis*) belongs to the most efficient venoms at all.

* *Calciseptin*, a highly efficient toxic neuropeptide, a selective blocker of L-type Ca^{2+} channels, isolated from the venom of the black mamba(*D. polylepis*).

* *HTe* and *HTg toxins*, neurotoxic PLA_2 isolated from the venom of the mainland tiger snake (*Notechis scutatus*).

* *Mojave toxin* (MoTX), neurotoxically acting PLA_2 that exists in all neurotoxic rattlesnakes of the *Crotalus* genus.

* *Notexin* (NoTX), neurotoxic PLA_2 and anticoagulation PLA_2 isolated from the venoms of the Russel's viper (*Daboia russelli*) and the mainland tiger snake (*Notechis scutatus*).

* *Paradoxin* (PDX), PLA_2 with neurotoxic and coagulation effects isolated from venoms of the coastal taipan (*Oxyuranus scutellatus*) and inland taipan (*O. microlepidotus*).

* *Pseudexins* (PsDX-A,-B,-C), a complex of isoenzymes of neurotoxic PLA_2 isolated from the venom of the red-bellied black snake (*Pseudechis porphyriacus*).

* *Taipoxin* (TaXn), a toxin with a strong neurotoxic PLA_2-like and coagulation effect. It prevents ACh to release from cholinergic nerve endings of the neuromuscular end-plate. The toxin was isolated from the venom of the coastal taipan (*Oxyuranus scutellatus*).

* *Textilotoxin* (TeTX), a complex of toxins possessing a coagulation, hemodestruction and thrombin-activating effect. Presynaptic neurotoxicity is also involved. Isolated from the venom of the eastern brown snake (*Pseudonaja textilis*).

* *Trimucrotoxin*, neurotoxic and myotoxic PLA_2 isolated from the venom of the brown-spotted pit viper [*Protobothrops* (formerly *Trimeresurus*) *mucrosquamatus*].

Postsynaptic Neurotoxins

Postsynaptic neurotoxins (α-type) bind with high affinity to the α-subunits of neuromuscular end-plate nicotinic cholinergic receptors, where they competitively inhibit ACh, through which they bring about a curare-like form of blocking and muscular paralysis affecting striated muscles. The molecule of these neurotoxins is relatively small, which facilitates the speed of penetration and distribution into the circulation following the bite. The onset of the effect is more rapid compared to presynaptic toxins, which sometimes require several minutes but often 30 minutes to 2 hours. The progress and lethality of the envenoming is more severe due to a paralyzing effect on striated muscles, i.e. respiratory muscles. The effect of postsynaptic neurotoxins is reversible and can be controlled by antitoxins, even in cases of insufficient immunogenicity, which could be explained by molecular size. In addition, a therapeutic effect can be reached by increasing the amount of ACh by administering AChE inhibitors, such as neostigmin.

Biochemically, postsynaptic neurotoxins are classified in two groups according to molecular size - short chain (60-62 amino acids) and long chain (70-74 amino acids) toxins.

Another type of toxin with postsynaptic action involves *kappa* neurotoxins that can block acetylcholine receptors of neuronal transmission, which largely affects vegetative functions.

Postsynaptic neurotoxins make up the main functional part of venom in coral and sea snakes. Only rarely are they found in small quantities in venoms of some viper and rattlesnake species; see presynaptic neurotoxins.

Toxins with a Postsynaptic Effect or Toxines where Such Effect is Predominant - Examples:

* *Bungarotoxin* α (BgTX-α), a neurotoxin from krait (*Bungarus* sp.) venoms. Causes postsynaptic blocks of neuromuscular end-plates.

* *Dendroaspin*, a neurotoxin found in the venom of the Jameson's and green mamba (*Dendroaspis jamesoni* and *D. viridis*, respectively).

* *Erabutoxins* (ErTX-A,-B,-C), postsynaptic nACh (nicotinic cholinergic receptor) blockers isolated from the venom of *Laticauda semifasciata*, a sea krait species.

* *Hannalgesin*, a neurotoxin of the king cobra (*Ophiophagus hannah*) with analgesic effects that can be blocked using Naloxon.

* α-*cobrotoxin* (*neurotoxin 3*), an effective blocker of nicotinic ACh receptors on neuromuscular end-plates. Isolated from the venom of the Indochinese spitting cobra (*Naja naja siamensis*).

3.3.2.3. Venom Components with Effects on the Cardiovascular Apparatus

Substances affecting the cardiovascular apparatus comprise a relatively diverse range of toxin and enzyme types, with varying target areas as well. Toxins decrease or conversely increase vessel resistance, thus modifying systemic pressure, and affect heart function - frequency, rhythm, myocardial contractility, and heart output.

Vasodilation is probably caused by both direct action of toxins on the vascular system and the release of kinin-based hypotensive substances into the circulation, which result in declining peripheral vessel resistance and hypotension, but in severe cases even circulation collapse and shock. The decrease in pressure and the shock status is partially caused by, amongst other things, damage to vascular epithelium at an endothelial level, endothelial

junctions, and basal membrane, which is made manifest by extravasation of liquids, both at a localized and systemic level. The mechanism, as well as a possible hemorrhaging, will greatly potentiate the occurrence of circulatory failure including tissue and organ perfusion disorder, with the symptomatology of capacity shock.

Since toxins damaging the integrity of vessel walls - hemorrhagins - affect at the same time a number of other systems, they are covered by a separate chapter despite their crucial role in potential fatal circulatory failure.

The venoms of burrowing asps (*Atractaspis*), contain sarafotoxins, substances increasing vessel resistance and decreasing heart output. Other toxins from burrowing asp venom cause coronary vasoconstriction, and ultimately bring on spasm, as well as changes in ECG (electrocardiogram) in terms of ST-segment elevation and AV-blocking (disorder of the atro-ventricular conduction in the heart), temporarily increasing myocardial contractility.

Specific substances affecting the heart occur as cardiotoxins in the venom of the cobra (*Naja*). Similar toxins are contained in that of the Gabon and rhinoceros vipers (*Bitis gabonica* and *B. nasicornis*, respectively). These toxins can cause rhythm and contractility disorders, a temporary increase in coronary flow, with a subsequent loss in coronary and systemic vessel resistance, and they can even cause direct damage to cardiac muscle. Cardiotoxic action, in terms of decrease in myocardial contractility, constriction of coronary flow, and decrease in systemic pressure, can be assigned to tumor necrosis factor (TNF) as well as other cytokines released under envenoming by venoms of certain viperid species (*Viperidae*), with examples including the asp viper (*Vipera aspis*).

Toxins, more particularly enzymes decreasing peripheral vessel resistance, thus systemic pressure, are contained in the toxin range of the majority of viperids (*Viperidae*), which specifically concerns *Crotalinae* snakes. Amongst others, these toxins were isolated from the venom of *Bitis* snakes of Africa. This involves kallikrein-like enzymes, collectively referred to as kinin or bradykinin releasing enzymes, which are obviously the most important cause of hypotension occurrence beyond extravasation and hemorrhaging . Bradykinin stimulates vascular endothelium to produce nitric oxide (NO), a substance that exerts significant vasodilation activity via action on the cells of a vessel wall's smooth muscles. The highest values of bradykinin-releasing activity were found in the venoms of the Northern Pacific and western diamond-backed rattlesnakes (*Crotalus viridis* or *C. atrox*, respectively), and the Gabon (*Bitis gabonica*) and nose-horned vipers (*Vipera ammodytes*). In venoms of elapids, kininogenases are only represented marginally or not at all. The highest level of activity has been recorded in the venom of the Chinese cobra (*Naja atra*).

Except for the enzymes above, the participation of other peptides acting at other levels, such as centrally, is presumed to occur.

Examples of Toxins and Enzymes with Effects on the Function of Heart and Vascular Apparatus:

* *Angiotensin converting enzyme inhibitors* (ACE), present for instance in venoms of lanceheads (*Bothrops* sp.). They can cause an acute hypotension by blocking conversion of angiotensin I to angiotensin II, and by decreasing degradation of bradykinin that is cleaved by ACE as well.

* Kallikrein-like *kinin-releasing enzymes*, for example a *bradykinin potentiating factor*, are contained in venoms of certain vipers (*Viperinae*) and rattlesnakes (*Crotalinae*).

* *Cobrotoxins* (Cbt), components of venoms of the cobra (*Naja*) and other coral snake genera; they include a cardiotoxin with arrhythmogenic effects reducing myocardial contractility.

* *Sarafotoxins* (Srt), vasoconstricting peptides increasing systemic vascular resistance and reducing heart output. A part of venoms in burrowing asps (*Atractaspididae*).

* *TaiCatoxin* (*taicatoxin*, TCX); a complex of toxins blocking Ca^{2+} channels of excitable membranes, for example in the heart. This toxin with a PLA_2 activity is contained in the venom of the coastal taipan (*Oxyuranus scutellatus*).

* *HTe toxin* that exists in the mainland tiger snake (*Notechis scutatus*) and black tiger snake (*N. ater*), a protein with a PLA_2 activity causing hypotension, etc.

3.3.2.4. Venom Components with Effects on the Vessel Wall

Vessel wall and function affecting toxins and enzymes are collectively termed *hemorrhagins.* They cause endothelial damage in form of swelling or even desquamation, and disorders to endothelial junctions. They could prove the reason for disruption of collagen fibrils, damage to vessel basal membrane, and myonecrosis. The actions mentioned above will result in vessel integrity disorders, largely manifesting themselves by extravasation in the capillary area, i.e. leakage of liquids, ions, and later even plasmatic proteins and blood elements outside the bloodstream. Clinical symptoms include edema that is mostly visible in the hypodermis of the affected area and, in the case of increased activity or a higher quantity of toxins, edema of the pulmonary interstitium with symptoms of acute pulmonary failure of the ALI/ARDS type (acute lung injury / acute respiratory distress syndrome). A more severe effect on vascular integrity will cause leakage of erythrocytes outside the bloodstream. In cases of mild exposure, only local hemorrhaging occurs along with petechiae, ecchymoses, and hemorrhagic vesicles, or combinations with the leakage of liquid, producing a hemorrhagic edema in the body part affected. If exposure is higher, severe hemorrhaging is manifest on mucous membranes and gums, in addition to near the bite wounds, whilst bleeding into the gastrointestinal tract or brain will also occur.

In certain hemorrhagins, even direct hemocoagulation activities may occur that will inhibit or conversely activate aggregation of blood platelets and possess a fibrinolytic effect.

The indirect impact of hemorrhagins on the hemocoagulation system involves endothelial cell function disorders and disintegration, and exposure of or damage to the collagen and basal membrane. For example, a tissue plasminogen activator (tPA) can be released, and fibrinolysis increased. Over the acute phase of the action, hemorrhagins will not primarily display procoagulation activities, nonetheless, as the envenomation proceeds, any procoagulation and prothrombotic effect upon the abatement of increased fibrinolysis and inhibiting action on platelets cannot be precluded due to damage to endothelium and sub-endothelial structures.

Due to leakage of liquids from the vascular system and hemorrhaging, as well as by stimulating endothelium to produce vasoactive mediators (NO, PGI_2), hemorrhagins play a great part in triggering hypotension, circulatory failure, and shock.

The majority of isolated hemorrhagins belong to a group of rather non-specific proteolytic zinc-containing enzymes - Zn metalloproteases. They are usually classified as two main groups according to molecular size and mechanism of effect. Typically, the first group with a lower molecular weight (20-25 kDa) will have hemorrhagic and fibrinogen-degrading

properties, while the other, possessing a larger protein molecule (50-90 kDa), will often have desintegrin properties - it inhibits platelet aggregation.

Hemorrhagins are contained in the venom of most viperid snakes (*Viperidae*), burrowing asps (*Atractaspididae*), as well as those of some Australian terrestrial elapid snakes.

Hemorrhagins isolated from various kinds of snake venoms are mostly termed on a basis of specific hemorrhagic activity when applied intradermally in the black rat. Naturally, one creature cannot fully express their systemic hemorrhagic effectiveness in the circulation as experienced by diverse animal species, which is due to wide species-specific variability concerning the representation of plasma protease inhibitors that exist in vertebrates. In most cases, non-specific metalloproteases can be expected to act locally; however, they are immediately inhibited in circulation by plasma inhibitors. That is why it is not fully clear as to what extent hemorrhagins are responsible for symptomatology of diffusion microvascular bleeding accompanied by heavy envenomation by the venom of viperids (*Echis*, *Daboia*, *Bothrops*) or boigas (*Dispholidus*, *Thelotornis*). The auto-aggressive action of inflammation mediators and, in particular, that of the coagulation enzymes like thrombin and plasmin, being explosively attacked by specific venom proteinases, is likely to play a more important role in this circumstance than the action of non-specific venom proteases.

Examples of Toxins Affecting the Vascular Wall:

* *Ac1 5*, *AaH I-III*; arrays of hemorrhagic metalloproteases from the venom of the Chinese moccasin (*Deinagkistrodon acutus*).

* *BaH 4*, a hemorrhagic metalloproteinase isolated from the venom of *Bothrops atrox asper* (*B. atrox*).

* *Bothropasin*, a hemorrhagic metalloproteinase from the venom of the jararaca (*Bothrops jararaca*).

* *Crotalotoxin*, a toxin with hemorrhagic, myolytic, fibrinolytic and neurotoxic properties isolated from the venom of *Crotalus durissus vegrandis*.

* *Hemorrhagic factors* (*HF*), metalloproteases from venoms of the Israeli mole viper (*Atractaspis engaddensis*), jararaca (*Bothrops jararaca*) and brown spotted pit viper [*Protobothrops* (formerly *Trimeresurus*) *mucrosquamatus*].

* *HP IV*, a hemorrhagic metalloproteinase with a fibrinolytic activity isolated from the venom of the timber rattlesnake (*Crotalus horridus*).

* *HR I, II*, arrays of hemorrhagic metalloproteinases with fibrinolytic activities isolated from venoms of the habu [*Protobothrops* (formerly *Trimeresurus*) *flavoviridis*] and the common bamboo viper (*T. gramineus*).

* *HT a, b, c, d, e, f, g, 1, 2, 3*, hemorrhagic metalloproteinases isolated from venoms of the western diamond-backed rattlesnake and red-diamond rattlesnake (*Crotalus atrox* and *C. ruber*, respectively), and also from those of the mainland tiger snake (*Notechis scutatusi*) and the black tiger snake (*N. ater*).

* *ICPP (increasing capillary permeability protein)*, a protein isolated from the venom of the Levantine viper (*Macrovipera lebetina*) with hemorrhagic properties.

* *Jararhagin*, a metalloproteinase with a hemorrhagic effects and anti-aggregation as well as fibrinolytic properties isolated from the venom of the jararaca (*Bothrops jararaca*).

* *Moojeni protease A*, a metalloproteinase from the venom of the Brazilian lancehead (*Bothrops moojeni*).

* *Mutalysin II*, a hemorrhagic metalloproteinase isolated from the venom of the South American bushmaster (*Lachesis muta*).

* *Mucrotoxin A*, one of the hemorrhagic metalloproteinases from the venom of the brown spotted pit viper [*Protobothrops* (formerly *Trimeresurus*) *mucrosquamatus*].

* *Proteinase H*, a metalloproteinase from the venom of the eastern diamond-backed rattlesnake (*Crotalus adamanteus*).

* *Rhodostoxin* (RhTX), a hemorrhagic toxin isolated from the venom of the Malayan pit viper (*Calloselasma rhodostoma*).

3.3.2.5. Venom Components with Effects on Hemocoagulation

Snake venoms contain a number of toxins and enzymes affecting the function of the hemocoagulation system - hemostasis. They interfere with the majority of processes in the plasma coagulation system (PCS), moreover, they have an impact on the functioning of platelets (PLT) as well as that of endothelium. The damage to endothelial and sub-endothelial function and morphology, which has an essential impact on hemocoagulation disregulation, is mentioned in the previous chapter covering hemorrhagins. The PCS and PLT functions can be affected in terms of both procoagulation and anticoagulation. The outcome is pre-determined specifically by the type of the toxin, but also by the level of exposure or pathophysiologic changes depending on the duration since the beginning of an envenoming. For such reasons, splitting the hemocoagulation-affecting toxins into groups according to the targeted point of their effect may prove more acceptable than by eventual effect.

Clinically, the effect of hemocoagulation toxins in humans will largely be manifest as hemorrhaging, even though in a hunted animal, a number of components will cause widespread acute thrombotization, which is solely pre-determined by the quantity of toxins related to the size of the prey. Again, disregulation of hemocoagulation proceeds subject to the dose and effectiveness of the venom, from mere laboratory abnormities like hypofibrinogenemia, prolonged PT (prothrombin time), APTT (activated partial thrombin time), TT (thrombin time), and RT (reptilase time), and an increase in FDP (fibrin degrading products) as far reaching as profuse and unmanageable bleeding from traumas, mucous membranes and into organs, which in a number of cases will eventually result in death and largely caused by DIC-like disorders with a great portion of hyperfibrinolysis. Toxins with hemocoagulation activity are probably responsible for the majority of fatal cases of envenomation by snake venoms around the world, largely those of *Echis* and *Daboia* snakes.

Hypercoagulation and thrombotic symptoms of envenoming will first manifest themselves in laboratory findings by shortening coagulation periods, decreased AT (antithrombin III) activity, and an increase in D-dim (D-dimer fibrin degradation product) to high pathologic values. Even clinical symptoms of thrombotization or microthrombotization, such as in bloodstream of the brain, mesenteric and coronary vessels, are nothing exceptional.

Hemocoagulation toxins are found in most venomous snakes, typically boigas (*Dispholidus* and *Thelotornis*), but also vipers (*Viperinae*) of the *Atheris*, *Bitis*, *Daboia*, *Echis,* and *Macrovipera* genera, and *Crotalinae* members, e.g. *Bothrops*, *Lachesis*, *Agkistrodon*, *Crotalus,* and *Trimeresurus* genera. They are also inherent in the venom of Australian terrestrial elapids, sea snakes and sea kraits, as well as that of some *Naja* cobras.

Hemostasis as such is determined by the action of toxins on diverse structures of the hemocoagulation system.

Venom Components with Effects on Platelets

The impact on the function of PLT is mostly determined by the action of the toxin on either the surface activating structures of platelets or von Willebrand's factor (vWF). Inhibition of platelet aggregation is caused by enzymes of PLA_2, fibrinogenase, nucleotidase, ADPase (adenosine diphosphatase), and L-amino-acid-oxidase types and non-enzymatic toxins. A number of enzymes, largely these of PLA_2 type, have a pro-aggregating and agglutinating effect on platelets as well, in addition to non-enzymatically acting components. A considerable quantity of venom components determining the function of PLT has been isolated, which largely belong to viperids (*Viperidae*).

Naturally, changes in the function, i.e. adherence of platelets, can be also triggered or potentiated by activation at the site of damage on the vessel wall and exposure of collagen to the basal membrane, both at a localized and systemic level. In laboratory findings, such a status will be manifest by a higher or lower level of thrombocytopenia.

Examples of Enzymes and Toxins Affecting Platelets:

* *PLT aggregation enzymatic inhibitors*, isolated from venoms of the Halys pit viper (*Gloydius halys*), Russel's viper (*Daboia russelli*), asp viper (*Vipera aspis*), Palestine viper (*Macrovipera palestinae*), eastern diamond-backed rattlesnake (*Crotalus adamanteus*), Chinese moccasin (*Deinagkistrodon acutus*), Asian pit viper (*Calloselasma rhodostoma*), brown spotted pit viper [*Protobothrops* (formerly *Trimeresurus*) *mucrosquamatus*], common bamboo viper (*T. gramineus*), and black-necked spitting cobra (*Naja nigricollis*).

* *Applaggin*, a protein PLT inhibitor from the venom of the western cottonmouth (*Agkistrodon piscivorus*).

* *Arietin*, *bitistatin*, a protein PLT inhibitor from the venom of the African puff adder (*Bitis arietans*).

* *Cardiotoxin* (CTX), a protein PLT inhibitor from the venom of the black-necked spitting cobra (*Naja nigricollis*).

* *Carinatin* and *echistatin*, peptide PLT inhibitors from the venom of the saw-scaled viper (*Echis carinatus*).

* *Desintegrin*, a common name for antagonists of surface glycoprotein PLT receptors preventing platelet activation, adhesion and aggregation (*arietin*, *bitistatin*, *gabonin*, *jaracetin,* etc.).

* *Lebetins*, PLT aggregation inhibitors from the venom of the Levantine viper (*Vipera lebetina*).

* *Enzymatic PLT aggregation activators*, isolated from venoms of the saw-scaled viper (*Echis carinatus*), timber rattlesnake (*Crotalus horridus*), common lancehead (*Bothrops atrox*), southern copperhead (*Agkistrodon contortrix*) and brown spotted pit viper [*Protobothrops* (formerly *Trimeresurus*) *mucrosquamatus*].

* *Aggregoserpentin*, a protein PLT aggregation activator isolated from venoms of the brown spotted pit viper [*Protobothrops* (formerly *Trimeresurus*) *mucrosquamatus*], common bamboo viper (*T. gramineus*), and Asian pit viper (*Calloselasma rhodostoma*).

* *Bitiscetin*; evokes PLT agglutination through binding to vWF. Isolated from the venom of the African puff adder (*Bitis arietans*).

* *Convulxin*, a protein PLT aggregation activator isolated from the venom of the South American rattlesnake (*Crotalus durissus*).

* *Mamushigin*, a platelet glycoprotein causing PLT aggregation, obtained from the mamushi (*Gloydius blomhoffii*).

* *Triwaglerin*, a protein PLT aggregation activator isolated from the venom of the Wagler's palm viper (*Trimeresurus wagleri* or *Tropidolaemus wagleri*).

Venom Components with Effects on the Contact Path of Hemocoagulation Activation.

Viperid snake (*Viperidae*) venoms contain kallikrein-like proteases that may activate FXII, thus the contact pathway of the hemocoagulation system.

Venom Components Activating Prothrombin

The end result of PCS stimulation with an increase in thrombin activity is caused by either activation of coagulation factors, mostly FV and FX, or direct intervention on the prothrombin molecule and its modification to become an active thrombin-like molecule. Such an action has a procoagulation effect with eventual consumption and exhaustion of the hemocoagulation system and clinical DIC-like bleeding symptoms.

The FV and FX activators have been isolated from the venom of the Russel's viper (*Daboia russelli*), Levantine viper (*Macrovipera lebetina*), desert horned viper (*Cerastes cerastes*), and other species.

A metalloproteinase entitled *ecarin*, from the venom of the saw-scaled viper (*Echis carinatus*), modifies prothrombin into an enzymatically active and physiologically non-inhibitive *meisothrombin*. A similar kind of toxicity is a feature of the South American lanceheads (*Bothrops* sp.), as well as some colubrids (*Colubridae*) - the African boomslang (*Dispholidus typus*) and *Thelotornis kirtlandii*, and the tiger grooved-neck keelback (*Rhabdophis tigrinus*), an opistoglyphous snake species.

Other types of thrombin-activating enzymes include serine proteases, which function due to the participation of phospholipids, and Ca^{2+}, such as *oscutatin*, derived from the venom of the coastal taipan (*Oxyuranus scutellatus*), the procoagulation protein from the venom of asp vipers (*Vipera aspis*), etc.

Again, the third activator group are serine proteases, like *notecarin* from the venom of the mainland tiger snake (*Notechis scutatus*), an Australian snake. These enzymes operate under the presence of FV, phospholipids and Ca^{2+} ions.

The thrombin activity that occurs, based on the action of the serine protease types above, can be inhibited by the heparin-AT complex.

Other Examples of Prothrombin-Activating Enzymes and Toxins:

* *Afaacytin*, a proteinase (α, β-fibrinogenase) that activates FX and other FF (hemocoagulation factors). Isolated from the venom of the desert horned viper (*Cerastes cerastes*).

* *Carinactivase* (CA-1), a toxin activating prothrombin depending on Ca^{2+} isolated from the Roman's saw-scaled viper's (*Echis leucogaster*) venom. Similar enzymes are found in venoms of *Daboia* and *Cerastes* genera and other *Echis* species, Asian pit vipers (*Calloselasma*) and lanceheads (*Bothrops*), where they are accompanied by the FX activator.* *Ecarin*, prothrombin activator, a metalloproteinase isolated from *Echis* venoms.

* *Multactivase*, a Ca^{2+} dependant prothrombin activator from the venom of *Echis multisquamatus*.

* *Textarin*, a toxin activating prothrombin in the presence of phospholipids, FV and Ca^{2+}. Isolated from venoms of Australian snake species - the eastern brown snake (*Pseudonaja textilis*) and the *Demansia* genus.

* *VLFVA* and *VLFXA*, FV and FX enzyme activators from the venom of the Levantine viper (*Macrovipera lebetina*).

* *VRV-V* and *VRV-X*, FV and FX enzyme activators from the venom of the Russel's viper (*Daboia russelli*).

Venom Components Converting Fibrinogen to Fibrin

The term thrombin-like substances is lent to serine protease-like snake venom enzymes that cleave fibrinopeptides - mostly FPA (fibrinopeptide A), from FBG (fibrinogen) molecules, hence causing fibrinogen conversion to fibrin. It is interesting that the sequence homology of these enzymes with thrombin is often a little bit lower than that of trypsin or kallikrein. Therefore, the enzymes resemble thrombin, especially in terms of their fibrinogen-converting activity. However, compared to thrombin, the substances above often lack other thrombin properties like platelet activation, stimulation of endothelium, activation of FV, FVIII and FXIII, stimulation of leucocytes, and others. A systemic conversion of fibrinogen results in plasmin activation and reactive hyperfibrinolysis. Intravenous application of purified FPA-cleaving enzymes, i.e. batroxobin from the common lancehead (*Bothrops atrox*) has been tested clinically. In humans, it results in afibrinogenemia without systemic endothelial damage and developed multi-organ disfunction. Naturally, afibrinogenemia is associated with symptoms of hemorrhaging even from minor traumas, as well as the erosion of mucous membranes.

In addition, certain enzymes that preferentially cleave FPB can probably induce endothelial damage. The activity of such enzymes can be described as of procoagulative type - generally, it cannot be influenced by physiological thrombin inhibitors. It may eventually result in clinical symptoms like those of the DIC syndrome, with hypercoagulation, microangiopathic hemolysis, and subsequent bleeding. The enzymes are contained in the venom range in viperids (*Viperidae*), which largely relates to the *Crotalinae* subfamily members, but is even visible in the African boomslang (*Dispholidus typus*) - a colubrid snake.

Examples of Thrombin-Like Enzymes Converting Fibrinogen to Fibrin (Fibrinogen-Converting Enzymes):

* *Acutin*, an FBG-converting enzyme from the venom of Chinese moccasin (*Deinagkistrodon acutus*).

* *Batroxobin* (BaXb), an FBG-converting enzyme cleaving FPA from FBG. Obtained from the venom of the common lancehead (*Bothrops atrox*).

* *Bilineobin*, a thrombin-like proteinase isolated from the venom of the cantil (*Agkistrodon bilineatus*).

* *Cerastobin*, an FBG-converting enzyme from the venom of the desert horned viper (*Cerastes cerastes*).

* *Clotase*, an FBG-converting enzyme from the venom of the South American bushmaster (*Lachesis muta*).

* *Crotalase* (CrTA), an FBG-converting enzyme from the venom of the eastern diamond-backed rattlesnake (*Crotalus adamanteus*).

* *Flavoxobin*, an FBG-converting enzyme cleaving FPA, isolated from the venom of the brown spotted pit viper [*Protobothrops* (formerly *Trimeresurus*) *mucrosquamatus*].

* *Gabonase*, an FBG-converting enzyme cleaving FPA as well as FPB, isolated from the venom of the Gabon viper (*Bitis gabonica*).

Venom Components Degrading Fibrinogen and Fibrin

Fibrinolytic and fibrinogenolytic activities of snake venoms stem from the enzymatic action of proteinases on fibrinogen or fibrin. Depending on the primary point of effect on fibrin and fibrinogen chains, α-fibrinogenase and β-fibrinogenase are differentiated. The clinical symptomatology response to these substances involves increased bleeding from wounds and symptomatology of hypofibrinogemia or even afibrinogenemia with FDP elevation. Unlike fibrinogen-converting enzymes, the fibrinolytic and fibrinogenolytic enzymes often present proteases with low specificity. While FBG and non-stabilized fibrin are cleaved by a wide range of snake venom proteases, any fibrinolytic activity towards stabilized fibrin or thrombus is displayed by a few of them.

Fibrinolytic and fibrinogenolytic proteases are inherent in the venom of numerous viperids (*Viperidae*), as well as some elapids (*Elapidae*).

Examples of Fibrinogen and Fibrin Degrading Enzymes:

* *Afaacytin*, α and β-fibrinogenase that activates FX and other factors at the same time. Isolated from the venom of the desert horned viper (*Cerastes cerastes*).

* *Ancrod*, an FBG-cleaving serine proteinase from the venom of the Asian pit viper (*Calloselasma rhodostoma*).

* *Atroxase*, a fibrinolytic and fibrinogenolytic enzyme from the venom of the western diamond-backed rattlesnake (*Crotalus atrox*).

* *Fibrolase*, a metalloproteinase with a fibrinolytic and fibrinogenolytic activity, obtained from the venom of the southern copperhead (*Agkistrodon contortrix*).

* *Lebetase*, a metalloproteinase with a fibrinolytic and fibrinogenolytic activity, obtained from the venom of the Levantine viper (*Vipera lebetina*).

* *Proteinase F-1*, an enzyme with a fibrinolytic and fibrinogenolytic activity, obtained from the venom of the African black-necked spitting cobra (*Naja nigricollis*).

* *VLAF*, fibrinogenase, an FBG-cleaving serine proteinase, isolated from the venom of the Levantine viper (*Vipera lebetina*).

Venom Components Inactivating Antithrombin and Other Serpins

Certain enzymes are capable of cleaving AT or other plasma inhibitors of serine proteases - serpins. Such serine proteinase - *CR serpinase* - was isolated from the venom of the common night adder (*Causus rhombeatus*). Even though it does not possess any thrombin or other procoagulation activity as such, this enzyme features a procoagulation action through destroying the thrombin inhibitor.

C Protein Activating Venom Components

A direct C protein activator was found in the venom of the southern copperhead (*Agkistrodon contortrix*) as well as in venoms of other rattlesnakes. Once activated, the C protein will inhibit thrombin physiologically; once eliminated, procoagulation status occurs as a result.

Venom Components Affecting Endothelium and the Vessel Wall

Action on endothelium and the vessel wall is inseparable from the hemocoagulation and hemostasis area. Nevertheless, the toxins and enzymes attacking endothelium and vessel walls possess other pathophysiological activities, causing them to be described as hemorrhagins under chapter 3. 3. 2. 4 Venom components with effects on the vessel wall.

3.3.2.6 Venom Components Affecting the Complement

Influencing the complement by snake venom components can proceed in terms of both activation and degradation. The venom of the cobra genus (*Naja* sp.) contains the so-called cobra venom factor (CVF), which is a glycoprotein that locally activates C3 and C5 complement elements. Thus, a systemic activation of the complement via an alternative route results in hemolysis, endothelial damage and activation of other inflammatory mechanisms. The subsequent increase in vascular permeability will not only cause edema, hypotension, hypoperfusion as far reaching as distribution shock, but is also likely to facilitate the entry of toxins into a victim's circulation. However, complement elements are inactivated by proteolytic enzymes largely contained in viperid (*Viperidae*) venom.

3.3.2.7. Venom Components Possessing a Myotoxic Activity

Substances destroying muscle cells are collectively termed myotoxins. They are represented by two types of toxins: firstly, this involves the basic proteins of lower molecular weight displaying no enzymatic activities - such as found the in venom of rattlesnakes (*Crotalus*). The second group consists of larger proteins with the molecular weight of 12-16 kDa and enzymatic activities of PLA_2 type. Myotoxins cause irreversible damage to muscular tissue as extreme as myonecrosis. In addition to rhabdomyolysis, enzymatic myotoxins can simultaneously exert other activities resulting from their nature. They could attack a cell membrane and act neurotoxically, cardiotoxically, and hemolytically, moreover, they have the ability to affect hemocoagulation and pose a risk of triggering other locally destructive activities.

The amount of myoglobin released through the action of myotoxins may cause or potentiate an occurrence of renal failure, especially oligoanuria. In addition, a considerable quantity of potassium is released during the destruction of muscle cells, resulting in hyperkalemia which may cause detriment to myocardial function.

Myotoxins are found in the venom of many viperid snakes (*Viperidae*); as regards the *Viperinae* subfamily, this namely involves the Russel's viper (*Daboia russelli*), while for the *Crotalinae* subfamily one example is the South American rattlesnake (*Crotalus durissus terrificus*). They are also present in the venom of some elapids (*Elapidae*), chiefly the *Hydrophiinae* subfamily, e.g. Australian terrestrial elapid snakes, as well as marine snakes - sea snakes and sea kraits.

Examples of Toxins and Enzymes Possessing Myotoxic Activities:

* *BAM*, an enzymatic myotoxin contained in the venom of the common lancehead (*Bothrops asper*).

* *CAM*, a low molecular myotoxin contained in the venom of the eastern diamond-backed rattlesnake (*Crotalus adamanteus*).

* *Crotamine*, a low molecular myotoxin contained in the venom of the South American rattlesnake (*Crotalus durissus terrificus*).

* *Crotoxin A, B and C*, enzymatic myotoxins contained in the venom of the South American rattlesnake (*Crotalus durissus terrificus*).

* *Myotoxin VI:5*, an enzymatic myotoxin of the venom of the common sea snake (*Enhydrina schistosa*).

* *Notexin*, an enzymatic myotoxin of the venom of the mainland tiger snake (*Notechis scutatus*).

* *Taipoxin* α, β *and* γ, enzymatic myotoxins of PLA_2 type in the venom of the coastal taipan (*Oxyuranus scutellatus*).

* *Trimucrotoxin*, an enzymatic myotoxin of PLA_2 activity type, with a parallel neurotoxic effect. Isolated from the venom of the brown-spotted pit viper [*Protobothrops* (formerly *Trimeresurus*) *mucrosquamatus*].

3.3.2.8. Venom Components Affecting the Kidneys

Any isolated effects of certain toxins on renal tissues, i.e. specific nephrotoxicity, have not been explicitly documented so far, although supposedly so by some authors. Nevertheless, the action of a number of substances of largely enzymatic type results in damage to renal functions and the onset of acute renal failure of predominantly the oliguric type.

Firstly, pre-renal elements are responsible for affecting renal functions, like systemic hypotension and hypoperfusion of the kidneys caused by vasodilation, extravasation, loss of liquids through diarrhea, vomiting and hemorrhaging. The effective components of kidney-damaging venoms include vasodilation kininogens, ACE inhibitors, hemorrhagins and hemocoagulation-affecting substances. The occurrence of this type of renal failure can be further assisted by insufficient or late compensation of the circulating volume, as well as insufficient blood pressure regulation.

Severe myoglobinemia and myoglobinuria, as a result of muscular tissue destruction by the action of myotoxin, is another cause for renal failure. Myotoxins cause nephrons capable of obstructing and disabling, especially in circumstances of insufficient blood flow through glomeruli and poor urine flow through tubules. In addition, phospholipases convert lecithin to nephrotoxic lysolecithin. Moreover, the hemolysis induced by the venom is a significant factor in developing renal failure.

A large quantity of microthrombi obturating blood flow through the glomeruli may occur due to the action of procoagulation components in venom, especially fibrinogen-conversion enzymes and prothrombin activators.

In addition, a destructive effect brought about by enzymes acting locally on tissues of the kidneys, glomeruli, and tubules cannot be precluded. Acute renal tubular necrosis can be caused by the direct action of specific nephrotoxins.

As a result of action of the particular components mentioned above, or more frequently through their interaction, acute renal failure develops, which is reversible in most cases.

However, even irreversible failure may occur if treatment is inadequate or exposure to the venom too high; in some cases, this can be accompanied by the onset of cortex necrosis.

The substances affecting renal functions and tissue are mostly found in venom from *Viperinae* and *Crotalinae* snakes, but also some elapids (*Elapidae*).

3.3.2.9. Allergenizing Venom Components

When discussing systemic symptoms of envenoming by snake venom, allergic responses following a bite are worthy of mention. These reactions are manifest through developments of skin changes, redness and urticaria, angioneurotic edema in the cranial region, bronchospasms resembling an asthma attack, and even anaphylactic shock.

The main reason for such complications is the entry of extraneous high molecular substances, largely glycoproteids and polysaccharides into the circulation. In addition, the phenomenon of cross reactivity between snake venom components and other allergens is also a factor for such responses developing as well. For instance, it seems that patients with an anaphylactic reaction to the bite by European vipers *Vipera berus* and *V. aspis* are, likewise, allergic to stings by *Hymenoptera* insects like bees, wasps and hornets, and that these symptoms are mediated through IgE antigens. Thus, it cannot be precluded that exposure to the poison following a sting by hymenoptera may cause similar sensitization to that of snakes.

An acute anaphylactic reaction following a snakebite, even though not specific and toxic, may pose a serious threat to a victim due to the speed of the onset and severity of symptoms, especially if associated with symptoms of hypotension and shock relating to envenoming.

3.3.2.10. Venom Components with Various Activitiesa and Non-Protein Components

Some of the symptoms not included in the groups of effects triggered by snake venom specified above, such as headaches and dizziness, nausea, vomiting, diarrhea, etc., may be caused by other unidentified protein or non-protein components.

Other substances contained in snake venom, such as lectins, growth factors of neural cells, polypeptide phospholipase and proteinase inhibitors, as well as other non-protein components like amino acids, biogenic amines, fatty substances, yellow riboflavin, simpler organic acids and ions, do not have a specific pathological effect in the envenomation of humans. Such substances may function to support toxin activities or to protect a snake venom gland, or are just by-products of the venom gland metabolism.

REFERENCES

ALLOATTI, G., GATTULLO, D., DALLA VALLE, R., et al. The haemodynamic effect of Bitis nasicornis (Rhinoceros Horned Viper) venom. *Gen Pharmacol*, 1991, 22, No. 1, pp. 203–206.

GANAIKABAHU, B., PUSHPARAJAN, K., et al. Myonecrosis due to Russell´s Viper bites in Sri Lanka. *Am J Trop Med Hyg*, 1994, 50, No. 5, pp. 597–601.

GOLD, BS. Neostigmine for the treatment of neurotoxicity following envenomation by the Asiatic Cobra. *Ann Emerg Med*, 1996, 28, No. 1, pp. 87–89.

GOLD, BS., PYLE, P. Successful treatment of neurotoxic King Cobra envenomation in Myrtle Beach, South Carolina. *Ann Emerg Med*, 1998, 32, No. 6, p. 736–738.

HRDINA, V., HRDINA, R., JAHODAR, L., et al. *Prirodií toxiny a jedy.* Praha : Galen, Karolinum, 2004, pp. 174–237. (in Czech)

CHIPPAUX, JP., GOYFFON, M. Venoms, antivenoms and immunotherapy. *Toxicon*, 1998, 36, No. 6, pp. 823–846.

JANSSEN, M., MEIER, J., FREYVOGEL, TA. Purification and charakterization of antithrombin III inactivating enzyme from the venom of the African Night Adder (Causus rhombeatus). *Toxicon*, 1992, 30, No. 9, pp. 985–999.

KHADWAL, A., BHARTI, B., PODDAR, B., et al. Persistent coagulopathy in snake bite. *Indian J Pediatr*, 2003, 70, No. 5, pp. 439–441.

KOMORI Y., NIKAI T., SUGIHARAH. Isolation and characterisation of procoagulant from the venom of Vipera aspis aspis. *Int J Biochem*, 1993, 25, No. 5, pp. 761–767.

KORNALIK, F. Prothrombin converting-and fibrinolytic effects of ecarin. *Czech Med*, 1985, 8, No. 1, p. 51–54. (in Czech)

KORNALIK, F. The influence of snake venom enzymes on blood coagulation. *Pharmacol Ther*, 1985, 29, No. 3, pp. 353–405. (in Czech)

KORNALIK, F. Toxins affecting blood coagulation and fibrinolysis. In SHIER, WT., MEBS, D. (Eds.), *Handbook of Toxinology.* New York : Marcel Dekker, 1990, pp. 683–759.

LEE, SY., LEE, CY., CHEN, YM., et al. Coronary vasospasm as the primary cause of death due to the venom of the Burrowing Asp, *Atractaspis engaddensis. Toxicon*, 1986, 24, No. 3, pp. 285–291.

MARSH, NA., WHALER, BC. The Gaboon Viper (*Bitis gabonica*): its biology, venom components and toxinology. *Toxicon*, 1984, 22, No. 5, pp. 669–694.

MEBS, D., KORNALIK, F. Intraspecific variation in content of a basic toxin in Eastern Diamondback Rattlesnake (*Crotalus adamanteus*) venom. *Toxicon*, 1984, 22, No. 5, p. 831–833.

MEIER, J., STOCKER, KF. Biology and distribution of venomous snakes of medical importance and the composition of snake venoms. In MEIER, J., WHITE, J. (Eds), *Handbook of clinical toxicology of animal venoms and poisons.* Boca Raton : CRC Press, 1995, pp. 364–412.

OSHIMA, G., SATO-OHMORI, T., SUZUKI, T. Proteinase, arginineester hydrolase and kinin releasing enzyme in snake venoms. *Toxicon*, 1969, 7, No. 3, pp. 229–233.

PHILLIPS, RE., THEAKSTON, RD., WARRELL, DA. Paralysis, rhabdomyolysis and haemolysis caused by bites of Russell´s Viper (*Vipera russelli pulchella*) in Sri Lanka: failure of Indian (Haffkine) antivenom. *Q J Med*, 1988, 68, No. 257, pp. 691–715.

REIMERS, AR., WEBER, M., MULLER, UR. Are anaphylactic reactions to snake bite immunoglobulin E-mediated? *Clin Exp Allergy*, 2000, 30, No. 2, pp. 276–282.

SEKOGUCHI, S., NIKAI, T., SUZUKI, Y., et al. Kinin-releasing enzyme from the venom of Bitis arietans (Puff Adder). *Biochim Biophys Acta*, 1986, 884, No. 3, pp. 502–509.

STÖCKLIN, R., CRETTON, G. *The ultimate database on venomous animals, snakes*. CD-rom, Geneva : Atheris Laboratories, 1998.

SZOLD, O., BEN-ABRAHAM, R., FROLKIS, I., et al. Tumor necrosis factor as a mediator of cardiac toxicity following snake envenomation. *Crit Care Med*, 2003, 31, No. 5, pp. 1449–1453.

TAKASAKI, C., TAMIYA, N., BDOLAH, A., et al. Sarafotoxins S6: several isotoxins from *Atractaspis engaddensis* (Burroving Asp) venom that affects the heart. *Toxicon*, 1988, 26, No. 6, pp. 543–548.

THEAKSTON, RD., WARRELL, DA., GRIFFITHS, E. Report of WHO workshop on standardization and control of antivenoms. *Toxicon*, 2003, 41, No. 5, pp. 541–557.

WATT, G., MEADE, BD., THEAKSTON, RD., et al. Comparison of Tensilon and antivenom for the treatment of Cobra-bite paralysis. *Trans R Soc Trop Med Hyg*, 1989, 83, p. 570–573.

WHITE, J., WARRELL, D., EDDLESTON, M., et al. Clinical toxinology – where are we now? *J Toxicol Clin Toxicol*, 2003, 41, No. 3, pp. 263–276.

WOLLBERG, Z., SHABO-SHINA, R., INTRATOR, N., et al. A novel cardiotoxic polypeptide from the venom of *Atractaspis engaddensis* (Burroving Asp): cardiac effects in mice and isolated rat and human heart preparations. *Toxicon*, 1988, 26, No. 6, pp. 523–534.

Chapter 4

SNAKE ANTIVENOMS

4.1. HISTORY

The first immunization using snake venom to demonstrate a boost in immunity was performed by Henry Sewall in 1887, by applying increased doses of venom from the massassauga (*Sistrurus catenatus*) to a pigeon, which subsequently survived exposure to six times the lethal dose. Then, in 1894, Phisalix and Bernard demonstrated the antivenomous activity of blood in animals immunized by heat-treated venom from the asp viper (*Vipera aspis*). Later in the same and the following year, effectiveness of serum obtained from animals immunized with cobra venom against subsequent envenomation was proven by Albert Calmette, who in 1895 was the first to prepare and administer a horse antivenom to a man envenomed by a cobra's venom.

The first horse antivenom produced commercially was again the work of Calmett - it was produced for use in Vietnam in 1898. At the cusp of the 19th and 20th centuries, production followed in the USA (McFarland, 1899), Australia (Tidwell, 1902), Brazil (Vital Brasil, 1905), and Japan (Ishizaka, 1907).

In the subsequent years, chiefly horse antivenoms were produced commercially. Although these were never - and are still not - used successfully as preventive vaccines against the effects of snake venom, their position as a specific therapeutic element in treating snakebite symptoms is unique.

4.2. IMMUNOGENICITY OF SNAKE VENOMS

In terms of composition and chemical properties, snake venoms and their components show a higher or lower level of immunogenicity in inducing antigens to develop. This kind of property is used when manufacturing antivenoms against the effects of snake venom.

Although snake venom toxins and enzymes are principally immunogenic, humans repeatedly exposed to snake venom will not be protected by the antigens developed. Any slight immunity increase via neutralizing a clinically important amount of toxins is insufficient. For example, Peter Gruber, a popular American snake hunter also known as Rattlesnake Pete, was bitten about thirty times without becoming immune. There is also the exceptional case of an Australian snake dealer with an allergy to horse antivenom, which was triggered following repeated snakebites and subsequent administration of antivenoms.

Lacking the possibility of specific treatment in case of further envenomation, the man was successively immunized using venom from the mainland tiger snake (*Notechis scutatus*) at his own request. This 'vaccination' provided him with immunity for four months, during which a snakebite by a highly venomous tiger snake exhibited only a minimal localized response (Wiener, 1960). However, repeated exposures to a venom will, in most cases, tend to result in hypersusceptibility with allergic symptoms. Nevertheless, indigenous people in Mexico and India are used to stabbing themselves with snake fangs, believing it will increase their immunity to snakebites, but this may be a dangerous habit with venom from certain snakes, such as *Echis* snakes. Several highly efficient venom components, e.g. prothrombin activators, are not very immunogenic; as a result, they are not neutralized by the antigens developed and can cause a serious reaction.

Differences in the immunogenicity of specific toxin and enzymatic venom components are determined by the size and type of the molecule. A number of protein toxins and enzymes belong to glycoproteins, in which immunogenicity is determined by the nature of the sugar component. A rule of thumb is that smaller and low-glycosylated molecules, such as those of certain neurotoxins or myotoxins, possess lower immunogenicity, i.e. the capability of inducing antigens to be produced against toxins.

4.3. Production, Composition and Types of Antivenom

Antivenom production is based on immunizing the animal selected by repeated progressive doses of venom and subsequently collecting and treating the hyperimmune serum. Various animals are used for laboratory and research purposes, for example the mouse, rabbit, ass, goat, cow, llama, etc. Experimentally, IgY antigens have been obtained from the yolks of immunized hens as well (Thalley, Carroll, 1990; Kiem, 2000). However, commercial production is limited only to horse and sheep antivenoms. Animals are immunized using fresh venom, with the resultant hyperimmune serum being subject to further treatment and purification.

If venom from a single snake species is used for animal immunization, the resulting serum is referred to as a monovalent or monospecific antivenom. Meanwhile, polyvalent or polyspecific antivenom is produced by immunization using venom from multiple snake species, which typically involves those inhabiting the territory for which the antivenom is designed.

Effective antivenom components include antigens of IgG type and its fractions. Antivenoms containing a whole IgG molecule are produced by precipitation of the serum IgG fraction by ammonium sulphate or capryl acid. Antivenoms, where the F $(ab')_2$ fragment is used as the effective antigen, are prepared by cleaving the Fc fragment from the whole IgG molecule using pepsin under pH 2 and subsequent precipitation, which is again performed using ammonium sulphate or capryl acid. By cleaving the IgG molecule using papain under pH 7-8, an antivenom with small Fab fragments is obtained. The final product is then pasteurized.

In principle, only healthy animals are used for immunization. Any presence of an infectious agent contagious to humans is eliminated by chemical treatment of the serum using pepsin, capryl acid, pH 2, pasteurization, etc. However, the procedures recommended are not

fully maintained by every producer, which may affect product effectiveness in addition to the number and severity of side-effects.

Antivenoms are supplied in the form of solution or lyophilized. When stored in a dark place under temperatures of 4 ^{o}C to 8°C, the liquid form will remain stable for approximately 5 years depending on type of stabilization, and the lyophilized form much longer. Naturally, expiry dates are shorter as instructed by manufacturers. Higher temperatures will proportionally reduce the content of effective antigens. Over a certain period of time, antivenoms are capable of being stored and used even in an extreme tropical climate. They can still remain effective for several months at temperatures of 20 ^{o}C to 37°C if stored in the dark.

4.4. ANTIVENOM EFFICIENCY

As indicated by studies, the neutralization capacities determined in a laboratory, i.e. the immunological properties of antigens as IgG and $F(ab')_2$ and Fab fragments, are generally comparable. However, differences may be insisted on for clinical use, which are determined normally by molecular size, i.e. penetration capacity, as well as distribution velocity and half-time excretion. The absence of the Fc-fragment in the antivenoms of $F(ab')_2$ and Fab types, bringing about a certain probability of reducing an antivenom's side effects, presents another difference.

The antigen of IgG type possesses the distribution volume of the plasma. Compartments with better accessibility can be reached by the antigens within 6 hours, while deeper and less accessible compartments are reached within 30 hours. These antigens are excreted by immunity system cells with a general half-time of 60 to 190 hours.

Antivenoms containing $F(ab')_2$ fragments have about double the distribution volume compared to that of plasma. They can reach accessible compartments in as little as an hour, while less accessible tissues are reached within some 6 hours. Their half-time in the body is from 20 to 50 hours, and are excreted in the form of IgG through the immunity system cells.

Fab-containing antivenoms possess the most rapid distribution to extravascular areas and the largest distribution volume. Their smaller molecules seem to have a greater affinity to tissue than other types of antigens. The half-time of Fab is very low - about four hours; with regard to molecular size, it is determined by elimination through glomerule filtration. Some works indicate that Fab fragments are less efficient than entire IgG molecules or $F(ab')_2$ fragments. Other disadvantages include a short half-time, more frequent instances of antigenemia and the necessity for repeated administration due to the recurrence of symptoms.

In general, antigens have a dual function - preventive and curative. In the former, antigens unbind available toxin molecules before they can attach to target receptors, whereas in the latter, they are capable of eliminating existing bound molecules of toxins, e.g. postsynaptically curare-form effective neurotoxins, from receptors.

Antigen-toxin complexes can persist in the body much longer than antigens are maintained in the circulation. Fab-toxin complexes have been discovered 9 days following administration of an antivenom. These complexes are progressively eliminated by immunity system cells.

Dissociation of such complexes prior to destruction by the immunity system results in an increasing level of the toxin, this being one of the reasons for recurrent envenomation. Another reason for this complication, which occurs quite frequently, involves the progressive release of toxins and enzymes from tissue at the bitten site, and successive unbinding of all present antigens. Typically, symptoms return in cases of coagulopathy within 2 to 14 days upon administration of antivenom. The occurrence of repeated deterioration is often in inverse proportion to the dose of the antivenom prescribed; it is more frequent upon administration of antigens of the Fab type, as already mentioned, however, this is no exception following treatment with antivenom containing whole molecules of IgG. To neutralize some venom components with low immunogenicity - e.g. prothrombin activators, certain neurotoxins and myotoxins - an extreme amount of antivenom, up to many dozens of doses, may be necessary to eliminate the effects of such substances.

In certain cases, antivenom appears not to be fully working due to envenomation symptoms not abating. If morphological damage to a tissue by a toxin, or more often by an enzyme, occurs prior to antivenom being administered, the antigens cannot treat the developed affection further. For instance, this involves local envenomation symptoms including necrosis, renal failure, presynaptic neurotoxicity, myonecrosis, etc. The affliction may be mitigated by prompt application of antivenom. Differences in the toxin range of snakes can be another reason for decreased antivenom efficiency. In most cases, this involves intra-species variability in venom composition. Another reason may be the variability in components of venom in snakes belonging to the same species but sourced from different areas; when the animal designed to produce the antivenom is immunized with the venom of a snake from a region different to that where the antivenom is to be used. If the effectiveness of the antivenom is clinically reduced and possible variability suspected, a useful solution would be to try applying antivenom from a different producer or region, if such is available.

A completely different situation is presented by cross immune response, which happens relatively often. It refers to the reactivity of an antivenom to a venom toxin or enzyme not used to produce the same antivenom. This is caused by the relationship or likeness of toxic component molecules in venoms of different species of snakes. The cross immune response was found by Lamb in 1902. A rabbit antivenom to counteract venom from the Indian cobra (*Naja naja*) also demonstrated activity against the venom of the Russel's viper (*Daboia russelli*).

The cross immune response exists between Asian and African cobras, except the *Naja nigricollis*. The Egyptian polyvalent antivenom is effective against the Sub-Saharan cobras as well except the Cape cobra (*Naja nivea*), and against the venom of the Gabon viper (*Bitis gabonica*). The antivenom produced to counteract the venom of the western diamond-backed rattlesnake (*Crotalus atrox*) will neutralize venoms of another five rattlesnakes, however, with the exception of the South American rattlesnake (*Crotalus durissus*), due to the presence of neurotoxic *crotoxin*.

Polyvalent antivenoms containing a component active against thrombin-like enzymes are capable of neutralizing these activities in venoms of other snakes too, for example the Gabon viper (*Bitis gabonica*), Chinese moccasin (*Deinagkistrodon acutus*), common lancehead (*Bothrops atrox*), and the eastern diamond-backed rattlesnake (*Crotalus adamanteus*). The venom of the western diamond-backed rattlesnake (*Crotalus atrox*) can be neutralized by antivenom treating the venom of the Russel's viper (*Daboia russelli*); the venoms of sea snakes and sea kraits can be neutralized by antivenom against the coastal taipan (*Oxyuranus*

scutellatus); and venoms of the Russel's viper (*Daboia russelli*), monocellate cobra (*Naja kaouthia*), and the western diamond-backed rattlesnake (*Crotalus atrox*) can be neutralized by anticobratoxin. An important and practical finding is presented by the possibility of neutralizing the kinin-releasing enzymes of venom from the rock viper (*Vipera xanthina*), Levantine viper (*Macrovipera lebetina*), asp viper (*Vipera aspis*), and common viper (*V. berus*) using a monospecific antivenom of the nose-horned viper (*V. ammodytes*) (Zagreb, Croatia). The cross immune response also occurs, vice versa, between snakes of different species: *Vipera*, *Cerastes*, or *Bitis*; with their antivenoms reacting against the components of night adders (*Causus*). Immunity responses have even been found throughout both snake antivenoms and the venoms of scorpions, bees and frogs, as well as in botulin.

The information above indicates that the specificity of monovalent or polyvalent antivenoms manufactured commercially may not always be strictly limited to the venoms of indicated use, especially if the antivenom for the species in question is not available or the snake cannot be identified. Conversely, one must consider that in circumstances of cross immune response (antivenom against venom A vs. venom B), the reciprocity of the effect may not and often does not exist (antivenom against venom B vs. venom A) and any prediction of response A is highly complicated.

4.5. Side-Effects of Antivenoms

Anaphylactic side-effects of antivenoms are caused by proteins and other antigens in the preparations that present extraneous matters to humans. Horse antivenoms show a higher rate of occurrence of anaphylactic reactions than those of sheep. The incidence and severity of the course will greatly differ depending on the type and producer.

Antivenoms containing whole IgG molecules seem to be responsible for the highest percentage, up to 30% of hypersensitive responses. The incidence is apparently increased by the presence of the Fc fragment in the molecule, and the capability of the fragment to activate the complement. Incidence upon application of $F(ab')_2$ fragment-containing antivenoms is lower; 10% is typically presented. In this case, i.e. in the absence of Fc-fragments, any complement activation is only possible through an alternative method. Finally, the lowest response incidence, about 0.8%, exists in antigens of Fab-fragment type. In such a circumstance, the complement is not activated at all.

Adverse responses may not necessarily be linked to the type of antigen but to method of production. A higher protein content, the presence of non-IgG proteins and protein clusters, pyrogens, endotoxin, and similar substances will result in an increase in the occurrence of anaphylactic reactions by up to 80%. Conversely, perfectly purified preparations, although they contain whole IgG molecules, show a low incidence of adverse responses. Nevertheless, it remains fully accepted that eliminating the Fc-fragment will reduce the risk of side-responses, especially severe ones, by preventing activation of the complement.

Generally, two types of anaphylactic reaction occur following administration of antivenom: early and late.

Early Anaphylactic Reactions

These involve an allergy to a serum administered repeatedly, in most cases a horse antivenom. In the past, the serum might have been applied not only as an antivenom against snake venom, but also as an antitetanic or antirabies serum. In some cases, the possibility of occurrence of this response has also been reported without any previous contact, this being termed an anaphylactoid reaction. Early reactions occur anywhere from the moment of application and up to three hours later. Incidence is very wide - it will increase with the size of the dose and speed of application, but decrease with the level of refinement and accuracy of development the preparation undergoes, as mentioned above.

Furthermore, it becomes apparent, depending on the severity and speed of its onset, in the form of itching and redness, the occurrence of widespread urticarial dermal efflorescence (hives), nausea, vomiting, and higher temperatures. In addition, as many as 40% of patients with such a reaction are affected by more adverse systemic symptoms: hypotension, bronchospasm, and the occurrence of angiotic edema. The most severe symptoms materialize as anaphylactic shock and Quinke's edema, obstructing upper respiratory airways. The rise in temperature may not be allergic in nature, but a response to the presence of pyrogens in the antivenom.

Therapy and prevention of allergic responses to antivenoms will not differ from procedures for anaphylactic symptoms of other etiology; these are listed in chapter 5.3.2 Prevention and treatment of serum anaphylactic reactions.

Late Anaphylactic Reaction - A Serum Sickness

Serum sickness typically occurs after several days, although can take up to three weeks to show itself, upon application of antivenom. Incidence is estimated at up to 75% and will rise in direct proportion to the quantity of antivenom applied. It becomes manifest via heightened temperatures, itching, and the occurrence of allergic dermal efflorescences, arthrodynia and articular edema, swollen lymph nodes, nephropathy with albuminuria, and by encephalopathy in some rare cases.

The serum sickness will abate spontaneously or following treatment using antihistaminics and corticosteroids for a few days. For therapy of serum disease, see chapter 5.3.2 Prevention and treatment of serum anaphylactic reactions.

REFERENCES

BOYER, LV., SEIFERT, SA., CLARK, RF., et al. Reccurent and persistant coagulopathy following Pit Viper envenomation. *Arch Intern Med*, 1999, 159, No. 7, pp. 706–710.

CLAUS, I., MEBS, D. Cross-neutralisation of thrombin-like enzyme in snake venoms by polyvalent antivenoms. *Toxicon*, 1989, 27, No. 12, pp. 1397–1399.

CHIPPAUX, JP., GOYFFON, M. Venoms, antivenoms and immunotherapy. *Toxicon*, 1998, 36, No. 6, pp. 823–846.

ISMAIL, M., MEMISH, ZA. Venomous snakes of Saudi Arabia and the Middle East: a keynote for travellers. *Int J Antimikrob Agents*, 2003, 21, pp. 164–169.

JANSSEN, M., FREYVOGEL, TA., MEIER, J. Antigenic relationship between the venom of the Night Adder Causus maculatus and venoms of other Viperids. *Toxicon*, 1990, 28, No. 8, pp. 975–983.

Al-JOUFI, A., BAILEY, GS., REDDI, K., et al. Neutralization of kinin-releasing enzymes from viperid venoms by antivenom IgG fragments. *Toxicon*, 1991, 29, No. 12, p. 1509–1511.

KHADWAL, A., BHARTI, B., PODDAR, B., et al. Persistent coagulopathy in snake bite. *Indian J Pediatr*, 2003, 70, No. 5, pp. 439–441.

KHOW, O., CHANHOME, L., OMORI-SATOH, T., et al. Effectiveness of Thai Cobra (*Naja kaouthia*) antivenom against Sea Snake (*Lapemis hardwickii*) venom: verification by affinity purified F(AB')2 fragments. *J Nat Toxins*, 2001, 10, No. 3, pp. 249–253.

KIEM, TX. The production of *Calloselasma rhodostoma* antivenom (C.R.A.V.) from egg yolk of hens immunized with venom: its application for treatment of snake bite patients in Vietnam. *Proceeding of the XIIIth World Congress of the Internetional Society of Toxinology*, Paris 2000.

KORNALIK, F., TABORSKA, E. Cross reactivity of mono- and polyvalent antivenoms with *Viperidae* and *Crotalidae* snake venoms. *Toxicon*, 1989, 27, No. 10, pp. 1135–1142.

LALLOO, DG., THEAKSTON, RD. Snake antivenoms. *J Toxicol Clin Toxicol*, 2003, 41, No. 3, pp. 227–290.

LIPPS, BV., KHAN, AA. Antigenic cross reactivity among the venoms and toxins from unrelated diverse sources. *Toxicon*, 2000, 38, pp. 973–980.

MEIER, J., WHITE, J. (Eds). *Handbook of clinical toxicology of animal venoms and poisons*. Boca Raton : CRC Press, 1995, 752 pp.

MOROZ, CH., de VRIES, A., GOLDBLUM, N. Preparation of an antivenin against Vipera palestinae venom with high antineurotic potency. *Toxicon*, 1966, 4, pp. 205–208.

SEDDIK, SS., WANAS, S., HELMY MA., et al. Cross neutralisation of dangerous snake venoms from Africa and Middle East using the VACSERA polyvalent antivenom. Egyptian Organisation for Biological Products and Vaccines. *J Nat Toxins*, 2002, 11, No. 4, pp. 329–335.

THALLEY, BS., CARROLL, SB. Rattlesnake and skorpion antivenoms from the egg yolks of immunized hens. *Biotechnology (NY)*, 1990, 8, No. 10, pp. 934–938.

THEAKSTON, RD., WARRELL, DA., GRIFFITHS, E. Report of WHO workshop on standardization and control of antivenoms. *Toxicon*, 2003, 41, No. 5, pp. 541–557.

WIENER, S. Active immunization of man against the venom of the Australian Tiger Snake (*Notechis scutatus*). *Am J Trop Med Hyg*, 1960, 9, pp. 284–292.

Chapter 5

SNAKEBITE: THERAPY AND PREVENTION

5.1. PREVENTION

There are essentially two circumstances under which humans and snakes interact, resulting in potential snakebites - keeping snakes and staying in the wild within the creatures' habitat. A rule of thumb relating to snakebites is that prevention is the best kind of therapy, as in any other affliction and disorder.

When addressing snake ownership, one should bear in mind that the animals not only prove a danger to their keepers, but pose a risk to others through handling and any chance of escape. A poorly secured snake could threaten visitors, family members, partners and, naturally, children. Closing and securing a terrarium in the presence of children should be an automatic reaction. Venomous snakes should be handled only to the extent necessary for successful breeding. Their adaptation and nature dictates that snakes are not designed for co-existence with man, with any unreasonable contact being potentially traumatic for both sides. Therefore, it is completely unacceptable to handle a snake in the presence of other individuals and do so under the influence of alcohol, which frequently has the effect of making people feel brave and inhibits reactions. Unfortunately, such situations often result in snakebites and envenomation. Indeed, it is not unreasonable to compare some especially perilous venomous snakes to an unlocked gun cabinet, which is not really overstating matters. Handling a gun is subject to the obligation to avoid the influence of alcohol and other substances affecting ones state of mind, much like driving a car. Therefore, the same rule should be adhered to when in contact with venomous snakes.

The most frequent causes of snakebite when keeping venomous snakes involve activities carried out in terrariums - cleaning, placing water, and the like. Any reliance on the snake maintaining a quiet, peaceful position in an opposite corner of the terrarium is foolhardy, as born witness to by many shamefaced snake holders. Feeding young snakes that refuse to eat can be another reason. Experience and concentration is essential when performing such an activity - nevertheless, injuries even occur amongst highly experienced keepers. However, handling snakes to collect venom is not a frequent reason for envenomation, apparently due to the immense professionalism of such practitioners.

Staying in countryside or the wild poses a threat in terms of actively being in the presence of snakes, i.e. via catching or passive unconscious contact. Snake hunters are ordinarily so skilled and experienced that their error free behavior in any situation can be presumed, although this is not always the case. Sometimes, a great desire on their part can make a hunter

reflexively grasp a disappearing snake by its body, even at a dangerous distance behind its head. The end result is obvious, much like that of a reputable herpetologist who went to look at a sleeping mamba. Let any such and similar situation serve as a warning to other owners and hunters.

Staying outside in areas with an increased occurrence of dangerous venomous snakes brings certain rules that are essential to follow. Clothing should include solid boots and long trousers; in addition, a shirt with long sleeves is advisable. Within the habitats of snakes or on a camp site, dropping litter is not recommended as rubbish attracts rodents, which in turn brings snakes. When out walking in the country, a point of destination should always be born in mind when conducting movements that cannot be interrupted, such as jumping over obstacles like stones, walking over a tree trunk lying across the road and the like. Turning over stones, poking hands into holes, under bark or into other places where it is unclear what lies within them is not wise. If a snake can be seen, a safe distance should be kept for observing or taking pictures, which may mean several meters for large snakes. If a snake is to be captured, two or three individuals should be in attendance.

In 1991, the US Navy issued *pre-emptive rules of behavior* for travelers in terrain rich with venomous snakes, summarized as follows:

- Do not put your hands and feet in areas that cannot be fully inspected or before you explore them
- Do not lift up and turn over stones and fallen logs using your bare hands - use a stick or your legs in solid footwear with well-protected ankles
- Do not disturb snakes
- Do not put a sleeping bag near rocks, stones, litter, and cave entrances
- Do not sit down before you thoroughly inspect a site
- Do not collect wood for a fire after dusk
- Do not walk over a fallen tree before you see the other side. Step up onto it first
- Do not visit places with increased occurrence of snakes without wearing suitable clothes and boots
- Do not handle freshly killed snakes
- Do not crawl under fences where the grass is high or ground enclosed
- Do not leave a trail to kill a snake. Thousands of people are bitten by venomous snakes when trying to kill them without firstly knowing their habits and patterns of behavior
- Last, but not least, do not panic

There is more worthwhile advice to add for those venturing into the countryside. As already mentioned, snakes cannot hear, so any noisy behavior in places where snakes are presumed to range just makes for an amusing scene rather than acts as a form of prevention. A heavy tread when walking and any thumping will cause the ground to vibrate, which is registered by snakes and will encourage snakes to leave the location. The common fear of snakes ranging around a dry area flooded by sun is a blatant untruth, as snakes' resistance to the sun is very low. However, spending a quiet night in the same location can be dangerous in the hot summer months, because a number of snakes hunt at dusk or even at night if temperatures are high during the day.

As is indicated by analysis of causes for snakebites amongst children by the common viper (*Vipera berus*) in the Czech and Slovak Republics (Dluhorucky et al., 2000), as well as the author's experience, there is a general lack of awareness of the danger posed, in addition to loss of inherited atavism relating to an unknown animal. Precautions to guard against this should include instructing children about the potential threats that close contact with snakes present to them. Naturally, any such guidance should not provoke any unnecessary fear and animosity, as this can stay with a person for their entire lifetime.

5.2. FIRST AID

5.2.1. First Aid for Laypersons

The basic rule of first aid is to *remain calm* and rational. The chances of rapidly occurring life-threatening symptoms are usually very low. Any excitement and movement will worsen an envenomation. Above all, the person affected must be settled down and put into a sitting or lying position.

If the snakebite occurs in the habitat of multiple venomous snake species, the *snake should be identified* or at least described to facilitate later identification. The time of the snakebite is also information of high importance.

The next thing to do is to call an *emergency service*. This should be done even in the case of an adult lacking any post-bite symptoms due to possible subsequent development of a toxic or allergic response. Of course, calling the emergency services is absolutely necessary if a child is affected.

Immobilizing the affected person and the limb is essential for delaying the progress of envenomation. Applying an ordinary constrictive tourniquet, in order to restrict return flow in the venous system, is not recommended, as slowing down venom distribution from the bitten site using a tourniquet has an uncertain result; in addition, this impacts upon damage to limb tissue by blood stasis and facilitating the likelihood of edema.

Venom distribution from the bitten site on a limb can provably by retarded by a *pressure immobilization bandage - PI*, according to Sutherland (Fig 5 and 6). PI will be fully indicated in snakebites by dangerously neurotoxic snakes that do not possess any potent necrotizing venom components, e.g. cobras, like the Indian cobra (*Naja naja*), king cobra (*Ophiophagus hannah*), Philippine cobra (*N. philippiensis*) and other elapids - *Micrurus*, kraits - *Bungarus*, mambas - *Dendroaspis*, as well as sea snakes and sea kraits. The safe use of PI with positive results has also been proven with Australian terrestrial elapid snakes, which possess highly effective venom. However, as regards bites by other snakes, including rattlesnakes, PI application is recommended only in special cases when timely aid from emergency services is not forthcoming, especially for children.

The pressure immobilization bandage is fitted by tightly strapping the affected limb with a wide elastic bandage to the greatest extent possible: from the fingers up to the trunk. Starting by bandaging above the bitten site towards its periphery and then back to the trunk is ideal, although less comfortable for the patient. Such a procedure is recommended for a shorter period of time. Should the bandage be in place for longer, wind it from fingers towards the trunk. This method protects the venous system, meaning it will not cause even the

least amount of venous stasis, whilst minimizing the risk of pushing the venom out into the circulation system. Finger tips must be kept unrestricted to maintain continual intact circulation in the limb so affected. The tightness of the bandage is often compared to that of bandaging an injured ankle. If the limb is painful upon PI application, the bandage is most probably too tight. The bandage can be placed over trousers or a shirt as well, as any limb moving whilst uncovered is undesirable. Of course, the strict rules mentioned above apply especially to bites by highly dangerous snakes, those possessing a potent neurotoxic component of venom. Following the application of the bandage, the limb must be secured well to avoid movement using a splint. The PI can remain in place for a number of hours as required; venom release is distinctively restricted even three hours afterwards. Naturally, any movement will greatly reduce the bandage's positive benefit. The PI will lose its function if too slack, sufficient immobilization of the limb is not assured, or the PI is applied once venom is already in the circulation. The PI should not be removed before reaching the place of final treatment or prior to antivenom being applied (Sutherland, 1979).

Figure 5. Pressure immobilization bandage for upper limbs (edited according to Sutherland, 1979).

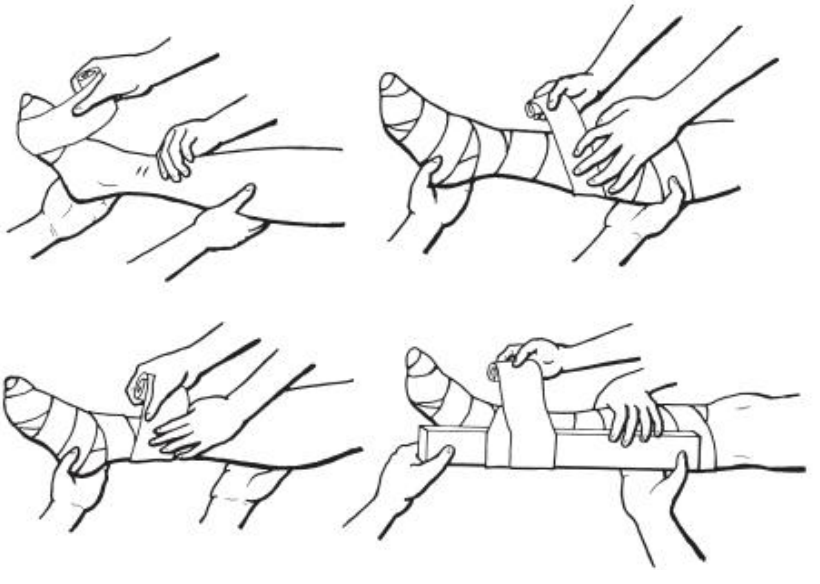

Figure 6. Pressure immobilization bandage for lower limbs (edited according to Sutherland, 1979).

If for some reason the PI cannot be applied in instances of apparent envenomation by a mortally dangerous neurotoxin from coral snake (*Elapidae*) venom, an *arterial tourniquet* can be applied to delay development of respiratory muscle paralysis. The device is placed above the bitten site towards the trunk; it may not be possible to feel the pulse at the limb's periphery upon applying the tourniquet. The applied tourniquet must be soft and elastic to avoid damaging the skin and neurovascular bundles at the site of application; the device must be released for 15 seconds every 30 minutes. The application period is limited to two hours. Although this method can save lives in certain extreme situations, it always increases the level of localized damage to affected tissue and could cause gangrene. Therefore, the implications of using one should be seriously considered.

Compression techniques should be applied as soon as possible following a bite, as the neurotoxins with a low molecular weight will expand relatively promptly from the bitten site with frequent parallel increases in capillary permeability. If a pressure immobilization bandage is not applied, the *limb must be immobilized* by applying a splint or at least by fixing it to the trunk.

Any traditional and commonly known techniques of handling the bitten site, like cutting it open, sucking the venom out by the mouth, burning, rinsing it with oxidizing agents, phenol, permanganate, hydrogen peroxide and others, are ineffective and involve potential risk, so are not recommended. Furthermore, the thinking behind electrical impulses or electric shock treatment, sometimes mentioned in literature for laypersons, is unfounded and naive. Sucking the wound using a Sawyer extractor, as recommended commercially in the US, seems to be ineffective, but will not cause any additional major damage to the tissue compared to other localized methods. When using the device, care should be taken to ensure accurate application on the bite openings, as for large rattlesnakes, such as the western diamond-backed rattlesnake (*Crotalus atrox*), the distance between the openings can be greater than the size of the suction opening of the extractor.

In case of pain and developing edema, especially if the pressure immobilization bandage has not been applied, the affected limb can be *slightly elevated by a support.*

If the emergency services are expected to arrive in good time, any increased supply of liquids by drinking is not recommended. In instances of serious complications, a full stomach may cause vomiting and subsequent aspiration of stomach content. Conversely, if the emergency services are hard to reach in extreme conditions, drinking liquids cautiously that are easy to absorb, such as slightly sweetened water, weak or herbal tea, etc., is possible, particularly after a bite by a viperid snake (*Viperidae*). The well-known practice of drinking coffee or alcohol cannot be generally considered as very helpful. In most cases, this is dangerous and can make the course of envenomation much worse.

Any layperson's use of analgesics and sedatives is generally not advisable, unless the situation is not extreme. If that is the case, *sedatives* of ordinary use or doses of sleeping pills can be administered. *Analgesics* should be free of acetyl salicylic acid, especially following envenomation by a venom containing hemocoagulation-affecting components.

If an eye is affected by venom from so-called spitting cobras (*Naja* and *Hemachatus*), the first thing to do is to rinse the eye so as to dilute or remove the contact-effective venom. The best way of doing this is to use a stream of clean water, eye-flushing preparations like boracic acid, or milk. If none from the above are available, cleansing the eye with any non-toxic, non-irritant and non-infectious liquid, such as soft drinks, is possible and beneficial.

Transport into a health facility should be facilitated by the emergency service called out or an available car. In less accessible places, a helicopter may be necessary. In extreme situations, efforts should be made to transport the affected person, with a minimum of physical exertion on their part, to a place where health or transport assistance is available.

5.2.2. Medicinal First Aid

The affected person should be first calmed down. Systemic administration of *sedatives* can be beneficial, especially in cases of anxious or hysterical behavior, with parenteral administration of benzodiazepines as the best option. Chlorpromazine with an anti-emetic effect following envenomation by viperid (*Viperidae*) venom can also be an option. The standard doses are 25 to 50 mg in adults, and 1 mg/kg of body weight in children. Any deep sedation is generally not desirable; in the indicated cases of its use, the essential life functions of the patient must be inspected and respiratory airways protected from aspiration of stomach content. The same steps must be taken should impaired consciousness be caused by the envenomation or resulting complications.

In the case of pain that can be extensive locally, *analgesics* are applied. Caution is necessary when administering opioids to a patient after possible envenomation by neurotoxins from a coral snake (*Elapidae*) in all situations where assisted pulmonary ventilation is necessary but cannot be provided. Any reduction in a patient's ventilation efforts may result in manifestation of respiratory failure. On the grounds of inhibition of platelet function, administering salicylates is contraindicated, especially when the snake venom contains hemocoagulation-affecting components, as found in *Echis* and *Macrovipera* species, *Bothrops*, *Lachesis,* and other snakes. Appropriate analgesics include paracetamol or non-steroid antiphlogistics with an analgesic effect, such as ibuprofen.

To avoid an allergic response to snake venom components and the onset of angioneurotic edema, parenteral administration of *corticosteroids* is possible - hydrocortisone in a dose of 2 to 4 mg/kg IV (intravenously) or methylprednisolone IV in an equivalent dose. This treatment can be supplemented with *antihistaminics.* Even though any positive effect of the preventive measures above cannot be guaranteed, the patient's potential responses should be eased.

Shortly following a snakebite, a *pressure immobilization bandage* (PI) should be applied in the cases indicated, unless previously done so by the affected person, see chapter 5. 2. 1 First aid for laypersons. Using a PI when dealing with snake venom containing locally acting cytotoxins and proteolytic enzymes is controversial. Under such circumstances a more severe localized affection, especially necroses, is likely to occur due to prolonged action by enzymes at the bite, as well as decreased perfusion of the tissue if edema develops under the bandage. Nevertheless, the benefits of a PI have been proved experimentally after envenomation by the eastern diamond-backed rattlesnake (*Crotalus adamanteus*), in addition to clinical tests on snakebites by the Russel's viper (*Daboia russelli*). In the cases above, a PI remained in place for up to 7 hours without any increased incidence of necroses. Furthermore, venom release from the bitten site following the PI's removal resulted in increased venom concentration in the circulation, on average rising from 5 to 30 ng/ml. Despite lacking clinical data concerning the benefits of PIs in relation to snakebites by European vipers, the effect of this method in preventing more severe symptoms from snakebites, in cases of high venom doses, can be

presumed positive. Certainly, putting on the bandage is advised if children are affected or a delay in eventual treatment of the envenomation is expected.

If a PI has been applied by a layperson, the quality of performance and tightness should be checked. The recommended pressure of the bandage is 40 to 70 mmHg (5.3-9.3 kPa) for the upper limbs, and 55 to 70 mmHg (7.3-9.3 kPa) for the lower limbs. Fingers must be perfused and appear normal; any ischemic painfulness in a limb indicates that the bandage is too tight.

The method of bandaging has been developed with regard to the fact that venom largely propagates from affected tissue into the circulation via lymphatic routes. The bandage will limit lymphatic drainage and immobilize the limb. Therefore, the importance of this method rests on compressing the lymph vessels in a wounded limb along the greatest section possible and immobilization of the limb with a splint. The limb's immobility is very important to eliminate the pumping action of muscles. Any compression without motional restraint is ineffective, and is also true vice versa. If well-applied, compression will virtually inhibit the venom's progress for hours without limiting oxygenation and venous drainage, which is a problem associated with a tourniquet; naturally, sufficient blood flow through the limb, which can be checked by perfusion of the finger tips, is a pre-condition.

If an arterial tourniquet has been applied by a non-expert following a bite by a mortally venomous snake, such as a coral snake (*Elapidae*) with venom of serious neurotoxicity, it must be removed, but only after application of a pressure immobilization bandage to the affected limb.

Moreover, the *bitten site* is locally disinfected. In countries such as Australia, where the venom can be identified using a kit should uncertainty exist concerning the snake species involved, the bitten site is not wiped and disinfected so as to maintain traces of the venom around the bite wounds.

To facilitate checking localized changes at the bite, a small hole can be cut out in the pressure bandage applied for viewing purposes.

The bitten site cannot be subject to any of the traditional actions propagated, see chapter 5. 2. 1 First aid by a layperson.

If a patient's vital functions, respiration, circulation, etc., are affected, securing or supporting the same is a clear priority. Nevertheless, if an affliction of such a level occurs and neither an acute anaphylactic reaction nor high exposure to neurotoxins are involved, the symptoms of envenomation will become apparent in the order of dozens of minutes following a snakebite.

An *anaphylactic shock* is subject to standard treatment methods. Epinephrine is administered as follows: 0.3-0.5 ml IM (0.3-0.5 mg), 1:1000 dilution; 0.01 ml/kg of weight in children IM (intramuscular); this is repeated as necessary every 5-15 minutes until the circulation is stabilized; then volumotherapy is supplemented. Furthermore, corticosteroids are administered: methylprednisolone 125 mg IV (1 mg/kg of weight in children), this is repeated every 6 hours; in addition, antihistaminics are applied. Circulation collapse or shock therapy must be accompanied by oxygen therapy.

Similarly, *hypotension* resulting from vasodilation and extravasation caused by toxins, subsequent shock, and collapse of circulation, is followed by symptomatic treatment, i.e. tonization of the vascular bloodstream by catecholamines and plasma expansion. In patients under threat of a hemocoagulation disorder, alternative solutions based on dextrans are not used due to their interference with platelet function.

Symptomatic treatment is also employed within urgent medical aid in cases of a *rhythm and contractility disorder* caused by cardiotoxin action. Any circulation affection treatment always includes oxygen therapy.

In situations of apparent envenomation by neurotoxins, which will typically start with *paralysis of facial muscles,* i.e. ptosis, ophtalmophlegia, dysarthria, and dysphagia, peroral intake is contraindicated as a consequence of possible aspiration caused by loss of the swallowing reflex. If *respiratory failure* is manifest, plus there is risk of aspiration, then intubation and mechanical ventilation are an option. A patient thus affected might be fully consciousness, therefore, adequate easing of their condition must be provided.

In cases of an eye being attacked by a spitting cobra (*Naja* and *Hemachatus*), see chapter 6. 3. 1. 5 *Naja* genus, the cobra and 6. 3. 1. 7 Other genera of African and Asian elapid snakes (formerly under the name of the *Bungarinae* family), the eye is rinsed or the process repeated if previously conducted by a non-expert. Clean water, a physiological saline solution, boracic acid, or another similar eye-flushing preparation can be used. For intense burning pain, application of a local anesthetic into a conjunctival sac is advisable. The analgesia will eliminate the blepharospasm occurring, allowing for examination of the eyes, and help calm the person affected. Epinephrin in the form of 0.1% drops may also be applied; dilution: 1:1000. See also chapter 5. 3. 3. 1 Localized damage.

Transport of the affected with suspected or apparent envenomation is carried out in a lying position to the nearest health institution capable of handling severe systemic symptoms, i.e. respiratory failure, severe hemostasis disorder, and circulatory failures. If doubts arise as to envenomation having occurred and neither a local nor systemic response is manifest, plus more than 24 hours has past since the attack, placing the patient within a standard department for examination and observation suffices.

The case should be consulted with a toxinology centre as soon as the phase of urgent medical aid has commenced to determine further steps, the need for potential hospitalization at a dedicated centre, and in order to provide specific immunotherapy.

5.3. Hospital Treatment

5.3.1. Specific Treatment - Immunotherapy

Specific therapy or immunotherapy (antivenom therapy) refers to the administration of snake antivenom. If a monovalent antivenom is available and the snake species identified, administration of the monovalent antivenom is preferable to a polyvalent antivenom. The latter is, however, administered more often. In the home ranges of venomous snakes in the wild, a species cannot be always identified with surety; in addition, where snakes are kept by non-experts, monovalent antivenoms are frequently not available.

Administration of an antivenom will in some cases greatly reduce morbidity and mortality. For example, following a snakebite by the saw-scaled viper (*Echis carinatus*), lethality will decrease from 20% to 3%, while in envenomations by the South American rattlesnake (*Crotalus durissus terrificus*), lethality will drop from 74% to 14%.

5.3.1.1. Indications of Antivenom Administration

Application of antivenoms must be always considered properly due to their severe potential side-effects. Generally, specific immunotherapy is indicated only in instances where signs of systemic envenomation exist, or if a localized finding is extensive and progressing. Localized indication schedules describing prodromes or early symptoms of systemic envenomation are in place for certain types of envenomation with epidemiological relevance, such as the Stockholm criteria (see Chart 4).

Chart 4. Stockholm criteria with indications for the use of antivenom

1. Hypotension and circulatory shock
2. Protracted severe gastrointestinal symptomatology
3. Mucous membrane edema with a risk of bronchial obstruction
4. Rapid extension of edema to an entire limb and the torso
5. Neurological symptomatology with depressed CNS and peripheral and central paresis
6. In extreme cases of insufficient clinical signs:
   Leukocytosis exceeding 15-20 x 10^9/l
   Metabolic acidosis
   Hemolysis
   ECG changes
   Hemocoagulation disorders

Gastrointestinal difficulties indicate early signs of systemic envenoming. They involve nausea, vomiting, abdominal pain, and diarrhea, occurring very frequently in envenomations by *Crotalinae* subfamily members and vipers (*Viperinae*). Slight symptoms of this type in a healthy adult person would not constitute a direct indication to administer an antivenom. However, for children such a situation must be considered more seriously, as the amount of venom is greater in proportion to the weight of the child, and could reach a level of risk as a result.

Another set of symptoms involves circulation being affected with signs of **reduced systemic pressure**, progressing in some cases to circulation collapse and shock. Accompanying symptoms may involve incidence of hypotension, including possible syncopes, and the patient turning pale and sweating. The indications for antivenom administration also involve **rhythm disorders and changes in ECG** under circumstances of envenomation by venom including a cardiotoxic component.

Envenoming by neurotoxins is initially manifest by **slack facial muscles**, including eyelid ptosis, external ophtalmoplegia with diplopia, dysphagia, dysarthria, salivation, and depression of the cheeks and corners of the mouth. Subsequently, on exposure to postsynaptic paralyzing neurotoxins, a feeling of general muscular weakness occurs, with eventual paralysis of respiratory muscles.

An indication for antivenom treatment should also emphasis a **finding involving hemocoagulation disorders**, which are based only in the laboratory in the initial phase of envenomation; clinical signs of hemocoagulation - mostly bleeding - are a definite indication of these. Abnormities reported by the laboratory, indicating administration of antivenom, include not only prolonged coagulation times, but also symptomatology involving

hypercoagulation, plus fibrinogen and fibrin degradation with a significant increase in total FDP or D-dim and clinical or laboratory findings of **hemolysis**.

Envenoming by myotoxins, i.e. rhabdomyolysis, will be expressed by tension and **pain in the muscles**, with later development of evident **myoglobinuria**. In this case, treatment with antivenom is also indicated.

Administration of antivenom is also indicated in any case of **impaired consciousness**, either qualitative or quantitative.

Damage to the kidneys will be mostly manifest by **oliguria** in later phases of envenomation, as this is not an early indicator; however, the onset of prodromes, such as pain in tapping the area above kidney, may indicate repetition of the dose of antivenom. If that is the case, non-specific treatment will be more important, see chapter 5. 3. 3 Symptomatic treatment.

From **laboratory examinations,** administration of antivenom is indicated by leukocytosis above 20 x 10^9/l, elevation of AST, ALT, CK or other enzymes, and acidosis, in addition to diagnosing hemocoagulation disorder.

Even though it is a well-known fact that antivenom therapy will, in most cases, neither eliminate nor aid any local affliction already in place, administration of antivenom can be indicated by **severe local reactions** as well, including sizeable edema, extensive ecchymoses or vesicles of an area exceeding one half of the affected limb. In addition, it is necessary to consider indications for administering, examples including the content of necrotizing enzymes in the venom, or attack by a venom producing heavy edema in a narrow fascial compartment, e.g. a finger, as well as development of local myonecrosis with a risk of compartment syndrome. Possible neutralization of a local pool will depend on the rapidity of antivenom penetration into the site of damage. The venom enzyme destructs the tissue immediately, while any antivenom administered will always enter the given site after a delay. Concerning penetration of the site of localized damage, the molecular size of the antigen - the type of the antivenom - will probably not play an important role in microvascular damage at the affected site. A large localized affliction can indirectly indicate the quantity and effect of certain venom components of a largely enzymatic nature, as well as possible systemic damage in future, which is another reason reinforcing it as an indication for administering antivenom.

In some cases, the positive effect of treatment will be determined by a short period between the bite and application of antivenom. *Timely antivenom therapy* and neutralization of certain venom components may prevent irreversible damage of attacked structures. This is true not only in a number of enzymes, but also toxins, including presynaptic neurotoxic PLA_2, myotoxic enzymes and nephrotoxins causing renal failure, thrombin-like components activating processes ending with microthrombosis occurring, endothelial damage, and other consequences, or even enzymes' destruction of tissues attacked at a greater distance around the bitten site as a result of their propagation. For any efforts to influence a localized affliction, administration of antivenom within 1 to 2 hours following a snakebite is essential. Therefore, indication of antivenom administration should be deduced quickly, although always based on the presence of systemic envenomation symptoms or extensive localized affection.

If for some reason prompt antivenom therapy is not available, *late administration of antivenom* is indicated provided treatment criteria are met, which will weaken the effectiveness of venom components flushed out of the bitten site and unbind the toxins temporarily, acting on specific receptors like postsynaptic neurotoxins, cardiotoxins, and

others. Late administration of antivenom has proven effective 2 days after envenomation by marine sea snakes, but even longer following the start of coagulopathy with envenomation by *Crotalinae* snakes and viperines (*Viperinae*). Thus, any further delay between the snakebite and the possibility of antivenom administration should not be excluded from subsequent treatment.

Repeated administration of antivenom is indicated if signs of systemic envenomation persist or when symptoms reoccur, which is typically recorded in venom components affecting hemocoagulation and in other cases of related symptomatology, such as in envenoming by *Echis* and *Daboia* snakes, rattlesnakes (*Crotalus*), Asian (*Trimeresurus*) or Malayan (*Calloselasma*) pit vipers; other examples include the Indian krait (*Bungarus caeruleus*), Indian cobra (*Naja naja*), etc. Returning symptoms will mostly manifest within 1 to 7 days following administration of antivenom, however, weaker symptomatology may appear even after 10 to 14 days.

The recurrence of envenomation symptoms is probably due to two things: the first is continued release of venom from the pool at the bite, while the second is the dissociation of the antigen-toxin complex and faster antitoxin clearance. The return of recurrent envenomation symptoms is in indirect proportion to the dose of the antivenom applied; in addition, it is more frequent following use of antivenom containing antigens with a shorter half-life, such as the Fab-fragment. When utilizing such antivenoms, repeated administration is taken into account due to the effective half-time of such substances probably lasting less then 12 hours. Of course, recurrence can still occur even if an antivenom is applied containing a whole IgG molecule with a half-time that may exceed as many as 150 hours.

5.3.1.2. Contraindication of Antivenom Administration

The contraindication for administering venom comes in the form of an allergic reaction to the animal serum involved, usually a horse serum. An absolute contra indicator as regards horse serum can be considered a severe response in anamnesis following application of either antitetanic or antirabies serum. Should an allergy be apparent to horse antivenom, a sheep antivenom can be administered if available. Naturally, such a contraindication is not to be considered in cases of severe life-threatening envenomation. The antivenom can be applied upon a vital indication following prophylactic antihistaminic preparation, and under the condition the patient's safety is ensured should anaphylactic complications appear, see chapter 5.3.2 Prevention and treatment of serum anaphylactic reactions.

Furthermore, a relative contraindication is the occurrence of another type of allergy or a polyvalent form. In such case, the practicalities of antivenom therapy or non-specific treatment should be thought over, depending on the envenomation's progress, options for symptomatic treatment, and the level of a patient's sensitization.

A similar consideration is needed for patients that have undergone repeated exposure to a horse antivenom. This circumstance cannot be termed as a contraindication; indeed, it just highlights the necessity for rational consideration of the potential disadvantages of administration and presumed immunotherapeutic effects. In instances of more severe envenomation, the administering of antivenom will be fully indicated, although antihistaminic premedication is a priority.

A relative contraindication may occur if a layperson or paramedic has given someone a dose of antivenom. It should only be administered in extreme situations, e.g. following a bite by a mortally venomous snake, and if prompt and adequate medical aid is otherwise

unavailable. The decision to do it must be preceded by the process of weighing up the risk of envenomation symptoms - such as imminent paralyzing neurotoxicity - against potential severe anaphylactic shock that cannot be resolved on the spot.

5.3.1.3 Dosage and Method of Antivenom Administration

The dose of antivenom that can unbind venom enzymes and toxins depends on the definite quantity of them in accessible compartments. Estimating the appropriate antivenom quantity to a certain degree is possible based on the snake's species, the speed of the onset, the severity of envenomation symptomatology, as well as the relevance of localized findings in some cases. In instances of bites by snakes not near the top of an imaginary hierarchy of mortality, e.g. *Vipera* and *Cerastes* snakes, Asian pit vipers (*Trimeresurus*), *Crotalus* rattlesnakes, *Agkistrodon* and *Gloydius* snakes, kraits - *Bungarus*, *Micrurus* coral snakes, and a number of other taxons, only one of two vials of the related antivenom can be applied to begin with. In heavy envenomations caused by a mortally venomous snake like the large cobras - *Naja* and *Ophiophagus*, mambas - *Dendroaspis*, taipans - *Oxyuranus*, tiger snakes - *Notechis* or large *Bothrops* and *Lachesis* snakes, the initial amount required increases to three and more vials, with subsequent repetition if antivenom effectiveness is low or symptoms return. The overall amount of antivenom applied is not limited in the course of heavy envenomations and may result in dozens of vials.

Even though intramuscular and localized administration is recommended by many manufacturers, it is obvious that antivenoms are practically ineffective when delivered in this form. Rapid intravenous delivery is the cause of the highest incidence of anaphylactic reactions. The most convenient method of antivenom application is intravenous infusion of diluted antivenom, preferably in 500 ml of electrolyte solution or 5% dextrose. The incidence of anaphylactic reaction generally equals that of intramuscular administration and its effectiveness in application is equivalent to that of intravenous administration. The recommended infusion velocity should not exceed 4 ml of undiluted serum per minute; however, instillation of the entire vial in 30 to 60 minutes is much more appropriate.

Dermal or conjunctival tests prior to applying antivenom will not always predict the occurrence of early anaphylactic reaction or serum sickness later and are not recommended in professional literature. Nevertheless, carrying them out remains a facultative practice and will be dependant on a physician's approach or the methods of a medical workplace.

In extreme conditions - see the contraindication of antivenom administration section above - the range of options available may involve intramuscular application of antivenom, depending on the situation and equipment at disposal. However, considering the reduced effectiveness of this method and that of delivering it very slowly intravenously, a greater risk is posed of an acute allergic response occurring or even anaphylactic shock.

5.3.2. Prevention and Treatment of Serum Anaphylactic Reactions

In *preventing an anaphylactic reaction,* the application of epinephrine prior to antivenom treatment has proven effective. The substance is administered subcutaneously, with a dosage of 0.25 ml (i.e. 0.25 mg of epinephrine) and dilution of 1:1000 (0.1%). Administered in this manner, epinephrine will greatly reduce the chances of early anaphylactic reaction. During the patient's preparation process, corticosteroids can also be used, with doses corresponding

to between 2-4 mg of hydrocortisone/kg of weight, while use of the sedative first-generation H_1-receptor-antagonists like promethasine seems to be ineffective.

Early anaphylaxis therapy does not differ from that of the same response in different etiology. In the case of minor symptoms like dermal manifestation, nausea, temperature, etc., intravenous application of corticosteroids at a dosage corresponding to 2-4 mg of hydrocortisone - potentially in combination with an antihistaminic - will be sufficient. In severe systemic reactions, including hypotension, circulation collapse, and anaphylactic shock, vasopressor treatment is indicated using 0.3-0.5 ml of epinephrine (0.3-0.5 mg), at a dilution of 1:1000 (0.1%), IM, with repeated doses as necessary, as are volumotherapy and the application of corticosteroids and antihistaminics, see chapter 5. 2. 2 Medical first aid. The treatment should include giving antihistaminics, H_1-receptor-antagonists (for instance chlorpheniramine maleate from the alkylamine group, dosage 10 mg per adult, 0.2 mg/kg of body weight per child). Circulation collapse or shock therapy must be accompanied by oxygen therapy. Any instance of bronchospasm as well as angioneurotic facial edema will require the application of corticosteroids. Should respiratory failure appear due to a bronchospasm or obstruction of the respiratory pathways caused by edema, tracheal intubation and mechanical ventilation is indicated.

Positive results have been achieved from corticosteroid treatment for *late anaphylactic reaction* - serum sickness, which can be treated, for instance, by prednisolone 5 mg PO every 6 hours over a period of 5-7 days. This can be supplemented by antihistaminics, especially if there is pruritic affection. Symptomatology will abate in 2-4 days, many times even spontaneously.

5.3.3. Clinical Symptoms of Envenomation and Symptomatic Treatment

5.3.3.1. Local Damage

Localized envenomation symptoms involve bite marks, pain, changes in the color of skin at and around the bitten site, development of petechiae, ecchymoses, vesicles and hemorrhagic efflorescences, as well as necrosis of affected structures and edema, the intensity of which may go as far as to cause ischemic damage to tissue through a perfusion disorder.

The depth of the *fang bite* may vary depending on fang size and how effectively the snake makes the bite. There are mostly two wounds, however, bite marks of just a single fang or more fangs in a row on a single side are not unheard of due to a snake growing new ones. Following a rapid fang stroke, only scratches of a varied length and depth can be evident on the skin, although even these may be affected by envenomation, just as the same is not precluded by a lack of bite marks. The small wounds including edges can be hemorrhagic, may show slight bleeding or can be a livid color, including the areas around them. If only a minimal quantity of locally acting components is present, there are no traces of these symptoms at the site of bite. A localized allergic response may cause urticarial symptomatology at the bitten site.

The pain experienced at and around a wound can be high in snakebites by the majority of species, such as viperids (*Viperidae*), low or even negligible in some snakes like the cobra (*Naja*), whilst locally reduced sensitivity to pain occurs in the case of snakebites by certain elapids (*Elapidae*). Pain typically appears immediately at the bitten site, progressing together with edema as far as the regional lymph nodes or even further. It persists on average between

a week and 10 days, with its intensity dependant on snake composition, quantity and degree of tissue damage. The overall painfulness of muscles caused by exposure to myotoxins, e.g. the Russel's viper (*Daboia russelli*), is considered a systemic envenomation symptom.

For giving analgesics, the principles apply as provided in chapter 5. 2. 2 Medical first aid. Should more severe pain be experienced, application of opiate analgesics is indicated. However, deep pharmacological analgesia is not always desirable as it may obscure the occurrence of ischemic pain should flow occlusion evolve. In addition, the pain's intensity indicates the progress or regression of the localized affection.

Dermal efflorescence appears around the affected site depending on the content of hemorrhagins and hemocoagulation-affecting components, indicating capillary affection and cutaneous or sub-cutaneous bleeding. Developed redness, petechiae and ecchymoses, as well as the bitten site, will not require any localized treatment.

The make-up and nature of proteolytic enzymes in the venom will cause more serious damage to affected tissue, including the development of *vesicles and even bullae***,** mostly *perfused*, and the occurrence of early *necrosis* in skin or even deeper structures. Any bullae and necrosis should be carefully removed surgically, the beds of which it is necessary to repeatedly clean gently, especially if hemorrhagic. Bullae and most necrosis will be limited to the surface structures of skin; the bed is usually vital and reparable after the hemorrhagic layer is removed. If deeper structures are affected, careful debridement should be repeated as necessary. The tissue healing process will take many days according to the level of damage. For instance, in the case of necrosis caused by the *Agkistrodon* and *Crotalus* snakes, tissue will recover in 14 to 77 days, with a mean period of 45 days. Cases of more extensive dermal necrosis are solved through transplantation of skin.

Edema can be simple, without hemorrhaging, affecting only a part of the limb or localized around the bite wound, with an intensity that will not prevent perfusion of tissues. Such edema will not require any other intervention beyond mild cooling and the light elevation of a limb. Hemorrhagic edema, often accompanied by hemorrhagic dermal efflorescences, can be more extensive and intense. In such instances, immobilization of an arm and routine monitoring of the intensity is necessary due to potential perfusion decrease and ischemization of relevant tissues. Any potential cooling must be exercised very gently; elevation of the arm will be limited by a possible decrease in perfusion pressure due to hydrostatic causes. Heavier forms of edema can move from limbs to the trunk and even to the other side of body.

The most severe form of localized affection involves intense edema preventing tissue perfusion by developing *compartment syndrome.* Without any effective action, this will inevitably result in deep necrosis and possibly amputation. Under circumstances of such a threat, careful monitoring of blood flow through the limb is of the utmost importance, but measuring or monitoring of pressure in each compartment affected is much better. The pressure in tissue should not exceed 45 mmHg (60 cm H_2O). If pressure values increase and perfusion fails, fasciotomy is fully justified, of course, only if administration of antivenom precedes this and changes in hemocoagulation are stabilized. Preventive execution of fasciotomy is not indicated, any deep and not fully justified surgical action on damaged structures may conversely induce a higher level of subsequent affection in the structures.

The duration of the edema's persistence will depend on the amount and composition of venom; the acute phase will mostly abate within 10 days. Sometimes, in efforts or other loads

on the tissue, edema as well as increased pain or other sensory or motional abnormities can be reversible where periods may vary.

Gangrene is a serious but infrequent complication in localized damage. It develops as a result of localized venom effects and tissue ischemia due to limited perfusion. Pre-emptive measures involve a protective approach to the affected tissue and avoiding limb ischemization - efforts to stabilize or minimize the severe edema and fasciotomy or rational anticoagulation therapy in thromboembolic complications, where indicated. If occurrence of gangrene is suspected, application of an anti-gangrene serum is indicated.

Apparent *lymphadenopathy* - an ailment affecting lymphatic tissue is brought on by venom spreading from the bitten site. It is manifest through not only potential affection of regional lymph vessels, but also more usually through the swelling of related lymph nodes.

Giving antibiotics to prevent localized *infection* is not always fully justified, even though it is recommended by some authors. In South America, with early infection incidence of over 10%, it is obviously of greater importance than in Europe, where the occurrence of phlegmons or abscesses at and around the bitten site is rather exceptional. Naturally, if localized infection is suspected or even manifest, administration of antibiotics will be fully indicated, as well as surgical drainage, where indicated. If the bacterial agent is unknown, antibiotics well capable of penetrating tissue and boasting a wide spectrum of effects, e.g. anaerobic flora, should be administered, examples being bactericide aminopenicillins containing a β-lactamase inhibitor, possibly supplemented by metronidasole; in contraindications, bacteriostatic clindamycine should be applied.

The provision of *antitetanic prevention* is fully indicated.

Tissue at the bitten site and surrounding it can often be seriously damaged by the venom components acting locally. The level and time of reparation depends on the medical approach taken in dealing with such tissue. Any approach of unjustified intensity and invasiveness may, in some cases, potentiate the developed affection iatrogenically. If there is no indication for medical action, any handling of the area of localized changes will be contraindicated. Any well-founded actions should be exercised very gently, with regard to potential traumatization of the tissue around the site.

The definition of localized damage includes *the eye being affected* by the venom of spitting cobras, see chapter 5. 2. 2 Medical first aid. Any corneal and conjunctival contact with the venom is very painful. The enzymatic destruction of surface corneal and conjunctival layers will cause corneal ulceration and severe conjunctival inflammation. As a complication, inflammation of the iris (anterior uveitis) is brought on. Ultimately, the damage can even result in permanent blindness. The rinsing procedure specified in the framework of first aid, see chapter 5.2.2 Medicinal first aid, should be followed by repeatedly instilling the affected eye using local anesthetics, antibiotics and corticoids to eliminate pain and avoid infection, corneal defects and the onset of post-inflammation changes. Any treatment should proceed under the surveillance of an optical specialist.

5.3.3.2. Absence of Symptoms, Envenomation Prodromes

In a number of cases, a snakebite will not cause clinical symptoms of envenomation, or the affection is limited to localized signs. The former is as a result of a warning defensive bite with no venom discharged - a dry bite. This occurs more often from solenoglyphous viperids (*Viperidae*) - in as many as 50% of attacks - than elapids (*Elapidae*), see chapter 1. 4 The venom apparatus in snakes. However, since the development of symptoms of envenomation

or onset of complications can be delayed by several hours, observing the patient for a day is useful. Whilst hospitalized, the following is tested as completely as possible in a laboratory on a routine basis: hemocoagulation (PT, APTT, TT, FBG, FDP, D-dim, AT, PLT), blood count, basic biochemical examination including hepatic tests (bilirubin, ALT, AST, GMT), renal function (urea - U, creatinine), or possibly other special analytes (myoglobin, available hemoglobin, etc.). If no clinical symptoms of envenomation occur within 24 hours and a second laboratory examination proves negative, the patient can be discharged.

If envenomation is limited to *localized symptoms,* it is likely only to be an envenoming by a small quantity of venom with largely localized effects, which mostly occurs following a snakebite by lesser rattlesnakes (*Crotalinae*) or viperines (*Viperinae*) of a less dangerous type. Under such circumstances, a patient is treated according to the damage sustained and its intensity. If the case requires no further intervention by a hospital, the patient is discharged home or placed in the care of a hospital ward following 24-hour observation in case of repeated negative or minor laboratory findings (see above). Nevertheless, a check-up or the provision of antitetanic prevention is required for both of the above.

Early prodromes of envenomation are largely of the gastrointestinal type: nausea and vomiting - happening soon after the incident in many cases - pain in the epigastrium or hypogastrium, and diarrhea. Affection of the central nerve system, CNS, is another case of non-specific symptomatology. It can be exhibited by cranial pain, languor and vertigo, but rarely by lightheadedness or syncopes, and loss of consciousness. If the effect on the CNS is more severe or persists, the reason must be found and resolved, e.g. hypotension or possible bleeding into the CNS. Increased body temperature may be involved, as well as shivering and feverishness, plus there will be profuse sweating and leukocytosis discovered by laboratory testing. Responses within the vegetative reactions may be affected in a non-specific manner.

Thirst, sinus tachycardia and hypertension that could occur in early phase of envenomation should be assigned to the previously specified affection of the vascular system with extravasation, or diagnosed as a psychosomatic reaction by the victim.

Treatment of the prodromal symptomatology comprises sedation and antiemetic therapy; chlorpromazine at a dosage of 25-50 mg per adult and 1 mg/kg of body weight per child is usually found as effective due to its strong antiemetic effect, sedative quality, and vegetative system stabilizing properties.

The above-mentioned signs of non-specific symptomatology point to specific antivenom therapy being required in most cases, and often precede other symptoms of systemic envenomation. Prodromes usually abate within several hours, but have been known to persist for 48 hours.

5.3.3.3. Affection of Nerve Tissue and Neuromuscular Connections

Neurotoxicity symptoms in their mildest form are almost indeterminable clinically, involving the impact of a low quantity of presynaptically acting neurotoxic PLA_2 from the venom of some viperine snakes (*Viperinae*), examples being the European viper species, *Vipera ammodytes* and *V. aspis*. However, extreme symptoms are exhibited as fatal respiratory muscle paralysis largely caused by the curare-like effect of postsynaptically acting neurotoxins or, most severely, their combination with potent neurotoxic PLA_2 from the venom of elapids (*Elapidae*).

The effect of the larger quantity of *presynaptically acting neurotoxins* of PLA_2 type contained in the venom of certain viperid snakes (*Viperidae*), like the Russel's snake (*Daboia*

russelli siamensis) or the South American rattlesnake (*Crotalus durissus*), can be clearly discerned clinically. If fully developed, it is principally manifest in the area of the cranial nerves not only through ptosis, ophtalmophlegia with double or fuzzy vision, dysphagia with increased salivation, dysarthria, a variable degree of visible facial muscle paralysis, but also through general muscular weakness. However, such apparent neurological symptomatology in envenomation by viperid snakes (*Viperidae*) is rather rare, plus paralysis of the respiratory muscles never occurs.

Any enzymatic damage to nerve endings by PLA_2 is largely irreversible; symptomatic treatment does not exist and would be unnecessary. Any further propagation of nerve ending damage can be only prevented by immunologically unbinding neurotoxic PLA_2 through early administration of a relevant antivenom.

Paralysis of striated muscles is characteristic for venom neurotoxicity by elapid snakes (*Elapidae*). *Curare-like neurotoxins* with postsynaptic effects, sometimes combined with highly effective presynaptically acting enzymes, are capable of invoking paralysis of respiratory muscles and fatal respiratory failure. The paralysis affecting the striated muscles proceeds craniocaudally, preceded by cranial nerve affection symptoms described in the previous section. Affliction by a venom possessing a substantial quantity of neurotoxins can cause fatal paralysis in just minutes, although it usually takes several dozen minutes, but up to 10 hours is not unheard of. In a number of cases, consciousness is not affected, with suffocation occurring whilst the victim is fully lucid.

Symptomatic treatment of such a status involves securing the patient's respiratory airways using *tracheal intubation and mechanical ventilation*. The postsynaptic curare-like action of neurotoxins can be diminished or eliminated by *acetylcholinesterase inhibitors*. To test the inhibitor's efficiency, 10 mg of edrophonium chloride can be administered to an adult patient. If positive, the victim's status is greatly improved, peaking after five minutes and then abating. Atropine sulphate, 0.5 mg for an adult patient, can be used as premedication to block the muscarinic effect. If the test proves effective, treatment can continue via applying neostigmine methylsulphate, a long-term cholinesterase inhibitor, at a dosage of 0.5 mg per adult IV or SC every 20 minutes.

The procedure above has been corroborated following envenomation by the neurotoxins of Asian cobra species: *Naja naja*, *N. kaouthia,* and *N. philippiensis*. However, it seems ineffective when envenoming has occurred by neurotoxins combined with a fatal component of presynaptically acting enzymes, as found in the venom of mambas (*Dendroaspis* sp.), kraits (*Bungarus* sp.), Australian tiger snakes (*Notechis* sp.), taipan (*Oxyuranus*), and other snakes. Successful symptomatic treatment should not be considered an alternative to applying antivenom, but rather a useful complement to specific immunotherapy, which must be administered in every case, unless contraindicated.

5.3.3.4. Rhythm and Cardiac Output Disorders

Heart function can be directly affected by the action of specific cardiotoxins, typically inherent in venoms of the cobra (*Naja*) and Gabon and rhinoceros vipers, *Bitis gabonica* or *B. nasicornis*, respectively. The effect of toxins on the conduction apparatus will be displayed in the form of *rhythm disorders* in terms of tachycardia or bradycardia including AV-blocks, plus the occurrence of non-physiological rhythms and extrasystoles. Myocardial affection results in reduced myocardial contractility, i.e. *cardiac output*, which potentiates circulation

collapse in the presence of both vasodilation and extravasation. Subsequently, the temporary increase in coronary flow brought on by vasodilation can collapse due to loss of vessel tone

Specific effects wrought by cardiotoxins may be controlled by administering antivenom, nevertheless, if the disorder is more severe and antivenom is not available or contraindicated, symptomatic treatment by *anti-arrhytmics* is justified depending on the particular circumstances, including the support of myocardial contractility using *catecholamines*, see chapter 5. 3. 3. 5 Hypotension and shock.

Arterial vascular resistance, including that of coronary arteries, is increased by the specific effect of sarafotoxins of *Atractaspididae* snakes. This will result in systemic hypertension and myocardial ischemia with the relevant ECG changes. If that is the case, vascular resistance and systemic pressure should be reduced with additional support of the coronary flow through *vasodilation therapy* using nitrates.

5.3.3.5. Hypotension and Shock

Decreasing blood pressure in envenomation by snakes may have multiple causes. Aside from hypotension, brought on by an anaphylactic reaction, see chapter 5. 2. 2 Medical first aid, an early cause for *vasodilatation* is the release of bradykinin and, obviously, certain venom components acting directly on the vessel wall or vasoregulation centre. Kininogens are venom components in viperid snakes (*Viperidae*), such as the snakes of *Bitis*, *Vipera* and *Macrovipera* genera, rattlesnakes (*Crotalus*), Australian terrestrial species, and other snakes, see chapter 3. 3. 2. 3 Venom components with effects on the cardiovascular apparatus.

Extravasation is another reason for this, either discernable at a varied systemic level or locally or severely, and is typically caused by hemorrhagins or other enzymes, resulting in reduced intravascular volume. Enzymes acting this way are contained in venoms of a number of viperids (*Viperidae*), such as the *Macrovipera* snakes, *Bothrops* and *Lachesis* snakes, *Crotalus* species, Asian pit vipers (*Trimeresurus*), and others, see chapter 3.3.2.4. Venom components with effects on the vessel wall. In addition, potential *bleeding* is another factor in reduced vascular volume as well. Naturally, the effects of both accumulate in some cases.

Severe hypotension may result in *circulation collapse*, and even in the *shock*, preceded by loss to adequate perfusion of tissues. In certain cases of envenomation, hemodynamic disorder can be potentiated by reduced myocardial contractility.

In cases of slight systemic pressure decrease, a mild increase in intravascular volume through the infusion of *crystalloids* is sufficient. If the hypotension is more severe, additional application of *colloids* infusions that can be maintained in the circulation over longer periods will be useful. Should hemocoagulation be affected in terms of diminished hemostasis, dextran preparations further dimming platelet function must not be applied. *Albumine* presents a superior means of compensation for volume. Administering at least 10 ml/kg of body weight of *fresh frozen plasma* (FFP) will provide for not only volumoexpansion, but also a certain level of normalization of potential DIC-like hemocoagulation disorder. Thus, applying the plasma will be the most helpful solution in cases of hypotension in the presence of a hemostasis disorder. By replenishing circulating volume or moderately increasing it, blood pressure can be stabilized in most cases, especially when an antivenom is administered at the same time. Moreover, increased diuresis induced by volume will also prevent renal failure from emerging.

If hypotension continues despite volume therapy, or circulation collapse and shock are intimated, administering *vasopressoric catecholamines* as an intravenous infusion is justified.

For a patient weighing 70 kg, a medium dose of norepinephrine, i.e. 0.1 µg/kg/min is achieved by diluting 4 mg in 50 ml of volume and applied at a speed of 5 ml per hour. The treatment will require continual monitoring of blood pressure and prompt infusion speed control depending on the actual situation. Measuring venous pressure is useful, even in instances of higher volumotherapy.

If envenomation has been caused by venom in which cardiotoxic myocardial contractility -reducing components - can be expected, see chapter 5. 3. 3. 4 Rhythm and heart output disorders, the giving of *catecholamines with a β-mimetic effect*, e.g. dobutamine with a mean dosage of 5 µg/kg/min, is justified in serious cases.

Circulatory failure therapy includes *oxygen therapy,* along with mechanical ventilation accompanied by comprehensive intensive care if severe shock associated with organ hypoperfusion develops.

5.3.3.6. Hemocoagulation Disorders

Hemocoagulation disregulation or disorder is caused by various kinds of intervention by venom components in the plasma coagulation system as well as platelet, endothelial and sub-endothelial function. Lighter disorders will be exhibited only via *laboratory findings*, while those more severe mostly manifest themselves through clinical signs of *increased hemorrhage* through to unmanageable bleeding from wounds, mucous membrane tissue, the nose, mouth, gums and conjunctiva, and up to bleeding into the organs - GIT, brain, body cavities, and hematuria. However, the influence may also be of a procoagulative nature, involving the developing of *microembolization* or *thromboembolism* in the early or late phase of the affliction.

Activating the hemocoagulation system results in a DIC-like consumption disorder. As this progresses, for instance, following envenomation by the venom of *Echis* snakes, especially in collaboration with hemorrhagins, a certain degree of multiple organ dysfunction syndrome (MODS) occurs, which is most frequently associated with pulmonary tissue of the ALI/ARDS type being affected and oliguric renal failure. One of the reasons for this development is the presence of microthrombotization and interstitial edema when capillary integrity is damaged; symptoms include varied levels of respiratory distress syndrome, anuria, elevation of bilirubin and hepatic enzymes, etc.

Hemocoagulation-affecting venom components are found in the majority of viperids (*Viperidae*), principally the *Echis* and *Daboia* snakes, *Bothrops* and *Lachesis* snakes, and certain *Crotalus* species. For other taxons, hemocoagulation is affected by the venoms of sea snakes and sea kraits, in addition to certain Australian terrestrial elapids and the *Naja* cobra genus, see chapter 3. 3. 2. 5 Venom components with effects on hemocoagulation.

Symptomatic treatment of hemorrhage is applied if antivenom administration is contraindicated or unavailable either temporarily or long-term, or merely to provide support for the primary treatment by antivenom. The priority of symptomatic treatment increases following envenomation by prothrombin activator-containing venoms that possess poor antigenicity, where specific immunotherapy may fail in some cases. The treatment must be based on laboratory results for the given disorder and presumed type of affection. In the later phases of developed DIC-like consumption disorder, which may already proceed as *circulus vitiosus* of pathophysiological mechanisms without the cooperation of venom components, symptomatic treatment is an option for managing status.

In the case of changes in *hemocoagulation examination*, the test must be repeated after a certain interval. In early phases, if any further development of the disorder is expected after at least four hours and in the phases of abatement and convalescence, a period of 12-24 hours until results normalize is sufficient.

Prolongation of PT, APTT and TT is usually the rule for the majority of PCS affection types. If the prolongation is not extreme, no further treatment is required. However, parallel RT prolongation means, together with high FDP levels, the presence of fibrin-soluble complexes in the circulation. These indicate increased fibrinogenolytic and fibrinolytic activity caused by hyperactivation of plasminogen or the presence of proteases of a similar activity contained in the snake venom. Consequently, the parallel presence of a high D-dim titer means a probability of widespread thrombin or thrombin-like activity with intravascular development of stabilized fibrin-polymer complexes - a DIC-like consumption disorder. Both types of affection will result in hypofibrinogenemia or even afibrinogenemia. In the initial stages of the DIC-like disorder, AT activity may not be reduced. This is brought about by a fundamental AT non-inhibitive enzyme with a thrombin-like activity, such as meisothrombin, on the development of the disorder.

Any changes to platelet function that may cooperate in the affection in a number of cases can be made evident through thromboelastographic blood examination - TEG.

Examining platelets using flow cytometry, as well as determining the activity of coagulation factors, tPA, PAI, FPA, PF1.2, TAT, vWF, and other hemocoagulation laboratory parameters, would be worthwhile for diagnosing the affection, however, it is not a routine procedure at health facilities.

If hypofibrinogenemia or defibrination occurs with values decreased near zero and the patient is not bleeding, applying a fibrinogen concentrate is not recommended. Replenishing its quantity in the circulation without eliminating the cause for the defibrination will result in a rise in FDP titer and fibrin-soluble complexes with possible consequent bleeding. If the patient is bleeding, fibrinogen is replenished to the level of at least 0.5-1.0 g/l using fibrinogen concentrates or *fresh-frozen plasma* that simultaneously contains coagulation factors and inhibitors; the amount should be 10-20 ml/kg of weight. Administration of *hemocoagulation factor concentrates* is indicated if a critical drop in the factors is found, with indications including persistent obstinated bleeding. Relative contraindication of the application is exhibited by an early phase of a DIC-like disorder with high D-dim values.

If *AT* activity has decreased due to insufficient production, consumption, or degradation by proteases contained in venoms, substitution is recommended.

Heparin treatment in hemocoagulation disorders is recommended in cases of DIC-like disorder following a snakebite by the *Echis*, *Daboia,* and *Macrovipera* snakes, as it will have a pre-emptive effect should fibrin formations develop. In addition, it seems to reduce the incidence of thrombocytopenia and DIC, but even hypotension and acute renal failure. According to the work of Paul et al., 2003, with doses of 5,000 units and a further 2,500 units every 8 hours, the treatment will reduce, in parallel with antivenom being administered, the mortality of persons envenomed by the saw-scaled viper (*Echis carinatus*) and the Russel's viper (*Daboia russelli*) from 26% to 19%. Of course, these results are not highly significant. Nevertheless, heparin therapy in terms of severe acute progress of DIC with associated bleeding is not fully indicated. Inhibition of thrombin activity is not always determined by the presence of the AT-heparin complex, consequently, heparin administration may not be helpful if the cause lies elsewhere. However, where a previously existent DIC syndrome has

been diagnosed and its status has been stabilized, i.e. bleeding has stopped, mini-heparinization using UFH (non-fractionated heparin), or more preferably a prophylactic dose of LMWH (low molecular heparin), is recommended until laboratory tests are fully normalized.

Applying *antifibrinolytics*, such as tranexam acid, can be effective if bleeding has been caused by increased plasminogen activation. Nevertheless, this concurrently results in blocking the physiological destruction of microembolizations that might develop, preventing recanalization of relevant sections, thereby potentiating the occurrence of organ failure as part of the DIC-like disorder.

It is recommended to substitute *platelets* if bleeding still continues, in decline under 20,000-50,000/mm^3, while the same action in erythrocytes should be taken in case of decrease in Hct, i.e. hematocrite - erythrocyte concentration, below 25% to 30%.

5.3.3.7. Affection of Muscles

In general, snake venom substances with myotoxic effects consist of two types of components: non-enzymatic toxins and enzymes of PLA_2 type; their effect is often associated with additional destructive activities; see chapter 3.3.2.7 Venom components possessing a myotoxic activity.

Myotoxic venom components are present in most viperids (*Viperidae*), Australian terrestrial elapid snakes and some sea snake species. For instance, a clinically relevant portion of myotoxins is in the venom of the Russel's viper (*Daboia russelli*), Levantine viper (*Macrovipera lebetina*), South American rattlesnake (*Crotalus durissus*), rattlesnakes (*Crotalus* sp.), lanceheads (*Bothrops* sp.), and Asian pit vipers (*Trimeresurus* sp.); as regards elapids, this concerns the mainland tiger snake (*Notechis scutatus*) and the coastal taipan (*Oxyuranus scutellatus*). Inherent in many snakes is a certain quantity of myotoxic components, therefore, rhabdomyolysis and its consequences should be considered every time envenomation occurs with a venom containing a high rate of enzyme activities.

The action of myotoxic components causes striated muscle cells to be destroyed, a process called *rhabdomyolysis,* which results in minor or even major *myonecrosis*. Muscular destruction is accompanied by *muscular pain,* such as in envenomations by the Russel's viper (*Daboia russelli*). *Myoglobin* and kalium ions are released into circulation. A higher amount of myoglobin will cause obstruction in the area of glomerular capillaries and renal tubules, especially if hemolysis proceeds concurrently, thus free hemoglobin is involved, presenting a predisposition for *renal insufficiency* through to *acute renal failure*.

Hyperkalemia resulting from surplus kalium via intracellular deposits released, together with oliguria, may eventually cause arrhythmia, which may even give rise to circulation blockage in a non-treated person.

One elementary form of treatment tackling exposure to a high amount of myotoxins involves *antivenom therapy***.** Enzyme neutralization and the prevention of continued destruction is only possible by an antigen, as well as for presynaptically acting enzyme neurotoxins. Accordingly, an antivenom should be given as soon as possible whenever a major proportion of myotoxins in the venom is expected.

Symptomatic treatment of status is limited to an adequate parenteral supply of liquids to prevent a decrease in perfusion pressure in glomerules and facilitate production of a sufficient quantity of primary urine. The importance of effective *infusion therapy* will be emphasized by

hypotension developing through the action of relevant venom components, which especially concerns envenomation by viperids (*Viperidae*).

Hyperkalemia may temporarily be stabilized by intravenous application of *calcium* in the form of gluconate or chloride, or by using an ion exchanger and peroral and rectal application of polystyrene sulphonic acid salts. If diuresis continues, it should be supported by a diuretics, such as *furosemid.*

5.3.3.8. Renal Failure

Acute renal failure, mostly of the oliguric type, occurs via envenomation by snake venoms through the action of several mechanisms. These include *myoglobinuria and hemoglobinuria*, see chapter 5. 3. 3. 7 Affection of muscles and decreased perfusion pressure and glomerule blood flow in *hypotension* due to vasodilatation and reduced intravasal volume through extravasation or hemorrhage, plus chapter 5. 3. 3. 5 Hypotension and shock. Acute renal failure may also be triggered due to glomerular perfusion obstruction by *microthrombi* in instances of DIC-like hemocoagulation disorder associated with insufficient fibrinolysis. The final specific cause presented is primary *nephrotoxicity*: direct damage of renal tissue - glomerules and tubules - by enzymatic venom components. This type of mechanism has been disputed by some authors, as venom components with a specific action on renal tissues remain to be evidenced. However, they cannot be definitely precluded, see chapter 3. 3. 2. 8 Venom components affecting the kidneys.

Affection of renal function can be expected namely following envenomation by viperine (*Viperinae*) and crotaline (*Crotalinae*) snakes. Nevertheless, renal damage cannot be precluded even after envenomation by other snakes. The risk of occurrence can be estimated according to the clinical progress of envenomation.

A key preventative action in renal failure following a snakebite is to secure adequate perfusion pressure and sufficient renal blood flow. If systemic pressure cannot be sustained by *increasing intravascular volume,* vasopressoric therapy is indicated, see chapter 5. 3. 3. 5 Hypotension and shock. As regards the necessity to maintain sufficient renal blood flow, *catecholamine*s are indicated if the condition of the circulation so allows, but not before intravasculer volume is increased. Urgent vasopressoric treatment is at all times supported by sufficient volume compensation, especially when liquids from the vessel bloodstream are being lost through widespread extravasation into edema or through bleeding.

Again, any myoglobinuria and hemoglobinuria will require increased intravascular volume and enhanced production of primary urine to reduce such molecules building up in renal tubules.

The application of heparin is recommended, i.e. just to avoid or at least reduce the development of fibrin formations and microthrombosis, including those decreasing glomerular perfusion and contributing towards emergent renal failure, see chapter 5. 3. 3. 6 Hemocoagulation disorders.

Once renal failure has occurred, treatment does not differ from that of failure based on a different etiology. If increasing vessel volume and application of diuretics proves insufficient to ensure adequate diuresis and satisfactory urea and creatinine values in the serum, either one of the continual renal replacement therapy (CRRT) methods - hemofiltration or hemodialysis, or intermittent hemodialysis is indicated depending on a patient's status and requirements plus the capabilities of the health facility. Execution of (C)RRT in cases of severe activation of DIC-like hemocoagulation disorder, such as by *Echis* snakes, may be frequently

complicated by coagula formed in the (C)RRT system, even if adequate heparinization is employed and heparinized hemofilters are used. If that is so, the regional citrate anticoagulation method is a suitable option according to the experience of the author's workplace.

The majority of cases of acute renal failure will have a reversible course. Nevertheless, severe envenomation with complications or inadequate treatment may ultimately result in irreversible damage and chronical renal failure could emerge.

5.3.4. Plasmaferesis Therapy

Plasmaferesis can be a satisfactory alternative to specific therapy by antivenoms whenever an antivenom is not available, or in the case of insufficient clinical effect of a usable dose. The method can be applied even when the affected individual suffers from an allergy to the antivenom. In the author's experience, using this method is helpful typically in envenomation involving more severe symptoms of hemocoagulation disorder. Its effectiveness can be found through both laboratory examination and clinically, for instance, by reducing PT and APTT.

Plasmaferesis can be combined with the administration of antivenom when recurrence of symptoms occur. In such cases, the application of antivenom should alternate plasmaferesis following recurrence of symptoms or serious laboratory findings. In severe cases, the method must be applied repeatedly subject to the progress of envenomation and as required. The benefits of plasmaferesis include an absence or at least reduced incidence of serum sickness caused by high doses of antivenoms, although the disadvantages include a necessary technical background for the same and the high cost in certain regions.

5.4. Convalescence Following Envenoming

The acute phase of common localized affection - edema - will mostly abate within 10 days. The time necessary for sufficient epithelization in instances of dermal damage, bullae, and surface dermal necrosis will be longer. Often such damage heals without any visible scarring unless the skin is affected by necrosis at full depth. Deep dermal necrosis to a large extent may require transplantation of skin following cleaning of the wound bed. Gross damage to deep tissue structures, muscles and nerves may result in permanent deformations including disorder of motional functions of the affected part of limb. In many cases, even slightly affected tissue suffers from a certain sensation or painful symptoms over longer periods in the order of months or years.

Convalescence following passed system envenomation depends on the severity of the process and degree of tissue damage. The severe action of proteolytic enzymes may even cause irreversible affection of certain systems, such as muscles, nerve endings, kidney, lungs, etc., which may become evident on the function or possible morphological reconstruction of such systems. Rehabilitation and convalescent care is symptomatic and will be implicated by the type and level of affection.

Envenomation by the majority of *Viperinae* and *Crotalinae* species is associated with affection as far reaching as partial desquamation of endothelium and activation of hemocoagulation processes at various levels. This will result, following completion of an acute phase, in persistent activation of the system and prothrombotic status of the patient, which is visible in most cases only through an increased amount of the final product formed throughout the hemocoagulation in process - D-dim. Such a status may pose a predisposition to thromboembolic complications occurring and should be rectified through application of low molecular heparins, as well as in patients at risk of deep venous thrombosis, until the cause abates, i.e. until hemocoagulation tests have been fully normalized.

REFERENCES

ALLOATTI, G., GATTULLO, D., DALLA VALLE, R., et al. The haemodynamic effect of *Bitis nasicornis* (Rhinoceros Horned Viper) venom. *Gen Pharmacol*, 1991, 22, No. 1, pp. 203–206.

AMSTUTZ, P., MOYO, JS. Disseminated intravascular coagulations. *Cah Anesthesiol*, 1996, 44, No. 3, pp. 219–228.

AN, Y., YANG, N., ZHU, X. Management of coagulation dysfunction in critically surgical patient. *Zhonghua Wai Ke Za Zhi*, 1996, 34, No. 6, pp. 348–351.

BLAYLOCK, RS. Pressure immobilisation for snakebite in southern Africa remains speculative. *S Afr Med J*, 1994, 84, No. 12, pp. 826–827.

BOYER, LV., SEIFERT, SA., CLARK, RF., et al. Reccurent and persistant coagulopathy following Pit Viper Envenomation. *Arch Intern Med*, 1999, 159, No. 7, pp. 706–710.

COWLES, RA., COLLETTI, LM. Presentation and treatment of venomous snakebites at a Nothern Academic Medical Center. *Am Surg*, 2003, 68, No. 5, pp. 445–449.

DART, RC., GUSTAFSON, RA. Failure of electric shock treatment for Rattlesnake envenomation. *Ann Emerg Med*, 1991, 20, No. 6, p. 659–661.

DASSANAYAKE, AS., KARUNANAYAKE, P., KASTURIRATNE, KT., et al. Safety of subcutaneous adrenalin as prophylaxis against acute adverse reaction to anti-venom serum in snakebite. *Ceylon Med J*, 2002, 47, No. 2, pp. 48–49.

ELLIS, AK., DAY, JH. Diagnosis and management of anaphylaxis. *Can Med Ass J*, 2003, 169, No. 4, pp. 307–311.

GERMAN, BT., HACK, JB., BREWER, KL., et al. Pressure-immobilization bandages delay toxicity in a porcine model of Eastern Coral Snake (*Micrurus fulvius fulvius*) envenomation. Ann Emerg Med, 2005, 45, No. 6, pp. 603–608.

GOLD, BS. Neostigmine for the treatment of neurotoxicity following envenomation by the Asiatic Cobra. *Ann Emerg Med*, 1996, 28, No. 1, pp. 87–89.

HABIB, AG., GEBI, UI., ONYEMELUKWE, GC. Snake bite in Nigeria. *Afr J Med Sci*, 2001, 30, pp. 171–178.

HOWARTH, DM., SOUTHEE, AE., WHYTE, IM. Lymphatic flow rates and first-aid in simulated peripheral snake envenomation. *Med J Austr*, 1994, 161, No. 11–12, pp. 695–700.

HOWE, NR., MEISENHEIMER, JL. Jr. Electric shock does not save snakebitten rats. *Ann Emerg Med*, 1988, 17, No. 3, pp. 254–256.

ISMAIL, M., MEMISH, ZA. Venomous snakes of Saudi Arabia and the Middle East: a keynote for travellers. *Int J of Antimikrob Agents*, 2003, 21, pp. 164–169.

JOHNSON, EK., KARDONG, KV., MACKESSY, SP. Electric shocks are ineffective in treatment of lethal effect of Rattlesnake envenomation in mice. *Toxicon*, 1987, 25, No. 12, pp. 1347–1349.

JOLY, LM., SERMET, A., TURAK, B., SAMAMA, CM. Massive haemorrhage after dorsal decompressive laminectomy. *Ann Fr Anesth Reanim*, 2005, 24, No. 10, pp. 1278–1281.

KORNALIK, F., VORLOVA, Z. Non-specific therapy of a hemorrhagic diathesis after a bite by a zouny *Bothrops asper* (Barba Amarilla): a case report. *Toxicon*, 1990, 28, No. 12, pp. 1497–1501.

LALLOO, DG., THEAKSTON, RD. Snake antivenoms. *J Toxicol Clin Toxicol*, 2003, 41, No. 3, pp. 227–290.

LEE, SY., LEE, CY., CHEN, YM., et al. Coronary vasospasm as the primary cause of death due to the venom of the burrowing asp, *Atractaspis engaddensis*. *Toxicon*, 1986, 24, No. 3, pp. 285–291.

LI, QB., HUANG, GW., KINJOH, K., et al. Hematological studies on DIC-like findings observed in patients with snakebite in south China. *Toxicon*, 2001, 39, No. 7, pp. 943–948.

MARSH, NA., WHALER, BC. The Gaboon Viper (*Bitis gabonica*): its biology, venom components and toxinology. *Toxicon*, 1984, 22, No. 5, pp. 669–694.

MCKINNEY, PE. Out-of-hospital and interhospital management of crotaline snakebite. *Ann Emerg Med*, 2001, 37, No. 2, pp. 168–174.

MEIER, J., WHITE, J. (Eds). *Handbook of clinical toxicology of animal venoms and poisons.* Boca Raton : CRC Press, 1995, 752 pp.

POCHANUGOOL, C., WILDDE, H., BHANGANADA, K., et al. Venomous snakebite in Thailand II: clinical experience. *Mil Med*, 1998, 163, No. 5, pp. 318–323.

PREMAWARDHENA, AP., De SILVA, CE., FONSEKA, MM., et al. Low dose subcutaneous adrenalin to prevent acute adverse reactions to antivenom serum in people bitten by snakes: randomised, placebo controlled trial. *Br Med J*, 1999, 318, No. 7190, pp. 1451–1452.

PAUL, V., PRAHLAD, KA., EARALI, J., et al. Trial of heparin in viper bites. *J Assoc Physicians India*, 2003, 51, pp. 163–166.

SPILLER, HA., BOSSE, GM. Prospective study of morbidity associated with snakebite envenomation. *J Toxicol Clin Toxicol*, 2003, 41, No. 2, pp. 125–130.

STEWARD, CJ. Snaker bite in Australia: first aid and envenomation management. *Accid Emerg Nurs*, 2003, 11, No. 2, pp. 106–111.

SUTHERLAND, SK. *First aid for snakebite in Australia.* Published by the Commonwealth Serum Laboratories Parkville 3052, 1979.

SUTHERLAND, SK. The pressure immobilisacion technique. *Med J Aust*, 1994, 161, pp. 700–701.

SUTHERLAND, SK. Treatment of snake bite. *Aust Fam Physisian*, 1990, 19, No. 1, pp. 21, 24–42.

SUTHERLAND, SK., COULTER, AR. Early management of bites by Eastern Diamondback Rattlesnake (*Crotalus adamanteus*): studies in monkeys (*Macaa fascicularis*). *Am J Trop Med Hyg*, 1981, 30, No. 2, pp. 497–500.

SUTHERLAND, SK., COULTER, AR., HARTUS, RD. Rationalisation of first-aid measures for Elapid Snakebite. *Lancet*, 1979, 1, No. 8109, pp. 183–185.

SUTHERLAND, SK., NOLCH, G. *Dangerous Australian animals.* Flemington : Hyland House Publishing, Australia, 2000.

THEAKSTON, RD., WARRELL, DA., GRIFFITHS, E. Report of WHO workshop on standardization and control of antivenoms. *Toxicon*, 2003, 41, No. 5, pp. 541–557.

VALENTA, J., SIMAK, J. Intoxikace zivocisnymi jedy. In POKORNY, J. (Ed.), *Urgentni medicina*. Praha : Galen, 2004, pp. 258–265 (in Czech).

WHITE, J., WARRELL, D., EDDLESTON, M., et al. Clinical toxinology – where are we now? *J Toxicol Clin Toxicol*, 2003, 41, No. 3, pp. 263–276.

WARRELL, DA. Bites of Venomous Snakes. *N Engl J Med*, 2002, 347, No. 22, pp. 1804–1805.

WATT, G., MEADE, BD., THEAKSTON, RD, et al. Comparison of Tensilon and antivenom for the treatment of Cobra-bite paralysis. *Trans R Soc Trop Med Hyg*, 1989, 83, pp. 570–573.

WATT, G., THEAKSTON, RD., HAYES, CG., et al. Positive response to edrophonium in patients with neurotoxic envenoming by Cobras (*Naja naja philippiensis*). *N Engl J Med*, 1986, 315, No. 23, pp. 1444–1448.

WINKEL, KD., HAWDON, GM., LEVICK, N. Pressure immobilisation for neurotoxic snake bites. *Ann Emerg Med*, 1999, 34, No. 2, pp. 294–295.

WOLLBERG, Z., SHABO-SHINA, R., INTRATOR, N., et al. A novel cardiotoxic polypeptide from the venom of *Atractaspis engaddensis* (Burroving Asp): cardiac effects in mice and isolated rat and human heart preparations. *Toxicon*, 1988, 26, No. 6, pp. 523–534.

ZAMUDIO, KR., HARDY, DL. Sr., MARTINS, M., et al. Fang tip spread, puncture distance, and suction for snake bite. *Toxicon*, 2000, 38, No. 5, pp. 723–728.

Chapter 6

ENVENOMING AND SNAKEBITE TREATMENT IN SPECIFIC SNAKE GROUPS

6.1. FAMILY: *COLUBRIDAE*, COLUBRIDS

The *Colubridae* family contains as many as 2,500 snake species classified into a number of sub-families, and recently into 305 genera, with only some of them ranked as venomous snakes.

The saliva gland in these snakes has modified into the venomous Duvernoy's gland, featuring a collecting duct that opens near enlarged grooved rear fangs. Due to the structure of their venom apparatus, such creatures are termed opistoglyphous snakes; see chapter 1. 4 The venom apparatus in snakes. Signs of envenoming in humans can be induced by as few as 30 species, with only five being capable of delivering a fatal course. The majority of the remainder only possess islets of Duvernoy's gland tissue beside the roots of teeth, which are not enlarged and lack grooves. This means they have no injecting mechanism and cannot be considered venomous animals, even though they are still capable of releasing a certain amount of venom into a victim after a bite. In such cases, envenoming is typically coincidental in nature; an example being a snakebite suffered by a frog taxidermist from the western hog-nosed snake (*Heterodon nasicus*) the creature reacting to the smell of frogs (Rehak, 1990). However, an exceptional local response after a snakebite by a non-venomous colubrid snake may even occur in humans. In the Czech Republic, two such events have been described, involving bites from the smooth snake (*Coronella austriaca*) (Rehak, 1992).

The venomousness of opistoglyphous snakes has always been underestimated; nonetheless, several species may cause severe envenomation, which could potentially prove fatal. For instance, two globally leading herpetologists died following bites by opistoglyphous colubrid snakes: Karl P. Schmidt (1890-1957), who was bitten by an African boomslang (*Dispholidus typus*) and Robert Mertens (1894-1975), bitten by a twig snake species (*Thelotornis kirtlandii*).

This chapter is going to provide more details on two groups of snakes: firstly, it will describe the five genera of the *Colubrinae* subfamily most important in terms of toxinology - *Boiga*, *Dispholidus*, *Malpolon*, and *Thelotornis*, formerly entitled *Boiginae*, a subfamily that was once considered separate but later disputed. The *Natricinae* subfamily, more specifically, *Rhabdophis* genus, makes up the second group.

As for other venomous and potentially venomous colubrids, only certain members are listed in brief below due to the extreme number of genera, their disputable classification as subfamilies, and the relatively low level of risk they pose.

6.1.1. *Rhabdophis* Genus

Species: The tiger grooved-neck keelback (*Rhabdophis tigrinus*), the cause of envenomation described in Japan, and the red-necked keelback (*Rhabdophis subminiatus*), with cases of envenoming described from European and North American captive collections, can be deemed the most significant species in terms of epidemiology of the 17 comprising this colubrid genus.

Other names: FR: Serpent tigrer d'Asie; JAP: Yamakagashi (*R. tigrinus*). In native languages: Ular Picung, Ular Lampeh (*R. subminiatus*).

*Description***:** Medium bodied colubrids that mostly grow to 100 cm, but rarely to 150 cm, they tend to possess large rear fangs placed in the anterior part of the upper jaw. They were considered non-venomous for a long time and used to be sold and kept as such.

Home range and habitat: The localities inhabited by *R. subminiatus* mostly concern the rather humid or wet and largely forested areas of NE India, S China, Hainan, the former Indochinese region (Vietnam, Laos, Cambodia), the Malayan Peninsula, and Indonesia, while the *R. tigrinus* resides in identical habitats in the territories of China, Hainan, Taiwan, Korea, Russia, and Japan.

Toxins: The Duvernoy's gland venoms of *R. subminiatus* and *R. tigrinus* are relatively effective, with LD_{50} for mice equalling 6.5 mg/kg or 0.26 mg/kg of body weight respectively. They contain a prothrombin-activator similar to ecarin in the saw-scaled viper (*Echis carinatus*). An FX activator is also possibly present. The process of C protein activation, increased fibrinolysis, and FBG degradation in envenoming are unlikely to be caused by direct action of the venom components; they tend to develop as pathophysiological results of thrombin activity at a systemic level and tPA impact.

Local symptoms of envenoming: Slight non-painful edema and bleeding from the bitten site can be followed by ecchymoses and petechiae developing around the affected area. More rarely, larger hematoms may appear.

*Systemic symptoms of envenoming***:** Prodromes, like headache, nausea, and vomiting, will commence anywhere between 30 minutes to several hours after a bite, resulting in fainting more occasionally. Moreover, hemocoagulation disorder of the DIC type evolves with symptoms apparent via laboratory testing, though these may take the form of clinical symptoms in more severe envenomations. Bleeding from incisions, small traumas and gums, epistaxis and perfused dermal efflorescences arise, followed by possible hematuria and hematemesis with resulting enterorrhage. The symptoms of bleeding can persist as long as five days, while changes in laboratory findings can be recorded for up to 40 days. Despite the DIC syndrome caused by the envenoming, signs of tissue and organ damage resulting in multiple organ dysfunction syndrome (MODS) are typically not present, although renal failure may follow in rare cases.

*Laboratory findings***:** Signs of DIC in progress are typically marked, i.e. decreased fibrinogen levels, extending as far as afibrinogenemia, increased FDP concentration (D-dim), thrombocytopenia, microangiopathic hemolysis, reduced AT activity, decreased levels of

other coagulation factors and increased fibrinolytic activity. Nevertheless, AT activity may remain intact, primarily as the envenoming begins. The ecarin-like prothrombin-activator will trigger a precursor to a form of thrombin that cannot be inhibited physiologically - meisothrombin, hence AT is not reduced. Neutrophilic leukocytosis is a factor in this and a number of other envenomations.

Mortality: Two cases following a bite from the tiger grooved-neck keelback, *R. tigrinus*, have been described in Japan. The first involved a 61-year-old man who died on day 62 with the symptomatology of pulmonary edema in the course of hemodialysis, with tubular necrosis and renal atrophy eventually discovered, while the second was a case of a 14-year old boy who died from fatal intracerebral hemorrhage.

Therapy: For first aid and general rules of treatment, see chapter 5 Snakebite: Therapy and prevention. Antivenom is not available. Symptomatic treatment as the hemocoagulation disorder develops should be based upon an estimated or examined degree of fibrinolysis and the progress of DIC present. Antifibrinolytics that are adequate for certain levels of fibrinolysis may, when applied in the procoagulation stage of DIC, block the physiological destruction of microthrombi developed, which can potentiate the resulting hypoperfusive failure of organs, such as renal failure. Under such circumstances, and should the patient not be bleeding, anticoagulation therapy is preferable, i.e. miniheparinisation in normal AT activity may be helpful. Sufficient hydration of the patient will be necessary to prevent renal failure.

6.1.2 .*Boiga* Genus

Species: Of the 30 *Boiga* genus members, the spectacular mangrove snake (*Boiga dendrophila*) is probably the best-known species. Aside from this, the brown tree snake (*Boiga irregularis*), Sri Lankan cat snake (*Boiga ceylonensis*), and Forsten's cat snake (*Boiga forsteni*) seem species affording more significant epidemiological relevance.

Other names: Cat snake. FR: Serpent ratier brun (*B. irregularis*). FR: Serpent d'arbre, Serpent des palètuviers, Serpent ratier des mangroves; in native languages: Ularburong (*B. dendrophila*).

Description: Slender tree snakes up to 200 cm long, with distinctive eyes and of largely nocturnal activity. They are strong swimmers.

Home range and habitat: The majority of the species range in forests and mangroves throughout India including Nepal, Sri Lanka, the former Indochinese region, Malaysia, Indonesia and the Philippines. New Guinea, N and W Australia and more recently also the Island of Guam, home of the brown tree snake (*B. irregularis*) and the place where the genus has been introduced. *B. blandingi* and the Fischer's cat snake (*B. pulverulenta*) dwell amongst the vegetation in central and western African territories.

Toxins: These are products of Duvernoy's gland. In certain species (*B. irregularis*), the venom contains the component of bungarotoxin-like postsynaptic neurotoxins and acetylcholinesterase. As regards locally acting enzymes, the venoms include a percentage of phospholipases and components displaying hemolytic activity; neither prothrombin activators nor thrombin-like components are present.

Local symptoms of envenoming: These are limited to small dermal efflorescences, e.g. vesicles with discoloration and the development of light edemas.

Systemic symptoms of envenoming: Despite the non-complicated process of envenomation described above, which applies even to children, snakebites should not be underestimated. Changes in sensory perception may be triggered as well as lethargy, fatigue and clinically insignificant symptoms of cranial nerve dysfunction, such as ptosis of eyelids. Two cases of respiratory difficulties in children have been described several hours following a snakebite (Fritts et al., 1990).

Laboratory findings: Not available.

Mortality: Not recorded.

Therapy: For first aid and general rules of treatment, see chapter 5 Snakebite: Therapy and prevention. No antivenom is available. Mechanical ventilation may be required for small children exposed to a high dose of venom in very special cases.

6.1.3. *Dispholidus* Genus

Species: The genus includes a single species, the African boomslang (*Dispholidus typus*).

Other names: Common African tree snake; FR: Serpent d'arbre du Cap.

Description: A slender-bodied arboreal and diurnal snake that can grow up to 200 cm. It possesses rear fangs at eye level and boasts large eyes with round pupils. Resembling a distant relative of the mamba, these snakes can be easily confused in the wild. The boomslang is hard to discern from moderately venomous colubrids of the *Thrasops* genus. Following a bite, the snake will hang down and chew prey. As a result of its toxicity, which is often belittled, plus the poor availability of antivenom, the boomslang could be looked upon as a time bomb in a non-expert's terrarium.

Home range and habitat: Boomslangs reside open bushland and savannah woodland almost throughout Sub-Saharan Africa from Senegal as far as Somalia and the Republic of South Africa. If hemocoagulation symptoms appear following a bite from an unidentified snake to the south of the home range of the African *Echis* saw-scaled vipers, the chances are high that it is one from *D. typus*.

Toxins: The venom is highly effective - LD_{50} for mice IV amounts to 0.07 mg/kg of body weight. An enzymatic prothrombin-activator is one of the main venom components; nevertheless, prothrombin is primarily converted to a form of thrombin which is impossible to inhibit physiologically - meisothrombin; see chapter 6. 1. 1 *Rhabdophis* genus. This will result in the hemocoagulation disorder of the DIC type, but direct activation of FX and other hemostasis elements is also possible. In addition, the action of toxins will activate complement via alternative route.

Local symptoms of envenoming: Mostly reduced to a minimum, typically, light edema develops, which in size and pain may increase in special cases. Incision will result in bleeding, with other possible local changes associated with the hemostasis disorder, such as petechiae, ecchymoses, perfused bullae, and smaller hematoms.

Systemic symptoms of envenoming: Mostly these begin as prodromes like nausea, vomiting, abdominal, and cranial pain, and feelings of anxiety. The hemostasis disorder of the DIC type, with symptoms such as bleeding from wounds, gums, nose and rectum, hematuria, hematemesis and enterorrhage, will develop almost immediately but more frequently within a few hours, exceptionally occurring after 48 hours. Rarely, intracerebral hemorrhage may follow as well. At the same time, there is a risk of developing microthrombus deposits and

their resultant obstructive action on the microcirculation, which may be co-responsible in fatal renal failure with acute tubular necrosis.

Laboratory findings: Hemocoagulation tests indicate a disorder of the DIC type. Coagulation times are prolonged or blood does not coagulate at all. Hypofibrinogenemia, extending as far as afibrinogenemia and thrombocytopenia, increased FDP (D-dim) levels and signs of microangiopathic hemolysis arise.

Mortality: Fatal courses of envenoming have been described, with several accompanied by renal failure.

Therapy: For first aid and general rules of treatment, see chapter 5 Snakebite: Therapy and prevention. Administration of antivenom is indicated in cases of systemic envenoming with clinical symptoms including light prodromes, as well as more significant laboratory findings resulting from hemocoagulation examination.

Applicable antivenom: SAIMR BOOMSLANG ANTIVENOM, SAIMR, the Republic of South Africa. Administration can prove effective in a later phase of envenomation too, even after 32 hours of bleeding.

In case of symptomatic treatment, rules for therapy of consumption disorder of the DIC type apply, i.e. supportive administration of fresh frozen plasma, at a dosage of 10-20 ml/kg, and application of AT if its activity is reduced. Substitution of platelets and erythrocytes is utilized should there be a significant decrease - see chapter 5. 3. 3. 6 Hemocoagulation disorders. Heparin therapy has been subject to discussion (du Toit, 1980). Most probably, it may worth considering as an option to prevent further development of microthrombosis in an activated field once bleeding has fully stopped.

A patient can be discharged for home treatment 24 hours following abatement of all systemic symptoms and significant laboratory tests. Any persisting laboratory symptomatology of moderate prothrombotic activity should be resolved by pre-emptive miniheparinisation, see chapter 5.4 Convalescence following envenoming.

6.1.4. *Malpolon* Genus

Species: In terms of epidemiology, the European Montpellier snake (*Malpolon monspessulanus*) is of greater significance than the African false cobra (*Malpolon moilensis*).

Other names: FR: Couleuvre de Montpellier; DE: Europäische Eidechsenatter (*M. monspessulanus*). Moila Snake; FR: Couleuvre de Moila (*M. moilensis*).

Description: Growing up to 200 cm long, these are diurnal and relatively heavy bodied snakes with large eyes and round pupils. Some will lift the anterior part of their body when threatened, expanding their neck like cobras, such as *M. moilensis*.

Home range and habitat: M. monspessulanus resides in the diverse, largely dry and shrubby habitats and semi deserts of Portugal, Spain, French coastal areas, NW Italy, Slovenia, Croatian coasts, Herzegovina, Montenegro, Albania, Greek coastland, part of Bulgaria, Turkey, specific Caucasian regions, and part of the western coast of the Caspian Sea. As for Africa, this snake is found along the African northern coast from Morocco to Egypt and N Sudan, in the Middle East (Jordan and Israel), Iraq, and Saudi Arabia. *M. moilensis* is found in part of central West Africa, N Africa, and the Middle East.

Toxins: The Duvernoy's gland venom contains a small but clinically recordable quantity of neurotoxic components and enzymes causing local damage to tissue, as well as

hemocoagulation-affecting components causing intrapulmonary hemorrhaging in mice, although the quantity is insignificant for humans. The venom does not seem to contain proteolytic and hemorrhagic enzymes and has no procoagulation effect. LD_{50} for mice amounts to 6.5 mg/kg of body weight.

Local symptoms of envenoming: The wound is painful; edema will develop - rather large in many cases - as well as lymphangitis and lymphadenitis. The changes on the skin do not heal very easily. Local symptoms of paresthesia or even paresis of the affected limb may follow.

Systemic symptoms of envenoming: Incidence of envenoming following a bite amounts to 15%. Common prodromes can be followed by affection of cranial nerves and eyelid ptosis, as well as by a sense of muscular weakness in, for example, respiratory muscles, plus dyspnea, and dysphagia in severe envenomations. Neurological symptoms will abate within 48 hours.

Laboratory findings: No specific changes.

Mortality: Not specified.

Therapy: For first aid and general rules of treatment, see Chapter 5 Snakebite: Therapy and prevention. No antivenom is available. Mechanical ventilation may be required for small children exposed to a high dose of venom in very special cases.

6.1.5. *Thelotornis* Genus

Species: The genus encompasses 3 species: the bird snake (*Thelotornis capensis*) including 3 subspecies, the forest vine snake (*Thelotornis kirtlandii*) and the Usambara vine snake (*Thelotornis usambaricus*).

Other names: Twig snake, vine snake; FR: Serpent liane du Cap (*T. capensis*). FR: Serpent liane de Kirtland (*T. kirtlandii*).

Description: Very slender arboreal diurnal snakes up to 200 cm long, often highly colored, with elongated heads, large eyes and horizontal pupils.

Home range and habitat: Arboreous and shrubwood savannahs (*T. capensis*) and rainforests (*T. kirtlandii*) of Sub-Saharan E Africa, and the zone extending from S Angola to the eastern coast.

Toxins: The venom resembles that of the African boomslang (*Dispholidus typus*), with LD_{50} for mice IV 1.23 mg/kg of body weight. It contains the activator of prothrombin and FX, the action of which accelerates fibrinolysis.

Local symptoms of envenoming: Local changes are not very distinctive; edema will be mostly small, incision wounds will bleed. Additional local symptoms of the hemostasis disorder are possible.

Systemic symptoms of envenoming: Bites will mostly pose no threat to humans; nevertheless, the risk should not be underestimated. Cases of snakebite with DIC symptoms, including lethal ones, have been described. The progress is identical to that of envenoming by the African boomslang (*D. typus*), see Chapter 6. 1. 3 *Dispholidus* genus.

Laboratory findings: Probably identical to those described under chapter 6.1.3 *Dispholidus* genus.

Mortality: Lethal cases of envenoming have been described, including the death of Prof Robert Mertens in 1975, the founder of modern herpetology. The courses of symptoms of

fatal envenomation were similar to those of envenoming by the African boomslang (*D. typus*).

Therapy: For first aid and general rules of treatment, see chapter 5 Snakebite: Therapy and prevention. No specific antivenom is available. The antivenom against the venom of the African boomslang (*D. typus*) is not effective, no cross immune response exists. In terms of symptomatic treatment, rules for therapy of DIC will apply, i.e. supportive administration of fresh frozen plasma, application of AT if its activity is reduced, and substitution of platelets and erythrocytes in case of significant decrease; see chapter 5. 3. 3. 6 Hemocoagulation disorders.

A patient can be discharged for home treatment 24 hours following abatement of all systemic symptoms and significant laboratory findings. Any persisting laboratory symptomatology of moderate prothrombotic activity should be resolved by pre-emptive miniheparinization, see Chapter 5.4 Convalescence following envenoming.

6.1.6. Some other Genera of Venomous Colubrid Snakes

Ahaetulla - formerly *Dryophis*, vine snakes, common green snakes, long-nosed whip snakes. Extremely slender arboreal snakes up to 200 cm long that possess rear fangs; they are found in the forests and tree plantations of India, Sri Lanka, China and SE Asia.

Amplorhinus, many-spotted snakes. Small snakes of largely green color up to 60 cm long with rear fangs and aggressive behavior found in rather humid habitats throughout S Africa.

Arrhyton. Small snakes with rear fangs found in the Caribbean Islands.

Balanophis. Small snakes with rear fangs that dwell in fallen leaves in Sri Lankan forests.

Calamodontophis. Small snakes with rear fangs from Brazil.

Cerberus. Medium-sized aquatic snakes with rear fangs. Found in mangroves and other wetlands and river mouths throughout SE Asia, Indonesia, New Guinea and N Australia.

Chrysopelea, flying snakes. Relatively long and slender-bodied arboreal snakes with rear fangs that can flatten and expand their body and move by means of gliding jumps from one tree to another. Found in the forests and tree plantations of India, Sri Lanka, Burma, Malaysia, S China, Philippines and Indonesia.

Clelia, mussuranas. Large snakes with mostly nocturnal activity found in the forests of Central and S America. In envenomings described, local edemas and ecchymoses were involved without hemocoagulation effects.

Coluber, racers. Only two species are considered moderately venomous: the spotted whip snake (*Coluber ravergieri*), and the braid snake (*Coluber rhodorachis*). These are medium-sized or large slender-bodied and quite aggressive snakes with large round eyes. Both species are found rather on the ground and in low vegetation in the territory from the Middle East as far as Mongolia and a part of China.

In terms of taxonomy, *Coluber* is a genus of collective nature that is in the process of splitting into a number of separate genera, meaning that according to the latest knowledge, the species mentioned above will be classified as *Hemorrhois ravergieri* and *Platyceps rhodorachis*.

Coniophanes, black-striped snakes. Small terrestrial snakes with rear fangs found in the southern part of North America, Central and South America.

Conophis, ES: Guarda camino. Medium-sized snakes growing up to 100 cm, with rear fangs, diurnal activity and relatively effective venoms. Found in the dry forests and coastal regions of Central America. Local symptoms of envenoming, pain at the bitten site and edema have been described.

Crotaphopeltis. Medium-sized ranivorous snakes with rear fangs; they range in the moist and swamp areas of S and W part of Africa.

*Dipsadoboa***.** Small slender-bodied arboreal snakes with rear fangs found in Africa.

Dromophis. Relatively long and slender-bodied snakes found in African humid areas and rainforests.

Elapomorphus. Small slender-bodied snakes that feature a small head and eyes, and boast mainly longitudinal stripes. They are mostly nocturnal burrowing snakes found in the forests of S America.

Enhydris, water snakes. Small up to medium-sized aquatic snakes up to 100 cm long, with a quite robust body. They are found in the water reservoirs, swamps and brooks of India, China, SE Asia, New Guinea and N Australia.

Eteirodipsas, Malagasy cat-eyed snakes. A monotypical genus of the Madagascar colubrids.

Ficimia, hooknosed snakes. Small colubrids with rear fangs found in diverse American arid habitats from S Texas as far as Honduras.

Fordonia. A monotypic genus containing a single species, the crab-eating water snake (*Fordonia leucobalia*). A small colubrid dwelling in the mangroves and swamps of SE Asian as far as N Australian coasts.

Heterodon. Small to medium-sized snakes 40 to 120 cm long that feature a robust body and relatively effective venoms containing a postsynaptic neurotoxin. They are not aggressive; when in danger, they will flatten their neck like cobras or play dead. They are mostly found in the grassy localities, both humid and arid, as well as sandy deserts of North America.

Homalopsis, water snakes. Medium-sized aquatic snakes with rear fangs. Their venom, relatively ineffective, contains hemorrhagic components. The water snakes are found in the freshwaters and brackish waters of India, Burma, the former Indochinese region and SE Asia.

Ialtris. Medium-sized and slender-bodied snakes with rear fangs found in Haiti and Dominican Republic.

Imantodes. Medium-sized and extremely slender-bodied snakes with large eyes that can grow up to 1 m. They possess rear fangs and nocturnal hunting habits. They are found in the forests of Central and S America.

Ithycyphus. Arboreal snakes that can grow up to 150 cm, with rear fangs. Found in the forest areas of Madagascar.

Langaha. Long and extremely slender-bodied arboreal snakes with rear fangs and a flattened and prominent snout. They are active in the morning and found in Madagascar rainforests.

*Leimadophis***.** Formerly, this genus encompassed a wide range of species that have been more recently classified under different genera like *Antillophis*, *Arrhyton*, *Dromicus*, *Liophis*, *Philodryas, Saphenophis* and *Umbrivaga*. Lesser colubrids with rear fangs found in the rainforests of Central and S America.

Leptodeira. Lesser and slender-bodied snakes with rear fangs found on the ground and in the lower stands of warm American areas from Texas to Paraguay.

Leptophis, parrot snakes. Long slender-bodied snakes with rear fangs found in trees as well as other sites of the warmer regions of C and S America.

*Liophis***.** A genus with a wide range of colubrid snakes of diverse size with rear fangs and diurnal activity. Certain species are classified into a separate *Lygophis* genus. Found in varied habitats throughout Central and South America including the Caribbean.

Lygophis see *Liophis*.

Macropisthodon. Medium-sized ranivorous snakes with rear fangs resembling copperheads that range in identical areas. Found in the fields and grassy localities of India, Sri Lanka, S China and a part of SE Asia.

*Macroprotodon***.** A small nocturnal snake with rear fangs found in dry and rocky places throughout SW Europe, N Africa and a part of the Middle East.

Madagascarophis. Terrestrial snakes with a more robust body and rear fangs found in the bushland of Madagascar. *M. meridionalis* snakebite is reported to have caused bruising, vesicles, and occasionally even cases of necrosis.

Masticophis. Long and slender-bodied diurnal snakes found in the deserts, beaches and open woodlands of North and Central America and in the north of South America.

*Myron***.** A monotypic species of small nocturnal snakes about 40 cm long found in the swamps and mangroves of N Australia and New Guinea. No envenoming has been reported; nevertheless, the venom is considered potentially dangerous.

Oxybelis, vine snakes. Relatively aggressive long and slender-bodied arboreal snakes with rear fangs found in the forest habitats of N and S America from Texas as far as Bolivia and Peru.

Oxyrhopus. Medium-sized, slender-bodied and largely nocturnal terrestrial snakes found in America from Mexico to Peru.

Philodryas, green snakes. Slender-bodied arboreal reptiles of mostly green color. They feature large eyes, round pupil and rear fangs; they are diurnal snakes up to 150 cm long found in the forests of S America. Symptoms described following a snakebite by *P. baroni* include local pain, edema with a peak in 24 hours that will recede after 48 hours, lymphadenitis without regional nodes enlarged, development of dermal ecchymoses and perfused bite wounds, without signs of systemic envenoming. Components showing a procoagulation action have been evidenced in the venom. The hemorrhagic activity of the venom can be neutralized using an antivenom against *Bothrops* snakes.

Philothamnus. Slender-bodied diurnal snakes of mostly green color. They feature large eyes, round pupil and rear fangs that can grow up to 130 cm. Found near the water surfaces, in humid woodland, and even in savannahs of W, E, and S Africa. Despite the content of effective procoagulation components in the venom of *P. natalensis*, more severe envenomings have not been described.

Psammophis. A number of slender-bodied diurnal snakes that possess rear fangs; they can grow up to 200 cm. Usually found in rather arid and open terrains and plantations of Africa, the Middle East and a part of Central Asia, W China, Burma and Thailand.

Psammophylax, Afrikaans: Skaapsteker (a sheep killer). Slender-bodied snakes about 100 cm long with rear fangs and relatively effective venoms found in the bushland of S Africa. These snakes are neither considered dangerous to humans nor to the sheep, despite their name.

Pseudoboa. Medium-sized nocturnal terrestrial snakes with rear fangs found in the rainforests of S America.

Ptychophis. Small ranivorous and piscivorous semi aquatic snakes with rear fangs that pose a potential threat to a human as well. Found in Brazilian wetlands.

Pythonodipsas. Up to 60 cm long snakes that possess large rear fangs; they are active at night and found in the rocky deserts of Namibia and Angola.

Siphlophis. Small up to medium-sized arboreal snakes with rear fangs and nocturnal activity found in the forests of Central and S America.

Spalerosophis. Over 100 cm long snakes found in the deserts and bushland of N Africa and the Middle East.

Stenorrhina. Medium-sized slender-bodied snakes with rear fangs found in the forests and grassy areas of America from Mexico to Ecuador. A single *Stenorrhina freminvillei* snakebite that has been described was accompanied by local pain and edema without any systemic reactions.

*Tachymenis***.** Small snakes with rear fangs found in the arid regions of NW South America.

Tantilla, centipede snakes**.** Small and slender-bodied snakes, the smallest members of the venomous snake group. Found in diverse terrains throughout America from central USA as far as Argentina.

Telescopus, formerly *Tarbophis*. A range of species that comprise 80 to 130 cm long medium-sized snakes boasting dark cross stripes, with rear fangs and nocturnal life. Found mostly in the arid and rocky localities in Africa, the Balkan, and the neighboring regions of Asia and Asia Minor.

Thamnodynastes. Small up to medium-sized terrestrial as well as arboreal snakes that feature a more robust body, rear fangs and largely nocturnal activity found in the forests of S America.

Thamnophis. A range of species that include lesser or medium-sized diurnal snakes found on humid sites throughout North and Central America.

Thrasops. Large arboreal colubrids that dwell in the forests of tropical Africa.

Trimorphodon**.** Medium-sized and slender-bodied snakes up to 100 cm long with rear fangs found in arid up to rocky and shrubby places throughout North and Central America.

Waglerophis. Medium-sized and quite robust ranivorous snakes with long rear fangs found on rather humid sites in the forests of South America.

Xenochrophis, painted keelbacks. Medium-sized colubrid snakes that can grow even more than 100 cm; they possess rear fangs. Found on humid localities and near water surfaces from Afghanistan through S Asia as far as Indonesia.

Xenodon. Medium-sized or even large ranivorous snakes with a rather robust body, rear fangs and aggressive behavior. Found in the humid forests and rainforests as well as near the water surfaces of America from Mexico as far as Argentina.

Toxins: For the majority of opistoglyphous colubrids, a lack of information on venom exists at laboratory and clinical level. Latest knowledge indicates that they primarily include neurotoxins, largely of a postsynaptic type, and hemocoagulation-affecting components, mostly in terms of prothrombin activation and development of the disorder of the DIC type. One of these groups of toxins is present in practically all the venoms of the colubrids listed above. Nevertheless, the concentration is typically so low that any clinical symptomatology of a serious disorder will frequently not develop.

Local symptoms of envenoming: Slight local damage can be expected such as insignificant edema and signs of inflammation, as well as erythema or paleness, temporary local bleeding, pain and burning, or conversely desensitization or even stiffness around the bitten site. In certain species, for instance *Homalopsis*, venom with hemorrhagic activity is found, meaning the bitten site can be subject to hemorrhagic changes. Snakebites can be accompanied by lymphadenitis either including or excluding lymphangitis.

Systemic symptoms of envenoming: Symptoms of systemic envenoming, if any, will be limited to prodromes, i.e. nausea, vomiting, abdominal and cranial pain, and shivering. In cases of more severe envenoming, depending on the content of venom components, minor signs of bleeding, such as in *Philothamnus*, or signs of languor and muscular pain can arise, such as in *Heterodon* and *Telescopus*.

For most of the genera listed above, envenomation has never been described due to the rarity and insignificant courses of the same, so they do not pose any major threat to humans. Nevertheless, snakebites should not be underestimated, reasons for this being simply the lack of information on specific cases as well as the potential for more severe or unexpected courses.

Laboratory findings: Leukocytosis can be expected; as for envenoming by a venom containing hemocoagulation-affecting components, in most cases a low level of consumption coagulopathy may follow.

Mortality: No lethal cases following a bite by the snakes of the genera listed above have been described.

Therapy: For first aid and general rules of treatment, see chapter 5 Snakebite: Therapy and prevention. Should rare symptoms of systemic envenoming be forthcoming, observation will be helpful; supportive symptomatic treatment will be necessary only in special cases.

A patient can be discharged for home treatment 24 hours following abatement of all possible symptoms and more significant laboratory findings.

REFERENCES

ATKINSON, PM., BRADLOW, BA., WHITE, JA., et al. Clinical features of Twig Snake (*Thelotornis capensis*) envenoming. *S Afr Med J*, 1980, 58, No. 25, pp. 1007-1011.

BROADERS, M., RYAN, MF. Enzymatic properties of the Duvernoy's secretion of Blanding's Tree Snake (*Boiga blandingi*) and of the Mangrove Snake (*Boiga dendrophila*). *Toxicon*, 1997, 35, No. 7, pp. 1143-1148.

COOK, DG. A case of envenoming by the neotropical Colubrid Snake, *Stenorrhina freminvillei*. *Toxicon*, 1984, 22, No. 5, pp. 823-827.

FAN, HW., CARDOSO, JL. Clinical toxicology of snake bites in South America. In MEIER, J., WHITE, J. (Eds), *Handbook of clinical toxicology of animal venoms and poisons.* Boca Raton : CRC Press, 1995, pp. 667-688.

FITZSIMONS, DC., SMITH, HM. Another rear-fanged South African snake lethal to humans. *Herpetologova*, 1958, 14, pp. 198-202.

FRITTS, TH., McCOID, MJ., HADDOCK, RL. Risk to infant on Guam from bites of the Brown Tree Snake (*Boiga irregularis*). *Am J Trop Med Hyg*, 1990, 42, No. 6, pp. 607-611.

GERBER, JD., ADENDORFF, HP. Boomslang (*Dispholidus typus*) bite: case report. *A Afr J*, 1980, 57, No. 17, pp. 710-711.

GONZALES, D. Epidemiological and clinical aspects of certain venomous animals in Spain. *Toxicon*, 1982, 20, p. 925.

GUILLIN, MC., BEZEAUD, A., MENACHE, D. The mechanism of activation of human prothrombin by an activator isolated from *Dispholidus typus* venom. *Biochim Biophys Acta*, 1978, 537, No. 1, pp. 160-168.

GUTIÉRREZ, JM. Clinical toxicology of snakebite in Central America. In MEIER, J., WHITE, J. (Eds), *Handbook of clinical toxicology of animal venoms and poisons*. Boca Raton : CRC Press, 1995.

De HAAN, CC. Sense-organ-like parietal pits found in *Psammophiini* (Serpentes, Colubridae). *CR Biol*, 2003, 326, No. 3, pp. 287-293.

HAYES, WK., LAVIN-MURCIO, P., KARDONG, KV. Delivery of Duvernoy's secretion into prey by the Brown Tree Snake, *Boiga irregularis* (Serpentes: Colubridae). *Toxicon*, 1993, 31, No. 7, pp. 881-887.

HILL, RE., MACKESSY, SP. Characterization of venom (Duvernoy's secretion) from twelve species of Colubrid Snakes and partial sequence of four venom proteins. *Toxicon*, 2000, 38, No. 12, pp. 1663-1687.

HOFFMANN, JJ., VIJGEN, M., SMEETS, RE., et al. Haemostatic effects in vivo after snakebite by the Red-necked Keelback (*Rhabdophis subminiatus*). *Blood Coagul Fibrinolysis*, 1992, 3, No. 4, pp. 461-464.

HUTTON, RA., WARRELL, DA. Action of snake venom components on the haemostatic system. *Blood Rev*, 1993, 7, No. 3, pp. 176-189.

ISMAIL, M., MEMISH, ZA. Venomous snakes of Saudi Arabia and the Middle East: a keynote for travellers. *Int J of Antimikrob Agents*, 2003, 21, pp. 164-169.

KORNALIK F, TABORSKA E. Procoagulant and defibrinating potency of the venom gland extract of Thelotornis kirtlandi. *Thromb Res*, 1978, 12, No. 6, pp. 991-1001.

KUCH, U., JESBERGER, U. Human envenoming from the bite of the South American Colubrid Snake species *Phylodrias baroni* Berg, 1895. *The Snake*, 1993, 25, p. 63.

LI, QB., HUANG, GW., KINJOH, K., et al. Hematological studies on DIC-like findings observed in patients with snakebite in south China. *Toxicon*, 2001, 39, No. 7, pp. 943-948.

LUMSDEN, NG., FRY, BG., MANJUNATHA KINI, R., et al. In vitro neuromuscular activity of Colubrid venoms: clinical and evolutionary implications. *Toxicon*, 2004, 43, No. 7, pp. 819-827.

MEIER, J., WHITE, J. (Eds). *Handbook of clinical toxicology of animal venoms and poisons.* Boca Raton : CRC Press, 1995, 752 pp.

MITTLEMAN, MB., GORIS, RC. Death caused by the bite of the Japanese Colubrid Snake *Rhabdophis tigrinus* (Boie) (Reptilia, Serpentes, Colubridae). *J Herpetol*, 1978, 12, No. 1, pp. 109-111.

OGAWA, H., SAWAI, Y. Fatal bite of the Yamakagashi (*Rhabdophis tigrinus*). *The Snake*, 1986, 18, pp. 53-54.

PERSSON, H. Clinical toxicology of snakebite in Europe. In MEIER, J., WHITE, J. (Eds), *Handbook of clinical toxicology of animal venoms and poisons.* Boca Raton : CRC Press, 1995.

REHAK, I. Reprodukcni biologie hada *Heterodon nasicus*. *Akvarium terarium*, 1990, 33, č. 8, pp. 30-32. (in Czech)

REHAK, I. Distribution, ecology and variability of snakes in Czechoslovakia. In KORSOS, Z., KISS, I. (Eds.), *Proc. Sixth Ord. Gen. Meet*. Budapest : S.E.H., 1991, 1992, pp. 383-388.

REHAK, I. Serpentes - Hadi, Hady. In BARUŠ, V., OLIVA, O. (Eds.), *Plazi - Reptilia*. Praha : Academia, Praha, 1992, pp. 106-172. (in Czech)

ROSENBERG, HI., BDOLAH, A., KOCHVA, E. Lethal factors and enzymes in the secretion from Duvernoy's gland of three Colubrid Snakes. *J Exp Zool*, 1985, 233, No. 1, pp. 5-14.

ROSENBERG, HI., KINAMON, S., KOCHVA, E., et al. The secretion of Duvernoy's gland of *Malpolon monspessulanus* induced haemorrhage in the lung of mice. *Toxicon*, 1992, 30, No. 8, pp. 920-924.

SEOW, E., KUPERAN, P., GOH, SK., et al. Morbidity after a bite from a »non-venomous« Pet Snake. *Singapore Med J*, 2000, 41, No. 1, pp. 34-35.

SMEETS, RE., PELMAN, PG., HOFFMANN, JJ., et al. Severe coagulopathy after a bite from a »harmless« snake (*Rhabdophis subminiatus*). *J Intern Med*, 1991, 230, No. 4, pp. 351-354.

Du TOIT, DM. Boomslang (*Dispholidus typus*) bite. A case report and a rewiew of diagnosis and management. *S Afr Med J*, 1980, 57, No. 13, pp. 507-510.

STÖCKLIN, R., CRETTON, G. *The ultimate database on venomous animals, snakes.* CD-rom, Geneva : Atheris Laboratories, 1998.

WARRELL, DA. Clinical toxicology of snakebite in Africa and the Middle East / Arabian Peninsula. In MEIER, J., WHITE, J. (Eds), *Handbook of clinical toxicology of animal venoms and poisons.* Boca Raton : CRC Press, 1995.

WARRELL, DA. Clinical toxicology of snakebite in Asia. In MEIER, J., WHITE, J. (Eds), *Handbook of clinical toxicology of animal venoms and poisons.* Boca Raton : CRC Press, 1995, pp. 493-594.

WEINSTEIN, SA., KARDONG, KV. Properties of Duvernoy's secretion from opistoglyphous and aglyphous Colubrid Snakes. *Toxicon*, 1994, 32, No. 10, pp. 1161-1185.

ZOTZ, RB., MEBS, D., HIRCHE, H., PAAR, D. Hemostatic changes due to the venom gland extract of the Red-necked Keelback Snake (*Rhabdophis subminiatus*). *Toxicon*, 1991, 29, No. 12, pp. 1501-1508.

6.2. FAMILY: ATRACTASPIDIDAE

This does not comprise a particularly extensive snake group, and is one which was formerly classified into other families due to the diversity of fang configuration. It has since been split into two subfamilies with approximately 10 genera and 70 species.

Members of this family, which was considered somewhat mysterious until very recently, mostly burrow underground in dens and tunnels. This has resulted in adaptation to their robust bodies and oval-shaped heads. The fangs are placed in either an anterior or posterior position.

If placed at the front, they are capable of being folded and moved - even to the sides - and can be used even if the mouth is closed (*Atractaspidinae*). If stationary, they are placed in either the front or rear (*Aparallactinae*).

The snakes of this family are largely found in Africa, with only a single species (*Atractaspis engaddensis*) ranging in the Middle East.

Bites or side stabbing by members of certain genera with large fangs and powerful venom can be dangerous, while other family members are harmless to humans.

6.2.1. Subfamily: *Atractaspidinae*

6.2.1.1. Atractaspis Genus

Species: Western forest mole viper (*Atractaspis atterina*), Battersby's mole viper (*Atractaspis battersbyi*), southern or Bibron's burrowing asp (*Atractaspis bibronii*), Boulenger's mole viper (*Atractaspis boulengeri*), mole viper (*Atractaspis coalescens*), Eastern Congo burrowing asp (*Atractaspis congica*), fat mole viper (*Atractaspis corpulenta*), Bocage's mole viper (*Atractaspis dahomeyensis*), Duerden's or beaked burrowing asp (*Atractaspis duerdeni*), Israeli mole viper (*Atractaspis engaddensis*), Engdahl's mole viper (*Atractaspis engdahli*), false mole viper (*Atractaspis fallax*), variable mole viper (*Atractaspis irregularis*), white mole viper (*Atractaspis leucomelas*), small-scaled burrowing asp (*Atractaspis microlepidota*), Sahelian burrowing asp (*Atractaspis micropholis*), *Atractaspis phillipsi*, reticulate mole viper (*Atractaspis reticulata*), and Scortecci's mole viper (*Atractaspis scortecii*), including numerous subspecies. Out of the species above, only *A. atterina*, *A. bibronii*, *A. corpulenta*, *A. dahomeyensis*, *A. engaddensis*, *A. irregularis*, and *A. microlepidota* present some danger for a human. Members of other species are incapable of posing any threat to man, either for their size or the small quantity of venom.

Other names: Burrowing asp or vipers, side-stabbing snakes, stiletto snakes; FR: Atractaspid (*Atractaspis sp.*). HE: Saraf 'En Gedi (*A. engaddensis*).

Description: Small to medium-sized and mostly slender bodied with a maximum length of 110 cm (*A. microlepidota*), these snakes feature an oval-shaped and highly flexible head shaped for digging, an indistinct neck and small eyes. As regards coloring, dark tints prevail on the top - black, or black and gray or brown, with the underside being pale or even white. The upper jaw, i.e. the maxilla, is extremely reduced, with embedded hollow front fangs. Their venom glands are extremely long and resemble those of coral snakes. The specialty of burrowing asps is to pop out their relatively long fangs to the side of the jaws with the mouth almost closed and to bite employing a lateral strike, which is made possible especially by the flexibility of the jaws. The reason for this action is the necessity to hunt in narrow tunnels created by rodents, lizards, and other animals dwelling underground. This specific kind of bite is significant for humans when holding the creature behind its neck, as it may stab the hand with repeated lateral strikes of its highly mobile head.

Home range and habitat: The *Atractaspis* species inhabit a major portion of Africa: the western part (*A. dahomeyensis*, *A. corpulenta*), the south-west and central part (*A. aterrima*), to the east, the territory from and including Ethiopia as far as the southern part of the continent - Namibia, Botswana, and north of the Republic of South Africa (*A. bibronii*). NE Egypt, Sinai, Israel, and Palestine (*A. engaddensis*) make up another part of their home range. A zone throughout Africa from Mauritania to Kenya is home to *A. irregularis*, which is found

in forests, in addition to *A. microlepidota*, the savannah-dwelling species that proves the most dangerous to humans. Burrowing species prevail, their incidence particularly increasing after rainfall in the territory of human settlements. They hunt at dusk and during the night.

Toxins: Characteristic toxins include sarafotoxin isolated from the venom of *A. engaddensis*; it is cardiotoxic, causing hypertension, oscillation of systemic pressure, and in certain phases also increased inotropy due to vasoconstriction, or even coronary vasospasm. As a result, changes in ST-segment and T wave, prolongation of PR-interval, AV-block, and cardiac failure can occur and are evident from ECG results due to myocardial ischemia. Toxin is effective especially in vertebrates, chiefly mammals; it resembles mammal endothelin in its composition and effects. Concerning other components, the venom contains mainly hemorrhagic and proteolytic enzymes.

The quantity of venom is low - a maximum of 9.6 µg of dry matter was obtained from *A. engaddensis* - nevertheless, the venom features a relatively high toxicity, with LD_{50} IV for mice starting from 0.075 mg/kg of body weight in *A. engaddensis*, and over 3 mg/kg of body weight in *A. micropholis*. Immunogenicity of venom components is very low - a minimum reaction has been achieved with the antivenoms available.

Local symptoms of envenoming: The bite wound immediately generates a varying level of discomfort - from moderate through to intense severe and stabbing pain - that can be accompanied by tingling and feelings of stiffness. Bleeding from the bitten site will persist. Very early on, within an hour at longest, a localized edema will appear with regional lymphadenopathy and palpable pain propagating into nodes. The bitten site is often surrounded by a decolorized area or, conversely, erythema. This can continue with blisters developing of hemorrhagic or suppurating content and dermal necrosis. The necrosis is likely to be caused by ischemia generated by the edema in the areas of tight compartments on fingers. Any potential abscesses under the skin are bacteriologically sterile and materialize based on direct action by the venom. The edema will peak within 24 to 48 hours and start to recede after 48 to 60 hours, typically disappearing within 4 to 7 days. Changes in the tone of skin and increased sensitivity at the affected site may well last for a number of months.

Systemic symptoms of envenoming: Systemic envenoming will manifest through headaches, a dry mouth, increased temperatures, rhonchus, pain through eye motions, paleness, increased sweating, nausea, vomiting, and water-based non-hemorrhagic diarrhea. Gastrointestinal symptomatology may not be present in cases of envenoming by *A. bibronii*. In rare instances, ophtalmoplegia, dysphagia, vertigo, muscle weakness, muscles fasciculations, and deafness occur. More severe envenoming presents itself through varying states of mind, including syncopes, tachycardia with a frequency as high as 130 beats per minute, hypertension of up to 180/110 mmHg, feelings of dyspnea, and changes in ECG in the shape of myocardial ischemia and AV-blocks. The most severe and fatal courses are signified by circulatory collapse and cardiac failure (*A. engaddensis*). No major signs of neurotoxicity are present, and hemocoagulation is seldom influenced to a greater extent.

Laboratory findings: Increased values in leukocytes (11 x 10^9/l) and platelets (600 x 10^9/l) have been recorded; in terms of other results, elevated APTT and PT (*A. bibronii*, *A. engaddensis*), alkaline phosphatases and liver enzymes (*A. engaddensis*) have been determined.

Mortality: Very low - a few fatal cases have been recorded, for instance, in Sudan and Nigeria following a bite from *A. irregularis* or *A. microlepidota*. An extreme case involved a bite by *A. engaddensis*, when death of the affected person occurred after 45 minutes with

symptomatology of respiratory and circulatory failure. A post mortem examination even revealed abnormal histological results from the liver.

Therapy: For first aid and general rules of treatment, see chapter 5 Snakebite: Therapy and prevention. No antivenom exists to counteract *Atractaspis* genus venoms and no cross-immunity effects from antigens for venoms of other African snakes occur, e.g. SAIMR Polyvalent Snake Antivenom, the Republic of South Africa.

Desirable local treatment methods include moderate cooling of the edema, limb elevation and immobilization, plus gentle treatment of defects and possible necrectomy. In some cases, drainage of large blisters and abscesses is necessary.

For eliminating pain, analgesics based on paracetamol or non-steroid antiphlogistics usually prove sufficient.

Symptoms of systemic envenoming are resolved symptomatically. Antibiotic treatment has no special indications; serious abscesses are typically primarily sterile. The most significant symptom concerns cardiac function, which will probably become apparent due to myocardial ischemia based on coronary spasms and a heavy increase in peripheral vessel resistance. In terms of therapy, using nitrates can be an option in extreme cases, although the procedure has not been verified clinically.

If symptoms do not materialize following a bite, patients should be observed for 24 hours. Following an envenoming, a patient can be discharged for home treatment after 24 hours once systemic symptoms recede.

6.2.2. Subfamily: *Aparallactinae*

Genera: Amblyodipsas, *Aparallactus*, *Brachyophis*, *Chilorhinophis*, *Elapocalmus*, *Elapotinus*, *Hypoptophis*, *Macrelaps*, *Micrelaps*, *Poecilopholis*, *Polemon*, and *Xenocalamus*. In addition, this list could include *Homoroselaps*, newly recognized as elapid snakes; however, formerly placed among colubrids.

Description: The snakes classified under the *Aparallactinae* subfamily are close relatives to the *Atractaspis* snakes described above, with whom they are typically confused. The way they live is similar to *Atractaspidinae*. Some of them possess fixed grooved fangs located in the anterior or posterior part of the upper jaw (*Aparralactus*, *Macrelaps*). Information is patchy for many examples of these snakes. Even though they are venomous, they pose no serious threat to humans with some exceptions.

Home range and habitat: The subfamily covers African snakes ranging from Saharan territories as far as the Republic of South Africa. They inhabit underground tunnels made in soil, sand (*Xenocalamus*) or fallen leaves (*Macrelaps*). They are largely nocturnal creatures.

*Toxins***:** A lack of information on toxins exists; a similar composition of venom to that of the Atractaspis snakes described above can be expected.

*Local symptoms of envenoming***:** Local affection is likely to be analogous to the symptoms of snakebites by Atractaspis genus but lighter in form.

Systemic symptoms of envenoming: In some of the snake species, similar envenoming as that already described under Atractaspis is possible. Nevertheless, nearly no systemic reaction will be caused. Symptoms of unconsciousness and collapse following a snakebite from *Macrelaps microlepidotus* have been reported in South Africa.

Laboratory findings: Not described.

Mortality: A possibility of even a fatal course of envenoming by *Macrelaps microlepidotus* is admitted.

Therapy: For symptoms of envenomation, therapy will follow the treatment described under the chapter *Atractaspis*.

REFERENCES

ALKAN, ML., SUKENIK, S. Atrioventricular block in a case of snakebite inflicted by Atractaspis engaddensis. *Trans. R. Soc. Trop. Med. Hyg.,* 1975, 69, p. 166.

BLAYLOCK, RS. Snake bites at Triangle Hospital January 1975 to June 1981. *Centr. Afr. J. Med*., 1982, 28, pp. 1–10.

BRITT, DP. Death following the bite of Burroving Viper. *Nigerian Field*, 1978, 43, pp. 41–42.

CORKILL, NL., IONDIES, CJP, PITMAN, CRS. Biting and poisoning by the Mole Viper of the genus Atractaspis. *Trans R. Soc. Trop. Med. Hyg.,* 1959, 53, pp. 95–101.

CRANKO, JAW. A snakebite from a Burrowing Adder. *Centr. Afr. J. Med*., 1961, 7, pp. 215–216.

CHRISTENSEN, PA.. Snakebite and the use of antivenom in Southern Africa. *S. Afr. Med. J.*, 1981, 59, pp. 934–938.

ISMAIL, M., MEMISH, ZA. Venomous snakes of Saudi Arabia and the Middle East: a keynote for travellers. *Int. J. of Antimikrob. Agents,* 2003, 21, pp. 164–169.

KIRCHBERG, JS., DAVIDSON, TM. Envenomation by the Colubrid Snake *Atractaspis bibronii*: a case report. *Toxicon*, 1991, 29, No. 3, pp. 379–381.

KURNIK, D., HAVIV, Y., KOCHVA, E. A snake bite by the Burroving Asp*, Atractaspis engaddensis*. *Toxicon*, 1999, 37, No. 1, pp. 223–227.

LEE, SY., LEE, CY., CHEN, YM., et al. Coronary vasospasm as the primary cause of death due to the venom of the Burrowing Asp, *Atractaspis engaddensis. Toxicon,* 1986, 24, No. 3, p. 285–291.

MEIER, J., WHITE, J. (Eds). *Handbook of clinical toxicology of animal venoms and poisons.* Boca Raton : CRC Press, 1995, 752 pp.

OVADIA, M. Isolation and charakterisation of a hemorrhagic factor from the venom of the snake *Atractaspis engaddensis* (Atractaspididae). *Toxicon,* 1987, 25, No. 6, pp. 621–630.

STÖCKLIN, R., CRETTON, G. *The ultimate database on venomous animals, snakes.* CD-rom, Geneva : Atheris Laboratories, 1998.

TILBURY, CR., BRANCH, WR. Observations on the bite of the Southern Burrowing Asp (*Atractaspis bibronii*) in Natal. *S. Afr. Med. J.*, 1989, pp. 327–331.

VISSER, J., CHAPMAN, DS. *Snakes and snakebite: venomous snakes and management of snakebite in Southern Africa*. Cape Town : Purnell, 1978, 152 pp.

WARRELL, DA. Clinical toxicology of snakebite in Africa and the Middle East / Arabien Peninsula. In MEIER, J., WHITE, J. (Eds), *Handbook of clinical toxicology of animal venoms and poisons.* Boca Raton : CRC Press, 1995, pp. 433–492.

WARRELL, DA., ORMEROD, LD., DAVIDSON, NM. Bites by the Night Adder (*Causus maculatus*) and Burrowing Vipers (genus *Atractaspis*) in Nigeria. *Am. J. Trop. Med. Hyg.*, 1976, 25, No. 3, pp. 517–24.

6.3. FAMILY: *ELAPIDAE*, ELAPID SNAKES

Elapid snakes (*Elapidae*) form an extensive family of venomous snakes, with opinions differing on further subdivision depending on the author, in fact, multiple subfamilies are often described. Decisive aspects for the current classification of elapid snakes include (1) as yet unclear phyletic links between a number of Eurasian, African and American snakes - therefore, these have been temporarily, until the classification issue is resolved, designated as a single subfamily, *Elapinae*, containing some 17 genera with over 130 species; (2) in addition, there is a well-founded relationship between Austropapuan elapids, sea snakes and sea kraits; i.e. proteroglyphous aquatic snakes formerly placed under a separate *Hydrophiidae* family. These snakes are now defined as a separate *Hydrophiinae* subfamily within the *Elapidae* family, which contains about 43 genera and 165 species.

Elapids show some external morphological parallelism with colubrid snakes; nevertheless, they differ from each other by the structure of the venom apparatus, this being just one example. Shared features of the *Elapidae* family include fixed and non-swinging fangs in the front section of the upper jaw (*Proteroglypha*), see chapter 1. 4 Venom apparatus of snakes. In addition, the majority of elapid snakes typically possess a significant level of effective neurotoxic venom components. In the wild, *Elapidae* family members inhabit almost the entire home range of venomous snakes except in Europe, where many such species are kept in captivity. Throughout their home range, certain coral snake family members are considered some of the most perilous snakes and the most venomous animals to inhabit these areas.

6.3.1. Subfamily: *Elapinae*

The recently recognized *Elapinae* subfamily consists of genera formerly classified as *Calliophinae*, *Bungarinae*, *Maticorinae,* and *Elapinae* subfamilies. The former *Bungarinae* family included 12 genera of venomous snakes that ranged almost throughout the whole of Africa and a part of Asia, a zone that stretches from Central Asia across the Indian subcontinent, S China and former Indochinese territory as far as the islands of the Philippines, Indonesia and Malaysia. Indeed, included in their number are some of the most dangerous snakes of all, such as representatives of the largest venomous snakes, the Asian king cobra (*Ophiophagus hannah*), and the African black mamba (*Dendroaspis polylepis*). Elapid snakes found throughout the American continent, formerly referred to as *Elapinae*, are another important group in terms of toxinology, along with the numerous *Micrurus* genus. Another two genera of this group, *Leptomicrurus* and *Micruroides*, merely include several snake species that are rare or less significant for epidemiology.

6.3.1.1. Aspidelaps Genus, Shield Nosed Cobras

Species: South African coral snake (*Aspidelaps lubricus*), intermediate shield-nose snake (*Aspidelaps scutatus*).

Description: Small to medium-sized snakes 45 to 75 cm in length of orange, salmon, brownish or even reddish color with crossing black rings (*A. lubricatus*), or a darker random

crosswise pattern and dark head (*A. scutatus*). They are active at night. When in danger, they moderately spread the area of the neck like the cobra.

Other names: Western coral snake; FR: Serpent corail d'Afrique du Sud, Serpent corail du Cap (*A. lubricus*). Shield-nose cobra (*A. scutatus*).

Home range and habitat: These snakes reside in sandy and rocky arid habitats of Namibia, Botswana, the Republic of South Africa, SE Zimbabwe and S Mozambique.

Toxins: The composition of venoms is not sufficiently known. The venoms largely contain neurotoxins. Other components include PLA_2, similar to the venoms of African cobras of the *Naja* genus, as well as cytotoxic components generally.

Local symptoms of envenoming: The bitten site is painful with the development of edema; lymphadenopathy occurs, including enlarged regional lymphatic nodes. Necrosis is possible. Local changes abate very slowly.

Systemic symptoms of envenoming: If the quantity of venom is large or the victim is a child, the neurotoxins may cause neurological symptomatology affecting cranial nerves and precipitating feelings of languor, as well as even respiratory failure, in special cases, by paralyzing the innervation of respiratory muscles.

*Laboratory findings***:** Not described; leukocytosis is possible.

Mortality: Fatal cases are known (van Egmond, 1984; Warrell, 1995).

*Therapy***:** For first aid and general rules of treatment, see chapter 5 Snakebite: Therapy and prevention. Application of the pressure immobilization bandage is indicated, namely for children and if any delay in definitive treatment is predicted. The bandage must not be removed either before treatment by a health facility capable of dealing with serious symptoms of muscular paralysis, or after systemic envenoming has been eliminated.

No antivenom is available, although a probability exists of cross-reactivity with the venom of African cobras (*Naja*), at least for certain inherent components.

Painful edema will require a light elevation of the limb, immobilization and moderate cooling. In cases of more severe affection, any subsequent larger necrosis may be solved by necrectomy following demarcation. Severe symptoms of neurotoxicity, involving loss of the ability to swallow, the cough reflex or apparent respiratory failure, will require airway management and mechanical ventilation.

Following envenomation, a patient can be discharged for home treatment after 24 hours once systemic symptoms recede. Any persisting local affection can be solved through treatment as an outpatient.

6.3.1.2. Bungarus Genus, Kraits

Species: Of the twelve krait species, see chapter 7 List of venomous snakes, the most common ones are the Indian krait (*Bungarus caeruleus*), blue krait (*Bungarus candidus*), Ceylon krait (*Bungarus ceylonicus*), banded krait (*Bungarus fasciatus*), red-headed krait (*Bungarus flaviceps*), many-banded krait (*Bungarus multicinctus*) and the Sind krait (*Bungarus sindanus*).

From an epidemiologic viewpoint, the most significant species include the Indian krait (*Bungarus caeruleus*), which is responsible for a number of fatal cases of snakebites in India, the blue krait (*Bungarus candidus*), and many-banded krait (*Bungarus multicinctus*), responsible for 8.4% of the total number of envenomings in S China.

Description: Snakes with large or medium-sized slender bodies. They grow to an average length of 100 to 150 cm, with the maximum of 195 cm documented for the red-headed krait

(*Bungarus flaviceps*). A deltoid-like or laterally compressed shape of body profile is typical for these snakes. The color is dark, with typical paler or whitish rings. Kraits are active at night; their behavior can be outlined as aggressive, with increased probability of strike, which is why people resting at night are bitten. If disturbed during the day, they tend not to attack, but rather keep their heads to the ground.

Other names: FR: Bongare (*Bungarus*). In native languages: Pama (*B. fasciatus*), Sangchur, i.e. a stone breaker, Pee-un, i.e. a drinker (*B. caeruleus*).

Home range and habitat: They inhabit both open and dense woodland or scrubland, mangrove stands and plantations - often near water - in the territory of SE Asia, from E Afghanistan and Pakistan through India, Sri Lanka, the former Indochinese territory as far as S China, including Taiwan and the Hainan islands, plus the islands of Malaysia and Indonesia.

Toxins: Neurotoxins present the most dangerous and fatal component in krait (*Bungarus*) venom, with α-bungarotoxin - a potent postsynaptically acting toxin - presumably responsible for the majority of fatal courses of envenoming. Candoxin is another type of postsynaptic neurotoxin. The effect of both is reversible and can be well controlled by inhibiting cholinesterase. However, the presence of β-bungarotoxin, a neurotoxic presynaptically acting PLA_2 that causes irreversible damage and apoptosis of affected neurons, is probably responsible for neurological affections that sometimes persist.

From the venom of *B. multicinctus*, polypeptidic cytotoxins/cardiotoxins have been isolated, similar to the components found in *Naja* cobras, but without the necrotizing effect on tissue.

The venoms of some kraits also contain myotoxically acting components, although at a minor level. If any venom includes hemocoagulation-affecting components as well as general cytotoxic enzymes, any such quantity is clinically negligible.

6 mg of dry matter of the venom of the Indian krait (*B. caeruleus*) is equivalent to a lethal dose for a human being.

Local symptoms of envenoming: The bitten site often does not hurt - many times people bitten whilst asleep do not sense any bite at all, but occasionally the site can be painful, with rare cases of swollen regional lymph nodes, reddish coloring around the site or minor bleeding from the bite wounds.

Systemic symptoms of envenoming: The absence of pain upon the snakebite and at the bitten site can sometimes trigger intriguing situations. For example, a person so affected, unaware of having been bitten when asleep, may not link developments to possible envenoming by a krait, which in turn can result in assigning symptoms of paralysis in the area of cranial and other nerves to acute idiopathic inflammatory polyneuropathy, cranial polyneuritis, myasthenia gravis attack or other similar neurological affections.

More often, the clinical symptoms of envenoming initially become apparent through prodromal symptoms such as nausea, vomiting, abdominal pain or feelings of discomfort in the abdominal region, headaches, pain in the neck, thirst, languor, increased temperatures, and anxiety. The onset of the symptoms occurs several minutes to several hours following a bite.

In most cases, neurotoxicity symptoms begin by affecting cranial nerves, with typical signs including ptosis, ophtalmoplegia including oculomotoric paralysis, dysarthria, dysphagia, difficulties with opening the mouth, a protruding tongue, increased salivation, and facial as well as pseudobulbar paralysis. In up to three quarters of those affected, the process is often accompanied by CNS affection, including alteration of consciousness, which is

largely manifest through weariness, but also consciousness disorders. These present themselves qualitatively, e.g. via lack of coordination, or via deep coma and anterograde amnesia. In about a third to a half of those affected, clinically significant paralysis of respiratory muscles occurs very early on, from as little as 30 minutes, but onset may commence even after 7-12 hours, with airway management and mechanical ventilation required. Presymptoms of this serious affection always include weakness in limbs, feelings of tightness around the chest or general muscle weakness. Other symptoms triggered by the action of neurotoxins can include influence of the vegetative system, largely in terms of reduced activity of parasympathicus. This is manifest through mydriasis, hypertension, tachycardia and paleness, but also through increased sweating, salivating and lacrimation.

The effect on respiratory muscles is reversible, largely abating within 4 days even without treatment. Nevertheless, there have been cases of long-term residual affection of motoric nerves (such as distal motoric neuropathy), as well as that of vegetative nerves (e.g. dysfunction of oculomotoric muscles, difficulties with urinating, obstipation persisting over a long time), which probably came to existence due to damage of related neurons by the action of presynaptic neurotoxic enzymes.

Some envenomings, e.g. by *B. caeruleus*, may even involve rhabdomyolysis, which is soon revealed through muscle pain; more severe myoglobinemia pre-determines renal failure.

Hemorrhaging has previously been described within the range of snakebites from the banded krait (*B. fasciatus*). However, the venom of this snake probably lacks hemocoagulation-affecting components; moreover, the species might be confused with other snakes. The cardiotoxicity evident from experiments with dogs has not been described in humans.

Laboratory findings: There is a shortage of findings through laboratory examinations, with only neutrophilic leukocytosis frequent. Findings of hypokalemia and metabolic acidosis are described. In cases of rhabdomyolysis, high serum levels of myoglobin and myoglobinuria are present. Examination following a snakebite from *B. fasciatus* in China produced the following laboratory findings, showing consumption coagulopathy that was, however, disputed: FBG decreases and FDP increases, reduced AT activity, and decreased α2-antiplasmin.

Mortality: Mortality following snakebites from kraits is high. Out of 210 snakebites recorded in Sri Lanka in 1996-1998, there were 16 fatal cases from envenomings treated, equivalent to 7.6%. In southern China, the number of fatal cases is 10%. In non-treated victims, a mortality rate of 77% and even 100% is recorded in India and Sri Lanka respectively. The interval from a snakebite from *B. candidus* until death varies widely - from 3 to 288 hours, on average 96 hours. A report on death within 30 minutes following a bite has been recorded in Java.

Therapy: For first aid and general rules of treatment, see chapter 5 Snakebite: Therapy and prevention. Immediate application of a pressure immobilization bandage is fully indicated. The bandage should be kept on until arrival at a health facility capable of dealing with potentially serious symptoms of muscular paralysis. If envenoming is proven, it is best to remove the bandage once antivenom is applied, if this is available, or at least until the administration of neostigmine, see below.

Any more effective antivenoms are available only against the venoms of *B. fasciatus*, *B. caeruleus* and *B. multicinctus*.

Bungarus fasciatus:
* ANTIVENIN POLYVALENT, Bio Farma, Indonesia;
* BANDED KRAIT ANTIVENIN, Thai Red Cross, Thailand;
* MONOVALENT KRAIT ANTIVENOM SERUM, Central Research Institute, India;
* POLYVALENT SNAKE ANTIVENOM SERUM, Central Research Institute, India.

Bungarus caeruleus:
* LYOPHILISED ANTI-SNAKE-VENOM SERUM Haffkine, India;
* MONOVALENT KRAIT ANTIVENOM SERUM Central Research Institute, India;
* POLYVALENT SNAKE ANTIVENOM SERUM Central Research Institute, India;
* SNAKE ANTIVENIN I.P. Haffkine, India.

Bungarus multicinctus:
* ANTIVENIN BUNGARUS MULTIC. AND NAJA NAJA ATRA Nat. Inst. Prev. Med., Taiwan.

Polyvalent antivenoms, even though designed for *B. caeruleus*, prove insufficient when it comes to reversing muscular paralysis or preventing later neurologic complications. No antivenom against the venom of *B. candidus* exists; cross-immunity with antivenoms to counteract that of other kraits is uncertain or does not exist.

Local findings to a minimum degree will not require any special treatment.

Symptomatic treatment in cases where antivenom is unavailable or not effective must be capable of tackling the most serious symptom of muscular paralysis - dyspnea. This is conducted by airway management using tracheal intubation and subsequent mechanical ventilation. Such a procedure is essential as it brings the mortality rate of envenomings down to a minimum. In addition, pharmacological inhibition of acetylcholinesterase using edrophonium or neostigmine, at a dosage of 0.5-1.0 mg IV (10-15 μ/kg of body weight) should follow premedication by 0.5 mg of atropine IV. Any late complications that arise due to the action of neurotoxic enzymes can be controlled by timely administration of effective antivenom, but not symptomatically. A sufficient supply of liquids reduces the probability of renal failure if rhabdomyolysis is in progress.

Should treatment prove fully effective, the symptoms of envenoming will completely abate within 6-14 days. However, minor neurological complications may persist over a period of several years.

When there is a lack of symptoms following a bite, a patient should be observed for 24 hours. Following envenomation, the patient can be discharged for home treatment after 24 hours once all symptoms recede.

6.3.1.3. Calliophis, Hemibungarus and Maticora Genera, Asian Coral Snakes

Genera and species. The group of the genera mentioned above is sometimes divided into separate subfamilies, *Calliophinae* and *Maticorinae*. The *Calliophis* genus includes the Bibron's coral snake (*Calliophis bibroni*), spotted coral snake (*Calliophis gracilis*), and Indian coral snake (*Calliophis melanurus*). The *Hemibungarus* genus members include *Hemibungarus calligaster*, Japanese coral snake (*Hemibungarus japonicus*), Kellog's coral snake (*Hemibungarus kelloggi*), and MacClelland's coral snake (*Hemibungarus macclellandi*). Some resources also list additional species or classify both species under a

common one. The *Maticora* genus includes *Maticora beddomei*, blue Malaysian coral snake (*Maticora bivirgata*), banded Malaysian coral snake (*Maticora intestinalis*), small-spotted coral snake (*Maticora maculiceps*), and black coral snake (*Maticora nigrescens*). The *Maticora* species and certain *Hemibungarus* species are by some authors newly placed in the *Calliophis* genus.

Other names: Oriental coral snakes (*Calliophis*), barred coral snake (*Hemibungarus calligaster*), long-glanded coral snake (*Maticora*). Beddome's coral snake (*Maticora beddomei*). JA: Iwasaki-Wamon-Beni-Hebi (*H. macclellandi*), Hyan, Amami, Hai (*H. japonicus*). Indonesia: Ular matahari (*M. intestinalis*).

Description: These are primarily small and slender bodied snakes 30-60 cm long, which live underground (*Calliophis*, *Hemibungarus*) and above ground (*Maticora*) with largely nocturnal activity. The largest members are the 90-cm-long *H. maclellandi* and the spectacular *M. bivirgata*, with a maximum documented length of 185 cm. *Maticora* snakes possess large venom glands that may comprise up to two thirds of their body.

Many species of the above genera above are quite rare or remain somewhat a mystery. It is possible to describe them as shy and non-aggressive creatures with some exceptions.

Home range and habitat: Asian coral snakes inhabit lowlands as well as mountainous forests, scrubland, and plantations in S and SE Asia - Nepal, India, Sri Lanka, former Indochina, S China including Taiwan and the Hainan islands, S Japan, the Philippines, Malaysia, and Indonesia. *H. macclellandi* has been known to reach an altitude of 4,000 m above sea level in Nepal.

Toxins: The composition of their venoms is little known, but does contain a certain quantity of largely postsynaptic neurotoxins, enzymes of the PLA_2 type and general cytotoxic substances. In some species, venoms are considered quite effective; nevertheless, only exceptions are of potential threat to humans - *C. bibroni*, *H. kellogi*, *H. macclellandi,* and *M. bivirgata*. Based on the composition of the venom of *M. bivirgata*, these snakes are believed to be closely related to the *Hemachatus* and *Naja* genera.

Local symptoms of envenoming: Any local symptoms described only include pain and edema. According to known or presumed venom composition, deeper affection of tissues, the development of bullae or minor necrosis is possible in severe cases or following bites from certain members of the genera, but usually only a clinically insignificant localized response develops.

*Systemic symptoms of envenoming***:** For the majority of incidents, no serious symptoms of envenoming occur. Symptomatology is largely limited to less significant prodromes, such as nausea, vomiting, abdominal pain and diarrhea. Nevertheless, cases of vertigo and dyspnea have also been described, e.g. from *M. intestinalis*. The nature of the venom in some species does not preclude clinical symptoms of neurotoxicity, such as affection of facial muscles including ptosis, external ophtalmoplegia and dysarthria. More rarely, in especially serious cases, even paralysis of swallowing and respiratory muscles with fatal consequences are known relating to *M. bivirgata* and *H. macclellandi*.

Laboratory findings: Results of laboratory examinations are unknown. Any larger primary changes cannot be expected, except for probably neutrophilic leukocytosis.

*Mortality***:** Three fatal cases have been reported: a two-year-old child died 2 hours after a snakebite from *M. bivirgata* (Harrison, 1957) - the same species might be the cause of death for a man in Singapore 5 minutes following a bite (Lim-Leong-Keng et al., 1989). 8 hours after a snakebite from a young specimen of *H. macclellandi*, an adult man died from

respiratory muscular paralysis in Nepal (Kramer, 1977). The native people of Borneo have handed down information on deaths following snakebites from *Maticora* snakes.

Therapy: For first aid and general rules of treatment, see chapter 5 Snakebite: Therapy and prevention. Following a bite, application of a pressure immobilization bandage is indicated, which is not to be removed before arrival at a health facility or before more serious symptoms of systemic envenoming can be ruled out. The bandage should not be kept on the body longer than necessary due to the possibility of causing localized damage to tissues.

No specific antivenom is available. In the case of systemic symptoms following a snakebite from *C. bibroni*, application of following antivenoms is recommended:

* MONOVALENT COBRA ANTIVENOM SERUM, Central Research Institute, India;
* POLYVALENT SNAKE ANTIVENOM SERUM, Central Research Institute, India.

As cross-immunity is also possible with the venom components of the remainder of Asian elapids, other related antivenoms can be administered where strictly indicated, even in the case of envenoming by other members of the genera mentioned above.

Local findings, if more significant, will require delicate handling because of pain and the possibility of greater damage to tissues. Moderate elevation and cautious cooling is helpful.

In the instance of symptoms of systemic envenoming, observation or symptomatic treatment depending on the type and severity of the affection is advisable, see chapter 5 Snakebite: Therapy and prevention. Extremely severe progress of a case may require airway management using tracheal intubation and mechanical ventilation.

Should there be a lack of symptoms following a bite, a patient should be observed for 24 hours. Following envenomation, the patient can be discharged for home treatment after 24 hours once systemic symptoms recede.

6.3.1.4. Dendroaspis Genus, Mambas

Species: Eastern green mamba (*Dendroaspis angusticeps*), Jameson's mamba (*Dendroaspis jamesoni*), black mamba (*Dendroaspis polylepis*), and western green mamba (*Dendroaspis viridis*).

Description: Snakes of medium-size to large, they have extremely slender bodies and can grow up to 150-250 cm, with the black mamba (*D. polylepis*) even capable of 250-350 cm. The documented maximum figure of 425 cm for the black mamba makes this snake the longest venomous snake in Africa and the second longest snake in the world. The black mamba boasts coloring of an olive-brown to dark gray and has a light underside, the name deriving from the black color inside its mouth. Other mambas are varying shades of green including bright green. These snakes have a narrow head and large and distinctive eyes with round pupils. They are arboreal animals, only the black mamba primarily lives a terrestrial life in open bush country. All are active at night.

Mambas rank among the fastest snakes both as regards moving and striking when disturbed. The speed and their short-tempered behavior make them highly dangerous creatures. Anything intruding near a mamba's shelter in a hollow tree or in the bush is likely to be attacked. There have been stories of humans being bitten that find themselves in the unfortunate position of between a snake and its nest. Mambas possess excellent vision and are attracted by movement, meaning they can sometimes get into an unsafe distance from a human. Mambas bite very swiftly and then promptly fall back, with strikes sometimes being

repeated. In South Africa, the number of mamba snakebites peaks in spring - September to February, then sharply decreases in the winter.

According to some, mambas compete with the African puff adder (*Bitis arietans*) and the saw-scaled viper (*Echis carinatus*) for the dubious honor of supremacy in terms of mortality from bites in Africa. However, the incidence of snakebites as well as the aggressiveness of mambas is probably overstated.

Other names: FR, DE, AF: Mamba.

Home range and habitat: Mambas inhabit forests, savannah woodlands and bush as well as tree plantations; the black mamba (*D. polylepis*) can also be found in open bushland and semi deserts. Their home range includes E, S and Central Africa including Zanzibar Island; from north to south mambas range through S Sudan to the Republic of South Africa, while from west to east they are found from Ghana to Kenya. The western green mamba (*D. viridis*) inhabits the humid forests of W Africa, in the zone from Senegal to Nigeria.

Toxins: The black mamba's venom glands contain approximately 8-16 ml of liquid venom. In the freshly hatched young, the amount is 1-2 ml of venom, which is sufficient quantity to have a lethal effect on a human.

Primary venom components concern highly effective neurotoxins. Although curare-like neurotoxins are not a feature of the mamba, their venom contains neurotoxically acting nicotine acetylcholine receptor antagonists analogical to the postsynaptic neurotoxins of other elapids (*Elapidae*) classified as α, β, γ and δ neurotoxins. Other neurotoxins are possibly those boasting the greatest effectiveness: DTX dendrotoxins - peptides causing inhibition by blocking voltage channeled by potassium for the re-polarization of neurons, thus causing extension of the process.

This way, the substances support muscular paralysis, either at a central level or by exhausting neuromuscular junctions by super-threshold stimulation. The effect of DTX is very probably manifest on the vegetative nerves as well. A number of peptides isolated from mamba's venom potentiate neurotransmission in the CNS as well as in peripheral nerves. They are limited only to the mamba's venom outfit. The peptides, acting as muscarine acetylcholine receptor ligands, may probably cause activation in the CNS. Fasciculins are peptide acetylcholinesterase inhibitors increasing the intrasynaptic amount of acetylcholine, which results in fasciculation of muscles. Dendroaspin natriuretic peptide DNP is a polypeptide analogous to the human atrial natriuretic peptide; it is responsible for causing diuresis through natriuresis and dilating the vessel bloodstream, which results in, among other things, acceleration of venom distribution in the body of the victim. A certain proportion of cardiotoxic components is also possible. The venom displays relatively high activity in terms of hyaluronidases, which is also essential in facilitating propagation of venom components.

Hemolytic, hemorrhagic, and coagulation activities are almost lacking in mamba's venom.

Local symptoms of envenoming: A mamba's (*Dendroaspis*) fangs are embedded in the maxilla, i.e. the upper jaw, rather in the anterior part; they form the only maxillary teeth. In the mandible, i.e. the lower jaw, there is a row of relatively massive non-venomous teeth. This can provide a typical mamba bite pattern provided the attack is complete. Indeed, the fangs may sometimes remain in the wound. Multiple bite wounds can be carried out depending on the nature of the attack. The wound is not very distinctive and pain in form of burning is quite low. Bleeding may occur from the bite wounds. Only minor redness tends to

appear around the bitten site, followed by moderate localized edema. Localized pain, inflammation, stiffening, and hypoesthesia, i.e. reduced sensitivity, will persist over a week.

Systemic symptoms of envenoming: Symptomatology, even highly serious, will often manifest very early on - within ten minutes. This will mostly begin with prodromes like nausea, vomiting, and abdominal pain. The envenoming process may continue with paleness, goose pimples (cutis anserina), sweating - even profusely, irritation to the throat and a potential cough, conjunctiva congestion (hyperemia), feelings of heat, photodysphoria and more intense sensation of light, vertigo, ataxia (affection of coordination), somnolence and languor, or conversely excitation and agitation through to loss of consciousness. Vascular and cardiac symptoms can occur, from acral chills all the way up to circulatory collapse, including peripheral vasoconstriction.

Neurological symptoms mostly start with cranial nerves being affected and muscular fasciculations of limbs or a trembling sensation in the face or around the body. Muscular dysfunctions are manifest as ptosis, ophtalmophlegia including unfocused, fuzzy or double vision with non-reactive mydriasis and subsequent inability to move the eyelids and balls. Dysphagia arises, sometimes including painful swallowing, and continues with paralysis of soft palate and swallowing muscles accompanied by loss of the swallowing reflex and a risk of aspiration of saliva or stomach content. Movements of the lower jaw and ability to lift the head cease. The face takes on the look of a mask. Sensation in the area of affected nerves is retained. A general sense of weakness through to loss of muscle strength in limbs occurs, as does a urinating disorder or failure - sometimes even before respiratory muscles are affected. Paralysis of respiratory muscles associated with possible affection of the respiratory centre causes a decrease in respiratory frequency and respiratory failure. Respiratory failure results in death if not adequately treated.

Laboratory findings: The results of laboratory examinations are not specific for envenoming.

Mortality: In untreated cases, lethality is near 100%, whilst for envenomings that are treated adequately and promptly, it can be almost zero (McNally, 1987; Warrell, 1995). Among native populations in the home range of the snakes, mortality is expected to be very high.

Therapy: For first aid and general rules of treatment, see chapter 5 Snakebite: Therapy and prevention. Immediate application of a pressure immobilization bandage is always fully indicated. The bandage must not be removed before arrival at a health facility capable of dealing with potentially serious symptoms of muscular paralysis. If envenoming is proven, the bandage is preferably removed only after application of antivenom, if available, or following one hour of observation without symptoms.

Applicable antivenoms:

* SAIMR POLYVALENT SNAKE ANTIVENOM, SAIMR, the Republic of South Africa (*D. polylepis*, *D. jamesoni*, *D. angusticeps*, etc.);
* FAV-AFRIQUE, Aventis Pasteur, France (*D. polylepis*, *D. jamesoni*, *D. viridis*, etc.).

If the envenoming has already developed, a larger quantity of the antivenom should be administered - up to 16-20 vials are recommended; the first 50 ml should be followed by additional vials every 30-60 minutes until serious symptoms abate.

There is only a minimal local affection that will not require any special treatment.

Swallowing and respiratory muscular paralysis will require airway management using tracheal intubation and mechanical ventilation if manifested clinically with subsequent risk of aspiration and respiratory failure. The same necessity arises in cases of a likely more serious disorder of consciousness, where a risk of insufficient passability of airways or aspiration may occur, principally for weakened swallowing and cough reflexes.

Nevertheless, consciousness is often retained even if muscular paralysis fully develops, therefore, sedation of the patient is desirable in the course of therapy, including managed ventilation.

Despite some recommendations, administration of cholinesterase inhibitors, like edrophonium or neostigmine, is not indicated due to the possibility of potentiating the effects of fasciculins.

Following successful therapy of the envenoming, the patient is detained another 12-24 hours in an intensive care unit and discharged during the following day for home treatment.

6.3.1.5. Naja Genus, Cobras

African species. Anchieta's cobra (*Naja anchietae*), snouted cobra (*Naja annulifera*), banded Egyptian cobra (*Naja haje*), Katian spitting cobra (*Naja katiensis*), black and white cobra (*Naja melanoleuca*), Mozambique spitting cobra (*Naja mossambica*), black-necked spitting cobra (*Naja nigricollis*), Cape cobra (*Naja nivea*), and Nubian spitting cobra (*Naja nubiae*), African cobra (*Naja pallida*).

Asian species. Chinese cobra (*Naja atra*), monocellate cobra (*Naja kaouthia*), Indian cobra (*Naja naja*), Central Asian cobra (*Naja oxiana*), *Naja mandalayensis*, Philippine cobra (*Naja philippiensis*), *Naja sagittifera,* Peters' cobra (*Naja samarensis*), Indochinese spitting cobra (*Naja siamensis*), Indonesian cobra (*Naja sputatrix*), and golden spitting cobra (*Naja sumatrana*).

Description: Cobras of the *Naja* genus are medium-sized snakes, with *N. atra* and *N. katiensis* 100-130 cm long, *N. kaouthia*, *N. annulifera* and *N. nivea* about 200 cm long. The length of 269 cm and weight of 3.2 kg for a *N. melanoleuca* is the documented record-breaker. At the same time, this largest member of the genus is considered by some herpetologists as the brainiest of all African elapid snakes. Cobras have a typical method of deterrent or position of attack, whereby the anterior part of the body is lifted up and the ribs expanded, forming a so-called hood, which makes the snake optically larger in front of an intruder. The dorsal coloring is diverse, ranging from black and gray through to a creamy brown or tones of red or yellow, including the typical speckled (*N. atra*, *N. kaouthia* or *N. naja*) or banded (*N. annulifera*, *N. melanoleuca* or *N. nigricollis*) pattern of some species. Cobras are relatively quick snakes, be it when moving or striking. Essentially, they are not typically aggressive snakes, preferring to escape, as do most snakes; however, they can carry out swift and targeted attacks if acutely threatened. These snakes are mostly night hunters, but diurnal activity is not unusual, particularly for young individuals or when temperatures are lower.

The structure of the venom apparatus, which features an open channel in the front part of the fang, allows some cobra species to defend themselves by what appears to be spitting the venom. In fact, this kind of action is not really spitting as the venom is discharged under pressure by anterior openings in fangs, resulting in microscopic droplets being sprinkled over a distance of approximately 2-4 m. This is dangerous if a face, or more particularly the eyes, of an intruder become the target, which is the snake's intention. Amongst the African cobras,

this ability is employed by *N. katiensis*, *N. mossambica*, *N. nigricollis,* and *N. pallida*; whereas for the Asian cobras, this method is used by *N. mandalayensis, N. philippiensis*, *N. siamensis*, *N. sputatrix* and *N. sumatrana*, and more rarely by *N. atra* and *N. samarensis*.

Other names: EN: Egyptian, Arabian, banded, brown, Angolan or snouted cobra (*N. haje*, *N. annulifera*). Mali or West African spitting cobra (*N. katiensis*). Forest cobra, black and white-lipped or black cobra (*N. melanoleuca*). EN: Mozambique spitting cobra; indigenous language: m'Fezi (*N. mossambica*). EN: black, black-necked or spitting cobra (*N. nigricollis*). Cape or yellow cobra (*N. nivea*). African or red spitting cobra (*N. pallida*). Chinese or Taiwan cobra (*N. atra*). Monocellate, common, Thai cobra, Andaman cobra (*N. sagittifera*, *N. kaouthia*). EN: Asian, Indian spectacled cobra (*N. naja*). Central Asian, Oxus cobra (*N. oxiana*). Visayan, Peter's cobra (*N. samarensis*). Indochinese, Indonesian, Malayan spitting cobra (*N. siamensis*, *N. sputatrix*). Golden, equatorial spitting cobra (*N. sumatrana*). FR: Cobra, Serpent à lunetes (*N. kaouthia*).

*Home range and habitat***:** In *Africa,* cobras (*Naja*) are found all across the continent except the Sahara and several other inhospitable localities. They tend to prefer more arid habitats, such as open savannahs, bush, open woodland and plantations, but always in close proximity to water.

* *Naja annulifera*: grassy savannahs and bush, sometimes near water surfaces in SE Africa, northwards to S Angola and northern Mozambique.

* *Naja haje*: savannahs, bush, open woodlands and plantations in N Africa from Morocco to Egypt; in S Sahara from Senegal and Mauritania to Somalia; to the east as far as Uganda and N Tanzania.

* *Naja katiensis*: dry savannahs in W Africa from Senegal as far as Central Nigeria and W Cameroon.

* *Naja melanoleuca*: the woodland areas of W and Central Africa from Senegal to Angola; eastward from Somalia to Zambia, as well as the islands of Zanzibar and São Tomé.

* *Naja mossambica*: savannahs and bush in SE Africa from S Tanzania and Angola as far as S Africa, as well as the islands of Zanzibar and Pemba.

* *Naja nigricollis*: bush and open woodlands in Sub-Saharan Africa from Senegal to SW Somalia, and from E Africa to the west of the Republic of South Africa. Local occurrence documented in Egypt as well (Rehak, Osborn, 1988).

* *Naja nivea*: arid areas of the western part of S Africa.

* *Naja pallida*: semi desert regions in NE Africa from S Egypt to NE Tanzania.

In *Asia,* the *Naja* genus cobras inhabit a vast area bordered by the eastern coast of the Caspian Sea to the west, by Nepal and S China to the north, by Sri Lanka and Malaysia to the south and by the Philippines to the east. They dwell in diverse habitats from arid and rocky regions of Central Asia as far as muddy areas and humid forests of SE Asia.

* *Naja atra*: sparse vegetation including fields and plantations in SE China, NE Laos, N Vietnam, Hainan, and Taiwan.

* *Naja kaouthia*: rather humid sites, in mountains they are found up to 1,600 m above sea level in NE India, SE Nepal, Bangladesh and SW China; the range continues to the south across the former territory of Indochina and Malaysian islands to the Andaman Islands.

* *Naja naja*: grassy and rather farm areas including fields, and in the neighborhood of settlement in E Pakistan, S Nepal, India, Sri Lanka and W Bangladesh. In the Himalaya, the range can extend up to the altitude of 4,000 m above sea level.

* *Naja oxiana*: rather arid and rocky areas and localities with sparse vegetation in NE Iran, S Turkmenistan, S Uzbekistan, W Tajikistan, Afghanistan, N Pakistan and N India.

* *Naja philippiensis*: forests of the islands of Luzon, Mindoro, Masbate and Marinduque, the Philippines.

* *Naja samarensis*: forests of the islands of Bohol, Leyte, Mindanao, Samar and Camiguin, the Philippines.

* *Naja siamensis*: rather humid habitats including rice fields and bamboo stands in Thailand, Cambodia, S Vietnam, W Laos and E Burma.

* *Naja sputatrix*: rather humid habitats, swamps, rice fields and forest edges in Indonesia – the islands of Java, Bali, Lombok, Sumbawa, Komodo and Flores as far as Lomblen.

* *Naja sumatrana*: forests and jungles in S Thailand, Malaysia, Singapore, Sumatra and Borneo as far as the Palawan Islands, the Philippines.

Toxins: The effectiveness of venom in the *Naja* genus, expressed as LD_{50} for mice, differs among the individual species and is possibly determined by the content of neurotoxins. The venom of *N. philippiensis* with LD_{50} for mice, 0.14 mg/kg of body weight, is probably the most effective. Values already described for venoms of other species per kg of body weight include 0.29 mg for *N. naja*, 0.49 mg for *N. oxiana*, 1.75 mg for *N. haje,* and 3.05 mg for *N. nigricollis*.

Neurotoxins and necrotizing components principally comprise the clinically effective venom substances. The proportional representation of these components determines the possible process of envenoming, where either neurotoxic symptoms (*N. philippiensis*) prevail or localized ones as extreme as excessive necrotic symptoms (*N. nigricollis*, *N. mossambica*). Nevertheless, neither development of necrosis nor neurotoxic symptoms can be precluded following a bite from any of the *Naja* cobras; essentially, the neurotoxic *N. phillipiensis* produces necrosis in 8% of cases, while *N. nigricollis* and *N. mossambica* primarily cause severe necrosis, although there is a low incidence of neurotoxic symptoms that pose a threat to children in particular.

Neurotoxins are largely proteins that produce postsynaptic anti-depolarization blockages. These α-neurotoxins are presented in the form of molecules with both long and short chains, see also chapter 3. 3. 2. 2 Venom components with neurotoxic activities. These are venom components found in all cobras of the *Naja* genus, but they form a fundamental and clinically significant proportion of the venoms in *N. philippiensis*, *N. naja*, *N. atra*, *N. kaouthia*, *N. sumatrana*, *N. haje*, *N. melanoleuca*, *N. nivea,* and possibly *N. oxiana*. The venoms of some cobras, e.g. *N. atra*, *N. kaouthia* and *N. sumatrana*, *N. haje*, *N. melanoleuca*, *M. mossambica*, *N. nigricollis,* and *N. nivea*, also contain presynaptically acting neurotoxic PLA_2. However, the clinical effect of these substances on a human is minimal or does not become manifest (*N. nigricollis*).

Even though the venoms of cobras of the *Naja* genus are generally lower in enzymes than those of viperids (*Viperidae*), namely in locally effective proteinases, they contain cytotoxic components causing serious localized damage - mostly necrosis. The necrotizing effect of the venom can be explained by the function of polypeptidic cytotoxins, locally and myotoxically

acting PLA_2, complements of activating substances, hyaluronidase, and a number of other venom components - largely enzymatic types.

Cardiotoxically acting substances - cardiotoxins - are components with the status of polypeptidic cytotoxins and membrane toxins, which produce irreversible damage to myocardial cells. Clinically, they can cause dysrhythmia, hypotension, and death.

The venoms contain components activating the complement via an alternative route: the venom of the black-necked spitting cobra (*N. nigricollis*), contains PLA_2 with an anticoagulation effect and hemorrhagic enzymes.

Local symptoms of envenoming: The bitten site will mostly display only minor wounds - at the beginning, any bite wound or scratching by an infant may not be noticeable at all. In the majority of cases, the bite is accompanied by immediate pain, which persists for several days. In some cases, severe pain may continue over the period of up to 10 days, e.g. *N. sumatrana*, while in other cases, numbness may tend to occur at the bitten site, such as caused by *N. melanoleuca*. Localized edema begins to develop 2-3 hours after the bite, typically peaking at around day 2 or 3. The edema will mostly affect only the bitten limb, but severe advancing edema may expand up to the torso, this is true except for a bite from *N. philippiensis*, which is not usually accompanied by edema. Regional lymphadenopathy develops including a feeling of strain or pain from enlarged regional lymph nodes.

Skin in the affected area darkens; peeling and sometimes ecchymoses can occur. By approximately day 3, blisters start to form, frequently with red and yellow necrotic or blood content. Additionally, necrosis develops in the skin, under the skin and in deeper tissues of the affected area, reaching as far as the tendons. Despite this, serious damage to muscle tissue and tendons is not a frequent occurrence. The process of tissue necrotization is accompanied by a putrid smell. Thrombosis and microthromboses, which sometimes form at the site of localized affection, can potentiate the extent of necrosis through perfusion disorders. Even formation of a deep venous thrombosis in the affected limb has been described.

Approximately in a half of cases, the necrotic tissue is affected by secondary infection involving generated phlegmons and fever. Bacteriological agents typically isolated include *Proteus rettgeri*, *P. morgani*, *Escherichia coli*, *Pseudomonas aeruginosa*, *Salmonela* sp., *Enterobacteriacae,* and *Staphylococcus aureus*.

Tissue destruction requires long-term treatment and may result in scarring as well as arthral damage as serious as ankylosis or limb deformation. The need to amputate is also possible, plus relapses of the affection may be triggered. Severe local damage with the development of excessive necrosis is typical for snakebites from the following African cobra species: *N. katiensis*, *N. mossambica*, *N. nigrocollis,* and *N. pallida*; for Asian species this concerns *N. atra*, *N. kaouthia,* and *N. sumatrana*. 40% of bites from the Chinese cobra (*N. atra*) will result in necrosis, with persisting dysfunction of limbs in 10% of those affected.

Effect on eyes. Venom droplets impacting on an eye will be immediately followed by severe pain, with subsequent blepharospasm, lacrimation, edema of the eyelid, fuzzy vision, conjunctivitis, conjunctival chemosis, a white discharge and inflammatory affection of the cornea - keratitis. Further developments, especially if treatment is inadequate, result in generating corneal ulcerations, frontal uveitis and panophtalmitis with consequent blindness, although attacks by Asian cobras do not result in such serious affection. Symptoms of systemic envenoming do not arise in this way; in rare cases, venom may be transferred from the conjunctival sac via lymph pathways to the distal parts of nervus facialis and thereby affect the function of this nerve.

Systemic symptoms of envenoming: Incidence of systemic envenoming following bites from the cobras of the *Naja* genus vary according to author and species, ranging from very low, i.e. 15% - 45% in the Malayan region (*N. kaouthia*, *N. sputatrix,* and *N. sumatrana*), up to an extreme of 97% following a bite from *N. philippiensis*.

The process of envenoming mostly commences with the following prodromes: nausea, vomiting, abdominal and cranial pain, hot skin and a sensation of the mouth being dry, increased temperatures, salivation, redness or paleness to the face, sweating and vertigo.

These prodromal symptoms may soon be followed by symptoms of circulatory or neural tissue affection, i.e. hypotension, reduced heartbeat, ataxia, and consciousness disorders, such as restlessness, euphoria or disorientation, fatigue, somnolence, and potential loss of consciousness; the latter of these symptoms can be also caused or potentiated by severe hypotension leading up to a status of shock.

The main symptom of severe systemic envenoming in the majority of cobras of the *Naja* genus involves that of neurotoxicity. Clinically significant affection of neuromuscular junctions will become manifest especially with envenomings by *N. philippiensis*, whose venom largely contains neurotoxins, with the proportion of neurotoxic symptoms to development of necrosis being 14:1. As regards Asian cobras, this concerns *N. naja* and *N. kaouthia*, where the neurotoxicity-necrosis rate is reversed: 1:3.7 (Davidson et al., 1995). In Africa, neurotoxicity is presented namely due to a bite from *N. haje*, *N. melanoleuca* and *N. nivea*. For the rest of cobra species, severe neurotoxic symptoms are less frequent or not described despite the proven existence of neurotoxic components.

In the area of cranial nerves, neurotoxic symptoms mostly start with ptosis, external ophtalmoplegia with dizziness or double vision, palatal and glossopharyngeal paralysis including dysphagia, dysarthria and excessive salivation, and an inability to open the mouth and stick out the tongue. Unilateral or bilateral auditory failure can also occur. The process continues with weakness of neck muscles, meaning the head is not controllable and droops, weakness of limbs including loss of reflexes and respiratory failure accompanied by shallow diaphragmatic breathing when the respiratory muscles are weakened. Without any treatment, death occurs due to respiratory failure associated with limited paralysis of striated muscles, i.e. including respiratory muscles, and all this is in full consciousness. In some cases, muscular fasciculations, spasms or tremors occur during the development of the neural affection. The neurotoxic symptomatology typically continues to evolve through to respiratory failure for duration of several hours. However, in the case of severe envenoming by highly effective neurotoxic venom (*N. philippiensis*, *N. melanoleuca,* and *N. kaouthia*), neuromuscular affection or the non-functioning of respiratory muscles is likely to occur 3-30 minutes following a bite. The commencement of neurotoxic symptoms after 24 hours in *N. philippiensis* is the extreme reverse of this situation. Muscular paralysis mostly persists for 2-3 days, but may do even more - for up to 14 days.

Envenomation by the majority of *Naja* cobras means that cardiotoxicity is not a major clinical issue, although its progress involving severe hypotension and heart arrhythmias or shock is possible. However, the effects of cardiotoxic components are largely limited to slight hypotension and the presence of reversible abnormities in ECG with elevated ST-segment and T wave inversion, which usually abate within a week, e.g. in *N. naja*.

An effect on hemocoagulation is not typical for envenomings by *Naja* cobras, but sometimes it may occur following a bite from some African cobras, for instance *N. nigricollis*; the incidence of which is about one third of those affected. The disorder is

typically either that DIC-like or hemolytic, and is manifest as bleeding from the nose, gums, and wounds. Even fatal subarachnoid hemorrhaging has occurred (Warrell, 1976).

Venom components in some cobras with largely cytotoxic venoms, like *N. nigricollis*, may also cause hepatocellular affection with subsequent jaundice and elevated hepatic enzymes.

Renal affection is rare and limited to proteinuria and microscopic hematuria. Any level of potential hemolysis is clinically insignificant too.

Laboratory findings: Laboratory findings are not specific for envenomings. Leukocytosis typically occurs - up to 30,000/mm^3 (*N. nigricollis*). A decrease in Hct will accompany hemorrhagic complications or hemolysis; decreased PLT and increased FDP may indicate consumption coagulopathy. In patients envenomed by cytotoxic venom components (*N. nigricollis* and *N. atra*) and displaying development of necrosis, hepatocellular affection occurs with increased bilirubin, ALT and AST. Temporarily, urobilinogen in urine will be found. Insignificant proteinuria, hemoglobinuria or microscopic hematuria also occur.

Mortality: Snakebites from the cobras of the *Naja* genus are believed to cause thousands of deaths of people in Asia and Africa. Although such a statement as this is exaggerated, envenomation by these snakes in their home range is epidemiologically significant, accounting for something like 25% of fatalities of all cases of envenoming in Thailand. Out of 47 snakebites from *N. sumatrana*, two resulted in death. As regards the Chinese cobra (*N. atra*) in China, responsible for a high incidence of cases, mortality is low - a mere 0.7%; in Taiwan, fatal cases were recorded in 14% of all cases in 1904-1971. In the home range of the Central Asian cobra (*N. oxiana*) of Iran and surrounding countries, from where information is rather incomplete, mortality is expected to be caused by neurotoxicity (Warrell, 1995). Mortality caused by the Indonesian cobra (*N. sputatrix*) is also presumed, most likely affecting children. Numbers concerning mortality following bites from the Indian cobra (*N. naja*) in India are very high, accounting for 50% - 70% of the victims being hospitalized, which includes patients treated with antivenoms.

In Africa, fatalities after snakebites from the black and white cobra (*N. melanoleuca*) and black-necked spitting cobra (*N. nigricollis*), with the development of pulmonary edema or bleeding into the brain have been reported. A higher mortality has also been observed following snakebites from the banded Egyptian cobra (*N. haje*). Out of 10 cases of envenoming after a bite from *N. nivea*, only a single case proved fatal.

Therapy: For first aid and general rules of treatment, see chapter 5 Snakebite: Therapy and prevention. Although disputed due to potential deterioration to local damage, putting on a pressure immobilization bandage is indicated following a bite from the majority of *Naja* cobras, especially those with significant content of neurotoxins in their venom - *N. haje*, *N. melanoleuca*, *N. nivea,* and Asian cobras of the *Naja* genus. The pressure immobilization bandage may delay any severe neurological symptomatology by up to 30 hours. The bandage is not recommended following bites from African spitting cobras with venoms that do not show neurotoxicity clinically, but cause excessive necrosis (*N. nigrocollis*, *N. mossambica*).

In nearly a half (42%) of those envenomed by *N. philippiensis*, neurological symptoms appeared due to neurotoxins released by removing the bandage. The bandage should not be removed before arrival at a health facility capable of dealing with potentially serious symptoms of muscular paralysis. If envenoming is proven, the bandage should be removed only after application of antivenom, if such is available.

Should no symptoms be displayed, the bandage may be removed following an hour of observation. Any administration of opioid analgesics as a part of first aid is relatively contraindicated as a result of loss of respiratory efforts and intensified respiratory failure caused by developing paralysis. The patient must be observed and discharge from hospital is possible following 24 hours of no symptomatic development.

The list below shows applicable *antivenoms against venoms of African cobras of the Naja* genus.

Naja haje:

* ANTIREPT PASTEUR, Aventis Pasteur, France;
* FAV-AFRIQUE, Aventis Pasteur, France;
* FAVIREPT, Aventis Pasteur, France;
* IPSER AFRIQUE PASTEUR, Aventis Pasteur, France;
* SERUM ANTIVENIMEUX BITIS ECHIS NAJA PASTEUR, Pasteur Merieux, France.

Other African Naja cobras:

* SAIMR POLYVALENT SNAKE ANTIVENOM, the Republic of South Africa;
* FAV-AFRIQUE, Aventis Pasteur, France.

If an envenoming has already commenced, a larger quantity of antivenom is administered, with up to 10-20 vials recommended; the first 3 vials, i.e. 30 ml, should be followed by additional doses every 30-60 minutes until the serious symptoms abate.

The list below shows applicable *antivenoms against venoms of Asian cobras of the Naja* genus.

Naja atra:

* ANTIVENIN BUNGARUS MULTIC. AND NAJA NAJA ATRA, Nat. Inst. Prev. Med., Taiwan.

Naja kaouthia:

* COBRA ANTIVENIN, Thai Red Cross, Thailand.

Naja naja:

* LYOPHILISED ANTI-SNAKE-VENOM SERUM Haffkine, India;
* MONOVALENT COBRA ANTIVENOM SERUM, Central Research Institute, India;
* POLYVALENT SNAKE ANTIVENOM SERUM, Central Research Institute, India;
* SNAKE ANTIVENIN I.P., Haffkine, India.

Naja sputatrix:

* COBRA ANTIVENIN, Thai Red Cross, Thailand.
* ANTIVENIN POLYVALENT, Bio Farma, Indonesia;
* NAJA NAJA SPUTATRIX, Twyford, Germany.

Specific antivenoms for counteracting venoms of other *Naja* cobras are not available. If necessary, some of the above-mentioned preparations can be used, preferably the polyvalent forms effective against *Naja naja*.

Again, a higher quantity of the antivenom is applied - up to 100 ml, but even as much as 450-600 ml. Naturally, such high a dosage is associated with a higher incidence of allergic reaction.

Respiratory insufficiency may occur even upon administration of adequate antivenom, however, with a shorter period of persistence of the insufficiency. If antivenom is applied only upon development of neurotoxic symptomatology, its effectiveness is reduced, in some cases of affected tissues, e.g. *N. nigricollis*, no positive effect may become manifest.

Slight elevation and moderate cooling of the affected limb is desirable; pain should be dimmed by analgesics. Any handling and treatment actions must be carried out delicately with a view to avoiding a potentially high level of tissue damage. Development and persistence of excessive edema may cause compartment syndrome to a certain extent; the syndrome is subsequently co-responsible for forming and propagating necrosis. Measuring compartment pressure is advisable; the values should not exceed 45 mmHg (6 kPa, 60 cm H_2O). Fasciotomy is indicated in the case of risk of closed tissue perfusion in any increase in compartment pressure or any pulsation closure. Naturally, the points of tight compartments and surroundings of finger joints are primarily exposed to the risk of necrosis forming.

The developed necrosis must be immediately removed surgically, which will reduce the risk of more severe localized infection. Timely implantation of skin to the points of removed necrosis will speed up the healing process. Any possible abscesses and fluctuating points are incised, evacuated and drained. Even though prompt administration of a sufficient amount of antivenom will neither prevent nor reduce the severity of any local tissue damage, it can possibly reduce propagation of edema and thus the probability of compartment syndrome with subsequent necessity for fasciotomy.

If at all possible, affected eyes should be rinsed with a stream of clean water, but more preferably by a physiological saline solution. Milk is an alternative due to a possible link between some venom components to its proteins. Pain can be eased by instillation of local anesthetics into the conjunctival sac. Treatment of affected eyes - administration of corticosteroids and antibiotics - should be managed by an eye specialist to minimize any secondary damage of more seriousness.

Swallowing and respiratory muscular paralysis will require airway management using tracheal intubation and mechanical ventilation if manifested clinically with a subsequent risk of aspiration and respiratory failure. The same necessity will arise in cases of potentially more serious consciousness disorders, where a risk of insufficient passability of airways or aspiration may occur, namely in instances of diminished swallowing and cough reflexes. Nevertheless, consciousness is typically retained even when muscular paralysis fully develops. Therefore, sedation of the patient is desirable in the course of therapy, with mechanical ventilation.

Symptomatic treatment must tackle the most serious symptom of muscular paralysis - dyspnea, and this is carried out by airway management using tracheal intubation and subsequent mechanical ventilation. This procedure is essential as it brings down the mortality rate of envenomings to a minimum. In symptoms of neuromuscular paralysis, inhibition of acetylcholinesterase using 10 mg of edrophonium IV (in children, 0.25 mg/kg of body weight) is indicated to test the positivity of the effect. This is followed by administering

neostigmine, at a dosage of 0.5-1.0 mg IV (10-15 μ/kg of body weight), with premedication by atropine, 0.5 mg IV (50 μ/kg of body weight). The dose can be repeated following 30-60 minutes. Instead of individual doses in form of bolus, infusion can be applied following the initial dose at a rate equal to a dose of neostigmine of 25 μ/kg/h. The procedure is indicated in instances where antivenom is administered, as it will significantly reduce the period of neuromuscular paralysis, which can persist for up to 7 days despite specific therapy. Muscular paralysis and respiratory insufficiency will abate spontaneously over the course of time without any further effects.

Any possible arrhythmias caused by cardiotoxins may recede following antivenom being given or the same are treated symptomatically. Reduced pressure, including a possible state of shock, will require volumoexpansion and vasopressoric treatment. In serious cases, a contractility disorder is possible with the necessity of β -mimetic support of the myocardium using dobutamine.

Discharge of the patient is advisable only 24 hours after the symptoms of systemic envenoming and more severe forms of localized damage have disappeared. Treatment of any minor or regressing localized affections can be completed in form of outpatient therapy.

6.3.1.6. Ophiophagus Genus

Species: A monotypic genus containing a single species, the king cobra (*Ophiophagus hannah*). The former subdivision to subspecies, i.e. *O. h. borneensis*, *bungarus*, *elaps*, *sinensis*, *vittata*, *brunnea* and *nordicus* is not valid anymore.

Description: The king cobra (*O. hannah*), is the largest venomous snake. It can grow to over 570 cm, the maximum being 600 cm although this has never been documented. Coloring is shades of gray and brown through to olive, the throat and ventral part of the neck are yellow. Sub-adult animals usually have darker bodies and light crossing stripes. A typical feature is an upright fighting and defensive position of the anterior part of the body with a spread hood. This way, a fully adult and well developed example can easily match the height of a human. Any aggressiveness associated with these creatures is unfounded - bites are rare. Of this low incidence affecting humans, the majority result from handling snakes or were caused by the creatures becoming irritated. The king cobra is principally a diurnal animal, hunting almost exclusively snakes and lizards. It will mostly bite the prey, holding it in its mouth until immobilized or dead. A long-held bite may occur to a human as well.

Other names: FR: Cobra royal; other languages: Hamadryad.

Home range and habitat: The king cobra inhabits dense tropical forests, bamboo grooves, mangroves, as well as plantations and open landscapes near water in the Indian Peninsula from E Pakistan and Nepal to Sri Lanka, and almost the entire territory of SE Asia from southern Chinese provinces - approximately to the 25th degree of northern latitude - including the islands of Hainan and Taiwan as far as Malaysia, Indonesia and some of the Philippine islands. In the Himalayas, their range can extend up to an elevation of 1,800 m above sea level.

Toxins: The venom apparatus of the king cobra - the fangs and the venom gland - is impressive and the amount of venom large, according to the size of the snake. The greatest amount of venom collected was equal to 900 mg in dry weight. LD_{50} for mice amounts to 1.73 mg/kg of the body weight.

The main effective components of the venom concern postsynaptic neurotoxins with a high binding affinity to nicotine acetylcholine receptors. Out of a number of isoforms with a long molecule, the neurotoxin identified as toxin b tends to be the most toxic example.

Other components include enzymes of PLA_2 type acting as cardiotoxins. In a trial carried out on mice, these caused the following ECG-abnormities: bradycardia, prolongation of the PR-interval, extension of QRS-complex through to a complete AV-block.

In terms of hemocoagulation-affecting substances, the venom contains a serine protease specifically activating X factor, which lacks a direct effect on prothrombin and FBG, PLA_2 with inhibiting impact on PLT, lectin ophioluxin acting as a potent PLT-agonist (the first toxin to be isolated from an elapid venom), enzymatic Hannahpep which causes fibrino(geno)lysis, and others. Laboratory findings are described as consumption DIC-like syndrome with decreased FBG, α2-antiplasmin and AT activity, and increased FDP; nonetheless, envenoming has not been manifest by a more serious affection of hemocoagulation clinically.

Furthermore, the venom contains components affecting the complement via an alternative route as well as hemorrhagic substances, for instance hannahtoxin, which is a metalloprotease.

Despite the large number of enzymatic components contained in the venom of the king cobra (*Ophiophagus*) the cytotoxic and necrotizing components are less active than those of *Naja* cobras.

Local symptoms of envenoming: Pain is felt at the bitten site very early on; edema is mostly of medium size and affects only the given limb. However, excessive edema may appear, spreading to the torso or to the neck via regional lymph nodes. Ecchymoses, erythemas and bullae are formed in the course of further development of the local affection, followed by necrosis of a minor size and extent from day 2 to 4, but only affecting some individuals so envenomed. *Proteus vulgaris* has grown repeatedly from infected wounds..

Systemic symptoms of envenoming: The technique of the bite by the king cobra, with its longer bite and method of venom delivery by 'chewing' increases the likelihood of envenomation. Based on the description of 35 snakebites, envenoming occurred in 33 cases, with 2 lacking any symptoms, meaning the rate of envenoming is very high.

Symptoms of systemic envenomation commence with the following prodromes: nausea, vomiting, abdominal and cranial pain, sweating, paleness to the skin and conjunctival perfusion, which can be followed by haziness, hypotension as far reaching as circulatory collapse and shock. Typically, hypotension is not severe in form and largely caused by hypovolemia when edema occurs. Affection of the circulation is also possible, with significant ECG changes and the onset of arrhythmia, including the slowing down or accelerating of heart action. Clinically significant effects on hemocoagulation in the sense of hemorrhaging are typically not involved in such envenomings.

Neurological symptomatology is the most serious. Developing in the order of minutes or hours, it starts with a disorder of neuromuscular junctions of cranial nerves - ptosis, external ophtalmophlegia including unfocused or double vision, increased salivation, dysphagia, dysarthria, and facial muscle weakness, and follows as overall muscle weakness, loss of reflexes and limited paralysis of striated muscles. As the affection develops, somnolence, haziness, and other consciousness disorders may become associated; nonetheless, consciousness is typically fully retained in terms of both quality and quantity. In over a half of those affected, the envenoming process peaks within a few dozen minutes with non-

functioning respiratory muscles and a certain period of shallow diaphragmatic breathing, followed by respiratory failure.

Laboratory findings: Neutrophilic leukocytosis prevails in laboratory findings. Elevated AST, ALT, CK, and LD (dehydrogenase lactate) is possible. Blood count including PLT count is typically not affected, as are the hemocoagulation lab tests. The finding of DIC-like consumption presented in the literature has been disputed, however, it cannot be definitely precluded, primarily due to the possible syndrome occurring secondarily.

Mortality: The lethality of bites from the *Ophiophagus* cobra genus is high, ranging from one third to a half of the affected persons according to resources, which might be close to 100% if left untreated. Neurotoxicity, in some cases with subsequent rapid death in the period from a few minutes to 12 hours following a snakebite is the main cause.

Therapy: For first aid and general rules of treatment, see chapter 5 Snakebite: Therapy and prevention. Application of a pressure immobilization bandage is indicated due to the high content of neurotoxins. The bandage can significantly help delay the onset of the neurotoxin effects as long as it is not removed before arrival at health facility capable of dealing with potentially serious symptoms of muscular paralysis. If envenoming is proven, the bandage should be removed only after application of antivenom, if such is available. Should no symptoms be apparent, the bandage is removed following an hour of the observation.

Any administration of opioid analgesics as a part of first aid is relatively contraindicated as a result of loss of respiratory efforts and intensified respiratory failure caused by oncoming paralysis. Every affected patient must be observed; discharge is possible only 24 hours after no symptoms are displayed.

Applicable antivenoms:

* KING COBRA ANTIVENIN, Thai Red Cross, Thailand;
* MONOVALENT KING COBRA ANTIVENOM SERUM, Central Research Institute, India;
* POLYVALENT SNAKE ANTIVENOM SERUM, Central Research Institute, India.

Usually a large quantity of antivenom is necessary: 15-20 or even more vials. The use of 1150 ml, i.e. 115 vials, seems to be the historical maximum. The initial 2-4 vials are followed by an infusion of additional antivenom dissolved in physiological saline solution. Any positive effect is typically recorded within several hours following application; analysis carried out eleven hours upon administration of the antivenom did not detect any venom in patients' serum. Even though the muscular paralysis formed is reversible over the course of time, any need for mechanical ventilation will be greatly reduced following specific therapy.

In spite of the fact that the venom of *Ophiphagus* does not show any significant level of cross-immunity with the venoms of the *Naja* cobras, maybe only with those of *N. oxiana* and *N. kaouthia* from Thailand, antivenom against venoms of cobras (*Naja*), death adders (*Acantophis* sp.), tiger snakes (*Notechis* sp.) or sea snakes could be administered if no specific antivenom is available.

Slight elevation of the affected limb is desirable; possible pain should be diminished by analgesics. Moderate cooling is advisable. Any handling and treatment must be carried out delicately with a view to further potential damage to tissues and the possible formation of necrosis, especially at points of tight compartments, i.e. on fingers. The content of blisters and bullae is exhausted in a sterile manner; microbiological examination of the content is

advisable. Any emerging necrosis must be surgically removed, which will reduce the risk of deterioration of status by a localized infection.

Swallowing and respiratory muscle paralysis brings a subsequent risk of aspiration of the stomach content and respiratory failure and will require airway management using tracheal intubation and mechanical ventilation. The same necessity will arise in cases of potentially more serious disorders of consciousness, where a risk of insufficient passability of airways or aspiration may occur, namely in case of diminished swallowing and cough reflexes. Nevertheless, consciousness is typically often retained even when muscular paralysis fully develops; therefore, sedation of the patient is desirable in the course of therapy, with managed ventilation.

Symptomatic treatment must tackle the most serious symptom of muscular paralysis - dyspnea, and this is managed by tracheal intubation and subsequent mechanical ventilation.

Acetylcholinesterase inhibitors, edrophonium and neostigmine, have been described as inefficient. Nevertheless, due to the lack of experience with the therapy as well as the presence of postsynaptic neurotoxins and absence of neurotoxins of the depolarization type possessed by mambas (*Dendroaspis*), the treatment or its support by inhibiting acetylcholinesterase is not contraindicated and is applicable.

Any possible hypotension caused by hypovolemia in cases of extravasation into edema may be regulated by replenishing the circulating volume by infusions; rare and benign arrhythmias can be corrected symptomatically if necessary.

Should a laboratory finding reveal a hemocoagulation imbalance, re-checks until the status becomes stable will be sufficient; any rising clinical symptoms are rare and can be corrected symptomatically as well; see 5.3.3.4, 5.3.3.5 and 5.3.3.6 in chapter 5.3.3 Clinical symptoms of envenomation and symptomatic treatment.

Discharge of the patient is possible 24 hours after the symptomatology of the envenoming has disappeared.

6.3.1.7. Other Genera of African and Asian Elapid Snakes of the Former Bungarinae Subfamily

Boulengerina, water cobras. This genus includes the following species: the ringed water cobra (*Boulengerina annulata*) and the Christy's water cobra (*Boulengerina christyi*), FR: Couleuvre annulaire.

These are robust snakes in tones of brown with lengths exceeding 200 cm, mostly featuring a lighter crosswise pattern in the anterior part of the body.

With habitats strictly bound to water, these snakes live along coastal regions, in still waters and streams of W and Central Africa.

No cases of envenoming have been registered, although stories of deaths amongst fishermen on Lake Tanganyika and the River Ivindo in Gabon are spoken of.

Antivenom is not available.

Elapsoidea, venomous garter snakes. A genus containing eight garter snake species, *Elapsoidea* sp. Note a possible confusion with the *Thamnophis* genus, also called garter snakes. FR: Serpent jarretière.

The species of this genus range from small to medium-sized snakes, but exceptions can reach 100 cm in length. They are largely active at night.

These garter snakes live underground, mostly in termite structures, in arid savannahs (*Elapsoidea sundevalli*), sparse and grassy savannahs or savannah woodlands (*Elapsoidea*

guentheri, Elapsoidea laticincta, Elapsoidea loveridgei, and *Elapsoidea semiannulata*), but even in the mountainous forests (*Elapsoidea nigra*) of Sub-Saharan Africa.

Only rarely do bites occur and they will probably not prove significant; no fatalities have been described.

Following a bite, there is localized pain, edema, and lymphadenopathy including enlarged regional nodes.

Antivenom is not available.

*Hemachatus***.** A monotypic genus including a single species - the rinkhals, *Hemachatus haemachatus*; other names: ringhals, ring-necked spitting cobra; FR: Cobra cracheur d'Afrique du Sud.

Rinkhalses are snakes of a variable dark brown color, mostly featuring crosswise lighter rings and a cross strip on the neck; they can grow up to 150 cm. They are classed among the so-called spitting snakes.

These creatures inhabit grassy and sparse bush in S Zimbabwe and South Africa.

Their venom is relatively potent, even though not as venomous as that of the *Naja* cobras. In addition, the glands contain only a small quantity of venom - approximately two human lethal doses.

The progress of the envenoming, similar to that by *Naja* cobras, is less severe at both a local and systemic level. Any venom hitting the eyes is not going to result in severe permanent affection. Light localized edema and bruises come up at the bitten site. At a systemic level, the envenoming will be manifest as somnolence, nausea, vomiting, vertigo, and increased temperatures. Atrial fibrillation was recorded in an older female patient. Neurotoxicity becomes apparent very rarely as diplopia, paralysis of the tongue, dysarthria, weakness in the limbs, as well as temporary loss of consciousness and dyspnea to a certain degree.

Fatalities are uncommon, but some have been described.

*Homoroselaps***.** This genus includes the following species: the striped harlequin snake (*Homoroselaps dorsalis*), and the spotted harlequin snake (*Homoroselaps lacteus*). FR: Serpent arlequin. Formerly, they were typically placed among the colubrids (*Colubridae*) or into the *Atrastaspididae* family.

Harlequins are snakes 30-60 cm long of a dark to black color, largely boasting a longitudinal or crosswise pattern in pale to yellow hues; they are active at night.

These animals often reside in termite structures in bush and mountainous localities in southern Africa.

A lack of information exists on these snakes; a bite is extremely rare.

Two cases have involved light or medium edema, locally increased hemorrhaging, 3-4 days of lymphadenopathy and headaches.

Antivenom is not available.

*Paranaja***.** A monotypic genus consisting of a single species - the many-banded snake (*Paranaja multifasciata*); other name: the burrowing cobra.

These cobras are under 80 cm long, being snakes of a brown hue with darker striping; they dwell underground, but may also be arboreal, at least in part. They mostly range in the forests of tropical W Africa. Their venom shows neurotoxic activity, although bites are rare. None have been registered, nevertheless, knowledge has been handed down about the danger they pose. Antivenom is not available.

Pseudohaje. The genus contains the following species: the African tree cobra (*Pseudohaje goldii*) and the hoodless cobra (*Pseudohaje nigra*). Other names: tree black forest or Gold's cobra (*P. goldii*).

Pseudohaje cobras are 150-200 cm long, grow to a maximum of 270 cm and are arboreal snakes; they have a black slender body with a yellowish head and neck.

They are forest dwellers, seeking out watery environments, their home range is W to Central Africa.

Nothing is known about the venom of these snakes. No snakebite has been registered, but knowledge concerning their dangerousness and lethality has been handed down.

No specific antivenom is available; paraspecifically, SAIMR POLYVALENT SNAKE ANTIVENOM produced in the Republic of South Africa can be used.

Walterinnesia. A monotypic genus with a single species - the desert cobra (*Walterinnesia aegyptia*). Other names: black desert cobra or snake; FR: Cobra noir du désert.

These are snakes of a dark brown to black hue growing to a size of 80-100 cm, and resemble *Naja* cobras. These nocturnal snakes can be active even in very low temperatures from 10 to 12 °C. When disturbed, they do not stand upright, but tend to nestle against the ground.

They reside in sandy and rocky habitats, but even in gardens and other irrigated environments of their home range bordered by NE Egypt, W Iran, and N Saudi Arabia. Their venom contains neurotoxins and any presence of specific cardiotoxins is uncertain.

A bite will probably not cause any serious affection. Symptoms include pain and edema at the bitten site, a temperature which persists for several days, cranial pain, nausea, vomiting, tachycardia, atrial extrasystoles, weakness, and discovery of leukocytosis. All of the persons so affected recovered within several days without specific therapy. Nevertheless, lethal cases have been spoken of, whilst two fatalities from Iraq remain unverified.

A monospecific antivenom is available upon request from the Department of Zoology, Tel Aviv University, Israel.

Toxins: A lack of information on the venoms of the genera listed above exists due to their low epidemiology relevance. For some of them, a certain level of neurotoxins is possible in snakes like the *Hemachatus*, *Paranaja,* and *Walterinnesia* genera with fundamentally a postsynaptic effect; nevertheless, their potency probably does not pose any significant threat to humans. A similar status exists concerning cardiotoxic venom components (*Hemachatus*, *Walterinnesia*), hemocoagulation-affecting components (*Homoroselaps*), and locally acting cytotoxic enzymes (*Elapsoidea*, *Hemachatus* and *Walterinnesia*).

Local symptoms of envenoming: A snakebite is followed by pain, usually also by edema to a minor extent and lymphadenopathy, including enlarged regional lymph nodes. In some cases, bruising and increased hemorrhaging appears at the bitten site. More serious local damage or destruction of tissue has not been described, although they are possible in extreme cases.

Systemic symptoms of envenoming: The scope of systemic symptoms will be mostly limited to nausea, vomiting, somnolence, vertigo, weakness, and increased temperatures. Changes to the heart have been recorded, e.g. tachycardia, atrial extrasystolia, atrial fibrillation (*Hemachatus*, *Walterinnesia*) as well as lighter neurotoxicity symptoms: diplopia, paralysis of the tongue, dysarthria, weakness in the limbs, and a certain level of dyspnea (*Hemachatus*). Temporary loss of consciousness has also been described.

Laboratory findings: Except for recurrent leukocytosis, no changes in laboratory findings are known.

Mortality: Cases of lethal snakebites are rare but documented in *Hemachatus*. As for snakebites from the rest of the genera, no lethal cases are known; evidence of snake identification was insufficient (*Walterinnesia*) or any deemed fatality is merely spoken of (*Boulengerina*, *Pseudohaje*).

Therapy: For first aid and general rules of treatment, see chapter 5 Snakebite: Therapy and prevention. Application of the pressure immobilization bandage is reasonable only following a snakebite from the rinkhals (*Hemachatus hemachatus*) or the *Boulengerina*, *Paranaja,* and *Pseudohaje* snakes due to the lack of data and possible content of neurotoxins, plus if the victim is a child. The bandage should be removed only after arrival at health facility capable of dealing with potentially serious symptoms of muscular paralysis.

Administration of antivenom, if such is available - see species-specific description - is indicated only in the instance of more severe systemic symptoms.

Slight elevation of the affected limb is desirable; possible pain should be eased by analgesics. Relief is achieved by moderate cooling. As deeper damage to tissues cannot be fully precluded, namely in the points of tight compartments, any handling and treatment is carried out delicately.

Eyes affected by a strike by the spitting cobra (*Hemachatus*) are rinsed with a stream of clean water if possible, though a physiological saline solution is more preferable. Milk can be used as well due to a possible link between some venom components and its proteins. Pain can be smoothed by instillation of local anesthetics into the conjunctival sac. Treatment of affected eyes - the administration of corticosteroids and antibiotics - should be managed by an eye specialist to minimize any further serious secondary damage.

Any administration of opioid analgesics as a part of first aid is relatively contraindicated because of loss of respiratory efforts and intensified, though rare, respiratory failure.

Other symptoms of systemic envenoming, including possible arrhythmia, are of lighter nature and can be treated symptomatically where necessary - see chapter 5.3.3 Clinical symptoms of envenomation and symptomatic treatment, and in most cases they abate spontaneously.

Every affected patient must be observed. Discharge is advisable after 24 hours following the absence of symptoms or once any systemic affection has abated.

6.3.1.8. Micrurus Genus, Coral Snakes

Species: The extensive *Micrurus* genus counts approximately some 60 species of coral snakes (*Micrurus*), see chapter 7 List of venomous snakes. The number provided by resources varies due to the unsettled system of classifying some species as subspecies and vice versa. Instances of better known or epidemiologically more significant species include the eastern coral snake (*Micrurus fulvius*) including several subspecies, painted coral snake (*Micrurus corallinus*), Central American coral snake (*Micrurus nigrocinctus*), southern coral snake (*Micrurus frontalis*), South American coral snake (*Micrurus lemniscus*), and aquatic coral snake (*Micrurus surinamensis*).

Description: Coral snakes are small to medium-sized snakes, with some of them reaching a length of over 100 cm (*M. fulvius, M. lemniscatus*, *M.surinamensis*). Their bodies boast rings, mostly of black, red or yellow-white. Exceptionally, shades of blue and orange may exist. The head, mouth and fangs are small. Coral snakes are largely active at night.

They are fundamentally very shy and non-aggressive animals. Incidence of snakebites is low, with fewer than 20-25 cases a year, most of which come from direct contact in the USA. They are frequently confused with non-venomous king snakes (*Lampropeltis*), which can successfully imitate the appearance of the eastern coral snake (*Micrurus fulvius*). Snakebites are rare even in South America: in 1986-1990, 415 bites were recorded in Brazil, chiefly by *M. corallinus*, *M. lemniscatus,* and *M. frontalis*. In the same country - the State of São Paulo, 110 bites by coral snakes were recorded in 1988-93, equivalent to 1% of all cases of attacks by snakes. As a consequence of the small mouth and fangs, it is the fingers and adjacent parts of the hand that are mostly affected. Any effective discharge of venom is determined by the snake maintaining its bite and chewing.

Other names: EN: coral snake, eastern (Texas) coral snake (*M. fasciatus*); FR: Serpent corail, ES and PT: Coralillo, Coralilla, Gargantilla (Central and South America).

Home range and habitat: The *Micrurus* snakes largely inhabit diverse types of woodlands from rather arid pine, oak and denser broad-leaved forests in Central America and southern North America, e.g. *M. browni*, *M. diastema* and *M. fulvius*, as far as the humid forests of Central and South America, like *M. alleni*, *M. annellatus*, *M. frontalis*, *M. lemniscatus* or *M. nigrocinctus*. Some species prefer rather arid and shrubby habitats, like *M. tschudii*, *M. frontalis* and *M. pyrrhus*, while others seek the neighborhood of water, for instance *M. fulvius* and *M. multifasciatus*. They can be found in farmed areas, for example *M. frontalis* and *M. mipartitus*.

The home range covers a major part of the American continent, with North America inhabited by *M. fulvius* including several subspecies dwelling the southern USA and NE Mexico, and all other coral snakes ranging in Central and South America: Mexico is a home range for some 13 species, e.g. *M. bogerti*, *M. browni*, *M. diastema*, *M. elegans*, *M. ephippifer* and *M. proximans*, while regions to the south are inhabited by a whole range of other species, such as *M. dumerili*, *M. frontalis*, *M. lemniscatus*, *M. nigrocinctus* and *M. tschudii*.

Toxins: Coral snakes of the *Micrurus* genus do not possess a large venom apparatus, hence the content of the venom gland and quantity of venom are low as well. A maximum amount obtained from great coral snakes equals 20 mg of venom. Nonetheless, the venom has great potency, with neurotoxins being its fundamental and most effective components. In the majority of species, these are usually made up of α-neurotoxins, i.e. proteins bound to postsynaptic nicotine acetylcholine receptors that produce a postsynaptic anti-depolarization block (*M. frontalis*, *M. lemniscatus*). At the same time, presynaptically acting neurotoxic components are also found in some species, e.g. *M. nigrocinctus*. In South American coral snakes (*M. corallinus*), this type of neurotoxin reduces the release of acetylcholine from nerve endings of neuromuscular junctions. The neurotoxic effect can be also present in the components discovered in the laboratory that display highly intense acetylcholinesterase activity.

Other venom components, those merely described biochemically and experimentally in most cases and seeming to lack any greater clinical relevance, include myotoxins and PLA_2 with myotoxic effects capable of evoking muscle necrosis in mice. Components with cardiotoxic, hemolytic and hemorrhagic effects have only ever been found in the laboratory and that rarely, with *M. averyi* being the first ever case. The venom of coral snakes displays only a minimal level of enzymatic and necrotizing activity with a low content of proteases and somewhat higher level of phospholipases and hyaluronidases.

Local symptoms of envenoming: As already mentioned, most bites take place on fingers and the areas between them. Even in apparent envenomings, local findings are minimal - the points of bite wound are typically diminutive, and in the majority of cases, a droplet of blood can be discharged from them. Typically light edema comes up, but not always. The skin around the bitten site can lose color or conversely turn slightly red. Rare paresthesia may spread on the entire limb. Owing to the extremely low proteolytic and cytotoxic activity of venom, despite a certain hemorrhagic activity found in *M. fulvius fulvius*, snakebites from coral snakes of the *Micrurus* genus are not followed by any deeper tissue affection. Administration of antibiotics is not indicated.

Systemic symptoms of envenoming: The degree of local symptoms is never equal to the presence or quantity of venom injected, and using it to estimate the relevance of the systemic envenoming is impossible. Nonetheless, some factors are useful for prediction purposes - the presence of a bite wound, from which there is a possibility of a droplet of blood being discharged, and a statement by the victim concerning the length and manner of the bite. This may have lasted from just a few to several dozen seconds, plus the chewing method of snakes could have been employed. All this indicates a high probability that systemic neurotoxic symptoms will follow. However, any absence of such marks does not preclude envenomation, although it may reduce its probability. The proportion of those envenomed in North America, i.e. following a bite from the eastern coral snake (*M. fulvius*) ranges from 40% to 75% of those affected.

Systemic envenoming is manifest through neurotoxic symptomatology largely within 2 to 6 hours, but it can take between 12 or even 24 hours following the snakebite. Prodromes of envenoming have not been described. Serious muscular paralysis, including delayed onset of the same, can appear relatively quickly and is difficult to control by specific therapy.

The first sign of neuromuscular affection symptoms is ptosis. Ophtalmophlegia will follow accompanied by double or indistinct vision, dysarthria and dysphagia including swallowing disorders, saliva accumulation and discharge from the mouth cavity. Facial paralysis produces a myasthenic effect. Pupil non-reactivity, contraction or anisocoria is typically present. The state can be accompanied by qualitative changes in consciousness - somnolence, languor or euphoria, with further development involving general muscle weakness, sometimes muscular fasciculations, loss of swallowing and cough reflexes, and fatal paralysis of respiratory muscles. The symptoms of neurotoxicity will peak after 72 hours, and their acute phase abates after 5 to 7 days without any bearing on the application or quantity of antivenom. The muscle weakness following an envenoming persists for 4 to 6 weeks.

The course of envenoming can be complicated by aspiration bronchopneumonia unless the airways are managed using tracheal intubation.

The envenomation involves neither signs of cardiotoxicity, including arrhythmias, nor hemocoagulation disorders.

Laboratory findings: CC and myoglobin values are typically increased in the serum. Myoglobin may occur in urine as well, causing it darken. Leukocytosis is possible. In general, laboratory findings are not typical for the envenoming.

Mortality: With no possibility of adequate treatment, the lethality of systemic envenoming used to be very high in the past, but today, with forced pulmonary ventilation and specific therapy, 3 fatalities were recorded from 415 snakebites described in Brazil during 1986-1990, with *M. corallinus*, *M. lemniscatus,* and *M. frontalis* co-responsible for the

deaths. In the Brazilian state of São Paulo, no fatality from the 110 snakebites recorded occurred between 1988 and 1993. The same goes for the 39 envenomings described in the USA.

Therapy: For first aid and general rules of treatment, see chapter 5 Snakebite: Therapy and prevention.

Immediate application of a pressure immobilization bandage is fully indicated. The bandage should not be removed before arrival at health facility capable of dealing with potentially serious symptoms of muscular paralysis. If envenoming is proven, the bandage should be removed only after application of antivenom or at least after administration of neostigmine, see below.

Applicable antivenoms:

* ANTICORAL, Instituto Clodomiro Picado, Costa Rica (*M. carinicauda* - synonym *M. dumerilii*, *M. f. fulvius*, *M. nigrocinctus*);
* ANTI-MIPARTITUS, Instituto Clodomiro Picado, Costa Rica (*M. mipartitus*);
* ANTIELAPIDICO, Instituto Butantan, Brazil (*M. corallinus*, *M. frontalis*);
* ANTIELAPIDICO, Lab. Vencofarma do Brasil, Brazil (*M. corallinus*, *M. frontalis*);
* ANTIVENIN (MICRURUS FULVIUS), Wyeth, USA (production closed).

Antivenom proves most effective if applied before the envenoming has fully developed. Once severe symptoms of muscular paralysis appear, the period of necessity for mechanical ventilation may not be reduced by applying the antivenom, even if a large quantity of 10 vials is administered, and any application before paralysis sets in may not always have a pre-emptive effect. Nevertheless, in cases of believed envenoming, see systemic symptoms of envenoming, or systemic symptoms commence, application of antivenom is indicated with a quantity of 3-6 vials; in Brazil, 10 vials are recommended. The time lapsed between the snakebite, or more specifically the rise of symptoms and application of antivenom, is important for further progress of the disease.

The specific antivenoms developed against coral snakes of the *Micrurus* genus do not seem to be reversible; cross-immunity is probably poor. Nonetheless, antivenoms prepared to counteract venoms of elapid snakes from the same hemisphere, i.e. northern antivenoms against northern species and southern antivenoms against southern species, can be applied when needed, as they show some level of immunogenic relationship. According to an experiment carried out on mice, cross-immunity exists between the venom of the North American eastern coral snakes (*M. fulvius*) and Mexican antivenom, or the antivenom for the Australian mainland tiger snake (*Notechis scutatus*). As for venoms of some Central American coral snakes, they are impossible to neutralize by any of the antivenoms available at all.

A rather disguised and local finding that is usually only moderately painful will not require any special care.

Application of an acetylcholinesterase inhibitor, edrophonium or neostigmine, may in some cases result in reducing muscular paralysis. The Brazilian ministry of health recommends for adult patients an application of 0.5 mg of neostigmine (approx. 10 µg/kg of body weight) in five doses at 30-minute periods, which is followed by a longer break and repeated as necessary; each administration is premedicated with 0.6 mg (50 µg/kg of body weight) of atropine sulphate to neutralize the muscarine effect. Cases of reversed block only

by inhibiting acetylcholinesterase are known from Brazil. However, in the case of snakebites from *M. nigrocinctus*, such a procedure is ineffective, as the venom contains clinically a distinctive proportion of presynaptic neurotoxins. The situation with coral snakes found in Mexico is similar.

As regards symptomatic treatment, its application can be delayed or prove ineffective if antivenom is unavailable. It must promptly manage any possible complications arising from muscular paralysis, i.e. aspiration and respiratory failure, airway management using tracheal intubation, and subsequent mechanical ventilation.

A sufficient supply of liquids will prevent any possible renal failure if a higher quantity of myoglobin is released.

Heparin is not indicated.

A patient can be discharged 24 to 48 hours after abatement of symptoms of systemic envenoming. Observation of an affected person with asymptomatic development should last for approximately 24 hours.

6.3.1.9. Leptomicrurus and Micruroides Genera

Genera: The *Leptomicrurus* genus including four species and *Micruroides*, a monotypic genus consisting of *Micruroides euryxanthus*.

Description: Small to medium-sized dark snakes that feature a light pattern (*Leptomicrurus*) or color rings like the coral snakes of the *Micrurus* genus (*Micruroides*). Epidemiological relevance of these snakes is very low (*Micruroides*) or insignificant.

Other names: EN: Arizona (Sonoran) coral snake; FR: Serpent corail d'l Arizona (*Micruroides*). EN: Thread coral snake; FR: Serpent corail fin (*Leptomicrurus*).

Home range and habitat: The *Leptomicrurus* snakes inhabit the forests of South America; *Micruroides euryxanthus* dwells in rocky and stony habitats of Mexico and southern USA.

Toxins: Insufficient information of venoms of the genera above is available. The neurotoxic components contained will be probably similar to the neurotoxins found in *Micrurus* snakes.

Local symptoms of envenoming: The bite wound is diminutive; the local pain is rather low. Paresthesia, locally reduced sensation and muscle strength occur at the bitten site, without any major progression. Other local alterations are typically absent (*M. euryxanthus*).

Systemic symptoms of envenoming: Not described except the envenoming by *M. euryxanthus*. Nausea, light muscle weakness and possibly somnolence can be involved. Accommodation and photophobia disorders have occurred. Primarily, a light form of envenoming similar to that caused by venoms of *Micrurus* snakes can be expected.

Laboratory findings: Not known.

Mortality: Not specified.

Therapy: For first aid and general rules of treatment, see Chapter 5 Snakebite: Therapy and prevention. Treatment is similar to that of snakebites from the coral snakes of the *Micrurus* genus. Specific antivenoms are not available. In the case of a more severe envenoming by *E. micruroides*, SORO ANTIELAPIDICO, Instituto Butantan, Brazil is an applicable antivenom.

Cross-reactivity with venoms of *Micrurus* snakes is insufficient; antivenoms against North American coral snakes are ineffective in case of envenoming by *Micruroides*.

The patient can be discharged 24 hours after abatement of symptoms of systemic envenoming. The same time applies to the observation of the affected person with symptomless development.

REFERENCES

Chapters 6.3.1.1 - 6.3.1.7:

BERNHEIM, A., LORENZETTI, E., LICHT, A. et al. Three cases of severe neurotoxicity after Cobra bite (*Naja kaouthia*). *Swiss Med Wkly*, 2001, 131, pp. 227–228.

BLAYLOCK, RS., LICHTMAN, AR., POTGIETER, PD. Clinical manifestation of Cape Cobra (*Naja nivea*) bites. A report of 2 cases. *S Afr Med J*, 1985, 68, No. 5, pp. 342–344.

BRITT, A., BURKHART, K. *Naja naja* Cobra bite. *Am J Emerg Med*, 1997, 15, No, 5, pp. 529–531.

CISZOWSKI, K., HARTWICH, A. Envenoming by Malayan Cobra (*Naja naja sputatrix*) – case report. *Przegl Lek*, 2004, 6, No. 4, pp. 412–416.

DAVIDSON, TM., SCHAFER, S., KILLFOIL, J. Cobras. *Wilderness Environ Med*, 1995, 6, pp. 203–219.

DU, XY., CLEMETSON, JM., NAVDAEV, A., et al. Ophioluxin, a convulxin-like C-type lectin from *Ophiophagus hannah* (King Cobra) is a powerful platelet activator via glycoprotein VI. *J Biol Chem*, 2002, 227, No. 38, pp. 35124–35132.

Van EGMOND, KC. A fatal bite by the Shield-nose Snake (*Aspidelaps scutatus*). *S Afr Med J*, 1984, 66, No. 19, p. 714.

FRIGG, C., SIEBER, T., PAGANONI, O., et al. Snakebite – intoxication by Cobra venom. *Anaesthesist*, 2001, 50, No. 11, pp. 856–860.

GOLD, BS. Neostigmine for the treatment of neurotoxicity following envenomation by the Asiatic Cobra. *Ann Emerg Med*, 1996, 28, No. 1, pp. 87–89.

GOLD, BS., PYLE, P. Succesful treatment of neurotoxic King Cobra envenomation in Myrtle Beach, South Carolina. *Ann Emerg Med*, 1988, 32, No. 6, pp. 736–738.

GOMEZ, HF., DAVIS, M., PHILLIPS, S., et al. Human envenomation from a wandering Garter Snake. *Ann Emerg Med*, 1994, 23, No. 5, pp. 1119–1122.

GOMES, A., DE, P. Hannahpep: a novel fibrinolytic peptide from the Indian King Cobra (*Ophiophagus hannah*) venom. *Biochem Biophys Res Commun*, 1999, 266, No. 2, pp. 488–491.

GRUSCHWITZ, MS., MAHLER, V., RUPPRECHT, M., et al. Snake bite by a poisonous snake. Report of an unusual case. *Hautarzt*, 1994, 45, No. 5, pp. 330–334.

HARRISON, JL. The bite of a blue Malaysian Coral Snake or Ular Matahari. *Malayan Nature Journal*, 1957, 11, pp. 130–132.

HILLIGAN, R. Black mamba bites: a report of 2 cases. *S Afr Med J*, 1987, 72, pp. 220–221.

HODGSON, SP., DAVIDSON, TM. Biology and treatment of the Mamba snakebite. *Wilderness Environ Med*, 1996, 2, pp. 133–145.

HUANG, MZ., WANG, QC., LIU, GF. Effect of acidic phospholiopase A2 purified from *Ophiophagus hannah* (King Cobra) venom on rat heart. *Toxicon*, 1993, 31, No. 5, pp. 627–635.

KANCHANAPONGKUL, J. Neurotoxic envenoming following bites by the Malayan Krait (*Bungarus candidus*). *J Med Assoc Thai*, 2002, 85, No. 8, pp. 945–948.

KARNCHANACHETANEE, C. King cobra bite. *J Med Assoc Thai*, 1994, 77, No. 12, pp. 646–651.

KRAMER, R. Zur Schlangen Fauna von Nepal. *Rev Suisse Zool*, 1977, 84, No. 3, pp. 721–761.

KRENGEL, B., WALTON, J. A case of Mamba bite. *S Afr Med J*, 1967, 41, pp. 1150–1151.

KULARATNE, SA. Common Krait (*Bungarus caeruleus*) bite in Anuradhapura, Sri Lanka: a prospectiv clinical study, 1996–1998. *Postgrad Med J*, 2002, 78, No. 919, pp. 276–280.

LATIFI, M. Variation in yield and letality of venoms from Iranian snakes. *Toxicon*, 1984, 22, No. 3, pp. 373–380.

LAOTHONG, C., SITPRIJA, V. Decreased parasympathetic activities in Malayan Krait (*Bungarus candidus*) envenoming. *Toxicon*, 2001, 39, No. 9, pp. 1353–1357.

LEE, WH., ZHANG, Y., WANG, WY., et al. Isolation and properties of a blood coagulation factor X activator from the venom of King Cobra (*Ophiophagus hannah*). *Toxicon*, 1995, 33, No. 10, pp. 1263–1276.

LI, QB., HUANG, GW., KINJOH, K., et al. Hematological studies on DIC-like findings observed in patients with snakebite in south China. *Toxicon*, 2001, 39, No. 7, pp. 943–948.

LIFSHITZ, M., MAIMON, N., LIVNAT, S. *Walterinnesia aegypia* envenomation in a 22-year-old female: a case report. *Toxicon*, 2003, 41, No. 4, pp. 535–537.

LIM-LEONG-KENG, F., LEE-TAT-MONG, M. *Fascinated snakes of Southeast Asia – an introduction*. Kuala Lumpur : Tropical Press, 1989.

MARKWALDER, K., KOLLER, M. Mamba bites. 2 case reports and observations on the therapy of neurotoxic poisonous snake bites. *Schweiz Rundsch Med Prax*, 1987, 76, No. 46, pp. 1281–1284.

McNALLY, SL., REITZ, CL. Victims of snake bite. A 5-year study at Shongwe Hospital, Kangwane, 1978–1982. *S Afr Med J*, 1987, 72, No. 12, pp. 855–860.

MEIER, J., WHITE, J. (Eds). *Handbook of clinical toxicology of animal venoms and poisons*. Boca Raton : CRC Press, 1995, 752 pp.

NIRTHANAN, S., CHARPANTIER, E., GOPALAKRISHNAKONE, P., et al. Neuromuscular effects of candoxin, a novel toxin from the venom of the Malayan Krait (*Bungarus candidus*). *Br J Pharmacol*, 2003, 139, pp. 832–844.

POCHANUGOOL, C., LIMTHONGKUL, S., SITPRIJA, V., et al. Managment of Cobra bite by arteficial respiration and supportive therapy. *J Med Assoc Thai*, 1994, 77, No. 3, pp. 161–164.

POCHANUGOOL, C., LIMTHONGKUL, S., WILDE, H. Management of Thai Cobra bites with a single bolus of antivenin. *Wilderness Environ Med*, 1997, 8, No. 1, pp. 20–23.

POCHANUGOOL, C., WILDE, H., JITAPUNKUL, S., et al. Spontaneus recovery from severe neurotoxic envenoming by a Malayan Krait Bungarus candidus (Linnaeus) in Thailand. *Wilderness Environ Med*, 1997, 8, No. 4, pp. 223–225.

REID, HA. Cobra-bites. *Br Med J*, 1964, 2, p. 540–545.

SAUNDERS, CR. Report of a Black Mamba bite of a medical colleague. *Cent Afr J Med*, 1980, 26, No. 6, pp. 121–122.

SHARMA, SK., KOIRALA, S., DAHAL, G. Krait bite requiring high dose antivenom: a case report. *Southeast Asian J Trop Med Public Health*, 2002, 33, No. 1, pp. 170–171.

SINGH, G., PANNU, HS., CHAWLA, PS., et al. Neuromuscular transmission failure due to Common Krait (*Bungarus caeruleus*) envenomation. *Muscle Nerve*, 1999, 22, No. 12, pp. 1637–1643.

STÖCKLIN, R., CRETTON, G. *The ultimate database on venomous animals, snakes*. CD-rom, Geneva : Atheris Laboratories, 1998.

TAKASAKI, C., YOSHIDA, H., SHIMAZU, T., et al. Studies on the venom components of the Long-glanded Coral Snake, *Maticora bivirgata*. *Toxicon*, 1991, 29, No. 2, pp. 191–200.

TRISHNANANDA, M., OONSOMBAT, P., DUMAVIBHAT, B., et al. Clinical manifestation of Cobra bite in the Thai farmer. *Am J Trop Med Hyg*, 1979, 28, No. 1, pp. 165–166.

TUN-PE, AYE-AYE-MYINT, WARRELL, DA., et al. King Cobra (*Ophiophagus hannah*) bites in Myanmar: venom antigen levels and development of venom antibodies. *Toxicon*, 1995, 33, No. 3, pp. 379–382.

WARRELL, DA. Clinical toxicology of snakebite in Africa and the Middle East / Arabien Peninsula. In MEIER, J., WHITE, J. (Eds), *Handbook of clinical toxicology of animal venoms and poisons*. Boca Raton : CRC Press, 1995.

WARRELL, DA. Clinical toxicology of snakebite in Asia. In MEIER, J., WHITE, J. (Eds), *Handbook of clinical toxicology of animal venoms and poisons*. Boca Raton : CRC Press, 1995.

WARRELL, DA., GREENWOOD, BM., DAVIDSON, NM., et al. Necrosis, haemorrhage and complement depletion following bites by the Spitting Cobra (*Naja nigricollis*). *Q J Med*, 1976, 45, No. 177, pp. 1–22.

WATT, G., MEADE, BD., THEAKSTON, RD., et al. Comparison of Tensilon and antivenom for the treatment of Cobra-bite paralysis. *Trans R Soc Trop Med Hyg*, 1989, 83, pp. 570–573.

WATT, G., PADRE, L., TUAZON, ML., et al. Bites by Philippine Cobra (*Naja naja philippinensis*): prominent neurotoxicity with minimal local signs. *Am J Trop Med Hyg*, 1988, 39, No. 3, pp. 306–311.

WATT, G., THEAKSTON, RD., HAYES, CG. Positive response to edrophonium in patients with neurotoxic envenoming by Cobras (*Naja naja philippiensis*). *N Engl J Med*, 1986, 315, No. 23, pp. 1444–1448.

ZALTZMAN, M., RUMBAK, M., RABIE, M., et al. Neurotoxicity due to the bite of the Shield-nose Snake (*Aspidelaps scutatus*). A case report. *S Afr Med J*, 1984, 66, No. 3, pp. 111–112.

Chapters 6.3.1.8 - 6.3.1.9:

BARROS, AC., FERNANDES, DP., FERREIRA, LC., et al. Lokal effect induced by venoms from species of genus *Micrurus* sp. (Coral Snakes). *Toxicon*, 1994, 32, No. 4, pp. 445–452.

FAN, HW., CARDOSO, JL. Clinical toxicology of snake bites in South America. In MEIER, J., WHITE, J. (Eds), *Handbook of clinical toxicology of animal venoms and poisons*. Boca Raton : CRC Press, 1995.

GERMAN, BT., HACK, JB., BREWER, KL., et al. Efficiecy of a pressure-immobilization bandage in delaying the onset of systemic toxicity in a porcine model of Eastern Coral Snake (*Micrurus fulvius*) envenomation. *Ann Emerg Med*, 2004, 44, No. 4, pp. 90.

GOMEZ, HF., DART, RC. Clinical toxicology of snakebite in North America. In MEIER, J., WHITE, J. (Eds), *Handbook of clinical toxicology of animal venoms and poisons*. Boca Raton : CRC Press, 1995, pp. 619–644.

GUTIÉRREZ, JM. Clinical toxicology of snakebite in Central America. In MEIER, J., WHITE, J. (Eds), *Handbook of clinical toxicology of animal venoms and poisons*. Boca Raton : CRC Press, 1995.

KITCHENS, CS., van MIEROP, LH. Envenomation by the Eastern Coral Snake (*Micrurus fulvius fulvius*). A study of 39 victims. *JAMA*, 1987, 258, No. 12, pp. 1615–1618.

LAMAR, WW. A new species of Slender Coralsnake from Colombia, and its clinal an ontogenetic variation (Serpentes, Elapidae: *Leptomicrurus*). *Rev Biol Trop*, 2003, 51, No. 3–4, pp. 805–810.

MEIER, J., WHITE, J. (Eds). *Handbook of clinical toxicology of animal venoms and poisons*. Boca Raton : CRC Press, 1995, 752 pp.

Nget-Hong Tan, Gnanajothy Ponnudrai. The biological properties of venoms of some American Coral Snakes (genus *Micrurus*). Comparative Biochemistry and Physiology Part B. *Biochemistry and Molecular Biology* 1992, 101, No. 3, pp. 471–474.

PETTIGREW, LC., GLASS, JP. Neurologic complications of a Coral Snake bite. *Neurology*, 1985, 35, No. 4, pp. 589–592.

RIBEIRO, LA., ALBUQUERQUE, MJ., De CAMPOS, VA., et al. Death caused by venomous snakes in the State of Sao Paulo, evaluation of 43 cases from 1988 to 1993. *Rev Assoc Med Bras*, 1998, 44, No. 4), pp. 312–318.

De RODT, AR., PANIAGUA-SOLIS, JF., DOLAB, JA., et al. Effectiveness of two common antivenoms for North, Central, South American *Micrurus* envenomations. *J Toxicol Clin Toxicol*, 2004, 42, No. 2, pp. 171–178.

ROSSO, JP., VARGAS-ROSSO, O., GUTIERREZ, JM., et al. Characterisation of α-neurotoxin and phospholipase A2 activities from *Micrurus* venom. Determination of the amino sequence and receptor-binding ability of the major α -neurotoxin from *Micturus nigrocinctus nigrocinctus*. *Eur J Biochem*, 1996, 238, No. 1, pp. 231–239.

RUSSEL, FE. Bites by the Sonoran Snake *Micruroides euryxanthus*. *Toxicon*, 1967, 5, No. 1, pp. 39–42.

SERAFIM, FG., REALI, M., CRUZ-HOFLING, MA, et al. Action of *Micrurus dumerilii carinicauda* Coral Snake venom on the mammalian neuromuscular junction. *Toxicon*, 2002, 40, No. 2, pp. 167–174.

STÖCKLIN, R., CRETTON, G. *The ultimate database on venomous animals, snakes*. CD-rom, Geneva : Atheris Laboratories, 1998.

WISNIEWSKI, MS., HILL, RE., HAVEY, JM., et al. Australien Tiger Snake *(Notechis scutatus*) and Mexican Coral Snake (*Micrurus* species) antivenoms prevent death from United States Coral Snake (*Micrurus fulvius fulvius*) venom in a mouse model. *J Toxicol Clin Toxicol*, 2003, 41, No. 1, pp. 7–10.

6.3.2. Subfamily: *Hydrophiinae*

The group of *Hydrophiinae* snakes is the second of two recently recognized subfamilies of the elapid family (*Elapidae*). Formerly the group only comprised aquatic snakes - sea snakes and sea kraits and was designated *Hydrophiidae*. The new *Hydrophiinae* subfamily

contains, aside from aquatic sea snakes and sea kraits, terrestrial Austropapuan elapids - snakes that were earlier categorized as a separate subfamily of taipans (*Oxyuraninae*). For reasons of better presentation of texts and similarities in both former snake groups as regards morphology and toxinology, the section below has been segmented in relation to historic groups, i.e. the terrestrial snakes of *Oxyuraninae*, and aquatic snakes of *Hydrophiidae*.

6.3.2.1. Terrestrial Austropapuan Elapids (Formerly: Oxyuraninae Subfamily)

Once entitled *Oxyuraninae*, a taipan subfamily, this group comprises all members of the elapid family (*Elapidae*) found in Australia, Tasmania, New Guinea, and other islands in the vicinity. Even though snakes of some genera display a certain morphological resemblance to those of other families, all members of this subfamily possess fixed anterior fangs that do not swing. Examples of similarities between snakes include the *Echiopsis* genus or death adders (*Acanthophis*) that resemble viperids (*Viperidae*) in appearance, the fang length in taipans (*Oxyuranus*) can reach up to 1.3 cm, which is rather typical for viperids, etc. Incidentally, Austropapuan elapids are proteroglyphous snakes, just like all elapids (*Elapidae*).

In terms of the seriousness of envenomation, eight genera, from which consequences of envenoming are known, are described below from the total of 27 genera comprising the group. The remaining varieties are briefly and generally addressed, although any possible outcome from a potential envenoming are mentioned.

***Acanthophis* Genus, Death Adders**

Species: Common death adder (Acanthophis antarcticus), Acanthophis hawkei, Acanthophis laevis, northern death adder (Acanthophis praelongus), desert death adder (Acanthophis pyrrhus), Acanthophis rugosus and Acanthophis wellsi.

*Description***:** This snake rather resembles a viperid due to the shape of its head and the thickset body of 40 to 90 cm long with a short tail. The tip of the tail is elongated and terminates in a thorn. When moved, the thorn looks like a worm, thereby attracting prey. The color range of the snake includes varied tints of brown and red-brown. The species is active at dusk and night, but bites have even been recorded during the day.

*Home range and habitat***:** Death adders mostly range in fairly arid and sandy areas with sparse vegetation in southern and eastern (A. antarcticus) or central and western Australia (A. pyrhus), as well as the damp tropical forests of N Australia, New Guinea and neighboring islands (A. hawkei, A. laevis, A. praelongus, A. rugosus), where the most common venomous snakes are found.

Toxins: Neurotoxins make up the most clinically important venom components. These are largely of the postsynaptic type, however, amongst their number is presynaptically acting PLA_2. Other components with much less distinctive effects concern enzymes with hemocoagulation effects, which in a human can be registered only in laboratory tests. These tend to be anticoagulant and fibrino(geno)lytic in nature, affecting platelet function. Proteinases and phospholipases (PLA_2) are substances predominantly responsible for the majority of the activities above. The venom does not contain components causing more serious rhabdomyolysis, although some evidence of myotoxicity is obvious based on increased CC in the plasma of the envenomated persons.

Local symptoms of envenoming: The afflicted site almost lacks any edema; only increased sensitivity and strain in lymphatic pathways will exist, in addition to enlarged lymph nodes of the region in question. In general, local affliction is discreet in form.

Systemic symptoms of envenoming: The majority of persons bitten are typically envenomed. Symptoms commence with the following prodromes: headache, languor, abdominal pain, nausea, and vomiting; in rare cases, collapse may occur.

In nearly every envenomed individual, neurotoxicity symptoms below will manifest clinically: ptosis, dysarthria, ophtalmophlegia with diplopia, dysphagia, and overall muscle weakness. For about a quarter of those so afflicted, the status of pseudobulbar difficulties or respiratory failure will require management of airways using intubation and mechanical ventilation for a period of between 2 to 24 hours. Neurotoxicity symptoms with varied intensity can persist for 72 hours; nevertheless, they tend to be fully reversible if adequate treatment is applied, unlike in cases of envenoming by taipan venom.

A more serious clinical impact on hemocoagulation - increased hemorrhaging - occurs very rarely and in a moderate form. In up to a third of those affected, ECG changes in terms of T wave inversion and rare instances of brachycardia will occur, with a possible second degree of AV-block as well. A single example of reversed renal failure has been described, apparently due to myoglobinuria.

Laboratory findings: Hemocoagulation laboratory tests reveal moderate prolongation of PT and APTT. A non-standard slight decrease in PLT occurs that persists for several days as well as insignificant leukocytosis. Tests may sometimes display a clear increase in plasmin activity. In general, results are ordinary and not very distinctive.

Mortality: 50% mortality of untreated persons was reported by Tidswell in 1906. Such a rate seems exaggerated even for this period. In 1981-1991, only a single lethal case was recorded in Australia, nonetheless, the need for mechanical ventilation in up to a quarter of those envenomated may mean high potential mortality in cases with no therapy.

Therapy: For first aid and general rules of treatment, see chapter 5 Snakebite: Therapy and prevention. Immediate application of a pressure immobilization bandage is fully indicated. The bandage should not be removed before arrival at a health facility capable of dealing with any possible serious symptoms of muscular paralysis. If envenomation is proven, the bandage should be removed only after application of antivenom or at least after administration of neostigmine, see below.

Applicable antivenoms:

* DEATH ADDER ANTIVENOM, Commonwealth Serum Laboratories, Victoria, Parkville, Australia (*Acanthophis antarcticus, A. praelongus, A. pyrrhus*);

* POLYVALENT SNAKE ANTIVENOM, Commonwealth Serum Laboratories, Victoria, Parkville, Australia (*Acanthophis antarcticus,* etc.).

Local affection is rather indistinct and usually only moderately painful, so should not require any special care.

Application of acetylcholinesterase inhibiting neostigmine, see below, will typically result in even dramatic momentary improvement of muscular paralysis. Ultimately, envenomation symptoms are typically fully controlled by the relevant antivenom.

Symptomatic treatment in instances where antivenom is unavailable or application is delayed must address possible complications that arise due to muscular paralysis - aspiration

and respiratory failure - by managing the airways using tracheal intubation and subsequent mechanical ventilation. In addition, pharmacological inhibition of acetylcholinesterase using neostigmine, at a dosage of 0.5-1.0 mg IV (10-15 μ/kg of body weight) with premedication by 0.5 mg of atropine IV is advisable as well.

Sufficient supply of liquids will prevent any possible renal failure if a higher quantity of myoglobin is released. In rare cases of possible increased hemorrhaging, either symptomatic treatment is applicable or antifibrinolytics if a DIC-like disorder can be excluded. Heparin is not indicated.

The patient can be discharged for home treatment after 24 hours once all systemic symptoms recede.

Austrelaps Genus, Australian Copperheads

Species: Pygmy copperhead (*Austrelaps labialis*), highlands copperhead (*Austrelaps ramsayi*), Australian copperhead (*Austrelaps superbus*).

Other names: Australian (Kangaroo Island or highland) copperhead (EN).

Description: In gray-black and shades of brown to red, these slender and small-headed snakes feature relatively large eyes and round pupils. They can grow up to 75-130 cm, with a maximum length of 170 cm. These snakes are mainly active during the day even if temperatures drop somewhat at times when other snakes are hibernating. If daytime temperatures are high, they become active at night as well. They are frequently found in colonies with higher numbers of individuals.

Home range and habitat: Australian copperheads reside in damp, wet localities and places near water in SE Australia, Tasmania, and neighboring islands (*A. superbus* and *A. labialis*), as well as the mountain ranges of SE Australia (*A. ramsay*).

Toxins: Based on LD_{50} for mice, the venom can be rated about 12th in the hierarchy of toxicity. Clinically, the powerful neurotoxins it contains are of maximum effectiveness. Myotoxins are another important component. The hemolytic enzymes present are of PLB type, those of PLA_2-like (superbins) weaken hemostasis by inhibiting PLT function and affecting the plasmatic coagulation system.

Local symptoms of envenoming: Changes at the bitten site are not major - in some cases, edema and erythema appear.

Systemic symptoms of envenoming: At a systemic level, the envenoming manifests itself as classic prodromes - nausea, vomiting, and headaches. Eventually, consciousness disorders and muscular paralysis can occur. The latter becomes apparent via typical symptoms in facial and swallowing muscles. In instances of severe envenomation, respiratory difficulties requiring intubation and mechanical ventilation are rare but do occur.

The high levels of myoglobin and hemoglobin generated from severe rhabdomyolysis and hemolysis can result in renal failure.

Laboratory findings: Myolysis and hemolysis are followed by increased levels of plasmatic CC and myoglobin, in addition to free hemoglobin found in the serum and urine.

Mortality: Not described.

Therapy: For first aid and general rules of treatment, see chapter 5 Snakebite: Therapy and prevention. The pressure immobilization bandage is fully indicated; it should only be removed after arrival at health facility capable of dealing with potentially serious symptoms of muscular paralysis.

Applicable antivenoms:

* POLYVALENT SNAKE ANTIVENOM, Commonwealth Serum Laboratories, Victoria, Parkville, Australia (*Austrelaps ramsayi*, *Austrelaps superbus*, etc.);
* TIGER SNAKE ANTIVENOM, Commonwealth Serum Laboratories, Victoria, Parkville, Australia (*Austrelaps superbus*, and others).

The local affection will not require any special care.

If antivenom is not available, severe envenomation may require management of airways and mechanical ventilation. Application of acetylcholinesterase inhibitors may well prove effective; see chapter 5. 3. 3. 3 Affliction of nerve tissue and neuromuscular connections.

Symptomatic therapy should reflect the risk of renal failure by boosting the supply of liquids with possible diuretic support. Hemocoagulation dysbalance will react positively to the specific treatment; nevertheless, a positive effect can also be expected from symptomatic treatment based on the type of affliction.

The patient can be discharged for home treatment after 24 hours once all systemic symptoms recede.

***Hoplocephalus* Genus**

Species: Pale-headed snake (*Hoplocephalus bitorquatus*), broad-headed snake (*Hoplocephalus bungaroides*) and Stephen's banded snake (*Hoplocephalus stephensi*).

Description: Gray to black or brownish snakes with a distinctive head, lighter ventral section, and whitish or yellowish pattern, they can grow up to 45-75 cm, the maximum length being 100 cm. They are shy, predominantly nocturnal creatures - when threatened, they carry out a swift strike without warning.

*Home range and habitat***:** Found in E Australia in humid forests and coastal woodlands, neighboring inland forests of the arid eucalyptus variety (*H. bitorquatus* and *H. stephensi*), and sandy or rocky areas (*H. bungaroides*).

Toxins: The venom is quite effective and can be fatal for a human. Fortunately, the production of venom in this snake group is only low. It contains powerful neurotoxins, enzymes with hemocoagulation effects (largely in terms of prothrombin activation, like hopsarin D, resembling the human FXa by structure and function), and myotoxins causing rhabdomyolysis. The effect of cardiotoxic components has also been described (Chew et al., 2003).

Local symptoms of envenoming: The edema that comes up at the bitten site is typically lesser or medium in nature; the area around the site is erythematous. Lymphadenopathy occurs, the limb is painful. Local signs of a hemostasis disorder may be present, e.g. bruises, intradermal bleeding, or direct hematoms.

Systemic symptoms of envenoming: Systemic envenomation mostly commences with headaches, plus nausea and vomiting may set in early with gastrointestinal hemorrhaging - hematemesis. In the envenomed person, neurotoxicity symptoms appear very soon, leading up to respiratory failure and, later, vertigo or even collapse.

A DIC-like hemocoagulation disorder of the DIC type occurs, which usually becomes clinically manifest as increased hemorrhaging, such as epistaxis, hematuria, and other symptoms. Procoagulative, i.e. (micro)thrombotic, complications are likely to arise.

The nature of the venom makes renal failure possible under the high levels of myoglobin due to rhabdomyolysis in progress, which will also be manifest as muscular pain. Naturally, the impact of neurotoxins is not the key factor in systemic envenoming, nor are neurotoxicity symptoms. It is the effect on hemocoagulation mentioned above that remains the most serious symptom.

Arrhythmia has been described in the form of nodal bradycardia with numerous supraventricular and ventricular extrasystoles, receding spontaneously after eight hours.

Laboratory findings: In envenoming by *H. bungaroides*, leukocytosis with a peak value 21 x 10^9/l was described. In hemocoagulation lab tests, a DIC-like disorder prevailed: thrombocytopenia, defibrination showing decreased values (reaching less than 0.5 g/l), prolongation of PT (INR 1.6), and APTT above 200. The D-dim level is above 20 mg/l (the normal amount being less than 0.3 mg/l), but the AT level still remains intact. In the serum, increased CC is typically found, i.e. 25.1 microcat/l (the normal amount being below 3.3 microcat/l). An increase in CRP to 59 mg/l was also recorded, the normal amount being less than 7 mg/l.

Mortality: Fatalities have not been described. Nevertheless, the effectiveness of the venom makes lethal progress of the envenoming possible.

Therapy: For first aid and general rules of treatment, see chapter 5 Snakebite: Therapy and prevention. Application of a pressure immobilization bandage is indicated.

The antivenom against the venom of tiger snakes (*Notechis*) is recommended for specific immunotherapy.

Any local affection can be smoothed by a cool compress - ice should be avoided; in cases of more intense pain, the limb is immobilized and elevated. Any large hematoms generated, although this is rare, must be evacuated; the measure needs to be carried out only once the coagulation disorder has abated.

In symptomatic therapy, the DIC-like hemocoagulation disorder can be treated by applying 10-20 ml/kg of body weight of fresh frozen plasma, and AT, if its activity has decreased; see also chapter 5. 3. 3. 6 Hemocoagulation disorders. Miniheparinization may probably have a positive effect on persisting signs of hypercoagulation once hemorrhaging has ceased, even though the merits of its application have been the subject of debate.

Increased supply of liquids will prevent renal failure. In cases of severe neurotoxicity symptoms, intubation and mechanical ventilation might be necessary, though very rarely.

The patient can be discharged for home treatment after 24 hours following abatement of systemic symptoms and more serious laboratory symptomatology.

Notechis Genus, Tiger Snakes

Species: The black tiger snake (*Notechis ater*) with a number of subspecies, and the mainland tiger snake (*Notechis scutatus*).

Description: Thickset snakes 100-150 cm long, exceptionally up to 250 cm. They are of dark color with possible lighter cross stripes. Largely active during the day and at dusk, they can be active at night as well in hot periods. Cases of aggressive behavior are possible; when threatened, the snake will spread its neck in a similar manner to cobras.

Home range and habitat: They mostly dwell in humid areas, forests and bushland, sometimes more open spaces, but they still prefer environments neighboring water, including coastal regions in SE and SW Australia, the surrounding islands and Tasmania.

Toxins: Ranked fourth in an imaginary hierarchy of snake venom due to its effectiveness on mice, its toxicity is always compared to that of taipans (*Oxyuranus*) (Sutherland et al., 2000). As for the impact on humans, this venom is considered one of the most effective of all. Fortunately, the quantity available in these snakes is only low.

From clinically relevant components, the venom contains both neurotoxic substances with a postsynaptic effect and PLA_2 with a presynaptic action. As for hemocoagulation components, the venom contains prothrombin specifically activating proteinases, including D group activators that are similar in function to human FXa (hopsarin-D).

Other venom compounds include myotoxins with significant effects and enzymes with less noteworthy hemolytic effects.

Local symptoms of envenoming: Local affliction is minor, with a bite being typically hard to discern. In some cases, venom droplets are evident at the bitten site. The wounds may bleed. Lymphadenopathy sets in; lymphangitis and lymphadenitis are manifest as strain and minor pain.

Systemic symptoms of envenoming: Systemic envenoming may become manifest very early on, within five minutes. It is most likely to begin with the following prodromes: headaches, nausea, and vomiting. Early hypotension is possible to occur.

Neurotoxicity is apparent due to hazy or double vision, facial and swallowing muscle innervation disorders, and dysarthria, followed by overall muscle weakness leading up to respiratory muscular paralysis, with which there is a risk of aspiration and respiratory failure requiring management of airways and mechanical ventilation. Should no adequate specific treatment be available, the development of this status may last for 5 hours.

Complications associated with a DIC-like hemocoagulation disorder may occur early-after 30 minutes following a bite, although such progress is usually slower. As a result, prothrombotic statuses arise with (micro)embolisms that trigger ischemia in tissues in the coronary and pulmonary bloodstreams, as well as other bloodstreams. Exhaustion of the coagulation system will manifest following the prior activation at a systemic level as fundamentally increased hemorrhaging, in addition to the possibility of hemorrhage into organs, e.g. the brain. As DIC proceeds, hemorrhaging will occur despite the application of antivenom.

Hemodynamic disorders may set in - decreased heart output and pulse volume, plus manifestation of heart failure with increased pulmonary vascular pressure. The changes described above can be evidently associated with ischemization of myocardium and pulmonary vessels by (micro)thrombi.

Myoglobinemia and myoglobinuria, together with less significant hemoglobinuria, generated in the course of proceeding rhabdomyolysis and hemolysis, are a predisposition for subsequent renal failure.

Laboratory findings: In hemocoagulation lab tests, symptomatology of consumption coagulopathy will prevail as follows: prolonged PT and APTT, plus FBG depletion up to afibrinogenemia and thrombocytopenia. Lab tests of VIII, IX, XI, and V factor levels revealed a loss of over 50% in some cases; the presence of components inhibiting these factors is also possible. Myoglobinemia is followed by the discovery of myoglobinuria. Leucopenia has also been recorded.

Mortality: In the period 1981-1991, 4 fatalities were registered. Fatal cerebral hemorrhaging in an eleven-year-old boy as well as several sudden deaths were described. As

for the number of fatalities in Australia, envenoming by the mainland tiger snake (*N. scutatus*) takes second place, with bites from brown snakes (*Pseudonaja*) in prime position.

Therapy: For first aid and general rules of treatment, see chapter 5 Snakebite: Therapy and prevention. Immediate application of a pressure immobilization bandage is fully indicated; the bandage should only be removed upon arrival at a health facility capable of dealing with systemic envenomation.

Satisfactory neutralization of venom components with neurotoxic and hemocoagulation effects can be achieved via application of an antivenom, usually if delivered in time.

Any later administration may not fully combat presynaptically acting neurotoxic enzymes and DIC-like hemocoagulation complications, if the same are already in progress. Nonetheless, it is indicated in such cases as well.

* TIGER SNAKE ANTIVENOM, Commonwealth Serum Laboratories, Victoria, Parkville, Australia (*Notechis ater*, *Notechis scutatus*, etc.);

* POLYVALENT SNAKE ANTIVENOM, Commonwealth Serum Laboratories, Victoria, Parkville, Australia (*Notechis scutatus*, and other snakes);

SEA SNAKE ANTIVENOM, Commonwealth Serum Laboratories, Victoria, Parkville, Australia (*Notechis scutatus*, and others).

A minimal local affliction will not require any special treatment.

Symptomatic therapy must primarily manage satisfactory ventilation and avoid possible aspiration when any specific immunotherapy is absent or necessarily delayed and severe systemic symptoms of neurotoxicity exist. If dysphagia and ventilatory insufficiency occur, tracheal intubation and mechanical ventilation will be indicated.

Hemocoagulation dysbalance will require treatment according to the type of affection. A procoagulative status as well as increased hemorrhaging can be treated by applying 10-20 ml/kg of body weight of fresh frozen plasma, and AT in instances of its decreased activity in the serum; see also chapter 5. 3. 3. 6 Hemocoagulation disorders. The merits of administering heparin have been debated. A positive effect of this substance is recorded in experiments on dogs, but only when administered before an envenoming. Application in minute doses is recommended in the period outside any clinically evident bleeding should there be signs of hypercoagulation based on a hemocoagulation test.

Myoglobinuria and hemoglobinuria will require raising the supply of liquids to prevent renal failure. Any further potential severe hemodynamic disorders must be treated symptomatically as individually manifested. If any occur, myocardial ischemia markers should be examined and any possible pulmonary embolism ruled out.

The patient can be discharged for home treatment after 24 hours following abatement of all systemic symptoms and normalization of significant laboratory symptomatology.

Oxyuranus Genus, Taipan

Species: Inland taipan (*Oxyuranus microlepidotus*) and coastal taipan (*Oxyuranus scutellatus*) including subspecies, the coastal taipan (*O. s. scutellatus*) and Papuan taipan (*O. s. canni*).

Other names: EN: Western taipan, fierce snake, small-scaled snake; scientific: *Parademandsia microlepidota* (*O. microlepidotus*). EN: Australian (New Guinea) taipan (*O. scutellatus*).

Description: Medium-sized, large or robust snakes up to 300 cm long, although 335 cm is possible in *O. scutellatus*, predominantly in hues of brown and light-bellied. The head is elongated; eyes are large with round pupils. Taipans are active in the day and at dusk, and in hot weather at night. Fangs are up to 1.3 cm long and larger than those of other coral snakes (*O. scutellatus*).

Home range and habitat: Taipans inhabit arid areas and sparse bush of the central part of eastern inland Australia (*O. microlepidotus*); humid forests plus arid areas with sparse vegetation along northern coastal Australia (*O. scutellatus scutellatus*), and the southern coast of Papua-New Guinea (*O. scutellatus canni*).

Toxins: The venom of the coastal taipan (*O. scutellatus*) is considered the third most effective in the world. A lethal dose for humans is approximately 5 mg of dry matter of venom; the mean quantity in the venom gland as usually specified is 120 mg of dry matter, with the maximum being 400 mg (Sutherland 1990, 2000). The inland taipan (*O. microlepidotus*) is probably the most venomous snake. The minimum specified LD_{50} for mice is a mere 0.01 mg/kg of live weight; the mean quantity of the venom discharged when biting is 17.3 mg. This produces an envenoming capacity equal to LD_{50} for 1,730 kg of mice, making it the record holder amongst venomous snakes (Morrison, 1983-4).

The venom primarily contains neurotoxins, with the major part formed by PLA_2 with presynaptic effects, and a lesser proportion of postsynaptic neurotoxins. The neurotoxic components found in taipan venom are recognized by some authors as being the most effective of all. PLA_2 with presynaptic neurotoxicity and a powerful procoagulative effect is formed from substances termed taipoxin (*O. scutellatus*) or paradoxin (*O. microlepidotus*).

The venom components can activate prothrombin to thrombin, with FXa- and FVa-like protein complexes and PLA_2 with coagulation effects, in addition to the previously mentioned components of taipoxin and paradoxin.

Taicatoxin, which blocks calcium channels of excitable membranes and may trigger arrhythmia, is another complex of venom components.

In addition, the venom also display myotoxic and a low fibrinolytic activity, causes aggregation and activation of platelets, and possesses insignificant hemorrhagic properties.

Local symptoms of envenoming: Bites are not painful, and might even go ignored. However, bleeding may occur. Lymphangitis and lymphadenitis are typically present, often with strain or even feelings of pain in 93% of snakebites. Nevertheless, such local signs may not necessarily mean a systemic envenomation has taken place.

Systemic symptoms of envenoming: The majority of taipan snakebites, over 80% of cases, are accompanied by a systemic envenomation. The process will typically begin with the following prodromes: headaches, nausea, vomiting, and bellyache.

The main affection symptoms concern manifestations of neurotoxicity and hemostasis disorder. Neuromuscular transmission disorders will appear in up to 85% of those concerned, usually beginning with ptosis, followed by ophtalmophlegia and double vision, facial muscle paralysis, pseudo-bulbar paralysis including dysarthria and dysphagia, and overall muscle weakness. In over 40% of cases of envenoming, paralysis of respiratory muscles occurs as well, with tracheal intubation and mechanical ventilation proving necessary.

Hemocoagulation disorders occur in the majority of affected persons, with over 90% of displaying at least laboratory symptomatology of coagulopathy, in nearly 80% non-coagulability of blood is found, and 35% - 50% show clinical signs of hemorrhaging - most frequently from the gums and nose - as well as hematuria and hemorrhagic diarrhea.

Bradycardia, possibly continuing through to AV-block with ECG changes in terms of T wave inversion, occur in the majority of those affected. Envenomation may be accompanied by periods of unconsciousness and hypertension. Any rhabdomyolysis in progress may even lead to secondary renal failure.

Laboratory findings: The prevailing laboratory result from the envenoming is hemocoagulation system disorder. The basic lab tests show prolonged PT and APTT, thrombocytopenia and hypo- or even afibrinogenemia occurring, and a highly distinct elevation in FDP levels, including that of D-dim, is found. A more detailed test will reveal signs of activated fibrinolysis, with the discovery of plasminogen and α 2-antiplasmin, as well as reduced activity of FV, VIII, IX, XII, and XIII. A clear decrease in C protein level occurs. Nevertheless, AT activity is typically not significantly affected. A triple increase in the level of von Willebrand's factor indicates endothelial activation and damage.

In biochemical laboratory tests, myoglobin is typically found in the serum and urine, with troponin level elevation present in about 8% of the patients.

Mortality: The historic mortality rate of 80% caused by taipan snakebites seems to be overstated - such a percentage would correspond to the occurrence of systemic envenomation following the bite. However, the severe symptoms of envenoming experienced by most victims can result in fatal courses unless adequate therapy is provided. The venom's potency may cause death very early on, in terms of minutes, especially in children repeatedly bitten.

In 1981-1991, there were two cases of death in Australia. In the group of 166 patients bitten by the Papuan taipan (*O. scutellatus canni*), lethality occurred in 4.3% of those envenomed. This relatively low level of mortality can be ascribed to prompt and adequate treatment, especially the opportunity to receive mechanical ventilation.

Therapy: For first aid and general rules of treatment, see chapter 5 Snakebite: Therapy and prevention. Immediate application of a pressure immobilization bandage is fully indicated. The bandage should not be removed before arrival at a health facility capable of dealing with serious systemic symptoms. If envenoming is proven, the bandage should be removed upon application of antivenom, or at least once the possibility of symptomatic treatment, principally mechanical ventilation, has been safeguarded.

Timely administration of appropriate antivenom, at best a species-specific one, will reduce the seriousness and period of neurotoxicity manifestation, namely by influencing PLA_2 with presynaptic effects.

Repeated application of antivenom, even for longer periods following the snakebite, will also have a positive effect. However, if antiserum application is delayed, neuromuscular affliction will persist. The specific immunotherapy necessary regulates the symptoms of hemocoagulation disorder relatively effectively.

Applicable antivenoms:

* TAIPAN ANTIVENOM, Commonwealth Serum Laboratories,Victoria, Parkville, Australia (*Oxyuranus microlepidotus*, *Oxyuranus scutellatus*);

* POLYVALENT SNAKE ANTIVENOM, Commonwealth Serum Laboratories, Victoria, Parkville, Australia (*Oxyuranus microlepidotus*, *Oxyuranus scutellatus*, etc.).

The minimal local affliction should not require any special treatment. In cases of painful lymphadenopathy, the limb can be elevated and moderately cooled.

If paralysis of swallowing and respiratory muscles is manifest, with a risk of aspiration and clinical signs of respiratory failure, airway management using tracheal intubation and subsequent mechanical ventilation is necessary without delay.

Any persisting DIC-like coagulopathy found can be corrected by applying fresh frozen plasma, 10-20 ml/kg of body weight. AT substitution is indicated by reduced AT activity. Any cases of a more intensive hemocoagulation disorder must be treated symptomatically in a complex manner; see chapter 5. 3. 3. 6 Hemocoagulation disorders. Heparin may be an effective option to help neutralize increased thrombin activity and the resulting prothrombotic status. However, application of heparin in instances of envenoming by taipan venom is considered to have a reduced effect and will be contraindicated whilst patients are bleeding. Nevertheless, miniheparinization by unfractionated heparin (UFH) or low LMWH doses can prove both pre-emptive and protective if subsequent complications occur due to persisting prothrombotic changes following endothelial damage within the preceding coagulation disorder.

The patient can be discharged for home treatment after 24 hours following abatement of all systemic symptoms and normalization of significant laboratory findings.

Pseudechis Genus, Black Snakes

Species: Mulga snake (*Pseudechis australis*), spotted mulga snake (*Pseudechis buttleri*), Collett's snake (*Pseudechis colletti*), blue-bellied black snake (*Pseudechis guttatus*), Papuan black snake (*Pseudechis papuanus*), red-bellied black snake (*Pseudechis porphyriacus*).

Other names: EN: king brown snake, black snake (*P. australis*).

Description: Robust snakes, they tend to grow to 120-200 cm, with the maximum of 275 cm recorded for *P. australis*. When threatened, they spread their necks in the manner of cobras (*Naja*). These snakes are active during the day and at dusk in colder periods; a very high increase in temperatures during the day makes them active at night.

P. australis can be extremely aggressive when provoked. Strikes can be repeated, with the snake chewing as it bites.

Home range and habitat: The snakes of this genus range in diverse habitats almost throughout Australia and New Guinea (*P. papuanus*), from semi desert regions, arid, rocky and hilly landscapes, as well as dense or even tropical forests (*P. australis*, *P. guttatus*), and swampy areas (*P. porphyriacus*).

Toxins: The venom is not of extreme danger; it contains neurotoxins plus components of hemorrhagic, myotoxic and hemolytic type and those of general cytotoxicity. Myotoxicity is caused by mulgatoxin of great potency. The venom's components affect hemocoagulation by activating prothrombin.

In 1986, herpetologist John Cann obtained an extreme quantity of venom from *P. australis*, a 250 cm long snake - 2.5 ml of liquid venom containing 1,350 mg of dry matter, this being at a time when the previous historic maximum of venom had been obtained from a king cobra (*Ophiophagus hannah*): 900 mg of dry matter.

Local symptoms of envenoming: Even though local damage is presented as the most significant affliction triggered by Austropapuan terrestrial elapid snakes, in most cases it is limited to edema with lymphadenitis and lymphangitis, including feelings of strain and medium pain in the limb and lymph nodes. However, the bite wound may drip; in the minority of cases, even subdermal abscesses may form due to tissue damage and decomposition rather than from the results of infection.

Systemic symptoms of envenoming: The process of envenoming will typically commence with the following prodromes: nausea, vomiting, headaches, and bellyache. Following a snakebite from the Papuan black snake (*P. papuanus*), the neurotoxicity manifest is registered, although rarely with the need for mechanical ventilation, unlike cases of snakebites from the mulga snake (*P. australis*) and red-bellied black snake (*P. porphyriacus*), where almost no clinical symptoms of acute neurotoxicity have been recorded. Exceptions include instances of loss of the senses of smell and taste for up to several months and a number of cases of epilepsia following envenoming by the red-bellied black snake (*P. porphyriacus*).

The process of envenomation typically includes hemocoagulation effects accompanied by spontaneous hemorrhaging and hematuria in more difficult cases.

Even though a serious effect triggered by myotoxins and hemolysis is not typical for envenoming, rhabdomyolysis may still occur, especially in instances involving delayed administration of antivenom following a bite from the mulga snake (*P. australis*). Symptoms of renal dysfunction are also possible.

Laboratory findings: Hemocoagulation analysis shows prolonged PT and APTT, hypofibrinogenemia, thrombocytopenia, FDP elevation, activated fibrinolysis, and depletion of hemocoagulation factors; even a high elevation of CC and myoglobin in the serum and myoglobinuria can be present.

Mortality: Since 1981, no fatality related to an attack by a *Pseudechis* snake has been registered in Australia and probably elsewhere.

Therapy: For first aid and general rules of treatment, see chapter 5 Snakebite: Therapy and prevention. Immediate application of a pressure immobilization bandage is indicated; the bandage should be removed only upon arrival at a health facility capable of dealing with systemic envenomation.

Administration of appropriate antivenom is indicated where a reaction at a systemic level occurs, as with other cases of envenoming.

Applicable antivenoms:

* BLACK SNAKE ANTIVENOM, Commonwealth Serum Laboratories, Victoria, Parkville, Australia (*Pseudechis australis*, *Pseudechis butleri*, *Pseudechis colletti*, *Pseudechis guttatus*, *Pseudechis papuanus*, *Pseudechis porphyriacus*);

* POLYVALENT SNAKE ANTIVENOM, Commonwealth Serum Laboratories, Victoria, Parkville, Australia (*Pseudechis australis*, *Pseudechis papuanus*, etc.);

* TIGER SNAKE ANTIVENOM, Commonwealth Serum Laboratories, Victoria, Parkville, Australia (*Pseudechis colletti*, *Pseudechis guttatus*, *Pseudechis porphyriacus*, and other snakes);

* SEA SNAKE ANTIVENOM, Commonwealth Serum Laboratories, Victoria, Parkville, Australia (*Pseudechis porphyriacus*, etc.).

As the venom of *Pseudechis* snakes displays cross-immunity with the venom components of tiger snakes (*Notechis*), a minor amount of this antivenom can be applied as an alternative. However, cross-immunity with *Pseudonaja* snakes does not exist.

Due to a greater chance of local affliction of tissue at the bitten site, it is recommended to remove the pressure immobilization bandage as soon as possible. Of course, this should not take place before the necessary treatment is available or a systemic envenomation is ruled out.

Special care and attention should be paid to the local affliction due to the likelihood of causing pain and potentially damaging tissue; the afflicted limb needs to be immobilized, elevated, mildly cooled, and possible subsequent trauma avoided. Abscesses at the bitten site, if any, should be drained with care. Antibiotics are indicated if infectious etiology or secondary local infection is suspected.

Rare cases of clinical symptoms of profound muscular paralysis will require management of airways and mechanical ventilation.

A potentially persisting hemocoagulation disorder can be treated symptomatically; a high myoglobin level in cases of rhabdomyolysis will require an increased supply of liquids in order to guard against renal failure.

A patient can be discharged for home treatment after 24 hours following abatement of all systemic symptoms and normalization of significant laboratory findings.

Pseudonaja Genus, Brown Snakes

Species: Dugite (*Pseudonaja affinis*), speckled brown snake (*Pseudonaja guttata*), peninsula brown snake (*Pseudonaja inframaculata*), Ingram's brown snake (*Pseudonaja ingrami*), ringed brown snake (*Pseudonaja modesta*), gwardar (*Pseudonaja nuchalis*), eastern brown snake (*Pseudonaja textilis*); with the most significant and dangerous species being *P. textilis*, *P. affinis* and *P. nuchalis*.

Other names: EN: Brown snake, dugit (*P. affinis*). Gwardar (*P. nuchalis*). Common or eastern brown snake (*P. textilis*).

Description: Largely slender bodied snakes that range from 50 to 150 cm in length; the largest species, i.e. *P. affinis* and *P. textilis*, can grow up to 150-200 cm, with *P. textilis* capable of reaching even 240 cm. They are mostly diurnal animals; nocturnal activity in hot periods is possible, but rare. *P. affinis* is a more short-tempered and lively species than the rest of the genus, which increases the level of risk of this snake.

Home range and habitat: Brown snakes reside in quite arid and open land, including the scrub and open bush of Australia; the most perilous (*P. textilis*) can even be found in humid localities in the eastern half of Australia, and Papua-New Guinea.

Toxins: The venom of *P. textilis* possesses potency of toxin about ten times higher than that of other *Pseudonaja* snakes, with LD_{50} for mice SC of 0.053 mg/kg of body weight, placing this species second in the chart of most effective snake venom.

The components responsible for such high and rapid fatality of envenoming in a human are probably those termed cardiotoxins by some authors, causing dramatic circulatory collapse.

The venom contains effective neurotoxic components of largely presynaptic action, as well as compounds with hemocoagulation effects, mostly by potent activation of prothrombin with a resulting DIC-like consumption disorder.

The presence of primarily nephrotoxic venom components is also possible. The effects of myolytic, hemolytic, and general cytotoxic enzymes are limited or not evident at all.

Local symptoms of envenoming: The bite, the area around it, and the limb are typically not painful. In some cases, bleeding from the bitten site and local formation of bruises may occur. The generation of moderate edema and lymphadenopathy is possible.

Systemic symptoms of envenoming: The process of envenoming normally commences with the following prodromes: nausea, vomiting, and headaches. Typically, neurotoxicity becomes apparent very early on, largely within 30 minutes, by afflicting facial muscles with

ptosis, ophtalmophlegia with double or hazy vision, and dysarthria. More serious signs of neurotoxicity are rare.

In acute and fatal cases of envenoming, severe circulatory collapse with hypotension and possible circulatory failure typically occur very soon, possibly caused by rapid intravascular coagulation in the coronary stream with myocardial ischemia, or deep hypotension for other cardiodepressive reasons.

In the majority of envenomings, a hemocoagulation disorder of the consumptive type prevails, largely with clinical signs of hemorrhaging, but even featuring (micro)thrombotic complications.

Renal failure, possibly with signs of acute tubular necrosis, occurs in up to 5% of those envenomated, which means the highest incidence among the terrestrial Austropapuan elapid snakes.

Laboratory findings: Hemocoagulation tests will typically reveal consumption coagulopathy with prolonged PT and APTT, hypofibrinogenemia, thrombocytopenia, and elevated FDP including D-dim.

Mortality: Bites by the eastern brown snake (*P. textilis*) are responsible for the largest proportion of fatalities caused by all such instances in Australia; 11 cases were recorded in 1981-1991. In some cases of envenoming by *Pseudonaja* snakes, sudden and unexpected death has occurred very soon, in just 35 to 90 minutes, following circulatory collapse and cardiac arrest with minimal changes found in the post mortem report. Other fatalities have been caused by endocranial hemorrhaging. Such facts make *Pseudonaja* snakes the most dangerous in the Austro-Papuan region.

Therapy: For first aid and general rules of treatment, see chapter 5 Snakebite: Therapy and prevention. Immediate application of a pressure immobilization bandage is fully indicated; the bandage should be removed only upon arrival at a health facility capable of dealing with systemic envenomation, either after antivenom is applied or once envenoming is ruled out. If envenoming is proven, the bandage should be removed once an antivenom is applied, or at least when there is a possibility of symptomatic treatment being provided.

Considering the potential seriousness of the envenomation process, administration of a relevant antivenom is indicated as soon as is possible if systemic symptoms occur.

Applicable antivenoms:

* BROWN SNAKE ANTIVENOM, Commonwealth Serum Laboratories, Victoria, Parkville, Australia (*Pseudonaja affinis*, *Psedonaja nuchalis*, *Pseudonaja textilis*);

* POLYVALENT SNAKE ANTIVENOM, Commonwealth Serum Laboratories, Victoria, Parkville, Australia (*Pseudonaja affinis*, *Psedonaja nuchalis*, etc.).

The local affliction is insignificant and will not require any special care.

The most dangerous signs of a severe envenoming are cardiac collapse with hypotension and potential circulatory failure. Hypotension requires intensive care without delay so as to strive to maintain hemodynamics by either increasing intravenous volume or supportive treatment by means of catecholamines. The latter involves application of either norepinephrin or medicine for β -mimetic support of myocardium, depending on the symptoms present.

As cardiodepressive symptomatology can be caused by myocardial ischemia via (micro)embolisms within the activation of thrombin at a systemic level, there is a theoretical option of heparinization for a threatened patient. However, the utilization of heparin is

contraindicated due to hemorrhagic complications of the envenoming. Nevertheless, evident myocardial ischemization found with corresponding biochemical and hemocoagulation laboratory results and absent clinical signs of hemorrhaging allow for use of heparin when there is a vital indication.

The DIC-like consumption disorder in progress can be treated symptomatically by applying fresh frozen plasma (10-20 ml/kg) and AT, if its activity has been critically reduced. In cases of more intensive consumption disorder and hemorrhaging, see chapter 5. 3. 3. 6 Hemocoagulation disorders.

Any threat of possible renal failure will require the sufficient supply of liquids, even though such instances are typically not caused by myoglobinuria but microembolisms in progress in the renal vascular system. Therefore, in order to prevent this consumption coagulopathy needs to be monitored.

The patient can be discharged for home treatment after 24 hours following abatement of all systemic symptoms and normalization of significant laboratory findings.

Tropidechis Genus

Species: Rough-scaled snake (*Tropidechis carinatus*), *Tropidechis sadlieri*.

Other names: EN: Clarence river snake (*T. carinatus*).

Description: These are snakes that can grow up to 60-70 cm, and rarely up to 100 cm. They feature large eyes and round pupils; their color is brown through to a gray-green with dark discontinuous stripes on the dorsal section of the body, the belly is pale in tone. They are mostly active during the day, but also at night if daytime temperatures are high. Their aggressive nature raises the potential danger they pose.

Home range and habitat: This group of snakes inhabits damp tropical forests, but is also found in the neighborhoods of settlements, gardens, parks, and golf clubs in the territory comprising the central and northern part of the coast and surrounding inland areas of Eastern Australia.

Toxins: These snakes produce a relatively high quantity of venom that possesses neurotoxic activities - both presynaptic and postsynaptic - as well as myotoxic and hemolytic components. In addition, it contains compounds with hemocoagulation effects, amongst them trocarin, a group D prothrombin activator, comparable with FXa in humans in terms of both structure and function.

Local symptoms of envenoming: Local changes are not very distinctive, with possible minor edema surrounded by erythema, painful lymphadenopathy, and bruising.

Systemic symptoms of envenoming: At a systemic level, the envenoming will be manifest through prodromal headaches and nausea; temporary loss of consciousness can occur very rapidly. A risk of muscular paralysis may require intubation and mechanical ventilation. When inadequate treatment is given, the rhabdomyolysis and hemolysis present will result in renal failure. Hemocoagulation disorders are possible following prothrombin activation, although they have not been clinically described.

Laboratory findings: Hemoglobinuria and myoglobinuria.

Mortality: Even though no fatalities have been described, the nature of the venom can cause fatalities in humans.

Therapy: For first aid and general rules of treatment, see chapter 5 Snakebite: Therapy and prevention. Immediate application of a pressure immobilization bandage is indicated; the

bandage should be removed only upon arrival at a health facility capable of dealing with systemic envenomation.

Applicable antivenoms:

* TIGER SNAKE ANTIVENOM, Commonwealth Serum Laboratories, Victoria, Parkville, Australia (*Tropidechis carinatus*, etc.);

* SEA SNAKE ANTIVENOM, Commonwealth Serum Laboratories, Victoria, Parkville, Australia (*Tropidechis carinatus*, and others).

The minor localized affliction will not require any special care.

Muscular paralysis can be successfully controlled through specific treatment, though mechanical ventilation may be necessary for a definite period of time. Hemocoagulation disorders may be treated symptomatically; heparinization using a small dosage can have a positive effect on persisting signs of hypercoagulation once hemorrhaging has abated, even though its application has been disputed. Increasing the supply of liquids could prevent renal failure.

The patient can be discharged for home treatment after 24 hours following abatement of all systemic symptoms and normalization of significant laboratory findings.

Other Species of Austropapuan Terrestrial Coral Snakes (A Former *Oxyuraninae* Subfamily)

Aspidomorphus. Not very large snakes up to 70 cm long, with brownish to brown-black color, ranging in New Guinea and the surrounding islands.

Cacophis, dwarf-crowned snakes. Small to medium-sized and non-aggressive snakes 25-70 cm long, with brownish, reddish and steel-gray color and largely nocturnal activity that inhabit forest localities in coastal E Australia.

Demansia. Medium-sized or even robust, these extremely slender snakes with large eyes can grow up to 200 cm in some species. They reside in diverse habitats of predominantly western and northern Australian regions.

Snakebites will in most cases cause only a localized and not very painful edema and livid color of skin at the bitten site. Arrhythmias in terms of stroke irregularities have been described as a part of systemic envenoming.

*Denisonia***.** Robust, but not very large snakes, less than 50 cm long, with a short tail and nocturnal activity found in NE Australia.

Even though their venom contains mainly neurotoxins, these snakes are not dangerous; envenomation will probably take place without coagulation defects.

Drysdalia. Not very large snakes, less than 75 cm long, with a robust body; they are mostly active at night. They inhabit the SE, S, and SW coasts of Australia including surrounding inland territories. The venom probably contains chiefly myotoxins causing rhabdomyolysis, but is not considered dangerous.

Echiopsis. Not very large but thickset snakes, less than 60 cm long, with a short tail. They are largely nocturnal animals ranging in grassy and shrubby territories in the southern part of W Australia and its southern coastland including surrounding inland territories.

Clinically, envenomings resemble those caused by the death adders (*Acanthophis*). Snakebites generate edema and coagulation defects, which could qualify these animals as potential dangerous snakes.

Elapognathus. Small brownish snakes less than 50 cm long with a thickset body found in SW Australia.

Furina. Small and slender gray-black snakes less than 50 cm long, predominantly active at night. They mostly reside in rather arid habitats of SE Australia; one of the species even ranges across the continent except the southern part, and also New Guinea and surrounding islands.

Glyphodon. Dark brown to black snakes with the length less than 90 cm; they are nocturnal animals found in the eastern part of the Cape York Peninsula.

Locally, envenomation will manifest with erythema and pain around the bitten site; at a systemic level, pain in epigastrium, nausea, vomiting and aqueous diarrhea occur. There is no effect on hemocoagulation. Envenomation is not considered dangerous; however, the venom is impossible to neutralize by any available antivenom.

Recently, members of the genus are classified under the *Furina* and *Cacophis* genera.

Hemiaspis. Not very large snakes - about 50 cm long, with maximum of 90 cm. Their dorsal part is grayish, olive or brownish, but populations with dark to black color, i.e. melanotic ones, exist as well. On hot days, these largely diurnal snakes can be also active at dusk. They mostly range in humid habitats in E Australia.

The snakebite is typically followed by distinctive pain at the bitten site; edema and lymphadenopathy occur, as well as benign laboratory signs of consumption coagulopathy.

Loveridgelaps. A monotypic genus containing the Solomon's small-eyed snake (*Loveridgelaps elapoides*), also referred to as the orange-banded snake. It is a relatively rare species that can grow 80-100 cm, but exceptionally even 150 cm long. It is active at dusk and in the night. The body of this snake boasts wide cross stripes, with light up to orange and black color; its head is light as well. This species dwells near waters in the tropical forests of the Solomon Islands.

Snakebites have not been registered; they can be potentially dangerous. Antivenom is not available.

Micropechis. Medium to large size, these surface or also burrowing snakes can grow as much as 150 cm, with the maximum of 200 cm. They feature variable coloring with a ring-like pattern in the rear part of the body. They are predominantly nocturnal snakes, and inhabit the tropical forests and swamp areas of New Guinea and the Aru Archipelago.

The course of envenoming can be potentially grievous or even fatal.

Ogmodon. A small burrowing snake of brownish color found in the Fiji Archipelago.

Parapistocalamus. A monotypic genus with a single species - Hediger's or also Bougainville snake (*Parapistocalamus hedigeri*). This species can achieve the length of 40-60 cm; it features dark up to black color with a light belly and cross stripe on its head. It is a burrowing nocturnal species that dwell in the forests of Papua-New Guinea and the Solomon Islands.

Paroplocephalus: see *Suta* below.

Rhinoplocephalus, synonym: *Unechis*. Small and slender nocturnal snakes with the maximal length of 50 cm. Found in SW, SE, E and N Australia and the southern part of Papua-New Guinea. No evidence for snakebites exists.

Salomonelaps. Medium-sized snakes that grow up to 100 cm. They are active in the night and range in the forest areas of the Solomon Islands. No evidence for snakebites exists.

Simoselaps. Small short-tailed burrowing snakes with variable patterns of rings along the body. They are primarily night hunters and range in diverse habitats of W and SE Australia. This snake genus is not considered dangerous.

*Suta***.** Small snakes with chiefly nocturnal activities. The majority of them feature black spots on their head. They inhabit diverse habitats of a greater part of Australian continent.

Toxicity of their venoms is only low.

Toxicocalamus. Small snakes that range in the island regions of Indonesia, New Guinea and Papua-New Guinea.

Vermicella. Not very sized snakes that can achieve a maximum of 30 cm; the young are a mere 17 cm long. They are found on diverse localities across the most of the Australian territory.

Effects of envenoming may include temporary hypotension. The course of envenoming is benign, with no indication for application of antivenom. The local affliction is typically insignificant.

*Toxins***:** The venom of the genera listed above is not very dangerous to humans, as a consequence of limited potency or the small amount available. Fundamentally, they are likely to consist of neurotoxins, components with hemocoagulation effects, myotoxins, plus hemolytic and cytotoxic enzymes that form mixtures of varied proportions, just as in other snakes of the *Oxyuraninae* subfamily.

*Local symptoms of envenoming***:** Snakebites from a majority of the genera above will be restricted to less significant local symptoms, such as pain, minor edema, erythema, and lymphadenopathy.

*Systemic symptoms of envenoming***:** If at all described, the symptoms of systemic envenoming are typically not serious; they will be limited to headaches, nausea, vomiting, possibly pain in the epigastrium, and diarrhea. Nevertheless, a more grievous course is also possible, namely in children, with possible manifestations of neurotoxicity, myotoxicity, hemocoagulation disorders, and renal failure.

Laboratory findings: The results of laboratory tests will correspond to the type of toxin loads and affection levels; changes will not be probably significant.

*Mortality***:** Even though fatalities in snakebites from the genera above have not been described, severe cases of envenoming are still possible.

Therapy: For first aid and general rules of treatment, see chapter 5 Snakebite: Therapy and prevention. Although envenoming by the above snakes will not be dangerous to a human in most cases, application of a pressure immobilization bandage in cases of snakebite can be recommended; the bandage should not be removed before arrival at a health facility or after any systemic affliction has been ruled out. In case of signs of systemic envenoming, symptomatic therapy is advisable based on the type of affliction; see chapter 5. 3. 3. Clinical symptoms of envenomation and symptomatic treatment.

The patient can be discharged for home treatment after 24 hours following abatement of all possible symptoms and normalization of potentially more significant laboratory findings.

REFERENCES

FATOVICH, DM., HITCHCOCK, T, WHITE, J. Mild snake envenomation. *Emerg Med (Fremantle)*, 2002, 14, pp. 85–88.

CHEW, MS., GUTTORMSEN, AB., METZSCH, C., et al. Exotic snake bite: a challenge for the Scandinavian anaesthesiologist? *Acta Anaest Scand*, 2003, 47, No. 2, p. 226.

ISBISTER, GK., DAWSON, AH., WHYTE, IM. Two cases of bites by the Black-bellied Swamp Snake (*Hemiaspis signata*). *Toxicon*, 2002, 40, No. 3, pp. 317–319.

JELINEK, GA., BREHENY, FX. Ten years of snake bites at Fremantle Hospital. *Med J Aust*, 1990, 153, No. 11–12, pp. 658–661.

LALOO, D., TREVETT, A., BLACK, J., et al. Neurotoxicity and haemostatic disturbances in patients envenomed by the Papuan Black Snake (*Pseudechis papuanus*). *Toxicon*, 1994, 32, No. 8, pp. 927–936.

LALOO, DG., TREVETT, AJ., BLACK, J., et al. Neurotoxicity, anticoagulant activity and evidence of rhabdomyolysis in patients bitten by Death Adders (*Acanthophis sp*.) in southern Papua New Guinea. *Q J Med*, 1996, 89, p. 25–35.

LALOO, DG., TREVETT, AJ., KORINHONA, A., et al. Snake bites by the Papuaa Taipan (*Oxyuranus scutellatus canni*): paralysis, haemostatic and elektrocardiografic abnormalities, and effect of antivenom. *Am J Trop Med Hyg*, 1995, 52, No. 6, pp. 525–531.

LALOO, DG., TREVETT, AJ., NWOKOLO, N., et al. Electrocardiografic abnormalities in patients bitten by Taipans (*Oxyuranus scutellatus canni*) and other Elapid snakes in Papua New Guinea. *Trans R Soc Trop Med Hyg*, 1997, 91, No. 1, pp. 53–56.

LALOO, DG., TREVETT, AJ., OWENS, D., et al. Coagulopathy following bites by the Papuan Taipan (*Oxyuranus scutellatus canni*). *Blood Coagulation and Fibrinolysis*, 1995, 6, No. 1, pp. 65–72.

MEIER, J., WHITE, J. (Eds). *Handbook of clinical toxicology of animal venoms and poisons*. Boca Raton : CRC Press, 1995, 752 pp.

MORRISON, J., PEARN, J., COVACEVICH, J., et al. Studies on the venom of *Oxyuranus microlepidotus*. *J Toxicol Clin Toxicol*, 1983–84, 21, No. 3, pp. 373–385.

PATTEN, BR., PEARN, JH., DEBUSE, P., et al. Prolonged intensive therapy after snake bite. A probable case of envenomation by the rough-scaled snake. *Med J Aust*, 1985, 142, No. 8, pp. 467–469.

RAO, VS., JOSEPH, JS., KINI, RM. Group D prothrombin activators from snake venom are structural homologues of mammalian blood coagulation factor Xa. *Biochem J*, 2003, 369, No. 3, pp. 635–642.

RAO, VS., KINI, RM. Pseutarin C, a protrombin activator from *Pseudonaja textilis* venom: its structural and functional similarity to mammalian coagulation factor Xa-Va complex. *Tromb Haemost*, 2002, 88, No. 4, pp. 611–619.

SOUTHERN, DA., CALLANAN, VI., GORDON, GS. Severe envenomation by the Taipan (*Oxyutanus scutellatus*). *Med J Aust*, 1996, 165, No. 11–12, pp. 662–664.

STÖCKLIN, R., CRETTON, G. *The ultimate database on venomous animals, snakes*. CD-rom, Geneva : Atheris Laboratories, 1998.

SUBBURAJU, S., KINI, RM. Isolation and purification of superbins I and II from *Austrelaps superbus* (copperhead) snake venom and their anticoagulant and antiplatelet effects. *Toxicon*, 1997, 35, No. 8, pp. 1239–1250.

SUTHERLAND, SK. Death from snake bite in Australia, 1981–1991. *Med J Aust*, 1992, 157, No. 11–12, p. 740–746.

SUTHERLAND, SK. *First aid for snakebite in Australia.* Published by the Commonwealth Serum Laboratories Parkville 3052, 1979.

SUTHERLAND, SK. Treatment of snake bite. *Australien Family Physisian*, 1990, 19, No. 1, pp. 21–41.

SUTHERLAND, SK., NOLCH, G. *Dangerous australian animals.* Flemington : Hyland House Publishing, Australia, 2000.

TIBBALLS, J. The cardiovascular, coagulation and haematological effects of Tiger Snake (*Notechis scutatus*) venom. *Anaesth Intensive Care*, 1998, 26, No. 5, pp. 529–535.

TIBBALLS, J. The cardiovascular, coagulation and haematological effects of Tiger Snake (*Notechis scutatus*) prothrombin activator and investigation of release of vasoactive substances. *Anaesth Intensive Care*, 1998, 26, No. 5, pp. 536–547.

TIBBALLS, J., HENNING, RD., SUTHERLAND, SK., et al. Fatal cerebral haemorrhage after Tiger Snake (*Notechis scutatus*) envenomation. *Med J Aust*, 1991, 154, No. 4, pp. 275–276.

TIDSWELL, F. *Researches on Australien venoms, snake-bite, snake-venoms and antivenene: the poison of the Platypus, the poison of the Red-Spoted Spider.* Sydney : NSW Department of Public Health, 1906.

TREVETT, AJ., LALOO, DG., NWOKOLO, NC., et al. The efficacy of antivenom in the treatment of bites by the Papuan Taipan (*Oxyuranus scutellatus canni*). *Trans R Soc Trop Med Hyg*, 1995, 89, No. 3, pp. 322–325.

6.3.2.2. Aquatic Genera of The Hydrophiinae Subfamily (A Former Hydrophiidae Family)

Genera and species. Consisting of over 50 species of snakes that dwell in tropical and subtropical seas, this group covers multiple genera of sea snakes and the *Laticauda* genus of sea kraits.

Members include the *Aipysurus* genus, Stoke's seasnake (*Astrotia stokesii*), *Disteira* snakes, turtle-headed seasnakes (*Emydocephalus*), *Enhydrina* seasnakes with the representatives being for example the common seasnake (*Enhydrina schistosa*), *Ephalophis* and *Hydrelaps* snakes, *Hydrophis* and *Kerilia* genera, *Kolpophis*, *Lapemis*, *Parahydrophis*, *Pelamis*, *Thalassophina* (*Praescutata*) and *Thalassophis* sea snakes; for a list of species, see chapter 7 List of venomous snakes.

The sea krait subfamily (*Laticaudinae*) comprises five species of these snakes, for example the common sea krait (*Laticauda laticauda*) or *Laticauda semifasciata*; for other species, see chapter 7 List of venomous snakes.

Other names: FR: Serpent de mer, JAP: Umi-Hebi (sea snakes and sea kraits).

Description: Sea snakes number almost 50 species of small-headed marine varieties, featuring a robust flattened tail and body lengths from 50 to 170 cm, the latter being the elegant sea snake (*Hydrophis elegans*), the largest Australian sea snake species. Some well-built animals of certain varieties may even grow up to 300 cm. Sea snakes vary in color; they are often darker, sometimes boasting crosswise stripes. The body is of a typical type, with a

vertically flattened tail adapted to fast swimming and a small head. The nostrils feature flap valves and the lung to the right is enlarged, this elongation up to the tail base forms an air reservoir allowing the creatures to remain submerged. These snakes are good divers - some of them are even capable of reaching depths of 100 m; nevertheless, they must always go back up to breathe. The venom apparatus consists of two venom glands, and 2-4 usually small and thin fixed fangs with channels placed in the anterior part of the maxilla, hence they are deemed proteroglyphous snakes.

The subfamily and genus of sea kraits (*Laticauda*) covers five members of semi terrestrial aquatic snakes approximately 100 cm long, reaching a maximum of 150 cm. In terms of body and venom apparatus structure they resemble sea snakes, but they boast more distinctive patterns of crosswise stripes, mostly in hues of yellow, blue, creamy white, and dark to black colors.

The composition of potent venoms of either snake subfamily brings to mind that of Austropapuan terrestrial elapid snakes (formerly *Oxyuraninae*), close relatives of marine varieties that are likely to have evolved from these snakes.

Sea snakes and sea kraits are not aggressive in nature - the victims of their bites are usually fishermen, in whose nets the snakes can get snarled. According to White (1995), there is such a high number of these snakes in certain localities that a single fisherman using a conventional net for fishing can encounter up to 100 snakes daily. In the 1950s, 150 envenomed fishermen were registered in 10% of Malayan villages to Reid (1975). The presumed annual incidence throughout Malaysia fluctuates around 1,500 cases, and the global number of bites suffered by fisherman from marine snakes is estimated as 15,000-75,000, with a fatality of several percent; the common seasnake (*Enhydrina schistosa*) being responsible for more than a half of bites. In addition, *E. schistosa* is held accountable for the majority of serious envenomings and fatalities. Other representatives typically referred to as highly dangerous include *Hydrophis cyanocinctus* and *Lapemis hardwickii*. Aside from snakebites caused to fishermen's hands while removing a snake from the net, or to a leg from the bottom of the boat, snake attacks also occur when a snake is stepped on in shallow water or handled, such as in an aquarium. Snakebites through swimming and diving are extremely rare. Marine snakes do accompany divers sometimes, although they will not attack them, even though cases of seeking out physical contact have occurred. Moreover, the fangs of the snake tend not to be sufficiently robust and long enough to gnaw through diving suits, but exceptions do exist, such as *Aipysurus laevis* and *Astrotia stokesii* with fangs of over 5 mm long.

Home range and habitat: Sea snakes predominantly inhabit coastal regions and coral reefs in the Indian and Pacific Ocean. Their home range is delimited by the entire eastern African shore to the west, the coasts of the northern part of Australia to the south, the southern and coastal regions of Korea (the Yellow Sea and South China Sea) and the Philippine Sea to the north, and the western coasts of Central America and upper South America. The maximum concentration of such snakes is probably in the coral reefs of the Australian northern coast. One of the species, the pelagic sea snake (*Pelamis platurus*), can be considered an ocean wanderer, as groups cross the entire sea snake home range. Concerns have been raised about this snake passing through the Panama Canal and subsequently settling in the Caribbean.

Sea kraits (*Laticauda*) inhabit SE Asia including certain islands of this region; they are rarely found in coastal N and E Australia. They dwell in reef areas, along the shore, in sludgy

estuaries, etc. Unlike sea snakes, sea kraits sometimes leave the water either for drinking or laying eggs. They can reside in water in caves along the coast or in lakes inland, for instance, on Te-Nggano, one of the Solomon Islands.

Toxins: The venoms of sea snakes and sea kraits are considered highly efficient, largely due to their extreme neurotoxic potency. The most dangerous species is likely to be the common sea snake (*Enhydrina schistosa*), which possesses about 8-15 mg of dry matter of venom with toxicity equal to LD_{50} 0.04 mg/kg of mice IP (*intra peritoneam*, within the peritoneal cavity); this is an extremely high value comparable only to that of taipan venom. With regard to human weight, this snake is capable of delivering approximately three or four lethal doses. However, in the relatively abundant pelagic sea snake (*Pelamis platurus*) with almost comparable venom toxicity, 0.09 mg/kg of mice IV, the available quantity of dry matter of venom is a mere 0.25 mg and bites from this snake are usually described as benign (White, 1995).

The basic venom components comprise neurotoxins and myotoxins of variable mutual proportion. As for playing a part in suspected muscular paralyses, myotoxic muscle affliction is probably responsible, while for certain members of the group, for instance, the Stoke's seasnake (*Astrotia stokesi*) and the yellow sea snake (*Hydrophis spiralis*), the venoms have neurotoxic effects without any clinical evidence of myotoxicity.

In nearly all cases, neurotoxins of the aquatic *Hydrophiinae* snakes are those with postsynaptic effects of α type bound to α-subunits of nicotine cholinergic receptors of neuromuscular end-plates, which predominantly come from the small-molecule neurotoxin group. Exceptionally, the venom may contain neurotoxins with presynaptic effects as well, such as PLA_2 isolated from the venom of *Laticauda semifasciata*.

Myotoxins are mainly members of the PLA_2-type enzyme group. In general, they form hyaline necrosis in striated muscles. They attack fibrils in diverse muscles and at varied intensity, with several per cent of cells afflicted, even resulting in total destruction of muscle.

Local symptoms of envenoming: Bites from marine snakes are usually not painful, although very rare cases of sharp pain (*Hydrophis spiralis*) or subsequent increased sensitivity lasting several days (*Pelamis platurus*) have been described. The bite marks are difficult to discern or are diminutive; however, small bites of other teeth - non-venomous ones - are sometimes evident, including those based in the mandible. The brittle and mostly very tiny fangs may be detained in the wound and covered by surface layers of the skin, so easily missed. Following a snakebite, edema will not form, except in rare exceptions (*P. platurus*); there is only some extent of lymphadenopathy with increased regional lymph nodes. Occurrence of a livid area around the bitten site is possible.

Waterborne injuries with more distinctive local affection, such as easily discernable stabs, edema, skin reactions, etc., are typically caused by other marine wildlife, either fish or invertebrates.

Systemic symptoms of envenoming: Approximately 80% cases of bites from marine snakes will either proceed without any symptoms of envenoming, or any affliction is only minor. Of the remaining 20% of cases of more severe affliction, about 40% were fatalities when untreated, but today the number of mortalities has almost dropped to zero owing to the possibility of treatment by antivenoms (Reid, 1975).

Systemic symptoms of envenoming commence with sensations of being cold or frozen, anxiety, languor and sleepiness, restlessness or euphoria, headaches, increased body temperatures, clammy and sticky sweating, thirst, and reduced heartbeat. Classic envenoming

prodromes may arise too, such as nausea, vomiting, abdominal pain, and convulsion. Although frequent and described in this kind of state, the feelings of fear and anxiety may not always indicate a systemic envenoming, but merely a general mental response to a snakebite. Initial symptomatology can sometimes occur very quickly following an attack, primarily in a serious envenoming, but a delay in onset of 2-4 hours is possible.

Neurotoxicity begins to manifest depending on the quantity and effectiveness of toxins, extending from several minutes to a number of hours, the average being 0.5 to 3.5 hours. It develops conventionally, with cranial nerves being the initial region afflicted, with following ptosis, mydriasis with a poor response to light exposure, and external ophtalmophlegia with diplopia or blurred vision. Subsequent vision disorders are indications of a highly severe envenoming. The affection continues with dysarthria, dysphagia including discharge of saliva difficult to control, inability to stick out the tongue, and a swallowing and cough disorder. A risk of regurgitation of stomach content and its aspiration into the lungs arises. Spasticity of certain groups of muscles, such as pseudotrismus of jaw muscles is presented; however, such a state is more probably caused by myotoxins rather than by a neurotoxic affection. Limited muscular paralysis is then transferred to the neck and back muscles disenabling the individual from sitting; tendon reflexes are reduced or disappear. Disabled respiratory muscles pose a fatal risk; clinically, this starts with accelerated shallow breathing and is followed by respiratory failure with cyanosis, hypoxic syncope, and possible death. Naturally, pain in the respiratory muscles damaged by rhabdomyolysis can be co-responsible for the affliction of the muscles. Paralysis of limb muscles does not usually occur.

Myotoxicity will mostly start to manifest as feelings of muscle strain or stiffness within 30 mins to 4 hours. Myalgia arises following pain developing in muscles under passive extension. In cases of severe envenoming, muscle pain becomes apparent within two hours following a bite. In some cases, the signs of myolysis can be the first or even only symptom of a systemic affliction. The effect on muscles is complemented by blocked transmission on neuromuscular end plates, thus potentiating a functional disorder of striated muscles. The fibrils will mostly regenerate 1-2 weeks following the damage – a biopsy carried out 6 months afterwards showed only minor changes in the muscular structure (White, 1995).

Hyperkalemia and myoglobinuria are integral parts of the myolysis.

Hyperkalemia becomes manifest as changes in ECG in terms of a prominent T wave, prolonged QRS-complex or occurrence of ventricular arrhythmia, or even circulatory failure in severe envenomings.

Myolysis and myoglobinuria result in oliguria and renal failure, principally if hydration and production of primary urine is insufficient. Necrosis of distal tubules was found in some fatalities involving renal failure.

In late phases of envenoming, hypertension and increased sweating was observed.

Laboratory findings: In rather poor laboratory results, increased CC, AST, kalemia and myoglobin values in the serum can be registered, aside from common neutrophilic leukocytosis. Myoglobinuria appears within approximately 3 to 6 hours. Changes accompanying hyperkalemia are evident from ECG - a prominent T wave, QRS-complex extension, or ventricular arrhythmia. In case of renal failure, serum urea and creatinine levels will increase and kalemia will rise. No signs of coagulopathy or hemolysis are evident from the lab tests.

Mortality: In an early phase, lethality in case of envenoming by marine snakes is caused by respiratory failure, while in the late phase, death is caused by complications due to oliguric renal failure.

The analysis of 101 treated snakebites in Malaysia during 1957-1964, as carried out by Reid, found 8 fatal cases, with the common sea snake (*Enhydrina schistosa*) responsible for seven of them. At a time before the advent of antivenom treatment and mechanical ventilation, generally prior to 1961, presumed lethality in Malaysia was 10% of those attacked (Reid, 1975). Lethality following a snakebite from the pelagic sea snake (*Pelamis platurus*) has not been sufficiently evidenced, but is presumed according to tradition in India, Costa Rica, Panama and Columbia.

Admitting the speculated incidence of 15,000-75,000 snakebites and the current mortality of 1-5% of this number, an approximate prediction of annual global lethality is probably in the region of 150-3,700 cases.

Therapy: For first aid and general rules of treatment, see chapter 5 Snakebite: Therapy and prevention. Immediate application of a pressure immobilization bandage based on research by Sutherland is fully indicated. The bandage should not be removed before arrival at a health facility capable of dealing with potentially serious symptoms of muscular paralysis. If envenoming is proven, the bandage should not be removed before application of antivenom or at least administration of neostigmine, see below.

Applicable antivenoms:

SEA SNAKE ANTIVENOM, Commonwealth Serum Laboratories, Victoria, Parkville, Australia.

If the preparation above is not available, the antivenom against the venom of the mainland tiger snake (*Notechis scutatus*) is applicable (Sutherland et al., 2000): TIGER SNAKE ANTIVENOM, Commonwealth Serum Laboratories, Victoria, Parkville, Australia.

Administration of antivenom is indicated whenever neurotoxic symptoms, clinical or laboratory signs of myolysis occur. The quantity of the antivenom is determined by the level of seriousness of envenoming, i.e. the severity of symptoms and the speed of their onset, with approximate requirement of 1 to 10 vials.

The rather indistinct and generally pain-free localized affection will not require any special care. Any inflammatory complications are rare. Pre-emptive administration of antibiotics is not indicated.

As for the critical proportion of neurotoxins with postsynaptic effects, application of acetylcholinesterase inhibiting neostigmine has proven useful in clinical manifestations of neurotoxicity, especially when no antivenom is available; dosage: 0.5-1.0 mg IV (10-15 μg/kg), with premedication of 0.5 mg of atropine IV. To eliminate neurotoxins, hemodialysis can also be employed due to the small size of the molecules. Symptomatic treatment should prevent any potential complications associated with possible muscular paralysis, such as aspiration of stomach content and respiratory failure, by airway management using tracheal intubation and subsequent mechanical ventilation.

Adequate hydration of the affected person is important when rhabdomyolysis is in progress. Increasing the supply of liquids, ideally in the form of crystalloid infusion, will provide for production of sufficient quantity of primary urine, thereby diluting the volume of myoglobin, hence generating a pre-emptive effect on possible renal failure. Alkalinization of

urine is likely to have a preventive effect as well. In cases of more serious myolysis, which is indicated by a sharp increase in CC and myoglobinuria, ECG and kalemia monitoring is essential. Efforts to control developing oliguria in a conservative manner are possible by means of diuretics. Hyperkalemia, just like the previously formed oliguria, must be solved through hemodialysis or hemofiltration.

Observation of those concerned for a least period of 24 hours is necessary in every case. This is true despite the probability of systemic envenoming being minimal if there are no symptoms of envenoming, including laboratory results, within 4 hours after a snakebite.

The patient can be discharged following systemic envenoming for home treatment after 24 hours once all systemic symptoms recede.

REFERENCES

AMARASEKERA, N., JAYAWARDENA, A., ARIYARATNAM, A., et al. Bite of sea snake (*Hydrophis spiralis*): a case report from Sri Lanka. *J Trop Med Hyg*, 1994, 97, pp. 195–198.

FULDE, GW., SMITH, F. Sea snake envenomation at Bondi. *Med J Aust*, 1984, 141, No. 1, pp. 44–45.

WHITE, J. Clinical toxicology of sea snakebites. In MEIER, J., WHITE, J. (Eds), *Handbook of clinical toxicology of animal venoms and poisons*. Boca Raton : CRC Press, 1995, pp. 159–170.

REID, HA. Antivenom in sea-snake bit poisoning. *Lancet*, 1975, 1, No. 7907, pp. 622–623.

REID, HA. Epidemiology and clinical aspects of the sea snake bites. In DUNSON, W.A. (Ed.), *The biology of the sea snakes.* Baltimore : University Park Press, 1975, pp. 417–462.

REID, HA. Epidemiology of sea-snake bites. *J Trop Med Hyg*, 1975, 78, No. 5, pp. 106–113.

SUTHERLAND, SK., NOLCH, G. *Dangerous Australian animals.* Flemington : Hyland House Publishing, 2000, 201 pp.

RUAL, F. Les envenomations marines: L´example de la Nouvelle-Caledonie. *Medicine Tropicale*, 1999, 59, No. 3, pp. 287–297.

SOLÓRZANO, A. A case of human bite by the Pelagic Sea Snake, *Pelamis platurus* (Serpentes: *Hydrophiidae*). *Rev. Biol. Trop*, 1995, 43, No. 1–3, pp. 321–322.

STÖCKLIN, R., CRETTON, G. *The ultimate database on venomous animals, snakes.* CD-rom, Geneva : Atheris Laboratories, 1998.

6.4. FAMILY: *VIPERIDAE*, VIPERIDS

The viperid family (*Viperidae*) forms a relatively extensive group of venomous snakes – this classification now covers in excess of 30 genera, numbering over 220 species. It can be subdivided into three subfamilies, with *Causinae* snakes discerned by some as a separate entity. One of the subfamilies - *Crotalinae* snakes - was earlier classified as another family.

Viperidae snakes as a whole possess perfect venom apparatus - large erectile fangs with a fully closed channel, and muscles capable of regulating the discharge of venom

(*Solenoglypha*); see chapter 1. 4 Venom apparatus of snakes. Their body is mostly thickset and rather short, whilst the triangular head is wide. The *Crotalinae* subfamily has one more sensitive sensory organ - a pair of heat-sensing pits. In some crotaline snakes, like *Crotalus* and *Sistrurus*, the tail includes a feature called a rattle; see chapter 1. 3 Snake morphology.

Viperid snakes (*Viperidae*) inhabit all continents except for Australia and, of course, the Antarctic. Highly adaptive in terms of evolution, members of this group make up the northern-most (the European viper, *Vipera berus*) and southern-most (the Patagonia lancehead, *Bothrops ammodytoides*) venomous snakes in existence. In addition, they also dwell at the highest elevation of all venomous snakes (the Himalayan pit viper, *Gloydius himalayanus*). Snakes of some genera are much sought after by hobbyists as pets, such as *Crotalus* snakes, nose-horned vipers (*Vipera ammodytes*), Asian pit vipers (*Trimeresurus* spp.), and others.

The venoms of *Viperidae* snakes primarily contain enzymatic components with locally destructive effects; in addition, they mostly attack vascular and hemocoagulation systems. Neurotoxic components in viper venoms, if at all present, possess an enzymatic structure and are mostly insignificant clinically.

6.4.1. Subfamily: *Azemiopinae*

Genera and species: This is a monotypic subfamily with a single genus, *Azemiops*, and a single species, the Fea's viper (*Azemiops feae*).

Other names: Vipére de Feae (FR).

Description: The Fea's viper is an extremely rare and attractively looking snake up to 90 cm long. It rather resembles a colubrid or elapid. Coloring varies from dark blue to black, with light - mostly yellowish - thin rings, and an orange head.

Home range and habitat: They reside in humid mountainous and sub-mountainous forests in S China, Tibet, N Burma, and N Vietnam.

Toxins: The venom is relatively potent; LD_{50} in mice IV is 0.52 mg/kg (Warrell, 1995). Activities correspond to the toxin composition in viperid snakes except for the absence of procoagulative, anticoagulative, and myolytic enzymes.

Local symptoms of envenoming: Only a few cases of envenoming have been described. At a local level, a snakebite will only manifest with pain and edema.

Systemic symptoms of envenoming: No systemic signs of envenoming are known. In more severe cases, hypotension is possible with potential manifestation of vegetative dystonia.

Laboratory findings: Not known; leukocytosis is possible.

Mortality: Mortality is neither described nor expected.

Therapy: Symptomatic treatment; antivenom is not available.

6.4.2 Subfamily: *Viperinae*

The *Viperinae* subfamily recently has been defined as covering approximately 13 genera of some 65 species.

The anatomy of viperine snakes is similar to that of most viperids (*Viperidae*); in addition, they resemble the rest of the family in many ways. They have a thickset body, largely with a broad distinctive head. Many of them feature dorsal serpentine or intermittent patterns made of blurred spots. According to the structure and function of their venom apparatus, featuring large erectile fangs embedded in maxilla, they may be ranked among solenoglyphous snakes; see chapter 1. 4 Venom apparatus of snakes. With some exceptions, they are surface foragers. The venom composition roughly corresponds to that of other viperids - there is a significant proportion of enzymes that sometimes have important destructive potency towards tissues, and in many cases also components afflicting hemocoagulation and the vascular system. Although sometimes clinically evident, potential neurotoxins form a less important component; they are always of an enzymatic nature with presynaptic effects.

The members of the *Viperinae* subfamily inhabit a predominant part of European and African regions and most of Asia. In the field of epidemiology of snake envenomings, they play a major role across Africa, Europe, and certain Asian regions.

6.4.2.1. Adenorhinosa and Atheris Genera

Species: The Uzungwe mountain bush viper (*Adenorhinos barbouri*) is the only member of the *Adenorhinos* genus; in addition, it has been recently reclassified under the *Atheris* genus as *Atheris barbouri*. The bush viper genus (*Atheris*) contains 10 species with the rough-scaled bush viper (*Atheris squamiger*) and the Great Lakes bush viper (*Atheris nitschei*) being probably the best known representatives; for other members, see chapter 7 List of venomous snakes. Two of the species above are now mostly classified as separate monotypic genera, *Montatheris* and *Proatheris*, with the Kenya mountain viper (*Montatheris hindi*) and lowland swamp viper (*Proatheris superciliaris*), respectively, being the only species.

Other names: FR: Vipére arboricole.

Description: The *Atheris* snakes are relatively slender viperines; they can grow up to 50-75 cm, but only 40 cm in case of *A. barbouri*. The body color is typically in hues of brown, olive or gray, through to gray/black, which is often combined with a light or yellowish pattern (*A. nitschei*). Head and neck scales can in some species stick out and form small horns or make the snake look hairy or spiny. The majority of these snakes possess a prehensile tail. They are largely shrub or tree dwellers, ranging anywhere from ground level to the height of about six meters; however, they can climb down and move along the surface as well. The rare snakes of the *Montatheris* and *Proatheris* genus live only a terrestrial life. Mostly active at dusk or at night, these snakes can hunt - or also bask - during the day in higher elevations when lower temperatures allow.

Home range and habitat: Bush vipers dwell in shrub, reed, bamboo, and tree stands including forests in diverse localities. *Atheris* snakes are predominantly found in Central-western and Eastern Africa, with fragments of populations reaching Central Africa west of Guinea-Bissau, to Kenya in the east and Malawi in the south. *A. squamiger* resides in SE Nigeria up to NW Angola, Congo-Brazzaville as far as S Uganda, W Kenya, and Ghana. As for the *Adenorhinos* bush vipers, S Tanzania is their home range.

Toxins: The venom of *Atheris* snakes is believed to be quite potent: LD_{50} for mice amounts to 5 mg/kg SC. Among others, it contains components affecting the vascular system in terms of vasodilation and endothelial damage, including hemorrhagic components and

hemocoagulation-afflicting compounds, such as FBG-converting enzymes, an FV and Ca^{2+} dependant prothrombin activator, and enzymes that activate PLT aggregability, etc.

Local symptoms of envenoming: The bite can be very painful, with possible immediate propagation as far as regional lymph nodes. The edema that generates at the bitten site is typically rather localized and not very large, but is rarely quite sizeable. Petechiae, bruises or even hemorrhagic blisters are formed, and regional lymphadenopathy occurs. Minor cases of necrosis are likely to occur at the bitten site, as well as peripheral cyanosis probably caused by tissue congestion and local hemorrhaging. The edema will, in most cases, disappear in two days. Residual pain may persist for about a week to a month, even at the points of related lymph nodes. A minor motional disorder at the bitten site can persist over a longer period.

Systemic symptoms of envenoming: All available clinical information on such envenomings is rather limited and generally based on bites from *Atheris squamiger*. Recently, two cases of envenoming by *Proatheris superciliaris* have been described (Valenta et al. 2008, Keyler 2008).

Early following the bite, envenoming is followed by nausea, vomiting, and diarrhea; symptoms may be even more severe. Vertigo, vision disorders, shivering, fever, increased sweating, hypertension, and pain when breathing occur. A bite from *P. superciliaris* has caused renal function disorders with oliguric renal failure and thrombotic angiopathy. Disorders of or reduced consciousness with respiratory difficulties can, very occasionally in severe cases, result in the necessity for tracheal intubation and mechanical ventilation. Early circulation collapse has also been described, as well as a serious hemocoagulation disorder with hematemesis and a fatal course. Nevertheless, the majority of envenomings will be not significant and should be of a benign type.

Laboratory findings: The blood count will reveal neutrophilic leukocytosis and hemolysis. Hemocoagulation test records prolonged PT, APTT and TT, up to extreme levels; FBG level is reduced, and FDP increased. AT activity - especially in early phases - is typically not reduced; plasminogen concentration decreases with settlement within three days have been described. Biochemical findings only reveal LD and CC level increases in serum of minor significance, and proteinuria.

Mortality: Lethality of the snakebite is rare. A fatal case was described (Lanoie et Branch, 1991) with production of massive edema, non-coagulable blood, hematemesis, and death on day 5, under a hemorrhagic shock.

Therapy: For first aid and general rules of treatment, see chapter 5 Snakebite: Therapy and prevention. Limb immobilization and delicate local treatment is advisable with moderate cooling and elevation if pain, edema, and congestion are present. Analgesics including opiates and antiphlogistics, except ASA, can be administered in cases of profound pain; sedation is also applicable.

No antivenom is available; Robinson et al. (2004) describe a positive effect from an antivenom no longer available: NEAR MIDDLE EAST ANTIVENOM, Behringwerke, Germany; with its range of effects including *Cerastes*, *Echis,* and *Vipera* snakes. Other antivenom containing effects against the viperids mentioned above, especially those of the *Echis* genus, may possess a certain level of effectiveness against the venoms of *Adenorhinos* and *Atheris* snakes as well. To eliminate toxin components, plasmaferesis has been employed too (Keyler 2008).

Any potential case of hypotension will require IV application of crystalloids or colloid solutions. At the same time, an increased supply of liquids will work to prevent renal failure.

The possible hemocoagulation disorder with hemorrhaging can be treated using an administration of 10-20 ml of fresh frozen plasma per kg; application of AT if its activity is reduced is advisable. For other treatment options in case of hemocoagulation disregulation, see chapter 5. 3. 3. 6 Hemocoagulation disorders. Heparinization may prove useful, except for the phase of bleeding: UFH, at a dosage of 70-200 units/kg (5,000-15,000 units/day per adult) or a relevant pre-emptive dose of LMWH.

Most envenomings will take place without any more serious systemic symptoms and abate the following day; in more severe cases, a normal status can be expected within a week. The patient can be discharged for home treatment after 24 hours following abatement of systemic symptoms and more serious laboratory symptomatology.

6.4.2.2. Bitis Genus, Puff Adders

Species: This snake genus contains approximately 14 species of African puff adders, with the most significant representatives being the African puff adder (*Bitis arietans*), Gabon viper (*Bitis gabonica*), and also the rhinoceros viper (*Bitis nasicornis*). For other members of this genus, see chapter 7 List of venomous snakes.

Other names: FR: Vipére heurtande, Vipére hébraique (*B. arietans*); Vipére du Gabon (*B. gabonica*). EN: Horned viper (*B. nasicornis*). Former names: *Bitis lachesis* (*B. arietans*).

Description: The lengths *Bitis* snakes grow to vary according to species, from 20 cm for the Peringueyi's adder (*B. peringueyi*) to 120-150 cm for the large and robust Gabon vipers (*B. gabonica*), the record holder for the greatest documented length in viperids (205 cm). The majority of these snakes are usually colored by a range of contrasting spots and stripes in shades of brown, gray to silver, olive, green with lighter tints, and yellow to a creamy tone. The Gabon viper (*B. gabonica*) is probably the snake with the most contrasting coloration, which paradoxically presents a very effective way of mimicking leaves on the forest floor for these snakes. Movements of the *Bitis* snakes, especially the robust and potent Gabon viper (*B. gabonica*), is relatively slow, meaning an increased risk of unwanted contact with humans. The Gabon viper is thought to be a calm and placid animal; allegedly, this snake tolerates handling and is even termed a toy for Gabonese children. Nevertheless, the striking speed and the record length of the fangs, a documented maximum being 5.5 cm, prompt a high level of cautiousness when in contact with this spectacular snake. Sensing danger, the Gabon viper will hiss loudly, puffing up its body. A subspecies, *B. gabonica rhinoceros*, alternatively now designated a separate species, *B. rhinoceros*, features scales placed on the end of its snout that elongate it into a distinctive horn. The rhinoceros viper (*B. nasicornis*) presents a similar, but lesser member of the genus. The African puff adder (*Bitis arietans*) is probably Africa's most widespread dangerous venomous snake, and one reportedly with the greatest share of human envenomings in Sub-Saharan Africa. This snake is apparently responsible for more bites and fatalities in people and domestic cattle than all of the remaining African snakes together, the reason for which might be the slow movement mentioned above. Snakebites from lesser African *Bitis* vipers are not usually dangerous to adults. Other members of the genus are rare, like the Angolan adder (*Bitis heraldica*) or still relatively unknown, e.g. the red adder (*Bitis rubida* - Branch, 1997, the species' discoverer).

Bitis vipers are largely nocturnal snakes; in colder periods of the year or in southern regions, they like basking in the sun.

Home range and habitat: The African puff adder (*B. arietans arietans*) lives in the savannahs of the Sub-Saharan region to S Africa, and the SW Arabian Peninsula,

predominantly in the grassy sections of the bush. *B. arietans somalica* inhabits Somalia, SE Ethiopia, and NE Kenya.

B. gabonica is found in woodland and forest localities in S Sudan, S Nigeria, Uganda, Tanzania, Congo-Brazzaville, Gabon, Angola, central and S Zambia, E Zimbabwe, Mozambique, and some of the western territory of the Republic of South Africa.

The rhinoceros viper (*B. nasicornis*) ranges in the woodland and primary forest habitats in W Kenya, S Sudan, Rwanda, Burundi, S Uganda, the central part of Congo Brazzaville, DRC, NW Angola, Gabon, Liberia, and S Guinea.

Toxins: *Bitis* snake venoms are far from the top of the list of effectiveness. LD_{100} of *B. arietans* venom for SC administration in mice is 6 mg/kg, which is approximately thirty times less than the effectiveness of toxins from sea snakes, taipans, or Indian cobras. Snakebite incidence, morbidity, and mortality of envenoming vary subject to venom quantity, which in *B. arietans* is theoretically sufficient to kill 4-5 persons, while in *B. gabonica* it can be up to 1 g of dry matter. In terms of their activities, the venoms of the African puff adders (*Bitis*) predominantly affect the cardiovascular and hemocoagulation system; they also possess hemorrhagic and destructive cytotoxic enzymes, such as proteinases, hyaluronidases, hydrolases, phospholipases, etc.

The venom of *B. arietans* contains, amongst other commonly given enzymes, also thrombolytic and fibrino(geno)lytic enzymes, bitistatin, a protein-like toxin inhibiting platelet aggregation and prolonging hemocoagulation time, and kinin, which releases an enzyme responsible for hypotension.

Compared to other species, *B. gabonica* features less effective venom, although a serious envenoming can be still secured due to the quantity of venom in the venom apparatus of this viper. The venom contains gabonase - an enzyme with a thrombin activity, and gabonine - an anti-PLT peptide that inhibits PLT aggregation induced by collagen - plus thrombin, and arachidon acid. The gabonase action brings about a DIC-like syndrome. The low FDP levels mentioned by some papers are not typical for the process of the disorder and can be probably caused by hindered immunodetection in partial cleavage of antigens by toxins. The activities of toxins, hemorrhagins and the pathophysiological changes induced by these substances will damage the capillary system with a clinical picture of pulmonary and GIT affection. The venom lacks neurotoxins; however, it contains cardiotoxins responsible for arrhythmias and myocardial contractility disorders with a reduced volume of heartbeat and heart output. In addition, it reduces peripheral vascular resistance either locally, i.e. through the bradykinin formations, or at a systemic level by its impact on vasomotoric centers. Furthermore, toxins cause a metabolic alteration with reduced oxygen utilization, increased lactatemia, and glycemia.

The venom composition of the rhinoceros viper (*B. nasicornis*) is very similar to that of *B. gabonica*: it mainly contains cardiotoxins, hemocoagulation-affecting enzymes, and proteinases damaging tissues. Local as well as systemic symptoms of envenoming correspond to the symptomatology of envenoming by the *B. gabonica* venom, although they do not reach its intensity due to venom quantity. The venom's components have an impact on activation of hemocoagulation in both an internal and external manner; at the same time, they potentiate the plasmin activity that is, however, inhibited when concentrations are larger. Similarly, platelet adhesion, which is increased by a low toxin concentration, is inhibited by reduced ADP-reactivity when toxin doses are higher.

Local symptoms of envenoming: With regard to the size of fangs, marks of bites can be evident at the bitten site as penetration by a single or two teeth, in rare cases also by three to four teeth. Such duplicity can occur by the frequent presence of growing teeth behind the first and functional fangs. Envenoming is also possible through merely a deep scratch by one or two fangs. The bitten site is painful, lymphadenopathy occurs with enlarged regional lymph nodes. The onset of edema production is relatively prompt; the edema is largely one of hemorrhagic nature and can spread around the torso, irrespective of applying antivenom. Even though its intensity will mostly not increase to the level required for compartment syndrome to occur, edema of the carpal channel with depressed nervus medianus and subsequent surgical release has been described (Wildi et al., 2001). Besides this, fasciotomy has had to be carried out at the author's workplace due to a precipitous development of compartment syndrome affecting a forearm. The presence of edema is typical in every envenomed person, reaching a maximum within 1-2 days and persisting for 5 days up to 3 weeks. Blisters, petechiae, ecchymoses, and extensive bruises through to localized hemorrhaging come up on the surface of the skin, with the subsequent spread of erythrodermia around the body. Several cases feature necrosis that occurs following a few days to a week; this can be superficial, but in some cases considerable and deep, with the necessity for debridement and even amputation. Less frequently, thrombosis may take place in the bloodstream of the affected region. Severe local reactions can follow in over a half of bites.

Systemic symptoms of envenoming: Systemic symptoms of envenoming following a snakebite from *Bitis* snakes, namely African puff adders (*B. arietans*), occur in less than half of afflicted persons, including increased temperatures and fevers of over 40 ^{o}C, fatigue, somnolence, nausea, vomiting, abdominal pain, and cold fevers with sweating. The symptoms appear very early on, but in some cases may be delayed by a number of hours after a bite; they will persist for a relatively long time - up to 8 days following an attack.

Affliction of the cardiovascular system will manifest itself via vasodilation, myocardial depression with bradycardia or tachycardia, and may even result into circulation collapse and shock. In case of envenoming by the Gabon viper (*B. gabonica*), which contains effective cardiotoxins, cases of circulatory failure crop up soon after a bite and resulting in possible unconsciousness. The effect of the cardiotoxins will be visible as tachycardia, severe hypotension, prolonged QT-interval, T wave inversion and potential cardiac arrest. Arrhythmias can persist for several days.

Coagulopathy, largely with clinical signs of increased hemorrhaging, is a serious aspect of the systemic envenoming process. Perfusion of the tissue at and around the bitten site is possible. If the progress of the hemostatic disorder is more severe, it is accompanied by epistaxis, bleeding from mucous membranes, gastrointestinal, chest and pelvis hemorrhaging, as well as hematuria. Even though certain signs indicate that coagulopathy will probably not always be that resembling DIC (low FDP), there is endothelial damage, probably also directly caused by toxins, with a clinical picture of extravasation from affected capillaries. The non-DIC-coagulopathy does not preclude any future conversion into DIC via the commencement of relevant pathophysiological mechanisms. Symptoms of microangiopathic hemolytic anemia can be present. Endothelial and capillary damage as such is accompanied by a risk of liquids and proteins being released into the pulmonary interstitium and subsequently producing a shock to the lungs in the form of respiratory failure.

A selective bond of the venom in the kidney associated with hematuria, hemoglobinuria, or myoglobinuria make some patients predisposed to renal failure. Hepatorenal failure is also known to occur.

Symptomatology may include a vague metabolic alteration with limited oxygen utilization, increased glycemia, and high lactatemia.

Laboratory findings: The existence of neutrophilic leukocytosis presents a non-specific test result. Hemocoagulation disorder is manifest via prolonged PT, APTT, and TT, thrombocytopenia and decreased FBG. Increased levels of FDP are possible, including D-dim in some cases, but normal FDP levels found are specified as well: 1.25-10 mg/l with standard values from 10 to 40 mg/l (Warrell et al, 1975). Decreased AT, PC, FV, and FVIII activities have also been determined. The presence of poikilocytes and schistocytes indicating microangiopathic hemolysis is possible. Naturally, hemorrhaging is accompanied by decreased Hb and Hct.

Biochemical lab tests typically show increased levels of bilirubin, AST, ALT, and LD. Hyperglycemia and hyperlactatemia are determined - up to 8.9 mmol/l. Erythrocytes, hemoglobin and myoglobin are found in urine.

Mortality: The mortality of snakebites from the African puff adder (*B. arietans*) is high, equaling 2 out of every 10 envenomed persons, even if antivenom is applied. Death can occur relatively early after a bite, with symptoms of circulatory failure or profound hemorrhaging. In the late phase of the diseases, an envenomed person can die from the consequences of gangrene, sepsis, and septic shock, i.e. multiple organ failure.

In case of the Gabon viper (*B. gabonica*), the mortality of any higher epidemiological significance following a snakebite is rather unexpected due to the low incidence of attacks by this snake. Nevertheless, any potential fatal envenoming after a successfully completed bite by this species will not differ in terms of mortality of snakebite to that of *B. arietans*.

Fatalities due to any other member of the *Bitis* genus are not known, but cannot be ruled out.

Therapy: For first aid and general rules of treatment, see chapter 5 Snakebite: Therapy and prevention. Limb immobilization and delicate local treatment is advisable, with moderate cooling and elevation in case of pain, edema, and congestion. Analgesics including opiates and antiphlogistics, except ASA, can be administered in case of intensive pain; sedation is also applicable.

If a proven envenoming is manifested, such as by hemorrhaging, thrombocytopenia, hypotension, bradycardia or other systemic symptoms, as well as edema enveloping over a half of a limb, or should severe local changes take place, administration of antivenom is fully indicated.

Applicable antivenoms:

* SAIMR POLYVALENT SNAKE ANTIVENOM, South African Institute for Medical Research, the Republic of South Africa (*Bitis arietans*, *Bitis gabonica*, and others);

* ANTIREPT PASTEUR, Aventis Pasteur, France (*Bitis lachesis-arietans*, etc.);

* FAV-AFRIQUE, Aventis Pasteur, France (*Bitis arietans*, *Bitis gabonica*, etc.);

* FAVIREPT, Aventis Pasteur, France (*Bitis arietans*, etc.);

* SERUM ANTIVENIMEUX BITIS ECHIS NAJA PASTEUR, Pasteur Merieux, France (*Bitis gabonica*, *Bitis lachesis-arietans*).

In certain cases, if symptoms of envenoming persist, a higher number of vials must be administered - up to 15. If applied early, immunotherapy may even reduce the development of necrosis.

In local treatment, the necessity to delicately handle damaged tissue, which is often perfused and tends to produce necrosis, is emphasized. When treating the affected parts with bullae and necrosis, surface removal and early necrectomy is advisable; in rarer cases - if gangrene sets in - amputation may be necessary.

Symptomatic treatment is subject to the status of the patient; circulation can be maintained by increasing intravasal volume and applying catecholamines, or α-sympathomimetics and β-sympathomimetics. In addition, boosting the supply of liquids will be essential for satisfactory diuresis to be retained. Any onset of arrhythmia, especially when persisting, must be solved symptomatically, which in extreme cases can even conducted by temporary cardiostimulation.

In cases of hemorrhaging, recommendations include the application of fresh frozen plasma, in a quantity from 10 to 20 ml/kg, or possibly AT if its activity has significantly reduced. For further information, see chapter 5. 3. 3. 6 Hemocoagulation disorders. If hemorrhaging continues due to increased fibrinolysis and any responsibility of DIC symptomatology has been ruled out, antifibrinolytics can be applied. Miniheparinizing the patient with a dose of 70-200 units UFH/kg/24 hours or an applicable pre-emptive dose of LMWH is advisable when bleeding has been paused. Applying leeches (Lavonas et Tomaszewski, 2002) is an intriguing form of therapy.

Respiratory insufficiency may even be a prompt for supportive mechanical ventilation; renal failure will require the use of extra-corporeal methods of elimination.

The preventive use of antibiotics is not indicated, but essential in case of development of inflammation from any bacteria found; this should even cover any potential anaerobic infection.

The patient can be discharged for home treatment after 24 hours following abatement of all systemic symptoms and normalization of significant laboratory findings; minor local afflictions can be solved via outpatient treatment. Any persisting laboratory indications of moderate prothrombotic activity should be managed by pre-emptive miniheparinization, see chapter 5.4 Convalescence following envenoming.

6.4.2.3. Causus Genus, Night Adders

Species: Sometimes placed into a separate subfamily, *Causinae*, this genus consists of six species including the night adder (*Causus defilippi*), green night adder (*Causus resimus*), common night adder (*Causus rhombeatus*), etc.; see chapter 7. List of venomous snakes.

Other names: FR: Vipere nokturne.

Description: Night adders are relatively slender snakes that grow up to approximately 60-70 cm. Their body is dorsally colored in shades of brown, gray, or green. They possess a large venom gland, and can inject an enormous quantity of venom when striking successfully. They are rather aggressive snakes; when attacking, they possess the ability to extend their necks like cobras do, but do not lift the anterior part of their bodies. They are largely active at night, which is also when the majority of bites occur.

Home range and habitat: Night adders inhabit rather humid as well as dry grassy parts of bush or forests and environments around of rivers, wetlands, and fields. They usually stay on

the ground, but sometimes are found in shrubs as well. Their home range involves E, SE, Central, and W Africa to the south of the Sahara.

Toxins: The venom of night adders contains a number of predominantly enzymatic toxins typical for viperid snakes, with hemocoagulation-afflicting compounds, numbering amongst them procoagulative and anticoagulative enzymes which are probably the most significant substances. In addition, the venom of *C. rhombeatus* possesses CR-serpinase, an enzyme that can inactivate AT. The venom neither possesses its own thrombin-like activity nor induces FBG. Furthermore, it contains a number of enzymes (proteinases, hyaluronidases, hydrolases, and phospholipases) with principally less serious cytotoxic activities clinically.

Local symptoms of envenoming: Locally, envenoming by a night adder (*Causus*) becomes manifest via pain, edema - mostly slight or medium, and lymphadenopathy with painful enlargement of lymph nodes in the related area in some cases. Minor hemorrhaging from the afflicted site is possible; necrosis is not formed.

Systemic symptoms of envenoming: Any systemic symptoms are mostly likely limited to increased temperature. Signs of languor, somnolence, and the occurrence of hypotension with tachycardia are less common. Cases of light hematuria settled spontaneously have been described.

Laboratory findings: There is only minor neutrophilic leukocytosis shown; hemocoagulation and biochemical values do not show any changes.

Mortality: Fatalities are not known.

Therapy: For first aid and general rules of treatment, see chapter 5 Snakebite: Therapy and prevention.

Limb immobilization and delicate local treatment is advisable, with moderate cooling and elevation in case of any pain, edema, and congestion present.

No antivenom is available; a certain probability of cross-reactivity with some African polyvalent antivenoms exists, although administration is not indicated. Symptoms of envenoming will abate spontaneously.

Should systemic symptoms exist, symptomatic treatment is applied.

An increased supply of liquids to protect against renal perfusion is advisable for potential hypotension in cases of severe envenoming, especially when hematuria occur at the same time.

The patient can be discharged for home treatment after 24 hours once all systemic symptoms recede.

6.4.2.4. Cerastes Genus, Desert Horned Vipers

Species: The *Cerastes* snake genus consists of three species, with the desert horned viper (*Cerastes cerastes*) being the one best-known, plus the Arabian horned viper (*Cerastes gasperettii*) and Sahara horned viper (*Cerastes vipera*).

Other names: EN: Sahara, African, Egyptian, desert, sand horned viper; FR: Vipére cornue (*C. cerastes*). EN: Sahara hornless, common sand, Avicennas, Cleopatra, lesser cerastes viper; FR: Vipére d'Avicena (*C. vipera*).

Description: Cerastes vipers do not exceed 70 cm in length. Their color is a gray/brown and tones of gray. The head is broad, with the desert horned and Arabian vipers boasting horn-like projections above their eyes. They like hiding in the sand with only the head protruding above the surface. When hidden, the snakes let humans pass by in close proximity. However, should a person stop, the viper will escape fearing it has been discovered, thereby

becoming of interest to the intruder. Sidewinders, they leave typical traces of their side movements on loose sand. They are predominantly nocturnal snakes. *Cerastes* snakes are much sought after by snake keepers, so bites from horned vipers are nothing rare.

Home range and habitat: These snakes typically reside in sandy and rocky regions of Saharan Africa, from SE Morocco as far as Egypt, and the central parts of Mali, Niger, Chad, and Somalia to the south. The home ranges of the desert horned viper (*C. cerastes*) and the Arabian horned viper (*C. gasperetti*) extend across Israel and the Arabian Peninsula as far as SW Iran.

Toxins: The venom of *Cerastes* snakes largely contains enzymatic compounds of proteolytic activity that impact on the hemocoagulation system. The components of the venom destroy, amongst other things, FBG molecules - afaacytin, cerastes F-4; they have thrombin-like properties - cerastocytin - and activate FX and PLT aggregability. The results of venom effects typically include localized destruction and a DIC-like hemocoagulation disorder.

Local symptoms of envenoming: Local symptoms of envenoming are mostly limited to formation of painful medium-sized, potentially hemorrhagic edema with lymphadenopathy and swollen lymph nodes in the related area. The bite wounds often display slight hemorrhaging. Petechiae and ecchymoses appear on the skin, with less frequent hemorrhagic vesicles and minor areas of necrosis. In rare cases, serious affliction of deeper tissues and muscles is possible with permanent deformities and persisting motional disorders, for example, if fine structures of the arm are hit.

*Systemic symptoms of envenoming***:** Envenoming by the *Cerastes* viper genus is typically not serious, hence the bibliography does not provide very numerous records. Systemic symptoms are largely not very distinctive or only manifest as minor discomfort, increased temperature, nausea, or vertigo and vomiting. Nonetheless, this will not eliminate any effect of procoagulative, anticoagulative, or platelet-aggregating venom components, which may be clinically evidenced by hemorrhaging or the tendency for (micro)thrombi to develop, predominantly on the bitten limb. Coagulation disorder typically resembles that of DIC; clinically, mostly minor bleeding from stab and bite wounds is present. Cases of five-day successful therapy of the DIC syndrome in a 3-year-old child and 18-year-old woman without using an antivenom are described, as well as tachycardia, hypertension, and urine retention in 2-year-old and 4-year old children. Serious or fatal courses of envenoming are rare. However, shock status with symptoms of pulmonary affliction and reversible oliguric renal failure with necessary hemodialysis has been described from the author's workplace.

In the Czech Republic, 9 cases of bites from the desert horned viper (*C. cerastes*) have been reported in the past 6 years, from which not one envenoming took place, in four cases only a local response occurred, and there were four cases of systemic envenoming, with two of them following a more intensive course: one of patients underwent shock status with incipient respiratory insufficiency, while in the other, symptoms of DIC and hemolysis occurred with subcapsular renal hematom, pancreatitis and oliguric renal failure, with hemodialysis required. A relatively serious edema of the arm was complicated by phlegm. Convalescence was approximately achieved within two months.

*Laboratory findings***:** Hemocoagulation values show prolonged PT, APTT and TT; the values of which are impossible to measure at the stage of developed envenoming. The FBG level decreases, while that of FDP, including D-dim, goes up. The level of thrombocytopenia

may not correspond to the significance of the consumption, as well as the potentially declined AT activity. More grievous hemorrhaging is accompanied by reduced Hb and Hct.

Mortality: No fatalities are known, but still possible because of the nature of the venom, especially in children and in case of insufficient treatment.

Therapy: Although in most instances of bites there is only a localized envenoming or a low-level systemic response, giving first aid to the fullest possible extent is advisable, and general rules of treatment apply; see chapter 5 Snakebite: Therapy and prevention.

Applying antivenom is indicated where a more significant systemic response occurs or if a patient's status is deteriorating, although this is only visible in laboratory results.

Applicable antivenoms:

* ANTIREPT PASTEUR, Aventis Pasteur, France (*Cerastes cerastes*, *Cerastes vipera*, and other snakes);
* FAVIREPT, Aventis Pasteur, France (*Cerastes cerastes*, and others);
* POLYVALENT SNAKE ANTIVENOM, Saud Arabia (*Cerastes*, etc.).

Antivenom is also applicable if a significant local affliction is found, although neither improvement of the affected tissue nor mitigation of the necrosis formed can be expected with certainty.

The affected limb should be elevated, immobilized and moderately cooled; administration of analgesics is advisable. If hemorrhagic bullae occur, their surface should be removed and the bed treated; in rather rare cases of necrosis, early necrectomy is indicated.

If a DIC-like hemocoagulation disorder is found, administration of fresh frozen plasma is applicable; the dosage being 10-20 ml/kg. For following steps of treatment based on the significance of the symptomatology, see chapter 5. 3. 3. 6 Hemocoagulation disorders. If the patient is not bleeding and an examination shows signs of increased thrombin activity and consumption - a significant increase in D-dim - miniheparinization by pre-emptive doses of UFH (Unfractionated Heparin) or LMWH is advisable.

The need for a sufficient supply of liquids to protect renal function applies. Any decrease in systemic pressure will be firstly corrected by supplying liquids; catecholamines can be applied only if this fails or critical hypotension occurs. Any other potential complications should be solved according to symptomatology.

Discharge of the patient is possible after 24 hours following abatement of all clinical symptoms and more significant laboratory abnormities. Any persisting laboratory symptomatology of rather moderate prothrombotic activity should be managed by pre-emptive miniheparinization, see chapter 5.4 Convalescence following envenoming.

6.4.2.5. Daboia Genus

Species: *Daboia* presents a monotypic genus consisting of the Russel's viper (*Daboia russelli*; formerly: *Vipera russelli*). This single species is subdivided into subspecies: *Daboia russelli russelli,* formerly called the *pulchella* or *nordicus* subspecies, or also the western form, and *Daboia russelli siamensis,* former also the *formosensis*, *limitis* or *sublimitis* subspecies, or also the eastern form.

Other names: EN: Taiwan Russell's viper; FR: Vipére de Russell; native names: Daboia, Tic-Polonga.

Description: The Russel's viper (*D. russelli*) is a large and thickset snake achieving a length of over 100 cm, with the greatest recorded length being 185 cm. Coloring is in the form of brownish or brown/gray shades with three rows of oval spots featuring a dark or light lining arranged lengthwise.

Daboia, as this animal is also called, is the snake with the highest epidemiological significance in its home range of Sri Lanka, with the incidence of 400 bites per 100,000 residents a year and a high mortality rate, see below. Victims include 93% of farmers - rice growers.

Home range and habitat: This viper can be found in almost any habitat except dense forests, often in paddy fields. *D. russelli russelli* ranges in Pakistan, India, Bangladesh, and Sri Lanka, and the home range for *D. russelli siamensis* is S China, Central and S Burma, Central Thailand, Taiwan, and a part of Indonesia - E Java, and the islands of Komodo, Flores, and Lomblen.

Toxins: The quantity of effective venom the Russel's viper (*D. russelli*) can produce is quite high, approximately up to 200 mg of dry matter. Naturally, the rule that not every bite could cause an envenoming applies in this case, as with other snakes: 28% of the envenomed were free of any clinical symptoms within one of the studies (Myint-Lwin et al., 1985). The venom includes enzymes with a procoagulative action, e.g. activation of FV, FIX, and FX, and those possessing a direct fibrino(geno)lytic activity, etc. The occurrence of DIC-like coagulopathy results in a severe disorder of coagulum production with hemorrhaging and endothelial damage. The venom of *D. russelli siamensis* possesses presynaptic neurotoxicity as well, probably caused by PLA_2 which cannot be controlled by anticholinesterase. In addition, PLA_2-like enzymes are responsible for myonecrosis to develop. Myoglobin, microthrombi in glomerular capillary beds, and the likelihood of toxins with a direct action on renal tubules cause renal damage including following tubular necrosis.

Local symptoms of envenoming: Pain is the initial sign of a snakebite, with subsequent edema. The bite wounds may bleed. The pain present in the majority of those afflicted will increase over time, and the sore edema spreads to related lymph nodes, and even to the torso within hours. Regional lymph nodes become enlarged. The strain and pain in the limb will mostly persist for 1-4 days. Petechiae, ecchymoses, and hemorrhagic blisters, and more rarely, in some 2-9% of cases, necrosis are formed on the skin in the area of envenoming. Local hemorrhaging occurs in about 30% of cases. Even though the severity of systemic symptoms of envenoming will be largely equal to the extent of the edema, some patients with systemic envenoming, about 6%, may exhibit merely minor local afflictions.

A higher proportion of afflicted persons, 14% - 77%, feature muscle pain caused by myonecrosis that can be discerned as either local pain upon palpation, or even pain at a systemic level that can persist for approximately 5-7 days regardless of early administration of venom.

Systemic symptoms of envenoming: As with the majority of vipers, prodromal symptoms of envenoming are displayed in form of nausea, vomiting, epigastric, and hypogastric pain, diarrhea, or possibly the onset of angioneurotic edema. Hypotension with tachycardia and circulation collapse in the early phase indicates a serious envenoming. In the late phase, hypertension, probably due to renal damage, is possible to register.

The most typical symptom of envenoming by the venom of *Daboia russelli* is a DIC-like hemocoagulation disorder in some 80% of the patients; in nearly a half of those envenomed this will manifest with spontaneous hemorrhaging, while some will exhibit thrombocytopenia

and signs of increased capillary permeability. Typical clinical symptoms are hematuria, hemorrhaging from mucous membranes and gastrointestinal hemorrhaging, including hematemesis and enterorrhage, as well as hemorrhaging into lungs, airways, from small wounds, and nose and subconjunctival hemorrhaging. Damage to the capillary endothelium will be displayed as facial edema - even after 12-50 hours, i.e. conjunctival chemosis; more rarely, fluidothorax and ascites are formed. Coagulopathy and related symptomatology will peak on days 1-3 and persist for about a week.

The procoagulative activity of toxins responsible for profound coagulopathy, at least to some extent, will be co-responsible for another symptom of envenoming and cause for mortality - renal failure. The causes for acute renal failure that can be present in nearly a half of afflicted persons involve formation of fibrin deposits and microthrombi in the renal capillary beds, a direct action of toxin on the renal tissue and myoglobinuria which will arise based on necrosis of muscles. The renal perfusion disorder is boosted by hypotension due to vasodilation, extravasation of liquids, and hypovolemia in instances of hemorrhaging. In nearly 10% of patients, this results in tubular necrosis with persisting oliguria. Renal failure occurs suddenly; in most of the patients, it is preceded and accompanied by a painful palpation in the lumbar region. This type of failure presents a significant prodromal symptom that can be utilized as an invaluable indication of future failure.

Further symptomatology of envenoming is based on presynaptic neurotoxicity. Conduction in motoric nerves will slow down; nevertheless, the intensity of damage will not increase to the level of paralysis of respiratory muscles. Clinically, this is manifest through overall weakness, bilateral ptosis, external ophtalmoplegia, double or blurred vision, dysphagia, dysarthria, and difficulties in opening the mouth. The onset of neurotoxicity that presents a predominant and distinctive feature of *Daboia russelli russelli* venom, apparent in nearly 80% of those affected, can be sometimes set in early - within an hour - but can occur later, even 48 hours after the envenoming.

Pain, increased sensitivity, and strain in muscles all over the body are caused by myonecrosis at a systemic level. This is typically assigned to the action of neuromyotoxic PLA_2 enzymes. Both neurological and myotoxic symptomatology will abate in about 5-7 days.

In some cases of systemic envenoming, cardiac damage with changes found in ECG lab tests can be also registered.

Severe envenoming after a snakebite from the Russel's viper is defined by the presence of at least one afflicted system, be it the nerve system - ptosis, ophtalmoplegia, dysphagia, etc.; circulation - hypotension, tachycardia, circulation collapse; hemocoagulation - hemorrhaging and extravasation; or the kidneys - renal failure, tubular necrosis; in addition, a consciousness disorder is also possible as part of a severe envenoming.

Laboratory findings: 70% - 90% of envenomings bring leukocytosis with a prevalence of polymorphonuclear leukocytes, which can be further escalated due to a response following administration of antivenom.

Hemocoagulation tests routinely reveal prolonged PT, APTT a TT and hypofibrinogenemia; plus thrombocytopenia in a lesser number of cases. Reduced levels of FV, FX, and APC found will also relate to the consumption disorder. High levels of FDP including D-dim indicate, besides reduced levels of plasminogen and α2-antiplasmin, to escalation of fibrinolysis. Increased levels of vWF are probably based on activation of the hemocoagulation system.

In the plasma, free hemoglobin and myoglobin can be discerned as an effect of hemolysis and rhabdomyolysis. CC may be elevated only marginally. A reduced level of Hb and Hct is a consequence of hemorrhaging or hemolysis; decreased albumin values correspond to increased capillary permeability and proteinuria.

Proteinuria, myoglobinuria, hemoglobinuria, extending to hematuria, may be found in urine; cylinders of erythrocytes and fibrin deposits can also be present.

In about a half of the concerned, myofibril separation and edema-borne fragmentation, dilated capillaries, myonecrosis, and mononuclear infiltration can be documented by histological laboratory tests.

Mortality: Mortality following a snakebite from the Russel's viper (*Daboia russelli*) is among the highest in terms of both epidemiology and percentage of deaths of those envenomed. According to diverse resources and types of evaluation, mortality ranges from 1.25% to 8% of those attacked and can achieve 19% - 24% of those envenomed.

In Burma, mortality in 1930 exceeded 2,000 cases, which equals to 15.4 per 100,000 inhabitants, while in the 1980s it was over 1,000 persons, i.e. 3.3 fatal cases per 100,000 inhabitants; in Sri Lanka, mortality accounts for 5 cases per 100,000 inhabitants, which is 1.25% of all envenomed.

In almost every person who died there was oliguric renal failure with symptoms of or estimated acute tubular necrosis. In some cases, the status was complicated by hypotension, gastrointestinal hemorrhaging, lung and pleural cavities, subendocardial hemorrhaging, and cerebral hemorrhaging. Death occurred within 15 hours to 7 days, with 2.5 hours in case of a 4-year child being an extreme figure.

Therapy: For first aid and general rules of treatment, see chapter 5 Snakebite: Therapy and prevention. Limb immobilization and gentle local treatment can be recommended, with mild cooling and elevation in the case of any pain, edema and congestion present. Analgesics including opiates and antiphlogistics, except ASA, may be administered in instances of intense pain; sedation is also possible.

Antivenom is indicated where systemic symptoms exist.

Applicable antivenoms:

* RUSSELL'S VIPER ANTIVENIN, Thai Red Cross, Thailand (*Daboia russelli siamensis*);
* LYOPHILISED ANTI-SNAKE-VENOM SERUM, Haffkine, India (*Daboia russelli*, etc.);
* SNAKE ANTIVENIN I. P., Haffkine, India (*Daboia russelli*, and others).

Repeated application is recommended depending on a patient's status; especially in cases of severe envenoming, the maximum recommended dose can be exceeded. If the antivenom is administered early, repeatedly and in high dosage, it will effectively influence recovery of hemocoagulation in most cases; this could eliminate the disorder within 10 hours. Application of antivenom, especially if not applied immediately, will mostly not have a pre-emptive effect on renal failure and the onset of myonecrosis; the same applies to manifest neurotoxicity.

Any potential blisters and less probable necrosis are treated in an ordinary and gentle manner once the coats of bullae have been removed and necrectomia carried out. If a rare occurrence of compartment syndrome is suspected, monitoring the significance of the syndrome's development and that of tissue perfusion is essential. The correct forms of

treatment include measuring pressure in the tissue, elevating the limb, administering manitol, and, in extreme cases, fasciotomy; see chapter 5. 3. 3. 1 Local damage and 6. 4. 3. 3 *Crotalus* and *Sistrurus* genera: rattlesnakes and ground rattlesnakes. The necessity for deeper debridement is very rare, just as is the occurrence of phlegmon.

In case of hypotension, which is an initial and key symptom of circulatory affliction, volumoexpansion and administration of catecholamines will be relevant. Experimental application of Naloxon (0.2 mg/kg IV) as well as high doses of methylprednisolone (30 mg/kg/10 min) did not bring about any effect. At the same time, volumotherapy, with diuresis still retained, is a proper form of avoiding renal failure.

A DIC-like hemostasis disorder, which is based on the level and phase of envenoming, will manifest via either intensified procoagulative processes, production of fibrin deposits, and microthrombi, namely evident in glomerular capillaries. In earlier phases or instances of hemorrhaging due to eventual exhaustion of the hemostatic mechanism and non-regulated fibrinolysis, it is typically easy to control by applying an antivenom. Nonetheless, as with the DIC syndrome, modulating a coagulation activity that develops for other reasons is advisable at the same time by administering fresh-frozen plasma (10-20 ml/kg) and AT, provided AT activity has been already reduced; for further details see chapter 5. 3. 3. 6 Hemocoagulation disorders. Despite the chances of escalated fibrinolysis occurring already, any antifibrinolytics applied will pose the risk of aggravating renal failure by fixation of glomerular microthrombosis, increasing the possibility of respiratory failure. Administering 5,000 units of heparin (70 units/kg) followed by 2,500 units (35 units/kg) after 8 hours, accompanied by the administration of antivenom, insignificantly improved the course of the DIC-like coagulation disorder in cases of envenomings by vipers. Thus, heparin can be applied, outside of periods of bleeding, not only in an early phase of envenoming with a manifested hemostasis disorder, but also in the phase of convalescence in order to manage any persisting thrombophilia with potential (micro)thrombotic complications.

Renal failure is difficult to tackle via both specific and symptomatic therapy. To help reduce the incidence, modulation of hemocoagulation activity with efforts to minimize the occurrence of microthrombosis, the sufficient supply of liquids, and maintaining perfusion pressure is applicable. In nearly a half of the envenomed, hemodialysis or an alternative (C)RRT method is necessary.

Any neurological and myotoxic symptoms developed cannot be practically managed by treatment, they will simply abate after some time. In patients with dysphagia, eliminating any peroral intake will be essential to avoid aspiration. In instances of obstructed respiratory airways due to paralysis of relevant muscles, the airways must be managed; if the disorder is severe, even tracheal intubation with potential mechanical ventilation could be necessary.

The patient can be discharged for home treatment after 24 hours following abatement of all systemic symptoms and normalization of significant laboratory results; minor local affliction can be treated by means of outpatient treatment. Any persisting laboratory picture indicating mild prothrombotic activity should be managed by pre-emptive miniheparinization; see chapter 5.4 Convalescence following envenoming.

6.4.2.6. Echis Genus, Saw-Scaled Vipers

Species: Recently, there are 15-16 species and subspecies contained in the genus of saw-scaled vipers (*Echis*), with taxonomy not yet normalized. The saw-scaled viper (*Echis carinatus*) with its two but probably even more subspecies presents the best-known and most

important species; other members of the genus include the Palestine saw-scaled viper (*Echis coloratus*), Roman's saw-scaled viper (*Echis leucogaster*), West African carpet viper (*Echis ocellatus*), and Egyptian saw-scaled viper (*Echis pyramidum*). Even though names like *Echis multisquamatus, sochureki, hughesi, jogeri, megalocephalus* etc. are sometimes ranked among species, other resources present them as the subspecies of *Echis carinatus* or *Echis pyramidum* - see chapter 7 List of venomous snakes; some may probably refer to local forms only.

Other names: EN: Carpet viper, Indian little viper; FR: Echide carénée. Other languages: Afai, Phoorsa, Bankoraj (*E. carinatus*).

Description: Saw-scaled vipers (*Echis*) tend to be smaller snakes of lengths ranging 20-30 cm (*E. carinatus sinhaleyus*) and 50-85 cm (*E. coloratus*, *E. pyramidum*), featuring a triangular head and quite large eyes with vertical pupils. They are predominantly brown in color, with relatively distinct dark and light spots that can be slightly yellow in hue, which often blend together to form a compact pattern. They possess good motional skills, and as such can be ranked among fast-moving and swift snakes. In general, they are considered short-tempered creatures. When in danger, the saw-scaled viper coils up, rubbing its lateral keel-like scales and producing a typical loud, dry sound that resembles that of a saw cutting wood, which probably serves the same purpose as the warning sound emitted by rattlesnakes.

Echis snakes are one of the most significant types in terms of epidemiology, responsible for the majority of fatal snakebites not only in their home range, where they are abundant - even appearing near human settlements - but globally too. They can be expected to cause injury and death to more people than any other snake. For example, victims in Nigeria occupy 10% of the beds in hospitals; in the savannah-like part of Nigeria alone, up to 23,000 people reportedly die from snakebites by saw-scaled vipers. Reports of serious envenomations from W, Central and N Africa, once attributed to the saw-scaled viper (*E. carinatus*), actually relate in all likelihood largely to *E. leucogaster* and *E. ocellatus*, a member of the former *E. carinatus* subspecies, as *E. carinatus* does not inhabit this area at all.

Echis genus snakes are mostly active at night, although they are also diurnal hunters in colder localities or periods.

Home range and habitat: The saw-scaled viper (*E. carinatus*) resides in sandy and stony or sparsely grassed habitats, which are generally arid and flat, in Central and S India, as well as N and E Sri-Lanka. The Palestine saw-scaled viper (*Echis coloratus*) ranges in the savannahs and stony areas of the Middle East, from E Egypt across Israel, Jordan, Lebanon, and the W part of the Arabian Peninsula as far as Yemen. The same terrain is inhabited by *E. multisquamatus* and *E. sochureki* in Central Asia from Azerbaijan and E Iran as far as Pakistan and NW India. The Roman's saw-scaled viper (*Echis leucogaster*) and the West African carpet viper (*Echis ocellatus*) reside in savannahs and semi deserts, but even forest boundaries in the Sub-Saharan region from Senegal as far as Sudan; whilst the Egyptian saw-scaled viper (*Echis pyramidum*) inhabits similar territories in NE Africa from Algeria throughout Egypt and as far as Somalia and Kenya.

Toxins: The toxin content in each of the genus members is similar within the range of known and typical differences; a specialty being a light neurotoxic affliction (ptosis) caused by *E. pyramidum*. Nevertheless, the course of envenomation and mortality indicate variability in the level of severity. For instance, the course of an envenoming following a snakebite from *E. carinatus* seems to be more dangerous than one by *E. coloratus* venom. However, one cannot rely upon a benign course of envenoming occurring, so every case concerning a saw-

scaled viper must be recognized and treated as one that could pose an immediate risk to life. As regards *E. carinatus* venom, the LD_{50} for mice IV equals about 0.3 mg/kg (Latifi, 1984).

Enzymes and toxins with an essential impact on hemocoagulation make up the key groups in the venom components in *Echis* snakes. The main effect of the venom is a procoagulative one; with the ecarin enzyme responsible for direct activation of prothrombin to a different type of thrombin - meisothrombin - which cannot be inhibited by AT-heparin complex. Although this substance does not seem to possess its own coagulation activity, ecarin is a potent prothrombin activator that is subsequently converted to α-thrombin. Even a small quantity of ecarin can result in a number of positive feedbacks that boost explosive thrombin activation, enabling meisothrombin to freely propagate in the circulation without any threat posed by inhibition. Thrombin converts FBG to fibrin, activates PLT and the complement, and causes chemotactical action on leukocytes. Emerging fibrin formations may be not fully stabilized and are promptly destroyed to form a large quantity of FDP; in some cases this does not correspond with the level of D-dim found. Plasminogen activation proceeds. A DIC-like consumption disorder and reactive fibrino(geno)lysis occur. This results in afibrinogenemia, formation of thrombogenic and disintegrated intima due to damaged endothelium and endothelial junctions, increased capillary permeability with symptoms of hemorrhaging, and interstitial edema. Other venom components concern fibrino(geno)lytic and fibrin-converting proteinases and echistatin, a desintegrin-like peptide which inhibits the PLT aggregation activated by thrombin, epinephrine, collagen, or PAF. Such an activity of echistatin can in some cases manifest via inadequate PLT participation in the consumption coagulopathy in progress. However, this does not eliminate the effect of venom components conversely causing increased PLT aggregability in parallel with formation of fibrin microthrombosis, which are produced as a result of a thrombin activity at a systemic level. The existing hemorrhagin-like substances participate in damaging vascular walls, including basal membranes and extracellular structures, thereby aggravating prothrombotic activation, intima disintegration, hemorrhaging, formation of fibrin deposits, and microthrombi.

The presence of presynaptic enzymatic neurotoxin is possible in some species, such as *E. pyramidum*, but with no clinical importance.

The venoms of the *Echis* snakes, as with the majority of vipers, contain a range of cytotoxic and destructive proteolytic enzymes, e.g. proteinases, hydrolases, hyaluronidases, phospholipases, and other substances causing local damage to tissues including small necrosis.

Cardiotoxic venom compounds must not be overlooked, even though arrhythmia can be a result of fibrin deposits and microthrombi present in the myocardium and conduction system.

A lethal dose of dry venom for an adult is approximately 5 mg; when biting, the saw-scaled viper (*E. carinatus*) can release up to 12 mg of venom. A certain but rather low percentage of bites without envenoming, which are called dry bites, can occur in this genus as with other venomous snakes. For instance, five cases out of 120 attacked persons proceeded without symptoms of envenoming, including local signs. The shortest snake that actually caused envenoming measured just 17.5 cm.

Local symptoms of envenoming: Bite marks ranging from scratching to multiple wounds, are rather indistinct; indeed, cases have existed where these are not visible at all. Consequently, vague bite marks from this diminutive viper will not preclude a possibility of envenoming. In almost every case, the initial symptom of envenoming involves pain at the bitten site with possible redness around the wound. For most victims, the pain will spread to

regional lymph nodes. In most cases, a moderately intense edema typically occurs, which extends over half of the limb and does not exceed beyond regional nodes. It usually persists for one to two weeks. In some envenomed persons, the edema can be described as a mild and localized one, disappearing as quickly as within 48 hours. The size of the edema does not relate with the severity of systemic symptoms and cannot be used as a criterion for the severity of envenoming.

Locally, most affected persons - up to 80% - will exhibit hemorrhaging and bruising. Cases of blisters and lesser necrosis are rather rare - only present in 10-15%.

Infection complications, phlegmons, and abscesses are not frequent but still possible. In rare cases, they can even extend to deeper structures including giving rise to osteomyelitis.

Systemic symptoms of envenoming: Typical prodromes of the envenoming include nausea, vomiting, and abdominal pain, but only in a quarter of those affected. However, some affected individuals do consume herbal mixtures boasting an emetic effect as a part of native treatment procedures. Other early symptoms of systemic envenoming include headache, shivering, increased temperature, and fatigue, extending to altered consciousness. Nevertheless, even a highly severe envenoming may not be accompanied by the prodromes listed above.

Hemocoagulation disorder - the DIC-like one in all cases - presents the most serious manifestation of envenoming, occurring as it does in the majority of the envenomed. Clinical symptoms of the hemostasis disorder can be registered within dozens of minutes up to 27 hours after the envenomation; in most cases, they will firstly manifest in hemocoagulation laboratory tests with prolonged times, defibrination, and increased FDP. Clinically, these are most often displayed in the form of bleeding from gums, mucous membranes, nose, small wounds, and stabs, as well as under the skin, and into muscles and the retroperitoneum. Subconjunctival and retroorbital hemorrhaging or hemorrhaging into retina also takes place. The persons affected exhibit gastrointestinal hemorrhage, which is manifest via hematemesis and enterorrhagia; furthermore, they suffer hematuria, pulmonary hemorrhage, genital tract hemorrhage, and hemorrhoids. Intracerebral hemorrhage is also possible. Miscarriages occur in pregnant women. The hemostasis disorder can persist for 10-14 days.

Nevertheless, every case of envenoming with consumption hemocoagulation disorder may not be accompanied by hemorrhaging - oliguric renal failure due to the formation of fibrin deposits and microthrombi in the glomerular system may be present early on, potentiated by hemoglobinuria in the case of intravasal hemolysis, and hypovolemia in instances of hemorrhaging and extravasation.

In late stages of more severe envenomings, dyspnea or even respiratory failure of ALI/ARDS type is possible, including such a level of severity that requires mechanical ventilation. The main reason for the complication above to occur is damage to pulmonary capillary integrity in cases of DIC-syndrome, including extravasation of liquid into the pulmonary interstitium, and symptoms of interstitial or even alveolar pulmonary edema, or again possible formation of fibrin deposits and microthromboses in the pulmonary vascular beds.

Hypotension following the envenoming mostly relates to the hemorrhaging or extravasation in progress.

Dysrythmias related to ventricular extrasystoles with drop-outs in the sinus node, junction rhythms with slight QRS-complexes or alternative junction or ventricular rhythms with wide complexes have been recorded in some cases; even T wave inversion and changes in ST

section have been described. As direct cardiotoxicity of *Echis* venoms is not known, although it probably cannot be precluded, microthrombotization into the myocardium and temporary myocardium ischemization might be involved.

Again, the recorded cases of reversible elevation of serum levels of hepatic enzymes, which peak as late as day 12 of envenoming and quickly abate, might probably be caused by hepatic tissue perfusion disorders due to microembolisms.

Neurotoxins present in rare cases in venoms of some species, e.g. *E. pyramidum*, can cause a very light and benign affliction of cranial nerves, for instance, ptosis. No reports concerning the presence of substances with neurotoxic actions in the venom of the saw-scaled viper (*E. carinatus*) are available.

Laboratory findings: Hemocoagulation laboratory tests exhibit key changes as well as early symptoms of systemic envenoming, with PT, APTT, and TT often prolonged to non-measurable values, the FBG level has decreased sometimes to zero values; FDP levels, including D-dim, typically increase. In some cases, D-fragment can also be present in form of monomers rather than dimers if stabilization of the intravascular fibrin through the action of FXIII does not take place. AT activity is typically not reduced; significant thrombocytopenia may or may not be recorded. Certain coagulation factors, like FV, FVIII, FII, and FXIII, exhibit reduced activity, while FX and FVII factors show normal values. Non-detectable PC levels are found, probably due to their activation and consumption. A laboratory hemocoagulation test is recommended every 6 hours until normalization is registered, and subsequently on a daily basis according to status to check if toxin release continues or not.

Leukocytosis and anemization as a result of hemorrhaging and hemolysis can be found in the blood count. Schistocytes, poikilocytes, and free hemoglobin can be detected as the microangiopathic hemolytic syndrome proceeds.

Biochemical findings lack typical specialties. The increased levels of conjugated bilirubin, ALT and AST probably relate to a hepatic parenchyme perfusion disorder. The increased levels of non-conjugated bilirubin relate to hemorrhaging.

Oliguric renal failure is accompanied with increased urea, creatinine, and kalium in the serum.

Urine, including residual urine, typically exhibits proteinuria and hemoglobinuria.

Mortality: Mortality is high; 7-20% of individuals without treatment probably die (Warrell et al., 1977; Coppola et Hogan, 1992). Total mortality is very difficult to estimate; victims without envenoming are not currently recorded, neither are certain fatal forms of envenoming in places where help is not available. Under adequate specific treatment, lethality described equates to nearly 3% from those affected. Intracerebral and profusive internal hemorrhage - mostly of the gastrointestinal type - with subsequent hypovolemic shock are considered the most frequent causes of death. Renal failure can be another; fatalities caused by respiratory failure are also possible. For their definitively high mortality, saw-scaled vipers (*Echis*) are probably the most significant venomous snakes worldwide in terms of epidemiology.

Therapy: For first aid and general rules of treatment, see chapter 5 Snakebite: Therapy and prevention. Limb immobilization and gentle local treatment can be recommended, with mild cooling and elevation in cases where pain, edema, and congestion are present. Analgesics including opiates and antiphlogistics, except ASA, can be administered for intense pain; sedation is also possible.

Antivenom is indicated where systemic symptoms exist.

Applicable antivenoms:

* LYOPHILISED ANTI-SNAKE-VENOM SERUM Haffkine, India (*Echis carinatus*, etc.);
* SNAKE ANTIVENIN I. P., Haffkine, India (*Echis carinatus*, and other snakes);
* IPSER AFRIQUE PASTEUR, Aventis Pasteur, France (*Echis carinatus*, etc.);
* ANTIREPT PASTEUR, Aventis Pasteur, France (*Echis carinatus*, *Echis coloratus*, *Echis pyramidum*, and others);
* FAV-AFRIQUE, Aventis Pasteur, France (*Echis leucogaster*, *Echis ocellatus*, etc.);
* FAVI-REPT, Aventis Pasteur, France (*Echis leucogaster*, and other snakes);
* SERUM ANTIVENIMEUX BITIS ECHIS NAJA PASTEUR, Pasteur Merieux, France (*Echis carinatus*, and others).
* SAIMR ECHIS ANTIVENOM, SAIMR, the Republic of South Africa (*Echis ocellatus*);
* ANTI ECHIS COLORATUS, Felsenstein Medical Research, Israel (*Echis coloratus*);
* MONOVALENT SAW-SCALED VIPER ANTIVENOM, Central Research Institute, India (*Echis carinatus*);
* POLYVALENT SNAKE ANTIVENOM SERUM, Central Research Institute, India (*Echis carinatus*, etc.).

Application of antivenom is indicated in cases of symptoms of systemic envenoming - both prodromal and specific, and when there is bleeding or early renal failure, but even in instances of more significant laboratory findings. In addition, application of antivenom can be indicated where local affliction is found, especially if localized hemorrhaging occurs and laboratory hemocoagulation laboratory tests are impossible. In cases of envenomation by the Palestine saw-scaled viper (*E. coloratus*), which is considered less dangerous, treatment by antivenom is recommended only beyond a certain level of seriousness of systemic symptoms of envenoming, for instance: hemorrhaging, existence of proteinuria, serum urea elevated above 7 μmol/l, PLT decrease below 100,000/mm^3 or Hb decrease below 130 g/l (Benbassat et Shalev, 1993).

The initial quantity of antivenom is subject to the severity of symptoms or laboratory findings; a range of 2-4 vials is recommended. Hemostasis becomes normalized after 2-40 hours following the first vial of antivenom; however, many times the administration of antivenom must be repeated after several dozen hours due to reoccurring venom component effects, which are evident from laboratory results based on repeated prolonged PT and APTT, as well as non-coagulable blood found or repeated hemorrhaging.

Antivenom treatment may not prove satisfactory, which is actually a rule of thumb for the saw-scaled vipers (*Echis*) and maybe more than any other species. This is not only due to species-specific antigenic variability in venom components within the *Echis* genus, but also to differences between specimens of the same species from various regions. The immense challenge faced when controlling prothrombin-activating components is another factor.

In case of unavailability, insufficient quantity, or low effectiveness of the antivenom, venom components can be eliminated by plasmaferesis and by repeating the same if applicable.

The effectiveness of treatment using an antivenom or plasmaferesis is evidenced by reduced times in the hemocoagulation test results.

Even though the local affliction, including formation of potential necrosis, cannot probably be influenced by giving antivenom, it still can be used to indicate the level of envenoming and prove of prognostic value due to systemic symptoms expected. The local affliction is typically not serious; standard treatment procedures can be applied. Gentle limb elevation is required due to pain and edema, as well as administration of analgesics; mild cooling of the limb can bring subjective relief. In rare cases, necrectomy must be applied in late phases, mostly to the maximum extent of 1-15 cm^2, but rarely with subsequent transplantation of skin.

Clinical but even more severe laboratory symptoms of hemocoagulation disorder will also require application of symptomatic therapy in most cases. The procedure is almost the same as that for treating the DIC-like hemostasis disorder for other reasons. AT substitution, which is typically not required at least in the early phase of envenoming, presents a certain kind of exception. Levels and activity of AT as such are usually not distinctively reduced; meisothrombin cannot be inhibited via AT. Otherwise, standard therapy and substitution methods apply. Administration of fresh frozen plasma, at a dosage of 10-20 ml/kg, might in some cases help combat the hemocoagulation disorder; in addition, it presents a quality form of compensation for lost volume, be it due to hemorrhaging or extravasation. Complementing the specific therapy using antivenom with heparinization, with a single dose of 70 units/kg followed by 35 units/kg after 8 hours or 100 units/kg over 24 hours continually IV, can have a positive effect on the results of the treatment (Paul et al., 2003), although this has not been confirmed by some research. However, in the period whilst patients bleed, the treatment method described above can be controversial. In case of lighter progress without bleeding, treatment using only heparin without an antivenom is recommended following a snakebite from the Palestine saw-scaled viper (*E. coloratus*)(Gilton et al., 1989).

To prevent (micro)thrombotic complications and inhibition of thrombin activity as such, administration of heparin, at a dosage of 70-200 units of UFH/kg over 24 hours, or a relevant pre-emptive dose of LMWH is applicable once bleeding has stopped. Of course, administration of the same is fully applicable if AT activity has decreased, which is possible any time later, in cases of potential induction of DIC or for patients with reduced levels already prior the disease. Application of concentrated FBG is not indicated in most cases. If integrity of the patient's vascular system has not been significantly affected by an accident or necessary surgery, hemorrhaging should not occur even if FBG values are near zero, although FDP levels can be increased by FBG administration, which would be contra-productive. Thus, FBG application is indicated only exceptionally, as well as that of coagulation factor concentrates, see chapter 5. 3. 3. 6 Hemocoagulation disorders. Naturally, hypotension and profound hemorrhaging will require substitution to retain vessel volume and perfusion pressure values; consequences of exsanguination present the main cause of mortality in this case.

In this way, volumotherapy and vasopressure treatment become another integral part of efforts to regulate hemostasis in cases of hemorrhaging. Increasing the supply of liquids - infusion of electrolytes - will be one of the measures to prevent renal failure. Less remarkable oliguria can be controlled by diuresis support using furosemide. If renal failure has already occurred - frequently the oligoanuric type, hemodialysis or another (C)RRT method will be required.

Oxygen therapy is indicated in cases of respiratory failure or decreased oxemia. Outside simple administration of oxygen, a continual positive airway pressure system, or at least

intermittent expiration against resistance in the rehabilitation period, can be applied. Any diuretics given will reduce a patient's intravasal volume as well as the quantity of extravascular pulmonary water, and can improve the existing level of pulmonary affliction.

The risk of renal failure in cases of intravasal volume restriction should be considered at all times.

Any further grievous forms of pulmonary damage will require managed ventilation.

The arrhythmia that has occurred and splanchnic or other types of hypoperfusion affliction, based on hypotension, that have taken place in the course of hemorrhaging, or based on microthrombosis, are solved symptomatically.

The patient can be discharged for home treatment after 24 hours following abatement of all systemic symptoms and normalization of laboratory findings. Any persisting laboratory results indicating mild prothrombotic activity should be managed by pre-emptive miniheparinization; see chapter 5.4 Convalescence following envenoming.

6.4.2.7. Eristicophis and Pseudocerastes

Species: The *Eristicophis* and *Pseudocerastes* are monotypic genera including the McMahon's desert viper (*Eristicophis macmahoni*) and Persian horned viper (*Pseudocerastes persicus*), respectively. As for the latter, *Pseudocerastes persicus fieldi* subspecies is considered to be a separate species. The *Pseudocerastes* snakes were formerly classified under the *Daboia* genus.

Other names: EN: Asian sand, Iranian horned, leaf-nosed viper; FR: Vipére de McMahon (*E. macmahoni*). EN: Asiatic horned, Field's horned viper, false-horned viper; FR: Pseudocéraste de Perse, Vipére des sables Perse (*P. persicus*).

Description: The MacMahon's viper (*E. macmahoni*) usually grows up to 60 cm, its maximum length being 80 cm. This snake features a pronounced head, and is colored in tones of light brown and darker spots.

The Persian horned viper (*P. persicus*) is a little bit larger, normally shorter than 85 cm, although the maximum length is 100 cm. It is gray to brown in color with darker spots. Its triangular head boasts small horns above the eyes. Both viperids are predominantly nocturnal snakes. Bites by the MacMahon's viper are very rare.

Home range and habitat: The MacMahon's viper (*E. macmahoni*) resides in sandy and sparsely vegetated stony areas in E Iran, S Afghanistan, and W Pakistan. The Persian horned viper's (*P. persicus*) habitats include the desert and stony territories of Iran, S Afghanistan, Pakistan, and N Oman for *P. persicus persicus;* whilst *P. persicus fieldi* is found in Iraq, N Saud Arabia, Jordan, Israel, and the Sinai region of Egypt.

Toxins: The venom of the MacMahon's viper (*E. macmahoni*) is considered highly potent; it may cause serious envenomings, including fatalities. Aside from hemocoagulation-afflicting components, locally acting enzymes, and other compounds presumed due to its closeness with the *Cerastes* and *Echis* genera, the presence of enzymatic neurotoxins is also possible.

The venom of the Persian horned viper (*P. persicus*) does not appear to possess such effectiveness, with LD_{50} for mice IV fluctuating around 1 mg/kg (Latifi, 1984). It may well exhibit procoagulative activity; neurotoxicity is probably determined by the presence of $PLA_{2,}$, which has been found in *P. persicus fieldi*; finally, the venom contains enzymatic components that are only likely to produce local effects on humans.

Local symptoms of envenoming: The bitten site and the developed edema - largely only localized or medium-sized - are painful; lymphadenopathy occurs, including enlargement of regional lymph nodes. Cases of small-sized necrosis are possible although not described.

*Systemic symptoms of envenoming***:** Only local symptoms of envenoming have been registered for a number of descriptions of snakebite from *P. persicus*. In cases of systemic symptoms, a moderate affliction can be probably expected, roughly similar to that caused by *Cerastes* snakes. A course of envenoming following snakebites by the MacMahon's viper (*E. macmahoni*) is described, involving abdominal pain, intestinal dystension, serosanguineous discharge from urethra, dysphagia, and ptosis.

*Laboratory findings***:** Not known; neutrophilic leukocytosis can be expected, or changes in hemocoagulation laboratory tests.

Mortality: In two of five cases of envenoming by the MacMahon's viper (*E. macmahoni*) described, death occurred within several hours after the attack.

Therapy: For first aid and general rules of treatment, see chapter 5 Snakebite: Therapy and prevention. Limb immobilization and gentle local treatment can be recommended, with mild cooling and elevation where pain, edema, and congestion are present. Analgesics including opiates and antiphlogistics, except ASA, can be administered in instances of severe pain; sedation is also possible.

Applicable antivenoms:

* *Eristicophis macmahoni* - no specific antivenom is available. In envenomings with severe clinical manifestation, administration of antivenoms against *Echis carinatus*, *Cerastes cerastes,* or *Macrovipera lebetina* can be tested for potential cross-reactivity of *E. macmahonii* toxins with those of these viperids.

* *Pseudocerastes persicus* - ANTIREPT PASTEUR, Aventis Pasteur, France (*Cerastes-Pseudocerastes persicus*, etc.). Monospecific antivenoms are manufactured in Iran. Again, if the envenoming displays severe clinical symptoms and no antivenom is available, administration of other antivenoms against *Echis carinatus, Cerastes cerastes,* and *Macrovipera lebetina* can be tried for potential cross-reactivity of *P. persicus* toxins with those of these viperid snakes.

Further treatment is symptomatic and based on the symptoms of envenoming; see chapter 5. 3. 3 Clinical symptoms of envenoming and symptomatic treatment.

Observation of patients is essential for 24 hours following a snakebite, even if no symptoms are apparent.

6.4.2.8. Macrovipera Genus, Large Palearctic Vipers

Species: The *Macrovipera* genus comprises four species: the desert viper (*Macrovipera deserti*), Levantine viper (*Macrovipera lebetina*), Moorish viper (*Macrovipera mauritanica*), and Cyclades blunt-nosed viper (*Macrovipera schweizeri*).

*Other names***:** EN: Leventin viper, bluntnose viper; FR: Vipére de Levant, viper minute; AR: Tagerza; RU: gjurza (*M. lebetina*). EN: Desert Leventin viper; FR: Vipére du Sahara (*M. deserti*). EN: Morocco viper; FR: Vipére de l'Atlas (*M. mauritanica*). EN: Leventin viper; FR: Vipére des Cyclades (*M. schweizeri*).

Description: The *Macrovipera* genus snakes are quite robust, lengths vary from 60-90 cm (*M. schweizeri*) to 120-150 cm, and rarely up to 200 cm (*M. lebetina*). The Levantine viper is

a viperine boasting a length that makes it one of the longest of the *Viperinae* subfamily. Another example is *Bitis arietans*, which is equally impressive size wise as one of its subspecies, *M. lebetina obtusa (euphratica)*, can measure 200 cm, although a specimen in Armenia reached an undocumented 218 cm. These viperids have triangular heads, large eyes and vertical pupils. They are mostly gray to brown in hue, with spots varying from red through green, yellow and darker shades, blurring into a lengthwise zigzag line or signs of crosswise stripes. They are snakes of largely nocturnal activity, but can be found also during the day following rain at night.

Home range and habitat: The desert viper (*Macrovipera deserti*) inhabits slopes covered with forest in the mountains of NE Algeria, Tunisia, and NW Libya. The Levantine viper (*M. lebetina*) including all of its subspecies, resides in stony and arid steppe localities in Cyprus, Turkey, Lebanon, Syria, Israel, Jordan, Saudi Arabia, Kuwait, Iraq, Iran, Afghanistan, Turkmenistan, Uzbekistan, Armenia, Pakistan, N India, and Kashmir.

The Moorish viper (*M. mauritanica*) can be found in steppe, stony and forested localities in hills and mountains in NW Morocco, and on the coasts of Algeria and Tunisia.

Cyclades blunt-nosed viper (*Macrovipera schweizeri*) is an inhabitant of the Greek islands of Kimolos, Milos, Polinos, and Siphnos.

Toxins: In terms of toxinology, the specifics of the species and subspecies only differ to an ordinary extent; the key toxin groups are probably identical in all species and subspecies; at a clinical level, the approach to envenoming can be generalized to either the *Macrovipera* genus or *M. lebetina*.

The *M. lebetina* venom is highly potent, with LD_{50} for mice IV fluctuating at about 0.4 mg/kg (Latifi, 1984); based on MLD, which is 3 mg/kg of mice SC; its toxicity is comparable to that of venoms from the common viper (*Vipera berus*), jararaca (*Bothrops jararaca*), or Egyptian cobra (*Naja haje*). A well-built adult snake has a relatively large amount of venom available. Some resources state that its bite can prove fatal even to a camel.

The venom contains components afflicting hemocoagulation in both a procoagulative and anticoagulative manner. Procoagulation action can be assigned to FV and FX activators, to name but two. These enzymes neither activate prothrombin nor participate in FBG degradation. Fibrinogenases contained in the venom possess a potent proteolytic activity and degrade the FBG α-chain, thereby altering its clotting ability by thrombin. As for anticoagulation components, these can involve lebetins, platelet activation inhibitors, fibrino(geno)lytic and other serum proteinases. Some of the subspecies, such as *M. lebetina turanica*, possess a FV inactivating protease. The venom contains a protein increasing capillary permeability, myotoxic lebetin, cardiotoxin, and a number of others.

Local symptoms of envenoming: Immediately upon a bite, pain in the wound occurs, with early onset of edema that can be large, often extending around the whole limb. The pain and edema propagate to the relevant regional lymph nodes preceding lymphangitis and lymphadenopathy, including enlargement of the relevant regional nodes. In some cases, the edema may even spread to the torso. Ecchymoses, hemorrhagic vesicles, and local hemorrhaging come up around the bitten site. Development of necrosis is frequent; even extreme forms can be expected. Occurrence of compartment syndrome is possible.

Systemic symptoms of envenoming: Systemic affliction may arise soon after a bite. In most cases, nausea, vomiting, epi- and hypogastric pain and diarrhea occur. The affected person also begins to sweat. A rising sensation of thirst is the result of extravascular hypovolemia, diarrhea, potential hemorrhaging, and a response of the vegetative system. A

tendency towards hypotension with tachycardia appears in the circulation with circulation collapse and shock possible in instances of no given treatment. ECG changes can be registered. Some forms of sharp envenoming may even result in cardiac syncope and circulatory failure.

Symptoms of a profound hemostasis disorder clearly indicate envenomation by the Levantine viper (*M. lebetina*). Clinically, they largely manifest as hemorrhaging from injuries, small wounds and stabs, as well as from mucous membranes and GIT, but also as hematuria, etc. As the hemocoagulation disorder is in part the one resembling DIC and the venom contains toxins directly destroying capillary integrity, extravasation of liquids occurs and microthromboses develop. Potential renal failure is triggered by microthromboses, as well as the persisting hypotension, insufficient perfusion of renal glomerules, free hemoglobin and myoglobin in the serum, and apparently the direct action of some toxins on kidney structure.

Laboratory findings: The examination of hemocoagulation in cases of more severe envenomation is in accord with the disorder of the consumption coagulopathy type. Hypofibrinogenemia exists due to both direct degradation of FBG and its consumption within the syndrome in process. PT and APTT will prolong; the decline of platelets may not be dramatic due to the toxic reduction of their function. An increased D-dim level does not always correspond to a sharp increase in all FDP. The discrepancy is based on the direct action of proteases on FBG cleavage. Declined AT activity can be registered even three hours after an attack; the chance of schistocytes being found is possible. Microangiopathic hemolysis is responsible for the free hemoglobin found.

Blood results typically reveal neutrophilic leukocytosis. Increased myoglobin levels can be caused by the lytic action of myotoxic enzymes. Later on, renal failure becomes manifest by an increase in serum urea and creatinine. In addition, potentially more severe splanchnic area perfusion disorders within a shock, or the significant presence of microthromboses, will result in elevation of transaminases or pancreatic amylase.

Mortality: The mortality rate for envenomings by the Levantine viper (*M. lebetina*) is high; resources show an extreme 30% for non-treated persons, with even 50% being reported for Iraq.

Therapy: For first aid and general rules of treatment, see chapter 5 Snakebite: Therapy and prevention. Limb immobilization and gentle local treatment can be recommended, with mild cooling and elevation where pain, edema, and congestion are present. Analgesics including opiates and antiphlogistics, except ASA, can be administered in cases of severe pain; sedation is also possible.

Applicable antivenoms:

* FAVI-REPT, Aventis Pasteur, France (*Macrovipera deserti*, etc.);
* ANTIREPT PASTEUR, Aventis Pasteur, France (*Vipera-Macrovipera lebetina*, and others);
* EUROPEAN VIPER VENOM ANTISERUM, Institute of Immunology, Croatia (*Macrovipera lebetina*, and other snakes).

Administration of antivenom is indicated for symptoms of clinical signs of envenoming at a systemic level, e.g. vomiting, abdominal pain, hypotension, arrhythmias, and any form of increased hemorrhaging; but even in instances of more significant pathology findings via a

laboratory hemocoagulation test, such as prolonged PT and APTT, hypofibrinogenemia, and high FBG or D-dim levels.

Moderate cooling and elevation of the afflicted limb during therapy is suitable, as is covering and treating any developing derma defects in accordance with common practice. Demarcation of any necrosis formed should be supported; deeper ones will require careful necrectomy and debridement. In cases of suspected compartment syndrome, measuring pressure in tissue and timely fasciotomy, enforced by hypoperfusion, is advisable; see chapter 5. 3. 3. 1 Local damage. Development of deep necrosis with infection in the afflicted tissue will require treatment using antibiotics impacting on anaerobic bacteria and of good penetrating capacity; however, pre-emptive administration of antibiotics is not indicated.

The existing hypotension requires intravascular volume to be increased; if necessary, sufficient systemic pressure must be managed using vasopressors.

Administration of fresh-frozen plasma, at an approximate quantity of 10-20 ml/kg, will provide for increases in intravasal volume, as well as help to reduce the level of DIC-like hemocoagulation dysregulation. If AT activity is reduced, boosting the AT-heparin inhibition complex by AT substitution is advisable. Non-fractionated heparin can be applied to prevent thrombophilia and production of (micro)thromboses if there is no serious hemorrhaging, this at an approximate dosage of 70-200 units/kg over 24 hours (Barkagan et al., 1988).

If laboratory results do not exhibit production of (micro)thromboses and their destruction based on the presence of high D-dim levels, plus significant hemorrhaging persists, antifibrinolytic therapy may be helpful, by using tranexam acid or aprotinin for example.

In circumstances of extravasation of a liquid into pulmonary interstitium with the possible formation of microthromboses, developing respiratory failure can be treated based on severity using oxygen therapy, with continuous positive airway pressure (CPAP) or mechanical ventilation as a last resort. Weakening the intensity of symptoms, i.e. decreasing the quantity of water in the pulmonary tissue, can be sometimes achieved by reducing intravasal volume through the support of diuresis. Nevertheless, maintaining sufficient perfusion of kidneys due to impending renal failure is essential even if this kind of therapy is employed. Thus, it is clear that treatment and prevention of pulmonary and renal failure will require a slightly controversial approach, where evaluation of priorities in terms of protecting and supporting organ functions is the physician's responsibility.

The patient can be discharged for home treatment after 24 hours following abatement of all systemic symptoms and normalization of significant laboratory results. Any persisting laboratory results indicating mild prothrombotic activity should be managed by pre-emptive miniheparinization; see chapter 5.4 Convalescence following envenoming.

6.4.2.9. Vipera Genus, Palearctic or Eurasian Vipers

Species: The *Vipera* genus numbers over 20 species and dozens of subspecies. The best-known species include the nosed-horn viper (*Vipera ammodytes*), asp viper (*Vipera aspis*), common viper (*Vipera berus*), Lataste's viper (*Vipera latastei*), Baskian viper (*Vipera seoanei*) and meadow viper (*Vipera ursini*) as the most widespread species in Europe; for Turkey and the Middle East, this involves the Palestinian viper (*Vipera palestinae*), Armenian mountain viper (*Vipera raddei*), and rock viper (*Vipera xanthina*) that has been proposed to be placed into a new separate genus as *Montivipera xanthina*. For other members of this genus, see chapter 7 List of venomous snakes.

Other names: FR: Vipére; DE: Otter, Viper; SK: vretenica; RU: zmeja.

Description: The members of the *Vipera* genus are snakes of a mean length ranging from 50 to 70 cm, with the meadow viper (*V. ursinii*) limited to 35 cm, whilst long robust snakes extend up to 1m. The rock viper (*V. xanthina*) grows to a maximum of 120 cm and the Palestinian viper (*V. palestinae*) 130 cm. Vipers possess typical, broad, triangular heads with large eyes and vertical pupils. The color of their backs ranges from a gray/brown through to brown, gray to gray/white, gray/black, and black. The spots on their back are mostly vague, forming a typical longitudinal zigzag line, for instance for *V. berus*, *V. latastei*, *V. palestinae,* and *V. ursinii*; although they may be distinctive, as seen on *V. aspis,* and *V. xanthina*. Black melanotic forms are known, for example, in the common viper (*V. berus*), *V. nikolskii,* and Baskian viper (*Vipera seoanei*); the back of the blackish *V. kaznakovi* exhibits two long pale stripes. Vipers are surface foragers; they are active mainly at night, but come out during the day in colder localities or periods.

Home range and habitat: In general, the *Vipera* genus members range in diverse habitats, from sandy and stony deserts and semi deserts, e.g. *V. latastei* or *V. palestinae*, through to mountain slopes, valleys and screes, for instance, *V. aspis*, *V. raddei*, *V. ursinii,* and *V. berus*, open woodlands - *V. ammodytes*, *V. ursinii*; forest clearances - *V. berus*; forests - *V. berus*, *V. palestinae,* and *V. xanthina;* humid places (*V. seoanei*, *V. xanthina*), and the outlying areas of swamps and bogs (*V. berus*).

The home range of vipers (*Vipera*) includes Europe (*V. ammodytes*, *V. aspis*, *V. berus*, *V. latastei*, *V. nikolskii*, *V. seoanei*, *V. ursinii,* and *V. wagneri*), Turkey, W and Central Asia and the Middle East (*V. albicornuta*, *V. barani*, *V. bornmuelleri*, *V. darevski*, *V. ebneri*, *V. erivanensis*, *V. kaznakovi*, *V. latifii*, *V. lotievi*, *V. palestinae*, *V. pontica*, *V. raddei,* and *V. xanthina*) and N Africa (*V. latastei,* and *V. monticola*). The steppe viper (*V. renardi*) is found in localities from NE Romania as far as China, the common viper (*V. berus*) reaches to the Far East, N China, and Korea, and the range of *V. berus sachalinensis* is Russia as far as Sakhalin Island (see figure 7).

Toxins: In the *Vipera* genus snakes, venoms are relatively potent, with effectiveness parameters like LD_{50} and DLM in mice comparable to the most powerful venoms of *Bothrops* or *Naja* and *Hemachatus* snakes. LD_{50} for mice IV of the *V. xanthina* venom is about 0.4 mg/kg (Latifi, 1984). Naturally, only a small quantity of venom is available in the majority of these vipers due to their size, which does not correspond to a lethal dose for a healthy adult. Naturally, this does not apply to the large members of the genus - the Palestinian, Armenian mountain viper, and rock viper (*V. palestinae*, *V. raddei* and *V. xanthina*).

In terms of toxin and enzyme structure, the venom does not fundamentally differ from those of other *Viperinae* snakes. The venom of most *Vipera* species contains hemorrhagic components that damage endothelial and subendothelial structures of vessels, thereby producing a prothrombotic terrain, causing hemorrhaging from places with capillary integrity disorder. Other venom components act on hemocoagulation, largely in terms of prothrombotic activation, changes in activity of platelets, increased fibrino(geno)lysis, and other impacts. There is a regular and typical presence of enzymes and toxins, which cause the release of histamine and plasmatic kinins with subsequent vasodilation, hypotension, reactive tachycardia, sweating, smooth GIT muscle and bronchiole contraction. In addition, the histamine released may bring about angioneurotic edema of the face. The minor neurotoxic effect of the venom in some *Vipera* genus species will typically not cause envenoming in a human.

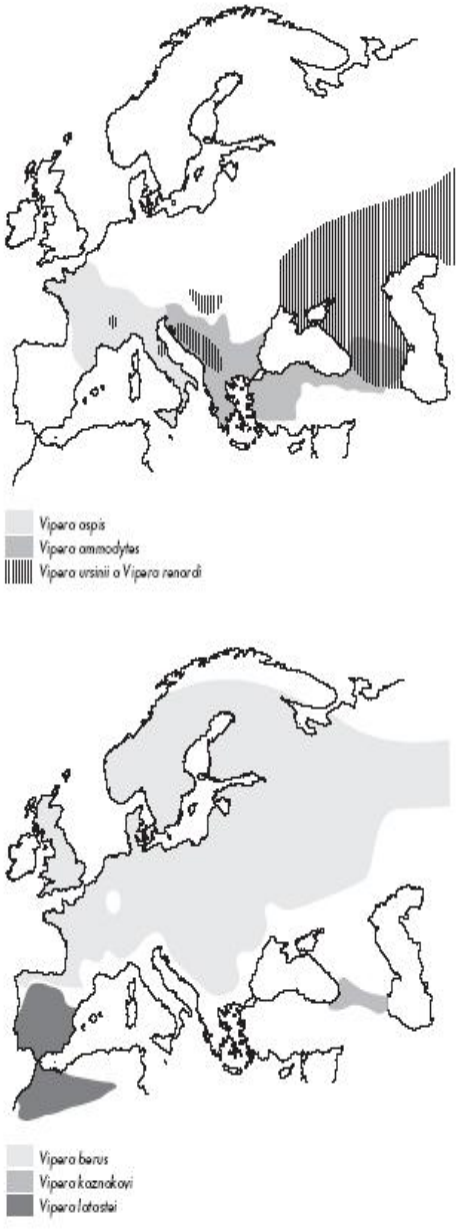

Figure 7. Range of certain vipers in Europe and Turkey (freely edited according to Bucherl, Buckley, and Deulofue, 1968).

Although this type of toxin activity has been described for certain members of the genus, such as *V. palestinae*, *V. xanthina, V. aspis, V. latastei, V. ursine,* and *V. berus bosniensis*, it is only neurotoxicity of presynaptic type based on a phospholipase effect with the potential cooperation of other enzymes. This kind of neurotoxicity may also participate in vasodilation and hypotension by reducing vasoregulating structures.

Aside from the venom components above, other enzymes that participate in local damage, or even formation of necrosis, are found in the *Vipera* genus members. Nevertheless, necrosis is not typical in an envenoming by these vipers, except for *V. ammodytes*, *V. aspis*, *V. latastei*, *V. palestinae,* and *V. xanthina*.

Due to the similarity in venom composition and the process of envenoming, details are provided only for the species below, including the nosed-horn viper (*V. ammodytes*) as it is the most significant European viper in terms of toxinology. In addition, the common viper is outlined (*V. berus*), being a representative of small snakes and the most abundant venomous snake in Europe. There is the inclusion of a section covering the asp viper (*V. aspis*) due to it possessing a wider range of toxins; the Palestinian viper (*V. palestinae*), as it is representative of the large members of the genus responsible for the most severe courses of envenoming, plus additional information on the Armenian mountain viper (*V. raddei*), and rock viper (*V. xanthina*).

As the common viper (*V. berus*) is a very widespread species in the wild across Europe, the related chapter provides an in-depth look at this species and includes data presented elsewhere in this book.

Vipera Ammodytes, the Nose-Horned Viper

Subspecies. V. ammodytes ammodytes including the former subspecies - *gregorwallneri*, *illyrica* and *ruffoi*; *V. ammodytes meridionalis* including the former montandoni subspecies and *V. ammodytes transcaucasiana*.

Other names: EN: western sand viper, sand viper, long-nosed viper; FR: Vipére ammodytes; DE: Sandotter, Hornotter.

Description: A medium-sized viper, it grows between 50-100 cm long and features a scaly horn on the tip of its snout. The color of the dorsal part errs towards brown, brown/red, gray to silver, often with a zigzag line along the back. When under threat, the snake easily becomes animated and bites; striking over a short distance is possible. Having said that, it may stay calm and hesitate before attacking and biting. It hunts at dusk; during colder months, it is active during the day as well.

Home range and habitat: The nose-horned viper mostly inhabits arid, stony, and shrubby terrains or open woodland, abandoned gardens, forest edges in lowlands and uplands to an altitude of 2,000 m (Mount Olympus); human settlements and water prove not to be a deterrent. The home range of *V. ammodytes ammodytes* includes S Austria, Hungary, SW Italy, Slovenia, Croatia, Bosnia, Serbia, Albania, SW Romania, and NW Bulgaria. It has also been introduced into Switzerland. *V. ammodytes meridionalis* extends the nose-horned viper's home range to Greece, the Cyclades, NW Turkey, NW Syria, and Lebanon. V. ammodytes transcaucasiana resides in NE Turkey, Georgia, Armenia, and Azerbaijan.

Toxins: Outside the territory of Turkey with *V. xanthina*, *V. ammodytes* is the most dangerous European viper boasting quite a potent range of toxic components, 20 mg of dry venom on average. In terms of toxin and enzyme content, this viper does not much differ from other viperid snakes. Circulation toxins releasing histamine, plasmatic kinins, and other circulation-afflicting substances, plus hemorrhagins and hemocoagulation-afflicting compounds comprise the key parts of the venom structure. The effect of destructive and digestion enzymes, i.e. proteases, esterases, phospholipases, etc., can most often be observed via local damage, including necrosis; local damage is also a prevailing symptom of envenomation following an attack by the nose-horned viper.

Local symptoms of envenoming: Marks of a bite can be discreet; nevertheless, envenoming cannot be precluded even if these are not apparent. The initial signs may not involve pain, but a tendency towards feelings of stiffness, the release of blood, and edema, plus difficult movements in lesser joints. The edema slowly expands, but in most cases it will remain lesser or medium in size. Lymphangitis and lymphadenitis occur in the related area. Even this phase may not exhibit any greater local pain. If the affliction is more severe, the edema is more distinct and hemorrhagic, with developing ecchymoses, blisters and maybe hemorrhagic bullae, and necrosis. Complications involving a perfusion disorder and formation of compartment syndrome are uncommon; nevertheless, gangrene may occur in cases of a highly severe local affliction.

Systemic symptoms of envenoming: As with the majority of the less venomous snake species, envenoming starts with prodromal symptomatology, e.g. nausea, cold sweats, vomiting, abdominal pain, and possibly diarrhea. Aside from these symptoms, a very intense or even intolerable pain in the epigastrium, sensations of difficulty in breathing and weakness, vertigo, shivering, syncope, angioneurotic syndrome with a swollen tongue and face, and dysphagia have also been described. In grievous envenomings, hypotension, and arrhythmias in terms of tachycardia occur, as does bradycardia. Hypotension can result in circulation collapse and shock. Hemostasis disorders appear as laboratory abnormities, or manifest via clinically evident gastrointestinal or urinary pathway hemorrhaging, mostly at a local and exceptionally at a systemic level. A case of multiple hemorrhagic brain attacks is known (Boviatsis et al., 2003).

Dyspnea may be caused by a certain level of pulmonary congestion, increased EVLW due to vasodilation and endothelial damage, and probably also by the presence of microthromboses in pulmonary vascular beds. Hematuria, hemoglobinuria, myoglobinuria, hypoperfusion due to microthrombosis and hypotension or relative hypovolemia are factors participating in renal failure; in addition, the direct impact of nephrotoxic venom components is possible.

Laboratory findings: Laboratory results reveal neutrophilic leukocytosis, prolonged PT and APTT, hypofibrinogenemia, thrombocytopenia, and increased FDP; urine exhibits proteinuria, hemoglobinuria, erythrocyturia, and possibly myoglobinuria.

Mortality: Fatalities are rare.

Therapy: For first aid and general rules of treatment, see chapter 5 Snakebite: Therapy and prevention. The patient, including the limb, should be kept rested and immobile; fix the limb to a splint using bandaging. Analgesia is usually not necessary.

Specific therapy in form of administration of antivenom against European vipers is only indicated in symptoms of systemic envenoming, such as prodromes, facial edema, hypotension, hemorrhaging, significant laboratory findings, or other symptoms of systemic envenoming.

Applicable antivenoms:

* EUROPEAN VIPER VENOM ANTISERUM, Institute of Immunology, Croatia;
*VIPERATAB, Protherics, USA, UK;
* VIPERFAV, Aventis Pasteur, France;

Local treatment methods desired include mild cooling of the edema, limb elevation, and gentle treatment of defects, and any necrectomy. The necessity for deeper debridement or even fasciotomy is very rare.

Symptomatic therapy is subject to clinical manifestation. Mild and mostly vegetative symptoms will require rest in bed with a temporary strict or very moderate sickness diet and plenty of liquids. In instances of more severe courses of envenoming, therapy will require an intense approach. Hypotension can be corrected by volumotherapy and administering vasopressors. Catecholamine therapy can be applied in bradycardia. Due to possible renal failure, sufficient hydration, intravasal volume, and diuresis must be maintained. The discovery of DIC-like consumption coagulopathy necessitates standard treatment based on the severity of the status, from boosting the AT-heparin inhibition complex and applying fresh-frozen plasma, through to essential PLT and erythrocyte substitution. In extreme cases, even the following steps are necessary based on vital indication: blocking fibrinolysis by antilysin and administering factor concentrates if any lack of the same is diagnosed. Any developing respiratory failure may require oxygen therapy, or even more rarely, application of continuous positive airway pressure (CPAP).

Although the kinds of severe systemic affliction mentioned above tend to be exceptions in cases of snakebite by *V. ammodytes*, and any therapeutic approach to the symptoms of envenoming will be mostly limited to local treatment, laboratory tests and observation, a bite from this viper species should not be underestimated.

Symptomatology of lighter and non-complicated envenomings will last 2-4 days. The patient can be discharged after 24 hours following abatement of systemic symptoms; less significant local damage can be resolved via outpatient treatment. Any persisting laboratory results indicating mild prothrombotic activity should be managed by pre-emptive miniheparinization; see chapter 5.4 Convalescence following envenoming.

Vipera Berus, the Common Viper

Subspecies. Vipera berus berus, *V. berus bosniensis*, *V. berus sachalinensis*.

Other names: EN: European or nordic viper (adder); FR: Vipére péliade; DE: Kreuzotter; SK: zmija severna, vretenica obycajna.

Description: The common viper is the last wild venomous snake species remaining in Central Europe. Its relatively heavy-set body can grow to 50-65 cm, with lengths documented at 85-92 cm. The coloring is variable, with basic tones of brown, gray and black, but even with tints of yellow, red, olive or blue, and silver. Their backs display a typical dark zigzag stripe, which may be discontinuous or scattered; exceptionally, it may be even completely missing. Specimens of the dark prester form and reddish chersea form lack this stripe. The head is triangular and can be clearly distinguished from the body. Compared to colubrids, the head possesses smaller scales. The pupil is vertically slotted. In the conditions of Central Europe, common vipers are mostly active during the day and at dusk, but also at night in warmer places and in hot summers.

Home range and habitat: The common viper dwells in a wide range of landscapes: clearings in forests, both natural and man-made, stony and rocky forested and open terrains. Furthermore, they can be found on vegetated and bare slopes and hillsides, plus those with screes, as well as meadows near water, and the edges of swamps and bogs. The viper can be also found in water in order to bypass an obstacle. Curiously, one case is described by Märtson et al. (2001) of a viper which caused a bite in salt water. In Central Europe, the

common viper ranges in altitudes of up to 1,500 m, although in the Alps and Balkan mountains it can be observed even at elevations of 2,000 to 2,500 m above sea level.

Vipera berus is found in Europe and Asia, in the zone bordered by England and Scotland to the west - except Ireland. To the south, its home range is delimited by Central France, N Italy and the Adriatic coasts as far as N Albania, Macedonia, and N Greece. The zone continues along the southern side through Serbia, Bulgaria, Romania (*V. berus bosniensis*), and Moldova, and then to the east through Ukraine, Russia, N Mongolia, N China, N Korea to the eastern Russian coast, and Sakhalin Island (*V. berus sachalinensis*), with the northern limit crossing Norway, Sweden, and Finland, except for the northernmost regions, from NW Russia, the line of the home range declines to the south-east as far as the 60th parallel.

Epidemiology of the snakebite. The registered incidence of bites by the common viper within individual European countries are in the order of dozens to hundreds of cases per year. Sweden, for example, registered 136 hospitalized individuals bitten by the common viper in 1975, of which 27% exhibited only a minor local response, and of the remaining 73% of those affected at a systemic level, 46% were described as light envenomings, 15% were moderate and 12% severe. The mortality of this sample was zero. However, 44 deaths related to a viper bite were recorded between 1911 and 1977 (Persson et Irestedt, 1981). In a Swiss sample of 113 bitten persons over a 16-year period, 13 lacked any signs of envenoming; of the remaining 100 envenomed, 62% displayed a local and light reaction, 24% a moderate response with vomiting, diarrhea, and hypotension, while 24% suffered a severe reaction with either shock or angioneurotic edema. Mortality was zero (Stahel et al., 1985). In the Czech Republic, 90 cases were consulted with the Toxinology Centre during 1999-2005, but over half of them reported no venom injection at all, meaning nil or merely a slight local response was registered. With this in mind, the case of a 3-year-old child bitten on the lower lip, while bending forward and studying an intriguing creature it had found, could be considered unique with a happy ending. 14 cases of systemic envenoming and 17 cases of isolated local reaction were found within the above reported bites. Out of a group of 11 envenomed and hospitalized children in Slovakia, venom was not injected at all in three of the patients, whereas a local reaction was registered in 8 patients, and systemic symptoms were only shown in a single child. Investigating the circumstances, localities, and, causes of bites proved very interesting, demonstrating a lack of knowledge and unsound judgment on the part of the children, as they attempted to catch or pet the snake (Dluhorucky et al., 2000).

Toxins: The venom of the common viper is that of enzymatic type; its composition is relatively unfavorable from a toxinologic and clinical aspect. The lethal dose for a human, 15-20 mg, can be compared to the venom of the Indian cobra (*Naja naja*) or the South American rattlesnake (*Crotalus durissus*); it is four times lower than that of the eastern diamond-backed rattlesnake (*Crotalus adamanteus*), even though the quantity of dry matter in the venom in an adult common viper usually does not exceed 15 mg, which is about 60% of a lethal dose estimated for a human. Nevertheless, research via collecting the venom from 20 adult vipers showed that the quantity of dry matter exceeded this traditional limit in 3 vipers, exhibiting values as great as 18, 28, and 39 mg (Vozenilek, 2000). Such a quantity of common viper venom could have severe after-effects if injected. Fortunately, a much lower quantity of venom - from 2 to 14 mg of dry matter - is found in most common vipers; moreover, a snake will only discharge a minor amount or none at all if displaying defensive behavior.

Out of the diverse range of snake venom components, the common viper lacks paralyzing postsynaptic neurotoxins, cardiotoxins, myotoxins, and necrotizing substances. However,

neurotoxic compounds, like PLA_2 with presynaptic effects, are still present in venoms of certain common viper subspecies or individuals, at a level that can induce systemic symptoms, for instance, in specific sections of the vegetative nerve system, but even in innervations of facial muscles.

Components affecting hemocoagulation and cytotoxic substances are contained in the venom to a negligible extent, so they generally apply merely at a local level. However, the common viper still contains clinically dangerous groups of substances - circulation toxins with vasodilation effects, and hemorrhagins increasing capillary permeability. These compounds can cause losses in liquid, ions and proteins; subsequently, in the cases of the highest severity, they can reduce blood elements in intravasal compartments.

*Local symptoms of envenoming***:** At the very least, a minimal application of a toxin will manifest itself by localized edema, which can sometimes exhibit a central livid tone; later on it progresses and is accompanied by swollen regional lymph nodes. Typically, the edema will reach maximum size within 48 hours following an attack; in more severe and rather rare cases, it will even propagate from the afflicted limb to the torso. It is also accompanied by feelings of pain and strain; in some cases the pain is simply nominal. The edema may be hemorrhagic and accompanied by ecchymoses and changes in skin tone at the afflicted site – turning red or livid; later on, bruises change their color to tints of green and yellow. Blisters, bullae, any significant localized bleeding or necrosis do not occur. Exceptionally, normally in children, edema can be extreme in sized and transfer from the limb via lymph nodes to the torso.

Sporadically, infection complications may occur – i.e. phlegmon at and around the bitten site.

Systemic symptoms of envenoming: A large number of common viper snakebite incidents will only exhibit symptoms of local affliction or light systemic changes. On some occasions, local signs are discreet and the envenomation manifests only with systemic symptoms.

To generalize the level of envenoming in *V. berus*, the Reid classification scheme is sometimes used (Reid, 1976).

* *A Minimum or zero reaction.* Local edema, no reaction or only that caused by a shock at a systemic level.

* *B Light reaction***.** A larger edema with or without gastrointestinal complications, however, no further affliction at a systemic level.

* *C Medium reaction.* Extensive edema, shock persists for less than two hours, further signs of a light systemic affliction.

* *D Severe reaction***.** Shock persists for over two hours or states of shock repeat. Further signs of a severe systemic affliction.

* *E Fatal reaction.*

Just like for most other vipers, the first symptoms of systemic envenoming include nausea, vomiting, excessive sweating, increased temperature, and thirst. Vomiting can occur even several minutes after the snakebite, and is typically accompanied by abdominal pain like colic, diarrhea - rarely with hemorrhaging - and sometimes incontinence. These symptoms indicate a moderate to more significant level of envenoming and may persist for 48 hours following the attack.

In less than 10% of cases, a severe type of affliction can be represented by an angioneurotic edema limited to the area of the lips, tongue, and face, perhaps assisted by anaphylaxis. Any respiratory difficulties reported are likely to be caused by anaphylactoid bronchospasm as well.

Other dangerous symptoms of envenoming include decreased systemic pressure, circulation collapse, or even shock accompanied by tachycardia, cold sweats, paleness, and altered consciousness. In the majority of cases, the circulation complication can be managed within 2 hours; a longer persistence is exceptional. Provided incidence of circulatory changes ranges from 20% to 40% of those envenomed; however, in other research such frequency is not reached (Persson et Irestedt, 1981, Stahel et al., 1985, Audebert et al., 1992). The vasoparalytic action of toxins and plasmatic kinins released is multiplied by extravasation of water into the interstitium, caused by damage to the endothelium, endothelial junctions, and subendothelium. The loss of water, ions, and proteins without blood elements will, if not compensated, increase Hct and Hb levels. Significant affection of capillary beds can even result in extravasation of erythrocytes, which will be conversely manifest via the discovery of anemia without apparent hemorrhaging. Besides this, moderate anemia may also occur in cases where the volume of dilated vascular system is replenished by using plasma volume substitutes. Spontaneous bleeding after a bite from the common viper is a rarity, however, it cannot be fully precluded. More often, even in 30% of severe envenomings, the course can be complicated by hematuria.

In addition, clinical symptoms of neurotoxicity have been recorded. Weinert et al. (2002) describe a case of persisting facial paresis that followed a bite to the face, probably caused by damage to nerve endings. Occasionally, symptoms like ophtalmoplegia, eyelid ptosis, dysphonia, and dysphagia have been registered in cases of *V. berus* snakebites, even though such types of affection are normally typical for the venom of the asp viper (*V. aspis*). In some cases of envenoming, CNS disorders like somnolence or fuzziness, and even unconsciousness may occur. Cederholm et Lennmarken (1987) describe convulsion attacks without an EEG correlate in a 15-month-old boy weighing 10 kg, with extensive local edema and suspected edema of brain caused by mobilization of edema liquid.

Renal failure with temporary oliguria, proteinuria, and hemoglobinuria can occur in up to 6% of envenomings, potentiated by hypotension, extravasation, and hemolysis.

In extraordinary cases, temporary ECG changes like low or inversed T wave can be registered; even atrioventricular block of stage 2 has occurred.

Cases described include an intrauterine fetal death following a snakebite suffered by a woman in the 7th month of pregnancy, development of paralytic ileus in a 4-year-old child, and successfully resuscitated respiratory and circulatory failure in a man, who reached a hospital one kilometer away by running following an attack by a common viper (Persson et Irestedt, 1981).

In cases of common envenoming with systemic symptoms, full normalization of systemic changes can be expected within 1-3 weeks. However, intermittent swelling and pain at the affected site may persist for a number of months. Reid (1976) states that the recovery in children is faster than in adults.

Laboratory findings: Leukocytosis presents the most frequent result found in envenoming by *V. berus*. If significant, especially when it exceeds 20 x 10^9/l, it predicts a more severe extent of envenoming. Increased Hb and Hct levels are caused by water that has escaped in capillary integrity disorder. In rare cases, coagulation tests show thrombocytopenia - up to 14

x 10^9/l, prolonged PT and APTT, increased levels of FDP with reduced FBG, and prothrombin complex.

Possible renal failure relates to creatinine and urea found in both serum and urine; nevertheless, the serum creatinine level might have been slightly increased even outside the affliction of kidneys. The occurrence of metabolic acidosis is due to organ hypoperfusion. In especially severe cases, an increased level of liver enzymes can be found.

Urine lab tests typically reveal proteinuria and hemoglobinuria, or erythrocyturia.

Mortality: Even though extremely rare after envenoming by European vipers, fatalities do exist.

50 cases of death occurred across Europe in 1984; however, they involved victims of snakebites from all European viper species, i.e. also *V. ammodytes*, *V. aspis,* and *V. xanthina* in addition to those from *V. berus*. In the United Kingdom, 14 people died after suffering a bite from the common viper over the last 100 years, with only a single fatality recorded in England and Wales in 1950-72 (Reid, 1976). Audebert et al. (1992) provide a single death in France for a set of 82 snakebites; another death in 1993 is presented by Bures et al. Sweden registered 44 fatalities in 1911-1978, while in recent decades mortality has been described as negligible. A single case of a fatality from obstructed airways and bronchospasm with angioneurotic edema is known; the woman died despite extensive symptomatic treatment (Karlson-Stiber et al., 1997).

Therapy: As a consequence of the high variability of venoms and their effects, each case of a snakebite by a venomous snake, including all European vipers, must be handled on an individual basis, and the possibility of unexpected complications arising may not be precluded. Although the symptoms of envenoming do not largely pose any significant danger for an adult, the approach taken to a snakebite from the common viper and other "small" snakes of this genus must be serious, and the patient should be fully managed. As regards children so affected, such an approach is mandatory as the quantity of venom in a possible dose may be lethal considering the potential weight of a child.

First aid, including immobilization of the patient and fixing the limb using a splint and loose bandage, is applicable even upon a bite from a small European viper, including the common viper. Such a procedure is definitely indicated in children. Applying a pressure immobilization bandage according to Sutherland is not indicated. For further aid and general rules of treatment, see chapter 5 Snakebite: Therapy and prevention. The affected person should be encouraged to calm down as well.

If there are no symptoms of reduced blood pressure, such as vertigo, weakness, or syncope, the individual affected can be allowed to sit. No unnecessary or straining movements are recommended. If medical aid is within a good reach, it should be called very promptly, especially when local afflictions or systemic symptoms become apparent early; in every case of a bitten child this is implicit.

Where pain is experienced that can be locally extensive, although this is not common, analgesics are applied. Although the common viper's venom does not contain any significant level of hemocoagulation-afflicting substances, administering salicylates is best avoided in the initial phase due to reduced platelet function and increases in local hemorrhaging in the edema, as well as encouraging a potential hemostasis disorder.

The development of any intense allergic reaction or anaphylactic shock is treated under common guidelines, using adrenaline, corticoids, replenishing circulating volume, or

management of the airways and mechanical ventilation; see chapter 5. 3. 2 Prevention and treatment of anaphylactic reactions.

Handling ordinary symptoms of systemic envenoming, such as nausea, vomiting, abdominal pain, diarrhea, weakness, sweating etc., is not necessary in this phase; just steady management and observation of vital functions whilst the patient is being transported will be satisfactory.

In hypotension due to vasodilation and extravasation, tension can be increased and stabilized through supplied volume; in instances of circulation collapse or shock, measures based on symptoms must be taken, i.e. volume compensation is supplemented by vasopressure therapy using norepinephrine and oxygen therapy. The presence of signs of systemic reaction indicates antivenom therapy should be applied.

Reid's criteria (1976) for application of antivenom include a condition that at least one of the following symptoms is detected:

* Persisting or repeated hypotension;
* Leukocytosis exceeding 20 x 10^9/l;
* Acidosis;
* ECG changes;
* Increased serum CC value;
* Extensive edema in adults.

According to stricter criteria, it is argued that indication presents grave symptoms of envenoming with severe hypotension and shock being found (Efrati, 1979). In children, early administration is recommended in the following symptoms of significant exposure: circulation reaction, CNS symptomatology, acidosis, and leukocytosis (Cederholm et Lennmarken, 1987). Another method involves the so-called Stockholm criteria, see chapter 5.3.1 Specific treatment - immunotherapy; Tab. 4. A clear benefit from applying antivenom was only found in severe envenomings within a group of 100 envenomed patients by Stahel et al. (1985), with hospitalization time reduced from 10 to 5 days, whilst in medium and mild reactions, the period remained unaffected. However, application of antivenom in cases with no symptoms of envenoming conversely prolonged the period of hospitalization from one to two days. Some authors suggest that aside from the positive effect on the course of systemic envenoming, treatment by antivenoms influence the size and severity of edema (Kleber et al., 1998).

With regard to the facts above, indications for implementation of specific immunotherapy, i.e. administration of a relevant antivenom, might be summed up as follows:

* Existing hypotension that is difficult or not possible to control by volumotherapy, the necessity to use catecholamines, the recurrence of hypotension, the onset of circulation collapse or shock;

* Clinical presence and recurrence of more severe systemic symptoms of envenoming, namely within GIT or CNS;

* Presence of a high level of leukocytosis (above 20 · 10^9/l), acidosis, ECG changes, increased levels of serum CC or other significant pathologic laboratory results, for instance, prolonged PT and APTT, laboratory evidence of DIC, more severe fibrinolysis, hematuria, proteinuria, or other symptoms of hemocoagulation dysregulation, etc.;

* Existence of extensive edema, especially the hemorrhagic form;
* Occurrence of any more severe or persisting symptoms of systemic envenoming in children without allergic anamnesis.

Applicable antivenoms:

* ANTITOXINUM VIPERICUM, Biomed, Poland;
* EUROPEAN VIPER VENOM ANTISERUM, Inst. of Immunology, Croatia;
* VIPERATAB, Protherics, USA, UK.

Currently, the use of VIPERATAB, Protherics, a sheep antivenom manufactured on the basis of purified Fab-fragments of antigens, can be recommended as preferable. With comparable clinical inhibiting effects, this preparation exhibits almost a zero incidence of allergic reactions, including serum sickness, when compared to horse antivenoms. Applying this antivenom will eliminate a number of objections against giving antivenom; nonetheless, the issue of immunotherapy benefits in medium or even light symptoms of envenoming remains unresolved. In such cases, a familiar pearl of wisdom should be applied: if administration of a medicine is not indicated, it is contraindicated.

The antivenoms mentioned above can be used when necessary for envenomings by other *Vipera* genus snakes as well.

The antivenom is applied preferably within a vein and diluted to 500 ml; see chapter 5. 3. 1 Specific treatment, immunotherapy. In children, the dose is not reduced.

Handling and therapy of a local affliction is not crucial, even though it can be extensive in some cases. As the damage to tissue is typically not significant and *V. berus* toxins lack necrotizing effects, gentle treatment of the afflicted tissue, limb elevation, and mild cooling is sufficient. Giving corticosteroids will probably not influence the course of local changes; nevertheless, early application of certain types of antivenoms can hinder development of edema, although this does not mean extending the criteria for their application.

In cases where systemic symptoms of envenoming occur by the common viper, with a subsequent decline in blood pressure leading up to circulatory failure, which is characterized as capacity shock, symptomatic treatment is infinitely preferred – plasma-expansion with tonization of vascular beds using catecholamines, or β-mimetic support of myocardium, when necessary. As the circulatory failure therapy proceeds, retaining sufficient organ perfusion is essential by providing adequate intravasal volume to avoid vasodilation and escape of liquids into the interstitium. This can eliminate or reduce the affliction of organs, such as renal failure, where severe cases involve symptoms of shock. In more severe local reactions with hemorrhaging, or in cases involving the hemostasis disorder, dextran-like volume expanders are not suitable to fill the circulation due to interference with platelet function. In addition, applying corticosteroids is adequate in instances of more severe angioneurotic edema, tongue edema, bronchospasm, etc. Tracheal intubation is indicated for occurrences of obstruction to upper airways, although this is rare.

Preventing renal failure can be managed by maintaining perfusion pressure and supplying liquids to retain adequate vascular volume and production of a satisfactory quantity of primary urine if hemoglobinuria and proteinuria are exhibited. Support of diuresis and mobilization of edemas, where indicated, can be achieved using manitol.

Antibiotics are not indicated as a means of prevention; any potential administration is dependant on a rise of inflammation determined by bacteria, such as phlegmons.

Symptomatology of lighter and uncomplicated envenomings will last approximately 2-4 days. The patient can be discharged for home treatment after 24 hours following abatement of systemic or severe local symptoms, which in most cases involves severe edema. Any potentially less significant local damage can be solved via treatment as an outpatient. Any potentially persisting laboratory results indicating mild prothrombotic activity can be managed by pre-emptive miniheparinization; see chapter 5.4 Convalescence following envenoming.

Vipera Aspis, the Asp Viper

Currently, the asp viper (*Vipera aspis*) comprises 5-6 subspecies. *Other names:* FR: Vipére aspic; DE: Aspisviper.

Resembling the common viper, this snake can grow to 45-65 cm, which is exceeded very rarely. Unlike the common viper, the asp features an elongated snout and yellowish tip to its tail. In most subspecies as well as individuals, the typical zigzag line splits into isolated spots.

The asp viper resides in mountainous and sub mountainous localities with sparse vegetation in Central and S France, NW Spain, Elba, Italy, and Sicily, Switzerland and along the south-western edge of Germany.

Some data related to a snakebite from the asp viper (*V. aspis*) indicate a more severe or slightly different course of envenoming is possible to that of the common viper. Certain subspecies or local forms seem to possess enhanced neurotoxic potency, in SE France this may involve hybrids of *V. ammodytes* and *V. aspis*, or procoagulative potency; in addition, higher rates of morbidity and mortality than those of toxins of *V. berus* cannot be fully precluded. Pozio (1988) presents 3 fatalities and the occurrence of a hemocoagulation disorder and ophtalmoplegia, in addition to conventional systemic reactions within a group of 286 persons envenomed in the Italian countryside, with *V. aspis* responsible for the most of cases. Furthermore, other neurological symptoms are described: bilateral ptosis, dysphagia, dysphonia, and paresthesia, with even paralysis at the bitten site not unheard of (Weinert et al., 2002).

The procoagulative potency of the asp viper (*V. aspis*) can be proven based on isolating the protein participating in direct prothrombin activation, as well as describing ileic and mesenterial thrombosis with necrosis of the colon, and the necessity for hemicolectomia.

Even if small necrosis is possible aside from typical results already described under the section related to *V. berus* in local afflictions upon envenoming by *V. aspis*, the course of envenoming and local or systemic affliction found in most cases is identical to that mentioned for *V. berus*. Envenomings by these two species are often very difficult to tell apart.

Applicable antivenoms:

* EUROPEAN VIPER VENOM ANTISERUM, Institute of Immunology, Croatia;
* VIPERATAB, Protherics, USA, UK.
* If applicable and if the antivenoms above are not available, ANTITOXINUM VIPERICUM, a monovalent antivenom produced by Biomed, Poland, can be applied as well owing to the high probability of identical venom components and their cross-immunity.

***Vipera Palestinae*, the Palestinian Viper**

Other names: FR: Vipére de Palestine; DE: Palästinaviper. Former names: *V. xanthina palestinae*, *Daboia palestinae*.

Description: This rather robust, spectacular, and variegated viper of mostly nocturnal activity is the largest *Vipera* genus member. It can grow up to 100 cm, with the maximum length being 130 cm. The dorsal part of body exhibits a grayish or umber color with brownish spots. It is the most common snake found in Israel. Of 826 treated snakebites in 1998-2001, 503 cases were accounted for by this species (Bentur et Cahana, 2003).

Home range and habitat: The species is an inhabitant of rocky, stony, as well as sandy localities, fields, plantations, and forests; it even does not avoid human settlements. Its home range includes the Middle East: Israel, Lebanon, W Jordan, and W Syria - largely the parts along the Mediterranean Sea and the Jordan Valley.

Toxins: The venom content is similar to that of the most of *Vipera* genus species; it contains hemorrhagins and hemocoagulation-active toxins, circulation toxins, and proteolytic enzymes, for instance, proteinases, hyaluronidase, phosphodiesterase, phospholipases, and a number of others. Toxin action causes among other things, the release of histamine and plasmatic kinins, PLT dysfunction, thrombin activation dysfunction, and increased fibrino(geno)lysis with subsequent hypofibrinogenemia. The quantity, nature, and effectiveness of enzymatic and toxin range of the Palestinian viper causes affliction to the circulatory system in particular, and explains the severity of endothelial damage, hemocoagulation disorder, and significant local changes.

Local symptoms of envenoming: Bite marks executed by either one or two fangs or possibly a deeper scratch may bleed slightly. The first symptom involves pain, localized redness and progressive swelling. In most cases, painful and strained hemorrhagic edema occur, maybe spreading over related lymph nodes to the torso, or even transferring to the opposite side of the body. Ecchymoses and hemorrhagic blisters, potentially extending to necrosis, appear on the skin near the site of the injury. Local changes are accompanied by lymphangitis and lymphadenitis. The edema peaks at around day 3 or 4, regression can be expected within a week, or even later.

Cases have been described of the edema progressing to the neck including dysphagia and a risk of obstruction of airways, as well as those of edema descending to the epigastrium with symptoms of urine retention and necessary catheterization.

Systemic symptoms of envenoming: Systemic envenoming can be noted through prodromes involving nausea and vomiting followed by abdominal pain, diarrhea, increased temperatures, sweating, restlessness, weakness, or even syncope. There is a risk of an angioneurotic edema on the tongue, lips, and face.

Circulation affection is manifest by hypotension, changes in rhythm, possible compensatory tachycardia, or conversely bradycardia; grievous cases may result in circulation collapse and shock.

Hemocoagulation defects cause hemorrhaging; firstly from wounds, but later on spontaneous bleeding from mucous membranes, into the organs and body cavities. Gastrointestinal hemorrhaging is evident due to hematemesis with subsequent enterorrhagia, but even via acute intestine hemorrhaging. Hematuria is relatively frequent; organ intradermal bleeding is also possible, for example, myocardial hemorrhaging. Congestion occurs on the lungs in the form of interstitial or even hemorrhagic edema, caused by endothelial damage

with increased capillary permeability and a hemostasis disorder in terms of activation and consumption.

Hemoglobinuria and myoglobinuria, accompanied by kidney perfusion disorder caused by hypotension, as well as microthrombotization, result in potential renal failure, although this is probably associated with a direct nephrotoxic effect of the venom's components.

Laboratory findings: Neutrophilic leukocytosis and anemia accompanying hemorrhaging is typically found. Consequences of hemocoagulation defects involve thrombocytopenia and hypoafibrinogenemia of variable levels with increased values of FDP and D-dim. PT and APTT may be prolonged. High CC, LD, and AST values with an almost normal ALT level have been recorded in biochemical laboratory tests, which ostensibly illustrates muscular decomposition rather than liver affliction. This corresponds with myoglobinuria, which is typically detected together with hemoglobinuria and proteinuria. The rest of the results are not specific and correspond to the clinical status and the level of hypoperfusion formed.

Mortality: Snakebites from the Palestinian viper (*V. palestinae*) produce up to 5% fatalities, which in most cases follow circulation shocks due to hypotension and extravasation, or massive hemorrhaging into soft tissues with profound thrombocytopenia and fibrinolysis. Lethality can probably be reduced by a suitable type of comprehensive treatment or timely administration of antivenom.

Therapy: For first aid and general rules of treatment, see chapter 5 Snakebite: Therapy and prevention. Limb immobilization and gentle local treatment can be recommended, with mild cooling and elevation where pain, edema, and congestion are present. Analgesics including opiates and antiphlogistics, except ASA, can be administered in case of intense pain; sedation is also possible.

In case of snakebite from *V. palestinae*, specific therapy by applying a relevant monovalent or polyvalent antivenom is indicated not only due to systemic affliction with existence of prodromes, circulatory complications or hemocoagulation disorder, even though manifest via laboratory results only, but also if progressive or severe local affliction exists.

Applicable antivenom:

* ANTI VIPERA PALESTINAE, Felsenstein Medical Research Center, Israel.

During hospitalization, mild cooling of the edema and elevation of the afflicted limb is recommended. Common methods of skin defect treatment are applicable, including early necrectomy. With regard to the serious local effects of toxins, potentially deeper debridement or even fasciotomy cannot be precluded.

Hypotension is handled through increased supply of liquids in the form of volume expanders and electrolytes; if this is ineffective, vasopressure therapy is applied. If bradycardia persists, symptomatic treatment using relevant catecholamines should follow.

Hemocoagulation disorder requires that the intensity of the therapy be regulated based on the severity of the process, from miniheparinization, including boosting AT activity as far as substitution of erythrocytes, consumed or sequestered platelets or degraded and consumed coagulation factors, see chapter 5. 3. 3. 6 Hemocoagulation disorders. In instances of uncontrollable hemorrhaging, primarily due to activated fibrino(geno)lysis, medicine that possesses antifibrinolytic effects can be also administered; however, avoiding potential microthrombosis in the capillary system should be borne in mind.

Respiratory failure in the form of incipient affection of the ALI/ARDS type will require oxygen therapy, possibly using continuous positive airway pressure (CPAP), or even mechanical ventilation.

The potential risk of renal failure can be tackled through increasing the supply of liquids to retain sufficient perfusion of kidneys and to ensure production of a satisfactory quantity of primary urine. However, any overdosing of liquids, especially with reduced diuresis, can potentiate the generation of pulmonary edema in the terrain of the damaged pulmonary capillary network.

The patient can be discharged for home treatment after 24 hours following abatement of all systemic symptoms and normalization of significant laboratory results. A lighter local affection can be solved by means of treatment as an outpatient. Any persisting laboratory results indicating mild prothrombotic activity, can be managed by pre-emptive miniheparinization; see chapter 5.4 Convalescence following envenoming.

Vipera Xanthina, the Rock Viper. *Vipera Raddei*, the Armenian Mountain Viper

The rock viper (*Vipera xanthina*) - whose scientific name should not be confused with the former name *V. xanthina palestinae* (currently *V. palestinae*) - and the Armenian mountain viper (*Vipera raddei*) rank alongside the Palestinian viper as the largest vipers in Turkey and the Middle East.

They can reach lengths of 70-100 cm. Coloring is in hues of gray or brown, with yellow tints in *V. xanthina*, mostly with a zigzag pattern on their backs.

They can be found in stony and often forested localities in the mountains and foothills of Armenia, NE Turkey, and NW Iran (*V. raddei*), and W and Central Turkey (*V. xanthina*).

In general, the venom's composition corresponds to that of other *Vipera* snakes - see above, with enzymatic components being the key parts; less significantly, the toxin range involves components of specific toxins with smaller molecules. Primarily, kininogen-like enzymes that attack vascular systems in terms of vasodilation and hemorrhagins can be expected; in addition, there are components afflicting hemocoagulation in some ways, and general cytotoxic enzymes: proteinases, hyaluronidase, esterases, phospholipases, etc.

Cases of envenoming by these two vipers have not been surveyed to a sufficient extent. It is highly probable that envenoming takes place in a similar way to envenomation caused by other *Vipera* subspecies, such as the Palestinian viper (*V. palestinae*). The Armenian mountain viper (*V. raddei*) is typically held responsible for fatal snakebites to animals in its home range.

The course of envenoming can be estimated based on the status of an adult man bitten by the Armenian mountain viper (*V. raddei*) and hospitalized at author's workplace. A double bite mark and localized edema without hemorrhagic signs were evident. Pain in the afflicted limb as well as nausea and vomiting came immediately, followed by shivering and dysesthesia of skin around the body. On entry, signs of a low-level reduction of hydration were apparent, but circulation still remained stable. The patient exhibited no signs of hemorrhagic diathesis. Laboratory findings did not show any apparent pathological values except for leukocytosis: 11,100-15,100 x 10^9/l; CRP below 2 mg/l increased to 55 mg/l within 12 hours, D-dim of 461 μ/l was still decreasing. No further development was exhibited so the patient was discharged for home treatment on day 3. However, such a light course documents exposure to a smaller quantity of venom from a bite; in other cases, a more severe envenoming can be expected, with hypotension, or even hemocoagulation disorder.

A severe localized affliction following a snakebite from the rock viper (*V. xanthina*) has been described, when fasciotomy of arm was required due to the formation of compartment syndrome, even after application of antivenom and without manifestation of systemic symptoms (Kuzbari et al., 1994).

No mortality has been described.

Applicable antivenoms:

EUROPEAN VIPER VENOM ANTISERUM, Institute of Immunology, Croatia (*V. xanthina*, etc.).

No antivenom against the Armenian mountain viper (*V. raddei*) is available; if necessary, some other antivenoms applicable for the *Vipera* genus members can be used owing to the likeness of venom components and probability of cross-immunity.

Therapy corresponds to the procedures mentioned for other *Vipera* species; see above. Potentially, the most severe symptoms of systemic envenoming include hypotension or even circulation collapse with the necessity for volume compensation and catecholamine support - see chapter 5. 3. 3. 5 Hypotension, shock, or hemocoagulation disorder - see chapter 5. 3. 3. 6 Hemocoagulation disorders.

REFERENCES

ALLOATTI, G., GATTULLO, D., DALLA VALLE, R., et al. The haemodynamic effect of *Bitis nasicornis* (Rhinoceros Horned Viper) venom. *Gen Pharmacol*, 1991, 22, No. 1, pp. 203–206.

AUDEBERT, F., SORKINE, M., BON, C. Envenoming by viper bites in France: clinical gradation and biological quantification by ELISA. *Toxicon*, 1992, 30, No. 5–6, pp. 599–609.

BARKAGAN, ZS., MAMOT, AP., GLAZUNOVA, GA., et al. Effect of heparin on fibrinogen formation during experimental toxic syndrome of disseminated intravascular coagulation. *Ukr Biokhim Zh*, 1988, 60, No. 1, pp. 23–29.

BEER, E., MUSIANI, R. A case of intestinal infarction following *Vipera aspis* bite. *Toxicon,* 1998, 36, No. 55, pp. 729–733.

BENBASSAT, J., SHALEV, O. Envenomation by *Echis coloratus* (Mid-East Saw-scaled Viper). *Isr J Med Sci*, 1993, 29, pp. 239–250.

BENTUR, Y, CAHANA, A. Unusual local complications of *Vipera palestinae* bite. *Toxicon*, 2003, 41, No. 5, pp. 633–635.

BOVIATSIS, EJ., KOUYIALIS, AT., PAPATHEODOROU, G., et al. Multiple hemorrhagic brain infarcts after Viper envenomation. *Am J Med Hyg*, 2003, 68, No. 2, pp. 253–257.

BURES, E., MALIN, F., FOURNIER, E., et al. A fatal case of Viper bite in adult in France. *Rev Med Interne*, 1993, 14, No. 3, pp. 174–176.

BÜCHERL, W., BUCKLEY, EE., DEULOFEU, V. (Eds). *Venomous animals and their venoms.* Volume I. New York : Academia Press, 1968.

CEDERHOLM, I., LENNMARKEN, C. *Vipera berus* bites in children – experience of early antivenom treatment. *Acta Paediatr Scand*, 1987, 76, No. 4, pp. 682–684.

COPPOLA, M., HOGAN, DE. Venomous snakes of southwest Asia. *Am J Emerg Med*, 1992, 10, No. 3, pp. 230–236.

EFRATI, P. Clinical manifestations and treatment of viper bite in Israel. *Toxicon*, 1969, 7, No. 1, pp. 29–31.

GALLISSEN, A., THEAKSTON, RD., BARTH, J., et al. Neurotoxicity, heamostatic disturbances and haemolytic anaemia after a bite by a Tunisian Saw-scaled or Carpet Viper (*Echis pyramidum* – complex): failure of antivenom treatment. *Toxicon*, 1994, 32, No. 8, pp. 937–944.

GAN, ZR., GOULD, RJ., JACOBS, JW., et al. Echistatin. A potent platelet aggregation inhibitor from the venom of the Viper, *Echis carinatus*. *J Biol Chem*, 1988, 263, No. 36, pp. 19827–19832.

GILTON, D., SHALEV, O., BENBASSAT, J. Treatment of envenomation by *Echis coloratus* (Mid-East Saw Scaled Viper): a decision tree. *Toxicon*, 1989, 27, No. 10, pp. 1105–1112.

GRÖNLUND, J., VUORI, A., NIEMINEN, S. Adder bites. A report of 68 cases. *Scand J of Surg*, 2003, 92, pp. 171–174.

GUILLEMIN, I., BOUCHIER, C., GARRIGUES, T. et al. Sequences and structural organization on phospholipase A2 genes from *Vipera aspis aspis*, *V. aspis zinnikeri* and *Vipera berus berus* venom. Identification of the origin of a new Viper population based on ammodytin I1 heterogenity. *Eur J Biochem*, 2003, 270, No. 13, pp. 2697–2706.

HUANG, TF., PENG, HC., PENG, JS., et al. An antiplatled peptide, gabonin, from *Bitis gabonica* snake venom. *Arch Biochem Biophys*, 1992, 298, No. 1, pp. 13–20.

ISMAIL, M., MEMISH, ZA. Venomous snakes of Saudi Arabia and the Middle East: a keynote for travellers. *Int J of Antimikrob Agents*, 2003, 21, p. 164–169.

JANSSEN, M., FREYVOGEL, TA., MEIER, J. Antigenic relationship between the veno, of the night adder *Causus maculatus* and venoms of other Viperids. *Toxicon,* 1990, 28, No. 8, pp. 975–983.

JANSSEN, M., MEIER, J., FREYVOGEL, TA. Purification and charakterization of antithrombin III inactivating enzyme from the venom of the African Night Adder (*Causus rhombeatus*). *Toxicon,* 1992, 30, No. 9, pp. 985–999.

KARLSON-STIBER, C., PERSSON, H. Antivenom treatment in *Vipera berus* envenoming – report of 30 cases. *J Intern Med*, 1994, 235, pp. 57–61.

KARLSON-STIBER, C., PERSSON, H., HEATH, A., et al. First clinical experience with specific sheep Fab fragments in snake bite. Report of a multicentre study of *Vipera berus* envenoming. *J Intern Med*, 1997, 241, p. 53–58.

KEYLER, DE. Envenomation by the lowland viper (*Proatheris superciliaris*): Severe case profile documentation. *Toxicon* 2008, 52, pp. 836-841.

KHADWAL, A., BHARTI, B., PODDAR, B., et al. Persistent coagulopathy in snake bite. *Indian J Pediatr*, 2003, 70, No. 5, pp. 439–441.

KLEBER, JJ., ZILKER, T. Adder bites in humans. *Tierarztl Prax Ausg K Klientiere Heimtiere*, 1998, 26, No. 2, pp. 95–100.

KNOEPFFLER, LF. Autoobservation d´envenomation par morsure d´Atheris sp. *Toxicon*, 1965, 2, pp. 257–276.

KOMORI,Y., NIKAI, T., SUGIHARA, H. Isolation and characterisation of procoagulant from the venom of *Vipera aspis aspis*. *Int J Biochem*, 1993, 25, No. 5, pp. 761–767.

KULARATNE, SA. Epidemiology and clinical picture of the Russell´s viper (*Daboia russelli russelli*) bite in Anuradhpura, Sri Lanka: a prospective study of 336 patients. *Southeast Asian J Trop Med Public Health*, 2003, 34, No. 4, pp. 855–862.

KUZBARI, R., SEIDLER, D. DEUTINGER, M. Lokal complications after poisonous snake bite. *Handchir Mikrochir Plast Chir*, 1994, 26, No. 1, pp. 48–50.

De HARO, L., ROBBE-VINCENT, A., SALIOU, B., et al. Unusual neurotoxic envenomations by *Vipera aspis aspis* snakes in France. *Hum Exp Toxicol*, 2002, 21, pp. 137–145.

LATIFI, M. Variation in yield and letality of venoms from Iranian snakes. *Toxicon*, 1984, 22, No. 3, pp. 373–380.

LANOIE, LO., BRANCH, WR. Venoms and snakebite. *J Herpetol Ass Afr*, 1991, 39, p. 29.

LAVONAS, EJ., TOMASZEWSKI, CA., FORD, MD., et al. Severe Puff Adder (*Bitis arietans*) envenomation with coagulopathy. *J Toxicol Clin Toxicol*, 2002, 40, No. 7, pp. 911–918.

LIFSHITZ, M., KAPELUSHNIK, J., BEN-HAROSH, M., et al. Disseminated intravascular coagulation after Cerastes vipera envenomation in 3-year-old child: a case report. *Toxicon*, 2000, 38, No. 11, pp. 1593–1598.

LIFSHITZ, M., KASTEL, H., HARMAN-BOEHM, I. *Cerastes cerastes* envenomation in an 18 year old female: a case report. *Toxicon*, 2002, 40, pp. 1227–1229.

LIFSHITZ, M., PHILLIP, M., BERNSTEIN, T., et al. Snake bite by Cerastes vipera in children: report of two cases. *Wilderness Environ Med*, 1995, 6, No. 3, pp. 269–272.

MacKAY, N., FERGUSON, JC., McNICOL, GP. Effects of the venom of Rhinoceros Horned Viper (*Bitis nasicornis*) on blood coagulation, platelet aggregation and fibrinolysis. *J Clin Pathol*, 1970, 23, pp. 789–796.

MARSH, N., GATTULLO, D., PAGLIARO, P., et al. The Gaboon Viper, *Bitis gabonica*: hemorrhagic, metabolit, cardiovascular and clinical effect of the venom. *Life Sci*, 1997, 61, No. 8, pp. 763–769.

MÄRTSON, M, TAITTONEN, M, ALANEN, M, et al. *Vipera berus* adder bite in the water, complicated by rapid shock. A case history. *Eur J Pediatr Surg*, 2001, 11, No. 5, pp. 358–360.

McNALLY, T., CONWAY, GS., JACKSON, L., et al. Accidental envenoming by a Gaboon Viper (*Bitis gabonica*): the haemostatic disturbances observed and investigation of in vitro haemostatic properties of whole venom. *Trans R Soc Trop Med Hyg*, 1993, 87, No. 1, pp. 66–70.

MEBS, D., HOLADA, K., KORNALÍK, F., et al. Severe coagulopathy after a bite of a Green Bush Viper (*Atheris squamiger*): case report and biochemical analysis of the venom. *Toxicon*, 1998, 36, No. 10, pp. 1333–1340.

MEBS, D., KUCH, U., MEIER, J. Studies on venom and venom apparatus on Fea´s viper, *Azemiops Feae*. *Toxicon*, 1994, 32, No. 10, pp. 1275–1278.

MEIER, J., WHITE, J. (Eds). *Handbook of clinical toxicology of animal venoms and poisons.* Boca Raton : CRC Press, 1995, 752 pp.

MYINT-LWIN, WARRELL, DA., PHILLIPS, RE., et al. Bites by Russell´s Viper (*Vipera russelli siamensis*) in Burma: haemostatic, vascular and renal disturbances and response to treatment. *Lancet,* 1985, 2, No. 8467, p. 1259–1264.

PAUL, V., PRAHLAD, KA., EARALI, J., et al. Trial of heparin in viper bites. *J Assoc Physicians India*, 2003, 51, pp. 163–166.

PE, T., MYA, S., MYINT, AA., et al. Field trial of efficacy of local compression immobilization first-aid technique in Russell´s Viper (*Daboia russelli siamensis*) bite patients. *Southeast Asian J Trop Med Public Health*, 2000, 31, No. 2, pp. 364–368.

PERSSON, H. Clinical toxicology of snakebite in Europe. In. MEIER, J., WHITE, J. (Eds), *Handbook of clinical toxicology of animal venoms and poisons.* Boca Raton : CRC Press, 1995.

PERSSON, H., IRESTEDT, B. A study of 136 cases of Adder bite treated in Swedish hospitals during one year. *Acta Med Scand*, 1981, 210, No. 6, p. 433–439.

PHILLIPS, RE., THEAKSTON, RD., WARRELL, DA. Paralysis, rhabdomyolysis and haemolysis caused by bites of Russell´s Viper (*Vipera russelli pulchella*) in Sri Lanka: failure of Indian (Haffkine) antivenom. *Q J Med*, 1988, 68, No. 257, pp. 691–715.

PORATH, A., GILON, D., SCHULCHYNSKA-CASTEL, H., et al. Risk indicators after envenomation in human by *Echis coloratus* (Mid-East Saw Scaled Viper). *Toxicon*, 1992, 30, No. 1, pp. 25–32.

POZIO, E. Venomous snake bites in Italy: epidemiological and clinical aspects. *Trop Med Parasitol*, 1988, 39, No. 1, pp. 62–66.

PUGH, RN., THEAKSTON, RD. A clinical study of viper bite poisoning. *Ann Trop Med Parasitol*, 1987, 81, No. 2, pp. 135–149.

RAMACHANDRAN, S., GANAIKABAHU, B., PUSHPARAJAN, K., et al. Myonecrosis due to Russell´s Viper bites in Sri Lanka. *Am J Trop Med Hyg*, 1994, 50, No. 5, pp. 597–601.

RATHOD, K., SHETH, R., CHAVHAN, G., et al. Hemoperitoneum complicating snake bite: rare CT features. *Abdom Imaging*, 2003, 28, No. 6, pp. 820–821.

REID, HA. Adder bites in Britain. *Br Med J*, 1976, 2, No. 6028, pp. 153–156.

ROBINSON, RF., BAKER, RS., MARTIN, S., et al. Use of »Near Middle East antivenom« to treat African Bush Viper envenomation. *Vet Hum Toxicol*, 2004, 46, No. 5, pp. 264–265.

SHEBUSKI, RJ., RAMJIT, DR., BENCEN, HG., et al. Characterization and platelet inhibitory activity of bitistatin, a potent arginine-glycine-aspartic acid-containing peptide from the venom of the Viper *Bitis arietans*. *J Biol Chem*, 1989, 264, No. 36, pp. 21550–21556.

SCHAEFFER, RC. Jr. Heterogenity of Echis venoms from different sources. *Toxicon,* 1987, 25, No. 12, pp. 1343–1346.

STAHEL, E., WELLAUER, R., FREYVOGEL, TA. Poisoning by domestic Vipers (*Vipera berus* and *Vipera aspis*). A retrospective study of 113 patients. *Schweiz Med Wochenschr*, 1985, 115, No. 26, pp. 890–896.

STÖCKLIN, R., CRETTON, G. *The ultimate database on venomous animals, snakes.* CD-rom, Geneva : Atheris Laboratories, 1998.

TAN, NH., PONNUDARAI, G. A comparativ study of the biological properties of venoms of some world Vipers (subfamily *Viperinae*). *Int J Biochem*, 1992, 24, No. 2, pp. 331–336.

TRAPE, JF., PEELMAN, P., CARME, B., et al. La gravite d´une morsuare de serpent a propos de trois observations au Congo. *Ann Soc Belge Med Trop*, 1992, 72, pp. 155–157.

VALENTA, J., STACH, Z., FRICOVA, D. et al. Envenoming by the viperid snake *Proatheris superciliaris*: A case report. *Toxicon,* 2008, 52, pp. 392-394.

VEST, DK. Preliminary studies on the venom of the Chinese snake *Azemiops feae*, Boulenger (Fea´s viper). *Toxicon,* 1986, 24, No. 5, pp. 510–513.

VOZENILEK, P. Ty zmije. Praha : Ministerstvo zivotniho prostředí CR, 2000, 79 pp.(in Czech)

WARRELL, DA. Clinical toxicology of snakebite in Africa and the Middle East / Arabien Peninsula. In MEIER, J., WHITE, J. (Eds), *Handbook of clinical toxicology of animal venoms and poisons.* Boca Raton : CRC Press, 1995.

WARRELL, DA. Clinical toxicology of snakebite in Asia. In MEIER, J., WHITE, J. (Eds), *Handbook of clinical toxicology of animal venoms and poisons.* Boca Raton : CRC Press, 1995.

WARRELL, DA., DAVIDSON, NM., GREENWOOD, BM., et al. Poisoning by bites of the Saw-Scaled or Carpet Viper (*Echis carinatus*) in Nigeria. *Q J Med*, 1977, 46, No. 181, pp. 33–62.

WARRELL, DA., ORMEROD, LD., DAVIDSON, NM. Bites by Puff-adder (*Bitis arietans*) in Nigeria, and value of antivenom. *Br Med J*, 1975, 4, No. 5998, p. 697–700.

WARRELL, DA., ORMEROD, LD., DAVIDSON, NM. Bites by the Night Adder (*Causus maculatus*) and Burrowing Vipers (genus *Atractaspis*) in Nigeria. *Am J Trop Med Hyg*, 1976, 25, No. 3, pp. 517–524.

WARRELL, DA., POPE, HM., PRENTICE, CR. Disseminated intravascular coagulation cause by the Carpet Viper (*Echis carinatus*): trial of heparin. *Br J Haematol*, 1976, 33, No. 3, pp. 335–342.

WEINERT, W., SATTLER, RW., MEBS, D. Persistent paresis of the facialis muscle after European Adder (*Vipera berus*) bite on the forehead. *Toxicon*, 2002, 40, No. 11, pp. 1627–1629.

WEIS, JR., WHATLEY, RE., GLENN, JL., et al. Prolonged hypofibrinogenemia and protein C activation after envenoming by *Echis carinatus sochureki*. *Am J Trop Med Hyg*, 1991, 44, No. 4, pp. 452–460.

WILDI, SM., GÄMPERLI, A., BEER, G., et al. Severe envenoming by a Gaboon Viper (*Bitis gabonica*). Swis Med Wkly, 2001, 131, No. 3–4, pp. 54–55.

6.4.3. Subfamily: *Crotalinae*

Formerly grouped under a separate family, the *Crotalinae* subfamily currently encompasses 18 genera including 154 species. More recently, the number of genera recognized has even increased.

The anatomy of *Crotaline* snakes is similar to that of most viperids (*Viperidae*); in addition, they resemble the rest of the family in many ways. According to the structure and function of their venom apparatus, featuring large erectile fangs embedded in the maxilla, they rank among solenoglyphous snakes, as well as other viperids. However, unlike the others of the family, they differ fundamentally due to possessing heat sensing organs - a pair of deep pits placed in the anterior part of their heads between the eyes and nostrils; see chapter 1. 3 Morphology of snakes.

Their venom composition roughly corresponds with that of other viperids, in that it contains a significant proportion of enzymes, typically with extensive destructive potency towards tissues, and frequently also components with hemocoagulation effects. Clinically, the role of neurotoxins is only visible occasionally, except for certain species that is, e.g. *C.*

durissus. Again, neurotoxins are those of enzymatic nature, being phospholipase-like substances, with presynaptic effects.

Crotalinae snakes inhabit a major part of the American continent, as well as central and south-eastern Asian regions. Within America and Japan, these animals are the most significant as regards epidemiology of envenoming by snakes. Some of the species are popular as pets, which again underlines their epidemiology significance.

6.4.3.1. Agkistrodon, Calloselasma, Deinagkistrodonon, Gloydius, and Hypnale Genera.

Species: Currently, only three species are included in the *Agkistrodon* genus: the cantil (*Agkistrodon bilineatus*), southern copperhead (*Agkistrodon contortrix*), and western cottonmouth (*Agkistrodon piscivorus*). The Mexican moccasin (*Agkistrodon taylori*) is now sometimes listed as a separate species. Other seven species formerly ranked among the genus are now listed as *Gloydius* genus comprising 10 species, such as the mamushi (*Gloydius blomhoffii*), Halys pit viper (*Gloydius halys*), Himalayan pit viper (*Gloydius himalayanus*), etc. Calloselasma and Deinagkistrodon are monotypic genera that include the Malayan pit viper (*Calloselasma rhodostoma*) and Chinese moccasin (*Deinagkistrodon acutus*), respectively. The *Hypnale* genus, i.e. hump-nosed pit vipers, contains three species: the hump-nosed moccasin (*Hypnale hypnale*), Sri Lanka hump-nosed viper (*Hypnale nepa*) and Wall's hump-nosed viper (*Hypnale walli*).

Other names: EN: cantil (*A. bilineatus*), copperhead (*A. contortrix*), water moccasin (*A. piscivorus*). FR: trigonocéphale à bouche rose (*C. rhodostoma*). EN: hundred-pace viper; FR: Agkistrodon rostre pointu (*D. acutus*). EN: Japanese or Chinese mamushi, doksa or Asiatic (Siberian, Himalayan) pit viper; JAP: mamushi (*Gloydius*). EN: humpnose viper (*Hypnale*). The *Gloydius* snakes are often still listed and named as *Agkistrodon*.

Description. Mamushis and pit vipers have a robust to heavyset and well-muscled medium-sized body with average length of 50-120 cm; 189 cm for the conanti (*Agkistrodon piscivorus*) is the maximum-evidenced length. The similar shape of body, but a lesser size: these are the features of the hump-nosed viper, *Hypnale*; they can grow up to the length of mere 30 to 45 cm, with the maximum of 56 cm. Their large head has a form of triangle. The color is brownish, ferruginous, rubiginous, grayish, or even blackish; they mostly feature big spots fused up to cross bands or also small pale or whitish spots on a dark background (*A. bilineatus*, *A. piscivorus*).

The most species of this group are active particularly at night; the species ranging in colder zones will be rather diurnal animals.

Mamushis and pit vipers are more or less nervous characters, with good motional skills and the possibility of relatively quick attack; however, they lack any apparent aggressiveness.

In Northern Carolina, U.S., bites by the copperhead (*A. contortrix*) form the highest percentage of cases of envenoming, while in the entire USA, 8.8% from the 4,400 snakebites including non-venomous snakes reported in 1991 involved *A. contortrix*, and 1.5% can be assigned to *A. piscivorus*. In Japan, roughly 3,000 mamushi (*G. blomhoffi*) bites have been reported per year. In Sri Lanka, *H. hypnale* bites present 27% from the total number of cases of envenoming. In terms of epidemiology, the *Gloydius* mamushis and pit vipers are an issue in China and Korea as well.

Habitat and range. The *Agkistrodon* snakes inhabit Northern America; they range from the southeast regions of the USA (*A. piscivorus*) over the central and southern part of the U.S.

and NE Mexico (*A. contortrix*) as far as the western Mexican coast and NW Costa Rica (*A. bilineatus*). Their habitats mostly involve forests and savannahs; they can often be found in hilly grounds or near water surfaces as well as in flood zones of rivers (*A. contortrix*). The conanti (*A. piscivorus*) is directly bound to the presence of water through the structure of its diet.

The rest of the genera are found in Asia. *Calloselasma rhodostoma* inhabits woodlands, primary forests and fields in the former territory of Indochina, while *Deinagkistrodon acutus* ranges in hilly landscapes near water in SE China, N Vietnam and Taiwan. The home range of the *Gloydius* snakes extends from N Iran (*G. intermedius*) and the coastland of the Caspian Sea (*G. halys*) over Central Asia, Pakistan, N India and Nepal (*G. himalayanus*), Mongolia and China (*G. blomhoffi*, *G. halys*, *G. monticola*, *G. stauchi*) as far as Korea and Japan (*G. blomhoffi, G. tsushimaensis*) and to the south and eastern Russian portion of Siberia (*G. saxatilis*, *G. ussuriensis*). They are in most cases inhabitants of woodland and stony habitats, often in the neighborhood of water surfaces or managed farmland, but even in steppes and semideserts (*G. halys*). *Hypnale* snakes live in S India and Sri Lanka, where they can be found in woodlands, fields and grassy areas.

The group includes a snake species living in the highest altitude - this is the Himalayan pit viper (*Gloydius himalayanus*), a dweller of forests in 3,000-4,000 m above sea level; this animals was even found on the edge of the permanent ice zone, 5,300 m above sea level.

Toxins: In snakes of this family, venom largely consists of enzymes; in *A. halys*, LD_{50} for mice IV is approximately about 0.8 mg/kg (Latifi 1984). Venom especially contains the components with hemocoagulation effects as follows: prothrombin activators (e.g. aharin, a kind of enzyme isolated from venom of *G. halys* that is similar to the venom components in *Echis* and *Bothrops* snakes), the components activating additional factors of the plasmatic coagulation system (such as F X from venom of *C. rhodostoma*), thrombin-like fibrinogen converting enzymes isolated e.g. from venom of *G. halys*, direct fibrino(geno)lytic enzymes isolated for example from venoms of *A. contortrix* and *H. hypnale*, platelets aggregation inhibitors isolated for instance from venom of *G. blomhoffi*, platelets aggregation activating elements (e.g. venom of *H. hypnale*) and others; generally, these components shows pro-coagulation and anticoagulation effects at the same time, which depends namely on the dose of venom.

Typical venom components include hemorrhagins and other substances increasing the level of capillary permeability; clinically, presynaptic enzymatic neurotoxins are active as well, such as agkistrodotoxin and PLA_2 from *G. blomhoffi* venom.

Concerning local affliction, proteolytic and other cytotoxic enzymes are responsible for affecting tissue, plus necrosis can arise as well.

*Local symptoms of intoxication***.** All bites from mamushis and pit vipers are painful. In the early stages, envenoming is accompanied by a development of edemas that will mostly affect half of a leg, but may extend to an entire limb or even the trunk. A bite injury often bleeds to a small extent; roughly, a quarter of those concerned (*H. hypnale*) exhibit painful lymphadenopathy, including swelling of lymphatic nodes in the region. In worse cases, the skin of the affected areas is erythematotic with developing petechiae and ecchymoses. More severely, even a subcutaneous hematoma might very rarely form. Vesicles and bullae, largely with blood content, precede the development of necrosis, with an incident rate of up to 10% (*A. contortrix*, *D. acutus*). In most cases, necrosis will only affect the skin and can be primarily found on fingers and after a use of a tourniquet. Exceptionally, they afflict deeper

structures, i.e. hypodermis and muscles; more often, myotoxins or infection agents are involved. Development of a compartment syndrome with the urgency of fasciotomy or a long-term or permanent functional effect on the legs is rare but also possible; see 5.3.3.1 Local damage.

Any infectious complications are chiefly associated with necrosis; even gangrene necessitating amputation or the development of sepsis may occur. Microorganisms isolated from necrosis and infections have mainly included *Enterococcus* sp., *Pseudomonas* sp., *Staphylococcus* sp., and *Clostridium* sp.

Systemic symptoms of envenoming: Symptoms of systemic envenoming appear in about one half of snakebites by the snakes of this group; the rest can be assessed as ,,dry bites'' with no venom released. A certain portion of snakebites by these snakes is associated with only mild symptoms or takes place without any systemic symptoms at all, limited to local affliction, such as in *A. contortix* and *G. himalayanus*.

Systemic envenoming mostly starts with the following prodromes: nausea, vomiting, abdominal pain, diarrhea and increased temperature. Worse courses continue with shivering, cold sweat, thirst, vertigo, weakness, palpitation, eye burning, stomach burning sensations (*H. hypnale*), intestine distension that can rarely change even into an ileous status, and, in the most severe cases of envenoming, lethargy to coma (*G. blomhoffi*, *H. hypnale*) or even syncope and respiratory failure (*D. acutus*).

Hemostatic disorder is the main and fundamentally the most severe symptom. Coagulopathy is manifest by defibrination, which is partly primary and partly secondary, as a result of a DIC-like consumption disorder induced by prothrombin and other activators of the plasmatic coagulation system or fibrinogen-converting enzymes. The hemostasis disorder is primarily demonstrated through laboratory results; clinically, worse cases usually exhibit hemorrhaging from the gums, nose, mucous membranes, small wounds, GIT, urinary tract, as well as airways; retinal hemorrhaging has even been rarely described. Hemorrhaging significant in terms of volume may even lead to symptoms of hypovolemic shock. Coronary hypoperfusion caused by either hypotension or microthrombosis may result in changes in ECG as regards T wave inversion and depressed ST section (*C. rhodostoma*). The incidence of symptoms of hemocoagulation disorder ranges from very rare, e.g. *A. contortrix* and *G. himalayanus* with over 10-24% of persons affected, just like *H. hypnale* and *C. rhodostoma*, but *D. acutus* causes up to 40% of such incidences.

Hemocoagulation disorder, in terms of developing fibrin deposits and microthrombi in glomerular capillaries, participates in oliguric renal failure, in association with possible hemolysis, myoglobinemia, hypotension, and the nephrotoxic effects of the venom components. An unusual yet possible occurrence of respiratory failure is respiratory failure of ALI/ARDS type via, for example, *G. blomhoffi*, in addition to which *H. hypnale* presents a similar complication with the participation of hemorrhagic venom components.

Other symptoms are associated with the presence of presynaptic neurotoxins. Within 1-48 hours following a snakebite, affliction of cranial nerves will occur and manifest as ptosis, diplopia, hazy vision, dysphagia, difficulties in opening the mouth, plus indistinct and generally myasthenic symptoms, as caused by *G. blomhoffi* and *G. halys* for instance. Cases of ventilatory muscle paralysis with necessary mechanical ventilation described from China seem not quite probable - the respiratory failure is more likely to derive from affection of pulmonary tissue related to the ALI/ARDS syndrome; see above.

The content of the myotoxic elements of the venom causes a certain extent of rhabdomyolysis, which is manifest by pain and strain in certain muscular parts including those of neck, back, chest, etc., e.g. in *G. blomhoffi* venom. In addition, neural or muscular damage, if any, also relates to potential motional dysfunctions of limbs that may persist as long as one year, e.g. *A. contortrix*.

Laboratory findings: Typical laboratory results include changes in hemocoagulation tests. Hypofibrinogenemia or even afibrinogenemia occur, and an increase in FDP, mostly with a significant percentage of D dim., as well as thrombocytopenia. A decrease in plasminogen, alfa2-antiplasmin and AT levels is also possible. In more severe instances, extension of PT, APTT, TT, and coagulation time according to Lee-White was discovered. However, hypofibrinogenemia up to afibrinogenemia will only prevail in some cases as a result of primary fibrinolysis, with no additional symptoms of consumption in progress.

Other laboratory tests may include indications of neutrophilic leukocytosis, hemolysis, myoglobin, increases in CK and CRP, and proteinuria, myoglobinuria, and hemoglobinuria through to hematuria can be found in urine.

Mortality: Cases of mortality following bites by some of the mamushi and pit viper snakes are not rare. Between 1904 and 1971, 66 fatalities occurred in Taiwan, which means 24% cases of envenoming out of the recorded total were caused by the venom of *D. acutus*. In *D. acutus*, present mortality following a bite ranges from 4.7 to 5.4%

In Thailand, envenoming by *C. rhodostoma* together with that by the Malayan krait (*Bungarus candidus*) constitutes the highest mortality, with each of these species sharing 13 victims from the total of 46 described. In Japan, two fatal cases per year occur on average out of approximately 3,000 bites by *G. blomhoffi*. Cases of death caused by *G. blomhoffi* and rarely by *H. hypnale* bites have been recorded in China.

Reasons for fatal courses of envenoming usually include hemorrhage, predominantly cerebral hemorrhage, DIC, respiratory and renal failure, shock and sepsis during gangrene and necrosis.

Therapy: For first aid treatment and common principles of therapy, see chapter 5, Snakebite: Therapy and precautions.

Application of a pressure immobilization bandage is not recommended due to the risk of extending local damage through the persistence of the high concentration of venomous hemorrhagic and cytotoxic components at the particular point. Nevertheless, immobilizing the leg by using a looser bandage is a useful solution. Exhaustion of venom from the wound by, for example, an extractor has not been proved as effective but not dangerous when compared to other practices like cutting the wound, tourniquet, etc. A presence of pain acting locally or in the leg may require opiate analgesics to be administered.

Applicable antivenoms:

* CROFAB, CROTALIDAE POLYVALENT IMMUNE FAB(OVINE), Protherics, the USA (*Agkistrodon contortrix*, *Agkistrodon piscivorus*, etc.);

* POLYVALENT ANTIVENOM, Instituto Clodomiro Picado, Costa Rica (*Agkistrodon bilineatus*, and other snakes);

* ANTIVENIN POLYVALENT, Bio Farma, Indonesia (*Calloselasma rhodostoma*, etc.);

* MALAYAN PIT VIPER ANTIVENIN, Thai Red Cross, Thailand (*Calloselasma rhodostoma*, and others);

* AGKISTRODON ACUTUS, Nat. Inst. Prev. Med., Taiwan (*Deinagkistrodon acutus*).

A certain level of cross immunity, thus the possibility of applying antivenoms in cases of bites by other mamushi, e.g. a pit viper species, may be anticipated. Nevertheless, the effect of certain severe venom components, such as prothrombin activators, is usually hard to influence by any specific immunotherapy in most cases.

No *H. hypnale* antivenom is available; HAFFKIN POLYVALENT antivenom administered in some cases has not been effective (Warrell 1995).

Applying antivenoms can be practicable in cases with the development of overall symptoms, hemorrhage, hypotension, heavier neurotoxic symptoms, rhabdomyolysis symptoms like muscle pain and tension, and in more serious laboratory findings, namely in hemocoagulation lab tests, or when a high level of myoglobin is discovered. The effective amount of antivenom will depend on the type and amount of venom or on the level of severity. Generally speaking, it can range from 1-4 vials (*D. acutus*) up to 5-10 vials (*C. rhodostoma*). Any positive effect should be demonstrated by an improved hemocoagulation test. However, recurrent coagulopathy, including common defibrinations, may occur, especially upon the application of antivenoms containing Fab (CroFab) accelerating elimination from circulation.

Any contraindication of application of the antivenom as well as its unavailability, insufficiency or low immunogenicity, and any persistence of severe symptoms of envenoming can be treated by repeated plasmaferesis.

In some circumstances, there may be more grievous local envenoming symptoms. Any developing dermal bullae or lesser necrosis as the predisposition of the occurrence of infectious complications should be hastily removed and the area of the affection treated adequately. In addition, the development of a compartment syndrome cannot be fully precluded. In cases of any suspected disorder of district perfusion, a leg must be treated by elevation and general administration of manitol, with doses of 0.5-2 g/kg IV, in the course of about 30 minutes. If the risk of ischemia in the relevant area does not abate, fasciotomy could be appropriate. However, this kind of treatment is never carried out preemptively; see also chapter 5.3.3.1 Local damage, and chapter 6.4.3.3 *Crotalus* and *Sistrurus* genera: rattlesnakes and ground rattlesnakes. There may be a necessity to amputate due to gangrene affecting fingers.

Pre-emptive administration of antibiotics is not indicated, although sometimes recommended; antibiotic therapy, if one is applied, is launched only upon occurrence of infectious complications.

In case of hypotension or circulatory failure and shock, treatment is initiated with volumotherapy, i.e. replenishing the circulating volume with infusions of crystalloids or colloids. Including fresh-frozen plasma in the therapy will also positively influence a DIC-like hemocoagulation disorder. If application of infusions fails to ensure satisfactory stabilization of the circulation, or hypotension persists or any further increase in volume is contraproductive, vasopressure therapy is indicated using norepinephrine in continual infusion, which will provide sufficient perfusion pressures; see chapter 5.3.3.5 Hypotension, shock.

Sufficient intravascular volume together with adequate perfusion pressure needs to be maintained to retain diuresis in efforts to prevent renal failure.

By default, the hemocoagulation balance disorder should be treated by giving a sufficient quantity of antivenom. Symptomatic therapy becomes necessary if antivenom cannot be

applied or exists in insufficient quantity, and proves necessary to influence any later secondary affliction that might occur, for instance, persisting prothrombotic activity.

Isolated hypofibrinogenemia without clinical signs of increased hemorrhaging will not require any special symptomatic treatment. If this caused by a direct effect of venom components on FBG, it cannot be controlled by means of symptomatic treatment, e.g. using heparin. FBG substitution is not recommended unless bleeding had been caused by its low level. A DIC-like consumption disorder, especially in the late phase, may not be sufficiently manageable by immunotherapy, thus will require a symptomatic approach: therapy in form of applying fresh-frozen plasma (10-20 ml/kg), and substituting AT with potential miniheparinization (70-210 units/kg/24 h) by means of UFH or LMWH with a beneficial and more intense anti-Xa effect based on the specific phase and course of the syndrome. Naturally, the heparin therapy will not be indicated over the period of increased bleeding; nevertheless, it may have a positive effect on managing hypercoagulation states associated with the development of microembolisms. For potential substitution of platelets, erythrocytes and FBG, ordinary guidelines will apply. Administering hemocoagulation factor concentrates is not recommended; see chapter 5.3.3.6. Hemocoagulation disorders.

Light symptoms of neurotoxicity, i.e. ptosis, diplopia, dysphagia, light myasthenic symptoms, etc. will abate without any specific therapy.

A patient can be discharged for home treatment after 24 hours following abatement of all systemic symptoms of envenoming, normalization of significant laboratory findings, and stabilization of the local affliction.

Any persisting laboratory symptomatology of less significant prothrombotic activity should be resolved by preemptive miniheparinization, see chapter 5.4 Convalescence following envenoming.

6.4.3.2. Atropoides, Bothriechis, Bothriopsis, Bothrocophias, Bothrops, Cerrophidion, Lachesis, Ophryacus, and Porthidium Genera

Species: The *Atropoides* genus comprises three species of jumping pit vipers originally classified into the *Porthidium* genus. Each of the *Bothriechis* and *Bothriopsis* genus, i.e. palm pit vipers or forest pit vipers, respectively, contains seven snake species, a part of which was once placed in *Bothrops*, the most extensive genus of this group, which now numbers 32 species, for example the common lancehead (*Bothrops atrox*), jararaca (*Bothrops jararaca*), jararacussu (*Bothrops jararacusu*), Brazilian lancehead (*Bothrops moojeni*), Neuwied's lancehead (*Bothrops neuwiedi*) and others. Note: former *Bothrops asper* seems to be only a subspecies of *B. atrox*. A lesser number of species can be found in the *Cerrophidion* genus with three members, formerly or even recently by some authors placed into the *Porthidium* genus, the *Lachesis* genus with its four species, and *Ophryacus*, a monotypic genus with a sole species - *Ophryacus undulatus*. On the other hand, the *Porthidium* genus currently comprises nine species. More recently, a new genus named *Bothrocophias* containing five species has been described, see chapter 7 List of venomous snakes.

Other names:

Barba amarilla, Caissaca, Mapanare, Terciopelo (*B. atrox*); Fer de Lance (*B. lanceolatus*, *B caribbaeus*); Urutu (*B. alternatus*); Surucucu (*Lachesis*); Jararaca ilhao (*B. insularis*); Jararaca pintada (*B. neuwiedi*); Jararacussu (*B. jararacussu*).

Description: Some snake species of the genera mentioned above typically reach lengths of between 50 and 70 cm (*Cerrophidion*, *Ophryacus*, *Porthidium*), some others 100-200 cm

(*Bothriechis*, *Bothriopsis*, *Bothrops*). The record is held by the viperids (*Viperidae*), in particular the South American bushmaster (*Lachesis muta*), which boasts a documented length of 365 cm and an unconfirmed 426 cm. The Fangs of this snake can measure up to 3.5 cm.

The majority of snakes of this group possess a rather slender, but well-muscled body. The head is of a typical triangular form, and often features a striking striped or spotted pattern, which is darker than overall coloring and also appears on their bodies. Background tones are hues of green, sandy shades, brown, brown/gray, and brown/red.

These snakes are mostly arboreal or semi-arboreal, but can be terrestrial, e.g. *Bothriechis taeniatus*, *Bothrops ammodytoides*, *Bothrops pictus*, *Porthidium,* and others. Most tend to be nocturnal animals.

Generally, they possess very good and fast motion skills, and err towards short-tempered behavior, whilst some are outright aggressive.

In terms of epidemiology, the lanceheads (*Bothrops*), especially *B. atrox*, *B. jararaca*, *B. moojenii*, etc., comprise the most significant representatives due to their relative abundance, extensive home ranges, high toxicity, and volume of venom. Some degree of preferring places close to human settlements is shown by some lanceheads (*Bothrops*), hence is also an essential factor. In the Brazilian state of Sao Paulo, 12,639 bites by a snake were recorded from 1988 to 1993. Of this number, as many as 9,828 snakebites, i.e. 87% of incidents, and 68.3% of fatalities were caused by *Bothrops* (Ribeiro et al., 1998). The Vital Brazil Hospital, Sao Paulo, experienced from 1989 to 1990 a total of 137 hospitalized cases of envenoming following bites by *B. jararaca* (Franca, et al., 2003). Annually, it is estimated that 20,000 snakebite incidents occur throughout Brazil, 85% of which were caused by *Bothrops* snakes (Benvenuti et al., 2003). In addition, members of this genus feature the greatest epidemiological relevance throughout South America - they are responsible for nearly 90% of all snakebites. Severe envenomation, though with a much lower incidence, is also accounted for by a somewhat rarer snake, the South American bushmaster (*Lachesis muta*).

Habitat and range. The representatives of the genera above are found in diverse habitats; most of them are forest dwellers, with a range of forest types from open and arid savannah-like stands (e.g. *Bothrops*, *Porthidium*), through to dense woods - often oak/pine woodlands (*Bothriechis*, *Bothriopsis*, *Bothrops*, *Cerrophidion*, *Ophryacus,* and *Porthidium*), with vast swathes of forest, including cloud forests, being home to *Atropoides*, *Bothrops,* and *Lachesis*. In addition, some species also seek out farmland and neighboring residential zones, as well as plantations, fields or cleared areas (e.g. *Bothrops* and *Lachesis*). Their home range includes Central and South America, from Central Mexico (*Ophryacus*, *Porthidium*) across Central America, covering the entire span of South America as far as the middle portion of Argentina in the south, i.e. *Bothrops ammodytoides*. They are absent only in Chile, their passage blocked by the Cordillera mountain ranges.

Toxins: All members of the genera, namely the larger species, have available a relatively good amount of venom. For example, at the Butantan Institute, Brazil, 1.76 mg of venom was extracted from the South American bushmaster (*Lachesis muta*). In general terms, the venom of adults in this snake group is not more highly effective than that of other snakes, at least when it comes to doses tested on mice; see chapter 3.2 Effectiveness of snake venoms. Nevertheless, this will not hinder its highly clinical effectiveness on humans, which is a given due to the large amount of venom produced and its clinically unfavorable composition.

The venoms usually contain components principally affecting hemocoagulation, hemorrhagins, and cytotoxic enzymes.

Dysregulation of the coagulation system is the co-responsibility of enzymes that directly activate prothrombin (*Bothrops*, *Lachesis*), thrombin-like fibrinogen-converting proteinases cleaving FPA and FPB (e.g. batroxobin from *B. atrox* venom which can cleave FPA; it is produced under the trade name of Reptilase and used in the laboratory to determine RT in hemocoagulation tests), and components activating FX and FVIII, hence the coagulation system. At the same time, PLT function is affected in terms of activation and increased aggregability. Furthermore, fibrinolysis is increased within the action on hemocoagulation, probably both primarily, i.e. by venom components, and secondarily - by hyperactivating plasminogen as consumption coagulopathy proceeds. The overall effect of hemocoagulation venom components of this snake group consists in initiating procoagulation. This is the way it manifests in prey, and potentially in human victims in cases of extremely high exposure to the venom. However, the majority of persons bitten arrive at medical facilities at the stage of afibrinogenemia, featuring developed DIC and various levels of hemorrhaging.

The venom's composition is subject to change in the course of ontogenesis: the venom of young common lanceheads (*B. atrox*) largely contains elements of prothrombin-converting activity, while the venom in adults chiefly possesses a thrombin-like activity with a prevailing effect of fibrinogen-converting enzymes.

Kininogenases comprise one type of clinically significant venom component - enzymes involved in releasing endogenic hypotension substances like histamine, serotonine, bradykinin, etc. In synergy with other components, they influence activation of inflammation mediators, such as leukotrienes, prostaglandins, and others.

Hemorrhagins accompanied by a number of other destructive proteases destroy basal membranes of peripheral vessels and capillaries, causing soluble components, and later also particle components, to escape into the interstitium. This results in intravasal hypovolemia, which causes or intensifies hypotension, potency of hemorrhagic complications, and affliction of interstitium tissues, which could prove especially dangerous to the lungs.

Local destruction of tissues, or even the occurrence of necrosis, is determined by the high activity of generally cytotoxic, largely enzymatic substances, such as proteinases, esterases, hyaluronidases, and PLA_2 including elements with myotoxic effects.

In some species of the *Bothrops* genus (*B. insularis*, *B. neuwiedi*), presynaptic and clinically insignificant neurotoxicity has been discovered as well.

Other components are those that possess direct nephrotoxic effects (*B. jararaca*), and are involved in resultant renal failure together with microthrombosis and hypovolemia.

The venom of freshly hatched common lanceheads (*B. atrox*) is more effective than that of adults; similarly, the venom of the jararaca (*B. jararaca*), with its significant action on hemocoagulation in subadult age, can largely cause local affliction if injected by an adult (Horte et al., 1995). However, unlike in the species above, the venom of a newborn South American bushmaster (*L. muta*) allegedly lacks almost any toxicity. Nevertheless, any such information obtained from a laboratory should not be considered as either reliable in husbandry practice or clinically. Indeed, the venoms of all species in the group must be treated as highly dangerous.

*Local symptoms of envenomation***.** The first signs of envenoming include pain and the almost immediate development of edema at the site of affection. Both symptoms crop up in 98% of cases. The marks of a bite may be evident, but this may not be true in the early phase,

especially if conducted by a young snake. Nevertheless, they frequently bleed. The painful edema often propagates across the limb; lymphadenopathy follows with erythemas along the lymph vessels, including painful enlargement of lymph nodes.

In further progress of the envenomation, ecchymoses occur on the skin in nearly a half of incidents. At around 12 hours following exposure, vesicles with hemorrhagic or necrotic content develop in 10% to 15% of persons affected, and necrosis forms in 5% to 10% (Horte et al., 1995). This chiefly occurs after an attack by *B. jararaca*, predominantly to the fingers, and if a constriction tourniquet is applied as a first aid measure. In most cases, necrosis is localized on and under the skin, but may affect even deeper structures, such as muscles, tendons, and bones. This leads to long-term disorders or even permanent damage, although rarely posing a reason for amputation. This is a necessity in less than 1% of those affected, as is treatment of compartment syndrome by means of fasciotomy. A severe local affliction is worsened by disorders of tissue perfusion due to developed microthromboses, potential myonecrosis, worsening local hemorrhages, and a severe edema of compartment syndrome nature.

Abscesses occur in 5% - 10% of cases; in Brazil, following *B. jararaca* and *B. moojeni* bites, even in 12% to 18% of cases. Infectious agents recorded include *Staphylococcus aureus*, *Morganella morganii*, *Escherichia coli*, *Providentia* sp., and some anaerobic bacteria.

A tragic but curious incident involved a 5-year-old child who suffered a bite to the eye by a Brazilian lancehead (*B. moojeni*), resulting in exophtalmus, necrosis, and necessary enucleation (Bryndao et al., 1993).

Systemic symptoms of envenoming: System envenoming may not always be preceded by prodromes, as is true of most snakebites; however, they do sometimes manifest, especially upon a bite from the South American bushmaster (*Lachesis muta*), whose venom exhibits neurotoxic activities on the autonomous system to some extent. This brings with it the usual nausea, vomiting, abdominal pain, and diarrhea. Half of the persons so afflicted suffer increased temperatures.

A severe case of envenoming appears as affection of the cardiovascular system. Envenomation by the South American bushmaster (*Lachesis muta*) may result in bradycardia or arrhythmia due to vagus nerve stimulation. Other cases produce hypotension or even shock resulting from a massive release of vasoactive substances of the bradykinin kind. Such a status is potentiated by sequestration of fluids to the site of edema and into the interstitium at a systemic level, as well as by loss of blood in profound hemorrhaging. Circulation collapse and shock may arise early on, and develop with extreme severity in some instances of major envenomation, particularly when caused by *Bothrops* and *Lachesis* snakes.

Hemocoagulation effects present a typical display of envenoming in nearly all species of this group, except for those triggered by *Bothriechis lateralis*, *Porthidium nasutum*, *P. ophryomegas,* and *P. picadoi*, as no coagulation disorders have been found following envenoming by these snakes. A less distinctive effect on the coagulation system is brought about by the venom of the Neuwied's lancehead (*Bothrops neuwiedi*). Symptoms of the affected hemocoagulation system will mostly occur after a certain time, 6-12 hours on average. In terms of *Bothrops* snakes, a hemostasis disorder is often the only sign indicating a systemic envenoming; it can only be registered through laboratory tests during the initial phase and in mild cases of envenoming. Potential hypofibrinogenemia or afibrinogenemia may not always result in hemorrhaging, although there are signs of increased bleeding in most cases. The symptoms start with bleeding from the gums, wounds, and stabs, with continued

hemoptysis, gastrointestinal hemorrhaging including hematemesis and later enterorrhage, as well as hematuria with diuresis maintained. In severe forms, intradermal bleeding occurs to organs, be it the lungs or brain. In a group of 309 patients bitten by *Bothrops* snakes in Ecuador, cerebral hemorrhaging occurred in eight persons, i.e. in 2.6% (Mosquera et al., 2003). Inducing a hemocoagulation disorder is not determined by a complete bite in which a large amount of venom is released. The potent venom of a young common lancehead (*B. athrox*) may produce a profound DIC-like disorder, even through a mere scratching by a single fang (Kornalik et Vorlova, 1990).

As a major portion of hemocoagulation disorders resemble DIC, i.e. procoagulation in certain stages and levels of severity, and microthromboses extending to thrombosis develop as well. For example, a bite by *Bothrops lanceolatus* caused 11 cases of intensive cerebral, pulmonary, and myocardial thrombotic complications requiring thrombolytic treatment within 12 to 96 hours in 50 patients in Martinique (Thomas et al., 1995). There has also been a description of thrombotic ischemia in the arteria mesenterica superior catchment area, which developed 3 days after a bite from the South American bushmaster (*L. muta*) (Rosenthal et al., 2002).

In the course of DIC-like consumption coagulopathy, affliction of endothelial and subendothelial structures is generated, including interstitial edema and microthromboses in lungs, amongst other things. This causes respiratory failure of the ALI/ARDS type that requires oxygen therapy or even mechanical ventilation. At the same time, hemorrhaging into lungs may occur.

Acute oliguric renal failure with necessary hemodialysis is a common type of complication and the most frequent cause of death reported. A prothrombotic status of the hemocoagulation system, with intraglomerular production of fibrin deposits, hypovolemia, and hypotension all giving rise to this kind of failure, plus there is probably a direct effect by venom components on renal tubules (*B. jararaca*). Thus, acute renal failure is typically a result of ischemia and direct toxin effects. Histologically, this involves acute tubular necrosis, and less frequently cortical necrosis.

Laboratory test results in instances of envenoming by snakes of this group mostly reveal symptomatology of a hemocoagulation disorder. In over half of those affected, coagulation of blood will not occur; in laboratory tests according to Lee-White, the time will prolong to over 30 minutes. The disorder is usually DIC-like consumption coagulopathy, including activation of fibrinolysis, i.e. PT, APTT, TT, and RT are prolonged. The FBG level is either lower or even zero; reciprocal to this result is a decrease in FDP, including D-dim. A certain level of thrombocytopenia is typical. AT activity could be just slightly decreased, especially in initial stages of the disorder.

Urine, including the residual urine in oliguria, typically exhibits proteinuria and hemoglobinuria. Renal failure will increase urea and creatinine serum levels.

ALI/ARDS pulmonary disorder is accompanied by a typical symptomatology of diffuse flocculent densities and decreased oxemia.

Mortality: Snakebites caused by this snake group, especially concerning Bothrops and Lachesis snakes, are associated with relatively high lethality. Fatality in most cases relates to acute renal failure, respiratory failure, hemorrhaging, thrombosis, shock, and sepsis. In a group of 309 envenomed persons in Ecuador, cerebral hemorrhaging was the cause in five out of eight deaths.

In Brazil, approximately 4,800 fatalities occurred in 1914. As therapeutic options increased, the mortality rate subsequently decreased to 2.43% in 1949, 1.75% in 1972, and to the recent figure of 0.59% of persons afflicted. In total, 60,647 cases of envenoming by *Bothrops* snakes were registered in Brazil from 1986 to 1990, from which 234 affected persons died, amounting to 0.39%. For the *Lachesis* genus, 1,529 cases of snakebite occurred with 19 fatalities, which is a rate of 1.24% in mortality. Fatalities in Argentina for 1979 equaled six cases from a total of 109 snakebites, i.e. 5.5%, while Ecuador reported 5.4% for the same period (Fan et Cardoso 1995).

Therapy: For first aid treatment and common principles of therapy, see chapter 5, Snakebite: Therapy and precautions.

Application of a pressure immobilization bandage is not recommended due to the risk of extension of local damage through the persistence of highly concentrated toxic hemorrhagic and cytotoxic components at the point in question. Nevertheless, immobilizing the leg by using a looser bandage is a useful option. Exhaustion of venom from the wound by, for example, an extractor has not proven effective, but does not pose a danger unlike other practices, e.g. cutting the wound, using a tourniquet, etc. Due to the potential risk of rapid circulatory failure (*L. muta*), prompt transportation to a medical facility is recommended.

Available antivenoms:

* SORO BOTROPICO, Instituto Butantan, Brazil (*Bothrops alternatus*, *B. jararaca*, *B. jararacusu*, *B. moojeni*, *B. neuwiedi*);

* POLYVALENT ANTIVENOM, Instituto Clodomiro Picado, Costa Rica (*Atropoides nummifer*, *Botriechis lateralis*, *Botriechis nigroviridis*, *Botriechis schlegeli*, *Bothrops asper*, *Cerrophidion godmani*, *Lachesis muta stenophrys*, *Porthidium nasutum*, *Porthidium ophryomegas*).

In Central America, there is a producer of a sheep polyvalent antivenom, the Instituto Clodomiro Picado in Costa Rica.

A certain level of cross immunity can be expected, i.e. the possibility of applying antivenom relevant for bites by other members of this group; nevertheless, the effects of certain significant venom components, such as prothrombin activators, are sometimes difficult to control via specific immunotherapy.

Administering antivenom is indicated should worse systemic symptoms develop, examples including hemorrhaging, hypotension, and a significant prolongation of blood coagulation time discovered via laboratory tests, be it according to Lee-White, or PT, APTT, and TT.

The low immunogenicity of certain venom components will be reason enough for the necessary application of larger amounts of antivenom, where indicated. For example, the Ministry of Health in Brazil recommends 10-20 vials of antivenom as an initial quantity in cases of evident envenomation by the South American bushmaster (*L. muta*); but sometimes a lower quantity may be sufficient. The initial two vials may settle the hemocoagulation disorder within 6 hours (Salligan et al., 2004). Potential coagulopathy should be primarily treated by means of sufficient quantity of antivenom.

In some circumstances, local envenoming symptoms may be more severe. Any developing dermal bullae or possibly lesser necrosis, which is a predisposition to infectious complications, should be hastily removed and the affected area treated adequately. In

addition, the development of compartment syndrome cannot be fully precluded. In cases of any suspected disorder of district perfusion, the limb must be treated by elevation and general administration of manitol, with doses of 0.5-2 g/kg IV, in the course of about 30 minutes. If the risk of ischemia in the relevant area does not abate, fasciotomy can be indicated. However, this kind of treatment is never carried out preemptively; see also chapter 6.4.3.3 *Crotalus* and *Sistrurus* genera: rattlesnakes and ground rattlesnakes. There may be a necessity to amputate due to gangrene afflicting fingers.

Pre-emptive administration of antibiotics is not indicated, although sometimes recommended; antibiotic therapy, if one is applied, is commenced only upon occurrence of infectious complications.

In hypotension of circulatory failure and shock, the treatment is initiated by volumotherapy: the circulating volume is replenished using an infusion of crystalloids or colloids. Including fresh-frozen plasma in the therapy can positively influence a DIC-like hemocoagulation disorder, if any. If application of infusions fails to ensure satisfactory stabilization of the circulation, or hypotension persists or any further increase in volume is contraproductive, vasopressure therapy is indicated using norepinephrine in continual infusion, which will provide sufficient perfusion pressures; see chapter 5.3.3.5 Hypotension, shock.

Sufficient intravascular volume together with adequate perfusion pressure needs to be continued in order to retain diuresis, thereby helping prevent renal failure.

The most typical symptom of envenoming - hemocoagulation disorder - should be primarily treated and regulated by means of administering antivenom in sufficient quantity. Symptomatic therapy becomes necessary if antivenom cannot be applied or insufficient quantity is available, or for later regulation of secondary changes, for instance persisting prothrombotic activity.

Isolated hypofibrinogenemia without clinical signs of increased hemorrhaging will not require any special symptomatic treatment. If caused by a direct effect of venom components on FBG, it cannot be controlled by means of symptomatic treatment, e.g. using heparin. FBG substitution is not recommended in this case, unless a sublimit level of FBG causes hemorrhaging (Fan et Cardoso, 1995).

A DIC-like consumption coagulopathy, especially in its later phase, may prove difficult to control by means of immunotherapy to a satisfactory extent and require symptomatic treatment: therapy using fresh-frozen plasma (10-20 ml/kg) and AT substitution with potential miniheparinization (70-210 units/kg/24 h) by means of UHF or LMWH with a beneficial and more intense anti-Xa effect based on the phase and progress of the syndrome.

Naturally, heparin therapy is not indicated during the period of increased bleeding; nevertheless, it may have a positive effect on managing hypercoagulation states associated with the development of microembolisms. For potential PLT, erythrocyte, and FBG substitution, ordinary guidelines apply; application of hemocoagulation factor concentrates is normally not recommended; see chapter 5. 3. 3. 6 Hemocoagulation disorders.

Contraindication of application, unavailability, insufficient quantity or poor effectiveness of antivenom, as well as cases of persisting severe symptoms of envenoming, can be resolved by repeated plasmaferesis.

A patient can be discharged for home treatment after 24 hours following abatement of all systemic symptoms of envenoming, normalization of significant laboratory values, and stabilization of the local affection. Any persisting laboratory symptomatology of less

significant prothrombotic activity should be resolved by preemptive miniheparinization, see chapter 5.4 Convalescence following envenoming.

6.4.3.3. Crotalus and Sistrurus Genera: Rattlesnakes and Ground Rattlesnakes

Overview of the species. The *Crotalus* genus comprises about 30 species and a number of subspecies of true rattlesnakes, see chapter 7 List of venomous snakes. The number provided in bibliography varies due to classifying some species as subspecies and vice versa. The best known rattlesnakes and at the same time the most significant species in terms of epidemiology include the eastern diamond-backed rattlesnake (*Crotalus adamanteus*), western diamond-backed rattlesnake (*Crotalus atrox*), South American rattlesnake (*Crotalus durissus*), timber rattlesnake (*Crotalus horridus*), red diamond rattlesnake (*Crotalus ruber*), Mojave rattlesnake (*Crotalus scutulatus*), and Northern Pacific rattlesnake (*Crotalus viridis*).

The *Sistrurus* genus, i.e. ground rattlesnakes, includes 3 species of lesser rattlesnakes: the massasauga (*Sistrurus catenatus*), pigmy rattlesnake (*Sistrurus miliarius*) and Mexican massasauga (*Sistrurus ravus*) that is now however placed into the *Crotalus* genus (*C. ravus* ssp.).

Other names: EN: Sidewinders (for rattlesnakes and ground rattlesnakes). Neotropical rattlesnake, cascabel, cascauella, maracaboia (*C. durissus*). Prairie rattlesnake (*C. viridis viridis*). Desert sidewinder (*C. cerastes*).

Description: *Crotalus* snakes come in sizes from 50 cm (*C. aquilus*, *C. cerastes*, *C. intermedius*, *C. pusillus*) to 200 cm (*C. adamanteus*, *C. atrox*), with the longest documented length of 244 cm attributed to the eastern diamond-backed rattlesnake (*C. adamanteus*), the largest venomous snake of North America. These creatures possess a robust body with a broad head and rather short tail featuring a rattle, which is a warning apparatus comprising several loosely articulated beads of hardened skin. Vibrating the rattle will produce an unmistakable and quite powerful sound that is used by the snake to alert and ward of potential intruders. Rattlesnake coloring usually is in shades of gray or brown, sometimes with a reddish tint; although they can also be olive, or sandy to yellow, with a varied linear, ring-like or spotted pattern. When they defend or attack, these snakes can form a very large coil, mostly to one side, from the anterior part of their body, thereby allowing them to deliver a strike over quite a distance. Despite their seemingly thick bodies and rather slower frontal movement, strikes can be carried out very swiftly.

Sistrurus snakes mostly grow to 45-90 cm in length; their body is covered in darker spots on light background; anatomically, they differ little to *Crotalus* snakes.

In terms of epidemiology, members of the *Crotalus* genus are the most significant snakes in North America. In the USA, bites by them account for 65% of the annual number of 7,000-8,000 bites by venomous snakes, with *C. adamanteus*, *C. atrox*, *C. viridis,* and *C. horridus* being held largely responsible. The epidemiological significance of *Sistrurus* snakes nowhere near matches that of the *Crotalus* variety, due to the smaller quantity of venom available and lower abundance.

In terms of private ownership, rattlesnakes are one of the snake genera favored by collectors. This corresponds to the incidence of bites outside their home range. In SE France and N Germany, 21 cases caused by rattlesnakes were registered in 20 years, while in the Czech Republic, there were 5 such occurrences in 10 years.

Habitat and range. The majority of *Crotalus* snakes reside rather arid habitats, for example sparse pine and broad-leaved forests (*C. adamanteus*, *C. pusillus*, *C. ruber*), bushes

and grass plains (*C. durissus*, *C. enyo*, *C. molossus*, *C. scutulatus*, *C. viridis*) and rocky or sandy semideserts (*C. atrox*, *C. cerastes*, *C. mitchelli*), but can be found even in humid places - cloud forests, swamps and flood areas (*C. horridus*, *C. intermedius*).

Their home range stretches from S Canada and eastern (*C. horridus*) as well as south-eastern part of the USA (*C. adamanteus,* with *C. atrox* ranging over a large part of this territory), western, south-western and southern USA (*C. mitchelli*, *C. molossus*, *C. ruber*, *C. scutulatus*) as well as Mexico (*C. atrox*, *C. basilicus*, *C. enyo*, *C. intermedius*, *C. mitchelli*, *C. molossus*, *C. ruber*, *C. viridis*) to Central and South America as far as SE Peru (*C. durissus*).

Sistrurus snakes inhabit diverse habitats, from swamps to peat-bogs and also arid woodland and mountain slopes across North America from Ontario, Canada, as far as Texas (*S. catenatus*), Florida (*S. miliarius*) and Central Mexico (*Sistrurus* i.e. *Crotalus ravus*).

*Toxins***:** In the venoms of *Crotalus* and *Sistrurus* snakes, similarly to those of other viperids (*Viperidae*), enzymatic compounds dominate over specific toxins with smaller molecules. Venom effects can be generally described as predisposed to causing hypotension due to vasodilation and extravasation, hemorrhaging, hemocoagulation effects, nephrotoxic effects, and cytotoxic actions, i.e. necrotizing and myotoxicity; in some species, even a neurotoxic impact is possible.

In particular, the venoms contain kallikrein-like enzymes, kininogenases releasing bradykinin, and other components causing vasodilation hypotension from kininogen. Hypotension can be intensified by a hemorrhagin present in the venom that damages endothelium and capillary integrity, and causes the fluid to escape into the interstitium. This can result in, aside from formation of edema and flushing inflammation mediators, in severe hypotension and circulation collapse up to shock.

Components with hemocoagulation effects, again largely those of enzymatic nature, are a typical complex of elements. They include fibrinogen-converting thrombin-like enzymes, for instance gyroxin, that have in experiments carried out on dogs caused intravascular coagulation in the lungs, heart, and liver. Another example is crotalase isolated from eastern diamond-backed rattlesnake (*C. adamanteus*) venom, which is capable of initiating or inducing a disorder of the consumption coagulopathy kind. Other components significantly involved in affecting hemostasis are fibrino(geno)lytic proteinases present in the venoms of probably all members of the genus, e.g. an isolate from so-called crotalotoxin in the venom of *C. durissus vegrandis*. The functioning of platelets is affected in terms of inhibited aggregation by crotaviridin and crotavirin, polypeptides isolated from *C. viridis* venom. Conversely, convulxin and crotalocytin actually activate platelets and increase their aggregation.

The action of components with hemocoagulation effects results in hemostasis disorders, largely including symptoms of increased hemorrhaging, as well as potential thrombotic complications. The hemostasis disorder is potentiated by the presence of hemorrhagin-like components.

Another important group of venom components comprises proteolytic enzymes and other general cytotoxic components causing local destruction of tissues and necrosis. Enzyme myotoxins, largely those of the PLA_2 type, responsible for local myonecrosis with the risk of rising compartment syndrome and myoglobinuria, can also be placed within this group of toxins. Damage to erythrocytes, including hemolysis, develops in a similar manner. In addition, venoms also contain locally acting hyaluronidases facilitating the venom to penetrate from the bitten site by damaging the extracellular matrix of affected tissue.

Precipitation of myoglobin and hemoglobin in renal tubules is typically indicated as the main reason for renal failure. Naturally, other factors causing damage to kidneys worthy of mention include microthrombi generated in renal glomerules as consumption coagulopathy proceeds, hypoperfusion in hypotension, and the direct action of venom components, such as that of nephrotoxic lysolecitin which is produced by PLA_2 cleaving lecithin.

Venoms from some members of the genera above, such as the South American rattlesnake (*C. durissus*) or Mojave rattlesnake (*C. scutulatus*), contain a clinically evident proportion of presynaptic neurotoxins, largely made up of PLA_2. Neurotoxic effects can be assigned to, for example, crotoxin and crotamine from *C. durissus terrificus* venom or Mojave toxin from *C. scutulatus*.

The previously mentioned crotoxin possesses a certain capacity for modulating the immunity response, in addition to the activities listed above.

The aggressiveness of *Crotalus* venoms, especially that of their cytotoxic component, may even become apparent via contact with mucous membranes. Despite existence of an overall normal course of envenoming, obturating edema affecting the mucous membrane in the airways, which necessitated fibrooptical intubation, occurred in a man who sucked a bite by *C. horridus*.

Local symptoms of envenoming: Following a snakebite, the wound or at least scratching is visible in almost every case due to the size of the fangs. In most persons afflicted, moderate or intense burning pain or feelings of strain set in early. A worse level of pain is not typical for a bite from the Mojave rattlesnake (*C. scutulatus*), while the South American rattlesnake (*C. durissus*) only causes pain in about a half of incidents. The bite wound may bleed. Painful edema develops that progressively expands to related lymph nodes, and even beyond, perhaps to the torso. Regional lymph nodes become swollen. Skin on the body part afflicted is erythemated, with developing ecchymoses, petechiae, and later also serous or hemorrhagic vesicles, which is a sign of local hemorrhagic and hemocoagulation dysfunction. A sensation of heat on the side of the envenomed area is usually reported. Within hours, ecchymoses as well as edema may move to the skin on the opposite side of body. Damage to skin and subcutaneous regions often results in necrosis at the bitten site and its surroundings. The necessity for partial amputation may arise if a finger has been affected.

Occurrence of compartment syndrome, including elevation of compartment pressure to levels constricting tissue perfusion (30-55 mmHg), means a severe local affliction, usually accounted for by profound myonecrosis, including an increase in the percentage of water in the damaged muscle possibly caused by penetrated myotoxic venom components, although more often by a direct bite into the subfascial area. Damage to the vascular integrity of tissue may be of secondary importance in syndrome development. In the early phase, this will be manifest by pain in the given area, or conversely hypesthesia, sensations of strain, and contraction of the muscle in question, with associated pain when passively extended. If smaller areas are affected, e.g. thenar, a pulse wave may still be evident in the limb as well as signs of venous return flow.

A worse course of local affliction is quite typical for envenomings by most rattlesnake genera, exceptions being the South American rattlesnake (*C. durissus*) and Mojave rattlesnake (*C. scutulatus*), whose venoms do not contain a high proportion of cytotoxic components.

Furthermore, abscesses formed as a result of secondary infection of tissue in the damaged area cannot be precluded.

Local affection, following a bite by snakes of the *Sistrurus* genus, is typically a factor in the majority of cases, this being of a less significant nature and only accompanied by pain, edema, lymphadenopathy, and erythema - no necrosis occurs.

Systemic symptoms of envenoming: About a quarter of bites by *Crotalus* and *Sistrurus* snakes will not be associated with the release of venom and will proceed without envenoming. If envenomation has occurred, symptoms or at least laboratory findings should become manifest within 8 hours following an incident. In order to facilitate judgment of the severity of envenomation by *Crotalus* snakes, namely those from North America, criteria that define the levels of affection have been developed and used in bibliography.

No envenoming:

* Bite marks are present;
* At a local level: no edema, skin changes, and paresthesia;
* At a system level: no symptoms;
* Laboratory: no findings.

Minimum envenoming:

* At a local level: edema, erythema or ecchymoses without progression;
* At a systemic level: none or minimal symptoms;
* Laboratory: no significant findings.

Mild envenoming:

* At a local level: the affliction spreads over a major part of the limb;
* At a systemic level: signs that pose no threat to life, e.g. nausea, vomiting, systolic pressure exceeding 80 mmHg, light tachycardia, paresthesia, etc., no signs of hemorrhaging;
* Laboratory: positive laboratory findings, but lacking significant abnormalities.

Severe envenoming:

* At a local level: edema and ecchymoses that rapidly spread all over the limb;
* At a systemic level: signs threatening life, e.g. altered consciousness, systolic pressure lower than 80 mmHg, severe tachycardia, signs of respiratory failure, etc., spontaneous hemorrhaging;
* Laboratory: severe affliction including significantly prolonged coagulation times, severe thrombocytopenia, hypofibrinogenemia, and other biochemical results in either serum or urine.

A systemic envenoming mostly proceeds with nausea and vomiting; diarrhea may follow. Paresthesia is quite common, either perioral that spreads to the tongue and crown of the head, or a tingling sensation in the fingertips. Furthermore, the envenoming is accompanied by spasms and fasciculations that may change from local sensations to those at a systemic level, myalgia, sensations of warmth or conversely cold and chill, including cold sweats, thirst, tastes in the mouth resembling chewing gum, menthol or metal, plus lethargy, overall weakness, and vertigo. Typically, the majority of those envenomed suffer tachycardia,

accelerated breathing, and slightly increased temperatures. Within milder cases of envenoming, blood pressure remains normal.

Worse cases of envenoming will continue with hypotension, which is partly due to dilation of the bloodstream in addition to extravasation, which is quite typical for severe cases of envenoming by rattlesnakes. Endothelial damage increases vascular permeability, as well as loss of water, electrolytes, albumin, other blood proteins, and even blood elements in cases of extreme damage. In places with the highest concentration of venom, i.e. largely locally at the bitten site, these symptoms are the worst. At a systemic level, the reduced circulating volume is followed by hypovolemia with hypoalbuminemia, and potentially hemoconcentration, which may result in distribution shock, including disorder of tissue perfusion, lactate acidosis and renal failure; see below. The sharp rise of intensive life threatening hypotension with shock typically poses a risk to as many as 7% of envenomed persons (Juckett et al., 2002). Capillary affliction includes respiratory failure based on the sequestration of water and ions into the pulmonary interstitium, or even the alveoli (ALI/ARDS, pulmonary edema) or pleural cavity. Gross endothelial damage may be exhibited by extravasation of erythrocytes, i.e. hemorrhaging, which affects the lungs, myocardium, kidneys, peritoneal cavity, and rarely the CNS.

Impact on hemocoagulation occurs fairly frequently, with severity ranging from a moderate level of hypofibrinogenemia or thrombocytopenia found via laboratory tests, extending as far as a serious hemostasis disorder with symptoms of spontaneous bleeding - from wounds, hematuria, hematemesis, enterorrhage, and internal hemorrhaging, thereby signifying symptomatology of DIC-like consumption coagulopathy. However, less significant cases of local hemorrhaging occur, with laboratory tests revealing thrombocytopenia, hypofibrinogenemia up to afibrinogenemia, prolonged coagulation times, and the discovery of FDP. Changes in hemocoagulation mostly persist for 7-14 days, with frequent recurrence, sometimes regardless of antivenom being applied; see chapter 5.3.1 Specific treatment, immunotherapy; particularly in relation to recurrent loss of PLT and FBG. Thrombocytopenia arises based on PLT activation with subsequent aggregation, consumption and platelet sequestration into the affected areas. It is the severity of local affliction, damaged vascular wall, and PLT sequestration into these areas that may determine the level of thrombocytopenia, especially a late or recurrent variety. The earlier occurrence of thrombocytopenia is typically caused by aggregation proteins of the venom, or through activation as consumption coagulopathy proceeds. Hypofibrinogenemia extending to afibrinogenemia, if isolated, i.e. probably generated by direct fibrinolytic action of venom components, will typically not result in symptoms of increased hemorrhaging.

Factors involved in the onset of renal failure include hypovolemia due to dilation and extravasation, microthrombosis of the kidney vascular beds within DIC, hemolysis with hemoglobinuria, rhabdomyolysis with myoglobinuria, and probably the direct nephrotoxic effect of some venom components. Renal failure potentiated by myonecrosis with CC elevation found in the laboratory is a relatively frequent complication of envenomings by South American subspecies of the South American rattlesnake (*C. durissus*), while bites from the Central American *C. durissus durissus* do not cause this type of affection.

A bite from rattlesnakes with venoms containing a clinically more significant proportion of neurotoxins, e.g. the South American rattlesnake (*C. durissus*), Mojave rattlesnake (*C. scutulatus*), and the timber rattlesnake (*C. horridus*), will generate disorders on neuromuscular end-plates with neurotoxic symptoms like weak paralysis, as manifest

clinically by ptosis, external ophtalmoplegia with blurred vision, anisocoria or mydriasis, overall muscle weakness, and exhaustion. Any possible affection of respiratory muscles is exhibited via accelerated shallow breathing; nevertheless, total paralysis of respiratory muscles is not probable. What remains of utmost importance is that local affection following an attack from the species above is mild, consequently giving no true indication as to the extent of systemic envenoming. Underestimating the severity and providing insufficient treatment can have significant after-effects.

Bites by *Sistrurus* snakes will proceed in most cases without a severe systemic response and significant laboratory findings, the envenoming only manifest by local affliction. However, even in such cases a snakebite should not be overly dismissed, as a systemic envenoming similar to that caused by exposure to the venom of *Crotalus* snakes is still possible, albeit rare.

Laboratory findings: As for non-specific findings, a mild level of neutrophilic leukocytosis about 10 x 10^9/l is typically present in worse envenomings. Frequently, CC is elevated, including MB-fraction, which in severe cases will average 5 µkat/l, but might exceed 33 µkat/l, indicating a high predisposition for renal failure occurring. Elevated levels of LD, myoglobin and AST are not unusual. The extent of elevated levels of tissue enzymes simulates biochemical symptomatology of myocardial damage; however, troponin I was found to be negative in children (Cupo et al., 2003). Intravascular hemolysis is accompanied by either evidence of free hemoglobin or a positive result of Coombs' test and decreased Hct.

Affected hemocoagulation is manifest by either ordinary hypofibrinogenemia, potentially extending to afibrinogenemia, as well as isolated thrombocytopenia, or symptomatology of a full DIC-like consumption disorder with prolonged PT, APTT, RT, and positive FDP results, including very high D-dim levels, which may extend beyond 8 mg/l (the standard level being below 0.5 mg/l). Thrombocytopenia as well as other symptoms found in the hemocoagulation laboratory tests may arrive relatively late (thrombocytopenia even after 72 hours), persist for several days, may react or not to the administration of antivenom, or possibly return to pathological levels within hours or 7 days. PLT may display hypoaggregability due to the impact of venom components. If that is the case, thrombocytopenia will not occur.

Glycosuria, proteinuria, hemoglobinuria, myoglobinuria, and even hematuria could be found in urine.

Mortality: A high number of the 138 cases resulting in death over 10 years in the USA involved cases of envenoming by *Crotalus* snakes. Out of 7,000-8,000 bites a year caused by *Crotalinae* snakes, there are 5-12 fatalities, of which 95% are due to attacks from the eastern diamond-backed rattlesnake (*Crotalus adamanteus*) and the western diamond-backed rattlesnake (*Crotalus atrox*) (Juckett et Hancox, 2002, Shaw et Hosalkar, 2002).

In the Brazilian state of Sao Paulo, over 12,000 snakebites were analyzed for the period from 1988 to 1993. From this number, 1,359 (12%) envenomings and 13 fatalities were assigned to the South American rattlesnake (*Crotalus durissus*) (Ribeiro et al., 1998). A different source calculates lethality via envenomation by this rattlesnake as 1.9% (Bucaretchi et al., 2002). A fatal course may include acute renal failure.

Therapy: For first aid treatment and common principles of therapy, see chapter 5, Snakebite: Therapy and precautions.

Application of a pressure immobilization bandage is debatable due to high local damage to tissues, so is not recommended in most cases. If, however, several hours' delay in receiving eventual treatment is expected, and it is possible to put on the bandage within a few minutes

of an attack, this can be a worthwhile option. In such cases, both arterial and venous bloodstreams must be unrestrained, and also monitored to ensure the presence of a pulse and to eliminate ischemic pain in the limb. Due to the general cytotoxic effect of the venom, this is of particularly heightened importance. If measurement is possible, the recommended pressure of the bandage is around 20 mmHg (Juckett et Hancox, 2002).

Even though using the widely recommended Sawyer's extractor has not been proven as effective in a satisfactory manner, it should not be ruled out. If one is applied, the process must be carried out very soon after a bite, approximately 3-5 minutes. The extractor is kept in place for about 30 minutes.

Available antivenoms:

* CROFAB CROTALIDAE POLYVALENT IMMUNE FAB (OVINE), Protherics, USA (*C. adamanteus*, *C. atrox*, *C. horridus*, *C. molossus*, *C. scutulatus*, *C. viridis*, etc.);

* SORO ANTICROTALICO, Instituto Butantan, Brazil (*C. durissus cascavella*, *C. durissus collineatus*, *C. durissus terrificus*);

* POLYVALENT ANTIVENOM, Instituto Clodomiro Picado, Costa Rica (*C. durissus durissus*, and others).

In approximate terms, CROFAB is five times more effective than ANTIVENIN (CROTALIDAE) POLYVALENT (ACP), Wyeth, USA, a horse antivenom produced in the past which usually triggered allergic responses. Acute reactions to the antivenom upon ACP administration reached 23-56%, while the figure for CROFAB is just 14%; as for serum sickness, incidence of reactions for the former amounted to 18-86% compared to 16% for CROFAB (Gold et al., 2002).

If envenomation is proven, even if only moderately severe local symptoms are exhibited, application of 4-6 vials of CROFAB is advisable. If the state consequently improves, 2 vials should be given at 6, 12, and 18 hours later. If symptoms still do not recede, the administration schedule should be repeated. Even higher amounts of antivenom are sometimes recommended, i.e. an initial 10-15 vials for mild envenomings and 15-20 vials in severe cases, a dosage which is subsequently repeated based on patient's status. Of course, often a lesser amount proves sufficient - a total of 8 vials or even less. The initial vial of antivenom should be diluted with 250-500 ml of electrolyte solution. A low rate of instillation should be used for application over the first 10 minutes, with the remainder being instilled within an hour. Application of the antivenom is recommended by the manufacturer of CROFAB within 6 hours following the bite; nevertheless, a beneficial effect has been demonstrated after 9 hours and even 52 hours. Treatment by means of giving a sufficient quantity of effective antivenom will no only mitigate or even eliminate systemic symptoms of envenoming, including early hemocoagulation disorders and laboratory results revealing thrombocytopenia and hypofibrinogenemia, but should positively and preemptively influence the severity of edema, development of compartment syndrome, and any necessary fasciotomy. If edema continues to spread and compartment pressure increases, controlling further development by administering additional vials of antivenom is advisable, see below.

Recurrence of symptoms or laboratory symptomatology is frequent, namely through the use of CROFAB. This is explained by the progressive release of venom components from the pool at the bitten site, but primarily due to rapid clearance of the antivenom.

Mild dermal manifestation of an allergy, urticaria, as the venom is being applied may not contraindicate the treatment and does not indicate the onset of anaphylaxis. Should there be a threat of fasciotomy or severe symptoms of systemic envenoming, specific immunotherapy of the patient can continue provided appropriate antiallergic measures are applied.

Special attention must be paid to local symptoms of envenoming as regards their severity. To inspect an increase in edema, the affected limb is measured at multiple points above and below the bitten site approximately every 15-20 minutes until the state becomes stabilized or abates. The progression of edema towards the torso should also be monitored and its edges recorded, for instance, by tracing lines on the skin. Skin afflicted by vesicles and necrosis must be kept under tight control, requiring prompt removal of bullae and necrotic tissue as well as proper care for the wound bed.

If severe edema has occurred and compartment syndrome is suspected, measuring compartment pressure is appropriate. If pressure values rise above 30 mmHg and clinical signs of the syndrome exist, applicable attempts to decrease pressure in the tissue include elevation of the limb and administration of manitol (0.5-2 g/kg of weight) during 30 minutes under parallel or even repeated application of a larger quantity of antivenom, i.e. 10-20 vials within 60 minutes (Gold et al., 2003). Benefits have also been recorded via hyperbaric oxygen therapy. Treating severe local symptoms of envenoming with a sufficient quantity of antivenom is typically effective enough to avoid compartment syndrome and any necessary fasciotomy. However, this must be applied if a risk of increased compartment pressure and clinical symptoms of the syndrome, particularly pain when the muscle is passively extended, still persist despite providing the adequate therapy discussed above. The time recommended for this is an additional 60 minutes once antivenom has been instilled. As fasciotomy can be associated with subsequent damage to nerves, contractures, skin deformities, and even partial loss of function of the limb, it is applied only once all remaining conservative medical procedures have been attempted. It must never be carried out preemptively.

As the incidence of primary infections is very low, antibiotics are not indicated; they are applied only when infectious complications occur.

Hypotension or circulatory failure and shock can mostly be avoided by volumotherapy: the circulating volume is replenished using an infusion of crystalloids or colloids. In addition, including fresh-frozen plasma in the therapy can positively influence a hemocoagulation disorder, if any. If application of infusions fails to ensure satisfactory stabilization of the circulation, or hypotension persists or any further increase in volume is contraproductive, such as in the case of respiratory failure (ALI/ARDS), vasopressure therapy is indicated using norepinephrine in continual infusion, which will provide sufficient perfusion pressures; see chapter 5.3.3.5 Hypotension, shock.

A satisfactory level of diuresis should be retained by maintaining sufficient intravascular volume together with adequate perfusion pressure. Urine volume higher than 90 ml/h has a preventative effect against renal failure.

Any persisting signs of hemocoagulation disorders must be treated symptomatically as necessary. Isolated hypofibrinogenemia without clinical signs of increased hemorrhaging, as well as persisting mild thrombocytopenia, will not require any special symptomatic treatment, indicating repeated application of antivenom in most cases, especially in early phases of envenoming. However, late and recurrent thrombocytopenia proves typically obstinate to specific immunotherapy. In instances of critical reduction of platelets despite repeated application of antivenom and symptomatic therapy of potential consumption element, the

platelets must be substituted. A DIC-like consumption coagulopathy, again chiefly in its later phase, may be difficult to control by means of immunotherapy to a satisfactory extent and will require symptomatic treatment: therapy by means of fresh-frozen plasma (10-20 ml/kg) and AT substitution with potential miniheparinization (70-210 units/kg/24 h). However, heparinization is not indicated whenever intense hemorrhaging occurs. For potential PLT, erythrocyte and FBG substitution, ordinary guidelines apply; application of hemocoagulation factor concentrates is usually not recommended; see chapter 5.3.3.6 Hemocoagulation disorders.

The level of severity of the clinically evident effect of neurotoxins in *C. durissus* and *C. scutulatus* will not cause respiratory failure requiring mechanical ventilation. Nevertheless, pulmonary affection of the ALI/ARDS type may still arise, and in very rare cases may reach a level where mechanical ventilation must be applied. Such cases will require tracheal intubation and supportive or managed mechanical ventilation.

Observation over 12-24 hours will be necessary in bites lacking evidence of envenoming, even if caused by *Sistrurus* snakes. Following 24-48 hours once all symptoms of severe local type and systemic envenoming have abated, a patient can be discharged from hospital. Stabilized and minor local damage can be dealt with by means of outpatient treatment. Any persisting laboratory symptomatology of less significant prothrombotic activity should be resolved by preemptive miniheparinization, see chapter 5.4 Convalescence following envenoming.

6.4.3.4. Ovophis - Mountain Pit Vipers, Protobothrops and Trimeresurus, Asian Pit Vipers and Tropidolaemus - Temple Vipers

Species: The relatively extensive *Trimeresurus* genus contains about 36 species of snakes. More recently, additional species have been described and others reclassified under two snake genera: the *Ovophis* genus with its four species, i.e. the Chinese mountain pit viper (*Ovophis monticola*), Ryukyu Island pit viper (*Ovophis okinavensis*), Tonkin pitviper (*Ovophis tonkinensis*), and Chasen's mountain pit viper (*Ovophis chaseni*); and the *Tropidolaemus* genus containing the Wagler's palm viper (*Tropidolaemus wagleri*). A new *Protobothrops* genus has been recognized, comprising several forms that were once placed into *Trimeresurus*, *Trigonocephalus*, and other genera - this involves *Protobothrops cornutus*, *Protobothrops elegans*, *Protobothrops flavoviridis*, *Protobothrops jerdonii*, *Protobothrops kaulbacki*, *Protobothrops mucrosquamatus*, *Protobothrops tokarensis*, and *Protobothrops xiangchengensis*. In addition, monotypic *Triceratolepidophis* and *Zhaoermia* genera have been described; the latter was formerly named *Ermia*, however, this name turned out to be reserved for a genus of the *Orthoptera* insects. Furthermore, separation of some additional genera from the *Trimeresurus* and *Ovophis* range has been suggested, such as *Garthius*, *Cryptelytrops*, *Parias*, *Viridovipera*, *Peltopelor*, *Popeia*, and *Himalayophis*; however, general acceptation of this proposal still remains an open issue.

Out of the number of snakes of the *Trimeresurus* and *Protobothrops* genera, the following are examples of epidemiological importance: the white-lipped tree viper (*Trimeresurus albolabris*), elegant pit viper [*Protobothrops* (*Trimeresurus*) *elegans*], redtail (bamboo) pit viper (*Trimeresurus erythrurus*), Philippine pitviper (*Trimeresurus flavomaculatus*), habu [*Protobothrops* (*Trimeresurus*) *flavoviridis*], common bamboo viper (*Trimeresurus gramineus*), Kramer's pit viper (*Trimeresurus macrops*), brown spotted pit viper [*Protobothrops* (*Trimeresurus*) *mucrosquamatus*], mangrove viper (*Trimeresurus*

purpureomaculatus), Stejneger's bamboo viper (*Trimeresurus stejnegeri*) and Sumatra pit viper (*Trimeresurus sumatranus*); for other species, see chapter 7 List of venomous snakes.

Other names: EN: Asian arboreal pit viper; FR: Fer-de-Lance asiatique; JAP: Habu (*Trimeresurus*). EN: (White-lipped) green pit viper; FR: Vipère des bambous (*T. albolabris*). EN: Japanese habu (*Protobothrops flavoviridis*), Chinese habu (*Protobothrops mucrosquamatus*), Chinese green pit viper (*T. stejnegeri*), Indo-Chinese mountain (pit) viper (*Ovophis*).

Description: This group of genera comprises small to medium-sized snakes at lengths from 40 cm (*Trimeresurus borneensis*, *T. gracilis*, *T. gramineus*) to 100-120 cm (*Protobothrops elegans*, *P. jerdoni*, *P. mucrosquamatus*, *P. tokarensis*, *Trimeresurus flavomaculatus*); the documented maximum of 160 cm attributed to *T. sumatranus*. Another variety, *Protobothrops flavoviridis*, normally grows to between 130-230 cm, but a stated length of 300 cm is unverified and would be an exceptional specimen of its genus. Snakes of the genera above are slender but well-muscled animals, with a typical triangular head often featuring a prominent snout. The color range may encompass green, green/yellow or green/blue, but also tints of brown, brown/gray, and brown/red.

A majority of these snakes are arboreal or at least semi arboreal creatures, normally active at night.

They can move relatively swiftly; some show quite short-tempered behavior with even signs of aggressiveness. The Sumatra pit viper is typically referred to as the most aggressive viperid. Nonetheless, this reputation does not put off snake keepers, in fact, the opposite is true. One factor for this may be the quite attractive appearance of these snakes. In the Czech Republic, 20 snakebites from *Trimeresurus* snakes were registered within the last 10 years.

In places within their home range, these snakes have a quite important role in terms of epidemiology: *Protobothrops mucrosquamatus* is responsible for 50% of all envenomations in the territories of Indonesia and Hong Kong, plus 30% of cases of envenoming in Taiwan from 1904 to 1971 were caused by this snake. In Thailand, where snakes of this group cause 27% of snake bites, 278 cases of envenomation by *Trimeresurus albolabris* and *T. macrops* were treated by just a single Bangkok hospital during 1987 to 1995 (Rojnuckarin et al., 1998).

Habitat and range. Pit vipers of the genera above inhabit scrubland, plantations, bamboo and mangrove stands, woods and forests, primarily in hilly areas, but often near water or in humid localities. Their home range covers a vast swathe of land in South and East Asia: Pakistan, the Indian Peninsula region (including Nepal and Sri Lanka), S China, Taiwan, the former Indochinese countries, Malaysia, Indonesia, the Philippines and the islands of Japan.

*Toxins***:** As with other viperids (*Viperidae*) and *Crotalinae* snakes, venoms of the genera above are largely composed of enzymatic components.

The venom contains kininogenases, kallikrein-like enzymes that can release bradykinin from kininogen, as well as directly active enzymes potentiating bradykinin function, and substances with direct effects on myocardium.

Furthermore, the venom contains components increasing vascular permeability, i.e. hemorrhagins, for example *mucrotoxin*, a hemorrhagic factor in *Protobothrops (Trimeresurus) mucrosquamatus* venom, and hemorrhagins isolated from *Protobothrops flavoviridis* venom.

Resulting effects may include hypotension, circulation collapse, and shock; cases have been reported of myocardial failure with increased pressure in the pulmonary trunk and bradycardia (*Protobothrops mucrosquamatus*, *P. flavoviridis*).

Hemocoagulation-affecting components, again largely those of an enzymatic nature, present another typical complex of elements, comprising fibrinogen-converting thrombin-like enzymes, such as *elegaxobin* from *Protobothrops elegans* venom, which cause consumption coagulopathy. In addition, there are fibrino(geno)lytic proteinases, like those in *Protobothrops mucrosquamatus*; specific inhibitors of plasmatic coagulation factors with anticoagulation effects, for instance in *T. stejnegeri* and *T. gramineus*; PLT activators, e.g. those in *Protobothrops mucrosquamatus*, and a number of others. The action of hemocoagulation-affecting components results in hemostasis disorders, principally featuring symptoms of increased hemorrhaging, as well as potential thrombotic complications.

Local damage of afflicted tissues is caused by a complex of cytotoxic enzymes. These may even cause a certain degree of rhabdomyolysis on occasion; they are also responsible for other things, such as necrosis and possible compartment syndrome.

Local symptoms of envenoming: Soon after envenomation, relatively intense pain is felt and spreads progressively along with developing edema and lymphadenopathy. Edema usually extends over a half of the limb, although it can rarely cross regional lymph nodes and expand to the torso. In a nearly half of cases of bites from *Trimeresurus albolabris*, lymphadenopathy occurs including swollen and painful regional lymph nodes. The skin of the afflicted area may turn red, with ecchymoses forming, and, more rarely, petechiae. The bite wound often bleeds, especially if cut open as part of incompetent first aid measures.

In the course of time, vesicles and later necrosis can develop. Necrosis primarily affects localities of tight compartments - fingers and toes. The incidence of necrosis fluctuates at around 2-3%, with the highest figure of 6.8% concerning bites by *Protobothrops flavoviridis*. Blisters and necrotic portions of skin and sub-cutaneous areas are subject to the occurrence of secondary infections, for which an incidence of about 5% is registered. Rarely, gangrene of the fingers occurs, necessitating amputation; within a group of 80 persons probably envenomed by *Trimeresurus albolabris* or *Trimeresurus macrops* in Bangkok, finger amputation was necessary in 2 out of 9 affected patients.

Compartment syndrome in the front tibial region following a bite of a lower limb, with tissue pressure that constricts perfusion, presents a significant local complication usually arising after attacks by *Prothobotrops flavoviridis*.

Proof of the cytotoxic aggressiveness of venoms in this snake group is evidenced by a case of lip and tongue edema which occurred following a wound being sucked after a bite.

Convalescence of a severe local affliction might last months; even permanent damage in the manner of deformities (*Protobothrops elegans*) and ankylosis might be caused.

Systemic symptoms of envenoming: The severity of a local affliction does not correspond to that of systemic affliction. Cases exist of severe local damage that presented minimum systemic symptoms, as do instances of a severe progress lacking necrosis. Thus, severity of a systemic envenomation should not be generally assessed according to the extent of local symptoms. Indeed, the reverse is true: cases with a harsh local response tend to accompany a lower degree of systemic response, while a less intensive local affliction is exhibited in cases of envenoming complicated by hemorrhaging. This situation can be explained by the establishment of a closed pool of venom in tight compartments, which will slow down penetration of venom into the system whilst increased local devastation of tissue is occurring.

Systemic envenoming mostly starts with the following prodromes: nausea, vomiting, abdominal pain, diarrhea, and increased temperatures. Harsher cases may include lethargy, or possibly temporary syncope. Envenoming primarily continues with hypotension and

hemocoagulation abnormities normally only found in laboratory tests. Decreased blood pressure caused by vasodilation and extravasation of fluids may result in circulation collapse or even shock, including tachypnea, cyanosis, and coma.

Hemostasis disorder is firstly evident only in laboratory results, but may not manifest clinically at all in lighter cases. However, in more severe instances, it results in hemorrhaging, usually of a local type, but also at a systemic level. Examples include hemorrhaging from the gums, nose and into the GIT, hematuria, and more unusually fatal cerebral hemorrhaging, e.g. via *Protobothrops mucrosquamatus*. Spontaneous bleeding occurs in nearly one fifth of those envenomed by *Trimeresurus albolabris*. Susceptibility to hemorrhaging mainly occurs in persons affected with whole blood clotting time (based on Lee-White) of longer than 15 minutes, the presence of thrombocytopenia with a platelet count less than $150 \cdot 10^9$/l, and a bite wound not localized in the tight compartment of fingers.

In some cases, the hemostasis disorder is not in the nature of consumption coagulopathy, but is probably due to increased fibrino(geno)lytic activity of venom components, resulting in isolated defibrination. In other cases, like *T. albolabris* and *T. stejnegeri*, the action of thrombin-like enzymes generates a DIC-like consumption disorder with relevant laboratory results found - hemorrhaging or suspected microembolism entry into the lungs or kidneys, including symptomatology of worsened oxemia or extraordinary cases of acute tubular necrosis of the kidneys.

Cases of envenoming by *Protobothrops flavoviridis* and *Trimeresurus macrops* are not associated with hemostasis disorders.

Other less frequent symptoms of envenoming described include a case of stool incontinency, difficulties urinating (*Ovophis chaseni*), oliguric renal failure, ECG changes (*Protobothrops mucrosquamatus*), and the death of a 10-week-old fetus in a pregnant woman in Japan, who featured only a relatively light course of envenomation without signs of increased bleeding (Nasu et al., 2004).

Generally, worse systemic envenomings can be expected following a snakebite from *Protobothrops elegans*, *P. flavoviridis*, *P. mucrosqamatus,* and *Trimeresurus albolabris*, while for the majority of other snakes of this group, the tendency is for a local affliction with lighter systemic reactions to arise.

In instances when no symptoms are exhibited, a patient is observed for 24 hours. If neither clinical nor laboratory symptoms of systemic response arise, a systemic envenomation can be ruled out.

Laboratory findings: Specific findings in cases of envenoming by this group of snakes are principally present in hemocoagulation laboratory tests; they normally resemble DIC. Prevailing symptomatology includes hypofibrinogenemia, potentially extending to afibrinogenemia, thrombocytopenia, and elevation of FDP, sometimes that of predominantly non-stabilized forms, but often D-dim. Reduced levels of α2-antiplasmin and AT are registered, probably a result of these substances being fully spent due to the inhibition of hyperactivities of plasmin and thrombin. In addition, increased levels of soluble fibrin-monomer complexes have been detected. In cases of worse hemostasis disorders, prolongation of PT, APTT, and TT occurs. A laboratory form of hemocoagulation dysbalance, such as a certain degree of hypofibrinogenemia and increased FDP (D-dim) level, may persist for 2 weeks.

Neutrophilic leukocytosis is obligatory; based on the increased myoglobin level in serum and urine, and signs of rhabdomyolysis cannot be precluded.

Mortality: Before antivenom therapy was implemented, i.e. prior to 1905, the fatality of envenomings by the habu (*Protobothrops flavoviridis*) in Japan amounted to 11-24%. Warrell (1995) states that the mortality rate dropped owing to improved therapy, principally antivenom treatment, to 0.9% in this country during 1962 to 1970, and even 0.54% between 1971 and 1984 from a total of 467 persons so affected.

In Taiwan, 8% of those envenomed by *Protobothrops mucrosquamatus* died in the period 1904 to 1971. In Indonesia, the lethality of snakebites from the white-lipped tree viper (*Trimeresurus albolabris*) accounts for 2.4%. Individual cases of fatalities from bites by the Chinese mountain pit viper (*Ovophis monticola*) and elegant pit viper (*Protobothrops elegans*) have been described, as well as relatively frequent bites caused to people harvesting tea in Java.

In the majority of victims, death was caused by hemorrhaging, namely of the cerebral form.

Therapy: For first-aid treatment and ordinary principles of therapy, see chapter 5, Snake bite: Therapy and precautions.

Application of a pressure immobilization bandage is not recommended due to the risk of extending local damage through the persistence of highly concentrated cytotoxic venom components at point in question. Nevertheless, immobilizing the leg by using a looser bandage is useful.

Antivenom available:

GREEN PIT VIPER ANTIVENIN, Thai Red Cross, Thailand (*T. albolabris* and other Thailand species).

For the remainder of the species, a certain level of cross-immunity is possible. Application of antivenom is indicated in cases where worse systemic symptoms develop, such as hemorrhaging and hypotension, or if laboratory findings show prolonged clotting time (according to Lee-White - over 15 minutes), and thrombocytopenia below $150 \cdot 10^9$/l, especially if a bite is located outside the tight compartment of a finger; this situation facilitates an increased level of hemorrhaging. Of course, the prolonged clotting time test can be replaced by another, e.g. PT, APTT, TT, or FBG level.

The antivenom is administered in an initial amount of 3-6 vials, which should establish hemocoagulation balance. Recurrence of symptoms or severe laboratory symptomatology will require repeated application of antivenom.

Special attention must be paid to local symptoms of envenoming for their relative severity. Developing dermal bullae and necrosis, although typically not very large, are a predisposition to occurrence of infectious complications. Prompt removal of bullae and necrotic tissue as well as proper care for the wound bed is advisable. Compartment syndrome, largely in the front tibial region following a bite in this area, presents a risk in exceptional cases. It must be treated by elevating the limb and administering manitol, with doses of 0.5-2 g/kg IV in the course of about 30 minutes. If the risk of perfusion failure in the relevant area does not abate, fasciotomy is indicated. However, this kind of treatment is never carried out preemptively; see also chapter 6.4.3.3 Crotalus and Sistrurus genera: rattlesnakes and pygmy rattlesnakes. There may be a necessity for amputation due to gangrene afflicting fingers.

Pre-emptive administration of antibiotics is not indicated, although sometimes recommended; antibiotic therapy, if one is applied, is introduced only upon the occurrence of infectious complications.

For hypotension of circulatory failure and shock, treatment is initiated by volumotherapy: the circulating volume is replenished using an infusion of crystalloids or colloid solutions, or fresh-frozen plasma. In addition, including fresh-frozen plasma in the therapy can positively influence a DIC-like hemocoagulation disorder, if any. If application of infusions fails to ensure satisfactory stabilization of the circulation, or hypotension persists or any further increase in volume is contraproductive, vasopressure therapy is indicated using norepinephrine in continual infusion, which will provide sufficient perfusion pressures; see chapter 5.3 3.5 Hypotension, shock.

Appropriate intravascular volume together with adequate perfusion pressure needs to be maintained to retain sufficient diuresis, and prevent potential but rare renal failure.

Any signs of hemocoagulation disorders must be treated symptomatically as necessary, in parallel with the application of antivenom. Isolated hypofibrinogenemia without clinical signs of increased hemorrhaging, as well as persisting mild thrombocytopenia, will not require any special symptomatic treatment and indicates repeated application of antivenom in most cases, especially in the early phases of envenoming. A DIC-like consumption coagulopathy, particularly in its later phase, may be difficult to control by means of immunotherapy to a satisfactory extent and will require symptomatic treatment: therapy using fresh-frozen plasma (10-20 ml/kg) and AT substitution with potential miniheparinization (70-210 units/kg/24 h) based on the phase and progress of the syndrome. Heparin therapy is not indicated over the period of increased bleeding; nevertheless, it may have a positive effect on managing hypercoagulation states that may sometimes even be associated with the development of microembolisms. For potential substitution of platelets, erythrocytes and FBG, ordinary guidelines will apply. Administering hemocoagulation factor concentrates is not recommended; see chapter 5.3.3.6. Hemocoagulation disorders.

A patient can be discharged for home treatment after 24 hours following abatement of all systemic symptoms of envenoming, normalization of significant laboratory values, and stabilization of the local affliction. Any persisting laboratory symptomatology of less significant prothrombotic activity should be resolved by preemptive miniheparinization, see chapter 5.4 Convalescence following envenoming.

REFERENCES

ANDREW, RK., GARDINER, EE., ASAZUMA, N., et al. A novel Viper venom metalloproteinase, alborhagin, is an agonist at the platelet collagen receptor GPVI. *J biol Chem,* 2001, 276, No. 30, pp. 28092–28097.

ANGEL, MF., ZHANG, F., JONES, M., et al. Nectotizing fasciitis of the upper extremity resulting from a Water Moccasin bite. *South Med J*, 2002, Sep, 95, No. 9, pp. 1090–1094.

ARI, AB. Patient with purely extraocular manifestation from a pit viper snakebite (*Agkistrodon halys brevicaudatus*). *Mil Med*, 2001, 166, No. 7, pp. 667–669.

De CASTRO, I., BURDMANN, EA., SEGURO, AC., et al. Bothrops venom induces direct renal tubular injury: role for lipid peroxidation and prevention by antivenom. *Toxicon*, 2004, 43, No. 7, pp. 833–839.

BERBARTA, V., DART, RC. Effectiveness of delayed use of Crotalidae polyvalent immune Fab (ovine) antivenom. *J Toxicol Clin Toxicol*, 2004, 42, No. 3, pp. 321–324.

BENVENUTI, LA., FRANCA, FO., BARBARO, KC., et al. Pulmonary haemorrhage causing rapid death after *Bothrops jararacussa* snakebite: a case report. *Toxicon*, 2003, 42, No. 3, pp. 331–334.

BRYNDAO, EO., de BASTOS, HC., NISHIOKA, SA., et al. Lance-headed Viper (*Bothrops moojeni*) bite wounding the eye. *Rev Inst Med Trop Sao Paulo*, 1993, 35, No. 4, pp. 381–383.

BUCARETCHI, F., HERRERA, SRF., HYSLOP, S., et al. Snakebites by *Crotalus durissus* ssp. in children in Campinas, Sao Paulo, Brazil. *Rev Inst Med Trop Sao Paulo*, 2002, 44, No. 3, pp. 133–138.

COWLES, RA., COLLETTI, LM. Presentation and treatment of venomous snakebites at a Nothern Academic Medical Center. *Am Surg*, 2003, 69, No. 5, pp. 445–449.

CUPO, P., de AZEVEDO-MARQUES, MM., HERING, SE. Absence of myocardial involvement in children victims of *Crotalus durissus terrificus* envenoming. *Toxicon*, 2003, 42, No. 7, pp. 741–745.

DUMAVIBHAT, B., VISUDHISPHAN, S., MALASIT, P. Severe cases of Green Pit Viper snake venom poisoning. *J Med Assoc Thai*, 1989, 72, No. 10, pp. 593–596.

FAN, HW., CARDOSO, JL. Clinical toxicology of snake bites in South America. In MEIER, J., WHITE, J. (Eds), *Handbook of clinical toxicology of animal venoms and poisons*. Boca Raton : CRC Press, 1995.

FRANCA, FO., BARBARO, KC., FAN, HW., et al. Envenoming by *Bothrops jararaca* in Brasil: association between venom antigenemia and severiny at admission to hospital. *Trans R Soc Trop Med Hyg*, 2003, 97, pp. 312–317.

GAO, R, ZHANG, Y., MENG, QL., et al. Characterization of the three fibrinogenolytic enzymes from Chinese Green Viper (*Trimeresurus stejnegeri*) venom. *Toxicon,* 1998, 36, No. 3, pp. 457–467.

GIBLY, RL., WALTER, FG., NOWLIN, SW., et al. Intravascular hemolysis associated with North American Crotalid envenomation. *J Toxicol Clin Toxicol*, 1998, 36, No. 4, pp. 337–343.

GOLD BS., BARISH, RA., DART, RC., et al. Resolution of compartemnt syndrome after Rattlesnake envenomation utilizing non-invasive measures. *J Emerg Med*, 2003, 24, No. 3, p. 285–288.

GOLD, BS., DART, RC., BARISH, RA. Bites of venomous snakes. *N Engl J Med*, 2002, 347, No. 5, pp. 347–356.

GOLD, BS., WINGERT, WA. Snake venom poisoning in the United States: a review of therapeutic practice. *South Med J*, 1994, 87, No. 6, pp. 579–590.

GOMEZ, HF., DART, RC. Clinical toxicology of snakebite in North America. In MEIER, J., WHITE, J. (Eds), *Handbook of clinical toxicology of animal venoms and poisons.* Boca Raton : CRC Press, 1995.

GUIMARARES, AQ., CRUZ-HOFLING, MA., FERREIRA De ARAUJO, PM., et al. Pharmacological and histopathological charakterization of *Bothrops lanceolatus* (Fer de lance) venom-induced edema. *Inflamm Res*, 2004, 53, No. 7, pp. 284–291.

GUTIÉRREZ, JM. Clinical toxicology of snakebite in Central America. In MEIER, J., WHITE, J. (Eds), *Handbook of clinical toxicology of animal venoms and poisons.* Boca Raton : CRC Press, 1995, pp. 645–666.

HOLSTEGE, CP., MILLER, MB., WERMUTH, M., et al. Crotalid snake envenomation. *Crit Care Clin*, 1997, 13, No. 4, pp. 889–921.

HORTE, MT., CARDOVO, JL., ASTRO, SC., et al. A randomised »blinded« comparison of two doses of antivenom in the treatment of *Bothrops* envenoming in Sao Paulo, Brazil. *Trans R Soc Trop Med Hyg*, 1995, 89, pp. 111–114.

HORTE, MT., RIBEIRO, LA. Envenoming by the South American Pit Viper *Bothrops neuwiedi* Wagner. *Ann Trop Med Parasitol*, 2000, 94, No. 7, pp. 731–734.

HUTTON, RA., LOOAREESUWAN, S., HO, M., et al. Arboreal Green Pit Vipers (genus *Trimeresurus*) of Southeast Asia: bites by *T. albolabris* and *T. macrops* in Thailand and review of the literature. *Trans R Soc Trop Med Hyg*, 1990, 84, No. 6, p. 866–874.

JUCKETT, G., HANCOX, JG. Venomous snakebites in the United States: management review and update. *Am Fam Physician*, 2002, 65, No. 7, pp. 1367–1374.

KERNS, W. 2nd, TOMASZEWSKI, C. Airway obstruction following Canebrake Rattlesnake envenomation. *J Emerg Med*, 2001, 20, No. 4, pp. 377–380.

KONG, YL., CHAN, GTC. Coagulation problems in Pit Viper bite. *J Hong Kong Med Assoc*, 1988, 40, No. 3, pp. 210–212.

KORNALIK, F., VORLOVA, Z. Non-specific therapy of a hemorrhagic diathesis after a bite by a young *Bothrops asper* (Barba amarilla): a case report. *Toxicon*, 1990, 28, No. 12, pp. 1497–1501.

KULARATNE, SA., RATNATUNGA, N. Severe systemic effects of Merrem´s Hump-nosed Viper bite. *Ceylon Med J*, 1999, 44, No. 4, pp. 169–170.

LATIFI, M. Variation in yield and letality of venoms from Iranian snakes. *Toxicon*, 1984, 22, No. 3, pp. 373–380.

LAVONAS, EJ., GERARDO, CJ., O´MALLEY, G., et al. Initial experience with Crotalidae polyvalent immune Fab (ovine) antivenom in the treatment of Copperhead Snakebite. *Ann Emerg Med*, 2004, 43, No. 2, pp. 200–206.

LONATI, D., BUTERA, R., CIMA, M., et al. Exotic snakes in Europe. A case of Mexican Moccasin (*Agkistrodon bilineatus*) snakebite. *Presse Med*, 2004, 33, No. 22, pp. 1582–1584.

LOVECCHIO, F., KLEMENT, J., WELCH, S., et al. Antibiotics after Rattlesnake envenomation. *J Emerg Med*, 2002, 23, No. 4, pp. 327–328.

MAGALHAES, A., FERREIRA, RN., RICHARDSON, M., et al. Coagulant trombin-like enzymes from the venoms of Brasilian and Peruvian Bushmaster (*Lachesis muta muta*) snakes. *Comp Biochem Physiol B Biochem Mol Biol*, 2003, 136, No. 2, pp. 255–266.

MARTINS, AM., TOYAMA, MH., HAVT, A., et al. Determination of *Crotalus durissus cascavella* venom components that induce renal toxicity in isolated rat kidneys. *Toxicon*, 2002, 40, No. 8, pp. 1165–1171.

MEIER, J., WHITE, J. (Eds). *Handbook of clinical toxicology of animal venoms and poisons.* Boca Raton : CRC Press, 1995, 752 pp.

MOSQUERA, A., IDROVO, LA., TAFUR, A., et al. Stroke following *Bothrops* spp. snakebite. *Neurology*, 2003, 60, No. 10, pp. 1577–1580.

NASU, K., UEDA, T., MIYAKAWA, I. Intrauterine fetal death cause by Pit Viper venom poisoning in early pregnancy. *Gynecol Obstet Incest*, 2004, 57, No. 2, pp. 114–116.

NISHIOKA, SA., JORGE, MT., SILVEIRA, PV., et al. South American Rattlesnake bite and soft-tissue infections: report of a case. *Rev Soc Bras Med Trop*, 2000, 33, No. 4, pp. 401–402.

OFFERMAN, SR., BARRY, JD., SCHNEIR, A., et al. Biphasic Rattlesnake venom-induced tropbocytopenia. *J Emerg Med*, 2003, 24, 3, pp. 289–293.

PINHO, FM., ZANETTA, DM., BURDMANN, EA. Acute renal failure after *Crotalus durissus* snakebite: a prospective survey on 100 patients. *Kidney Int*, 2005, 67, No. 2, pp. 659–667.

PREMAWARDENA, AP., SENEVIRATNE, SL., GUNATILAKE, SB., et al. Excessive fybrinolysis: the coagulopathy following Merrem´s Hump-nosed Viper (*Hypnale hypnale*) bites. *Am J Trop Med Hyg*, 1998, 58, No. 6, pp. 821–823.

RIBEIRO, LA., ALBUQUERQUE, MJ., de CAMPOS, VA., et al. Death caused by venomous snakes in the State of Sao Paulo, evaluation of 43 cases from 1988 to 1993. *Rev Assoc Med Bras*, 1998, 44, No. 4, pp. 312–318.

RODRIGUES-SIMONI, L., ZAMUNER, SR., COGO, JC., et al. Pharmacological evidence for a presynaptic action of venoms from *Bothrops insularis* (Jararaca Ilhoa) and *Bothrops neuwiedi* (Jararaca Pintada). *Toxicon*, 2004, 43, No. 6, pp. 633–638.

ROJNUCKARIN, P., MAHASANDANA, S., INTRAGUMTHORNCHAI, T., et al. Prognostic factors of Green Pit Vipers bites. *Am J Trop Med Hyg*, 1998, 58, No. 1, pp. 22–25.

ROSENTHAL, R., MEIER, J., KOELZ, A., et al. Intestinal ischemia after Buschmaster (*Lachesis muta*) snakebite – a case report. *Toxicon*, 2002, 40, No. 2, pp. 217–220.

SALLIGAN, R., COLE, J., BRITO, N., et al. Crotaline snake bite in the Ecuadorian Amazon: Randomised double blind comparative trial of three South American polyspecific antivenoms. *BMJ*, 2004, 329, No. 7475, pp. 1129.

SCHARMAN, EJ., NOFFSINGER, VD. Copperhead snakebites: clinical severiny of local effects. *Ann Emerg Med*, 2001, 38, No. 1, pp. 55–61.

SCHIER, JG., WIENER, SW., TOUGER, M., et al. Efficacy of Crotalidae polyvalent antivenin for the treatment of Hognosed Viper (*Porthidium nasutum*) envenomation. *Ann Emerg Med*, 2003, 41, No. 3, pp. 391–395.

SELLAHEWA, KH., KUMARARATNE, MP. Envenomation by the Hump-nosed Viper (*Hypnale hypnale*). *Am J Trop Med Hyg*, 1994, 51, No. 6, pp. 823–825.

SHAW, BA., HOSALKAR, HS. Rattlesnake bites in children: antivenin treatment and surgical indication. *J Bone Joint Surg Am*, 2002, 84–A, No. 9, pp. 1624–1629.

SCHAPER, A., de HARO, L., DESEL, H., et al. Rattlesnake bites in Europe – experiences from southestern France and northern Germany. *J Toxicol Clin Toxicol*, 2004, 42, No. 5, pp. 635–641.

De SILVA, A. *Trimeresurus trigonocephalus* bites. *The Snake*, 1983, 15, pp. 91–94.

De SILVA, A., WIJEKOON, AS., JAYASENA, L., et al. Haemostatic dysfunction and acute renal failure following envenoming by Merrem´s Hump-nosed Viper (*Hypnale hypnale*) in Sri Lanka: first autentic case. *Trans R Soc Trop Med Hyg*, 1994, 88, No. 2, pp. 209–212.

SILVEIRA, KS., BOECHEM, NT., de NASCIMENTO, SM., et al. Pulmonary mechanics and lung histology in acute lung injury induced by *Bothrops jararaca* venom. *Respir Physiol Neurobiol*, 2004, 139, No. 2, pp. 167–177.

SOTELO-CRUZ, N. Rattlesnake bite poisoning, health damage and treatment in children. *Gac Med Mex*, 2003, 139, No. 4, pp. 317–324.

STÖCKLIN, R., CRETTON, G. *The ultimate database on venomous animals, snakes.* CD-rom, Geneva : Atheris Laboratories, 1998.

TAKESHITA, T., YAMADA, K., HANADA, M., et al. Case report: extraocular muscle paresis caused by snakebite. *Kobe J Med Sci*, 2003, 49, No. 1, pp. 11–15.

TANEN, DA., RUHA, AM., GRAME, KA., et al. Rattlesnake envenomations: unusual case presentation. *Arch Intern Med*, 2001, 161, No. 3, pp. 474–479.

THOMAS, L., TYBURN, B., BUCHER, B., et al. Prevention of thromboses in human patiens with *Bothrops lanceolatus* envenoming in Martinique: failure of anticoagulants and efficacy of a monospecific antivenom. *Am J Trop Med Hyg*, 1995, 52, No. 5, pp. 419–426.

THORSON, A., LAVONAS, EJ., ROUSE, AM., et al. Copperhead envenomation in the Karolina. *J Toxicol Clin Toxicol*, 2003, 41, No. 1, pp. 29–35.

VISUDHIPHAN, S., TONMUKAYAKUL, A., TUMLIANG, S., et al. Dark Green Pit Viper (*Trimeresurus popeorum*) bite: clinical and serial coagulation profiles in 51 cases. *Am J Trop Med Hyg*, 1989, 41, No. 5, pp. 570–575.

WARRELL, DA. Clinical toxicology of snakebite in Asia. In MEIER, J., WHITE, J. (Eds), *Handbook of clinical toxicology of animal venoms and poisons.* Boca Raton, New York, London, Tokyo : CRC Press, 1995.

WINGERT, WA., CHAN, L. Rattlesnake bites in southern California and rationale for recomended treatment. *West J Med*, 1988, 148, No.1, pp. 37–44.

WHITAKER, R. Pit viper (*Trimeresurus macrolepis* Beddome) bites at a South Indian tea estate. *J Bombay Nat Hist Soc*, 1973, 70, No. 1, pp. 207–208.

ZAMUDIO, KR., HARDY, DL. Sr., MARTINS, M., et al. Fang tip spread, puncture distance, and suction for snake bite. *Toxicon*, 2000, 38, No. 5, pp. 723–728.

ZAMUNER, SR., da CRUZ-HOFLING, MA., CORADO, AP., et al. Comparison of the neurotoxic and myotoxic effect of Brasilian *Bothrops* venom and their neutralisation by commercial antivenom. *Toxicon*, 2004, 44, No. 3, pp. 259–271.

ZHANG, Y., LEE, WH., GAO, R., et al. Effects of Palla´s Viper (*Agkistrodon halys pallas*) venom on blood coagulation and characterization of a protrombin activator. *Toxicon*, 1998, 36, No. 1, pp. 143–152.

Chapter 7

LIST OF VENOMOUS SNAKES

The aim of the venomous snake overview below is not to provide full and complex taxonomy in terms of zoology and systematics. Instead, the purpose is to catalog the names of known venomous snakes, as well as those, namely from the colubrid family (*Colubridae*), capable of causing envenomation through bites, even though they may merely cause a local or a very light affection. The list of potentially venomous snakes may not be comprehensive due to the general shortage of information available. In addition, it features snakes that are known to possess venom apparatus, but for which no envenoming has been described as a result of rarity or a benign course.

7.1. FAMILY: *COLUBRIDAE*, COLUBRIDS

Genus: *Ahaetulla*, formerly *Dryophis*, vine snakes

Ahaetulla dispar[1] * Günther's vine snake or Indian bronzeback (India)

*Ahaetulla fasciolata** Speckle-headed whipsnake (Indonesia, Malaysia, Singapore, Thailand)

*Ahaetulla fronticincta** Burmese vine snake (India and Burma)

*Ahaetulla nasuta** Long-nosed whipsnake (Sri Lanka, India, Malaysia)

*Ahaetulla mycterizans** Malayan green whipsnake (Indonesia, Thailand, Laos, W Malaysia)

*Ahaetulla perroteti** Western Ghats bronzeback (India)

Ahaetulla prasina ssp.* Oriental whipsnake or Asian vine snake (Sri Lanka, India, Malaysia)

*Ahaetulla pulverulenta** Brown-speckled whipsnake (E Himalayas, former Indochinese region and sea along the archipelagos between E India and N Australia)

Genus: *Amblyodipsas*, purple-glossed snakes, see *Atractaspididae, Aparallactinae*

Genus: *Amplorhinus*

---

1 * This snake taxon features animals with venom of limited effectiveness or quantity. Snakebites by this species are not dangerous, and do not pose a threat to the life of a human, except in remote cases or due to extreme allergic reaction. In some instances, this asterisk may mark a species of unknown toxicity or unproven clinical course of envenoming, and for which a low level of peril is expected; examples include some members of the colubrid family (Colubridae). Nonetheless, even these snakes should not be underestimated and any unnecessary exposure to risk should be avoided.

*Amplorhinus multimaculatus** Cape reed snake (S and E South Africa and E Zimbabwe)
Genus: *Arrhyton* (coasts of the Caribbean Gulf and Cuba)
*Arrhyton ainictum** Cuban island racer
*Arrhyton callilaemum**
*Arrhyton dolichura** Habana island racer
*Arrhyton exiguum** Ground snake
*Arrhyton funereum**
*Arrhyton landoi** Schwartz's island racer
*Arrhyton polylepis**
*Arrhyton procerum**
*Arrhyton redimitum**
*Arrhyton supernum**
*Arrhyton taeniatum** Günther's island racer
*Arrhyton tanyplectum** St Vincent island racer
*Arrhyton vittatum** Common island racer
Genus: *Balanophis*
*Balanophis ceylonensis** Sri Lankan keelback blossom krait (Sri Lanka)
Genus: *Boiga*, boigas or cat snakes
Boiga andamanensis[2]** Andaman cat snake (India and the Andaman Islands)
*Boiga angulata*** Leyte cat snake (the Philippines)
*Boiga barnesi*** Barnes' cat snake (Sri Lanka)
*Boiga beddomei*** Beddome's cat snake (Sri Lanka and India)
*Boiga bengkuluensis*** (Sumatra)
*Boiga blandingii*** (Uganda and W Kenya)
*Boiga bourreti*** Blandings tree snake (Vietnam)
*Boiga ceylonensis*** Sri Lankan cat snake (Sri Lanka, India, the Andaman Islands)
*Boiga cyanea*** Green cat snake (India, former Indochina, S China)
*Boiga cynodon*** Dog-toothed cat snake (SE Asia and the Philippines)
*Boiga dendrophila*** Gold-ringed cat snake or mangrove snake
-- *B. dendrophila annectens* (Borneo)
-- *B. dendrophila dendrophil* (Java)
-- *B. dendrophila divergens* (the Philippines)
-- *B. dendrophila gemmicincta* (Indonesia - Sulawesi)
-- *B. dendrophila latifasciata* (the Philippines)
-- *B. dendrophila levitoni* (the Philippines - Panay)
-- *B. dendrophila melanota* (mainland SE Asia, Malayan Peninsula, Indonesia)
-- *B. dendrophila multicincta* (the Philippines)
-- *B. dendrophila occidentalis* (Indonesia)
*Boiga dightoni*** Pirmad cat snake (India)
*Boiga drapiezii*** White-spotted cat snake (Indonesia, Malaysia, the Philippines, Singapore, Thailand)

2 ** This snake is one of a low to moderately dangerous taxon. In most cases, health complications arise following envenomation by these snakes. Cases of grievous affliction and threat to life of a healthy adult are rare; nevertheless, fatalities have been described involving some of these species, especially when adequate treatment is absent. Therefore, the twin asterisks also refer to snake taxons where a clinical course of envenoming has not been described, but an indicated level of risk can be analogically presumed.

Boiga flavescens see *B. irregularis*
*Boiga forsteni*** Forsten's cat snake (India and Sri Lanka)
*Boiga gokool*** Arrowback tree snake (India)
*Boiga guangxiensis*** (China and Vietnam)
Boiga hexagonata see *B. cyanea*
*Boiga irregularis*** Brown catsnake or brown tree snake (Indonesia, New Guinea, Australia)
*Boiga jaspidea*** Jasper cat snake (SE Asia)
*Boiga kraepelini*** Kelung cat snake (N Taiwan and S China)
*Boiga multifasciata*** Many-banded tree snake (India, Nepal, Bhutan)
*Boia multimaculata (multomaculata)*** Many-spotted cat snake (SE Asia and Indonesia)
*Boiga nigriceps*** Black-headed cat snake (Thailand, China, Indonesia, Malaysia)
*Boiga nuchalis*** (India and Nepal)
*Boiga ocellata*** Gray cat snake or eyed cat snake (India, Bangladesh, former Indochina, NW Malaysia)
*Boiga ochracea*** Orange cat snake (India and Bhutan)
*Boiga philippina*** Philippine cat snake (the Philippines)
*Boiga pulverulenta*** Fischer's cat snake (W and C Africa)
*Boiga quincunciata*** (India and Burma)
*Boiga saengsomi*** Banded cat snake (Thailand)
*Boiga schultzei*** (the Philippines)
*Boiga tanahjampeana*** Tanahjampea cat snake (Tanahjampea Island near Indonesia)
*Boiga trigonata*** Indian gamma snake (Iran, Afghanistan, Pakistan, Nepal, India, Sri Lanka)
*Boiga wallachi*** Nicobar cat snake (India and the Nicobar Islands)
Genus: *Calamodontophis*
*Calamodontophis paucidens** Tropical forest snake (S Brazil)
Genus: *Cerberus*
*Cerberus microlepis** Dog-faced water snake (coastal S India, SE Asia, N Australia)
*Cerberus rynchops** New Guinea bockadam (coastal S India, SE Asia, N Australia)
Genus: *Clelia*, mussuranas
*Clelia bicolor** Two-colored mussurana (Brazil and Argentina)
Clelia clelia ssp.* (N Central America, N South America)
*Clelia equatoriana** Equatorial mussurana (E Panama, NW Ecuador, Colombia)
*Clelia errabunda** Underwood's mussurana (the Antilles - Saint Lucia)
*Clelia husami** (Brazil)
*Clelia montana** (Brazil - Sao Paulo)
*Clelia occipitolutea** Black mussurana (N Brazil, Uruguay, Argentina)
*Clelia quimi** (Brazil)
*Clelia plumbea** (N Central America and N South America)
*Clelia rustica** (Brazil, Uruguay, Argentina)
*Clelia scytalina** Mexican snake eater (Central America)
Genus: *Coluber*, racers
Coluber sp. A genus of a collective nature with a rather diverse taxonomy, it comprises some 30 species of slightly venomous or non-venomous colubrids. More recently, species

once ranked amongst the genus have been reclassified under other genera, for instance *Hierophis*, *Hemorrhois*, *Platyceps*, etc.

Coluber ravergieri see *Hemorrhois ravergieri*

Coluber rhodorachis see *Platyceps rhodorachis*

Genus: *Coniophanes*, black-striped snakes (North, Central and South America, Texas to Peru)

*Coniophanes alvarezi** Chiapan stripeless snake

*Coniophanes andresensis** Andresen's snake

*Coniophanes bipunctatus** Two-spotted snake

*Coniophanes dromiciformis** Peters' running snake

*Coniophanes fissidens** Yellowbelly snake

*Coniophanes imperialis** Black-striped snake

*Coniophanes joanae**

*Coniophanes lateritius** Stripeless snake

*Coniophanes longinquus**

*Coniophanes meridanus** Peninsula stripeless snake

Coniophanes piceivittis ssp.* Cope's black-striped snake

-- *Coniophanes piceivittis frangivirgatus**

*Coniophanes quinquevittatus** Five-striped snake

*Coniophanes schmidti** Faded black-striped snake

Genus: *Conophis* (Central America)

Conophis biserialis see *Conopsis biserialis*

*Conophis lineatus** Road guarder

*Conophis morai**

Conophis nasus see *Conopsis nasus*

*Conophis pulcher** Beautiful road guarder

*Conophis vittatus** Striped road guarder

Genus: *Conopsis* (Central America)

*Conopsis biserialis** Two-lined Mexican earth snake

*Conopsis nasus** Largenose earth snake

Genus: *Crotaphopeltis*

Crotaphopeltis acarina see *C. braestrupi* and *C. hippocrepis*

*Crotaphopeltis barotseensis** Barotse water snake (Zambia and N Botswana)

*Crotaphopeltis braestrupi** (Somalia and Burkina Faso)

*Crotaphopeltis degeni** (N Sudan, Uganda, Kenya)

*Crotaphopeltis hippocrepis** (W and C Africa)

*Crotaphopeltis hotamboeia** Red-lipped snake (E Africa from Somalia as far as RSA)

*Crotaphopeltis tornieri** Werner's water snake (Tanzania and N Malawi)

Genus: *Dipsadoboa* (Africa)

*Dipsadoboa aulica** Marbled tree snake

*Dipsadoboa duchesnei**

*Dipsadoboa elongata**

Dipsadoboa flavida ssp.* Cross-bared tree snake

*Dipsadoboa shrevei** Shreve's tree snake

*Dipsadoboa underwoodi**

*Dipsadoboa unicolor** Günther's green tree snake

Dipsadoboa viridis ssp.*
*Dipsadoboa werneri** Werner's tree snake
Genus: *Dispholidus*
Dispholidus typus[3]*** African boomslang
-- *D. typus kivuensis* (N Zambia to SW Kenya)
-- *D. typus punctatus* (N Angola, W Democratic Republic of Congo - DRC, NW Zambia)
-- *D. typus typus* (Sub-Saharan Africa)
Genus: *Dromophis*
*Dromophis lineatus** Lined Olympic snake (C Africa)
*Dromophis praeornatus** Striped swamp snake (W Africa)
Genus: *Dryophis* see *Ahaetulla*
Genus: *Elapomorphus*
Elapomorphus lemniscatus ssp.* Dumeril's diadem snake (Brazil, Uruguay, Paraguay, Bolivia, Argentina)
*Elapomorphus lepidus** Minas Gerais snake (Brazil)
Elapomorphus mertensi see *Phalotris mertensi*
Elapomorphus nasutus see *Phalotris nasutus*
Elapomorphus punctatus see *Phalotris punctatus*
*Elapomorphus quinquelineatus** Raddi's lizard-eating snake (Brazil)
Elapomophus spegazzinii ssp.* Spegazzini's diadem snake (Argentina)
Elapomorphus tricolor see *Phalotris tricolor*
*Elapomorphus wuchereri** Wucherer's lizard-eating snake (Brazil)
Genus: *Enhydris*, water snakes
*Enhydris albomaculata** (Indonesia)
*Enhydris alternans** Reuss' water snake (Indonesia)
*Enhydris bennetti** Bennett's water snake (SE China)
*Enhydris bocourti** Bocourt's water snake (Vietnam, Thailand, Cambodia, W Malaysia)
*Enhydris chinensis** Chinese water snake (N China, Taiwan, Hainan, N Vietnam)
*Enhydris doriae** (Sarawak)
*Enhydris dussumieri** Dussumier's water snake (India and Bangladesh)
*Enhydris enhydris** Rainbow water snake (Pakistan, India, Malaysia, S China, SE Asia)
*Enhydris indica** (W Malaysia)
*Enhydris innominata** Tay Minh water snake (Vietnam and Thailand)
*Enhydris jagori** Jagor's water snake (Former Indochina)
*Enhydris longicauda** Longhead water snake (Cambodia)
*Enhydris maculosa** Blanford's spotted water snake (Burma, Indonesia, probably SE China)
*Enhydris matannensis** Boulenger's water snake (Indonesia)
*Enhydris pahangensis** Pahang water snake (W Malaysia)
*Enhydris pakistanica** Sind River snake (Pakistan)

---

3 *** This snake taxon is classified as highly dangerous. Envenoming following a snakebite to a human is typically a serious process often resulting in death unless adequate and full-ranging treatment is provided.

In certain descriptions of home range, the following abbreviations have been used: N (north, northern), NW and NE (north-west, north-western or north-east, north-eastern, respectively), S (south, southern), SW and SE (south-west, south-western or south-east, south-eastern, respectively), W (west, western), E (east, eastern), C (central).

*Enhydris plumbea** Yellowbelly water snake (SE China, former Indochina, Malaysia)
*Enhydris polylepis** Macleay's water snake (Papua-New Guinea and N Australia)
*Enhydris punctata** Spotted water snake (NE India)
*Enhydris sieboldi** Siebold's water snake (India and W Malaysia)
*Enhydris smithi** Smith's water snake (Thailand)
Genus: *Eteirodipsas*
Eteirodipsas colubrina see *Madagascarophis colubrinus*
Genus: *Ficimia*, hooknosed snakes (North and Central America, S Texas to N Honduras)
*Ficimia hardyi** Hardy's hook-nosed snake
*Ficimia olivacea** Mexican hook-nosed snake
*Ficimia publia** Blotched hook-nosed snake
*Ficimia ramirezi** Ramirez's hook-nosed snake
*Ficimia ruspator** Guerreran hook-nosed snake
*Ficimia streckeri** Strecker's hook-nosed snake
*Ficimia variegata** Tehuantepec hook-nosed snake
Genus: *Fordonia*
*Fordonia leucobalia** Crab-eating water snake or white-bellied mangrove snake (India, former Indochina, Malaysia, the Philippines, Papua-New Guinea, N Australia)
Genus: *Heterodon*
Heterodon nasicus ssp.* Western hog-nosed snake (from the south to the north throughout the central zone of the USA)
*Heterodon platirhinos** Eastern hog-nosed snake (E USA)
*Heterodon simus** Southern hog-nosed snake (N USA)
Genus: *Hemorrhois*
*Hemorrhois ravergieri** Spotted whip snake (Kos Island near Greece, Turkey, the Middle East and a part of Central Asia to China)
Genus: *Homalopsis*, water snake
*Homalopsis buccata** Puff-faced water snake or masked water snake (India to SE Asia)
Genus: *Chrysopelea*, flying snakes (Sri Lanka, S India, Burma, Malaysia, Indonesia, the Philippines)
*Chrysopelea ornata** Golden tree snake or ornate flying snake
*Chrysopelea paradisi** Paradise tree snake
*Chrysopelea pelias** Twin-barred tree snake or banded flying snake
*Chrysopelea rhodepleuron** Moluccan flying snake
*Chrysopelea taprobanica** Indian flying snake
Genus: *Ialtris* (Dominican Republic and Haiti)
*Ialtris agyrtes** Barreras fanged snake
*Ialtris dorsalis** Brown fanged snake
*Ialtris parishi** Parish's fanged snake
Genus: *Imantodes*
Imantodes cenchoa ssp.* Blunt-headed treesnake (tropical South America and Central America)
*Imantodes gemmistratus** Central American tree snake (Mexico to Colombia)
*Imantodes inornatus** Western tree snake (Honduras to Ecuador)
*Imantodes lentiferus** Amazon Basin tree snake (Ecuador, Colombia, Brazil, Venezuela, French Guyana, Peru, Bolivia)

*Imantodes phantasma** Phantasma tree snake (Panama)
*Imantodes tenuissimus** Yucatán blunthead snake (Mexico)
Genus: *Ithycyphus* (Madagascar)
*Ithycyphus blanci**
*Ithycyphus goudoti** Forest night snake
*Ithycyphus miniatus** Tiny night snake
*Ithycyphus oursi**
*Ithycyphus perineti**
Genus: *Langaha* (Madagascar)
*Langaha alluaudi** Southern leafnose snake
*Langaha madagascariensis**
Langaha nasuta see *L. madagascariensis*
*Langaha pseudoalluaudi**
Genus: *Leimadophis* (Central and South America)
Leimadophis attahuallpae see *Saphenophis atahuallpae*
Leimadophis pygmeus see *Umbrivaga pygmaea*
Leimadophis simonsii see *Philodryas simonsii*
Genus: *Leptodeira*
*Leptodeira annulata** Banded cat-eyed snake (tropical South America)
*Leptodeira bakeri** Baker's cat-eyed snake (Venezuela and Aruba)
Leptodeira frenata ssp.* Rainforest cat-eyed snake (Mexico, Guatemala, Belize)
*Leptodeira maculata** Southwestern cat-eyed snake (Mexico and Panama)
*Leptodeira nigrofasciata** Black-banded cat-eyed snake (Mexico to Panama)
*Leptodeira punctata** Western cat-eyed snake (Mexico)
*Leptodeira rubricata** Costa Rican cat-eyed snake (Costa Rica)
*Leptodeira septentrionalis** Northern cat-eyed snake (N Texas and NE Mexico)
Leptodeira splendida ssp.* Splendid cat-eyed snake (Mexico)
Genus: *Leptophis* (Central and South America)
Leptophis ahaetulla ssp.* Parrot snake
*Leptophis cupreus** Copper parrot snake
*Leptophis depressirostris** Cope's parrot snake
Leptophis diplotropis ssp.* Pacific Coast parrot snake
Leptophis mexicanus ssp.* Mexican parrot snake
*Leptophis modestus** Cloud forest parrot snake
*Leptophis nebulosus** Oliver's parrot snake
*Leptophis riveti** Despax's parrot snake
*Leptophis santamartensis**
*Leptophis stimsoni** Gray lora
Genus: *Liophis* (Central and South America, the Caribbean)
*Liophis albiceps**
Liophis albiventris see *L. epinephelus* ssp.
*Liophis almadensis** Almaden ground snake
*Liophis amarali** Amaral's ground snake
Liophis amazonicus see *L. miliaris* ssp.
*Liophis andinus**
*Liophis angustilineatus**

*Liophis anomalus**
*Liophis atraventer**
Liophis bimaculatus see *L. epinephelus* ssp.
*Liophis boursieri**
Liophis brazili see *L. frenatus*
Liophis breviceps ssp.* Short ground snake
Liophis canaima see *L. breviceps* ssp.
Liophis carajascinsis see *L. carajasensis*
*Liophis carajasensis**
*Liophis ceii**
Liophis chrysostomus see *L. miliaris* ssp.
Liophis cobellus ssp.*
Liophis coralliventris see *L. jaegeri* ssp.
*Liophis cursor** Lacépède's ground snake
*Liophis dilepis** Lema's ground snake
*Liophis elegantissimus**
Liophis epinephelus ssp.*
*Liophis festae** Drab ground snake
*Liophis flavifrenatus** Fronted ground snake
Liophis fraseri see *L. epinephelus* ssp.
*Liophis frenatus**
*Liophis guentheri**
Liophis ingeri see *L. cobellus*
Liophis jaegeri ssp.* Jaeger's ground snake
*Liophis joberti**
*Liophis juliae** Julia's ground snake
*Liophis leucogaster**
*Liophis lineatus** Lined ground snake
*Liophis longiventris** Long ground snake
*Liophis maryellanae** Maryellen's ground snake
*Liophis melanauchen**
*Liophis melanostigma**
*Liophis melanotus** Shaw's black-backed snake
*Liophis meridionalis**
Liophis miliaris ssp.* Military ground snake
Liophis mossoroensis see *L. miliaris* ssp.
*Liophis obtusus**
*Liophis oligolepis**
*Liophis ornatus** Ornate ground snake
*Liophis paucidens** Hoge's ground snake
*Liophis perfuscus** Tan ground snake
Liophis poecilogyrus ssp.*
*Liophis problematicus** Problem ground snake
Liophis pseudocobella see *L. epinephelus* ssp.
Liophis purpurans see *L. miliaris*
Liophis reginae ssp.* Royal ground snake

Liophis sagittifer ssp.* Arrow ground snake
*Liophis steinbachi**
*Liophis subocularis**
*Liophis tachymenoides** syn. *Philodryas tachymenoides*
*Liophis taeniurus** Thin ground snake
*Liophis torrenicolus**
*Liophis triscalis** Three-scaled ground snake
*Liophis tristriatus**
Liophis typhlus ssp.* Blind ground snake
*Liophis vanzolinii**
*Liophis viridis** Crown ground snake
*Liophis vitti**
*Liophis williamsi** Williams' ground snake
Liophis zweifeli see *L. reginae* ssp.
Genus: *Lygophis*
Lygophis coralliventris see *Liophis coralliventris*
Lygophis flavifrenatus see *Liophis flavifrenatus*
Lygophis lineatus see *Liophis lineatus*
Lygophis paucidens see *Liophis paucidens*
Genus: *Macropisthodon*
*Macropisthodon flaviceps** Orangeneck keelback or yellow-headed keelback (Indonesia, Malaysia, Thailand)
Macropisthodon plumbicolor ssp.* Lead keelback (India and Sri Lanka)
*Macropisthodon rhodomelas** Blueneck keelback (Indonesia, Malaysia, Singapore, Thailand)
Macropisthodon rudis ssp.* Red keelback (Taiwan and the neighboring part of China)
Genus: *Macroprotodon*
Macroprotodon cucullatus ssp.* False smooth snake (N Pyrenean Peninsula, across N Africa as far as Israel)
Genus: *Madagascarophis*, Malagasy cat-eyed snakes
*Madagascarophis citrinus** (Madagascar)
*Madagascarophis colubrinus** (Madagascar)
*Madagascarophis meridionalis** (Madagascar)
*Madagascarophis ocellatus** (Madagascar)
Genus: *Malpolon*
*Malpolon moilensis** False cobra or Moila snake (N Africa and Near East)
*Malpolon monspessulanus** Montpellier snake (SE Europe, NE Africa, Pyrenean Peninsula, N Sahara)
-- *M. monsspesulanus insignitus* (Balkans, NE Africa, Middle East)
-- *M. monsspesulanus monsspesulanus* (SW Europe, Greece, NW Africa)
Genus: *Masticophis* (North and Central America and N South America)
*Masticophis anthonyi** Clarion Island whip snake
*Masticophis aurigulus** Baja California striped whip snake
Masticophis bilineatus ssp.* Sonoran whip snake
Masticophis flagellum ssp.* Coach whip
Masticophis lateralis ssp.* California whipsnake

Masticophis lineolatus see *M. bilineatus* ssp.
Masticophis mentovarius ssp.* Neotropical whip snake
*Masticophis pulchericeps**
*Masticophis schotti** Schott's whip snake
Masticophis taeniatus ssp.* Striped whipsnake
Genus: *Myron*
*Myron richardsonii** Richardson's grey mangrove snake (coastal N Australia, New Guinea, and the Aru Archipelago)
Genus: *Oxybelis*, vine snakes
*Oxybelis aeneus** Mexican vine snake (Arizona to N South America)
*Oxybelis acuminatus** (Central and South America)
*Oxybelis argentus (argenteus)** syn. *Xenoxybelis argenteus* (South America - Colombia to Bolivia)
*Oxybelis brevirostris** Cope's vine snake (Honduras to NW South America)
*Oxybelis fulgidus** Amazonian vine snake (N Central America and N South America)
Oxybelis microphthalmu see *O. aeneus*
*Oxybelis wilsoni** (Honduras)
Genus: *Oxyrhopus* (Central and South America, Mexico to Peru)
*Oxyrhopus clathratus** Duméril's false coral snake
*Oxyrhopus doliatus** Bibron's false coral snake
Oxyrhopus fitzingeri ssp.* Fitzinger's false coral snake
*Oxyrhopus formosus** Formosa false coral snake
*Oxyrhopus guibei**
*Oxyrhopus leucomelas** Werner's false coral snake
*Oxyrhopus marcapatae** Boulenger's false coral snake
Oxyrhopus melanogenys ssp.* Tschudi's false coral snake
*Oxyrhopus occipitalis**
Oxyrhopus petola ssp.* Calico false coral snake
Oxyrhopus rhombifer ssp.* Amazon false coral snake
*Oxyrhopus trigeminus** Brazilian false coral snake
*Oxyrhopus venezuelanus**
Genus: *Phalotris*
*Phalotris mertensi** formerly *Elapomorphus mertensi* (Brazil)
*Phalotris nasutus** formerly *Elapomorphus nasutus* (Brazil)
*Phalotris punctatus** formerly *Elapomorphus punctatus* (NE Argentina)
*Phalotris tricolor** (Brazil, Bolivia, Argentina, Uruguay)
Genus: *Philodryas*, green snakes
Philodryas aestiva ssp.* Brazilian green racer (SW Brazil to N Argentina and Uruguay)
*Philodryas arnaldoi** Arnaldo's green racer (Brazil)
*Philodryas baroni** Baron's green racer (Argentina)
*Philodryas bolivianus** (Bolivia)
Philodryas borelli see *P. varius*
Philodryas burmeisteri see *P. trilineata*
Philodryas carbonelli see *P. olfersii*
*Philodryas chamissonis** Chilean green racer (Chile)
*Philodryas cordata** (Venezuela)

*Philodryas elegans** syn. *Alsophis elegans* (Ecuador, Peru, Chile)
*Philodryas hoodensis** Hood racer (the Galapagos and Ecuador)
*Philodryas inca** Tropical green racer (South America)
*Philodryas laticeps** (Bolivia)
*Philodryas latirostris** (Bolivia)
*Philodryas livida** (Brazil)
*Philodryas mattogrossensis** Miranda green racer (SW Brazil, Paraguay, Bolivia)
*Philodryas nattereri** Paraguay green racer (Paraguay, C and W Brazil)
Philodryas olfersii ssp.* Lichtenstein's green racer (Brazil to Argentina and Uruguay)
*Philodryas oligolepis** Gomes' green racer (Brazil)
*Philodryas patagoniensis** Patagonia green racer (Brazil to Argentina and Uruguay)
*Philodryas psammophidea** Günther's green racer (Brazil to Argentina)
*Philodryas pseudoserra** syn. *Tropidodryas striaticeps* (Brazil)
*Philodryas serra** syn. *Tropidodryas serra* (Brazil)
*Philodryas simonsii** (South America)
*Philodryas tachymenoides** Schmidt's green racer (South America)
*Philodryas trilineata** (Argentina, maybe up to Bolivia)
*Philodryas varius** Jan's green racer (Bolivia)
*Philodryas viridissima** Common green racer (N Venezuela to Argentina)

Genus: *Philothamnus*

*Philothamnus angolensis** Western green snake (Cameroon and Congo-Brazzaville to Namibia and S Mozambique)
*Philothamnus battersbyi** Battersby's green snake (NE Africa: Ethiopia to Tanzania)
*Philothamnus bequaerti** Bequaert's green snake (the Central African Republic, Cameroon, Uganda, S Sudan, W Ethiopia, W and N DRC)
*Philothamnus carinatus** Thirteen-scaled green snake (W, C and E Africa: Guinea to Kenya)
*Philothamnus dorsalis** Striped green snake (coastal W Africa, Gabon to Angola)
*Philothamnus girardi** Girard's green snake (the Gulf of Guinea countries)
Philothamnus heterodermus ssp.* Variable green snake (W and C Africa)
*Philothamnus heterolepidotus** Slender green snake (W, C and E Africa)
*Philothamnus hoplogaster** green water snake (E Africa)
*Philothamnus hughesi** Hughes' green snake (W, C and N DRC, Congo-Brazzaville, Cameroon)
*Philothamnus irregularis** Northern green bush snake (E Africa)
*Philothamnus macrops** Usambara green snake (coastal Tanzania)
Philothamnus natalensis ssp.* Natal green snake (SE Africa: Mozambique to the Republic of South Africa - SA)
Philothamnus nitidus ssp.* Green bush snake (W and C Africa: Ghana to Congo-Brazzaville)
*Philothamnus ornatus** Ornate green snake (Angola, Zambia to N Botswana)
*Philothamnus punctatus** Spotted green snake (Mozambique, E Tanzania, Kenya, Somalia, E Ethiopia, N Malawi)
*Philothamnus semivariegatus** Variegated green snake (Sub-Saharan Africa)
*Philothamnus thomensis** (São Tomé)

Genus: *Platyceps*

*Platyceps rhodorhachis** Braid snake or Jan's cliff racer (NE Africa, Near and Middle East to NW India)

Genus: *Psammophis*

*Psammophis aegiptius** (N Africa: SE Algeria to Israel)

*Psammophis angolensis** Dwarf sand snake (Tanzania and Zanzibar)

*Psammophis ansorgii** Link-marked sand racer (Angola)

*Psammophis biseriatus** Two-striped sand racer (NE Africa)

*Psammophys brevirostris** (N, W and S Africa)

Psammophis condanarus ssp.* Sand snake (N India and Burma)

*Psammophis crucifer** Cross-marked or montane grass snake (SE RSA and S Zimbabwe)

Psammophis elegans ssp.* Elegant sand racer (W Africa)

*Psammophis jallae** Jalla's sand snake (N Africa)

Psammophis leightoni ssp.* Cape sand snake (N Africa)

*Psammophis leithii** Pakistan sand racer (Afghanistan, Pakistan and W India)

*Psammophis leopardinus** Leopard grass snake (Angola and Zambia)

*Psammophis lineolatus** syn. *Taphrometopon lineolatum*, Steppe ribbon racer (C Asia to Mongolia and China)

*Psammophis longifrons** Long sand racer (India)

*Psammophis namibensis** Namib sand snake (N Africa))

*Psammophis notosticus** Karoo sand snake Or whip snake (N Africa)

*Psammophys orientalis** Eastern stripe-bellied sand snake (N Africa to Ethiopia and Sudan)

Psammophis phillipsi ssp.* Phillips' sand snake (V, C and W Africa)

*Psammophis pulcher** Boulenger's sand racer (Ethiopia)

Psammophis punctulatus ssp.* Speckled sand racer (NE Africa)

Psammophis rukwae ssp.* Rukwa sand racer (NW Africa)

*Psammophis schokari** Schokari sand racer (N Africa, SW Asia, Pakistan, NW India)

Psammophis sibilans ssp.* Short-snouted grass snake (N, W and S Africa)

Psammophis subteniatus ssp.* Stripe-bellied sand snake (N Africa)

*Psammophis tanganicus** Western link-marked sand racer (NE Africa: from S Libya as far as Tanzania)

*Psammophis trigrammus** Western sand snake (Namibia, Angolan and RSA border regions)

*Psammophys trinasalis** Fork-marked sand snake (N Africa)

*Psammophis zambiensis** (Zambia)

Genus: *Psammophylax*

*Psammophylax rhombeatus** Spotted or Rhombic skaapsteker (N Africa and SW Angola)

*Psammophylax tritaeniatus** Striped skaapsteker (Angola and SE Africa)

Psammophylax variabilis ssp.* Grey-bellied grass snake (E Africa)

Genus: *Pseudoboa* (Central and South America)

*Pseudoboa coronata** Crowned false boa

*Pseudoboa haasi** Paraná false boa

*Pseudoboa neuwiedii** Neuwied's false boa

*Pseudoboa nigra** Black false boa

*Pseudoboa serrana**

Genus: *Ptychophis*

*Ptychophis flavovirgatus** (Brazil)
Genus: *Pythonodispas*
*Pythonodispas carinata** Western keeled snake (Namibia and Angola)
Genus: *Rhabdophis*, keelback snakes
*Rhabdophis adleri*** (Hainan and China)
*Rhabdophis angeli*** (Vietnam)
Rhabdophis auriculata ssp.** (the Philippines)
*Rhabdophis barbouri*** Barbour's water snake (the Philippines)
*Rhabdophis callichroma*** (Vietnam, S China - Hainan)
*Rhabdophis chrysargoides*** (Indonesia)
*Rhabdophis chrysargo*** Speckle-bellied keelback (SE Asia: Burma to the Philippines)
*Rhabdophis conspicillatus*** (Malaysia and Indonesia)
*Rhabdophis himalayanus*** Orange-collared keelback (N India, Nepal, Burma, SW China)
*Rhabdophis leonardi*** Burmese keelback (China and Burma)
*Rhabdophis lineata*** Zigzag-lined water snake (the Philippines)
*Rhabdophis murudensis*** (Malaysia)
*Rhabdophis nigrocincta*** Black-striped keelback (Thailand, Vietnam, China)
*Rhabdophis nuchalis***
-- *R. nuchalis nuchalis* (N Vietnam and China)
-- *R. nuchalis pentasupralabialis* (China and W Sichuan)
*Rhabdophis spilogaster*** Northern water snake (the Philippines)
*Rhabdophis subminiatus*** Red-necked keelback (N China, Hainan, Vietnam, Thailand, Burma, NE India, Sumatra, Java, Borneo)
-- *R. subminiatus helleri* (N China, Hong Kong, Laos, N Thailand)
-- *R. subminiatus subminiatus* (mainland SE Asia, Hainan)
*Rhabdophis swinhonis*** Swinhoe's grass snake (Taiwan)
*Rhabdophis tigrinus,*** Tiger grooved-neck keelback or tiger keelback or Japanese grass snake
-- *R. tigrinus tigrinus* (Japan)
-- *R. tigrinus formosanus* (Taiwan)
-- *R. tigrinus lateralis* (China, Korea, E Russia)
Genus: *Saphenophis* (Central and South America)
*Saphenophis atahuallpae** Atahuallpa saphenophis snake
Genus: *Siphlophis* (Central and South America)
*Siphlophis cervinus** Panama spotted night snake
*Siphlophis compressus** Tropical flat snake
*Siphlophis leucocephalus** Common spotted night snake
*Siphlophis longicaudatus** Brazilian spotted night snake
*Siphlophis pulcher** Guanabara spotted night snake
*Siphlophis worontzowi** Worontzow's spotted night snake
Genus: *Spalerosophis* (N Africa to the Middle East)
*Spalerosophis arenarius**
*Spalerosophis atriceps**
Spalerosophis diademy ssp.*
*Spalerosophis dolichospilus** Mograbin diadem snake

*Spalerosophis josephscotreccii**
*Spalerosophis microlepis**
Genus: *Stenorrhina* (Central and South America, from Mexico as far as Ecuador)
Stenorrhina degenhardtii ssp.* Degenhardt's Scorpion-eating snake
*Stenorrhina freminvillei** Slaty grey snake
Genus: *Tachymenis*
*Tachymenis affinis** Boulenger's slender snake (Peru)
Tachymenis attenuata ssp.* Walker's slender snake (Bolivia and Peru)
*Tachymenis elongata** Depax's slender snake (Peru)
Tachymenis chilensis ssp.* Chilean slender snake (Chile and Argentina)
Tachymenis peruviana ssp.* Peru slender snake (SW Bolivia, Peru, Argentina)
*Tachymenis surinamensis** (Surinam)
*Tachymenis tarmensis** Slender snake (Peru)
Genus: *Tantilla* (North, Central and South America, from the central zones of the USA as far as Argentina)
*Tantilla albiceps** Barbour's centipede snake
*Tantilla alticola** Boulenger's centipede snake
*Tantilla andinista** Andes centipede snake
*Tantilla armillata**
*Tantilla atriceps** Mexican blackhead snake
*Tantilla bairdi** Baird's blackhead snake
*Tantilla bocourti** Bocourt's blackhead snake
*Tantilla boipiranga**
*Tantilla brevicaudata (brevicauda)** Mertens' centipede snake
*Tantilla brevis** syn. *Tantillita canula*
*Tantilla briggsi** Briggs' centipede snake
*Tantilla calamarina** Pacific Coast centipede snake
*Tantilla canula** syn. *Tantillita canula*
*Tantilla capistrata** Capistrata centipede snake
*Tantilla cascadae** Michoacán centipede snake
*Tantilla coronadoi** Guerreran centipede snake
*Tantilla coronata** Southeastern crowned snake
*Tantilla cucullata** Big bend blackhead snake
*Tantilla cuesta** Wilson's centipede snake
*Tantilla cuniculator** Peten centipede snake
*Tantilla deppei** Deppe's centipede snake
*Tantilla deviatrix**
Tantilla eiseni see *T. rubra*
*Tantilla equatoriana** Equator centipede snake
*Tantilla excubitor** syn. *Tantillita brevissima*
*Tantilla flavilineata** Yellow-lined centipede snake
*Tantilla fraseri**
*Tantilla gracilis** Flathead snake
*Tantilla hendersoni** Peten centipede snake
*Tantilla hobartsmithi** Southwestern blackhead snake
*Tantilla impensa**

*Tantilla insulamontana** Mountain centipede snake
*Tantilla jani** Jan's centipede snake
*Tantilla johnsoni**
*Tantilla lempira** Mena's centipede snake
*Tantilla longifrontalis**
*Tantilla melanocephala** Blackhead snake
*Tantilla mexicana**
Tantilla miniata see *T. rubra*
*Tantilla miyatai**
*Tantilla moesta** Blackbelly centipede snake
Tantilla morgana see *T. rubra*
*Tantilla nigra** Black centipede snake
*Tantilla nigriceps** Plains blackhead snake
*Tantilla oaxacae** Oaxacan centipede snake
*Tantilla oolitica** Rim rock crowned snake
*Tantilla petersi** Peters' blackhead snake
*Tantilla planiceps** Western blackhead snake
Tantilla relicta ssp.* Florida crowned snake
*Tantilla reticulata** Reticulate centipede snake
*Tantilla robusta**
*Tantilla rubra** Big bend blackhead snake
*Tantilla schistosa** Red earth centipede snake
*Tantilla semicincta** Ringed centipede snake
*Tantilla sertula**
*Tantilla shawi** Potos' centipede snake
*Tantilla slavensi** Slavens' centipede snake
*Tantilla striata** Striped centipede snake
*Tantilla supracincta** Banded centipede snake
*Tantilla taeniata** Central American centipede snake
*Tantilla tayrae** Volcan Tacana centipede snake
*Tantilla tecta**
*Tantilla trilineata** Brazilian three-lined centipede snake
*Tantilla triseriata** Mexican three-lined centipede snake
*Tantilla tritaeniata** Three-banded centipede snake
*Tantilla vermiformis** Hallowell's centipede snake
Tantilla virgata see *T. reticulata*
*Tantilla vulcani**
*Tantilla wilcoxi** Chihuahuan blackhead snake
*Tantilla yaquia** Yaqui blackhead snake
Genus: *Taphrometopon*
Taphrometopon lineolatum see *Psammophis lineolatus*
Genus: *Tarbophis*
Tarbophis see *Telescopus*
Genus: *Telescopus*
*Telescopus dhara** Arabian tiger snake (Z, C and NE Africa)
Telescopus fallax ssp.* Mediterranean cat snake (Balkans, Syria, Iran, Georgia, Armenia)

Telescopus gabesiensis see *T. obtusus*
*Telescopus gezirae** (E Sudan)
Telescopus guentheri see *T. dhara*
Telescopus guidimakaensis see *T. obtusus*
*Telescopus hoogstraali** (Israel)
*Telescopus iberus** (E Turkey, S Iran, S Russia)
*Telescopus nigriceps** (Jordan and Iraq)
*Telescopus obtusus** (N and NE Africa)
*Telescopus pulcher** (Somalia)
*Telescopus rhinopoma** Indian desert tiger snake (the Middle East)
*Telescopus semiannulatus** Western tiger snake (SE Africa)
Telescopus tessellatus * Soosan tiger snake (Iraq)
*Telescopus variegatus** (W Africa)
Genus: *Thamnodynastes* (South America)
*Thamnodynastes almae**
*Thamnodynastes chaquensis**
*Thamnodynastes chimanta** Roze's coastal house snake
*Thamnodynastes corocoroensis**
*Thamnodynastes duida**
*Thamnodynastes gambotensis**
*Thamnodynastes hypoconia**
*Thamnodynastes longicaudus**
*Thamnodynastes marahuaquensis**
*Thamnodynastes pallidus** Northern coastal house snake
*Thamnodynastes rutilus**
*Thamnodynastes strigatus** Coastal house snake
*Thamnodynastes strigilis**
Genus: *Thamnophis* (North and Central America)
*Thamnophis angustirostris** Longnose garter snake
Thamnophis atratus ssp.* Aquatic garter snake
*Thamnophis brachystoma** Shorthead garter snake
*Thamnophis butleri** Butler's garter snake
*Thamnophis chrysocephalus** Goldenhead garter snake
*Thamnophis couchii** Western Aquatic garter snake (Oregon and California, the USA)
Thamnophis cyrtopsis ssp.* Blackneck garter snake
Thamnophis elegans ssp.* Western terrestrial garter snake
Thamnophis eques ssp.*
*Thamnophis exsul** Montane garter snake
*Thamnophis fulvus** Highland garter snake
*Thamnophis gigas** Giant garter snake
*Thamnophis godmani** Godman's garter snake
*Thamnophis hammondii** Two-striped garter snake
Thamnophis marcianus ssp.* Checkered garter snake
*Thamnophis melanogaster** Blackbelly garter snake
*Thamnophis mendax** Tamaulipan montane garter snake
*Thamnophis ordinoides** Northwestern garter snake

Thamnophis proximus ssp.* Western ribbon snake
Thamnophis radix ssp.* Eastern Plains garter snake
*Thamnophis rossmani** Rossman's garter snake
Thamnophis rufipunctatus ssp.* Narrowhead garter snake
Thamnophis sauritus ssp.* Eastern ribbon snake
*Thamnophis scalaris** Longtail Alpine garter snake
*Thamnophis scaliger** Short-tail Alpine garter snake
Thamnophis sirtalis ssp.* Common garter snake
*Thamnophis sumichrasti** Sumichrast's garter snake
Thamnophis valida ssp.* West Coast garter snake
Thamnophis vicinus viz. T. cyrtopsis
Genus: *Thelotornis, twig snakes*
*Thelotornis capensis*** Bird snake, twig snake or vine snake
-- *T. capensis capensis* (E Botswana and NE RSA)
-- *T. capensis mossambicanus* (Mozambique, as far as S Somalia to the north)
-- *T. capensis oatesi* (Lake Tanganyika, as far as C Angola to the west)
-- *T. capensis schilsi* (Burundi)
*Thelotornis kirtlandii*** Forest twig snake (W and C Equatorial Africa)
*Thelotornis usambaricus*** Usambara vine snake (Tanzania and Kenya)
Genus: Thrasops (Tropical Africa)
*Thrasops aethiopissa** syn. *Rhamnophis aethiopissa* Large-eyed green treesnake or splendid dagger-tooth tree snake
*Thrasops flavigularis** Yellow-throated bold-eyed tree snake
*Thrasops jacksonii** Black tree snake
*Thrasops occidentalis** (Western) Black tree snake
Genus: *Trimorphodon*, lyre snakes (North and Central America)
Trimorphodon biscutatus ssp.* Chihuahuan desert lyre snake
Trimorphodon lyrophanes see *T. biscutatus* ssp.
*Trimorphodon tau** Mexican lyre snake
Trimorphodon vandeburghi see *T. biscutatus* ssp.
*Trimorphodon vilkinsonii** Texas lyre snake
Genus: *Umbrivaga* (Central and South America)
*Umbrivaga pygmaea** Amazon tropical forest snake
Genus: *Waglerophis*
*Waglerophis merremi** Wagler's snake (South America)
Genus: *Xenochrophis*, painted keelbacks (Asia, from Afghanistan as far as Indonesia)
*Xenochrophis asperrimus** Boulenger's keelback
*Xenochrophis bellula**
*Xenochrophis cerasogaster** Painted keelback
Xenochrophis flavipunctatus ssp.* Yellow-spotted keelback
*Xenochrophis maculatus**
*Xenochrophis piscator** Asiatic water snakes
*Xenochrophis punctulatus**
*Xenochrophis sanctijohannis** St. John's keelback
*Xenochrophis trianguligerus** Triangle keelback
*Xenochrophis vittatus** Striped keelback

Genus: *Xenodon* (Central and South America, Mexico to Argentina)
Xenodon bertholdi see *X. rabdocephalus*
*Xenodon guentheri**
*Xenodon neuwiedii** Neuwied's false fer-de-lance
*Xenodon rabdocephalus** False fer-de-lance
*Xenodon severus** Amazon false fer-de-lance
Xenodon suspectus see *X. rabdocephalus*
*Xenodon werneri**
Genus: *Xylodentophis*
*Xyelodontophis ulugurensis*** (Tanzania - the Uluguru mountain range)

7.2. FAMILY: ATRACTASPIDIDAE

7.2.1. Subfamily: *Atractaspidinae*

Genus: *Atractaspis*
*Atractaspis aterriima** Western forest mole viper (W and C Africa)
*Atractaspis battersbyi** Battersby's mole viper (DRC)
*Atractaspis bibronii*** Southern or Bibron's burrowing asp (N Africa)
*Atractaspis boulengeri** Boulenger's mole viper
-- *A. boulengeri boulengeri* Boulenger's mole viper (Gabon)
-- *A. boulengeri matschiensis* (Cameroon)
-- *A. boulengeri mixta* (DRC)
-- *A. boulengeri schmidti* (DRC)
-- *A. boulengeri schultzei* (DRC)
-- *A. boulengeri vanderborghti* (DRC)
*Atractaspis coalescens** Mole viper (Cameroon)
*Atractaspis congica** Eastern Congo burrowing asp
-- *A. congica congica* Eastern Congo burrowing asp (Cameroon, N Angola, DRC)
-- *A. congica leleupi* (DRC)
-- *A. congica orientalis* (DRC and N Zambia)
*Atractaspis corpulenta** Fat mole viper
-- *A. corpulenta corpulenta* Fat mole viper (Cameroon, Gabon, Congo-Brazzaville, DRC)
-- *A. corpulenta kivuenzis* (DRC)
-- *A. corpulenta leucura* (Liberia, Côte d'Ivoire, Ghana)
*Atractaspis dahomeyensis** Bocage's mole viper (SW Africa, Guinea to Cameroon)
*Atractaspis duerdeni** Duerden's or beaked burrowing asp (N Africa)
*Atractaspis engaddensis*** Israeli mole viper (Israel and Sinai)
*Atractaspis engdahli** Engdahl's mole viper (Somalia)
*Atractaspis fallax** False mole viper (Ethiopia, Somalia, Kenya)
*Atractaspis irregularis*** Variable mole viper
-- *A. irregularis angeli* (Eritrea)
-- *A. irregularis bipostocularis* (Kenya, NW Tanzania, Uganda, Rwanda, DRC)

-- *A. irregularis irregularis* Variable mole viper (Guinea and Liberia to Cameroon, Gabon)
-- *A. irregularis parkeri* (W DRC, Cameroon, Congo, N Angola)
-- *A. irregularis uelensis* (DRC, NW Uganda and the neighboring territory of Sudan)
*Atractaspis leucomelas** White mole viper (Ethiopia and Somalia)
*Atractaspis microlepidota*** Small-scaled burrowing asp
-- *A. microlepidota andersonii* (NE Egypt, Israel, SW Arabian Peninsula)
-- *A. microlepidota magrettii* (E Sudan, Ethiopia, Eritrea, N Somalia)
-- *A. microlepidota microlepidota* Small-scaled burrowing asp (Sub-Saharan Africa: the zone from Senegal as far as Somalia)
*Atractaspis micropholis** Sahelian burrowing asp (C to W Africa, Mauritania to Mali)
Atractaspis phillipsi see *A. microlepidota andersonii*
*Atractaspis reticulata** Reticulate mole viper
-- *A. reticulata brieni* (DRC)
-- *A. reticulata heterochilus* (C Africa, Cameroon to DRC)
-- *A. reticulata reticulata* (Cameroon)
*Atractaspis scorteccii** Scortecci's mole viper (Somalia)

7.2.2 Subfamily: *Aparallactinae*

Genus: *Amblyodipsas*, glossy snakes (Sub-Saharan Africa)
*Amblyodipsas concolor** Natal purple-glossed snake (RSA and Swaziland)
*Amblyodipsas dimidiata** Mpwapwa purple-glossed snake (N Tanzania)
*Amblyodipsas katangensis** Katanga purple-glossed snake (DRC and N Zambia)
*Amblyodipsas micropthalma** Eastern purple-glossed snake (RSA and S Mozambique)
*Amblyodipsas polylepis** Common purple-glossed snake (Angola, Namibia, Botswana, DRC, Zambia, Mozambique, Zimbabwe, Malawi, RSA, Tanzania, Kenya)
-- *Amblyodipsas polylepis hildebrandtii** Common purple-glossed snake (sometimes classified as a separate subspecies described from Zanzibar)
*Amblyodipsas rodhaini** (DRC) Rodhain's purple-glossed snake
*Amblyodipsas teitana** (Kenya) Teitana purple-glossed snake
*Amblyodipsas unicolor** Western purple-glossed snake (Senegal to Tanzania)
*Amblyodipsas ventrimaculata** Kalahari purple-glossed snake (Namibia, Botswana, Zimbabwe, Zambia)
Genus: *Aparallactus, centipede eaters* (Sub-Saharan Africa)
*Aparallactus capensis** Cape centipede eater
*Aparallactus guentheri** Black centipede eater
*Aparallactus jacksonii**
*Aparallactus lineatus** Lined centipede-eater
*Aparallactus lunulatus** Reticulated centipede eater
*Aparallactus modestus** Western Forest centipede-eater
*Aparallactus moeruensis** Zaire centipede-eater
*Aparallactus niger**
*Aparallactus nigriceps** Mozambique centipede eater
*Aparallactus turneri** Malindi centipede-eater

*Aparallactus werneri** Usambara centipede-eater
Genus: *Brachyophis*
*Brachyophis revoili** Revoil's Short snake (Kenya and Somalia)
Genus: *Cyanodontophis* see *Polemon*
Genus: *Chilorhinophis*
*Chilorhinophis butleri** Butler's two-headed snake (N Sudan)
*Chilorhinophis carpenteri** Liwale two-headed snake (Mozambique and Tanzania)
*Chilorhinophis gerardi** Gerard's black and yellow burrowing snake (DRC, Zambia, Zimbabwe, Tanzania)
Genus: *Hypoptophis*
*Hypoptophis wilsoni** African bighead snake (C Africa)
Genus: *Homoroselaps* see *Elapidae*
Genus: *Macrelaps*
*Macrelaps microlepidotus*** Natal black snake (N Africa)
Genus: *Micrelaps*
*Micrelaps bicoloratus** Kenya two-headed snake (Kenya and Tanzania)
*Micrelaps boettgeri** Boettger's two-headed snake (NE Africa, Somalia to Kenya)
*Micrelaps muelleri** (Israel)
*Micrelaps vaillanti** Somali two-headed snake (Somalia)
Genus: *Elapocalmus* see *Polemon*
Genus: *Elapotinus* (in parallel listed under *Colubridae*)
*Elapotinus picteti** Jan's snake (tropical Africa)
Genus: *Miodon* see *Polemon*
Genus: *Polemon*, formerly also *Cyanodontophis*, *Elapocalmus*, *Miodon* (W and C Africa)
*Polemon acanthias** Reinhardt's snake-eater
*Polemon barthii** Guinea snake-eater
*Polemon bocourti** Bocourt's snake-eater
*Polemon christyi** Eastern snake-eater
*Polemon collaris** Collared snake-eater
*Polemon fulvicollis** African snake eater
*Polemon gabonensis** Gabon snake-eater
*Polemon gracilis** Graceful snake-eater
*Polemon griseiceps** Cameroon snake-eater
*Polemon leopoldi**
*Polemon neuwiedi** Ivory Coast snake-eater
*Polemon notatus** syn. *P. notatum*
*Polemon robustus** Zaire snake-eater
Genus: *Xenocalamus* (C and S Africa)
*Xenocalamus bicolor** Slender quill-snouted snake
*Xenocalamus mechowii** Elongate quill-Snouted snake
-- *X. mechowii inornatus*
-- *X. mechowii mechowii*
*Xenocalamus michelli** Michell's quill-snouted snake
*Xenocalamus sabiensis** Sabi quill-snouted snake
*Xenocalamus transvaalensis** Transvaal quill-snouted snake

7.3. FAMILY: *ELAPIDAE*, ELAPIDS

7.3.1. Subfamily: *Elapinae*

Genus: *Aspidelaps*, shield-nosed cobras
*Aspidelaps lubricus** South African coral snake (N Africa)
-- *A. lubricus cowlesi* (SW Angola and NW Namibia)
-- *A. lubricus infuscatus* (C Namibia)
-- *A. lubricus lubricus* South African coral snake (RSA and S Namibia)
*Aspidelaps scutatus** Intermediate shield-nose snake (N Africa)
-- *A. scutatus intermedius* (RSA)
-- *A. scutatus fulafula* (SE Zimbabwe and S Mozambique)
-- *A. scutatus scutatus*, syn. *A. scutatus bachrani* Intermediate shield-nose snake (RSA, Botswana, SW Zimbabwe, Namibia)
Genus: *Boulengerina*, water cobras
*Boulengerina annulata**** Ringed water cobra
-- *B. annulata annulata* (E Cameroon, Gabon, DRC, Congo-Brazzaville)
-- *B. annulata stormsi* (sides of the Lake Tanganyika)
*Boulengerina christyi**** Christy's water cobra (N Congo-Brazzaville, W DRC, probably inc. NW Angola)
Genus: *Bungarus*, kraits
*Bungarus andamanensis**** South Andaman krait (the Andaman Islands)
*Bungarus bungaroides**** Northeastern Hill krait (India and N Burma)
*Bungarus caeruleus**** Indian krait (Indian subcontinent and Sri Lanka)
*Bungarus candidus**** Blue krait (Vietnam, Malaysia, Sumatra, Java, Bali, Celebes)
*Bungarus ceylonicus**** Ceylon krait (Sri Lanka)
*Bungarus fasciatus**** Banded krait (N India, Indonesia, SE Asia)
*Bungarus flaviceps**** Red-headed krait (mainland SE Asia, Malaysia, Indonesia)
-- *B. flaviceps baluensis* (Borneo)
-- *B. flaviceps flaviceps* (N Thailand, S Burma, S Cambodia, Vietnam, Malaysia, Indonesia)
Bungarus javanicus see *B. candidus*
*Bungarus lividus**** Lesser black krait (India)
*Bungarus magnimaculatus**** Burmese krait (N Burma)
*Bungarus multicinctus**** Many-banded krait (Burma, S China, Taiwan)
-- *B. multicinctus multicinctus* (N China, Taiwan, Hainan, Hong Kong)
-- *B. multicinctus wanghaotingi* (Burma, NW Laos, SW China, N Vietnam)
*Bungarus niger**** Greater black krait (E Himalayas and Assam)
*Bungarus sindanus**** Sind krait
-- *B. sindanus razai* (E Afghanistan and NW Pakistan)
-- *B. sindanus sindanus* (N Pakistan and the neighboring part of W India)
-- *B. sindanus walli* (India)
Bungarus walli see *Bungarus sindanus walli*
Genus: *Calliophis*, Oriental coral snakes or Asian coral snakes
*Caliophis beddomei** (SW India)

*Calliophis bibroni** Bibron's coral snake (India)
*Calliophis bivirgata**** Blue Malaysian coral snake
-- *C. bivirgatus bivirgatus* (Java)
-- *C. bivirgatus flaviceps* (Burma, Thailand, Cambodia, Malayan Peninsula, Singapore, Indonesia)
-- *C. bivirgatus tetrataenia* (Borneo)
*Calliophis calligaster** syn. *Hemibungarus calligaster*
-- *C. calligaster calligaster* (the Philippines, Luzon and Mindoro islands)
-- *C. calligaster gemiannulis* (the Philippines, Cebu, Negros, Panay and Masbate islands)
-- *C. calligaster mcclungi* (Polillo Island near the Philippines)
*Calliophis gracilis** Spotted coral snake (Malaysia, Sumatra, Singapore)
*Calliophis intestinalis** Banded Malaysian coral snake
-- *C. intestinalis bilineata* (the Philippines)
-- *C. intestinalis everetti* (Borneo - Sabah)
-- *C. intestinalis intestinalis* (Indonesia)
-- *C. intestinalis lineata*, syn. *C. nigrotaeniata, C. sumatrana* (N Thailand, Malayan Peninsula, Indonesia)
-- *C. intestinalis philippina* (the Philippines)
-- *C. intestinalis suluensis* (the Philippines)
-- *C. intestinalis thepassi* (Borneo and E Malaysia)
*Calliophis japonicus** see *Hemibungarus japonicus* Japanese coral snake
*Calliophis kellogi** syn. *Sinomicrurus kelloggi*, see *Hemibungarus kellogi*
*Calliophis macclellandi*** Macclelland's coral snake, syn. *Sinomicrurus macclellandi*
-- *C. macclellandi macclellandi* (India, N Burma, S China, Vietnam, Thailand, Hainan)
-- *C. macclellandi iwasakii* (Japan)
-- *C. macclellandi swinhoei* (Taiwan)
-- *C. macclellandi univirgatus* (Nepal and India)
*Calliophis maculiceps** Small-spotted coral snake
-- *C. maculiceps atrofrontalis* (N Vietnam and Cambodia)
-- *C. maculiceps hughi* (Thailand)
-- *C. maculiceps maculiceps* Small-spotted coral snake (N Burma, S Thailand, N Malayan Peninsula)
-- *C. maculiceps michaelis* (C and S Laos)
-- *C. maculiceps smithi* (C Thailand)
*Calliophis melanurus** Indian coral snake
-- *C. melanurus melanurus* (N and E India)
-- *C. melanurus sinhaleyus* (Sri Lanka)
*Calliophis nigrescens** Black coral snake (N and W India)
Calliophis sauteri see *Hemibungarus japonicus sauteri*
Genus: *Dendroaspis*, mambas
*Dendroaspis angusticeps**** Eastern green mamba (Tanzania, Mozambique, RSA)
*Dendroaspis jamesoni**** Jameson's mamba (W and C Equatorial Africa)
-- *D. jamesoni jamesoni* (Ghana to Central African Republic, Congo-Brazzaville, E DRC, Angola)
-- *D. jamesoni kaimosae* (E DRC, Rwanda, Uganda, W Kenya)
*Dendroaspis polylepis**** Black mamba (C Africa)

*Dendroaspis viridis**** Western green mamba (W Africa, São Tomé, probably S Senegal and Togo)

Genus: *Elapsoidea*, venomous or African garter snakes

Elapsoidea boulengeri see *E. semiannulata boulengeri*

*Elapsoidea broadleyi** (N Somalia)

*Elapsoidea chelazzii** Somali garter snake syn. *E. chelazziorum* (a type locality near Afgoi, S Somalia)

*Elapsoidea guentherii** (N Congo-Brazzaville, S DRC, N and C Angola, C Zambia, N and C Zimbabwe)

*Elapsoidea laticincta** Werner's garter snake (N Sudan, Central African Republic, N Uganda, N DRC to SW Ethiopia)

*Elapsoidea loveridgei** Loveridge's garter snake

-- *E. loveridgei colleti* (E DRC, SW Uganda, Rwanda, Burundi)

-- *E. loveridgei loveridgei* (C and S Kenya, N Tanzania)

-- *E. loveridgei multicincta* (NE DRC, Uganda, W Kenya, NW Tanzania, S Ethiopia)

-- *E. loveridgei scalaris* see *E. guentherii*

*Elapsoidea nigra** Black garter snake (NE Tanzania)

*Elapsoidea semiannulata** Angolan garter snake

-- *E. semiannulata boulengeri* Boulenger's garter snake (N Tanzania to RSA)

-- *E. semiannulata moebiusi* (N Mauritania, Senegal to Central African Republic, Cameroon, Congo-Brazzaville, DRC)

-- *E. semiannulata semiannulata* (Angola, SW DRC, NW RSA, W Zambia to N Namibia)

*Elapsoidea sundevalli*** Sundevall's garter snake or African garter snake

-- *E. sundevalli decosteri* (N Mozambique and NE RSA)

-- *E. sundevalli fitzsimonsi* (W Botswana, Namibia and the neighboring territory of RSA)

-- *E. sundevalli longicauda* (SE Zimbabwe, S Mozambique, RSA)

-- *E. sundevalli media* (RSA)

-- *E. sundevalli sundevalli* (RSA and Swaziland)

*Elapsoidea trapei** (Senegal)

Genus: *Hemachatus*, cobra

*Hemachatus haemachatus**** Rinkhals, ring-necked spitting cobra, or ringhals (N Africa)

Genus: *Hemibungarus*, Asian or oriental coral snakes

Hemibungarus calligaster see *Calliophis calligaster*

*Hemibungarus hatori** syn. *Sinomicrurus hatori* (NE Taiwan)

*Hemibungarus japonicus**, syn. *Sinomicrurus japonicus*, Japanese coral snake, see *Calliophis japonicus*

-- *H. japonicus boettgeri* (Japan)

-- *H. japonicus japonicus* (Japan)

-- *H. japonicus sauteri* see *H. sauteri*

-- *H. japonicus takarai* (Okinawa)

*Hemibungarus kelloggi** Kellogg's coral snake (N China)

Hemibungarus macclellandi see *Calliophis macclellandi*

*Hemibungarus sauteri** syn. *Sinomicrurus sauteri* (Taiwan)

Genus: *Homoroselaps*

*Homoroselaps dorsalis** Striped harlequin snake or striped dwarf garter snake (NE RSA and W Swaziland)
*Homoroselaps lacteus** Spotted harlequin snake (N RSA)
Genus: *Leptomicrurus* (sometimes included in *Micrurus* genus synonyms)
*Leptomicrurus collaris*** Guyana blackback coral snake
-- *L. collaris breviventris* (Venezuela and Guyana)
-- *L. collaris collaris* (SE Venezuela to French Guyana and the neighboring territory of Brazil)
*Leptomicrurus narduccii*** Andean blackback coral snake
-- *L. narduccii melanotus* (Colombia, Ecuador, Peru, Brazil)
-- *L. narduccii narduccii* (Bolivia)
*Leptomicrurus renjifoi*** (E Colombia)
*Leptomicrurus scutiventris*** (the border region of SE Colombia, S Venezuela, NW Brazil and NE Peru)
Genus: *Maticora*
*Maticora beddomei** see *Calliophis beddomei*
*Maticora bivirgatus**** see *Calliophis bivirgatus*
*Maticora intestinalis** see *Calliophis intestinalis*
*Maticora maculiceps** see *Calliophis maculiceps*
*Maticora nigrescens** see *Calliophis nigriscens*
Genus: *Micruroides*
*Micruroides euryxanthus*** Western coral snake
-- *M. euryxanthus australis* (Mexico)
-- *M. euryxanthus euryxanthus* (the USA, N Mexico, Tiburón)
-- *M. euryxanthus neglectus* (Mexico)
Genus: *Micrurus*, coral snake
*Micrurus albicinctus*** (NW Brazil)
*Micrurus alleni*** Allen's coral snake (E Nicaragua, Costa Rica to W Panama)
*Micrurus altirostris*** (Uruguay, NE Argentina, S Brazil)
*Micrurus ancoralis*** Regal coral snake
-- *M. ancoralis ancoralis* (SW Colombia and NW Ecuador)
-- *M. ancoralis jani* (E Panama and Colombia - the Pacific part)
*Micrurus annellatus*** Annellated coral snake
-- *M. annellatus annellatus* (SE Ecuador, C and SE Peru)
-- *M. annellatus balzani* (Peru and W Bolivia)
-- *M. annellatus bolivianus* (C Bolivia)
*Micrurus averyi*** Black-headed coral snake (N Guyana, Brazil - the Manaus territory)
*Micrurus baliocoryphus*** (NE Argentina, between the Paraná and Uruguay rivers)
*Micrurus bernardi*** (Mexico)
*Micrurus bocourti*** Ecuadorian coral snake (coastal Ecuador, probably inc. the neighboring territory of NW Peru)
*Micrurus bogerti*** Bogert's coral snake (Mexico)
*Micrurus brasiliensis*** (Brazil)
*Micrurus browni*** Brown's coral snake (N Mexico)
-- *M. browni browni* (N Mexico to W Guatemala mountains)
-- *M. browni importunus* (Guatemala)

-- *M. browni taylori* (Mexico)
*Micrurus catamayensis*** Catamayo coral snake (Ecuador)
*Micrurus circinalis*** (Trinidad and Gaspareé islands, NE Venezuela)
*Micrurus clarki*** Clark's coral snake (N Costa Rica, Panama to W coast of Colombia)
*Micrurus corallinus*** Painted coral snake (N Brazil, N Argentina, S Paraguay)
*Micrurus decoratus*** Brazilian coral snake (SE Brazil)
*Micrurus diana*** (E Bolivia)
*Micrurus diastema*** Variable coral snake
-- *M. diastema affinis* (N Mexico)
-- *M. diastema aglaeope* (NW Honduras)
-- *M. diastema alienus* (N Mexico - N Yucatán)
-- *M. diastema apiatus* (N Mexico and Guatemala)
-- *M. diastema bernadi* see *M. bernardi*
-- *M. diastema diastema* (N Mexico, Belize, N and C Guatemala, NW Honduras)
-- *M. diastema macdougalli* (N Mexico)
-- *M. diastema sapperi* (N Mexico, W Guatemala, Belize)
*Micrurus dissoleucus*** Pygmy coral snake
-- *M. dissoleucus dissoleucus* (NE Colombia and Venezuela)
-- *M. dissoleucus dunni* (Panama Canal as far as NW Colombia)
-- *M. dissoleucus melanogenys* (NE Colombia)
-- *M. dissoleucus meridensis* see *M. meridensis*
-- *M. dissoleucus nigrirostris* (N Colombia)
*Micrurus distans*** West Mexican coral snake
-- *M. distans distans* (Mexico)
-- *M. distans michoacanensis* (Mexico)
-- *M. distans oliveri* (Mexico)
-- *M. distans zweifeli* (Mexico)
*Micrurus dumerilii***
-- *M. dumerilii antoquiensis* (Colombia)
-- *M. dumerilii carinicauda* (Colombia to NW Venezuela)
-- *M. dumerilii colombianus* (NE Colombia)
-- *M. dumerilii dumerili* (Colombia)
-- *M. dumerilii transandinus* (N Panama and W Colombia)
-- *M. dumerilii venezuelensis* (N Venezuela)
*Micrurus elegans*** Elegant coral snake
-- *M. elegans elegans* (Mexico)
-- *M. elegans veraepacis* (Mexico and Guatemala)
*Micrurus ephippifer*** Oaxacan coral snake
-- *M. ephippifer ephippifer* (Mexico - Oaxaca, the Pacific part)
-- *M. ephippifer zapotecus* (Mexico - Oaxaca)
*Micrurus filiformis*** Slender coral snake
-- *M. filiformis filiformis* (Brazil)
-- *M. filiformis subtilis* (N and SE Colombia, E Ecuador, N Peru, W Brazil as far as Manaus)
*Micrurus frontalis**** Southern coral snake
-- *M. frontalis altirostris* see *M. altirostris*

-- *M. frontalis baliocoryphus* see *M. baliocoryphus*
-- *M. frontalis brasiliensis* see *M. brasiliensis*
-- *M. frontalis diana* see *M. diana*
-- *M. frontalis frontalis* (N Brazil, S Paraguay and the neighboring areas of NE Argentina)
-- *M. frontalis multicinctus* see *M. altirostris*
-- *M. frontalis pyrhocryptus* see *M. pyrhocryptus pyrhocryptus*
-- *M. frontalis tricolor* see *M. pyrhocryptus tricolor*
Micrurus frontifasciatus, Bolivian coral snake see *M. lemniscatus*
*Micrurus fulvius*** Eastern coral snake
-- *M. fulvius fitzingeri* see *M. tener fitzingeri*
-- *M. fulvius fulvius* (SE USA)
-- *M. fulvius maculatus* see *M. tener maculatus*
-- *M. fulvius microgalbineus* see *M. tener microgalbineus*
-- *M. fulvius tener* see *M. tener tener*
*Micrurus hemprichii*** Hemprich's coral snake
-- *M. hemprichii hemprichii* (E Colombia, S Venezuela to French Guyana and the neighboring territories of NE Brazil)
-- *M. hemprichii ortoni* (Colombia, Ecuador, N Peru and the neighboring territory of Brazil as far as NE Bolivia)
-- *M. hemprichii rondonianus* (a type locality - Usina hidroelectrica Samuel, a water power plant, the State of Rondonia, W Brazil)
*Micrurus hippocrepis*** Mayan coral snake (N Belize and E Guatemala)
*Micrurus ibiboboca*** Caatinga coral snake (E Brazil, N Surinam, N French Guyana)
*Micrurus isozonus*** Venezuela coral snake (NE Colombia, N and C Venezuela)
*Micrurus langsdorffi*** Langsdorff's coral snake
-- *M. langsdorffi langsdorffi* (N Colombia, E Ecuador, N Peru, Colombia)
-- *M. langsdorffi ornatissimus* see *M. ornatissimus*
*Micrurus laticollaris*** Balsan coral snake
-- *M. laticollaris laticollaris* (N Mexico - the Balsas River valley)
-- *M. laticollaris maculirostris* (N Mexico - the states of Colima and Jalisco)
*Micrurus latifasciatus*** Broad-ringed coral snake (N Mexico and SE Guatemala)
*Micrurus lemniscatus**** South American coral snake
-- *M. lemniscatus carvalhoi* (NE and C Brazil)
-- *M. lemniscatus diutius* (E and SE Venezuela, Trinidad, C and S Guyana, Surinam, French Guyana)
-- *M. lemniscatus helleri* (N Colombia, S Venezuela, NW Brazil, Bolivia)
-- *M. lemniscatus lemniscatus* (NE Brazil, N Guyana, Surinam)
*Micrurus limbatus*** Tuxtlan coral snake
-- *M. limbatus limbatus* (the northern coast of the Mexican state of Veracruz)
-- *limbatus spilosomus* (Mexico - S Veracruz)
*Micrurus margaritiferus*** Speckled coral snake (Peru)
*Micrurus medemi*** (C Colombia)
*Micrurus meridensis*** (Venezuela)
*Micrurus mertensi*** Mertens' coral snake (SW Ecuador and W Peru)
*Micrurus mipartitus*** Redtail coral snake

-- *M. mipartitus anomalus* (E Colombia, the neighboring part of NW Venezuela)
-- *M. mipartitus decussatus* (W and C Colombian Andes, W Ecuador)
-- *M. mipartitus mipartitus* (E Panama and W Colombia)
-- *M. mipartitus popayanensis* (Colombia - the Popayan and Cauca regions)
-- *M. mipartitus semipartitus* see *M. mipartitus rozei*
-- *M. mipartitus rozei* (N Venezuela)
*Micrurus multifasciatus*** Many-banded coral snake
-- *M. multifasciatus hertwigi* (N Nicaragua to W Panama)
-- *M. multifasciatus multifasciatus* (C Panama)
*Micrurus multiscutatus*** Cauca coral snake (Colombia)
*Micrurus nebularis*** Cloud forest coral snake (Mexico)
*Micrurus nigrocinctus*** Central American coral snake
-- *M. nigrocinctus babaspul* (Nicaragua)
-- *M. nigrocinctus coibensis* (Panama)
-- *M. nigrocinctus divaricatus* (N and C Honduras to C Belize)
-- *M. nigrocinctus mosquitensis* (Costa Rica and NW Panama)
-- *M. nigrocinctus nigrocinctus* (W Nicaragua, W Costa Rica, Panama)
-- *M. nigrocinctus ruatanus* see *M. ruatanus*
-- *M. nigrocinctus zunilensis* (N Mexico, Guatemala, Salvador, S Honduras)
*Micrurus oligoannelatus*** (Colombia - Cauca region)
*Micrurus ornatissimus*** (N Colombia, E Ecuador, N Peru, NW Brazil)
*Micrurus pachecogili*** (C Mexico)
*Micrurus paraensis*** (NE and C Brazil)
*Micrurus ornatissimus*** (N Colombia, E Ecuador, N Peru, NW Brazil)
*Micrurus peruvianus*** Peruvian coral snake (Peru)
*Micrurus petersi*** Peters' coral snake (Ecuador)
*Micrurus proximans*** Nayarit coral snake (Mexico)
*Micrurus psyches*** Carib coral snake
-- *M. psyches circinalis* see *M. circinalis*
-- *M. psyches donosoi* see *M. paraensis*
-- *M. psyches medemi* see *M. medemi*
-- *M. psyches paraensis* see *M. paraensis*
-- *M. psyches psyches* (SE Colombia to French Guyana)
-- *M. psyches remotus* see *M. remotus*
*Micrurus putumayensis*** Putumayo coral snake (SE Colombia, NE Peru, NW Brazil)
*Micrurus pyrhocryptus***
-- *M. pyrhocryptus pyrhocryptus* (Brazil, W and SW Bolivia, the neighboring part of Paraguay, N Argentina)
-- *M. pyrhocryptus tricolor* (Brazil and E Paraguay)
*Mircurus remotus*** (the border regions of Venezuela, Brazil, and Colombia)
Micrurus rondonianus see *M. hemprichii rondonianus*
*Micrurus ruatanus*** Roatan coral snake (Honduras)
*Micrurus sangilensis*** Santander coral snake (N Colombia)
*Micrurus serranus*** (Bolivia)
*Micrurus spixii*** Amazon coral snake
-- *M. spixii martiusi* (E Brazil)

-- *M. spixii obscurus* (E Colombia, E Ecuador, E Peru, S Venezuela, NW Brazil to Bolivia)
-- *M. spixii princeps* (NW and C Bolivia)
-- *M. spixii spixii* (Brazil)
*Micrurus spurrelli*** (W and C Colombia)
*Micrurus steindachneri*** Steindachner's coral snake
-- *M. steindachneri orcesi* (C Ecuador)
-- *M. steindachneri steindachneri* (SE Ecuador)
*Micrurus stewarti*** Panamanian coral snake (Panama)
*Micrurus stuarti*** Stuart's coral snake (SW Guatemala)
*Micrurus surinamensis**** Aquatic coral snake
-- *M. surinamensis nattereri* (E Colombia, S Venezuela, Brazil)
-- *M. surinamensis surinamensis* (Colombia to French Guyana, Brazil - Amazon Basin, Bolivia)
*Micrurus tener*** Texas coral snake
-- *M. tener tener* (the USA - SW Arkansas to S Texas, Mexico - N Coahuila, Nuevo León, Tamaulipas)
-- *M. tener fitzingeri* (the Mexican State of Guanajuato to the State of Morelos, probably inc. Zacatecas)
-- *M. tener maculatus* (Mexico - the State of Tamaulipas)
-- *M. tener microgalbineus* (Mexico - S Tamaulipas to C Guanujato)
*Micrurus tschudii*** Desert coral snake
-- *M. tschudii olssoni* (SW Ecuador and NW Peru)
-- *M. tschudii tschudii* (the Pacific part of the Andes in Peru)
Genus: *Naja*, cobras
*Naja anchietae**** Anchieta's cobra (N Angola, S DRC, N and C Namibia, N Botswana, W Zambia, NW Zimbabwe)
*Naja annulifera**** Snouted cobra
-- *N. annulifera anchietae* see *N. anchietae*
-- *N. annulifera annulifera* (N Zambia, Malawi, Mozambique, Zimbabwe, E Botswana)
*Naja atra**** Chinese cobra (N China, Taiwan, Mainland Southeast Asia)
*Naja haje**** Egyptian cobra
-- *N. haje arabica* (SW Saudi Arabia, Yemen, SW Oman)
-- *N. haje legionis* (SE Morocco, NW Western Sahara to N Algeria)
-- *N. haje haje* Egyptian cobra (C Tunisia, N Libya to Egypt, the southern edge of Sahara to Ethiopia to the north, NE DRC, Uganda, Kenya)
*Naja kaouthia**** Monocellate cobra (Bengal, Nepal, E Himalayas, SW China)
*Naja katiensis**** Katian spitting cobra (W Africa)
*Naja mandalayensis**** (Burma)
*Naja melanoleuca**** Black and white cobra (African forests and savannahs)
*Naja mossambica**** Mozambique spitting cobra (SE Tanzania, S Zambia, Malawi, Mozambique to RSA, SE Angola)
*Naja naja**** Indian cobra (E Pakistan, S Nepal, India, Sri Lanka, W Bangladesh)
*Naja nigricollis**** Black-necked spitting cobra
-- *N. nigricollis nigricincta* (N Namibia and SW Angola)
-- *N. nigricollis nigricollis* (Senegal, S Mauritania to S Sudan, Ethiopia, Angola, Malawi)

-- *N. nigricollis woodi* (RSA, Namibia)
*Naja nivea**** Cape cobra (RSA and SW Africa)
*Naja nubiae**** Nubian spitting cobra (Egypt, Sudan, Chad, Niger, Eritrea)
*Naja oxiana**** Central Asian cobra (the Southern Caucasus to Afghanistan and Kashmir)
*Naja pallida**** African cobra or red spitting cobra (N Egypt, NE Sudan, Ethiopia, Eritrea, Somalia, Kenya, NE Tanzania)
*Naja philippinensis**** Philippine cobra (the Philippines)
*Naja sagittifera**** (Andaman)
*Naja samarensis**** Peters' cobra (the Philippines)
*Naja siamensis**** Indochinese spitting cobra (E Burma, Thailand, W Laos, Cambodia, S Vietnam)
*Naja sputatrix**** Indonesian cobra (Malaysia; Java, Bali, Sumbawa, Flores, Komodo and Sulawesi islands)
*Naja sumatrana**** Equatorial spitting cobra or golden spitting cobra (N Thailand, Malaysia, Singapore, Indonesia to the Philippines)
Genus: *Ophiophagus*
*Ophiophagus hannah**** King cobra (SE and S Asia)
Genus: *Paranaja*
*Paranaja multifasciata*** Many-banded snake
-- *P. multifasciata anomala* (E Cameroon)
-- *P. multifasciata duttoni* (DRC)
-- *P. multifasciata multifasciata* (N DRC and Congo-Brazzaville)
Genus: *Pseudohaje*
*Pseudohaje goldii*** African tree cobra, Gold's forest cobra, Goldie's false cobra, or tree cobra (Africa from Nigeria as far as Uganda)
*Pseudohaje nigra*** Hoodless cobra (Sierra Leone, Liberia, Ghana, Togo)
Genus: *Walterinnesia*
*Walterinnesia aegyptia*** Desert cobra (Egypt, Israel, Syria, Iraq, Iran, Lebanon, Jordan)

7.3.2. Subfamily: *Hydrophiinae*

7.3.2.1. Terrestrial Species (Formerly: Oxyuraninae Subfamily)

Genus: *Acanthophis*, death adders
*Acanthophis antarcticus**** Common death adder (Australia and New Guinea)
-- *A. antarcticus antarcticus* Common death adder
-- *A. antarcticus cliffrosswelingtoni*
-- *A. antarcticus schistos*
Acanthophis barnetti see *A. laevis*
Acanthophis crotalusei see *A. laevis*
Acanthophis cummingi see *A. hawkei*
Acanthophis groenveldi see *A. laevis*
*Acanthophis hawkei**** (N Australia)
*Acanthophis laevis**** (New Guinea, Indonesia - Seram and Tanimbar islands)
Acanthophis macgregori see *A. laevis*

*Acanthophis praelongus**** Northern death adder (N Australia, New Guinea, Torres Strait Islands, Seram Island and Tanimbar Islands to the west)
*Acanthophis pyrrhus**** Desert death adder (C and W Australia)
*Acanthophis rugosus**** (N Australia and Irian Jaya, Indonesia)
*Acanthophis wellsi**** (Pilbara, Australia)
Genus: *Aspidomorphus*
Aspidomorphus diadema see *Furina diadema*
Aspidomorphus lineaticollis * Striped crown snake (NE Papua-New Guinea)
Aspidomorphus muelleri * Müller's crown snake (New Guinea as far as Misool, Salawati and Seram islands to the west, and New Britain as well as New Ireland islands to the east)
-- *A. muelleri muelleri* Müller's crown snake (New Guinea)
-- *A. muelleri interruptus* (New Britain, Duke of York and New Ireland islands)
Aspidomorphus schlegeli * Schlegel's crown snake (E Indonesia and NW Papua-New Guinea)
Genus: *Austrelaps*, copperheads or Australian copperheads
*Austrelaps labialis*** Pygmy copperhead (N Australia)
*Austrelaps ramsayi*** Highlands copperhead (Australian mountain ranges from E Victoria as far as New South Wales)
*Austrelaps superbus*** Australian copperhead (SE Australia, Tasmania and Bass Straits Islands)
Genus: *Cacophis*, dwarf-crowned snakes
*Cacophis churchilli** (Australia)
*Cacophis harriettae** White-crowned snake (Australia)
*Cacophis krefftii** Krefft's dwarf snake (Australia)
*Cacophis squamulosus** (Australia)
Genus: *Demansia*
Demansia atra see *D. vestigiata*
*Demansia calodera** Black-necked whipsnake (W Australia, S Papua-New Guinea)
*Demansia olivacea*** Marble-headed whip snake (N and NW Australia)
*Demansia papuensis*** Papuan whip snake
-- *D. papuensis melanea* (N Australia)
-- *D. papuensis papuensis* (SE Irian Jaya and NE Australia)
*Demansia psammophis*** Yellow-faced whip snake
-- *D. psammophis cupreiceps* (W Australia)
-- *D. psammophis psammophis* (SE to E Australia)
-- *D. psammophis reticulata* (coastal W Australia)
*Demansia rufescens** (W Australia)
*Demansia simplex** Grey whipsnake (W Australia)
*Demansia torquata** Collared whip snake (Australia)
*Demansia vestigiata*** Black whip snake (N Indonesian New Guinea)
Demansia textilis see *Pseudonaja textilis*
Genus: *Denisonia*
*Denisonia devisi*** De Vis's banded snake (Australia)
*Denisonia maculata*** Ornamental snake (Australia)
Denisonia superba see *Austrelaps superbus*

Denisonia gouldii see *Suta gouldii*
Genus: *Drysdalia*, crowned snakes
Drysdalia coronata see *Elapognathus coronata*
*Drysdalia coronoides** White-lipped snake (SE Australia, Tasmania and Bass Straits Islands)
*Drysdalia mastersii** Masters' snake (SE coast of W Australia, coastal S Australia)
*Drysdalia rhodogaster** Mustard-bellied snake (Australia)
Genus: *Echiopsis*
Echopsis atriceps see *Paroplocephalus atriceps*
*Echiopsis curta*** Bardick snake (southern W Australia, coastal S Australia, SW New South Wales, NW Victoria and the neighboring part of S Australia)
Genus: *Elapognathus*
*Elapognathus coronata** Crowned snake (SW part of West Australia and the neighboring islets)
*Elapognathus minor** Short-nosed snake or little brown snake (SW Australia)
Genus: *Furina*
*Furina barnardi** Yellow-naped snake (NW Australia)
*Furina diadema** Red-naped snake (W Australia)
*Furina dunmalli** Dunmall's snake (W Australia)
*Furina ornata** Orange-naped snake (Australia)
*Furina tristis** Brown-headed or grey-naped snake (N and NE Australia, Papua-New Guinea)
Genus: *Glyphodon*
Glyphodon tristis see *Furina tristis*
Glyphodon barnardi see *Furina barnardi*
Glyphodon harriettae see *Cacophis harriettae*
Genus: *Hemiaspis*
*Hemiaspis damelii*** Grey snake (inland SE Australia as far as the eastern coast)
*Hemiaspis signata*** Marsh snake, swamp snake, or black-bellied swamp snake (coastal E Australia)
Genus: *Hoplocephalus*
*Hoplocephalus bitorquatus*** Pale-headed snake (Australia)
*Hoplocephalus bungaroides*** Broad-headed snake (Australia)
*Hoplocephalus stephensii*** Stephens's banded snake (Australia)
Genus: *Loveridgelaps*
*Loveridgelaps elapoides*** Solomon's small-eyed snake (the Solomon Islands)
Genus: *Micropechis*
*Micropechis ikaheka**** New Guinea small-eyed or Ikaheka snake
-- *M. ikaheka ikaheka* (New Guinea and the neighboring islands)
-- *M. ikaheka fasciatus* (Aru Archipelago)
Genus: *Notechis*, tiger snakes
*Notechis ater**** Black tiger snake
-- *N. ater ater* (SE part of S Australia)
-- *N. ater humpreysi* (Tasmania and the neighboring islands)
-- *N. ater niger* (Spencer Gulf islands)
-- *N. ater occidentalis* see *N. scutatus occidentalis*

-- *N. ater serventyi* (Chappel and Badger islands, Bass Strait islets)
*Notechis scutatus**** Mainland tiger snake (SE Australia)
-- *N. scutatus occidentalis* (SW part of W Australia and the neighboring islets)
Genus: *Ogmodon*
*Ogmodon vitianus** Fiji cobra (Fiji)
Genus: *Oxyuranus*, taipans
*Oxyuranus microlepidotus**** Fierce snake or inland taipan (inland Australia, border of Victoria and New South Wales)
*Oxyuranus scutellatus**** Coastal taipan
-- *O. scutellatus canni* Papuan taipan (N coast of Papua-New Guinea)
-- *O. scutellatus scutellatus* Coastal taipan (N and NE Australia)
Genus: *Parapistocalamus*
*Parapistocalamus hedigeri** Bougainville or Hediger's coral snake (Bouganville Island, the Solomon Islands)
Genus: *Paroplocephalus*
*Paroplocephalus atriceps** Lake Cronin snake (SW coast of W Australia)
Genus: *Pseudechis*, black snakes
*Pseudechis australis**** Mulga snake or king brown snake (Australia and New Guinea)
*Pseudechis butleri*** Spotted mulga snake (the middle-west part of W Australia)
*Pseudechis colletti*** Collett's snake (NE Australia)
*Pseudechis guttatus*** Blue-bellied black snake (E Australia)
*Pseudechis papuans*** Papuan black snake (E New Guinea and neighboring islands)
Pseudechis pailsei (Validity of the species has been disputed.)
*Pseudechis porphyriacus*** Red-bellied black snake (E and SE Australia)
-- *P. porphyriacus eipperi* (Validity of the subspecies has been disputed.)
-- *P. porphyriacus rentoni* (Validity of the subspecies has been disputed.)
Genus: *Pseudonaja*, brown snakes
*Pseudonaja affinis*** Dugite or spotted brown snake
-- *P. affinis affinis* (coastal SW Australia)
-- *P. affinis exilis* (Rottnest Island)
-- *P. affinis tanneri* (Boxer's Island)
*Pseudonaja elliotti*** (Australia - W part of New South Wales)
*Pseudonaja guttata*** Speckled brown snake or spotted brown snake (Australia)
*Pseudonaja inframacula*** Peninsula brown snake (N Australia)
*Pseudonaja ingrami*** Ingram's brown snake (Australia, the Barkly Tableland region)
*Pseudonaja modesta*** Ringed brown snake (W Australia to the north of the Northern Territory, inland S Australia, SW Queensland)
*Pseudonaja nuchalis*** Gwardar or western brown snake (W and S Australia, the Northern Territory, W New South Wales, NW Victoria)
*Pseudonaja textilis**** Eastern brown snake (NE Australia)
-- *P. textilis pughi* (ssp. described in 2003.)
Genus: *Rhinoplocephalus*
*Rhinoplocephalus bicolor** Square-nosed snake (SW part of West Australia)
*Rhinoplocephalus boschmai** syn. *Unechis boschmai, U. carpentariae* Carpentaria whip snake (Australia and Indonesian part of New Guinea)
*Rhinoplocephalus incredibilis** (Prince of Wales Island, Torres Straits)

Rhinoplocephalus nigrescens * Eastern small-eyed snake (E Australia)
Rhinoplocephalus nigrostriatus * Australian black-striped snake (Australia, S Papua-New Guinea)
Rhinoplocephalus pallidiceps * Western Carpentaria snake (N Australia)
Genus: *Salomonelaps*
*Salomonelaps par*** Solomons coral snake (the Solomon Islands)
Genus: *Simoselaps*
Simoselaps anomalus * Northern desert banded snake (NW coast of W Australia to SW Northern Territory and NW part of S Australia)
Simoselaps approximans * North-western shovel-nosed snake (NW Australia)
*Simoselaps australis** Eastern shovel-nosed snake, coral snake, Australian coral snake (E Australia)
*Simoselaps bertholdi** Southern desert banded snake, desert banded snake (Australia)
*Simoselaps bimaculatus** Black-naped burrowing snake (SW Australia to C S Australia)
*Simoselaps calonotus** Black-striped burrowing snake (SW coast of Australia)
*Simoselaps fasciolatus** Narrow-banded shovel-nosed snake
-- *S. fasciolatus fasciatus* (Central S Australia)
-- *S. fasciolatus fasciolatus* (SW Australia)
Simoselaps incinctus * Unbanded shovel-nosed snake (Australia)
Simoselaps littoralis * West-coast banded snake (C part of W coast of West Australia)
Simoselaps minimus * Dampierland burrowing snake (NW West Australia)
*Simoselaps morrisi** (Australia - the Northern Territory)
Simoselaps roperi Northern shovel-nosed snake (W Australia to the Northern Territory)
*Simoselaps semifasciatus**Southern shovel-nosed snake, half-girdled snake
-- *S. semifasciatus campbelli* (NE Queensland)
-- *S. semifasciatus roperi*
-- *S. semifasciatus semifasciatus* Southern shovel-nosed snake (SW and S Australia)
-- *S. semifasciatus woodjonesii* Cape York shovel-nosed snake (N Queensland)
*Simoselaps warro** North-eastern plain-nosed (Australia)
Genus: *Suta*
Suta atriceps see *Paroplocephalus atriceps*
Suta dwyeri * Variable black-naped snake (Australia)
*Suta fasciata** Rosen's snake (W Australia)
*Suta flagellum** Whip hooded snake (SE Australia)
*Suta gouldii** Australian black-headed snake (SW West Australia)
*Suta monachus** Hooded snake (Australia)
*Suta nigriceps** Günther's black-headed snake (N West Australia to NW Victoria and SW New South Wales)
*Suta ordensis** Ord curl snake (NW Australia)
Suta punctata * Little spotted snake (NW West Australia to C Australia and W C Queensland)
*Suta spectabilis** Spectacled hooded snake
-- *S. spectabilis bushi* (a type locality - Scaddan in W Australia)
-- *S. spectabilis nullarbor* (Australia - Nullarbor Plain)
-- *S. spectabilis spectabilis* Spectacled hooded snake (SE Australia)
*Suta suta** Curl snake (C and E Australia)

Genus: *Toxicocalamus*
*Toxicocalamus buergersi** Buerger's forest snake (N Papua-New Guinea)
*Toxicocalamus grandis** Setekwa River forest snake (a type locality - River Setekwa, Indonesian New Guinea)
*Toxicocalamus holopelturus** Mt Rossel forest snake (Mt Rossel, Rossel Island)
*Toxicocalamus longissimus** Woodlark or Fergusson Island forest snake (Woodlark and Ferguson islands)
*Toxicocalamus loriae** (New Guinea and Papua-New Guinea)
*Toxicocalamus misimae** Misima Island forest snake (Misima Island near Papua-New Guinea)
*Toxicocalamus preussi** Preuss's Sepik forest snake (N New Guinea)
-- *T. preussi angusticinctus*
-- *T. preussi preussi* Preuss's forest snake
*Toxicocalamus spilolepidotus** (a type locality - Papua-New Guinea, only two individuals)
*Toxicocalamus stanleyanus** (Indonesia)
Genus: *Tropidechis*
*Tropidechis carinatus*** Rough-scaled snake or Clarence River snake (coastal zones, NE and E Australia)
*Tropidechis sadlieri*** (Australia - N Queensland)
Genus: *Unechis* see *Rhinoplocephalus*
Genus: *Vermicella*
*Vermicella annulata** Eastern bandy bandy
-- *V. annnulata annulata* (Australia except NE and SE territories)
-- *V. annulata snelli* see *V. snelli*
*Vermicella intermedia**
*Vermicella snelli** (W Australia, Pilbara to S Northern Territory)
*Vermicella multifasciata** Northern bandy bandy (N W Australia to Northern Territory)
*Vermicella vermiformis**

7.3.2.2. Aquatic Species: True Sea Snakes and Sea Kraits

(formerly: *Hydrophiidae* family, *Hydrophiinae* and *Laticaudinae* subfamilies)
Genus: *Acalyptophis*
*Acalyptophis peronii*** Spiny-headed seasnake (the sea territories between China, Taiwan and Australia)
Genus: *Aipysurus*
*Aipysurus apraefrontalis*** Short-nosed seasnake (Australian and Indonesian seas)
*Aipysurus duboisii*** Reef shallows seasnake (Melanesian, Australian and New Guinea sea)
*Aipysurus eydouxii*** Spine-tailed seasnake (Thailand, Indonesian and N Australia sea)
*Aipysurus foliosquama*** Leaf-scaled seasnake (Indonesian and Australian sea)
*Aipysurus fuscus*** Timor reef snake (Sulawesi and Timor sea)
*Aipysurus laevis*** Olive-brown seasnake
-- *A. laevis laevis* (New Guinea, Australia, Melanesia)
-- *A. laevis pooleorum* see *A. pooleorum*
*Aipysurus pooleorum*** (coastal W Australia)

*Aipysurus tenuis*** (coastal NW Australia)
Genus: *Astrotia*
*Astrotia stokesi**** Stoke's seasnake (E Pacific Ocean and N Australia)
Genus: *Disteira*
*Disteira kingii*** Spectacled or king's seasnake (V, N and W coast of Australia)
*Disteira major*** see Hydrophis Olive-headed or greater seasnake (V, S and W coast of Australia)
*Disteira nigrocincta*** (the sea along E India and around Sri Lanka)
*Disteira walli*** Wall's sea snake (Malayan Archipelago sea)
Genus: *Emydocephalus*
*Emydocephalus annulatus*** Turtle-headed seasnake, egg-eating sea snake (W Pacific Ocean to N coast of Australia)
*Emydocephalus ijimae*** Turtlehead sea snake (S Chinese, Taiwan and Japanese sea)
Genus: *Enhydrina*, seasnakes
*Enhydrina schistosa**** Common or beaked seasnake (the Indian Ocean, the sea territory between E India and N Australia)
*Enhydrina zweifeli**** Sepik or Zweifel's beaked seasnake (New Guinea)
Genus: *Ephalophis*
Ephalophis greyi (*greyae*)** North-western mangrove seasnake (coastal W Australia)
Genus: *Hydrelaps*
*Hydrelaps darwiniensis*** Port Darwin seasnake (the sea territory between N Australia and S New Guinea)
Genus: *Hydrophis*, seasnakes
*Hydrophis atriceps*** Black-headed seasnake (the Burmese sea to Thailand, Java, New Guinea, Australia and the Philippines)
*Hydrophis belcheri*** Faint-banded seasnake (Thailand, Indonesian and New Guinea sea)
*Hydrophis bituberculatus*** Peters' sea snake (Sri Lanka and Thailand sea)
Hydrophis brookei (*brookii*)** (Malaysian, Thailand, Vietnamese and Indonesian sea)
*Hydrophis caerulescens*** syn. *Polyodontognathus caerulescens* Dark blue-banded sea snake (S and SE Asia and Indonesian sea)
*Hydrophis cantoris*** syn. Microcephalophis cantoris (the seas of Pakistan, India, Sri Lanka, Burma, Thailand, and Malaysia)
*Hydrophis coggeri*** Slender-necked seasnake (Oceania)
*Hydrophis cyanocinctus*** Asian annulated sea snake (the southern coast of Asia as far as Japan)
*Hydrophis czeblukovi*** Fine-spined seasnake (Arafura Sea)
*Hydrophis elegans*** Elegant or bar-bellied seasnake (E, S, W coast of Australia)
*Hydrophis fasciatus*** Striped sea snake (the Indian Ocean to the northern coast of Australia)
*Hydrophis geometricus*** (N coast of W Australia)
*Hydrophis gracilis*** syn. Microcephalophis gracilis (the coast of the Indian Ocean from the Gulf of Persia as far as Australia and Melanesia)
*Hydrophis inornatus*** Plain seasnake (Indonesian, Philippines and Australian sea)
*Hydrophis klossi*** Kloss' sea snake (Thailand, Malaysian and Indonesian sea)
*Hydrophis laboutei*** (New Caledonian sea)
*Hydrophis lamberti*** Lambert's sea snake (Thailand, Singapore and Philippine sea)

*Hydrophis lapemoides*** Persian Gulf sea snake (the coast of the Indian Ocean from the Gulf of Persia as far as Malaysia)
Hydrophis major see *Disteira major*
*Hydrophis mamillaris*** Bombay sea snake (coastal Pakistan, India and Sri Lanka)
*Hydrophis macdowelli*** Small-headed Or McDowell's seasnake (N coast of Australia)
*Hydrophis melanocaphalus*** Slender-necked seasnake (waters of SE Asia, from Australia as far as S Japan)
*Hydrophis melanosoma*** Black-banded or robust seasnake (Malaysian, Indonesian and Australian sea)
*Hydrophis obscurus*** Russel's sea snake (coastal E India, Sri Lanka and Burma)
Hydrophis ornatus ssp.** Ornate reef seasnake (the Indian Ocean, W Pacific Ocean)
*Hydrophis pacificus*** Pacific seasnake (Australia and New Guinea)
*Hydrophis parviceps*** (the South China Sea and coastal Vietnam)
*Hydrophis semperi*** Lake Taal snake (the Lake Taal, Luzon, the Philippines)
*Hydrophis sibauensis*** (Sibau River, W Borneo, Indonesia)
*Hydrophis spiralis*** Yellow sea snake (the Indian Ocean, the waters of archipelagos between E India and N Australia)
*Hydrophis stricticollis*** Collared sea snake (coastal E India, Sri Lanka, Burma)
Hydrophis torquatus ssp.** West Coast black-headed sea snake (the South China Sea to the waters near Borneo and Sumatra)
*Hydrophis vorisi*** Estuarine seasnake (New Guinea)
Genus: *Kerilia*
Kerilia jerdonii ssp.** Jerdon's sea snake (Indian, Sri Lankan and Borneo seas)
Genus: *Kolpophis*
*Kolpophis annandalei*** Bighead sea snake (the South China Sea from Thailand as far as Indonesia)
Genus: *Lapemis*
*Lapemis curtus*** Shaw's sea snake (the Indian Ocean)
*Lapemis hardwickii*** Hardwicke's spine-bellied seasnake (the sea territory from E India to Australia)
Genus: *Laticauda*, Sea kraits
*Laticauda colubrina*** Colubrine or yellow-lipped sea krait (the sea territory between E India, Japan and Australia)
*Laticauda crockeri*** Crocker's sea snake (the Lake Te Nggano, Rennell Island - the Solomon Islands)
*Laticauda laticaudata*** Common or blue-lipped sea krait (the sea territory between E India, Japan, Australia and Polynesia)
-- *L. laticaudata affinis*
-- *L. laticaudata wolffi*
*Laticauda schistorhynchus*** (New Guinea, Melanesian and Polynesian seas)
*Laticauda semifasciata*** (Philippine, Chinese, Taiwan and Japanese seas)
Genus: *Microcephalophis*
Microcephalophis gracilis see *Hydrophis gracilis*
Microcephalophis cantoris see *Hydrophis cantoris*
Genus: *Parahydrophis*

Parahydrophis mertoni** Arafura smooth or northern mangrove seasnake (Indonesian, New Guinea and Australian seas)

Genus: *Pelamis*

*Pelamis platurus*** Yellowbelly sea snake or pelagic sea snake (tropical zones of the Indian and Pacific Ocean)

Genus: *Polyodontognathus*

Polyodontognathus caerulescens see *Hydrophis caerulescens*

Genus: *Praescutata*

Praescutata viperina see *Thalassophina viperina*

Genus: *Thalassophis*

*Thalassophis anomalus*** Anomalous sea snake (the Gulf of Siam and Indonesian seas)

Genus: *Thalassophina*

*Thalassophina viperina*** Schmidt's sea snake (the Indian Ocean: the Persian Gulf to the South China Sea)

7.4. FAMILY: *VIPERIDAE*, VIPERIDS

7.4.1. Subfamily: *Azemiopinae*

Genus: *Azemiops*

*Azemiops feae** Fea's viper (Burma, S China, N Vietnam)

7.4.2. Subfamily: *Viperinae*

Genus: *Adenorhinos*

*Adenorhinos barbouri** Uzungwe Mountain bush viper (SW Tanzania)

Genus: *Atheris*, bush vipers

*Atheris acuminata** Acuminate bush viper (W Uganda)

Atheris anisolepis see *Atheris squamiger anisolepis*

Atheris barbouri see *Adenorhinos barbouri*

*Atheris broadley** (Cameroon)

*Atheris ceratophorus** syn. *A. ceratophora* (E Tanzania)

*Atheris chloroechis** syn. *A. chlorechis* (Africa from Guinea as far as Gabon)

*Atheris desaixi** Ashe's bush viper (Kenya)

Atheris hindii see *Montatheris hindii*

*Atheris hirsuta** (Côte d'Ivoire)

*Atheris hispidus** African hairy bush viper, syn. *A. hispida* (DRC, isolated patches of populations in SW Uganda and W Kenya)

*Atheris katangensis** Katanga Mountain bush viper (DRC)

Atheris laeviceps see *A. squamiger anisolepis*

*Atheris nitschei** Great Lakes bush viper (E DRC, Rwanda, SW Uganda, Burundi to NW Tanzania)

-- *A. nitschei nitschei* see *A. nitschei*

-- *A. nitschei rungweensis* see *A. rungweensis*
*Atheris rungweensis** Mt Rungwe bush viper (SW Tanzania, NE Zambia, N Malawi)
*Atheris squamiger*** Rough-scaled bush viper, syn. *A. squamigera*
-- *A. squamiger anisolepis* (N Congo-Brazzaville and N Angola)
-- *A. squamiger robustus* (the province of Orientale, DRC)
-- *A. squamiger squamiger* (SE Nigeria to NW Angola, DRC to S Uganda, W Kenya, Ghana)
Atheris superciliaris see *Proatheris superciliaris*
*Atheris subocularis** (Cameroon)
Genus: *Bitis*, puff or African adders, or African vipers
*Bitis albanica*** (RSA - E Cape Region)
*Bitis arietans**** African puff adder
-- *B. arietans arietans* African puff adder (Africa, the savannahs from Morocco to S Africa and Arabia)
-- *B. arietans somalica* (Somalia, N Kenya, SE Ethiopia)
*Bitis armata** (RSA)
Bitis atropoides see *B. armata*
*Bitis atropos*** Mountain adder
-- *B. atropos atropos* Mountain adder (RSA, Swaziland, Lesotho and Zimbabwe)
-- *B. atropos unicolor* (N Africa)
*Bitis caudalis** Horned puff adder (SW Angola, Namibia, Botswana, SW Zimbabwe, RSA)
*Bitis cornuta*** Many-horned adder (W RSA and SW Namibia)
-- *B. cornuta albanica* see *Bitis albanica*
-- *B. cornuta cornuta* see *Bitis cornuta*
*Bitis gabonica**** Gabon viper
-- *B. gabonica gabonica* Gabon adder (Nigeria, S Sudan, Uganda, W Kenya, S Tanzania, Mozambique, RSA)
-- *B. gabonica rhinoceros* see *B. rhinoceros*
*Bitis heraldica** Angolan adder or Bocage's horned adder (NW and C Angola)
*Bitis inornata** Plain mountain adder (N RSA)
Bitis lachesis see *B. arietans*
*Bitis nasicornis**** Rhinoceros viper (N Sudan, Uganda, Congo-Brazzaville, Gabon)
*Bitis parviocula*** Ethiopian mountain adder (C and SW Ethiopia)
*Bitis peringueyi** Peringuey's adder (Angola and SW Africa)
*Bitis rhinoceros**** (Guinea and Sierra Leone to Togo)
*Bitis rubida** Red adder (RSA)
*Bitis shneideri** Namaqua dwarf adder (Namibia)
*Bitis worthingtoni** Kenya horned viper (Kenya)
*Bitis xeropaga** Desert mountain adder (NW RSA and SW Namibia)
Genus: *Causus*, night adders
*Causus bilineatus** Two-lined night adder (C Angola, NW Zambia, S DRC, Rwanda)
*Causus defilippii** Snouted night adder (the SE coasts of Kenya, E and S Tanzania, Malawi, Mozambique, E Zambia, Zimbabwe to RSA)
*Causus lichtensteinii** Forest night adder (N Guinea, Sierra Leone to W Kenya and S Sudan)

*Causus maculatus** West-African night adder (Senegal and Gambia to Cameroon, S Chad, Central African Republic and S Sudan)
*Causus resimus** Green night adder (C and E Africa)
*Causus rhombeatus** Common or rhombic night adder (C Africa)
Genus: *Cerastes*
*Cerastes cerastes*** Desert horned viper (Sahara to Arabia)
-- *C. cerastes hoofieni* (recently reclassified as a separate subspecies - SW Arabian Peninsula)
-- *C. cerastes karlhartli*, *C. cerastes mutila* (formerly separate subspecies, recently included in synonyms of a nominotypic subspecies)
*Cerastes gasperettii*** Arabian horned viper (Jordan, Iraq, Kuwait, Arabian Peninsula to SW Iran)
-- *C. gasperetti mendelssohni* (Jordan and Israel)
*Cerastes vipera** Sahara sand viper (Sahara inc. edges)
Genus: *Daboia*
*Daboia russelli**** Russell's or chain viper, syn. *Vipera russelli*
-- *D. russelli russelli*, includes the formerly separate *D. r. pulchella* and *nordicus* subspecies (E Pakistan, India, W Bangladesh, Sri Lanka),
-- *D. russelli siamensis*, includes the formerly separate *D. r. formosensis*, *limitis*, and *sublimitis* subspecies (N China, C and S Burma, C Thailand, Taiwan, Indonesia),
Genus: *Echis*, saw-scaled or carpet vipers
*Echis carinatus**** Saw-scaled viper
-- *E. carinatus astolae* (Astola Island near Pakistan)
-- *E. carinarus carinatus* Saw-scaled viper (C and S India)
-- *E. carinatus multisquamatus* (SE Azerbaijan, Iran, Turkmenistan, Uzbekistan, SW Tajikistan, N Afghanistan)
-- *E. carinatus sinhaleyus* (N and E part of Sri Lanka)
-- *E. carinatus sochureki* (Oman, S Afghanistan, Pakistan, N India)
*Echis coloratus**** Palestine saw-scaled viper (the Arabian Peninsula, SE Egypt, Israel, Jordan, Oman)
-- *E. coloratus terraesanctae* (recently reclassified as a separate subspecies - Israel and Jordan)
*Echis hughesi**** Hughes' saw-scaled viper (Somalia)
*Echis jogeri**** Joger's saw-scaled viper (Mali)
*Echis leucogaster**** Roman's saw-scaled viper (Senegal, Mauritania, the southern edge of Sahara as far as Sudan, SE Morocco, S Algeria)
*Echis megalocephalus**** Cherlin's saw-scaled viper (Eritrea)
Echis multisquamatus see *E. carinatus multisquamatus*
*Echis ocellatus**** West African carpet viper (Senegal, SW Mauritania, S Mali, Sahel as far as SW Chad)
*Echis omanensis**** (E Oman, the United Arabian Emirates)
*Echis pyramidum**** Egyptian saw-scaled viper (NE Algeria, Tunisia, coastal Libya as far as Egypt)
-- *E. pyramidum aliaborri* (sometimes also listed as a subspecies of *E. carinatus*) (NE Kenya)
-- *E. pyramidum leakeyi* (W Kenya)

-- *E. pyramidum lucidus* (Tunisia, N Libya, NW Egypt)
-- *E. pyramidum pyramidum* (NE Egypt, as far as S Sudan, Eritrea, N Somalia and NE Kenya)
Echis sochureki see *E. carinatus sochureki*
Genus: *Eristicophis*
*Eristicophis macmahoni**** McMahons desert viper (the Afghanistan and Pakistan border, E Iran)
Genus: *Macrovipera*, large Palearctic vipers, formerly *Vipera* and *Daboia* genera
*Macrovipera deserti**** Desert viper, syn. *Daboia* (C and S Tunisia, NW Libya, NE Algeria)
*Macrovipera lebetina**** Levantine viper
-- *M. lebetina lebetina* Levantine viper (Cyprus and Turkey)
-- *M. lebetina chernovi* (Turkmenistan)
-- *M. lebetina obtusa,* syn. *M. lebetina euphratica* (from N Syria across Turkey, Iraq, Iran and W Pakistan as far as Afghanistan)
-- *M. lebetina transmediterranea* (Algeria)
-- *M. lebetina turanica* (NE Iran, Turkmenistan, Uzbekistan, Afghanistan, N Pakistan, N India)
*Macrovipera mauritanica**** Moorish viper, sometimes also listed as a species of *Daboia* genus (NW Morocco and N Algeria)
*Macrovipera schweizeri**** Cyclades blunt-nosed viper (Milos, Kimolos, Polinos, and Siphnos islands, Greece)
Genus: *Montatheris*, Kenya mountain or Hind's viper
*Montatheris hindii** (Kenya)
Genus: *Montivipera*
A proposal exists that a group containing species from the range of *Vipera xanthina* (i.e. *V. xanthina*, *V. albizona*, *V. bornmuelleri*, *V. bulgardaghica* and *V. wagneri*) and *Vipera raddei* (i.e. *V. raddei*, *V. albicornuta* and *V. latifii*) should be isolated and listed under a separate genus *Montivipera*.
Genus: *Proatheris*
*Proatheris superciliaris*** Lowland swamp viper (SW Tanzania, S Malawi to C Mozambique)
Genus: *Pseudocerastes*
Pseudocerastes fieldi see *P. persicus fieldi*
*Pseudocerastes persicus*** Persian horned viper
-- *P. persicus fieldi* Field's horned viper (Iraq, Jordan, Israel, Sinai)
-- *P. persicus persicus* (Iran, Pakistan, E part of the Arabian Peninsula)
Genus: *Vipera*, Palearctic or Eurasian vipers
*Vipera albizona**** Central Turkish mountain viper (the province of Sivas, Turkey)
Vipera albicornuta see *V. raddei albicornuta*
*Vipera ammodytes*** Nose-horned viper
-- *V. ammodytes ammodytes* (N Tyrol, Austria, former Yugoslavia, Romania, NW Bulgaria)
-- *V. ammodytes meridionalis* (Greece, Albania, Asia Minor, Syria, the Cyclades)
-- *V. ammodytes montandoni* (W Black Sea region)
-- *V. ammodytes transcaucasiana* (South Caucasus)

*Vipera anatolica** (Taurus Mountains, S Turkey)
*Vipera aspis*** Asp viper
-- *V. aspis aspis* European asp (Pyrenean Mountains, S France, S Black Forest, the Alps, Elba, the northern part of former Yugoslavia)
-- *V. aspis atra* Black asp (C Switzerland to N Italy, the neighboring part of SE France)
-- *V. aspis francisciredi* Central Italian asp (N and C Italy, Elba)
-- *V. aspis hugyi,* syn. *montecristi* Southern Italian asp (Calabria and Sicily)
-- *V. aspis zinnikeri* Gascony asp (SW France)
Vipera atra see *V. aspis atra*
*Vipera barani*** Turkish viper (NW, NE Turkey, possibly the neighboring part of Georgia)
*Vipera berus*** Common or European viper
-- *V. berus berus* Common or European viper (N and C Europe, southwards to N Italy, Russia)
-- *V. berus bosniensis* Balkan cross adder (former Yugoslavia, Bulgaria)
-- *V. berus sachalinensis* Sakhalin Island adder (Sakhalin and Far East)
*Vipera bornmuelleri*** Lebanon viper (Lebanon and the neighboring parts of Jordan, Syria and Israel)
*Vipera darevskii*** Darevsky's viper (SE Armenia and the neighboring part of Georgia)
*Vipera dinnicki*** Dinnik's viper (the Greater Caucasus)
*Vipera ebneri** (SW Turkmenistan and the neighboring territory of N Iran)
*Vipera eriwanensis** (NE Turkey to S Caucasus and E Uzbekistan)
Vipera hugyi see *V. aspis hugyi*
*Vipera kaznakovi*** Kaznakov's viper (W Caucasus and Turkey)
*Vipera latastei*** Lataste's viper
-- *V. latastei gaditana* (coastal S Portugal and SW Spain, Morocco, N coast of Algeria to NW Tunisia)
-- *V. latastei latastei* (N Portugal and Spain)
*Vipera latifii**** Latifi's viper (Iran)
*Vipera lotievi** Caucasian meadow viper (the northern slopes of the Greater Caucasus)
*Vipera magnifica** (W Caucasus)
*Vipera monticola** Atlas mountain viper (Morocco – the Greater Atlas)
*Vipera nikolskii*** Nikolski's viper (SW Russia and Ukraine to W Kazakhstan)
*Vipera orlovi** (W Caucasus)
*Vipera palestinae**** Palestine viper, syn. *Daboia palestinae* (Israel, W Jordan, W Syria)
Vipera pontica Pontic adder see *V. barani*
*Vipera raddei**** Armenian mountain viper
-- *V. raddei albicornuta* (N Iran)
-- *V. raddei kurdistanica* (SE Turkey)
-- *V. raddei latifi* see *Vipera latifii*
-- *V. raddei raddei* (Armenia, NE Turkey, NW Iran)
*Vipera renardi** Steppe viper
-- *V. renardi renardi* (Ukraine, Russia, Kazakhstan, Azerbaijan, China)
-- *V. renardi parursinii* (NW China)
-- *V. renardi tienshanica* (Tian Shan in Kazakhstan, Kyrgyzstan and NW China)
Vipera russellii see *Daboia russelli*

Vipera sachalinensis see *V. berus sachalinensis*
*Vipera seoanei*** Baskian viper
-- *V. seoanei cantabrica* (C Spain)
-- *V. seoanei seoanei* Baskian viper (N Spain, N Portugal, SW France)
Vipera transcaucasiana see *V. ammodytes transcaucasiana*
*Vipera ursinii** Meadow viper
-- *V. ursinii rakosiensis* (originally isolated patches of populations in SE Austria, Hungary and W Romania; the subspecies is now getting extinct)
-- *V. ursinii ursinii* (Italy and SE France)
-- *V. ursinii anatolica* see *V. anatolica*
-- *V. ursinii graeca* (the Pindos Mountains, Greece)
-- *V. ursinii macrops* (Krk Island near Greece, Bosnia and Herzegovina, Montenegro, N Macedonia, NE Albania)
-- *V. ursinii moldavica* (lowlands from Romania across Moldavia as far as W Ukraine steppes)
-- *V. ursinii wettsteini* see *V. ursinii ursinii*
*Vipera wagneri*** Ocellated mountain viper (NE Turkey and NW Iran)
*Vipera xanthina**** Rock viper (the European part of Turkey, W Asia)
-- *V. xanthina bornmuelleri* see *V. bornmuelleri*
-- *V. xanthina xanthina* see *V. xanthina*
-- *V. xanthina albizona* see *V. albizona*
-- *V. xanthina bulgardaghica* - considered by some as a separate species, but disputed by others who list the subspecies as a variation of *V. xanthina* (Bulgar-Dagh Mountains, S Turkey)
Vipera zinnikeri see *V. aspis zinnikeri*

7.4.3. Subfamily: *Crotalinae*

Genus: *Agkistrodon*
Agkistrodon acutus see *Deinagkistrodon acutus*
*Agkistrodon bilineatus**** Cantil (Mexico to Nicaragua)
-- *A. bilineatus bilineatus* (the Pacific coastal plains of Mexico, Guatemala, Salvador)
-- *A. bilineatus howardgloydi* (Honduras, Nicaragua, NW Costa Rica)
-- *A. bilineatus russeolus* (N Yucatán and the N part of Belize)
-- *A. bilineatus taylori* see *A. taylori*
Agkistrodon blomhoffii see *Gloydius blomhoffii*
*Agkistrodon contortrix*** Southern copperhead (C and S USA and NE Mexico)
-- *A. contortrix contortrix* (Maryland to Texas and Oklahoma)
-- *A. contortrix laticinctus* (C and N Texas to Kansas)
-- *A. contortrix mokasen* (Connecticut to Virginia and Carolina, Indiana)
-- *A. contortrix phaeogaster* (NE Oklahoma, E Kansas, C and W Missouri, SE Iowa, Nebraska)
-- *A. contortrix pictigaster* (Mexico - Coahuila, Chihuahua; Texas - the Trans-Pecos region)
Agkistrodon halys see *Gloydius halys*

Agkistrodon intermedius see *Gloydius intermedius*
Agkistrodon monticola see *Gloydius monticola*
*Agkistrodon piscivorus**** Western cottonmouth (SE USA)
-- *A. piscivorus conanti* (Florida and the neighboring areas of S Georgia and SE Alabama)
-- *A. piscivorus leucostoma* (the USA and Mexican border - E Oklahoma, S Illinois and SW Alabama)
-- *A. piscivorus piscivorus* (SE Virginia, C Georgia, E Alabama)
Agkistrodon rhodostoma see *Calloselasma rhodostoma*
Agkistrodon saxalis see *Gloydius intermedius saxatilis*
Agkistrodon shedaoensis see *Gloydius shedaoensis*
Agkistrodon strauchi see *Gloydius strauchi*
*Agkistrodon taylori**** Mexican Moccasin (NE Mexico)
Agkistrodon ussuriensis see *Gloydius ussuriensis*
Genus: *Atropoides*, jumping pit vipers
*Atropoides mexicanus*** Central American jumping pitviper (Central America - Belize to C Panama)
*Atropoides nummifer*** Jumping pit viper
-- *A. nummifer mexicanus* see *A. mexicanus*
-- *A. nummifer nummifer* Jumping pit viper (Mexico)
-- *A. nummifer occiduus* see *A. occiduus*
*Atropoides occiduus*** (Central America - Mexico to Salvador)
*Atropoides olmec*** Olmecan pit viper (N Mexico)
*Atropoides picadoi*** Picado's Jumping pitviper (Costa Rica and NW Panama)
Genus: *Bothriechis*, palm pit vipers
*Bothriechis aurifer*** Yellow-blotched palm pit viper (Mexico and C Guatemala)
*Bothriechis bicolor*** Guatemala palm pit viper (Mexico, Guatemala, isolated patches of populations in W Honduras)
Bothriechis bilineatus see *Bothriopsis bilineata*
*Bothriechis lateralis*** Side-striped palm pit viper (Costa Rica to inland Panama)
*Bothriechis marchi*** March's palm pit viper (isolated patches of populations in NW Honduras)
*Bothriechis nigroviridis*** Black-speckled palm pit viper (C Costa Rica to W Panama)
Bothriechis oligolepis see *Bothriopsis oligolepis*
Bothriechis punctatus see *Bothrops punctatus*
*Bothriechis rowleyi*** Rowley's palm pit viper (Mexico)
*Bothriechis schlegelii*** Eyelash palm pit viper (from S Mexico across Central America as far as W Colombia)
*Bothriechis supraciliaris*** (SW Costa Rica)
*Bothriechis thalassinus*** (E Guatemala and W Honduras)
Bothriechis taeniatus see *Bothriopsis taeniata*
Genus: *Bothriopsis*, forest pit vipers
Bothriopsis albocarinata see *B. pulchra*
*Bothriopsis bilineata*** Two-striped forest pit viper (N Colombia, SW Venezuela, Ecuador, Bolivia, Brazil)
*Bothriopsis chloromelas*** (the Peruvian Andes)

*Bothriopsis medusa*** Venezuela forest pit viper (Venezuela)
*Bothriopsis oligolepis*** Inca forest pit viper
-- *B. oligolepis oligolepis* (N Peru and NW Bolivia)
-- *B. oligolepis albocarinata* see *Bothriopsis pulchra*
Bothriopsis peruviana, Peru forest pit viper, syn. *B. chloromelas and B. oligolepis*
*Bothriopsis pulchra*** (the Andes to the east, from S and C Colombia across Ecuador to N Peru)
Bothriopsis punctata see *Bothrops punctatus*
*Bothriopsis taeniata*** Speckled forest pit viper (Colombia, Venezuela, Guyana, Brazil, Bolivia, Peru, Ecuador)
Genus: *Bothrocophias*
*Bothrocophias campbelli**** (the NW coasts of S America)
*Bothrocophias colombianus*** (Colombia)
*Bothrocophias hyoprora*** (N Colombia, E Ecuador, NE Peru, W Brazil, N Bolivia)
*Bothrocophias microphthalmus**** (C Colombia, C Ecuador, Peru to NW Bolivia)
*Bothrocophias myersi**** (the NW coasts of S America)
Genus: *Bothrops*, lanceheads, American lanceheads, or American lance-headed vipers
*Bothrops alcatraz**** Alcatrazes lancehead (Alcatrazes Island near Brazil)
*Bothrops alternatus**** Urutu (NE and C Argentina, Uruguay, S Paraguay, S Brazil, isolated patches in E Argentina)
*Bothrops ammodytoides** Patagonia lancehead (W and C Argentina)
*Bothrops andianus*** Andean lancehead (Peru)
Bothrops asper see *Bothrops atrox*
*Bothrops atrox**** Common lancehead (Central and South America)
-- *B. atrox atrox*, *B. atrox xanthogrammus*; more recently not listed as subspecies
*Bothrops barnetti*** Barnett's lancehead (the N coast of Peru and the neighboring territory of SW Ecuador)
Bothrops bilineatus see *Bothriopsis bilineata*
*Bothrops brazili**** Brazil's lancehead (N Colombia to French Guyana, E Ecuador, NE and E Peru)
Bothrops campbelli see *Bothrocophias campbelli and Bothrocophias myersi* in part.
*Bothrops caribbaeus**** Saint Lucia lancehead (Saint Lucia Island)
Bothrops castelnaudi see *Bothriopsis taeniata*
Bothrops colombianus see *Bothrocophias colombianus*
*Bothrops cotiara**** Cotiara (N Brazil and NE Argentina)
*Bothrops diporus*** Chaco lancehead (N and E Paraguay and the neighboring areas of S Brazil, Argentina)
*Bothrops erythromelas**** Caatinga lancehead (NE Brazil)
*Bothrops fonsecai**** Fonseca's lancehead (SE coast of Brazil)
Bothrops iglesiasi see *Bothrops lutzi*
*Bothrops insularis**** Queimada jararaca (Queimada Grande Island)
Bothrops isabelae see *Bothrops atrox*
*Bothrops itapetiningae**** Sao Paulo lancehead (N C Brazil)
*Bothrops jararaca**** Jararaca (Brazil and N Argentina)
*Bothrops jararacussu**** Jararacussu (Brazil, Bolivia, Paraguay, N Argentina)
*Bothrops jonathani**** Jonathan's lancehead (Bolivia)

*Bothrops lanceolatus**** Martinique lancehead (Martinique)
*Bothrops leucurus**** Whitetail lancehead (Brazil)
*Bothrops lojanus**** Lojan lancehead (Ecuador)
*Bothrops lutzi**** Sertao lancehead (Brazil)
*Bothrops marajoensis**** Marajó lancehead (N Brazil)
*Bothrops mattogrossensis*** Mato Grosso lancehead (Bolivia and the neighboring part of Brazil)
Bothrops medusa see *Bothriopsis medusa*
Bothrops microphthalmus see *Bothrocophias microphthalmus*
*Bothrops moojeni**** Brazilian lancehead (E Paraguay to C Brazil and NE Argentina)
*Bothrops muriciensis**** Murici lancehead (the Murici Forest region, E Brazil)
*Bothrops neuwiedi*** Neuwied's lancehead (Brazil, Bolivia, Paraguay, N Argentina)
-- *B. neuwiedi bolivianus* see *B. mattogrossensis*
-- *B. neuwiedi diporus* see *B. diporus*
-- *B. neuwiedi goyazensis*
-- *B. neuwiedi lutzi*, syn. *bahiensis* see *B. lutzi*
-- *B. neuwiedi mattogrossensis* see *B. mattogrossensis*
-- *B. neuwiedi meridionalis*, syn. *fluminensis* see *B. neuwiedi*
-- *B. neuwiedi neuwiedi* Neuwied's lancehead
-- *B. neuwiedi paranaensis* (Brazil)
-- *B. neuwidei pauloensis* see *B. pauloensis*
-- *B. neuwiedi piauhyensis* see *B. lutzi*
-- *B. neuwiedi pubescens*, syn. *B. riograndensis* see *B. pubescens*
-- *B. neuwiedi urutu*
Bothrops nummifer see *Atropoides nummifer*
Bothrops oligolepis see *Bothriopsis oligolepis*
Bothrops osbornei see *Bothrops punctatus*
*Bothrops pauloensis*** Black-faced lancehead (Brazil)
Bothrops peruvianus see *Bothriopsis oligolepis*
*Bothrops pictus**** Desert lancehead (coastal Peru)
*Bothrops pirajai**** Piraja's lancehead (Brazil)
Bothrops pradoi see *B. leucurus*
*Bothrops pubescens*** Pampas lancehead (Brazil)
Bothrops pulcher see *Bothrocophias myersi*
*Bothrops punctatus**** (Pacific Panama across Colombia to Ecuador)
*Bothrops sanctaecrucis**** Bolivian lancehead (Bolivia)
Bothrops schlegelii see *Bothriechis schlegeli*
Bothrops taeniatus see *Bothriopsis taeniata*
*Bothrops venezuelensis**** Venezuela lancehead (N and C Venezuela)
Bothrops xanthogrammus see *B. atrox*
Genus: *Calloselasma*
*Calloselasma rhodostoma*** Malayan pit viper (N Burma, Thailand, Cambodia, Laos, Vietnam)
Genus: *Cerrophidion*, montane pit vipers
*Cerrophidion barbouri**** Barbour's montane pit viper (Mexico)

*Cerrophidion godmani**** Godman's montane pit viper (Central America - from Mexico as far as Costa Rica)
*Cerrophidion petlalcalensis**** (E Mexico)
*Cerrophidion tzotzilorum**** Tzotzil montane pit viper (Mexico)
Genus: *Crotalus*, rattlesnakes
Crotalus abysus see *C. oreganus abyssus*
*Crotalus adamanteus**** Eastern diamond-backed rattlesnake (SE USA - from SE Carolina as far as Florida, and S Mississippi and SE Louisiana to the west)
Crotalus angelensis see *C. mitcheli angelensis*
*Crotalus aquilus*** Queretaran dusky rattlesnake (C Mexico)
*Crotalus atrox**** Western diamond-backed rattlesnake (Oklahoma to C Mexico and California)
*Crotalus basiliscus**** Mexican West Coast rattlesnake (the W coast of Mexico)
*Crotalus catalinensis*** Santa Catalina Island rattlesnake (the Santa Catalina Islands near California)
*Crotalus cerastes*** Sidewinder
-- *C. cerastes cerastes* Mojave Desert sidewinder (the Mojave Desert)
-- *C. cerastes cercobombus* Sonoran sidewinder (the Sonora Desert, N Mexico)
-- *C. cerastes laterorepens* Colorado Desert sidewinder (the Colorado Desert, NW Mexico)
*Crotalus cerberus**** (the USA)
*Crotalus concolor**** (the USA)
*Crotalus durissus**** South American rattlesnake
-- *C. durissus cascavella* (Brazil)
-- *C. durissus collilineatus* (Brazil)
-- *C. durissus culminatus* see *Crotalus simus culminatus*
-- *C. durissus cumanensis,* syn. *C. durissus pifanorum* (NE Colombia, Venezuela, W Guyana)
-- *C. durissus dryinas* - more recently one of *C. durissus durissus* synonyms (Guyana, French Guyana, Surinam)
-- *C. durissus durissus* (SE Mexico, SW Nicaragua, Honduras to NW and C Costa Rica)
-- *C. durissus marajoensis* (Marajó Island)
-- *C. durissus ruruima* (Venezuela, N Brazil, and the neighboring part of Guyana)
-- *C. durissus terrificus* (SE Peru, Bolivia, Paraguay, N Uruguay, C Argentina, S Brazil)
-- *C. durissus totonacus* see *C. totonacus*
-- *C. durissus trigonicus* (SW Guyana)
-- *C. durissus tzabcan* see *C. simus tzabcan*
-- *C. durissus unicolor* Aruba Island rattlesnake (Aruba Island)
-- *C. durissus vegrandis* (Venezuela and the neighboring areas of Colombia)
*Crotalus enyo*** Lower California rattlesnake
-- *C. enyo cerralvensis* (the island of Cerralvo near Mexico)
-- *C. enyo enyo* (Mexico - N and C part of the Californian Peninsula and the neighboring islands)
-- *C. enyo furvus* (Mexico - W Californian Peninsula)
Crotalus exsul see *C. ruber exsul*
*Crotalus helleri**** (Coronado del Sur Island, the USA as far as Mexico)

*Crotalus horridus**** Timber rattlesnake (SE, NE and E of the central USA, Canada - Ontario)
-- *C. horridus atricaudatus*, *C. horridus horridus* - more recently not listed as a subspecies
*Crotalus intermedius*** Mexican smallhead rattlesnake
-- *C. intermedius gloydi* (SW USA, N Mexico)
-- *C. intermedius intermedius* (N Mexico)
-- *C. intermedius omiltemanus* (N Mexico)
*Crotalus lannomi*** Autlan long-tailed rattlesnake (Mexico - Jalisco, Puerto los Mazos)
*Crotalus lepidus*** Rock rattlesnake
-- *C. lepidus klauberi* Banded rock rattlesnake (N USA, NW Mexico)
-- *C. lepidus lepidus* Mottled rock rattlesnake (N USA and the neighboring areas of NE Mexico)
-- *C. lepidus maculosus* (Mexican Sierra Madre Occidental)
-- *C. lepidus morulus* (Mexico)
*Crotalus lutosus**** (the USA)
*Crotalus mitcheli**** Southwestern speckled rattlesnake
-- *C. mitcheli angelensis* (Angel de la Guarda Island)
-- *C. mitcheli mitcheli* (W Mexico)
-- *C. mitcheli muertensis* (El Muerto Island)
-- *C. mitcheli pyrrhus* (SW USA)
-- *C. mitcheli stephensis* (east of C California and SW Nevada)
*Crotalus molossus**** Black-tailed rattlesnake
-- *C. molossus estebanensis* (San Estéban Island)
-- *C. molossus molossus* (SW USA, the neighboring areas of Mexico, Tiburón Island)
-- *C. molossus nigrescens* (Mexico)
-- *C. molossus oaxacus* (Mexico)
*Crotalus oreganus****
-- *C. oreganus abyssus* (Arizona)
-- *C. oreganus caliginis* see *C. helleri*
-- *C. oreganus cerberus* see *C. cerberus*
-- *C. oreganus concolor* see *C. concolor*
-- *C. oreganus helleri* see *C. helleri*
-- *C. oreganus lutosus* see *C. lutosus*
-- *C. oreganus oreganus* (SW Canada to W coast of the USA and NE Karolina)
*Crotalus polystictus*** Mexican lancehead rattlesnake (the N part of the Mexican Plateau)
*Crotalus pricei*** Twin-spotted rattlesnake
-- *C. pricei miquihuanus* (Mexican Sierra Madre Oriental)
-- *C. pricei pricei* (SE Arizona)
*Crotalus pusillus*** Tancitaran dusky rattlesnake (Mexico)
*Crotalus ravus*** Mexican massasauga
-- *C. ravus brunneus* (Mexico - the mountain range of the State of Oaxaca)
-- *C. ravus exiguus* (Mexico - the State of Guerrerro)
-- *C. ravus ravus* (Mexico - the central plains of Altiplanicia)
*Crotalus ruber**** Red diamond rattlesnake (SW USA and NW Mexico)

-- *C. ruber exsul* (Cedros Island, Mexico)
-- *C. ruber lorenzoensis* (San Lorenzo Sur Island, Mexico)
-- *C. ruber lucasensis* (the southern part of the Californian Peninsula, San Margarita and San José islands)
-- *C. ruber ruber*, syn. *C. ruber monserratensis, C. ruber elegans* (SW USA, NW Mexico)
*Crotalus scutulatus**** Mojave rattlesnake (SW USA to C Mexico)
-- *C. scutulatus scutulatus* (the USA to C Mexico)
-- *C. scutulatus salvini* (Mexico)
*Crotalus simus****
-- *C. simus simus* (Mexico to Costa Rica)
-- *C. simus culminatus* (SW Mexico)
-- *C. simus tzabcan* (from Yucatán as far as North Belize and Guatemala)
*Crotalus stejnegeri*** Longtail rattlesnake (Mexico)
*Crotalus tancitarensis*** (Mexico - the State of Michoacan)
*Crotalus tigris***Tiger rattlesnake (the USA, NW Mexico)
*Crotalus tortugensis*** Tortuga Island rattlesnake (Tortuga Island)
*Crotalus totonacus**** (NE Mexico)
*Crotalus transversus*** Cross-banded mountain rattlesnake (Mexico)
*Crotalus triseriatus*** Central Plateau dusky rattlesnake
-- *C. triseriatus aquilus* see *Crotalus aquilus*
-- *C. triseriatus armstrongi* (Mexico, the Mesa Central and Sierra Madre Occidental mountains)
-- *C. triseriatus triseriatus* (Mexico, the Transverse Volcanic Cordillera mountains)
Crotalus unicolor see *Crotalus durissus unicolor*
Crotalus vegrandis see *Crotalus durissus vegrandis*
*Crotalus viridis**** Northern Pacific rattlesnake (SW USA and N Mexico)
-- *C. viridis abyssus* see *C. oreganus abyssus*
-- *C. viridis caliginis* see *C. helleri*
-- *C. viridis cerberus* see *C. cerberus*
-- *C. viridis concolor*, syn. *C. viridis decolor* see *Crotalus concolor*
-- *C. viridis helleri* see *C. helleri*
-- *C. viridis lutosus* see *C. lutosus*
-- *C. viridis nuntius* (the USA)
-- *C. viridis oreganus* see *C. oreganus oreganus*
-- *C. viridis viridis* (the USA, S Canada, Mexico)
*Crotalus willardi*** Ridge-nosed rattlesnake
-- *C. willardi amabilis* (Sierra del Nido, Mexico)
-- *C. willardi meridionalis* (Mexico)
-- *C. willardi obscurus* (Mexico and New Mexico, the USA)
-- *C. willardi silus* (Mexico)
-- *C. willardi willardi* (the USA and Mexico)
Genus: *Cryptelytrops* see *Trimeresurus*
Genus: *Deinagkistrodon*
*Deinagkistrodon acutus**** Chinese moccasin (SE China, N Vietnam, Taiwan, Laos)
Genus: *Garthius* see *Ovophis*

Genus: *Gloydius*, Asian moccasins
*Gloydius blomhoffii*** Mamushi
-- *G. blomhoffii blomhoffii* (Japan)
-- *G. blomhoffii brevicaudus*, syn. *G. blomhoffii dubitatus* see *G. brevicaudus*
-- *G. blomhoffii ussuriensis* see *G. ussuriensis*
-- *G. blomhoffii siniticus* (China)
Gloydius caliginosus see *G. ussuriensis*
*Gloydius brevicaudus*** (Korea and NE China)
*Gloydius halys*** Halys pit viper
-- *G. halys boehmei* (E Afghanistan)
-- *G. halys caraganus* (from the Volga River delta to E Kazakhstan as far as Tajikistan to the south, and Kyrgyzstan and NW China to the east)
-- *G. halys cognatus* (N China)
-- *G. halys halys* (Russia, Mongolia, China)
-- *G. halys mogoi* (Mongolia and S Siberia), more recently included in *G. halys halys* synonyms
-- *G. halys caucasicus* (SE Azerbaijan, North Iran, S Turkmenistan, NW Afghanistan)
-- *G. halys stejnegeri* (N and SE Mongolia and the neighboring part of China)
*Gloydius himalayanus*** Himalayan pit viper (NE Pakistan, N India to C Nepal)
*Gloydius intermedius*** Central Asian pit viper (E Turkmenistan, E Kazakhstan, S Siberia, SE Russia, Mongolia, China, Korea)
-- *G. intermedius caucasicus* see *G. halys caucasicus*
-- *G. intermedius intermedius*
-- *G. intermedius saxatilis*
-- *G. intermedius stejnegeri* see *G. halys stejnegeri*
*Gloydius monticola*** Likiang pit viper (China)
Gloydius saxatilis see *G. intermedius saxatilis*
*Gloydius shedaoensis*** Shedao Island pit viper (Shedao Island)
*Gloydius strauchi*** Strauch's pit viper (SW China)
*Gloydius tsushimaensis*** Tsushima Island pit viper (Japan)
*Gloydius ussuriensis*** Ussuri mamushi (Korea, E China, SE Russia)
Genus: *Himalayophis* see *Trimeresurus*
Genus: *Hypnale*, hump-nosed pit vipers
*Hypnale hypnale*** Hump-nosed moccasin (N India)
*Hypnale nepa** Sri Lanka hump-nosed viper (SW Sri Lanka)
*Hypnale walli** Wall's hump-nosed viper (SW Sri Lanka)
Genus: *Lachesis*, bushmasters
*Lachesis acrochorda**** (Panama across Colombia to Ecuador)
*Lachesis melanocephala**** Black-headed bushmaster (SE Costa Rica)
*Lachesis muta**** South American bushmaster
-- *L. muta melanocephala* see *L. melanocephala*
-- *L. muta muta* (Colombian equatorial forests to Trinidad, southwards as far as Bolivia, the Andes - Ecuador and Colombia)
-- *L. muta rhombeata*, syn. *L. muta noctivaga* (the SE coast of Brazil), more recently included in *Lachesis muta* synonyms
-- *L. muta stenophrys* see *L. stenophrys*

*Lachesis stenophrys**** Central American bushmaster (Costa Rica to Panama)
Genus: *Ophryacus*, Mexican horned pit vipers
*Ophryacus melanurus*** (N Mexico)
*Ophryacus undulatus*** Mexican horned pit viper (Mexico)
Genus: *Ovophis*, mountain pit vipers
*Ovophis chaseni*** Chasen's mountain pitviper (a type locality - Kiau, Mt. Kinabalu, the province of Sabah, Borneo) - also listed under a newly recognized *Garthius* genus
*Ovophis monticola*** Chinese mountain pit viper
-- *O. monticola convictus* (Vietnam, Cambodia, Thailand, W Malaysia, Indonesia)
-- *O. monticola makazayazaya* (N China and Taiwan)
-- *O. monticola monticola* (India, Nepal, Bangladesh, Burma, S China)
-- *O. monticola orientalis* (N and SE China)
-- *O. monticola zayuensis* see *O. zayuensis*
-- *O. monticola zhaokentangi* (China)
*Ovophis okinavensis*** Ryukyu Island pit viper (Japan)
*Ovophis tonkinensis*** Tonkin pitviper (Vietnam)
*Ovophis zayuensis*** (Tibet)
Genus: *Parias* see *Trimeresurus*
Genus: *Peltopelor* see *Trimeresurus*
Genus: *Popeia* see *Trimeresurus*
Genus: *Porthidium*, hognosed pit vipers
*Porthidium arcosae*** (type localities - Aqua Blanca, Manabí, Mexico)
Porthidium almawebi see *Bothrocophias campbelli* and *Bothrocophias myersi*
Porthidium barbouri see *Cerrophidion barbouri*
Porthidium colombianum see *Bothrocophias colombianus*
*Porthidium dunni*** Dunn's hognose viper (Mexico)
Porthidium godmani see *Cerrophidion godmani*
*Porthidium hespere*** Western hognose viper (a type locality - Municipio de Ixlahuacán, Colima, Mexico)
Porthidium hyoprora see *Bothrocophias hyoprora*
*Porthidium lansbergii***
-- *P. lansbergii arcosae* see *Porthidium acrosae*
-- *P. lansbergii lansbergi* (C Panama, N Colombia, W Venezuela)
-- *P. lansbergii rozei*, syn. *P. lansbergii venezuelensis* (coastal Venezuela), more recently *Porthidium lansbergii* synonyms
Porthidium melanurum see *Ophryacus melanurus*
Porthidium microphtalmum see *Bothrocophias microphthalmus*
*Porthidium nasutum*** Rainforest hognosed pitviper (isolated patches of populations in S Mexico to W Colombia and NW Ecuador)
Porthidium nummifer see *Atropoides nummifer*
Porthidium olmec see *Atropoides olmec*
*Porthidium ophryomegas*** Slender hog-nosed pitviper (Pacific Central America from Guatemala as far as Panama)
*Porthidium porrasi*** (Costa Rica)
Porthidium picadoi see *Atropoides picadoi*
Porthidium tzotzilorum see *Cerrophidion tzotzilorum*

*Porthidium volcanicum*** (Costa Rica)
*Porthidium yucatanicum*** Yucatán hognose viper (Mexico)
Genus: *Protobothrops*, Asian pit vipers
*Protobothrops cornutus*** Fan-Si-Pan horned pit viper (N Vietnam)
*Protobothrops elegans*** Elegant pit viper (Japan)
*Protobothrops flavoviridis**** Habu (Japan)
*Protobothrops jerdonii*** Bourret's pit viper
-- *P. jerdoni bourreti* (N Vietnam)
-- *P. jerdoni jerdoni* (India, Nepal, Burma, China)
-- *P. jerdoni xanthomelas* (N China)
*Protobothrops kaulbacki*** Kaulback's lance-headed pit viper (a type locality - Pang-nam-dim, N Burma)
*Protobothrops mucrosquamatus**** Brown spotted pit viper (India, Bangladesh, S China, Burma, N Vietnam, Taiwan, Hainan)
*Protobothrops tokarensis*** Tokara habu (Japan)
*Protobothrops xiangchengensis*** Kham Plateau pit viper (China - W Sichuan and Yunnan)
Genus: *Sistrurus*, ground rattlesnakes
*Sistrurus catenatus*** Massasauga
-- *S. catenatus catenatus* (SE Canada and the USA)
-- *S. catenatus edwardsii* (the USA and N Mexico)
-- *S. catenatus tergeminus* (SW plains, the USA)
*Sistrurus miliarius*** Pigmy rattlesnake
-- *S. miliarius barbouri* (the USA - SW South Carolina to Florida)
-- *S. miliarius miliarius* (the USA - the lowlands along the coast of the Atlantic Ocean from North Carolina as far as Georgia and C Alabama)
-- *S. miliarius streckeri* (the USA - SW Kentucky, western C Alabama, W Mississippi to SW Tennessee, E Texas)
Sistrurus ravus Mexican Massasauga see *Crotalus ravus* ssp
Genus: *Triceratolepidophis*
*Triceratolepidophis sieversorum*** Three horned-scaled pit viper (Vietnam - the province of Quang Binh and the neighboring areas of Laos)
Genus: *Trimeresurus*, Asian pit vipers, Asian lanceheads or lance-headed vipers
*Trimeresurus albolabris*** White-lipped tree viper (NE India, S China, Hainan, Thailand, Vietnam, Hong Kong, Malayan Peninsula) - also listed under a newly recognized *Cryptelytrops* genus
-- *T. albolabris albolabris*
-- *T. albolabris insularis* see *T. insularis*
-- *T. albolabris septentrionalis* see *T. septentrionalis*
*Trimeresurus andersoni*** Anderson's pitviper - also listed under a newly recognized *Cryptelytrops* genus (the Andaman and Nicobar Islands)
*Trimeresurus barati*** Barat bamboo pitviper (Indonesia)
*Trimeresurus borneensis*** Borneo pit viper (N Thailand, Malaysia, Indonesia, Brunei)
*Trimeresurus brongersmai*** Brongersma's pit viper (Indonesia)
*Trimeresurus cantori*** Cantor's pit viper - also listed under a newly recognized *Cryptelytrops* genus (the Nicobar Islands)

Trimeresurus convictus see *Ovophis monticola convictus*
Trimeresurus cornutus see *Protobothrops cornutus*
Trimeresurus elegans see *Protobothrops elegans*
*Trimeresurus erythrurus*** Redtail (bamboo) pit viper - also listed under a newly recognized *Cryptelytrops* genus (India, E Bengal, Burma, Bangladesh)
*Trimeresurus fasciatus*** Banded pit viper - also listed under a newly recognized *Cryptelytrops* genus (Indonesia)
*Trimeresurus flavomaculatus*** Philippine pitviper - also listed under a newly recognized *Parias* genus (the Philippines - Balete, Camiguin, Jolo, Luzon, Mindanao, Mindoro, and Polillo islands)
-- *T. flavomaculatus flavomaculatus*
-- *T. flavomaculatus halieus*
-- *T. flavomaculatus mcgregori* see *T. mcgregori*
Trimeresurus flavoviridis see *Protobothrops flavoviridis*
*Trimeresurus fucatus*** Siamese Peninsula pitviper - also listed under a newly recognized *Popeia* genus (N Thailand)
*Trimeresurus gracilis*** Kikuchi habu (inland Taiwan, mountain ranges)
*Trimeresurus gramineus*** Common bamboo viper (N and C India)
*Trimeresurus gumprechti*** Gumprecht's green pitviper - also listed under a newly recognized *Viridovipera* genus (NE Thailand, China - Yunnan, Hainan, NW Vietnam, Laos, Burma)
*Trimeresurus hageni*** Indonesian pit viper or Hagen's pitviper - also listed under a newly recognized *Parias* genus (N Thailand, Malayan Peninsula, Indonesia).
Trimeresurus huttoni see *Tropidolaemus huttoni*
*Trimeresurus insularis*** White-lipped island pitviper - also listed under a newly recognized *Cryptelytrops* genus (E Indonesia)
Trimeresurus jerdoni see *Protobothrops jerdoni* ssp.
*Trimeresurus kanburiensis*** Kanburi pit viper - also listed under a newly recognized *Cryptelytrops* genus (Kanburi, SW Thailand)
Trimeresurus kaulbacki see *Protobothrops kaulbacki*
*Trimeresurus labialis*** Island pit viper, Nicobar bamboo pitviper - also listed under a newly recognized *Cryptelytrops* genus (the Andaman and Nicobar Islands)
*Trimeresurus macrolepis*** Large-scaled pit viper - also listed under a newly recognized *Peltopelor* genus (N India).
*Trimeresurus macrops*** Kramer's pit viper, large-eyed pitviper - also listed under a newly recognized *Cryptelytrops* genus (Thailand, Cambodia to S Vietnam).
*Trimeresurus malabaricus*** Malabarian pit viper (SW coast of India)
*Trimeresurus malcolmi*** Malcolm's pitviper - also listed under a newly recognized *Parias* genus (Borneo)
*Trimeresurus mangshanensis*** Mangshan pitviper - also listed under a newly recognized *Zhaoermia* genus (a type locality - Mangshan, the province of Hunan, China)
*Trimeresurus mcgregori*** McGregor's pitviper - also listed under a newly recognized *Parias* genus (the Philippines - Batan)
*Trimeresurus medoensis*** Green bamboo leaf pit viper, Motuo bamboo pitviper - also listed under a newly recognized *Viridovipera* genus (India, N Burma, SE China)
Trimeresurus monticola see *Ovophis monticola* ssp.

Trimeresurus mucrosquamatus see *Protobothrops mucrosquamatus*
*Trimeresurus nebularis*** Cameron highlands pit viper - also listed under a newly recognized *Popeia* genus (Malaysia)
*Trimeresurus popeiorum*** Pope's tree viper or Pope's bamboo pit viper - also listed under a newly recognized *Popeia* genus
-- *T. popeiorum barati* see *T. barati*
-- *T. popeiorum popeiorum* (E India to Malayan Peninsula)
-- *T. popeiorum sabahi* see *T. sabahi*
*Trimeresurus puniceus*** Ashy pit viper, flat-nosed pitviper (Indonesia)
*Trimeresurus purpureomaculatus*** Shore pit viper or mangrove viper - also listed under a newly recognized *Cryptelytrops* genus (W Thailand, Burma, Malaysia, Indonesia)
-- *T. purpureomaculatus andersoni* see *T. andersoni*
-- *T. purpureomaculatus purpureomaculatus*
*Trimeresurus sabahi*** Sabah bamboo viper (Borneo)
*Trimeresurus septentrionalis*** - also listed under a newly recognized *Cryptelytrops* genus (Nepal, India, Bangladesh)
*Trimeresurus schultzei*** Schultze's pit viper - also listed under a newly recognized *Parias* genus (the Philippines)
*Trimeresurus stejnegeri*** Chinese green tree viper, Stejneger's bamboo pitviper - also listed under a newly recognized *Viridovipera* genus
-- *T. stejnegeri stejnegeri* (N China, N Vietnam, Cambodia, E Thailand, Hainan, Taiwan)
-- *T. stejnegeri chenbihuii* (Hainan, China)
-- *T. stejnegeri yunnanensis* see *T. yunnanensis*
*Trimeresurus strigatus*** Horseshoe pitviper (N India)
*Trimeresurus sumatranus*** Sumatra pit viper - also listed under a newly recognized *Parias* genus (Indonesia, Malaysia)
-- *T. sumatranus malcolmi* see *T. malcolmi*
-- *T. sumatranus sumatranus*
*Trimeresurus tibetanus*** Tibetan bamboo pitviper (a type locality - Chokosumo, Nyalam Co., Tibet, China), also listed under a newly recognized *Himalayophis* genus
Trimeresurus tokarensis see *Protobothrops tokarensis*
Trimeresurus tonkinensis see *Ovophis tonkinensis*
*Trimeresurus trigonocephalus*** Ceylon pit viper, Sri Lankan green pitviper (Sri Lanka)
*Trimeresurus truongsonensis*** (C Vietnam)
*Trimeresurus venustus*** Beautiful pitviper - also listed under a newly recognized *Cryptelytrops* genus (a type locality - Thung Song, Nakhon Si Thammart, Thailand)
*Trimeresurus vogeli*** Vogel's pit viper - also listed under a newly recognized *Viridovipera* genus (Thailand, Cambodia, Laos, Vietnam)
Trimeresurus xiangchengensis see *Protobothrops xiangchengensis*
*Trimeresurus yunnanensis*** Yunnan bamboo pitviper - also listed under a newly recognized *Viridovipera* genus (Nepal, E India, China, N Burma)
Trimeresurus zayuensis see *Ovophis zayuensis*
Genus: *Tropidolaemus*, temple vipers
*Tropidolaemus huttoni*** Hutton's pitviper (N India)
*Tropidolaemus wagleri*** Wagler's palm viper, Wagler's pit viper, temple pitviper (Borneo, Malaysia, Sumatra, Sulawesi, the Philippines)

-- *T. wagleri alboviridis*
-- *T. wagleri celebensis*
-- *T. wagleri philippensis*
-- *T. wagleri schlegelii*
-- *T. wagleri wagleri*
Genus: *Viridovipera* see *Trimeresurus*
Genus: *Zhaoermia* see *Trimeresurus*

REFERENCES

CAMPBELL, JA., LAMAR, WW. *The venomous Reptiles of the western hemisphere.* Comstock, Ithaca, London : Cornell University Press, 2004, 1032 pp.

CAMPBELL, JA., LAMAR, WW. *The venomous Reptiles of Latin America.* Ithaca, London : Cornell University Press, 1989, 425 pp.

McDIARMID, RW., CAMPBELL, JA., TOURE, TA. *Snake species of the world. A taxonomic and geographic reference.* Vol. 1. Washington DC : Herpetologists' League, 1999, 512 pp.

GOLAY, P. *Checklist and keys to the Terrestrial Proteroglyphs of the world.* Geneva : Elapsoidea, 1985, 91 pp.

GOLAY, P., SMITH, HM., et al. *Endoglyphs and other major venomous snakes of the world.* Geneva : Azemiops S.A. Herpetological Data Center, 1993, 478 pp.

GUMPRECHT, A., TILLACK, F., et al. *Asian Pitvipers.* Berlin : GeitjeBooks, 2004, 368 pp.

HARDING, KA., WELCH, KRG. *Venomous snakes of the world – a checklist.* Oxford : Pergamon Press, 1980.

HUTCHINSON, MN. *The generic classification of the Australian terrestrial Elapid snakes.* Memoirs of the Queensland Museum, 1990, 28, pp. 397–405.

O´SHEA, M. *Venomous snakes of the world.* London : New Holland Publishers, 2005.

STÖCKLIN, R., CRETTON, G. *The ultimate database on venomous animals, snakes.* CD-rom, Geneva : Atheris Laboratories, 1998.

WÜSTER, W., BUSH, B., et al. Taxonomic contributions in the »amateur« literature: comments on recent descriptions of new genera and species by Raymond Hoser. *Litteratura Serpentium*, 2001, 21, pp. 67–79, 86–91.

GLOSSARY

(hemo)coagulation	A complex process by which blood forms clots.
abscess	Limited suppurative inflammation.
acidosis	An increased acidity of tissues, when tissue ph falls below 7.38.
adaptive radiation	Evolution of an animal or plant group into a wide variety of types adapted to specialized modes of life.
adherence	Adhesion
affection	Affection in terms of a disease or a morbid symptom.
affinity	An inherent likeness or relationship.
agent	A substance causing a disease.
agglutination	The act of clumping together or adhesion of particles.
aggravation	An increasing in seriousness or severity of subjective symptoms of disease.
aggregability	A tendency to aggregate.
aggregation	The act of aggregating, or the state of being aggregated.
albuminuria	A pathological condition where albumin is present in the urine. It is a type of proteinuria.
alteration	A pathological change or disorder.
alveolus	A small cell containing air in the lungs, a sac-like dilation of the alveolar ducts in the lung.
amnesia	A short-term memory condition in which memory is disturbed; the loss of memory.
analgesia	The inability to feel pain while still conscious.
analgesic	A medicine used to relieve pain.
anaphylactic shock	Anaphylactic shock, the most severe type of anaphylaxis leading to systemic vasodilation associated with a sudden drop in blood pressure.
anaphylactoid	Anaphylactic-like reaction.
ancestral	Of, relating to, or evolved from an ancestor or ancestors.
angioneurotic edema	The rapid edema of the lips, eyes, tongue, and neck of mostly allergic origin.
anguimorph	A member of the Anguimorpha taxon.
anisocoria	A condition characterized by an unequal size of the pupils.
ankylosis	A stiffness of a joint.

anticoagulant	A substance that prevents coagulation and can be used in vivo as a medication for thrombotic disorders.
antiemetic	Preventing or alleviating vomiting.
antigenemia	The level of an antigen in circulating blood.
antihistaminics	Anti-allergic medicaments.
antiphlogistics	Medicaments that reduce inflammation.
anuria	Nonpassage of urine.
anxiety	Anxiety is a psychological and physiological state characterized by cognitive, somatic, emotional, and behavioral components.
anxious	Causing or fraught with or showing anxiety.
apoptosis	The process of cell death.
aquatic	Relating to water; living in or near water, taking place in water.
arteria mesenterica superior	Superior mesenteric artery; arises from the anterior surface of the abdominal aorta.
ascites	A pathologic accumulation of fluid in the peritoneal cavity.
aspiration	The entry of secretions or foreign material (herein the stomach content) into the trachea and lungs.
ataxia	Unsteady and clumsy motion of the limbs or trunk due to a failure of the gross coordination of muscle movements.
axon or nerve fiber	A long, slender projection of a nerve cell, or neuron, that conducts electrical impulses away from the neuron's cell body or soma.
basic	Denoting or of the nature of or containing a base.
benign	Not dangerous to health; not recurrent or progressive.
blepharospasm	Twitching of an eyelid.
blood circulation	The course of the blood from the heart through the arteries, capillaries, and veins back again to the heart.
blood clot or thrombus	A coagulated mass of blood.
bolus	Referring to an injection or treatment given over a short period of time.
bradycardia	Excessively slow heart beat.
bronchial	Relating to or associated with the bronchi.
bronchopneumonia	An inflammation of the lungs.
bronchospasm	A sudden constriction of the muscles in the walls of the bronchioles accompanied by dyspnea; mostly of an allergic nature.
cardiotoxic	Causing damage to the tissues of the heart; toxic for the heart.
circulus vitiosus	Vicious circle.
clearance	The rate at which a substance is removed or cleared from the body.
clotting ability	The ability of clotting.
coagulation	The process by which blood forms solid clots.

coagulopathy	A disease, which limits the coagulation ability of the blood.
compartment	One of the parts in which an area is either partially or fully subdivided.
compartment syndrome	Compartment syndrome is an acute medical problem following injury, surgery or in most cases repetitive and extensive muscle use, in which increased pressure (usually caused by edema of tissues) within a confined space (fascial compartment) in the body impairs blood supply. Without prompt recognizing and treatment, it may lead to necrosis of the tissues, with possible necessity of limb amputation.
complement system	A cascade of proteins in the blood that form part of innate immunity.
congestion	Overfullness of the tissue.
conjunctival	Of or relating to the conjunctiva.
conjunctivitis	An inflammation of the conjunctiva.
constipation	Irregular and infrequent or difficult evacuation of the bowels.
contractility	The capability or quality of shrinking or contracting.
contracture	A pathological contraction of a muscle, a spasm, either temporary or as a result of fibrous conversion.
convulsion	A medical condition where body muscles contract and relax rapidly and repeatedly, resulting in an uncontrolled shaking of the body.
corneal	Of or related to the cornea.
coronarospasm	A contraction in one location in the muscles in the wall of an artery in the heart.
coronary: coronary vessels	Blood vessels surrounding the heart.
cranial polyneuritis	Multiple mononeuropathy involving several cranial nerves.
craniocaudally	From head end to opposite end of body or lower limbs.
curare-like	A neurotoxin with effects similar to that of curare, i.e. muscular paralysis.
cytotoxic	The quality of being toxic to cells.
debridement	The removal, typically surgical, of necrotic, infected or foreign material from a severe wound.
defibrination	Removal of fibrin from the blood.
demarcation	The boundary of a specific area.
deposit	Matter that has been deposited by some natural process (herein used for fibrin deposits).
desquamation	The shedding of epithelial elements, chiefly of the skin, in scales or small sheets, exfoliation.
diaphragmatic	Pertaining to diaphragm.
diathesis	Constitutional predisposition to a particular disease or abnormality.
diplopia	Visual impairment in which an object is seen as two objects.
discrepancy	A difference between conflicting facts.

distal motor neuropathy	Damage of peripheral sections of motor nerves.
distension	Enlargement.
diuresis	Excretion of urine.
diversification	The back of the body of a vertebrate or any analogous surface (as the upper or outer surface of an organ or appendage or part).
dorsum	The back of the body of a vertebrate or any analogous surface (as the upper or outer surface of an organ or appendage or part).
dysarthria	A speech disorder.
dysesthesia	A sensation disorder.
dysfunction	Any disturbance in the function of an organ or body part.
dysphagia	A difficulty in swallowing.
dysphonia	A phonation disorder.
dyspnea	Shortness of breath.
ecchymosis	The escape of blood from ruptured blood vessels into the surrounding tissue to form a purple or black-and-blue spot on the skin.
efflorescence	Any red eruption of the skin.
Emetic	A medicine that induces nausea and vomiting.
encephalopathy	Any disorder or disease of the brain.
endothelium	The thin layer of cells that line the interior surface of blood vessels.
Enucleation	Surgical removal of a ball-like formation, e.g. an eye, without cutting into or dissecting it.
Epigastrium	The upper central region of the abdomen.
epistaxis	Occurrence of hemorrhage from the nose.
erythema	Redness of the skin.
erythrocyturia	Occurrence of red blood cells in urine.
etiology	The cause of a disease.
excretion	The process of eliminating waste products of metabolism and other non-useful materials.
exhaustion	Serious weakening and loss of energy.
expiration,	see shelf life
extracellular	Located or occurring outside a cell or cells.
Extrasystole	Premature heart contraction.
extravasation	A discharge or escape of fluid or even blood elements outside a vascular system.
extravascular	Situated or occurring outside a vessel or the vessels.
eye accommodation	A process by which the vertebrate eye changes optical power to maintain a clear image (focus) on an object as its distance changes.
facial	Of or concerning the face.
fascia	The soft tissue component of the connective tissue system that permeates the human body.

fasciculation	Rapid muscular twitching of contiguous groups of muscle fibers.
fasciotomy	Incision through a fascia.
fatality	An individual instance of death.
fever	A frequent medical sign that describes an increase in internal body temperature to levels above normal.
fibrin	A fibrous protein (also called Factor Ia) involved in the clotting of blood.
fibrinogen	A protein present in blood plasma; converts to fibrin through the action of enzymes when blood clots.
fibrinogenolysis	The proteolytic destruction of fibrinogen in circulating blood.
fibrinolysis	The process wherein a fibrin clot, the product of coagulation, is broken down.
fluid therapy	Therapy whose basic objective is to restore the volume and composition of the body fluids to normal with respect to water-electrolyte balance.
fluidothorax	see pleural effusion
gastrointestinal	Of or relating to the stomach and intestines.
glomerulus	A capillary tuft surrounded by Bowman's capsule in nephrons of the vertebrate kidney.
glycemia	The concentration of glucose in the blood.
glycosylation	The enzymatic process that links saccharides to produce glycans.
half-life	The interval required for the quantity to be excreted or decayed to half of its initial value.
hematemesis	Vomiting of blood.
hematolysis	Lysis of erythrocytes with the release of hemoglobin.
hematuria	The presence of erythrocytes in the urine that is manifest by red color.
hemicolectomy	The surgical resection of a half of the large intestine.
hemocoagulation	A process of blood clotting.
hemoconcentration	A condition of decrease in the volume of plasma in relation to the number of red blood cells; increase in the concentration of red blood cells in the circulating blood.
hemodialysis	A method for removing waste products from the blood by means of a dialysis machine.
hemodynamic	Relating to or involved in hemodynamics.
hemoglobin	The red blood pigment contained in the red blood cells.
hemoglobinuria	A condition in which hemoglobin is found in abnormally high concentrations in the urine, which is manifest by red color of the urine.
hemolytic	Relating to or involving or causing hemolysis.
hemoptysis	The expectoration (coughing up) of blood or of bloodstained sputum from the lungs.

hemorrhage	Bleeding, i.e. the loss of blood from the circulatory system.
hemostasis	A complex process, which causes the bleeding process to stop.
heparin	Heparin, a polysaccharide, widely used as an anticoagulant in medicine.
heparinization	A process of treating with heparin.
hibernation	A state of inactivity and metabolic depression in animals, e.g. in winter.
hyalinous	Herein amorphous or fibrous.
hyperbaric medicine	Also known as hyperbaric oxygen therapy (HBOT), the medical use of oxygen at a level higher than atmospheric pressure.
hypercoagulation	An increased tendency for clotting of the blood.
hyperfibrinolysis	Markedly increased fibrinolysis.
hyperkalemia	An elevated blood level of the electrolyte potassium.
hypertension	High blood pressure.
hypoalbuminemia	A medical condition where levels of albumin in blood serum are abnormally low.
hypoesthesia	A reduced sense of touch or sensation, or a partial loss of sensitivity to sensory stimuli.
hypogastrium	An area of the human abdomen residing below the umbilicus.
hypotension	A condition of abnormally low blood pressure.
hypovolemia	A state of decreased blood volume; more specifically, decrease in volume of blood plasma.
chemosis	The swelling (or edema) of the conjunctiva.
iatrogenic	Caused by or resulting from medical treatment or advice.
idiopathic	Arising spontaneously or from an obscure or unknown cause.
ileus	An obstruction of the intestines.
immunogenicity	The ability of an antigen to provoke an immune response.
incidence	A number of new cases of disease within a specified period of time.
incipient	Only partly in existence; imperfectly formed.
induce	Cause to occur.
inhibit	Limit the range or extent of.
inhibitor	A molecule, which represses or prevents another molecule from engaging in a reaction.
inotropy	The force of muscle contraction.
instillation	The introduction of a fluid (by pouring or injection) drop by drop.
insufficiency	The condition of being insufficient or inadequate to the performance of the allotted duty.
intact	Not impaired or diminished in any way.
interference	The act of hindering or obstructing or impeding.
intermittent	Occurring at separated intervals, having periods of cessation

	of activity.
interstitium	Thin connective tissue, which surrounds the nerves and vessels.
intima	The innermost layer of a vessel.
intracerebral	Occurring or situated within the cerebrum.
intradermal	Within a dermal tissue layer.
intramuscular	Inside a muscle or the muscles.
intrauterine	Inside the uterus.
intravenous	Inside the vein.
intubation	The introduction of a tube into the trachea to allow for breathing.
ischemia	A restriction in blood supply.
junction	A type of structure connecting e.g. cells.
lactatemia or blood lactate	The concentration of lactates dissolved in the blood.
leukocytosis	An elevated white blood cell count above the normal range.
leucopenia	A decrease in the number of leukocytes found in the blood.
lucidity	A lucid state of mind; not confused.
lymphadenitis	A disease or swelling of the lymph nodes.
lymphadenopathy	A disease of the lymphatic tissue.
lymphangitis	A disease or inflammation of the lymphatic channels.
lymphatic	Of or relating to or produced by lymph.
lyophilization	A method of drying without destroying physical structure; material is frozen and then warmed in a vacuum so that the ice sublimes.
mandible	The lower jawbone.
maxilla	The upper jawbone.
median	The middle value of an ordered set of values.
melena	Abnormally dark tarry feces containing predigested blood.
mesentery	The peritoneum responsible for connecting the jejunum and ileum to the back wall of the abdomen.
micturition	Urination.
monophyletic taxon	A taxon genetically deriving from a common ancestor.
monotypic taxon	Any taxon that has a single immediately subordinate taxon.
morbidity	The proportion of people getting ill during a given time interval.
mortality	The ratio of the total number of deaths to the total population.
mortality	The proportion of people dying during a given time interval.
muscarinic effect	A vegetative reaction characterized by symptoms including increased salivation, decreased heartbeat, increased tension of splanchnic muscles, etc.
muscular	Of or relating to or consisting of muscle.
myasthenia	A disease characterized by muscular weakness.
mydriasis	Reflex pupillary dilation.
myocardium	The heart muscle.

myoglobin	A protein of muscular cells that is released in the process of decomposition of the cells.
myoglobinemia	Concentration of free myoglobin in the blood.
myoglobinuria	The presence of myoglobin in the urine, which is manifest by dark color of the urine.
myolysis	Breakdown of muscular tissue.
myonecrosis	Myonecrosis is a condition of necrotic damage to muscle tissue.
myotoxin	A substance that induce rapid necrosis of muscle.
nausea	A state of sickness.
necrectomy	Surgical removal of necrosed tissue.
necrosis	Death of tissue.
nephron	A basic structural and functional unit of the kidney consisting of glomerules and tubules.
nephropathy	Damage to or disease of the kidney.
nervus facialis	The facial nerve.
nervus medianus	Median nerve; a major nerve of the upper limb.
neuropathy	Any pathology of the peripheral nerves.
neurotoxic	Damaging a nerve tissue.
nomenclature	A system of words used to name organisms.
occlusion	Closure or blockage.
oculomotor paralysis	A condition of paralysis of muscles controlling eye movements.
oliguria	Abnormally small production of urine.
ontogenesis	The process of an individual development of an organism.
ophtalmoplegia	Paralysis of the one or more extraocular muscles.
oxygen therapy	The administration of oxygen as a medical intervention.
oxygenation	The process of providing with oxygen.
palatal and glossopharyngeal paralysis	Paralysis of palate and glossopharyngeal nerve (IX).
panophtalmitis	Inflammation of the whole eye.
paralysis	Loss of the ability to move a body part.
paraphyletic taxon	A group composed of a collection of organisms, including the most recent common ancestor of all those organisms. Unlike a monophyletic group, a paraphyletic taxon does not include all the descendants of the most recent common ancestor.
parenteral	Administered by means other than through the alimentary tract (as by intramuscular or intravenous injection).
paresis	A slight or partial paralysis.
paresthesia	Abnormal skin sensations.
pelagic	Relating to or occurring or living in or frequenting the open ocean.
perception	The process of perceiving.
perfusion	Flow; herein a flow of blood through organs or tissues.
perioral	Situated or occurring around the mouth.

peritoneum	A transparent membrane that lines the abdominal cavity and covers most of the viscera.
petechiae	Minute red or purple spots on the surface of the skin as the result of tiny hemorrhages of blood vessels in the skin.
phlegmon	A spreading diffuse inflammatory process of a subcutaneous or submucous tissue.
photophobia	A symptom of excessive sensitivity to light.
phyletic order	A sequence followed in listing of taxa which aids ease of use and roughly reflects the evolutionary relationships among the taxa.
pleural	Of or pertaining to the pleura or pleurae, or to the sides of the thorax.
pleural effusion	An abnormal accumulation of fluid in the pleural space.
poikilocyte	A degenerated form of an erythrocyte.
polyneuritis	A state of inflammation of many nerves simultaneously.
polyneuropathy	A neurological disorder that occurs when many peripheral nerves throughout the body malfunction simultaneously.
polyphyletic taxon	A taxon composed of unrelated organisms descended from more than one ancestor.
pool	Herein a deposit of venom.
precipitation	The condensation of a solid from a solution during a chemical reaction.
precursor	A compound that participates in the chemical reaction that produces another compound.
prevalence	In epidemiology, the total number of cases of the disease in the population at a given time.
prodromes	An early unspecific symptom that a disease, herein envenomation, is developing.
proteinuria	The presence of excessive protein in the urine.
pseudobulbar palsy	A disorder of the swallowing reflex and speech caused by damage to the nerves of the related area.
ptosis	Dropping of the upper eyelid caused by muscle paralysis and weakness.
putrid	In an advanced state of decomposition.
pyrogen	A substance that induces fever.
Quincke‘s edema	Involves swelling of tissues under the skin of the neck and face, often caused by an allergic reaction. It can result in suffocation.
rabies	An acute viral disease of the nervous system of warm-blooded animals.
recanalization	Restoration of the continuity of a lumen.
rectal	Of or involving the rectum.
regurgitation	A back movement, e.g. the reflex act of ejecting the contents of the stomach through the mouth.
relapse	The return of symptoms and signs of a disease after a period of improvement.

renal	Pertaining to the kidney.
retroperitoneum/extraperitoneum	An area occupying the most posterior aspect of the abdominal cavity.
reversible	Capable of going through a series of changes in either direction, forward or backward, as a reversible chemical reaction.
rhabdomyolysis	The destruction of skeletal muscle cells.
salivation	The secretion of saliva.
sedation	The act of calming, especially by the administration of a sedative.
sedative	A medication with tranquilizing properties.
sequence homology	The situation where nucleic acid or protein sequences are similar because they have a common evolutionary origin.
shelf life	Shelf life is that length of time that medicine is given before it is considered unsuitable for sale or consumption.
schistocytes	Fragments of red blood cells found in the circulation.
spasm	A convulsive contraction of a muscle.
spasticity	A state of hypertonicity or increase over the normal tone of a muscle, with heightened deep tendon reflexes.
stasis	An abnormal state in which the normal flow of a fluid (such as blood) is slowed or stopped.
stereotaxy	A surgical technique that uses medical imaging to precisely locate in three dimensions an anatomical site to which a surgical instrument or a beam of radiation is directed.
ST-segment	A part of the electrocardiographic tracing.
subarachnoid	Beneath the arachnoid membrane.
subcapsular	Situated or occurring below a capsule.
subconjunctival	Situated or occurring beneath the conjunctiva.
subfascial	Situated or occurring beneath a fascia.
subspecies	A taxonomic group that is a division of a species.
subterrestrial	Subterranean; dwelling underground.
superficial	Being or affecting or concerned with a surface.
tachycardia	The excessive rapidity in the action of the heart.
taxon	An animal or plant group or category, at any level, in a system for classifying plants or animals.
taxonomy	Classification or division of living organisms into ordered groups or categories.
terrestrial	Of or relating to or inhabiting the land.
thenar	The prominence of the palm above the base of the thumb.
thrombin	An enzyme (hemocoagulation factor) that acts on fibrinogen to produce fibrin.
thrombocytopenia	A decrease in the number of platelets in the blood.
thrombophilia	A pathologic tendency to the occurrence of thrombi.
thrombosis, thrombotization	The formation, development or presence of a thrombus.
thrombus	A coagulated mass of blood.
tibial	Relating to or located near a tibia.

transgression	The spreading of the sea over land.
trauma	Any physical damage to the body caused by violence or accident or fracture.
tremor	An involuntary trembling or quivering.
tubulus or tubule	A minute tube lined with glandular epithelium; as, the uriniferous tubules of the kidney.
ulceration	The formation or development of an ulcer.
urethra	The tube that conveys urine from the bladder to the outside.
urticarial	Relating to or marked by urticaria.
uveitis	An inflammation of part or all of the uvea.
varanoid	A member of the Varanoidea taxon.
vascular	Of or relating to or having vessels.
vasoconstriction	The functional diminution of the caliber of vessels.
vasodilation, vasodilatation	The increase in the internal diameter of a blood vessel that results from relaxation of smooth muscle within the wall of the vessel.
vasodilating	Causing vasodilation.
vasopressor	An agent causing elevation of blood pressure by stimulating contraction of the muscular tissue of the capillaries and arteries.
vasospasm	The contraction of smooth muscle within the wall of the vessel, mostly of pathologic origin, that causes a decrease in blood flow.
vegetative	Relating to bodily functions mediated by involuntary vegetative nerves.
vertigo	A reeling sensation.
volume expansion	An increase in the amount of fluid in the vessels (intravasal volume).
vomiting or emesis	The act of repeated regurgitation of stomach contents.

AUTHOR'S AFFILIATION

Dr Jiri Valenta, an anesthesia resuscitation and intensive care specialist, has worked for 20 years as the head of the intensive care unit in the Department of Anesthesia, Resuscitation and Intensive Care at the General Teaching Hospital, Charles University, Prague.

In cooperation with the world renowned expert on toxinology, Professor Dr Frantisek Kornalik, DrSc, he founded the Clinical Toxinology Center for the consultation and treatment of patients envenomed by snakes and other venomous creatures.

This center has assisted hundreds of victims bitten by either European vipers or other snakes exotic to Europe. None of these cases has resulted in mortality, irrespective of their seriousness. Dr Valenta also functions as a keeper of antivenoms for the Czech Republic.

Furthermore, the author has published articles on intensive care and clinical toxinology in the Czech Republic as well as abroad.

INDEX

abscess 73
abdominal pain 67
Acalyptophis 268
Acanthophis 23, 29, 30, 35, **134**, 135, 148, 263, 264
- *antarcticus* 323 (Fig)
acanthoxin 35
Acrochordoidea 2
acutin 43
adder 134, 161, 165, 188
Adenorhinos **159**, 271
afaacytin 42, 44, 167
Afai 173
Afghanistan 94, 104, 113, 179, 181, 237, 246, 251, 255, 263, 273, 274, 283
Afgoi 257
afibrinogenemia 43, 44, 78, 86, 89, 139, 142, 174, 197, 207, 211, 220, 227
Africa 20, 37, 88-94, 98, 102, 108, 109, 112, 115, 116, 123, 159, 161, 166, 167, 238, 239, 245, 253, 254, 263, 271, 272
- Central 109, 112, 122, 124, 159, 173, 237-239, 245, 254, 256, 273
- East 90, 93, 109, 112, 236, 238, 245, 273
- North 89, 93, 94, 112, 173, 184, 243, 246, 254, 255, 257, 272
- North-eastern 112, 173, 245, 246, 254
- South 88, 89, 91-93, 98, 100, 103, 109, 112, 123, 161, 162, 236, 245, 246, 254, 263, 272
- West 89, 92, 93, 109, 112, 122-124, 159, 173, 237-239, 245, 246, 254, 256, 257, 262
African puff adder 20, 29, 41, 109, 161-164, 272
African tree snake 88
aggregoserpentin 41
Agkistrodon 12, 14, 29, 35, 41, 43, 44, 45, 70, 72, **204**, 205, 207, 276, 277
Agkistrodon bilineatus 324 (Fig)
- *contortrix* 324 (Fig)
- *taylori* 324 (Fig)
agkistrodotoxin 35, 205
Aglypha 7
Ahaetulla **91**, 235, 239
- *prasina* 324 (Fig)
Aipysurus **152**, 153, 268, 269
Alabama 277, 285
Albania 89, 186, 189, 274, 276
Alcatrazes Island 278
Algeria 173, 181, 246, 273-275
ALI/ARDS 38, 77, 175, 198, 206, 213, 220, 223, 224
Alps 12, 189, 275
Altiplanicia 281
Amazon 240, 244, 251, 252, 261, 262
America 5, 12, 91, 93, 94, 204
- Central 12, 94, 126, 153, 237-240, 243, 277, 280, 284
- Central and South 22, 91-94, 210, 217, 240-252, 278
- North 2, 5, 11, 21, 22, 92-94, 126, 127, 204, 216-219, 240, 243, 250, 251

- South 22, 23, 73, 92-94, 126, 129, 153, 241, 244, 245, 250, 251, 278
Amblyodipsas **100**, 235, 253
ammodytin 35
Amplorhinus **91**, 235, 236
anaphylaxis 71, 191, 223, 289
ancrod 44
Andaman Island 112, 236, 255
Andes 11, 248, 261, 262, 277, 278, 283
Angel de la Guarda 281
angiotensin 37
angiotensin converting enzyme 37
Angola 90, 94, 112, 159, 162, 239, 245, 246, 251-253, 255-257, 262, 272
Aniliidae 1
Antarctica 2, 11
antibiotic 73, 100, 118, 125, 127, 145, 156, 165, 183, 195, 208, 215, 223, 229
antigens 47, 51-55, 69, 100, 162, 194
antihistaminic 56, 64, 65, 69, 71
Antilles 237
Antillophis 92
antithrombin 40, 44
antivenom 34, 51-56, 62, 66-72, 74-79, 81
Aparallactinae 4, 98, 100, 235, 253
Aparallactus **100**, 253, 254
applaggin 41
Aqua Blanca 284
Arabian horned viper 166, 167, 273
Arabian Peninsula 161, 167, 173, 253, 273, 274
Arafura Sea 269
Argentina 94, 210, 214, 237, 239, 244, 245, 248, 252, 258-261, 278-280
arietin 41
Arizona 129, 244, 281
- (Sonoran) coral snake 129
Arkansas 262
Armenia 181, 186, 198, 249, 275
Armenian mountain viper 183, 184, 186, 198, 199, 275
arrhythmia 79, 115, 119, 120, 122, 125, 127, 138, 141, 148, 155, 162, 163, 165, 174, 179, 182, 187, 212
Arrhyton **91**, 92, 236
Aru Archipelago 149, 244, 265
Aruba 241, 280
Asia 2, 11, 12, 21, 94, 102, 112, 116, 159, 189, 205, 251, 269, 274
- Central 93, 112, 173, 184, 205, 240, 246
- East 225
- South 94, 107, 225, 263, 269
- South-eastern 91-93, 104, 107, 112
- South-western 246
- West 184, 276
Asia Minor 94, 274
Asian arboreal pit viper 225
asp viper 18, 34, 37, 41, 51, 55, 183, 186, 191, 195, 275
Aspidelaps **102**, 255
- *lubricus* 324 (Fig)
Aspidomorphus **148**, 264
Aspisviper 195
Assam 255
asthma attack 47
Astola 273
Astrotia **152**-154, 269
Atheris 12, 40, **159**, 160, 271, 272
- *nitschei* 324 (Fig)
- *squamiger* 324 (Fig)
Atlantic Ocean 11, 12, 285
Atractaspid 98
Atractaspididae 2, 4, 9, 12, 13, 38, 39, 76, **97**, 235, 252
Atractaspidinae 4, **98**, 100, 252
Atractaspis 13, 37, 39, **98**-101, 252, 253
- *irregularis* 324 (Fig)
atrioventricular block *see* AV-block
Atropoides **209**, 210, 214, 277, 279, 284
- *nummifer* 325 (Fig)
atroxase 44
Australia 1, 23, 51, 65, 134, 135, 140-145, 149, 153, 158, 237, 263-270
- East 137, 147-149, 153, 264-269
- North 91-93, 134, 153, 235, 240, 244, 264, 269
- North-eastern 148, 265, 266
- North-western 87, 265
- South 148, 265, 267

- South-eastern 136, 138, 148-150, 264-268
- South-western 137, 148, 149, 265, 267
- West 134, 148, 150, 264-269
Austrelaps 136, 137, 264
Austria 186, 274, 276
AV-block 99, 120, 135, 142
Avicena viper 166
Azemiopinae 4, **158**, 271
Azemiops **158**, 271
Azerbaijan 173, 186, 273, 275, 282
Badger 266
Balanophis **91**, 236
Balearic Islands 12
Balete 286
Bali 113, 255, 263
Balkan, Balkans 94, 189, 275
Balkans 243, 249
Balsas River 260
bandage, pressure immobilization 61-65, 103, 105, 108, 110, 116, 117, 121, 125, 128, 135, 138, 140, 142, 144, 146-150, 156, 193, 207, 214, 221, 222, 228
banded coral snake 261
bandy bandy 268
Bangladesh 112, 113, 169, 237, 239, 262, 273, 284-287
Bankoraj 173
Barba amarilla 209
Barkly Tableland 266
Baskian viper 183, 184, 276
Bass Straits Islands 264-266
Batan 286
batroxobin 43, 211
Belize 241, 259-261, 276, 277, 282
Bengal 262, 286
Benin 20
Bhutan 237
bilineobin 43
bird snake 90, 251
bite wound 72, 99, 114, 127, 129, 143, 218, 226, 227
Bitis 5, 9-11, 14, 20, 29, 33-35, 37, 40, 41, 44, 54, 55, 75, 76, 109, **161**-164, 181, 272
- *arietans* 325 (Fig)
- *gabonica* 325 (Fig)
- *nasicornis* 325 (Fig)
bitiscetin 41
bitistatin 41, 162
black desert cobra 124
Black Forest 124, 275
Black Sea region 274
black snake 29,35, 143, 144, 254, 266
- tiger snake 38, 39, 138, 265
bleeding 143, 145,161, 163, 165, 167, 168, 172, 175, 177, 178, 190,196, 209, 212, 213, 215, 220, 227, 229
blepharospasm 66, 114
blue-bellied black snake 143, 266
bluntnose viper 180
Boidae 2
Boiga 85, **87**, 236, 237
- *cyanea* 325, 326 (Fig)
- *dendrophila* 326 (Fig)
boigas *see Boiga*
Bolivia 93, 239, 240, 244, 245, 248, 258-262, 277-280, 283
Bongare 104
Booidea 2
boomslang 31, 42, 43, 85, 88, 90, 91
Borneo 108, 113, 236, 247, 255, 256, 270, 284-287
Bosnia 186, 276
- and Herzegovina 76
Bothriechis **209**, 210, 212, 277, 279
- *schlegelii* 326 (Fig)
Bothriopsis **209**, 210, 277-279
Bothrocophias **209**, 278, 279, 284
bothropasin 39
Bothrops 11, 12, 15, 22, 29, 31, 37, 39-43, 46, 54, 64, 70, 77, 79, 93, 181, 184, 205, **209**, 210-214, 277-279
- *alternatus* 326 (Fig)
- *atrox* 326 (Fig)
- *neuwiedi* 327 (Fig)
Botswana 98, 103, 238, 245, 251, 253, 255, 257, 262
Bouganville Island 266
Boulengerina **122**, 125, 255
- *christyi* 327 (Fig)

Brachyophis **100**, 254
bradycardia 75, 120, 138, 142, 163, 187, 188, 196, 197, 212, 225
bradykinin 37, 76, 162, 211, 212, 217, 225
Brazil 22, 51, 91, 126-129, 210, 214, 237, 239, 244, 245, 247, 248-262, 277-280, 283
bronchospasm 56, 71, 191, 192
brown snake 35, 43, 143, 145, 146, 265, 266
- tree snake 87, 237
Brunei 285
Bulgar-Dagh 276
Bulgaria 89, 186, 189, 274, 275
Bungarinae 66, 102, 122
bungarotoxin 35, 36, 87, 104
Bungarus 21, 35, 36, 61, 69, 70, 75, **103**, 104, 106, 117, 119, 207, 236, 255
Burkina Faso 238
Burma 21, 91-93, 113, 158, 169, 171, 235, 237, 239, 246, 247, 255, 256, 262, 263, 270, 271, 273, 279, 285-287
Burrowing asp 37, 98, 252, 253
- cobra 123
Burundi 162, 251, 257, 271
bushmaster 22, 40, 43, 210-214, 283, 284
C protein 45, 86, 142
Cacophis **148**, 149, 264, 265
Caenophidia 2
Caissaca 209
Calabria 275
Calamodontophis **91**, 237
calciseptin 35
California 243, 250, 280, 281
Californian Peninsula 280, 282
Calliophinae 102, 106
Calliophis **106**, 107, 256-258
Calloselasma 21, 40, 41, 42, 44, 69, **204**, 205, 207, 277, 279
Cambodia 86, 113, 139, 255, 256, 263, 279, 284, 286, 287
Cameroon 112, 245, 252, 253, 255, 257, 263, 271-273
Camiguin 113, 286
Canada 11, 21, 22, 217, 281, 282, 285
Canary Islands 12
cantil 43, 204
Cape Region 272
Cape Verde Islands 12
cardiac failure 99
cardiotoxin, cardiotoxins 37, 38, 41, 66, 75, 76, 104, 114, 118-120, 124, 145, 162, 163, 189
cardiovascular system 163, 212
Caribbean 12, 91, 93, 153, 236, 241
Caribbean Gulf 236
Caribbean Islands 91
carinactivase 42
carinatin 41
Carolina 47, 130, 204, 276, 280, 285
carpet viper 173, 273
Cascabel 216
Cascauella 216
Caspian Sea 89, 112, 205
cat snake 87, 236, 237, 249
Cauca 261
Caucasus 263, 274, 275
caudoxin 35
Causinae 157, 165
Causus 20, 44, 55, **165**, 166, 272, 273
- *rhombeatus* 327 (Fig)
Cebu 256
Cedros 282
centipede eaters 253
Central African Republic 245, 256, 257, 273
Cerastes 14, 19, 42-44, 55, 70, 160, **166**-168, 179, 180, 216, 217, 273
- *cerastes* 327 (Fig)
- *vipera* 327 (Fig)
cerastobin 43
Cerberus sp. **91**, 237
Cerralvo 280
Cerrophidion **209**, 210, 214, 279, 280, 284
- *godmani* 327 (Fig)
Chad 167, 263, 273
Chappel 266
Charina 2
chemosis, conjunctival 114, 170
Chihuahua 276

Chile 11, 210, 244, 248
Chilorhinophis **100**, 254
China 86, 91, 92, 105, 116, 184, 204-207, 237, 240, 243, 246, 247, 268, 270, 275, 283-287
- East 283
- North 184, 189, 239, 247, 255, 257, 262, 273, 283-285, 287
- North-eastern 283
- North-western 275, 283
- South 86, 91, 93, 102-105, 107, 112, 153, 158, 169, 225, 236, 237, 239, 247, 255, 256, 270, 271, 284, 285
- South-eastern 112, 205, 239, 240, 284, 286
- South-western 112, 247, 255, 262, 283
- West 93
Chinese green pit viper 225
habu 39, 225, 228, 285, 286
Chinese moccasin 39, 41, 43, 54, 204, 282
Chinese mountain pit viper 224, 228, 284
Chokosumo 287
Cholophidia 1
Chrysopelea **91**, 240
- *ornata* 328 (Fig)
Clarence River snake 147, 268
Clelia **91**, 237
Cleopatra viper 166
clotase 43
coagulation 32, 35, 39, 40, 42, 67, 77, 78, 87, 89, 109, 131, 136, 138, 139, 141, 143, 146, 148, 167, 172, 174, 178, 191, 197, 205-207, 211, 212, 214, 217, 219, 220, 226
coagulopathy 54, 69, 95, 105, 116, 139, 141, 143, 146, 147, 149, 155, 163, 169, 170, 174, 182, 188, 206, 208, 211, 213, 214, 218, 220, 224, 227, 229
- consumption see coagulation
- disseminated intravascular see DIC
Coahuila 262, 276
Cobra 5, 9, 12-15, 20, 21, 28-31, 36-38, 41, 44-47, 51, 54, 55, 61, 66, 69, 71, 75, 77, 89, 102, 103, 108, 111, 112, 114-117, 119-125, 255, 257, 262, 263, 266
Cobra
- African tree 124, 263
- black and white 20, 111, 112, 116, 262
- black-necked spitting 20, 41, 44, 111, 112, 114, 116, 262
- Central Asian 111, 112, 116, 263
- desert 124, 263
- Egyptian 29, 111, 112, 116, 181, 262
- hoodless 124, 263
- Chinese 37, 111, 114, 116, 262
- Indian 21, 28-31, 54, 61, 69, 111, 116, 189, 262
- Indochinese spitting 36, 111, 112, 263
- king 5, 14, 36, 61, 102, 119, 120, 143, 263
- monocellate 55, 111, 112, 262
- Mozambique spitting 111, 112, 262
- ringed water 122, 255
cobrotoxin, cobrotoxins 36, 38
Colima 260, 284
Collett's snake 266
Colombia 237, 240, 244, 258-262, 277-280, 283, 284
Colorado 280
Coluber 91, 237, 238
colubrid, colubrids 2-6, 9, 12, 13, 18, 30, 31, 42, 43, 85, 86, 88, 91-95, 100, 102, 123, 158, 188,235, 237
Colubridae 2-5, 8, 13, 30, 42, **85**, 123, 235, 254
Colubrinae 3, 4, **85**
Colubroidea 2-4
common viper 11, 12, 18, 19, 29, 30, 34, 55, 61, 181, 183, 184, 186, 188-192, 194, 195, 275
compartment syndrome, pressure 68, 72, 118, 163, 171, 181, 183, 187, 199, 206, 208, 212, 215, 217, 218, 222, 223, 226-228
complement 45, 55, 75, 88, 114, 120, 174
Congo 98, 159, 162, 239, 245, 252, 253, 255-257, 263, 272
Coniophanes **91**, 238

conjunctivitis 114
Connecticut 276
Conophis **92**, 238
convalescence 78, 81
convulxin 41
copperhead 29, 41, 44, 45, 136, 204, 264, 276
coral snake 29, 30, 38, 64, 65, 102, 103, 106, 107, 125-127, 129, 244, 255-262, 267
Coralilla, Coralillo 126
Coronado del Sur 280
Coronella austriaca 85
Corsica 12
corticosteroids 56, 64, 65, 70, 71, 118, 125, 194
Costa Rica 22, 156, 205, 214, 241, 248, 259, 261, 276, 277, 280, 282-285
cottonmouth 14, 29, 41, 204, 277
Couleuvre de Moila 89
- de Montpellier 89
Crete 12
Croatia 55, 186
cross-immunity 106, 108, 121, 128, 144, 195, 199, 228
crotalase 44, 217
Crotalidae 3, 222
Crotalinae 5, 6, 12, 33, 34, 37, 40, 43, 45, 47, 67, 69, 74, 80, 82, 157, 158, **203**, 204, 221, 225, 276
crotalotoxin 39, 217
Crotalus 5, 6, 12, 14, 15, 22, 29-31, 33-35, 37, 39-41, 44-46, 54, 55, 63, 64, 66, 69, 70, 72, 75-77, 79, 158, 172, 189, 208, 215, **216**-221, 280-282
- *adamanteus* 328 (Fig)
- *atrox* 328 (Fig)
- *cerastes* 328 (Fig)
- *cerberus* 328 (Fig)
- *durissus* 328 (Fig)
- *durissus unicolor* 329 (Fig)
- *helleri* 329 (Fig)
- *horridus* 329 (Fig)
- *lutosus* 329 (Fig)
- *mitcheli* 329 (Fig)
- *ravus* 329 (Fig)
- *ruber* 330 (Fig)
- *scutulatus* 330 (Fig)
- *tigris* 330 (Fig)
- *viridis* 330 (Fig)
Crotaphopeltis **92**, 238
crotoxin 35, 46, 54, 218
Cryptelytrops **224**, 282, 285-287
Cuba 236
Cyanodontophis 254
Cyclades 180, 181, 186, 274
Cyprus 181, 274
Czech Republic 18, 19, 85, 167, 189, 216, 225
Daboia 21, 30, 31, 33-35, 39-45, 54, 55, 64, 69, 72, 74, 77-79, **168**-171, 179, 196, 273-275
- *russelli* 330 (Fig)
daboiatoxin 35
death adder 23, 29,30, 35, 134,263, 264
Deinagkistrodon 39, 41, 43, 54, **204**, 205, 207, 276, 282
Demansia 43, **148**, 264
dendroaspin 36, 109
Dendroaspis 5, 13, 14, 29, 31, 34-36, 61, 70, 75, 102, **108**, 109, 122, 256, 257
- *angusticeps* 330 (Fig)
- *jamesoni* 331 (Fig)
- *polylepis* 331 (Fig)
- *viridis* 331 (Fig)
dendrotoxins 34, 35, 109
Denisonia **148**, 264, 265
desert horned viper 42-44, 166, 167, 273
desert Leventin viper 180
- sidewinder 216, 280
- viper 179, 180, 181, 274
diadem snake 239, 247
diarrhea 46, 47,67, 74, 99, 107, 141, 149, 150, 160, 169, 181, 187, 189, 190, 193, 196, 206, 212, 219, 226
DIC 40, 42, 43, 76-80, 86-91, 94, 116, 120, 121, 136-140, 143, 145, 147, 162, 163, 165, 167-169, 172, 174, 175, 178, 182, 183, 188, 193, 206-209, 211, 213, 215, 220, 221, 224, 227, 229
Dinilysia 1

Dipsadoboa **92**, 238, 239
Dispholidus 13, 31, 39, 40, 42, 43, 85, **88**, 239
- *typus* 331 (Fig)
disseminated intravascular coagulation *see* DIC
Disteira **152**, 269, 270
Doksa 204
Dominican Republic 92, 240
Dromicus 92
Dromophis 6, **92**, 239
Dryophis 91, 235, 239
Drysdalia **148**, 265
dugit 145
Duke of York 264
Duvernoy's gland 8, 85 -87, 89
dwarf-crowned snakes 148, 264
dysarthria 33, 66, 67, 75, 104, 107, 115, 120, 123, 124, 127, 135, 139, 141, 146, 155, 170
dysphagia 33, 66, 67, 75, 90, 99, 104, 110, 115, 120, 127, 135, 140, 141, 155, 170, 172, 180, 187, 191, 195, 196, 206, 209
dysrhythmia 32, 114
eastern brown snake 35, 43, 145, 146, 266
eastern coral snake 125-127, 260
eastern diamond-backed rattlesnake 5, 22, 30, 40, 41, 54, 64, 189, 216, 217, 221
- coral snake 125-127, 260
ecarin 42, 86, 87, 174
ECG 37, 67, 76, 99, 115, 120, 135, 142, 155, 157, 170, 182, 191, 193, 206, 227
Echide carénée 173
Echiopsis 134, **148**, 265
Echis 6, 14, 20, 21, 30, 31, 33, 39-43, 52, 64, 66, 69, 77, 78, 80, 86, 88, 109, 160, **172**-174, 176, 177, 179, 180, 205, 273, 274
- *carinatus* 331 (Fig)
- *ocellatus* 332 (Fig)
- *pyramidum* 332 (Fig)
echistatin 41, 174
Ecuador 22, 94, 213, 214, 237, 240, 245, 248, 258-262, 277-279, 283, 284
edema 38, 45, 47, 56, 61, 63, 64, 67, 68, 71-73, 77, 81, 114, 118, 120, 123, 148, 158, 160, 163, 166, 167, 169, 175, 180, 181, 187, 190, 193-196, 211, 212, 218, 219, 223, 226
- angioneurotic 56, 64, 71, 169, 184, 189
- pulmonary 38, 87, 116, 175, 198, 220
- Quinke's 56
edrophonium 75, 106, 111, 118, 122, 128
Egypt 89, 98, 112, 124, 127, 173, 179, 253, 262, 263, 273, 274
El Muerto 281
elapid snakes, elapids, *Elapidae* 2-4, 8, 9, 12-14, 28, 30, 33, 37, 39, 40, 44, 45, 47, 61, 66, 71, 73-75, 77, 79, 100, **102,** 108, 109, 111, 122, 134, 143, 146
- terrestrial, Austropapuan 39, 40, 45, 61, 76, 77, 79, **134**, 143, 146, 148, 153, 263
Elapinae 3, 4, **102**, 255
Elapocalmus **100**, 254
Elapognathus **149**, 265
Elapomorphus **92**, 239, 244
Elapotinus **100**, 254
Elapsoidea **122**-124, 257
Elba 195, 275
Emydocephalus **152**, 269
endothelium 32, 33, 37, 38, 40, 43, 45, 82, 170, 174, 191, 217
England 19, 189, 192
Enhydrina 28-30, 46, **152**-154, 156, 269
Enhydris **92**, 239, 240
enzymes 27, 28, 32-46, 68, 72, 75-79, 81
Ephalophis **152**, 269
Eristicophis **179**, 180, 274
- *macmahoni* 332 (Fig)
Eritrea 252, 253, 263, 273, 274
Ermia 224
Eteirodipsas **92**, 240
Ethiopia 98, 162, 245, 246, 252, 253, 257, 262, 263, 272
Europäische Eidechsenatter 89
Europe 2, 11, 18, 102, 159, 183-186, 189, 192
- Central 183, 188, 275

- North 275
- South-eastern 243
- South-western 93, 243
European adder *see* European viper
- viper 5, 74, 158, 186, 192, 275
extravasation 32, 33, 37, 38, 46, 65, 74, 76, 80, 122, 163, 170, 175, 178, 182, 183, 191, 193, 197, 217, 220, 227
exuvia 6
eyelash palm pit viper 277
eyes, affection 114, 118, 123, 125
False Fer de Lance 252
false-horned viper 179
fangs, aglyphous 8, 10
- erectile 10, 157, 159, 203
- opistoglyphous 8, 10
- proteroglyphous 8, 10
- solenoglyphous 8, 10
Far East 184, 275
fasciculation 109
fasciculins 34, 109, 111
fasciotomy 72, 73, 118, 163, 172, 183, 188, 197, 199, 206, 208, 212, 215, 222, 223, 228
Fea's viper 158, 271
Fer de Lance 209
Fer de Lance asiatique 225
Ferguson 268
fever 114, 160
fibrin 40, 43, 44, 68, 78, 80, 170-172, 174-176, 206, 213
fibrinogen 38, 43, 44, 46, 68, 78, 86, 205, 206, 211, 217, 226
fibrinolysis 38, 80, 86, 87, 90, 142, 165, 170, 172, 188, 193, 197, 207, 211, 213
fibrolase 44
Ficimia **92**, 240
Field's horned viper 179, 274
fierce snake 140
Fiji 149, 266
Finland 11, 18, 189
flavoxobin 44
Flores 113, 169, 263
Florida 217, 249, 277, 280, 285
flying snake 240
Fordonia **92**, 240
forest pit viper 209, 277, 278
forest twig snake 251
France 19, 110, 164, 189, 192, 195, 216, 275, 276
French Guyana 240, 258, 260-262, 278, 280
Furina **149**, 264, 265
Gabon 122, 162, 245, 252, 253, 255, 271
Gabon adder *see* Gabon viper
Gabon viper 11, 14, 15, 29, 44, 54, 161, 163, 164, 272
gabonase 44, 162
gabonin 41
Galapagos 245
Gambia 273
gangrene 63, 73, 164, 165, 187, 206-208, 215, 226, 228
Gargantilla 126
garter snakes 122, 257
Garthius 224, 282, 284
Gaspareé 259
gastrointestinal (affection) 67, 99, 137, 163, 171, 175, 176, 187, 190, 196, 213
Georgia 186, 249, 275
Georgia (U.S.) 277, 285
Germany 160, 195, 216
Ghana 20, 109, 159, 245, 252, 256, 263, 272
Gigantophis 1
gjurza 180
glandula maxillaris 7
Gloydius 12, 34, 41, 42, 70, 158, **204**, 205, 276, 277, 283
- *halys* 332 (Fig)
- *intermedius* 332 (Fig)
Glyphodon **149**, 265
Glyphodonta 8
Gold's cobra 124
Golden tree snake 240
gold-ringed cat snake 236
Great Lakes bush viper 159, 271
Greater Atlas 275
- Caucasus 275
Greece 186, 189, 240, 243, 274, 276

- Pindos Mountains 276
Green cat snake 236
green pit viper 225
Greenland 11
Guam 87
Guanajuato 262
Guarda camino 92
Guatemala 241, 258-262, 276, 277, 282, 284
Guerrerro 281
Guinea 271, 272
Gulf of Persia 12, 269, 270
Gulf of Siam 271
Guyana 240, 258, 260-262, 278, 280
Gwardar 145, 266
gwardar or western brown snake 266
habu 39, 224, 225, 228, 285, 286
Hainan 86, 104, 107, 112, 119, 239, 247, 255, 256, 285-287
Haiti 92, 240
Halys pit viper 35, 41, 204, 283
Hamadryad 119
hannalgesin 36
harlequin snake 123, 258
Hawaiian Islands 11
Hemachatus 15, 63, 66, 107, **123**-125, 184, 257
hematoma 167, 205
Hemiaspis **149**, 265
Hemibungarus **106**, 107, 256, 267
hemocoagulation 20, 31, 38, 40, 42, 45, 46, 63-65, 67-69, 72, 74, 76, **77**, 78, 80, 81, 86, 88-91, 94, 95, 99, 104, 105, 115, 120, 124, 127, 134, 135, 137-150, 158-162, 164-172, 174-178, 180-184, 190-193, 195-199, 203, 205-209, 211-215, 217, 218, 220-224, 226-229
hemoglobinuria 80, 116, 139, 140, 147, 164, 171, 175, 176, 187, 191, 192, 194, 197, 207, 213, 220, 221
hemorrhage 31, 77, 80, 87, 88, 139, 175, 176, 207, 208
hemorrhagins 33, 37-40, 45, 46, 72, 76, 77, 162, 186, 190, 196, 198, 205, 211, 225
Hemorrhois **91**, 238, 240
hemostasis 40, 45, 46, 76, 88, 90, 136, 137, 141, 172, 175, 177, 178, 182, 187, 192, 194, 197, 206, 212, 217, 220, 226. 227
heparin 42, 78-80, 89, 129, 136, 140, 143, 146, 147, 168, 172, 174, 178, 183, 188, 209, 215, 229
- low molecular weight heparin 79, 143, 161, 165, 168, 178, 209, 215
heparinization 81, 146, 148, 161, 178, 224
Herzegovina 89, 276
Heterodon 85, **92**, 95, 240
Hierophis 238
Himalaya 113
Himalayan pit viper 12, 158, 204, 205, 283
Himalayophis 224, 283, 287
Homalopsinae 4
Homalopsis **92**, 95, 240
Homoroselaps 100, **123**, 124, 254, 257, 258
Honduras 92, 240, 244, 259, 261, 276, 277, 280
Hong Kong 225, 247, 255, 285
Hoodless cobra 124, 263
Hoplocephalus **137**, 265
horned pit viper 284, 285
horned puff adder 35, 272
Hornotter 186
humpnose viper 204
hump-nosed pit vipers 204, 283
hundred-pace viper 204
Hungary 186, 276
hyaluronidases 33, 109, 126, 162, 166, 174, 211, 217
Hydrelaps **152**, 269
Hydrophiidae 3, 102, 133, 134, **152**, 268
Hydrophiinae 4, 45, 102, **133**, **152**, 154, 263, 268
Hydrophis **152**-154,269-271
hypercoagulation 40, 43, 68, 138, 140, 148, 209, 215, 229
hyperkalemia 45, 79, 80, 155, 157
hypertension

Hypnale **204**-208, 283, 333 (Fig)
hypofibrinogenemia 40, 78, 89, 144, 146, 170, 182, 183, 187, 196, 207, 209, 212, 215, 219-223, 227, 229
Hypoptophis **100**, 254
hypotension 31, 32, 36-38, 45-47, 56, 65, 67, 71, 74, **76**, 78, 80, 114, 115, 120, 122, 139, 146, 150, 158, 160, 162-164, 166, 168-172, 179, 182-184, 187-189, 191, 193, 196-199, 206, 208, 211-215, 217, 218, 220, 223, 225, 226, 228, 229
Ialtris **92**, 240
Iceland 11
Illinois 277
Imantodes **92**, 240, 241
immunity 51-55, 106, 108, 121, 128, 144, 195, 199, 208, 214, 218, 228
immunogenicity 28, 36, 51, 52, 54, 99, 208, 214
immunotherapy **66**, 67, 75, 77, 138, 140, 142, 165, 193, 194, 208, 209, 214, 215, 220, 223, 224, 229
India 21, 52, 86, 87, 91-93, 102-108, 112, 113, 116, 119, 155, 156, 169, 173, 181, 205, 225, 235-237, 239, 240, 243, 246, 247, 255, 256, 262, 269, 270, 273, 274, 283-287
Indian Ocean 23, 269-271
Indian Peninsula *see* India
Indian subcontinent *see* India
Indiana 276
Indochina 107, 112, 205, 236, 237, 239, 240
Indo-Chinese mountain (pit) viper 225
Indonesia 86, 87, 91, 84, 102, 104, 107, 113, 119, 150, 169, 225, 228, 235-237, 239, 240, 243, 247, 251, 255, 256, 253, 264, 268, 270, 273, 284-287
infection 73, 114, 118, 122, 143, 145, 165, 175, 183, 190, 206, 218
inhibitor 41, 44, 73, 75, 128
Inland (western) taipan 28, 35, 140, 141
Iowa 276
Iran 113, 116, 124, 167, 173, 179-181, 189, 205, 237, 249, 250, 253, 273-276, 283
Iraq 89, 124, 179, 181, 182, 250, 263, 273, 274
Ireland 11, 189, 264
Irian Jaya 264
Israel 1, 19, 89, 98, 124, 167, 173, 179, 181, 196, 197, 243, 246, 250, 252-254, 263, 273-275
Italy 18, 89, 186, 189, 195, 275, 276
Ithycyphus **92**, 241
Jacobson's organ 6
Jalisco 260, 281
Japan 21, 51, 86, 87, 107, 204, 205, 207, 225, 227, 228, 247, 256, 257, 269, 270, 283-285
Japanese habu 225
jararaca 22, 29, 31, 39, 181, 209-214, 278
Jararaca ilhao 209
- pintada 209
jararacussu 22, 29, 209, 278
jararhagin 39
Java 105, 113, 169, 228, 236, 247, 255, 256, 263, 269
Jolo 286
Jordan 89, 173, 179, 181, 196, 250, 263, 273-275
jumping pit viper 277
Kanburi 286
Kangaroo Island 136
Kansas 276
Kashmir 181, 263
Kazakhstan 275, 283
Kentucky 285
Kenya 20, 98, 109, 159, 162, 173, 236, 238, 239, 245, 251-254, 256, 257, 262, 263, 271-274
keratitis 114
Kerilia **152**, 270
Kiau 284
kidney failure *see* renal failure
kidneys 46, 68, 80, 170, 183, 192, 198, 218, 220, 227
Kimolos 181, 274
King brown snake 143, 266

- cobra 5, 14, 36, 47, 61, 102, 119, 120, 143, 263
kinin 24, 36, 37, 55, 162
kininogenases 37, 211, 217, 225
Kolpophis **152**, 270
Komodo 113, 169, 263
Korea 86, 153, 184, 189, 204, 205, 247, 283
Kos 240
krait (sea) 3, 36, 45, 54, 61, 77, 102, 133, 134, **152**-154, 268
krait *see Bungarus*
Kreuzotter 188
Krk 276
Kuwait 181, 273
Kyrgyzstan 275, 283
Lachesis 22, 40, 43, 64, 70, 76, 77, 161, **209**-214, 283, 284
Lake Taal, Luzon 270
- Te-Nggano, Solomon Island 154
Lamprophiinae 3, 4
lancehead *see Bothrops*
Langaha **92**, 241
- *madagascariensis* 333 (Fig)
languor 74, 95, 103, 104, 110, 135, 154, 166
Laos 86, 112, 113, 135, 247, 255, 256, 263, 279, 282, 285-287
Lapemis **152**, 153, 270
Lapparentophis defrennei 1
Lataste's viper 183, 275
Laticauda 36, **152**-154, 270
Laticaudinae 3, **152**, 268
LD_0 28
LD_{100} 28, 29, 161
LD_{50} 28, 86, 88, 90, 99, 113, 119, 136, 141, 145, 154, 158, 159, 174, 179, 181, 184, 205
leaf-nosed viper 179
Lebanon 173, 181, 186, 196, 263, 275
lebetase 44
lebetin 181
Leimadophis **92**, 241
Lepidosauria 4
Leptodeira **92**, 241
Leptomicrurus 102, **129**, 258
Leptophis **93**, 241
Lesotho 272
lesser cerastes viper 166
leukocytosis 67, 68, 74, 87, 95, 103, 105, 107, 116, 121, 124, 125, 127, 135, 138, 155, 158, 160, 164, 166, 170, 176, 180, 182, 187, 191, 193, 197, 198, 207, 221, 227
Leventin viper 180
Liberia 162, 252, 253, 263
Libya 181, 246, 262, 273, 274
Liophis 92, **93**, 241- 243
lizard-eating snake 239
LMWH *see* heparin, low molecular weight heparin
Lomblen 113, 169
long-glanded coral snake 107
Long-nosed viper 186
Louisiana 280
Loveridgelaps **149**, 265
Lowland swamp viper 159, 274
Luzon 113, 256, 270, 286
Lygophis **93**, 243
lymph nodes 56, 71, 73, 104, 114, 120, 124, 135, 143, 154, 160, 163, 166, 167, 169, 175, 180, 181, 190, 196, 212, 218, 226
lymphadenitis 90, 93, 95, 139, 141, 143, 187, 196
lymphadenopathy 73, 99, 103, 114, 123, 124, 137, 139, 142, 145, 147, 149, 150, 154, 160, 163, 166, 167, 180, 181, 205, 212, 219, 226
m'Fezi 112
Macedonia 189, 276
MacMahon´s viper 179
Macrelaps **100**, 101, 154
Macropisthodon **93**, 243
Macroprotodon **93**, 243
Macrovipera 19, 20, 33, 39-43, 55, 64, 76, 78, 79, **180**-182, 274
- *lebetina* 333 (Fig)
- *mauritanica* 333 (Fig)
- *schweizeri* 333 (Fig)
Madagascar 11, 92, 93, 241, 243
Madagascarophis **93**, 240, 243

Madtsoia 1
mainland Southeast Asia 262
mainland tiger snake 28, 29, 35, 38, 39, 42, 46, 52, 79, 128, 138, 140, 146, 266
Malawi 159, 238, 245, 253, 262, 272, 274
Malayan pit viper 21, 40, 204, 279, 313
Malaysia 87, 91, 102, 104, 107, 112, 113, 119, 153, 156, 225, 235-237, 239, 240, 243, 247, 255, 256, 263, 269, 270, 284, 285, 287
Mali 112, 167, 253, 273
Malpolon 6, 18, 85, **89**, 243
- *monspessulanus* 333 (Fig)
Malta 12
mamba *see* Dendroaspis
mamushi 42, 204, 207, 208, 283
mamushigin 42
Manabí 284
Manaus 258, 259
mangrove snake 236
Mangshan 286
Mangashan pit viper 286
many-banded snake 123, 263
many-spotted snake 291, 237
Mapanare 209
Maracaboia 216
Marajó 279, 280
Martinique 12, 213, 279
Maryland 276
Masbate 113, 256
massasauga 216, 281, 285
Masticophis **93**, 243, 444
Maticora **106**-108, 285
Maticorinae 102, 106
Mauritania 98, 112, 253, 277, 262, 273
meadow viper 183, 184, 275, 276
Mediterranean Sea 12, 196
meisothrombin 42, 78, 87, 88, 174, 178
Melanesia 268, 269
Mesa Central 282
metalloproteinases 32, 39, 40
Mexican Plateau 281
Mexico 22, 52, 93, 94, 126, 129, 205, 210, 217, 240, 241, 244, 248, 252, 258-262, 276, 277, 279-282, 284, 285
- Coahuila 262, 276
- Chihuahua 276
Michoacán 248
Micrelaps **100**, 254
Microcephalophis 269, 270
microembolization *see* microthrombi
Micronesia 11
Micropechis **149**, 265
microthrombi 46, 77, 80, 87, 88, 169, 170, 172, 174, 175, 206, 218
Micruroides 102, **129**, 258
Micrurus 12, 22, 29, 30, 61, 70, 102, **125**-129, 258-262
- *fulvius* 334 (Fig)
Middle East 19, 20, 24, 89, 91, 93, 94, 98, 160, 173, 183, 184, 196, 198, 240, 243, 246, 247, 250
Milos 181, 274
Mindanao 113, 286
Mindoro 113, 256, 286
Miodon 254
Misima 268
Misool 264
Mississippi 280, 285
Missouri 276
MLD 181
MODS 77, 86
Moila snake 89, 243
Mojave
- desert sidewinder 280
- rattlesnake 216, 218, 220, 282
- toxin 35, 218
Moldova 189
Mole viper 39, 98, 252, 253
Mongolia 91, 189, 205, 246, 283
montane pit viper 279, 280
Montatheris **159**, 271, 274
Montenegro 89, 276
Montivipera 183, 274
Montpellier snake 89, 243
moojeni protease A 39
Moorish viper 180, 181, 274
Morelos 262
Morocco 89, 112, 167, 180, 181, 262, 272-275

Mozambique 103, 111, 112, 162, 245, 251, 253-257, 262, 172, 174
Mt Kinabalu 284
mucrotoxin 40, 225
multiple organ dysfunction syndrome *see* MODS
mulga 143, 144, 266
multactivase 43
Municipio de Ixlahuacán 284
Murici 279
mussurana 237
mutalysin II 40
Myanmar 21
mydriasis 105, 110, 155, 221
myocardial ischemia 76, 99, 100, 140, 146
myoglobin 45, 46, 74, 79, 105, 127, 129, 136, 138, 139, 142, 144, 145, 155, 156, 164, 169, 171, 182, 206-208, 218, 221, 227
myoglobinemia *see* myoglobin
myoglobinuria 33, 46, 68, 80, 105, 135, 139, 140, 144, 147, 155, 157, 164, 170, 171, 187, 197, 207, 217, 220
myonecrosis 32, 38, 45, 47, 54, 68, 79, 169-171, 212, 217, 218, 220
myotoxicity 134, 143, 150, 154, 155, 217
myotoxin, myotoxins 33, 45, 46, 52, 54, 68, 72, 79, 126, 136, 137, 139, 144, 148, 150, 154, 155, 189, 206, 217
Myron **93**, 244
Naja 12, 20, 21, 28-31, 33, 36-38, 40, 41, 44, 45, 54, 55, 61, 63, 66, 69-71, 75, 77, 103, 104, 107, **111**-113, 115-118, 120, 121, 123, 124, 181, 184, 189, 262, 263
- *annulifera* 334 (Fig)
- *atra* 334 (Fig)
- *haje* 335 (Fig)
- *kaouthia* 335 (Fig)
- *mossambica* 335 (Fig)
- *naja* 335 (Fig)
- *oxiana* 335 (Fig)
Nakhon Si Thammart 287
Namibia 94, 98, 103, 245-247, 253, 255, 257, 262, 263, 272
Natricinae 3, 4, 12, 85
nausea 27, 47, 56, 67, 71, 74
Nebraska 276
necrosis (tissue) 32, 33, 54, 71, 72, 81, 93, 99, 103, 113-116, 118, 121, 122, 126, 154, 165, 167-170, 181, 183, 186, 187, 195, 196, 205-208, 212, 214, 217-219, 223, 226, 228
necrosis (tubular, cortical) 46, 47, 87, 89, 169-171, 213
Negros 256
neostigmine 75, 105, 106, 111, 119, 122, 128, 135, 136, 156
neotropical rattlesnake 216
Nepal 87, 107, 108, 112, 113, 119, 205, 225, 237, 247, 256, 262, 283-285, 287
nephrotoxicity 46, 80
neurotoxicity 31, 35, 47, 54, 65, 70, 74, 75, 99, 103, 104, 107, 115, 116, 121, 124, 127, 135, 137-142, 144-146, 150, 155, 156, 169-171, 179, 185, 191, 211
neurotoxins 13, 30-34, 36, 53, 54, 63-68, 74, 75, 79, 87, 94, 103, 104, 107, 109, 113, 116, 120, 124, 126, 129, 134, 136, 137, 141, 143, 150, 154, 179, 205, 220
Neuwied's lancehead 209, 212, 279
Nevada 281
New Britain 264
- Ireland 264
New Guinea 23, 87, 91-93, 134, 140, 141, 143, 145, 148-150, 237, 240, 244, 263-271
New Hebrides 11
New South Wales 264-267
New Zealand 11
Nicaragua 258, 261, 276, 280
Nicobar Islands 237, 285, 286
Niger 167, 263
Nigeria 20, 99, 109, 112, 159, 162, 173, 263, 272
night adder 20, 44, 165, 166, 272, 273
nordic viper 188
North America *see* America North
Norway 11, 189
nose-horned viper 18, 35, 55, 186, 274

notecarin 42
Notechis 23, 28, 29, 35, 38, 38, 42, 46, 52, 70, 75, 79, 121, 128, **138**, 140, 144, 265, 266
notexin 35, 46
Nuevo León 262
Nullarbor Plain 267
Nyalam Co. 287
Oaxaca 259, 281
Oceania 11, 23, 269
ocellated mountain viper 276
Ogmodon **149**, 266
Okinawa 257
Oklahoma 276, 277, 280
Oman 179, 262, 273
Ontario 217, 281
Ophidia 4, 5
Ophiophagus 5, 12, 14, 36, 61, 70, 102, **119**-121, 143, 263
- *hannah* 336 (Fig)
Ophryacus **209**, 210, 284
ophtalmoplegia 67, 99, 104, 107, 115, 170, 191, 195, 221
Opistoglypha 8
ornate flying snake 240
orange-banded snake 149
Oregon 250
organ, Jacobson's 6
- auditory 6
- vomeronasal 6
- thermo-sensitive 6
Oriental (Asian) coral snake 107, 255, 257
Oriental whipsnake or Asian vine snake 235
oscutatin 42
Otter 183
Ovophis **224**, 225, 227, 228, 282, 284, 286, 287
Oxybelis **93**, 244
Oxyrhopus **93**, 244
Oxyuraninae 134, 148, 150, 153, 263
Oxyuranus 5, 23, 28-30, 35, 38, 42, 46, 54, 70, 75, 79, 134, 139, **140**, 142, 266
Pachyrhachis problematicus 1, 2
Pacific Ocean 11, 12, 23, 155, 169-171
painted keelbacks 94, 251
Pakistan 21, 104, 113, 119, 169, 173, 179, 181, 205, 225, 237, 239, 346, 355, 262, 269, 270, 273, 274, 283
Palaeonaja 2
Palästinaviper 196
Palawan 113
pale (broad) headed snake 137
Palestine
Palestine saw-scaled viper 173, 178, 273
Palestine viper 19, 41, 275
palm pit viper 277
Pama 104
Panama 153, 156, 237, 241, 258, 259, 261, 262, 277, 279, 283, 284
Panay 236, 256
Papua-New Guinea 23, 141, 145, 149, 150, 240, 264-268
Parademansia microlepidota 28
paradoxin 35, 141
Paraguay 92, 239, 245, 259-261, 278-280
Parahydrophis **152**, 270, 271
paralysis (muscular) 33, 34, 36, 63, 66, 67, 74, 75, 103-111, 115-125, 127-129, 135, 136, 139, 141, 143, 145, 147, 148, 155, 156, 170, 172, 206, 220, 221
Paraná 246, 258
Paranaja **123**-125, 263
Parapistocalamus **149**, 266
Parias 224, 284, 286, 287
Paroplocephalus **149**, 265-267
parrot snakes 93
Pee-un 104
Pelamis **152**-154, 156, 271
Peltopelor **224**, 284, 286
peninsula brown snake 145, 266
Persian horned viper 179, 274
Peru 93, 217, 238, 240, 244, 245, 248, 258-262, 278-280
Peruvian Andes 277
Phalotris 239, 244
Philippines 87, 91, 102, 107, 112, 113, 119, 153, 225, 236, 237, 240, 247, 256, 263, 269, 270, 286, 287

Philodryas 92, **93**, 241, 243-245
Philothamnus **93**, 95, 245
phlegmon 172, 190
Phoorsa 173
phospholipase A *see* PLA_2
pigmy rattlesnake 216, 285
Pilbara 264, 268
Pindos 276
pit viper 12, 21, 35, 39-41, 44, 46, 56, 158, 204, 205, 207, 208, 224, 225, 228, 229, 277-280, 283-287
PLA_2 32-35, 38, 41, 45-47, 74, 79, 103, 107, 113, 120, 134, 136, 139, 141, 154, 169, 179, 190, 205, 211, 217
plasmaferesis 81, 160, 177, 208, 215
plasmin 39, 43, 135, 162, 227
platelets *see* PLT
Platyceps **91**, 238, 245, 246
PLT 32, 38, 40-42, 74, 78, 79, 89, 91, 99, 116, 120, 121, 135, 136, 141, 160, 162, 167, 174, 177, 182, 184, 188, 196, 197, 205, 209, 211, 215, 217, 220, 221, 223, 224, 229
Poecilopholis 100
Poland 19, 194
Polemon **100**, 254
Polillo 256, 286
Polinos 281, 274
Polynesia 11, 270
Polyodontognathus 269, 271
Pontic adder 275
Popayan 261
Popeia **224**, 284, 286, 287
Porthidium **209**, 210, 212, 214, 284, 285
Porthidium ophryomegas 336 (Fig)
Portugal 89, 275, 276
Praescutata **152**, 271
prairie rattlesnake 216
Prince of Wales Island 266
Proatheris **159**, 160, 272, 274
prodromes of envenoming 73, 74
proteases 32, 33, 39, 42, 44, 78, 126, 182, 186, 211
proteinases *see* proteases
Proteroglypha 9, 10, 102
prothrombin 40, 42, 43, 46, 54, 77, 86-88, 90, 94, 120, 137, 139, 141, 143, 145, 147, 160, 174, 177, 181, 192, 195, 205, 206, 208, 211, 214
Protobothrops 35, 39-41, 44, 46, **224**-228, 285-287
- *flavoviridis* 336 (Fig)
Psammophis 6, **93**, 246, 249, 164
- *lineolatus* 336 (Fig)
Psammophylax **93**, 246
Pseudechis 29, 35, **143**, 144, 266
pseudexins 35
Pseudoboa **93**, 246
Pseudocéraste de Perse 179
Pseudocerastes 19, **179**, 180, 274
- *persicus* 336 (Fig)
Pseudohaje **124**, 125, 263
Pseudonaja 23, 30, 35, 43, 140, 144, **145**, 146, 264, 266
ptosis 33, 66, 67, 75
Ptychophis **94**, 246, 247
Puerto los Mazos 281
Puff adder 20, 29, 35, 41, 109, 161, 164, 272
Pyrenean Mountains 275
Pyrenean Peninsula 243
Python reticulatus 5
Pythonodipsas 94
Quang Binh 285
Queensland 266-268
Queimada Grande 278
Quinke's edema 56
racers 91, 237
rainbow water snake 239
rattlesnake 5, 6, 12, 15, 22, 29, 30, 34, 35, 39-41, 44-46, 51, 54, 55, 63, 64, 66, 75, 79, 189, **216**-221, 280-282, 285
recurrence of symptoms 53, 69, 81, 193, 220, 222, 228
red diamond rattlesnake 30, 39, 216, 281
red-bellied black snake 29, 35, 143, 144, 266
red-lipped snake 238
rednecked keelback 86
Reid's criteria 193

renal failure 33, 45, 46, 54, 68, 76-**80**, 81, 86-89, 105, 106, 129, 135-142, 145-148, 150, 155, 156, 160, 164, 165, 167, 170-172, 175-179, 182, 183, 187, 188, 191-194, 197, 198, 206-208, 211, 213, 215, 218, 220, 221, 223, 227, 229
Reptilase 40, 211
Reptilia 4
Republic of South Africa 88, 89, 98, 100, 103, 109, 110, 112, 117, 124, 162, 164, 245
resistance, vascular 32, 36-38, 76, 100, 162
respiratory failure *see* ALI/ARDS
rhabdomyolysis 45, 68, 79, 105, 106, 134, 136-139, 142, 144, 145, 147, 148, 155, 156, 171, 207, 208, 220, 226, 227
Rhabdophis 9, 42, 85, **86**, 88, 247
Rhamphiophis 6
rhinoceros viper 161, 272
Rhinoplocephalus **149**, 266-268
rhodostoxin
ringed brown snake 145, 266
ringhals 15, 123, 257
rock viper 18, 19, 55, 183, 184, 186, 198, 199, 276
Roman's saw-scaled viper 42, 173, 273
Romania 184, 186, 189, 274, 276
Rondonia 260
Rossel 268
Rottnest 266
rough-scaled bush viper 272
rough-scaled snake 174, 268
Russell's viper *see* Daboia
Russia 11, 86, 184, 189, 247, 250, 275, 283
Rwanda 162, 252, 256, 257, 271, 272
Sabah 256, 284, 287
Sahara 112, 166, 243, 262, 273
- horned (sand) viper 166
Sahel 273
Sakhalin 11, 184, 189, 275
Salawati 264
Salomonelaps **149**, 267
Salvador 261, 276, 277
San Estéban 281
- José 282
- Lorenzo Sur 282
- Margarita 282
Sand horned viper 166
Sandotter 186
Sangchur 104
Santa Catalina 280
São Paulo 126, 128
São Tomé 112, 245, 257
Saphenophis **92**, 241, 247
Saraf'En Gedi 98
sarafotoxins 37, 38, 76
Sarawak 239
Sardinia 12
Saudi Arabia 89, 124, 181, 262
saw-scaled viper *see Echis*
Sawyer extractor 63
Scaddan 267
Scotland 189
sea kraits 3, 9, 10, 14, 36, 45, 54, 61, 77, 133, 134, **152**, 154, 128, 270
sea snakes 3, 9, 10, 11, 12, 14, 28, 34, 36, 40, 45, 54, 61, 69, 77, 102, 121, 133, 134, **152**-154, 268
Senegal 13, 20, 88, 109, 112, 173, 253, 257, 262, 273
Seram 263, 264
Serbia 186, 189
Serpent à lunetes 112
- arlequin 123
- corail 103, 126, 129
- - d'Afrique du Sud 103
- - d'l Arizona 129
Serpent corail du Cap 103
- - fin 129
- d'arbre 87
- - du Cap 88
- de mer 152
- des palètuviers 87
- jarretière 122
- liane de Kirtland 90
- - du Cap 90
- ratier brun 87
- - des mangroves 87

- tigrer d'Asie 86
Serpentes 4
serpins 44
serum sickness **56**, 70, 71, 81, 194, 222
Setekwa 268
Shedao 283
shield-nose snake 102, 255
shivering 74, 95, 160, 175, 187, 198, 206
shock
- anaphylactic 47, 56, 65, 70, 71
- circulatory 32, 36-38, 45, 47, 67, 71, **76**, 77, 80
shore pit viper or mangrove viper 287
Sibau 270
Siberia 205, 283
Siberian (Himalayan) pit viper 204
Sichuan 247, 284
Sicily 195, 275
side-stabbing snakes 98
sidewinder 216, 280
Sierra del Nido 282
- Leone 263, 272
- Madre Occidental 281
- - Oriental 281
Simoliophis 1
Simoselaps **150**, 267
Sinai 98, 179, 252, 274
Singapore 107, 113, 235, 236, 243, 256, 263, 269
Siphlophis **94**, 247
Siphnos 181, 274
Sistrurus 6, 51, 158, 172, 208, 215, **216**, 217, 119, 221, 224, 228, 285
- *catenatus* 336 (Fig)
Sivas 274
skaapsteker 93, 246
slender hog-nosed pitviper 284
slough 6
Slovakia 189
Slovenia 89, 186
small-scaled snake 140
smooth snake 85, 243
snakes, opistoglyphous 3, 8, 10, 30, 42, 85
- proteroglyphous 3, 8, 10, 30, 102, 134, 153
- solenoglyphous 3, 8, 10, 30, 73, 159, 203
Solenoglypha see snakes solenoglyphous
Solomon Islands 149, 154, 265-267, 270
Somalia 88, 112, 162, 167, 173, 238, 245, 250-254, 257, 263, 272-274
Sonora Desert 280
South African (western) coral snake 102, 255
South American bushmaster *see Lachesis*
South Carolina 47, 285
South China Sea 153, 270, 271
Southern Caucasus 263
southern copperhead 29, 41, 44, 45, 204, 276
Spain 89, 195, 275, 276
Spalerosophis **94**, 247, 248
speed of attack 5
spitting cobra 20, 36, 41, 44, 66, **111,** 112, 114, 116, 123, 125, 257, 262, 263
Squamata 4
Sri Lanka 21, 47, 87, 91, 93, 104, 105, 107, 112, 113, 119, 169, 171, 173, 204, 205, 225, 235-237, 240, 243, 255, 256, 262, 269, 270, 273, 283, 287
Stenorrhina **94**, 248
Stephen's banded snake 137
steppe ribbon racer 246
Stiletto snakes 98
Stockholm criteria 67, 193
stone breaker 104
Straits 264-266
Sudan 89, 99, 109, 162, 173, 238, 245, 246, 250, 253, 254, 257, 262, 263, 272-274
Sulawesi 236, 263, 268, 287
Sumatra 113, 225, 236, 247, 255, 256, 270, 287
Sumbawa 113, 263
Surinam 248, 260, 280
Surucucu 209
Suta 149, **150**, 265, 267
Swaziland 253, 257, 258, 272

sweating 67, 74, 99, 105, 110, 115, 120, 154, 155, 160, 163, 184, 190, 193, 196
Sweden 11, 18, 189, 192
swelling 73, 191, 196, 205, *see* also edema
Switzerland 19, 186, 195, 275
Syria 181, 186, 196, 249, 263, 274, 275
system, hemocoagulation *see* hemocoagulation
- cardiovascular *see* cardiovascular
Taal 270
tachycardia 74, 75, 99, 105, 124, 163, 166, 167, 169, 170, 182, 184, 187, 191, 196, 219
Tachymenis **94**, 248
Tagerza 180
taicatoxin 38, 141
taipan 28, 135, 141-143, 154, *see* also *Oxyuranus*
taipoxin 35, 46, 141
Taiwan 86, 104, 107, 112, 116, 119, 168, 169, 205, 207, 225, 228, 237, 239, 243, 247, 255-257, 262, 268-270, 273, 282, 284-287
Taiwan Russell's viper 168
Tajikistan 113, 273, 283
Tamaulipas 262
Tanahjampea 237
Tanganyika 122, 251, 255
Tanimbar 263, 264
Tantilla 5, **94**, 248, 249
Tanzania 112, 159, 162, 238, 245, 246, 251-254, 256, 257, 262, 263, 271, 272, 274
Taphrometopon 146, 249
Tarbophis 94, 249
Tasmania 23, 134, 136, 138, 264, 265
Taurus 275
Telescopus **94**, 95, 249, 250
Te-Nggano 154
Terciopelo 209
test, conjunctival 70
- dermal 70
Texas 92, 93, 126, 217, 238, 240, 241, 251, 262, 276, 285
textarin 43
textilotoxin 35
Thailand 93, 113, 116, 121, 169, 207, 225, 228, 235-237, 239, 240, 243, 247, 255, 256, 263, 268-270, 273, 279, 284-287
Thalassophina **152**, 271
Thalassophis **152**, 271
Thamnodynastes **94**, 250
Thamnophis **94**, 122, 250, 251
thanatosis 15
Thelotornis 13, 39, 40, 42, 85, **90**, 251
Thrasops 88, **94**, 251
thread coral snake 129
thrombin 35, 39, 40, 42-45, 54, 68, 78, 86-88, 141, 143, 146, 162, 166-168, 174, 178, 181, 196, 205, 211, 217, 226, 227
thrombocytopenia 41, 78, 86, 89, 138, 139, 142, 144, 146, 164, 167, 169, 170, 176, 187, 191, 197, 207, 213, 219-223, 227-229
thrombotization 40
Thung Song 287
Tian Shan 275
Tibet 158, 284, 287
Tiburón 258, 281
Tic-Polonga 168
tiger grooved-neck keelback 42, 86, 87, 247
tiger snake 38, 39, 52, 137, 140, 144, 149, 250 *see* also *Notechis*, *Telescopus*
timber rattlesnake 39, 41, 216, 220, 281
Timor 268
TNF 37
Tobago 12
Togo 257, 263, 272
tongue 6, 104, 115, 123, 124, 155, 187, 191, 194, 196, 219, 226
Torres Straits 266
Tortuga 282
tourniquet 61, 63, 65, 205, 207, 212, 214
Toxicocalamus **150**, 268
toxins 13, **27**-46
Trans-Pecos 276
Transverse Volcanic Cordillera 282

tree black forest cobra 124
Triceratolepidophis 224, 285
Trigonocéphale à bouche rose 204
Trimeresurus 12, 15, 21, 35, 39-42, 44, 46, 69, 70, 76, 79, 158, **224**-228, 282-288
- *albolabris* 337 (Fig)
- *gumprechti* 337 (Fig)
- *popeiorum* 337 (Fig)
- *purpureomaculatus* 337 (Fig)
Trimorphodon **94**, 251
trimucrotoxin 35, 46
Trinidad 12, 259, 260, 283
triwaglerin 42
Tropidechis **147**, 148, 168
Tropidolaemus 42, **224**, 286, 287
- *wagleri* 337 (Fig)
Tropidophiidae 2
tumor necrosis factor *see* TNF
Tunisia 181, 262, 273-275
Turkey 18, 89, 181, 183-186, 198, 204, 250, 274-276
- Bulgar-Dagh Mountains 276
- province of Sivas 274
- Taurus Mountains 275
Turkmenistan 113, 181, 273-275, 283
turtle-headed seasnake 269
twig snake 85, 90, 251
Tyrol 274
Uganda 112, 159, 162, 236, 238, 245, 252, 253, 256, 257, 262, 263, 271, 272
Ukraine 189, 275, 276
Ular Lampeh 86
- Picung 86
Ularburong 87
Uluguru 252
Umbrivaga 92, 241, 251
Umi-Hebi 152
Unechis 149, 266, 268
United Arabian Emirates 273
United Kingdom 19, 192
Uruguay 237, 239, 244, 245, 258, 280
Urutu 209, 278, 279
USA 17, 18, 21, 22, 51, 94, 126, 128, 129, 187, 194, 195, 204, 207, 216, 217, 221, 222, 240, 248, 250, 258, 260, 262, 276, 277, 280-282, 285
Uzbekistan 113, 181, 273-275
Uzungwe mountain bush viper 159, 271
variable mole viper 98, 252, 253
vascular resistance 38, 76, 162
vasoconstriction 37, 99, 110
vasodilation 31, 36, 37, 46, 65, 76, 159, 163, 170, 184, 185, 187, 190, 193, 194, 198, 217, 227
vasospasm, coronary 99
Venezuela 23, 240, 241, 244, 245, 258-262, 277-280, 284
venom components 29-47
venomous garter snakes 122
ventilation (pulmonary, mechanical) 64, 66, 71, 75, 77, 88, 90, 103, 105, 106, 108, 111, 118, 121, 122, 127-129, 135-145, 147, 148, 156, 160, 172, 175, 179, 183, 193, 198, 206, 213, 224
Veracruz 260
Vermicella **150**, 268
vertigo 74, 99, 107, 110, 115, 123, 124, 137, 160, 167, 187, 192, 206, 219
Victoria 264-267
Vietnam 52, 86, 112, 113, 158, 205, 236, 237, 239, 247, 255, 256, 263, 270, 271, 279, 282, 284-287
vine snake 90, 236, 244, 251
viper *see Bitis, Daboia, Echis, Macrovipera, Vipera*
viper minute 180
Vipera 2, 11, 18, 19, 29, 30, 34, 35, 37, 41, 42, 44, 47, 74, 76, 158, 168, 181, **183**, 184, 186, 188, 189, 195, 196, 198, 273-276
- *albizona* 340 (Fig)
- *ammodytes* 338 (Fig)
- *aspis* 338 (Fig)
- *berus* 338 (Fig)
- *dinnicki* 338 (Fig)
- *ebneri* 339 (Fig)
- *kaznakovi* 339 (Fig)
- *latifii 340* (Fig)
- *nikolskii* 339 (Fig)

- *palestinae* 339 (Fig)
- *raddei* 339 (Fig)
- *renardi* 339 (Fig)
- *seoanei* 340 (Fig)
- *wagneri* 340 (Fig)
Vipére 158, 159, 161, 166, 168, 179, 180, 183, 186, 188, 195, 196
- ammodytes 186
- arboricole 159
- aspic 195
- cornue 166
- d'Avicena 166
- de l'Atlas 180
- de Levant 180
- de McMahon 179
- de Palestine 196
- de Russell 168
- des bambous 225
- des Cyclades 180
- des sables Perse 179
- du Gabon 161
- du Sahara 180
- hébraique 161
- heurtande 161
- péliade 188
viperid snakes 7, 9, 33, 39, 45, 74-76, 158, 166, 180, 186
Viperidae 2, 4, 14, 28, 30, 31, 33, 34, 37, 39, 41-45, 63, 64, 71, 74-77, 79, 80, 113, 134, **157**-159, 203, 210, 225, 271
Viperinae 5, 12, 14, 34, 37, 40, 45, 47, 67, 69, 74, 80, 82, **158**, 159, 181, 184, 271
Viridovipera 224, 286-288
Volga 283
vomiting *see* nausea
von Willebrand's factor 41, 142
Wagler's pit viper 287
Waglerophis **94**, 251
Walterinnesia **124**, 125, 263
water cobras 122, 255
water moccasin 204
water snakes 92, 239, 251
West African carpet viper 173, 273
western cottonmouth 14, 29, 41, 204, 277
whip snake 91, 240, 243, 244, 246, 264, 266
white-lipped green pit viper 225
white-lipped tree viper 224, 228, 285
Wonambi 1
Woodlark 268
Xenocalamus **100**, 254
Xenochrophis **94**, 251
Xenodon **94**, 252
Xenodontinae 4
Yamakagashi 86
Yemen 173, 262
Yugoslavia 274, 275
Yunnan 285-287
Zacatecas 262
Zambia 112, 162, 238, 239, 245, 246, 252-254, 257, 262, 272
Zanzibar 109, 112, 246, 253
Zhaoermia 224, 286, 288
Zimbabwe 103, 123, 162, 236, 246, 253-255, 257, 262, 272
zmeja 183
zmija severna 188

PICTURES

Acanthophis antarcticus, photo V.T. Jirousek

Agkistrodon bilineatus, photo V.T. Jirousek

Agkistrodon contortrix, photo P. Velensky

Agkistrodon taylori, photo V.T. Jirousek

Ahaetula prasina, photo P. Velensky

Aspidelaps lubricus, photo P. Velensky

Atheris nitschei, photo V.T. Jirousek

Atheris squamiger, photo V.T. Jirousek

Atractaspis irregularis, photo V.T. Jirousek

Atropoides nummifer, photo V.T. Jirousek

Bitis arietans, photo P. Velensky

Bitis gabonica gabonica, photo V.T. Jirousek

Bitis nasicornis 1, photo V.T. Jirousek

Bitis nasocornis, photo V.T. Jirousek

Boiga cyanea, photo P. Velensky

Boiga cyanea, photo V.T. Jirousek

Boiga dendrophila, photo V.T. Jirousek

Bothriechis schlegelii, photo V.T. Jirousek

Bothrops alternatus, photo P. Velensky

Bothrops atrox, photo J. Valenta

Bothrops atrox, photo V.T. Jirousek

Bothrops neuwiedi, photo V.T. Jirousek

Boulengerina christyi, photo V.T. Jirousek

Causus rhombeatus, photo V.T. Jirousek

Cerastes cerastes, photo P. Velensky

Cerastes vipera, photo P. Velensky

Cerrophidion godmani, photo V.T. Jirousek

Chrysopelea ornata, photo V.T. Jirousek

Crotalus adamanteus, photo V.T. Jirousek

Crotalus atrox, photo V.T. Jirousek

Crotalus cerastes, photo P. Velensky

Crotalus cerberus, photo V.T. Jirousek

Crotalus durissus terrificus, photo P. Velensky

Crotalus durissus unicolor, photo P. Velensky

Crotalus helleri, photo V.T. Jirousek

Crotalus horridus, photo P. Velensky

Crotalus lutosus, photo V.T. Jirousek

Crotalus mitscheli stephensis, photo V.T. Jirousek

Crotalus ravus, photo V.T. Jirousek

Crotalus ruber, photo V.T. Jirousek

Crotalus viridis, photo P. Velensky

Crotalus scutulatus, photo V.T. Jirousek

Daboia russelli, photo V.T. Jirousek

Crotalus tigris, photo V.T. Jirousek

Dendroaspis angusticeps, photo P. Velensky

Dendroaspis jamesoni, photo V.T. Jirousek

Dispholidus typus, photo V.T. Jirousek

Dendroapis polylepis, photo P. Velensky

Echis carinatus, photo J. Valenta

Dendroaspis viridis, photo P. Velensky

Echis carnatus, photo V.T. Jirousek

Eristicophis macmahoni, photo V.T. Jirousek

Echis ocellatus, photo V.T. Jirousek

Echis pyramidium pyramidium, photo V.T. Jirousek

Gloydius halys caraganus, photo V.T. Jirousek

Gloydius intermedius saxatilis, photo V.T. Jirousek

Hemachtus haemachatus, photo V.T. Jirousek

Hypnale sp., photo V.T. Jirousek

Langaha madagascariensis, photo P. Velensky

Macrovipera lebetina obtusa, photo V.T. Jirousek

Macrovipera mauritanica, photo P. Velensky

Macrovipera schweizeri, photo V.T. Jirousek

Malpolon monspessulanus, photo P. Velensky

Micrurus fulvius, photo V.T. Jirousek

Naja annulifera, photo V.T. Jirousek



Naja atra albinic form, photo V.T. Jirousek

Naja atra, photo V.T. Jirousek

Naja haje haje, photo V.T. Jirousek

Naja kaouthia, photo V.T. Jirousek

Naja mossambica, photo V.T. Jirousek

Naja naja, photo V.T. Jirousek

Naja oxiana, photo V.T. Jirousek

Ophiophagus hannah, photo P. Velensky

Porthidium ophryomegas, photo V.T. Jirousek

Protobothrops flavoviridis, photo V.T. Jirousek

Psammophis linoleatus, photo P. Velensky

Pseudocerastes persicus, photo V.T. Jirousek

Sistrurus catenatus tergeminus, photo V.T. Jirousek

Sistrurus miliarius, photo P. Velensky

Trimeresurus albolabris, photo V.T. Jirousek

Trimeresurus gumprechti, photo V.T. Jirousek

Trimeresurus popeiorum, photo P. Velensky

Trimeresurus purpureomaculus, photo V.T. Jirousek

Tropidolaemus wagleri, photo V.T. Jirousek

Vipera ammodytes montandoni, female, photo P. Velensky

Vipera aspis atra, photo V.T. Jirousek

Vipera berus, female, photo P. Velensky

Vipera berus, male, photo P. Velensky

Vipera berus melanotic form, photo V.T. Jirousek



Vipera dinnicki, photo V.T. Jirousek

Vipera ebneri, photo V.T. Jirousek

Vipera kaznakovi, photo V.T. Jirousek

Vipera nikolskii, photo V.T. Jirousek

Vipera palaestinae, photo V.T. Jirousek

Vipera raddei, photo V.T. Jirousek

Vipera renardi, photo P. Velensky

Vipera seoanei seoanei, photo V.T. Jirousek

Vipera wagneri, photo V.T. Jirousek

Vipera albizona, photo V.T. Jirousek

Vipera latifii, photo V.T. Jirousek