SAM SILVERMAN
LISA A. TELL

RADIOLOGY OF BIRDS

An Atlas of Normal Anatomy and Positioning

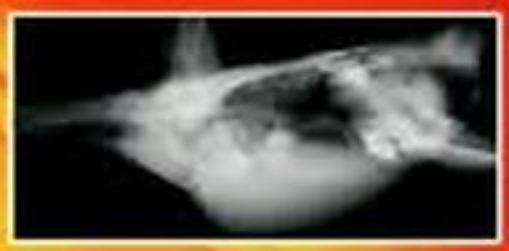

SAUNDERS
ELSEVIER

All Images From Book
Included on CD!

RADIOLOGY OF BIRDS

An Atlas of Normal Anatomy and Positioning

RADIOLOGY OF BIRDS

An Atlas of Normal Anatomy and Positioning

SAM SILVERMAN, DVM, PHD, DIPL ACVR
Clinical Professor
Department of Surgical and Radiological Sciences
School of Veterinary Medicine
University of California, Davis
Davis, California

LISA A. TELL, DVM, DIPL ABVP (AVIAN), ACZM
Professor
Department of Medicine and Epidemiology
School of Veterinary Medicine
University of California, Davis
Davis, California

RADIOGRAPHIC and TECHNICAL ASSISTANCE
JODY NUGENT-DEAL and KRISTINA PALMER-HOLTRY
Registered Veterinary Technicians
Companion Avian and Exotic Pet Medicine Service
Veterinary Medical Teaching Hospital
University of California, Davis
Davis, California

ARTISTIC ILLUSTRATIONS
KATHY WEST, M.SC.
Scientific and Medical Illustrator
Davis, California

with 485 illustrations

SAUNDERS
ELSEVIER

11830 Westline Industrial Drive
St. Louis, Missouri 63146

RADIOLOGY OF BIRDS

ISBN-13: 978-0-7216-0635-4
ISBN-10: 0-7216-0635-0

Copyright © 2010 by Saunders, an imprint of Elsevier Inc.

All rights reserved. No part of this publication may be reproduced or transmitted in any form or by any means, electronic or mechanical, including photocopying, recording, or any information storage and retrieval system, without permission in writing from the publisher. Permissions may be sought directly from Elsevier's Rights Department: phone: (+1) 215 239 3804 (US) or (+44) 1865 843830 (UK); fax: (+44) 1865 853333; e-mail: healthpermissions@elsevier.com. You may also complete your request on-line via the Elsevier website at http://www.elsevier.com/permissions

Notice

Neither the Publisher nor the [Authors] assume any responsibility for any loss or injury and/or damage to persons or property arising out of or related to any use of the material contained in this book. It is the responsibility of the treating practitioner, relying on independent expertise and knowledge of the patient, to determine the best treatment and method of application for the patient.

The Publisher

Library of Congress Cataloging-in-Publication Data

Silverman, Sam.
Radiology of birds : an atlas of normal anatomy and positioning / Sam Silverman, Lisa A. Tell ; radiographic and technical assistance, Jody Nugent-Deal and Kristina Palmer-Holtry ; artistic illustrations, Kathy West.
p. ; cm.
Includes index.
ISBN-13: 978-0-7216-0635-4 (hardcover : alk. paper)
ISBN-10: 0-7216-0635-0 (hardcover : alk. paper) 1. Birds--Anatomy--Atlases. 2. Veterinary radiography--Atlases. I. Tell, Lisa A. II. Title.
[DNLM: 1. Birds--anatomy & histology. 2. Radiography--veterinary. QL 697 S587r 2010]
SF767.B57S55 2010
636.6'08960757--dc22

2009008520

Vice President and Publisher: Linda Duncan
Senior Acquisitions Editor: Anthony Winkel
Associate Developmental Editor: Lauren Harms
Publishing Services Manager: Julie Eddy
Senior Project Manager: Celeste Clingan
Design Direction: Kim Denando

Printed in China

Last digit is the print number: 9 8 7 6 5 4 3 2 1

Working together to grow
libraries in developing countries
www.elsevier.com | www.bookaid.org | www.sabre.org
ELSEVIER BOOK AID International Sabre Foundation

PREFACE

The species included in this text are either popular companion pets or birds that are commonly presented to rehabilitation facilities. Documentation of radiographic and alternative imaging findings associated with disease conditions of these species continues to expand. There are several other textbook references documenting normal radiographic imaging anatomy for birds; however, this text was designed to provide additional radiographic information regarding normal anatomy and provide examples of contrast radiographic studies and advanced imaging procedures.

Given the limitations in printing, reproducing radiographic images of animal subjects such as birds is a challenge. It is difficult to obtain print quality that will allow the reader to appreciate subtle changes in the contrast and detail while still making the text affordable. Therefore, images in this text may not fully represent the image quality of the original radiographs for some avian species. In order to supplement the printed version of the text, a companion CD containing the images has been included and the images on this format medium are a closer approximation of the image quality of the original studies.

The purpose of this atlas is to provide veterinarians with normal radiographic images, contrast studies, and alternative imaging studies. We hope this atlas increases the utilization and accuracy of diagnostic imaging of these avian species and enhances their medical care.

DEDICATION

This book is dedicated to the veterinarians, technicians, and students who have helped to advance the medical care of our feathered companions.

Sam Silverman and Lisa Tell

This text and its companion volume, *Radiology of Rodents, Rabbits, and Ferrets,* are the product of 7 years of effort by the authors. I could not ask for a harder working, more conscientious, and organized co-author than Dr. Lisa Tell.

The support and encouragement of my mentors must be recognized. Dr. James Ticer, the first radiologist to enter full-time private radiology practice, encouraged me to pursue radiology as a specialty and provided me the opportunity to author a chapter in his textbook, *Radiographic Technique in Small Animal Practice*. To the best of my knowledge, this is the first inclusion of an avian radiology chapter in a veterinary radiology textbook. My career has been shaped by many, but Drs. Joe P. Morgan, Peter F. Suter, and Timothy R. O'Brien provided the best veterinary radiology training imaginable, encouraged me to apply my skills to the imaging of avian patients, and stressed the importance the discipline and the scientific method. The knowledge and techniques I have gained through the years are a product of their dedication to teaching.

There were many long days, weekends, and evenings involved in the production of these texts and they were never questioned by my family. I acknowledge the sacrifices made by my wife, Debrah Tom, and children, Naomi, Emily, and Darrell.

Sam Silverman

The journey that I embarked upon in the creation of Volumes 1 and 2 of these radiology texts was initiated by Dr. Sam Silverman. For giving me this opportunity and for his ability to remind me of the amazing gifts of life and health, I will always be grateful. Kathy West was an incredible person to work with and I especially appreciated her balanced approach to life. In the process of creating this book, I have gained lifelong friends in both Sam and Kathy.

My career in veterinary medicine has been deeply enriched by several of my mentors for whom I will forever be appreciative for all they have done for me. My interest in birds was sparked by my high school biology teacher, Mr. Larry Thorngren, who taught me to look in the sky and enjoy the feathered animals with which we share our world. Drs. Mitchell Bush and Scott Citino are amazing veterinarians; their dedication to teaching and passion for veterinary medicine were the basis for my training in the true "art" of zoological veterinary medicine. Lastly, I would like to thank Dr. Bill Lasley for providing endless encouragement and support and for mentoring me through my academic career.

I would also like to dedicate this book to my parents, William and Bette Tell, and sister, Lee Ann Hughes, for all of their love, support, and inspiration. Their encouragement has allowed me to follow my passion for veterinary medicine. My life would not be complete without my husband, Don Preisler, and children, Nicholas and Alexander Preisler, and mother-in-law, Dawn Preisler, as they are a constant source of love and happiness.

Lisa Tell

ACKNOWLEDGMENTS

The untiring and talented efforts of many individuals made this atlas a reality. Hundreds of radiographic images were produced by Jody Nugent-Deal and Kristina Palmer-Holtry. Candi Stafford and Michelle Santoro provided technical advice and assistance to optimize image quality and develop radiographic protocols. Bob Smith was our technical liaison with the 3M Corporation. Jason Peters and Richard Larson developed the protocols for the computed tomography and magnetic resonance examinations. Dr. Allison Zwingenberger was exceptionally helpful evaluating the computed tomography and magnetic resonance studies. John Doval provided technical advice on the reproduction of images. Jacki Pessenti and Brett Stedman were responsible for the care of some of the birds used for imaging. Debrah Tom paid exceptional attention to detail required in developing the keys for the text. Kathy West's artistic, organizational, and scientific skills are responsible for the high quality of the text's medical illustrations. The fortitude, resourcefulness, and attention to detail of the aforementioned individuals resulted in production of quality images that serve as the basis of this text.

The animals imaged were integral to this text's creation. They were housed and maintained in compliance with the Animal Welfare Act and the Guidelines for the Care and Use of Laboratory Animals. All radiographic and alternative imaging procedures were performed according to an approved animal care and use committee protocol. We are indebted to the individuals who cared for these animals and provided permanent homes for them when imaging was completed.

The concept of this atlas evolved because of the vision of Ray Kersey, former Executive Editor of Veterinary Medicine for Elsevier. His dedication to disseminating veterinary medical knowledge cannot be understated.

Dr. Anthony Winkel, Linda McKinley, Maureen Slaten, and Lauren Harms of Elsevier provided invaluable assistance during the development of this textbook and at the final production phase of this atlas. Their dedication, hard work, and guidance regarding technical and esthetic matters were crucial and greatly appreciated.

Production of this atlas entailed four years of work and we would be remiss not to acknowledge the goodwill, support, and understanding of our friends and families. Our spouses, Don Preisler and Debrah Tom, constantly provided support and encouraged us to continue even though there were many hours devoted to the creation of the atlas rather than family affairs. Alexander and Nicki Preisler were good sports and were willing to lend their "Mom" to the spending time with the "Bird Book." Kathy West's husband, Ed West, was always willing to open his home to endless weekends and cooked delicious meals when we worked late into the night.

In closing, we would like to extend our appreciation to all of these individuals for their encouragement, efforts, and sacrifices. We are indebted to them for their persistence and dedication.

Sam Silverman and Lisa Tell

CONTENTS

1 Radiology Equipment and Positioning Techniques, 1

2 Anatomic Art, 17

3 Budgerigar *(Melopsittacus undulatus)*, 25

4 Peach-Faced Lovebird *(Agapornis roseicollis)*, 29

5 Cockatiel *(Nymphicus hollandicus)*, 39

6 Sun Conure *(Aratinga solstitialis)*, 47

7 Senegal Parrot *(Poicephalus senegalus)*, 51

8 African Grey Parrot *(Psittacus erithacus erithacus)*, 67

9 Orange-Winged Amazon Parrot *(Amazona amazonica)*, 75

10 Blue and Gold Macaw *(Ara ararauna)*, 125

11 Goffin Cockatoo *(Cacatua goffiniana)*, 147

12 Sulphur-Crested Cockatoo *(Cacatua galerita)*, 151

13 Umbrella Cockatoo *(Cacatua alba)*, 155

14 Moluccan Cockatoo *(Cacatua moluccensis)*, 159

15 Pigeon *(Columba livia)*, 179

16 Mallard Duck *(Anas platyrhynchos)*, 203

17 Red Tailed Hawk *(Buteo jamaicensis)*, 227

18 Great Horned Owl *(Bubo virginianus)*, 249

DETAILED CONTENTS

1 Radiology Equipment and Positioning Techniques, 1

2 Anatomic Art, 17
Viscera of the Avian Coelom: Lateral, 18
Viscera of the Avian Coelom: Ventral, 19
Avian Skull: Lateral, 20
Avian Skull: Ventral, 21
Avian Skeleton: Lateral, 22
Avian Skeleton: Ventral, 23

3 Budgerigar *(Melopsittacus undulatus)*, 25
Radiographic Studies, 26
Viscera of the Coelom: Laterolateral, 26
Viscera of the Coelom: Ventrodorsal, 27

4 Peach-Faced Lovebird *(Agapornis roseicollis)*, 29
Radiographic Studies, 30
Viscera of the Coelom: Laterolateral, 30
Viscera of the Coelom: Ventrodorsal, 31
Radiographic Contrast Studies, 32
Gastrointestinal Positive Contrast: Laterolateral, 32
Gastrointestinal Positive Contrast: Ventrodorsal, 35

5 Cockatiel *(Nymphicus hollandicus)*, 39
Radiographic Studies, 40
Viscera of the Coelom: Laterolateral, 40
Viscera of the Coelom: Ventrodorsal, 41
Radiographic Contrast Studies, 42
Gastrointestinal Positive Contrast: Laterolateral, 00
Gastrointestinal Positive Contrast: Ventrodorsal, 42

6 Sun Conure *(Aratinga solstitialis)*, 47
Radiographic Studies, 48
Viscera of the Coelom: Laterolateral, 48
Viscera of the Coelom: Ventrodorsal, 49

7 Senegal Parrot *(Poicephalus senegalus)*, 51
Radiographic Studies, 52
Viscera of the Coelom: Laterolateral, 52
Viscera of the Coelom: Ventrodorsal, 53
Radiographic Contrast Studies, 54
Gastrointestinal Positive Contrast: Laterolateral, 54
Gastrointestinal Positive Contrast: Ventrodorsal, 58
Gastrointestinal Double Contrast: Laterolateral, 62
Gastrointestinal Double Contrast: Ventrodorsal, 64

8 African Grey Parrot *(Psittacus erithacus erithacus)*, 67
Radiographic Studies, 68
Viscera of the Coelom: Laterolateral, 68
Viscera of the Coelom: Ventrodorsal, 69
Skeleton, 70
Axial Skeleton: Laterolateral, 70
Axial Skeleton: Ventrodorsal, 71
Radiographic Contrast Studies, 72
Positive Contrast Rhinogram: Laterolateral, 72
Positive Contrast Rhinogram: Ventrodorsal, 73

9 Orange-Winged Amazon Parrot Radiographic Studies *(Amazona amazonica)*, 75
Radiographic Studies, 76
Viscera of the Coelom (Normal Bird): Laterolateral, 76

Viscera of the Coelom (Normal Bird): Ventrodorsal, 77
Viscera of the Coelom (Obese Bird): Laterolateral, 78
Viscera of the Coelom (Obese Bird): Ventrodorsal, 79
Skeleton, 80
Head: Laterolateral, 80
Head: Oblique (30 Degrees), 81
Head: Ventrodorsal, 82
Axial Skeleton: Laterolateral, 84
Axial Skeleton: Ventrodorsal, 85
Wing: Mediolateral, 86
Wing: Caudocranial, 87
Pelvic Limb: Mediolateral, 88
Pelvic Limb: Craniocaudal, 89
Distal Pelvic Limb: Mediolateral, 90
Distal Pelvic Limb: Dorsoplantar, 91
Radiographic Contrast Studies, 92
Gastrointestinal Positive Contrast: Laterolateral, 92
Gastrointestinal Positive Contrast: Ventrodorsal, 93
Gastrointestinal Double Contrast: Laterolateral, 98
Gastrointestinal Double Contrast: Ventrodorsal, 100
Cloacagram (Retrograde, Positive and Double Contrast): Laterolateral, 102
Cloacagram (Retrograde, Positive and Double Contrast): Ventrodorsal, 103
Excretory Urogram: Laterolateral, 106
Excretory Urogram: Ventrodorsal, 108
Computed Tomography Studies, 110
Head: Transverse, 110
Coelom: Transverse, 113
Coelom (Post-contrast): Transverse, 116
Magnetic Resonance Imaging Studies, 118
Head: Sagittal, 118
Head (Post-contrast): Sagittal, 120
Head: Transverse, 121
Head (Post-contrast): Transverse, 123
Ultrasound of Liver, 124

10 Blue and Gold Macaw *(Ara ararauna)*, 125
Radiographic Studies, 126
Viscera of the Coelom: Laterolateral, 126
Viscera of the Coelom: Ventrodorsal, 127
Skeleton, 128
Head: Laterolateral, 128
Head: Ventrodorsal, 129
Axial Skeleton: Laterolateral, 130
Axial Skeleton: Ventrodorsal, 131
Wing: Mediolateral, 132
Wing: Caudocranial, 133
Pelvic Limb: Mediolateral, 134
Pelvic Limb: Craniocaudal, 135
Radiographic Contrast Studies, 136
Gastrointestinal Positive Contrast: Laterolateral, 136
Gastrointestinal Positive Contrast: Ventrodorsal, 139
Computed Tomography Study, 142
Head: Transverse, 142

11 Goffin Cockatoo *(Cacatua goffiniana)*, 147
Radiographic Studies, 148
Viscera of the Coelom: Laterolateral, 148
Viscera of the Coelom: Ventrodorsal, 149

12 Sulphur-Crested Cockatoo *(Cacatua galerita)*, 151
Computed Tomography Study, 152
Head: Transverse, 152

13 Umbrella Cockatoo *(Cacatua alba)*, 155
Radiographic Studies, 156
Viscera of the Coelom: Laterolateral, 156
Viscera of the Coelom: Ventrodorsal, 157

14 Moluccan Cockatoo *(Cacatua moluccensis)*, 159
Radiographic Studies, 160
Viscera of the Coelom (Fasted Bird): Laterolateral, 160
Viscera of the Coelom (Fasted Bird): Ventrodorsal, 161
Viscera of the Coelom (Pellet-fed Bird): Laterolateral, 162
Viscera of the Coelom (Pellet-fed Bird): Ventrodorsal, 163
Skeleton, 164
Head: Laterolateral, 164
Head: Ventrodorsal, 165
Axial Skeleton: Laterolateral, 166
Axial Skeleton: Ventrodorsal:, 167
Wing: Mediolateral, 168
Wing: Caudocranial, 169
Pelvic Limb: Mediolateral, 170
Pelvic Limb: Craniocaudal, 171
Distal Pelvic Limb: Mediolateral, 172
Distal Pelvic Limb: Dorsoplantar, 173
Radiographic Contrast Studies, 174
Gastrointestinal Positive Contrast: Laterolateral, 174
Gastrointestinal Positive Contrast: Ventrodorsal, 175
Computed Tomography Study, 176
Head: Transverse, 176

15 Pigeon *(Columba livia)*, 179
Radiographic Studies, 180
Viscera of the Coelom: Laterolateral, 180
Viscera of the Coelom: Ventrodorsal, 181
Skeleton, 182
Head: Laterolateral, 182
Head: Ventrodorsal, 183
Axial Skeleton: Laterolateral, 184
Axial Skeleton: Ventrodorsal, 185
Wing: Mediolateral, 186
Wing: Caudocranial, 187
Pelvic Limb: Mediolateral, 188
Pelvic Limb: Craniocaudal, 189
Distal Pelvic Limb: Mediolateral, 190
Distal Pelvic Limb: Dorsoplantar, 191
Respiratory Series: Spontaneous Ventilation, 192
Respiratory Series: Manual Assisted Inspiration, 192
Respiratory Series: Mechanical Ventilator Assisted Inspiration, 192
Radiographic Contrast Studies, 194
Gastrointestinal Positive Contrast: Laterolateral, 194
Gastrointestinal Positive Contrast: Ventrodorsal:, 197
Cloacagram (Retrograde, Positive Contrast): Laterolateral, 200
Cloacagram (Retrograde, Positive Contrast): Ventrodorsal, 201

16 Mallard Duck *(Anas platyrhynchos)*, 203
Radiographic Studies, 204
Viscera of the Coelom: Laterolateral, 204
Viscera of the Coelom: Ventrodorsal, 205
Skeleton, 206
Head: Laterolateral, 206
Head: Ventrodorsal, 207
Axial Skeleton: Laterolateral:, 208
Axial Skeleton: Ventrodorsal:, 209
Wing: Mediolateral, 210
Wing: Caudocranial, 211
Pelvic Limb: Mediolateral, 212
Pelvic Limb: Craniocaudal, 213
Distal Pelvic Limb: Mediolateral, 214
Distal Pelvic Limb: Dorsoplantar, 215
Radiographic Contrast Studies, 216
Gastrointestinal Positive Contrast: Laterolateral, 216
Gastrointestinal Positive Contrast: Ventrodorsal, 217
Excretory Urogram (Cutaneous Ulnar Vein Contrast Administration): Laterolateral, 219

Excretory Urogram (Medial Metatarsal Vein Contrast Administration): Laterolateral, 220
Computed Tomography Studies, 221
Head: Transverse, 221
Coelom: Transverse, 225

17 Red Tailed Hawk *(Buteo jamaicensis)*, 227
Radiographic Studies, 228
Viscera of the Coelom: Laterolateral, 228
Viscera of the Coelom: Ventrodorsal, 229
Skeleton, 230
Head: Laterolateral, 230
Head: Ventrodorsal, 231
Axial Skeleton: Laterolateral, 232
Axial Skeleton: Ventrodorsal, 233
Wing: Mediolateral, 234
Wing: Caudocranial:, 235
Pelvic Limb: Mediolateral, 235
Pelvic Limb: Craniocaudal, 236
Distal Pelvic Limb: Mediolateral, 237
Distal Pelvic Limb: Dorsoplantar, 238
Radiographic Contrast Studies, 239
Gastrointestinal Positive Contrast: Laterolateral, 239
Gastrointestinal Positive Contrast: Ventrodorsal, 242
Computed Tomography Study, 245
Coelom: Transverse, 245

18 Great Horned Owl *(Bubo virginianus)*, 249
Radiographic Studies, 250
Viscera of the Coelom: Laterolateral, 250
Viscera of the Coelom: Ventrodorsal, 251
Skeleton, 252
Head: Laterolateral, 252
Head: Ventrodorsal, 253
Axial Skeleton: Laterolateral, 254
Axial Skeleton: Ventrodorsal, 255
Wing: Mediolateral, 256
Wing: Caudocranial, 257
Pelvic Limb: Mediolateral, 258
Pelvic Limb: Craniocaudal, 259
Distal Pelvic Limb: Mediolateral, 260
Distal Pelvic Limb: Dorsoplantar, 261
Radiographic Contrast Studies, 262
Gastrointestinal Positive Contrast: Laterolateral, 262
Gastrointestinal Positive Contrast: Ventrodorsal, 265
Computed Tomography Study, 268
Head: Transverse, 268

CHAPTER • 1

Radiology Equipment and Positioning Techniques

ANATOMIC REFERENCES

Anatomic drawings demonstrating the spatial relationship of the internal organs are provided in Chapter 2. They should be used as general reference material. Individual organs are not always clearly visualized on all radiographs. There are species variations in the size, shape, and location of internal organs. The radiographic appearance of the viscera is also affected by the birds' reproductive status and digestive tract contents. In the case of this text, the reproductive organs were labeled as "gonads" (versus ovary or testes) if no specific anatomic structure (i.e., the syrinx in male duck) could be identified on the radiograph to indicate the bird's sex.

Images in this text were anatomically labeled to coincide with illustrations from several textbooks, including *Atlas of Avian Anatomy Osteology-Arthrology-Myology* (Chamberlain FW, East Lansing, Mich, 1943, Michigan State College Agricultural Experiment Station), *Atlas of Radiographic Anatomy and Diagnosis of Cage Birds* (Krautwald ME et al., Berlin and Hamburg, 1992, Paul Parey Scientific Publishers), *A Color Atlas of Avian Anatomy* (McLelland J, Philadelphia, 1991, Saunders), *Anatomy of the Domestic Birds* (Nickel R et al., 1977, Berlin and Hamburg, Verlag Paul Parey), and *Atlas of Avian Radiographic Anatomy* (Smith S, Smith B, 1992, Philadelphia, Saunders).

EQUIPMENT FOR RADIOGRAPHIC STUDIES

RADIOGRAPHIC UNITS

It is sometimes erroneously presumed that the relatively small body size of birds allows for the use of low-capacity radiology equipment. However, in order to make high-quality radiographic images of birds, the x-ray generator should be capable of producing at least 300 milliamps (mA), the exposure time capability should be .017 (1/60) second or shorter, the kilovolt peak (kVp) settings should have a range of 40-90 kVp, and kVp settings should be adjustable in 2 kVp increments. High-frequency x-ray generators are recommended because they produce uniform x-ray output. Radiographic exposure factors are more critical in birds than in mammals. Small variations in x-ray output are very noticeable on avian radiographs, especially those made with lower kVp techniques. Small variations in x-ray tube output are more obvious on avian radiographs than on radiographs of dogs and cats; therefore the x-ray generator must be in excellent condition. Older generators are not recommended because they may have mechanical exposure timers that are less accurate than electronic timers and the x-ray output may vary between exposures with identical settings even though the exposure settings are similar.

Over time, use of x-ray tubes causes pitting of the anode or filament damage, resulting in degradation of x-ray output. Radiographs made with damaged tubes may be diagnostic, but the variation in image quality among studies can affect interpretation, especially in sequential examinations monitoring the response to therapy or the progression of disease (e.g., pneumonia). Lung and air sac image opacities are very susceptible to variations in radiographic techniques. If variables in radiographic techniques are not identified, increased pulmonary or air sac opacity caused by underexposure can be misdiagnosed as pulmonary consolidation or air sac membrane thickening. Overexposure, if unrecognized, may result in a misdiagnosis of a positive response to treatment.

Short exposure times (i.e., .017 [1/60] second or shorter) are essential to minimize motion artifact associated with the rapid respiratory rate and generalized muscular tremors that are common in birds. Short exposure times dictate high mA settings to generate sufficient x-ray output (i.e., milliampseconds [mAs]).

Low kVp techniques (40-60 kVp) are preferred for most film screen systems because they produce a long scale of contrast compared with higher kVp techniques. The ability to make small kVp adjustments is essential to optimize image detail. Digital radiology systems usually use higher kVp techniques than film screen systems, but the ability to adjust the kVp in 2 kVp increments remains desirable.

The generation of the x-ray beam is initiated by the production of electrons in the x-ray tube filament. Diagnostic radiology tubes (except for dental units) have two filaments (focal spots). Smaller focal spot tubes generally produce superior image detail compared with larger focal spot tubes. Focal spot size and tube x-ray output are inversely related. In order to obtain enhanced detail, the smaller focal spot should be selected. Selection of the smaller focal spot may require manual override of preprogrammed settings. For larger birds, higher mAs techniques may not be possible with the small focal spot.

Tabletop (nongrid) techniques are standard for avian radiography. Grids are typically employed to minimize the deleterious effects of scatter radiation generated by larger patients that have a body thickness greater than 10 cm. Although some birds' bodies are greater than 10 cm, grids are typically not necessary because the air within the air sacs does not generate significant scatter radiation.

The x-ray tube stand should allow for adjustments of the focal film distance (FFD). Adjustment of the FFD is used to make small variations in the effective mAs (x-ray exposure reaching the film). The mAs reaching the film is inversely proportional to the square of the distance from the x-ray source (focal spot). To compensate for the lower mA output of the small focal spot, while maintaining the short exposure time, avian radiographic techniques frequently utilize shorter FFDs than typically used for canine and feline radiography. The alteration of the FFD can also be used to make small adjustments to the effective mAs that cannot otherwise be made. Excessive reduction of the FFD distorts the image; therefore FFDs of less than 30 inches (76 cm) are discouraged.

Many types of equipment have been used for making radiographic images of birds. If patient motion is not a factor (i.e., the patient is anesthetized, thus minimizing the respiratory and muscular motion) and the bird is small (less than 20 gm body weight), dental units may be utilized. However, dental radiography units are generally not well-suited for avian radiography because of their relatively large focal spot size, low mA capacity, lack of adjustable collimation, and inability to make short exposure times. For most birds dental radiography film is too small for imaging the entire head or coelom, and the range of contrast for dental film is much lower than for general radiology film. Nevertheless, some detailed images can be made with dental radiology units and film, especially for examinations of the distal extremities. Portable x-ray radiographic units designed for large animal extremity work are not optimal for the radiographic examination of birds because these units are incapable of producing sufficient mA at the required short exposure times without severely reducing the FFD.

Standard diagnostic radiology equipment in good condition designed for small animal (feline and canine) practice should be utilized for making radiographic images of birds. An Innovet Select X-ray System (Summit Industries, Inc., Chicago) was used to produce the radiographic images in this book.

RADIOGRAPHIC FILM-INTENSIFYING SCREENS

Selection of radiographic film and intensifying screens is based on the speed of the system (i.e., mAs required to produce a high-quality diagnostic image). Film-screen speed and detail are inversely related. Faster systems are usually capable of producing less detail than slower systems. Asymetrix Detail Intensifying Screens (3M Animal Care Products, 3M Center, St. Paul, Minn.) and Ultra Detail Plus or SE + radiographic film (3M Animal Care Products, 3M Center, St. Paul, Minn.) were used to produce the radiographic images in this book. This film-screen combination produced a radiographic system speed of 100 to 350. Table 1-1 summarizes radiographic exposure factors used for creating this text's radiographic images using a tabletop technique. These settings are intended to be

Table • 1-1

Radiographic exposure guidelines for several species of birds.

Body Weight (gm)	Avian Species	Film-Screen Systems*	mAs	kVp
30-100	Budgie, Cockatiel	2	7.5	50
100-300	Senegal, Amazon	2	7.5-9.0	52
100-300	Senegal, Amazon	1	6	44
300-600	Amazon, Cockatoo	1	6	46
600-900	Cockatoo, Macaw	1	6	48
900-1200	Macaw, Red-Tailed Hawk	1	6	50

Focal film distance =102 cm (40 inches), table top technique
*Film-Screen Systems:
1. 3M Asymetrix detail green light emitting rare earth screens and 3M Ultra Detail Plus film (3M Animal Care Products, St. Paul MN).
2. Asymetrix Detail green light emitting rare earth screen with 3M SE + film (3M Animal Care Products, St. Paul MN).

guidelines and may require modification depending on the x-ray generator, film-screen combination, radiographic film processing, and patient size. Other film-screen combinations of similar speed and resolution can also be used if they are of sufficient detail and speed.

The same technique is usually used for the laterolateral and ventrodorsal coelomic radiographic studies. For radiographic studies of the distal extremities (foot and distal portion of the wing), the kVps used for coelomic radiographic studies are usually reduced by 2 to 3 kVp to prevent overexposure of the distal extremities.

DIGITAL RADIOLOGY SYSTEMS

Digital radiographic image capture (e.g., direct digital, computed radiography) is slowly replacing film-screen systems in veterinary medicine and will eventually predominate. Non-screen film and high-detail film-screen systems produce images with superior detail compared with digital systems; however, digital systems are capable of producing a higher image contrast range than is possible with film. This results in improved image quality. Other advantages of digital radiography include images that can be electronically manipulated, do not require film processing, and are immediately viewable. In addition, digital systems result in fewer repeat exposures caused by incorrect exposure factors and film processing errors. Digital systems often use higher kVp and mAs techniques (10%-15% higher kVp and mAs) than film-screen systems. Special algorithms are required for avian patients, but they are increasingly available from the manufacturers that produce the digital radiology systems.

THE RADIOGRAPHIC EXAMINATION

PATIENT PREPARATION

Birds utilized in this text were healthy and were fasted before radiographic examinations. Birds weighing less than 100 grams were fasted for 2 hours, and larger birds were fasted for 3 to 5 hours before the radiographic procedure. Avian patients, especially those that are debilitated, are more easily compromised by food deprivation than are mammals. The decision to withhold food in a clinical situation is therefore complex. Even more important than restricting free access to food is the recommendation not to administer nutrients by gavage for 4 hours before the radiographic study, especially in debilitated birds in which crop and proventricular emptying times may be prolonged. The stress associated with manual restraint or anesthesia required for the radiographic examination increases the potential for regurgitation and airway aspiration of the digestive tract contents.

Digestive tract filling affects the radiographic appearance of internal organs. An example of this is included in the section on the Moluccan cockatoo. Postprandial digestive tract distention can displace the liver cranially. A distended proventriculus often obscures visualization of the spleen. Some of the misdiagnoses associated with failure to recognize the effects of a recent feeding include hepatomegaly and cardiomegaly. Mass lesions, free coelomic fluid, or enlargement of internal organs can also be obscured by ingesta. This is caused by the added opacity of the ingesta, which alters the appearance of the coelomic organs. When two organs of similar opacity are in direct contact, their individual outlines can merge together. The physical characteristics of the ingesta can also variably affect the appearance of the digestive tract. High-fiber (e.g., beans), high-fluid–content (e.g., fruit), and some pelleted diets can produce dramatic digestive tract distention, simulating pathologic conditions. Pelleted diets can sometimes cause the interface between the contrast medium and digestive tract mucosa to be indistinct in digestive tract contrast studies. This can simulate the radiographic appearance of enteritis or excessive intestinal mucus.

Rapid respiratory movements and muscle fasciculations (fine motor movements) are common in birds and can degrade the radiographic detail. The muscle fasciculations can be associated with hypothermia, stress, or a light plane of anesthesia. All of these factors should be addressed before proceeding with the radiographic study.

TIMING THE RADIOGRAPHIC EXPOSURE

The avian respiratory rate is more rapid than that of most mammals, the lungs are nonexpansile, and during both inspiration and expiration air is continuously moving into the pulmonary parenchyma and the air sacs. In general, the effect of the respiratory cycle on the radiographic appearance of the pulmonary parenchyma is less in birds than in mammals because avian lungs are nonexpansile. In some cases, distention of the abdominal air sacs is preferred because the increased air sac distention can improve the visibility of the viscera, especially in birds with large amounts of coelomic fat. Timing the radiographic exposure to coincide with air sac inflation is difficult in nonanesthetized birds as a result of the rapid respiratory rate and inability to directly visualize the respiratory movements through the pelage. If timing the radiographic exposure to coincide with inspiration is not possible, the exposure should coincide with a pause in the respiratory cycle. In the case of intubated anesthetized birds, air sac inflation can be achieved by applying positive pressure to the anesthetic circuit reservoir bag. Positive pressure ventilation of 4 to 6 cm of water is recommended, with 8 to 10 cm of water being the maximum amount for most avian species.

ANESTHESIA

Radiographic studies for which the birds are anesthetized with inhalation gas anesthetics are generally completed in less time and are of higher quality than studies in which the birds are not anesthetized. Anesthetized birds are easily positioned with less physical restraint, and the potential for iatrogenic fractures is minimized. It is also possible to inflate the air sacs

with positive pressure ventilation in the intubated bird. Motion artifacts are also reduced with anesthesia. All birds in this text were healthy, and the majority of the studies were performed using inhalation anesthesia or chemical sedation. Birds seen in clinical practice may be severely debilitated, and general anesthesia may be contraindicated; however, it is recommended whenever the anesthetic procedure is deemed safe.

POSITIONING DEVICES

For production of the images for this text, smaller birds (i.e., less than 100 grams body weight) were positioned directly on the radiographic cassette and secured with masking tape, but an acrylic positioning device (Bird Board, 8205 Alba Ct., Citrus Heights, Calif.) was used to facilitate positioning of larger birds. Many avian positioning devices are commercially available. If positioning devices are interposed between the bird and the film or digital sensor, a small increase in kVp (2-4 kVp) may be required to compensate for x-ray beam filtration caused by the device. The need for exposure compensation is especially necessary with low kVp techniques (40-50 kVp) and thicker positioning devices. Positioning devices placed on the x-ray cassette or used with a digital system increase the object film or sensor distance. The increased object film or sensor distance may decrease image detail, but the magnitude of loss is usually minimal. A modified version of the Bird Board is available that allows for direct contact of the bird and the radiographic cassette (Figure 1-1).

PATIENT POSITIONING

Orthogonal projection radiographs (i.e., two projections made at 90 degrees to each other) are indicated for all radiographic studies unless the patient's condition is compromised and the stress involved with restraint and/or anesthesia is deemed too great to obtain both projections.

The standard avian radiographic study includes laterolateral and ventrodorsal studies of the coelom. For radiographic images of the coelom right lateral and ventrodorsal projections were standard in this text. Pectoral extremity (wing) studies include the mediolateral and caudocranial projections. Given the natural curvature of the skeletal structures of the wing, the laterolateral and ventrodorsal projections of the coelom result in similar-appearing images (mediolateral and lateromedial) of the wing, thus the necessity to make the caudocranial projection of the wing. Manual positioning is required for the caudocranial projection of the wing. The whole body techniques do result in orthogonal projections of the pelvic extremities and therefore do not require additional positioning techniques.

POSITIONING TECHNIQUES FOR LATEROLATERAL AND VENTRODORSAL RADIOGRAPHIC STUDIES OF THE AVIAN HEAD

Radiographic studies of the head include laterolateral and ventrodorsal radiographic projections and, when necessary, oblique views. Small wedges of radiolucent foam may be of assistance for precise positioning of the head. For laterolateral and oblique projections, the patient is placed in a lateral recumbent position. Oblique radiographic projections require rotation of 15 to 30 degrees or less off the straight lateral projection. Oblique projections are described by the point of entrance of the x-ray beam to the point of exit. For ventrodorsal projections, the patient is positioned in dorsal recumbency and tape is applied to the ventral aspect of the rhinotheca so that the maxilla is closer to the cassette. This positioning of the head changes the orientation from a rostrocaudal to a ventrodorsal projection (Figures 1-2 to 1-3).

POSITIONING TECHNIQUE FOR THE LATEROLATERAL RADIOGRAPHIC STUDY OF THE AVIAN COELOM

Before positioning the bird for radiographic examination, strips of paper bandage or masking tape are prepared. Paper tape is less traumatic to the pelage and skin than fabric bandage tape,

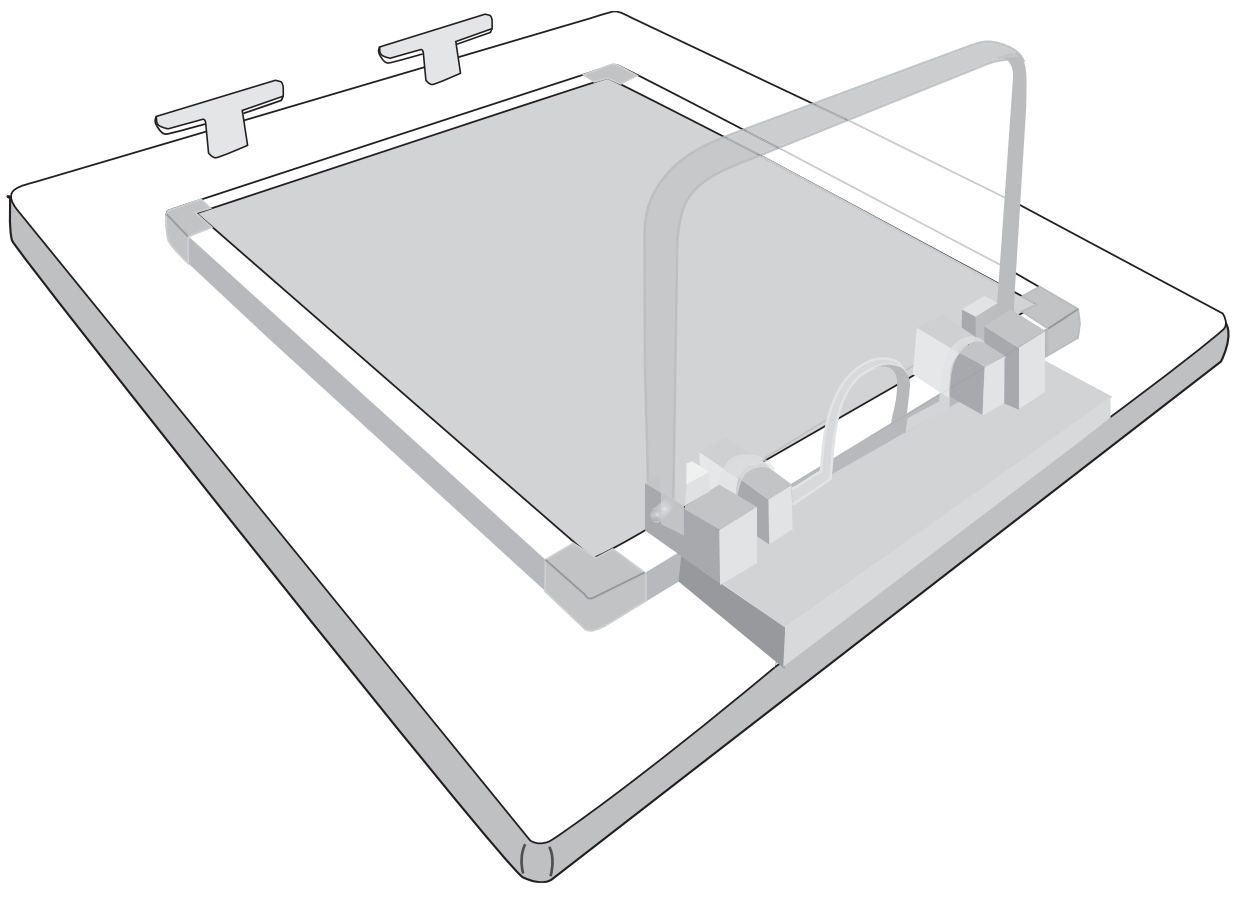

Figure 1-1 Figure positioning equipment. A modified version of the traditional "Bird Board" is commercially available and allows for direct contact of the bird and the radiographic cassette.

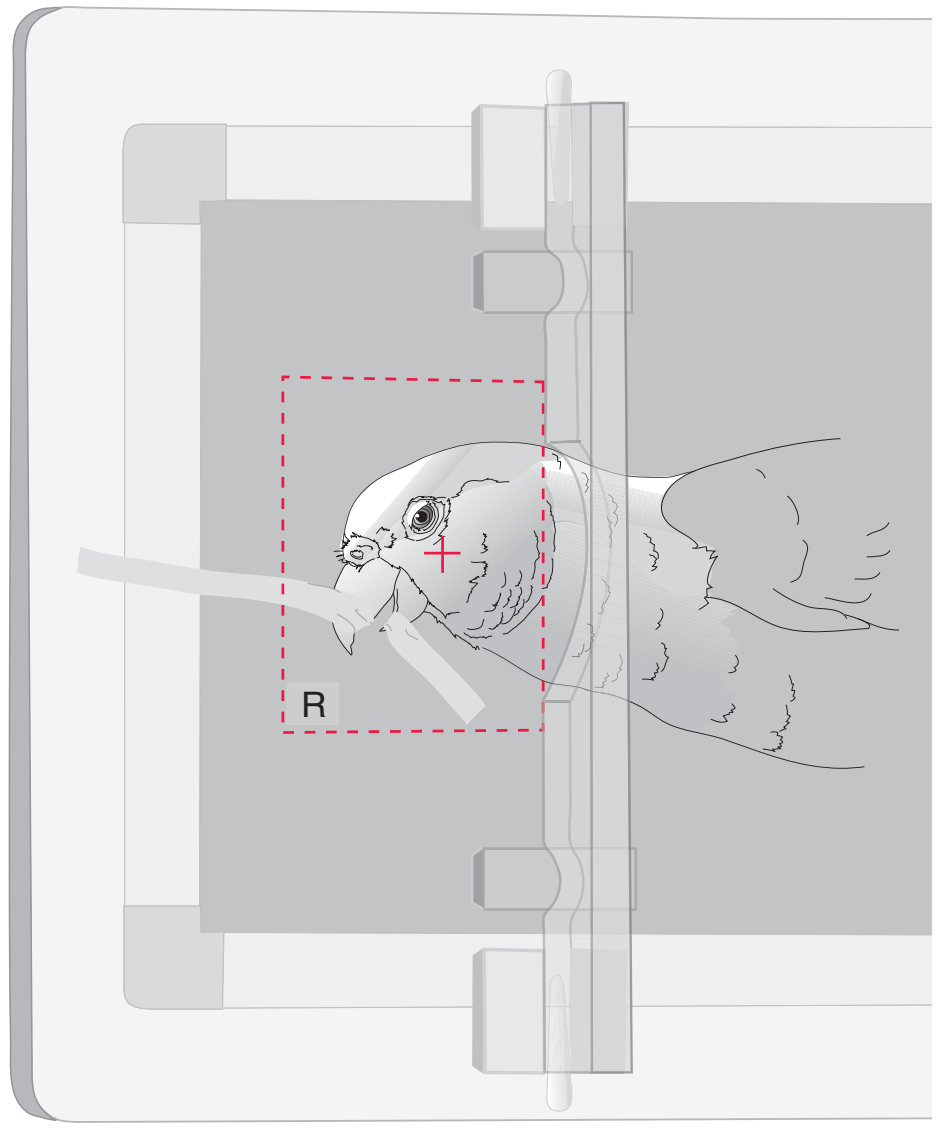

Figure 1-2 Positioning technique for the laterolateral radiographic study of the avian head. The bird is placed in right lateral recumbency with the head resting on the cassette. Stabilization is achieved using radiolucent tape to secure the maxilla and mandible. Care should be taken to avoid applying tape over the eyelids. The x-ray beam is centered (+) ventral to the eye, and the x-ray beam field *(dotted lines)* includes the entire head and extends to the cervical region. Use of positioning device is optional. A metallic "R" marker is placed on the radiographic cassette indicating that the right side is dependent.

can be removed easily with minimal residue left on the feathers, and is less radiopaque than fabric tapes. The ends of the tape are folded over on themselves for approximately ¼ (0.25) inch to facilitate tape removal when the examination is complete or if patient repositioning is required.

Laterolateral radiographic studies in this text were made with the bird in right lateral recumbency (i.e., the right side of the bird is on the x-ray table or positioning device). The laterolateral positioning technique begins with placing the bird's neck in the cervical restraint portion (guillotine) of the positioning device. The body is then gently moved caudally to reduce curvature of the neck. Further gentle traction is applied to the bird's body by immobilizing the legs with tape or strips of bandage gauze attached to the positioning device. To immobilize the legs, bandage gauze can be looped around the distal tarsometatarsus of each leg and then attached to the cleat on the positioning device. The dependent leg is positioned first, and the contralateral leg is then superimposed on the dependent leg. Occasionally, small pieces of radiolucent sponge are placed between the legs to minimize rotation. Finally, the wings are fully extended dorsally to minimize their superimposition on the cranial dorsal thorax, especially the pulmonary parenchyma. To minimize rotation of the body, the wings should be secured individually using tape. The dependent wing is positioned and taped first. Two pieces of tape are used and crossed at the carpal region of each wing separately. If necessary, another piece of tape can be applied across the wings in the humeral region. The primary flight feathers can be separated to allow increased contact between the tape and the surface of the cassette, positioning device, or table. Rotational malpositioning of the body can be associated with asymmetric leg extension or if excessive pressure is applied to the upper wing when it is secured. A metallic "R" marker is placed adjacent to the bird, indicating that the right side is dependent. Proper positioning is confirmed visually and by palpation of the sternum and vertebral column.

Proper patient positioning is essential because any rotation of the bird's body results in distortion of the coelomic organs and can result in misinterpretation of the radiographic findings. On the laterolateral radiographic studies of the coelom in this text, the extremities are superimposed on each

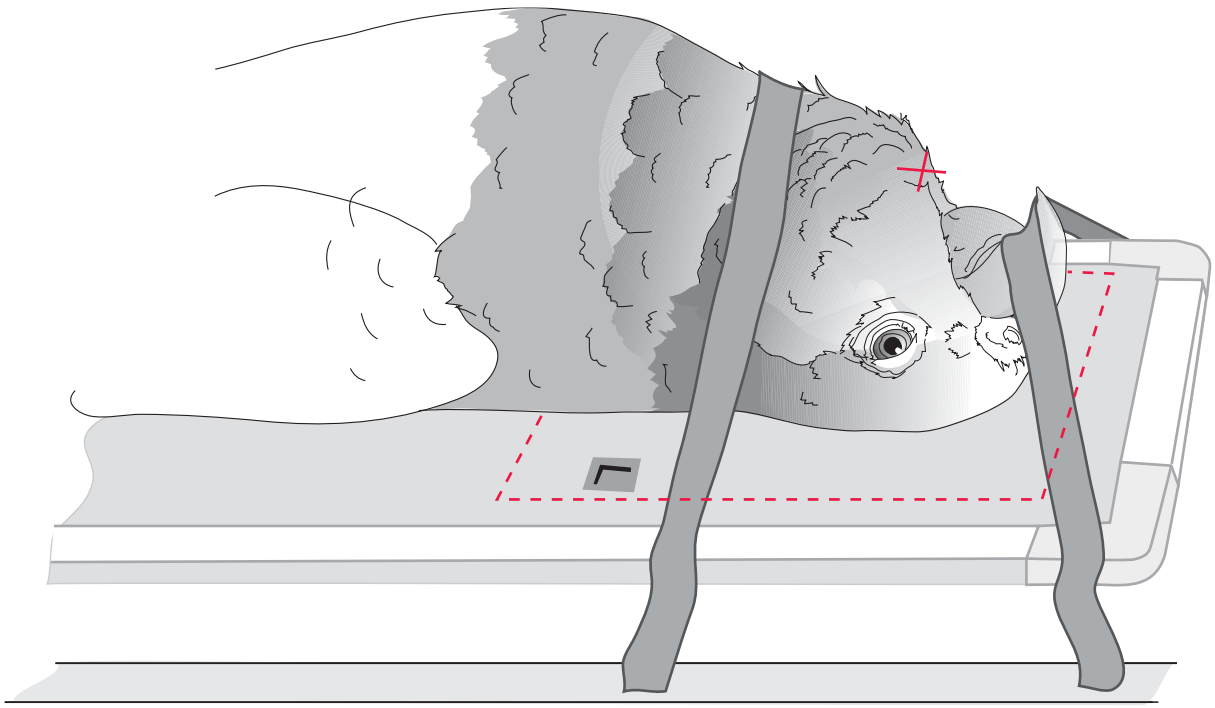

Figure 1-3 Positioning technique for the ventrodorsal radiographic study of the avian head. The patient is positioned in dorsal recumbency. Radiolucent tape is applied to the ventral aspect of the rhinotheca to hyperextend the maxilla at an angle closer to the radiographic cassette. The x-ray beam (+) is centered between the eyes on the midline, and the x-ray beam field *(dotted lines)* includes the entire head and extends to the region of the cervical vertebrae. Metallic "R" and "L" markers are placed on the radiographic cassette indicating the laterality of the patient.

other. The authors prefer this method of positioning because it results in less rotation of the bird's body. Because the dependent extremities are closer to the film or digital sensor than the contralateral extremity, the dependent extremities can usually be differentiated. Cortical borders are sharper and the bones are less magnified than in the nondependent extremity. In smaller birds, laterality can be difficult to determine because the magnitude of magnification in the nondependent extremities is minimal. An alternative technique to superimposing the extremities is to position the dependent extremity slightly cranial to the contralateral extremity, but this may result in rotation of the body (Figure 1-4).

POSITIONING TECHNIQUE FOR THE VENTRODORSAL RADIOGRAPHIC STUDY OF THE AVIAN COELOM

Precut strips of paper tape, as described for the laterolateral radiographic study of the coelom, are prepared. For the ventrodorsal projection, the bird is placed on the positioning device in dorsal recumbency. The neck is placed in the guillotine and the head is adjusted to the straight rostrocaudal position. Further gentle traction is applied to the bird's body by extending the pelvic limbs slightly caudally and securing them with gauze to the positioning device's cleats. The wings are fully and symmetrically extended laterally and secured with paper tape. Two pieces of tape are crossed at the carpal region of each wing. The sternum (keel) is palpated to confirm that it is superimposed on the vertebral column. Positions of the extremities (legs and wings) are also evaluated for bilateral symmetry. Metallic "R" and "L" markers should be placed on the radiographic cassette indicating the laterality of the patient (Figure 1-5).

POSITIONING TECHNIQUE FOR THE MEDIOLATERAL RADIOGRAPHIC STUDY OF THE AVIAN THORACIC EXTREMITY (WING)

Positioning the body for a mediolateral radiographic study of the thoracic extremity (wing) is similar to the ventrodorsal coelomic study and results in both wings having a mediolateral projection. In contrast, the mediolateral view of the wing with the bird in lateral recumbency requires positional modification to reduce superimposition of the wings, and only the nondependent wing results in a true mediolateral view; the dependent wing results in a lateromedial view. When the patient is positioned in dorsal recumbency, the mediolateral radiographic study of the wing is preferred over the lateromedial study of the wing (which would require the patient to be in ventral recumbency) because of decreased object film distance (OFD). Positioning the patient for the mediolateral radiographic study of the wing requires that the patient be placed in dorsal recumbency and the body placed to the edge of the cassette so that the entire wing of interest will be included on the radiographic image (Figure 1-6). If the body of the bird is placed on the center of the radiographic cassette, the film size might be insufficient to include the entire wing. Birds with large wing spans may require that the wing be positioned diagonally across the film cassette to maximize the length of the x-ray field.

POSITIONING TECHNIQUE FOR THE CAUDOCRANIAL RADIOGRAPHIC STUDY OF THE AVIAN THORACIC EXTREMITY (WING)

Lateral or supine (dorsal recumbency) positioning of the patient produces similar radiographic images of the wing (i.e., lateromedial and mediolateral). It is therefore necessary to make a caudocranial image of the wing, which is the orthogonal projection of the mediolateral and lateromedial studies. Positioning the avian patient for the caudocranial projection of the wing presents a unique challenge to the technician or veterinarian. To facilitate patient positioning and decrease the chance of iatrogenic fractures, many avian patients require anesthesia or sedation to make the orthogonal caudocranial projection of the wing. The bird is held in an inverted position with the head directed toward the floor and the long axis of the bird's body perpendicular to the surface of the x-ray table. This results in a caudocranial projection of the wing. The leading edge of the wing is placed on the

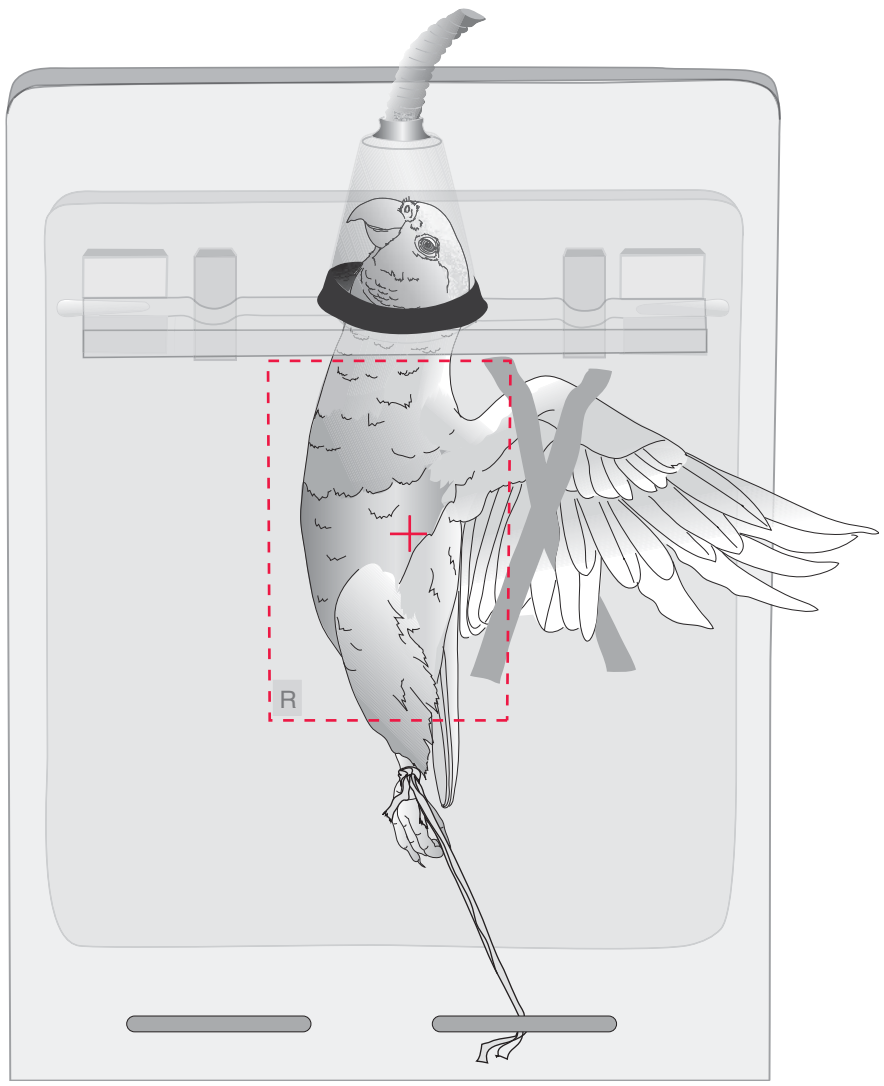

Figure 1-4 Positioning technique for the laterolateral radiographic study of the avian coelom. The bird is placed in right lateral recumbency on the positioning device, and the guillotine device is applied to the neck. The bird's body is then gently moved caudally to extend the neck. Further gentle traction is applied to the bird's body by extending the pelvic limbs slightly caudally and securing them with gauze to the positioning device's cleats. The wings are then secured to the positioning device in full extension using radiolucent tape. Rotation of the bird's body can result if excessive pressure is applied to the upper wing when it is secured to the positioning device. All extremities (wings and legs) are positioned so that they are superimposed on their contralateral extremity. This helps to minimize rotation of the bird's body. The x-ray beam (+) is centered on the middle portion of the body, and the x-ray beam field *(dotted lines)* includes the entire bird for small birds. For medium and large birds, the x-ray field includes the body, proximal extremities, and caudal cervical regions. A metallic "R" marker is placed on the radiographic cassette indicating that the right side is dependent.

cassette and the wing is extended manually while the body or legs are held with the other hand.The appropriate metallic "R" or "L" marker is placed on the radiographic cassette indicating whether the radiographic image is of the right or left wing, respectively (Figure 1-7). A lead apron and gloves are worn for the procedure. The technician's hands should not be in the primary x-ray beam. This caudocranial projection is more difficult to make with direct digital radiology units because it may not be possible to move the x-ray sensor (located under the table top) to the edge of the table. In contrast, the craniocaudal projection of the wing is not practical because the length of the flight feathers precludes close apposition of the bones of the wing with the radiographic cassette. In addition, craniocaudal positioning of the wing results in increased OFD, thereby degrading image quality.

POSITIONING TECHNIQUE FOR THE MEDIOLATERAL RADIOGRAPHIC STUDY OF THE AVIAN PELVIC LIMB (LEG)

Mediolateral radiographic images of the pelvic limbs are made with the patient in right lateral recumbency for the right leg and left lateral recumbency for the left leg. Mediolateral projections are preferred to the lateromedial projections of the pelvic limbs because the OFD is less with the mediolateral projection. Positioning and securing the leg of interest are similar as described for the laterolateral radiographic projection of the coelom, except the contralateral leg is rotated dorsal and pulled caudally to minimize superimposition on the leg of interest. Placement of the bird on the positioning device, application of the guillotine to the neck, and circumferential application of bandage gauze around the distal aspects of tarsometatarsi facilitate application of traction on both legs for positioning purposes. The appropriate metallic "R" or "L" marker is placed on the radiographic cassette indicating whether the radiographic image is of the right or left leg, respectively (Figure 1-8).

POSITIONING TECHNIQUE FOR THE CRANIOCAUDAL RADIOGRAPHIC STUDY OF THE AVIAN PELVIC LIMB (LEG)

Craniocaudal radiographic images of the pelvic limbs are made with the patient in a supine (dorsal recumbency) position. Craniocaudal projections of the pelvic limb are optimal as a result of the reduction in OFD. Positioning and securing the leg of interest are similar as described for ventrodorsal radiographic projection of the coelom. Placement of the bird on the positioning device, application of the guillotine to the neck, and circumferential application of bandage gauze around the distal aspect of the tarsometatarsus facilitate application of traction on the leg of interest. The appropriate metallic "R" or "L" marker is placed on the radiographic cassette indicating whether the radiographic image is of the right or left leg, respectively (Figure 1-9).

POSITIONING TECHNIQUES FOR THE MEDIOLATERAL AND DORSOPLANTAR RADIOGRAPHIC STUDIES OF THE AVIAN DISTAL PELVIC EXTREMITY (FOOT)

Mediolateral and dorsoplantar radiographic studies of the foot are made with the patient in the lateral and supine positions, respectively. The mediolateral projection is preferred over the lateromedial study because of decreased OFD. Positioning

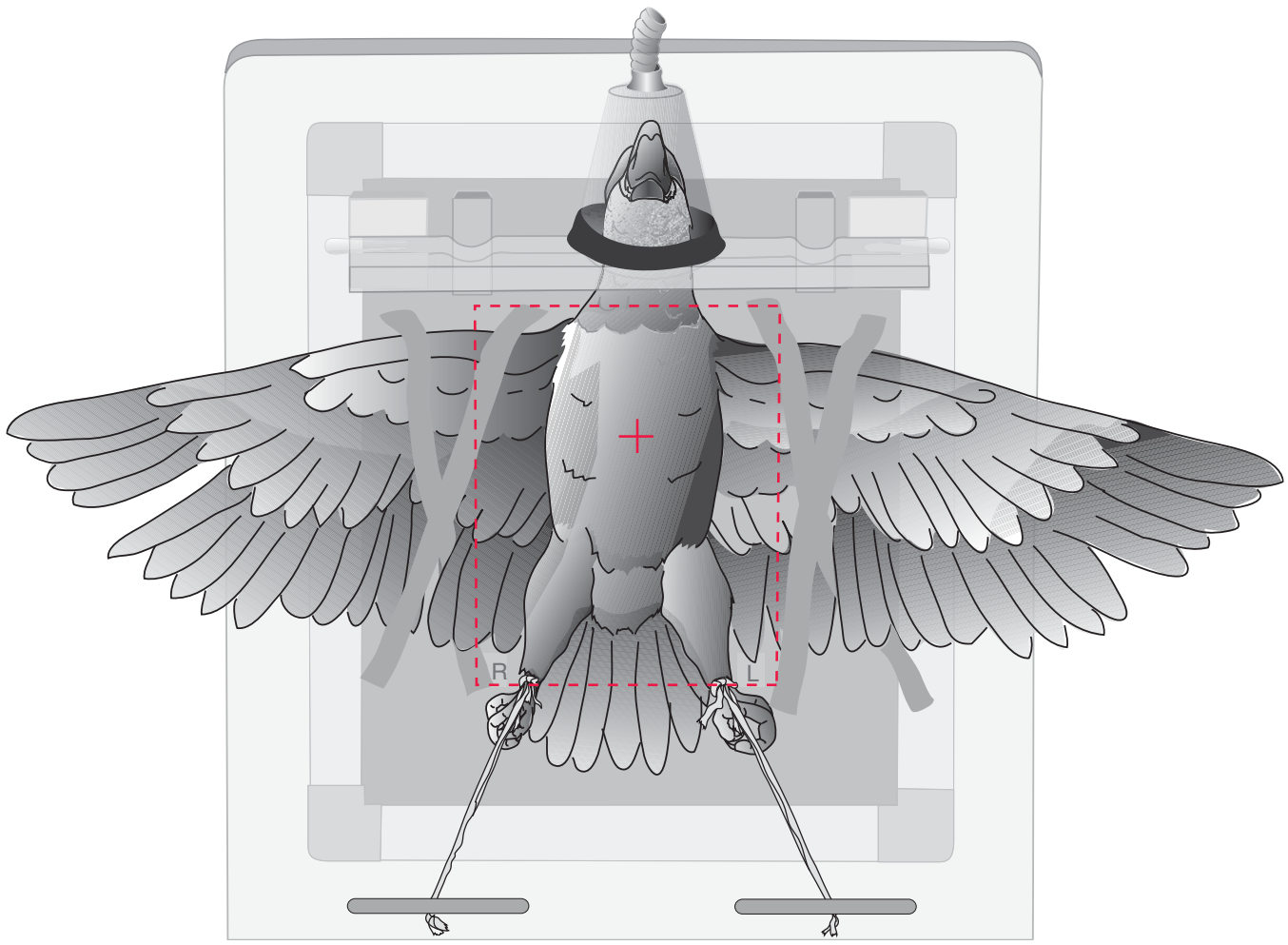

Figure 1-5 Positioning technique for the ventrodorsal radiographic study of the avian coelom. The bird is placed on the positioning device in dorsal recumbency. The neck is placed in the guillotine, and gentle traction is applied to the bird's body by extending the pelvic limbs slightly caudally and securing them with gauze to the positioning device's cleats. The wings are secured to the positioning device in full extension using radiolucent tape. Two strips of tape are crossed at the carpal region of each wing. The x-ray beam (+) is centered midline on the caudal portion of the sternum, and the x-ray beam field *(dotted lines)* includes the coelom, head, and extremities for small birds. For medium and large birds, the x-ray field includes the body, proximal extremities, and caudal cervical regions. Metallic "R" and "L" markers are placed on the radiographic cassette indicating the laterality of the patient.

techniques are similar as described for the pelvic limb radiographic examinations, but the positioning device is not utilized and the foot is secured directly to the film cassette with paper tape. Special attention is paid to separating the digits of the foot to minimize superimposition of the digits. For both projections the toes are spread apart and individual digits secured with individual pieces of radiolucent tape. On the mediolateral view of the foot, superimposition of the phalanges makes it difficult to count them. When interpreting the radiographs, counting the phalanges aids in the identification of the specific digit (i.e., the number of phalange bones in each digit is one greater than the number of the digit itself). Radiopaque numeral markers can be placed adjacent to the digits to help identify them on the radiographs. The markers are taped to the surface of the film cassette with radiolucent tape (Figures 1-10 and 1-11).

RADIOGRAPHIC CONTRAST STUDIES OF THE GASTROINTESTINAL TRACT

The rapid digestive tract transit time of birds and the anatomy of their digestive tract make it possible to study the majority of the digestive tract using a single radiographic protocol. The digestive tract from the esophagus to the large intestine can be radiographically evaluated by administering contrast medium orally. The term "UGI" (upper gastrointestinal) tract contrast study is a misnomer in birds because the colon, and occasionally the cloaca, is also evaluated on these studies. Evaluation of the cloaca is best performed with retrograde studies, wherein the contrast medium is administered directly into the cloaca.

Ideally, the ingluvies (crop) and proventriculus should be empty before beginning a digestive tract contrast medium study, although the effects of food deprivation must be considered. A fasting period before administration of the contrast medium is recommended, and the duration of the fasting period depends on the metabolic requirements of the bird and its overall health. Smaller birds do not tolerate food restriction as well as larger birds because of their higher metabolic rate. Recommendations for food restriction are provided in the discussion on patient preparation. The presence of food in the ingluvies (crop) decreases the volume of contrast medium that can be safely administered. Ingesta in the gastrointestinal tract also degrades the detail of the interface between contrast medium and the digestive tract mucosa by absorbing the contrast medium and impeding full contact of the contrast medium with the digestive tract mucosa. Ingesta may also delay passage

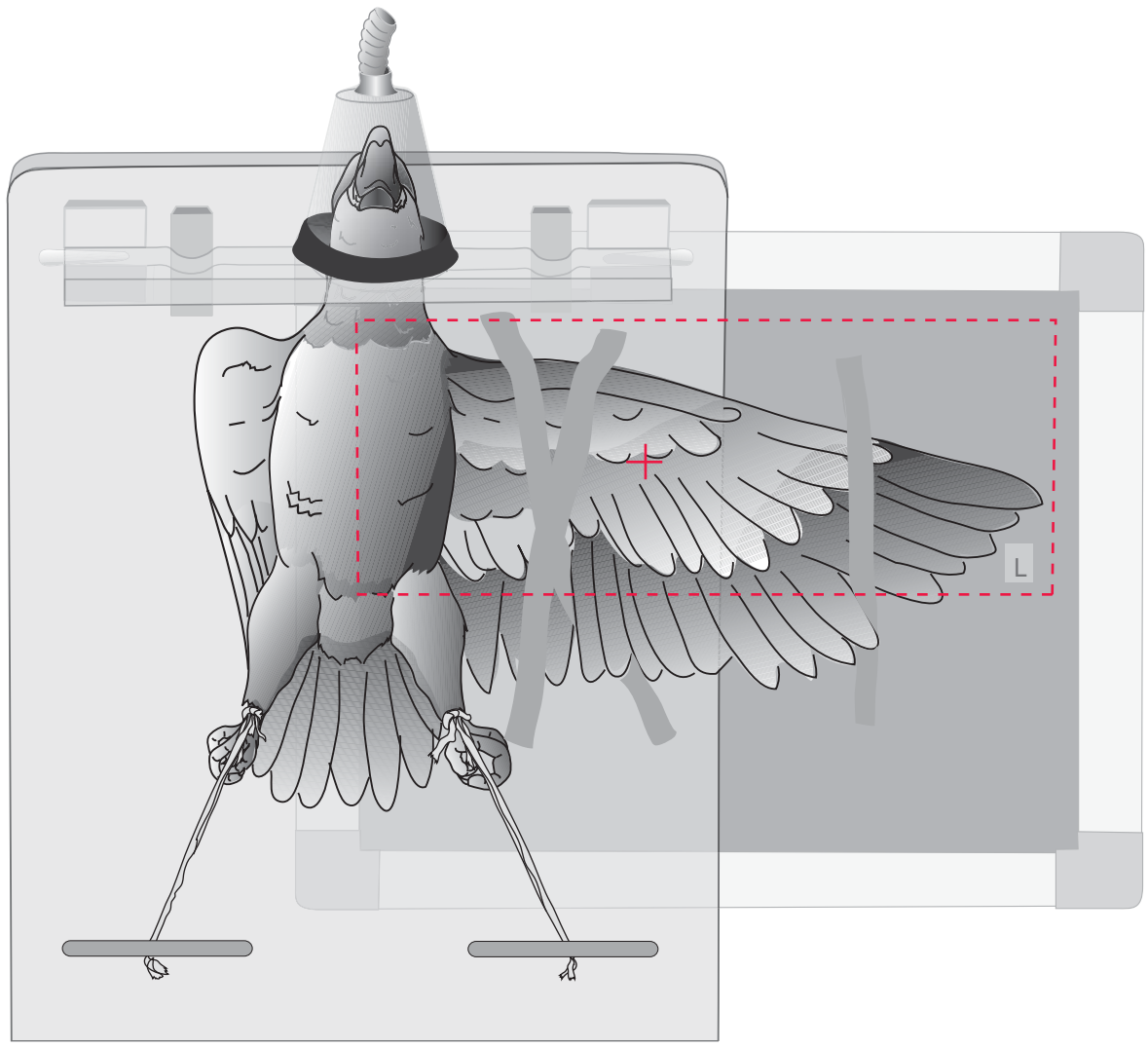

Figure 1-6 Positioning technique for the mediolateral radiographic study of the avian thoracic extremity (wing) with the patient in dorsal recumbency. Positioning of the body for the mediolateral radiographic study of the wing is similar to that described for the ventrodorsal coelomic study, except the body is positioned to the side of the cassette so that the entire wing of interest will be included on the radiographic image. The wing is fully extended laterally from the pectoral girdle and taped directly to the radiographic cassette. Immobilization of the wing is best achieved by crossing the tape in the region of the carpus. Additional tape can be applied to the proximal and distal aspects of the wing if necessary. The x-ray beam (+) is centered in the mid-diaphyseal region of the radius and ulna. The x-ray beam field *(dotted lines)* encompasses the entire wing, including the scapulo-humeral joint. Metallic "R" and "L" markers are placed on the radiographic cassette indicating the laterality of the patient.

of the contrast medium through the digestive tract. Hyperalimentation preparations are particularly unpredictable in the way they mix with contrast media. Pelleted foods also affect the appearance of the intestinal mucosal contrast medium interface. Birds eating pelleted diets often have an indistinct intestinal contrast medium mucosal interface on radiographs. The cause of this is unknown. It is recommended that birds weighing more than 300 grams not be fed pelleted diets within 4 hours of digestive tract contrast studies if their health status allows such a fasting period. This general recommendation is based on clinical experience, and currently no scientific studies have been performed to validate this theory.

Survey ventrodorsal and right laterolateral radiographs are made immediately before digestive tract contrast studies are initiated. The caudal cervical area and the entire coelom are included on the images. These survey radiographs provide information regarding the distention and location of the digestive tract and are essential for confirming that the radiographic exposure factors are optimized. Radiographs made on previous days are not sufficient to serve as survey radiographs because they may not reflect the current status of the digestive tract. As a general rule, positive contrast medium studies utilize slightly higher kVp settings (2-4 kVp) than those kVp settings used for survey radiographs. This compensates for the increased opacity of the contrast medium.

The contrast medium used for the digestive tract studies in this text was barium sulfate 30% weight to volume (w/v). The contrast medium can be warmed to a temperature slightly greater than room temperature by immersing the syringe containing the contrast medium in warm water. Just prior to contrast medium administration, the liquid in the syringe should be mixed and tested to check the temperature. Warming the contrast medium decreases abnormal peristalsis and hypothermia caused by chilled contrast medium. The dose of contrast medium/gram body weight varies among species of birds. A very broad recommendation would be

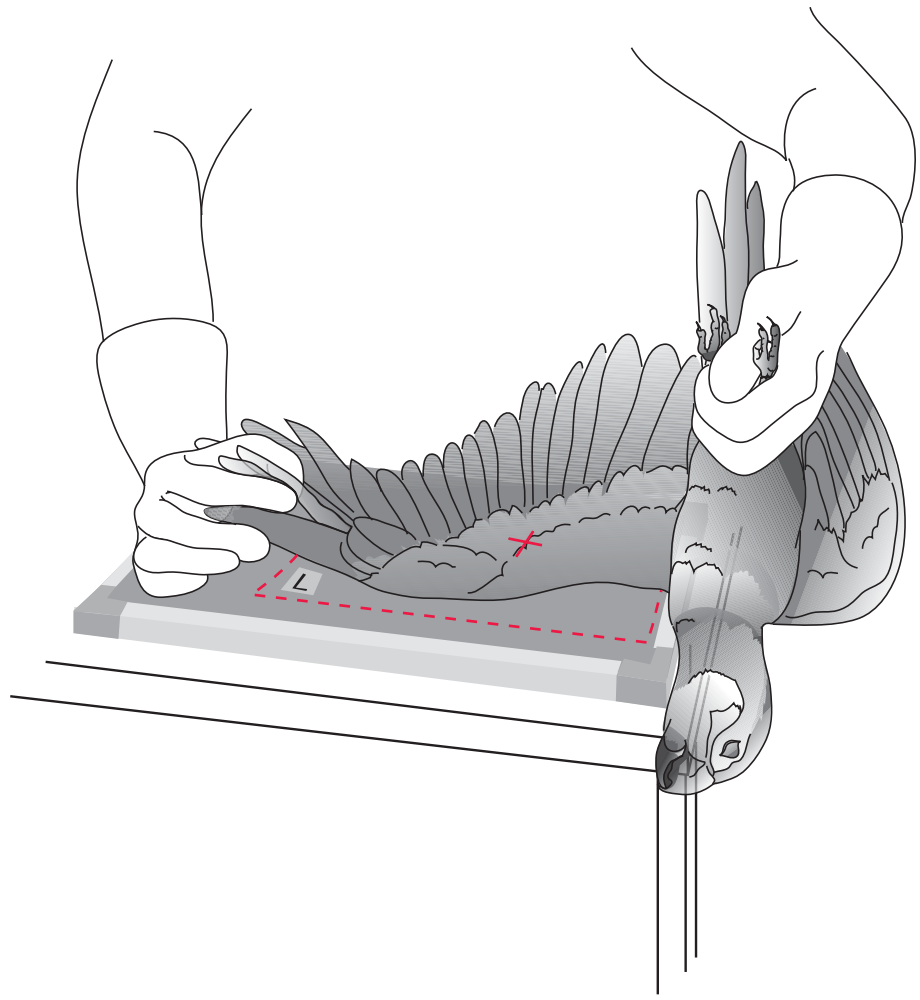

Figure 1-7 Positioning technique for the caudocranial radiographic study of the avian thoracic extremity (wing). The anesthetized bird is held in an inverted position with the head directed toward the floor and long axis of the bird's body perpendicular to the surface of the x-ray table. The wing to be imaged is fully extended, and the cranial (leading) edge of the wing is placed on the film cassette. The bird is angled so that the x-ray beam is aligned in a true caudocranial direction through the wing. The x-ray beam (+) is centered in the middle of the wing, which is usually the mid-diaphyseal region of the radius and ulna. The x-ray beam field *(dotted lines)* encompasses the entire wing, including the scapulo-humeral joint. Care should be exercised so that the technician's hands are outside of primary x-ray beam. The appropriate metallic "R" or "L" marker is placed on the radiographic cassette indicating whether the radiographic image is of the right or left wing, respectively.

25 to 50 ml/kg body weight. An alternative method of dose calculation is to estimate the volume of food that could be safely administered to the patient via crop gavage and administer 50% to 75% of this amount of contrast medium. Species variation in crop and proventricular volume and the presence of generalized disease or digestive tract pathology, including suspected obstruction, necessitate reducing the amount of contrast medium administered. The survey radiographs made just prior to the administration of contrast medium provide information regarding the digestive tract volume and mitigating circumstances that could affect the volume of contrast medium administered. Hygroscopic water-soluble contrast media (e.g., diatrizoate meglumine and diatrizoate sodium, Gastrografin®, Bracco Pharmaceuticals, Princeton, N.J.) used in mammals are not recommended for radiographic studies of the digestive tract of birds because they can precipitate severe metabolic and fluid imbalances. In addition, the mucosal detail using hygroscopic water-soluble contrast media is less than with barium sulfate. The double contrast studies utilize a combination of positive contrast medium and air. These studies are intended to speed the progression of the contrast medium through the digestive tract. Double contrast studies may also produce superior proventricular mucosal detail. It is important for the clinician to be aware of the potential for regurgitation of the contrast material that may occur as a result of the increased volume of room air in the gastrointestinal tract.

For the radiographic studies in this text, the contrast medium was administered via a rigid or soft gavage tube passed into the crop. Before administering the contrast medium, the position of the gavage tube was verified by palpation to ensure that the tube was not intratracheal. The right cervical area can be palpated as the tube is passed. If the tube is within the trachea, the gavage tube will not be palpable as a separate entity from the trachea. While the contrast material is being administered, the bird's oral cavity should be visually monitored constantly to ensure that fluid is not accumulating in the oropharynx.

For the digestive tract contrast studies published in this text, birds were anesthetized to facilitate administration of the contrast medium, optimize patient positioning, and reduce handling. These concepts also apply to clinical patients; however, the overall health of the patients should be evaluated to determine if anesthesia is safe. In general, it is recommended that birds be anesthetized for the survey radiographs, then administered the contrast medium while still under anesthesia and subsequent images acquired before the patient is allowed to recover from anesthesia. In our practice we typically acquire the survey, 0.25 and 0.5 hour radiographic images under anesthesia if the patient's health allows. Tracheal intubation to maintain anesthesia should be utilized to minimize aspiration of contrast material while the series of radiographic images are acquired for the study. Anesthesia of smaller patients (e.g., lovebirds, cockatiels) can be maintained utilizing an anesthetic cone. Patients of this size are typically not intubated because of the risk of tracheal mucosal irritation, and subsequent formation of a transluminal membrane which outweighs the risk of contrast medium aspiration. For both the intubated and the nonintubated birds, the cranial portion of the bird's body can be elevated by securing the bird to the acrylic positioning device and elevating the cranial end of the board by sliding an object such as a sandbag under it. Elevation of the cranial portion of the bird's body can minimize retrograde flow of the contrast medium into the oral cavity. Minimizing retrograde flow of contrast medium into the oral cavity can also be

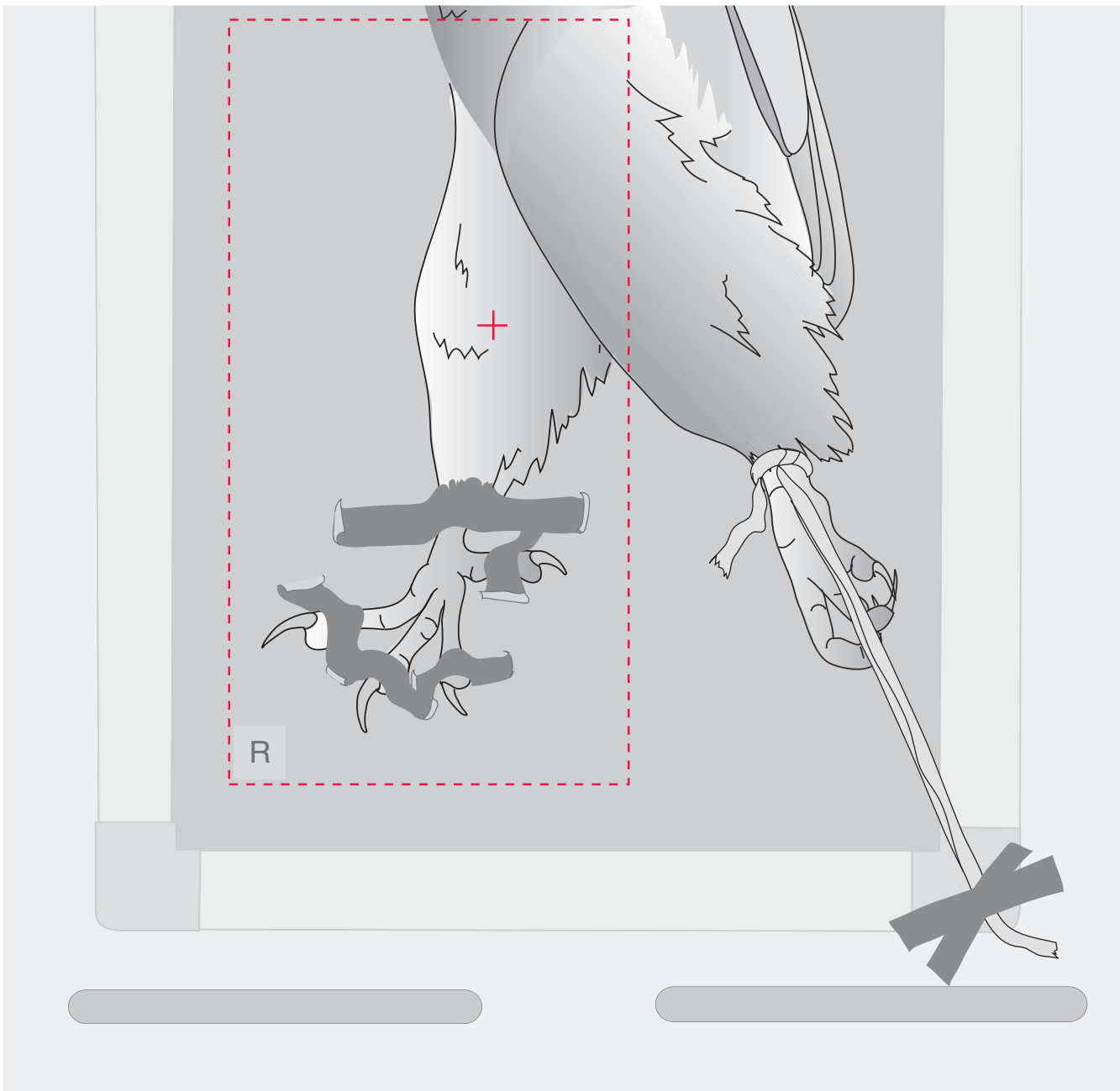

Figure 1-8 Positioning technique for the mediolateral radiographic study of the avian pelvic limb. The bird is positioned in lateral recumbency on the positioning device so that the limb of interest is dependent and fully extended. Radiolucent tape is applied to the distal tarsometatarsus and digits of the leg of interest. The contralateral limb is pulled caudally and dorsally to minimize superimposition. In order to apply enough traction to the contralateral limb, gauze bandage is wrapped around the distal tarsometatarsus and secured with tape. The x-ray beam is centered (+) on the mid-diaphyseal region of the tibiotarsal bone, and the x-ray beam field *(dotted lines)* includes the entire limb of interest (including the coxofemoral joint). The appropriate metallic "R" or "L" marker is placed on the radiographic cassette indicating whether the radiographic image is of the right or left leg, respectively.

achieved by placing loose elastic bandage material around the bird's neck to partially occlude the cervical esophagus, but care should be exercised to ensure that the bandage does not compress the trachea. During the entire procedure and immediately before extubation, the oral cavity should be monitored for the presence of regurgitated contrast medium. The impact of anesthetic protocols on gastrointestinal transit time has not been scientifically studied in avian patients; however, given their rapid digestive tract transit time, the impacts appear to be minimal in healthy avian patients. It is important to note that in some birds, hypersensitivity to the gas anesthetic may induce vomiting and the bird may vomit upon recovery from the anesthetic event.

Contrast medium regurgitation and subsequent tracheal aspiration can occur when performing digestive tract contrast studies and is most common when larger volumes of contrast medium are administered. The authors find regurgitation to be less frequent in anesthetized birds than non-anesthetized birds. If contrast medium regurgitation does occur and the bird is anesthetized, attempts to remove the contrast medium from the oropharynx should be immediately initiated to minimize tracheal aspiration and reflux of

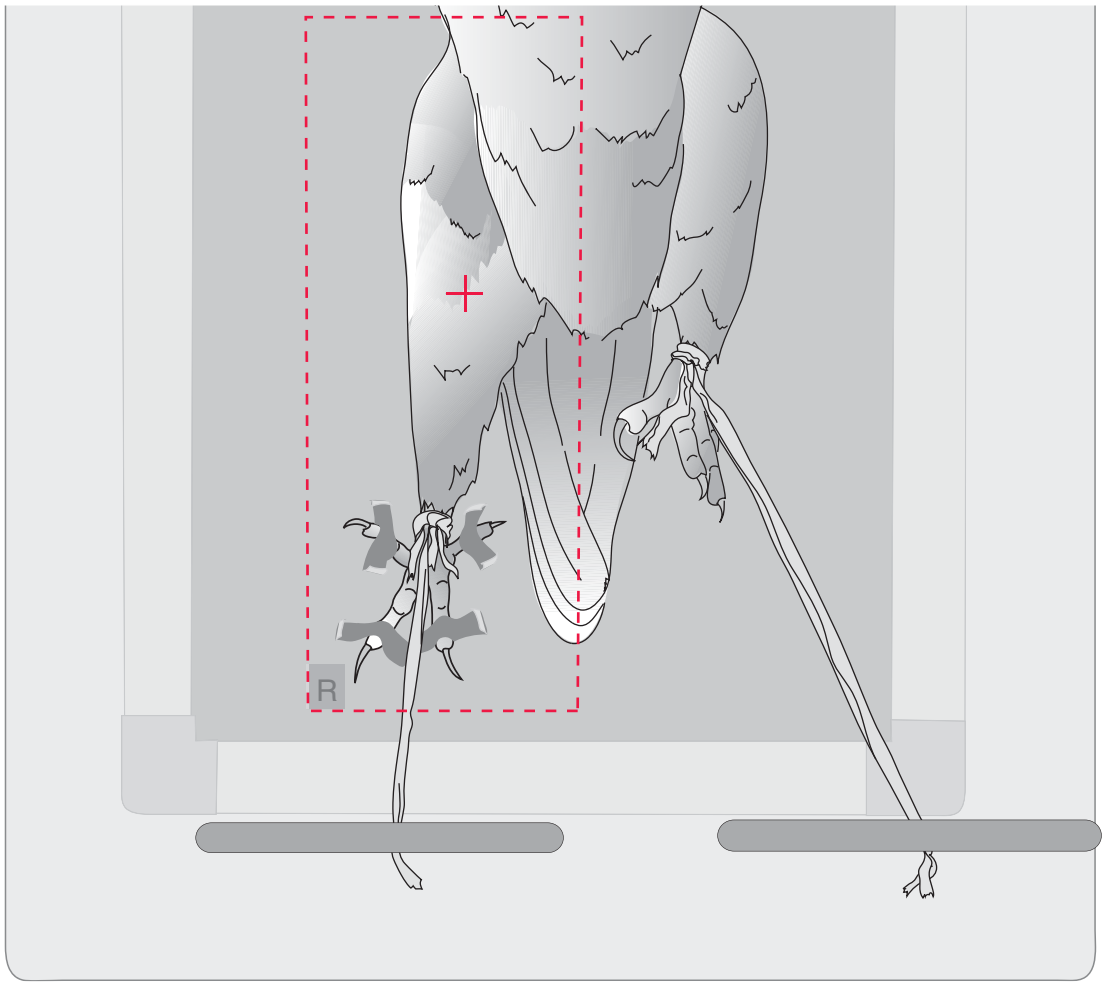

Figure 1-9 Positioning technique for the craniocaudal radiographic study of the avian pelvic limb. The bird is positioned in dorsal recumbency on the positioning device. Gauze bandage is wrapped around the distal tarsometatarsus and traction applied to fully extend the pelvic limb. The toes are individually secured using radiolucent tape. The x-ray beam is centered (+) on the mid-diaphyseal region of the tibiotarsal bone, and the x-ray beam field *(dotted lines)* includes the entire limb of interest (including the coxofemoral joint). The appropriate metallic "R" or "L" marker is placed on the radiographic cassette indicating whether the radiographic image is of the right or left leg, respectively.

contrast medium through the choanal slit into the nasal cavity. Cotton-tipped applicators can be used to remove the contrast medium from the mouth. Contrast medium aspirated into the trachea can be identified on radiographs. In addition to seeing contrast material in the trachea, it may also be visualized in the major bronchi and air sacs, most commonly the left caudal thoracic air sac. Small volumes of aspirated contrast medium are usually well tolerated; however, larger volumes may result in bronchial obstruction. Contrast medium in the pulmonary parenchyma is rarely identified and seen only in cases in which the bird has aspirated a large volume of material. If the contrast medium is aspirated into the lungs, it is usually associated with severe respiratory distress.

Digestive tract transit time is generally more rapid in birds than mammals, especially in the smaller birds and the frugivorous species. In order to perform a complete digestive tract study, each segment of the digestive tract (i.e., cervical esophagus, crop, thoracic esophagus, proventriculus, ventriculus, small intestines, large intestines, and occasionally the cloaca when it is distended with contrast medium) should be documented. Documentation of proventricular emptying is also helpful.

Timing of the radiographic exposures for digestive tract radiographic studies is based on many factors, but all studies should include laterolateral and ventrodorsal projections made immediately after the administration of the contrast medium, especially if the esophagus, crop, and proventriculus are of primary interest. In some species (i.e., ducks and geese), the gastrointestinal transit times are extremely rapid and the contrast medium may have already entered the small intestines on the first set of radiographs. In such a case, additional radiographs are then made at 15- to 30-minute intervals and then hourly. Because of the variation in digestive tract transit times of different species of birds, the contrast material, and the effects of systemic disease, it is very difficult to propose rigid guidelines for timing the exposures. The timing is usually determined by evaluating the progress of the contrast medium on the initial set of radiographs. If contrast medium has entered the intestines on the immediate postcontrast administration radiographs, the next series of radiographs are taken in 15 minutes. If only a small volume of contrast medium has exited the crop, the next series of radiographs are taken 30 to 60 minutes postcontrast medium administration. Ventrodorsal and laterolateral radiographs are then made every 30 minutes until contrast medium has entered the colon.

Double contrast digestive tract studies usually have shorter transit times and produce superior mucosal detail than is seen on the positive contrast study. Because the crop and proventriculus are more fully distended on double contrast proce-

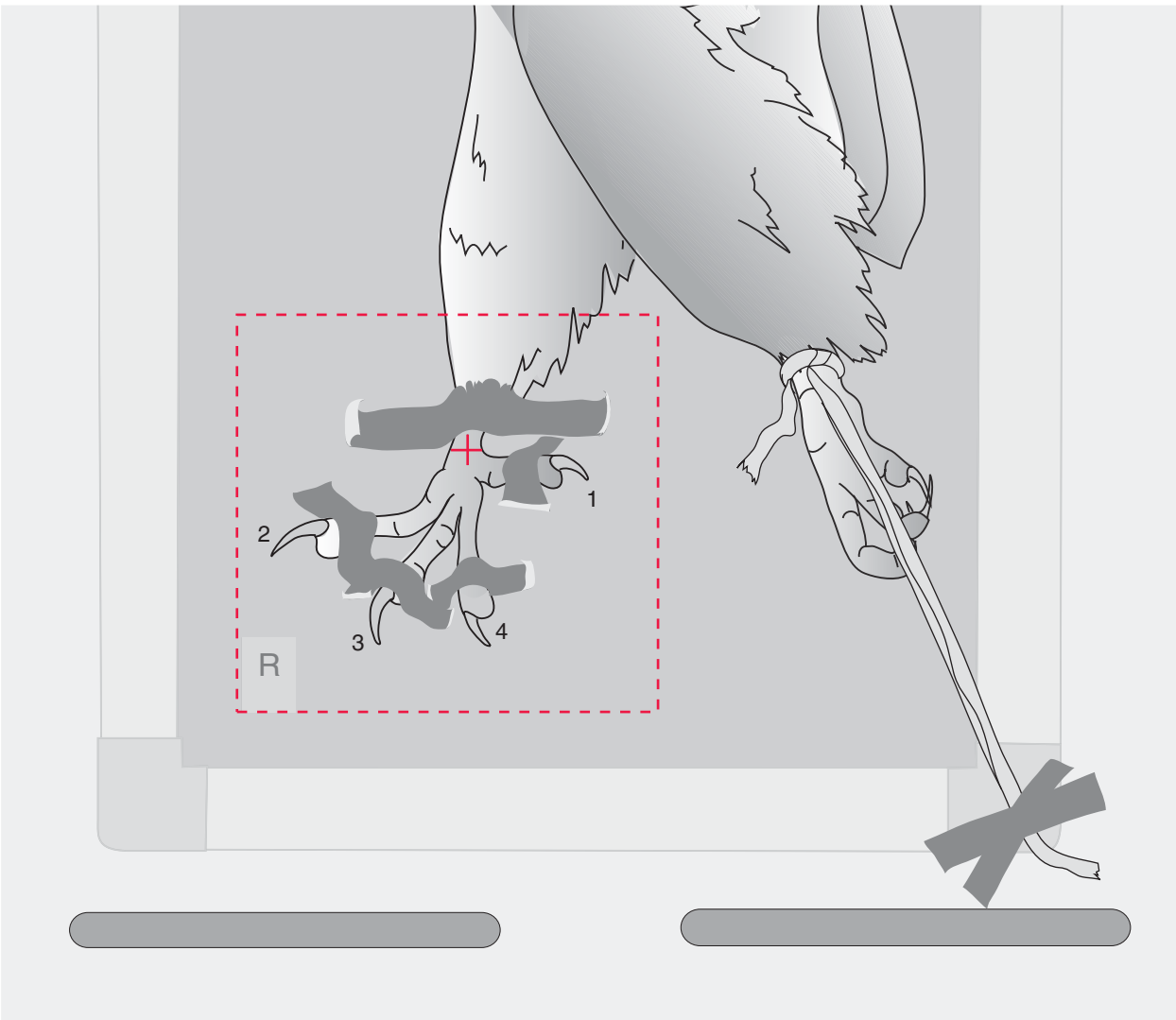

Figure 1-10 Positioning technique for the mediolateral radiographic study of the avian distal pelvic extremity (foot). The bird is placed in lateral recumbency with the leg of interest in the dependent position. The distal portion of the leg is taped at the distal aspect of the tarsometatarsus. The digits of the foot are also secured with individual pieces of radiolucent tape. Radiopaque numeral markers can be placed adjacent to the digits to assist in their identification on the radiograph. Radiolucent tape is preferred over gauze because it allows more precise positioning of the digits. The nondependent foot is extended caudally to separate the feet and minimize superimposition. The kVP is slightly reduced (i.e., 2-4 kVP) from the technique used for the laterolateral radiographic examination of the coelom, to prevent overexposure of the digits. The x-ray beam is centered (+) on the condyles of the tarsometatarsal bone, and the x-ray beam field *(dotted lines)* includes all of the phalanges. The appropriate metallic "R" or "L" marker is placed on the radiographic cassette indicating whether the radiographic image is of the right or left foot, respectively.

dures, the double contrast procedures may be better suited for evaluation of mural thickness and mucosal patterns of these organs than the single contrast studies. Double contrast procedures usually require anesthesia because the gas infused into the crop will be regurgitated in most awake birds. If air is immediately expelled, it is acceptable to administer additional volumes of air to distend the crop. Because of the smaller amount of contrast medium used and the faster time in which the contrast medium evacuates the crop, the potential for contrast medium aspiration into the respiratory tract may be less than in the positive contrast studies.

Optimal evaluation of hollow organs requires that they be fully distended at the time of image capture. Orally administered contrast medium does not predictably result in cloacal distention. Therefore retrograde administration of contrast medium (i.e., via the vent) is required. Before administration of the contrast medium, the cloaca can be gently flushed with isotonic saline. Positive and double contrast procedures can be performed. The double contrast cloacagram usually follows the positive contrast cloacagram and requires removal of the positive contrast medium before administration of room air or carbon dioxide. Carbon dioxide is favored over room air to minimize the potential for intravascular air embolization. Removal of positive contrast medium pooled in the cloaca should be performed before the negative contrast (i.e., room air or carbon dioxide) is introduced. This facilitates visualization of the cloacal mucosal surface. Theoretically, it is possible to reflux fecal matter into the ureters when performing retrograde cloacograms, but this phenomenon has not been recognized in our studies.

Because radiographic images are two-dimensional representations of three-dimensional objects, additional studies

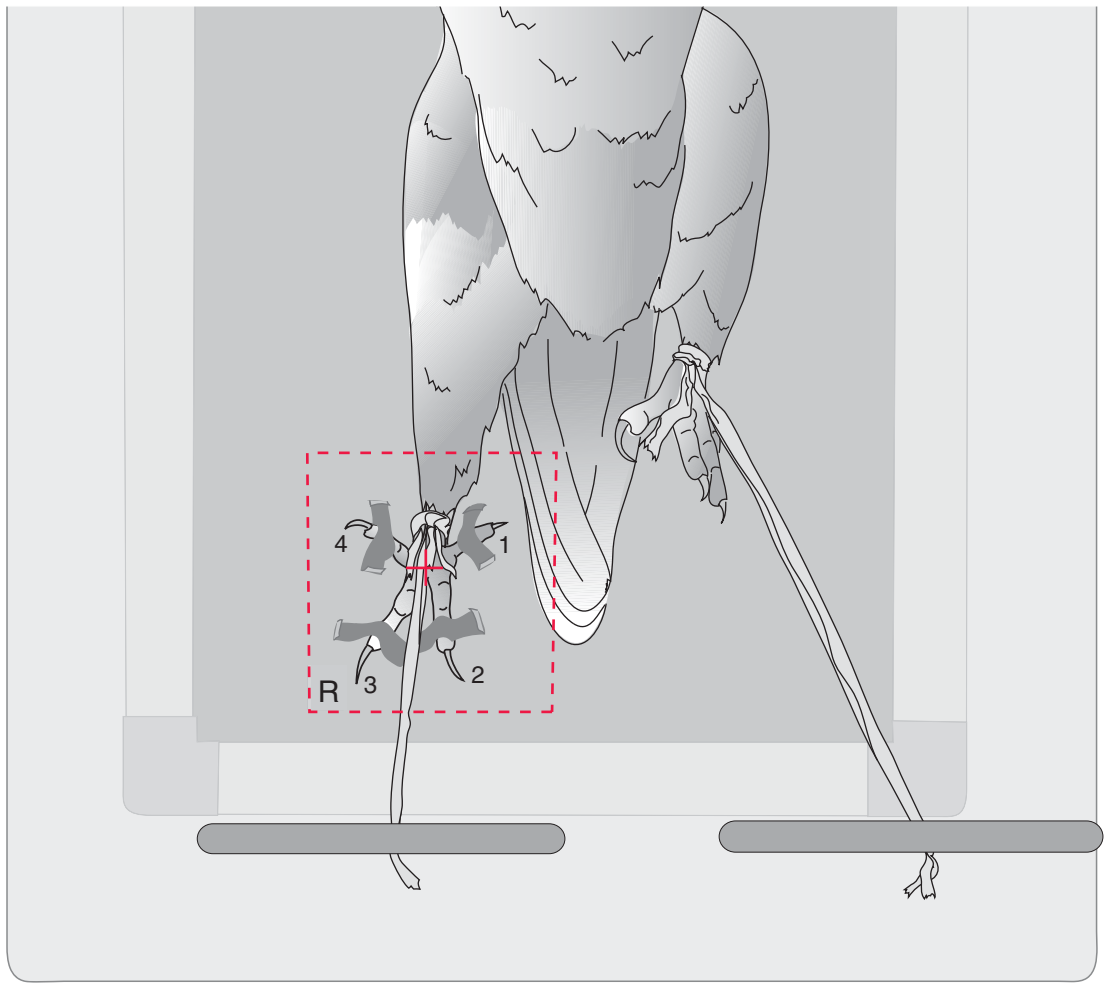

Figure 1-11 Positioning technique for the dorsoplantar radiographic study of the avian distal pelvic extremity (foot). The bird is placed in dorsal recumbency, and the distal portion of the leg is secured with radiolucent tape. The digits of the foot are fully extended and separated using individual pieces of radiolucent tape. The kVP is reduced slightly (i.e., 2-4 kVP) from the technique used for the ventrodorsal radiographic examination of the coelom to prevent overexposure of the digits. The x-ray beam is centered (+) on the condyles of the tarsometatarsal bone, and the x-ray beam field *(dotted lines)* includes all of the phalanges. The appropriate metallic "R" or "L" marker is placed on the radiographic cassette indicating whether the radiographic image is of the right or left foot, respectively.

may be required to fully assess the motility of the digestive tract. Flouroscopy can be used to evaluate proventricular and ventricular motility, but this requires specialized equipment.

RADIOGRAPHIC CONTRAST STUDIES OF THE URINARY TRACT

Survey radiographs are essential for establishing the radiographic technique and identifying subtle radiographic changes in the avian urinary tract after administration of contrast. Radiographic exposures should be made immediately after injection of the contrast medium. The contrast medium should be injected as a bolus directly into the intravenous catheter. Our clinical experience has led us to use nonionic iodinated contrast media for excretory urography. We have not performed double blind studies, but the nonionic agents seem to be associated with fewer anesthetic issues and less nausea and regurgitation. A general recommendation for the volume of contrast medium to administer is to calculate 50% of the recommended mammalian dose/kg body weight. Extremely concentrated products are not recommended because of their potential hyperosmotic effects. The selection of contrast medium is also affected by the volume of contrast medium required.

Because of the renal portal system, the injection sight dramatically affects urinary tract opacification. Injection of the contrast material into the medial metatarsal vein results in superior ureteral opacification compared with cutaneous ulnar vein or jugular vein injections. The contrast medium delivered to the renal parenchyma by the renal portal system after being injected into the medial metatarsal vein is less dilute compared with when it is injected into other cranially located peripheral veins. Thus administration of contrast material via the medial metatarsal vein produces a superior urogram, but the authors have not performed studies to document the safety of this route of administration of contrast medium.

COMPUTERIZED TOMOGRAPHY (CT) AND MAGNETIC RESONANCE IMAGING (MRI)

The advantages of advanced imaging modalities, commonly accepted in mammalian imaging, are less obvious in avian patients. This is primarily due to the small body size of birds. Resolution depends greatly on the quality of the equipment

and software. All of the advanced imaging modalities require general anesthesia because image acquisition time can be prolonged.

Computed tomography (CT) and magnetic resonance imaging (MRI) are very helpful for identifying the origin of mass lesions and complex skull abnormalities, but are limited in their capability to evaluate subtle soft tissue and skeletal lesions in birds. CT is very effective for identifying focal pulmonary lesions if the size of the patient and the size of the lesion are sufficient for detection. MRI has been very useful in evaluating the diverticuli of the infraorbital sinus. Three-dimensional CT reconstructions are especially helpful in evaluating the sinuses and skull bones.

Birds potentially undergoing MRI examinations should be radiographed to verify that they do not have internal foreign metallic material within their digestive tract or elsewhere. This is especially true with free-ranging birds. Ferrous metals can migrate through soft tissue planes if placed in the MR field.

Contrast medium can be used to enhance information obtained from CT and MRI studies. In this text a lower dose of contrast medium than is recommended for mammals was used for the CT studies. For MRI studies the contrast medium should be injected directly into the intravenous catheter and not diluted. This practice delivers a more concentrated bolus of contrast medium to the patient than would occur if the contrast medium were injected into the intravenous extension tubing. Further scientific evaluation of optimal doses and safety is required.

CHAPTER • 2

Anatomic Art

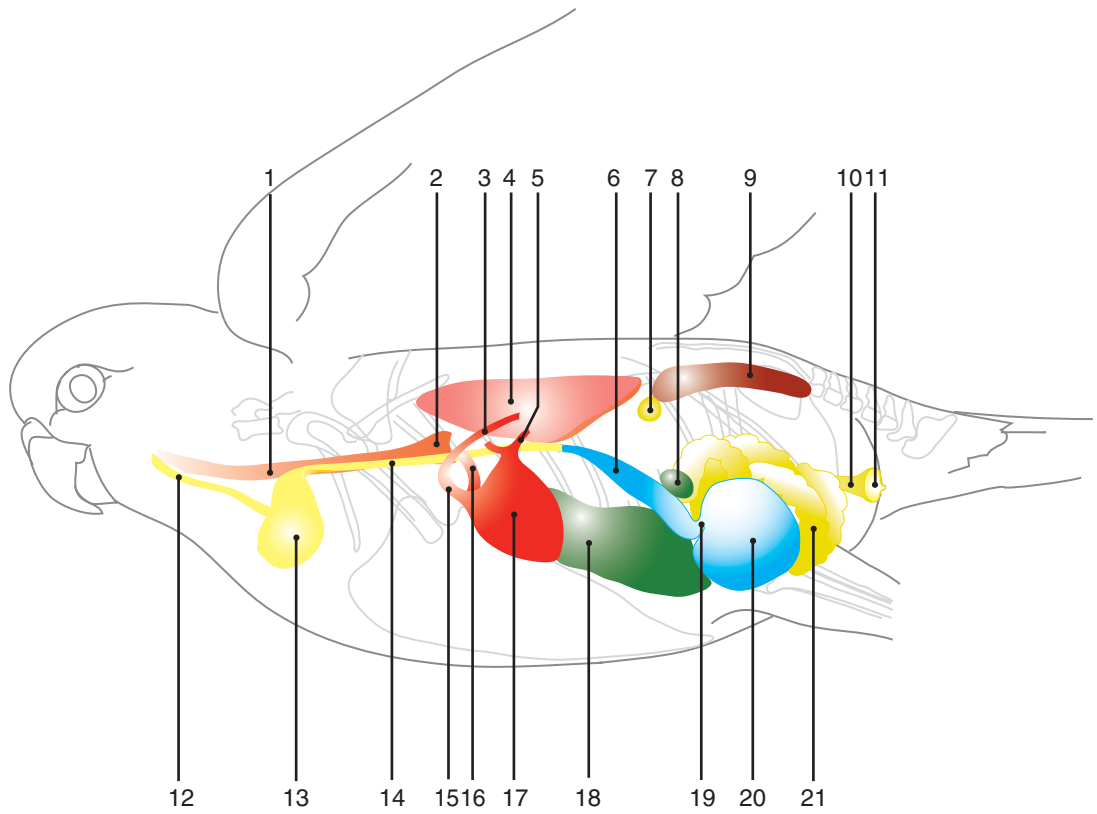

Figure 2-1 Anatomic drawing (view of the left side) of the viscera of an adult bird.

1. Trachea
2. Syrinx
3. Aorta
4. Lung
5. Pulmonary vein
6. Proventriculus
7. Gonad
8. Spleen
9. Kidney
10. Colon
11. Cloaca
12. Cervical esophagus
13. Crop
14. Thoracic esophagus
15. Brachiocephalic artery and aorta
16. Pulmonary artery
17. Heart
18. Liver
19. Proventricular-ventricular isthmus
20. Ventriculus
21. Intestines

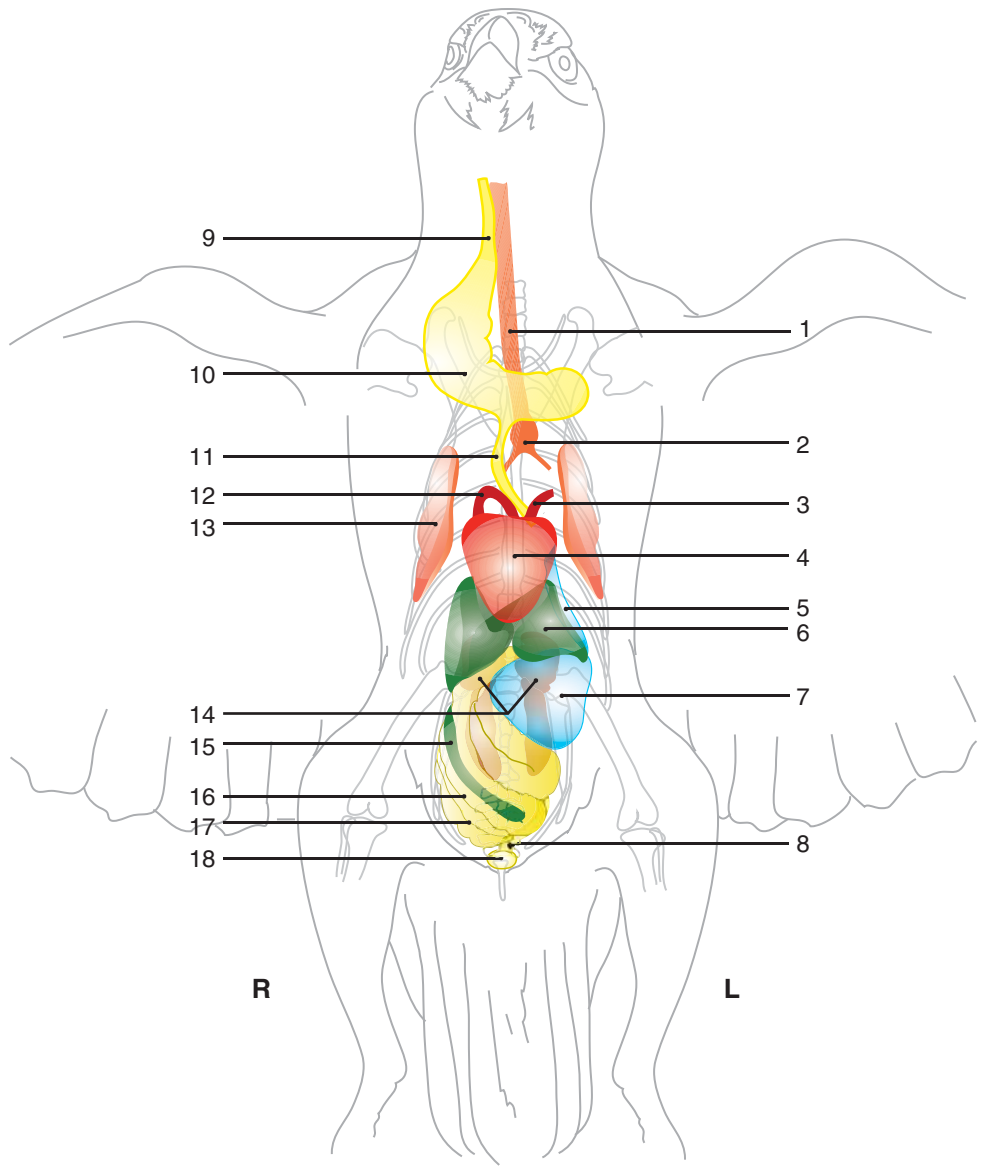

Figure 2-2 Anatomic drawing (ventrodorsal view) of the viscera of an adult bird.

1. Trachea
2. Syrinx
3. Heart base vessel
4. Heart
5. Proventriculus
6. Liver
7. Ventriculus
8. Colon
9. Cervical esophagus
10. Crop
11. Thoracic esophagus
12. Brachiocephalic artery and aorta
13. Lung
14. Kidneys
15. Pancreas
16. Duodenum
17. Intestines
18. Cloaca

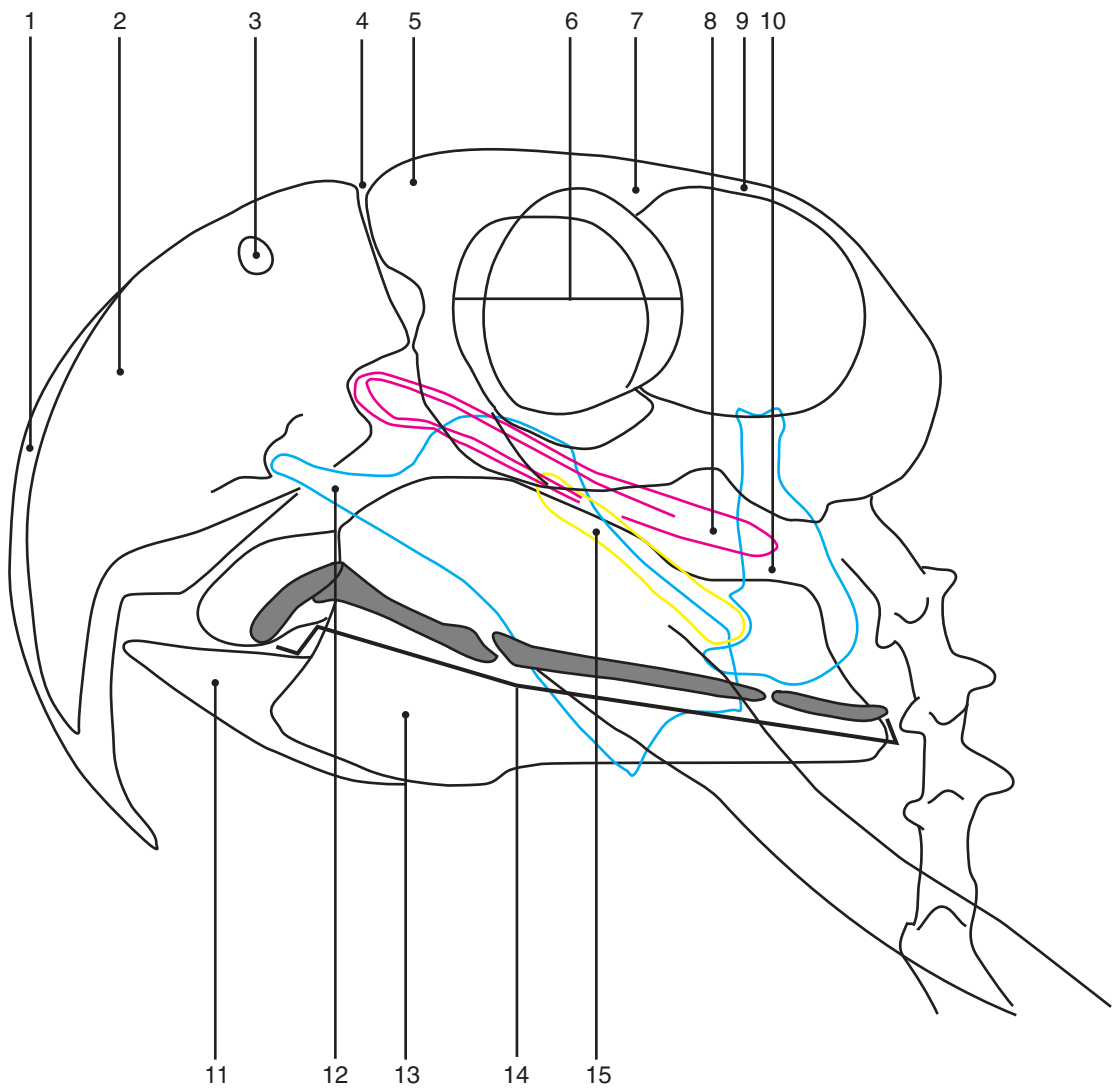

Figure 2-3 Anatomic drawing (view of the left side) of the skull of an adult bird.

1. Keratinized maxillary beak
2. Premaxillary bone
3. External nare
4. Craniofacial flexion zone
5. Frontal bone
6. Orbit
7. Cranium
8. Jugal [zygomatic] bone
9. Parietal bone
10. Quadrate bone
11. Keratinized mandibular beak
12. Palatine bone
13. Mandible
14. Hyoid bones
15. Pterygoid bone

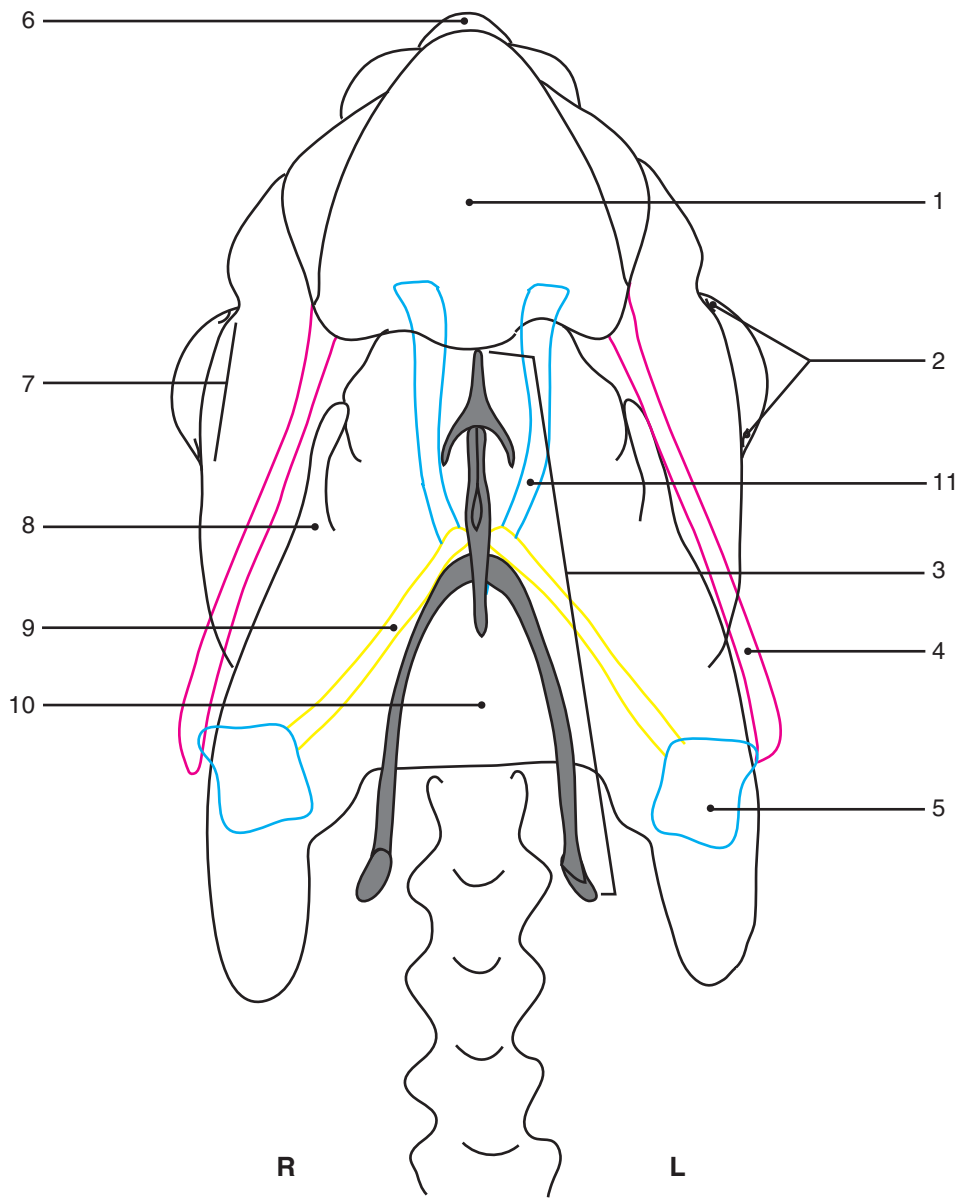

Figure 2-4 Anatomic drawing (ventral view) of the skull of an adult bird.

1. Premaxillary bone
2. Scleral ossicles
3. Hyoid bones
4. Jugal (zygomatic) bone
5. Quadrate bone
6. Keratinized maxillary beak
7. Orbit
8. Mandible
9. Pterygoid bone
10. Cranium
11. Palatine bone

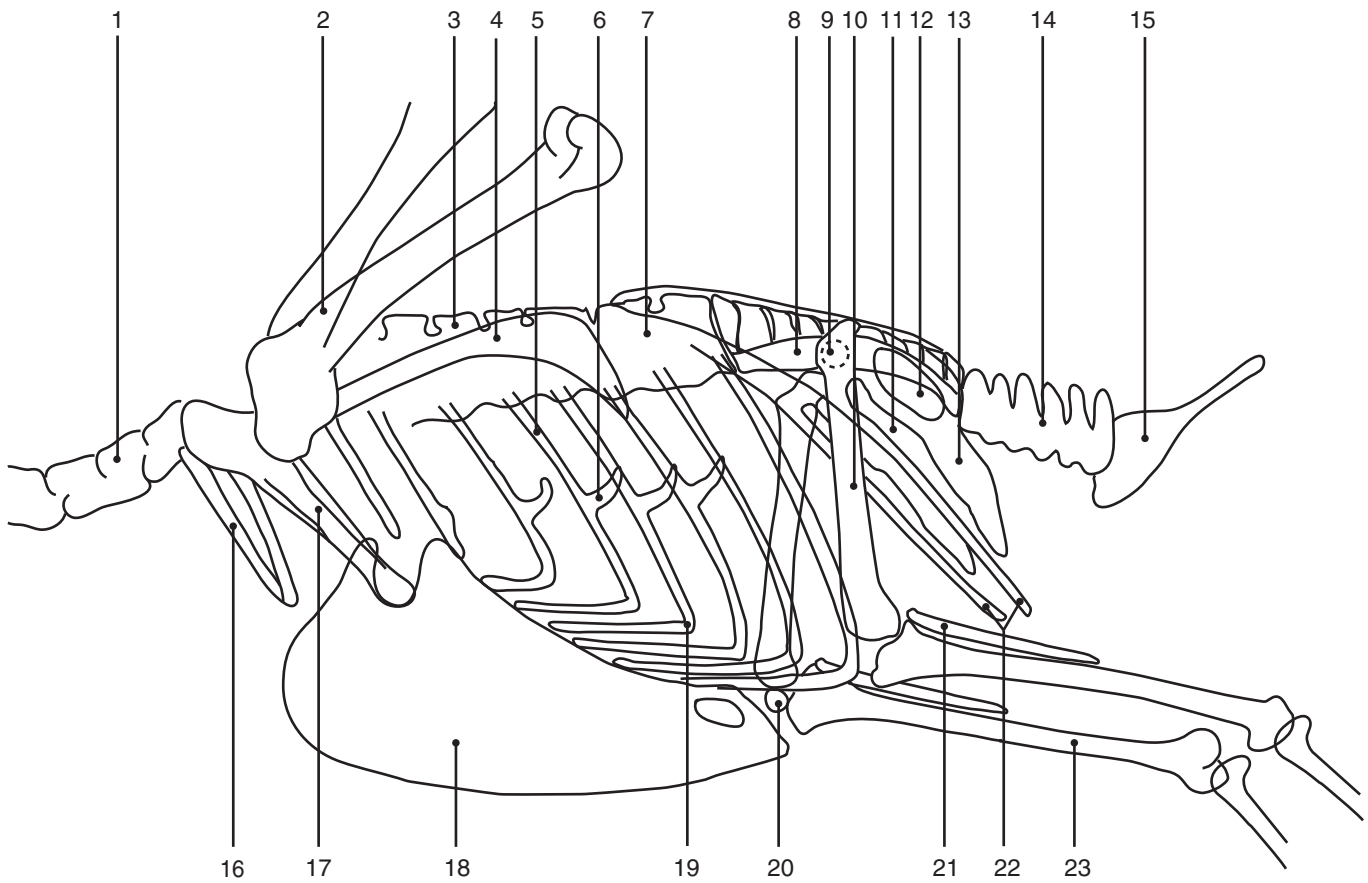

Figure 2-5 Anatomic drawing (view of the left side) of the skeleton of an adult bird.

1. Cervical vertebra
2. Humerus
3. Thoracic vertebra
4. Scapula
5. Rib
6. Uncinate process of rib
7. Ilium
8. Synsacrum
9. Head of femur
10. Femur
11. Obturator foramen
12. Ilioischiadic foramen
13. Ischium
14. Caudal vertebra
15. Pygostyle
16. Clavicle
17. Coracoid
18. Sternum
19. Costochondral junction of rib
20. Patella
21. Fibula
22. Pubic bones
23. Tibiotarsal bone

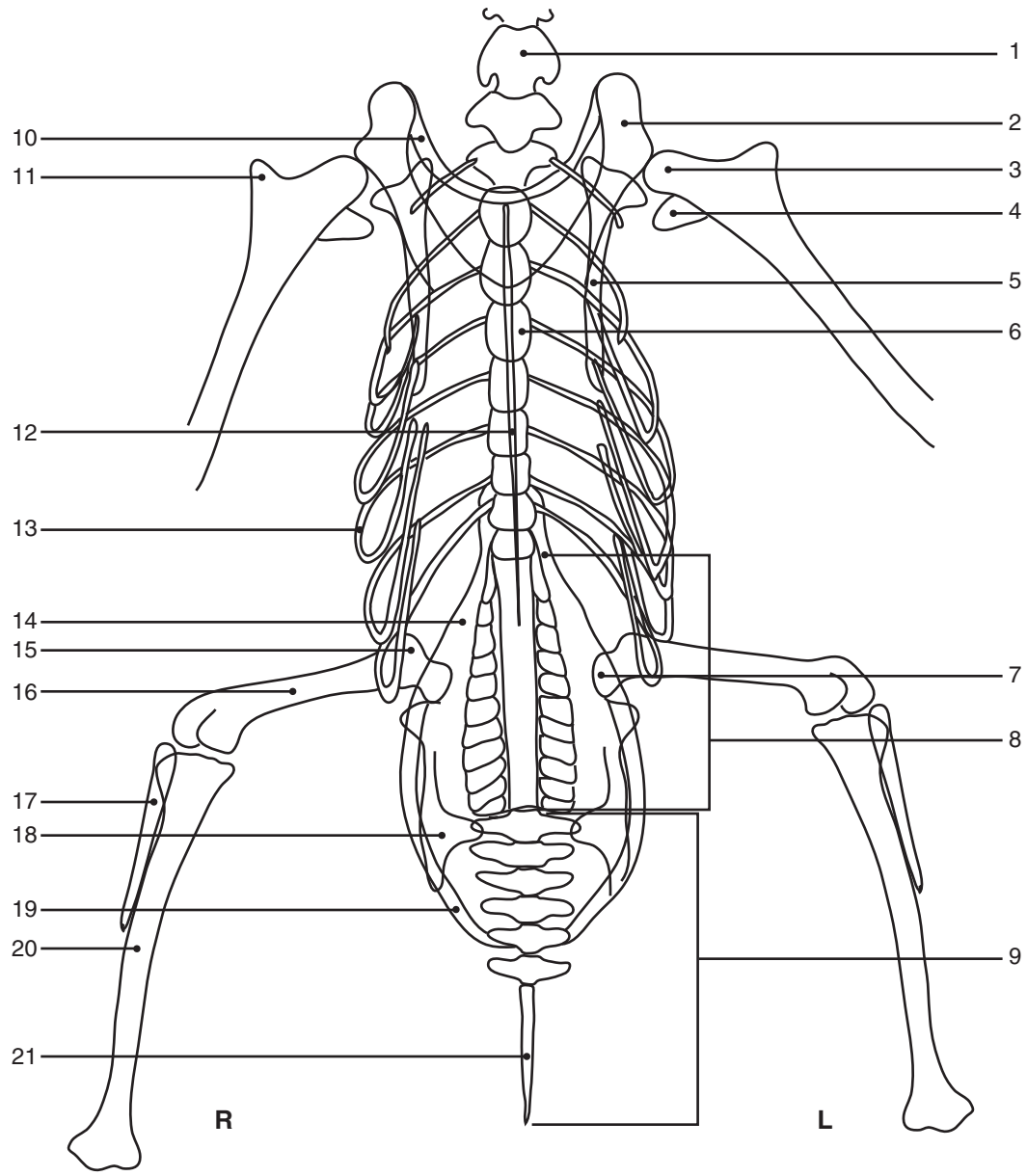

Figure 2-6 Anatomic drawing (ventral view) of the skeleton of an adult bird.

1. Cervical vertebra
2. Coracoid
3. Head of humerus
4. Ventral tubercle of humerus
5. Scapula
6. Thoracic vertebra
7. Head of femur
8. Synsacrum
9. Caudal vertebrae
10. Clavicle
11. Dorsal tubercle of humerus
12. Sternum
13. Rib
14. Ilium
15. Trochanter of femur
16. Femur
17. Fibula
18. Ischium
19. Pubic bone
20. Tibiotarsal bone
21. Pygostyle

CHAPTER • 3

Budgerigar
(Melopsittacus undulatus)

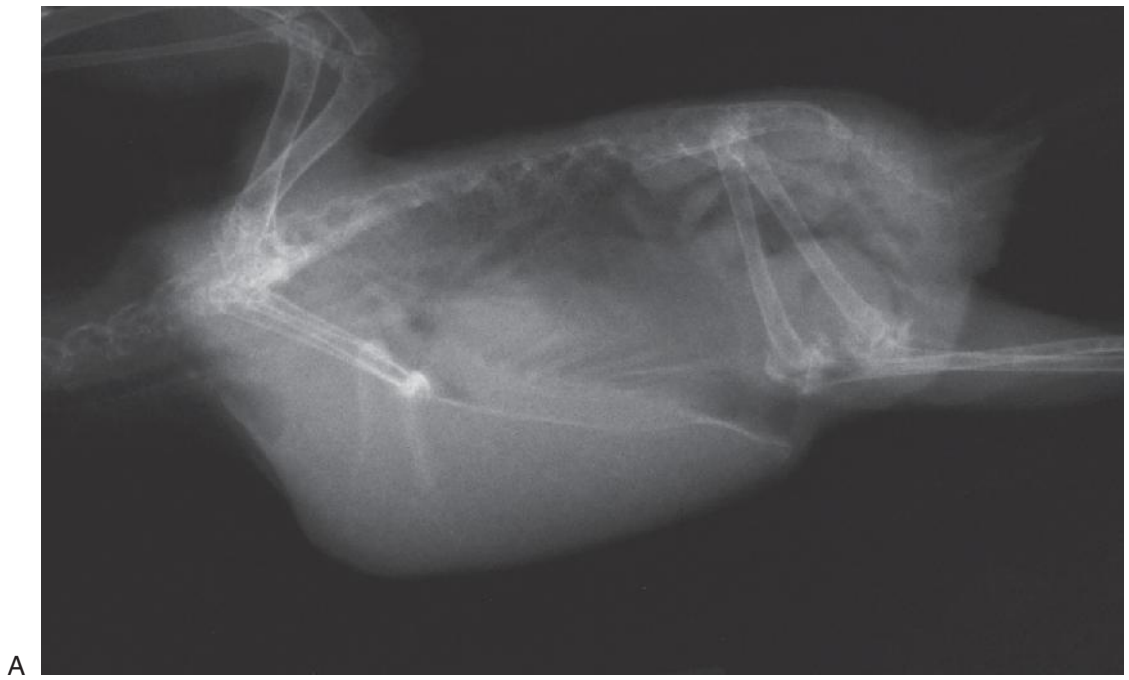

A

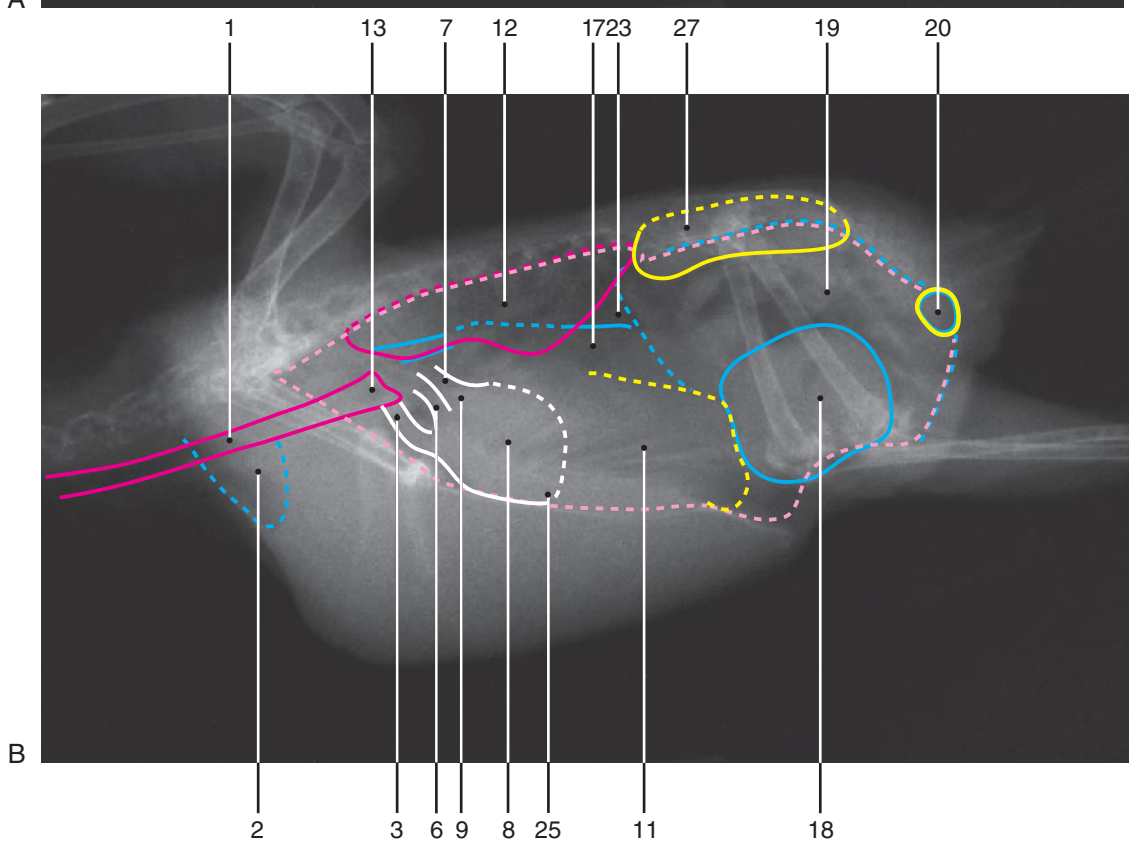

B

Figure 3-1, A-B
Type of Bird: Budgerigar
Type of Study: Viscera of the coelom
Projection: Laterolateral (right lateral recumbency)
Weight of Bird: 30 g
Gender: Unknown
Reproductive Status: Intact
Age: Adult

1. Trachea
2. Crop
3. Brachiocephalic artery and aorta
4. (Brachiocephalic artery)
5. (Aorta)
6. Pulmonary artery
7. Pulmonary vein
8. Heart
9. Left atrium
10. (Esophagus)
11. Liver
12. Lung
13. Syrinx
14. (Gonad)
15. (Ovary)
16. (Testes)
17. Proventriculus
18. Ventriculus
19. Intestines
20. Cloaca
21. (Cervical air sac)
22. (Clavicular air sac)
23. Thoracic air sac
24. (Abdominal air sac)
25. Apex of heart
26. (Interface between caudal thoracic and abdominal air sacs)
27. Kidneys
28. (Spleen)

NOTE: Structures in parentheses are not labeled.

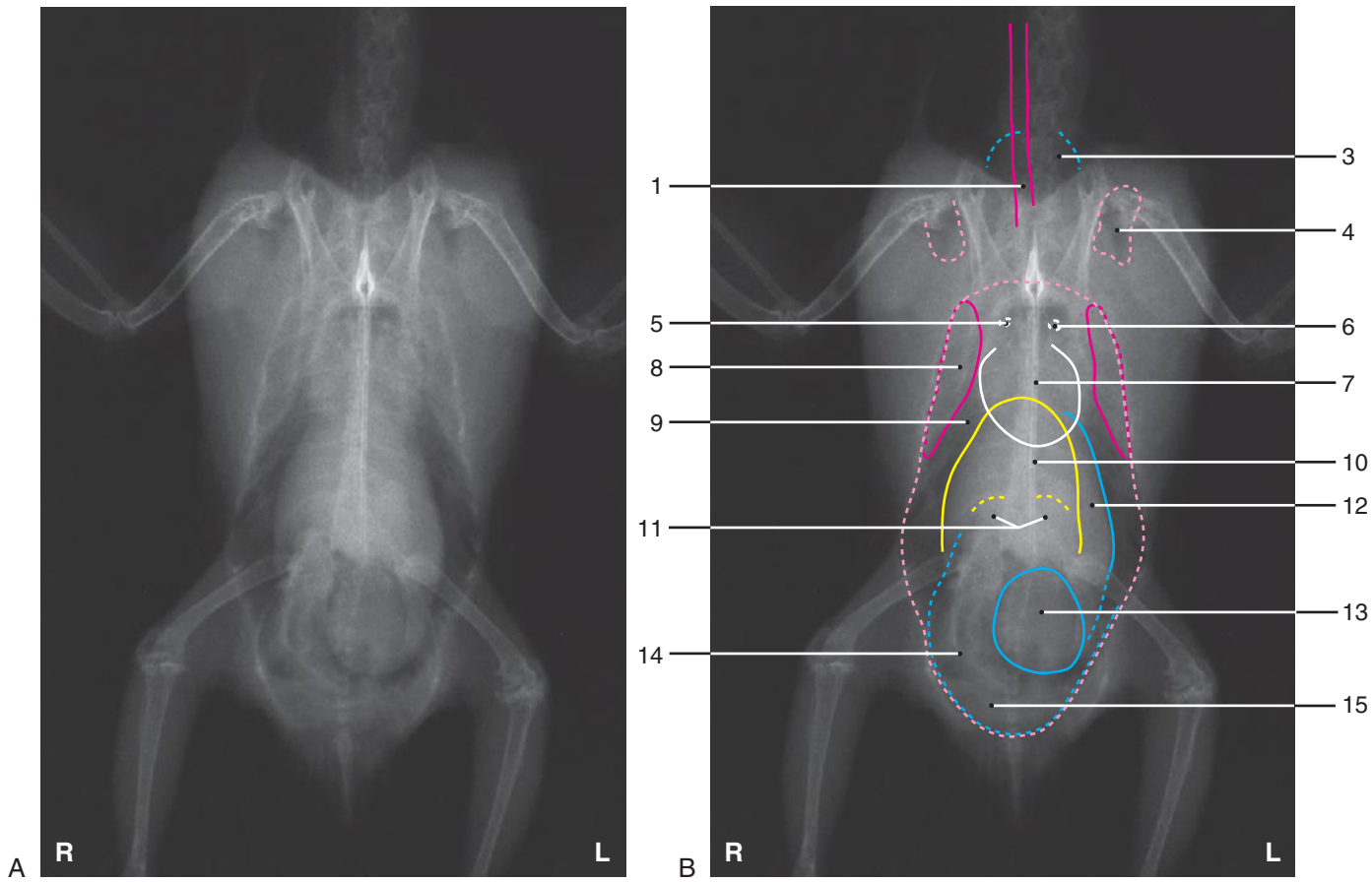

Figure 3-2, A-B
Type of Bird: Budgerigar
Type of Study: Viscera of the coelom
Projection: Ventrodorsal
Weight of Bird: 30 g
Gender: Unknown
Reproductive Status: Intact
Age: Adult

1. Trachea
2. (Cervical air sac)
3. Crop
4. Clavicular air sac
5. Brachiocephalic artery and aorta
6. Heart base vessel
7. Heart
8. Lung
9. Thoracic air sac
10. Liver
11. Kidneys
12. Proventriculus
13. Ventriculus
14. Intestines
15. Abdominal air sac
16. (Cloaca)

NOTE: Structures in parentheses are not labeled.

CHAPTER • 4

Peach-Faced Lovebird
(Agapornis roseicollis)

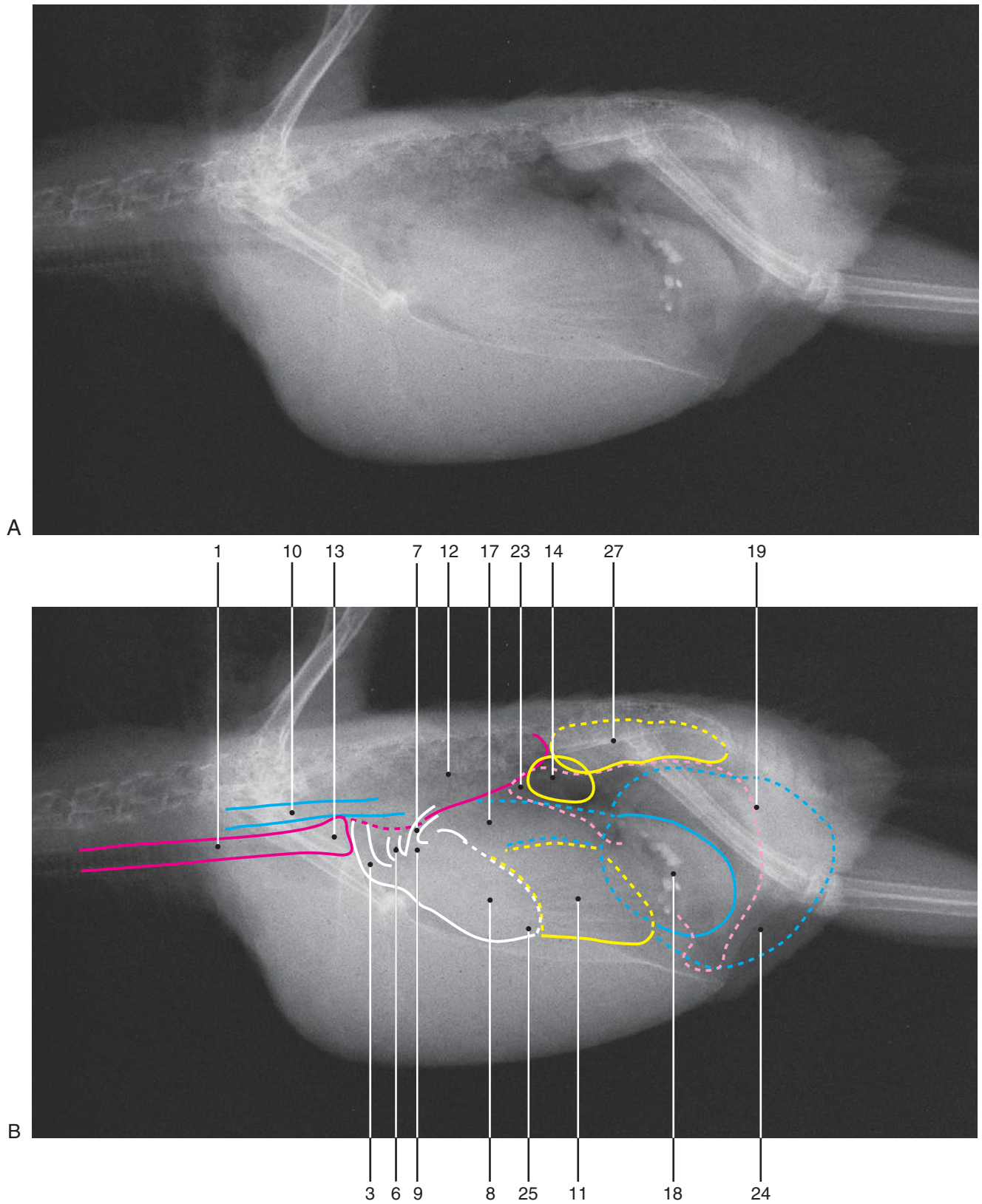

Figure 4-1, A-B
Type of Bird: Peach-Faced Lovebird
Type of Study: Viscera of the coelom
Projection: Laterolateral (right lateral recumbency)
Weight of Bird: 50 g
Gender: Unknown
Reproductive Status: Intact
Age: Adult

1. Trachea
2. (Crop)
3. Brachiocephalic artery and aorta
4. (Brachiocephalic artery)
5. (Aorta)
6. Pulmonary artery
7. Pulmonary vein
8. Heart
9. Left atrium
10. Esophagus
11. Liver
12. Lung
13. Syrinx
14. Gonad
15. (Ovary)
16. (Testes)
17. Proventriculus
18. Ventriculus
19. Intestines
20. (Cloaca)
21. (Cervical air sac)
22. (Clavicular air sac)
23. Thoracic air sac
24. Abdominal air sac
25. Apex of heart
26. (Interface between caudal thoracic and abdominal air sacs)
27. Kidneys
28. (Spleen)

NOTE: Structures in parentheses are not labeled.

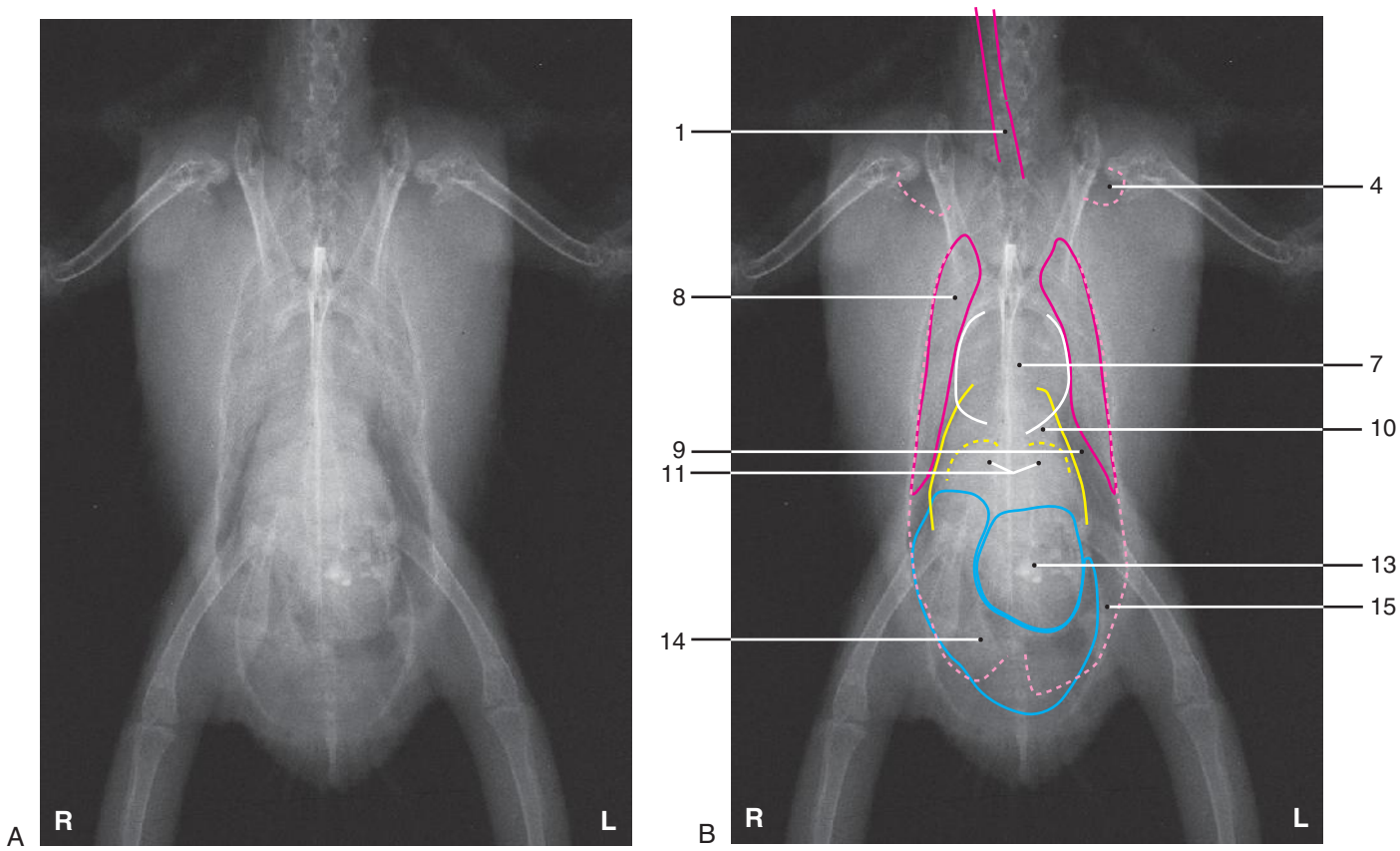

Figure 4-2, A-B
Type of Bird: Peach-Faced Lovebird
Type of Study: Viscera of the coelom
Projection: Ventrodorsal
Weight of Bird: 50 g
Gender: Unknown
Reproductive Status: Intact
Age: Adult

1. Trachea
2. (Cervical air sac)
3. (Crop)
4. Clavicular air sac
5. (Brachiocephalic artery and aorta)
6. (Heart base vessel)
7. Heart
8. Lung
9. Thoracic air sac
10. Liver
11. Kidneys
12. (Proventriculus)
13. Ventriculus
14. Intestines
15. Abdominal air sac
16. (Cloaca)

NOTE: Structures in parentheses are not labeled.

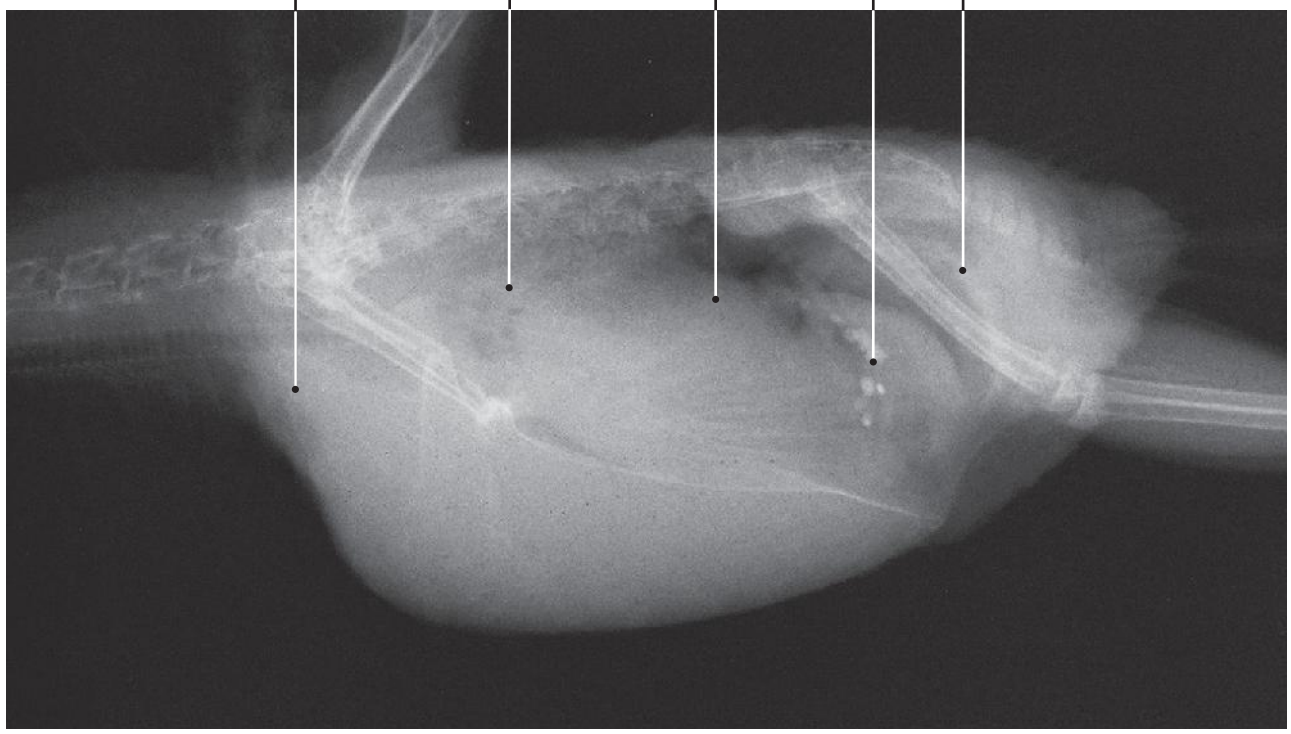

A

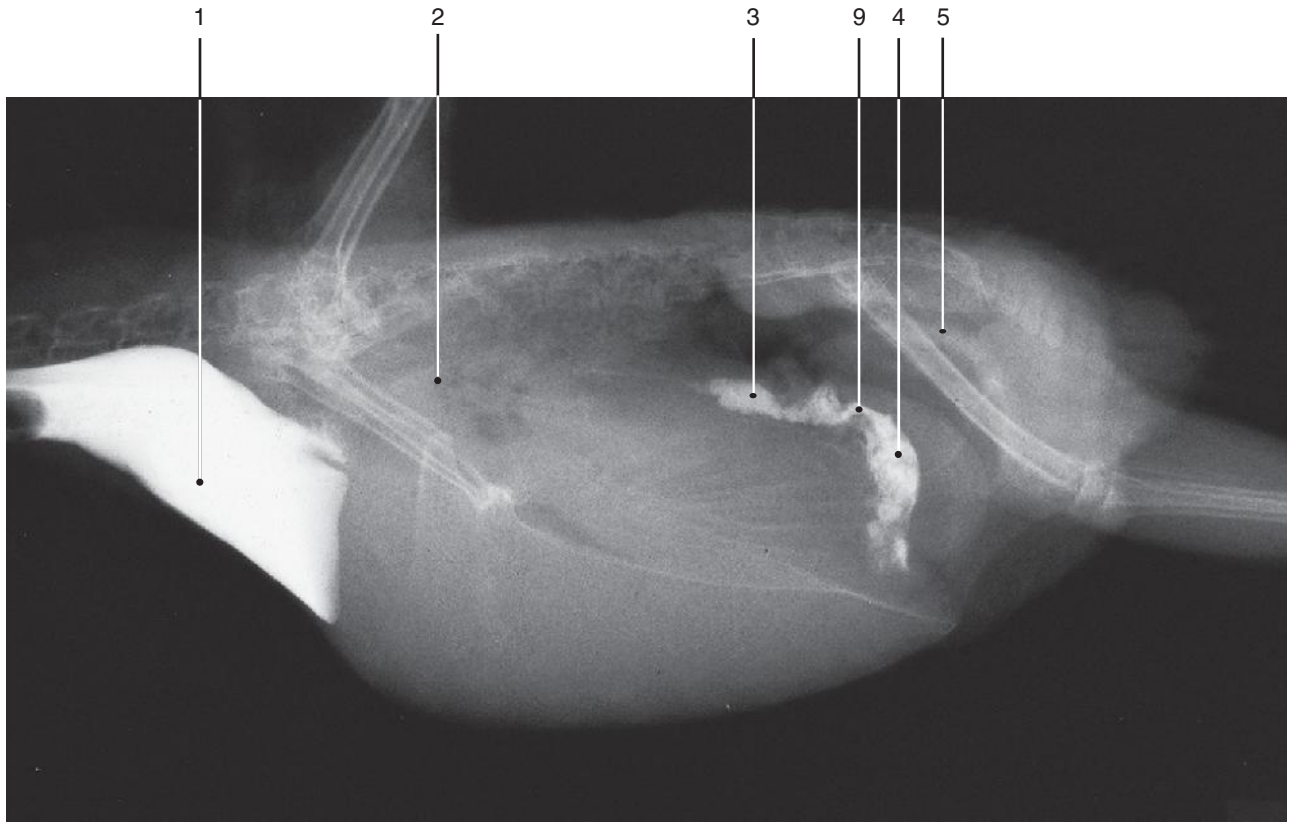

B

Figure 4-3, A-B
Type of Bird: Peach-Faced Lovebird
Type of Study: Gastrointestinal positive contrast study
Contrast Medium: Barium sulfate suspension (Novopaque® 30% w/v; Lafayette Pharmaceutical, Inc., Lafayette, IN) 3 ml administered via gavage tube
Projection: Laterolateral (right lateral recumbency)
Weight of Bird: 50 g
Gender: Unknown
Reproductive Status: Intact
Age: Adult

Image	Time (hr)
A	Scout
B	0.25

1. Crop
2. Esophagus
3. Proventriculus
4. Ventriculus
5. Intestines
6. (Duodenum)
7. (Large intestine)
8. (Cloaca)
9. Proventricular-ventricular isthmus

NOTE: Structures in parentheses are not labeled.

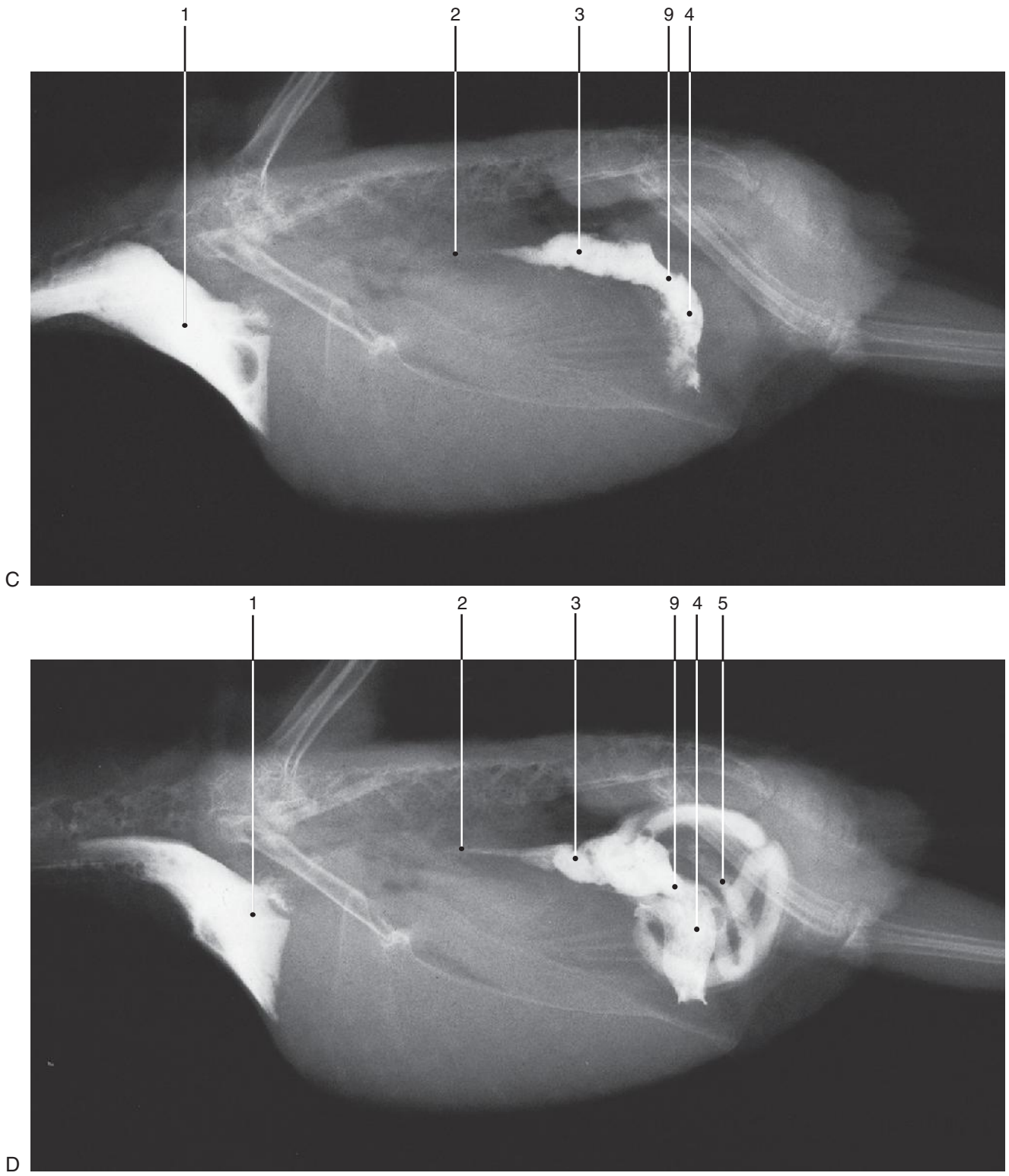

Figure 4-3, C-D
Type of Bird: Peach-Faced Lovebird
Type of Study: Gastrointestinal positive contrast study
Contrast Medium: Barium sulfate suspension (Novopaque® 30% w/v; Lafayette Pharmaceutical, Inc., Lafayette, IN) 3 ml administered via gavage tube
Projection: Laterolateral (right lateral recumbency)
Weight of Bird: 50 g
Gender: Unknown
Reproductive Status: Intact
Age: Adult

Image	Time (hr)
C	2.0
D	4.0

1. Crop
2. Esophagus
3. Proventriculus
4. Ventriculus
5. Intestines
6. (Duodenum)
7. (Large intestine)
8. (Cloaca)
9. Proventricular-ventricular isthmus

NOTE: Structures in parentheses are not labeled.

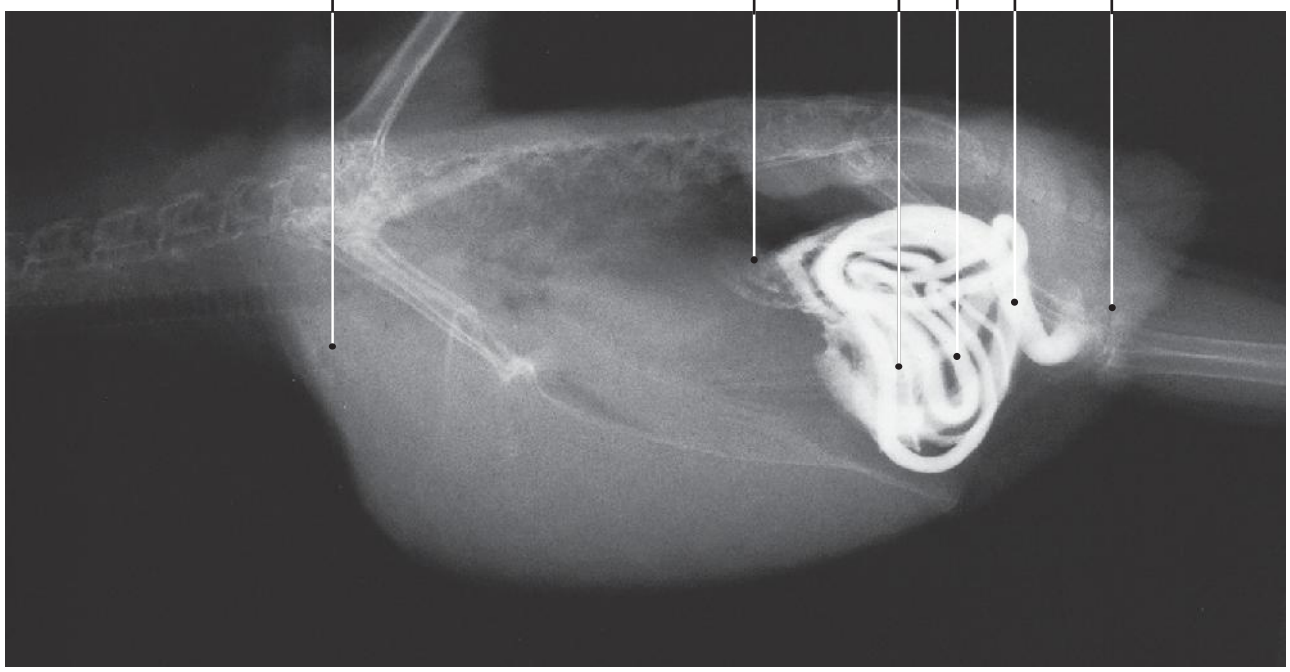

E

Figure 4-3, E
Type of Bird: Peach-Faced Lovebird
Type of Study: Gastrointestinal positive contrast study
Contrast Medium: Barium sulfate suspension (Novopaque® 30% w/v; Lafayette Pharmaceutical, Inc., Lafayette, IN) 3 ml administered via gavage tube
Projection: Laterolateral (right lateral recumbency)
Weight of Bird: 50 g
Gender: Unknown
Reproductive Status: Intact
Age: Adult

Image	Time (hr)
E	7.5

1. Crop
2. (Esophagus)
3. Proventriculus
4. Ventriculus
5. Intestines
6. (Duodenum)
7. Large intestine
8. Cloaca
9. (Proventricular-ventricular isthmus)

NOTE: Structures in parentheses are not labeled.

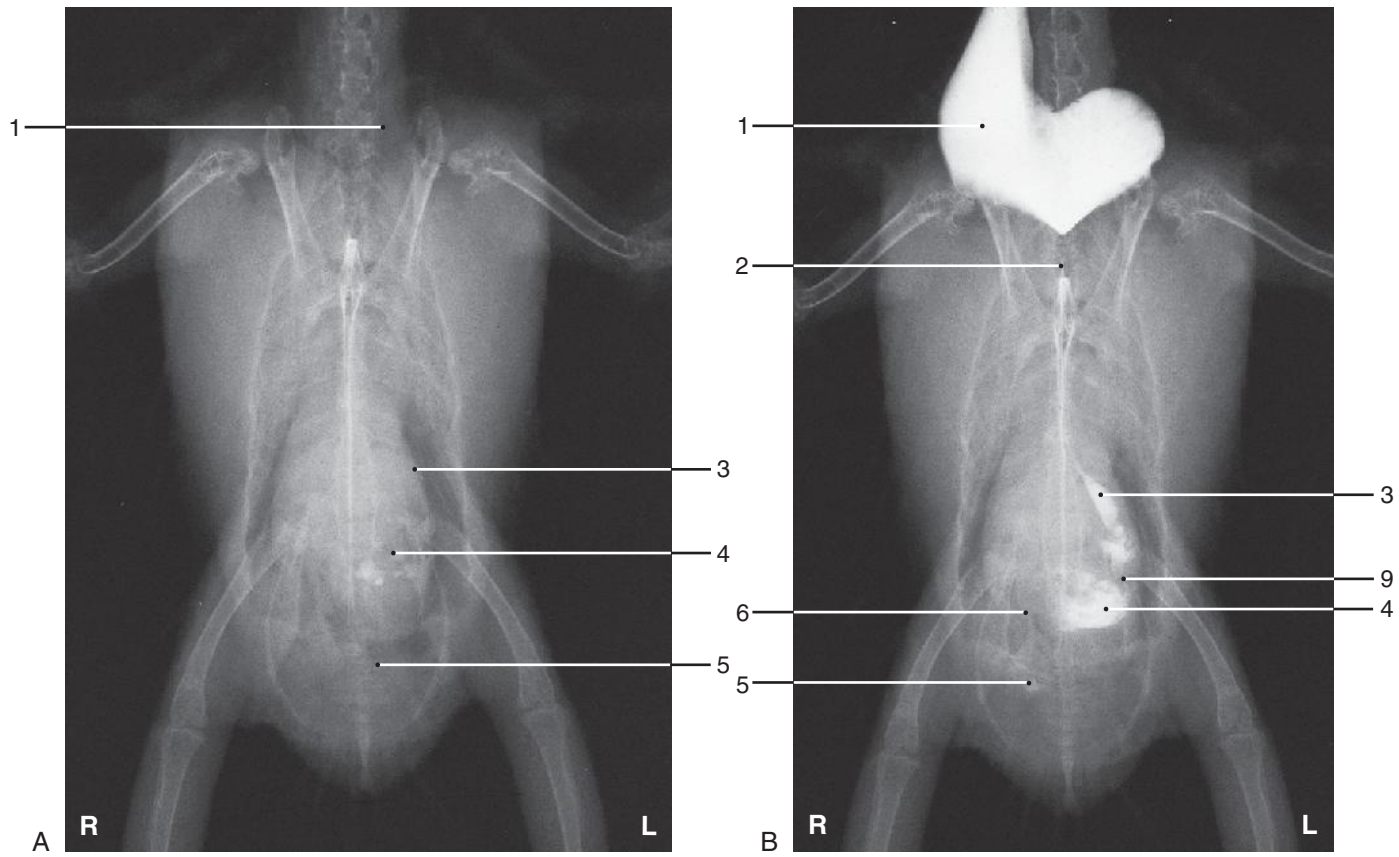

Figure 4-4, A-B
Type of Bird: Peach-Faced Lovebird
Type of Study: Gastrointestinal positive contrast study
Contrast Medium: Barium sulfate suspension (Novopaque® 30% w/v; Lafayette Pharmaceutical, Inc., Lafayette, IN) 3 ml administered via gavage tube
Projection: Ventrodorsal
Weight of Bird: 50 g
Gender: Unknown
Reproductive Status: Intact
Age: Adult

Image	Time (hr)
A	Scout
B	0.25

1. Crop
2. Esophagus
3. Proventriculus
4. Ventriculus
5. Intestines
6. Duodenum
7. (Large intestine)
8. (Cloaca)
9. Proventricular-ventricular isthmus

NOTE: Structures in parentheses are not labeled.

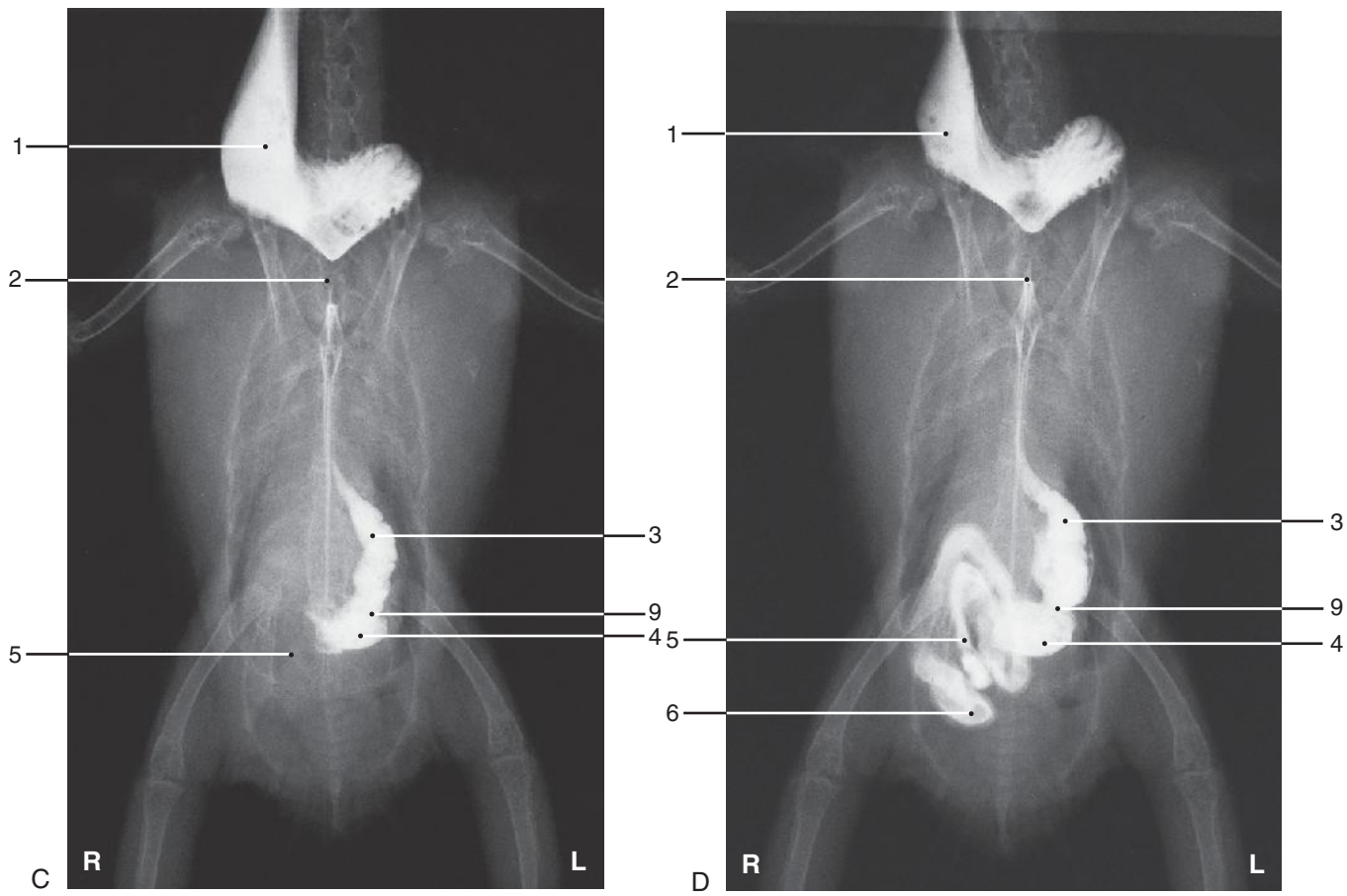

Figure 4-4, C-D

Type of Bird: Peach-Faced Lovebird
Type of Study: Gastrointestinal positive contrast study
Contrast Medium: Barium sulfate suspension (Novopaque® 30% w/v; Lafayette Pharmaceutical, Inc., Lafayette, IN) 3 ml administered via gavage tube
Projection: Ventrodorsal
Weight of Bird: 50 g
Gender: Unknown
Reproductive Status: Intact
Age: Adult

Image	Time (hr)
C	2.0
D	4.0

1. Crop
2. Esophagus
3. Proventriculus
4. Ventriculus
5. Intestines
6. Duodenum
7. (Large intestine)
8. (Cloaca)
9. Proventricular-ventricular isthmus

NOTE: Structures in parentheses are not labeled.

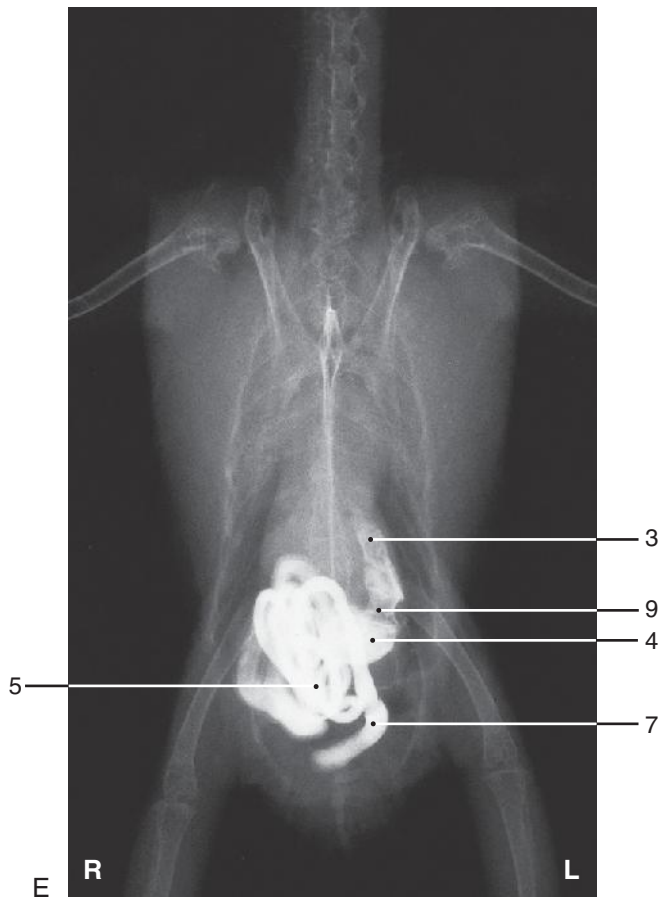

Figure 4-4, E
Type of Bird: Peach-Faced Lovebird
Type of Study: Gastrointestinal positive contrast study
Contrast Medium: Barium sulfate suspension (Novopaque® 30% w/v; Lafayette Pharmaceutical, Inc., Lafayette, IN) 3 ml administered via gavage tube
Projection: Ventrodorsal
Weight of Bird: 50 g
Gender: Unknown
Reproductive Status: Intact
Age: Adult

Image	Time (hr)
E	7.5

1. (Crop)
2. (Esophagus)
3. Proventriculus
4. Ventriculus
5. Intestines
6. (Duodenum)
7. Large intestine
8. (Cloaca)
9. Proventricular-ventricular isthmus

NOTE: Structures in parentheses are not labeled.

CHAPTER • 5

Cockatiel
(Nymphicus hollandicus)

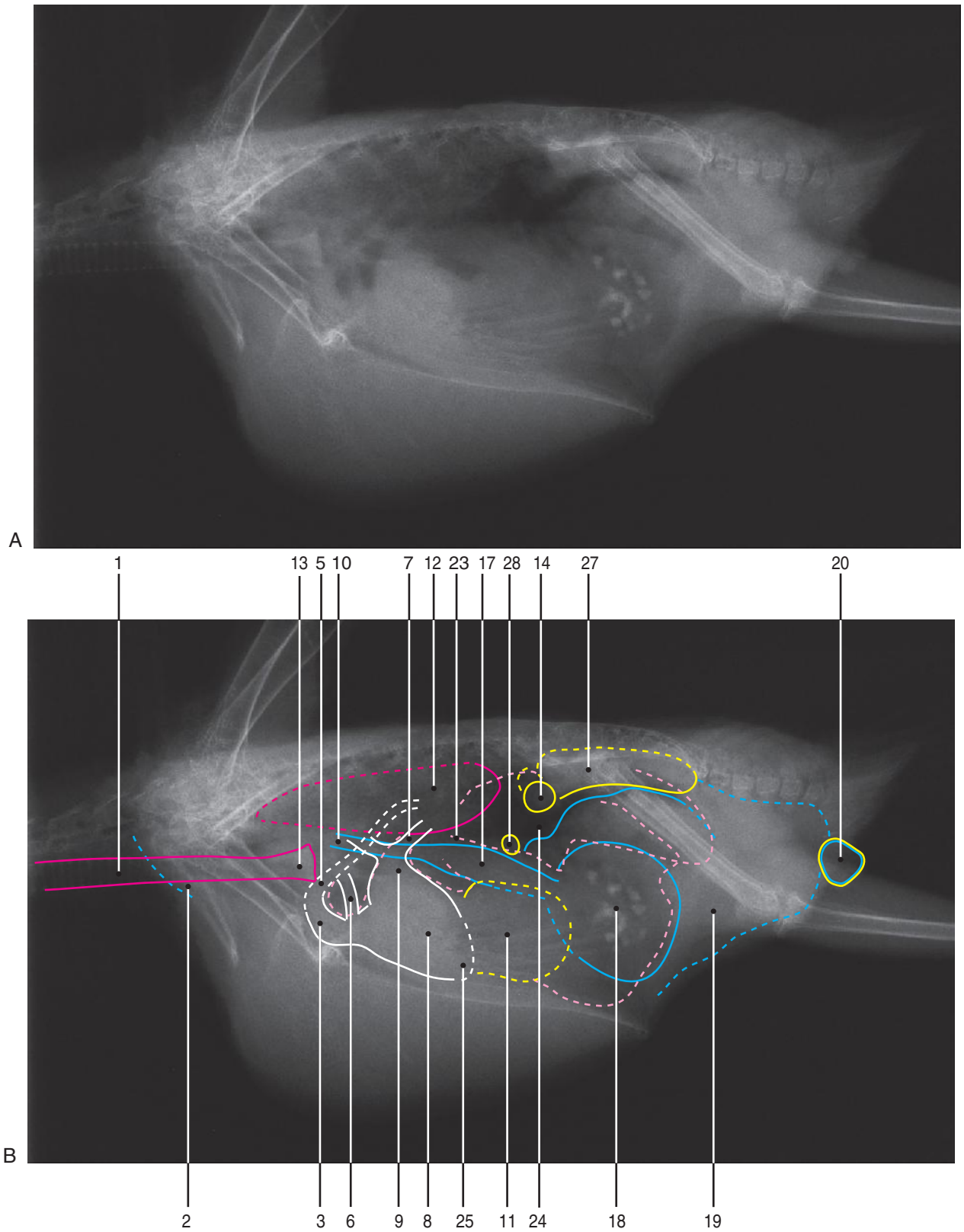

Figure 5-1, A-B
Type of Bird: Cockatiel
Type of Study: Viscera of the coelom
Projection: Laterolateral (right lateral recumbency)
Weight of Bird: 98 g
Gender: Male
Reproductive Status: Intact
Age: Adult

1. Trachea
2. Crop
3. Brachiocephalic artery and aorta
4. (Brachiocephalic artery)
5. Aorta
6. Pulmonary artery
7. Pulmonary vein
8. Heart
9. Left atrium
10. Esophagus
11. Liver
12. Lung
13. Syrinx
14. Gonad
15. (Ovary)
16. (Testes)
17. Proventriculus
18. Ventriculus
19. Intestines
20. Cloaca
21. (Cervical air sac)
22. (Clavicular air sac)
23. Thoracic air sac
24. Abdominal air sac
25. Apex of heart
26. (Interface between caudal thoracic and abdominal air sacs)
27. Kidneys
28. Spleen

NOTE: Structures in parentheses are not labeled.

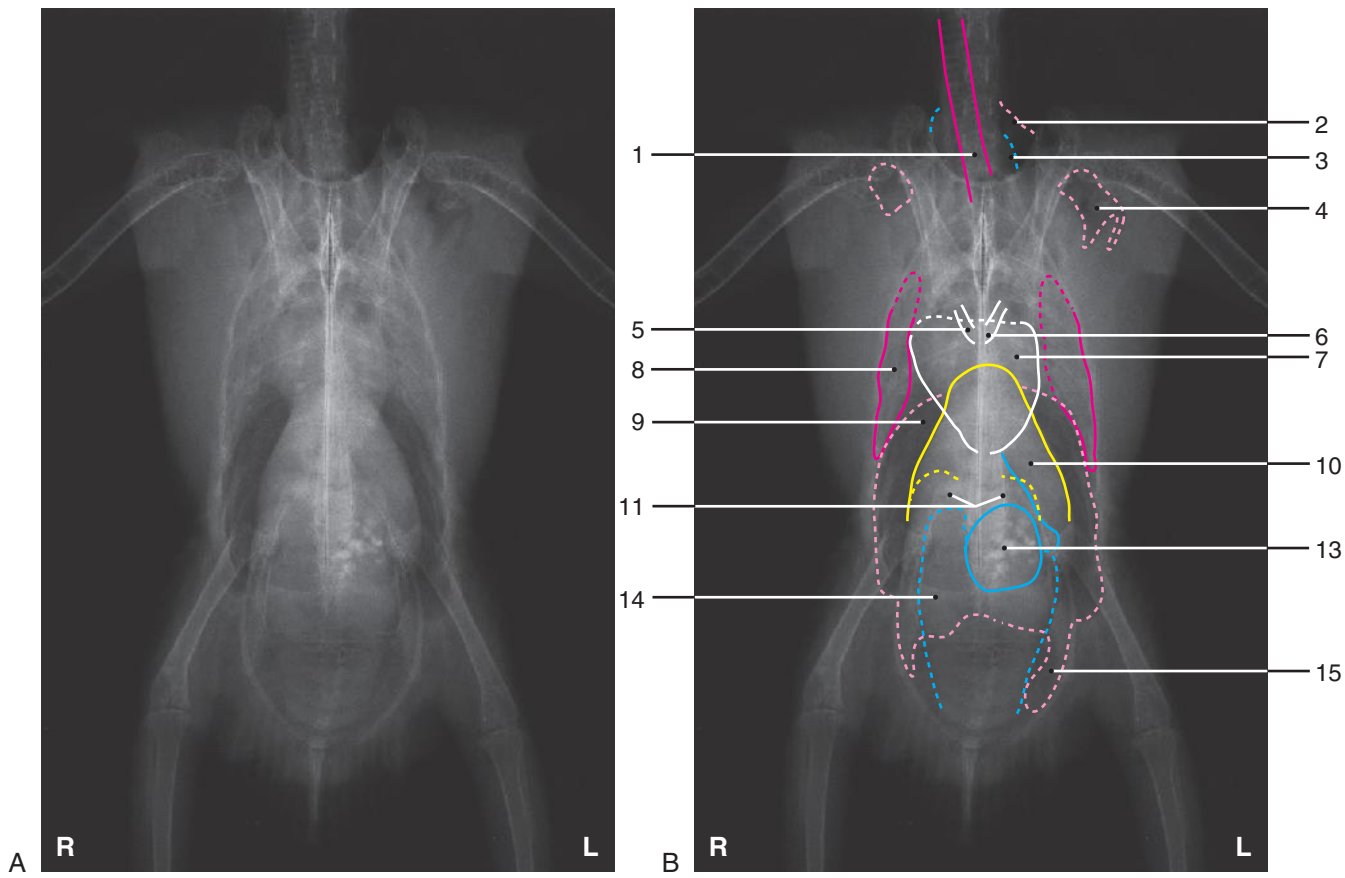

Figure 5-2, A-B
Type of Bird: Cockatiel
Type of Study: Viscera of the coelom
Projection: Ventrodorsal
Weight of Bird: 98 g
Gender: Male
Reproductive Status: Intact
Age: Adult

1. Trachea
2. Cervical air sac
3. Crop
4. Clavicular air sac
5. Brachiocephalic artery and aorta
6. Heart base vessel
7. Heart
8. Lung
9. Thoracic air sac
10. Liver
11. Kidneys
12. (Proventriculus)
13. Ventriculus
14. Intestines
15. Abdominal air sac
16. (Cloaca)

NOTE: Structures in parentheses are not labeled.

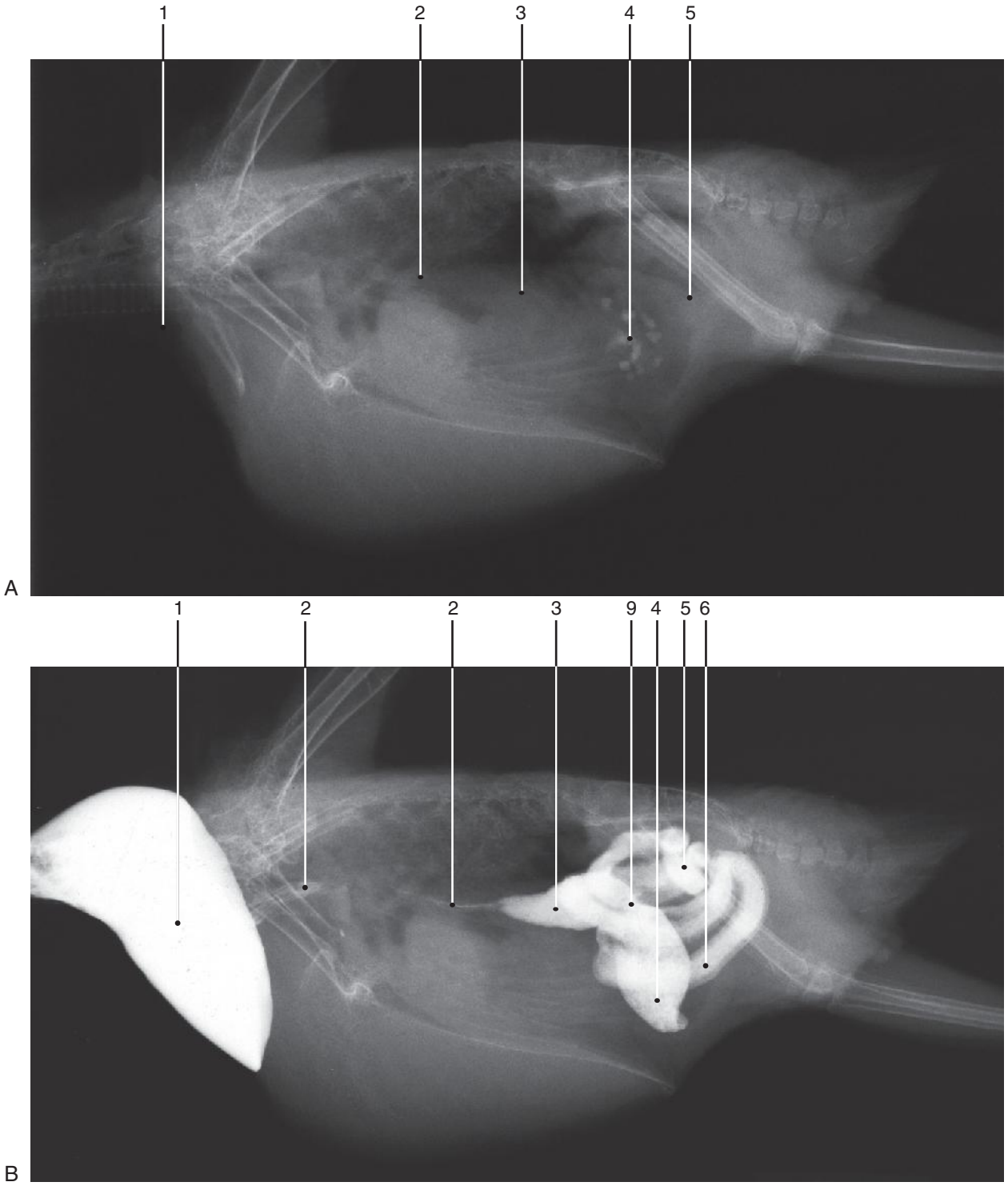

Figure 5-3, A-B
Type of Bird: Cockatiel
Type of Study: Gastrointestinal positive contrast study
Contrast Medium: Barium sulfate suspension (Novopaque® 30% w/v; Lafayette Pharmaceutical, Inc., Lafayette, IN) 5 ml administered via gavage tube
Projection: Ventrodorsal
Weight of Bird: 98 g
Gender: Male
Reproductive Status: Intact
Age: Adult

Image	Time (hr)
A	Scout
B	0.25

1. Crop
2. Esophagus
3. Proventriculus
4. Ventriculus
5. Intestines
6. Duodenum
7. (Large intestine)
8. (Cloaca)
9. Proventricular-ventricular isthmus

NOTE: Structures in parentheses are not labeled.

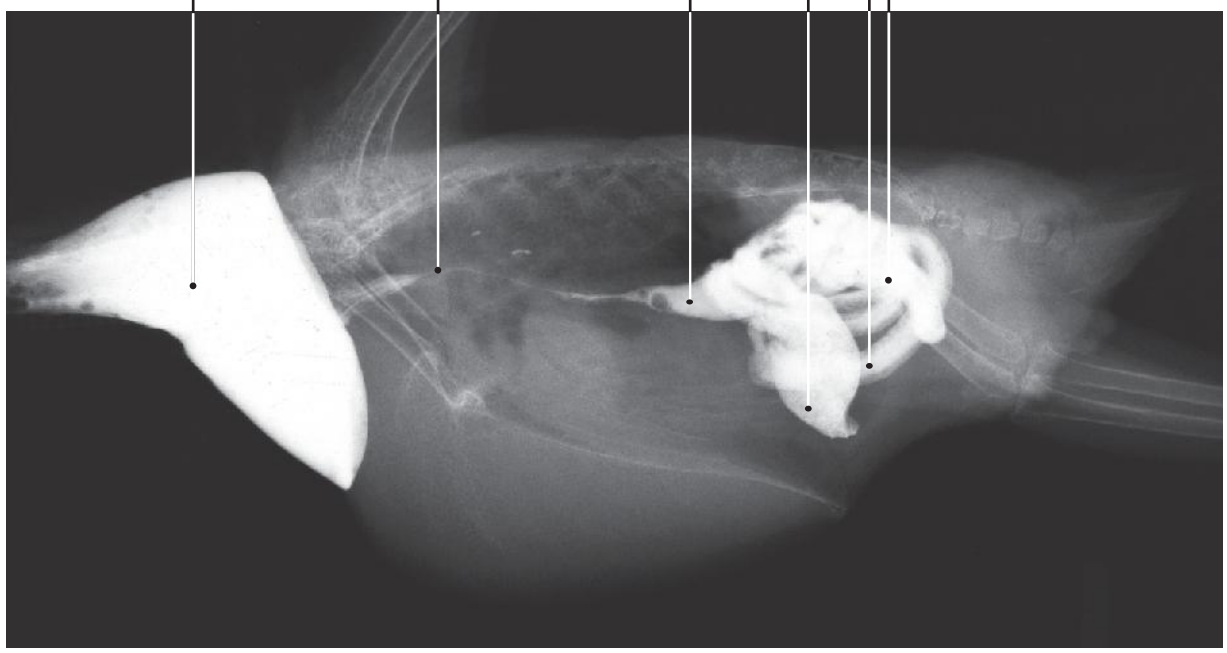

C

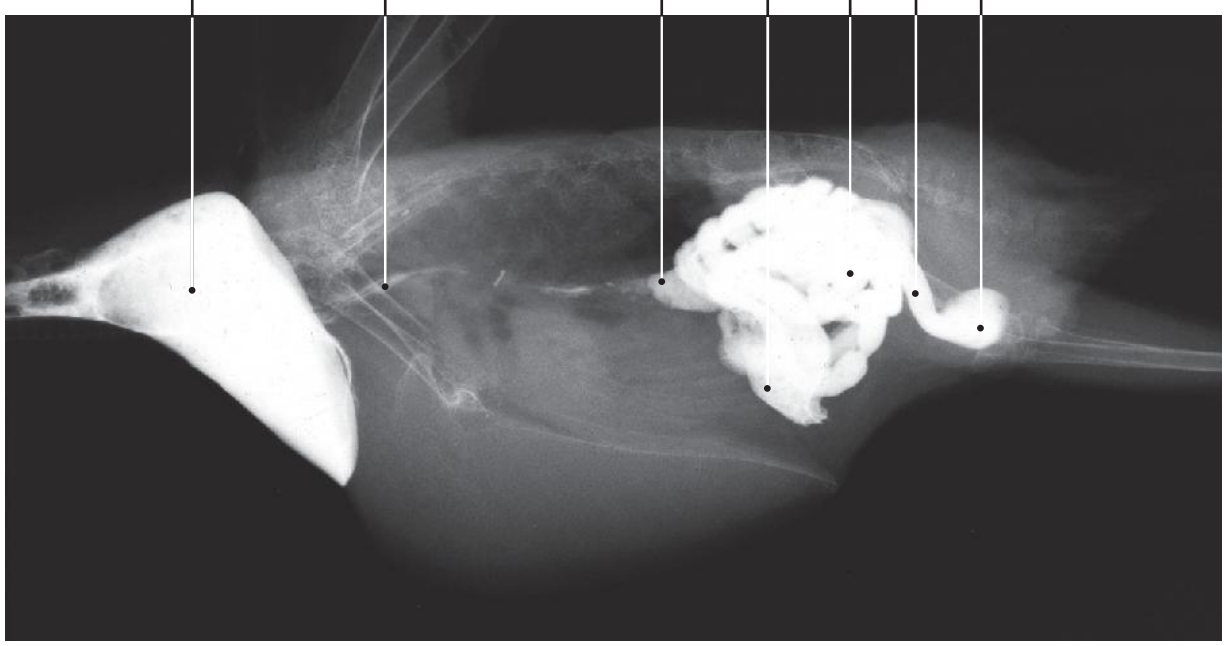

D

Figure 5-3, C-D
Type of Bird: Cockatiel
Type of Study: Gastrointestinal positive contrast study
Contrast Medium: Barium sulfate suspension (Novopaque® 30% w/v; Lafayette Pharmaceutical, Inc., Lafayette, IN) 5 ml administered via gavage tube
Projection: Ventrodorsal
Weight of Animal: 98 g
Gender: Male
Reproductive Status: Intact
Age: Adult

Image	Time (hr)
C	0.5
D	2.0

1. Crop
2. Esophagus
3. Proventriculus
4. Ventriculus
5. Intestines
6. Duodenum
7. Large intestine
8. Cloaca
9. (Proventricular-ventricular isthmus)

NOTE: Structures in parentheses are not labeled.

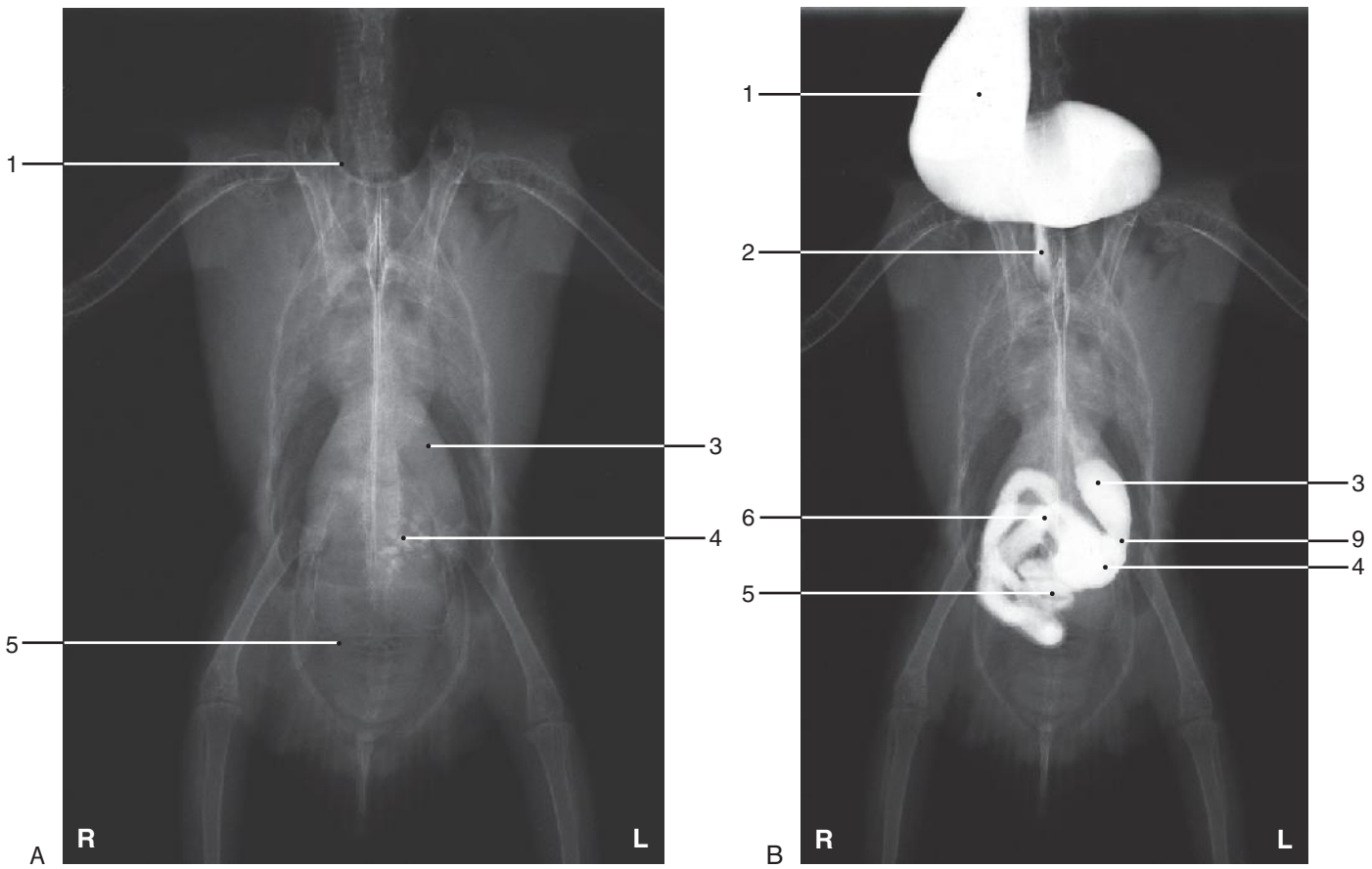

Figure 5-4, A-B
Type of Bird: Cockatiel
Type of Study: Gastrointestinal positive contrast study
Contrast Medium: Barium sulfate suspension (Novopaque® 30% w/v; Lafayette Pharmaceutical, Inc., Lafayette, IN) 5 ml administered via gavage tube
Projection: Ventrodorsal
Weight of Bird: 98 g
Gender: Male
Reproductive Status: Intact
Age: Adult

Image	Time (hr)
A	Scout
B	0.25

1. Crop
2. Esophagus
3. Proventriculus
4. Ventriculus
5. Intestines
6. Duodenum
7. (Large intestine)
8. (Cloaca)
9. Proventricular-ventricular isthmus

NOTE: Structures in parentheses are not labeled.

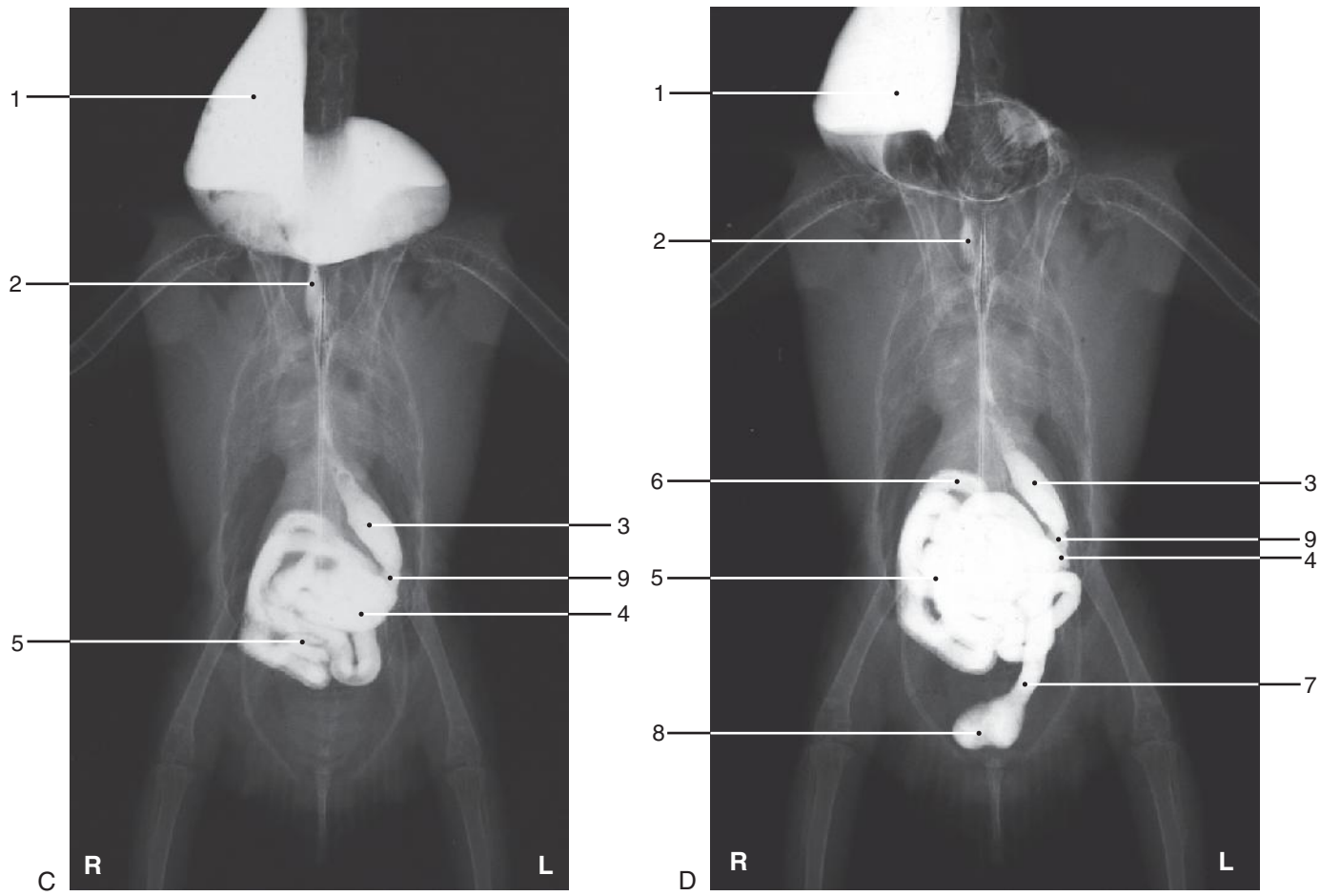

Figure 5-4, C-D

Type of Bird: Cockatiel
Type of Study: Gastrointestinal positive contrast study
Contrast Medium: Barium sulfate suspension (Novopaque® 30% w/v; Lafayette Pharmaceutical, Inc., Lafayette, IN) 5 ml administered via gavage tube
Projection: Ventrodorsal
Weight of Bird: 98 g
Gender: Male
Reproductive Status: Intact
Age: Adult

Image	Time (hr)
C	0.5
D	2.0

1. Crop
2. Esophagus
3. Proventriculus
4. Ventriculus
5. Intestines
6. Duodenum
7. Large intestine
8. Cloaca
9. Proventricular-ventricular isthmus

CHAPTER • 6

Sun Conure
(Aratinga solstitialis)

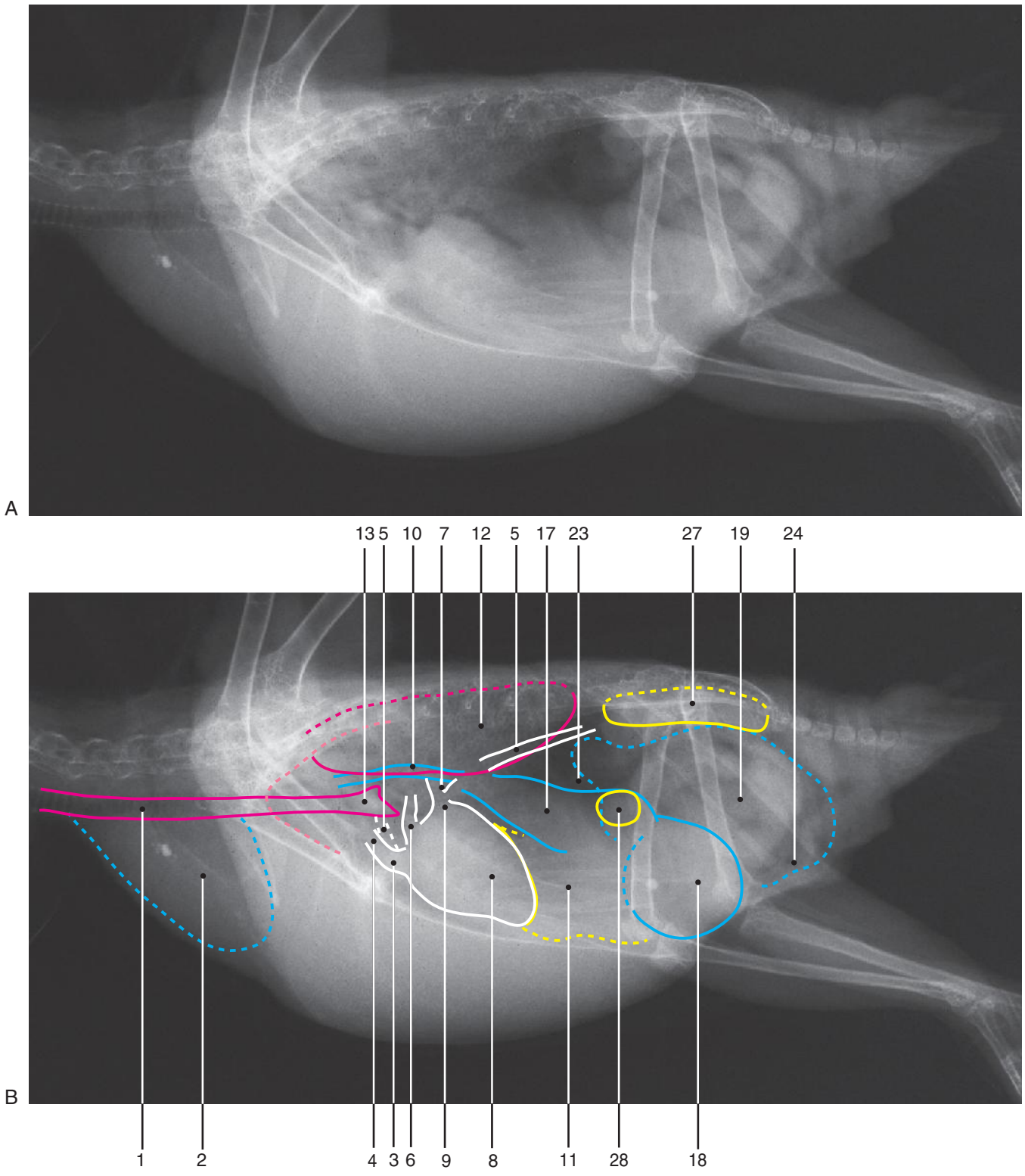

Figure 6-1, A-B
Type of Bird: Sun Conure
Type of Study: Viscera of the coelom
Projection: Laterolateral (right lateral recumbency)
Weight of Bird: 126 g
Gender: Unknown
Reproductive Status: Intact
Age: Adult

1. Trachea
2. Crop
3. Brachiocephalic artery and aorta
4. Brachiocephalic artery
5. Aorta
6. Pulmonary artery
7. Pulmonary vein
8. Heart
9. Left atrium
10. Esophagus
11. Liver
12. Lung
13. Syrinx
14. (Gonad)
15. (Ovary)
16. (Testes)
17. Proventriculus
18. Ventriculus
19. Intestines
20. (Cloaca)
21. (Cervical air sac)
22. (Clavicular air sac)
23. Thoracic air sac
24. Abdominal air sac
25. (Apex of heart)
26. (Interface between caudal thoracic and abdominal air sacs)
27. Kidneys
28. Spleen

NOTE: Structures in parentheses are not labeled.

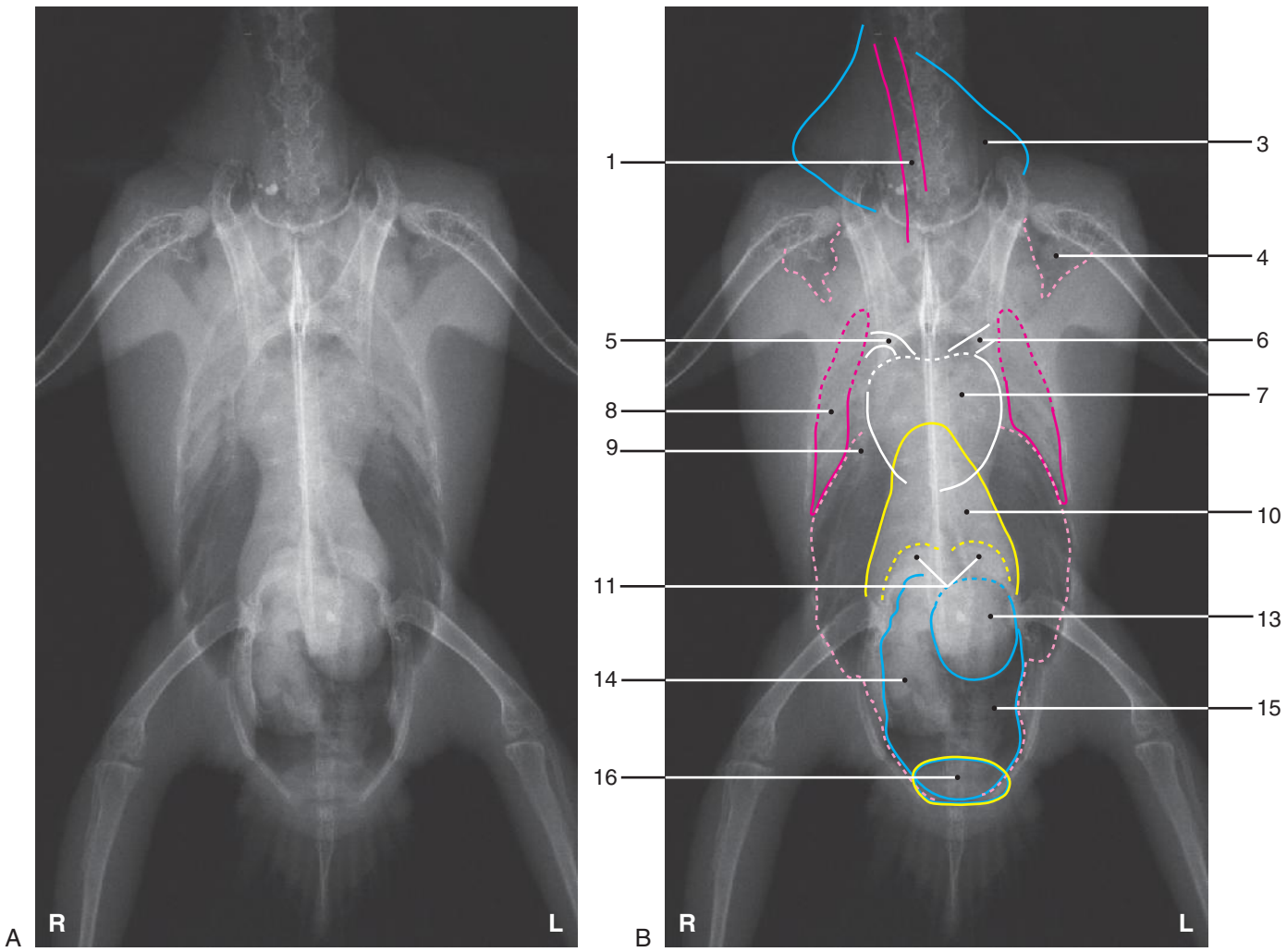

Figure 6-2, A-B
Type of Bird: Sun Conure
Type of Study: Viscera of the coelom
Projection: Ventrodorsal
Weight of Bird: 126 g
Gender: Unknown
Reproductive Status: Intact
Age: Adult

1. Trachea
2. (Cervical air sac)
3. Crop
4. Clavicular air sac
5. Brachiocephalic artery and aorta
6. Heart base vessel
7. Heart
8. Lung
9. Thoracic air sac
10. Liver
11. Kidneys
12. (Proventriculus)
13. Ventriculus
14. Intestines
15. Abdominal air sac
16. Cloaca

NOTE: Structures in parentheses are not labeled.

CHAPTER • 7

Senegal Parrot
(Poicephalus senegalus)

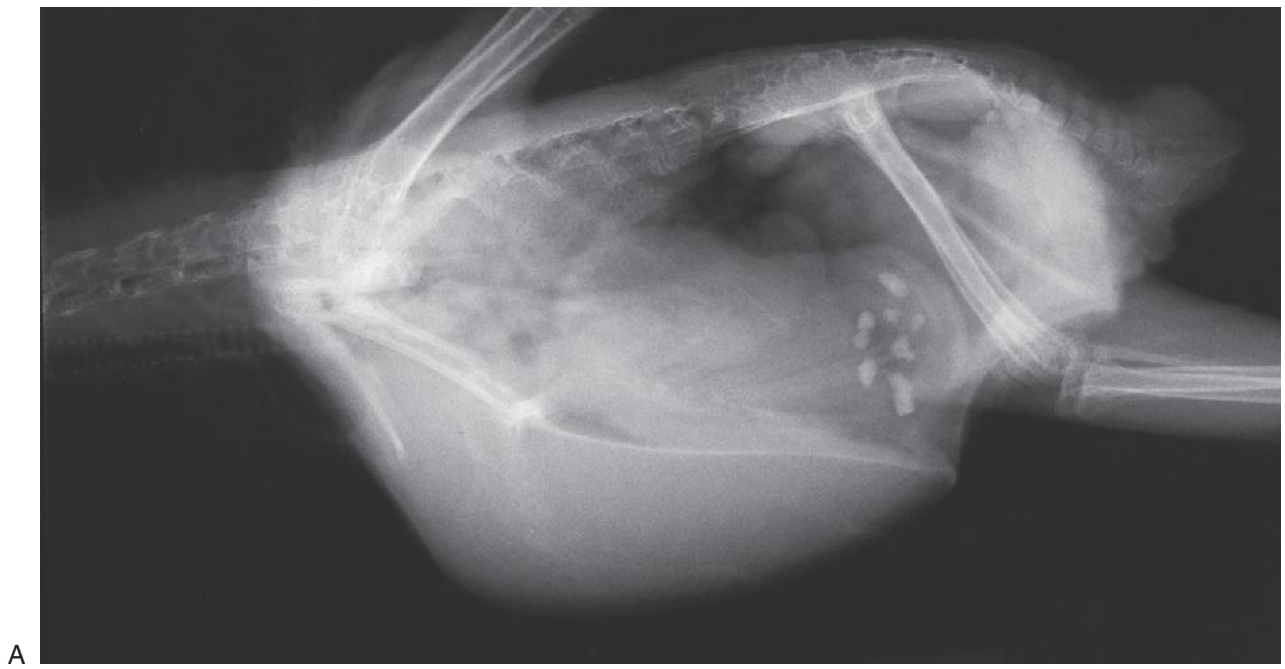

A

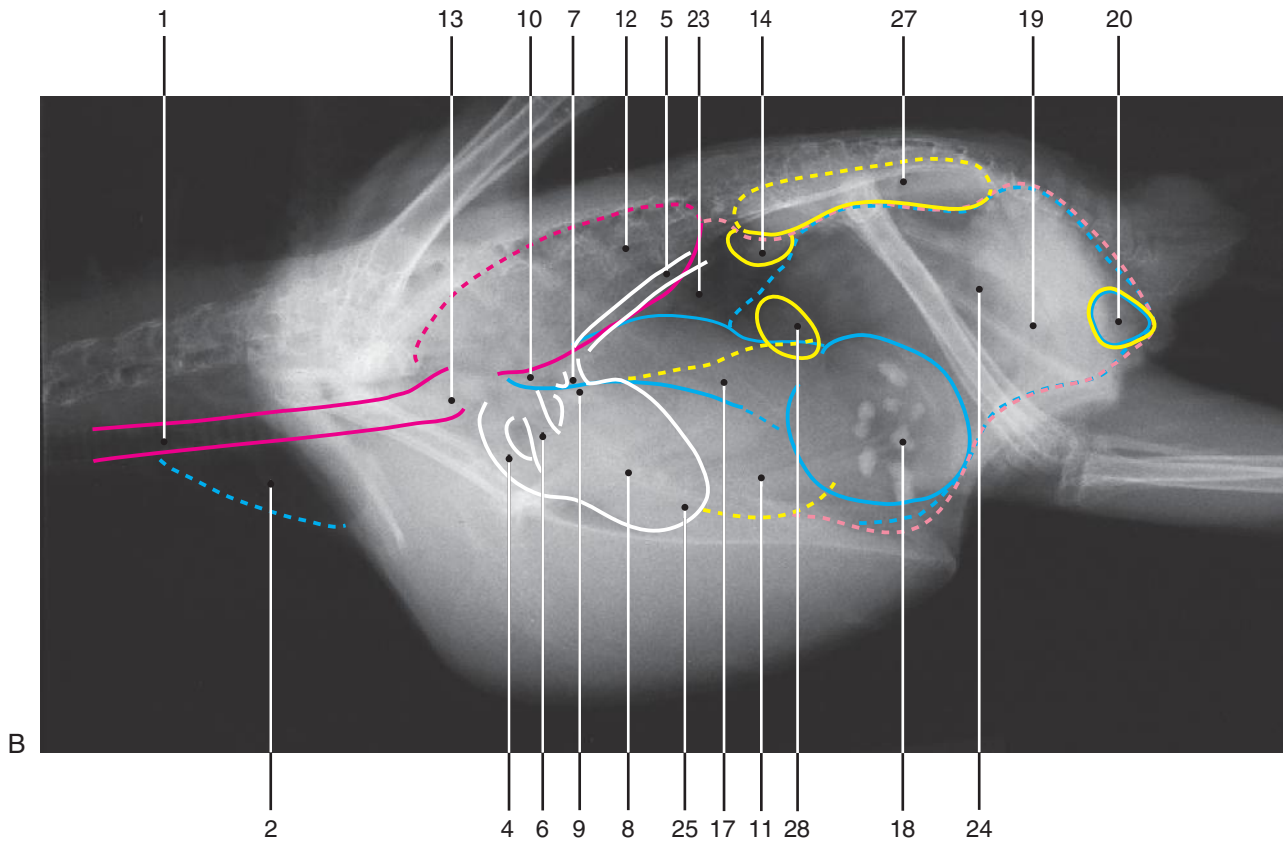

B

Figure 7-1, A-B
Type of Bird: Senegal Parrot
Type of Study: Viscera of the coelom
Projection: Laterolateral (right lateral recumbency)
Weight of Animal: 146 g
Gender: Unknown
Reproductive Status: Intact
Age: Adult

1. Trachea
2. Crop
3. (Brachiocephalic artery and aorta)
4. Brachiocephalic artery
5. Aorta
6. Pulmonary artery
7. Pulmonary vein
8. Heart
9. Left atrium
10. Esophagus
11. Liver
12. Lung
13. Syrinx
14. Gonad
15. (Ovary)
16. (Testes)
17. Proventriculus
18. Ventriculus
19. Intestines
20. Cloaca
21. (Cervical air sac)
22. (Clavicular air sac)
23. Thoracic air sac
24. Abdominal air sac
25. Apex of heart
26. (Interface between caudal thoracic and abdominal air sacs)
27. Kidneys
28. Spleen

NOTE: Structures in parentheses are not labeled.

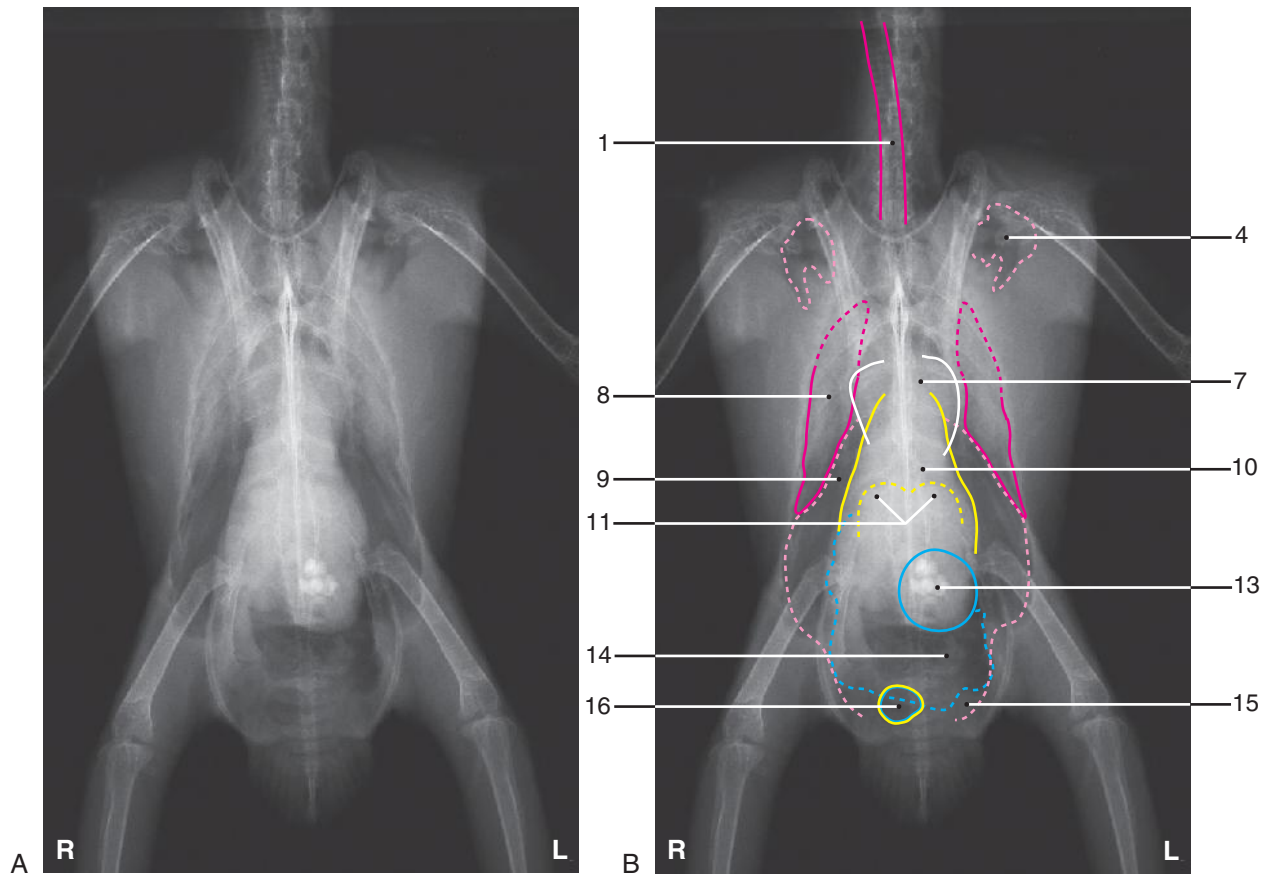

Figure 7-2, A-B
Type of Bird: Senegal Parrot
Type of Study: Viscera of the coelom
Projection: Ventrodorsal
Weight of Animal: 146 g
Gender: Unknown
Reproductive Status: Intact
Age: Adult

1. Trachea
2. (Cervical air sac)
3. (Crop)
4. Clavicular air sac
5. (Brachiocephalic artery and aorta)
6. (Heart base vessel)
7. Heart
8. Lung
9. Thoracic air sac
10. Liver
11. Kidneys
12. (Proventriculus)
13. Ventriculus
14. Intestines
15. Abdominal air sac
16. Cloaca

NOTE: Structures in parentheses are not labeled.

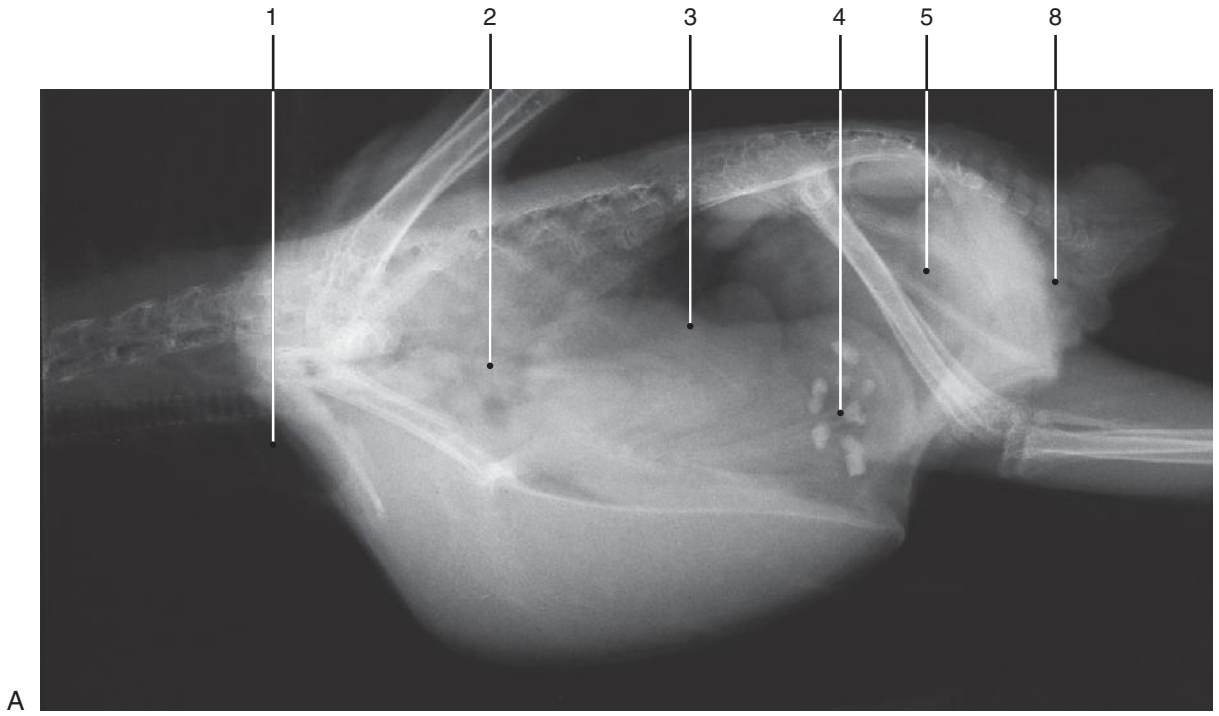

A

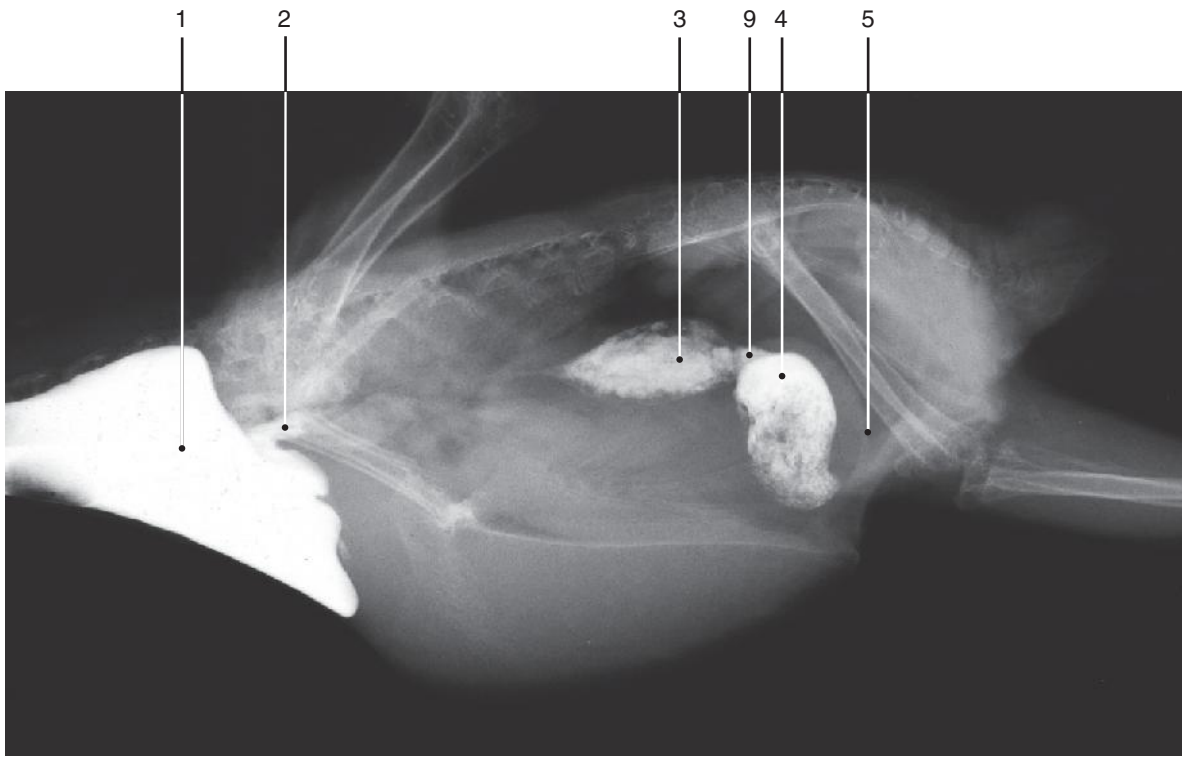

B

Figure 7-3, A-B
Type of Bird: Senegal Parrot
Type of Study: Gastrointestinal positive contrast study
Contrast Medium: Barium sulfate suspension (Novopaque® 30% w/v; Lafayette Pharmaceutical, Inc., Lafayette, IN) 7 ml administered via gavage tube
Projection: Laterolateral (right lateral recumbency)
Weight of Animal: 146 g
Gender: Unknown
Reproductive Status: Intact
Age: Adult

Image	Time (hr)
A	Scout
B	0.5

1. Crop
2. Esophagus
3. Proventriculus
4. Ventriculus
5. Intestines
6. (Duodenum)
7. (Large intestine)
8. Cloaca
9. Proventricular-ventricular isthmus

NOTE: Structures in parentheses are not labeled.

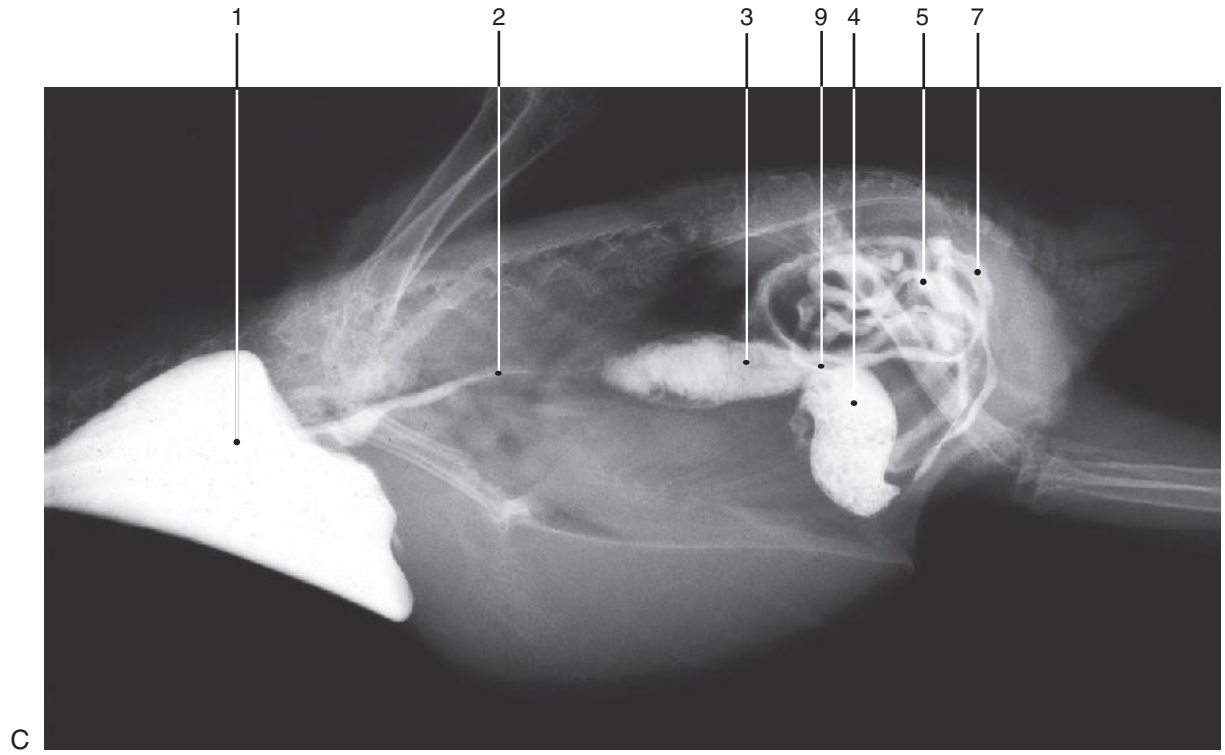

C

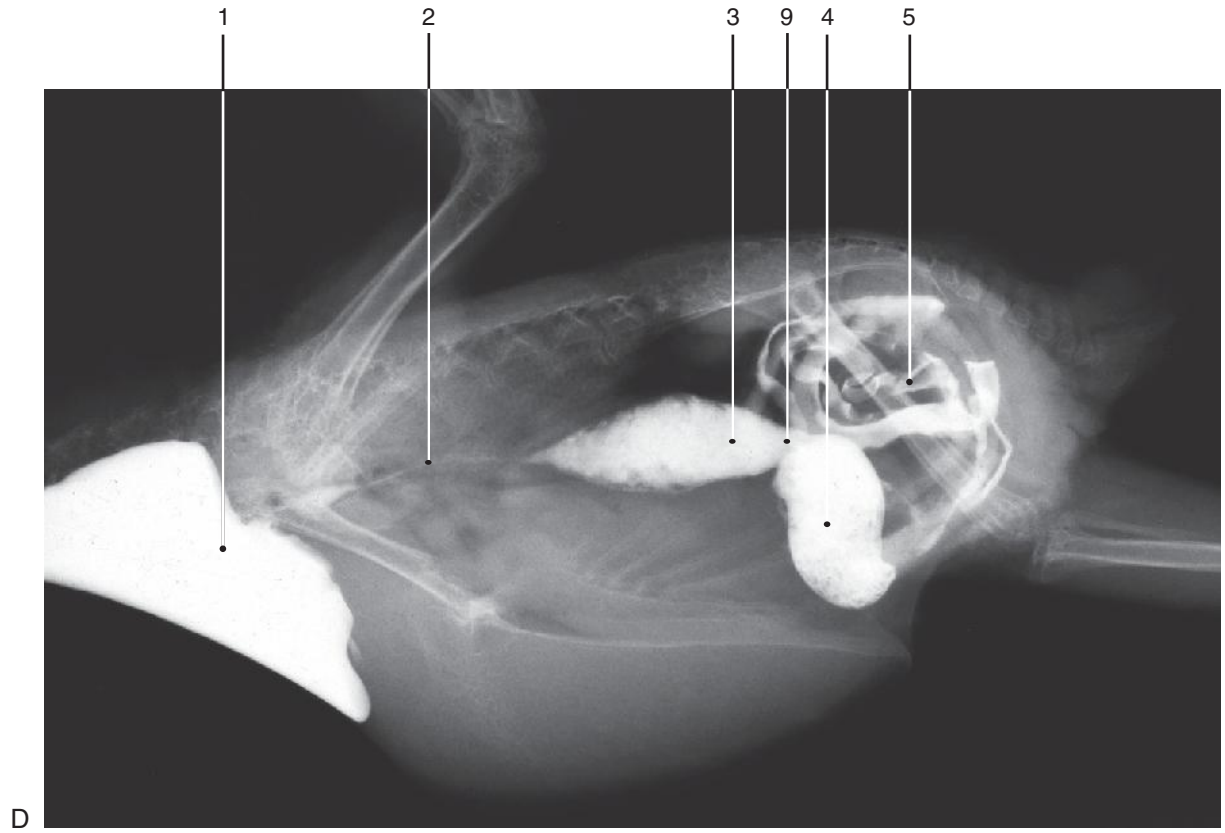

D

Figure 7-3, C-D
Type of Bird: Senegal Parrot
Type of Study: Gastrointestinal positive contrast study
Contrast Medium: Barium sulfate suspension (Novopaque® 30% w/v; Lafayette Pharmaceutical, Inc., Lafayette, IN) 7 ml administered via gavage tube
Projection: Laterolateral (right lateral recumbency)
Weight of Animal: 146 g
Gender: Unknown
Reproductive Status: Intact
Age: Adult

Image	Time (hr)
C	1.5
D	2.5

1. Crop
2. Esophagus
3. Proventriculus
4. Ventriculus
5. Intestines
6. (Duodenum)
7. Large intestine
8. (Cloaca)
9. Proventricular-ventricular isthmus

NOTE: Structures in parentheses are not labeled.

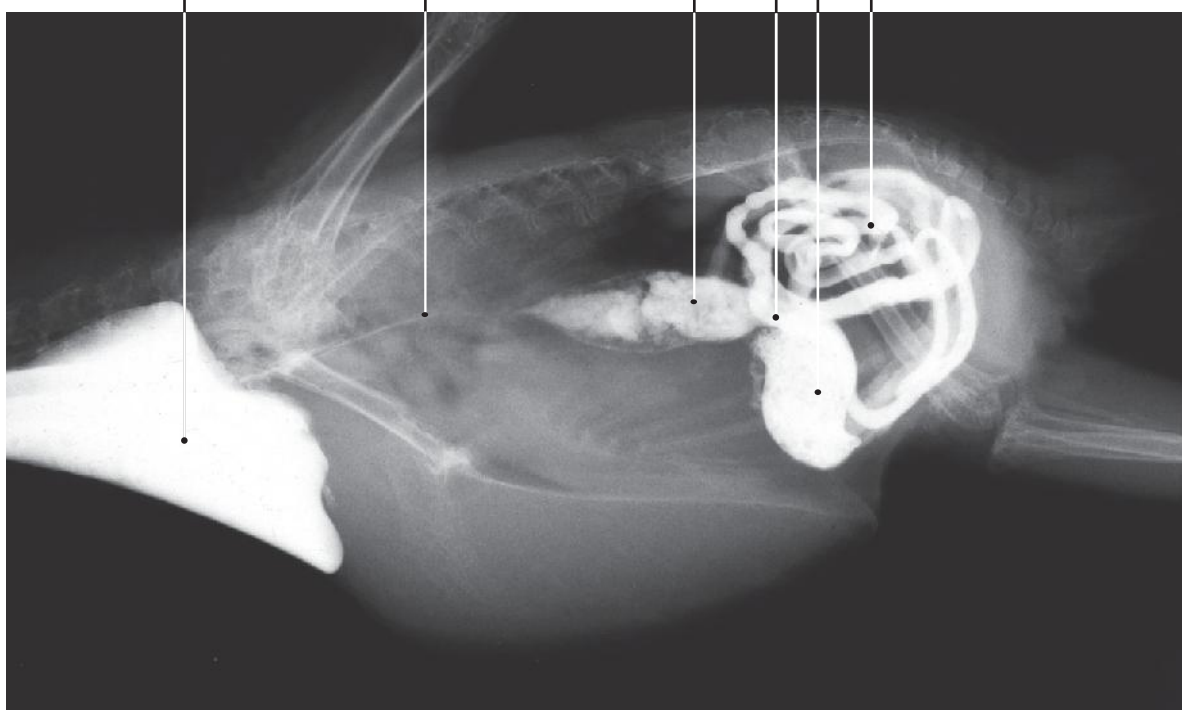

E

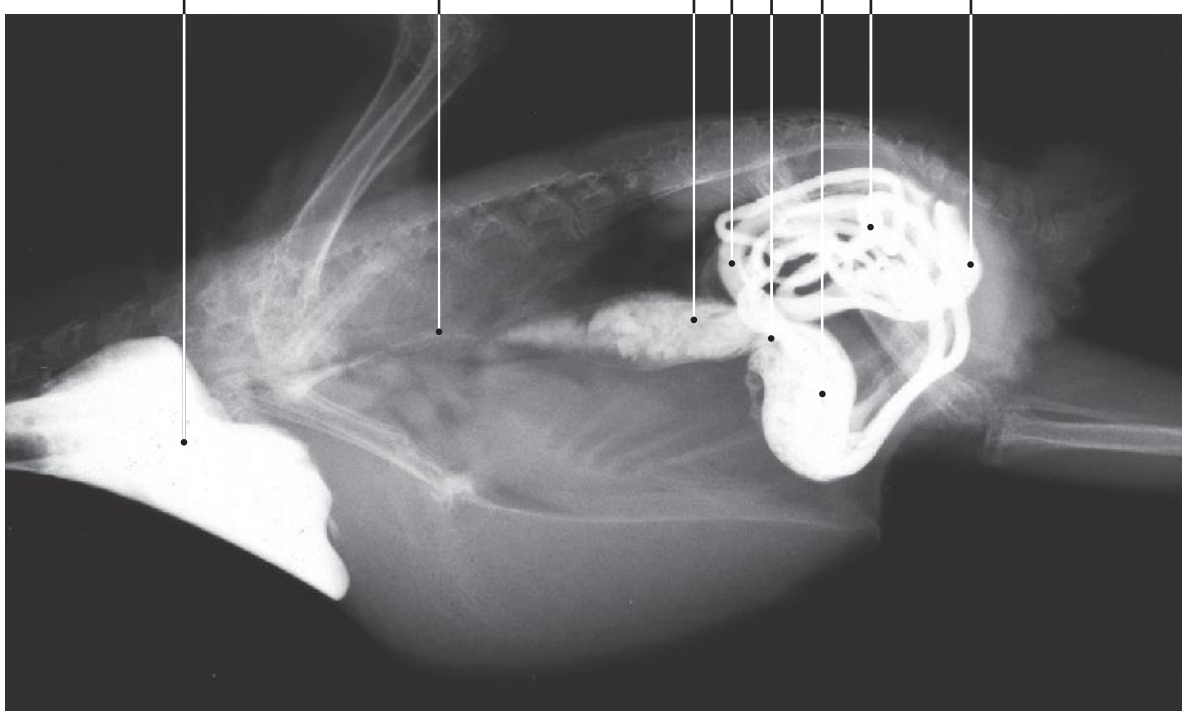

F

Figure 7-3, E-F
Type of Bird: Senegal Parrot
Type of Study: Gastrointestinal positive contrast study
Contrast Medium: Barium sulfate suspension (Novopaque® 30% w/v; Lafayette Pharmaceutical, Inc., Lafayette, IN) 7 ml administered via gavage tube
Projection: Laterolateral (right lateral recumbency)
Weight of Animal: 146 g
Gender: Unknown
Reproductive Status: Intact
Age: Adult

Image	Time (hr)
E	3.5
F	5.5

1. Crop
2. Esophagus
3. Proventriculus
4. Ventriculus
5. Intestines
6. Duodenum
7. Large intestine
8. (Cloaca)
9. Proventricular-ventricular isthmus

NOTE: Structures in parentheses are not labeled.

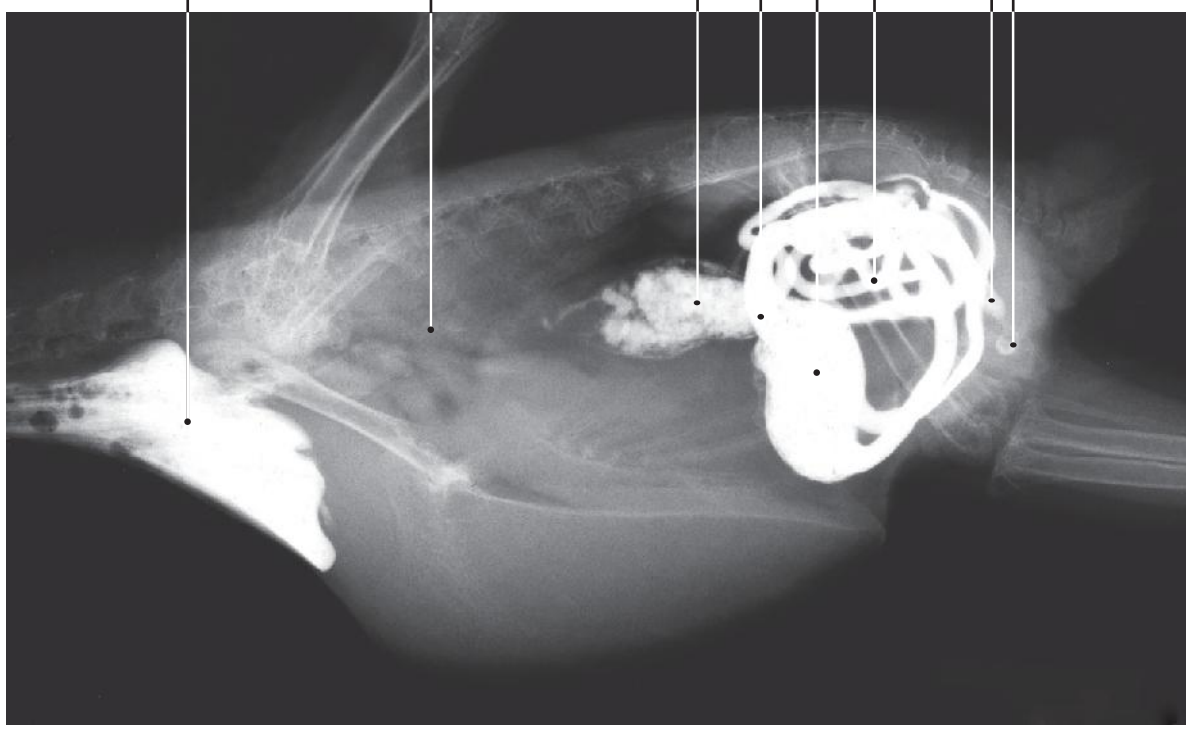

G

Figure 7-3, G
Type of Bird: Senegal Parrot
Type of Study: Gastrointestinal positive contrast study
Contrast Medium: Barium sulfate suspension (Novopaque® 30% w/v; Lafayette Pharmaceutical, Inc., Lafayette, IN) 7 ml administered via gavage tube
Projection: Laterolateral (right lateral recumbency)
Weight of Animal: 146 g
Gender: Unknown
Reproductive Status: Intact
Age: Adult

Image	Time (hr)
G	7.5

1. Crop
2. Esophagus
3. Proventriculus
4. Ventriculus
5. Intestines
6. (Duodenum)
7. Large intestine
8. Cloaca
9. Proventricular-ventricular isthmus

NOTE: Structures in parentheses are not labeled.

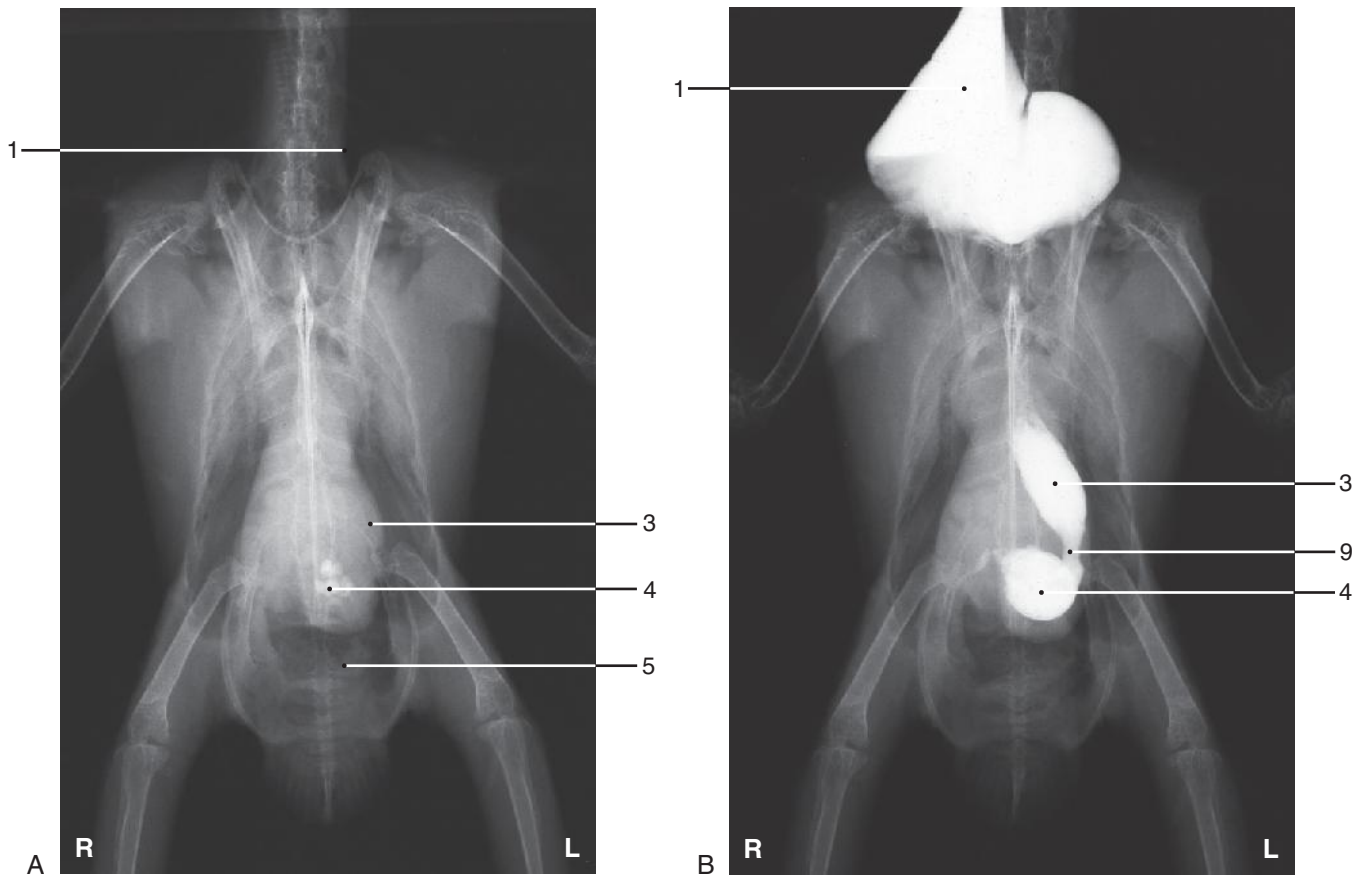

Figure 7-4, A-B
Type of Bird: Senegal Parrot
Type of Study: Gastrointestinal positive contrast study
Contrast Medium: Barium sulfate suspension (Novopaque® 30% w/v; Lafayette Pharmaceutical, Inc., Lafayette, IN) 7 ml administered via gavage tube
Projection: Ventrodorsal
Weight of Animal: 146 g
Gender: Unknown
Reproductive Status: Intact
Age: Adult

Image	Time (hr)
A	Scout
B	0.5

1. Crop
2. (Esophagus)
3. Proventriculus
4. Ventriculus
5. Intestines
6. (Duodenum)
7. (Large intestine)
8. (Cloaca)
9. Proventricular-ventricular isthmus

NOTE: Structures in parentheses are not labeled.

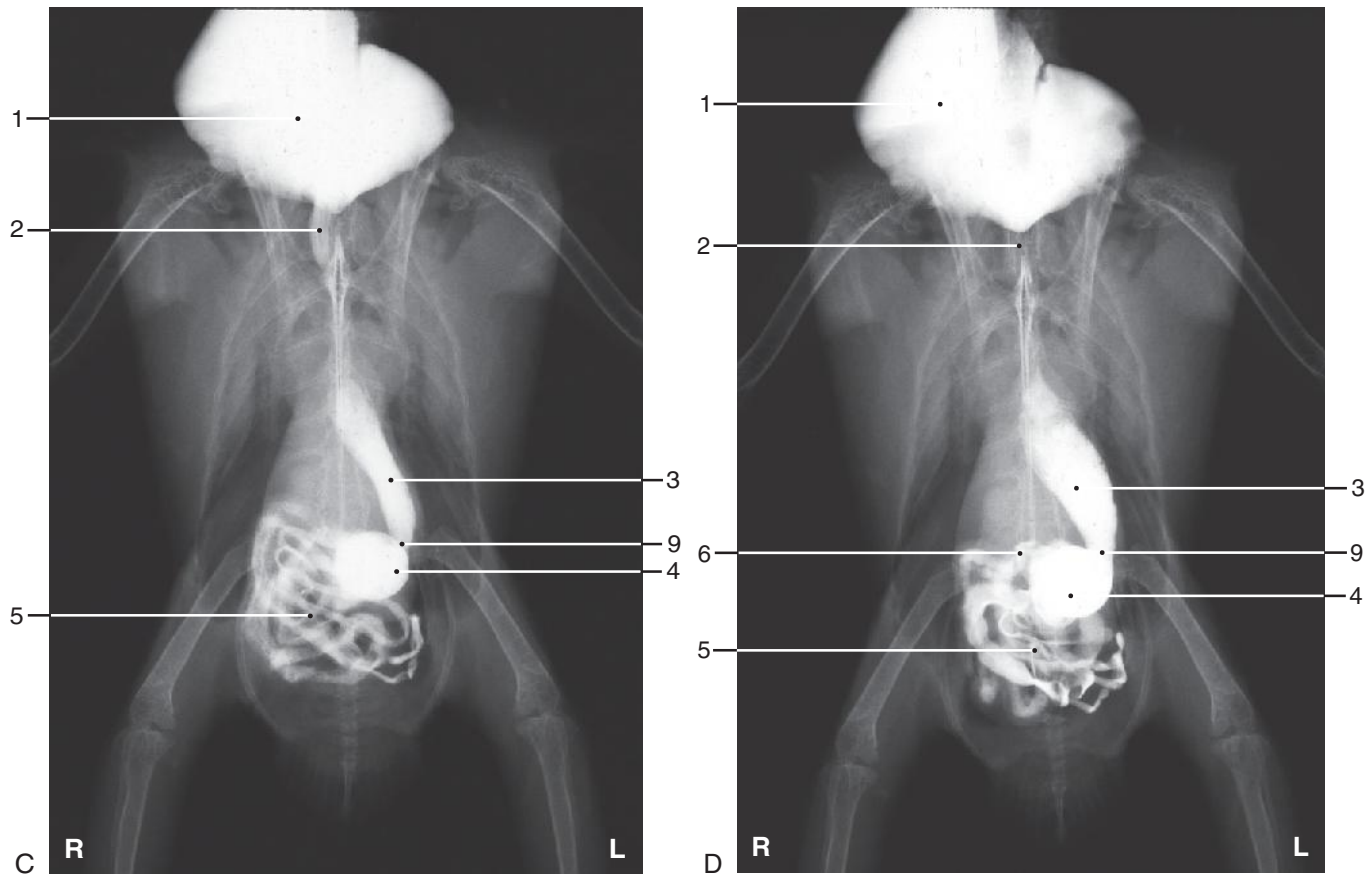

Figure 7-4, C-D
Type of Bird: Senegal Parrot
Type of Study: Gastrointestinal positive contrast study
Contrast Medium: Barium sulfate suspension (Novopaque® 30% w/v; Lafayette Pharmaceutical, Inc., Lafayette, IN) 7 ml administered via gavage tube
Projection: Ventrodorsal
Weight of Animal: 146 g
Gender: Unknown
Reproductive Status: Intact
Age: Adult

Image	Time (hr)
C	1.5
D	2.5

1. Crop
2. Esophagus
3. Proventriculus
4. Ventriculus
5. Intestines
6. Duodenum
7. (Large intestine)
8. (Cloaca)
9. Proventricular-ventricular isthmus

NOTE: Structures in parentheses are not labeled.

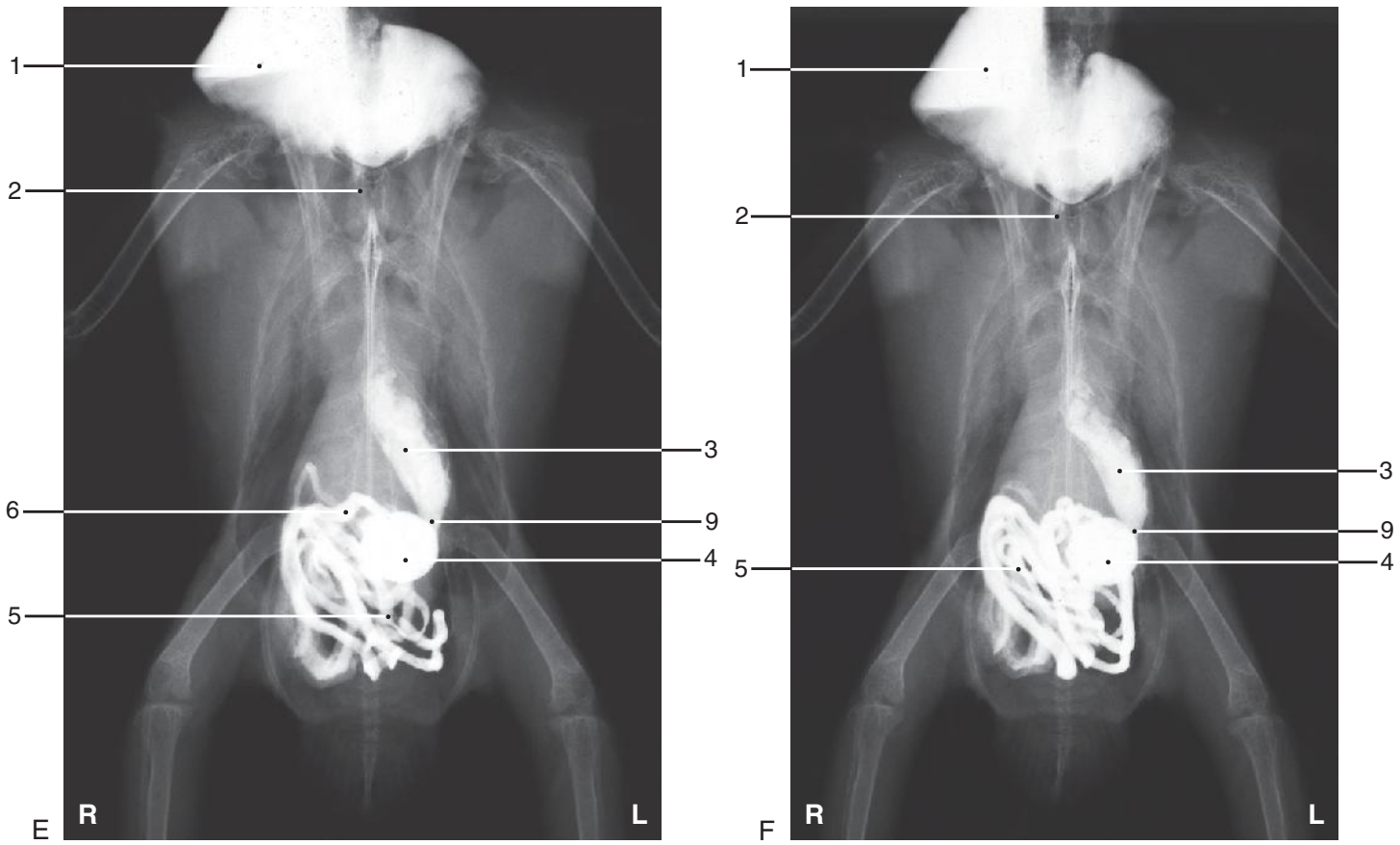

Figure 7-4, E-F
Type of Bird: Senegal Parrot
Type of Study: Gastrointestinal positive contrast study
Contrast Medium: Barium sulfate suspension (Novopaque® 30% w/v; Lafayette Pharmaceutical, Inc., Lafayette, IN) 7 ml administered via gavage tube
Projection: Ventrodorsal
Weight of Animal: 146 g
Gender: Unknown
Reproductive Status: Intact
Age: Adult

Image	Time (hr)
E	3.5
F	5.5

1. Crop
2. Esophagus
3. Proventriculus
4. Ventriculus
5. Intestines
6. Duodenum
7. (Large intestine)
8. (Cloaca)
9. Proventricular-ventricular isthmus

NOTE: Structures in parentheses are not labeled.

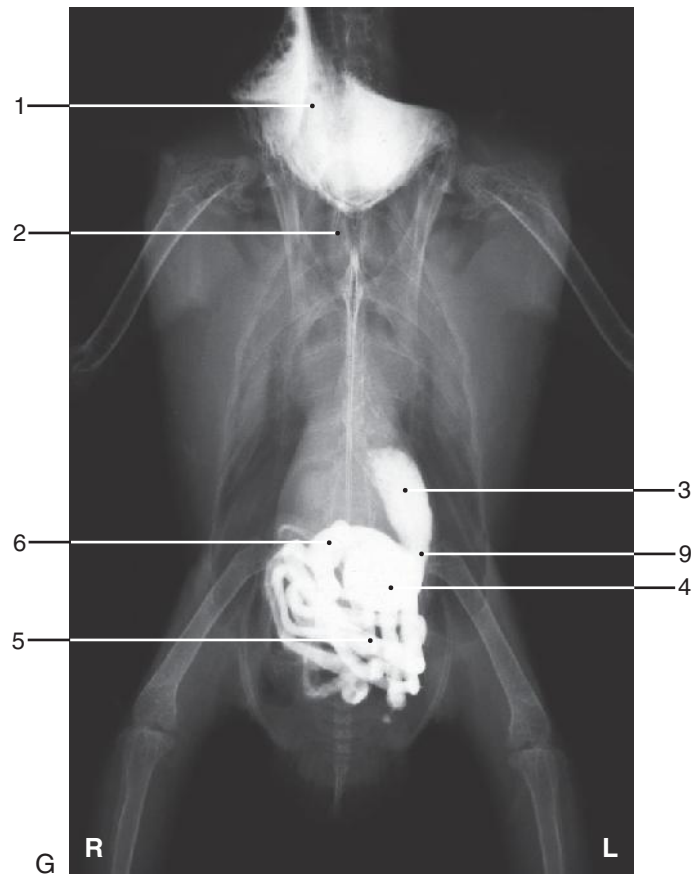

Figure 7-4, G
Type of Bird: Senegal Parrot
Type of Study: Gastrointestinal positive contrast study
Contrast Medium: Barium sulfate suspension (Novopaque® 30% w/v; Lafayette Pharmaceutical, Inc., Lafayette, IN) 7 ml administered via gavage tube
Projection: Ventrodorsal
Weight of Animal: 146 g
Gender: Unknown
Reproductive Status: Intact
Age: Adult

Image	Time (hr)
G	7.5

1. Crop
2. Esophagus
3. Proventriculus
4. Ventriculus
5. Intestines
6. Duodenum
7. (Large intestine)
8. (Cloaca)
9. Proventricular-ventricular isthmus

NOTE: Structures in parentheses are not labeled.

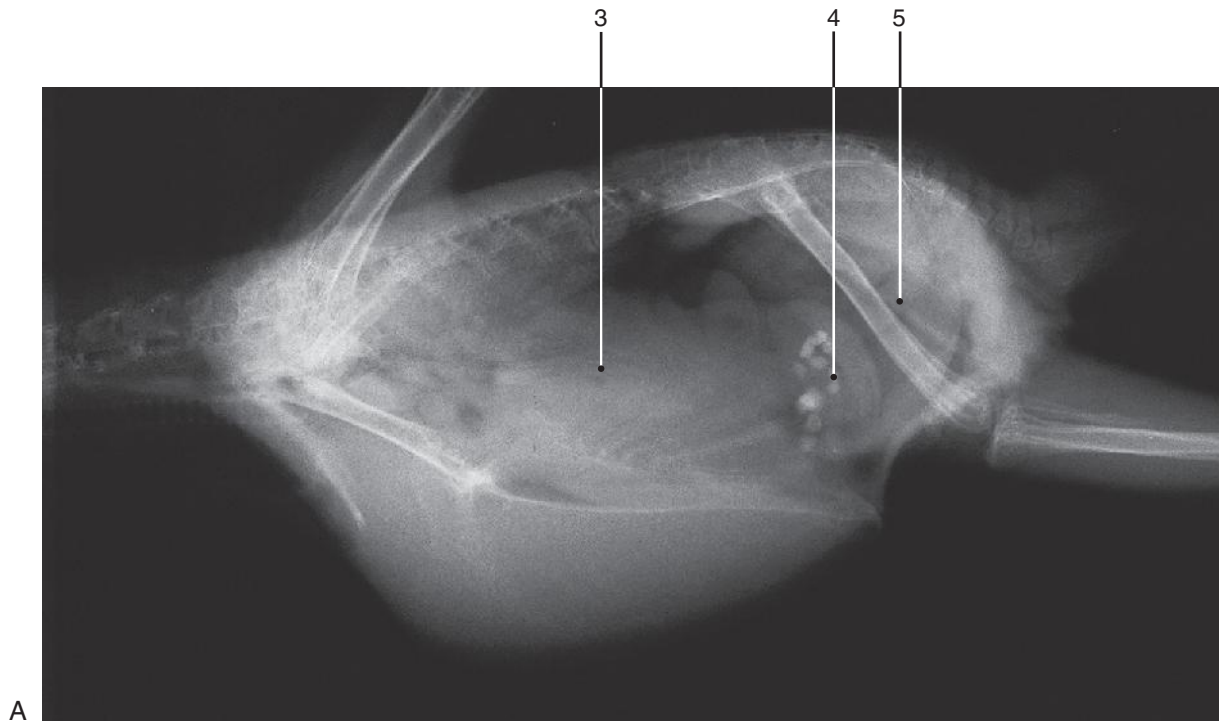

A

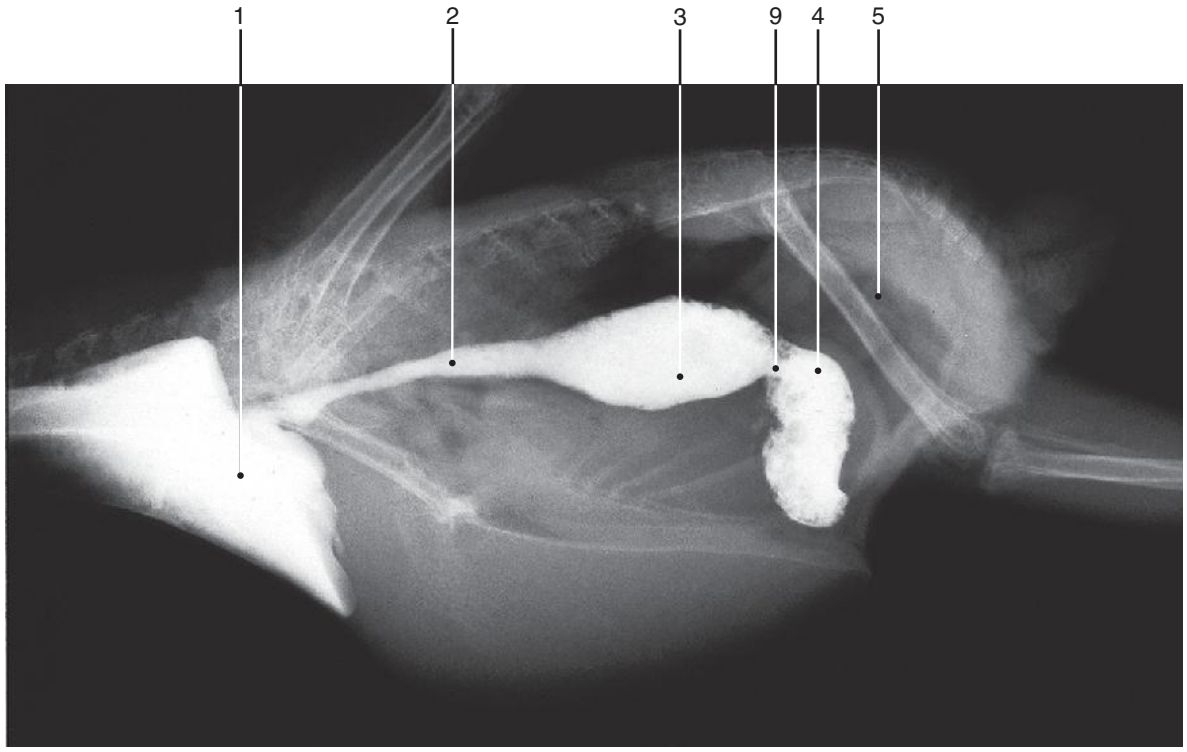

B

Figure 7-5, A-B
Type of Bird: Senegal Parrot
Type of Study: Gastrointestinal double contrast study
Contrast Medium: Barium sulfate suspension (Novopaque® 30% w/v; Lafayette Pharmaceutical, Inc., Lafayette, IN) 7 ml and room air 7 ml administered via gavage tube
Projection: Laterolateral (right lateral recumbency)
Weight of Animal: 146 g
Gender: Unknown
Reproductive Status: Intact
Age: Adult

Image	Time (hr)
A	Scout
B	0.25

1. Crop
2. Esophagus
3. Proventriculus
4. Ventriculus
5. Intestines
6. (Duodenum)
7. (Large intestine)
8. (Cloaca)
9. Proventricular-ventricular isthmus

NOTE: Structures in parentheses are not labeled.

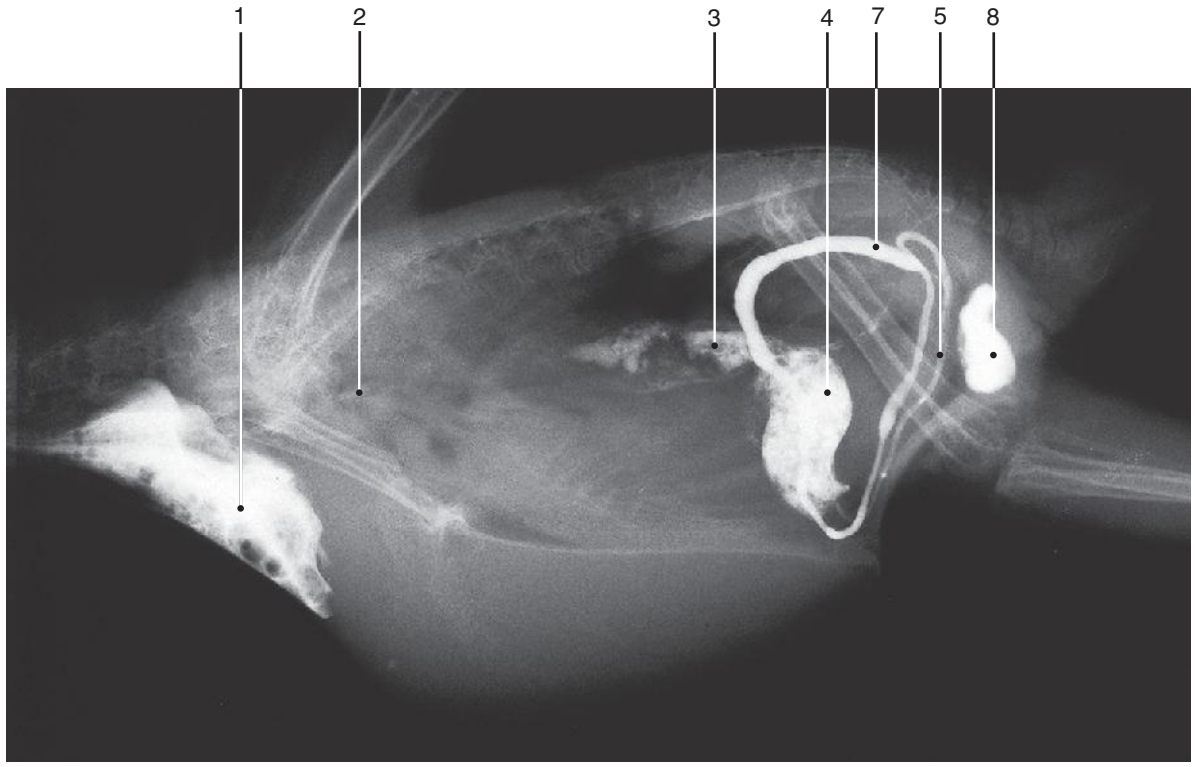

C

Figure 7-5, C
Type of Bird: Senegal Parrot
Type of Study: Gastrointestinal double contrast study
Contrast Medium: Barium sulfate suspension (Novopaque® 30% w/v; Lafayette Pharmaceutical, Inc., Lafayette, IN) 7 ml and room air 7 ml administered via gavage tube
Projection: Laterolateral (right lateral recumbency)
Weight of Animal: 146 g
Gender: Unknown
Reproductive Status: Intact
Age: Adult

Image	Time (hr)
C	2.0

1. Crop
2. Esophagus
3. Proventriculus
4. Ventriculus
5. Intestines
6. (Duodenum)
7. Large intestine
8. Cloaca
9. (Proventricular-ventricular isthmus)

NOTE: Structures in parentheses are not labeled.

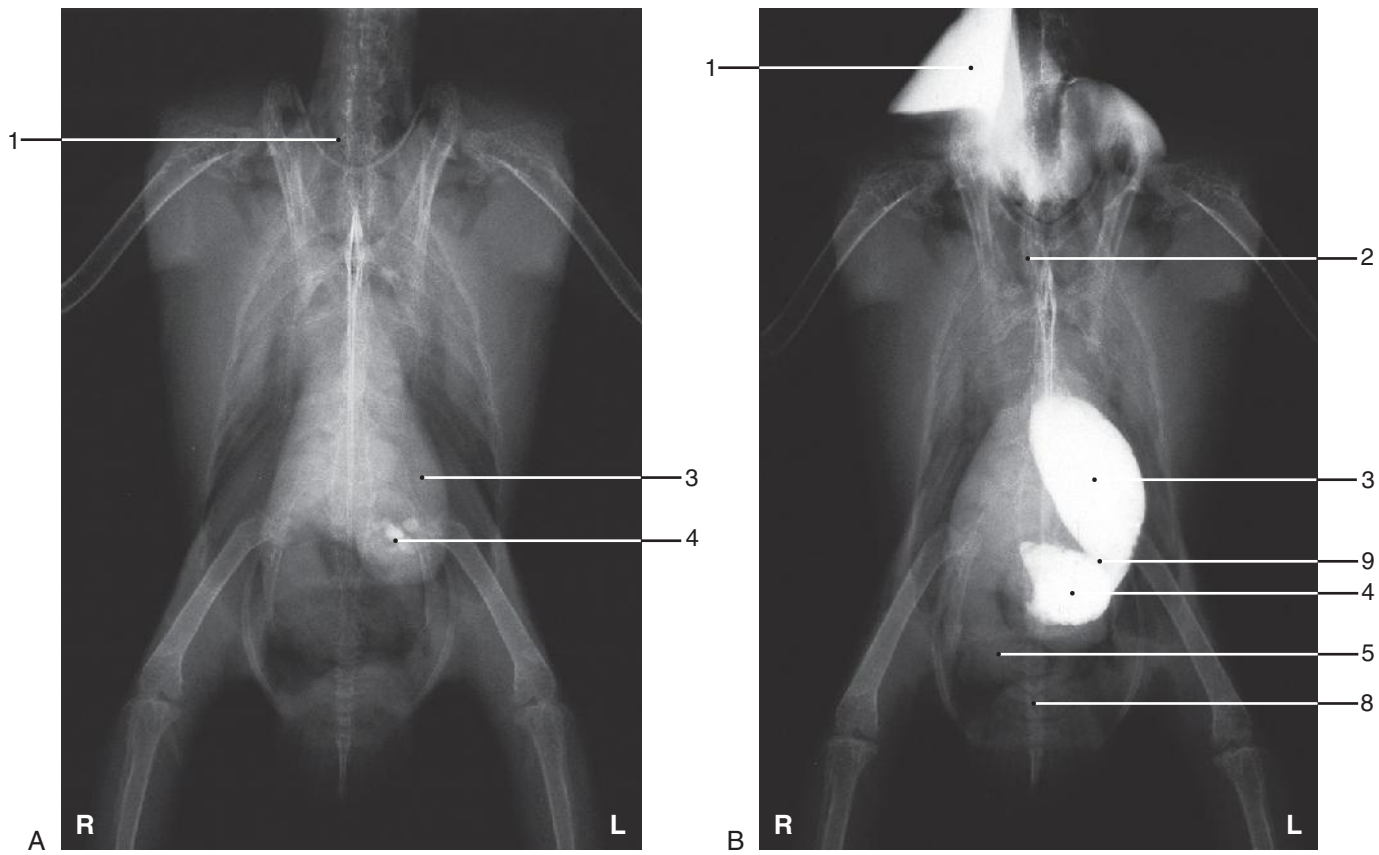

Figure 7-6, A-B
Type of Bird: Senegal Parrot
Type of Study: Gastrointestinal double contrast study
Contrast Medium: Barium sulfate suspension (Novopaque® 30% w/v; Lafayette Pharmaceutical, Inc., Lafayette, IN) 7 ml and room air 7 ml administered via gavage tube
Projection: Ventrodorsal
Weight of Bird: 146 g
Gender: Unknown
Reproductive Status: Intact
Age: Adult

Image	Time (hr)
A	Scout
B	0.25

1. Crop
2. Esophagus
3. Proventriculus
4. Ventriculus
5. Intestines
6. (Duodenum)
7. (Large intestine)
8. Cloaca
9. Proventricular-ventricular isthmus

NOTE: Structures in parentheses are not labeled.

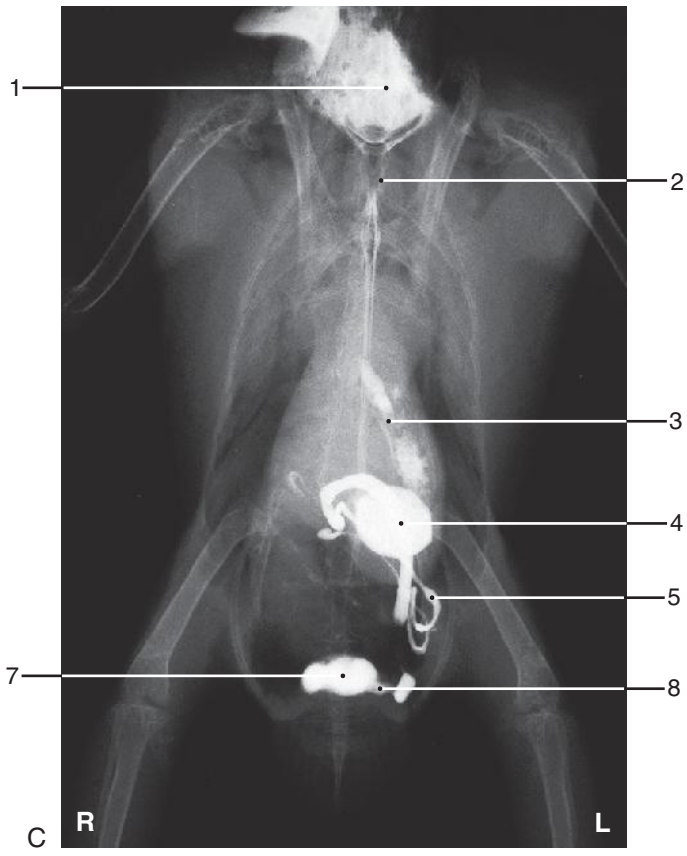

Figure 7-6, C
Type of Bird: Senegal Parrot
Type of Study: Gastrointestinal double contrast study
Contrast Medium: Barium sulfate suspension (Novopaque® 30% w/v; Lafayette Pharmaceutical, Inc., Lafayette, IN) 7 ml and room air 7 ml administered via gavage tube
Projection: Ventrodorsal
Weight of Bird: 146 g
Gender: Unknown
Reproductive Status: Intact
Age: Adult

Image	Time (hr)
C	2.0

1. Crop
2. (Esophagus)
3. Proventriculus
4. Ventriculus
5. Intestines
6. Duodenum
7. Large intestine
8. Cloaca
9. (Proventricular-ventricular isthmus)

NOTE: Structures in parentheses are not labeled.

CHAPTER • 8

African Grey Parrot
(Psittacus erithacus erithacus)

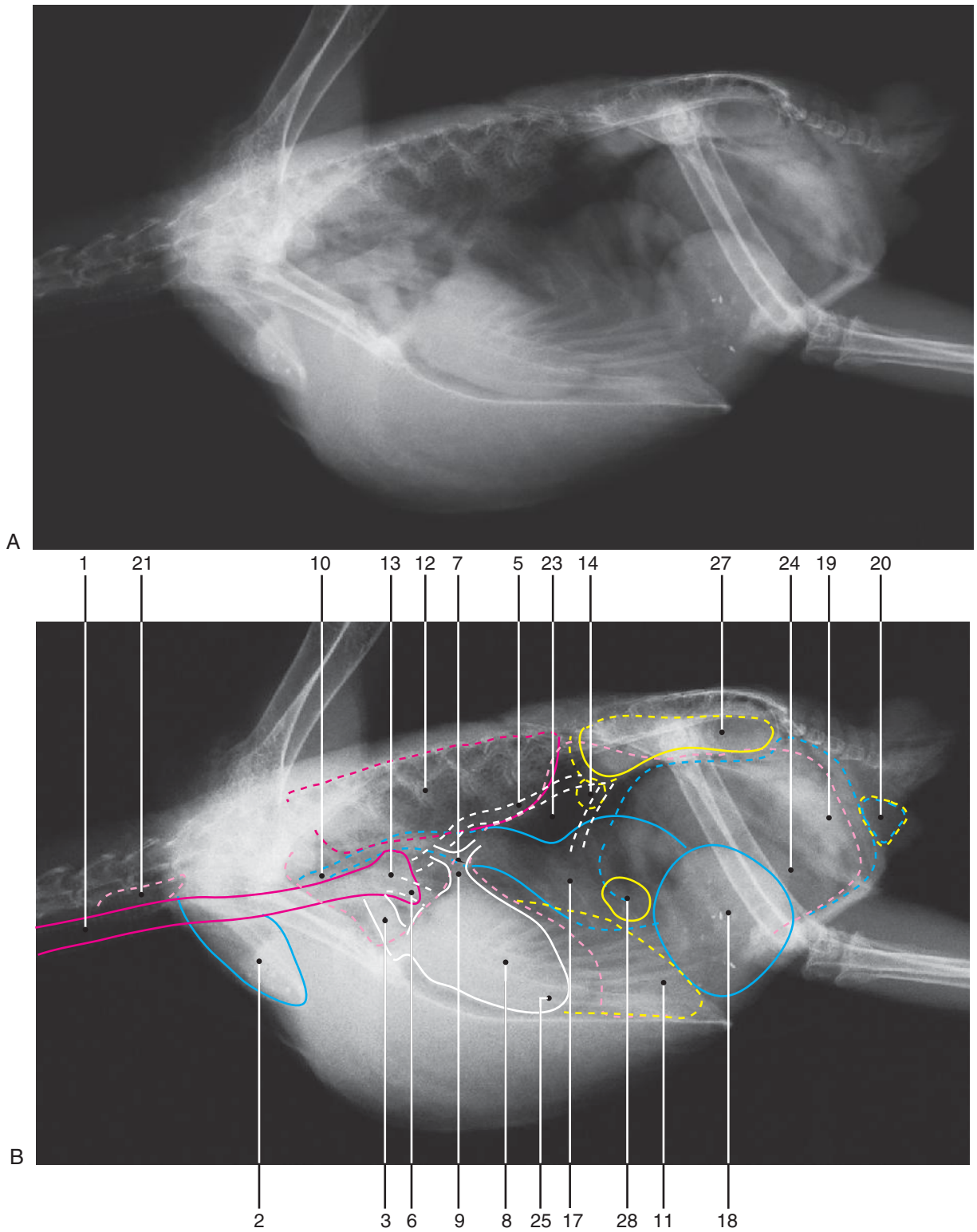

Figure 8-1, A-B
Type of Bird: African Grey Parrot
Type of Study: Viscera of the coelom
Projection: Laterolateral (right lateral recumbency)
Weight of Animal: 546 g
Gender: Unknown
Reproductive Status: Intact
Age: Adult

1. Trachea
2. Crop
3. Brachiocephalic artery and aorta
4. (Brachiocephalic artery)
5. (Aorta)
6. Pulmonary artery
7. Pulmonary vein
8. Heart
9. Left atrium
10. Esophagus
11. Liver
12. Lung
13. Syrinx
14. Gonad
15. (Ovary)
16. (Testes)
17. Proventriculus
18. Ventriculus
19. Intestines
20. Cloaca
21. Cervical air sac
22. (Clavicular air sac)
23. Thoracic air sac
24. Abdominal air sac
25. Apex of heart
26. (Interface between caudal thoracic and abdominal air sacs)
27. Kidneys
28. Spleen

NOTE: Structures in parentheses are not labeled.

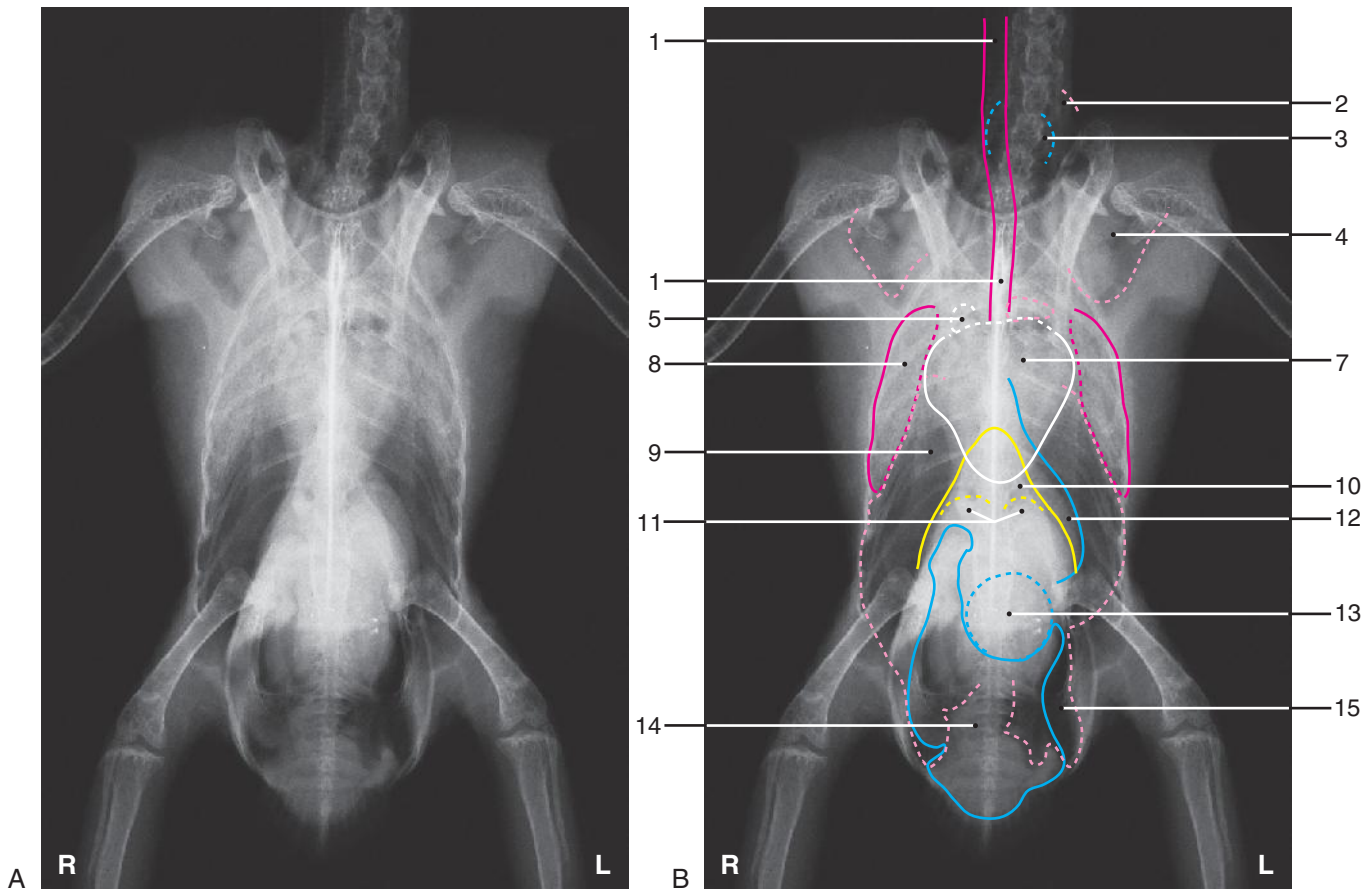

Figure 8-2, A-B
Type of Bird: African Grey Parrot
Type of Study: Viscera of the coelom
Projection: Ventrodorsal
Weight of Animal: 546 g
Gender: Unknown
Reproductive Status: Intact
Age: Adult

1. Trachea
2. Cervical air sac
3. Crop
4. Clavicular air sac
5. Brachiocephalic artery and aorta
6. (Heart base vessel)
7. Heart
8. Lung
9. Thoracic air sac
10. Liver
11. Kidneys
12. Proventriculus
13. Ventriculus
14. Intestines
15. Abdominal air sac
16. (Cloaca)

NOTE: Structures in parentheses are not labeled.

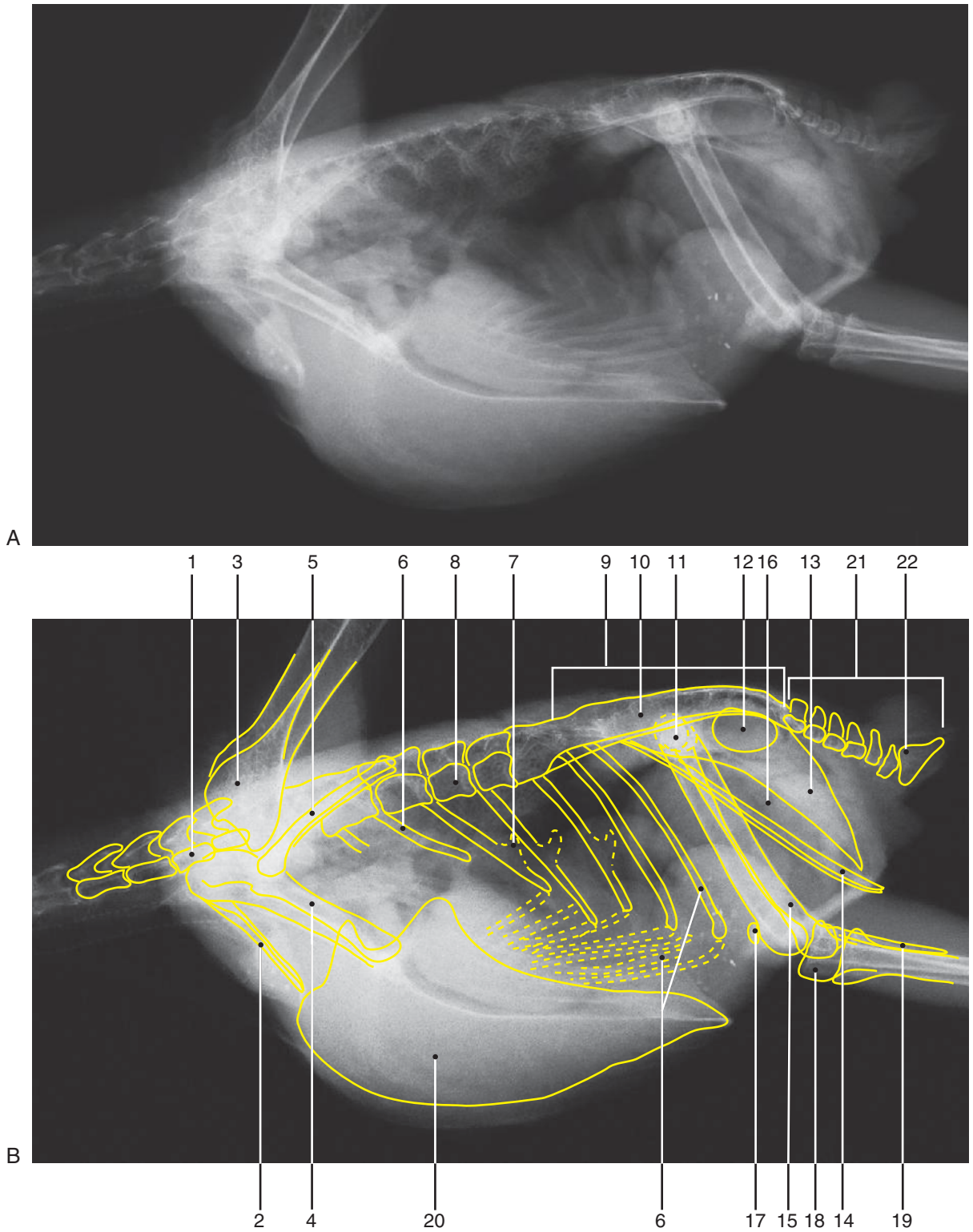

Figure 8-3, A-B
Type of Bird: African Grey Parrot
Type of Study: Whole body skeleton
Projection: Laterolateral (right lateral recumbency)
Weight of Animal: 546 g
Gender: Unknown
Reproductive Status: Intact
Age: Adult

1. Cervical vertebra
2. Clavicle
3. Humerus
4. Coracoid
5. Scapula
6. Rib
7. Uncinate process of rib
8. Thoracic vertebra
9. Synsacrum
10. Ilium
11. Head of femur
12. Ilioischiadiac foramen
13. Ischium
14. Pubis
15. Femur
16. Obturator foramen
17. Patella
18. Tibiotarsal bone
19. Fibula
20. Sternum
21. Caudal vertebrae
22. Pygostyle

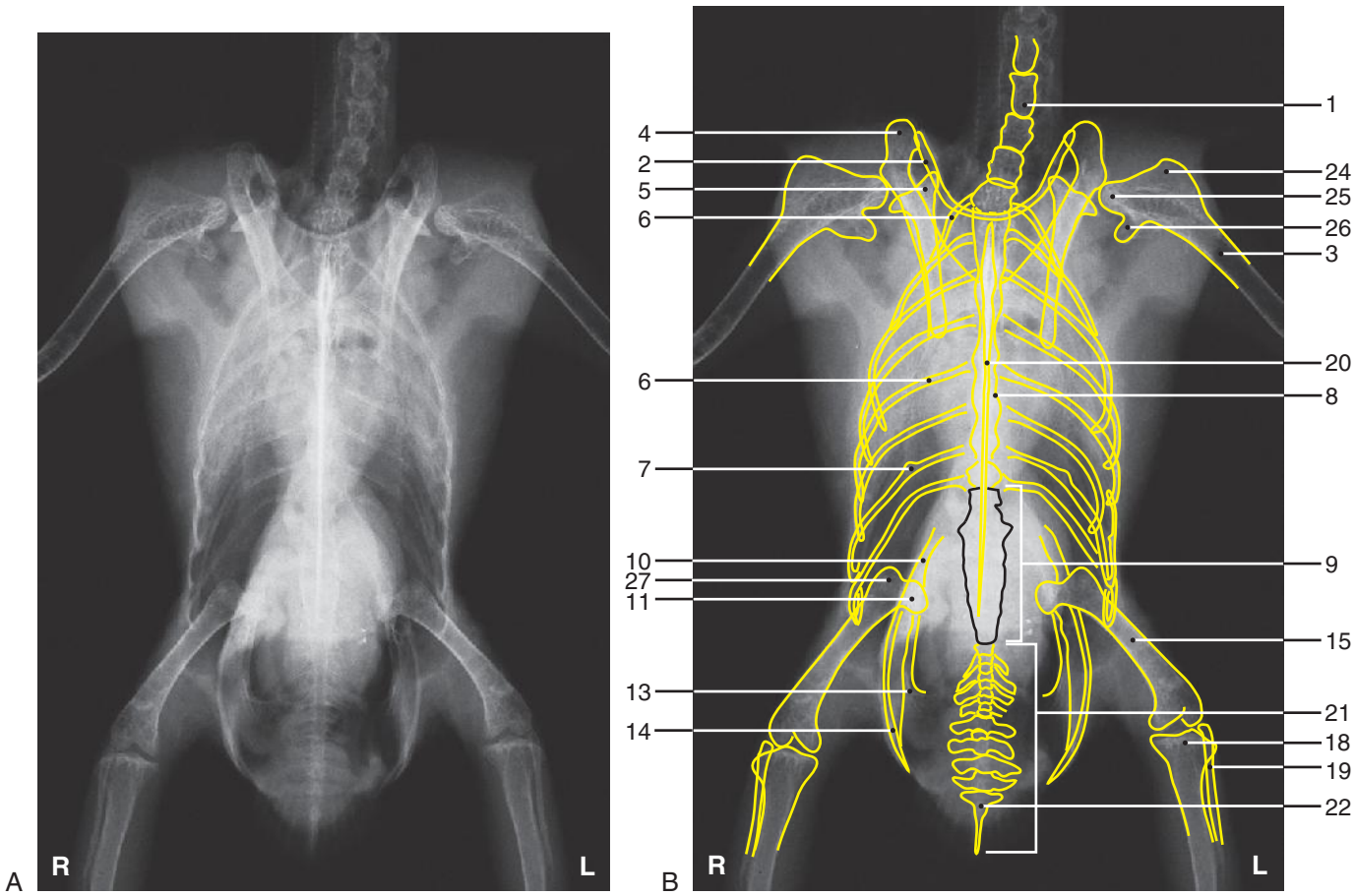

Figure 8-4, A-B
Type of Bird: African Grey Parrot
Type of Study: Whole body skeleton
Projection: Ventrodorsal
Weight of Animal: 546 g
Gender: Unknown
Reproductive Status: Intact
Age: Adult

1. Cervical vertebra
2. Clavicle
3. Humerus
4. Coracoid
5. Scapula
6. Rib
7. Uncinate process of rib
8. Thoracic vertebra
9. Synsacrum
10. Ilium
11. Head of femur
12. (Ilioischiadiac foramen)
13. Ischium
14. Pubis
15. Femur
16. (Obturator foramen)
17. (Patella)
18. Tibiotarsal bone
19. Fibula
20. Sternum
21. Caudal vertebrae
22. Pygostyle
23. (Apex carinae)
24. Dorsal tubercle of humerus
25. Head of humerus
26. Ventral tubercle of humerus
27. Trochanter of femur

NOTE: Structures in parentheses are not labeled.

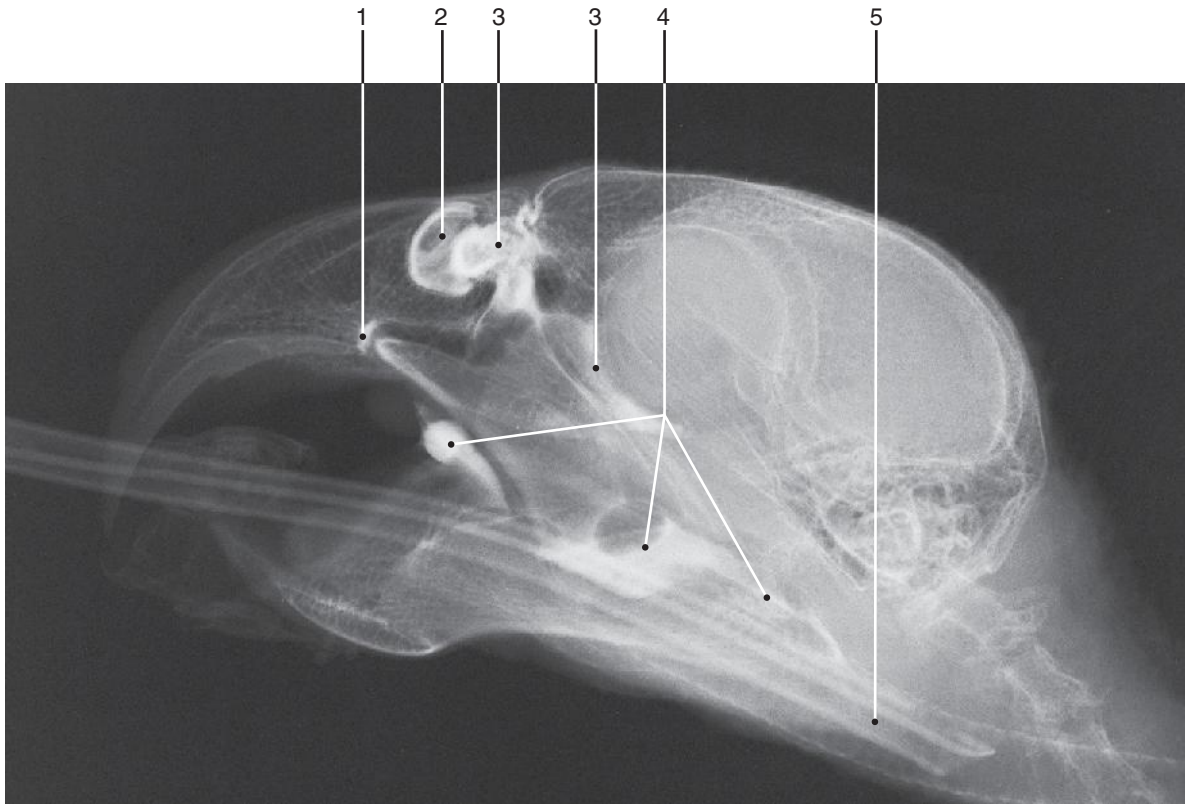

Figure 8-5
Type of Bird: African Grey Parrot
Type of Study: Infraorbital sinus contrast study
Contrast Medium: Iopamidol injection 41% (Isovue®-200, Bracco Diagnostics Inc., Princeton, NJ 08543) 6 ml instilled into the right nare
Projection: Laterolateral (right lateral recumbency)
Weight of Animal: 422 g
Gender: Male
Reproductive Status: Intact
Age: 2 years

1. Choana
2. External nares
3. Infraorbital sinus
4. Contrast medium in pharynx
5. Endotracheal tube

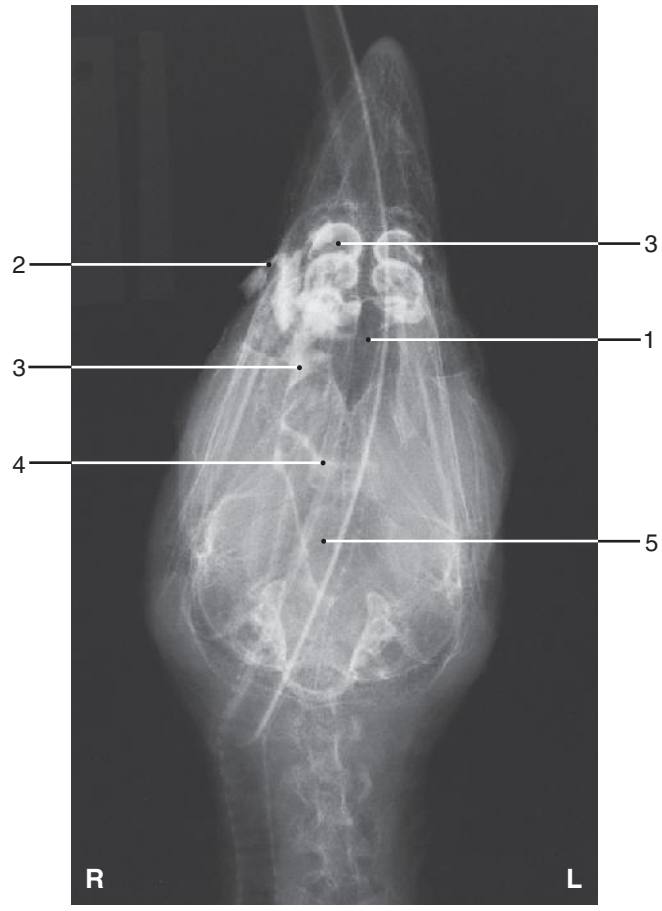

Figure 8-6
Type of Bird: African Grey Parrot
Type of Study: Infraorbital sinus contrast study
Contrast Medium: Iopamidol injection 41% (Isovue®-200, Bracco Diagnostics Inc., Princeton, NJ 08543) 6 ml instilled into the right nare
Projection: Ventrodorsal
Weight of Animal: 422 g
Gender: Male
Reproductive Status: Intact
Age: 2 years

1. Choana
2. External nare
3. Infraorbital sinus
4. Contrast medium in pharynx
5. Endotracheal tube

CHAPTER • 9

Orange-Winged Amazon Parrot (*Amazona amazonica*)

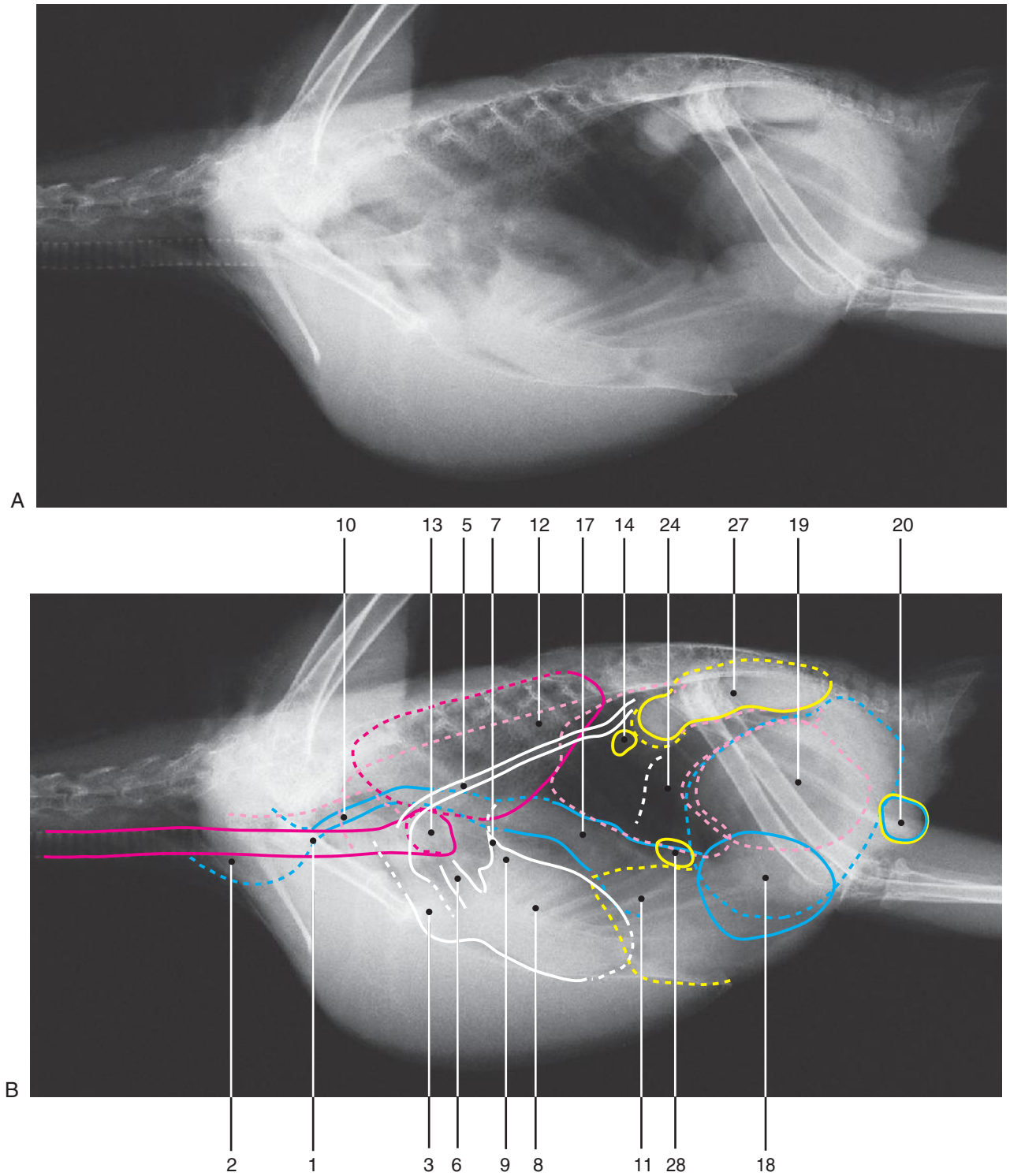

Figure 9-1, A-B
Type of Bird: Orange-Winged Amazon Parrot
Body Condition: Normal
Type of Study: Viscera of the coelom
Projection: Laterolateral (right lateral recumbency)
Weight of Bird: 412 g
Gender: Unknown
Reproductive Status: Intact
Age: 13 years

1. Trachea
2. Crop
3. Brachiocephalic artery and aorta
4. (Brachiocephalic artery)
5. Aorta
6. Pulmonary artery
7. Pulmonary vein
8. Heart
9. Left atrium
10. Esophagus
11. Liver
12. Lung
13. Syrinx
14. Gonad
15. (Ovary)
16. (Testes)
17. Proventriculus
18. Ventriculus
19. Intestines
20. Cloaca
21. (Cervical air sac)
22. (Clavicular air sac)
23. (Thoracic air sac)
24. Abdominal air sac
25. (Apex of heart)
26. (Interface between caudal thoracic and abdominal air sacs)
27. Kidneys
28. Spleen

NOTE: Structures in parentheses are not labeled.

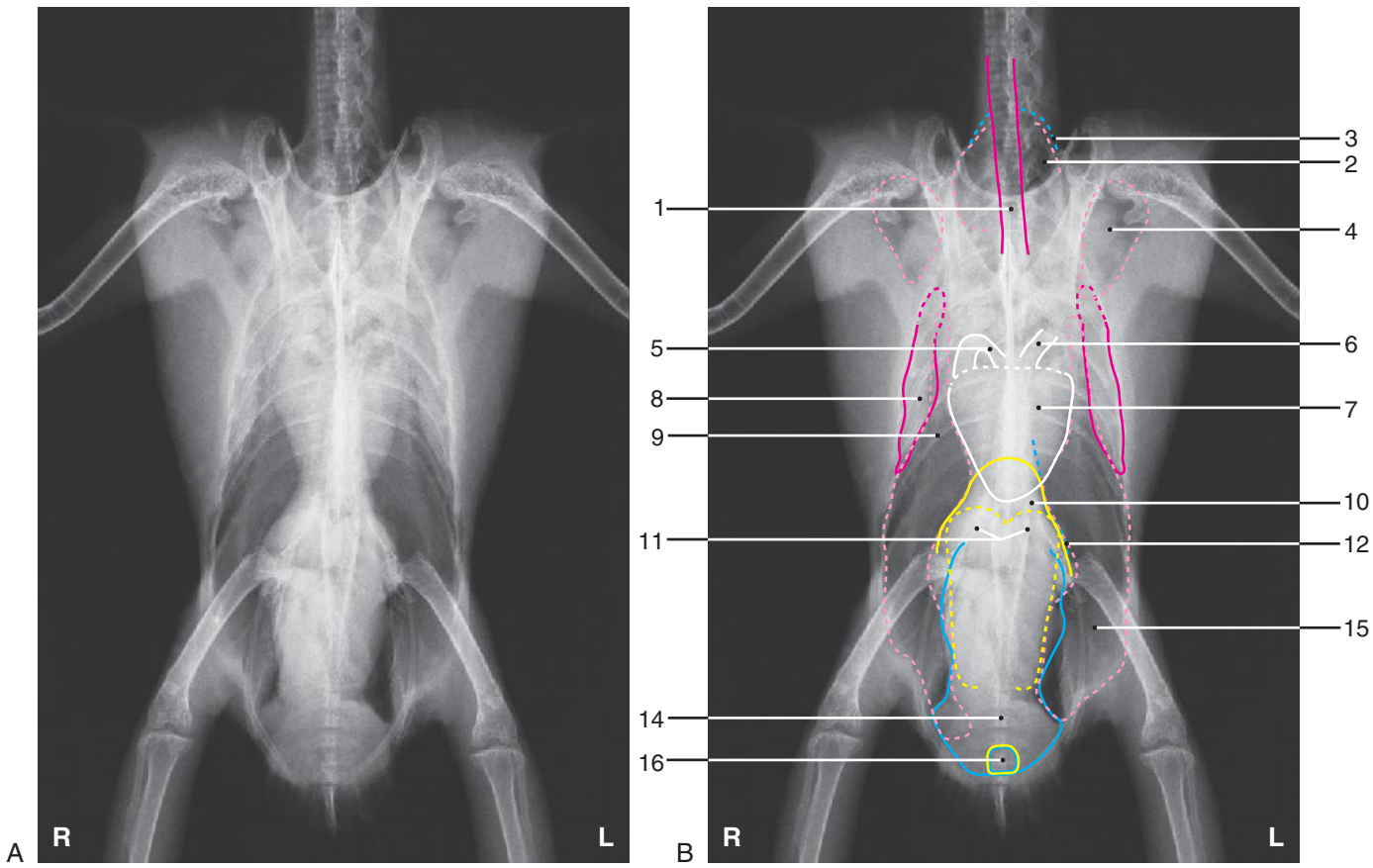

Figure 9-2, A-B
Type of Bird: Orange-Winged Amazon Parrot
Body Condition: Normal
Type of Study: Viscera of the coelom
Projection: Ventrodorsal
Weight of Bird: 412 g
Gender: Unknown
Reproductive Status: Intact
Age: 13 years

1. Trachea
2. Cervical air sac
3. Crop
4. Clavicular air sac
5. Brachiocephalic artery and aorta
6. Heart base vessel
7. Heart
8. Lung
9. Thoracic air sac
10. Liver
11. Kidneys
12. Proventriculus
13. (Ventriculus)
14. Intestines
15. Abdominal air sac
16. Cloaca

NOTE: Structures in parentheses are not labeled.

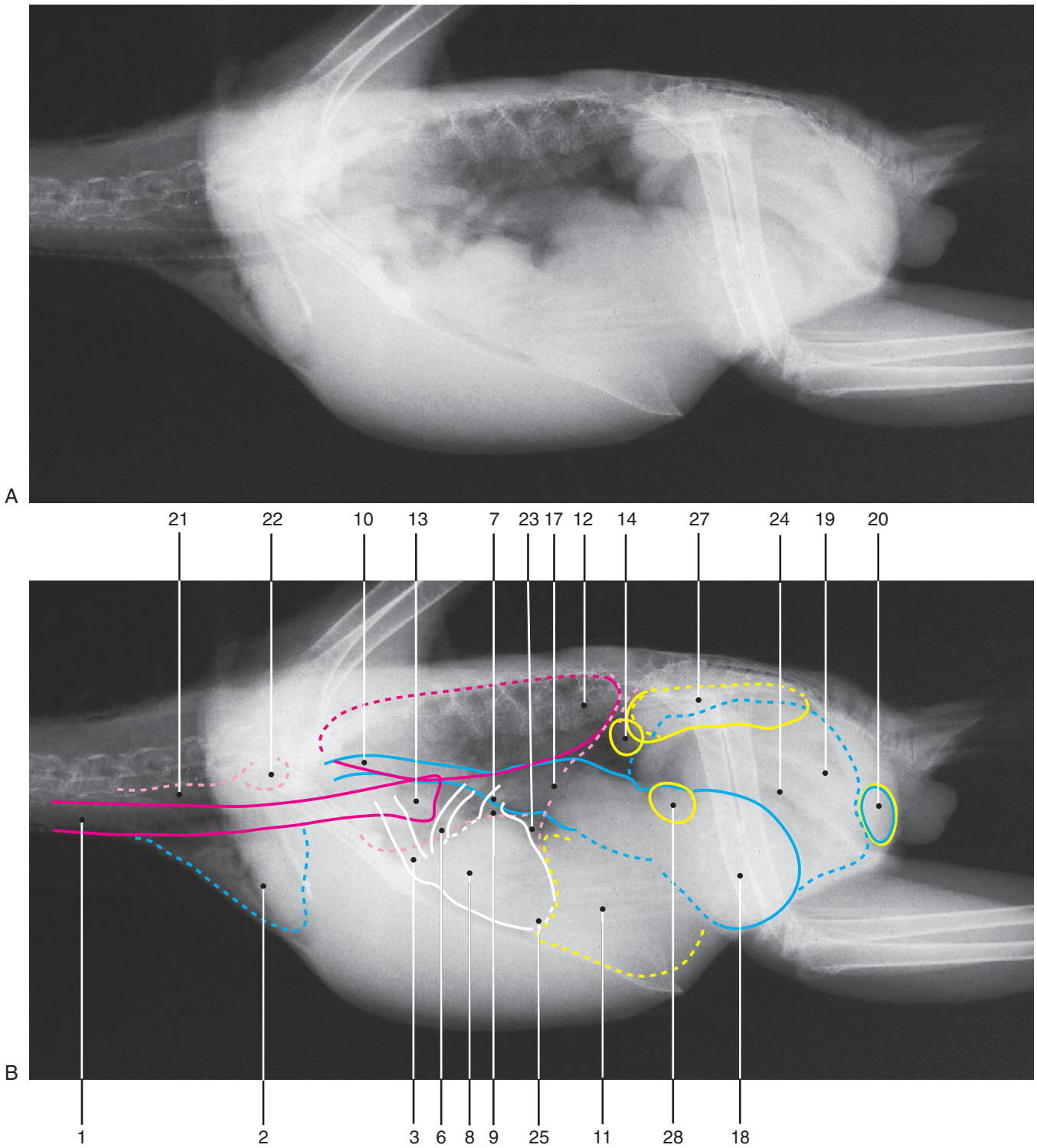

Figure 9-3, A-B
Type of Bird: Orange-Winged Amazon Parrot
Body Condition: Obese
Type of Study: Viscera of the coelom
Projection: Laterolateral (right lateral recumbency)
Weight of Bird: 580 g
Gender: Unknown
Reproductive Status: Intact
Age: Adult

1. Trachea
2. Crop
3. Brachiocephalic artery and aorta
4. (Brachiocephalic artery)
5. (Aorta)
6. Pulmonary artery
7. Pulmonary vein
8. Heart
9. Left atrium
10. Esophagus
11. Liver
12. Lung
13. Syrinx
14. Gonad
15. (Ovary)
16. (Testes)
17. Proventriculus
18. Ventriculus
19. Intestines
20. Cloaca
21. Cervical air sac
22. Clavicular air sac
23. Thoracic air sac
24. Abdominal air sac
25. Apex of heart
26. (Interface between caudal thoracic and abdominal air sacs)
27. Kidneys
28. Spleen

NOTE: Structures in parentheses are not labeled.

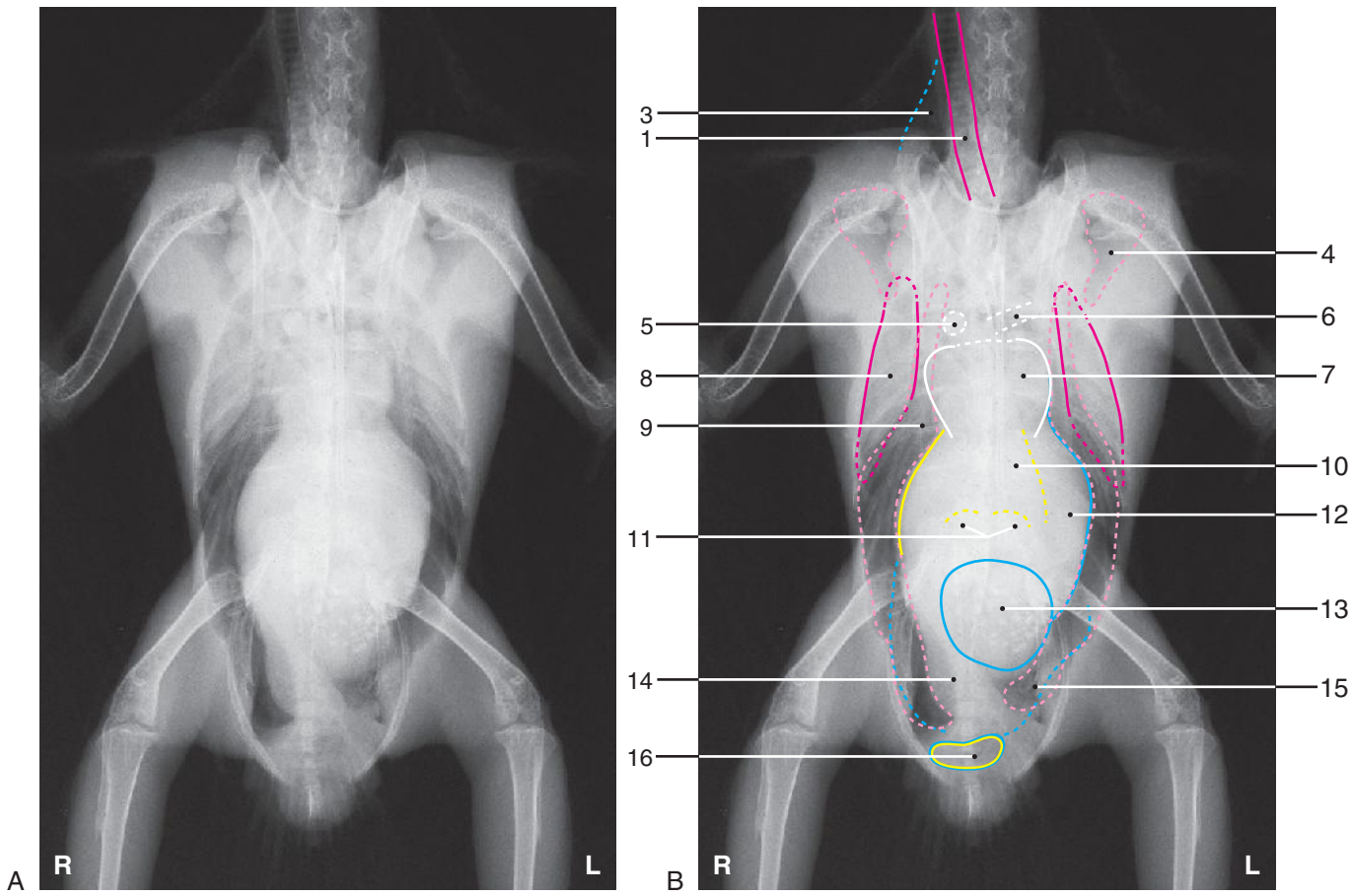

Figure 9-4, A-B
Type of Bird: Orange-Winged Amazon Parrot
Body Condition: Obese
Type of Study: Viscera of the coelom
Projection: Ventrodorsal
Weight of Bird: 580 g
Gender: Unknown
Reproductive Status: Intact
Age: Adult

1. Trachea
2. (Cervical air sac)
3. Crop
4. Clavicular air sac
5. Brachiocephalic artery and aorta
6. Heart base vessel
7. Heart
8. Lung
9. Thoracic air sac
10. Liver
11. Kidneys
12. Proventriculus
13. Ventriculus
14. Intestines
15. Abdominal air sac
16. Cloaca

NOTE: Structures in parentheses are not labeled.

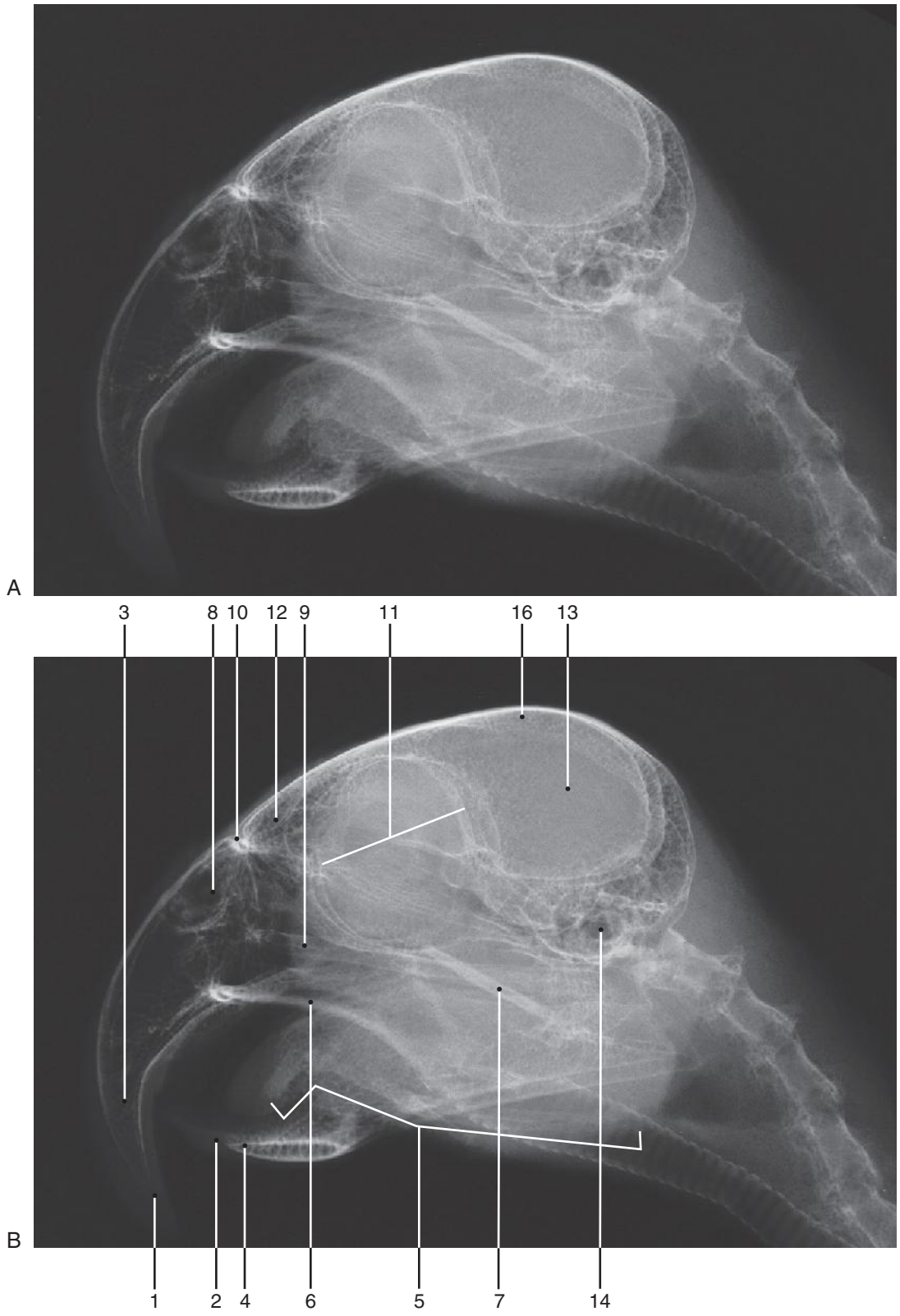

Figure 9-5, A-B

Type of Bird: Orange-Winged Amazon Parrot
Type of Study: Head
Projection: Laterolateral (right lateral recumbency)
Weight of Bird: 412 g
Gender: Unknown
Reproductive Status: Intact
Age: 13 years

1. Keratinized maxillary beak
2. Keratinized mandibular beak
3. Premaxillary bone
4. Mandible
5. Hyoid bones
6. Palatine bone
7. Pterygoid bone
8. External nares
9. Jugal [zygomatic] bone
10. Craniofacial flexion zone
11. Orbit
12. Frontal bone
13. Cranium
14. Temporal bone
15. (Quadrate bone)
16. Parietal bone

NOTE: Structures in parentheses are not labeled.

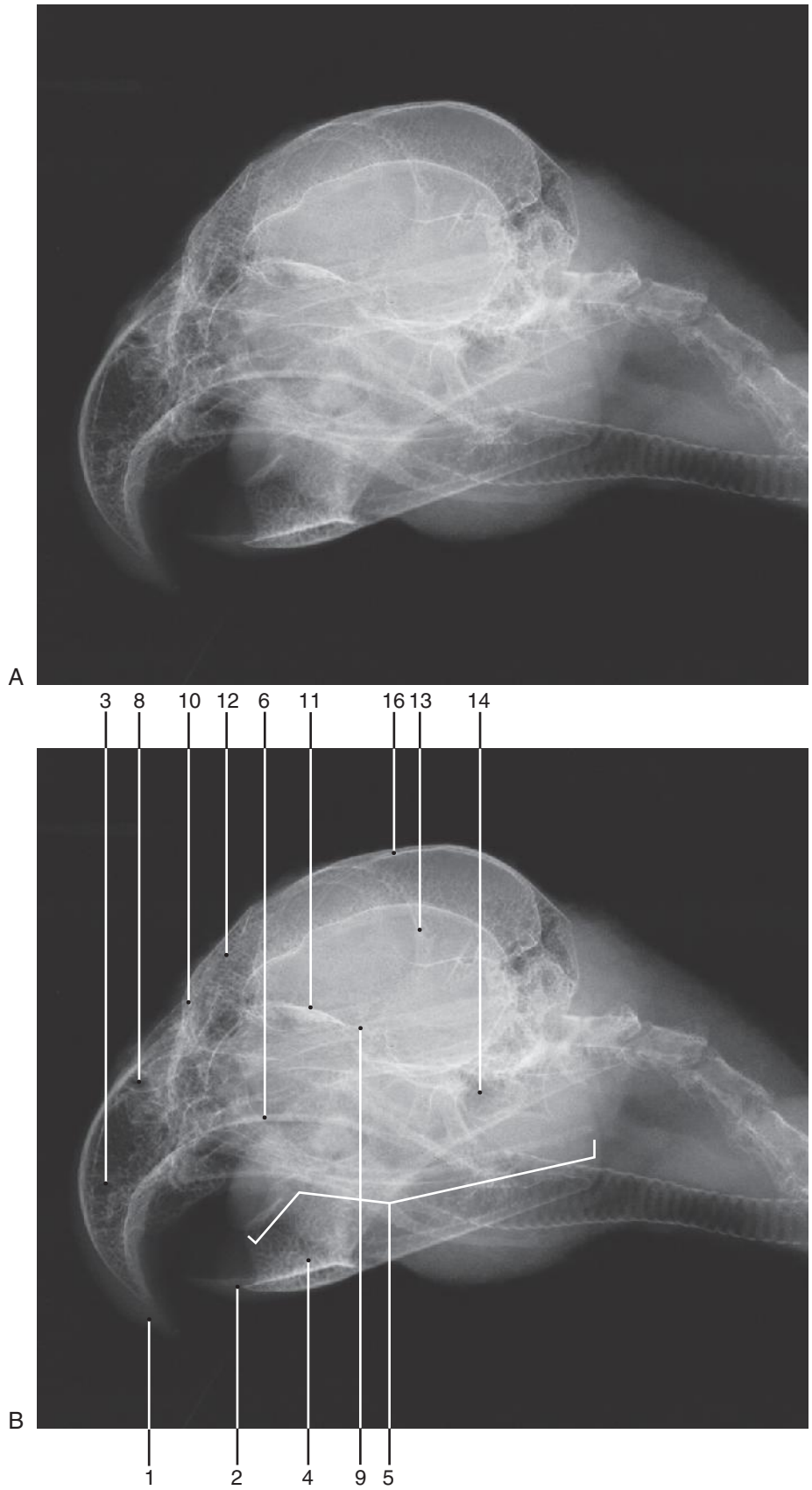

Figure 9-6, A-B
Type of Bird: Orange-Winged Amazon Parrot
Type of Study: Head
Projection: Oblique 30%
Weight of Bird: 412 g
Gender: Unknown
Reproductive Status: Intact
Age: 13 years

1. Keratinized maxillary beak
2. Keratinized mandibular beak
3. Premaxillary bone
4. Mandible
5. Hyoid bones
6. Palatine bone
7. (Pterygoid bone)
8. External nares
9. Jugal [zygomatic] bone
10. Craniofacial flexion zone
11. Orbit
12. Frontal bone
13. Cranium
14. Temporal bone
15. (Quadrate bone)
16. Parietal bone

NOTE: Structures in parentheses are not labeled.

A

Figure 9-7, A
Type of Bird: Orange-Winged Amazon Parrot
Type of Study: Head
Projection: Ventrodorsal
Weight of Bird: 412 g
Gender: Unknown
Reproductive Status: Intact
Age: 13 years

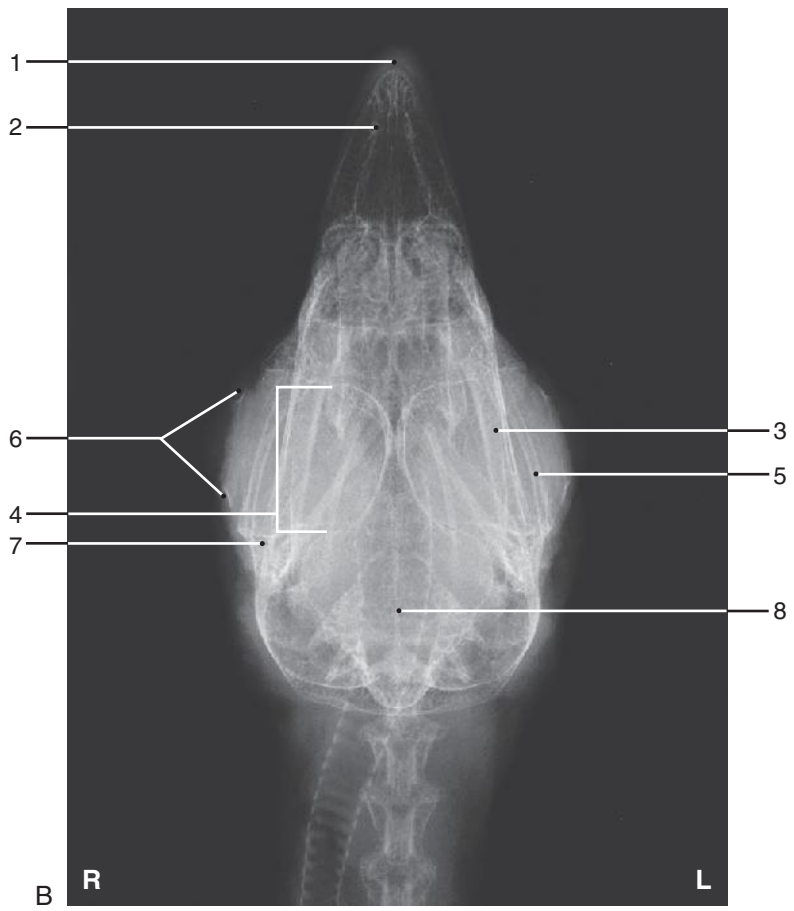

Figure 9-7, B
Type of Bird: Orange-Winged Amazon Parrot
Type of Study: Head
Projection: Ventrodorsal
Weight of Bird: 412 g
Gender: Unknown
Reproductive Status: Intact
Age: 13 years

1. Keratinized maxillary beak
2. Premaxillary bone
3. Mandible
4. Orbit
5. Jugal [zygomatic] bone
6. Scleral ossicles
7. Quadrate bone
8. Cranium

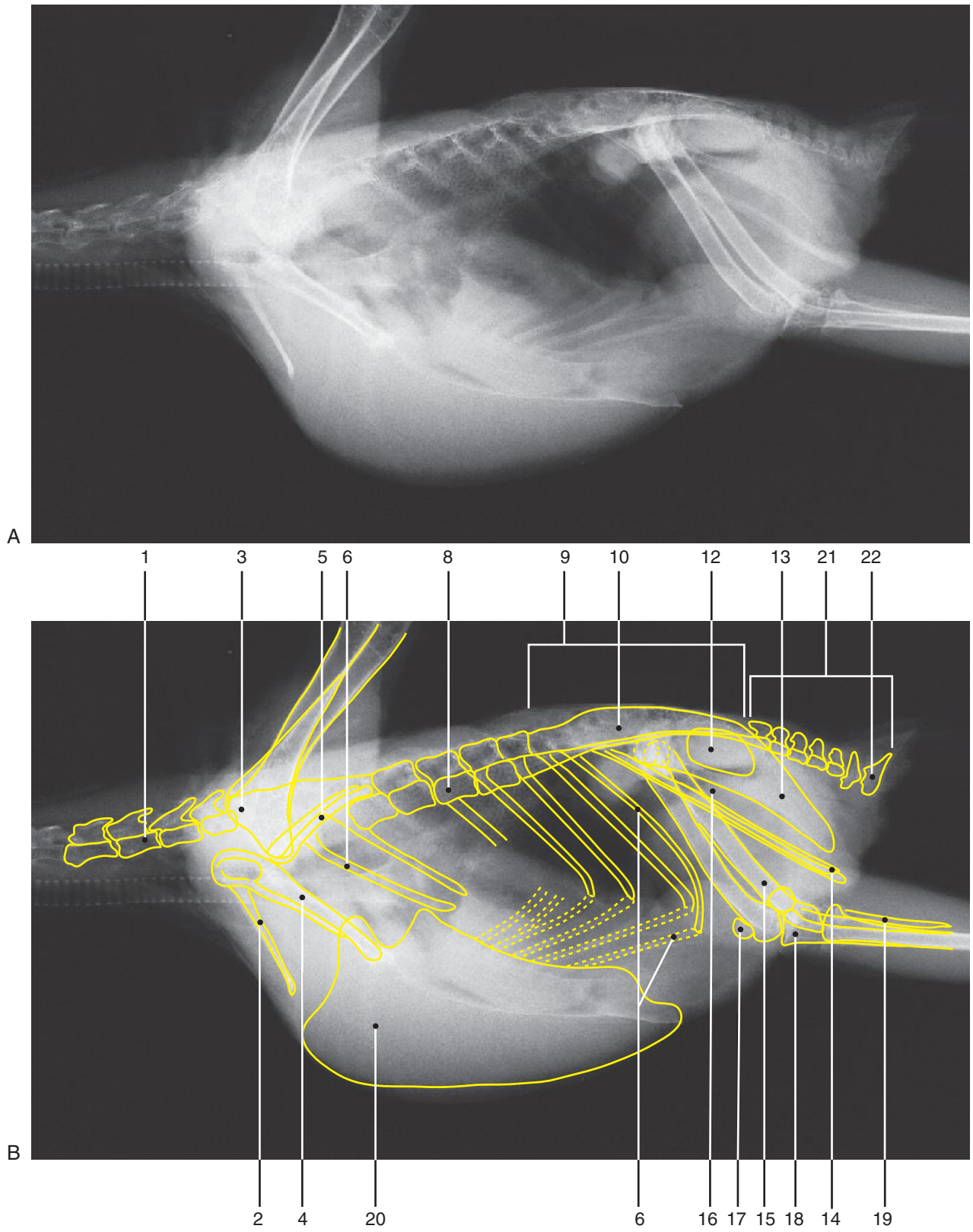

Figure 9-8, A-B
Type of Bird: Orange-Winged Amazon Parrot
Type of Study: Whole body skeleton
Projection: Laterolateral (right lateral recumbency)
Weight of Bird: 412 g
Gender: Unknown
Reproductive Status: Intact
Age: 13 years

1. Cervical vertebra
2. Clavicle
3. Humerus
4. Coracoid
5. Scapula
6. Rib
7. (Uncinate process of rib)
8. Thoracic vertebra
9. Synsacrum
10. Ilium
11. (Head of femur)
12. Ilioischiadiac foramen
13. Ischium
14. Pubis
15. Femur
16. Obturator foramen
17. Patella
18. Tibiotarsal bone
19. Fibula
20. Sternum
21. Caudal vertebrae
22. Pygostyle

NOTE: Structures in parentheses are not labeled.

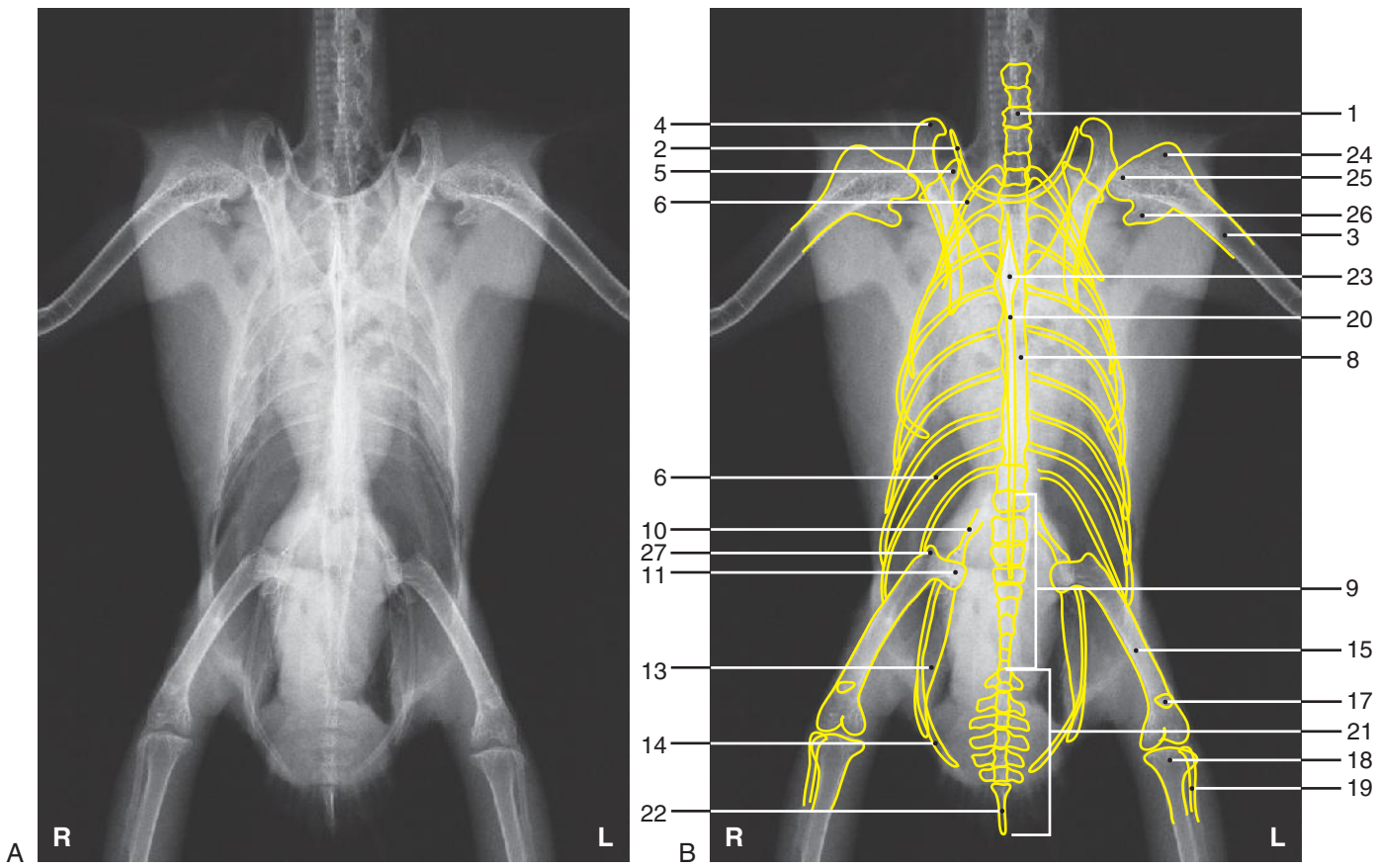

Figure 9-9, A-B
Type of Bird: Orange-Winged Amazon Parrot
Type of Study: Whole body skeleton
Projection: Ventrodorsal
Weight of Bird: 412 g
Gender: Unknown
Reproductive Status: Intact
Age: 13 years

1. Cervical vertebra
2. Clavicle
3. Humerus
4. Coracoid
5. Scapula
6. Rib
7. (Uncinate process of rib)
8. Thoracic vertebra
9. Synsacrum
10. Ilium
11. Head of femur
12. (Ilioischiadiac foramen)
13. Ischium
14. Pubis
15. Femur
16. (Obturator foramen)
17. Patella
18. Tibiotarsal bone
19. Fibula
20. Sternum
21. Caudal vertebrae
22. Pygostyle
23. Apex carinae
24. Dorsal tubercle of humerus
25. Head of humerus
26. Ventral tubercle of humerus
27. Trochanter of femur

NOTE: Structures in parentheses are not labeled.

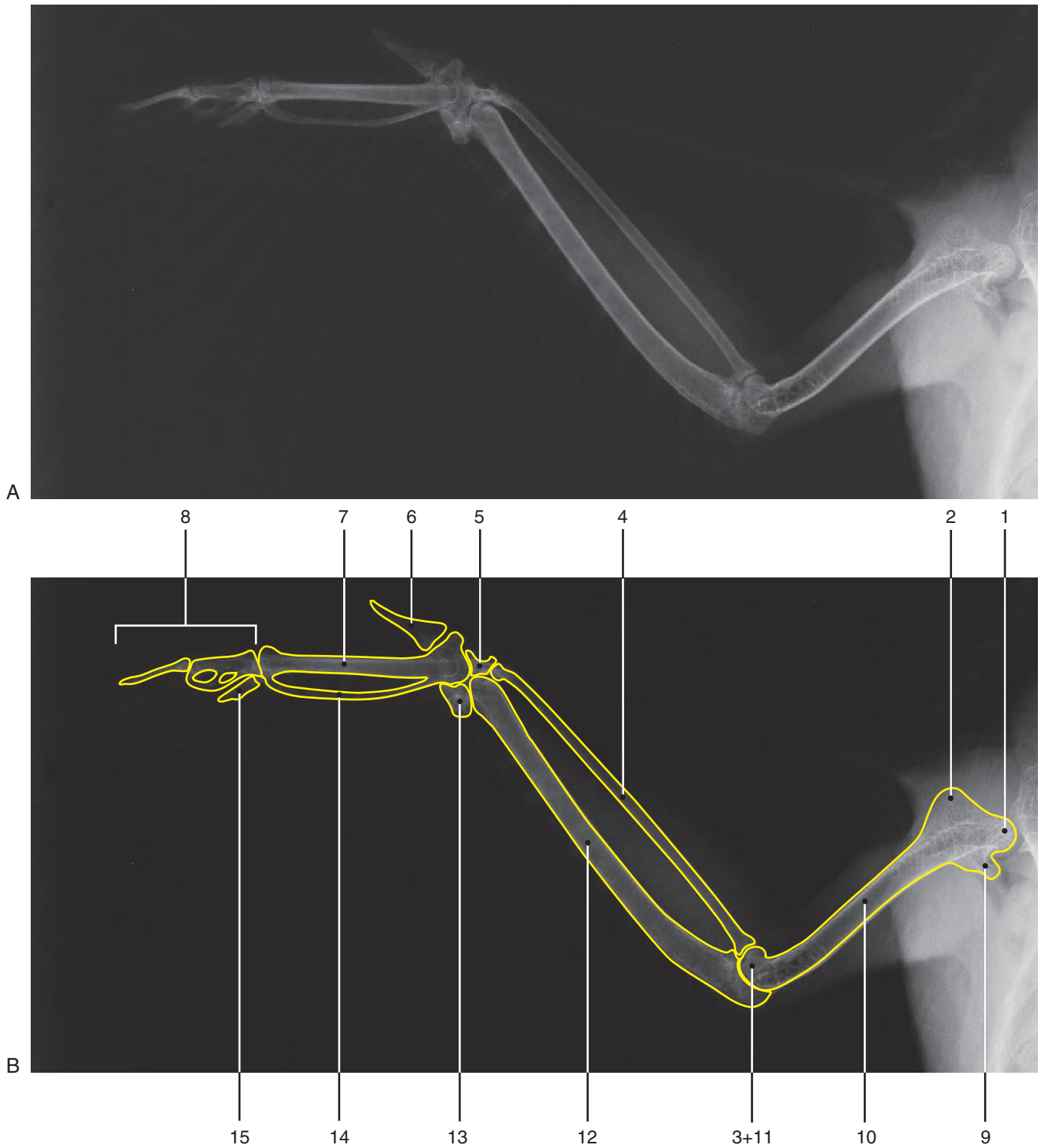

Figure 9-10, A-B
Type of Bird: Orange-Winged Amazon Parrot
Type of Study: Wing
Projection: Mediolateral
Weight of Bird: 412 g
Gender: Unknown
Reproductive Status: Intact
Age: 13 years

1. Head of humerus
2. Dorsal tubercle of humerus
3. Dorsal condyle of humerus
4. Radius
5. Radial carpal bone
6. Alula
7. Major metacarpal bone
8. Phalanges of major digit
9. Ventral tubercle of humerus
10. Humerus
11. Ventral condyle of humerus
12. Ulna
13. Ulnar carpal bone
14. Minor metacarpal bone
15. Phalanges of minor digit

A

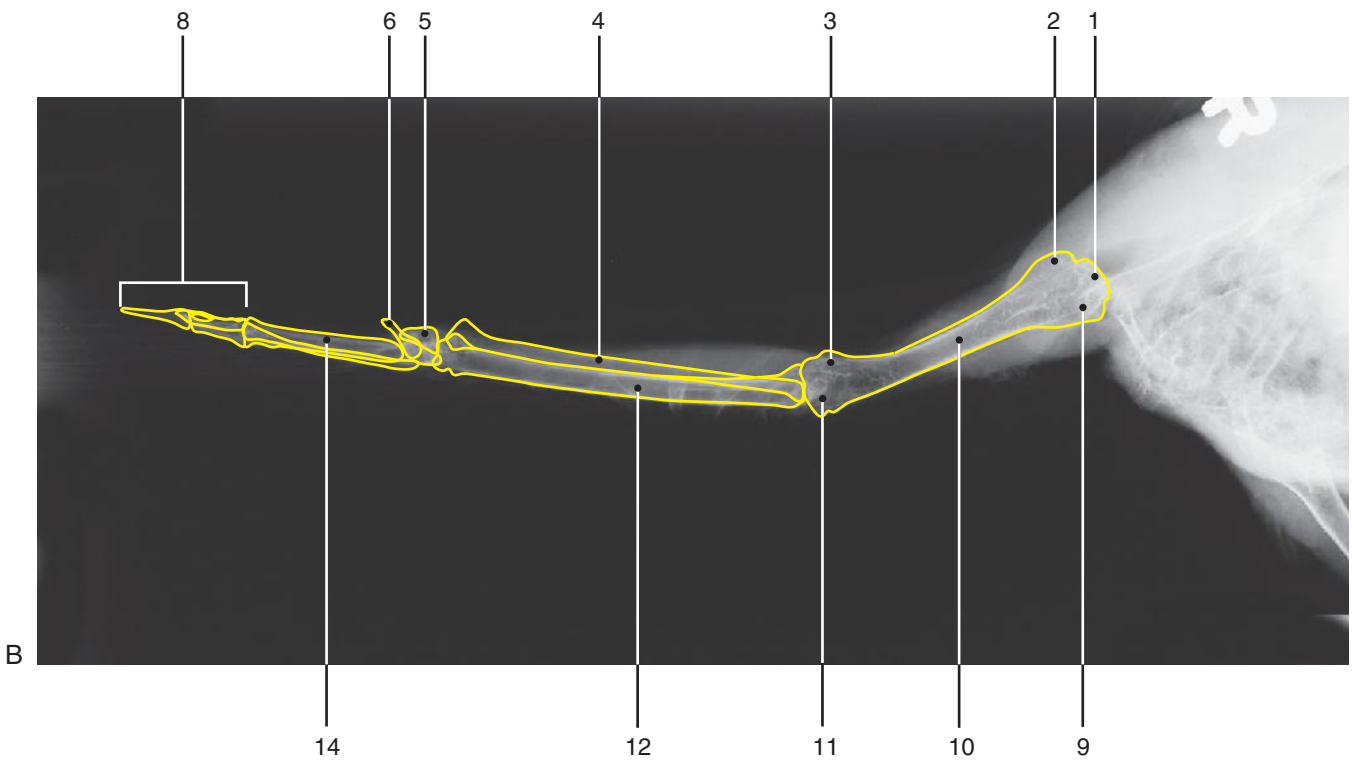

B

Figure 9-11, A-B

Type of Bird: Orange-Winged Amazon Parrot
Type of Study: Wing
Projection: Caudocranial
Weight of Bird: 412 g
Gender: Unknown
Reproductive Status: Intact
Age: 13 years

1. Head of humerus
2. Ventral tubercle of humerus
3. Ventral condyle of humerus
4. Radius
5. Radial carpal bone
6. Alula
7. (Minor metacarpal bone)
8. Phalanges of major digit
9. Dorsal tubercle of humerus
10. Humerus
11. Dorsal condyle of humerus
12. Ulna
13. (Ulnar carpal bone)
14. Major metacarpal bone
15. (Phalanges of minor digit)

NOTE: Structures in parentheses are not labeled.

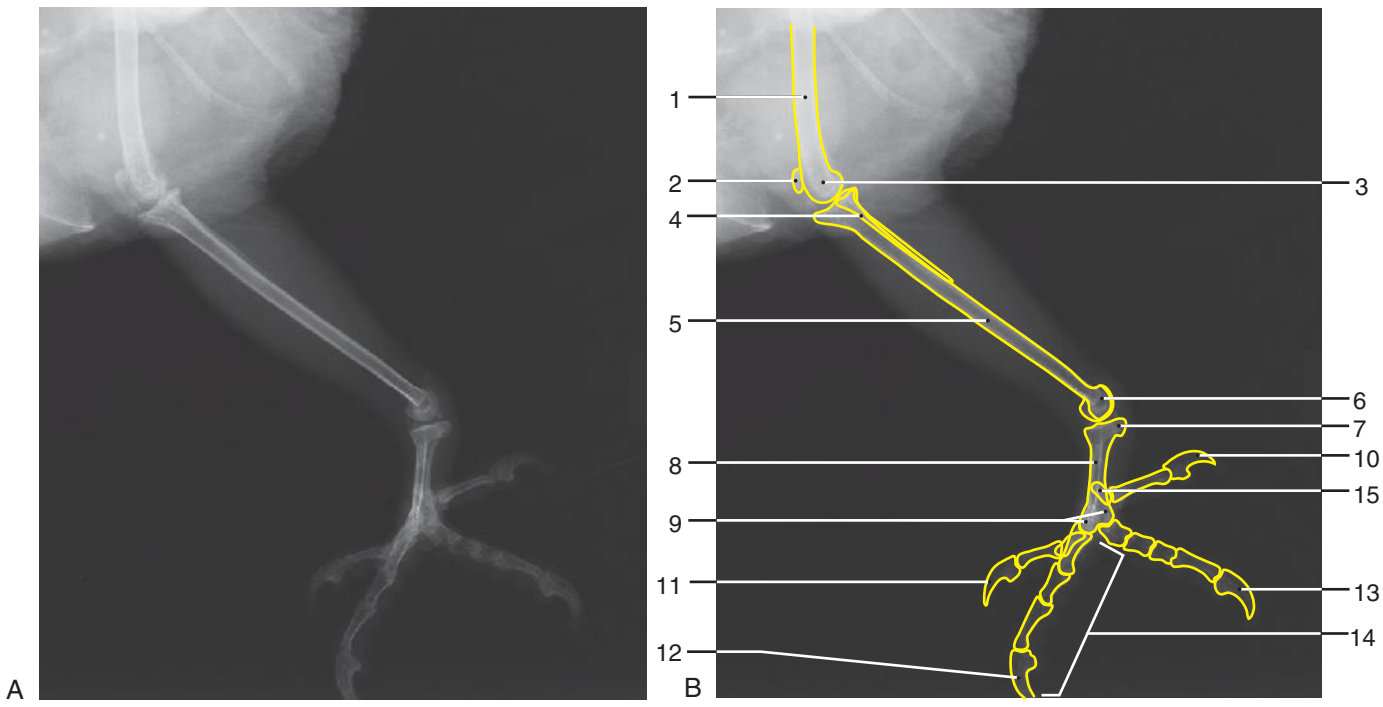

Figure 9-12, A-B
Type of Bird: Orange-Winged Amazon Parrot
Type of Study: Pelvic limb
Projection: Mediolateral
Weight of Bird: 412 g
Gender: Unknown
Reproductive Status: Intact
Age: 13 years

1. Femur
2. Patella
3. Condyles of femur
4. Fibula
5. Tibiotarsal bone
6. Condyles of tibiotarsal bone
7. Hypotarsal crest of tarsometatarsal bone
8. Tarsometatarsal bone
9. Trochlea of tarsometatarsal bone
10. Digit I
11. Digit II
12. Digit III
13. Digit IV
14. Phalanges
15. Metatarsal I

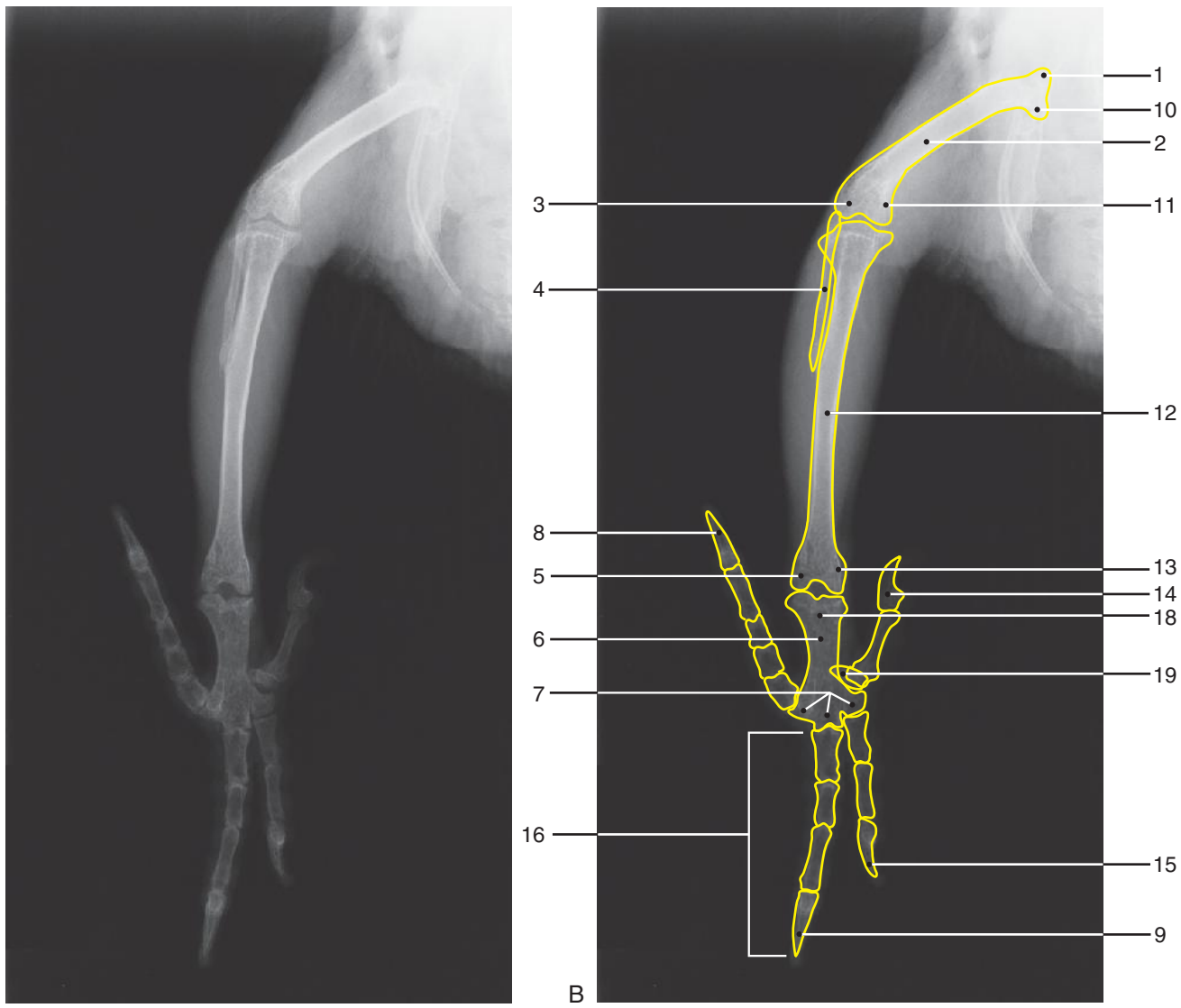

Figure 9-13, A-B
Type of Bird: Orange-Winged Amazon Parrot
Type of Study: Pelvic limb
Projection: Craniocaudal
Weight of Bird: 412 g
Gender: Unknown
Reproductive Status: Intact
Age: 13 years

1. Trochanter of femur
2. Femur
3. Lateral condyle of femur
4. Fibula
5. Lateral condyle of tibiotarsal bone
6. Tarsometatarsal bone
7. Trochlea of tarsometatarsal bone
8. Digit IV
9. Digit III
10. Head of femur
11. Medial condyle of femur
12. Tibiotarsal bone
13. Medial condyle of tibiotarsal bone
14. Digit I
15. Digit II
16. Phalanges
17. (Patella)
18. Hypotarsal crest of tarsometatarsal bone
19. Metatarsal I

NOTE: Structures in parentheses are not labeled.

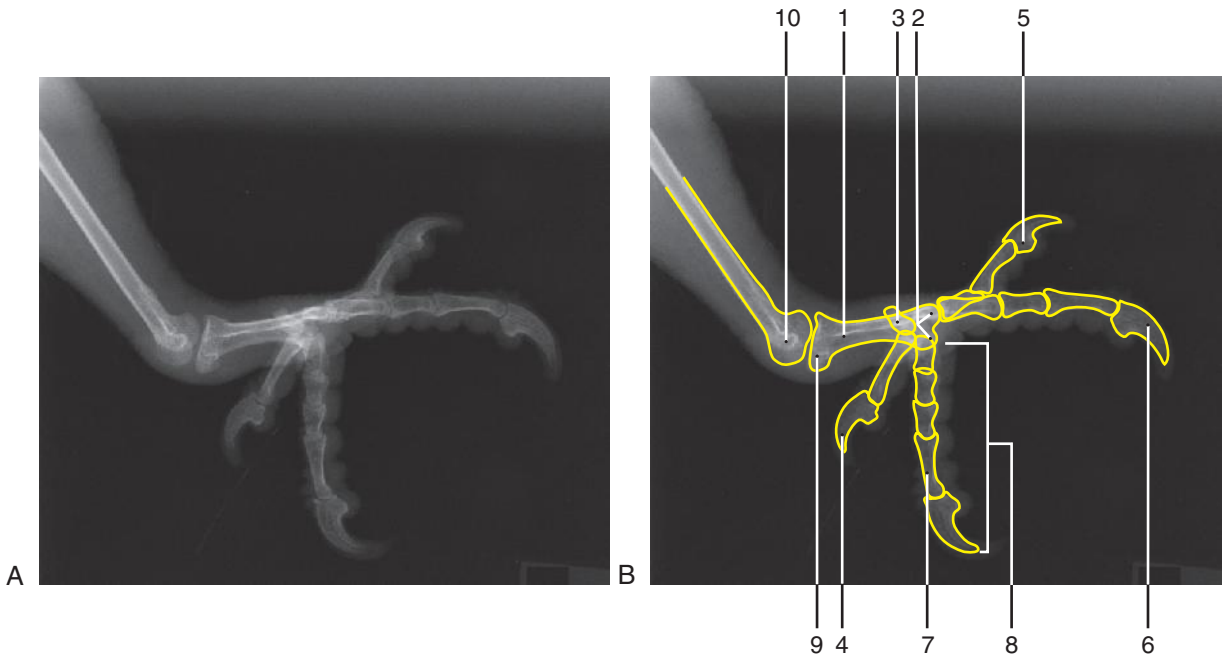

Figure 9-14, A-B
Type of Bird: Orange-Winged Amazon Parrot
Type of Study: Distal pelvic limb
Projection: Mediolateral
Weight of Bird: 412 g
Gender: Unknown
Reproductive Status: Intact
Age: 13 years

1. Tarsometatarsal bone
2. Trochlea of tarsometatarsal bone
3. Metatarsal bone I
4. Digit I
5. Digit II
6. Digit III
7. Digit IV
8. Phalanges
9. Hypotarsal crest of tarsometatarsal bone
10. Condyles of tibiotarsal bone

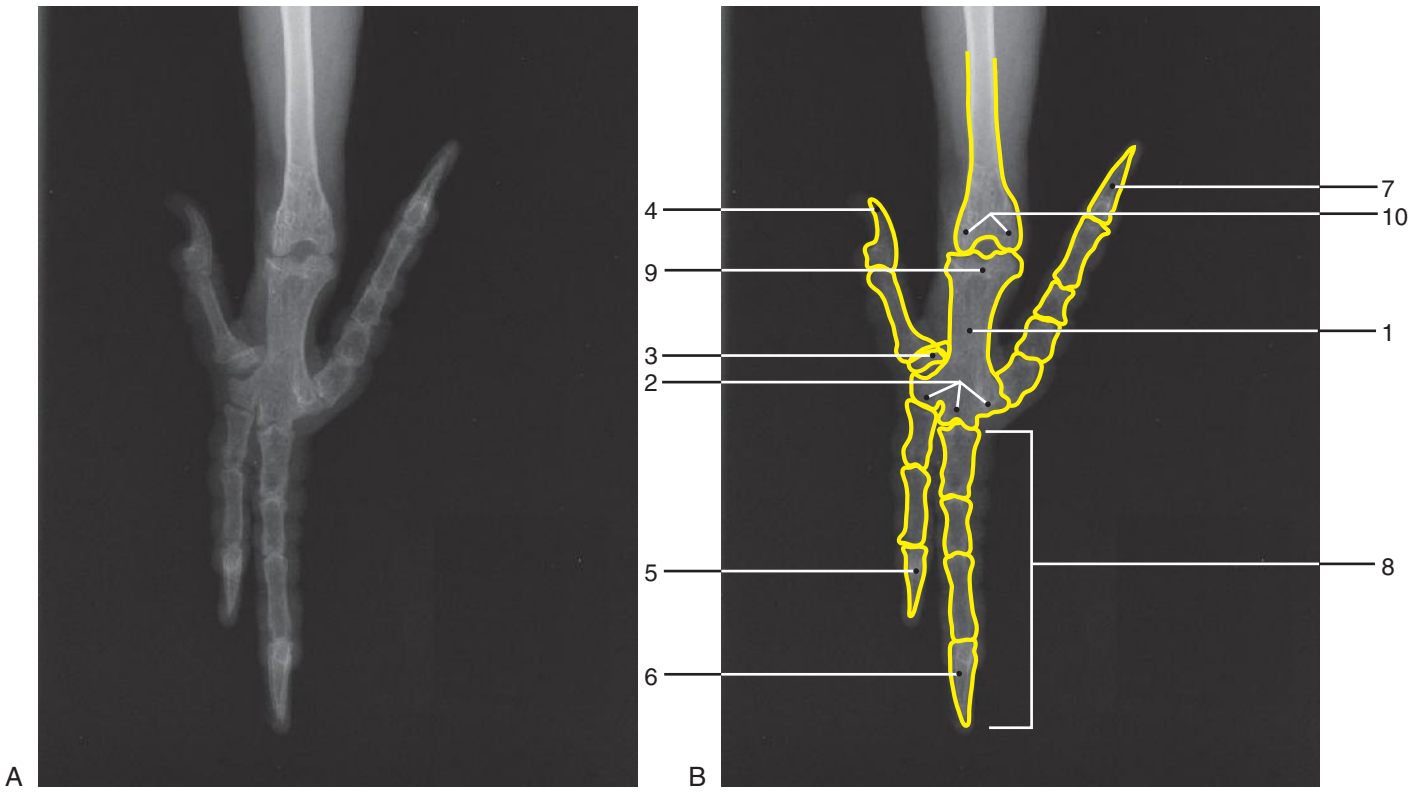

Figure 9-15, A-B
Type of Bird: Orange-Winged Amazon Parrot
Type of Study: Distal pelvic limb
Projection: Dorsoplantar
Weight of Bird: 412 g
Gender: Unknown
Reproductive Status: Intact
Age: 13 years

1. Tarsometatarsal bone
2. Trochlea of tarsometatarsal bone
3. Metatarsal bone I
4. Digit I
5. Digit II
6. Digit III
7. Digit IV
8. Phalanges
9. Hypotarsal crest of tarsometatarsal bone
10. Condyles of tibiotarsal bone

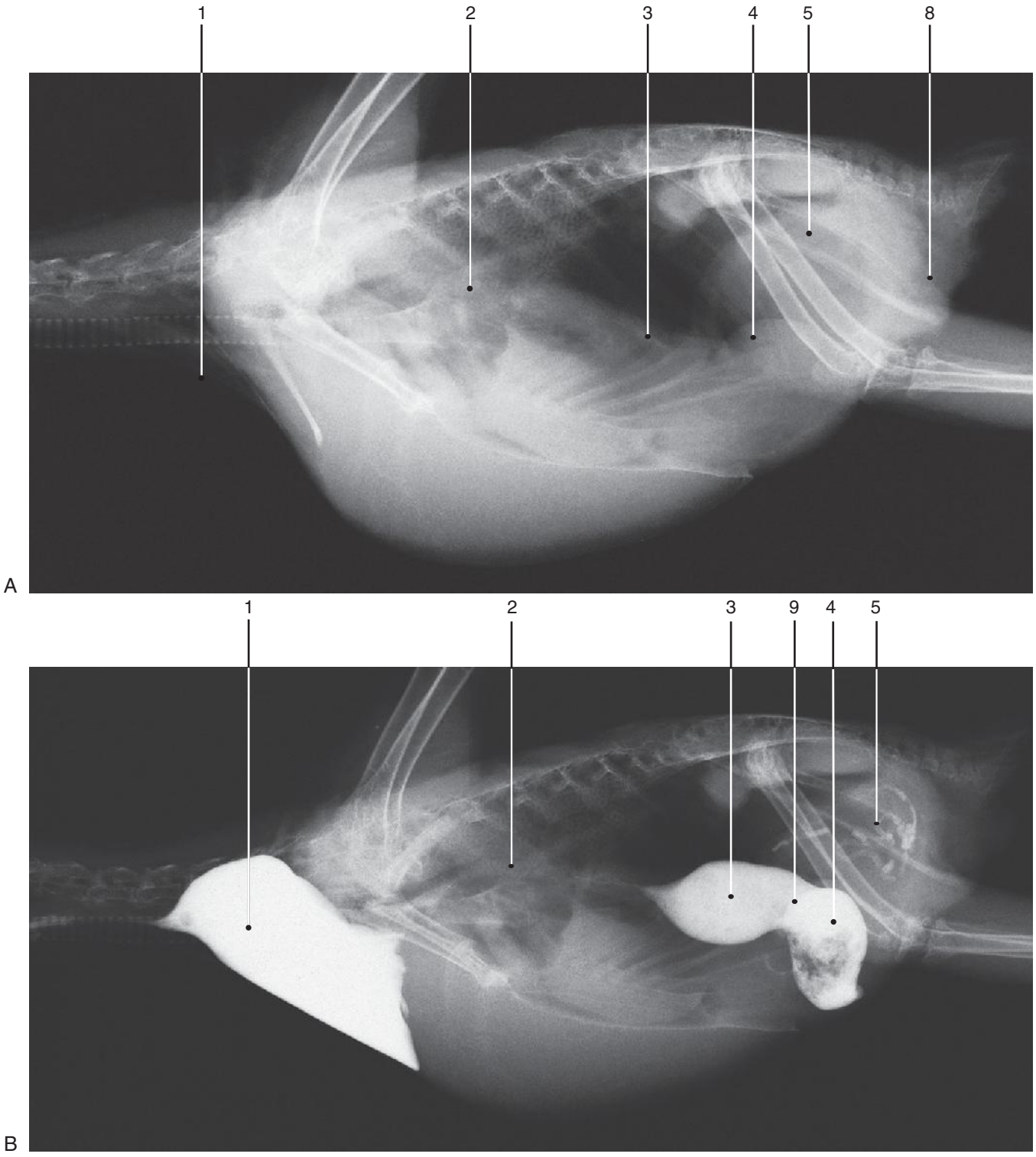

Figure 9-16, A-B

Type of Bird: Orange-Winged Amazon Parrot
Type of Study: Gastrointestinal positive contrast study
Contrast Medium: Barium sulfate suspension (Novopaque® 30% w/v; Lafayette Pharmaceutical, Inc., Lafayette, IN) 15 ml administered via gavage tube
Projection: Laterolateral (right lateral recumbency)
Weight of Bird: 412 g
Gender: Unknown
Reproductive Status: Intact
Age: 13 years

Image	Time (hr)
A	Scout
B	0.25

1. Crop
2. Esophagus
3. Proventriculus
4. Ventriculus
5. Intestines
6. (Duodenum)
7. (Large intestine)
8. Cloaca
9. Proventricular-ventricular isthmus

NOTE: Structures in parentheses are not labeled.

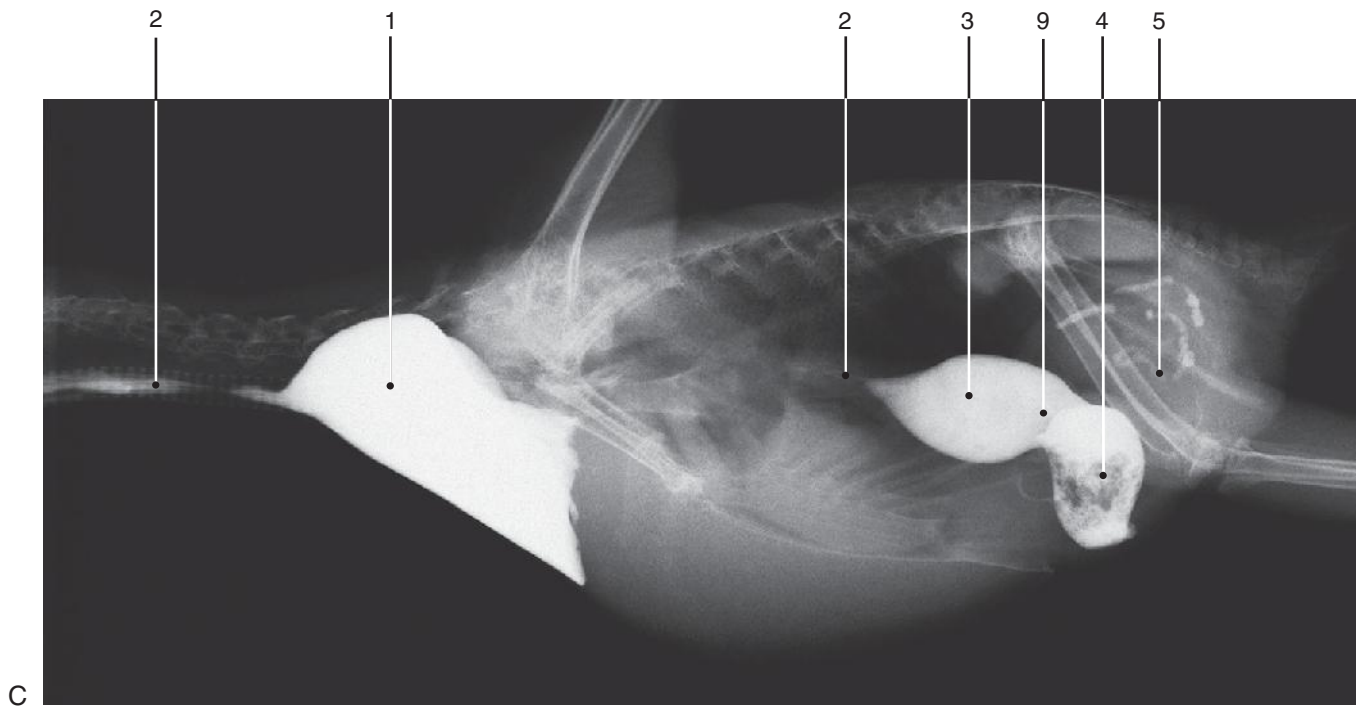

C

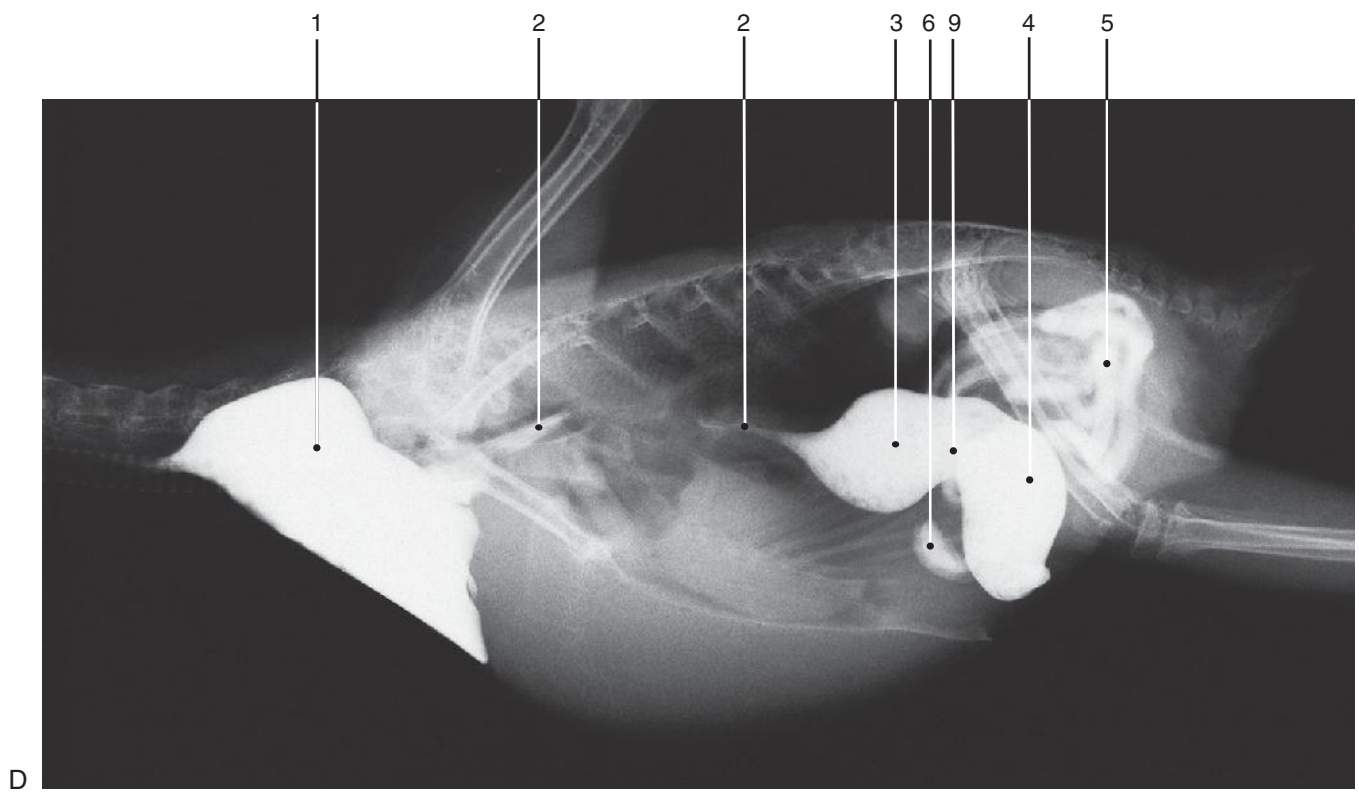

D

Figure 9-16, C-D
Type of Bird: Orange-Winged Amazon Parrot
Type of Study: Gastrointestinal positive contrast study
Contrast Medium: Barium sulfate suspension (Novopaque® 30% w/v; Lafayette Pharmaceutical, Inc., Lafayette, IN) 15 ml administered via gavage tube
Projection: Laterolateral (right lateral recumbency)
Weight of Bird: 412 g
Gender: Unknown
Reproductive Status: Intact
Age: 13 years

Image	Time (hr)
C	0.5
D	1.0

1. Crop
2. Esophagus
3. Proventriculus
4. Ventriculus
5. Intestines
6. Duodenum
7. (Large intestine)
8. (Cloaca)
9. Proventricular-ventricular isthmus

NOTE: Structures in parentheses are not labeled.

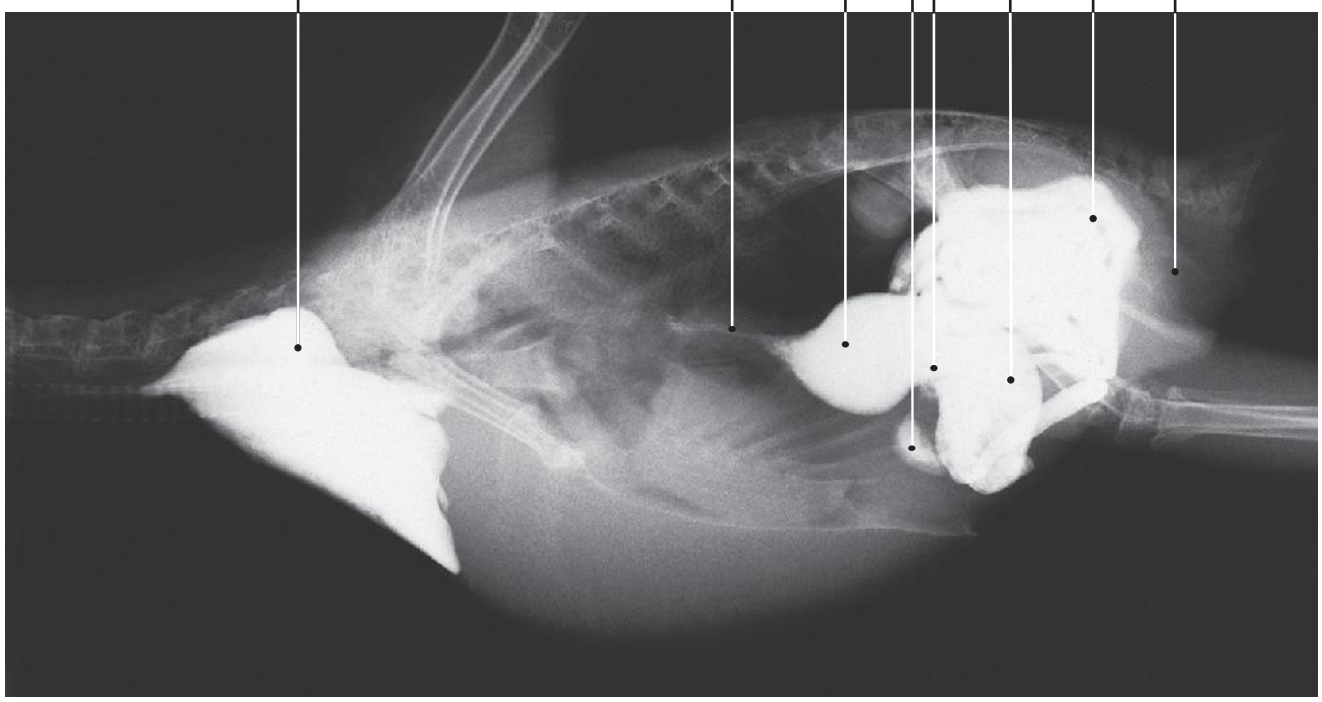

E

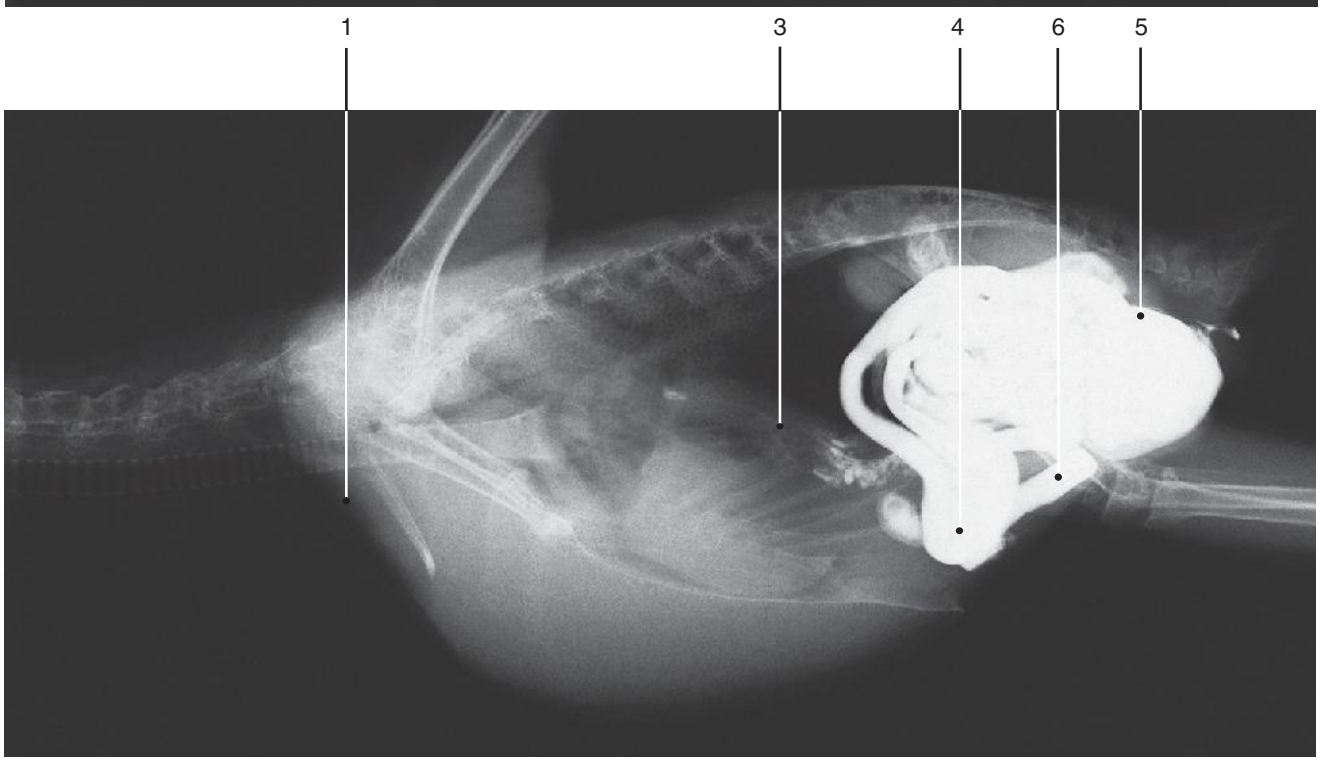

F

Figure 9-16, E-F

Type of Bird: Orange-Winged Amazon Parrot
Type of Study: Gastrointestinal positive contrast study
Contrast Medium: Barium sulfate suspension (Novopaque® 30% w/v; Lafayette Pharmaceutical, Inc., Lafayette, IN) 15 ml administered via gavage tube
Projection: Laterolateral (right lateral recumbency)
Weight of Bird: 412 g
Gender: Unknown
Reproductive Status: Intact
Age: 13 years

Image	Time (hr)
E	2.0
F	4.0

1. Crop
2. Esophagus
3. Proventriculus
4. Ventriculus
5. Intestines
6. Duodenum
7. (Large intestine)
8. Cloaca
9. Proventricular-ventricular isthmus

NOTE: Structures in parentheses are not labeled.

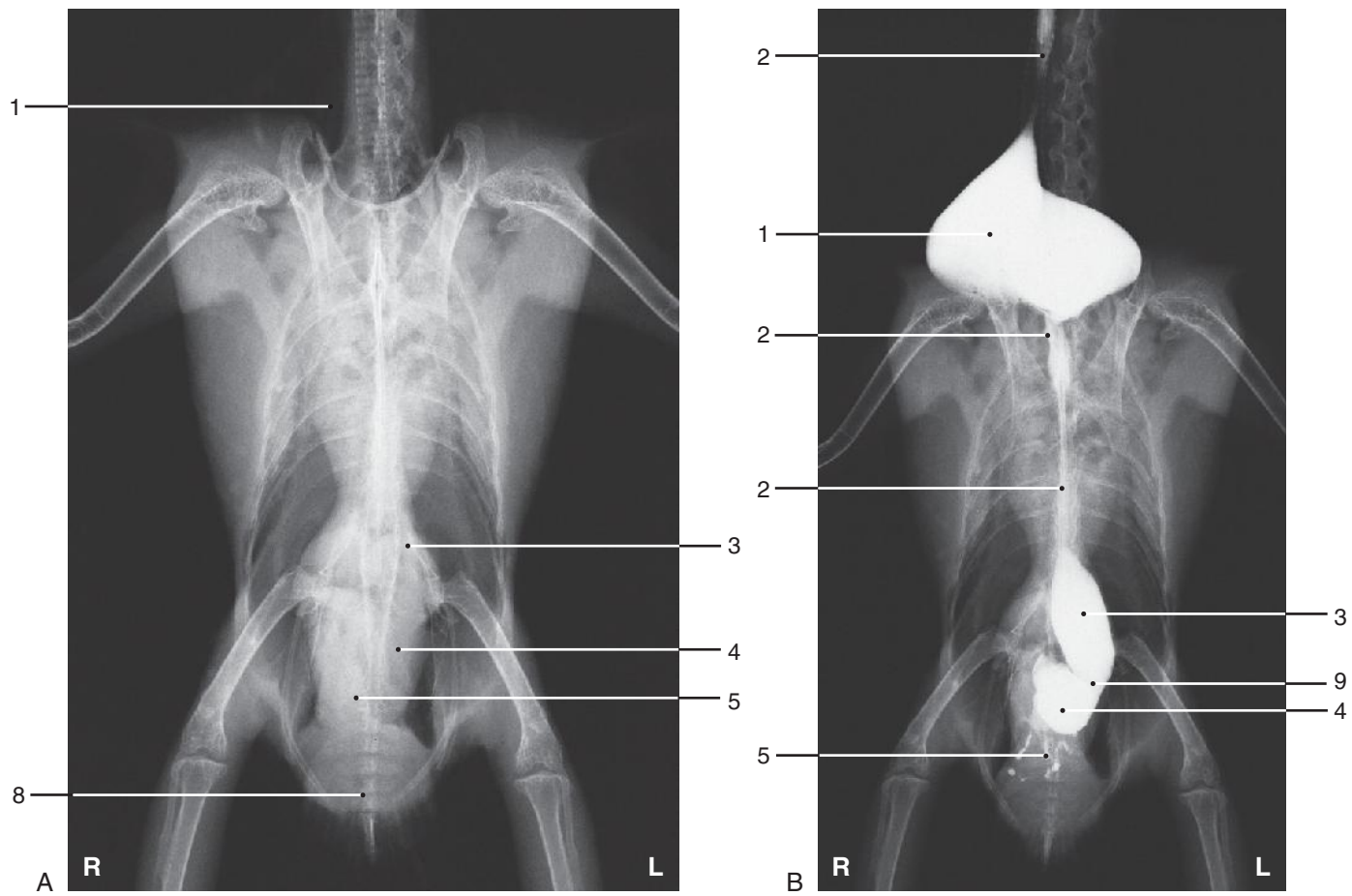

Figure 9-17, A-B

Type of Bird: Orange-Winged Amazon Parrot
Type of Study: Gastrointestinal positive contrast study
Contrast Medium: Barium sulfate suspension (Novopaque® 30% w/v; Lafayette Pharmaceutical, Inc., Lafayette, IN) 15 ml administered via gavage tube
Projection: Ventrodorsal
Weight of Bird: 412 g
Gender: Unknown
Reproductive Status: Intact
Age: 13 years

Image	Time (hr)
A	Scout
B	0.25

1. Crop
2. Esophagus
3. Proventriculus
4. Ventriculus
5. Intestines
6. (Duodenum)
7. (Large intestine)
8. Cloaca
9. Proventricular-ventricular isthmus

NOTE: Structures in parentheses are not labeled.

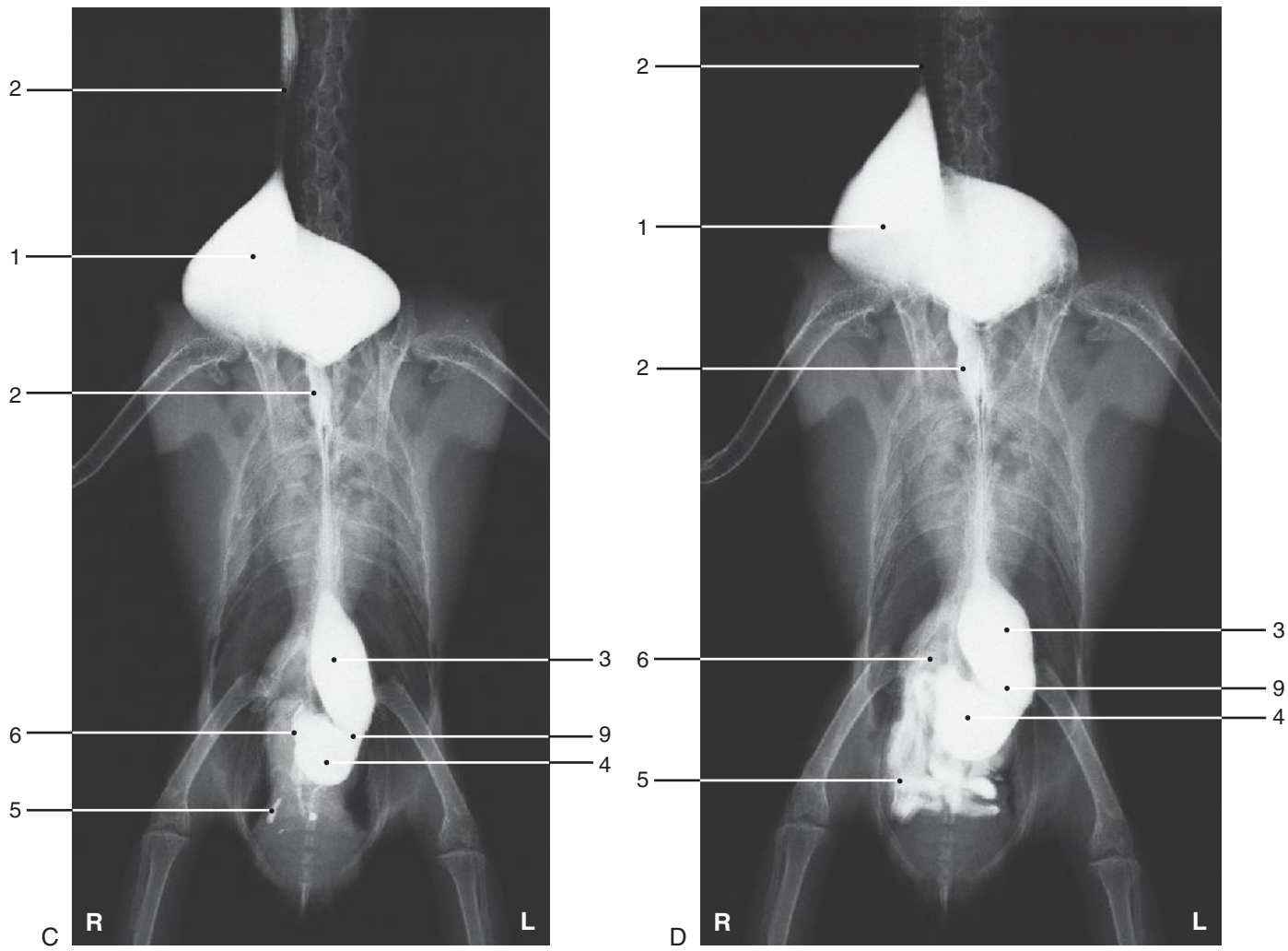

Figure 9-17, C-D

Type of Bird: Orange-Winged Amazon Parrot
Type of Study: Gastrointestinal positive contrast study
Contrast Medium: Barium sulfate suspension (Novopaque® 30% w/v; Lafayette Pharmaceutical, Inc., Lafayette, IN) 15 ml administered via gavage tube
Projection: Ventrodorsal
Weight of Bird: 412 g
Gender: Unknown
Reproductive Status: Intact
Age: 13 years

Image	Time (hr)
C	0.5
D	1.0

1. Crop
2. Esophagus
3. Proventriculus
4. Ventriculus
5. Intestines
6. Duodenum
7. (Large intestine)
8. (Cloaca)
9. Proventricular-ventricular isthmus

NOTE: Structures in parentheses are not labeled.

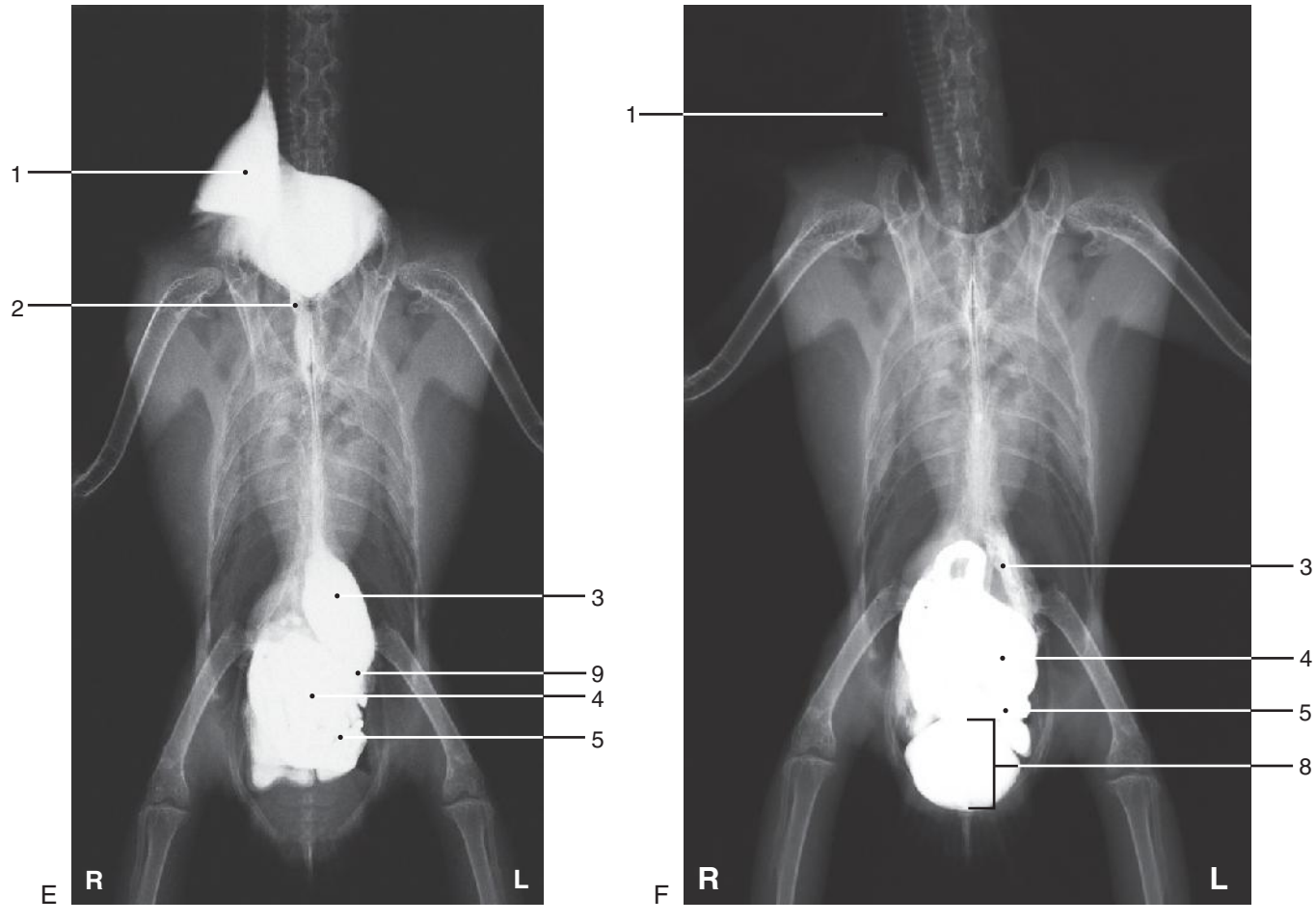

Figure 9-17, E-F

Type of Bird: Orange-Winged Amazon Parrot
Type of Study: Gastrointestinal positive contrast study
Contrast Medium: Barium sulfate suspension (Novopaque® 30% w/v; Lafayette Pharmaceutical, Inc., Lafayette, IN) 15 ml administered via gavage tube
Projection: Ventrodorsal
Weight of Bird: 412 g
Gender: Unknown
Reproductive Status: Intact
Age: 13 years

Image	Time (hr)
E	2.0
F	4.0

1. Crop
2. Esophagus
3. Proventriculus
4. Ventriculus
5. Intestines
6. (Duodenum)
7. (Large intestine)
8. Cloaca
9. Proventricular-ventricular isthmus

NOTE: Structures in parentheses are not labeled.

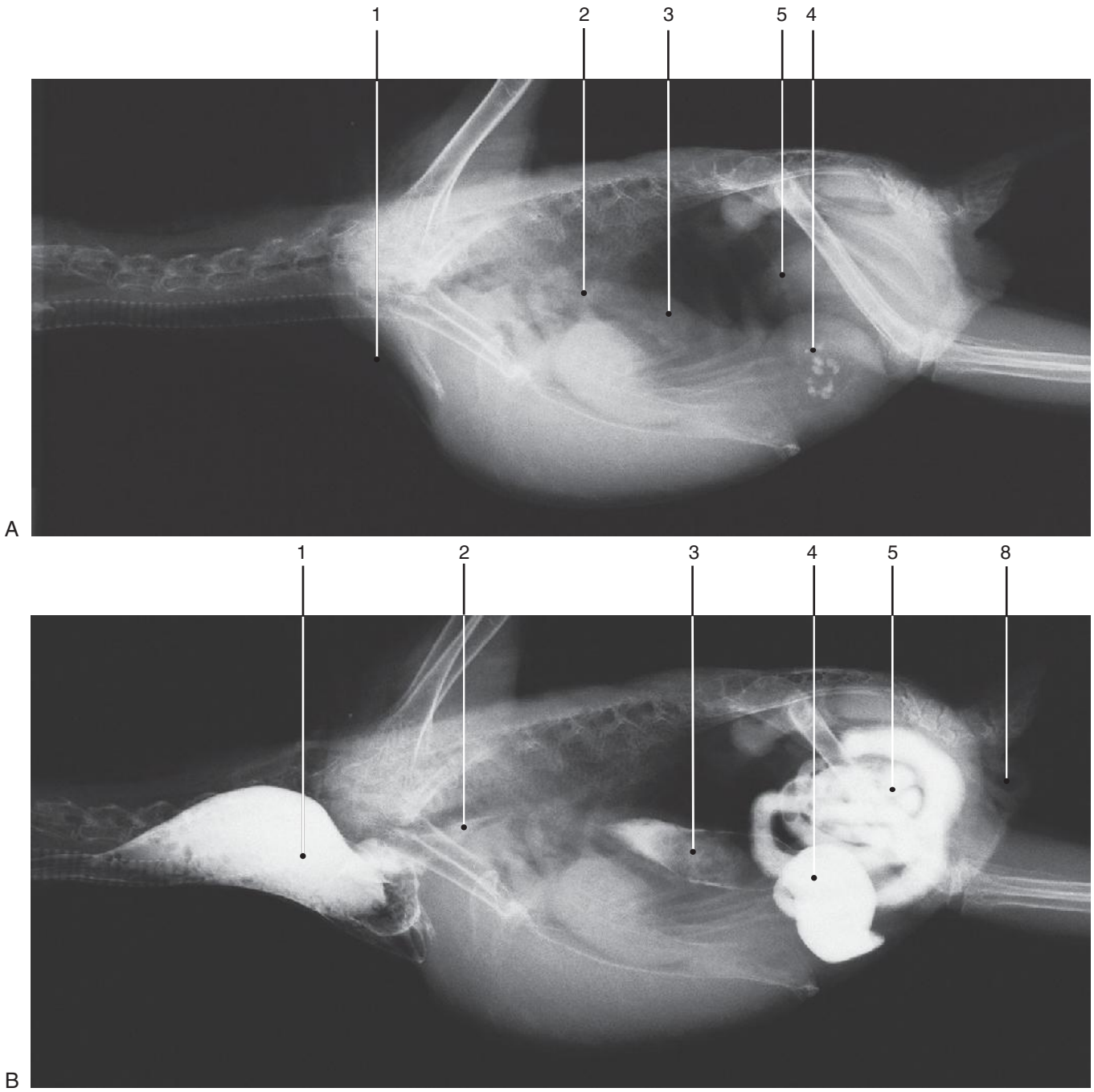

Figure 9-18, A-B

Type of Bird: Orange-Winged Amazon Parrot
Type of Study: Gastrointestinal double contrast study
Contrast Medium: Barium sulfate suspension (Novopaque® 30% w/v; Lafayette Pharmaceutical, Inc., Lafayette, IN) 10 ml and room air 60 ml administered via gavage tube
Projection: Laterolateral (right lateral recumbency)
Weight of Bird: 360 g
Gender: Male
Reproductive Status: Intact
Age: 15 years

Image	Time (hr)
A	Scout
B	0.083

1. Crop
2. Esophagus
3. Proventriculus
4. Ventriculus
5. Intestines
6. (Duodenum)
7. (Large intestine)
8. Cloaca
9. (Proventricular-ventricular isthmus)

NOTE: Structures in parentheses are not labeled.

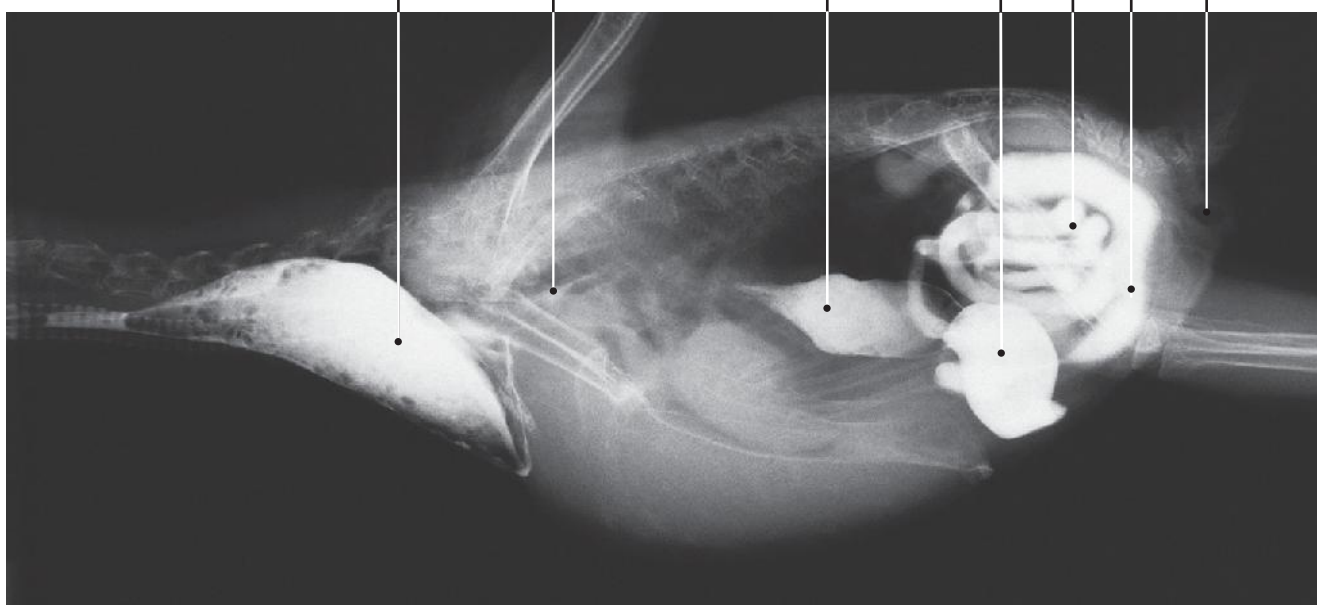

C

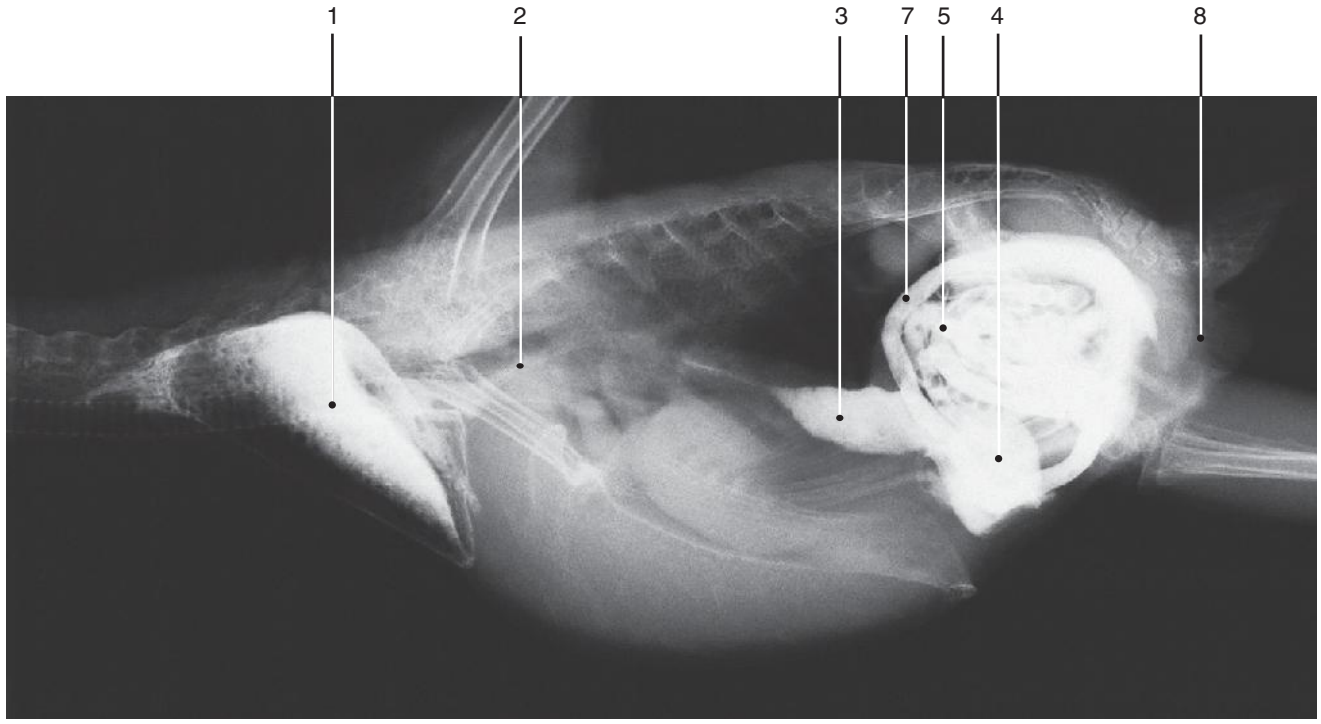

D

Figure 9-18, C-D

Type of Bird: Orange-Winged Amazon Parrot
Type of Study: Gastrointestinal double contrast study
Contrast Medium: Barium sulfate suspension (Novopaque® 30% w/v; Lafayette Pharmaceutical, Inc., Lafayette, IN) 10 ml and room air 60 ml administered via gavage tube
Projection: Laterolateral (right lateral recumbency)
Weight of Bird: 360 g
Gender: Male
Reproductive Status: Intact
Age: 15 years

Image	Time (hr)
C	0.25
D	1.0

1. Crop
2. Esophagus
3. Proventriculus
4. Ventriculus
5. Intestines
6. Duodenum
7. Large intestine
8. Cloaca
9. (Proventricular-ventricular isthmus)

NOTE: Structures in parentheses are not labeled.

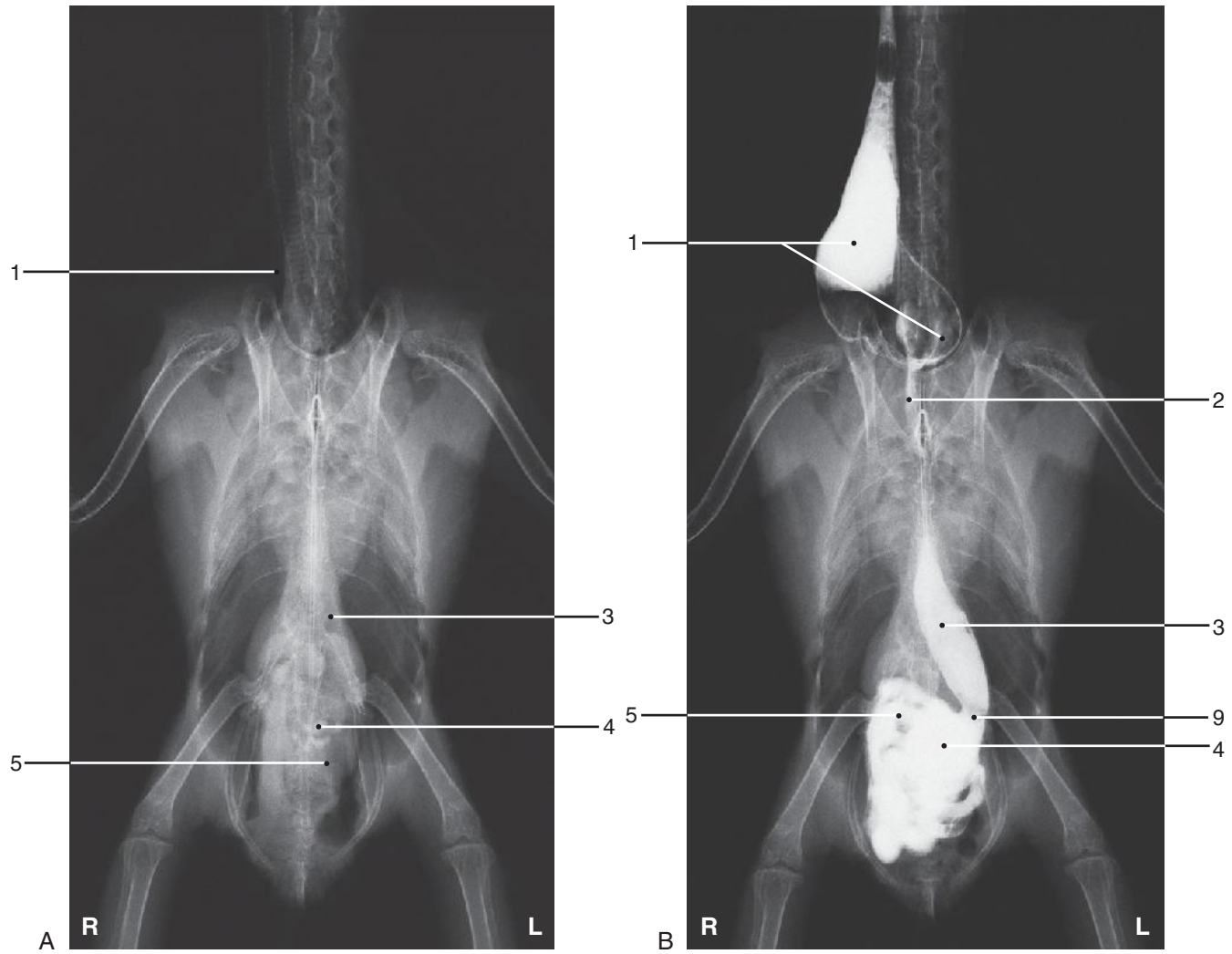

Figure 9-19, A-B

Type of Bird: Orange-Winged Amazon Parrot
Type of Study: Gastrointestinal double contrast study
Contrast Medium: Barium sulfate suspension (Novopaque® 30% w/v; Lafayette Pharmaceutical, Inc., Lafayette, IN) 10 ml and room air 60 ml administered via gavage tube
Projection: Ventrodorsal
Weight of Bird: 360 g
Gender: Male
Reproductive Status: Intact
Age: 15 years

Image	Time (hr)
A	Scout
B	0.083

1. Crop
2. Esophagus
3. Proventriculus
4. Ventriculus
5. Intestines
6. (Duodenum)
7. (Large intestine)
8. (Cloaca)
9. Proventricular-ventricular isthmus

NOTE: Structures in parentheses are not labeled.

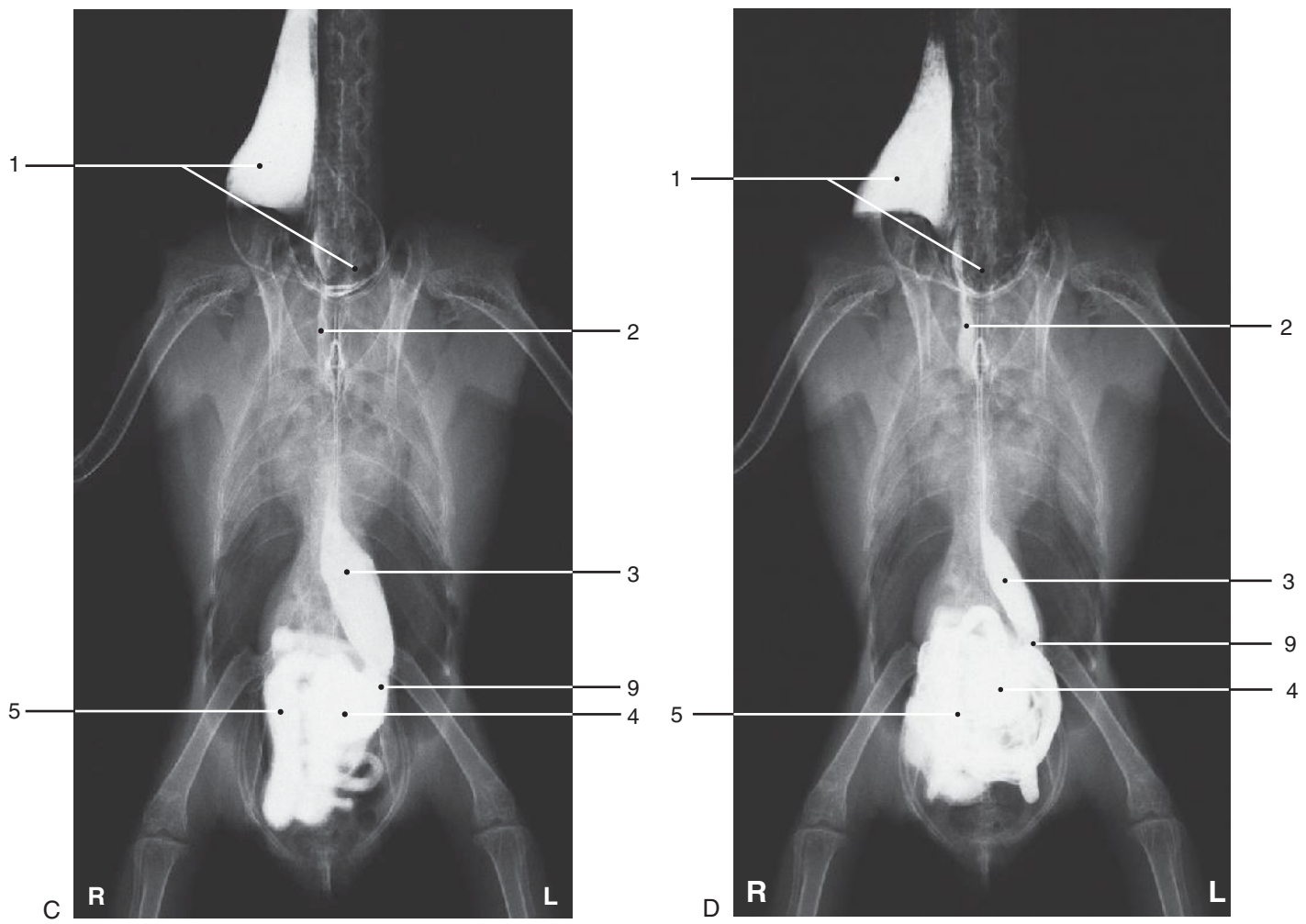

Figure 9-19, C-D

Type of Bird: Orange-Winged Amazon Parrot
Type of Study: Gastrointestinal double contrast study
Contrast Medium: Barium sulfate suspension (Novopaque® 30% w/v; Lafayette Pharmaceutical, Inc., Lafayette, IN) 10 ml and room air 60 ml administered via gavage tube
Projection: Ventrodorsal
Weight of Bird: 360 g
Gender: Male
Reproductive Status: Intact
Age: 15 years

Image	Time (hr)
C	0.25
D	1.0

1. Crop
2. Esophagus
3. Proventriculus
4. Ventriculus
5. Intestines
6. (Duodenum)
7. (Large intestine)
8. (Cloaca)
9. Proventricular-ventricular isthmus

NOTE: Structures in parentheses are not labeled.

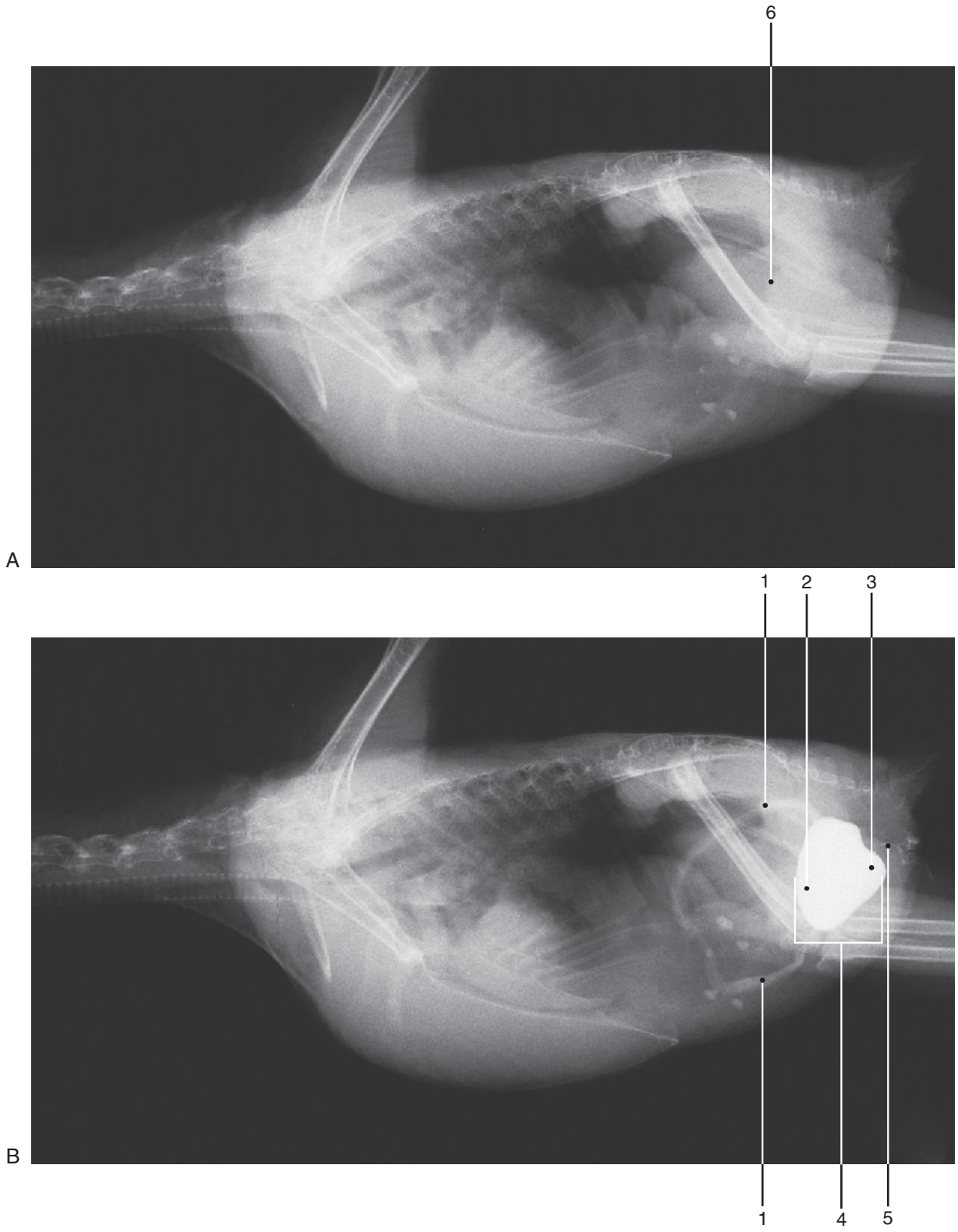

Figure 9-20, A-B

Type of Bird: Orange-Winged Amazon Parrot
Type of Study: Cloacagram (retrograde, positive and double contrast)
Contrast Medium: Iopamidol injection 41% (Isovue®-200, Bracco Diagnostics Inc., Princeton, NJ 08543) 1.8 ml (positive contrast study); followed by room air 3 ml via vent (double contrast study) after partial removal of contrast medium
Projection: Laterolateral (right lateral recumbency)
Weight of Bird: 412 g
Gender: Unknown
Reproductive Status: Intact
Age: 13 years

Image	Study Type
A	Scout
B	Retrograde Positive Contrast Study

1. Colon
2. Coprodeum
3. Urodeum
4. Cloaca
5. Vent
6. Intestines

C

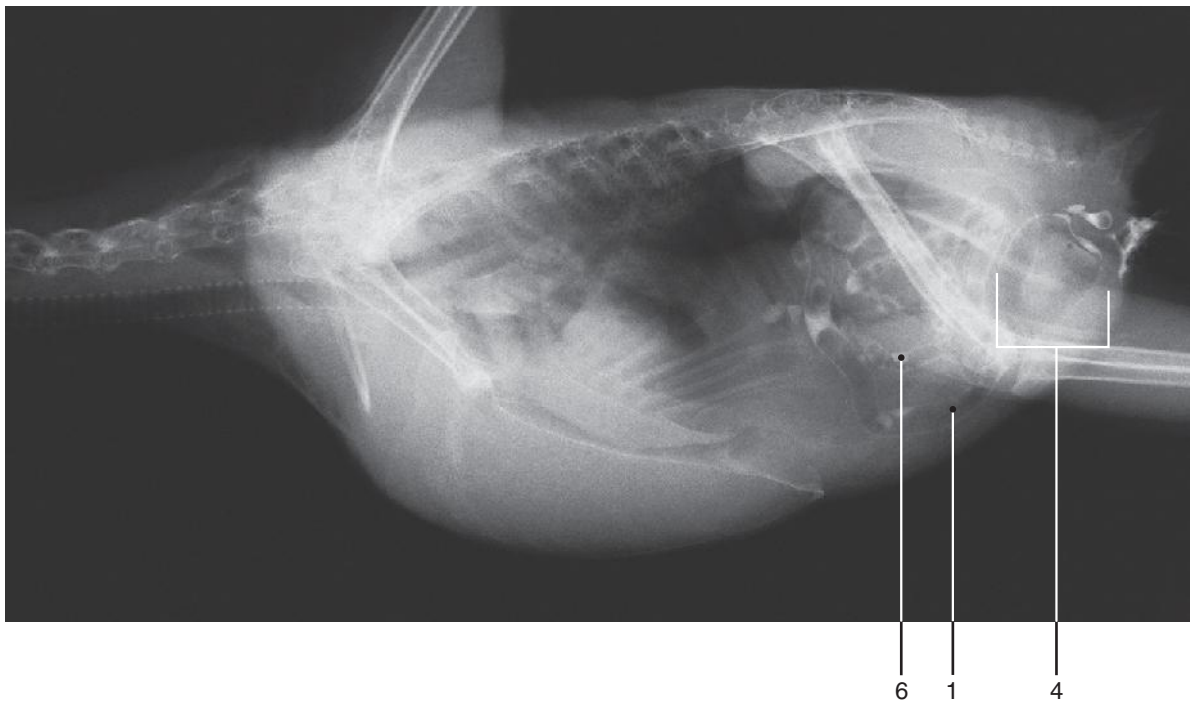

Figure 9-20, C
Type of Bird: Orange-Winged Amazon Parrot
Type of Study: Cloacagram (retrograde, positive and double contrast)
Contrast Medium: Iopamidol injection 41% (Isovue®-200, Bracco Diagnostics Inc., Princeton, NJ 08543) 1.8 ml (positive contrast study); followed by room air 3 ml via vent (double contrast study) after partial removal of contrast medium
Projection: Laterolateral (right lateral recumbency)
Weight of Bird: 412 g
Gender: Unknown
Reproductive Status: Intact
Age: 13 years

Image	Study Type
C	Double Contrast Study

1. Colon
2. (Coprodeum)
3. (Urodeum)
4. Cloaca
5. (Vent)
6. Intestines

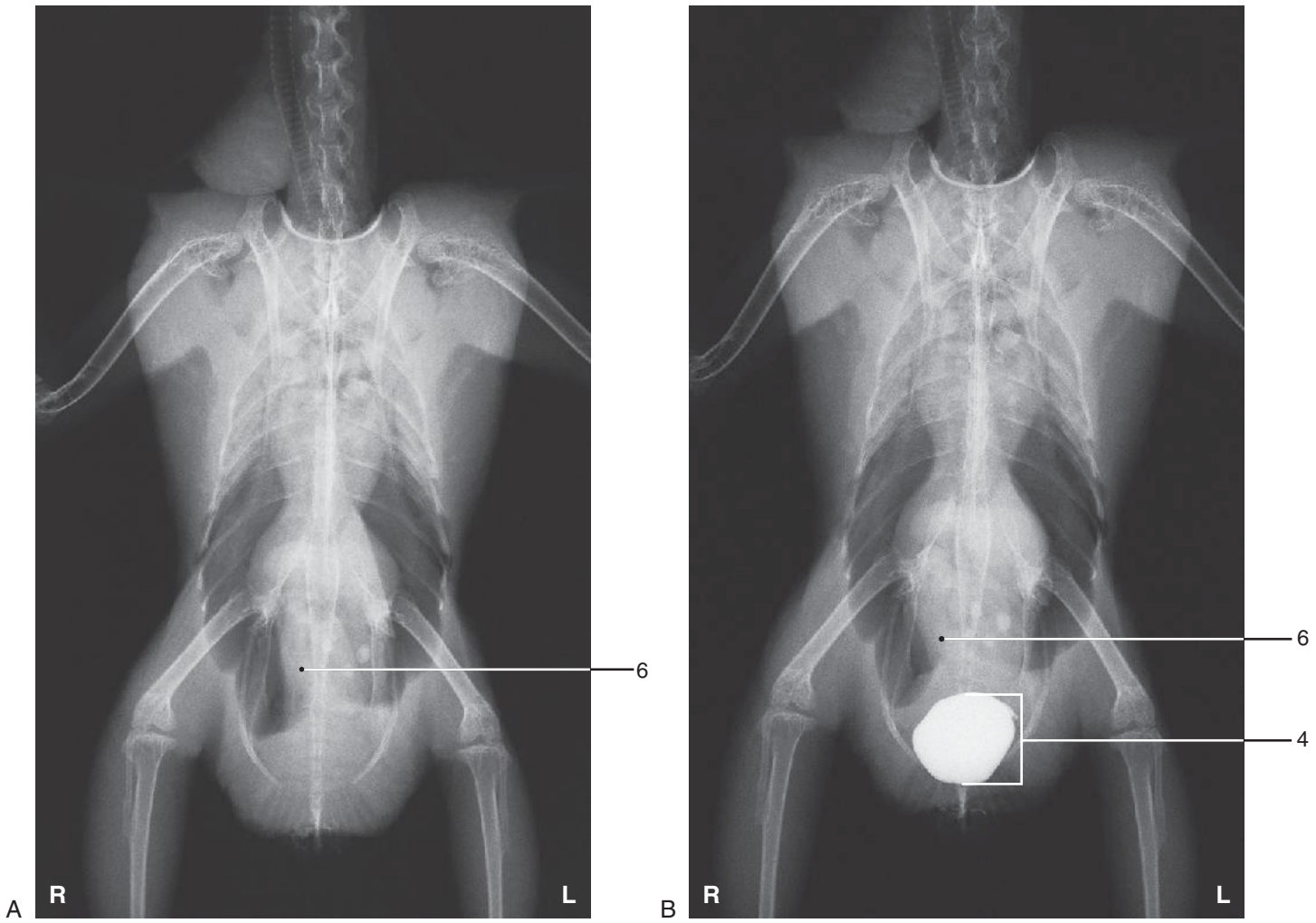

Figure 9-21, A-B

Type of Bird: Orange-Winged Amazon Parrot
Type of Study: Cloacagram (retrograde, positive and double contrast)
Contrast Medium: Iopamidol injection 41% (Isovue®-200, Bracco Diagnostics Inc., Princeton, NJ 08543) 1.8 ml (positive contrast study) followed by room air 3 ml via vent (double contrast study) after partial removal of contrast medium
Projection: Ventrodorsal
Weight of Bird: 412 g
Gender: Unknown
Reproductive Status: Intact
Age: 13 years

Image	Study Type
A	Scout
B	Retrograde Positive Contrast Study

1. (Colon)
2. (Coprodeum)
3. (Urodeum)
4. Cloaca
5. (Vent)
6. Intestines

NOTE: Structures in parentheses are not labeled.

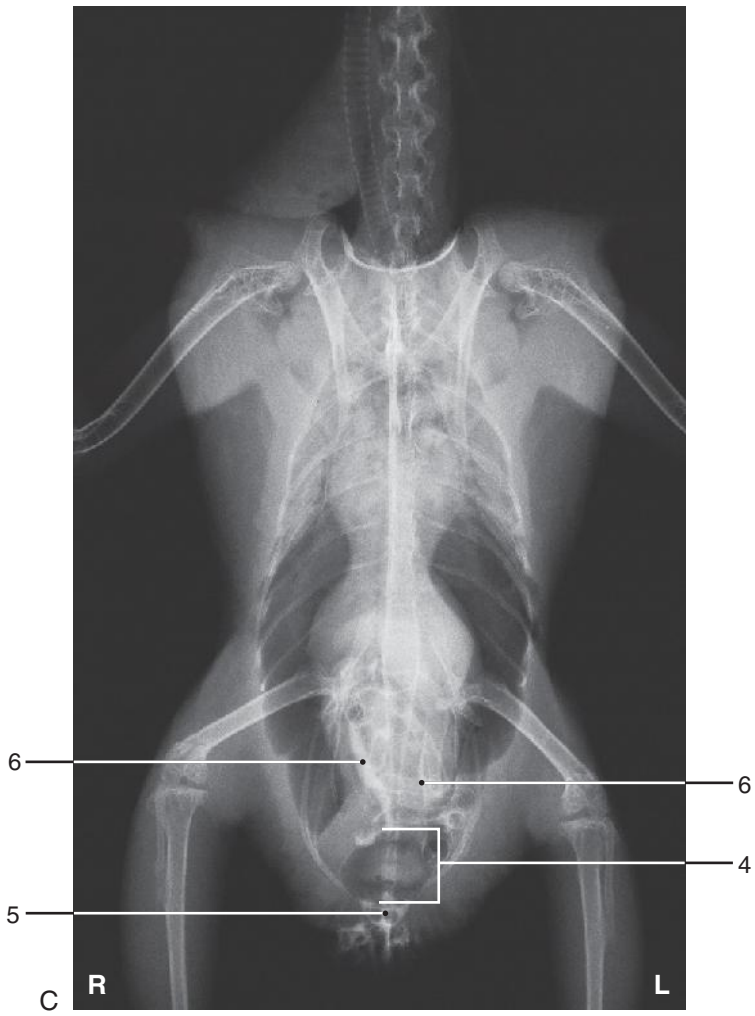

C

Figure 9-21, C

Type of Bird: Orange-Winged Amazon Parrot
Type of Study: Cloacagram (retrograde, positive and double contrast)
Contrast Medium: Iopamidol injection 41% (Isovue®-200, Bracco Diagnostics Inc., Princeton, NJ 08543) 1.8 ml (positive contrast study) followed by room air 3 ml via vent (double contrast study) after partial removal of contrast medium
Projection: Ventrodorsal
Weight of Bird: 412 g
Gender: Unknown
Reproductive Status: Intact
Age: 13 years

Image	Study Type
C	Double Contrast Study

1. (Colon)
2. (Coprodeum)
3. (Urodeum)
4. Cloaca
5. Vent
6. Intestines

NOTE: Structures in parentheses are not labeled.

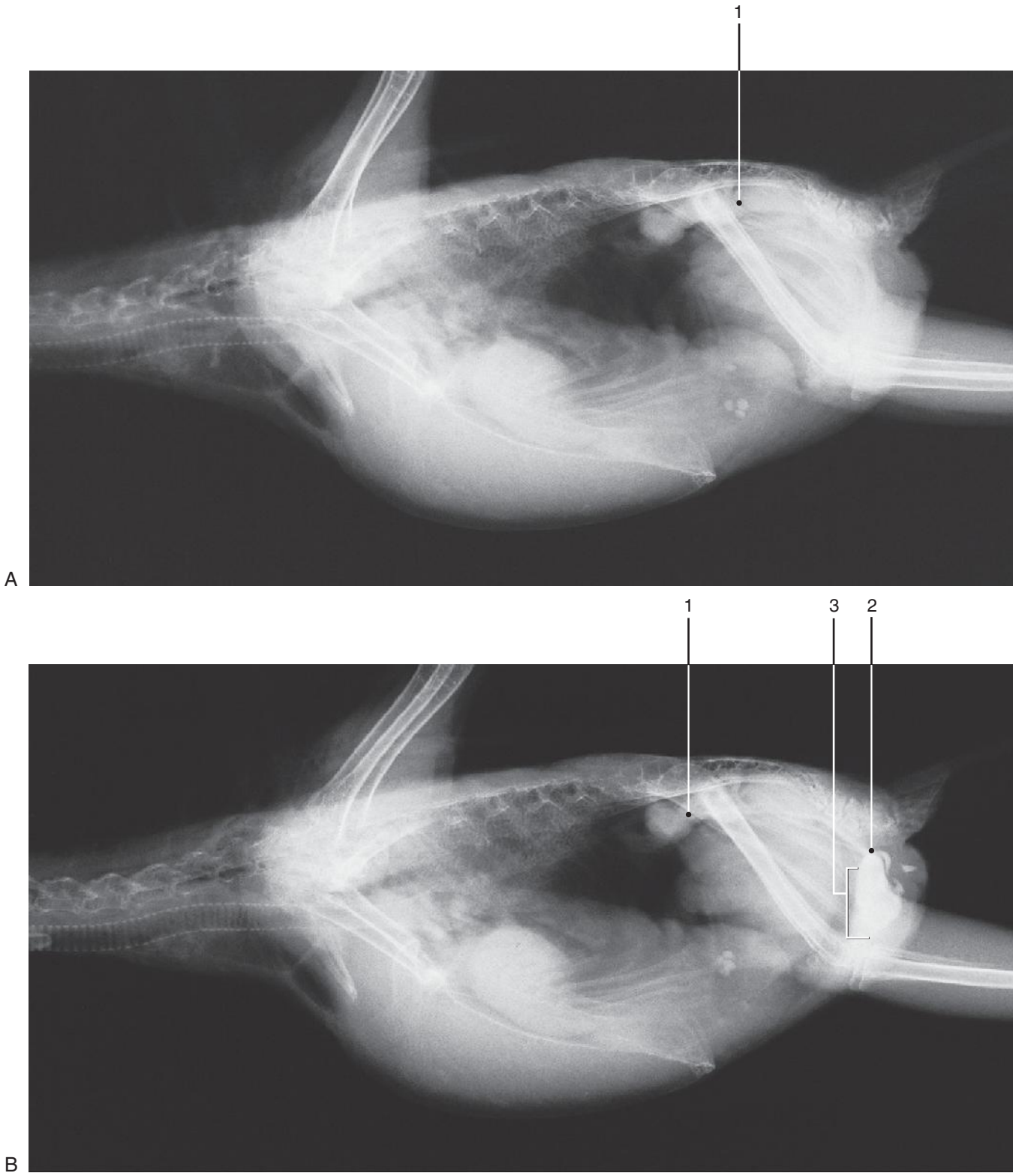

Figure 9-22, A-B
Type of Bird: Orange-Winged Amazon Parrot
Type of Study: Excretory urogram
Contrast Medium: Diatrizoate meglumine, diatrizoate sodium (RenoCal – 76® 37% organically bound iodine; Bracco Diagnostics, Inc., Princeton, NJ) 0.72 ml IV (2 ml/kg) via cutaneous ulnar vein
Projection: Laterolateral (right lateral recumbency)
Weight of Bird: 360 g
Gender: Male
Reproductive Status: Intact
Age: 15 years

Image	Time (min)
A	Scout
B	10

1. Kidneys
2. Ureter
3. Cloaca

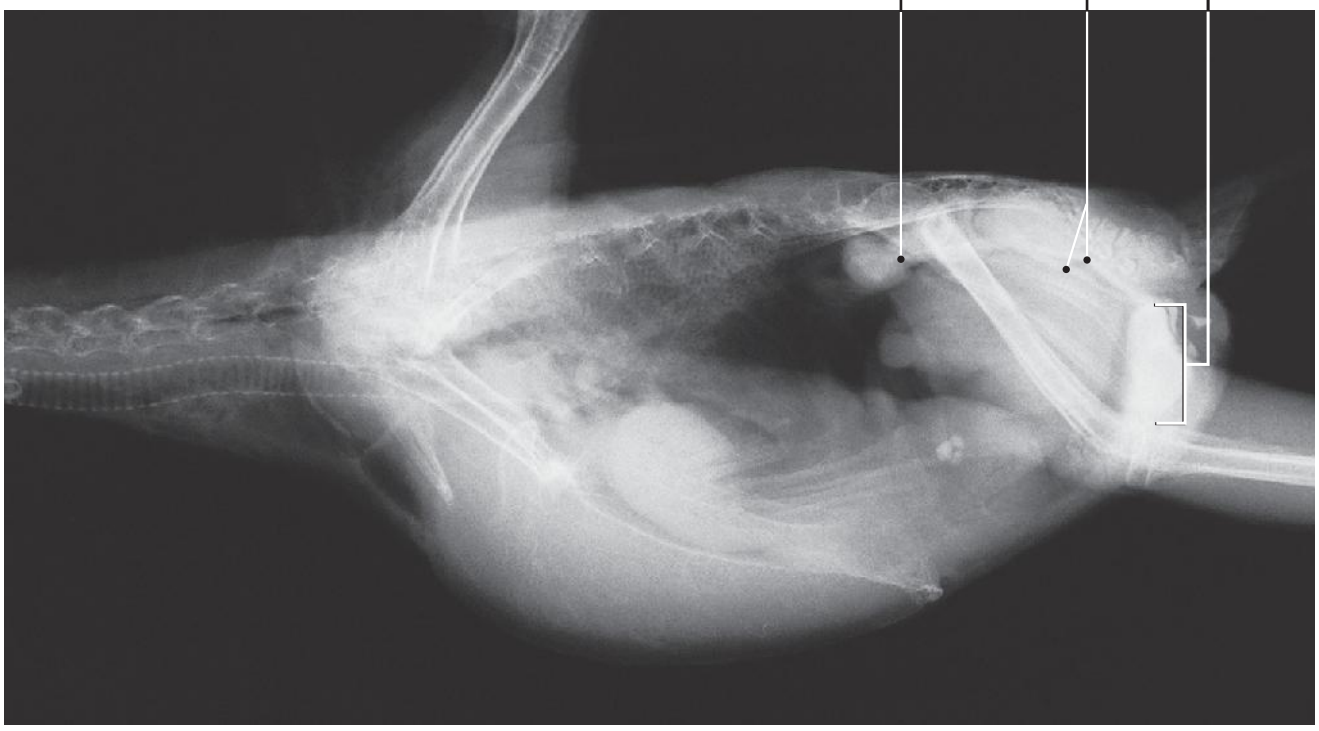

C

Figure 9-22, C
Type of Bird: Orange-Winged Amazon Parrot
Type of Study: Excretory urogram
Contrast Medium: Diatrizoate meglumine, diatrizoate sodium (RenoCal–76® 37% organically bound iodine; Bracco Diagnostics, Inc., Princeton, NJ) 0.72 ml IV (2 ml/kg) via cutaneous ulnar vein
Projection: Laterolateral (right lateral recumbency)
Weight of Animal: 360 g
Gender: Male
Reproductive Status: Intact
Age: 15 years

Image	Time (min)
C	15

1. Kidneys
2. Ureter
3. Cloaca

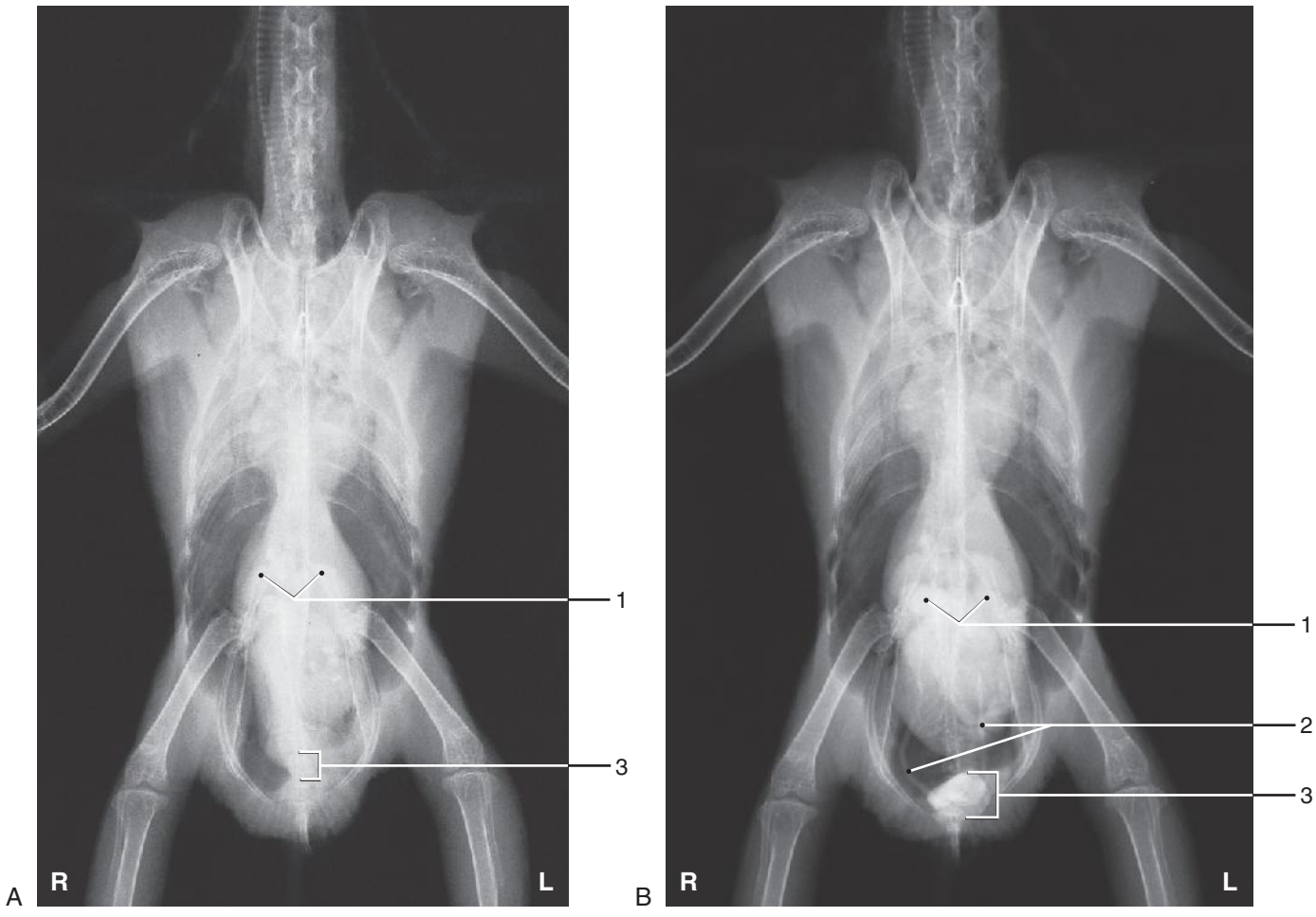

Figure 9-23, A-B

Type of Bird: Orange-Winged Amazon Parrot
Type of Study: Excretory urogram
Contrast Medium: Diatrizoate meglumine, diatrizoate sodium (RenoCal–76® 37% organically bound iodine; Bracco Diagnostics, Inc., Princeton, NJ) 0.72 ml IV (2 ml/kg) via cutaneous ulnar vein
Projection: Ventrodorsal
Weight of Bird: 360 g
Gender: Male
Reproductive Status: Intact
Age: 15 years

Image	Time (min)
A	Scout
B	10

1. Kidneys
2. Ureter
3. Cloaca

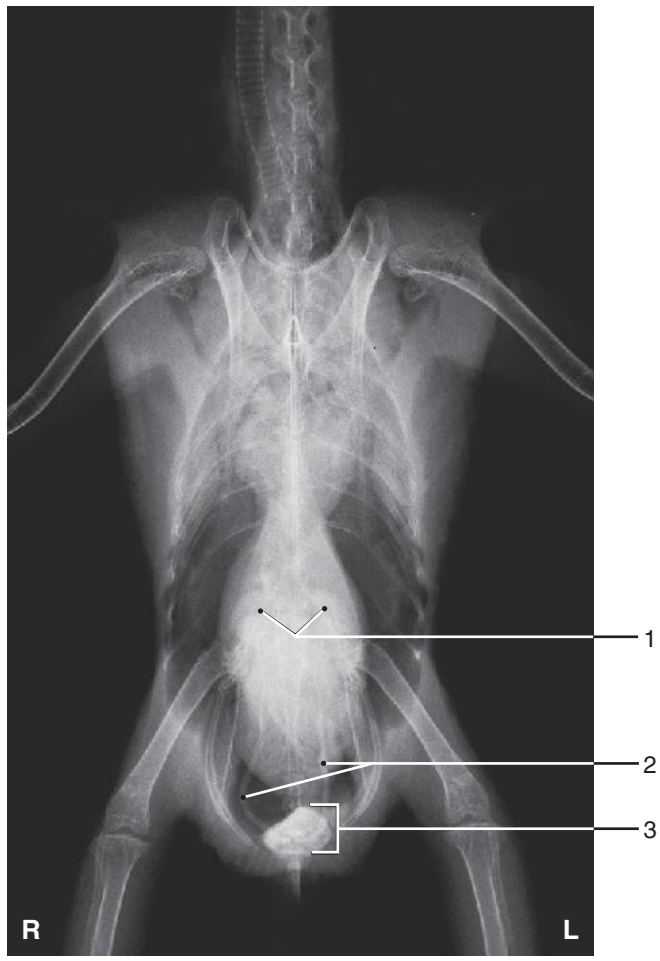

C

Figure 9-23, C

Type of Bird: Orange-Winged Amazon Parrot
Type of Study: Excretory urogram
Contrast Medium: Diatrizoate meglumine, diatrizoate sodium (RenoCal–76® 37% organically bound iodine; Bracco Diagnostics, Inc., Princeton, NJ) 0.72 ml IV (2 ml/kg) via cutaneous ulnar vein
Projection: Ventrodorsal
Weight of Bird: 360 g
Gender: Male
Reproductive Status: Intact
Age: 15 years

Image	Time (min)
C	15

1. Kidneys
2. Ureter
3. Cloaca

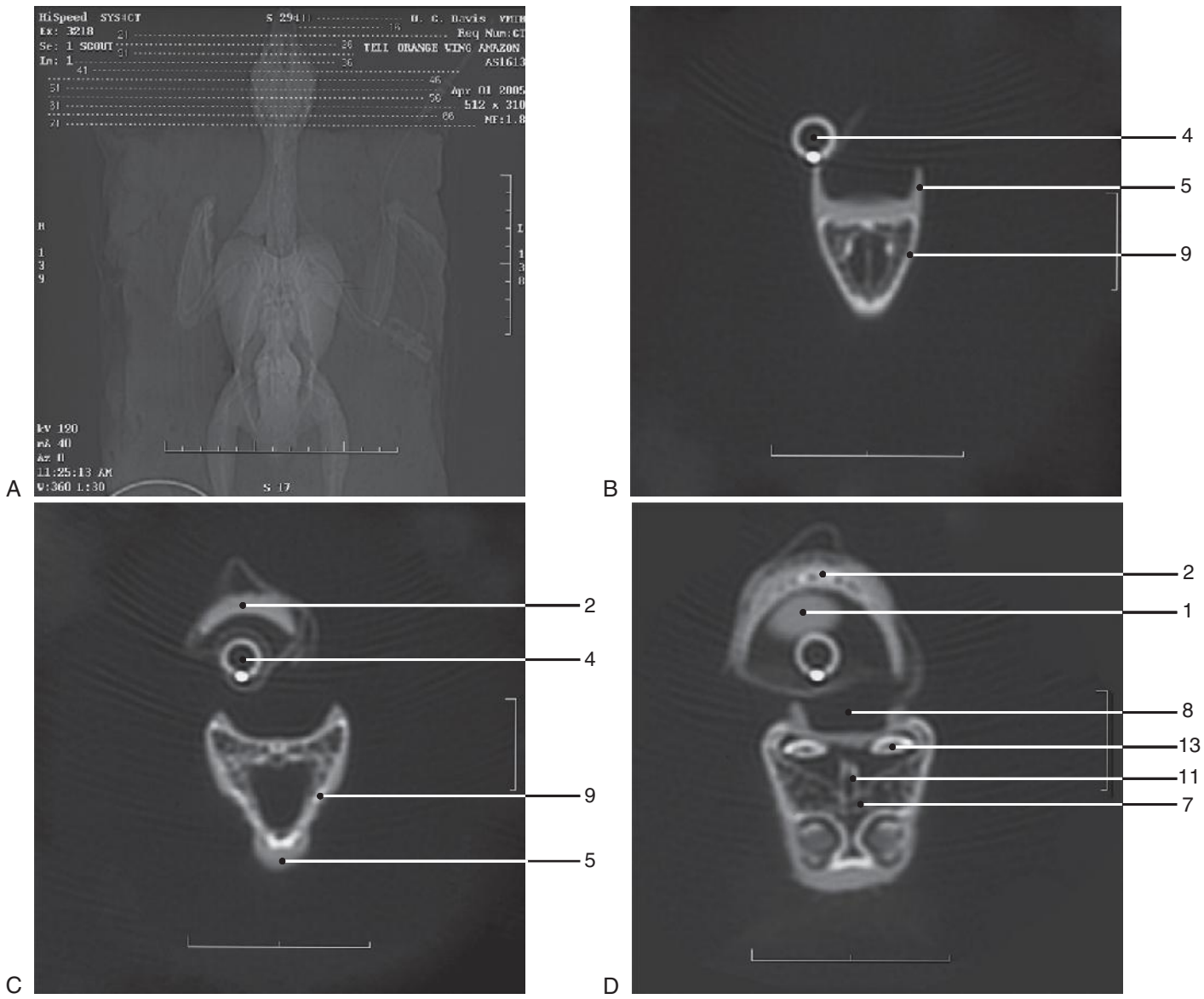

Figure 9-24, A-D
Type of Bird: Orange-Winged Parrot
Type of Study: CT head
Contrast Medium: None
Imaging Plane: Transverse
Weight of Bird: 412 kg
Age: 13 years

1. Tongue
2. Mandible
3. (Hyoid bone)
4. Endotracheal tube
5. Keratinized maxillary beak
6. (Nasal cavity)
7. Nasal concha
8. Pharynx
9. Premaxillary bone
10. (Infraorbital sinus)
11. Nasal septum
12. (Choana)
13. Palatine bone
14. (Sphenoid bone)
15. (Jugal [zygomatic] bone)
16. (Frontal bone)
17. (Pterygoid bone)
18. (Eyeball)
19. (Scleral ossicle)
20. (Interorbital septum)
21. (Lens of eyeball)
22. (Trachea)
23. (Cerebrum)
24. (External ear canal)
25. (Cerebellum)
26. (Spinal cord)
27. (Dens)
28. (Cere)
29. (Nare[s])
30. (Feather)
31. (Pons)
32. (Occipital bone)
33. (Cervical vertebra)

NOTE: Structures in parentheses are not labeled.

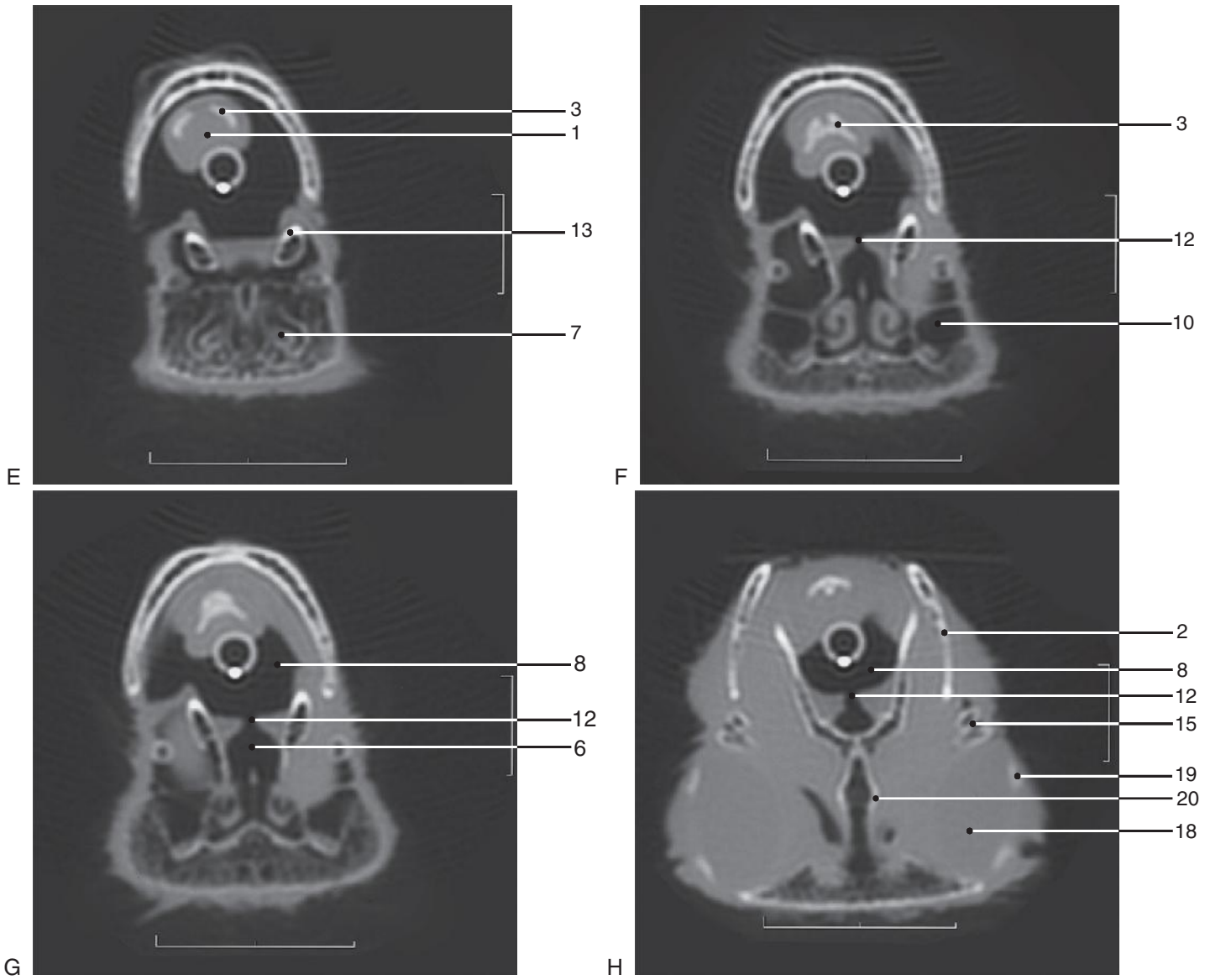

Figure 9-24, E-H
Type of Bird: Orange-Winged Amazon Parrot
Type of Study: CT head
Contrast Medium: None
Imaging Plane: Transverse
Weight of Bird: 412 kg
Age: 13 years

1. Tongue
2. Mandible
3. Hyoid bone
4. (Endotracheal tube)
5. (Keratinized maxillary beak)
6. Nasal cavity
7. Nasal concha
8. Pharynx
9. (Premaxillary bone)
10. Infraorbital sinus
11. (Nasal septum)
12. Choana
13. Palatine bone
14. (Sphenoid bone)
15. Jugal [zygomatic] bone
16. (Frontal bone)
17. (Pterygoid bone)
18. Eyeball
19. Scleral ossicle
20. Interorbital septum
21. (Lens of eyeball)
22. (Trachea)
23. (Cerebrum)
24. (External ear canal)
25. (Cerebellum)
26. (Spinal cord)
27. (Dens)
28. (Cere)
29. (Nare[s])
30. (Feather)
31. (Pons)
32. (Occipital bone)
33. (Cervical vertebra)

NOTE: Structures in parentheses are not labeled.

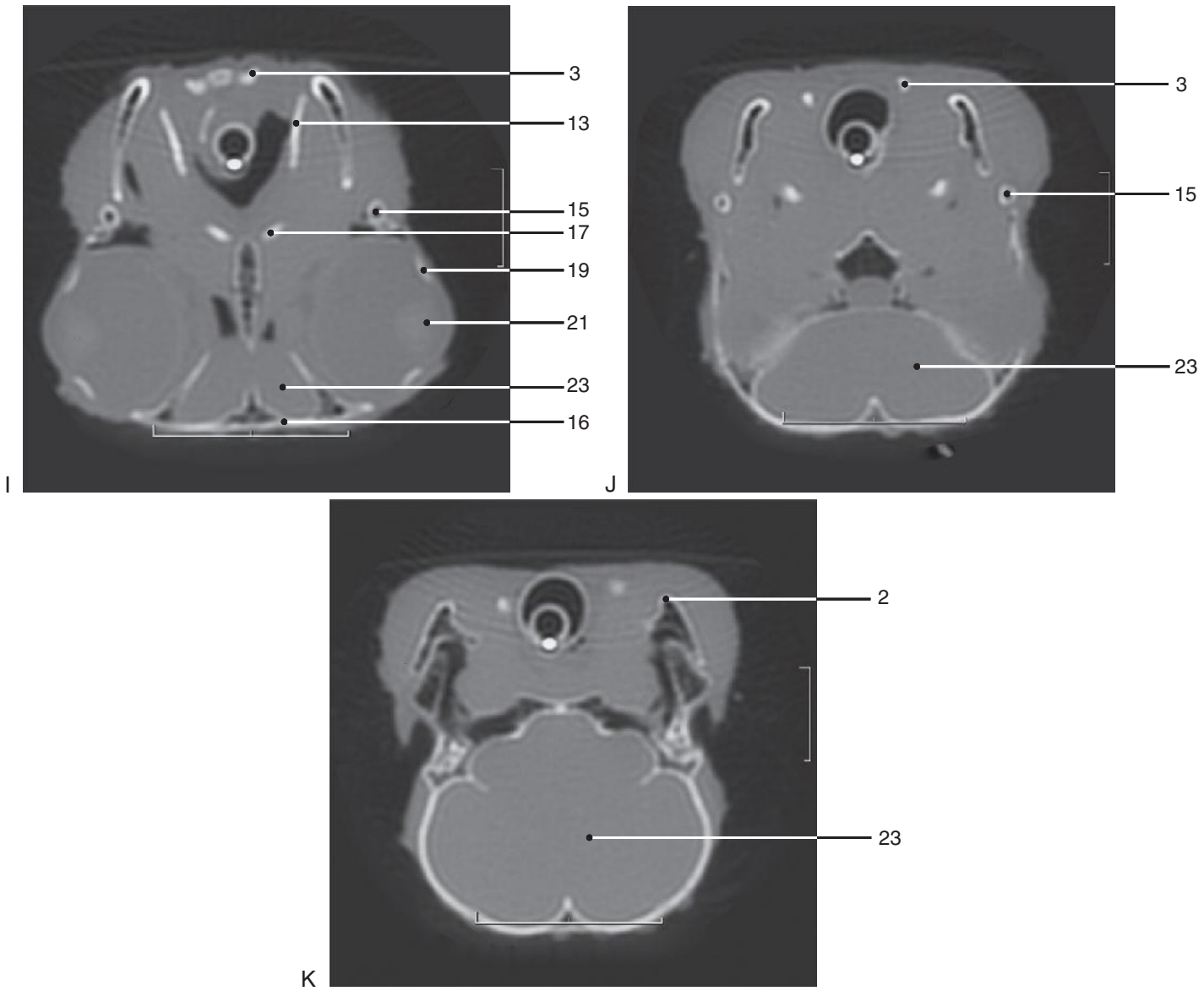

Figure 9-24, I-K
Type of Bird: Orange-Winged Amazon Parrot
Type of Study: CT head
Contrast Medium: None
Imaging Plane: Transverse
Weight of Bird: 412 kg
Age: 13 years

1. (Tongue)
2. Mandible
3. Hyoid bone
4. (Endotracheal tube)
5. (Keratinized maxillary beak)
6. (Nasal cavity)
7. (Nasal concha)
8. (Pharynx)
9. (Premaxillary bone)
10. (Infraorbital sinus)
11. (Nasal septum)
12. (Choana)
13. Palatine bone
14. (Sphenoid bone)
15. Jugal [zygomatic] bone
16. Frontal bone
17. Pterygoid bone
18. (Eyeball)
19. Scleral ossicle
20. (Interorbital septum)
21. Lens of eyeball
22. (Trachea)
23. Cerebrum
24. (External ear canal)
25. (Cerebellum)
26. (Spinal cord)
27. (Dens)
28. (Cere)
29. (Nare[s])
30. (Feather)
31. (Pons)
32. (Occipital bone)
33. (Cervical vertebra)

NOTE: Structures in parentheses are not labeled.

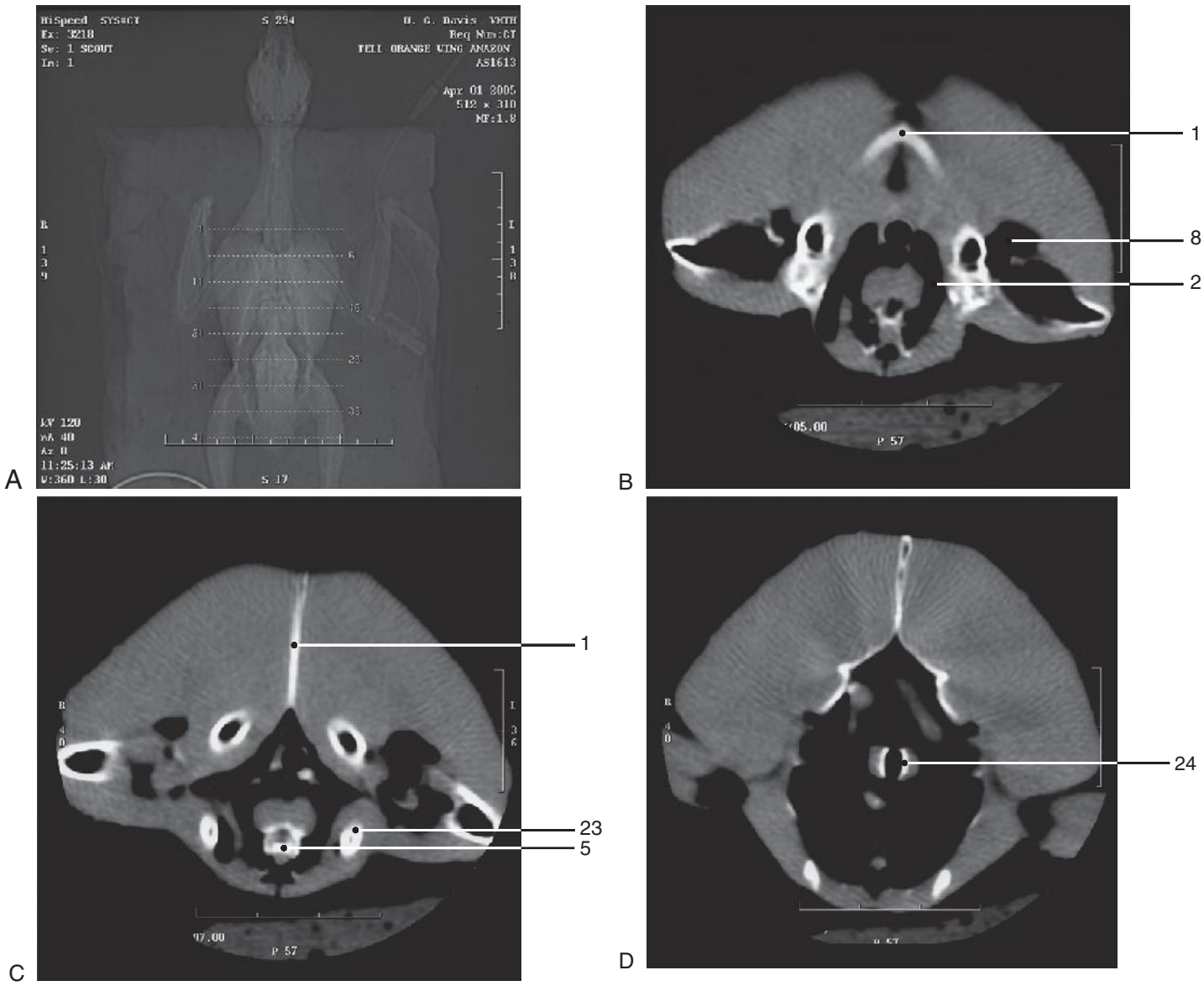

Figure 9-25, A-D
Type of Bird: Orange-Winged Amazon Parrot
Type of Study: CT coelom
Contrast Medium: None
Imaging Plane: Transverse
Weight of bird: 412 kg
Age: 13 years

1. Sternum
2. Thoracic air sac
3. (Lung)
4. (Esophagus)
5. Thoracic vertebra
6. (Heart)
7. (Blood vessels)
8. Thoracic extremity [wing]
9. (Proventriculus)
10. (Ventriculus)
11. (Intestines)
12. (Pelvic extremity [leg])
13. (Abdominal air sac)
14. (Ilium)
15. (Liver)
16. (Kidney)
17. (Caudal vertebra)
18. (Rib)
19. (Aorta)
20. (Pubic bone)
21. (Cloaca)
22. (Clavicular air sac)
23. Scapula
24. Syrinx
25. (Ischium)
26. (Colon)
27. (Spinal cord)

NOTE: Structures in parentheses are not labeled.

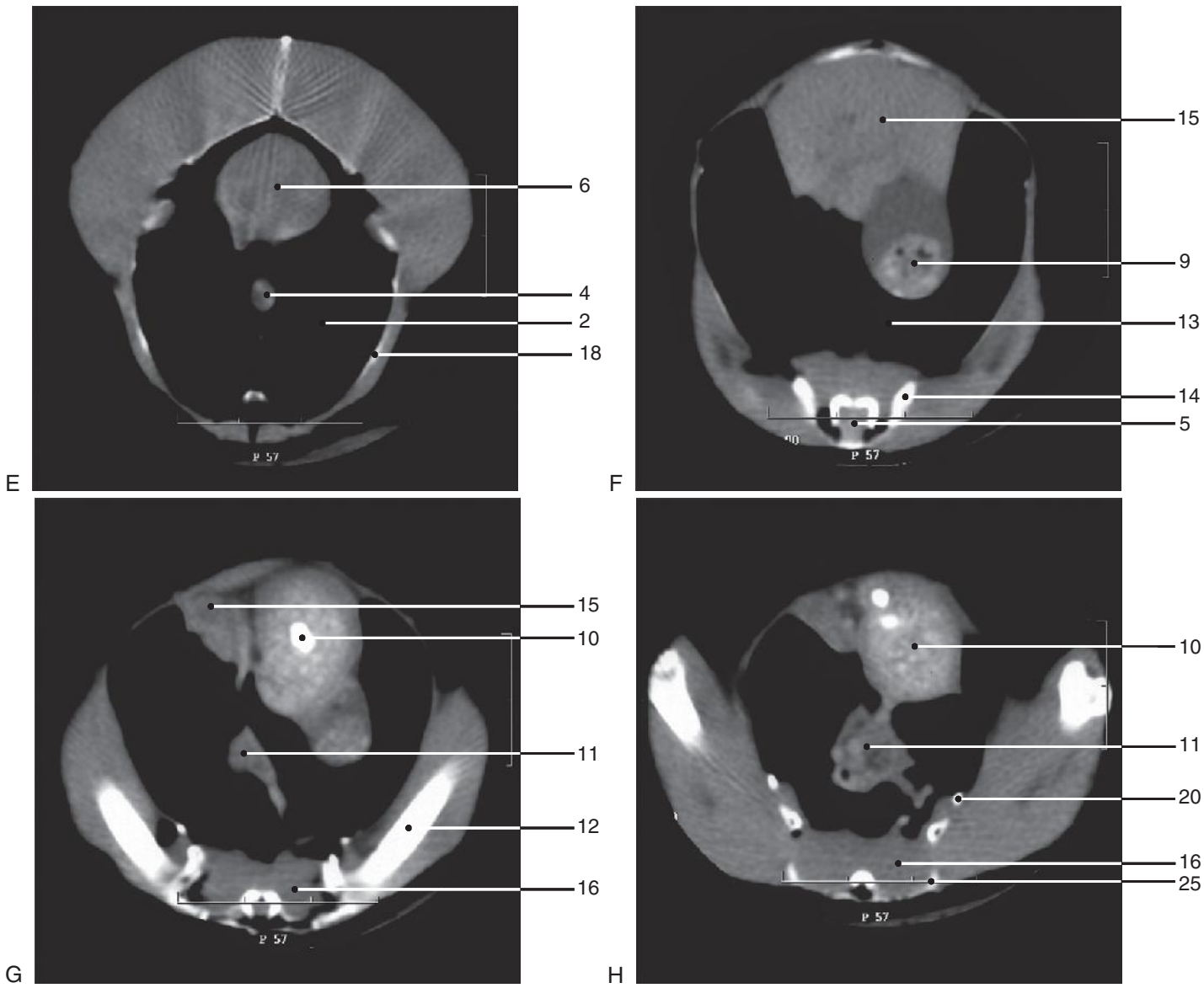

Figure 9-25, E-H
Type of Bird: Orange-Winged Amazon Parrot
Type of Study: CT coelom
Contrast Medium: None
Imaging Plane: Transverse
Weight of Bird: 412 kg
Age: 13 years

1. (Sternum)
2. Thoracic air sac
3. (Lung)
4. Esophagus
5. Thoracic vertebra
6. Heart
7. Blood vessels
8. (Thoracic extremity [wing])
9. Proventriculus
10. Ventriculus
11. Intestines
12. Pelvic extremity [leg]
13. Abdominal air sac
14. Ilium
15. Liver
16. Kidney
17. (Caudal vertebra)
18. Rib
19. (Aorta)
20. Pubic bone
21. (Cloaca)
22. (Clavicular air sac)
23. (Scapula)
24. (Syrinx)
25. Ischium
26. (Colon)
27. (Spinal cord)

NOTE: Structures in parentheses are not labeled.

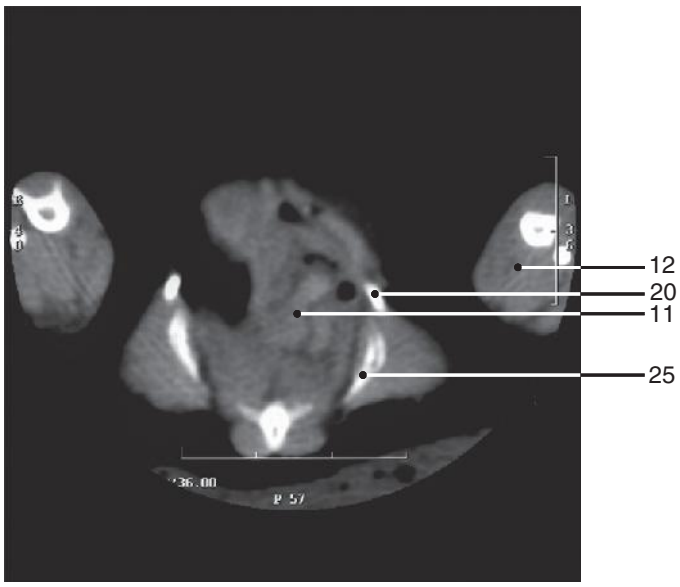

I

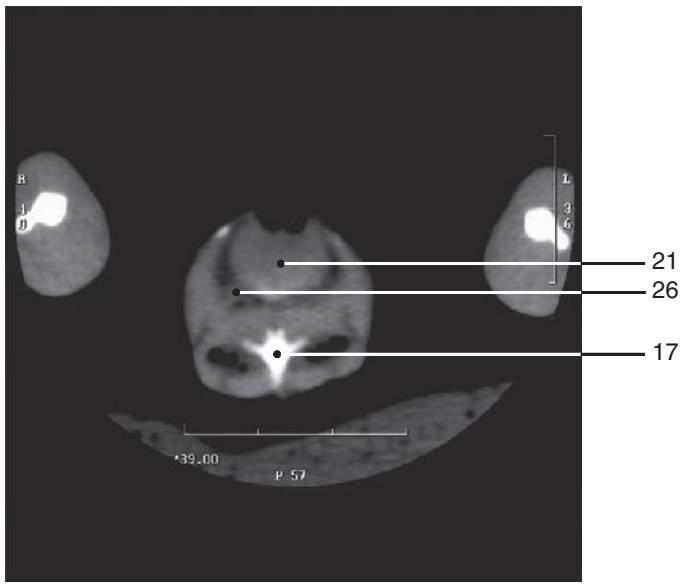

J

Figure 9-25, I-J
Type of Bird: Orange-Winged Amazon Parrot
Type of Study: CT coelom
Contrast Medium: None
Imaging Plane: Transverse
Weight of Bird: 412 kg
Age: 13 years

1. (Sternum)
2. (Thoracic air sac)
3. (Lung)
4. (Esophagus)
5. (Thoracic vertebra)
6. (Heart)
7. (Blood vessels)
8. (Thoracic extremity [wing])
9. (Proventriculus)
10. (Ventriculus)
11. Intestines
12. Pelvic extremity [leg]
13. (Abdominal air sac)
14. (Ilium)
15. (Liver)
16. (Kidney)
17. Caudal vertebra
18. (Rib)
19. (Aorta)
20. Pubic bone
21. Cloaca
22. (Clavicular air sac)
23. (Scapula)
24. (Syrinx)
25. Ischium
26. Colon
27. (Spinal cord)

NOTE: Structures in parentheses are not labeled.

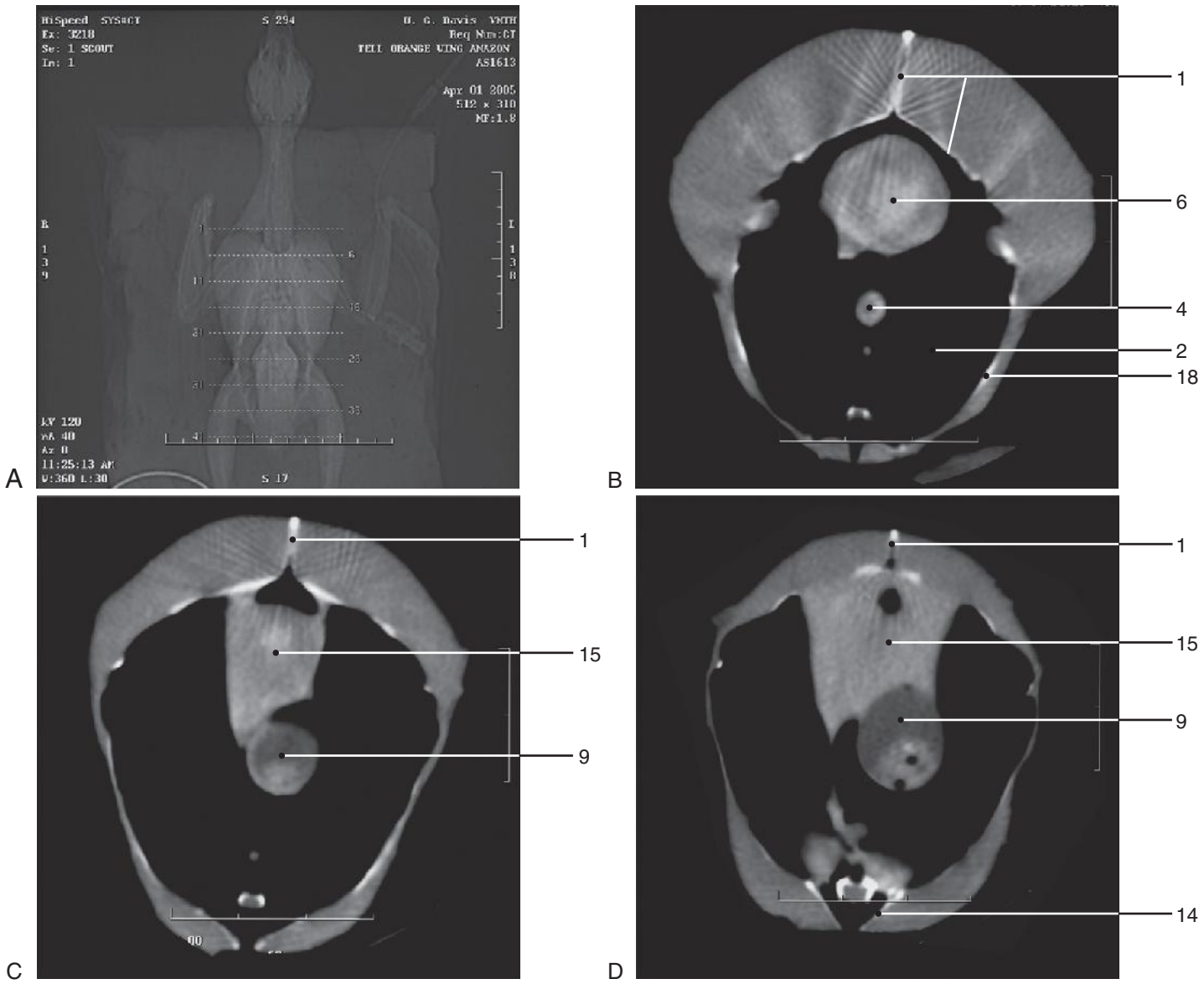

Figure 9-26, A-D

Type of Bird: Orange-Winged Amazon Parrot
Type of Study: CT coelom (post-contrast)
Contrast Medium: Iopamidol injection 41% (Isovue®-200, Bracco Diagnostics Inc., Princeton, NJ 08543) 0.4 ml (1 ml/kg) intravenously via cutaneous ulnar vein
Imaging Plane: Transverse
Weight of Bird: 412 kg
Age: 13 years

1. Sternum
2. Thoracic air sac
3. (Lung)
4. Esophagus
5. (Thoracic vertebra)
6. Heart
7. (Blood vessels)
8. (Thoracic extremity [wing])
9. Proventriculus
10. (Ventriculus)
11. (Intestines)
12. (Pelvic extremity [leg])
13. (Abdominal air sac)
14. Ilium
15. Liver
16. (Kidney)
17. (Caudal vertebra)
18. Rib
19. (Aorta)
20. (Pubic bone)
21. (Cloaca)
22. (Clavicular air sac)
23. (Scapula)
24. (Syrinx)
25. (Ischium)
26. (Colon)
27. (Spinal cord)

NOTE: Structures in parentheses are not labeled.

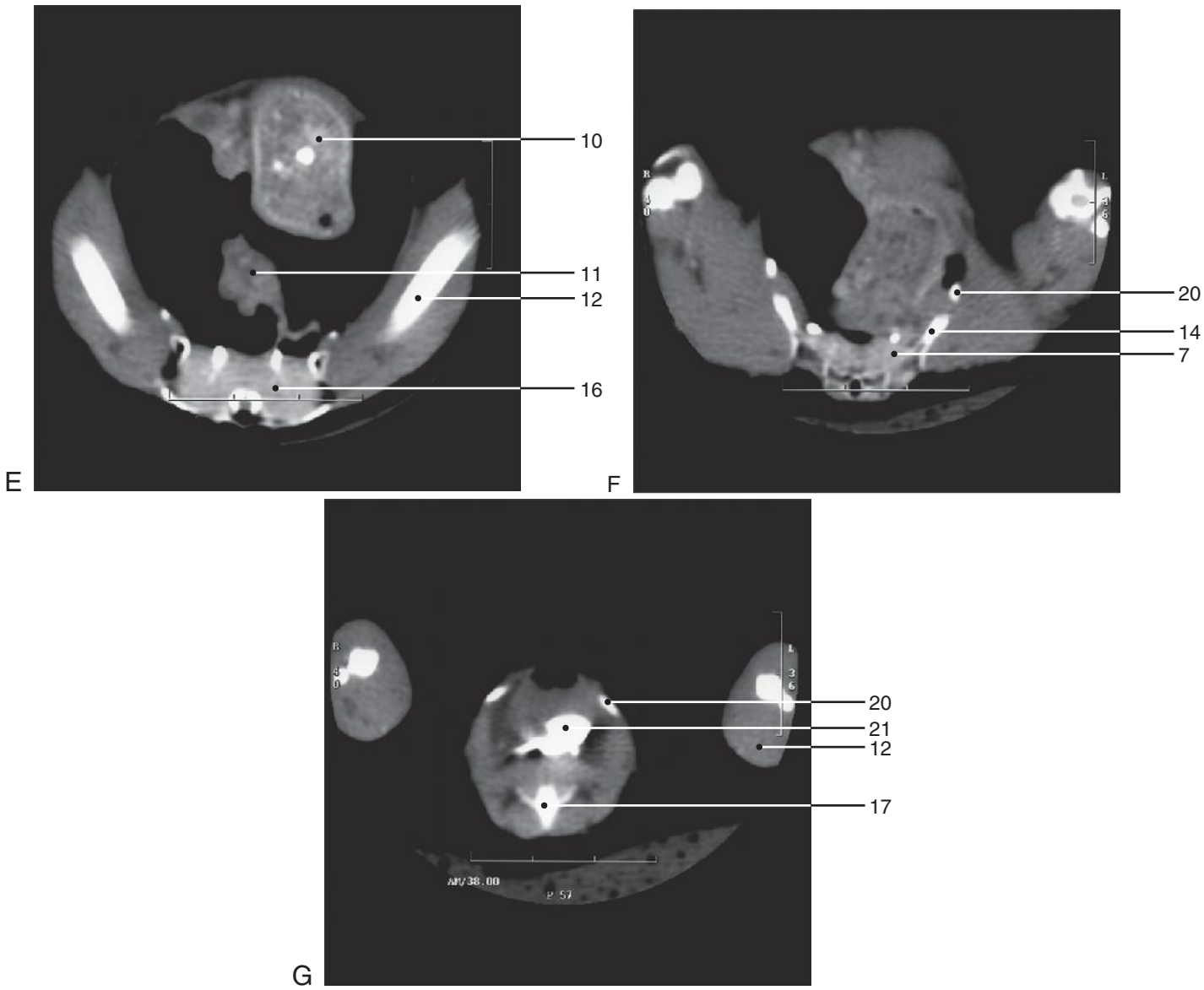

Figure 9-26, E-G
Type of Bird: Orange-Winged Amazon Parrot
Type of Study: CT coelom (post-contrast)
Contrast Medium: Iopamidol injection 41% (Isovue®-200, Bracco Diagnostics Inc., Princeton, NJ 08543) 0.4 ml (1 ml/kg) intravenously via cutaneous ulnar vein
Imaging Plane: Transverse
Weight of Bird: 412 kg
Age: 13 years

1. (Sternum)
2. (Thoracic air sac)
3. (Lung)
4. (Esophagus)
5. (Thoracic vertebra)
6. (Heart)
7. Blood vessels
8. (Thoracic extremity [wing])
9. (Proventriculus)
10. Ventriculus
11. Intestines
12. Pelvic extremity [leg]
13. (Abdominal air sac)
14. Ilium
15. (Liver)
16. Kidney
17. Caudal vertebra
18. (Rib)
19. (Aorta)
20. Pubic bone
21. Cloaca
22. (Clavicular air sac)
23. (Scapula)
24. (Syrinx)
25. (Ischium)
26. (Colon)
27. (Spinal cord)

NOTE: Structures in parentheses are not labeled.

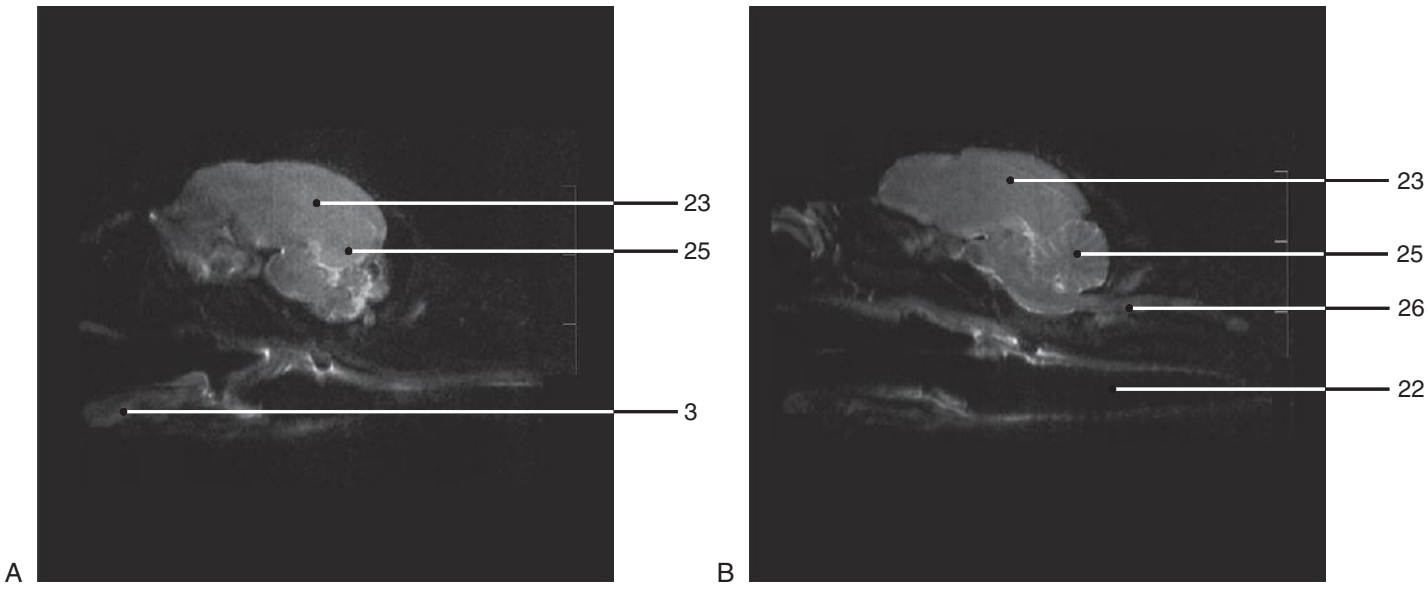

Figure 9-27, A-B
Type of Bird: Orange-Winged Amazon Parrot
Type of Study: MRI head (T1)
Contrast Medium: None
Imaging Plane: Sagittal
Weight of Bird: 360 g
Age: 15 years

1. (Tongue)
2. (Mandible)
3. Hyoid bone
4. (Endotracheal tube)
5. (Keratinized maxillary beak)
6. (Nasal cavity)
7. (Nasal concha)
8. (Pharynx)
9. (Premaxillary bone)
10. (Infraorbital sinus)
11. (Nasal septum)
12. (Choana)
13. (Palatine bone)
14. (Sphenoid bone)
15. (Jugal [zygomatic] bone)
16. (Frontal bone)
17. (Pterygoid bone)
18. (Eyeball)
19. (Scleral ossicle)
20. (Interorbital septum)
21. (Lens of eyeball)
22. Trachea
23. Cerebrum
24. (External ear canal)
25. Cerebellum
26. Spinal cord
27. (Dens)
28. (Cere)
29. (Nare[s])
30. (Feather)
31. (Pons)
32. (Occipital bone)
33. (Cervical vertebra)

NOTE: Structures in parentheses are not labeled.

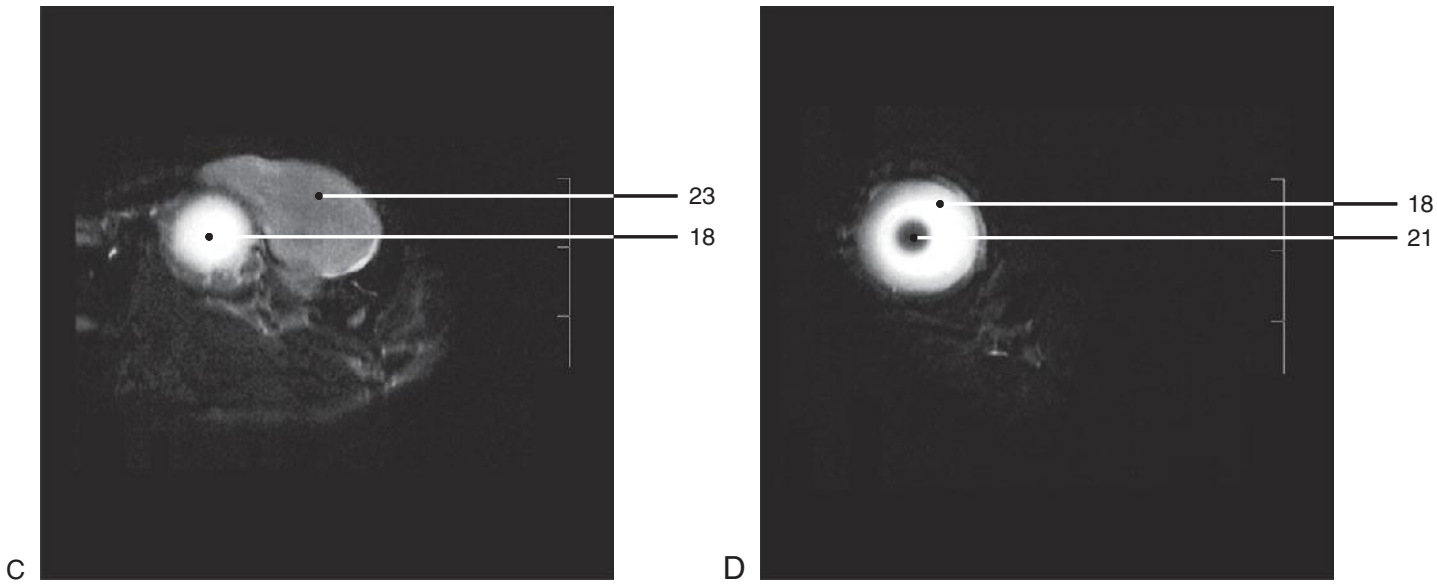

Figure 9-27, C-D
Type of Bird: Orange-Winged Amazon Parrot
Type of Study: MRI head (T1)
Contrast Medium: None
Imaging Plane: Sagittal
Weight of Bird: 360 g
Age: 15 years

1. (Tongue)
2. (Mandible)
3. (Hyoid bone)
4. (Endotracheal tube)
5. (Keratinized maxillary beak)
6. (Nasal cavity)
7. (Nasal concha)
8. (Pharynx)
9. (Premaxillary bone)
10. (Infraorbital sinus)
11. (Nasal septum)
12. (Choana)
13. (Palatine bone)
14. (Sphenoid bone)
15. (Jugal [zygomatic] bone)
16. (Frontal bone)
17. (Pterygoid bone)
18. Eyeball
19. (Scleral ossicle)
20. (Interorbital septum)
21. Lens of eyeball
22. (Trachea)
23. Cerebrum
24. (External ear canal)
25. (Cerebellum)
26. (Spinal cord)
27. (Dens)
28. (Cere)
29. (Nare[s])
30. (Feather)
31. (Pons)
32. (Occipital bone)
33. (Cervical vertebra)

NOTE: Structures in parentheses are not labeled.

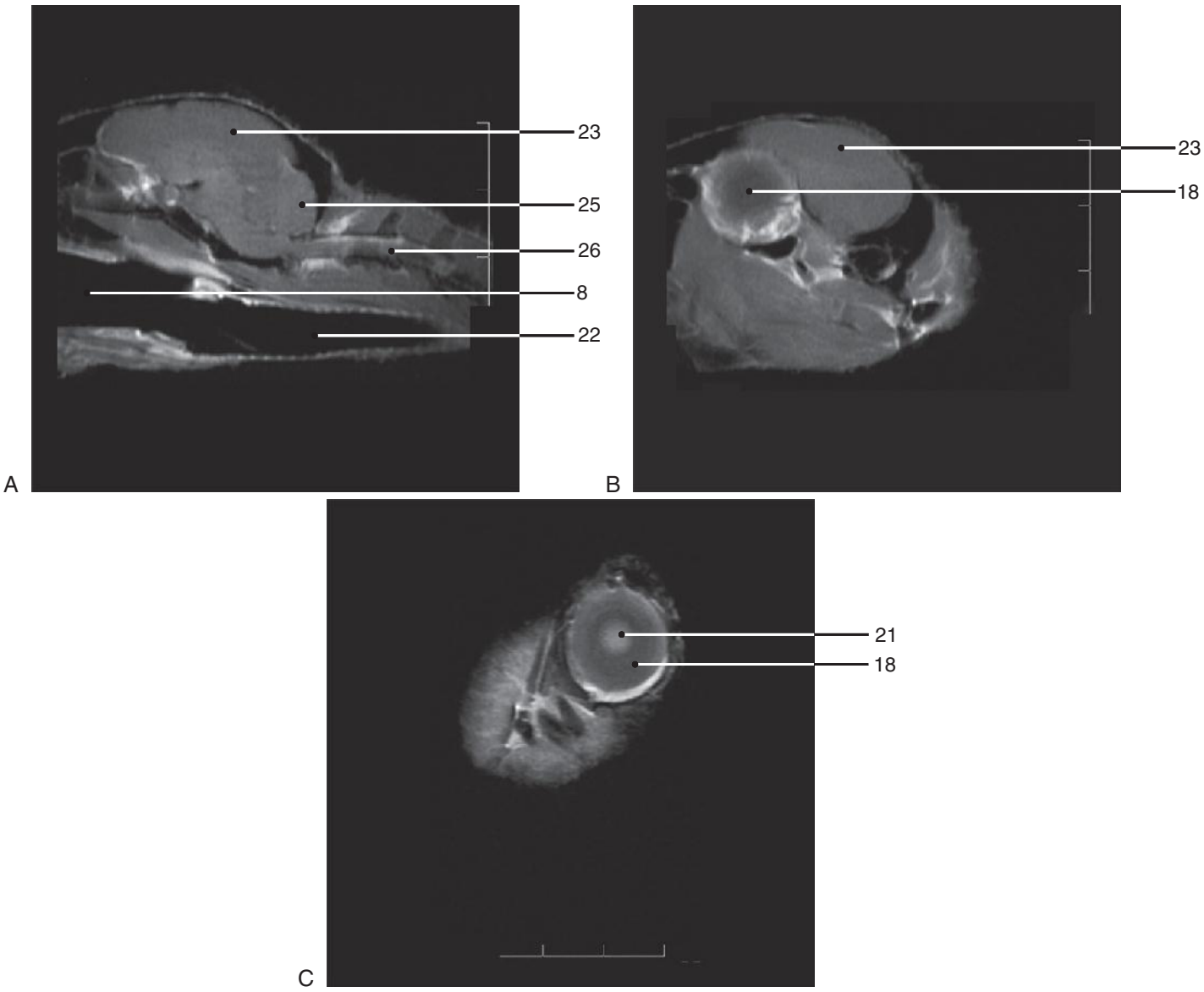

Figure 9-28, A-C

Type of Bird: Orange-Winged Amazon Parrot
Type of Study: MRI head (T1 post-contrast)
Contrast Medium: Gadopentetate dimeglumine (Magnevist® injection, Bayer Health Care Pharmaceuticals, Wayne NJ 07470) 0.07 ml (0.2 ml/kg) administered directly into a catheter in the cutaneous ulnar vein.
Imaging Plane: Sagittal
Weight of Bird: 360 g
Age: 15 years

1. (Tongue)
2. (Mandible)
3. (Hyoid bone)
4. (Endotracheal tube)
5. (Keratinized maxillary beak)
6. (Nasal cavity)
7. (Nasal concha)
8. Pharynx
9. (Premaxillary bone)
10. (Infraorbital sinus)
11. (Nasal septum)
12. (Choana)
13. (Palatine bone)
14. (Sphenoid bone)
15. (Jugal [zygomatic] bone)
16. (Frontal bone)
17. (Pterygoid bone)
18. Eyeball
19. (Scleral ossicle)
20. (Interorbital septum)
21. Lens of eyeball
22. Trachea
23. Cerebrum
24. (External ear canal)
25. Cerebellum
26. Spinal cord
27. (Dens)
28. (Cere)
29. (Nare[s])
30. (Feather)
31. (Pons)
32. (Occipital bone)
33. (Cervical vertebra)

NOTE: Structures in parentheses are not labeled.

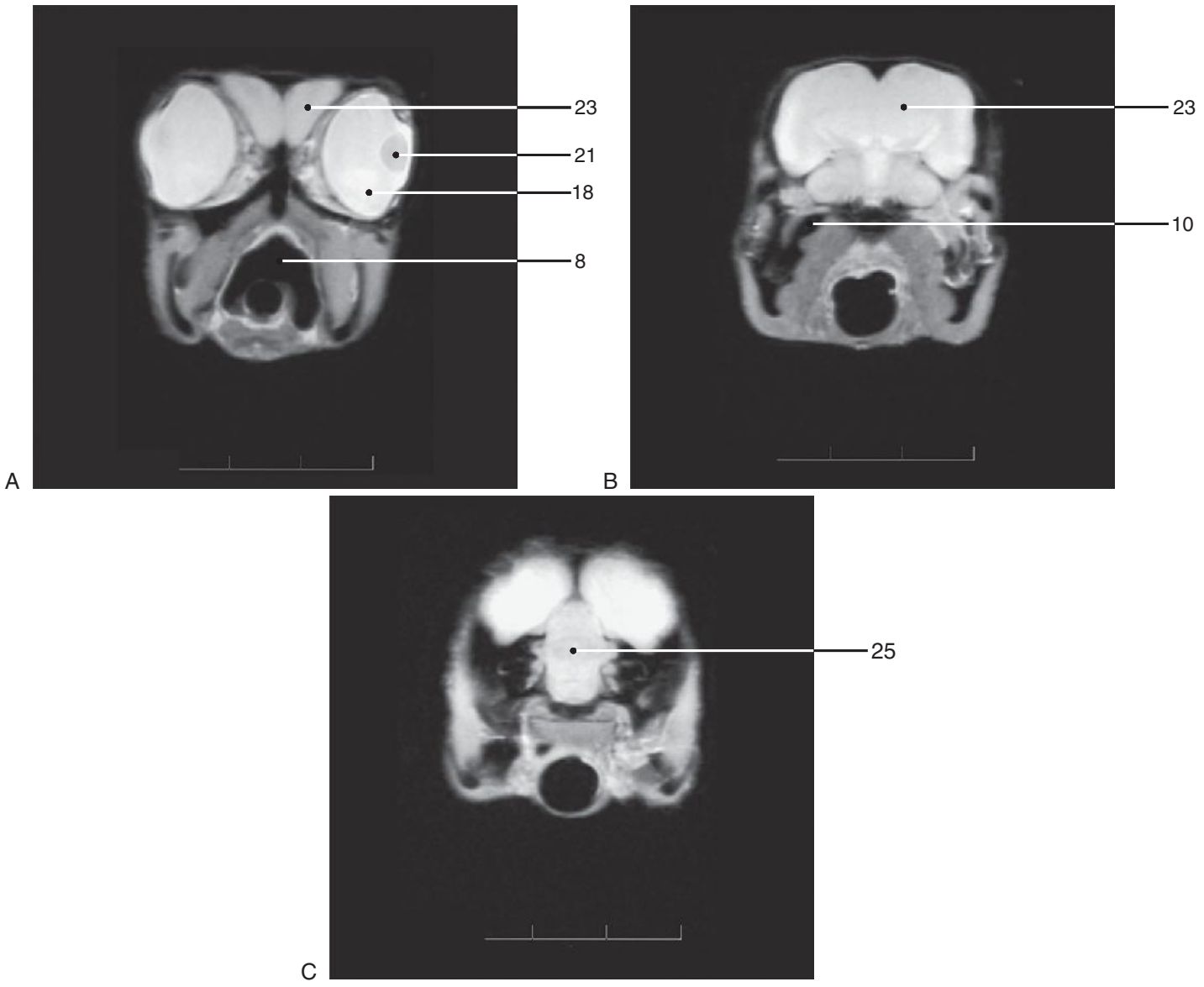

Figure 9-29, A-C
Type of Bird: Orange-Winged Amazon Parrot
Type of Study: MRI head (T1)
Contrast Medium: None
Imaging Plane: Transverse
Weight of Bird: 360 g
Age: 15 years

1. (Tongue)
2. (Mandible)
3. (Hyoid bone)
4. (Endotracheal tube)
5. (Keratinized maxillary beak)
6. (Nasal cavity)
7. (Nasal concha)
8. Pharynx
9. (Premaxillary bone)
10. Infraorbital sinus
11. (Nasal septum)
12. (Choana)
13. (Palatine bone)
14. (Sphenoid bone)
15. (Jugal [zygomatic] bone)
16. (Frontal bone)
17. (Pterygoid bone)
18. Eyeball
19. (Scleral ossicle)
20. (Interorbital septum)
21. Lens of eyeball
22. (Trachea)
23. Cerebrum
24. (External ear canal)
25. Cerebellum
26. (Spinal cord)
27. (Dens)
28. (Cere)
29. (Nare[s])
30. (Feather)
31. (Pons)
32. (Occipital bone)
33. (Cervical vertebra)

NOTE: Structures in parentheses are not labeled.

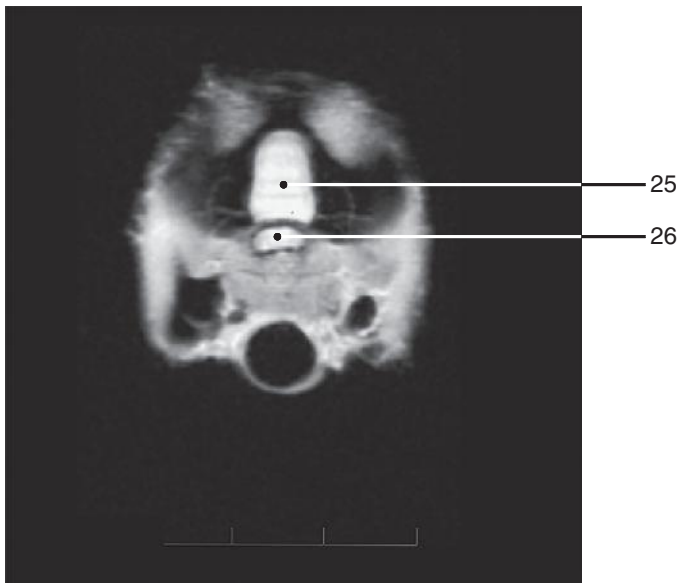

D

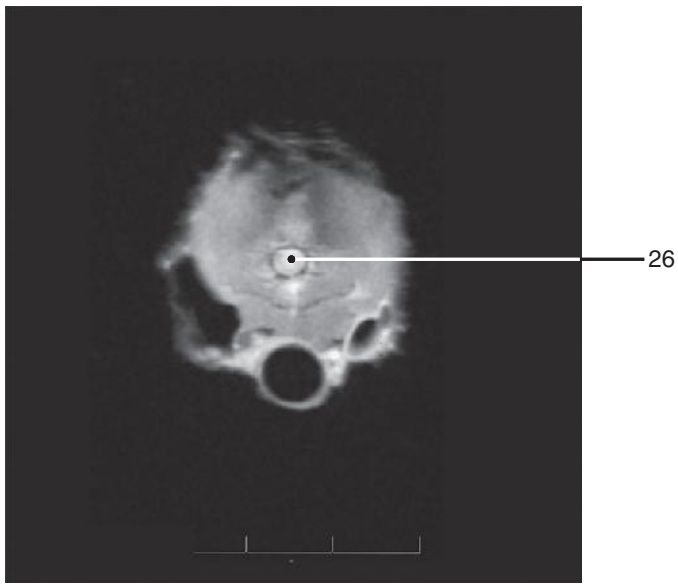

E

Figure 9-29, D-E
Type of Bird: Orange-Winged Amazon Parrot
Type of Study: MRI head (T1)
Contrast Medium: None
Imaging Plane: Transverse
Weight of Bird: 360 g
Age: 15 years

1. (Tongue)
2. (Mandible)
3. (Hyoid bone)
4. (Endotracheal tube)
5. (Keratinized maxillary beak)
6. (Nasal cavity)
7. (Nasal concha)
8. (Pharynx)
9. (Premaxillary bone)
10. (Infraorbital sinus)
11. (Nasal septum)
12. (Choana)
13. (Palatine bone)
14. (Sphenoid bone)
15. (Jugal [zygomatic] bone)
16. (Frontal bone)
17. (Pterygoid bone)
18. (Eyeball)
19. (Scleral ossicle)
20. (Interorbital septum)
21. (Lens of eyeball)
22. (Trachea)
23. (Cerebrum)
24. (External ear canal)
25. Cerebellum
26. Spinal cord
27. (Dens)
28. (Cere)
29. (Nare[s])
30. (Feather)
31. (Pons)
32. (Occipital bone)
33. (Cervical vertebra)

NOTE: Structures in parentheses are not labeled.

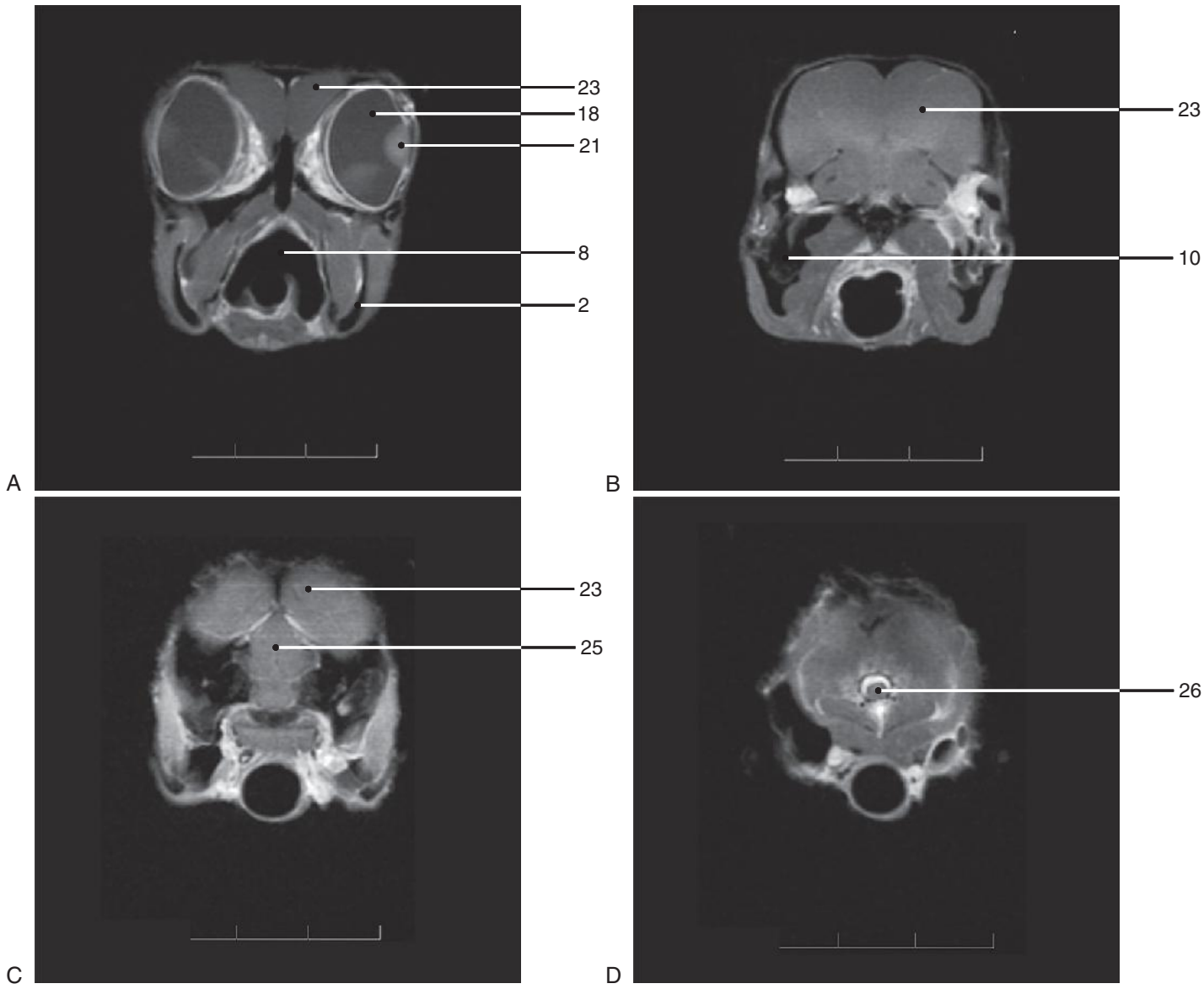

Figure 9-30, A-D

Type of Bird: Orange-Winged Amazon Parrot
Type of Study: MRI head (T1 post-contrast)
Contrast Medium: Gadopentetate dimeglumine (Magnevist® injection, Bayer Health Care Pharmaceuticals, Wayne NJ 07470) 0.07 ml (0.2 ml/kg) administered directly into a catheter in the cutaneous ulnar vein.
Imaging Plane: Transverse
Weight of Bird: 360 g
Age: 15 years

1. (Tongue)
2. Mandible
3. (Hyoid bone)
4. (Endotracheal tube)
5. (Keratinized maxillary beak)
6. (Nasal cavity)
7. (Nasal concha)
8. Pharynx
9. (Premaxillary bone)
10. Infraorbital sinus
11. (Nasal septum)
12. (Choana)
13. (Palatine bone)
14. (Sphenoid bone)
15. (Jugal [zygomatic] bone)
16. (Frontal bone)
17. (Pterygoid bone)
18. Eyeball
19. (Scleral ossicle)
20. (Interorbital septum)
21. Lens of eyeball
22. (Trachea)
23. Cerebrum
24. (External ear canal)
25. Cerebellum
26. Spinal cord
27. (Dens)
28. (Cere)
29. (Nare[s])
30. (Feather)
31. (Pons)
32. (Occipital bone)
33. (Cervical vertebra)

NOTE: Structures in parentheses are not labeled.

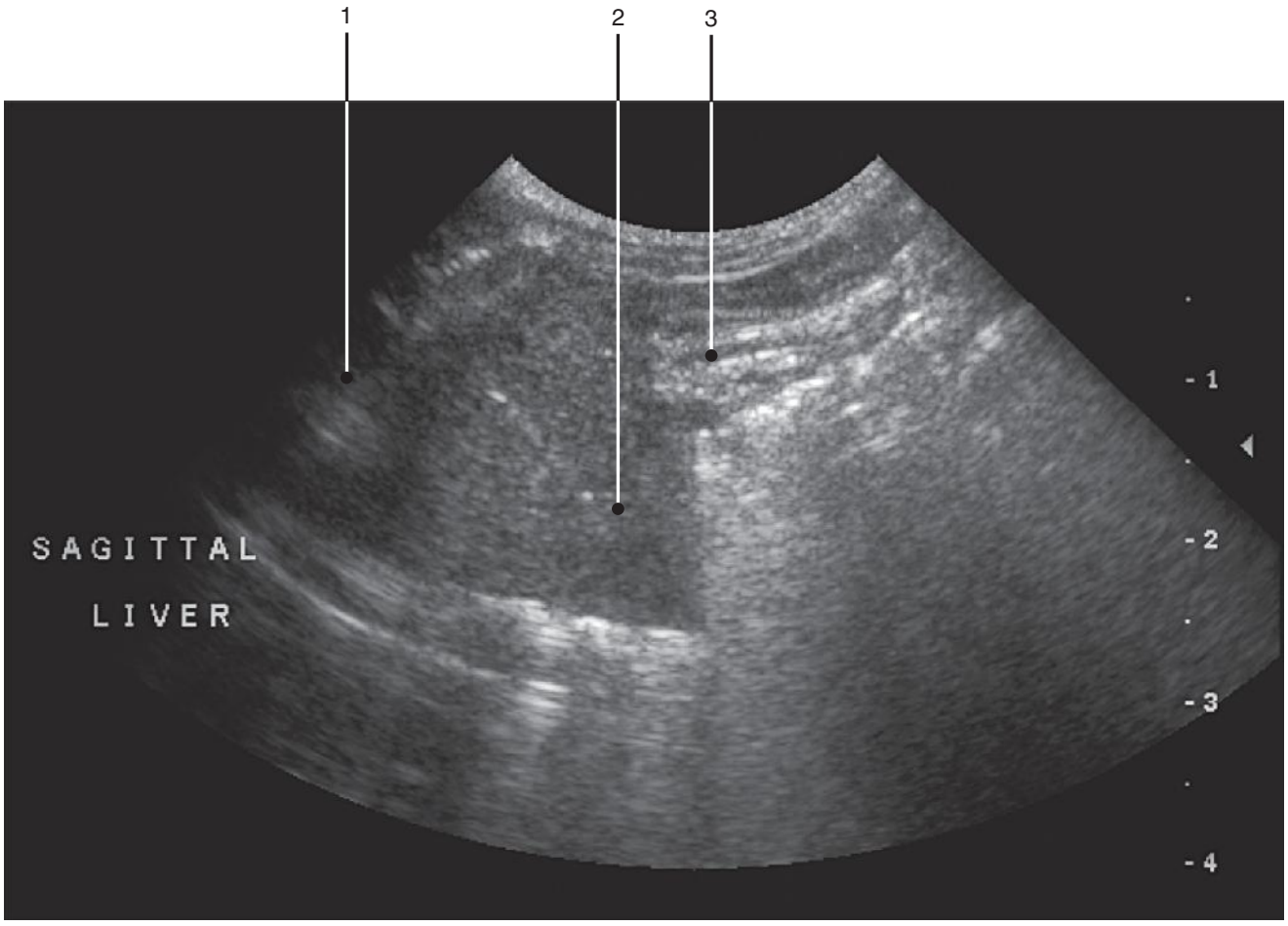

Figure 9-31
Type of Bird: Orange-Winged Amazon Parrot
Body Condition: Normal
Type of Study: Ultrasound study of the liver
Projection: Sagittal
Weight of Animal: 412 g
Gender: Unknown
Reproductive Status: Intact
Age: 13 years

1. Heart
2. Liver
3. Intestines

CHAPTER • 10

Blue and Gold Macaw
(Ara ararauna)

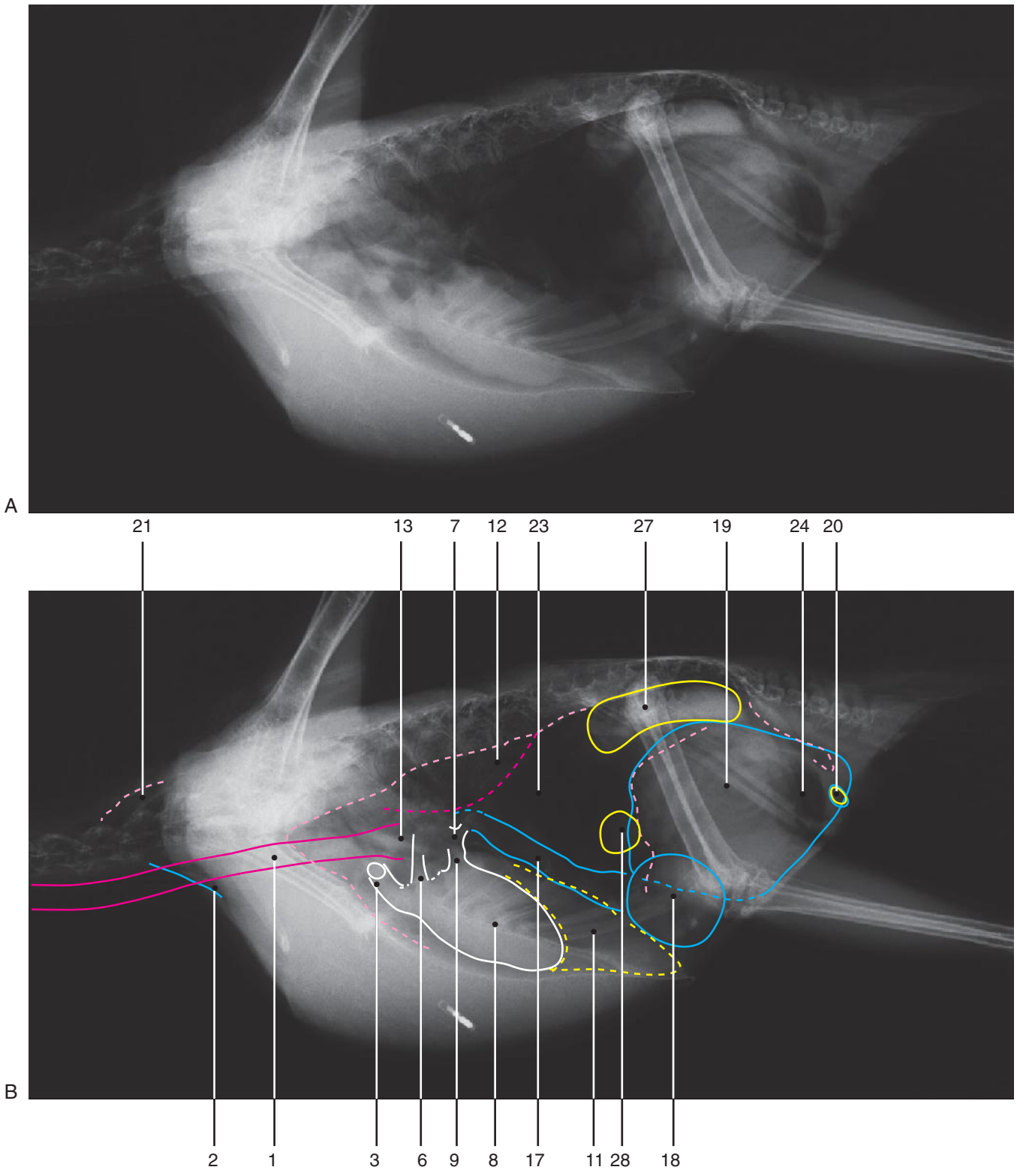

Figure 10-1, A-B
Type of Bird: Blue and Gold Macaw
Type of Study: Viscera of the coelom
Projection: Laterolateral (right lateral recumbency)
Weight of Bird: 1.1 kg
Gender: Female
Reproductive Status: Intact
Age: Adult

1. Trachea
2. Crop
3. Brachiocephalic artery and aorta
4. (Brachiocephalic artery)
5. (Aorta)
6. Pulmonary artery
7. Pulmonary vein
8. Heart
9. Left atrium
10. (Esophagus)
11. Liver
12. Lung
13. Syrinx
14. (Gonad)
15. (Ovary)
16. (Testes)
17. Proventriculus
18. Ventriculus
19. Intestines
20. Cloaca
21. Cervical air sac
22. (Clavicular air sac)
23. Thoracic air sac
24. Abdominal air sac
25. (Apex of heart)
26. (Interface between caudal thoracic and abdominal air sacs)
27. Kidneys
28. Spleen

NOTE: Structures in parentheses are not labeled.

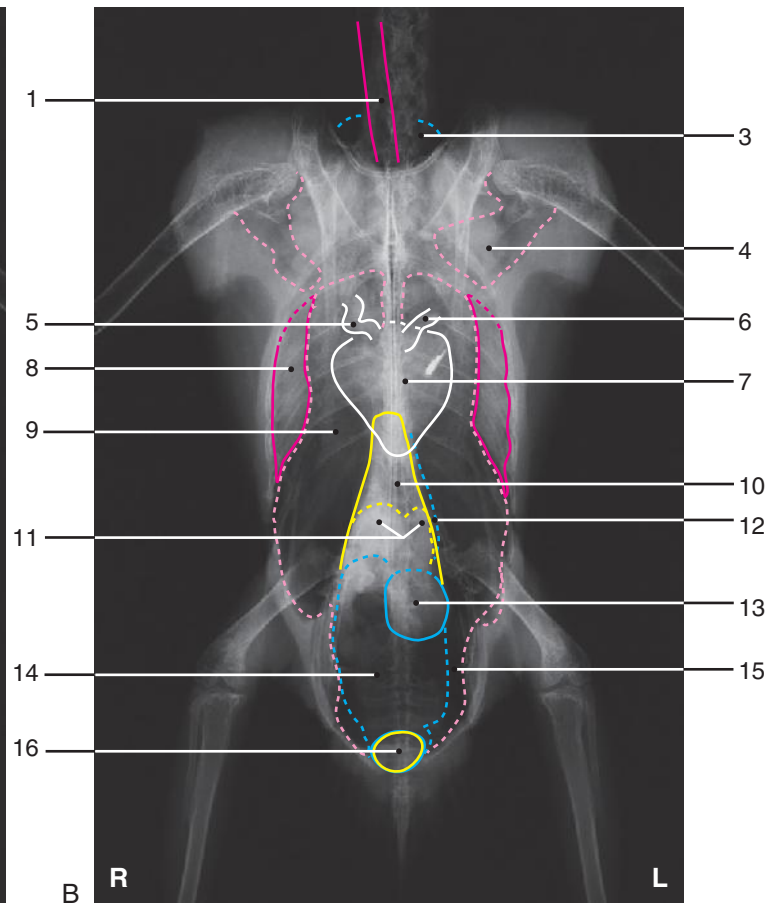

Figure 10-2, A-B
Type of Bird: Blue and Gold Macaw
Type of Study: Viscera of the coelom
Projection: Ventrodorsal
Weight of Bird: 1.1 kg
Gender: Female
Reproductive Status: Intact
Age: Adult

1. Trachea
2. (Cervical air sac)
3. Crop
4. Clavicular air sac
5. Brachiocephalic artery and aorta
6. Heart base vessel
7. Heart
8. Lung
9. Thoracic air sac
10. Liver
11. Kidneys
12. Proventriculus
13. Ventriculus
14. Intestines
15. Abdominal air sac
16. Cloaca

NOTE: Structures in parentheses are not labeled.

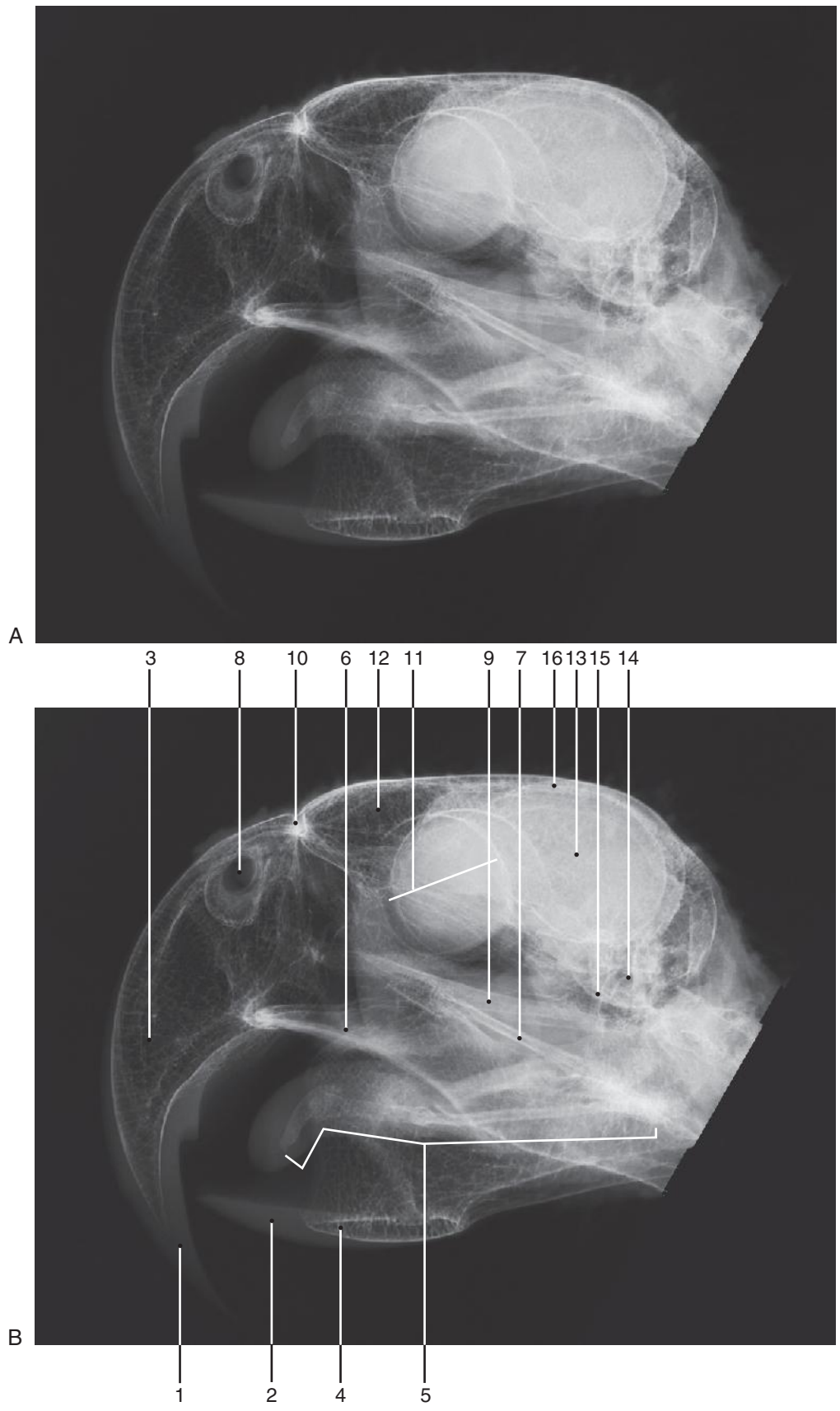

Figure 10-3, A-B
Type of Bird: Blue and Gold Macaw
Type of Study: Head
Projection: Laterolateral (right lateral recumbency)
Weight of Bird: 1.1 kg
Gender: Female
Reproductive Status: Intact
Age: Adult

1. Keratinized maxillary beak
2. Keratinized mandibular beak
3. Premaxillary bone
4. Mandible
5. Hyoid bones
6. Palatine bone
7. Pterygoid bone
8. External nares
9. Jugal (zygomatic) bone
10. Craniofacial flexion zone
11. Orbit
12. Frontal bone
13. Cranium
14. Temporal bone
15. Quadrate bone
16. Parietal bone

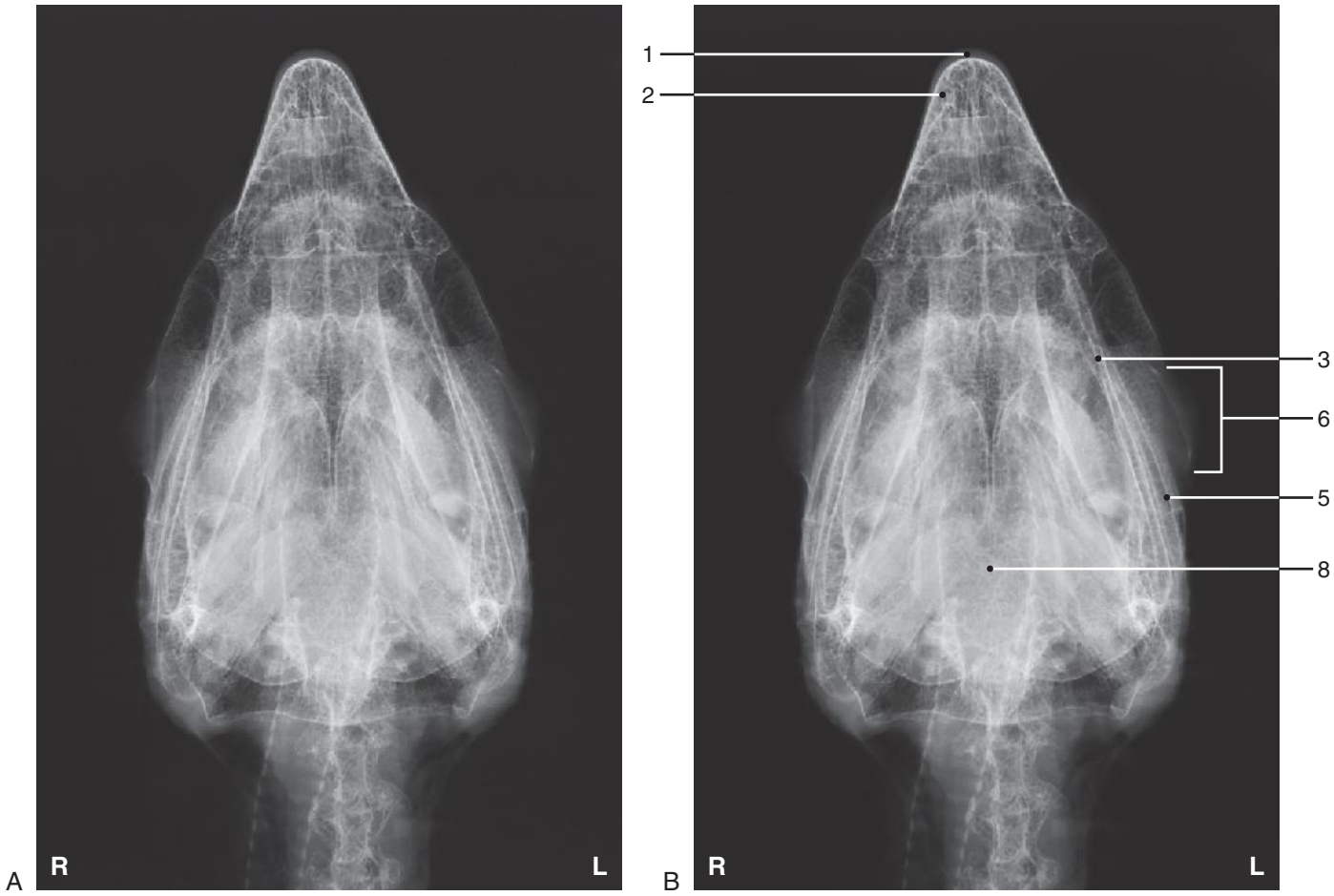

Figure 10-4, A-B
Type of Bird: Blue and Gold Macaw
Type of Study: Head
Projection: Ventrodorsal
Weight of Bird: 1.1 kg
Gender: Female
Reproductive Status: Intact
Age: Adult

1. Keratinized maxillary beak
2. Premaxillary bone
3. Mandible
4. (Orbit)
5. Jugal (zygomatic) bone
6. Scleral ossicles
7. (Quadrate bone)
8. Cranium

NOTE: Structures in parentheses are not labeled.

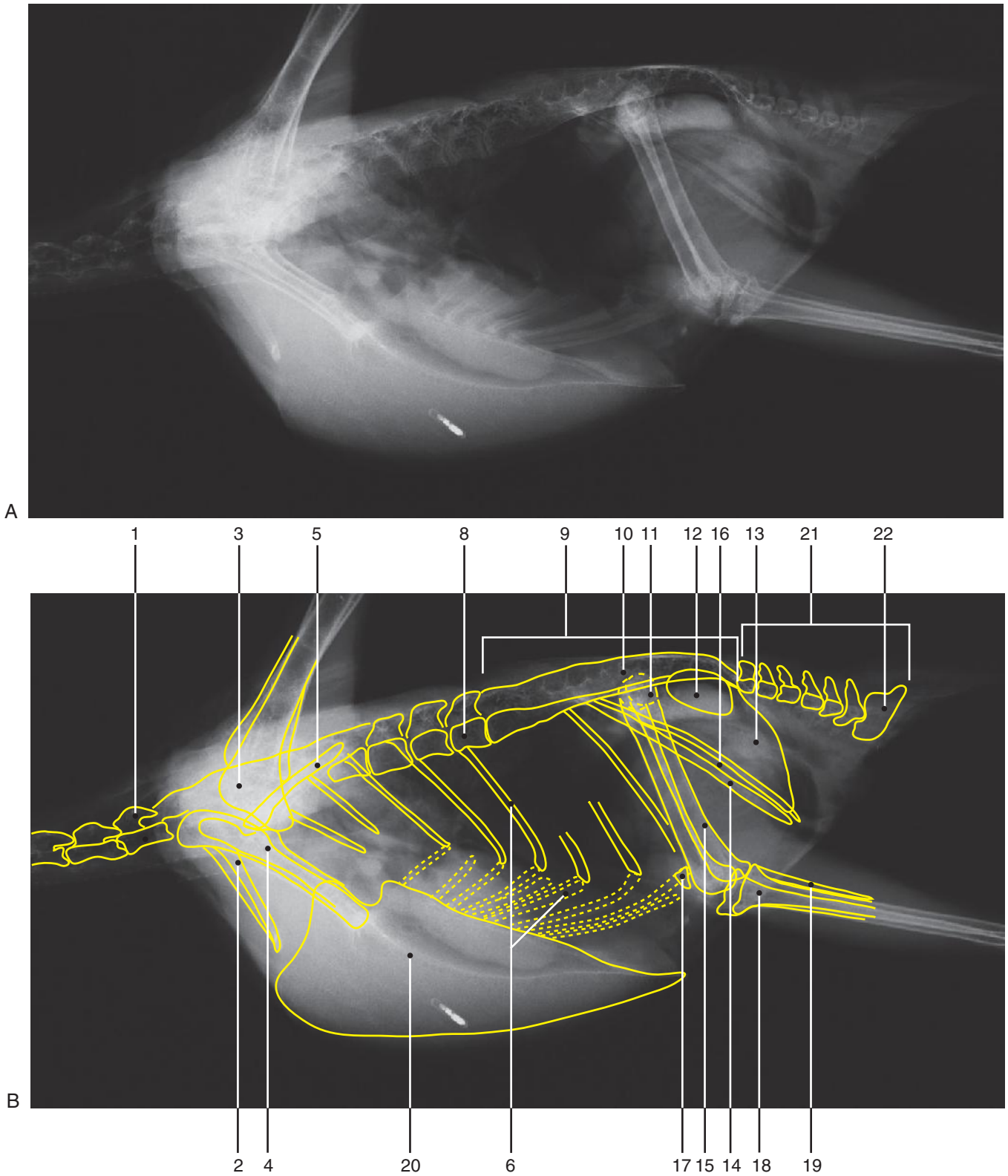

Figure 10-5, A-B
Type of Bird: Blue and Gold Macaw
Type of Study: Whole body skeleton
Projection: Laterolateral (right lateral recumbency)
Weight of Bird: 1.1 kg
Gender: Female
Reproductive Status: Intact
Age: Adult

1. Cervical vertebra
2. Clavicle
3. Humerus
4. Coracoid
5. Scapula
6. Rib
7. (Uncinate process of rib)
8. Thoracic vertebra
9. Synsacrum
10. Ilium
11. Head of femur
12. Ilioischiadiac foramen
13. Ischium
14. Pubis
15. Femur
16. Obturator foramen
17. Patella
18. Tibiotarsal bone
19. Fibula
20. Sternum
21. Caudal vertebrae
22. Pygostyle

NOTE: Structures in parentheses are not labeled.

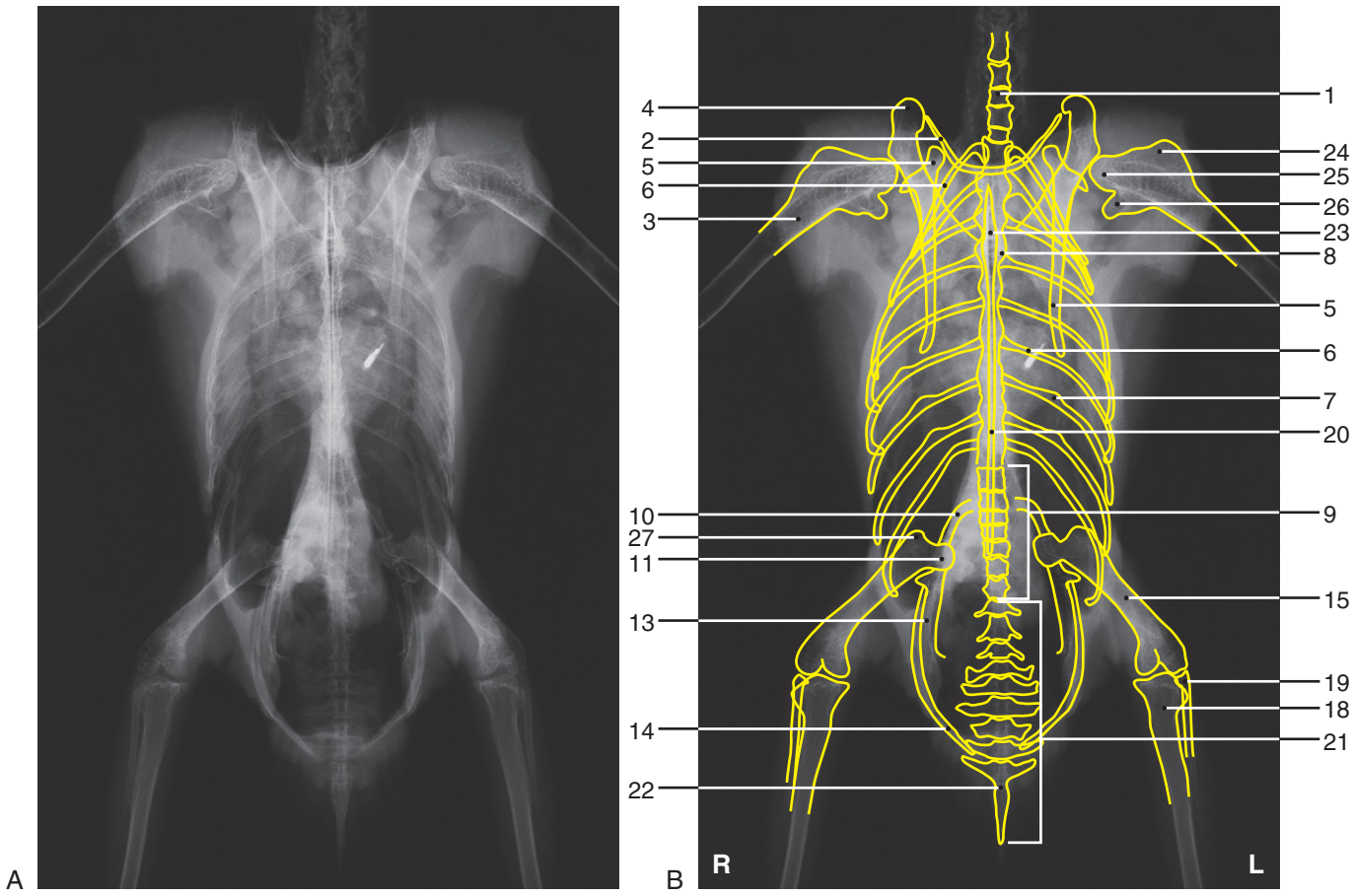

Figure 10-6, A-B
Type of Bird: Blue and Gold Macaw
Type of Study: Whole body skeleton
Projection: Ventrodorsal
Weight of Bird: 1.1 kg
Gender: Female
Reproductive Status: Intact
Age: Adult

1. Cervical vertebra
2. Clavicle
3. Humerus
4. Coracoid
5. Scapula
6. Rib
7. Uncinate process of rib
8. Thoracic vertebra
9. Synsacrum
10. Ilium
11. Head of femur
12. (Ilioischiadiac foramen)
13. Ischium
14. Pubis
15. Femur
16. (Obturator foramen)
17. (Patella)
18. Tibiotarsal bone
19. Fibula
20. Sternum
21. Caudal vertebrae
22. Pygostyle
23. Apex carinae
24. Dorsal tubercle of humerus
25. Head of humerus
26. Ventral tubercle of humerus
27. Trochanter of femur

NOTE: Structures in parentheses are not labeled.

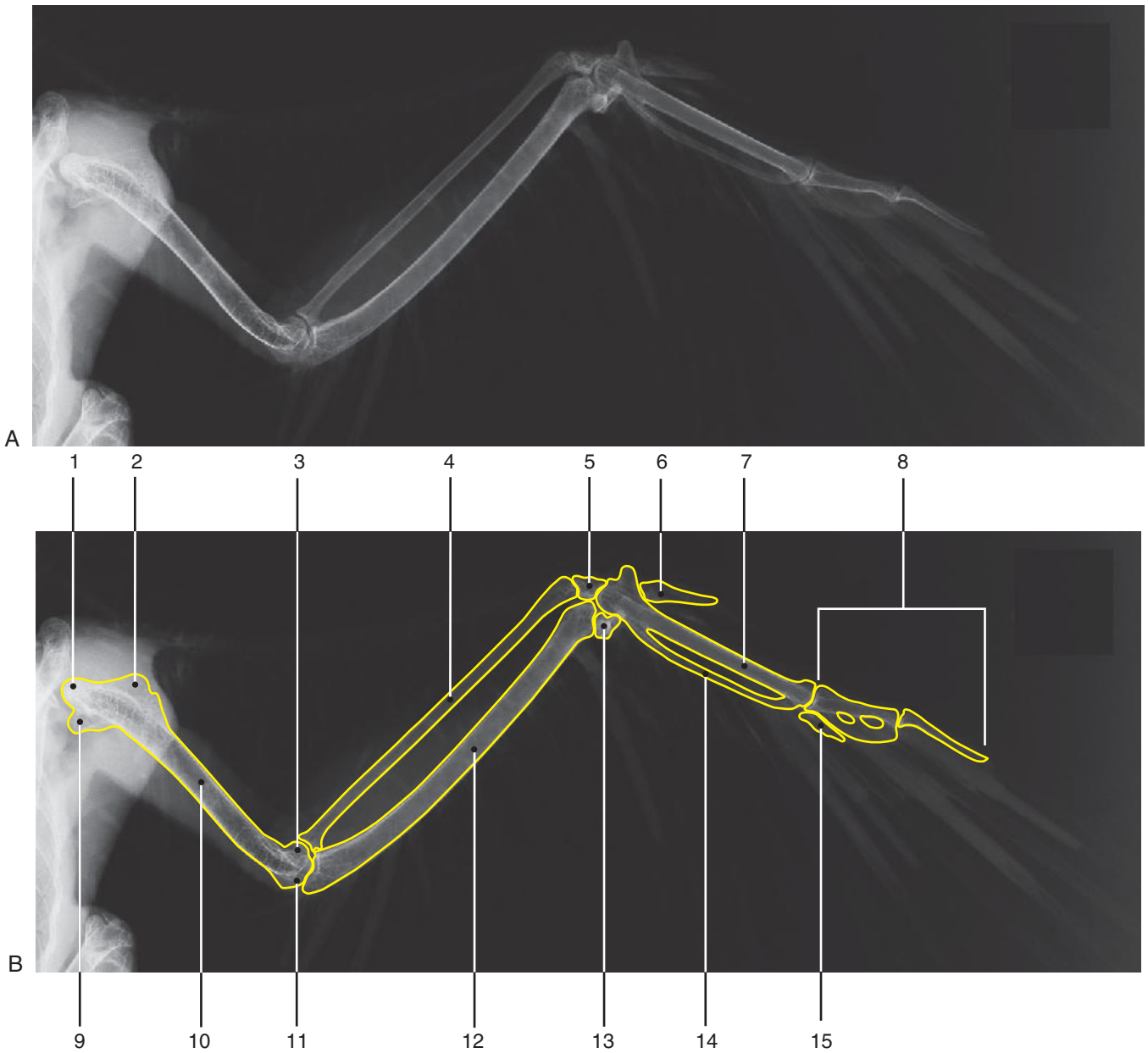

Figure 10-7, A-B
Type of Bird: Blue and Gold Macaw
Type of Study: Wing
Projection: Mediolateral
Weight of Bird: 1.1 kg
Gender: Female
Reproductive Status: Intact
Age: Adult

1. Head of humerus
2. Dorsal tubercle of humerus
3. Dorsal condyle of humerus
4. Radius
5. Radial carpal bone
6. Alula
7. Major metacarpal bone
8. Phalanges of major digit
9. Ventral tubercle of humerus
10. Humerus
11. Ventral condyle of humerus
12. Ulna
13. Ulnar carpal bone
14. Minor metacarpal bone
15. Phalanges of minor digit

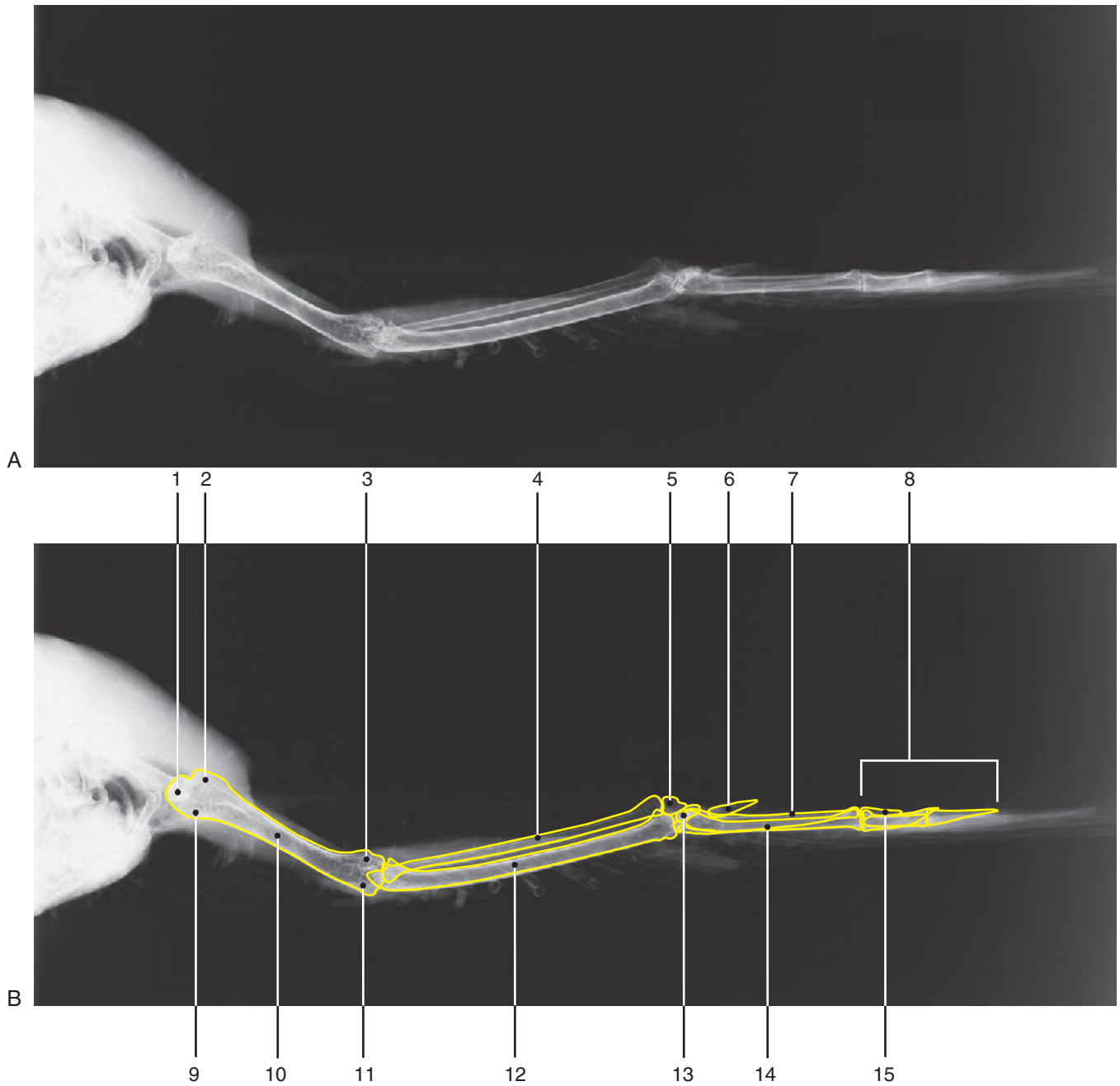

Figure 10-8, A-B
Type of Bird: Blue and Gold Macaw
Type of Study: Wing
Projection: Caudocranial
Weight of Bird: 1.1 kg
Gender: Female
Reproductive Status: Intact
Age: Adult

1. Head of humerus
2. Ventral tubercle of humerus
3. Ventral condyle of humerus
4. Radius
5. Radial carpal bone
6. Alula
7. Minor metacarpal bone
8. Phalanges of major digit
9. Dorsal tubercle of humerus
10. Humerus
11. Dorsal condyle of humerus
12. Ulna
13. Ulnar carpal bone
14. Major metacarpal bone
15. Phalanges of minor digit

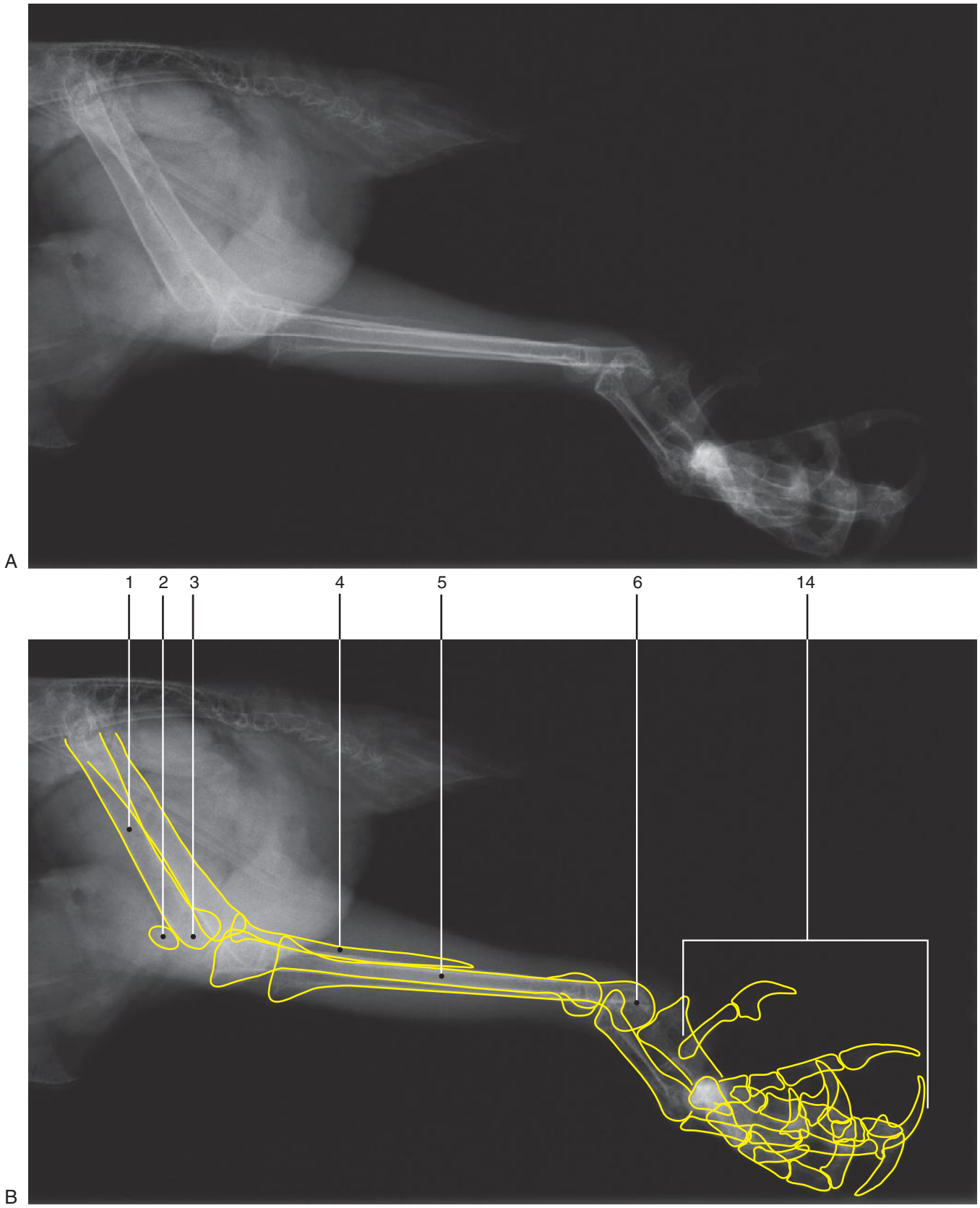

Figure 10-9, A-B
Type of Bird: Blue and Gold Macaw
Type of Study: Pelvic limb
Projection: Mediolateral
Weight of Bird: 1.1 kg
Gender: Female
Reproductive Status: Intact
Age: Adult

1. Femur
2. Patella
3. Condyles of femur
4. Fibula
5. Tibiotarsal bone
6. Condyles of tibiotarsal bone
7. (Hypotarsal crest of tarsometatarsal bone)
8. (Tarsometatarsal bone)
9. (Trochlea of tarsometatarsal bone)
10. (Digit I)
11. (Digit II)
12. (Digit III)
13. (Digit IV)
14. Phalanges
15. (Metatarsal I)

NOTE: Structures in parentheses are not labeled.

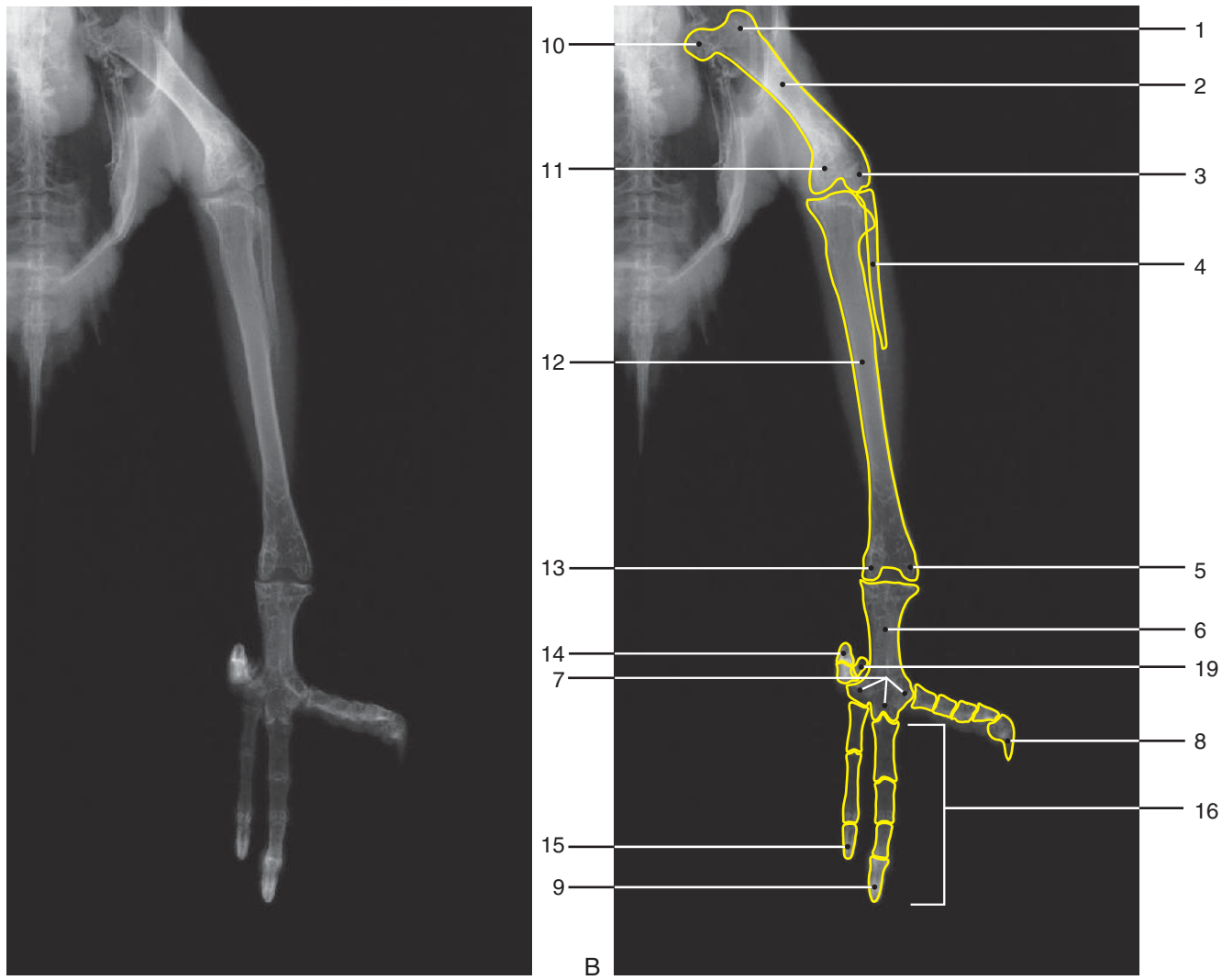

Figure 10-10, A-B
Type of Bird: Blue and Gold Macaw
Type of Study: Pelvic limb
Projection: Craniocaudal
Weight of Bird: 1.1 kg
Gender: Female
Reproductive Status: Intact
Age: Adult

1. Trochanter of femur
2. Femur
3. Lateral condyle of femur
4. Fibula
5. Lateral condyle of tibiotarsal bone
6. Tarsometatarsal bone
7. Trochlea of tarsometatarsal bone
8. Digit IV
9. Digit III
10. Head of femur
11. Medial condyle of femur
12. Tibiotarsal bone
13. Medial condyle of tibiotarsal bone
14. Digit I
15. Digit II
16. Phalanges
17. (Patella)
18. (Hypotarsal crest of tarsometatarsal bone)
19. Metatarsal I

NOTE: Structures in parentheses are not labeled.

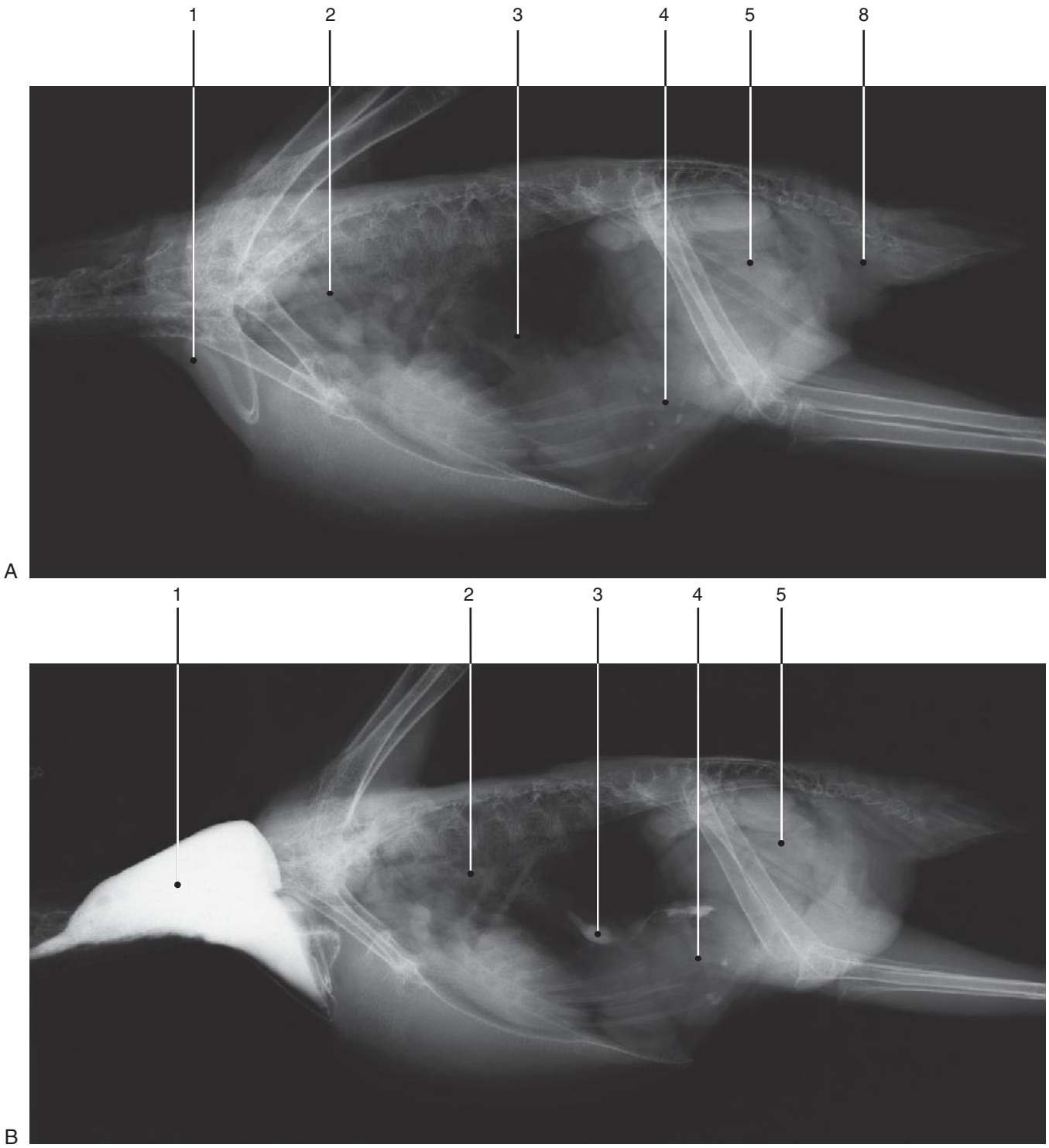

Figure 10-11, A-B
Type of Bird: Blue and Gold Macaw
Type of Study: Gastrointestinal positive contrast study
Contrast Medium: Barium sulfate suspension (Novopaque® 30% w/v; Lafayette Pharmaceutical, Inc., Lafayette, IN) 30 ml administered via gavage tube
Projection: Laterolateral (right lateral recumbency)
Weight of Bird: 1.1 kg
Gender: Female
Reproductive Status: Intact
Age: Adult

Image	Time (hr)
A	Scout
B	Immediate

1. Crop
2. Esophagus
3. Proventriculus
4. Ventriculus
5. Intestines
6. (Duodenum)
7. (Large intestine)
8. Cloaca
9. (Proventricular-ventricular isthmus)

NOTE: Structures in parentheses are not labeled.

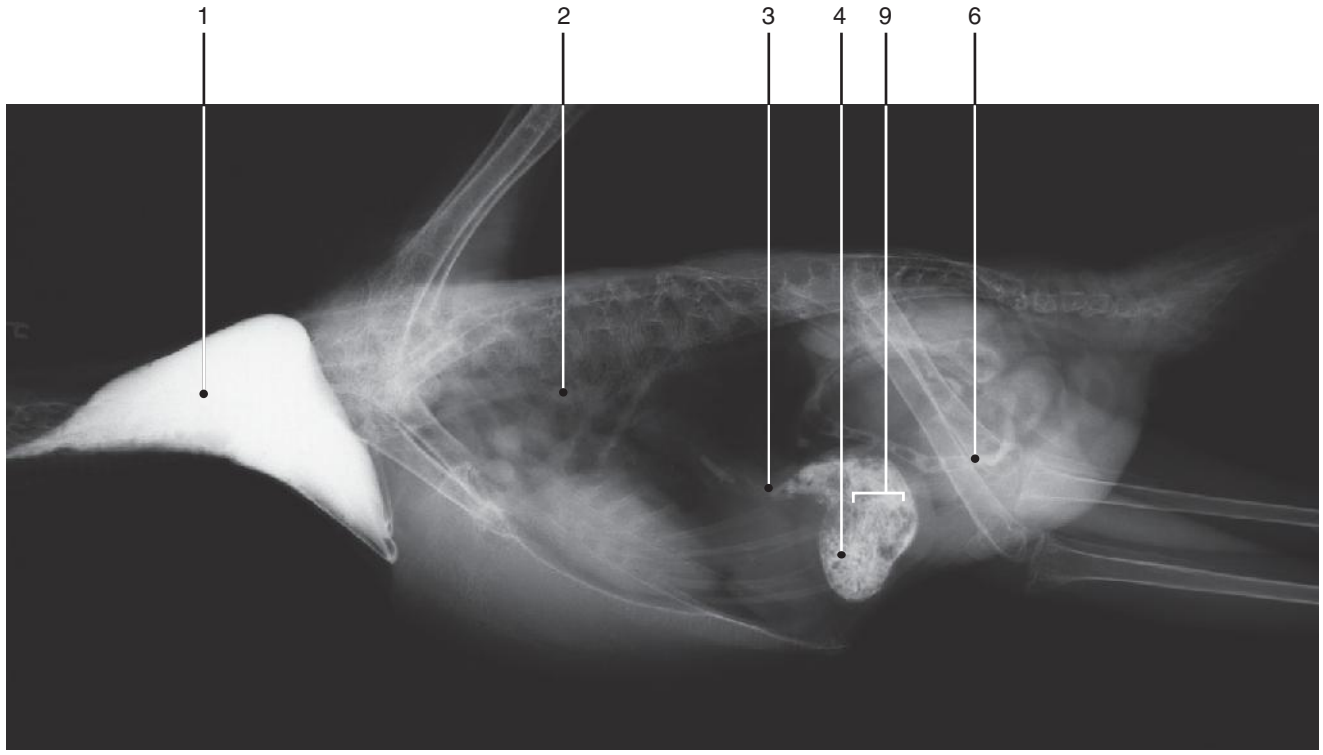

C

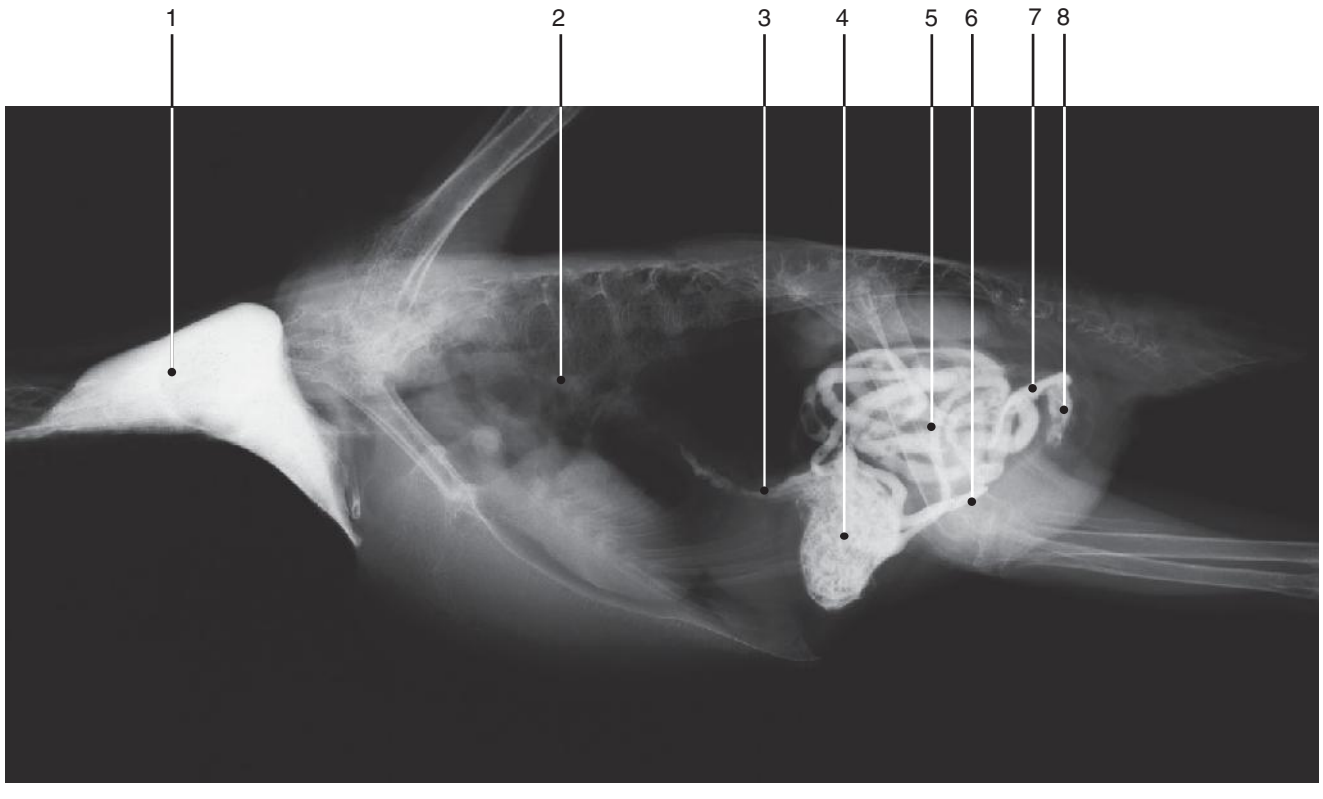

D

Figure 10-11, C-D
Type of Bird: Blue and Gold Macaw
Type of Study: Gastrointestinal positive contrast study
Contrast Medium: Barium sulfate suspension (Novopaque® 30% w/v; Lafayette Pharmaceutical, Inc., Lafayette, IN) 30 ml administered via gavage tube
Projection: Laterolateral (right lateral recumbency)
Weight of Bird: 1.1 kg
Gender: Female
Reproductive Status: Intact
Age: Adult

Image	Time (hr)
C	0.17
D	1.0

1. Crop
2. Esophagus
3. Proventriculus
4. Ventriculus
5. Intestines
6. Duodenum
7. Large intestine
8. Cloaca
9. Proventricular-ventricular isthmus

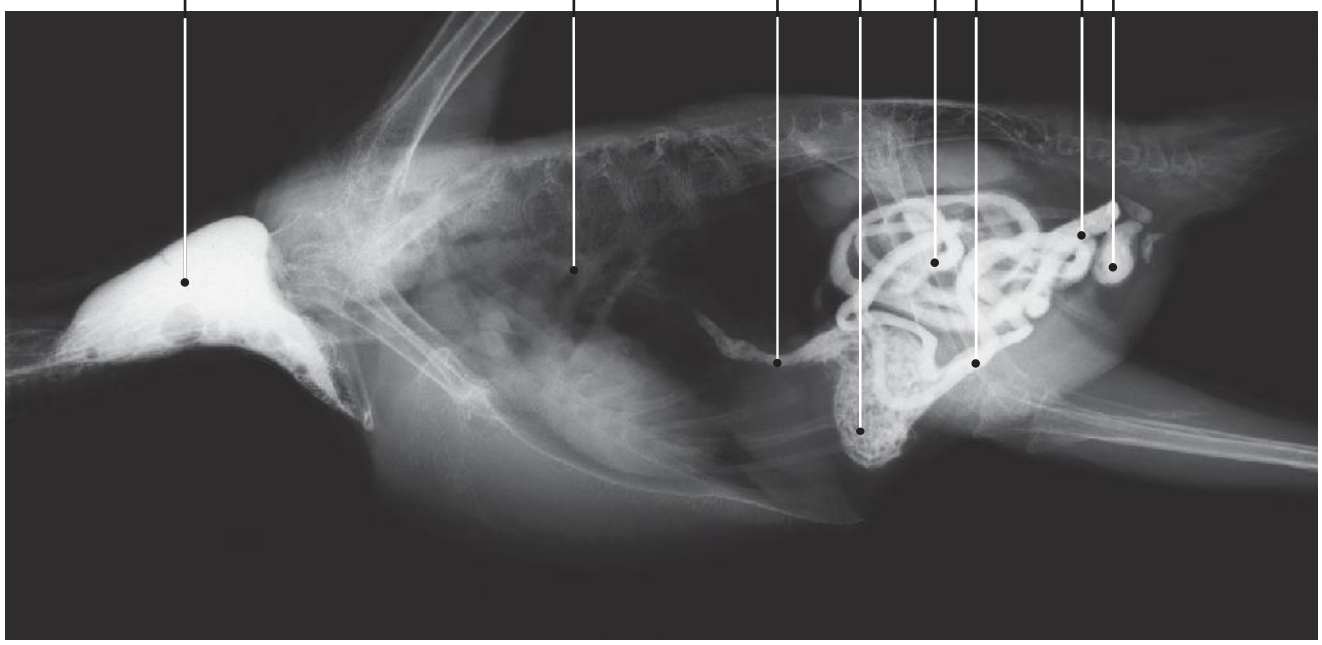

E

Figure 10-11, E
Type of Bird: Blue and Gold Macaw
Type of Study: Gastrointestinal positive contrast study
Contrast Medium: Barium sulfate suspension (Novopaque® 30% w/v; Lafayette Pharmaceutical, Inc., Lafayette, IN) 30 ml administered via gavage tube
Projection: Laterolateral (right lateral recumbency)
Weight of Bird: 1.1 kg
Gender: Female
Reproductive Status: Intact
Age: Adult

Image	Time (hr)
E	2.0

1. Crop
2. Esophagus
3. Proventriculus
4. Ventriculus
5. Intestines
6. Duodenum
7. Large intestine
8. Cloaca

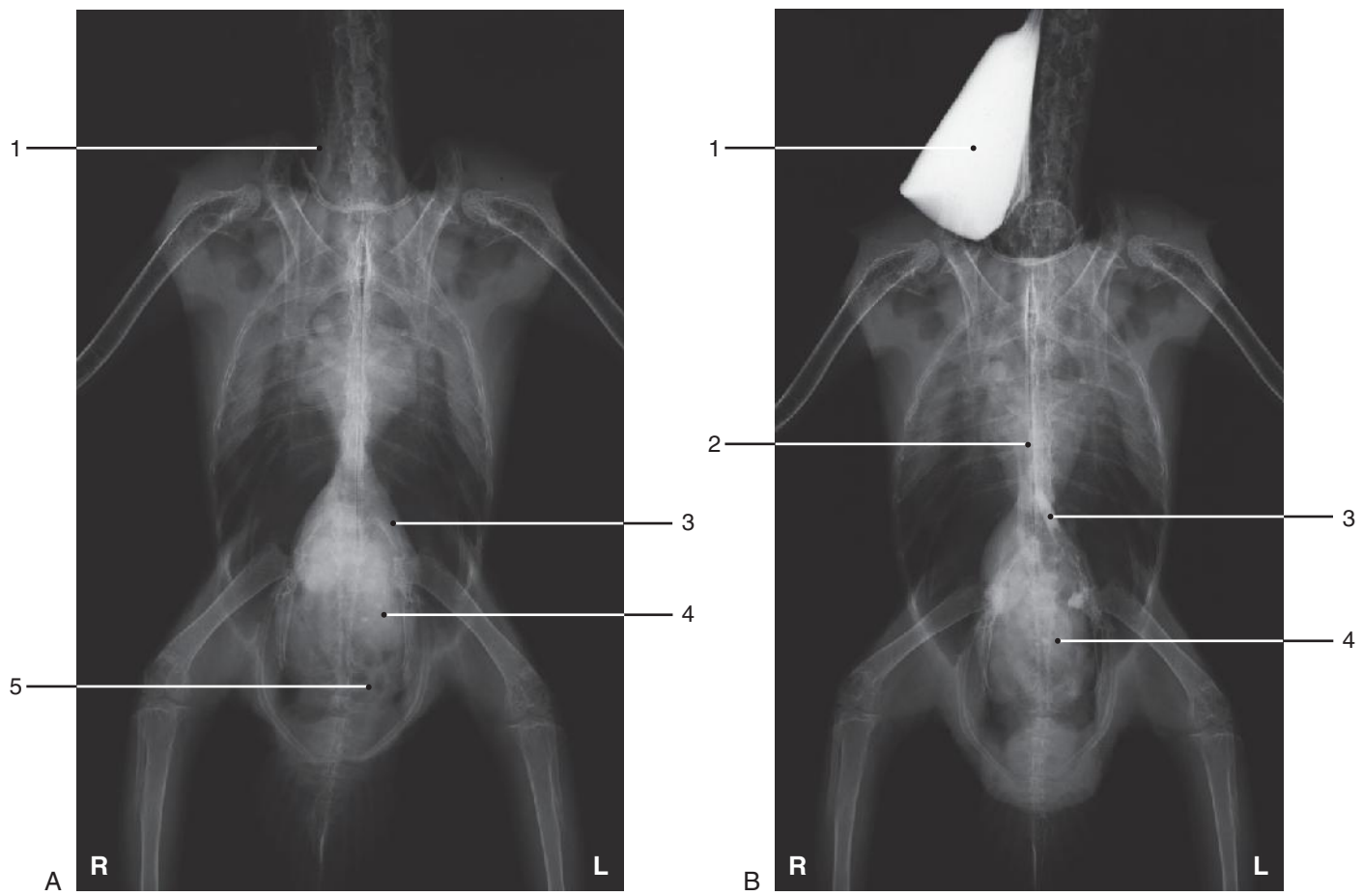

Figure 10-12, A-B

Type of Bird: Blue and Gold Macaw
Type of Study: Gastrointestinal positive contrast study
Contrast Medium: Barium sulfate suspension (Novopaque® 30% w/v; Lafayette Pharmaceutical, Inc., Lafayette, IN) 30 ml administered via gavage tube
Projection: Ventrodorsal
Weight of Bird: 1.1 kg
Gender: Female
Reproductive Status: Intact
Age: Adult

Image	Time (hr)
A	Scout
B	Immediate

1. Crop
2. Esophagus
3. Proventriculus
4. Ventriculus
5. Intestines
6. (Duodenum)
7. (Large intestine)
8. (Cloaca)
9. (Proventricular-ventricular isthmus)

NOTE: Structures in parentheses are not labeled.

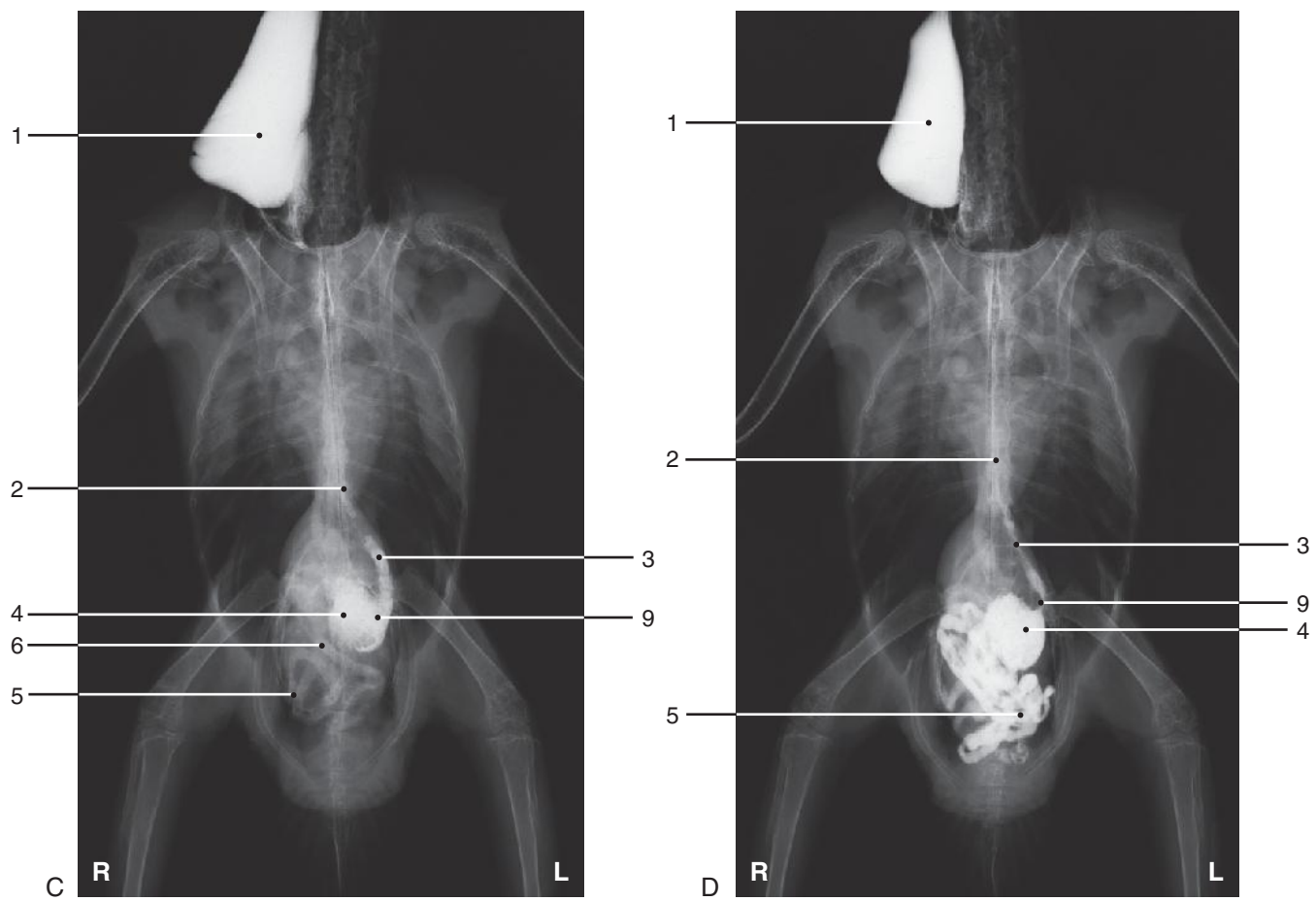

Figure 10-12, C-D

Type of Bird: Blue and Gold Macaw
Type of Study: Gastrointestinal positive contrast study
Contrast Medium: Barium sulfate suspension (Novopaque® 30% w/v; Lafayette Pharmaceutical, Inc., Lafayette, IN) 30 ml administered via gavage tube
Projection: Ventrodorsal
Weight of Bird: 1.1 kg
Gender: Female
Reproductive Status: Intact
Age: Adult

Image	Time (hr)
C	0.17
D	1.0

1. Crop
2. Esophagus
3. Proventriculus
4. Ventriculus
5. Intestines
6. Duodenum
7. (Large intestine)
8. (Cloaca)
9. Proventricular-ventricular isthmus

NOTE: Structures in parentheses are not labeled.

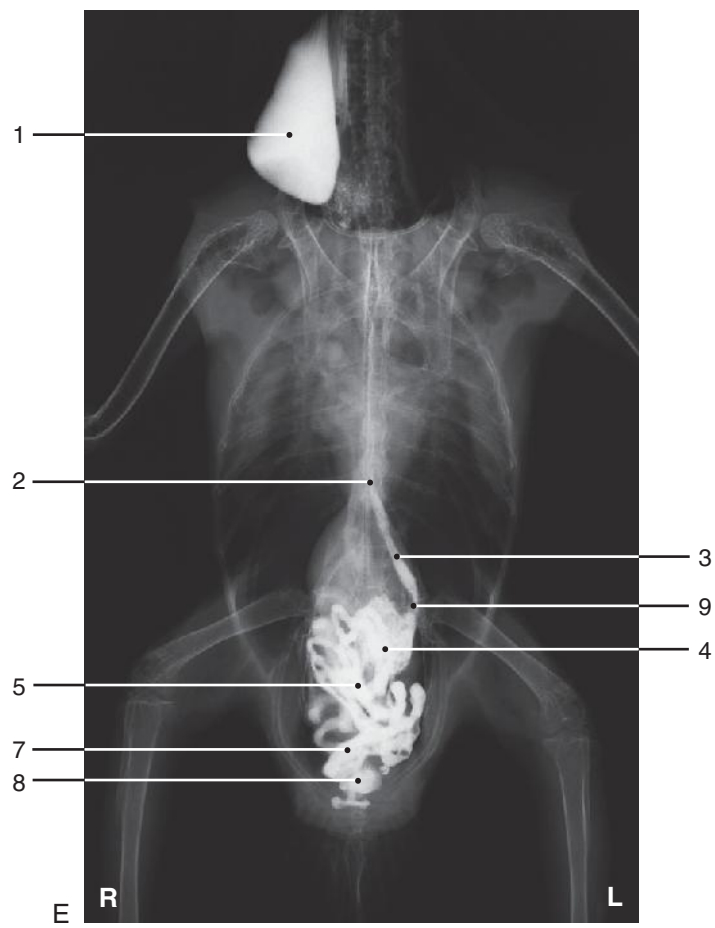

E

Figure 10-12, E

Type of Bird: Blue and Gold Macaw
Type of Study: Gastrointestinal positive contrast study
Contrast Medium: Barium sulfate suspension (Novopaque® 30% w/v; Lafayette Pharmaceutical, Inc., Lafayette, IN) 30 ml administered via gavage tube
Projection: Ventrodorsal
Weight of Bird: 1.1 kg
Gender: Female
Reproductive Status: Intact
Age: Adult

Image	Time (hr)
E	2.0

1. Crop
2. Esophagus
3. Proventriculus
4. Ventriculus
5. Intestines
6. (Duodenum)
7. Large intestine
8. Cloaca
9. Proventricular-ventricular isthmus

NOTE: Structures in parentheses are not labeled.

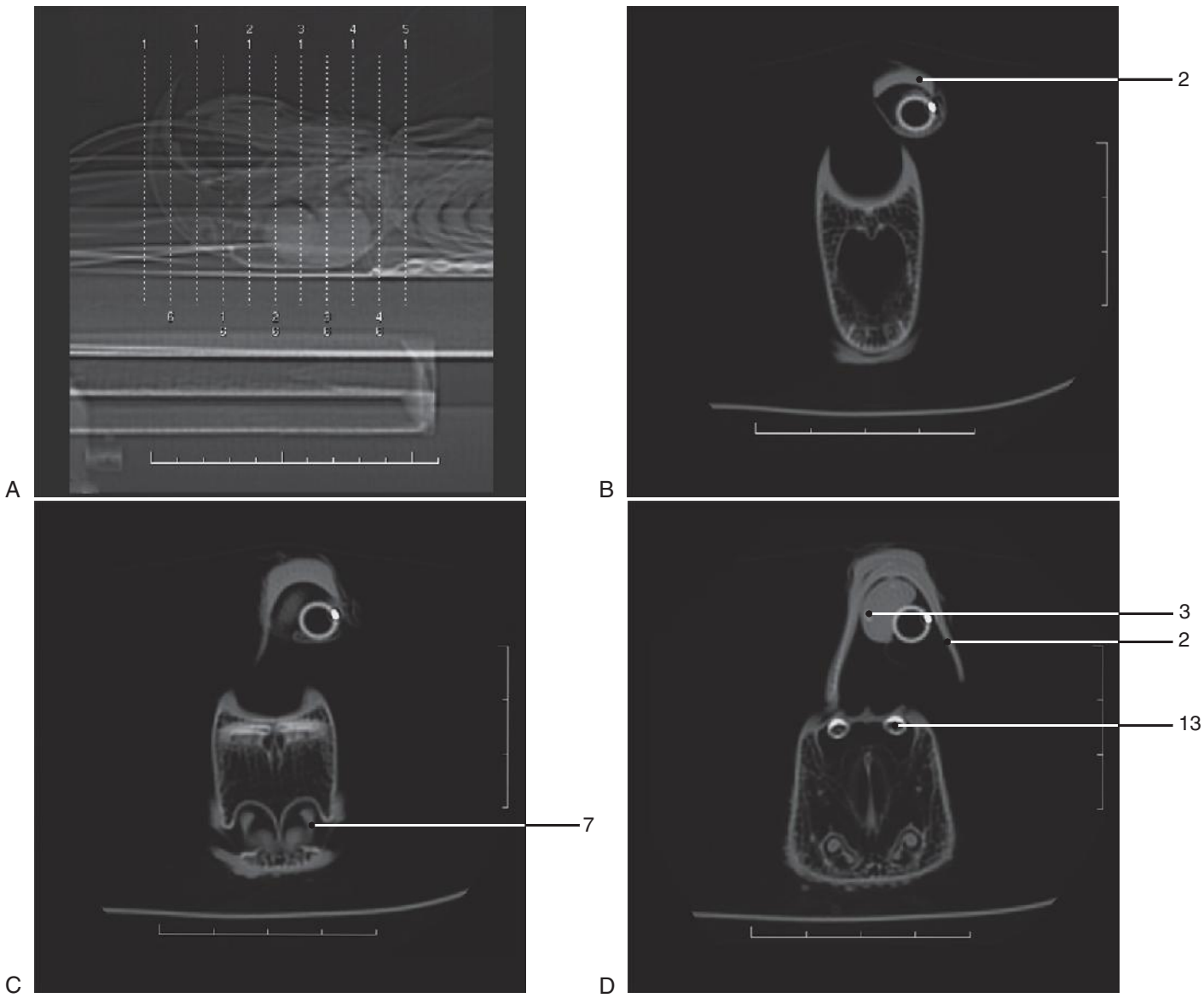

Figure 10-13, A-D
Type of Bird: Blue and Gold Macaw
Type of Study: CT head
Contrast Medium: None
Imaging Plane: Transverse
Weight of Bird: 1.3 kg
Age: Adult

1. (Tongue)
2. Mandible
3. Hyoid bone
4. (Endotracheal tube)
5. (Keratinized maxillary beak)
6. (Nasal cavity)
7. Nasal concha
8. (Pharynx)
9. (Premaxillary bone)
10. (Infraorbital sinus)
11. (Nasal septum)
12. (Choana)
13. Palatine bone
14. (Sphenoid bone)
15. (Jugal [zygomatic] bone)
16. (Frontal bone)
17. (Pterygoid bone)
18. (Eyeball)
19. (Scleral ossicle)
20. (Interorbital septum)
21. (Lens of eyeball)
22. (Trachea)
23. (Cerebrum)
24. (External ear canal)
25. (Cerebellum)
26. (Spinal cord)
27. (Dens)
28. (Cere)
29. (Nare[s])
30. (Feather)
31. (Pons)
32. (Occipital bone)
33. (Cervical vertebra)

NOTE: Structures in parentheses are not labeled.

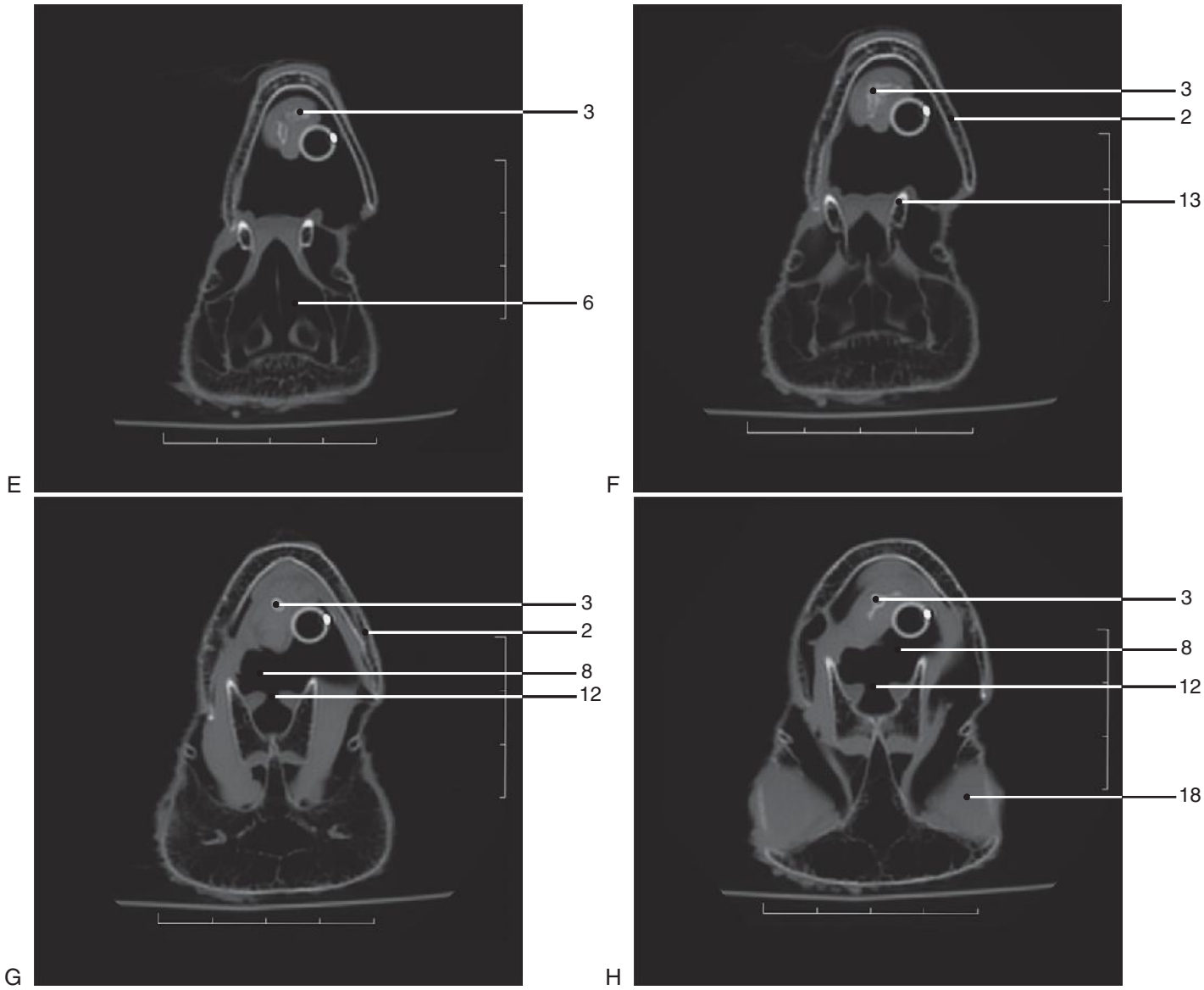

Figure 10-13, E-H
Type of Bird: Blue and Gold Macaw
Type of Study: CT head
Contrast Medium: None
Imaging Plane: Transverse
Weight of Bird: 1.3 kg
Age: Adult

1. (Tongue)
2. Mandible
3. Hyoid bone
4. (Endotracheal tube)
5. (Keratinized maxillary beak)
6. Nasal cavity
7. (Nasal concha)
8. Pharynx
9. (Premaxillary bone)
10. (Infraorbital sinus)
11. (Nasal septum)
12. Choana
13. Palatine bone
14. (Sphenoid bone)
15. (Jugal [zygomatic] bone)
16. (Frontal bone)
17. (Pterygoid bone)
18. Eyeball
19. (Scleral ossicle)
20. (Interorbital septum)
21. (Lens of eyeball)
22. (Trachea)
23. (Cerebrum)
24. (External ear canal)
25. (Cerebellum)
26. (Spinal cord)
27. (Dens)
28. (Cere)
29. (Nare[s])
30. (Feather)
31. (Pons)
32. (Occipital bone)
33. (Cervical vertebra)

NOTE: Structures in parentheses are not labeled.

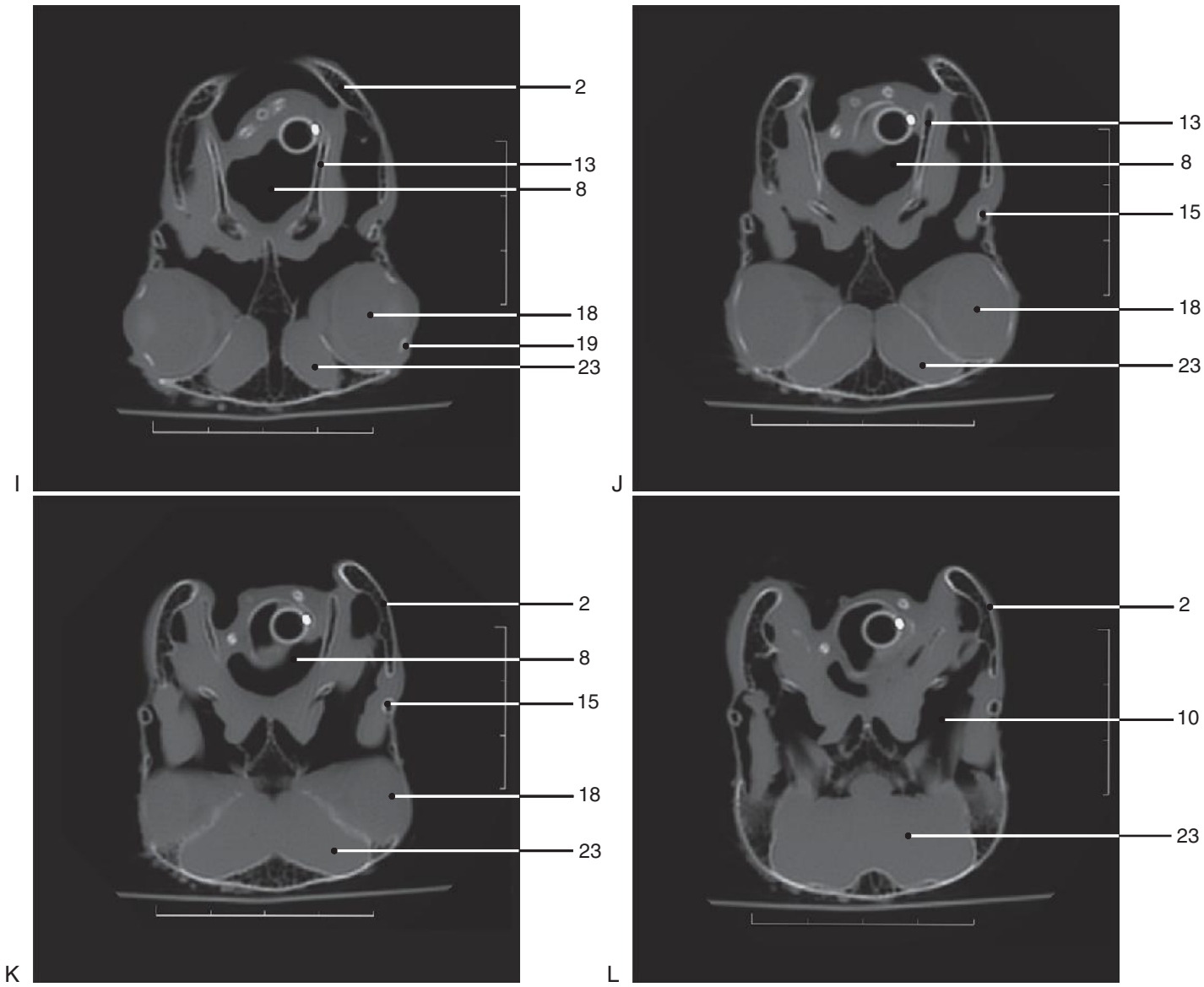

Figure 10-13, I-L
Type of Bird: Blue and Gold Macaw
Type of Study: CT head
Contrast Medium: None
Imaging Plane: Transverse
Weight of Bird: 1.3 kg
Age: Adult

1. (Tongue)
2. Mandible
3. (Hyoid bone)
4. (Endotracheal tube)
5. (Keratinized maxillary beak)
6. (Nasal cavity)
7. (Nasal concha)
8. Pharynx
9. (Premaxillary bone)
10. Infraorbital sinus
11. (Nasal septum)
12. (Choana)
13. Palatine bone
14. (Sphenoid bone)
15. Jugal [zygomatic] bone
16. (Frontal bone)
17. (Pterygoid bone)
18. Eyeball
19. Scleral ossicle
20. (Interorbital septum)
21. (Lens of eyeball)
22. (Trachea)
23. Cerebrum
24. (External ear canal)
25. (Cerebellum)
26. (Spinal cord)
27. (Dens)
28. (Cere)
29. (Nare[s])
30. (Feather)
31. (Pons)
32. (Occipital bone)
33. (Cervical vertebra)

NOTE: Structures in parentheses are not labeled.

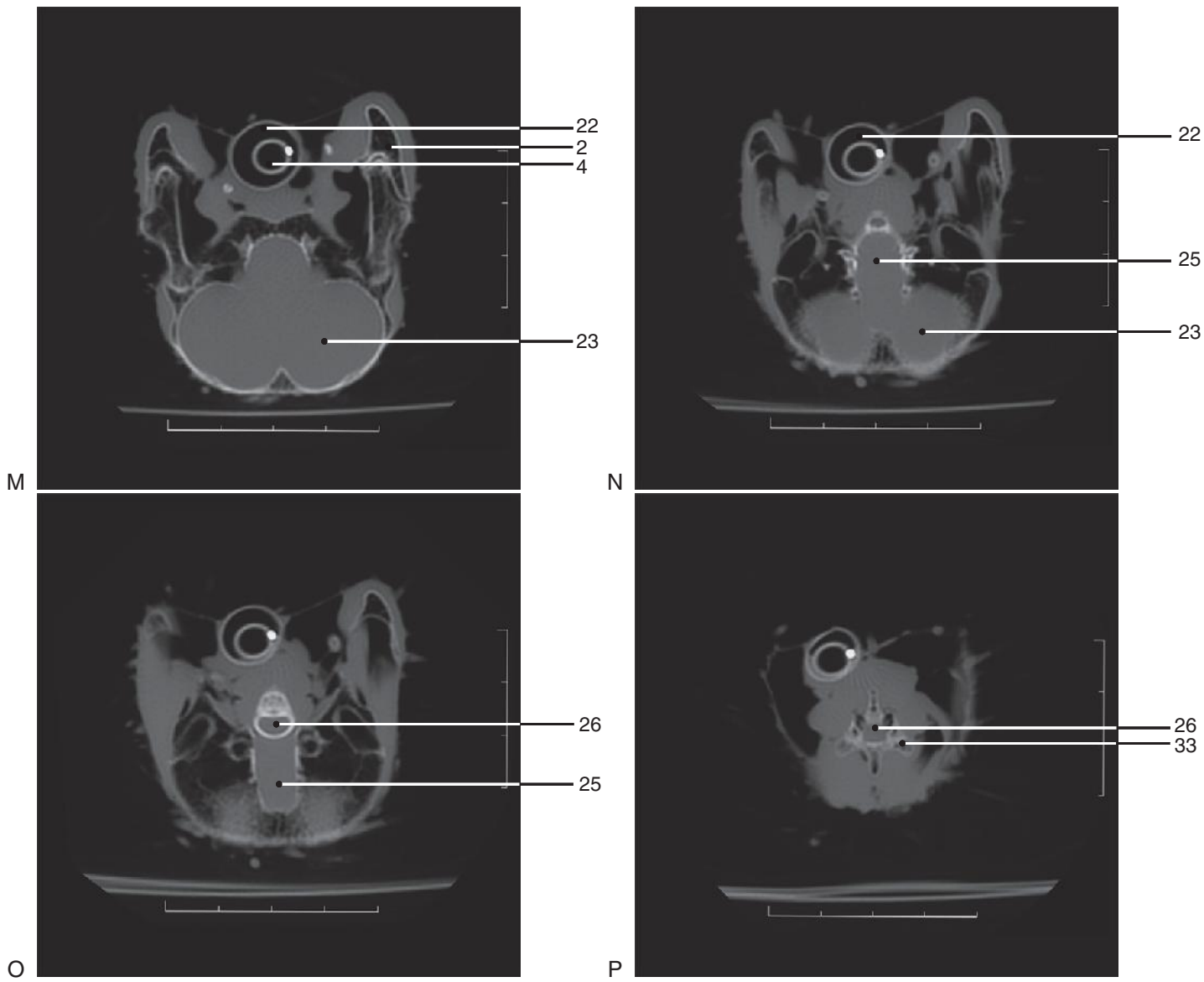

Figure 10-13, M-P
Type of Bird: Blue and Gold Macaw
Type of Study: CT head
Contrast Medium: None
Imaging Plane: Transverse
Weight of Bird: 1.3 kg
Age: Adult

1. (Tongue)
2. Mandible
3. (Hyoid bone)
4. Endotracheal tube
5. (Keratinized maxillary beak)
6. (Nasal cavity)
7. (Nasal concha)
8. (Pharynx)
9. (Premaxillary bone)
10. (Infraorbital sinus)
11. (Nasal septum)
12. (Choana)
13. (Palatine bone)
14. (Sphenoid bone)
15. (Jugal [zygomatic] bone)
16. (Frontal bone)
17. (Pterygoid bone)
18. (Eyeball)
19. (Scleral ossicle)
20. (Interorbital septum)
21. (Lens of eyeball)
22. Trachea
23. Cerebrum
24. (External ear canal)
25. Cerebellum
26. Spinal cord
27. (Dens)
28. (Cere)
29. (Nare[s])
30. (Feather)
31. (Pons)
32. (Occipital bone)
33. Cervical vertebra

NOTE: Structures in parentheses are not labeled.

CHAPTER • 11

Goffin Cockatoo
(Cacatua goffiniana)

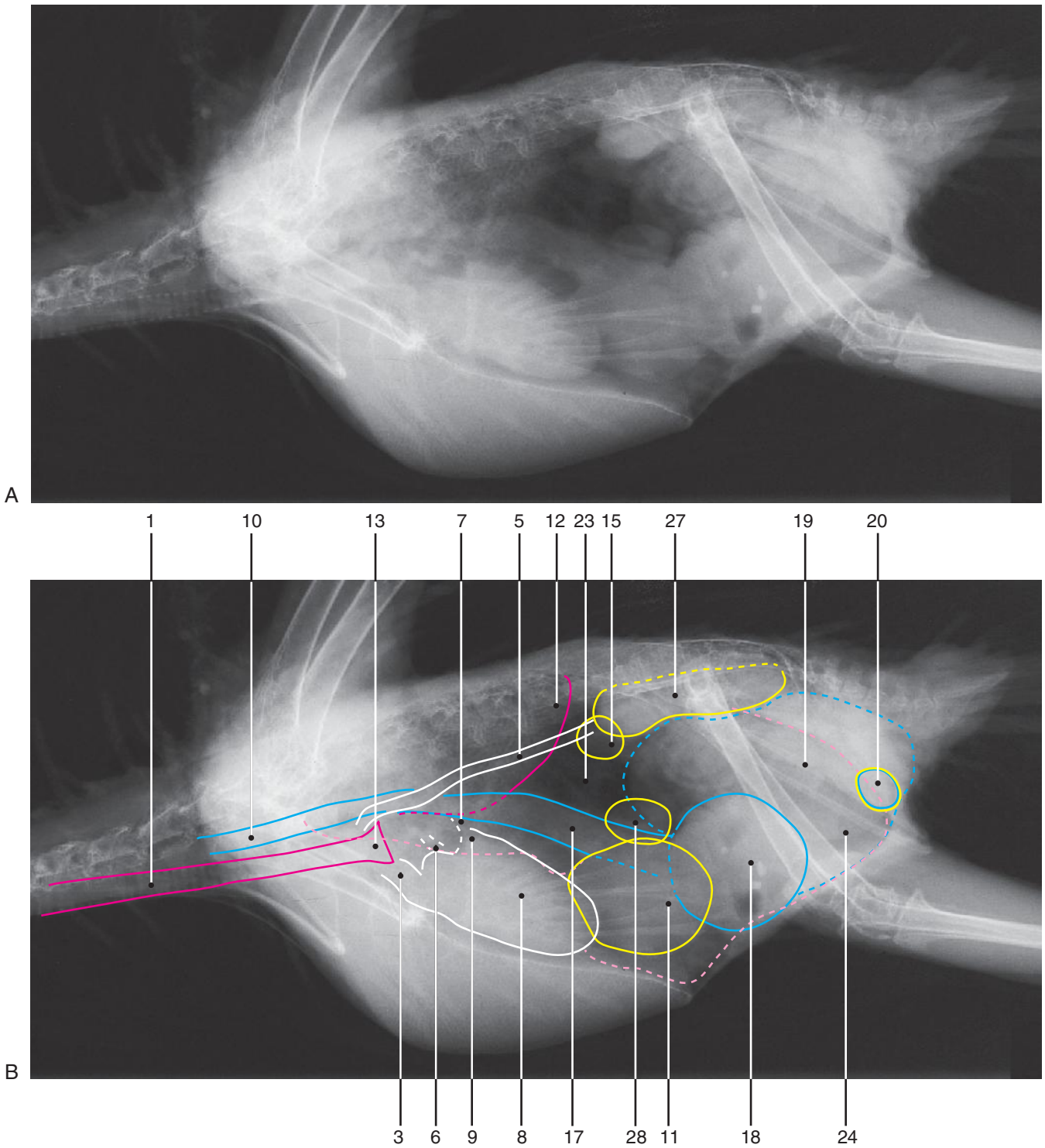

Figure 11-1, A-B
Type of Bird: Goffin Cockatoo
Type of Study: Viscera of the coelom
Projection: Laterolateral (right lateral recumbency)
Weight of Bird: 225 g
Gender: Female
Reproductive Status: Intact
Age: Adult

1. Trachea
2. (Crop)
3. Brachiocephalic artery and aorta
4. (Brachiocephalic artery)
5. Aorta
6. Pulmonary artery
7. Pulmonary vein
8. Heart
9. Left atrium
10. Esophagus
11. Liver
12. Lung
13. Syrinx
14. (Gonad)
15. Ovary
16. (Testes)
17. Proventriculus
18. Ventriculus
19. Intestines
20. Cloaca
21. (Cervical air sac)
22. (Clavicular air sac)
23. Thoracic air sac
24. Abdominal air sac
25. (Apex of heart)
26. (Interface between caudal thoracic and abdominal air sacs)
27. Kidneys
28. Spleen

NOTE: Structures in parentheses are not labeled.

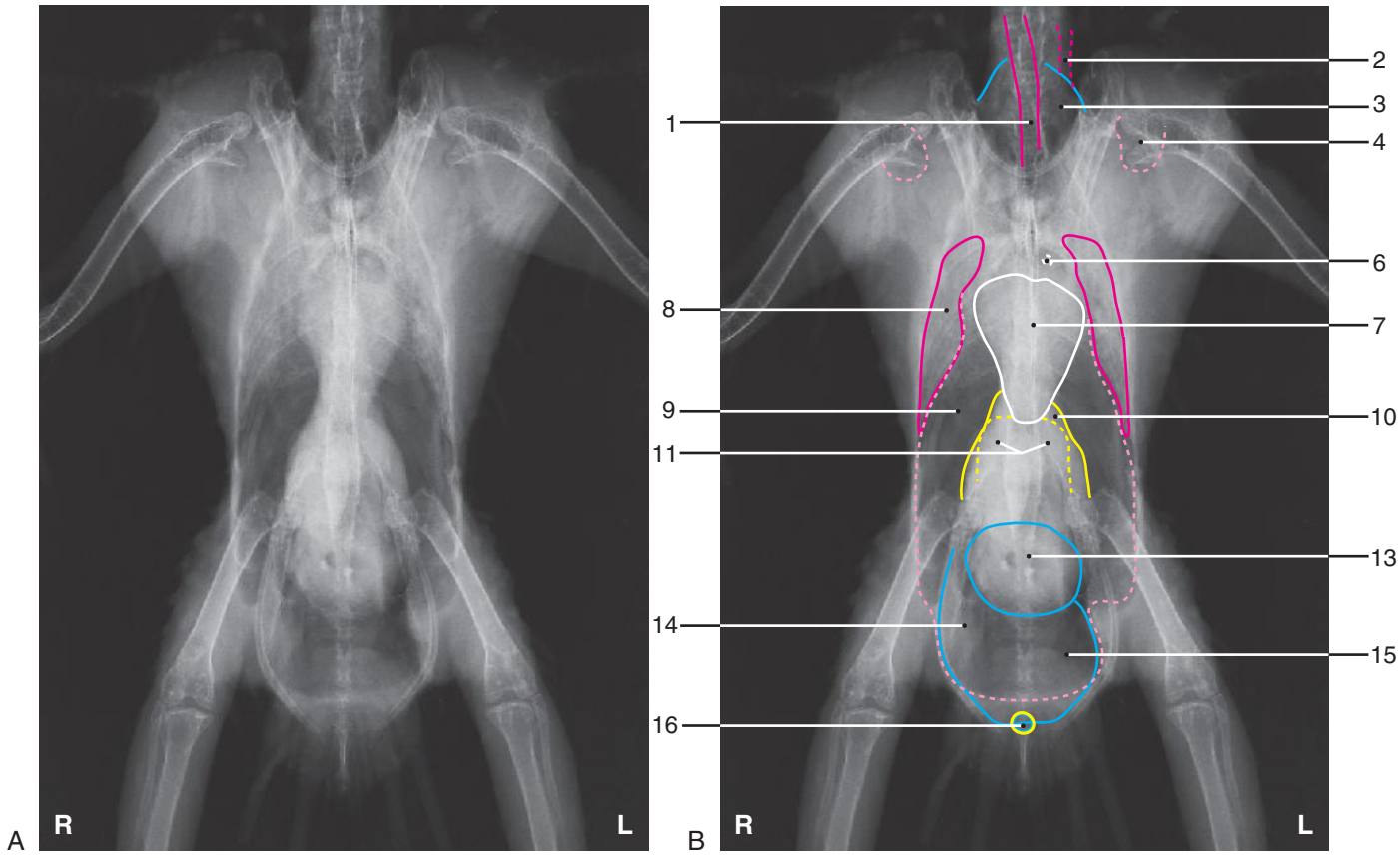

Figure 11-2, A-B
Type of Bird: Goffin Cockatoo
Type of Study: Viscera of the coelom
Projection: Ventrodorsal
Weight of Bird: 225 g
Gender: Female
Reproductive Status: Intact
Age: Adult

1. Trachea
2. Cervical air sac
3. Crop
4. Clavicular air sac
5. (Brachiocephalic artery and aorta)
6. Heart base vessel
7. Heart
8. Lung
9. Thoracic air sac
10. Liver
11. Kidneys
12. (Proventriculus)
13. Ventriculus
14. Intestines
15. Abdominal air sac
16. Cloaca

NOTE: Structures in parentheses are not labeled.

CHAPTER • 12

Sulphur-Crested Cockatoo *(Cacatua galerita)*

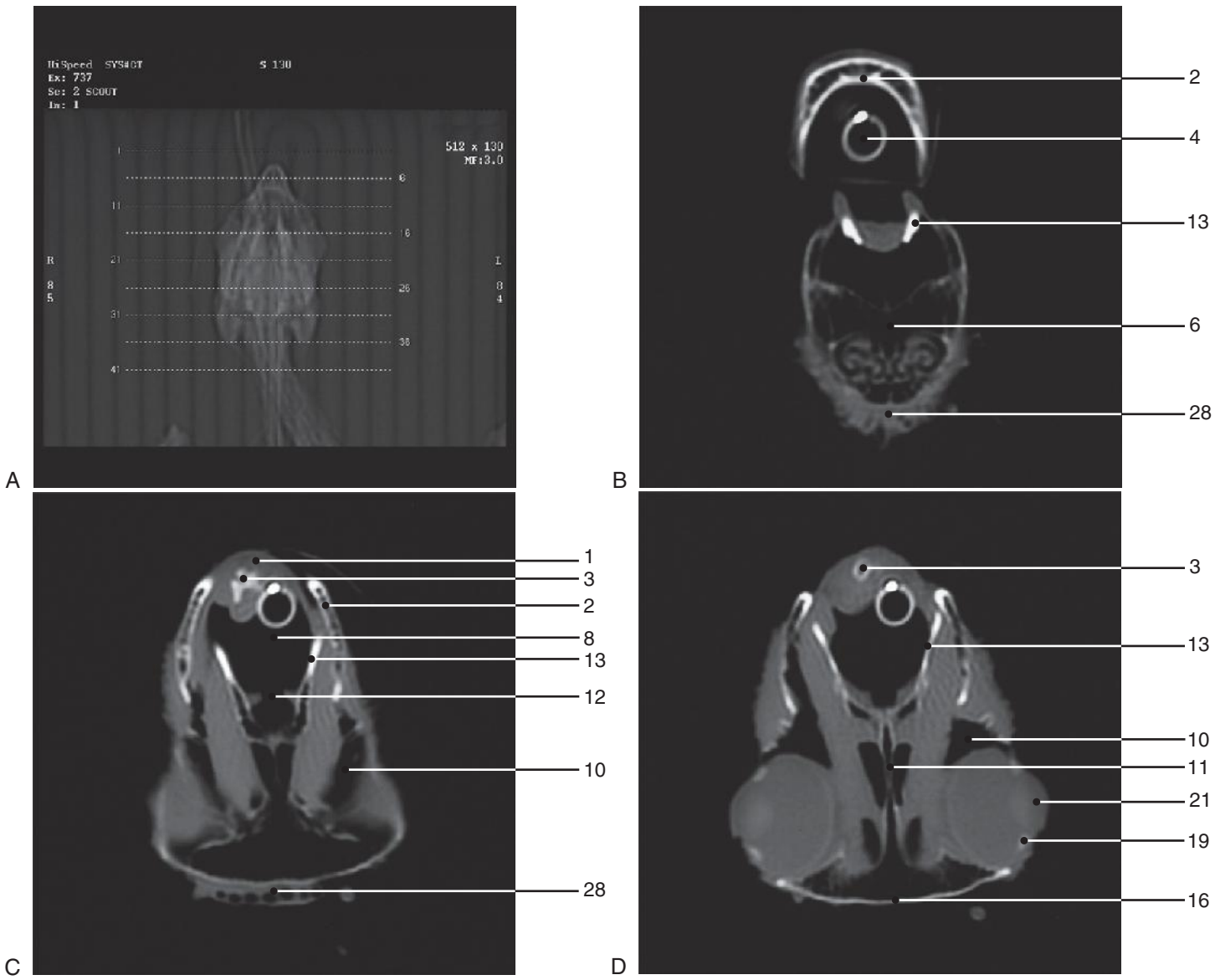

Figure 12-1, A-D
Type of Bird: Sulphur-Crested Cockatoo
Type of Study: CT head
Contrast Medium: None
Imaging Plane: Transverse
Weight of Bird: 395 g
Age: Adult

1. Tongue
2. Mandible
3. Hyoid bone
4. Endotracheal tube
5. (Keratinized maxillary beak)
6. Nasal cavity
7. (Nasal concha)
8. Pharynx
9. (Premaxillary bone)
10. Infraorbital sinus
11. Nasal septum
12. Choana
13. Palatine bone
14. (Sphenoid bone)
15. (Jugal [zygomatic] bone)
16. Frontal bone
17. (Pterygoid bone)
18. (Eyeball)
19. Scleral ossicle
20. (Interorbital septum)
21. Lens of eyeball
22. (Trachea)
23. (Cerebrum)
24. (External ear canal)
25. (Cerebellum)
26. (Spinal cord)
27. (Dens)
28. Cere
29. (Nare[s])
30. (Feather)
31. (Pons)
32. (Occipital bone)
33. (Cervical vertebra)

NOTE: Structures in parentheses are not labeled.

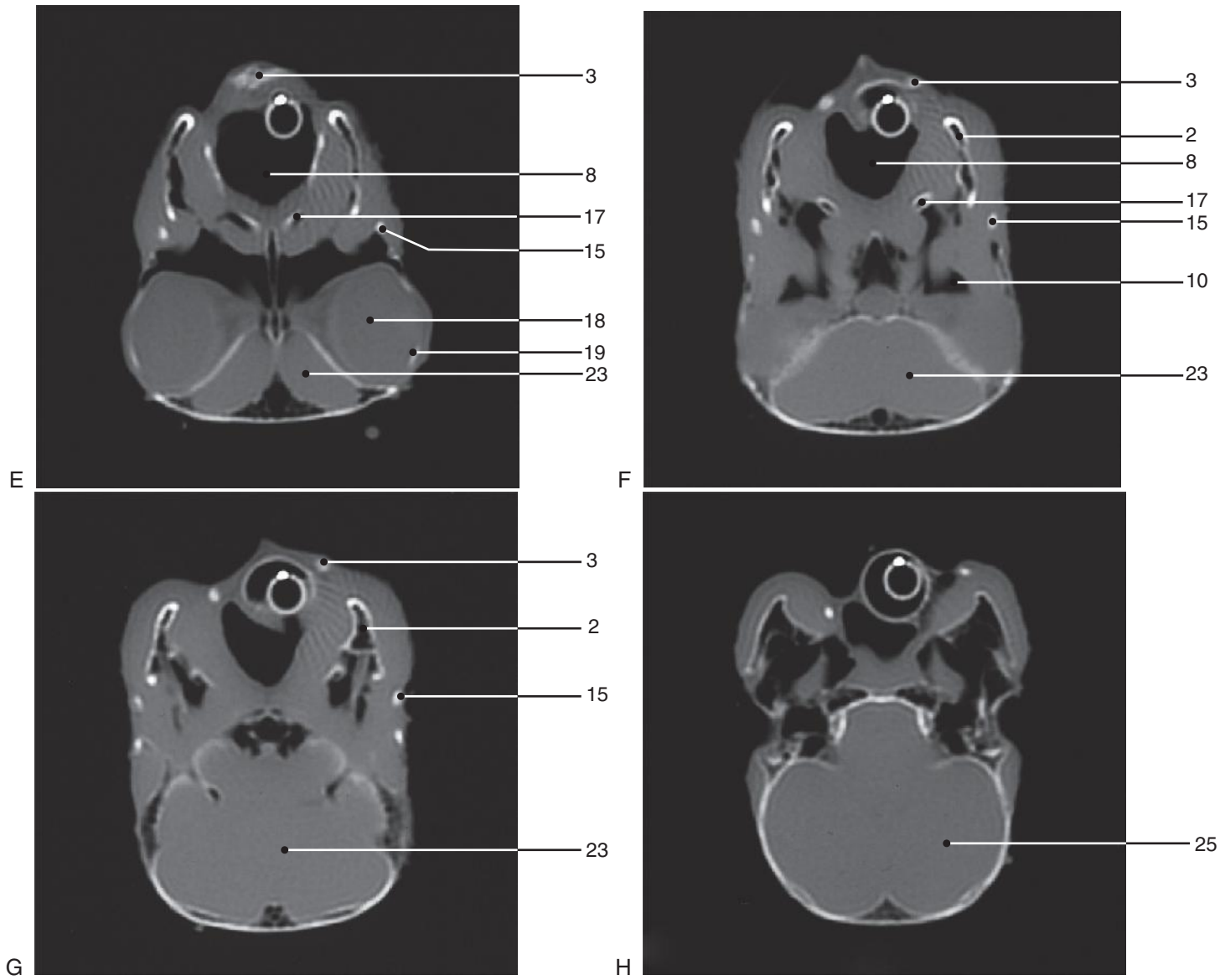

Figure 12-1, E-H
Type of Bird: Sulphur-Crested Cockatoo
Type of Study: CT head
Contrast Medium: None
Imaging Plane: Transverse
Weight of Bird: 395 g
Age: Adult

1. (Tongue)
2. Mandible
3. Hyoid bone
4. (Endotracheal tube)
5. (Keratinized maxillary beak)
6. (Nasal cavity)
7. (Nasal concha)
8. Pharynx
9. (Premaxillary bone)
10. Infraorbital sinus
11. (Nasal septum)
12. (Choana)
13. (Palatine bone)
14. (Sphenoid bone)
15. Jugal [zygomatic] bone
16. (Frontal bone)
17. Pterygoid bone
18. Eyeball
19. Scleral ossicle
20. (Interorbital septum)
21. (Lens of eyeball)
22. (Trachea)
23. Cerebrum
24. (External ear canal)
25. Cerebellum
26. (Spinal cord)
27. (Dens)
28. (Cere)
29. (Nare[s])
30. (Feather)
31. (Pons)
32. (Occipital bone)
33. (Cervical vertebra)

NOTE: Structures in parentheses are not labeled.

CHAPTER • 13

Umbrella Cockatoo
(Cacatua alba)

A

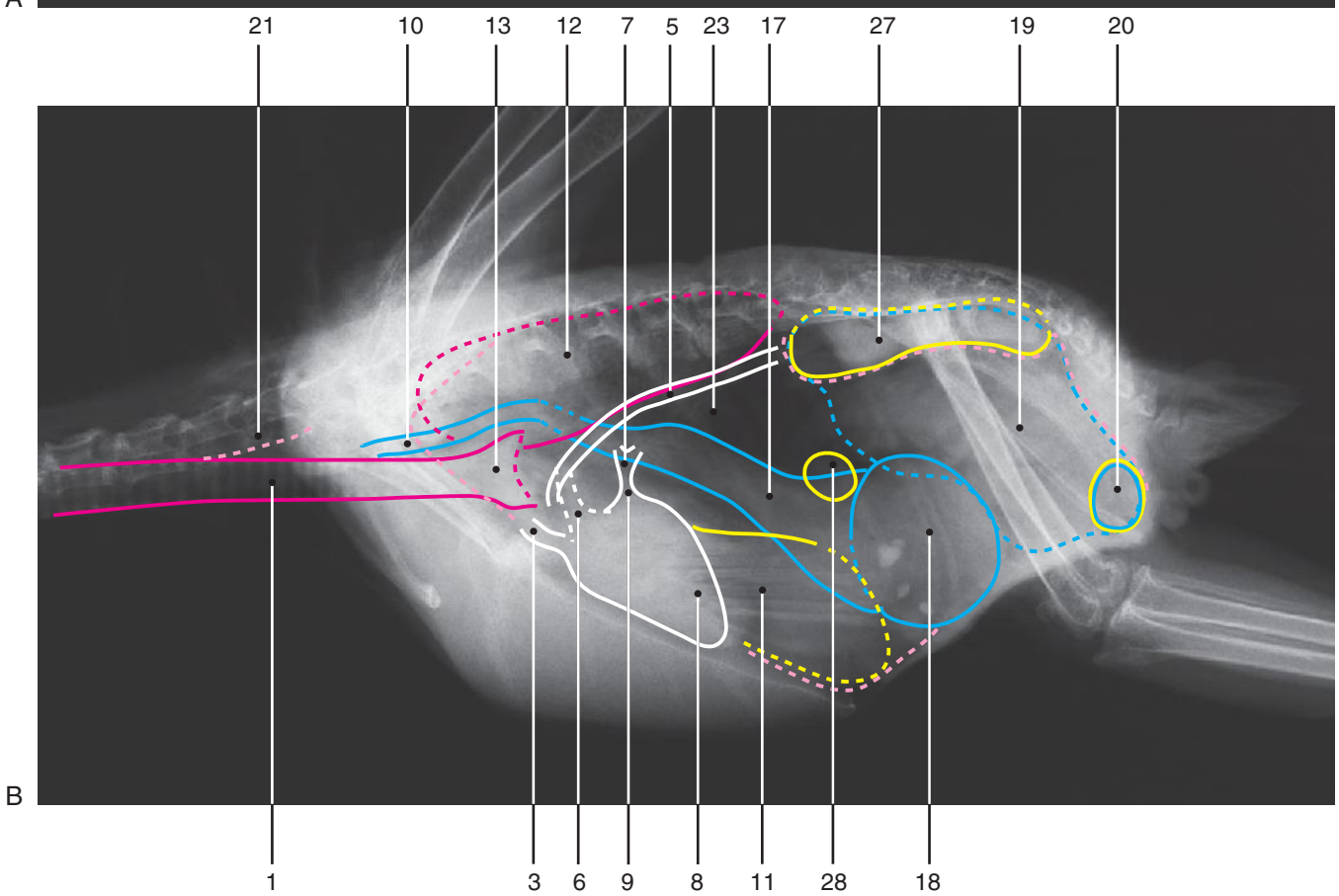

B

Figure 13-1, A-B
Type of Bird: Umbrella Cockatoo
Type of Study: Viscera of the coelom
Projection: Laterolateral (right lateral recumbency)
Weight of Bird: 450 g
Gender: Female
Reproductive Status: Intact
Age: 3 years

1. Trachea
2. (Crop)
3. Brachiocephalic artery and aorta
4. (Brachiocephalic artery)
5. Aorta
6. Pulmonary artery
7. Pulmonary vein
8. Heart
9. Left atrium
10. Esophagus
11. Liver
12. Lung
13. Syrinx
14. (Gonad)
15. (Ovary)
16. (Testes)
17. Proventriculus
18. Ventriculus
19. Intestines
20. Cloaca
21. Cervical air sac
22. (Clavicular air sac)
23. Thoracic air sac
24. (Abdominal air sac)
25. (Apex of heart)
26. (Interface between caudal thoracic and abdominal air sacs)
27. Kidneys
28. Spleen

NOTE: Structures in parentheses are not labeled.

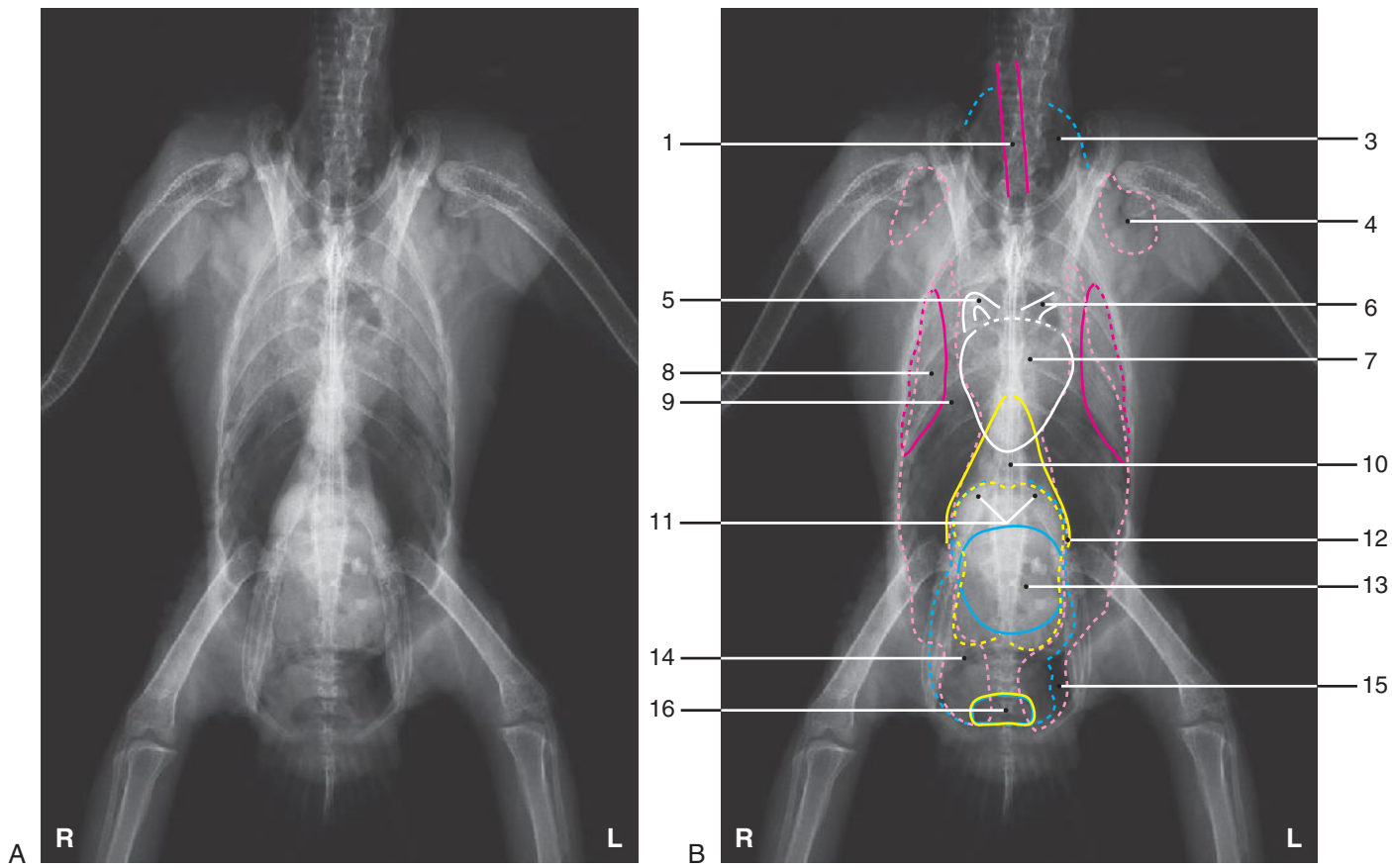

Figure 13-2, A-B
Type of Bird: Umbrella Cockatoo
Type of Study: Viscera of the coelom
Projection: Ventrodorsal
Weight of Bird: 450 g
Gender: Female
Reproductive Status: Intact
Age: 3 years

1. Trachea
2. (Cervical air sac)
3. Crop
4. Clavicular air sac
5. Brachiocephalic artery and aorta
6. Heart base vessel
7. Heart
8. Lung
9. Thoracic air sac
10. Liver
11. Kidneys
12. Proventriculus
13. Ventriculus
14. Intestines
15. Abdominal air sac
16. Cloaca

NOTE: Structures in parentheses are not labeled.

CHAPTER • 14

Moluccan Cockatoo
(Cacatua moluccensis)

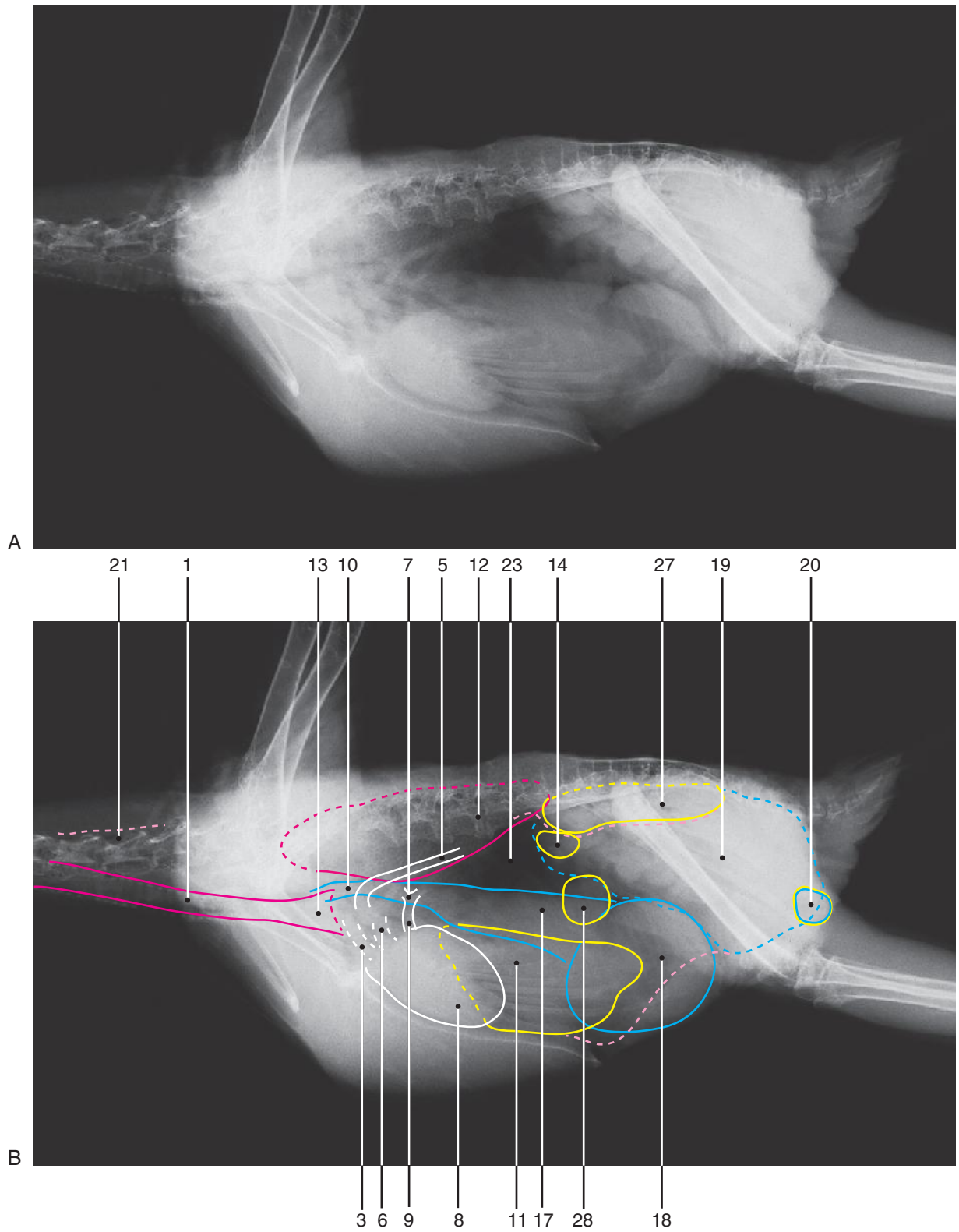

Figure 14-1, A-B
Type of Bird: Moluccan cockatoo
Prandial Condition: Fasted
Type of Study: Viscera of the coelom
Projection: Laterolateral (right lateral recumbency)
Weight of Bird: 800 g
Gender: Female
Reproductive Status: Intact
Age: Adult

1. Trachea
2. (Crop)
3. Brachiocephalic artery and aorta
4. (Brachiocephalic artery)
5. Aorta
6. Pulmonary artery
7. Pulmonary vein
8. Heart
9. Left atrium
10. Esophagus
11. Liver
12. Lung
13. Syrinx
14. (Gonad)
15. Ovary
16. (Testes)
17. Proventriculus
18. Ventriculus
19. Intestines
20. Cloaca
21. Cervical air sac
22. (Clavicular air sac)
23. Thoracic air sac
24. (Abdominal air sac)
25. (Apex of heart)
26. (Interface between caudal thoracic and abdominal air sacs)
27. Kidneys
28. Spleen

NOTE: Structures in parentheses are not labeled.

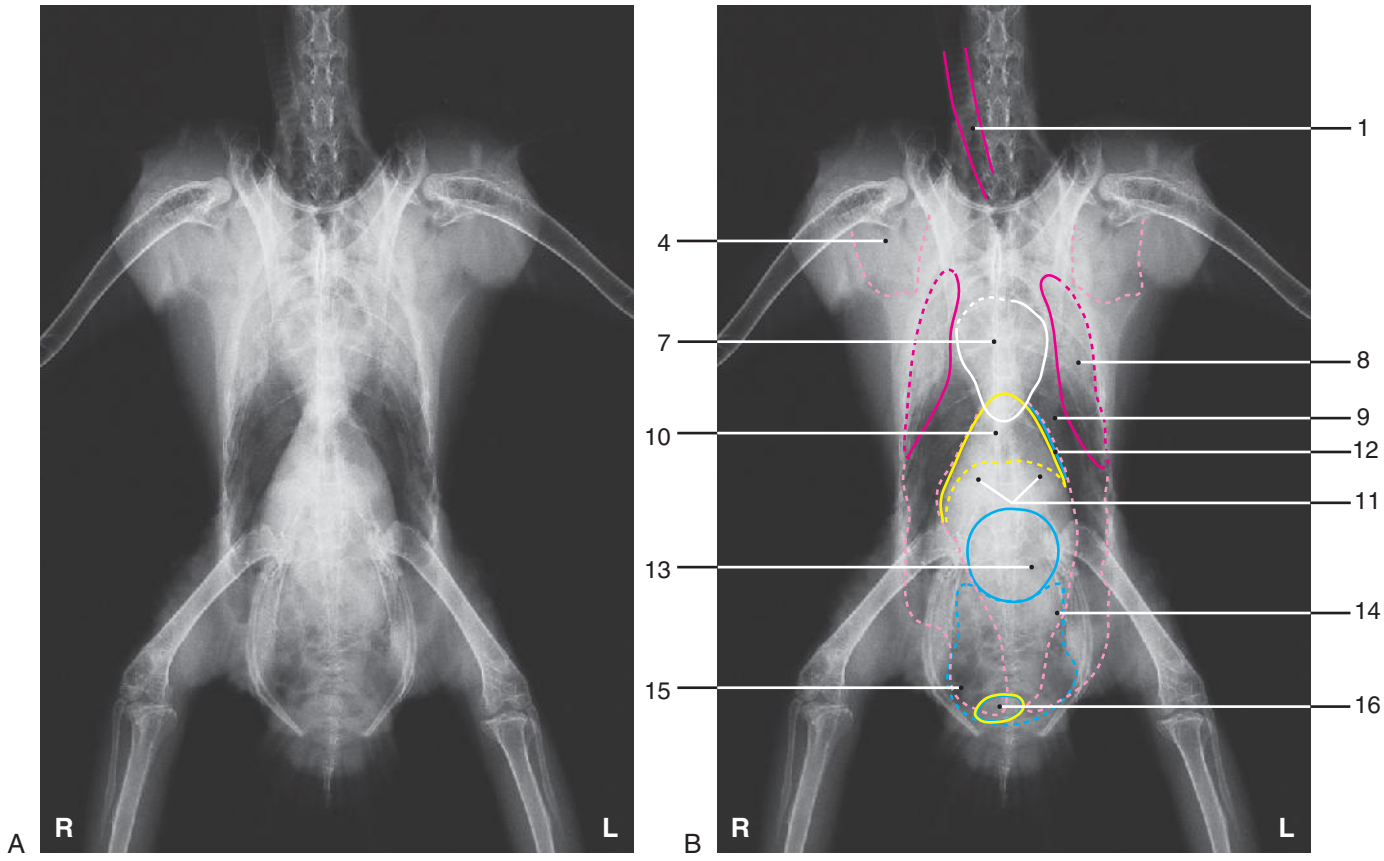

Figure 14-2, A-B
Type of Bird: Moluccan Cockatoo
Prandial Condition: Fasted
Type of Study: Viscera of the coelom
Projection: Ventrodorsal
Weight of Bird: 800 g
Gender: Female
Reproductive Status: Intact
Age: Adult

1. Trachea
2. (Cervical air sac)
3. (Crop)
4. Clavicular air sac
5. (Brachiocephalic artery and aorta)
6. (Heart base vessel)
7. Heart
8. Lung
9. Thoracic air sac
10. Liver
11. Kidneys
12. Proventriculus
13. Ventriculus
14. Intestines
15. Abdominal air sac
16. Cloaca

NOTE: Structures in parentheses are not labeled.

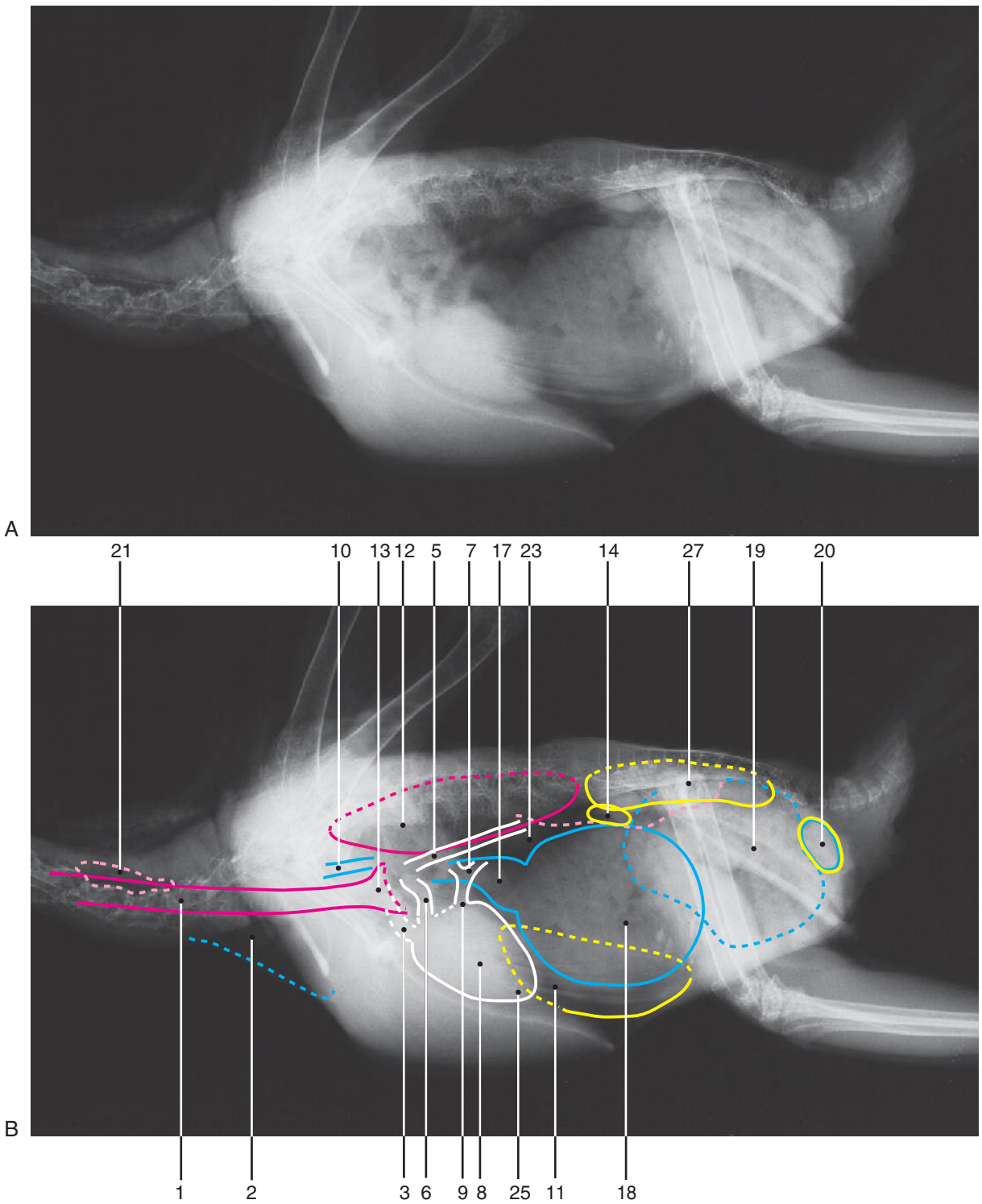

Figure 14-3, A-B
Type of Bird: Moluccan Cockatoo
Prandial Condition: Fed (pelleted diet)
Type of Study: Viscera of the coelom
Projection: Laterolateral (right lateral recumbency)
Weight of Bird: 800 g
Gender: Female
Reproductive Status: Intact
Age: Adult

1. Trachea
2. Crop
3. Brachiocephalic artery and aorta
4. (Brachiocephalic artery)
5. Aorta
6. Pulmonary artery
7. Pulmonary vein
8. Heart
9. Left atrium
10. Esophagus
11. Liver
12. Lung
13. Syrinx
14. (Gonad)
15. Ovary
16. (Testes)
17. Proventriculus
18. Ventriculus
19. Intestines
20. Cloaca
21. Cervical air sac
22. (Clavicular air sac)
23. Thoracic air sac
24. (Abdominal air sac)
25. Apex of heart
26. (Interface between caudal thoracic and abdominal air sacs)
27. Kidneys
28. (Spleen)

NOTE: Structures in parentheses are not labeled.

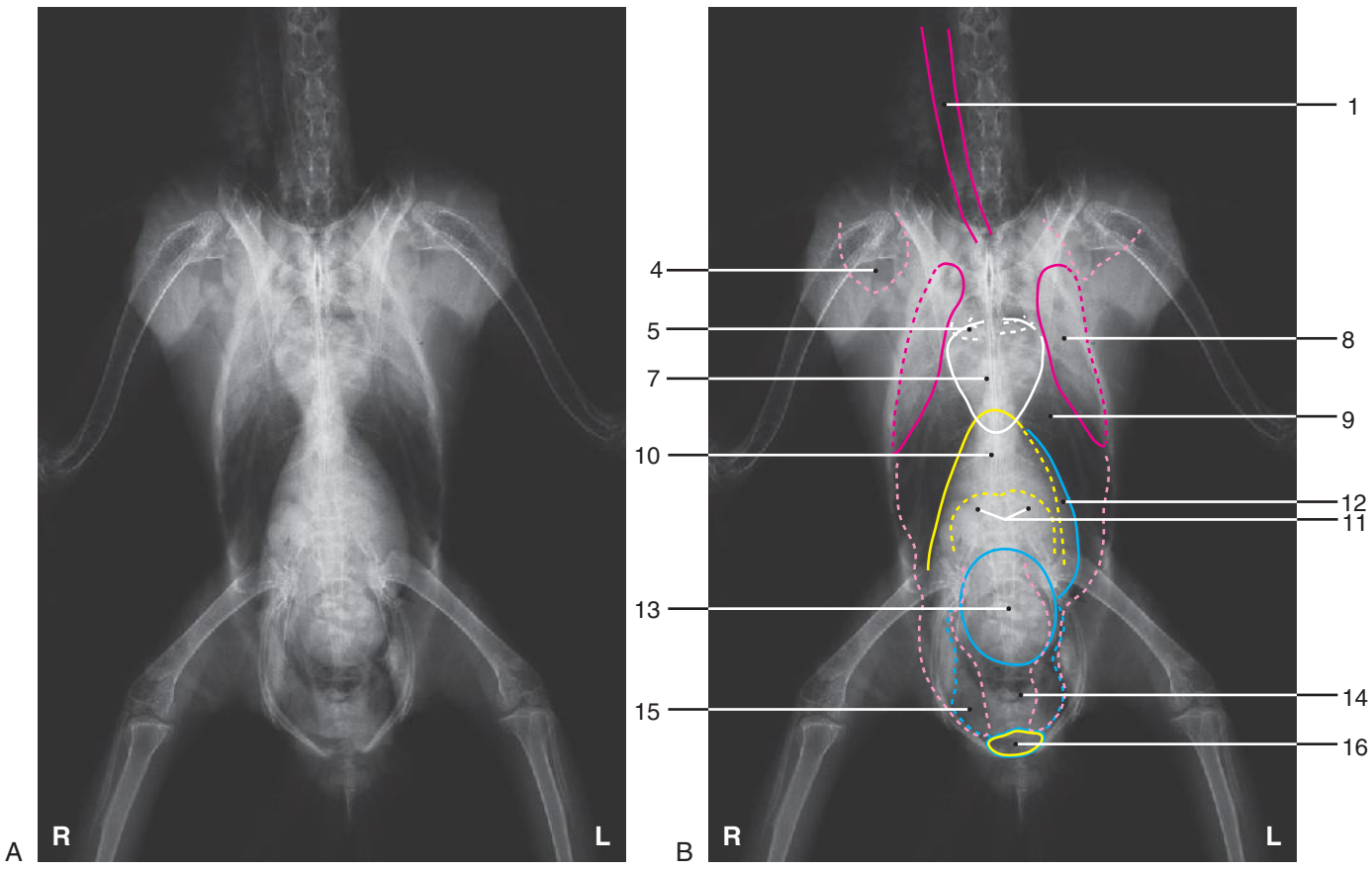

Figure 14-4, A-B
Type of Bird: Moluccan Cockatoo
Prandial condition: Fed (pelleted diet)
Type of Study: Viscera of the coelom
Projection: Ventrodorsal
Weight of Bird: 800 g
Gender: Female
Reproductive Status: Intact
Age: Adult

1. Trachea
2. (Cervical air sac)
3. (Crop)
4. Clavicular air sac
5. Brachiocephalic artery and aorta
6. (Heart base vessel)
7. Heart
8. Lung
9. Thoracic air sac
10. Liver
11. Kidneys
12. Proventriculus
13. Ventriculus
14. Intestines
15. Abdominal air sac
16. Cloaca

NOTE: Structures in parentheses are not labeled.

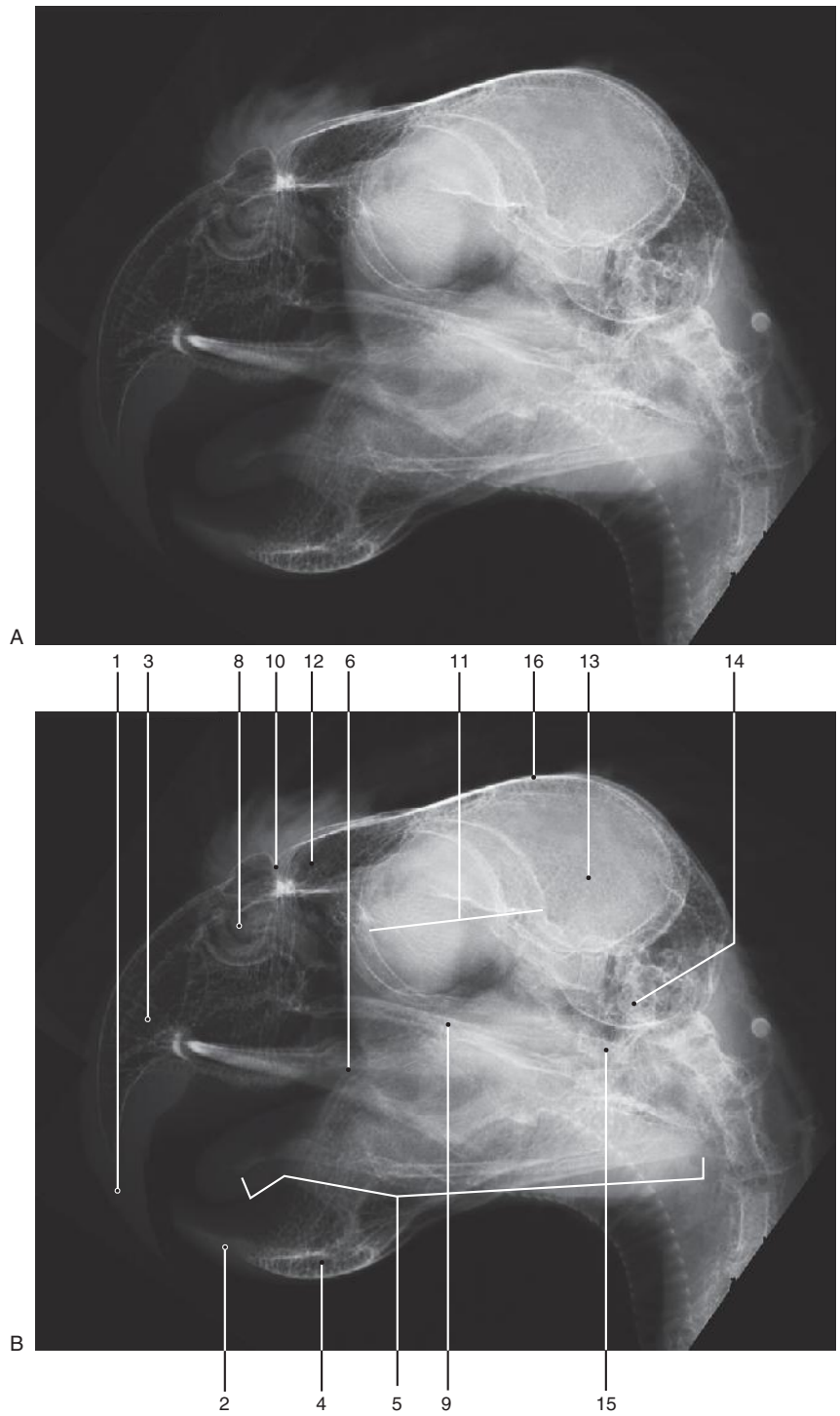

Figure 14-5, A-B
Type of Bird: Moluccan Cockatoo
Type of Study: Head
Projection: Laterolateral (right lateral recumbency)
Weight of Bird: 800 g
Gender: Female
Reproductive Status: Intact
Age: Adult

1. Keratinized maxillary beak
2. Keratinized mandibular beak
3. Premaxillary bone
4. Mandible
5. Hyoid bones
6. Palatine bone
7. (Pterygoid bone)
8. External nares
9. Jugal [zygomatic] bone
10. Craniofacial flexion zone
11. Orbit
12. Frontal bone
13. Cranium
14. Temporal bone
15. Quadrate bone
16. Parietal bone

NOTE: Structures in parentheses are not labeled.

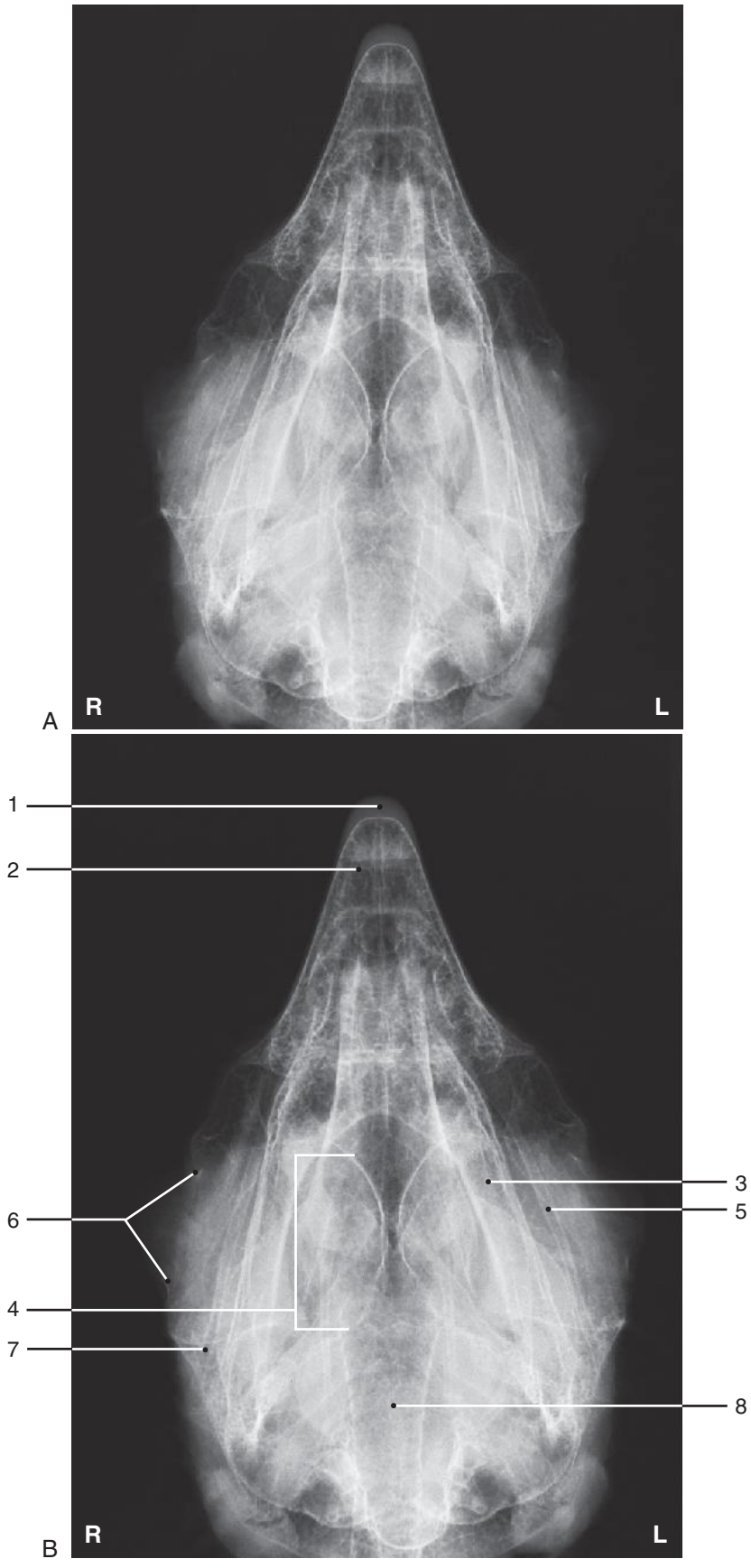

Figure 14-6, A-B
Type of Bird: Moluccan Cockatoo
Type of Study: Head
Projection: Ventrodorsal
Weight of Bird: 800 g
Gender: Female
Reproductive Status: Intact
Age: Adult

1. Keratinized maxillary beak
2. Premaxillary bone
3. Mandible
4. Orbit
5. Jugal [zygomatic] bone
6. Scleral ossicles
7. Quadrate bone
8. Cranium

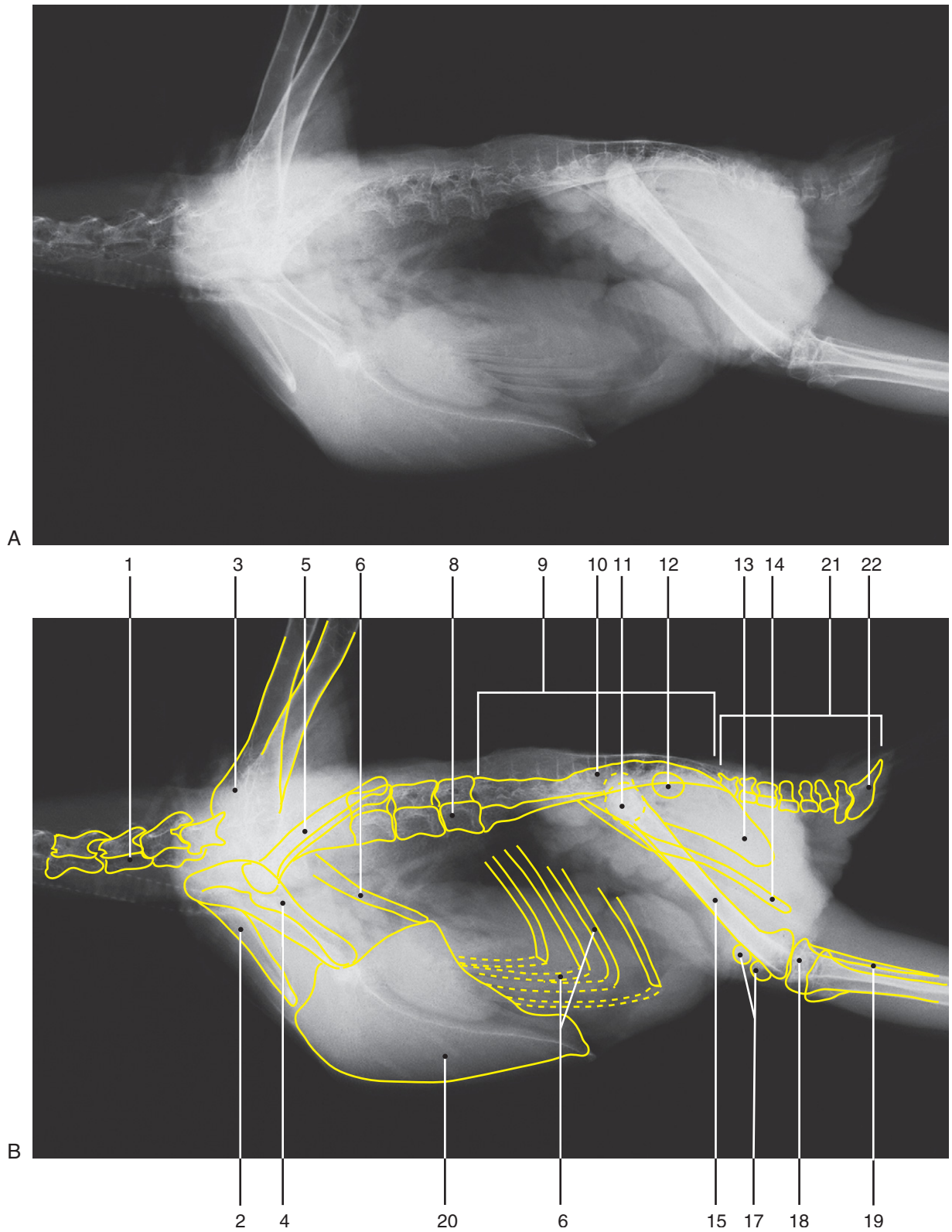

Figure 14-7, A-B
Type of Bird: Moluccan Cockatoo
Type of Study: Whole body skeleton
Projection: Laterolateral (right lateral recumbency)
Weight of Bird: 800 g
Gender: Female
Reproductive Status: Intact
Age: Adult

1. Cervical vertebra
2. Clavicle
3. Humerus
4. Coracoid
5. Scapula
6. Rib
7. (Uncinate process of rib)
8. Thoracic vertebra
9. Synsacrum
10. Ilium
11. Head of femur
12. Ilioischiadiac foramen
13. Ischium
14. Pubis
15. Femur
16. (Obturator foramen)
17. Patella
18. Tibiotarsal bone
19. Fibula
20. Sternum
21. Caudal vertebrae
22. Pygostyle

NOTE: Structures in parentheses are not labeled.

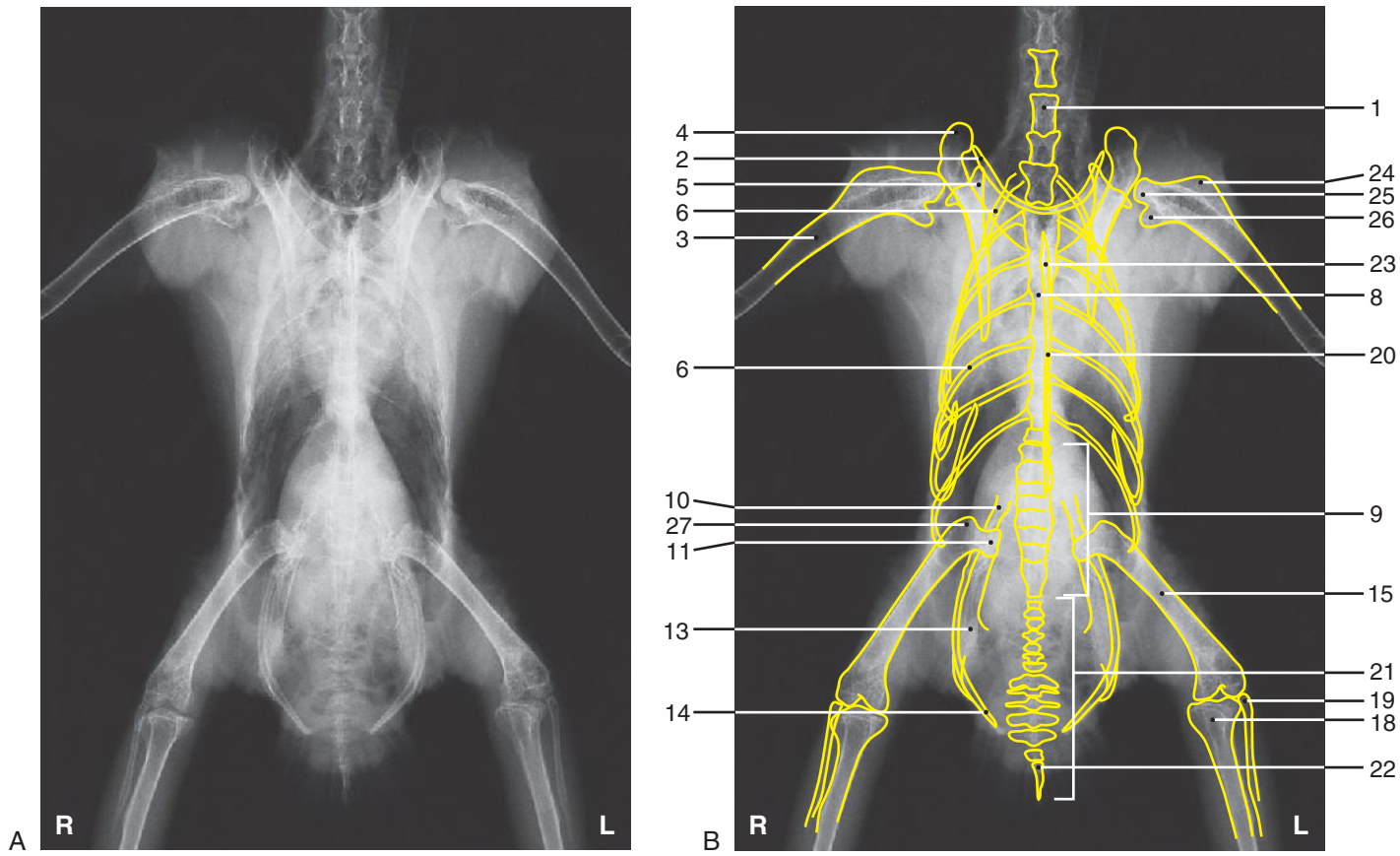

Figure 14-8, A-B
Type of Bird: Moluccan Cockatoo
Type of Study: Whole body skeleton
Projection: Ventrodorsal
Weight of Bird: 800 g
Gender: Female
Reproductive Status: Intact
Age: Adult

1. Cervical vertebra
2. Clavicle
3. Humerus
4. Coracoid
5. Scapula
6. Rib
7. (Uncinate process of rib)
8. Thoracic vertebra
9. Synsacrum
10. Ilium
11. Head of femur
12. (Ilioischiadiac foramen)
13. Ischium
14. Pubis
15. Femur
16. (Obturator foramen)
17. (Patella)
18. Tibiotarsal bone
19. Fibula
20. Sternum
21. Caudal vertebrae
22. Pygostyle
23. Apex carinae
24. Dorsal tubercle of humerus
25. Head of humerus
26. Ventral tubercle of humerus
27. Trochanter of femur

NOTE: Structures in parentheses are not labeled.

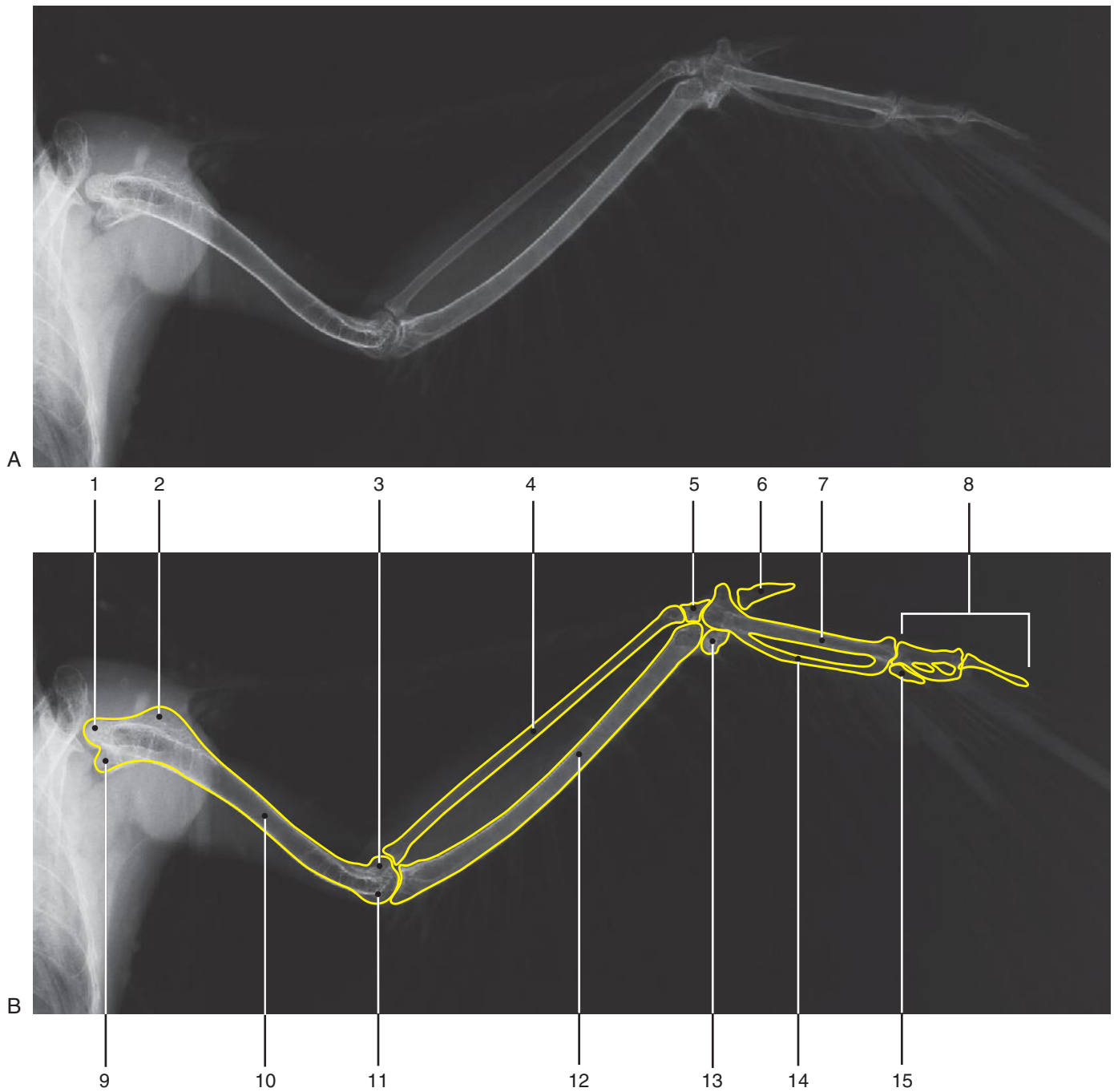

Figure 14-9, A-B
Type of Bird: Moluccan Cockatoo
Type of Study: Wing
Projection: Mediolateral
Weight of Bird: 800 g
Gender: Female
Reproductive Status: Intact
Age: Adult

1. Head of humerus
2. Dorsal tubercle of humerus
3. Dorsal condyle of humerus
4. Radius
5. Radial carpal bone
6. Alula
7. Major metacarpal bone
8. Phalanges of major digit
9. Ventral tubercle of humerus
10. Humerus
11. Ventral condyle of humerus
12. Ulna
13. Ulnar carpal bone
14. Minor metacarpal bone
15. Phalanges of minor digit

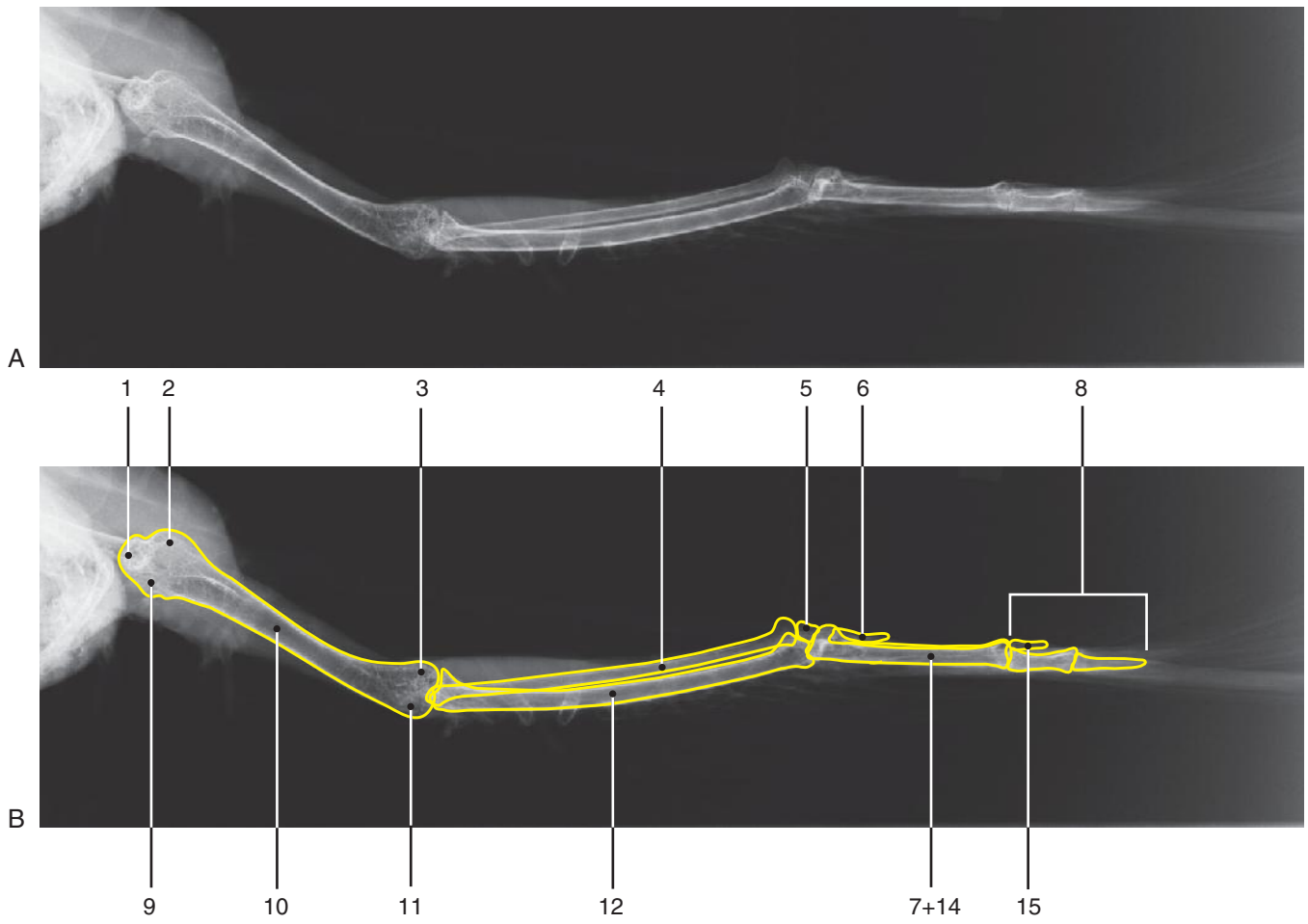

Figure 14-10, A-B
Type of Bird: Moluccan Cockatoo
Type of Study: Wing
Projection: Caudocranial
Weight of Bird: 800 g
Gender: Female
Reproductive Status: Intact
Age: Adult

1. Head of humerus
2. Ventral tubercle of humerus
3. Ventral condyle of humerus
4. Radius
5. Radial carpal bone
6. Alula
7. Minor metacarpal bone
8. Phalanges of major digit
9. Dorsal tubercle of humerus
10. Humerus
11. Dorsal condyle of humerus
12. Ulna
13. (Ulnar carpal bone)
14. Major metacarpal bone
15. Phalanges of minor digit

NOTE: Structures in parentheses are not labeled.

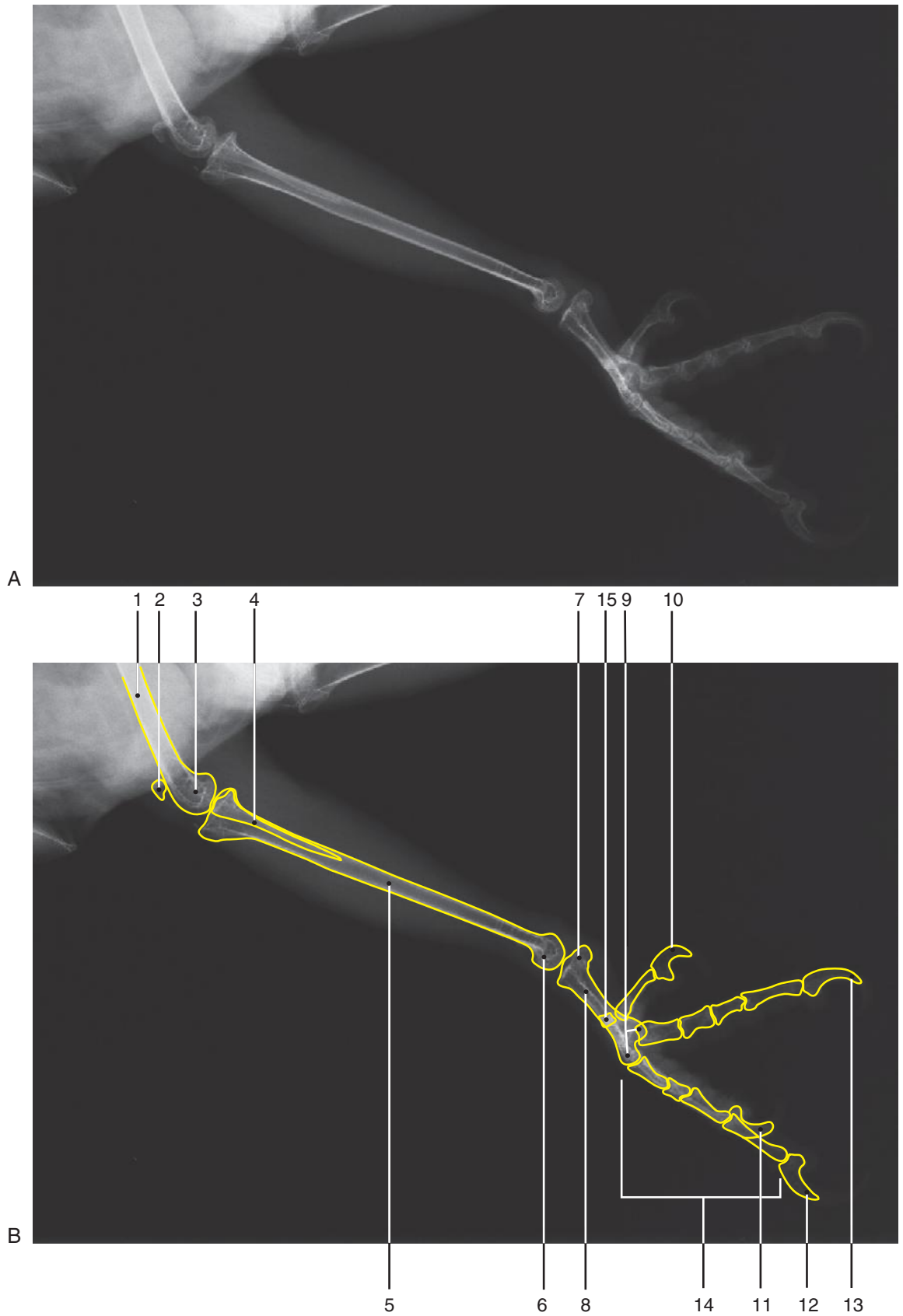

Figure 14-11, A-B
Type of Bird: Moluccan Cockatoo
Type of Study: Pelvic limb
Projection: Mediolateral
Weight of Bird: 800 g
Gender: Female
Reproductive Status: Intact
Age: Adult

1. Femur
2. Patella
3. Condyles of femur
4. Fibula
5. Tibiotarsal bone
6. Condyles of tibiotarsal bone
7. Hypotarsal crest of tarsometatarsal bone
8. Tarsometatarsal bone
9. Trochlea of tarsometatarsal bone
10. Digit I
11. Digit II
12. Digit III
13. Digit IV
14. Phalanges
15. Metatarsal I

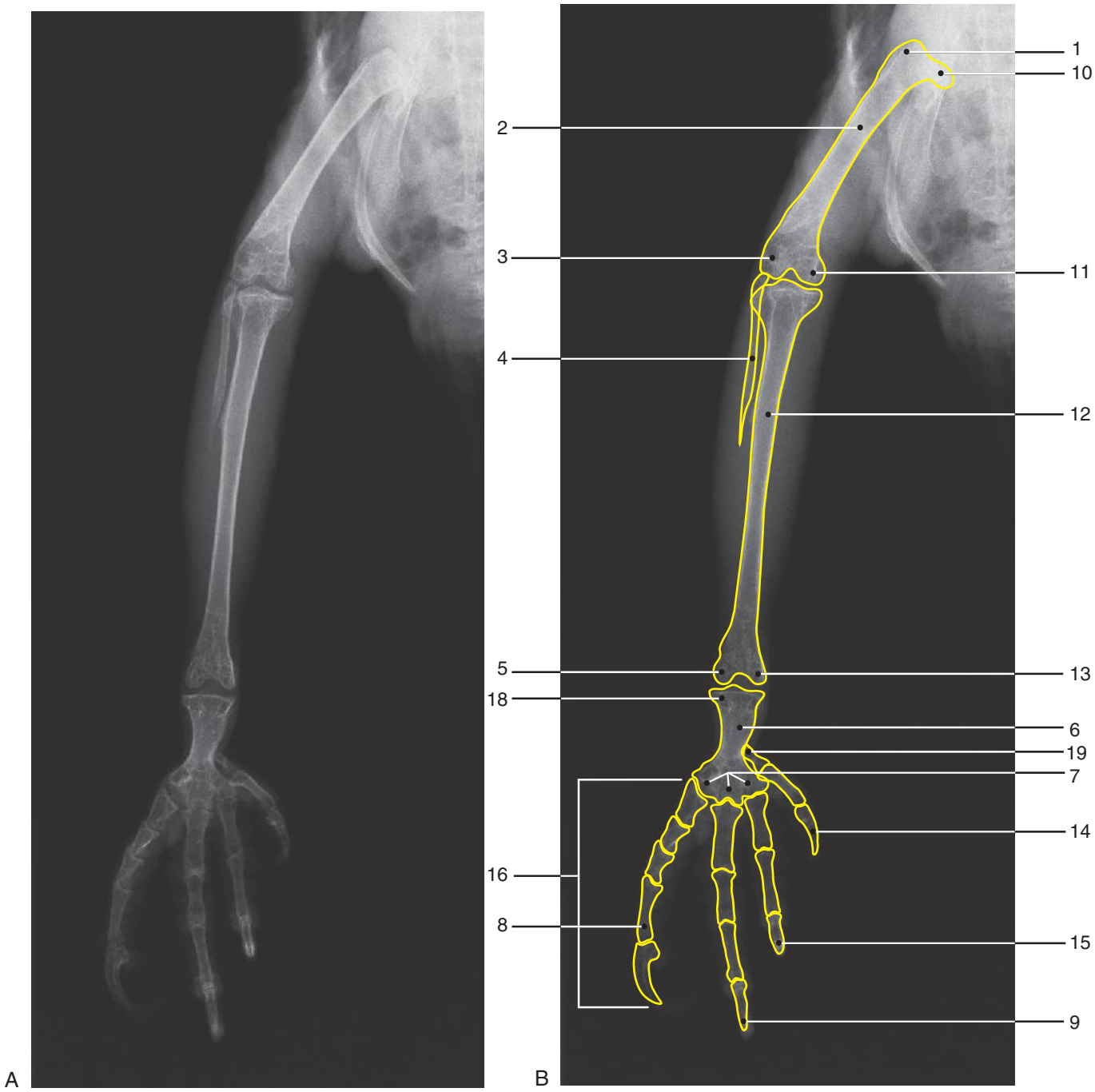

Figure 14-12, A-B
Type of Bird: Moluccan Cockatoo
Type of Study: Pelvic limb
Projection: Craniocaudal
Weight of Bird: 800 g
Gender: Female
Reproductive Status: Intact
Age: Adult

1. Trochanter of femur
2. Femur
3. Lateral condyle of femur
4. Fibula
5. Lateral condyle of tibiotarsal bone
6. Tarsometatarsal bone
7. Trochlea of tarsometatarsal bone
8. Digit IV
9. Digit III
10. Head of femur
11. Medial condyle of femur
12. Tibiotarsal bone
13. Medial condyle of tibiotarsal bone
14. Digit I
15. Digit II
16. Phalanges
17. (Patella)
18. Hypotarsal crest of tarsometatarsal bone
19. Metatarsal I

NOTE: Structures in parentheses are not labeled.

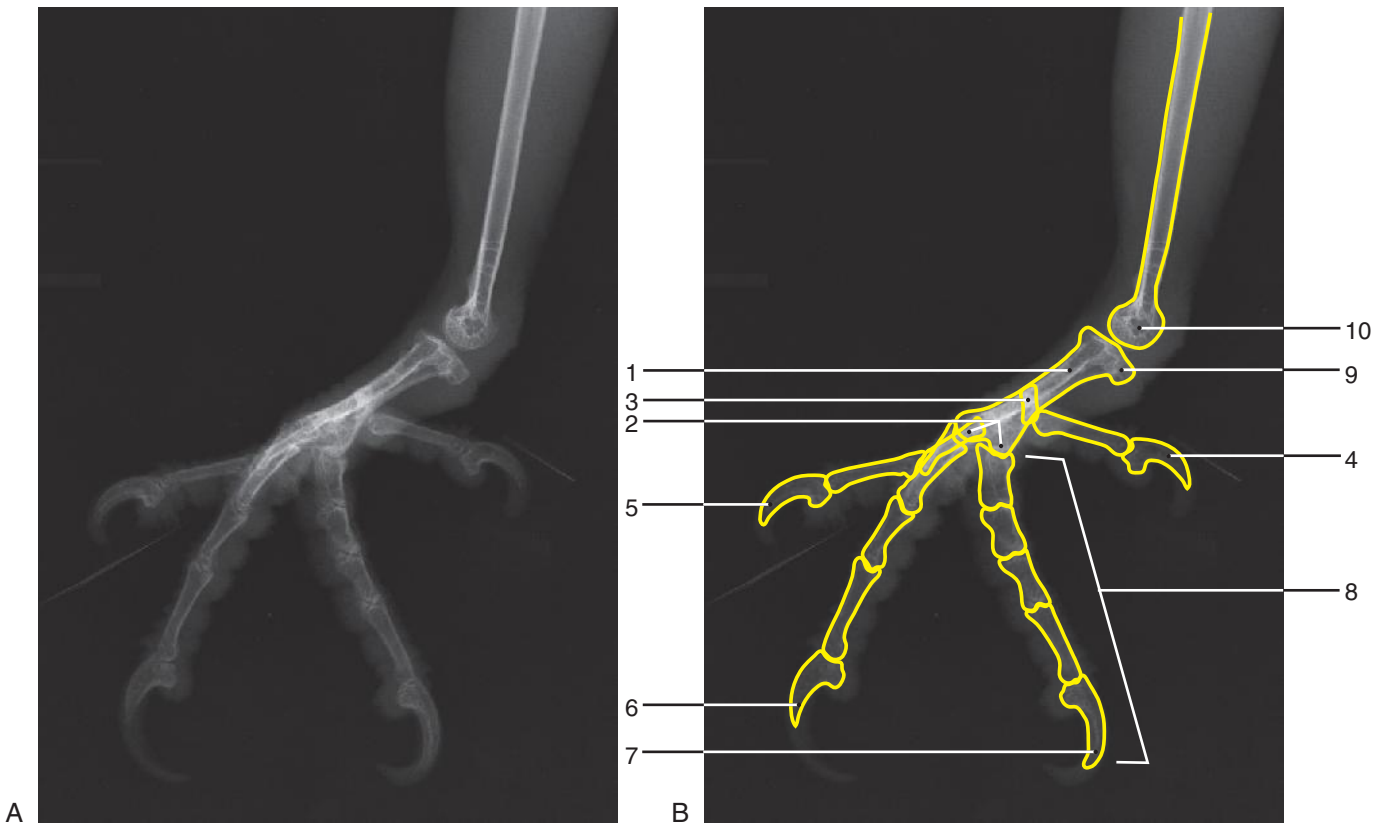

Figure 14-13, A-B
Type of Bird: Moluccan Cockatoo
Type of Study: Distal pelvic limb
Projection: Mediolateral
Weight of Bird: 800 g
Gender: Female
Reproductive Status: Intact
Age: Adult

1. Tarsometatarsal bone
2. Trochlea of tarsometatarsal bone
3. Metatarsal bone I
4. Digit I
5. Digit II
6. Digit III
7. Digit IV
8. Phalanges
9. Hypotarsal crest of tarsometatarsal bone
10. Condyles of tibiotarsal bone

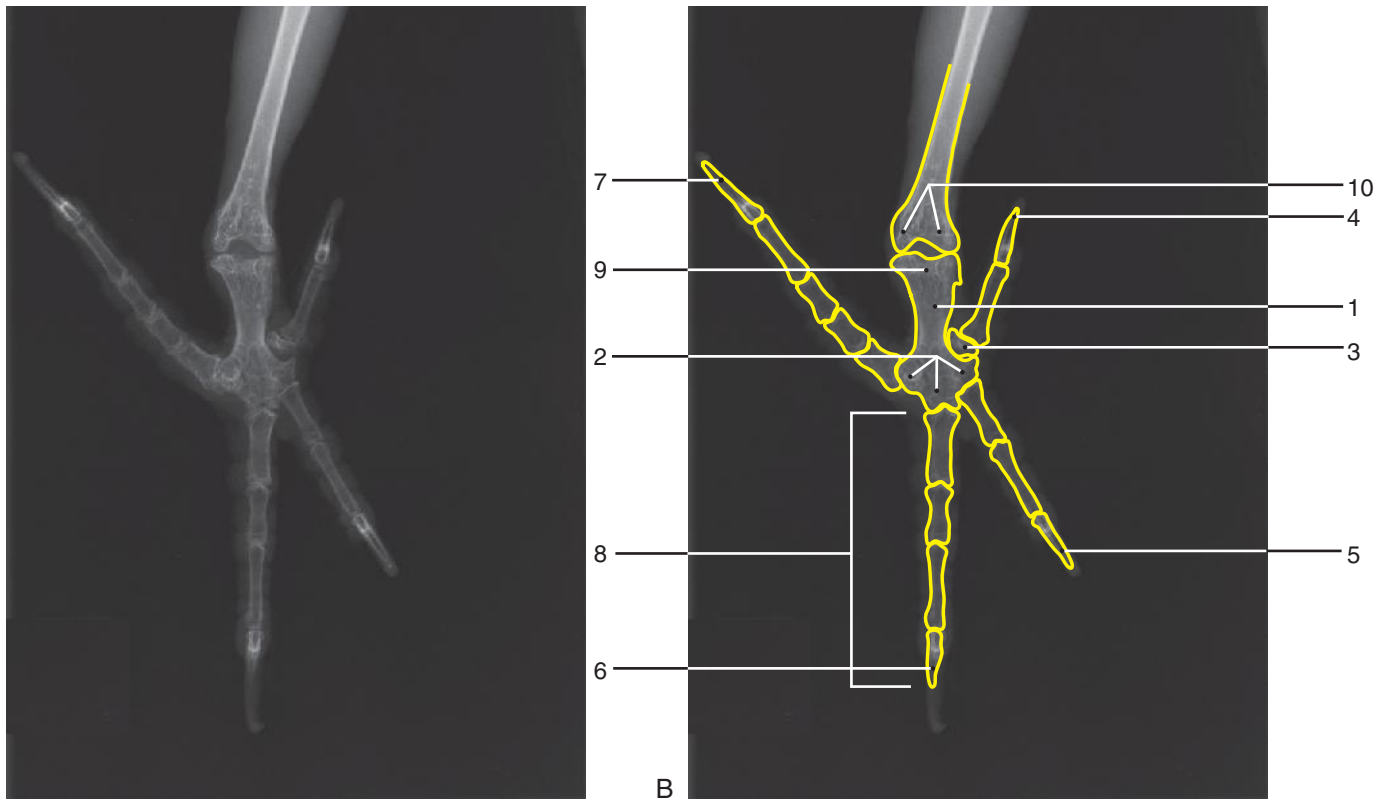

Figure 14-14, A-B
Type of Bird: Moluccan Cockatoo
Type of Study: Distal pelvic limb
Projection: Dorsoplantar
Weight of Bird: 800 g
Gender: Female
Reproductive Status: Intact
Age: Adult

1. Tarsometatarsal bone
2. Trochlea of tarsometatarsal bone
3. Metatarsal bone I
4. Digit I
5. Digit II
6. Digit III
7. Digit IV
8. Phalanges
9. Hypotarsal crest of tarsometatarsal bone
10. Condyles of tibiotarsal bone

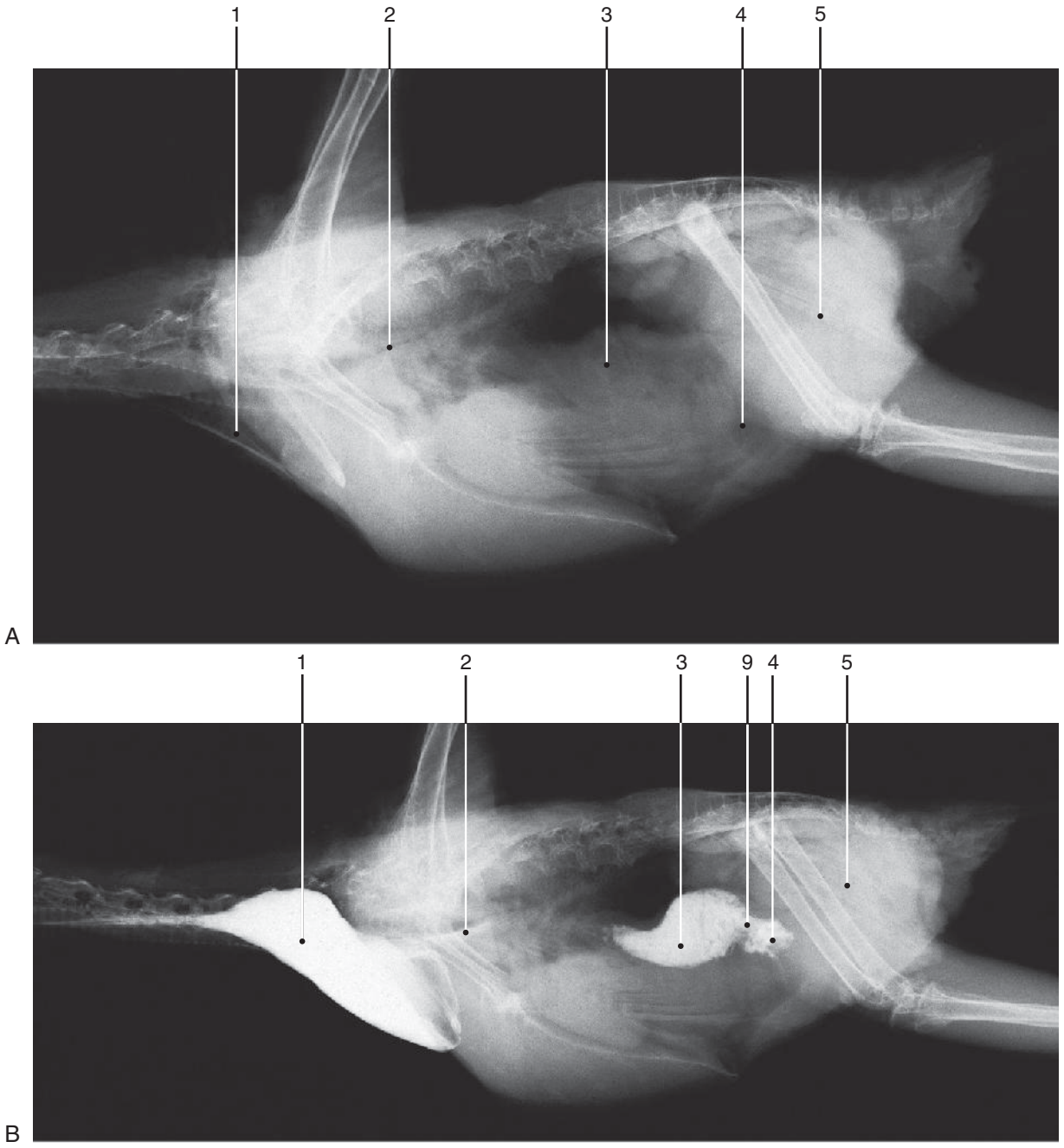

Figure 14-15, A-B
Type of Bird: Moluccan Cockatoo
Type of Study: Gastrointestinal positive contrast study
Contrast Medium: Barium sulfate suspension (Novopaque® 30% w/v; Lafayette Pharmaceutical, Inc., Lafayette, IN) 25 ml administered via gavage tube
Projection: Laterolateral (right lateral recumbency)
Weight of Bird: 820 g
Gender: Female
Reproductive Status: Intact
Age: Adult

Image	Time (hr)
A	Scout
B	0.25

1. Crop
2. Esophagus
3. Proventriculus
4. Ventriculus
5. Intestines
6. (Duodenum)
7. (Large intestine)
8. (Cloaca)
9. Proventricular-ventricular isthmus

NOTE: Structures in parentheses are not labeled.

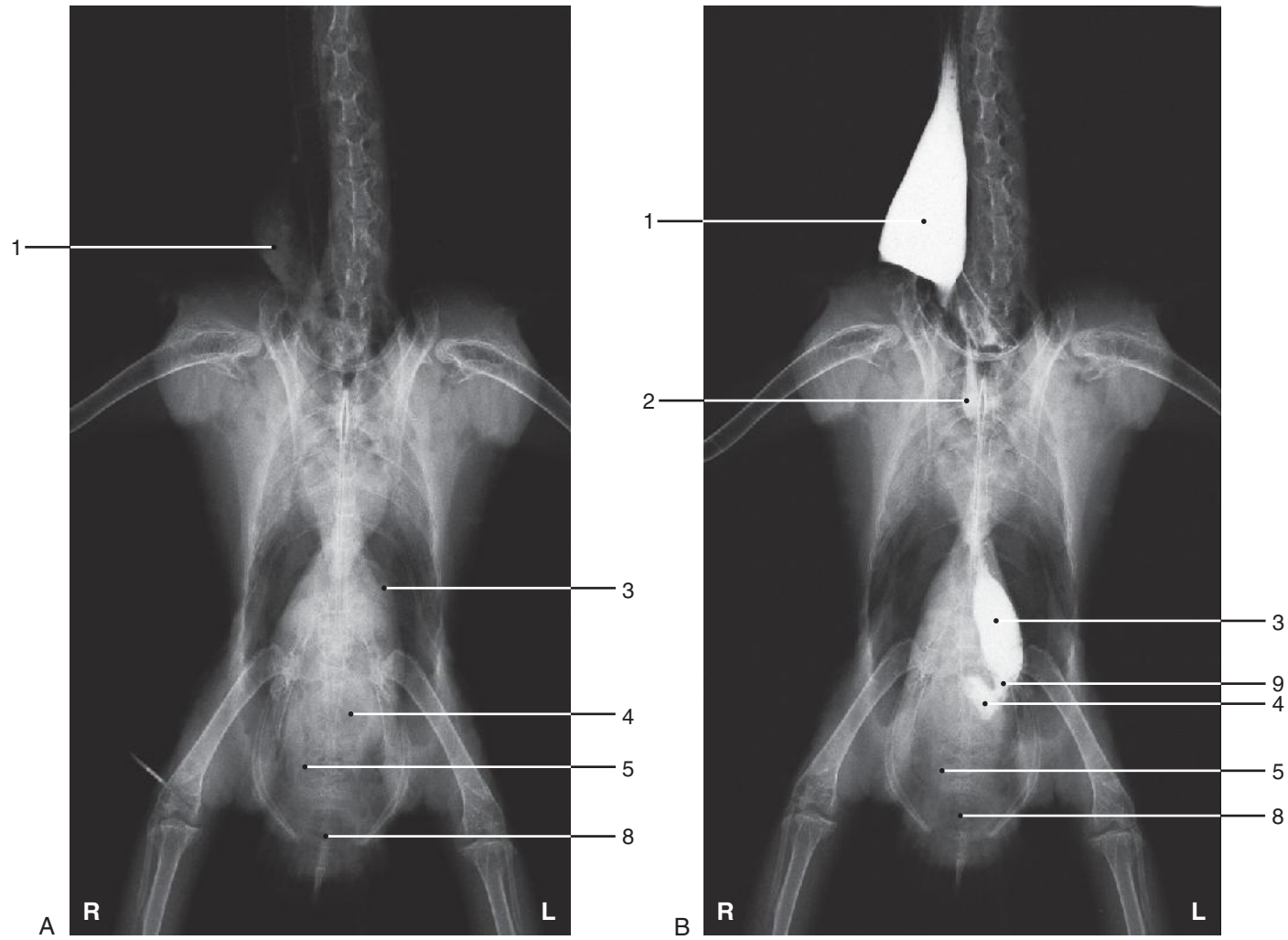

Figure 14-16, A-B
Type of Bird: Moluccan Cockatoo
Type of Study: Gastrointestinal positive contrast study
Contrast Medium: Barium sulfate suspension (Novopaque® 30% w/v; Lafayette Pharmaceutical, Inc., Lafayette, IN) 25 ml administered via gavage tube
Projection: Ventrodorsal
Weight of Bird: 820 g
Gender: Female
Reproductive Status: Intact
Age: Adult

Image	Time (hr)
A	Scout
B	0.25

1. Crop
2. Esophagus
3. Proventriculus
4. Ventriculus
5. Intestines
6. (Duodenum)
7. (Large intestine)
8. Cloaca
9. Proventricular-ventricular isthmus

NOTE: Structures in parentheses are not labeled.

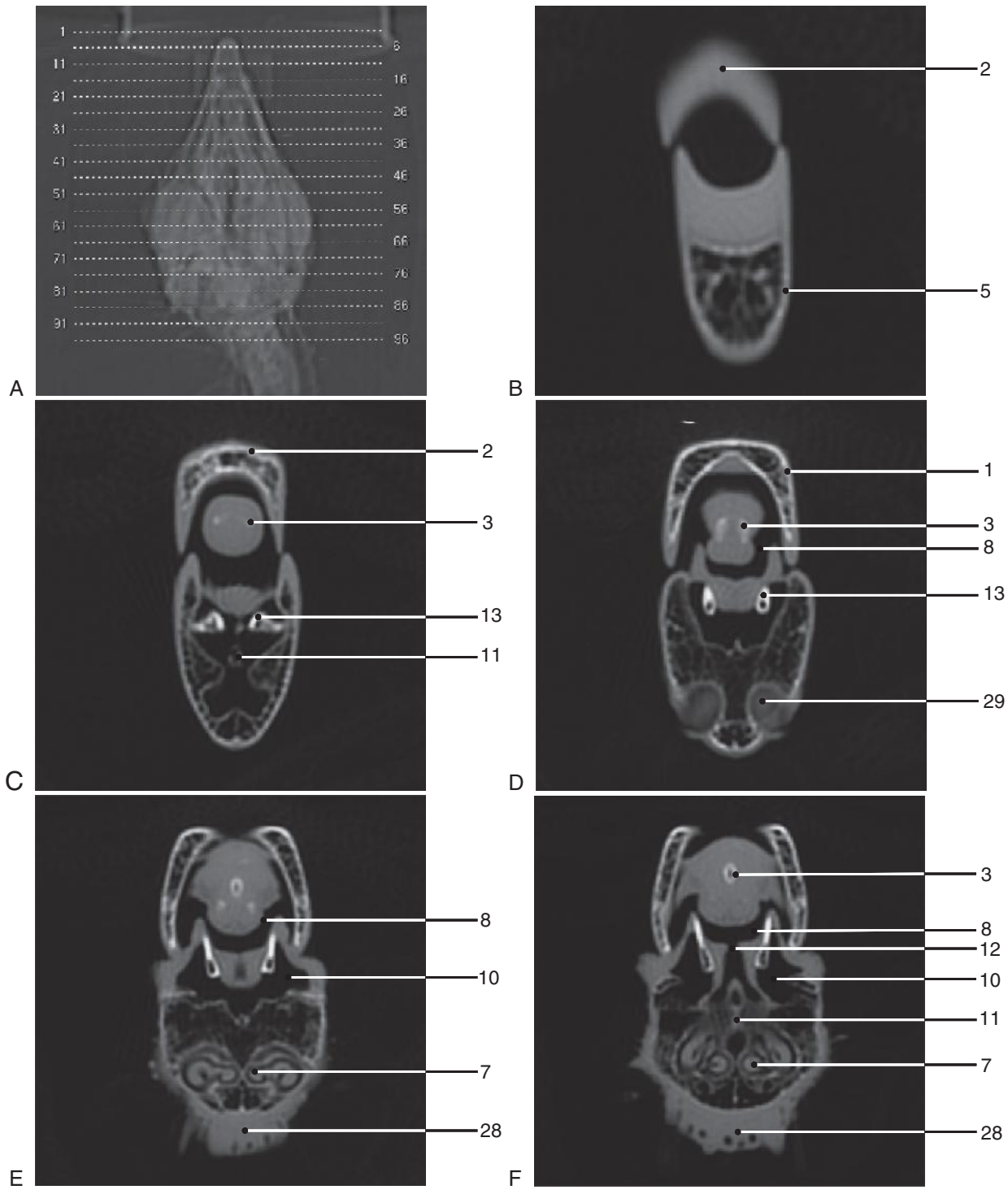

Figure 14-17, A-F
Type of Bird: Moluccan Cockatoo
Type of Study: CT head
Contrast Medium: None
Imaging Plane: Transverse
Weight of Bird: 820 g
Age: Adult

1. Tongue
2. Mandible
3. Hyoid bone
4. (Endotracheal tube)
5. Keratinized maxillary beak
6. (Nasal cavity)
7. Nasal concha
8. Pharynx
9. (Premaxillary bone)
10. Infraorbital sinus
11. Nasal septum
12. Choana
13. Palatine bone
14. (Sphenoid bone)
15. (Jugal [zygomatic] bone)
16. (Frontal bone)
17. (Pterygoid bone)
18. (Eyeball)
19. (Scleral ossicle)
20. (Interorbital septum)
21. (Lens of eyeball)
22. (Trachea)
23. (Cerebrum)
24. (External ear canal)
25. (Cerebellum)
26. (Spinal cord)
27. (Dens)
28. Cere
29. Nare[s]
30. (Feather)
31. (Pons)
32. (Occipital bone)
33. (Cervical vertebra)

NOTE: Structures in parentheses are not labeled.

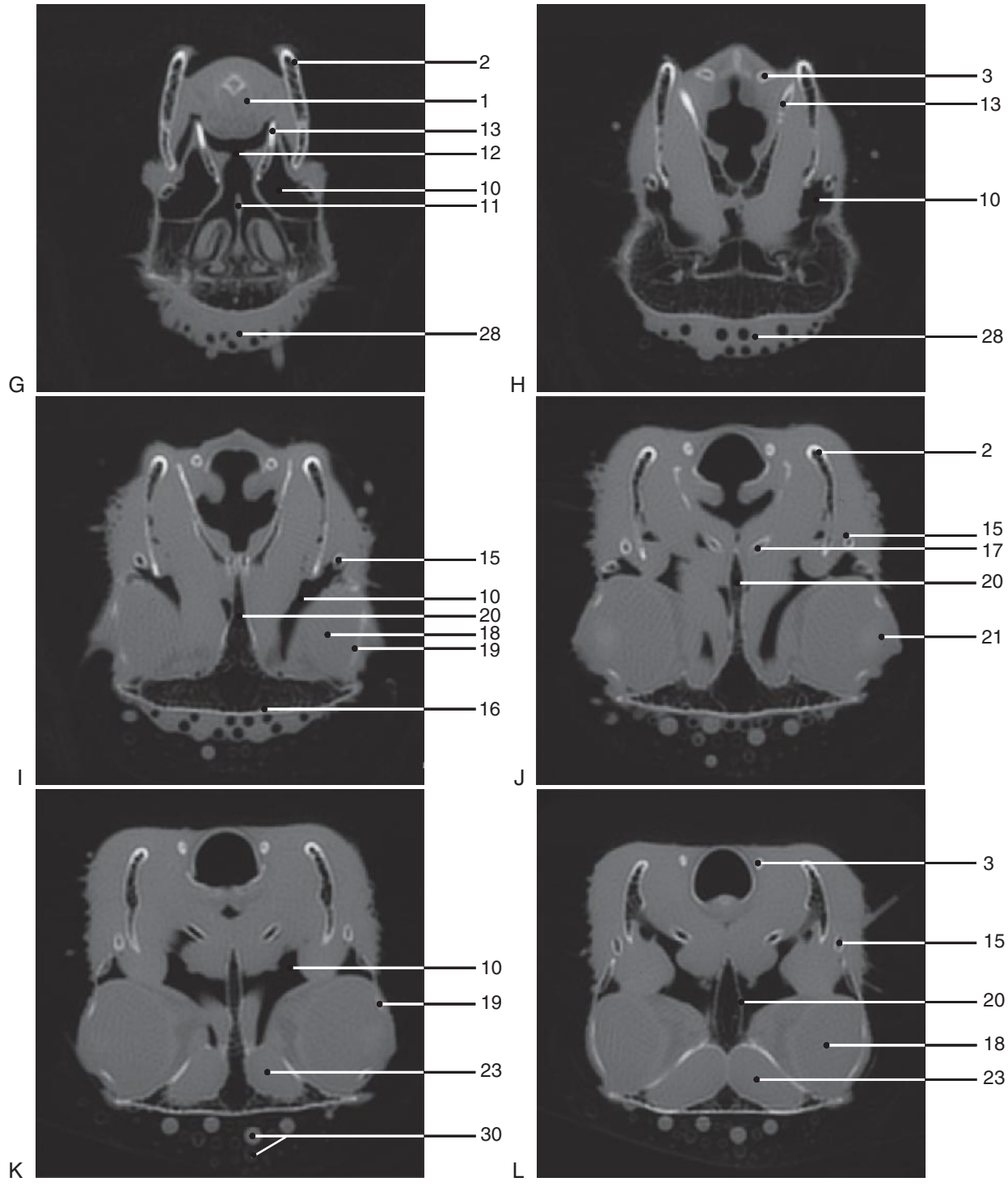

Figure 14-17, G-L
Type of Bird: Moluccan Cockatoo
Type of Study: CT head
Contrast Medium: None
Imaging Plane: Transverse
Weight of Bird: 820 g
Age: Adult

1. Tongue
2. Mandible
3. Hyoid bone
4. (Endotracheal tube)
5. (Keratinized maxillary beak)
6. (Nasal cavity)
7. (Nasal concha)
8. (Pharynx)
9. (Premaxillary bone)
10. Infraorbital sinus
11. Nasal septum
12. Choana
13. Palatine bone
14. (Sphenoid bone)
15. Jugal [zygomatic] bone
16. Frontal bone
17. Pterygoid bone
18. Eyeball
19. Scleral ossicle
20. Interorbital septum
21. Lens of eyeball
22. (Trachea)
23. Cerebrum
24. (External ear canal)
25. (Cerebellum)
26. (Spinal cord)
27. (Dens)
28. Cere
29. (Nare[s])
30. Feather
31. (Pons)
32. (Occipital bone)
33. (Cervical vertebra)

NOTE: Structures in parentheses are not labeled.

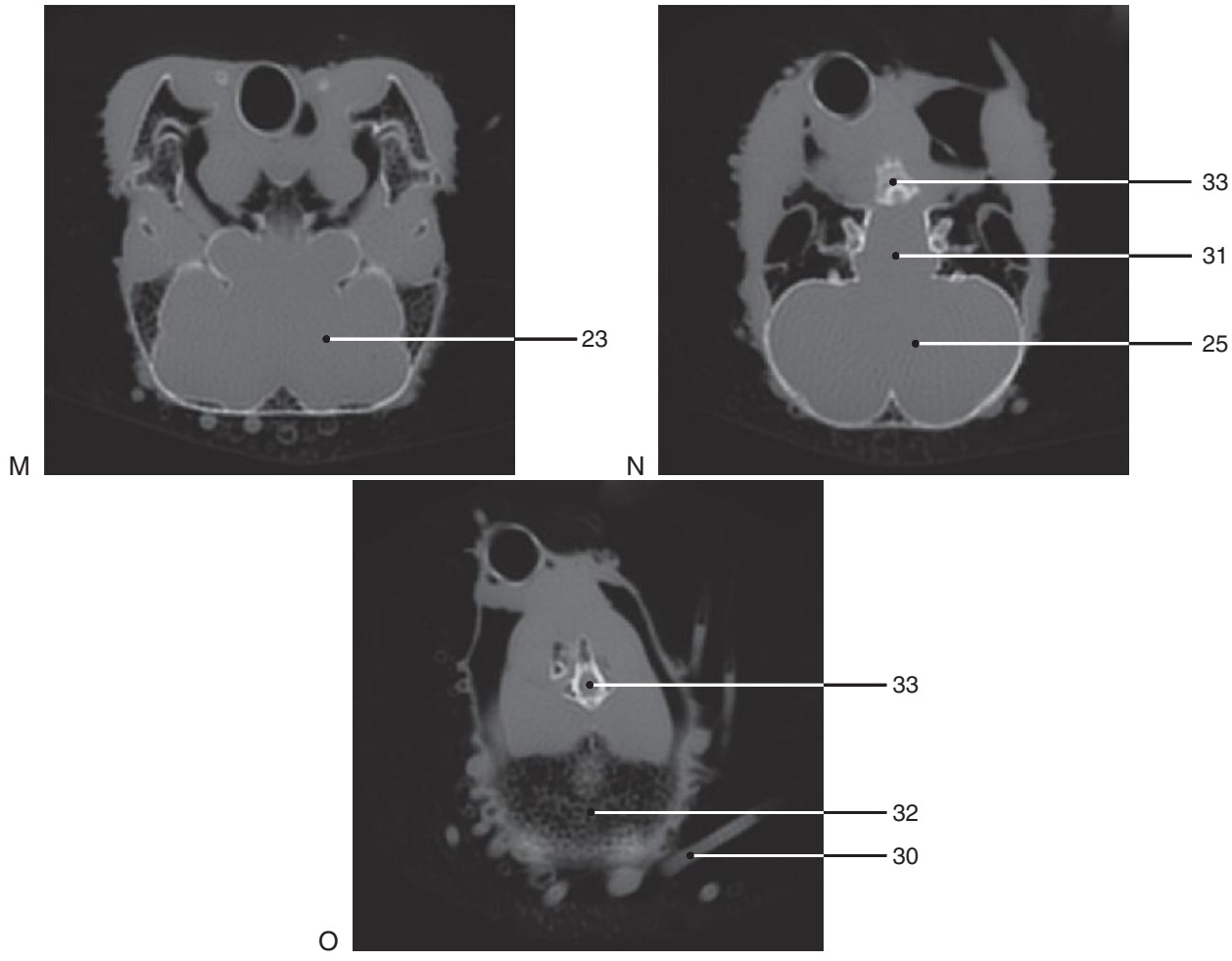

Figure 14-17, M-O
Type of Bird: Moluccan Cockatoo
Type of Study: CT head
Contrast Medium: None
Imaging Plane: Transverse
Weight of Bird: 820 g
Age: Adult

1. (Tongue)
2. (Mandible)
3. (Hyoid bone)
4. (Endotracheal tube)
5. (Keratinized maxillary beak)
6. (Nasal cavity)
7. (Nasal concha)
8. (Pharynx)
9. (Premaxillary bone)
10. (Infraorbital sinus)
11. (Nasal septum)
12. (Choana)
13. (Palatine bone)
14. (Sphenoid bone)
15. (Jugal [zygomatic] bone)
16. (Frontal bone)
17. (Pterygoid bone)
18. (Eyeball)
19. (Scleral ossicle)
20. (Interorbital septum)
21. (Lens of eyeball)
22. (Trachea)
23. (Cerebrum)
24. (External ear canal)
25. Cerebellum
26. (Spinal cord)
27. (Dens)
28. (Cere)
29. (Nare[s])
30. Feather
31. Pons
32. Occipital bone
33. Cervical vertebra

NOTE: Structures in parentheses are not labeled.

CHAPTER • 15

Pigeon *(Columba livia)*

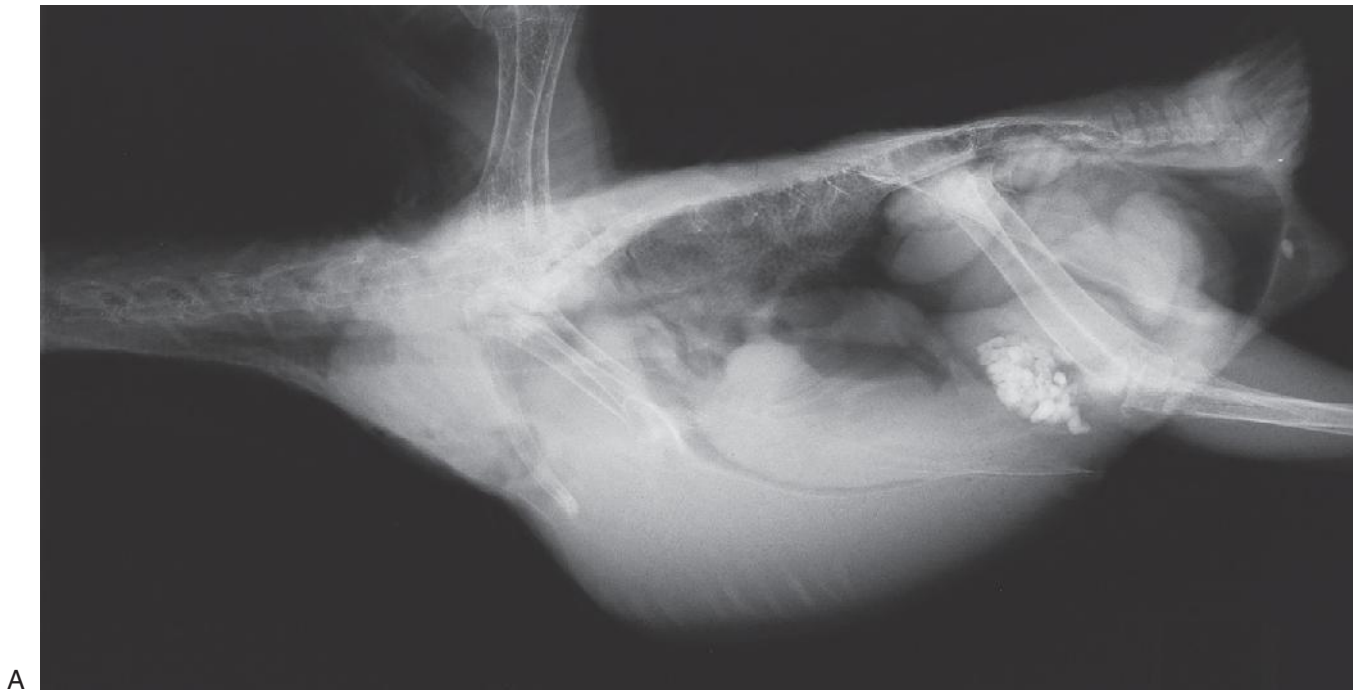

A

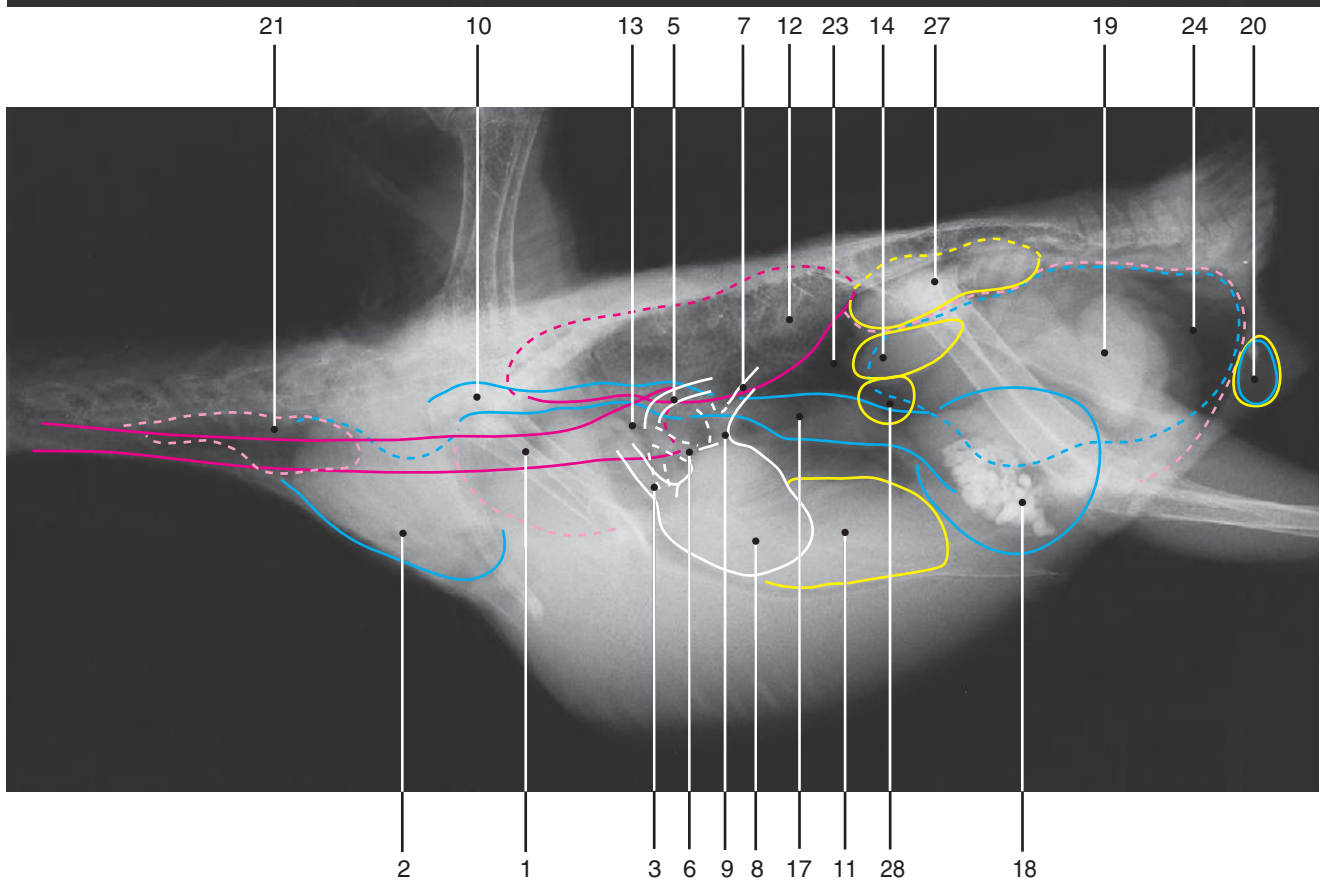

B

Figure 15-1, A-B
Type of Bird: Pigeon
Type of Study: Viscera of the coelom
Projection: Laterolateral (right lateral recumbency)
Weight of Bird: 545 g
Gender: Unknown
Reproductive Status: Intact
Age: Adult

1. Trachea
2. Crop
3. Brachiocephalic artery and aorta
4. (Brachiocephalic artery)
5. Aorta
6. Pulmonary artery
7. Pulmonary vein
8. Heart
9. Left atrium
10. Esophagus
11. Liver
12. Lung
13. Syrinx
14. Gonad
15. (Ovary)
16. (Testes)
17. Proventriculus
18. Ventriculus
19. Intestines
20. Cloaca
21. Cervical air sac
22. (Clavicular air sac)
23. Thoracic air sac
24. Abdominal air sac
25. (Apex of heart)
26. (Interface between caudal thoracic and abdominal air sacs)
27. Kidneys
28. Spleen

NOTE: Structures in parentheses are not labeled.

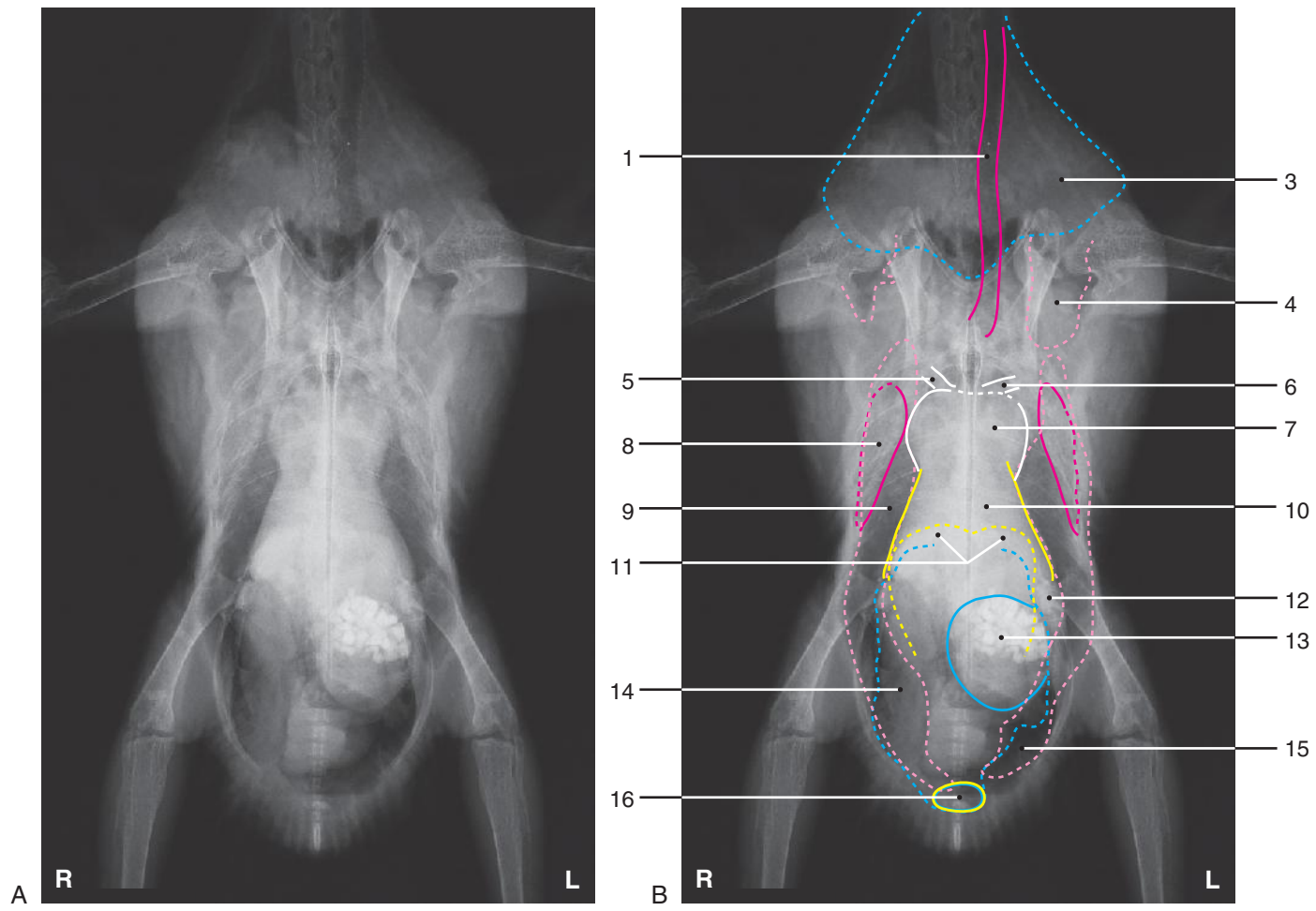

Figure 15-2, A-B
Type of Bird: Pigeon
Type of Study: Viscera of the coelom
Projection: Ventrodorsal
Weight of Bird: 545 g
Gender: Unknown
Reproductive Status: Intact
Age: Adult

1. Trachea
2. (Cervical air sac)
3. Crop
4. Clavicular air sac
5. Brachiocephalic artery and aorta
6. Heart base vessel
7. Heart
8. Lung
9. Thoracic air sac
10. Liver
11. Kidneys
12. Proventriculus
13. Ventriculus
14. Intestines
15. Abdominal air sac
16. Cloaca

NOTE: Structures in parentheses are not labeled.

A

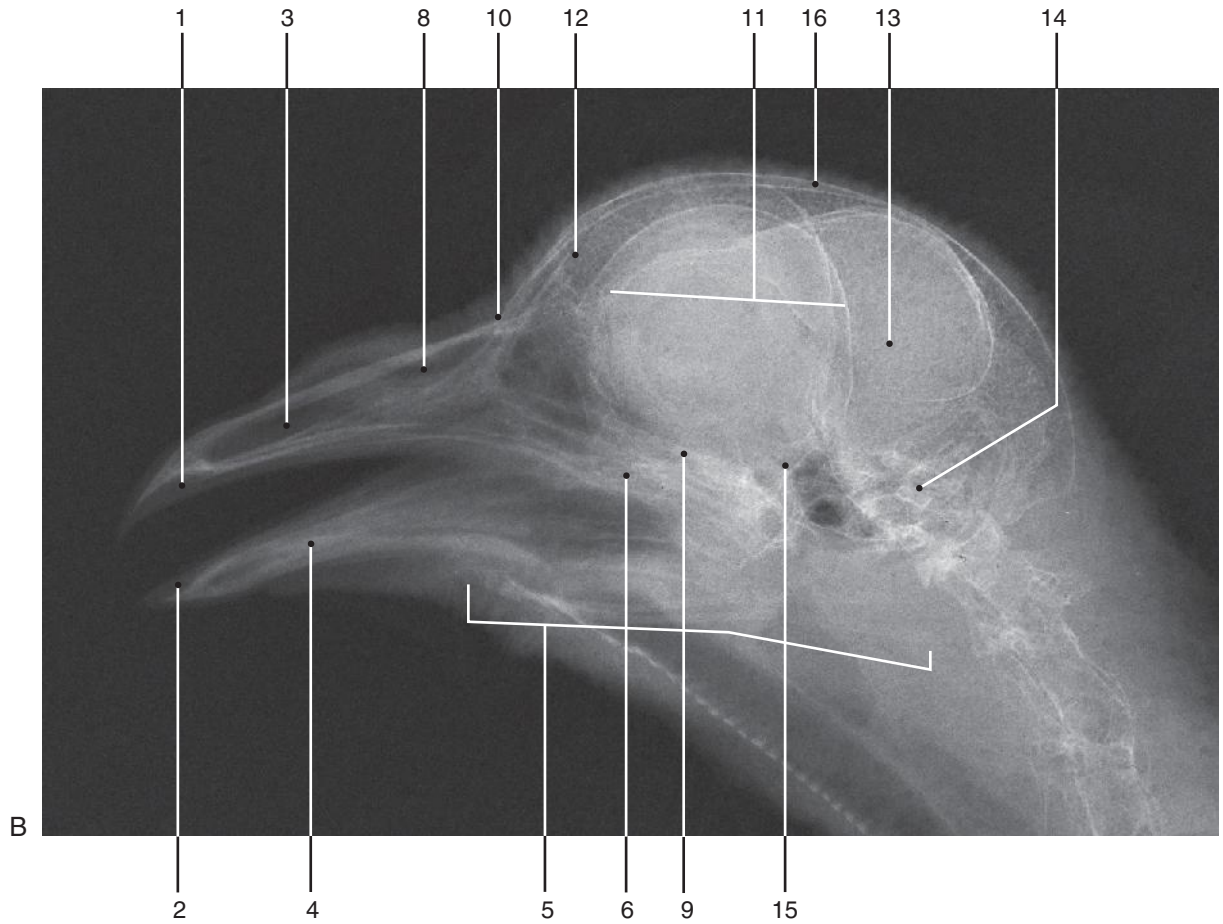

B

Figure 15-3, A-B
Type of Bird: Pigeon
Type of Study: Head
Projection: Laterolateral (right lateral recumbency)
Weight of Bird: 590 g
Gender: Unknown
Reproductive Status: Intact
Age: Adult

1. Keratinized maxillary beak
2. Keratinized mandibular beak
3. Premaxillary bone
4. Mandible
5. Hyoid bones
6. Palatine bone
7. (Pterygoid bone)
8. External nares
9. Jugal [zygomatic] bone
10. Craniofacial flexion zone
11. Orbit
12. Frontal bone
13. Cranium
14. Temporal bone
15. Quadrate bone
16. Parietal bone

NOTE: Structures in parentheses are not labeled.

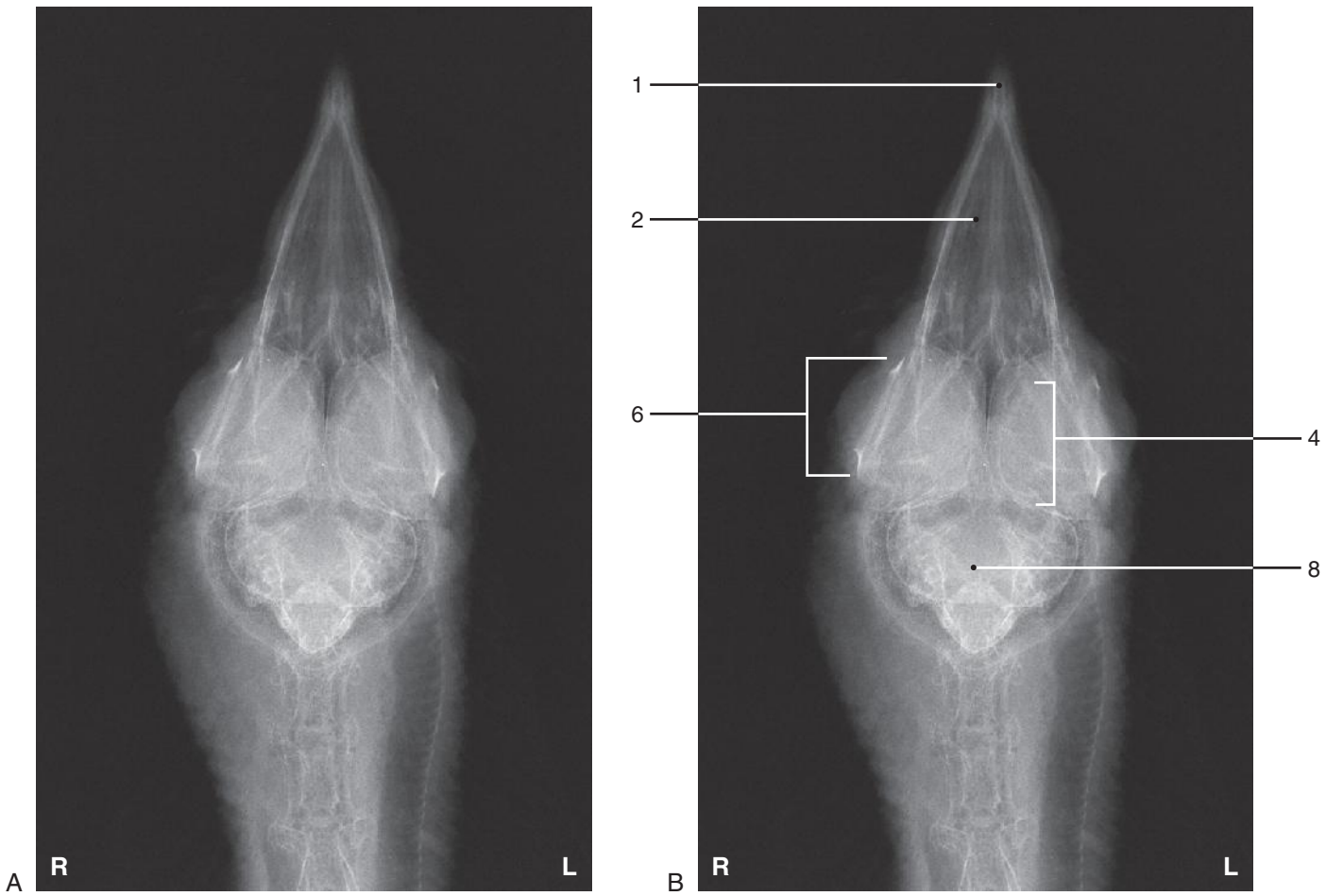

Figure 15-4, A-B
Type of Bird: Pigeon
Type of Study: Head
Projection: Ventrodorsal
Weight of Bird: 590 g
Gender: Unknown
Reproductive Status: Intact
Age: Adult

1. Keratinized maxillary beak
2. Premaxillary bone
3. (Mandible)
4. Orbit
5. (Jugal [zygomatic] bone)
6. Scleral ossicles
7. (Quadrate bone)
8. Cranium

NOTE: Structures in parentheses are not labeled.

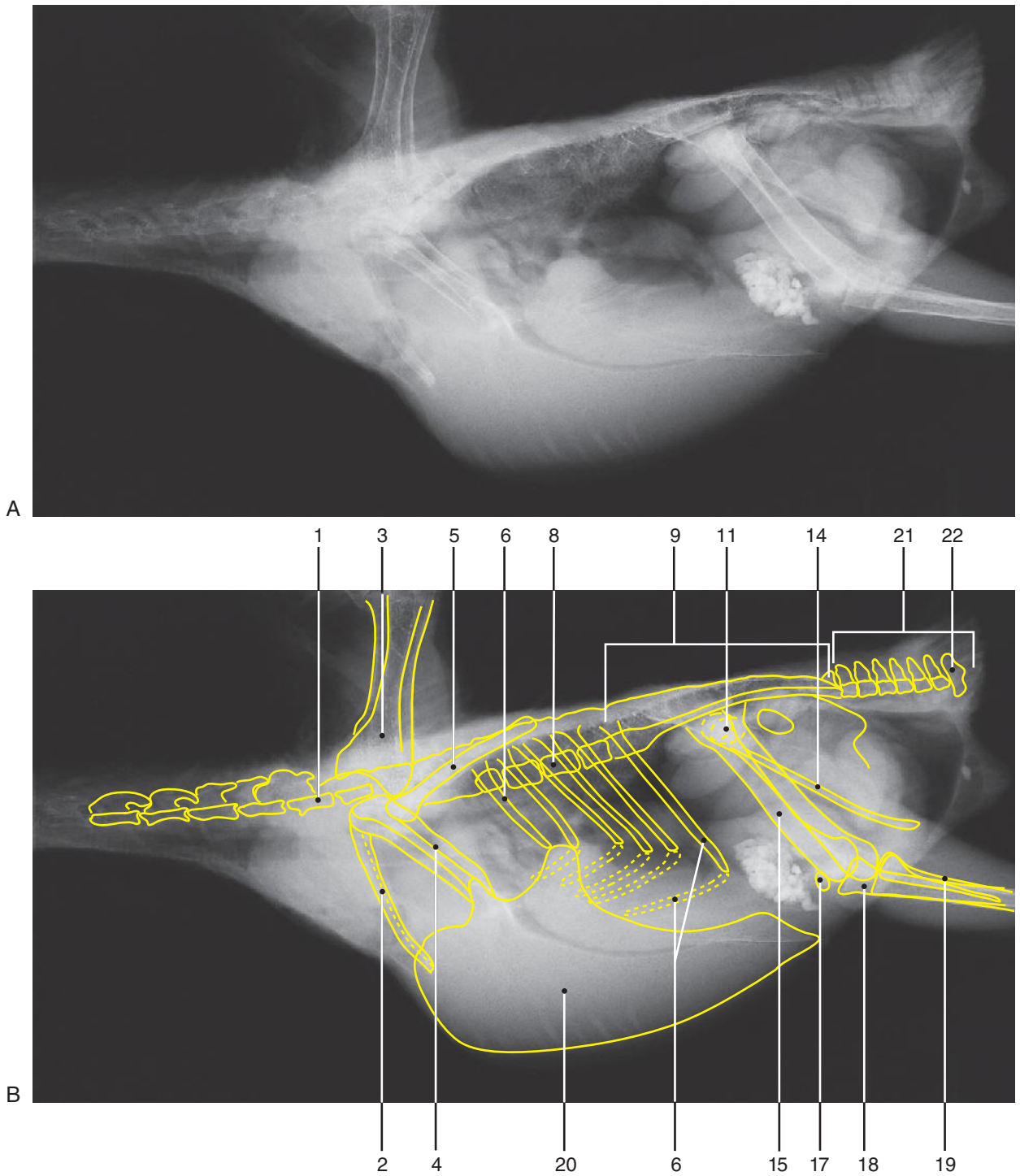

Figure 15-5, A-B
Type of Bird: Pigeon
Type of Study: Whole body skeleton
Projection: Laterolateral (right lateral recumbency)
Weight of Bird: 590 g
Gender: Unknown
Reproductive Status: Intact
Age: Adult

1. Cervical vertebra
2. Clavicle
3. Humerus
4. Coracoid
5. Scapula
6. Rib
7. (Uncinate process of rib)
8. Thoracic vertebra
9. Synsacrum
10. (Ilium)
11. Head of femur
12. (Ilioischiadiac foramen)
13. (Ischium)
14. Pubis
15. Femur
16. (Obturator foramen)
17. Patella
18. Tibiotarsal bone
19. Fibula
20. Sternum
21. Caudal vertebrae
22. Pygostyle

NOTE: Structures in parentheses are not labeled.

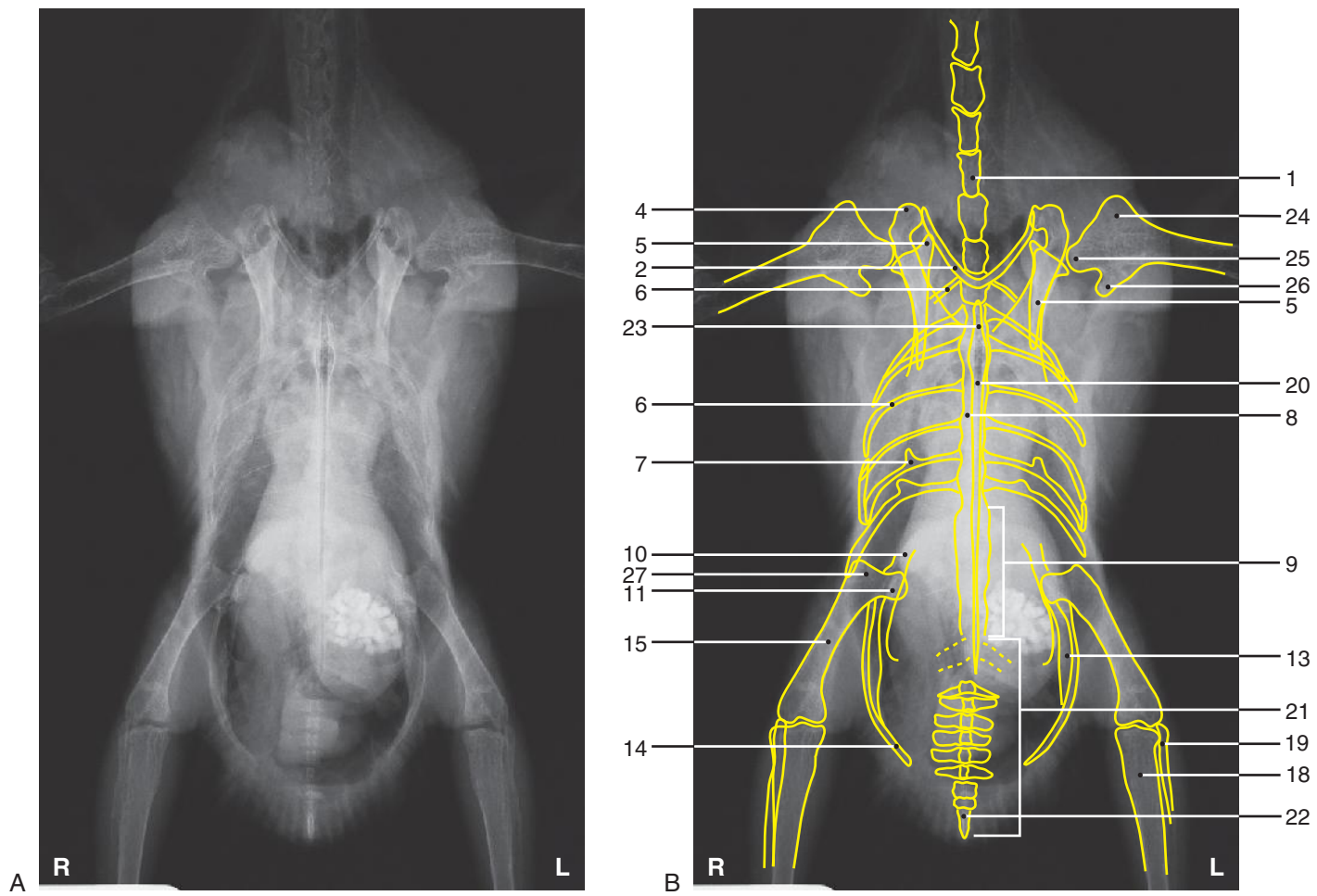

Figure 15-6, A-B
Type of Bird: Pigeon
Type of Study: Whole body skeleton
Projection: Ventrodorsal
Weight of Bird: 590 g
Gender: Unknown
Reproductive Status: Intact
Age: Adult

1. Cervical vertebra
2. Clavicle
3. (Humerus)
4. Coracoid
5. Scapula
6. Rib
7. Uncinate process of rib
8. Thoracic vertebra
9. Synsacrum
10. Ilium
11. Head of femur
12. (Ilioischiadiac foramen)
13. Ischium
14. Pubis
15. Femur
16. (Obturator foramen)
17. (Patella)
18. Tibiotarsal bone
19. Fibula
20. Sternum
21. Caudal vertebrae
22. Pygostyle
23. Apex carinae
24. Dorsal tubercle of humerus
25. Head of humerus
26. Ventral tubercle of humerus
27. Trochanter of femur

NOTE: Structures in parentheses are not labeled.

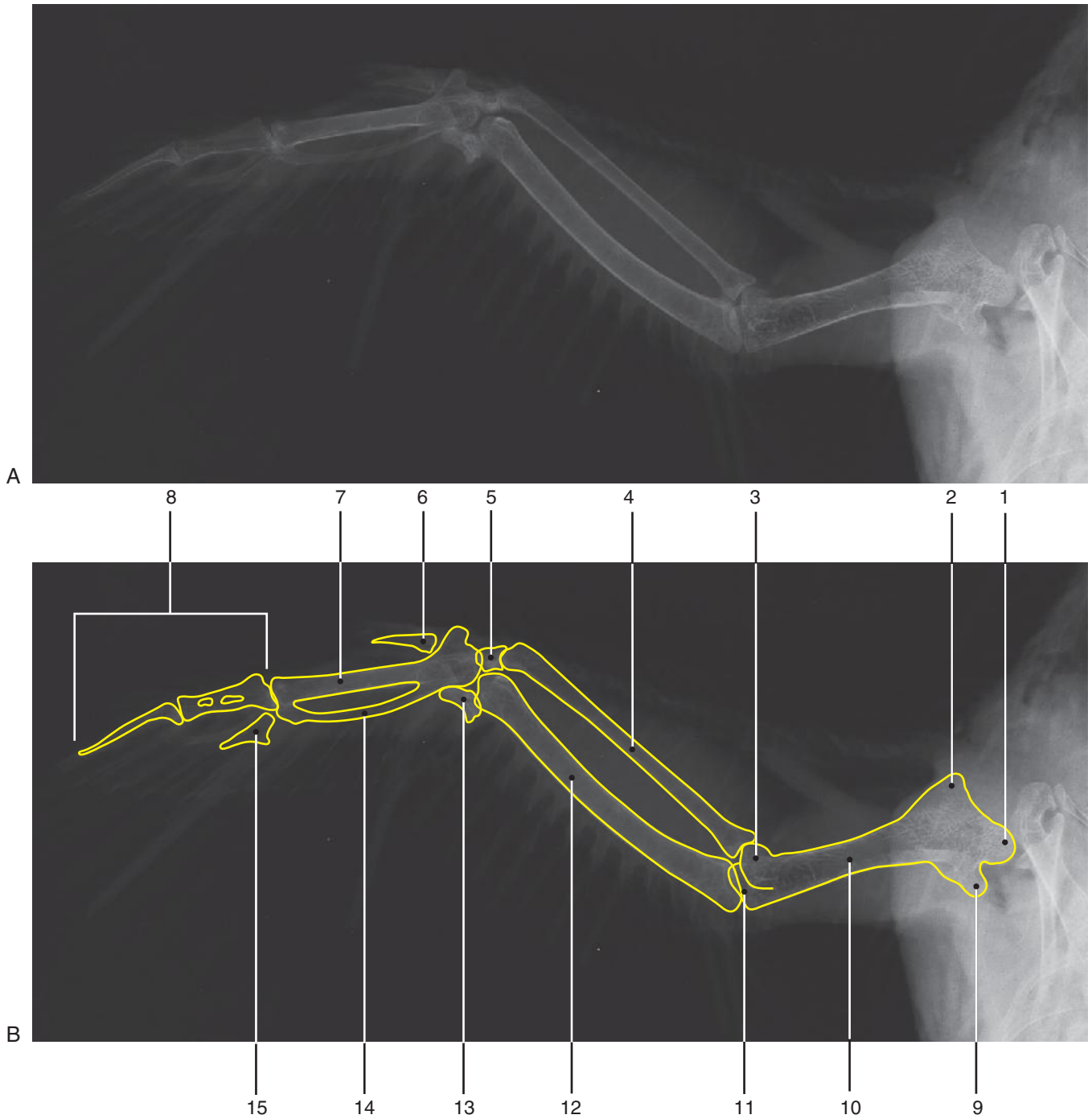

Figure 15-7, A-B
Type of Bird: Pigeon
Type of Study: Wing
Projection: Mediolateral
Weight of Bird: 590 g
Gender: Unknown
Reproductive Status: Intact
Age: Adult

1. Head of humerus
2. Dorsal tubercle of humerus
3. Dorsal condyle of humerus
4. Radius
5. Radial carpal bone
6. Alula
7. Major metacarpal bone
8. Phalanges of major digit
9. Ventral tubercle of humerus
10. Humerus
11. Ventral condyle of humerus
12. Ulna
13. Ulnar carpal bone
14. Minor metacarpal bone
15. Phalanges of minor digit

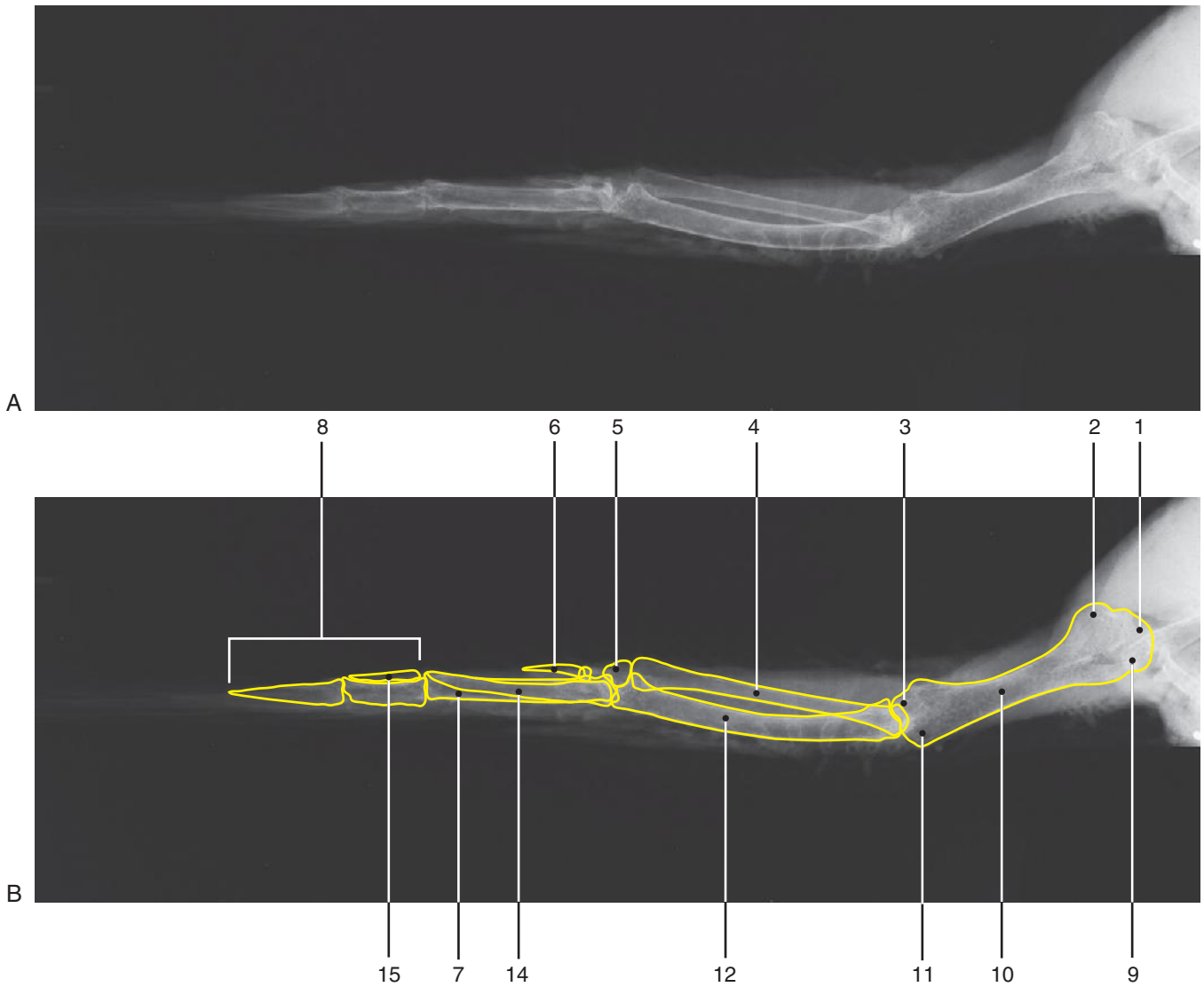

Figure 15-8, A-B
Type of Bird: Pigeon
Type of Study: Wing
Projection: Caudocranial
Weight of Bird: 590 g
Gender: Unknown
Reproductive Status: Intact
Age: Adult

1. Head of humerus
2. Ventral tubercle of humerus
3. Ventral condyle of humerus
4. Radius
5. Radial carpal bone
6. Alula
7. Minor metacarpal bone
8. Phalanges of major digit
9. Dorsal tubercle of humerus
10. Humerus
11. Dorsal condyle of humerus
12. Ulna
13. (Ulnar carpal bone)
14. Major metacarpal bone
15. Phalanges of minor digit

NOTE: Structures in parentheses are not labeled.

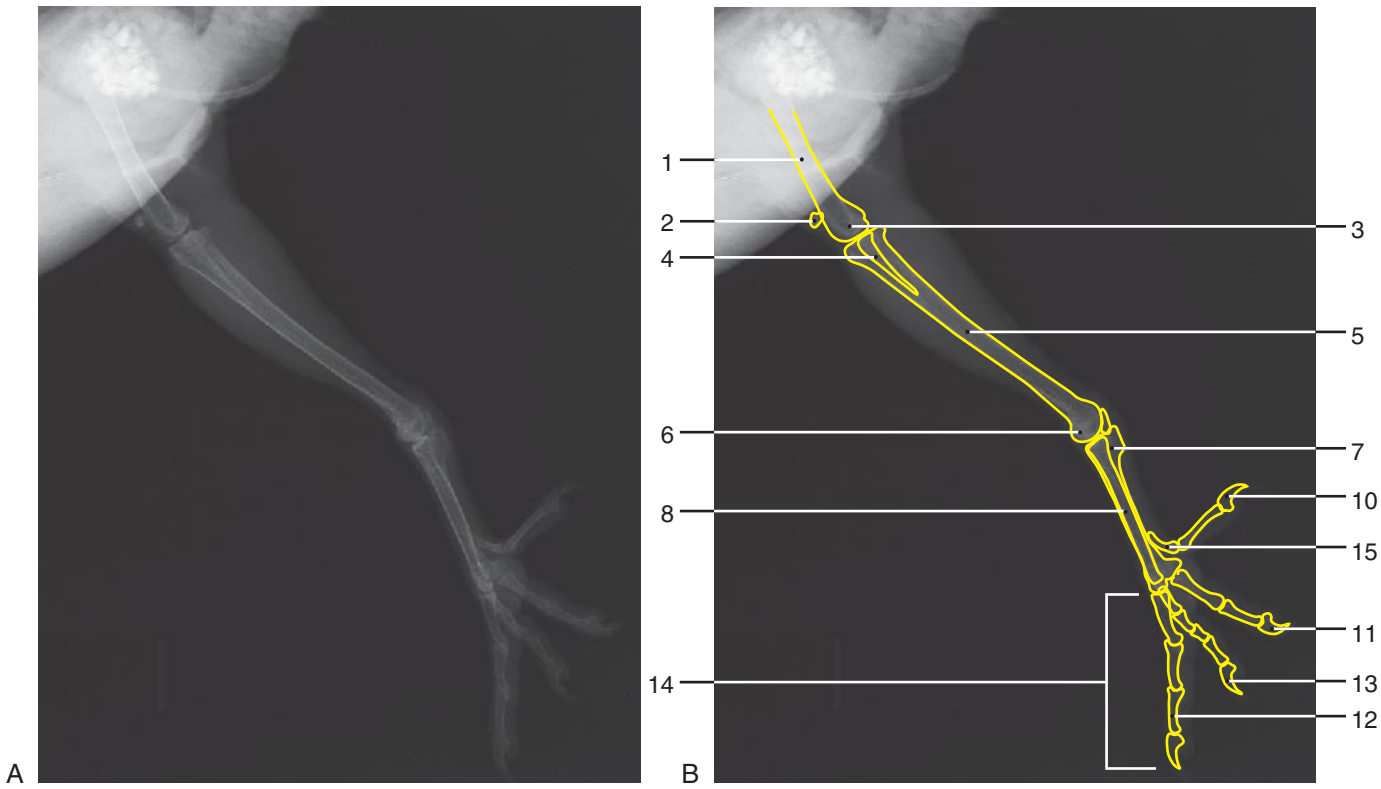

Figure 15-9, A-B
Type of Bird: Pigeon
Type of Study: Pelvic limb
Projection: Mediolateral
Weight of Bird: 590 g
Gender: Unknown
Reproductive Status: Intact
Age: Adult

1. Femur
2. Patella
3. Condyles of femur
4. Fibula
5. Tibiotarsal bone
6. Condyles of tibiotarsal bone
7. Hypotarsal crest of tarsometatarsal bone
8. Tarsometatarsal bone
9. (Trochlea of tarsometatarsal bone)
10. Digit I
11. Digit II
12. Digit III
13. Digit IV
14. Phalanges
15. Metatarsal I

NOTE: Structures in parentheses are not labeled.

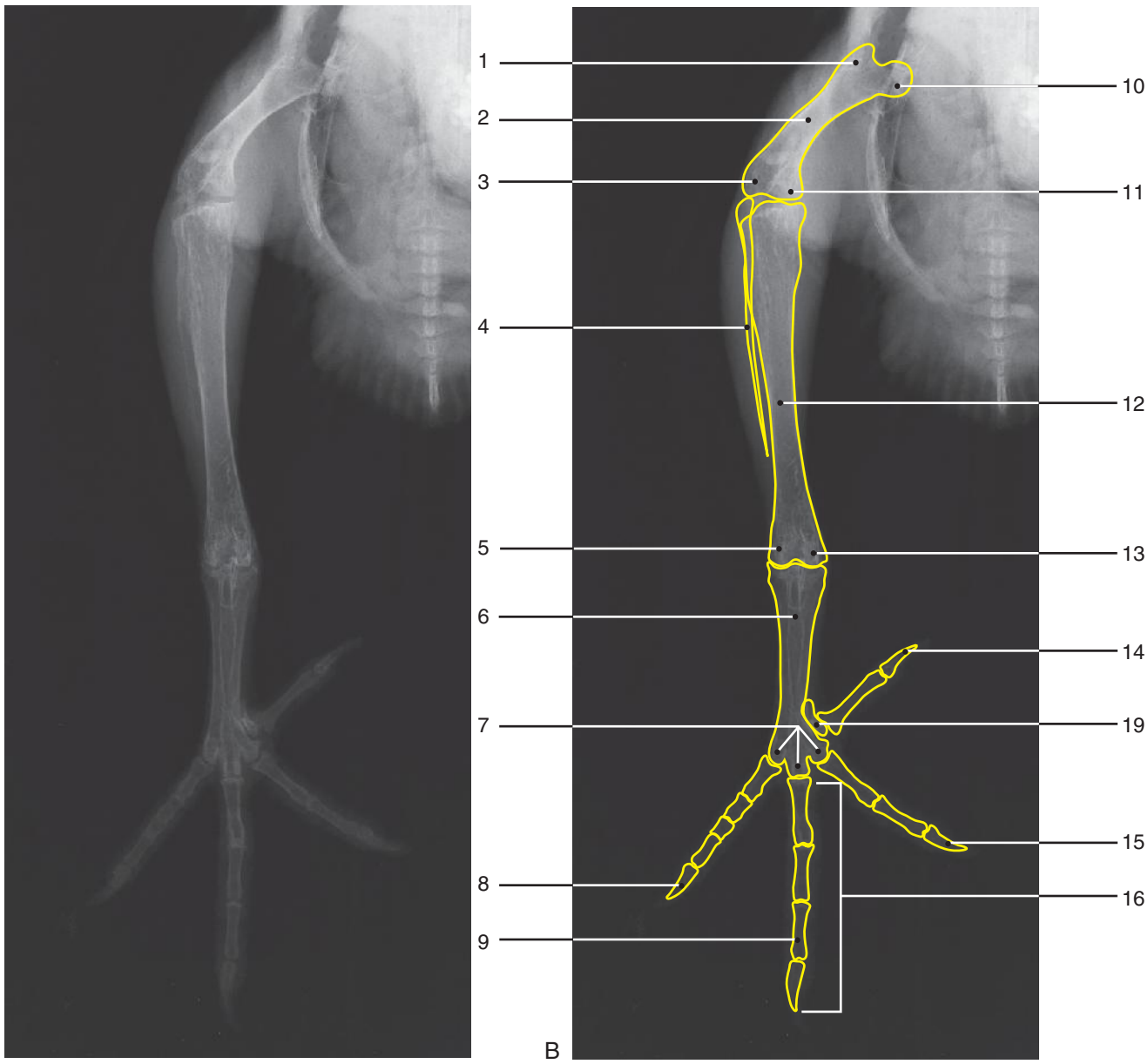

Figure 15-10, A-B
Type of Bird: Pigeon
Type of Study: Pelvic limb
Projection: Craniocaudal
Weight of Bird: 590 g
Gender: Unknown
Reproductive Status: Intact
Age: Adult

1. Trochanter of femur
2. Femur
3. Lateral condyle of femur
4. Fibula
5. Lateral condyle of tibiotarsal bone
6. Tarsometatarsal bone
7. Trochlea of tarsometatarsal bone
8. Digit IV
9. Digit III
10. Head of femur
11. Medial condyle of femur
12. Tibiotarsal bone
13. Medial condyle of tibiotarsal bone
14. Digit I
15. Digit II
16. Phalanges
17. (Patella)
18. (Hypotarsal crest of tarsometatarsal bone)
19. Metatarsal I

NOTE: Structures in parentheses are not labeled.

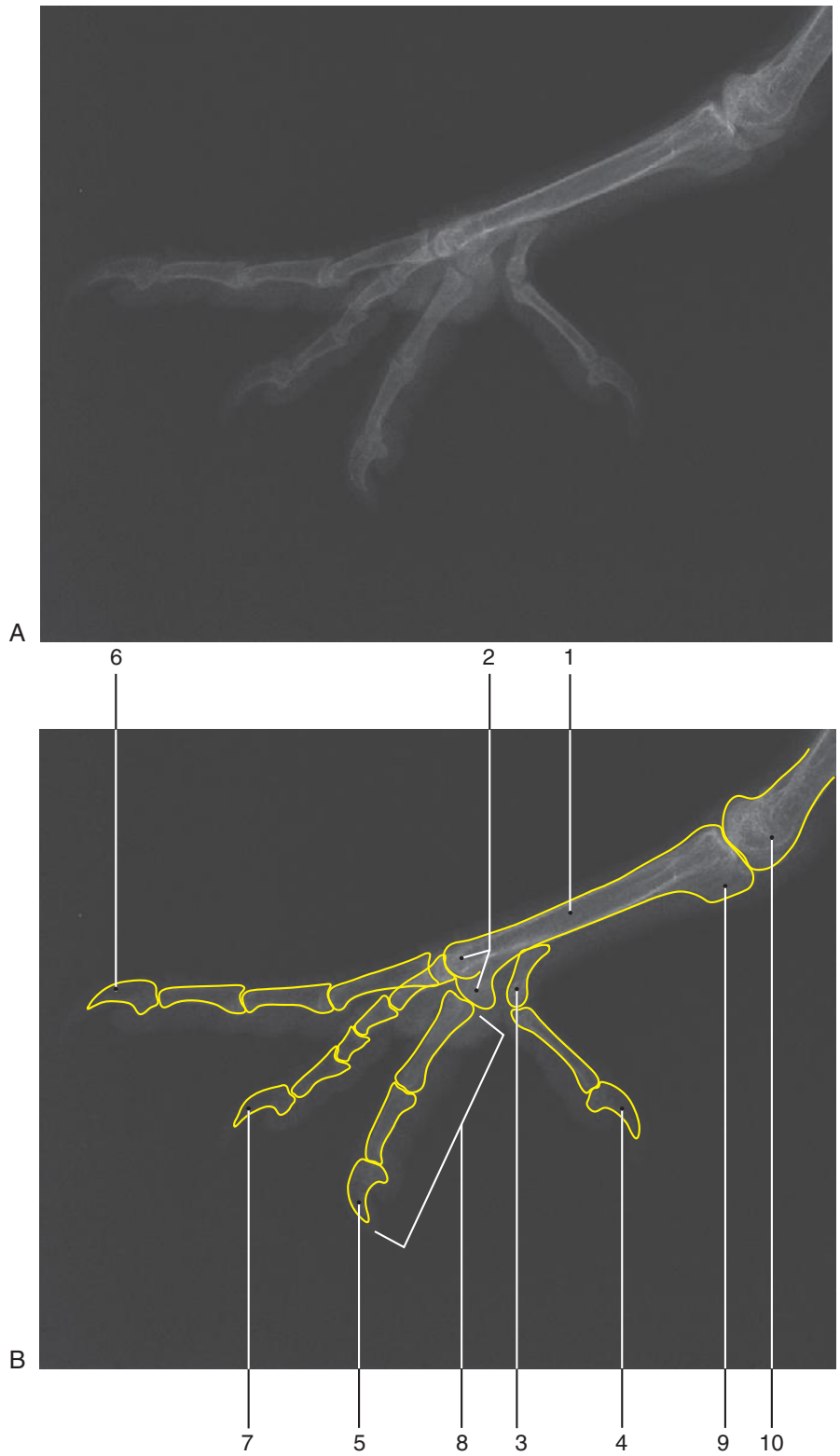

Figure 15-11, A-B
Type of Bird: Pigeon
Type of Study: Distal pelvic limb
Projection: Mediolateral
Weight of Bird: 590 g
Gender: Unknown
Reproductive Status: Intact
Age: Adult

1. Tarsometatarsal bone
2. Trochlea of tarsometatarsal bone
3. Metatarsal bone I
4. Digit I
5. Digit II
6. Digit III
7. Digit IV
8. Phalanges
9. Hypotarsal crest of tarsometatarsal bone
10. Condyles of tibiotarsal bone

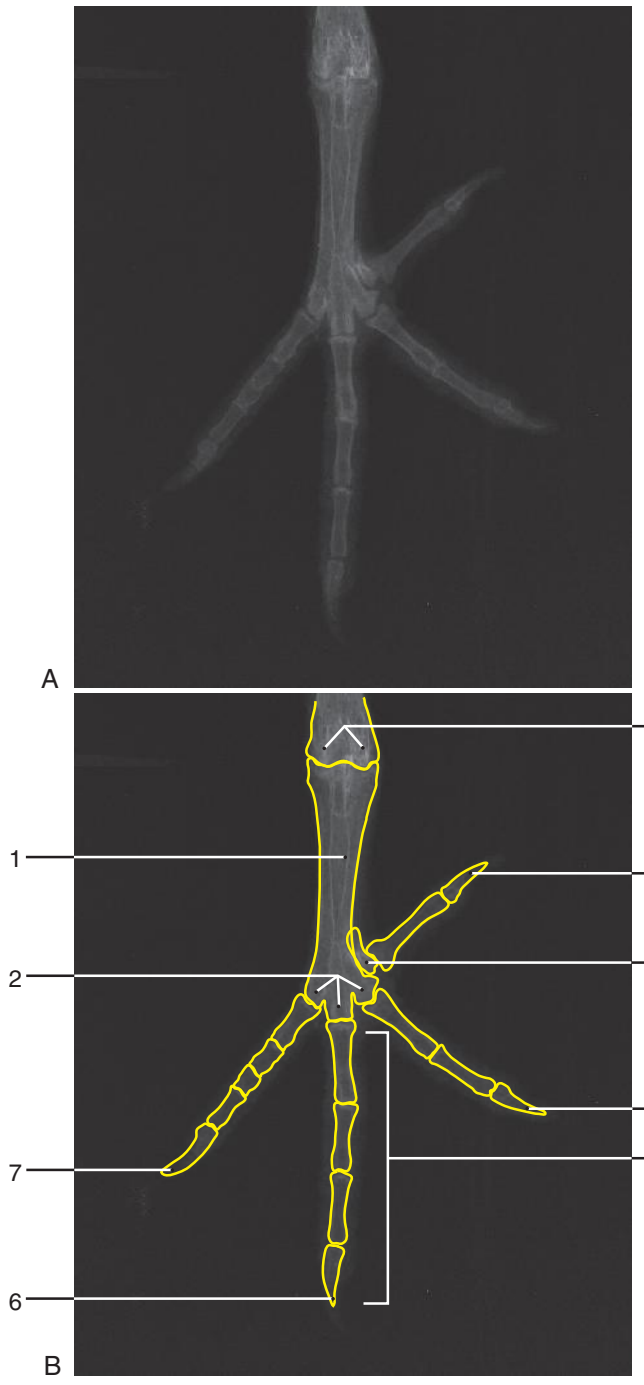

Figure 15-12, A-B
Type of Bird: Pigeon
Type of Study: Distal pelvic limb
Projection: Dorsoplantar
Weight of Bird: 590 g
Gender: Unknown
Reproductive Status: Intact
Age: Adult

1. Tarsometatarsal bone
2. Trochlea of tarsometatarsal bone
3. Metatarsal bone I
4. Digit I
5. Digit II
6. Digit III
7. Digit IV
8. Phalanges
9. (Hypotarsal crest of tarsometatarsal bone)
10. Condyles of tibiotarsal bone

NOTE: Structures in parentheses are not labeled.

A

B

Figure 15-13, A-B
Type of Bird: Pigeon
Type of Study: Respiratory series
Projection: Laterolateral (right lateral recumbency)
Weight of Bird: 545 g
Gender: Unknown
Reproductive Status: Intact
Age: Adult

Image	Phase of Respiration
A	Inspiration, spontaneous ventilation
B	Inspiration, manual assistance (5 cm H_2O)

C

Figure 15-13, C
Type of Bird: Pigeon
Type of Study: Respiratory series
Projection: Laterolateral (right lateral recumbency)
Weight of Bird: 545 g
Gender: Unknown
Reproductive Status: Intact
Age: Adult

Image	Phase of Respiration
C	Inspiration, ventilator assisted (8 cm H_2O)

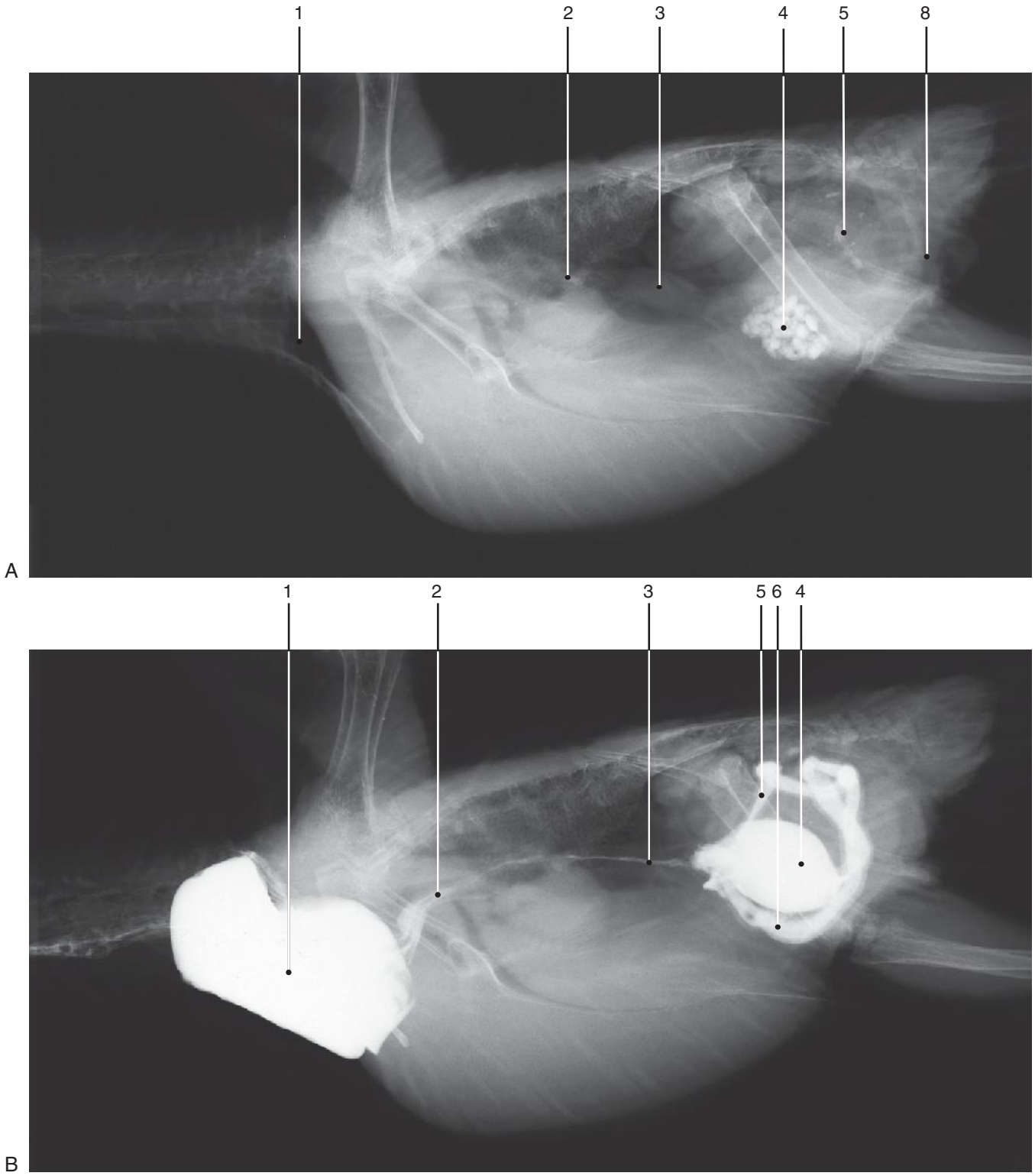

Figure 15-14, A-B
Type of Bird: Pigeon
Type of Study: Gastrointestinal positive contrast study
Contrast Medium: Barium sulfate suspension (Novopaque® 30% w/v; Lafayette Pharmaceutical, Inc., Lafayette, IN) 20 ml administered via gavage tube
Projection: Laterolateral (right lateral recumbency)
Weight of Bird: 545 g
Gender: Unknown
Reproductive Status: Intact
Age: Adult

Image	Time (hr)
A	Scout
B	0.25

1. Crop
2. Esophagus
3. Proventriculus
4. Ventriculus
5. Intestines
6. Duodenum
7. (Large intestine)
8. Cloaca
9. (Proventricular-ventricular isthmus)

NOTE: Structures in parentheses are not labeled.

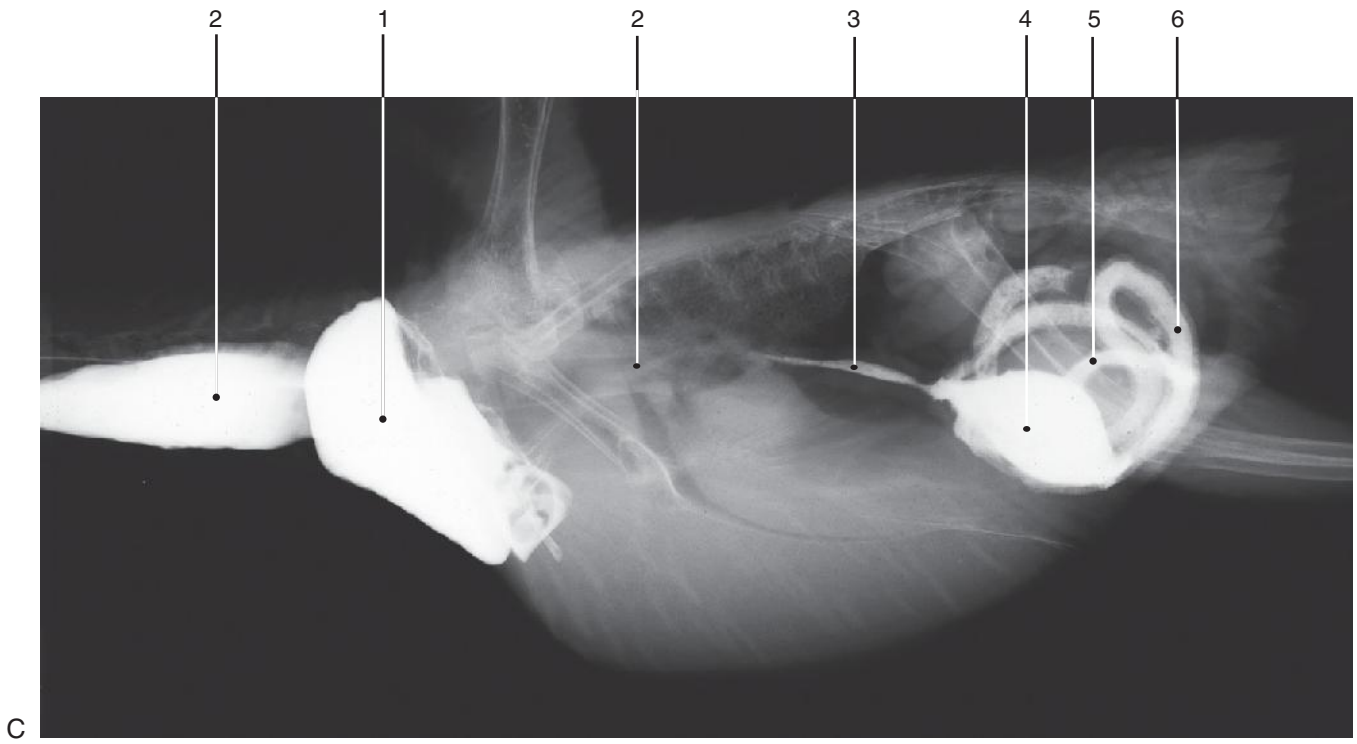

C

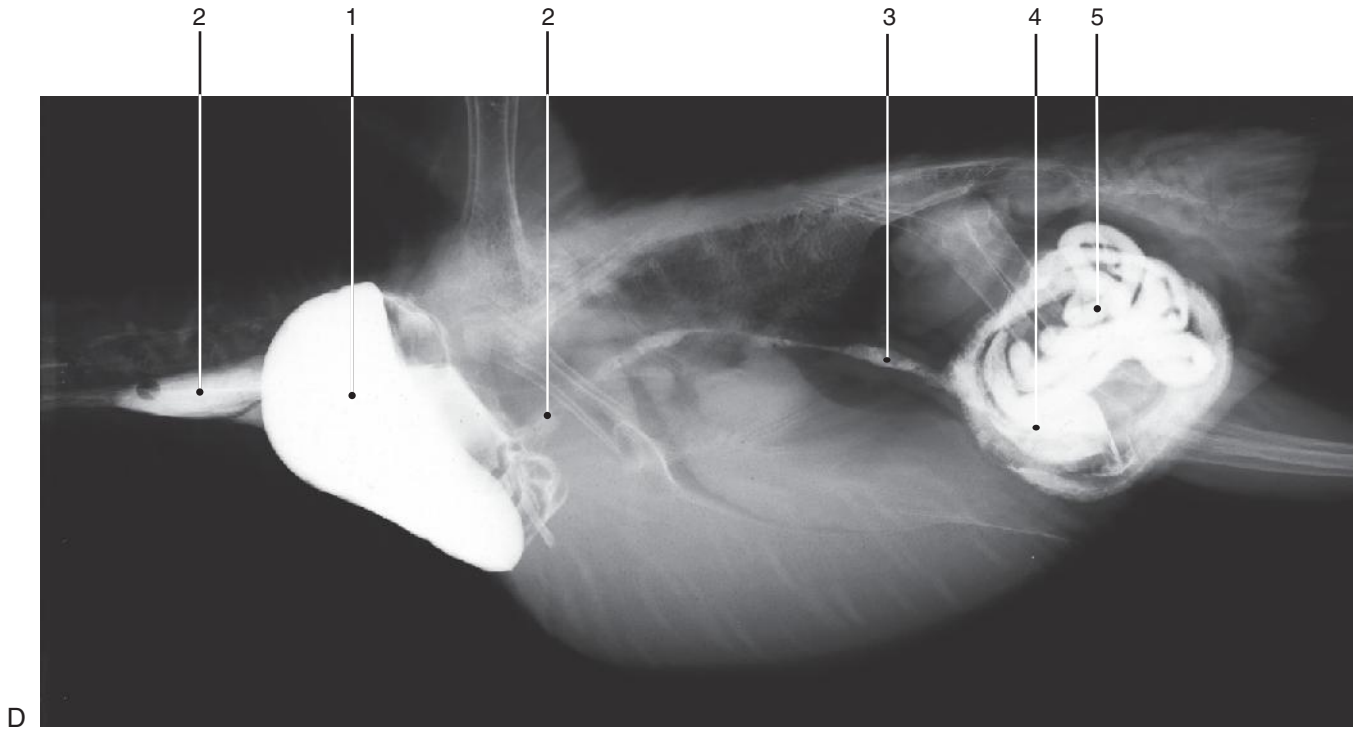

D

Figure 15-14, C-D
Type of Bird: Pigeon
Type of Study: Gastrointestinal positive contrast study
Contrast Medium: Barium sulfate suspension (Novopaque® 30% w/v; Lafayette Pharmaceutical, Inc., Lafayette, IN) 20 ml administered via gavage tube
Projection: Laterolateral (right lateral recumbency)
Weight of Bird: 545 g
Gender: Unknown
Reproductive Status: Intact
Age: Adult

Image	Time (hr)
C	1.0
D	2.0

1. Crop
2. Esophagus
3. Proventriculus
4. Ventriculus
5. Intestines
6. Duodenum
7. (Large intestine)
8. (Cloaca)
9. (Proventricular-ventricular isthmus)

NOTE: Structures in parentheses are not labeled.

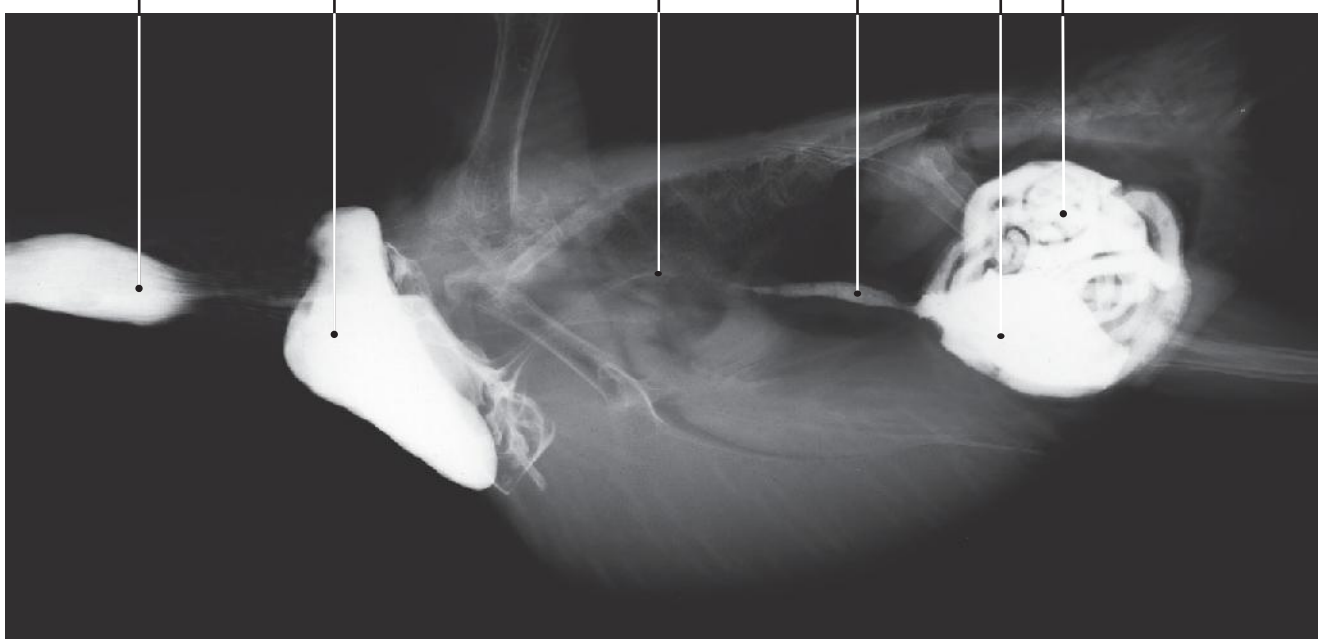

E

Figure 15-14, E
Type of Bird: Pigeon
Type of Study: Gastrointestinal positive contrast study
Contrast Medium: Barium sulfate suspension (Novopaque® 30% w/v; Lafayette Pharmaceutical, Inc., Lafayette, IN) 20 ml administered via gavage tube
Projection: Laterolateral (right lateral recumbency)
Weight of Bird: 545 g
Gender: Unknown
Reproductive Status: Intact
Age: Adult

Image	Time (hr)
E	3.0

1. Crop
2. Esophagus
3. Proventriculus
4. Ventriculus
5. Intestines
6. (Duodenum)
7. (Large intestine)
8. (Cloaca)
9. (Proventricular-ventricular isthmus)

NOTE: Structures in parentheses are not labeled.

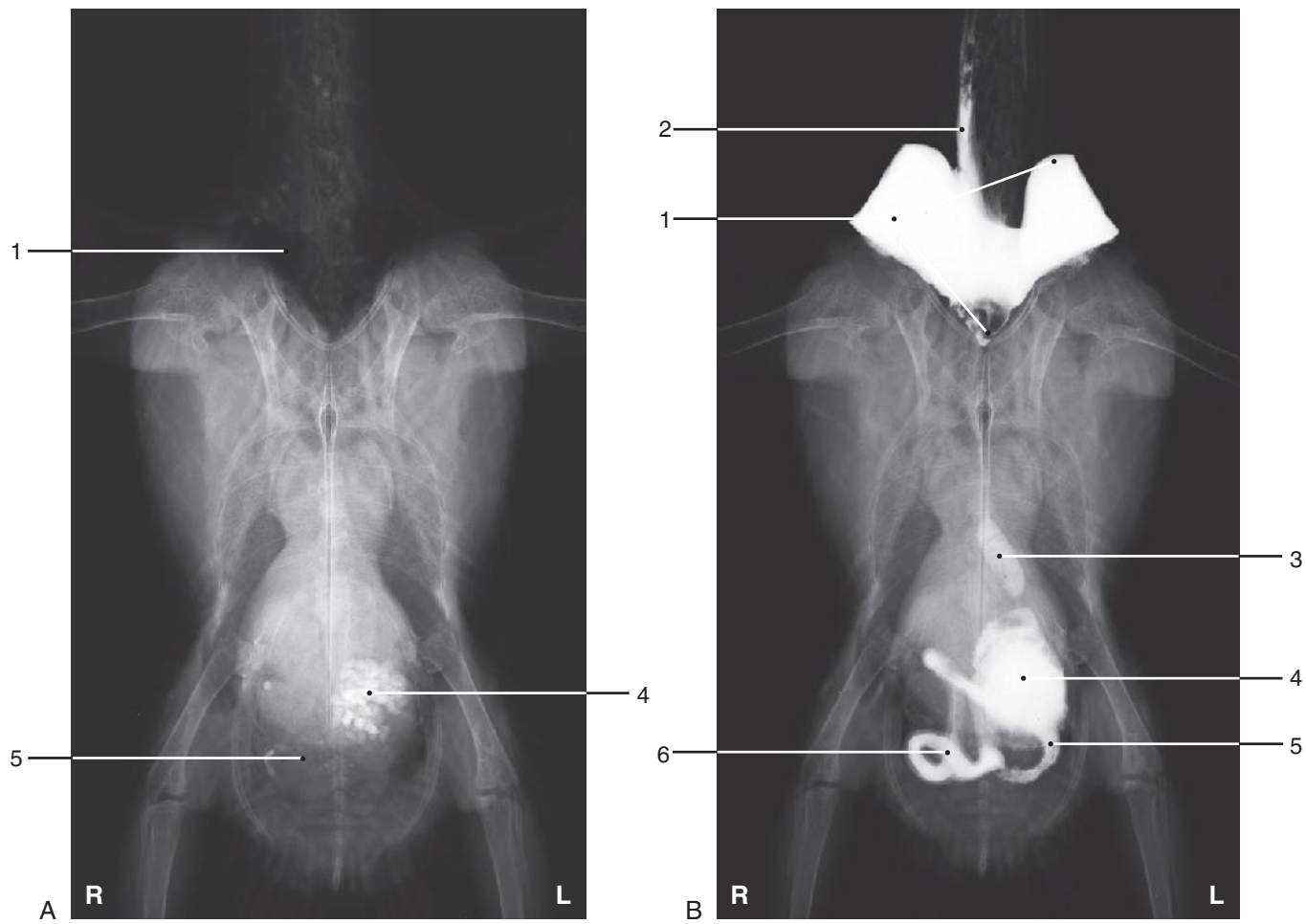

Figure 15-15, A-B

Type of Bird: Pigeon
Type of Study: Gastrointestinal positive contrast study
Contrast Medium: Barium sulfate suspension (Novopaque® 30% w/v; Lafayette Pharmaceutical, Inc., Lafayette, IN) 20 ml administered via gavage tube
Projection: Ventrodorsal
Weight of Bird: 545 g
Gender: Unknown
Reproductive Status: Intact
Age: Adult

Image	Time (hr)
A	Scout
B	0.25

1. Crop
2. Esophagus
3. Proventriculus
4. Ventriculus
5. Intestines
6. Duodenum
7. (Large intestine)
8. (Cloaca)
9. (Proventricular-ventricular isthmus)

NOTE: Structures in parentheses are not labeled.

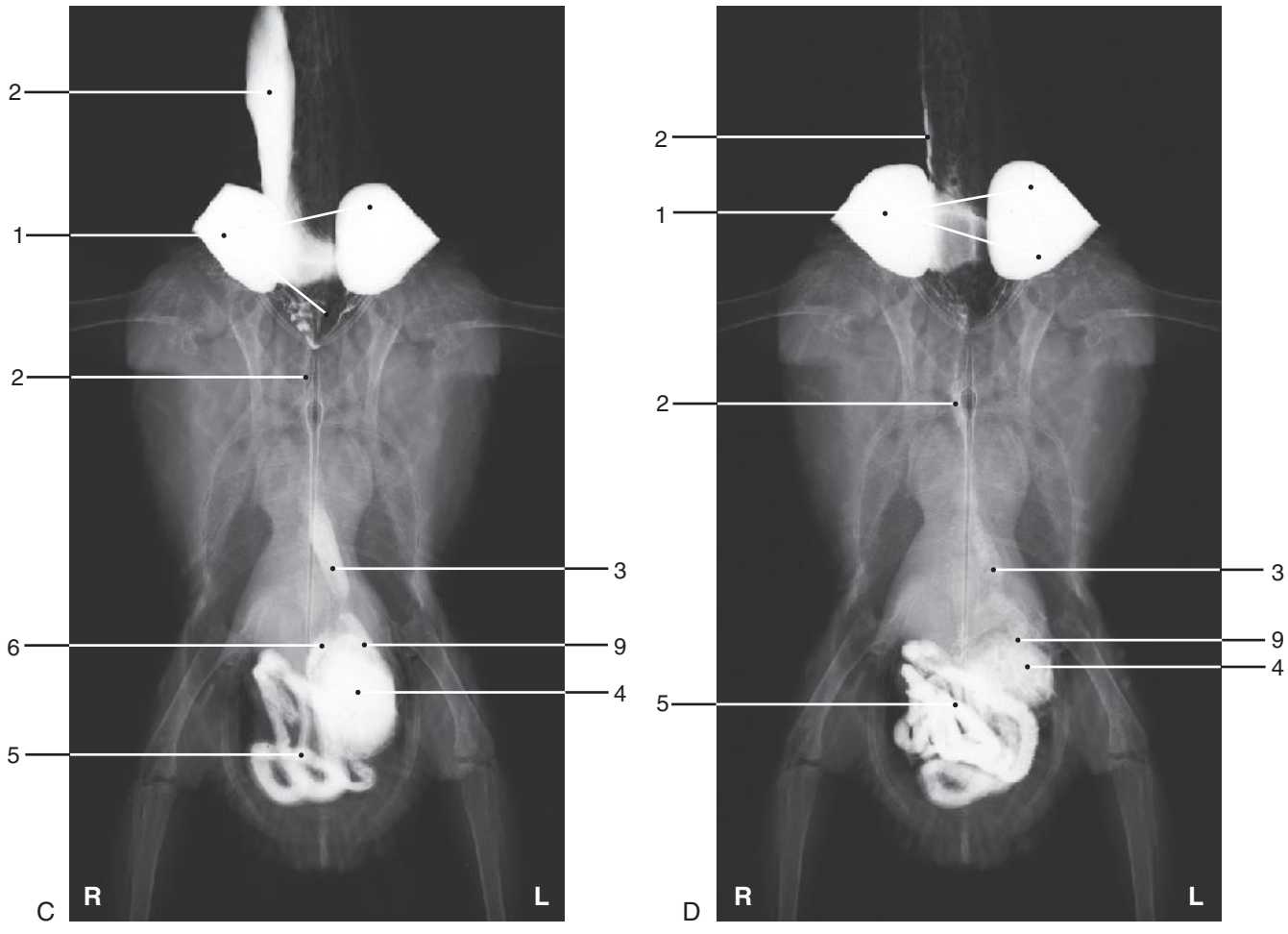

Figure 15-15, C-D
Type of Bird: Pigeon
Type of Study: Gastrointestinal positive contrast study
Contrast Medium: Barium sulfate suspension (Novopaque® 30% w/v; Lafayette Pharmaceutical, Inc., Lafayette, IN) 20 ml administered via gavage tube
Projection: Ventrodorsal
Weight of Bird: 545 g
Gender: Unknown
Reproductive Status: Intact
Age: Adult

Image	Time (hr)
C	1.0
D	2.0

1. Crop
2. Esophagus
3. Proventriculus
4. Ventriculus
5. Intestines
6. Duodenum
7. (Large intestine)
8. (Cloaca)
9. Proventricular-ventricular isthmus

NOTE: Structures in parentheses are not labeled.

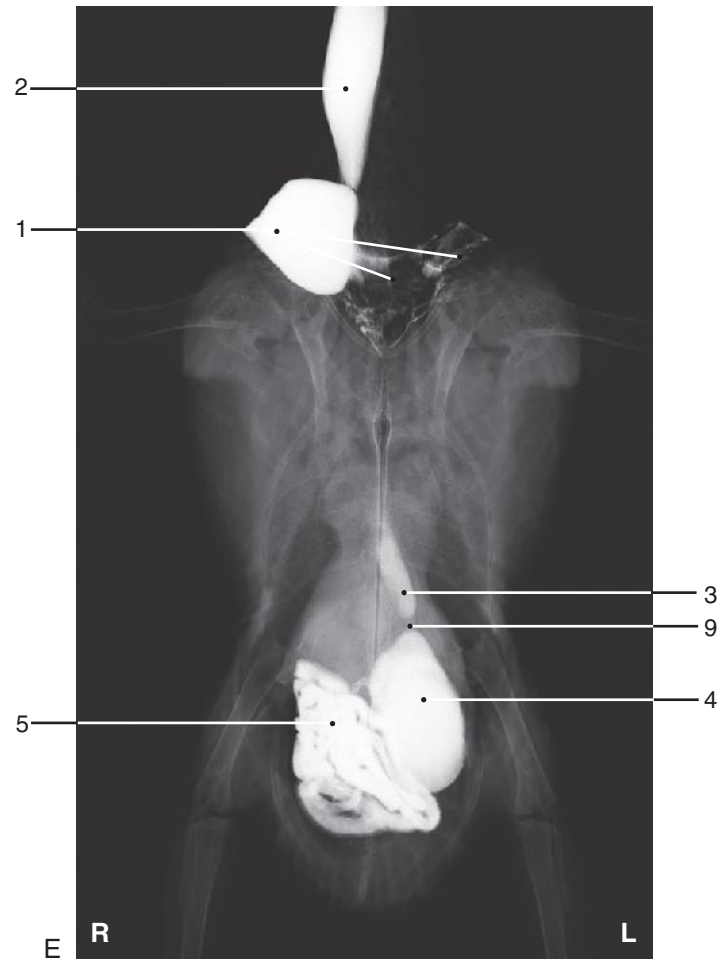

E

Figure 15-15, E

Type of Bird: Pigeon
Type of Study: Gastrointestinal positive contrast study
Contrast Medium: Barium sulfate suspension (Novopaque® 30% w/v; Lafayette Pharmaceutical, Inc., Lafayette, IN) 20 ml administered via gavage tube
Projection: Ventrodorsal
Weight of Bird: 545 g
Gender: Unknown
Reproductive Status: Intact
Age: Adult

Image	Time (hr)
E	3.0

1. Crop
2. Esophagus
3. Proventriculus
4. Ventriculus
5. Intestines
6. Duodenum
7. (Large intestine)
8. (Cloaca)
9. Proventricular-ventricular isthmus

NOTE: Structures in parentheses are not labeled.

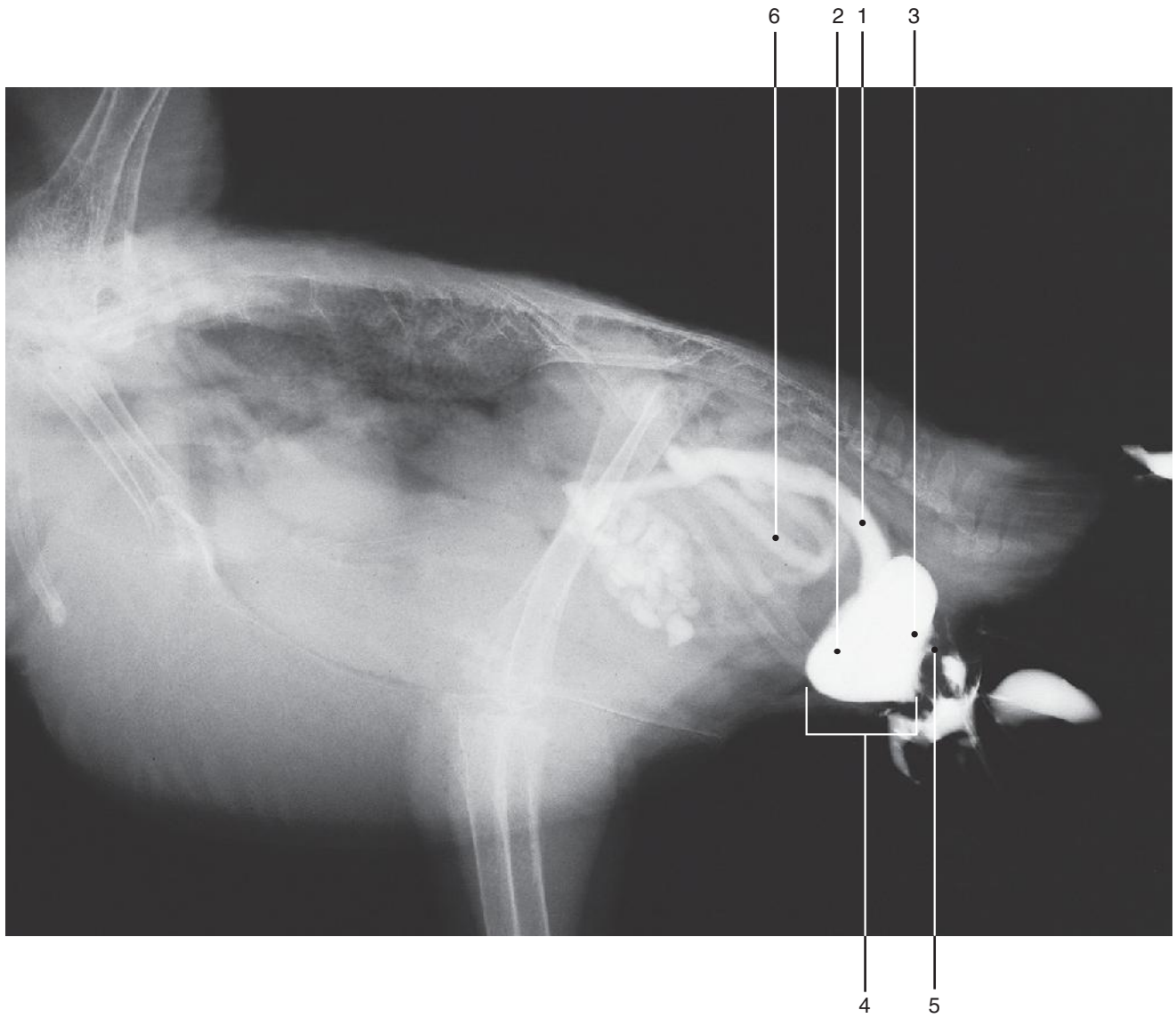

Figure 15-16
Type of Bird: Pigeon
Type of Study: Cloacagram (retrograde, positive contrast)
Contrast Medium: Diatrizoate meglumine, diatrizoate sodium (RenoCal–76® 37% organically bound iodine; Bracco Diagnostics, Inc., Princeton, NJ) 5 ml administered via vent
Projection: Laterolateral (right lateral recumbency)
Weight of Bird: 545 g
Gender: Unknown
Reproductive Status: Intact
Age: Adult

Image	Time (hr)
15-16	Immediate

1. Colon
2. Coprodeum
3. Urodeum
4. Cloaca
5. Vent
6. Intestines

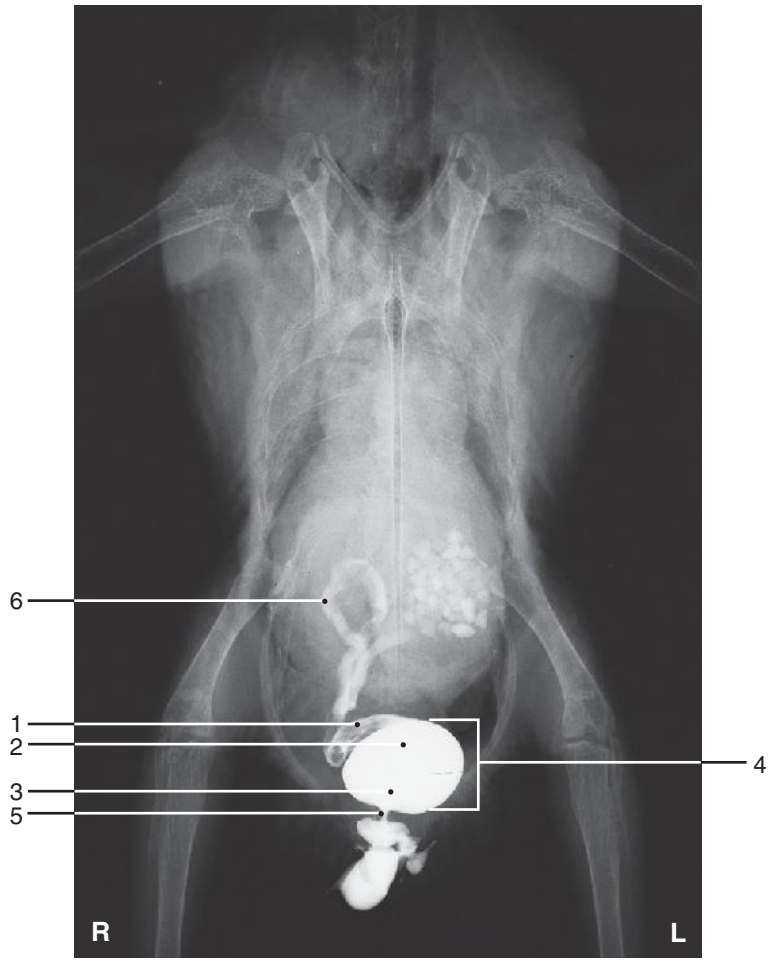

Figure 15-17
Type of Bird: Pigeon
Type of Study: Cloacagram (retrograde, positive contrast)
Contrast Medium: Diatrizoate meglumine, diatrizoate sodium (RenoCal–76® 37% organically bound iodine; Bracco Diagnostics, Inc., Princeton, NJ) 5 ml administered via vent
Projection: Ventrodorsal
Weight of Bird: 545 g
Gender: Unknown
Reproductive Status: Intact
Age: Adult

Image	Time (hr)
15-17	Immediate

1. Colon
2. Coprodeum
3. Urodeum
4. Cloaca
5. Vent
6. Intestines

CHAPTER • 16

Mallard Duck
(Anas platyrhynchos)

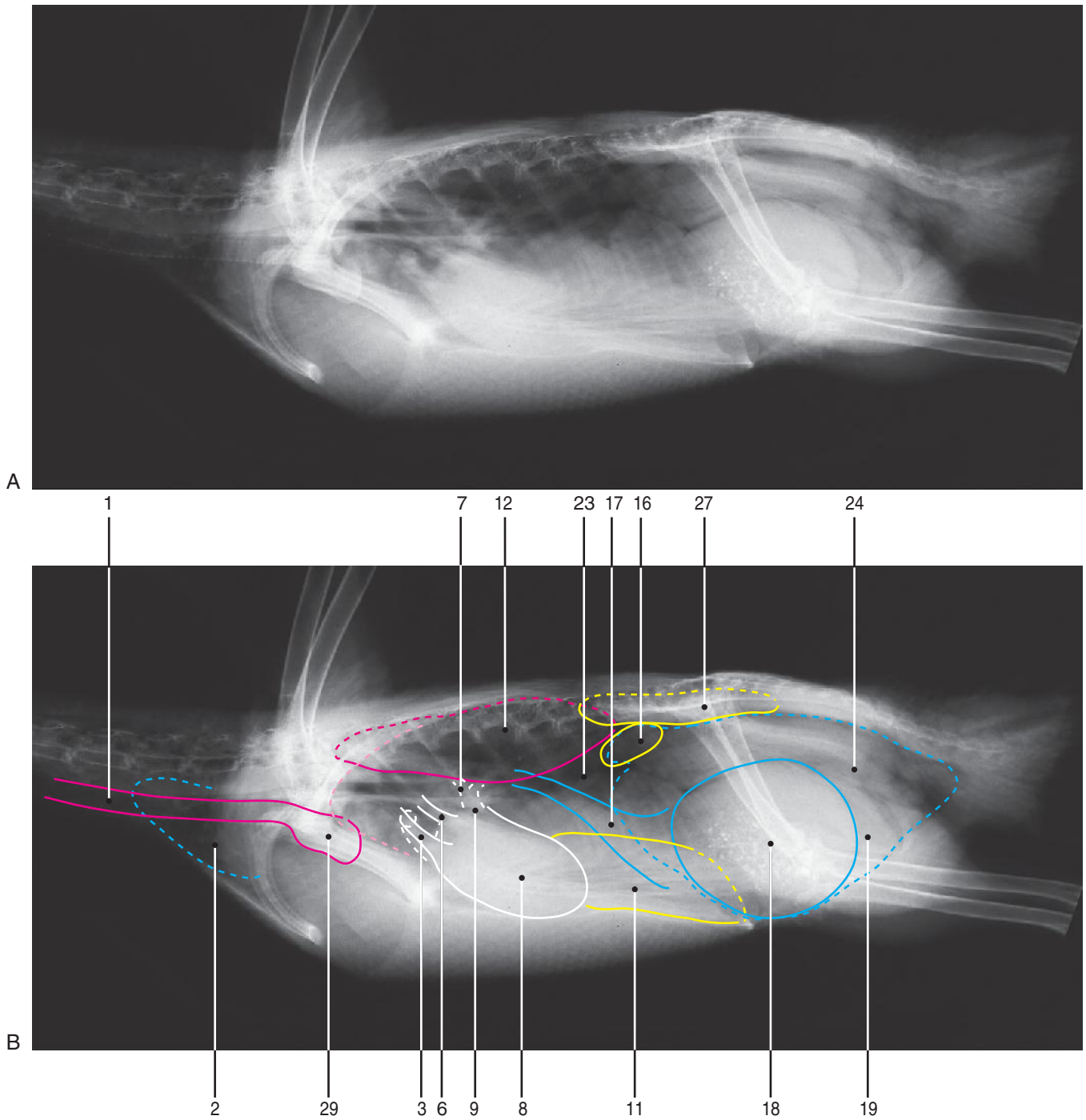

Figure 16-1, A-B
Type of Bird: Mallard Duck
Type of Study: Viscera of the coelom
Projection: Laterolateral (right lateral recumbency)
Weight of Bird: 1.2 kg
Gender: Male
Reproductive Status: Intact
Age: Adult

1. Trachea
2. Crop
3. Brachiocephalic artery and aorta
4. (Brachiocephalic artery)
5. (Aorta)
6. Pulmonary artery
7. Pulmonary vein
8. Heart
9. Left atrium
10. (Esophagus)
11. Liver
12. Lung
13. (Syrinx)
14. (Gonad)
15. (Ovary)
16. Testes
17. Proventriculus
18. Ventriculus
19. Intestines
20. (Cloaca)
21. (Cervical air sac)
22. (Clavicular air sac)
23. Thoracic air sac
24. Abdominal air sac
25. (Apex of heart)
26. (Interface between caudal thoracic and abdominal air sacs)
27. Kidneys
28. (Spleen)
29. Syringeal bulla

NOTE: Structures in parentheses are not labeled.

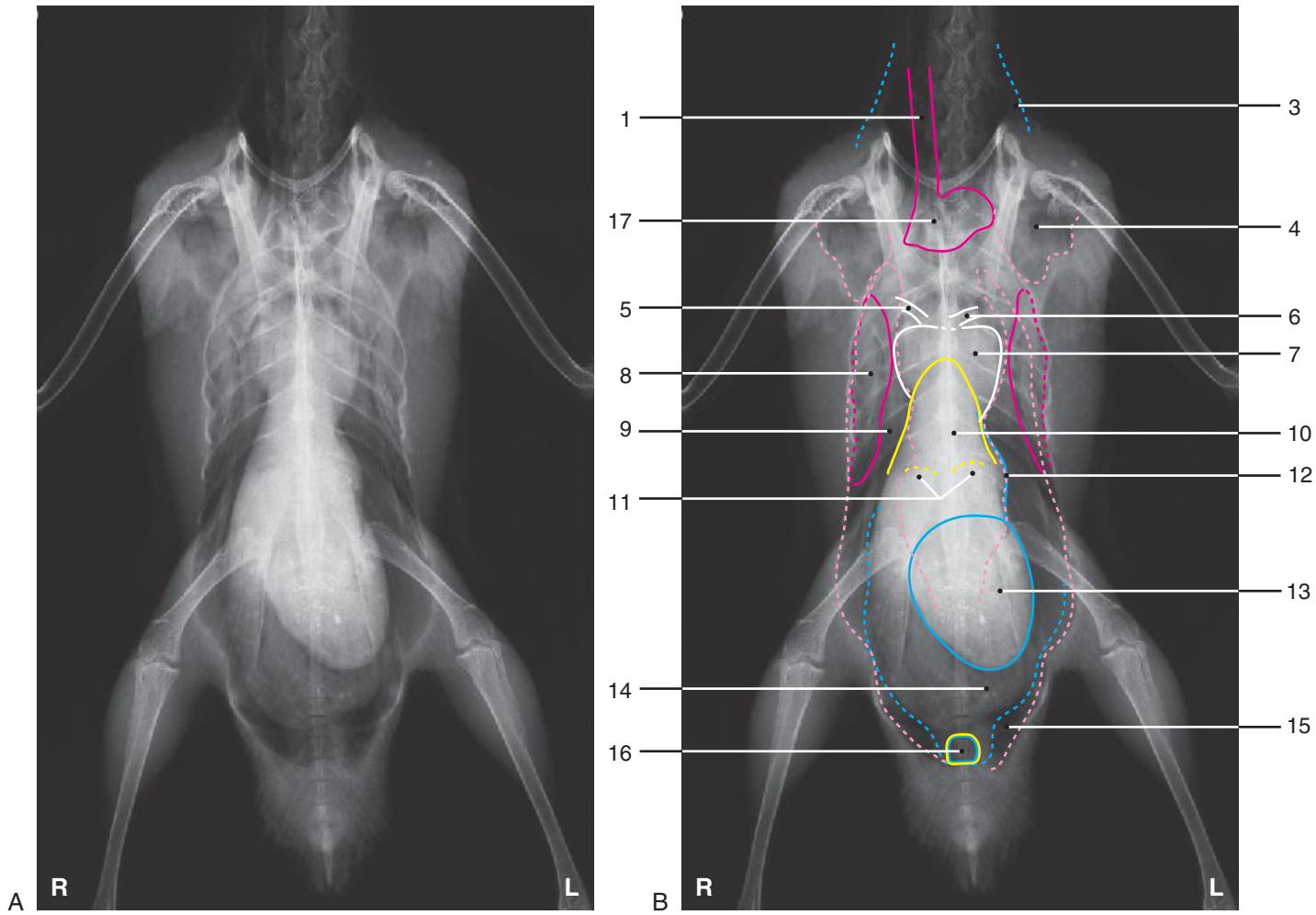

Figure 16-2, A-B
Type of Bird: Mallard Duck
Type of Study: Viscera of the coelom
Projection: Ventrodorsal
Weight of Bird: 1.2 kg
Gender: Male
Reproductive Status: Intact
Age: Adult

1. Trachea
2. (Cervical air sac)
3. Crop
4. Clavicular air sac
5. Brachiocephalic artery and aorta
6. Heart base vessel
7. Heart
8. Lung
9. Thoracic air sac
10. Liver
11. Kidneys
12. (Proventriculus)
13. Ventriculus
14. Intestines
15. Abdominal air sac
16. Cloaca
17. Syringeal bulla

NOTE: Structures in parentheses are not labeled.

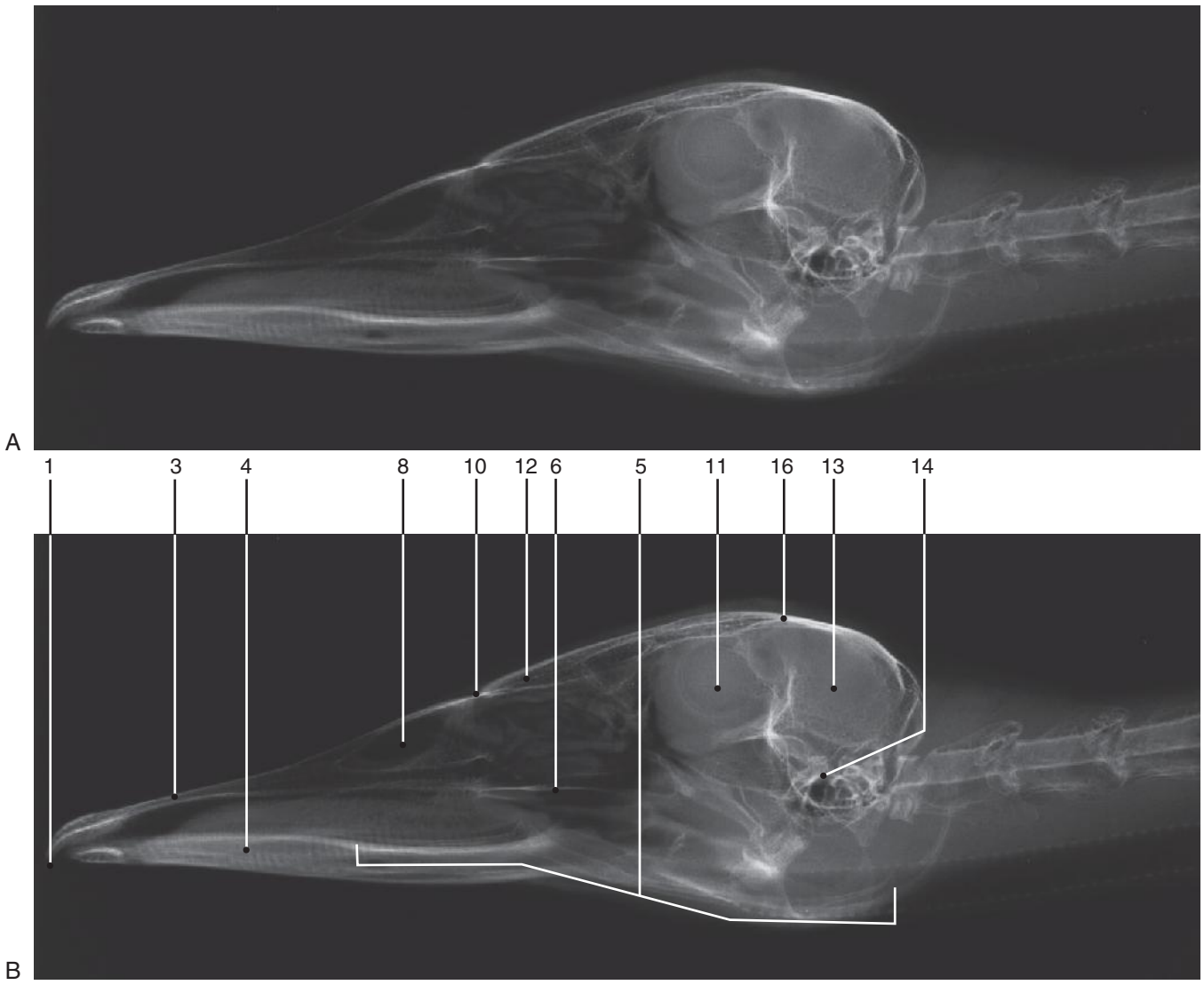

Figure 16-3, A-B
Type of Bird: Mallard Duck
Type of Study: Head
Projection: Laterolateral (right lateral recumbency)
Weight of Bird: 1.2 kg
Gender: Male
Reproductive Status: Intact
Age: Adult

1. Keratinized maxillary beak
2. (Keratinized mandibular beak)
3. Premaxillary bone
4. Mandible
5. Hyoid bones
6. Palatine bone
7. (Pterygoid bone)
8. External nares
9. (Jugal [zygomatic] bone)
10. Craniofacial flexion zone
11. Orbit
12. Frontal bone
13. Cranium
14. Temporal bone
15. (Quadrate bone)
16. Parietal bone

NOTE: Structures in parentheses are not labeled.

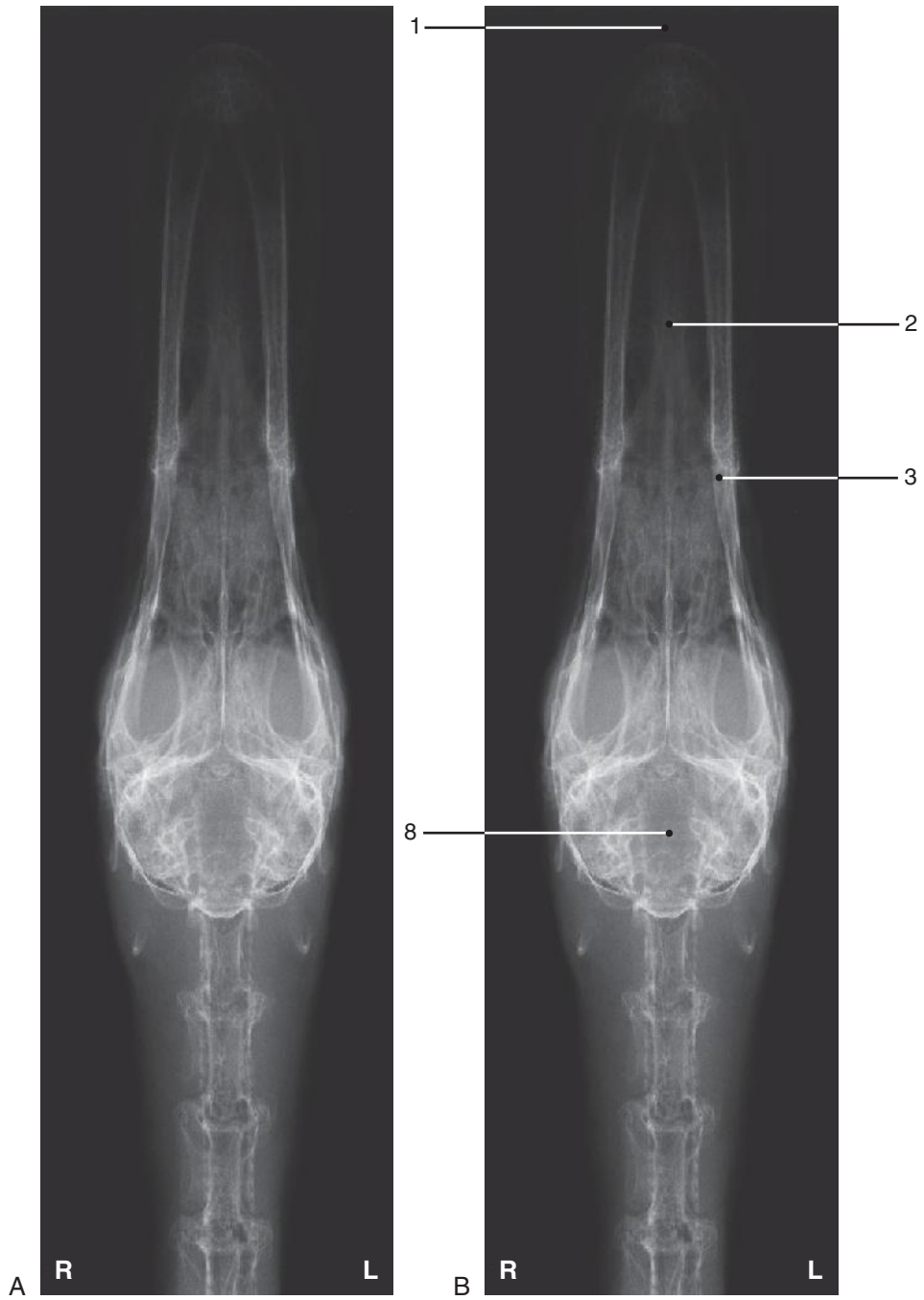

Figure 16-4, A-B
Type of Bird: Mallard Duck
Type of Study: Head
Projection: Ventrodorsal
Weight of Bird: 1.2 kg
Gender: Male
Reproductive Status: Intact
Age: Adult

1. Keratinized maxillary beak
2. Premaxillary bone
3. Mandible
4. (Orbit)
5. (Jugal [zygomatic] bone)
6. (Scleral ossicles)
7. (Quadrate bone)
8. Cranium

NOTE: Structures in parentheses are not labeled.

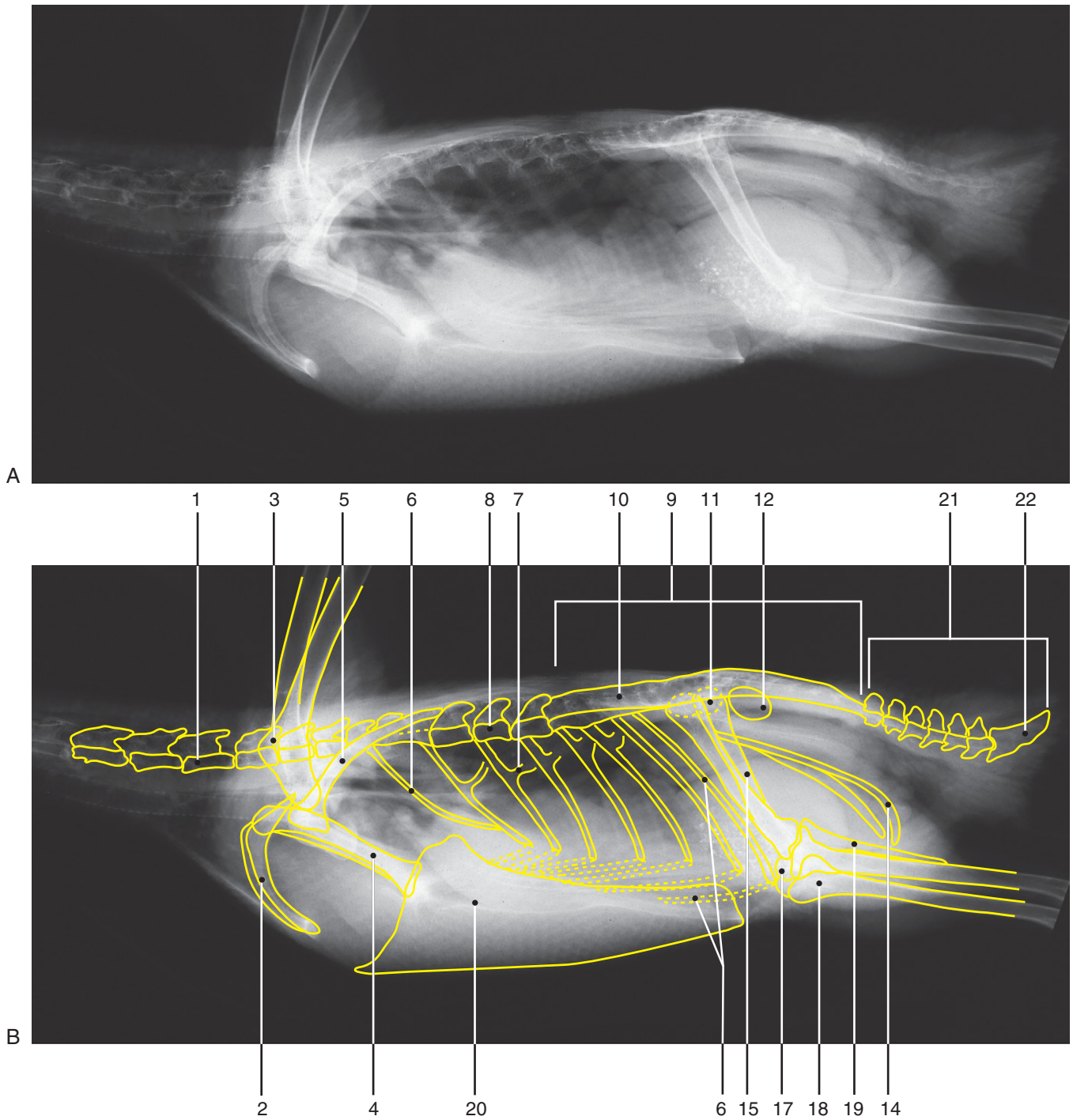

Figure 16-5, A-B
Type of Bird: Mallard Duck
Type of Study: Whole body skeleton
Projection: Laterolateral (right lateral recumbency)
Weight of Bird: 1.2 kg
Gender: Male
Reproductive Status: Intact
Age: Adult

1. Cervical vertebra
2. Clavicle
3. Humerus
4. Coracoid
5. Scapula
6. Rib
7. Uncinate process of rib
8. Thoracic vertebra
9. Synsacrum
10. Ilium
11. Head of femur
12. Ilioischiadiac foramen
13. (Ischium)
14. Pubis
15. Femur
16. (Obturator foramen)
17. Patella
18. Tibiotarsal bone
19. Fibula
20. Sternum
21. Caudal vertebrae
22. Pygostyle

NOTE: Structures in parentheses are not labeled.

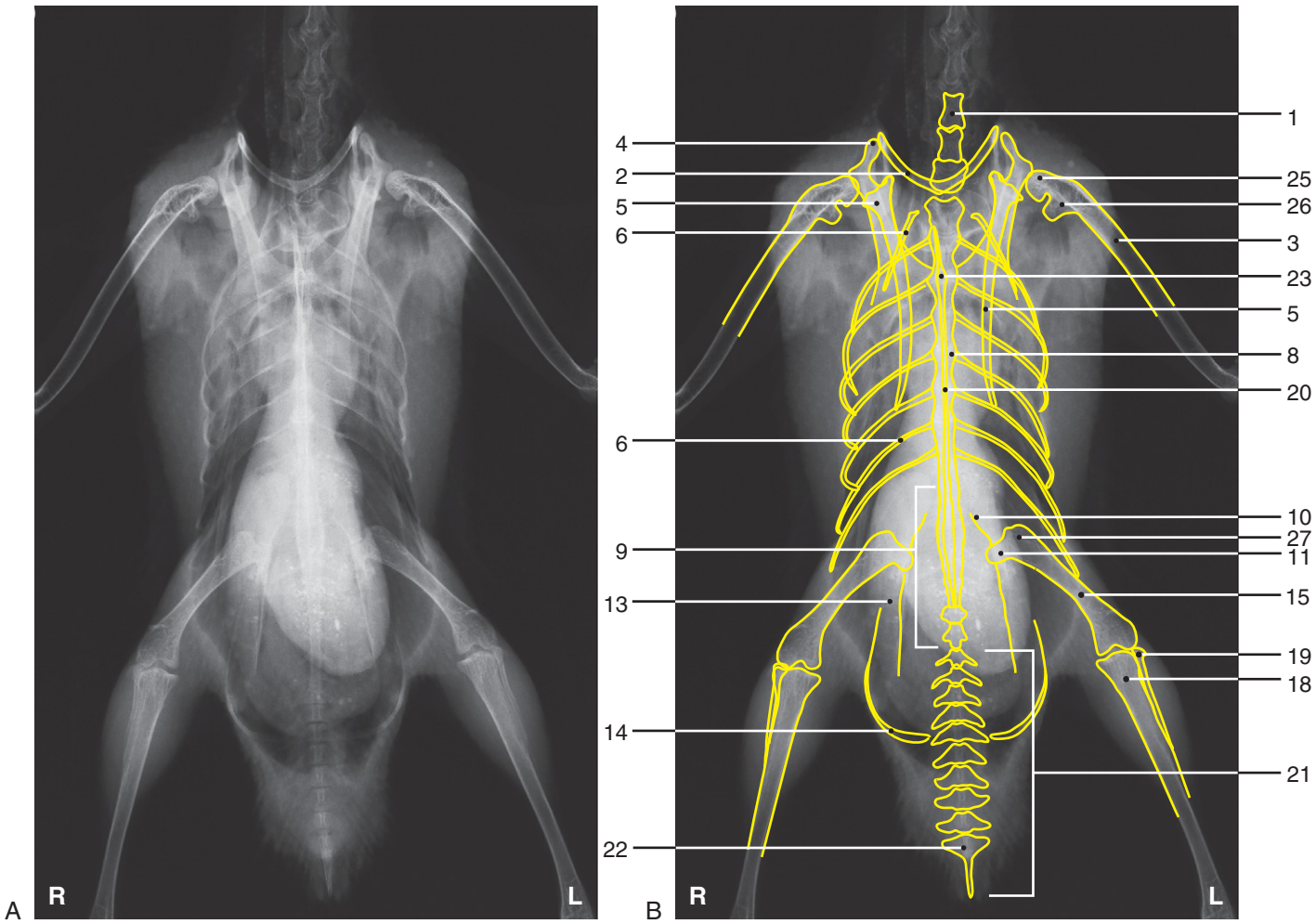

Figure 16-6, A-B
Type of Bird: Mallard Duck
Type of Study: Whole body skeleton
Projection: Ventrodorsal
Weight of Bird: 1.2 kg
Gender: Male
Reproductive Status: Intact
Age: Adult

1. Cervical vertebra
2. Clavicle
3. Humerus
4. Coracoid
5. Scapula
6. Rib
7. (Uncinate process of rib)
8. Thoracic vertebra
9. Synsacrum
10. Ilium
11. Head of femur
12. (Ilioischiadiac foramen)
13. Ischium
14. Pubis
15. Femur
16. (Obturator foramen)
17. (Patella)
18. Tibiotarsal bone
19. Fibula
20. Sternum
21. Caudal vertebrae
22. Pygostyle
23. Apex carinae
24. (Dorsal tubercle of humerus)
25. Head of humerus
26. Ventral tubercle of humerus
27. Trochanter of femur

NOTE: Structures in parentheses are not labeled.

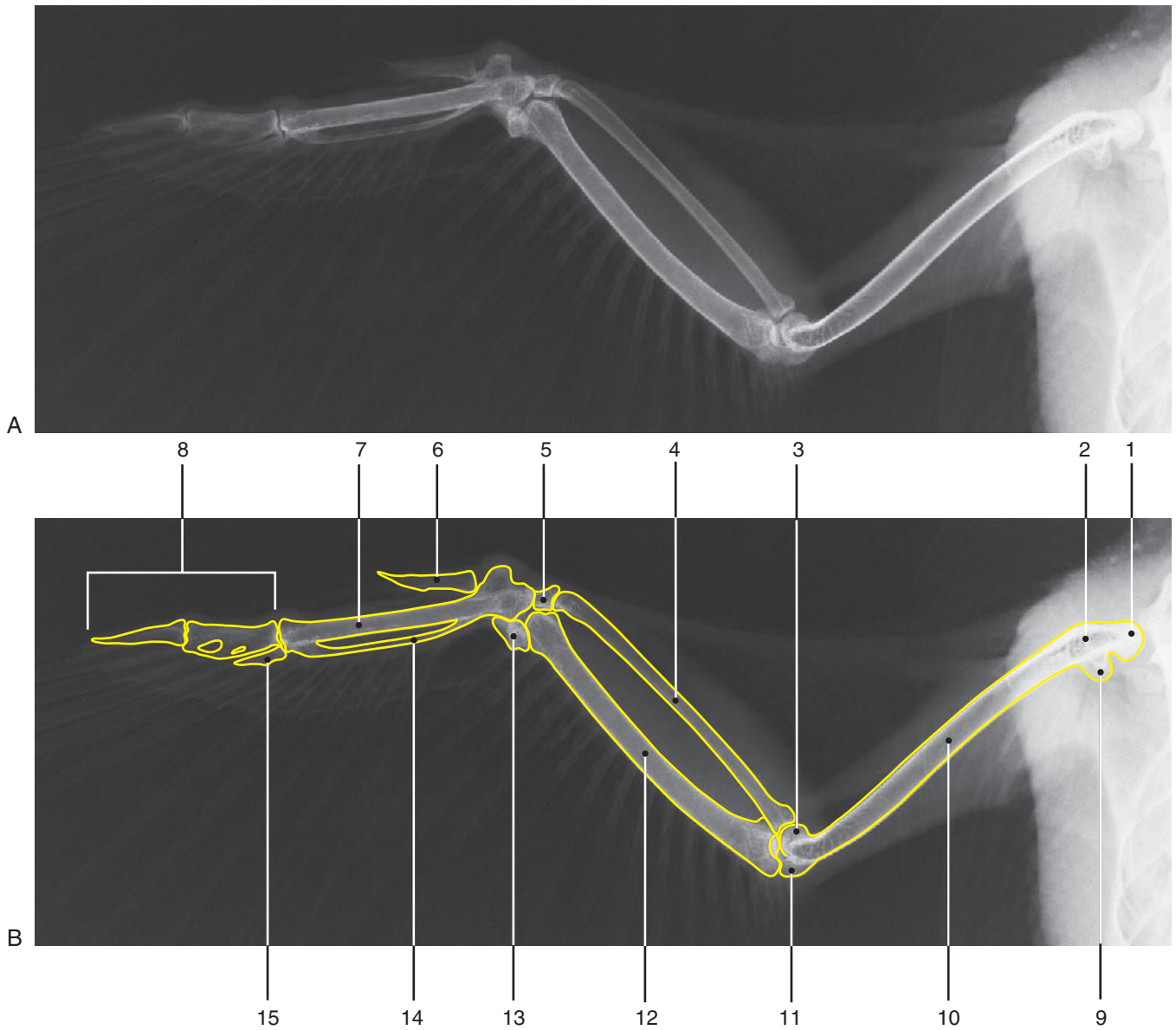

Figure 16-7, A-B
Type of Bird: Mallard Duck
Type of Study: Wing
Projection: Mediolateral
Weight of Bird: 1.2 kg
Gender: Male
Reproductive Status: Intact
Age: Adult

1. Head of humerus
2. Dorsal tubercle of humerus
3. Dorsal condyle of humerus
4. Radius
5. Radial carpal bone
6. Alula
7. Major metacarpal bone
8. Phalanges of major digit
9. Ventral tubercle of humerus
10. Humerus
11. Ventral condyle of humerus
12. Ulna
13. Ulnar carpal bone
14. Minor metacarpal bone
15. Phalanges of minor digit

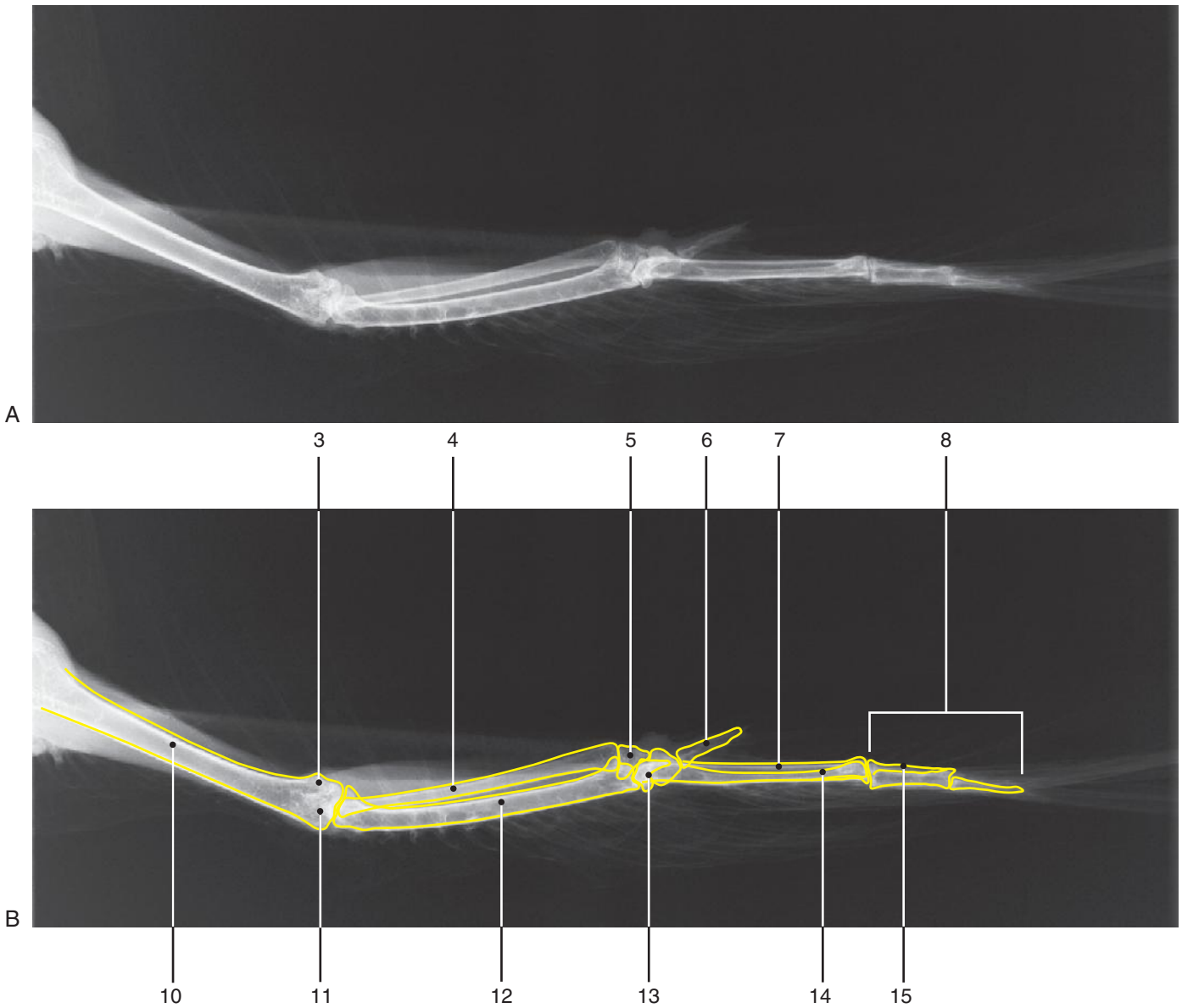

Figure 16-8, A-B
Type of Bird: Mallard Duck
Type of Study: Wing
Projection: Caudocranial
Weight of Bird: 1.2 kg
Gender: Male
Reproductive Status: Intact
Age: Adult

1. (Head of humerus)
2. (Ventral tubercle of humerus)
3. Ventral condyle of humerus
4. Radius
5. Radial carpal bone
6. Alula
7. Minor metacarpal bone
8. Phalanges of major digit
9. (Dorsal tubercle of humerus)
10. Humerus
11. Dorsal condyle of humerus
12. Ulna
13. Ulnar carpal bone
14. Major metacarpal bone
15. Phalanges of minor digit

NOTE: Structures in parentheses are not labeled.

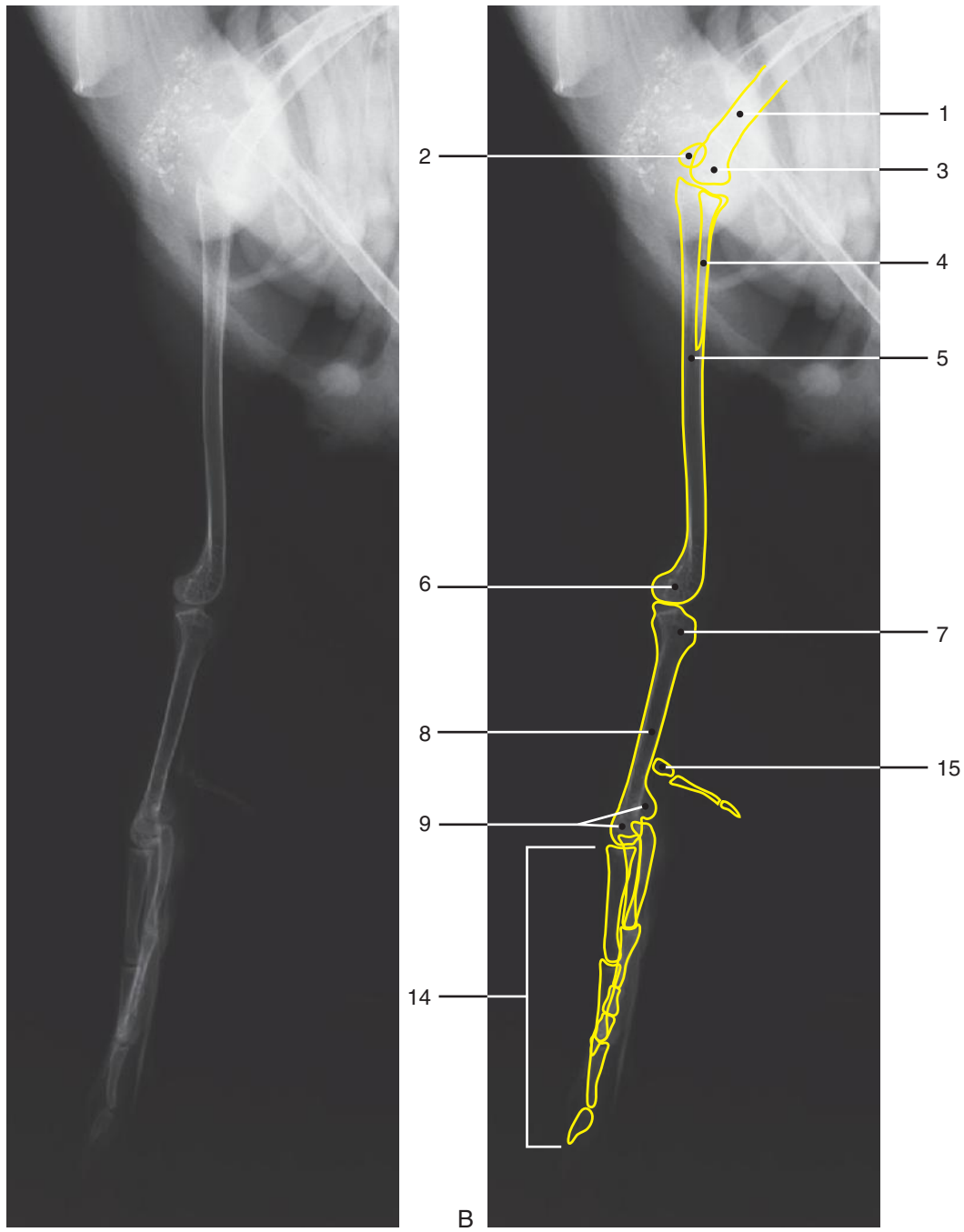

Figure 16-9, A-B
Type of Bird: Mallard Duck
Type of Study: Pelvic limb
Projection: Mediolateral
Weight of Bird: 1.2 kg
Gender: Male
Reproductive Status: Intact
Age: Adult

1. Femur
2. Patella
3. Condyles of femur
4. Fibula
5. Tibiotarsal bone
6. Condyles of tibiotarsal bone
7. Hypotarsal crest of tarsometatarsal bone
8. Tarsometatarsal bone
9. Trochlea of tarsometatarsal bone
10. (Digit I)
11. (Digit II)
12. (Digit III)
13. (Digit IV)
14. Phalanges
15. Metatarsal I

NOTE: Structures in parentheses are not labeled.

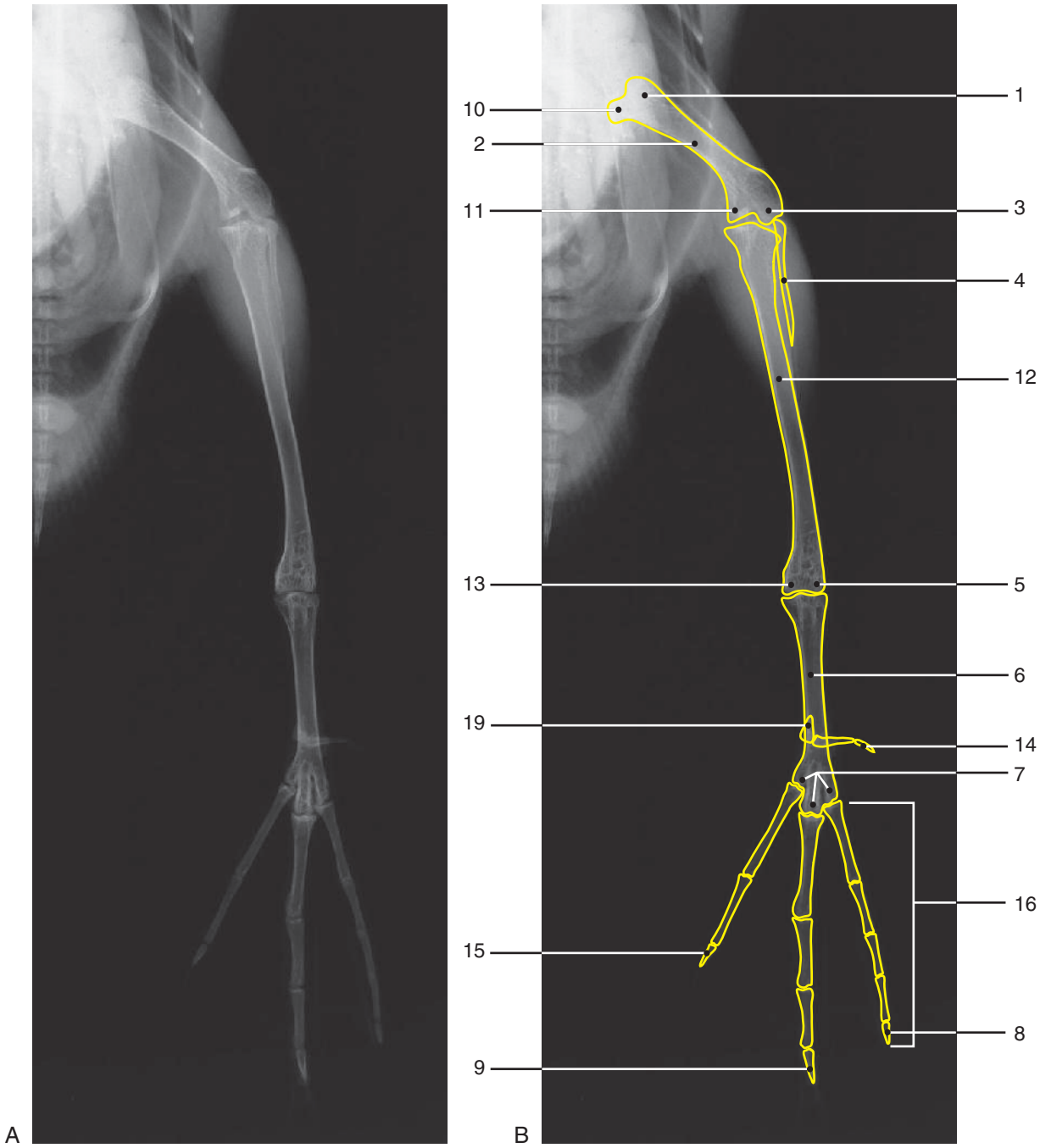

Figure 16-10, A-B
Type of Bird: Mallard Duck
Type of Study: Pelvic limb
Projection: Craniocaudal
Weight of Bird: 1.2 kg
Gender: Male
Reproductive Status: Intact
Age: Adult

1. Trochanter of femur
2. Femur
3. Lateral condyle of femur
4. Fibula
5. Lateral condyle of tibiotarsal bone
6. Tarsometatarsal bone
7. Trochlea of tarsometatarsal bone
8. Digit IV
9. Digit III
10. Head of femur
11. Medial condyle of femur
12. Tibiotarsal bone
13. Medial condyle of tibiotarsal bone
14. Digit I
15. Digit II
16. Phalanges
17. (Patella)
18. (Hypotarsal crest of tarsometatarsal bone)
19. Metatarsal I

NOTE: Structures in parentheses are not labeled.

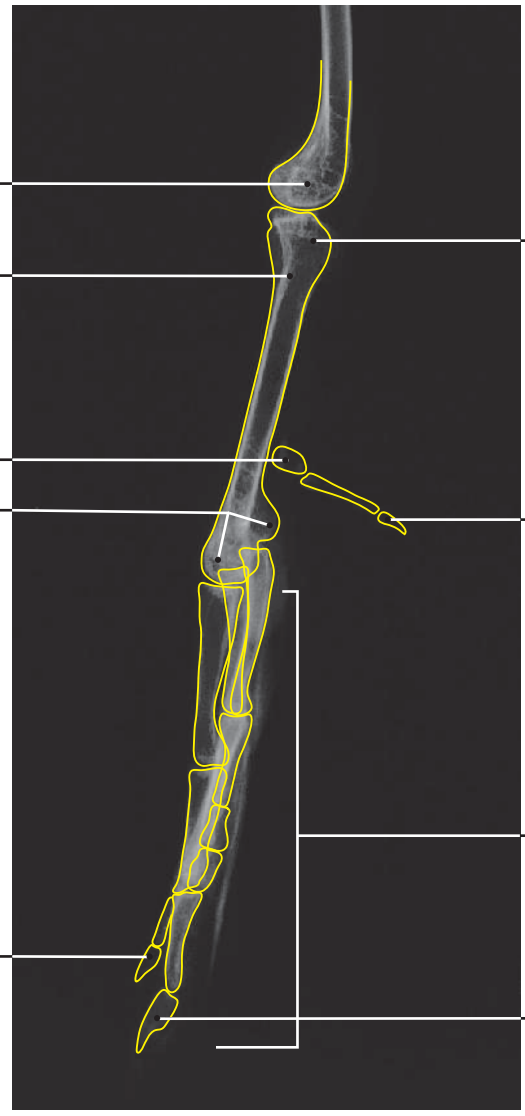

Figure 16-11, A-B
Type of Bird: Mallard Duck
Type of Study: Distal pelvic limb
Projection: Mediolateral
Weight of Bird: 1.2 kg
Gender: Male
Reproductive Status: Intact
Age: Adult

1. Tarsometatarsal bone
2. Trochlea of tarsometatarsal bone
3. Metatarsal bone I
4. Digit I
5. Digit II
6. Digit III
7. (Digit IV)
8. Phalanges
9. Hypotarsal crest of tarsometatarsal bone
10. Condyles of tibiotarsal bone

NOTE: Structures in parentheses are not labeled.

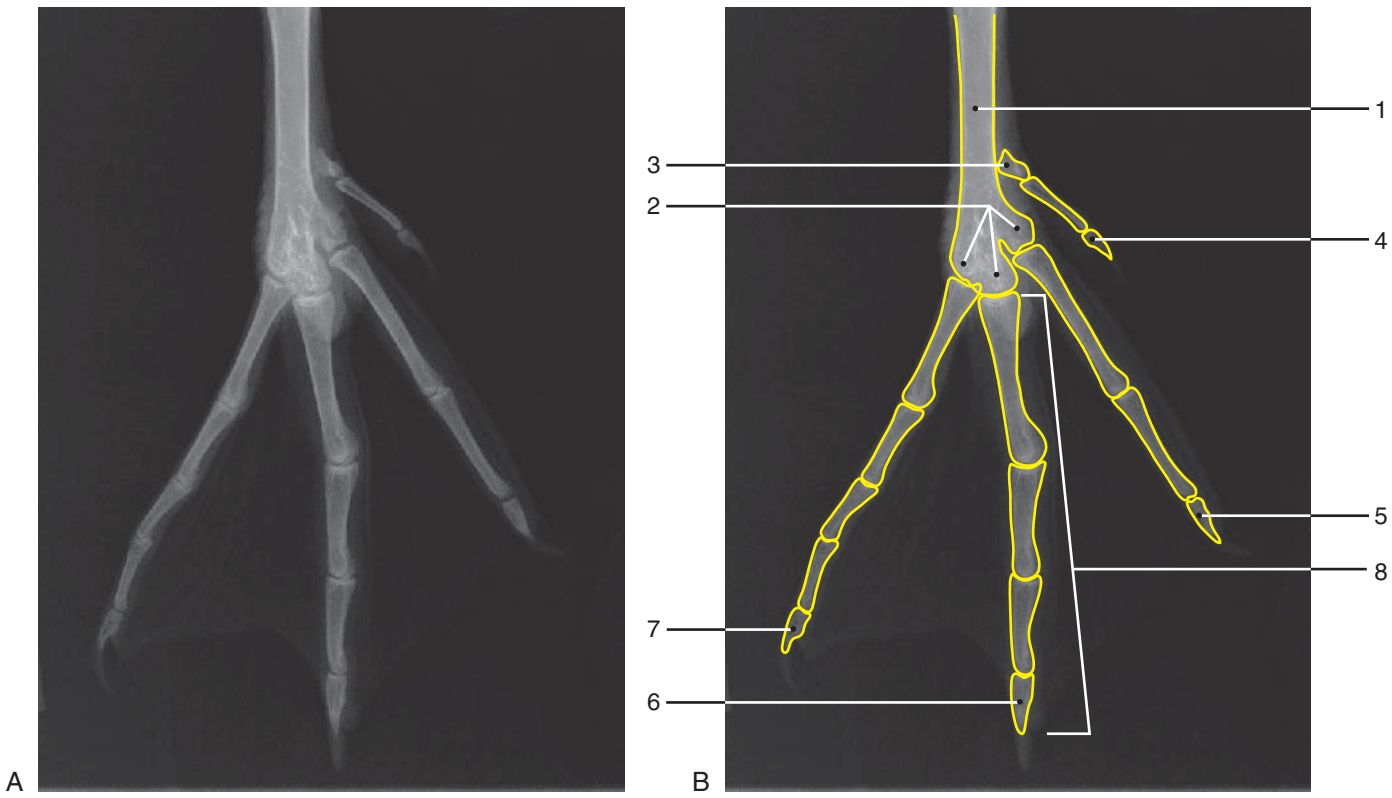

Figure 16-12, A-B
Type of Bird: Mallard Duck
Type of Study: Distal pelvic limb
Projection: Dorsoplantar
Weight of Bird: 1.2 kg
Gender: Male
Reproductive Status: Intact
Age: Adult

1. Tarsometatarsal bone
2. Trochlea of tarsometatarsal bone
3. Metatarsal bone I
4. Digit I
5. Digit II
6. Digit III
7. Digit IV
8. Phalanges
9. (Hypotarsal crest of tarsometatarsal bone)
10. (Condyles of tibiotarsal bone)

NOTE: Structures in parentheses are not labeled.

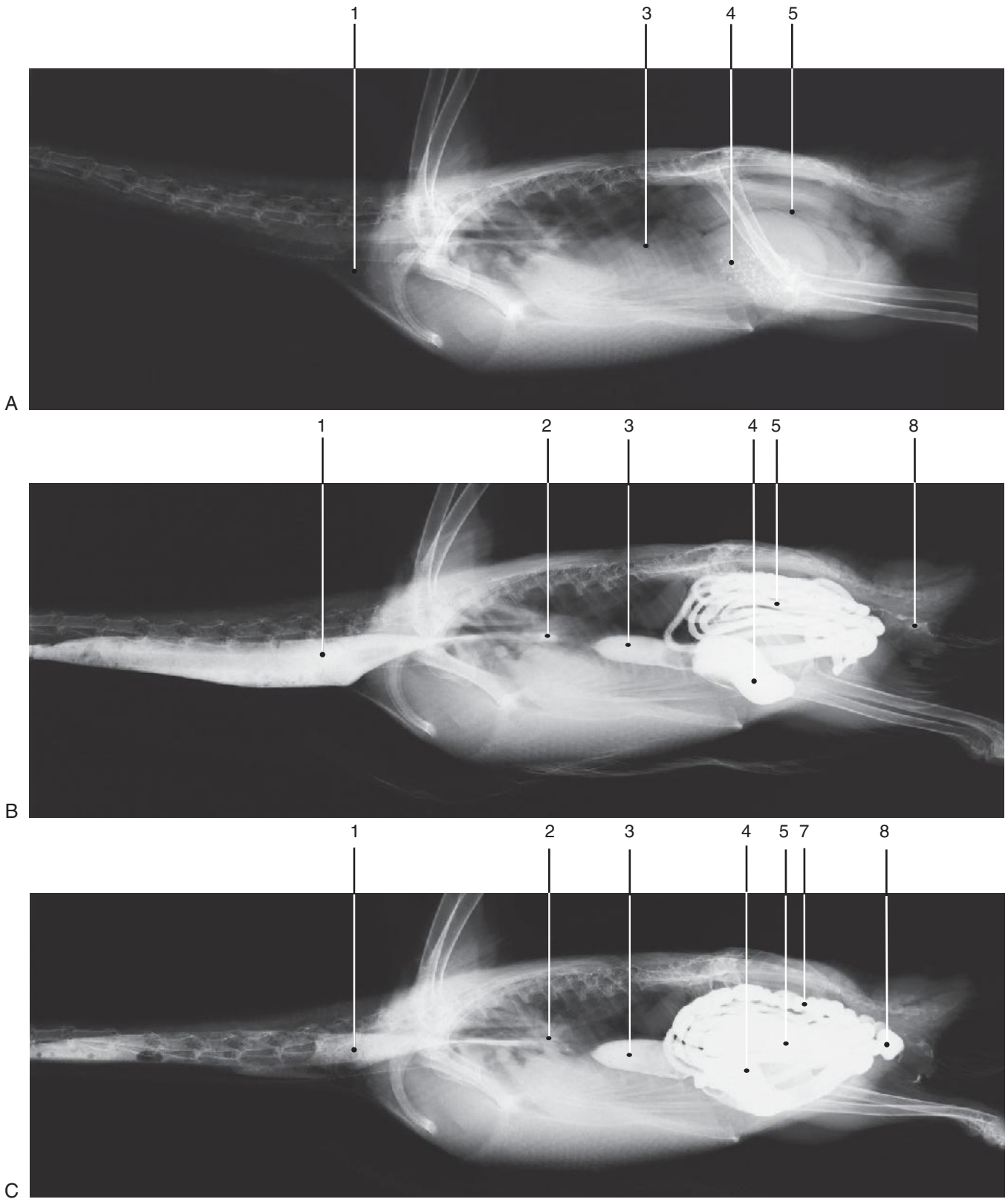

Figure 16-13, A-C
Type of Bird: Mallard Duck
Type of Study: Gastrointestinal positive contrast study
Contrast Medium: Barium sulfate suspension (Novopaque® 30% w/v; Lafayette Pharmaceutical, Inc., Lafayette, IN) 35 ml administered via gavage tube
Projection: Laterolateral (right lateral recumbency)
Weight of Bird: 1.2 kg
Gender: Male
Reproductive Status: Intact
Age: Adult

Image	Time (hr)
A	Scout
B	0.25
C	1.0

1. Crop
2. Esophagus
3. Proventriculus
4. Ventriculus
5. Intestines
6. (Duodenum)
7. Large intestine
8. Cloaca
9. (Proventricular-ventricular isthmus)

NOTE: Structures in parentheses are not labeled.

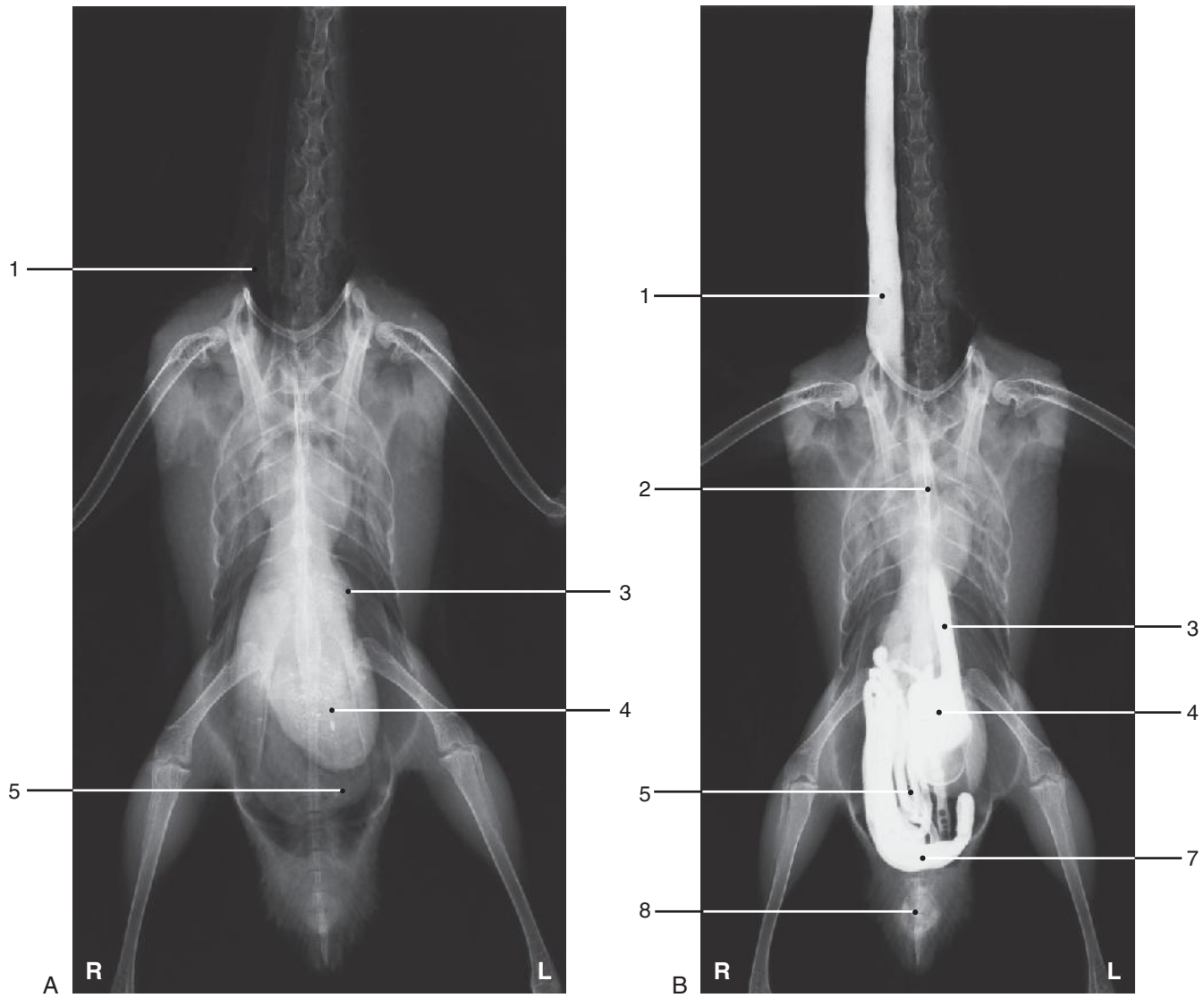

Figure 16-14, A-B
Type of Bird: Mallard Duck
Type of Study: Gastrointestinal positive contrast study
Contrast Medium: Barium sulfate suspension (Novopaque® 30% w/v; Lafayette Pharmaceutical, Inc., Lafayette, IN) 35 ml administered via gavage tube
Projection: Ventrodorsal
Weight of Bird: 1.2 kg
Gender: Male
Reproductive Status: Intact
Age: Adult

Image	Time (hr)
A	Scout
B	0.25

1. Crop
2. Esophagus
3. Proventriculus
4. Ventriculus
5. Intestines
6. (Duodenum)
7. Large intestine
8. Cloaca
9. (Proventricular-ventricular isthmus)

NOTE: Structures in parentheses are not labeled.

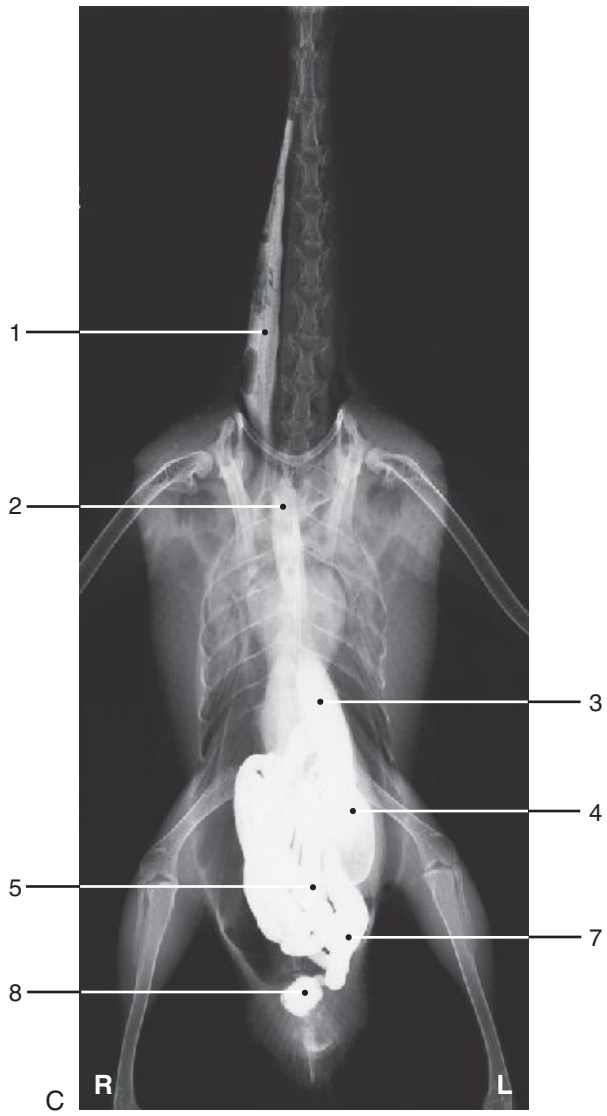

Figure 16-14, C
Type of Bird: Mallard Duck
Type of Study: Gastrointestinal positive contrast study
Contrast Medium: Barium sulfate suspension (Novopaque® 30% w/v; Lafayette Pharmaceutical, Inc., Lafayette, IN) 35 ml administered via gavage tube
Projection: Ventrodorsal
Weight of Bird: 1.2 kg
Gender: Male
Reproductive Status: Intact
Age: Adult

Image	Time (hr)
C	1.0

1. Crop
2. Esophagus
3. Proventriculus
4. Ventriculus
5. Intestines
6. (Duodenum)
7. Large intestine
8. Cloaca
9. (Proventricular-ventricular isthmus)

NOTE: Structures in parentheses are not labeled.

Figure 16-15
Type of Bird: Mallard Duck
Type of Study: Excretory urogram-cutaneous ulnar vein contrast medium administration
Contrast Medium: Diatrizoate meglumine, diatrizoate sodium (RenoCal–76® 37% organically bound iodine; Bracco Diagnostics, Inc., Princeton, NJ) 1.2 ml IV (1 ml/kg) via cutaneous ulnar vein
Projection: Laterolateral (right lateral recumbency)
Weight of Bird: 1.2 kg
Gender: Male
Reproductive Status: Intact
Age: Adult

Image	Time (min)
16-15	Immediate

1. Kidneys
2. Ureter
3. Cloaca

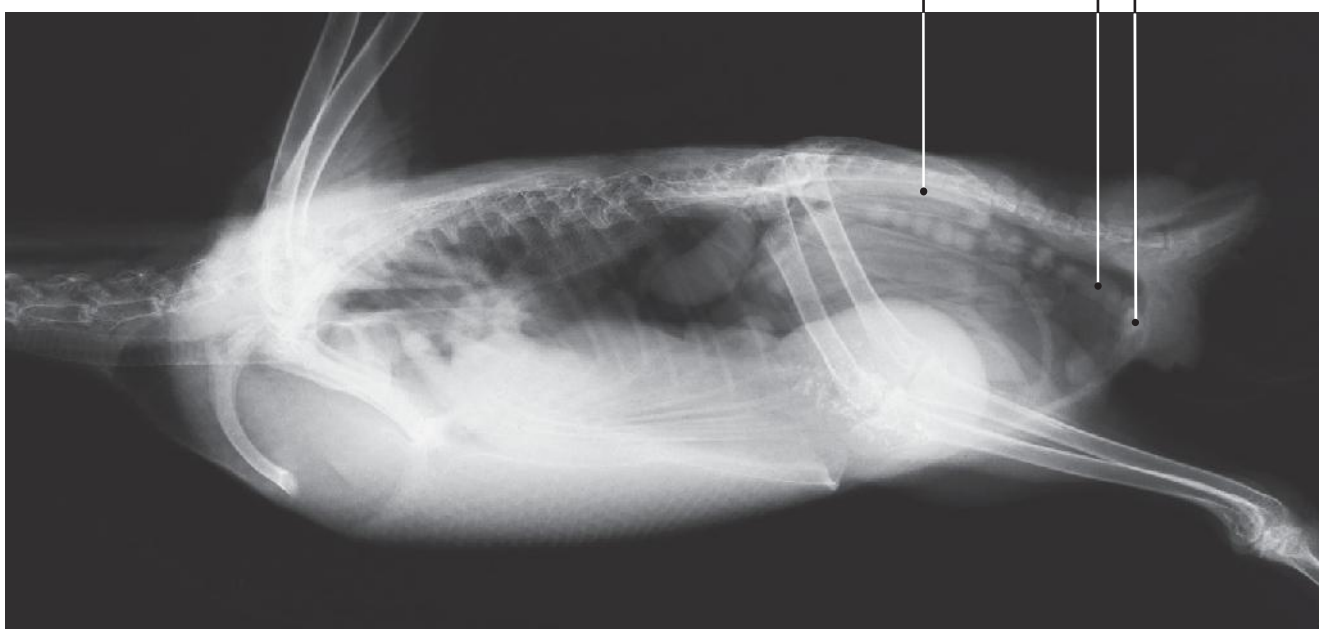

Figure 16-16
Type of Bird: Mallard Duck
Type of Study: Excretory urogram-medial metatarsal vein contrast administration.
Contrast Medium: Diatrizoate meglumine, diatrizoate sodium (RenoCal–76® 37% organically bound iodine; Bracco Diagnostics, Inc., Princeton, NJ) 1.2 ml IV (1 ml/kg) via medial metatarsal vein
Projection: Laterolateral (right lateral recumbency)
Weight of Bird: 1.2 kg
Gender: Male
Reproductive Status: Intact
Age: Adult

Image	Time (min)
16-16	Immediate

1. Kidneys
2. Ureter
3. Cloaca

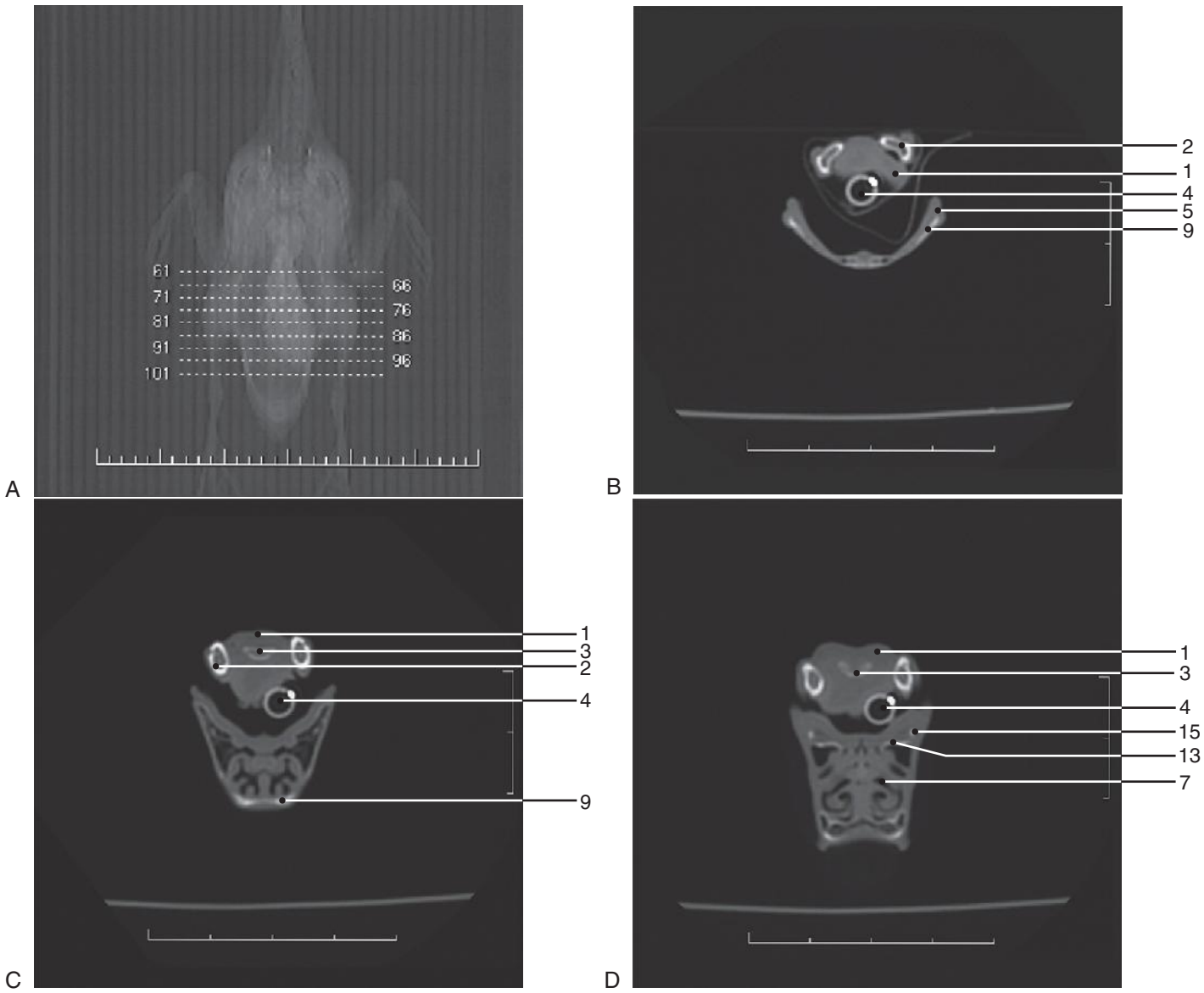

Figure 16-17, A-D
Type of Bird: Mallard Duck
Type of Study: CT head
Contrast Medium: None
Imaging Plane: Transverse
Weight of Bird: 1.4 kg
Age: Adult

1. Tongue
2. Mandible
3. Hyoid bone
4. Endotracheal tube
5. Keratinized maxillary beak
6. (Nasal cavity)
7. Nasal concha
8. (Pharynx)
9. Premaxillary bone
10. (Infraorbital sinus)
11. (Nasal septum)
12. (Choana)
13. Palatine bone
14. (Sphenoid bone)
15. Jugal [zygomatic] bone
16. (Frontal bone)
17. (Pterygoid bone)
18. (Eyeball)
19. (Scleral ossicle)
20. (Interorbital septum)
21. (Lens of eyeball)
22. (Trachea)
23. (Cerebrum)
24. (External ear canal)
25. (Cerebellum)
26. (Spinal cord)
27. (Dens)
28. (Cere)
29. (Nare[s])
30. (Feather)
31. (Pons)
32. (Occipital bone)
33. (Cervical vertebra)

NOTE: Structures in parentheses are not labeled.

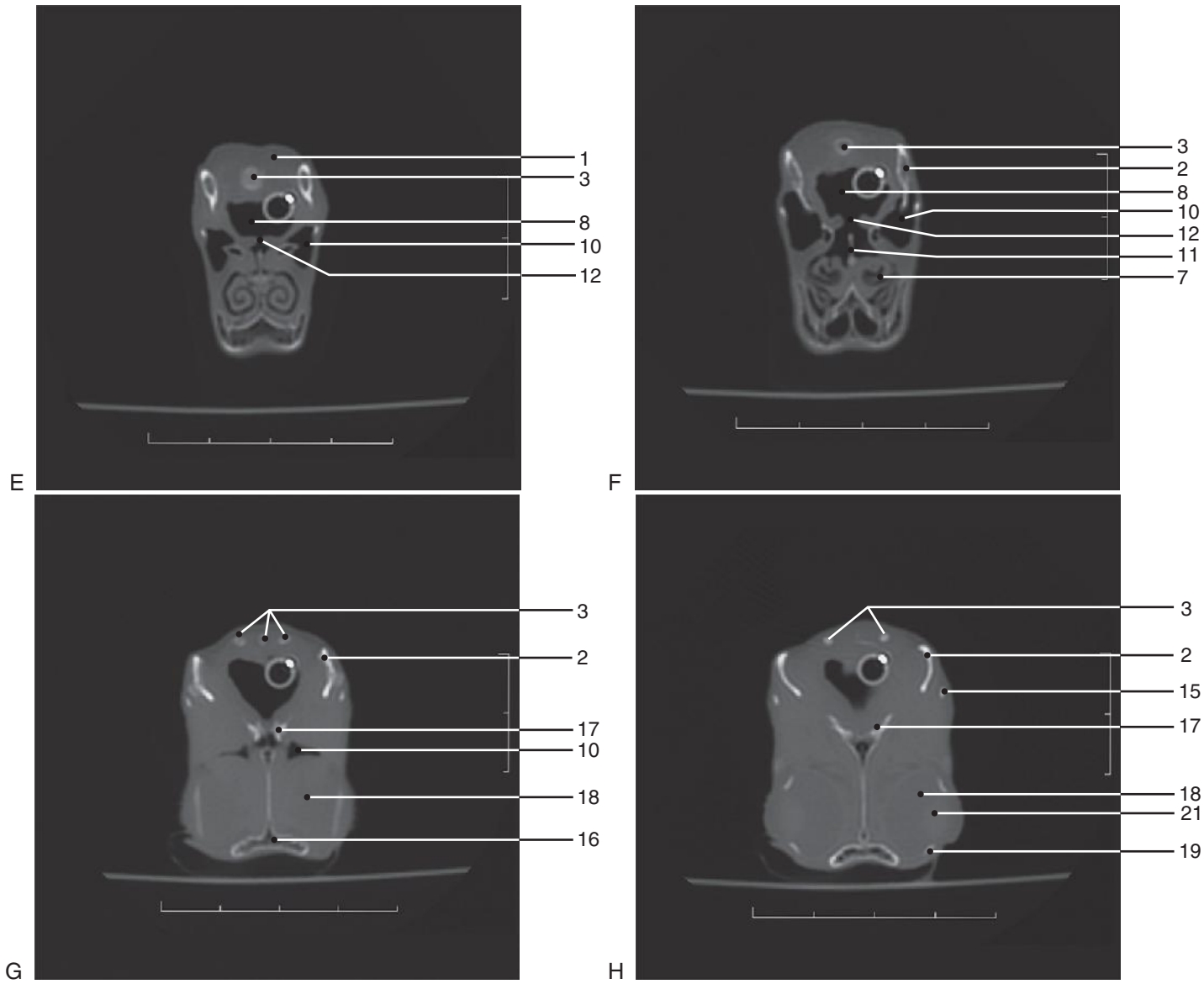

Figure 16-17, E-H
Type of Bird: Mallard Duck
Type of Study: CT head
Contrast Medium: None
Imaging Plane: Transverse
Weight of Bird: 1.4 kg
Age: Adult

1. Tongue
2. Mandible
3. Hyoid bone
4. (Endotracheal tube)
5. (Keratinized maxillary beak)
6. (Nasal cavity)
7. Nasal concha
8. Pharynx
9. (Premaxillary bone)
10. Infraorbital sinus
11. Nasal septum
12. Choana
13. (Palatine bone)
14. (Sphenoid bone)
15. Jugal [zygomatic] bone
16. Frontal bone
17. Pterygoid bone
18. Eyeball
19. Scleral ossicle
20. (Interorbital septum)
21. Lens of eyeball
22. (Trachea)
23. (Cerebrum)
24. (External ear canal)
25. (Cerebellum)
26. (Spinal cord)
27. (Dens)
28. (Cere)
29. (Nare[s])
30. (Feather)
31. (Pons)
32. (Occipital bone)
33. (Cervical vertebra)

NOTE: Structures in parentheses are not labeled.

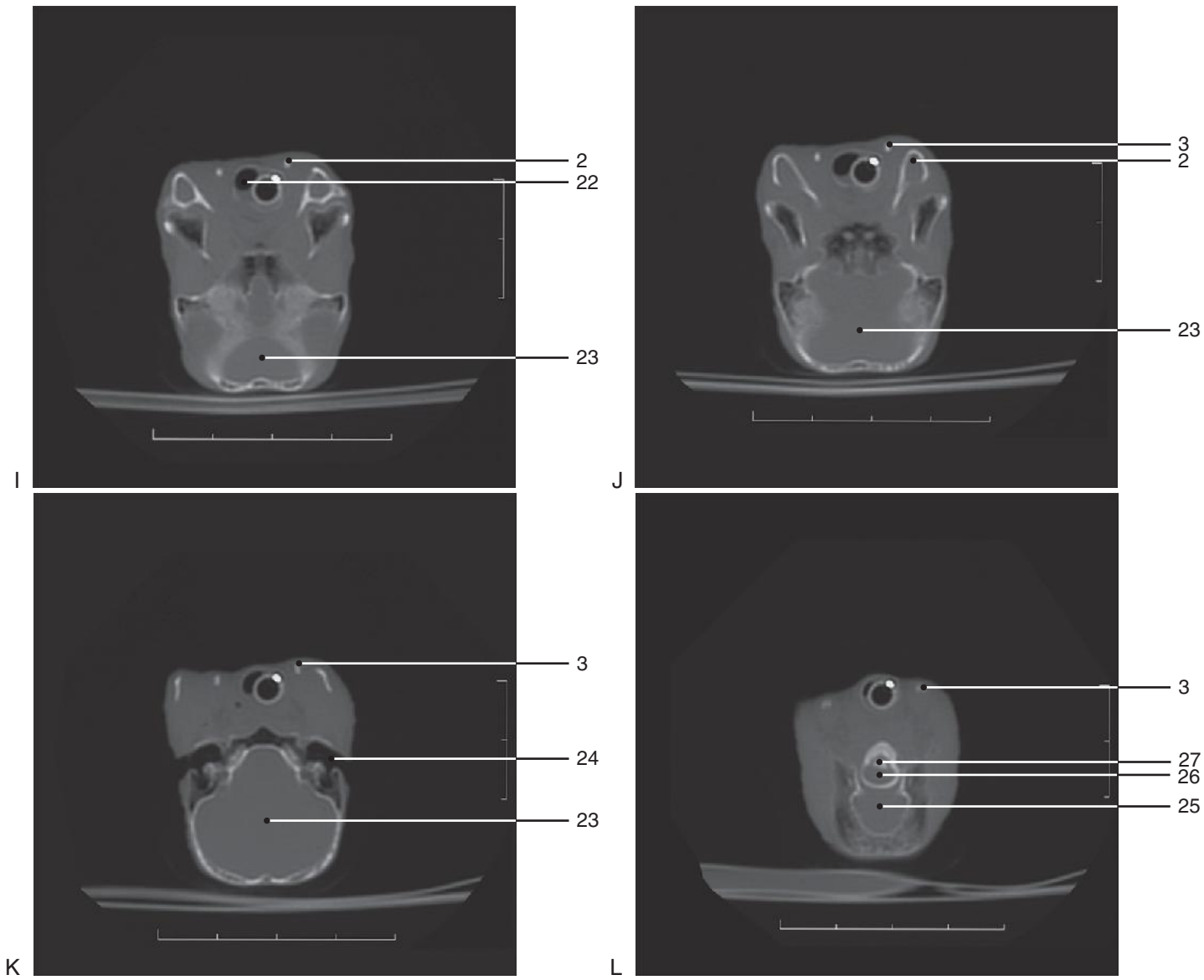

Figure 16-17, I-L
Type of Bird: Mallard Duck
Type of Study: CT head
Contrast Medium: None
Imaging Plane: Transverse
Weight of Bird: 1.4 kg
Age: Adult

1. (Tongue)
2. Mandible
3. Hyoid bone
4. (Endotracheal tube)
5. (Keratinized maxillary beak)
6. (Nasal cavity)
7. (Nasal concha)
8. (Pharynx)
9. (Premaxillary bone)
10. (Infraorbital sinus)
11. (Nasal septum)
12. (Choana)
13. (Palatine bone)
14. (Sphenoid bone)
15. (Jugal [zygomatic] bone)
16. (Frontal bone)
17. (Pterygoid bone)
18. (Eyeball)
19. (Scleral ossicle)
20. (Interorbital septum)
21. (Lens of eyeball)
22. Trachea
23. Cerebrum
24. External ear canal
25. Cerebellum
26. Spinal cord
27. Dens
28. (Cere)
29. (Nare[s])
30. (Feather)
31. (Pons)
32. (Occipital bone)
33. (Cervical vertebra)

NOTE: Structures in parentheses are not labeled.

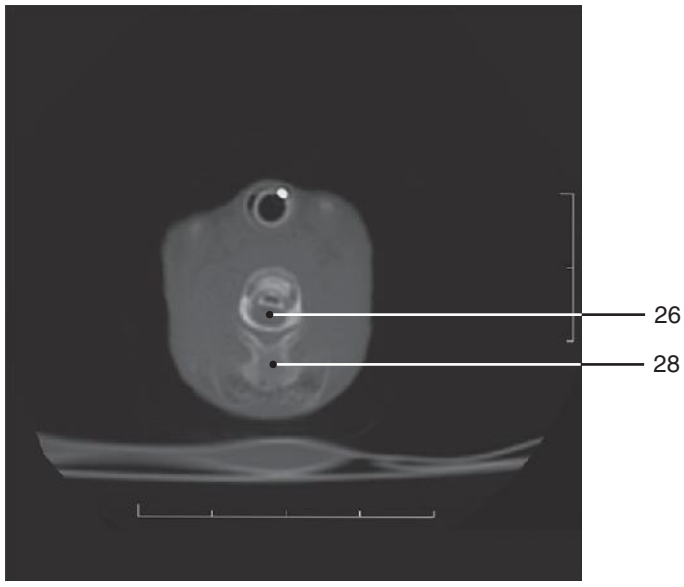

Figure 16-17, M
Type of Bird: Mallard Duck
Type of Study: CT head
Contrast Medium: None
Imaging Plane: Transverse
Weight of Bird: 1.4 kg
Age: Adult

1. (Tongue)
2. (Mandible)
3. (Hyoid bone)
4. (Endotracheal tube)
5. (Keratinized maxillary beak)
6. (Nasal cavity)
7. (Nasal concha)
8. (Pharynx)
9. (Premaxillary bone)
10. (Infraorbital sinus)
11. (Nasal septum)
12. (Choana)
13. (Palatine bone)
14. (Sphenoid bone)
15. (Jugal [zygomatic] bone)
16. (Frontal bone)
17. (Pterygoid bone)
18. (Eyeball)
19. (Scleral ossicle)
20. (Interorbital septum)
21. (Lens of eyeball)
22. (Trachea)
23. (Cerebrum)
24. (External ear canal)
25. (Cerebellum)
26. Spinal cord
27. (Dens)
28. Cere
29. (Nare[s])
30. (Feather)
31. (Pons)
32. (Occipital bone)
33. (Cervical vertebra)

NOTE: Structures in parentheses are not labeled.

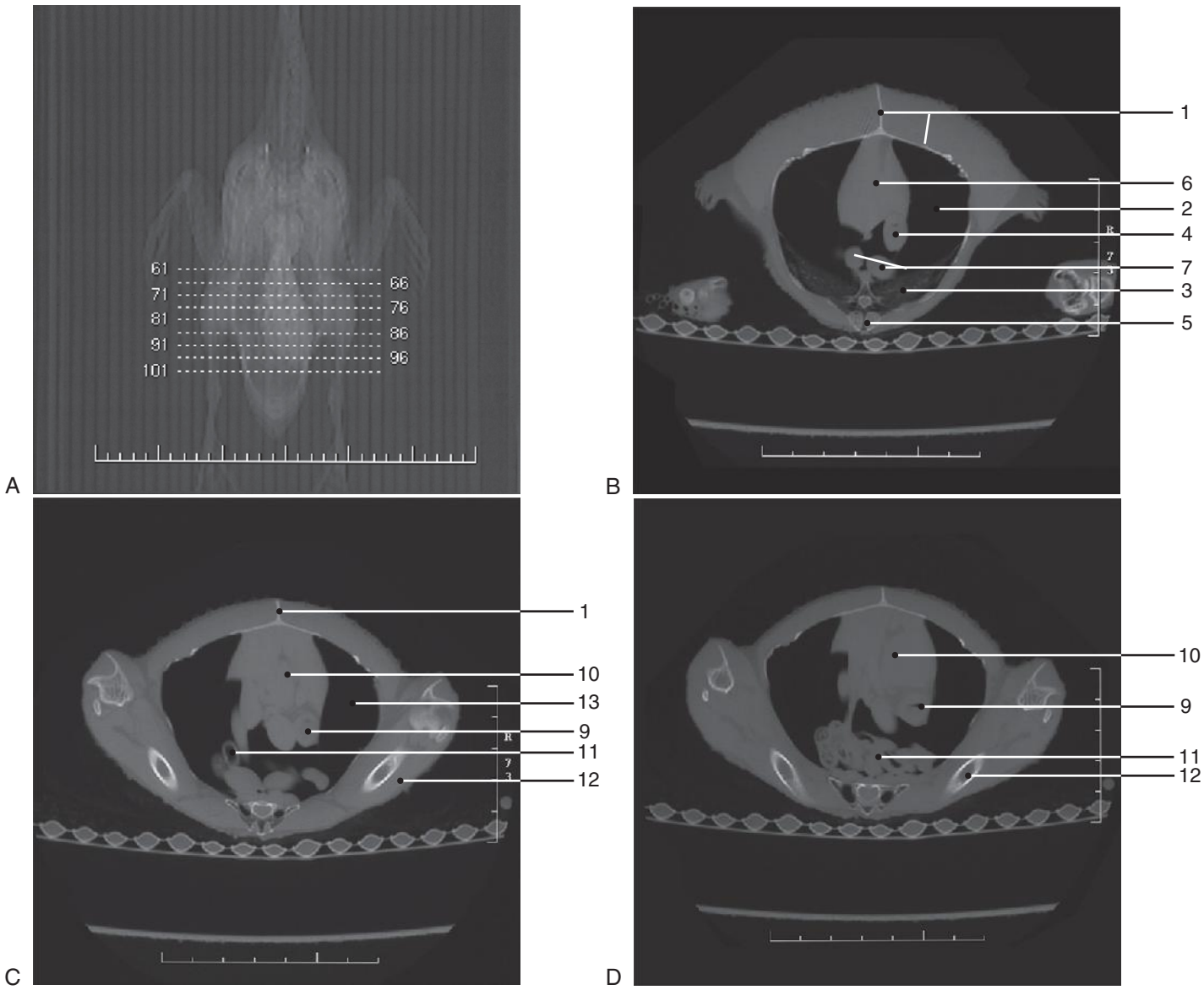

Figure 16-18, A-D
Type of Bird: Mallard Duck
Type of Study: CT coelom
Contrast Medium: None
Imaging Plane: Transverse
Weight of Bird: 1.4 kg
Age: Adult

1. Sternum
2. Thoracic air sac
3. Lung
4. Esophagus
5. Thoracic vertebra
6. Heart
7. Blood vessels
8. (Thoracic extremity [wing])
9. Proventriculus
10. Ventriculus
11. Intestines
12. Pelvic extremity [leg]
13. Abdominal air sac
14. (Ilium)
15. (Liver)
16. (Kidney)
17. (Caudal vertebra)
18. (Rib)
19. (Aorta)
20. (Pubic bone)
21. (Cloaca)
22. (Clavicular air sac)
23. (Scapula)
24. (Syrinx)
25. (Ischium)
26. (Colon)
27. (Spinal cord)

NOTE: Structures in parentheses are not labeled.

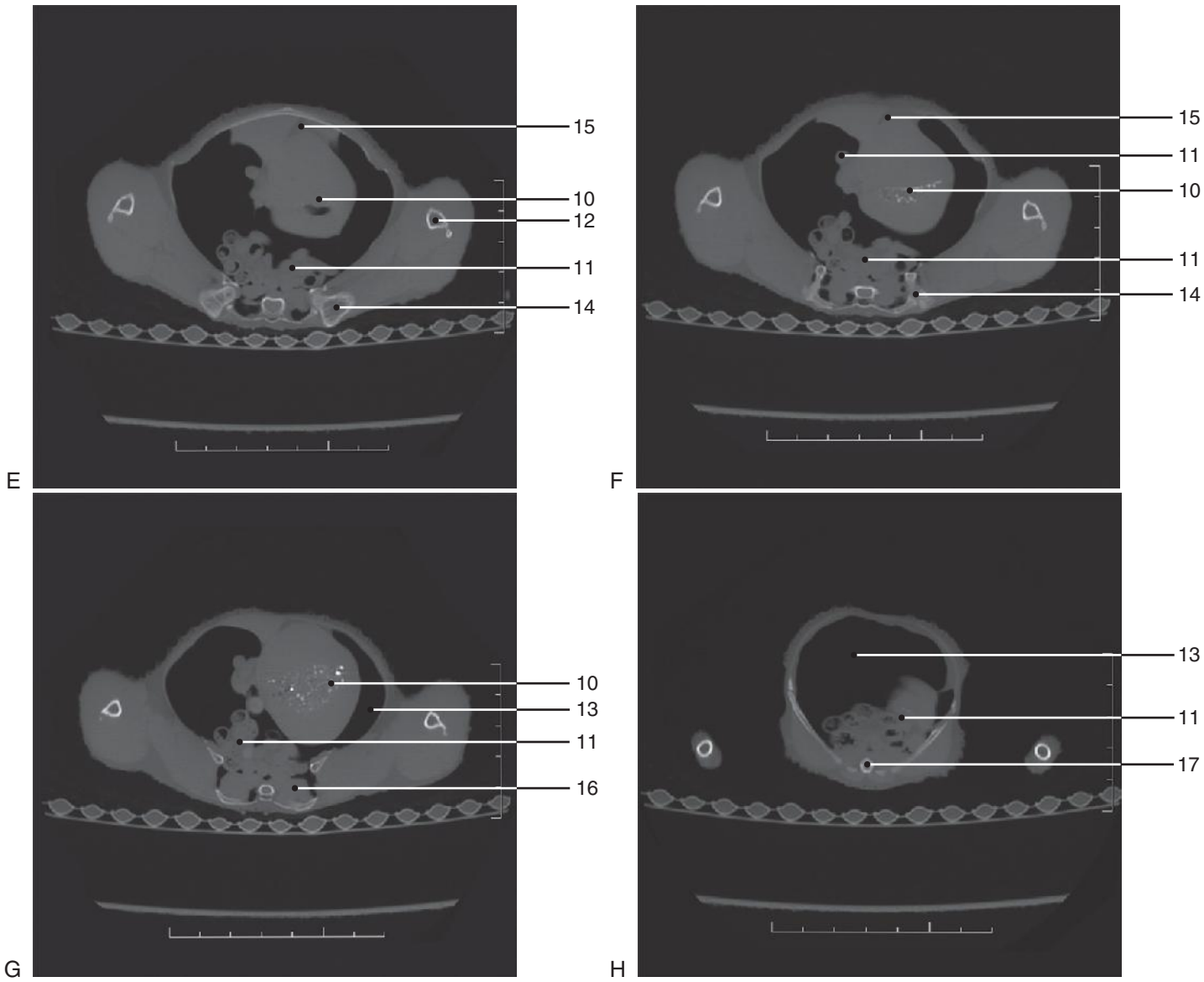

Figure 16-18, E-H
Type of Bird: Mallard Duck
Type of Study: CT coelom
Contrast Medium: None
Imaging Plane: Transverse
Weight of Bird: 1.4 kg
Age: Adult

1. (Sternum)
2. (Thoracic air sac)
3. (Lung)
4. (Esophagus)
5. (Thoracic vertebra)
6. (Heart)
7. (Blood vessels)
8. (Thoracic extremity [wing])
9. (Proventriculus)
10. Ventriculus
11. Intestines
12. Pelvic extremity [leg]
13. Abdominal air sac
14. Ilium
15. Liver
16. Kidney
17. Caudal vertebra
18. (Rib)
19. (Aorta)
20. (Pubic bone)
21. (Cloaca)
22. (Clavicular air sac)
23. (Scapula)
24. (Syrinx)
25. (Ischium)
26. (Colon)
27. (Spinal cord)

NOTE: Structures in parentheses are not labeled.

CHAPTER • 17

Red Tailed Hawk
(Buteo jamaicensis)

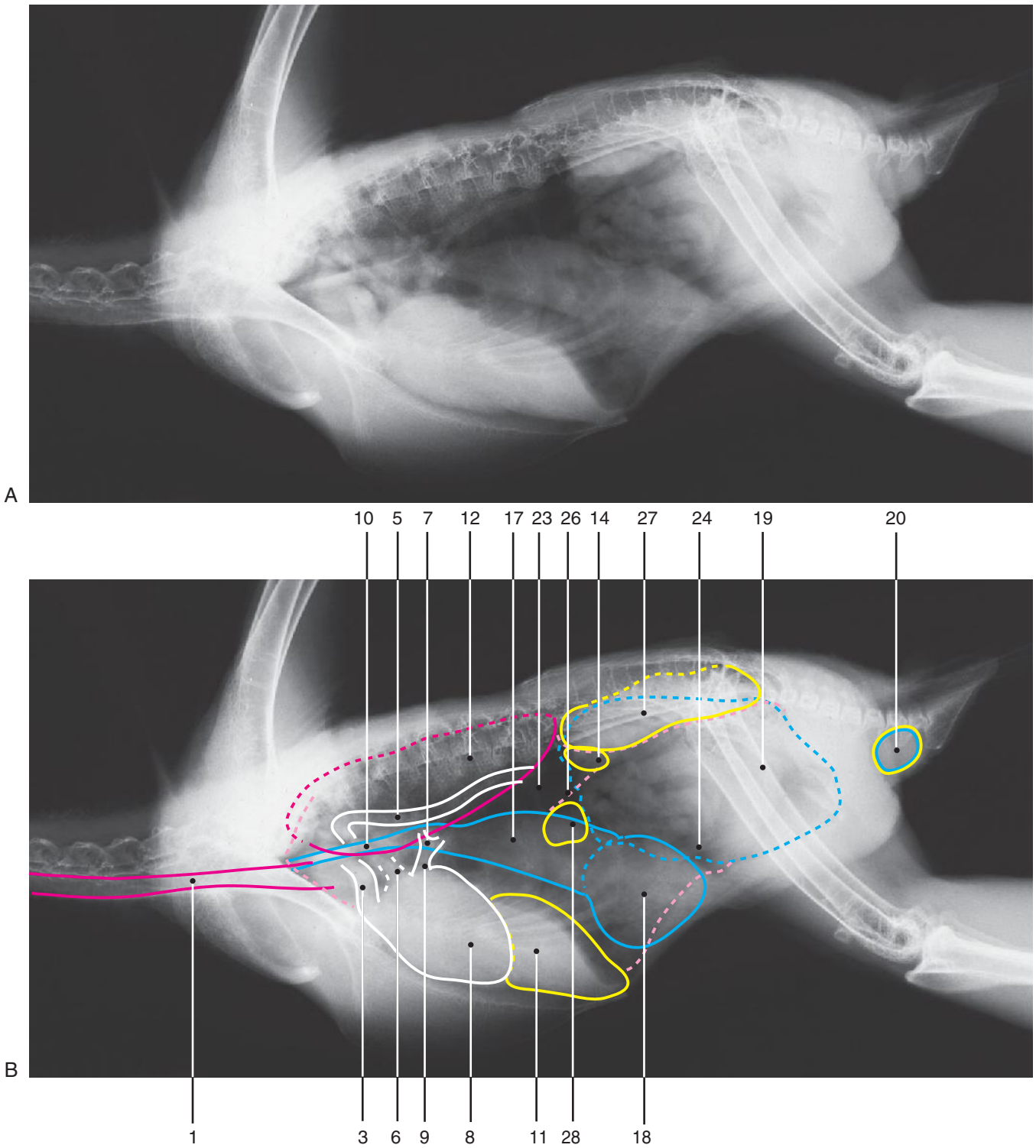

Figure 17-1, A-B
Type of Bird: Red Tailed Hawk
Type of Study: Viscera of the coelom
Projection: Laterolateral (right lateral recumbency)
Weight of Bird: 1 kg
Gender: Unknown
Reproductive Status: Intact
Age: Young adult

1. Trachea
2. (Crop)
3. Brachiocephalic artery and aorta
4. (Brachiocephalic artery)
5. Aorta
6. Pulmonary artery
7. Pulmonary vein
8. Heart
9. Left atrium
10. Esophagus
11. Liver
12. Lung
13. (Syrinx)
14. Gonad
15. (Ovary)
16. (Testes)
17. Proventriculus
18. Ventriculus
19. Intestines
20. Cloaca
21. (Cervical air sac)
22. (Clavicular air sac)
23. Thoracic air sac
24. Abdominal air sac
25. (Apex of heart)
26. Interface between caudal thoracic and abdominal air sacs
27. Kidneys
28. Spleen

NOTE: Structures in parentheses are not labeled.

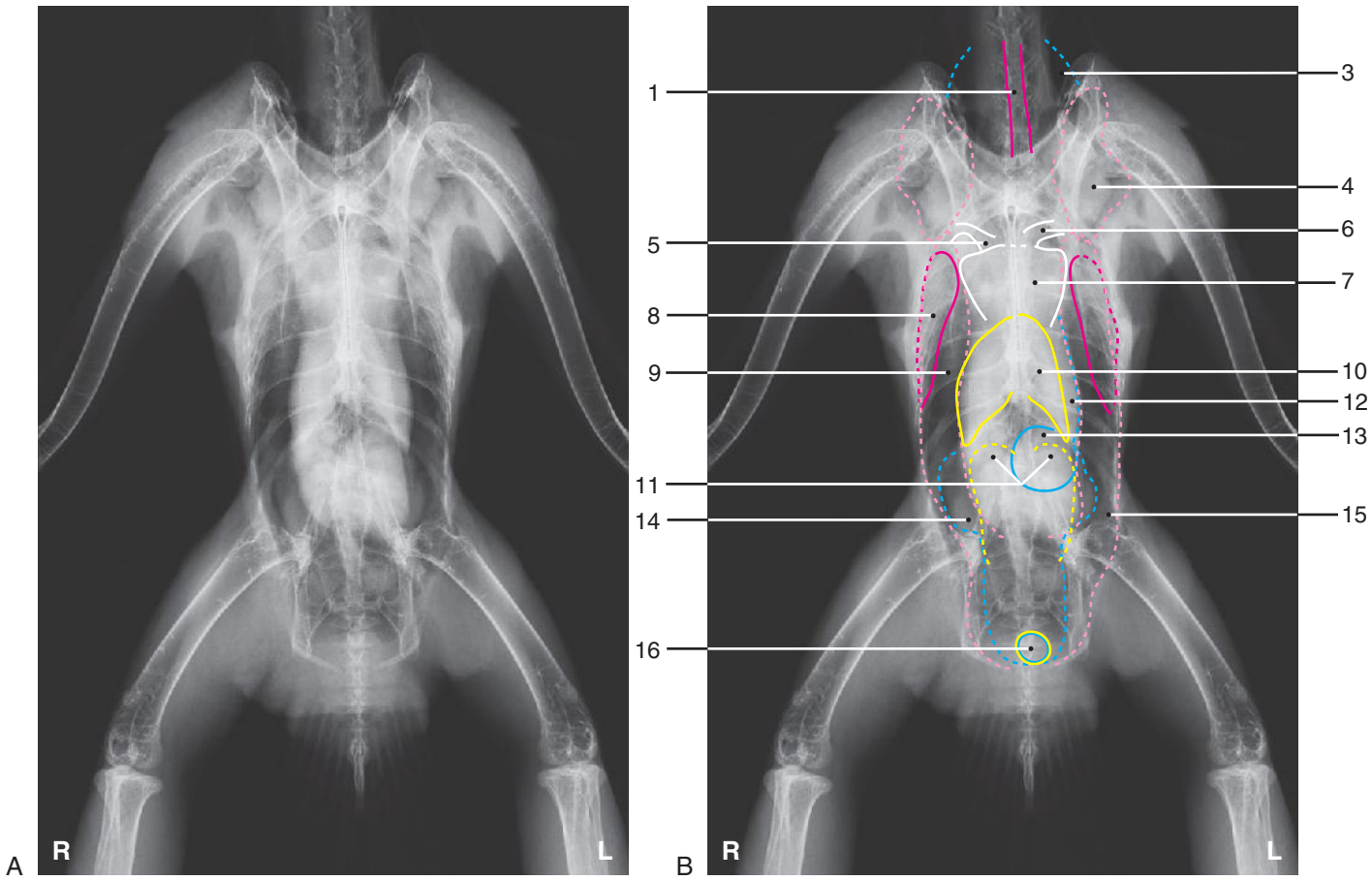

Figure 17-2, A-B
Type of Bird: Red Tailed Hawk
Type of Study: Viscera of the coelom
Projection: Ventrodorsal
Weight of Bird: 1 kg
Gender: Unknown
Reproductive Status: Intact
Age: Young adult

1. Trachea
2. (Cervical air sac)
3. Crop
4. Clavicular air sac
5. Brachiocephalic artery and aorta
6. Heart base vessel
7. Heart
8. Lung
9. Thoracic air sac
10. Liver
11. Kidneys
12. Proventriculus
13. Ventriculus
14. Intestines
15. Abdominal air sac
16. Cloaca

NOTE: Structures in parentheses are not labeled.

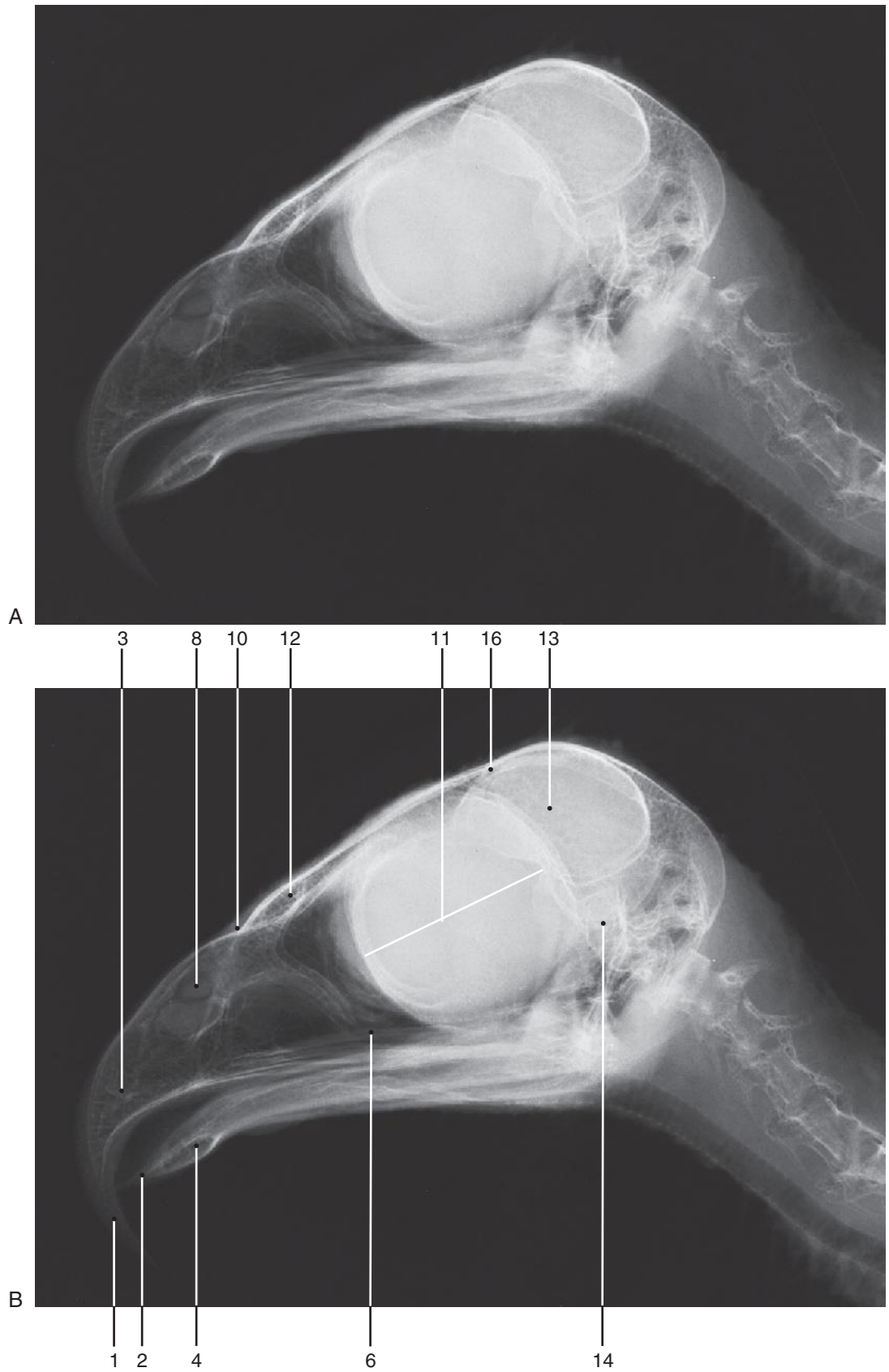

Figure 17-3, A-B
Type of Bird: Red Tailed Hawk
Type of Study: Head
Projection: Laterolateral (right lateral recumbency)
Weight of Bird: 1.2 kg
Gender: Unknown
Reproductive Status: Intact
Age: Young adult

1. Keratinized maxillary beak
2. Keratinized mandibular beak
3. Premaxillary bone
4. Mandible
5. (Hyoid bones)
6. Palatine bone
7. (Pterygoid bone)
8. External nares
9. (Jugal [zygomatic] bone)
10. Craniofacial flexion zone
11. Orbit
12. Frontal bone
13. Cranium
14. Temporal bone
15. (Quadrate bone)
16. Parietal bone

NOTE: Structures in parentheses are not labeled.

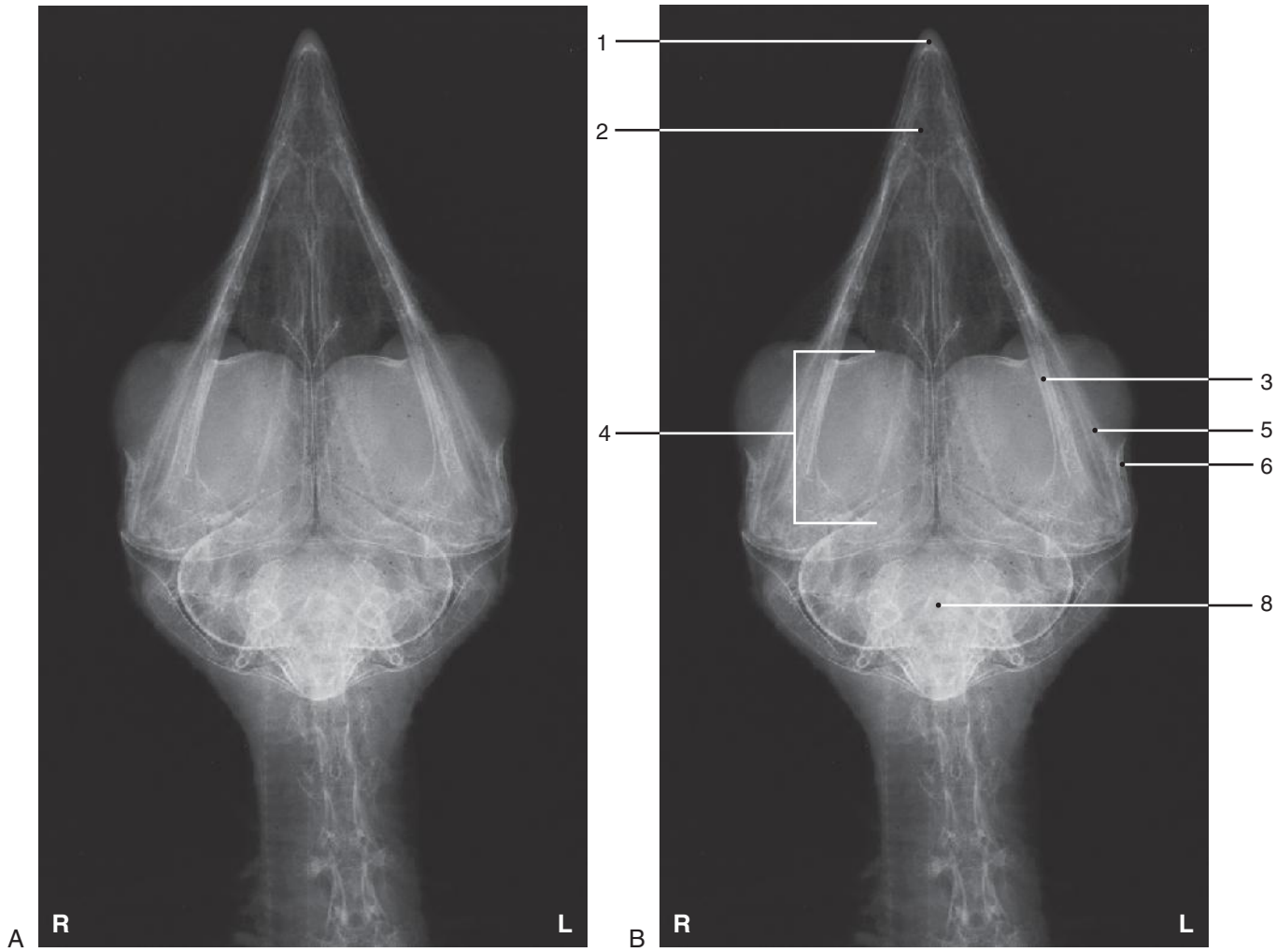

Figure 17-4, A-B
Type of Bird: Red Tailed Hawk
Type of Study: Head
Projection: Ventrodorsal
Weight of Bird: 1.2 kg
Gender: Unknown
Reproductive Status: Intact
Age: Young adult

1. Keratinized maxillary beak
2. Premaxillary bone
3. Mandible
4. Orbit
5. Jugal [zygomatic] bone
6. Scleral ossicles
7. (Quadrate bone)
8. Cranium

NOTE: Structures in parentheses are not labeled.

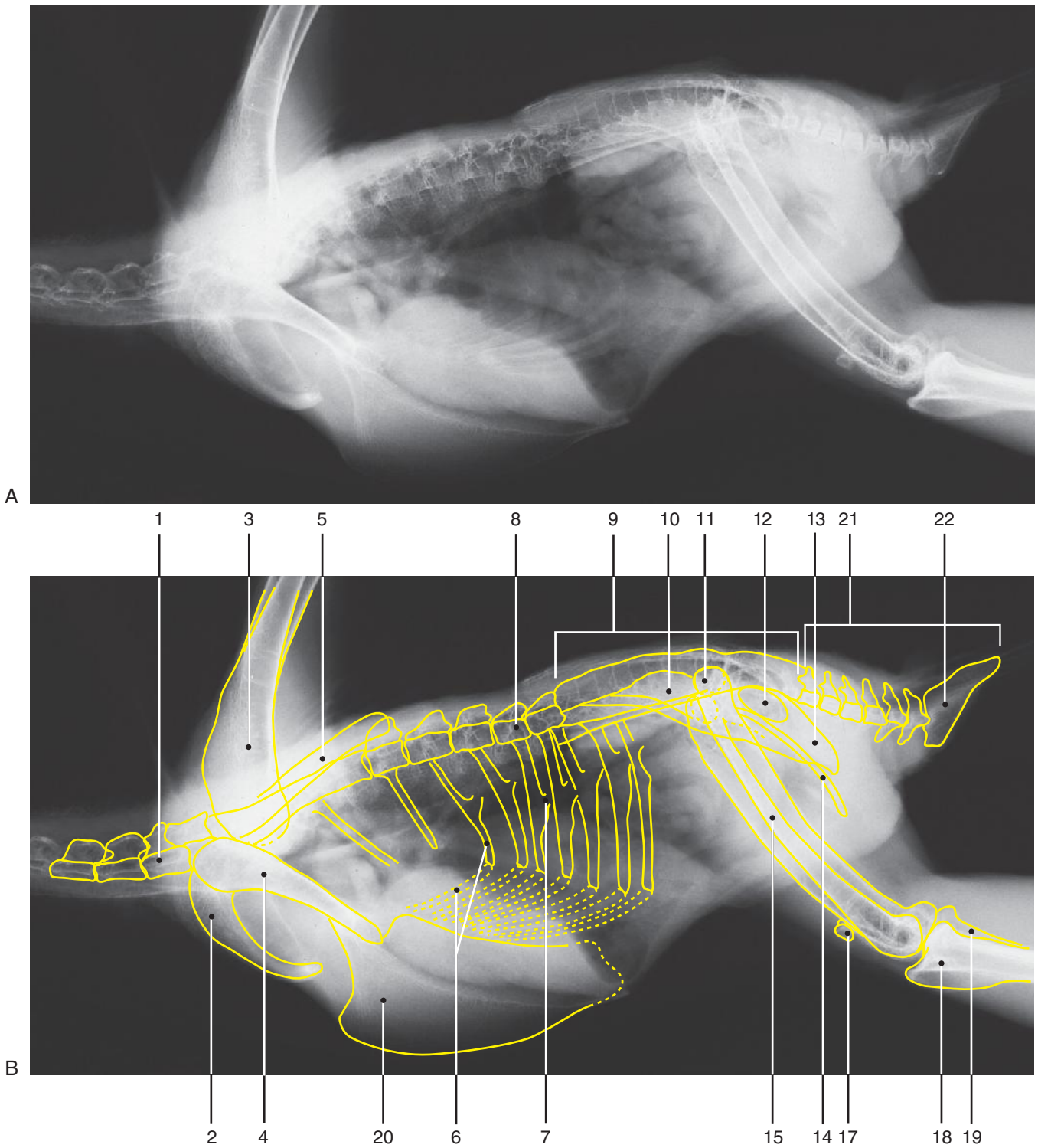

Figure 17-5, A-B
Type of Bird: Red Tailed Hawk
Type of Study: Whole body skeleton
Projection: Laterolateral (right lateral recumbency)
Weight of Bird: 1 kg
Gender: Unknown
Reproductive Status: Intact
Age: Young adult

1. Cervical vertebra
2. Clavicle
3. Humerus
4. Coracoid
5. Scapula
6. Rib
7. Uncinate process of rib
8. Thoracic vertebra
9. Synsacrum
10. Ilium
11. Head of femur
12. Ilioischiadiac foramen
13. Ischium
14. Pubis
15. Femur
16. (Obturator foramen)
17. Patella
18. Tibiotarsal bone
19. Fibula
20. Sternum
21. Caudal vertebrae
22. Pygostyle

NOTE: Structures in parentheses are not labeled.

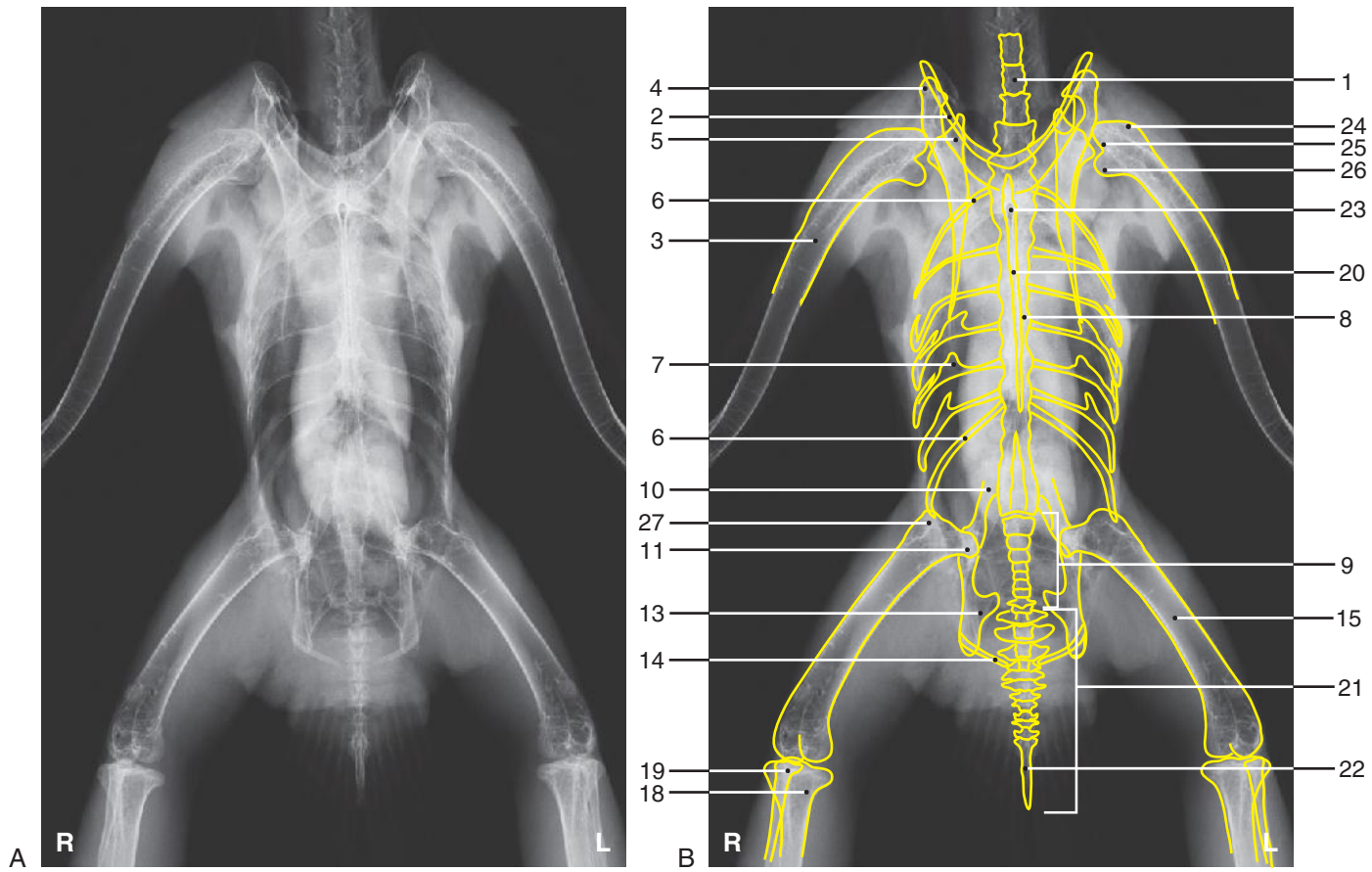

Figure 17-6, A-B
Type of Bird: Red Tailed Hawk
Type of Study: Whole body skeleton
Projection: Ventrodorsal
Weight of Bird: 1 kg
Gender: Unknown
Reproductive Status: Intact
Age: Young adult

1. Cervical vertebra
2. Clavicle
3. Humerus
4. Coracoid
5. Scapula
6. Rib
7. Uncinate process of rib
8. Thoracic vertebra
9. Synsacrum
10. Ilium
11. Head of femur
12. (Ilioischiadiac foramen)
13. Ischium
14. Pubis
15. Femur
16. (Obturator foramen)
17. (Patella)
18. Tibiotarsal bone
19. Fibula
20. Sternum
21. Caudal vertebrae
22. Pygostyle
23. Apex carinae
24. Dorsal tubercle of humerus
25. Head of humerus
26. Ventral tubercle of humerus
27. Trochanter of femur

NOTE: Structures in parentheses are not labeled.

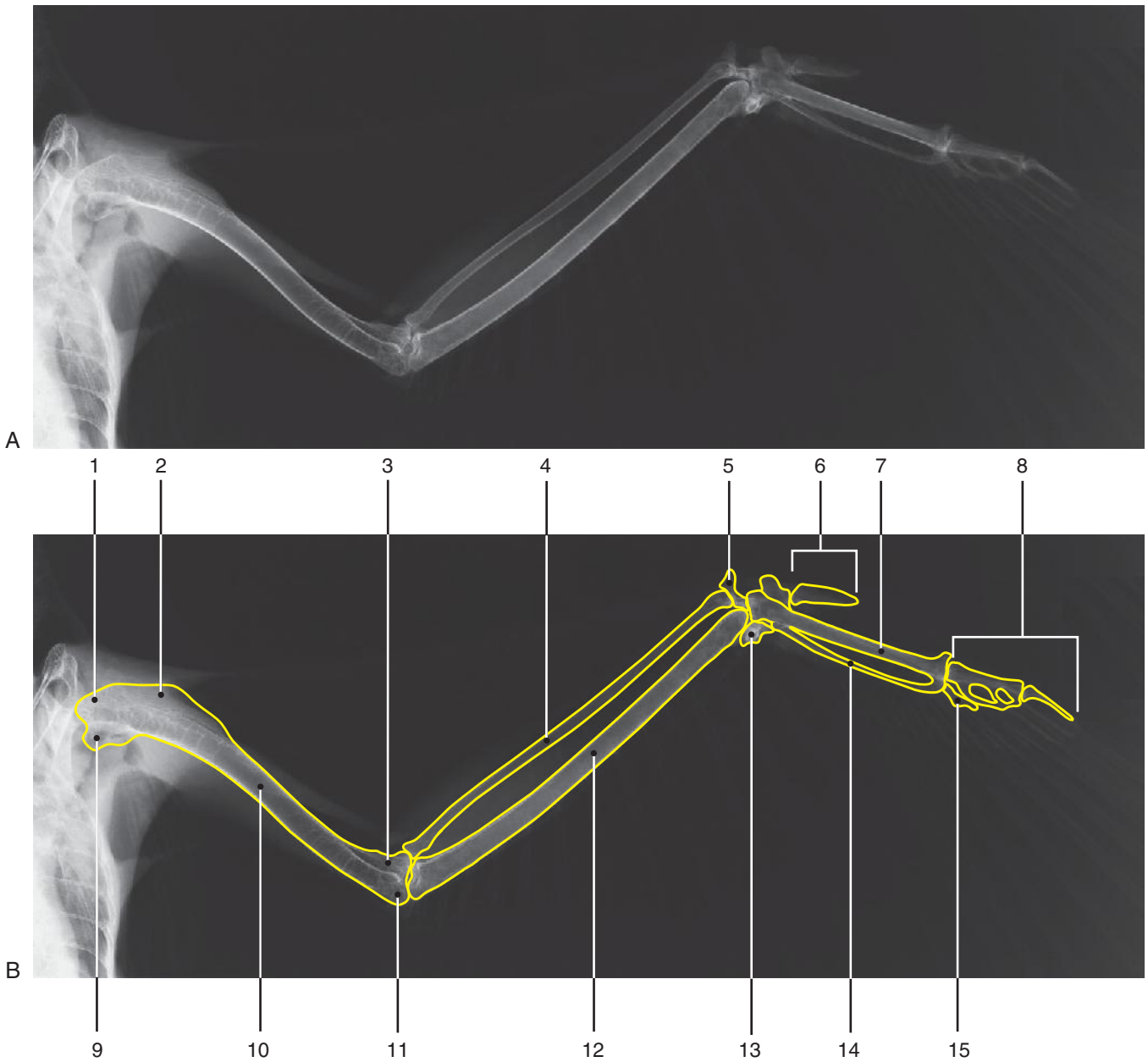

Figure 17-7, A-B
Type of Bird: Red Tailed Hawk
Type of Study: Wing
Projection: Mediolateral
Weight of Bird: 1 kg
Gender: Unknown
Reproductive Status: Intact
Age: Young adult

1. Head of humerus
2. Dorsal tubercle of humerus
3. Dorsal condyle of humerus
4. Radius
5. Radial carpal bone
6. Alula
7. Major metacarpal bone
8. Phalanges of major digit
9. Ventral tubercle of humerus
10. Humerus
11. Ventral condyle of humerus
12. Ulna
13. Ulnar carpal bone
14. Minor metacarpal bone
15. Phalanges of minor digit

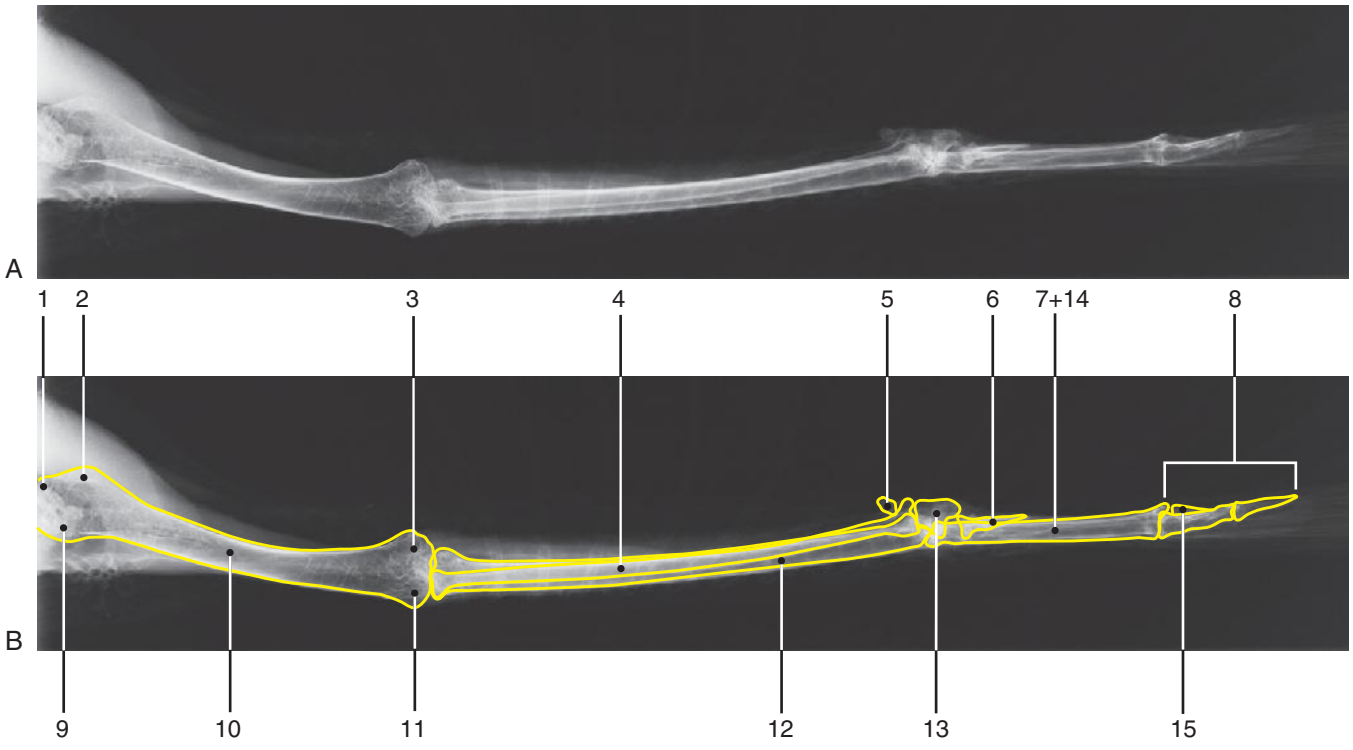

Figure 17-8, A-B
Type of Bird: Red Tailed Hawk
Type of Study: Wing
Projection: Caudocranial
Weight of Bird: 1 kg
Gender: Unknown
Reproductive Status: Intact
Age: Young adult

1. Head of humerus
2. Ventral tubercle of humerus
3. Ventral condyle of humerus
4. Radius
5. Radial carpal bone
6. Alula
7. Minor metacarpal bone
8. Phalanges of major digit
9. Dorsal tubercle of humerus
10. Humerus
11. Dorsal condyle of humerus
12. Ulna
13. Ulnar carpal bone
14. Major metacarpal bone
15. Phalanges of minor digit

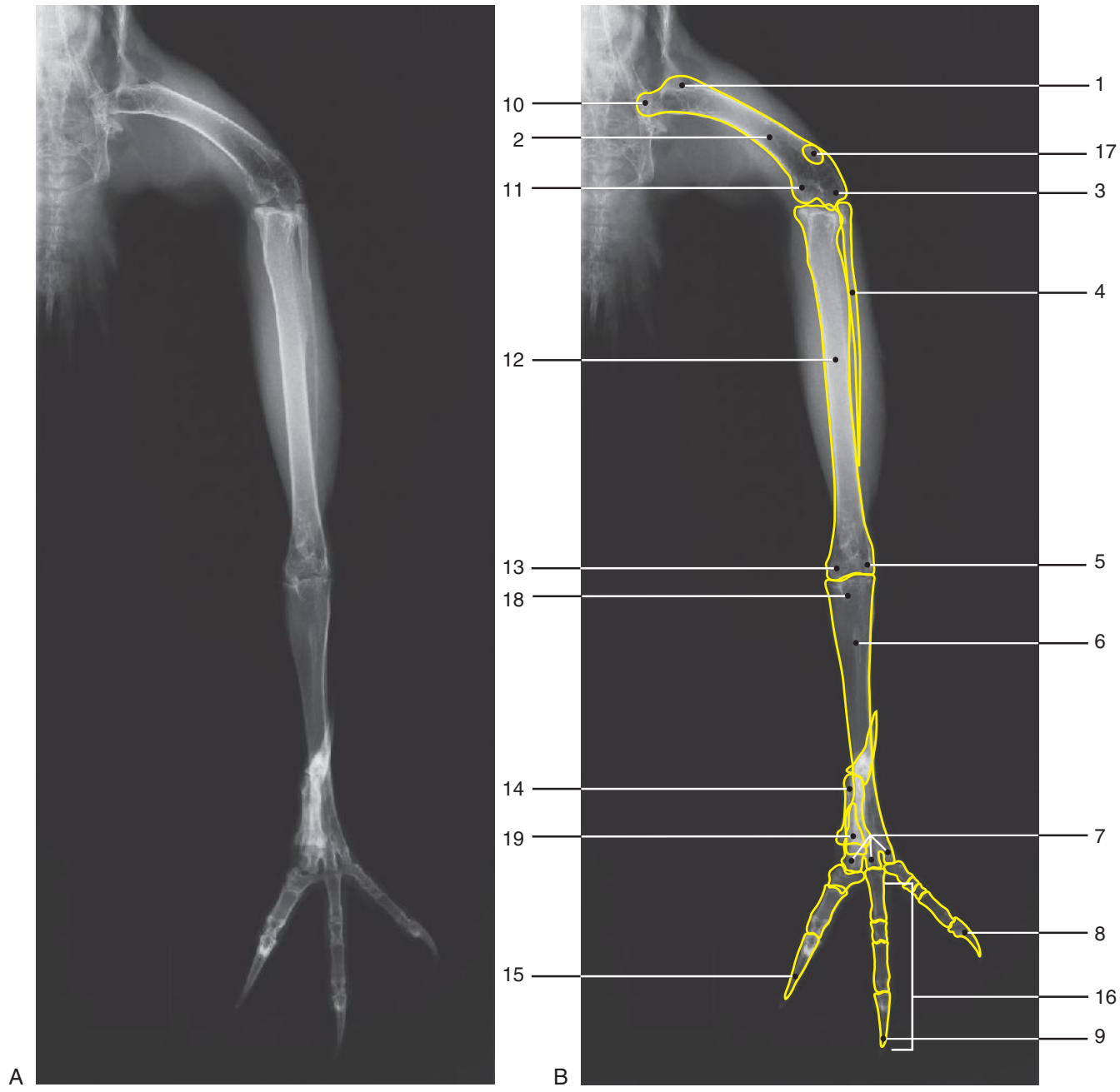

Figure 17-9, A-B
Type of Bird: Red Tailed Hawk
Type of Study: Pelvic limb
Projection: Craniocaudal
Weight of Bird: 1.2 kg
Gender: Unknown
Reproductive Status: Intact
Age: Young adult

1. Trochanter of femur
2. Femur
3. Lateral condyle of femur
4. Fibula
5. Lateral condyle of tibiotarsal bone
6. Tarsometatarsal bone
7. Trochlea of tarsometatarsal bone
8. Digit IV
9. Digit III
10. Head of femur
11. Medial condyle of femur
12. Tibiotarsal bone
13. Medial condyle of tibiotarsal bone
14. Digit I
15. Digit II
16. Phalanges
17. Patella
18. Hypotarsal crest of tarsometatarsal bone
19. Metatarsal I

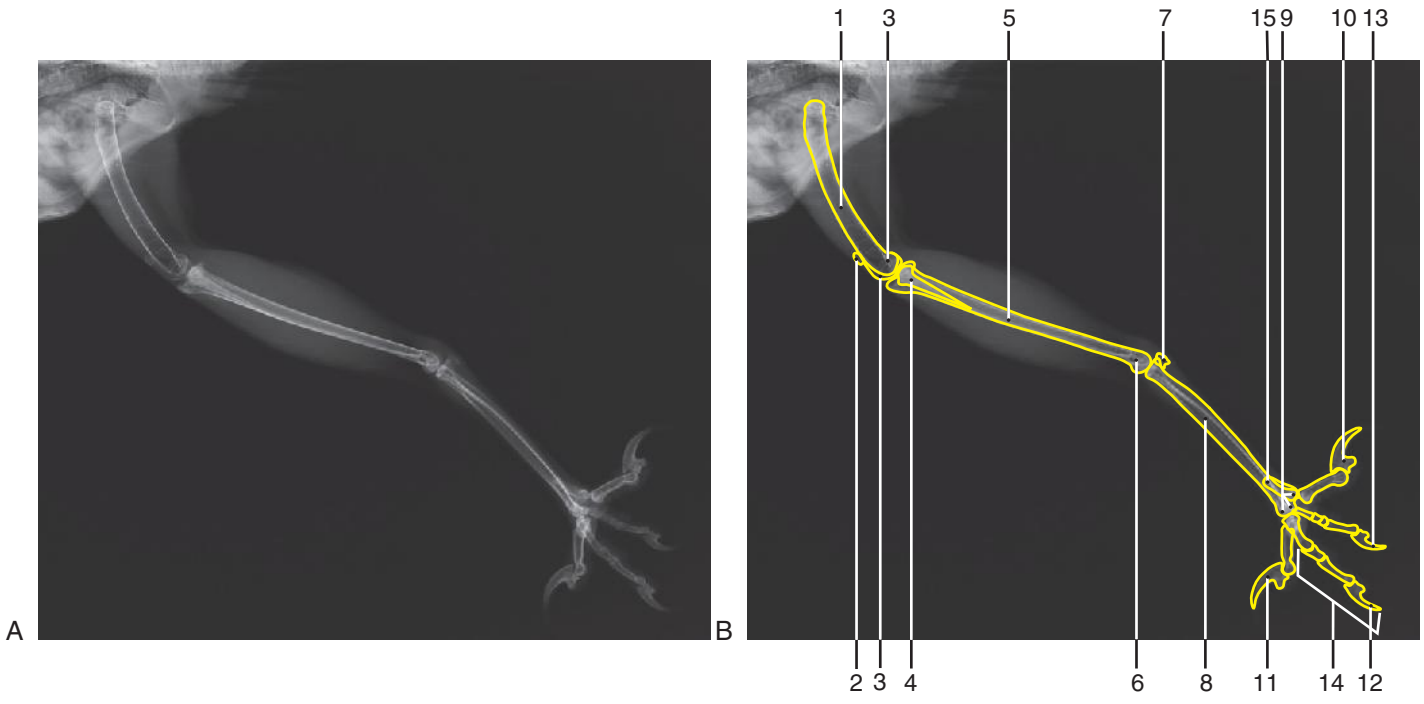

Figure 17-10, A-B
Type of Bird: Red Tailed Hawk
Type of Study: Pelvic limb
Projection: Mediolateral
Weight of Bird: 1.2 kg
Gender: Unknown
Reproductive Status: Intact
Age: Young adult

1. Femur
2. Patella
3. Condyles of femur
4. Fibula
5. Tibiotarsal bone
6. Condyles of tibiotarsal bone
7. Hypotarsal crest of tarsometatarsal bone
8. Tarsometatarsal bone
9. Trochlea of tarsometatarsal bone
10. Digit I
11. Digit II
12. Digit III
13. Digit IV
14. Phalanges
15. Metatarsal I

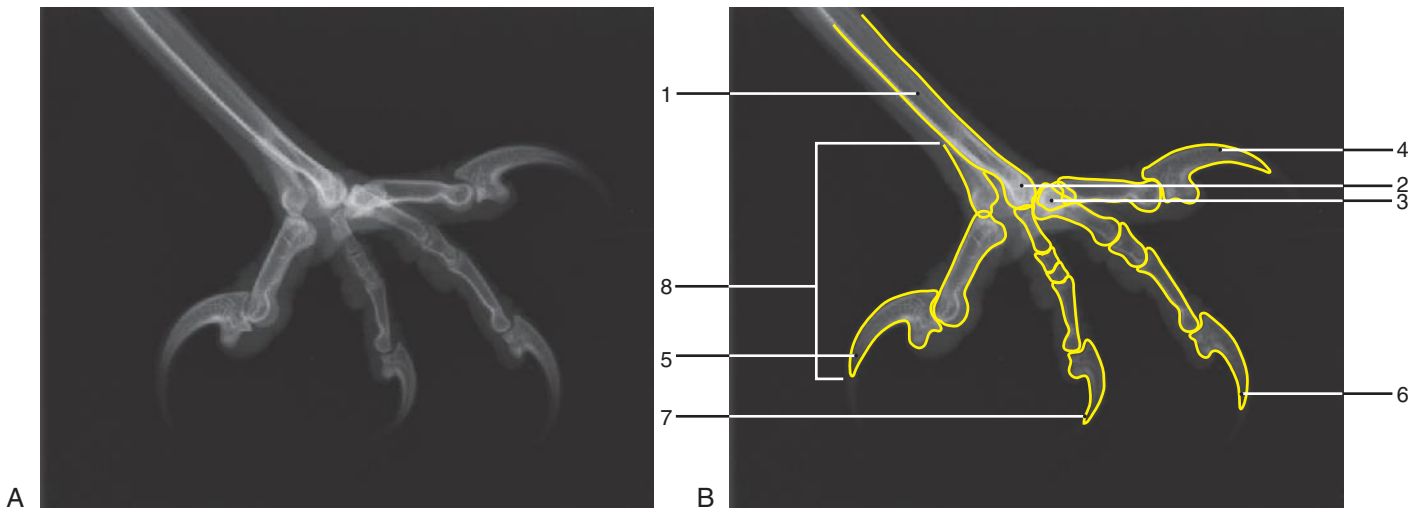

Figure 17-11, A-B
Type of Bird: Red Tailed Hawk
Type of Study: Distal pelvic limb
Projection: Mediolateral
Weight of Bird: 1.2 kg
Gender: Unknown
Reproductive Status: Intact
Age: Young adult

1. Tarsometatarsal bone
2. Trochlea of tarsometatarsal bone
3. Metatarsal bone I
4. Digit I
5. Digit II
6. Digit III
7. Digit IV
8. Phalanges
9. (Hypotarsal crest of tarsometatarsal bone)
10. (Condyles of tibiotarsal bone)

NOTE: Structures in parentheses are not labeled.

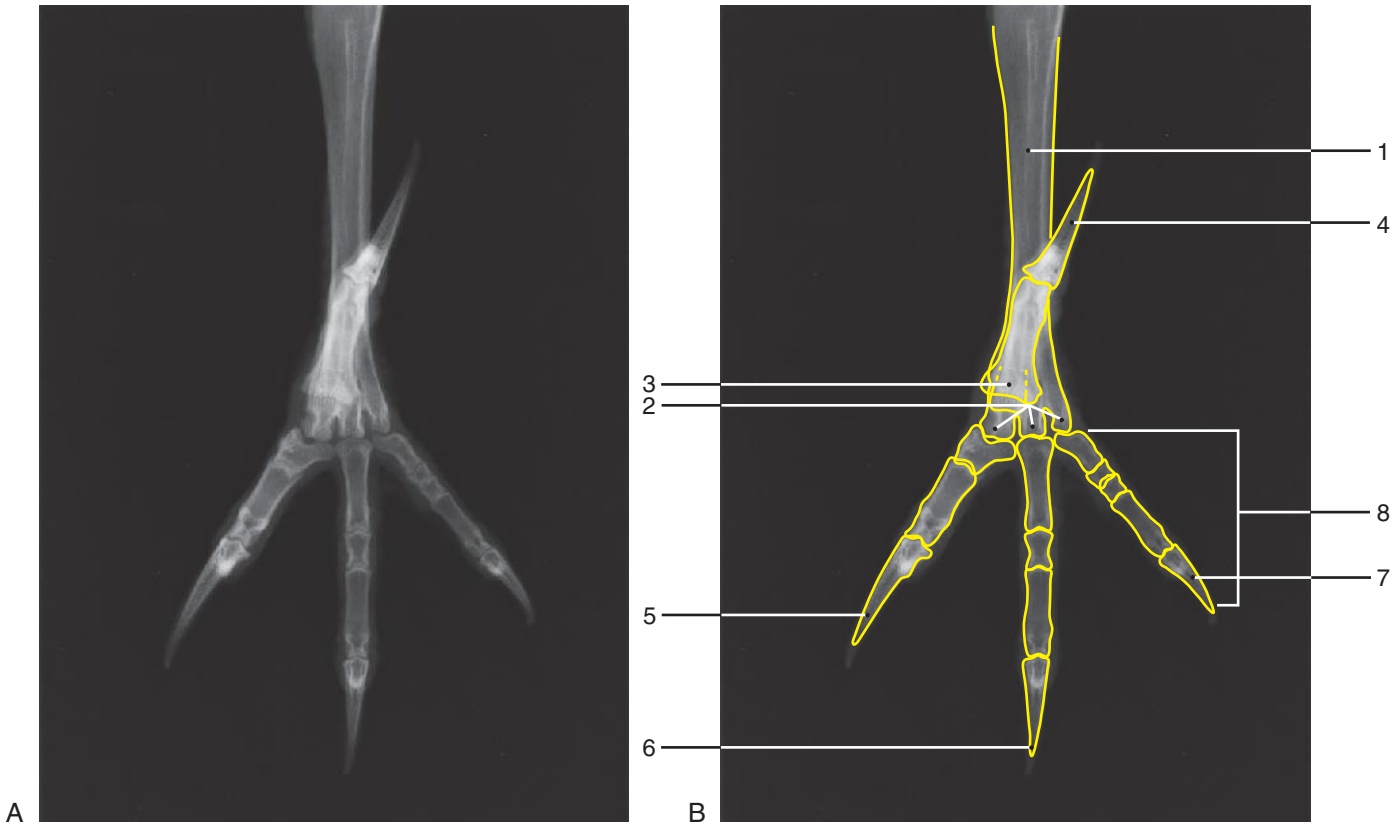

Figure 17-12, A-B
Type of Bird: Red Tailed Hawk
Type of Study: Distal pelvic limb
Projection: Dorsoplantar
Weight of Bird: 1.2 kg
Gender: Unknown
Reproductive Status: Intact
Age: Young adult

1. Tarsometatarsal bone
2. Trochlea of tarsometatarsal bone
3. Metatarsal bone I
4. Digit I
5. Digit II
6. Digit III
7. Digit IV
8. Phalanges
9. (Hypotarsal crest of tarsometatarsal bone)
10. (Condyles of tibiotarsal bone)

NOTE: Structures in parentheses are not labeled.

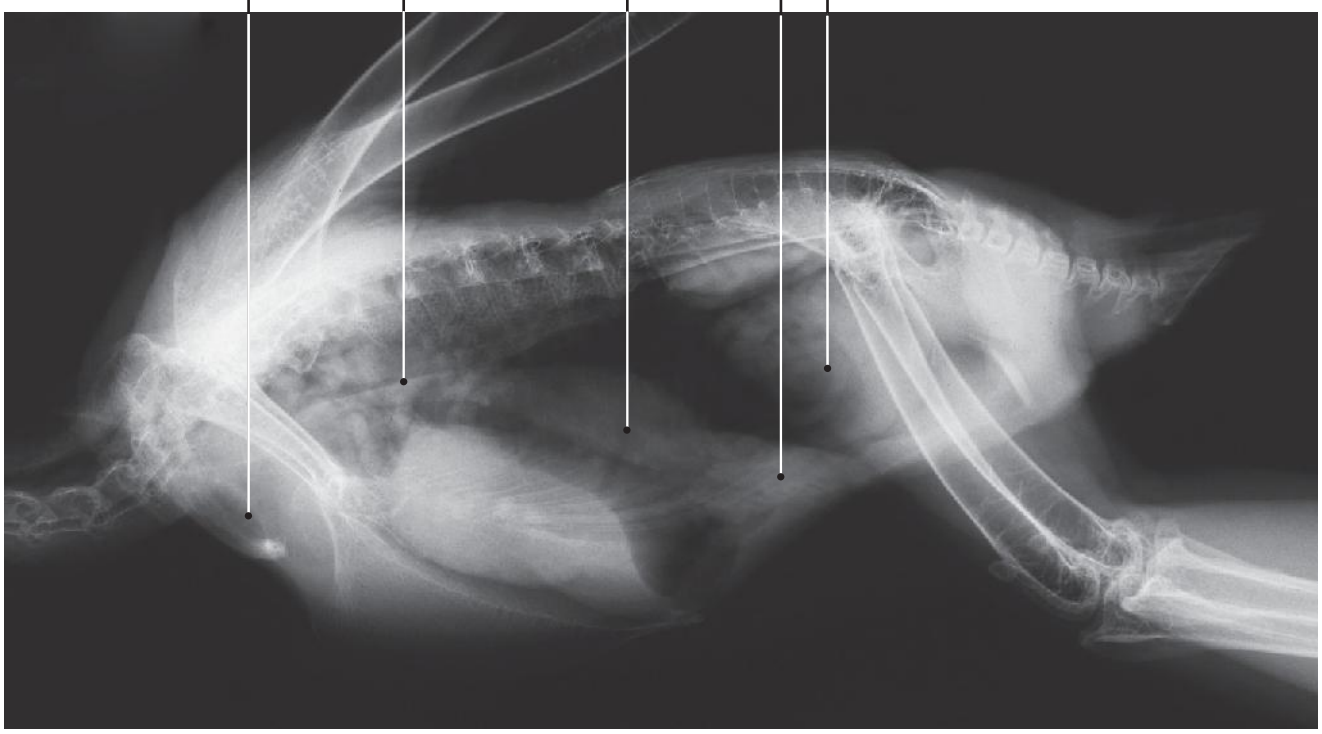

A

Figure 17-13, A
Type of Bird: Red Tailed Hawk
Type of Study: Gastrointestinal positive contrast study
Contrast Medium: Barium sulfate suspension (Novopaque® 30% w/v; Lafayette Pharmaceutical, Inc., Lafayette, IN) 20 ml administered via gavage tube
Projection: Laterolateral (right lateral recumbency)
Weight of Bird: 1.2 kg
Gender: Unknown
Reproductive Status: Intact
Age: Young adult

Image	Time (hr)
A	Scout

1. Crop
2. Esophagus
3. Proventriculus
4. Ventriculus
5. Intestines
6. Duodenum
7. (Large intestine)
8. (Cloaca)
9. (Proventricular-ventricular isthmus)

NOTE: Structures in parentheses are not labeled.

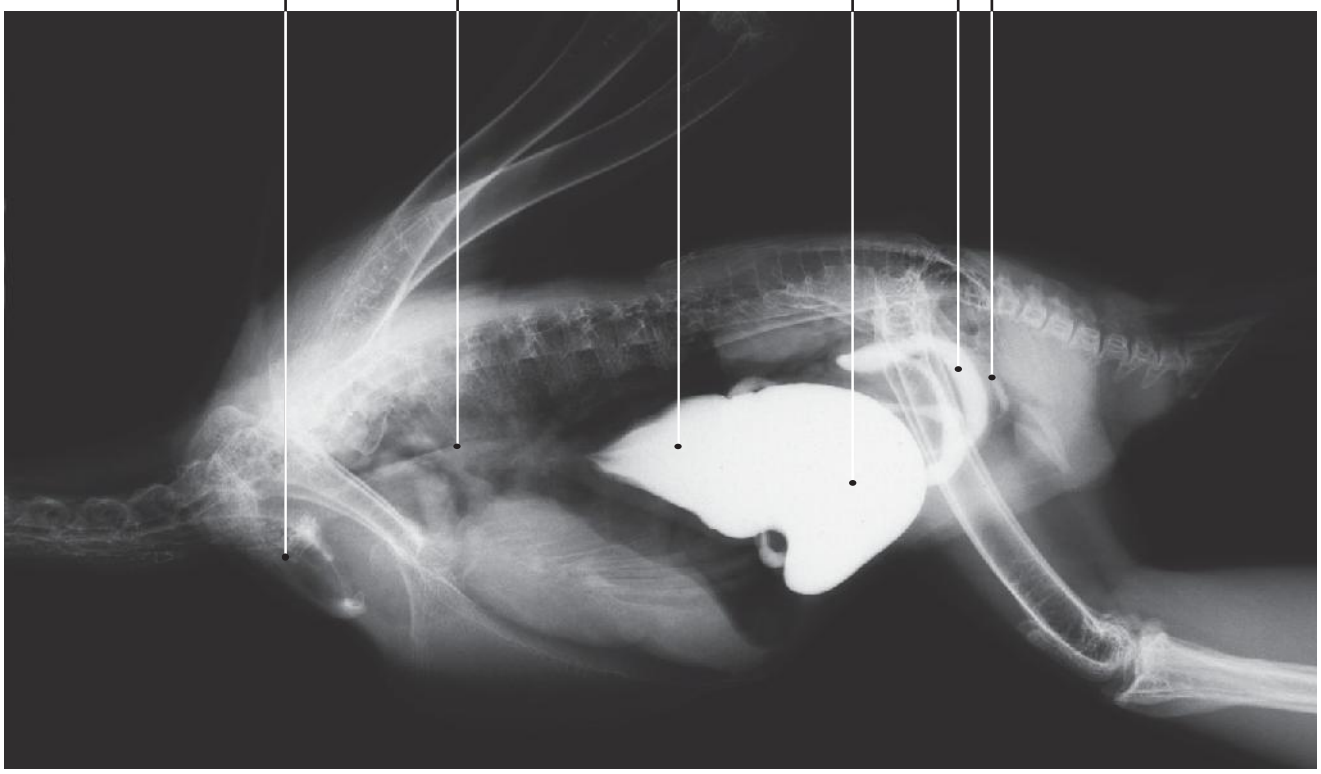

B

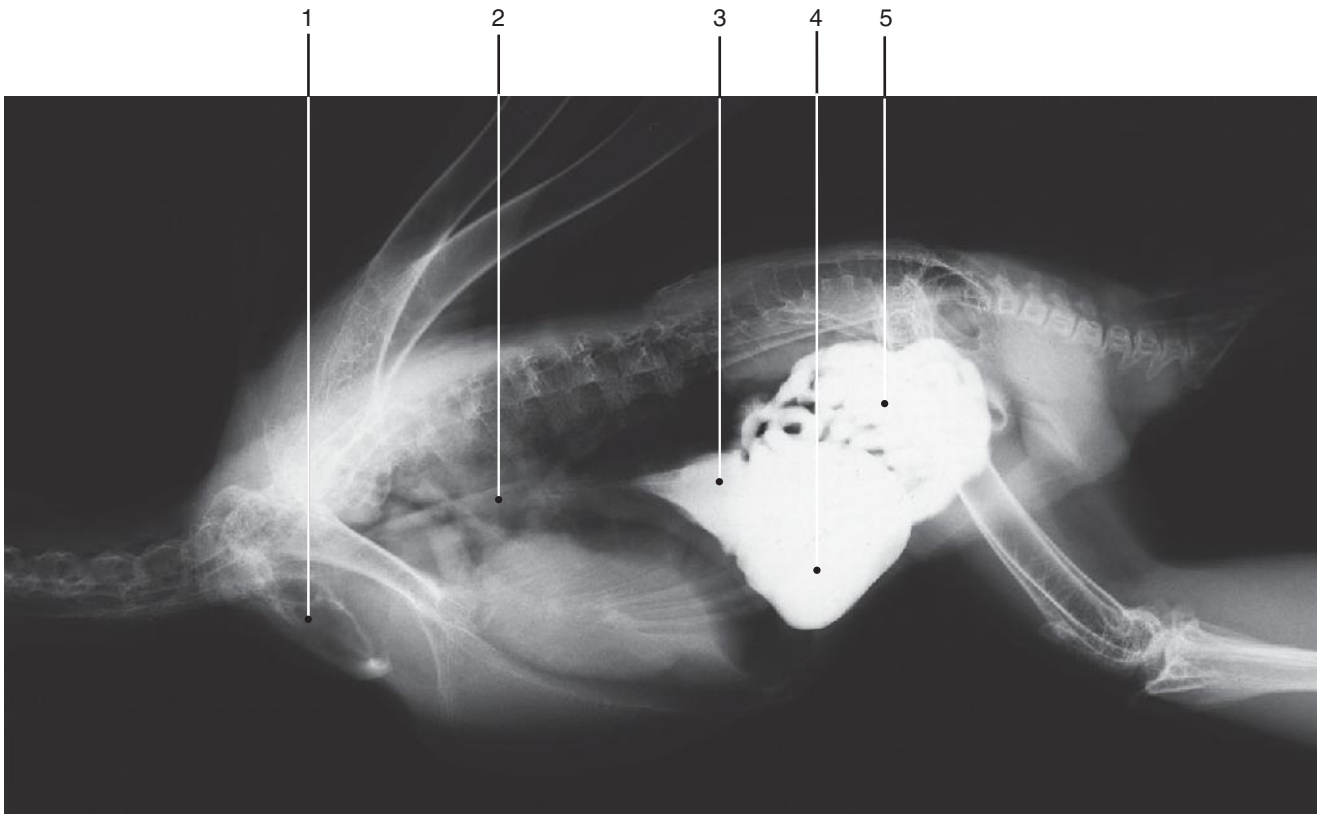

C

Figure 17-13, B-C
Type of Bird: Red Tailed Hawk
Type of Study: Gastrointestinal positive contrast study
Contrast Medium: Barium sulfate suspension (Novopaque® 30% w/v; Lafayette Pharmaceutical, Inc., Lafayette, IN) 20 ml administered via gavage tube
Projection: Laterolateral (right lateral recumbency)
Weight of Animal: 1.2 kg
Gender: Unknown
Reproductive Status: Intact
Age: Young adult

Image	Time (hr)
B	0.25
C	1.0

1. Crop
2. Esophagus
3. Proventriculus
4. Ventriculus
5. Intestines
6. (Duodenum)
7. Large intestine
8. Cloaca
9. (Proventricular-ventricular isthmus)

NOTE: Structures in parentheses are not labeled.

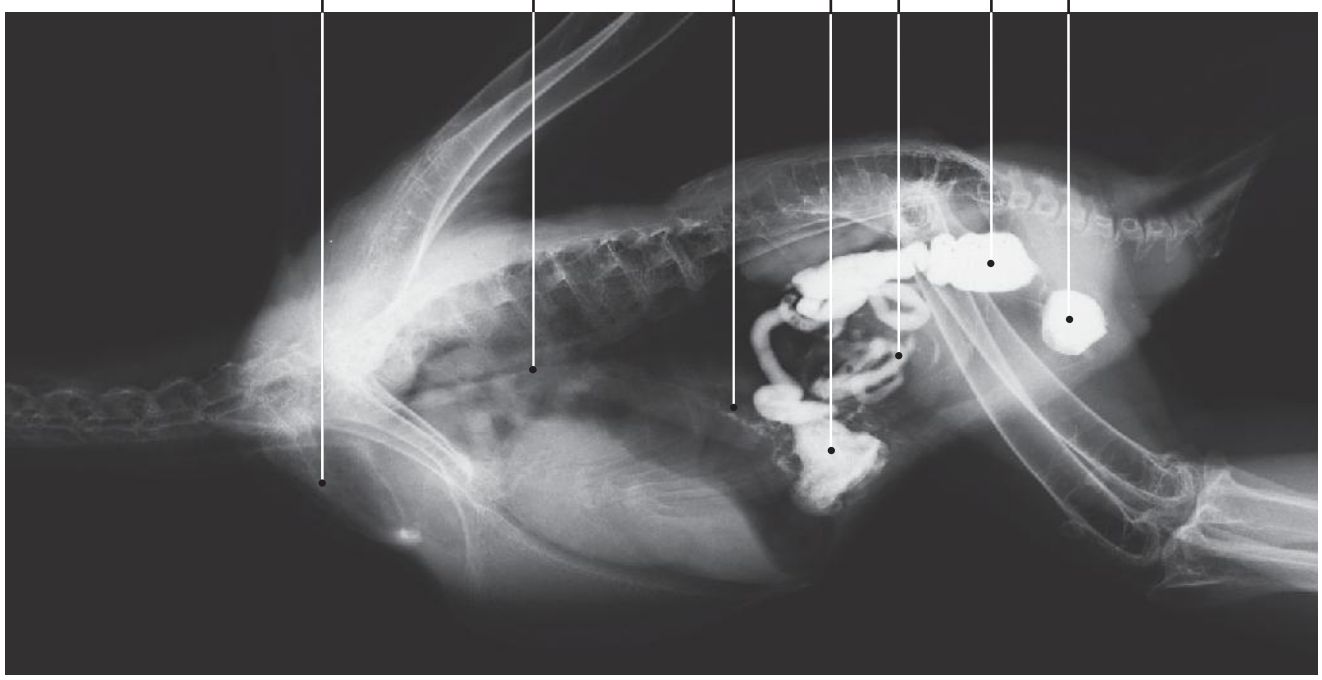

D

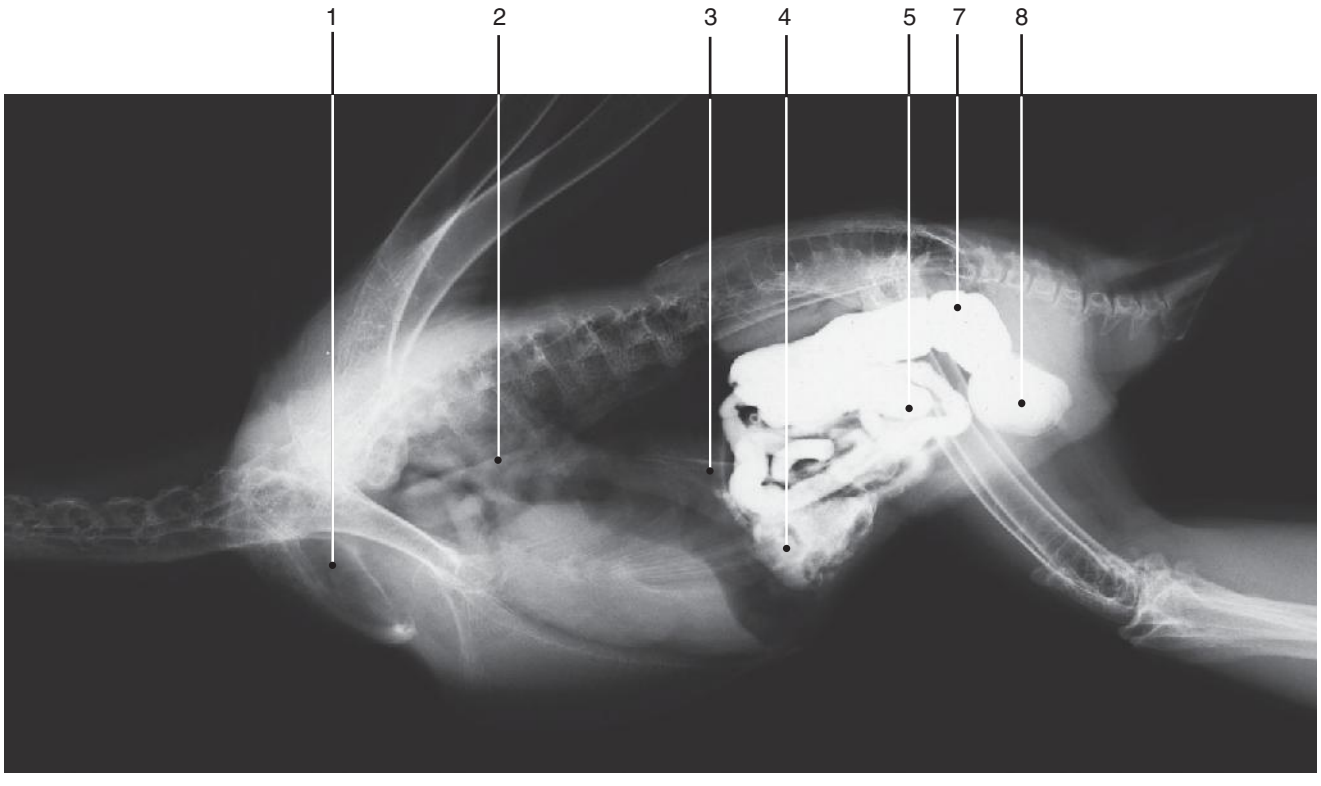

E

Figure 17-13, D-E
Type of Bird: Red Tailed Hawk
Type of Study: Gastrointestinal positive contrast study
Contrast Medium: Barium sulfate suspension (Novopaque® 30% w/v; Lafayette Pharmaceutical, Inc., Lafayette, IN) 20 ml administered via gavage tube
Projection: Laterolateral (right lateral recumbency)
Weight of Bird: 1.2 kg
Gender: Unknown
Reproductive Status: Intact
Age: Young adult

Image	Time (hr)
D	3.0
E	5.0

1. Crop
2. Esophagus
3. Proventriculus
4. Ventriculus
5. Intestines
6. (Duodenum)
7. Large intestine
8. Cloaca
9. (Proventricular-ventricular isthmus)

NOTE: Structures in parentheses are not labeled.

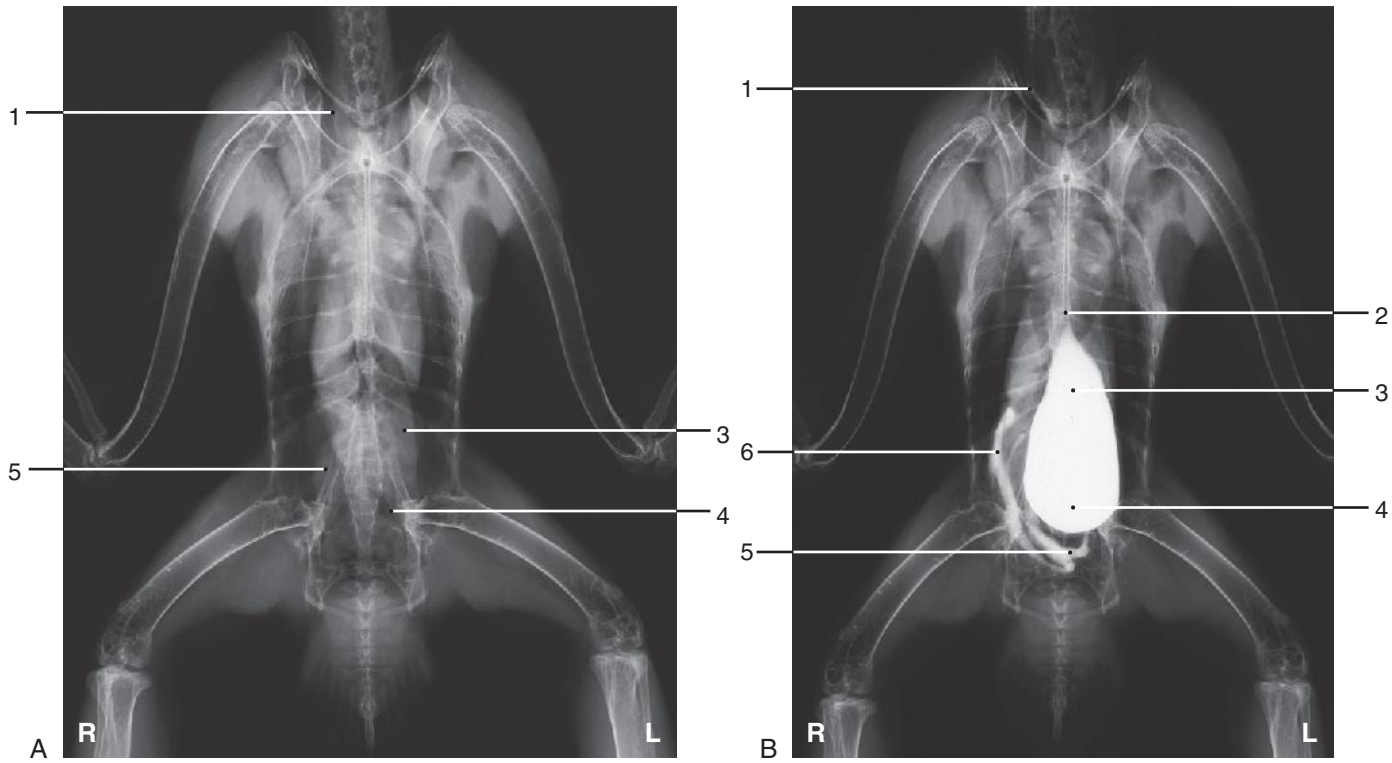

Figure 17-14, A-B
Type of Bird: Red Tailed Hawk
Type of Study: Gastrointestinal positive contrast study
Contrast Medium: Barium sulfate suspension (Novopaque® 30% w/v; Lafayette Pharmaceutical, Inc., Lafayette, IN) 20 ml administered via gavage tube
Projection: Ventrodorsal
Weight of Bird: 1.2 kg
Gender: Unknown
Reproductive Status: Intact
Age: Young adult

Image	Time (hr)
A	Scout
B	0.25

1. Crop
2. Esophagus
3. Proventriculus
4. Ventriculus
5. Intestines
6. Duodenum
7. (Large intestine)
8. (Cloaca)
9. (Proventricular-ventricular isthmus)

NOTE: Structures in parentheses are not labeled.

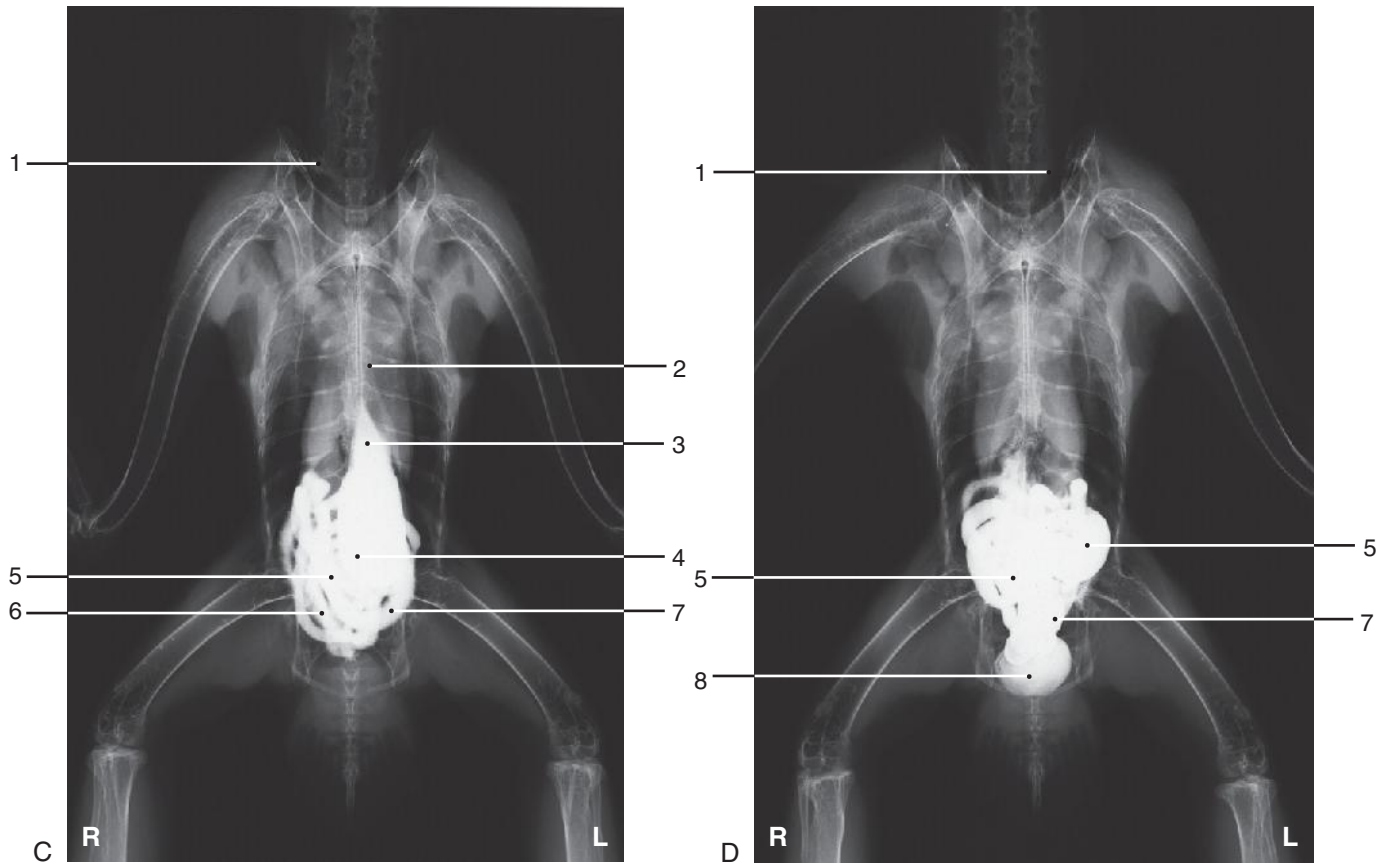

Figure 17-14, C-D
Type of Bird: Red Tailed Hawk
Type of Study: Gastrointestinal positive contrast study
Contrast Medium: Barium sulfate suspension (Novopaque® 30% w/v; Lafayette Pharmaceutical, Inc., Lafayette, IN) 20 ml administered via gavage tube
Projection: Ventrodorsal
Weight of Bird: 1.2 kg
Gender: Unknown
Reproductive Status: Intact
Age: Young adult

Image	Time (hr)
C	1.0
D	3.0

1. Crop
2. Esophagus
3. Proventriculus
4. Ventriculus
5. Intestines
6. Duodenum
7. Large intestine
8. Cloaca
9. (Proventricular-ventricular isthmus)

NOTE: Structures in parentheses are not labeled.

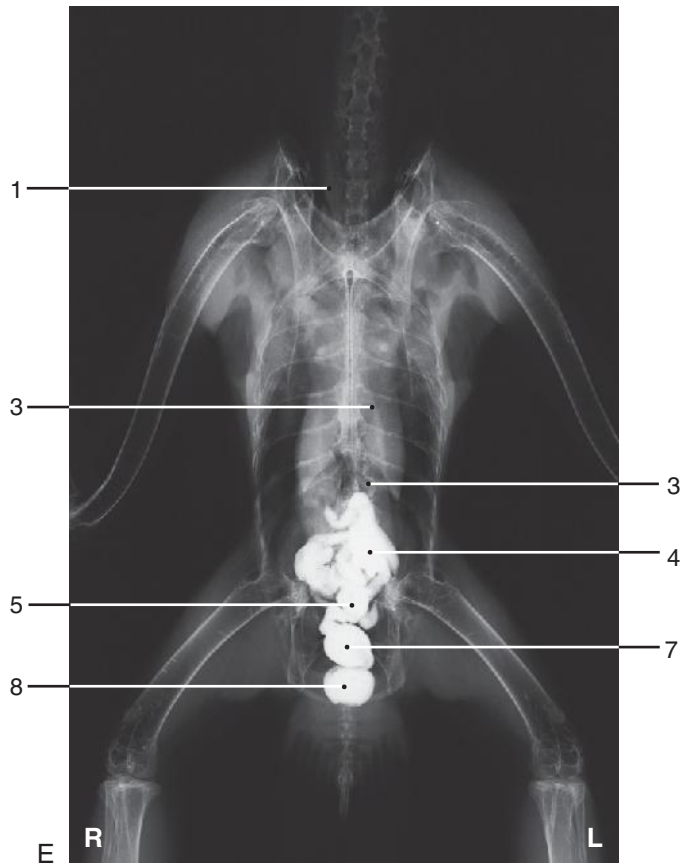

E

Figure 17-14, E
Type of Bird: Red Tailed Hawk
Type of Study: Gastrointestinal positive contrast study
Contrast Medium: Barium sulfate suspension (Novopaque® 30% w/v; Lafayette Pharmaceutical, Inc., Lafayette, IN) 20 ml administered via gavage tube
Projection: Ventrodorsal
Weight of Bird: 1.2 kg
Gender: Unknown
Reproductive Status: Intact
Age: Young adult

Image	Time (hr)
E	5.0

1. Crop
2. (Esophagus)
3. Proventriculus
4. Ventriculus
5. Intestines
6. (Duodenum)
7. Large intestine
8. Cloaca
9. (Proventricular-ventricular isthmus)

NOTE: Structures in parentheses are not labeled.

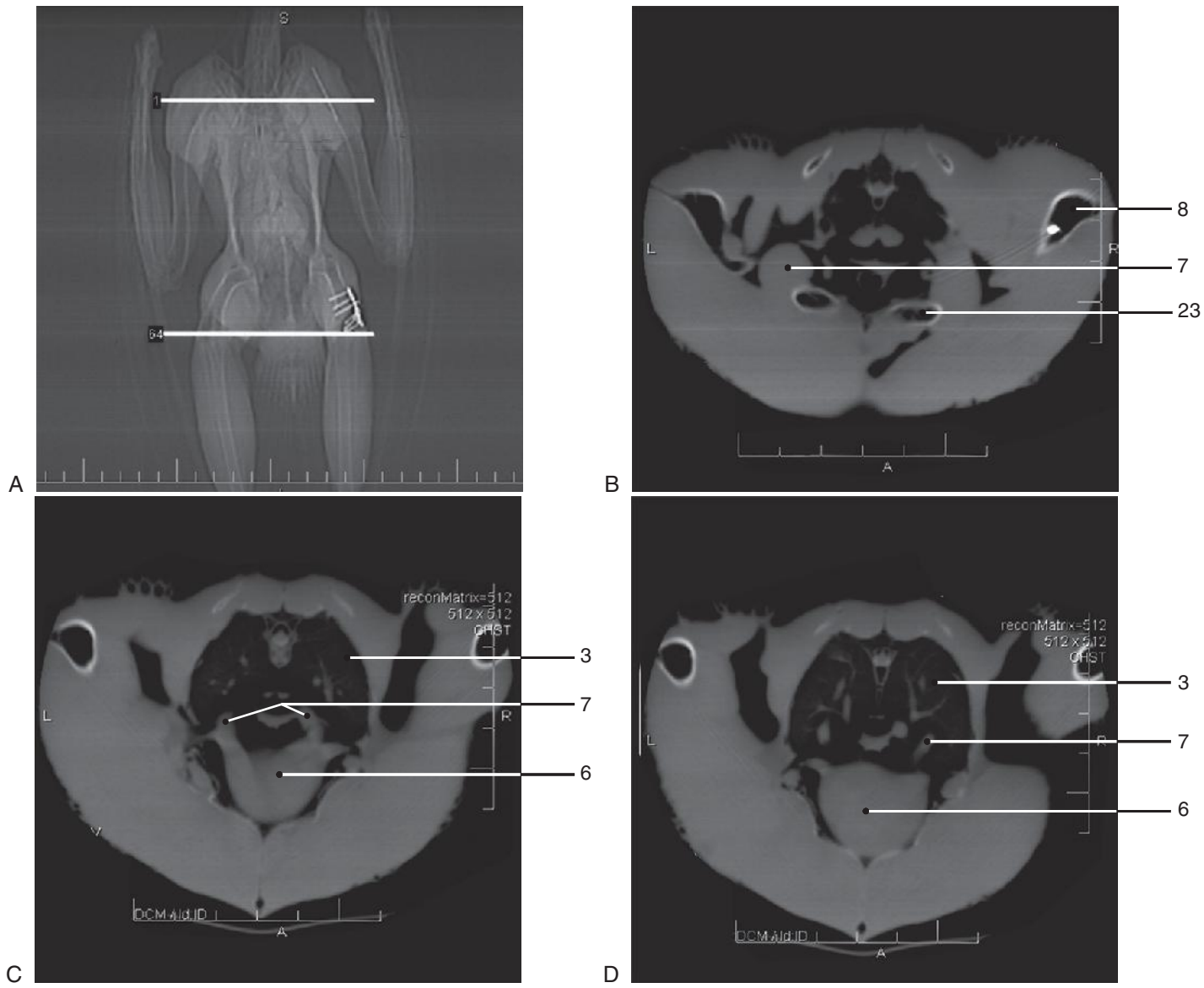

Figure 17-15, A-D
Type of Bird: Red Tailed Hawk
Type of Study: CT coelom
Contrast Medium: None
Imaging Plane: Transverse
Weight of Bird: 1.1 kg
Age: Adult

1. (Sternum)
2. (Thoracic air sac)
3. Lung
4. (Esophagus)
5. (Thoracic vertebra)
6. Heart
7. Blood vessels
8. Thoracic extremity (wing)
9. (Proventriculus)
10. (Ventriculus)
11. (Intestines)
12. (Pelvic extremity (leg))
13. (Abdominal air sac)
14. (Ilium)
15. (Liver)
16. (Kidney)
17. (Caudal vertebra)
18. (Rib)
19. (Aorta)
20. (Pubic bone)
21. (Cloaca)
22. (Clavicular air sac)
23. Scapula
24. (Syrinx)
25. (Ischium)
26. (Colon)
27. (Spinal cord)

NOTE: Structures in parentheses are not labeled.

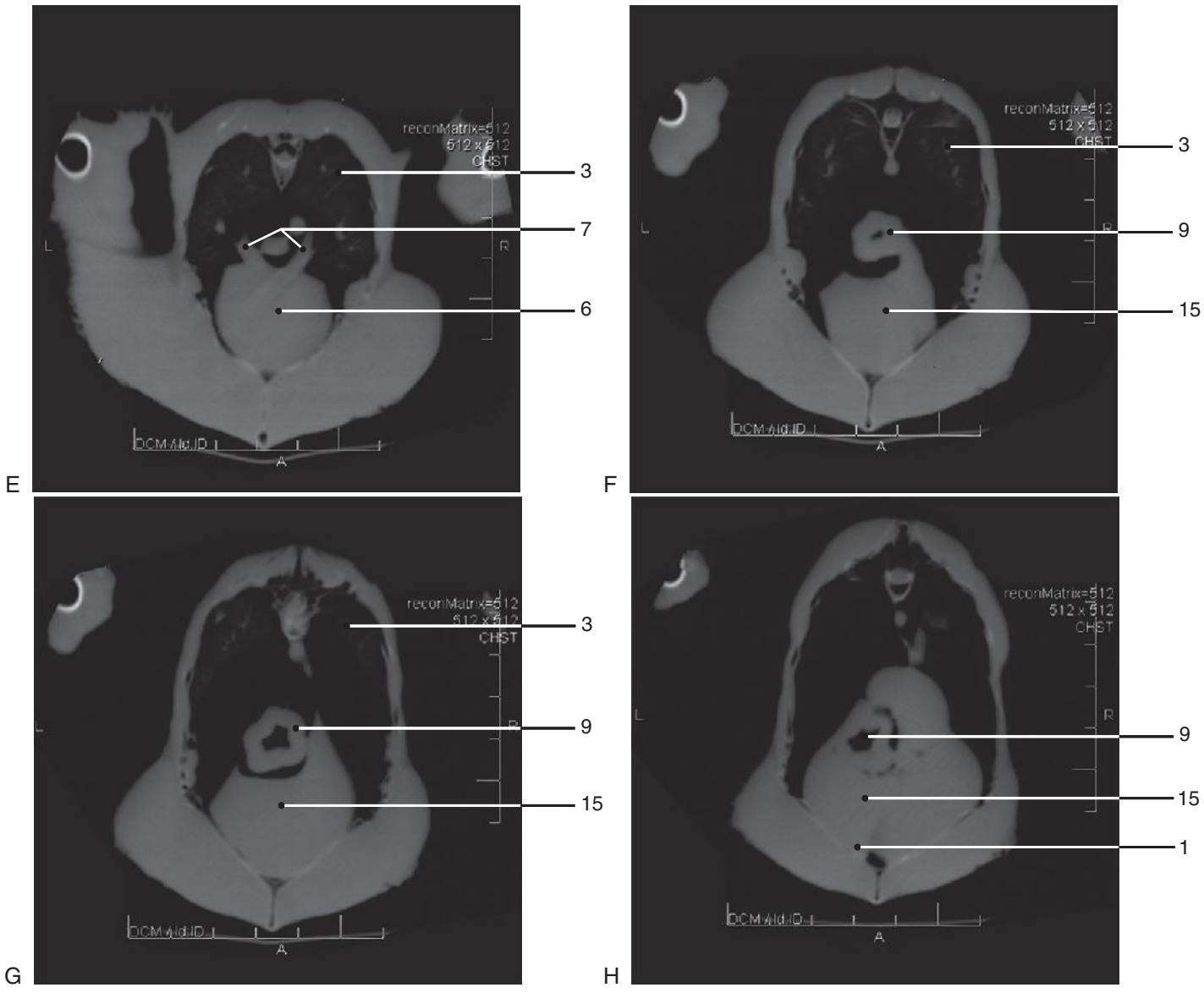

Figure 17-15, E-H
Type of Bird: Red Tailed Hawk
Type of Study: CT coelom
Contrast Medium: None
Imaging Plane: Transverse
Weight of Bird: 1.1 kg
Age: Adult

1. Sternum
2. (Thoracic air sac)
3. Lung
4. (Esophagus)
5. (Thoracic vertebra)
6. Heart
7. Blood vessels
8. (Thoracic extremity (wing))
9. Proventriculus
10. (Ventriculus)
11. (Intestines)
12. (Pelvic extremity (leg))
13. (Abdominal air sac)
14. (Ilium)
15. Liver
16. (Kidney)
17. (Caudal vertebra)
18. (Rib)
19. (Aorta)
20. (Pubic bone)
21. (Cloaca)
22. (Clavicular air sac)
23. (Scapula)
24. (Syrinx)
25. (Ischium)
26. (Colon)
27. (Spinal cord)

NOTE: Structures in parentheses are not labeled.

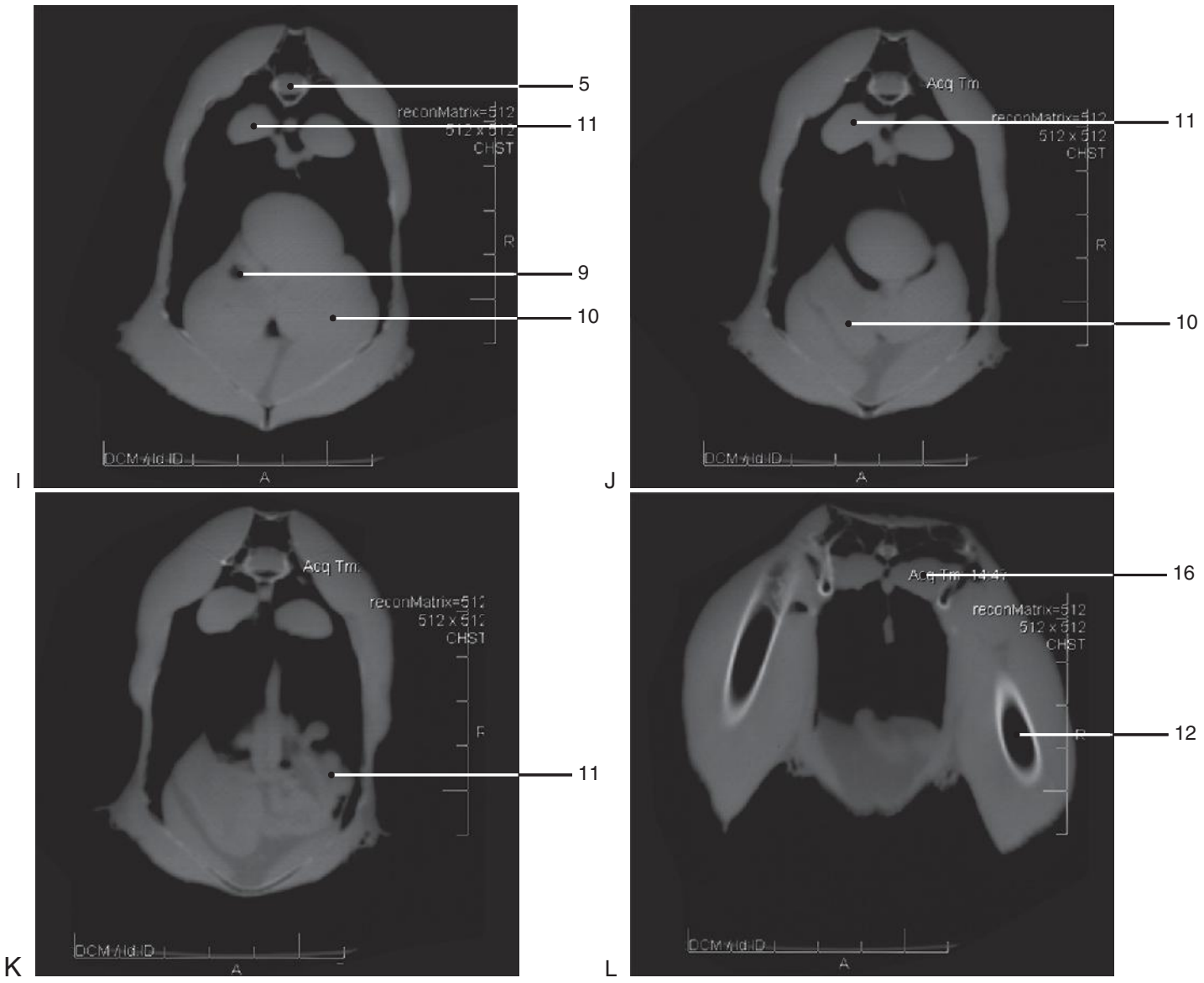

Figure 17-15, I-L
Type of Bird: Red Tailed Hawk
Type of Study: CT coelom
Contrast Medium: None
Imaging Plane: Transverse
Weight of Bird: 1.1 kg
Age: Adult

1. (Sternum)
2. (Thoracic air sac)
3. (Lung)
4. (Esophagus)
5. Thoracic vertebra
6. (Heart)
7. (Blood vessels)
8. (Thoracic extremity (wing))
9. Proventriculus
10. Ventriculus
11. Intestines
12. Pelvic extremity (leg)
13. (Abdominal air sac)
14. (Ilium)
15. (Liver)
16. Kidney
17. (Caudal vertebra)
18. (Rib)
19. (Aorta)
20. (Pubic bone)
21. (Cloaca)
22. (Clavicular air sac)
23. (Scapula)
24. (Syrinx)
25. (Ischium)
26. (Colon)
27. (Spinal cord)

NOTE: Structures in parentheses are not labeled.

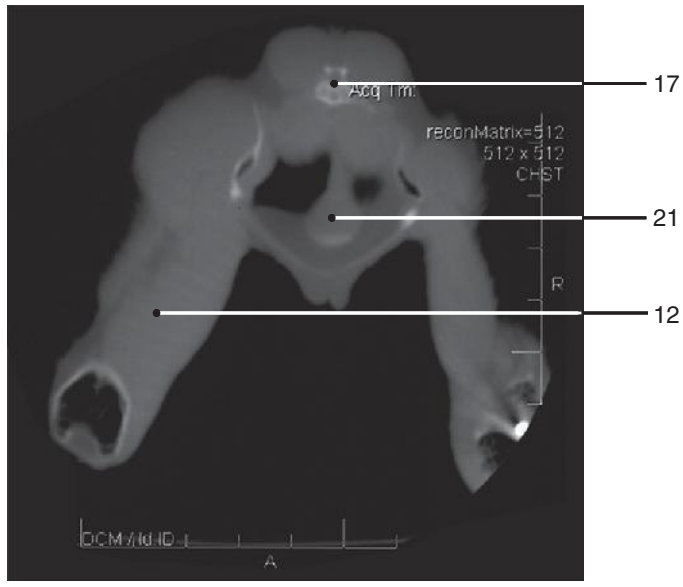

M

Figure 17-15, M
Type of Bird: Red Tailed Hawk
Type of Study: CT coelom
Contrast Medium: None
Imaging Plane: Transverse
Weight of Bird: 1.1 kg
Age: Adult

1. (Sternum)
2. (Thoracic air sac)
3. (Lung)
4. (Esophagus)
5. (Thoracic vertebra)
6. (Heart)
7. (Blood vessels)
8. (Thoracic extremity (wing))
9. (Proventriculus)
10. (Ventriculus)
11. (Intestines)
12. Pelvic extremity (leg)
13. (Abdominal air sac)
14. (Ilium)
15. (Liver)
16. (Kidney)
17. Caudal vertebra
18. (Rib)
19. (Aorta)
20. (Pubic bone)
21. Cloaca
22. (Clavicular air sac)
23. (Scapula)
24. (Syrinx)
25. (Ischium)
26. (Colon)
27. (Spinal cord)

NOTE: Structures in parentheses are not labeled.

CHAPTER • 18

Great Horned Owl
(Bubo virginianus)

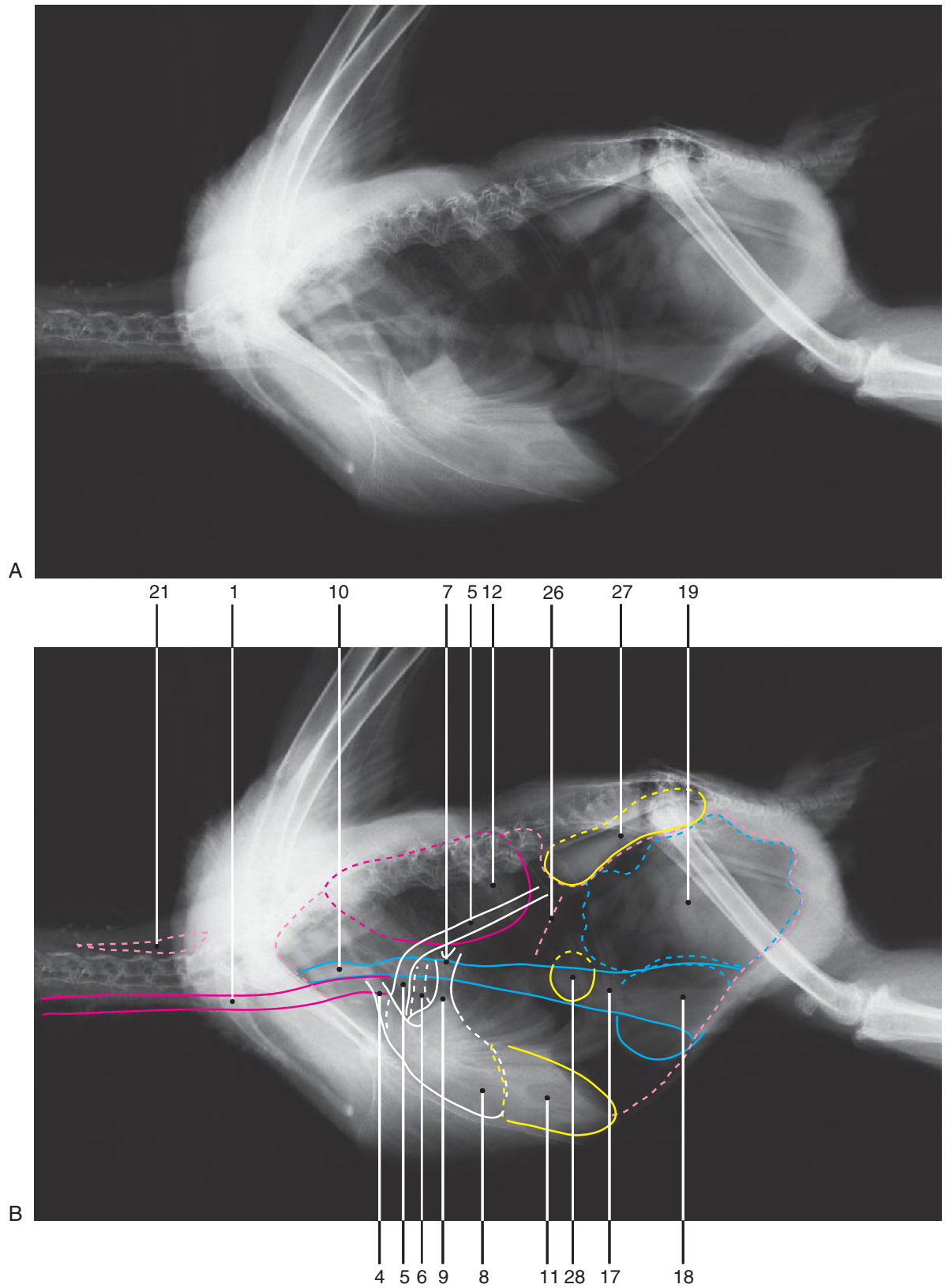

Figure 18-1, A-B
Type of Bird: Great Horned Owl
Type of Study: Viscera of the coelom
Projection: Laterolateral (right lateral recumbency)
Weight of Bird: 1.3 kg
Gender: Unknown
Reproductive Status: Intact
Age: Adult

1. Trachea
2. (Crop)
3. (Brachiocephalic artery and aorta)
4. Brachiocephalic artery
5. Aorta
6. Pulmonary artery
7. Pulmonary vein
8. Heart
9. Left atrium
10. Esophagus
11. Liver
12. Lung
13. (Syrinx)
14. (Gonad)
15. (Ovary)
16. (Testes)
17. Proventriculus
18. Ventriculus
19. Intestines
20. (Cloaca)
21. Cervical air sac
22. (Clavicular air sac)
23. (Thoracic air sac)
24. (Abdominal air sac)
25. (Apex of heart)
26. Interface between caudal thoracic and abdominal air sacs
27. Kidneys
28. Spleen

NOTE: Structures in parentheses are not labeled.

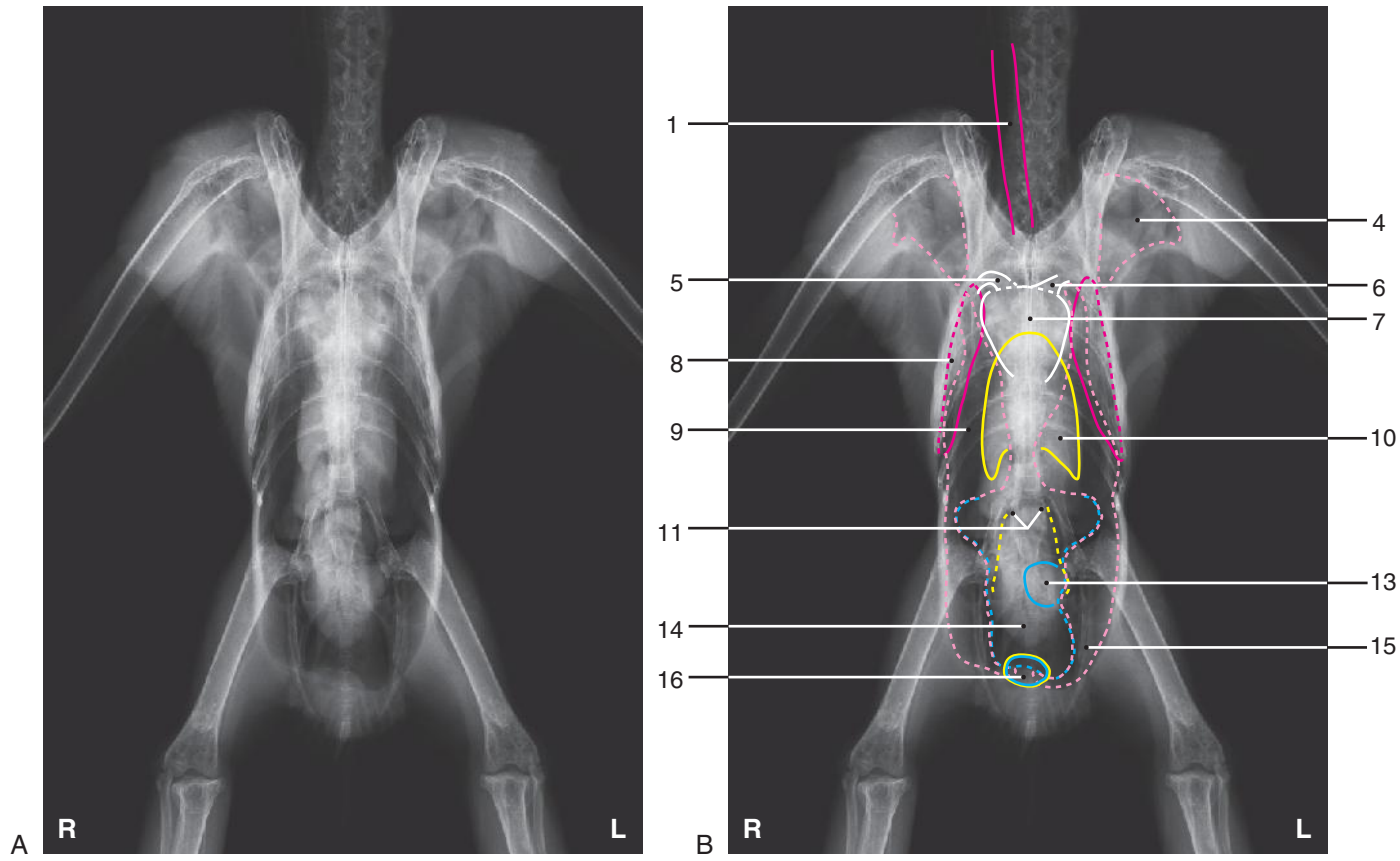

Figure 18-2, A-B
Type of Bird: Great Horned Owl
Type of Study: Viscera of the coelom
Projection: Ventrodorsal
Weight of Bird: 1.3 kg
Gender: Unknown
Reproductive Status: Intact
Age: Adult

1. Trachea
2. (Cervical air sac)
3. (Crop)
4. Clavicular air sac
5. Brachiocephalic artery and aorta
6. Heart base vessel
7. Heart
8. Lung
9. Thoracic air sac
10. Liver
11. Kidneys
12. (Proventriculus)
13. Ventriculus
14. Intestines
15. Abdominal air sac
16. Cloaca

NOTE: Structures in parentheses are not labeled.

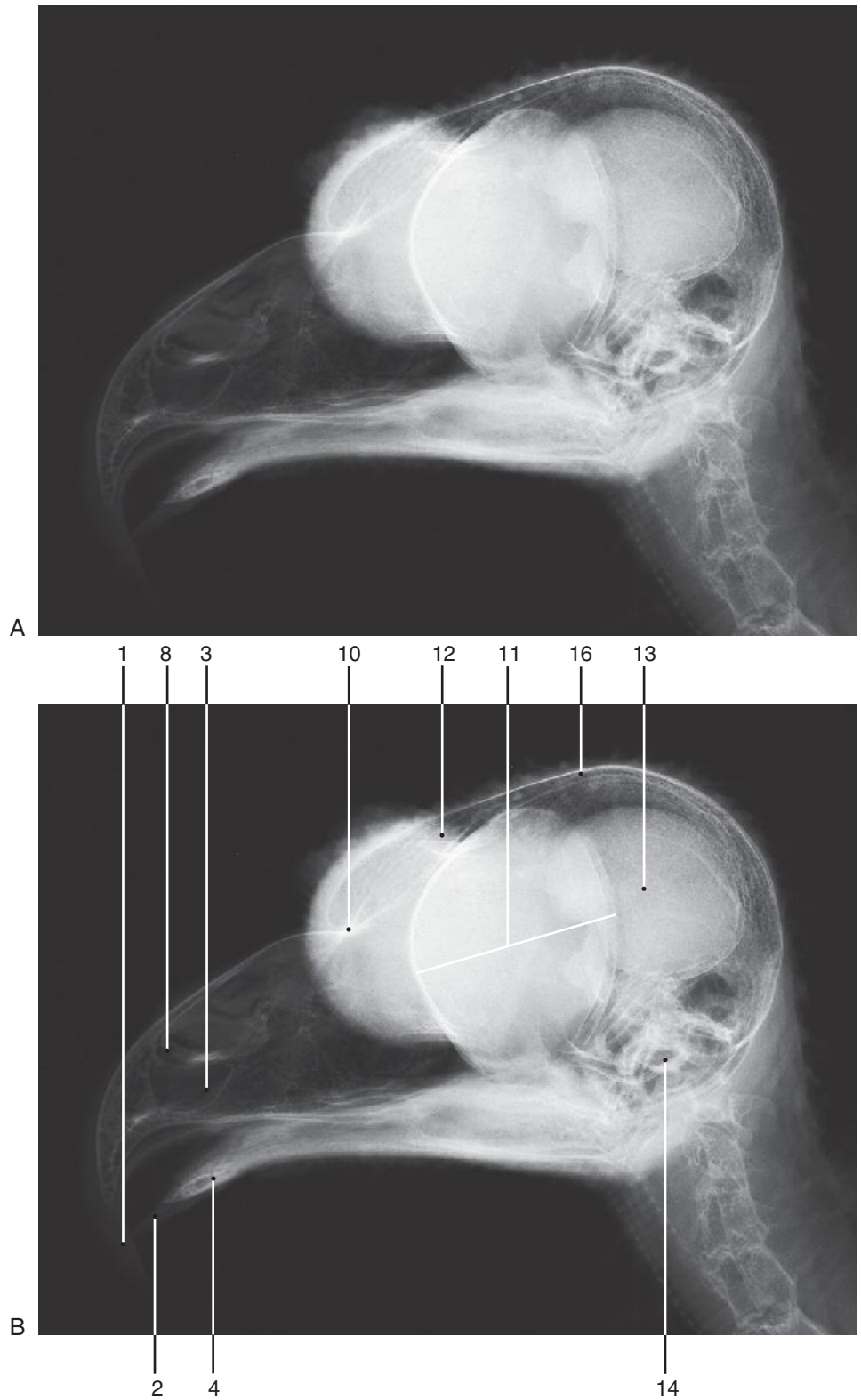

Figure 18-3, A-B
Type of Bird: Great Horned Owl
Type of Study: Head
Projection: Laterolateral (right lateral recumbency)
Weight of Bird: 1.3 kg
Gender: Unknown
Reproductive Status: Intact
Age: Adult

1. Keratinized maxillary beak
2. Keratinized mandibular beak
3. Premaxillary bone
4. Mandible
5. (Hyoid bones)
6. (Palatine bone)
7. (Pterygoid bone)
8. External nares
9. (Jugal [zygomatic] bone)
10. Craniofacial flexion zone
11. Orbit
12. Frontal bone
13. Cranium
14. Temporal bone
15. (Quadrate bone)
16. Parietal bone

NOTE: Structures in parentheses are not labeled.

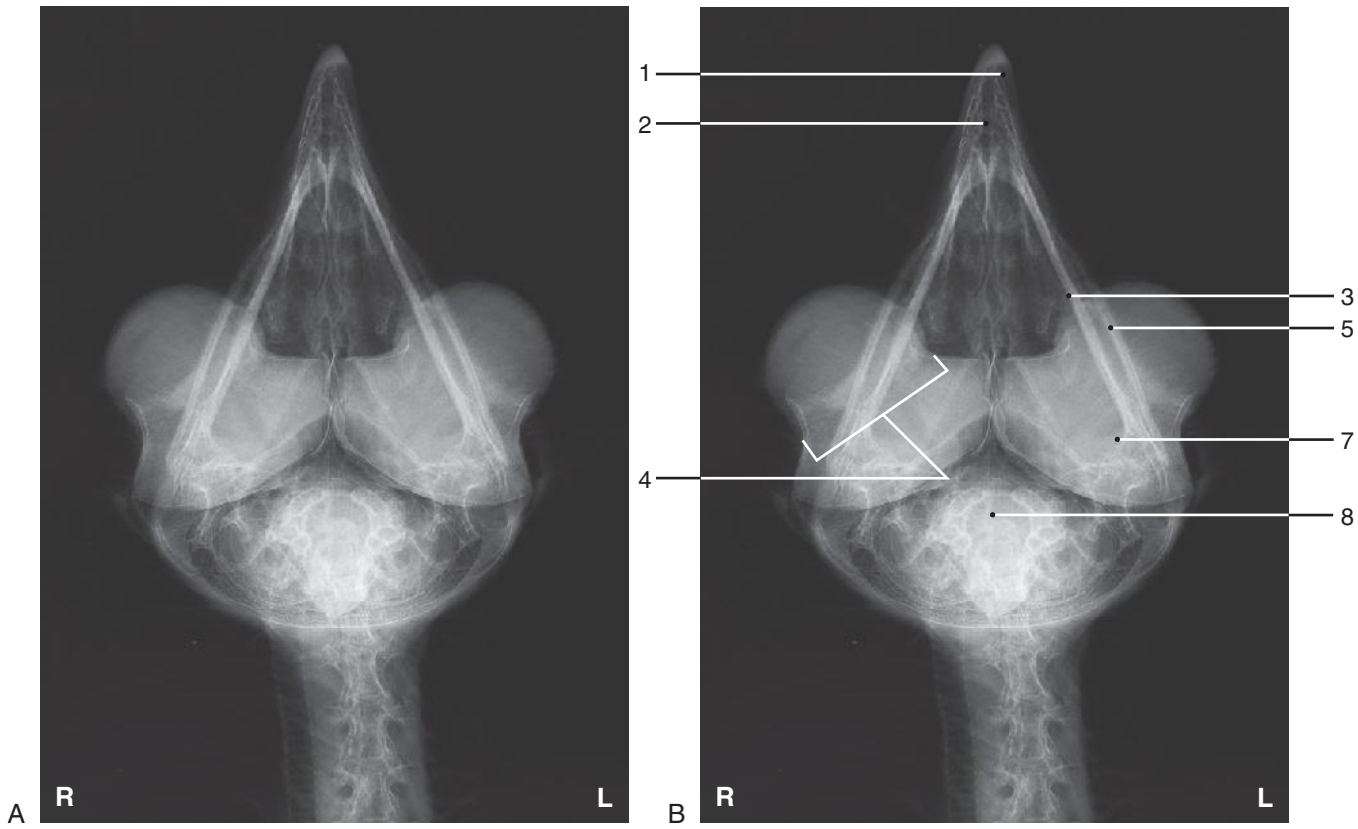

Figure 18-4, A-B
Type of Bird: Great Horned Owl
Type of Study: Head
Projection: Ventrodorsal
Weight of Bird: 1.3 kg
Gender: Unknown
Reproductive Status: Intact
Age: Adult

1. Keratinized maxillary beak
2. Premaxillary bone
3. Mandible
4. Orbit
5. Jugal [zygomatic] bone
6. (Scleral ossicles)
7. Quadrate bone
8. Cranium

NOTE: Structures in parentheses are not labeled.

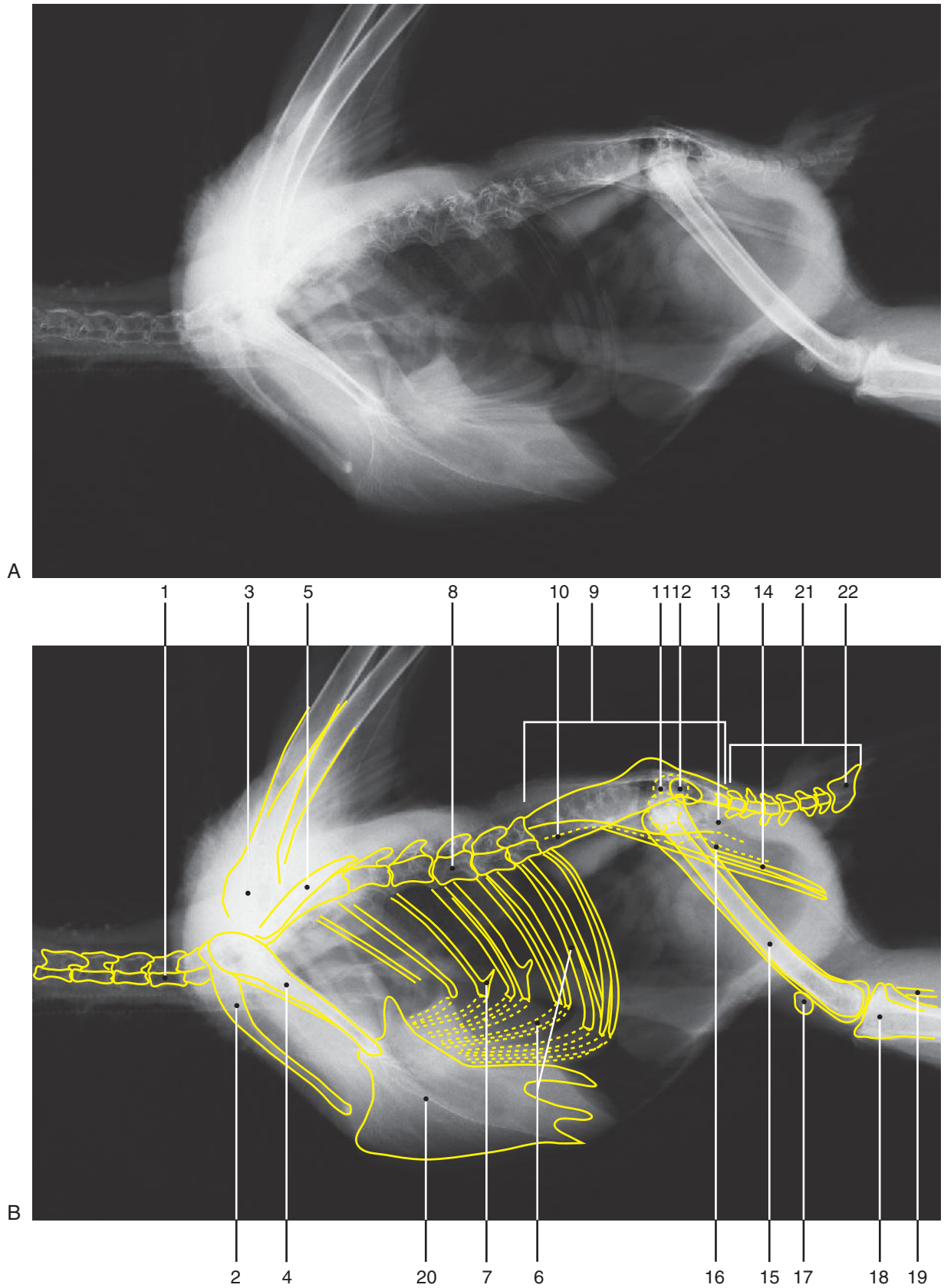

Figure 18-5, A-B
Type of Bird: Great Horned Owl
Type of Study: Whole body skeleton
Projection: Laterolateral (right lateral recumbency)
Weight of Bird: 1.3 kg
Gender: Unknown
Reproductive Status: Intact
Age: Adult

1. Cervical vertebra
2. Clavicle
3. Humerus
4. Coracoid
5. Scapula
6. Rib
7. Uncinate process of rib
8. Thoracic vertebra
9. Synsacrum
10. Ilium
11. Head of femur
12. Ilioischiadiac foramen
13. Ischium
14. Pubis
15. Femur
16. Obturator foramen
17. Patella
18. Tibiotarsal bone
19. Fibula
20. Sternum
21. Caudal vertebrae
22. Pygostyle

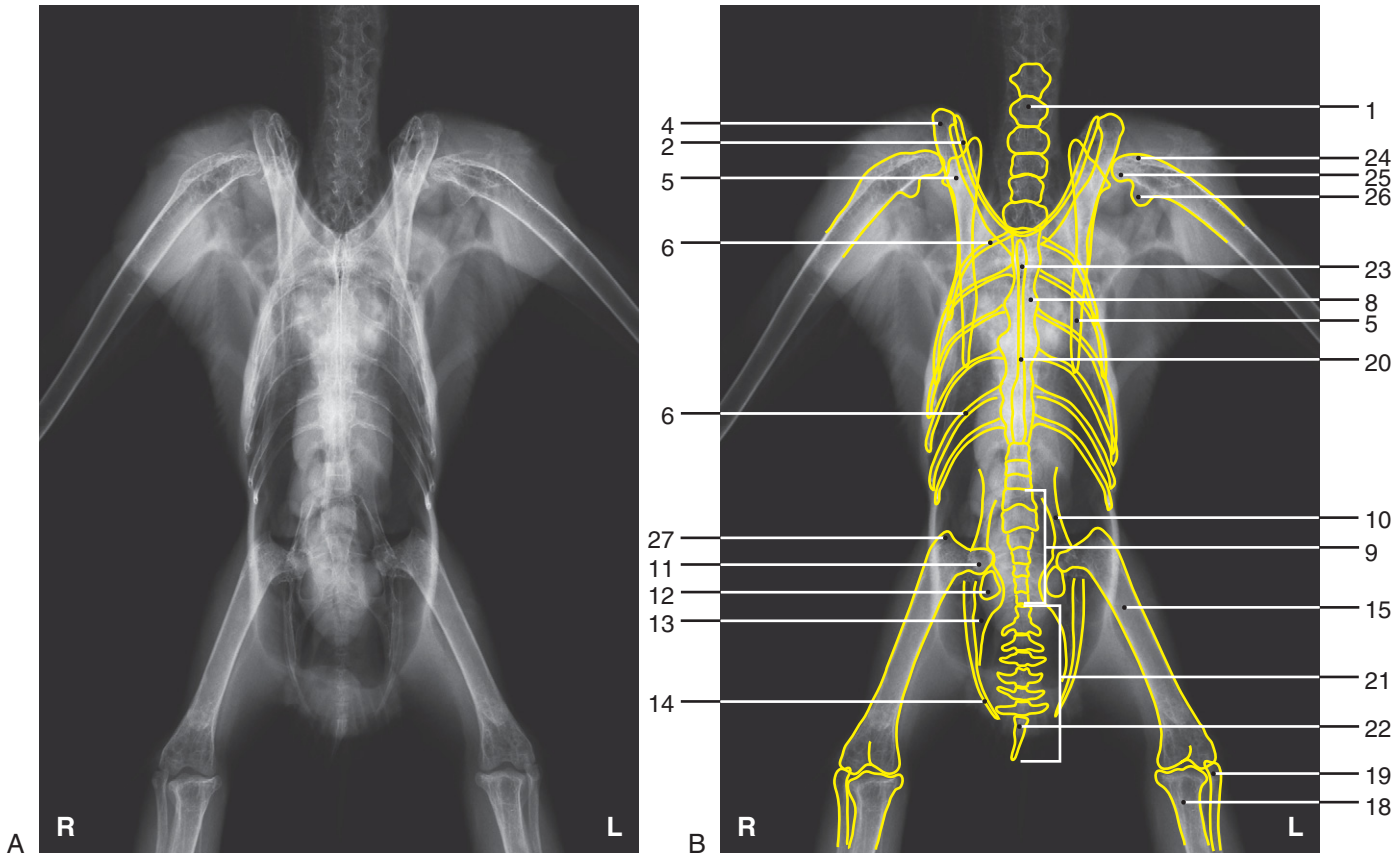

Figure 18-6, A-B
Type of Bird: Great Horned Owl
Type of Study: Whole body skeleton
Projection: Ventrodorsal
Weight of Bird: 1.3 kg
Gender: Unknown
Reproductive Status: Intact
Age: Adult

1. Cervical vertebra
2. Clavicle
3. (Humerus)
4. Coracoid
5. Scapula
6. Rib
7. (Uncinate process of rib)
8. Thoracic vertebra
9. Synsacrum
10. Ilium
11. Head of femur
12. Ilioischiadiac foramen
13. Ischium
14. Pubis
15. Femur
16. (Obturator foramen)
17. (Patella)
18. Tibiotarsal bone
19. Fibula
20. Sternum
21. Caudal vertebrae
22. Pygostyle
23. Apex carinae
24. Dorsal tubercle of humerus
25. Head of humerus
26. Ventral tubercle of humerus
27. Trochanter of femur

NOTE: Structures in parentheses are not labeled.

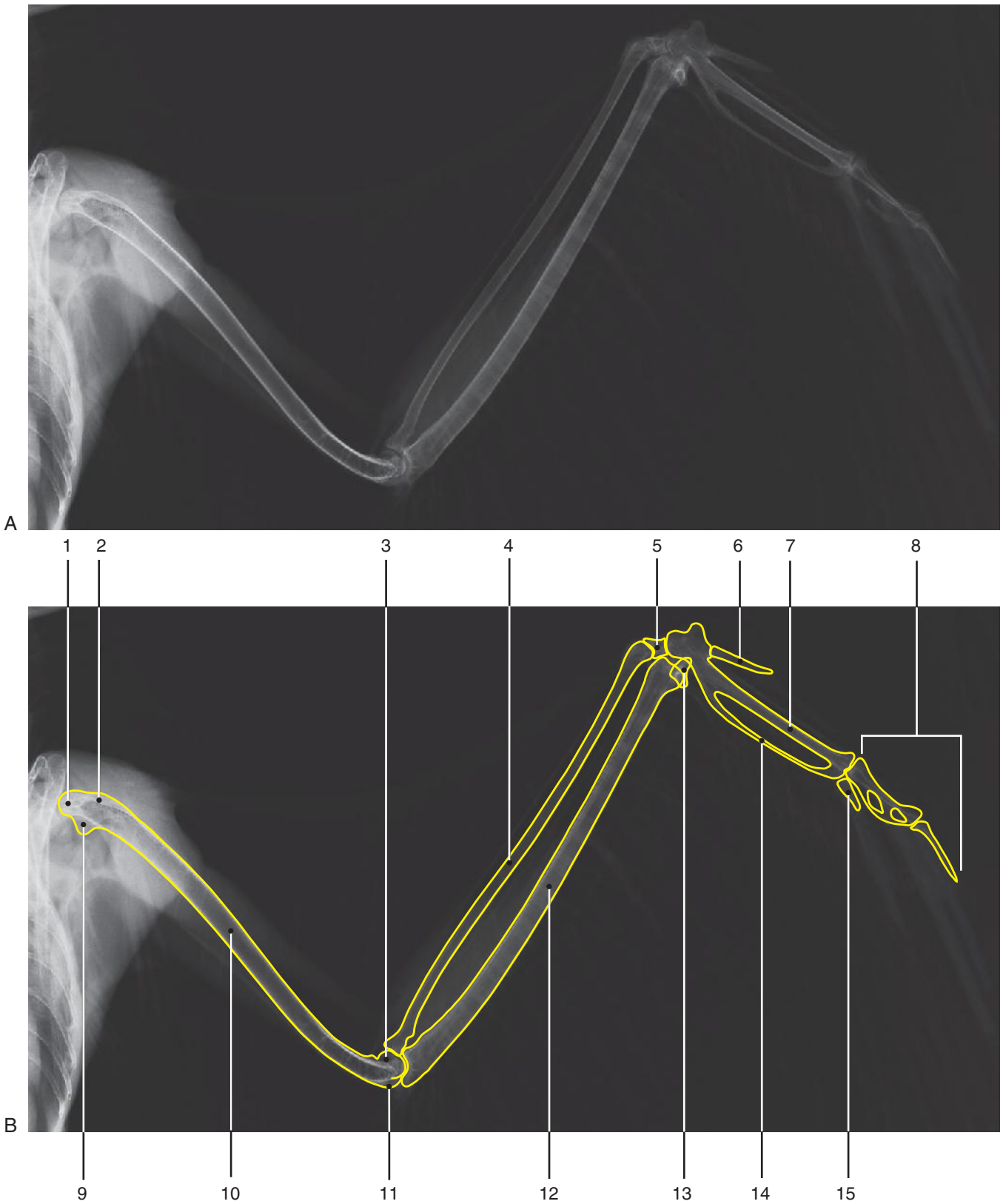

Figure 18-7, A-B
Type of Bird: Great Horned Owl
Type of Study: Wing
Projection: Mediolateral
Weight of Bird: 1.3 kg
Gender: Unknown
Reproductive Status: Intact
Age: Adult

1. Head of humerus
2. Dorsal tubercle of humerus
3. Dorsal condyle of humerus
4. Radius
5. Radial carpal bone
6. Alula
7. Major metacarpal bone
8. Phalanges of major digit
9. Ventral tubercle of humerus
10. Humerus
11. Ventral condyle of humerus
12. Ulna
13. Ulnar carpal bone
14. Minor metacarpal bone
15. Phalanges of minor digit

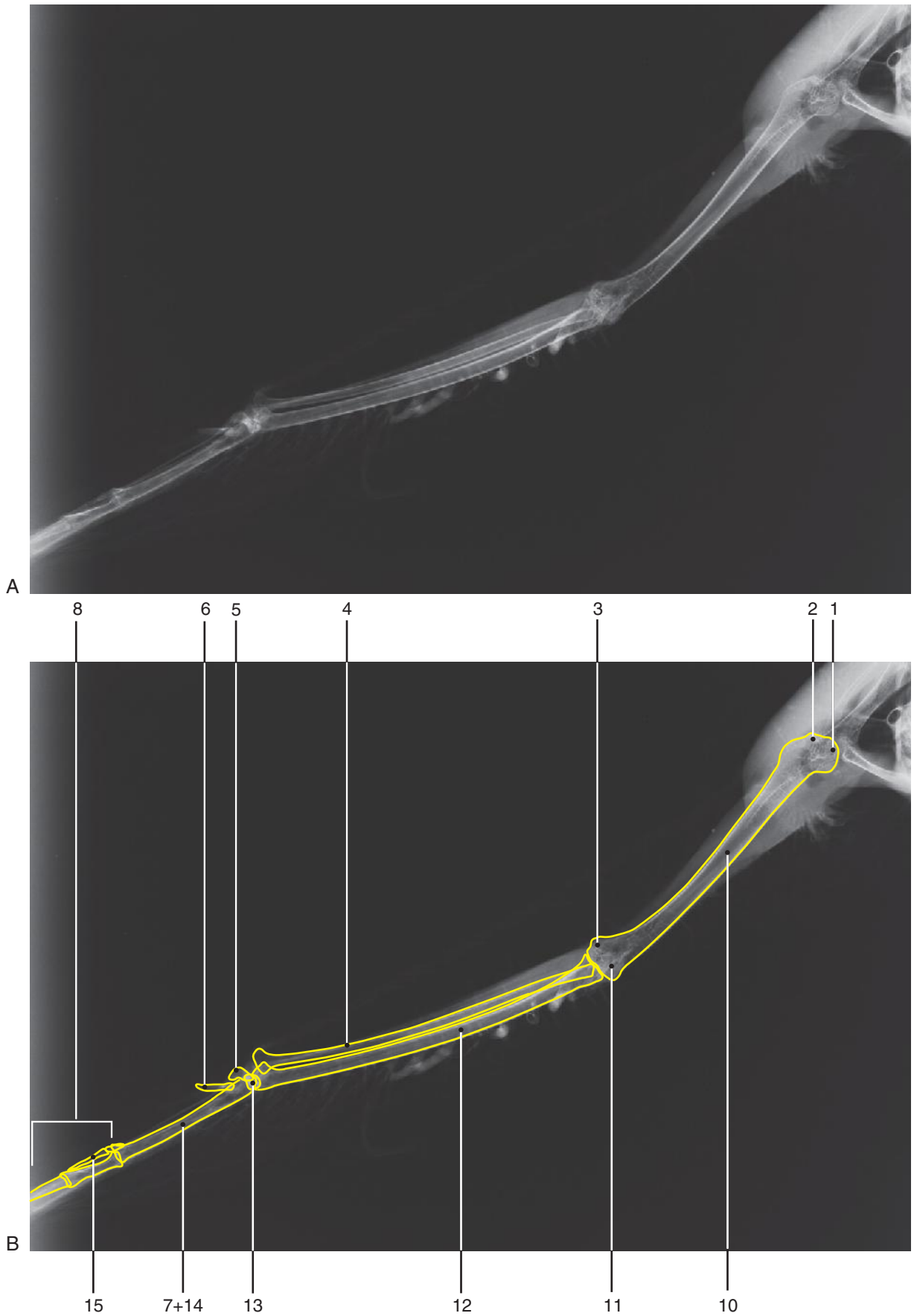

Figure 18-8, A-B
Type of Bird: Great Horned Owl
Type of Study: Wing
Projection: Caudocranial
Weight of Bird: 1.3 kg
Gender: Unknown
Reproductive Status: Intact
Age: Adult

1. Head of humerus
2. Ventral tubercle of humerus
3. Ventral condyle of humerus
4. Radius
5. Radial carpal bone
6. Alula
7. Minor metacarpal bone
8. Phalanges of major digit
9. (Dorsal tubercle of humerus)
10. Humerus
11. Dorsal condyle of humerus
12. Ulna
13. Ulnar carpal bone
14. Major metacarpal bone
15. Phalanges of minor digit

NOTE: Structures in parentheses are not labeled.

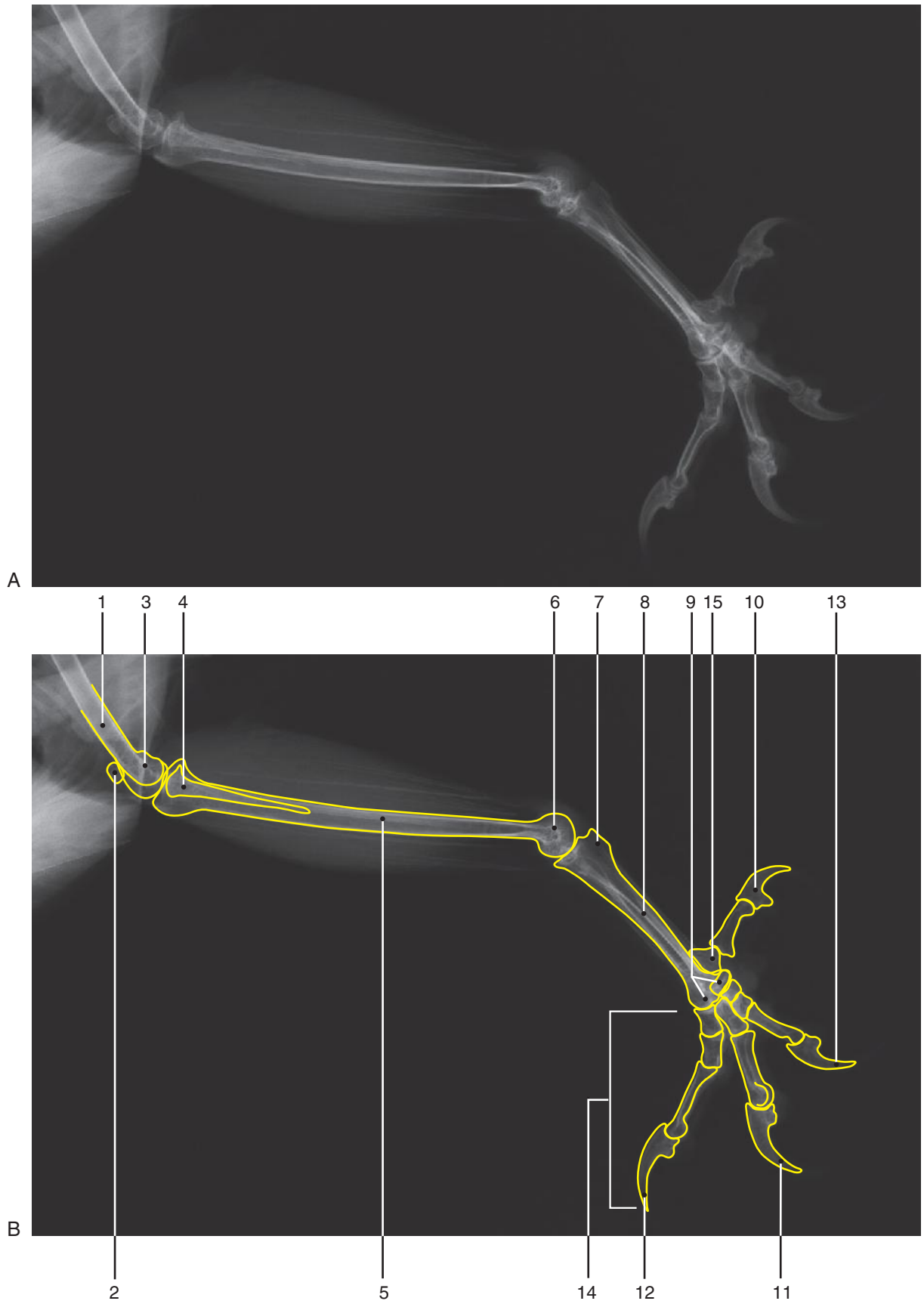

Figure 18-9, A-B
Type of Bird: Great Horned Owl
Type of Study: Pelvic limb
Projection: Mediolateral
Weight of Bird: 1.3 kg
Gender: Unknown
Reproductive Status: Intact
Age: Adult

1. Femur
2. Patella
3. Condyles of femur
4. Fibula
5. Tibiotarsal bone
6. Condyles of tibiotarsal bone
7. Hypotarsal crest of tarsometatarsal bone
8. Tarsometatarsal bone
9. Trochlea of tarsometatarsal bone
10. Digit I
11. Digit II
12. Digit III
13. Digit IV
14. Phalanges
15. Metatarsal I

Figure 18-10, A-B
Type of Bird: Great Horned Owl
Type of Study: Pelvic limb
Projection: Craniocaudal
Weight of Bird: 1.3 kg
Gender: Unknown
Reproductive Status: Intact
Age: Adult

1. Trochanter of femur
2. Femur
3. Lateral condyle of femur
4. Fibula
5. Lateral condyle of tibiotarsal bone
6. Tarsometatarsal bone
7. Trochlea of tarsometatarsal bone
8. Digit IV
9. Digit III
10. Head of femur
11. Medial condyle of femur
12. Tibiotarsal bone
13. Medial condyle of tibiotarsal bone
14. Digit I
15. Digit II
16. Phalanges
17. (Patella)
18. (Hypotarsal crest of tarsometatarsal bone)
19. Metatarsal I

NOTE: Structures in parentheses are not labeled.

A

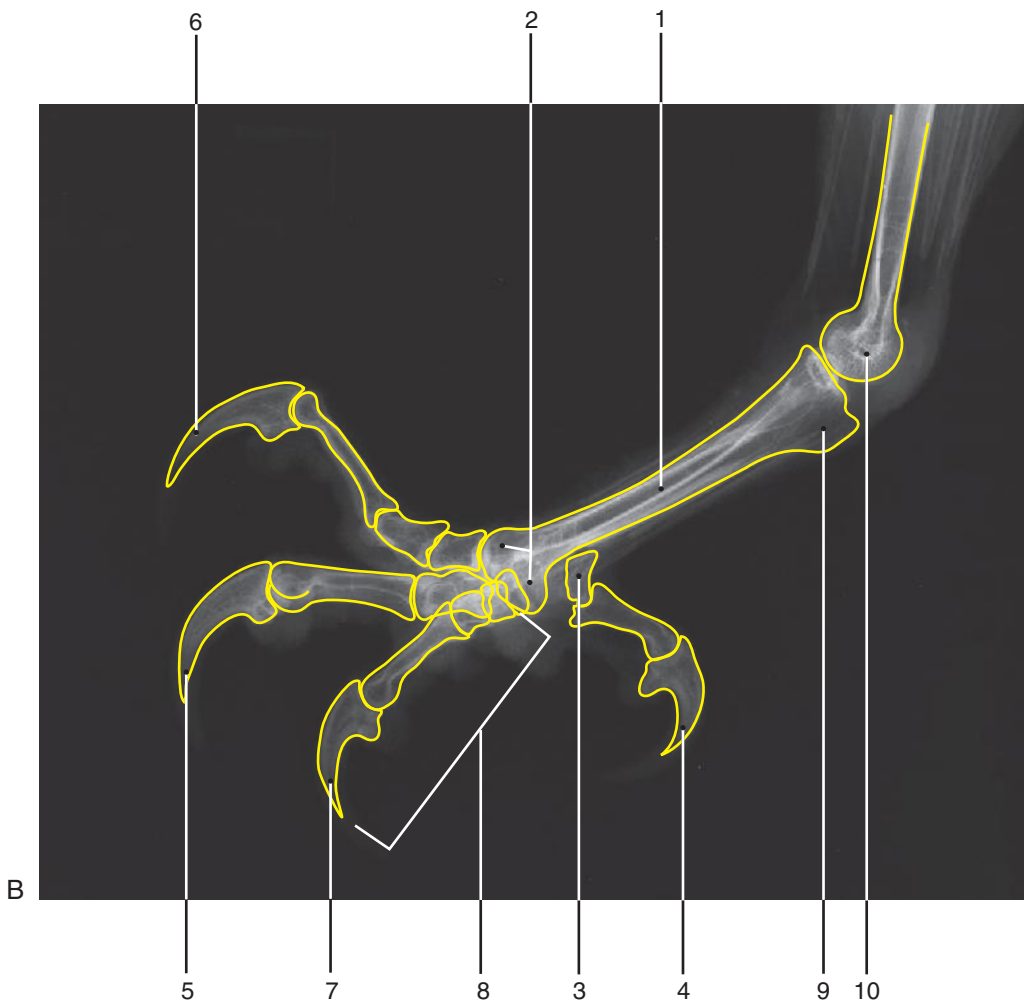

B

Figure 18-11, A-B
Type of Bird: Great Horned Owl
Type of Study: Distal pelvic limb
Projection: Mediolateral
Weight of Bird: 1.3 kg
Gender: Unknown
Reproductive Status: Intact
Age: Adult

1. Tarsometatarsal bone
2. Trochlea of tarsometatarsal bone
3. Metatarsal bone I
4. Digit I
5. Digit II
6. Digit III
7. Digit IV
8. Phalanges
9. Hypotarsal crest of tarsometatarsal bone
10. Condyles of tibiotarsal bone

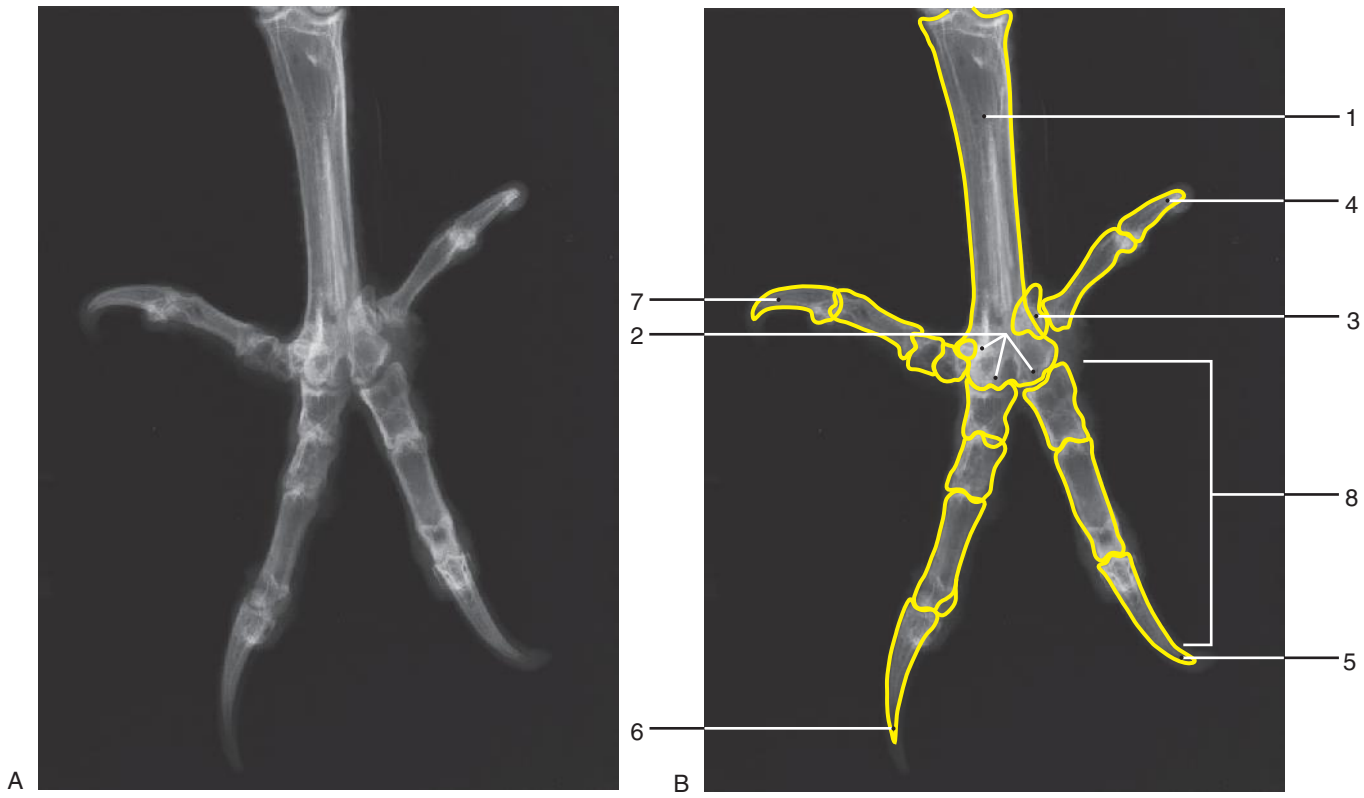

Figure 18-12, A-B
Type of Bird: Great Horned Owl
Type of Study: Distal pelvic limb
Projection: Dorsoplantar
Weight of Bird: 1.3 kg
Gender: Unknown
Reproductive Status: Intact
Age: Adult

1. Tarsometatarsal bone
2. Trochlea of tarsometatarsal bone
3. Metatarsal bone I
4. Digit I
5. Digit II
6. Digit III
7. Digit IV
8. Phalanges
9. (Hypotarsal crest of tarsometatarsal bone)
10. (Condyles of tibiotarsal bone)

NOTE: Structures in parentheses are not labeled.

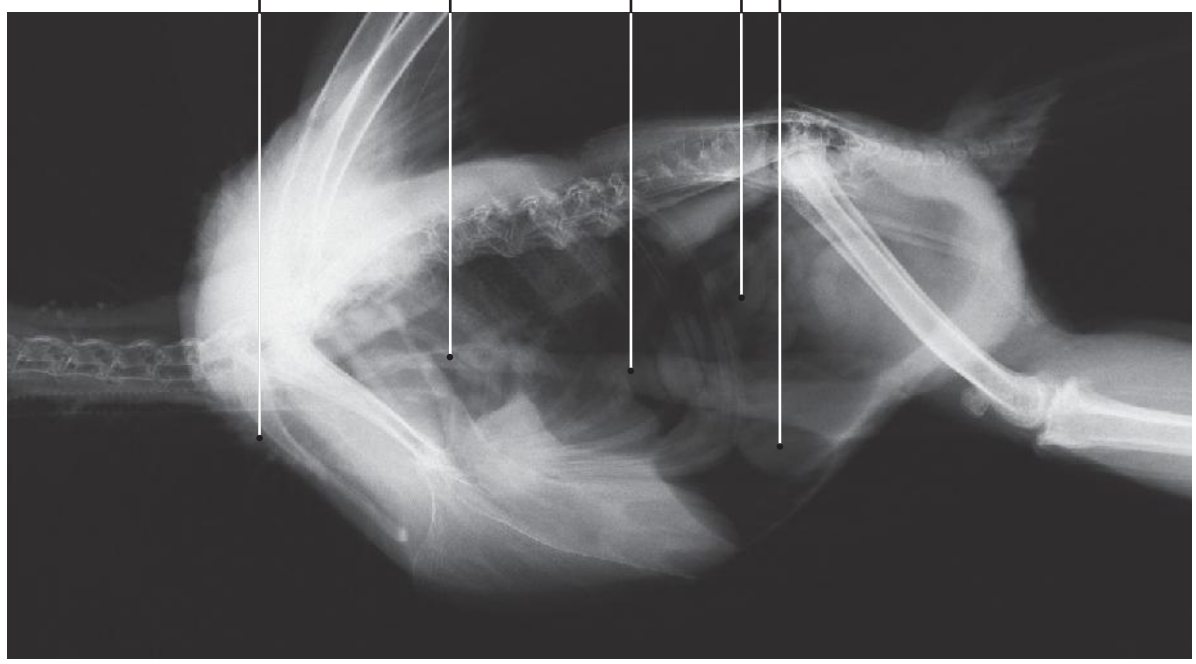

A

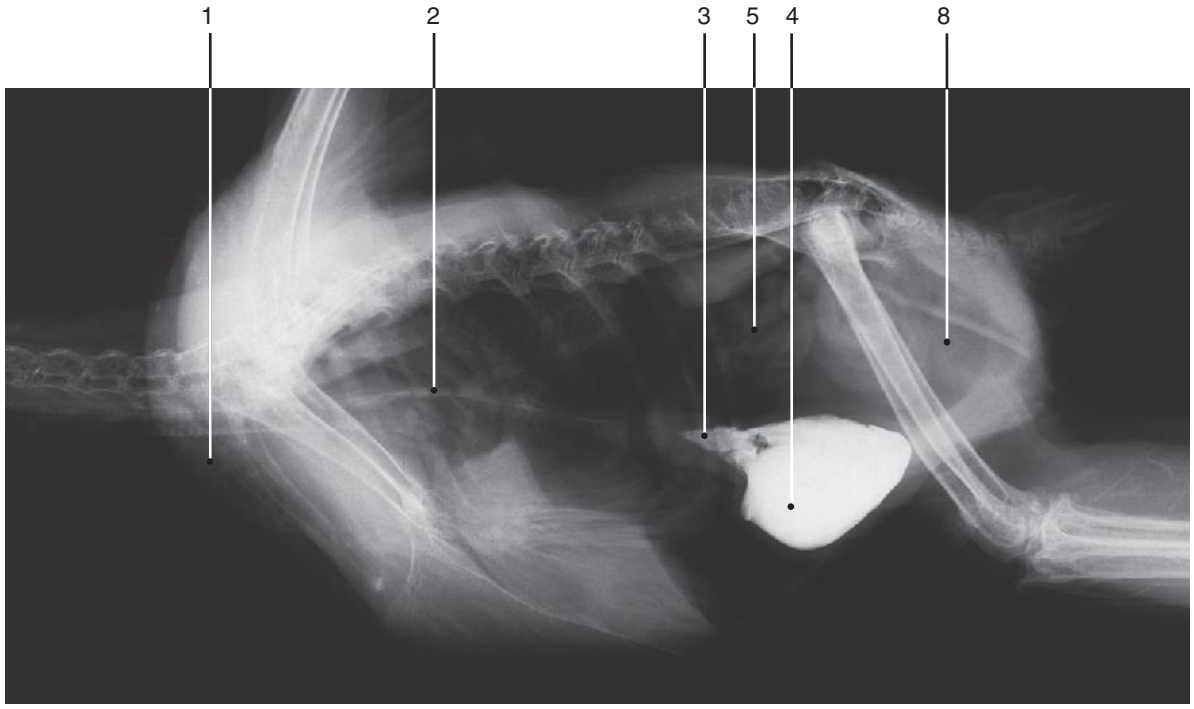

B

Figure 18-13, A-B
Type of Bird: Great Horned Owl
Type of Study: Gastrointestinal positive contrast study
Contrast Medium: Barium sulfate suspension (Novopaque® 30% w/v; Lafayette Pharmaceutical, Inc., Lafayette, IN) 23 ml administered via gavage tube
Projection: Laterolateral (right lateral recumbency)
Weight of Bird: 1.3 kg
Gender: Unknown
Reproductive Status: Intact
Age: Adult

Image	Time (hr)
A	Scout
B	0.25

1. Crop
2. Esophagus
3. Proventriculus
4. Ventriculus
5. Intestines
6. (Duodenum)
7. (Large intestine)
8. Cloaca
9. (Proventricular-ventricular isthmus)

NOTE: Structures in parentheses are not labeled.

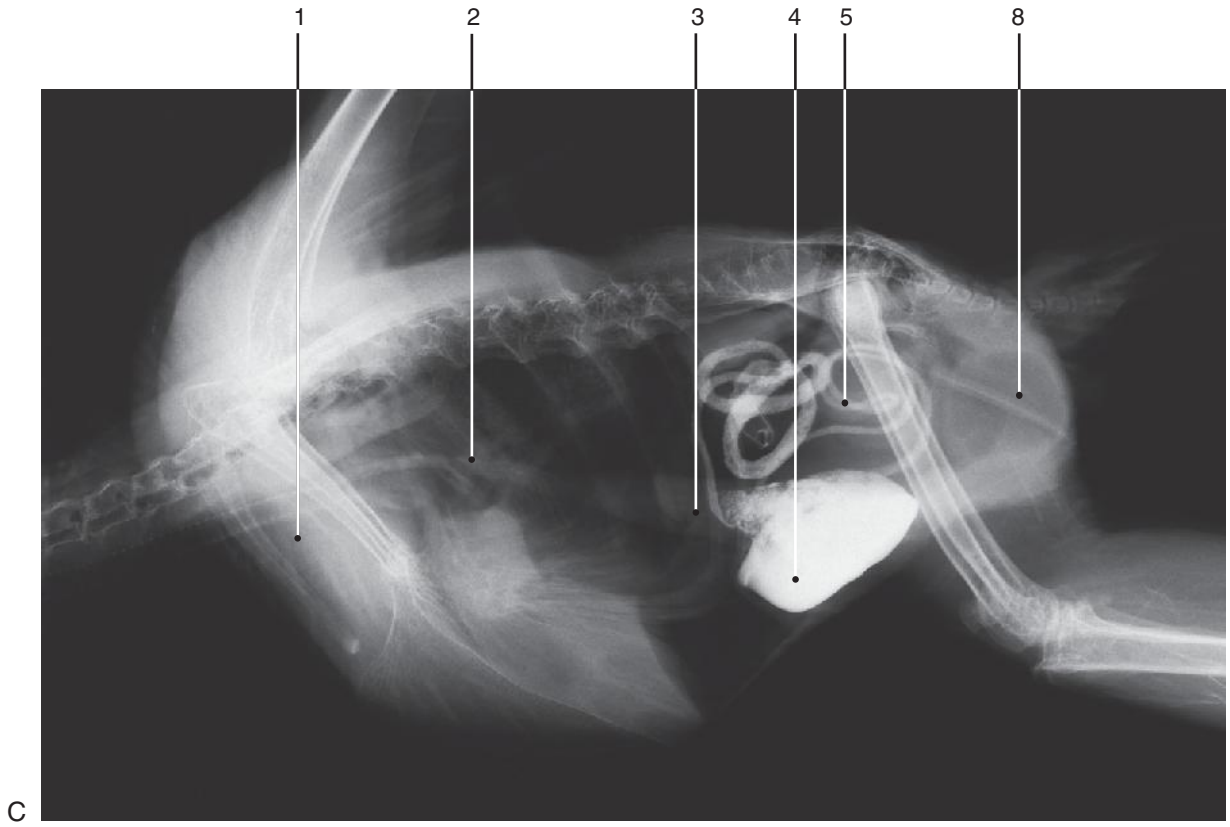

C

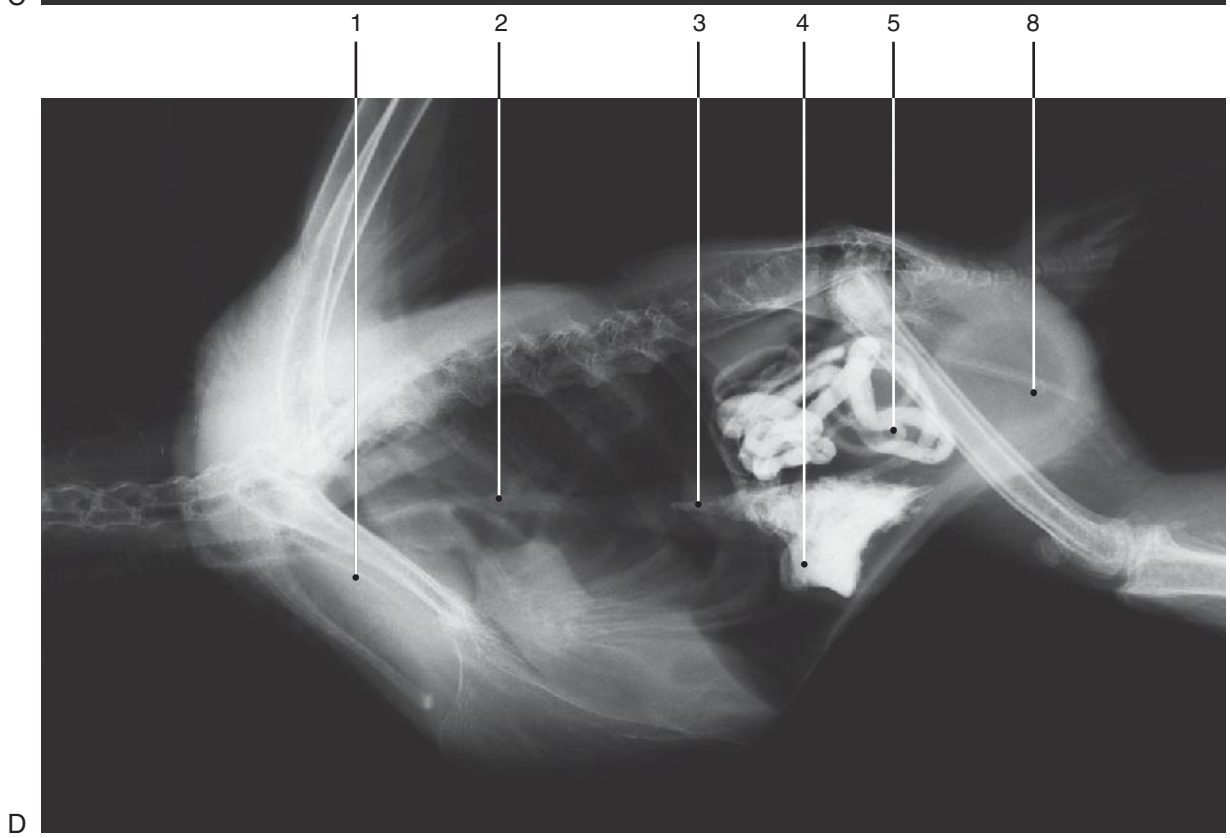

D

Figure 18-13, C-D
Type of Bird: Great Horned Owl
Type of Study: Gastrointestinal positive contrast study
Contrast Medium: Barium sulfate suspension (Novopaque® 30% w/v; Lafayette Pharmaceutical, Inc., Lafayette, IN) 23 ml administered via gavage tube
Projection: Laterolateral (right lateral recumbency)
Weight of Bird: 1.3 kg
Gender: Unknown
Reproductive Status: Intact
Age: Adult

Image	Time (hr)
C	1.0
D	3.0

1. Crop
2. Esophagus
3. Proventriculus
4. Ventriculus
5. Intestines
6. (Duodenum)
7. (Large intestine)
8. Cloaca
9. (Proventricular-ventricular isthmus)

NOTE: Structures in parentheses are not labeled.

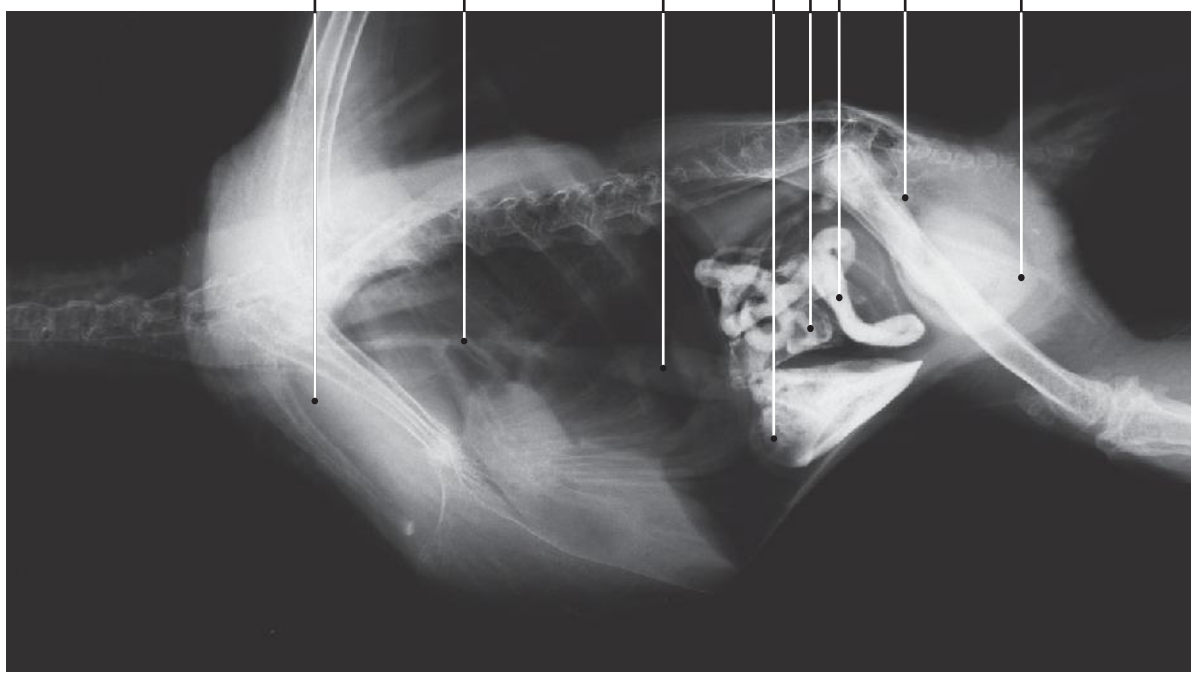

E

Figure 18-13, E
Type of Bird: Great Horned Owl
Type of Study: Gastrointestinal positive contrast study
Contrast Medium: Barium sulfate suspension (Novopaque® 30% w/v; Lafayette Pharmaceutical, Inc., Lafayette, IN) 23 ml administered via gavage tube
Projection: Laterolateral (right lateral recumbency)
Weight of Bird: 1.3 kg
Gender: Unknown
Reproductive Status: Intact
Age: Adult

Image	Time (hr)
E	5.0

1. Crop
2. Esophagus
3. Proventriculus
4. Ventriculus
5. Intestines
6. Duodenum
7. Large intestine
8. Cloaca
9. (Proventricular-ventricular isthmus)

NOTE: Structures in parentheses are not labeled.

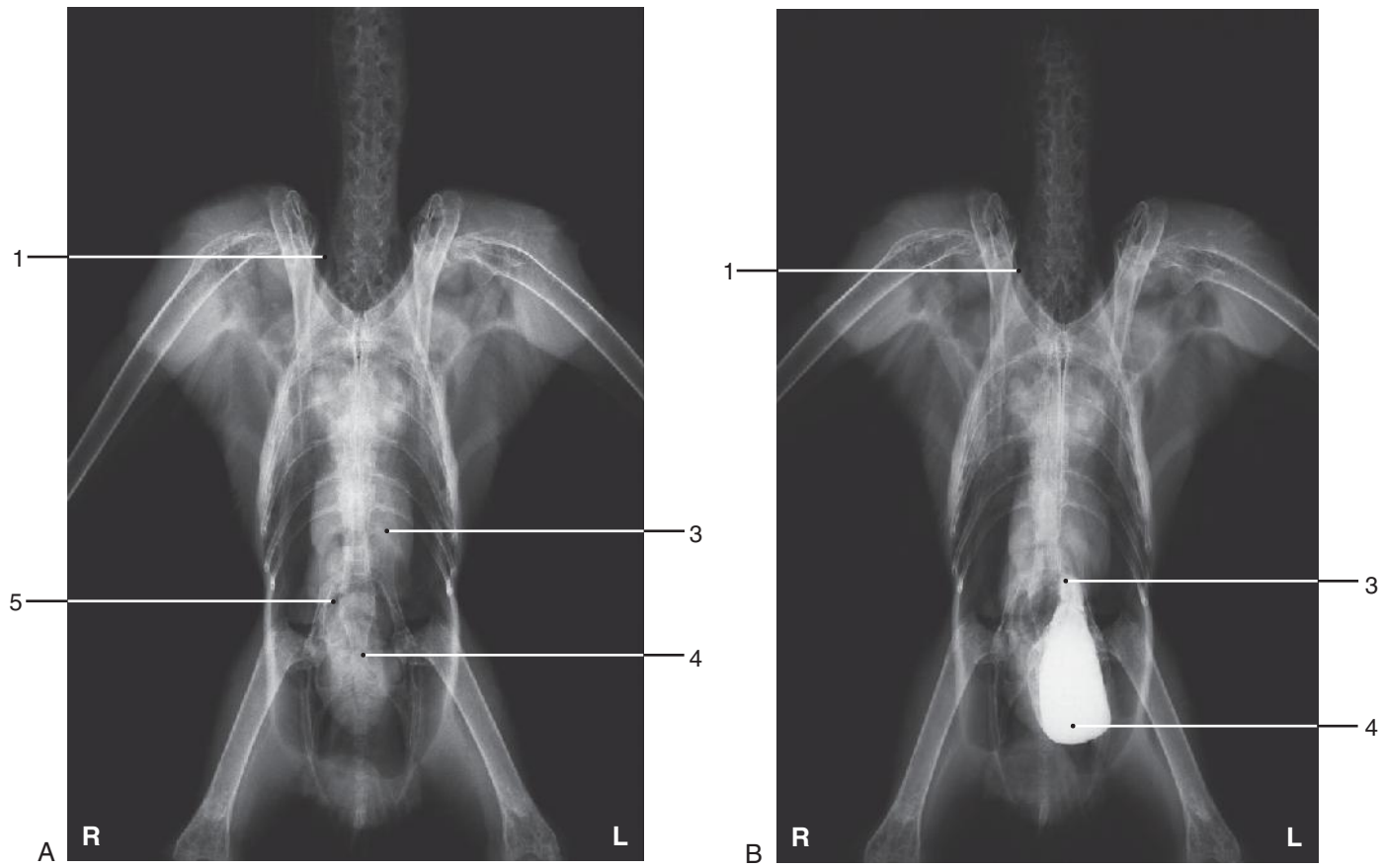

Figure 18-14, A-B
Type of Bird: Great Horned Owl
Type of Study: Gastrointestinal positive contrast study
Contrast Medium: Barium sulfate suspension (Novopaque® 30% w/v; Lafayette Pharmaceutical, Inc., Lafayette, IN) 23 ml administered via gavage tube
Projection: Ventrodorsal
Weight of Bird: 1.3 kg
Gender: Unknown
Reproductive Status: Intact
Age: Adult

Image	Time (hr)
A	Scout
B	0.25

1. Crop
2. (Esophagus)
3. Proventriculus
4. Ventriculus
5. Intestines
6. (Duodenum)
7. Large intestine
8. Cloaca
9. (Proventricular-ventricular isthmus)

NOTE: Structures in parentheses are not labeled.

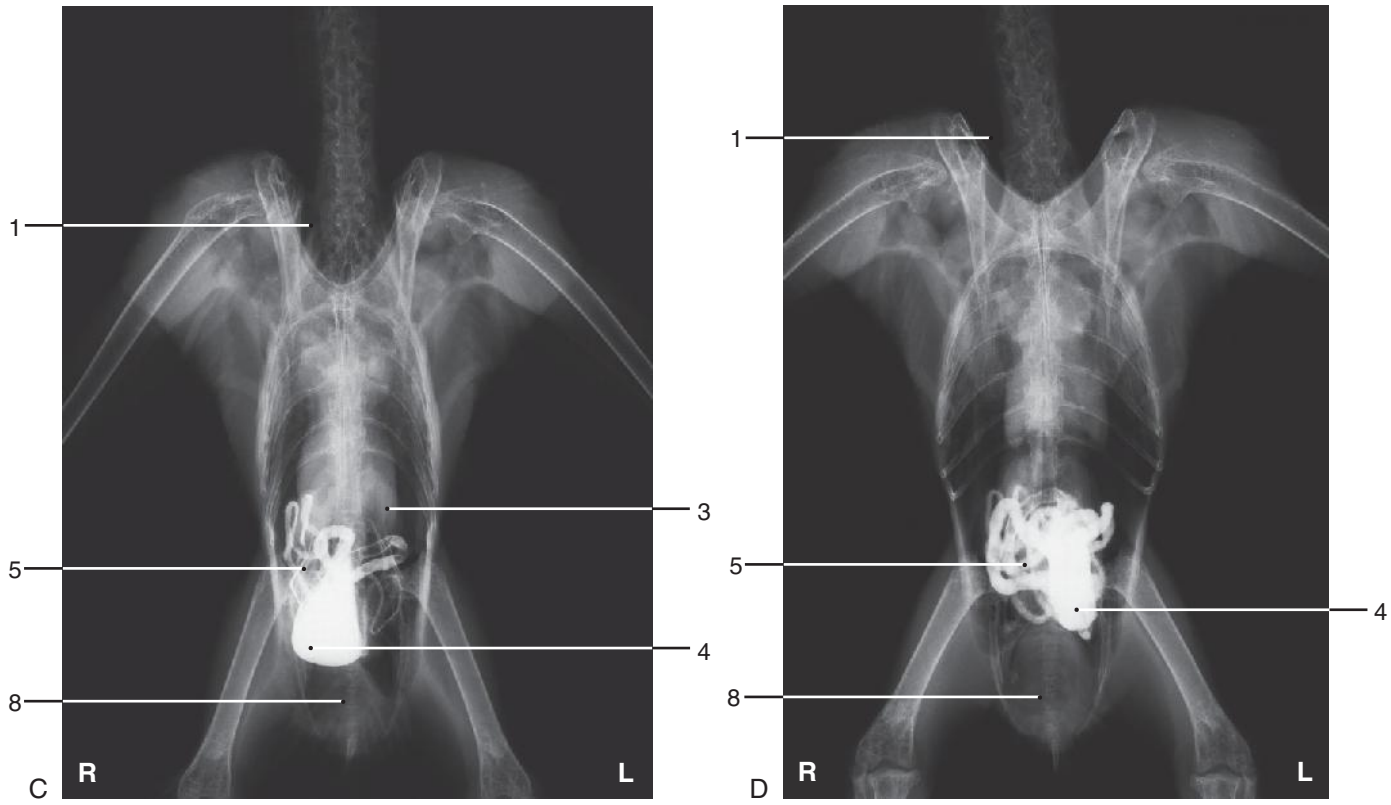

Figure 18-14, C-D
Type of Bird: Great Horned Owl
Type of Study: Gastrointestinal positive contrast study
Contrast Medium: Barium sulfate suspension (Novopaque® 30% w/v; Lafayette Pharmaceutical, Inc., Lafayette, IN) 23 ml administered via gavage tube
Projection: Ventrodorsal
Weight of Bird: 1.3 kg
Gender: Unknown
Reproductive Status: Intact
Age: Adult

Image	Time (hr)
C	1.0
D	3.0

1. Crop
2. (Esophagus)
3. Proventriculus
4. Ventriculus
5. Intestines
6. (Duodenum)
7. Large intestine
8. Cloaca
9. (Proventricular-ventricular isthmus)

NOTE: Structures in parentheses are not labeled.

E

Figure 18-14, E
Type of Bird: Great Horned Owl
Type of Study: Gastrointestinal positive contrast study
Contrast Medium: Barium sulfate suspension (Novopaque® 30% w/v; Lafayette Pharmaceutical, Inc., Lafayette, IN) 23 ml administered via gavage tube
Projection: Ventrodorsal
Weight of Bird: 1.3 kg
Gender: Unknown
Reproductive Status: Intact
Age: Adult

Image	Time (hr)
E	5.0

1. Crop
2. (Esophagus)
3. Proventriculus
4. Ventriculus
5. Intestines
6. (Duodenum)
7. Large intestine
8. Cloaca
9. (Proventricular-ventricular isthmus)

NOTE: Structures in parentheses are not labeled.

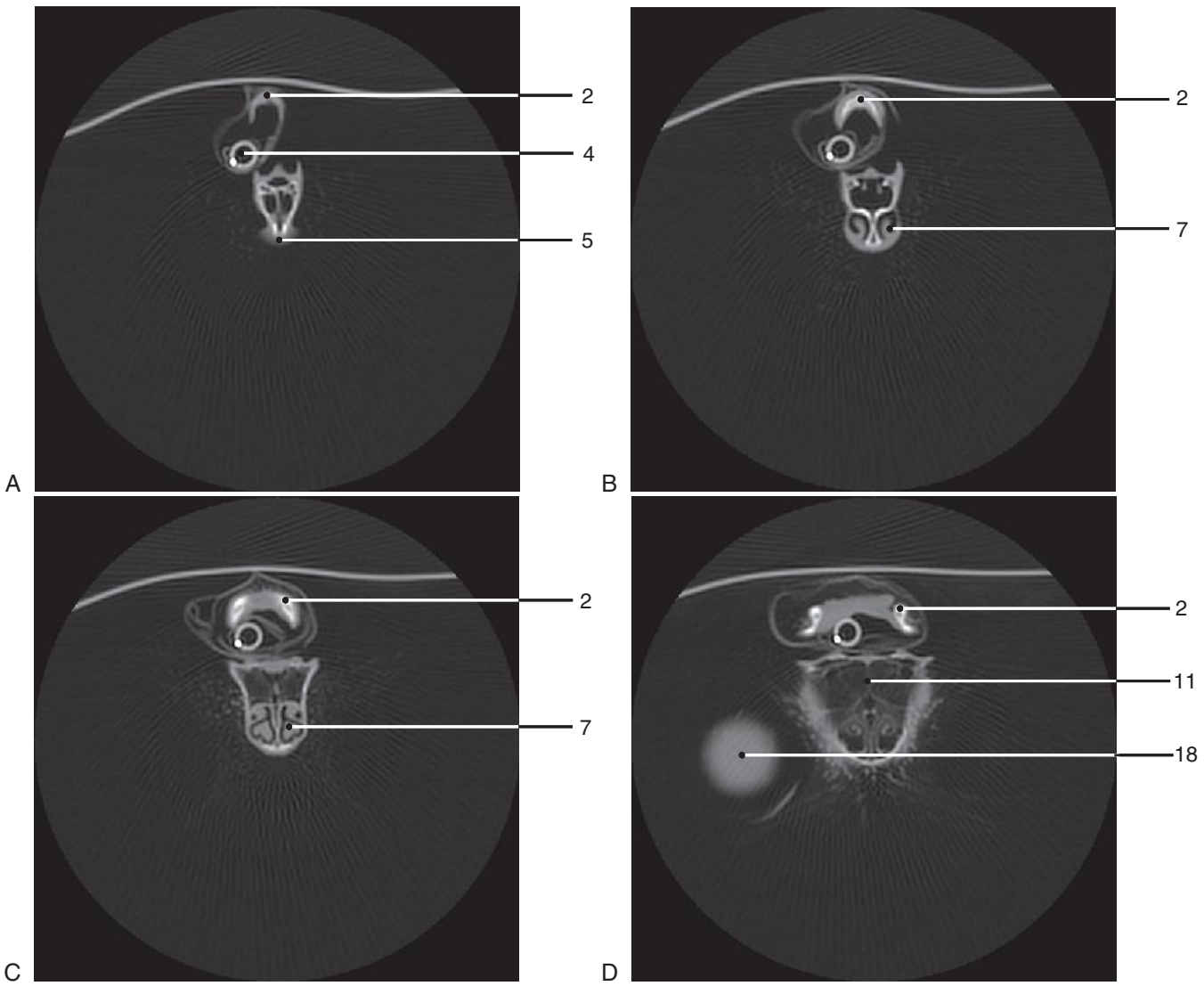

Figure 18-15, A-D
Type of Bird: Great Horned Owl
Type of Study: CT head
Contrast Medium: None
Imaging Plane: Transverse
Weight of Bird: 1.4 kg
Age: Adult

1. (Tongue)
2. Mandible
3. (Hyoid bone)
4. Endotracheal tube
5. Keratinized maxillary beak
6. (Nasal cavity)
7. Nasal concha
8. (Pharynx)
9. (Premaxillary bone)
10. (Infraorbital sinus)
11. Nasal septum
12. (Choana)
13. (Palatine bone)
14. (Sphenoid bone)
15. (Jugal [zygomatic] bone)
16. (Frontal bone)
17. (Pterygoid bone)
18. Eyeball
19. (Scleral ossicle)
20. (Interorbital septum)
21. (Lens of eyeball)
22. (Trachea)
23. (Cerebrum)
24. (External ear canal)
25. (Cerebellum)
26. (Spinal cord)
27. (Dens)
28. (Cere)
29. (Nare[s])
30. (Feather)
31. (Pons)
32. (Occipital bone)
33. Cervical vertebra

NOTE: Structures in parentheses are not labeled.

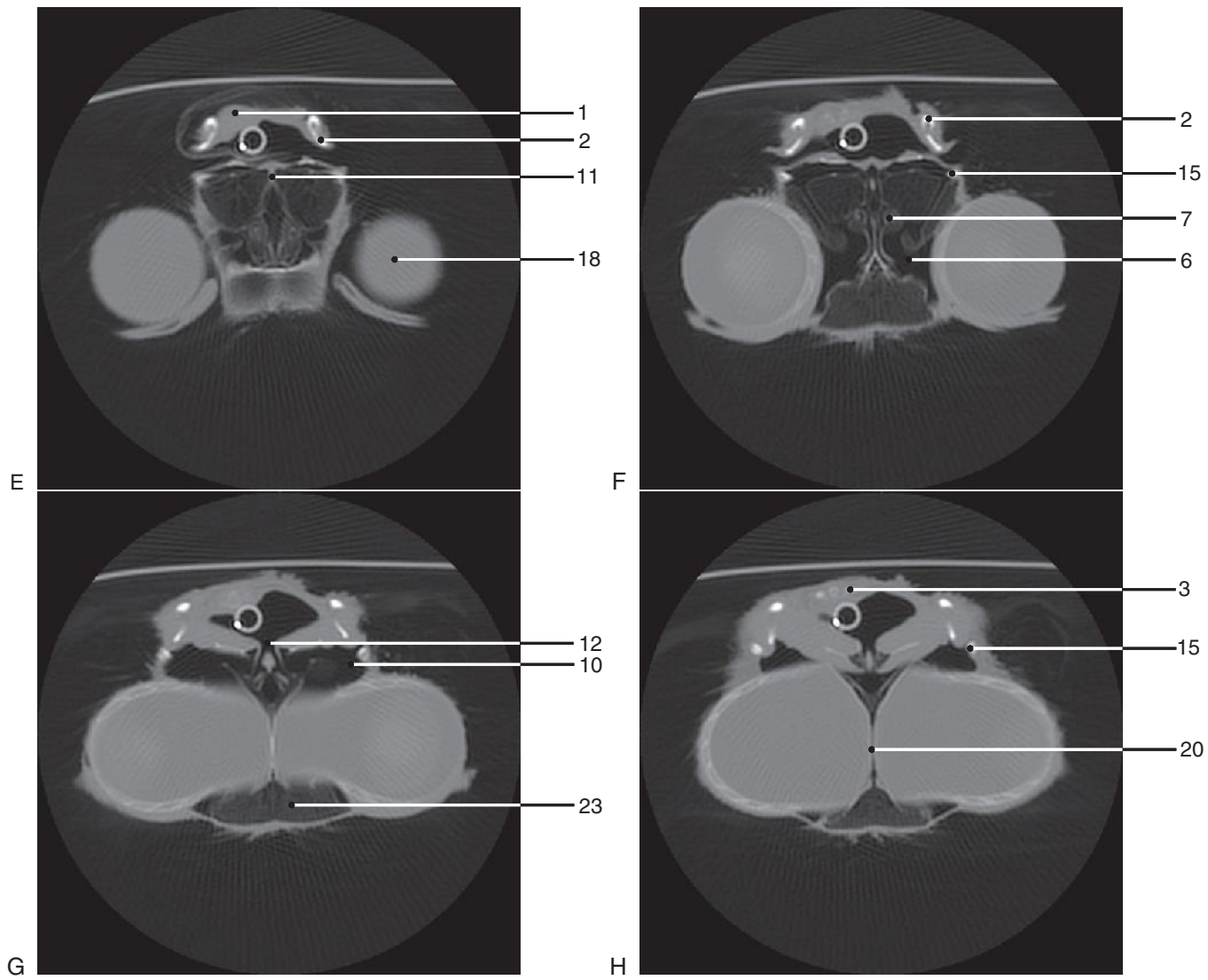

Figure 18-15, E-H
Type of Bird: Great Horned Owl
Type of Study: CT head
Contrast Medium: None
Imaging Plane: Transverse
Weight of Bird: 1.4 kg
Age: Adult

1. Tongue
2. Mandible
3. Hyoid bone
4. (Endotracheal tube)
5. (Keratinized maxillary beak)
6. Nasal cavity
7. Nasal concha
8. (Pharynx)
9. (Premaxillary bone)
10. Infraorbital sinus
11. Nasal septum
12. Choana
13. (Palatine bone)
14. (Sphenoid bone)
15. Jugal [zygomatic] bone
16. (Frontal bone)
17. (Pterygoid bone)
18. Eyeball
19. (Scleral ossicle)
20. Interorbital septum
21. (Lens of eyeball)
22. (Trachea)
23. Cerebrum
24. (External ear canal)
25. (Cerebellum)
26. (Spinal cord)
27. (Dens)
28. (Cere)
29. (Nare[s])
30. (Feather)
31. (Pons)
32. (Occipital bone)
33. Cervical vertebra

NOTE: Structures in parentheses are not labeled.

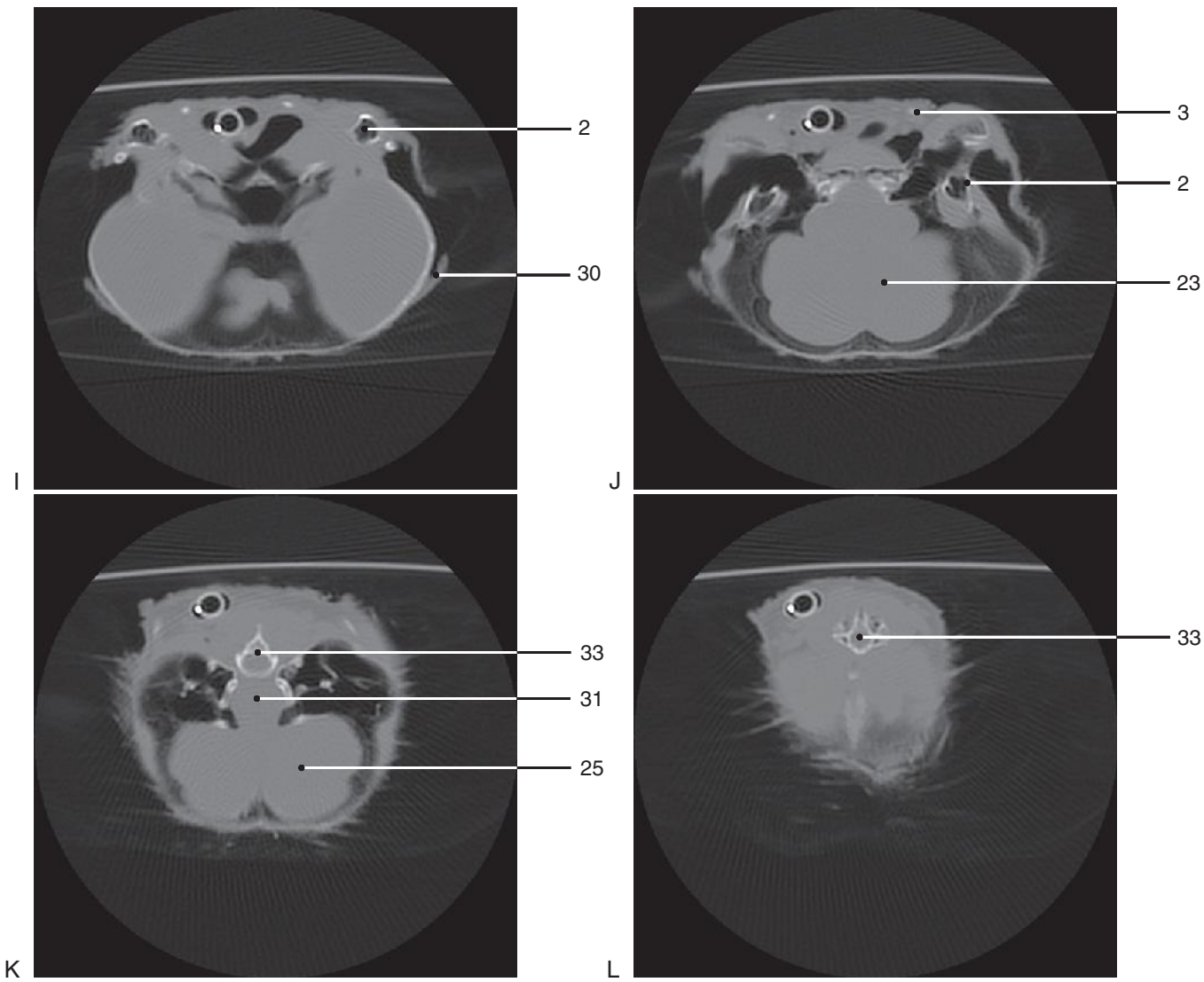

Figure 18-15, I-L
Type of Bird: Great Horned Owl
Type of Study: CT head
Contrast Medium: None
Imaging Plane: Transverse
Weight of Bird: 1.4 kg
Age: Adult

1. (Tongue)
2. Mandible
3. Hyoid bone
4. (Endotracheal tube)
5. (Keratinized maxillary beak)
6. (Nasal cavity)
7. (Nasal concha)
8. (Pharynx)
9. (Premaxillary bone)
10. (Infraorbital sinus)
11. (Nasal septum)
12. (Choana)
13. (Palatine bone)
14. (Sphenoid bone)
15. (Jugal [zygomatic] bone)
16. (Frontal bone)
17. (Pterygoid bone)
18. (Eyeball)
19. (Scleral ossicle)
20. (Interorbital septum)
21. (Lens of eyeball)
22. (Trachea)
23. Cerebrum
24. (External ear canal)
25. Cerebellum
26. (Spinal cord)
27. (Dens)
28. (Cere)
29. (Nare[s])
30. Feather
31. Pons
32. (Occipital bone)
33. Cervical vertebra

NOTE: Structures in parentheses are not labeled.

INDEX

A

African grey parrot *(Psittacus erithacus erithacus)*, 67-73
  infraorbital sinus contrast study
    laterolateral view of, 72*f*
    ventrodorsal view of, 73*f*
  viscera of coelom
    laterolateral view of, 68*f*
    ventrodorsal view of, 69*f*
  whole body skeleton
    laterolateral view of, 70*f*
    ventrodorsal view of, 71*f*
Agapornis roseicollis. *See* Peach-faced lovebird.
Air sacs
  See also Viscera.
  inflation of, 3
Airway aspiration during radiography, 3-4
Alula. *See* Wing.
Amazona amazonica. *See* Orange-winged Amazon parrot.
Anas platyrhynchos. *See* Mallard duck.
Anatomic art, 17-23
  lateral view
    of skeleton, 22*f*
    of skull, 20*f*
    of viscera, 18*f*
  ventral view
    of skeleton, 23*f*
    of skull, 21*f*
    of viscera, 19*f*
Anatomy of the Domestic Birds, 2
Anesthesia
  for digestive tract contrast studies, 10
  for radiography, 3-4, 6
Ara ararauna. *See* Blue and gold macaw.
Aratinga solstitialis. *See* Sun conure.
Arteries. *See* Viscera.
Asymetrix Detail Intensifying Screen, 2
Atlas of Avian Anatomy: Osteology-Arthrology-Mycology, 2
Atlas of Avian Radiographic Anatomy, 2
Atlas of Radiographic Anatomy and Diagnosis of Cage Birds, 2

B

Bandage gauze, in positioning, 5, 7
Barium sulfate as contrast medium, 9
Beak, maxillary and mandibular. *See* Head.
Bird Board, 4, 4*f*
Blue and gold macaw (*Ara ararauna)*, 125-145
  CT head, transverse view of, 142-145*f*
  gastrointestinal positive contrast study
    laterolateral view of, 136-138*f*
    ventrodorsal view of, 139-141*f*
  head
    laterolateral view of, 128*f*
    ventrodorsal view of, 129*f*
  pelvic limb, mediolateral view of, 134*f*
  skeleton, whole body
Blue and gold macaw (*Ara ararauna) (Continued)*
    laterolateral view of, 130*f*
    ventrodorsal view of, 131*f*
  viscera of coelom
    laterolateral view of, 126*f*
    ventrodorsal view of, 127*f*
  wing
    caudocranial view, 133*f*
    mediolateral view, 132*f*
Bones. *See* Head; Pelvic limb; Skeleton, whole body; Wing.
Bubo virginianus. *See* Great horned owl.
Budgerigar (*Melopsittacus undulates)*, 25-27
  viscera of coelom
    laterolateral view of, 26*f*
    ventrodorsal view of, 27*f*
Buteo jamaicensis. *See* Red tailed hawk.

C

Cacatua (Cacatua) alba. *See* Umbrella cockatoo.
Cacatua galerita. *See* Sulphur-crested cockatoo.
Cacatua (Licmetis) goffini). *See* Goffin cockatoo.
Cacatua moluccensis. *See* Moluccan cockatoo.
Carbon dioxide for contrast medium removal, 13
Caudocranial view
  of pelvic limb
    of great horned owl, 259*f*
    of mallard duck, 213*f*
    of Moluccan cockatoo, 171*f*
    of orange-winged Amazon parrot, 89*f*
    of pigeon, 189*f*
    of red tailed hawk, 236*f*
  positioning techniques
    of leg, 7, 12*f*
    of wing, 6-7, 10*f*
  of wing
    of blue and gold macaw, 133*f*
    of great horned owl, 257*f*
    of mallard duck, 211*f*
    of Moluccan cockatoo, 169*f*
    of orange-winged Amazon parrot, 87*f*
    of pigeon, 187*f*
    of red tailed hawk, 235*f*
Cerebellum. *See* Head.
Cerebrum. *See* Head.
Clavicle. *See* Skeleton, whole body.
Cloaca
  See also Viscera.
  double contrast studies of, 13
  laterolateral view
    of orange-winged Amazon parrot, 102*f*-103*f*
    of pigeon, 200*f*
  ventrodorsal view
    of orange-winged Amazon parrot, 104*f*-105*f*
    of pigeon, 201*f*
Cockatiel *(Nymphicus hollandicus)*, 39-45
  gastrointestinal positive contrast study

Note: page numbers followed by *f* indicate figures, *t* indicate tables.

Cockatiel *(Nymphicus hollandicus) (Continued)*
ventrodorsal view of, 42*f*-43*f*, 44*f*-45*f*
viscera of coelom
laterolateral view of, 40*f*
ventrodorsal view of, 41*f*
Cockatoo. *See* Goffin cockatoo; Moluccan cockatoo; Sulphur-crested cockatoo; Umbrella cockatoo.
Coelom
See also Viscera of coelom.
CT transverse view
of mallard duck, 225*f*-226*f*
of red tailed hawk, 245*f*-248*f*
Color Atlas of Avian Anatomy, 2
Columba livia. *See* Pigeon.
Computerized tomography (CT), 14-15
transverse view
coelom
of mallard duck, 225*f*-226*f*
of orange-winged Amazon parrot, 113*f*-117*f*
of red tailed hawk, 245*f*-248*f*
head
of great horned owl, 268*f*-270*f*
of mallard duck, 221*f*-224*f*
of orange-winged Amazon parrot, 110*f*-112*f*
of sulphur-crested cockatoo, 152*f*, 153*f*
Contrast studies
of gastrointestinal tract, 8-14
of urinary tract, 14
Coracoid. *See* Skeleton, whole body.
Craniofacial flexion zone. *See* Head.
Cranium. *See* Head.
Crop. *See* Viscera.
CT. *See* Computerized tomography.

D

Diatrizoate meglumine, 10
Digestive tract. *See* Gastrointestinal tract.
Digital radiology systems, 3
Digits of foot, positioning of, 8
Dorsoplantar view of pelvic limb
of great horned owl, 261*f*
of mallard duck, 215*f*
of Moluccan cockatoo, 173*f*
of orange-winged Amazon parrot, 91*f*
of pigeon, 191*f*
positioning techniques for, 7-8, 13*f*, 14*f*
of red tailed hawk, 238*f*
Dose of contrast medium, 10
Double contrast digestive tract studies, 12-13
Duck. *See* Mallard duck.

E

Equipment for radiology. *See* Radiology, equipment for.
Esophagus. *See* Viscera.
Excretory urogram
laterolateral view
of mallard duck, 219*f*, 220*f*
of orange-winged Amazon parrot, 106*f*-107*f*
ventrodorsal view of orange-winged Amazon parrot, 108*f*-109*f*
Exposure factors, timing of, 2, 3, 3*t*
Eyeball. *See* Head.

F

Fasting period, 8
Feather. *See* Head.
Feeding before radiography, 3, 9
Femur. *See* Skeleton, whole body.
Fibula. *See* Skeleton, whole body.
Film, radiographic, 2-3
Flight feathers, positioning of, 5
Focal film distance (FFD), 2
Focal spot, 2
Food deprivation, 3
Foot, mediolateral and dorsoplantar studies of, 7-8, 13, 14*f*
Foramina. *See* Skeleton, whole body.

G

Gastrografin, 10
Gastrointestinal tract
distension during radiography, 3-4
double contrast study
laterolateral view
of orange-winged Amazon parrot, 98*f*-99*f*
of Senegal parrot, 62*f*-63*f*
ventrodorsal view of orange-winged Amazon parrot, 100*f*-101*f*
positive contrast study
laterolateral view
of blue and gold macaw, 136*f*-138*f*
of great horned owl, 262*f*-264*f*
of mallard duck, 216*f*
of Moluccan cockatoo, 174*f*
of orange-winged Amazon parrot, 92*f*-94*f*
of peach-faced lovebird, 32*f*-34*f*
of pigeon, 184*f*-186*f*
of red tailed hawk, 239*f*-241*f*
of Senegal parrot, 54*f*-57*f*
ventrodorsal view
of blue and gold macaw, 139*f*-141*f*
of cockatiel, 42*f*-45*f*
of great horned owl, 265*f*-267*f*
of mallard duck, 217*f*-218*f*
of Moluccan cockatoo, 175
of orange-winged Amazon parrot, 95*f*-96*f*
of peach-faced lovebird, 35*f*-37*f*
of pigeon, 197-199
of red tailed hawk, 242-244
of Senegal parrot, 58*f*-61*f*
radiographic contrast studies of, 8-14
Gavage tube, 10
Goffin cockatoo (*Cacatua [Licmetis] goffini)*, 147-149
viscera of coelom
laterolateral view of, 148*f*
ventrodorsal view of, 149*f*
Gonads. *See* Viscera.
Great horned owl (*Bubo virginianus)*, 249-270
gastrointestinal positive contrast study
laterolateral view of 262*f*-264*f*
ventrodorsal view of, 265*f*-267*f*
head, CT transverse view, 268*f*-270*f*
laterolateral view of, 252*f*
ventrodorsal view of, 253*f*
pelvic limb
caudocranial view of, 259*f*
dorsoplantar view of, 261*f*
mediolateral view of, 258*f*, 260*f*
skeleton, whole body
laterolateral view of, 254*f*
ventrodorsal view of, 255*f*
viscera of coelom
laterolateral view of, 250
ventrodorsal view of, 251*f*
wing
caudocranial view of, 257*f*
mediolateral view of, 256*f*
Guillotine, in positioning, 5-7

H

Hawk, red tailed. *See* Red tailed hawk.
Head
CT transverse view
of blue and gold macaw, 142*f*-145*f*
of great horned owl, 268*f*-270*f*
of mallard duck, 221*f*-224*f*
of Moluccan cockatoo, 176*f*-178*f*
of sulphur-crested cockatoo, 152*f*, 153*f*

Head *(Continued)*
laterolateral and ventrodorsal studies, 4, 5*f*, 6*f*
laterolateral view
of blue and gold macaw, 128*f*
of great horned owl, 252*f*
of mallard duck, 206*f*
of Moluccan cockatoo, 164*f*
of orange-winged Amazon parrot, 80f
of pigeon, 182*f*
of red tailed hawk, 230*f*
oblique view of orange-winged Amazon parrot, 81*f*
ventrodorsal view
of blue and gold macaw, 129*f*
of great horned owl, 253*f*
of mallard duck, 207*f*
of Moluccan cockatoo, 165*f*
of orange-winged Amazon parrot, 82*f*-83*f*
of pigeon, 183*f*
of red tailed hawk, 231*f*
Heart. *See* Viscera.
Humerus. *See* Skeleton, whole body; Wing.
Hyperalimentation preparations, 9

I

Ilium. *See* Skeleton, whole body.
Infraorbital sinus contrast study
of African grey parrot
laterolateral view of, 72*f*
ventrodorsal view of, 73*f*
MRI studies, 15
Inglovies (crop), emptying of, 8
Innovet Select 20kHz High-Frequency Radiographic Machine, 2
Intestines. *See* Viscera.
Ischium. *See* Skeleton, whole body.

K

Kidney. *See* Viscera.
Killivolt settings, 2

L

Lateral view
of skeleton, 22*f*
of skull, 20*f*
of viscera, 18*f*
Laterolateral view
of cloaca
of orange-winged Amazon parrot, 102*f*-103*f*
of pigeon, 200*f*
of excretory urogram
of mallard duck, 219*f*, 220*f*
of orange-winged Amazon parrot, 106*f*-107*f*
of gastrointestinal double contrast study
of orange-winged Amazon parrot, 98*f*-99*f*
of Senegal parrot, 62*f*-63*f*
of gastrointestinal positive contrast study
of blue and gold macaw, 136*f*-138*f*
of great horned owl, 262*f*-264
of mallard duck, 216*f*
of Moluccan cockatoo, 174*f*
of orange-winged Amazon parrot, 91*f*-94*f*
of peach-faced lovebird, 32*f*-34*f*
of pigeon, 184*f*-186*f*
of red tailed hawk, 239*f*-241*f*
of head
of blue and gold macaw, 128*f*
of great horned owl, 252*f*
of mallard duck, 206*f*
of Moluccan cockatoo, 164*f*
of orange-winged Amazon parrot, 80*f*
of pigeon, 182*f*
of red tailed hawk, 230*f*
infraorbital sinus contrast study of African grey parrot, 72*f*
positioning techniques

Laterolateral view *(Continued)*
of coelom, 4-5, 7*f*
of head, 4, 5*f*, 6*f*
respiratory series of pigeon, 192*f*-193*f*
of skeleton, whole body
of African grey parrot, 70*f*
of blue and gold macaw, 130*f*
of great horned owl, 254*f*
of mallard duck, 208*f*
of Moluccan cockatoo, 166*f*
of orange-winged Amazon parrot, 84*f*
of pigeon, 184*f*
of red tailed hawk, 232*f*
of viscera of coelom
of African grey parrot, 68*f*
of blue and gold macaw, 126*f*
of budgerigar, 26*f*
of cockatiel, 40*f*
of Goffin cockatoo, 148
of great horned owl, 250*f*
of mallard duck, 204*f*
of Moluccan cockatoo, 160*f*, 162*f*
of orange-winged Amazon parrot, 76*f*, 78*f*
of peach-faced lovebird, 30*f*
of pigeon, 180*f*
of red tailed hawk, 228*f*
of Senegal parrot, 52*f*
of sun conure, 48*f*
of umbrella cockatoo, 156*f*
Leg
See also Pelvic limb.
craniocaudal study of, 7, 12*f*
mediolateral study of, 7, 11*f*
Liver
See also Viscera.
ultrasound of orange-winged Amazon parrot, 124*f*
Lovebird, peach-faced. *See* Peach-faced lovebird.
Lungs
See also Viscera.
aspiration of contrast medium, 12
CT studies of, 15

M

Macaw. *See* Blue and gold macaw.
Magnetic resonance imaging (MRI), 14-15
Mallard duck (*Anas platyrhynchos*), 203*f*-226*f*
coelom, CT transverse view of, 225*f*-226*f*
excretory urogram, laterolateral view of, 219*f*, 220*f*
gastrointestinal positive contrast study
laterolateral view of, 216*f*
ventrodorsal view of, 217*f*-218*f*
head
CT transverse view of, 221*f*-224*f*
laterolateral view of, 206*f*
ventrodorsal view of, 207*f*
pelvic limb
caudocranial view of, 213*f*
dorsoplantar view of, 215*f*
mediolateral view of, 212*f*, 214*f*
skeleton, whole body
laterolateral view, 208*f*
ventrodorsal view, 209*f*
viscera of coelom
laterolateral view, 204*f*
ventrodorsal view, 205*f*
wing
caudocranial view, 211*f*
mediolateral view, 210*f*
Mandible
See Head.
Masking tape. *See* Positioning techniques.

Mediolateral view
of pelvic limb
of blue and gold macaw, 134*f*
of great horned owl, 258*f*, 260*f*
of mallard duck, 212*f*, 214*f*
of Moluccan cockatoo, 170*f*, 172*f*
of orange-winged Amazon parrot, 88*f*, 90*f*
of pigeon, 188*f*, 190*f*
of red tailed hawk, 235*f*, 237*f*
positioning techniques
of foot, 7-8, 13*f*, 14*f*
of leg, 7, 11*f*
of wing, 6, 9*f*
of wing
of blue and gold macaw, 132*f*
of great horned owl, 256*f*
of mallard duck, 210*f*
of Moluccan cockatoo, 168*f*
of orange-winged Amazon parrot, 86*f*
of pigeon, 186*f*
of red tailed hawk, 234*f*
Melopsittacus undulates. *See* Budgerigar.
Metallic markers, in positioning, 5-7
Metals in MRI studies, 15
Moluccan cockatoo (*Cacatua moluccensis)*, 159-178
CT head, 176*f*-178*f*
gastrointestinal positive contrast study
laterolateral view of, 174*f*
ventrodorsal view of, 175*f*
head
laterolateral view of, 164*f*
ventrodorsal view of 165*f*
pelvic limb
caudocranial view of, 171*f*
dorsoplantar limb of, 173*f*
mediolateral view, 170*f*, 172*f*
skeleton, whole body
laterolateral view, 166*f*
ventrodorsal view, 167*f*
viscera of coelom
laterolateral view, 160*f*, 162*f*
ventrodorsal view, 161*f*, 163*f*
wing
caudocranial view, 169*f*
mediolateral view, 168*f*
MRI of head, of orange-winged Amazon parrot
sagittal view, 118*f*-120*f*
transverse view, 121*f*-123*f*
Muscle movements, 3

N

Novopaque. *See* Barium sulfate.
Nymphicus hollandicus. *See* Cockatiel.

O

Object film distance (OFD), 6, 7
Oblique view of head, of orange-winged Amazon parrot, 81*f*
Orange-winged Amazon parrot *(Amazona amazonica)*, 75-124
cloacogram
laterolateral view of, 102*f*-103*f*
ventrodorsal view of, 104*f*-105*f*
CT, transverse view
of coelom, 113*f*-115*f*, 116*f*-117*f*
head, 110*f*-112*f*
excretory urogram
laterolateral view of, 106*f*-107*f*
ventrodorsal view of, 108*f*-109*f*
gastrointestinal double contrast study
laterolateral view of, 98*f*-99*f*
ventrodorsal view of, 100*f*-101*f*
gastrointestinal positive contrast study
laterolateral view of, 92*f*-94*f*
ventrodorsal view of, 95*f*-97*f*
Orange-winged Amazon parrot *(Amazona amazonica)* *(Continued)*
head
laterolateral view of, 80*f*
oblique view, 81*f*
ventrodorsal view, 82*f*-83*f*
liver ultrasound, sagittal view, 124*f*
MRI of head
sagittal view, 118*f*-120*f*
transverse view, 121*f*-123*f*
pelvic limb
craniocaudal view of, 89*f*
dorsoplantar view of, 91*f*
mediolateral view of, 88*f*, 90*f*
skeleton, whole body
laterolateral view of, 84*f*
ventrodorsal view of, 85*f*
viscera of coelom
laterolateral view of, 76*f*, 78*f*
ventrodorsal view of, 77*f*, 79*f*
wing
caudocranial view of, 87*f*
mediolateral view of, 86*f*
Orbit. *See* Head.
Ovary. *See* Viscera.
Owl, great horned. *See* Great horned owl.

P

Parrot. *See* African grey parrot; Orange-winged Amazon parrot; Senegal parrot.
Patella. *See* Skeleton, whole body.
Patient positioning. *See* Positioning techniques.
Peach-faced lovebird *(Agapornis roseicollis)*, 29-37
gastrointestinal positive contrast
laterolateral view of, 32*f*-34*f*
ventrodorsal view of, 35*f*-37*f*
viscera of coelom
laterolateral view of, 30*f*
ventrodorsal view of, 31*f*
Pelleted food, 3, 9
Pelvic extremity. *See* Foot.
Pelvic limb
See also Leg.
caudocranial view
of great horned owl, 259*f*
of mallard duck, 213*f*
of Moluccan cockatoo, 171*f*
of orange-winged Amazon parrot, 89*f*
of pigeon, 189*f*
of red tailed hawk, 236*f*
dorsoplantar view
of great horned owl, 261*f*
of mallard duck, 215
of Moluccan cockatoo, 173*f*
of orange-winged Amazon parrot, 91*f*
of pigeon, 191*f*
of red tailed hawk, 238*f*
mediolateral view
of blue and gold macaw, 134*f*
of great horned owl, 258*f*, 260*f*
of mallard duck, 212*f*, 214*f*
of Moluccan cockatoo, 170*f*, 172*f*
of orange-winged Amazon parrot, 88*f*, 90*f*
of pigeon, 188*f*, 190*f*
of red tailed hawk, 235*f*, 237*f*
Phalanges
See also Pelvic limb; Wing.
positioning of, 8
Pharynx. *See* Head.
Pigeon (*Columba livia)*, 179-201
cloaca
laterolateral view of, 200*f*
ventrodorsal view of, 201*f*

Pigeon (*Columba livia*) *(Continued)*
gastrointestinal positive contrast study
laterolateral view of, 184*f*-186*f*
ventrodorsal view of, 197*f*-199*f*
head
laterolateral view of, 182*f*
ventrodorsal view of, 183*f*
pelvic limb
caudocranial view of, 189*f*
dorsoplantar view of, 191*f*
mediolateral view of, 188*f*, 190*f*
respiratory series, laterolateral view of, 192*f*-193*f*
skeleton, whole body
laterolateral view of, 184*f*
ventrodorsal view of, 185*f*
viscera of coelom
laterolateral view of 180*f*
ventrodorsal view of, 181*f*
wing
caudocranial view of, 187*f*
mediolateral view of, 186*f*
Poicephalus senegalus. See Senegal parrot.
Positioning techniques, 4-8
for caudocranial study of thoracic extremity, 6-7, 10*f*
for craniocaudal study of pelvic limb, 7, 12*f*
devices for, 4, 4*f*
for laterolateral and ventrodorsal studies of head, 4, 5*f*, 6*f*
for laterolateral study of coelom, 4-5, 7*f*
for mediolateral and dorsoplantar study of foot, 7-8, 13*f*, 14*f*
for mediolateral study
of pelvic limb, 7, 11*f*
of thoracic extremity, 6, 9*f*
for ventrodorsal study of coelom, 6, 8*f*
Proventriculus
See also Viscera.
emptying of, 8
Psittacus erithacus erithacus. See African grey parrot.
Pubis. *See* Skeleton, whole body.
Pygostyle. *See* Skeleton, whole body.

R

Radiology
equipment for
digital systems, 3
film-intensifying screens, 2-3, 2*t*
radiographic units, 2
examination for
anesthesia, 3-4
patient preparation, 3
positioning devices, 2*f*, 4
timing of exposure, 3
Radius. *See* Wing.
Red tailed hawk (*Buteo jamaicensis*), 227-248
coelom, CT transverse view of, 245*f*-248*f*
gastrointestinal positive contrast study
laterolateral view of, 239*f*-241*f*
ventrodorsal view of, 242*f*-244*f*
head
laterolateral view of, 230*f*
ventrodorsal view of, 231*f*
pelvic limb
caudocranial view of, 236*f*
dorsoplantar view of, 238*f*
mediolateral view of, 235*f*, 237*f*
skeleton, whole body
laterolateral view of, 232*f*
ventrodorsal view of, 233*f*
viscera of coelom
laterolateral view of, 228*f*
ventrodorsal view of, 229*f*
wing
caudocranial view of, 235*f*
mediolateral view of, 234*f*
References, anatomic, 2
Regurgitation
of contrast medium, 11
during radiography, 3-4
Respiratory movements, 3
Respiratory series, laterolateral view of pigeon, 192*f*-193*f*
Ribs. *See* Skeleton, whole body.

S

Sagittal view
of liver ultrasound, of orange-winged Amazon parrot, 124*f*
MRI head, of orange-winged Amazon parrot, 118*f*-120*f*
Scapula. *See* Skeleton, whole body.
Scatter radiation, 2
Screens, intensifying, 2-3
Sedation for radiography, 4
Senegal parrot *(Poicephalus senegalus)*, 51-64
gastrointestinal double contrast study, laterolateral view, 62*f*-63*f*
gastrointestinal positive contrast study
laterolateral view of, 54*f*-57*f*
ventrodorsal view of, 58*f*-61*f*
viscera of coelom
laterolateral view of, 52*f*
ventrodorsal view of, 53*f*
Skeleton, whole body
lateral view of, 22*f*
laterolateral view
of African grey parrot, 70*f*
of blue and gold macaw, 130*f*
of great horned owl, 254*f*
of mallard duck, 208*f*
of Moluccan cockatoo, 166*f*
of orange-winged Amazon parrot, 83*f*-84*f*
of pigeon, 184*f*
of red tailed hawk, 232*f*
ventral view of, 23*f*
ventrodorsal view
of African grey parrot, 71*f*
of blue and gold macaw, 130*f*
of great horned owl, 255
of mallard duck, 209*f*
of Moluccan cockatoo, 167*f*
of orange-winged Amazon parrot, 85*f*
of pigeon, 185*f*
of red tailed hawk, 233*f*
Skull
CT and MRI studies, 15
lateral view of, 20*f*
ventral view of, 21*f*
Spinal cord. *See* Head.
Spleen. *See* Viscera.
Sponge, radiolucent, in positioning, 5
Sternum. *See* Skeleton, whole body.
Sulphur-crested cockatoo (*Cacatua galerita*), 151-153
CT head transverse view, 152, 153
Sun conure *(Aratinga solstitialis)*, 47-49
viscera of coelom
laterolateral view, 48*f*
ventrodorsal view, 49*f*
Survey radiography, 9, 14
Synsacrum. *See* Skeleton, whole body.
Syrinx. *See* Viscera.

T

Temperature of contrast medium, 9
Testes. *See* Viscera.
Textbook references, 2
Thoracic extremity. *See* Wing.
Timing of digestive tract radiography, 12
Tongue. *See* Head.

Trachea
See also Viscera.
aspiration of contrast medium, 11
Transit times in digestive tract, 12
Transverse view
CT
of coelom
of mallard duck, 225*f*-226*f*
of orange-winged Amazon parrot, 113*f*-115*f*, 116*f*-117*f*
of red tailed hawk, 245*f*-248*f*
of head
of blue and gold macaw, 142*f*-145*f*
of great horned owl, 268*f*-270*f*
of mallard duck, 221*f*-224*f*
of Moluccan cockatoo, 176*f*-178*f*
of orange-winged Amazon parrot, 110*f*-112*f*
of sulphur-crested cockatoo, 152*f*, 153*f*
MRI of head, of orange-winged Amazon parrot, 121*f*-123*f*
Tubes, X-ray, 2

U
Ulna. *See* Wing.
Ultra Detail Plus radiographic film, 2
Ultrasonography of liver, of orange-winged Amazon parrot, 124*f*
Umbrella cockatoo (*Cacatua [Cacatua] alba)*, 155*f*-157*f*
viscera of coelom
laterolateral view, 156*f*
ventrodorsal view, 157*f*
Units, radiographic, 2
Urinary tract
See also Excretory urogram.
radiographic contrast studies of, 14

V
Veins. *See* Viscera.
Ventilation, positive pressure, 3
Ventral view
of skeleton, 23*f*
of skull, 21*f*
of viscera, 19*f*
Ventriculus. *See* Viscera.
Ventrodorsal view
of cloaca
of orange-winged Amazon parrot, 104*f*-105*f*
of pigeon, 201*f*
of excretory urogram, of orange-winged Amazon parrot, 108*f*-109*f*
of gastrointestinal double contrast study, of orange-winged Amazon parrot, 100*f*-101*f*
of gastrointestinal positive contrast study
of blue and gold macaw, 139*f*-141*f*
of cockatiel, 42*f*-45*f*
of great horned owl, 265*f*-267*f*
of mallard duck, 217*f*-218*f*
of Moluccan cockatoo, 175*f*
of orange-winged Amazon parrot, 95*f*-97*f*
of peach-faced lovebird, 35*f*-37*f*
of pigeon, 197*f*-199*f*
of red tailed hawk, 242*f*-244*f*
of head
of blue and gold macaw, 129*f*
of great horned owl, 253*f*
of mallard duck, 207*f*
of Moluccan cockatoo, 165*f*
of orange-winged Amazon parrot, 82*f*
of pigeon, 183*f*
of red tailed hawk, 231*f*
infraorbital sinus contrast study, of African grey parrot, 73*f*
positioning techniques
of coelom, 6, 8*f*
of head, 4, 5*f*, 6*f*
Ventrodorsal view *(Continued)*
of skeleton, whole body
of African grey parrot, 71*f*
of blue and gold macaw, 131*f*
of great horned owl, 255*f*
of mallard duck, 209*f*
of Moluccan cockatoo, 167*f*
of orange-winged Amazon parrot, 85*f*
of pigeon, 185*f*
of red tailed hawk, 233*f*
of viscera of coelom
of African grey parrot, 69*f*
of blue and gold macaw, 127*f*
of budgerigar, 27*f*
of cockatiel, 41*f*
of Goffin cockatoo, 149*f*
of great horned owl, 251*f*
of mallard duck, 205*f*
of Moluccan cockatoo, 161*f*, 163*f*
of orange-winged Amazon parrot, 77*f*, 79*f*
of peach-faced lovebird, 31*f*
of pigeon, 181*f*
of red tailed hawk, 229*f*
of Senegal parrot, 53*f*
of sun conure, 49*f*
of umbrella cockatoo, 157*f*
Vertebra. *See* Skeleton, whole body.
Viscera of coelom
drawings
of lateral view, 18*f*
of ventral view, 19*f*
laterolateral view
of African grey parrot, 68*f*
of blue and gold macaw, 126*f*
of budgerigar, 26*f*
of cockatiel, 40*f*
of Goffin cockatoo, 148*f*
of great horned owl, 250*f*
of mallard duck, 204*f*
of Moluccan cockatoo, 160*f*, 162*f*
of orange-winged Amazon parrot, 76*f*, 78*f*
of peach-faced lovebird, 30*f*
of pigeon, 180*f*
of red tailed hawk, 228*f*
of Senegal parrot, 52*f*
of sun conure, 48*f*
of umbrella cockatoo, 156
ventrodorsal view
of African grey parrot, 69*f*
of blue and gold macaw, 127*f*
of budgerigar, 27*f*
of cockatiel, 31*f*
of Goffin cockatoo, 149*f*
of great horned owl, 251*f*
of mallard duck, 205*f*
of Moluccan cockatoo, 161*f*, 163*f*
of orange-winged Amazon parrot, 77*f*, 79*f*
of peach-faced lovebird, 31*f*
of pigeon, 181*f*
of red tailed hawk, 229*f*
of Senegal parrot, 53*f*
of sun conure, 49*f*
of umbrella cockatoo, 157*f*
Vomiting from gut anesthetic, 11

W
Wing
caudocranial study, 6-7, 10*f*
of blue and gold macaw, 133*f*
of great horned owl, 257*f*
of mallard duck, 211*f*
of Moluccan cockatoo, 169*f*
of orange-winged Amazon parrot, 87*f*

Wing *(Continued)*
of pigeon, 187*f*
of red tailed hawk, 235*f*
mediolateral study, 6, 9*f*
of blue and gold macaw, 132*f*
of great horned owl, 256*f*
of mallard duck, 210*f*
of Moluccan cockatoo, 168*f*
Wing *(Continued)*
of orange-winged Amazon parrot, 86*f*
of pigeon, 186*f*
of red tailed hawk, 234*f*

X

X-ray generator, radiographic, 2