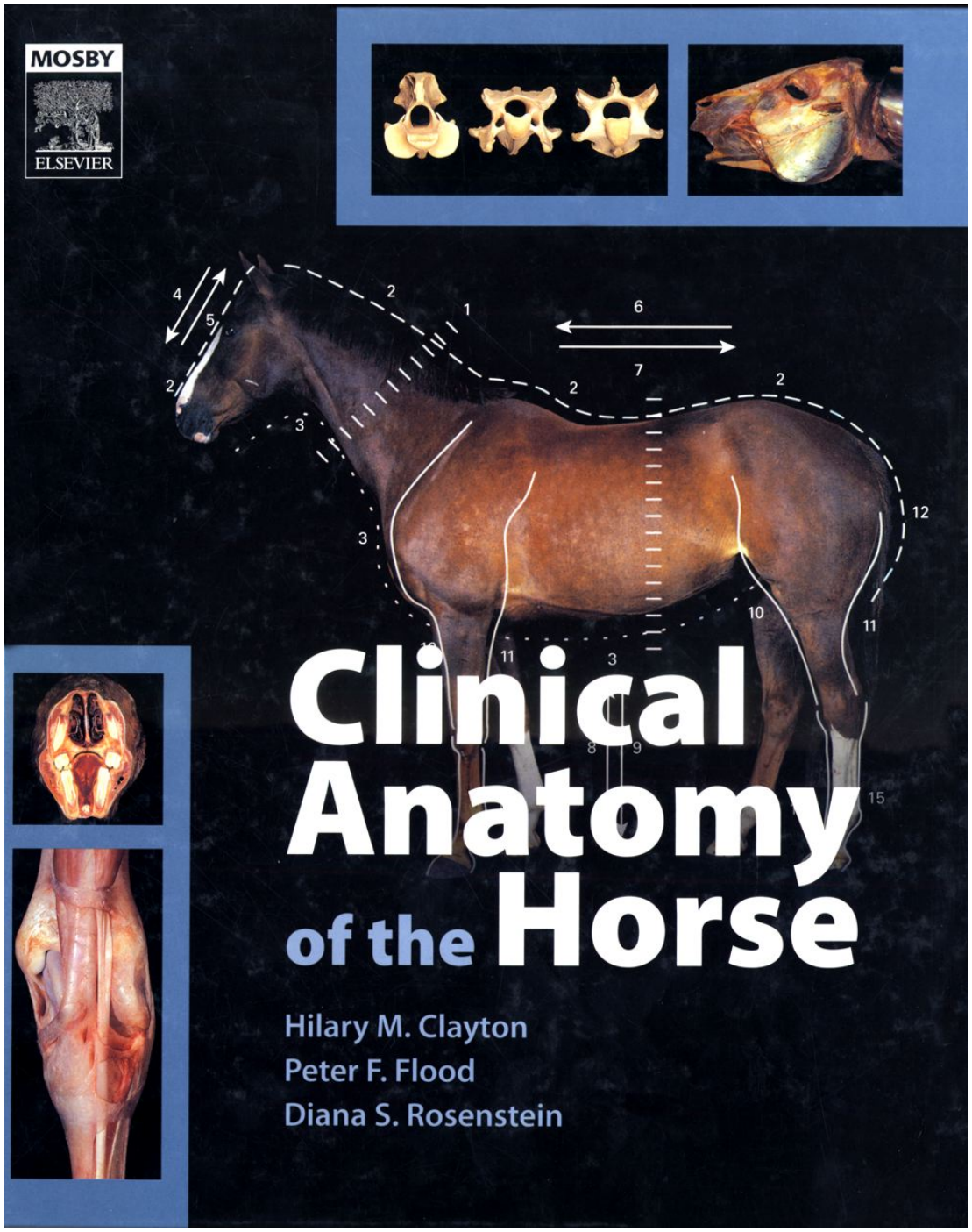
MOSBY
ELSEVIER
Clinical Anatomy of the Horse
Hilary M. Clayton
Peter F. Flood
Diana S. Rosenstein

Clinical Anatomy of the Horse

iii

1st ed.

Hilary M. Clayton, BVMS PhD MRCVS

Mary Anne McPhail Dressage Chair in Equine Sports Medicine, College of Veterinary Medicine, Michigan State University, East Lansing MI 48824-1314, USA

Peter F. Flood, BVSc MSc PhD MRCVS

Professor Emeritus of Veterinary Anatomy, Western College of Veterinary Medicine, University of Saskatchewan, 52 Campus Drive, Saskatoon, Saskatchewan, S7N 5B4, Canada

Diana S. Rosenstein, DVM, MS, DipACVR

Associate Professor of Large Animal Clinical Sciences, College of Veterinary Medicine, Michigan State University, East Lansing MI 48824-1314, USA

David Mandeville

Division of Media Technology, University of Saskatchewan, 28 Campus Drive, Saskatoon, Saskatchewan, S7N 0X1, Canada

0-7234-3302-X

iii

iv

MOSBY ELSEVIER

An affiliate of Elsevier Limited

© Elsevier Limited 2005. All rights reserved.

No part of this publication may be reproduced, stored in a retrieval system, or transmitted in any form or by any means, electronic, mechanical, photocopying, recording or otherwise, without either the prior permission of the publishers or a licence permitting restricted copying in the United Kingdom issued by the Copyright Licensing Agency, 90 Tottenham Court Road, London W1T 4LP. Permissions may be sought directly from Elsevier's Health Sciences Rights Department in Philadelphia, USA: phone: (+1) 215 238 7869, fax: (+1) 215 238 2239, e-mail: healthpermissions@elsevier.com. You may also complete your request on-line via the Elsevier Science homepage (http://www.elsevier.com), by selecting 'Customer Support' and then 'Obtaining Permissions'.

First edition 2005

ISBN 07234 3302 X

British Library Cataloguing in Publication Data

A catalogue record for this book is available from the British Library

Library of Congress Cataloging in Publication Data

A catalog record for this book is available from the Library of Congress

Note

Veterinary knowledge and best practice in this field are constantly changing. As new research and experience broaden our knowledge, changes in practice, treatment and drug therapy may become necessary or appropriate. Readers are advised to check the most current information provided (i) on procedures featured or (ii) by the manufacturer of each product to be administered, to verify the recommended dose or formula, the method and duration of administration, and contraindications. It is the responsibility of the practitioner, relying on their own experience and knowledge of the patient, to make diagnoses, to determine dosages and the best treatment for each individual patient, and to take all appropriate safety precautions. To the fullest extent of the law, neither the publisher nor the authors assume any liability for any injury and/or damage.

Commissioning Editor: Joyce Rodenhuis

Senior Development Editors: Zoë A Youd, Rita Demetriou-Swanwick

Project Manager: Andrew Palfreyman

Design Direction: Stewart Larking

Printed in China

Front Matter iv

1 1 Introduction 1 1

2 2 Head 5 5

3 3 Spinal Column 25 25

4 4 Forelimb and Digit 35 35

5 5 Hindlimb 65 65

6 6 Thoracic Viscera 89 89

7 7 Abdominal and Pelvic Viscera 97

1 Introduction

The illustrations in this atlas include photographs of skeletal preparations, dissections and endoscopic views as well as images obtained by radiology, ultrasonography and computerized tomography. These techniques contribute in different but complementary ways to our understanding of the anatomy of the horse (*Equus caballus*). The atlas is not intended to be a comprehensive anatomical reference book, of which there are several; instead, it is an illuminating companion to these texts. Our intent is to portray those aspects of equine anatomy that are particularly relevant to clinical practice as well as to students of anatomy.

Modern photographic and color printing techniques have been used to provide the best possible images of prepared bones and rapidly dissected, unfixed tissues, giving detailed conceptual information that cannot be readily obtained by other means. Some structures, such as the abdominal viscera, deteriorate rapidly in the fresh state, and in these cases we have given high priority to the accurate portrayal of color and texture.

Anatomy concerns the form and relationships of the parts of the body. Communication between anatomists is facilitated by the use of agreed standardized terms and a list of these has been developed and periodically revised by the International Committee on Veterinary Anatomical Nomenclature. The list, which forms a small book known as the *Nomina Anatomica Veterinaria*[1] (NAV), provides general descriptive terms applicable to all vertebrates, and specific terms related to the structure of the horse. During the preparation of the NAV, every effort has been made to maximize conformity between the human and domestic animal nomenclatures, but because veterinary terminology must be based on the normal quadrupedal stance, rather than the erect human position, there are distinct differences in the terms used for direction. The veterinary terms are related to parts of the body, thus blood that flows towards the head is said to be moving cranially and that flowing towards the tail moves caudally. The directional terms are described in detail in this chapter through annotated photographs of a horse.

The NAV uses Latin to identify anatomical structures. Anatomists are encouraged to translate the original Latin terms into their own languages unless this leads to obvious ambiguity. In general, anglicized terms have been used in this atlas, though the Latin terms have been retained for most muscles. When a structure has a synonym or well-known name in common usage, it is shown in brackets.

1.1 Live horse, lateral view. Topographic terms.

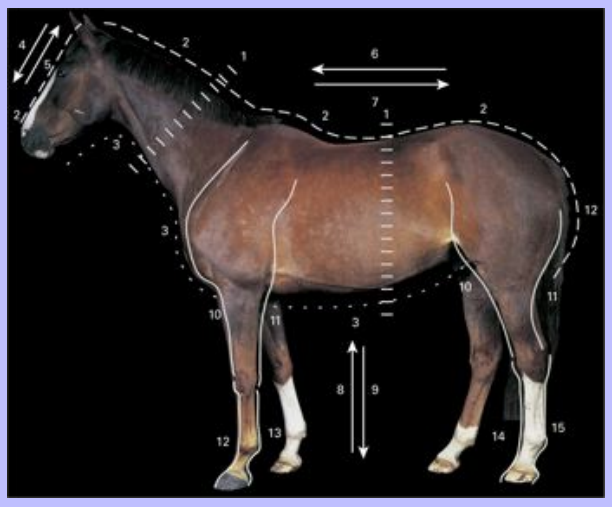

1 Transverse plane – neck, trunk

2 Dorsal – head, neck, trunk, tail

3 Ventral – head, neck, trunk, tail

4 Rostral – head

5 Caudal – head

6 Cranial – neck, trunk, tail

7 Caudal – neck, trunk, tail

8 Proximal – limb

9 Distal – limb

10 Cranial – proximal limb

11 Caudal – proximal limb

12 Dorsal – carpus and digit

13 Palmar – carpus and digit

14 Dorsal – tarsus and digit

15 Plantar – tarsus and digit

Downloaded from Vet-eBooks.com

1.2 Live horse, frontal view. Topographic terms.

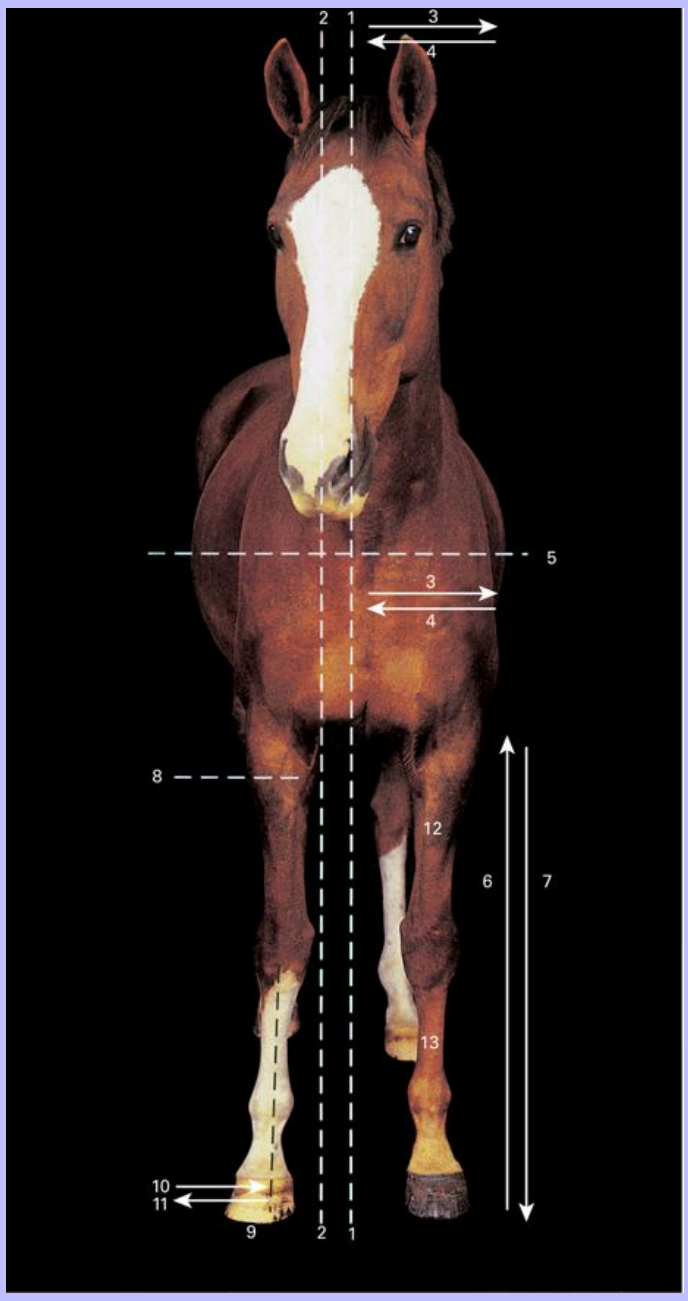

Head, neck, trunk

1 Median plane

Downloaded from Vet-eBooks.com

2 Sagittal plane

3 Lateral

4 Medial

5 Dorsal plane

Limbs

6 Proximal

7 Distal

8 Transverse plane

9 Axial plane

10 Axial

11 Abaxial

12 Cranial

13 Dorsal

3

Downloaded from Vet-eBooks.com

1.3 Live horse, caudal view. Topographic terms.

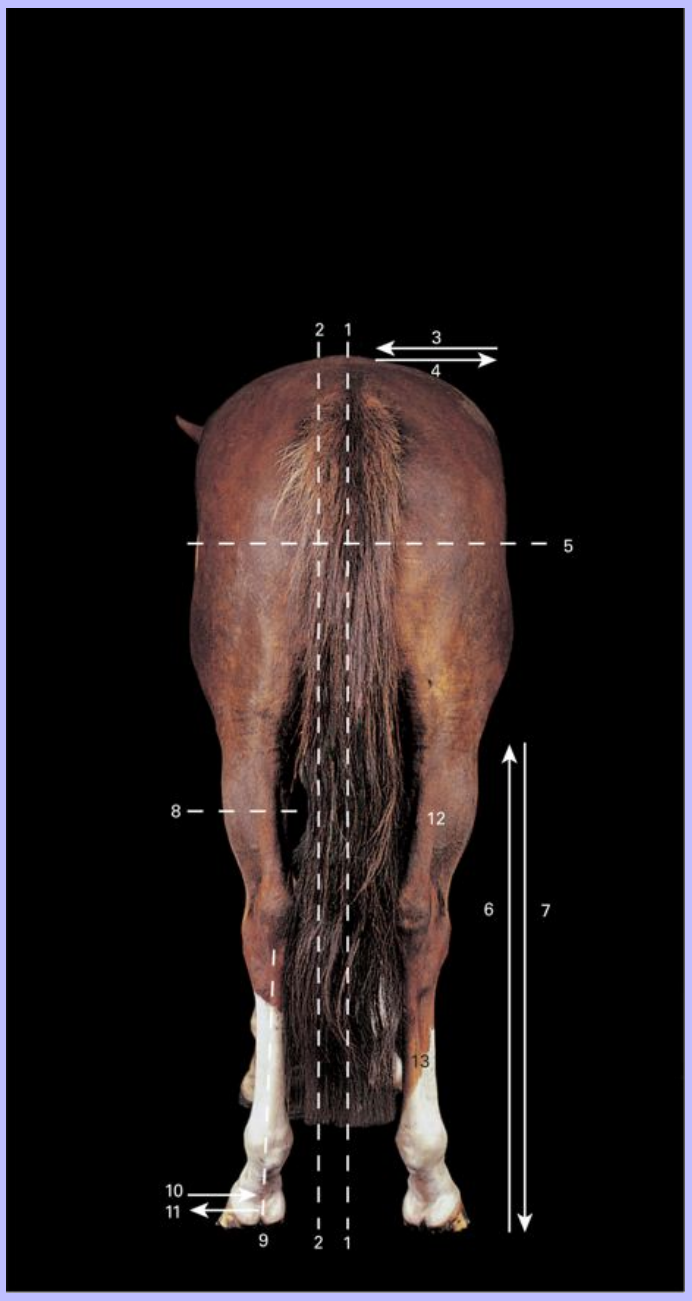

Head, neck, trunk

1 Median plane

Downloaded from Vet-eBooks.com

2 Sagittal plane

3 Medial

4 Lateral

5 Dorsal plane

Limbs

6 Proximal

7 Distal

8 Transverse plane

9 Axial plane

10 Axial

11 Abaxial

12 Caudal

13 Plantar

1 *Nomina Anatomica Veterinaria* (1983, 3rd edition). International Committee on Veterinary Gross Anatomical Nomenclature, Ithaca, New York.

Downloaded from Vet-eBooks.com

2 Head

In this chapter palpable landmarks are indicated on photographs of live animals, osteological features are shown on bone specimens and radiographs, and soft-tissue structures are revealed using a series of prepared dissections, endoscopic views, radiographs and computed tomographic images. Topographical relationships between the bones and soft-tissue structures are clarified using specimens that have been sectioned in various orientations and accompanying images.

Downloaded from Vet-eBooks.com

2.1 Head and neck of live horse, lateral view, demonstrating visible and/or palpable landmarks.

1 Upper lip

2 Cornu of alar cartilage

3 Nostril

4 Lamina of alar cartilage

5 Nasoincisive notch

Downloaded from Vet-eBooks.com

6 Infraorbital foramen

7 Facial crest

8 Facial nerve (VII)

9 Medial commissure of eyelids

10 Sclera (unpigmented in this horse)

11 Zygomatic process

12 Lateral commissure of eyelids

13 Zygomatic arch

14 Pinna

15 Mane

16 Jugular groove

17 M. brachiocephalicus

18 M. sternocephalicus

19 Parotid gland

20 M. masseter

21 Mandible

22 M. depressor labii inferioris

23 M. zygomaticus

24 Commissure of lips

25 Chin

26 Lower lip

5

Downloaded from Vet-eBooks.com

2.2 Bones of skull, dorsal view.

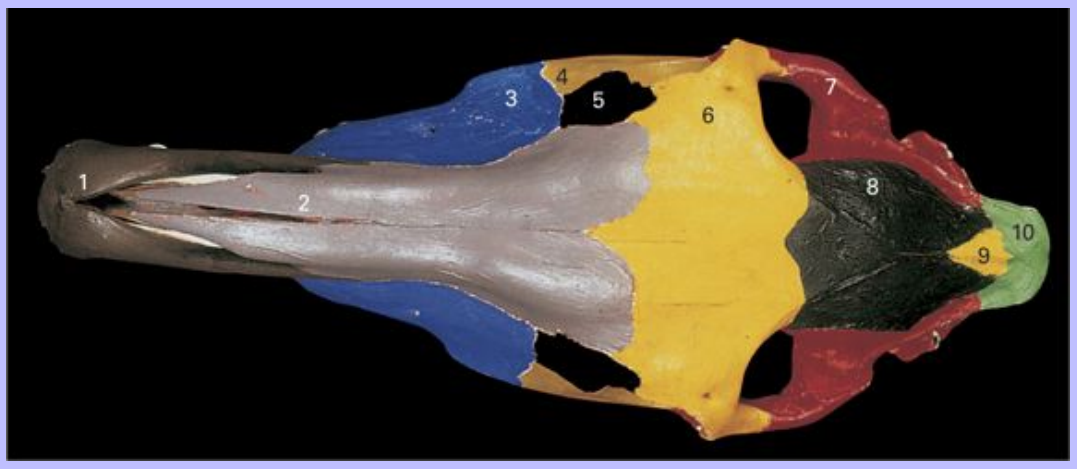

1 Incisive bone

2 Nasal bone

3 Maxilla

4 Zygomatic bone

5 Lacrimal bone

6 Frontal bone

7 Temporal bone

8 Parietal bone

9 Interparietal bone

10 Occipital bone, squamous part

Downloaded from Vet-eBooks.com

2.3 Bones of skull, lateral view.

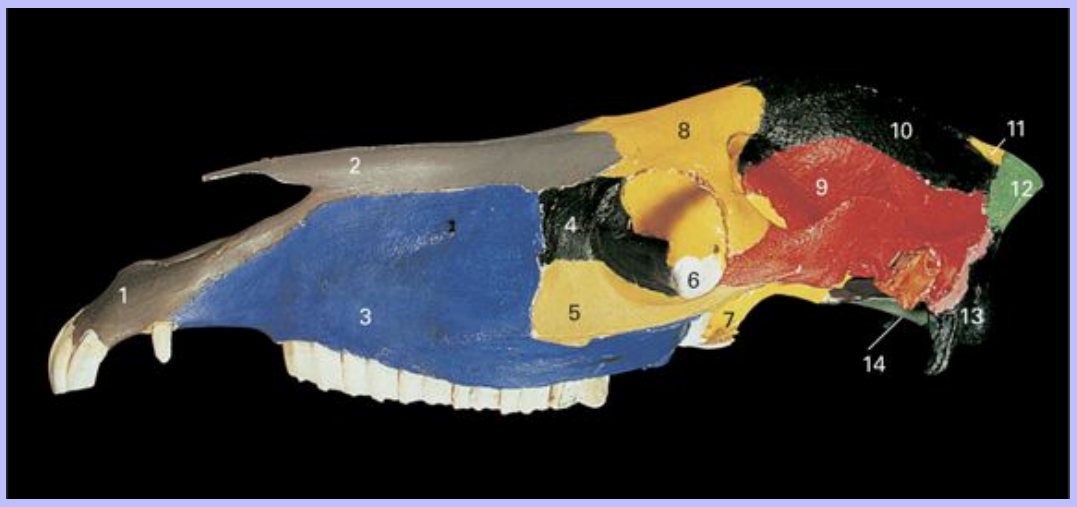

1 Incisive bone

2 Nasal bone

3 Maxilla

4 Lacrimal bone

5 Zygomatic bone

6 Palatine bone, perpendicular plate

7 Presphenoid bone

8 Frontal bone

9 Temporal bone

10 Parietal bone

11 Interparietal bone

12 Occipital bone, squamous part

13 Occipital bone, lateral part

14 Occipital bone, basilar part

Downloaded from Vet-eBooks.com

2.4 Bones of skull, ventral view.

1 Incisive bone

2 Maxilla

3 Palatine bone

4 Vomer

5 Zygomatic bone

6 Frontal bone

7 Sphenoid bone

8 Temporal bone, squamous part

9 Temporal bone, tympanic and petrous parts

10 Occipital bone, basilar part

11 Occipital bone, lateral part

6

Downloaded from Vet-eBooks.com

2.5 Bony features of skull, dorsal view.

1 Interincisive canal

2 Body of incisive bone

3 Nasal process of incisive bone

4 Infraorbital foramen

5 Facial crest

6 Orbit

7 Zygomatic process of frontal bone

8 Zygomatic arch

9 Temporal line

10 Nuchal crest

11 External sagittal crest

12 Temporal fossa

13 Supraorbital foramen

14 Rostral lacrimal process

15 Nasoincisive notch

Downloaded from Vet-eBooks.com

2.6 Bony features of skull, lateral view.

1 Incisor teeth

2 Body of incisive bone

3 Nasal process of incisive bone

4 Nasoincisive notch

5 Infraorbital foramen

6 Facial crest

7 Fossa for lacrimal sac

8 Zygomatic arch

9 Zygomatic process of frontal bone

10 Temporal fossa

11 External sagittal crest

12 Nuchal crest

Downloaded from Vet-eBooks.com

13 Condyloid fossa

14 Occipital condyle

15 Jugular process

16 Mastoid process

17 Stylomastoid foramen

18 Styloid process

19 External acoustic meatus

20 Retroarticular process

21 Mandibular fossa

22 Articular tubercle

23 Condylar process

24 Molar teeth (M^1, M^2, M^3)

25 Premolar teeth (P^2, P^3, P^4)

Downloaded from Vet-eBooks.com

2.7 Skull of mare, ventral view.

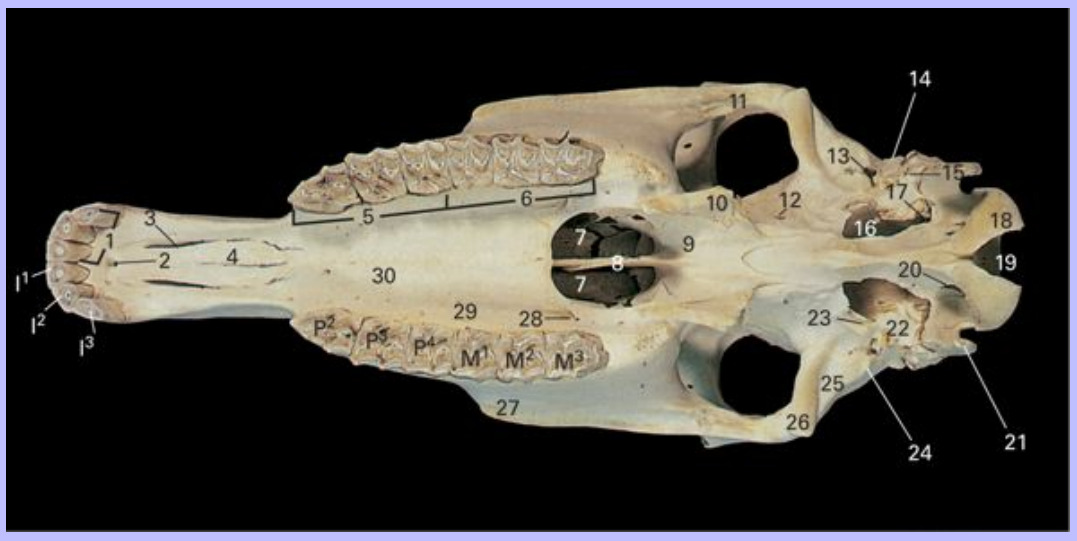

1 Incisor teeth (I^1, I^2, I^3)

2 Interincisive canal

3 Palatine fissure

4 Palatine process of incisive bone

5 Premolar teeth (P^2, P^3, P^4)

6 Molar teeth (M^1, M^2, M^3)

7 Choanae

8 Vomer

9 Wings of vomer

10 Hamulus of pterygoid bone

11 Zygomatic arch

12 Caudal alar foramen

13 Petrotympanic fissure

14 External acoustic meatus

Downloaded from Vet-eBooks.com

15 Stylomastoid foramen

16 Foramen lacerum

17 Jugular foramen

18 Occipital condyle

19 Foramen magnum

20 Hypoglossal canal

21 Jugular process

22 Tympanic bulla

23 Osseous part of auditory tube

24 Retroarticular process

25 Mandibular fossa

26 Articular tubercle

27 Rostral end of facial crest

28 Major palatine foramen

29 Palatine groove

30 Palatine process of maxilla

7

Downloaded from Vet-eBooks.com

2.8 Mandible of mare, dorsal oblique view. Canine teeth are absent.

1 Incisor teeth (I_1, I_2, I_3)

2 Interalveolar border

3 Premolar teeth (P_2, P_3, P_4)

4 Molar teeth (M_1, M_2, M_3)

5 Coronoid process

6 Condylar process

7 Mandibular foramen

8 Ramus of mandible

9 Body of mandible

10 Mental foramen

Downloaded from Vet-eBooks.com

2.9 Skull and mandible of female horse, lateral view.

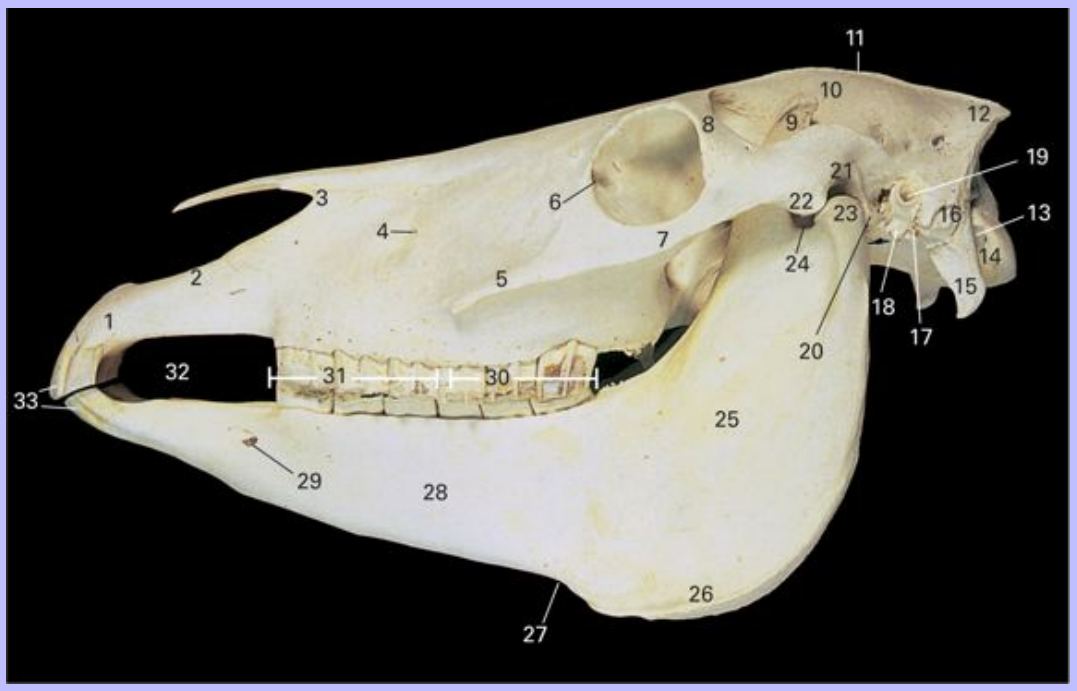

1 Body of incisive bone

2 Nasal process of incisive bone

3 Nasoincisive notch

4 Infraorbital foramen

5 Facial crest

6 Fossa for lacrimal soc

7 Zygomatic arch

8 Zygomatic process of frontal bone

9 Coronoid process

10 Temporal fossa

11 External sagittal crest

12 Nuchal crest

Downloaded from Vet-eBooks.com

13 Condyloid fossa

14 Occipital condyle

15 Jugular process

16 Mastoid process

17 Stylomastoid foramen

18 Styloid process

19 External acoustic meatus

20 Retroarticular process

21 Mandibular fossa

22 Articular tubercle

23 Condylar process

24 Mandibular notch

25 Ramus of mandible

26 Angle of mandible

27 Notch for facial vessels

28 Body of mandible

29 Mental foramen

30 Molar teeth

31 Premolar teeth

32 Interalveolar border

33 Incisor teeth

Downloaded from Vet-eBooks.com

2.10 Lateral view radiograph of horse head.

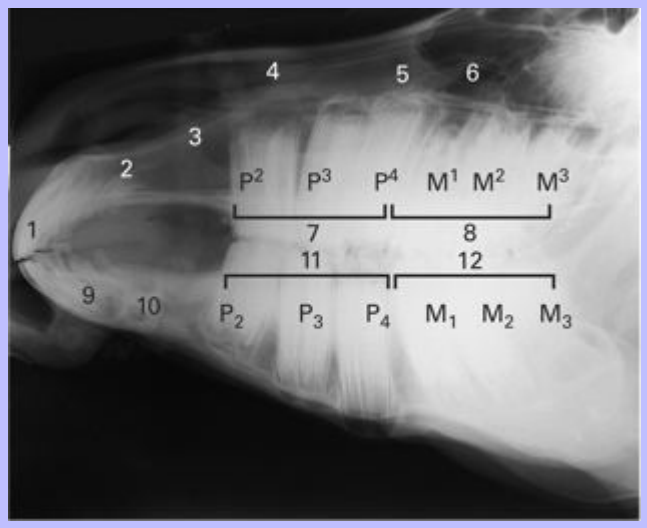

1 Upper incisor teeth

2 Incisive bone

3 Nasal process of incisive bone

4 Nasoincisive notch

5 Maxilla

6 Rostral compartment of maxillary sinus

7 Upper premolar teeth (P^2, P^3, P^4)

8 Upper molar teeth (M^1, M^2, M^3)

9 Lower incisor teeth

10 Mandible

11 Lower premolar teeth (P_2, P_3, P_4)

12 Lower molar teeth (M_1, M_2, M_3)

8

Downloaded from Vet-eBooks.com

2.11 Skull and mandible, caudal view.

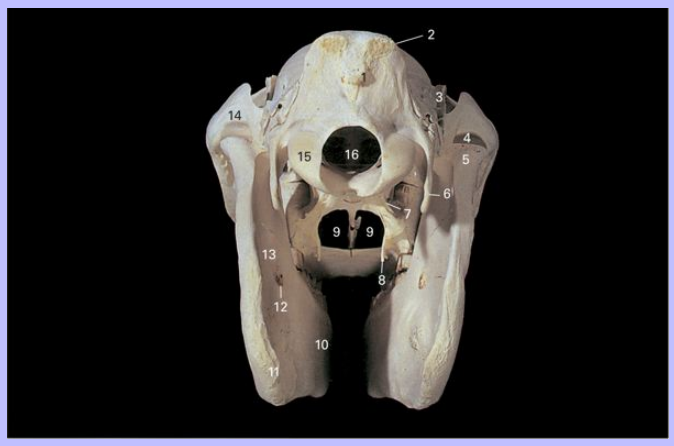

1 External occipital protuberance

2 Nuchal crest

3 Coronoid process

4 Mandibular fossa

5 Condylar process

6 Jugular process

7 Caudal alar foramen

8 Hamulus of pterygoid

9 Choanae

10 Body of mandible

11 Angle of mandible

12 Mandibular foramen

13 Ramus of mandible

14 Zygomatic arch

15 Occipital condyle

16 Foramen magnum

Downloaded from Vet-eBooks.com

Deciduous dentition of horse

$$2\{Di\tfrac{3}{3}\ Dp\tfrac{3}{3}\}$$

Permanent dentition of horse

$$\text{Male}\quad 2\{I\tfrac{3}{3}\ C\tfrac{1}{1}\ P\tfrac{3\text{ or }4}{3}\ M\tfrac{3}{3}\}$$
$$\text{Female}\quad 2\{I\tfrac{3}{3}\ C\tfrac{0}{0}\ P\tfrac{3\text{ or }4}{3}\ M\tfrac{3}{3}\}$$

The second, third and fourth premolars are consistently present in the upper and lower jaws in male and female horses. The presence of the first upper premolar (wolf tooth) is variable; it is usually absent in both sexes, but may be present in vestigial form in horses of either sex. When present, it forms part of the permanent dentition. Canine teeth are present in male horses (stallions and geldings), but are usually absent, or small and poorly developed in mares.

2.12 Rostral part of skull of mare, ventral view, showing the position of the first premolar (wolf) tooth.

1 Incisor teeth (I^1, I^2, I^3)

2 Interincisive canal

3 Palatine fissure

4 Palatine process of incisive bone

5 First upper premolar (wolf) tooth (P^1)

6 Premolar teeth (P^2, P^3, P^4)

Downloaded from Vet-eBooks.com

2.13 Rostral part of skull of male horse with canine teeth, ventral view.

1 Incisor teeth (I^1, I^2, I^3)

2 Interincisive canal

3 Canine tooth

4 Palatine fissure

5 Palatine process

6 Premolar teeth (P^2, P^3, P^4)

2.14 Rostral part of mandible of male horse with canine teeth, dorsal view.

1 Incisor teeth (I_1, I_2, I_3)

2 Canine tooth

3 Interalveolar border

4 Premolar teeth (P_2, P_3, P_4)

9

Downloaded from Vet-eBooks.com

2.15 Incisor tooth of young horse cut in longitudinal section.

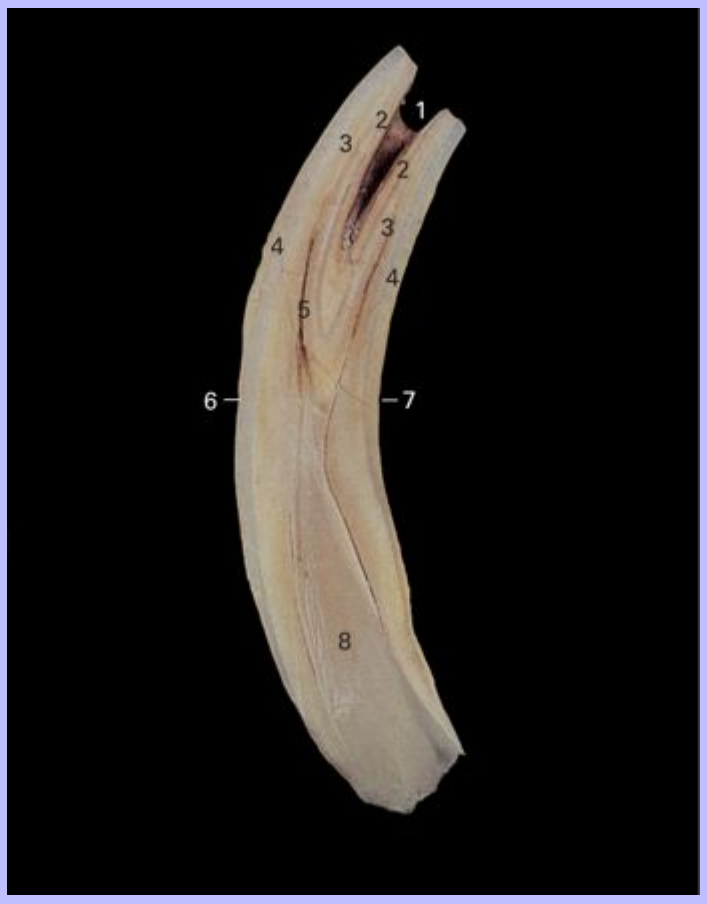

1 Infundibulum

2 Central enamel

3 Dentin

4 Peripheral enamel

5 Secondary dentin will appear as the dental star

6 Rostral (buccal) surface

7 Caudal (lingual) surface

8 Pulp cavity

Downloaded from Vet-eBooks.com

2.16 Incisor tooth cut in transverse section at the levels shown, which correspond approximately with ages 3 years, 9 years, 15 years, 20 years, 25 years. As the horse ages, the shape and contours of the table change. The pulp cavity fills with secondary dentin, which is darker than primary dentin, and appears on the table as the dental star.

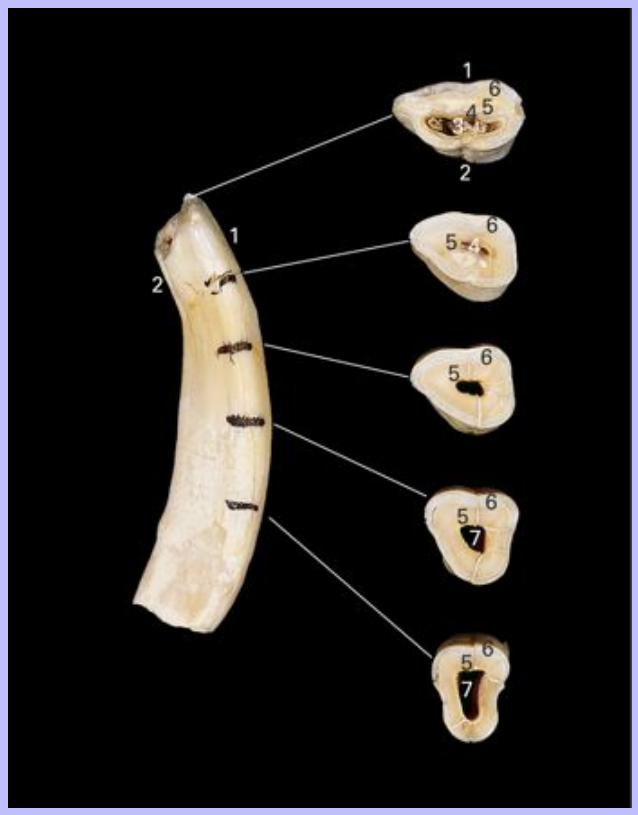

1 Rostral (buccal) surface

2 Caudal (lingual) surface

3 Infundibulum

4 Central enamel

5 Dentin

6 Peripheral enamel

7 Pulp cavity

Downloaded from Vet-eBooks.com

2.17 Skull of young adult horse, lateral view. The bones have been sculptured to show the extent of the reserve crowns of the incisors, premolars and molars.

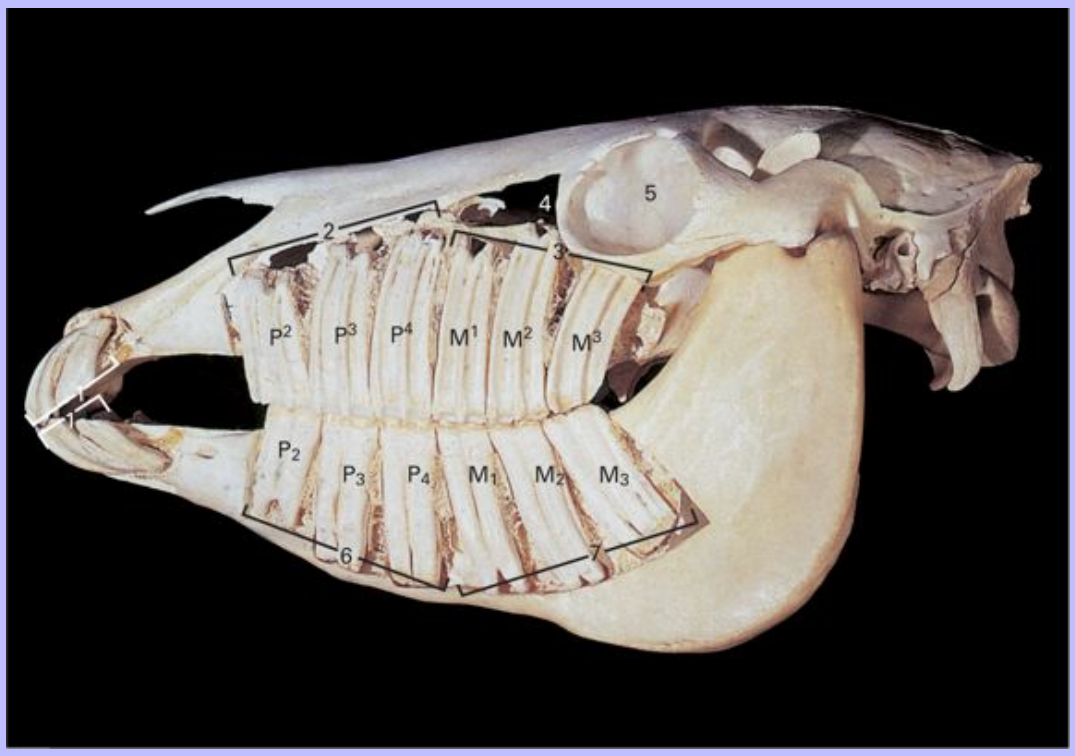

1 Incisor teeth

2 Upper premolar teeth (P^2, P^3, P^4)

3 Upper molar teeth (M^1, M^2, M^3)

4 Maxillary sinus

5 Orbit

6 Lower premolar teeth (P_2, P_3, P_4)

7 Lower molar teeth (M_1, M_2, M_3)

10

Downloaded from Vet-eBooks.com

2.18 Lateral view radiograph of head of 1-day-old foal.

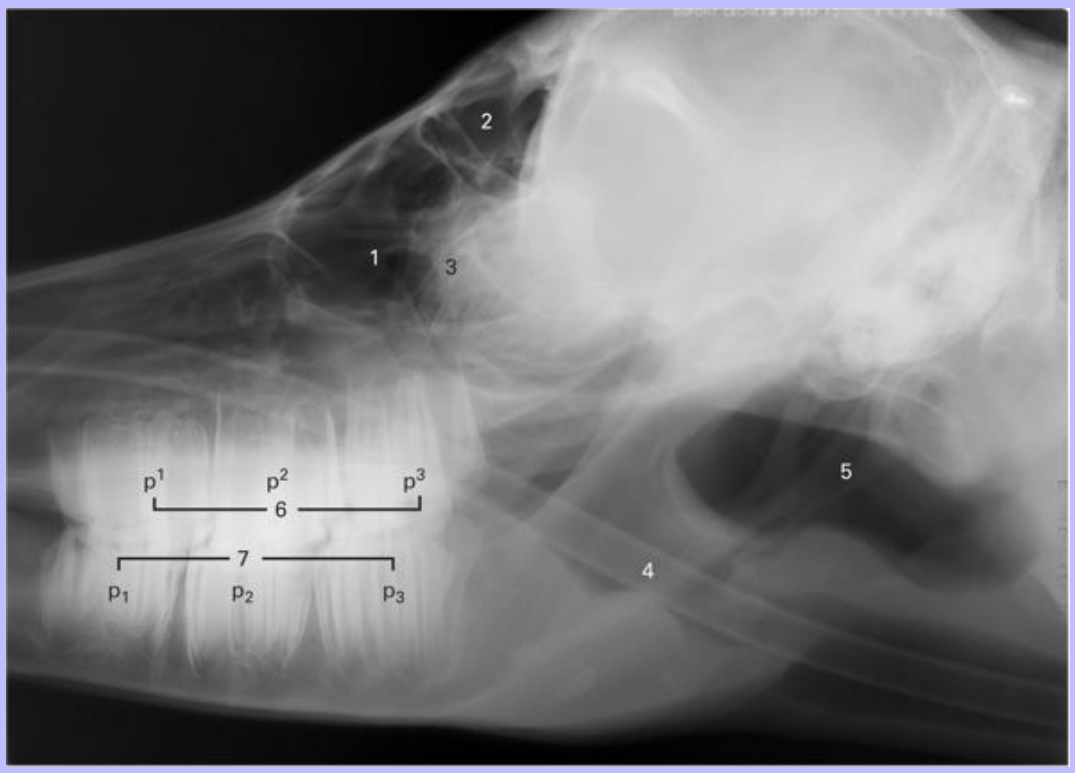

1 Maxillary sinus

2 Frontal sinus

3 Ethmoid turbinates

4 Nasotracheal oxygen tube

5 Auditory tube diverticulum

6 Upper deciduous premolar teeth (P^1, P^2, P^3)

7 Lower deciduous premolar teeth (P_1, P_2, P_3)

Downloaded from Vet-eBooks.com

2.19 Lateral view radiograph of maxillary tooth roots and paranasal sinuses of mature horse.

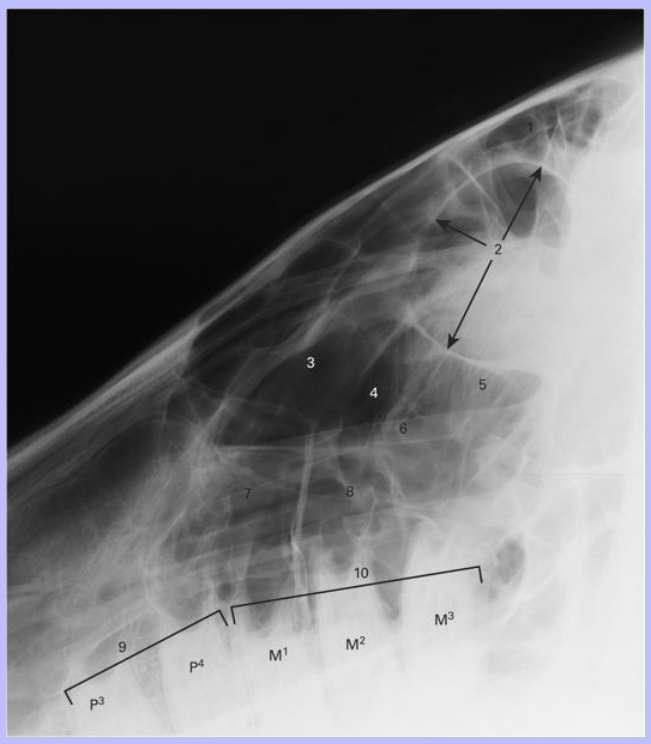

1 Frontal sinus

2 Orbit

3 Dorsal conchal frontal sinus

4 Caudal compartment of maxillary sinus

5 Ethmoid turbinates

6 Infraorbital canal

7 Rostral compartment of maxillary sinus

8 Ventral conchal sinus

9 Upper premolar teeth (P^3, P^4)

10 Upper molar teeth (M^1, M^2, M^3)

11

Downloaded from Vet-eBooks.com

2.20 Superficial dissection of head, lateral view. Cutaneous muscles have been removed.

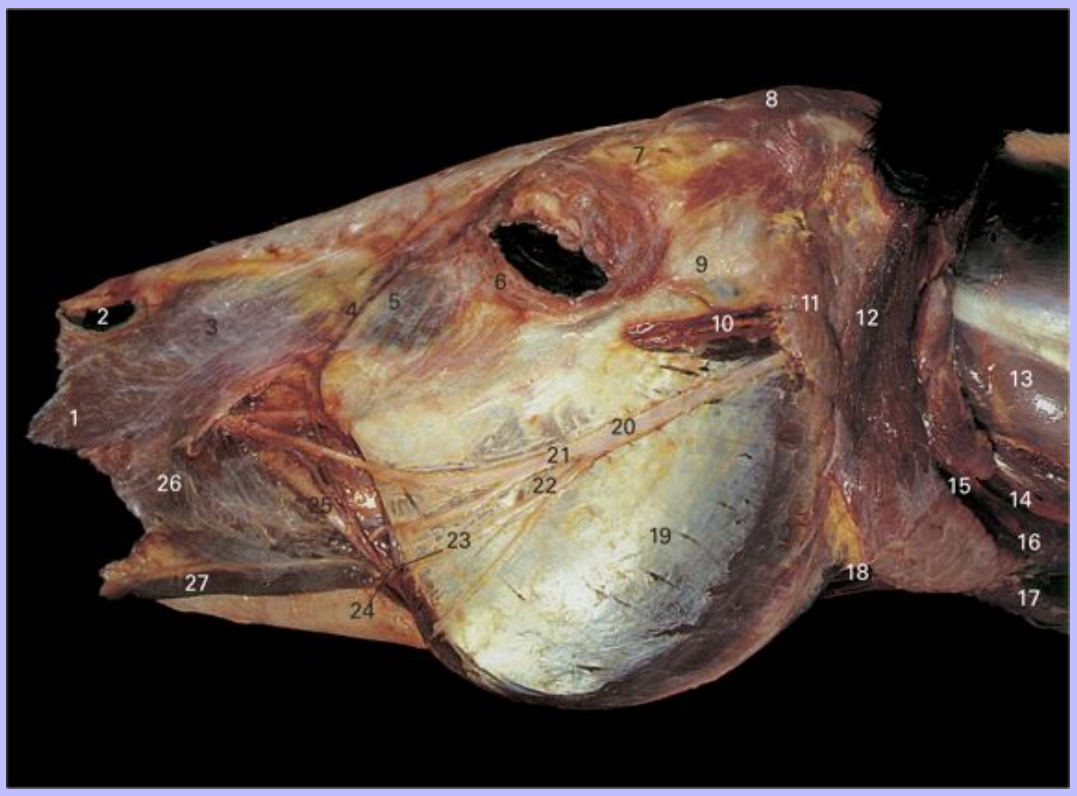

1 M. caninus

2 Nasal diverticulum

3 M. levator nasolabialis

4 Angular vein of eye

5 M. levator labii superioris

6 M. orbicularis oculi

7 Supraorbital fat pad

8 M. temporalis

9 Zygomatic arch

10 Transverse facial vessels

Downloaded from Vet-eBooks.com

11 Parotid gland

12 M. parotidoauricularis

13 M. brachiocephalicus

14 Common carotid artery

15 Maxillary vein

16 Jugular vein

17 M. sternocephalicus

18 M. sternohyoideus

19 M. masseter

20 Facial nerve (VII)

21 Dorsal buccal branch of facial nerve

22 Ventral buccal branch of facial nerve

23 Facial vein

24 Facial artery

25 Parotid duct

26 M. buccinator

27 M. depressor labii inferioris

Downloaded from Vet-eBooks.com

2.21 Superficial dissection of caudal mandibular region, lateral view. Cutaneous muscles and M. parotidoauricularis have been removed.

1 Supraorbital fat pad

2 Zygomatic arch

3 Transverse facial vessels

4 Parotid gland

5 Maxillary vein

6 External jugular vein

7 Linguofacial vein

8 M. sternocephalicus

9 M. sternohyoideus and M. omohyoideus

Downloaded from Vet-eBooks.com

10 Parotid duct

11 Tendon of M. sternocephalicus

12 Edge of mandible

13 M. masseter

14 Facial nerve (VII)

15 Ventral buccal branch of facial nerve

16 Dorsal buccal branch of facial nerve

17 Facial crest

Downloaded from Vet-eBooks.com

2.22 Deep dissection of caudal mandibular region, ventrolateral view. The M. parotidoauricularis, the parotid gland and the mandibular gland have been removed. The maxillary vein has been retracted rostrally.

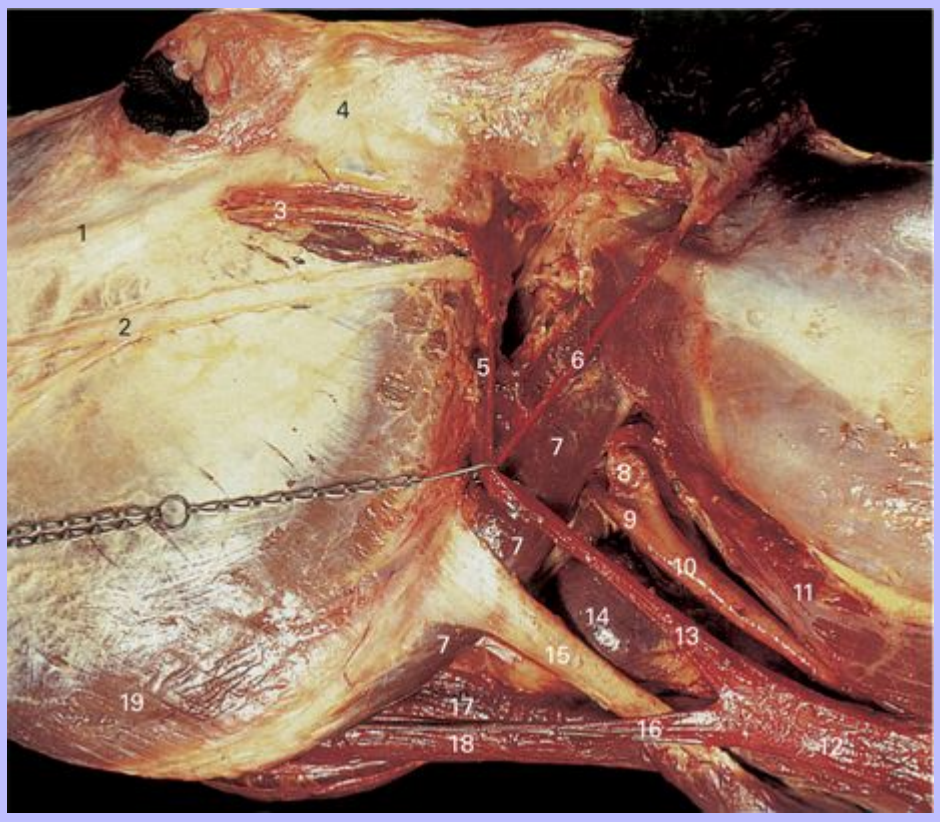

1 Facial crest

2 Buccal branch of facial nerve

3 Transverse facial vessels and nerve

4 Zygomatic arch

5 Superficial temporal vein

6 Caudal auricular vein

7 M. digastricus

8 Carotid sinus on internal carotid artery

Downloaded from Vet-eBooks.com

9 External carotid artery

10 Common carotid artery

11 M. omotransversarius

12 External jugular vein

13 Maxillary vein

14 Thyroid gland

15 Tendon of M. sternocephalicus

16 Linguofacial vein

17 M. sternothyroideus

18 M. omohyoideus and M. sternohyoideus

19 M. masseter

12

Downloaded from Vet-eBooks.com

2.23 Superficial dissection of head of horse, ventral view. Cutaneous muscles have been removed.

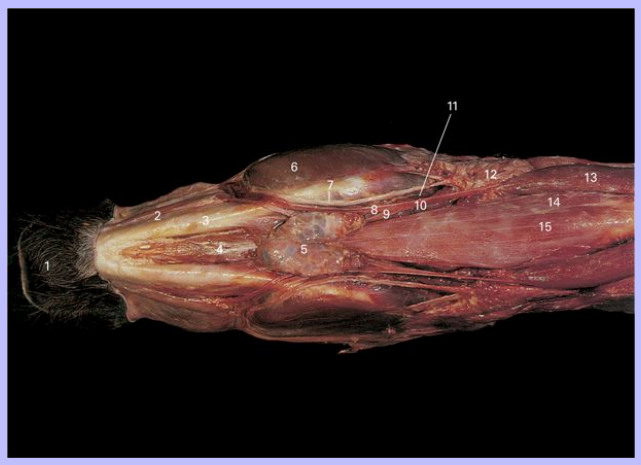

1 Chin

2 M. depressor labii inferioris

3 Mandible

4 M. mylohyoideus

5 Mandibular lymph node

6 M. masseter

7 Parotid duct

8 Facial vein

9 Lingual vein

10 Linguofacial vein

11 Facial artery

12 Parotid gland

13 M. sternocephalicus

14 M. omohyoideus

15 M. sternohyoideus

Downloaded from Vet-eBooks.com

2.24 Dorsoventral view radiograph of rostral horse head.

1 Upper incisor teeth (I^1, I^2, I^3)

2 Upper canine teeth

3 Interalveolar space

4 Nasal passages

Downloaded from Vet-eBooks.com

2.25 Dorsoventral view radiograph of caudal horse head.

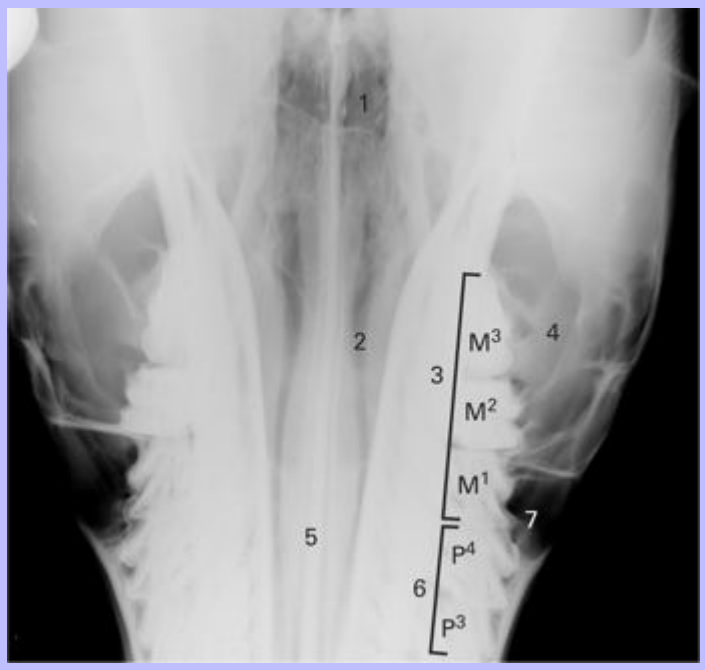

1 Ethmoidal conchae

2 Nasal passages

3 Upper molar teeth (M^1, M^2, M^3)

4 Caudal compartment of maxillary sinus

5 Nasal septum

6 Upper premolar teeth (P^3, P^4)

7 Rostral compartment of maxillary sinus

13

Downloaded from Vet-eBooks.com

2.26 Dissection of frontal and maxillary region of head, dorsal view. Overlying bone has been removed to expose the interior of the frontal and maxillary sinuses.

1 Nasal bone

2 Rostral maxillary sinus

3 Maxillary sinus septum

4 Caudal maxillary sinus

5 M. obicularis oculi

6 Conchal part of frontal sinus

7 Frontomaxillary opening

8 Ethmoidal conchae in frontal sinus

9 Frontal sinus

10 M. temporalis

Downloaded from Vet-eBooks.com

2.27 Dissection of frontal and maxillary region of head, lateral view. Overlying bone has been removed to expose the interior of the frontal and maxillary sinuses.

1 Nasal bone

2 Conchal part of frontal sinus

3 Frontal sinus

4 Supraorbital fat pad

5 M. temporalis

6 Transverse facial vessels

7 Zygomatic arch

8 Facial crest

9 M. orbicularis oculi

10 Infraorbital canal

11 Caudal maxillary sinus

12 Maxillary sinus septum

13 Rostral maxillary sinus

14 Infraorbital foramen

Downloaded from Vet-eBooks.com

2.28 Paramedian section through head. Nasal septum has been removed.

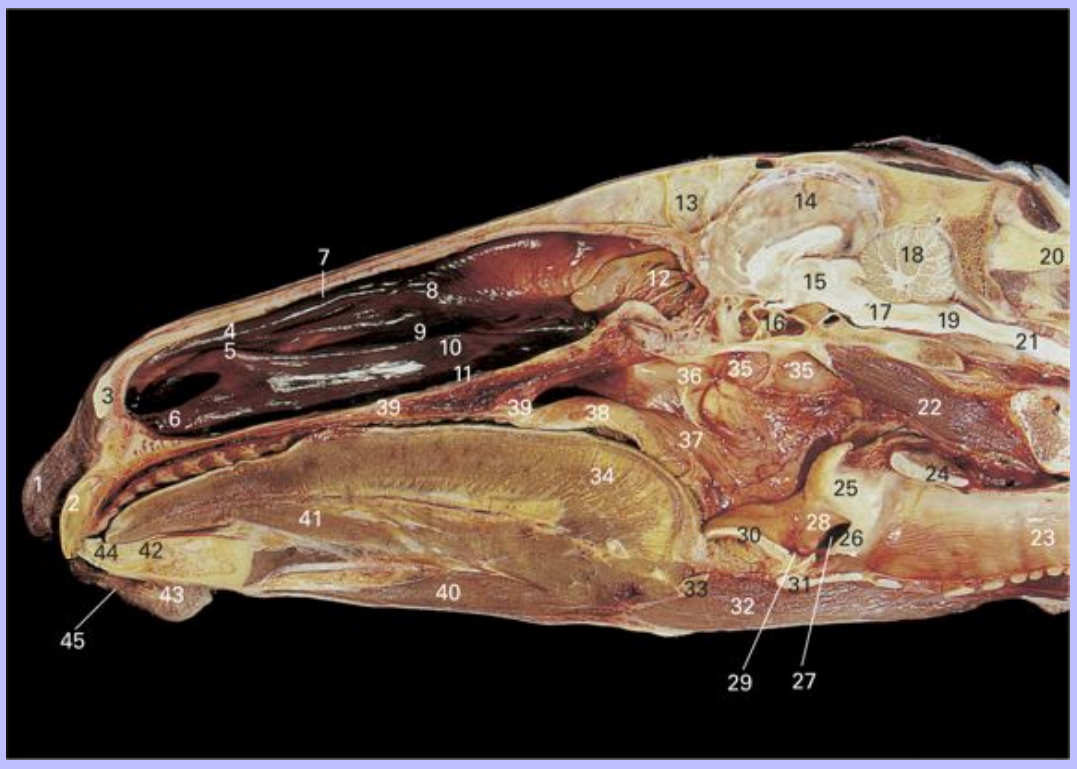

1 Upper lip

2 Incisor tooth (I^1)

3 Alar cartilage

4 Straight fold

5 Alar fold

6 Basal fold

7 Dorsal meatus

8 Dorsal nasal concha

9 Middle meatus

10 Ventral nasal concha

11 Ventral meatus

Downloaded from Vet-eBooks.com

12 Ethmoidal conchae

13 Septum separating left and right frontal sinuses

14 Cerebral hemisphere

15 Cerebral crura

16 Sphenopalatine sinus

17 Pons

18 Cerebellum

19 Medulla oblongata

20 Nuchal ligament

21 Spinal cord

22 M. longus capitis

23 Trachea

24 Cricoid cartilage

25 Arytenoid cartilage

26 Vocal fold

27 Lateral laryngeal ventricle

28 Vestibular fold

29 Median laryngeal ventricle

30 Epiglottis

31 Thyroid cartilage

32 M. sternohyoideus

33 Basihyoid bone

34 M. genioglossus

35 Mucosa separating left and right auditory tube diverticulae

36 Opening of auditory tube

37 Nasopharynx

Downloaded from Vet-eBooks.com

38 Soft palate

39 Hard palate

40 M. geniohyoideus

41 M. styloglossus

42 Mandible

43 Chin

44 Incisor tooth (I_1)

45 Lower lip

14

Downloaded from Vet-eBooks.com

2.29 Paramedian section through head. The medial walls of the dorsal and ventral conchae have been removed.

1 Nasal bone

2 Dorsal meatus

3 Scrolled portion of dorsal nasal concha

4 Conchal portion of frontal sinus

5 Frontal sinus

6 Middle meatus

Downloaded from Vet-eBooks.com

7 Ethmoidal conchae

8 Conchal portion of rostral maxillary sinus

9 Nasopharynx

10 Ventral meatus

11 Hard palate

12 Soft palate

13 Opening of auditory tube

14 Auditory tube diverticulum (guttural pouch)

15 Epiglottis

16 Basihyoid bone

17 Tongue

18 M. geniohyoideus

19 M. hyoglossus

Downloaded from Vet-eBooks.com

2.30 Endoscopic view of caudal nasal cavity and nasopharynx.

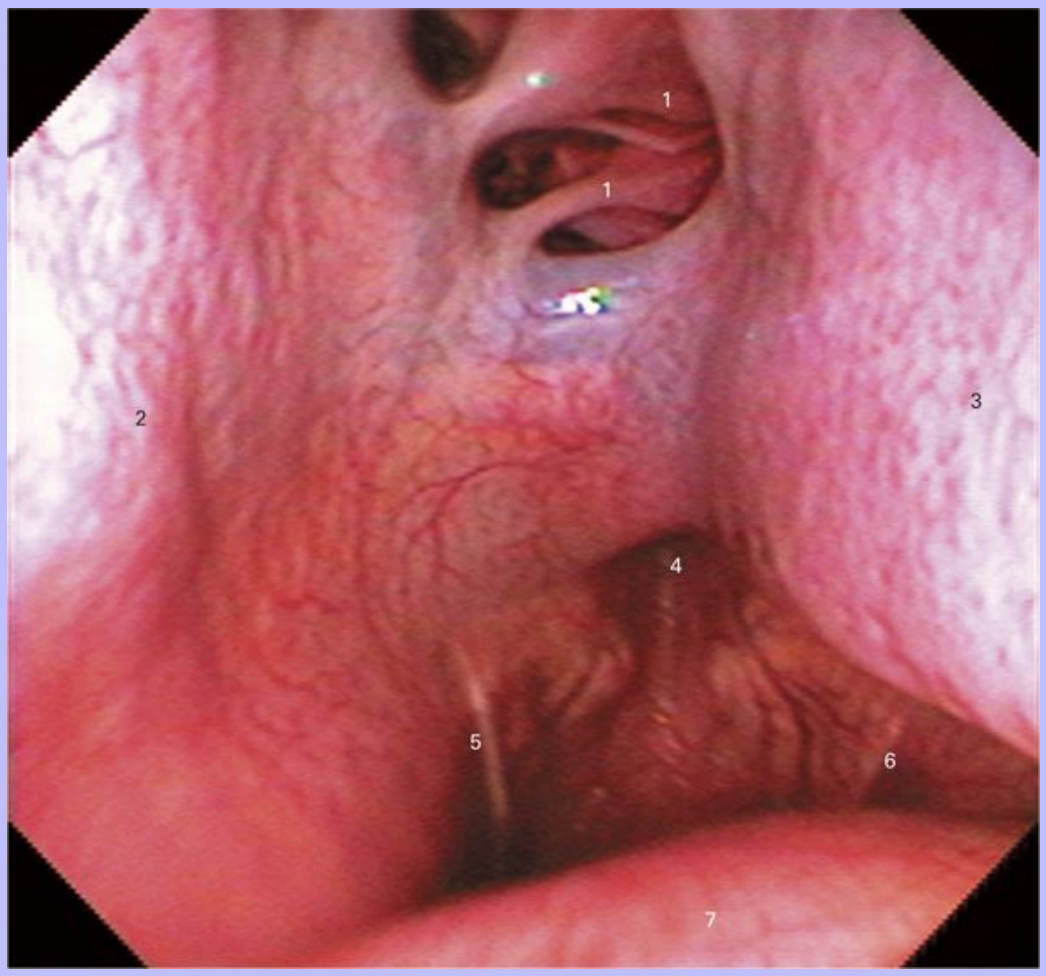

1 Ethmoidal conchae

2 Ventral nasal concha

3 Nasal septum

4 Nasopharyngeal recess

5 Opening of right auditory tube

6 Opening of left auditory tube

7 Soft palate

15

Downloaded from Vet-eBooks.com

2.31 Skull of horse, lateral view. The external auditory canals, auditory tubes and auditory tube diverticulae (guttural pouches) have been filled with yellow latex.

1 Orbit

2 Facial crest

3 Zygomatic arch

4 Mandibular fossa

5 Pterygopalatine fossa

6 Hamulus of pterygoid bone

7 Auditory tube

8 Lateral compartment of auditory tube diverticulum

9 External acoustic meatus

10 Mastoid process

11 Stylohyoid bone

12 Medial compartment of auditory tube diverticulum

13 Paracondylar process

14 Occipital condyle

Downloaded from Vet-eBooks.com

2.32 Skull of horse, ventral view. The external auditory canals, auditory tubes and auditory tube diverticulae (guttural pouches) have been filled with yellow latex.

1 Vomer

2 Choana

3 Major palatine foramen

4 Second upper molar

5 Third upper molar

6 Facial crest

7 Zygomatic arch

8 Stylohyoid bone

9 Auditory tube

10 Medial compartment of auditory tube diverticulum

11 Lateral compartment of auditory tube diverticulum

12 External auditory canal

13 Occipital condyle

14 Foramen magnum

Downloaded from Vet-eBooks.com

2.33 Lateral view radiograph of head showing auditory tube diverticulae.

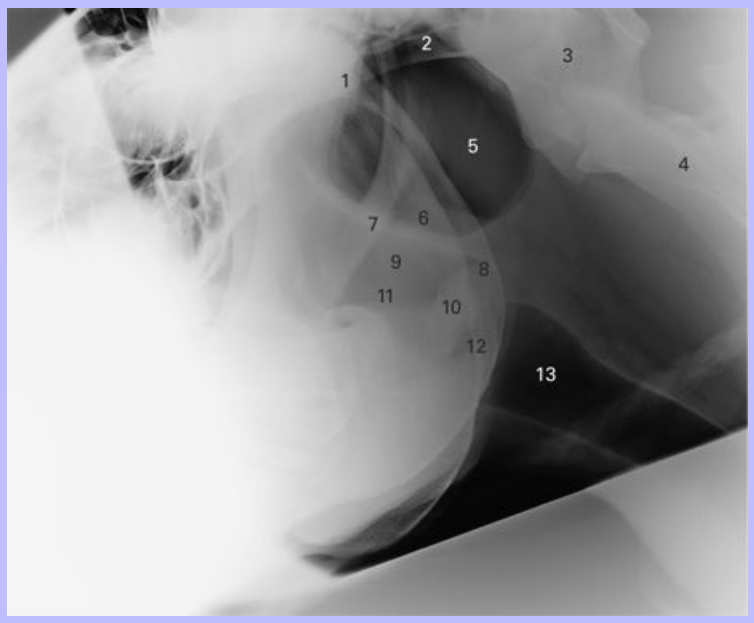

1 Basisphenoid bone

2 Basioccipital bone

3 Atlas (C1)

4 Axis (C2)

5 Auditory tube diverticulum, lateral compartment

6 Auditory tube diverticulum, medial compartment

7 Stylohyoid bone

8 Ramus of mandible

9 Nasopharynx

10 Arytenoid cartilage

11 Epiglottis

12 Laryngeal ventricle

13 Trachea

16

Downloaded from Vet-eBooks.com

2.34 Paramedian section through pharynx and larynx. The floor of the auditory tube diverticulum has been retracted ventrally to reveal its interior.

1 Ethmoidal conchae

2 Midline septum between left and right frontal sinuses

3 Cerebral hemisphere

4 Corpus callosum

Downloaded from Vet-eBooks.com

5 Interthalamic adhesion

6 Mesencephalon

7 Cerebellum

8 Occipital bone

9 Nuchal ligament

10 Medulla oblongata

11 Spinal cord

12 Sphenoidal sinus

13 Basisphenoid and presphenoid bones

14 Auditory tube

15 Medial compartment of auditory tube diverticulum

16 Stylohyoid bone

17 Lateral compartment of auditory tube diverticulum

18 Glossopharyngeal nerve (IX)

19 Hypoglossal nerve (XII)

20 Esophagus

21 Trachea

22 Cricoid cartilage

23 Corniculate process

24 Arytenoid cartilage

25 Vocal fold

26 Laryngeal ventricle

27 Vestibular fold

28 Thyroid cartilage

29 M. sternohyoideus and M. omohyoideus

30 Basihyoid bone

Downloaded from Vet-eBooks.com

31 Epiglottis

32 Nasopharynx

33 Soft palate

2.35 Endoscopic view of the lateral compartment of the right auditory tube diverticulum.

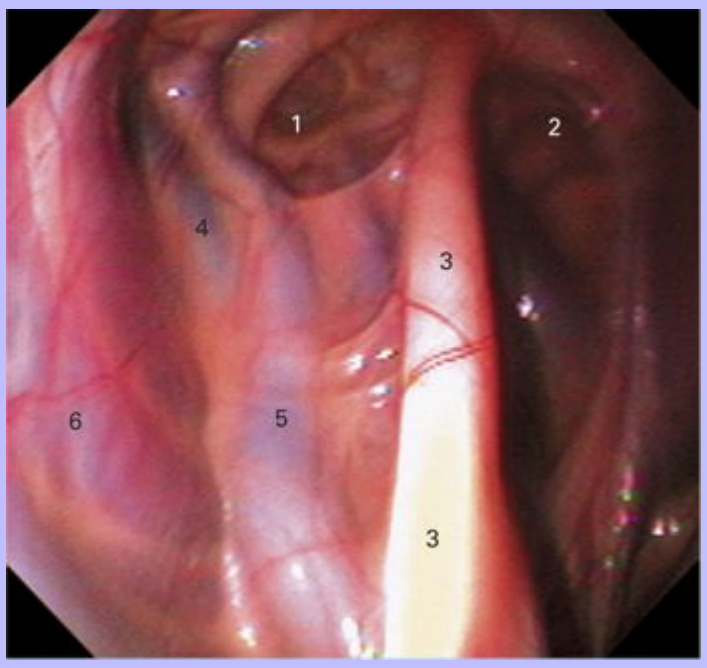

1 Lateral compartment of auditory tube diverticulum

2 Medial compartment of auditory tube diverticulum

3 Stylohyoid bone

4 Maxillary vein

5 External carotid artery

6 M. digastricus

Downloaded from Vet-eBooks.com

2.36 Endoscopic view of the medial compartment of the right auditory tube diverticulum.

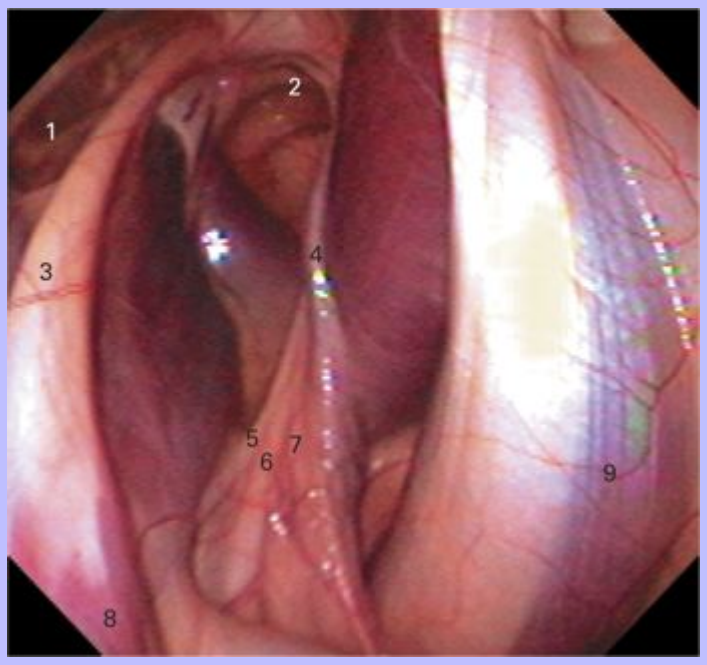

1 Lateral compartment of auditory tube diverticulum

2 Medial compartment of auditory tube diverticulum

3 Stylohyoid bone

4 Internal carotid artery

5 Glossopharyngeal nerve (IX)

6 Hypoglossal nerve (XII)

7 Vagus nerve (X)

8 M. stylopharyngeus

9 M. longus capitis

17

Downloaded from Vet-eBooks.com

2.37 Deep dissection of caudal mandibular region of foal. Left mandible has been removed.

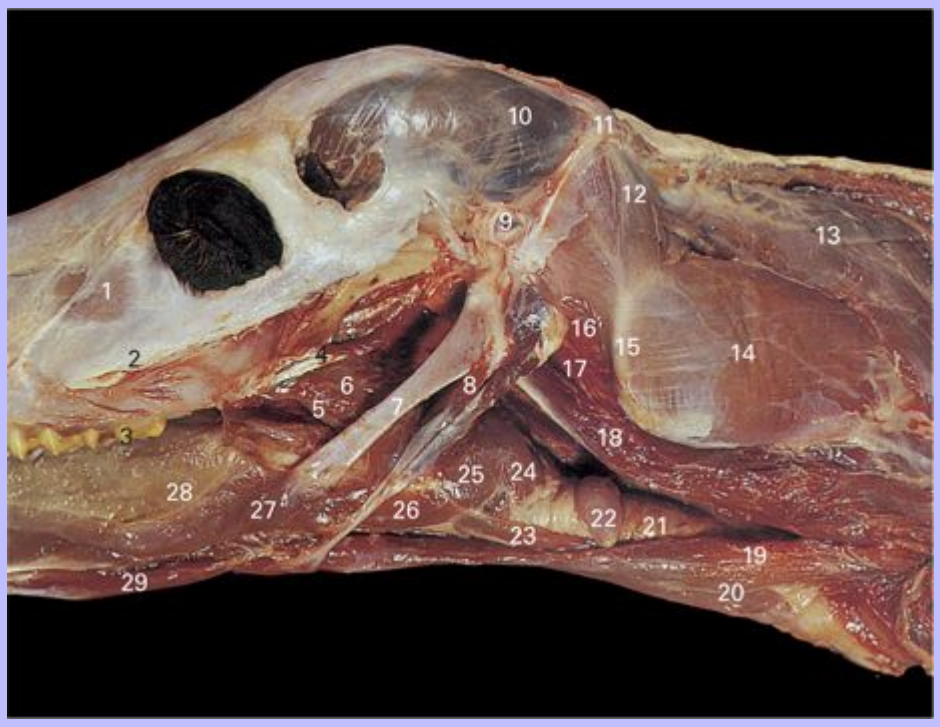

1 M. levator labii superioris

2 Facial crest

3 First upper molar tooth (m^1)

4 M. tensor veli palatini

5 M. palatopharyngeus

6 M. pterygopharyngeus

7 Stylohyoid bone

8 M. stylohyoideus

9 External auditory canal

10 M. temporalis

11 Nuchal crest

Downloaded from Vet-eBooks.com

12 M. obliquus capitis cranialis

13 M. splenius

14 M. brachiocephalicus

15 Wing of atlas

16 M. rectus capitis lateralis

17 M. rectus capitis ventralis

18 M. longus capitis

19 M. omohyoideus

20 M. sternohyoideus

21 Trachea

22 Thyroid gland

23 M. sternothyroideus

24 M. cricopharyngeus

25 M. thyropharyngeus

26 M. thyrohyoideus

27 M. styloglossus

28 Tongue

29 M. geniohyoideus

Downloaded from Vet-eBooks.com

2.38 Lateral view radiograph of head, laryngeal region.

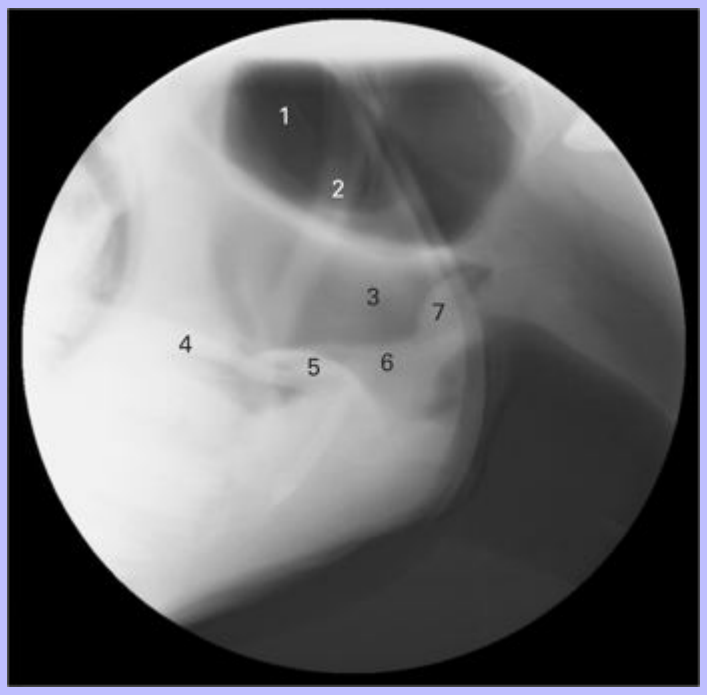

1 Auditory tube diverticulum

2 Stylohyoid bone

3 Nasopharynx

4 Soft palate

5 Epiglottis

6 Aryepiglottic fold

7 Arytenoid cartilage

Downloaded from Vet-eBooks.com

2.39 Larynx and hyoid bones, lateral view.

1 Tympanohyoid bone

2 Stylohyoid bone

3 Ceratohyoid bone

4 Lingual process

5 M. ceratohyoideus

6 Thyrohyoid bone

7 Epiglottis

8 Arytenoid cartilage

9 M. arytenoideus transversus

10 M. cricoarytenoideus dorsalis

11 M. thyrohyoideus

12 Thyroid cartilage

13 M. cricothyroideus

14 Cricoid cartilage

15 First tracheal ring

16 Esophagus

Downloaded from Vet-eBooks.com

2.40 Laryngeal cartilages and intrinsic musculature, lateral view (above) and dorsal view (below).

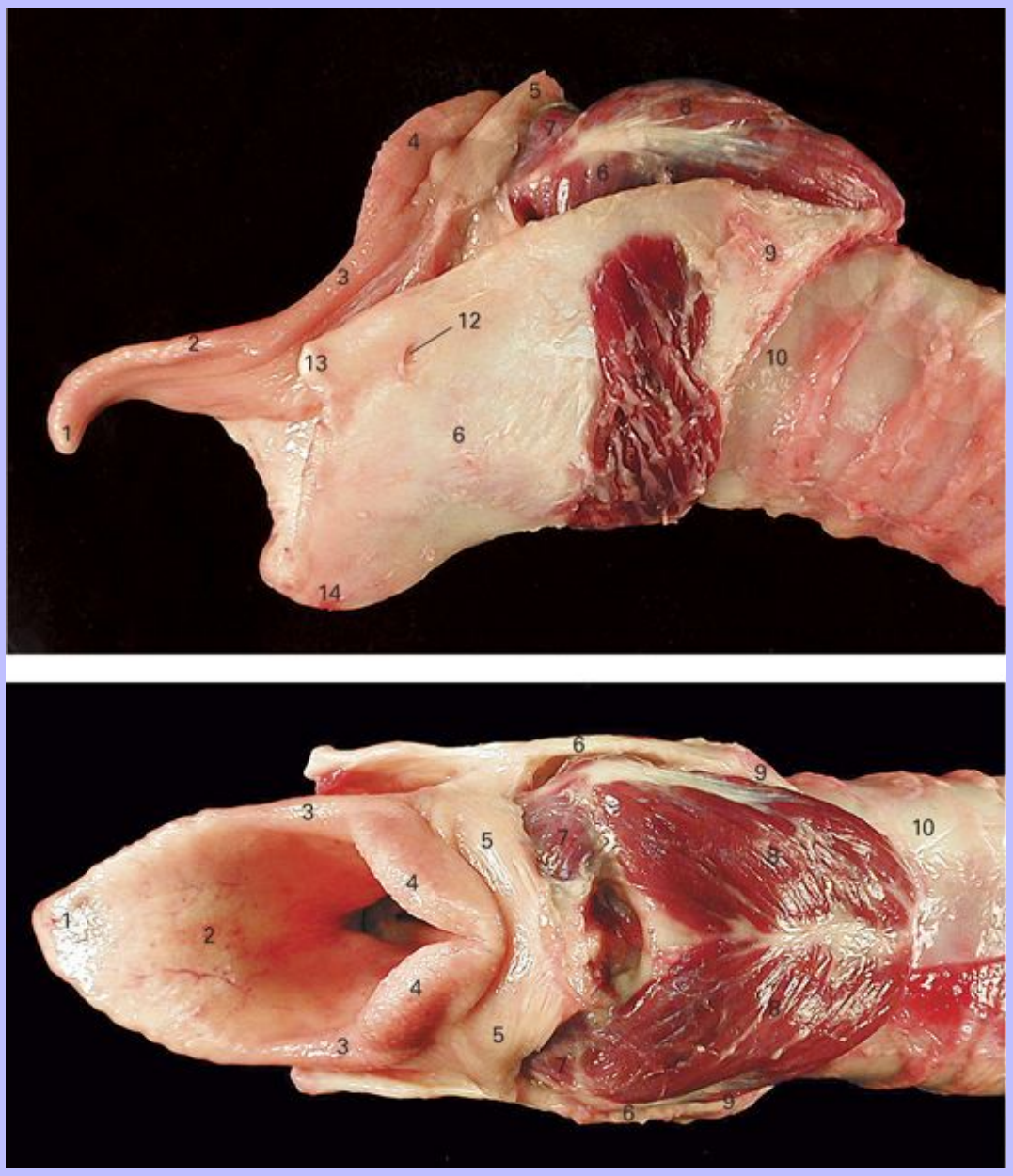

1 Apex of epiglottis

2 Epiglottis

Downloaded from Vet-eBooks.com

3 Aryepiglottic fold

4 Arytenoid

5 Palatopharyngeal arch

6 Thyroid

7 M. arytenoideus transversus

8 M. cricoarytenoideus dorsalis

9 Cricoid

10 First tracheal ring

11 M. cricothyroideus

12 Foramen for cranial laryngeal nerve

13 Cranial cornu of thyroid

14 Laryngeal prominence

Downloaded from Vet-eBooks.com

2.41 Left lateral view of larynx after removal of the wing of the thyroid cartilage.

1 Aryepiglottic fold

2 Arytenoid cartilage

3 M. arytenoideus transversus

4 M. cricoarytenoideus dorsalis

5 First tracheal ring

6 Cricoid cartilage

7 Thyroid cartilage

8 M. cricothyroideus

9 M. cricoarytenoideus lateralis

10 M. vocalis

11 Laryngeal ventricle

12 M. ventricularis

13 Epiglottis

19

Downloaded from Vet-eBooks.com

2.42 Median section through larynx.

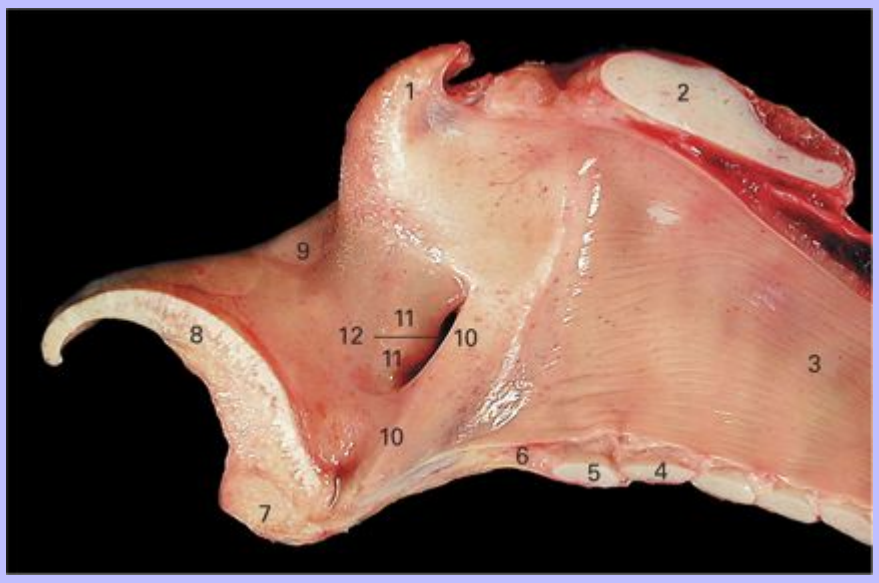

1 Corniculate process of arytenoid cartilage

2 Lamina of cricoid cartilage

3 Tracheal mucosa

4 First tracheal ring

5 Ring of cricoid

6 Cricothyroid ligament

7 Thyroid cartilage

8 Epiglottis

9 Aryepiglottic fold

10 Vocal fold

11 Vestibular fold

12 Laryngeal ventricle

Downloaded from Vet-eBooks.com

2.43 Tongue and larynx. The aditus laryngis has been exposed by opening the pharynx dorsally.

1 Dorsum of tongue

2 Vallate papilla

3 Foliate papilla

4 Palatoglossal fold

5 Stylohyoid bone

6 Root of tongue

7 Caudal extremity of soft palate

8 Epiglottis

9 Median ventricle of larynx

10 Wall of pharynx

11 Piriform recess (lateral food channel)

12 Aryepiglottic fold

13 Dorsal part of palatopharyngeal arch

14 Corniculate process of arytenoid cartilage

15 Vocal fold

16 Laryngeal ventricle

Downloaded from Vet-eBooks.com

2.44 Endoscopic view of larynx.

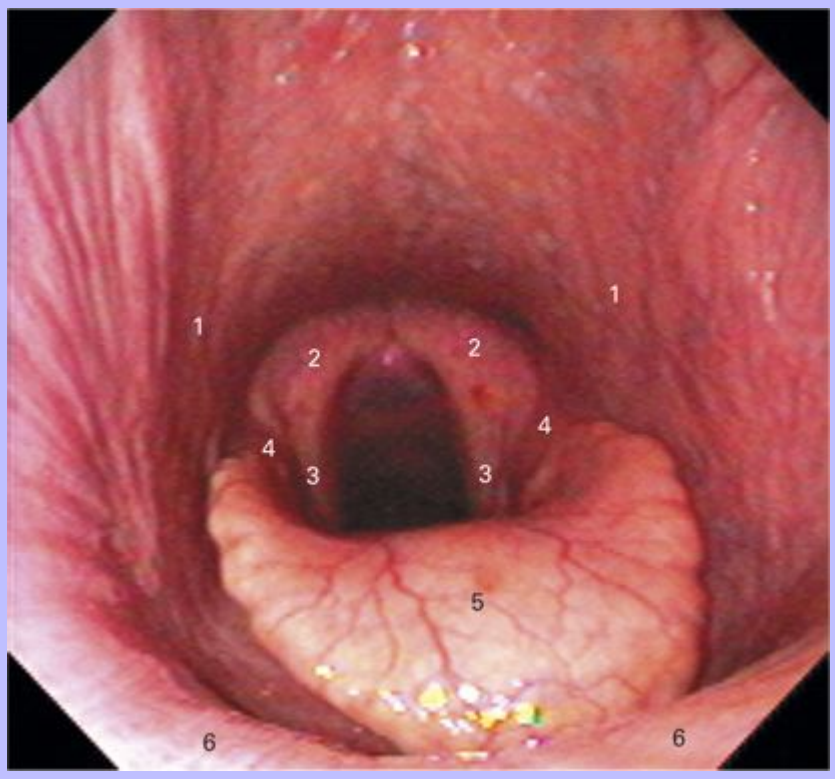

1 Palatopharyngeal arch

2 Arytenoid cartilage

3 Vocal fold

4 Aryepiglottic fold

5 Epiglottis

6 Soft palate

20

Downloaded from Vet-eBooks.com

2.45 Transverse section through head at third premolar tooth.

1 Mandible

2 Lower third premolar (P_3)

3 M. masseter

4 Buccal glands

5 Upper third premolar (P^3)

6 Reserve crown and root of upper second premolar (P^2)

7 M. levator nasolabialis

8 M. levator labii superioris

9 Dorsal nasal meatus

10 Dorsal nasal concha

Downloaded from Vet-eBooks.com

11 Common nasal meatus

12 Middle nasal meatus

13 Ventral nasal concha

14 Ventral nasal meatus

15 Nasal septum

16 Nasal venous plexus

17 Body of tongue

18 M. hyoglossus

19 M. genioglossus

20 Sublingual gland

21 M. geniohyoideus

Downloaded from Vet-eBooks.com

2.46 Computed tomographic image of head at third premolar tooth.

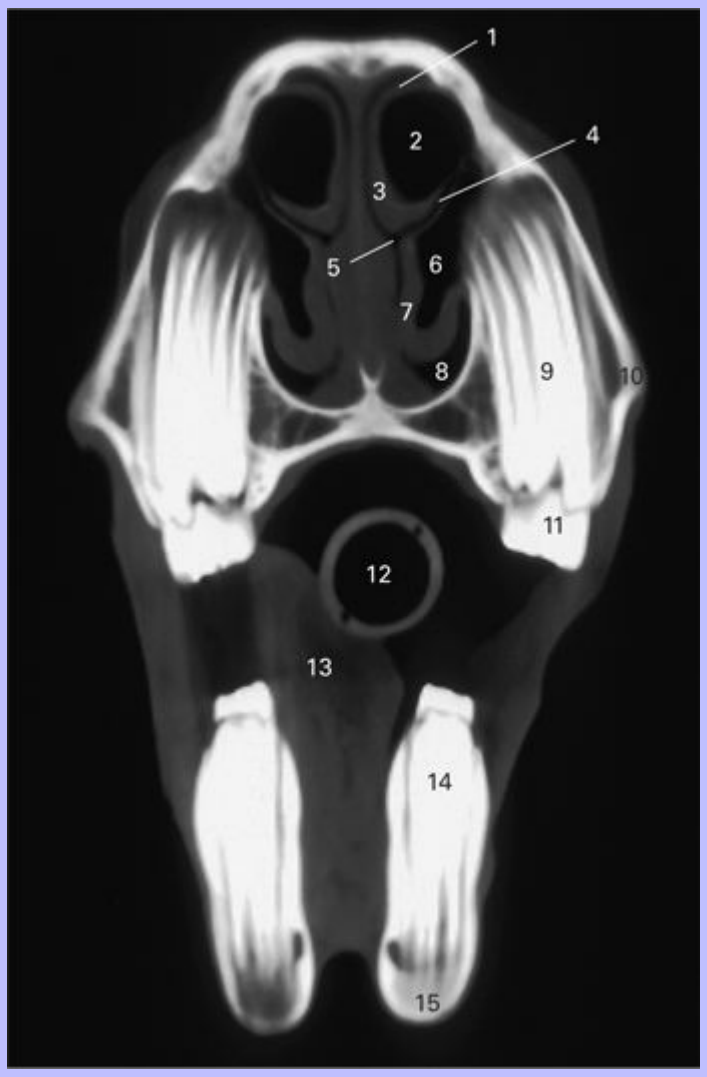

1 Dorsal nasal meatus

2 Dorsal conchal sinus

3 Dorsal concha

4 Middle nasal meatus

5 Common nasal meatus

Downloaded from Vet-eBooks.com

6 Ventral conchal sinus

7 Ventral concha

8 Ventral nasal meatus

9 Upper third premolar (permanent)

10 Maxilla

11 Cap of upper deciduous third premolar

12 Endotracheal tube

13 Tongue

14 Lower third premolar

15 Mandible

21

Downloaded from Vet-eBooks.com

2.47 Transverse section through head at third molar tooth.

1 Mandible

2 M. masseter

3 Reserve crown and root of lower second premolar (P_2)

4 Lower third premolar (P_3)

5 Upper third premolar (P^3)

6 M. levator labii superioris and M. levator nasolabialis

7 Nasolacrimal duct

8 Conchofrontal sinus

9 Rostral part of maxillary sinus

Downloaded from Vet-eBooks.com

10 Caudal part of maxillary sinus

11 Conchal part of maxillary sinus

12 Infraorbital canal

13 Nasal septum

14 Hard palate

15 Body of tongue

16 M. genioglossus

17 M. hyoglossus

18 Mandibular duct

19 Sublingual vessels

20 M. geniohyoideus

21 M. mylohyoideus

Downloaded from Vet-eBooks.com

2.48 Computed tomographic image of head at third molar tooth.

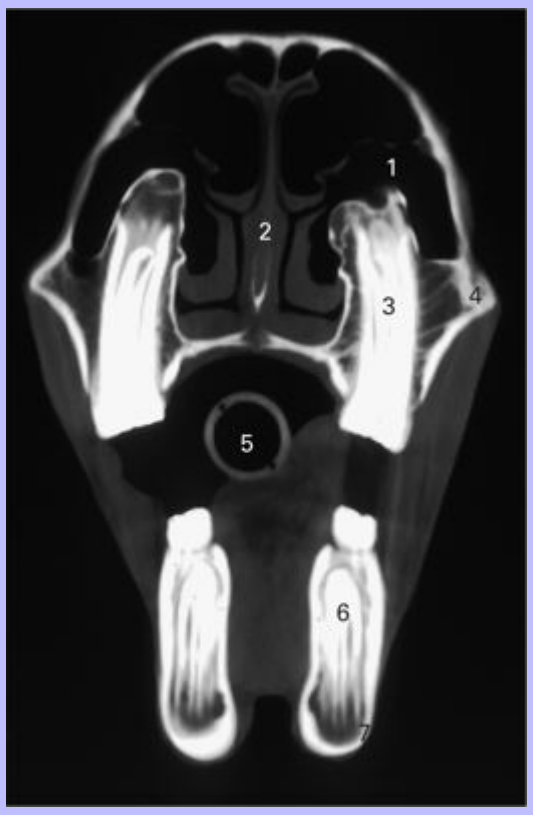

1 Maxillary sinus

2 Nasal septum

3 Upper third molar (M^3)

4 Maxilla

5 Endotracheal tube

6 Lower third molar (M_3)

7 Mandible

22

Downloaded from Vet-eBooks.com

2.49 Transverse section through head at temporomandibular joint.

1 Mandible

2 M. masseter

3 M. pterygoideus medialis

4 Maxillary vein

5 M. pterygoideus lateralis

6 Transverse facial vessels

7 Mandibular condyle

8 Articular disk

Downloaded from Vet-eBooks.com

9 Mandibular fossa

10 M. temporalis

11 Cerebral hemisphere

12 Lateral ventricle of brain

13 M. tensor veli palatini

14 Auditory tube diverticulum (guttural pouch)

15 Midline septum

16 M. stylopharyngeus

17 Stylohyoid bone

18 Lingual artery and nerve

19 M. hyopharyngeus

20 Epiglottis

21 Facial artery

22 Rostral cornu of thyroid cartilage

23 Tendon of M. digastricus

24 Thyroid cartilage

25 M. thyrohyoideus

26 Mandibular gland

27 Median ventricle of larynx

28 M. omohyoideus and M. sternohyoideus

29 M. cutaneus fasciei

30 Linguofacial vein

Downloaded from Vet-eBooks.com

2.50 Computed tomographic image of head at temporomandibular joint.

1 Temporal bone

2 Cerebrum

3 Zygomatic process of temporal bone

4 Temporomandibular joint

5 Condylar process of mandible

6 Basioccipital bone

7 Auditory tube diverticuli

8 Vertical ramus of mandible

9 Endotracheal tube

10 Stylohyoid bone

11 Epiglottis

12 Basihyoid bone

Downloaded from Vet-eBooks.com

2.51 Radiograph showing the position of a jointed snaffle bit in the horse's oral cavity, lateral view.

1 Second upper premolar tooth (P^2)

2 Hard palate

3 Upper incisor teeth

4 Lower incisor teeth

5 Tongue

6 Joint of bit

7 Mouthpiece of bit

8 Rings of bit

9 Second lower premolar tooth (P_2)

Downloaded from Vet-eBooks.com

3 3 Spinal Column

The osteology of the vertebral column is illustrated using bone specimens and the associated musculature is shown on dissected specimens.

Downloaded from Vet-eBooks.com

3.1 Atlas (C1), axis (C2), fifth (C5) and seventh (C7) cervical vertebrae, cranial view.

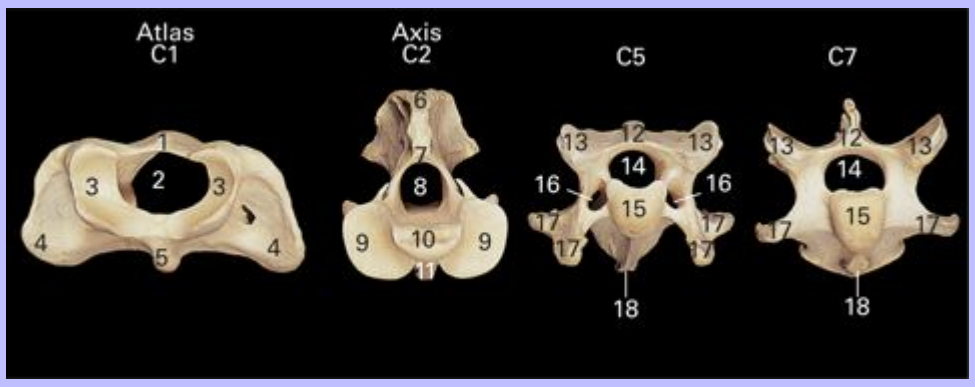

Atlas (C1)

1 Dorsal arch

2 Vertebral foramen

3 Cranial articular cavities

4 Transverse process (wing)

5 Ventral tubercle

Axis (C2)

6 Spinous process

7 Arch

8 Vertebral foramen

9 Cranial articular process

10 Dens

11 Ventral crest

C5, C7

12 Spinous process

13 Cranial articular process

14 Vertebral foramen

Downloaded from Vet-eBooks.com

15 Body

16 Transverse foramen

17 Transverse process

3.2 First (T1), fifth (T5), twelfth (T12) and eighteenth (T18) thoracic vertebrae, cranial view.

1 Spinous process

2 Cranial articular process

3 Vertebral foramen

4 Transverse process

5 Body

6 Cranial costal fovea

7 Facet for tubercle of rib

8 Mamillary process

9 Ventral tubercle

Downloaded from Vet-eBooks.com

3.3 First (L1), fifth (L5) and sixth (L6) lumbar vertebrae, cranial view.

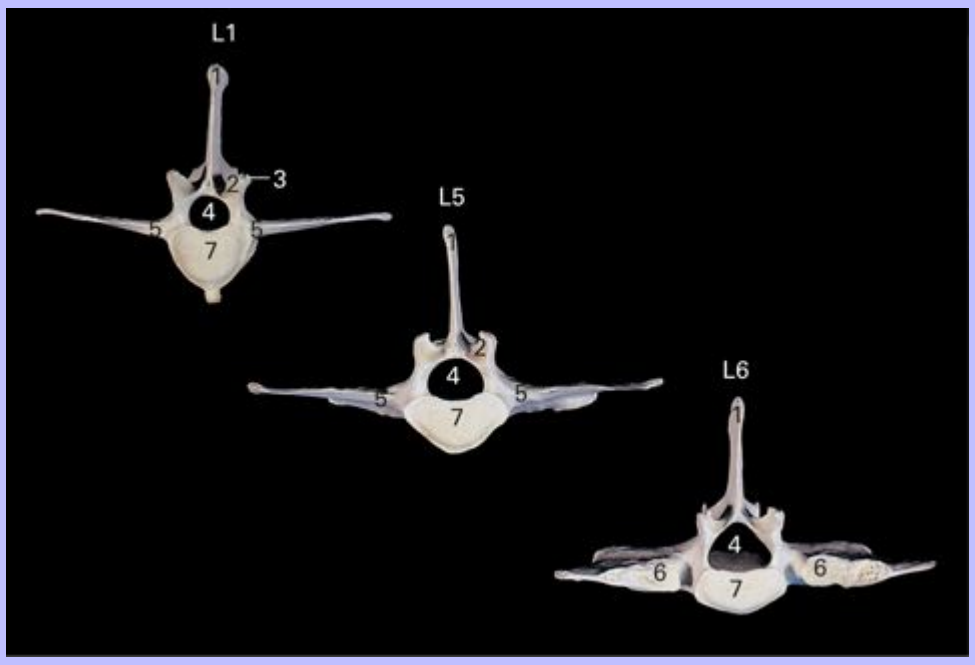

1 Spinous process

2 Cranial articular process

3 Mamillary process

4 Vertebral foramen

5 Transverse process

6 Articular surface of transverse process

7 Body

25

Downloaded from Vet-eBooks.com

3.4 Cervical vertebrae (C1–C7), lateral view.

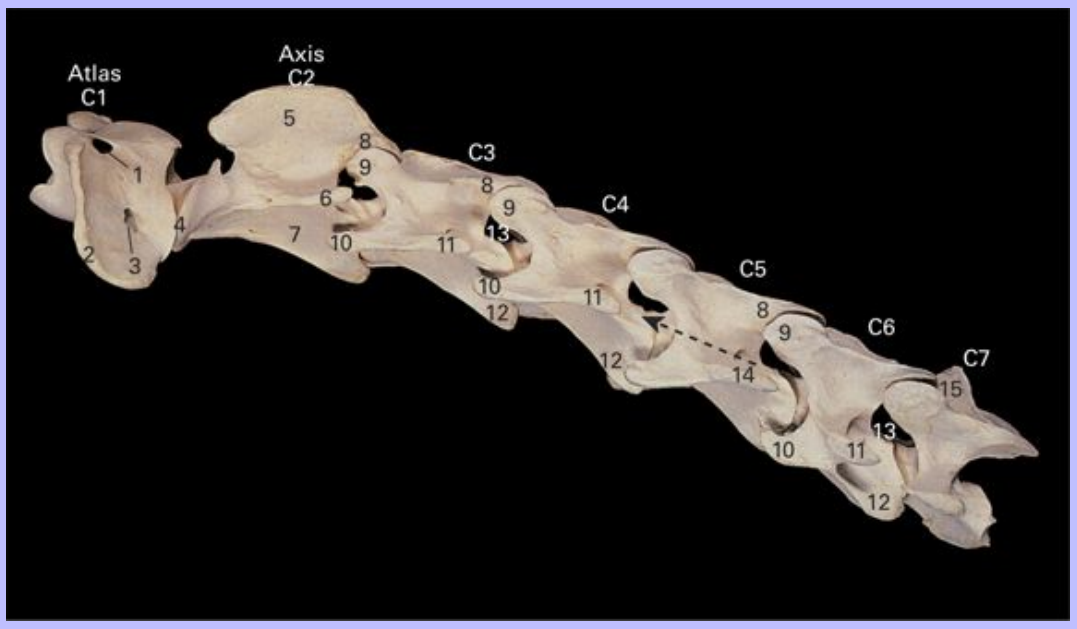

Atlas (C1)

1 Alar foramen

2 Transverse process (wing)

3 Transverse foramen

4 Cranial articular process

Axis (C2)

5 Spinous process

6 Transverse process

7 Body

C3–C7

8 Caudal articular process

9 Cranial articular process

10 Ventral tubercle of transverse process

Downloaded from Vet-eBooks.com

11 Dorsal tubercle of transverse process

12 Ventral crest

13 Intervertebral foramen

14 Transverse foramen

15 Spinous process

3.5 Cervical vertebrae (C1–C7), dorsal view.

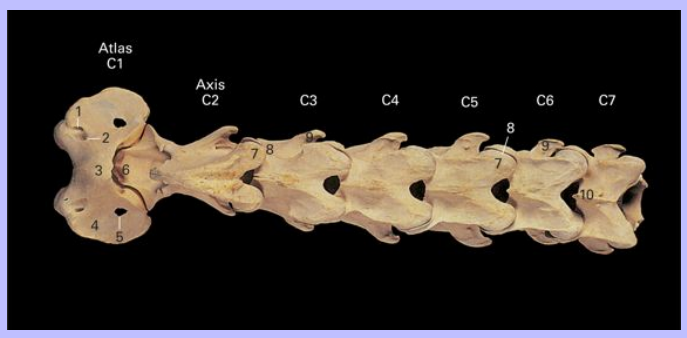

Atlas (C1)

1 Alar foramen

2 Lateral vertebral foramen

3 Dorsal arch

4 Transverse process (wing)

5 Transverse foramen

C2–C7

6 Dens (odontoid process) of axis

7 Caudal articular process

8 Cranial articular process

9 Transverse process

10 Spinous process

Downloaded from Vet-eBooks.com

3.6 Lateral view radiograph of the neck of a 1-day-old foal.

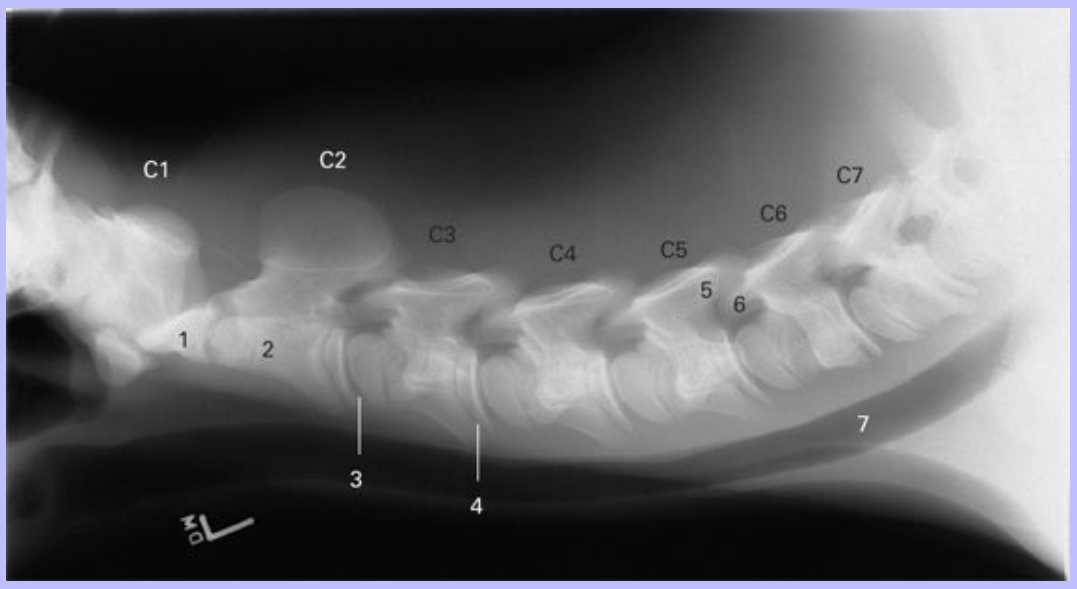

Atlas (C1)

Axis (C2)

1 Dens (odontoid process of axis)

2 Body

C3–C7

3 Cranial physis of C3

4 Caudal physis of C3

5 Caudal articular process of C5

6 Cranial articular process of C6

7 Trachea

26

Downloaded from Vet-eBooks.com

3.7 Lateral view radiograph of cranial cervical vertebrae of mature horse.

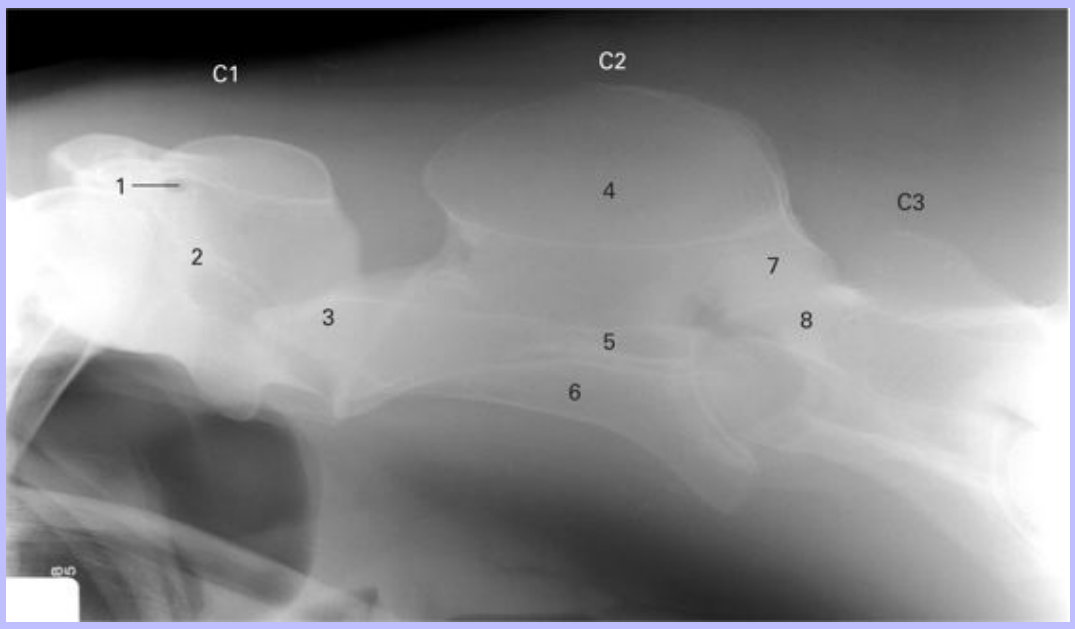

Atlas (C1)

1 Alar foramen

2 Transverse process

Axis (C2)

3 Dens (odontoid process of axis)

4 Spinous process

5 Transverse process

6 Body

7 Caudal articular process

C3

8 Cranial articular process

Downloaded from Vet-eBooks.com

3.8 Lateral view radiographs of neck showing individual cervical vertebrae (C1–C7).

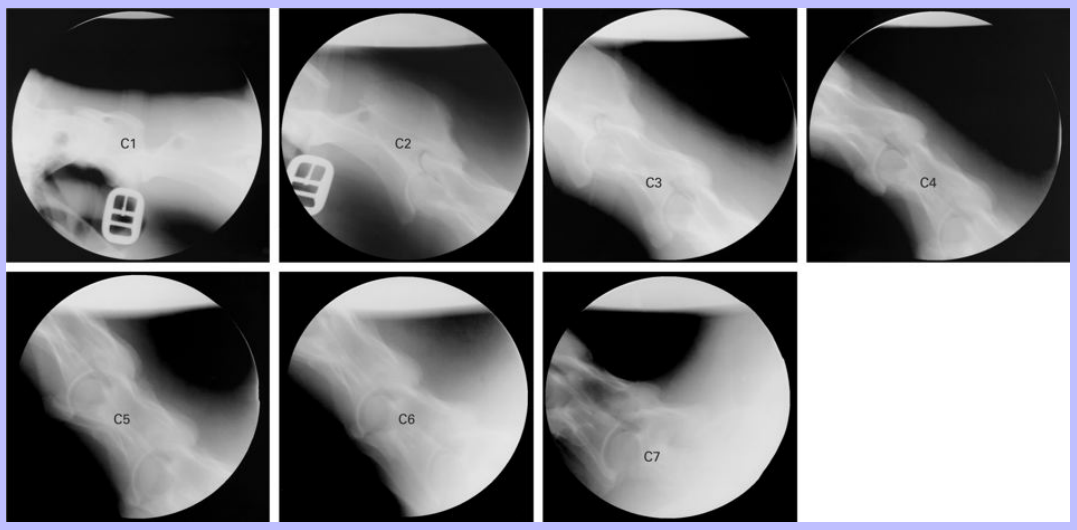

27

Downloaded from Vet-eBooks.com

3.9 First to ninth thoracic vertebrae (T1–T9), lateral view.

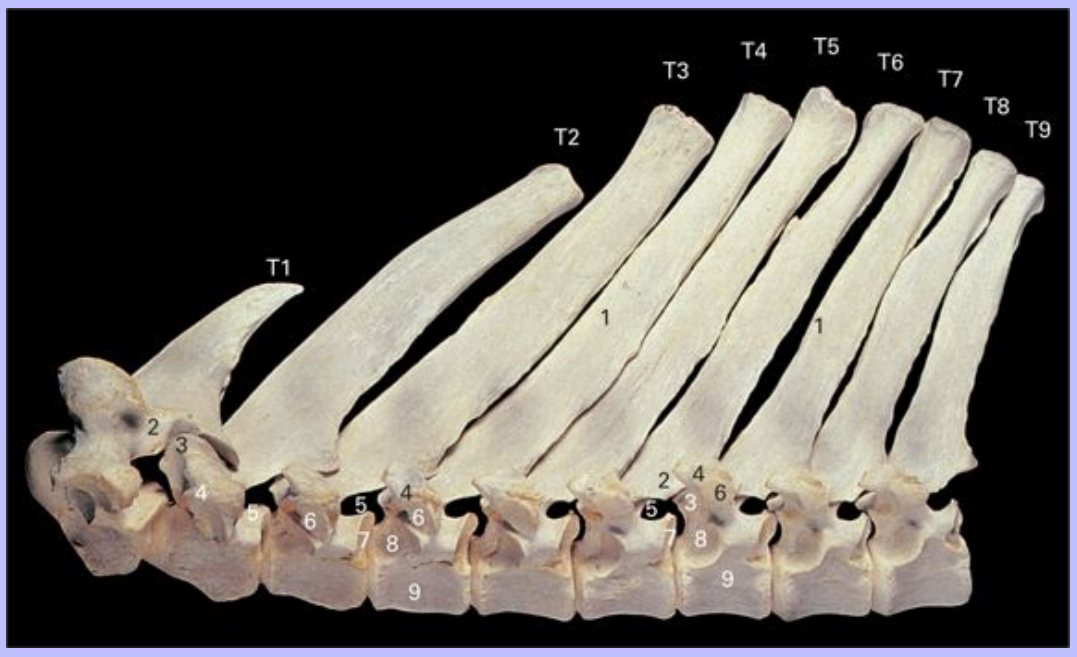

1 Spinous process

2 Caudal articular process

3 Cranial articular process

4 Transverse process

5 Intervertebral foramen

6 Facet for tubercle of rib

7 Cranial costal fovea

8 Caudal costal fovea

9 Body

Downloaded from Vet-eBooks.com

3.10 Tenth to eighteenth thoracic vertebrae (T10–T18), lateral view.

1 Spinous process

2 Caudal articular process

3 Cranial articular process

4 Mamillary process

5 Transverse process

6 Intervertebral foramen

7 Facet for tubercle of rib

8 Cranial costal fovea

9 Caudal costal fovea

10 Body

Downloaded from Vet-eBooks.com

3.11 Sternum, lateral view.

1 Cartilage of manubrium

2 Manubrium

3 Second sternebra

4 Costal cartilage

5 Xiphoid cartilage

Downloaded from Vet-eBooks.com

3.12 Left eighth rib, cranial view.

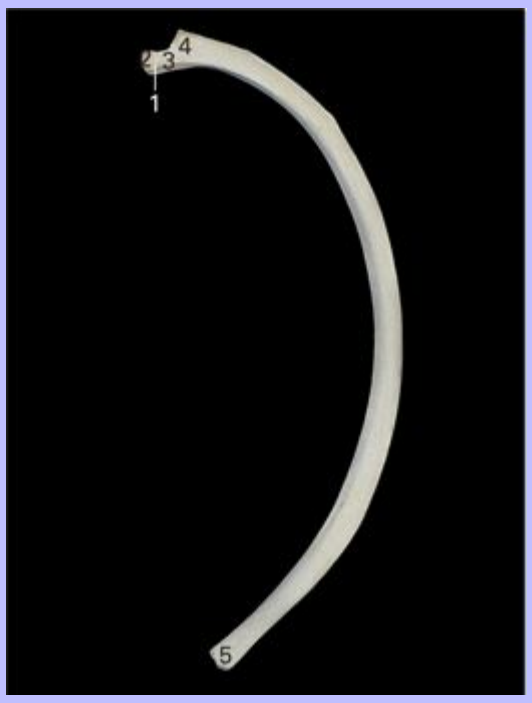

1 Costal groove

2 Head

3 Neck

4 Tubercle

5 Sternal extremity

28

Downloaded from Vet-eBooks.com

3.13 Lateral view radiograph of thoracic vertebral spinous processes (T2–T7).

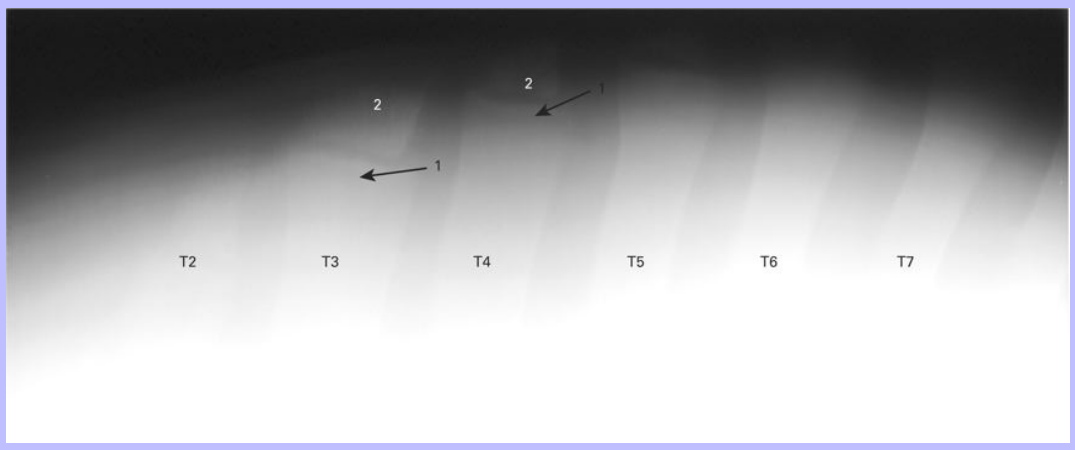

1 Physis

2 Separate center of ossification

3.14 Lateral view radiograph of thoracic spine.

1 Thoracic vertebral body

2 Rib

3 Pulmonary vessels

Downloaded from Vet-eBooks.com

3.15 Lumbar vertebrae (L1–L6), lateral view.

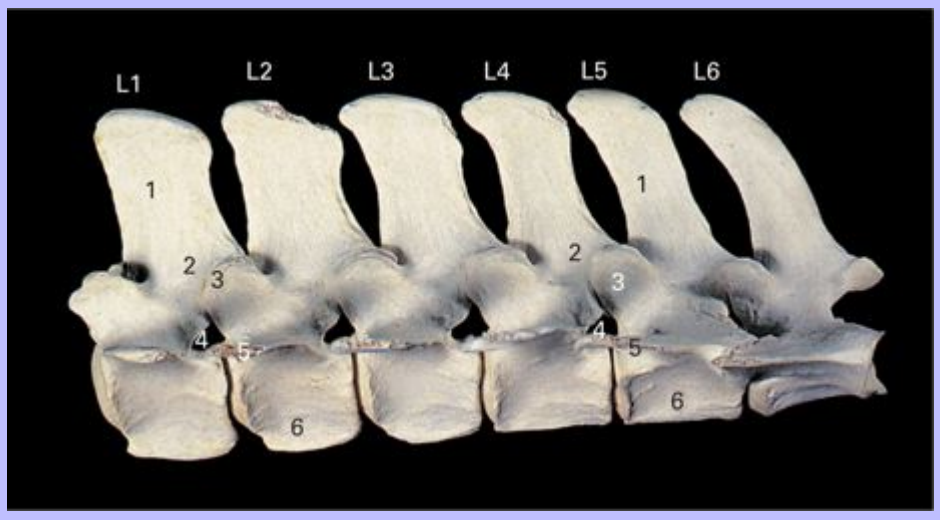

1 Spinous process

2 Caudal articular process

3 Cranial articular process

4 Intervertebral foramen

5 Transverse process

6 Body

Downloaded from Vet-eBooks.com

3.16 Lumbar vertebrae (L1–L6), dorsal view. Note fusion of transverse processes of fifth and sixth lumbar vertebrae.

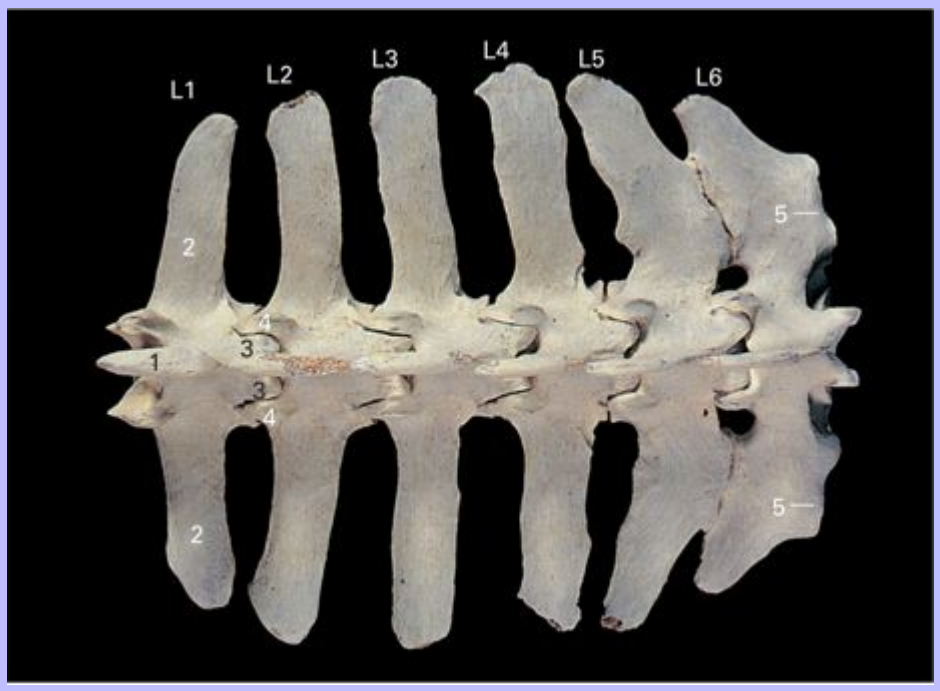

1 Spinous process

2 Transverse process

3 Caudal articular process

4 Cranial articular process

5 Surface of transverse process for articulation with wing of sacrum

Downloaded from Vet-eBooks.com

3.17 Lateral view radiograph of the lumbar spine.

1 Body

2 Transverse process

3 Caudal articular process

4 Cranial articular process

30

Downloaded from Vet-eBooks.com

31

3.18 Sacrum (S1–S5) and first caudal (Ca1) vertebra, lateral view.

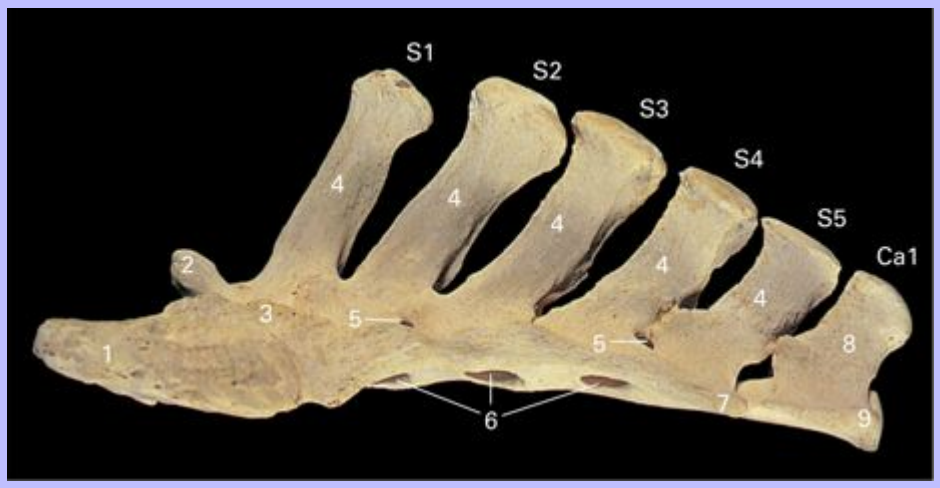

1 Auricular surface

2 Articular process

3 Wing

4 Spinous process of sacral vertebra

5 Dorsal sacral foramen

6 Ventral sacral foramen

7 Transverse process of sacrum

8 Spinous process of first caudal vertebra

9 Transverse process of first caudal vertebra

Downloaded from Vet-eBooks.com

3.19 Sacrum, cranial view.

1 Spinous process

2 Articular process

3 Lateral crest

4 Wing

5 Articular surface of wing

6 Notch

7 Body

Downloaded from Vet-eBooks.com

3.20 Cutaneous musculature of foal, lateral view.

1 M. cutaneus fasciei, part of M. platysma

2 M. cutaneus colli, part of M. platysma

3 M. cutaneus omobrachialis

4 M. cutaneus trunci

31

Downloaded from Vet-eBooks.com

32

3.21 Superficial dissection of musculature of neck, shoulder, and thoracic wall of foal, lateral view. The cutaneous muscles and cervical part of the M. trapezius have been removed.

1 M. splenius

2 M. rhomboideus cervicis

3 M. serratus ventralis cervicis

4 M. trapezius, thoracic part

5 M. latissimus dorsi

6 M. intercostales externi

7 M. pectoralis ascendens

8 M. triceps brachii, long head

9 M. triceps brachii, lateral head

Downloaded from Vet-eBooks.com

10 M. deltoideus

11 M. infraspinatus

12 M. supraspinatus

13 M. subclavius

14 M. brachiocephalicus

15 M. sternocephalicus

Downloaded from Vet-eBooks.com

3.22 Deep dissection of musculature of neck, shoulder, and thoracic wall of foal, lateral view. The cutaneous muscles, M. trapezius, M. brachiocephalicus and M. sternocephalicus have been removed.

1 M. splenius

2 M. serratus ventralis cervicis

3 M. rhomboideus cervicis

4 Nuchal ligament

5 M. rhomboideus thoracis

6 Scapular cartilage

7 M. spinalis thoracis

8 M. longissimus thoracis

9 M. intercostales externi

10 M. obliquus externus abdominis

Downloaded from Vet-eBooks.com

11 M. serratus ventralis thoracis

12 M. triceps brachii, long head

13 M. triceps brachii, lateral head

14 Greater tubercle of humerus

15 M. infraspinatus

16 Spine of scapula

17 M. supraspinatus

18 M. subclavius

19 M. sternohyoideus

20 M. sternothyroideus

21 Esophagus

22 Trachea

32

Downloaded from Vet-eBooks.com

33

3.23 Deep dissection of musculature of neck and thoracic wall of foal, lateral view. The left front limb has been removed with the M. serratus dorsalis, M. serratus ventralis, M. trapezius, and M. rhomboideus.

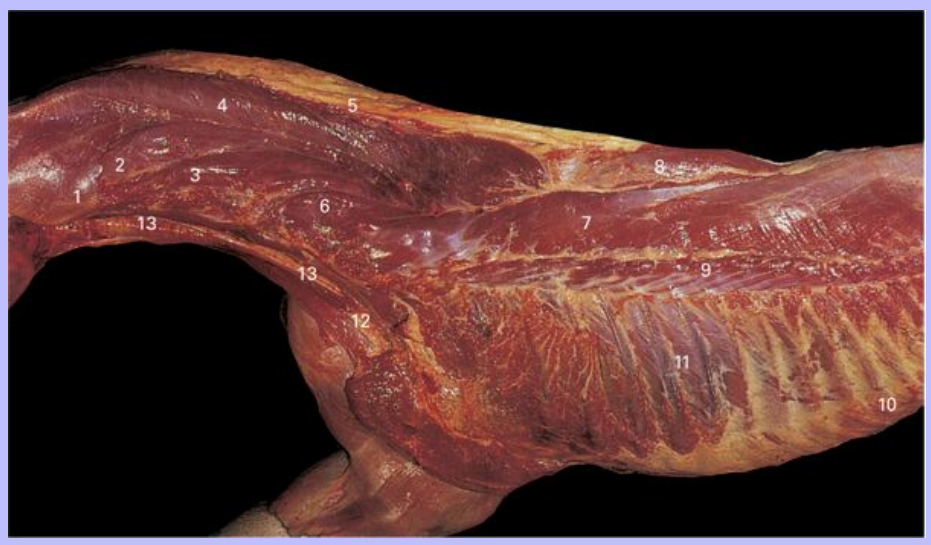

1 M. obliquus capitis caudalis

2 Cut edge of M. longissimus capitis

3 M. longissimus atlantis

4 M. semispinalis capitis

5 Nuchal ligament, funicular part

6 M. longissimus cervicis

7 M. longissimus thoracis

8 M. spinalis thoracis

9 M. iliocostalis thoracis

10 M. obliquus externus abdominis

11 M. intercostales externi

12 M. sternohyoideus and M. sternothyroideus

13 Trachea

Downloaded from Vet-eBooks.com

3.24 Superficial (left side) and deep (right side) dissections of musculature of neck and trunk of foal, dorsal view. The cutaneous muscles, M. trapezius, and M. latissimus dorsi have been removed on the right side.

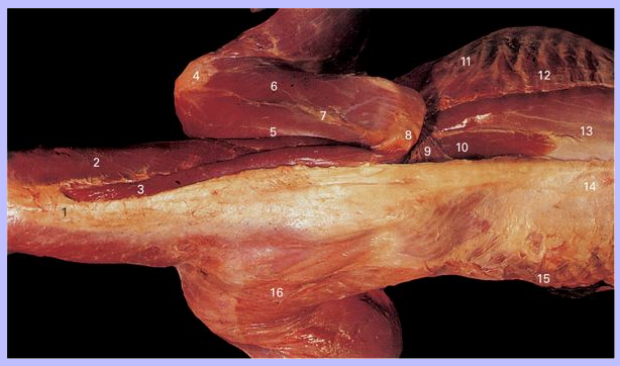

1 Funicular part of ligamentum nuchae

2 M. splenius

3 M. rhomboideus cervicis

4 Greater tubercle of humerus

5 M. supraspinatus

6 M. infraspinatus

7 Spine of scapula

8 Cartilage of scapula

9 M. rhomboideus thoracis

10 M. spinalis thoracis

11 M. intercostales externi

12 M. serratus dorsalis caudalis

13 M. longissimus thoracis

14 Lumbodorsal fascia

15 M. cutaneus trunci

16 M. cutaneus omobrachialis

Downloaded from Vet-e-Books.com

3.25 Superficial dissection of musculature of neck and pectoral region of foal, ventral view.

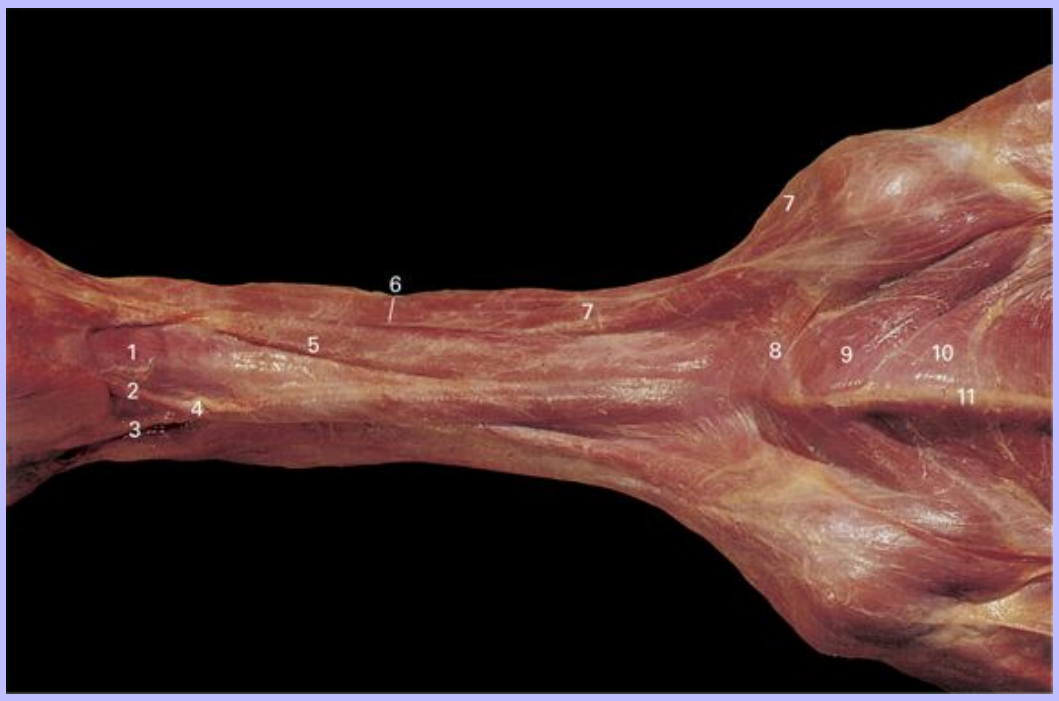

1 M. sternohyoideus and M. omohyoideus

2 Maxillary vein

3 Linguofacial vein

4 External jugular vein

5 M. sternocephalicus

6 Jugular groove

7 M. brachiocephalicus

8 M. cutaneus colli

9 M. pectoralis transversus

10 M. pectoralis descendens

11 Sternum

Downloaded from Vet-eBooks.com

3.26 Transverse section through neck of horse at the level of the second cervical vertebra, cranial view. The vertebra is slightly twisted.

1 Nuchal adipose body (crest)

2 Nuchal ligament, funicular part

3 M. rectus capitis dorsalis major

4 M. splenius

5 M. semispinalis capitis

6 M. obliquus capitis dorsalis

7 M. multifidus cervicis

Downloaded from Vet-eBooks.com

8 Second cervical vertebra (axis)

9 Spinal cord

10 Internal vertebral plexus

11 Vertebral artery and vein

12 M. longissimus capitis

13 M. brachiocephalicus

14 M. longissimus atlantis

15 M. longus capitis

16 M. longus colli

17 Oesophagus

18 Vagosympathetic trunk

19 Common carotid artery

20 Recurrent laryngeal nerve

21 External jugular vein

22 M. omohyoideus

23 M. sternocephalicus

24 M. cutaneus colli

25 M. sternohyoideus

26 M. sternothyroideus

27 Trachea

Downloaded from Vet-eBooks.com

4 Forelimb and Digit

4.1 Skeleton of left forelimb, lateral view.

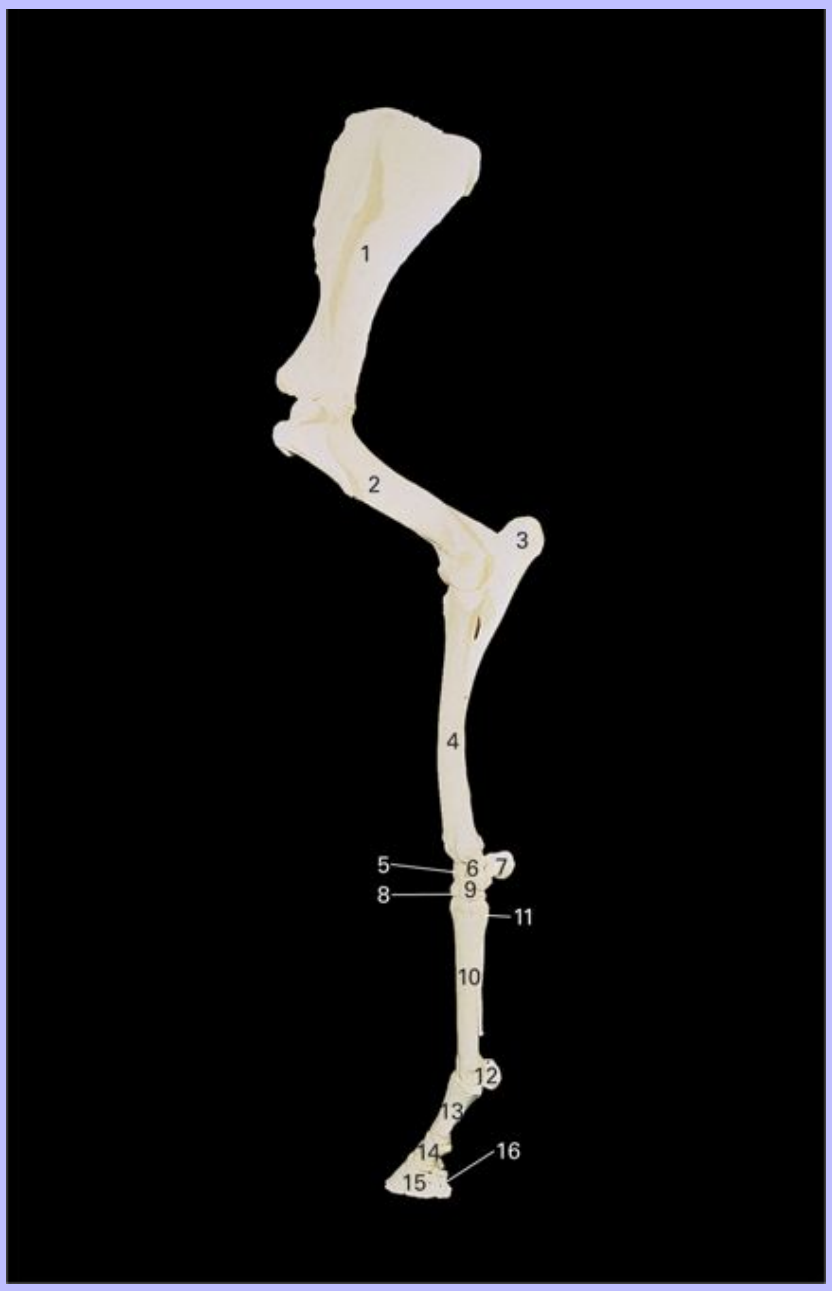

1 Scapula

Downloaded from Vet-eBooks.com

2 Humerus

3 Ulna

4 Radius

5 Intermediate carpal bone

6 Ulnar carpal bone

7 Accessory carpal bone

8 Third carpal bone

9 Fourth carpal bone

10 Metacarpal III (cannon bone)

11 Metacarpal IV (lateral splint bone)

12 Lateral proximal sesamoid bone

13 Proximal phalanx (P1, long pastern bone)

14 Middle phalanx (P2, short pastern bone)

15 Distal phalanx (P3, coffin bone, pedal bone)

16 Distal sesamoid (navicular) bone

Downloaded from Vet-eBooks.com

4.2 Skeleton of left forelimb, medial view.

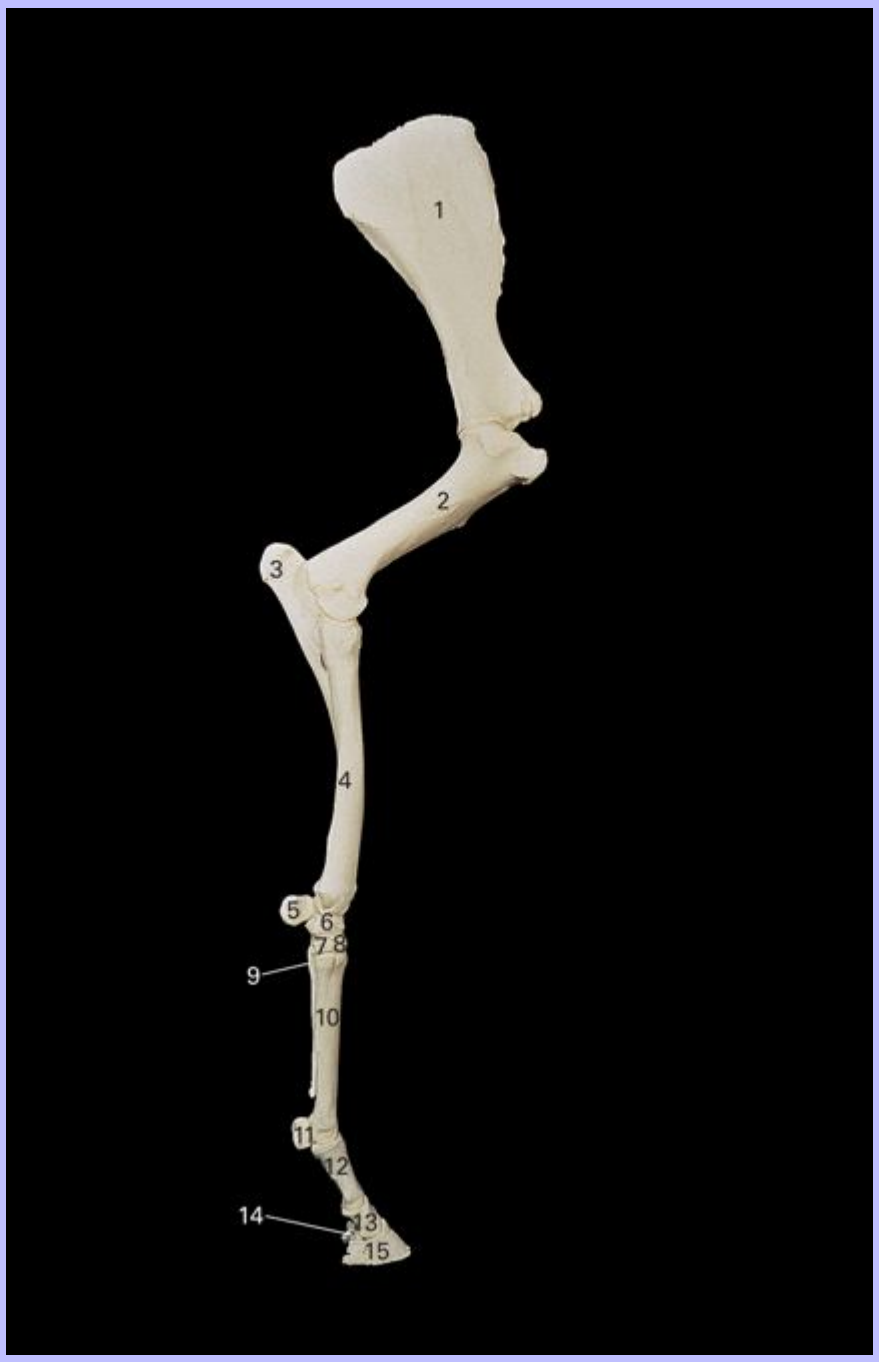

1 Scapula

Downloaded from Vet-eBooks.com

2 Humerus

3 Ulna

4 Radius

5 Accessory carpal bone

6 Radial carpal bone

7 Second carpal bone

8 Third carpal bone

9 Metacarpal II (medial splint bone)

10 Metacarpal III (cannon bone)

11 Medial proximal sesamoid bone

12 Proximal phalanx (P1, long pastern bone)

13 Middle phalanx (P2, short pastern bone)

14 Distal sesamoid (navicular) bone

15 Distal phalanx (P3, coffin bone, pedal bone)

35

Downloaded from Vet-eBooks.com

4.3 Left scapula, lateral view.

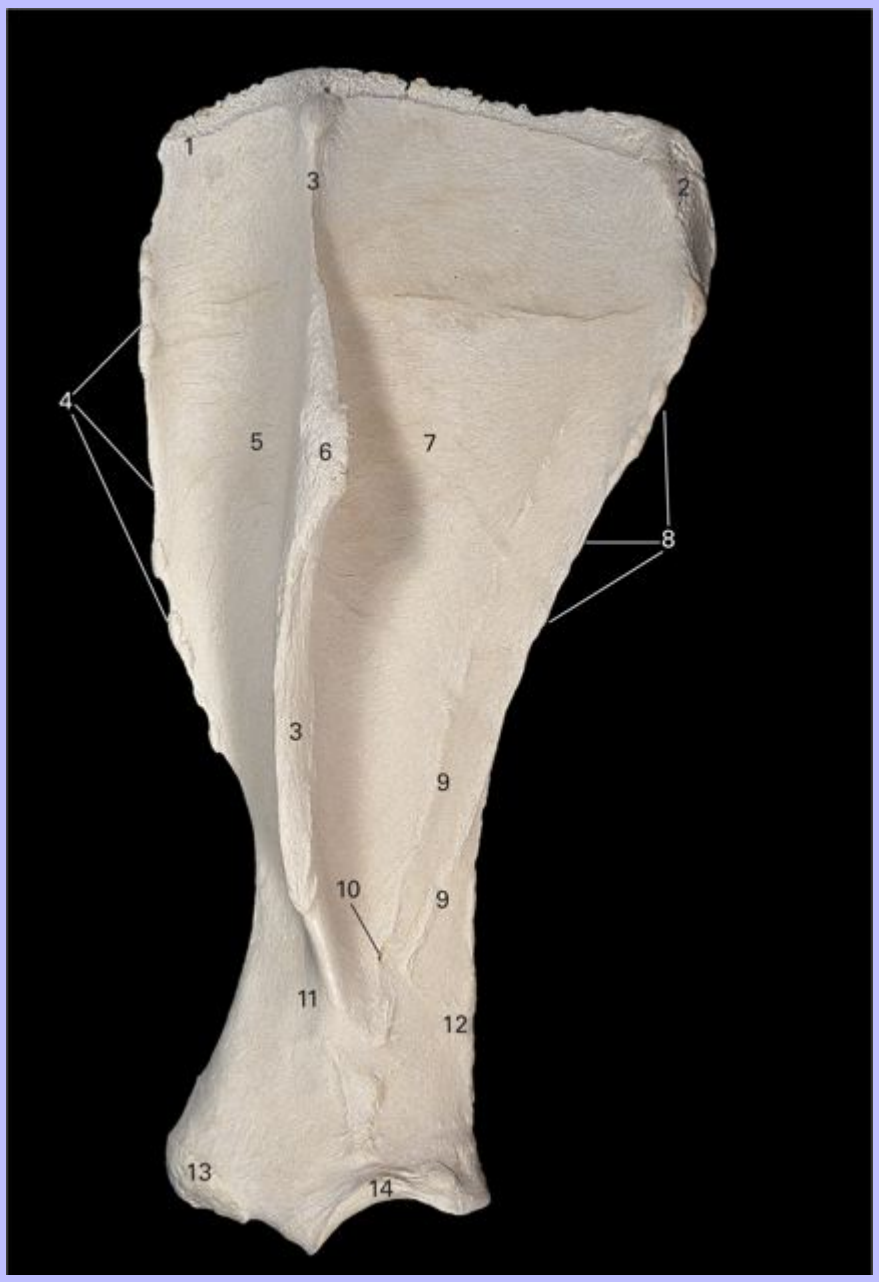

1 Cranial angle

2 Caudal angle

Downloaded from Vet-eBooks.com

3 Spine of scapula

4 Cranial border

5 Supraspinous fossa

6 Tuber of scapular spine

7 Infraspinous fossa

8 Caudal border

9 Muscular lines

10 Nutrient foramen

11 Neck

12 Vascular groove

13 Supraglenoid tubercle

14 Glenoid cavity

Downloaded from Vet-eBooks.com

4.4 Left scapula, medial view.

1 Caudal angle

2 Cranial angle

Downloaded from Vet-eBooks.com

3 Facies serrata

4 Subscapular fossa

5 Caudal border

6 Cranial border

7 Neck

8 Vascular groove

9 Glenoid cavity

10 Coracoid process

11 Supraglenoid tubercle

36

Downloaded from Vet-eBooks.com

4.5 Left humerus, cranial view.

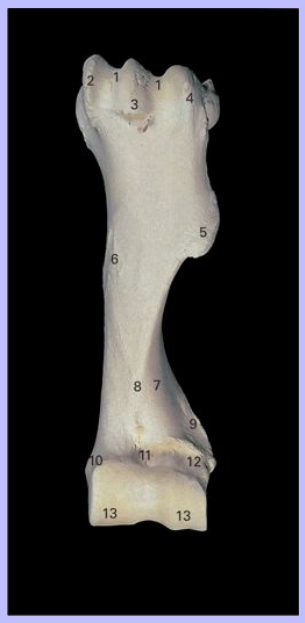

1 Intertuberal groove

2 Lesser tubercle

3 Intermediate tubercle

4 Greater tubercle

5 Deltoid tuberosity

6 Teres major tuberosity

7 Groove for M. brachialis (musculospiral groove)

8 Humeral crest

9 Lateral epicondyloid crest

10 Medial epicondyle

11 Radial fossa

12 Lateral epicondyle

13 Trochlea

Downloaded from Vet-eBooks.com

4.6 Left humerus, caudal view.

1 Greater tubercle

2 Intertuberal groove

3 Lesser tubercle

4 Head

5 Tricipital line

6 Deltoid tuberosity

7 Groove for M. brachialis (musculospiral groove)

8 Teres major tuberosity

9 Olecranon fossa

10 Lateral epicondyloid crest

11 Lateral epicondyle

12 Medial epicondyle

13 Trochlea

Downloaded from Vet-eBooks.com

4.7 Left humerus, lateral view.

1 Intertuberal groove

2 Greater tubercle

3 Head

4 Neck

5 Tricipital line

6 Deltoid tuberosity

7 Radial fossa

8 Lateral epicondyloid crest

9 Olecranon fossa

10 Medial epicondyle

11 Lateral epicondyle

12 Capitulum

13 Trochlea

14 Coronoid fossa

Downloaded from Vet-eBooks.com

4.8 Left humerus, medial view.

1 Lesser tubercle

2 Head

3 Neck

4 Teres major tuberosity

5 Nutrient foramen

6 Medial epicondyle

7 Tubercle for attachment of medial collateral ligament

8 Trochlea

Downloaded from Vet-eBooks.com

38

4.9 Left radius and ulna, cranial view.

Ulna

1 Olecranon tuberosity

2 Anconeal process

3 Trochlear notch

Radius

4 Medial tuberosity

5 Radial tuberosity

Downloaded from Vet-eBooks.com

6 Lateral tuberosity

7 Groove for M. brachialis

8 Body

9 Groove for tendon of M. abductor digiti I longus

10 Groove for tendon of M. extensor carpi radialis

11 Groove for tendon of M. extensor digitorum communis

12 Groove for tendon of M. extensor digitorum lateralis

13 Medial styloid process

14 Lateral styloid process

Downloaded from Vet-eBooks.com

4.10 Left radius and ulna, caudal view.

Ulna

1 Olecranon tuberosity

2 Body

Radius

3 Lateral tuberosity

4 Medial tuberosity

5 Interosseous space

6 Body

7 Groove for tendon of M. extensor digitorum lateralis

8 Transverse crest

9 Lateral styloid process

10 Medial styloid process

Downloaded from Vet-eBooks.com

4.11 Left radius and ulna, lateral view.

Ulna

1 Olecranon tuberosity

2 Anconeal process

3 Trochlear notch

4 Shaft of ulna

Radius

5 Capitular fovea

Downloaded from Vet-eBooks.com

6 Radial tuberosity

7 Lateral tuberosity for attachment of lateral collateral ligament of elbow and M. extensor digitorum communis

8 Interosseous space

9 Shaft of radius

10 Groove for tendon of M. extensor digitorum communis

11 Tuberosity for attachment of lateral collateral ligament of carpus

12 Groove for tendon of M. extensor digitorum lateralis

Downloaded from Vet-eBooks.com

4.12 Left radius and ulna, medial view.

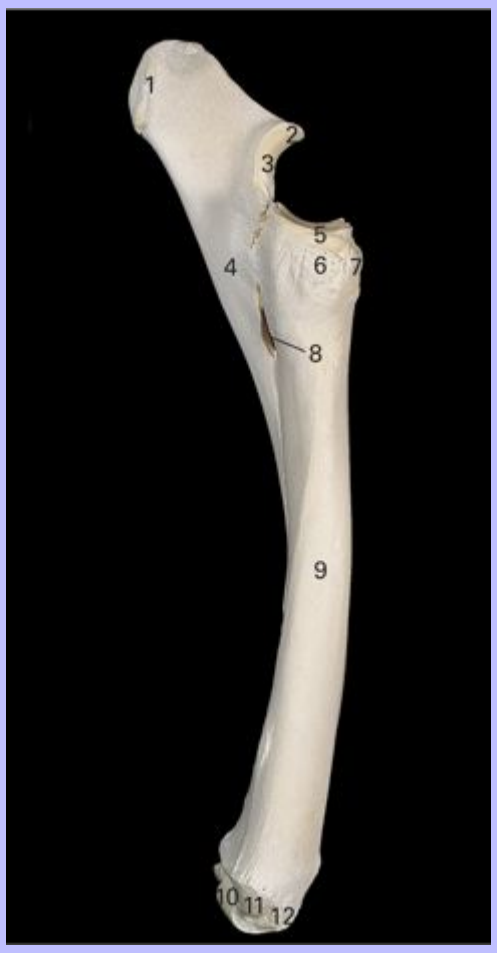

Ulna

1 Olecranon tuberosity

2 Anconeal process

3 Trochlear notch

4 Shaft of ulna

Radius

5 Capitular fovea

Downloaded from Vet-eBooks.com

6 Medial tuberosity for attachment of short part of medial collateral ligament of elbow

7 Radial tuberosity

8 Interosseous space

9 Shaft of radius

10 Carpal articular surface

11 Medial tuberosity for attachment of carpal medial collateral ligament

12 Oblique groove for tendon of M. abductor digiti I longus

38

39

4.13 Left carpal bones, dorsal view.

1 Radial carpal bone

2 Intermediate carpal bone

3 Ulnar carpal bone

4 Second carpal bone

5 Third carpal bone

6 Fourth carpal bone

Downloaded from Vet-eBooks.com

4.14 Left carpal bones, palmar view.

1 Accessory carpal bone

2 Ulnar carpal bone

3 Intermediate carpal bone

4 Radial carpal bone

5 Fourth carpal bone

6 Third carpal bone

7 Second carpal bone

8 First carpal bone (inconstant)

Downloaded from Vet-eBooks.com

4.15 Left carpal bones, lateral view.

1 Intermediate carpal bone

2 Ulnar carpal bone

3 Accessory carpal bone

4 Third carpal bone

5 Fourth carpal bone

Downloaded from Vet-eBooks.com

4.16 Left carpal bones, medial view.

1 Accessory carpal bone

2 Radial carpal bone

3 First carpal bone (inconstant)

4 Second carpal bone

5 Third carpal bone

39

Downloaded from Vet-eBooks.com

4.17 Left metacarpal bones, dorsal view.

1 Metacarpal tuberosity

2 Metacarpal II (medial splint bone)

3 Metacarpal III (cannon bone)

4 Metacarpal IV (lateral splint bone)

5 Sagittal ridge

Downloaded from Vet-eBooks.com

4.18 Left metacarpal and proximal sesamoid bones, palmar view.

1 Metacarpal IV (lateral splint bone)

2 Metacarpal III (cannon bone)

3 Metacarpal II (medial splint bone)

4 Nutrient foramen

5 Metacarpal IV, distal extremity (button)

6 Metacarpal II, distal extremity (button)

Downloaded from Vet-eBooks.com

7 Lateral proximal sesamoid bone

8 Medial proximal sesamoid bone

9 Abaxial surface

10 Axial surface

11 Apex

12 Base

13 Sagittal ridge

Downloaded from Vet-eBooks.com

4.19 Left metacarpal and proximal sesamoid bones, lateral view.

1 Metacarpal tuberosity

2 Base (head) of metacarpal IV (lateral splint bone)

3 Shaft of metacarpal III (cannon bone)

4 Shaft of metacarpal IV

5 Distal extremity (button) of metacarpal IV

6 Fossa for attachment of metacarpophalangeal lateral collateral ligament

7 Lateral proximal sesamoid bone

8 Sagittal ridge

Downloaded from Vet-eBooks.com

41

4.20 Bones of left digit, dorsal view.

Proximal phalanx

1 Eminences for attachment of collateral ligaments of metacarpophalangeal joint

2 Eminence for attachment of digital extensor tendons

3 Body

4 Eminences for attachment of collateral ligaments of proximal interphalangeal joint

Downloaded from Vet-eBooks.com

5 Distal articular surface

Middle phalanx

6 Proximal articular surface

7 Extensor process

8 Distal articular surface

Distal sesamoid (navicular) bone

9 Articular surface

Distal phalanx

10 Medial palmar process

11 Lateral palmar process

12 Medial parietal sulcus

13 Lateral parietal sulcus

14 Articular surface

15 Extensor process

16 Parietal surface

17 Crena

18 Solar border

Downloaded from Vet-eBooks.com

4.21 Bones of left digit, palmar view.

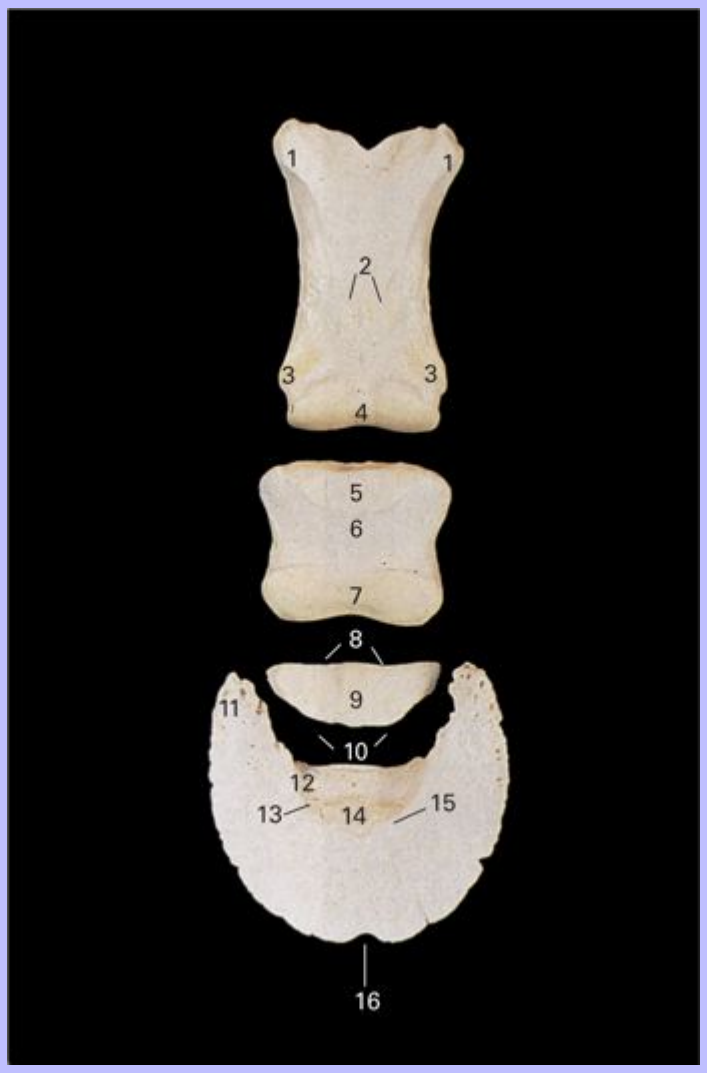

Proximal phalanx

1 Eminences for attachment of collateral ligaments of metacarpophalangeal joint

2 Triangular rough area

3 Eminences for attachment of collateral ligaments of proximal interphalangeal joint

4 Condyle

Downloaded from Vet-eBooks.com

Middle phalanx

5 Articular fovea

6 Flexor tuberosity

7 Condyle

Distal sesamoid (navicular) bone

8 Proximal border

9 Flexor surface

10 Distal border

Distal phalanx

11 Lateral palmar process

12 Lateral solar groove

13 Lateral solar foramen

14 Flexor surface

15 Semilunar line

16 Crena

41

Downloaded from Vet-eBooks.com

4.22 Superficial dissection of musculature of left forelimb, lateral view.

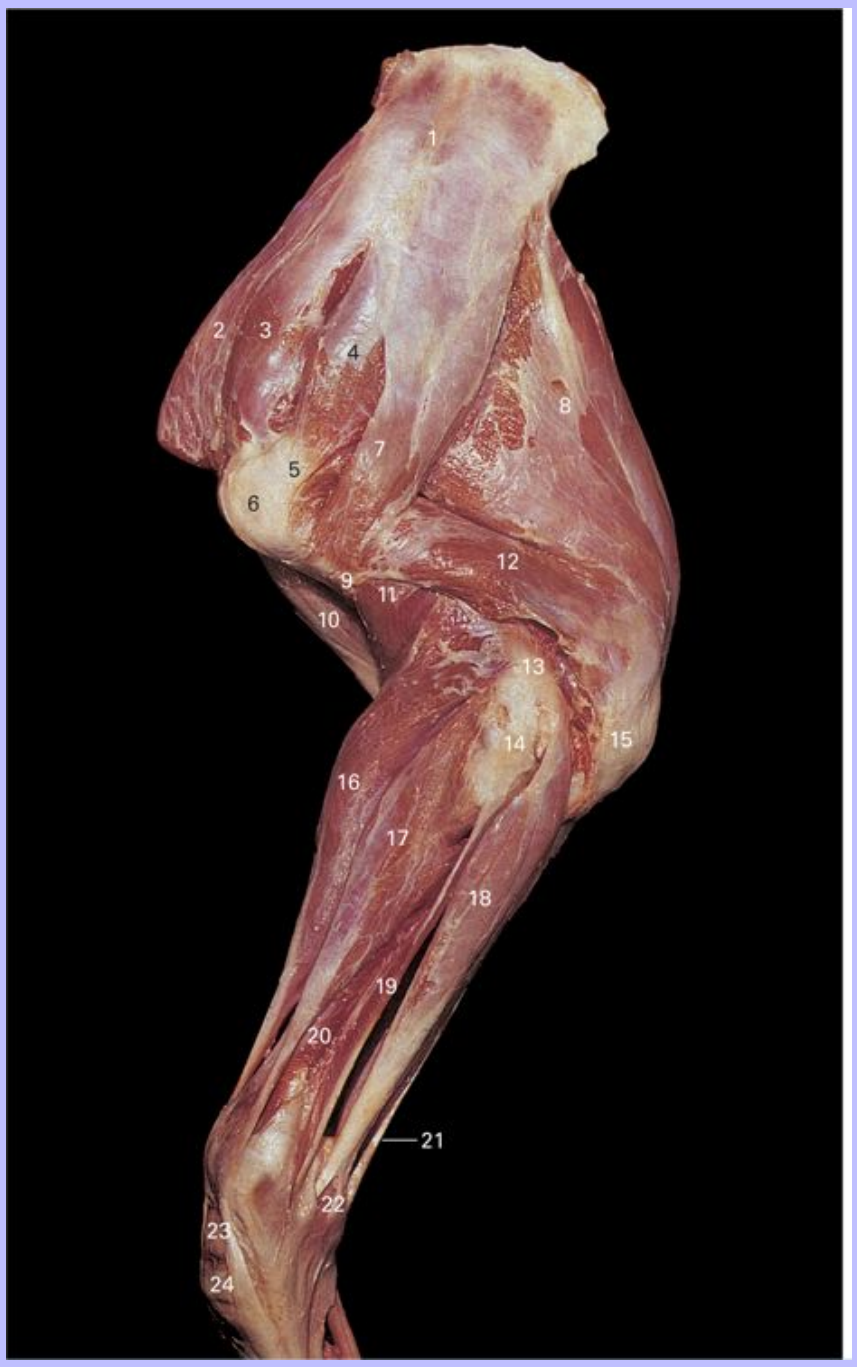

1 Spine of scapula

Downloaded from Vet-eBooks.com

2 M. subclavius

3 M. supraspinatus

4 M. infraspinatus

5 Tendon of M. infraspinatus

6 Greater tubercle of humerus

7 M. deltoideus

8 M. triceps brachii, long head

9 Deltoid tuberosity

10 M. biceps brachii

11 M. brachialis

12 M. triceps brachii, lateral head

13 Lateral epicondyle of humerus

14 Olecranon

15 Olecranon tuberosity

16 M. extensor carpi radialis

17 M. extensor digitorum communis

18 M. extensor carpi ulnaris (M. ulnaris lateralis)

19 M. extensor digitorum lateralis

20 M. abductor digiti I longus

21 M. flexor carpi ulnaris

22 Accessory carpal bone

23 Intermediate carpal bone

24 Third carpal bone

Downloaded From Vet-eBooks.com

4.23 Dissection of musculature of left forelimb, medial view. The M. tensor fascia antebrachii has been removed.

1 Attachment of M. rhomboideus

Downloaded from Vet-eBooks.com

2 Attachment of M. serratus ventralis

3 M. teres major

4 M. subscapularis

5 M. supraspinatus

6 M. subclavius

7 M. triceps brachii, long head

8 M. triceps brachii, medial head

9 M. coracobrachialis

10 M. biceps brachii

11 Olecranon tuberosity

12 Medial epicondyle

13 M. flexor digitorum profundus, ulnar head

14 M. flexor carpi ulnaris

15 M. flexor carpi radialis

16 Radius

17 M. extensor carpi radialis

18 Lacertus fibrosus

19 M. flexor digitorum superficialis

20 Carpal flexor retinaculum

21 Medial collateral carpal ligament

22 Tendon of M. abductor digiti I longus

23 Tendon of M. extensor carpi radialis

42

Downloaded from Vet-eBooks.com

4.24 Superficial dissection of musculature of left forelimb, cranial view. The pectoral muscles and M. subclavius have been removed.

1 Scapular cartilage

Downloaded from Vet-eBooks.com

2 M. supraspinatus

3 M. deltoideus

4 Greater tubercle of humerus

5 M. biceps brachii

6 Deltoid tuberosity

7 Tendinous intersection of M. biceps brachii

8 M. brachialis

9 M. extensor carpi radialis

10 M. flexor carpi radialis

11 M. extensor digitorum communis

12 Radius

13 M. abductor digiti I longus

14 Extensor retinaculum of carpus

Downloaded from Vet-eBooks.com

4.25 Superficial dissection of musculature of left forelimb, caudal view.

1 M. triceps brachii, lateral head

Downloaded from Vet-eBooks.com

2 M. triceps brachii, long head

3 M. triceps brachii, medial head

4 M. tensor fascia antebrachii

5 Olecranon tuberosity

6 M. flexor carpi radialis

7 M. extensor carpi ulnaris (M. ulnaris lateralis)

8 M. flexor digitorum profundus, ulnar head

9 M. flexor carpi ulnaris

10 M. flexor carpi radialis

11 Tendon of M. extensor digitorum lateralis

12 Accessory carpal bone

13 Medial collateral carpal ligament

14 Carpal flexor retinaculum

43

Downloaded from Vet-eBooks.com

4.26 Deep dissection of left shoulder joint, medial view.

1 Subscapular fossa

2 Caudal border of scapula

3 Cranial border of scapula

4 Supraglenoid tubercle

5 Cut edge of M. subscapularis

6 Cut edge of M. supraspinatus

7 Head of humerus

8 M. articularis humeri

9 Cut edge of M. coracobrachialis

10 M. biceps brachii

11 Humerus

Downloaded from Vet-eBooks.com

4.27 Lateromedial view radiograph of shoulder joint.

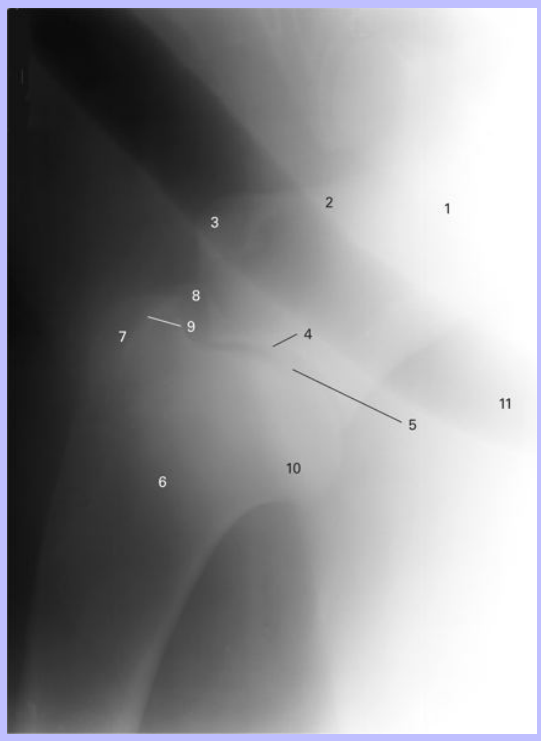

1 Scapula

2 Neck

3 Supraglenoid tubercle

4 Glenoid cavity

5 Scapulohumeral (shoulder) joint

6 Humerus

7 Greater tubercle

8 Lesser tubercle

9 Intertuberal groove

10 Head

11 Trachea

Downloaded from Vet-eBooks.com

4.28 Deep dissection of left shoulder joint, cranial view.

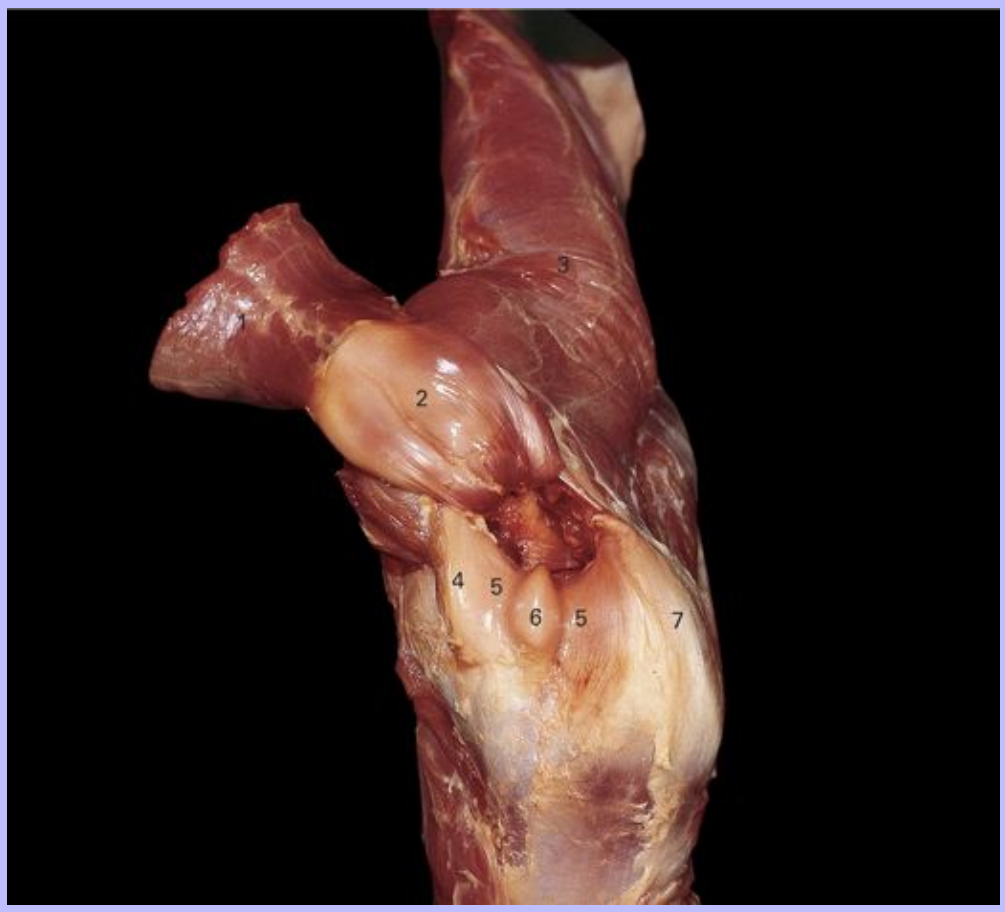

1 M. biceps brachii, sectioned and reflected craniomedially from its origin on the supraglenoid tubercle

2 Tendon of M. biceps brachii covered by synovial membrane of the bicipital bursa where it runs through the intertuberal groove

3 M. brachiocephalicus

4 Lesser tubercle

5 Inter-tuberal groove

6 Intermediate tubercle

7 Greater tubercle

Downloaded from Vet-eBooks.com

4.29 Proximocranial-distocranial view radiograph of proximal humerus.



1 Greater tubercle

2 Intermediate ridge

3 Lesser tubercle

4 Intertuberal groove

45

Downloaded from Vet-eBooks.com

4.30 Deep dissection of left cubital (elbow) joint, lateral view.

1 Greater tubercle

2 Tendon of M. infraspinatus

3 Head of humerus

4 Deltoid tuberosity

5 M. brachialis

6 Lateral epicondyloid crest

Downloaded from Vet-eBooks.com

7 Olecranon fossa

8 Olecranon tuberosity

9 Lateral epicondyle

10 Lateral collateral ligament

11 Trochlea

12 Trochlear notch of ulna

13 Interosseous space

14 Radius

15 Ulna

Downloaded from Vet-eBooks.com

4.31 Deep dissection of left cubital (elbow) joint, medial view.

1 Head of humerus

2 Lesser tubercle

3 M. brachialis

4 Olecranon tuberosity

5 Medial epicondyle

6 Trochlea

7 Capitular fovea

8 Short part of medial collateral ligament

9 Long part of medial collateral ligament

10 Ulna

11 Interosseous space

12 Radius

Downloaded from Vet-eBooks.com

4.32 Lateromedial view radiograph of cubital (elbow) joint.



1 Humerus

2 Lateral supracondyloid crest

3 Radial fossa

4 Olecranon fossa

5 Medial epicondyle

6 Lateral epicondyle

7 Condyles

8 Cubital joint

9 Ulna

10 Anconeal process

11 Olecranon tuberosity

12 Interosseous space

13 Radius

14 Radial tuberosity

Downloaded from Vet-eBooks.com

4.33 Deep dissection of left cubital (elbow) joint, cranial view.

1 Lesser tubercle

2 Intermediate tubercle

3 Greater tubercle

4 Intertuberal groove

5 Deltoid tuberosity

6 M. brachialis

7 Trochlea

8 Lateral collateral ligament

9 Attachment site of M. extensor digitorum communis and M. extensor digitorum lateralis

10 Long part of medial collateral ligament

Downloaded from Vet-e-Books.com

4.34 Deep dissection of left cubital (elbow) joint, caudal view.

1 Greater tubercle

2 Head of humerus

3 Deltoid tuberosity

4 M. brachialis

5 Lateral epicondyloid crest

Downloaded from Vet-eBooks.com

6 Olecranon fossa

7 Lateral epicondyle

8 Olecranon tuberosity

9 Medial epicondyle

10 Short part of medial collateral ligament

11 Lateral collateral ligament

12 Attachment site of M. extensor digitorum communis and M. extensor digitorum lateralis

13 Ulna

14 Radius

15 Long part of medial collateral ligament

Downloaded from Vet-eBooks.com

4.35 Craniocaudal view radiograph of cubital (elbow) joint.

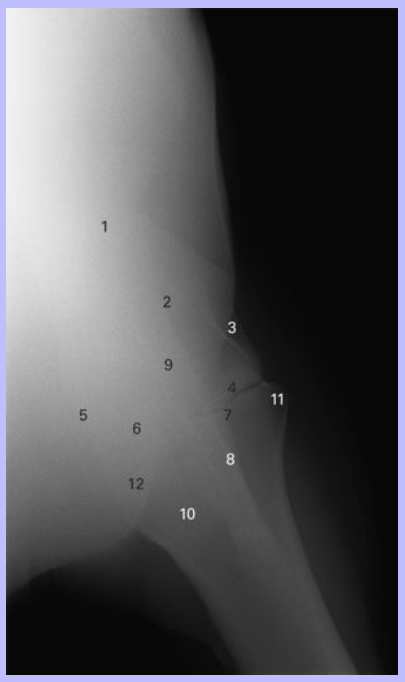

1 Humerus

2 Olecranon fossa

3 Lateral epicondyle

4 Lateral condyle

5 Medial epicondyle

6 Medial condyle

7 Cubital joint

8 Ulna

9 Olecranon tuberosity

10 Radius

11 Lateral tuberosity

12 Medial tuberosity

Downloaded from Vet-eBooks.com

4.36 Deep dissection of left forelimb, medial view. The M. flexor carpi radialis, M. flexor carpi ulnaris and M. flexor digitorum superficialis have been removed. The tendons of the M. flexor digitorum superficialis and M. flexor digitorum profundus have been retracted to expose the accessory ligaments.

1 M. flexor digitorum profundus, ulnar head

Downloaded from Vet-eBooks.com

2 Stump of M. flexor digitorum superficialis

3 Stump of M. flexor carpi ulnaris

4 Stump of M. flexor carpi radialis

5 M. biceps brachii

6 M. brachialis

7 Tendon of M. flexor digitorum profundus, ulnar head

8 M. flexor digitorum profundus, humeral head

9 Radius

10 M. extensor carpi radialis

11 Tendon of M. flexor digitorum superficialis

12 Accessory ligament of M. flexor digitorum superficialis (proximal check ligament)

13 Accessory carpal bone

14 Cut edge of tendon of M. flexor carpi radialis

15 Tendon of M. flexor digitorum superficialis

16 Tendon of M. flexor digitorum profundus

17 Accessory ligament of M. flexor digitorum profundus (distal check ligament)

18 M. interosseus medius (suspensory ligament)

19 Metacarpal III (cannon bone)

20 Tendon of M. extensor digitorum communis

21 Superficial transverse metacarpal ligament (palmar annular ligament)

22 Medial extensor branch of M. interosseus medius to tendon of M. extensor digitorum communis

Downloaded from Vet-eBooks.com

4.37 Transverse section through left antebrachium, distal view.

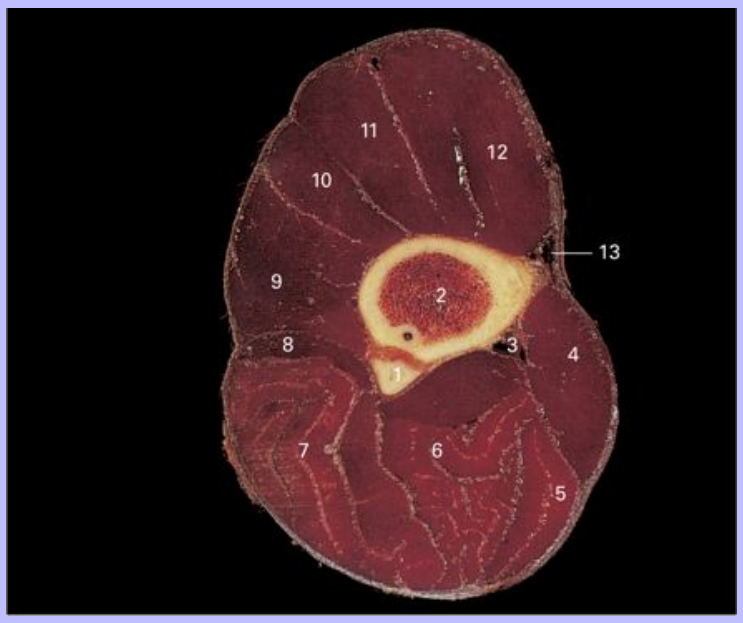

1 Ulna

2 Radius

3 Median vessels and nerve

4 M. flexor carpi radialis

5 M. flexor carpi ulnaris

6 M. flexor digitorum superficialis

7 M. flexor digitorum profundus, humeral head

8 M. flexor digitorum profundus, ulnar head

9 M. extensor carpi ulnaris (M. ulnaris lateralis)

10 M. extensor digitorum lateralis

11 M. extensor digitorum communis

12 M. extensor carpi radialis

13 Cephalic vein

Downloaded from Vet-eBooks.com

4.38 Superficial dissection of left carpus, dorsal view.

1 Radius

2 Tendon of M. extensor carpi radialis

3 Tendon of M. abductor digiti I longus

4 Tendon of M. extensor digitorum communis

5 Extensor retinaculum

6 Metacarpal tuberosity

7 Tendon of M. extensor digitorum lateralis

Downloaded from Vet-eBooks.com

4.39 Deep dissection of left carpus, dorsal view.

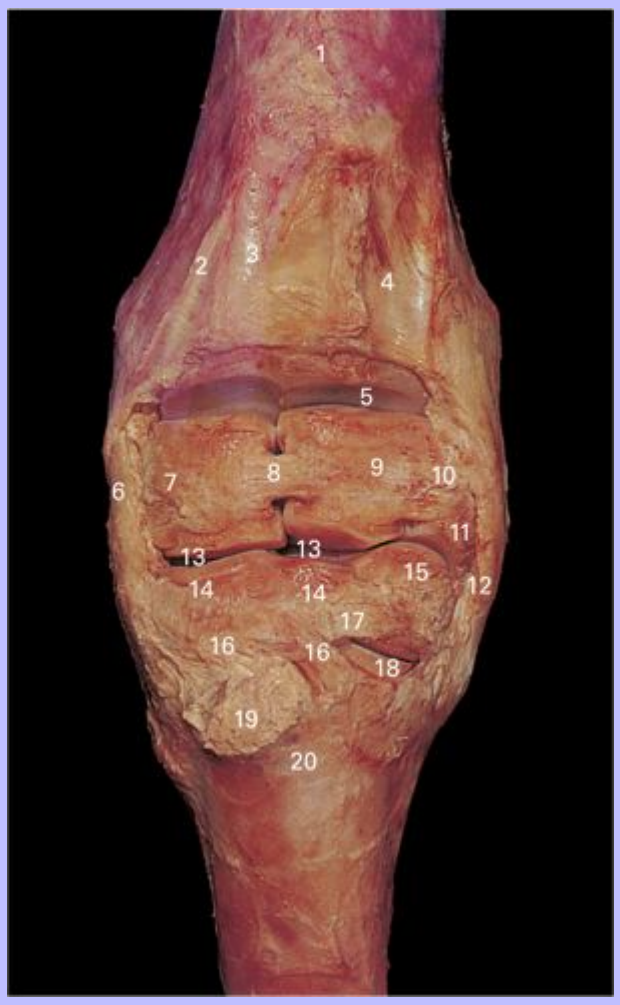

1 Radius

2 Groove for tendon of M. abductor digiti I longus

3 Groove for tendon of M. extensor carpi radialis

4 Groove for tendon of M. extensor digitorum communis

5 Antebrachiocarpal joint

6 Medial collateral carpal ligament

7 Radial carpal bone

Downloaded from Vet-eBooks.com

8 Dorsal intercarpal ligament between radial and intermediate carpal bones

9 Intermediate carpal bone

10 Dorsal intercarpal ligament between intermediate and ulnar carpal bones

11 Ulnar carpal bone

12 Lateral collateral carpal ligament

13 Intercarpal joint

14 Third carpal bone

15 Fourth carpal bone

16 Dorsal metacarpal ligament

17 Dorsal intercarpal ligament between third and fourth carpal bones

18 Carpometacarpal joint

19 Metacarpal tuberosity

20 Metacarpal III (cannon bone)

Downloaded From Vet-eBooks.com

4.40 Superficial dissection of left carpus, palmar view. Flexor retinaculum has been removed.

1 Tendon of M. extensor carpi ulnaris (M. ulnaris lateralis)

2 Tendon of M. flexor digitorum profundus

3 Tendon of M. flexor carpi ulnaris

4 Tendon of M. flexor carpi radialis

5 Tendon of M. extensor digitorum lateralis

6 Tendon of M. extensor carpi ulnaris to accessory carpal bone

7 Tendon of M. extensor carpi ulnaris to metacarpal IV

8 Accessory carpal bone

9 Metacarpal IV (lateral splint bone)

10 Tendon of M. flexor digitorum superficialis

11 Metacarpal II (medial splint bone)

Downloaded from Vet-eBooks.com

4.41 Dorsopalmar view radiograph of the carpus.

1 Radius

2 Lateral styloid process

3 Medial styloid process

4 Antebrachiocarpal (radiocarpal) joint

5 Accessory carpal bone

6 Ulnar carpal bone

7 Intermediate carpal bone

8 Radial carpal bone

9 Intercarpal joint

10 Fourth carpal bone

11 Third carpal bone

Downloaded from Vet-eBooks.com

12 Second carpal bone

13 Carpometacarpal joint

14 Metacarpal IV (lateral splint bone)

15 Metacarpal III (cannon bone)

16 Metacarpal II (medial splint bone)

49

Downloaded from Vet-eBooks.com

4.42 Superficial dissection of left carpus, lateral view.

1 Tendon of M. extensor carpi radialis

2 M. abductor digiti I longus

3 Tendon of M. extensor digitorum communis

4 Tendon of M. extensor digitorum lateralis

5 M. flexor digitorum profundus, humeral head

Downloaded from Vet-eBooks.com

6 Tendon of M. extensor carpi ulnaris (M. ulnaris lateralis)

7 M. flexor digitorum profundus, ulnar head

8 Tendon of M. flexor carpi ulnaris

9 Extensor retinaculum

10 Accessory carpal bone

11 Lateral collateral carpal ligament

12 Accessoriocarpoulnar ligament

13 Accessorioquartal ligament

14 Accessoriometacarpal ligament

Downloaded from Vet-eBooks.com

4.43 Deep dissection of left carpus, lateral view.

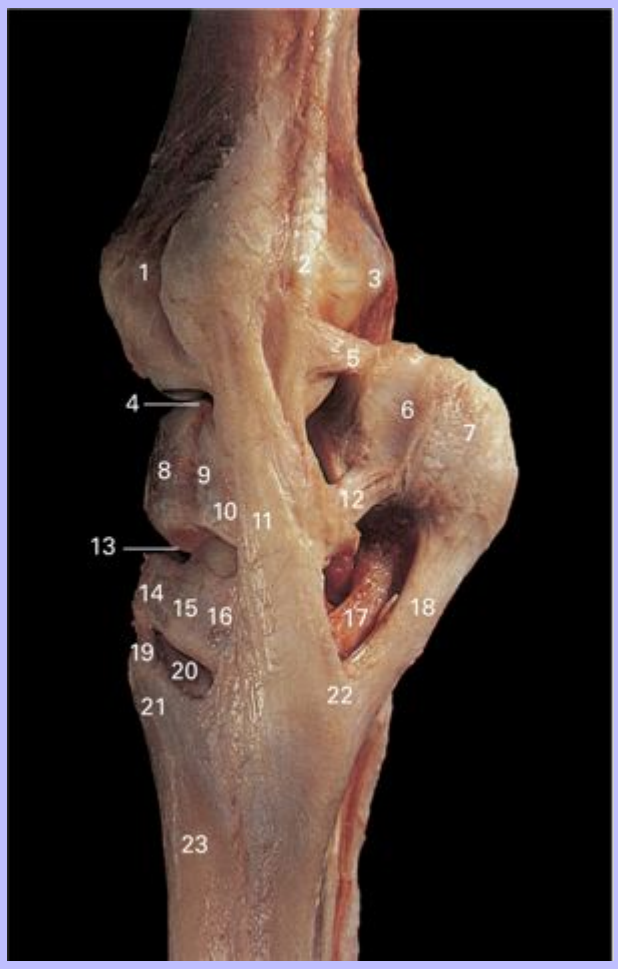

1 Groove for tendon of M. extensor digitorum communis

2 Tendon of M. extensor digitorum lateralis

3 Transverse crest of radius

4 Antebrachiocarpal joint

5 Accessorioulnar ligament

6 Groove for tendon of M. ulnaris lateralis

7 Accessory carpal bone

Downloaded from Vet-eBooks.com

8 Intermediate carpal bone

9 Dorsal intercarpal ligament between intermediate and ulnar carpal bones

10 Ulnar carpal bone

11 Lateral collateral carpal ligament

12 Accessoriocarpoulnar ligament

13 Intercarpal joint

14 Third carpal bone

15 Dorsal intercarpal ligament between third and fourth carpal bones

16 Fourth carpal bone

17 Accessorioquartal ligament

18 Accessoriometacarpal ligament

19 Dorsal metacarpal ligament

20 Carpometacarpal joint

21 Metacarpal tuberosity

22 Base of metacarpal IV (lateral splint bone)

23 Metacarpal III (cannon bone)

Downloaded from Vet-eBooks.com

4.44 Superficial dissection of left carpus, medial view. Flexor retinaculum has been removed to expose contents of the carpal canal.

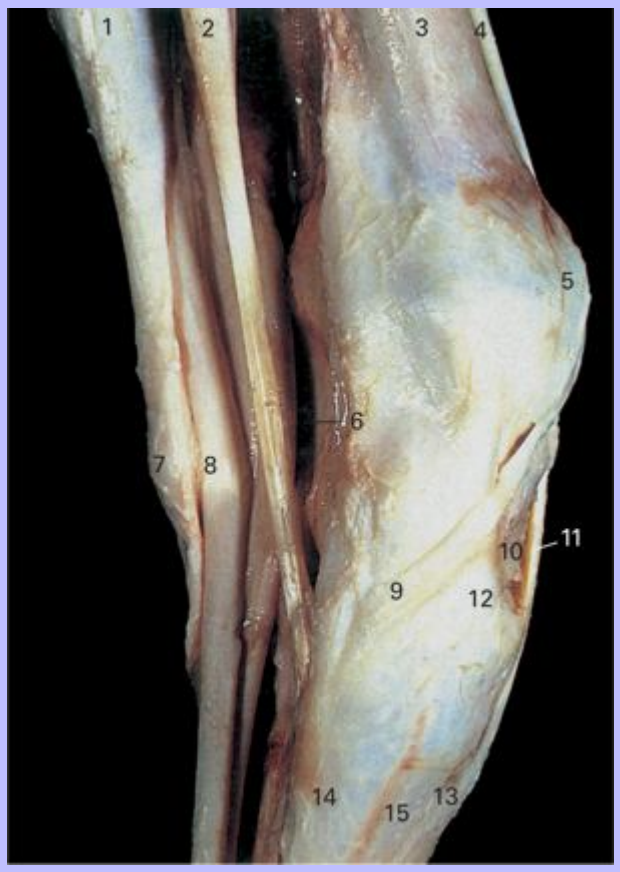

1 M. flexor carpi ulnaris

2 M. flexor carpi radialis

3 Radius

4 M. extensor carpi radialis

5 Extensor retinaculum of carpus

6 Cut edge of flexor retinaculum

7 Accessory carpal bone

8 Tendon of M. flexor digitorum superficialis passing through carpal canal

Downloaded from Vet-eBooks.com

9 Tendon of M. extensor digiti I longus

10 Third carpal bone

11 Tendon of M. extensor carpi radialis

12 Medial collateral carpal ligament

13 Metacarpal tuberosity

14 Metacarpal II (medial splint bone)

15 Metacarpal III (cannon bone)

Downloaded from Vet-eBooks.com

4.45 Deep dissection of left carpus, medial view.

1 Radius

2 Medial styloid process

3 Medial collateral carpal ligament

4 Groove for tendon of M. abductor digiti I longus

5 Antebrachiocarpal joint

6 Accessory carpal bone

7 Radial carpal bone

8 Intercarpal joint

9 Third carpal bone

10 Carpometacarpal joint

11 Metacarpal tuberosity

12 Metacarpal II (medial splint bone)

13 Metacarpal III (cannon bone)

Downloaded from Vet-eBooks.com

4.46 Lateromedial view radiograph of carpus.

1 Radius

2 Antebrachiocarpal (radiocarpal) joint

3 Radial, intermediate and ulnar carpal bones

4 Accessory carpal bone

5 Intercarpal joint

6 Second, third and fourth carpal bones

7 Carpometacarpal joint

8 Metacarpal III (cannon bone)

9 Metacarpal tuberosity

10 Metacarpals II and IV (medial and lateral splint bones)

Downloaded from Vet-eBooks.com

4.47 Dorsolateral-palmaromedial oblique view radiograph of carpus.

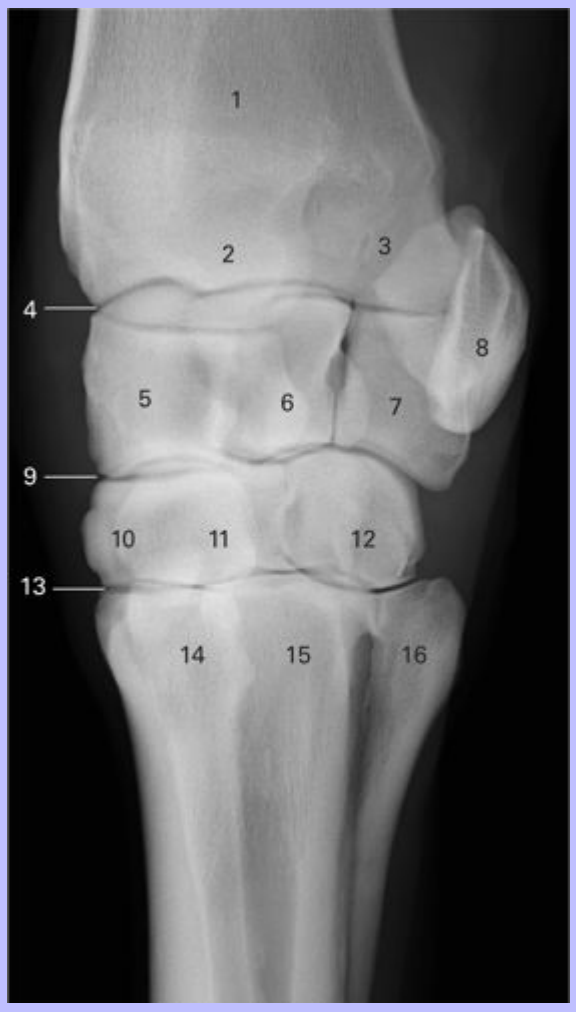

1 Radius

2 Medial styloid process

3 Lateral styloid process

4 Antebrachiocarpal (radiocarpal) joint

5 Radial carpal bone

6 Intermediate carpal bone

7 Ulnar carpal bone

Downloaded from Vet-eBooks.com

8 Accessory carpal bone

9 Intercarpal joint

10 Third carpal bone

11 Second carpal bone

12 Fourth carpal bone

13 Carpometacarpal joint

14 Metacarpal II (medial splint bone)

15 Metacarpal III (cannon bone)

16 Metacarpal IV (lateral splint bone)

Downloaded from Vet-eBooks.com

4.48 Dorsomedial-palmarolateral oblique view radiograph of carpus.

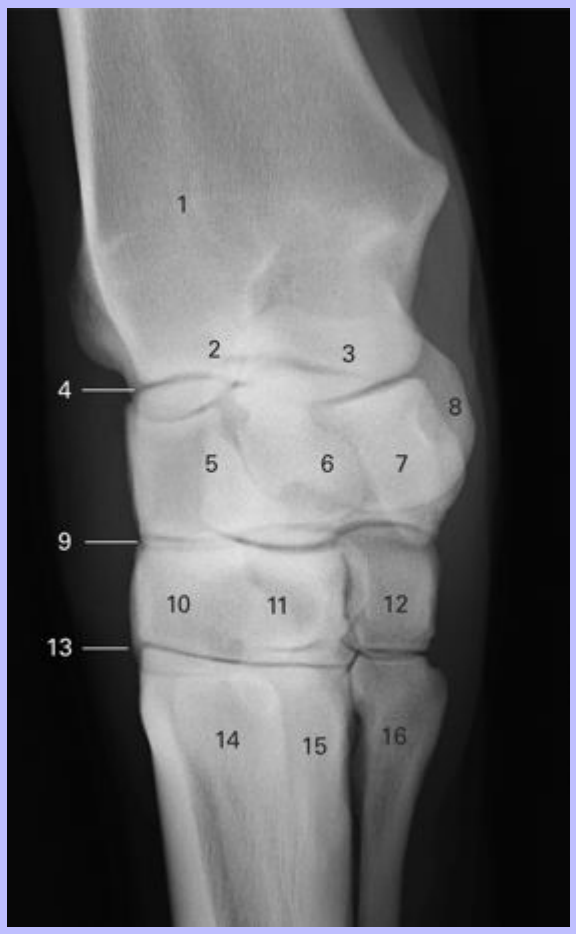

1 Radius

2 Lateral styloid process

3 Medial styloid process

4 Radiocarpal (antebrachiocarpal) joint

5 Ulnar carpal bone

6 Intermediate carpal bone

7 Radial carpal bone

8 Accessory carpal bone

Downloaded from Vet-eBooks.com

9 Intercarpal joint

10 Third carpal bone

11 Fourth carpal bone

12 Second carpal bone

13 Carpometacarpal joint

14 Metacarpal IV (lateral splint bone)

15 Metacarpal III (cannon bone)

16 Metacarpal II (medial splint bone)

51

Downloaded from Vet-eBooks.com

4.49 Deep dissection of left carpus, flexed dorsal view.

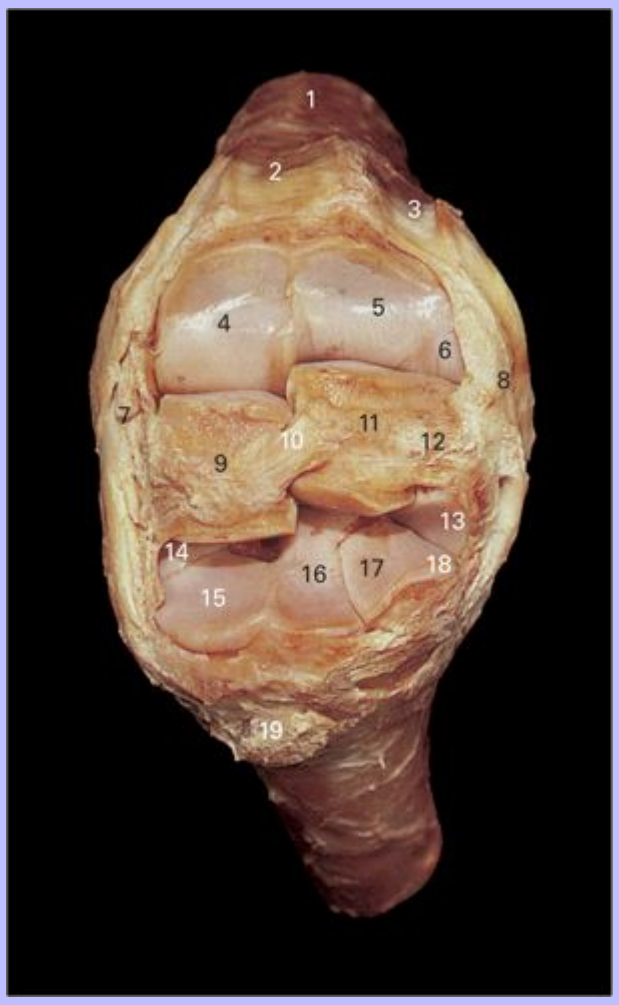

1 Radius

2 Groove for tendon of M. extensor carpi radialis

3 Groove for tendon of M. extensor digitorum lateralis

4 Facet on radius for articulation with radial carpal bone

5 Facet on radius for articulation with intermediate carpal bone

6 Facet on lateral styloid process for articulation with ulnar carpal bone

7 Medial collateral carpal ligament

Downloaded from Vet-eBooks.com

8 Lateral collateral carpal ligament

9 Radial carpal bone

10 Dorsal intercarpal ligament between radial and intermediate carpal bones

11 Intermediate carpal bone

12 Dorsal intercarpal ligament between ulnar and intermediate carpal bones

13 Facet on ulnar carpal bone for articulation with fourth carpal bone

14 Facet on second carpal bone for articulation with radial carpal bone

15 Facet on third carpal bone for articulation with radial carpal bone

16 Facet on third carpal bone for articulation with intermediate carpal bone

17 Facet on fourth carpal bone for articulation with intermediate carpal bone

18 Facet on fourth carpal bone for articulation with ulnar carpal bone

19 Metacarpal tuberosity

Downloaded from Vet-eBooks.com

4.50 Flexed lateromedial view radiograph of carpus.

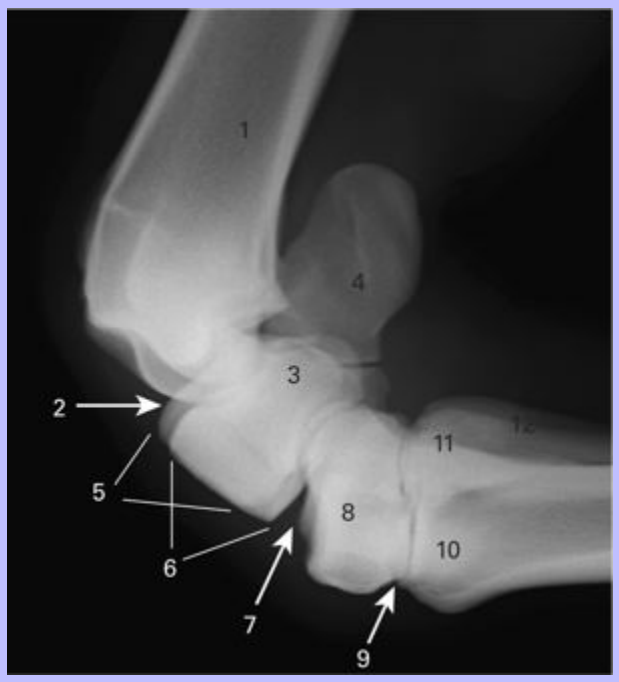

1 Radius

2 Antebrachiocarpal (radiocarpal) joint

3 Ulnar carpal bone

4 Accessory carpal bone

5 Intermediate carpal bone

6 Radial carpal bone

7 Intercarpal joint

8 Second, third and fourth carpal bones

9 Carpometacarpal joint

10 Metacarpal III (cannon bone)

11 Metacarpal II (medial splint bone)

12 Metacarpal IV (lateral splint bone)

Downloaded from Vet-eBooks.com

4.51 Transverse section through left carpus at level of proximal row of carpal bones, distal view.

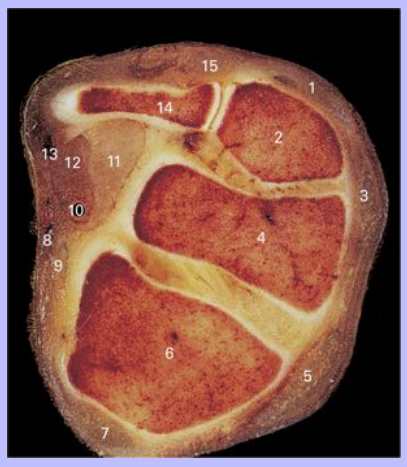

1 Tendon of M. extensor digitorum lateralis

2 Ulnar carpal bone

3 Tendon of M. extensor digitorum communis

4 Intermediate carpal bone

5 Tendon of M. extensor carpi radialis

6 Radial carpal bone

7 Tendon of M. abductor digiti I longus

8 Medial palmar vein

9 Tendon of M. flexor carpi radialis

10 Medial palmar artery and nerve

11 Tendon of M. flexor digitorum profundus

12 Tendon of M. flexor digitorum superficialis

13 Lateral palmar vessels and nerve

14 Accessory carpal bone

15 Tendon of M. extensor carpi ulnaris

52

Downloaded from Vet-eBooks.com

4.52 Left manus, dorsal view.

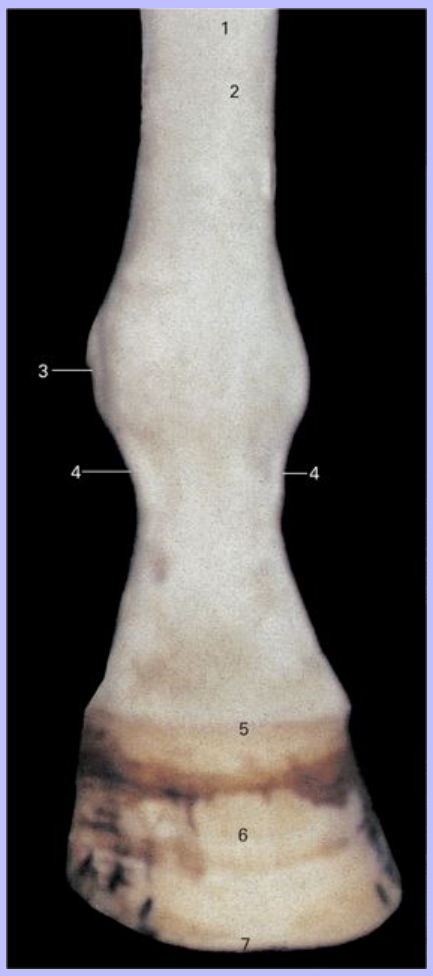

1 Metacarpal region

2 Tendon of M. extensor digitorum communis

3 Level of metacarpophalangeal (fetlock) joint

4 Extensor branches of M. interosseus medius to tendon of M. extensor digitorum communis

5 Coronet

6 Wall of hoof

7 Toe

Downloaded from Vet-eBooks.com

4.53 Left manus, lateral view.

1 Metacarpal III (cannon bone)

2 Metacarpal IV (lateral splint bone)

Downloaded from Vet-eBooks.com

3 M. interosseus medius (suspensory ligament)

4 Tendons of M. flexor digitorum superficialis and M. flexor digitorum profundus

5 Level of metacarpophalangeal (fetlock) joint

6 Lateral extensor branch of M. interosseus medius

7 Ergot

8 Lateral cartilage of distal phalanx

9 Coronet

10 Wall of hoof

11 Toe

12 Quarter

13 Heel

Downloaded from Vet-eBooks.com

4.54 Left manus, palmar view.

1 Metacarpal region

2 Proximal sesamoid bones

3 Level of metacarpophalangeal (fetlock) joint

4 Ergot

5 Lateral cartilage of distal phalanx

6 Medial cartilage of distal phalanx

7 Cleft of frog

8 Bulbs of heels

9 Hoof wall

53

Downloaded from Vet-eBooks.com

54

4.55 Left manus (A) showing six levels at which images were made using a 7.5 MHz ultrasound sector scanner with standoff pad (pictures B–G), and computed tomography (pictures H–M). The leg was then sectioned at the six levels (pictures N–S).

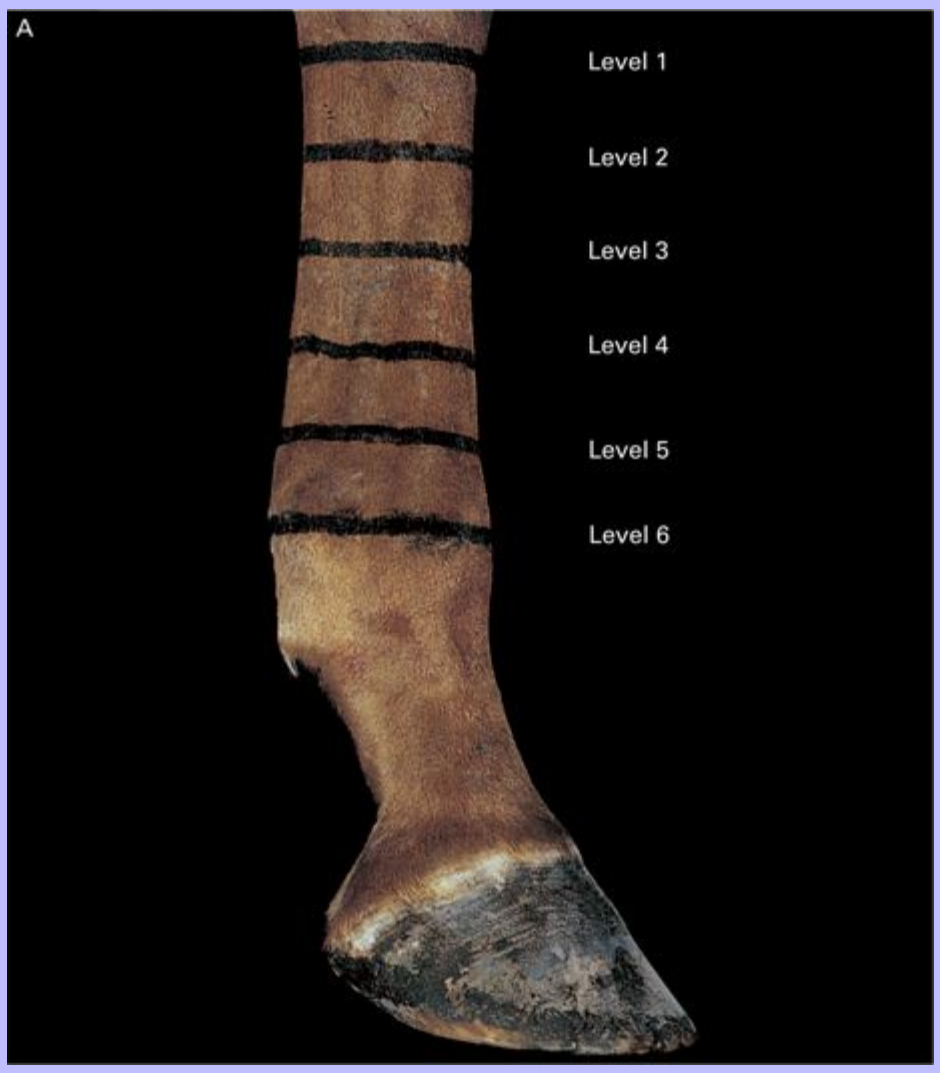

Downloaded from Vet-eBooks.com

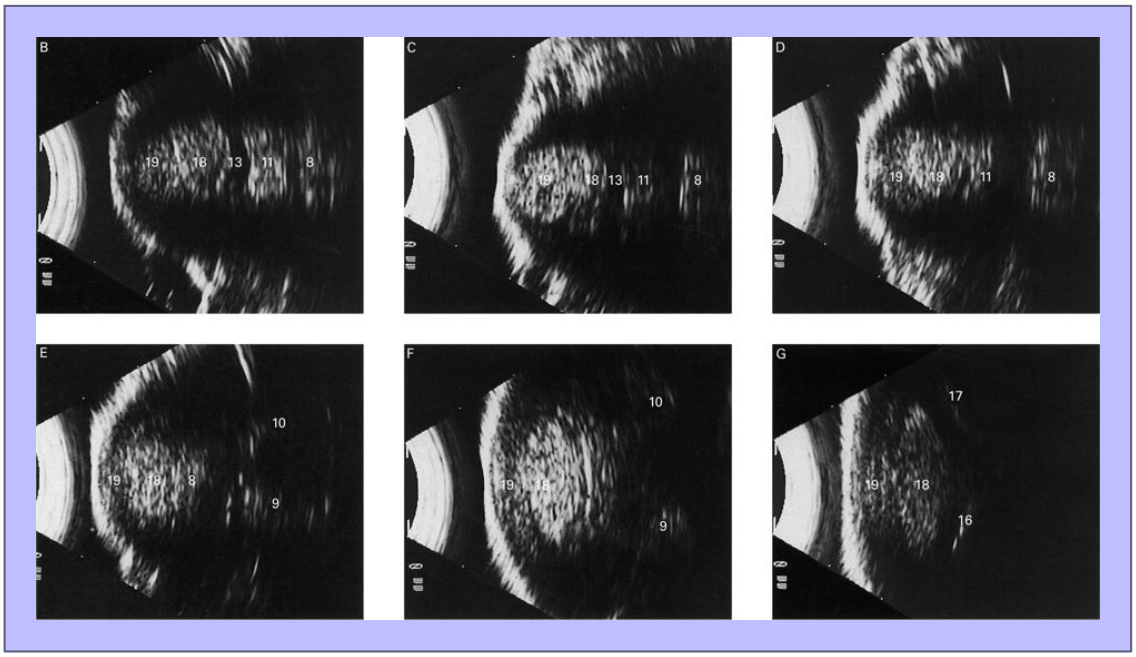

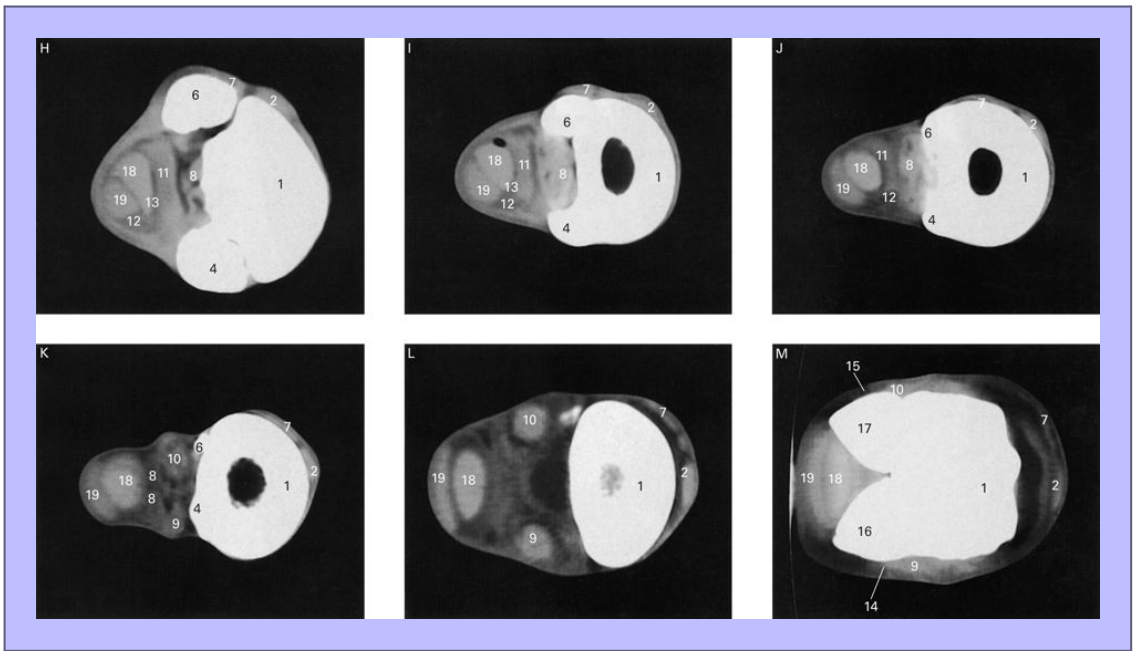

Downloaded from Vet-eBooks.com

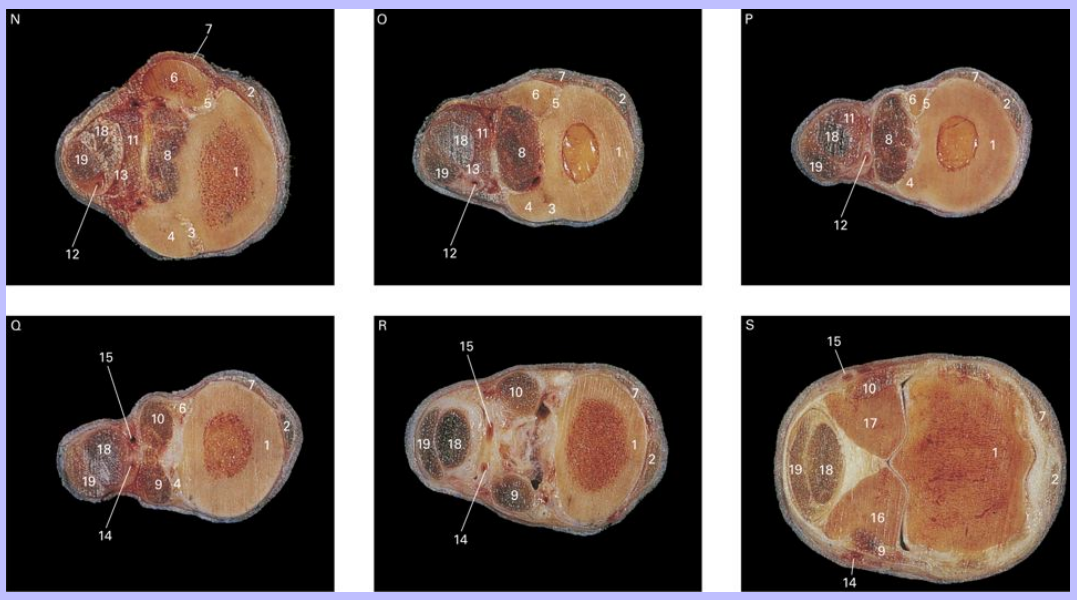

1 Metacarpal III (cannon bone)

2 Tendon of M. extensor digitorum communis

3 Interosseus metacarpal ligament between metacarpals II and III

4 Metacarpal II (medial splint bone)

5 Interosseus metacarpal ligament between metacarpals III and IV

6 Metacarpal IV (lateral splint bone)

7 Tendon of M. extensor digitorum lateralis

8 M. interosseus medius (suspensory ligament)

9 Medial extensor branch of M. interosseus medius

10 Lateral extensor branch of M. interosseus medius

11 Accessory ligament of M. flexor digitorum profundus (distal check ligament)

12 Medial palmar artery

13 Carpal sheath

14 Medial palmar digital artery

Downloaded from Vet-eBooks.com

15 Lateral palmar digital artery

16 Medial proximal sesamoid bone

17 Lateral proximal sesamoid bone

18 Tendon of M. flexor digitorum profundus

19 Tendon of M. flexor digitorum superficialis

54

Downloaded from Vet-eBooks.com

56

4.56 Superficial dissection of digit of left forelimb, lateral view.

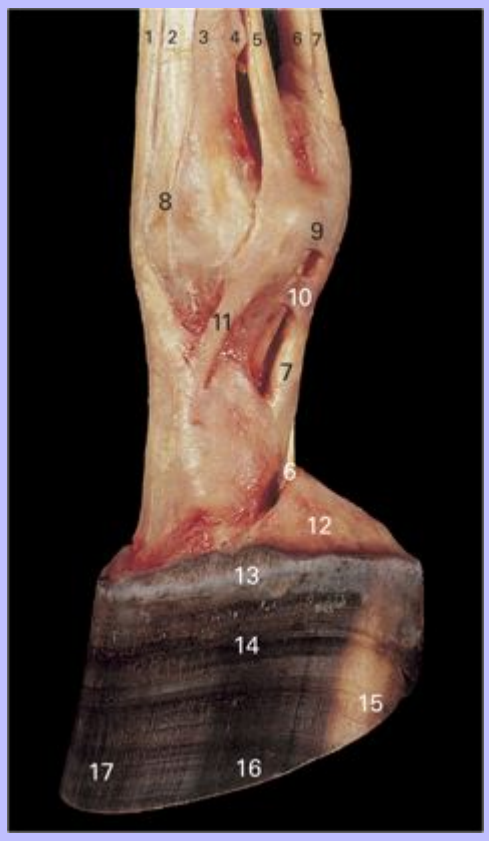

1 Tendon of M. extensor digitorum communis

2 Tendon of M. extensor digitorum lateralis

3 Metacarpal III (cannon bone)

4 Metacarpal IV (lateral splint bone)

5 M. interosseus medius (suspensory ligament)

6 Tendon of M. flexor digitorum profundus

7 Tendon of M. flexor digitorum superficialis

8 Attachment of tendon of M. extensor digitorum lateralis

9 Superficial transverse metacarpal ligament (palmar annular ligament)

Downloaded from Vet-eBooks.com

10 Vagina fibrosa (proximal digital annular ligament)

11 Lateral extensor branch of M. interosseus medius

12 Lateral cartilage of distal phalanx

13 Coronet

14 Wall of hoof

15 Heel

16 Quarter

17 Toe

Downloaded from Vet-eBooks.com

4.57 Deep dissection of digit of left forelimb, lateral view. The following structures have been removed: transverse metacarpal ligament; vagina fibrosa; tendons of the M. extensor digitorum communis, M. extensor digitorum lateralis, M. flexor digitorum superficialis and M. flexor digitorum profundus; lateral extensor branch of M. interosseus medius; wall, sole and frog of the hoof.

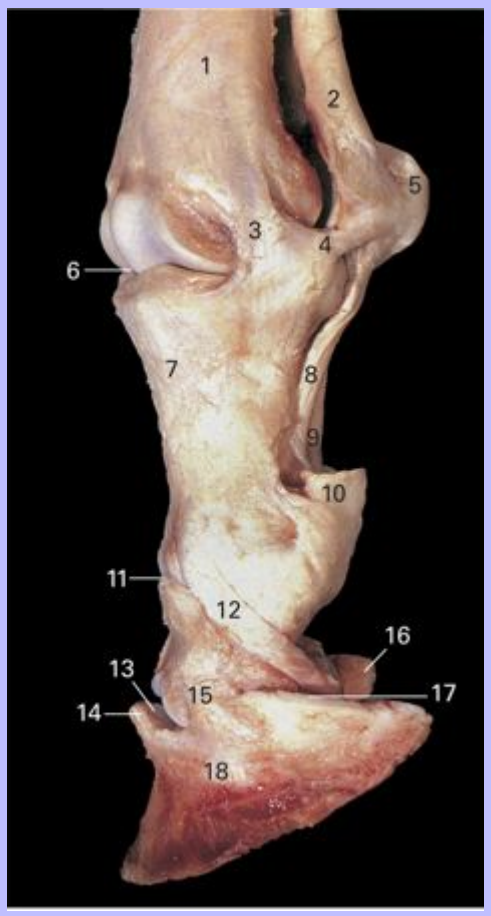

1 Metacarpal II (medial splint bone)

2 M. interosseus medius (suspensory ligament)

3 Lateral collateral metacarpophalangeal ligament

4 Lateral collateral sesamoidean ligament

5 Lateral proximal sesamoid bone

Downloaded from Vet-eBooks.com

6 Metacarpophalangeal (fetlock) joint

7 Proximal phalanx

8 Oblique sesamoidean ligament

9 Straight sesamoidean ligament

10 Cut edge of tendon of M. flexor digitorum superficialis

11 Proximal interphalangeal (pastern) joint

12 Lateral collateral ligament of distal sesamoid bone (suspensory navicular ligament)

13 Distal interphalangeal (coffin) joint

14 Extensor process of distal phalanx

15 Lateral collateral ligament of distal interphalangeal joint

16 Medial process of distal phalanx

17 Cut edge of lateral cartilage of distal phalanx

18 Distal phalanx (coffin bone)

Downloaded From Vet-eBooks.com

4.58 Superficial dissection of digit of left forelimb, medial view.

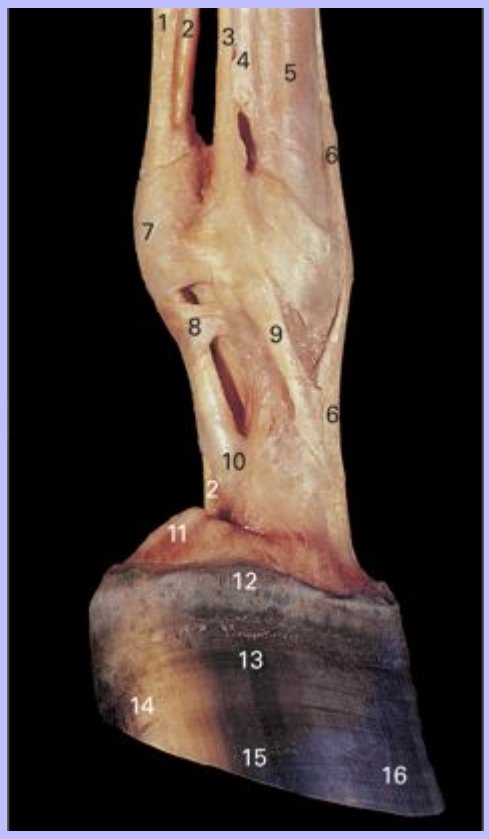

1 Tendon of M. flexor digitorum superficialis

2 Tendon of M. flexor digitorum profundus

3 M. interosseus medius (suspensory ligament)

4 Metacarpal II (medial splint bone)

5 Metacarpal III (cannon bone)

6 Tendon of M. extensor digitorum communis

7 Superficial transverse metacarpal ligament (palmar annular ligament)

8 Vagina fibrosa (proximal digital annular ligament)

9 Medial extensor branch of M. interosseus medius

Downloaded from Vet-eBooks.com

10 Vagina fibrosa (distal digital annular ligament)

11 Medial cartilage of distal phalanx

12 Coronet

13 Wall of hoof

14 Heel

15 Quarter

16 Toe

Downloaded from Vet-eBooks.com

4.59 Deep dissection of digit of left forelimb, medial view. The superficial transverse metacarpal ligament and the vagina fibrosa have been removed.

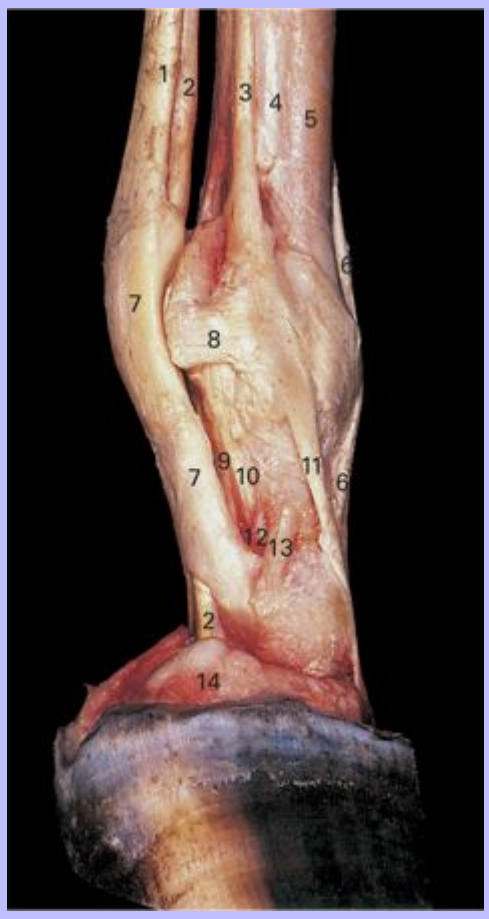

1 Tendon of M. flexor digitorum superficialis

2 Tendon of M. flexor digitorum profundus

3 M. interosseus medius (suspensory ligament)

4 Metacarpal II (medial splint bone)

5 Metacarpal III (cannon bone)

6 Tendon of M. extensor digitorum communis

7 Manica flexoria

Downloaded from Vet-eBooks.com

8 Medial collateral sesamoidean ligament

9 Straight sesamoidean ligament

10 Oblique sesamoidean ligament

11 Medial extensor branch of M. interosseus medius

12 Palmar ligament of proximal interphalangeal joint

13 Medial collateral ligament of proximal interphalangeal joint

14 Medial cartilage of distal phalanx

56

Downloaded from Vet-eBooks.com

57

4.60 Lateromedial view radiograph of metacarpophalangeal (fetlock) joint.

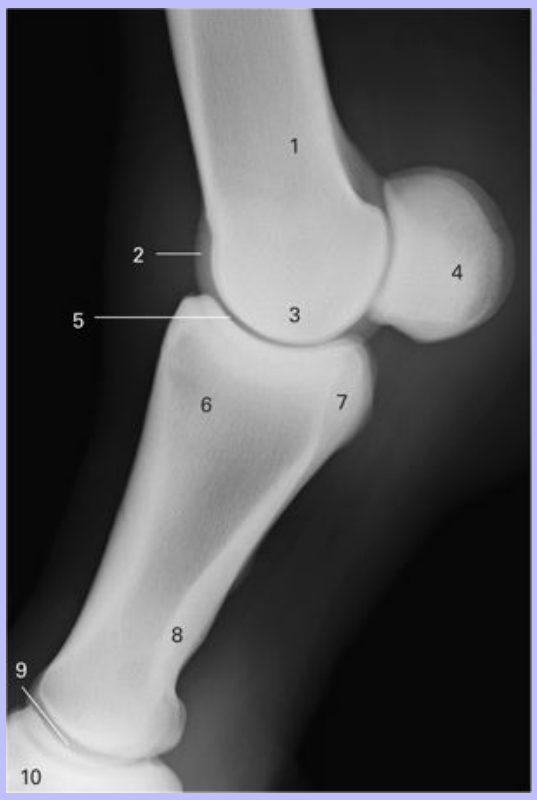

1 Metacarpal III (cannon bone)

2 Sagittal ridge

3 Medial and lateral condyles

4 Medial and lateral proximal sesamoid bones

5 Metacarpophalangeal (fetlock) joint

6 Proximal phalanx (P1, long pastern bone)

7 Palmar tubercles (eminences)

8 Eminence for attachment of distal sesamoidean ligaments

9 Proximal interphalangeal (pastern) joint

10 Middle phalanx (P2, short pastern bone)

Downloaded from Vet-eBooks.com

4.61 Dorsolateral-palmaromedial oblique view radiograph of metacarpophalangeal (fetlock) joint.

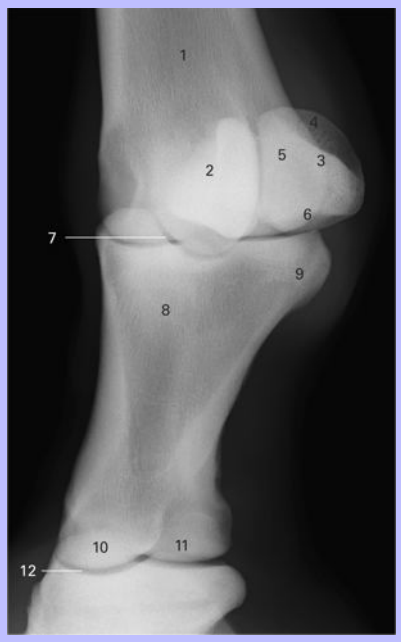

1 Metacarpal III (cannon bone)

2 Medial proximal sesamoid bone

3 Lateral proximal sesamoid bone

4 Apex

5 Articular surface

6 Base

7 Metacarpophalangeal (fetlock) joint

8 Proximal phalanx (P1, long pastern bone)

9 Lateral palmar tubercle (eminence)

10 Medial condyle

11 Lateral condyle

12 Proximal interphalangeal (pastern) joint

Downloaded from Vet-eBooks.com

4.62 Dorsomedial-palmarolateral oblique view radiograph of metacarpophalangeal (fetlock) joint.

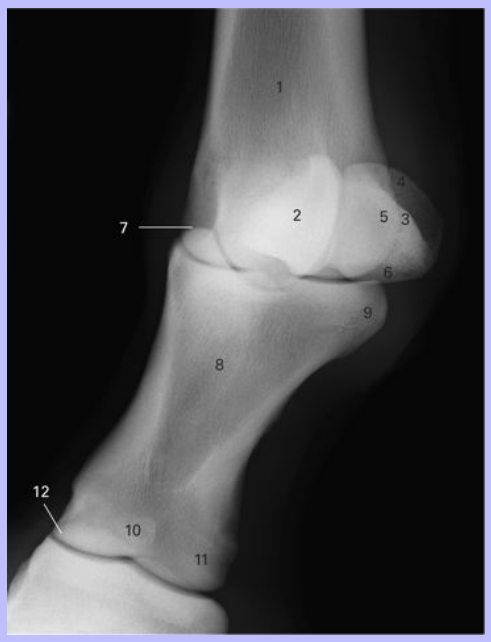

1 Metacarpal III (cannon bone)

2 Lateral proximal sesamoid bone

3 Medial proximal sesamoid bone

4 Apex

5 Articular surface

6 Base

7 Metacarpophalangeal (fetlock) joint

8 Proximal phalanx (P1, long pastern bone)

9 Medial palmar tubercle (eminence)

10 Lateral condyle

11 Medial condyle

12 Proximal interphalangeal (pastern) joint

Downloaded from Vet-eBooks.com

4.63 Superficial dissection of left manus, dorsal view.

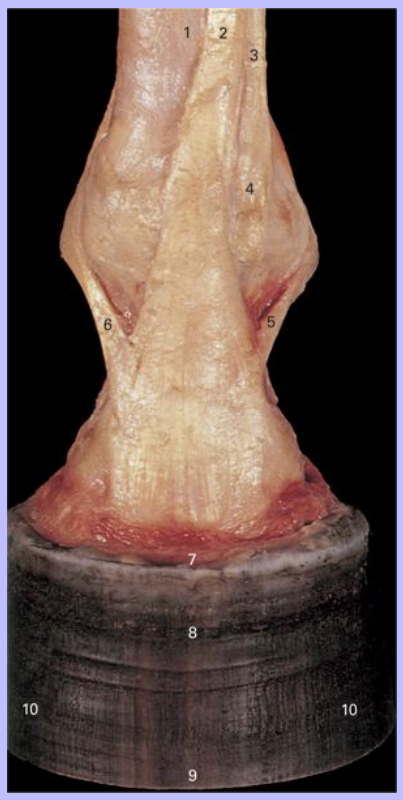

1 Metacarpal III (cannon bone)

2 Tendon of M. extensor digitorum communis

3 Tendon of M. extensor digitorum lateralis

4 Distal attachment of tendon of M. extensor digitorum lateralis

5 Lateral extensor branch of M. interosseus medius

6 Medial extensor branch of M. interosseus medius

7 Coronet

8 Wall of hoof

9 Toe

10 Quarters

Downloaded from Vet-eBooks.com

4.64 Superficial dissection of left manus, palmar view.

1 Tendon of M. flexor digitorum superficialis

2 Tendon of M. extensor digitorum lateralis

3 M. interosseus medius (suspensory ligament)

Downloaded from Vet-eBooks.com

4 Superficial transverse metacarpal ligament (palmar annular ligament)

5 Vagina fibrosa (proximal digital annular ligament)

6 Manica flexoria

7 Tendon of M. flexor digitorum profundus

8 Lateral cartilage of distal phalanx

9 Medial cartilage of distal phalanx

10 Coronet

11 Cleft of frog

12 Bulbs of heel

13 Wall of hoof

14 Sole of hoof

Downloaded from Vet-eBooks.com

4.65 Dorsopalmar view radiograph of metacarpophalangeal (fetlock) joint.

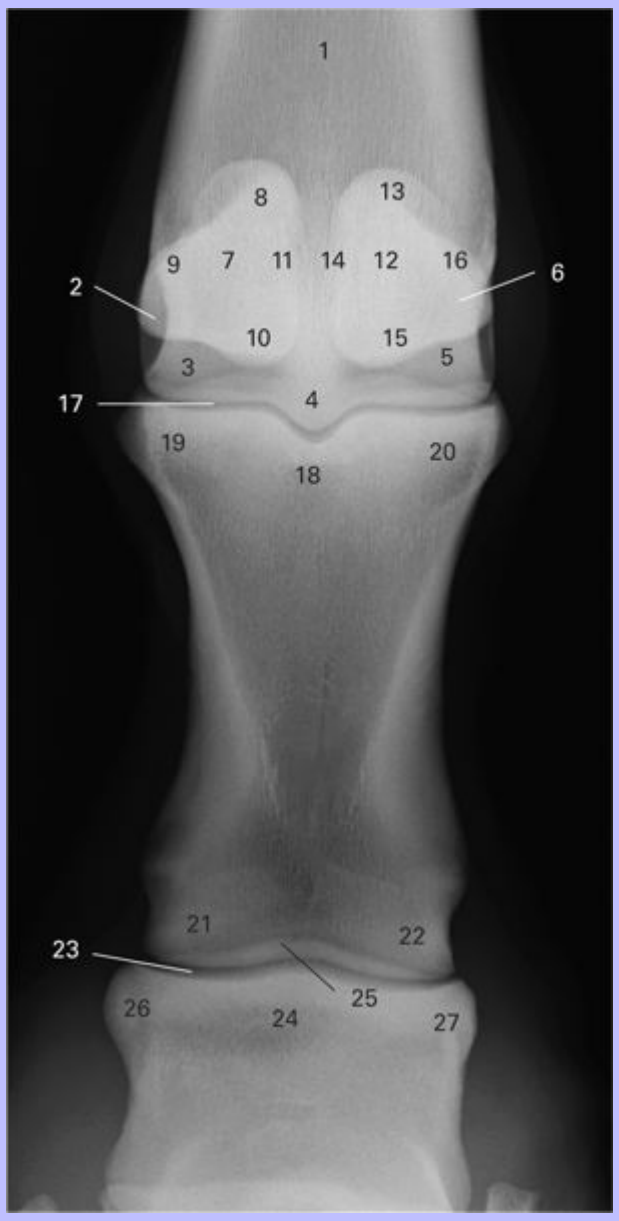

1 Metacarpal III (cannon bone)

2 Lateral epicondyle

3 Lateral condyle

Downloaded from Vet-eBooks.com

4 Sagittal ridge

5 Medial condyle

6 Medial epicondyle

7 Lateral proximal sesamoid bone

8 Apex

9 Abaxial margin

10 Base

11 Axial margin

12 Medial proximal sesamoid bone

13 Apex

14 Axial margin

15 Base

16 Abaxial margin

17 Metacarpophalangeal (fetlock) joint

18 Proximal phalanx (P1, long pastern bone)

19 Lateral proximal tubercle

20 Medial proximal tubercle

21 Lateral condyle

22 Medial condyle

23 Proximal interphalangeal (pastern) joint

24 Middle phalanx (P2, short pastern bone)

25 Extensor process

26 Lateral eminence of proximal P2

27 Medial eminence of proximal P2

58

Downloaded from Vet-eBooks.com

4.66 Deep dissection of digit of left forelimb, palmar view. The superficial transverse metacarpal ligament and the vaginae fibrosae have been removed. The tendon of the M. flexor digitorum superficialis has been reflected.

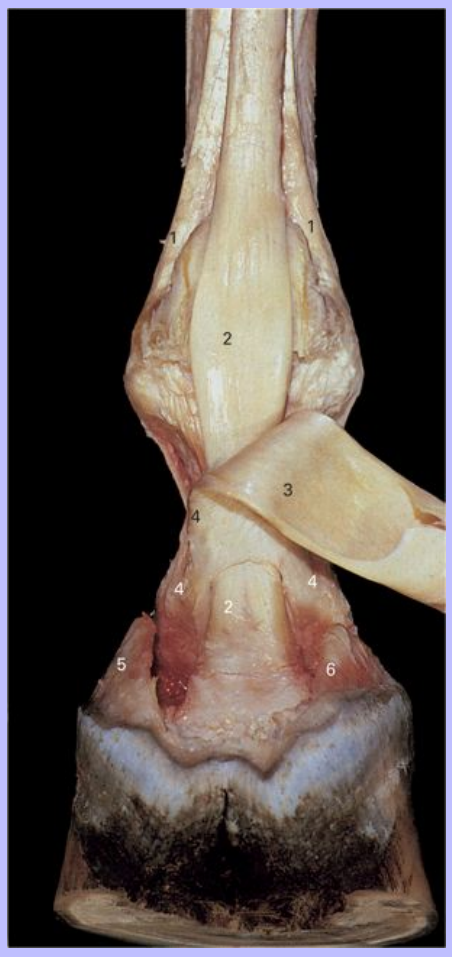

1 Extensor branches of M. interosseus medius

2 Tendon of M. flexor digitorum profundus

3 Tendon of M. flexor digitorum superficialis (reflected)

4 Manica flexoria

5 Lateral cartilage of distal phalanx

6 Medial cartilage of distal phalanx

Downloaded from Vet-eBooks.com

4.67 Deep dissection of digit of left forelimb, palmar view. The superficial transverse metacarpal ligament and the vaginae fibrosae have been removed. The tendons of the M. flexor digitorum superficialis and M. flexor digitorum profundus have been reflected.

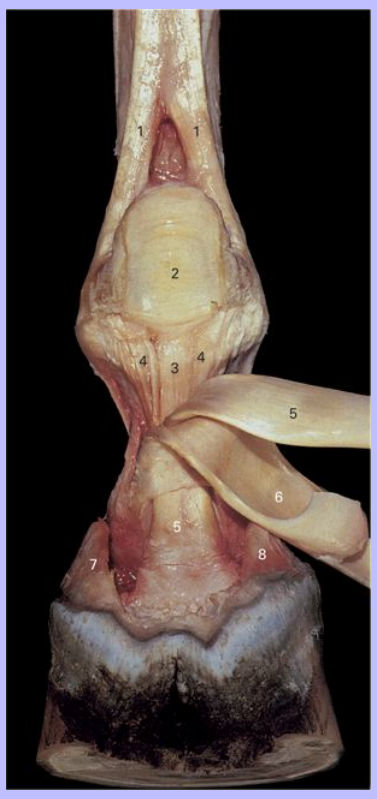

1 Extensor branches of M. interosseus medius

2 Palmar (intersesamoidean) ligament

3 Straight sesamoidean ligament

4 Oblique sesamoidean ligament

5 Tendon of M. flexor digitorum profundus

6 Tendon of M. flexor digitorum superficialis

7 Lateral cartilage of distal phalanx

8 Medial cartilage of distal phalanx

Downloaded from Vet-eBooks.com

4.68 Deep dissection of digit of left forelimb, palmar view. The superficial transverse metacarpal ligament, vagina fibrosa, tendon of the M. flexor digitorum superficialis, and tendon of the M. flexor digitorum profundus have been removed. The wall, sole and frog of the hoof have been removed.

1 Extensor branches of M. interosseus medius

Downloaded from Vet-eBooks.com

2 Palmar (intersesamoidean) ligament

3 Straight sesamoidean ligament

4 Oblique sesamoidean ligament

5 Fibrocartilaginous plate

6 Flexor surface of distal sesamoid bone

7 Lateral cartilage of hoof

8 Medial cartilage of hoof

9 Flexor surface of distal phalanx

10 Semilunar line

11 Solar surface of distal phalanx

59

Downloaded from Vet-eBooks.com

60

4.69 Dissection of nerves and vessels of distal left limb, medial view.

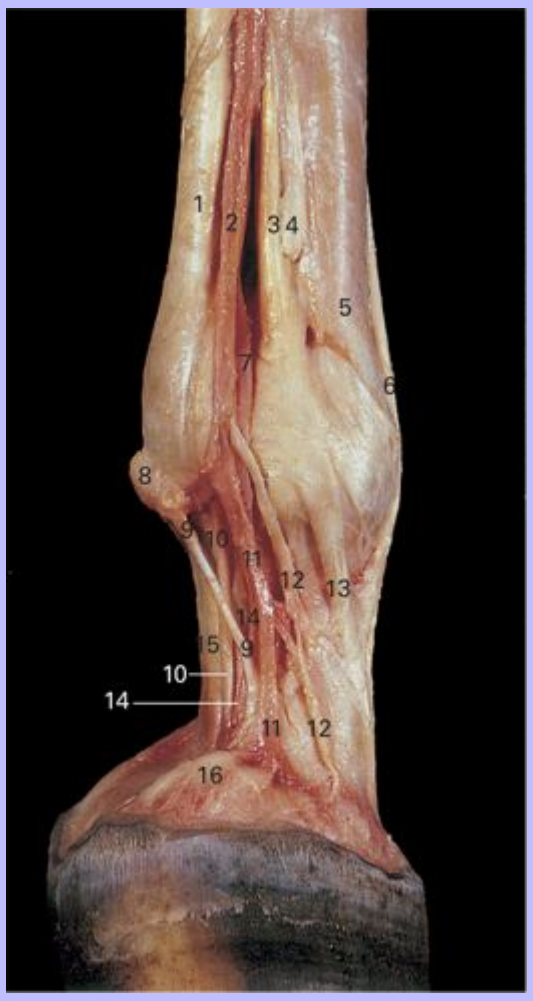

1 Tendon of M. flexor digitorum superficialis

2 Medial palmar vein

3 M. interosseus medius (suspensory ligament)

4 Distal end of metacarpal II (button of medial splint bone)

5 Metacarpal III (cannon bone)

6 Tendon of M. extensor digitorum communis

7 Medial palmar artery

Downloaded from Vet-eBooks.com

8 Ergot

9 Ligament of ergot

10 Medial palmar digital nerve

11 Medial palmar digital vein

12 Dorsal branch of medial palmar digital nerve

13 Medial extensor branch of M. interosseus medius

14 Medial palmar digital artery

15 Tendon of M. flexor digitorum profundus

16 Medial cartilage of distal phalanx

Downloaded from Vet-eBooks.com

4.70 Median section through digit of left forelimb.

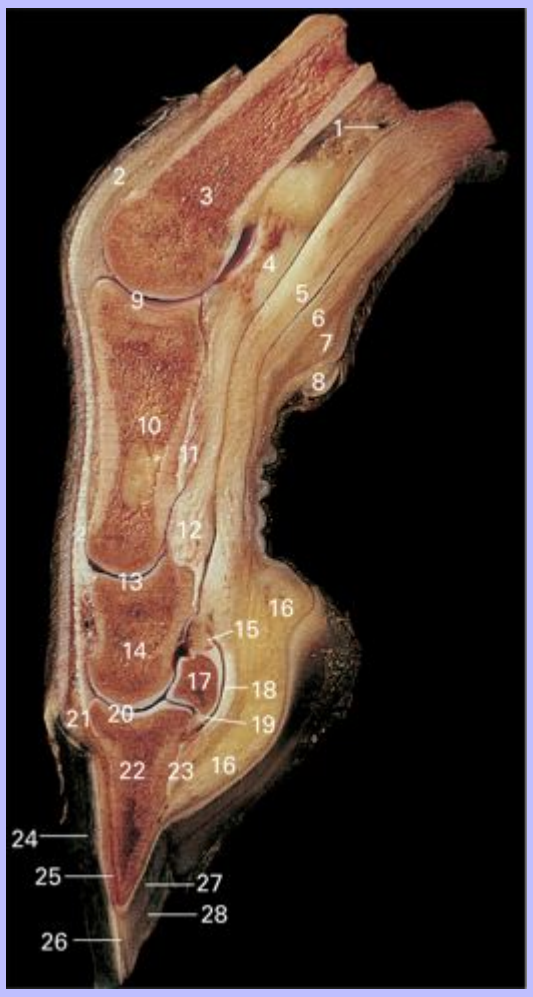

1 Proximal extent of digital synovial sheath

2 Tendon of M. extensor digitorum communis

3 Metacarpal III (cannon bone)

4 Palmar ligament

5 Tendon of M. flexor digitorum profundus

6 Tendon of M. flexor digitorum superficialis

7 Fibrous tissue underlying ergot

Downloaded from Vet-eBooks.com

8 Ergot

9 Metacarpophalangeal (fetlock) joint

10 Proximal phalanx (P1, long pastern bone)

11 Oblique sesamoidean ligament

12 Straight sesamoidean ligament

13 Proximal interphalangeal (pastern) joint

14 Middle phalanx (P2, short pastern bone)

15 Collateral sesamoidean (suspensory navicular) ligament

16 Digital cushion

17 Distal sesamoid (navicular) bone

18 Podotrochlear (navicular) bursa

19 Distal sesamoid impar ligament

20 Distal interphalangeal (coffin) joint

21 Coronary corium

22 Distal phalanx (P3, coffin bone, pedal bone)

23 Insertion of tendon of M. flexor digitorum profundus

24 Wall of hoof

25 Laminae

26 White zone

27 Sole corium

28 Sole of hoof

Downloaded from Vet-eBooks.com

4.71 Lateromedial view radiograph of foot.

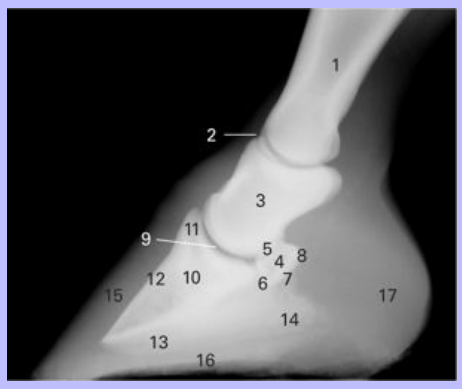

1 Proximal phalanx (P1, long pastern bone)

2 Proximal interphalangeal (pastern) joint

3 Middle phalanx (P2, short pastern bone)

4 Distal sesamoid (navicular) bone

5 Articular margin

6 Distal margin

7 Flexor surface

8 Proximal margin

9 Distal interphalangeal (coffin) joint

10 Distal phalanx (P3)

11 Extensor process

12 Dorsal margin

13 Solar margin

14 Palmar processes

15 Hoof wall

16 Sole

17 Bulbs

Downloaded from Vet-eBooks.com

4.72 Left hoof, solar view.

1 Bulbs of heel

2 Coronet

3 Lateral paracuneal sulcus

4 Lateral crus of frog

5 Central sulcus of frog

6 Medial crus of frog

7 Medial paracuneal sulcus

8 Lateral angle of sole

9 Lateral bar of hoof wall

10 Medial bar of hoof wall

11 Medial angle of sole

12 Apex of frog

Downloaded from Vet-eBooks.com

13 Lateral crus of sole

14 Medial crus of sole

15 Central part of sole

16 White zone

17 Hoof wall (stratum medium)

Downloaded from Vet-eBooks.com

4.73 Dorsopalmar view radiograph of distal phalanx.

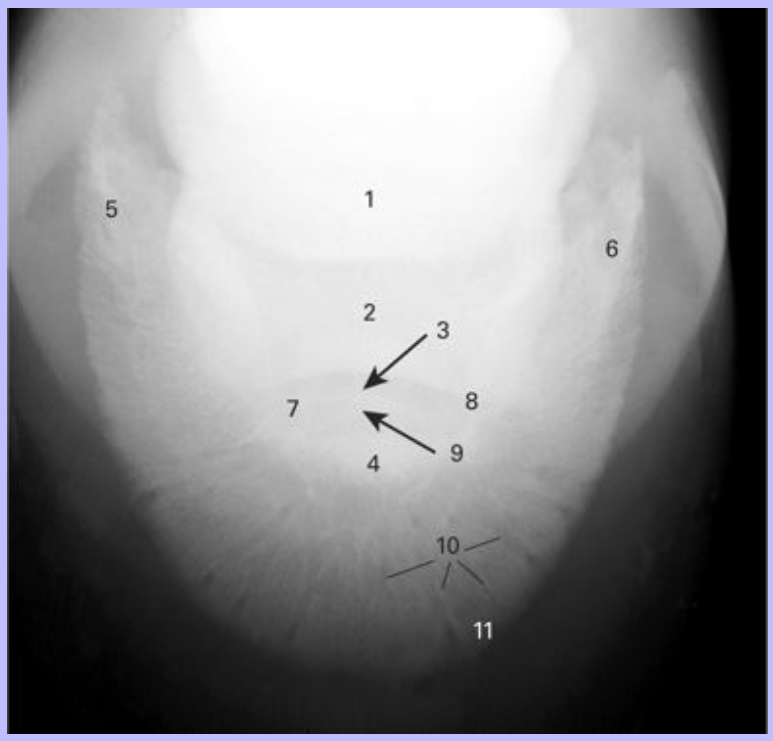

1 Distal sesamoid (navicular) bone

2 Middle phalanx (P2, short pastern bone)

3 Distal interphalangeal (coffin) joint

4 Distal phalanx (P3, coffin bone, pedal bone)

5 Lateral palmar process

6 Medial palmar process

7 Lateral parietal sulcus

8 Medial parietal sulcus

9 Extensor process

10 Vascular channels

11 Solar margin

Downloaded from Vet-eBooks.com

62

4.74 Transverse section through foot, distal view. Sections are cut parallel to the coronary border: A, three fourths of the distance from the coronet to the distal border of the hoof wall; B, midway between the coronet and distal border of the hoof wall; C, just distal to the coronet.

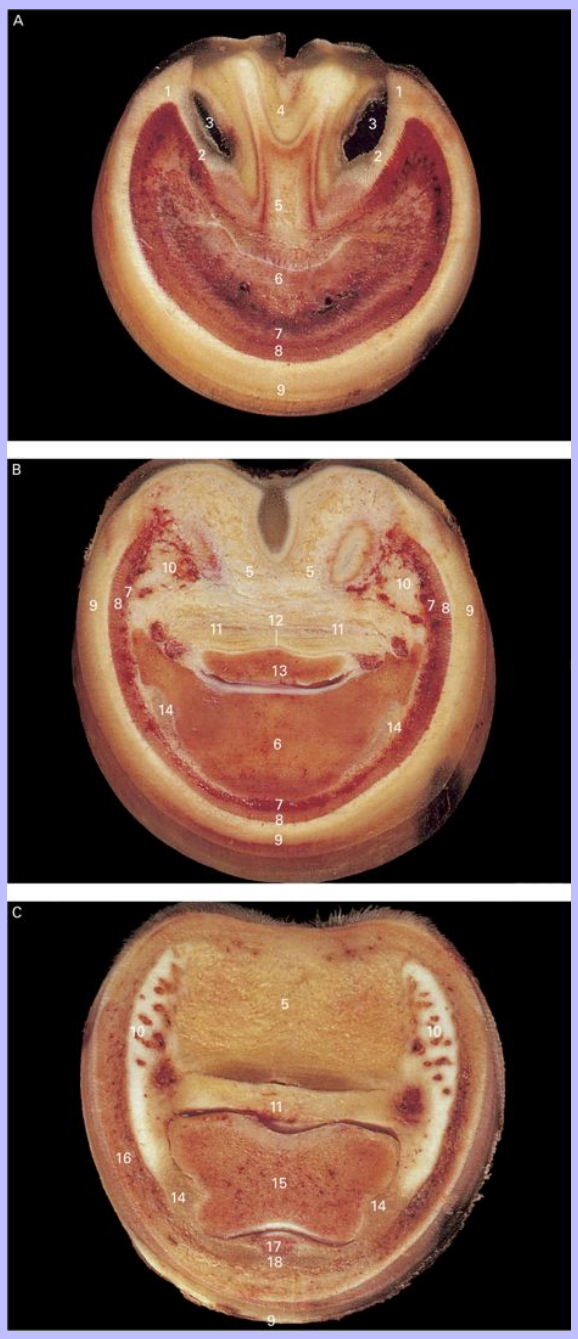

Downloaded from Vet-eBooks.com

1 Angle

2 Bar

3 Space between frog and bar

4 Frog

5 Digital cushion

6 Distal phalanx (P3, coffin bone, pedal bone)

7 Lamellar corium (dermal lamellae)

8 Lamellae of wall (epidermal lamellae)

9 Wall

10 Cartilage of distal phalanx and associated vascular plexus

11 Tendon of M. flexor digitorum profundus

12 Podotrochlear (navicular) bursa

13 Distal sesamoid (navicular) bone

14 Collateral ligament of distal interphalangeal (coffin) joint

15 Middle phalanx (P2, short pastern bone)

16 Coronary corium

17 Extensor process of distal phalanx

18 Tendon of M. extensor digitorum communis

62

Downloaded from Vet-eBooks.com

4.75 Dorsopalmar view radiograph of distal sesamoid (navicular) bone.

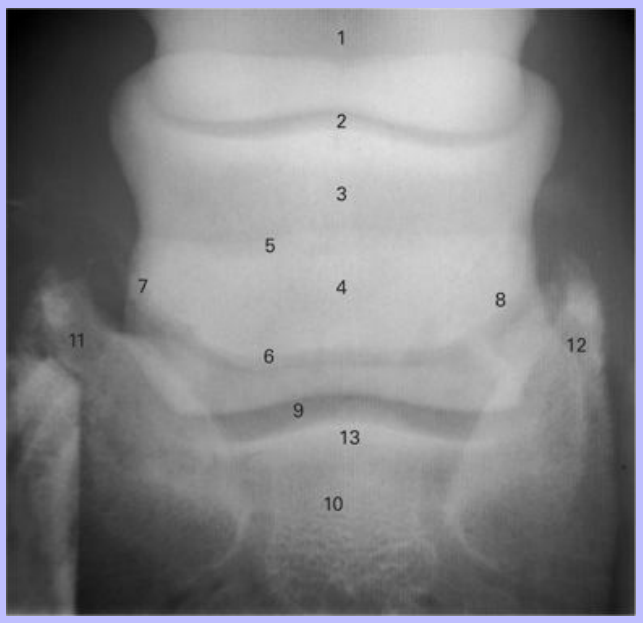

1 Proximal phalanx (P1, long pastern bone)

2 Proximal interphalangeal (pastern) joint

3 Middle phalanx (P2, short pastern bone)

4 Distal sesamoid (navicular) bone

5 Proximal margin

6 Distal margin

7 Lateral margin

8 Medial margin

9 Distal interphalangeal (coffin) joint

10 Distal phalanx (P3, coffin bone, pedal bone)

11 Lateral palmar process

12 Medial palmar process

13 Extensor process

Downloaded from Vet-eBooks.com

4.76 Proximopalmar-distopalmar view radiograph of the distal sesamoid (navicular) bone.

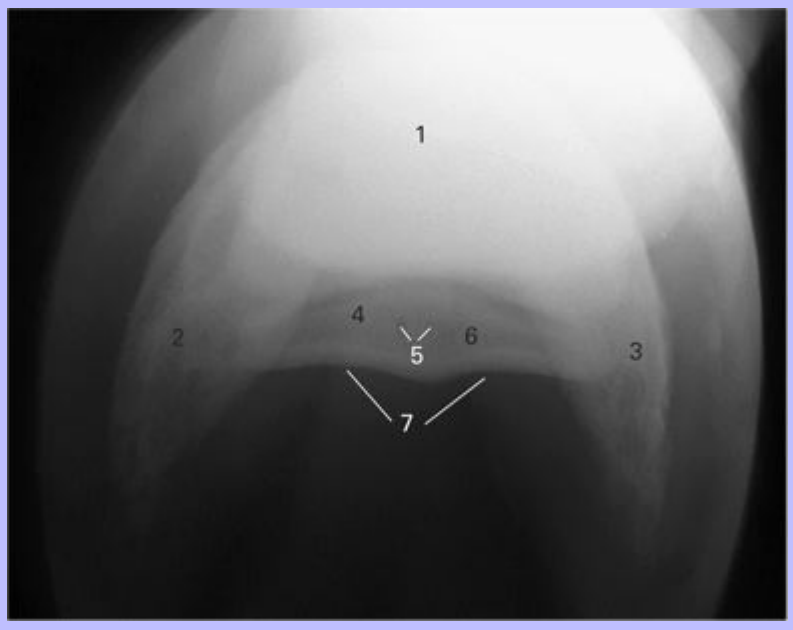

1 Distal phalanx (P3, coffin bone, pedal bone)

2 Lateral palmar process

3 Medial palmar process

4 Distal sesamoid (navicular) bone

5 Vascular channels

6 Medullary cavity

7 Flexor surface

Downloaded from Vet-eBooks.com

4.77 Frontal section of left hoof, palmar view. Section is cut through the heels.

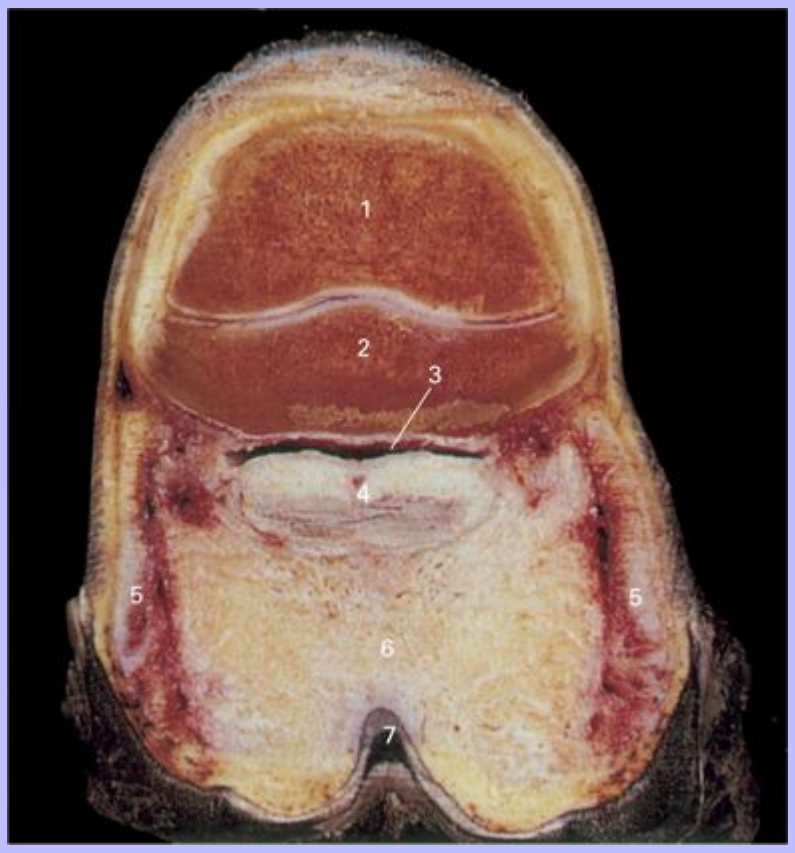

1 Middle phalanx (P2, short pastern bone)

2 Distal sesamoid (navicular) bone

3 Podotrochlear (navicular) bursa

4 Tendon of M. flexor digitorum profundus

5 Cartilages of distal phalanx with associated vascular plexus

6 Digital cushion

7 Cleft of frog

63

Downloaded from Vet-eBooks.com

4.78 Foot, solar view. The epidermal tissues have been reflected upwards. The wall and epidermal lamellae have been removed.

1 Dorsal surface of sole

2 Central furrow over apex of frog

3 Spine of frog (frog stay)

4 Junction of frog and bar

5 Lamellae of bar

6 Lamellar corium

7 Corium of frog

8 Corium of sole

Downloaded from Vet-eBooks.com

4.79 Corium of foot, lateral view. The wall and epidermal lamellae have been removed.

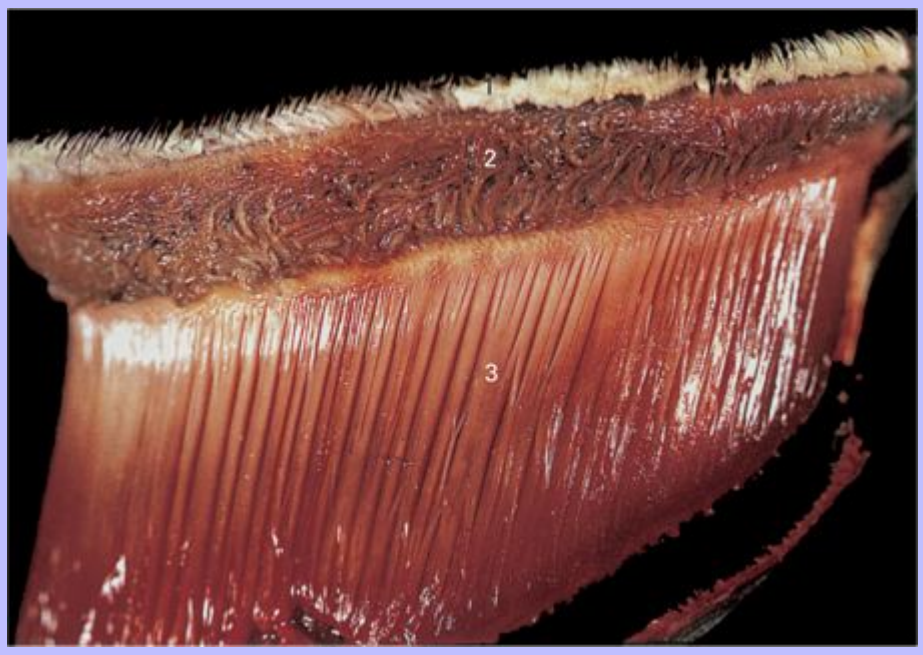

1 Corium of periople

2 Coronary corium

3 Lamellar corium (dermal lamellae)

Downloaded from Vet-eBooks.com

5 5 Hindlimb

5.1 Ossa coxarum, craniodorsal view.

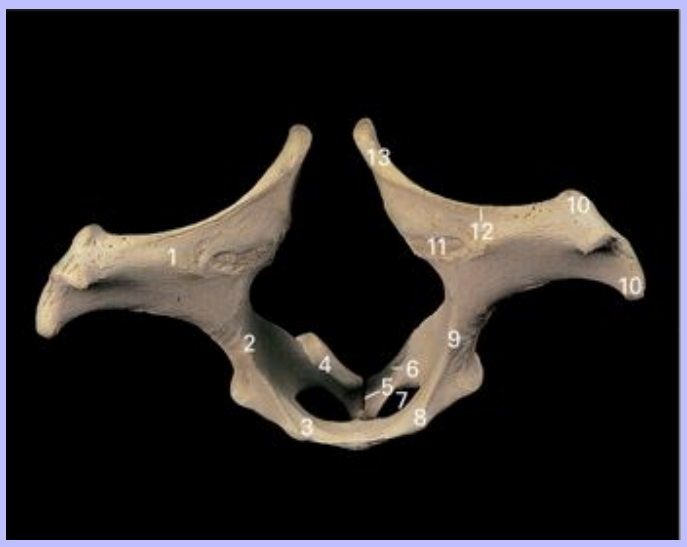

1 Wing of ilium

2 Body of ilium

3 Pubis

4 Ischium

5 Pelvic symphysis, ischiatic part

6 Ischiatic arch

7 Obturator foramen

8 Pubic tubercle

9 Arcuate (iliopectineal) line

10 Coxal tuberosity

11 Auricular surface

12 Iliac crest

13 Sacral tuberosity

Downloaded from Vet-eBooks.com

5.2 Ossa coxarum, left lateral view.

1 Coxal tuberosity

2 Crest of ilium

3 Sacral tuberosity

4 Greater ischiatic notch

5 Ischiatic spine

6 Lesser ischiatic notch

7 Ischiatic tuberosity

8 Articular surface of acetabulum

9 Acetabular fossa

10 Acetabular notch

11 Obturator foramen

Downloaded from Vet-eBooks.com

5.3 Ossa coxarum, dorsal view.

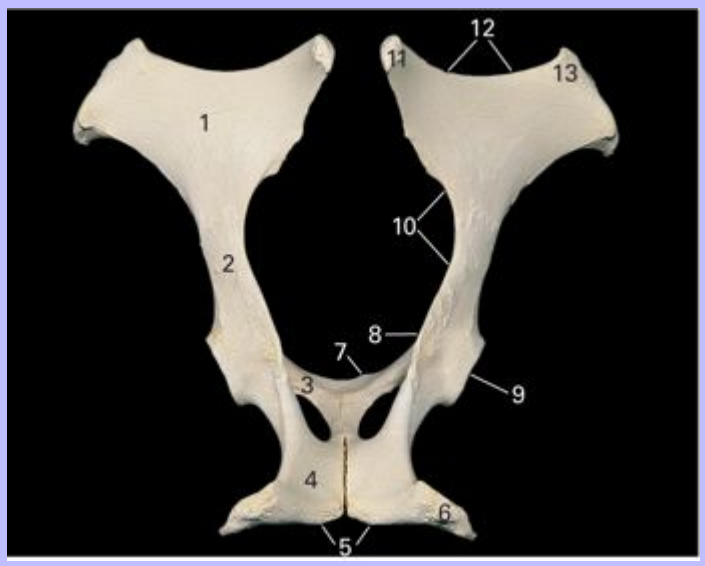

1 Wing of ilium

2 Body of ilium

3 Pubis

4 Ischium

5 Ischial arch

6 Ischiatic tuberosity

7 Pubic tubercle

8 Ischiatic spine

9 Acetabulum

10 Greater ischiatic notch

11 Sacral tuberosity

12 Crest of ilium

13 Coxal tuberosity

Downloaded from Vet-eBooks.com

5.4 Skeleton of left hindlimb, lateral view.

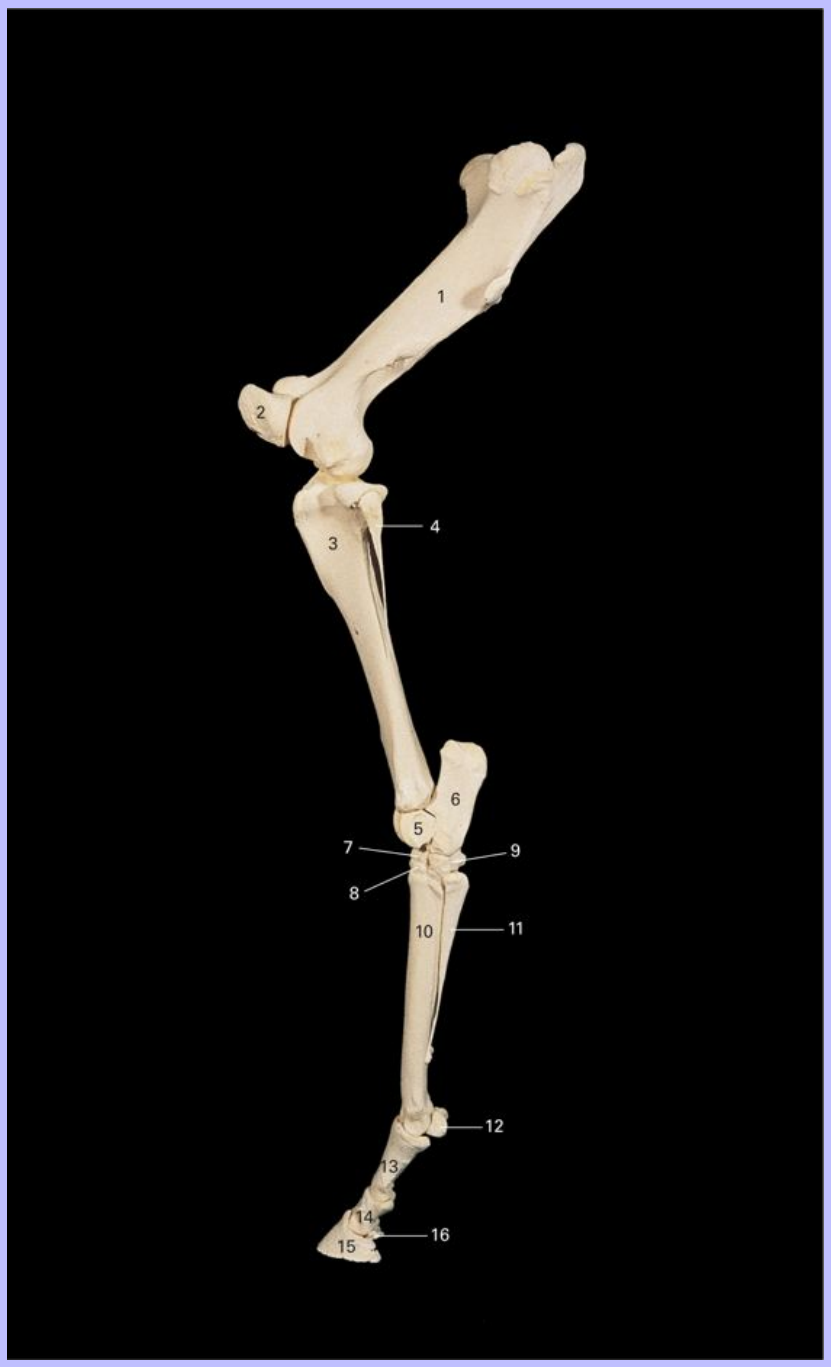

1 Femur

Downloaded from Vet-eBooks.com

2 Patella

3 Tibia

4 Fibula

5 Talus

6 Calcaneus

7 Central tarsal bone

8 Third tarsal bone

9 Fourth tarsal bone

10 Metatarsal III (cannon bone)

11 Metatarsal IV (lateral splint bone)

12 Lateral proximal sesamoid bone

13 Proximal phalanx (P1, long pastern bone)

14 Middle phalanx (P2, short pastern bone)

15 Distal phalanx (P3, coffin bone, pedal bone)

16 Distal sesamoid (navicular) bone

66

Downloaded from Vet-eBooks.com

5.5 Skeleton of left hindlimb, medial view.

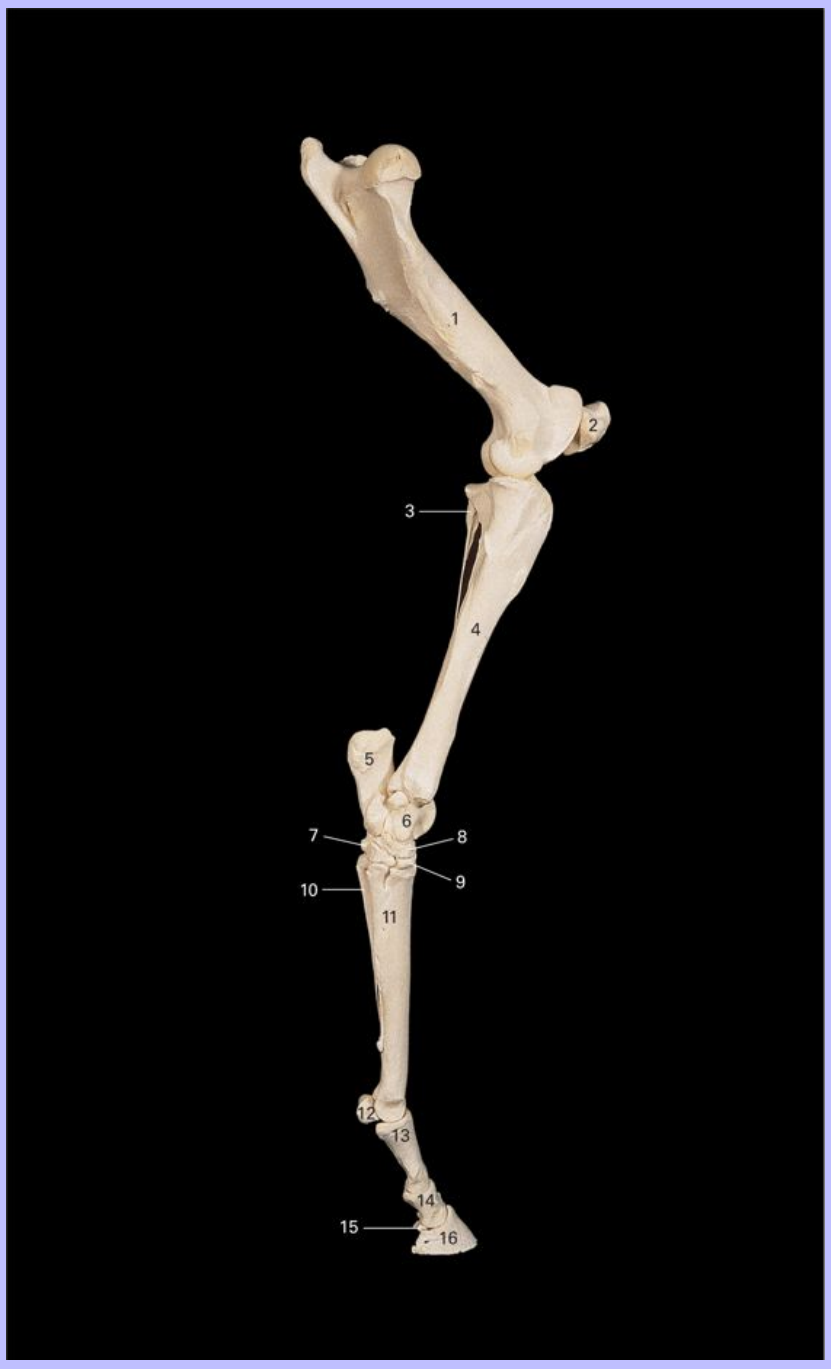

1 Femur

Downloaded from Vet-eBooks.com

2 Patella

3 Fibula

4 Tibia

5 Calcaneus

6 Talus

7 First and second tarsal bone (fused)

8 Central tarsal bone

9 Third tarsal bone

10 Metatarsal II (medial splint bone)

11 Metatarsal III (cannon bone)

12 Proximal sesamoid bone

13 Proximal phalanx (P1, long pastern bone)

14 Middle phalanx (P2, short pastern bone)

15 Distal sesamoid (navicular) bone

16 Distal phalanx (P3, coffin bone, pedal bone)

67

Downloaded from Vet-eBooks.com

5.6 Left femur, cranial view.

1 Greater trochanter

2 Head

3 Neck

4 Lesser trochanter

5 Third trochanter

6 Body

7 Trochlea

8 Lateral epicondyle

Downloaded from Vet-eBooks.com

5.7 Left femur, caudal view.

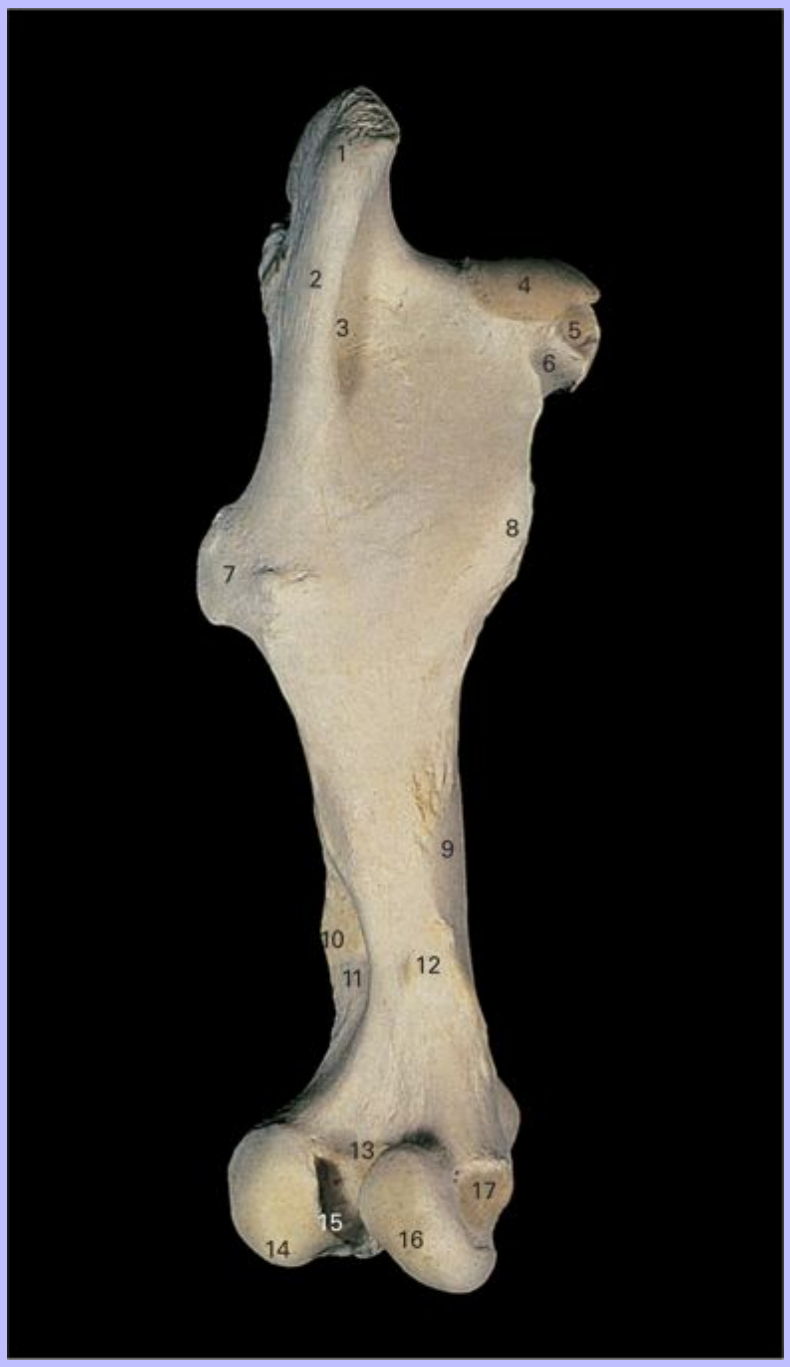

1 Greater trochanter

Downloaded from Vet-eBooks.com

2 Intertrochanteric crest

3 Trochanteric fossa

4 Head

5 Fovea

6 Neck

7 Third trochanter

8 Lesser trochanter

9 Groove for femoral vessels

10 Lateral supracondyloid tuberosity

11 Supracondyloid fossa

12 Medial supracondyloid tuberosity

13 Intercondylar line

14 Lateral condyle

15 Intercondylar fossa

16 Medial condyle

17 Medial epicondyle

68

Downloaded from Vet-eBooks.com

5.8 Left femur, lateral view.

1 Greater trochanter

2 Third trochanter

3 Supracondyloid fossa

4 Medial ridge of trochlea

5 Lateral ridge of trochlea

6 Lateral condyle

7 Medial condyle

Downloaded from Vet-eBooks.com

5.9 Left femur, medial view.

1 Greater trochanter

Downloaded from Vet-eBooks.com

2 Head

3 Fovea

4 Neck

5 Intertrochanteric crest

6 Trochanteric fossa

7 Lesser trochanter

8 Nutrient foramen

9 Medial condyle

10 Medial epicondyle

11 Trochlea

69

Downloaded from Vet-eBooks.com

5.10 Left tibia and fibula, cranial view.

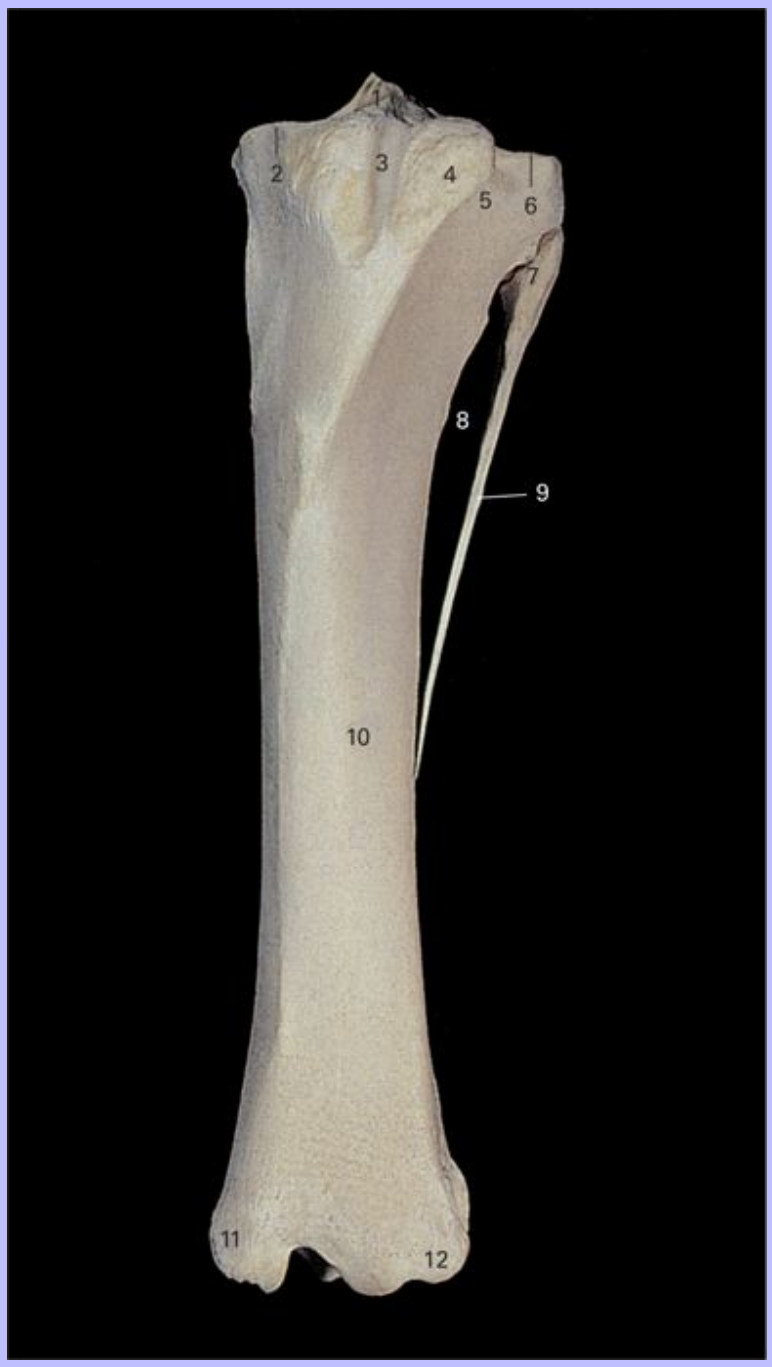

1 Intercondylar eminence

Downloaded from Vet-eBooks.com

2 Medial condyle

3 Groove for middle patellar ligament

4 Tuberosity

5 Extensor sulcus

6 Lateral condyle

7 Head of fibula

8 Interosseous space

9 Body of fibula

10 Body of tibia

11 Medial malleolus

12 Lateral malleolus

Downloaded from Vet-eBooks.com

5.11 Left tibia and fibula, caudal view.

1 Intercondylar eminence

Downloaded from Vet-eBooks.com

2 Lateral intercondylar tubercle

3 Medial intercondylar tubercle

4 Lateral condyle

5 Head of fibula

6 Popliteal notch

7 Medial condyle

8 Body of fibula

9 Interosseous space

10 Nutrient foramen

11 Body of tibia

12 Lateral malleolus

13 Groove for tendon of M. extensor digitorum lateralis

14 Groove for tendon of M. flexor digitorum longus

15 Medial malleolus

70

Downloaded from Vet-eBooks.com

5.12 Left tibia and fibula, lateral view.

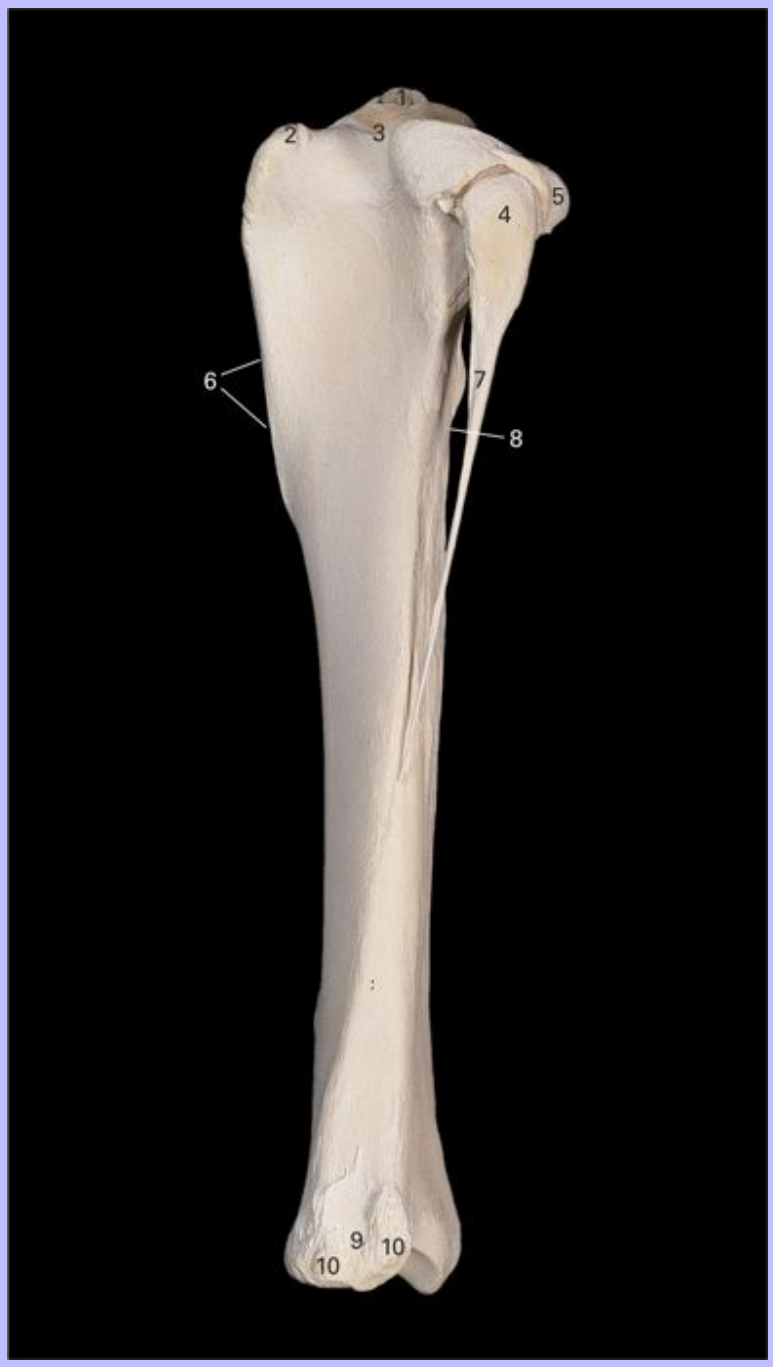

1 Intercondylar eminence

Downloaded from Vet-eBooks.com

2 Tibial tuberosity

3 Extensor sulcus

4 Head of fibula

5 Lateral condyle

6 Cranial border

7 Shaft of fibula

8 Interosseous space

9 Groove for tendon of M. extensor digitorum lateralis

10 Lateral malleolus

Downloaded from Vet-eBooks.com

5.13 Left tibia and fibula, medial view.

1 Intercondylar eminence

2 Lateral condyle

3 Tibial tuberosity

4 Cranial border

5 Medial malleolus

6 Lateral malleolus

7 Articular surface

Downloaded from Vet-eBooks.com

5.14 Left tarsal bones, dorsal view.

1 Calcaneal tuber

2 Calcaneus

3 Talus

4 Distal tuberosity of talus

5 Trochlea

6 Central tarsal bone

7 Third tarsal bone

8 Vascular canal

9 Fourth tarsal bone

Downloaded from Vet-eBooks.com

5.15 Left tarsal bones, plantar view.

1 Calcaneal tuber

2 Calcaneus

3 Tarsal groove for tendon of M. flexor digitorum profundus

4 Talus

5 Sustentaculum tali

6 Central tarsal bone

7 Fourth tarsal bone

8 Vascular canal

9 First and second tarsal bones (fused)

Downloaded from Vet-eBooks.com

5.16 Left tarsal bones, lateral view.

1 Calcaneal tuber

2 Calcaneus

3 Coracoid process

4 Talus

5 Depression for attachment of tarsal lateral collateral ligament

6 Central tarsal bone

7 Third tarsal bone

8 Fourth tarsal bone

72

Downloaded from Vet-eBooks.com

5.17 Left tarsal bones, medial view.

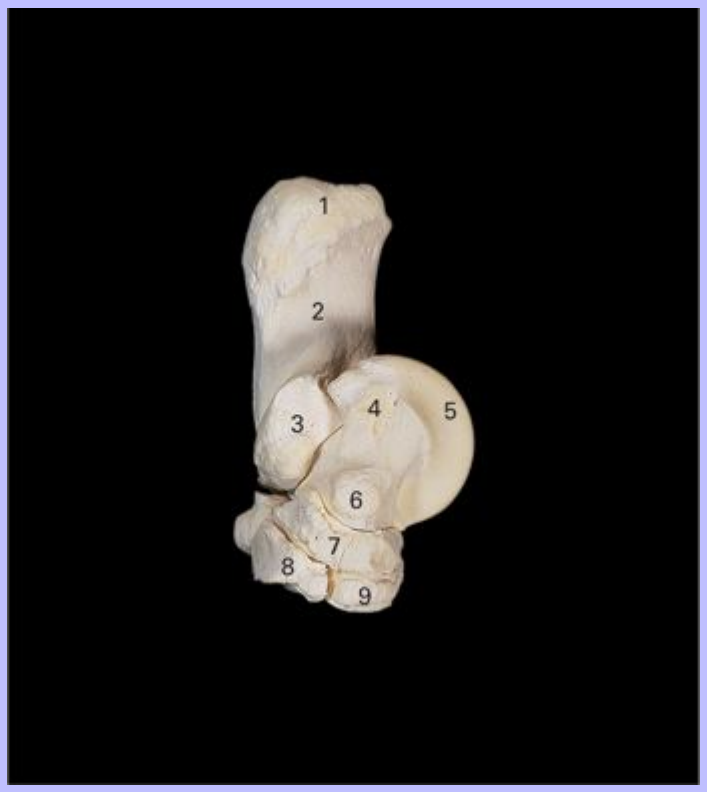

1 Calcaneal tuber

2 Calcaneus

3 Sustentaculum

4 Proximal tuberosity of talus

5 Talus

6 Distal tuberosity of talus

7 Central tarsal bone

8 First and second tarsal bones (fused)

9 Third tarsal bone

Downloaded from Vet-eBooks.com

5.18 Left patella, cranial view

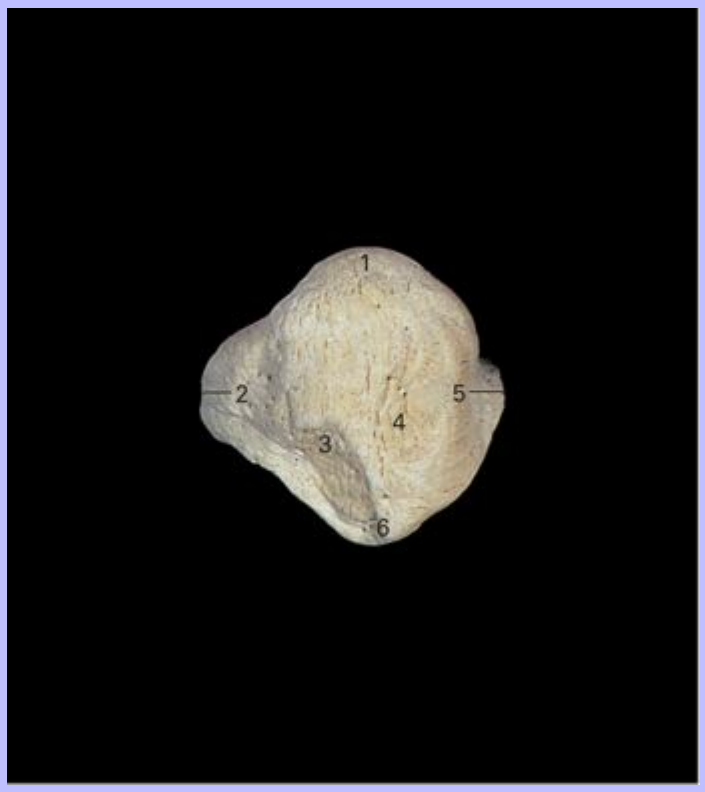

1 Base

2 Medial border

3 Attachment area of middle patellar ligament

4 Attachment area of lateral patellar ligament

5 Lateral border

6 Apex

73

Downloaded from Vet-eBooks.com

5.19 Superficial dissection of left pelvis and thigh of foal, lateral view. Fascia lata has been removed to show M. rectus femoris and M. vastus lateralis.

1 M. tensor fascia lata

Downloaded from Vet-eBooks.com

2 M. gluteus superficialis

3 M. biceps femoris

4 M. semitendinosus

5 M. semimembranosus

6 M. rectus femoris

7 M. vastus lateralis

8 Patella

9 Lateral condyle of tibia

10 M. gastrocnemius, lateral head

11 M. soleus

12 M. extensor digitorum longus

13 M. extensor digitorum lateralis

14 M. flexor digitorum profundus

Downloaded from Vet-eBooks.com

5.20 Deep dissection of left pelvis and thigh of foal, lateral view. M. tensor fascia lata, M. gluteus superficialis and M. biceps femoris have been removed.

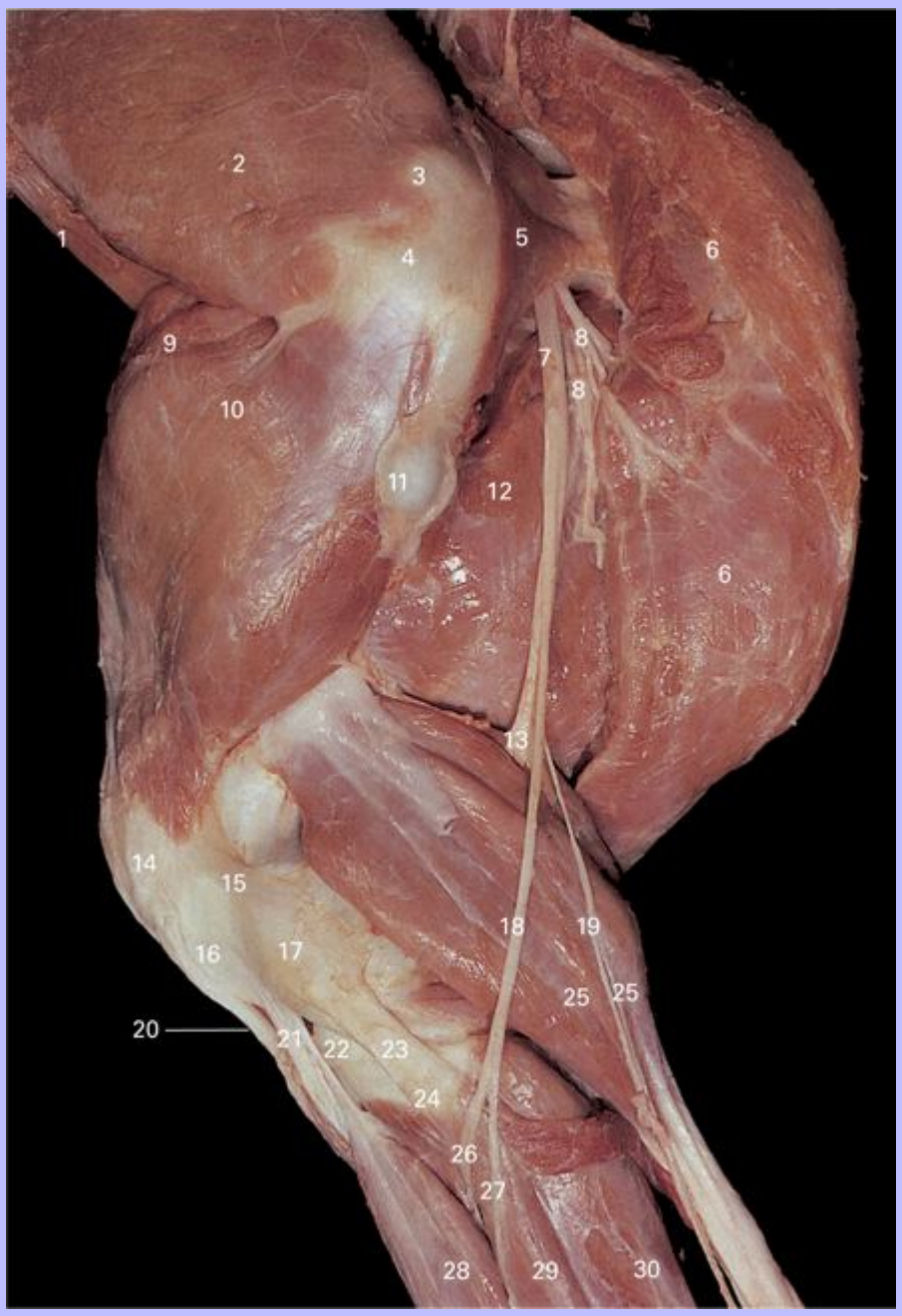

1 M. iliacus

Downloaded from Vet-eBooks.com

2 M. gluteus medius

3 Trochanteric bursa

4 Greater trochanter

5 M. piriformis

6 M. semimembranosus

7 Ischiatic nerve

8 Muscular branches of tibial nerve

9 M. rectus femoris

10 M. vastus lateralis

11 Third trochanter

12 M. adductor

13 Tibial nerve

14 Common peroneal (fibular) nerve

15 Caudal cutaneous sural nerve

16 Patella

17 Lateral epicondyle of femur

18 M. soleus

19 M. gastrocnemius, lateral head

20 Middle patellar ligament

21 Lateral patellar ligament

22 Lateral meniscus

23 Lateral collateral femorotibial ligament

24 Lateral condyle of tibia

25 M. flexor digitorum profundus

26 Deep peroneal (fibular) nerve

27 Superficial peroneal (fibular) nerve

Downloaded from Vet-eBooks.com

28 M. extensor digitorum longus

29 M. extensor digitorum lateralis

30 M. flexor digitorum profundus

74

Downloaded from Vet-eBooks.com

5.21 Superficial dissection of left pelvis and thigh of foal, medial view. The trunk has been sectioned in a median plane, and the viscera removed.

1 Umbilical artery (cut)

Downloaded from Vet-eBooks.com

2 M. psoas minor

3 Pubis

4 Femoral nerve

5 M. iliopsoas

6 M. tensor fascia lata

7 M. semimembranosus

8 M. pectineus

9 Deep inguinal lymph nodes

10 M. sartorius

11 M. rectus femoris

12 M. gracilis

13 M. vastus medialis

14 Saphenous vessels and nerve

15 Patella

16 Medial epicondyle of femur

17 Medial patellar ligament

18 Middle patellar ligament

19 M. semitendinosus

20 M. gastrocnemius, medial head

21 Common calcaneal tendon

22 M. flexor digitorum superficialis

23 Tibial nerve

24 Medial condyle of tibia

Downloaded from Vet-eBooks.com

5.22 Deep dissection of left pelvis and thigh of foal, medial view. The trunk has been sectioned in a median plane and the viscera removed. The deep inguinal lymph nodes, M. gracilis, and M. sartorius have been removed.

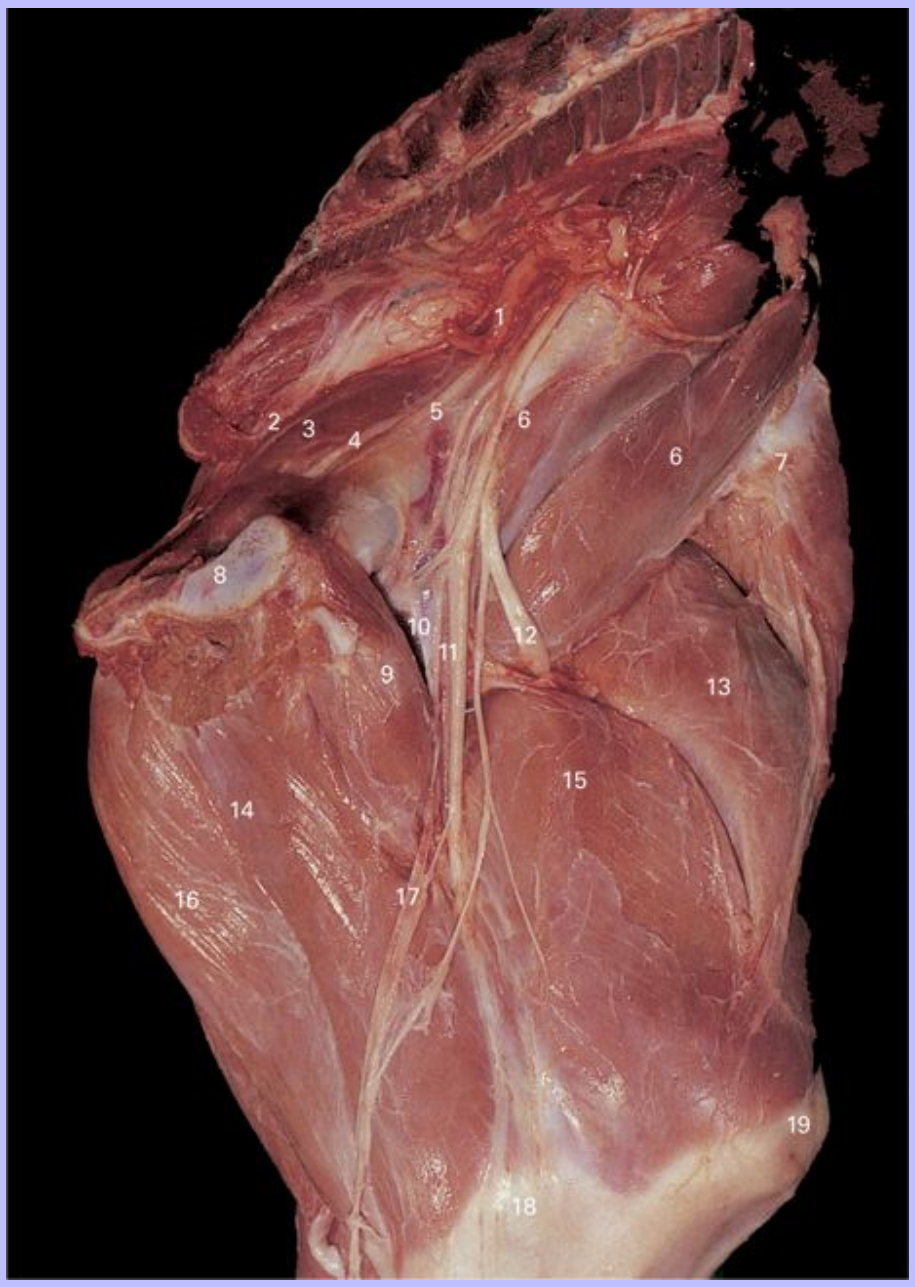

1 Umbilical artery (cut)

Downloaded from Vet-eBooks.com

2 Internal iliac artery

3 M. obturator internus

4 Obturator artery

5 Obturator nerve

6 M. iliopsoas

7 M. tensor fascia lata

8 Pubis

9 M. pectineus

10 Femoral vessels

11 Saphenous nerve

12 Femoral nerve

13 M. rectus femoris

14 M. adductor

15 M. vastus medialis

16 M. semimembranosus

17 Saphenous vessels

18 Medial epicondyle of femur

19 Patella

75

Downloaded from Vet-eBooks.com

5.23 Superficial dissection of left pelvis and thigh of foal, cranial view. The trunk has been sectioned in a median plane and the viscera removed. The fascia lata has been removed to expose M. rectus femoris and M. vastus lateralis.

1 M. iliopsoas

Downloaded from Vet-eBooks.com

2 M. tensor fascia lata

3 M. biceps femoris

4 Femoral nerve

5 Deep inguinal lymph nodes

6 M. sartorius

7 M. vastus medialis

8 M. rectus femoris

9 M. vastus lateralis

10 Patella

11 Medial patellar ligament

12 Middle patellar ligament

13 Lateral patellar ligament

14 Lateral meniscus

15 Lateral condyle of tibia

16 Tibial tuberosity

17 M. tibialis cranialis

18 M. extensor digitorum longus

Downloaded from Vet-eBooks.com

5.24 Superficial dissection of left pelvis and thigh of foal, caudal view. The trunk has been sectioned in a median plane, and the viscera removed.

1 M. gluteus superficialis

Downloaded from Vet-eBooks.com

2 M. biceps femoris

3 M. semitendinosus

4 M. semimembranosus

5 M. gastrocnemius, lateral head

6 M. flexor digitorum superficialis

7 M. gastrocnemius, medial head

8 M. soleus

9 M. flexor digitorum longus

10 Common calcaneal tendon

76

Downloaded from Vet-eBooks.com

5.25 Deep dissection of pelvic ligaments on left side, lateral view.

1 Coxal tuberosity

2 Sacral tuberosity

3 Dorsal sacroiliac ligament

4 Lateral sacroiliac ligament

5 Greater ischiatic foramen

6 Sacrosciatic ligament

7 Shaft of ilium

8 Lesser ischiatic foramen

9 Ischial tuberosity

10 Acetabulum

Downloaded from Vet-eBooks.com

5.26 Deep dissection of left hip joint, caudal view.

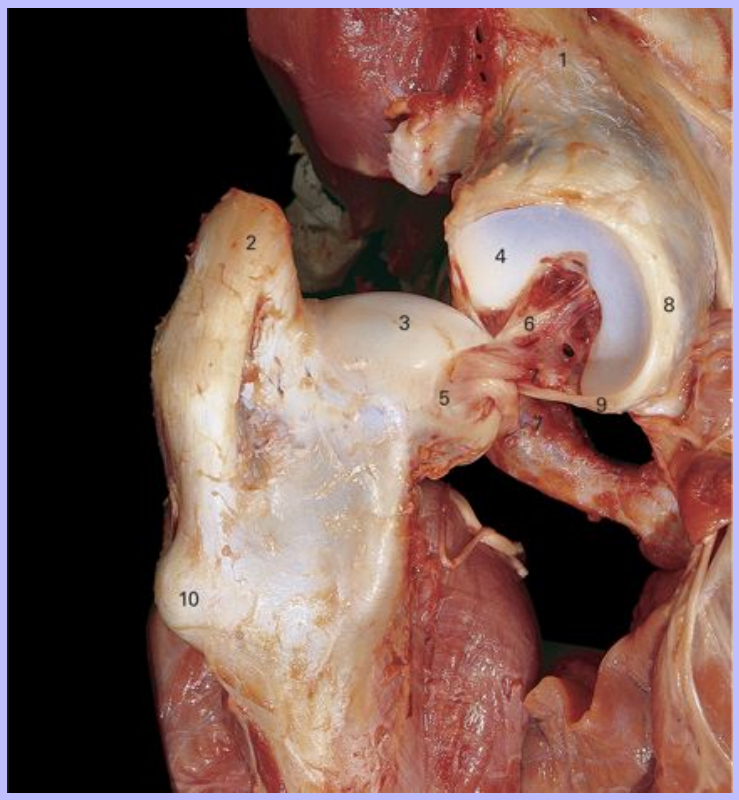

1 Body of ilium

2 Greater trochanter

3 Head of femur

4 Acetabulum

5 Fovea

6 Ligament of the head of the femur (round ligament)

7 Accessory ligament

8 Labrum

9 Transverse acetabular ligament

10 Third trochanter

Downloaded from Vet-eBooks.com

5.27 Deep dissection of left femorotibial joint, cranial view. The joint is extended with the medial femoral condyle engaged between the middle and medial patellar ligaments.

1 Patella

2 Medial trochlear ridge of femur

3 Lateral trochlear ridge of femur

4 Medial collateral femorotibial ligament

5 Medial meniscus

6 Medial patellar ligament

7 Middle patellar ligament

8 Lateral meniscus

Downloaded from Vet-eBooks.com

9 Lateral patellar ligament

10 Tendon of M. peroneus (fibularis) tertius

11 Lateral collateral femorotibial ligament

12 Medial condyle of tibia

13 Lateral condyle of tibia

14 Tibial tuberosity

15 M. tibialis cranialis

16 M. extensor digitorum longus

17 M. extensor digitorum lateralis

Downloaded from Vet-eBooks.com

5.28 Deep dissection of left femorotibial joint, caudal view.

1 Lateral condyle of femur

2 Cranial cruciate ligament

3 Meniscofemoral ligament of lateral meniscus

4 Medial condyle of femur

5 Lateral collateral femorotibial ligament

6 Lateral meniscus

7 Caudal ligament of lateral meniscus

8 Caudal cruciate ligament

9 Caudal ligament of medial meniscus

10 Medial meniscus

11 Medial collateral femorotibial ligament

12 Lateral condyle of tibia

13 Medial condyle of tibia

14 Head of fibula

15 Interosseous space

16 Tibia

Downloaded from Vet-eBooks.com

5.29 Deep dissection of left femorotibial joint, dorsomedial view. The joint is partially flexed.

1 Patella

2 Medial trochlear ridge

3 Medial epicondyle of femur

4 Medial patellar ligament

5 Middle patellar ligament

6 Lateral patellar ligament

7 Medial collateral femorotibial ligament

8 Medial condyle of femur

9 Intercondyloid fossa of femur

Downloaded from Vet-eBooks.com

10 Medial meniscus

11 Medial condyle of tibia

12 Cranial cruciate ligament

13 Lateral meniscus

14 Lateral condyle of tibia

15 Tibial tuberosity

78

Downloaded from Vet-eBooks.com

5.30 Caudocranial view radiograph of genual (stifle) joint.

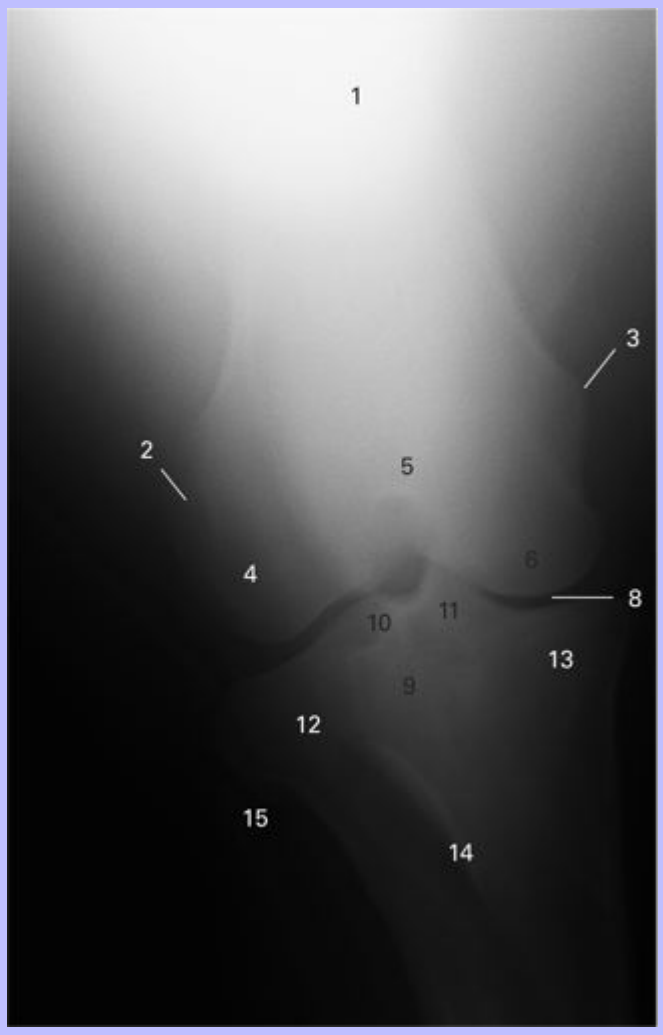

1 Femur

2 Lateral epicondyle

3 Medial epicondyle

4 Lateral condyle

5 Intercondylar fossa

6 Medial condyle

Downloaded from Vet-eBooks.com

7 Lateral femorotibial joint

8 Medial femorotibial joint

9 Tibia

10 Lateral intercondylar tubercle (eminence)

11 Medial intercondylar tubercle (eminence)

12 Lateral condyle

13 Medial condyle

14 Tibial tuberosity

15 Fibula

Downloaded from Vet-eBooks.com

5.31 Lateromedial view radiograph of genual (stifle) joint.

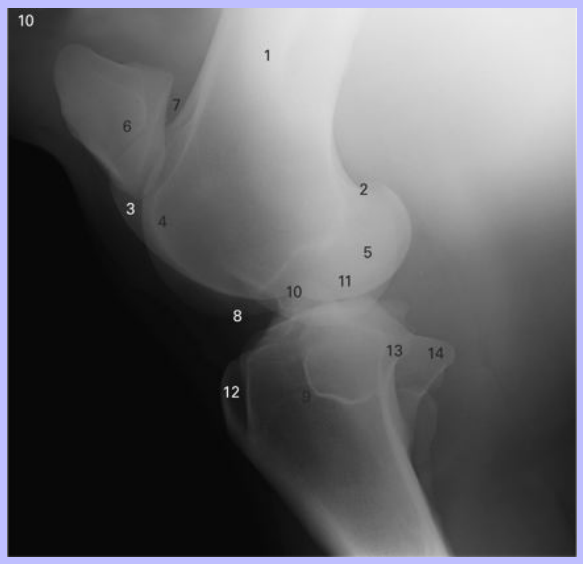

1 Femur

2 Supracondyloid fossa

3 Medial trochlea

4 Lateral trochlea

5 Medial and lateral condyles

6 Patella

7 Femoropatellar joint

8 Femorotibial joint

9 Tibia

10 Medial intercondylar tubercle

11 Lateral intercondylar tubercle

12 Tibial tuberosity

13 Medial condyle

14 Lateral condyle

Downloaded from Vet-eBooks.com

5.32 Deep dissection of left femorotibial joint, cranial view. The cranial cruciate ligament has been removed, and the patellar ligaments have been cut and reflected distally. The joint is fully flexed to show the distal extremity of the femur.

1 Medial trochlear ridge of femur

2 Lateral trochlear ridge of femur

3 Medial epicondyle

4 Extensor fossa

5 Lateral epicondyle

6 Medial collateral femorotibial ligament

7 Medial condyle of femur

Downloaded from Vet-eBooks.com

8 Intercondyloid fossa

9 Caudal cruciate ligament

10 Lateral condyle of femur

11 Lateral collateral femorotibial ligament

12 Medial meniscus

13 Medial condyle of tibia

14 Cranial ligaments of menisci

15 Lateral meniscus

16 Lateral condyle of tibia

17 Tibial tuberosity

18 Medial patellar ligament (reflected)

19 Middle patellar ligament (reflected)

20 Lateral patellar ligament (reflected)

21 Articular face of patella

Downloaded from Vet-eBooks.com

5.33 Left tibia and menisci, proximal view.

1 Lateral patellar ligament

2 Middle patellar ligament

3 Medial patellar ligament

4 Cranial ligaments of menisci

5 Lateral collateral femorotibial ligament

6 Lateral meniscus

Downloaded from Vet-eBooks.com

7 Lateral condyle of tibia

8 Cranial cruciate ligament

9 Spine of tibia

10 Medial condyle of tibia

11 Medial meniscus

12 Medial collateral femorotibial ligament

13 Caudal cruciate ligament

14 Caudal ligament of medial meniscus

15 Meniscofemoral ligament of lateral meniscus

80

Downloaded from Vet-eBooks.com

5.34 Superficial dissection of left crus, cranial view.

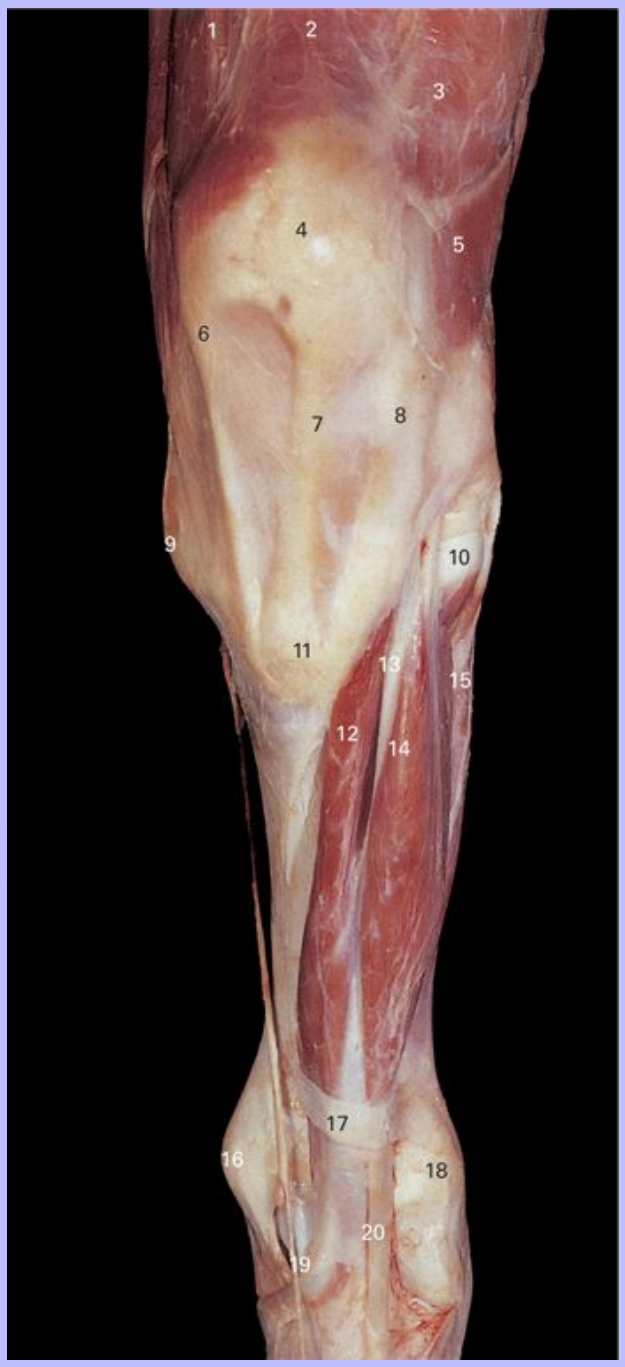

1 M. vastus medialis

Downloaded from Vet-eBooks.com

2 M. rectus femoris

3 M. vastus lateralis

4 Patella

5 M. biceps femoris

6 Medial patellar ligament

7 Middle patellar ligament

8 Lateral patellar ligament

9 Medial condyle of tibia

10 Lateral condyle of tibia

11 Tibial tuberosity

12 M. tibialis cranialis

13 Tendon of M. peroneus (fibularis) tertius

14 M. extensor digitorum longus

15 M. extensor digitorum lateralis

16 Medial malleolus

17 Proximal extensor retinaculum of tarsus

18 Lateral malleolus

19 Medial tendon of M. tibialis cranialis (cunean tendon)

20 Tendon of M. extensor digitorum longus

81

Downloaded from Vet-eBooks.com

5.35 Superficial dissection of left crus, caudal view.

1 M. semimembranosus

Downloaded from Vet-eBooks.com

2 M. semitendinosus

3 M. biceps femoris

4 M. gracilis

5 M. soleus

6 M. gastrocnemius, medial head

7 M. gastrocnemius, lateral head

8 Common calcaneal tendon

9 M. extensor digitorum lateralis

10 M. flexor digitorum profundus

11 Tendon of M. flexor digitorum superficialis

12 Lateral malleolus

13 Calcaneal tuber

14 Medial malleolus

Downloaded from Vet-eBooks.com

5.36 Superficial dissection of left crus, lateral view.

1 Patella

Downloaded from Vet-eBooks.com

2 M. biceps femoris

3 Middle patellar ligament

4 Lateral patellar ligament

5 Lateral epicondyle of femur

6 Lateral meniscus

7 Lateral collateral femorotibial ligament

8 Lateral condyle of tibia

9 M. gastrocnemius, lateral head

10 M. semitendinosus

11 M. extensor digitorum longus

12 Deep peroneal (fibular) nerve

13 Superficial peroneal (fibular) nerve

14 Caudal cutaneous sural nerve

15 M. extensor digitorum lateralis

16 M. flexor digitorum profundus

17 Common calcanean tendon

18 Tendon of M. flexor digitorum superficialis

19 Calcaneal tuber

20 Lateral malleolus

82

Downloaded from Vet-eBooks.com

5.37 Superficial dissection of left crus, medial view.

1 M. semimembranosus

Downloaded from Vet-eBooks.com

2 M. semitendinosus

3 M. gastrocnemius, medial head

4 Common calcanean tendon

5 Medial saphenous vein, cranial branch

6 Tendon of M. flexor digitorum superficialis

7 Tibial nerve

8 Saphenous artery

9 Medial saphenous vein, caudal branch

10 Calcaneal tuber

11 Medial malleolus

Downloaded from Vet-eBooks.com

5.38 Transverse section through left crus at the level of the junction between the proximal and middle third, distal view.

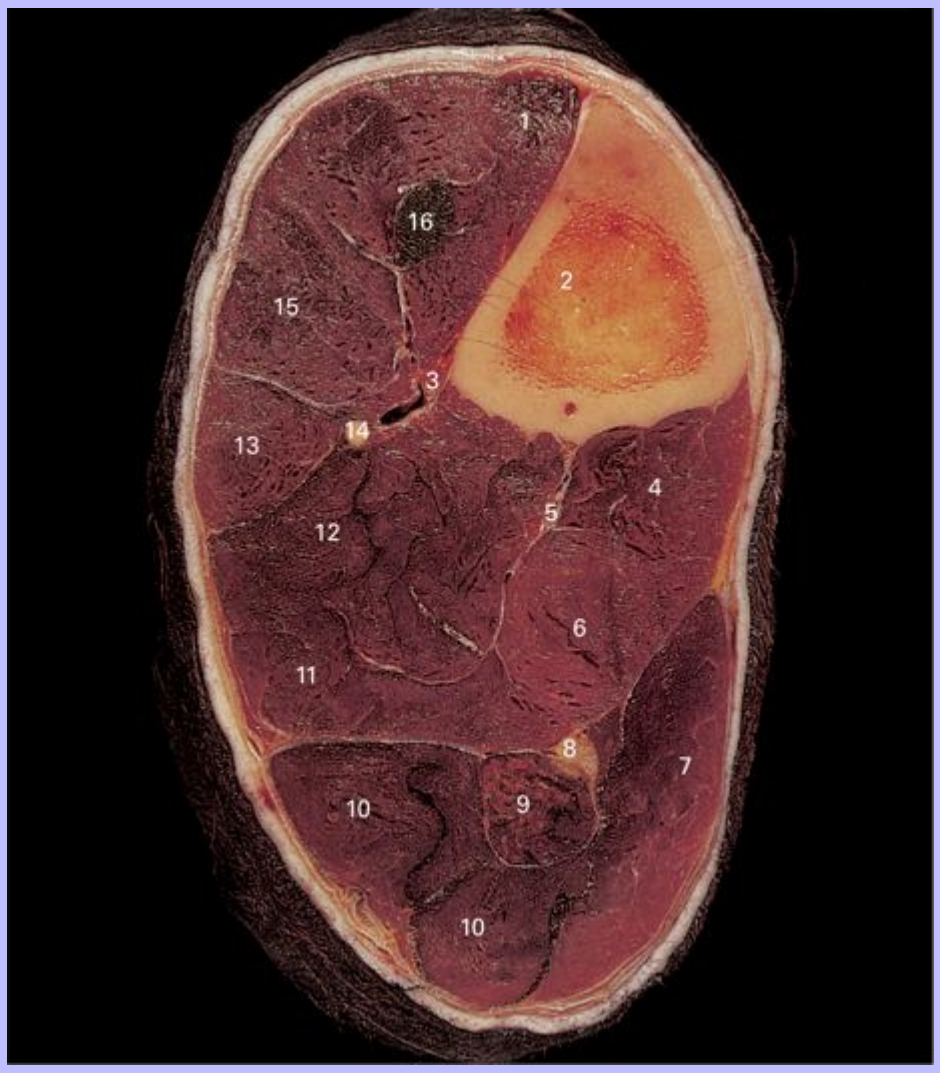

1 M. tibialis cranialis

2 Tibia

3 Cranial tibial vessels

4 M. popliteus

5 Caudal tibial vessels

Downloaded from Vet-eBooks.com

6 M. flexor digitorum longus

7 M. gastrocnemius, medial head

8 Tibial nerve

9 M. flexor digitorum superficialis

10 M. gastrocnemius, lateral head

11 M. tibialis caudalis

12 M. flexor digitorum profundus

13 M. extensor digitorum lateralis

14 Fibula

15 M. extensor digitorum longus

16 M. peroneus (fibularis) tertius

83

Downloaded from Vet-eBooks.com

5.39 Superficial dissection of left tarsus, lateral view.

1 M. tibialis cranialis

2 M. extensor digitorum lateralis

3 M. flexor digitorum profundus

Downloaded from Vet-eBooks.com

4 Tendon of M. flexor digitorum superficialis

5 Proximal extensor retinaculum

6 Lateral malleolus

7 Middle extensor retinaculum

8 Tendon of M. extensor digitorum longus

9 M. extensor digitorum brevis

10 Tendon of M. extensor digitorum lateralis

11 Distal extensor retinaculum

12 Dorsal metatarsal artery III

13 Metatarsal III (cannon bone)

14 Metatarsal IV (lateral splint bone)

Downloaded from Vet-eBooks.com

5.40 Superficial dissection of left tarsus, medial view. Tendons of M. flexor digitorum profundus and M. flexor digitorum superficialis have been retracted in a plantar direction in the metatarsal region.

1 Tendon of M. flexor digitorum superficialis

2 Tendon of M. gastrocnemius

Downloaded from Vet-eBooks.com

3 Tibia

4 M. tibialis cranialis

5 Proximal extensor retinaculum

6 Calcaneal tuber

7 Lateral malleolus

8 Tendon of M. flexor digitorum superficialis

9 Plantar ligament

10 Tendon of M. flexor digitorum profundus

11 Tendon of M. flexor digitorum longus

12 Medial collateral tarsal ligament

13 Trochlea of talus

14 Medial tendon of M. tibialis cranialis (cunean tendon)

15 Dorsal tendon of M. peroneus (fibularis) longus

16 Metatarsal II (medial splint bone)

17 Metatarsal III (cannon bone)

18 Tendon of M. extensor digitorum longus

19 Accessory ligament of M. extensor digitorum profundus (distal check ligament)

Downloaded from Vet-eBooks.com

5.41 Lateromedial view radiograph of tarsal joint.

1 Tibia

2 Tarsocrural joint

3 Calcaneus

4 Talus

Downloaded from Vet-eBooks.com

5 Lateral trochlea

6 Medial trochlea

7 Talocalcaneal joint

8 Sustentaculum tali

9 Proximal intertarsal joint

10 Central tarsal bone

11 Fourth tarsal bone

12 Distal intertarsal joint

13 Third tarsal bone

14 First and second tarsal bone (fused)

15 Tarsometatarsal joint

16 Metatarsal III (cannon bone)

17 Metatarsal II (medial splint bone)

18 Metatarsal IV (lateral splint bone)

Downloaded from Vet-eBooks.com

5.42 Sagittal section through left tarsus.

1 Tibia

2 M. flexor digitorum profundus

3 Tendon of M. gastrocnemius

4 Calcaneal tuber

Downloaded from Vet-eBooks.com

5 Tendon of M. flexor digitorum superficialis

6 Tibiotarsal joint

7 Thick part of joint capsule

8 Tendon of M. flexor digitorum profundus

9 Medial tendon of M. tibialis cranialis (cunean tendon)

10 Talus

11 Sustentaculum tali

12 Long plantar ligament

13 Flexor retinaculum

14 Fibrous joint capsule

15 Proximal intertarsal joint

16 Central tarsal bone

17 Distal intertarsal joint

18 Third tarsal bone

19 Tarsometatarsal joint

20 Joint capsule (tarsometatarsal ligament)

21 Proximal perforating tarsal vein

22 Accessory ligament of M. flexor digitorum profundus (distal check ligament)

23 Metatarsal III (cannon bone)

24 M. interosseus medius (suspensory ligament)

85

Downloaded from Vet-eBooks.com

5.43 Superficial dissection of left tarsus, dorsal view.

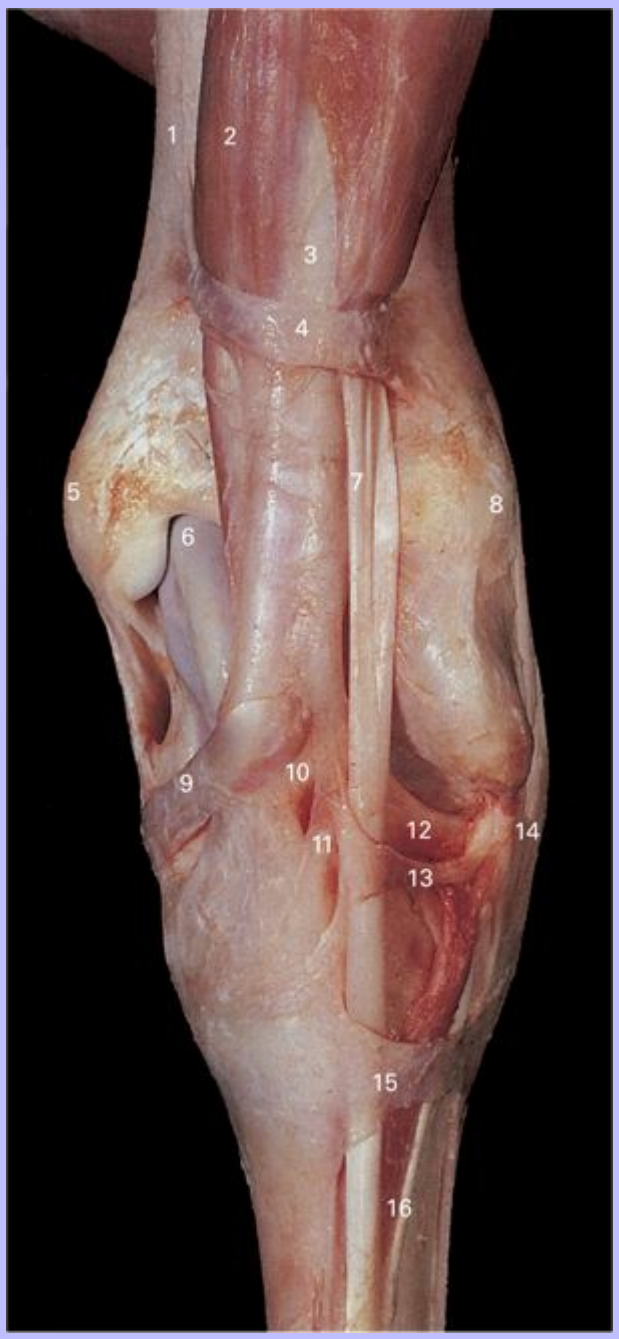

1 Tibia

Downloaded from Vet-eBooks.com

2 M. tibialis cranialis

3 Tendon of M. peroneus (fibularis) tertius

4 Proximal extensor retinaculum

5 Medial malleolus

6 Trochlea of talus

7 Tendon of M. extensor digitorum longus

8 Lateral malleolus

9 Medial tendon of M. tibialis cranialis (cunean tendon)

10 Dorsal tendon of M. peroneus (fibularis) tertius

11 Dorsal tendon of M. tibialis cranialis

12 Lateral tendon of M. peroneus (fibularis) tertius

13 Middle extensor retinaculum

14 Long lateral collateral tarsal ligament

15 Distal extensor retinaculum

16 Tendon of M. extensor digitorum lateralis

Downloaded from Vet-eBooks.com

5.44 Superficial dissection of left tarsus, caudal view.

1 M. flexor digitorum profundus, superficial head

2 Tendon of M. gastrocnemius

3 Tendon of M. flexor digitorum superficialis

4 M. extensor digitorum lateralis

5 M. flexor digitorum profundus, medial head

6 Tibia

7 Calcaneal tuber

8 Medial malleolus

9 Tendon of M. flexor digitorum profundus

Downloaded from Vet-eBooks.com

5.45 Dorsoplantar view radiograph of tarsal joint.

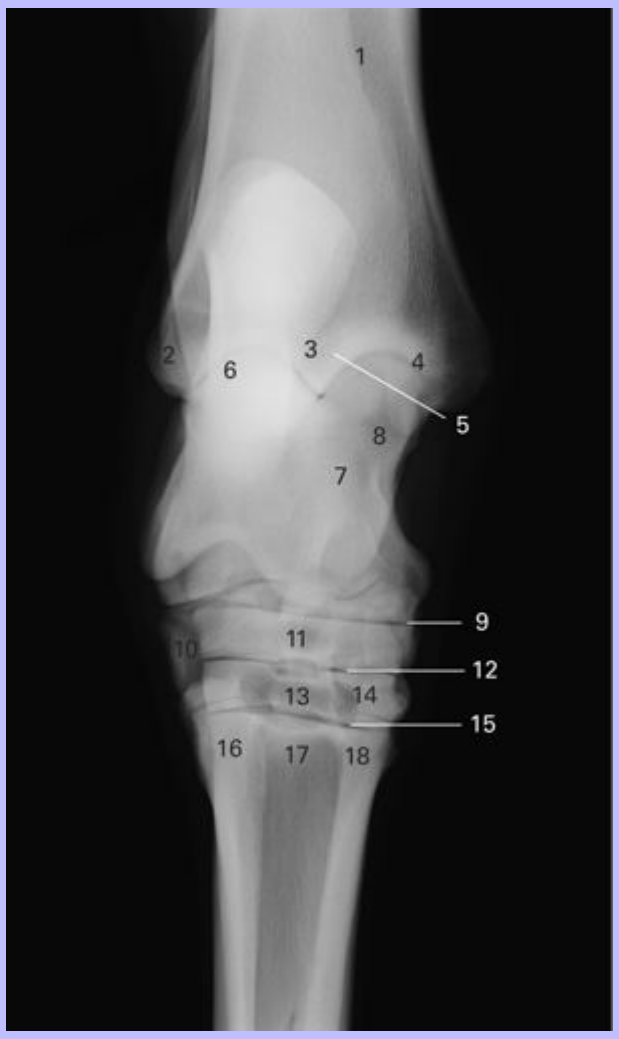

1 Tibia

2 Lateral malleolus

3 Sagittal ridge

4 Medial malleolus

5 Tarsocrural joint

6 Calcaneus

Downloaded from Vet-eBooks.com

7 Talus

8 Medial trochlea

9 Proximal intertarsal joint

10 Fourth tarsal bone

11 Central tarsal bone

12 Distal intertarsal joint

13 Third tarsal bone

14 First and second tarsal bone (fused)

15 Tarsometatarsal joint

16 Metatarsal IV (lateral splint bone)

17 Metatarsal III (cannon bone)

18 Metatarsal II (medial splint bone)

86

Downloaded from Vet-eBooks.com

5.46 Dorsolateral-plantaromedial oblique view radiograph of tarsal joint.

1 Tibia

2 Medial malleolus

3 Medial groove

4 Lateral groove

5 Tarsocrural joint

6 Talus

7 Medial trochlea

Downloaded from Vet-eBooks.com

8 Lateral trochlea

9 Calcaneus

10 Proximal intertarsal joint

11 Central tarsal bone

12 Fourth tarsal bone

13 Distal intertarsal joint

14 Third tarsal bone

15 First and second tarsal bone (fused)

16 Tarsometatarsal joint

17 Metatarsal III (cannon bone)

18 Metatarsal II (medial splint bone)

19 Metatarsal IV (lateral splint bone)

Downloaded from Vet-eBooks.com

5.47 Dorsomedial-plantarolateral oblique view radiograph of tarsal joint.

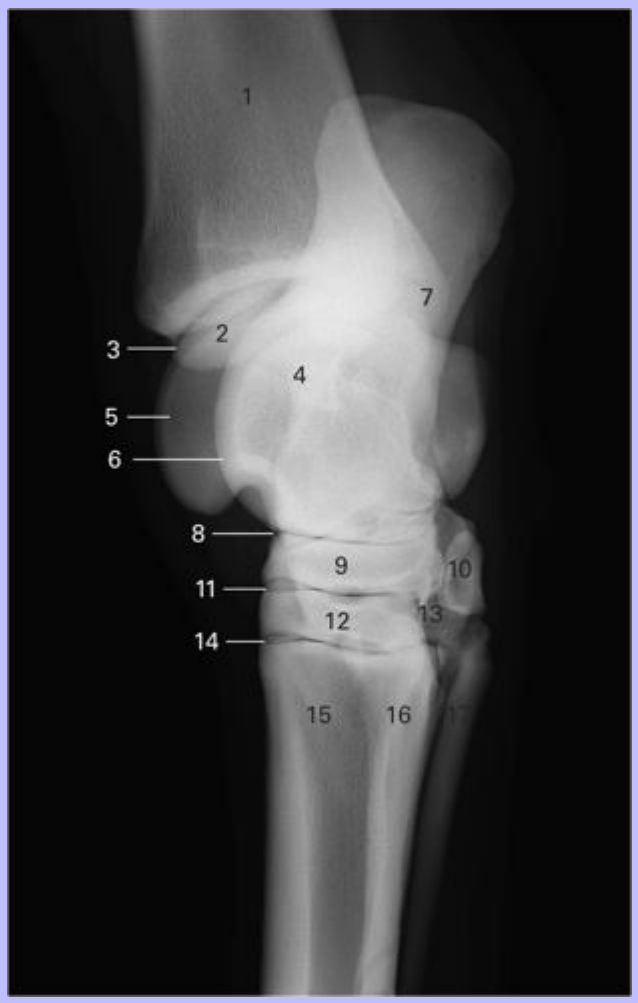

1 Tibia

2 Sagittal ridge

3 Tarsocrural joint

4 Talus

5 Lateral trochlea

6 Medial trochlea

7 Calcaneus

Downloaded from Vet-eBooks.com

8 Proximal intertarsal joint

9 Central tarsal bone

10 Fourth tarsal bone

11 Distal intertarsal joint

12 Third tarsal bone

13 First and second tarsal bone (fused)

14 Tarsometatarsal joint

15 Metatarsal III (cannon bone)

16 Metatarsal IV (lateral splint bone)

17 Metatarsal II (medial splint bone)

Downloaded from Vet-eBooks.com

5.48 Deep dissection of left tarsal joint, flexed lateral view.

1 Lateral malleolus

2 Trochlea of talus

3 Calcaneal tuber

4 Short lateral collateral tarsal ligament

5 Long lateral collateral tarsal ligament

6 Central tarsal bone

7 Third tarsal bone

8 Long plantar ligament

9 Metatarsal III (cannon bone)

10 Metatarsal IV (lateral splint bone)

Downloaded from Vet-eBooks.com

5.49 Deep dissection of left tarsal joint, flexed medial view.

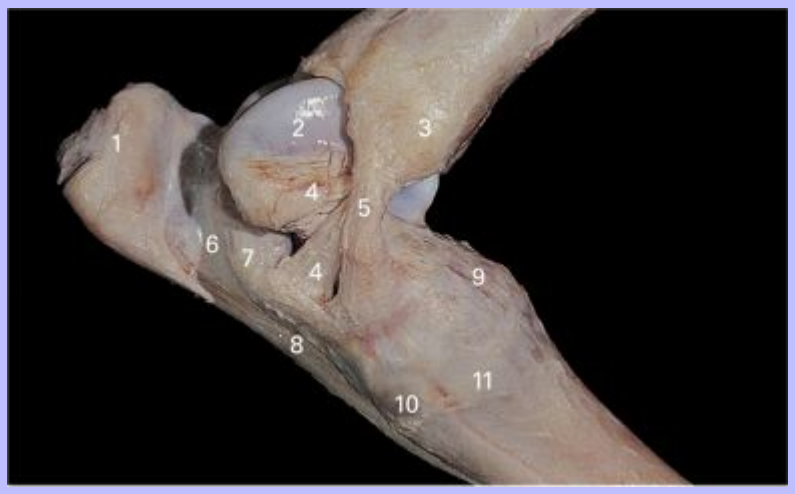

1 Calcaneal tuber

2 Trochlea of talus

3 Medial malleolus

4 Short medial collateral tarsal ligament

5 Long medial collateral tarsal ligament

6 Groove for tendon of M. flexor digitorum profundus

7 Sustentaculum tali

8 Long plantar ligament

9 Dorsal tarsal ligament

10 Metatarsal II (medial splint bone)

11 Metatarsal III (cannon bone)

87

Downloaded from Vet-eBooks.com

88

5.50 Metacarpal (left) and metatarsal (right) bones.

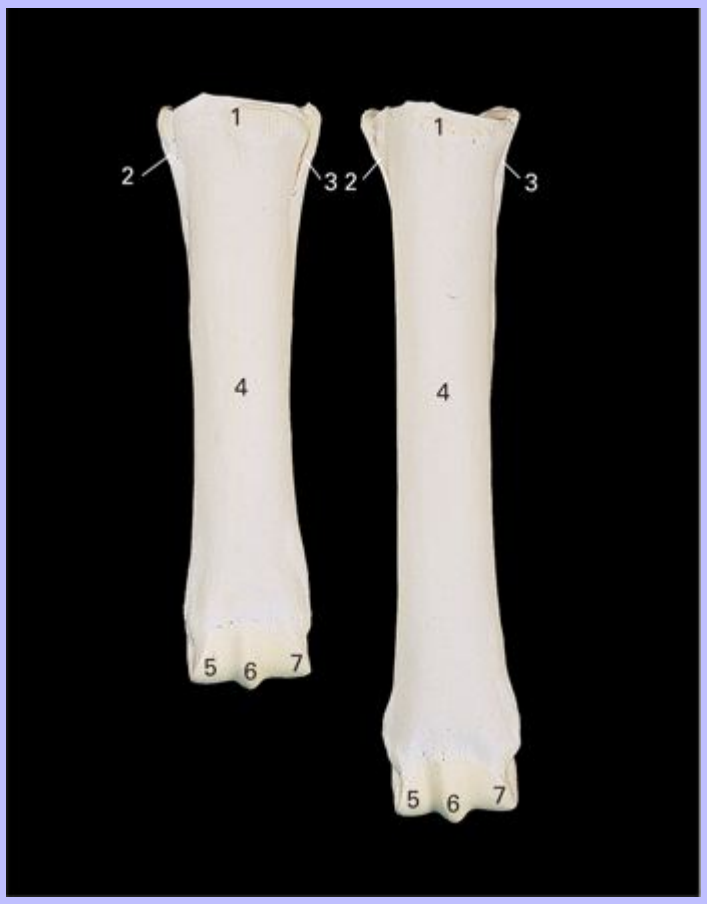

1 Metacarpal/metatarsal tuberosity

2 Second metacarpal/metatarsal bone

3 Fourth metacarpal/metatarsal bone

4 Third metacarpal/metatarsal bone

5 Medial condyle

6 Sagittal ridge

7 Lateral condyle

Downloaded from Vet-eBooks.com

5.51 Distal phalanx of forelimb (left) and hindlimb (right), dorsal view.

1 Palmar process

2 Parietal sulcus

3 Articular surface

4 Extensor process

5 Parietal surface

6 Crena

7 Solar border

Downloaded from Vet-eBooks.com

5.52 Dorsoplantar view radiograph of hind distal phalanx.

1 Distal sesamoid (navicular) bone

2 Middle phalanx (P2, short postern bone)

3 Distal interphalangeal (coffin) joint

4 Distal phalanx (P3, coffin bone, pedal bone)

5 Lateral plantar process

6 Medial plantar process

7 Lateral parietal sulcus

8 Medial parietal sulcus

9 Extensor process

10 Solar canal

11 Vascular channels

12 Solar margin

13 Crena

Downloaded from Vet-eBooks.com

6 6 Thoracic Viscera

6.1 Left view of the thorax. Ribs 2-12 and the associated soft tissues have been removed to expose the thoracic viscera. The pericardium is still in place.

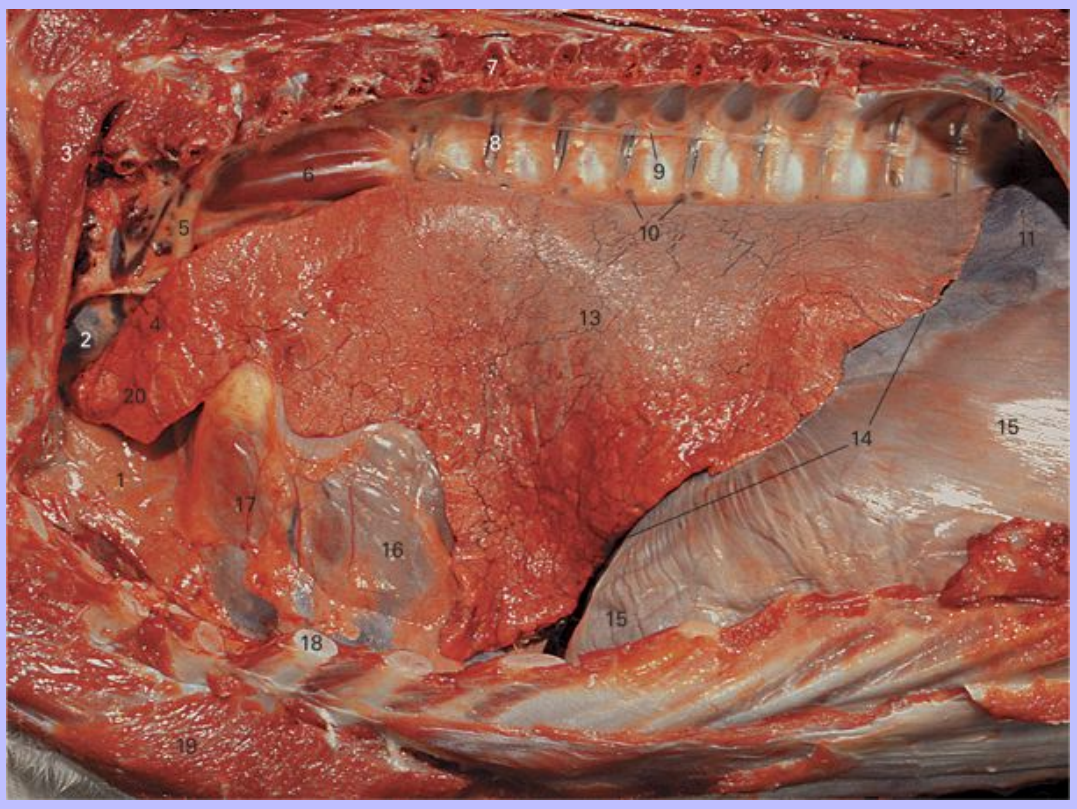

1 Thymus

2 Cranial vena cava

3 Rib 1 with some overlying muscle

4 Vagosympathetic trunk

5 Costocervical trunk

6 M. longus colli

7 Cut dorsal end of rib 7

8 Origin of the intercostal vessels that will come to lie caudal to rib 7

Downloaded from Vet-eBooks.com

9 Sympathetic trunk

10 Aortic lymph nodes

11 Tendinous center of the diaphragm

12 Rib 13

13 Costal surface of the caudal lobe of the left lung

14 Basal border of the left lung

15 Costal part of the diaphragm

16 Left ventricle seen through the pericardium

17 Right ventricle seen through the pericardium

18 Cut cartilage of rib 5

19 Cut pectoral muscles

20 Costal surface of the cranial lobe of the left lung

Downloaded from Vet-eBooks.com

6.2 Left view of the thorax. Ribs 2-12 and the associated soft tissues have been removed to expose the thoracic viscera. The left lung has been reflected ventrally.

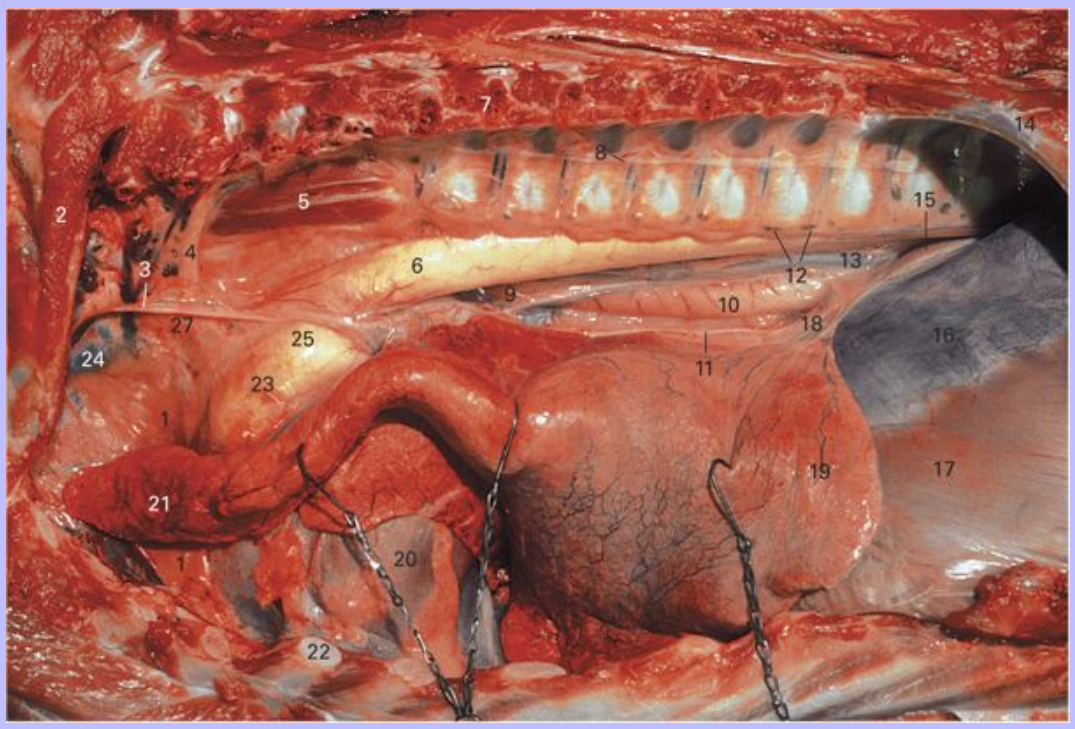

1 Thymus

2 Rib 1 with some overlying muscle

3 Vagosympathetic trunk

4 Costocervical trunk

5 M. longus colli

6 Aorta

7 Cut dorsal end of rib 7

8 Sympathetic trunk

9 Dorsal trunk of the vagus nerve

10 Esophagus

Downloaded from Vet-eBooks.com

11 Ventral trunk of the vagus nerve

12 Aortic lymph nodes

13 Caudal mediastinum

14 Rib 13

15 Left crus of the diaphragm

16 Tendinous center of the diaphragm

17 Costal part of the diaphragm

18 Ligament of the lung

19 Caudal lobe of the left lung

20 Heart lying in the cardiac notch of the lung and surrounded by the pericardium

21 Reflected cranial lobe of the left lung

22 Cut costal cartilage of rib 5

23 Pulmonary trunk

24 Cranial vena cava

25 Arterial ligament

89

Downloaded from Vet-eBooks.com

6.3 Left view of the thorax. Ribs 2–12 and the associated soft tissues have been removed to expose the thoracic viscera. The left side of the pericardial sac has been removed and the lung has been reflected dorsally.

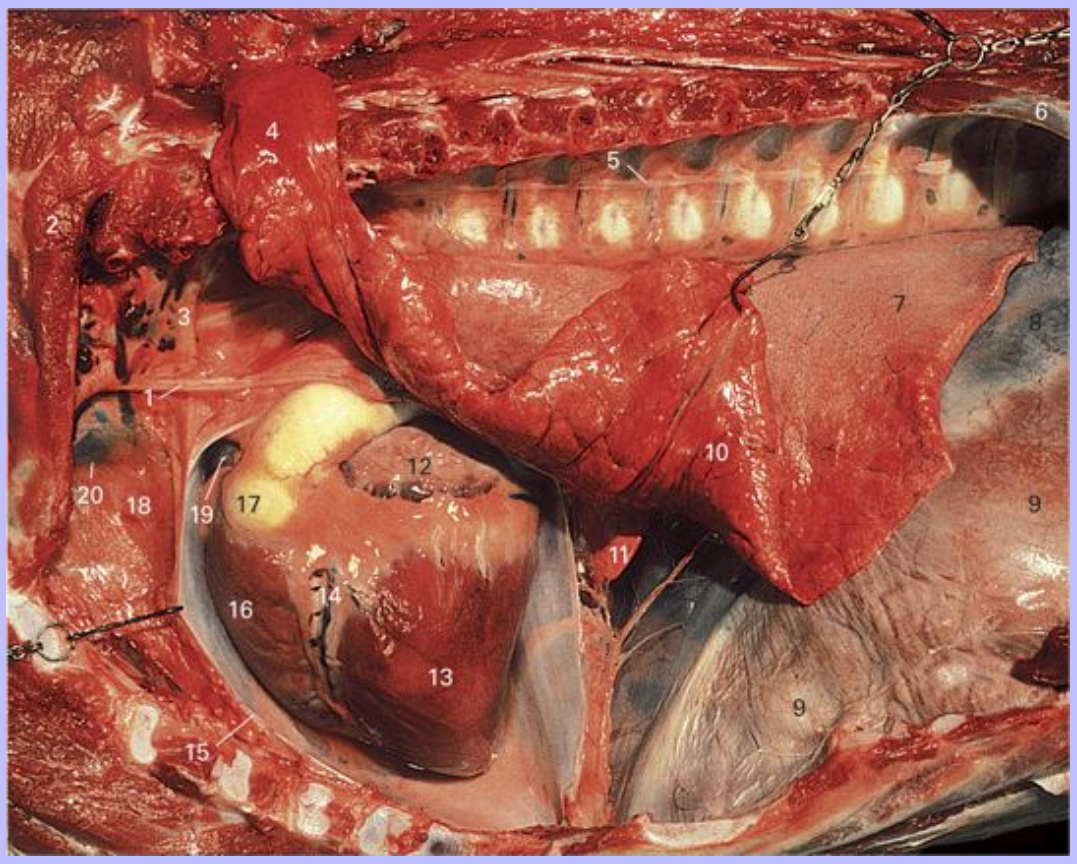

1 Vagosympathetic trunk

2 Rib 1 with some overlying muscle

3 Costocervical trunk

4 Reflected cranial lobe of the left lung

5 Sympathetic trunk

6 Rib 13

7 Caudal lobe of the left lung

8 Tendinous center of the diaphragm

Downloaded from Vet-eBooks.com

9 Costal part of the diaphragm

10 Diaphragmatic surface of the reflected caudal lobe of the left lung

11 Accessory lobe of the right lung seen through the caudal mediastinum

12 Left auricle

13 Left ventricle

14 Paraconal interventricular groove

15 Cut edge of the pericardial sac

16 Right ventricle

17 Beginning of the pulmonary trunk

18 Thymus

19 Left extremity of the right auricle

20 Cranial vena cava

Downloaded from Vet-eBooks.com

6.4 The thoracic cavity seen from the right side. Ribs 1–13 and the associated soft tissues have been removed.

1 Rib 14

2 Tendinous center of the diaphragm

3 Costal surface of the caudal lobe of the right lung

4 Cut proximal end of rib 4

5 Costal surface of the cranial lobe of the right lung (discolored by aspirated blood)

6 Right ventricle seen through the pericardium

7 The caval fold of the pleura containing abundant fat

8 Costal part of the diaphragm

9 Tunica flava abdominis overlying the abdominal muscles

Downloaded from Vet-eBooks.com

6.5 Right view of the mediastinum and associated structures in a 2-year-old quarter horse. The right side of the pericardium has been removed.

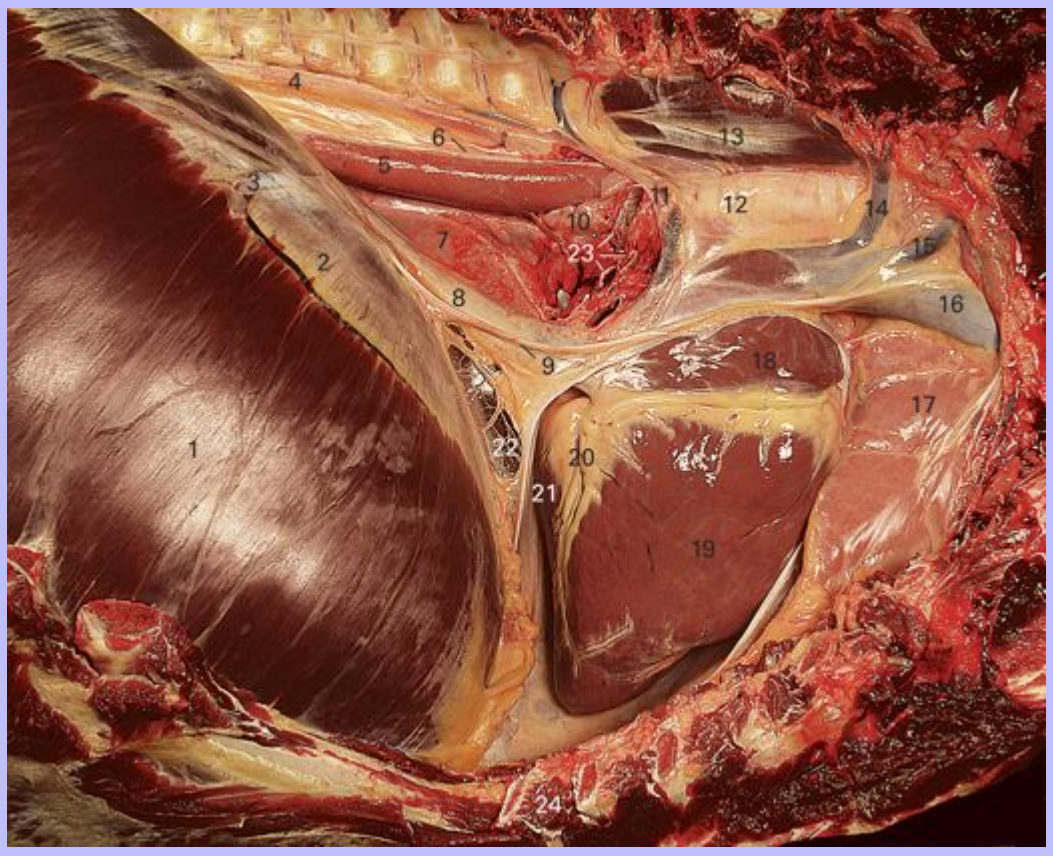

1 Costal part of the diaphragm

2 Tendinous center of the diaphragm

3 Right cranial phrenic vein

4 Thoracic duct

5 Esophagus

6 Dorsal trunk of the vagus

7 Left lung seen through the caudal mediastinum

8 Caudal vena cava (partially drained of blood)

9 Right phrenic nerve

Downloaded from Vet-eBooks.com

10 Tracheobronchial lymph node

11 Azygos vein (partially drained of blood)

12 Trachea

13 M. longus colli

14 Costocervical vein

15 Deep cervical vein

16 Cranial vena cava

17 Thymus

18 Right atrium with the coronary groove lying ventral to it

19 Right ventricle

20 Subsinuosal interventricular groove

21 Left ventricle

22 Caval fold of pleura

23 Structures in the root of the right lung. From dorsal to ventral: principal bronchus, pulmonary artery, pulmonary veins

24 Cut cartilage of rib 6

Downloaded From Vet-eBooks.com

6.6 Detail of the ventral part of the mediastinum in a 2-year-old quarter horse. Right view.

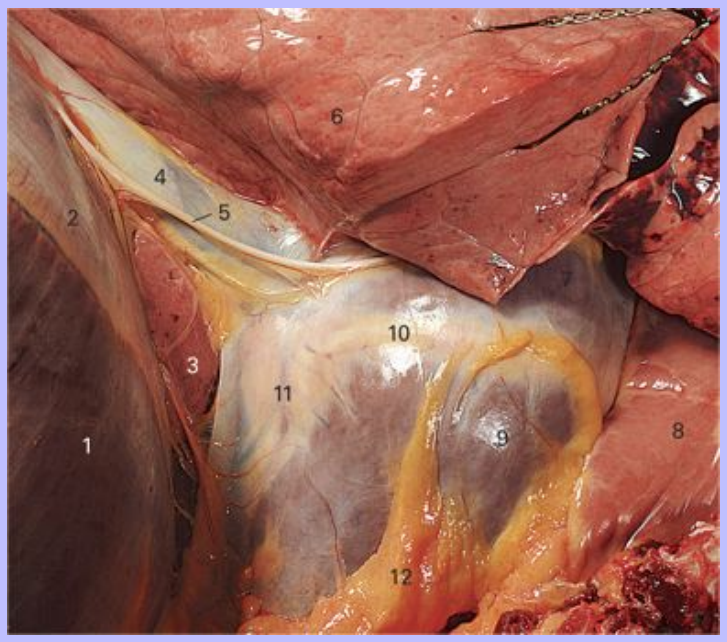

1 Costal part of the diaphragm

2 Tendinous center of the diaphragm

3 Accessory lobe of the right lung seen through the delicate caval fold of pleura

4 Caudal vena cava (partially drained of blood)

5 Right phrenic nerve covered by a narrow fold of pleura

6 Diaphragmatic surface of the caudal lobe of the right lung

7 Right atrium seen through the pericardium

8 Thymus within the cranial mediastinum

9 Right ventricle seen through the pericardium

10 Coronary groove seen through the pericardium

11 Subsinuosal interventricular groove seen through the pericardium

12 Fat beneath the pericardial pleura

Downloaded from Vet-eBooks.com

6.7 Left view of the heart showing the auricular surface.

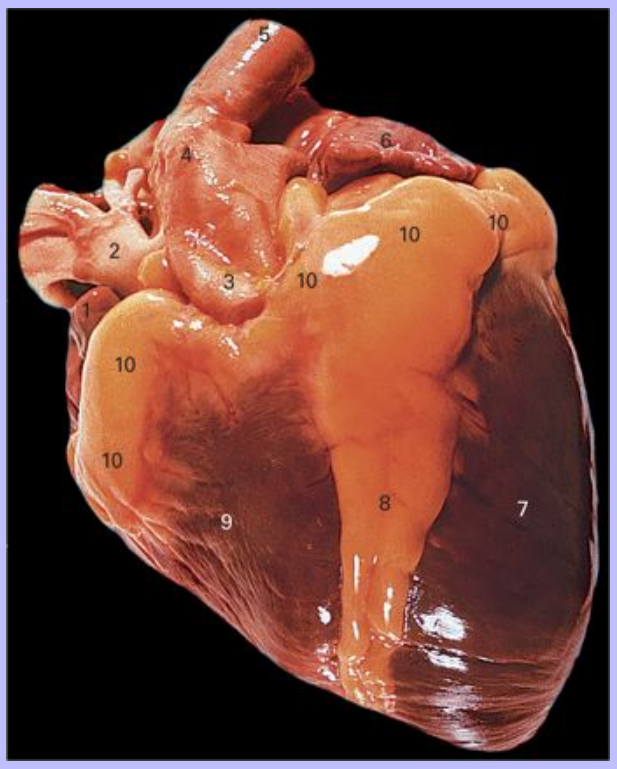

1 Right auricle

2 Brachiocephalic trunk

3 Pulmonary trunk

4 Arterial ligament

5 Aorta

6 Left auricle

7 Left ventricle

8 Paraconal interventricular groove containing abundant fat in this specimen as well as the paraconal interventricular branches of the left coronary artery and the great cardiac vein

9 Right ventricle

10 Coronary groove containing abundant fat in this specimen as well as the coronary vessels

Downloaded from Vet-eBooks.com

6.8 Right view of the heart showing the atrial surface.

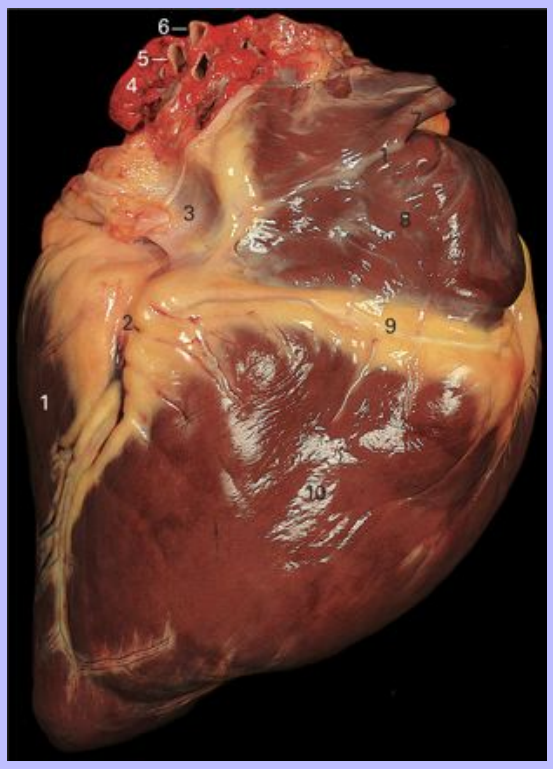

1 Left ventricle

2 Subsinuosal interventricular groove containing the interventricular branch of the right coronary artery and the middle cardiac vein

3 Terminal part of the caudal vena cava (collapsed)

4 Remnants of lung tissue adherent to the dorsal aspect of the left atrium

5 One of several cut pulmonary veins

6 Cut pulmonary artery

7 Terminal part of the cranial vena cava

8 Right atrium

9 Coronary groove containing the right coronary artery

10 Right ventricle

Downloaded from Vet-eBooks.com

6.9 Left view of the heart with part of the wall of the right ventricle removed.

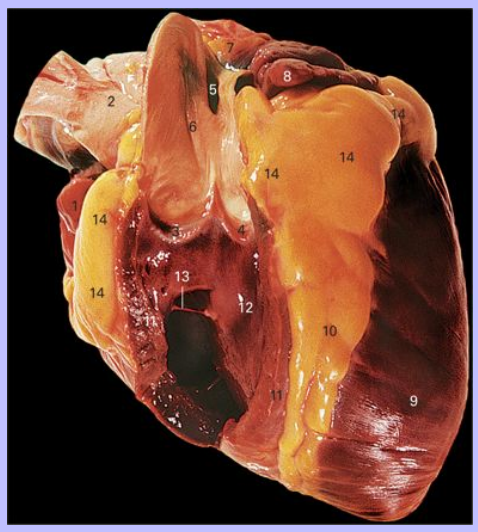

1 Right auricle

2 Brachiocephalic trunk

3 Intermediate cusp of the pulmonary valve

4 Right cusp of the pulmonary valve

5 Depression marking the attachment of the arterial ligament to the outside of the pulmonary trunk

6 Pulmonary trunk

7 Part of the left atrium

8 Left auricle

9 Left ventricle

10 Paraconal interventricular groove

11 Wall of the right ventricle

12 Interventricular septum

13 Septomarginal band

14 Coronary groove

Downloaded from Vet-eBooks.com

6.10 The heart sectioned transversely through the left atrioventricular valve. The specimen is viewed from the caudal aspect.

1 Cut wall of the left ventricle

2 Fat filling the coronary groove on the left side

3 Cut wall of the left atrium

4 Interior of the left atrium

5 Interior of the left auricle showing pectinate muscles

6 Part of the interatrial septum

7 Septal cusp of the left atrioventricular valve

8 Arrow pointing towards the aortic valve

9 Tendinous cords

10 Papillary muscle

Downloaded from Vet-eBooks.com

6.11 Dorsal view of the base of the heart. The atria and great vessels have been removed. The cranial aspect is towards the top of the page.

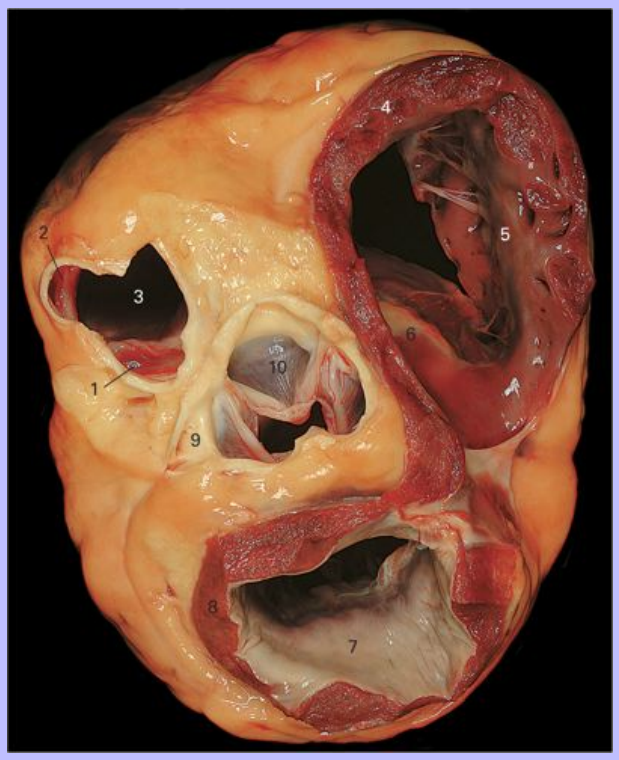

1 Left semilunar cusp of the pulmonary valve

2 Intermediate semilunar cusp of the pulmonary valve

3 Opening into the pulmonary trunk

4 Cut wall of the right atrium

5 Parietal cusp of the right atrioventricular valve

6 Septal cusp of the right atrioventricular valve

7 Parietal cusp of the left atrioventricular valve

8 Cut wall of the left atrium

9 Beginning of the left coronary artery

10 Right semilunar cusp of the aortic valve

Downloaded from Vet-eBooks.com

6.12 The aortic valve opened to show detail of the right semilunar cusp. The artery forceps are attached to the free edge of the cusp and are used to direct it somewhat towards the closed position.

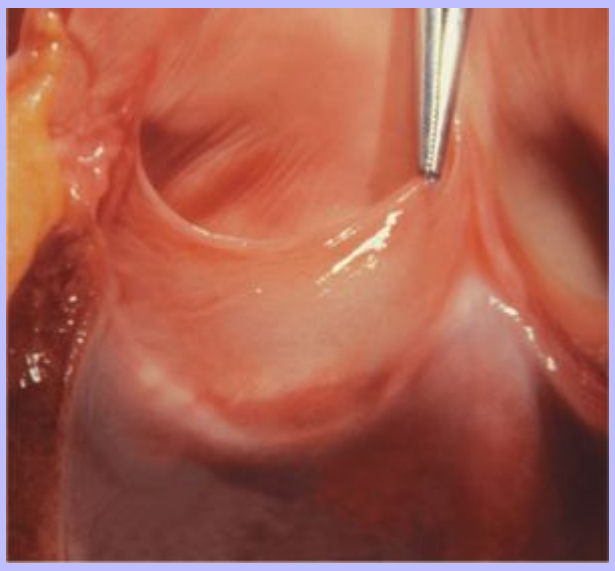

Downloaded from Vet-eBooks.com

6.13 Dorsal section of the ventricles of the heart midway between the coronary groove and the apex. The specimen is viewed from the dorsal aspect and its cranial part is towards the top of the page.

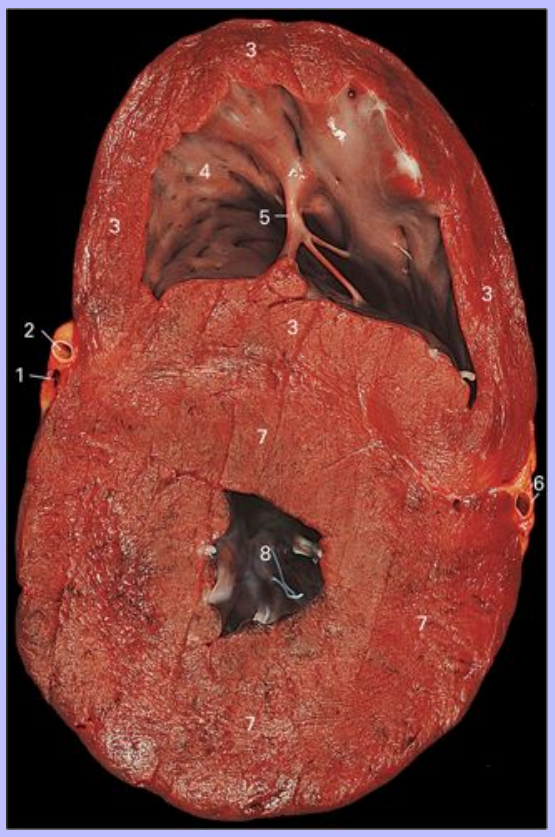

1 Paraconal interventricular vein in section

2 Paraconal interventricular branch of the left coronary artery in section

3 Right ventricular myocardium

4 Endocardium of the right ventricle

5 Septomarginal band

6 Subsinuosal interventricular branch of the right coronary artery in section

7 Left ventricular myocardium

8 Lumen of the left ventricle

Downloaded from Vet-eBooks.com

6.14 Ultrasound image of the heart made with a 5MHz sector scanner placed just behind the caudal border of the triceps brachii on the left side.

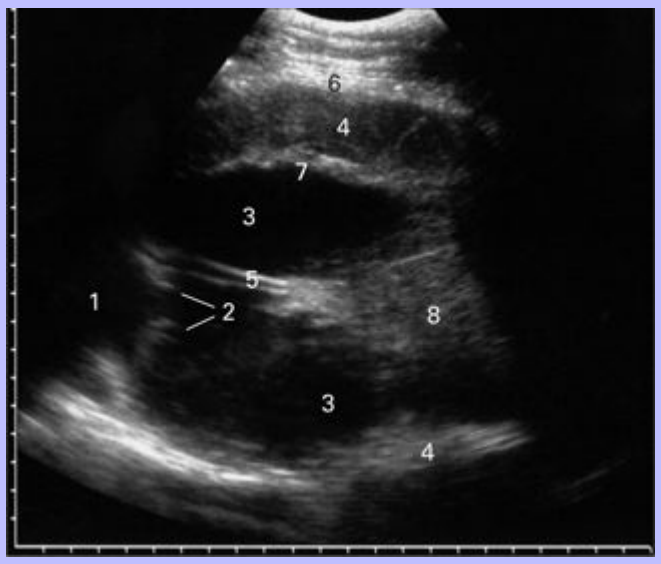

1 Lumen of the left atrium

2 Left atrioventricular valve

3 Lumen of the left ventricle

4 Myocardium

5 Tendinous cords

6 Pericardium

7 Endocardium

8 Papillary muscle

93

Downloaded from Vet-eBooks.com

6.15 Both lungs attached to the bronchi and the terminal part of the trachea. They have been laid out so that the costal surfaces are uppermost. Note the larger size of the right lung and the larger cardiac notch on the left.

Downloaded from Vet-eBooks.com

6.16 Lateral view of the left lung. This animal had longstanding recurrent airway obstruction so the lung has retained the shape and dimensions of the pleural cavity without collapsing in the normal manner.

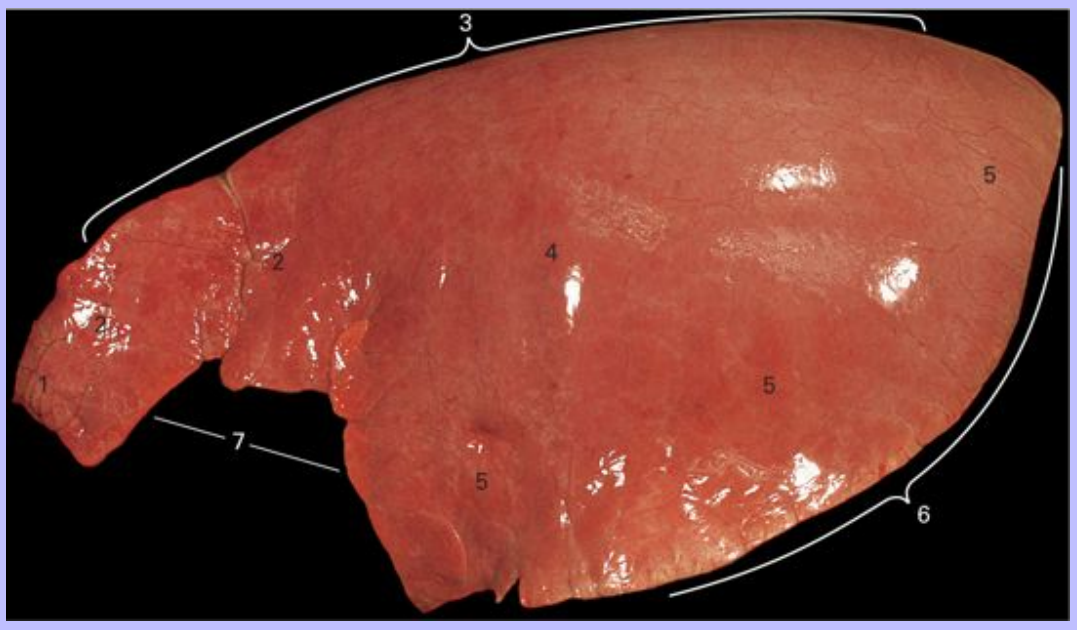

1 Apex of the lung

2 Cranial lobe

3 Dorsal border

4 Costal surface

5 Caudal lobe

6 Basal border

7 Cardiac notch

Downloaded from Vet-eBooks.com

6.17 Medial view of the left lung.

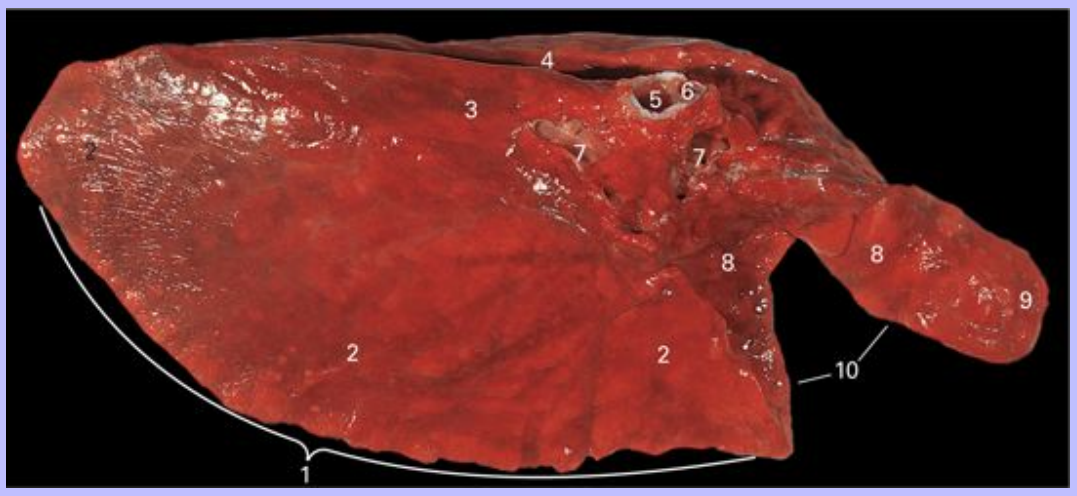

1 Basal border

2 Diaphragmatic surface

3 Medial surface

4 Aortic impression

5 Lobar bronchus supplying the caudal lobe

6 Lobar bronchus supplying the cranial lobe

7 Pulmonary blood vessels

8 Cardiac impression

9 Apex of the lung

10 Cardiac notch

94

Downloaded from Vet-eBooks.com

6.18 Medial view of the right lung.

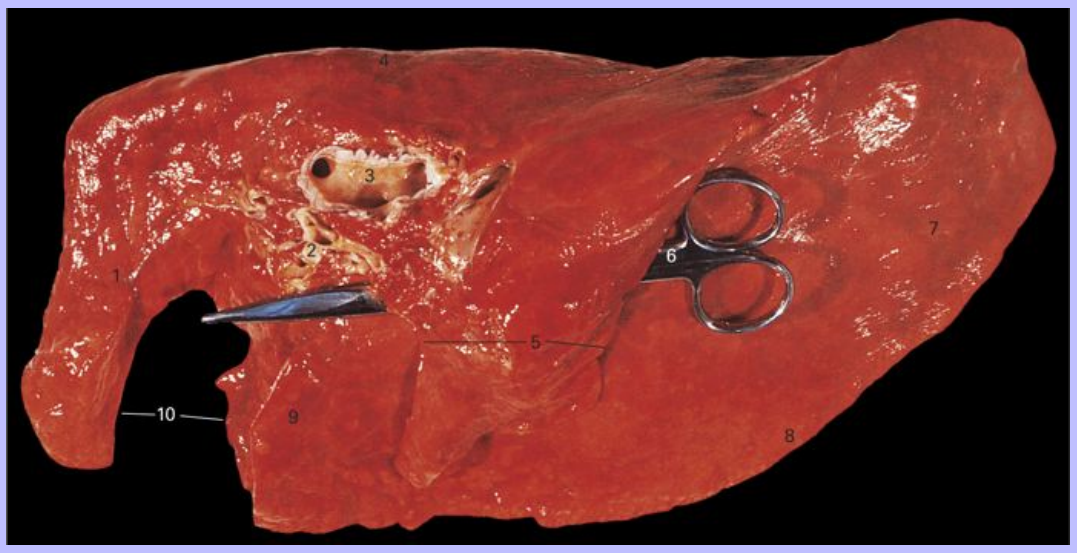

1 Cranial lobe

2 Pulmonary arteries

3 Right principal bronchus with its medial wall removed

4 Dorsal border

5 Accessory lobe

6 Scissors indicating the course followed by the caudal vena cava

7 Diaphragmatic surface of the caudal lobe

8 Basal border

9 Part of cranial lobe caudal to the cardiac notch

10 Cardiac notch bounded by the ventral border of the lung

Downloaded from Vet-eBooks.com

6.19 Medial view of the right lung dissected to show the lobar bronchi.

1 Cranial lobe

2 Cranial lobar bronchus

3 Pulmonary arteries

4 Caudal lobar bronchus

5 Segmental bronchi leaving the caudal lobar bronchus

6 Accessory lobe

7 Accessory lobar bronchus

8 Segmental bronchus supplying the part of the caudal lobe that is homologous with the middle lobe of other species

95

Downloaded from Vet-eBooks.com

6.20 Lateral radiograph of the cranial thorax immediately caudal to the shoulder joint.

1 Caudal border of the humerus

2 Cranial lobes of the lungs including shadows of the pulmonary vessels

3 Cranial vena cava

4 Rib 2, left side

5 Caudal border of the neck of the scapula

6 Rib 2, right side

7 Trachea

8 Cranial border of the aortic arch

9 Ventricles

Downloaded from Vet-eBooks.com

6.21 Lateral radiograph of the mid-thorax immediately caudal to the heart.

1 Left atrium

2 Trachea

3 Bifurcation of the trachea and the two principal bronchi

4 Descending aorta

5 Rib 8 on both sides superimposed

6 Mainly pulmonary arteries entering the lung

7 Mainly pulmonary veins leaving the lung

8 Caudal vena cava

9 Dome of the diaphragm

Downloaded from Vet-eBooks.com

6.22 Lateral radiograph of the caudal part of the thoracic region.

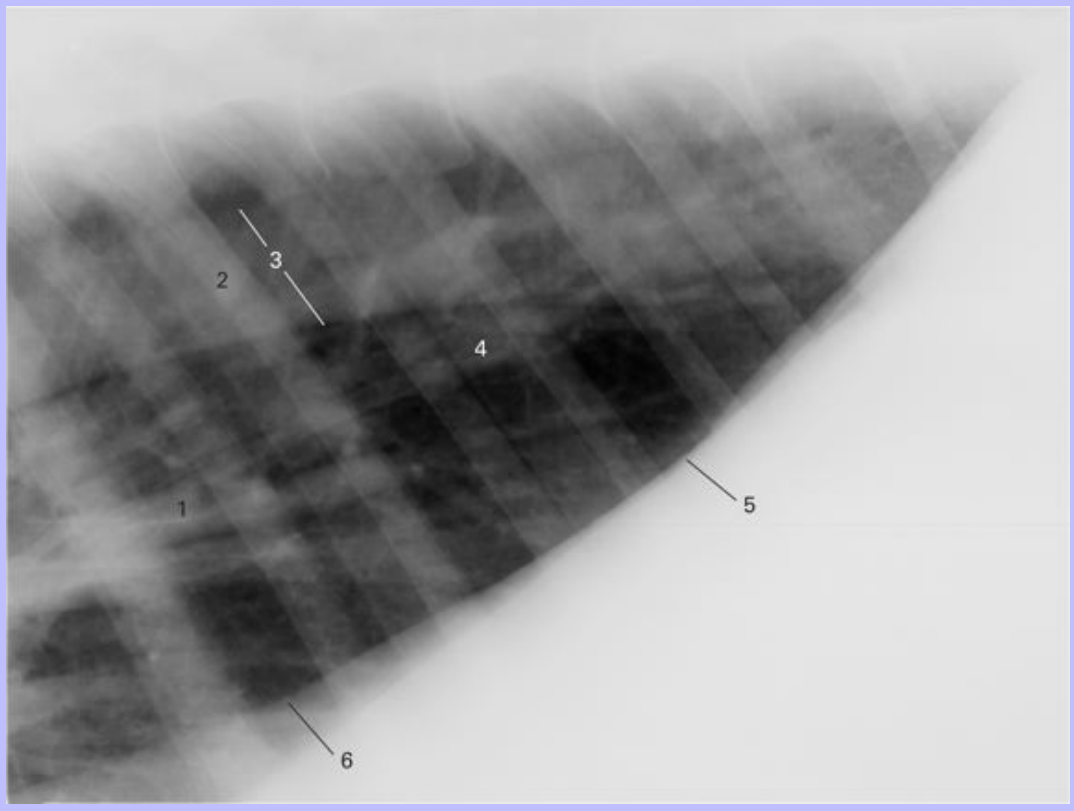

1 Pulmonary vessels

2 Rib 9 of each side partially superimposed

3 Descending aorta

4 Caudal lobes of the lungs

5 Dorsocranial surface of the diaphragm

6 Dorsal edge of the caudal vena cava

Downloaded from Vet-eBooks.com

7 7 Abdominal and Pelvic Viscera

7.1 Left view of the abdominal contents of a mature gelding with the costal arch intact.

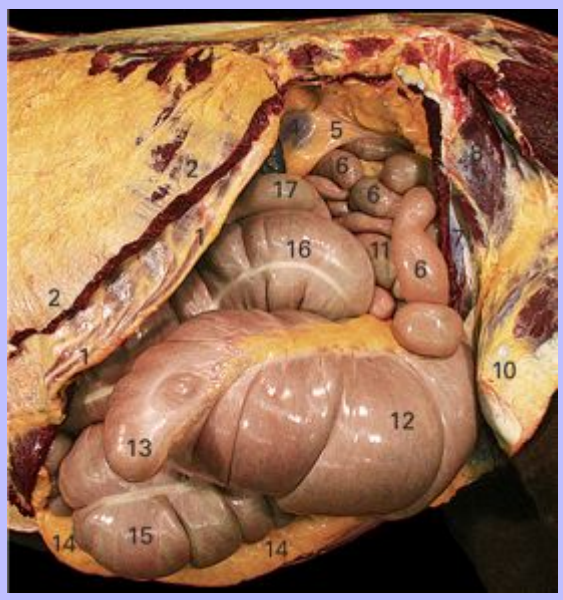

1 Conjoined costal cartilages forming the costal arch

2 Cut origin of M. abdominis obliquus externus (covered by the tunica flava abdominis)

3 Most caudal part of the dorsal end (base) of the spleen

4 Caudal pole of the left kidney

5 Perirenal fat

6 Loops of small intestine

7 Caudal part of M. abdominis obliquus internus

8 M. tensor fasciae latae

9 M. gluteus medius

10 Stifle joint

11 Loop of descending colon

12 Body of the cecum

Downloaded from Vet-eBooks.com

13 Apex of the cecum

14 Retroperitoneal fat

15 Right ventral colon

16 Left ventral colon

17 Left dorsal colon

Downloaded from Vet-eBooks.com

7.2 The abdominal and thoracic viscera exposed by removal of the left body wall (with the exception of rib 1) and the left half of the diaphragm. Left view. This animal had longstanding recurrent airway obstruction so the lung has retained a shape and size that are probably close to those of a normal living horse.

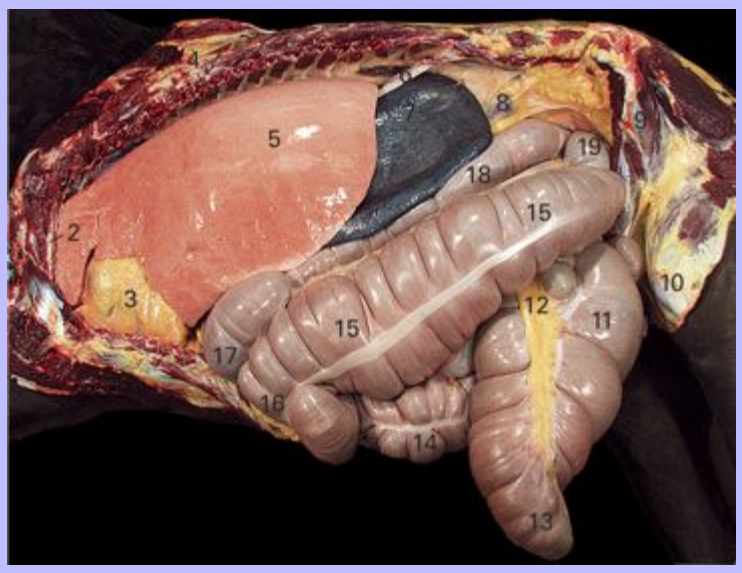

1 Cut pectoral musculature

2 Rib 1

3 Pericardium (there is much fat in the loose connective tissue overlying the fibrous pericardium)

4 Rib 8 (cut)

5 Costal surface of the left lung

6 Remnant of the diaphragm

7 Spleen

8 Caudal pole of the left kidney

9 M. tensor fasciae latae

10 Stifle joint

11 Body of the cecum

12 Ileocecal fold (only partially exposed)

Downloaded from Vet-eBooks.com

13 Apex of the cecum

14 Right ventral colon

15 Left ventral colon (with prominent lateral free muscular band)

16 Sternal flexure

17 Diaphragmatic flexure

18 Left dorsal colon

19 Pelvic flexure

Downloaded from Vet-eBooks.com

7.3 The contents of the thorax and cranial abdomen after removal of the body wall, the left lung and the left half of the diaphragm. Left view.

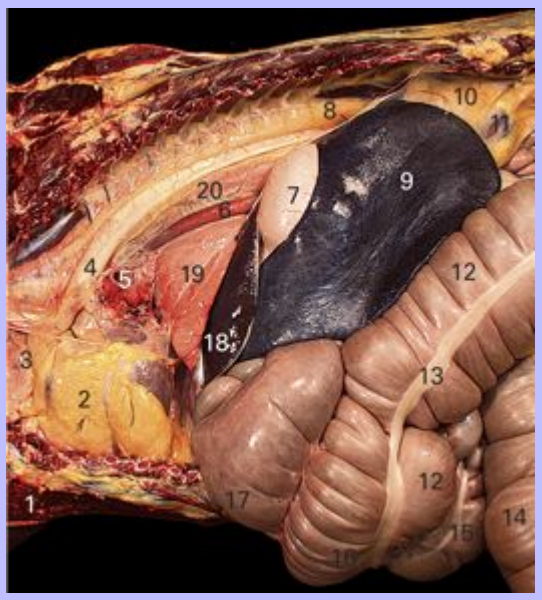

1 Cut pectoral musculature

2 Pericardium (there is much fat in the loose connective tissue overlying the fibrous pericardium)

3 Left phrenic nerve

4 Aortic arch

5 Left principal bronchus (cut)

6 Esophagus

7 Parietal surface of the blind sac (fundus) of the stomach

8 Cut edge of the diaphragm

9 Spleen (the ventral extremity is hidden behind the liver)

10 Perirenal fat

11 Caudal pole of the kidney

12 Left ventral colon

13 Lateral free muscular band of the left ventral colon

Downloaded from Vet-eBooks.com

14 Body of the cecum

15 Right ventral colon

16 Sternal flexure

17 Diaphragmatic flexure

18 Left lateral lobe of the liver

19 Accessory lobe of the lung visible through the mediastinal pleura

20 Dorsal part of the mediastinum

Downloaded from Vet-eBooks.com

7.4 The contents of the cranial abdomen seen through the diaphragmatic peritoneum on the right side. The thoracic wall was excised as far caudally as rib 13, the right lung was removed and the costal part of the diaphragmatic musculature was dissected away leaving the peritoneum (and the immediately associated connective tissue) retaining the abdominal viscera in place. Structures 10–14 are, therefore, seen through the peritoneum.

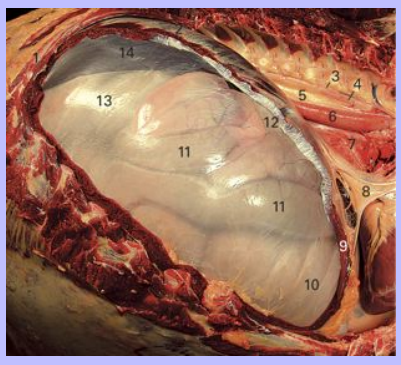

1 Rib 14

2 Tendinous center of the diaphragm

3 Azygos vein

4 Thoracic duct

5 Descending aorta

6 Esophagus

7 Caudal mediastinum

8 Caval fold containing the right phrenic nerve

9 Cut edge of the sternal part of the diaphragm

10 Sternal flexure of the ascending colon

11 Loops of small intestine overlying the ascending colon

12 Diaphragmatic flexure of the ascending colon

13 Right dorsal colon

14 Right lobe of the liver

Downloaded from Vet-eBooks.com

7.5 The contents of the abdomen and caudal thorax of a large horse seen from the right side after removal of the body wall. The undisturbed viscera were photographed as soon as the abdomen was opened. The colon and cecum are distended by enteric gas and the pelvic flexure of the colon has moved across the pelvic inlet to the right and is now tucked behind the body of the cecum.

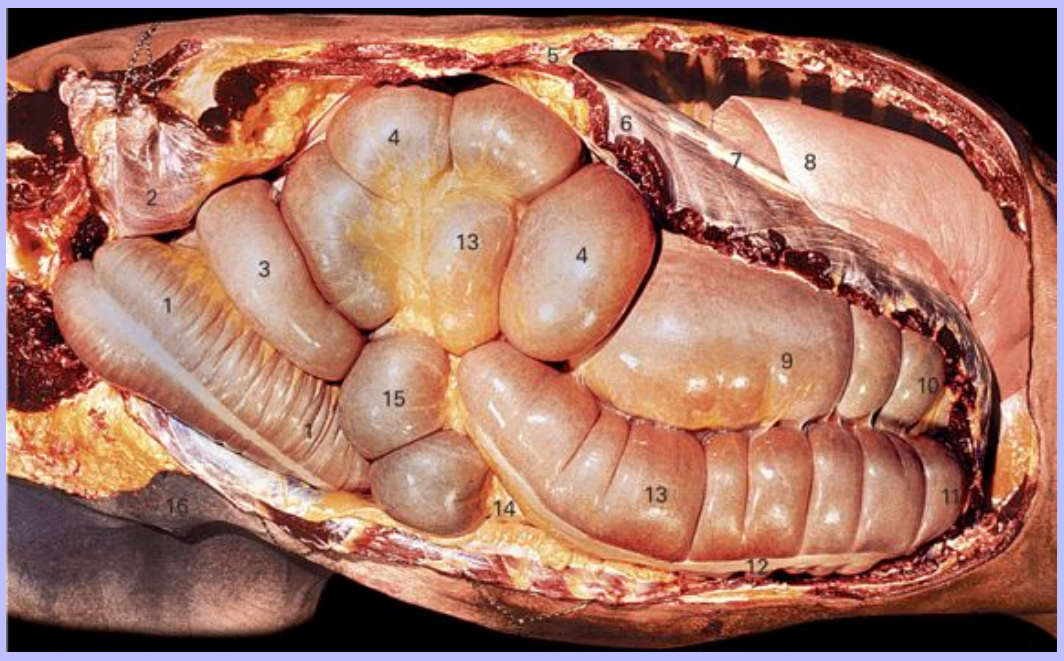

1 Left ventral part of the ascending colon

2 M. abdominis obliquus internus, reflected and seen from the medial aspect through the peritoneum

3 Left dorsal part of the ascending colon

4 Base of the cecum

5 Cut dorsal end of rib 18

6 Costal part of the diaphragm

7 Tendinous center of the diaphragm

8 Costal surface of the right lung

9 Right dorsal part of the ascending colon

Downloaded from Vet-eBooks.com

10 Diaphragmatic flexure of the ascending colon

11 Sternal flexure of the ascending colon

12 Lateral free muscular band of the left ventral colon

13 Right ventral part of the ascending colon

14 Cecocolic fold

15 Body of the cecum (the apex lies behind the right ventral part of the colon)

16 Mammary gland

7.6 Detail from Fig. 7.5 after removal of the right half of the diaphragm to reveal part of the liver.

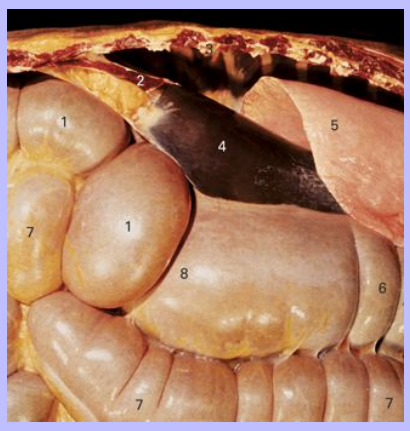

1 Base of the cecum

2 Right crus of the diaphragm seen in paramedian section

3 Cut dorsal end of rib 16

4 Right lobe of the liver

5 Costal surface of the caudal lobe of the right lung

6 Right dorsal part of the ascending colon

7 Right ventral part of the ascending colon

8 Right extremity of the transverse colon

Downloaded from Vet-eBooks.com

7.7 The parietal surface of the stomach. The parietal branches of the left gastric artery, and their satellite veins, can be seen ramifying over the surface.

1 Esophagus

2 Cardia

3 Fundus (blind sac)

4 Greater curvature (attachment of the greater omentum)

5 Body of the stomach

6 Pyloric region of the stomach

7 Lesser curvature (attachment of the lesser omentum)

8 Pylorus

9 Duodenum

Downloaded from Vet-eBooks.com

7.8 The visceral surface of the stomach. The visceral branches of the left gastric artery, and their satellite veins, can be seen ramifying over the surface.

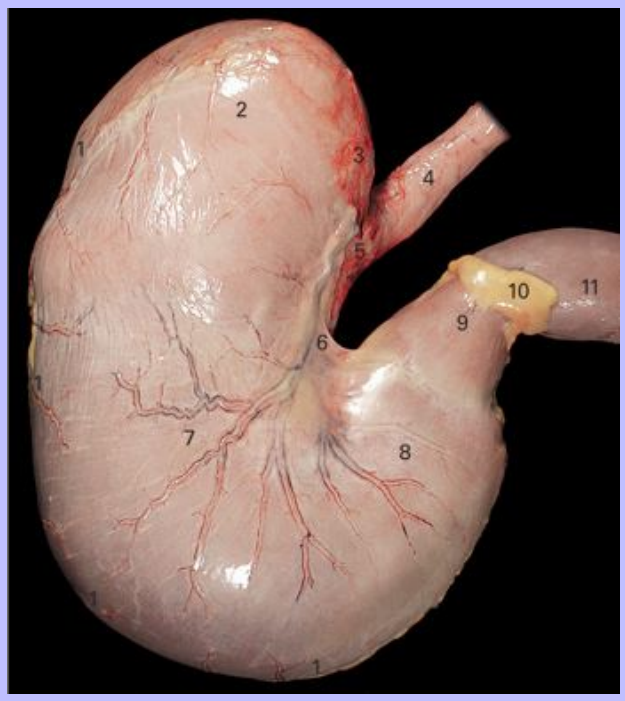

1 Greater curvature (attachment of the greater omentum)

2 Fundus (blind sac)

3 Area of direct adhesion to the diaphragm

4 Esophagus

5 Cardia

6 Lesser curvature (attachment of the lesser omentum)

7 Body of the stomach

8 Pyloric region of the stomach

9 Pylorus

10 Attachment of the greater omentum crossing the duodenum

11 Duodenum

Downloaded from Vet-eBooks.com

7.9 The stomach, with part of the esophagus and duodenum, opened and laid flat to show the mucosa. The stomach was opened along the greater curvature.

1 Proper gastric gland area

2 Cardiac gland area (with two *Gastrophilus* larvae attached)

3 Nonglandular part of the stomach lined by keratinized squamous epithelium

4 Esophagus

5 Cardia

6 Pyloric gland area

7 Pylorus

8 Duodenum

Downloaded from Vet-eBooks.com

7.10 Detail of the gastric mucosa showing the junction of the nonglandular part (top) and the cardiac gland area (bottom). The raised edge of the keratinized epithelium is known as the margo plicatus.

7.11 Part of the duodenal mucosa showing the duodenal papillae.

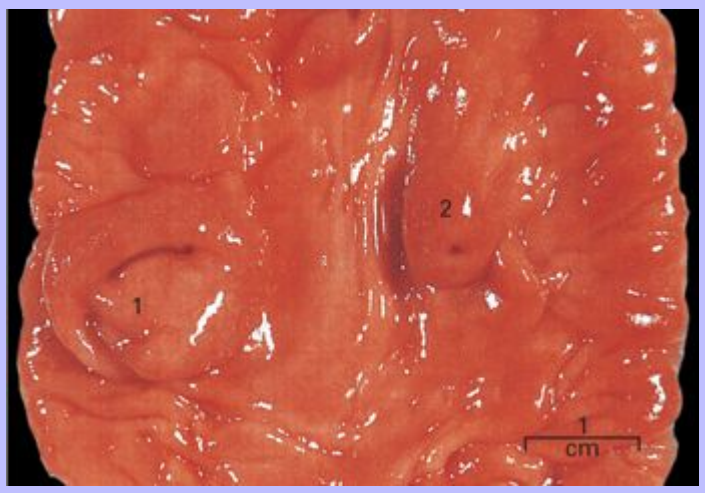

1 Major duodenal papilla (opening of the bile duct and pancreatic duct)

2 Minor duodenal papilla (opening of the accessory pancreatic duct)

99

Downloaded from Vet-eBooks.com

7.12 Ventrolateral view of the right dorsal part of the abdomen showing the region of the omental foramen. The right lobe of the liver has been reflected dorsally and the base of the cecum has been compressed and drawn ventrally.

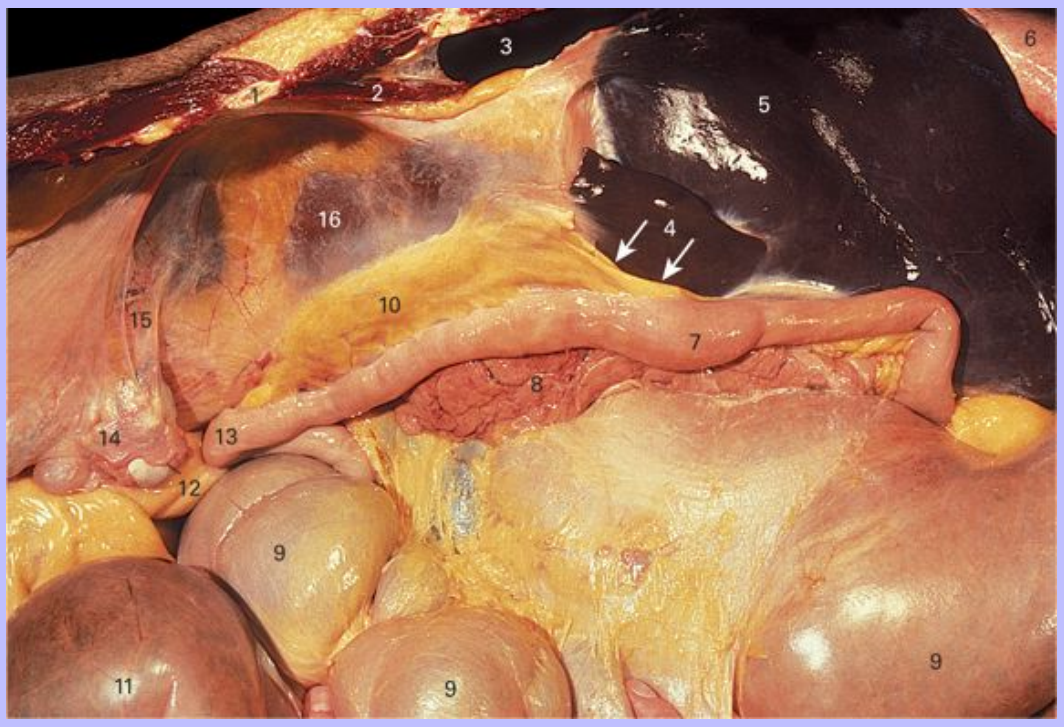

1 Cut dorsal end of rib 18

2 Right crus of the diaphragm in paramedian section

3 Caudodorsal part of the pleural cavity

4 Caudate lobe of the liver [the arrows indicate the opening of the omental (epiploic) foramen]

5 Visceral surface of the right lobe of the liver

6 Caudal part of the right lung

7 Duodenum

8 Right lobe of the pancreas

9 Base of the cecum

10 Mesoduodenum

Downloaded from Vet-eBooks.com

11 Loop of the left dorsal part of the ascending colon

12 Uterine tube (oviduct)

13 Duodenal flexure

14 Ovary

15 Suspensory ligament of the ovary

16 Ventral surface of the right kidney

7.13 The small intestine of a 4-month-old foal removed from the abdomen and spread out as much as the mesentery will allow.

1 Terminal part of the ileum

2 Terminal part of the ascending duodenum

3 Beginning of the jejunum

4 Mesenteric lymph nodes

5 Jejunal blood vessels traversing the (great) mesentery

Downloaded from Vet-eBooks.com

7.14 The abdomen dissected to show the termination of the ileum. Both the body of the cecum and the ascending colon have been lifted out of the abdomen and reflected dorsally and to the right but none of their attachments have been cut.

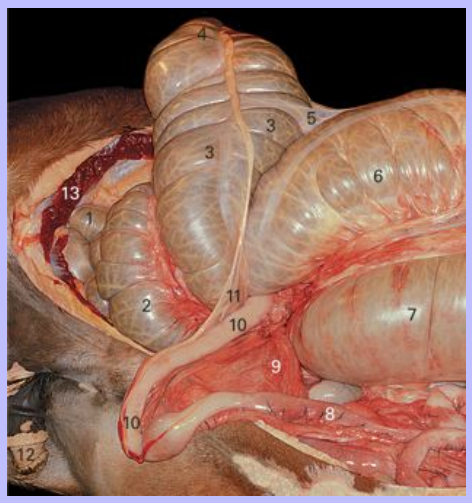

1 Loop of descending colon

2 Left side of the cecal base

3 Body of the cecum

4 Apex of the cecum

5 Edge of the cecocolic fold

6 Left side of the beginning of the right ventral part of the ascending colon

7 Right dorsal part of the ascending colon at its junction with the transverse colon

8 Jejunum near its termination

9 Mesentery

10 Ileum

11 Ileocecal fold

12 Penis

13 Cut surface of M. obliquus internus abdominis

Downloaded from Vet-eBooks.com

7.15 Section of jejunum opened along the mesenteric side.

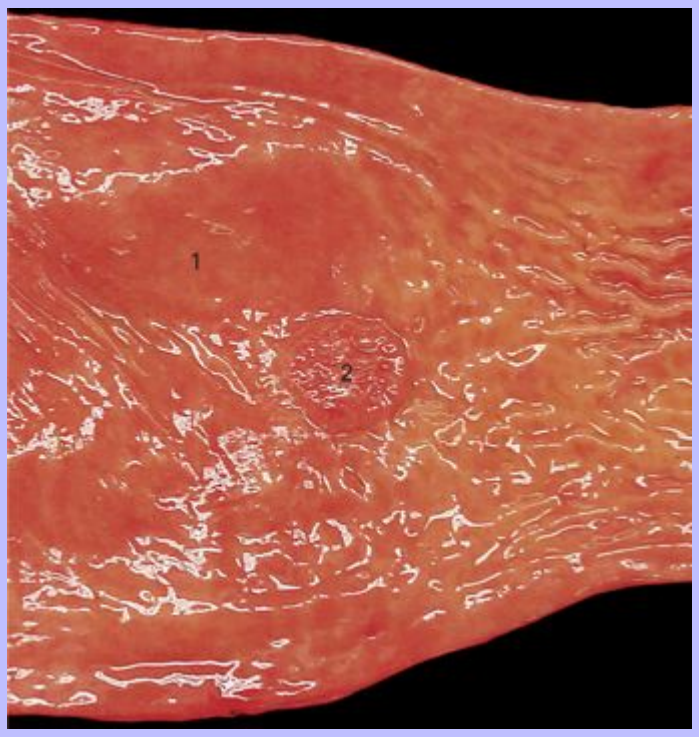

1 Mucosal surface

2 Aggregated lymphatic nodule (Peyer's patch)

Downloaded from Vet-eBooks.com

7.16 The base of the cecum opened from the dorsal side to show the mucosa and the openings into the ileum and the right ventral colon.

1 Ileocecal orifice on a low projection

2 Mucosa of the cecum

3 The cecocolic orifice. This is a wide and ill-defined slit with no change in the appearance of the mucosa

Downloaded from Vet-eBooks.com

7.17 Detail of the cecal mucosa showing solitary lymphatic nodules (oval grayish areas).

Downloaded from Vet-eBooks.com

7.18 The cecum and ascending colon of a 4-month-old foal. The organs have been removed from the abdomen and the sternal and diaphragmatic flexures have been straightened. The surfaces shown are normally lateral; thus the part on the left of the photograph lies against the right flank, and that on the right lies against the left flank.

1 Base of the cecum

2 Transverse colon

3 Right dorsal part of the ascending colon

4 Diaphragmatic flexure

5 Left dorsal part of the ascending colon

6 Pelvic flexure

7 Mesocolon

8 Left ventral part of the ascending colon

9 Lateral free muscular band

10 Sternal flexure

11 Right ventral part of the ascending colon

12 Apex of the cecum

13 Body of the cecum

14 Beginning of the right ventral part of the ascending colon

15 Cecocolic fold

Downloaded from Vet-eBooks.com

7.19 The cecum and ascending colon of a 4-month-old foal. The organs have been removed from the abdomen and the sternal and diaphragmatic flexures have been straightened. The surfaces shown normally face medially and are related to each other or to loops of the small intestine or descending colon.

1 Pelvic flexure

2 Mesocolon

3 Left dorsal part of the ascending colon

4 Diaphragmatic flexure

5 Right colic artery

6 Medial free muscular band

7 Right dorsal part of the ascending colon close to the junction with the transverse colon

8 Junction of the transverse and descending colon

9 Left side of the base of the cecum

10 Medial cecal artery

11 Body of the cecum

Downloaded from Vet-eBooks.com

12 Apex of the cecum

13 Terminal part of the ileum

14 Right ventral part of the ascending colon

15 Sternal flexure

16 Colic branch of the ileocolic artery

17 Left ventral part of the ascending colon

7.20 Groove overlying the medial free muscular band of the cecum. It contains abundant fat and large numbers of lymph nodes.

Downloaded from Vet-eBooks.com

7.21 The pelvic flexure of the ascending colon seen from the lateral and distal aspect.

1 End of the ventral part of the ascending colon

2 End of the lateral free muscular band

3 End of the lateral mesocolic muscular band (no longer mesocolic at this point)

4 Mesocolon

5 Pelvic flexure

6 Beginning of the dorsal part of the ascending colon

102

103

7.22 A short segment of the descending colon taken from near its distal end. The mesocolon has been removed from the concave side. The outlines of successive fecal balls and the wide antimesenteric muscular band are evident.

Downloaded from Vet-eBooks.com

7.23 The parietal surface of the liver of a 4-month-old foal.

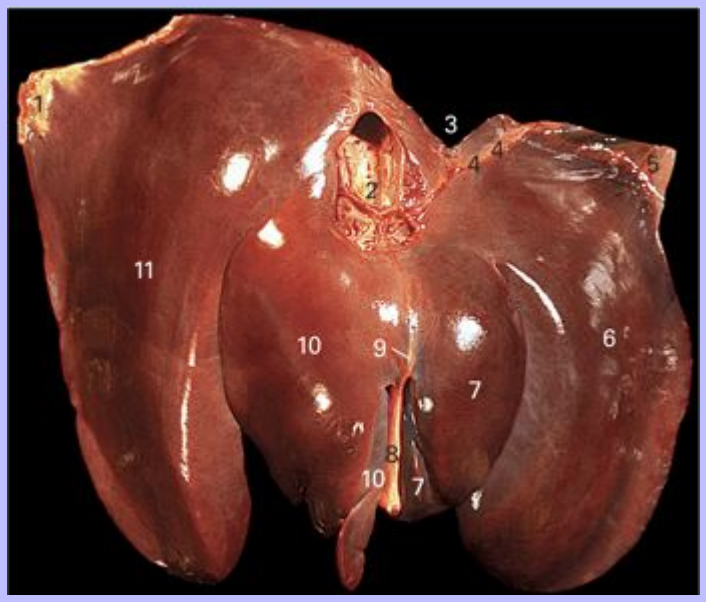

1 Right triangular ligament

2 Caudal vena cava passing cranioventrally through the liver; numerous hepatic veins of various sizes can be seen joining it

3 Esophageal notch

4 Left coronary ligament

5 Left triangular ligament

6 Left lateral lobe

7 Left medial lobe

8 Falciform ligament containing the remnant of the umbilical vein in its free edge

9 Line of attachment of the narrow part of the falciform ligament connecting the liver to the diaphragm

10 Quadrate lobe

11 Right lobe

Downloaded from Vet-eBooks.com

7.24 The visceral surface of the liver of a 4-month-old foal. A blue plastic rod has been inserted into the caudal vena cava to make its position clear.

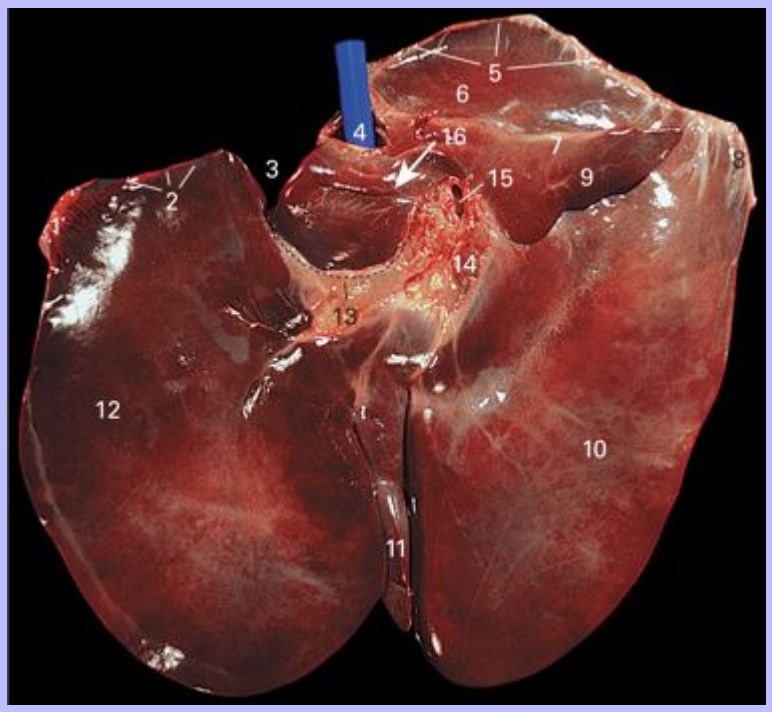

1 Left triangular ligament

2 Left coronary ligament

3 Esophageal notch

4 Plastic rod lying in the caudal vena cava

5 Right coronary ligament

6 Renal impression

7 Hepatorenal ligament

8 Right triangular ligament

9 Caudate lobe

10 Right lobe

11 Quadrate lobe

Downloaded from Vet-eBooks.com

12 Left lateral lobe

13 Line of attachment of the lesser omentum

14 Hepatic lymph nodes at the porta of the liver

15 Portal vein entering the liver

16 Path of the omental (epiploic) foramen

7.25 The visceral surface of the liver of a mature horse showing the change in shape with age when compared with Fig. 7.24. This change is much more extreme in old animals. The caudal vena cava and the portal vein have been dissected to show a little of their interior.

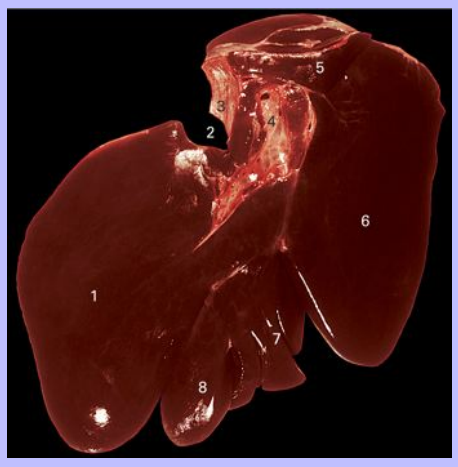

1 Left lateral lobe

2 Esophageal notch

3 Inner surface of the caudal vena cava

4 Portal vein opened to show part of its course within the liver

5 Caudate lobe

6 Right lobe

7 Quadrate lobe with small subdivisions

8 Left medial lobe

Downloaded from Vet-eBooks.com

7.26 Endoscopic view of the right triangular ligament. The endoscope was inserted through the right flank and directed cranially in a standing horse. (Image kindly supplied by Dr. D. G. Wilson.)

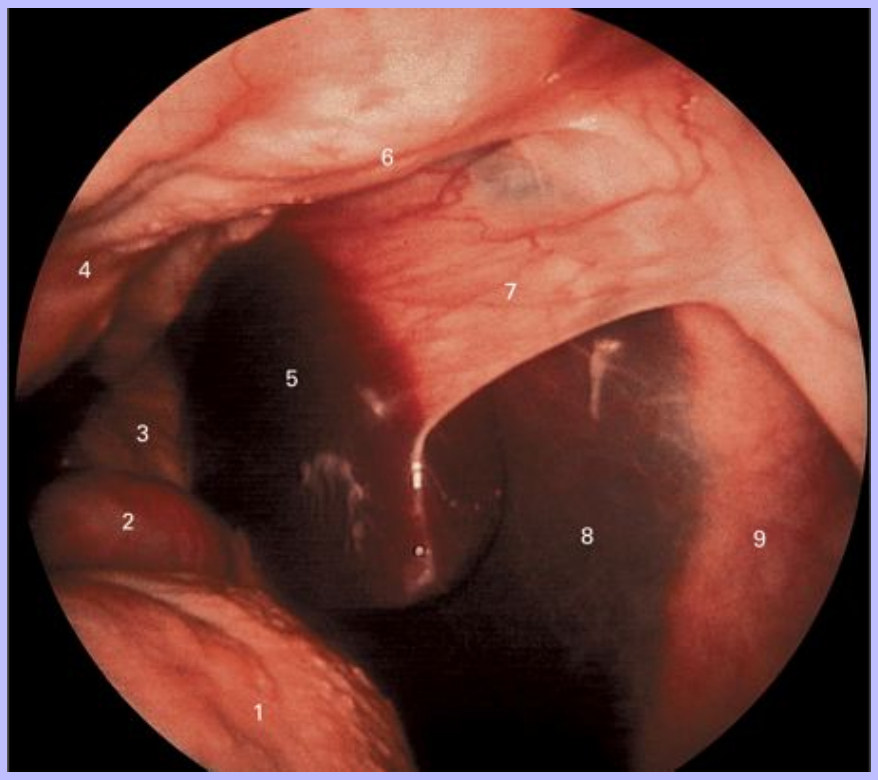

1 Right side of the base of the cecum

2 Duodenum

3 Mesoduodenum

4 Perirenal fat

5 Caudolateral angle of the right lobe of the liver

6 Phrenicorenal fold

7 Right triangular ligament

8 Tendinous center of the diaphragm

9 Right costal part of the diaphragm

Downloaded from Vet-eBooks.com

7.27 Parietal surface of the spleen.

1 Dorsal end

2 Caudal border

3 Ventral end

4 Cranial border

Downloaded from Vet-eBooks.com

7.28 Visceral surface of the spleen.

1 Caudal border

2 Dorsal end

3 Cranial border

4 Hilus

5 Ventral end

Downloaded from Vet-eBooks.com

7.29 Ventral view of the kidneys and related structures. Cranial is towards the top.

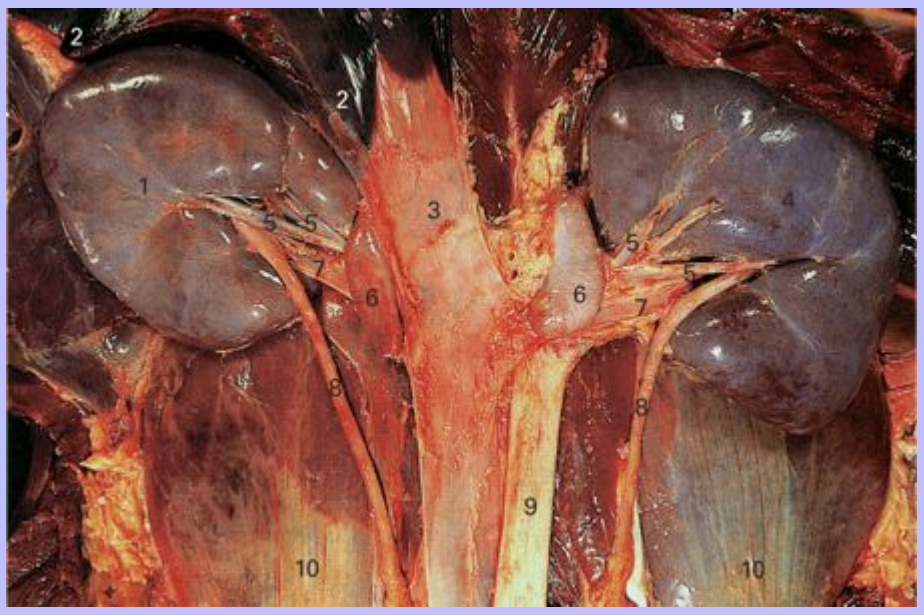

1 Ventral surface of the right kidney

2 Most caudal part of the caudate lobe of the liver

3 Caudal vena cava

4 Ventral surface of the left kidney

5 Renal arteries

6 Adrenal glands

7 Renal veins

8 Ureter

9 Aorta

10 M. iliopsoas

104

Downloaded from Vet-eBooks.com

7.30 The right kidney seen from the ventral aspect.

1 Ventral surface

2 Cranial pole

3 Branches of the renal artery entering the kidney

4 Beginning of the ureter

5 Caudal pole

Downloaded from Vet-eBooks.com

7.31 A dorsal section of the right kidney seen from the ventral aspect.

1 Renal cortex

2 Lobar vessels seen in section

3 Mucosa lining the renal pelvis and ureter

4 Oblique section of the terminal recess of the cranial pole surrounded by the pale striated tissue of the inner medulla

5 Cranial pole

6 Renal hilus

7 Renal veins seen in section leaving the renal tissue

8 Fat lying in the renal sinus

9 Caudal pole

10 Terminal recess of the caudal pole

11 Branch of the renal artery entering the kidney

12 Renal medulla

13 Renal crest

14 Renal pelvis

Downloaded from Vet-eBooks.com

7.32 Detail of the renal pelvis. The kidney is sectioned in dorsal plane and is seen from the dorsal side. This section passes just dorsal to the renal crest.

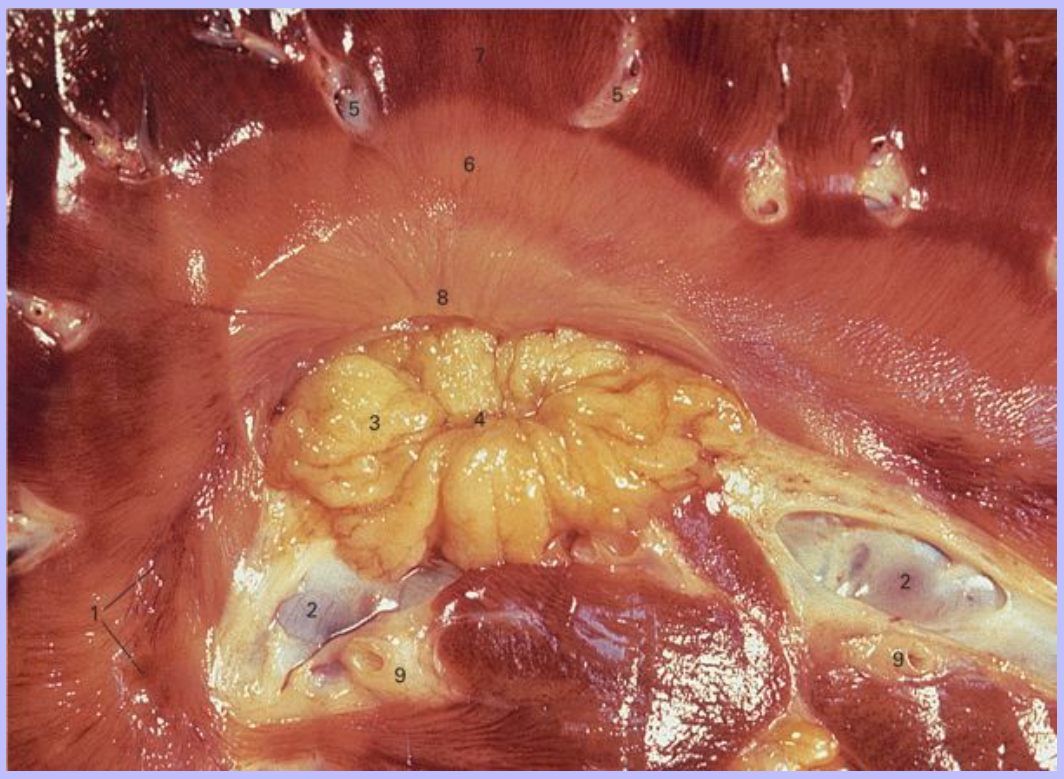

1 One of the terminal recesses cut obliquely

2 Branches of the renal vein in longitudinal section

3 Mucosa of the renal pelvis

4 Opening into the ureter

5 Lobar vessels seen in section

6 Pale inner medulla

7 Dark outer medulla

8 Renal crest

9 Branches of the renal artery

105

Downloaded from Vet-eBooks.com

7.33 Ventral view of the adrenal glands. The left gland has been sectioned in a dorsal plane and the ventral half of the gland has been reflected towards the animal's right (the left of the photograph) so that both halves are shown. Cranial is towards the top.

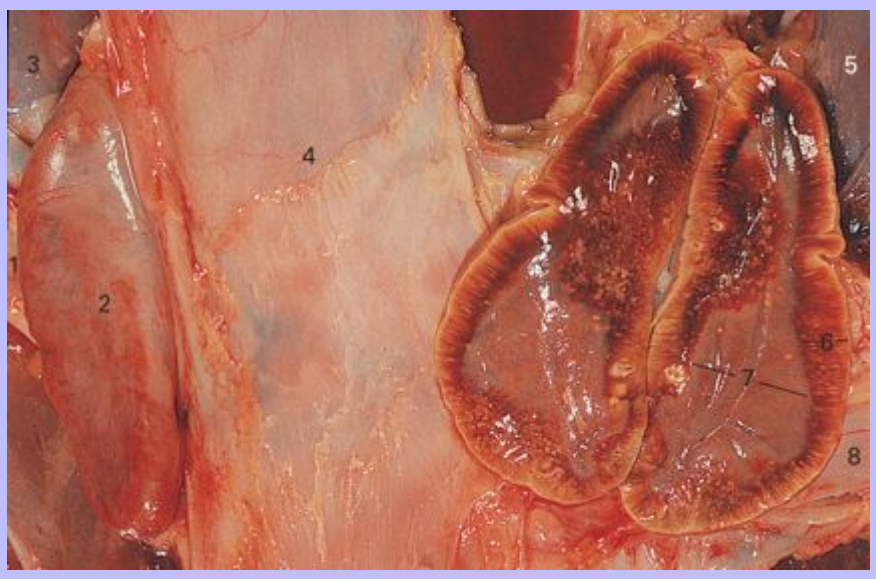

1 Right renal vein

2 Right adrenal gland

3 Medial border of the cranial part of the right kidney

4 Ventral surface of the caudal vena cava

5 Medial border of the cranial part of the left kidney

6 Adrenal cortex

7 Adrenal medulla

8 Left renal vein

Downloaded from Vet-eBooks.com

7.34 Cranial, lateral and ventral view of the pelvic inlet in a stallion. The rectum has been ligated and largely removed.

1 M. rectus abdominis

2 Middle ligament of the bladder

3 M. obliquus internus abdominis

4 The ductus deferens together with the testicular vessels and nerves of the right side entering the vaginal process, and thence the deep inguinal ring

5 The cranial border of the right lateral ligament of the bladder containing the right round ligament of the bladder

6 Genital fold

7 Apex of the bladder

8 Rectum

Downloaded from Vet-eBooks.com

9 Fat-filled folds of peritoneum containing the ureters

10 Left deferent duct and the associated artery

11 Testicular vessels and nerves

12 Caudal epigastric vessels

13 Ventral surface of the left kidney

14 Peritoneal fold forming the medial entrance to the vaginal process

106

Downloaded from Vet-eBooks.com

7.35 Endoscopic view of the deep inguinal region in a normal stallion. The horse was anesthetized and placed on its back. The endoscope was inserted into the peritoneal cavity through the right flank and directed caudally. Ventral is towards the top. (Image kindly supplied by Dr D. G. Wilson.)

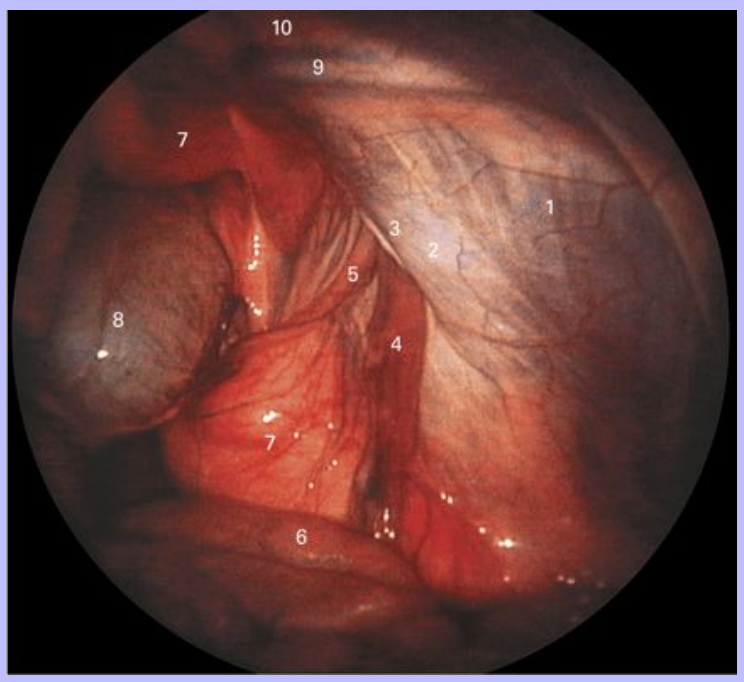

1 M. transversus abdominis

2 Caudal edge of the M. obliquus internus abdominis

3 Craniomedial border of the deep inguinal ring

4 Testicular vessels

5 Ductus deferens

6 Loops of intestine

7 Pelvic fat seen through the peritoneum

8 Bladder

9 Caudal epigastric vessels

10 M. rectus abdominis

Downloaded from Vet-eBooks.com

7.36 The left inguinal region of a cryptorchid stallion. The right testis is abnormally small and situated high in the inguinal region, but just outside the superficial inguinal ring. Its long axis runs dorsoventrally unlike the normally descended testis in the horse in which it runs craniocaudally. Lateral view.

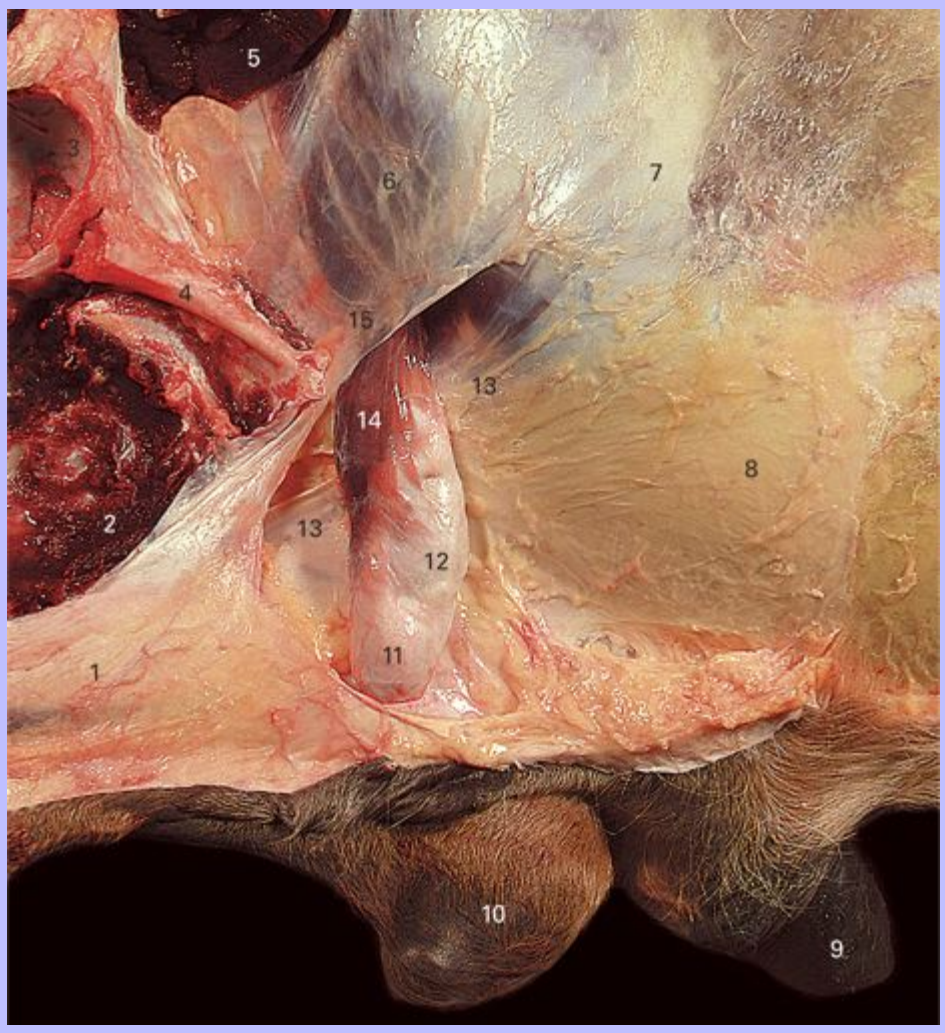

1 Loose connective tissue lying over the body of the penis

2 Cut adductor muscles

3 Acetabulum

4 Accessory ligament of the hip joint lying cranioventral to the pubis

Downloaded from Vet-eBooks.com

5 Cut iliopsoas muscle

6 M. obliquus internus abdominis visible through the aponeurosis of M. obliquus externus abdominis

7 The aponeurosis of M. obliquus externus abdominis

8 Tunica flava abdominis (layer of elastic fascia)

9 Exposed preputial fold

10 Hemiscrotum of the left side containing the normally descended left testis

11 Cauda epididymis visible through the spermatic fascia

12 Testis visible through the spermatic fascia

13 Medial crus of the aponeurosis of M. obliquus externus abdominis forming the medial boundary of the superficial inguinal ring

14 Cremaster muscle seen emerging from superficial inguinal ring and inserting on the spermatic fascia

15 Lateral crus of the aponeurosis of M. obliquus externus abdominis (inguinal ligament) forming the lateral boundary of the superficial inguinal ring

107

Downloaded from Vet-eBooks.com

7.37 The left testis within the spermatic fascia, and related structures. Ventral view. The testis and penis have been reflected towards the right giving a direct view of the exit from the inguinal canal.

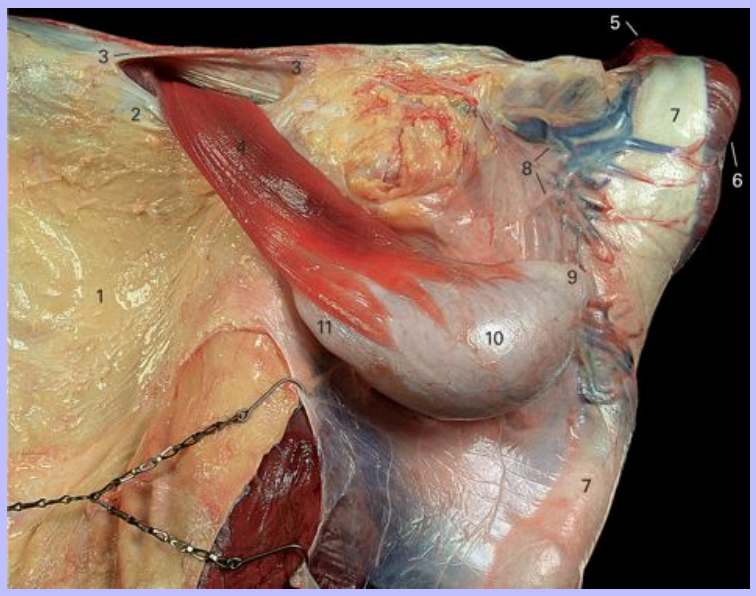

1 Tunica flava abdominis overlying the aponeurosis of M. obliquus externus abdominis

2 Medial crus of the aponeurosis of M. obliquus externus abdominis forming the medial boundary of the superficial inguinal ring

3 Lateral crus of the aponeurosis of M. obliquus externus abdominis (inguinal ligament) forming the lateral boundary of the superficial inguinal ring

4 Cremaster muscle inserting on the spermatic fascia

5 Ischiocavenosus muscle covering the left crus of the penis

6 Bulbospongiosus muscle

7 Body of the penis enclosed in loose connective tissue

8 Part of the extensive vasculature lying dorsal to the penis

9 Cauda epididymis beneath the spermatic fascia

10 Testis beneath the spermatic fascia

11 Caput epididymis beneath the spermatic fascia

Downloaded from Vet-eBooks.com

7.38 Lateral view of the left testis. Cranial is towards the left.

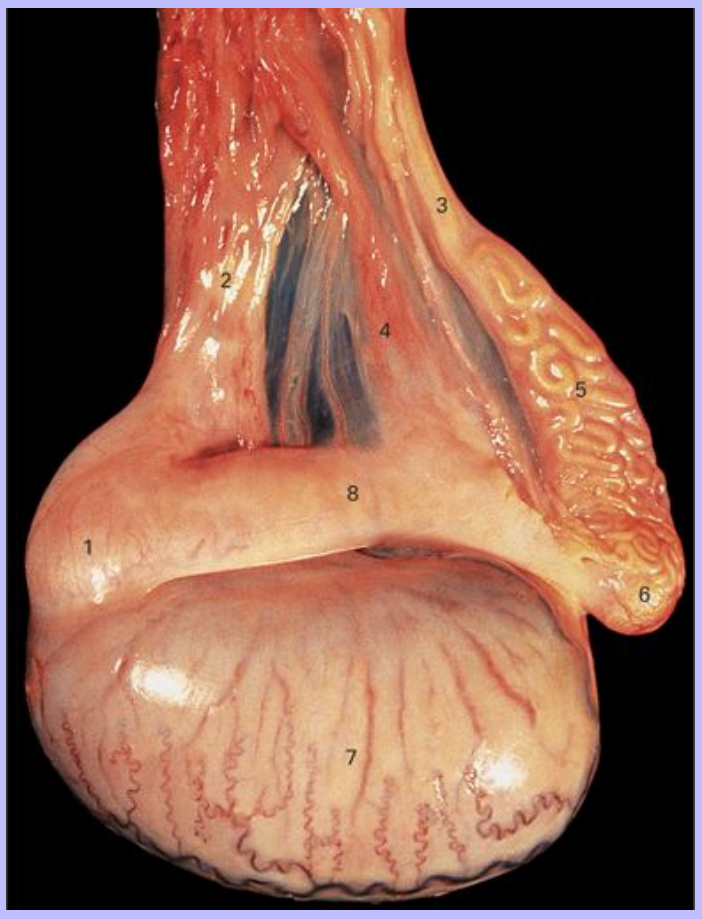

1 Head of the epididymis consisting mainly of efferent ductules

2 Vascular cone of the testis; individual vessels cannot be seen through the connective tissue

3 Beginning of the straight part of the deferent duct

4 Mesorchium

5 Convoluted part of the deferent duct

6 Tail of the epididymis

7 Lateral surface of the testis

8 Body of the epididymis

Downloaded from Vet-eBooks.com

7.39 Medial view of the left testis. Cranial is towards the right.

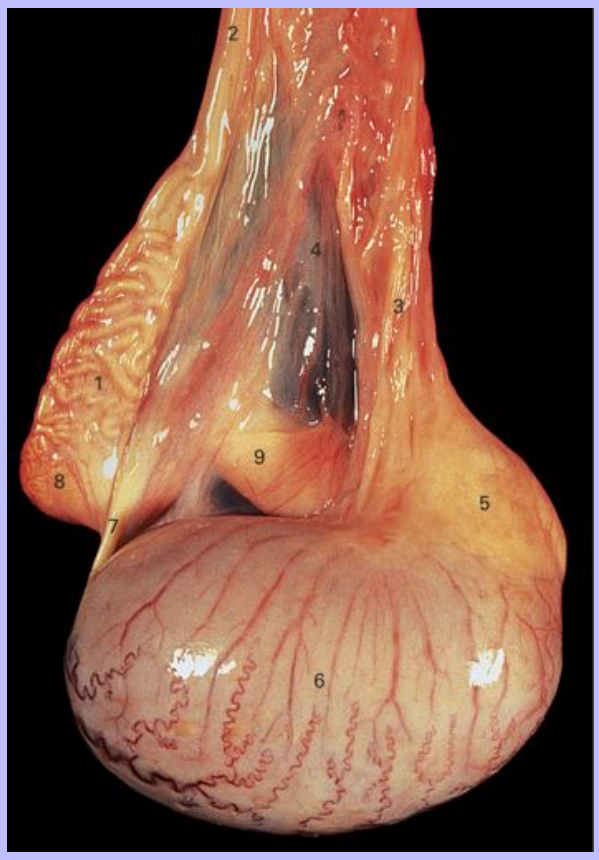

1 Convoluted part of the deferent duct

2 Beginning of the straight part of the deferent duct

3 Vascular cone of the testis; individual vessels cannot be seen through the connective tissue

4 Mesorchium

5 Head of the epididymis consisting mainly of efferent ductules

6 Medial surface of the testis

7 Ligament of the tail of the epididymis

8 Tail of the epididymis

9 Body of the epididymis seen through the mesorchium

Downloaded from Vet-eBooks.com

7.40 The left testis and the body of the epididymis sectioned in a sagittal plane passing through the middle of the testis.

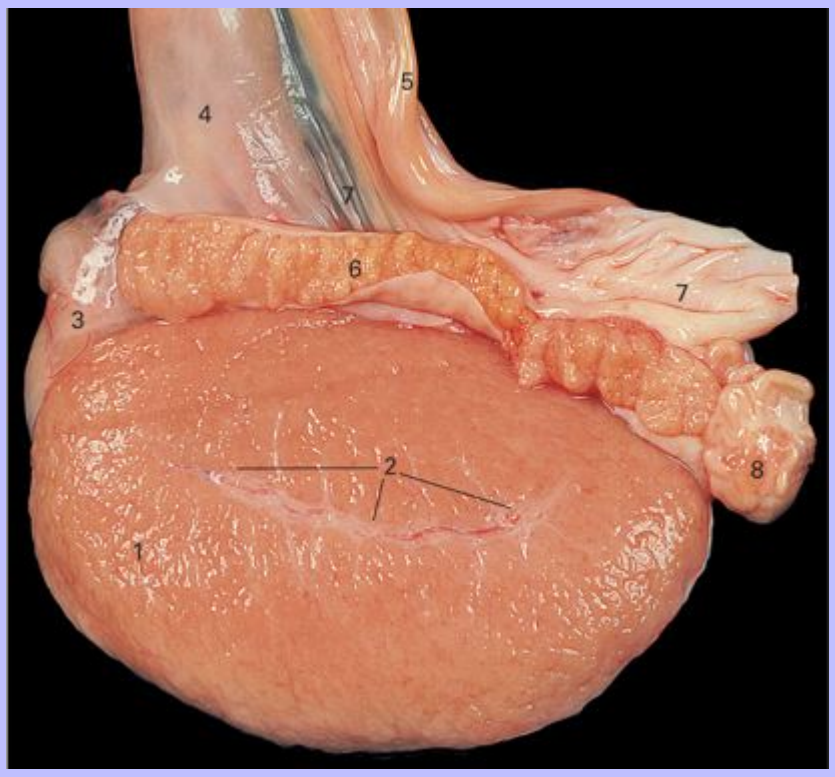

1 Testicular tissue

2 Mediastinum testis containing the rete testis

3 Head of the epididymis

4 Vascular cone of the testis; individual vessels cannot be seen through the connective tissue

5 Deferent duct

6 Body of the epididymis in section

7 Mesorchium

8 Tail of the epididymis in section showing the large diameter of the epididymal tubule in this region

Downloaded from Vet-eBooks.com

7.41 Dorsal view of the bladder, pelvic urethra and accessory genital glands in a 2-year-old stallion.

1 Ureters

Downloaded from Vet-eBooks.com

2 Bladder, partially filled

3 Deferent ducts

4 Ampullae of the deferent ducts

5 Vesicular glands (seminal vesicles)

6 Left and right lobes of the prostate gland

7 Pelvic part of the urethra surrounded by the urethral muscle

8 Left and right bulbourethral glands; almost all of the surrounding urethral muscle has been removed

9 Bulbospongiosus muscle surrounding the bulb of the penis

Downloaded from Vet-eBooks.com

7.42 The bladder and pelvic urethra opened from the ventral aspect in a 2-year-old stallion. The tip of a probe can be seen emerging from the opening of the right ureter.

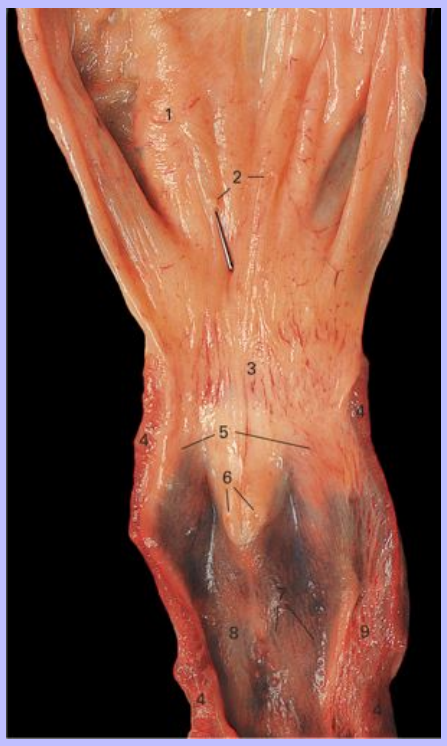

1 Mucosa of the bladder

2 Openings of the ureters

3 Neck of the bladder (internal urethral orifice)

4 Cut urethral muscle

5 Areas where the prostatic ducts open; the openings themselves are not readily visible in the photograph

6 Openings of the ejaculatory ducts on the summit of the colliculus seminalis

7 Lateral and medial openings of the bulbourethral ducts

8 Mucosa of the pelvic urethra

9 Layer of erectile tissue surrounding the pelvic urethra

Downloaded from Vet-eBooks.com

7.43 Caudal view of the root of the penis in a gelding.

1 Ventral surfaces of the ischia

2 Ischial tuberosities

3 Ischiocavernosus muscles surrounding the crura of the penis

4 Bulbospongiosus muscle surrounding the bulb of the penis

5 Retractor penis muscle (severed just below the terminal part of the rectum)

6 Body of the penis composed of the tunica albuginea enclosing the corpus cavernosum

Downloaded from Vet-eBooks.com

7.44 Ventrolateral view of the root of the penis in a 2-year-old stallion. The distal end of the penis is deflected to the right.

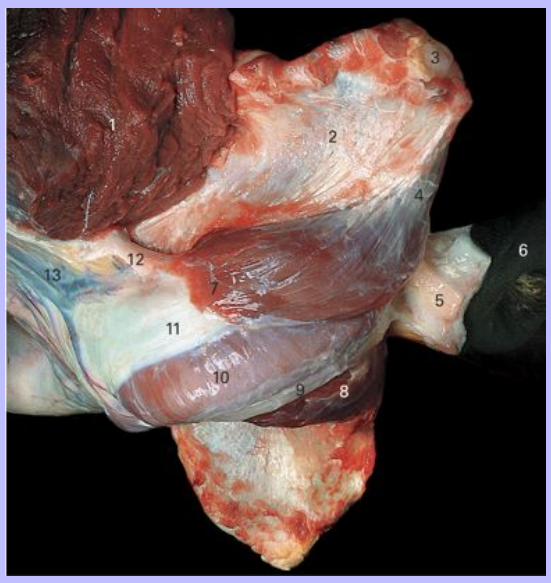

1 Adductor muscles (cut)

2 Ventral surface of the left ischium

3 Left ischial tuberosity

4 Origin of the left ischiocavernosus muscle

5 Connective tissue surrounding the distal part of the rectum

6 Skin overlying the external anal sphincter

7 Insertion of the left ischiocavernosus muscle onto the body of the penis

8 Right ischiocavernosus muscle

9 Retractor penis muscle

10 Bulbospongiosus muscle extending beneath the body of the penis

11 Body of the penis

12 Suspensory ligament of the penis

13 Part of the extensive vasculature lying dorsal to the penis

Downloaded from Vet-eBooks.com

7.45 The penis in a 2-year-old stallion. The skin has been removed except at the distal end. Left lateral view.

1 Skin overlying the glans

2 Tunica albuginea covering the corpus cavernosum

3 Bulbospongiosus muscle; in horses this extends to the tip of the penis

4 Ischiocavernosus muscle

5 Retractor penis muscle

110

Downloaded from Vet-eBooks.com

7.46 Dorsal section of the penis of a stallion at the level of the ischial arch. The section is seen from the dorsal aspect and cranial is towards the top. At this level the left and right crura have just fused to form the corpus cavernosum.

1 Ischiocavernosus muscle

2 Tunica albuginea

3 Corpus cavernosum

4 Fibrous trabeculae within the corpus cavernosum

5 Bulbospongiosus muscle

6 Corpus spongiosum

7 Urethra

Downloaded from Vet-eBooks.com

7.47 Transverse section of the body of the penis.

1 Tunica albuginea

2 Corpus cavernosum

3 Bulbospongiosus muscle

4 Corpus spongiosum

5 Urethra

Downloaded from Vet-eBooks.com

7.48 Lateral view of the distal end of the penis when drawn out of the prepuce.

1 Preputial skin lining the part of the preputial cavity outside the preputial fold; it is frequently associated with large amounts of smegma

2 Skin forming the edge of the preputial fold that becomes evident when the penis is retracted; it bears the vestigial nipples of the male

3 Edge of the corona (crown) of the glans

4 Position of the urethral opening

Downloaded from Vet-eBooks.com

7.49 The glans penis seen from the ventral aspect.

1 Preputial skin lining the part of the preputial cavity inside the preputial fold

2 Corona (crown) of the glans

3 Fossa glandis

4 Urethral process

5 Urethral opening

111

Downloaded from Vet-eBooks.com

7.50 Dorsal view of the female reproductive tract. The vagina and vestibule have been opened from the dorsal side.

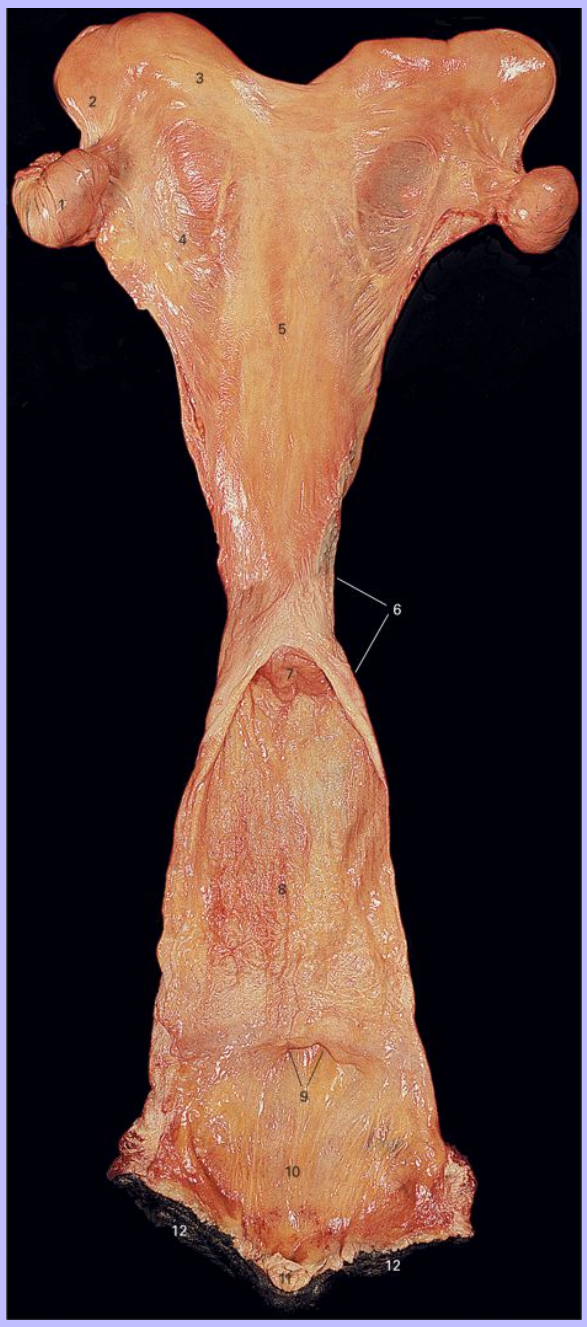

1 Ovary

Downloaded from Vet-eBooks.com

2 Tip of the left uterine horn

3 Left uterine horn

4 Broad ligament

5 Body of the uterus

6 Position of the cervix

7 External opening of the cervix

8 Vagina

9 Urethral opening

10 Vestibule

11 Clitoris

12 Vulva

112

Downloaded from Vet-eBooks.com

7.51 The ventral commissure of the vulva of a mare everted to show the clitoris. The rim of the clitoridal fossa surrounds the glans of the clitoris. The clitoris is incompletely extruded from the fossa so that only the distal surface of the glans is revealed.

1 Glans of the clitoris

2 Skin of the vulva

3 Mucosa of the vestibule

4 Position of the opening of the clitoridal sinus

5 Ventral part of the clitoridal fossa

Downloaded from Vet-eBooks.com

7.52 Ventral view of the uterus and related structures.

1 Ovary

2 Uterine tube (oviduct)

3 Para-ovarian cyst, a common and innocuous abnormality

4 Right horn of the uterus

5 Body of the uterus

6 Broad ligament

7 Round ligament of the uterus

8 Fimbria of the uterine tube (oviduct)

9 Position of the cervix

Downloaded from Vet-eBooks.com

7.53 Dorsal view of the uterus opened from the dorsal side.

1 Ovary

2 Tip of the left uterine horn

3 Mucosa of the left uterine horn

4 Mucosa of the body of the uterus

5 Para-ovarian cyst, a common and innocuous abnormality

6 Cervix

7 Vagina

113

Downloaded from Vet-eBooks.com

7.54 Ultrasound image of the uterus showing a transverse section of one of the horns. (The 7 MHz probe lies at the top of the image; the scale on the left shows centimeters. Image kindly supplied by Dr G. P. Adams.)

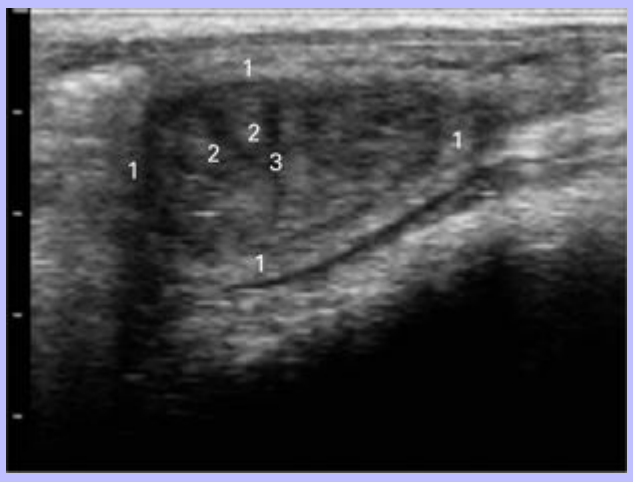

1 Myometrium

2 Endometrial folds

3 Uterine lumen

Downloaded from Vet-eBooks.com

7.55 Ultrasound image of the cervix showing a median section in which the uterine end is towards the left. (The image was produced by combining two fixed frames. The 7 MHz probe lies at the top of the image; the scale on the left shows centimeters. Image kindly supplied by Dr G. P. Adams.)

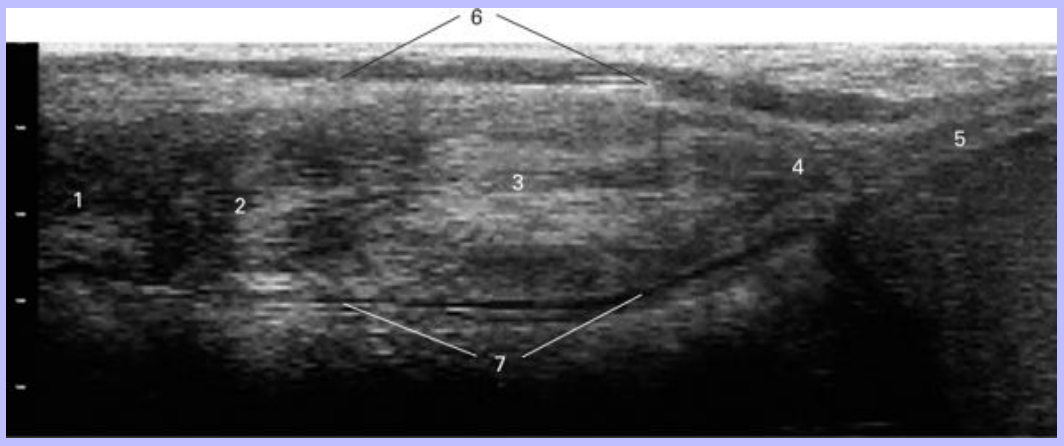

1 Body of the uterus sectioned longitudinally

2 Internal end of the cervical canal

3 Cervical canal

4 External end of the cervical canal protruding into the vagina

5 Lumen of the vagina

6 Dorsal surface of the cervix

7 Ventral surface of the cervix

Downloaded from Vet-eBooks.com

7.56 The left ovary rotated to show the entrance to the ovarian bursa. Ventromedial view. Cranial is towards the right.

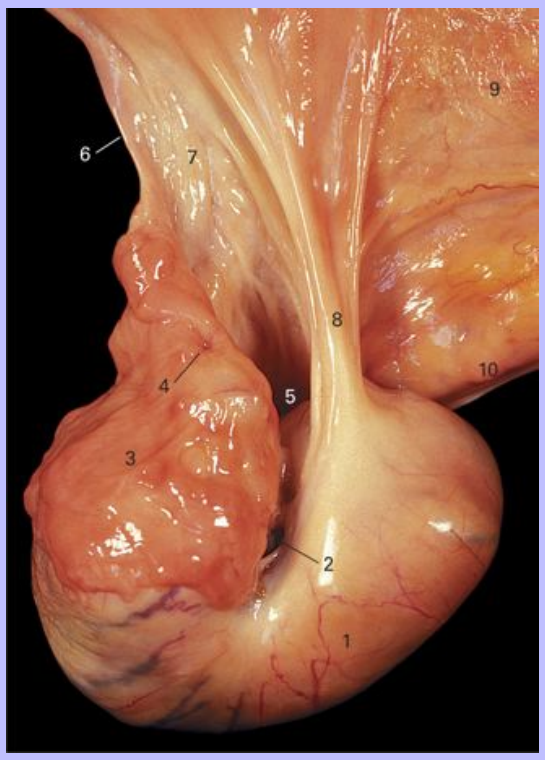

1 Ovarian surface covered by peritoneum

2 Ovarian (ovulation) fossa

3 Everted infundibulum of the uterine tube edged by the fimbriae

4 Entrance to the ampulla of the uterine tube

5 Ovarian bursa

6 Uterine tube (oviduct)

7 Mesosalpinx

8 Proper ligament of the ovary

9 Medial surface of the broad ligament

10 Suspensory ligament of the ovary (free border of the broad ligament)

Downloaded from Vet-eBooks.com

7.57 The female reproductive tract, and related structures, suspended from the abdominal and pelvic roof. The animal is in the standing position. The intestines have been removed with the exception of the terminal part of the descending colon. The observer is looking caudally and a little to the left.

1 Fat lying in the ventral ligament of the bladder

2 M. rectus abdominis seen through the transverse fascia

3 Caudal epigastric vessels

4 M. obliquus internus abdominis

5 Round ligament of the bladder lying in the cranial border of the lateral ligament of the bladder

6 Round ligament of the uterus

7 Suspensory ligament of the ovary

8 Right ovary

9 Uterine tube (oviduct)

10 Apex of the bladder

Downloaded from Vet-eBooks.com

11 Proper ligament of the ovary

12 Tip of the right uterine horn

13 Mesocolon

14 Cut descending colon

15 Base of the left uterine horn

16 Left broad ligament of the uterus

17 Transverse fascia

114

Downloaded from Vet-eBooks.com

7.58 The caudal abdomen and pelvis of a mare held in the standing position. The intestines have been removed with the exception of the terminal part of the descending colon. The observer is looking caudally and to the left.

1 M. obliquus internus abdominis

2 Right broad ligament of the uterus

3 Apex of the bladder

4 Lateral ligament of the bladder

5 Location of the deep inguinal ring

6 Round ligament of the uterus

7 Suspensory ligament of the ovary

8 Mesocolon

9 Right ovary

10 Infundibular part of the uterine tube (oviduct)

11 Left broad ligament of the uterus

12 Proper ligament of the ovary

13 Uterine artery

Downloaded from Vet-e-Books.com

7.59 An equine ovary sectioned from the convex mesovarial border to the free concave border bearing the ovarian (ovulation) fossa.

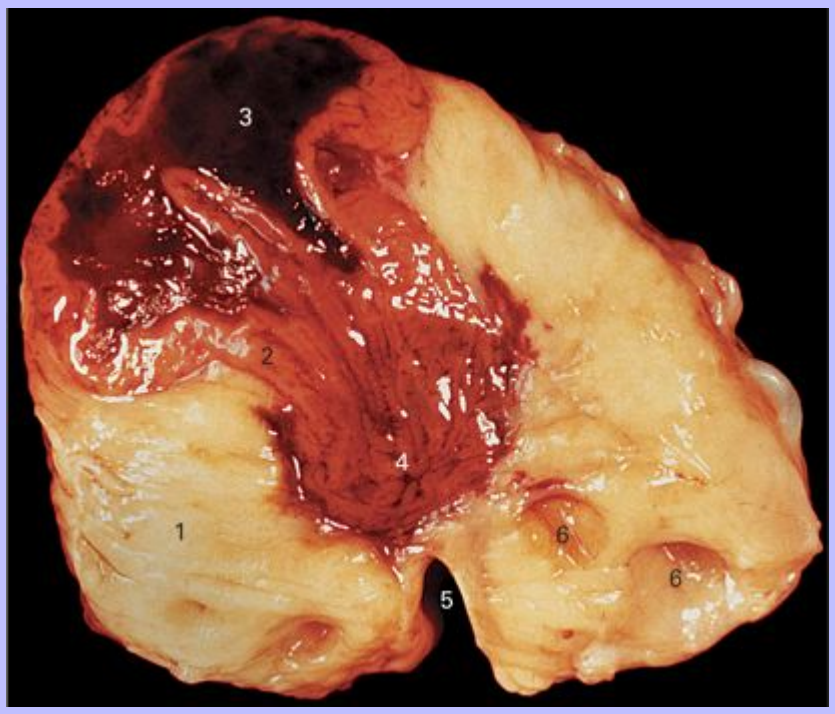

1 Interstitial tissue of the ovary

2 Luteal tissue

3 Central clot in a recently formed corpus luteum

4 Tongue of luteal tissue extending towards the ovarian fossa indicating the route followed at ovulation

5 Ovarian fossa (ovulation) fossa

6 Small ovarian follicles

Downloaded from Vet-eBooks.com

7.60 Ultrasound image of the ovary showing an oblique section including both a young corpus luteum and two medium-sized follicles. (The 7 MHz probe lies at the top of the image; the scale on the left is in centimeters. Image kindly supplied by Dr G. P. Adams.)

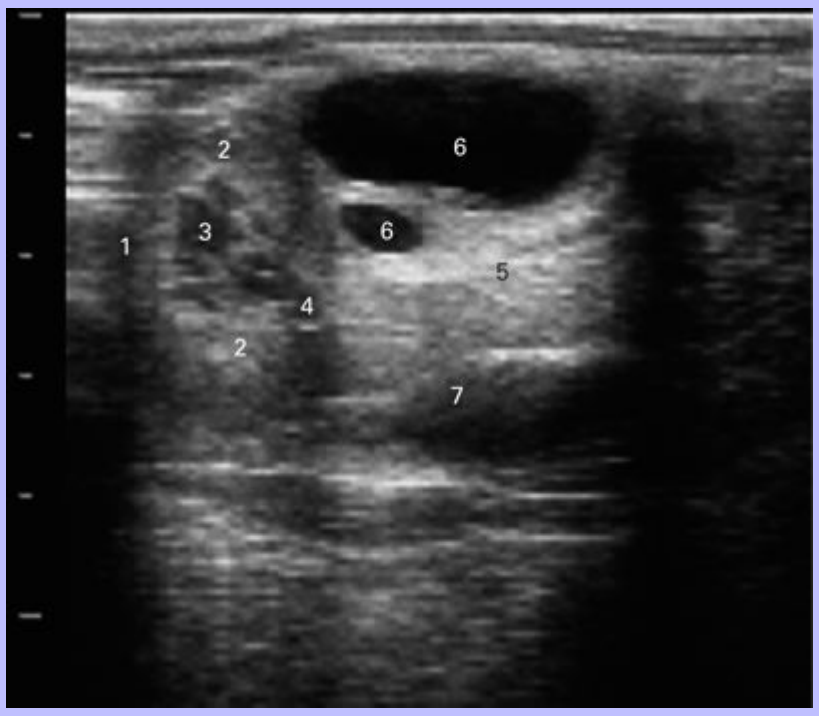

1 The position of the cranial pole of the ovary

2 Luteal tissue

3 Central blood clot beginning to organize

4 Tongue of the corpus luteum extending towards the ovarian fossa indicating the path followed at ovulation

5 Interstitial tissue of the ovary

6 Medium-sized follicles

7 Depression in the ovarian surface close to the ovarian (ovulation) fossa

Downloaded from Vet-eBooks.com

7.61 Ultrasound image of the ovary showing a plane passing through both poles and perpendicular to the plane extending from the attachment of the mesovarium to the ovulation fossa. In this case neither pole is within the confines of the image. (The 7 MHz probe lies at the top of the image; the scale on the left is in centimeters. Image kindly supplied by Dr G. P. Adams.)

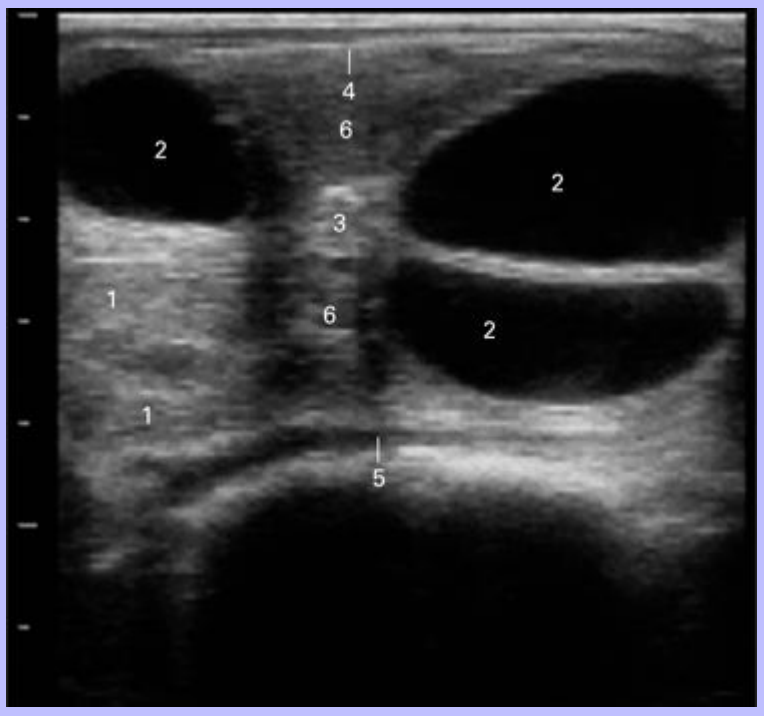

1 Tissue of a regressing corpus luteum

2 Large follicles with their points converging on the ovarian (ovulation) fossa

3 Dense ovarian tissue adjacent to the ovarian (ovulation) fossa

4 Surface of the ovary closest to the probe

5 Surface of the ovary farthest from the probe

6 Interstitial tissue of the ovary

115

Downloaded from Vet-eBooks.com

7.62 Dorsal view of the uterus of a pregnant mare 13 days after ovulation. It has been opened from the dorsal side.

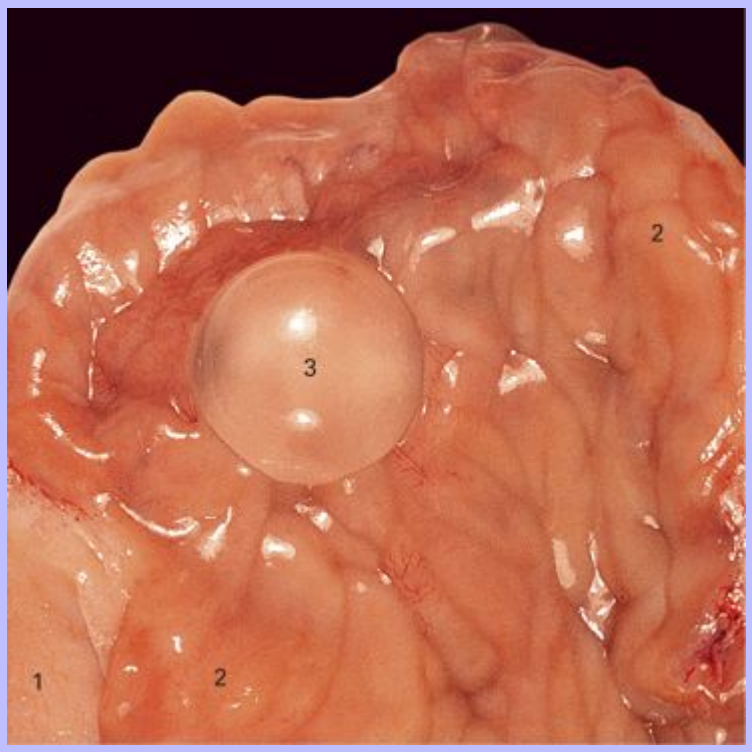

1 Unopened part of the uterine horn

2 Endometrium

3 Encapsulated embryo lying on the endometrium (2 cm in diameter)

Downloaded from Vet-eBooks.com

7.63 A 34-day-old conceptus seen from the mesometrial aspect. It is about 8 cm in diameter.

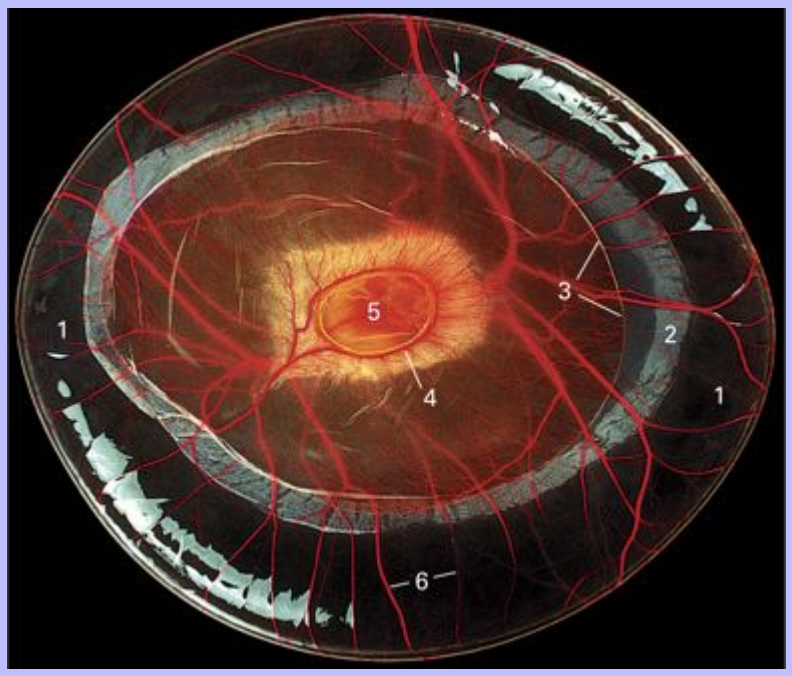

1 Undifferentiated allantochorion

2 Chorionic girdle

3 Margin of the yolk sac

4 Sinus terminalis

5 Remnant of the bilaminar omphalopleure

6 Allantoic vessels

Downloaded from Vet-eBooks.com

7.64 A 39-day-old conceptus with the yolk sac uppermost. The embryo proper is 2 cm in length.

1 Undifferentiated allantochorion

2 Position of the chorionic girdle; the girdle cells have now invaded the endometrium

3 Sinus terminalis

4 Yolk sac

5 Embryo proper

6 Amnion

Downloaded from Vet-eBooks.com

7.65 A 98-day-old conceptus with the yolk sac uppermost. The fetus is 20 cm in length.

1 Part of the allantochorion occupying the body of the uterus

2 Part of the allantochorion occupying the horn of the uterus in which the conceptus originally attached

3 Parts of the allantochorion lacking microvilli because of their proximity to the endometrial cups

4 Part of the allantochorion occupying the horn of the uterus in which the conceptus did not originally attach

5 Amniotic portion of the umbilical cord visible through the fetal membranes

6 Allantoic portion of the umbilical cord visible through the allantochorion

116

Downloaded from Vet-eBooks.com

7.66 A near-term foal and its membranes. The allantochorion has been opened to show the fetus within the amnion.

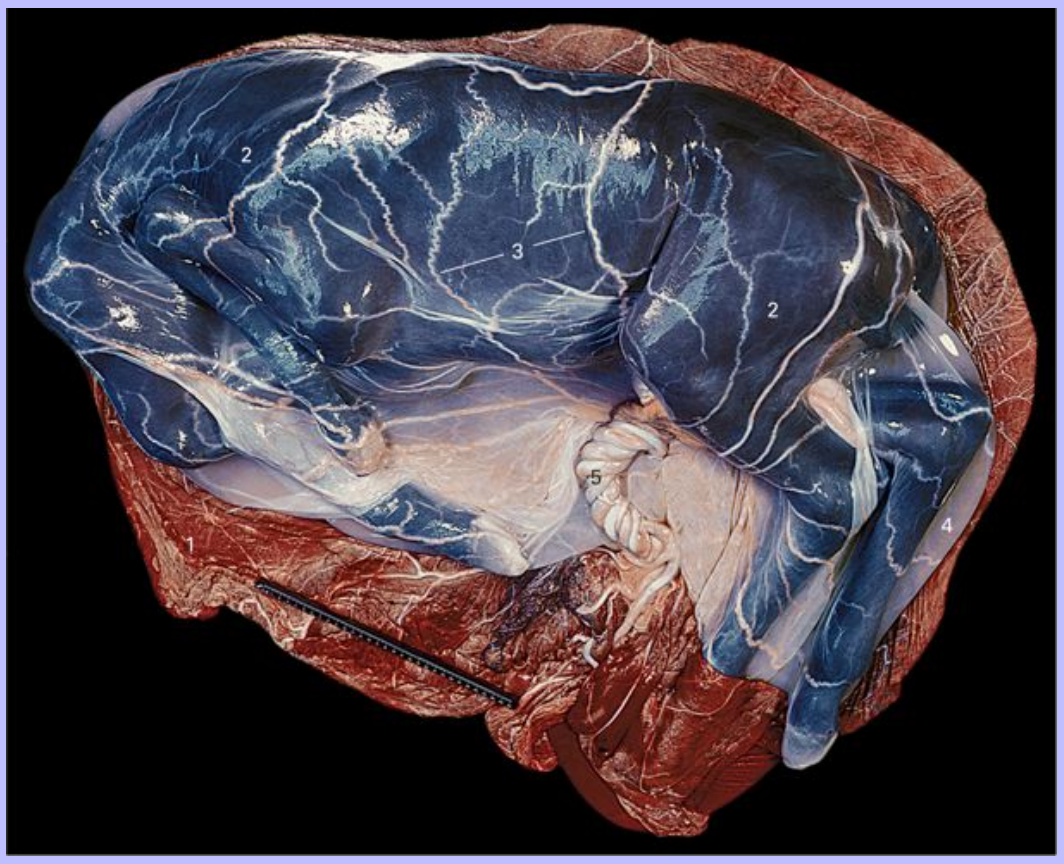

1 Inner surface of the allantochorion

2 Amnion overlying the fetus

3 Branches of the allantoic vessels supplying the amnion

4 Part of the amnion containing amniotic fluid

5 Allantoic part of the umbilical cord

Downloaded from Vet-eBooks.com

7.67 The gravid horn of the uterus of a 63-day-pregnant mare opened to show the endometrial cups. The fetus and its membranes have been removed. The line of endometrial cups would have formed an almost complete circle before the uterus was opened. (Photo kindly supplied by Professor W. R. Allen.)

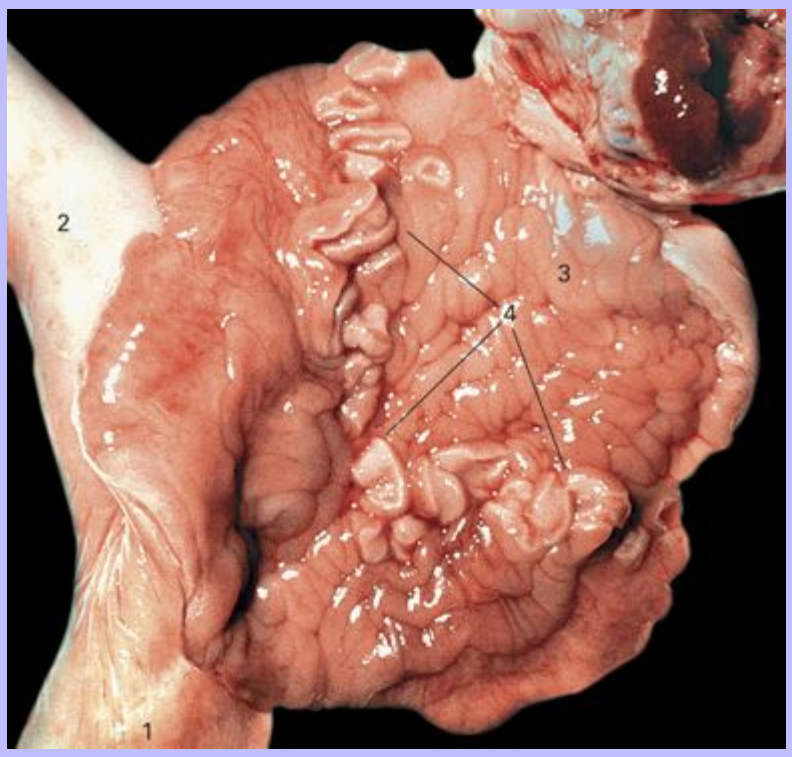

1 Body of the uterus

2 Non-gravid horn of the uterus

3 Endometrium of the gravid horn

4 Endometrial cups forming an arc

Downloaded from Vet-eBooks.com

7.68 Detail of the endometrial cups and related structures at 84 days' gestation. The allantochorion has been lifted away from the cups and towards the top of the photograph to reveal the cups. (Photo kindly supplied by Professor W. R. Allen.)

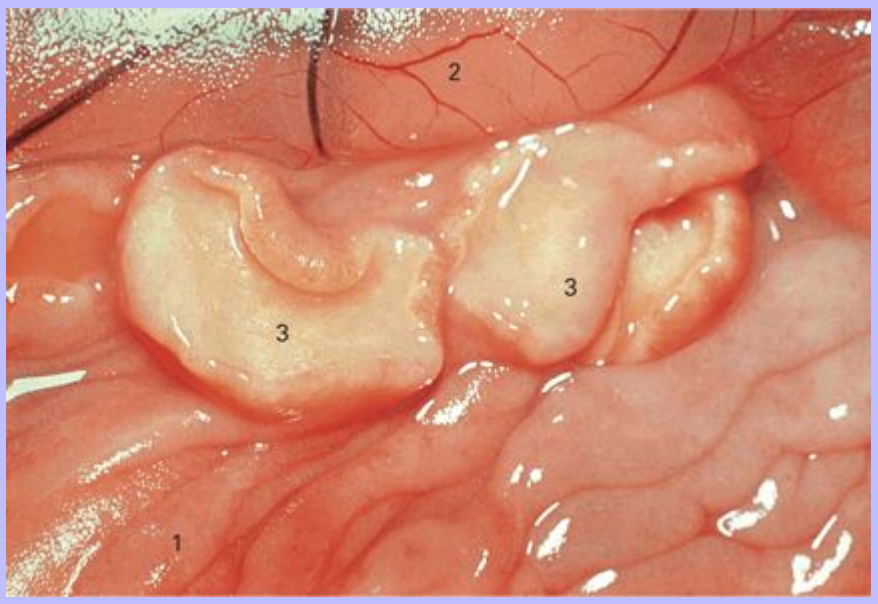

1 Endometrial surface

2 Allantochorion

3 Endometrial cups

117

Downloaded from Vet-eBooks.com

7.69 The udder of a lactating mare seen from a ventral, caudal and lateral viewpoint.

1 Left teat: the openings of both papillary ducts are visible at its tip

2 Cranial extremity of the udder

3 Caudal extremity of the udder

Downloaded from Vet-eBooks.com

7.70 The left teat and the adjacent part of the udder of a lactating mare cut in sagittal section.

1 Subcutaneous connective tissue; it is somewhat edematous in this case

2 Papillary part of the more cranial of the two lactiferous sinuses; the much narrower teat canal can be seen at the tip of the teat

3 Glandular part of the more cranial of the two lactiferous sinuses

4 Secretory tissue

5 Lactiferous ducts

Downloaded from Vet-eBooks.com