Feline Medicine and Therapeutics

Third Edition

Edited by

E.A. Chandler
BVetMed, FRCVS

C.J. Gaskell
BVSc, PhD, DVR, MRCVS

R.M. Gaskell
BVSc, PhD, MRCVS

for the
British Small Animal Veterinary Association

Blackwell
Publishing

B·S·A·V·A

Feline Medicine and Therapeutics

Feline Medicine and Therapeutics

Third Edition

Edited by

E.A. Chandler
BVetMed, FRCVS

C.J. Gaskell
BVSc, PhD, DVR, MRCVS

R.M. Gaskell
BVSc, PhD, MRCVS

for the
British Small Animal Veterinary Association

Blackwell
Publishing

B·S·A·V·A

© 2004 by the British Small Animal Veterinary Association

Published by Blackwell Publishing
Editorial Offices:
Blackwell Publishing Ltd, 9600 Garsington Road, Oxford OX4 2DQ, UK
Tel: +44 (0)1865 776868
Iowa State Press, a Blackwell Publishing Company, 2121 State Avenue, Ames, Iowa 50014-8300, USA
Tel: +1 515 292 0140
Blackwell Publishing Asia, 550 Swanston Street, Carlton, Victoria 3053, Australia
Tel: +61 (0)3 8359 1011

The right of the Author to be identified as the Author of this Work has been asserted in accordance with the Copyright, Designs and Patents Act 1988.

All rights reserved. No part of this publication may be reproduced, stored in a retrieval system, or transmitted, in any form or by any means, electronic, mechanical, photocopying, recording or otherwise, except as permitted by the UK Copyright, Designs and Patents Act 1988, without the prior permission of the publisher.

First edition published 1985
Second edition published by Blackwell Science 1994
Reissued in paperback 1996
Third edition published by Blackwell Publishing 2004

Library of Congress Cataloging-in-Publication Data
Feline medicine and therapeutics / edited by E.A. Chandler, C.J. Gaskell, R.M. Gaskell for the British Small Animal Veterinary Association.-- 3rd ed.
p. cm.
Includes bibliographical references.
ISBN 1-4051-0032-X (hardback : alk. paper)
1. Cats--Diseases. I. Chandler, E. A. II. Gaskell, C. J. III. Gaskell, Rosalind M. IV. British Small Animal Veterinary Association. V. Title.
SF985.F45 2004
636.8'089--dc22
2003021331

ISBN 1-4051-0032-X

A catalogue record for this title is available from the British Library

Set in Minion and Helvetica
by Gray Publishing, Tunbridge Wells
Printed and bound in Denmark using acid-free paper
by Narayana Press, Odder

For further information on Blackwell Publishing, visit our website:
www.blackwellpublishing.com

CONTENTS

Preface vii

Contributors ix

PART 1 GENERAL CONSIDERATIONS 1

Chapter 1 Special considerations in feline therapeutics
J.E. Maddison 3

Chapter 2 Vaccination
R.M. Gaskell, A.D. Radford and S. Dawson 13

Chapter 3 Chemotherapy in the treatment of neoplasia
A.J. Stell and J.M. Dobson 19

Chapter 4 An approach to toxicology
R. Breathnach 39

Chapter 5 Common feline behavioural problems
S. Heath 51

PART 2 MAJOR SYSTEMS 71

Chapter 6 The skin
A.P. Foster 73

Chapter 7 The nervous system
B.R. Jones 125

Chapter 8 The musculoskeletal system
D. Bennett 173

Chapter 9 The blood
C.M. Knottenbelt and L. Blackwood 235

Chapter 10 The kidney
P.J. Barber 281

Chapter 11 The lower urinary tract
C.J. Gaskell 313

Chapter 12 The respiratory system
A.M. Kerins and R. Breathnach 325

Chapter 13 The reproductive system
T.J. Gruffydd-Jones 345

Chapter 14 Paediatrics and inherited diseases
K.Willoughby 355

Chapter 15 The oral cavity
C.E. Harvey 379

Chapter 16 The gastrointestinal tract
C.G. Ruaux, J.M. Steiner and D.A. Williams 397

Chapter 17 The liver and pancreas
J. Stonehewer 435

Chapter 18 The eye
L. Waters and K.C. Barnett 455

Chapter 19 The cardiovascular system
A. French and P. Wotton 493

Chapter 20 The endocrine system
C.T. Mooney, J.S. Rand and L.M. Fleeman 527

PART 3 INFECTIOUS DISEASES 569

Chapter 21 Feline panleucopenia/feline parvovirus infection
D.D. Addie and H. Thompson 571

Chapter 22 Feline infectious respiratory disease
R.M. Gaskell, A.D. Radford and S. Dawson 577

Chapter 23 Feline leukaemia virus infection
O. Jarrett and M.J. Hosie 597

Chapter 24 Feline immunodeficiency virus infection
D.A. Harbour, S.M.A. Caney and A.H. Sparkes 607

Chapter 25 Feline coronavirus infection
A.H. Sparkes 623

Chapter 26 Rabies virus infection
P.P. Pastoret, B. Brochier and R.M. Gaskell 637

Chapter 27 Chlamydial infections
J.E. Sykes 651

Chapter 28 Feline toxoplasmosis
M.R. Lappin 659

Chapter 29 Feline infectious anaemia
S. Tasker 669

Chapter 30 Other infections
K. Willoughby and M. Bennett 679

Chapter 31 Endoparasites
A.J. Trees 697

Index 709

PREFACE

It is now almost 10 years since the publication of the second edition of *Feline Medicine and Therapeutics* and almost 20 years since the first edition. The prime objective of this textbook remains, and that is, the education of students and the continuing professional development of veterinary surgeons wherever they are practising the art and science of feline medicine.

During the past decade there has been a further increase in the popularity of cats. This is almost certainly linked with increasing numbers of households where both partners are working. While the desire for pet animals remains high, the cat may be far more convenient in this context than the dog. This last period has also seen a sustained growth in the companion animal aspect of veterinary practice and owners and breeders quite rightly require more skills and treatment options for their cats.

Consequently, this edition of *Feline Medicine* is larger in a number of areas than both previous editions, reflecting the considerable increase of knowledge in feline medicine. The author list is expanded and we welcome new contributors as well as those from previous editions, together with feline specialists from the USA, Australia, Ireland and Belgium, as well as six veterinary institutes in the UK and the pet food industry.

Once again the editors acknowledge with much gratitude the contributions from others not included in the author list, as well as the increasing support from funding-bodies for the essential research needed to improve veterinary welfare of the feline species.

E.A. Chandler
C.J. Gaskell
R.M. Gaskell

CONTRIBUTORS

D.D. Addie PhD, BVMS
University of Glasgow Veterinary School
Glasgow, UK

P.J. Barber BVM&S, PhD, DSAM(Fel), DipECVIM-CA, ILTM, MRCVS
Small Animal Hospital
University of Liverpool, Liverpool, UK

K.C. Barnett MA, PhD, BSc, DipECVO, DVOphthal, FRCVS
The Grange, Woodlands Close
Onehouse
Stowmarket, UK

D. Bennett BSc, BVetMed, PhD, DSAO, ILTM, MRCVS
Small Animal Clinical Studies
University of Glasgow Veterinary School
Glasgow, UK

M. Bennett BVSc, PhD, MRCVS, MRCPath
Department of Veterinary Pathology
University of Liverpool
Liverpool, UK

L. Blackwood BVMS, PhD, MVM, Cert VR, MRCVS
Department of Veterinary Clinical Science and Animal Husbandry
University of Liverpool
Liverpool, UK

R. Breathnach MVB, MRCVS
Small Animal Clinical Studies
University College Dublin
Dublin, Ireland

B. Brochier DVM, PhD
Unit of Immunology and Vaccinology
Faculty of Veterinary Medicine
University of Liege
Liege, Belgium

S.M.A. Caney BVSc, CertSAM, MRCVS
Department of Clinical Veterinary Science
University of Bristol
Bristol, UK

S. Dawson BVMS, PhD, MRCVS
Department of Veterinary Clinical Science
University of Liverpool
Liverpool, UK

J.M. Dobson BVetMed, DVetMed, DipECVIM, MRCVS
University of Cambridge
Cambridge, UK

L.M. Fleeman BVSc
CAMS School of Veterinary Science
St Lucia
Queensland, Australia

A.P. Foster BVSc, BSc, PhD, DipACVD, CertSAD, MRCVS
Department of Clinical Veterinary Science
University of Bristol
Bristol, UK

A. French MVB, BSc, PhD, DipACVD, CertSAD
Department of Veterinary Clinical Studies
University of Edinburgh
Hospital for Small Animals
Easter Bush Veterinary Centre
Roslin, Midlothian, UK

C.J. Gaskell BVSc, PhD, DVR, MRCVS
Department of Veterinary Clinical Science and Animal Husbandry
University of Liverpool
Liverpool, UK

R.M. Gaskell BVSc, PhD, MRCVS
Department of Veterinary Pathology
University of Liverpool
Liverpool, UK

T.J. Gruffydd-Jones PhD, BVetMed, MRCVS
Department of Clinical Veterinary Science
University of Bristol
Bristol, UK

D.A. Harbour BSc, PhD
Department of Clinical Veterinary Science
University of Bristol
Bristol, UK

C.E. Harvey BVSc, FRCVS, DipACVS, DipAVDC, DipEVDC
University of Pennsylvania
School of Veterinary Medicine
Philadelphia, Pennsylvania, USA

S.E. Heath BVSc, MRCVS
Small Animal Teaching Hospital
University of Liverpool
Liverpool, UK

M.J. Hosie BVMS, BSc, PhD, MRCVS
Department of Veterinary Pathology
University of Glasgow Veterinary School
Glasgow, UK

O. Jarrett BVMS, PhD, MRCVS, FRSE
Department of Veterinary Pathology
University of Glasgow Veterinary School
Glasgow, UK

B.R. Jones BVSc (Massey), FACBSc, DipECVIM-Ca, MRCVS
University College of Dublin
Faculty of Veterinary Medicine
Dublin, Ireland

A.M. Kerins MVB, CertSAM, MRCVS
Small Animal Teaching Hospital
University of Liverpool
Liverpool, UK

C. Knottenbelt BVSc, MSc, DSAM, MRCVS
University of Glasgow Veterinary School
Glasgow, UK

M.R. Lappin DVM, PhD
Department of Clinical Sciences
College of Veterinary Medicine
Colorado State University
Fort Collins, Colorado, USA

J.E. Maddison BVSc, DipVetClinStud, PhD, FACVSc, MRCVS
University of Cambridge
Cambridge, UK

C.T. Mooney MVB, MPhil, PhD, DECVIM-CA, MRCV
Small Animal Clinical Studies
University College Dublin
Dublin, Ireland

P.P. Pastoret DVM, PhD
Unit of Immunology and Vaccinology
Faculty of Veterinary Medicine
University of Liege
Liege, Belgium

A.D. Radford BVSc, BSc, PhD, MRCVS
Department of Veterinary Clinical Science
University of Liverpool
Liverpool, UK

J.S. Rand BVSc, DVSc, DACVIM
CAMS School of Veterinary Science
St Lucia
Queensland, Australia

C.G. Ruaux BVSc(Hons), PhD, MACVSc
Department of Small Animal Medicine and Surgery
College of Veterinary Medicine
Texas A&M University
College Station, Texas, USA

A.H. Sparkes BVetMed, PhD, DipEDVIM, MRCV
The Animal Health Trust
Newmarket, UK

J.M. Steiner Dr med vet, PhD, DACVIM, DACVIM(CA)
Department of Small Animal Medicine and Surgery
College of Veterinary Medicine
Texas A&M University
College Station, Texas, USA

A.J. Stell BVM&S, DSAM, MRCVS
Queen's Veterinary School Hospital
University of Cambridge
Cambridge, UK

J. Stonehewer BVM&S, DSAM, MRCVS
IAMS UK Ltd
Stockton Heath
Cheshire, UK

J.E. Sykes BVSc(Hons), PhD, DipACVIM
Department of Veterinary Medicine
University of California, Davis
Davis, California, USA

S. Tasker BVSc, BSc, DSAM, MRCVS
Department of Clinical Veterinary Science
University of Bristol
Bristol, UK

H. Thompson BVMS, PhD, MRCVS
University of Glasgow Veterinary School
Glasgow, UK

A.J. Trees BVM&S, PhD, MRCVS
Department of Veterinary Parasitology
University of Liverpool
Liverpool, UK

L. Waters BVetMed, Cert VOphthal, MRCVS
The Animal Health Trust
Newmarket, UK

D.A. Williams BA, Vet MB, PhD, DACVIM, DACVIM(CA)
Department of Small Animal Medicine and Surgery
College of Veterinary Medicine
Texas A&M University
College Station, Texas, USA

K. Willoughby BVMS, PhD, MRCVS
Diagnostic Virology
Moreden Research Institute
Pentland Science Park
Edinburgh, UK

P. Wooton BVSc, DVC, PhD, MRCVS
Davies White Veterinary Specialists
Higham Gobion
Herts, UK

PART 1

GENERAL CONSIDERATIONS

Chapter 1

SPECIAL CONSIDERATIONS IN FELINE THERAPEUTICS

J.E. Maddison

Introduction

Cats and dogs are physiologically similar in many respects, and dosing regimens recommended for dogs can frequently be extrapolated to cats. However, there are some important differences in drug disposition between the two species that can have a profound influence on dosing recommendations for cats in comparison to dogs. The majority of differences relate to pharmacokinetic differences in drug metabolism (Boothe, 1990a). However, differences in haemoglobin structure, receptors and behaviour may also account for differences in drug disposition between the two species.

Absorption and distribution

The kinetics of drug absorption appear to be similar in dogs and cats regardless of the route of administration. There are minor differences in factors that influence drug distribution between dogs and cats. For example, cats have a smaller blood volume per kilogram (66–70 ml/kg body weight) than dogs (90 ml/kg) and therefore plasma drug concentrations may differ between the two species for drugs that are confined to the plasma compartment (Turnwald & Pichler, 1985; Boothe, 1990a).

Metabolism

To understand how drug metabolism can differ between dogs and cats it is necessary to have a basic understanding of drug metabolism in general. In contrast to water-soluble drugs, which can be excreted in urine without being metabolised, drugs that are lipid soluble must be metabolised so that they can be converted to water-soluble metabolites that can be excreted, usually by the kidney. Drug metabolism occurs in the liver in two phases (I and II). Most differences between dogs and cats in drug disposition relate to differences in phase II metabolism, although there is some evidence that deficiencies in phase I metabolism may be involved in some drug toxicities in cats, including chloramphenicol toxicity (Boothe, 1990c).

Phase I reactions usually convert the parent drug to a more polar metabolite. The reaction usually involves oxidation (requiring mixed function oxidases, including cytochrome P450), reduction or hydrolysis. Often the metabolites are inactive, although occasionally activity may be modified rather than terminated. If phase I metabolites are sufficiently polar they may be readily excreted by the kidney. However, often further reaction is required to form a sufficiently polar compound.

Phase II reactions involve conjugation of the products of phase I reactions with natural substrates. The process requires input of energy and results in the formation of a compound with increased polarity which can be readily excreted by the kidney. Glucuronic acid and glutathione are two of the most common conjugates, others include acetylation, methylation or conjugation with sulfate or glycine groups. The dog has essentially no acetylation activity, while the cat is deficient in glucuronidation. Phase II reactions involve specific transfer enzymes (transferases) which may be located in the microsome or the cytoplasm. Although in general drug conjugation is a true detoxification

process, in some cases certain conjugation reactions may lead to the formation of reactive species responsible for the hepatotoxicity of the drug (Dyke *et al.*, 2002).

Cats tend to be deficient in some glucuronyl transferases, which are important for glucuronidation. As a result, drugs that are excreted as glucuronide conjugates in other species, such as aspirin, benzoic acid, paracetamol (acetaminophen), morphine and hexachlorophene, may have a prolonged half-life in cats, increasing the risk of toxicity due to drug accumulation (Page & Maddison, 2002). This is not a problem for all drugs that are glucuronidated, as cats are only deficient in certain families of glucuronyl transferases (Boothe, 1990a). A drug normally metabolised by glucuronidation may have a wide safety margin or the drug may be metabolised by a different route in cats (although this can result in toxicity for some drugs). For example, sulfation is well developed in cats compared with dogs, and acetylation, which is deficient in dogs, appears to be well developed in cats.

Other drugs displaying pharmacokinetic differences include succinylcholine, which is metabolised more slowly in the cat than in the dog, presumably because of reduced blood pseudocholinesterase activity (Page & Maddison, 2002).

Haemoglobin

Another species difference that may increase the risk of adverse reactions in cats compared with dogs is the increased susceptibility of feline haemoglobin to oxidation and therefore methaemoglobinaemia (Boothe, 1990a). There are a number of mechanisms postulated to explain this, including the different structure of feline haemoglobin, lower concentrations or activities of intracellular repair enzymes and differences in intracellular concentrations of glutathione-conjugating enzymes. Drugs affecting oxidative processes include some of the sulphonamides, nitrofurans and sulphones.

Receptors

Differences between dogs and cats with respect to drug receptor distribution and affinity have been described, with morphine representing the archetypal example. In addition to a slower rate of biotransformation due to the deficiency of glucuronidation in the cat, differences observed in the pharmacodynamic effects of morphine in the cat compared with the dog include central nervous system (CNS) stimulation (CNS depression in the dog), reduced sensitivity to centrally mediated emesis compared with the dog (dog requires a dose 1/740 that of cat), and pupillary dilation (miosis in the dog). However, at a dose rate of 0.1 mg/kg subcutaneously (compared with 0.1–2 mg/kg in the dog), morphine provides effective analgesia (Page & Maddison, 2002).

Other drug effects

Other drugs that have different effects in cats compared with dogs include xylazine and febantel (which induce emesis much more readily in cats than in dogs) and digitalis glycosides (the cat is less tolerant than the dog, presumably because of the increased sensitivity of feline cardiac Na^+/K^+-ATPase to inhibition).

Behavioural differences

The grooming behaviour of cats increases the likelihood that topically applied medications will be ingested. Advantage can be taken of this behaviour by applying medications intended for ingestion to accessible parts of the cat's body (e.g. anthelmintic or antibiotic paste preparations). However, cats are at greater risk of exposure to purposefully or adventitiously applied topical toxicants such as disinfectants (particularly phenolics that are principally candidates for glucuronidation) or pesticides. Indeed, concentrated preparations of permethrin applied topically to cats can be lethal when ingested.

Other physiological factors that influence drug disposition

Other physiological factors that may influence drug disposition are similar in dogs and cats.

Age

Age-related differences should always be considered. Paediatric and geriatric animals are potentially more susceptible to adverse drug effects owing to:

- alterations in drug distribution (greater volume of distribution in paediatric animals, reduced lean body mass and total body water in geriatric animals)

- lower plasma protein in young and old animals
- drug metabolism (reduced hepatic metabolism in neonates, and reduced hepatic blood flow and reduced hepatocyte mass and function in geriatric animals)
- drug elimination (glomerular and tubular function reduced in neonates and old animals).

Pathology

Febrile state, dysfunction of organs of metabolism and excretion, cardiovascular and renal dysfunction affecting water balance and drug distribution, and gastrointestinal disorders affecting drug absorption can all account for significant within-species differences in drug disposition. Adjustment of dosage regimens or avoidance of use of particular drugs may be necessitated in patients with particular disease states. Such disease factors that influence drug disposition have a similar importance in cats and dogs.

The effect of inappetance in diseased cats is important as dietary protein is an important source of sulfate and other compounds used in phase II drug metabolism in cats. Taurine may also be important. Anorexic cats therefore may be more susceptible to adverse drug reactions because of reduced drug metabolism.

Drugs not recommended for use in cats

There are several drugs that should not be used in cats because safe dosage regimes cannot be determined for this species. Some of these drugs are discussed in detail below, others are listed in Table 1.1.

Azathioprine

Azathioprine is a purine antagonist the active metabolite of which is 6-mercaptopurine. Although azathioprine has been used successfully to treat immune-mediated disease in cats, serious bone-marrow suppression has been reported in cats treated with doses used in dogs (2.2 mg/kg and 1.1 mg/kg on alternate days; Beale *et al.*, 1992). In addition to dose-related marrow toxicity, idiosyncratic severe, irreversible, fatal leucopenia and thrombocytopenia have been reported in cats. The recommended dose in cats is 1.5–3.125 mg/cat every 48 h; this is equivalent to about one-tenth to one-eighth of a 25 mg tablet and clearly very difficult to achieve accurately. Many authors do not recommend the use of azathioprine in cats and chlorambucil is often used as an alternative

Table 1.1 Drugs not recommended for use in cats

Drug	Signs of toxicity	Alternative drug
Apomorphine	Significant CNS depression	
Azathioprine	Bone marrow suppression: dose related and idiosyncratic	Chlorambucil
Benzocaine	Methaemoglobinaemia Laryngeal oedema	Lignocaine
Cisplatin	Fatal, acute pulmonary oedema[a]	Other cytotoxic drugs
Paracetamol (acetominophen)	Methemoglobinaemia	Aspirin (decrease dose interval), ketoprofen, meloxicam
Propylthiouracil	Lethargy Weakness Anorexia Bleeding diathesis	Methimazole
Phenytoin	Sedation Ataxia Anorexia Dermal atrophy	Phenobarbitone Diazepam Potassium bromide
Scopolamine	Tendency to cause behavioural changes	Other anticholinergics
Sodium phosphate enemas	Depression Ataxia Vomiting Bloody diarrhoea	

[a] Knapp *et al*. (1987).

in the management of immune-mediated disease in this species.

Paracetamol (acetominophen)

Paracetamol is a non-steroidal drug which has analgesic and antipyretic actions through presumed central cyclo-oxygenase (COX) inhibition. It does not inhibit peripheral COX. Although paracetamol is believed to have no significant anti-inflammatory activity it has been reported to be as effective as aspirin in the treatment of musculoskeletal pain in dogs. However, severe toxicity can result from its use in cats (Boothe, 1990c).

The clinical signs of paracetamol toxicity in cats are oedema of the face (mechanism unknown), cyanosis, methaemoglobinaemia, anaemia, haemoglobinuria and icterus.

Methaemoglobinuria occurs as a result of oxidation of haem, which allows methaemoglobin, which is not capable of binding oxygen, to accumulate. Oxidised haem also shifts the oxydissociation curve to the left, which impairs the unloading of oxygen in tissues, exacerbating the tissue anoxia. The sulfhydryl-containing tripeptide-reduced glutathione is thought to be important in methaemoglobin production. Cat haemoglobin has at least eight sulfhydryl groups per molecule, more than are found in other species, which may render it particularly sensitive to oxidation when glutathione levels fall.

Intravascular or extravascular haemolysis occurs because of Heinz body formation. Oxidation of globin sulfhydryl groups causes conformational changes in haemoglobin molecules, making them unstable. Heinz bodies form following the coalescence of many denatured haemoglobin molecules and generally increase in size for 1–2 days after exposure to the oxidant.

Oxidatively damaged erythrocytes have increased membrane rigidity and decreased deformability, making them more likely to be removed from the circulation. Clinical reports of paracetamol toxicity in cats suggest that erythrocyte destruction can occur for up to 3 weeks. In one cat, haemoglobin casts caused urethral obstruction, an unusual but potentially fatal sequela.

Icterus in cats with paracetamol toxicity is probably more likely to result from haemolysis than hepatocellular necrosis. In contrast to humans and dogs, hepatocellular necrosis is reported to be of less significance in cats with paracetamol toxicosis. The reason for this species difference is unclear and difficult to understand.

Paracetamol in all species is metabolised by three pathways: glucuronidation, sulfation and cytochrome P450-mediated oxidation. The metabolites of glucuronidation and sulfation are not toxic, but the oxidation pathway yields a reactive toxic metabolite (thought to be *N*-acetyl-*p*-benzoquinoneimine). This metabolite is normally conjugated with glutathione, but when hepatic glutathione is depleted the metabolite binds covalently to amino acid residues of protein in the liver, resulting in centrilobular hepatic necrosis.

Glucuronidation is the major metabolic pathway in most species, but cats have a low concentration of glucuronyl transferase, which catalyses the final step, so excretion via this pathway is small. Sulfation is the major metabolic pathway in the cat, but its capacity is limited so as the dose is increased a greater percentage of the drug is oxidised.

It is not understood why less hepatic necrosis occurs in cats than in other species, as high concentrations of the drug remain in the blood for a long time and a greater proportion is oxidised. A similar anomaly occurs in humans, where doses high enough to cause hepatic necrosis in adults cause very little damage in children.

Therapy

Treatment of paracetamol toxicity involves supportive therapy (intravenous fluids, typed blood transfusion if required) as well as more specific therapy.

N-acetylcysteine (140 mg/kg p.o. followed by 70 mg/kg p.o. every 6 h) is efficacious in the treatment of paracetamol toxicity in humans and dogs if given within a few hours following drug administration. In cats paracetamol is slowly eliminated, so *N*-acetylcysteine should be given if clinical signs are present, regardless of the time elapsed since drug administration.

There are several mechanisms by which *N*-acetylcysteine is thought to act. It is rapidly hydrolysed to cysteine and therefore can provide a substrate for glutathione in erythrocytes and the liver. It has been shown to react directly with the reactive metabolite of paracetamol to form an acetylcysteine conjugate. It has also been shown to increase sulfate conjugation.

Other glutathione and sulfate precursors such as methionine (70 mg/kg t.d.) have also been used successfully. The use of ascorbate to reduce methaemoglobin has been recommended, but has been shown not to be effective in dogs and has not been evaluated in cats.

It has been suggested that cimetidine may be useful for treatment of paracetamol toxicity as it is a potent inhibitor of cytochrome P450-mediated drug metabolism. In rats it is as efficacious as *N*-acetylcysteine

in protecting against paracetamol-induced hepatic necrosis. However, its use in cats has not been evaluated and the potential benefit may be less in this species because hepatocellular damage is not as extensive as in other species.

Phenytoin

Although phenytoin is a very effective anticonvulsant agent in humans, it is not useful in dogs or cats owing to marked pharmacokinetic differences between species.

Phenytoin has a prolonged half-life (>40 h) in cats compared with dogs because of the inability of cats to hydroxylate phenolic compounds (Boothe, 1990b). This results in rapid accumulation and development of adverse signs such as sedation, ataxia and anorexia. Dermal atrophy has also been reported in a cat treated with phenytoin (Barthold *et al.*, 1980).

Propylthiouracil

Propylthiouracil is an antithyroid drug which has been used in the past to treat hyperthyroidism. It inhibits thyroid hormone synthesis by:

- blocking the incorporation of iodine into tyrosol groups in thyroglobulin
- interfering with the synthesis of thyroxine by preventing the coupling of monoiodotyrosine and diiodotyrosine into thyroxine (T_4) and triiodothyronine (T_3)
- inhibiting of the peripheral conversion of T_4 to T_3.

Propylthiouracil produces a high incidence of serious adverse side-effects in cats: anorexia, vomiting, lethargy, immune-mediated haemolytic anaemia, thrombocytopenia and positive antinuclear antibody (ANA) titres. Nine of 105 cats developed serious side-effects in a study of cats with hyperthyroidism (Peterson *et al.*, 1984). In another study 50% of normal healthy cats receiving 150 mg of propylthiouracil daily developed an immune-mediated disease within 6 weeks (Aucoin *et al.*, 1985). Because of these predictable side-effects propylthiouracil is no longer recommended and methimazole is the drug of choice for treating feline hyperthyroidism.

Sodium phosphate

Sodium phosphate is a component of retention enemas used in humans and dogs to treat constipation. These enemas should not be used in cats because the active ingredients can be rapidly absorbed through the rectal mucosa, resulting in potentially fatal hyperphosphataemia, hypocalcaemia, hypernatraemia, hyperosmolality and metabolic acidosis (Atkins *et al.*, 1985).

Clinical signs observed in affected cats include depression, ataxia, vomiting and bloody diarrhoea. Dehydrated or debilitated cats are particularly susceptible.

Drugs that are therapeutically useful in cats but that may have different toxicity/activity profiles than in dogs

A summary is given in Table 1.2.

Aspirin

Aspirin is a non-steroidal anti-inflammatory drug (NSAID) which is used in cats in the management of osteoarthritis and for the prevention of thromboemboli in cats with hypertrophic cardiomyopathy. Aspirin is deacetylated to form salicylate and the parent compound has a very short half-life. It is believed that salicylate accounts for most of the analgesic and anti-inflammatory properties of aspirin, whereas aspirin itself provides the antithrombotic activity. Salicylates induce an irreversible inhibition of COX; thus, the pharmacological effect persists until new enzyme is synthesised. Platelets have no ability to synthesise new proteins as they are anuclear; therefore, inhibition of thromboxane synthesis will last for the life of the platelet, resulting in decreased coagulability. With other NSAIDs COX inhibition only lasts while the drug is present.

There are major species differences in the metabolism of aspirin. Of particular relevance to cats is the observation that the half-life of salicylate is approximately four times longer than in dogs (38 h vs 9 h). Cats are relatively deficient in glucuronyl transferase, which is responsible for conjugating salicylate with glucuronic acid. Thus, hepatic clearance in the cat is very prolonged (Boothe, 1990c). Clinical signs of toxicity include hypernoea, hypersensitivity and hyperthermia.

The recommended dose in the cat is 10–20 mg/kg every 48 h.

Chloramphenicol

Chloramphenicol is a broad-spectrum antimicrobial drug. In small animals, chloramphenicol is now

Table 1.2 Drugs that are therapeutically useful in cats but that may have different dosing/toxicity/activity profiles than in dogs

Drug	Toxicity that may be observed	Difference in dosing compared with dogs
Aspirin	Hypernoea Hypersensitivity Hyperthermia	Increased dosing interval Lower end of dose/kg range
Chloramphenicol	Anaemia	Lower dose
Diazepam	Idiosyncratic hepatotoxicity[a]	
Doxorubicin	Renal failure	Lower dose
Frusemide	Dehydration Hypokalaemia	Use lower end of dose range
Griseofulvin	Leucopenia and thrombocytopenia Non-reversible ataxia	Check FIV status
Ketoconazole	Dry hair coat Weight loss	
Lignocaine	Myocardial and CNS depression	Lower dose
Megestrol acetate	Mammary hypertrophy and neoplasia Cystic endometritis Diabetes mellitus	
Metronidazole	Disorientation Ataxia Seizures Blindness	Lower dose
Opioids	Inconsistent sedation	Lower dose
Morphine derivatives [excluding meperidine (pethidine), butorphanol and buprenorphine]	Increased risk of excitation	
Organophosphates	Acute toxicity: hypersalivation vomiting, diarrhoea, muscle tremors Chronic or delayed toxicity: paresis or paralysis which may or may not be reversible	Use with care, ensure product rinsed off coat
Tetracyclines	Hepatic lipidosis Increased ALT activity Ptyalism Anorexia	
Thiacetarsamide	Drug fever Respiratory distress Fulminant pulmonary oedema	

[a] Center *et al*. (1996).
ALT: alanine transferase; FIV: feline immunodeficiency virus.

probably the drug of first choice only for bacterial infection of the chambers of the eye. There is mixed opinion as to whether chloramphenicol is the drug of choice for CNS infections (rare), but it does achieve high levels in the CNS and has a very broad spectrum. However, many other drugs also effectively cross the blood–brain barrier in the presence of meningitis and may be more effective and bactericidal. Chloramphenicol is a good alternative for anaerobic infections. It is eliminated primarily by hepatic glucuronide conjugation in the dog and only 5–10% is excreted unchanged in the urine.

Although the elimination half-life of chloramphenicol is similar in both species (4 h after intravenous administration, 7–8 h after oral administration), in contrast to the dog more than 25% of drug is excreted unchanged in the feline urine owing to the reduced ability of cats to glucuronidate drugs. This difference in

metabolism results in a very different dosing schedule in cats (50 mg/cat b.d.) compared with dogs (50 mg/kg b.d.).

Reversible non-regenerative anaemia can occur in both dogs and cats. Cats may be more susceptible, but the increased incidence is probably related to relative overdosing of cats when using a dog dosing schedule, which is approximately five times higher per kilogram (Watson, 1991).

Digoxin

Digoxin is a positive ionotropic and negative chronotropic used in the management of cardiac failure in dogs and cats. It competitively binds to the site at which potassium normally attaches on the Na^+/K^+-ATPase pumps located on myocardial cell membranes. A therapeutic concentration of digitalis 'poisons' approximately 30% of the pumps. Inhibition of Na^+/K^+-ATPase causes increased intracellular concentrations of sodium that is available for exchange with calcium (via the Na^+/Ca^{2+} cation exchanger), resulting in increased intracellular calcium, increased storage of calcium in the sarcoplasmic reticulum and greater release of calcium with each action potential, cumulating in increased excitation–contraction coupling of actin–myosin.

Cats are more sensitive than dogs to digitalis-induced toxicosis (Boothe, 1990b). This is presumed to be because of the increased sensitivity of feline cardiac Na^+/K^+-ATPase to inhibition. The dosage should be reduced compared with dogs and further reduced if given concurrently with aspirin and furosemide (Atkins *et al.*, 1988).

The half-life of digoxin is extremely variable in cats, ranging from 25 to 173 h in various reports. The elixir form results in serum concentrations approximately 50% higher than the tablet. However, cats generally dislike the taste of the alcohol-based elixir. When digoxin tablets are administered with food to cats, serum concentration is reduced by about 50% compared with the concentration without food (Kittelson, 2002).

The recommended doses of digoxin in cats are:

- cat 2–3 kg 0.0312 mg every 48 h
- cat 4–5 kg 0.0312 mg every 24–48 h
- cat > 6 kg 0.0312 mg every 12 h.

Doxorubicin (see also Chapter 3)

Doxorubicin is an anthracycline antibiotic that penetrates cells, fixes to nuclear structures and intercalates with DNA, thus inhibiting DNA-dependent RNA synthesis as well as DNA duplication. It is used as a single agent or in combination protocols (particularly for treatment of lymphosarcoma). Doxorubicin is potent against a range of tumours and is the most common single agent used for solid tumours.

Doxorubicin when used at the 'dog dose' of 30 mg/m^2 has been associated with induction of renal failure in cats (Cotter *et al.*, 1985). The optimal dose has not been determined in the cat. Doses ranging from 20 to 30 mg/m^2 and 1 mg/kg have been recommended. Because the cat is relatively resistant to developing doxorubicin-induced cardiomyopathy, no cumulative dose recommendation has been made.

Enrofloxacin

Enrofloxacin is a fluoroquinolone antimicrobial agent that has broad-spectrum antimicrobial activity, especially against Gram-negative bacteria as well as *Brucella, Mycoplasma, Chlamydia* and *Mycobacterium* infections. Adverse effects are uncommon in dogs and cats. An apparent species-specific toxicity is acute retinal degeneration, recently reported in cats. Blindness often results, but some cats may regain vision. In a recent study of affected cats (Gelatt *et al.*, 2001), the daily and total doses of enrofloxacin administered and the duration of treatment were highly variable.

Frusemide

Frusemide is a loop diuretic that is secreted into the proximal tubule by the organic acid secretory mechanism. Loop diuretics inhibit sodium chloride (NaCl) reabsorption at the lumenal face of the cells in the thick ascending loop of Henle by actively blocking sodium–potassium–chloride cotransport. Because of the large NaCl absorptive capacity of this segment, diuretics that act at this site produce a diuretic effect much greater than other classes of diuretics.

Cats are more sensitive than dogs to frusemide (Boothe, 1990b; Kittleson, 2002). The increase in urine volume is comparable between normal cats and normal dogs in doses from 0.625 to 10 mg/kg i.m. However, in cats sodium excretion is between 1.3 and 2.2 times (average 1.7 times) that seen in dogs at each dosage.

The recommended dose in cats is 1–2 mg/kg b.d.

Griseofulvin

Griseofulvin is a fungistatic drug used primarily for the treatment of dermatophycosis in cats and dogs

caused by *Trichophyton* and *Microsporum* spp. It has no effect on other fungi. Although griseofulvin has traditionally been considered the drug of choice for systemic therapy of dermatophytosis in dogs and cats, it has been replaced to some degree by itraconazole, which is often better tolerated (especially in cats) and may be more efficacious for the treatment of *M. canis*.

Bone-marrow suppression (usually manifested as neutropenia) may occur as an idiosyncratic reaction, especially in kittens (Shelton *et al.*, 1990). For this reason, griseofulvin should not be used in kittens under 8 weeks of age, and many authors recommend a minimum age of 12 weeks. In addition, neutropenic reactions are more common in cats infected with feline immunodeficiency virus (FIV). Consequently, FIV testing should be performed before the initiation of griseofulvin therapy, and cats that are FIV positive should receive an alternative therapy (such as itraconazole or terbinafine).

In general, adverse reactions to griseofulvin therapy occur more often in Himalayan, Abyssinian, Persian and Siamese cats than in other breeds (Taboada & Grooters, 2002). Non-reversible ataxia has been reported in a kitten treated with the drug.

The recommended dose in cats is 20–50 mg/kg per day p.o. (It may be given in divided doses and should be administered with a fatty meal to enhance absorption.)

Ketoconazole

Ketoconazole is an azole antifungal drug that blocks biosynthesis of fungal lipids, especially the ergosterol in cell membranes. It inhibits fungal ergosterol biosynthesis 30–70 times more readily than mammalian cholesterol metabolism; thus, fungal membrane permeability is affected.

In contrast to the effect in dogs, ketoconazole does not alter production of steroid hormones such as cortisol, testosterone and progesterone in cats. However, dose-related gastrointestinal side-effects (anorexia and vomiting) are relatively common in this species.

The recommended dose is 5–10 mg/kg p.o. every 8–12 h.

Lignocaine

Lignocaine is used clinically to treat acute life-threatening ventricular arrhythmias in many different clinical settings. Cats develop seizures with lignocaine more commonly than dogs and it must be used cautiously in this species.

In cats the initial dose is 0.25–0.75 mg/kg i.v., followed by an infusion administered at 10–40 μg/kg per minute.

Megestrol acetate

Megestrol acetate is a synthetic progestagen that has been used for reproductive, behavioural and dermatological disorders in cats. However, it is not recommended for the treatment of behavioural or dermatological disorders owing to the risk of serious side-effects.

The most serious side-effects associated with megestrol acetate treatment in cats include mammary hypertrophy and neoplasia, cystic endometritis and diabetes mellitus. The mechanism for diabetes mellitus appears to be different to that in the dog (where it relates to increased growth hormone production). Megestrol-induced diabetes in the cat may be transient or permanent. Megestrol acetate also causes adrenal suppression in the cat (Boothe, 1990c).

The recommended dose for control of oestrus can be achieved by using 5 mg/cat for 3 days then 2.5–5 mg once a week for 10 weeks.

Morphine

Cats appear to be more sensitive to the effects of several opioid analgesics, particularly morphine. Adverse effects observed include inconsistent sedation and increased risk of excitation. This may be due to differences in the type or concentration of opioid receptors in cats as well as decreased rate of metabolism (Page & Maddison, 2002).

The recommended dose is 0.1 mg/kg s.c. or i.m.

Organophosphates

Organophosphates are used widely in the control of ectoparasites, especially fleas in cats, although their use is declining as a result of newer flea treatments that more specifically target the flea.

Cats are more sensitive than dogs to the effects of organophosphates, although the mechanism for this is unknown (Boothe, 1990c). It is not related to different hepatic metabolising capacity as organophosphates are metabolised by cholinesterases located at nerve endings.

Toxicity may be acute (similar signs to dogs), or chronic or delayed. Chronic or delayed toxicity manifests as paresis or paralysis, which may or may not be reversible. Toxic epidermal necrolysis has been reported

in cats treated topically with organophosphate-based flea rinses. A survey of the effects of flea collars in cats revealed a high number of adverse reactions, ranging from dermatitis to death (Wilkins, 1980).

Tetracyclines

Tetracycline are bacteriostatic antibiotics with a broad spectrum of activity. They have been used clinically since the 1940s and as a result acquired resistance to them is widespread. In veterinary medicine tetracyclines are used most frequently for atypical bacterial diseases due to *Chlamydia* (particularly in cats), *Borrelia*, *Rickettsia*, *Haemobartonella* and *Mycoplasma*. Tetracyclines are the drugs of choice for *Erlichia canis* and *Rickettsia rickettsii* infections.

Adverse effects that have been reported in cats include hepatic lipidosis, increased alanine transferase (ALT) activity, ptyalism and anorexia. It has been speculated that cats may be more susceptible than other species to tetracycline-induced hepatotoxicosis, owing to their unique protein metabolism and requirements.

References

Atkins C.E., Tyler R. & Greenlee P. (1985) Clinical, biochemical, acid–base, and electrolyte abnormalities in cats after hypertonic sodium phosphate enema administration. *Am J Vet Res* **46**, 980–988.

Atkins C.E., Snyder P.S. & Keene B.W. (1988) Effect of aspirin, furosemide, and commercial low-salt diet on digoxin pharmacokinetic properties in clinically normal cats. *J Am Vet Med Assoc* **193**, 1264–1268.

Aucoin D.P., Peterson M.E., Hurvitz A.I., *et al.* (1985) Propylthiouracil-induced immune-mediated disease in the cat. *J Pharmacol Exp Ther* **234**, 13–18.

Barthold S.W., Kaplan B.J. & Schwartz A. (1980) Reversible dermal atrophy in a cat treated with phenytoin. *Vet Pathol* **17**, 469–476.

Beale K.M., Altman D., Clemmons R.R. & Bolon B. (1992) Systemic toxicosis associated with azathioprine administration in domestic cats. *Am J Vet Res* **53**, 1236–1240.

Boothe D.M. (1990a) Drug therapy in cats: mechanisms and avoidance of adverse drug reactions. *J Am Vet Med Assoc* **196**, 1297–1305.

Boothe D.M. (1990b) Drug therapy in cats: a systems approach. *J Am Vet Med Assoc* **196**, 1502–1511.

Boothe D.M. (1990c) Drug therapy in cats: a therapeutic category approach. *J Am Vet Med Assoc* **196**, 1659–1669.

Center S.A., Elston T.H., Rowland P.H., *et al.* (1996) Fulminant hepatic failure associated with oral administration of diazepam in 11 cats. *J Am Vet Med Assoc* **209**, 618–625.

Cotter S.M., Kanki P.J., Simon M. (1985) Renal disease in five tumour-bearing cats treated with adriamycin. *J Am Hosp Assoc* **21**, 405–409.

Dyke T., Page S.W. & Maddison J.E. (2002) Clinical pharmacokinetics. In *Small Animal Clinical Pharmacology* (eds Maddison J.E., Page S.W. & Church D.B.). WB Saunders, Philadelphia, PA, pp. 27–40.

Gelatt K.N., Woerdt A. van der, Ketring K.L., *et al.* (2001) Enrofloxacin-associated retinal degeneration in cats. *Vet Ophthalmol* **4**, 99–106.

Kittleson M. (2002) Drugs used in the management of cardiac disorders. In *Small Animal Clinical Pharmacology* (eds Maddison J.E., Page S.W. & Church D.B.). WB Saunders, Philadelphia, PA, pp. 343–416.

Knapp D.W., Richardson R.C., DeNicola D.B., *et al.* (1987) Cisplatin toxicity in cats. *J Vet Intern Med* **1**, 29–35.

Page S.W. & Maddison J.E. (2002) Principles of clinical pharmacology. In *Small Animal Clinical Pharmacology* (eds Maddison J.E., Page S.W. & Church D.B). WB Saunders, Philadelphia, PA, pp. 1–26.

Peterson M.E., Hurvitz A.I., Leib M.S., *et al.* (1984) Propylthiouracil-associated hemolytic anemia, thrombocytopenia, and antinuclear antibodies in cats with hyperthyroidism. *JAMA* **184**, 806–808.

Shelton G.H., Grant C.K., Linenberger M.L., Abkowitz J.L. (1990) Severe neutropenia associated with griseofulvin therapy in cats with feline immunodeficiency virus infection. *J Vet Intern Med* **4**, 317–319.

Taboada J. & Grooters A. (2002) Anitfungal drugs. In *Small Animal Clinical Pharmacology*. (eds Maddison J.E., Page S.W. & Church D.B.). WB Saunders, Philadelphia, PA, pp. 149–162.

Turnwald G.H. & Pichler M.E. (1985) Blood transfusion in dogs and cats. Part II. Administration, adverse effects, and component therapy. *Compendium on Continuing Education for the Practicing Veterinarian* **7**, 115–125.

Watson A.D.J. (1991) Chloramphenicol. 2. Clinical pharmacology in cats and dogs. *Aust Vet J* **68**, 2–5.

Wilkins D.B. (1980) Problems in cats caused by flea collars. *Vet Rec* **107**, 311.

Chapter 2

VACCINATION

R.M. Gaskell, A.D. Radford and S. Dawson

Introduction

Vaccination has been used very successfully for a number of years to control the major infectious diseases of cats. This chapter deals with some of the basic principles of feline vaccination, and outlines possible problems that may be associated with this procedure.

Vaccines currently available against cat diseases are shown in Table 2.1. The main diseases against which cats are vaccinated are feline panleucopenia, feline herpesvirus and feline calicivirus infection. Estimates suggest that each year approximately one-third of cats in the UK are vaccinated against these diseases (Gaskell *et al*., 2002a). Feline leukaemia virus vaccines are also used, although figures suggest that only 14% of the population are vaccinated against this disease in any individual year. In the UK, rabies vaccines are used only for dogs and cats in quarantine or for export, and under the Pet Travel Scheme (PETS) (Chapter 26). At present the only other vaccines marketed for cats in the UK are against *Chlamydophila felis* (formerly feline *Chlamydia psittaci*) and recently, an intranasal *Bordetella bronchiseptica* vaccine. Other vaccines available for cats in some countries outside the UK include those against feline infectious peritonitis, *Microsporum canis*, *Giardia lamblia* and *Bordetella bronchiseptica*.

Types of vaccine

Cat vaccines generally comprise either modified live, or inactivated (killed) adjuvanted vaccines administered subcutaneously (Table 2.1). Modified live vaccines have been attenuated or altered to eliminate or reduce their virulence. Attenuation can be achieved in a number of ways, including serial passage in cell culture in the laboratory or by genetic manipulation, or by the choice of a naturally occurring apathogenic strain. Live vaccines have the disadvantage of an increased possibility of causing disease and also the potential of reversion to virulence.

In traditional killed vaccines the whole agent has been inactivated chemically, whereas in subunit vaccines the agent has been dissembled and only certain parts are incorporated into the vaccine. Both traditional and subunit killed vaccines contain adjuvants to increase the immunogenicity of the vaccine. More recently, genetically engineered subunit vaccines have recently been produced for feline leukaemia virus vaccines where the relevant viral protein has been produced in large quantities by growth in bacteria. The use of inactivated vaccines in cats has increased in recent years, partly because of the development of inactivated vaccines against feline leukaemia, and also because of increased efficacy due to improvements in adjuvants.

In some other countries, but not currently in the UK, modified live intranasal vaccines are available against feline herpesvirus and feline calicivirus infection, and also feline infectious peritonitis.

Several recombinant vector vaccines have been developed for use in cats; for example, canarypox vectors incorporating either feline leukaemia virus or rabies genes have recently been marketed. Other examples, not yet commercially available, include feline herpesvirus–calicivirus recombinants, where a DNA copy of the feline calicivirus capsid gene has been inserted into a non-essential gene of feline herpesvirus. Such vaccines may offer advantages over conventional vaccines in terms of improved safety and efficacy.

Table 2.1 Vaccines available for cats in the UK (2002)

Vaccine name	Company	Components	Killed or live
Eurifel FeLV	Merial	FeLV	Recombinant canarypox
Eurifel P	Merial	Feline panleucopenia	Live
Eurifel RC	Merial	Feline herpesvirus Feline calicivirus	Killed Killed
Eurifel RCPFeLV	Merial	Feline panleucopenia Feline herpesvirus Feline calicivirus FeLV	Live Killed Killed Recombinant canarypox
Feligen RCP	Virbac	Feline panleucopenia Feline herpesvirus Feline calicivirus	Live Live Live
Felocell CVR	Pfizer	Feline panleucopenia Feline herpesvirus Feline calicivirus	Live Live Live
Fevaxyn iCHPChlam	Fort Dodge	Feline panleucopenia Feline herpesvirus Feline calicivirus Feline Chlamydia	Killed, adjuvanted Killed, adjuvanted Killed, adjuvanted Killed, adjuvanted
Fevaxyn Pentofel	Fort Dodge	Feline panleucopenia Feline herpesvirus Feline calicivirus Feline Chlamydia FeLV	Killed, adjuvanted Killed, adjuvanted Killed, adjuvanted Killed, adjuvanted Killed, adjuvanted
Fevaxyn FeLV	Fort Dodge	FeLV	Killed, adjuvanted
Katavac CHP	Fort Dodge	Feline panleucopenia Feline herpesvirus Feline calicivirus	Live Live Live
Katavac Eclipse	Fort Dodge	Feline panleucopenia Feline herpesvirus Feline calicivirus FeLV	Live Live Live Killed, adjuvanted
Leucogen	Virbac	FeLV	Killed, adjuvanted
Leukocell 2	Pfizer Ltd	FeLV	Killed, adjuvanted
Nobivac FeLV	Intervet UK Ltd	FeLV	Killed, adjuvanted
Nobivac Rabies	Intervet UK Ltd	Rabies virus	Killed, adjuvanted
Nobivac Tricat	Intervet UK Ltd	Feline panleucopenia Feline herpesvirus Feline calicivirus	Live Live Live
Quantum Cat CVRP	Schering-Plough	Feline panleucopenia Feline herpesvirus Feline calicivirus	Live Live Live
Quantum Cat FeLV	Schering-Plough	FeLV	Killed, adjuvanted
Rabisin	Merial	Rabies virus	Killed

Vaccination schedules

Most data sheets recommend primary vaccination for kittens followed by annual boosters thereafter. Such regimens maximise protection for the individual and are generally based on both experimental challenge studies and field data provided by the manufacturer. However, in recent years there has been considerable discussion as to whether such schedules are always appropriate, largely because of concerns about possible safety issues. These issues have been particularly highlighted by the increasing use of inactivated adjuvanted vaccines in cats, and the possible association between such vaccines and the formation of vaccine-associated sarcomas.

Because of these concerns, some authorities in the USA have designated certain vaccines as 'core' vaccines, such that all animals should undergo primary vaccination as indicated by the manufacturer, followed by revaccination 1 year later and then boosters every 3 years. A vaccine is designated as core either if the consequences of infection are particularly severe (e.g. feline panleucopenia) or the prevalence of disease is high and the disease is easily transmitted (e.g. feline herpesvirus and feline calicivirus infection). In the USA and some other countries where rabies is endemic and poses a substantial zoonotic risk, rabies vaccines are mandatory and are also considered core vaccines. Other vaccines are designated 'non-core' and it is recommended that they should only be used following a risk/benefit assessment.

In the UK a recent Veterinary Products Committee working group report on feline and canine vaccination concluded that, based on currently available evidence, booster vaccination protocols recommended by the manufacturer should in general be adhered to (Gaskell *et al.*, 2002a, b). However, it was emphasised that the regimen for booster vaccination is based on a minimum duration of immunity rather than a maximum and that a risk–benefit assessment should be carried out for each individual animal by the veterinary surgeon in consultation with the owner. Thus, an informed choice may be made by the owner with respect to the necessity of a particular vaccine and the frequency of its use. Such a consultation should include discussion on the likelihood of exposure, available data on the duration of immunity, and the risks related to vaccination. It was also suggested by the working group that, where possible, manufacturers should continue to market single-component as well as multivalent products to retain flexibility.

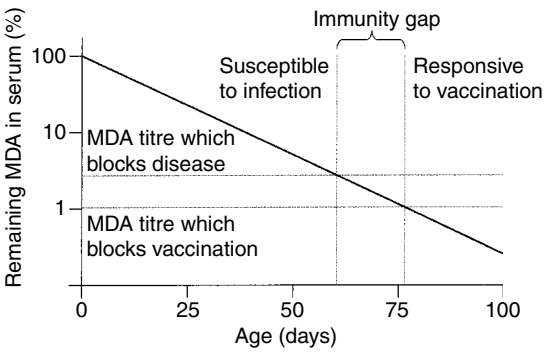

Figure 2.1 Diagrammatic representation of the concept of the immunity gap. The actual age at which the immunity gap develops depends on the amount of maternally derived antibody (MDA) transferred to each kitten.

Vaccination of kittens

The aim of kitten vaccinations is to provide active, vaccine-derived immunity as early as possible. However, maternally derived antibody (MDA), which is essentially colostrally derived in kittens, may interfere with effective vaccination. As MDA declines, kittens may become susceptible to infection before they are responsive to vaccination, leaving an immunity gap (Figure 2.1). Some vaccines are better at overcoming MDA than others; classically, intranasal vaccines are not interfered with by levels of antibodies that would interfere with systemic vaccines. However, with improvements in vaccines including newer types of adjuvant, other vaccines may also induce protection in the presence of low levels of MDA.

In most diseases of cats, MDA declines to non-interfering levels in the majority of animals by 9–12 weeks of age. The standard protocol is therefore to vaccinate kittens at 8 or 9 weeks and then repeat in 3–4 weeks' time. However, the duration of MDA may be variable between different litters of kittens and even between kittens in a litter, depending on the antibody levels in the queen and the intake of colostrum. MDA against feline herpesvirus has been shown to last for 2–10 weeks, and against feline calicivirus for up to 10–14 weeks (Chapter 22). For feline panleucopenia the majority of kittens born to queens with moderate titres will lose their MDA by 8–12 weeks, but for those born to queens with high titres, MDA may persist for 16 weeks or more (Chapters 14 and 21). Serology for antibody level estimation can be carried out where

an accurate timing of first vaccination is required, although in practice this is rarely done.

In some situations earlier vaccination schedules may be appropriate, for example where there is a high risk of disease or where kittens are deprived of colostrum and therefore more likely to be at risk. However, vaccines are generally not licensed for use in younger animals, and therefore care should be taken in making a risk–benefit assessment for the animal in terms of safety and efficacy, and in obtaining informed consent from the owner. An alternative strategy to boost kitten MDA is to vaccinate queens before breeding (or in pregnancy, providing this is indicated on the data sheet).

Vaccination of adult cats

In previously unvaccinated cats, or animals of unknown vaccination history, a primary vaccination course of two doses 3–4 weeks apart should be undertaken. In cats vaccinated as kittens, the first booster at 1 year of age is important in case the first vaccination course was ineffective (e.g. if MDA was still at interfering levels). The onset of immunity is 7–10 days after systemic vaccination and 2–4 days after an intranasal vaccine. Although annual boosters are generally recommended for all injectable vaccines, there is some evidence that for panleucopenia the duration of immunity may be longer, up to several years (Gaskell *et al.*, 2002a, b). However, clearly a number of variables may influence this, including the potency of the actual product. For feline herpesvirus and feline calicivirus, although immunity may again last for up to several years, it is only partial in most animals (Scott & Geissinger, 1997, 1999). For feline leukaemia, there is limited evidence that, after natural challenge, immunity may last for 1–3 years (Gaskell *et al.*, 2002a, b). However, long-term challenge studies can be difficult to carry out for feline leukaemia, partly because of an age-related immunity to persistent infection and therefore disease.

As with the natural disease, immunity following the use of *C. felis* vaccine is incomplete, but some protection has been shown for up to a year (Chapter 27). Other vaccines, such as those against *B. bronchiseptica* and feline infectious peritonitis, are mucosal, intranasal vaccines giving a good local immunity. In general, the immunity for such vaccines tends to be of shorter duration, although recent evidence suggests that immunity to the recently marketed feline intranasal *B. bronchiseptica* vaccine may last for at least 1 year (Williams *et al.*, 2002).

On balance, therefore, current available evidence suggests that booster vaccination protocols recommended by the manufacturer should in general be adhered to. In the absence of a high level of population immunity, such a regimen will maximise protection for the individual. However, it should be emphasised that the protocols in the product literature are based on a minimum, rather than a maximum duration of immunity, and that a risk–benefit assessment should be conducted for each individual animal with respect to the necessity for vaccination, as discussed previously.

Problems with vaccination

The majority of vaccinations that take place are both safe and efficacious. However, sometimes adverse reactions occur, and in some instances there may be an unexpected lack of efficacy. If such a problem is suspected in the UK it should be reported to the Veterinary Medicines Directorate (VMD) via the yellow form at the back of the Veterinary Data Sheet Compendium and or from the VMD (www.vmd.gov.uk). The VMD organises a Suspected Adverse Reaction Surveillance Scheme, which covers both immunological and pharmaceutical products. Although there may be underreporting with such schemes, important trends with respect to possible adverse reactions can generally be seen.

Adverse reactions

Adverse reactions include both recognised side-effects, which are essentially expected (although they may be more severe or frequent than expected), and unexpected reactions. Some adverse reactions may be hard to relate to vaccination, particularly if they occur infrequently or a long time after vaccination. Adverse reactions may be due to a number of reasons, including operator error, vaccine and host factors.

Operator error

- Vaccines may be administered incorrectly (e.g. wrong vaccine or wrong route).

Vaccine

- The bacterium or virus strain used in the vaccine may be incompletely attenuated or inactivated.

Table 2.2 Vaccine-Associated Feline Sarcoma Task Force (VAFSTF) recommendations for the treatment of vaccine site masses in cats (www.avma.org/vafstf)

Any vaccine site masses:
- that persist for greater than 3 months following vaccination
- that are greater than 2 cm in diameter, or
- that are increasing in size 1 month after vaccination

should be biopsied and, if malignant, be surgically excised. Advanced diagnostic imaging to identify the full extent of the tumour is suggested before extensive surgical excision is carried out. If the mass is confirmed as a sarcoma, radiotherapy and possibly chemotherapy may also have some beneficial effect. However, local recurrence is common and even wide surgical excision results in a high failure rate.

- There may be an inappropriate response to an adjuvant or excipient. These may be systemic, or local, injection site reactions (see below).

  Injection site reactions. Adjuvants are known to sometimes cause mild generalised reactions such as transient depression or pyrexia in cats. They also tend to cause local granulomatous reactions at the site of vaccination. Although these generally resolve, in recent years it has become apparent that, rarely, some cats may develop sarcomas at the site of vaccination. This appears to be associated particularly, but not exclusively, with an inappropriate inflammatory response, following the use of adjuvanted vaccines, especially those containing aluminium. The incidence of such sarcomas in the USA is estimated to be 1–10 per 10 000 doses of feline leukaemia virus or rabies vaccines used (Macy, 1999). In the UK, where there is no mandatory rabies vaccination and exposure to adjuvanted vaccines is less, the incidence of such sarcomas is lower (0.045 per 10 000 doses of leukaemia vaccines), although the incidence appears to be rising (Gaskell *et al*., 2000a, b).

In the USA the Vaccine-Associated Feline Sarcoma Task Force (VAFSTF) (www.avma.org/vafstf) was set up to advise on this condition. Since mortality associated with such sarcomas is relatively high, it is important that veterinary surgeons are aware of their diagnosis and appropriate treatment, and also possible preventive measures. A summary of recommendations from the task force for the treatment of vaccine site masses is given in Table 2.2. Other recommendations are presented in Table 2.3, but these measures are not necessarily all appropriate for every situation and should be considered against the background of local vaccine usage and incidence of the condition.

Table 2.3 Vaccine-Associated Feline Sarcoma Task Force (VAFSTF) recommendations to help identify causes, aid treatment and reduce the prevalence of vaccine-associated sarcomas (www.avma.org/vafstf)

- Vaccines containing rabies antigen should be given as distally as possible in the right rear limb.
- Vaccines containing feline leukaemia virus antigen should be given as distally as possible in the left rear limb.
- Vaccines containing any other antigens except rabies or feline leukaemia virus are given on the right shoulder, being careful to avoid the midline or interscapular space.
- Vaccines should be given subcutaneously rather than intramuscularly.
- A core/non-core approach to vaccination with a risk–benefit analysis should be used.
- Alternative vaccination routes, e.g. intranasal, should be used if possible.
- Ensure medical records are kept of the date, site of injection, type, serial number and manufacturer of the vaccine.
- Report any adverse reactions to the appropriate authorities.

Host factors

- A young or an immunocompromised animal may be more susceptible than normal to disease caused by a live attenuated vaccine strain.
- The animal may be incubating the disease at the time of vaccination. This is particularly true of young kittens vaccinated as their MDA wanes. Although this is not a true vaccine reaction, it is probably the single most common reason for apparent adverse reactions in this age group.

Lack of efficacy

Suspected lack of efficacy (i.e. development of disease despite vaccination) may be difficult to relate to vaccination, since this may occur some time after the vaccination took place. However, by definition it occurs within the normal prescribed period of immunity. Again, lack of efficacy may be due to a number of reasons, including operator error, vaccine and host factors.

Operator error

- Vaccines may be incorrectly stored or administered.

Vaccine

- The vaccine may not be sufficiently potent: despite rigorous quality control by the licensing authorities, occasional batch failure may occur.

- For some agents (e.g. feline calicivirus) the strain incorporated in the vaccine may not cross-protect against the field viruses present.

Host factors

- Owing to normal biological variation not all animals may respond fully.
- There may be interference from MDA in young kittens.
- The cat may be suffering from immunosuppression or intercurrent disease and therefore may not respond adequately to antigenic stimulation.
- In some cases there may be overwhelming infection, possibly exacerbated by poor husbandry conditions such as overcrowding or stress.
- The cat may already be a carrier of the disease, and subject to persistent or recurrent signs.
- The animal may be undergoing infection with different organisms to those contained in the vaccine. This is particularly true of conditions such as respiratory disease where the aetiology is multifactorial.

In conclusion, vaccination plays a very valuable role in the prevention and control of the major infectious diseases of cats. However, it is important that vaccine use is tailored to the infectious challenges that each individual cat is likely to meet. In addition, it should be recognised that as knowledge increases and newer vaccines are developed, the way in which we use such products may alter.

References

Gaskell R.M., Gettingby G., Graham S. & Skilton D. (2002a) *Veterinary Products Committee (VPC) Working Group on Feline and Canine Vaccination. Final Report to the VPC.* DEFRA Publications, London, PB 6432 (www.vpc.gov.uk).

Gaskell R.M., Gettingby G., Graham S. & Skilton D. (2002b) Veterinary Products Committee working group report on feline and canine vaccination. *Vet Rec* **150**, 126–134.

Macy D.W. (1999) Current understanding of vaccination site-associated sarcomas in the cat. *J Feline Med Surg* **1**, 15–21.

Scott F.W. & Geissinger C.M. (1997) Duration of immunity in cats vaccinated with an inactivated feline panleucopenia, herpesvirus and calicivirus vaccine. *Feline Pract* **25**(4), 12–19.

Scott F.W. & Geissinger C.M. (1999) Long-term immunity in cats vaccinated with an inactivated trivalent vaccine. *Am J Vet Res* **60**, 652–658.

Williams J., Laris R., Gray A.W. & Jacobs A.A. (2002) Studies on the efficacy of a novel intranasal vaccine against feline bordetellosis. *Vet Rec* **150**, 439–442.

Chapter 3

CHEMOTHERAPY IN THE TREATMENT OF NEOPLASIA

A.J. Stell and J.M. Dobson

Introduction

Cancer is a common disease in cats, as in other domestic species and humans. Public awareness of cancer and its treatment is increasing, leading to increased demand for chemotherapy for pets. It is important for the veterinary practitioner to possess knowledge of the various chemotherapeutic agents in veterinary use, including their indications and toxicities, in order to offer the best advice to the owner of cat with cancer. Most of the cytotoxic drugs discussed in this chapter are not licensed for animal use and were developed for the treatment of human cancer. Experience gained from human medicine has led to the development of anticancer chemotherapy in animals, and there are increasing data to support the efficacy of these drugs for selected tumours in the cat. Not all tumours are amenable to chemotherapy, however, and every patient must be considered as an individual in assessing suitability for treatment. Cats also have some special species considerations which will be highlighted in the text; some cytotoxic drugs used in dogs and humans are not suitable for cats and many cats will be anorexic while receiving chemotherapy. It should be remembered that the actions of cytotoxic agents are not selective for neoplastic cells and toxicity to normal tissues can be life threatening if these drugs are used inappropriately. Great care must always be taken when prescribing chemotherapy drugs.

Basic principles of chemotherapy

The use of cytotoxic drugs in cancer treatment involves a basic understanding of both tumour biology and the pharmacology of cytotoxic drugs.

Tumour biology

Growth characteristics

Most tumours arise from the neoplastic transformation of a single stem cell. Initially tumours grow rapidly, but the rate of growth slows to a plateau phase as the tumour enlarges (Figure 3.1).

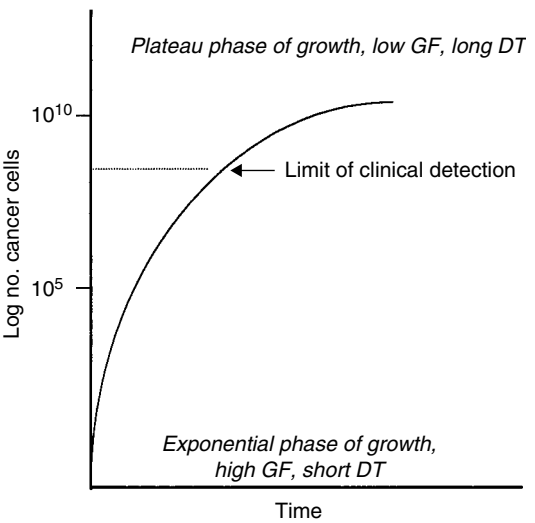

Figure 3.1 Growth characteristics of a tumour. A tumour is not detectable by palpation or radiography until it reaches approximately 1 cm in diameter or 0.5–1 g in weight. By this time it has undergone approximately 30 doublings and contains around 10^8 to 10^9 cells. In the early stages of tumour growth, a high proportion of tumour cells is actively dividing (i.e. the growth fraction, GF, is high and the doubling time, DT, is short). By the time most solid tumours can be detected, only a small proportion of the cells is dividing (i.e. the GF is low and the DT is long).

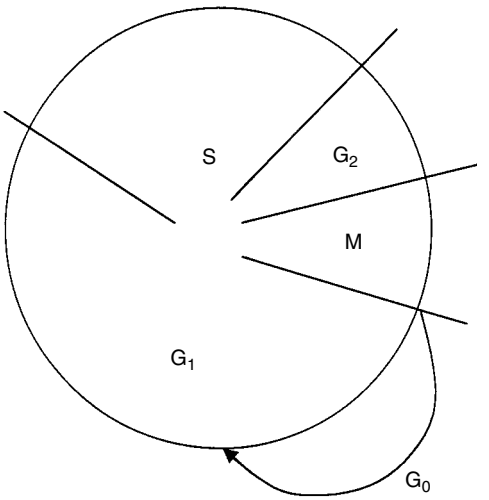

Figure 3.2 The cell cycle. The cell cycle is divided into five main stages: G_0, the resting phase; G_1, the intermitotic phase; S, the DNA synthesis phase; G_2, the premitotic interval; and M, mitosis.

The **doubling time** is the time it takes for a tumour to double in size and is a function of:

- growth fraction: the number of dividing cells within the tumour (cells in phases G_1, S, G_2 and M of the cell cycle; see Figure 3.2)
- cell cycle time
- cell loss factor: the number of cells lost through death.

The growth fraction is the most important factor governing tumour response to chemotherapy, as most cytotoxic drugs are only active against growing and dividing cells. It can be seen from Figure 3.1 that the ideal time to treat a tumour with chemotherapy is early on in its course of its development, when the tumour burden is low, the doubling time is short and the growth fraction is high.

The resting cells within a tumour (those in G_0) are also important, as these cells form a protected reservoir from which the tumour can repopulate. These cells therefore govern the ultimate outcome of treatment.

Tumour composition

Initially tumours are composed of a fairly homogeneous group of cells, but with successive cell divisions, genetic mutations occur which confer different phenotypic properties on the daughter cells. The cell population of a tumour thus becomes heterogeneous with respect to biochemical, morphological and drug response characteristics.

The problem of drug resistance

Some tumours are intrinsically resistant to chemotherapy; for example, many carcinomas and malignant melanoma. Large, slow-growing tumours are also relatively resistant, owing to the low growth fraction. Tumour cells may also acquire resistance by mutation to a drug-resistant phenotype. Thus, a tumour that has previously been responding well to a particular drug may cease to respond. Various drug resistance mechanisms have been identified and are detailed for different drugs in Boxes 3.1–3.5. Multidrug resistance (MDR) is a phenomenon by which a tumour cell becomes resistant to multiple drugs, including some to which the tumour may not have been exposed. MDR can occur as a result of the expression of a membrane P-glycoprotein pump, which expels the drug from the cytoplasm, lowering the intracellular concentration of the drug so that the tumour cell survives. The vinca alkaloids and doxorubicin act as substrates for this pump.

Pharmacological principles of chemotherapy

Mechanisms of action of cytotoxic drugs

Cytotoxic drugs inhibit cell growth and division by a variety of methods. They can be divided into five major groups:

- alkylating agents
- antimetabolites
- antitumour (cytotoxic) antibiotics
- vinca alkaloids
- miscellaneous agents.

Details of each of these groups of agents and their actions are shown in Boxes 3.1–3.5. Most cytotoxic drugs interfere with cell growth and division. The alkylating agents, antitumour antibiotics and some of the miscellaneous agents interfere with the replication of DNA. Antimetabolites are structural analogues of normal metabolites needed for purine or pyrimidine synthesis. They prevent the synthesis of DNA or RNA by enzyme inhibition or cause the production of non-functional molecules. The vinca alkaloids bind to tubulin and inhibit the formation of the mitotic spindle, causing a metaphase arrest in dividing cells, blocking progression beyond the M phase of cell division.

Box 3.1 Alkylating agents

Mechanism of action: substitute alkyl radicals ($R–CH_2–CH_3$) for hydrogen atoms in the DNA molecule. Alkylation of nucleotide bases causes breaks, cross-linkages and abnormal base pairing in DNA, all of which interfere with replication of DNA and transcription of RNA. These actions are not cell cycle specific.

Mechanisms of resistance: defective transport mechanisms, intracellular inactivation of the drug and/or increased DNA repair.

Main tumour activities: variable, see below.

Major toxicities: myelosuppression is the major side-effect of alkylating agents. They also affect the gastrointestinal tract and can cause anorexia, vomiting and diarrhoea. May affect gametogenesis and cause alopecia or thinning of the coat and loss of whiskers.

Individual agents	*Indications*	*Toxicity*
Nitrogen mustard derivatives	Lymphoproliferative disorders	Myelosuppression
Cyclophosphamide	Myeloproliferative disorders Multiple myeloma (certain sarcomas/ carcinomas in combination protocols)	Gastrointestinal (vomiting and diarrhoea) Alopecia or thinning of coat
Chlorambucil	Chronic lymphocytic leukaemia Multiple myeloma Lymphoma (maintenance)	Myelosuppression (mild)
Melphalan	Multiple myeloma Lymphoproliferative disorders (certain carcinomas and sarcomas in combination protocols)	Myelosuppression (may be delayed) Gastrointestinal (vomiting and diarrhoea)

Box 3.2 Antimetabolites

Mechanism of action: generally structural analogues of metabolites required for purine and/or pyrimidine synthesis. They interfere with DNA and RNA synthesis by enzyme inhibition or by causing synthesis of non-functional molecules. Antimetabolites are cell cycle specific, acting during the S phase of the cell cycle.

Mechanisms of resistance: deactivation by intracellular enzymes, defective transport – reduced uptake, use of alternative metabolic pathways.

Main tumour activities: variable, see below.

Major toxicities: myelosuppression, gastrointestinal (anorexia, vomiting and diarrhoea).

Individual agents	*Indications*	*Toxicity*
Antifolates		
Methotrexate	Lymphoproliferative diseases (as part of a protocol)	Myelosuppression Gastrointestinal Renal tubular necrosis (with high-dose regimens)
Purine analogues		
6-Thioguanine	Lymphoproliferative diseases Myeloproliferative diseases	Myelosuppression Gastrointestinal (rare)
Pyrimidine analogues		
Cytarabine (cytosine arabinoside)	Lymphoproliferative disease Myeloproliferative disease Acute myelogenous leukaemia Acute lymphoblastic leukaemia	Myelosuppression Gastrointestinal

Box 3.3 Antitumour antibiotics

Antitumour antibiotics are a group of compounds derived mainly from soil fungi which have inhibitory actions on the growth of tumour cells. This group contains some of the most potent, broad-spectrum anticancer agents identified to date.

Mechanism of action: form stable complexes with DNA, thus inhibiting DNA synthesis and transcription. These actions are not cell cycle specific.

Mechanisms of resistance: decrease in membrane binding and uptake, inactivation by intracellular enzymes, multidrug resistance.

Main tumour activities: broad spectrum of antitumour activity (see below).

Major toxicities: myelosuppression is the major side-effect of antitumour antibiotics (with the exception of bleomycin). They also cause a dose-related gastrointestinal toxicity with anorexia, vomiting and diarrhoea. There is a diverse range of selective toxicities of individual members of the group (see below).

Individual agents	*Indications*	*Toxicity*
Bleomycin	Lymphoproliferative disorders (squamous cell carcinoma, although responses generally incomplete and of short duration)	Minimal myelosuppression Hypersensitivity reactions Pulmonary fibrosis Gastrointestinal
Doxorubicin	Lymphoproliferative diseases Myeloproliferative diseases (Soft-tissue sarcoma) (Carcinoma)	Vesicant Myelosuppression Gastrointestinal (vomiting, diarrhoea and anorexia) Cardiac (acute and chronic) Nephrotoxicity Thinning of hair Hypersensitivity reactions
Idarubicin	Lymphoproliferative diseases	Vesicant Myelosuppression Gastrointestinal (vomiting and anorexia) Cardiac (acute and chronic)
Mitoxantrone	Lymphoproliferative diseases Soft-tissue sarcoma Carcinoma	Myelosuppression Gastrointestinal Cardiac (acute and chronic; less than doxorubicin)

Box 3.4 Vinca alkaloids

Plant alkaloids extracted from the periwinkle *Vinca rosea*.

Mechanism of action: bind specifically to microtubular proteins (tubulin) and inhibit the formation of the mitotic spindle, thus blocking mitosis and causing a metaphase arrest. These actions are cell cycle specific, acting during the M phase. (May have other, less well-documented cytotoxic effects including enzyme inhibition.)

Mechanisms of resistance: reduced efficiency of binding to tubulin, multidrug resistance.

Main tumour activities: variable (see below).

Major toxicities: vesicant, neurological complications documented in humans.

Individual agents	*Indications*	*Toxicity*
Vincristine	Lymphoproliferative diseases Myeloproliferative diseases	Vesicant (perivascular reactions) Alopecia (mild) Neurological
Vinblastine	Lymphoproliferative diseases	Myelosuppression Vesicant (perivascular reactions) Neurological Gastrointestinal

Box 3.5 Miscellaneous agents

(a) Corticosteroids

Widely used in the management of cancer for both therapy and palliation.

Mechanism of action: anti-inflammatory/immunosuppressive actions, lympholytic, suppress mitosis in lymphocytes and cause redistribution of circulating lymphocytes.

Individual agents	*Indications*	*Toxicity*
Prednisolone	Lymphoproliferative diseases Myeloproliferative diseases Mast cell tumours Brain tumours Management of complications of neoplasia Palliation of advanced neoplastic disease Immune-mediated disease	Iatrogenic hyperadrenocorticism Immunosuppression

(b) Platinum co-ordination compounds

Mechanism of action: inhibit protein synthesis by the formation of both inter- and intracross links in the strands of DNA. The N7 atom of guanine is particularly reactive and platinum cross-links between adjacent guanines on the same DNA strand are most readily demonstrated. These agents also react with other nucleophiles such as the sulfydryl groups of proteins and these reactions may produce some of the toxic effects.

Mechanisms of resistance: ? decreased drug uptake and increased DNA repair.

Main tumour activities: broad spectrum of activity against solid tumours (see below).

Major toxicities: myelosuppression; gastrointestinal toxicity may occur; vomiting due to direct actions on chemoreceptor trigger zone and anorexia.

Individual agents	*Indications*	*Toxicity*
Carboplatin	Veterinary experience limited in the cat Sarcomas Carcinomas	Myelosuppression (occurs late, maximal 21 days post-treatment) Anorexia and vomiting (mild)

(c) Others

Individual agents	*Mechanism of action and indications*	*Toxicity*
L-Asparaginase–Crisantaspase	L-Asparaginase is an enzyme which hydrolyses asparagine. Although most normal mammalian tissues synthesise asparagine in amounts sufficient for protein synthesis, lymphoid tumours do not have this ability. Lymphoproliferative disease	Hypersenstivity reactions Gastrointestinal
Hydroxyurea	Inhibits DNA synthesis. Acts by inhibiting the enzyme ribonucleoside diphosphate reductase. This enzyme acts at a critical and rate limiting step in the biosynthesis of DNA. This action is cell cycle specific (S phase) Polycythaemia rubra vera Chronic granulocytic leukaemia	Myelosuppression

The theoretical basis for cytotoxic drug administration

The theoretical aim of any cancer treatment is to reduce the tumour cell population to zero.

The 'fractional cell kill' hypothesis (Skipper *et al.*, 1964), states that cytotoxic drugs kill tumour cells according to first order kinetics, that is, a given dose of drug kills a fixed percentage of the total tumour cell population, as opposed to a set number of cells. This is a theoretical model based on some assumptions that are not completely true in naturally occurring tumours, but forms the basis of the following principles of chemotherapy:

- Cytotoxic drugs should be used at the highest possible dose to produce the highest possible fractional kill.
- Even a highly effective drug acting on a highly sensitive tumour is unlikely to eradicate the tumour cell population in a single dose.
- Chemotherapy should be instituted when the tumour burden is small.
- Chemotherapy is unlikely to be effective if used as a last resort treatment for extensive and advanced disease.

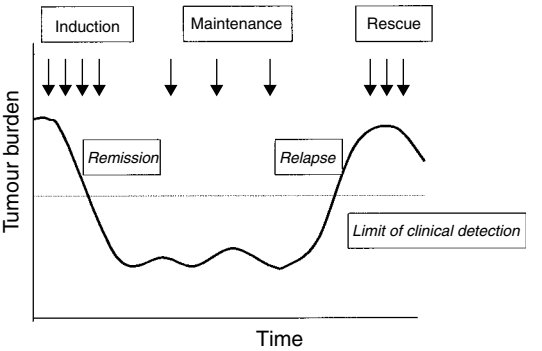

Figure 3.3 Stages of chemotherapy. Chemotherapy is usually divided into three different phases: induction therapy, maintenance therapy and rescue therapy. The initial induction therapy is intensive and often results in clinical remission of a tumour. The maintenance therapy is less intensive and eventually the residual (subclinical) tumour becomes resistant, leading to tumour regrowth and 'relapse'. Rescue therapy or intensification therapy may be attempted at this stage, but the tumour is rarely as responsive to rescue treatment as it was to induction therapy, usually as a result of drug resistance.

Stages of therapy

It is important to define the aims of treatment at the outset so that the owner knows what to expect. Radical chemotherapy regimens may be used if the intention is to cure the tumour. However, in veterinary medicine, a balance between treatment efficacy and toxicity has to be reached, so that quality of life is maintained. In most cases, chemotherapy is given in a palliative fashion; the goal would be to control the tumour for a while, but not to achieve cure.

Chemotherapy usually involves a course of treatment in three phases as detailed below and represented in Figure 3.3:

- **Induction therapy**: the aim of induction therapy is to reduce the tumour to a clinically undetectable level, i.e. clinical remission. This usually involves an initial intensive period of drug administration. Remission is not synonymous with cure, as subclinical disease often remains; and the disease would recur without continued treatment.
- **Maintenance therapy**: if clinical remission is achieved by the induction therapy, a less intensive treatment regimen is then instituted to maintain the remission.
- **Rescue therapy** (also called intensification therapy) is required if the tumour does not respond to the induction regimen, or in cases where the initial response appears to be good but the tumour recurs or relapses despite continued treatment (usually as a result of acquired drug resistance). The aim is to establish remission of the tumour again and usually involves more aggressive therapy, preferably using drugs to which the tumour has not been exposed previously. Drugs with similar chemistry or with the same mode of action are likely to share resistance mechanisms.

Single-agent versus combination chemotherapy

It is generally accepted that combination chemotherapy is more effective than single-agent chemotherapy. Using a combination of drugs with different mechanisms of action and different toxicities means that the overall tumour response can be enhanced without an increase in toxicity to normal tissues. Each component of a combination protocol should have proven efficacy when used in isolation and ideally the drugs

should not have overlapping toxicities. Examples of protocols are given later in this chapter.

Timing of treatments

Rather than cytotoxic drugs being given continuously, they are often administered in pulses, thus allowing normal body tissues to recover between treatments. The timing of pulses is critical, such that recovery of normal tissues occurs without allowing significant regrowth of the tumour. For most myelosuppressive agents, bone-marrow suppression is maximal around days 7–11 post-treatment, with recovery around day 21, meaning that 3 weekly cycles may be used. For example, doxorubicin can be administered at 25 mg/m^2 to cats at 21 day intervals (O'Keefe & Schaeffer, 1992). Other agents may be given at weekly intervals or on a semicontinuous basis.

Dosage

Chemotherapy agents are not used as aggressively in cats as in humans, because the same degree of toxicity cannot be managed routinely in veterinary practice and most owners would not tolerate severe toxic effects in their pet.

There is an ongoing debate as to whether doses for cats are optimally calculated on a body surface area basis or on a body weight basis. This matter has not yet been resolved and the reader is likely to encounter regimens involving both methods. A conversion table is included to convert body weight in kilograms to surface area in metres squared (Table 3.1).

Table 3.1 Conversion chart from body weight to surface area for cats

Body weight (kg)	Surface area (m^2)
2.0	0.159
2.2	0.169
2.4	0.179
2.6	0.189
2.8	0.199
3.0	0.208
3.2	0.217
3.4	0.226
3.6	0.235
3.8	0.244
4.0	0.252
4.2	0.260
4.4	0.269
4.6	0.277
4.8	0.285
5.0	0.292
5.5	0.311
6.0	0.330

Complications of chemotherapy

A number of complications can arise while an animal is receiving chemotherapy. Many of the intravenous injectable agents are either irritant or vesicant if perivascular injection occurs and prompt action should be taken (see below). Immediate hypersensitivity reactions can happen with some drugs. Cytotoxic drugs are not specific to tumour cells in their action and normal body tissues that contain a large proportion of dividing cells, such as the bone marrow and the epithelium of the gastrointestinal tract, are susceptible to toxicity. These normal tissues can recover by recruitment of stem cells and so effects on these organs are usually readily reversible on stopping chemotherapy. Loss of whiskers is common in cats receiving chemotherapy (Plate 3.1); some thinning of the coat may also occur. Some agents have specific toxicities that are less reversible, such as nephrotoxicity and cardiotoxicity with doxorubicin.

Myelosuppression

Most cytotoxic drugs can cause bone-marrow toxicity (myelosuppression). Vincristine is generally regarded as minimally myelosuppressive in dogs, but has been reported to cause significant myelosuppression in cats (Hahn *et al.*, 1996). Neutropenia is one of the more common complications of chemotherapy and is the major dose-limiting factor. Neutrophil counts $<2 \times 10^9$/l can be life threatening, with a risk of overwhelming sepsis. Thrombocytopenia can occur, but is rarely severe enough to cause bleeding. Mild anaemia may also occur, but is often indistinguishable from anaemia of chronic disease. It is essential that a blood sample is taken for full haematology as a baseline before embarking on a course of chemotherapy and regular monitoring will be required to assess for myelosuppression throughout treatment (at least every 3–4 weeks, or more frequently depending on the protocol used).

The most common cause of sepsis in the neutropenic cancer patient is absorption of enteric bacteria (e.g. *Escherichia coli, Klebsiella pneumoniae*) through damaged gastrointestinal mucosa. Pyrexia is the most common sign of sepsis, but any illness in a patient on chemotherapy should be attended to promptly and the clinician should be alerted to the possibility of

Table 3.2 Management of the neutropenic cancer patient

Neutrophil count ($\times 10^9$/l)	Status of patient	Action
>3	Normal	Continue chemotherapy Monitor WBC count according to protocol used
2–3	Evidence of myelosuppression	Decrease dose of myelosuppressive drug(s) by 50% or delay chemotherapy Repeat WBC count in 1–2 weeks
<2	Moderate myelosuppression	Stop myelosuppresssive chemotherapy Monitor patient and WBC count carefully If patient has a predisposition to infection, e.g. ulcerating tumour, administer potentiated sulphonamide or fluoroquinolone antibiotics
<1	Severe myelosuppression Asymptomatic/afebrile	Stop all cytotoxic treatment Administer potentiated sulphonamide or fluoroquinolone antibiotics
	Clinically ill/pyrexic	Collect samples to try to identify infective agent (e.g. blood and urine cultures) Supportive therapy (intravenous fluid therapy and other as indicated) Antibiotics: a penicillin or cephalosporin plus gentamycin, or fluoroquinolone plus clindamycin or metronidazole (can be altered according to culture and sensitivity later)

WBC: white blood cell.

neutropenia. Cats tend to cope with low numbers of neutrophils better than dogs; nevertheless, prophylactic measures should be taken as indicated in Table 3.2.

Gastrointestinal toxicity

The gut lining contains large numbers of rapidly dividing cells and is relatively susceptible to the toxic effects of chemotherapy agents. Death and desquamation of the alimentary epithelium usually occur 5–10 days after drug administration and effects such as stomatitis, vomiting and mucoid or haemorrhagic diarrhoea can be seen. Some drugs can cause nausea and vomiting by direct stimulation of the chemoreceptor trigger zone (e.g. doxorubicin).

These effects are usually self-limiting and symptomatic management is usually sufficient (e.g. a period of starvation for 24 h followed by a bland diet offered little and often). Occasionally patients will require hospitalisation, intravenous fluid therapy and antibiotics. If gastric ulceration is suspected, H_2 blockers such as cimetidine or ranitidine may be used, plus the gastric protectant sucralfate.

Cats are particularly prone to anorexia when receiving chemotherapy. This is a problem that the owner can find very distressing and also prevents the cat from receiving adequate nutrition, so must be avoided if at all possible. Anorexia may due to nausea, or may occur as a result of altered taste sensation, as is reported by some human patients. The possibility that the cat could be in pain should also be addressed, depending on the site and type of tumour.

Antiemetics such as metoclopramide (0.5–1 mg/kg i.m., s.c. or p.o. every 6–8 h) or ondansetron may be required to help prevent nausea and vomiting. Ondansetron is a serotonin antagonist and a very potent antiemetic; it may be useful when signs are not controlled by other drugs. An intravenous loading dose of 0.5 mg/kg should be given, followed by either an intravenous infusion of 0.5 mg/kg per hour for 6 h or oral therapy at 0.5–1 mg/kg every 12–24 h. Appetite stimulants may also be useful, such as cyproheptadine, an antihistamine with serotonin antagonistic effects (0.1–0.5 mg/kg p.o. every 8–12 h). Megoestrol acetate can also be used as an appetite stimulant (2.5 mg per cat p.o. daily for 4 days, then every 2–3

days). If a cat suffers from persistent anorexia, it may require feeding via a nasogastric or gastrostomy tube.

Hypersensitivity/anaphylaxis

Hypersensitivity reactions are a rare possibility following cytotoxic drug administration. Immune-mediated reactions are the most common (e.g. following administration of L-asparaginase), whereas doxorubicin can cause direct degranulation of mast cells and some agents can activate the alternative complement pathway.

In the unfortunate event of anaphylaxis occurring:

- Stop administration of the drug immediately.
- Treat with intravenous fluid therapy, soluble corticosteroids, adrenaline and antihistamines.

Phlebitis and tissue necrosis

Many cytotoxic drugs are irritant (e.g. carboplatin, mitoxantrone) or vesicant (e.g. vincristine, vinblastine and doxorubicin) and may cause severe local tissue necrosis if injected perivascularly. This can be prevented by good restraint of the cat and using an intravenous catheter, flushing with saline before and after administration of the drug to check catheter placement (Plate 3.2).

In the event of extravasation of a vesicant drug, the following action should be taken immediately:

- Stop the infusion, but do not remove the catheter.
- Aspirate the extravasated drug from the affected area; this may be assisted by subcutaneous injection of normal saline to dilute any residual drug.
- Remove the catheter.
- Administer soluble corticosteroids (e.g. hydrocortisone or dexamethasone) intravenously, locally (as subcutaneous injections) and topically (as cream) around the site of extravasation.
- Cold compresses may help to reduce the inflammatory response.

In humans there are specific recommendations for extravasation of certain drugs, (Allwood & Wright, 2002).

Specific drug-associated toxicities

Some drugs should never be used in the cat owing to extreme toxicity effects:

- **Cisplatin** causes fatal pulmonary oedema in cats (Knapp *et al.*, 1987).
- **5-Fluorouracil** causes severe neurotoxicity and death (Harvey *et al.*, 1977, Hennes *et al.*, 1977).

Other drugs have known specific toxicities and should be used with care:

- **Doxorubicin and related drugs**: as well as myelosuppression and anorexia, doxorubicin is known to cause acute and chronic cardiotoxicity through its actions on myocardial calcium metabolism. The rate of infusion can influence cardiotoxicity and it is recommended that the drug is administered as an infusion over at least 15 min.

  Dysrhythmias have been reported in cats receiving doxorubicin (Jeglum *et al.*, 1985, Mauldin *et al.*, 1988) and so the pulse rate should be monitored and the heart auscultated during infusion and immediately afterwards. Tachycardia has been reported in dogs. If any problems occur, the infusion should be slowed or stopped. Cumulative doses of doxorubicin cause chronic cardiotoxicity. Although clinical heart disease is rare in cats, echocardiographic changes consistent with cardiomyopathy (reduced fractional shortening) have been observed, and pathological changes such as cardiac myocyte vacuolisation and myocytolysis have been demonstrated post mortem (O'Keefe *et al.*, 1993). These changes occurred after a cumulative dose of 170–240 mg/m^2.

  Nephrotoxicity is another problem reported in cats following doxorubicin treatment. Glomerular and tubular lesions plus interstitial fibrosis have been described, and monitoring of blood urea, creatinine and urine specific gravity is recommended before each doxorubicin treatment (O'Keefe *et al.*, 1993).
- **Cyclophosphamide**: haemorrhagic cystitis is extremely rare in the cat compared with the dog and monitoring of urine for haematuria is not usually warranted.
- **Carboplatin** appears to be safe for use in the cat (unlike its related compound cisplatin). More work is required to define the clinical efficacy of this drug in cats, but it has been suggested for use in head and neck carcinomas, soft-tissue sarcomas and mammary carcinomas (Mauldin, 1997). It should be noted that the nadir of neutropenia occurs late with this drug, around 21 days post-treatment, and 4 weekly dosing intervals have been recommended (Mauldin, 1997).

Indications for chemotherapy

Chemotherapy should be reserved for malignant tumours that are known to respond to cytotoxic drugs

and is indicated for widespread or systemic disease. Examples where chemotherapy would be the first line of treatment are lymphoproliferative and myeloproliferative diseases (lymphoma, myeloma and some leukaemias). Chemotherapy is rarely of value as the sole treatment for solid (non-lymphoid) tumours such as carcinomas, sarcomas or melanomas. Here, surgery or radiotherapy would be the first choice of treatment; however, cytotoxic drugs may be useful in an adjuvant setting for the treatment of metastatic disease.

Criteria to be fulfilled before starting chemotherapy

- **Histological diagnosis and grading of the tumour**: malignancy must be confirmed and the tumour should be documented as sensitive to chemotherapy.
- **Clinical staging to determine the extent of disease**: this is important prognostically before starting treatment.
- **Patient considerations**: the temperament of the cat is an important factor to consider before embarking on a course of chemotherapy, as treatment will require frequent transportation to the veterinary clinic and regular blood sampling for haematological monitoring. The cat must be amenable to drug administration such as oral dosing with tablets and will need to tolerate restraint for intravenous catheter placement and injection for many protocols. Attempting to administer cytotoxic agents to poorly restrained fractious cats poses significant danger to all concerned. The general state of health and condition of the patient should also be evaluated.
- **Identification and correction of any tumour-related or other medical complications**: the doses of cytotoxic drugs quoted in this chapter are generally well tolerated in healthy cats, but in the event of concurrent renal, hepatic or cardiac disease, dose reduction in proportion with the degree of organ dysfunction may be required. For example, doxorubicin and vincristine doses should be reduced in the presence of liver dysfunction. Carboplatin and cyclophosphamide doses should be reduced if there is renal dysfunction. It should also be noted that activation of cyclophosphamide may be reduced with liver dysfunction, leading to reduced drug efficacy. Hypercalcaemia is relatively rare in cats with neoplasia compared with dogs, but will require urgent attention when it does occur (rehydration followed by diuresis with 0.9% saline at three times maintenance rates plus frusemide at 2–3 mg/kg twice daily).
- **Baseline parameters**: a baseline haematology including full white blood cell differential and platelet count should always be taken before starting chemotherapy, as most cytotoxic drugs are myelosuppressive. Biochemistry and urinalysis are also important to assess general health status and organ function.
- **Owner compliance and consent**: good communication with the owner is essential before treatment. The owner must want to treat the cat with chemotherapy. Treatment goals should be established at the outset and the owner should be advised of potential complications. Cost is another important factor to discuss. Many chemotherapy drugs are expensive, but the cost of monitoring should also be accounted for. It is irresponsible to prescribe chemotherapy drugs without adequate monitoring.

Treatment of selected specific diseases with chemotherapy

Lymphoma (see Chapters 9 and 23)

Lymphoma is the most common tumour in the cat, accounting for up to 30% of all feline malignancies (Priester & McKay, 1980). The high prevalence is due to its association with feline leukaemia virus (FeLV). Although many cases of lymphoma will be FeLV negative on antigen testing (i.e. not viraemic), it is thought that previous exposure to FeLV and retroviral transformation are important in the development of most cases. Some feline cases do occur spontaneously without prior FeLV exposure. Cats that are feline immunodeficiency virus (FIV) positive are at increased risk of developing lymphoma (Shelton *et al.*, 1990; Hutson *et al.*, 1991), but the exact role of FIV in lymphomagenesis is not known.

Lymphoma arises from the neoplastic transformation and proliferation of lymphoid cells in solid organs (e.g. lymph nodes, liver, spleen). A tumour may develop in one site and spread to others, or may develop in multiple sites simultaneously. Mediastinal (thymic) (Figures 3.4, 3.5) and alimentary lymphoma (Plate 3.3) are more common than the multicentric form (Plate 3.4) in the cat. Extranodal forms also occur (e.g. renal, central nervous system, ocular, nasal and cutaneous lymphomas) (Plates 3.5, 3.6, Figure 3.6).

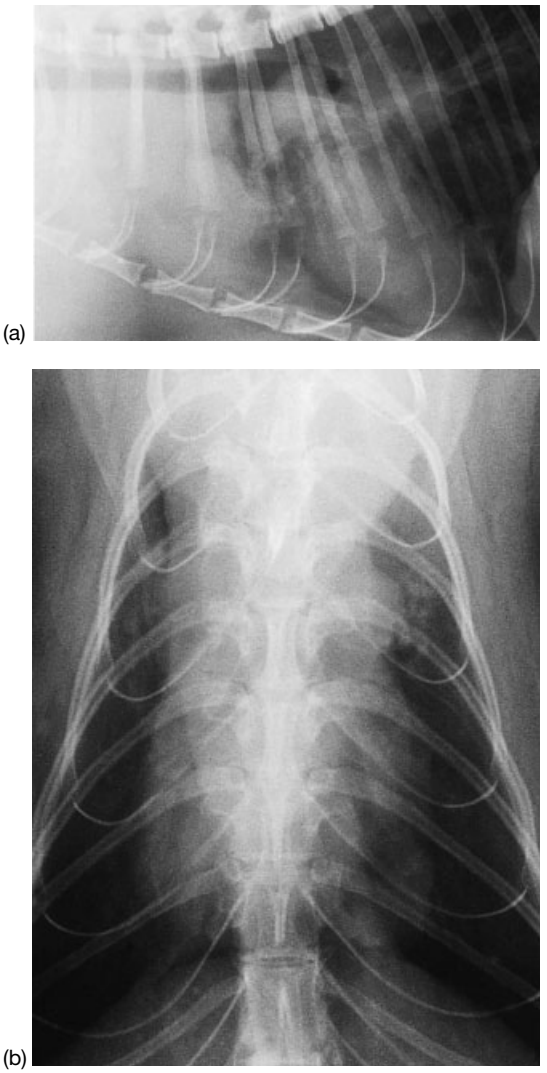

Figure 3.4 Mediastinal lymphoma before treatment. (a) Lateral radiograph of the thorax showing increased soft-tissue opacity in the cranial thorax with dorsal displacement of the trachea; (b) dorsoventral radiograph of the thorax showing widening of the cranial mediastinum.

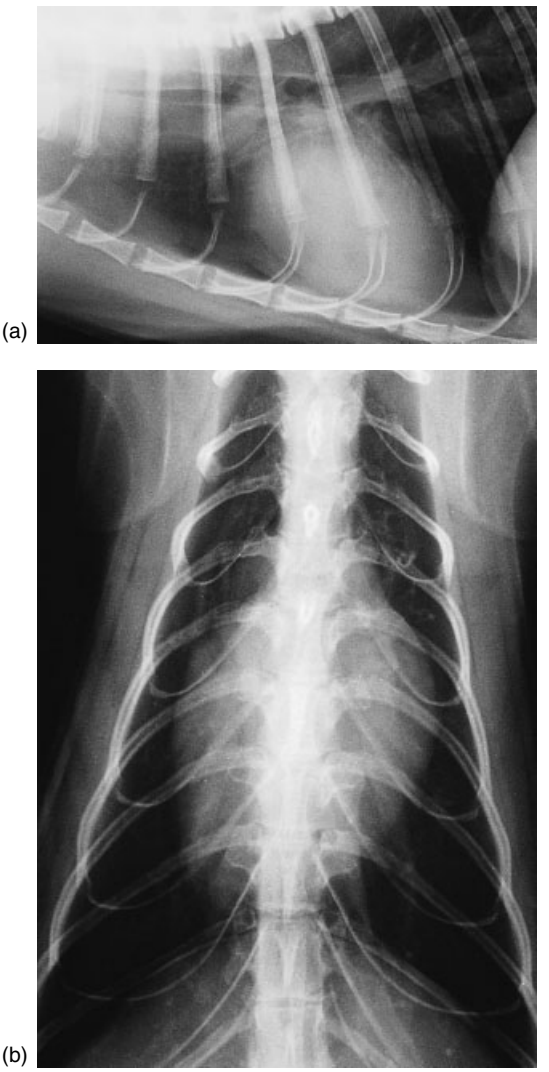

Figure 3.5 Mediastinal lymphoma 2 weeks after starting COP treatment (same case as Figure 3.4). (a) Lateral radiograph of the thorax showing diminished soft-tissue opacity cranial to the heart; (b) dorsoventral view of the thorax. The cranial mediastinum is no longer widened.

Clinical signs will vary depending on site. Diagnosis is made on the basis of clinical and radiographic/ultrasonographic findings of lymphadenopathy plus histological or cytological confirmation of neoplastic populations of lymphoid cells in affected organs or lymph nodes (Plate 3.7). Bone-marrow aspiration may be indicated if haematology reveals circulating abnormal lymphoid cells or cytopenias.

Treatment

Without any treatment, most affected cats will die within 4–6 weeks. Short-term palliation (in the order of 2–3 months) can be achieved using prednisolone alone. Various combined chemotherapy protocols have been advocated for induction. In practice, the high-dose COP or COAP protocols [cyclophos-

Figure 3.6 Nasal lymphoma. Loss of turbinates and increased soft-tissue density can be seen in the left nasal passages of this cat with intranasal lymphoma.

Table 3.3 High-dose COP protocol for lymphoma treatment

Cyclophosphamide	250–300 mg/m^2 i.v. or p.o. every 21 days (low end of dose range may be preferable owing to myelosuppression)
Vincristine	0.75 mg/m^2 i.v. every 7 days for 4 weeks, then every 21 days
Prednisolone	1 mg/kg p.o. daily for 4 weeks, then every 48 h

Provided the animal achieves a complete response, this 3 weekly cycle is continued for 1 year, then every 4 weeks for another 6 months.
Note: Haematology should be monitored every 2–3 weeks during induction phase.
For a ***modified COAP protocol***, cytosine arabinoside can be added to the above protocol in one of the following ways. The ideal dose has not been established for the cat and recommended regimens include:
100 mg/m^2 i.v. for the first 2 days of treatment, or
100 mg/m^2 given by infusion over 2–3 days, or
150 mg/m^2 s.c. every 12 h for 48 h, or
30 mg/kg s.c. divided into 4 doses given every 12 h
Source: Cotter (1983).
Cytosine arabinoside has been recommended in all cases of renal lymphoma (Mooney *et al*., 1987).

phamide, vincristine, (cytosine arabinoside), and prednisolone] are often selected because of ease of administration, familiarity with drugs of proven efficacy, low incidence of side-effects and relatively low cost (Table 3.3). The high-dose COP protocol (Cotter, 1983) involves giving cyclophosphamide as a pulse every 21 days, which allows the bone marrow to recover between treatments.

Table 3.4 Low-dose COP protocol for lymphoma treatment

Cyclophosphamide	50 mg p.o. every 7–14 days (equivalent to 50 mg/m^2 every other day)
Vincristine	0.5 mg/m^2 i.v. every 7 days
Prednisolone	40 mg/m^2 p.o. daily for 7 days, then 20 mg/m^2 every 48 h (with cyclophos phamide)

Maintenance
If the disease is in remission after 8 weeks, reduce to alternate week treatment for a further 4 months. If the disease is still in remission at 6 months, reduce to 1 week of treatment in 3; and after 1 year to 1 week in 4. Treatment should not be stopped in cases maintaining complete remission until 2 years after starting therapy.
L-Asparaginase (400 IU/kg or 10 000 IU/m^2 by intramuscular injection weekly) may be used for rescue, or doxorubicin, or mitoxantrone.
Cytosine arabinoside can be added to this protocol initially, as detailed in Table 3.3, to give a **COAP** protocol.
See text for explanation of modifications needed for the cat.

The low-dose COP protocol (Table 3.4) is difficult to use because of tablet size, as cyclophosphamide tablets should not be divided. The protocol can be adapted to achieve an equivalent dose to 50 mg/m^2 every other day, and for most cats this means giving a 50 mg tablet every 7–10 days during the induction period and then one tablet at the time of each fortnightly or 3–4 weekly vincristine injection during maintenance.

For example:

3.6 kg cat, body surface area = 0.235 m^2

Dose rate of cyclophosphamide = 50 mg/m^2 every other day

The cat requires 11.75 mg of cyclophosphamide every other day, but 50 mg tablets must not be split

By multiplying this by 7, the cat's requirement for a fortnight is 82 mg. One tablet a week would be too much and one tablet a fortnight would be too little.

For 4 weeks the requirement would be 164 mg.

Therefore, one 50 mg tablet every 10 days is ideal.

This method of oral pulse dosing every 7–14 days can result in cumulative myelosuppression, since each new tablet is given at the time when myelosuppression is likely to be maximal from the previous dose.

Most studies of feline lymphoma tend to group the different anatomical forms of lymphoma together to produce remission and survival data. Using most combination chemotherapy protocols, approximately 60–75% of cats with lymphoma can be expected to attain remission, with median survival times of around 5–7 months (Cotter, 1983; Mooney *et al.*, 1989; Teske *et al.*, 2002). For alimentary lymphoma the prognosis is generally poorer, particularly if the disease is diffuse. In one study of 28 cats with alimentary lymphoma receiving combined chemotherapy (not including doxorubicin), the overall median survival rate was 50 days (Ogilvie & Moore, 1995). In another study of 31 cats with alimentary lymphoma treated with a doxorubicin-containing protocol, the median survival was 201 days (Rassnick *et al.*, 1999). There is a risk of intestinal perforation and peritonitis if the lymphoma has affected the full thickness of the gut. In a study of 28 cats with primary renal lymphoma treated with a combination of vincristine, cyclophosphamide, methotrexate, prednisolone and cytosine arabinoside, 61% of cats showed a complete response with a median survival of 5.7 months (Mooney *et al.*, 1987). Mediastinal lymphoma (usually young FeLV-positive cats) has been reported to carry a poor prognosis, with expected survival times of 2–3 months (Jeglum *et al.*, 1987; Vail *et al.*, 1998; Peaston & Maddison, 1999). However, a more recent study reported a complete response rate of over 80% with a median disease-free interval of 251 days in 22 cats with mediastinal lymphoma treated by COP (Teske *et al.*, 2002). The prognosis for spinal lymphoma is usually poor.

Some studies have indicated that protocols containing doxorubicin may achieve longer remission times than COP alone in the treatment of feline lymphoma. An example of a more complicated doxorubicin-containing protocol is given in Table 3.5 (Vail & MacEwen, 2001). Moore *et al.* (1996) performed a study that compared single-agent doxorubicin therapy to continued COP therapy for maintenance, following successful induction with 4 weeks of COP (high dose). The total treatment period was 6 months. The seven cats that received doxorubicin at 25 mg/m^2 every 3 weeks from week 4 had a median remission duration of 281 days, compared with 83 days for the 11 cats continuing to receive COP. However, the value of doxorubicin in the treatment of feline lymphoma remains the subject of some controversy. A recent study showed that doxorubicin was not very effective as a single agent in induction of remission in cats with lymphoma, which calls into question its value in combined protocols (Kristal *et al.*, 2001). Idarubicin has also recently been evaluated as an agent that can be given orally to maintain remission (Moore *et al.*, 1995) and appears to offer similar remission times to COP. Both doxorubicin and idarubicin can cause anorexia in cats.

It should be noted that attempts at rescue therapy in cats are frequently unsuccessful. Reinduction may be attempted, using the original induction protocol, or different drugs may be tried.

FeLV- or FIV-positive cats can be treated with chemotherapy provided they appear otherwise well, but control measures should be instituted to

Table 3.5 University of Wisconsin–Madison School of Veterinary Medicine protocol for the treatment of feline lymphoma

Week	
1	Vincristine 0.5–0.7 mg/m^2 i.v. once
	Asparaginase 400 IU/kg s.c. once
	Prednisolone 2 mg/kg p.o. once daily
2	Cyclophosphamide 200 mg/m^2 i.v. once
	Prednisolone 2 mg/kg p.o. once daily
3	Vincristine 0.5–0.7 mg/m^2 i.v. once
	Prednisolone 1 mg/kg p.o. once daily
4	Doxorubicin 25 mg/m^2 i.v. once
	Prednisolone 1 mg/kg p.o. every other day[a]
6	Vincristine 0.5–0.7 mg/m^2 i.v. once
7[b]	Cyclophosphamide 200 mg/m^2 i.v. once
8	Vincristine 0.5–0.7 mg/m^2 i.v. once
9[c]	Doxorubicin 25 mg/m^2 i.v. once
11	Vincristine 0.5–0.7 mg/m^2 i.v. once
13[b]	Cyclophosphamide 200 mg/m^2 i.v. once
15	Vincristine 0.5–0.7 mg/m^2 i.v. once
17	Doxorubicin 25 mg/m^2 i.v. once
19	Vincristine 0.5–0.7 mg/m^2 i.v. once
21[b]	Cyclophosphamide 200 mg/m^2
23	Vincristine 0.5–0.7 mg/m^2 i.v. once
25[d]	Doxorubicin 20 mg/m^2 i.v. once

Source: Vail & MacEwen (2001).
[a] Prednisolone is continued (1 mg/kg p.o. every other day from this point).
[b] If renal or CNS lymphoma is present, substitute cytosine arabinoside at 600 mg/m^2 divided s.c. twice daily over 2 days at these treatments.
[c] If in complete remission at week 9, continue to week 11.
[d] If in complete remission at week 25, therapy is discontinued and cat is checked monthly for recurrence.

Haematology should be performed before each cyclophosphamide and doxorubicin chemotherapy. If neutrophils are $<2.0 \times 10^9$/l, wait 5–7 days, repeat haematology, then administer the drug if neutrophils have risen above the 2.0×10^9/l cut-off.

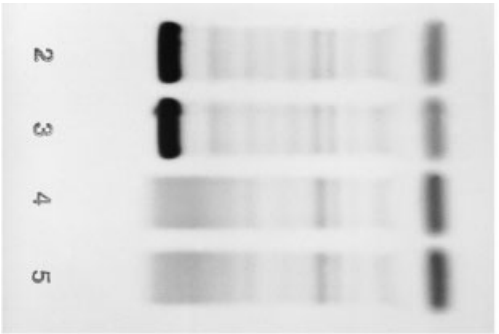

(a)

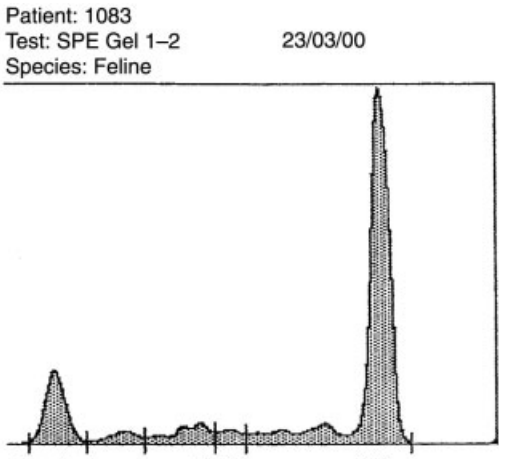

Fraction	Rel %	G/L
Albumin	13.8	20.15
Alpha 1	3.9	5.69
Alpha 2	7.2	10.51
Beta	3.2	4.67
Gamma	72.0	105.12

(b) Total G/L 146.00 A/G: 0.16

Figure 3.7 Serum globulin electrophoresis trace from a case of myeloma. A monoclonal globulin spike is present, due to excessive production of immunoglobulin of one type from the neoplastic plasma cells.

prevent transmission of these viruses to other cats. FeLV-positive cats tend to have a poorer prognosis than FeLV-negative cats and have shorter survival times (Mooney *et al.*, 1989) (see Chapters 23 and 24).

Myeloma (see Chapter 9)

Myeloma caused by neoplastic proliferation of plasma cells in the bone marrow, is a relatively infrequent cancer in cats. Usually these plasma cells will produce excessive amounts of immunoglobulin of one type.

Animals may present with:

- haematological abnormalities: anaemia, thrombocytopenia and neutropenia because of reduced haematopoiesis due to neoplastic plasma cells proliferating in the bone marrow
- weight loss, lethargy, pyrexia and petechial haemorrhages
- hyperviscosity sydromes (e.g. retinal haemorrhage/detachment, neurological signs) due to monoclonal immunoglobulin M (IgM) or IgA hypergammaglobulinaemia (Figure 3.7).

Skeletal pain due to localised tumour-mediated osteolysis is rare in cats.

Table 3.6 Protocol for canine myeloma and suggested adaptation for the cat

	Canine dose	Suggested modification for cat
Melphalan	1.5–2 mg/m^2 p.o. daily for 3–6 weeks then every 48 h	One 2 mg tablet every 3–6 days p.o. to give equivalent dose in whole number of tablets, then reduce frequency to effect
plus		
Prednisolone	40 mg/m^2 p.o. daily, reducing to 20 mg/m^2 every 48 h depending on response	As for dog

Diagnosis is based on the presenting clinical signs, monoclonal hypergammaglobulinaemia and the demonstration of neoplastic plasma cells in the bone marrow (Plate 3.8). Myeloma can be treated with melphalan plus prednisolone, by adjusting the protocol used in dogs, as tablets should not be split (Table 3.6).

The aim of induction therapy is to lower plasma immunoglobulin concentration to within normal limits. Once this has been achieved, the dose rate and frequency of drugs are reduced to maintain this situation. Response rates are poorer in the cat than in the dog. Combined evidence from a variety of case reports gives an estimated response rate of 40%, with a median survival of 170 days (Ogilvie & Moore, 1995).

Leukaemias (see Chapters 9 and 23)

Leukaemias are malignant neoplasms that arise from haemopoietic precursor cells in the bone marrow. They are relatively rare in the cat. Approximately two-thirds of leukaemias in the cat are myeloid in origin and one-third is lymphoid on the basis of cytochemical staining (Couto, 1998). FeLV can cause lymphoid or myeloid leukaemia due to retroviral transformation, but the role of FIV remains unclear. Acute leukaemias are more common than chronic leukaemias in the cat. Clinical signs are often vague and include lethargy, anorexia, weight loss, fever, mild lymphadenopathy, hepatosplenomegaly, pallor and petechiae. Diagnosis is based on the presence of cytopenias plus neoplastic circulating cells in most cases. Bone-marrow aspiration or biopsy is needed to confirm leukaemia (Plates 3.9–3.12).

Treatment of acute leukaemia is fraught with difficulties and euthanasia should be considered as an option. Untreated cats are likely to die within a couple of weeks. Should chemotherapy be considered, intensive supportive therapy may be required. Severe cytopenias preclude the use of myelosuppressive agents and result in significant risk of sepsis and bleeding. Organ failure due to neoplastic invasion and disseminated intravascular coagulation are potential sequelae. Potential protocols are detailed in Table 3.7. For acute myeloid leukaemia (AML) median survival times are in the order of 3 weeks (range 2–10 weeks) (Couto, 1998). Cases of acute lymphoblastic leukaemia (ALL) may live longer, but the prognosis is still grave.

Chronic leukaemias are extremely rare. Chronic lymphocytic leukaemia (CLL) is milder than ALL and runs a more protracted course. Response to therapy with chlorambucil and prednisolone appears to be good. Chronic myeloid leukaemia (CML) is poorly characterised in cats.

Other miscellaneous tumours

The role of chemotherapy in the treatment of feline carcinomas and sarcomas is poorly documented, either as a sole treatment for unresectable disease, or as adjuvant therapy following surgical resection, to try to prevent or retard metastatic growth. Although there are reports of using chemotherapy in these situations in small numbers of animals, data from large-scale clinical studies are lacking. Doxorubicin has been recommended as a single agent or in combination with cyclophosphamide or cyclophosphamide and vincristine for some sarcomas and carcinomas (Table 3.8) (MacEwen *et al.*, 2001). Mitoxantrone has also been used as a single agent with some success in the treatment of a variety of carcinomas and sarcomas (Ogilvie *et al.*, 1993). Carboplatin is currently being evaluated (Mauldin, 1997).

Mammary carcinomas

Some 80–90% of mammary tumours in the cat are malignant, with adenocarcinoma being the most frequent histological diagnosis (Hayden & Nielsen, 1971; Hayes *et al.*, 1981; Moulton, 1990). Feline mammary malignancies are aggressive and highly metastatic, spreading to the lungs, regional lymph nodes, pleura, liver and other organs. Chemotherapy is not well established as an effective adjuvant strategy following mastectomy in cats. In cats with metastatic or non-resectable tumours, a combination protocol of doxorubicin with cyclophosphamide has been shown to produce a short-term response in approximately 50% of cases in two studies (Jeglum *et al.*, 1985; Mauldin *et al.*, 1988). The number of cats in both of these studies was small and toxic effects were seen (anorexia and myelosuppression). Mauldin's study (1988) showed a median survival time of 5 months in the responders versus 2.5 months in the non-responders.

Haemangiosarcoma

Haemangiosarcoma is a rare neoplasm in the cat that arises in the subcutis or within abdominal organs. Tumours in the subcutis have a low rate of metastasis, whereas abdominal haemangiosarcoma is highly metastatic and aggressive (Scavelli *et al.*, 1985; Miller *et al.*, 1992). Some authors have suggested doxorubicin as a single agent or in combination with cyclophosphamide plus or minus vincristine, following surgery for intra-abdominal haemangiosarcoma (Table 3.8) (MacEwen & Withrow, 1996).

Mast cell tumours

Cutaneous mast cell tumours in the cat are usually solitary and benign in nature (Molander-McCrary *et al.*, 1998). Surgery is the treatment of choice in most

Table 3.7 Suggested chemotherapy protocols for treatment of leukaemias in the cat

Type of leukaemia	Suggested drugs	Comment
Acute lymphoblastic leukaemia (ALL)	1. Vincristine 0.5 mg/m^2 i.v. weekly Prednisolone 40 mg/m^2 p.o. once daily for a week then 20 mg/m^2 every other day (Couto, 1998) or	
	2. High-dose COP protocol (see Table 3.3) (Cotter, 1983) or	2. Do not use if significant myelosuppression
	3. Cytosine arabinoside 10 mg/m^2 s.c. twice daily (Helfand, 1987)	3. Do not use if significant myelosuppression
Chronic lymphocytic leukaemia (CLL)	1. Chlorambucil at 20 mg/m^2 p.o. once every 2 weeks (Couto, 1998) or 2. Chlorambucil as above plus prednisolone at 50 mg/m^2 p.o. once daily for a week, then 20 mg/m^2 every other day (Couto, 1998)	1 and 2. Severe myelosuppression is less likely with CLL, but monitor haematology regularly
Acute myeloid leukaemia (AML)	1. Cytosine arabinoside 5–10 mg/m^2 s.c. twice daily for 2–3 weeks, then alternate weeks (Couto, 1998) or 2. Cytosine arabinoside 100 mg/m^2 s.c.or i.v. daily for 2–6 days plus 6- Thioguanine at dose equivalent to 50 mg/m^2 daily or every other day (do not split tablets) or 3. Cytosine arabinoside and 6-thioguanine as above plus Doxorubicin 10 mg/m^2 every 7 days or 4. Cytosine arabinoside 100–200 mg/m^2 in i.v. drip over 4 h plus Mitoxantrone 4–6 mg/m^2 in i.v. drip over 4 h repeat every 3 weeks (Couto, 1998)	1–4. Do not use if significant myelosuppression
Chronic myeloid leukaemia (CML)	Hydroxyurea 500 mg every 5–7 days as tablets should not be split (equivalent to 25–50 mg/kg p.o. daily) (Vail & MacEwen, 2001)	Methaemoglobinaemia and Heinz body haemolytic anaemia have been observed, Monitor haematology
Primary erythrocytosis (red cell leukaemia)	Hydroxyurea as above, phlebotomy may also be required (Watson *et al*., 1994)	As above

cases, but if a cat develops multiple tumours (Plate 3.13) they can be palliated by prednisolone at 1 mg/kg daily (Ogilvie & Moore, 1995). Visceral and systemic forms of mast cell tumour are also recognised in the cat. The visceral form is very malignant and carries a poor prognosis; successful chemotherapy has not been documented. The systemic form is usually associated with splenomegaly and bone-marrow infiltration. Long-term survivals has been reported in such cats following splenectomy (Liska *et al*., 1979).

Table 3.8 Suggested chemotherapy protocols for the management of soft-tissue sarcomas

	Usual dosage	Comments
Single agents		
Doxorubicin	20 mg/m^2 or 1 mg/kg i.v. every 21 days (4–6 cycles)	Monitor haematology before each chemotherapy
Mitoxantrone	5 mg/m^2 i.v. every 21 days	Monitor haematology before each chemotherapy
Combination chemotherapy		
VAC:		
Vincristine	0.7 mg/m^2 i.v. day 8, 15	Monitor haematology before each chemotherapy
Doxorubicin	20 mg/m^2 or 1 mg/kg i.v. day 1	Prophylactic antibiotics may be needed
Cyclophosphamide	100–150 mg/m^2 i.v. day 1	Repeat cycle day 21 for 4–6 cycles
AC:		
Doxorubicin	20 mg/m^2 or 1 mg/kg i.v. day 1	Monitor haematology before each chemotherapy
Cyclophosphamide	150 mg/m^2 i.v. day 1	Prophylactic antibiotics may be needed Repeat cycle day 21 for 4–6 cycles

Modified from MacEwen (2001).

Safe handling of cytotoxic drugs

Many cytotoxic drugs are carcinogenic and mutagenic, and some are teratogenic. These agents are frequently irritant and cause harmful local effects on direct contact with the skin or the eyes. People handling and administering these drugs should be properly instructed so they are aware of potential hazards to themselves, their clients and their patients. Data and health hazard sheets should be consulted before using any cytotoxic agent for the first time. Detailed local rules and practices should be established in the workplace for the safe handling of these substances. Cytotoxic drugs should not be handled by pregnant women.

Cytotoxic drugs are commonly available in two forms:

- tablets or capsules for oral administration
- powder or solutions for injection.

Tablets/capsules

- Tablets should never be broken or crushed and capsules should not be opened.
- Disposable latex gloves should be worn when handling any tablet that does not have an inert barrier coat.
- Where tablets are provided in individual wrappers or a blister pack, they should always be dispensed in this form.
- In addition to the statutory requirements for the labelling of all medicinal products, all containers used for dispensing cytotoxic drugs must be child-proof and carry a clear warning to keep out of the reach of children. Containers should be labelled with the name of the agent.
- Staff and owners should receive clear instructions on how to administer the tablets. Disposable plastic or latex gloves should always be worn when administering these tablets because the protective barrier coat may break down on contact with saliva.
- Hands must always be washed following handling of any drug.
- Excess or unwanted drugs should be disposed of by high-temperature chemical incineration by a licensed authority.

Injectables

The main risk to operators is in the preparation and administration of injectable cytotoxics, some of which come as a freeze-dried material or powder that requires reconstitution with a diluent. Great care must be taken not to create aerosols during reconstitution or preparation of the agent and to avoid accidental spillage.

Reconstitution

- Reconstitution should only be performed by trained members of staff.
- Cytotoxic drugs should be prepared in a designated area which is free from draughts, and well away from thoroughfares and food.
- Care should be taken to prevent high pressure being generated within the vials and to minimise the risk of creating aerosols. If it is necessary to expel air from a filled syringe, it should be exhausted into a pad and not directly into the atmosphere.
- Drugs such as doxorubicin should only be reconstituted in a protective vertical-flow biological safety cabinet.

Protective clothing should be worn during the reconstitution, administration and disposal of injectable cytotoxics. (In the UK Chemoprotect® protective clothing is available from Codan Limited, Eastheath Avenue, Wokingham RG41 2PR). The level of protection required varies depending on the agent, but the minimum requirement would be:

- latex gloves
- a gown with long sleeves to protect the skin
- goggles or a face visor, to protect the eyes
- a surgical mask to provide some protection against splashes to the face (although this provides no protection against inhalation of aerosols).

Administration

- Luer–Lok fittings should be used in preference to push connections on syringes, tubing and giving sets, for increased safety.
- Satisfactory patient restraint by trained personnel is essential. Both the person administering the agent and the person restraining the animal should be equipped with protective clothing. Some animals may require sedation.
- If spillage occurs, the agent should be mopped up with absorbent towels (these should be dampened if a powder is spilt). Towels should be disposed of as detailed below. Contaminated surfaces should be washed with plenty of water, avoiding splashing.

Waste disposal

Proper care must be taken to ensure safe disposal of agents and equipment used for cytotoxic drug adminstration.

- Sharps should be placed in an impenetrable container specified for the purpose and should be sent for high-temperature incineration.
- Solid waste (contaminated equipment, absorbent towels, etc.) should be placed in double-sealed polythene bags, labelled as cytotoxic waste and incinerated at high temperature by a licensed authority.

References

Allwood M. & Wright P. (1993) Extravasation. In *The Cytotoxics Handbook*. 2nd edn. (eds Allwood M & Wright P.). Radcliffe Medical Press, Oxford, pp. 77–89.

Cotter S.M. (1983) Treatment of lymphoma and leukaemia with cyclophosphamide, vincristine and prednisone: treatment of cats. *J Am Anim Hosp Assoc* **19**, 166–172.

Couto C.G. (1998) Leukaemias. In *Small Animal Internal Medicine*. 2nd edn. (eds Nelson R.W. & Couto C.G.). Mosby, St Louis, MO, Chapters 82 and 83, pp. 1134–1142.

Hahn K.A., Fletcher C.M. & Legendre A.M. (1996) Marked neutropenia in five tumor-bearing cats one week following single-agent vincristine sulfate chemotherapy. *Vet Clin Pathol* **25**, 121–123.

Harvey H.J., MacEwen E.G. & Hayes A.A. (1977) Neurotoxicity associated with use of 5-fluorouracil in five dogs and one cat. *J Am Vet Med Assoc* **171**, 277–278.

Hayden D.W. & Nielsen S.W. (1971) Feline mammary tumors. *J Small Anim Pract* **12**, 687–697.

Hayes H.M. Jr, Milne K.L. & Mandell C.P. (1981) Epidemiological features of feline mammary carcinomas. *Vet Rec* **108**, 476–479.

Helfand S.C. (1987) Low dose cytosine arabinoside-induced remission of lymphoblastic leukaemia in a cat. *J Am Vet Med Assoc* **191**, 707–710.

Hennes A.M., Theilen G.H., Madewell B.R. & Crow S.E. (1977) Neurotoxicosis associated with use of 5-fluorouracil. *J Am Vet Med Assoc* **171**, 692.

Hutson C.A., Rideout B.A. & Pederson N.C. (1991) Neoplasia associated with feline immunodeficiency virus infection in cats of southern California. *J Am Vet Med Assoc* **199**, 1357–1362.

Jeglum K.A., deGuzman E. & Young K.M. (1985) Chemotherapy of advanced mammary carcinoma in 14 cats. *J Am Vet Med Assoc* **187**, 157–160.

Jeglum K.A., Whereat B.A. & Young K. (1987) Chemotherapy of lymphoma in 75 cats. *J Am Vet Med Assoc* **190**, 174–178.

Knapp D.W., Richardson R.C., DeNicola D.B., *et al.* (1987) Cisplatin toxicity in cats. *J Vet Intern Med* **1**, 29–35.

Kristal O., Lana S., Ogilvie G.K., *et al.* (2001) Single agent chemotherapy with doxorubicin for feline lymphoma: a retrospective study of 19 cases (1994–1997). *J Vet Intern Med* **15**, 125–130.

Liska W.D., MacEwen E.G., Zaki F.A. & Garvey M. (1979) Feline systemic mastocytosis: a review and results of splenectomy in seven cases. *J Am Anim Hosp Assoc* **15**, 589–597.

MacEwen E.G. (2001) Miscellaneous tumors. In *Small Animal Clinical Oncology*. 3rd edn. (eds Withrow S.J. & MacEwen E.G.). W.B. Saunders, Philadelphia, PA, Chapter 29, pp. 639–646.

MacEwen E.G., Powers B.E., Macy D. & Withrow S.J. (2001) Soft tissue sarcomas. In *Small Animal Clinical Oncology*. 3rd edn. (eds Withrow S.J. & MacEwen E.G.). W.B. Saunders, Philadelphia, PA, Chapter 17, pp. 283–304.

Mauldin G.E. (1997) Recent advances in feline oncology. *Proceedings 15th ACVIM Forum*, pp. 165–166.

Mauldin G.N., Matus R.E., Patnaik A.K., *et al.* (1988) Efficacy and toxicity of doxorubicin and cyclophosphamide used in the treatment of selected malignant tumors in 23 cats. *J Vet Intern Med* **2**, 60–65.

Miller M.A., Ramos J.A., Kreeger J.M. (1992) Cutaneous vascular neoplasia in 15 cats: clincial, morphologic and immunohistochemical studies. *Vet Pathol* **29**, 329–336.

Molander-McCrary H., Henry C.J., Potter K., *et al.* (1998) Cutaneous mast cell tumours in cats: 32 cases (1991–1994). *J Am Anim Hosp Assoc* **34**, 281–284.

Mooney S.C., Hayes A.A., Matus R.E. & MacEwen E.G. (1987) Renal lymphoma in cats: 28 cases (1977–1984). *J Am Vet Med Assoc* **191**, 1473–1477.

Mooney S.C., Hayes A.A., MacEwen E.G., *et al.* (1989) Treatment and prognostic factors in lymphoma in cats: 103 cases (1977–1981). *J Am Vet Med Assoc* **194**, 696–702.

Moore A.S., Ruslander D., Cotter S.M., *et al.* (1995) Efficacy of, and toxicoses associated with, oral idarubicin administration in cats with neoplasia. *J Am Vet Med Assoc* **206**, 1550–1554.

Moore A.S., Cotter S.M., Frimberger A.E., *et al.* (1996) A comparison of doxorubicin and COP for maintenance of remission in cats with lymphoma. *J Vet Intern Med* **10**, 372–375.

Moulton J.E. (1990) Mammary tumors of the cat. In *Tumors in Domestic Animals*. 3rd edn. University of California Press, Berkeley, CA, pp. 547–548.

Ogilvie G.K. & Moore A.S. (1995) Lymphoma in cats; Multiple myeloma in cats; Mast cell tumours in cats. In *Managing the Veterinary Cancer Patient*. Veterinary Learning Systems Co., New Jersey, pp. 249–259, 285–289, 510–513.

Ogilvie G.E., Moore A.S., Obradovich J.E., *et al.* (1993) Toxicoses and efficacy associated with administration of mitoxantrone to cats with malignant tumors. *J Am Vet Med Assoc* **202**, 1839–1844.

O'Keefe D.A. & Schaeffer D.J. (1992) Hematologic toxicosis associated with doxorubicin administration in cats. *J Vet Inter Med* **6**, 276–282.

O'Keefe D.A., Sisson D.D., Gelberg H.B., *et al.* (1993) Systemic toxicity associated with doxorubicin administration in cats. *J Vet Intern Med* **7**, 309–317.

Peaston A.E. & Maddison J.E. (1999) Efficacy of doxorubicin as an induction agent for cats with lymphosarcoma. *Aust Vet J* **77**, 442–444.

Priester W.A. & McKay F.W. (1980) The occurrence of tumours in domestic animals. *National Cancer Institute Monograph* **54**.

Rassnick K.M., Mauldin G.N., Moroff S.D., *et al.* (1999) Prognostic value of argyrophilic nucleolar organizer region (AgNOR) staining in feline intestinal lymphoma. *J Vet Intern Med* **13**, 187–190.

Scavelli T.D., Patnaik A.K., Mehlhaff C.J. & Hayes A.A. (1985) Hemangiosarcoma in the cat: retrospective evaluation of 31 surgical cases. *J Am Vet Med Assoc* **187**, 817–819.

Shelton G.H., Grant C.K., Cotter S.M., *et al.* (1990) Feline immunodeficiency virus and feline leukemia virus infections and their relationships to lymphoid malignancies in cats: a retrospective study (1968–1988). *J Acquir Immune Defic Syndr* **3**, 623–630.

Skipper H.E., Schabel F.M. & Wilcox W.S. (1964) Experimental evaluation of potential anticancer agents XIII: on the criteria and kinetics associated with curability of experimental leukaemia. *Cancer Chemother Rep* **35**, 1–111.

Teske E., van Straten G., van Noort R. & Rutteman G.R. (2002) Chemotherapy with cyclophosphamide, vincristine and prednisolone (COP) in cats with malignant lymphpoma: new results with an old protocol. *J Vet Intern Med* **16**, 179–186.

Vail D.M. & MacEwen E.G. (2001) Feline lymphoma and leukaemias. In *Small Animal Clinical Oncology*. 3rd edn. (eds Withrow S.J. & MacEwen E.G.). WB Saunders, Philadelphia, PA, Chapter 28C, pp. 590–611.

Vail D.M., Moore A.S., Ogilvie G.K. & Volk L.M. (1998) Proliferation indices, cluster of differentiation 3 immunoreactivity, and their association with prognosis in 90 cats. *J Vet Intern Med* **12**, 349–354.

Watson A.D.J., Moore A.S. & Helfand S.C. (1994) Primary erythrocytosis in the cat: treatment with hydroxyurea. *J Small Anim Pract* **35**, 320–325.

Further reading

Allwood M., Stanley A. & Wright P. (eds) (2002) *The Cytotoxics Handbook*. 4th edn. Radcliffe Medical Press, Oxford.

Chun R., Garrett L. & MacEwen E.G. (2001) Cancer chemotherapy. In *Small Animal Clinical Oncology*. 3rd edn. (eds Withrow S.J. & MacEwen E.G.). WB Saunders, Philadelphia, PA, Chapter 9, pp. 92–118.

COSHH Regulations (1988) *Approved Code of Practice: Control of Substances Hazardous to Health and Approved Code of Practice: Control of Carcinogenic Substances*, 3rd edn. COSHH, London.

Couto C.G. (1990) Management of the complications of cancer chemotherapy. *Vet Clin North Am Small Anim Pract* **20**, 1037–1054.

Couto C.G. (1998) Lymphoma in the cat and dog; Leukaemias. In *Small Animal Internal Medicine*. 2nd edn. (eds Nelson R.W. & Couto C.G.). Mosby, St Louis, MO, Chapters 82 and 83, pp. 1123–1142.

Dobson J.M. & Gorman N.T. (1993) *Cancer Chemotherapy in Small Animal Practice*. Blackwell Science, Oxford.

Hahn K.A. & Richardson R.C. (1995) *Cancer Chemotherapy: A Veterinary Handbook*. Williams and Wilkins, Baltimore, MD.

Helfand S.C. (1990) Principles and applications of chemotherapy. *Vet Clin North Am Small Anim Pract* **20**, 987–1013.

HMSO (1983) HMSO Guidance Notes MS21 from the Health and Safety Executive. *Precautions for the Safe Handling of Cytotoxic Drugs*. HMSO, London.

Morrison W.B. (1999) Chemotherapy; Cancer drug pharmacology and clinical experience; Providing chemotherapy safely; Principles of treating chemotherapy complications. In *Chemotherapy in the Dog and Cat*. 1st edn. Williams and Wilkins, Baltimore, MD, Chapters 22–25, pp. 351–397.

Ogilvie G.K. & Moore A.S. (1995) *Managing the Veterinary Cancer Patient*. Veterinary Learning Systems Co., New Jersey.

Chapter 4

AN APPROACH TO TOXICOLOGY

R. Breathnach

Introduction

The incidence of feline toxicoses encountered in general veterinary practice is often underestimated. One of the principal reasons for this is the misconception that there is only a limited pool of common poisons available to pet animals; this inaccuracy is further compounded by the belief in certain quarters that cats are far too fastidious to ingest a whole variety of toxicants. From the outset, it must be appreciated that cats are exposed to a large range of potential toxins, including agents as diverse as prescription drugs, chemicals, household products and plants. Furthermore, exposure is not limited to the oral route, but may also involve inhalation, and percutaneous or parenteral administration.

Incidence figures for feline toxicoses are only available from a limited number of sources. Hornfeldt and Murphy (2000) reported that out of a total case number of 6091 poison exposures documented in small animals by the Hennepin Regional Poison Centre in the USA in 1995, just over 16% of the total case number involved the cat. Although this caseload represented less than one-quarter of that recorded for the dog, the overall number should still be considered significant. Most cases of feline toxicoses are accidental, rather than intentional or iatrogenic in nature. Acute exposure is more common than chronic, repeat-dose exposure. Furthermore, despite the claim commonly made by distraught owners that their pet may have been poisoned intentionally, in the author's experience malicious poisoning is an infrequent event. The incidence of certain types of poisoning may vary with the season or time of year. For example, accidental poisoning with insecticidal compounds often increases at times of the year when parasite numbers, and consequently the incidence of use, are highest.

The aim of this chapter is not to detail every possible source of poisoning to which cats may be exposed, but rather to consider the general approach that should be adopted when attempting to diagnose and treat feline toxicoses. While the more common and potentially serious poisons will be dealt with in greater detail, the reader is encouraged to remember that even seemingly innocuous substances may prove to be toxic when administered by accident or in excess. Thus, a whole variety of commonly used agents, such as herbicides, household products and medicinal preparations, are all potential sources of danger to even the most discerning cat.

Why are cats prone to certain toxicoses?

Cats are by nature highly inquisitive animals that explore their environment and in the process accidentally expose themselves to a variety of poisonous agents. Cats possess finnicky eating habits, and although such habits undoubtedly offer some degree of protection from toxins in food, their concerted grooming and foraging behaviour may still lead to the ingestion of agents such as insecticides and various plants. The fact that many cats are maintained in an indoor environment for prolonged periods may be an additional important factor in their being exposed to household products and various drugs.

However, one of the major factors responsible for the susceptibility of felines to various toxic compounds relates directly to their limited ability to metabolise and detoxify such compounds, particularly compared with other species such as the dog. The list of agents affected by this phenomenon includes many commonly used veterinary medicinal products, household chemicals

and environmental toxins. The metabolism of a foreign compound can proceed along different routes in the body. Phase I metabolism involves procedures such as oxidation, reduction or hydrolysis, with the subsequent metabolite being generally, but not always, less active than the parent compound. Phase II metabolism is typified by synthesis or conjugation, in which glucuronide and sulfate groups, for example, are added to the xenobiotic to facilitate its elimination. Cats have long been known to possess deficient activity of the key enzyme uridine diphosphate (UDP)-glucuronyl transferase. This enzyme plays a vital role in the formation of glucuronide conjugates of various xenobiotics. In most species, glucuronic acid can be transferred to a variety of chemical groups on exogenous compounds and, as such, glucuronide metabolites are known to represent major metabolites for agents such as phenols, morphine, salicylic acid, chloramphenicol and certain sulfonamides. The significantly reduced ability of felines to synthesise glucuronide metabolites is a major factor in the toxicity of these compounds to this species. It should be emphasised that the defect in glucuronide synthesis is not total, but instead is directed towards certain substances. For example, the cat is well able to form glucuronide metabolites of endogenous molecules, such as bilirubin, at rates that are comparable to other species. The major substrate utilised for conjugation in the cat is sulfate, with the resultant molecules being eliminated in either the urine or bile. Whether or not the reduced ability to form glucuronide conjugates will pose a significant problem to the cat will depend on the specific substance in question, and on any alternative pathways available for that molecule. A drug or chemical may accumulate in the cat if the alternative pathways are unable to cope with a specific molecule, or the amount of chemical present. This point is of critical importance when extrapolating drug data from another species to the cat. If no pharmacokinetic data are available for felines, the risk of drug accumulation is very real if dosage rates are merely interchanged between species, without any consideration being given to differences in drug disposition. In certain cases, the reduced clearance of a drug from the cat, compared with another species, may be offset by allowing for a longer interdosage interval or a reduced dosage rate.

Other factors play a role in the increased susceptibility of the cat to certain poisons. One interesting feature of the cat is the unusual receptor-site sensitivity of this species to certain drugs. A classical example of this is the excitation produced by morphine in the cat, in contrast to the sedative effect noted in other species. Furthermore, oxidative damage to the red blood cell, resulting in the formation of Heinz bodies and methaemoglobin, is a feature of several different foreign compounds in felines (Rumbeiha *et al.*, 1994).

Approach to the poisoned cat

The approach to a case of feline toxicosis will vary according to many factors, including the severity of the condition and whether the identity of the poison is known. General principles that can be applied to all cases should include the following:

- Any further source of toxicant should be removed, to prevent further ingestion, inhalation, etc. This advice may need to be relayed over the telephone, if the animal is not present in the surgery.
- A detailed history must be obtained to establish answers to vital questions. These include efforts to establish the identity of the poison, its source and the likely volume to which the animal was exposed. The history taking may need to occur simultaneously while attempts are made to treat life-threatening clinical signs and prevent any further toxin exposure. It is important to assess how long has elapsed between exposure and the time of presentation, and what clinical signs, if any, have been displayed. Questions as to whether the animal vomited up any of the poison and, if so, whether a sample of gastric contents was saved are also valuable.
- A clinical examination will reveal whether the signs exhibited are indicative of any specific toxicant, and how advanced or severe the intoxication appears to be for that suspected agent. Such information may allow for a more appropriate choice of drugs, e.g. antidotes or sedatives.
- If a specific antidote is available or indicated, then it should be administered without delay.
- Attempts should be made to remove or prevent further absorption of the poison from the gastrointestinal tract, or whatever the route of exposure may be (e.g. skin). One of the most commonly adopted approaches is to use an emetic to attempt to eliminate the toxin before it leaves the stomach and is absorbed from the small intestine. This procedure is of most benefit within the first 2 h postexposure, and is of limited benefit when more than 4 h have passed. Emetics are contraindicated if the cat is convulsing or if it is comatose. Emetics are also

contraindicated if the ingested material is corrosive. If advice is sought over the telephone, then home-made emetics may be indicated. Washing soda and hydrogen peroxide (3%: do not exceed a total dose of 10 ml per cat) are potentially suitable agents. Agents available to the veterinarian include ipecac (3 ml/kg) and xylazine (1.1 mg/kg i.m.). The latter agent may cause respiratory depression and sedation. Apomorphine is not suitable for use in the cat.

Gastric lavage is a suitable mechanism to remove toxins from those animals in which emesis is unsuccessful or not indicated. Water or saline may be flushed in and out of the stomach repeatedly through a large-bore stomach tube. The procedure should be repeated until such time as the lavage fluid is clear. Care must be taken to prevent any aspiration of stomach contents. Adsorption therapy is a particularly effective form of therapy to try to reduce further gastrointestinal tract absorption. Activated charcoal may be mixed with water (1 g/5 ml) and administered at a rate of 2–5 g of charcoal/kg body weight. Osmotic cathartics may be indicated if the animal is not exhibiting diarrhoea. Agents such as sodium sulfate and sorbitol are often used for this purpose, and are sometimes preceded by the activated charcoal detailed above. In extreme cases, if previous attempts to limit absorption of the toxin have failed, or if potentially fatal concentrations are present in the systemic circulation, then peritoneal dialysis may be considered. Relevant texts should be consulted for advice on methodology.

Appropriate decontamination measures should be attempted in those cases in which the cat has been exposed by routes other than ingestion. For example, bathing of the skin with a mild shampoo or liquid dishwashing detergent, or clipping of matted hair may be indicated for cats contaminated with oil on their coat.

- Efforts can sometimes be made to hasten metabolism and excretion of a toxin, such as by stimulating a diuresis with fluids, frusemide or mannitol. Efforts to stimulate hepatic metabolism are generally still experimental. Laboratory samples, particularly bloods and urinalysis, may be helpful in assessing the extent of damage, e.g. by ethylene glycol. Radiographs should be performed if internal haemorrhage is suspected. Stomach contents and urine can be collected for forensic analysis. Samples of liver, kidney, lung, urine and bile should be retained if the cat dies.

In many cases, whether the identity of the poison is known or not, emergency therapy may be indicated if life-threatening clinical signs are evident. These measures may need to be instigated before other events such as gastric lavage if the animal's overall condition so dictates. Thus, the timing and the order of the events outlined may vary from case to case, and should always be based on clinical judgement. Treatment is largely symptomatic and, in most cases, will be covered elsewhere in the text. However, particular attention should be paid to the following:

- Any respiratory compromise, such as severe dyspnoea or cyanosis, may be countered by establishing a patent airway and using supplemental oxygen (endotracheal tube or oxygen mask/chamber). Doxapram may be required for stimulation of the respiratory centre in the brain. Blood gas and oxygen saturation values may need to be monitored.
- Cardiac disturbances or arrhythmias often require emergency treatment, e.g. with atropine, dopamine or procainamide. The choice of drug will depend on the nature of the cardiac event (see Chapter 19).
- Shock is a frequent finding in poisoning cases and may be countered with crystalloid fluids, plasma volume expanders or even whole blood for cases of anticoagulant poisoning. Many poisons can cause acute renal failure, and aggressive treatment with fluids, dopamine/frusemide, etc., may need to be implemented. These cats should be monitored for hyperkalaemia. Acid–base balance problems due to renal or respiratory toxicity also need to be addressed.
- Any seizures, spasms or other central nervous system (CNS) signs must be treated. Drugs such as diazepam (0.1–0.2 mg/kg body weight i.v.) or midazolam (0.1–0.2 mg/kg body weight i.v. or i.m.) may be tried initially, with refractory cases being given phenobarbital or pentobarbitone (20–30 mg/kg i.v., slowly, titrating to the desired effect). Muscle relaxants may be indicated on some occasions.
- Hypothermia, hyperthermia and gastrointestinal tract signs, if present, should be treated symptomatically.

It is essential for the patient to be continually monitored to allow for appropriate alterations to the treatment strategy based on any improvement or deterioration, further knowledge of the likely toxicant and the results of blood work or urinalysis. Such an approach can often be invaluable in achieving a successful outcome.

Specific toxins

Rodenticides

Rodenticide poisoning is a common phenomenon in cats, with animals being exposed by a variety of means including negligent setting of bait, secondary poisoning via ingestion of rodents and occasional cases of malicious intent. Although this class of compounds is most commonly represented by the anticoagulant coumarin-type rodenticides, other agents belonging to this group include agents such as strychnine and cholecalciferol.

Coumarin-type products

These anticoagulant rodenticides are extremely potent compounds, which act by inhibiting the key enzyme vitamin K epoxide reductase. This inhibition results in the reduced conversion of precursor forms of clotting factors 2, 7, 9 and 10 to their physiologically active forms, leading to a bleeding tendency in affected cats. This family can be subdivided into first generation compounds such as warfarin, and second generation compounds such as bromadiolone. In general, the second generation compounds are more potent and have a longer lasting effect than the older, first generation compounds. As some stores of vitamin K and active forms of the various clotting factors are likely to be already present and functioning at the time of initial toxin ingestion, a lag phase may be evident before clinical signs arise. The major clinical sign of poisoning is haemorrhage. This bleeding tendency may be evident at virtually any site of the body, and is often induced by episodes of mild to minimal trauma. Buccal bleeding may be induced with finger trauma. Cats may bleed from a variety of body orifices, or haemorrhage may be evident either within or underneath the skin. Haematomas over body prominences or at the site of injections may be particularly evident. For many cats, internal haemorrhage is the dominant feature, with presenting signs of dyspnoea related to pulmonary or pleural bleeding, or ascites due to haemoperitoneum. Most affected animals will exhibit a moderate to severe decrease in the packed cell volume (PCV). However, care must be exercised in interpreting such results, as recent haemorrhage may not be immediately accompanied by a decline in the PCV. Owing to the mode of action of this class of toxins, various laboratory procedures can be used to aid in confirming a diagnosis. Thus, prolongation of the one-stage prothrombin time and the activated partial thromboplastin time are normally in evidence. It should be emphasised that more than a 70% decrease in the activity of an individual clotting agent may be necessary before a prolongation of these assays is evident. Additional tests can be used to differentiate between other causes of coagulopathies, such as thrombocytopenia or diffuse intravascular coagulation, and those caused by this class of compound. Furthermore, assays are available in certain laboratories to detect and measure concentrations of various anticoagulant rodenticides in blood. In recent times, much attention has focused on assays that measure the prothrombin time in a manner that is uniquely sensitive to proteins invoked by vitamin K absence (PIVKA). In this assay, the accumulated procoagulants of the vitamin K-dependent clotting factors act as substrate analogues delaying thrombin activation. Center *et al.* (2000) reported that the available methodology is sensitive for feline PIVKA proteins and that the test reflects vitamin K depletion in this species. Treatment of anticoagulant rodenticide poisoning involves the administration of vitamin K_1. Various protocols are available, but doses of 2.5–5 mg/kg per day (p.o., i.v., i.m. or s.c.) are usually safe and effective. The use of the intramuscular or intravenous route must involve consideration of the dangers of iatrogenic haemorrhage. This daily dose should be administered for at least 7–10 days for first generatious compounds. The treatment period is significantly longer for second generation compounds, usually 3–4 weeks, although advice should be sought from a poisons control centre. Fluid therapy is the second essential element of effective treatment, as shock is a major complicating factor. Animals with a PCV below 0.15 l/l generally require a blood transfusion, which allows for the replacement of both missing cofactors and fluid volume. Symptomatic and supportive care should be instigated as appropriate. However, the benefits of measures such as draining blood from the chest cavity must be counterbalanced against the possible risk of further haemorrhage.

Strychnine

Owing to restricted access as a result of poisons regulations in many countries, the incidence of intoxication by strychnine has reduced fairly dramatically in recent times. However, it still remains a significant poison to cats, and is one of the principal agents used in malicious cases. Strychnine is extremely potent, with dosage levels of 1–2 mg/kg body weight frequently

proving fatal in the cat. The onset of clinical signs is usually a matter of minutes to hours postexposure. Strychnine interferes with the postsynaptic inhibitory cells of the spinal cord and medulla. The net effect is a failure to modify sensory responses and, thus, uncontrolled reflex activity leads to overstimulation of motor responses (Rumbeiha *et al.*, 1994). Initial clinical signs consist of anxiety and hyperaesthesia. The muscles become tense, developing into tonic or clonic rigidity (Murphy, 2000). The muscle seizures become more violent upon stimulation by light, sound or touch. The tetanic spasms result in the animal becoming laterally recumbent, with the legs and body rigidly extended. The ears are often held in an erect position and opisthotonus is common. The pupils may be dilated. Periods of relaxation may occur between tetanic bouts during the early phase of the condition; however, such periods gradually disappear. In the absence of treatment, death usually occurs within 2 h, principally as a result of respiratory paralysis. Treatment is aimed primarily at controlling the seizures, with diazepam being the initial drug of choice at a dose of 0.2–0.5 mg/kg body weight. If this approach is unsuccessful, then sodium pentobarbitone or inhalation anaesthesia may be attempted. The use of an emetic is generally contraindicated for such cases, unless the cat is seen before convulsions begin. Gastric lavage may be attempted using potassium permanganate, or activated charcoal followed by a cathartic. It is important to maintain the cat in a warm, quiet and dark room to minimise stimuli. Some authors advocate the acidification of urine, in company with forced diuresis once urine flow is established, to enhance the excretion of strychnine.

α-Chloralose

Although considered an older compound, α-chloralose is still used in certain countries to eliminate mice and scavenger birds. This product has an unusual mode of action, which is capable of inducing paradoxical signs depending on the dose administered. In most cases, depression of neuronal activity of the ascending reticular formation results in a reduced arousal response in poisoned animals. However, low doses have a stimulatory effect on the CNS. Initial clinical signs include hyperaesthesia and aggression. Animals may then enter a phase in which they become lethargic and weak, and exhibit shallow respiratory efforts. During this period of low metabolic activity, profound hypothermia is commonly reported. Treatment is symptomatic, involving the use of diazepam for excited cats and supportive care for depressed animals. As well as efforts to keep the cat warm, analeptics may be required to stimulate respiration in severe cases. Most affected cats will survive, with the glucuronide conjugate being eventually excreted in urine.

Cholecalciferol

Cholecalciferol or vitamin D_3 is a more recently introduced rodenticide, which acts by disrupting calcium homoeostasis. This results in the elevation of serum calcium concentrations and subsequent deposition of calcium in various locations, including the kidneys. The toxic dose can be relatively low. Cats normally present with dullness, vomiting and diarrhoea approximately 2 days after ingestion. Renal failure often develops soon afterwards, with a high subsequent mortality rate. The metastatic calcification is observed in many soft tissues at post mortem. Treatment should concentrate on minimising gastrointestinal tract absorption, maintaining renal function and supporting the renal excretion of calcium. Saline diuresis, combined with prednisolone (1–2 mg/kg p.o. twice daily) and frusemide (1–4 mg/kg i.v., s.c. or p.o. twice daily), is normally beneficial in enhancing calcium excretion. Refractory cases have been treated with calcitonin. Successful treatment of cholecalciferol poisoning may take several weeks.

Thallium

Thallium is a potent rodenticide that has largely fallen out of favour since the 1980s owing to its toxicity. The use of this agent is banned in some countries. Its mode of action involves interference with nerve transmission and mitochondrial function. Clinical signs of toxicity are either acute or chronic in nature. The acute form is characterised by vomiting, depression and marked abdominal pain, whereas chronic cases are manifested by neurological deficits and severe skin and mucosal changes, such as erythema, alopecia and ulceration. The prognosis is usually poor in such cases, with treatment being principally directed at minimising any further gastrointestinal tract absorption using Prussian blue or activated charcoal. Potassium chloride has been used to accelerate renal excretion of thallium. The use of chelating agents, such as diphenylthiocarbazone, is controversial, and generally no longer recommended.

Insecticides

Organophosphates and carbamates

These compounds represent a common source of poisoning to cats, due in no small part to the multitude of potential sources available. Intoxication usually follows the application or ingestion of organophosphates (OPs) or carbamates used as insecticides, either intentionally or accidentally. Although the cat is considered particularly sensitive to OP compounds, collars, spot-ons and sprays incorporating these active ingredients are still commercially available. Both OPs and carbamates act by inhibiting the key enzyme acetylcholinesterase (AChE). This results in marked cholinergic stimulation owing to the ineffective degradation of acetylcholine at receptor level. Clinical signs therefore arise through overstimulation of nicotinic receptors in skeletal muscle, autonomic preganglionic junctions, parasympathetic postganglionic junctions and a small number of sites in the CNS. The initial clinical picture in the cat is often characterised by anxiety, hyperexcitability and muscle twitching. This can progress to vomiting, diarrhoea, pollakiuria and abdominal pain. The pupils are normally constricted and many cats exhibit bradycardia. Excess licking and salivation are also commonly reported. The muscle twitching progresses in more severe cases to include the entire body, and may lead to convulsive seizures. Paradoxically, some cats will exhibit CNS depression and present with muscle weakness or paralysis. A diagnosis is normally suspected on history and clinical signs alone; however, confirmation has been attempted by measuring depressions in cholinesterase activity in red blood cells (RBCs), whole blood or brain tissue (at post mortem). Care must be exercised in interpreting such data, as biological variability is a significant factor. Treatment involves the use of atropine (0.2–0.5 mg/kg i.v.), with careful titration of the dose to effect, or alternatively, administering one-quarter of the dose intravenously and the remainder intramuscularly or subcutaneously. Reduced doses (generally one half) are normally administered subcutaneously once clinical signs recur, although one must beware of overdosing. The muscle twitching or convulsions are generally controlled using diazepam, midazolam or sodium pentobarbitone. Oxime compounds are used to uncouple the bond between the OPs and the AChE molecule, but are generally only effective if administered within the first 24–48 h. Pralidoxime chloride (20 mg/kg i.m. twice or three times daily) has prove effective in this regard. Supportive care should be provided as required, as many cats will continue to exhibit clinical signs for days to weeks following exposure.

Organochlorines

The incidence of organochlorine poisoning in the cat has declined significantly, in association with the reduced use of these agents as animal insecticides. Most toxicities in the past related to the intentional or accidental exposure (e.g. contact with sprayed surfaces) of cats to agents such as benzene hexachloride, dieldrin and dichlorodiphenyltrichloroethane (DDT). Cats are generally considered to be highly susceptible to this group of compounds. The mode of action is largely unknown, although some evidence exists to show that ion transport across nerve cell membranes can be interrupted via inhibition of adenosine triphosphate (ATP) production. The clinical signs of poisoning are quite similar to those observed for OPs, with affected cats displaying hyperaesthesia, ataxia, tremors, convulsions and gastrointestinal tract disturbances. The tonic spasms may lead to lateral recumbency and opisthotonos. As with the OPs, some members of this chemical family may give rise to signs of depressed activity. Treatment is again aimed at controlling the nervous signs with appropriate sedation and providing supportive and symptomatic care.

Pyrethrins and pyrethroids

Natural pyrethrins, and their synthetic analogues the pyrethroids, have been used for many years as topical insecticides on cats, particularly for the treatment of fleas. In most cases, these compounds are combined with a synergist, usually piperonyl butoxide. Although these agents generally have a favourable safety profile, the cat appears to be more susceptible to toxicity than other mammalian species, owing to its lower biotransformation capabilities. The mode of action of these compounds is incompletely understood, but stimulation of the insect's CNS via opening of sodium nerve channels is quickly followed by knockdown and lethality. Toxicity in cats normally involves significant overdosage by the topical route or ingestion of the active ingredient. Clinical signs include lethargy, salivation, tremors, ataxia and seizures (Nicholson, 2000). Fatalities are uncommon. Treatment is largely symptomatic, while the active ingredient is metabolised by the patient. Flea powders containing pyrethrins can be washed off using non-medicated shampoos.

The use of atropine and diazepam is usually successful at controlling signs, with clinical recovery in 24–36 h.

Molluscicides and herbicides

Metaldehyde

The normal route of exposure is through the use of metaldehyde in gardening products, such as slug or snail pellets. Many councils spread slug pellets on flowerbeds and on parkland. Metaldehyde can be quite palatable for cats and repeat episodes of poisoning are not known. The active principle is metabolised in the body to acetaldehyde. The onset of signs tends to be fairly rapid following ingestion, with most cases lasting for 24–48 h. Clinical signs may include hyperaesthesia, tremors, convulsions, recumbency, opisthotonus and drooling of saliva. Vomiting and diarrhoea are not prominent features, unlike in OP poisoning. Temperature and pulse rates tend to be elevated during the periods of muscle twitching. Nystagmus has been reported in many affected cats. Treatment involves sedating the cat or lightly anaesthetising with sodium pentobarbitone. If the cat is anaesthetised, gastric lavage can be performed, preferably with sodium bicarbonate. The use of calcium borogluconate is generally unnecessary, but supportive care and correction of any acid–base balance problems are indicated.

Dipyridals

Toxicity with paraquat and diquat is relatively rare in the cat, with most case reports involving ingestion of commercial formulations (Humphreys, 1988). Paraquat enters various tissues and body compartments at different rates, following absorption from the small intestine. The kidneys accumulate large quantities, with renal failure being a common early complication of poisoning. Redox cycling of the molecule leads to the generation of oxygen free radicals, with subsequent damage to affected cells. Lipid peroxidation may be additionally involved in the pathogenesis of disease. The clinical signs of early intoxication include depression, inappetance and vomiting. Paraquat is corrosive, so ulceration of the mouth and oesophagus may be evident. The compound then slowly accumulates in pulmonary alveolar cells, with the progressive development of respiratory signs such as tachypnoea, dyspnoea, cyanosis and open mouth breathing. The changes recorded in lung tissue include a proliferative alveolitis and bronchiolitis, with pulmonary haemorrhage also being reported. Many cases prove fatal within a period of 7–10 days. Diagnosis is normally suspected on history, clinical signs, elevated renal parameters and thoracic radiography. Paraquat can be detected in urine within the first 48 h of exposure, and forensic analysis can also be performed on lung tissue. There is no specific antidote. Initial treatment is aimed at minimising gastrointestinal tract absorption and maintaining urine flow. Corticosteroids, vitamins and antioxidants have all been used in cases with laboured breathing. Antibacterial therapy should be instituted if appropriate, but supplemental oxygen is usually contraindicated, as it may lead to increased free radical formation. Euthanasia should be considered for cases with a grave prognosis.

Most other herbicides in normal everyday use tend to be less toxic to the cat. As such, most of the data available on agents such as glyphosate and aminotriazole are based on the results of experiments in laboratory animals, and are less relevant to the everyday, practice-type situation. However, in the event of significant exposure, clinical signs of poisoning would be possible in the cat.

Metals

Lead

Despite the decreased incidence of lead poisoning reported in practice, sources of lead are still to be found in paints, lubricants, batteries, toys and many other household items to which cats have access. Younger cats appear to be more susceptible to lead poisoning. This phenomenon may be the result of increased exposure through playing and chewing behaviour, as well as the higher gastrointestinal tract absorption and transfer of lead across the blood–brain barrier observed in the young. Lead is stored in bony tissue in the body, but these stores can be exceeded. The mode of action of lead on nervous tissue is incompletely understood, although interference with thiol groups on certain key enzymes has been demonstrated. Clinical signs of intoxication in the cat include gastrointestinal tract upsets, weight loss, depression and inappetance. Neurological signs appear later and can vary markedly from one cat to another. Alterations in gait, hyperaesthesia, blindness and seizures are all commonly reported. Other signs may include clamping of the jaws, vocalisation, aggression

and paralysis. The diagnosis is based on changes on haematology (neutrophilia, monocytosis, basophilia and basophilic stippling of RBCs) and measurement of the lead concentration in blood. Urinary concentrations of δ-aminolevulinic acid are invariably increased. Treatment involves the use of calcium–EDTA (75–110 mg/kg per day, in three or four divided doses, diluted to 1 g/ml in 5% dextrose) or D-penicillamine (10–15 mg/kg p.o. twice daily for 1–2 weeks). Care must be exercised when using D-penicillamine, as excessive dosage levels may result in toxicity, manifested by anorexia, vomiting, renal failure and a clotting disorder. Sedation would be indicated in cases presenting with seizures or hyperexcitability.

Arsenic

The overall incidence of arsenical poisoning in the cat has declined quite dramatically, in line with the gradual reduction in the use of arsenicals in a range of commercial products. Sodium arsenate is still available on certain markets as an insect poison, with some authors reporting an oral lethal dose as low as 20 mg/ kg body weight. Inhibition of key thiol groups on various enzymes is again proposed as the likely mode of action. The onset of clinical signs is sometimes delayed for several days, and cats invariably present with vomiting, diarrhoea, abdominal pain and weakness (Osweiler *et al.*, 1985). Some cases go on to develop polydipsia, inappetance, hypothermia and ataxia. Cats can be treated with dimercaprol (3 mg/kg body weight i.m., initially six times daily for the first 2 days, reducing to twice daily for up to 10 days). Renal function should be monitored during therapy in these patients.

Mercury

Most cases of mercury poisoning reported in the literature relate to contamination of dietary fish sources with various mercury-containing industrial pollutants. Affected cats usually present with insidious signs of neurotoxicity due to chronic exposure. As such, paresis, ataxia, tremors, convulsions and blindness would be commonly observed. Acute exposure to high doses of mercury results in significant damage to the pulmonary vasculature. The diagnosis can be confirmed on histopathology of affected brain tissue and measurement of mercury concentrations in blood and various tissues, such as liver and kidney. Unfortunately, treatment is often instigated too late to be of meaningful benefit to many patients. The recommended treatments include dimercaprol or penicillamine (see above).

Household products

Ethylene glycol

Ethylene glycol is a pleasant-tasting, colourless solvent used in a variety of commercial solvents, of which antifreeze is the most relevant. Cats are generally considered to be more sensitive to this form of toxicity than dogs. The incidence of poisoning often peaks in association with the seasonal use of antifreeze. Ethylene glycol is rapidly absorbed from the gut, and is then sequentially metabolised in the liver to an aldehyde intermediate, glycolic acid and finally glyoxalate. Glyoxalate is further transformed to several final metabolites, including oxalate. Various key enzymes are involved in these steps, with the metabolites being generally more toxic than the parent compound. Glycolic and lactic acid are principally responsible for the severe metabolic acidosis that occurs within hours of ingestion. Oxalate anion binds to plasma calcium to form calcium oxalate crystals in the blood vessels and renal tubules, with possible subsequent obstruction of the renal tubules. Initial clinical signs consist of depression, inappetance, vomiting and incoordination (Rumbeiha *et al.*, 1994). Polyuria and polydipsia may be evident. Hours later, the cat may exhibit tachycardia, tachypnoea and possibly coma. The previous clinical signs may also increase in severity. In surviving animals, signs of acute renal failure normally develop within 1–3 days postexposure, and signal a poor prognosis. This phase of disease is usually characterised by vomiting, oliguria/anuria and significant uraemia. A suspicion of ethylene glycol poisoning can be based on history, clinical signs and the results of blood work-up and urinalysis. Findings may vary somewhat with the stage of disease, with elevated blood urea and creatinine values, hypocalcaemia and isothenuria being commonly reported. Increased numbers of calcium oxalate crystals in urine would be expected. Diagnosis can be confirmed on microscopy by detecting birefringent polarising crystals in and around the renal convoluted tubules. Treatment is principally aimed at providing a competitive inhibitor for alcohol dehydrogenase and providing supportive therapy to counter the dehydration and severe metabolic acidosis. Ethanol (20%) is administered intravenously at a dose rate of 5 ml/kg every 6 h for five treatments, then every 8 h for four treatments. Sodium bicarbonate is administered intravenously to correct the acidosis, with the dose rate being decided by the blood deficit of bicarbonate. Fluid therapy is essential in the effort to establish urine flow, and the

chapter on the urinary system should be consulted. Calcium may be administered to control any neurological signs resulting from hypocalcaemia.

Phenols

Phenols and other coal and wood tar derivatives can be highly toxic to cats, due again in no small part to the cat's limited ability to glucuronidate such compounds. Marked irritation to the skin and mucosal surfaces is often encountered following exposure, which usually arises from environmental sources. One of the most significant aspects of the pathogenesis of intoxication is the development of methaemoglobinaemia. Affected cats commonly display anorexia, depression, weakness, jaundice, anaemia and neurological signs, such as seizures or coma. Pathological changes to both the liver and kidneys are often present on post-mortem examination. Symptomatic treatment is the rule of thumb, combined with efforts to remove or minimise enteric absorption of the toxin. Agents such as milk or egg white have been used to achieve this latter purpose, followed by gastric lavage. Appropriate bathing of the skin is indicated for cases of cutaneous contamination.

Acids and alkalis

Exposure to corrosive acids and alkalis is most commonly encountered by the dermal route, as ingestion of such caustic compounds would be most unusual in the cat. Treatment is primarily aimed at removing the irritant substance from the skin by extensive washing with water. Attempts to neutralise the offending substance can also be attempted, for example, using vinegar to neutralise alkaline material. If significant quantities of acidic or alkaline material are ingested, gastric lavage should only be performed with an appropriate neutralising agent, as corrosive damage to the upper alimentary tract is possible. Pain relief (e.g. buprenorphine) and the use of gastric protective agents are indicated. Appropriate steps should be taken to address any acid–base balance disturbance, should a metabolic acidosis or alkalosis develop.

In a domestic situation, cats are often exposed to various disinfectants and biological preparations. Most such agents are considered relatively non-toxic to the cat, unless exposure to significant amounts of undiluted material occurs. Exposure in such cases is usually by the dermal route. Cats should avoid areas on which large amounts of bleach have been applied, owing to its caustic nature.

Medicinal preparations

Salicylates

Although acetylsalicylic acid can be well tolerated by the cat in carefully controlled dosages, toxicity can arise when owners administer excessively high dose rates at home. The half-life of acetylsalicyclic acid is exceptionally long in feline plasma ($\geqslant$40 h). As such, the administration of aspirin to cats is normally accompanied by an extended interdosage interval. The clinical signs of aspirin toxicity include vomiting, depression and tachypnoea, with occasional cases also exhibiting an increase in rectal temperature. The gastrointestinal disturbances often increase in intensity as the situation progresses, with haemorrhagic gastroenteritis being commonly reported, as well as jaundice related to toxic changes in the liver. Nervous system involvement is manifested by incoordination, nystagmus and seizures. Bone-marrow toxicity is reflected in the blood picture, which often reveals significant changes in the form of anaemia, thrombocytopenia, haemolysis and Heinz body formation. There is no specific antidote to aspirin poisoning, and attention must focus on supportive and symptomatic treatment of the patient (Burger & Flecknell, 1994). As well as efforts to minimise further drug absorption from the gastrointestinal tract, efforts to stimulate a diuresis and to alkalinise the urine (administer sodium bicarbonate) can be made. Fatalities are not uncommon.

Paracetamol

The incidence of accidental poisoning of cats with this common antipyretic and analgesic agent can be alarmingly high. Although small doses can be adequately detoxified by glucuronidation and sulfation steps, larger doses are more likely to give rise to significant concentrations of a toxic intermediate metabolite, which is capable of causing a potentially fatal hepatotoxicity. This susceptibility to paracetamol toxicity is again a reflection of the reduced conjugation capacity of this species. The clinical signs of intoxication are manifested by depression, anorexia, vomiting, salivation and dyspnoea. Cats rapidly develop a haemolytic anaemia and methaemoglobinaemia. Death may ensue within 48 h of ingestion, and the post-mortem picture is dominated by pulmonary and hepatic changes.

Therapy is directed at minimising further gastrointestinal tract absorption and the use of a 5% solution of *N*-acetylcysteine to act as an antidote or 'mopping-up' agent for the toxic metabolite (initial dose of 140 mg/kg body weight i.v. or p.o., followed by 70 mg/kg body weight i.v. or p.o. every 4 h for four additional treatments). A blood transfusion can be administered if the anaemia is severe and vitamin C is additionally recommended.

Dietary toxins and contaminants

The adverse effects of excessive vitamin A in the cat's diet have been known for a long time, but occasional cases are still reported in those cats fed excessive amounts of raw liver, often as a result of the owners' ignorance. The clinical picture is characterised by lameness in long bones, painful or stiff necks, abnormal gingival mucosa and depression. Toxicity has been recorded both in young kittens and in adult cats. Diagnosis is based on dietary history and radiographic findings of bony exostoses of the spine, or abnormalities in the length of the long bones. While the bony abnormalities may persist, the progression of such lesions can normally be halted by dietary correction.

Most toxicities that occur in domestic cats, even those that are dietary in nature, are relatively well recognised and occur on a repeat basis worldwide. However, our profession must always be open to the idea that a particular problem may arise for the first time, with no previous reports existing. Thus, the literature contains several case reports of interesting, yet unusual reactions that could not be ascribed to any previously known toxicants. One such example involved the recent report of salinomycin-induced polyneuropathy in a significant number of cats in the Netherlands that had been fed on two separate diets produced by the one manufacturer (van der Linde-Sipman *et al.*, 1999). Approximately 1% of the exposed cats presented with clinical disease. The affected animals exhibited an acute onset of lameness and paralysis of the hindlimbs, followed at a later stage by the forelimbs. Further testing revealed a distal polyneuropathy involving both the sensory and motor nerves. Analysis of the diet revealed contamination with the anticoccidial drug salinomycin. Those cats that died usually did so within 48 h. Many surviving cats gradually improved over a period of several weeks.

Thiamin deficiency is a sporadically occurring phenomenon in the cat. Heating is known to destroy a significant proportion of the thiamin present in food, so most commercial manufacturers factor in an additional amount of thiamin in the diet to counter this effect. However, another significant factor is the high concentration of the enzyme thiaminase, which is found in several species of fish (e.g. herring). Thus, cats that are fed on a substantially fish-based diet may also be prone to thiamin deficiency. The clinical presentation of thiamin deficiency may be quite dramatic, and will often affect a number of cats in a multipet household or testing establishment. Signs include inappetance and significant neurological abnormalities, such as blindness, paralysis, impaired postural or righting reflexes, dilated pupils and ventroflexion of the head. If left untreated, many cats deteriorate fairly rapidly with progressive weakness, recumbency and death. Diagnosis is normally based on clinical signs, dietary history and the results of blood thiamin pyrophosphate measurements. Treatment involves the administration of thiamin parenterally and correction of the underlying dietary problem.

Benzoic acid, propylene glycol and a range of other food additives are capable of causing toxicity if ingested in sufficient quantities by the cat. However, it is hoped that exposure to such lethal doses would be a rare event in practice. One of the most potent forms of poisoning related to contamination of the cat's diet involves the presence of microbial toxins and, in this regard, toxaemia resulting from infections with staphylococci, salmonella and toxigenic fungi has been reported (Rumbeiha *et al.*, 1994).

References

Burger I.H. & Flecknell P.A. (1994) Poisoning. In *Feline Medicine and Therapeutics*. 2nd edn. (eds Chandler E.A., Gaskell C.J. & Gaskell R.M.). Blackwell Science, Oxford, pp. 656–678.

Center S.A., Warner K., Corbett J., *et al.* (2000) Proteins invoked by vitamin K absence in clotting times in chronically ill cats. *J Vet Intern Med* **14**, 292–297.

Hornfeldt C.S. & Murphy M.J. (2000) Summary of small poison exposures in a major metropolitan area. In *Kirk's Current Veterinary Therapy*, Vol. 13 (ed. Bonagura J.D.). WB Saunders, Philadelphia, PA, p. 206.

Humphreys D.J. (1988) *Veterinary Toxicology*. 3rd edn. Baillière Tindall, London, pp. 129–208.

Linde-Sipman J.S. van der, Ingh T.S.G.A.M. van den, Ness J.J. van, *et al.* (1999) Salinomycin-induced polyneuropathy in cats: morphologic and epidemiologic data. *Vet Pathol* **36**, 152–156.

Murphy M.J. (2000) Toxicologic disorders. In *Kirk's Current Veterinary Therapy*, Vol. 13 (ed. Bonagura J.D.). WB Saunders, Philadelphia, PA, pp. 207–243.

Nicholson S.S. (2000) Toxicology. In *Textbook of Veterinary Internal Medicine*. 5th edn. (eds Ettinger S.J. & Feldman E.C.). WB Saunders, Philadelphia, PA, pp. 357–362.

Osweiler G.D., Carson T.L., Buck W.B. & Van Gelden G.A. (1985) *Clinical and Diagnostic Veterinary Toxicology*. 3rd edn. Kendall/Hunt, Iowa, pp. 379–402.

Rumbeiha W.K., Oehme F.W. & Reid F.M. (1994) Toxicoses. In *The Cat, Diseases and Clinical Management*. 2nd edn. (ed. Sherding R.G.). WB Saunders, Philadelphia, PA, pp. 215–250.

Further reading

Campbell A. & Chapman M. (2000) *Handbook of Poisoning in Dogs and Cats*. Blackwell Science, Oxford.

Osweiler G.D. (1996) *Toxicology*. The National Veterinary Medical Series for Independent Study. Williams and Wilkins, Philadelphia, PA.

Useful address

Veterinary Poisons Information Service, Medical Toxicology Unit, Avonley Road, London SE14 5ER, UK

Chapter 5

COMMON FELINE BEHAVIOURAL PROBLEMS

S. Heath

Introduction

Over recent years the relationship between humans and cats has changed significantly and the cat is now regarded as one of the most important companion animal species. It has overtaken the dog in popularity in the UK, and one of the main reasons for this shift appears to be the fact that cats fit more conveniently into the modern human lifestyle of long working hours and reduced leisure time. However, the increased demands that have been placed upon the cat in terms of companionship have resulted in an increase in the reporting of feline behaviour problems. Some of these problems may be linked to physical disease and a full veterinary examination should be carried out whenever a cat presents with behavioural changes. However, when the cat is found to be in good physical health it is necessary to consider the role of miscommunication between people and cats in the development of behavioural problems and to consider the fundamental behavioural needs of our feline companions.

Incidence of feline behavioural problems

The Association of Pet Behaviour Counsellors (APBC) produces an annual review of cases referred to its members (and their associates) and the results of the 2000 review are illustrated in Figure 5.1 (Turner *et al.*, 2000).

The most common behavioural problem in this survey was aggression towards other cats (23% of cases), and this category included territorial aggression, redirected aggression and social aggression within the home. Both indoor marking and house-training problems were observed in 21% of cases, with the indoor marking category including spraying, middening and scratching, and the house-training category including inappropriate toileting and lack of appropriate training.

The third most commonly referred feline behaviour problem was aggression towards people (12% of cases referred). This category included redirected aggression, predatory aggression, fear aggression, food guarding, aggression associated with handling, learned aggression and idiopathic aggression.

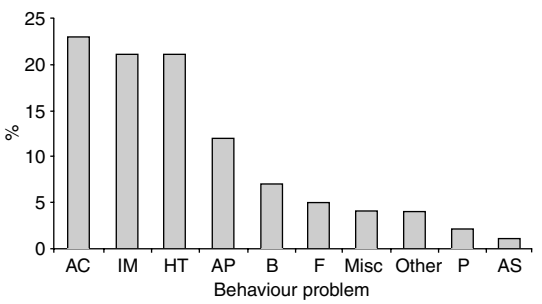

Figure 5.1 Behavioural problems in cats referred during 2000. AC: Aggression towards cats (possible causes include territory or social); IM: indoor marking (includes spraying, middening or scratching); HT: house training problems; AP: aggression towards people (possible causes include fear); B: bonding problems (e.g. overattachment); F: fearful and phobic behaviour to auditory or visual stimuli; Misc: miscellaneous behavioural problems (e.g. repetitive behaviours); Other: other behavioural problems not classified; P: pica; AS: attention-seeking behaviours. (Reproduced with permission from the APBC.)

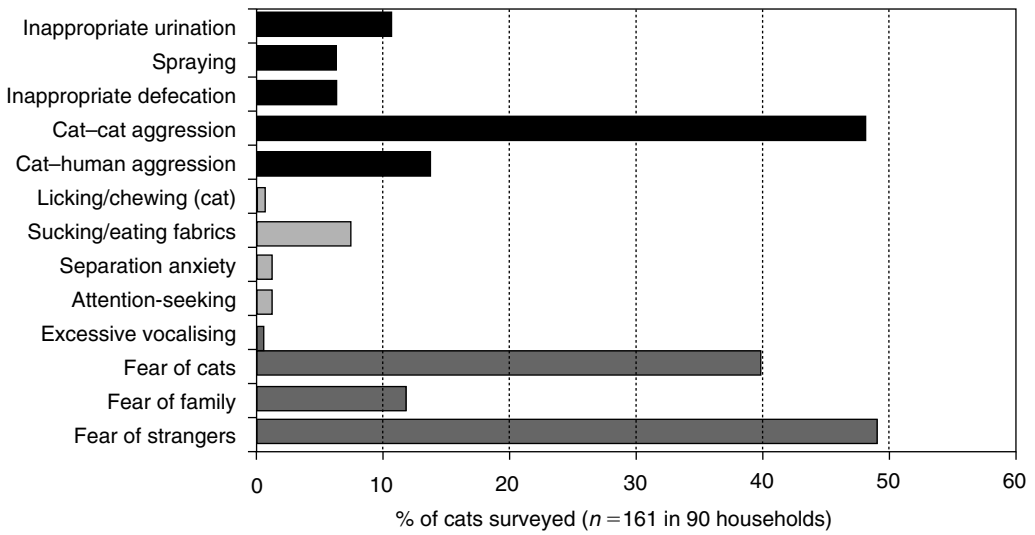

Figure 5.2 Incidence of behaviour problems in the domestic cat population (Bradshaw *et al*., 2000).

It is important to remember that these figures relate to cases that have been referred for behavioural therapy, and work by Bradshaw *et al*. (2000) at the University of Southampton has suggested that the profile of behavioural problems present in the domestic cat population is actually quite different (Figure 5.2). In a survey of cat owners in the Southampton area these researchers found that the incidence of fearful behaviours towards other cats, owners and strangers was far higher than that reported in the APBC review or in an analysis of referred cases seen at the University of Southampton behaviour clinic. The survey also identified significant differences in the levels of aggression towards cats and people compared with the APBC figures, with a higher percentage of such cases being reported in the population at large. The percentage of indoor marking and house-training problems was significantly lower in the general population survey than in the population of referred cases.

Explanations for the discrepancies between the two populations are probably related to the potential impact of these different behaviours on the owners, and also to the level of knowledge among the general cat-owning population about behavioural therapy for cats. Problems of house soiling and aggression between cats can be very difficult to live with and a high percentage of owners will be driven to seek help to resolve these issues. In contrast, cats that run and hide from fear-inducing situations do not pose any direct challenge to their owners and are often dismissed as being 'a bit nervous'.

Dealing with feline behaviour cases

One of the stumbling blocks in relation to acceptance of behavioural medicine in a feline context is the general belief that cats are beyond human control and are unable to be trained. The fact that cats retain a high degree of independence often leads owners to have very low expectations of their ability to influence their pet's behaviour. However, feline behavioural medicine has advanced significantly since the early 1990s and owners of problem cats can now be offered a range of behavioural therapy and psychoactive medication, where appropriate, to assist in the treatment of behavioural disorders in their pets. The understanding of natural feline behaviour has also improved, and with a sound knowledge of feline social systems and communication it is possible to offer practical advice to cat owners that can help to resolve a range of behavioural problems related to natural behaviours being expressed in inappropriate or inconvenient contexts.

Links between behavioural symptoms and clinical disease

It is true that many feline behavioural cases that are presented to the veterinary practice involve normal feline behaviour. However, when dealing with a behavioural

case in any species it is important to remember that alterations in behaviour can also be associated with the presence of clinical disease. In a feline context, links between lower urinary tract disease (FLUTD) and indoor house soiling highlight the need for any animal presented with a potentially behavioural condition to be given a full clinical examination before any attempts at behavioural therapy are instituted. Cats with a history of FLUTD are not only overrepresented among cats that are referred for problems of house soiling (Olm & Houpt, 1988) but also presented in behavioural practice as a result of overgrooming, especially over the caudal lower abdomen. It is important to remember that pathological conditions can lead to continuing behavioural issues even when the disease condition has been resolved, and problems of both house soiling and overgrooming may continue when FLUTD appears to be clinically resolved. Diabetes mellitus has also been diagnosed in cats that were originally presented for a breakdown in house training, and aggression either to owners or to other cats in the household is sometimes the first sign of hyperthyroidism in older cats. In addition to behavioural manifestations of physical disease, it is important to remember that behavioural symptoms can result from alterations in neurochemical balance within the central nervous system (CNS), and conditions such as feline hyperaesthesia syndrome and feline compulsive disorders illustrate the overlap between behavioural medicine and other veterinary disciplines such as neurology. Fears, phobias and anxiety disorders also bring the subject of behaviour well within the context of veterinary medicine, and treatment with psychoactive medication may be appropriate in some of these cases.

Collecting relevant information

The ability to take a good history is central to all aspects of veterinary work and is arguably the most important skill for a veterinary surgeon to possess. It is essential to be able to differentiate between peripheral information and crucial details, and in a behavioural context history taking can be a very time-consuming business. At the start it is important to determine what the problem is from the client's point of view and how they expect you to be able to help, but it is also important not to focus exclusively on the presenting behaviour. The importance of information regarding the cat's environment, both physical and social, should not be overlooked. The history needs to cover the medical background to the case, the early experiences of the individual animal, its present lifestyle and the details of the specific problem under investigation.

In summary, a behavioural history should include:

- relevant clinical history
- present medication
- previous behavioural therapy
- animal's temperament
- frequency of behaviour
- predictability of behaviour
- genetics and early experiences
- present lifestyle
- interactions between pet and owner
- detailed description of the problem
- details of onset and development
- client's response to the problem.

House soiling

In cases of feline house soiling it is essential that medical causes are eliminated by appropriate investigations before making a diagnosis. The next step is differentiating between cases where urine and/or faeces are being used as olfactory and visual markers, and those of inappropriate elimination. That may sound simple, but in some cases it can be very difficult to pinpoint accurately the motivation for the behaviour, and certain pieces of information will help in the process, including:

- posture during deposition of urine
- location of deposits
- use of existing litter facilities
- the cat's personality.

Posture

Cats that are using urine as a marker will most typically deposit the urine at nose height to facilitate investigation by other felines, and to do this the cat adopts a standing posture. Typically, the cat will sniff at the area to be marked before turning round and backing up to the area. It will then stand with its back slightly arched and tail upright and spray a small volume of urine in a horizontal jet onto the vertical surface. During the spraying action the tip of the tail usually quivers and the cat will pad rhythmically with its back feet while staring in a very concentrated fashion into the distance. When owners describe this sort of posture it is

logical to pursue a diagnosis of indoor marking, but it is important to remember that cats suffering from FLUTD may adopt a very similar position when passing urine, and therefore a comprehensive medical investigation is always called for when investigating cases of feline house soiling. Occasionally, the deposition of urine from a squatting position can be used as a form of marking behaviour and it is important to consider other factors, such as the history in terms of social and environmental change and the social significance of the object that is being targeted, in order to differentiate such behaviour from urinary elimination (Olm & Houpt, 1988). In cases of inappropriate elimination the adopted posture is usually a squat, and the passing of urine is accompanied by characteristic digging and raking behaviours, which are designed to prepare a pit in which to deposit the urine and then cover the deposit. It is believed that this innate digging, burying and raking behaviour is derived from behaviour of the African wild cat (*Felis silvestris lybica*), which lived in semi-desert conditions and buried its excrement as a means of reducing scent signals to potential predators and reducing the risk of transfer of both infection and parasites (Borchelt, 1991). The behaviour develops as early as 4 weeks of age and the fact that kittens will behave in this way irrespective of whether they have observed their mother using litter refutes the previous belief that kittens learn to dig and bury by observing the actions of their mother (Bradshaw, 1992).

Location of deposits

When attempting to differentiate between marking and elimination, the location of the urine and/or faeces can provide important clues. In general, marking deposits will be found in places of behavioural significance, such as points of entry and exit or positions of new furniture or invading novel objects, and will be clearly evident to passing cats and people. Elimination deposits, however, are more likely to be found in quiet and secluded locations, which mimic natural feline latrine sites. A plan of the owner's property can be a very useful tool in distinguishing between marking and elimination cases, and it is important to ask the owner to mark points of entry and exit such as windows, doors and cat flaps, sites of feeding stations, litter trays and sleeping areas, and positions of major items of furniture such as sofas, tables, human beds, televisions and kitchen appliances. Once the plan has been drawn the owner should be asked to mark those places where deposits of urine and/or faeces have been found and to indicate the chronological order of those deposits. This helps not only to identify the motivation of the behaviour but also to illustrate the development of the problem behaviour. It can also be a useful means of identifying initiating factors for the problem behaviour that may no longer be present.

Use of existing litter facilities

When questioning owners about cats that are depositing urine and/or faeces in the house it is important to ask about previous toileting behaviour and about the locations that had been used as latrines before the onset of the problem. It is also necessary to know whether the cat's reaction to these established latrines has altered, since cats that are marking within the house are unlikely to have changed their urination and defecation habits, whereas those that are exhibiting elimination disorders will be more likely to show a reluctance to use previously favoured locations (Borchelt, 1991). Cats that have previously eliminated in the garden or surrounding area may be reluctant to do so because of tension with other cats in the neighbourhood, whereas cats that are refusing to use the litter tray may be reacting to inappropriate litter or an unacceptable litter-tray location. All of this information helps to piece together the behavioural jigsaw and to accurately establish the reason for the deposition of urine and/or faeces within the home.

Cat's personality

Another factor that needs to be taken into consideration when determining the motivation for house soiling is the personality of the cat, and it is helpful to gain information about the cat's behaviour in general, as well as in specific relation to the presenting problem. In the case of indoor elimination the problem behaviour appears to be largely independent of personality, except in those cases where use of the provided facilities is inhibited by a fear response. For example, in some multicat households where there is tension between feline residents it is not uncommon for access to the litter tray to be blocked by the more aggressive individuals and for the victim to elect to toilet in more secluded and less accessible locations, such as behind furniture. It has been suggested that the majority of cats that spray in a reactionary sense within the home are of a timid or nervous personality, and information about early socialisation and

habituation experiences, together with the behavioural characteristics of the parental queen and tom, may be significant in these cases (McCune, 1995). Some authors have suggested that urine spraying can be a passive form of aggression used by cats with a low level of control over their environment (Overall, 1997), and that timid cats are more inclined to spray in situations of social conflict because they are not temperamentally suited to physical confrontation. However, it has also been suggested that bold and confident cats may use spraying in a controlling fashion, and not all cases of indoor urine marking can be attributed to cats of anxious or timid personality types. The incidence of spraying appears to rise in multicat households and males in multisex households show an increased tendency to spray. Females in multicat households appear to be less affected by the presence of other cats (Hart & Cooper, 1984).

Composition of the urine

Urine deposits attract the attention of cats irrespective of whether they were deposited from a spraying or a squatting position, but cats will spend longer investigating urine that has been deposited in a marking role than that which has been passed during the act of elimination, and this has led to speculation that the two types of urine differ in the information that they are used to convey. It has been proposed that the sprayed urine contains more socially significant information and that there are important chemical differences between the composition of the two types of urinary deposit. Spray urine has been characterised as a cloudy liquid that contains lipid material, which may originate from the anal sacs, and the characteristic odour of urine that has been deposited by intact toms has been attributed to the anal sac contribution (Wolski, 1982; cited in Bradshaw, 1992). However, other possible explanations for the pungency of sprayed tom cat urine include the addition of a strong-smelling clear fluid, which is produced from the undertail region, or the presence of the microbial breakdown products of the amino acids felinine and cysteine-*S*-isopentanol, which are produced in the kidneys and excreted in the urine (Bradshaw, 1992).

Indoor marking

A good understanding of feline communication is needed to understand the issue of indoor marking. Educating owners about the way in which urine and faeces can be used as a means of leaving important messages in the feline world is often a major step in dealing with these problems. Cats have a highly developed olfactory sense and social odours have particular significance in social communication in the feline world (Bradshaw, 1992). The role of urine marking in communication between intact males and females at breeding times is well documented (Gorman & Trowbridge, 1989), but urine is also used to provide temporal information. The role of marking in feline time-sharing systems or as a form of territorial identification is likely to be more relevant in cases of indoor urine marking in domestic cats (Leyhausen, 1965).

Although urine spraying is the most common form of indoor marking to be referred for behavioural therapy, cats can also mark their territory by depositing faeces in prominent places (middening), by squat marking with urine (Borchelt, 1991), and by scratching to leave both a visual and an olfactory message. Whatever the outward manifestation of the marking, it is important to understand why the cat feels the need to deposit messages within its core territory. In the wild, cats use the central part of their territory for the activities of eating, sleeping and playing, and marking behaviours are only performed at the periphery of the territory or out in the home range beyond (Bradshaw, 1992).

In the past, marking has been associated with confident individuals who are trying to assert their control, but it is now thought that marking is the act of an insecure cat that feels the need to identify with the territory. The presence of scent signals that identify the location as their own appears to result in increased confidence, and while spray marking is important for communication with other cats when it is used in the great outdoors, it is thought that indoor spraying is an important method of self-reassurance (Hart & Hart, 1985).

Potential causes of indoor marking

Sexually motivated urine marking

This form of marking is limited to entire males and females and is associated with the oestrus cycle of the female. The main distinguishing feature of this form of marking appears to be the presence of vocalisation, which is believed to improve the likelihood of other cats orientating towards the chemical signal (Bradshaw, 1992). In the domestic cat population sexually motivated urine marking is relatively rare as a presented behavioural problem due to the high percentage of neutered individuals.

Reactional urine marking

This class of urine-marking problems includes those that are motivated by anxiety and those that occur as a territorial reaction to potential threats either outside or within the home territory. In these cases the cat is using urine marking as a reaction to something or someone and there is a huge range of potential triggers for this behaviour (Heath, 1993). It is possible for a territorial motivation to coexist with anxiety and it should be remembered that many cases of indoor marking are likely to be multifactorial in their origins. Characteristics that help to determine the underlying motivation for marking include the temperament of the cat, the timing of the marking behaviour, the location of the deposits and the frequency of the behaviour. For example, territorial behaviour is most likely to occur when a new cat enters the neighbourhood, when there are alterations to the cat's social group through the arrival of a new baby, partner, cat or other domestic pet, when the protective nature of the core territory boundary is threatened by the installation of a cat flap or when the cat is forced to endure changes to its territory through a house move. Anxiety-related marking also occurs in response to major changes in territory or social grouping, but the history is also likely to include information about a lack of socialisation and habituation, exposure to traumatic experiences in the past, or the presence of actual or perceived threats from outside.

Frustration-related urine marking

In addition to the relatively common scenario of reactional marking, cats can sometimes begin to mark within the home as a response to frustration and in some cases this behaviour can become established as an attention-seeking behaviour as a result of the owner's reaction and the cat's subsequent learning. In cases of attention seeking the history is likely to include information about a high level of requirement for social interaction and the owners are likely to remark that the cat only ever sprays in their presence. Frustration-related cases are also likely to show an increased incidence when the owners are at home, and this sort of marking appears to be more common among the oriental breeds and in individuals that have been hand reared or are understimulated within their present environment. Investigation of these cases will require an in-depth behavioural history and additional information about the early life experience of the cat and the present relationship between cat and owner.

Treatment rationales

The most important step in treating cases of indoor marking is to cease all physical confrontation and punitive attempts at control. After all, if the cat is depositing urine within the home as a means of increasing its feeling of security it is likely that punishment will be counterproductive in dealing with such behaviour. An increased understanding of the function of marking behaviour usually leads most owners to their own realisation that punishment is not appropriate.

The two main aims of treatment for marking cats are to remove the need for the cat to behave in this way within the home and to break the habitual component of the behaviour, which has inevitably established over time. In cases of longstanding marking problems it is possible that the original trigger for the behaviour is no longer present and in these cases it is the habitual component that needs to be focused on.

Cleaning appropriately

Because of the communication function of marking behaviour cats are driven to top up decaying scent marks and therefore cleaning previous deposits appropriately is one of the most important keys to success. Although ammonia is a smell that humans associate with cleanliness it has to be remembered that it is also a constituent of cat urine, and in many cases problems of indoor marking and inappropriate elimination are perpetuated by the inappropriate use of ammonia-based cleaning products, which signal to the cat that another cat has been and deposited urine in the same location. Several products on the market are designed to deal with stale pet deposits, but one of the cheapest and most effective cleaning regimens is one that combines the protein-attacking action of a biological washing powder and the fat degradation of an alcohol such as surgical spirit (Neville, 1992). The regimen is as follows:

(1) Clean the area with a 10% solution of a biological washing powder (making sure to test fabric for colour-fast properties before use).
(2) Rinse the area with cold water and dab dry with a dry cloth.
(3) Spray the area with a fine mist of alcohol such as surgical spirit.
(4) Leave to dry before allowing cat access to the area again.

Removing the need

To remove the need for cats to mark indoors it is important to identify the trigger for the behaviour and isolate, eliminate or control it as appropriate. This relies on accurate history taking and the work-up in cases of indoor marking is the most important part of the consultation. Where the source of stress cannot be identified and the cat is showing signs of severe lack of confidence, the use of a small room or even an indoor pen to decrease the size of the cat's defendable territory can help. Provision of a pen where the cat can safely retreat can increase confidence and, provided it is coupled with other measures to increase home security, it can be very successful.

In addition to dealing with the specific trigger it is important to increase the signals of security within the home and to redefine it as a core territory. This can be achieved by providing increased opportunities for the cat to perform those behaviours that are carried out within core territories of feral and wild cats, namely eating, sleeping and playing. By increasing the number of feeding stations, feeding smaller but more frequent meals or changing from a timed feeding regimen to one of self-service, the cat will see the home as a source of valuable resources. Provision of extra high-up resting places and increased opportunities for owner-directed and independent play will also improve the security of the home from a feline perspective.

Use of social odours

It has long been recognised that the presence of facial scent signals appear to increase feline confidence and act as a way of familiarising territory and removing the need to mark. Owners in the past have been advised to use a cloth that they first rub over the facial glands of their cat, especially in the cheek area, and then apply to those areas in the house that have been previously marked with urine but have been appropriately cleaned. Recent developments in 'pheromonotherapy' have resulted in the production of a synthetic analogue of one fraction of the social odour complex that comes from the face of the cat, and the product is marketed under the trade name 'Feliway' (Ceva Animal Health). Feliway is known as the 'familiarisation pheromone' and it is believed to provide a feeling of security for cats in unfamiliar or stressful situations. Its applications reflect this belief, although the exact mode of action is as yet unclear. When it was first produced Feliway was only available as a spray, and regular application of the product to previously soiled sites and also to regular walkways through the house and to points of entry and exit was shown to help significantly in treating problems of indoor urine marking (White & Mills, 1997). However, cleaning regimens needed to be adjusted when this product was being used and this often led to breakdowns in the success of treatment. The ideal approach was to allow 24 h from the time of cleaning with the regimen outlined earlier to the application of the Feliway spray, but when this was not possible it was preferable to omit the biological washing powder part of the regimen and simply wash down with water, apply surgical spirit and then wait for 30 min before applying Feliway. These problems have been overcome by the recent production of a diffuser device which emits the 'pheromone' directly into the atmosphere, rather than applying it to the previously soiled locations. This device is plugged into a conventional power socket and left switched on for 24 h a day. Its simple application helps to improve client compliance and the results in trials suggest that this device is an important part of the therapeutic approach to indoor urine marking (Mills & Mills, 2001).

The role of drug support

When drug support is used in cases of indoor marking it is important that it is seen as an adjunct to behavioural therapy and not a substitute for it. Drugs such as the tricyclic antidepressants, for example clomipramine, can be used to give a rapid cessation of the behaviour, which is good for owner compliance but also serves to break the habit of spraying (Overall, 1997). The starting dose for clomipramine is 0.25–0.5 mg/kg once daily and treatment is usually needed for between 3 and 6 months, during which time behavioural therapy should be instituted. Withdrawal of clomipramine should not take place until the cat has been symptom free for a period of at least 4 weeks and then the dose should be decreased on a gradual basis. There has been a lot of interest in the use of buspirone, which appears to give promising results and have a lower recurrence rate than diazepam. However, it should be remembered that buspirone can lead to a side-effect of increased intercat aggression and its use in multicat households is therefore not recommended. The dosage regimen for buspirone is 5 mg/cat twice daily for 7 days. If the patient responds treatment should be continued for 8 weeks and then gradually withdrawn (Hart *et al.*, 1993). Diazepam and megoestrol acetate have both been advocated as treatments for urine spraying in the

past, but it is largely agreed that their use is no longer appropriate in view of potential side-effects and effective alternatives.

Inappropriate elimination

In cases where cats are toileting inappropriately in the house, two important questions need to be answered. First, why is the cat reluctant to use the facilities that are being provided, and secondly, why is the cat favouring the inappropriate location?

To answer these questions an accurate history together with a plan of the house, indicating the actual locations of the inappropriate elimination and the chronological appearance of those deposits, will be essential. Certain factors in the history will point towards particular causes of the inappropriate toileting behaviour, but before concentrating on possible behavioural motivations it is important to ensure that all potential medical causes have been ruled out. FLUTD is common and clinical signs include increased frequency of urination (Osborne, 1989), which can lead to problems of inappropriate toileting. Education of owners is an important step when dealing with inappropriate toileting. If people understand the motivation from a feline perspective and can relate their cat's behaviour to the natural drives that govern normal feline eliminatory behaviour, they often find it easier to embark on a treatment plan.

Potential causes of indoor toileting

Initial learning failure

Poor maternal example has been put forward as a potential reason for kittens failing to learn appropriate toileting behaviour. Persians are overrepresented within the population of cats referred for problems of indoor toileting and this might suggest some form of genetic influence over the development of such problems (Neville, 1990). However, direct observational learning is now believed to be irrelevant in the development of appropriate toileting behaviour, and if the mother's poor example is important it is likely that the influence relates to decreased opportunities for the kittens to investigate litter material because their mother fails to encourage them to approach such materials during normal exploratory behaviour. Lack of facilities near to the nest will also result in kittens that fail to learn to use litter appropriately and sometimes, even though there is a litter tray provided, the kittens fail to bond to the substrate provided. These cats have not had the opportunity to bond to soft, rakeable litter materials, and it can be hard to train them to use litter in the new home.

Breakdown in house training

By far the majority of referred cases of inappropriate indoor elimination occur in cats that have been appropriately house trained and subsequently lose their clean habits and start to urinate or defecate in inappropriate locations. In these cases it is important to consider issues relating to the location of elimination and the substrate on which elimination is occurring. Investigations need to concentrate on the possible reasons for an aversion to the location or substrate that is being provided and a preference for the location and substrate that is being targeted.

Location aversion

When cats have previously gone outdoors to eliminate it is important to consider possible factors that may make the cat reluctant to do so now. The presence of other threatening cats in the neighbourhood is one of the most common explanations, but any factor that contributes to the cat's fear of being outside, such as fear of noises or of people, should also be considered.

Reluctance to use the litter facilities within the home may be related to location aversion, in the form of aversion either to the designated site of the tray or to the tray itself (Borchelt, 1991). Inappropriate tray size and type are possible factors and the provision of too few trays in a multicat household should also be considered. When trays are positioned in locations that are very public and lack privacy or are too close to food bowls, sleeping areas or potential threats such as the bed of the family dog, a location aversion is a likely explanation for the development of the inappropriate behaviour. Avoidance of provided facilities may also occur when the cat forms an aversive association with the location, for example through the experience of pain while urinating on the tray due to FLUTD or the experience of being terrorised while on the tray, either by children or by other household pets. Cats will avoid trays that have been cleaned with strong-smelling disinfectants and in some cases the concentration of stale urine odour caused by the cover on hooded trays can lead to an aversion. However, open trays can also cause problems for some cats owing to the lack of privacy and, provided that covered trays

are cleaned out frequently enough, these cats will opt for the increased seclusion.

Location preference

The location of the inappropriate elimination can also provide a lot of information about the motivation for the behaviour (Horwitz, 1997), and the fact that cats will actively seek quiet and secluded locations for elimination when in the wild is highly significant in their selection of toileting location within the home (O'Farrell & Neville, 1994). When cats develop a location preference the inappropriate elimination is usually restricted to one or two sites within the house (Overall, 1997) and the diagnosis can be tested by providing litter trays in the selected locations.

Substrate aversion

Litter aversions are one of the most common reasons for the onset of a house-training breakdown and one of the first questions to ask is, what sort of litter is being used and when was it last altered? In situations where an aversion to the litter has developed it is not necessarily the case that the cat totally refuses to use the tray, and in cases of mild aversion the cat will either use it intermittently or continue to use the tray, but show behavioural signs that all is not right with the litter. In these mild cases the owner will often report that the cat fails to cover its eliminations in the tray or shows other behaviour that indicates a reluctance to make contact with the litter, such as straddling the tray, shaking its paws after getting out of the tray, or running rapidly from the tray after it has eliminated. In more severe aversions the cat may react by depositing urine and/or faeces right next to the tray but not in it. Litter can be aversive for a number of reasons, but being uncomfortable underfoot (e.g. in the case of the hard, wooden pelleted litters), being aversive in terms of odour (e.g. in the case of deodourising litters) and being unacceptable because it is not replaced frequently enough (Borchelt, 1991) are probably the most common ones. Cats naturally select a soft, fine rakeable substrate for elimination, and when preference tests have been carried out it has been shown that cats who use hard pelleted litters at home will still select a fine, sand-like material when one is available (Neville, 1990).

Substrate preference

When a substrate preference occurs there is usually some evidence of a concurrent litter aversion (Borchelt, 1991) and this is helpful when considering potential motivations. In accordance with cats' natural preference for fine latrine substrates, they will often target sand in children's sand pits, but within the home the preferences tend to relate to soft materials rather than rakeable ones. Carpets, rugs, bedding and clothing are the most common targets and the cat will often display digging and covering behaviour when in contact with these substrates. Unlike location preferences, which tend to lead to a limited number of sites, cats that are displaying substrate preference may urinate and defecate in a number of inappropriate locations. In situations where cats have been unable to reach the appropriate substrate, or have developed a conditioned avoidance of it, development of a secondary substrate preference is common and that preference will usually persist even when the underlying cause of the avoidance behaviour has been removed. A classic example of this is when a cat with FLUTD associates pain with the sensation of cat litter and begins to urinate on the carpet, but then continues to select carpet as its preferred substrate when the pain has been removed through appropriate medication.

Other possible causes of indoor elimination

Security problems in the cat can have marked effects on their behaviour, and nervousness and incompetence can result in cats with elimination problems. Approximately 5% of cases may involve nervous cats and in these cases it is essential to aim treatment not at the presenting problem directly, but rather at increasing the cat's security. Some cats are globally fearful, while for others their fear is triggered by an initial stimulus, such as a strange noise or visitors, and behavioural treatment will be determined by an accurate history relating to the fearful behaviour as well as the indoor toileting.

Alterations to the core territory can also lead to a loss of security and this should be considered, especially if the cat is a nervous individual, before undertaking major redecorating or structural alterations. Any changes in access to existing latrine sites may lead to disruption in toileting behaviour.

Old age is another factor that is often overlooked and it must be remembered that sometimes toileting problems are simply the result of the cat being unable to get to the right place in time. Perhaps the tray is positioned up some steps and the cat is arthritic. It is important to ensure that trays are readily available to

older cats, and geriatric cat management should include attention to litter facilities, for example putting the tray a little closer to the resting places and perhaps providing more trays. True incontinence also exists and it is important to realise that, as with all elderly animals, there comes a time where the quality of life needs to be considered.

Treatment rationales

Cleaning appropriately

The principles of cleaning apply equally to cases of indoor toileting as to marking problems, since the smell of stale urine is one of the signals that attracts cats back to use latrine sites on a repeated basis. The regimen outlined in the section on treating marking problems is therefore applicable to toileting cases. Avoidance of ammonia-based cleaning products is important since these will serve to identify inappropriate locations as a latrine rather than discourage the cat from soiling in those sites inappropriately.

Re-establishing appropriate associations

In addition to breaking the latrine association through appropriate cleaning it is important to aim treatment at improving the cat's perception of the provided facilities as an appropriate latrine. To this end it is important to 'think cat' and to ensure that the litter facilities fulfil the cat's natural requirements in terms of privacy, cleanliness and substrate.

In cases where there is a particular trigger for aversion to the provided facilities it is important to work to identify that trigger and then remove it. However, this is not always possible and in many cases the original trigger is no longer evident by the time the owner seeks advice.

Punishment techniques should be avoided since they are likely to increase conflict and confusion and in some cases may lead to toileting in less accessible or noticeable locations. Short-term restriction is often indicated in the treatment of indoor toileting, since by offering a restricted number of options in terms of potential latrine sites it is possible to increase the likelihood of the cat selecting the appropriate location. Where there has been a longstanding preference for an inappropriate site it can be helpful to incorporate some of the features of that site into the provided facilities. For example, where a cat shows an obvious preference for carpet as a substrate it can be beneficial to place a piece of previously soiled carpet in the litter tray. Once the habit of toileting in the tray has been re-established the owner can then cover the carpet with an ever-increasing layer of fine cat litter until the litter layer is thick enough for the carpet to be removed (O'Farrell & Neville, 1994). At the same time the cat can be allowed access on a gradual and supervised basis to the places where inappropriate toileting has previously occurred. Making these sites uninviting by altering the function of the location and redefining them as eating, sleeping and playing areas can be very effective (O'Farrell & Neville, 1994).

Drug support

In general, drug support is not necessary or appropriate in cases of indoor toileting. One exception is for cases where the toileting is a manifestation of fear, but in these cases the drugs are prescribed to deal with the inappropriate fear rather than the toileting.

Feline fears and behavioural consequences

Although fears and phobias are perhaps more closely associated with dogs, feline fear is a real issue in behavioural medicine and the behavioural consequences can be many and varied. Some cats that are fearful may become more dependent on the owner, while others may lack confidence in dealing with family members. In extreme cases fearful cats can go on to form abnormal attachments with their owners and may display separation-related behaviours. Cats can also become agoraphobic and may show reactions to sounds, people and other animals, which are indicative of a fearful motivation. The most commonly documented fear-inducing stimuli in cats include other animals (both cats and other species), strangers (human), noises, and unusual experiences such as travelling or visiting the veterinary surgery.

Possible influences on fearful behaviour in cats

Cats that are reacting in a fearful manner to stimuli that are not innately fear inducing may do so for a variety of reasons. One of the most common is a lack of appropriate socialisation and habituation, and fearful behaviours highlight just how important it is for kittens to be given the best start in life. The important period of behavioural development is called the

socialisation period and in kittens it runs from approximately 2 to 7 weeks of age (Karsh, 1983). During this time kittens need to be introduced to a wide range of people, animals, situations and experiences if they are to grow up to be adaptable domestic pets, and owners wishing to avoid fear-related behaviour problems in their pet would do well to select cats from breeders who pay attention to the socialisation and habituation process.

Another factor that is important in determining feline personality is genetics, and the specific influence on boldness and timidity is something that needs to be taken into consideration. Kittens can be reliably identified from the behaviour of their fathers even when they have never met (Turner *et al.*, 1986) and inheritance of the 'boldness' trait is believed to be an important factor in avoiding problems of fearful behaviour in later life (McCune, 1995). Research has concentrated on the paternal component of this aspect of behaviour, since it is easier to separate genetic and observational influences on kitten behaviour when the tom is not in direct contact with the kittens after birth. However, this does not mean that the queen is insignificant in her contribution to the personality of her offspring, and maternal genetic influences should also be considered.

The role of one-off traumatic incidents in the development of fears and phobias is something to investigate and during history taking it is important to look for evidence of changes in behaviour being directly attributed to a particular event (Askew, 1996). It may be that the pattern of the fear has altered with time and that generalisation has led to the cat being fearful of a wide range of related situations or stimuli. This should become apparent if the owner is asked to give a chronological description of the cat's behaviour.

Old age may be a factor in the onset of fearful behaviour, and a loss of social competence and an increase in general fearfulness in geriatric cats are well recognised. In some cases signs of dementia may also be apparent, and in these circumstances specific treatment for that condition should be considered, but other old cats retain their cognitive ability but show behaviour consistent with anticipatory anxiety or specific fear.

Another important influence on the development of fear-related responses in cats is the reaction of the owner, and unintentional owner reinforcement of fearful responses is common. Attempts to reassure cats, to help them to confront their fears and to prevent them from escaping fearful situations all backfire, and owners find that their well-intentioned actions lead to an escalation of the problem behaviour.

Behavioural consequences of feline fear

In fear situations cats can either withdraw from the environment, both social and physical, or show a decreased threshold of reactivity to stimuli, leading to reactive behavioural manifestations of the fear.

Withdrawal from the environment can lead to an increase in withdrawn and secretive behaviour, including hiding, a reluctance to go outdoors or to enter open spaces within the home and a desire to climb onto high, inaccessible resting places within the home. These behaviours are all part of the cat's normal coping strategy in the face of stress (Carlstead *et al.*, 1993), but these cats are often more at risk in terms of their welfare than the other more active stress responders, since withdrawal symptoms can easily be overlooked and these cats are likely to be left untreated. A decrease in desire for interactive behaviour with familiar humans and a decrease in interest in play, both social and locomotory, are other possible features and although these may be noticed by owners they often fail to lead to a true recognition of the cat's behavioural problem.

Cats that show a decreased threshold of reactivity to stimuli as a result of their fear are prone to more obviously reactive signs of fear and these include a range of behaviours that are unlikely to be overlooked by owners. Indoor marking behaviours, such as urine spraying, loss of house training due to some fearful association with the facilities, and defensive aggression are all likely to result in owners seeking some form of advice, and these cats are therefore more likely to receive treatment than the passive responders. However, active manifestations of fear that are more introverted in nature, such as wool eating and other pica, overgrooming and even self-mutilation, also run the risk of being ignored and may only be seen for treatment when they have been in existence for some time.

Prevention

As with fear in any species, the rule of prevention being better than cure applies. It is essential to remember that cats need to be taught to live in human society and to accept that all of signs of human activity are normal. To this end it is paramount that breeders understand the importance of the socialisation period and ensure that there is sufficient and appropriate socialisation and habituation of very small kittens.

Many of the principles of the origins of feline fears are the same as those that apply to canine fears, and the influence of the cat, the owner and the environment

needs to be considered. Once kittens are living in their new homes a variety of potential factors can contribute to the establishing of feline fears, and new owners need to be advised on how to minimise the risk factors. Owners need to be aware of the risks of unintentional reinforcement of fear-related responses and they should ensure that when the cat is showing signs of fear they do not react in a way that could be misinterpreted. To this end it is essential to cease untimely reassurance, but also to avoid all confrontation and physical punishment. Minimising upheaval in the core territory during major renovation or redecoration will help in the prevention of fearful behaviour, as will the prevention of overattachment by encouraging access to outdoors, to enable the cat to express its full range of natural behaviours.

Grooming problems

One specific consequence of feline fear can be the onset of grooming-related behavioural problems. Most cats groom their flanks when confused, mildly upset or unable to avoid some threatening stimulus. The behaviour seems to have little effect on the layering or the quality of the coat, but is believed to have a stress-relieving function, possibly mediated by the release of opiates. Such stress-induced grooming is usually harmless, but in some cases cats will overgroom in response to continued stress (Luescher *et al.*, 1991) and the resultant hair loss will induce many owners to seek veterinary advice. Before reaching a diagnosis of stress-related hair loss it is important to rule out all likely dermatological reasons for the overgrooming, and investigation of conditions such as flea allergic dermatitis and food hypersensitivity should always be carried out before referral. When the hair loss is located on the caudal ventral abdomen the potential for an underlying cause such as FLUTD should also be thoroughly investigated.

Once medical causes of hair loss have been eliminated the potential behavioural factors that need to be considered include the presence of too many cats in the house leading to social stress, isolation from the owner in situations of overattachment, emotional disturbance within the household or neighbourhood, and fear of a specific stimulus combined with the inability to escape it.

Signs of overgrooming

The classic presentation of behaviourally motivated hair loss is a balding appearance to the flanks, the base of the tail, the ventral abdomen and medial thighs. Hair shafts will be broken by the action of grooming and relatively large bald patches can appear quite quickly as a result of the cat plucking out large quantities of hair.

Actual self-mutilation of body tissue is extremely rare, but if it does occur it is often directed at infected and pruritic plucked areas or sometimes at the tail (Luescher *et al.*, 1991). In these cases the behaviour is usually manic and occurs in frequent episodes, which are believed to be self-reinforcing, possibly through the euphoria engendered by the release of opiates. The pain of mutilation certainly appears to be overridden, although the cats usually show normal responses to pain at other times.

Prevention

Prevention of grooming disorders involves paying adequate attention to skin care and parasite control, as well as adopting strategies for the prevention of fears, as outlined above. Temporary prevention of grooming behaviour if it appears to be becoming excessive, such as, by the use of an Elizabethan collar, can be beneficial since it will give time to enable the coat or skin to heal and will also help to prevent the development of a learned component to the behaviour.

Treating feline fears

Behavioural modification techniques used in the management of feline fears are the same as those used in the canine field, but the way in which they are applied is modified to take into account differences between cats and dogs in terms of natural behaviour and perception of reward. One of the most important factors in the success of any behavioural treatment for feline fears is the correct application of reinforcement and therefore an understanding of the relative value of resources for cats is essential.

Selecting rewards of sufficient value to override the fear response can be difficult, and with a high priority for flight as a defence strategy in cats it can be difficult to keep them in the vicinity of the fear-inducing stimulus while behavioural modification techniques are applied.

When dealing with cats that are exhibiting fear-related behaviour problems it is essential for owners to realise that the cat needs to feel in control of the situation and therefore forcing the cat to confront its fear is unlikely to be effective. However the fact that flight is so

highly motivated means that in some cases it may be necessary to block the flight route while desensitisation and counterconditioning is carried out. This approach is sometimes referred to as controlled introduction to the fear-inducing stimulus and it involves exposure to a diluted form of the stimulus which differentiates it from the technique of flooding, in which the animal is subjected to the full-blown stimulus without the opportunity to escape.

Flooding is not recommended as a treatment option since the panic induced by the lack of opportunity to escape can potentiate rather than ameliorate the condition and there are significant welfare implications from the use of this technique. Controlled exposure, systematic desensitisation and counterconditioning can be useful techniques and, provided that the fear stimulus is diluted sufficiently, it should be possible to override the flight response and teach new pleasurable associations (Voith & Borchelt, 1996).

Examples of behavioural modification techniques include:

- **systematic desensitisation**: the reduction of the response to a noxious stimulus by relaxation rather than the introduction of a second unconditioned stimulus (O'Farrell, 1986)
- **counterconditioning**: the process whereby a behavioural response is altered by associating a previously conditioned stimulus with a new unconditioned stimulus to produce a response that is behaviourally and physiologically incompatible with the undesirable behaviour
- **habituation**: a form of non-associative learning whereby a behavioural response is reduced through repeated exposure to the stimulus
- **flooding**: exposure to a noxious stimulus without the opportunity to escape (Katzev & Berman, 1974) (not recommended in feline behavioural medicine)
- **controlled exposure**: the presentation of a fear-inducing stimulus in a controlled manner while limiting the animal's opportunities for escape. In contrast to flooding, the aversive effects of the exposure are limited by ensuring that the stimulus is diluted when it is presented.

Pharmacological intervention

Medication may be indicated in cases of feline fear for various reasons, but it is certainly not necessary in every case. Cases involving CNS pathology may require medication on a long-term basis, and in situations where the fear-inducing stimuli are either unidentifiable or uncontrollable, long-term or recurring medication may be indicated. In other cases where medication is necessary as an adjunct to behavioural therapy owing to the severity of the fear response and the adverse effect that it has on learning process, the usual aim is to have short-term drug support.

Drug classes that have been advocated for the treatment of fear-related behaviours in cats include benzodiazepines, barbiturates, β-blockers, tricyclic antidepressants and monoamine oxidase inhibitors (Bishop, 2001).

As with behavioural therapy, it is important not simply to transfer treatment regimens from the canine world, and to consider the differences between cats and dogs in terms of metabolism and potential side-effects. Some authors have advocated combination therapy using drugs from more than one class, for example using phenobarbitone and propanolol in combination. Anecdotal results have been promising, but there is a lack of scientific evidence to support this therapy. Benzodiazepines have very limited application in the treatment of fears in cats owing to the potential hepatotoxic side-effects, and when cats are allowed access to outdoors the effect of diazepam on depth perception can lead to problems in relation to traffic and the risk of road accidents. Tricyclic antidepressants need to be used with care in cats with any history of renal disease or urinary retention, and it is essential that a pretreatment clinical examination and biochemical analysis are carried out. Selegiline has shown very promising results in the treatment of feline fears and the incidence of recorded side effects is very low, but pretreatment work-up is still essential.

The final part of the equation when dealing with feline fears is to modify the owner's reaction to the cat's behaviour. Unintentional reinforcement of fears is most likely to occur in cats when they flee and escape the stimulus, but owner interaction, both vocal and tactile, may be seen by some cats as a reward for their response. Punishment will always be counterproductive and techniques designed to make the animal 'confront its fear', such as flooding, have limitations, which have already been discussed.

Feline aggression

Although aggression problems are more commonly associated with canine behaviour, the danger associated with aggression in cats should not be underestimated. Cats sometimes engage in aggressive displays

either towards their owners or towards other cats, and owners are increasingly turning to veterinary surgeons for advice. Within a behavioural context aggression is often subdivided into categories according to the perceived cause, for example learned aggression, play-elicited aggression or redirected aggression. These definitions can be helpful in guiding and advising the client, but it is also important to appreciate whether the aggression is offensive or defensive in motivation, as this may seriously affect the prognosis for reform.

Using aggression as a form of defence

Aggression is, in most instances, a defensive action. For the cat, which is essentially a solitary predator, it is most commonly used in disputes over food sources and territory boundaries. It is not in the cat's interest to engage in unnecessary outbursts of aggression, since any conflict brings with it the risk of injury which could, in turn, jeopardise the individual's survival. Without a pack to protect it, the independent feline relies on its own ability to hunt and any threat to that ability is avoided if at all possible. Instead of jumping in with teeth glistening, the cat engages in elaborate displays of body language and vocalisation which are designed to diffuse the situation and remove the need for actual fighting. Feline tricks of fluffing out the coat, arching the back and sitting sideways on to the opponent combine to give the impression that the cat is bigger than it really is. Such trickery is then combined with a series of low-pitched warning growls, a series of subtle variations in body posture and a range of facial expressions that all convey the unmistakable message to the opponent that confrontation is not advisable. Such displays are fascinating to observe and most people who live in areas with a relatively high feline population will have witnessed confrontations of this sort between their own cats and those of the immediate neighbours.

In the majority of feline encounters out-and-out aggression is very much a last resort. In common with other mammalian species, a cat's defence mechanism incorporates the four important strategies, namely fight, flight, freeze and appease. If a cat is challenged it may momentarily freeze, but given an easy escape route most cats will take the flight option and rapidly remove themselves from the confrontation. It is usually only when such avoiding action is blocked in some way that the claws and teeth really come into play, and if cats are resorting more readily to violence we need to ask ourselves why their tolerance level is decreased. In some cases it may be readily apparent, but in many there will be a subtle interaction of factors such as early experience, illness, inadvertent learning, behavioural frustration, compromised competence and even pain all contributing to the cat's behaviour (Borchelt & Voith, 1982). History taking is essential to establish which factors are involved in each individual case, as the treatment plan will vary accordingly. Recipe approaches are always dangerous in the behavioural field and never more so than in cases of feline aggression.

When investigating any case of feline aggression it is essential to perform a full medical work-up to rule out potential medical causes, including pain, and to take a full behavioural history, including a detailed description of the cat's facial expression and body posture during the aggressive displays. It is also important to gain full details of the situations in which the aggression occurs and it is useful to observe the behaviour either directly or by using video footage.

Cat-to-human aggression

Aggression to people was the third most commonly referred feline behavioural problem in 2000 according to the APBC annual review, with 12% of cases referred falling into this category (Turner *et al.*, 2000). Implications of feline aggression towards people include the potential for injury, breakdown in the relationship between pet and owner, reduced quality of life for pet and owner, and risk to the cat's welfare through rehoming, euthanasia or inappropriate treatment methods.

The normal human reaction when faced with aggression is to counter it with aggression, but in cases of feline aggression such an approach is futile and provocative and can lead to an increase in both the incidence and the intensity of the conflict.

Causes of cat-to-human aggression are varied (Chapman & Voith, 1990; Chapman, 1991), but the most common ones are fear-related aggression, frustration-related aggression, associated with hand rearing in some cases, and misdirected predatory behaviour.

Fear-related aggression

Fear is a very common reason for aggression in cats and occurs when the cat feels threatened by someone or something in its environment. In most cases the fear results from a lack of socialisation and habituation, and a consequently limited experience of novel people and situations. Other possible causes of the fear may be a particularly traumatic experience or the

presentation of a normally accepted stimulus at an unusually high intensity.

Cats will naturally select flight as their primary defence strategy, but when a cat is unable to retreat it is likely to show aggressive behaviour to make the threat go away. This is most likely to occur when the cat is cornered in a cage or small room or when the cat is being restrained, either during petting or during veterinary examination.

The increase in distance from the threatening stimulus, either by it moving away or the cat being removed from the situation, reinforces the behaviour. The cat's perception of success increases the potential for it to resort to aggression the next time the stimulus is presented and encourages it to display it more overtly. Eventually, the displays of aggression can become so apparently overt that without taking an in-depth behavioural history the element of fear can be difficult to identify. Fear aggression is often said to be unpredictable. However, the behaviour is easier to predict if you know how reactive the cat is likely to be to the stimulus, the salience of the stimulus to the cat and the cat's previous learning experiences.

Fear-related aggression is characterised by vocalisations such as hissing, spitting and growling, a crouched body position and defensive ear position, the baring of teeth and the swiping of paws. Typical causes include lack of appropriate socialisation and habituation and subsequent limited experience, genetic predisposition to fear-related behaviours, a traumatic experience involving interaction with people, the inappropriate use of punitive control measures and the delivery of inappropriate rewards, both intentional and unintentional.

Treatment rationales

Increasing the owner's understanding of the behaviour will be vital to the success of treatment, but in the short term the priority must be to limit the potential for injury. Barrier methods such as keeping the cat isolated from potential victims, such as children and elderly people, are a sensible first-aid approach, but in the long term it will be essential to identify the fear-inducing stimulus and to use desensitisation and counterconditioning techniques to alter the cat's response. Removal of punishments and unintentional reinforcement of inappropriate responses will be essential, and in some cases where the fear is so severe as to be detrimental to the learning of new appropriate responses, short-term drug therapy with the monoamine oxidase B inhibitor selegiline may be considered.

Serious cases of fear aggression must be treated by someone who has specialised knowledge and as a general rule it is sensible to refer cases of feline aggression towards people to a colleague working in the field of behavioural medicine.

Frustration-related aggression

Over recent years there has been much interest in the subject of hand-rearing kittens and in particular in the behavioural problems that can result from this process if it is not carefully carried out. One of the major problems that has been highlighted is aggression to humans and this may seem somewhat paradoxical. After all, the usual perception of a hand-reared animal is of one that is particularly sociable to people. The socialisation process would appear to be ideal and yet these kittens can be extremely aggressive to the people they live with. The proposed reason for this is that the kittens never learn to deal with frustration and conflict. To prevent these problems it is important to ensure that kittens experience the four stages of behavioural weaning (Neville & Bessant, 1997) and that they are not always allowed to succeed when they demand food or attention.

Four stages of behavioural weaning

Stage 1

The kittens are fed each and every time they approach the mother, or the hand rearer, and they are therefore on a schedule of continuous reinforcement.

Stage 2

The queen begins to spend more time away from the nest and on her return she does not always allow the kittens to feed, despite very obvious demands by them to do so. She may allow them to start suckling, but stop them midflow by getting up and walking away from the nest. The kittens can see the milk bar, and more importantly smell it, but they cannot reach it. This causes frustration. In terms of hand rearing this stage should involve mimicking this process of restricting access to the milk even when the kittens can smell and see it.

Stage 3

The frustration of not always being able to reach the milk increases the kittens' motivation to work harder for their food and at this stage the mother, or the

hand rearer, needs to bring other potential food items to the kittens and encourage them to investigate and ingest these. In the case of the mother this will involve bringing back dead rodents, then moving on to bringing home semi-dead ones for the kittens to practise their hunting skills on.

Stage 4
Now the kittens begin to alter in their approach to their mother as they no longer see her simply as a milk bar but also as a provider of food of other types. In the hand-rearing situation the kittens move onto a more conventional feeding regimen and have learnt that the human is not a constant source of food on demand.

Treatment rationales

When treating cats displaying frustration-related aggression towards their owners it is important to increase the individual's capacity to deal with frustration. In cases where there is a history of hand rearing it can be beneficial to wean the individual behaviourally, and in all cases the aim is to teach the cat to be more independent by encouraging independent play and reinforcing decision making. Punishment or unintentional reinforcement of responses must be stopped as this is likely to escalate the aggression and make injury more likely.

Misdirected predatory behaviour

The motivation to hunt and the sensation of hunger are separately controlled in the cat and therefore even a very well-fed cat will still have the desire to hunt (Turner & Meister, 1988). This means that all cats need the opportunity to express this important aspect of their behaviour and when the opportunity is denied there is a potential for the behavioural sequences to be redirected onto other targets, such as people. Such misdirected predation is invariably triggered by movement. The behaviour may begin as a form of play in young kittens, but develop into a problem if the behaviour is not redirected onto real prey as the kitten enters adulthood. This form of 'aggressive' behaviour towards people involves elements of predation, including exploration and investigation, stalking, chasing, attacking, pouncing, fighting, wrestling, swatting and biting. Preventing misdirected predatory behaviour relies on providing suitable socialisation and habituation of kittens, together with appropriate physical and mental stimulation. Avoiding inappropriate play with young kittens and ensuring that predatory behaviour is focused onto suitable targets such as toys will also help.

Managing misdirected predatory behaviour

The aim when managing cases of inappropriate predatory behaviour is to redirect the behaviour into acceptable outlets, and it is therefore very important to provide adequate opportunity for the cat to act out predatory sequences, preferably by allowing access to outdoors. If the cat must stay indoors owners must ensure that there is access to suitable objects that will stimulate predatory behaviour, such as chasing and pouncing, and they must play appropriate predatory games using food on the end of string or food hidden in toys. Appropriate behaviour in the presence of any stimuli that potentially induce the predatory sequences should be reinforced, whereas predatory games with human hands and feet should be avoided. If necessary, the predatory behaviour can be made inherently unrewarding by the use of taste deterrents, but owners should resist the temptation to respond to pouncing attacks by the cat with any form of counter-aggression or punishment.

Cat-to-cat aggression

The identification and treatment of aggression, which is motivated by fear, frustration or misdirected predatory behaviour and is directed towards a fellow feline, will be very similar to that directed towards people, but in addition to these common motivations cat-to-cat aggression is often motivated by territorial responses and problems of social integration.

Territorial aggression between cats

Unlike the feral cat, which selects its home base and maps out its own territory, the domestic cat has to establish itself in territory that is thrust upon it. Often this will involve vying for position with already well-established residents, and most owners can expect their cats to receive some degree of injury during the first few weeks in a new home, even if it is only a torn ear margin or a scratched nose. However, the cat's natural tendency to avoid physical conflict comes into play in most situations and rather than wading in with claws flying most cats will quietly and slowly integrate into the existing population. In the feral situation the size of the home range and the density of feline inhab-

itants will be directly affected by the level of food availability. Feral cats that live in urban areas are often provided with a combination of discarded food from dustbins and supplies of proprietary cat food from local cat lovers. Consequently, the home range can support a far greater number of cats than a truly rural range, where food consists of live prey that must be hunted and killed before feeding can take place (Bradshaw, 1992). For the domestic cat that is provided with an abundance of tasty easily digestible food on demand it is not surprising that the home range requirements are relatively small. Routine neutering further reduces the space requirement by removing any sexual determination of territory size and as a result housing estates can support large numbers of cats living relatively peacefully together (Bradshaw, 1992). However, fights do occur and they are more likely when the local cat population is destabilised by the introduction of a newcomer, when one or more of the males in the local population is entire, or when there is a feline despot in the neighbourhood.

Preventing territorial aggression

Since feline society is naturally composed of related individuals it is not surprising that the close coexistence of high numbers of unrelated cats can sometimes cause tension. However, problems of aggression between cats in the neighbourhood can be minimised by providing adequate socialisation with other cats before 7 weeks of age and by ensuring the security of the home base for each cat. Owners should be advised not to encourage other cats to enter the territory, for example by feeding them, and to control entry of other cats by either boarding up the cat flap or using one that is lockable. Co-operation between owners in the neighbourhood is always beneficial when seeking to resolve aggression between cats, and the use of time schedules so that the cats have minimal interaction with one another can be useful. In addition, owners need to encourage their cats to spend more time at home by making the home territory more appealing, and this can be achieved by increasing access to valuable resources, such as food, warmth and playful interaction.

Aggression between cats in the same household

One of the most common sources of enquiries made to veterinary practices on the subject of feline behaviour relates to introducing new cats or maintaining harmony in multicat households. Intercat aggression within the household is most likely to occur when a new cat is being introduced into the household, when one of the resident cats has been absent from the home for a period, for example because it has been at the veterinary surgery or cattery, or when there is a high level of competition over resources within the household. Situations of high-level competition may arise when there is a high density of cats in a small house and there is a shortage of high resting places, when the owner has limited time to give attention to all cats or when the food supply is restricted.

When introducing cats for the first time or reintegrating cats after a period of separation there are certain rules that help to prevent intercat aggression from developing. Introductions should be gradual and owners need to be patient, being careful not to rush the cats. It is important to be particularly attentive to the cat who was first in residence, and provision of separate resting, feeding and toileting places in the early stages can be a sensible precaution. It is necessary to allow time for the scent of the new cat to become incorporated into the household and for the new cat to pick up the home scents before face-to-face introductions are attempted. Rotating bedding, feeding utensils and toys between the cats' respective sleeping areas will help in the integration of their scent.

When the time comes for physical introduction it is important to prevent a cycle of chase and escape behaviour, and the provision of an indoor pen may need to be considered. If this approach is used it is essential that the cats are introduced to the pen in a rewarding manner so that the pen itself does not act as a stressor and, when cat-to-cat introductions are being carried out, the cats should take turns at being in the pen so that each of them has an opportunity to explore the home territory freely. When introductions without a physical barrier are attempted owners should distract quarrelling cats with chase objects, or possibly titbits, rather than attempt to intervene directly in any confrontation. They should play with the cats as much as possible and provide outlets for run and chase behaviours to minimise the possibility of misdirected predatory behaviour complicating the integration process.

Some authors advocate the prophylactic use of the feline facial 'pheromone' fraction F3 (Feliway; Ceva Animal Health) to make each cat feel more secure and relaxed within the home, and the diffuser device has been associated with success in situations of reintegration of warring housemates. The fraction F4 (Felifriend; Ceva Animal Health), which is an 'appeasing pheromone', has also been advocated as a means of preventing intraspecific aggression when introducing

an unfamiliar feline to an existing resident (Pageat & Tessier, 1997), but reports on the success of this approach are mixed.

Limitations

In some cases, despite the sound ethological basis of the introduction process, owners may find that their cat will simply not tolerate the introduction of another individual. The immense range in degrees of sociability in cats means that there can be no hard and fast rules in this area, and in some cases the combination of sociability of the two individual cats concerned means that integration is highly unlikely to be successful. If each cat is permanently aroused by the presence of the other, the potential for confrontation and resulting aggression is high, and the prognosis for establishing any sort of social relationship is poor. In some cases it is possible to reach a state of tolerance and appropriate avoidance even though total integration is never achieved, and some cats may develop time-share systems within the house. These appear to operate in a similar way to those developed to control access to pathways in the outdoor environment and as a result cats are able to avoid potential conflicts over resources such as food, human company, and so on, within the house.

References

Askew H. (1996) *Treatment of Behavioural Problems in Dogs and Cats*. Blackwell Science, Oxford.

Bishop Y. (2001) *The Veterinary Formulary*. Section 6.11. *Drugs Used to Modify Behaviour*. Pharmaceutical Press.

Borchelt P.L. (1991) Cat elimination behaviour problems. *Vet Clin North Am Small Anim Pract* **21**, 257–264.

Borchelt P.L. & Voith V.L. (1982) Diagnosis and treatment of aggression problems in cats. *Vet Clin North Am Small Anim Pract* **12**, 673–680.

Bradshaw J.S.W. (1992) *The Behaviour of the Domestic Cat*. CAB International, Wallingford.

Bradshaw J.W.S., Casey R.A. & MacDonald J.M. (2000) The occurrence of unwanted behaviour in the pet cat population. *Proceedings of the Companion Animal Behaviour. Therapy Study Group Day*, Birmingham, 5 April 2000, pp. 41–2.

Carlstead C., Brown J.L. & Strawn W. (1993) Behavioural and physiological correlates of stress in laboratory cats. *Appl Anim Behav Sci* **38**, 143–158.

Chapman B.L. (1991) Feline aggression – classification, diagnosis and treatment. *Vet Clin North Am Small Anim Pract* **21**, 315–327.

Chapman B.L. & Voith V.L. (1990) Cat aggression redirected to people: 14 cases (1981–1987). *J Am Vet Med Assoc* **196**, 947–950.

Gorman M.L. & Trowbridge B.J. (1989) The role of odour in the social lives of carnivores. In *Carnivore Behaviour, Ecology and Evolution* (ed. Gittleman J.L.). Cornell University Press, Ithaca, NY, pp. 57–88.

Hart B.L. & Cooper L.C. (1984) Factors relating to urine spraying and fighting in pre-pubertal gonadectomised cats. *J Am Vet Med Assoc* **184**, 1255–1258.

Hart B.L. & Hart L.A. (1985) *Canine and Feline Behavioral Therapy*. Lea and Febiger, Philadelphia, PA.

Hart B.L., Eckstein R.A., Powell K.L. & Dodman N.H. (1993) Effectiveness of buspirone on urine spraying and inappropriate urination in cats. *J Am Vet Med Assoc* **203**, 254–258.

Heath S. (2000) *Why Does My Cat…*? Souvenir Press, London.

Horwitz D.F. (1997) Behavioral and environmental factors associated wth elimination behavior problems in cats: a retrospective study. *Appl Anim Behav Sci* **52**, 129–137.

Karsh E.B. (1983) The effects of early handling on the development of social bonds between cats and people. In *The Pet Connection, Conference Proceedings* (eds Anderson R.K., Hart B.L. & Hart L.A.). Globe Press, St Paul, MN.

Katzev R.D. & Berman J.S. (1974) Effect of exposure to conditioned stimulus and control of its termination in the extinction of avoidance behaviour. *J Comp Physiol Psychol* **87**, 347–353.

Leyhausen P. (1965) The communal organisation of social mammals. *Symposium of the Zoological Society of London* **14**, 249–263.

Luescher U.A., McKeown D.B. & Halip J. (1991) Stereotypic and obsessive compulsive disorders in dogs and cats. *Vet Clin North Am Small Anim Pract* **21**, 401–413.

McCune S. (1995) The impact of paternity and early socialisation on the development of cats behaviour to people and novel objects. *Appl Anim Behav Sci* **45**, 109–124.

MacDonald J.M., Bradshaw J.W.S. & Casey R.A. (2000).

Mills D.S. & Mills C.B. (2001) Evaluation of a novel method of delivering a synthetic analogue of feline facial pheromone to control of feline urine spraying. *Vet Rec* **149**, 197–199.

Neville P.F. (1990) *Do Cats Need Shrinks*? Sidgwick and Jackson, London.

Neville P.F. (1992) Behaviour patterns that conflict with domestication. In *The Behaviour of the Domestic Cat* (ed. Bradshaw J.S.W.). CAB International, Wallingford, pp. 187–204.

Neville P.F. & Bessant C. (1997) *The Perfect Kitten*. Hamlyn, London, pp. 128–129.

O'Farrell V. (1986) *Manual of Canine Behaviour*. British Small Animal Veterinary Association, Cheltenham.

O'Farrell V. & Neville P.F. (1994) *Manual of Feline Behaviour*. (ed .C. St C. Ross). British Small Animal Veterina Association, Cheltenham.

Olm D.D. & Houpt K.A. (1988) Feline house soiling problems. *Appl Anim Behav Sci* **20**, 335–345.

Osborne C.A. (1989) Feline lower urinary tract disorders. In *Textbook of Veterinary Internal Medicine*, 3rd edn (ed. Ettinger S.J.). WB Saunders, Philadelphia, PA, pp. 2057–2082.

Overall K.L. (1997) *Clinical Behavioral Medicine for Small Animals*. Mosby, St Louis, MO.

Pageat P. and Tessier Y. (1997) Use of the F4 synthetic pheromone for prevention of intraspective aggression – poorly socialised cats. In *Proceedings of the First International Conferecnce on Veterinary Behavioural Medicine*, UFAW, UK.

Turner D.C. & Meister O. (1988) Hunting behaviour of the domestic cat. In *The Domestic Cat – The Biology of its Behaviour* (eds Turner D. & Bateson P.). Cambridge University Press, Cambridge, pp. 111–21.

Turner D.C., Feaver J., Mendl M. & Bateson P. (1986) Variations in domestic cat behaviour toward humans: a paternal effect. *Anim Behav* **34**, 1890–1901.

Turner D., Appleby D. & Magnus E. (2000) *Association of Pet Behaviour Counsellors Annual Review of Cases*. APBC, Worcester (www.apbc.org.uk).

Voith V.L. & Borchelt P.L. (1996) Fears and phobias in companion animals. In *Readings in Companion Animal Behaviour* (eds Voith V.L. & Borchelt P.L.). Veterinary Learning Systems, Trenton, NJ, pp. 140–152.

White J.C. & Mills D.S. (1997) Efficacy of synthetic feline facial pheromone (F3) analogue (Feliway) for the treatment of chronic non-sexual urine spraying by the domestic cat. In *Proceedings of the First International Conference on Veterinary Behavioural Medicine*. UFAW, Wheathampstead, p. 242.

Wolski D.V.M. (1982) Social behavior of the cat. *Vet Clin North Am Small Anim Pract* **12**, 693–706.

Further reading

Heath S. (2002) *The Henston Guide to Feline and Canine Behavioural Medicine*. Henston.

Horuitz D., Mills D. & Heath S. (2002) *The BSAVA Manual of Canine and Feline Behavioural Medicine*. British Small Animal Veterinary Association, Chelterk.

Lansberg G. & Hunthausen W. (1995) *A Practitioner Guide to Pet Behavior Problems.* American Animal Hospital Association.

Lansberg G., Hunthausen W. & Ackerman L. (1997) *Handbook of Behaviour Problems of the Dog and Cat.* Butterworth Heinemann, Oxford.

Lieberman, D.A. (1993) *Learning, Behaviour and Cognition*. 2nd edn. Brooks/Cole, California.

Lifelearn Behaviour Handouts (in disc form). Lifelearn Ltd, Newmarket (Lifelearn@btinternet.com).

Robinson I. (ed.) (1995) *The Waltham Book of Human Animal Interaction*. Pergamon Press, Oxford.

Turner D. & Bateson P. (eds) (1988) *The Domestic Cat – The Biology of its Behaviour*. Cambridge University Press, Cambridge.

PART 2

MAJOR SYSTEMS

Chapter 6

THE SKIN

A.P. Foster

Introduction

The field of feline dermatology has continued to grow considerably since the previous editions of this book (Thoday, 1985; Van den Broek & Thoday, 1994). The aim of this chapter is to provide an overview of some of the skin diseases that may be observed in the cat. The objectives within that aim include:

- to describe an approach to skin disease, with particular reference to the important features of the owner's history and the physical examination
- to describe the clinical features, diagnostic methods and therapeutic options for common and emerging skin conditions that may be associated with allergic, parasitic, infectious, immune-mediated, endocrine, neoplastic and miscellaneous disorders.

The reader is directed to the list of Further Reading for detailed information about the skin conditions mentioned hereafter and for topics such as structure and function that cannot be covered in detail owing to a lack of space.

The approach to the skin case

The investigation of a skin problem should always start with the collection of comprehensive historical data and a thorough physical examination. The major clinical problems can then be determined, followed by a list of differential diagnoses, which in turn determines the diagnostic methods. This is most applicable when the skin condition has been longstanding.

History

- Establish the age, sex and breed of the cat. Cats older than 3 years of age are unlikely to develop atopic dermatitis. Oriental breeds are supposedly at risk of developing psychogenic dermatitis. Entire male cats may be predisposed to stud tail or feline immunodeficiency virus (FIV). Ask whether the owner is aware of littermates or parents being affected – this information is rarely available.
- Vaccination and worming: viral diseases are associated occasionally with skin conditions; *Dipyllidium* infestation usually correlates with flea exposure.

Questions to consider

Skin condition

- When did the owner obtain the cat? At what age and when did the skin disease develop? Consequently, how long has the condition being going on for? Dermatophyte and cowpox infections are usually self-limiting within 3–4 months, whereas allergic conditions tend to last longer.
- What did the owner first notice and on which part of the body? For example, food allergy may start on the head and flea allergy on the dorsal tailbase; both conditions are associated with pruritus.
- Was the onset of signs sudden or gradual? For example, pruritic cats are more likely to be parasitised in the former and allergic in the latter case.
- Has the condition spread to other parts of the body, or changed in the type of signs observed? Some

infectious conditions are associated with an initial fight, e.g. a wound or lesion and the subsequent development of lesions elsewhere, e.g. cowpox infection.

- Can the owner appreciate signs of pruritus, alopecia, erythema, scaling, crusting, ulceration, nodule formation, scaling, papules, an odour to the skin and coat, or changes in skin or coat colour (i.e. hyperpigmentation and leukotrichia)?
- If the condition is pruritic and longstanding does it have a seasonal pattern, and how pruritic is the cat? Some cats are blatantly very pruritic, whereas others with just alopecia are more secretive about their overgrooming and consequent alopecia.

Environment

- Who does the cat live with? Are other cats or dogs also affected? Does the owner have skin lesions associated with the onset of the cat's skin condition? (Most notable considerations are parasitism due to fleas, *Cheyletiella* and dermatophyte infection.)
- Does the cat spend time outdoors, overnight or for shorter periods? This may compromise opportunities for maintaining good compliance for food trials and preventing exposure to fleas.
- Where does the cat sleep? Where does it have access in the home?
- Has the cat been into a cattery or away from the home (e.g. to a cat show) before or during the course of the skin disease? What impact, if any, did this have on the skin condition?
- Once outdoors, does the cat have an urban or rural environment? Is there possible exposure to wildlife? Are there cats and dogs living in close proximity? Such factors may influence the potential for exposure to parasitic and infectious diseases.
- Is the cat a hunter? This is a risk factor for infectious diseases such as cowpox infection.
- Is the cat a fighter? Again, infectious diseases are a consideration.

Diet

- What does the cat routinely eat? Have any special diet regimens been tried? For how long? Was there good compliance? What other food source could have been accessed?

General health

- Many cats with skin conditions do not have concurrent disease beyond the skin. However, the presence of systemic signs reported by the owner may help to establish an underlying problem.
- Some cats overgroom in association with other behavioural abnormalities linked to various stimuli, e.g. moving home, or the addition of a new cat, dog or human to the family group.
- Gastrointestinal disease such as vomiting and diarrhoea may be associated with food allergy or hypereosinophilic syndrome.
- Weight loss and lethargy in older cats can be associated with neoplastic disease such as paraneoplastic alopecia.
- Changes in drinking and eating habits may be associated with hyperadrenocorticism, hyperthyroidism and abdominal neoplasia.
- Respiratory signs such as sneezing and naso-ocular discharges may be associated with viral infections, or occasionally respiratory signs may be associated with neoplastic disorders involving the thorax, such as thymoma and lung-digit syndrome with bronchial carcinoma.

Therapy

- What treatments have been tried? Have any been successful? Most notably, flea control, antibacterial, antifungal and anti-inflammatory therapies.
- With pruritic cats the flea-control programme has to be very carefully pursued in terms of the individual cat treatment, in-contact cats and dogs, and the environment. It is particularly important to establish the potential for flea exposure through hotspots in the home or contact with infested areas outside the home visited by other cats and dogs.
- Cutaneous manifestations are associated with drug reactions to some drugs. This is particularly pertinent in the case of otitis, where overuse of medication may exacerbate rather than control otitis.

Diagnostic tests

- What previous tests have been performed? What were the results? Some cases need to have even simple tests repeated before moving on to more expensive and invasive procedures.

Physical examination

Once the history has been gleaned one can move on to a thorough examination of the cat. One also has to appreciate the definition of the lesion types as given in Table 6.1.

The whole animal should be examined, especially the oral cavity, eyes and ear canals. The general body condition can be appreciated and the coat inspected. The lymph nodes and abdominal cavity should be palpated; the thorax auscultated and in some cats the body temperature measured. The skin and coat should be examined closely, including particularly the feet, ears, perineum and ventral surfaces.

Problem list

At this point the major problems are identified based on the history and the physical examination. Some problems are secondary to a major problem and more than one major problem may be present.

Table 6.1 Dermatology vocabulary

Primary lesions	
Alopecia	Hair loss
Papule	Solid elevation of the skin, due to infiltration with cells, fluid or foreign material (calcium)
Pustule	Small, circumscribed, elevated and full of pus
Macule	Flat spot with a change of colour; a patch is a big macule
Plaque	Large papule, but flatter than a nodule
Nodule	Circumscribed solid elevation greater than 1 cm, usually extending into the dermis
Secondary lesions	
Ulceration	Full thickness loss of the epidermis exposing the dermis
Excoriation	Superficial damage to the epidermis
Scale	Accumulation of loose fragments of the cornified layer of the skin
Lichenification	Thickening of the skin resulting in a cobblestone appearance
Hyperpigmentation	An increase in pigment deposition, usually leading to dark to black coloration
Hypopigmentation	A decrease in pigment deposition
Hyperkeratosis	Increase in thickness of the cornified layer of the skin
Fissure	Linear cleavage into the epidermis
Crust	Dried exudate, cells, pus and scale adherent to the surface
Comedone	Dilated hair follicle filled with cornified cells and sebaceous material

Differential diagnoses

The major problems should generate a list of potential differential diagnoses and these will determine the diagnostic tests that should be performed, although financial and other owner issues may also determine what can be done.

Diagnostic techniques in dermatology

Only a few diagnostic techniques are available to the clinician: use of them can establish a quick diagnosis in some cases and in others merely help to reduce the list of differential diagnoses. In chronic cases careful consideration of the simple tests should be given before moving on to the more expensive and invasive procedures.

Acetate tape

- To pick up debris attached to the hair and skin (lice or *Cheyletiella* eggs and adults): the tape is applied directly to the microscope slide with a small amount of liquid paraffin to facilitate recognition of such parasites.
- To prepare a slide for cytology, especially for yeast (*Malassezia*).

Skin scrapings

- Deep: there must be a bloody discharge, material is collected with a blunted number 10 scalpel blade and liquid paraffin applied to the skin, the scrape is mounted in liquid paraffin and a coverslip applied. The slide should be examined immediately at low power (×40) for demodex mites.
- Superficial: for *Cheyletiella*, *Sarcoptes* and *Notoedres* mites.

Hair plucks

- Demodex mites from feet and other areas: a pair of forceps is used to collect a number of hairs for mounting in liquid paraffin and a coverslip applied.
- Samples for a trichogram and for dermatophyte culture are collected using sterile forceps and container.

Impression smears

- Use a dry microscope slide for a direct impression, or a swab or acetate tape to collect material for preparation of a sample for staining.
- One may appreciate inflammatory cells, yeast organisms (*Malassezia*), bacteria such as staphylococci and *Dermatophilus* (rare).
- Slides are stained with a modified Wright stain such as Diff Quik™ stain, air dried and examined under oil.

Flea comb

- Fleas and faeces: moistened paper is used to detect blood from the latter. *Cheyletiella* mites or lice, and their eggs, may be found in this way with good eyesight.

Trichogram

- Potentially useful for evaluating anagen versus telogen hairs.
- Detection of mites, lice and parasite eggs.
- Evidence of pruritus with the fractured end of the shaft.
- Detection of dermatophytosis with arthroconidia in the hair shaft cortex.
- Hair shaft abnormalities: rare but an important means of making a diagnosis.

Dermatophytosis

- Woods lamp has limited value; it should be left on for 5 min before observation in a darkened room; there can be confusion with topical therapies and false fluorescence.
- Microscopy: requires some experience to see ectothrix spores.
- Dermatophyte culture media using Sabauraud's medium and then lactophenol cotton blue preparation is used for visualising the macroconidia that enable identification.

Diascopy

- Haemorrhage or vascular engorgement? A glass slide is pressed evenly onto the skin; if it blanches then vascular engorgement is present.

Exfoliative cytology

- Fine-needle aspirates of nodules or direct smears from ulcerated lesions after removing surface debris can establish the presence of an inflammatory or a neoplastic lesion. In some cases the cell type may be apparent, e.g. mast cell tumour.

Skin biopsy

Indications

- Neoplasia suspected.
- Condition poorly responsive to therapy.
- Vesicles, bullae, erosions, ulceration.
- Unusual or serious generalised dermatosis.
- Other diagnostic tests not helpful.

Technique

- Multiple sites are chosen and each sample is placed in a separate pot of formalin.
- Fully developed lesions should be chosen, avoiding chronic or traumatised skin lesions.
- Local anaesthetic is applied with lignocaine and no adrenaline, usually with sedation for most cats using medetomidine and reversing with atipamezole. If the face, ears or feet need to be biopsied then a general anaesthetic is preferable.
- The hair is clipped very carefully at the site of the biopsy. The skin surface should not be prepared because some diseases have histological changes only in the surface layers, which are readily removed to some extent with routine processing.
- A biopsy-punch tool, 4, 6 or 8 mm in diameter, will suffice for most lesions, especially small lesions such as pustules.
- An excision biopsy is required for nodules and diseases involving the panniculus.
- A shave biopsy, especially for nasal lesions such as tumours, may require very little tissue.
- Biopsies can be submitted for routine histopathology and in some cases bacterial and fungal culture, with most laboratories doing Ziehl–Neelsen staining when they are asked to consider mycobacterial culture. The investigation of suspected mycobacterial disease is discussed later in this chapter.
- Immunohistochemistry with immunoperoxidase staining techniques is available from some laboratories; some immune-mediated skin diseases are diagnosed with the help of such techniques, but the histological findings are usually more valuable.

Results
The diagnostic ability of the pathologist is strongly influenced by the submission of a history, some description of the clinical signs and the list of differential diagnoses. A biopsy is not a shortcut to a diagnosis and treatment plan.

Otitis externa/media
This is discussed later in this chapter.

Indications for intradermal skin test or blood test for allergic skin diseases
See section below on allergic skin conditions.

Parasites

Further information about the parasites discussed below may be found in the books by Scott *et al.* (2001) and Wall and Shearer (2001).

Flea-bite hypersensitivity

The flea, *Ctenocephalides felis*, is the most common ectoparasite of the cat in the UK. The term 'flea-bite hypersensitivity' is used to describe the clinical condition seen in animals that have become sensitised to antigenic components of flea saliva. The immunopathogenesis of the condition in the dog is thought to involve both type I and type IV hypersensitivity reactions, with a late-onset immunoglobulin E (IgE) and cutaneous basophil response; similar mechanisms have been proposed for the cat. In many cases this reaction manifests clinically as pruritus and secondary self-trauma, leading to symmetrical alopecia of the ventral abdomen, dorsum and tailhead region (Plate 6.1). Other clinical syndromes associated with flea-bite hypersensitivity in the cat are papulocrusting (miliary) dermatitis and eosinophilic granuloma complex. The haematophagous activities of the fleas, females in particular, can lead to life-threatening anaemia for kittens with heavy infestations.

Aids to diagnosis of flea-bite hypersensitivity

- History.
- Compatible clinical signs.
- Evidence of fleas or flea excreta in the haircoat.
- Evidence of flea infestation on in-contact animals.
- Evidence of *Dipylidium caninum* infestation (the flea is the most common intermediate host).
- Positive response to flea-control programme.
- Elimination of differential diagnoses.
- Positive response to intradermal skin testing with flea saliva allergen.

Although the presence of fleas or flea excreta in the haircoat has been described as a strong indication of underlying flea-bite hypersensitivity, the clinician should be aware that the lack of gross flea presence does not negate the diagnosis, especially in cats. Increased grooming reactions in affected cats often removes evidence of flea presence. Close examination of the coats of other pets in the same household may provide supporting evidence of ectoparasite infestation.

The value of intradermal skin testing with flea allergen is debatable (Moriello & McMurdy, 1989). The presence of a positive intradermal skin response to flea allergen is supportive but not diagnostic. It may occasionally be used as supportive and demonstrative evidence in convincing a client to undertake more rigorous flea-control measures. Successful treatment of flea-bite hypersensitivity is based on correct management of the flea infestation. In many cases, the response to flea eradication measures is the best confirmation of a putative diagnosis of flea-bite hypersensitivity. The response may take at least 4–6 weeks, so owners must be advised accordingly.

Flea control and management

It is important to appreciate the life cycle of the flea in order to be effective in controlling flea populations (Dryden & Rust, 1994). The most important feature of the flea's life cycle is that most of the intermediate stages may be found in the host's environment. For example, the larvae, although susceptible to desiccation, move away from light and crawl downwards into carpets and other safe areas, including under furniture. It has been shown that flea larvae can crawl up to 50 cm through a carpet while feeding on organic debris, including flea faeces produced by adult fleas and tapeworm segments from *Dipylidium caninum*. The pupae spin a cocoon and sit deep in the carpet pile and bedding areas protected from topical ectoparasticidal products. Adult fleas may remain quiescent in the cocoon stage for weeks to months, depending on the environmental conditions and stimuli for emergence.

A number of factors will influence the type of flea-control programme that should be implemented to deal with cats that have either flea infestation or flea allergy. Such factors include:

- the age and number of animals involved
- the owner's ability to treat all of the animals in the home and the home environment
- the formulation of the product used to treat the cat
- the lifestyle of the cat. For example, cats that have access to the outdoors may continue to be reinfested with fleas, thus complicating a strict indoor flea-control programme.

The control programme will rely on the application of a parasiticidal product on the cat and usually a product designed for the environment to deal with the potentially substantial flea population in the home. There have been several attempts to manipulate the immune response to fleas, but such vaccination studies have proven unsuccessful (Kunkle & Milcarsky, 1985).

Product formulation

For cats with flea allergy it is preferable to use a spray or spot-on product formulation because it is important to attempt to prevent fleas reaching the skin to bite and such products tend to have a rapid onset, and long duration, of activity. Such products include fipronil, imidocloprid and selamectin; they can usually be administered on a monthly basis as part of a flea-control programme. Other spray products may contain organophosphates and permethrins and last for 7–14 days. Spray products tend to be difficult to apply to cats that resent restraint. It is important to consider the weight of the cat and coat length when applying sprays, to ensure that appropriate quantities and coverage of the coat are achieved. The spot-on products are very convenient to apply to cats and are rarely associated with adverse reactions such as alopecia at the site of application.

Cats that are flea infested but not suffering from flea-bite hypersensitivity may benefit from a flea collar or powder, but such formulations are most appropriate for situations where fleas numbers are low. Collars may have a long duration of activity, but are associated with contact dermatitis and may be a problem for outdoor cats that can become hung up. Powders tend to have a short duration of activity and there is poor penetration of the coat.

It would be preferable for all adult cats that are suffering from flea-bite hypersensitivity or are flea infested to receive regular (at least monthly) applications of a spot-on or spray product, especially during the spring and summer months when fleas are most active.

Treatment of the environment

The flea-allergic cat requires a flea-control programme that incorporates the use of environmental control measures. These measures should include thorough vacuuming, which can remove up to 20% of larvae and 32–59% of eggs. It will also remove organic debris and flea faeces that are nutritional support for flea larvae. Vacuuming of carpet before the administration of an environmental spray can increase the penetration and consequently the contact of insect growth regulators and adulticides with larvae and pupae by aerating the carpet pile. Carpet shampooing and steam cleaning are not recommended as control measures because the residual humidity is ideal for hatching and larval development.

Environmental control measures should include a product containing an insect growth or development inhibitor with a flea adulticide. The growth inhibitors prevent the successful development of the larvae and pupae, and influence egg viability, but do not kill adult fleas. The pre-emerged adult fleas and pupae residing in the carpet pile are protected from growth inhibitors and vacuuming, consequently they may be killed by the residual effect of the adulticide applied with the growth inhibitor.

The products formulated for use as house sprays with growth inhibitors include methoprene, pyriproxifen and cyromazine, usually with permethrin as the flea adulticide. The former may be active for up to 6 months or more, the latter for several weeks. The apparent failure of a house spray to reduce flea numbers may be due to several factors, including failure to apply an adulticide to the affected cat to prevent fleas emerging from a heavily infested environment moving onto the cat. This situation may also reflect the potential existence of hotspots, areas of the home where fleas are able to survive owing to a lack of cleaning or application of the household sprays. This may be due to lack of appreciation of the ability of the flea larvae to move into protected locations to pupate under furniture and in animal bedding. Since pupae and pre-emerged adults can survive for months in carpet pile, it is possible for heavily infested homes to have a chronic problem with fleas. A major factor that

influences successful control is the ability of the cat to access fleas outside the home, via outbuildings, a vehicle or the home of a neighbour, friend or relative, particularly cats that stay outdoors overnight and or hunt. Stray and feral cats may also contribute to the environmental flea burden.

Insect growth inhibitors have also been formulated for use on the cat as collars and body sprays. The chitin synthesis inhibitor lufenuron is administered systemically to cats either once a month in the food or as an injection once every 6 months. The flea feeding on the cat will absorb the lufenuron and this will render the eggs laid thereafter moribund and unable to hatch.

Environmental control in the home may also utilise sodium polyborate, which desiccates the flea egg and larval stages. It is formulated as a powder for direct application to carpeted surfaces, where it adheres for extended periods and has residual activity for 12 months or more. It has low mammalian toxicity and also has activity against cockroaches, ants and house dust mites.

Flea control for kittens

Heavily infested preweaned kittens can be treated with topical fipronil, permethrin powder and selamectin according to the manufacturer's data sheet. Some owners may elect to avoid treating the kitten and use a flea comb to remove adult fleas. A flea shampoo or powder could be applied briefly, but rinsed thoroughly or combed out to avoid ingestion and possible toxicity. The kitten's local environment should be carefully cleaned, with removal of bedding materials and consideration of treatment of the mother with imidocloprid or a shampoo, which should be thoroughly rinsed.

*Rabbit flea (*Spilopsyllus cuniculi*)*

These are commonly seen on the ear tips of those cats that successfully indulge in hunting rabbits. Some cats develop a crusting dermatitis on the pinnal margin where the fleas have attached. Some owners elect to remove manually such fleas, which are a temporary parasite for the cat (Plate 6.2).

Otodectic mange (*Otodectes cynotis*)

This mite is the common cause of otitis externa and pinnal dermatitis in the cat. *Otodectes* is a free-living surface mite, which lives in the external ear canal where it feeds on epidermal debris and tissue fluids. The mites cause mechanical irritation and there may be a hypersensitivity response to mite and/or mite-derived products.

The mites are a major cause of otitis externa; occasionally they can be found beyond the ear canal, including the head, neck, dorsum and tailhead regions, where they may cause pruritus and papular dermatitis. Acute signs of irritation may accompany the onset of infection. Some cats develop a profound hypersensitivity reaction to the feeding mites.

The diagnosis is readily made with otoscopy and confirmed with the identification of mites or eggs in coat brushings, scrapings and ear wax impressions (Plate 6.3).

Various treatment options are available. All of the cats and dogs in the home should be treated because of the potential for cross-infection. The copious quantities of wax that frequently accompany infestation should be removed with an ear cleaner before instilling ear medication that is licensed for mite therapy. Some vets use 1 week of therapy followed by a rest for 1 week then a further week of therapy to remove any mites that have emerged from residual eggs hatching. Cases that appear to fail therapy should be carefully evaluated for infestation before retreating the ear canal. It is possible for some cats to develop skin reactions to topical therapy that promotes the otitis externa condition when mites have long gone.

Selamectin is licensed for use in cats as a spot-on product that is applied, on one occasion, directly onto the animal and not into the ear canal (Shanks *et al.*, 2000). Cats may be treated with one drop of ivermectin (10 mg/ml) directly into the ear canal on a weekly basis for 3 weeks or by injection for recalcitrant cases of ear mite infestation. This is a potentially useful approach for feral cats. Fipronil has also been reported as a therapy when used as a drop formulation (0.05 ml) directly into the ear canal as a one-off dose (Coleman & Atwell, 1999).

Avermectin therapy

Several avermectin-based products are available that have similar therapeutic activity against ectoparasites of cats. Most notably, selamectin has been licensed for the treatment of *Otodectes* and lice; initial studies also report it to be effective for *Notoedres* and *Cheyletiella*, but not demodicosis.

Ivermectin has been a recommended therapy option for cats with mites including *Otodectes*, *Cheyletiella*, *Notoedres*, *Sarcoptes* and *Lynxacarus*. A dosing regimen is 200 μg/kg on three occasions over 2 weeks administered orally or subcutaneously. The propylene glycol diluent can be an irritant and some cats may resent injection and develop localised alopecia. Ivermectin seems to be a safe means of treating skin parasites, but it is not licensed in the UK for veterinary use in this species. Care should be exercised in using this product in cats less than 6 months of age. Adverse reactions to ivermectin have followed both oral and injection use and include neurological signs (Lewis *et al.*, 1994; Paradis, 1998). Ivermectin has also been applied topically for effective control of ear mites and *Cheyletiella* (Page *et al.*, 2000).

Harvest mites (trombiculids)

The six-legged larvae of *Trombicula autumnalis* are a common seasonal cause of pruritic skin disease affecting cats in certain parts of the UK. The large orange–yellow larvae are present on vegetation in mid to late summer and autumn, particularly in areas of chalk upland. The larvae attach to the host and transiently (3 days) feed on tissue fluid, after which they fall off to complete their life cycle in the environment. Development of a hypersensitivity response to the mite or its products may occur and severe pruritus may result.

The larvae parasitise relatively hairless skin that is most likely to be in contact with vegetation. Prized areas include Henry's pocket of the pinnae, the preauricular regions, the interdigital spaces, the eyelids and ventrum. The larvae are visible with the naked eye and tend to congregate in clusters. Infestation results in erythema, papules and crusting, with the degree of pruritus depending on the development of hypersensitivity.

The diagnosis is made by observation of the orange (0.2 mm) six-legged larvae and confirmed by microscopy (Plate 6.4).

Treatment options include spraying with flea products containing fipronil or permethrins (Nuttall *et al.*, 1998). The presence of an apparent hypersensitivity response may require glucocorticoid therapy for a short period until the mites have reduced in number. Fipronil spray can be applied every 2 weeks in this situation to attempt to provide a deterrent for mite attachment to the affected parts.

Cheyletiellosis

Cheyletiella species are large surface mites associated with cats (*C. blakei*), dogs (*C. yasguri*) and rabbits (*C. parasitivorax*). The mites live in epidermal pseudotunnels and feed on tissue fluids. They lay eggs that are attached to the hair by fine filaments. They are obligate parasites, with the entire 35 day life cycle occurring on the host, with eggs, nymphs, larvae and adults observed in samples from the cat. The adult females may survive for up to 10 days away from the host under appropriate conditions. A hypersensitivity response to mites can develop. Transmission between host species and humans may occur; the mite is highly contagious and zoonotic. The prevalence of such mites has been presumed to drop with the use of flea-control measures on cats.

Clinical signs are variable and are most commonly observed in young animals. The skin lesions include scaling, which can be associated with the mites themselves, so-called walking dandruff, with mild pruritus. In cats, miliary dermatitis or symmetrical alopecia may be seen.

The diagnosis is made by microscopic identification of mites or eggs from coat brushings, hair plucks, superficial skin scrapings and acetate tape impressions (Plate 6.5).

There are no products specifically licensed for the treatment of *Cheyletiella* mites in the UK. Treatment options include spraying with flea products containing fipronil or permethrins. Bathing with selenium sulfide or flea shampoos, or dipping with lime sulfur once weekly for 6 weeks can be effective if the cat will tolerate such handling; this licensed product is available in the USA but not the UK. Some authors do not recommend selenium sulfide for cats. Ivermectin has also been shown to be effective against such mites. Selamectin applied monthly has been reported to be effective against *Cheyletiella* mites in cats (Chailleux & Paradis, 2001).

Insect bite allergy

A seasonal pruritic dermatitis in cats has been described secondary to mosquito bites in the USA, Australia, New Zealand and Japan, and may occur in other areas (Mueller, 2001). Allowing mosquitoes to feed on the nasal skin has reproduced the lesions (Nagata & Ishida, 1997).

The skin signs include papulocrustous dermatitis affecting the nose, muzzle, pinnae, preauricular region, flexor carpi, and the junction of the footpad and haired

skin. These lesions may progress to erosions and are associated with depigmentation. The footpads of affected cats may be ulcerated, swollen and hypopigmented. There may be a peripheral eosinophilia and marked peripheral lymphadenopathy may be observed. Histopathological findings may include an intraepidermal eosinophilic infiltrate, micropustule formation, focal epidermal necrosis, serocellular crusting, spongiosis, eosinophilic cellulitis and palisading eosinophilic granuloma, thereby confirming that this syndrome is a variant of the eosinophilic granuloma complex (EGC) (see later). In some cases there may also be eosinophilic furunculosis, which is not a feature of EGC.

It is recommended that animals be kept in an insect-free environment. Cats protected by insect screening have shown resolution of signs within 7 days. The response to glucocorticoids is usually rapid and dramatic.

Sarcoptes mites

The life cycle of the *Sarcoptes* mite is essentially a 3 week period which involves the laying of eggs on the host deep in burrows excavated by the female. The larvae hatch out and develop into nymphs and thence adults, which may move to the skin surface and may wander to a greater or lesser extent on the skin surface. They may reside in moulting pockets, which are extensions of the tunnels excavated by the gravid female mite. In the epithelium the mites are most likely to feed on tissue fluid oozing into the burrows. The cardinal sign of the infestation is profound pruritus, which in part is due to the activity of the mites in the skin and in part probably due to the development of a hypersensitivity response. Sarcoptid mites are capable of burrowing, feeding and producing eggs in human skin; however, these are self-limiting infestations.

There are occasional reports of cats with scabies due to *Sarcoptes scabiei* mites, presumably with mites originating from dogs or foxes (Ferguson, 1994). The head may be affected or lesions can be generalised. Pruritus is usually severe and in-contact people may report lesions. The clinical presentation can be confused with allergic diseases such as food allergy and atopy, or other parasites including *Otodectes*, and in cases with severe crusting autoimmune skin diseases such as pemphigus foliaceus should be considered.

Diagnosis is achieved with multiple skin scrapes from the affected parts (Plate 6.6).

Therapy should be administered for a period of 6 weeks to cover two life cycles and thereby kill all of the eggs that may have hatched. In chronic infestations one should consider thorough vacuum cleaning to remove possible fomites and the use of a household flea spray to kill mites in the environment. Options for therapy include fipronil spray, selenium sulfide baths, lime sulfur dips, and avermectins such as moxidectin, doramectin and selamectin. Ivermectin is discussed above.

It is important to consider that amitraz is neither licensed nor recommended for the treatment of scabies or other parasites in the cat, owing to fears about adverse reactions including hypotension, bradycardia and anorexia.

Notoedric mange (*Notoedres cati*)

Notoedric mange is an uncommon contagious disease of the cat and is responsible for isolated epizootic outbreaks in Europe. Human infection has been reported.

Miliary dermatitis of the pinnae, head and neck with associated pruritus may be initial signs, but ulceration and crusting follow chronic infection. A more generalised distribution of lesions occurs in cats treated with immunosuppressive drugs or in cats which have intercurrent disease.

Diagnosis is usually confirmed by the microscopic demonstration of mites and eggs in skin scrapings. Treatment options may include selamectin applied monthly (Beale & Fujioka, 2001), ivermectin, doramectin (Delucchi & Castro, 2000) and lime sulfur.

Demodicosis

Demodicosis has been reported as an uncommon disease associated with a variety of dermatological manifestations, including ceruminous otitis externa; localised alopecia, erythema, scaling, crusting and pyoderma of the head, neck and ears; and generalised alopecia, erythema, variable scaling, papulocrusting dermatitis and secondary pyoderma. Clinical disease has been reported in cases associated with two species of mite. The long, slender form, *Demodex cati*, has been reported since the mid-nineteenth century and inhabits the hair follicle. The second species of mite has a short abdomen and may be found in the stratum corneum. Previously termed the stubby feline demodex mite, it is called *Demodex gatoi* (Desch & Stewart, 1999).

Infestation with *D. cati* and generalised skin disease involving the head neck, trunk and limbs may be associated with variable pruritus and should prompt a close examination for underlying factors. These may include feline leukaemia virus (FeLV) infection, FIV infection, toxoplasmosis, long-term glucocorticoid therapy, iatrogenic hyperadrenocorticism, diabetes mellitus, upper respiratory tract infection and systemic lupus erythematosus (SLE).

Infestation with *D. gatoi* may resemble allergic skin disease with pruritus, and excessive grooming leading to alopecia, scaling, crusting, erythema and broken hairs. The pruritus may involve the head, neck, elbows, legs, flank and ventral abdomen.

The diagnosis is usually readily achieved because the numerous mites are relatively superficial, whether living in the hair follicles or in the stratum corneum (Plate 6.7).

Treatment can be rapidly effective unless there is an underlying cause of immunosuppression. The choice of topical agent is limited to amitraz [although because of potential adverse effects (see earlier) this is not recommended by some authors], carbaryl and selenium sulfide shampoos, and lime sulfur dips, applied on a weekly basis. There are anecdotal reports of the use of ivermectin on a daily regimen of 300 μg/kg p.o. for several weeks, but as before, this is not a licensed product for this disease. Selamectin has been shown to be ineffective in the treatment of feline demodicosis (Beale & Rustemeyer-May, 2001).

Lice

The biting louse *Felicola subrostratus* may be found on cats. The life cycle is confined to the host and takes 14–21 days. The eggs are firmly attached to the hairs. After hatching, there are three nymph stages before the adult develops. Lice are very host specific and are highly contagious, either directly or via grooming implements.

Pruritus and scaling of the dorsum are the primary clinical signs. These are usually mild, but an occasional case may develop severe self-trauma. Lice infestations are most common in young or debilitated animals, and in overcrowded or multi-animal households.

A diagnosis is made by carefully examining the coat for adults or eggs. Both are visible to the naked eye and can be confirmed with microscopy. An acetate tape impression is a convenient way to pick up lice from the coat, but coat brushings and hair pluckings are also useful.

Treatment options include selamectin, which is licensed for feline lice infestation. There are also reports of the use of fipronil spray applied on one occasion. Lime sulfur dips, permethrin or selenium sulfide shampoos can be applied weekly for two life cycles over 6 weeks. It is useful to clip heavily infested animals to reduce the burden of eggs and adults and allow effective use of topical therapies. Ivermectin has also been shown to be effective and may be useful for feral cats.

Ticks

Three species of tick have been found in the UK attached to cats: *Ixodes ricinus* (sheep and deer tick), *Ixodes hexagonus* (hedgehog tick) and *Ixodes canisuga* (dog tick). They have complex multihost life cycles taking up to 12 months. Each stage requires a short period of parasitism on a different host, between which the intermediate stages rest in the environment. They are not species specific and human infestation can occur from the infested environment (see Shaw *et al.*, 2001 for a review).

The cutaneous response to tick bites is variable. Some animals show a marked inflammation followed by necrosis at the bite site. Embedded tick mouthparts may be the target for a foreign body reaction. Ticks are associated with the transmission of numerous kinds of infectious disease, most of which are not commonly reported in cats at present, but this situation may change with improvements in diagnostic methods. Ticks will release within 24–48 h and die when sprayed with products such as fipronil.

Tick infestation can be routinely prevented with a product such as fipronil (spray or spot-on) applied once a month to those cats that regularly become exposed in a rural environment. The ticks will still attach but they die within 24–48 h and release from the skin.

Cat fur mite (*Lynxacarus radovskyi*)

Infection with *Lynxacarus radovskyi* (cat fur mite) is occasionally reported in humid tropical parts, including the USA, Australia, Fiji, Puerto Rico and Hawaii, and causes mild pruritus, regional alopecia and scaling. Diagnosis is by identification of mites or intermediate stages on skin scrapings, hair brushings and hair pluckings. Treatment options include permethrin baths, lime sulfur dips and ivermectin.

Poultry mite (*Dermanyssus gallinae*)

These rarely affect cats and cause erythema, papules, crusts and pruritus that can be intense. The cat can be

treated in a similar fashion to that for other skin ectoparasites, but the environment from which the mites originated must be treated because reinfestation can occur (Plate 6.8).

Zoonoses

There is a potential for transient parasite infection in humans handling cats infested with *Cheyletiella*, *Dermanyssus*, fleas, *Lynxacarus*, *Notoedres*, *Otodectes*, *Sarcoptes* and trombiculid parasites. Lesions usually consist of erythematous pruritic papules present on the forearms, abdomen and upper legs.

Allergic skin diseases

Allergic skin diseases are important because they form the majority of skin diseases observed in the cat. Cats may present with a variety of manifestations of allergic skin disease, including papulocrusting (miliary) dermatitis, symmetrical alopecia and EGC. Such diseases most often are caused by allergic reactions to parasites (most notably fleas, but also mosquitoes, occasionally *Otodectes* ear mites and possibly trombiculids), food allergens and inhaled allergens (atopic disease).

The concept of pruritic threshold has been used to describe the roles of a variety of flare factors that interact before a cat will become pruritic. These factors must be investigated and reflect the potential complexity of the cat's problem. The potential of flare factors to precipitate pruritus makes interpretation of the relevance of *in vivo* or *in vitro* tests in the cat vital.

These allergic diseases are usually assumed to be associated with a type I hypersensitivity reaction involving, in part, IgE, mast cells, Langerhans' cells and T-cells. While there is extensive knowledge of the role of these elements in human, and to some extent canine, atopic dermatitis, the allergic cat remains their poorly understood companion (see review by Roosje *et al.*, 2002).

Various studies have used sera from cats infested with parasites to demonstrate the presence of a heat-labile serum antibody that has characteristics consistent with an IgE isotype. One good example of this is a form of EGC associated with mosquito bites on the face, especially the bridge of the nose (Wilkinson & Bate, 1984; Mason & Evans, 1991). Reaginic antibodies were demonstrated in the skin by positive reactions to mosquito bite exposure, intradermal skin testing and Prausnitz–Küstner (PK) tests (Nagata & Ishida, 1997). The advent of molecular cloning techniques may allow the development of feline-specific reagents that measure the IgE molecule directly or indirectly via the high-affinity $Fc_{\varepsilon}RI$ receptor. Several laboratories have cloned and sequenced the feline IgE heavy-chain gene, and such studies potentially enable the development of IgE-specific antibodies that can measure feline IgE in serum and various tissues (Weber *et al.*, 2000; Griot-Wenk *et al.*, 2000).

In the course of a type I hypersensitivity reaction allergens are exposed to mast cell-bound IgE and specifically stimulate the degranulation of the mast cells to release their granules. The granules contain a variety of proinflammatory mediators that attract and activate eosinophils and neutrophils, so that following degranulation a late-phase reaction (LPR) is generated. Consequently, within 4–8 h an inflammatory infiltrate of mainly eosinophils and neutrophils is observed, with some basophils, lymphocytes and macrophages. Antigen-induced mast cell degranulation has been reported in cat skin (Bevier, 1998) but there is a dearth of information about the LPR, if it exists, in the cat.

In human atopic dermatitis Langerhans' cells can also bind IgE via the high-affinity $Fc_{\varepsilon}RI$ receptor and then present antigens to T-cells in the dermis and local lymph nodes (Leung, 2000). Evidence for the role of T-cells in the dermis of cats with allergic dermatitis has been reported and Langerhans' cells have been shown to migrate to local lymph nodes (Roosje *et al.*, 1997, 1998; Marchal *et al.*, 1998). The T-cells were shown to be positive on double staining with anti-CD4 and interleukin-4 (IL-4) antibodies, in keeping with studies performed in human atopic dermatitis where IL-4 is an important component of the T-cell response. Much remains to be learnt about the immune mechanisms involved in feline allergic skin disease, especially that associated with IgE antibodies.

Food allergy/intolerance

Food allergy in the cat may be associated with concurrent flea bite, inhalant or flea-collar hypersensitivity (White & Sequoia, 1989). Food allergy as a disease is a well-recognised cause of feline dermatological problems (Carlotti *et al.*, 1990; Rosser, 1993), the prevalence of which varies from rare to common according to different authors. The pathophysiology of this syndrome is not completely understood. Adverse reactions to food may be either toxic or non-toxic; if they are non-toxic they may be either due to intolerance or to immunological (allergic) reactions.

Food allergy may be defined as an immunologically mediated excessive reaction to food substances, to be distinguished from food intolerance where enzyme deficiencies, pharmacological factors and toxic reactions, among others, may be implicated.

Allergens implicated include milk, beef, mutton, pork, chicken, rabbit, horse, eggs and fish. In principle there is no hypoallergenic protein source for a cat: it is possible for any protein source to be an allergen. Adverse reactions to artificial flavours, dyes and preservatives are considered rare. Additives are usually too small to be antigenic and they are more likely to cause a reaction via intolerance mechanisms.

Clinical signs include non-seasonal pruritus often affecting the head and neck, including otitis externa (Plate 6.9). Miliary dermatitis, symmetrical alopecia, eosinophilic plaque and ulcerative dermatitis secondary to severe self-trauma may also be seen. Gastrointestinal signs of vomiting or diarrhoea occur occasionally.

The diagnosis of food allergy is achieved with a diet trial using a source of protein and carbohydrate to which the cat has had no or minimal exposure. This may be home cooked or, more commonly, a commercially prepared diet. There is debate about the value of home-cooked versus commercial diets. The home-cooked diet may not be balanced and can be a considerable practical challenge for the owner to prepare; however, according to some authors this is preferable to commercial diets that may contain the same dietary constituents but through food processing the antigenicity of the food is altered.

There is controversy over the optimum period for which the diet is fed. This may range from 3 to 9 weeks. The author recommends a period of 8 weeks with a commercial diet. The commercial diets currently available include lamb and barley, capelin and tapioca, lamb and rice, turkey and rice, and chicken and rice. The choice of diet will depend on the previous food items fed, although it may not be possible to know about all of the minor food ingredients in feline diets. The compliance with the diet trial will depend on the willingness of the cat to eat the food and not being able to access other sources of food; for example, by hunting or being outdoors for long periods and eating food at another home, or even just eating cat food for other cats in the house. Consequently, it may prove difficult to evaluate a suspected food allergy problem for a cat allowed outdoors. The ideal candidate would be a single cat living exclusively indoors and willing to eat any diet provided.

Amelioration of signs following an elimination diet can only be confirmed by the return of pruritus after rechallenge with the previous diet; this may take up to 7 days and even 14 days in some cases. Provocative exposure may be tried sequentially with a new protein item added to the hypoallergenic diet; this is not very often pursued.

It is possible for the food-allergic cat to relapse while eating the hypoallergenic diet that initially cured the problem. That is, the cat could become allergic to the new protein source and require a second diet trial. In some cases, if the first trial fails and there is no evidence for other causes a second diet trial may be required to establish a diagnosis.

Intradermal testing and *in vitro* tests are not useful in the diagnosis of this syndrome.

Feline atopy

Atopic disease of domestic animals has been defined as the inherited predisposition to develop IgE antibodies to environmental allergens, resulting in allergic disease (Halliwell & Gorman, 1989). The condition in dogs has been thoroughly reviewed by a task force of the American College of Veterinary Dermatology (Olivry *et al.*, 2001). The nomenclature used for the dog ought to be considered for use in the feline condition.

The condition of feline atopic disease has been reported and reviewed on a number of occasions (O'Dair *et al.*, 1996; Bevier, 1997; Reedy *et al.*, 1997; Gilbert *et al.*, 1999; Bettenay, 2000; Roosje *et al.*, 2002), but remains poorly understood and ill defined. The immunopathogenesis of atopic disease in the cat has been presumed to be similar to that in the dog, although much of the relevant work remains to be done. There are limited reports for an inherited basis in the cat and Abyssinian cats have been suggested to be at risk in one report. Previous reports of atopic dermatitis suggest that such candidates have no breed predispositions (Foster & O'Dair, 1993; Bevier, 1997; Bettenay, 1998a). The age of onset is usually before 3 years (Bevier, 1997); therefore, middle-aged or older cats that suddenly develop skin disease are unlikely to be atopic. Cats that present with a short history of several months' duration, especially during the summer months, are not good candidates for investigation of atopy because they may have flea, pollen, insects or trombiculid mites as the cause of their allergic response.

Atopic disease may be associated with the cutaneous reaction patterns given above that are associated with other allergic diseases. This gives rise to a long list of possible differential diagnoses. The hallmark of the presenting signs is pruritus, with

secondary lesions usually arising from overgrooming. In terms of clinical signs the cat is unlike the dog and humans with atopic dermatitis, where an eczematous dermatitis and distinct location of signs can be observed.

Infectious diseases can complicate and confuse the clinical presentation, including dermatophytes and *Malassezia* (Mason, 1997; Bond *et al.*, 1997), and occasionally bacteria. Hair plucks for fungal culture and impression smears for skin cytology are routine diagnostic tests to consider in a standard work-up.

Differential diagnoses to consider include parasitic causes, notably, in the vast majority of cases, fleas, but mites such as *Cheyletiella*, *Demodex*, *Notoedres* and *Sarcoptes*, trombiculids and lice should also be considered. Flea combing, adhesive tape preps, superficial skin scrapes and hair examination help to rule out such parasites. Trial therapy for such mites, especially *Cheyletiella*, may be considered with ivermectin, using 200 μg/kg, given every 2 weeks for three injections subcutaneously or orally. A recent study reported that selamectin applied monthly provided successful control of *Cheyletiella* mites in cats (Chailleux & Paradis, 2001).

An alternative for ruling out mites is lime sulfur dips (Lym dip) on a weekly basis for up to 6 weeks. Unfortunately the dip can stain objects and has an unpleasant odour. It is, however, safe, cheap and effective for all feline ectoparasites. Side-effects may include nausea and this can be avoided by using an E-collar until the dip has dried on the coat so that grooming will not lead to ingestion. Some cats may also develop a dry brittle coat and dry skin requiring application of a lotion to provide some moisture.

Allergic causes considered are usually fleas and food. Methods for trying to rule out such diseases are given elsewhere in this chapter.

The diagnosis of atopic disease in this species relies substantially on a critical evaluation of clinical history and signs with the appropriate use of diagnostic tests. The concept of pruritic threshold has been used to describe the roles of a variety of flare factors that interact before a cat will become pruritic. These factors must be investigated and reflect the potential complexity of the cat's skin problem. The potential of flare factors to precipitate pruritus makes interpretation of the relevance of *in vivo* or *in vitro* tests in a cat vital. Assuming that all of the above factors have been considered, one may have a candidate for testing for allergen-specific IgE to confirm a tentative diagnosis of atopy, although some authors remain sceptical of the value of such tests for making a diagnosis (Gilbert *et al.*, 1999).

Intradermal testing (IDT) may help to establish a diagnosis of atopic disease and provide a basis for immunotherapy. The cat may be skin tested with similar allergen concentrations to those used in the dog, although some cats with no evidence of skin disease may give positive skin reactions reflecting allergen exposure (Bevier, 1990). Several studies have demonstrated that cats may respond to IDT in a similar manner to dogs (Kunkle, 1984; Gross *et al.*, 1986; Bevier, 1990; Codner, 1996). Cats are sedated with ketamine and diazepam, tiletamine–zolazepam, or ketamine and xylazine before testing (Mueller *et al.*, 1991; Foster & O'Dair, 1993). The author uses medetomidine (Domitor; Pfizer) followed by atipamezole (Antisedan; Pfizer), both by intramuscular injection. Cats are reported to have weak skin-test reactivity, and one reason for this may be that during handling and skin-testing procedures plasma cortisol, corticotropin and α-melanocyte-stimulating hormone concentrations are raised. A study by Willemse *et al.* (1993) suggested that skin testing cats with or without sedation may be associated with increased levels of plasma cortisol, and this may help to explain weak weal formation in skin tests. Recent drug therapy, inappropriate allergen selection or preparation and technical difficulties in carrying out the test make the use of intradermal skin testing in cats a challenge. A negative test could imply that either the significant allergens for that case are not included or there are other possible causes of the pruritus that need to be investigated, such as fleas, mites, food allergy and secondary infections due to bacteria and yeast.

In the author's experience allergens implicated by IDT are usually fleas and house dust mites, in keeping with other studies (Gilbert & Halliwell, 1998; Prost, 1998). The clinical diagnosis often suggests a role for multiple allergens, with fleas and environmental allergens (Foster & O'Dair, 1993; O'Dair *et al.*, 1996; Bevier, 1997; Prost, 1998) and occasionally concurrent food allergy (Foster & O'Dair, 1993; O'Dair *et al.*, 1996; Bettenay, 1998b).

IDT and *in vitro* methods to measure IgE antibodies have been used to test for atopy. The *in vitro* methods are attractive because patients can be tested despite the presence of extensive and severe skin disease, and sedation is usually not needed. One test that is widely available is the Heska Allercept™ test, which the author has used for a limited number of cats in conjunction with IDT. The test technique is based in part on the capture of IgE antibody by the receptor that normally binds it to a mast cell *in vivo*, the $Fc_{\varepsilon}RI$ receptor. This binding is highly specific for IgE

antibody. Blood tests are particularly attractive when the skin lesions are so extensive that an intradermal skin test would be difficult to perform, or where the owner will not allow sedation of the cat. Blood tests are likely to be affected by corticosteroid therapy; it is unlikely that medications such as antibiotics, essential fatty acids (EFAs) or antihistamines will influence the results of the tests. Allergy tests for IgE merely measure serum antibody and imply clinical significance if present in large quantities; positive results do not unequivocally indicate allergy to that allergen. They are no substitute for looking at the cat in terms of the clinical signs and history.

The diagnosis of feline atopy has been considered appropriate where there has been a favourable response to hyposensitisation based on results of IDT [also termed allergen-specific immunotherapy (ASIT); Olivry *et al.*, 2001]. Hyposensitisation appears to be helpful in some cases of feline atopy where injection regimens are borrowed from those used in the dog. Successful responses may be seen in up to 70% of cases and adverse side-effects seem to be rare (Bevier, 1997; Bettenay, 2000). The response to immunotherapy will be influenced by the appropriate choice of allergens and the control of secondary flare factors such as fleas. Further studies of immunotherapy are clearly warranted, not least a placebo-controlled trial that demonstrates unequivocally that cats respond to immunotherapy. There is also a need to explore the specific allergens involved in feline atopic skin disease as a basis for improving methods of diagnosis and possible responses to immunotherapy.

Therapeutic protocols for feline allergic skin disease

In many cases the pruritic (and presumed allergic) cat has to be managed with medical therapy because a definitive diagnosis has not been achieved despite measures to implement effective flea control, the pursuit of diet trials and tests for allergen-specific IgE. The clinician is then left with the obligation to try and make the disease manageable without causing problems from adverse drug reactions. The mainstay of therapy for allergic and pruritic cats has been a heavily reliance on the use of glucocorticoids. In some cases antihistamines may be useful (Messinger, 1995; Bevier, 1997; Bettenay, 2000). EFAs are safe and may help in some cases, and the author frequently recommends such therapy while underlying factors are being investigated.

Antihistamines

The use of antihistamines usually stems from a reluctance to rely on glucocorticoid therapy to establish or maintain control of pruritus. The first generation H_1 antagonists have been used in veterinary dermatology, with variable efficacy reported. First generation antihistamines are associated with blocking histamine, muscarinic cholinergic, serotonin and α-adrenergic receptors. The main side-effects include sedation, although there can be paradoxical hyperexcitability, and changes in appetite. The antimuscarinic effects may account for the disturbance of the intestine and diarrhoea (Table 6.2).

A variety of antihistamines has been used in the cat, although there are no placebo-controlled studies of this type of drug and dosages recommended are somewhat empirical and based on open trials. Efficacy is usually low and cats are often difficult to dose with such medications on a regular basis. Trial therapy should rely on 2–3 weeks of medication before the response is evaluated. Side-effects are usually related to the ability of these drugs to penetrate the blood–brain barrier and cause sedation. While they may stabilise mast cell membranes from degranulation it is unclear how they influence pruritus in the allergic cat. There may be a synergistic response with glucocorticoid or EFA therapy, allowing a reduction in the dose of glucocorticoid required to maintain control of the pruritus. If proven to be effective the antihistamine usually has to be given on a daily basis.

Essential fatty acids

EFAs are polyunsaturated fatty acids that are important dietary factors because they cannot be synthesised *de novo*. They are constituents of all cell membranes, influencing their biological function, and they are involved in the formation of eicosanoids such as prostaglandins, leukotrienes, thromboxanes and hydroxyeicosatetraenoic acids. There are two series of EFAs: the n-6, derived from *cis*-linoleic acid (LA) and the n-3 derived from alpha-linolenic acid (ALA) and eicosapentaenoic acid (EPA). The n-6 series is derived primarily from vegetable oils [e.g. evening primrose oil (EPO)] and some dairy products; the n-3 series is derived from green leafy vegetables (ALA) and fish oil (EPA), especially marine fish oil. The *cis*-linoleic acid is converted to gamma-linolenic acid (GLA), which has an important role in EFA therapy and may be found in evening primrose (*Oenothera biennis*) oil, blackcurrant oil and borage

Table 6.2 Antihistamines and side-effects in the cat

Antihistamine	Effects	Dose	Comments
Clemastine (Tavegil) 1 mg	Centrally mediated; synergistic with essential fatty acids	0.34–0.68 mg/cat twice daily	Diarrhoea, lethargy, fixed drug eruption
Hydroxyzine (Atarax) 10, 25, 50 mg	Stabilises mast cell membranes; centrally active	1–2 mg/kg, 5–10 mg/cat twice or three times	Behavioural side-effects, hyperexcitability, depression
Chlorpheniramine (Piriton) 4 mg	Centrally mediated	2–4 mg/cat once, twice or three times daily	Transient drowsiness, unpalatable
Cyproheptadine (Periactin) 4 mg	Serotonin antagonist	2 mg/cat twice daily	Polyphagia, behavioural changes
Diphenhydramine		0.5 mg/kg twice daily	Hyperexcitability

oil (also called starflower, *Barrago officinales*). The n-6 series fatty acids are converted to arachidonic acid (AA) and the n-3 series to EPA. They exist as part of the phospholipid component of cell membranes or in plasma or tissue reservoirs. The fatty acids are released from these reservoirs by phospholipases A_2 and C, allowing the formation of various eicosanoids with a proinflammatory action under the influence of oxygenase and lipoxygenase enzymes. It is thought that n-6 and n-3 EFAs have anti-inflammatory effects via inhibition of the oxygenase enzymes by direct competition and by an increase in anti-inflammatory eicosanoids such as prostaglandin E_1 and leukotriene B_5. The n-3 and n-6 pathways are not interchangeable, but use the same enzymes, thereby helping to block the formation of AA and its proinflammatory metabolites.

There has been some debate about which fatty acids may be considered essential in the cat, as it has been shown that the liver of the cat has a limited ability to metabolise the parent compounds of LA and ALA. This is due to a relative inactivity of the δ_5 and δ_6 desaturases. Initial studies of EFA deficiency in the domestic cat suggested that since they cannot desaturase the parent EFA compounds LA and ALA, animal fats containing the derived EFAs GLA and EPA must be included in the diet, as well as AA.

A long-term study over 101 weeks demonstrated that feeding cats a linoleate-deficient diet resulted in reduced feed efficiency, high rates of transepidermal water loss, poor skin and coat condition, and fatty liver. Supplementation with safflower seed oil, with or without tuna oil, led to prevention of the signs noted above. Further studies reported the pathological changes in various organs after feeding the linoleate-deficient diet, including severe fatty degeneration of the liver, excessive fat in the kidneys, dystrophic mineralisation of the adrenal glands, degeneration of the testes and hyperkeratosis of the skin. Linoleate therefore has an important role in membrane function in that it influences growth, lipid transport, normal skin and coat condition, and maintenance of the epidermal permeability barrier. The cat is unable to synthesise significant quantities of AA and dietary sources are essential.

In several open trials cats with papulocrusting dermatitis, and with suspected flea allergy or atopy, were treated with various combinations of EPO and fish oil. There was a favourable response with EPO, or EPO with fish oil. Another open study suggested that cats presenting with EGC also respond to EFA supplementation.

There are no adverse side-effects with EFA therapy, apart from occasional vomiting, and the main problem is palatability. There are no apparent effects on clotting factors. A study showed that sunflower oil was just as effective as EPO in reducing papulocrusting dermatitis in a group of cats with flea allergy. This suggests that since cats cannot metabolise sunflower oil to EFAs such oils may have an effect on epidermal barrier function rather than anti-inflammatory factors influencing pruritus. It is recommended to administer EFAs in food as a capsule, oil or spray for 4–6 weeks to determine a beneficial response.

Glucocorticoids

The long-term use of glucocorticoids in a cat with a chronic skin problem must be assessed with careful evaluation of the underlying causes of the disease and

management, where possible, of these causes. There are many cases where a definitive diagnosis cannot be achieved because of the owner's unwillingness to pursue further investigation or because the cat is not compliant with diet trials and other measures that would potentially allow identification of such underlying causes.

Glucocorticoids can be administered by injection, by mouth and topically. It is unusual to rely on topical therapy because cats are adept at grooming away topical products. Injectable products are popular, especially with cats that are difficult to pill. It is often the case that an initial response to injectable preparations is followed by a reduction in the interval between the injections, and the owner will then, reluctantly perhaps, have to resort to oral therapy. Injectables such as methylprednisolone acetate can be given for most cats at a dose of 20 mg (or 4 mg/kg) every 2–3 weeks in three subcutaneous injections. This usually brings the dermatosis under control and then maintenance doses may be given every 6–12 weeks.

The long-term use of oral steroids usually relies on prednisolone or methylprednisolone, using an initial anti-inflammatory dose of 1–2 mg/kg per day, although in severe cases, especially with EGC, this dose can be increased to 3–5 mg/kg per day. After 7 days the dose can be reduced by 50% for a further 7 days and then alternate-day therapy initiated. The alternate-day dose can be modified every 2–3 weeks. Some cases require 1–2 mg/kg every other day to maintain alleviation of the pruritus. The reader should appreciate that while cats are remarkably tolerant of the side-effects of steroids, compared with dogs and humans, that dosage ranges are somewhat empirical. If the skin condition gets worse on an alternate-day dose then one should carefully consider the role of complicating factors for the condition, such as the addition of fleas as a flare factor. It is usually difficult to attain control by increasing the alternate-day dose and it is preferable to adopt a daily dosing scheme.

Occasionally oral dexamethasone is used; however, in view of the long duration of action of this glucocorticoid it is prudent to reduce from the induction dose of 0.1–0.2 mg/kg per day to a maintenance dose of 0.05–0.1 mg/kg every 72 h.

It is often stated that cats are resistant to the side-effects of corticosteroid therapy, but they can develop signs with long-term therapy, including polydypsia, polyphagia, weight gain, diabetes mellitus, bacterial cystitis, iatrogenic hyperadrenocorticism, dermatophytosis, demodicosis and gastric ulceration.

Cyclosporine has been used for renal transplants in cats in combination with glucocorticoids; it has been used in human and more recently canine atopic dermatitis (Matthews & Gregory, 1997). The mode of action involves the inhibition of T-cell activation; the synthesis of various cytokines, especially IL-2, inhibits T-cell proliferation and the formation of cytotoxic lymphocytes. The drug is available as either an emulsion or a capsule formulation and consists of a microemulsion preconcentrate of cyclosporine (e.g. Neoral; Novartis). Initial reports of its use in cats with EGC, as a manifestation of allergic skin disease, used a dose of 7.5–10 mg/kg per day for up to 1 month. There are studies of feline asthma that report the use of the drug administered with food. It is unclear what role, if any, food has on the absorption of cyclosporine in cats. Side-effects include a poor appetite and long-term use may predispose to bacterial and fungal infections. Some renal transplant cases have marked hair growth. Some caution should be exercised when using cyclosporine because a variety of drug interactions is recognised in other species, including a synergistic effect with glucocorticoids. It is prudent to check the FIV and FeLV status and serology for toxoplasmosis before embarking on therapy (Bernsteen *et al.*, 1999).

The expense of this drug is considerable, but long-term use may include twice-weekly maintenance doses. As with many therapies used in dermatology there is a need for double-blind, placebo-controlled studies to determine the degree of efficacy and the optimum dosage scheme for the use of cyclosporine in feline allergic skin disease.

Eosinophilic granuloma complex

The complex traditionally includes three major forms: eosinophilic plaque, eosinophilic ulcer and collagenolytic granuloma (Plate 6.10). These forms have distinct histological patterns and may be regarded as different cutaneous reactions patterns to the same underlying cause, and all three may be observed in the one cat. There is some discussion about the use of the term complex because it has similarities with miliary dermatitis – it is not a specific diagnosis – and a primary underlying cause is likely to be present. The large number of therapeutic modalities recommended for this complex reflects the considerable difficulties in treatment, even when the underlying cause is known or suspected. Power and Ihrke (1995) have extensively reviewed the complex.

Eosinophilic plaque

The plaque is a pruritic, raised, ulcerated, plaque-like lesion found anywhere on the body, but particularly on the ventral abdomen. The lesions may be seen concurrently with miliary dermatitis and eosinophilic granuloma of the chin. The plaque is considered to be a manifestation of allergic skin disease and tends to be seen in younger cats (2–6 years of age), and this is supported by the presence of a circulating eosinophilia. Histopathologically there are several features, including severe epidermal and follicular acanthosis and prominent eosinophilic exocytosis and spongiosis. With self-trauma there will be erosions and ulceration of the epidermis. The dermis will contain a diffuse to perivascular infiltrate of eosinophils. There may be concurrent epidermal and follicular mucinosis. These histological findings are similar to those of miliary dermatitis. There may be intramural eosinophils within the venules, veins and arterioles of the deep dermis and superficial panniculus.

The underlying allergic disease may include hypersensitivity responses to fleas, food and environmental allergens (atopic disease). The diagnostic approach and therapeutic management should be similar to those used for atopic disease, given above, notably ruling out flea allergy as the most likely diagnosis.

Indolent/eosinophilic/rodent ulcer

This entity is readily recognised, with distinct well-demarcated unilateral or bilateral ulcers, occurring at the philtrum of the upper lip or adjacent to the upper canine tooth. The periphery is raised and surrounds a pinkish yellow ulcerated surface. With large lesions there may be facial distortion. The lesions may occur alone or seen in combination with miliary dermatitis, eosinophilic plaque and eosinophilic granuloma. The latter may be found in the mouth. There is evidence that the lesions are part of an allergic response to fleas and other allergens (Colombini *et al.*, 1999); in other situations there has been a genetic basis suspected, with the development of lesions in a colony of related specific pathogen-free cats. In many situations there is no apparent cause established for the lesions. The lesions are neither painful nor pruritic and the cat may not be obviously pruritic.

With chronic lesions, tissue should be biopsied for ruling out neoplasia, and bacterial and fungal infections. The histological findings include hyperplastic, ulcerated superficial perivascular and fibrosing dermatitis with neutrophils and mononuclear cells. If lesions are biopsied at an early stage there may be changes more consistent with eosinophilic granuloma, with an eosinophilic infiltrate and collagen degeneration. Indolent ulcers are rarely accompanied by peripheral eosinophilia. In this respect the indolent ulcer is not readily recognised as a member of the EGC group.

The clinician's approach to the lesions will depend on the extent of the disease and the presence of other skin lesions consistent with an allergic response. With small single lesions one might leave the cat untreated, with more extensive disease one should consider the response to antibiotic therapy. The antibiotics used include trimethoprim sulfa (120 mg twice daily), amoxycillin with clavulanic acid (62.5 mg twice daily) and cefadroxil (100 mg twice daily) for 3–6 weeks. If this approach does not prove effective, and even if it does it is unknown how such antibiotics influence the ulcer process, then one could consider glucocorticoids, including intralesional injections for single lesions. In severe cases, especially with EGC lesions elsewhere, it may be indicated to attempt management of disease with immunosuppressive therapy such as chlorambucil and chrysotherapy (aurothioglucose).

Single lesions may be removed with surgical excision; cryosurgery, laser therapy and radiation therapies have also been recommended.

Eosinophilic (collagenolytic/linear) granuloma

The eosinophilic granuloma is the only true granuloma within this complex and is associated with peripheral circulating eosinophilia. There are no breed, age or sex predispositions, although cats less than 2 years of age may have spontaneous resolution. In a similar fashion to the plaque, the granuloma lesions are associated with allergic diseases in some cases, and may have a genetic basis in certain colony situations and within litters, and some are idiopathic. A distinct form associated with mosquito bites has helped to focus interest on the concept of the pathogenesis of eosinophilic granuloma being associated with cutaneous penetration of a wide variety of antigens that may incite the formation of a granuloma. Pruritus is not a consistent feature in all cases.

Clinically, nodular granulomas may be seen within the oral cavity on the tongue, hard palate and palatine arches, concurrently with or without cutaneous eosinophilic granulomas and plaques. Oral cavity disease may be associated with halitosis, anorexia and hypersalivation. Lesions of eosinophilic granuloma may be single or grouped, nodular, linear, papular

and ulcerated, and present anywhere on the body. The areas commonly affected include the medial aspect of the forelegs and caudal aspect of the thighs, with a linear orientation and associated with the skin grooming pathways. There is a distinct form associated with the chin and lower lip ('pouting' or 'button lip') that may wax and wane. The dorsum of the nose, the pinnae and footpads may be affected. Occasionally, ulcerative lesions of the upper lip have histopathological features in common with the collagenolytic granuloma.

The lesions are usually erythemic, raised and alopecic, with pale gritty foci within them that are assumed to be areas of collagen degeneration. There may be some ulceration and cavitation. The differential diagnoses considered should include neoplasia, especially squamous cell carcinoma (SCC) in the mouth, cat-bite abscess, foreign body reaction, deep fungal infection, sterile granuloma and cowpox. Histopathological evaluation of the nodules is usually required to make a specific diagnosis. Tissue submitted for histology will have changes of deep dermal eosinophilic degranulation and collagen degeneration, with palisading macrophages and giant cells and granuloma formation.

The causes of eosinophilic granuloma are postulated to include hypersensitivity responses to flea, food and environmental allergens and, as before, mosquito bites. The most difficult form to manage is the oral cavity lesion, which may require surgical debulking and high-dose glucocorticoids just to manage the problem. In young cats with single lesions and no overt signs of pruritus and allergic skin disease it may be prudent to leave the lesion alone. In cases where the underlying allergens are known and there is a poor response to avoiding the allergens then the cat may require treatment in a similar manner to that described for eosinophilic plaque.

Papulocrusting dermatitis (miliary dermatitis)

The clinical diagnosis of miliary dermatitis is readily made from the observation and palpation of the typical skin lesions of an erythematous papulocrusting eruption along the back, neck and ventrum. The lesions resemble millet seeds and the disease derives its name from this similarity (Plate 6.11). It is possible for the cat to be very pruritic with this condition and there may also be early-stage eosinophilic plaques on the ventrum.

Miliary dermatitis is a cutaneous reaction pattern; a response to a variety of stimuli that induce self trauma and overlicking. The principal differential diagnosis is flea-bite hypersensitivity; other allergic causes include food allergy, atopy and possibly intestinal parasite hypersensitivity, although the latter is considered exceptionally rare. Infectious causes include dermatophytosis and bacterial folliculitis. Parasitic causes may include lice, *Cheyletiella*, *Otodectes* and trombiculid mites. Rare causes include EFA deficiency and hypereosinophilic syndrome.

The histological findings in miliary dermatitis have been reported as superficial, perivascular and interstitial dermal inflammation with eosinophils, mononuclear cells, mast cells and neutrophils. Epidermal features include focal serocellular crusting, spongiosis and vesiculation, with intraepidermal pustules subtending the crusting.

Therapy for miliary dermatitis relies on accurate diagnosis of the underlying cause and specific treatment thereafter. The differential diagnoses considered above are discussed elsewhere in the text. The general diagnostic and therapeutic approach for the cat with miliary dermatitis is similar to that given above for atopic disease.

Psychogenic alopecia

Psychogenic alopecia is considered to be uncommon as a single primary clinical entity (Sawyer *et al.*, 1999). It is difficult to assess how often cats with a pruritic skin disease develop a stereotypic component to the overgrooming. In some cases the initial pruritic trigger may no longer be present, but the overgrooming has become self-perpetuating. The underlying pathogenesis of stereotypic behaviour such as incessant overgrooming, hair pulling and self-licking may include pituitary hormones such as α-melatonin-stimulating hormone (α-MSH). This is produced as part of a stress response and leads to the production of endorphins that reduce further self-grooming but have an addictive reinforcement role.

The clinical presentation of psychogenic alopecia may include generalised symmetrical alopecia, particularly of the medial forearms, caudal abdomen, inguinal region and dorsal lumbar areas, and occasionally focal areas may be affected, such as the tail or a limb. In chronic cases the lesions may become thickened and hyperpigmented, but they are not associated with ulceration or crusting. The oriental breeds are supposed to be predisposed, but in one

study the cats were all domestic shorthairs (Sawyer *et al.*, 1999). It may be associated with a change in the cat's lifestyle with the addition or loss of a human family member, the loss of a feline companion or the unwarranted attention of another cat in the home environment, including the garden and the house, and a change of home environment. Some affected cats seem to have a nervous, shy or socially inferior character. The history may also suggest a psychogenic component, with the waxing and waning of the disease when certain events take place; for example, when the owners leave for a holiday.

Some authors include a subgroup of cats with alopecia that also develop dermatitis with excoriations and crusting.

On close examination of the coat and skin there are short broken hairs that are easily palpated on stroking the affected area, with broken shafts visible on microscopic examination. Hair can regrow if an Elizabethan collar is fitted and there may be considerable quantities of hair on faecal examination. There are usually no significant histopathological findings and the presence of small numbers of mast cells, macrophages or eosinophils in the superficial dermis indicates a potential for underlying allergic or parasitic disease.

In many cases there may be suspicions of a role for psychogenic alopecia, but the clinician must carefully evaluate for other causes of pruritus, as given for atopy. Thereafter, one should consider referral to a behaviour consultant before committing to long-term drug therapy for suspected psychogenic disorders. A wide variety of drug therapies has been recommended for use in the cat and they are mainly off-label unlicensed products. Some medication may be contemplated as an interim approach while the environmental factors are addressed that have stimulated or perpetuate the overgrooming behaviour and stress.

In exceptional cases some clinicians will use progestagen compounds such as megestrol acetate because they have effects on hypothalamic nuclei and have glucocorticoid-like activity. However, long-term use has been associated with polyuria, polydypsia, mammary gland hyperplasia, and possibly neoplasia, diabetes mellitus (potentially irreversible) and iatrogenic Cushing's syndrome. Occasionally, cutaneous changes of ventral abdominal alopecia may develop which will confuse the clinical presentation. The progestagens are not recommended for the control of skin disease, including psychogenic alopecia and allergic skin diseases.

The use of tranquillisers such as diazepam (1–2 mg/cat twice daily) and phenobarbitone (8–15 mg/cat once or twice daily) has traditionally been suggested, but these drugs have variable success and with long-term use there is a potential for addiction or hepatopathy developing. The tricyclic antidepressants (TCA) such as amitryptilline HCl have been recommended at a dose of 2.5–10 mg/cat per day or 0.5–1.0 mg/kg p.o. every 12–24 h. Some authors recommend the TCA clomipramine (0.5 mg/kg p.o. every 24 h, or 1–2.5 mg/cat per day). It may take up to 1 month to see a favorable response to TCA therapy. Haloperidol has been recommended at 1 mg/kg twice daily for 4–8 weeks, although initially it may cause hallucinations and the cat should be hospitalised during this period. Once the dose is lowered the side-effects are reversed.

If steroids are used and appear to be helpful, one should consider that if the skin condition responds to such therapy then there must be a pruritic component of more importance and one should re-evaluate for other causes of overgrooming and subsequent alopecia. It is probably more prudent to use corticosteroid therapy initially, rather than other drugs, and if there is a favorable response one should investigate for an allergic or a parasitic cause before going ahead with long-term mood-modifying drugs such as TCA. There are few long-term controlled studies on the effectiveness and safety of such drugs in cats with psychogenic disorders.

Psychogenic alopecia should be distinguished from hyperaesthesia syndrome, which is a complex of behaviours that may include excessive grooming of the tail, flank and lumbar areas. There may be behaviour similar to that seen in oestrous females, and rippling of the skin, muscle spasm and twitching, particularly of the dorsum, with vocalisation. The affected cat may be difficult to distract from the various behaviours.

Infectious diseases

The reader is encouraged to read other chapters in this book that relate to specific infectious diseases; for more details refer to Greene (1998).

Bacterial infections

Beyond the common situation of a cat-fight abscess, the cat seems to be infrequently affected with bacterial skin infections compared with the dog.

Cat-fight abscesses (see also Chapter 30)

A cat-fight abscess is usually readily identified by clinical signs that may include pyrexia, lethargy, anorexia,

regional lymphadenopathy and a fluctuating painful nodule on the face, limbs or tail area, that may have a purulent discharge. Organisms isolated may include aerobes such as *Pasteurella multocida*, *Actinomyces* spp., staphylococci, rhodococci, enterococci and streptococci, and anaerobes such as *Porphyromonas* (formerly *Bacteroides*), *Fusobacterium* and *Peptostreptococcus* spp. that represent the resident oral flora.

Treatment is aimed at establishing drainage, flushing the abscess with a chlorhexidine solution (0.5%) and systemic antimicrobial treatment for 5–10 days: common choices are ampicillin, clavulanic acid and amoxicillin, and clindamycin, although in principle penicillin G 30 000–50 000 U/kg twice daily would also be effective. See Table 6.3 for dosages.

Recurrent abscess formation should warrant investigation for underlying disease including retrovirus infection, osteomyelitis or a foreign body reaction. Chronic infection may be associated with actinomycetes, mycobacteria, bacterial L-forms and fungi. Swab samples submitted for bacterial (aerobic and anaerobic) culture may help to establish the bacterial nature of the abscess infection, but if routine antimicrobial treatment based on sensitivity testing is not effective then one should look deeper for the cause of the abscess.

Superficial pyoderma

Bacterial pyodermas are uncommon to rare in the cat, and they may be associated with underlying allergic, parasitic, immune-mediated and systemic diseases and may present with papules to pustules. In some cases the lesions may be papulocrusting, erosive, ulcerative and plaques. The organism cultured may be *Staphylococcus intermedius*, *S. aureus* or *S. simulans* from swabs of pustular lesions or from skin biopsy samples (Medleau & Blue, 1988; Patel *et al.*, 1999). The diagnosis can be achieved with pustule cytology and in recurrent cases bacterial culture and sensitivity testing. Coccoid bacteria may be found in the surface keratin and exudate in skin biopsies, but antibacterial therapy based on such histological findings will not usually lead to clinical improvement (Scott, 1992). The histological findings usually include a mixed (particularly neutrophilic) inflammatory process including folliculitis and furunculosis. Antibacterial therapy is recommended for 3 weeks using cephalexin, clavulanic acid and amoxicillin, enrofloxacin, clindamycin or trimethoprim-potentiated sulfonamides. In recurrent cases the underlying disease must be investigated.

Table 6.3 Antibacterial therapy for feline bacterial skin infections

Antibacterial agent	Dose
Ampicillin/amoxicillin	20 mg/kg twice or three times daily
Clarithromycin	5–10 mg/kg twice daily
Clavulanic acid and amoxicillin	12.5–25 mg/kg twice daily
Clindamycin	5.5–10 mg/kg twice daily
Clofazimine	4–8 mg/kg once daily
Cephalexin	20–30 mg/kg twice or three times daily
Doxycycline	5–10 mg/kg once or twice daily
Metronidazole	10 mg/kg twice or three times daily
Rifampin	10–20 mg/kg once daily
Trimethoprim/sulphonamides	15–30 mg/kg twice daily
Enrofloxacin	5 mg/kg once daily

Actinomycetes and Nocardia (see also Chapter 30)

These organisms are uncommonly recovered from skin abscesses in cats, associated with traumatic wounds due to a penetrating foreign body, scratch or bite wound. The lesions tend to be found on the head and neck, limbs and feet. The lesions may be draining a serosanguinous fluid of variable colour and the discharge may include (sulfur) granules or grains. The exudate should be examined cytologically to look for the granules and organisms; a fine-needle aspirate of the lesion may also reveal the granules. There may be systemic signs of disease that reflect systemic infection, particularly of the thoracic cavity.

Actinomycetes cultured from cats include *Actinomyces viscosus* and *A. meyeri*, which reside in the mouth and gastrointestinal tract, and are opportunistic infections. They are difficult to isolate in culture and respond readily to antibacterial therapy. Clinical signs in cats may include pyothorax and subcutaneous draining abscesses. With anaerobic culture there tends to be a mixed infection of organisms and the anaerobic actinomycetes may be overlooked. On histopathology the pyogranulomatous dermatitis and panniculitis may contain sulfur granules or grains that contain within them Gram (or Brown and Brenn)-positive staining branching filamentous rods that may be admixed with Gram-positive or Gram-negative

non-filamentous bacteria. While the organisms are sensitive to high-dose penicillins it is important to consider surgical drainage of the infection with flushing, before following up with penicillin G, clindamycin, ampicillin, tetracycline and doxycycline. Prolonged antibacterial therapy over several weeks to months may be associated with a good response to infection.

Nocardia infections are associated with cutaneous to subcutaneous lesions of abscesses or mycetoma, with aerobic culture revealing single infections of Gram-positive, partially acid-fast, *Nocardia asteroides* or *N. brasiliensis*, which are soil saprophytes. Treatment is usually based on sulfonamides and trimethoprim, although ideally therapy should be based on sensitivity testing. There tends to be a guarded prognosis with this infection and the response to therapy can be very slow over weeks to months, especially if there is underlying immune suppression.

L-Form infections

These are bacterial infections closely related to *Mycoplasma* spp. that are deficient in a cell wall; they have been isolated from cats with draining wounds, cellulitis and synovitis. The source of infection is considered to be via penetrating wounds such as bites and surgical incisions. The diagnosis is difficult to achieve, especially because the organisms are difficult to culture. Therapy usually relies upon tetracycline 20 mg/kg three times daily and there is usually a rapid recovery within days to several weeks.

Mycobacteria (see also Chapter 30)

Four groups of mycobacteria are associated with skin disease in the cat, including classical tuberculosis, feline tuberculosis syndrome, feline leprosy and opportunistic mycobacteria (reviewed by Roccabianca *et al.*, 1996; Gunn-Moore *et al.*, 1996; Lemarie, 1999; Malik *et al.*, 2000). The mycobacteria tend to be saprophytic; some are pathogens and others are opportunists. They may cause skin disease in cats, with signs of nodules, draining sinus tracts and ulceration. In some cases the infection may become generalised, especially with the tubercular forms. Routine histology usually shows a granulomatous reaction pattern with few to many organisms, apparent with Ziehl–Neelsen staining, present within foamy macrophages. The diagnosis of mycobacterial infection is confirmed with bacterial culture; this may take up to 6 weeks, and in the interim one may consider enrofloxacin therapy (5 mg/kg once daily) until the culture results are reported.

The opportunistic mycobacteria may grow readily and rapidly in culture. They include *Mycobacteria smegmatis*, *M. fortuitum*, *M. chelonae*, *M. abscessus* and *M. thermoresistibile*. These organisms are found in the soil and water, and gain entry to the body through wounds such as bites. They have a tropism for the subcuticular fat and this is often associated with draining skin lesions on the ventral trunk of the infected cat. The clinical signs may include a plaque or a nodule, with alopecia, purpuric macules and thickening of the subcutis as the panniculus becomes more evidently involved. There may be draining punctate fistulae and lesions spread over the thorax and abdomen. The early lesions may resemble cat-fight abscesses. In general the infection tends to remain within the subcutis and the organisms are usually difficult to find on routine histopathology.

Diagnosis is usually achieved with skin biopsies of the deep subcutis that demonstrate a pyogranulomatous reaction pattern with Ziehl–Neelsen-positive staining for organisms in macrophages and lipid vacuoles. Culture of infected tissues should be submitted to a specialist laboratory and a positive culture may take up to 6 weeks to identify the organism involved. Treatment of chronic cases is laborious and demanding. Extensive surgical débridement and surgical reconstruction are best done in association with antimicrobial therapy, if possible based on *in vitro* testing for susceptibility. Antibacterial agents commonly recommended include single or combination regimens based on enrofloxacin, clarithromycin and doxycycline for weeks to months, including up to 6 months.

The slow-growing atypical mycobacteria include *M. avium* and *M. intracellulare*, and are termed the *M. avium* complex. Skin disease in the cat is rare and this may be due to resistance to infection, unless there is immunosuppression due to concurrent retrovirus infection (Hughes *et al.*, 1999).

Tubercular mycobacterial infections are rare and usually associated with *M. bovis*, occasionally *M. tuberculosis* and rarely *M. microti*. The route of infection may lead to systemic disease including the gastrointestinal and/or respiratory tract or localised skin disease. Skin lesions may be present as draining sinus tracts, nodules, plaques, abscesses and ulcers, present on the head, neck and limbs as single or multiple lesions. A diagnosis is achieved from the skin in the same way as for other mycobacteria, although the organism may be difficult to find in skin sections and

they are slow growing in culture. Treatment is debatable with a disease that is a zoonosis and where the prognosis tends to be guarded (see also Chapter 30).

A distinct form of feline tubercular mycobacterial infection has been described (Gunn-Moore *et al.*, 1996) and the cultured organism has some shared characteristics with *M. tuberculosis*, *M. bovis* and *M. microti*. The route of infection is thought to be via rodent bites. The lesions tend to be found at bite and fight sites, including the face, extremities, tailbase and perineum. Skin lesions may be associated with regional lymphadenopathy and include firm raised nodules and draining sinus tracts, and there may be extension into bone and muscle tissues. Systemic signs may include anorexia, weight loss, arthritis and pneumonia. There is uncertainty about the zoonotic risk of this organism and therefore treatment cannot be initiated without careful consideration of this factor, the extent of the disease and the ability of the cat to be treated long-term. Some authors recommend initially using triple antibacterial therapy for tubercular disease, especially with systemic disease, consisting of rifampicin, enrofloxacin and clarithromycin. The following continuation phase may be based on rifampicin plus either enrofloxacin or clarithromycin.

Feline leprosy (see also Chapter 30) is very uncommon and has been reported in North America, the UK, Australia and New Zealand. Infection is considered to be through infected rat bites. The skin lesions are usually present on the limbs, head and trunk, and are single to multiple, firm to soft nodules that may be ulcerated. Dissemination of the disease is rare. The distinct features of leprosy include numerous organisms in cytology or histological preparations, yet no growth on routine mycobacterial media. The inoculation of infected tissue into rats or mice can reproduce the infection and help to confirm the diagnosis. Treatment options include clofazimine and dapsone in combination with surgical excision.

Superficial fungal infections

Malassezia

Malassezia infection in the cat has become a recognised entity in recent years. *Malassezia pachydermatis* is an opportunistic yeast pathogen that may be associated with significant skin disease. Predisposing factors for its establishment may include alterations in skin microclimate associated with underlying allergic skin disease or chronic glucocorticoid and antibacterial therapy for allergic skin diseases. There may be a breed predisposition for cats with abnormal hair coats, such as sphinx and Devon rex breeds. Some cases have been associated with retrovirus and herpes viral infections, and underlying neoplasia including thymoma and paraneoplastic alopecia syndrome associated with hepatic and pancreatic neoplasia.

Clinical signs may be either generalised, often with a ventral distribution, or localised to the feet, ears or chin. Pruritus is common and can be severe. Examination of the skin reveals erythema, scale, hyperpigmentation, oily scale and malodour. A black waxy otitis externa can be a major sign of *Malassezia* infection; a similar waxy exudate may be observed around the base of the claws in some cases.

Diagnosis is based on cytological examination of acetate strip preparations, skin impression smears with a dry swab or direct slide contact, and culture using Sabouraud's media. The *Malassezia* genus can be divided into lipid-dependent yeasts, including *M. furfur*, *M. sympodialis*, *M. globosa*, *M. obtusa*, *M. restricta* and *M. slooffiae*, and non-lipid-dependent yeasts, such as *M. pachydermatis*, which is relatively easy to grow on routine laboratory media. Routine culture techniques do not usually speciate the isolates from veterinary patients. The use of partial sequence data of the large subunit of ribosomal RNA has enabled the investigation of the species diversity to be explored in a variety of host species. Consequently, several species of *Malassezia* are recognised in cats, beyond the usual *M. pachydermatis*, including *M. furfur*, *M. globosa* and *M. sympodialis*, although it is unclear what role they may play in causing skin disease.

In cases with generalised skin infection it is important to consider collection of skin biopsies. The histological changes may include a mixed superficial dermal infiltrate with epidermal hyperplasia, spongiosis and lymphocytic exocytosis. There may be focal basal keratinocyte hydropic changes and vacuolar alteration of the basement membrane zone, with yeast organisms in the surface scale and crust.

Therapy is usually based on topical therapy with twice-weekly bathing using miconazole–chlorhexidine shampoo (Malaseb; Leo). Bathing with shampoos that have keratolytic effects, selenium sulfide and chlorhexidine-based products will also have some efficacy against the yeast. Enilconazole and ketoconazole washes have also been used. Systemic therapy with the fungistatic azole drugs, including itraconazole and fluconazole, has been recommended. They should be administered with food at a dose of 5–10 mg/kg. Azoles are potentially teratogenic (in other species) and are not recommended for pregnant or

breeding animals, although the risk is likely to be low at the recommended dose.

In recurrent infection the cat should be investigated for underlying disease, notably allergic disease, viral infections and neoplasia, to prevent recurrence. Otitis externa can be a frustrating manifestation of *Malassezia* infection in some cases. The ceruminous glands provide a lipid-rich medium for the organisms, which are commensals in this environment, to survive. In some cases topical or oral steroids will help to control the glandular hyperplasia and cerumen production within the ear canal and, consequently, 'starve' the yeast and improve the condition of the ear.

Dermatophytosis

Microsporum canis (>90%), *Trichophyton mentagrophytes* and *M. gypseum* are the most commonly isolated dermatophytes from infected cats (Wright, 1989). *Trichophyton* infections may reflect exposure to rodents and *M. gypseum* to contaminated soil. Many other species of *Trichophyton*, *Microsporum* and *Epidermophyton* may rarely cause sporadic disease.

The pathogenesis of dermatophyte infection is poorly understood, but may have some similarities with the situation observed in human dermatophyte infections. Initially there must be adherence between keratinocytes and arthrospores, followed by invasion of the superficial layers of the skin with enzymes such as proteases contributing to breakdown of the keratinocytes (Hay, 1998).

The host will usually respond to infection with an increased turnover of the epidermis and the production of factors that may bind to fungal membranes and inhibit growth, such as transferrin. The epidermal response to infection includes the production of proinflammatory mediators that are also stimulated by fungal cell wall antigens, leading to the influx of neutrophils and macrophages. These cells produce a variety of enzymes that can kill the fungus, such as proteases. Infection may be exacerbated by a variety of factors, including the ability of the host to mount an effective T-lymphocyte response. This response may be abrogated by the production of dermatophyte inhibitory factors (DIFs), which are glycoproteins that inhibit the host immune response.

Factors that may influence the outcome of infection include the age of the host, since young cats may be more at risk, and animals given glucocorticoids for other conditions. Retrovirus infection is considered to be an important predisposing factor in cats. In one study there appeared to be differences in the susceptibility of the hair shaft to invasion according to the age of the cat. The humoral response to dermatophyte infection has been studied in cats but does not appear to be significant in terms of the outcome and clearance of infection. Infection is by contact with infected animals or contaminated hair or scale in the environment. Infected hairs may remain viable for up to 18 months. The incubation period may vary from 1 to 3 weeks.

There is some debate about the increased risk of longhaired cats being a source of subclinical infection. Longhaired cats may be a source of infection because they are less able to remove effectively all of the infected hairs through grooming compared with shorthaired cats (Moriello & DeBoer, 1997). Persian cats may be especially at risk, suggesting a genetic and/or immunological problem with this breed, but there is no firm evidence for this proposition.

Clinical signs

Dermatophytosis has been called one of the great pretenders because there are so many potential kinds of presentation. The classic signs include alopecia and scale with central healing. One can also see just alopecia, (nasal/facial) folliculitis and furunculosis, onychomycosis and granulomas. Paronychia may be the only sign in some cats. Occasionally one may see a pustular form that may appear like a bacterial pyoderma or even mimic pemphigus foliaceus or erythematosus (Plate 6.12).

Diagnosis

In view of the presenting signs one should collect samples for ruling out demodicosis and bacterial infection. In the former case one should consider deep skin scrapings, hair plucks and possibly biopsy.

The mainstay of diagnostic techniques is culture of hair and scale samples collected by scraping, plucking or brushing the affected areas (with a Mackenzie brush or sterile toothbrush). These samples can initially be examined by microscopy for the identification of ectothrix arthroconidia spores. Microscopy examination can be enhanced with calcofluor white, which requires a fluorescence microscope system.

Diagnosis for some strains can be achieved using a Wood's lamp for apple-green fluorescence. The lamp should be warmed up for 5 min and the animal should be examined in a darkened room for several minutes to allow lesions to fluoresce. This technique may only be useful for up to 50% of *M. canis* isolates. The technique may also facilitate choice of hairs for

subsequent culture. Hairs can retain positive fluorescence for long periods but be culture negative. It is possible for dermatophytes to be seen in serocellular crust, but the organism should be seen to invade the hairs or the stratum corneum to be considered significant.

The author uses a commercial laboratory for fungal culture using Sabouraud's media. Some authors recommend collecting hair samples from clipped areas gently patted clean with alcohol to reduce surface contamination. Skin biopsies may be submitted for fungal culture and histological examination. However, the use of histological examination alone is not as sensitive as culture. Samples are cultured at a temperature of 30°C, for up to 14 days before reporting.

The author does not use dermatophyte test media (DTM) because it is much easier and cost-effective to use a local laboratory, especially when trying to identify *Trichophyton* spp., which may not readily produce characteristic macroconidia. It is important to identify the species of fungus cultured because this may influence the therapy and prognosis for the case. One has to be careful with DTM, because not all that turns the growth media red is a dermatophyte. Numerous saprophytic fungi may be isolated from the coat of cats, including *Scopulariopsis*. This saprophyte, like some other species can use the carbohydrate component in the media preferentially and turn the DTM plate red, thereby behaving as if it were a dermatophyte.

The macroconidia of dermatophytes are not always well formed unless a second normal Sabouraud's media plate is included. One should collect a touch preparation from the surface of the colony, which should have appropriate colony morphology, and place on a slide for microscopy using lactophenol blue mounting solution to identify the macroconidia and morphological characteristics of the dermatophyte present (Plate 6.13).

The isolation of *M. canis*, in particular, does not necessarily imply active disease – it may represent a fomite carrier. A culture derived from a sample collected with a toothbrush or Mackenzie brush may not be able to distinguish between active infection and asymptomatic infection. The apparently normal cat with asymptomatic subclinical infection or the fomite carrier that mechanically carries *M. canis* infection varies in prevalence, ranging from 2 to 39% of the various populations studied (Sparkes *et al.*, 1994; reviewed by Boyanowski *et al.*, 2000).

A positive culture requires a thorough investigation of the clinical situation because *M. canis* is not a part of the normal fungal flora of cats; microscopic evidence of infection is also required.

Sylvatic infections due to *Trichophyton mentagrophytes* and *M. gypseum* seem to respond well to therapy and are uncommon to rare.

Therapy

Treatment of dermatophytosis may involve a variety of steps. Clipping will help to reduce the environmental and host burden of infection and will help to reduce the risk of spread of the infection to humans. However, clipping may also help to spread the disease on the affected animal.

There is debate about the value of topical therapy for the animal in view of studies performed with cats. Various products are available for localised lesions, such as creams and ointments, but the apparent cure with such products may simply reflect the host's immune response and clearance of the infection. The infection may spread up to 6 cm from the site of obvious lesions, so it is debatable what value such products offer.

An apparent clinical cure should be confirmed subsequently by evidence of a mycological cure. Self-resolution may occur within 60–100 days and assumes a normal immune response and general good health. The potential for spread of the infection to other cats and humans is a major factor that will influence the decision to treat. Dips such as enilconazole (Imaverol; Janssen Animal Health; licensed for topical use on the dog in the UK) and shampoos such as Malaseb™ (Leo Animal Health) containing 2% miconazole and chlorhexidine, and licensed for feline and canine dermatophyte infection, should be considered. Malaseb™ has been shown to have beneficial effects for infected cats and for decontamination of the environment with *M. canis* infection (Paterson, 1999).

The infected cat should be washed twice weekly with Malaseb and rinsed after 10 min throughout the treatment period. Care should be taken with applying dips around the eyes and protective eye lubrication may be preferable. There is some concern about toxic reactions when using enilconazole topically on cats, and to avoid ingestion it may be prudent to apply an Elizabethan collar until the coat has dried.

Systemic therapy

Animals with generalised or chronic infection warrant systemic therapy. This is particularly the case with chronic infections associated with *Trichophyton* and *M. persicolor* type infections (Hill *et al.*, 1995). All of the medications considered below are

contraindicated for pregnant animals and this reflects, in part, limited use of the drug in cats in terms of safety issues.

- *Griseofulvin* at a dose of 50 mg/kg per day, i.e. considerably greater than that recommended in the data sheet, is administered with (fatty) food, potentially for weeks, until the infection has resolved – in terms of a negative culture, rather than the improvement in clinical signs. Cultures should be collected every 1–2 weeks. A response may be observed within 4–6 weeks but may take longer with non-*M. canis* infections. Griseofulvin has anti-inflammatory actions that may allow other skin diseases to improve slightly before the clinician realises that dermatophytosis is not involved. It is not effective against bacteria, yeast or non-dermatophyte species of fungi. Cats can have adverse reactions, including vomiting, diarrhoea and anorexia. Bone-marrow suppression has been reported, notably in FIV-infected cats.
- *Imidazole* drugs such as ketoconazole have found favour for the treatment of dermatophytes, but are associated with potential side-effects such as vomiting and hepatotoxicity. Ketoconazole has been largely replaced by itraconazole, although this drug can be prohibitively expensive. The azole drugs are fungistatic and are best given with food. Previous evidence of liver disease should preclude the use of this drug.
- *Itraconazole* is available as a 100 mg capsule (Sporanox; Janssen). There is some evidence that itraconazole is more effective than griseofulvin for *M. canis* in the cat. The usual dose is 5–10 mg/kg for 4–6 weeks, and potentially longer with some infections such as *M. persicolor* and *Trichophyton* (Boothe *et al.*, 1997; Mancianti *et al.*, 1998).
- *Terbinafine* (Lamisil; Sandoz), a prohibitively expensive product used for various persistent human dermatophyte infections, has been used in cats. There is a long duration of activity and this may allow relatively short courses of therapy followed by careful monitoring. The recommended dose in cats is in the order of 10–30 mg/kg per day. With 2–6 weeks of therapy there is a persistent effect for several more weeks (Mancianti *et al.*, 1999).
- *Lufenuron* (Program; Novartis): a study suggested that administration of lufenuron by mouth (60 mg/kg) was associated with effective and rapid treatment of *M. canis* infection in cats and dogs. An initial dosage is repeated after 2 weeks and then monthly, the latter at 30–50 mg/kg. Cats in single-cat households are more likely to improve than those in multicat households and environmental treatment should still be included. The mode of action of lufenuron is unclear and further studies will hopefully clarify the possible value of this product for feline dermatophytosis (Ben-Ziony & Arzi, 2000).

Vaccination

Vaccines for the prevention of *M. canis* infection in cats have been investigated using killed products. One such vaccine is available in North America and is recommended as an adjunct measure for the treatment of dermatophytosis in cats. There is no evidence that such vaccines have a role in providing protection against infection. Studies are ongoing to find an efficacious product for cats.

Environmental contamination

The major source of contamination is the fungal spores on hairs. These may be removed with a combination of physical cleaning and using chemical agents to kill the spores. Grooming utensils, bedding and collars should be removed and thrown away. Items that can be washed, such as protective clothing, should be soaked in an antifungal disinfectant and then washed at a temperature of at least 50°C. Thorough vacuuming of the (suspected) contaminated rooms on a daily basis should be considered, with careful removal of the contents of the vacuum cleaner.

Chemicals are potentially difficult to use because they may stain and damage soft furnishings. The most effective products are bleach (dilutions up to 1 in 10 of household bleach with water). Enilconazole is available specifically for environmental treatment, formulated as either a spray or a smoke generator (Clinafarm; Janssen). Virkon-S is a disinfectant powder (a peroxide-based product) that is made up with water to a 1% solution.

Subcutaneous mycoses

Subcutaneous mycoses include phaeohyphomycosis, eumycotic mycetoma, sporotrichosis and pythiosis; only the first two will be covered in detail in this chapter. They constitute a heterogeneous group of diseases in which the traumatic implantation of a fungal agent induces slowly progressive cutaneous lesions.

Phaeohyphomycosis

Phaeohyphomycosis is a collective name for a group of infections caused by a number of species of dematiaceous, or pigmented, fungi. Lesions of phaeohyphomycosis in the cat tend to occur on the face or distal extremities and may resemble chronic bacterial abscesses with single or multiple subcutaneous nodules that may drain a purulent discharge.

The diagnosis of phaeohyphomycosis is confirmed by histopathological changes consistent with fungal infection and culturing the organism from the purulent discharge or preferably from a biopsy. Aetiological agents of phaeohyphomycosis may occur in tissues as yeast-like cells, pseudohyphal-like elements or hyphae, which may be short, elongate, regular, moniliform or distorted. Although these fungi always form pigment in culture, pigment may not be seen in tissue sections.

In cats a variety of phaeohyphomycotic infections have been reported. There has been a case of infection with *Staphylotrichum coccosporum* (Fuchs *et al*., 1996). A further 37 cases were reviewed by Chermette *et al.* (1997), and isolates have included *Exophiala jeanselmei*, *Exophiala spinifer*, *Drechslera spicifera*, *Moniliella suaveolens*, *Cochliobolus lunatus*, *Scolecobasidium humicola*, *Stemphylium* and *Cladosporium* infections, *Ochroconis gallopavum*, *Phialophora verrucosa* and *Alternaria* spp., including *A. alternata*. An example of the latter is illustrated in Plate 6.14.

The management of discrete fungal granulomas usually involves surgery with or without antifungal agents given either preoperatively or postoperatively. Surgery should include a margin of adjacent healthy tissue and meticulous care to avoid reimplantation of fungal tissue, which may result in recurrence and spread of disease. Itraconazole 5–10 mg/kg day for several weeks to months (Sporanox; Janssen Animal Health) may be helpful in some cases in conjunction with surgery. However, since the liver clears this drug, it is advisable to monitor liver biochemistry regularly to avoid hepatotoxicity.

Mycetomas: eumycotic and dermatophytic mycetoma

A mycetoma is a nodular pyogranulomatous dermal reaction composed of tissue grains or granules, with dense colonies of organisms and necrotic debris. The mycetoma may involve eumycotic fungi (eumycotic), actinomycetes, bacteria (botryomycosis) and dermatophytes (also termed pseudomycetoma or dermatophytic mycetoma).

Eumycotic mycetomas may be associated with black-grain pigmented organisms such as *Curvularia*, *Madurella* and *Torula*. Clinical signs may be associated with draining nodules, single to multiple, that involve the skin and may spread to underlying cutaneous tissues including bone and muscle. The route of entry is considered to be via traumatised skin, such as bites, on the extremities and face, and the organisms are ubiquitous in the environment.

Dermatophytic mycetomas have been described, particularly in the Persian breed, but other breeds can be affected and there may be an association with FIV infection. There is usually a history of superficial dermatophyte infection with *M. canis* and the mycetoma is usually found on the head, dorsal trunk or tail regions (Medleau & Rakich, 1994).

Diagnosis of a mycetoma is achieved by cytology of the exudate from a draining wound revealing grains or granules, or hyphae. The grains may be crushed onto a slide and digested with potassium hydroxide before using a staining technique. The diagnosis is confirmed by collecting tissue biopsies for routine fungal culture and histopathology with fungal elements embedded in a granulomatous reaction that includes periodic acid–Schiff-positive eosinophilic material, termed the Splendore–Hoeppli reaction.

Therapy is based on wide surgical excision and griseofulvin or itraconazole drug therapy for several months thereafter; recurrence can be a problem even after radical surgery and long-term antifungal therapy (Pin & Carlotti, 2000).

Sporotrichosis

Infection is due to *Sporothrix schenckii*, a soil saprophyte that gains entry via wounds. It may lead to infection of the skin, extend to the lymphatics or become systemic. Cats may present with draining sinus tracts in fight and bite sites. The organism may be detected by cytology from the exudate from lesions, by histopathology and culture of tissues. Infected cats should be handled with care because of the zoonotic potential of this organism. The reader is recommended to consult Greene (1998) for further details.

Pythiosis

Pythiosis is a rare disease in cats caused by *Pythium insidiosum*, a protoctistid organism in the class Oomycetes. Although it is not a fungus it can be grown on fungal culture media. Infection is reported

in tropical and subtropical climates, including the southern USA. Signs of infection may be associated with gastrointestinal disease and less commonly with subcutaneous and nasopharyngeal disease. Antifungal therapy is usually unsuccessful and surgical intervention has to be early to be successful. The reader is recommended to consult Greene (1998) for further details.

Systemic mycoses

The systemic mycoses that have cutaneous manifestations arise from implantation into the skin via trauma, bite or wound contamination. There are several types of infection, including blastomycosis, coccidioidomycosis, protothecosis, paecilomycosis, histoplasmosis and cryptococcosis, but only the latter will be considered here (Davis & Troy, 1996; Greene, 1998) (see also Chapter 30).

Cryptococcosis

The presenting signs of infection may include skin lesions of multiple draining sinus tracts, abscesses, ulcers, papules and nodules, particularly located on the face, paws and pinnae. Infection may be associated with immune suppression due to glucocorticoid therapy and possibly retrovirus infection. The upper respiratory tract may be involved and the initial presentation may look like the cat illustrated in Plate 6.14. The diagnostic and therapeutic approach is similar to that for phaeohyphomycosis, with the notable addition of radiography of the nasal cavity to determine the extent of infection and to rule out neoplasia. Serology for cryptococcal capsular antigen by the latex agglutination test may be useful to confirm infection, but a positive result may not be associated with clinical signs and the test can be negative in cases with single cutaneous lesions. The diagnosis is confirmed by culture of *Cryptococcus neoformans* from skin biopsy tissue. The therapy options may include surgical excision or debulking, but with multiple skin lesions the use of azole therapy, notably itraconazole at 10 mg/kg per day, is recommended. In one study the median dose used was 13.8 mg/kg per day and the median duration of treatment was 8.5 months (range 4–16 months) (Medleau *et al.*, 1995). Other options include fluconazole 25–50 mg twice daily for 2–4 months and combination therapy with amphotericin B, although the latter is known to cause renal problems in some cats and requires careful monitoring. The serological test has been used to monitor for response to therapy.

Viral infections

Feline cowpox (see also Chapter 30)

Cats infected with cowpox are usually avid hunters that come into contact with infected prey items, especially voles and mice. Following inoculation of a bite wound the viral infection becomes apparent 10 days to several weeks later, with numerous cutaneous nodules and plaques (Plate 6.15). Infection is usually self-resolving over 6–8 weeks, unless the cutaneous lesions are mistaken for eosinophilic granulomas and steroids are administered. Infection may generalise with immune deficiency such as that associated with FIV or FeLV infection. The mouth, nasal passages, lungs and gut may be affected, with oral and gastrointestinal ulceration, nasal discharge, (necrotising) pneumonia and diarrhoea.

The disorder is reported throughout Western Europe, and in the UK is most commonly seen from July to November, when rodents are most common and presumably there is an increased risk of infection for their feline predators. Once the cat has had the infection there appears to be good immunity (Groux *et al.*, 1999).

The diagnosis is confirmed with skin biopsies, especially of the generalised skin lesions that may demonstrate the characteristic histological findings. A rise in the titre of virus neutralising antibody is supportive and crust material submitted in viral transport media can be used for viral culture.

One can only offer supportive care, including antibacterial therapy, although the lesions usually heal within weeks of infection. It is very important to avoid administration of glucocorticoid therapy because the clinical signs may become much worse if there is concurrent immunosuppression. There is a very slight risk of cat-to-cat transmission. There are some reports of human patients, usually immature or elderly people receiving immunosuppressive therapy or afflicted with immunosuppressive conditions, becoming infected with feline cowpox. Sadly, in one case the human patient died (Baxby & Bennett, 1997; Bennett *et al.*, 1997).

Feline herpesvirus-1 (see also Chapter 22)

The cutaneous manifestations of feline herpesvirus-1 (FHV-1) infection are uncommon, and may include

an ulcerative dermatitis with vesicles, ulcers and crusts of the nasal planum and haired skin of the face. In some cases there may be multifocal areas of ulceration and a generalised distribution. There may be concurrent signs of conjunctivitis, keratitis, ocular discharge and repeated or persistent upper respiratory tract infection with sinusitis. The skin lesions may persist for weeks to months. There is no effective treatment and the condition may resolve spontaneously. Skin biopsy sections can reveal intranuclear inclusion bodies within the necrotic epidermis, with a mixed dermal infiltrate that may include numerous eosinophils, and this can lead to a misdiagnosis of EGC and allergy in some cases. Ultrastructural examination, polymerase chain reaction (PCR) and DNA sequencing (Hargis *et al.*, 1999) have confirmed the presence of FHV-1.

Feline leukaemia and feline immunodeficiency virus

(see also Chapters 23 and 24)

The initial reports of FeLV and FIV infection associated with dermatitis and abscesses were lacking in clear evidence of a causal link between viral infection leading to the skin infection and the type of dermatitis. There have also been associations with otitis externa and notoedric mange. There is more likely to be a direct link between retrovirus infection and chronic dermatophytosis, mycobacterial infection and demodicosis, where immune suppression could promote persistent skin disease. It is prudent to evaluate cats with chronic infectious skin disease, including cowpox infection, for underlying immune suppression due to retrovirus infection.

FIV infection has been associated with Bowen's disease (SCC *in situ*) and concurrent demodicosis. There have been reports of FIV infection in cats with plasma cell pododermatitis, stomatitis and chondritis, and FeLV has been associated rarely with cutaneous horns and vasculitis.

Leishmaniasis

Natural infection and clinical disease caused by *Leishmania* spp. are rare in domestic cats. Whether the low prevalence of infection and disease in endemic areas is due to underreporting or to the fact that cats have a high degree of natural resistance is unknown. It has been shown that cats experimentally infected with *L. chagasi* and *L. donovani* appear to be resistant. However, cases of clinical disease and asymptomatic infection due to *L. infantum* and other species are reported, and wild cats have been incriminated as reservoirs for leishmaniasis in endemic Mediterranean countries. Cutaneous lesions alone have been reported in association with *L. venezuelensis* and unspecified *Leishmania* spp. in Europe, South America and the southern USA. Lesions have included diffuse areas of alopecia and granulomatous dermatitis of the head, scaling and pinnal dermatitis, and ulceration and nodules. Systemic involvement with *L. infantum* has been reported in association with jaundice, vomiting, hepatomegaly, splenomegaly, lymphadenomegaly, membranous glomerulonephritis and granulomatous gastroenteritis. There is a report of successful treatment of one cat with cutaneous disease using meglumine antimonate (Hervas *et al.*, 1999).

Immune-mediated skin diseases

Immune-mediated skin diseases are usually associated with ulceration and crusting of the skin. This implies the absence of the surface epithelium, including the basement membrane in some situations, down to the dermis. The protective function of the skin is compromised, potentially leading to localised or systemic infection.

The targeting of the epidermis may be associated with a variety of disorders in which there is usually an infiltrate of cells, and in certain situations an aberrant immune response, due to infection, drugs, immune-mediated skin disease, neoplasia, vasculitis, erythema multiforme and metabolic or nutritional disorders.

In general these disorders are uncommon and potentially life-threatening. The diagnostic approach should be extensive including investigation of possible trigger factors from internal disease. Consequently, one may have to collect samples for routine haematology, serum biochemistry and urinalysis. Imaging (radiography and ultrasonography) of the thorax and abdomen may be critical in establishing underlying disorders. Immune-mediated disease may require routine histopathology of the skin and other tissues plus immune function tests [e.g. antinuclear antibody (ANA) titres, Coombs tests, rheumatoid factor]. Infectious agents may require tissue culture, serology and molecular identification (PCR) using peripheral blood cells.

In terms of therapeutic options there may be only supportive therapy available for some disorders.

Occasionally, the epithelial damage is repaired and there is self-resolution. In other cases there is a dependence on immunosuppressive therapy to prevent further epithelial damage.

Pemphigus foliaceus

Pemphigus foliaceus is the most common form of autoimmune skin condition in the cat and an important cause of pedal lesions (Griffin, 1991). Very little is understood about the pathogenesis of feline pemphigus, although it is assumed that some of the features of canine pemphigus may apply. In some cases a drug eruption has been documented as the underlying cause; for example, cimetidine and ampicillin.

The disease remains a persistent problem for some, for others there is waxing and waning. There is usually no association with other chronic dermatoses, although one retrospective study documented a large number of mast cells in the superficial dermis. A possible association with allergic dermatoses was suggested as an explanation for these findings; alternatively, the histopathological changes of pemphigus foliaceus in the cat are different to those in other species.

There are no breed, sex or age predilections. The skin lesions are usually observed around the head, especially the pinnae and planum nasale, and the claw beds, with extension to the face (bridge of the nose, muzzle, around the eyes), tail and ventral abdomen, including around the nipples. The claw beds tend to have a thick caseous green purulent discharge of multiple digits and feet (Plate 6.16). The claws are usually normal in appearance (cracked claws have been seen in feline pemphigus foliaceus, onychomadesis has been reported in pemphigus vulgaris in the cat). The skin lesions consist of pustules and vesicles, although they are transient and readily replaced by erosions and overlying crusts and alopecia. The cats may resent handling of the skin and may be pyrexic, lethargic and lame, with peripheral lymphadenopathy. One may also appreciate weight loss. The footpads may be hyperkeratotic.

The diagnosis is usually fairly straightforward once one has observed the involvement of the claw beds of several feet. The other clinical signs may lead to some confusion with dermatophytosis and cats receive therapy for such disease until more typical signs appear, including pustules on the pinnae or the caseous exudate from the feet. Some cats are also treated with antibiotics for paronychia. This is based on cytological examination of the exudate and/or a positive bacterial culture; however, these organisms are usually secondary. The ability of some cases to wax and wane may suggest a positive response to antimicrobial therapy.

Blood samples for haematology may show eosinophilia; an ANA test will usually be negative. Fungal cultures will be negative and cytology from an undisturbed pustule will reveal numerous neutrophils or eosinophils with acanthocytes.

Skin biopsies may be collected with a punch tool, although some lesions are best removed with an elliptical incision. The cat should be sedated and in some cases general anaesthesia will allow successful collection of diagnostic samples. The pustules are extremely delicate and readily damaged when incised. Lesions on the top of the head or from the pinnae may be most fruitful.

Therapeutic options for immune-mediated skin diseases

Initial therapy is prednisolone at 2 mg/kg twice daily for 10–14 days, followed by reduction to alternate-day therapy. In some cases therapy can be stopped for several weeks before the condition relapses. It is usually stated that cats are very tolerant of glucocorticoid therapy, and initial dosages may be as high as 8.8 mg/kg per day. However, diabetes mellitus is a potential complication for cats receiving long-term steroid therapy. Some authors recommend other steroids such as dexamethasone at 0.1–0.2 mg/kg, tapering to once every other day.

Cats that are responding poorly with steroid therapy are potential candidates for chlorambucil therapy daily or every other day, in combination with steroids, using 0.1–0.2 mg/kg. Tablet size is 2 mg, so most cats receive half a tablet per day. The mode of action is on DNA synthesis and inhibition of rapidly proliferating cells at all stages of the cell cycle. Therapy has to be given for 4–8 weeks and side-effects may include vomiting, diarrhoea, anorexia and, more importantly, bone-marrow suppression. The initial therapy can be combined with prednisolone at 2 mg/kg per day. After initial therapy an alternate-day dose regimen is given for the chlorambucil and prednisolone; thereafter, one should be able to stop chlorambucil and use glucocorticoids alone. Cats should be monitored with haematology samples for white cell and platelet counts, every 2 weeks (Helton-Rhodes, 1995).

Aurothioglucose (gold salt therapy) is used in immune-mediated diseases because it has a variety of influences on immune functions, including neutrophil

migration, lymphocyte function and immunoglobulin production. It may take 6–12 weeks to see the full response to gold therapy, before changing from a weekly dose of 1.0 mg/kg (by intramuscular injection) to once every 2 or 4 weeks. Adverse effects may include glomerulonephritis, bone-marrow suppression, thrombocytopenia and cutaneous eruptions. Monitoring should include collection of samples every 2 weeks for haematology, serum biochemistry and urinalysis.

Azathioprine (Immuran; Wellcome) has been used as an immunosuppressive and immunomodulatory agent for the treatment of autoimmune skin diseases, polyarthritis and inflammatory bowel disease in the cat. Adverse reactions may include myelosuppression, hepatotoxicosis, vomiting, panniculitis, drug eruptions and alopecia. These reactions have limited the use of this drug in the cat. Azathioprine is a prodrug, being converted principally within the liver to the purine analogue 6-mercaptopurine (6-MP). The 6-MP is converted into cytotoxic thioguanine nucleotides, which suppress immune cell replication and response, while xanthine oxidase and thiopurine methyltransferase (TPMT) catalyse the conversion of 6-MP to the inactive metabolites. The administration of azathioprine to cats at dosages of 1.1–2.2 mg/kg body weight on alternate days has been associated with thrombocytopenia and leucopenia while treating pemphigus foliaceus. There are no clear indications for the use of this drug for pemphigus foliaceus in the cat.

If there is a poor response to therapy one should reconsider the original diagnosis and especially the possibility of concurrent disease that has initiated the aberrant immune response with pemphigus foliaceus. There should be a re-evaluation of the possible role of drug therapies.

Plasma cell pododermatitis

This is an uncommon but well-recognised disease, although some cases are subtle in terms of their clinical presentation (Guaguère *et al.*, 1992). The presenting signs usually involve gross swelling of multiple metacarpal and metatarsal pads, and occasionally the footpads. There may be some ulceration and the owners may report lameness, pain and sometimes pruritus with excessive licking. The author has heard of one colony of feral cats that had several individuals affected at one time. In the case illustrated in Plate 6.17 the main presenting sign was pad ulceration and lameness.

There is thought to be an immune-mediated basis for this disorder, but the exact aetiology is unknown. For example, there may be anaemia, hypergammaglobulinaemia, IgG deposition with direct immunofluorescence at the basement membrane zone and lymphocytosis of the affected tissue, and ANA titres may be positive. These findings are inconsistent and in other cases there has been evidence of FIV infection.

Diagnosis is usually achieved with collection of deep skin biopsies from the affected pads and the demonstration of numerous plasma cells and lymphocytes in the dermis.

In some cases there may be resolution without therapy and seasonal recurrence of the lesions, suggesting an allergic basis for the disorder. Other cases can be harder to manage and may require glucocorticoids (e.g. prednisolone 4 mg/kg per day initially), gold salts or chlorambucil in conjunction with steroids. Surgery has been reported to be effective in severe cases, especially where bleeding may be a major problem. Pad tissue apparently regrows after surgery. An interesting approach that has been reported anecdotally is the use of doxycycline (2.5–5 mg/kg twice daily for up to 6 weeks); there may be initial improvement allowing pulse therapy or low-dose continuous therapy. The mode of action may include suppression of leucocyte chemotaxis.

Bullous pemphigoid

Bullous pemphigoid disease is a rare blistering disorder recently described in cats that involves the formation of autoantibodies to the basement membrane type XVII collagen molecule (also termed BPAG2 bullous pemphigoid antigen 2, or BP180) which is a 180 kDa transmembrane protein. Clinical signs are vesicular, erosive and crusting dermatitis of the lips, pinnae, hard and soft palate, and the digits. Microscopic examination of skin biopsy sections shows characteristic subepidermal vesicles, clefting with minimal inflammation (Olivry *et al.*, 1999).

Discoid lupus erythematosus

Although discoid lupus erythematosus (DLE) is well recognised as a dermatological entity in dogs it is rarely reported in cats. There is no apparent age, sex or breed predisposition. Clinical signs consist of periocular crusts, erythema, vesicles and papules on the pinnae, and scaling and crusting of the footpads with focal depigmentation. There may be plaque-like erythematous excoriations involving the pinnae, neck, abdomen and groin, or generalised crusting and scaling. Skin biopsies have shown histological changes of

an interface dermatitis with hydropic degeneration of basal cells, and a mononuclear infiltrate with positive immunofluorescence for IgM and complement. ANA titres are low. Treatment has consisted of oral prednisolone or dexamethasone or injectable methylprednisolone. One case developed signs consistent with SLE (Willemse & Koeman, 1989).

Systemic lupus erythematosus

SLE is a rare disease in the cat. Several sets of criteria have been proposed for the diagnosis of SLE, but the simplest requires the presence of two seropositive manifestations of autoimmunity and a significantly titred serum ANA.

SLE is considered to be a rare, multisystemic, autoimmune disorder that most frequently involves the musculoskeletal, haematopoietic, cutaneous and urinary systems. Cutaneous manifestations of feline SLE are exceptionally rare and may include generalised alopecia, scaling and crusting, involving the face, pinnae, neck, ventrum and limbs, and crusting of all digital pads. The histological features may include interface dermatitis, interface folliculitis, epidermal basal cell and follicular basal cell vacuolation with necrosis. The immunological basis for the latter changes is thought to involve keratinocyte apoptosis mediated by T-lymphocytes that infiltrate the epidermis; evidence for this process is lacking in the cat. In addition, there is often immunohistochemical evidence of immune complex deposition at the basement membrane zone. Glucocorticoid therapy with 4 mg/kg per day for 1 month initially was effective in establishing control of one case with a positive ANA titre, oral ulceration, thrombocytopenia and characteristic cutaneous changes (Vitale *et al.*, 1997).

Hypereosinophilic syndrome

This syndrome is rare; the aetiology is unknown and it occasionally involves the skin. The typical findings are a persistent idiopathic peripheral blood eosinophilia (greater than 1.5×10^3 cells/μl), hyperplasia of the bone-marrow precursors for eosinophils and organ infiltration with eosinophils. The gastrointestinal tract, liver, spleen and myocardium are some of the organs infiltrated and this may lead to the clinical signs of a pronounced appetite, weight loss, vomiting and diarrhoea. The cutaneous findings include generalised maculocrusting lesions and an exfoliative erythroderma, and serpigenous erythematous weals. There is no effective treatment for this condition.

Vasculitis

Vasculitis is rarely reported in cats. Clinical signs may include ulceration of the footpads, pinnae and lips. Vasculitides in veterinary medicine are a diagnostic challenge, since small blood vessel damage is a consequence of a variety of disease processes where the immune system targets blood vessel walls. True vasculitis is often a transient process followed by more chronic changes, sometimes termed vasculopathy. The diagnosis usually relies on carefully collected skin biopsies and appropriate histological findings. In many other cases there is an exhaustive investigation for an underlying cause of the vasculitis/vasculopathy, with many cases proving idiopathic. If there is no evidence for drugs, neoplasia, infection or immune-mediated diseases as the cause then one is left with a variety of possible therapeutic modalities; the mainstay of therapy has been steroids and in some cases sulpha drugs, but these are often associated with marked side-effects.

Erythema multiforme and toxic epidermal necrolysis

Erythema multiforme is a rare disease in the cat and is usually associated with drug administration, particularly cephalexin, penicillin, aurothioglucose and sulfadiazine. The disease in humans is associated with drug administration, viral diseases and neoplasia. The pathogenesis of the feline disease may be similar to that observed in the dog, with up-regulation of the expression of major histocompatibility complex class II, CD44 and intercellular adhesion molecule-1 on keratinocytes. $CD8^+$ T-lymphocytes are recruited to the epidermis and dermis and these are thought to be responsible for the keratinocyte apoptosis that is a characteristic feature of erythema multiforme. Clinical signs observed in cats include vesiculobullous and ulcerative lesions, or maculopapular eruptions. The lesions are most likely to be found at mucocutaneous junctions and on the trunk. A skin biopsy of a vesicular lesion should reveal histopathological changes of full-thickness necrosis of the epidermis with subepidermal clefting. The maculopapular lesions are associated with histopathological changes of an interface dermatitis, with single-cell keratinocyte necrosis, and lymphocyte and macrophage satellitosis. In principle there should be a potentially good response to the withdrawal of the medication responsible for initiating the disease.

Toxic epidermal necrolysis (TEN) is a rare disease involving the skin and oral mucosa. It has been

described in cats in association with various drug therapies. In some cases the aetiology is unknown. The histological hallmark of TEN is full-thickness epidermal necrosis and minimal dermal inflammation. There may also be basal cell hydropic degeneration. In effect, this is a cutaneous reaction pattern that warrants close investigation for underlying causes. Even so, the clinical signs of generalised vesiculobullous disease with

Table 6.4 Drug therapies associated with cutaneous reactions in cats

Drug	Lesion
Antibacterial agents	
Sulphadiazine	Erythema multiforme, interface dermatitis, exudative dermatitis with ulceration
Sulfisoxazole	Papulocrusting dermatitis, alopecia
Penicillin	Papulocrusting dermatitis, urticaria–angioedema, erythema multiforme
Hetacillin	Multifocal alopecia, pruritus, toxic epidermal necrolysis
Ampicillin	Multifocal alopecia, pruritus, toxic epidermal necrolysis, pemphigus foliaceus-like disease
Cephaloridine	Papulocrusting dermatitis, toxic epidermal necrolysis
Cephalexin	Papulocrusting dermatitis, erythema multiforme
Tetracycline	Urticaria–angioedema
Gentamycin	Erythema, alopecia pruritus
Neomycin	Contact dermatitis
Antifungal agents	
Griseofulvin	Papulocrusting dermatitis, toxic epidermal necrolysis
Miconazole	Contact dermatitis
Parasiticides	
Dichlorvos	Contact dermatitis
Carbamates	Contact dermatitis
Dichlorophen	Crusts, caseous paronychia
D-Limonene	Toxic epidermal necrolysis
Phosmet	Toxic epidermal necrolysis
Antithyroid drugs	
Propylthiouracil	Facial swelling, pruritus
Methimazole and carbamazole	Pruritus, excoriation, especially of face
Glucocorticoids	
Injectable preps	Alopecia, atrophy
Prednisolone	Atrophy, fragility
Antihistamines	
Cimetidine	Pemphigus foliaceus-like disease
Anticonvulsants	
Phenytoin	Atrophy, fragility
Vaccines and antisera	
Panleucopenia vaccine	Angioedema
Leukaemia virus vaccine	Erythema, alopecia, angioedema
Intranasal herpes and calicivirus vaccine	Alopecia erosions
Parenteral water in oil emulsion	Lipophagic granuloma
Leukaemia virus antisera	Toxic epidermal necrolysis
Anaesthetic agents and bases	
Polyoxyethylated castor oil	Erythema, angioedema
Benzocaine skin cream	Methaemoglobinaemia
Aurothioglucose	Erythema multiforme

Modified after Van den Broek and Thoday (1994).
A definitive role for the drug is not proven in all cases because of failure to perform challenge studies with the suspected drug.

stomatitis and, in some cases, footpad lesions, pyrexia, pain and lethargy, are usually followed in due course by a fatal outcome. Supportive therapy to provide fluids and control of secondary infection is important. As in erythema multiforme, there is debate about the value of treatment with steroids.

Drug reactions

The drugs associated with cutaneous reactions are listed in Table 6.4. The mechanisms involved in such reactions are potentially complex and may include specific immunological mechanisms. The consequent clinical signs can be variable and lead to the observation that cutaneous drug reactions are great pretenders, looking like many other skin diseases. The specific diagnosis is often difficult to achieve because the range of substances that may initiate a cutaneous reaction goes beyond the conventional consideration of a drug. They may include substances used in the preparation of drugs, food and cosmetics. Even if the drug therapy administered before the development of the cutaneous reaction is suspected, the owner will usually be unwilling to challenge the animal with the suspected drug once it has been stopped and the animal has recovered. This in part is due to the severity of the drug reaction, which may involve most of the skin. The management of such cases usually demands careful consideration of the previous drug therapy and stopping all therapy if possible. The severe cases may require hospitalisation and supportive therapy. Drug reactions may be underreported but are very uncommon, and diagnostic tests such as skin biopsy and histopathology are potentially very helpful in reaching a specific diagnosis. However, pemphigus foliaceus, erythema multiforme, TEN, lichenoid dermatitis and vasculitis may occur as cutaneous manifestations of a drug reaction. The discontinuation of the drug will potentially enable a rapid resolution of the skin disease.

Contact dermatitis

The immune mechanisms involved in contact dermatitis are assumed to include delayed type IV hypersensitivity reactions, in contact allergy, to be distinguished from contact irritant dermatitis where there is direct damage to epidermal keratinocytes. In either situation contact dermatitis appears to be rare in cats. Contact irritant dermatitis may range from epidermal oedema to a chemical burn, and could be associated with acids, alkalis, surfactants, solvents and so on. Contact allergens are poorly determined in veterinary dermatology and are assumed to involve low molecular weight lipid-soluble molecules that can act as haptens. The histopathological findings in contact dermatitis may be indistinguishable between irritant and allergic. The latter may involve an epidermal spongiosis with a neutrophilic superficial interstitial dermatitis.

The usual course to establishing a diagnosis is to avoid the contact irritant and then do provocative challenge to repeat the clinical findings, or perform patch testing with suspected allergens and evaluate the cutaneous response. Patch testing is rarely carried out with cats; one report used closed patch testing with a neomycin-based topical preparation. The cat had bilateral otitis externa, which improved when the ear medication was discontinued. There was an erythematous reaction at 5 days to the patch test, with no reaction to the petrolatum base. The histological findings included microvesicle formation and an eosinophilic infiltrate (Thoday, 1985).

In another case allergic contact dermatitis was suspected to be due to carpet deodorant. The cat was presented with alopecia and crusts on the plantar surfaces of the metacarpal and metatarsal areas, and crusting and cracking of the pads. The histopathological findings included acanthosis, mild to moderate perivascular to interface dermatitis, with lymphocytes, some macrophages and eosinophils. There was mild intracellular oedema and crusting of the pad epithelium. Removal of the deodorant was associated with an improvement and there was a subsequent relapse with re-exposure to a deodorant-based product.

Endocrine and metabolic disorders

Hypothyroidism (see also Chapter 20)

Feline hypothyroidism is a rare condition. A congenital aetiology appears to be more common than acquired hypothyroidism. Congenital hypothyroidism has been associated with thickened skin, soft fluffy coat and alopecia. In a tiger cub with congenital disease there was bilateral alopecia behind the ears, and alopecia of the dorsal aspect of the neck and the palmar aspect of the forelimbs. In acquired hypothyroidism signs may include generalised erythematous dermatitis, a dry, dull coat with seborrhoea sicca, poor hair growth and easily epilated hairs on the trunk and abdomen. One case had a non-healing wound, poor hair coat and generalised fine scale (Daigle *et al.*, 2000).

Experimentally induced hypothyroidism has been associated with seborrhoea sicca and bilateral alopecia of the pinnae (Van den Broek & Thoday, 1994).

Hyperthyroidism (see also Chapter 20)

This disease complex is discussed in depth elsewhere. Several notable dermatological signs are associated with hyperthyroidism, including excessive shedding of the coat, overgrooming leading to alopecia, excess scale or grease, increased claw growth rate and thinning of the skin in chronic cases.

Hyperadrenocorticism (see also Chapter 20)

This rare disease complex is discussed in depth elsewhere. Major systemic signs associated with excess adrenal cortisol (and rarely progesterone) production include polyuria, polydypsia, an increase in appetite, muscle wasting, pot-bellied appearance and lethargy (Duesburg & Peterson, 1997; Helton-Rhodes, 1997; Boord & Griffin, 1999). Alopecia may be seen in up to 50% of cats with hyperadrenocorticism. An unusual cutaneous sign is fragile skin syndrome, in which the thin skin readily tears and leads to non-healing wounds that may be secondarily infected. The fragile skin syndrome is rare; it may also be associated with excessive use of glucocorticoids and megestrol acetate, diabetes mellitus, hepatic lipidosis and cholangiocarcinoma, and is often idiopathic.

Xanthomas

Xanthomas are uncommon benign granulomatous lesions in cats with lipid metabolism abnormalities including diabetes mellitus, megestrol acetate administration and presumed hereditary hyperlipoproteinaemia. White to yellow plaque-like, papular and nodular lesions have been observed on the face, head, axillae, carpus, digital pad, interdigital skin, medial thighs and ventral abdomen. The lesions can be painful and pruritic. There are distinct changes on biopsy, which include foamy macrophages and multinucleated giant cells. If the underlying lipid metabolism abnormality is corrected the lesions can regress.

Neoplasia

A variety of skin tumours has been described in the cat. They tend to be seen in middle-aged animals and in over 65% of cases they are malignant (see Fox, 1995, for an excellent review). The approach to skin nodules that are suspected of being tumours should be aggressive, with an initial excision biopsy submitted for histopathology. A tentative diagnosis of mast cell and lymphoma tumours can be achieved using fine-needle aspirates.

Tables 6.5 and 6.6 list the neoplastic and non-neoplastic skin tumours described in the cat (Van den Broek & Thoday, 1994).

Numerous reviews show that basal cell tumours, mast cell tumours, SCC and fibrosarcoma comprise the majority of tumour types (60–80% of cases) (Miller *et al.*, 1991). These tumour types will be described in some detail.

Squamous cell carcinoma complex

The mainstay of diagnosis of this readily recognised, common skin tumour is the collection of tissue samples for histopathology.

Actinic keratosis

The poorly haired, pale and non-pigmented areas on the pinnae, nasal planum and muzzle are susceptible to the influence of ultraviolet radiation and the development of erythema, crusts, ulceration and plaques. These lesions are indistinguishable from the invasive form of SCC and SCC *in situ*.

Multiple squamous cell carcinoma in situ *(Bowen's disease)*

This variant of SCC is confined to the epidermis and hair follicles. It is very similar to the human disease termed Bowen's disease. There may be an association with papilloma and FeLV viral infections. The skin lesions are seen in middle-aged and older cats, and include papules, nodules and plaques with crusting and alopecia. An important feature is that haired and pigmented areas are affected. Treatment options may include surgery, although new lesions tend to develop. Retinoids have been recommended, but are expensive, and such therapy should be carefully monitored (Guaguère *et al.*, 1999).

Squamous cell carcinoma

Invasive SCC is associated with neoplastic keratinocytes invading below the basement membrane

Table 6.5 Incidence, clinical features and management of feline skin tumours

Tumour	Incidence	Patient predisposition	Site predisposition	Gross appearance	Behaviour	Treatment	Comments
Epithelial tumours							
Papilloma	Rare	Middle-aged to old	Head, eyelids, feet	Usually solitary, Small well-circumscribed. May be pedunculated or cauliflower like. Alopecic, occasionally ulcerated and bleeding	Benign	None or surgical excision, cryotherapy, or electrotherapy	
Intracutaneous cornifying epithelioma (keratoacanthoma)	Very rare				Benign	Surgical excision	One question-able report
Squamous cell carcinoma	Common	Blue-eyed, white-haired, middle-aged to old	Hypopigmented, sparsely or non-haired skin (particularly pinnae, lips, nose, eyelids)	Usually solitary, sometimes multiple. Firm, poorly circumscribed and ulcerated. Occasionally proliferative	Malignant. Highly locally invasive but slow to metastasise (local lymph nodes and lungs)	Wide surgical excision or amputation (digits). Also cryotherapy, electrosurgery, hyperthermia, radiotherapy, chemotherapy	Exposure to ultraviolet light correlates with development
Basal cell tumour	Common	Siamese, middle-aged to old	Head, neck, thorax	Usually solitary, occasionally multiple. Variable size, often oval–round, firm, raised, well-circumscribed nodules. May be pedunculated. Often pigmented. May be alopecic, ulcerated and bleeding	Usually benign and slow-growing. Rarely malignant; may metastasise to local lymph nodes	Wide surgical excision or cryotherapy	Most common melanotic skin neoplasm
Hair-follicle tumours							
Trichoepithelioma	Rare	Middle-aged	Possibly head	Usually solitary, occasionally multiple. Small, round, firm, raised, well-circumscribed. May be alopecic and ulcerated	Benign	None, wide surgical excision, cryotherapy, electrotherapy	
Dilated pore of Winer	Rare	Old, male	Face and neck	Solitary, Round, firm, raised, well-circumscribed with wide-mouthed, keratin-filled, central pore	Benign	None or surgical excision	

(continued)

Table 6.5 *(continued)*

Tumour	Incidence	Patient predisposition	Site predisposition	Gross appearance	Behaviour	Treatment	Comments
Pilomatrixoma	Very rare			Solitary, Round, soft to firm, raised, well-circumscribed. May be alopecic and ulcerated	Benign	None, surgical excision, cryotherapy	
Sebaceous gland tumours							
Nodular sebaceous hyperplasia	Uncommon	Middle-aged	Head, external ear canal	Usually solitary, may be multiple. Usually small, firm, raised, well-circumscribed. May be lobulated (nodular hyperplasia, epithelioma), pedunculated (external ear canal); may be alopecic and ulcerated	Benign	None, surgical excision, cryotherapy, electrosurgery	
Adenoma	Very rare	Middle-aged to old					
Epithelioma	Very rare	Middle-aged to old					
Adenocarcinoma	Very rare	Middle-aged to old		Solitary. Variable size, firm, raised, poorly circumscribed. May be alopecic and ulcerated	Malignant, locally invasive, rarely metastasises	Wide surgical excision, cryotherapy, electrosurgery	
Sweat gland tumours							
Epitrichial (apocrine and ceruminous) glands							
Cysts	Rare (apocrine) Frequent (ceruminous)	Middle-aged	Head (apocrine) Ear canal (ceruminous)	Solitary, often multiple. Small, oval–round, fluctuant, raised, well-circumscribed, blue–black occasionally pinkish colour (ceruminous gland). May be alopecic	Benign	None,wide surgical excision (lateral wall resection or external ear canal ablation if affecting the ear), cryotherapy, electrosurgery	Ceruminous gland lesions are often accompanied by otitis externa
Adenoma	Frequent	Middle-aged to old	Head and neck (apocrine) Ear canal (ceruminous)	Usually small, firm, raised, fluctuant, well-circumscribed, white/red/blue–black colour. Rarely ulcerated	Benign		
Adenocarcinoma	Frequent	Middle-aged to old	Ear canal (ceruminous)	Variable size, firm, poorly circumscribed. May be inflamed, ulcerated and bleeding	Malignant, highly locally invasive. May metastasise (local lymph nodes and lungs)	Wide surgical excision (lateral wall resection or external ear canal ablation if affecting the ear)	

Atrichial (eccrine)							
Adenoma	Very rare		Confined to footpads	Solitary. Firm, well to poorly circumscribed May be ulcerated	Benign	Wide surgical excision	
Adenocarcinoma	Very care				Malignant, locally invasive		
Epithelioid sarcoma	Rare	Middle-aged	Proximal limbs	Solitary. Firm, poorly circumscribed nodules. May be ulcerated	Malignant, May metastasise (local lymph nodes and lungs)	Wide surgical excision	
Mesenchymal tumours							
Fibroma	Uncommon	Middle-aged to old	External ear canal, limbs and body	Solitary. Small, soft to firm, well-circumscribed. May be pedunculated, alopecic and ulcerated	Benign	None, wide surgical excision, cryotherapy electrosurgery	
Fibrosarcoma	Common	Wide age range	Head, proximal limbs	Solitary, may be multiple. Variable size, firm, poorly circumscribed. May be alopecic and ulcerated	Malignant, locally invasive, occasionally metastasise (lungs)	Wide surgical excision, amputation, chemotherapy. Local recurrence common	Feline sarcoma virus (facilitated by FeLV) induces multiple fibrosarcomas in cats less than 3 years old
Myxoma and myxosarcoma (fibrosarcoma with abundant myxomatous substance)	Rare	Old		Solitary, poorly circumscribed, wide variation in shape	Myxoma–benign; myxosarcoma–malignant. Locally infiltrative. Rarely metastasises (lungs)	Wide surgical excision. Local recurrence is common	
Undifferentiated sarcoma	Rare	Old	Footpads	Pads soft, ulcerated and painful	Malignant, locally invasive, slow to metastasise	Wide surgical excision	
Nodular fasciitis (aggressive fibromatosis)	Rare		Face	Solitary or multiple. Varible size, firm, poorly circumscribed	Benign	Wide surgical excision. Glucocorticoids. Local recurrence may occur	May represent an aggressive inflammatory process suggestive of locally invasive neoplasia
Leiomyoma and leiomyosarcoma	Very rare			Solitary. Firm, well-circumscribed	Leiomyoma–benign; leiomyosarcoma–malignant	Wide surgical excision	

(continued)

Table 6.5 *(continued)*

Tumour	Incidence	Patient predisposition	Site predisposition	Gross appearance	Behaviour	Treatment	Comments
Schwannoma	Uncommon	Middle-aged	Head, neck and forelimbs	Varible size, firm, well- to poorly circumscribed. White to pinkish-grey in colour. May ulcerate	Often malignant, rarely metastasises	Wide surgical excision, amputation. Local recurrence	
Lipoma	Uncommon	Middle-aged to old	Thorax, abdomen, proximal limbs	Solitary or multple. Variable size, soft to firm (fibrolipoma) usually well-circumscribed. May be infiltrative (lipomatosis). Occasionally pedunculated	Benign	Surgical excision	
Liposarcoma	Very rare	Old		Usually solitary, occasionally multiple, poorly circumscribed, may ulcerate.	Malignant. Locally invasive but rarely metastasises (local lymph nodes and lungs)	Wide surgical excision	Has been induced experimentally by injection of FeLV
Tumours of vascular origin							
Haemangioma	Rare	Middle-aged to old	Limbs, flank head and neck	Usually solitary, but may be multiple. Small, firm to fluctuant, well-circumscribed. Red to bluish-black colour. Alopecic. May ulcerate and bleed	Benign	None, wide surgical excision, cryotherapy electrosurgery	C-type viral particles isolated from one subcutaneous haemangioma
Haemangiosarcoma	Uncommon	Middle-aged to old	Head, axillae, inguinal area, limbs	Usually solitary. Variable size, soft and friable, poorly circumscribed. Red–black colour. Often ulcerate and bleed	Malignant. May be quiescent then grow rapidly. Highly locally invasive. Occasionally metastasise (lungs)	Wide surgical excision. Local recurrence	Poor prognosis
Haemangiopericytoma	Very rare			Solitary. Friable to firm, multinodular	Rarely metastasise	Surgical excision	

Lymphangioma Lymphangiosarcoma	Very rare Rare	Wide age range	Ventrum limbs	Variable size, cystic fluctuant swelling possibly with tracts discharging a pale-yellow fluid	Benign Locally invasive, rarely metastasise (lungs)	Wide surgical excision. Local recurrence common	Poor prognosis
Mast cell tumour	Common	Siamese, older males	Head, neck	Solitary or multiple, variable size, soft to firm, raised nodules/plaques. Poorly to well-circumscribed. May be erythematous, ulcerated and pruritic	Usually benign may be malignant. May metastasise (local lymph nodes and lungs). May be accompanied by splenomegaly and hepatomegaly	Wide surgical excision for solitary tumours, chemotherapy for disseminated tumours (glucocorticoids alone or in combination with other agents; no evidence combination therapy is superior to glucocorticoids alone). Radiotherapy. Local recurrence or dissemination common	
Lymphohistiocytic tumours							
Histiocytoma	Very rare		Possibly head	Solitary. Small, firm, dome to button-shaped, well-circumscribed	Benign	None, surgical excision, cryotherapy, electrosurgery	
Fibrous histiocytoma	Rare		Face, limbs	Multiple. Firm, poorly circumscribed, may be alopecic	Benign but locally invasive. Does not metastasise	Surgical excision, glucocorticoids	
Malignant fibrous histiocytoma (extraskeletal giant cell tumour)	Rare	Middle-aged to old	Limbs and neck	Solitary. Variable size and shape, poorly cirumscribed	Malignant, locally invasive, does not metastasise	Radical surgical excision or amputation	
Cutaneous lymphoma Primary lymphoma Non-epitheliotropic (B-cell origin) Epitheliotropic (T-cell origin) Mycosis fungoides	Rare	Middle-aged to old	Generalised or multifocal, rarely solitary	Nodules/plaques or ulcers. May be accompanied by inflammation, exfoliative dermatitis and pruritus	May be accompanied by lymphomegaly, hepatomegaly and splenomegaly in later stages	Chemotherapy (glucocorticoids, cyclophosphamide, vincristine)	Poor prognosis

(continued)

Table 6.5 *(continued)*

Tumour	Incidence	Patient predisposition	Site predisposition	Gross appearance	Behaviour	Treatment	Comments
Secondary lymphoma	Rare	Middle-aged to old		Plaques or nodules. May ulcerate. Commonly pruritic	Accompanied by signs of other system involvement (alimentary, thymic, multicentric)	As for other lymphomas	Results from dissemination from other sites. Poor prognosis
Alopecia mucinosa	Rare		Head, ears, neck	Areas of alopecia and scaling			Precursor of mycosis fungoides
Plasmacytoma	Very rare			Raised, firm, well-circumscribed. May be ulcerated	May be confined to the skin (primary) or associated with myelomatosis (multiple myeloma) (secondary)	Surgical excision if primary	May be accompanied by monoclonal gammopathy if associated with myelomatosis
Melanocytic tumours							
Melanoma	Rare	Middle-aged to old	Head, ears eyelids	Solitary. Variable size. Macules/nodules/plaques. Brown to black to light colour. May be pedunculated, alopecic and ulcerated (malignant)	Usually malignant, rapid growth, commonly metastasise (local lymph nodes and lungs)	Radical surgical excision, radiotherapy. Poor prognosis	Have been produced experimentally by injection of feline sarcoma virus
Secondary skin neoplasia (Metastasis to skin from other organs)	Rare						
Examples:							
Bronchogenic carcinoma			Digits	Ulcerative lesions			
Pancreatic and jejunal adenocarcinoma			Umbilical area	Cutaneous nodules			
Mammary gland adenocarcinoma			Head	Subcutaneous nodules			

Modified from Van den Broek and Thoday (1994, pp. 56–62).
FeLV: feline leukaemia virus.

Table 6.6 Incidence, clinical features and management of feline non-neoplastic tumours

Tumour	Incidence	Patient predisposition	Site predisposition	Gross appearance	Behaviour	Treatment	Comments
Cutaneous cysts							
Epidermoid cysts	Uncommon		Head, neck, proximal limbs	Usually solitary, occasionally multiple. Well-circumscribed, round, fluctuant to firm. May discharge a grey/yellow/white cheesy material		Surgical excision	Should never be manually evacuated (increased chance of expression into dermis/subcutis with foreign body reaction and infection)
Follicular cysts (milia)	Common			Small, white to yellow, resembling pustules		None or surgical excision	Develop from retention of follicular or glandular products
Keratoses							
Actinic keratoses		*See* squamous cell carcinoma	*See* squamous cell carcinoma	Solitary or multiple. Erythema, scale, crust and occasionally nodule/plaque formation	Premalignant state, capable of progression to squamous cell carcinoma	Surgical excision, cryotherapy, possibly topical 5-fluorouracil	Result from excessive exposure to ultraviolet light
Cutaneous horn	Uncommon		Footpads (in association with FeLV infection), neck, axillae	Multiple (footpads) or solitary, firm horn-like projections		Surgical excision. No satisfactory treatment for FeLV-associated cutaneous horns	May be idiopathic, associated with FeLV infection, or arise from papillomas, basal cell tumours or keratoacanthomas

(continued)

Table 6.6 *(continued)*

Tumour	Incidence	Patient predisposition	Site predisposition	Gross appearance	Behaviour	Treatment	Comments
Naevi (circumscribed developmental defects)							
Organoid (hair follicle and epitrichial sweat glands)	Rare		Head, (proximal limbs (organoid), trunk (melanocytic)	Single or multiple. Soft to firm nodules (organoid); brown to black macules or papules (melanocytic). Well-circumscribed, may be pedunculated		None, surgical excision or cryotherapy	
Melanocytic							
Inflammatory polyp	Common		External ear canal, nasal cavity, nasopharynx, middle ear	Pedunculated mass. May be associated with otitis externa		Gentle traction (lateral vertical canal resection, slit soft palate if necessary)	

Modified from Van den Broek and Thoday (1994, pp. 63–64).
FeLV: feline leukaemia virus.

to the dermis and in some cases metastasis to the local lymph node and lungs. The clinical lesions include erythema, crusting and progressive ulceration with elevated indurated borders, on the ears, eyelids, nasal planum, lips and face. Various treatment protocols have been recommended, reflecting the difficulties in treating a locally invasive tumour process. Radical and early removal of the tumour can be successful in achieving clean margins. Follow-up therapy, especially for recurrence, may include various radiation therapy protocols. Therapeutic modalities undergoing investigation include photodynamic therapy, laser surgery and intralesional chemotherapy. Cryosurgery and chemotherapy (including retinoids) are not associated with good responses (Ruslander *et al.*, 1997). It is difficult to prevent cats from sunbathing. The application of topical sunscreen (above factor 15) may help, but it is readily removed by the cat.

Mast cell tumours

The cutaneous form of mastocytosis tends to occur in middle-aged to older cats with single to multiple skin nodules, particularly on the head but potentially all over the body. They variably present as discrete to poorly demarcated, variably sized, raised, soft to firm, round, erythematous to white or yellow, alopecic, dermal papules, nodules and plaques. A skin biopsy will usually enable a rapid diagnosis. There is no association between the histological grading and the clinical outcome. Paraneoplastic syndromes such as gastroduodenal ulceration are uncommon and may be treated with H_2 blockers. Treatment usually relies upon surgical excision, although there is some debate about the likelihood of metastasis. Recurrence at the site of excision is likely to be a new tumour developing. Adjunct therapy options to surgery include radiation when complete excision is not attained and chemotherapy with multiple lesions. Prednisolone at 40 mg/m^2 per day for 7 days, then 20 mg/m^2 every other day, has been recommended. There is an uncommon to rare and unusual histiocytic form of mast cell tumour associated with Siamese cats less than 4 years old in which electron microscopy helps to confirm the type of cell involved as a mast cell. The disease spontaneously regresses. Clinical signs include multiple subcutaneous nodules, especially on the head and pinnae. Another uncommon form of cutaneous mastocytosis has been reported in related Sphinx cats, although other breeds could be affected. Clinical signs include a pruritic erythemic, symmetric maculopapular eruption of the ventrum, head, neck and extremities. The histological findings included perivascular and superficial dermatitis, and subcuticular infiltrates of numerous mast cells consistent with urticaria pigmentosa. Therapy options include antihistamines and glucocorticoids.

Basal cell tumour

These tumours are derived from the basal epithelium of the epidermis and adnexal tissues. They are usually seen as single blue to grey to non-pigmented nodules in middle-aged and older cats, and particularly in Siamese, Persian and Himalayan breeds. They rarely metastasise and are slow growing; surgical excision is usually curative (Plate 6.18).

Fibrosarcoma

There are three variants of this type of tumour. Feline sarcoma virus infection may be associated with simultaneous infection with FeLV and the development of an aggressive form of multiple fibrosarcoma in cats less than 5 years of age. The tumours are rapidly growing, firm and often attached to adjacent tissues. Treatment is not recommended and the prognosis for this uncommon tumour is grave.

Solitary fibrosarcomas of older cats (>8 years old) tend to be firm, slow growing and poorly demarcated, and found anywhere on the body. They have a tendency to regrow after surgery and may metastasise to the lungs. Treatment should be multimodal and include a combination of radical surgical resection with radiation and possibly chemotherapy combined with biological response modification with acemannan. The prognosis is dependent on the location, with a good outcome for tumours of the pinnae and flank areas that are readily resected. Tumours are difficult to resect if present on the head, back and limbs, in which case the outcome is related to the mitotic index.

The pattern of disease with sarcomas in cats has changed, especially in North America, with the advent of vaccine-associated sarcomas, notably fibrosarcomas, but also malignant fibrous histiocytoma, osteosarcoma, chondrosarcoma, undifferentiated sarcomas and rhabdomyosarcomas. Vaccines containing aluminium adjuvants for rabies and FeLV are particularly implicated. However, it is generally accepted that the induction of such tumours can be associated with a variety of injectable preparations stimulating localised inflammation that then leads to tumour formation.

The tumours are found in the subcutis of the neck or back; they are rapidly growing and infiltrative and tend to recur after surgery, although metastasis is uncommon. Treatment is a challenge and radical surgery is initially critical in attempting to prevent recurrence. There is considerable debate about the best practice for preventing these tumours and the reader is directed to the reviews by Macey (1999) and McEntee and Page (2001), and the report from a working group of the Veterinary Products Committee (Gaskell *et al.*, 2002a, b) for further information about proposals for vaccine use.

Paraneoplastic syndromes

The skin may be affected in a variety of ways, both clinically and histologically, by underlying disease processes. In paraneoplastic disease a tumour process has an indirect effect on the skin without invading the skin. In recent years several syndromes have been recognised that have cutaneous manifestations for underlying neoplastic processes. The pathogenesis of such syndromes is poorly understood.

Pancreatic paraneoplastic alopecia

This syndrome is also termed 'shiny cat syndrome' because of the profound shiny appearance of the skin on the ventrum. The relationship between the pancreatic (and occasional hepatic) carcinoma to the skin lesions is unknown. The clinical signs are observed in moribund to lethargic aged cats, and include bilateral symmetrical alopecia of the ventrum and limbs, dry fissured to crusting footpads and a shiny appearance to the skin in some cases, possibly due to excessive grooming. Systemic signs are profound and include anorexia, weight loss and lethargy. The diagnosis is achieved from a thorough physical examination that may reveal abdominal abnormalities confirmed with imaging, especially with ultrasound, that allows the collection of a fine-needle aspirate (or biopsy at laparotomy) to obtain tissue samples. There are no distinct changes in serum biochemistry or haematology. The histological changes in a skin biopsy are very helpful, and include marked follicle atrophy and miniaturisation, minimal superficial perivascular dermatitis, mild acanthosis and absence of the stratum corneum, moderate epidermal hyperplasia and hyperkeratosis with laminated orthokeratosis and focal parakeratosis. Removal of the tumour may allow some improvement and helps to confirm the relationship between the skin disease and the tumour, but relapse is likely because these tumours are highly metastatic (Tasker *et al.*, 1999).

Metabolic epidermal necrosis

A rare syndrome, also called hepatocutaneous syndrome and superficial necrolytic dermatitis, has been described in three cases, with some features resembling the condition observed in the dog. A pancreatic tumour was diagnosed in a 11-year-old ovariohysterectomised female Abyssinian cat with gingivitis, stomatitis and hepatomegaly. There was alopecia, erythema and exudation in the axillae. Scaling and patchy alopecia of the distal extremities was noted and the footpads were unaffected. Histological findings of skin biopsies were supportive of a diagnosis of metabolic epidermal necrosis (Patel *et al.*, 1996). However, unlike the usual clinical presentation in the dog, the feet were not affected. In another case the feet were affected and the cat had a hepatopathy (Godfrey & Rest, 2000). There is no effective therapy and the affected cat usually undergoes euthanasia.

Thymoma and exfoliative dermatitis

At least seven cases of this syndrome have been reported in the cat. The removal of the tumour and the regression of clinical signs have confirmed the association between the presence of a thymoma and the development of skin lesions. Cytotoxic T-lymphocytes ($CD8^+$) have been observed in lesional epidermal tissue sections, suggesting a role for autoreactive T-cells attacking keratinocytes in the epidermis, hair follicle and sebaceous glands (Rivierre & Olivry, 1999). The clinical signs tend to occur in older cats and include localised to generalised erythroderma with exfoliation (Plate 6.19). The cat may be weak and anorexic, and have signs suggestive of thoracic disease including coughing and dyspnoea. The histological findings in skin biopsies include an interface dermatitis, hydropic degeneration of epidermal basal cells, and apoptotic keratinocytes in the epidermis and hair follicle. Radiography will reveal a mass in the cranial mediastinum of the thorax and ultrasound may allow collection of needle aspirates for cytology. Alternatively, the tumour can be confirmed at thoracotomy. The condition may be complicated by the presence of bacteria and yeast organisms in the stratum corneum, which may be associated with some degree of pruritus.

There is no effective therapy unless the tumour can be removed completely.

Miscellaneous conditions

Acne

Feline acne is a well-recognised clinical entity with a poorly understood pathogenesis, although the current view is that it represents a form of keratinisation disorder with secondary bacterial infection. Lesions are usually localised to the chin, but may also be located on the upper and lower lips and commissures of the lips (White *et al.*, 1997). Clinical signs may include pruritus, although this is not a consistent finding; in some cases the signs of acne are part of a variety of clinical signs observed over the whole body. The clinical signs are similar to demodicosis, dermatophytosis, *Malassezia* infection, eosinophilic granuloma and bacterial pyoderma. As such, it is unclear whether these diseases are a potential cause of the acne. Lesions observed include keratinous debris attached to the base of the hair shafts (i.e. follicular casts), comedones, papules, pustules to draining furuncles with a purulent exudate and swelling of the chin (Plate 6.20).

Skin cytology and hair plucks for demodex and dermatophyte culture help to establish a diagnosis. Skin biopsies may show dilated hair follicles, follicular pustulosis, furunculosis, pyogranulomatous dermatitis and sebaceous adenitis.

When a purulent discharge is present with numerous bacteria and phagocytic cells found on cytology, the cat should receive up to 4–6 weeks of antibacterial therapy orally, as for superficial bacterial pyoderma. The apparent response to antibacterial therapy tends to suggest that infection due to pasteurellae, staphylococci and streptococci is a major cause of the disease; *Malassezia* may also be found occasionally. Severe cases may warrant steroid therapy to reduce the considerable inflammatory component of acne. Maintenance therapy is principally based on topical therapy and may include initial clipping and daily application of chlorhexidine soaks. Benzoyl peroxide has been recommended, but can be an irritant. An open trial with mupirocin (2%) reported a favourable response in 24 out of 25 cases with twice-daily application for at least 3 weeks. The application of topical retinoids has been recommended and may be worth considering for long-term control of the mild form of the disease to reduce the accumulation of follicular keratin that is assumed to be the underlying keratinisation disorder.

Idiopathic facial dermatitis of Persian cats

This disease has been termed dirty face syndrome by some clinicians. It is a poorly understood condition that is recognised in the Persian breed only, with no clear underlying aetiology, and provides a considerable challenge to the clinician to manage (Bond *et al.*, 2000).

The presenting clinical signs are observed in Persian cats and in an initial case series the age of onset ranged from 4 months to 5 years. The dermatological examination reveals black waxy material on the distal portion of the hairs in a symmetrical pattern on the face, particularly on the chin, perioral and periocular areas. There is bilateral erythematous otitis externa with black waxy material in some cases. Pruritus is minimal at the outset and becomes severe in some cases (Plate 6.21).

Differential diagnoses usually considered include ectoparasitism, dermatophytosis, food allergy and herpes infection. Various food trials are usually unhelpful, and evidence for the other differentials is frequently not found. There may be secondary bacterial and yeast infections readily demonstrated with skin cytology. The histological changes in skin biopsies include acanthosis, crusting, hydropic degeneration of basal cells and occasional dyskeratotic keratinocytes including the follicular epithelium. An intense mixed superficial dermal infiltrate accompanies the epidermal changes.

There may be a partial response to topical and systemic antimicrobial therapy, including chlorhexidine and miconazole-based products. Systemic antimicrobials (cephalexin, clavulanic acid plus amoxycillin, enrofloxacin) and ketoconazole (10 mg/kg per day) for up to 21 days may be useful depending on the results from cytology samples and swabs for culture. Glucocorticoids given orally at initial doses of up to 3 mg/kg may have a palliative effect and some cases also respond to depo-steroid injections. The pruritus can become so severe that euthanasia is the final outcome.

Hereditary primary seborrhoea oleosa in Persian cats

Dirty face syndrome has been compared with hereditary primary seborrhoea oleosa in Persian cats, which

is considered to be a primary form of keratinisation defect; however, there seem to be no obvious similarities apart from the same breed being affected. The mode of inheritance of the seborrhoea is suspected to be autosomal recessive. Kittens are affected within 6 weeks of age, with generalised mild to severe scaling, a greasy coat and a rancid smell. Alopecia may develop to include most of the body. The histological changes in skin biopsies include hyperplastic superficial lymphocytic perivascular dermatitis with papillomatosis and diffuse orthokeratotic hyperkeratosis affecting the skin surface and follicles. There is no effective treatment for these cats, which are most unsuitable as pets. This is not a pruritic condition.

Otitis externa

The external ear canal and pinna may be affected in a variety of conditions, including infectious (bacterial, yeast and dermatophyte), allergic (food allergy, atopy, *Otodectes* hypersensitivity, contact and drug reactions), parasitic (*Otodectes*, trombiculids, *Demodex*, *Notoedres*) and neoplastic (actinic dermatitis, SCC, ceruminous gland hyperplasia, adenoma and adenocarcinoma, nasopharyngeal polyps). Many of these conditions are discussed elsewhere in this chapter.

Diagnostic approach to ear disease

Signs of ear disease may include head shaking and scratching. Changes to the pinnae include erythema, scaling and alopecia. There may be discomfort and resentment of palpation of the ear canal and an odiferous discharge. The presence of abnormal ear carriage, aggression on examination, head tilt and other neurological signs are further indications of potentially severe otitis.

It is important to establish whether there is skin disease elsewhere on the body, because in some situations the ears are very much part of a wider skin problem. For example, food allergy often involves the head and neck, and may include the ear canals. An appropriate food trial may resolve the otitis externa completely (see Plate 6.9).

It is very important to establish the nature of the topical products used to treat the ear disease. Cats are particularly overtreated for ear mites; therefore, if mites are not readily seen with otoscopy then it would be prudent to collect an ear swab, roll it out on a glass slide and examine microscopically for mites before committing to topical therapy for mites. Some cases may improve dramatically when all topical therapy is discontinued, including ear cleaner preparations, supporting a tentative diagnosis of a drug (contact) reaction causing the otitis.

The physical examination should include inspection of the external auditory meatus and appreciation of the nature of any exudate. Samples can be collected for visual inspection directly for mites and cytologically for yeast, bacteria and inflammatory cells. Chronic cases with a purulent exudate, the presence of rod-shaped bacteria on cytology or ulceration of the canal are grounds for collecting a swab for culture of bacteria and yeast. Thereafter, the sensitivity testing may be critical for appropriate systemic antibacterial therapy.

If the pinnae are affected with pustules, crusts and exudate, one should consider scrapings for mites and impression smears. Hair plucks and scrapes should be cultured for dermatophytes, especially with focal alopecia and scaling.

Otoscopy can be a challenge in the conscious cat, especially one with painful or inflamed ear canals. Under sedation one should be able to inspect the tympanic membranes. If the ear canal cannot be fully inspected, especially in chronic cases, then the cat may have to be anaesthetised, in which case it would be feasible to collect radiographs of the tympanic bullae. Alternatively, one may have access to computerised tomography (CT) or magnetic resonance imaging (MRI) which are very useful for detecting soft-tissue changes such as nasopharyngeal polyps (Plate 6.22). The ear canal should be very carefully cleaned to inspect the tympanic membranes, removing purulent or waxy debris with saline or a proprietary ear cleaner and carefully removing all fluid from the canal with gentle suction. The cat is very sensitive to ear cleaning and may even develop neurological signs postcleaning, such as head tilt and Horner's syndrome. In some cases the tympanic membrane may appear intact but abnormal, and one should consider myringotomy to inspect further the middle ear and collect samples for bacterial culture and cytology. In some cases the only means of determining the extent of the disease process is to perform bulla osteotomy.

Nodules, plaques and pustules in the ear canal or on the pinnae should be biopsied to rule out neoplasia and immune-mediated disease (e.g. pemphigus foliaceus).

Pedal dermatoses

Pedal dermatoses may involve the claw, claw fold, pad and interdigital skin to a varying extent. The diagnostic approach has to reflect the potentially daunting

Table 6.7 Overview of pedal dermatoses, including the claws, in the cat

Infectious
Pyoderma – bacterial
Mycobacteria
Nocardia, actinomycosis
Malassezia
Dermatophytes (rare to uncommon)
Subcutaneous and systemic fungal (e.g. sporotrichosis, mycetoma, blastomycosis, cryptococcosis, histoplasmosis)
Poxvirus
Feline herpesvirus-1
Calicivirus
Cutaneous horns with feline leukaemia virus
Parasitic
Trombiculids
Demodicosis
Notoedres
Leishmaniasis
Anatrichosomiasis
Endocrine
Hyperadrenocorticism
Hyperthyroidism
Hypothyroidism
Superficial necrolytic dermatitis (multiple endocrine neoplasia)
Diabetes mellitus
Allergic
Atopy
Mosquito bite-related hypersensitivity
Contact
Food
Environmental
Irritant contact
Burns
Frostbite
Foreign body – plant material
Immune-mediated
Pemphigus foliaceus, pemphigus vulgaris
Bullous pemphigoid
Lupus cutaneous and systemic
Vasculitis
Cold agglutinin disease
Drug reaction
Erythema multiforme
Neoplastic
Fibrosarcomas
Benign adnexal tumour
Feline disseminated pulmonary bronchogenic (adeno)carcinoma
Disseminated squamous cell carcinoma
Disseminated sweat gland adenocarcinoma
Cutaneous T-cell lymphoma
Paraneoplastic alopecia syndrome (pancreatic/liver neoplasia)
Exfoliative dermatitis associated with thymoma
Miscellaneous
Feline xanthomatosis
Sterile pyogranulomas
Sebaceous adenitis
Eosinophilic granuloma
Plasma cell pododermatitis
Mural folliculitis related
Vitiligo
Trauma

list of causes given in Table 6.7, some of which are covered in some detail elsewhere in this and other chapters. A thorough history and physical examination are essential, even if the gross skin lesions appear limited to the paws. Systemic signs may initiate a search for underlying microbial and neoplastic diseases. Samples may need to be collected for routine haematology and serum biochemistry analysis; radiography and ultrasound investigation of the thorax and abdomen may reveal neoplasms. Skin biopsy can often be useful in narrowing the differential list and should be collected with the cat deeply sedated or anaesthetised.

An example of a neoplastic process that involves the digits is the lung digit syndrome (Jacobs & Tomlinson, 1997). The initial clinical presentation may include multiple digit lesions with inflamed swollen digits and ulcerated paronychial infections. Skin biopsy will show bronchial or squamous carcinoma or adenocarcinoma, which has originated from the lung. This should be distinguished from a local primary SCC, which rarely metastasises. Metastasis from primary lung tumours may go to the regional lymph nodes, pleura, mediastinum, long bones, vertebrae, kidney, bladder, adrenal glands, liver, skeletal muscle, heart, brain, spleen, diaphragm, ocular tissue, intestine, oesophagus and pancreas.

Mural folliculitis

Mural folliculitis is a term that denotes a new syndrome recognised in cats. The common histological theme is lymphocytic and histiocytic infiltrate of the hair follicle in the outer sheath in the isthmus and infundibular regions. The infiltrate may extend to the epidermis, including neutrophils and eosinophils, and the follicles may be ablated by a pyogranulomatous inflammation leading to atrophy.

The main presenting clinical signs include generalised alopecia and scaling. There are five forms of this syndrome, which loosely groups different disease processes with a range of similar histological features.

One form of this condition is associated with epitheliotropic lymphoma, another with sebaceous gland atrophy and sebaceous adenitis. The latter has been described in two forms. In one report a 10-year-old cat developed extensive hair loss and skin biopsies revealed an absence of sebaceous glands and pyogranulomatous inflammation around the hair follicles. In two other cases there was generalised heavy scaling of the body, partial alopecia and distinct rims of brown to black thick adherent scale along the margins of the

eyelids; the author has seen a similar case. Histologically, there were similar changes in biopsies from both cats with no sebaceous glands. There is no effective treatment for sebaceous adenitis, although it may respond slightly to topical bathing. Glucocorticoids and retinoids may be worth considering if the condition proves to be similar to that reported in the dog.

Another form of mural folliculitis is associated with dermatophyte infection.

A fourth form is associated with pseudopelade-like disease. Pseudopelade is a rare condition reported in a cat, with clinical signs of alopecia, variable hyperpigmentation and mild scaling. Histologically, evidence of cytotoxic T-lymphocytes targeting the follicle isthmus has been reported.

Other cases of mural folliculitis are associated with a variety of underlying causes. In some cases the cats seem to have a poor prognosis and may succumb to a neoplastic process, suggesting that mural folliculitis is a cutaneous reaction pattern, in some instances, for neoplasia – akin to paraneoplastic alopecia, hepatocutaneous syndrome and thymoma disease. There may be an association with diet in some cases: in one report the lesions were histologically associated with an lymphocytic interface dermatitis and some apoptotic epidermal cells – the cutaneous lesions of thickened skin with adherent crusts over the head, dorsal neck and trunk. The footpads were dry and scaly. The cutaneous signs resolved with a change of diet.

The clinician should be mindful that this syndrome remains poorly understood and that a histological report including mural folliculitis should prompt a careful evaluation for a variety of possible underlying diseases.

References

Baxby D. & Bennett M. (1997) Cowpox: a re-evaluation of the risks of human cowpox based on new epidemiological information. *Arch Virol* **S13**, 1–12.

Beale K.M. & Fujioka C. (2001) Effectiveness of selamectin in the treatment of *Notoedres cati* infestation in cats (Abstract). *Vet Dermatol* **12**, 237.

Beale K.M. & Rustemeyer-May E. (2001) Selamectin in the treatment of feline Demodex (Abstract). *Vet Dermatol* **12**, 237.

Ben-Ziony Y. & Arzi B. (2000) Use of Lufenuron for treating fungal infections of dogs and cats: 297 cases (1997–1999). *J Am Vet Med Assoc* **217**, 1510–1513.

Bennett M., Crouch A.J., Begon M., *et al.* (1997) Cowpox in British voles and mice. *J Comp Pathol* **116,** 35–44.

Bernsteen L., Gregory C.R., Aronson L.R., *et al.* (1999) Acute toxoplasmosis following renal transplantation in three cats and a dog. *J Am Vet Med Assoc* **215**, 1123–1126.

Bettenay S.V. (1998a) Feline atopy approach to diagnosis and management. *Proceedings of the 14th Annual Meeting of the American Association of Veterinary Dermatology/American College of Veterinary Dermatology*, San Antonio. Concurrent session notes, pp. 21–25.

Bettenay S.V. (1998b) Response to hyposensitization in 29 atopic cats. In *Advances in Veterinary Dermatology*, Vol 3 (eds Tscharner C. von, Kwochka K.W. & Willemse T.). Butterworth Heinemann, Oxford, pp. 517–518.

Bettenay S.V. (2000) Feline atopy. In *Kirk's Current Veterinary Therapy*, Vol. XIII (ed. Bonagura J.D.). WB Saunders, Philadelphia, PA, pp. 564–569.

Bevier D.E. (1990) The reaction of feline skin to the intradermal injection of allergenic extracts and passive cutaneous anaphylaxis using serum from skin test positive cats. In *Advances in Veterinary Dermatology*, Vol. 1 (eds Tscharner C. von & Halliwell R.E.W.). Baillière Tindall, London, pp. 126 –136.

Bevier D.E. (1997) Atopy: advances in diagnosis and management. In *Consultations in Feline Medicine*, Vol. 3 (ed. August J.R.). WB Saunders, Philadelphia, PA, pp. 214–220.

Bevier D.E. (1998) Ultrastructural changes in feline dermal mast cells during antigen-induced degranulation *in vivo*. In *Advances in Veterinary Dermatology*, Vol. 3 (eds Tscharner C. von, Kwochka K.W. & Willemse T.). Butterworth Heinemann, Oxford, pp. 213–222.

Bond R., Howell S.A., Haywood P.J. & Lloyd D.H. (1997) Isolation of *Malassezia sympodialis* and *Malassezia globosa* from healthy pet cats. *Vet Rec* **141,** 200–201.

Bond R., Curtis C.F., Ferguson E.A., *et al.* (2000) An idiopathic facial dermatitis of Persian cats. *Vet Dermatol*, **11**, 35–41.

Boord M. & Griffin C. (1999) Progesterone secreting adrenal mass in a cat with clinical signs of hyperadrenocorticism. *J Am Vet Med Assoc* **214,** 666–669.

Boothe D.M., Herring I., Calvin J., *et al.* (1997) Itraconazole disposition after single oral and intravenous and multiple oral dosing in healthy cats. *Am J Vet Res* **58,** 872–877.

Boyanowski K.J., Ihrke P.J., Moriello K.A. & Kass P.H. (2000) Isolation of fungal flora from the hair coats of shelter cats in the Pacific coastal USA. *Vet Dermatol* **11,** 143–150.

Carlotti D.N., Remy I. & Prost C. (1990) Food allergy in dogs and cats. A review and report of 43 cases. *Vet Dermatol* **1,** 55–62.

Chailleux N. & Paradis M. (2001) Efficacy of selamectin in the treatment of naturally acquired cheyletiellosis in cats (Abstract). *Vet Dermatol* **12**, 229.

Chermette R., Ferreiro L. & Debieve C. (1997) *Exophiala spinifera* nasal infection in a cat and a literature review of feline phaeohyphomycoses. *J Mycol Med* **7**, 149–158.

Codner E.C. (1996) Reactivity to intradermal injection of extracts of housedust mites and flea antigens in normal cats and cats suspected of being allergic. *Proceedings of the 12th Annual Meeting of the American Association of Veterinary Dermatology/American College of Veterinary Dermatology*, Las Vegas, pp. 26–27.

Coleman G.T. & Atwell R.B. (1999) Use of fipronil to treat ear mites in cats. *Aust Vet Pract* **29**, 166–168.

Colombini S., Hodgin E.C., Foil C.S., *et al.* (1999) Induction of feline flea allergy dermatitis and the incidence and

histopathological characteristics of concurrent indolent ulcers. *Proceedings of the 15th Annual Meeting of the American Association of Veterinary Dermatology/American College of Veterinary Dermatology*, Hawaii, pp. 45–46.

Daigle J.C., Foil C.S. & Wolfsheimer K. (2000) Primary hypothyroidism in a cat. P-7. *Vet Dermatol* **11** (Suppl. 1), 43.

Davis C. & Troy G.C. (1996) Deep mycotic infections in cats. *J Am Anim Hosp Assoc* **32**, 380–391.

Delucchi L. & Castro E. (2000) Use of doramectin for treatment of notoedric mange in five cats. *J Am Vet Med Assoc* **216**, 215–216.

Desch C.E. & Stewart T.B. (1999) *Demodex gatoi*: new species of hair follicle mite (Acari: Demodecidae) from the domestic cat (Carnivora: Felidae). *J Med Entomol* **36**, 167–170.

Dryden M.W. & Rust M.K. (1994) The cat flea biology, ecology and control. *Vet Parasitol* **52**, 1–19.

Duesburg C. & Peterson M.E. (1997) Adrenal disorders in cats. *Vet Clin North Am* **27**, 321–347.

Ferguson E.A. (1994) Four cases of acariasis in the cat caused by *Sarcoptes scabiei. British Veterinary Dermatology Study Group Proceedings*, pp. 9–10.

Foster A.P. & O'Dair H.A. (1993) Allergy testing for skin disease in the cat *in vivo* vs *in vitro* tests. *Vet Dermatol* **4**, 111–115.

Fox L.E. (1995) Feline cutaneous and subcutaneous neoplasms. *Vet Clin North Am* **25**, 961–979.

Fuchs A., Axmann H., Zuckermann A. & Kuttin E.S. (1996) Subcutaneous mycosis in a cat due to *Staphylotrichum coccosporum. Mycoses* **39**, 381–385.

Gaskell R.M., Gettinby G., Graham S.J. & Skilton D. (2002a) Veterinary Products Committee working group report on feline and canine vaccination. *Vet Rec* **150**, 126–134.

Gaskell R.M., Gettinby G., Graham S.J. & Skilton D. (2002b) Veterinary Products Committee (VPC) Working Group on Feline and Canine Vaccination. Final report to the VPC. DEFRA Publications, London, PB 6432 (http://www.vpc.gov.uk), February 2002.

Gilbert S. & Halliwell R.E.W. (1998) Feline immunoglobulin E: induction of antigen-specific antibody in normal cats and levels in spontaneously allergic cats. *Vet Immunol immunopathol* **63**, 235–252.

Gilbert S., Prélaud P. & Guaguère E. (1999) Feline atopy. *Pratique Médicale et Chirurgicale d l'Animal de Compagnie* **34**, 15–31.

Godfrey D.R. & Rest J.R. (2000) Suspected necrolytic migratory erythema associated with chronic hepatopathy in a cat. *J Small Anim Pract* **41**, 324–328.

Greene C.E. (ed.) (1998) *Infectious Diseases of the Dog and Cat*. 2nd edn. WB Saunders, Philadelphia, PA.

Griffin C.E. (1991) Recognising and treating pemphigus foliaceus in cats. *Vet Med* **86**, 513–516.

Griot-Wenk M.E., Obexer-Ruff G., Fluri A. & Marti E. (2000) Partial sequences of feline and caprine immunoglobulin epsilon heavy chain cDNA and comparative binding studies of recombinant IgE fragment-specific antibodies across different species. *Vet Immunol Immunopathol* **75**, 59–69.

Gross T.L., Kwochka K.W. & Kunkle G.A. (1986) Correlation of histologic and immunologic findings in cats with miliary dermatitis. *J Am Vet Med Assoc* **189**, 1322–1325.

Groux D., Degorce-Rubiales F. & Capelli J.L. (1999) Feline poxvirus, a report concerning two cases. *Pratique Médicale et Chirurgicale d l'Animal de Compagnie* **34**, 215–229.

Guaguère E., Hubert B. & Delabre C. (1992) Feline pododermatoses. *Vet Dermatol* **3**, 1–12.

Guaguère E., Olivry T., Delverdier-Poujade A., *et al.* (1999) *Demodex cati* infestation in association with feline cutaneous squamous cell carcinoma *in situ*: a report of five cases. *Vet Dermatol* **10**, 61–67.

Gunn-Moore D.A., Jenkins P.A. & Lucke V.M. (1996) Feline tuberculosis: a literature review and discussion of 19 cases caused by an unusual mycobacterial variant. *Vet Rec* **138**, 53–58.

Halliwell R.E.W. & Gorman N.T. (1989) Atopic diseases. In *Veterinary Clinical Immunology* (eds Halliwell R.E.W. & Gorman N.T.). WB Saunders, Philadelphia, PA, pp. 232–252.

Hargis A.M., Ginn P.E., Mansell J.E.K.L. & Garber R.L. (1999) Ulcerative facial and nasal dermatitis and stomatitis in cats associated with feline herpesvirus 1. *Vet Dermatol* **10**, 267–274.

Hay R.J. (1998) Host resistance and superficial fungal infections. In *Advances in Veterinary Dermatology*, Vol. 3. (eds Tscharner C. von, Kwochka K.W. & Willemse T.). Butterworth Heinemann, Oxford, pp. 261–270.

Helton-Rhodes K. (1995) Feline immunomodulators. In *Current Veterinary Therapy,* Vol. XII (ed. Bonagura J.D.). WB Saunders, Philadelphia, PA, pp. 581–584.

Helton-Rhodes K. (1997) Feline HAC. In *Consultations in Feline Internal Medicine*, Vol. 3 (ed. August J.R.). WB Saunders, Philadelphia, PA, pp. 191–198.

Hervas J., Chacón-M De Lara F., Sanchez-Isarria M.A. *et al.* (1999) Two cases of feline visceral and cutaneous leishmaniasis in Spain. *J Feline Med Surg* **1**, 101–105.

Hill P.B., Moriello K.A. & Shaw S.E. (1995) A review of systemic antifungal agents. *Vet Dermatol* **6**, 59–66.

Hughes M.S., Ball N.W., Love D.N., *et al.* (1999) Disseminated *Mycobacterium genavense* infection in a FIV-positive cat. *J Feline Med Surg* **1**, 23–29.

Jacobs T.M. & Tomlinson M.J. (1997) The lung digit syndrome in a cat. *Feline Pract* **25**, 31–36.

Kunkle G.A. (1984) Feline dermatology. *Vet Clin North Am Small Anim Pract* **14**, 1065–1087.

Kunkle G.A. & Milcarsky J. (1985) Double-blind flea hyposensitization trial in cats. *J Am Vet Med Assoc* **186**, 677–680.

Lemarie S.L. (1999) Mycobacterial dermatitis. *Vet Clin North Am Small Anim Pract* **29**, 1291–1301.

Leung D.Y.M. (2000) Atopic dermatitis: new insights and opportunities for therapeutic intervention. *J Allergy Clinical Immunol* **105**, 860–876.

Lewis D.T., Merchant S.R. & Neer T.M. (1994) Ivermectin toxicosis in a kitten. *J Am Vet Med Assoc* **205**, 584–586.

McEntee M.C. & Page R.L. (2001) Feline vaccine-associated sarcomas. *J Vet Intern Med* **15**, 176–182.

Macey D.W. (1999) Current understanding of vaccination site-associated sarcomas in the cat. *J Feline Med Surg* **1**, 15–21.

Malik R., Wigney D.I., Dawson D., *et al.* (2000) Infection of the subcutis and the skin of cats with rapidly growing myco-

bacteria: a review of microbiological and clinical findings. *J Feline Med Surg* **2**, 35–48.

Mancianti F., Pedonese F. & Zullino C. (1998) Efficacy of oral administration of itraconazole to cats with dermatophytosis caused by *Microsporum canis*. *J Am Vet Med Assoc* **213**, 993–997.

Mancianti F., Pedonese F., Millanta F. & Guarnieri L. (1999) Efficacy of oral terbinafine in feline dermatophytosis due to *Microsporum canis*. *J Feline Med Surg* **1**, 37–41.

Marchal I.S., Martin J.P., Kirn A., *et al*. (1998) Feline Langerhans cells migrate from the skin and vaginal mucosa to regional lymph nodes during experimental contact sensitization with fluorescein isothiocyanate. *Vet Dermatol* **9**, 9–17.

Mason K.V. (1997) *Malassezia pachydermatis*-associated dermatitis. In *Consultations in Feline Medicine*, Vol. 3 (ed. August J.R.). WB Saunders, Philadelphia, PA, pp. 221–222.

Mason K.V. & Evans A.G. (1991) Mosquito bite-caused eosinophilic dermatitis in cats. *J Am Vet Med Assoc* **198**, 2086–2088.

Matthews K.G. & Gregory C.R. (1997) Renal transplants in cats: 66 cases. *J Am Vet Med Assoc* **211**, 1432–1436.

Medleau L. & Blue J.L. (1988) Frequency and antimicrobial susceptibility of *Staphylococcus* spp. isolated from feline skin lesions. *J Am Vet Med Assoc* **193**, 1080–1081.

Medleau L. & Rakich P.M. (1994) *Microsporum-canis* pseudomycetomas in a cat. *J Am Anim Hosp Assoc* **30**, 573–576.

Medleau L., Jacobs G.J. & Marks M.A. (1995) Itraconazole for the treatment of Cryptococcosis in cats. *J Vet Intern Med* **9**, 39–42.

Messinger L.M. (1995) Therapy for feline dermatoses. *Vet Clin North Am Small Anim Pract* **25**, 981–1005.

Miller M.A., Nelson S.L., Turk J.R., *et al*. (1991) Cutaneous neoplasia in 340 cats. *Vet Pathol* **28**, 389–395.

Moriello K.A. & DeBoer D.J. (1997) Dermatophytosis: advances in therapy and control. In *Consultations in Feline Internal Medicine*, Vol. 3 (ed. August J.R.). WB Saunders, Philadelphia, PA, pp. 177–190.

Moriello K.A. & McMurdy M.A. (1989) The prevalence of positive intradermal skin test reactions to flea extract in clinically normal cats. *Companion Anim Pract* **19**, 28–30.

Mueller R.S. (2001) Mosquito-bite hypersensitivity. In *Consultations in Feline Medicine*, Vol. 4 (ed. August J.R.). WB Saunders, Philadelphia, PA, pp. 186–189.

Mueller R.S., Ihrke P.J., Kass P.H. & Bettenay S.V. (1991) The effect of tiletamine–zolazepam anesthesia on the response to intradermally injected histamine in cats. *Vet Dermatol* **2**, 119–123.

Nagata M. & Ishida T. (1997) Cutaneous reactivity to mosquito bites and its antigens in cats. *Vet Dermatol* **8**, 19–26.

Nuttall T.J., French A.T., Cheetham H.C. & Proctor F.J. (1998) Treatment of *Trombicula autumnalis* infestation in dogs and cats with a 0.25% fipronil pump spray. *J Small Anim Pract* **39**, 237–239.

O'Dair H.A., Markwell P.J. & Maskell I.E. (1996) An open prospective investigation into aetiology in a group of cats with suspected allergic skin disease. *Vet Dermatol* **7**, 193–200.

Olivry T., Chan L.S., Xu L., *et al*. (1999) Novel feline autoimmune blistering disease resembling bullous pemphigoid in humans: IgG autoantibodies target the NC16A ectodomain of type XVII collagen (BP180/BPAG2). *Vet Pathol* **36**, 328–335.

Olivry T., DeBoer D.J., Griffin C.E., *et al*. (2001) The ACVD task force on canine atopic dermatitis: forewords and lexicon. *Vet Immunol Immunopathol* **81**, 143–146.

Page N., Jaham C., de & Paradis M. (2000) Observations on topical ivermectin in the treatment of otoacariosis, cheyletiellosis, and toxocariasis in cats. *Can Vet J* **41**, 773–776.

Paradis M. (1998) Ivermectin in Small Animal Dermatology. *Compendium of Continuing Education for the Practising Veterinarian* **20**, 193–200.

Patel A., Whitbread T.J. & McNeil P.E. (1996) A case of metabolic epidermal necrosis in a cat. *Vet Dermatol* **7**, 221–226.

Patel A., Lloyd D.H. & Lamport A.I. (1999) Antimicrobial resistance of feline staphylococci in southeastern England. *Vet Dermatol* **10**, 257–261.

Paterson S. (1999) Miconazole/chlorhexidine shampoo as an adjunct to systemic therapy in controlling dermatophytosis in cats. *J Small Anim Pract* **40**, 163–166.

Pin D. & Carlotti D.-N. (2000) A case of dermatophytic mycetoma caused by *Microsporum canis* in a Persian cat. *Pratique Médicale et Chirurgicale d l'Animal de Compagnie*, **35**, 105–112.

Power H.T. & Ihrke P.J. (1995) Selected feline eosinophilic skin diseases. *Vet Clin North Am Small Anim Pract* **25**, 833–850.

Prost, C. (1998) Diagnosis of feline allergic diseases: a study of 90 cats. In *Advances in Veterinary Dermatology*, Vol. 3 (eds Tscharner C. von, Kwochka K.W. & Willemse T.). Butterworth Heinemann, Oxford, pp. 516–517.

Reedy L.M., Miller W.H. & Willemse T. (1997) *Allergic Skin Diseases of Dogs and Cats*. 2nd edn. WB Saunders Philadelphia, PA.

Rivierre C. & Olivry T. (1999) Paraneoplastic exfoliative dermatitis associated with thymoma in cats. The resolution of symptoms after thymectomy. *Pratique Médicale et Chirurgicale d l'Animal de Compagnie* **34**, 531–537.

Roccabianca P., Caniatti M., Scanziani E. & Penati V. (1996) Feline leprosy: spontaneous remission in a cat. *J Am Anim Hosp Assoc* **32**, 189–193.

Roosje P.J., Whitaker-Menezes D., Golschmidt M.H., *et al*. (1997) Feline atopic dermatitis: a model for Langerhans cell participation. *Am J Pathol* **151**, 927–932.

Roosje P.J., Kooten P.J.S. van, Thepen T., *et al*. (1998) Increased numbers of $CD4^+$ and $CD8^+$ T cells in the lesional skin of cats with allergic dermatitis. *Vet Pathol* **35**, 268–273.

Roosje P.M., Thepen T.H., Rutten V.P.M.G. & Willemse T. (2002) Feline atopic dermatitis: a review. In *Advances in Veterinary Dermatology*, Vol. 4 (eds Bond R., Foil C. & Thoday K.). Blackwell, Oxford, pp. 178–87.

Rosser, E.J. (1993) Food allergy in the cat: a prospective study of 13 cats. In *Advances in Veterinary Dermatology*, Vol. 2 (eds

Ihrke P.J., Mason I.S. & White S.D.). Pergamon Press, Oxford, pp. 33–39.

Ruslander D., Kaser-Hotz B. & Sardinas J.C. (1997) Cutaneous squamous cell carcinoma in cats. *Compendium of Continuing Education for the Practising Veterinarian* **19**, 1119–1129.

Sawyer L.S., Moon-Fanelli A.A. & Dodman N.H. (1999) Psychogenic alopecia in cats: 11 cases (1993–1996). *J Am Vet Med Assoc* **214**, 71–74.

Scott D.W. (1992) Bacteria and yeast on the surface and within non-inflamed hair follicles of skin biopsies from cats with non-neoplastic dermatoses. *Cornell Veterinarian* **82**, 371–377.

Scott D.W., Miller W.H. & Griffin C.E. (2001) *Muller & Kirks Small Animal Dermatology*. 6th edn. WB Saunders, Philadelphia, PA.

Shanks D.J., McTier T.L., Rowan T.G., *et al.* (2000) The efficacy of selamectin in the treatment of naturally acquired aural infections of *Otodectes cynotis* on dogs and cats. *Vet Parasitol* **91**, 283–290.

Shaw S.E., Birtles R.J. & Day M.J. (2001) Arthropod-transmitted infectious diseases of cats. *J Feline Med Surg* **3**, 193–209.

Sparkes A.H., Werrett G., Stokes C.R. & Gruffydd-Jones T.J. (1994) *Microsporum-canis* – inapparent carriage by cats and the viability of arthrospores. *J Small Anim Pract* **35**, 397–401.

Tasker S., Griffon D.J., Nuttall T.J. & Hill P.B. (1999) Resolution of paraneoplastic alopecia following surgical removal of a pancreatic carcinoma in a cat. *J Small Anim Pract* **40**, 16–19.

Thoday K.L. (1985) The skin. In *Feline Medicine and Therapeutics*. 1st edn (eds Chandler E.A., Gaskell C.J. & Hilberry A.D.R.). Blackwell Science, Oxford, pp. 3–38.

Van den Broek A.H.M. & Thoday K.L. (1994) The skin. In *Feline Medicine and Therapeutics.* 2nd edn (eds Chandler E.A., Gaskell C.J. & Gaskell R.M.). Blackwell Science, Oxford, pp. 3–83.

Vitale C.B., Ihrke P.J., Gross T.L. & Werner L.L. (1997) Systemic lupus erythematosus in a cat: fulfillment of the American Rheumatism Association criteria with supportive skin histopathology. *Vet Dermatol* **8**, 133–8.

Wall R. & Shearer D.H. (2001) *Veterinary Ectoparasites: Biology, Pathology and Control*. 2nd edn. Blackwell Science, Oxford.

Weber E., Helps C.R., Foster A.P., *et al.* (2000) Sequence of the feline immunoglobulin epsilon constant region. *Vet Immunol Immunopathol* **76**, 299–308.

White S.D. & Sequoia, D. (1989) Food hypersensitivity in cats: 14 cases (1982–1987). *J Am Vet Med Assoc* **194**, 692–695.

White S.D., Bordeau P.B., Blumstein P., *et al.* (1997) Feline acne and results of treatment with mupirocin in an open clinical trial: 25 cases (1994–1996). *Vet Dermatol* **8**, 157–164.

Wilkinson G.T. & Bate M.J. (1984) A possible further clinical manifestation of the feline eosinophilic granuloma complex. *J Am Anim Hosp Assoc* **20**, 325–331.

Willemse T. & Koeman J.P. (1989) Discoid lupus erythematosus in cats. *Vet Dermatol* **1**, 19–24.

Willemse T., Vroom M.W., Mol J. & Rijnberk A. (1993) Changes in plasma cortisol, corticotropin and α-melanocyte-stimulating hormone in cats before and after physical restraint and intradermal testing. *Am J Vet Res* **54**, 69–72.

Wright A.I. (1989) Ringworm in dogs and cats. *J Small Anim Pract* **30**, 242–249.

Further reading

Goldschmidt M.H. & Shofer F.S. (1992) *Skin Tumors of the Dog and Cat*. Pergamon Press, Oxford.

Gross T.L., Ihrke P.J. & Walder E.J. (1992) *Veterinary Dermatopathology: A Macroscopic and Microscopic Evaluation of Canine and Feline Skin Disease*. Mosby Year Book, St Louis, MO.

Guaguère É & Prélaud, P. (eds) (2000) *A Practical Guide to Feline Dermatology*. Merial, London.

Kunkle G.A. (1995) Feline dermatology. *Vet Clin North Am Small Anim Pract* **25**, 767–1006.

Scott D.W. (1980) Feline dermatology 1900–1978: a monograph. *J Am Anim Hosp Assoc* **16**, 331–459.

Scott D.W. (1984) Feline dermatology 1979–1982: introspective retrospections. *J Am Anim Hosp Assoc* **20,** 537–564.

Scott D.W. (1987) Feline dermatology 1983–1985: 'the secret sits'. *J Am Anim Hosp Assoc* **23**, 255–274.

Scott D.W. (1990) Feline dermatology 1986 to 1988: looking to the 1990s through the eyes of many counsellors. *J Am Anim Hosp Assoc* **26,** 515–537.

Chapter 7

THE NERVOUS SYSTEM

B.R. Jones

Introduction

Clinical examination and diagnosis of cats suspected of having nervous system disease requires a knowledge of neuroanatomy and neurophysiology. Most important is an understanding of how the functions of specific areas of the nervous system are integrated to allow the cat to perform normal actions and functions.

Knowledge of the location of an area of the nervous system and its normal functions will enable abnormal signs to be recognised, allow one to determine that an area or areas of the central nervous system (CNS) are abnormal, and enable a differential diagnosis and plan for investigation or management to be formulated. Nervous tissue is very limited in the way it can react to injury of any type. There is either excitation (stimulation of neurons or release phenomena) or inhibition of neurons. Recognition of signs of excitation (e.g. seizures, exaggerated reflexes, opisthotonus) or inhibition (e.g. paralysis or anaesthesia to painful stimuli) is important. Not only will an area of the CNS be identified as being affected, but possibly the pathogenesis or nature of the lesion can be defined.

Cats have many primary diseases of the CNS, and the nervous system is also affected in many systemic and metabolic diseases. The cat can frequently be a 'difficult' patient, and accurate clinical and neurological examination can be difficult to perform because of temperament.

The purpose of this chapter is to provide information on neurological dysfunction in the cat, the neurological examination, and the more common diseases of the brain, spinal cord, peripheral nerves and muscles of the cat.

Functional areas of the nervous system

The major components of the nervous system include the brain, the cranial nerves, the spinal cord and the peripheral nerves. These components are connected to, and interact with each other to control most bodily functions.

The brain is important for controlling consciousness (mental status, awareness), behaviour, voluntary and reflex movements of the head, body and limbs, vital functions such as sleep, eating, drinking and respiration, and conscious recognition through sight, hearing, taste, touch and pain. With the tentorium cerebelli as the dividing point, the brain can be separated into the structures rostral to the tentorium cerebelli (i.e. the supratentorial structures or forebrain) and those caudal to the tentorium (i.e. the infratentorial structures). This anatomical division is also convenient for dividing the brain into functional areas (Figure 7.1). The supratentorial structures include the cerebral hemispheres, basal nuclei and diencephalon. Infratentorial structures include midbrain, pons, medulla oblongata and cerebellum.

Supratentorial structures provide for many conscious functions such as sight and voluntary movement. Portions of the cerebral hemispheres (e.g. the parietal cortex) sense where the limbs and head are in space. Recognition of the orientation of where the body is in relation to gravity is referred to as proprioception. The diencephalon (hypothalamus and thalamus) controls many autonomic and basic life-support functions (e.g. hunger, thirst, body temperature and temperature regulation).

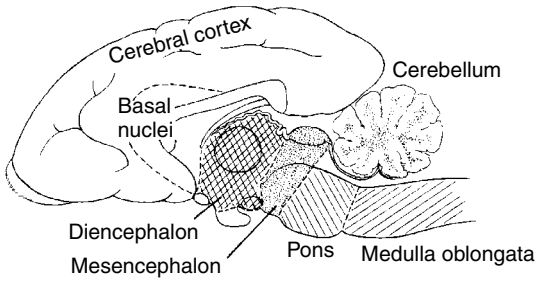

Figure 7.1 Segmental organisation of the brain. Supratentional structures include; the diencephalon, basal nuclei and cerebral cortex. Infratentional structures are located caudal to the diencephalon; the pons, cerebellum and medulla (Oliver, 1990).

The brainstem contains the groups of neurons (nuclei) that make up many of the cranial nerves (III–XII), as well as the reticular activating system (which via the cerebral cortex keeps the body in an alert and awake state). Respiration is controlled by areas within the caudal brainstem. Many ascending and descending neural pathways important for movement pass through, or originate within, the brainstem.

The cerebellum immediately dorsal to the pons and medulla oblongata co-ordinates movements and is important for the unconscious control of proprioceptive functions.

The spinal cord contains tracts, which connect the brain to the peripheral nerves. It contains spinal cord segments, which are anatomically divided into cervical (eight segments), thoracic (13 segments), lumbar (five to seven segments) and sacral (three segments) segments or regions (Figure 7.2). Clinical signs of spinal cord dysfunction often manifest as abnormalities of limb strength and movement.

The peripheral nerves arise from within the spinal cord (motor nerves) or nerve root ganglia (sensory nerves) and bring information from (sensory) or carry information to (motor) parts of the body such as the muscles of the limbs. Motor nerves provide information to the muscle through the neuromuscular junction. The motor components of these nerves form the final pathway wherein information from the brain is transmitted to the body to perform a specific function or muscle movement. Components of the clinical neurological examination are used to test the complex normal interactions of these structures to determine whether the nervous system is working in a proper and co-ordinated manner.

Evaluation of the head

Any head abnormalities must be due to disease of the nervous system above the foramen magnum: the cerebral cortex, the cerebellum and the brainstem segments, that is, the diencephalon, midbrain, pons and medulla oblongata. Changes in personality, mental attitude and behaviour may be observed or are described by owners. Lesions in the frontal cerebral cortex may result in a cat that does not recognise the owner or surroundings. The cat may lack natural curiosity or be uninterested in its environment, and may stare at the sky or roof and appear blind, but may not bump into objects. Lesions in the temporal lobe can produce vicious animals that have seizures characterised by hysterical running (psychomotor seizures). Lesions in the diencephalon may produce both docile and demented and vicious behaviour. Compulsive pacing or circling has also been associated with frontal cerebral cortex and diencephalon lesions. The cats generally circle towards the side of the lesion. This type of circling can be differentiated from a lesion in the vestibular system because there is no head tilt or loss of balance and the cats are generally demented and compulsive. Abnormal appetite, thirst and urination may be due to a lesion of the diencephalon.

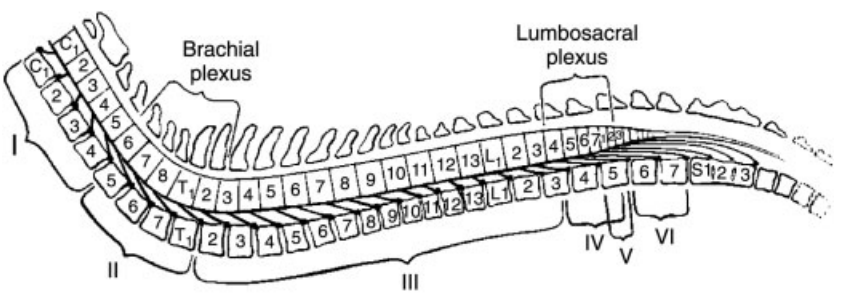

Figure 7.2 The sequential arrangement of the spinal cord; each segment has a pair of spinal nerves. The approximate relationship of the spinal cord segments is shown (Oliver, 1990).

If head and eye movements are jerky and incoordinated or a head tremor is noted, a lesion of the cerebellum is likely. A head tilt, usually towards the lesion, is characteristic of unilateral vestibular disease. The head tilt is away from the lesion in disease of the flocculonodular lobe of the cerebellum.

Abnormalities of the cranial nerves are helpful to localise lesions in the brainstem segment where the cranial nerve has its nuclei or in the peripheral cranial nerve itself. If a lesion in the brainstem is present, then abnormalities in the cat's gait, forelimbs and hindlimbs will be found. Bumping into objects and decreased menace response suggest visual defects and may be produced by lesions of the optic nerve, or tracts through the diencephalon or occipital cortex. Optic nerve lesions most often produce blindness with pupils that do not constrict to light stimulus. Blindness with normal pupils is usually associated with a lesion of the occipital cerebral cortex on the opposite side. Normal vision with a dilated pupil (with or without ventrolateral deviation) may occur with oculomotor nerve or midbrain lesions affecting the occulomotor nucleus.

Unilateral lesions of the vestibular nerve or nucleus or the flucculonodular lobe of the cerebellum produce a loss of balance to one side, head tilt, circling, rolling, positional strabismus (eye drop on the affected side), and positional and spontaneous nystagmus.

Inability to move the lip or ear, and/or to close the eyelid is due to facial nerve or nucleus damage. Inability to close the jaw is due often to a lesion of the trigeminal nerve or pons. Swallowing difficulties, regurgitation from megaoesophagus or change in voice may be produced by lesions of the vagus nerve or caudal medulla, or dysautonomia.

Tongue paralysis and atrophy are associated with hypoglossal nerve lesions. Hypertrophy of the tongue occurs in some myopathies. Abnormal heart and respiratory rate and rhythm and changes in blood pressure may be due to a lesion of the pons and medulla.

Table 7.1 gives guidelines for localisation of lesions to specific areas of the CNS.

Table 7.1 Evaluation of the head

Seizures (cerebrum, diencephalon)
Personality and mental attitude (cerebrum, diencephalon)
Consciousness (cerebrum, diencephalon, midbrain)
Endocrinopathies (diencephalon, pituitary)
Head co-ordination (cerebellum)
Cranial nerves:
Olfaction (olfactory nerves, diencephalon)
Menace (optic nerve, diencephalon, cerebrum, facial nerve and cerebellum)
Pupillary reflex (optic and oculomotor nerves)
Pupil size (oculomotor and cervical sympathetic nerves)
Pupil symmetry (oculomotor and cervical sympathetic nerves)
Strabismus (oculomotor, trochlear and midbrain; abducens and medulla)
Vestibular nystagamus (vestibular nerve, medulla, pons, midbrain; oculomotor and adducens nerves)
Spontaneous nystagamus (vestibular nerve, medulla and cerebellum)
Ear, lip and eye reflexes (facial nerve and medulla)
Temporal and masseter (trigeminal nerve and pons)
Hearing (cochlear nerve)
Swallowing (glossopharyngeal and vagus nerves, caudal medulla)
Regurgitation (vagus nerve and caudal medulla)
Larynx (vagus nerve, accessory and caudal medulla)
Tongue (hypoglossal nerve and caudal medulla)
Vital signs (pons and medulla)

Table 7.2 Evaluation of gait and strength

Normal: cerebrum and diencephalon
Hemiparesis, quadriparesis: brainstem and cervical spinal cord
Incoordination of all four limbs: cerebellum and cervical spinal cord
Posterior: thoracolumbar spinal cord

Evaluation of gait and strength

Cerebral and diencephalic lesions often produce no detectable abnormalities in gait. Acute lesions may produce a mild transient hemiparesis on the opposite side. Lesions of the midbrain, pons and medulla oblongata produce ipsilateral hemiparesis or quadriparesis, but the cranial nerve signs help to localise a lesion to the brainstem. A lesion of the cerebellum will produce generalised incoordination of the limbs as well as the head. Cats with cerebellar disease are ataxic but there is no weakness.

If there are no clinical signs attributable to the brain, then hemiparesis is most likely to be due to an ipsilateral cervical spinal cord lesion, quadriparesis due to a focal cervical spinal cord or diffuse neuromuscular disease, and paresis due to thoracolumbar spinal cord disease.

Abnormalities of gait can be very difficult to assess in cats in a strange environment as they are reluctant to move and may crouch close to the ground. Owner observations of the cat at home are important.

Table 7.2 summarises localisations based on evaluation of the gait and strength.

Evaluation of forelimbs and neck

Wheelbarrowing, hopping and placing, and proprioception can confirm forelimb abnormalities. Diencephalic lesions may not affect gait greatly but will produce hopping and placing, and conscious propriceptive deficits on the opposite side. Cerebellar lesions produce incoordinated wheelbarrow, hopping and placing attempts, but no conscious proprioceptive deficits.

Caudal midbrain, pons and medulla oblongata lesions also alter wheelbarrowing, hopping and placing, and conscious proprioception on the ipsilateral side.

Cervical pain most frequently is associated with a cervical cord lesion. If no abnormalities are found on the evaluation of the head, abnormalities of the forelimbs are due to lesions of the cervical spinal cord or brachial plexus nerves. Spinal reflex depression or loss and muscle atrophy can localise lesions to the spinal cord segments and nerves of the brachial plexus supplying the muscles and reflexes. Normal or hyperactive reflexes of the forelimb and crossed extensor reflexes may be seen in lesions of the cerebrum, diencephalon, midbrain, pons, medulla oblongata and C1–5 spinal cord. Ventroflexion of the head and neck is a consistent sign of weakness due to neuromuscular disease.

Table 7.3 shows localisation based on examination of the forelimb and neck.

Table 7.3 Evaluation of forelimbs and neck

Wheelbarrowing (may be abnormal with lesions above C7)
Hopping (may be abnormal with lesions above C7)
Placing (may be abnormal with lesions above C7)
Proprioception (may be abnormal with lesions above C7)
Extensor strength (may be abnormal with lesions above C7) (Schiff–Sherrington)
Biceps reflex (depressed or absent if lesion C6–C7; hyperactive above C6)
Triceps reflex (depressed or absent if lesion C7–T2; hyperactive above C7)
Flexor reflex (depressed or absent if lesion C7–T2)
Crossed extensor (present if lesion above C7)
Deep pain (present if nerve and spinal cord, brainstem and cerebrum intact)
Superficial sensation (local nerves, spinal cord, brainstem)
Neck pain (cervical lesion)
Muscle atrophy [lesions affecting nerve(s) of brachial plexus (C6–T2)]

Evaluation of rear limbs, tail and anus

Lesions of the cerebrum and diencephalon may not affect gait but may affect postural reactions on the contralateral side. Cerebellar lesions may produce incoordinated movements during hopping and placing, and should not produce conscious proprioceptive deficits. Midbrain, pons and medulla oblongata lesions alter wheelbarrowing, hopping and placing the hindlimbs, as well as conscious propriception. If no abnormalities are found on examination of the head and forelimbs but abnormalities are detected in the hindlimbs, then a thoracolumbar spinal cord or lumbosacral plexus lesion must be suspected, which may produce ipsilateral wheelbarrowing, hopping and placing, and conscious propriceptive deficits as well as ataxia, paresis or paralysis of the hindlimbs.

Back pain or anaesthesia caudal to the thoracolumbar region is due most often to a lesion at that site. Depressed or absent spinal reflexes and muscle atrophy of the limbs localise lesions to the spinal cord segments and nerves of the lumbosacral plexus which supply those reflexes and muscles. Hyperactive hindlimb spinal reflexes and a crossed extensor reflex suggest a lesion of the cerebrum, diencephalon, midbrain, pons and medulla oblongata, and cervical, thoracic and lumbar (L1–3) spinal cord segments.

Table 7.4 Evaluation of rear limbs, anus and tail

Wheelbarrowing (may be abnormal with lesions L7 and above)
Hopping (may be abnormal with lesions L7 and above)
Placing (may be abnormal with lesions L7 and above)
Proprioception (may be abnormal with lesions L7 and above)
Extensor strength (may be abnormal with lesions L7 and above)
Patellar reflex (depressed or absent L4–5 lesions, hyperactive L3 and above)
Flexor reflex (depressed or absent L6–S2 lesions; hyperactive L5 and above)
Crossed extension (lesions above L6)
Deep pain (present if nerves, spinal cord, brainstem and cerebrum intact)
Anal reflex (depressed or absent S1–S3 lesions)
Tail response (depressed or absent CY1–CY5 lesions)
Panniculus (present if local sensory nerves, spinal cord and T1–T2 cord intact)
Sensory deficit (anaesthesia caudal to lesion or nerve supplying dermatome)
Muscle atrophy (lesion affecting nerve or muscle)

A dilated anus or a distended, easily expressed flaccid bladder and paretic tail are signs of sacrococcygeal spinal cord and nerve lesions.

Table 7.4 shows localisation of lesions with hindlimb, anal or tail abnormalities.

Cranial nerves

Cranial nerve deficits result from damage to the cranial nerve itself, or to the nucleus within the brainstem. Cranial nerve lesions may occur singly or in groups. They are important not only because of the effect of the paralysis, but also because they provide information for localisation of both intracranial (Figure 7.3) and extracranial lesions. The cranial nerves, their function and signs of dysfunction are shown in Table 7.5.

The investigation of any cranial nerve injury will depend on whether one nerve or two or more nerves are involved unilaterally or bilaterally. If a single nerve is involved, trauma, tumour or idiopathic causes are

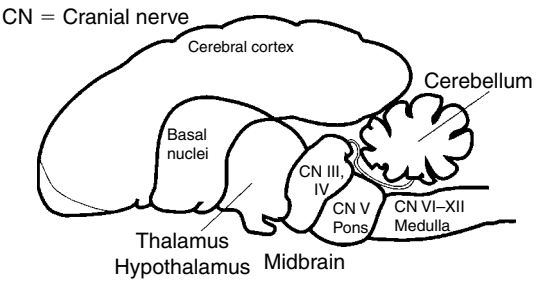

Figure 7.3 Schematic drawing of region of the brain and origins of cranial nerves III to XII.

Table 7.5 The cranial nerves, their function and signs of dysfunction

	Nerve	Function	Signs of dysfunction
I	Olfactory	*Sensory*: olfactory	Anosmia (absence of smell) Hyposmia (decreased smell)
II	Optic	*Sensory*: vision	Blindness (total or partial)
III	Oculumotor	*Motor*: external ocular muscles Parasympathetic fibres for constriction of the pupil	Ptosis Strabismus (ventrolateral) Mydriasis, fixed pupil not responsive to light
IV	Trochlear	*Motor*: dorsal oblique muscle	Strabismus (dorsolateral)
V	Trigeminal	*Sensory*: skin of the face *Motor*: muscles of mastication	Facial hypoaesthesia or hyperaesthesia Dropped jaw if bilateral Atrophy of temporal muscles
VI	Abducens	*Motor*: lateral rectus and retractor bulbi muscles	Medial strabismus Inability to retract globe
VII	Facial	*Motor*: muscles of facial expression *Sensory*: rostral two-thirds of tongue Parasympathetic fibres to lacrimal gland and salivary glands (mandibular and sublingual)	Dropped ear, lip, inability to close eyelids, drooling Hypoaesthesia of tongue Decreased tear production
VIII	Vestibulocochlear	*Sensory*: hearing *Sensory*: balance	Deafness or impaired hearing Vestibular syndrome
IX	Glossopharyngeal	*Sensory*: pharynx, caudal tongue *Motor*: pharynx	Dysphagia Regurgitation
X	Vagus	*Sensory*: larynx, pharynx, abdominal and thoracic viscera *Motor*: larynx, pharynx Parasympathetic fibres to viscera	Dysphagia Salivation disorders Altered meow, dyspnoea Regurgitation Cardiac or gastrointestinal signs
XI	Accessory	*Motor*: trapezius muscle	Atrophy of neck muscles
XII	Hypoglossal	*Motor*: tongue	Paralysis and atrophy of tongue

After Moreau and Wheeler (1995).

more likely than infectious, metabolic or immune-mediated conditions. Careful palpation around the skull may detect a mass (tumour) or sensitive areas. Radiographs of the skull, computed tomographic (CT) or magnetic resonance imaging (MRI) scans, cerebrospinal fluid (CSF) analysis or other tests may be required to localise a lesion and determine a cause.

Cranial nerve I

The absence of smell resulting from olfactory nerve damage is difficult to test. Lesions in the area of the cribiform plate may affect the nerve. There may be nasal discharge and concurrent forebrain signs. Cats that cannot smell their food frequently will not eat.

Cranial nerve II (optic)

The optic nerve contains visual pathways from the retina to the optic chiasm, where fibres enter the optic tract after partial (approximately 65%) decussation. The optic tracts pass to the geniculate nuclei, from where there is radiation to the pretectal nuclei and the ipsilateral occipital lobe. Lesions of the optic nerve, optic chiasm and optic tract result in blindness (Figure 7.4).

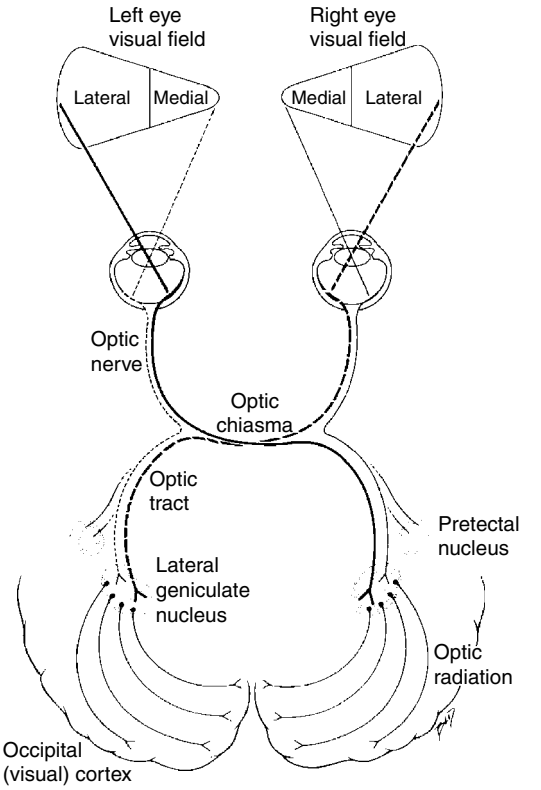

Figure 7.4 Shows the central visual pathways. (Reproduced from Petersen-Jones, 1995 with permission of BSAVA.)

Cranial nerve III (oculomotor)

The oculomotor nerve nucleus is in the pretectal area of the brain. The nerve is the motor nerve to the ventral, medial and dorsal rectus muscles, the superior oblique muscles of the orbit and the levator palpetral muscle. The nerve enters the orbit through the cavernous sinus. The oculomotor nerve also contains parasympathetic fibres from the Edinger–Westpal nucleus, the motor nerve to the ciliary muscle.

Abnormalities of motor function result in ventrolateral strabisimus, reduced or absent abduction of the eye in the horizontal plane and ptosis. Abnormality of the parasympathetic function of the oculumotor nerve results in a dilated pupil that is unresponsive to light stimulation (Figure 7.5).

Figure 7.5 Bilateral oculomotor nerve (III) paralysis showing pupillary dilation without response to light. (Reproduced with permission from Manson Publishing.)

Cranial nerve IV (trochlear)

Rarely are clinical signs seen. However, cats that have vertical, slit-like pupils have a slight dorsolateral rotation of the affected eye and the corresponding alteration in alignment of the pupil may be noted.

Cranial nerve V

This cranial nerve arises from three nuclei located in the pons. The combined sensory and motor nerve leaves from the skull close to the seventh and eighth nerves. The trigeminal ganglion is located in the petrous temporal bone.

The maxillary branch of the nerve is sensory to the skin of the face and cheek, the soft palate and the upper jaw. The mandibular nerve is the motor nerve to muscles of mastication and is sensory to the face, lower jaw and tongue. Motor nerve paralysis results in dropped jaw, inability to chew and atrophy in the muscles of mastication. Affected cats try to immerse their face in food and water to eat and drink. Sensory paralysis will result in anaesthesia of the face and absent corneal and palpebral reflexes.

Cranial nerve VII (facial)

The facial nerve nucleus is located in the medulla. The nerve exits the brain close to the fifth and eighth nerves from the petrous temporal bone. Facial nerve palsies are common as the nerve is vulnerable to injury at several sites. The facial muscles are paralysed, the lip is loose and flaccid, the ear is immobile and the affected nostril does not dilate. There may be drooling from the mouth on the affected side. The cornea will dry and corneal ulceration is a consequence. Peripheral injury to the facial nerve from injury and otitis media are common. Central lesions (usually neoplastic) in the cerebellar pontine region frequently affect the seventh nerve.

Cranial nerve VIII

The eighth cranial nerve consists of the cochlear branch, which is concerned with hearing, and the vestibular branch, concerned with balance. The vestibular nuclei are located in the medulla. The nerve enters the petrous temporal bone to meet the receptor organ.

Conditions affecting the vestibular system are common.

Cranial nerves IX and X

Involvement of the vagus and glossopharyngeal nerves is associated with dysphagia, regurgitation, altered meow and inspiratory dyspnoea. Nerve X is sensory to the larynx, pharynx, and abdominal and thoracic viscera. The glossopharyngeal nerve (IX) is sensory to the pharynx and caudal tongue, and motor to the larynx. A normal gag reflex confirms some nerve IX and X functions.

Cranial nerve XII

The nucleus in the caudal medulla and the nerve exits the skull close to the foramen magnum. The nerve innervates the muscles of the tongue. Injury to nerve XII is not common, but results in paralysis, flaccidity and inability to withdraw the tongue if there is bilateral damage.

The neurological examination

The objectives of performing a neurological examination are to confirm that the disease involves the nervous system, to localise the site of the lesion within the nervous system, to determine the extent of involvement of the nervous system (single versus multifocal lesions), to determine which additional diagnostic tests are required, to confirm a diagnosis and to determine the prognosis.

The examination consists of observing the patient, watching its gait and movements and conducting an examination, which is methodical, logical and consistent. The neurological examination is the foundation for the accurate clinical management of cats with neurological diseases. Any diagnostic or treatment plan is dependent on accurate lesion localisation; therefore, a fully recorded neurological examination should be made. A systematic approach is helpful to ensure that each functional area of the nervous system is examined and there are no omissions.

The examination should include general observation, evaluation of the head and mental status, evaluation of posture gait and strength, evaluation of the forelimbs and neck, including spinal reflexes, and evaluation of the hindlimbs, tail and anus, including spinal reflexes and sensation. In the cat, any assessment of sensation or pain must be left until last as any cat can become fractious and difficult if it feels pain or is hyperaesthetic. It will not be possible to complete the full examination if this occurs.

Little equipment is needed: a reflex hammer, penlight, 20 gauge needle (to test superficial pain) and haemostat forceps are all that is required (Figure 7.6). A complete physical examination should be completed before the neurological examination proper as there may be evidence of systemic disease or abnormalities of other organ systems. When a cat has significant physical findings in addition to neurological dysfunction and no history of trauma, then metabolic and infectious diseases are more likely. The history also provides the main complaint and clinical course (progressive,

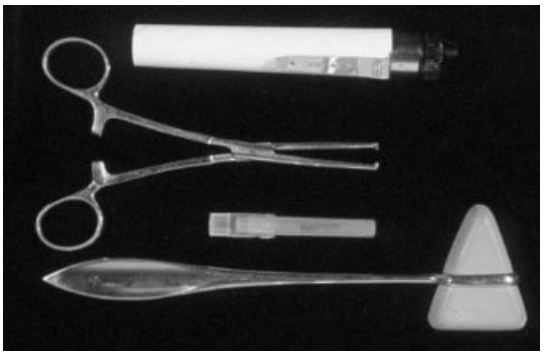

Figure 7.6 Equipment required for a neurological examination of a cat: pen torch, forceps, needle and reflex hammer. (Reproduced from Shaer, 2002, with permission of Manson Publishing.)

improving, unchanged, episodic, etc.). The history also provides information on the onset of signs (acute versus slow onset), in contact animals, vaccination status and disease testing history, diet, drug therapies, and so on. The breed of cat may make a particular diagnosis more likely; for example, hypokalaemia and weakness in Burmese cats.

The four stages of the examination are:

- evaluation of the head and neck
- evaluation of gait strength and posture
- evaluation of forelimbs and neck
- evaluation of thoracolumbar spine, hindlimbs, tail and anus.

Evaluation of the head

Knowledge of function of the regions of CNS is necessary to interpret head signs and distinguish supratentorial from infratentorial signs. Table 7.1 summarises the main functions of the brain. Unilateral cerebral lesions cause contralateral abnormalities. Brainstem and cerebellar lesions cause ipsilateral signs. Observation should be made to assess mental state, personality and behaviour, alteration of posture and co-ordination and the abnormalities recorded.

Examination of the cranial nerves is a simple and quick procedure: by following the checklist in Table 7.6 important tests will not be missed.

- The palpebral reflex is elicited by touching the medial canthus of the eye to elicit a blink (sensory V and motor VII).
- The corneal refex is performed by touching the cornea (V) gently and observing a blink (VII) and retraction of the globe (VI).

Table 7.6 Examination of the cranial nerves

Test	Cranial nerves involved
Palpebral reflex	V, VII
Menace response	II, VII (and optic cortex)
Pupillary light reflexes	II, III
Pupil symmetry	III
Strabismus	III, IV, VI
Corneal reflex	V, VI, VII
Muscles of mastication	V
Facial motor nerve response: nasal, buccal, temporal	V, VII
Nystagmus	VIII
Oculocephalic reflex	VIII
Oculocardiac reflex	V, X
Tongue movement and position	XII
Pharyngeal (gag) reflex (cough/swallow)	IX, X

- The menace response is tested by rapidly advancing a finger towards the eye, or a threatening gesture, to elicit a blink. This test evaluates vision, the retina, optic nerve, occipital cortex and facial nerve. One must be careful not to touch whiskers on the face or to create air currents.
- Other methods of determining vision include the animal's ability to observe cottonwool balls thrown in the air, and to avoid obstacles in an unfamiliar room, and visual placing reactions; when the cat is held near a table, a normal animal will see the table and will raise and extend its forelimbs as it approaches.
- Pupillary light reflexes evaluate nerves II and III. A light beam is directed into the eye and the pupillary response in both eyes is observed. Normally there will be constriction of the pupil that is being directly examined (direct response) and the other pupil (consensual or indirect response). Pupils should be symmetrical. Anisocoria is a difference in pupil size, which may be due to a defect of the autonomic nervous system, oculomotor nerve, optic nerve, optic chiasm or optic tract.
- The globes should be symmetrical. Enophthalmia (retracted globe) may be associated with Horner's syndrome.
- Nystagmus is a spontaneous jerking movement of the eye and indicates vestibular dysfunction. The cat's head is moved from side to side and up and down to elicit physiological nystagmus (horizontal and vertical, respectively). When the head is

then held still the nystagmus should cease. This is the oculocephalic reflex.
- Sensation (V) is evaluated by pinching the skin of the face, or gently probing the nasal mucosa, and observing for a blink (VII), twitch or more aggressive response.
- The oculocardiac reflex involves applying digital pressure to the globes, resulting in a reflex bradycardia (V, X).
- Jaw tone is evaluated by opening and closing the mouth. The resistance and strength of the muscles can be assessed. Alcohol swabs can be placed near the nostril to evaluate the sense of smell and tongue movements (I, IX, X, XII). A finger or tongue depressor is inserted towards the pharynx to stimulate gag or cough (IX, X), and the larynx is palpated to induce a cough or swallow.

Evaluation of posture, gait and strength

The patient is observed at rest for abnormalities in body posture and limb position and tone. Increased muscle tone is judged by increased resistance to flexion. The claws are checked for wear and for scars indicating previous trauma. The skeleton is palpated for crepitus, masses, deviation of the normal contour and motion (e.g. fractures and luxations). The muscles are palpated to check for size and symmetry.

Abnormal body posture may be due to a congenital or an acquired lesion in the vertebrae, reduced muscle tone, or a brain or spinal cord lesion. Deviation of the spine may be lateral (scoliosis), dorsal (kyphosis) or ventral (lordosis – sway back). A wide base stance may be present in cerebellar and vestibular ataxia, or if there is general weakness. Knuckling of the paw indicates a proprioceptive deficit or paresis.

A reduction in muscle tone indicates a lower motor neuron (LMN) lesion and an increase indicates an upper motor neuron (UMN) lesion. Opisthotonus is dorsiflexion of the neck. Decerebrate rigidity is characterised by rigid extension of all four limbs and is due to a brainstem lesion. Muscle atrophy indicates disuse or LMN disease.

Paresis (weakness) is a deficit in voluntary movement. Plegia (paralysis) is the complete loss of voluntary movement. The prefixes mono-, para-, tetra- or quadri- and hemi- can be used before paresis and plegia to denote which limbs are involved.

Ataxia is a lack of co-ordination without spasticity or paresis. An ataxic cat may sway from side to side when walking or turning with crossing of limbs. Dysmetria may be hypermetria or hypometria. Cats walk with a goosestep characteristic of a cerebellar lesion. Involuntary tremors of the head or muscle group should be noted.

Postural reactions

Postural reactions are easy to perform in cats. Careful testing of postural mechanisms is important to expose subtle neurological deficits. The postural reactions (wheelbarrowing, hopping, righting, hemiwalking and hemistanding and placing) assess touch receptors, ascending and descending pathways in the spinal cord and brain. Postural reaction deficits are observed on the side opposite the cerebral or midbrain lesion.

Wheelbarrowing

This is demonstrated by supporting the cat under the abdomen so that the pelvic limbs do not touch the ground and forcing it to walk with the forelimbs. Normal cats walk with a symmetrical, alternate forelimb movement with the head extended. Cats with lesions of the peripheral nerves, cervical spinal cord, brainstem or higher centres may show asymmetrical movements, stumbling or knuckling.

Hemistanding and hemiwalking

Hemistanding and hemiwalking reactions test the cat's ability to stand or walk with the pelvic and thoracic limbs on one side only by holding the ipsilateral pelvic and thoracic limbs off the ground and forcing the cat to move either forwards or sideways. This test determines the functional integrity of the motor cortex and the spinal cord.

Cats with a unilateral lesion in the cerebrum may have a normal gait when all four limbs are used, but during hemiwalking a contralateral deficit may be observed, such as scuffing of the claws, knuckling or delayed positioning of the limb.

Hopping

These reactions involve the cerebrum, cerebellum, brainstem, spinal cord, and touch-pressure and pressure-stretch receptors in the joints, muscles and tendons. Hopping reactions are tested by holding the animal in a horizontal position with three limbs off the table so that they do not touch the examination table and the cat is supporting its weight on one limb. The cat is moved forwards and to each side. The cat

should hop on the supporting leg in the direction of the displacement while keeping the foot directly under its body to support its weight. This reaction should be attempted on each of the four limbs.

Extensor postural thrust reaction

This reaction involves touch, pressure and stretch receptors. The cerebrum, vestibulocerebellar system and spinal cord must be intact for this reaction to occur. The cat is held by the axillae and lowered until its pelvic limbs touch the floor. The limbs should stiffen in extension and should support weight. If the lesion is complete, there is no extension on either side. If there is a cerebral lesion, the contralateral side may be abnormal. This reaction can be assessed in the thoracic limbs by holding the cat by the pelvis.

Righting reactions

The ability of a cat to maintain its normal position in relation to gravity involves the visual system, the vestibular system and the contact-pressure proprioceptive system. The cat is suspended by the pelvis and the position of the head observed. The head should assume a position in space at approximately a 45 degree angle to the horizontal and in line with the body, not rotating to one side or the other, and the limbs should be held in an extended position. To test vestibular function alone, the cat should be blindfolded. An alternative is to place the cat in a lateral recumbent position on each side, and to observe the cat's ability to right itself. The contact-pressure receptors on the side of the body are stimulated and the cat should right itself normally. If unilateral vestibular disease is present, this righting reaction is abnormal on the ipsilateral side.

Placing reactions

Placing reactions involve both tactile and visual pathways.

To test tactile placing reactions, the blindfolded cat is held under the thorax in an horizontal position in the air with the thoracic limbs hanging. It is then moved towards the edge of a table to contact with the dorsal surface of the limbs. This contact should result in accurate and immediate placing of the paws in a supporting position on the table surface. The thoracic limb response is tested in both limbs at the same time and then in each limb separately. The pelvic limb responses are tested in a similar manner.

Healthy cats can give very variable responses for placing reactions and care with interpretation is advised.

To test visual placing reactions, the cat is supported exactly as for the tactile placing reaction test. As the table is approached, the cat's normal response is to place both paws on the surface of the table.

Proprioception

Tests for proprioception evaluate both the sensory system, which determines the patient's ability to recognise consciously the position of the limb when it has been flexed, extended or positioned abnormally, and the motor system, which returns the limb to a normal position.

The cat's paw is flexed so that the dorsal surface is on the table surface, and the response is observed. A normal cat should return the paw to its usual position so that it supports its weight. This response should occur within 1–3 s. In cats with peripheral nerve disease or lesions of the spinal cord or higher ascending pathways, the proprioceptive–positioning reaction may be delayed or absent. This reaction may be sluggish in cats with paresis caused by lesions in the major descending motor pathways (e.g. corticospinal tract or rubrospinal tract).

Postural reaction deficits identify that a nervous lesion is present and also provide regional localisation. They provide a guide for more definitive localisation with cranial nerve and spinal reflex and sensory examination.

Evaluation of the forelimbs, thoracolumbar spine, hindlimbs and tail

Spinal reflex testing assesses the reflex arc and cord segments in which the reflexes are involved (Table 7.7). All reflexes are modified or co-ordinated by higher centres. The examination of spinal reflexes is best performed when the cat is in lateral recumbancy, gently restrained by an assistant. Flexor reflex abnormalities include areflexia, hyporeflexia, hyperreflexia, clonus and a crossed extensor response.

Limbs

Flexor reflex (withdrawal)

The interdigital skin is pinched and the foot observed for withdrawal. Several areas of skin should be pinched to test the various sensory components; for example, dorsal forepaw (radial, peroneal), medial (musculocutaneous, femoral). Extension of the contralateral limb when the leg flexes (crossed extensor) is also assessed.

Table 7.7 Spinal reflexes

Reflex	Peripheral nerve	Spinal cord origin
Thoracic limb		
Flexor	Axillary	C7–C8
	Musculocutaneous	C6–T1
	Median and ulnar	C7–T2
Biceps	Musculocutaneous	C6–T1
Triceps	Radial	C6–T2
Extensor carpi radialis	Radial	C6–T2
Pelvic limb		
Flexor	Sciatic	L6–S1
Patellar	Femoral	L4–L6
Cranial tibial	Common peroneal	L6–L7 (S1)[a]
Gastrocnemius	Tibial	(L6) L7–S1[a]
Other spinal cord reflexes		
Anal (perineal)	Pudendal	S1–S3
Panniculus	Spinal nerves (sensory)	
	Thoracodorsal nerve (motor)	C8–T2
Defecation	Pelvic	S1–S3
Micturition	Pelvic	S1–S3

After Braund (1994).
[a]Spinal cord segment in parentheses reflects a minor contribution to the reflex.

Crossed extensor reflex

When a painful stimulus is applied to one limb of a cat in lateral recumbancy, the opposite (contralateral) limb extends. The crossed extensor reflex is not seen in a normal cat. Its presence is indicative of spinal cord pathology above the spinal cord segments controlling the reflex. Its presence has no prognostic significance.

Patellar reflex

The patellar reflex is mediated via the spinal cord segments L4–6. With the pelvic limb in a relaxed, semi-flexed position, the straight patellar ligament is lightly tapped with a hammer. The normal response is a quick extension of the stifle joint.

Patellar reflex abnormalities include absence of response (areflexia), depressed response (hyporeflexia), increased response (hyperreflexia) and repetitive response (clonus). The first two abnormal reflexes are indicative of peripheral nerve disorders and/or of the spinal cord segments in which the reflexes are involved (ventral horn cells in the spinal cord and their axons represent the LMN). Increased reflexes are usually seen with lesions of the cerebral cortex, brainstem or spinal cord regions rostral to the L4 cord segment. The hyperreflexia is due to the release of myotatic reflexes from the effects of the descending inhibitory pathways.

Other tendon reflexes in the hindlimbs are the cranial tibial reflex and the gastrocnemius reflex. These reflexes are not reliable and should be interpreted with caution.

Biceps, triceps and extensor carpi radialis reflexes

In the thoracic limb these tendon reflexes can be elicited in cats that are relaxed in a lateral recumbent position. The biceps reflex is elicited by placing the forefinger on the biceps tendon on the anteromedial aspect of the elbow and tapping the finger with a percussion hammer. A slight flexion of the elbow occurs in a normal cat.

The triceps reflex is tested by tapping the tendon of insertion of the triceps proximal to the olecranon, or by placing the forefinger or thumb on the tendon and tapping the finger or thumb with the hammer. The normal response is a slight extension of the elbow.

The extensor carpi radialis reflex is elicited by tapping the distal to the elbow. The carpus should extend.

Anal reflex

The anal or perineal reflex is mediated via the pudendal nerve and cord segments S1–3. This reflex can be elicited by tactile stimulation of the perineal region. The normal response is contraction of the external anal sphincter.

Panniculus reflex

The panniculus reflex helps to localise lesions between T2 and L3. The afferent limb of this reflex is the segmental sensory nerve and the efferent nerve is the lateral thoracic nerve from spinal cord segments C8 to T2. The nerve innervates the cutaneous trunci muscles. If the cord is damaged at C8 to T2, there is no panniculus reflex. To elicit the panniculus reflex the skin is lightly pinched 1–2 cm from the dorsal midline along the thoracolumbar spine. The normal response is twitching of the cutaneous trunci muscles. If the spinal cord is damaged, the reflex will be absent caudal to the damaged area. There may be exaggerated contraction just anterior to the area of damage. In dehydrated cats the reflex may be unreliable.

To interpret spinal reflex responses the concept of upper and lower neurons (UMN and LMN) is help-

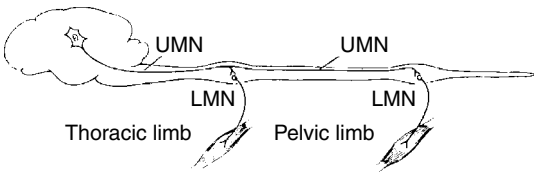

Figure 7.7 Diagnostic representation of upper (UMN) and lower (LMN) motor neurones supplying the limbs. The VMN is shown as a single neuronal pathway with no interneurones included. (Reproduced from Griffiths, 1995 with permission from BSAVA.)

Table 7.8 Summary of upper and lower motor neuron (UMN and LMN) signs

Function	UMN	LMN
Motor function	Paresis to paralysis, loss of voluntary movement	Flaccid paralysis
Spinal reflexes	Hyperreflexia	Hyporeflexia/ areflexia
Muscle atrophy	Occurs late and is mild; is disuse atrophy	Early and severe neurogenic atrophy
Muscle tone	Normal or increased	Reduced
Sensory function	Loss of propriception	Anaesthesia of dermatome
Bladder	Small, distended bladder; hard to express	Large bladder, overflow; easily expressed

ful. An LMN is an efferent neuron. Its cell body is in the ventral horn of the grey matter. The axon is found in the ventral nerve root and peripheral nerve and innerv-ates a muscle. UMNs have their body in the motor cortex, basal nuclei or brainstem. The axons travel in the spinal cord and synapse, via interneurons, with an LMN (Figure 7.7). Table 7.8 summarises the clinical signs of UMN and LMN injury and Figure 7.8 shows how damage to particular segments of the spinal cord can affect motor function in the thoracic and pelvic limbs.

The UMN has an inhibitory effect on the LMN reflex arc. UMN lesions may therefore be associated with an exaggerated spinal reflex. The UMNs are responsible for initiation and maintenance of muscle movement and tone.

Sensation

Superficial pain sensation is easily tested. A superficial pain sensation is elicited by pinching or pricking the skin with a needle or forceps. A deep pain sensa-

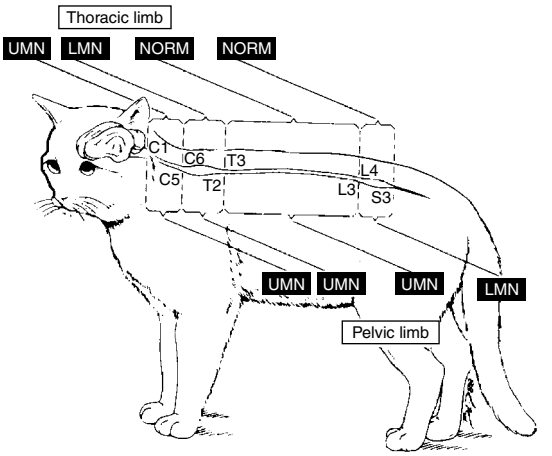

Figure 7.8 Shows how damage to particular segments of the spinal cord can affect motor function in thoracic or pelvic limbs with a UMN or LMN dysfunction. (Reproduced from Griffiths, 1995 with permission from BSAVA.)

tion is elicited by pinching the base of the claws with forceps. The normal response is retraction of the limb, turning the head towards the site of the stimulus, meowing or attempting to bite and scratch the tester.

The perception of pain requires the ascent of information via the spinal cord to the thalamus and is confirmed by the cat's response. Pain sensation is best tested over known dermatomes. However, autonomous zones, which are innervated by only one nerve, are known, and testing at these sites can help to confirm and localise peripheral nerve injury.

Sensory abnormalities include analgesia, reduced pain sensation, hyperaesthesia and muscle fasciculation. In spinal lesions absence of a pain response caudal to the lesion carries a poor prognosis.

Tail, anus and bladder

Tail

Tail movement should be assessed by lifting the tail, observing movement and testing pain sensation. Paralysis of the tail is common. The anal reflexes are elicited and the bladder is palpated and, if it is full, the ease of expression of urine is noted.

When the bladder is distended, sensory impulses from the bladder pass to the brainstem. Motor fibres from the brainstem pass to the sacral cord segments and activate the pelvic (parasympathetic) nerves, which cause the bladder to contract. Normal micturition also requires synchronised contraction and relaxation of

the urethral skeletal muscle. Urethral smooth muscle is supplied by pelvic and hypogastric (sympathetic) nerves from the pelvic plexus. The urethral skeletal muscle is innervated by the pudendal nerve. The micturition reflex is abolished by lesions of the pelvic nerves, sacral cord segments or pathways to and from the brainstem. Consequently, the bladder distends with urine and eventually overflows.

With reduced urethral resistance, it is easy to express the bladder manually, and animals with sacral cord lesions may have continual overflow incontinence. In contrast, spinal cord lesions cranial to the sacral segments result in increased tone in the urethral skeletal muscle, making the bladder difficult to express.

Defecation

Voluntary defecation is controlled by sensory and motor pathways passing between the brain (cerebral cortex brainstem centres) and the sacral cord segments. The rectum is innervated by the pelvic (parasympathetic) nerves, which originated in the sacral segments. However, even with disruption of sacral innervation, emptying of the rectum can result from intrinsic innervation within the bowel wall. Because the external anal sphincter is innervated by the pudendal nerve, which also originates in the sacral segments, the anal reflex reliably assesses sacral spinal cord function.

Abnormal reflexes and other signs of spinal cord injury

Spinal shock

Functional transection of the spinal cord may lead to transient areflexia caudal to the lesion. Spinal shock lasts for only hours in cats and has usually disappeared by the time most cats with spinal injury are examined by a veterinary surgeon.

Mass reflex

Hyperreflexia can be very dramatic in some cats several months after functional spinal cord transection. Mass reflex activity is initiated by peripheral stimulation, such as squeezing a toe, and consists of bilateral, rapid limb flexion, tail twitching, and sometimes bowel and bladder evacuation. It occurs because of synaptic contacts between afferent fibres and interneurons and α-motor neurons of more than one muscle. Mass reflex can be mistaken for voluntary muscle activity, particularly when it takes the form of spinal walking.

Crossed-extensor reflex

Stimuli applied to one limb result in stimulation of neurons contributing to muscles of the other three limbs. These long spinal reflexes co-ordinate the movements of all four limbs and are suppressed by descending supraspinal input. Spinal injury removes this inhibitory influence and flexion of one pelvic limb is accompanied by extension of the opposite pelvic limb (crossed-extensor reflex) and a reversed pattern in the thoracic limbs.

Schiff–Sherrington phenomenon

Ascending spinal cord tracts in the ventral funiculi of the thoracolumbar spinal cord inhibit extensor muscles of the thoracic limbs. Functional transection of these pathways leaves this facilitory input unopposed and the thoracic limb extends. This process is termed the Schiff–Sherrington phenomenon.

Ancillary aids

The history and findings of the clinical and neurological examination provide most information required for making a clinical diagnosis. There are specific circumstances where other diagnostic tests or ancillary aids are required to confirm the clinical diagnosis or provide more specific data.

Clinical pathology

Haematology and biochemistry are essential in most investigations. There are many systemic disorders in which neurological signs predominate and that have characteristic clinicopathological changes, for example, hypergammaglobulaemia in, feline infectious peritonitis (FIP), hypokalaemia and portosystemic shunts. Clinical pathology is of less value in the diagnosis of primary nervous diseases.

Urinalysis may help occasionally with specific diseases (e.g. glucose present in diabetes mellitus and biurate crystals in portosystemic shunts).

Measurement of serum bile acids or blood ammonia concentration can assist in the diagnosis of portosystemic shunts in cats with intermittent cerebral signs.

Serology

In a number of infectious diseases serological testing can assist in the diagnosis (e.g. toxoplasmosis, cryptococcosis, FIP).

Cerebrospinal fluid collection

CSF can be collected for analysis from either the cysterna magna or the lumbar subarachnoid space. Lumbar puncture is technically more difficult, there is greater risk of blood contamination and the sample collected is smaller. Collection from the cysterna magna is recommended. A 22 or 20 g plastic-hub disposable spinal needle is suitable for collection. Cysternal puncture is performed with the cat anaesthetised and intubated. The fur should be clipped over the site and the skin surgically disinfected. With the cat in lateral recumbancy, the neck is flexed. The landmarks are the occipital prominence and the wing of the atlas. The spinal needle should be inserted midway between these two sites. The needle should be advanced slowly and with caution. The cistern is not very deep (0.6–1 cm) and there is often little resistance to the needle. The stylet should be removed to determine that the cistern has been reached. CSF should be allowed to drip slowly from the needle and is collected into a sterile plain tube. About 1 ml can be safely removed from the average adult cat. Inhalation anaesthesia and intubation are essential. If the patient has suspected increased intracranial pressure there is a risk of herniation of the cerebellum into the foramen magnum, especially if pressure is reduced rapidly by the removal of CSF. The potential risks of anaesthesia and herniation must be considered.

Normal CSF is clear and colourless. The presence of a pink, yellow or orange colour that persists after collection represents xanthochromia, indicating previous haemorrhage. In contrast, CSF with iatrogenic blood contamination has a clear supernatant when centrifuged. A visible increase in turbidity will be seen when the white blood cells are >200 cells/μl or erythrocytes are >700 cells/μl. Cell counts should be made within 30 min of collection if possible. The addition of bovine serum to the sample will preserve cells when processing is delayed.

The normal cell count in CSF for red and white blood cells is 5 cells/μl. The white cell count is elevated (pleocytosis) in inflammation. If the predominant cell type is mononuclear a viral disease or toxoplasmosis is more likely. If the cytology contains both mononuclear cells and granulomatous neutrophil, inflammation is more likely (e.g. FIP). Neoplastic cells can be detected occasionally and some microorganisms can be identified (e.g. *Cryptococcus* spp.). Protein concentrations in CSF are frequently elevated in inflammation or if the blood–brain barrier is interrupted (e.g. neoplasms, vascular injury, encephalitis). Serology can be completed on CSF and polymerase chain reaction (PCR) analysis can be performed for specific pathogens.

Radiology

Radiology is of limited value in the diagnosis of intracranial disease, but is most useful for spinal cord diseases. Skull radiography is helpful for the diagnosis of otitis media, fractures, bone proliferation and lysis, and abnormalities of the shape of the skull and vertebrae. Complete information on radiographic technique and positioning for skull and spinal column radiographs is available in radiology textbooks. Correct positioning is essential for accurate neurological interpretation. Contrast radiological techniques, especially myelography, have been applied to the diagnosis of spinal cord disease in the cat. Myelography is indicated to define the nature and location of a spinal cord condition when there is clinical evidence of a lesion that is not visible on plain radiographs, when there are multiple spinal column lesions and it is necessary to determine which are significant, and when the cat's neurological signs are not compatible with changes in plain radiographs. The procedure is not without risk and potential complications.

Water-soluble contrast agents (Iohexol or Iopamidol) are injected into the lumbar or cysternal subarachnoid space. Careful assessment of myelographic images provides a more accurate diagnosis and provides important information for the prognosis and for planning treatment. Morgan (1999) has discussed the radiographic and myelographic diagnosis of spinal disease in the cat in an excellent review.

Specialised imaging techniques

CT and MRI are the two main techniques available. Both are available at referral centres and institutions. Availability and cost are the two main factors limiting their use.

Computed tomography

CT, which provides cross-sectional images of the body using rays and computers, has advanced the diagnosis of intracranial disease in all species, including the cat. CT scanning has been applied to the diagnosis of intracranial disease and provides excellent information on the size, shape, position and density of the brain, as well as on the presence of abnormalities such as tumours. Contrast techniques are also available to

increase the normal contrast between healthy and abnormal tissue.

Magnetic resonance imaging

MRI produces cross-sectional images of the brain but using different technology to CT, over which it has certain advantages. There is better imaging and resolution of soft tissues. In addition to axial images, sagittal and dorsal images can be produced and no ionising radiation is produced. MRI produces excellent images of nervous tissue and is suitable for the diagnosis of intracranial CNS disease. Contrast techniques are also available to produce better tissue contrast.

Electrodiagnostic testing

There is widespread use of electrodiagnostic testing and all techniques are applicable to the cat. Most are available only at specialist practices and referral centres. Electromyography and measurement of motor and sensory nerve conduction velocities aid the diagnosis of neuromuscular disease and are in common use. Audio amplification of some electromyographic (EMG) signals has become an important part of the neuromuscular examination to detect denervated or diseased muscle groups.

Evoked activity in the spinal cord and brain has been measured to determine the location and severity of spinal cord lesions or lesions affecting the dorsal roots of spinal nerves. Brainstem auditory-evoked potentials are produced in response to auditory stimulation and provide a means of assessing auditory function. Visual-evoked potentials are used to test retinal function and optic nerve function. Electroencephalomyography is applied less in the cat than in the dog.

Nerve and muscle biopsy

Nerve and muscle biopsy is essential for the accurate diagnosis of many neuropathies and myopathies. The application of special staining techniques and quantitative analysis has contributed significantly to our understanding of neuromuscular disease in cats. Careful tissue sampling and processing are essential for accurate histochemistry, immunocytochemistry, and morphometric and morphological evaluation of nerve and muscle samples.

Readers are referred to Dickinson and Le Couteur (2002) for further information on sampling procedures and diagnostic information.

Brain biopsy

Brain biopsy techniques have been combined with CT scanning and applied to the tissue diagnosis of neoplastic disease within and surrounding the brain.

Congenital and developmental defects

Malformations of the CNS are caused by abnormalities in embryogenesis associated with the neural tube and neuronal migration (Coates & Sullivan, 2001). It is important to recognise that, although the defects are congenital, they may not be inherited. Teratogens (e.g. griseofulvin or panleucopenia virus) may cause damage to the foetus *in utero*. Inherited defects have a genetic basis and arise spontaneously from mutation or inadvertently by breeder selection, line breeding, inbreeding, and so on.

The congenital and inherited defects of the nervous system are shown in Table 7.9. The teratogenic agents associated with congenital cranial malformation are shown in Table 7.10.

Readers are referred to other texts for more detailed information on the embryology of cranial and spinal cord disorders. The important conditions will be described here.

Table 7.9 Congenital and intracranial defects of cats

Forebrain malformations
Hydrocephalus
Hydranencephaly
Neural tube defects
Primary neural tube closure defects:
Exencephaly/anencephaly
Primary axial mesodermal defects:
Encephalocoele/meningocoele
Craniofacial mesodermal defects in Burmese cats
Cleft palate
Disorders of forebrain induction
Holoprosencephaly
Agenesis of corpus callosum
Disorders of neuronal migration
Lissencephaly
Hindbrain malformations
Dandy Walker syndrome
Chiari malformation
Parvoviral (feline panleukopenia virus)-induced cerebellar degeneration (hypoplasia)
Hereditary cerebellar cortical atrophy

After Coates and Sullivan (2001).

Table 7.10 Teratogenic agents causing congenital cranial malformations in cats

Teratogen	Malformation
Parvovirus (feline panleukopenia)	Hydranencephaly, hydrocephalus, cerebellar hypoplasia
Methylmercury	Encephaly, decreased cellular density in external granular cell layer, cerebellar hypoplasia
Griseofulvin	Exencephaly, hydrocephalus, holoprosencephaly, corpus callosal agenesis, cranium bifidum, spina bifida, cleft palate, absence of maxillae, cyclopia, anophthalmia
Hydroxyurea	Cyclopia, cleft palate, exencephaly, microcephaly, cyclopia
Diphenylhydantion	Cleft palate

Hydrocephalus

Hydrocephalus is the accumulation of excess CSF associated with enlargement of the ventricular system and subarachnoid space. It is one of the most common congenital disorders and may be the result of autosomal recessive inheritance in the Siamese breed. Congenital hydrocephalus may result from perinatal or *in utero* infections (parvovirus) or teratogens (griseofulvin). The underlying lesion in these animals is stenosis of the aqueduct. The cause is frequently unidentified.

The clinical signs of hydrocephalus include a dome-shaped cranium with open fontanelles. There is frequently ventrolateral strabismus. The neurological signs are predominantly associated with central dysfunction: disorientation, stupor, behavioural changes, visual deficits and blindness, circling, gait abnormalities and learning difficulties. Hydrocephalic kittens frequently do not develop as rapidly as unaffected kittens, and are slow to suckle and house train. In some, seizures may be the only clinical sign.

Diagnosis is based on the clinical signs and domed cranium. If the fontanelles are open, enlarged ventricles can be confirmed by ultrasound through the fontanelles, MRI or CT scans.

Treatment of hydrocephalus is limited and the prognosis poor. Shunting procedures have been reported in cats. Medical management has focused on reducing CSF production (acetazolamide 0.1 mg/kg p.o. every 8 h or frusemide 0.5–20 mg/kg every 12–24 h) and, when required, anticonvulsant treatment.

Cerebellar hypoplasia

Cerebellar hypoplasia is a non-progressive disease, which results from *in utero* destruction of the granular cell layer of the cerebellum. Panleucopenia is reported as the most common cause, but is now rare. The severity of signs is variable.

The clinical signs are those of cerebellar dysfunction, including ataxia when the kittens first start to walk, head tremor, intention tremor and pronounced hypermetria. Kittens compensate and walk with a wide-based stance, but the gait is dysmetric. An absent menace response but with normal vision is often detected. The clinical signs do not progress and kittens frequently compensate. Importantly, kittens are strong, bright and healthy. Diagnosis is based on the characteristic clinical features and exclusion of other potential causes. All kittens in a litter may not be similarly affected. MRI scan can detect a reduction in the size of the cerebellum. There is no effective treatment.

Sacrocaudal dysgenesis in Manx cats

Manx cats have varying degrees of sacral and/or caudal vertebral deformities. Some tailless cats have a normal sacrum, spinal cord and cauda equina. Others show varying dysgenesis or agenesis of the sacral and/or caudal vertebrae that may be associated with spina bifida, malformations of the terminal spinal cord and cauda equina. Spinal cord malformations include the absence or partial development of sacral and caudal spinal cord segments or cauda equina, myelodysplasia, meningocoele, meningomyelocoele, duplication of sacral segments, myeloschisis (cleft within the spinal cord), syringomyelia in the lumbar and sacral spinal cord segments, shortening of the spinal cord and subcutaneous cyst formation. These spinal cord and cauda equina malformations are associated with variable neurological deficits.

Sacrocaudal dysgenesis is inherited as an autosomal dominant trait and may be lethal in some homozygote cats. The condition and its associated malformations have been recognised in most breeds of cats, many not of true Manx breeding.

Clinical signs are variable depending on the degree of spinal cord and cauda equina malformation, and include paraparesis, paraplegia, megacolon, atonic bladder, absent anal and urinary bladder sphincter tone, absent anal reflex, urinary and faecal incontinence, and perineal analgesia (Figure 7.9). Affected cats often walk with a plantigrade posture of the hindlimbs and a 'bunny-hopping' gait. Vertebral abnormalities may

Figure 7.9 A Manx cat with urinary and faecal incontinence and soiling of the perineum. (Courtesy of BRH Farrow.)

be palpable in the lumbosacral region, and in some cats a meningocoele may be detected in the skin and CSF may drain from the site.

Clinical signs are usually evident soon after birth and may progress or remain static. Worsening of neurological deficits may be due to progressive syringomyelia in the lumbar and sacral spinal cord.

Diagnosis is made on the basis of clinical and radiological findings indicating dysgenesis or agenesis of the sacral and caudal vertebrae. Myelography may demonstrate meningocoele or attachment of spinal cord to subcutaneous tissues in the lumbosacral region. The degree of spinal deformity does not always correspond to the severity of the neurological signs. Clinical signs are the most important factors to consider in determining prognosis.

The prognosis for severely affected cats is frequently hopeless and treatment is not available. Cats with urinary and faecal incontinence may be managed with manual bladder expression and faecal softening agents, but recurrent urinary tract infection, megacolon and chronic constipation are common problems. Meningocoele in cats with minimal neurological deficits may be surgically correctable. Many tailless cats do not have neurological signs, and sacral and caudal deformities often are incidental radiological findings.

Lysosomal storage diseases

Numerous conditions in which there is an inherited deficiency of enzymes necessary for hydrolysis of proteins, polysaccharides and complex lipids have been described in cats (March, 2001). These enzymes are present in lysosomes and, when deficient, there is the intracellular accumulation of substrate, hence the collective term lysosomal storage diseases. Neurons are preferentially affected by some of these diseases (neuronal storage diseases, lipodystrophies), whereas others principally affect white matter (leucodystrophies).

Clinical effects of the lysosomal storage diseases are due to the deleterious effects on cell function that result from intracellular accumulation of substrate. Most of the lysosomal diseases are inherited as autosomal recessive traits and result from mutation in the coding sequence of one of the acid hydrolases in the lysosomes. The more important lysosomal storage diseases, the defective enzyme and the breeds that are affected are listed in Table 7.11.

Mulitfocal neurological involvement is seen, although some affected animals may have deficits that suggest a focal lesion. Common signs include change in attitude, seizures, tetraparesis, intention tremor and blindness. Clinical signs generally are noted within the first months of life and are progressive over the first year, by which time most animals have undergone euthanasia. Some diseases, particularly ceroid lipofuscinosis, may occur late in life.

Lysosomal storage diseases should be considered in cats with signs of mulifocal neurological involvement, particularly if inflammatory disease has been excluded. Characteristic lesions may be seen upon biopsy of affected tissues. Enzyme tests and molecular diagnostic screening tests, which detect affected and carrier animals, are available for many of the lysosomal storage diseases (Table 7.12).

Providing a source of normal enzyme to abnormal cells permits the enzyme to be taken up by the plasma enzyme receptor, resulting in the delivery of normal enzyme to lysosomes where it can catabolise stored substrate. Current research to achieve this includes:

- parenteral injection of purified recombinant normal enzyme
- heterologous bone-marrow transplantation (BMT), which provides a continuous source of normal enzyme
- gene therapy, whereby a viral vector is used to transfer a copy of the normal DNA to a patient's own, which then acts as a source of enzyme.

Encouraging experiments on BMT with GM gangliosidosis resulted in slower disease progression, but CNS lesions did not appear to be significantly improved.

Mucopolysaccharidosis

The mucopolysaccharidoses are a group of genetic diseases that result from defects in the metabolism of glycosaminoglycans (Thrall, 2001). Two substances

Table 7.11 Lysosomal storage disorders of cats

Disorder	Enzyme defect	Material accumulating	Nervous system cells involved	Breed, age, etc.	Presenting clinical signs
GMI gangliosidosis	β-Galactosidase	GMI ganglioside	Neurons	Siamese, Korat and other cats 3–6 months	Ataxia, head tremors, spastic quadriparesis
GM2 gangliosidosis	Hexasaminidase A and B	GM2 ganglioside	Neurons	Cats 6–12 months	Dementia, blindness, seizures
Sphingomyelinosis (Niemann–Pick disease)	Sphingomyelinase (phosphocholine hydrolase)	Sphingomyelin	Neurons	Siamese and DSH	Ataxia, head tremors, hypermetria
Ceroid lipofuscinosis (amaurotic familial idiocy)	P-phenylenediamine-mediated peroxidase	Ceroid and lipofuscin	Neurons	Siamese cats 6–12 months	Dementia, blindness, seizures
Globoid cell leucodystrophy (Krabbe's disease)	β-Galactocerebrosidase	Galactocerebrosidase	Macrophages (globoid cells) in white matter	Cats 6–12 months	Rear limb ataxia or paresis, quadriparesis
Glycogen storage disease type II (Pompe's disease)	α-Glucosidase	Type II glycogen	Neurons, neuroglia	Cats 12 months	Generalised muscle weakness, seizures
α-mannosidosis	α-Mannosidase	Oligosaccharides	Neurons, neuroglia	Persians 2–4 months, DLH and DSH 6–12 months	Generalised tremors, ataxia, head tremors, spastic paraplegia, opisthotonus
Lysosomal storage disease	Not identified	Lecithin	Neurons, macrophages, spleen and lymph nodes	Abyssinian	Incoordination, body tremor, seizures

DSH: domestic shorthair; DLH: domestic longhair.

have been reported in Siamese cats with mucopolysaccharidosis VI (MPS VI). This condition is the result of a deficiency of the lysosomal enzyme arysulfatase B, and in addition to causing characteristic physical deformities it can result in skeletal changes. These include fusion of the cervical vertebrae, variable fusion of thoracic and lumbar vertebrae, bony proliferation and protrusion into the thoracic and lumbar vertebral canal, causing compression of the spinal cord, and similar proliferation in the intervertebral foramina, causing nerve root compression. Bony proliferative changes and associated spinal cord compression occur before, or at the time of, epiphyseal closure (about 9 months of age) and are probably non-progressive after this time. MPS IV is inherited with an autosomal recessive mode of inheritance.

The characteristic physical findings in MPS VI are a small head, flat broad face, widely spaced eyes, corneal clouding, small ears, depressed bridge of nose, large forepaws and concave deformity of the sternum (Figure 7.10). Affected kittens are smaller than normal littermates, and the physical deformities are noticeable by 8 weeks of age. Neurological deficits due to skeletal changes and spinal cord compression are seen between 4 and 7 months of age, and progress over 2–4 weeks. Neurological findings indicate a transverse myelopathy between T3 and L3, and include absent conscious proprioception, normal to exaggerated hindlimb reflexes and decreased pain perception in the hindlimbs. Forelimb gait may be normal, or affected cats may have a crouching posture. Spinal reflexes in the forelimbs are normal.

Table 7.12 Ante-mortem diagnosis of lysosomal storage diseases

Disorder	Clinicopathology	Biopsy
GM1 gangliosidosis	Assay for β-galactosidase in leucoytes and skin fibroblast cultures. Can detect heterozygote carriers. Molecular test available	Lymph node: stored materal in lymphocytes and macophages Cerebellum: stored material in Purkinje cells
GM2 gangliosidosis	Assay for hexosaminidase A and B in leucocytes. Can detect heterozygote carriers. Molecular test available	Cerebrum: stored material in neurons
Sphingomyelinosis	Assay for sphingomyelinase in leucocytes, bone marrow and skin fibroblast cultures. Can detect heterozygote carriers. Molecular test available	Bone marrow: vacuolated histiocytes Cerebellum: stored material in Purkinje cells
Globoid cell leucodystrophy	Cerebrospinal fluid analysis: presence of macrophages filled with myelin (globoid cells) Assay for β-galactocerebrosidase in leucocytes. Can detect heterozygote carriers. Molecular test available	Peripheral nerve: myelin loss Lymph nodes: globoid cells
Ceroid lipofuscinosis		Lymph nodes: yellow–green granular deposits Cerebellum: stored material in Purkinje cells
α-mannosidosis	Assay urine for elevated concentrations of oliogosaccharide (hexasaccharides) and bound mannose	

Figure 7.10 A normal and abnormal 16 month old Siamese cats with MPSV1. (Courtesy of A. Crawley.)

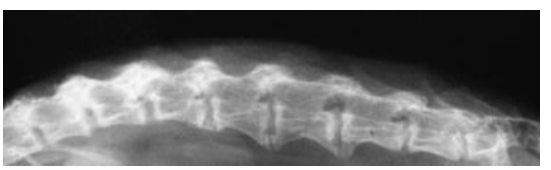

Figure 7.11 Lateral radiograph of the lumber spine of a 30 month old Siamese cat with MPS VI showing vertebrae fusion. (Courtesy of A. Crawley.)

Radiographs of the spine show vertebral fusion and bony protrusions into the spinal canal and intervertebral foramina of the thoracolumbar spine (Figure 7.11). However, bony proliferation may not correlate with neurological dysfunction. Myelography is necessary to demonstrate spinal cord compression. Subarachnoid CSF puncture may be difficult as a result of proliferative changes around the vertebrae. MBS VI can be confirmed by measurement of arylsulfatase B activity in leucocytes. Molecular diagnostic tests are available.

The skeletal changes are non-progressive after about 9 months of age. Decompressive surgery may improve the neurological status, but compression may be present at more than one site. BMT is a potential therapy

for MPS VI. Carriers of the genetic defect can be identified.

MPS I has been reported in domestic shorthaired cats, but is not associated with spinal cord compression.

Encephalopathies

Encephalomyelopathy of Birmans

This is a disease of Birman kittens, with onset at about 2–5 months of age (Jones *et al.*, 1992). Affected animals show hindlimb paresis and ataxia, which progresses to hindlimb paralysis. Bilateral nuclear cataracts may be present. Affected kittens are usually related and the condition is inherited.

The major histopathological features are spongy changes, vacuolation and wallerian degeneration, mainly in the thoracolumbar spinal cord. Diffuse lesions are also present in the brain and other areas of the spinal cord. As the disease is inherited there is no treatment.

Borna disease (see Chapter 30)

Borna disease virus (BDV) infection of cats ('staggering disease') has been described in Sweden and an antibody to BDV has been detected in cats in the UK (Reeves *et al.*, 1997). This neurological disease is seen most often in male cats from 5 months to 11 years of age. Young adults or outdoor cats are most at risk, and more cases are reported in spring and summer. Natural infections are believed to be transmitted via saliva or nasal secretions from affected or carrier animals, but the natural reservoir for infection is not known.

Clinical signs are characterised by behavioural changes and motor disturbances resulting from meningoencephalomyelitis. Naturally affected cats have progressive hindlimb ataxia, loss of appetite, fever, behavioural changes, a staring expression, hyperaesthesia to touch and light, seizures and sometimes excess salivation. The disease course is from 1 to 6 weeks, warranting euthanasia. Cats surviving initial episodes may recover but remain chronically affected and experience recurrent episodes of neurological signs.

Diagnosis is difficult and is based on signs if from an endemic area. Detection of serum antibodies is unreliable as more than 50% of cats with the disease may be antibody negative (Gunn-Moore & Harbour, 2001). Serum biochemistry and haematology are within reference ranges. CSF may show increased protein concentration and pleocytosis, with a predominance of mononuclear cells. BDV RNA can be detected in peripheral white blood cells. Histopathology of the brain confirms a non-suppurative meningencephalomyelitis with neuronophagia, microgliosis and mononuclear cell vascular 'cuffing'.

The significance of BDV infection as a neurological disease of cats has to be defined. In northern Europe there appears to be significant risk. Differentiation from other non-suppurative encephalomyelitides of cats is the major concern.

Rabies encephalitis (see Chapter 26)

Rabies is an unlikely diagnosis in the UK, but veterinary surgeons must be aware of the clinical features of the disease to ensure early identification in a suspect case. Rabies encephalitis is caused by a highly neurotropic rhabdovirus, which has a long incubation period of up to 6 months or longer in the natural disease.

The earliest signs, the prodromal phase, consist of restlessness, personality changes and apprehensive behaviour. This phase generally lasts for less than 5 days. In cats, this period is generally followed by the furious stage; approximately 55% of rabid cats have a furious form of rabies. The furious stage of rabies is characterised by aggression, convulsions, severe behavioural disturbances and excessive salivation. Some cats may develop the paralytic form, characterised by progressive weakness of the limbs and development of cranial nerve deficits. As this phase progresses, there is paralysis of the jaw and the muscles of the throat. Death normally occurs within 10 days from the onset of signs, regardless of the clinical course of the disease. However, a more chronic disease course has been reported in cats, which is a concern for diagnosis.

The diagnosis of rabies is made at post-mortem examination. Cats that die of neurological disease should be considered rabies suspects if they are from endemic areas or have been newly introduced to the country. If a diagnosis of rabies is suspected ante mortem in rabies-free countries as in the UK, the veterinary surgeon must isolate the cat and inform DEFRA (see Chapter 26). Repetitive vaccination of cats with inactivated adjuvanted vaccines appears to be safe and effective.

Aujeszky's disease (pseudorabies) (see Chapter 30)

This is a rapidly progressive viral disease characterised by severe pruritus, self-mutilation and nervous

signs, seizures and coma. The hallmark of the disease is the rapid progression of signs within 24 h. Infection is from contact with infected pigs or pig meat, and thus farm cats are more at risk in countries where Aujeszky's disease is endemic. Confirmation should be made by post-mortem examination.

Feline infectious peritonitis

(see Chapter 25)

Progressive neurological involvement is common in cats with the non-effusive form of FIP. Severe pyogranulomatous meningencephalomyelitis and ocular signs may be seen. Multifocal neurological signs are most common, especially cerebellar signs. Other common abnormalities include hindlimb paresis and ataxia, central vestibular signs, seizures and paralysis. This form of the disease is most common in cats younger than 2 years of age and cats older than 9 years of age. Most affected cats show fever and systemic signs such as anorexia and depression. Concurrent uveitis and chorioretinitis are common, which should increase suspicion of this disease. Other systemic signs of FIP may be present.

Haematology typically reveals an inflammatory leucogram. Serum globulin concentrations are very high. Tests for serum coronavirus antibody concentrations are often non-diagnostic; although an extremely high titre in the presence of typical findings suggests a diagnosis of FIP, a negative titre does not rule out FIP. PCR analysis for the detection of feline coronavirus sequences in CSF may be useful. Concurrent FeLV infection and immunosuppression may predispose cats to developing FIP. Typical findings on CSF analysis include non-septic inflammation with many neutrophils, macrophages and lymphocytes, and markedly elevated problem content (>2 g/l). The prognosis for cats with CNS FIP is poor, but steroid administration may provide temporary improvement.

Feline polioencephalomyelitis

A non-suppurative encephalomyelitis suggestive of a viral or immune-mediated aetiology has been identified as a cause of progressive seizures or spinal cord signs in young adult cats (Quesnel & Parent, 1999). Affected cats range from 3 months to 6 years of age, with most cats younger than 2 years old. Affected animals have subacute to chronic progressive neurological signs. Ataxia and paresis of the pelvic limbs may be accompanied by intention tremors of the head and seizures. Seizures and behavioural change may be the only and most important signs observed in some cats (Quesnal & Parent, 1999).

Clinicopathological findings are within reference ranges in most cats. CSF analysis reveals a mild increase in CSF mononuclear cells and a normal or slightly increased CSF protein concentration, findings suggestive of a viral aetiology. Other causes of encephalomyelitis, such as FIP, feline immunodeficiency virus (FIV) or toxoplasmosis, must be eliminated. Definitive diagnosis can be confirmed only at post mortem. Lesions include perivascular cuffing with mononuclear cells, lymphocytic meningitis, neuronophagia, formation of glial nodules, white matter degeneration and demyelination. The prognosis is poor, although reports exist of spontaneous recovery in a few cats. Steroid therapy is indicated and some cats show a prolonged response to prednisone. Anticonvulsants are indicated if seizures are the predominant sign.

Feline immunodeficiency virus encephalopathy (see Chapter 24)

Neurological disease has been identified in FIV-infected cats and has been studied in both clinical cases and experimental infection. Neurological abnormalities are reported to be common, with up to 30% of FIV-infected cats showing clinical signs. Importantly, the neurological signs are mostly related to behavioural signs, including changes in attitude, altered level of awareness, stereotypic behaviour and altered sleep patterns. Clinical and experimental studies confirm that the neurological consequences of FIV infection are mild. Rarely are severe neurological signs observed and, if present, they are related to another concurrent cause, such as neoplasia.

A presumptive diagnosis of FIV encephalopathy is made based on clinical signs, positive FIV serology and the exclusion of other diseases.

CSF analysis may reveal a slight lymphocytosis and a normal or slight increase in the protein content. However, two tests on CSF are useful: detection of antiviral antibodies and viral isolation. FIV antibodies can be detected in CSF by Western blot analysis or immunoprecipitation. The presence of FIV antibodies in CSF is sound evidence for infection, but it is essential to avoid blood contamination when collecting the CSF sample.

There is no specific treatment for FIV encephalopathy. Corticosteroids and or human immunodeficiency virus (HIV) antiviral agents may be expected to help affected cats.

Spongiform encephalopathy

With the development of the bovine spongiform encephalopathy (BSE) epidemic in the UK, cases of feline spongiform encephalopathy have been described (Gunn-Moore & Harbour, 2001). All affected cats showed progressive neurological signs, including head tremor, ataxia, muscle fasciculation, locomotor abnormalities, behavioural changes and altered sensory responses, especially hyperaesthesia. Histological findings are identical to those of scrapie in sheep and BSE, with discrete vacuolation of grey matter throughout the CNS.

Protozoal encephalitis (see Chapter 28)

Toxoplasmosis is often suspected in cats with neurological signs. However, *Toxoplasma gondii* is an opportunistic pathogen and while subclinical infection is common, clinical disease occurs rarely. Cats are the definitive host. There is no breed, sex or age distribution, but immunosuppression, concurrent illness or drugs can predispose to development. The most frequent systemic manifestations are hepatitis, pneumonia, iridocyclitis and chorioretinitis. Neurological signs, if they occur, are referable to a multifocal non-suppurative encephalomyelitis, but occasional focal lesions are present. In young cats, a generalised myositis and inflammation of nerve roots is a more common manifestation. Most cases of toxoplasmosis are acute, with a clinical course of a few weeks.

Toxoplasmosis is not common, but elimination of the disease is important in any neurological investigation. The diagnosis of toxoplasmosis is difficult because there are non-specific signs of illness. Investigation should include retinal examination, CSF analysis and serology. There are frequently retinal lesions, which adds support to this diagnosis. When neurological signs are present, the CSF is usually abnormal, with a mixed pleiocytosis and increased protein. Tachyzoites may be seen in CSF very rarely. Focal lesions can be difficult to differentiate from neoplasms. Serology is available for toxoplasma immunoglobulin M (IgM) and IgG specific antibodies in both serum and CSF, but a rising titre is required to confirm an active infection.

Neospora caninum has been shown to cause infection experimentally in cats, but naturally occurring infection due to this organism in cats has not been confirmed.

Treatment of toxoplasma encephalitis requires treatment with clindamycin 12 mg/kg every 12 h for 4–6 weeks or a combination of sulfonamides and trimethoprim or pyramethamine. These drugs are active against the non-encysted form of the parasite. Neurological signs typically improve, but damage caused by the organism may be permanent.

Mycotic encephalomyelitis

Several fungal species may invade the CNS. The most common of these is *Cryptococcus neoformans*, a saphrophytic yeast with worldwide distribution.

Clinical cryptococcosis is seen in all ages of cat, with no sex or breed distribution. Outdoor cats are most susceptible. Neurological involvement is from haematogenous spread or local infection via the cribiform plate. In addition to the nervous signs there may be signs of systemic disease, such as nasal swelling and respiratory disease, and there may be a history of chronic nasal discharge, weight loss or lymphadenopathy. Neurological signs are subtle in onset, and include depression, behavioural changes and altered mental attitude, but are followed by more severe signs of blindness, seizures, circling, ataxia, paresis and cranial nerve deficits. Neurological signs progress rapidly and reflect the area(s) of the brain affected. There may be concurrent chorioretinitis, which can be seen ophthalmoscopically.

Diagnosis depends on identification of the organism and serological support. The organism may be seen in nasal discharge or CSF. CSF analysis is the most helpful diagnostic test in cats with neurological signs only. An increase in neutrophils and eosinophils may be present and cryptococcal organisms may be seen with indian ink stain. Serological testing is helpful if the organism is not identified by detecting cryptococcal capsular antigen or antibodies.

Treatment of *Cryptococcus* spp. is frequently unrewarding. Itraconzole and fluconazole are the drugs of choice for treating CNS cryptococcosis. Fluconazole 50 mg p.o. every 12 h and itraconazole 50 mg/day for cats less than 3 kg and 100 mg/day for cats over 3 kg is recommended. Treatment should be continued for several months to a year, with treatment continuing for up to 2 months after clinical signs have resolved. Affected cats may be feline leukaemia virus (FeLV) or FIV positive; therefore, testing before treatment is mandatory.

Bacterial encephalitis

Bacterial encephalitis is rare, but occurs secondary to direct extension across the meninges into the CNS.

Infection occurs most commonly as a sequela to chronic nasal infection, otitis media, otitis interna and penetrating bite wounds. Clinical signs reflect the site of infection. The cats are febrile and clinical signs progress rapidly. Culture of CSF may identify the causative organism. Effective treatment depends on appropriate antibiotic treatment. Sulfonamides, trimethoprim and the newer generation cephalosporins all penetrate the blood–brain barrier and should be effective in the treatment of bacterial meningitis. A better prognosis is expected with early treatment.

Trauma

Traumatic injuries to the brain and spinal cord are common and are a significant concern for most veterinary surgeons. Many issues regarding the management of trauma to the nervous system are controversial and a consensus on appropriate management of traumatic injuries does not exist (Bagley, 1999).

Pathophysiology

Trauma to the brain occurs most commonly from extreme trauma (e.g. automobile trauma), blunt trauma or ischaemia (e.g. vascular diseases).

There may be mechanical damage to the brain tissue, with secondary metabolic alteration to glial cells and neurons, ischaemia, impairment of cerebrovascular autoregulation, haemorrhage (intraparenchymal, extradural, subdural, intraventricular), irritation (seizures), obstruction of ventricular drainage, oedema, increased intracranial pressure and production of physiologically active products that can exacerbate damage. The pathophysiology is complex and a full description is inappropriate for this textbook.

Cerebral oedema is common after brain trauma and is maximal between 24 and 48 h after injury. Haemorrhage can occur either within or around the brain or spinal cord and results in a rapid onset of nervous dysfunction.

The severity of the haemorrhage is variable and the occurrence of subarachnoid or subdural haemorrhage is unpredictable. There may be bleeding into CSF. Vascular changes in the brain or spinal cord affect normal blood supply, resulting in hypoxia and/or ischaemia due to physical impairment of blood flow. Cerebral blood flow is dependent on systemic output and local cerebrovascular autoregulation. Trauma to the brain can disrupt vascular autoregulatory mechanisms, leading to poor cerebral perfusion. If pressure autoregulation is impaired significant increases in arterial blood pressure will increase both cerebral blood flow and intracranial pressure. Local increases in arterial carbon dioxide tension ($PaCO_2$) can alter blood flow within the brain. Local vascular changes, oedema and haemorrhage contribute to the most significant sequela of head trauma, increased intracranial pressure. There is initial compensation, but as compliance is exhausted there is a shift in brain parenchyma, which can result in severe neurological signs and death. There is herniation of the cerebral cortex under the tentorium cerebelli, with compression of the oculomotor nerve, which results in pupillary changes; for example, if there is left cerebral herniation the ipsilateral pupil will dilate and not respond to light. Herniation of the cerebellum into the foramen magnum results in impaired respiration due to pressure on the caudal medulla. Cerebral blood flow is diminished when intracranial pressure increases, with a reflex systemic hypertension and bradycardia indicating increased intracranial pressure. There may be systemic signs of increased intracranial pressure, such as cardiac arrhythmias and neurogenic pulmonary oedema.

Clinical signs

Clinical signs of brain trauma are variable and depend on the areas of the nervous system involved. The signs of trauma may evolve and change significantly in the period after the primary injury. Repeat examination after injury may confirm that the signs are static, improving or deteriorating. A logical assessment of CNS function and progression of clinical signs is important. Recognition of signs of progressing neurological deterioration or signs of herniation is extremely important as immediate treatment is required to reduce intracranial pressure.

Mildly affected cats may be obtunded and show disorientation. There may be mild weakness, ataxia and transient anisocoria, but the pupils are responsive to light, and cranial nerve and spinal reflexes are present. Consciousness is retained.

In moderate trauma there may be altered consciousness, with coma or temporary loss of consciousness. There may be visual deficits (contralateral or bilateral), and paresis with impaired proprioception and postural reactions.

If brain oedema occurs, increased intracranial pressure will result in progression of nervous signs to tentorial herniation and brainstem compression, unilateral then bilateral pupillary dilation, together with

a transition from consciousness to coma. There are alterations in muscle tone, which progresses from weakness to rigidity, decerebrate rigidity with extension of forelimbs and hindlimbs, and opisthotonus. In a recumbent cat spasticity and/or opisthotonus may be seen, with decerebrate and decerebellate rigidity.

Respiratory abnormalities occur with increased intracranial pressure; these include shallow irregular breathing patterns, Cheyne–Stokes respiration and Biot's breathing. There may be a significant bradycardia.

In severe brain injury from trauma there will be florid diffuse signs, with coma, seizures, tetraparesis, decerebrate or decerebellate rigidity. Pupils are often constricted, fixed and unresponsive, but become dilated terminally. Cranial nerve deficits indicate brainstem lesions and generally a poorer prognosis.

Diagnosis

A diagnosis of CNS trauma is usually obvious as there is an acute onset of neurological signs and a history of trauma and external signs of injury, such as lacerations and haemorrhage from the ears. In some cases the history may be unknown, but if trauma is suspected the cat should be hospitalised and examined frequently to detect worsening of clinical signs from secondary pathological sequelae. Further diagnostic tests may be required and treatment is essential.

CT or MRI is useful for determining any need for surgical treatment, such as depressed skull fracture, subdural haematoma, removal of foreign material or surgical decompression. Radiographs can also identify fractures of the skull or spinal column. CSF collection and analysis should be avoided.

Management of CNS trauma

For most veterinary surgeons practical management of cats with head trauma involves sequential neurological examination to confirm improvement or deterioration. After suspected intracranial trauma there should be a complete neurological evaluation and signs should be recorded for further comparison. Many cats improve quickly, often without treatment, after the initial injury. If clinical signs are severe initially or worsen progressively evidence of increased intracranial pressure should be based on clinical signs unless intracranial pressure can be measured. A decision to undertake CT or MRI scan is often indicated in cats with severe signs.

Basic life support measures are indicated and standard critical care protocols followed; these include isotonic fluid administration, clear airways and blood administration. The following guidelines for head trauma patients (Bagley, 1999) should be followed.

The head should be elevated about 30 degrees above the level of the heart to reduce intracranial pressure. Hyperinflation decreases intracranial pressure by reducing the effect of increased $PaCO_2$. Corticosteroid use in head trauma is widespread and often based on anecdotal evidence of efficacy. The role of methylprednisolone sodium succinate in spinal trauma is widely accepted and scientifically defensible. Beneficial effects of methylprednisolone in nervous system injury include inhibition of lipid peroxidation and its associated detrimental effects. The role of corticosteroids in the treatment of head trauma is unclear. Whether corticosteroid use is beneficial or detrimental in head trauma must await further experimental data. This author recommends treatment for spinal cord trauma using methylprednisolone sodium succinate (Solumedrone Pharmacia & UpJohn):

- Use within 1–2 h of injury
- Administer 30 mg/kg slowly intravenously
- Then administer 15 mg/kg every 2–6 h
- Treatment should not extend beyond 24 h.

Treatments are available to decrease cerebral oedema and lower intracranial pressure. Diuretics including mannitol and frusemide are commonly used. Mannitol not only decreases cerebral oedema by its osmotic effect but also has beneficial effects on blood viscosity and is a free radical scavenger. Mannitol is administered at 1 g/kg i.v. over 5–10 min. There is a rapid effect with lowering of intracranial pressure in 10–20 min. Hypovolaemia and ongoing intracranial haemorrhage are contraindications for mannitol infusion. Frusemide (0.5–0.7 mg/kg i.v.) may potentiate the effects of mannitol and can have a primary effect in lowering intracranial pressure.

Surgical decompression is indicated when a subdural haematoma is confirmed or depressed fractures of the cranial vault are found.

If seizures occur soon after head trauma, diazepam (0.25 mg/kg i.v.) should be administered. If the patient remains seizure free, diazepam should be discontinued. If seizures continue, oral anticonvulsants should be administered.

Prognosis

The prognosis largely depends on the severity and location of the lesion. After the acute effects of the injury have been controlled time is required for healing and

full recovery. Good nursing care is essential; clean soft bedding, frequent turning, monitoring for infection, and evacuating the bladder and bowel are essential for recumbent animals.

Feeding tubes are essential if the cat is anorexic or if there are injuries to the jaw or skull. Daily records should include neurological examination to determine improved function. Cats with cerebral trauma improve for up to 4 weeks after injury, but there may sequelae of residual mild paresis, central blindness or seizures. Cats that show brainstem signs have a poorer prognosis and residual signs may be permanent.

Ischaemic encephalopathy

Feline ischaemic encephalopathy (FIE) is characterised by the acute onset of non-progressive cerebral dysfunction. The signs are mostly unilateral, but occasionally bilateral cerebral dysfunction and brainstem lesions occur. There is an association with *Culebra* spp. larvae and migration, and this condition is more common in areas where this parasite is found.

Characteristic signs include depression, blindness with normal pupillary light reflexes, pacing and circling, contralateral hemiparesis, hypotonia, hyperreflexia and postural reaction deficits. These signs are acute, but improve within 24–48 h as the associated oedema resolves. If the areas of ischaemia are small, there may only be altered behaviour or seizures. There is improvement after weeks and there may be residual signs, such as epilepsy or visual deficits. There may be unilateral ischaemic necrosis of one or both hemispheres, particularly those areas supplied by the middle cerebral artery (parietal and temporal lobes). The diagnosis of FIE must be suspected with the sudden onset of cerebral signs without a history of trauma. There appears to be no correlation between FIE and hypertension, FeLV infection or cardiomyopathy. CSF pressure may be elevated, with an increase in protein and a mild pleiocytosis, comprising neutrophils initially and large mononuclear cells later. MRI scan is the most suitable diagnostic tool. Asymmetry of the cerebral hemispheres and pooling of CSF in the parietotemporal subarachnoid space over the lesion are supportive features. Treatment in the acute stage is with mannitol 1 g/kg i.v. every 6 h or 0.25 g/kg i.v. every 3 h.

If seizures are present, antiseizure medication (diazepam 0.5–1.0 mg/kg i.v. as required) will help to control seizures. Ongoing seizure management may be required and in the 3–4 days after onset, nursing care, evacuation of the bladder, fluid therapy and possibly enemas are indicated.

Hepatic encephalopathy (see Chapter 17)

Hepatic encephalopathy is an important cause of cerebral dysfunction in young cats with congenital vascular anomalies and adult cats with severe liver disease, such as hepatic lipidosis (Baxter *et al.*, 1988). The cerebral signs are due to the effect of by-products of digestion, which are normally detoxified by the liver, reaching the brain and altering neuronal function. There are many publications debating the role of metabolites affecting brain function in hepatic encephalopathy, and readers should consult these sources for further information on the pathogenesis.

The clinical signs of hepatic encephalopathy can be spectacular and are due to dysfunction of the cerebral cortex: waxing and waning dementia, visual deficits, apparent intermittent blindness, compulsive behaviour, head pressing and circling. There may be concurrent signs of liver disease, as well as gastrointestinal signs, such as vomiting and weight loss. Clinical signs may be exacerbated by feeding, especially a high-protein diet.

An increase in serum fasting bile acid or blood ammonia concentrations will support a diagnosis of hepatic encephalopathy. Ultrasonography and/or radiographic examination may demonstrate a vascular anomaly and other laboratory values may indicate hepatic dysfunction.

Treatment of hepatic encephalopathy is based on relieving the clinical signs and treating the underlying hepatic lesion. Treatment involves decreasing the protein content of the diet, administering enteric antibiotics (neomycin or metronidazole) and altering the pH of the large bowel by administering cathartics. Surgical ligation of portocaval shunts, most of which are extrahepatic in the cat, is the treatment of choice. With primary liver disease, a more guarded prognosis must be given.

Thiamin deficiency

Thiamin (vitamin B_1) deficiency may occur in cats fed a diet of fish that contains naturally occurring thiaminase. It may also occur in cats after a period of anorexia due to illness. However, it is most commonly seen in cats being fed processed (commercial) food

Figure 7.12 Ventroflexion of the neck – a cat with thiamine deficiency. (Reproduced from Shaer, 2002, with permission of Manson Publishing.)

where thiamin has been destroyed by excessive cooking or by the addition of preservatives (e.g. sulfur dioxide).

Thiamin deficiency results in abnormal glucose metabolism in the brain, encephalopathy and haemorrhage of upper brainstem nuclei. Clinical signs in cats are variable and, importantly, cats fed thiamin-deficient commercial diets are often in excellent bodily condition.

Clinical signs initially include ataxia and depression. Ventroflexion of the head when suspended above the ground (Figure 7.12), pupillary dilation and absent pupillary light reflex, dementia and seizures are later signs. Seizures may be stimulated by handling. The diagnosis is based on the history and clinical signs, and further supported by the remission of signs after the administration of thiamin (10–20 mg i.m.). The concurrent administration of corticosteroids (dexamethasone 2 mg/kg i.v.) may help recovery in severely affected cats. Treatment with thiamin is continued for 5 days or until there is full remission of signs. The diet must be changed to a commercial brand containing sufficient thiamin.

Hypoglycaemia

Glucose is the major energy source for neurons. Low blood glucose concentrations can have a profound effect on CNS function, especially cerebral function. The clinical signs shown by cats with hypoglycaemia depend not only on the absolute serum glucose concentration, but also on the rate of change. Compensatory mechanisms are in place for any chronic cause of hypoglycaemia (e.g. insulinoma). The most common cause of hypoglycaemia is insulin overdosage in a diabetic cat, manifesting with stupor, depression, seizures and coma. Insulin-secreting islet cell tumours are very uncommon in cats and hypoglycaemia associated with other neoplasms, such as hepatoma, is uncommon. Affected cats are frequently normal between episodes. Young kittens with anorexia from systemic disease or other causes can become hypoglycaemic rapidly, and become stuporous and comatose. The demonstration of a low blood glucose concentration ($<$2 mmol/l) with signs of cerebral dysfunction is supportive of hypoglycaemia. In an older cat, if the hypoglycaemia is not associated with diabetes and insulin administration, investigation of insulinoma or other tumours is indicated, by ultrasonography of the liver and pancreas, and calculation of the insulin: glucose ratio. Most insulinomas reported in cats are malignant. Surgical excision provides temporary improvement, but the long-term prognosis is poor. Oral glucose or intravenous dextrose 5% dextrose saline will correct the signs of hypoglycaemia. The administration of glucocorticoids and frequent feeding are recommended for patients who are not candidates for surgical treatment for insulinoma.

Central nervous system neoplasia

Neoplasia of the CNS is uncommon in the cat, representing less than 5% of all feline neoplasms. These figures are based on post-mortem studies, but with improved clinical diagnosis with MRI and CT scans, this figure may increase, especially as surgical or radi ation treatment is being undertaken more often. Most CNS tumours are primary and not malignant, and arise from nervous tissue or closely associated tissue. Secondary or metastatic tumours metastasise to the CNS from distant sites or invade by extension from non-nervous tissue, for example the skull or cribriform plate (Smith, 1999). The primary tumours and their origins in the nervous system are shown in Table 7.13.

Most affected cats are middle-aged or older ($>$6–7 years of age). Meningiomas have been reported in males more frequently. Tumours cause clinical signs by compression or infiltration of adjacent nervous tissue, interference with the circulation with ischaemia or infarction, or interference with CSF flow with secondary hydrocephalus. The clinical signs depend on the location of the lesion. The tumour usually grows slowly,

Table 7.13 Origins of primary nervous system tumours in cats

Ectodermal	Neurectodermal	Mesodermal	Nerve root
Pituitary tumour	Astrocytoma Glioma Ependymoma Choroid plexus Papilloma	Meningioma	Neurofibrosarcoma Neurilemoma Neurofibroma

so that there is a slow onset of clinical signs with progressive deterioration. The deterioration of signs may be from months to years, but the usual course is weeks to months. Vague clinical signs of ill health, such as depression, lethargy, anorexia or weight loss, may precede more overt nervous signs.

Nervous signs are often focal, frequently with lateralising signs. Occasionally acute onset of signs is seen with tumours, for example blindness (pituitary tumour), where there is a sudden decompression of the expanding intracranial mass and termination.

Meningioma

This is the most prevalent CNS tumour in cats, accounting for 50% of all CNS tumours. It is an important tumour because it is discrete, focal and frequently amenable to surgical excision (Le Couteur, 2001). It is attached to the dura and compresses the adjacent nervous tissue. There may be hyperostosis of the skull bone adjacent to the tumour, a change seen on radiographs.

The most common site for meningoma is one the cerebral hemispheres – frontal, parietal and occipital lobes – but other locations include the floor of the cranial vault and the tentorium cerebelli. Spinal meningiomas occur, but are uncommon. Meningioma may be multiple in 20% of cases, an important consideration for diagnosis and prognosis.

Meningiomas are readily detected by MRI and CT with and without contrast enhancement. There is an association of meningioma with MPS I in young cats, which suggests that this metabolic disease may predispose to development of this neoplasm (LeCouteur, 2001) Meningiomas may occur without significant neurological signs. Peritumoural brain oedema is responsible for significant clinical signs in humans and dogs, but the degree of oedema in cats is variable.

Astrocytomas

Gliomas, ependymomas and other tumours result in focal CNS dysfunction, depending on their location. They may be differentiated by their pattern of enhancement on CT or MRI. In addition to identification of the site of a tumour, secondary effects of the tumour, such as changes in vascularity, secondary hydrocephalus and peritumoral oedema, can be detected.

Metastatic tumours

A large number of neoplasms, including mammary gland carcinoma, haemangiosarcoma and bronchogenic carcinoma, may metastasise to the brain. The clinician must ensure that a full examination and assessment of any patient with CNS signs is made to attempt to detect a primary neoplasm.

Locally invasive tumours, such as squamous cell carcinoma may invade locally from the ear or from the orbit. Lymphoma is the most common tumour in cats, occurring in younger cats (>5 years) particularly males. A high proportion (5–12%) of cats with lymphoreticular neoplasia have neurological involvement and most are FeLV positive. The site of predilection is the epidural space of the thoracic and lumbar spinal cord.

Diagnosis

Clinical signs of a focal, progressive CNS disease in an older cat provide a high index of suspicion for a brain tumour. Skull radiographs may show mineralisation of a tumour, hyperostosis or lysis of the cranium from a meningioma.

CSF analysis is mostly unhelpful. There may be increased pressure and increased proteins, but exfoliated neoplastic cells are uncommon. Definitive diagnosis requires advanced diagnostic imaging CT and MRI, and diagnostic or excisional biopsy. CT-guided brain biopsy has been applied to the diagnosis of brain tumours in cats.

Treatment and prognosis

Treatment of meningiomas is usually by surgical resection. They are discrete and well demarcated,

and their superficial location over the cerebral hemispheres makes access and excision practical. Prognosis after surgery is good, with a survival rate of 50% or more, with many cats surviving for 2 years or more.

Recurrence of the neoplasm at the site or another site is reported. Surgical excision of a meningioma may result in the resolution of neurological signs, but seizures may persist and require anticonvulsant treatment.

Radiation treatment of tumours of the nervous system is now more available and there are data available on which tumours are likely to respond. Radiation therapy is not curative, but long periods of remission can be achieved (months to years). Radiation treatment is not without complications and, if considered, a qualified radiotherapist must be consulted regarding the type of treatment and procedure.

Chemotherapy is suitable for treating lymphoma of the nervous system, but not other tumours. Survival times are short (3–6 months) (see Chapter 3).

The owners of many cats with CNS neoplasms elect not to undertake advanced diagnostic imaging or surgical or radiation treatment for a cerebral neoplasm. Palliative treatment for these patients may give temporary relief of clinical signs by relieving peritumoral oedema, reducing CSF production and reducing inflammation. Corticosteroid treatment (dexamethasone sodium phosphate 2 mg/kg i.v. or methyl prednisone sodium succinate 30 mg/kg i.v.) may give an immediate response, and prednisone continued for control maintenance at 1 mg/kg every 12 h. This dose can be modified downwards according to response. Deteriorating neurological function or steroid therapies necessitate euthanasia of the cat.

New treatment strategies include hormone therapy, and gene therapy may play a future role in the management of meningioma in particular.

Seizures

Epilepsy may occur where there are no identifiable structural changes in the brain. There may be genetic or unidentified biochemical causes. These cases are classified as idiopathic epilepsy, with the diagnosis being made by exclusion of underlying structural lesions (e.g. neoplasms, infection, ischaemia) and extracranial causes of seizures. Idiopathic epilepsy is less common in cats than in dogs and most seizures are associated with structural brain lesions. The possible causes of seizures in cats are listed in Table 7.14.

Table 7.14 Causes of seizures in cats

Congenital	Lysosomal storage diseases, hydrocephalus
Metabolic	Hepatic encephalopathy, hypoglycaemia, hypocalcaemia, polycythaemia
Neoplasm	Primary brain tumours, metastatic tumours
Traumatic	Head trauma
Nutritional	Thiamin deficiency
Toxic	Pyrethrins, lead, organophosphates, other toxins
Vascular	Stroke
Parasitic	Larval migration
Inflammatory	FIP, FIV, toxoplasmosis, viral, polioencephalomyelitis, bacterial infection (abscess)
Idiopathic	Primary epilepsy

FIP: feline infectious peritonitis; FIV: feline immunodeficiency virus.

Seizures result from altered brain activity and are associated with loss or change in consciousness, change in temperament, involuntary limb movements, muscle twitching, salivation, urination or defecation. Changes last from seconds to minutes. After a seizure, cats may be normal or show signs of ataxia, changes in temperament, or behavioural changes or confusion. These postictal signs can last from minutes to hours.

Seizures are defined as generalised, grand mal or partial. Partial motor seizures are most often associated with structural brain damage (e.g. neoplasia), involve one side of the body only, but may become generalised. Owners should be asked about the appearance of the seizure to determine whether there are localising signs that support a lesion in a part of the brain.

Epilepsy is manifest as recurrent seizures that recur days, weeks or months apart.

Diagnosis

Most cats with idiopathic epilepsy have a normal physical and neurological examination and laboratory values within reference ranges, and the diagnosis is by exclusion. The key role of the clinician is to distinguish between cats with idiopathic epilepsy and those with structural lesions of the brain or extracranial causes of epilepsy. An accurate neurological examination is essential to try to detect a focal lesion.

Table 7.15 Anticonvulsant drugs in cats

Drug	Dose rate (mg/kg every 12 h)	Half-life (h)	Therapeutic range (μg/ml)
Phenobarbitone	1.5–2.5	34–43	10–30
Diazepam	0.25–0.5	15–20	0.5–0.7
Primidone	40	40	10–30 (phenobarbitone)
Potassium bromide	10 mg/kg q12 h	24 days	1–1.5

Ophthalmological examination may detect abnormalities such as inflammation and vasculitis, which assist diagnosis. A minimum investigation should include haematology, a serum chemistry profile, urinalysis, and testing for FeLV and FIV. Analysis of this database may identify extracranial diseases or concurrent diseases, such as renal disease, which may preclude significant investigation. The frequency of the seizures is important. A work-up is required when the seizure episodes are increasing in severity or frequency. Cats that are abnormal between seizures frequently have intracranial disease. Other tests include CSF analysis and CT or MRI scans, and should be applied if inflammatory or neoplastic disease is suspected.

Treatment

If a cat is having a seizure, diazepam administered at a dose of 0.5–1 mg/kg i.v. is recommended. One dose is often effective but, if necessary, further doses (up to three per hour) may be administered. Diazepam may also be administered per rectum. An alternative to diazepam is phenobarbitone, administered at a dose of 2 mg/kg i.v. or i.m. every 6–8 h. It is essential to maintain fluid balance, and if hypoglycaemia is suspected 5% dextrose saline should be administered.

Maintenance therapy

If seizures are of sufficient frequency, with at least three or four seizure episodes within a year, anticonvulsant treatment is recommended. Not all seizure patients warrant treatment. The goal of anticonvulsant treatment is to reduce the frequency and severity of seizures without untoward side-effects of drug therapy. It is essential that owners understand that complete control may not be possible, that further diagnostic investigation may be required and that therapeutic drug monitoring is essential. The owner should keep a record of any seizure episodes and their nature while the cat is on anticonvulsant treatment. Any improvement or deterioration can be identified quickly.

The anticonvulsants available for cats, their dose rates, half-lives and therapeutic ranges are shown in Table 7.15.

Phenobarbitone is the drug of choice, A blood concentration should be measured after 2 weeks or if at any time seizure control is inadequate to ensure that therapeutic concentrations are achieved. There are common side-effects with phenonbarbitone treatment, but these usually reduce if the dose is reduced or withdrawn. Side-effects can be expected at the start of treatment.

Diazepam is an effective oral anticonvulsant in cats, as cats do not develop tolerance, but hepatotoxicity is reported in some cats after 5–10 days of oral administration at recommended doses. Serum biochemistry including liver enzyme measurement is recommended if any cat becomes ill when being treated with diazepam.

Primidone is metabolised to phenobarbitone and this drug has little advantage over phenobarbitone.

Potassium bromide can be administered with phenobarbitone to cats with refractory seizures. There are few studies on the use of bromide in cats. Steady state is reached at 7–8 weeks in healthy cats and the mean elimination half-life is 1.5 weeks. There are no reports of significant side-effects, but they could be expected.

Other anticonvulsants

Phenytoin is not used as an anticonvulsant in cats because it has a long half-life (41.5 h). Signs of toxicity are common (Table 7.16).

There are many new anticonvulsants available for use in humans and dogs, and some of these may be suitable for the treatment of seizures in cats. More kinetic and pharmacological data are required before any can be recommended.

Management

It is important for the owner to keep a record of the cat's seizures, including their frequency and severity,

Table 7.16 Toxicities of anticonvulsants used in cats

Drug	Toxicities
Phenobarbitone	Ataxia, lethargy, increased thirst, bone-marrow hypoplasia
Diazepam	Hepatotoxicity after 5–10 days, vomiting, lethargy, ataxia
Potassium bromide	None reported in cats

the presence of other clinical signs, and the time and frequency of drug doses. These data provide a baseline for assessing control. If seizures are increasing in frequency, then the blood concentration of the anticonvulsant should be measured and the dose adjusted upwards if blood concentrations are not in the therapeutic range. If blood concentrations are in the therapeutic range, then the cats should be re-evaluated to ensure that any underlying disease has not been missed. If not, another anticonvulsant (e.g. bromide) can be administered alone or concurrently with the existing anticonvulsant.

If a cat is free from seizures for a year or more it may be possible to wean the cat off anticonvulsant therapy, but this process must be completed slowly. The anticonvulsant dose should be reduced by one-eighth to one-fifth every 2–3 weeks. If the seizures return the cat should be maintained on the anticonvulsant.

Deafness

Congenital deafness

Congenital deafness occurring in the cat is most often associated with a white coat colour. The dominant white gene is associated with deafness and also affects the colour of the iris. The underlying defect is degeneration of the organ of Corti. One or both ears may be affected. The deaf cats may have two blue eyes, yellow eyes or odd coloured eyes. There is no treatment.

Acquired deafness

Acquired deafness occurs with damage to the eighth nerve or its nuclei or sensory apparatus. In most cases vestibular signs are also seen as the vestibular branch of the nerve is also affected. Otitis media and interna can be accompanied by unilateral deafness, but auditory defects are less common.

Tumours, trauma, degenerative disease and toxins (aminoglycoside antibotics) can all cause deafness, but acquired deafness due to a specific cause is rarely diagnosed. Assessment is also difficult, but measurement of brainstem auditory-evoked potentials can provide a quantitative measurement of hearing loss. However, for investigation subjective assessment by the owners is frequently the only available assessment.

Vestibular disease

The vestibular system is the primary sensory system that maintains balance and posture and normal orientation of the body relative to gravity. Disorders of the vestibular system are common in the cat. Vestibular disorders have been reviewed by Le Couteur and Vernau (1999a, b) and readers are referred to these papers, especially the one on the anatomy and physiology of the ear and vestibular system.

The afferent fibres from vestibular receptors within the vestibular cochlear nerve enter the brainstem at the rostal medulla. Most fibres synapse in one of the four vestibular nuclei, but some enter the cerebellum via the caudal cerebellar peduncle. Nerve fibres from all of the vestibular nuclei synapse with neurons of the third, fourth and sixth cranial nerves, which innervate the ocular muscles. Fibres also descend in the vestibulospinal tract to the LMNs of the neck, thoracic limbs and pelvic limbs.

The medial vestibulospinal tract descends in the medial longitudinal fasiculus to the extensor muscles of the neck and back (Figure 7.13).

Clinical signs

A cat with vestibular injury will have varying degrees of loss of balance, ataxia and nystagmus. Signs may be unilateral (most common) or bilateral. Strength is not affected, therefore paresis is not observed. The characteristic features of cats with unilateral vestibular disease are: head tilt, asymmetrical ataxia, nystagamus or strabismus. Most clinical signs of vestibular disease are present and more severe at the onset of any injury, but are frequently transient. Cats quickly compensate for any deficit. Clinical signs of vestibular disease are similar whether the injury is to the peripheral vestibular apparatus or to the vestibular nuclei in the brainstem.

The head is usually tilted towards the side of the lesion. Animals can roll to the side of the lesion because of reduced extensor tone on that side and increased tone on the other side. Cats adopt a wide-based stance to prevent them falling. Circling towards the side of the lesion is common. Nystagmus, involuntary rhyth-

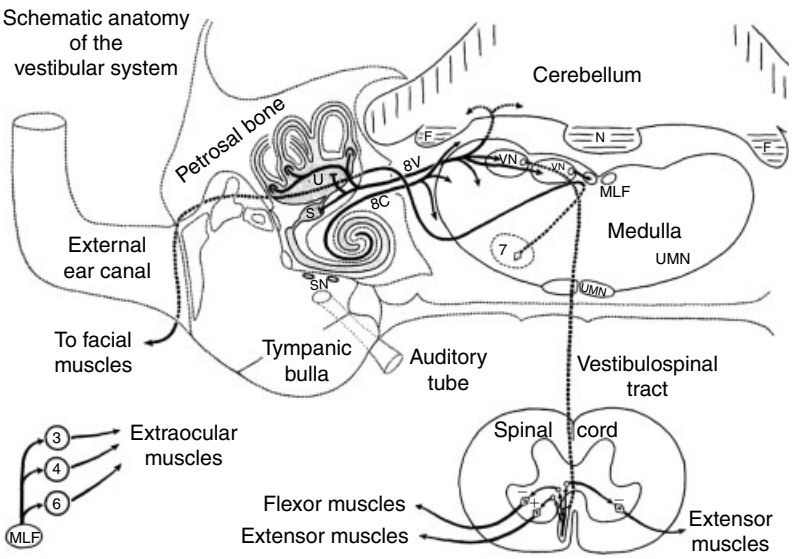

Figure 7.13 Schematic anatomy of the vestibular system. N: nodulus; F: flocculus; UMN: upper motor neuron; MLF: medial longitudinal fasciculus; VN: vestibular nucleus; 8V: cranial nerve VIII, vestibular portion; 8C: cranial nerve VIII, cochlear portion; U: utricle; S: saccule; SN: sympathetic neurons; 3: oculomotor nucleus; 4: trochlear nucleus; 6: abucens nucleus; 7: facial nucleus. (De Lahunta, 1977, reproduced with permission of Elsevier Science.)

mic oscillation of the eye, is often associated with vestibular dysfunction. Abnormal nystagmus occurs because of disturbed vestibular input to neurons innervating the extraocular muscles. Nystagmus is described in terms of its direction, horizontal or vertical, whether it occurs when the head position is altered and whether it is the same in both eyes. The direction of nystagmus is determined by the direction of the fast phase. With peripheral lesions, the fast phase is directed away from the side of the lesion. With central lesions, the direction of the slow phase in relation to the side of the lesion can vary. Blindfolding a cat with a suspected vestibular disease may exacerbate the clinical signs of circling or head tilt.

Once vestibular dysfunction has been recognised it is important to determine whether the signs are due to a peripheral or a central disorder (Table 7.17).

Cats with peripheral vestibular disease may show signs of otitis externa and otitis media with extension to the labyrinth. Horner's syndrome and/or facial nerve paralysis may be present with middle and inner ear disease. Nystagmus is present in horizontal and head tilt and circling to the side of the lesion. No proprioceptive abnormalities are present and the cat's mental status is normal.

With central vestibular disease, there may be altered postural reactions, paresis and proprioceptive abnormalities on the side of the lesion. Nystagmus is variable in direction with changes in head position. There may be other signs of brainstem disease or other neurological signs, such as seizures. Head tilt and circling are normally to the affected side.

Table 7.17 Clinical signs of peripheral and central vestibular disease

Neurological sign	Peripheral	Central
Head tilt	Yes	Yes
Nystagmus	Yes	Yes
Horizontal	Yes	Yes
Rotary	Yes	Yes
Vertical	No	Yes
Positional	No	Yes
Non-positional	Yes	Yes
Conjugate	Yes	Yes
Dysconjugate	No	Yes
Strabismus	Yes	Yes
Asymmetrical ataxia	Yes	Yes
Cranial nerve deficits	VII possible	V, VI, VII possible
Horner's syndrome	Yes	No
Cerebellar signs	No	Possible
Mentation	Normal	Possibly reduced
Hemiparesis	No	Possible
Proprioceptive deficits	No	Possible

After Le Couteur and Vernau (1999a).

Lesions of the central vestibular system that affect the rostral and medial vestibular nuclei, caudal cerebellar peduncle and flocculonodular lobe of the cerebellum produce clinical signs of vestibular disease dysfunction that occur on the side opposite the lesion, termed paradoxical central vestibular disease. Postural reactions, proprioceptive and cranial nerve deficits occur on the same side of the lesion.

Cats with *bilateral vestibular dysfunction* have neither postural asymmetry nor nystagmus. They are ataxic, fall to either side, maintain a crouched posture and show wide oscillation of the head. The eyes do not move when the head is moved.

Diseases of the peripheral vestibular system

Congenital vestibular disease

Congenital peripheral vestibular disease is reported in Siamese, Burmese and Birman kittens. Some kittens may be deaf as well. Clinical signs occur from 4 weeks to 4 months of age. Affected kittens improve, but residual head tilt may be permanent. Signs are non-progressive. An inherited defect is suspected, but not proven, and no pathological lesions have been found.

Nasopharyngeal polyps

Nasopharyngeal polyps can grow into the middle ear, nasopharynx or external ear canal. Clinical signs include dysphagia, inspiratory stridor, voice change, sneezing, rhinitis, otitis media and otitis interna, sometimes with signs of peripheral vestibular disease.

Otitis media and otitis interna

Otitis media or labyrinthitis is a common cause of peripheral vestibular dysfunction. Bacterial infection, extension from otitis media and otitis externa or from the pharynx via the eustachian tube, fungal infection (e.g. *Cryptococcus*), parasites and grass awns are also potential causes. Ipsilateral facial nerve paralysis and Horner's syndrome may be present.

Diagnosis is based on otoscopic examination demonstrating an abnormal and discoloured tympanic membrane and the presence of purulent exudate.

Imaging (skull radiographs, CT, MRI) demonstrates increased density of the bulla, with or without sclerosis or lysis of the tympanic bulla in chronic cases. Exudate should be obtained for cytology and culture. Oral antibiotic treatment based on sensitivity testing is recommended for at least 6 weeks. Improvement can occur quickly, but the full course of treatment is essential.

In chronic cases unresponsive to medical treatment, surgical drainage of the tympanic bulla is required by lateral or ventral bulla osteotomy.

Idiopathic vestibular disease

This condition is common in all ages of cats, particularly in the summer months in the USA, but also in other countries (Jones B.R., unpublished data). There is an acute onset of peripheral vestibular signs without other neurological signs. There may be a history of illness, for example respiratory infection, before the onset of signs.

Clinical signs are severe but improve spontaneously over 48 h; however, full recovery may require weeks. In some cats there may be residual nervous signs, such as mild head tilt. The cause of this important vestibular syndrome is unknown.

Diagnosis is based on exclusion of other causes of vestibular disease. There is no specific treatment, but cage confinement is helpful to prevent the cat rolling and falling, and the cage walls provide external support. Steroids appear to have no significant effect. The prognosis is good.

Trauma

Trauma to the skull can result in fracture of the temporal bone or bulla and associated peripheral vestibular signs.

Neoplasia

Neoplasms involving the ear canal may result in peripheral vestibular signs when the temporal bone is affected or when otitis media or interna is associated with the neoplasm. Squamous cell carcinoma is the most common neoplasm of the middle ear, but many other neoplasms, such as fibrosarcoma, osteosarcoma, ceruminous gland adenocarcinoma and lymphoma, occur. Diagnosis is based on radiography and scan findings, cytology or biopsy.

Toxicities

Several drugs and toxins result in dysfunction of vestibular and/or auditory receptors, usually permanently. All aminoglycoside antibiotics have a toxic

effect on the vestibular or auditory system, or both. Ear canal cleaners (e.g. cetrimide, chlorhexidine, propylene glycol) can be toxic if the tympanic membrane is ruptured.

Central vestibular disease

The central vestibular nuclei within the brainstem can be affected specifically (e.g. in thiamin deficiency) or be involved in inflammatory, neoplastic disease or trauma along with other areas of the nervous system. The signs of central vestibular disease may predominate, but other nervous signs will be shown and detected.

Neoplasms located at the cerebellomedullary angle affect the central vestibular nuclei. Central vestibular signs often occur as a sequela to severe head trauma. Some drugs (e.g. metronidazole) cause central vestibular and cerebellar signs if cats are overdosed. Withdrawal of the drug and supportive care result in complete recovery.

Infectious diseases of the CNS such as FIP (especially in young cats), toxoplasmosis, cryptcoccosis, bacterial meningitis and viral encephalomyelitis can result in central vestibular signs.

Discospondylitis

Discospondylitis is infection of the intervertebral disc and the adjacent vertebrae. The infection is usually bacterial (*Staphylococcus* spp., *Streptococcus* spp.), but fungal infections occur occasionally. The usual route of infection is haematogenous. There may be a history of abscesses resulting from fighting. Male cats are more often affected and may test FIV positive.

The most common clinical signs are pain over the infected area of the spine or pain when moving. There may be pyrexia and depression and signs of systemic disease. Paresis or paralysis results from compression due to proliferative and inflammatory changes at the site of the lesion or from pathological fracture of bone.

Radiographs will confirm the characteristic features of discospondylitis, such as lysis of bone with proliferation and sclerosis of the endplates of the vertebrae. Culture of blood, urine or aspirate from the lesion may identify the causal organism and its sensitivity to antibiotics. Cephalosporin, fluroquinolones, amoxycillin and clavulanate are the preferred antibiotics for Gram-positive organisms. Antibiotic therapy should be continued for 4–6 weeks and the spine radiographed again. Itraconazole is recommended for fungal infection. If there is cord compression, surgery may be indicated to decompress the cord, débride infected tissue and provide stabilisation. The prognosis is usually good. Analgesics and cage confinement are helpful if pain is significant.

Intervertebral disc disease

Intervertebral disc degeneration without calcification is common in cats, although clinical signs resulting from disc protrusion are uncommon.

There are reports of intervertebral disc protrusions causing clinical signs in the cat with compression of the spinal cord and/or nerve roots. Disc protrusion should be considered in any cat with spinal cord pain or paresis but other causes are more likely. Radiographs will confirm disc protrusion by demonstrating a narrowed disc space at a site consistent with neurological signs shown by the cat. Myelography may be required to confirm cord compression. If signs are not severe, conservative treatment (cage confinement, analgesics) is recommended.

The peripheral nervous system

Diseases causing peripheral neuropathies may affect motor, sensory and autonomic neurons in the peripheral nervous system. Several congenital, inherited and acquired diseases affect the LMN and there may be significant variation in clinical signs. Involvement of motor fibres usually manifests as muscle tremor, muscle atrophy and weakness. Involvement of sensory nerves results in proprioceptive deficits, ataxia, anaesthesia, hyperaesthesia or paraesthesias. Spinal reflexes are depressed or absent with sensory or motor nerve damage. Diseases that affect all or most peripheral nerves or nerve roots are referred to as polyneuropathies. Neuropathies affecting one nerve or a small number of nerves are referred to as focal neuropathies. Clinical signs are referable to one limb or to one body region. The most significant autonomic neuropathy in the cat is dysautonomia, which involves degeneration of the cell bodies of the autonomic ganglia.

Diagnosis

The diagnosis of peripheral nerve disease can be difficult. Diagnostic aids of importance include neurological examination, radiography, serum biochemistry, serology for infectious diseases, CSF

collection and analysis, and PCR analysis for inherited disease. The diagnosis of neuropathy and location of lesions within the nerves are confirmed by EMG and nerve conduction velocity measurements. The reader should refer to an appropriate neurology textbook for the characteristic features of LMN injury.

To determine the type of neuropathy a biopsy of a fascicle of a nerve and histological examination can provide information on the pathological changes.

Inherited polyneuropathies

Most inherited polyneuropathies are congenital, progressive and ultimately fatal.

Hyperoxaluric neuropathy

Cats with low concentrations of the enzyme D-glycerate dehydrogenase develop an unexplained axonopathy. Affected cats excrete excessive amounts of L-glycerate in their urine and have intermittent oxalaturia. There is oxalate crystal deposition in the kidneys, which are large and painful. Affected cats are young (5–9 months) and die from renal failure before 1 year of age. Inheritance is autosomal recessive.

Hypertrophic polyneuropathy

Hypertrophic polyneuropathy is characterised by generalised tremors that worsen with activity, ataxia, hypermetria, a plantigrade stance, depressed tendon reflexes, and reduced paw and facial sensation. Clinical signs begin between 7 and 12 months of age. Weakness and muscle atrophy are mild. Neurological signs progressively worsen. Peripheral nerves are thickened, with subperineurial masses of mucoid gelatinous material. A schwann cell defect resulting in an inability to form and maintain stable myelin is suspected.

Sphingomyelinase deficiency

Sphingomyelinase deficiency has been described in 4–7-month-old related Siamese cats, which developed progressive ataxia, tremors, LMN paresis and hepatosplenomegaly. There is a deficiency of the enzyme sphingomyelinase, which results in polyneuropathy. EMG will confirm the presence of a neuropathy, but tissue (liver, nerve, skin) biopsies are required to confirm this lysosomal storage disease.

Distal axonopathy of Birman cats

A diffuse neuroaxonal degeneration of central and peripheral neurons occurs in 8–10-week-old male Birman kittens. Hypermetria, hindlimb weakness and ataxia with a plantigrade stance and conscious proprioceptive deficits are seen. Fibrillation potentials are recorded on EMG, indicating that peripheral motor nerve conduction velocity is normal. Histopathological examination confirms a central and peripheral distal axonopathy.

Inherited primary hyperchylomicronaemia

Domestic shorthaired cats with an inherited primary hyperchylomicronaemia develop multifocal neuropathies from compression of peripheral nerves by lipid granulomata. A fasting lipaemia, hypertriglyceridaemia and hypercholesterolaemia are present. Most cats develop clinical signs before 1 year of age. Neurological signs include one or more of the following: Horner's syndrome, facial, trigeminal or recurrent laryngeal nerve paralysis, tibial nerve paralysis with a plantigrade stance, and peroneal and femoral nerve paralysis. Feeding a low-fat diet results in resolution of hypelipidaemia and improvement in neurological function over a 3 month period.

Acquired neuropathies

Diabetic neuropathy

Some cats with diabetes mellitus develop a distal polyneuropathy, usually involving the hindlimbs. There is a plantigrade posture, and progressive paresis, hyporeflexia, muscle atrophy and depressed patellar reflexes (Figure 7.14). Some cats are hyperaesthetic and irritable when handled or touched. Proprioception may be impaired. Most cats are polydipsic and polyuric, with fasting hyperglycaemia and glucosuria. Many present with hindlimb weakness but have not been diagnosed with diabetes before nervous signs occur.

The pathological changes present are axonal degeneration, demyelination and remyelination, with distal portions of nerves most affected. Positive sharp waves, fibrillation potentials and slowed motor nerve conduction velocity are found in the ulnar and sciatic nerves on EMG. Good glycaemic control with insulin and appropriate dietary management results in resolution of the neuropathy in most cats unless the neuropathy

Figure 7.14 Diabetic cat with a tibial nerve neuropathy and characteristic plantigrade posture. (Courtesy of M. Schaer.)

is chronic. Even though this is one of the most common neuropathies of the cat, the mechanism by which it develops is unknown, but it probably involves metabolic derangements in schwann cells and axons.

Ischaemic polyneuropathy

Thromboembolism of the terminal aorta occurs in cats with hypertrophic cardiomyopathy, and results in ischaemia of muscles and nerves of one or both pelvic limbs. The ischaemia is produced by vasoconstriction of collateral circulation induced by serotonin and thromboxane A_2 from platelets. Clinical signs include paresis or paraplegia with cold extremities, absent femoral pulses, firm painful muscles and absent sensation. There is evidence of concurrent cardiomyopathy. Treatment is directed towards the underlying cardiomyopathy with aspirin to prevent further thrombosis. Some cats recover, but with permanent neurological disability and a high chance of recurrence.

Neoplasia

Neoplasia of the peripheral nervous system usually results in a focal neuropathy, the exception being lymphoma, which may affect multiple nerve roots. Peripheral nerves may be compressed by adjacent neoplasms, especially lymphomas. Primary neoplasms of nervous tissue include schwannomas, neurofibromas and neurilemmomas. Schwannomas in cats are frequently located in the distal nerve and are associated with swelling of the nerve, paraesthesia, hyperaesthesia and excessive licking at the site of the sensory dermatome (Figure 7.15). Clinical signs are usually gradual in onset and become progressively worse.

Figure 7.15 Schwanoma of the distal extremity showing swelling and excoriation from excessive licking.

If the tumour grows along the nerve into the spinal canal, there will be spinal cord compression and paresis of other limbs as well. The only treatment for peripheral nerve tumours is surgical excision of the tumour and affected nerve, which can potentially result in a permanent neurological deficit or amputation of the limb.

The clinical signs shown will depend on which nerves are affected; this can be confirmed by EMG. CT or MRI is helpful in confirming the nerve affected and the extent involvement of the nerve and whether the neoplasm involves the spinal canal.

Toxic polyneuropathies

Toxic neuropathies have been reported in the cats as a result of ingesting toxins or being exposed to environmental toxins. Toxic neuropathy is possible in any cat that shows an acute onset of paresis, hyporeflexia

and muscle tremors. There was a major outbreak of neurological dysfunction characterised by mild and severe tetraparesis, hyporeflexia, muscle tremor, dysphagia and autonomic signs in cats in the Netherlands in 1998. The cats had ingested the chicken coccidiostat salinomycin, which resulted in a distal axonopathy of peripheral nerves with both motor and sensory nerve affected. Other toxins incriminated in causing axonal degeneration in cats include chlorpyrophos (organophosphate) and acrylamide. The chemotherapeutic agent vincristine, frequently used in cats for cancer chemotherapy, can induce sensory motor polymyopathy and quadriparesis. Clinical signs will improve if vincristine is discontinued.

Chronic relapsing polyradiculoneuropathy

Cats with chronic progressive tremors, ataxia and weakness from polyneuropathy, which progresses to tetraparesis over weeks, are reported. Spinal reflexes are absent and evidence of paraesthesia is present. Nerve biopsy has identified axonal loss and demyelination. An immune-mediated pathogenesis is suspected and some improvement occurs with oral prednisone treatment (2–3 mg/kg daily) for 2 weeks, then reducing to alternate-day therapy.

Acute idiopathic polyneuropathy

Clinical signs begin with paraparesis, which often rapidly progresses to tetraparesis within 72 h. All spinal reflexes are depressed or absent. Sensation may be normal. In most cases of acute idiopathic polyneuropathy an underlying initiating cause cannot be determined. The disease is similar to 'coon hound' paralysis in dogs or Guillain–Barrésyndrome in humans. The motor nerve conduction velocity (MNCV) is normal or slowed, and fibrillation potentials and positive sharp waves are present after several days.

Mild cases may spontaneously recover with only supportive nursing care. In the acute phase in cases with severe tetraplagia, 10–15 mg/kg methylprednisone sodium succinate (SoluMedrol given every 6–8 h i.v. for the first 24 h may reduce the progression and severity of clinical signs. Then, 1 mg/kg per day oral prednisone may be given for 3 days. If the clinical signs remain stable, the dosage of prednisone may be tapered by reducing to 0.5 mg/kg per day for 3 days, then 0.25 mg/kg per day for 3 days, then 0.25 mg/kg every other day three times, then discontinued. Cats stabilise in 6–7 days and make a complete recovery in 4–6 weeks.

Feline dysautonomia (Key–Gaskell syndrome)

Feline dysautonomia is a polyneuropathy of unknown cause that affects autonomic ganglia, resulting in failure of the autonomic nervous system. The disease was first reported in the UK in the 1980s but has since been uncommon until increased numbers of cases were diagnosed in the early 2000s. There is usually a rapid onset of clinical signs, developing over 48 h, but slower progressive development can occur. Clinical signs include dilated pupils, prolapsed nictitating membranes, bradycardia, dry mucous membranes, megaoesophagus, regurgitation, constipation, bladder atony, dysuria, urinary incontinence, loss of anal tone and reflex, and anorexia. Cats become dehydrated and without nursing support and fluid replacement will deteriorate rapidly.

There is no breed or sex predisposition and the underlying cause is unknown, but a viral or toxic cause is suspected. There is a loss of neurons throughout the autonomic ganglia of the sympathetic and parasympathetic nervous system. Diagnosis is based on the characteristic clinical signs.

Pharmacological testing of ocular function (1% pilocarpine drops) to the eye results in pupillary constriction. Abdominal and thoracic radiography (distended bladder, megaoesphagus) and decreased plasma catecholamine concentrations may support a diagnosis.

Treatment is palliative and consists of fluid therapy, parenteral feeding (nasal or gastrostomy feeding tubes), laxatives, artificial tears, pilocarpine eye drops (one drop to both eyes every 12 h). The bladder should be emptied manually or by administering bethanecol hydrochloride (1.5–2.5 mg p.o. every 8 h). Metaclopramide (0.2–0.4 mg/kg p.o. every 8 h) may improve gastric emptying.

The survival rate is poor – only 20–30% of cats recover. If the cat resumes eating and drinking and oral secretion returns, the prognosis is good. Recovery can take months, but months of rigorous care are required assisting the cat to eat, giving enemas, emptying the bladder, and so on. Some that survive may have residual defects (e.g. pupillary abnormalities and faecal incontinence).

Localised tetanus

The cat is much more resistant to tetanus than most domestic animals. The resistance is because of the

inability of the toxin to penetrate the nervous system and attach to binding sites. Early investigators who injected tetanus toxin into cats found that the disease remained localised in the majority of cases. The diagnosis of generalised tetanus is straightforward because of the distinctive signs, of extensor rigidity, opisthotonus hyperaesthesia, trismus. Most cases have a history of a wound or injury 3–18 days before the development of clinical signs (Lee & Jones, 1996).

Localised tetanus involving an extremity with a contaminated wound is also uncommon and may progress to generalised tetanus, but signs usually remain mild, involving only those muscle groups controlled by adjacent spinal cord segments. The contaminated wound is often distal in the limb or in close proximity to the affected muscle groups. Localised tetanus has been diagnosed after surgery (ovariohysterectomy).

Diagnosis is suspected where there is spasticity of a limb or group of muscles, especially if there is a contaminated wound (Figure 7.16). The criteria for the diagnosis of localised tetanus are listed in Table 7.18. Treatment is directed at controlling the infection and spasticity, and neutralising the toxin. Cleaning the wound, and administering penicillin or amoxycilllin are recommended, along with tetanus antitoxin (10 000 IU i.v.). Diazepam (5 mg every 12 h) is effective in relieving spasticity.

Figure 7.16 Kitten with right forelimb spasticity suspected to be from local tetanus.

Table 7.18 Criteria required for a diagnosis of localised tetanus

An alert, healthy cat
Spasticity of a limb or group of muscles innervated by the same or adjacent spinal nerves
A wound (including surgical wounds) up to 3 weeks before the onset of signs
A wound close to or distal to the spastic muscle groups
Post-needle insertion electromyographic activity in affected muscle groups
The presence of clostridial organisms in Gram-stained smears from the contaminated wound
Elevated serum tetanus antibody concentrations

Trauma

Trauma to a peripheral nerve will result in altered or loss of function of the specific nerve. Relevant motor and sensory deficits and reflex change can be identified. Several characteristic peripheral nerve syndromes that are common in cats and are worthy of emphasis: nerve injuries associated with sacrococcygeal fractures, brachial plexus injuries with nerve root avulsion, radial nerve injury with humeral fractures and sciatic nerve damage from injection trauma or fractures.

Sacrococcygeal fractures

Injury to the sacrococcygeal area is common, often causing damage to nerve roots or the cauda equina.

There is usually history or evidence of trauma, the tail is paralysed and there is frequently urinary and faecal incontinence. The bladder is distended and may be difficult to express as the internal sphincter (hypogastric nerve) is intact and functional. The anus may be flaccid and areflexic. There is no voluntary urination. If the cauda equina and L7–S1 nerve roots are involved there may be a plantigrade posture (tibial nerve).

Radiography will determine the location of any fracture (Figure 7.17). If the fracture involves coccygeal vertebrae there is a better prognosis than if the sacrum is involved. Therapy is directed at relieving bruising and inflammation of nerves at the time of

Figure 7.17 Lateral radiograph showing a fracture of the sacrococcygeal vertebrae. The cat had faecal and urinary incontinence.

trauma by administering steroids (methylprednisone sodium succinate). Ongoing treatment is to empty the bladder manually two or three times daily, or bethanecol (1.5–2.5 mg every 8 h) can be used as an alternative in some patients. Phenoxybenzamine can be administered to relax the internal urethral sphincter before bethanecol administration. It is essential not to allow overdistension of the bladder, which can result in atony. Faecal softeners and/or enemas should be administered to relieve constipation. Function of the bladder and bowel may return, but nursing and care may need to be continued for several months.

Brachial plexus avulsion

As a result of trauma the nerve roots of the brachial plexus are stretched and pulled from the spinal cord. Ventral and distal nerve roots are involved but sensory roots are often spared. All nerves of the plexus can be affected, but C8–T1 roots are more often involved. The cats show a radial nerve paralysis and cannot bear weight, but if the musculocutaneous nerve roots are spared, the cat can flex the elbow and hold the limb off the ground. If the caudal nerve roots (C8–T2) are involved there is an absence of the panniculus reflex on the affected side and Horner's syndrome on that side. There will be sensory loss, but in this author's experience, the sensory pattern of loss can be confusing. The prognosis is guarded as, if there is avulsion of nerve roots from the spinal cord, there will be no recovery. Electrodiagnostic investigation can help to determine which nerve roots are involved and the extent of the injury, and assist in a prognosis. Amputation of the limb is recommended if avulsion is confirmed. The absence of Horner's syndrome and panniculus deficits makes a diagnosis of nerve root avulsion less likely and conservative treatment acceptable.

Radial nerve injury

Radial nerve injuries are not common in cats but do occur as a result of fractures of the humerus. The cat is non-weight-bearing in the affected limb, with analgesia of the cranial and lateral aspect of the forelimb, and the dorsal and lateral aspect of the paw. The principal differential diagnosis is made by a history of major external trauma and radiographs of the humerus. The principal differential diagnosis is brachial plexus nerve root avulsion. The presence of Horner's syndrome, loss of panniculus reflex or involvement of any additional nerve suggests that the injury is probably in the nerve roots and not in the radial nerve. Therapy consists of relieving the nerve compression and repairing the associated humeral fracture. The prognosis is generally fair to good.

Sciatic nerve injury

Sciatic nerve injury may result from sacroiliac luxation, pelvic fractures or injection trauma, and as a complication of femoral fractures or their repair. The peroneal nerve component causes loss of proprioception, so the cat walks on the dorsum of its toes. The tibial nerve component causes a dropped hock. These cats also have decreased flexor reflex.

Horner's syndrome

Horner's syndrome results from damage to the cervical sympathetic nerve and is characterised by a combination of miosis, ptosis enophthalmos and partial prolapse of the nictitating membrane of the affected eye (Figure 7.18); dilatation of the blood vessels on that side of the face and hyperaemia of the nose on the affected side may be seen (Figure 7.19). Oriental cats, whose coat colour is heat dependent, may show lighting of the mask on the affected side. Not all clinical signs will be present; miosis is most common sign. The common causes of Horner's syndrome are listed in Table 7.19. The presence of Horner's syndrome may be a helpful diagnostic aid. Treating the primary cause may result in recovery.

Pharmacological tests can localise the lesion to the preganglionic and postganglionic nerves; for example, 1% phenylephrine drops administered into the eyes will result in greater dilation of the normal pupil in postganglionic lesions. This is important because most postganglionic lesions are benign.

Figure 7.18 Horner's Syndrome in a young cat with chylomicronaemia

Table 7.19 Causes of Horner's syndrome

Upper motor neuron lesions	Intracranial neoplasia, trauma, infarct Cervical spinal cord lesion trauma, neoplasm
Preganglionic lesions	Spinal cord lesion T1–T3 (trauma, neoplasia, fibrocartilaginous embolus) Brachial plexus avulsion Cranial mediastinal mass (tumours) Cervical soft-tissue neoplasia, trauma Xanthomata (hyperchylomicronaemia)
Postganglionic lesions	Otitis media/interna Middle ear neoplasia Retrobulbar injury, neoplasia Idiopathic/unknown/feline leukaemia virus infection

Hypervitaminosis A

This is now an uncommon disease, but cats fed predominantly liver diets containing excess vitamin A can develop spinal lesions. Vertebral exostoses arising from the dietary imbalance produce compression of the peripheral nerve roots and/or spinal cord. The cervical spinal column is most often affected, with neurological signs predominantly affecting the forelimbs, paresis, muscle atrophy and hyperaesthesia. The neck may be rigid because of the exostoses fusing the vertebrae. Radiography will show the typical changes. Withdrawal of liver from the diet prevents further damage, but in severe cases the neurological defects may persist.

Myopathies

Myopathies, both inflammatory and non-inflammatory, are uncommon in the cat, with most of the non-inflammatory group classified as inherited dystrophies (Table 7.20).

Clinical signs and diagnosis

The clinical sign common to all neuromuscular diseases in the cat is weakness. The affected cat is frequently 'floppy', often with ventroflexion of the neck and reduced muscle tone (Figure 7.20). Muscle atrophy is expected, but in some dystrophies (e.g. myotonia and X-linked dystrophy), muscle hypertrophy is present. The severity of the weakness may be variable and muscle involvement can be focal.

Disorders of the neuromuscular junction present with varying clinical signs ranging from weakness with exercise to complete flaccid paralysis. Regurgitation, dysphonia or dysphagia may be present if oesophageal and pharyngeal muscles are involved and their function is affected. Pain on palpation can occur with

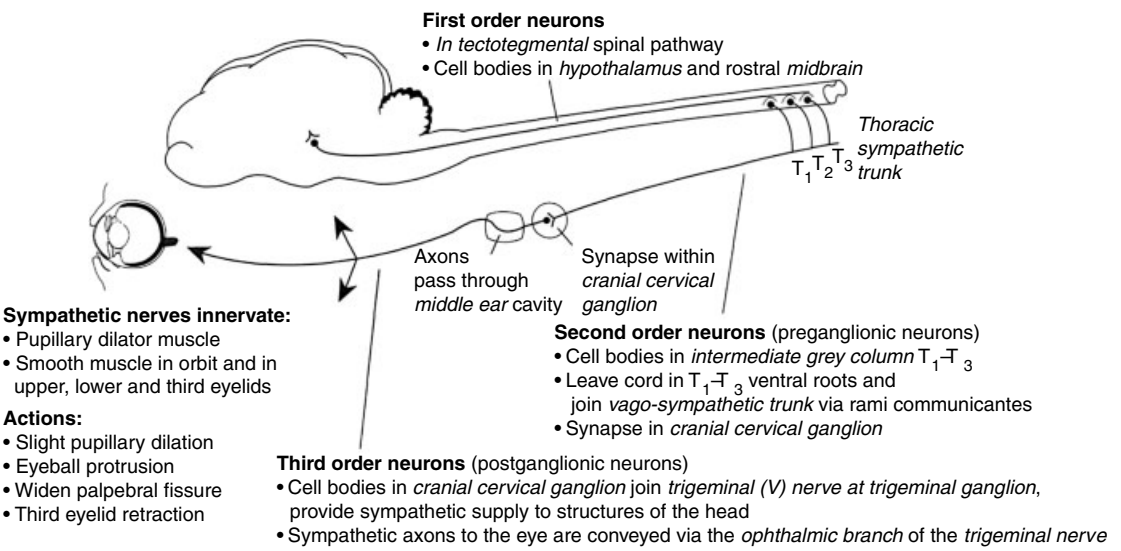

Figure 7.19 Sympathetic innervation to the eye and adnexia. (Reproduced from Petersen-Jones, 1995, with permission from BSAVA.)

Table 7.20 Congenital myopathies in cats

Disease	Affected breeds and geographical distribution	Mode of inheritance	Underlying effect	Clinical signs	Prognosis
Congenital myotonia	DSH (NZ, USA)	Autosomal recessive	Probable defect in chloride channels	Stiff gait; hyperactivity of selected muscle groups when startled; percussion dimple	Fair to good (non-progressive condi tion, cats enjoy a normal quality of life)
Devon Rex myopathy	Devon Rex (AUS, GB)	Autosomal recessive	Unknown	Cervical ventroflexion; generalised muscle weakness; abnormal gait; megaoesophagus	Poor (many cats die of asphyxiation)
Dystrophin deficiency	DSH (USA, NL, CH)	X-linked recessive	Dystrophin deficiency	Skeletal muscle hypertrophy with possible complications; sensitivity to stress; stiff gait	Guarded to fair (cats can have almost normal quality of life, but may require more frequent veterinary visits)
Glycogen storage disease type IV	Norwegian forest cats (USA, Europe)	Autosomal recessive	Glycogen branching enzyme deficiency	Stillbirth; muscle tremor; muscle atrophy, cardiomyopathy	Poor (all cats eventually die)
Hypokalaemic myopathy	Burmese (AUS, NZ, GB, NL)	Probably autosomal recessive	Unknown	Transient, paroxysmal clinical signs with generalised muscle weakness, cervical ventroflexion	Good response to potassium supplementation
Merosin-deficient myopathy	DSH, Siamese (USA)	Unknown	Merosin (laminin α_2) deficiency	Hindlimb weakness from 6 months old, worsening to muscle atrophy and contractures at 1 year old	Poor (both reported cats underwent euthanasia before 2 years of age)
Myasthenia gravis	DSH	Unknown	Lack of acetycholine receptors	Generalised muscle weakness	Fair, generally good response to therapy
Nemaline myopathy	DSH (USA)	Possibly autosomal recessive	Unknown	Progressive weakness (6–18 months old); rapid, choppy, hypermetric gait, tremor, exercise intolerance	Poor (all five reported cats died or underwent euthanasia)

DSH: domestic shorthair; NZ: New Zealand; USA: United States of America; AUS: Australia; GB: Great Britain; NL: Netherlands; CH: Switzerland.

Figure 7.20 Adult cat with organophosphate toxicity and ventroflexion of the head.

inflammatory myopathies. Hypotonia and hyporeflexia may occur, but these signs are mild and sensation is not impaired as it is with neuropathies.

Differentiation of individual myopathies from their clinical signs can be difficult, and diagnosis depends on the results and interpretation of ancilliary tests. A haemogram and serum chemistries including electrolytes and creatine kinase (CK) should be performed. Electrolyte abnormalities are readily detected. Elevation of CK supports myofibre necrosis or leakage of the myofibre membrane and an elevated value is supportive of muscle disease. Specific diagnostic tests (e.g. *Toxoplasma* spp. serology, radiology, detection of acetylcholine receptor antibodies) may be indicated to confirm or support a specific diagnosis.

Electrodiagnostic testing, includes EMG, measurement of nerve conduction velocity and measurement of evoked compound muscle action potentials. If these diagnostic procedures support a myopathy, muscle and peripheral nerve biopsies are indicated. Electrodiagnostic testing can confirm which muscles are involved and which should be biopsied.

Histopathological examination of the muscle specimen can confirm muscle involvement and rule out peripheral nerve disease. The biopsy should provide information for the diagnosis of a specific disease (dystrophy) and the severity of the disease. Further biochemical, ultrastructural or immunohistochemical studies may be indicated. Veterinary surgeons are advised to contact their diagnostic laboratory before performing a biopsy to ensure that precise requirements are followed regarding sampling, handling and shipping the specimens. The correct collection and processing of muscle specimens is essential; fresh or frozen samples are easiest to analyse and give the greatest flexibility for special investigation. Formalin-fixed tissue is less valuable.

Hereditary non-inflammatory myopathies

Muscular dystrophies

These are inherited progressive non-inflammatory myopathies. Several are reported in cats and for some diseases the molecular and biochemical defects have been defined.

Dystrophin-deficient myopathy

Dystrophin-deficient myopathy is a rare disease caused by an almost total lack of dystrophin, a large protein indirectly connecting the internal cytoskeleton with the extracellular matrix. Dystrophin deficiency is due to a mutation in the dystrophin gene, a very large gene located on the X-chromosome, and is transmitted according to an X-linked recessive inheritance pattern (Gaschen *et al.*, 1992).

Contrary to what is seen in affected humans and dogs with Duchenne dystrophy, the hallmark of the disease in cats is severe hypertrophy of the axial and proximal appendicular skeletal muscles. It is, therefore, given the name hypertrophic feline muscular dystrophy (HFMD). The tongue and diaphragm also show massive hypertrophy in some individuals. Cats may develop potentially lethal complications due to hypertrophy of selected muscles, such as oesphageal compression by hypertrophic diaphragmatic pillars, or insufficient water intake and severe hyperosmolality due to dysfunction of the tongue. Dystrophin-deficient cats may succumb to peracute rhabdomyolysis occurring in association with general anaesthesia, intense physical activity or, sometimes, stress.

Dystrophin-deficient kittens cannot be differentiated from healthy kittens at birth, although they have a slower growth rate than their normal littermates. Appendicular muscular hypertrophy is evident at around 10 weeks of age, and is followed by hypertrophy in the axial musculature, especially the cervical muscles. White nodules consisting of dystrophic calcifications may appear on the edges of the enlarged tongue and disappear spontaneously a few weeks later (Figure 7.21). Cats with HFMD have a slightly stilted gait, and they 'bunny hop' when they run. Occasionally, the gait is more abnormal, with marked stiffness and reluctance to move, probably associated with episodes of increased muscle fibre necrosis.

Dystrophin-deficient cats develop a subclinical cardiomyopathy. Cardiomegaly and changes indicative

Figure 7.21 An adult dystrophin deficient cat with muscular hypertrophy and hypertrophy of the tongue. (Courtesy of F. Gaschen.)

of progressive concentric myocardial hypertrophy are observed in cats from 6 to 9 months of age. The appearance of the myocardium is abnormal. However, fractional shortening of the left ventricle is usually normal, suggesting normal left ventricular contractility. These cats only infrequently develop clinical features of heart failure.

EMG findings include a variety of anomalies, including myotonic discharges, fibrillation potentials, prolonged insertional activities, complex repetitive discharges and positive sharp waves.

In young and adult cats with HFMD, serum CK activity remains markedly increased. However, serum CK concentrations do not allow a differentiation between dystrophin-deficient kittens and their healthy littermates at birth. The CK values progressively increase in the weeks after birth. Serum activities of aspartate aminotransferase (AST) and alanine aminotransferase (ALT) are also increased.

Histopathological changes include degeneration and regeneration of fibres. There is a wide variation in myofibre diameter, with large myofibres showing splitting, foci of degeneration and regeneration, and minimal mononuclear infiltration. A unique feature of this myopathy is the frequency and severity of foci of dystrophic calcification. A definitive diagnosis can be made when fresh-frozen sections immunohistochemically stained for dystrophin show a lack of dystrophin at the sarcolemma.

There is no treatment, but the prognosis for HFMD is fair. Most animals can enjoy a nearly normal quality of life with support when needed. However, stress, intense physical activity and inhalant anaesthesia should be avoided.

Myotonia

Myotonia is the continued active contraction of a muscle after the cessation of voluntary effort and is characterised by muscle spasm and stiffness. Hereditary myotonia has been reported in a variety of species, but only recently in the cat (Hickford *et al.*, 1998). The disease has an autosomal recessive mode of inheritance. Myotonia can occur either secondary to other diseases (e.g. muscular dystrophies and endocrinopathies) or as a primary disorder, myotonia congenita, but only primary congenital myotonia has been described in the cat.

The affected cats walk with a stiff, awkward gait. The limbs are abducted when walking, owing to poor flexion of proximal limb joints. There is hypertrophy of muscle groups. The stiffness is worse on awakening and in cold weather, but improves with exercise. When affected kittens are startled they may stiffen and fall into lateral recumbency with their legs extended. Spasm of the eyelids and facial muscles also occurs when they are startled (Figure 7.22). Their jaws cannot be opened fully and there is sometimes mild dysphagia. Haematology and clinical chemistry, including CK, cholesterol and electrolytes, are normal.

Figure 7.22 An affected myotonic cat showing flattening of the ears and retraction of the ear after receiving a fright. (Reproduced from Jones, 2000, with permission of WB Saunders).

The presence of a dimple on percussion of muscle (tongue or skeletal muscle) and the occurrence of spontaneous high-frequency discharges which wax and wane after insertion of a needle electrode are features of all affected cats. EMG amplification produces the 'dive bomber' sound, a feature of myotonia.

Histological sectioning of muscle shows a variation in fibre size diameter, central nuclei and proliferation of sarcolemmal nuclei.

The pathophysiology of myotonia has been intensely investigated in other species. A primary defect in chloride conductance in the sarcolemma is the underlying abnormality in most species, but the sarcolemmal and genetic defects have not been investigated in the cat.

The reports of myotonia in cats neither described treatment nor emphasised that drug therapy was needed.

Glycogen storage disease type IV

A myopathy associated with glycogen storage disease type IV has been reported in Norwegian forest cats in the USA. The disease is caused by a lack of the glycogen branching enzyme (GBE) and is characterised by an accumulation of abnormal glycogen in several tissues, including skeletal muscle. There is accompanying severe degeneration of the central and peripheral nervous system. Hereditary transmission occurs according to an autosomal recessive pattern. Affected cats are homozygous for a deletion in the GBE gene, causing instability of mRNA.

Many affected cats are stillborn or die within the first few days of life. The surviving cats are often normal until they reach 5–7 months of age. At that time, they show persistent pyrexia, generalised muscle tremors, listlessness and a 'bunny-hopping' gait. Muscle weakness and muscle atrophy progress rapidly, resulting in inability to chew, fibrotic contractures of some joints and tetraplegia. The disease often leads to the death of the cat around the age of 10–14 months.

Analysis of glycogen in affected cats demonstrates less than 10% of normal concentration of branching enzyme in liver and muscle. Laboratory abnormalities include the increases in serum CK and ALT. Fibrillation potentials and bizarre high-frequency discharges are present on the EMG. There is currently no treatment available for this disease.

A DNA-based carrier test is available in selected laboratories to screen problem breeding families.

Laminin α_2 (merosin) deficiency

Laminin α_2 is a glycoprotein indirectly anchoring the cell membrane and the basal lamina in skeletal muscle and Schwann cells. Two merosin-deficient cats have been investigated. Both animals had hindlimb weakness starting at 6 months of age. When they were presented at the age of 12 months, generalised muscle atrophy was noticed. One cat had marked hindlimb extensor muscle contractures and was unable to walk on the hindlegs. The disease progressed to involve thoracic and masticatory muscles by 19 months of age. The other cat was presented in recumbency, was hypotonic and hyporeflexive, and showed generalised muscle atrophy.

Serum CK is markedly increased. Histopathological examination reveals dystrophic changes with marked endomysial fibrosis in all muscles. Myofibre necrosis, variation in fibre size and lipid accumulation are also present. Axonal demyelination is present in peripheral nerves and motor nerve condition velocity reduced. Immunohistochemical stains reveal a lack of or a decrease in laminin α_2 in skeletal muscle. No specific therapy is available.

Myopathy of Devon Rex cats

An inherited muscular dystrophy characterised by muscle weakness has been recognised in the Devon Rex breed since 1974 (Malik *et al.*, 1993). The condition has been seen throughout the world and is erroneously called 'spasticity' by many Devon Rex breeders.

The most obvious and consistent clinical sign is passive ventroflexion of the head and neck. Ventroflexion is frequently accentuated when walking, and during micturition and defecation. Muscle weakness is particularly evident during exertion, excitement or stress. Typically, there is a high-stepping forelimb gait, head bobbing and dorsal protrusion of the scapulae owing to weakness of the shoulder girdle musculature. With exertion they tire easily and eventually collapse in sternal recumbency with their head at rest on one side of their front paws.

Affected cats frequently rest in a characteristic 'dog-begging' position with their front paws resting on a supporting object. This position allows them to maintain a normal orientation of their head despite weakness of the cervical muscles.

One of the significant features of the disease is the difficulty that affected cats have taking food and swallowing. They frequently develop upper airway obstruction and 'choking' due to the accumulation of food in

the region of the larynx. Asphyxiation is a common cause of death. Feeding cats from a raised platform minimises the risk of asphyxiation. The severity of signs often fluctuates from day to day and week to week. Stress, concurrent illness and cold all accentuate weakness.

The age of onset is variable and less seriously affected kittens may go unnoticed for several months. Breeders normally identify the affected kittens at about the time they start to walk. The disease is inherited as an autosomal recessive trait.

Some affected cats have oespohageal hypomotility and megaoesophagus. Haematological and serum biochemistry values including electrolytes and CK are within reference ranges.

Neurophysiological findings are variable. Sparse fibrillation potentials and positive sharp-wave activity may be detected on electrode insertion into cervical and upper limb muscles.

Skeletal muscles appear grossly normal, but histological changes are best identified in dorsal cervical and proximal forelimb muscles. The severity of the changes present correlates with both the severity of signs and the age at the time of biopsy. The significant lesions on muscle biopsies are variation in cross-sectional area, more rounded fibres, occasional degenerating fibres, some fibre segmentation and increased subsarcolemmal nuclei. There is no fibre type distribution of lesions and dystrophin is present. The above signs are characteristic of a muscular dystrophy and, although the disease is inherited, the underlying pathogenesis and the genetic basis of the metabolic defect have not been defined.

Nemaline myopathy

In this familial myopathy, nemaline rod accumulation in myofibres is a characteristic finding. The onset of clinical signs varies from 6 to 18 months of age and consists of proximal muscle atrophy, hyporeflexia, reluctance to move, muscle twitching and an abnormal, stiff gait. Nemaline rods are found within skeletal muscle fibres that ultrastructurally resemble those described in human nemaline myopathy.

Generalised ossifying myositis

Two young cats have been described with ossification affecting skeletal muscle and fibrous connective tissue. Clinical presentation was for progressive weakness, stiffness, difficulty in jumping, decreased range of limb motion and pain on movement. Diagnosis was based on radiological changes, which included extensive soft-tissue mineralisation, and pathological changes within muscle, including ossification with well-differentiated cartilage and bone. The condition is progressive and the prognosis poor.

Hypokalaemic polymyopathy

There have been numerous reports of polymyopathy in cats associated with a variety of different causes of hypokalaemia. Burmese kittens develop hypokalaemia associated with disturbances of the intracellular and extracellular balance of potassium. The syndrome in Burmese kittens bears many similarities to hypokalaemic periodic paralysis of humans, a condition that is thought to be related to a calcium channel disorder. However, gene sequence data show no evidence for a mutation in the gene for the calcium channel in Burmese cats. The condition has a familial and inherited basis (putative autosomal recessive trait), and has been reported in Burmese kittens in the UK, Australia and New Zealand (Jones, 2000).

The clinical signs are frequently transient, with moderate to severe episodes followed by improvement (with or without treatment), but sometimes clinical signs are persistent. There is generalised muscle weakness with persistent ventroflexion of the neck with the head tucked into the sternum. Affected kittens are intolerant of exercise and walk with a stiff, stilted, awkward gait. There may be exertional muscle tremor followed by sudden fatigue and collapse. Severely affected cats are reluctant to move and show pain when their muscles are palpated.

The presence of a low serum potassium (<3.0 mmol/l) will confirm a diagnosis of hypokalaemia, although serum potassium values can be higher in some cats showing clinical signs. The low serum potassium value is frequently accompanied by increased serum activity of CK. CK is released only when the concentration of potassium in the muscle is very low. CK values can be very elevated ($>50\,000$ IU/l). There is no evidence for reduced potassium intake or urinary potassium loss in affected Burmese cats.

Diffuse EMG abnormalities are sometimes present (e.g. positive sharp waves may be recorded). Muscle biopsy specimens are mostly normal on microscopy, but mild myofibre necrosis is occasionally observed. Severe rhabdomyolysis is absent.

The clinical signs of muscle weakness are reversible and the response to potassium supplements is rapid. Continued treatment with oral potassium (potassium gluconate; 2–4 mmol/cat p.o. daily) is safe and effective. The signs in some kittens resolve without further treatment.

Acquired myopathies

Polymyositis has been associated with infectious diseases (toxoplasmosis and retroviral infections), thymoma and immune-mediated diseases, and may occur concurrently with myasthenia gravis (MG).

Protozoal myositis

Toxoplasma gondii may cause myositis in cats. It occurs most frequently in association with postnatal infection, and there may be associated clinical signs referable to other organ systems, including the eyes and CNS. Serum CK is usually elevated. The administration of corticosteroids or concurrent infection with either FeLV or FIV may predispose cats reactivation of a latent infection. Protozoal cysts may be observed within muscle biopsy samples, but the absence of the cysts does not rule out this protozoan. Definitive diagnosis usually depends on positive serology. Recommended treatment is with either clindamycin (25–50 mg/kg p.o. or i.m. every 8–12 h) or trimethoprim–sulfonamide (30 mg/kg p.o. every 12 h). (See Chapter 28 for a complete discussion of toxoplasmosis.)

Immune-mediated polymyositis

Polymyositis with a presumed immune-mediated aetiology occurs in the cat. Hyperthyroid cats treated with methimazole have developed immune-mediated polymyositis. Clinical signs include muscle weakness and ventroflexion of the neck muscles, which may be painful. Dysphagia may be observed. Serum CK concentrations are usually moderately to markedly elevated. Muscle biopsies from affected cats demonstrate mutifocal areas of mononuclear cell infiltration, with an endomysial or perimysial distribution with invasion of myofibres. Immunosuppressive doses of corticosteroids (prednisone 2 mg/kg p.o. every 12 h) are recommended. Many cats improve but the prognosis is guarded, especially if thymoma and/or myasthenia occur concurrently.

Potassium-depletion polymyopathy

This polymyopathy results from a severe total body potassium depletion, a reduced potassium intake and/or an increased loss of potassium in urine owing to renal disease, with chronic renal failure the most common cause. The potential causes of hypokalaemia are listed in Table 7.21. Clinical signs include muscle weakness, cervical ventroflexion, stiff and stilted gait, muscle pain and clinical signs of renal disease (azotaemia, polyuria, etc.).

The ingestion of certain commercial diets and underlying renal disease have been associated with increased occurrence of severe hypokalaemia in cats. Excessive potassium loss occurs as renal function deteriorates, and clinical signs result if the dietary intake of potassium is inadequate to replace the loss.

An improvement in muscle strength results from changing the diet to one with a higher potassium content or after dietary supplementation with potassium.

For cats with mild to moderate hyokalaemia, treatment includes oral supplementation of potassium gluconate (Tumil-K powder) and dietary modification. In cats with severe hypokalaemia, parenteral potassium therapy is required.

Disorders of the neuromuscular junction

Several disorders of neuromuscular transmission result in presynaptic or postsynaptic defects at the neuromuscular junction, acquired MG being the most important disease. Tick paralysis, toxins, snakebite (Elapidae), neurotoxins and botulinum toxin interfere with

Table 7.21 Conditions associated with hypokalaemia in cats

Hyperaldosteronism (Conn's syndrome) caused by an adrenocortical tumour
Renal tubular acidosis
Thyrotoxicosis
Chronic renal failure
Metabolic acidosis
Dietary (potassium deficiency, acidified diet)
Insulin overdosage
Diuretic therapy (frusemide)
Chronic vomiting and diarrhoea
Fluid administration (plasma dilution and induced diuresis)
Idiopathic (Burmese breed)
Systemic disease (hepatic disease, infectious disease)

acetylcholine release and synaptic transmission. There may be significant CK elevation (e.g. after tiger snake bite). Some of these conditions are confined to certain countries.

Organophosphate toxicity

A delayed form of neurotoxicity can occur in cats with prolonged exposure to organophosphate compounds, even days to weeks after initial exposure. The delayed form of toxicity is characterised by neuromuscular weakness without autonomic dysfunction. Low serum cholinesterase values (<25% reference values) may confirm a diagnosis. Cats improve without treatment if there is no further exposure to organophosphates, however, diphenhydramine (4 mg/kg every 8 h) can hasten recovery. Dihenhydramine blocks the effect of nicotinic receptor overstimulation.

Myasthenia gravis (see Chapter 8)

Muscular weakness due to congenital or acquired MG is the result of a postsynaptic defect at the nicotinic neuromuscular junction. Both congenital and acquired MG have been documented in the cat (Ducoté & Dewey, 2001). There may be a higher incidence in Somali and Abyssinian cats. Both forms are rare compared with the dog. In the acquired form autoantibodies directed against nicotinic acetylcholine receptors result in a decreased receptor content on the postsynaptic membrane. Autoantibodies against acetylcholine receptors are present in acquired MG. Both forms of the disorder cause defective neuromuscular transmission and muscle weakness.

Myasthenia gravis has been associated with thymoma and immune-mediated myositis.

General weakness is brought on by exercise. The focal form of MG is described but is rare. Affected cats tire easily, are reluctant to move and show muscle tremors. They move with a crouching gait and then flop onto their sides with their head resting on their paws. Megaoesophagus can occur with regurgitation of food, and there may be an altered meow and dysphagia. After resting, clinical signs will improve until the cat exercises again.

Diagnosis is made through these suggestive clinical signs, demonstration of increased muscle strength after the administration of the cholinesterase inhibitor edrophonium chloride (Tensilon 0.1 mg/kg i.v.) and decrement of the evoked muscle action potential after repetitive nerve stimulation.

Demonstration of the presence of antibodies against the nicotinic acetylcholine receptor is a specific and sensitive diagnostic test, but this test cannot diagnose the congenital form of the disease.

Treatment

Anticholinesterase drugs are recommended for both acquired and congenital MG. Pyridostigmine bromide (Mestinon) is a long-acting anticholinesterase drug. The recommended dose is 0.5–2.0 mg/kg p.o. every 12 h, with adjustments in dosage based on improvement in muscle strength and the duration of improvement. Immunosuppressive dosages of corticosteroids (prednisone 2–4 mg/kg p.o. daily) with a gradual reduction in this dose over 6–10 weeks are indicated, especially if there is concurrent myositis. If thymoma is present, thymectomy (which is preferred) or chemotherapy is indicated.

References

Bagley R.S. (1999) Traumatic brain disease. In *Consultations in Feline Internal Medicine*. 3rd edn (ed. August J.). WB Saunders, Philadelphia, PA, pp. 406–415.

Baxter A.C., Holt P.E. & Pearson G.R. (1988) Congenital portosystemic shunts in the cat: a report of nine cases. *J Small Anim Pract* **29**, 631–639.

Bonagura J. (ed.) (1999) *Kirk's Current Veterinary Therapy*, Vol. XIII. WB Saunders, Philadelphia, PA.

Braund K.G. (1994) Diagnostic techniques. In *Clinical Syndromes in Veterinary Neurology*. 2nd edn (ed. Braund K.G.). Mosby, St Louis, MO, pp. 333–421.

Coates J.R. & Sullivan S.A. (2001) Congenital cranial and intracranial malformation. In *Consultations in Feline Internal Medicine*. 4th edn (ed. August J.R.). WB Saunders, Philadelphia, PA, pp. 413–423.

Cuddon P.A. (2002) Electrophysiology in neuromuscular disease. *Vet Clin North Am* **32**, 31–62.

De Lahunta A. (1977) Vestibular system – special proprioception. In *Veterinary Neuroanatomy and Clinical Neurology*. WB Saunders, Philadelphia, PA, p. 227.

Dickinson P.J. & Le Couteur R.A. (2002) Muscle and nerve biopsy. *Vet Clin North Am* **32**, 63–102.

Ducoté J.M. & Dewey C.W. (2001) Acquired myasthenia gravis and other disorders of the neuromuscular junction. In *Consultations in Feline Internal Medicine*. 4th edn (ed. August J.R.). WB Saunders, Philadelphia, PA, pp. 374–379.

Gachen F., Hoffman E.P., Gorospe J.R.M., *et al*. (1992) Dystrophin deficiency causes lethal muscle hypertrophy in cats. *J Neurol Sci* **110**, 149–159.

Griffiths I.R. (1995) Neurological examination of the limbs and body. In *BSAVA Manual of Small Animal Neurology*. British

Small Animal Veterinary Association, Cheltenham, pp. 27–39.

Gunn-Moore D.A. & Harbour D.A. (2001) Feline spongiform encephalopathy and borna disease. In *Consultations in Feline Internal Medicine*. 4th edn (ed. August J.R.). WB Saunders, Philadelphia, PA, pp. 62–70.

Hickford F.H., Jones B.R. Gething M.A., *et al.* (1998) Congenital myotonia in related kittens. *J Small Anim Pract* **39**, 281–285.

Jones B.R. (1999) Hypokalemic myopathy in cats. In *Kirk's Current Veterinary Therapy*, Vol. XIII (ed. Bonagura J.). WB Saunders, Philadelphia, PA, pp. 985–987.

Jones B.R., Alley M.R., Shimada A. & Lyon M. (1992) An encephalopathy in related Birman kittens. *N Z Vet J* **40**, 160–163.

Le Couteur R.A. (2001) Cerebral meningiomas: diagnostic and therapeutic considerations. In *Consultations in Feline Medicine*. 4th edn (ed. August J.R.). WB Saunders, Philadelphia, PA, pp. 385–392.

Le Couteur R.A. & Vernau K. (1999a) Feline vestibular disorders. Part I. Anatomy and clinical signs. *J Feline Med Surg* **1**, 71–80.

Le Couteur R.A. & Vernau K. (1999b) Feline vestibular disorders. Part II. Diagnostic approach and differential diagnosis. *J Feline Med Surg* **1**, 81–88.

Lee E.A. & Jones B.R. (1996) Localised tetanus in two cats after ovariohysterectomy. *N Z Vet J* **44**, 105–108.

Malik R., Mepstead K., Yang F. & Harper C. (1993) Hereditary myopathy of Devon Rex cats. *J Small Anim Pract* **34**, 539–546.

March P.A. (2001) Neuronal storage diseases. In *Consultations in Feline Internal Medicine*. 4th edn (ed. August J.R.). WB Saunders, Philadelphia, PA, pp. 393–404.

Moreau P.M. & Wheeler S.J. (1995) Examination of the head. In *BSAVA Manual of Small Animal Neurology*. British Small Animal Veterinary Association, Cheltenham, pp. 15–17.

Morgan J.S. (1999) Radiographic and myelographic diagnosis of spinal disease. In *Consultations in Feline Internal Medicine*. 3rd edn (ed. August J.R.). WB Saunders, Philadelphia, PA, pp. 425–458.

Oliver J.E. (1990) Localisation of lesions: the anatomic diagnosis. *Prog Vet Neurol* **1**, 28–39.

Petersen-Jones S.M. (1995) Abnormalities of eyes and vision. In *BSAVA Manual of Small Animal Neurology*. 2nd edn (ed. Wheeler S.J.). British Small Animal Veterinary Association, Cheltenham, pp. 125–142.

Quesnel A.D. & Parent J. (1999) Diagnostic approach and medical treatment of seizure disorders. In *Consultations in Feline Internal Medicine*. 3rd edn (ed. August J.R.). WB Saunders, Philadelphia, PA, pp. 389–402.

Reeves N.A., Helps C.R., & Gunn-Moore D.A. (1997) Natural Borna disease virus infection in cats in the United Kingdom. *Vet Rec* **143**, 523–526.

Schaer M. (ed.) (2002) *Clinical Medicine of the Cat and Dog*. Manson Publishing, London.

Shell L.G. (1990) The cranial nerves and brain stem. *Prog Vet Neurol* **1**, 223–246.

Smith M.O. (1999) Nervous system neoplasia. In *Consultations in Feline Internal Medicine*. 3rd edn (ed. August J.R.). WB Saunders, Philadelphia, PA, pp. 418–424.

Thrall M.A. (2001) Mucopolysaccharidosis. In *Consultations in Feline Internal Medicine*. 4th edn (ed. August J.R.). WB Saunders, Philadelphia, PA, pp. 450–459.

Chapter 8

THE MUSCULOSKELETAL SYSTEM

D. Bennett

Introduction

There are several possible ways of classifying the musculoskeletal diseases and the accuracy of any classification depends on the available information. The classification used here (Table 8.1) is simple and probably most relevant to the clinician.

Traumatic disease

Fractures

Bone fractures are not uncommon in cats. The exact traumatic episode is generally unknown; cats either arrive home or are found in an injured state. Road traffic accidents or falls from a height are the most likely cause. Various surveys have been reported and indicate that the femur, tibia, mandible and pelvis are the most commonly fractured bones (Carter, 1964; Hill, 1977; Knecht, 1978). In a survey of feline pelvic fractures (Bennett, 1975) the average age of cats sustaining pelvic injury was 1.3 years; it is suggested that young animals learn to cope with their environmental hazards through experience, but the very young cat is more likely to remain close to the home environment and is thus more protected.

The repair of fractures is beyond the scope of this chapter. Various surgical techniques can be used, although conservative treatment is often gratifying as,

Table 8.1 Classification of diseases of the feline musculoskeletal system

Traumatic disease
Fractures
Luxations/subluxations
Tendon injuries

Bone infections
Bacterial
Mycotic

Metabolic bone diseases
Nutritional secondary hyperparathyroidism
Osteodystrophy of mature cats
Rickets (osteomalacia)
Hypervitaminosis A
Hypovitaminosis A
Renal secondary hyperparathyroidism
Primary hyperparathyroidism
Primary hypoparathyroidism

Arthritis
Traumatic arthritis
Osteoarthritis
Infective arthritis
Immune-based arthritis

Neoplastic and neoplastic-like lesions
Osteocartilaginous exostoses
Osteosarcoma
Extraskeletal osteosarcoma
Extraskeletal osteoma
Parosteal osteoma
Chondrosarcoma
Osteoma
Osteoid osteoma
Multilobular chondromas
Osteoclastoma
Giant cell sarcoma
Spindle cell sarcoma
Fibrosarcoma
Synovioma
Synovial sarcoma
Aneurysmal bone cyst
Fibrous dysplasia

Continued

Table 8.1 (*continued*)

Neoplastic and neoplastic-like lesions (*continued*)
Metastatic neoplasms of bones and joints
Direct extension of neoplasms to bone
Synovial cyst
Synovial osteochondrometaplasia

Inherited, congenital and developmental disorders
Osteogenesis imperfecta
Sacrocaudal dysgenesis in Manx Cats
Kinked tail
Polydactylia
Ectrodactylia
Syndactylia
Amelia and hemimelia
Arrested development of long bones of forelimbs
Mandible ramus aplasia
Congenital duplication
Arthrogryposis
Chondrodysplasia
Achondroplasia
Congenital hypothyroidism
Maxillofacial compression
Craniofacial malformation in Burmese cats
Pectus excavatum
Other skeletal abnormalities
Other congenital abnormalities
Mucopolysaccharidosis
Other lysosomal storage diseases
Patellar luxation
Proximal femoral metaphyseal osteopathy
Feline capital physeal dysplasia syndrome
Hip dysplasia
Osteochondrosis

Neuromuscular diseases
Inherited myopathies
Feline X-linked muscular dystrophy
Nemaline myopathy
Generalised ossifying myositis
Myotonia
Hereditary myopathy of the Devon Rex
Glycogen storage diseases

Acquired myopathies
Myositis
Hypokalaemic polmyopathy
Burmese sporadic myopathy
Localised ossifying myositis

Neuromuscular junction disorders
Myasthenia gravis
Organophosphate toxicity

Inherited neuropathies
Hyperoxaluric neuropathy
Neuropathy associated with hyperchylomicronaemia
Neuropathy associated with sphingomyelinase deficiency
Distal axonopathy of Birman cats

Acquired neuropathies
Ischaemic polyneuropathy (aortic thromboembolism)
Polyneuropathy associated with salinomycin
Diabetic polyneuropathy
Traumatic neuropathy
Neoplasia

Other myopathies
Tetanus
Fibrotic myopathy
Contracture of the gastrocmenius muscle/tendon
Dystrophy-like myopathies
Others

Diseases of the vertebral column
Intervertebral disc protrusions
Spondylosis deformans and ankylosing hyperostosis
Bacterial discospondylitis
Atlantoaxial subluxation

Miscellaneous diseases
Hypertrophic pulmonary osteoarthropathy
Disuse osteopenia
Osteopetrosis
Myelofibrosis/osteosclerosis syndrome
Feline hyperaesthesia syndrome

for example, with pelvic fractures. Recent studies have shown that the external fixator is well tolerated by the cat and can be used to treat a number of fracture problems in this species (Langley-Hobbs *et al.*, 1997). In general, cats are very co-operative orthopaedic patients and healing complications are relatively rare.

Luxations/subluxations

Traumatic luxations of joints usually follow a suspected road accident or fall from a height. The hip is the most commonly dislocated joint of the cat (Figure 8.1) (Bennett, 1975). This is usually treated successfully by external reduction under general anaesthesia. Strapping of the leg is not advisable in cats, since they tend not to tolerate the sling at all well. Recurrent hip luxations may be treated by transarticular pinning (Bennett & Duff, 1980) or by femoral head excision, although cats can often manage well with a permanently luxated hip (Bennett, 1975).

Total luxation or subluxation of the femorotibial joint may occasionally be seen following road traffic injuries (Figure 8.2). Such luxations are associated with cruciate and collateral ligament rupture. Careful

Figure 8.1 Craniodorsal radiograph of the pelvis showing a craniodorsal hip luxation.

Figure 8.2 Mediolateral radiograph of the stifle joint of the cat showing luxation of the femorotibial joint.

Figure 8.3 Mediolateral radiograph of the stifle joint of the cat showing a cross-pinning technique to stabilise a luxated stifle.

reconstruction of the damaged ligaments is recommended in these cases, although stabilisation of the joint with cross-pins or a single transarticular pin has been described (Figure 8.3); the pins are removed after 3 weeks. Antebrachiocarpal luxation in the cat is occasionally encountered and is best treated by carpal arthrodesis using a 2.7/2.0 mm hybrid carpal arthrodesis plate (Li *et al.*, 1999). The femoropatellar joint may also luxate secondary to trauma and usually responds to capsular tightening. The patella may also luxate in association with a dislocated hip joint. The tarsocrural joint is commonly luxated or subluxated, often associated with fractures of the medial and/or lateral malleoli of the hock (Figure 8.4). Treatment is by fixation of the fractured malleoli, usually by a tension band wiring technique or by reconstructing the collateral ligaments of the hock. Although most ligament tears in cats are associated with major trauma, there is a report suggesting that there may be a gradual failure of the cranial cruciate rupture akin to that seen in dogs (Janssens *et al.*, 1991; Schrauwers & Appeldoorn, 1991). Furthermore, a tentative association between cruciate failure and cardiomyopathy in the cat has been suggested (Janssens *et al.*, 1991). However, most cranial cruciate ligament failures in the cat are caused by major trauma and are associated with other stifle injuries (Tacke & Schimke, 1995).

Falls may sometimes dislocate the temporomandibular joint, either unilaterally or bilaterally. Occasionally, there is also a fracture of the mandibular symphysis or horizontal/vertical rami. Reduction of the dislocation under anaesthesia is not difficult, using a small rod as a fulcrum inserted into the angles of the jaw.

Figure 8.4 Dorsoplantar radiograph of the hock joint showing a bilateral malleolar fracture. There is subluxation of the tarsocrural joint.

Temporomandibular ankylosis has been reported in the cat (Bennett & Campbell, 1976; Sullivan, 1989). These cats present with difficulty in opening their mouths, resulting in difficulty in eating and grooming. There is obvious mechanical impediment to jaw opening and any attempt to force open the jaws produces pain. Radiography may show loss of the temporomandibular joint space and proliferation of bone around the joints, which is often most evident within the zygomatic space on the ventrodorsal view. Although there may be no history of trauma, it is thought that this is the most likely explanation. The trauma may occur several months before the onset of clinical signs and in some cases may be severe enough to cause an intra-articular fracture. Surgical resection of part of the zygoma, mandibular condyle and vertical ramus may be necessary to free the ankylosis.

Tendon injuries

Severance of tendons is not uncommon, associated with penetrating, sharp foreign bodies. Suturing of a severed tendon is always recommended and is imperative for some of the larger tendons, such as that of the gastrocnemius muscle. Many surgeons do not attempt to suture the small digital tendons and although the animal can adjust, a permanent postural defect may remain which would not be acceptable for a show animal. Infection of tendons and tendon sheaths may follow penetrating wounds, particularly bites. Rupture of the Achilles tendon can be seen, particularly in overweight middle-aged cats, as a spontaneous, gradual entity. In these cases an obvious severance of the tendon may not be apparent. Surgery of the Achilles tendon must be accompanied by postoperative immobilisation of the hock joint in extension by use of an external fixator or a positional screw inserted caudally through the calcaneus into the tibia. Rupture of the gastrocnemius tendon will result in a plantigrade stance and this must be distinguished from diabetic polyneuropathy which can produce similar clinical signs (Kramek *et al.*, 1984). In these cats, clinical signs will generally resolve following insulin therapy and blood glucose regulation. Tendon surgery is again outside the scope of this chapter.

Bone infections

Bacterial infective (suppurative) osteomyelitis

Aetiology and pathogenesis

Osteomyelitis is most often caused by a bacterial infection of bone. Bacteria may reach bone by the haematogenous route, by extension from adjacent soft tissues, for example nail-bed infections, or by direct contact, for example bite wounds, compound fractures or surgical fixation of fractures. Once bacteria are present, bone mounts an inflammatory response similar to that seen in other tissues. It takes approximately 6 h for contamination to become infection and correct management during this period is essential.

The severity of the osteomyelitis depends on many factors; for example, the initial site of infection within the bone, the exact organism, the contribution of other disease to bone abnormality, the presence of vascular ischaemia, and the animal's age and general health. In some cases the animal's responses will contain the infection; in others the infection will disseminate within the bone.

Infection may spread subperiosteally or within the Haversian system of cortical bone, or within the medullary cavity. As infection spreads, vascular thrombosis occurs, resulting in localised areas of cortical bone ischaemia, and there may be complete bony death or increased bone production around the area of infection. Complete bone death may result in sequestrum formation, where a piece of dead bone sits within a granulation-filled bony depression or involucrum. Alternatively, dead bone may be resorbed and replaced by new bone. The subperiosteal spread of infection appears more common in the cat than in other species.

Acute osteomyelitis refers to the early stages described above and where treatment is initiated promptly. Chronic osteomyelitis occurs when the process continues for an extended period and may result in disseminated infection within the bone. The most frequent organism is *Staphylococcus*, although many other organisms including *Streptococcus* spp. and *Pseudomas* spp. can be involved; mixed infections are not uncommon. Pure anaerobic or mixed aerobic and anaerobic infections of bone can also occur (Berg *et al.*, 1979; Walker *et al.*, 1983). Anaerobic infections can be difficult to diagnose since special culture conditions are necessary and samples need to be processed rapidly. Many cases of 'sterile' osteomyelitis are probably due to anaerobic organisms that have failed to grow in the laboratory.

Figure 8.5 Dorsopalmar radiograph of the right forefoot showing osteomyelitis following a penetrating bite wound. There is obvious destruction of the distal end of the metacarpal bone of digit 3. Extensive periosteal new bone is present on all the metacarpal bones (small arrows). Soft-tissue calcification is seen within the digital pad of digit 3 (large arrows). There is gross soft-tissue swelling of the foot.

Clinical signs

There is usually an obvious lameness associated with localised bone pain and swelling. Other signs may be related to fracture of the bone, penetrating wound or infected soft tissue; fever and systemic illness may or may not be present. Weight loss may occur, especially in chronic osteomyelitis cases. With chronicity, discharging sinus tracts may be obvious. Local lymph nodes are often enlarged.

Laboratory features

Culture of the organism is useful for confirmation of the diagnosis and providing antimicrobial drug sensitivities for treatment. Most animals do not show an obvious leucocytosis or shift to the left.

Radiography

There is little to see in acute osteomyelitis. In cases of chronic osteomyelitis there may be bony lysis and/or increased bone density (Figure 8.5). Periosteal new bone, which may extend a considerable distance along the length of the affected bone, may be present. Sequestra may be obvious (Figure 8.6). Soft-tissue swelling, loss of fascial planes and increased soft-tissue density are also features.

Figure 8.6 Dorsopalmar radiograph of the left forefoot showing osteomyelitis of the metacarpus of digit 5. There is a sequestrum (small arrows) associated with periosteal new bone forming a bridge (large arrows) alongside the sequestrum.

Treatment

Treatment of bacterial osteomyelitis is often a combination of surgical drainage and antibiotic therapy. Acute osteomyelitis is difficult to distinguish clinically from uncomplicated soft-tissue infection and treatment is often confined to systemic antibiotics. Drainage, however, is often of benefit, in order to release exudate. Surgical drains can be inserted, and in some cases multiple drill holes are made through the bone cortex to allow drainage from the medullary cavity. The drain may be protected against contamination from the environment by bandaging. Inserted drains also allow irrigation with saline. Enforced rest of the animal is important, even to the extent of hospitalisation and immobilisation of the affected limb by bandage or splint. The antibiotic of choice should be based on laboratory culture and sensitivity. However, treatment should always be started while awaiting the laboratory results. Most organisms are susceptible to ampicillin, clindamycin, cephalexin, trimethoprim–sulfonamide combinations, amoxycillin–clavulanic acid combination and enrofloxacin. Some Gram-negative organisms only respond to gentamycin or kanamycin. Anaerobic infections usually respond to lincomycin, ampicillin, chloramphenicol, clindamycin, metronidazole and cephalexin. The drugs are given systemically (preferably orally) and locally if possible. Systemic administration is often necessary for several weeks. Surgical drains are normally only left in place for 4–7 days.

The treatment of chronic osteomyelitis may be similar to that of acute osteomyelitis. In addition, areas of dead bone, or sequestra, must be surgically removed. Surgical implants may also need to be removed if they are not contributing to the stability of the fracture. The insertion of drains is recommended. Chronic osteomyelitis may resolve completely with treatment, although some cases may fail to respond. Some cases apparently resolve but are subject to periodic relapses of the osteomyelitic process, presumably associated with residual quiescent infection becoming activated. Some cases that do not clear may be treated by limb amputation or local resection of the diseased bone and the insertion of a replacement bone graft. Infected nail beds with osteomyelitis of the digital bones are often better treated by amputation of the digit; care should be taken to distinguish between osteomyelitis and carcinoma of the digit (see below).

Treatment of a compound fracture should be by immediate local antisepsis, systemic antibiotics and support bandaging/splinting of the limb. The fracture may be repaired a few days later and antibiotic therapy continued for 3–4 weeks. Potentially infected fractures must be rigidly fixed, and compression plating or the external fixator offers the best approach.

Non-suppurative osteomyelitis

Mycotic infection of bone, sometimes associated with infection of other tissues, has been reported in the cat.

Coccidioidomycosis

Coccidioides immitis is endemic in south-western USA. It is believed that most infections are contracted from soil and dust. Granulomatous lesions can occur in many different organs, for example lung, liver, kidney,

lymph nodes and skin. In one case reported by Reed *et al.* (1963) there was radiographical and pathological evidence of fungal spread to bone. Biopsy and culture are necessary for a definitive diagnosis, although serological tests are also used. Treatment necessitates the use of antifungal drugs such as amphotericin B.

Cryptococcosis

Infection with the yeast-like fungus *Cryptococcus neoformans* is the most common systemic fungal disease of cats. The organism is widely distributed in nature, although pigeon faeces are the most frequently reported source. Four main clinical syndromes are reported in the cat: respiratory, neurological, cutaneous and ocular. The organism is regarded as an opportunist invader in animals that are compromised by, for example, immunodeficiency, debility, and malnutrition. Lytic bony lesions of the head and sinuses have been documented (Rutman *et al.*, 1975). Diagnosis depends on finding the organisms in material from infected tissues or in discharges. Immunological tests are also available. Antifungal agents are used in treatment (Wilkinson, 1984a).

Blastomycosis

Blastomyces dermatitis is rare in the cat. It is endemic in certain areas of North America and has been isolated from the soil. It may cause just pulmonary disease, skin disease, central nervous system (CNS) and ocular disease, although some cases have had widespread systemic involvement. Skeletal lesions may develop via haematogenous or subcutaneous spread, or by extension from a subcutaneous nodule (Horne, 1964). Oedema, pain and occasionally draining tracts are found in the affected area. There is radiographic evidence of bone destruction with resulting periosteal new bone. Biopsy and culture are necessary for a definitive diagnosis.

Histoplasmosis

This disease is caused by the yeast-like fungus *Histoplasma capsulatum*. It is a disease mainly of the reticuloendothelial system and two forms have been described: a benign form involving the lungs and associated lymph nodes, and a disseminated form involving several organs including liver, spleen, intestine, bone and lung. Mahaffey *et al.* (1977) described joint lesions characterised by a soft-tissue thickening and, in some cases, by bony destruction within the joint. Discharging sinuses were associated with some infected joints. Goad and Roenick (1983) described a disseminated case in a 1-year-old domestic shorthair cat that had multiple osteomyelitis lesions. Successful treatment is unlikely.

Aspergillosis

Aspergillus fumigatus infection may cause either a necrotising or a granulomatous disease, usually affecting the lung and intestine. Infection can localise to the frontal sinuses and cause local bone destruction (Wilkinson, 1984a). Diagnosis is made from a biopsy or serological examination. Treatment with thiabendazole-type drugs can be attempted.

Streptomyces

A streptomycete infection involving the scapula of a cat has been reported (Lewis *et al.*, 1972). The infection was apparently introduced by gunshot. Surgical resection of the lesion was unsuccessful.

Metabolic bone diseases

Nutritional secondary hyperparathyroidism in kittens (nutritional osteopenia, juvenile osteopenia)

Aetiology and pathogenesis

This disease is characterised by a reduced mineralisation of the skeleton and is normally seen in young kittens, particularly of the Siamese breed, fed a meat-rich diet (Krook *et al.*, 1963; Bennett, 1976a, b). Cats kept indoors and fed abnormal diets are more susceptible to disease since they cannot supplement their diet by hunting and catching prey. The disease is now rarer than it was, mainly because commercial balanced diets are readily available and generally accepted as the diet of choice. However, there is evidence that, more recently, there has been an increase in case numbers because of owners' concern over the production methods used with commercial diets, thus encouraging owners to provide their own diets (Tomsa *et al.*, 1999). There is a trend for owners to feed 'natural' foods and vegetarian diets. Meat is rich in phosphorus but has a low calcium content; for example, horsemeat has a Ca:P ratio of 1:10, liver 1:50 and heart 1:50. The feeding of a diet low in calcium and/or rich in phosphorus leads to a transient hypocalcaemia. This stimulates the release of parathyroid hormone, which acts on bone, kidney and intestine to help to restore cal-

cium levels to normal. Resorption of bone to release calcium into the bloodstream is an important homoeostatic mechanism, but after prolonged release of parathyroid hormone, the skeleton becomes significantly weakened. The bone turnover is greatly increased, with resorption occurring more rapidly than formation. Resorbed bone tends to be replaced, to a limited extent, by fibrous tissue. The parathyroid glands become hyperplastic showing enlargement, increased cellularity and the presence of increased numbers of light chief cells and 'water clear' cells.

The most significant aetiological factor is the feeding of calcium-deficient diets to the young cat. Meat, cereal, grain, fruit and nuts are all deficient in calcium, and excessive phosphorus in the diet is also a problem since it will interfere with the normal absorption of calcium. Other factors can interfere with calcium absorption, for example gastrointestinal disease, thyroid disease, vitamins A and D, renal insufficiency, magnesium, phytate and fluorine. The rate of growth is probably important too, the faster growing kittens being more susceptible, and there may be other genetic predisposing factors to explain why only certain kittens in a litter may be clinically affected. Certainly, there are obvious differences between individual cats in their ability to retain calcium and utilise it on a low intake (Scott, 1964). Milk is a reasonable source of calcium but is generally not given to cats because of the possibility of initiating gastrointestinal upset.

Clinical signs

Young kittens of a few weeks or months of age are affected. Lameness is often the presenting sign and this may be due to apparent musculoskeletal pain or to pathological fractures of the bones. The latter often show little displacement. Pathological fractures of the vertebrae can occur and may cause profound neurological disturbances and provide a hopeless prognosis.

Bone weakness may cause obvious bending of the limbs and it is common to have deformity of the thoracic wall, sternum and pelvis. Epiphyseal growth is usually stunted and sometimes deformed, and normal tooth development and maintenance can be adversely affected. There is often apparent weakness and laxity of joints and a flat-footed appearance. Very severely ill kittens can become so hypocalcaemic that they will suffer tetanic spasms (Tomsa *et al.*, 1999).

Radiography

The most obvious feature is a loss of bone density (Figures 8.7, 8.8). The contrast between bone and soft tissue is poor. The cortices appear very thin. Pathological fractures are usually obvious and may show as 'folding' fractures (Figure 8.7). There may be evidence of healing fractures that were not detectable clinically. The growth plates are of normal dimensions. There is often an area of increased mineralisation within the metaphysis, an area of preferential mineralisation. Deformity of bones may be assessed on radiography and it is often worthwhile radiographing the pelvis and thorax as a routine to check for any deformities, since they can affect the prognosis. Any cat showing paraplegia or paraparesis should have a careful spinal evaluation.

Laboratory features

Blood calcium and phosphorus levels are usually in the normal range (Krook, 1971), except in extreme cases. Urinary calcium and phosphorus levels are also of limited help in aiding diagnosis, although a reduced urinary calcium level may be seen. Radioimmunoassay of circulating parathyroid hormone levels is a useful test but is not routinely available for the cat.

Treatment and prognosis

The feeding of a meat-rich diet should be terminated and a nutritionally balanced diet substituted. Calcium and phosphorus supplementation is recommended. Sterilised bone meal or calcium phosphate is the most commonly used, but will not readily correct an abnormal dietary Ca:P ratio and must thus be used with a balanced diet. Calcium lactate and borogluconate can be used to provide calcium without phosphorus, but relatively large amounts are necessary. The use of a calcium preparation with aluminium carbonate gel will provide calcium and help to remove excess phosphorus (Miller, 1969).

Cage rest of the affected animal is helpful and analgesics may be necessary. In many cases, the animals will respond within a short time. There may be residual stunting and deformity, pelvic collapse can lead to defecatory and obstetric problems, and thoracic deformity may cause respiratory problems. Surgical treatment of the pelvic and thoracic deformities is possible, but often difficult and unrewarding. Pathological fractures often require no treatment other than rest, although intramedullary pinning and external fixator techniques are sometimes advantageous and fractures affecting the lower limbs can be externally supported. Fractures of the vertebral col-

Figure 8.7 Lateral radiograph of the femur and tibia of a cat with nutritional secondary hyperparathyroidism. The cortices are thin and the contrast between bone and soft tissue is poor. There is a 'folding' fracture of the distal femur (arrow).

umn often have a poor prognosis; euthanasia of the cat is necessary if the neurological deficit is severe.

Osteodystrophy of mature cats

The exact aetiology and pathogenesis of this disease are unknown. It is described in the American literature (Riser *et al*., 1968; Herron, 1983). It is possibly associated with long-term meat or liver-rich diets fed to confined cats. Bone demineralisation occurs, possibly as a result of secondary hyperparathyroidism. Bone cortices become thinned, but periosteal new bone along the shafts of the long bones is a feature. This hyperostosis is difficult to explain; it may be an effect of excess vitamin A, although the pattern of bony overgrowth differs from that normally seen in hypervitaminosis A (see below). Affected cats are sluggish, and may present with constipation due to a narrowed pelvic canal caused by pelvic collapse. Treatment is to correct the diet. Medicinal or surgical treatment may be required for the constipatory problem.

Rickets (osteomalacia)

Rickets, although often confused with nutritional secondary hyperparathyroidism, is virtually unknown in the cat. The exact aetiology of rickets is uncertain, although dietary deficiency of vitamin D and a deficiency of phosphorus and/or calcium are important. There is some evidence that high-cereal, low-meat diets are rachitogenic, not just because of the mineral/vitamin imbalance. The feeding of such diets to cats is very unusual.

The main pathological feature of rickets is a failure of bone and cartilage matrix to calcify. In the young animal, the physis becomes very much widened because of the failure of the growing cartilage to calcify and ossify. There is poor skeletal mineralisation. Secondary hyperparathyroidism may also be involved in the pathogenesis, resulting from calcium deficiency.

The clinical signs are similar to those of nutritional hyperparathyroidism. Radiography reveals poorly mineralised bones and, in the young animal, widening of growth plates. Treatment includes the provision of a balanced diet and vitamin D supplementation (e.g. 80 IU/day). Excess vitamin D can easily reach toxic levels, resulting in soft-tissue calcification and even more serious effects, and thus supplementation should be carefully controlled and never used as a routine measure in young kittens.

Hypervitaminosis A

Aetiology and pathogenesis

The daily vitamin A requirement of cats is relatively high, 1600–2000 IU (Gershoff *et al*., 1957; Moore *et al*., 1963; Scott, 1964). The reasons for this are the poor absorption of carotene, the precursor of vitamin A, from the intestine and the limited conversion of carotene to vitamin A. It is probably the awareness of this potential deficiency problem that has encouraged owners to supplement cats' diets with vitamin A, usually in the form of liver. Unfortunately, cats enjoy liver and become habituated to it. The feeding of

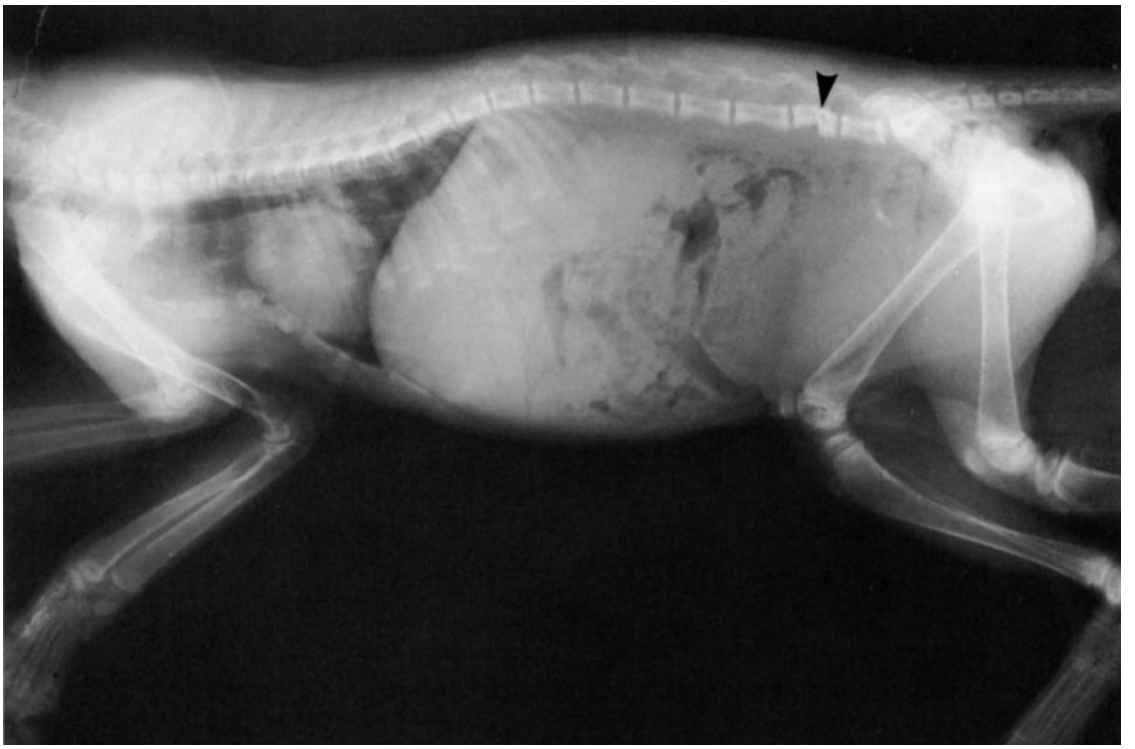

Figure 8.8 Lateral survey radiograph of a cat with nutritional secondary hyperparathyroidism. The cortices of the long bones are thin and there is a pathological fracture of L6 (arrow). The cat was paraparetic.

excess liver, particularly to the exclusion of anything else, causes hypervitaminosis A (Seawright *et al.*, 1967; Baker & Hughes, 1968; Fry, 1968; Lucke *et al.*, 1968; Bennett, 1976a, b).

The effects of excess vitamin A vary according to the age of the cat, the chronicity and possibly the actual level of vitamin intake. Basically, there appears to be a disturbance in osteoblastic and osteoclastic functions. In young cats, there is a suppression of osteoblast activity and degenerative changes in the cartilaginous epiphyseal plates, and the appositional and longitudinal growth of long bones is reduced (Clark & Seawright, 1968; Clark *et al.*, 1970; Clark, 1970, 1971a). Exostoses associated with ligaments and tendons, particularly affecting the cervical/thoracic spine, but also the limb joints, are more characteristic of a chronic toxicity in the mature cat. In addition to skeletal changes, there is extensive lipid infiltration of parenchymatous organs, which may predispose the animal to secondary disease (Clark, 1971b).

A liver-rich diet in the immature cat also leads to nutritional secondary hyperparathyroidism, because of the poor Ca:P ratio.

Clinical signs

The most typical case is the adult cat, presented 1–5 years after starting a virtually all-liver diet. The initial signs may be lameness, stiffness and pain. The cats are obviously uncomfortable and become reluctant to move. The spine is often partly ankylosed and the cats can sometimes be held 'like a board'. The neck shows reduced motion. Affected limb joints may be enlarged and painful and show a reduced range of motion. Occasionally, a foreleg lameness can be associated with a neurological deficit due to spinal exostoses compressing the peripheral nerves to the forelimb. Pathological changes may be confined to just the spine or just limb joints, or may affect both together.

Occasionally, the main sign noticed by the owner is an unkempt coat. This is a result of the spinal ankylosis, the cat being unable to turn its head sufficiently for grooming. The animals are sometimes obese through inactivity, although anorexia and weight loss can occur. The teeth often show a yellow discoloration and gum problems are not uncommon.

Radiography

Radiography of the spine will show the typical exostoses affecting the cervical and thoracic vertebrae (Figure 8.9). Exostoses can also be seen in affected limb joints, the bony proliferation often associated with the ligaments and joint capsules (Figure 8.10). In the young kitten, radiographic features might include poor mineralisation, bony deformity and uneven growth of epiphyseal plates.

Treatment

Dietary liver should be stopped although, in practice, this is difficult to achieve since the cat often refuses to eat anything other than liver. The bony exostoses will not resolve, but pain relief and clinical improvement do occur. Bone deformities in the kitten are likely to persist. Analgesics can be tried and surgical removal of exostoses is possible in certain limb joints, but any resultant damage to the ligaments must be corrected.

Hypovitaminosis A

Scott (1964) reported that hypovitaminosis A is 'fairly common' in cats, although often unrecognised. Certainly, as discussed, the feline requirement for vitamin A is comparatively high.

A deficiency of vitamin A again causes an imbalance between bone production (osteoblastosis) and resorption (osteoclastosis). The disease is seen mainly in young kittens, particularly if the maternal supply of the vitamin is deficient. There is distortion and malformation of long bones, cranial bones and the vertebral column (Mellanby, 1941, 1950). The bones become bulky and, with the cranial and vertebral bones, this results in a reduced size of the vertebral canal, cranial vault and foraminae, through which pass nerves and blood vessels.

The overall result is pressure on the brain, spinal cord, cranial nerves and spinal nerves, causing a variety of neurological symptoms. Scott (1964) states that skull and vertebral changes develop at about the fifth week of life. Gershoff *et al.* (1957) failed to show changes in the skeletal and nervous tissues of experimentally deficient cats, but did report squamous metaplasia of various epithelial structures (e.g. respiratory tract, conjunctivae, salivary glands and endometrium). Corneal vascularisation and ulceration, retinal degeneration, poor reproductive function, anorexia, weight loss, muscular weakness and ocular discharge are also documented (Gershoff *et al.*, 1957; Scott, 1964).

The deformed cranial and vertebral bones may cause difficult parturition, as well as interfering with

Figure 8.9 Lateral radiograph of the cervical and thoracic spine of a cat with hypervitaminosis A. There is a typical bony proliferation along the spine.

Figure 8.10 Craniocaudal radiograph of the elbow joint of a cat with hypervitaminosis A. There is extensive bony proliferation involving the collateral ligament (arrow).

the hearing, sight and survival of the kitten. Radiography of the skull will show increased thickness of bones, especially those surrounding the posterior fossa of the brain. The long bones may show deformities, the shaft may not show an obvious compact cortex and the endosteum may be indistinct.

Dietary supplementation with vitamin A, up to 2000 IU/day, is the treatment of choice.

Renal secondary hyperparathyroidism

Aetiology and pathogenesis

This bone disease is related to chronic renal insufficiency. The underlying renal lesion is variable and may be acquired (e.g. chronic nephritis, glomerulonephritis, nephrosclerosis, amyloidosis) or congenital (e.g. polycystic kidneys). Once the renal disease causes a reduction in the glomerular filtration rate, phosphorus is retained and hyperphosphataemia develops; there is a compensatory fall in blood calcium which stimulates the release of parathyroid hormone, causing bone breakdown and the release of calcium into the blood. The renal damage may also interfere with production of 1,25-dihydroxycholecalciferol, the active metabolite of vitamin D, which could interfere with normal calcium absorption from the gut and also lead to osteomalacia.

Clinical signs

It is often the old cat that is affected. Signs related to the renal dysfunction (e.g. vomiting, polydipsia, dehydration, weight loss and depression) are often present. Signs of skeletal demineralisation may not be apparent although softened jaw bones, loose teeth, generalised stiffness and lameness, and even pathological fractures, may be present. Affected jaw bones are susceptible to fracture during dentistry.

Radiography

Poor bone mineralisation may be seen. Resorption of alveolar socket bone and loss of the lamina dura dentes are fairly typical. Soft-tissue calcification may also be seen.

Laboratory features

Laboratory tests for impaired renal function are useful. Serum analyses for calcium and phosphorus levels are often unrewarding, although the latter may be elevated. Urinary excretion of calcium and phosphorus is usually decreased. Alkaline phosphatase is often elevated in the blood and increased levels of parathyroid hormone may be detectable.

Treatment

Ideally, the aim of treatment is to halt the progression of the renal disease. Often this is not feasible. Realistically, treatment is directed towards reducing the excretory load of the kidneys and to provide substances that the kidney is failing to conserve. A low-protein diet is recommended, although this is often not acceptable to the cat. Calcium should be provided as the gluconate or lactate and vitamin D supplementation may be helpful (see Chapter 10).

Primary hyperparathyroidism

Primary hyperparathyroidism has been attributed to a primary hyperplasia or to a neoplastic change of the parathyroid glands (adenoma or carcinoma). Primary

hyperparathyroidism is very rare in the cat; a case of hyperplasia was described by Blunden *et al.* (1986). The cat presented with lethargy, reluctance to move and pain along the back. Radiological examination revealed multifocal and polyostotic lesions, particularly of the axial skeleton.

Primary hypoparathyroidism

Forbes *et al.* (1990) described primary hypoparathyroidism in a 1-year-old cat. The clinical features included anorexia, muscle spasms, lethargy and mild tetany of the hindlimbs. There was hypocalcaemia and hyperphosphataemia. Histological examination of the left excised thyroid and parathyroid glands suggested a diagnosis of lymphocytic parathyroiditis of possible autoimmune origin. Successful treatment includes initial intravenous and subcutaneous calcium, followed by oral calcium lactate and vitamin D. Although mobilisation of calcium from the skeleton is reduced in this condition, the effect on the skeleton itself is of no consequence.

Iatrogenic primary hypoparathyroidism can also develop as a sequela to injury or removal of the parathyroid glands at the time of thyroid surgery, for example in hyperthyroid cats after bilateral thyroidectomy.

Arthritis

Although the term 'arthritis' literally means inflammation of a joint it is used in a broader sense to cover a number of well-defined joint diseases which may be characterised by both inflammatory and degenerative changes. Traditionally, arthritis is broadly divided into the degenerative arthropathies (traumatic, osteoarthritis) and the inflammatory arthropathies (infective, immune-based) according to which pathological process is most in evidence. The feline species is now known to suffer many different types of arthritis. The classification of arthritis is shown in Figure 8.11. Table 8.2 summarises the main features of the feline arthritides.

Traumatic arthritis

This type of arthritis follows a single acute injury to the joint. The trauma may result from traffic accidents, fights with other animals, abuse from people, awkward falls and excessive stresses on joints, or from gunshot wounds.

The articular damage caused is variable. There may be just a mild inflammation of the joint capsule or ligaments (a 'sprain') or more severe damage may be evident, for example, intra-articular bony or cartilage fractures, torn or stretched ligaments, lacerated joint capsule and displaced or torn menisci.

There is usually a synovitis, which may be localised, and haemorrhage or increased synovia present within the joint cavity. The synovitis is characterised by hyperplasia and hypertrophy of the lining layer, and a few inflammatory cells within the supporting layer, and areas of haemorrhage and haemosiderin deposits within the synovium.

The animal is presented with an obvious lameness and there is pain and swelling associated with the affected joint. Care must be taken to check for any serious bone or ligament damage; radiography is helpful for this. A synovial fluid sample from a traumatised joint may contain blood; it usually shows some loss of viscosity, a normal mucin clot and a normal or slightly elevated white cell count, most of which are mononuclear cells. Large quantities of fat within the fluid may indicate an articular fracture.

Treatment depends on the severity of the injury. Some cases may necessitate surgical intervention (e.g. fracture repair, ligament replacement) or support bandaging for a few days. Milder cases may only require restricted exercise and/or anti-inflammatory drugs. Traumatic arthritis can predispose a joint to bacterial infective arthritis, the infection usually developing a few days after the initial trauma. Such cases can be difficult to diagnose without examining a synovial fluid sample. Osteoarthritis can also follow a traumatic arthritis, especially after repeated traumatic episodes, or severe trauma causing significant joint damage.

Osteoarthritis

Osteoarthritis is defined as a disorder of movable joints characterised by deterioration and abrasion of articular cartilage and by the formation of new bone at the articular margins. There are two main forms of the disease, primary and secondary. Secondary osteoarthritis is where the disease is secondary to some other joint disorder. In the cat it may follow repeated joint trauma, perhaps associated with their agile lifestyle. Osteoarthritis of the hips and elbows is most common in the older cat. Osteoarthritis secondary to articular fractures, ligament tears and joint luxation/subluxation is also recognised. Hip dysplasia, patellar luxation and congenital elbow luxation/subluxation can also lead to osteoarthritis. Acromegaly in middle-aged to old cats

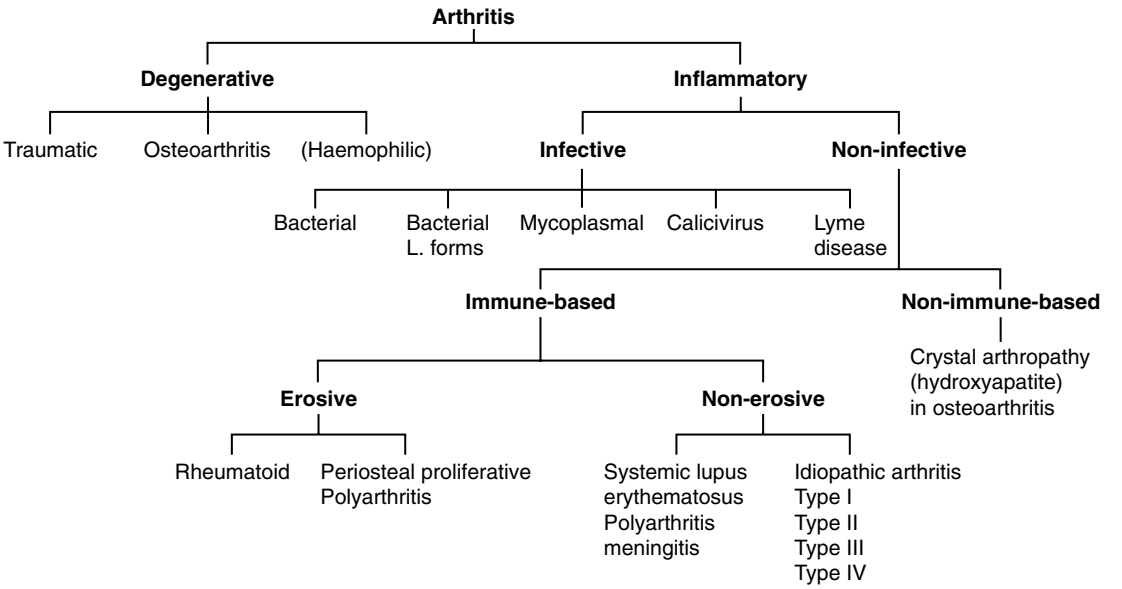

Figure 8.11 Classification of feline arthritis.

caused by pituitary adenomas has been associated with osteoarthritis (Peterson *et al.*, 1990); affected joints included the shoulder, elbow, carpus, digits, stifle and spine. The pathogenesis of acromegalic arthropathy is not completely understood, but cartilage hypertrophy and hyperplasia may interfere with cartilage metabolism, leading to cartilage degeneration. Many cases of feline osteoarthritis may be primary.

Pathological features

Degeneration of articular cartilage is an important part of osteoarthritis. This may be seen grossly as an increase in dullness accompanied by a colour change from white to white–grey or yellow. The surface may appear fissured and disrupted and there may be obvious erosion or ulceration. Histologically, cartilage degeneration is seen as a loss of the superficial layers, horizontal flaking and fibrillation, and vertical splits. There is a loss of metachromatic staining. Ultimately, cartilage may be completely lost exposing the underlying subchondral bone, which often responds by becoming thickened.

The other main feature of osteoarthritis is the production of osteophytes or bony outgrowths, which occur principally at the marginal zone, where articular

Figure 8.12 Photomicrograph of a synovial membrane biopsy from an osteoarthritic joint. The lining layer shows hyperplasia and hypertrophy (arrows). There is a small accumulation of mononuclear inflammatory cells (M) within the supporting layer (H&E) (×50).

cartilage and synovium meet, and at the attachment of joint capsule and ligaments. These osteophytes initially develop outside the epiphysis of the joint but with time can become an integral part of the joint, such that the joint takes on a completely different shape. This process of remodelling is an important feature of osteoarthritis and is thought to be the mechanism by which the joint is trying to cope with altered stresses placed upon it. Osteophytosis is generally not a marked feature of feline osteoarthritis, as it is in the dog. Changes in the fine trabecular pattern of the epiphyses are also seen in osteoarthritis but are difficult to appreciate.

Hypertrophy and hyperplasia of the lining layer of the synovial membrane are regularly seen in osteoarthritic joints; accumulations of mononuclear inflammatory cells are often seen, but the degree of inflammatory change is usually mild (Figure 8.12).

Subchondral cysts are sometimes seen; they arise from the replacement of bony trabeculae and marrow by mixed connective tissue. Degeneration of intra-articular menisci and vascular abnormalities are also features of osteoarthritis.

Clinical signs

Many joints affected with osteoarthritis are asymptomatic. Although lameness can be a cardinal sign of osteoarthritis, it is now believed that behavioural changes reflecting chronic pain are more relevant in the cat. These include inactivity, seeking seclusion, unwillingness to jump, resenting being handled, aggressiveness, increased micturition and reduced appetite. Since these behavioural signs can be associated with many other diseases, a very detailed clinical assessment is necessary, often with laboratory and radiographical evaluation. If present, the lameness is generally of a chronic nature, of insidious onset, and there is usually a progressive deterioration with time. As the disease progresses, stiffness becomes more pronounced following rest. Cold and damp weather will often exacerbate the clinical signs. A sudden-onset lameness may occur with established osteoarthritis; this can be due to a joint 'sprain' since osteoarthritic joints are susceptible to trauma, or to an exacerbation of the synovitis caused by, for example, the release of cartilage breakdown products or hydroxyapatite crystals into the articular cavity. Osteoarthritic joints are also predisposed to infection from the bloodstream and this can also cause a sudden-onset lameness.

Affected joints may be obviously enlarged owing to osteophyte formation, bony remodelling and joint capsule fibrosis, although obvious abnormalities may not be readily apparent on palpation. Increased synovial fluid within the articular cavity may be evident. Pain and crepitus are sometimes appreciated and reduced joint motion may be (but often is not) a feature.

In cases of secondary osteoarthritis, clinical signs referable to the underlying joint disorder may also be apparent.

Radiography

The most typical feature is the presence of new bone deposits, referred to as osteophytes, spurs, exostoses or as a 'lipping' of the joint margin, although these are often less apparent than seen in other species. They are visualised as an irregularity or roughening of the bony outline, as obvious masses of bone protruding from the normal bone margin, or as irregular densities of bone where the deposits are superimposed on the normal osseous architecture (Figures 8.13, 8.14). Sclerosis of subchondral bone may be seen in long-standing cases and subchondral cysts are sometimes seen as discrete radiolucent defects.

Narrowing of the joint space is a feature indicative of articular cartilage loss, but such narrowing is difficult to appreciate without weight-bearing films, and the technical problems of obtaining these are obvious.

Intra-articular or peri-articular calcification may be seen in osteoarthritic joints; such calcification occurs within the synovial membrane, ligaments, tendons or menisci (Figure 8.15). However, mineralisation, particularly within the menisci of the stifle joint of the cat, is commonly seen in joints that are otherwise normal and in which there is no clinical problem (Figure 8.16).

Radiography is also useful in assessing joint remodelling and in assessing other joint diseases that might have initiated the osteoarthritis.

Laboratory features

Synovial fluid is often increased in quantity and has reduced viscosity. The white cell count may be slightly elevated and the majority of cells are macrophages and lymphocytes. Synovial lining cells, cartilage cells, and very occasionally bone cells, may be seen, The fluid does not clot on exposure to air, and the mucin clot test is normal.

Treatment

General

It is difficult to modify a cat's exercise regimen, but it is desirable to keep exercise as regular as possible by try-

Table 8.2 Summary of the main diagnostic features of feline arthritis

Type of arthritis	Clinical features	Radiographic features	Laboratory features
Traumatic	Single joint, history of trauma	Increased soft-tissue density, fractures, ligament damage	Synovial fluid viscous; normal or increased white cells, mainly mononuclear; may contain blood
Osteoarthritis	Usually single joint, lameness and/or behaviour changes	Osteophyte development, increased soft-tissue density	Synovial fluid viscous; normal or increased white cells, mainly mononuclear
Bacterial infective	Usually single joint	Increased soft-tissue density; loss of bone, periosteal new bone; soft-tissue calcification	Synovial fluid watery; increased quantity; increased white cells, mainly polymorphonuclear; culture organism from synovial fluid and/or membrane
Infective bacterial L-forms	Multiple joints, subcutaneous abscesses	Increased soft-tissue density, bone destruction	Synovial fluid watery, increased in quantity; increased numbers of polymorphonuclear cells; difficult to culture organism
Mycoplasmal	Multiple joints; old/debilitated animals	Increased soft-tissue density, bone destruction	Synovial fluid watery, increased in quantity; increased numbers of polymorphonuclear cells; may see organisms in synovial fluid smear; difficult to culture; evidence of immunosuppression
Calicivirus	One or more joints	Very little; soft-tissue changes	Synovial fluid increased in quantity; increased white cells
Lyme disease (borreliosis)	One or more joints; other signs, history of tick infestation; rapid response to antibiotic therapy; definite disease not proven in cat	Increased soft-tissue density	Synovial fluid increased in quantity; increased numbers of polymorphonuclear cells; positive serum titre to *Borrelia burgdorferi*; difficult to culture
Ehrlichia, hepatozoon, babesia leishmania	Multiple joints, history of travel or living abroad, other signs	Mainly soft-tissue changes	Inflammatory synovial fluid if joints involved; serological testing; identify organism by polymerase chain reaction
Rheumatoid	Multiple joints, bilaterally symmetrical	Increased soft-tissue density; loss of bone, erosions, generalised loss of mineral, periosteal new bone	Synovial fluid watery; increased quantity; increased white cells; rheumatoid factor in blood in some cases

Periosteal proliferative polyarthritis	Multiple joints, bilaterally symmetrical; mainly carpi and hocks; mainly male and male castrated cats	Very extensive periosteal new bone; erosive changes; increased soft-tissue density	Synovial fluid watery; increased quantity; increased white cells, mainly polymorphonuclear
Systemic lupus erythematosus	Multiple joints, bilaterally symmetrical; other features of a multisystemic disease	Mainly soft-tissue changes	Synovial fluid watery; increased white cells, mainly polymorphonuclear; antinuclear antibody in blood
Polyarthritis/meningitis	Young adults or older kittens; pyrexia, stiffness, neck pain, multiple joints, nervous signs	Mainly soft-tissue changes	Increased synovial fluid; high white cell count, mainly polymorphonuclear; cerebrospinal fluid: increased protein, white cells, creatine phosphokinase
Idiopathic arthritis	Multiple joints, bilaterally symmetrical Type I: uncomplicated; type II: infection elsewhere in the body; type III: gastrointestinal disease; type IV: neoplastic disease, usually myeloproliferative disease	Increased soft-tissue density; slight periosteal new bone in some cases	Synovial fluid watery, increased white cells, mainly polymorphonuclear
'Vaccine reactions'	Young kittens, first inoculation; stiffness, pyrexia, lameness 5–7days after vaccination; self-limiting	Mainly soft-tissue changes	Synovial fluid shows inflammatory characteristics in some cases
Feline relapsing polychondritis	Joint involvement not proven; mainly disease of auricular cartilage		

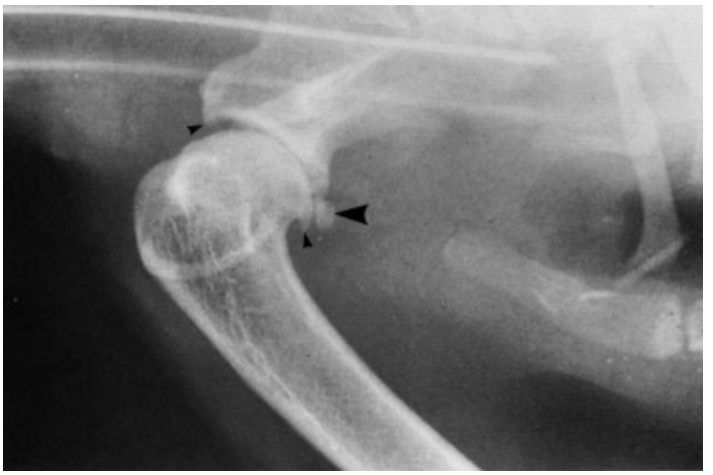

Figure 8.13 Mediolateral radiograph of the left shoulder joint showing advanced osteoarthritis. There is osteophyte development on the caudal humeral head and tuber scapula (small arrows) and there appears to be a separate ossicle at the caudal margin of the glenoid (large arrow).

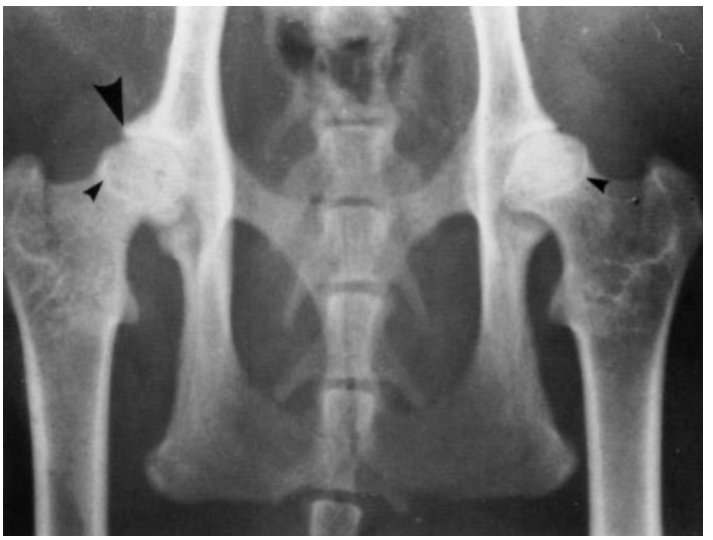

Figure 8.14 Ventrodorsal radiograph of the pelvis, showing bilateral osteoarthritis of the hip joints. There is a collar of new bone on each femoral neck (small arrows) with new bone on the cranial effective acetabular rim (large arrow). There is slight dysplasia.

ing to encourage the cat to exercise at certain set times of the day. If the clinical problem is particularly bad at any time, strict rest by confinement for a few days is recommended. If the cat is obese, then weight reduction is very important, using one of the weight-reducing diets.

Non-steroidal anti-inflammatory drugs

The use of non-steroidal anti-inflammatory drugs (NSAIDs) is restricted because of the many toxicity problems that occur. Many drugs that are used in dogs and humans are untried in cats and it is unwise to experiment with these drugs. Some NSAIDs are licensed for use in the cat, but only for short-term use (Table 8.3). The author has used meloxicam on a continuous basis for treating osteoarthritis in the cat. In these cases, the dose can be reduced below the recommended level, (e.g. every other day, or even once or twice a week), to minimise the possibility of side-effects. Phenylbutazone has been used in the cat (6–12 mg/kg in a divided dose), but renal damage has been reported. Although a single injection of carprofen is licensed in the cat, oral therapy is not and should not be used since toxic side-effects have been reported. There is also a study suggesting that flunixin may be used in the cat at a dose of 1.0 mg/kg once a day (Lees & Taylor, 1991), although no clinical trials involving repeated dosing have been done.

Corticosteroids

There is much argument as to the value of corticosteroids in the treatment of arthritis. They are relatively safe to use in the cat and can produce obvious

Figure 8.15 Mediolateral radiograph of the stifle joint showing extensive calcification within the cranial cruciate ligament (large arrow). There is also calcification within the soft tissues of the joint on the caudal aspect of the femorotibial joint (small arrows). There is new bone formation on the caudal aspect of the tibia (open arrow). This cat was not lame.

Figure 8.16 Mediolateral radiograph of the stifle joint showing mineralisation within the joint space (arrow). A craniocaudal view suggested that this was within the medial meniscus. This is a common incidental finding in the feline knee joint.

clinical improvement, even at relatively low doses (0.1–0.5 mg prednisolone/kg body weight). There is some evidence that high doses of corticosteroids promote cartilage degeneration and can thus speed up the osteoarthritic process. Short courses are preferable and should only be repeated if the clinical problem is particularly severe. Corticosteroids are useful in those joints showing acute flare-ups of lameness, providing infection is not suspected. If long-term steroid therapy is given, the minimal effective dose should be titrated against clinical signs, and this might be every other day or once a week, for example.

Matrix supplements/viscosupplements

Although the use of these compounds is well documented in humans and dogs, there is very little information on their use in cats. The injectable matrix supplements (e.g. pentosan polysulfate, polysulfated glycosaminoglycans) have no product licence for use in the cat, although the author has used them with some success. There are now several oral preparations available for use in the cat. These are classified as nutraceuticals, defined as 'substances produced in a purified or extracted form that are administered orally to provide or stimulate production of raw materials required for normal bodily functions'. These compounds are not classified as pharmaceuticals and are therefore not subject to the rigorous licensing procedures that apply to these drugs. Their mode of action is not clear, but they have been associated with an improvement in clinical signs. They may have anti-inflammatory/analgesic properties, improve synovial fluid viscosity and stimulate cartilage repair. Most nutraceuticals contain glucosamine and

Table 8.3 Non-steroidal anti-inflammatory drugs for use in the cat

Drug (trade name)	Dose	Route	Notes
Meloxicam[a]	0.3 mg/kg	p.o.	Once daily for first day
(Metacam)	then 0.1 mg/kg	p.o.	Once daily for 5 days
	then smallest effective dose (e.g. 0.025 mg/kg)	p.o.	Continuous
	0.3 mg/kg	s.c./i.v.	Single injection
Carprofen (Rimadyl)[b]	4 mg/kg	s.c./i.v.	Single injection
Tolfenamic acid[c]	4 mg/kg	p.o.	Once daily for 3 days
(Tolfedine)	4 mg/kg	i.m./s.c.	Single dose, repeat after 24 h if required (antipyretic)
Ketoprofen	1 mg/kg	p.o.	Once daily for 5 days
(Ketofen)	2 mg/kg	s.c.	Once daily for 3 days

[a] No product licence for oral use.
[b] Injection only.
[c] Licensed only as an antipyretic.

chondroitin sulfate as the main components. They are very safe to use and can be used in combination with NSAIDs. The injectable polysulfated preparations, however, should not be used in combination with NSAIDs since the former have anticoagulant properties which could potentiate any gastrointestinal bleeding caused by NSAID toxicity.

The intra-articular injection of sodium hyaluronate (a viscosupplement) is occasionally used by the author (0.1 ml once a week for 4 weeks), although there is no product licence for its use in the cat. The main effect is thought to be stimulation of synovial fluid production and improved synovial fluid viscosity (viscosupplementation). It is used in cases of osteoarthritis where either there is very little fluid being produced or the fluid is of poor viscosity.

Surgical treatment

- **Correction of any underlying cause and debridement:** in cases of secondary osteoarthritis, correction of the underlying cause may be possible, for example the insertion of a prosthetic ligament into an unstable joint. In some cases, debridement of the joint is feasible, and includes the removal of osteophytes if they are thought to be a source of pain and loose bodies.
- **Joint lavage:** irrigation of an osteoarthritic joint with sterile saline or lactated Ringer's solution can result in significant clinical improvement for several months. The cat is anaesthetised and a small catheter is inserted into the joint through a small arthrotomy; the joint is irrigated with 100–200 ml of fluid. This procedure can be combined with arthroscopy.
- **Excision arthroplasty:** the destruction of a joint by removing one of the bony components can often help in producing a pain-free articulation, for example femoral head resection of the hip or condylectomy of the mandible.
- **Replacement arthroplasty:** the replacement of a diseased joint with a prosthetic one has been used in the cat, but technical and financial restrictions are significant. Purpose-made joint prostheses are not available for the cat.
- **Arthrodesis:** surgical fusion of an arthritic joint can be helpful in removing pain. However, joint motion is lost and therefore the animal has a stiff limb. Most of the major limb joints of the cat can be arthrodesed: elbow, carpus, stifle and hock joints. The main reason for arthrodesis is chronic instability of the joint associated with extensive ligament damage and osteoarthritis.

Infective arthritis

Infective arthritis is defined as an inflammatory arthropathy caused by a living microbial agent, which can usually be isolated from the joint.

Bacterial arthritis (septic arthritis)

Bacteria may enter a joint from a penetrating wound, or by extension of infection from surrounding tissues,

including bone and soft tissue, or by haematogenous localisation. The most common cases in the cat are penetrating bite wounds sustained during fights with other cats. Any joint can be affected, although the carpus is most commonly involved. Haematogenous spread is associated with an infected focus elsewhere in the body from which the organisms originate, for example oral, respiratory, genitourinary and skin infections. Single joint involvement is usual. Bacterial endocarditis, although rare in the cat, is another possible source of infection and may involve several joints. In young kittens, an infective arthritis can be associated with an infected umbilicus or postparturient uterine and mammary gland infections of the queen. Again, in these cases, several joints can become infected. Joint abscessation may be evident and severe joint destruction can occur, in which case euthanasia is often necessary. Haematogenous infection is more likely to localise to a joint that has been traumatised and thus an initial lameness due to a 'sprain' may become complicated by infection within a few days. Osteoarthritis also predisposes a joint to infection. Spinal joints can become infected (discospondylitis).

Various organisms can be involved, including *Staphylococcus* spp., *Streptococcus* spp., *Pasteurella* spp., coliforms and anaerobes.

Clinical signs

In general, only a single joint is affected and the joint is usually swollen, hot and painful. There may be loss of joint movement and crepitus, if present, generally indicates extensive bony and cartilage damage. Systemic illness may be present, but not in all cases. Other signs may be present in specific cases, for example skin wounds with bites, or neurological signs with discospondylitis.

Radiography

Soft-tissue swelling is the most obvious feature in the early stages. The joint capsule may be obviously thickened or distended, causing displacement of fascial planes. Intra-articular fat pads may lose their radiolucency as exudate accumulates. Destruction of articular cartilage may be seen as a loss of joint space. Periosteal new bone, which can often be extensive, is another feature (Figures 8.17, 8.18). Bony destruction will also occur with time and may be seen as an erosive change or as a more obvious loss of bone with an irregular widening of the joint space (Figure 8.17). Periarticular calcification is sometimes seen.

Ligament damage can be a complication to infective arthritis and may be appreciated on radiography. Secondary osteoarthritic changes may also occur. Advancing osteomyelitis in adjacent bones may occur and this can sometimes result in the infection spreading to other joints. Sclerosis of bone adjacent to the infection may be seen and bony ankylosis sometimes occurs.

Laboratory features

A leucocytosis may or may not be present. Aspiration of synovial fluid from the affected joint is a useful procedure for diagnostic confirmation. The fluid is increased in quantity, turbid and watery, and sometimes bloody. The mucin clot is poor and the fibrinogen clot positive. White cells are increased in number and the majority are polymorphs. The presence of toxic, ruptured and degranulated neutrophils is often associated with bacterial arthritis.

Figure 8.17 Mediolateral radiograph of the left elbow illustrating a bacterial infective arthritis. There is a widened, irregular humeroulnar joint space (small black arrows), an erosive destruction of bone in the radial head (white arrow) and extensive periosteal new bone deposited along the ulnar shaft (large black arrow).

Figure 8.18 Dorsopalmar radiograph of the left carpus and foot illustrating a bacterial infective arthritis of the carpus. The carpal bones show obvious destruction. There is periosteal new bone on the distal radius and ulna and along the metacarpal bones. Infection has obviously extended the length of metacarpal bone 3 and into the metacarpophalangeal joint, causing its destruction.

Synovial fluid can be cultured for bacterial organisms and antibiotic sensitivity testing performed, although in some cases the organisms cannot be grown; culture of synovial membrane is more likely than synovial fluid to yield the organism.

Treatment

Systemic antibiotic administration, preferably based on sensitivity testing, is the treatment of choice. Treatment for several weeks (4–6 weeks) is generally the rule. In some cases, a drainage tube can be inserted into the joint to allow drainage and local irrigation (Figure 8.19). Commonly used antibiotics are amoxycillin–clavulanate, cephalexin, clindamycin, enrofloxacin and metronidazole.

If articular damage is severe, surgical treatment may be necessary, for example arthrodesis, excision arthroplasty or even amputation.

Once the infection has been cleared, any residual lameness can be treated with short-term corticosteroids; some cases of bacterial infective arthritis are complicated by a persisting synovitis associated with non-viable microbial antigens. Corticosteroids can control this inflammation. These drugs may also help to reduce soft-tissue swelling and joint stiffness.

Arthritis associated with bacterial L-forms

Cats with pyogenic subcutaneous abscesses and arthritis associated with a probable bacterial L-form (i.e. a cell wall-deficient bacterium) were first described by Carro *et al.* (1989). The infection spreads locally and haematogenously to involve other joints and subcutaneous sites. Joint destruction is evident on radiography of some joints. Although the infection is resistant to many broad-spectrum antibiotics, it is readily susceptible to tetracycline. These organisms are very difficult to grow in the laboratory, and routine cultures of the abscesses and joints will be negative.

Tubercular arthritis

In a series of cats with tuberculosis, one case had unilateral elbow arthritis (Gunn-Moore *et al.*, 1996). The cat had a history of malaise and weight loss in addition to lameness. Thoracic radiography revealed diffuse lung densities. Diagnosis was made through a synovial biopsy and treatment involved isoniazid, rifampicin and dihydrostreptomycin.

Mycoplasmal arthritis

There are several different feline isolates of mycoplasmas, and most are found naturally in the upper respiratory and urogenital tracts of healthy cats. A case of

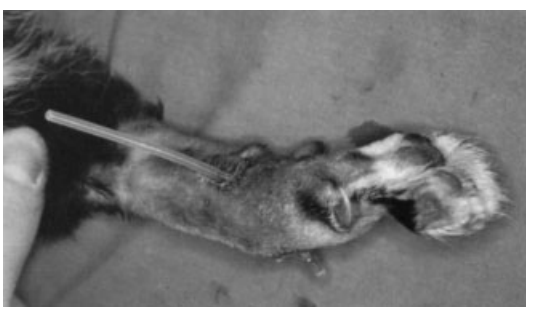

Figure 8.19 Photograph showing a drainage tube inserted into an infected carpus.

Mycoplasma gateae infection in a cat has been reported (Moise *et al.*, 1983). The cat suffered a polyarthritis and tenosynovitis and there were bone and cartilage erosions. It was likely that the cat was immunosuppressed. Pedersen *et al.* (1983b) also reported a single case in an old debilitated cat being treated with surgery and radiation for an oral squamous cell carcinoma. *Mycoplasma felis* was isolated from a young cat with fibrinopurulent polyarthritis and tenosynovitis and, again, there were thought to be underlying immunodeficiencies (Hooper *et al.*, 1985).

The synovial fluid is thin and cloudy and contains large numbers of white cells, most of which are neutrophils. The neutrophils are not toxic, degranulated or ruptured. The organisms can be cultured on special media or sometimes visualised in the fluid using Wright–Leishmann or Giemsa stains. Mycoplasmal arthritis can be treated with tylosin, gentamycin, erythromycin or tetracycline.

Calicivirus arthritis

A fleeting stiffness, soreness and lameness with high fever has been reported in young kittens, 6–12 weeks of age, possibly caused by certain strains of calicivirus infection (Pedersen *et al.*, 1983a). The kittens are often ill for 2–4 days and demonstrate pain when muscles and joints are manipulated. During the acute phase of illness, calicivirus can be recovered from the blood and at least one strain has not been neutralised by antibodies produced by the more commonly used vaccine strains. The condition can therefore occur in kittens vaccinated with some calicivirus vaccines. The prognosis is good, as the disease seems self-limiting.

An experimental study with two strains of calicivirus (FCV-2280 and FCV-LLIC) produced a transient 'limping' syndrome in young kittens (Pedersen *et al.*, 1983a). Joints appeared to be painful on manipulation, but examination of synovial fluid and synovial membrane did not show an active arthritis. Fluorescent antibody techniques also failed to demonstrate a virus within the joints. The author has also reported arthritis and lameness in cats experimentally infected with field strains of calicivirus, and has cultured live virus from the diseased joint (Dawson *et al.*, 1993).

A transient, sometimes protracted, inflammatory (poly)arthropathy occurs as an uncommon complication to vaccination (Dawson *et al.*, 1992). The component of the multivalent vaccines that is responsible is calicivirus, since calicivirus antigens have been demonstrated within synovial macrophages of vaccinated cats (Bennett *et al.*, 1989). Treatment is usually unnecessary, although corticosteroids can be given in persistent cases.

Calicivirus can certainly produce an acute arthritis in the cat following either natural infection or live virus vaccination, and this may be associated with intra-articular live virus or non-viable virus antigens, indicating that calicivirus can produce a true infective viral arthritis and also an immune-based arthritis. Immune-based arthritis mainly follows vaccination (Dawson *et al.*, 1992), and the infective calicivirus arthritis is mainly associated with field strains in a cattery environment and can affect both young and old cats (Bennett D. & Dawson S., unpublished data). In most cases the arthritis is short lived. The role of calicivirus in chronic arthritis is uncertain.

Lyme disease

Lyme disease as first described in humans is a multisystemic illness associated with infection by the tick-borne spirochaete *Borrelia burgdorferi*. The terms borreliosis, Lyme borreliosis and Lyme arthritis are also used to describe the disease attributed to *B. burgdorferi*. The infection appears to be widespread and has been described in many domestic animals (e.g. dogs, cats, horses and cattle) as well as humans in the USA, Europe and Asia. Magnarelli *et al.* (1990) reported that 10 of 71 serum samples taken from cats that had been infested with ticks were positive for *B. burgdorferi* antibodies. They also reported that of two larvae and 20 nymphs removed from cats, one larva and two nymphs were infected with the spirochaete. Jacobson and Saidla (1990) reported seropositivity in 15% of feline sera samples submitted for *B. burgdorferi* titres. A study by May *et al.* (1994) reported a seropositivity of 4.2% in a hospital population of cats; the authors also examined sera from 67 specific pathogen-free cats to provide an accurate baseline; all of the latter cats were seronegative. The hospital cats were commonly infected with *Leptospira interrogans* serovars but there was no cross-reaction between Leptospira and Borrelia antibodies. There was also no cross-reaction between calvicirus and Borrelia (eight of the 16 cats positive for Borrelia were also positive for calicivirus). Only one of nine Borrelia positive cats was positive for feline leukaemia virus (FeLV) and feline immunodeficiency virus (FIV). Although cats can become infected and seroconvert, there is disagreement as to whether they suffer clinical disease. Worldwide, it has been reported that very few cats develop clinical disease (Magnarelli *et al.*, 1990), and no cats in the UK have been reported with clinical dis-

ease (May *et al.*, 1994). Clinical signs in experimental cats infected with large inoculum doses of *B. burgdorferi* have been reported (Gibson *et al.*, 1993), although other authors have failed to induce clinical disease in experimentally infected cats (Burgess, 1992). The clinical signs reported in domestic animals, especially the dog, include fever, anorexia, lethargy, lymphadenopathy and lameness. The lameness is generally, but not always, localised to one or more joints, which may be swollen, hot and painful on manipulation. Muscle disease, meningitis, carditis, renal disease and neurological disease have also been reported. Because the clinical signs can be somewhat vague and because infection can occur without clinical disease, it is difficult to diagnose Lyme disease accurately.

The criteria for diagnosis are discussed in a review by Bennett *et al.* (1992), but basically these should be:

- history of exposure to ticks
- clinical disease consistent with borreliosis
- laboratory features consistent with clinical disease
- positive serological test for Borrelia antibodies
- prompt response to antibiotic therapy in most cases
- exclusion of other possible diagnoses.

Culture of the organism from disease tissues would confirm the diagnosis, but the organism is very fastidious and difficult to grow in the laboratory.

There are many possible reasons why cats do not readily exhibit clinical signs of Lyme disease. One explanation is a difference in the immune response. May *et al.* (1994) showed that the immune response of cats to *B. burgdorferi* differs from that of humans and dogs, in the variability of the antibody responses to the 41 kDa, 60 kDa, OspA and OspB proteins. Most noticeable is the early response to OspA and OspB not exhibited by dogs and humans. A similar response is seen in mice (Simon *et al.*, 1991), which are an important vector of *B. burgdorferi*, and although they are commonly infected they also show no clinical illness.

Other infective arthropathies

It is likely that with the changes in the quarantine laws, other infections more usually associated with hotter climates may be encountered in cats that have visited mainland Europe. It is thought, for example, that cats can be infected by one or more rickettsia of the *Ehrlichia* genus. These organisms are, like Borrelia, transmitted by ticks and polyarthritis is one of several possible clinical manifestations. Infection by *Hepatozoon canis* is reported in the cat; infection is by ingestion of the brown dog tick containing the protozoan organism within its digestive system and not by the tick biting its host. There are many different clinical manifestations, including polyarthritis and polymyositis. Babesiosis is also recognised in the cat; the infectious agents are *Babesia felis*, *cati*, *herpailuri* and *pantherae*; they are transmitted by Ixodidae ticks. Babesiosis is mainly associated with anaemia, but polyarthritis and polymyositis are also reported. Babesia and hepatozoon infections often occur together.

Leishmania donovani infection can occur in the cat, but clinical disease is very rare. This protozoal infection is transmitted by sandflies. Toxoplasmosis (infection by *Toxoplasma gondii*) is well known in the cat and can be associated with a number of clinical signs that can include lameness; asymptomatic infection is common. *Neospora caninum* infection has only been reported as an experimental infection in the cat; clinical signs included myositis.

Immune-based arthritis

There are several different types and, in all, the main pathological feature is a chronic active synovitis (Figure 8.20) generally affecting several joints in a bilaterally symmetrical fashion. The aetiology of all these types of arthritis is unknown, and although underlying microbial infections may be suspected, no microorganisms can be cultured from the joint; they are referred to as the non-infective inflammatory polyarthropathies but their aetiopathogenesis may involve persisting microbial antigens in the joints of susceptible individuals.

They can be distinguished from other types of arthritis because of their multiple joint involvement, the presence of watery synovial fluid within affected joints containing large numbers of polymorphonuclear cells, and the radiographic features. As a group, they are rare and this makes accurate descriptions difficult. The following account is based on the author's cases (Bennett & Nash, 1988) and those reported by Pedersen *et al.* (1980), Wilkinson and Robins (1979), Moise and Crissman (1982) and Robertson (1982). They can be subdivided into two broad groups according to whether or not there are destructive changes visible on the radiographs. Where such changes are present the arthritis is classsified as an erosive type, and when not present as a non-erosive type.

Erosive types

Rheumatoid arthritis (RA)

This may be defined as a chronic, progressive and destructive polyarthritis. The criteria used to stand-

Figure 8.20 Photomicrograph of a synovial membrane biopsy from a cat with periosteal proliferative polyarthritis. There is an extensive mononuclear cell infiltrate (H&E) (×50).

ardise the diagnosis of this disease are based on those used in human rheumatology:

(1) stiffness after rest
(2) pain or tenderness on motion of at least one joint
(3) swelling of at least one joint
(4) swelling of one other joint within a 2 month period
(5) symmetrical joint swelling
(6) subcutaneous nodules (not yet reported in the cat)
(7) radiographic changes suggestive of rheumatoid arthritis
(8) serological evidence of rheumatoid factor (RF)
(9) abnormal synovial fluid
(10) characteristic histological changes in the synovium
(11) characteristic histological changes in subcutaneous nodules.

To diagnose classical RA, seven criteria must be fulfilled, and five fulfilled to diagnose definite RA. In addition, two of criteria 7, 8 and 10 should be satisfied. Also, with criteria 1–5, they should be present for at least 6 weeks.

RA is classed as an autoimmune disease and RF, an autoantibody against immunoglobulin, is often present although it is not always detectable and can occur in other joint diseases. The pathogenesis of the synovitis involves immune complex formation within the joint, and these complexes include RF.

Periosteal proliferative polyarthritis (PPP)

This disease is characterised by extensive periosteal new bone around affected joints, mainly the hocks and carpi (Figure 8.21). Erosive changes in the joints usually occur, and pathology also occurs at the attachment of ligaments and tendons (enthesiopathies).

Pedersen *et al.* (1980, 1983b) related the aetiology of PPP to FeLV and feline syncytia-forming virus infections. They suggest that FeLV produces immunosuppression and allows syncytia-forming virus to multiply in the joints of certain genetically predisposed individuals to cause the disease. However, the incidence of FeLV in affected cats is no greater than in a control population of hospital cats (Bennett D., unpublished data) and feline syncytia-forming virus has not been successful in producing the disease experimentally (Pedersen *et al.*, 1980). The virus is regularly cultured from the tissues of normal cats, including the joints, and it may be that an inflamed joint, containing many actively dividing cells, is an ideal environment for the virus to grow as a secondary event. Also, there appears to be no relationship between FIV and PPP or indeed any other immune-based arthritis (Bennett D., unpublished data).

Non-erosive types

Arthritis associated with systemic lupus erythematosus (SLE)

This is a non-erosive symmetrical polyarthritis and is only one feature of a multisystemic disease. The three criteria used to diagnose this disease are as follows:

(1) Multisystemic involvement: the common manifestations are polyarthritis, autoimmune haemolytic anaemia, immune-mediated thrombocytopenia, leucopenia, pyrexia, glomerulonephritis, skin disease and meningitis. It can be several weeks

Figure 8.21 Photomicrograph of a joint with periosteal proliferative polyarthritis. Extensive new bone is present (arrows) (×35).

before multisystemic involvement is apparent. It is rare to have more than two body systems involved at any one time.

(2) Antinuclear antibody (ANA) is detectable in the blood.

(3) The immunopathological features consistent with the clinical involvement should be demonstrable: for example, antibodies against red cells, platelets and white cells should be shown in cases with anaemia, thrombocytopenia and leucopenia; and immunoglobulin and complement deposits should be shown in tissue biopsies of the synovium, kidney and skin in cases showing arthritis, glomerulonephritis and dermatitis.

Criteria 1 and 2 must always be satisfied; if only 1 and 2 are fulfilled, then probable SLE is diagnosed; if all three are satisfied, definite SLE is diagnosed.

SLE is an autoimmune disease associated with the presence of autoantibodies, which play an important role in the pathogenesis of the disease: antibodies against red blood cells, platelets and white cells and against nuclear antigens. Complexes of ANA, nuclear antigens and complement are thought to be involved in the pathogenesis of the arthritis, glomerulonephritis and dermatitis.

Polyarthritis/meningitis syndrome (PMS)

This is a rare entity in the cat. These animals are generally young adults or older kittens that present with pyrexia, stiffness and neck pain, in addition to joint disease. Some cases exhibit nervous signs. Cerebrospinal fluid (CSF) shows increased protein, white cells and creatine phosphokinase (CPK) levels. These cats are negative for serum ANA.

Idiopathic polyarthritis

All cats with polyarthritis that do not satisfy the criteria for RA, PPP, SLE or PMS are included in this category. Idiopathic arthritis is subdivided into four subtypes:

- type I: uncomplicated polyarthritis (i.e. uncomplicated by the associations described in other subtypes)
- type II: polyarthritis associated with infection elsewhere in the body (e.g. conjunctivitis, respiratory tract infection, urinary tract infection, skin infection)
- type III: polyarthritis associated with gastrointestinal disease
- type IV: polyarthritis associated with neoplastic disease.

Again, these types of arthritis are thought to be mediated by immune complex hypersensitivity reactions. Other organs can be involved in the immune complex hypersensitivity, for example kidneys (glomerulonephritis), eyes (uveitis, retinitis) and skin (dermatitis), and thus these cats with multisystemic involvement can resemble cases of SLE, but they are consistently negative for ANA.

The significance of the associations described above is not clear. They may be coincidental or part of the same disease process. Alternatively, they may represent antigenic foci for immune complex formation.

Some cases of type I and even type II polyarthritis will, over a period of time, progress into cases of erosive arthritis (rheumatoid or periosteal proliferative).

Vaccine 'reactions'
These have been discussed above. They generally occur in young kittens receiving their first inoculation and the calicivirus component of the vaccine appears to be the triggering factor (Dawson *et al.*, 1992). Calicivirus antigens are detectable within the synovium (Bennett *et al.*, 1989). In most cases the calicivirus strain equates with that of the vaccine virus. The kittens are often stiff and pyrexic, signs appearing 5–7 days after vaccination. The arthritis is self-limiting and treatment is generally not required.

Clinical signs

The features of cats with polyarthritis are very similar, no matter which type. RA is more chronic in both its onset and clinical course. These cats usually show a generalised stiffness of increasing severity over several months. Reluctance to jump and exercise becomes apparent. Behavioural changes as discussed with osteoarthritis are common. The joints may be swollen and painful on manipulation, and crepitus and reduced movement are common. In some cases, joint laxity is appreciated and some cats have obvious joint deformities. Any age of cat can be affected. The periosteal proliferative polyarthritis is, again, often chronic in nature and is more commonly seen in male and male-castrate cats. The cats are stiff, and may show periods of pyrexia, inappetence and lethargy. The affected joints (mainly hocks and carpi) become thickened. With both rheumatoid and periosteal proliferative arthritis, it is not unusual for the clinical signs to wax and wane.

The arthritis of SLE, polyarthritis/meningitis and of the idiopathic types generally has a more rapid onset. The cats are often very uncomfortable and appear sore all over. They become unwilling to exercise and may favour particular limbs. They resent being handled and can become uncooperative. Fever, malaise and stiffness may be present. In many cases, joints are obviously swollen and painful, although in some cases it can be difficult to appreciate either periarticular swelling or synovial distension. SLE and idiopathic polyarthritis are more common in young adult cats. Vaccine reactions are seen in young kittens, following recent vaccination.

Cats with SLE and with the idiopathic forms of arthritis may show other signs of immune complex disease, for example skin disease, glomerulonephritis and retinitis. The idiopathic type II cats will also show signs related to infection elsewhere in the body, for example conjunctivitis and respiratory disease. The author has seen lame cats associated with chlamydial conjunctivitis (*Chlamydia psittaci* infection), and prolonged treatment of the conjunctivitis with local and oral tetracyclines will resolve the lameness. Chlamydia can be cultured from diseased conjunctiva or the presence of antigens can be demonstrated in conjunctival smears. Chlamydial serum antibodies are generally increased in cats with chlamydial conjunctivitis (Wills *et al.*, 1988). The type III cats will have gastrointestinal signs. The type IV cats may have signs related to the neoplastic lesion. All cats seen by the authors with idiopathic type IV polyarthritis have had myeloproliferative disease, which can be diagnosed by a bone-marrow biopsy examination; not all of these cases are positive for FeLV.

Radiography

The radiographic signs of the different types of inflammatory polyarthropathy can be very similar. RA is characterised typically by bony destructive changes, which can show as obvious erosions in the joint margin, as an increased, often irregular joint space or as an overall loss of mineralisation of the bones of the joint (Figure 8.22). The fine trabecular pattern seen in the bones of feline joints does make it difficult to appreciate the erosive/destructive change. Destructive changes are also seen in PPP, but are usually less extensive. This form of arthritis is characterised particularly by extensive 'fluffy' deposits of periosteal new bone (Figures 8.23–8.27). These new bone deposits usually extend beyond the confines of the joint. Bony deposits and, sometimes, local erosion of bone may also occur where muscles, ligaments and tendons insert, for example the triceps brachi attachment on the olecranon and the gastrocnemius tendon on the os calcis (Figure 8.25). In some cases, extensive new articular bone may develop, causing partial or even complete ankylosis. Periosteal new bone can occur in the other inflammatory arthropathies, but to a lesser degree.

Soft-tissue changes may be seen in all cases of polyarthritis and include periarticular thickening, distension of the joint capsule and loss of intra-articular fat shadows (Figure 8.28). These changes are often the only ones seen in SLE and idiopathic polyarthritis, but they do consistently occur in other forms and, indeed, in the early stages of RA and PPP, soft-tissue change may be all that is evident, the bony changes occurring later.

Repeated radiography of joints is helpful in monitoring the progression of the arthritis. Some cases, for example, may progress from non-erosive to erosive disease. With time, secondary osteoarthritic changes

Figure 8.22 Dorsopalmar radiograph of the right carpus of a cat with rheumatoid arthritis. There are obvious erosions within the radial and ulnar carpal bones (small arrows). There is some periosteal new bone production on the radius and proximal metacarpus (small white arrows). There is also increased soft-tissue density and swelling (large white arrow).

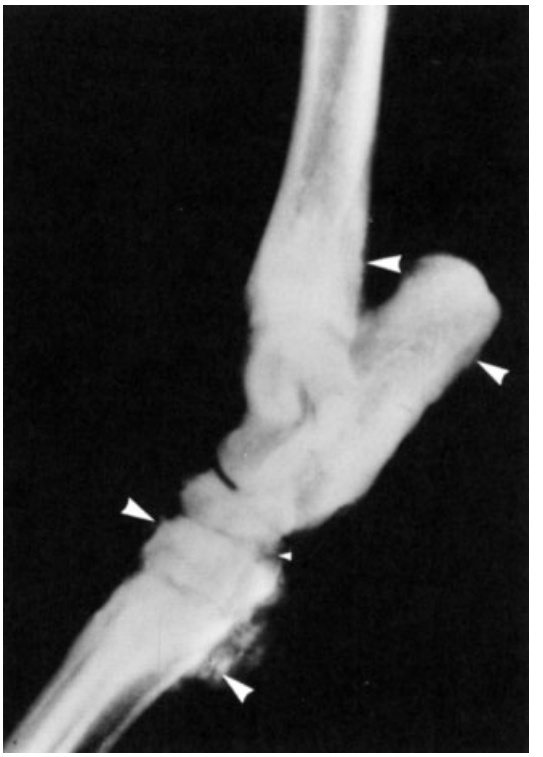

Figure 8.23 Mediolateral radiograph of the left hock joint of a cat with periosteal proliferative polyarthritis. There is an erosive change within the distal intertarsal joint (small arrow). There is an extensive 'fluffy' periosteal deposition of new bone (large arrows) involving all the tarsal bones, distal tibia and proximal metatarsus. The reaction extends well beyond the confines of the hock joint, and is very different to the osteophyte development seen in osteoarthritis.

may become apparent as joints become damaged and unstable. Radiography of other body systems may be relevant, for example, to look for evidence of respiratory tract infections in idiopathic type II arthritis.

Laboratory features

Some cases show anaemia, leucocytosis or leucopenia. Serum globulin levels are generally increased, either absolutely or relatively. Blood enzymes (alkaline phosphatase, alanine transaminase, aspartate transaminase) may be increased.

Synovial fluid analysis is useful to confirm an inflammatory arthropathy and abnormalities will be found in multiple joint samples. The fluid is generally watery and turbid. There is a poor mucin clot and a high white cell count, most of which are polymorphonuclear cells. The fibrinogen clot test may be positive (i.e. the sample may clot on standing if not collected in anticoagulant). Cultural examination of synovial fluid or synovial membrane samples is negative.

Cats with RA may show RF in the blood, as detected by enzyme-linked immunosorbent assay (ELISA), and ANA must be present before SLE can be diagnosed. ANA is usually detected by an indirect immunofluorescence test (Figure 8.29).

Cats with SLE may show red blood cell autoantibodies, autoantibodies against platelets and against

Figure 8.24 Dorsopalmar radiograph of the carpus of a cat with periosteal proliferative polyarthritis. There is extensive new bone formation. Some of the joint spaces appear widened and irregular, consistent with bony destruction.

leucocytes. Immunological testing in the cat is not readily available; species-specific reagents are necessary and it is thus important to check with particular diagnostic laboratories as to what is available.

Treatment

Glucocorticoids are the drugs of choice and prednisolone is the most commonly used. For the acute-onset cases a dose of between 2 and 4 mg/kg body weight is used, and after 2 weeks the dose is gradually reduced. The dose is reduced over a period of 6–8 weeks, providing clinical remission persists. In some cases the drug can be stopped completely, in others a low maintenance dose is necessary. Ideally, alternate-day therapy should be used in the latter. If remission does not occur or occurs only at high doses of steroids, then a combination of cytotoxic drugs and prednisolone should be tried. Cyclophosphamide is the most commonly used cytotoxic drug, at an approximate dose of 2.0–2.5 mg/kg body weight. The dose is given orally,

Figure 8.25 Mediolateral radiograph of the hock joint of a cat with periosteal proliferative polyarthritis. There is great deal of new bone production on the tarsal bones, metatarsus and distal tibia. There is new bone on the tuber calcis, together with a small erosion (arrow), consistent with an erosive enthesiopathy.

Figure 8.26 Dorsopalmar radiograph of the carpus of a cat with periosteal proliferative polyarthritis. There is ankylosis of some joints (large arrows) and destructive changes are also seen (small arrows). The metacarpophalangeal joints also show destruction and bony proliferation.

Figure 8.27 Ventrodorsal radiograph of the pelvis of the same cat as in Figure 8.26. There is extensive bony proliferation around both hip joints resulting in almost total ankylosis. There was also ankylosis of the left sacroiliac joint of this cat.

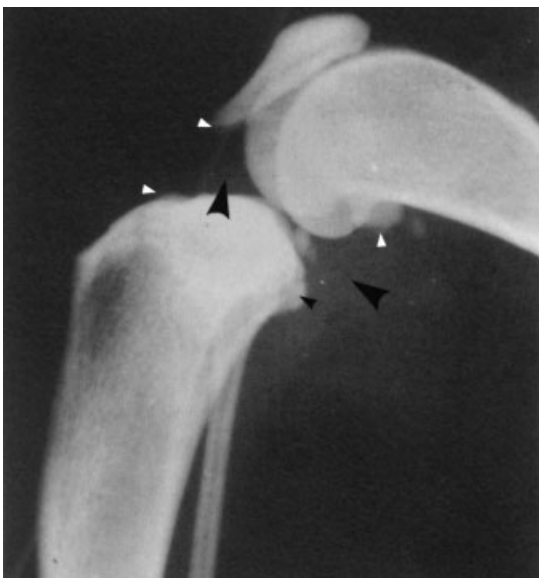

Figure 8.28 Mediolateral radiograph of the stifle joint of a cat with idiopathic polyarthritis. There is some loss of the intra-articular fat shadow and distension of the joint capsule on the caudal aspect (large arrows). There are slight secondary osteoathritic changes (small arrows).

once daily on four consecutive days each week or as as close to this regimen as possible. Corticosteroids are used at an anti-inflammatory dose (0.1–0.5 mg/kg). It is useful to repeat arthrocentesis and synovial fluid cytology 2 weeks after introducing a therapeutic regimen to check on the pathological response. If cell counts are significantly lowered or normal with a preponderance of mononuclear cells the prognosis is reasonably good and the therapeutic regimen continued; if not, then the therapy may need modifying, for example by changing from a steroid-only approach to a combination of steroids and cytotoxic drugs. Complete blood cell counts are done each week when-

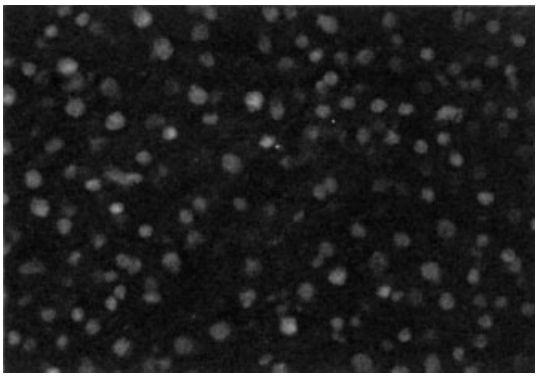

Figure 8.29 Photomicrograph showing fluorescence of nuclei indicating the presence of antinuclear antibody in a case of systemic lupus erythematosus. Indirect immunofluorescence test, substrate rat liver, anti-feline IgG, FITC (×900).

ever an animal is receiving cytotoxic drugs. If the white cell count falls below 6000/mm^3, the dose is decreased by one-quarter; if it falls below 4000/mm^3, the drug should be discontinued for 1 week and then reinstated at one-half of the original dose. Cytotoxic drugs are stopped 1 month after complete remission is achieved, although steroids may be continued for longer. Cyclophosphamide should not be used for longer than 4 months because of the potential bladder complications. Cats receiving steroids and cytotoxic drugs should be protected, as far as possible, from infections, which could be fatal in an immunosuppressed patient.

With the chronic erosive rheumatoid and periosteal proliferative arthritis cases, where the prognosis for recovery is poor, it is often better to treat these cats with low-dose prednisolone for short periods when the clinical signs are particularly bad.

In case of idiopathic polyarthritis of types II, III and IV, treatment of the infective, gastrointestinal or neoplastic process is relevant. If these can be successfully treated, the arthritic problem may resolve without anti-inflammatory or immunosuppressive therapy. If not, these drugs have to be introduced.

The prognosis of immune-based arthritis in cats is variable, and some cases will not respond very well. Since affected cats can be depressed and lethargic, euthanasia is often a consideration, although many cats can cope with their disability and retain a reasonable quality of life.

Feline relapsing polychondritis

There are 13 case reports of this condition in the literature which are well reviewed by Gerber *et al.* (2001). Unfortunately, the term has been taken from the human literature and it is far from clear as to whether the feline and human diseases are equivalent. In humans it is characterised by recurring episodes of inflammation of cartilaginous tissues throughout the body and is considered to be an immune-mediated disease of type II collagen. Antibodies against type II collagen (and some other types) have been demonstrated. In cats it is mainly a disease of the auricular cartilages. Most are young to middle age and present with erythema, swelling, alopecia and crusting of the pinnae. The ears are pruritic and the margins will curl. Inflammatory cells are present within the pinnae and are seen to invade the cartilage. Other lesions may be seen: corneal opacification and cardiac abnormalities were reported by Bunge *et al.* (1992). Only one case has shown lameness and this could be explained by a coexisting patellar luxation. Joint disease is the most common sign in humans, which is obviously very different the case in cats. Also, the disease is very much episodic in humans with a poor prognosis, again different to the situation in cats.

Neoplastic and neoplastic-like lesions

The classification used here is based on published reports and the author's accumulated cases.

Osteocartilaginous exostoses (osteochondromatosis)

These lesions occur in a solitary form (solitary osteocartilaginous exostoses or solitary osteochondromatosis) or as a multiple disease (multiple osteocartilaginous exostoses or feline osteochondromatosis) (Pool, 1981). The solitary lesions are benign, slow-growing tumours of cartilage origin, and have a cartilaginous cap that gives rise to cancellous bone by endochondral ossification (Turrel & Pool, 1982). They occur at the ends of bones (generally the long bones), most frequently in mature cats, and will cause lameness. The exostoses are seen on radiography; they appear dense and have a slightly irregular but clearly defined border. Treatment is by surgically removing the exostosis; the prognosis is good, although local regrowth can occur. Malignant transformation can sometimes occur (to osteosarcoma, juxtacortical osteosarcoma or chondrosarcoma), and this may necessitate amputation.

The multiple lesions have been reported in the cat by Jubb and Kennedy (1963), Riddle and Leighton (1970), Brown *et al.* (1972), Pool and Carrig (1972), Pool and Harris (1975) and Hubler *et al.* (1986). Most cases have been seen in the Siamese breed, although the domestic

shorthair has also been affected. The lesions are partially ossified protuberances arising from the cortex of bones. Initially, the histological features are similar to the solitary form, but eventually they become more like a sarcoma. They occur over the scapulae, sternum, ribs, pelvis and cervical/lumbar vertebrae, and less often affect the limb bones. Radiography shows these to be extensive calcified masses. A retrovirus infection has been suggested as an aetiology for the multiple disease since C-type virus particles have been found in the tumour, and several cats have been FeLV positive. The prognosis with feline osteochondromatosis is poor, most cats surviving for less than a year after the onset of clinical signs (enlarging masses over the skeleton, lameness, paresis). There is no helpful treatment.

Osteosarcoma

Osteosarcoma is the most common primary bone neoplasm of the cat, accounting for 70% of all primary bone tumours (Purdy, 1961; Schmidt & Langham, 1967; Engle & Brodey, 1969; Jacobson, 1971; Liu *et al.*, 1974). Osteosarcoma was reported to occur in aged, female domestic shorthair cats: the average age is approximately 12 years with a range of 2–20 years (Cotchin, 1956, 1957, 1984), although Bitetto *et al.* (1987) reported it more commonly in castrated males. More recently, in a review of 145 cases, no sex predisposition was seen and the mean age for appendicular tumours was 8.03 years (Heldmann *et al.*, 2000). The study by Heldmann *et al.* (2000), of 145 cases, reported 90 cases (62%) in the skeleton and 55 (38%) in extraskeletal sites; 50 of the skeletal cases involved the appendicular skeleton and 40 the axial skeleton. The humerus, femur and tibia are commonly affected (Cotchin, 1984; Bitetto *et al.*, 1987); the tumour may localise in any part of the bone, although some authors report a predilection in the metaphyses (Bitetto *et al.*, 1987). Most limb bones can be affected, as can the sacrum, coccyx, lumbar vertebra, pelvis, ribs and skull; two studies reported that hindlimbs were more affected than forelimbs (Kessler *et al.*, 1997; Heldmann *et al.*, 2000). Osteosarcoma associated with a previous fracture has been reported (Bennett *et al.*, 1979; Fry and Jukes, 1995).

The cats are obviously lame. Swelling at the site of the neoplasm is a consistent feature. Pain over the area and reduced movement in the associated joints is common. The radiographical features are variable (Liu *et al.*, 1974). There may be predominant osteolysis, characterised by radiolucency of the bone, with thinning and loss of the cortices, and this is most likely with tumours of the appendicular skeleton (Figures 8.30, 8.31). Sunbursting and periosteal new bone, including the Codman's triangle phenomenon, may be seen. In other cases, the tumours appear very radiodense and the radiodensity extends into the soft tissues with an irregular outline (Figure 8.32). Pathological fractures are not uncommon. Confirmation of the diagnosis may be made by the histological examination of a biopsy.

In general, osteosarcomas metastasise slowly in cats (only one in 19 cases according to Quigley & Leedale, 1983), although spread to the lungs, regional lymph nodes and kidneys has been reported. Treatment by surgical excision of the mass or amputation of the affected limb has been apparently successful, with no sign of metastatic disease (Liu *et al.*, 1974; Bitetto *et al.*, 1987), although in a recent review of 74 cases the mean survival time was only approximately 12 months for appendicular osteosarcoma (Heldmann *et al.*, 2000). The prognosis with osteosarcoma of the axial skeleton is worse (average survival time 6 months) because the site of the tumour often precludes its total surgical removal (Heldmann *et al.*, 2000).

Extraskeletal osteosarcoma

Extraskeletal osteosarcomas have been defined as malignant bone-forming tumours arising from somatic soft tissue without connection to any osseous structures (Arnone *et al.*, 1984). Extraskeletal osteosarcoma accounted for 38% of all feline osteosarcomas in a recent study by Heldmann *et al.* (2000), with an apparent prevalence for subcutaneous sites commonly used for vaccination. The mean survival time after surgical excision was 13 months.

Extraskeletal osteoma

A benign osseous neoplasm was described in the foreleg of an 8-year-old spayed female cat (Jobora & Paton, 1984). It was described as an osteoma and was surgically excised. A similar lesion described by Jacobson (1971) was classified as an ossifying fibroma–osteoma; this tumour recurred after local excision.

Parosteal osteoma (feline osteoma, parosteal osteosarcoma, juxtacortical osteosarcoma)

This is a rare tumour in the cat. It arises from the outer surface of the cortex of bones. Four cases were reported by Liu *et al.* (1974); three developed in the frontal bone and one in the mandible. Jacobson (1971) and Banks (1971) reported the tumour in

Figure 8.30 Lateral radiograph of the left femur showing an osteosarcoma which had apparently arisen from a previous fracture site. There is obvious destruction of bone with a small amount of periosteal new bone. Increased soft-tissue density is evident. The stifle joint shows calcified masses within the soft tissues (incidental finding).

limb bones. Bitetto *et al.* (1987) reported one case affecting the distal humerus, and Cottrill *et al.* (1987) described the tumour affecting both orbits in an 8-year-old cat. Clinically, a hard mass can be palpated and is firmly attached to the bone. The owners usually notice the developing mass. Radiography shows irregular, poorly defined masses of variable mineral density. They are usually attached to the underlying bone cortex, but in some planes may appear not to contact the regional bone. The neoplasms appear not to metastasise and thus surgical excision or debulking may be attempted.

Chondrosarcoma

Chondrosarcoma was reported in three cats by Liu *et al.* (1974). The neoplasms were located in the right ramus of the mandible, the left proximal tibia and the right posterior scapula. The obvious clinical feature was a firm, fixed mass involving bone. The two cats with limb bone involvement were lame. Radiography demonstrated a lobulated, radiopaque mass that had destroyed portions of the affected bones. Metastases are unlikely and thus radical local excision or limb amputation may be considered. An intranasal chondrosarcoma was reported by Straw *et al.* (1986) and was treated unsuccessfully by radiotherapy.

Osteoma

Osteomas are benign tumours of osteoblastic origin, and have been reported arising from the zygoma and mandible (Knecht & Greene, 1977) and at the dorsum sellae turcicae of the skull (Liu *et al.*, 1974). The masses are firm, non-painful and slow growing. On radiography they appear well circumscribed and radiopaque, with a smooth border. They may be treated by local excision.

Osteoid osteoma

This tumour is composed of a small core or nidus of osteoid tissue surrounded by a mantle of sclerotic bone. Only one case has been reported in the cat (Liu *et al.*,

Figure 8.31 Lateral radiograph of the lower limb showing an osteosarcoma of the mid-shaft ulna. There is obvious bone destruction with minimal periosteal new bone. Soft-tissue swelling is obvious.

1974). The tumour occurred in the 10th thoracic vertebra of a 14-year-old cat. The clinical features included pain and inability to jump and groom. Radiography revealed a densely radiopaque vertebral body that contained a rounded zone of increased radiodensity. This dense nidus was demarcated by a thin radiolucent zone in the otherwise sclerotic body of the vertebra. The mass had expanded and was impinging on the spinal cord.

Multilobular chondromas (chondroma rodens)

These are locally invasive mesenchymal tumours that usually arise from the flat bones of the skull. They are characterised by multiple lobules, each possessing a mature fibrous outer layer, a poorly differentiated mesenchymal middle layer and a central core of cartilage or bone. There are two reports of these tumours affecting the skull of the cat (Jacobson, 1971; Morton, 1985). They can be excised if surgical access allows. Malignant transformation can occur and there is one example of a chondrosarcoma arising from a multilobular chondroma in the cat (Morton, 1985).

Osteoclastoma

Several cases of osteoclastoma (giant cell tumours) have been described in the cat; for example, affecting the distal femur in a 1-year-old cat (Howard & Kenyon, 1967), the distal tibia of an 8-year-old white Persian (McClelland, 1941), the radius of a 6-year-old cat (Crocker, 1919) and the ulna of 12-year-old domestic shorthair (Bennett & Duff, 1983).

Figure 8.32 Ventrodorsal radiograph of the pelvis showing an osteosarcoma arising in the vicinity of the acetabulum. There is extensive new bone which has an irregular border.

The clinical features include lameness, which may not be severe, and swelling over the affected bone. Pain on pressure is another feature. Radiography shows osteolysis of bone. The lesions appear expansile with thinning of the cortices. Fine bony trabeculae may be seen within the radiolucent area, giving a 'soap-bubble' appearance (Figure 8.33). Periosteal bone reaction is generally absent.

Osteoclastomata are usually slow growing and the degree of malignancy is variable. Secondary spread of the tumour to the lungs and kidneys has been reported (Howard & Kenyon, 1967). The case reported by Bennett and Duff (1983) was successfully treated by resection of the lower two-thirds of the ulna.

Figure 8.33 Lateral radiograph of the lower limb showing an osteoclastoma of the distal ulna. There is an expansile lesion forming a radiolucent defect in which there are several bony trabeculae giving a 'soap-bubble' appearance. The ulnar cortices are thinned.

Giant cell sarcoma

Two giant cell sarcomas of periosteal origin were reported in the pelvis of two cats; the left ilium of one cat and the left ischium of the other (Bennett, 1975). Radiography showed irregular destructive changes in the ilium together with periosteal new bone; a pathological fracture was also evident (Figure 8.34). Bony destruction was also visible in the ischium and again a pathological fracture was present (Figure 8.35).

Spindle cell sarcoma

A spindle cell sarcoma of periosteal origin was reported in the right ilium of a cat (Bennett, 1975). Radiography revealed a very dense, oval, calcified mass with an irregular border, replacing a large area of the ilium (Figure 8.36). Secondary tumour deposits were present in the lungs.

Figure 8.34 Ventrodorsal radiograph of the pelvis showing a giant cell sarcoma of the ilium. There is bony destruction with some periosteal new bone and soft-tissue calcification. A pathological fracture is present (arrows). Osteoarthritis of the hip joints is present (incidental finding).

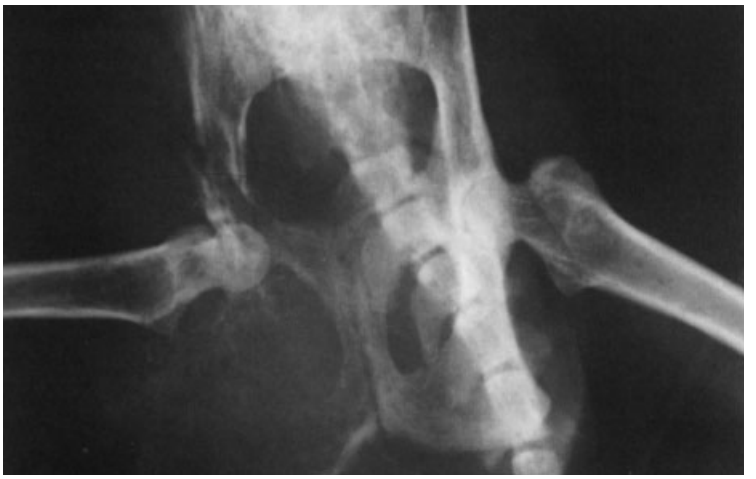

Figure 8.35 Ventrodorsal radiograph of the pelvis showing a giant cell sarcoma involving the ischium and ilium. There is extensive bony destruction. A pathological fracture of the ilium is present.

Fibrosarcoma

A primary intraosseous (medullary) fibrosarcoma was reported in the olecranon of a 1.5-year-old cat (Levitt & Doige, 1989). Radiography revealed osteolysis with minimal new bone production. Amputation of the limb was carried out and although local venous and lymph-node metastases were present, the cat was well at a 1 year follow-up. A similar lesion was reported in the distal ulna of a 9.5-year-old cat by Tischler and Owens (1986). Fox *et al.* (1995) also reported a primary intraosseous fibrosarcoma in the cat.

Synovioma

Synovioma is a rare neoplastic lesion of the cat (Nielsen, 1952; Hulse, 1966; Davies & Little, 1972; Thoday & Evans, 1972). The tumours tend to occur in the distal limbs and are intimately associated with the tendon sheaths, from which they presumably arise. Local recurrence is common and thus amputation of the limb proximal to the lesion is probably the best treatment, although local resection has been successful (Thoday & Evans, 1972). Metastatic spread is rare.

Synovial sarcoma

The synovial sarcoma or malignant synovioma is a very rare neoplasm of the cat. Gresti (1975) reported two cases, both of which were bilateral, and Silva-Krott *et al.* (1993) described a case affecting the elbow joint. The tumours are particularly destructive and radiography reveals soft-tissue swelling and bone destruction within the joint with an irregular periosteal response. These tumours rapidly metastasise and thus the prognosis is poor. Limb amputation may be attempted.

Figure 8.36 Ventrodorsal radiograph of the pelvis showing a spindle cell sarcoma of the ilium. There is a very dense mass of new bone.

Aneurysmal bone cyst

This is a benign lesion of bone characterised by blood-filled spaces and solid areas with spindle cell stroma, containing osteoid and multinucleated giant cells (Spjut *et al.*, 1971). Jacobson (1971) reported a single case and Liu *et al.* (1974) reported three cases in domestic shorthair cats. In the latter series, the lesions arose from the sacrum, coccygeal vertebrae and wing of the left ilium. Swelling and tenderness were the obvious clinical features. Radiographically, the lesion was characterised by a circumscribed eccentrically located rarefaction in the affected bone. The cortex was thin but remained intact. In some radiographs, a lobulated soap-bubble-like trabecular structure extended into the rarefied area. Euthanasia of all three cats was carried out. A case reported in the ribs of a 3.5-year-old domestic shorthair cat was treated by surgical resection (Biller *et al.*, 1987) and another case in the scapula of a 15-month-old domestic shorthair cat by amputation (Walker *et al.*, 1975). A case reported in the pelvis of a 3.5-year-old domestic shorthair cat required euthanasia owing to extensive bony destruction (Saunders *et al.*, 2001).

Fibrous dysplasia

Fibrous dysplasia is a developmental abnormality of bone characterised by the presence of immature osseous trabeculae in a fibrous matrix (Jaffe, 1958). The lesion was described in the right ramus of the mandible of an 11-year-old cat and in the distal ulna of a 3-year-old cat (Liu *et al.*, 1974). The mandibular swelling was painless, but was associated with difficulty in opening the mouth. The other cat was lame on the affected foreleg. Radiographically, the affected bone showed a marked homogeneous radiodensity. There was also periosteal new bone formation affecting the ulna. Excision of the mandibular lesion and amputation of the distal ulna were carried out with no recurrence reported.

A generalised congenital case has been seen by the author in a 9-week-old male domestic shorthair kitten (Bennett D. & Kelly D.F., unpublished data, 1984). The kitten was undersized for its age and presented with a watery nasal discharge and generalised stiffness and an obvious right foreleg lameness. There was pain on pressure of the long bones and on manipulation of some of the joints; the cat held its lower jaw partly open.

Radiography showed a bizarre striped appearance to all the bones of the skeleton, both axial and appendicular (Figure 8.37). Multiple bone biopsies showed woven bone covering mature lamellar bone. Intertrabecular fibrous connective tissue was conspicuous and varied in density throughout the biopsies.

Figure 8.37 Lateral radiograph of the forelimb of a 9-week-old kitten with a generalised fibrous dysplasia. There is a bizarre appearance of the long bones; the cortices are thickened and there are areas of radiolucency and radiodensity often giving a 'striped' appearance. There are several irregular areas of radiolucency in the distal radius and ulna.

Metastatic neoplasms of bone and joints

Secondary spread of primary soft-tissue neoplasms to the skeletal system seems to be rare in the cat (Russell & Walker, 1983). They include mammary gland carcinoma (Kas *et al.*, 1970; Waters *et al.*, 1998) and bronchial

carcinoma (Gustafsson & Wolfe, 1968; Pool *et al.*, 1974; Pollack *et al.*, 1984; May & Newsholme, 1989). Metastasis of pulmonary carcinoma to the digits is an interesting syndrome; metastases generally affect multiple digits (Pool *et al.*, 1974; Pollock *et al.*, 1984; May & Newsholme, 1989; Scott-Moncrieff *et al.*, 1989). The pulmonary lesion may be very small and difficult to identify even at post-mortem examination, and certainly can be present without respiratory signs (May & Newsholme, 1989). Cats with digital involvement present with multiple digital swelling and painful lameness and frequently a permanent exsheathment of the claw of the affected digit. Initially, these cases are commonly diagnosed as nail-bed infections. Radiography shows bone loss of the third (and sometimes second) phalanx with irregular mineralisation and obvious soft-tissue opacity (Figure 8.38). These pulmonary carcinomas can metastasise to other sites, such as muscle, kidney, heart and skin (Schmitz, 1978; May & Newsholme, 1989); metastasis to the muscle also produces a painful lameness. Affected cats present with lameness and in a recent review of 36 cases, none had respiratory signs (Gottfried *et al.*, 2000).

Figure 8.38 Dorsopalmar radiograph of the forefoot of an 8-year-old cat with a bronchial carcinoma metastasis to digit 3. The digital pad is swollen and there is extensive calcification within the soft tissues. The third phalanx shows local osteolysis.

The difficulty in identifying the primary pulmonary lesion may indicate that some cases of 'primary' digital carcinoma (Brown *et al.*, 1985) may in fact have been misdiagnosed. The mean survival time of these cases from the time of presentation is 58 days (Gottfried *et al.*, 2000).

Lymphosarcoma affecting the tarsi of the cat has been reported (Barclay, 1979) and presumably represented a metastatic spread.

Direct extension of neoplasms to bone

Fibrosarcoma

Liu *et al.* (1974) reported 11 cases where a fibrosarcoma had invaded local bone, for example maxilla, frontal bone, mandible, humerus, digital bones, carpus and ribs. The tumour invades and causes lysis of the bone. Many cases do not metastasise and local resection can be successful. With mandibular involvement, partial resection of the lower jaw is feasible (Penwick & Nunamaker, 1987; Withrow & Holmberg, 1983). Despite expectations, the cosmetic and functional results of mandibulectomy are surprisingly good. Similarly, premaxillectomy and maxillectomy have also been used in the cat to treat oral neoplasms involving bone (Salisbury *et al.*, 1986), although recurrence with some tumours is likely (Emms & Harvey, 1986).

A neoplastic syndrome characterised by multicentric subcutaneous fibrosarcomas has been reported (Hardy, 1976; Susanek, 1983). These tumours are fast growing, developing in cats less than 5 years old, and are associated with a C-type oncornavirus (feline sarcoma virus). Metastases of these tumours to muscle and lung as well as local invasion of bone can occur. The prognosis is poor.

Carcinomas

Of eight cats with squamous cell carcinoma involving bone, invasion of the skull bones occurred in six cases and of the bones of the digits in two (Liu *et al.*, 1974). Radiography shows loss of bone mineralisation with erosion and soft-tissue swelling. Periosteal new bone is also sometimes evident. Oral carcinomas involving the bones of the skull have also been reported by Emms and Harvey (1986), Salisbury *et al.* (1986) and Straw *et al.* (1986).

Other neoplasms

Lymphosarcoma, lymphoma, rhabdomyosarcoma, melanoma, haemangiosarcoma, reticulum cell sarcoma and meningiosarcoma have all been associated with bony involvement (Liu *et al.*, 1974; Straw *et al.*, 1986). A mandibular epidermoid carcinoma associated with extensive bony proliferation has been reported in the cat (Miller *et al.*, 1969). In young cats, fibromeloblastoma is generally invasive into the maxilla, and has been reported in Siamese and shorthaired cats (Engle & Brodey, 1969; Dubielzig *et al.*, 1979). Neurofibrosarcoma (Brown *et al.*, 1978), fibromatous epulis (Salisbury *et al.*, 1986) and malignant fibrous histiocytoma (Gleiser *et al.*, 1979) are other examples of soft-tissue neoplasms invading adjacent bone.

Synovial cyst

A subcutaneous synovial cyst was described in a 16.5-year-old spayed domestic shorthair cat (Prymak & Goldschmidt, 1991). It was located over the medial aspect of the elbow joint and was surgically excised without complications or recurrence. Another three cases were reported by Stead *et al.* (1995), all affecting the elbow joint. Synovial cysts have been seen by the author, associated with the shoulder and stifle joints (Figure 8.39). They are benign lesions which originate from the synovium of joints, bursae or tendon sheaths. These are usually noticed as a developing mass, although they can occasionally result in skin ulceration. They should be included in a differential diagnosis of tumours in the subcutaneous tissues of the extremities. Their exact pathogenesis is unknown. They are usually non-painful and if they do cause lameness, it is usually mechanical. Fluid is easily aspirated from these cysts and has all the characteristics of synovial fluid.

Figure 8.39 Mediolateral radiograph of the shoulder region of a cat with an extensive synovial cyst. There is a large fluid filled swelling associated with the shoulder joint. This cyst was causing a mechanical lameness, but no pain, and although the cyst was drained on one occasion, it rapidly re-formed. No attempt was made to excise the cyst surgically.

Synovial osteochondrometaplasia

This condition (also called synovial osteochondromatosis) is characterised by osseous and cartilaginous masses formed by hyperplastic metaplasia of synovial cells (Freund, 1937). The cartilaginous masses often undergo calcification. The bony and cartilaginous lesions are found embedded within the synovial layer. The disease is most often monoarticular and can cause lameness, particularly in the later stages. It has been reported in metacarpal joints (Pool, 1981) and in the stifle and elbow (Hubler *et al.*, 1986). The lesions are readily apparent on radiography and often have the appearance of being free joint bodies. However, because they are within the synovium they are very difficult to remove surgically. Surgical stripping of the synovium with the lesions is possible, but surgical access will always be limited. Palliative treatment with NSAIDs is often acceptable. Synovial osteochondrometaplasia has been linked to osteochondromatosis (multiple cartilaginous exostoses) (Hubler *et al.*, 1986).

Inherited, congenital and developmental disorders

Osteogenesis imperfecta

This is an inherited bone disease characterised by poor mineralisation and excessive bone fragility. Although this term was commonly used in the early literature to describe poor bony mineralisation in young cats and dogs, most of these cases were purely nutritional in aetiology (nutritional secondary hyperparathyroidism) and thus the term was incorrectly used. However, the author has seen cases of osteopenia in kittens not related to nutrition which could be classified as osteogenesis imperfecta. Such cases usually present with bone pain, sometimes associated with pathological fractures. The cats are usually stunted and reluctant to move, and often have periods of

depression and inappetence. The diet is satisfactory (a low-calcium, high-phosphorus diet will exacerbate the clinical signs) and blood calcium and phosphorus levels are normal. Radiography reveals a poorly mineralised skeleton and evidence of pathological fractures. There are two forms of this disease: osteogenesis imperfecta congenita, which is the more serious, and osteogenesis imperfecta tarda. The former is often complicated by other signs such as thin ('blue') sclera, translucent teeth, thoracic abnormalities, thin skin, herniae, deafness and wormian bones visible on skull radiographs. Treatment of these conditions is often unrewarding and euthanasia is generally necessary. Supplementation of the diet with calcium and phosphorus is necessary to help skeletal mineralisation and pain has to be controlled with either NSAIDs or low doses of corticosteroids (corticosteroids may inhibit skeletal mineralisation). The author has only seen cases that would fit the osteogenesis imperfecta tarda category and this is the only type described elsewhere (Gehring, 1975; Jezyk, 1985; Cohn & Meuten, 1990).

Juvenile idiopathic osteoporosis or osteopenia is a similar disorder of decreased skeletal density which differs from osteogenesis imperfecta only in that the prognosis is good (the animals improve as they mature) and there are no abnormalities seen on the skull radiographs.

Sacrocaudal dysgenesis in Manx cats

Manx cats have varying degrees of 'taillessness' associated with sacral and/or caudal vertebral deformities. Some tailless cats have a normal sacrum, spinal cord and cauda equina. Others show varying dysgenesis or agenesis of the sacral and/or caudal vertebrae which may be asssociated with spina bifida and/or malformations of the terminal spinal cord and/or cauda equina. Spinal cord malformations include the absence or partial development of sacral and caudal spinal cord segments or cauda equina, myelodysplasia, meningocoele, meningomyelocoele, diastematomyelia of the sacral segments (duplication), myeloschisis (cleft within spinal cord), syringomyelia in the lumbar and sacral spinal cord segments, shortening of the spinal cord and subcutaneous cyst formation. These spinal cord and cauda equina malformations are associated with variable neurological deficits.

Absence of a tail in the Manx breed is inherited as an autosomal dominant trait and Manx homozygotes die before birth. The Manx gene is apparently semilethal in that females are in preponderance. Sacrocaudal dysgenesis has been recognised in most breeds of cat, many not of true Manx breeding.

There are four expressions of the Manx gene which are controlled by modifying polygenes (Wilkinson, 1984c). The 'rumpy' is the true Manx cat without tail vertebrae. The 'rumpy-riser' has a small number of coccygeal vertebrae forming a usually immobile upright projection. The 'stumpy' has a longer, usually mobile tail, although it is often kinked, knobbly and deformed. The rarer 'longie' has a longer but still short tail of normal appearance.

Clinical signs are variable depending on the degree of spinal cord and cauda equina malformation. They include paraparesis, paraplegia, megacolon, atonic bladder, absent anal and urinary bladder sphincter tone, absent anal reflex, urinary and faecal incontinence and perineal analgesia. Affected cats often walk plantigrade with a 'bunny-hopping' gait. Vertebral abnormalities may be palpable in the lumbosacral region, and in some cats a meningocoele, congenital or as the result of necrosis of the overlying skin, may exit through the skin and drain CSF. Clinical signs are usually evident soon after birth and may progress or remain static. Worsening of neurological signs may be due to progressive syringomyelia in the lumbar and sacral spinal cord. Diagnosis is made on the basis of clinical and radiological findings indicating dysgenesis or agenesis of the sacral and caudal vertebrae; myelography may demonstrate meningocoele or attachment of spinal cord to subcutaneous tissues in the lumbosacral region. The degree of spinal deformity does not always correspond with the severity of clinical signs.

The prognosis for severely affected cats is hopeless. Cats with urinary and faecal incontinence may be managed with manual bladder expression and faecal softening agents; recurrent urinary tract infection, megacolon and chronic constipation are common problems. Meningocoele in cats with minimal neurological deficits may be surgically correctable. Many tailless cats do not have neurological signs, and sacral and caudal deformities are often incidental findings.

Kinked tail

A kink between the coccygeal vertebrae has been reported as a recessive trait in domestic cats (Catcott, 1964; Saperstein *et al.*, 1976).

Polydactylia

The presence of extra digits on one or more feet is not uncommon (Danforth, 1947a, b; Chapman & Zeiner, 1961; Sis & Getty, 1968). The forefeet are most often affected and usually five toes are present in addition to the dew claws. The condition is inherited as an autosomal, single dominant trait, the probable effect of

which is to incite some change in the pre-axial (i.e. medial) part of the limb bud, causing an excess of growth in that area (Sis & Getty, 1968); the gene has variable expressivity. Affected cats can normally cope, although regular trimming of the nails is often necessary. Amputation of extra digits is sometimes indicated if secondary complications occur, such as recurrent interdigital infections or recurrent traumatic injury.

Ectrodactylia

The congenital absence of one or more toes or parts of a digit is rare in the cat (Searle, 1952–1953; Schneck, 1974a). Schneck (1974a) described a kitten with only two toes on the left forefoot.

Syndactylia

Fusion of the digits in a cat has been reported (Hays, 1917–1918), but it is rare.

Amelia and hemimelia

The congenital absence of a limb or limbs (amelia) and the congenital absence of the whole or part of the distal limb (hemimelia) occur occasionally in kittens (Catcott, 1964; Lewis & Van Sickle, 1970; Schneck, 1974b; Jezyk, 1985). Radial and ulnar hemimelia are most often seen. Agenesis of the hindlimb is described as peromelus ascelus and is very rare.

Arrested development of the long bones of the forelimbs

A congenital failure of the forelimb bones to grow to their natural length has been reported in the cat (Williams-Jones, 1944; Robinson, 1971). Such cats are referred to as 'kangaroo cats'.

Mandible ramus aplasia

Abnormal ossification of the mandible resulting in micrognathia has been reported in the cat (Ingham, 1970).

Congenital duplication

Various types of duplication have been described (Saperstein *et al.*, 1976).

Arthrogryposis

A 2-month-old domestic shorthair cat was presented with an inability to flex and extend its joints (Saperstein *et al.*, 1976). There was marked fatty atrophy of all the limb muscles.

Chondrodysplasia

The Scottish fold-ear cat arises from a single dominant gene, which if homozygous results in the ear fold, accompanied by skeletal abnormalities of the tail and lower extremities (Jackson, 1975). The tail is short and stumpy owing to the gross reduction in length of coccygeal vertebrae with expansion of the epiphyseal plates. There is also shortening of the feet owing to a decreased length of metacarpal, metatarsal and phalangeal bones. Certain bones tend to fuse and a large, easily recognised tarsal exostosis is formed. These deformities can be avoided and the fold ear retained by always mating fold-ear to normal prick-ear cats.

Achondroplasia

This form of dwarfism was described in the cat by Hegreberg and colleagues (Hegreberg & Norby, 1973; Hegreberg *et al.*, 1974). Such cats die between 1 and 4 months of age. In addition to the dwarfism, there is muscle weakness, particularly of the hindlimbs, and enlarged liver, spleen and lymph nodes with ascites. The disease is inherited as an autosomal recessive trait.

Congenital hypothyroidism

This is rare in the cat. Affected kittens show disproportionate dwarfism, lethargy, constipation and a juvenile hair coat. Mental retardation may be a feature, as may hydrocephalus. Radiographically, there is delayed closure of fontanelles, delayed appearance of epiphyses, which when they do appear are irregular and fragmented, and cortical thickening of the long bones.

Maxillofacial compression

Shortening of the maxilla and mandible, as in the Persian, Angora and Himalayan breeds, has been exaggerated by inbreeding of lines of breeding cats with brachycephalic traits. The condition predisposes to respiratory, pharyngeal and ocular disease. This deformity is also referred to as 'peke face' or 'dish face' (Catcott, 1964).

Craniofacial malformation in Burmese kittens

This malformation affects the brain, cranial cavity and face (Anon., 1982). The cranial cavity is enlarged and the cerebral hemispheres are duplicated. The eyes may be missing or small and there may be no nostrils

or nasal cavities. The upper jaw and palate may be partially duplicated.

Pectus excavatum

This condition refers to a deformity of the sternum where the sternebrae are displaced dorsally such that the diameter of the thoracic cavity is reduced (Figure 8.40). The deformity has been associated with nutritional secondary hyperparathyroidism and mucopolysaccharidosis, although some cases seems to represent a distinct entity. One such case, reported by Bennett (1973), showed chronic respiratory disease, presumably due to long-term displacement of the heart, lungs and trachea. The diagnosis is easily confirmed by thoracic radiography. The case was successfully treated by surgical resection of the deformed sternum (Figure 8.41). The condition has also been reported by Green and Lindo (1968).

Other skeletal abnormalities

The presence of 14 thoracic vertebrae, 14 pairs of ribs and nine sternebrae segments has been documented (Lindsay, 1968). This was associated with a caudal displacement of the heart. Fusion of the cervical spine associated with neurological manifestations (Klippel–Feil anomaly) has been described (Jezyk, 1985).

Other congenital abnormalities

Boehringer (1975) described a 1.5-year-old tortoiseshell domestic shorthair queen with abnormal development of an extremity. The phalanges of digits 2 and 3 were enclosed in a common skin, the second and third phalanges were fused and two claws arose from the common stump. The phalanges of digit 4 were absent.

Figure 8.40 Lateral radiograph of the thoracic cavity of a cat with pectus excavatum. The caudal sternebrae are displaced dorsally, causing displacement of the heart and trachea. The cat was presented with chronic coughing and tachypnoea.

Figure 8.41 Lateral radiograph of the thoracic cavity of the cat shown in Figure 8.40. Surgical resection of the deformed sternebrae has been carried out. The heart and trachea are better positioned.

Mucopolysaccharidosis

Aetiology and pathogenesis

The mucopolysaccharidoses are a group of diseases due to inborn errors of mucopolysaccharide metabolism; they are classed as lysosomal storage diseases (Jezyk, 1985). At least 12 specific forms are recognised in humans, each due to a defect in a different lysosomal enzyme concerned with the degradation of glycosaminoglycans. There is incomplete degradation of mucopolysaccharides, which accumulate or are stored in lysosomes. Two forms have been described in the cat: mucopolysaccharidosis type I and type VI (Cowell *et al.*, 1976; Jezyk *et al.*, 1977; Langweiler *et al.*, 1978). Skeletal deformities are seen in both diseases, but are only one of several types of abnormality present. Mucopolysaccharidosis type VI has been reported in Siamese and Siamese-cross cats, and type I in white domestic shorthair cats. Both types I and VI have been shown to be autosomal recessive diseases. Type I is characterised by a deficiency of the enzyme α-L-iduronidase, such that the normal degradation of dermatan and heparin sulfates is impaired. Type VI is characterised by a deficiency of aryl-sulfatase B, again involved in the breakdown of dermatan sulfate.

Clinical signs

In type I there is deformity of the skull bones; the head appears broad with a short maxilla, frontal bossing, depressed nasal bridge and small ears. The corneas are cloudy. The animal has a crouched gait with the stifles abducted and the forelegs widely placed, and a wheelbarrow posture of the hindlegs during locomotion has been observed. The sternum is concave and the dorsal neck skin thickened. Manipulation of the head, neck and joints may be painful. Skeletal abnormalities include wide and asymmetrical cervical vertebrae, which may be partly fused, subluxation of the hip joints and pectus excavatum. Chronic upper respiratory tract infection, ocular discharges and chronic diarrhoea may be present.

Type VI mucopolysaccharidosis may also be associated with a short, broad head. Drooping and swelling of the upper eyelids and absence of the lower incisor teeth are also documented. A crouching gait is again common; abduction of the stifles and pain and crepitus in several joints is reported. The epiphyseal and metaphyseal areas of the long bones are enlarged and irregularly shaped. Neck manipulation is painful and there is increased muscle tone in some limbs. Neurological deficits may be present, suggesting multifocal disease in the brainstem and cervical/thoracic spinal cord. Spinal cord compression can be a feature, resulting from vertebral fusion and bony proliferations which can protrude into the vertebral canal; bony proliferation around the intervertebral foraminae can cause nerve root compression. Slight diffuse corneal clouding, retinal atrophy and deformity of the vertebrae with bony proliferation around limb joints are also features. Thoracic deformity (pectus excavatum) and hip subluxation are also reported. Radiography often shows a variable generalised osteopenia with sclerosis of the vertebral endplates and articular facets; the long bones have marked epiphyseal dysplasia accompanied by severe degenerative joint disease. The animals may be several months of age or even young adults when first presented.

Radiography

Radiography will demonstrate the various bony deformities, as discussed above. Radiography of the cervical/thoracic spine and limb joints may show bony proliferation: the appearance can be similar to hypervitaminosis A.

Laboratory features

In type VI, examination of a blood smear may help in the diagnosis since the majority of neutrophils contain excessive coarse metachromatic granular material and 3% of leucocytes are large cells containing basophilic granules. The urine of affected cats shows the presence of excessive amounts of the mucopolysaccharides, dermatan sulfate and sometimes chondroitin sulphate in both types I and VI; this is readily demonstrated by allowing a drop of urine to dry on a microscope slide and then staining the mucopolysaccharide with toluidine blue. Actual levels of mucopolysaccharide can be measured and compared with controls; affected animals have much higher levels.

Deficiencies of the specific lysosomal enzymes, namely arylsulfatase B (Langweiler *et al.*, 1978) and α-L-iduronidase (Haskins *et al.*, 1979), may be demonstrated.

Treatment

The main aim of therapy is to alleviate symptoms: these animals may live comfortably as pets if symptomatic treatment is given. Decompressive spinal surgery may help, although compression may be present at more than one site. Carriers for the genetic defects can be identified.

Enzyme replacement therapy has been reported in mucopolysaccharidosis type VI. Cats were given weekly intravenous injections of human recombinant *N*-acetylgalactosamine-4-sulfatase at 1 and 5 mg/kg, from birth (Crawley *et al.*, 1997); they were heavier, had greatly reduced or no spinal cord compression and had almost normal urinary glcosaminoglycan levels. There was reversal of lysosomal storage in several different tissues, although not the cartilage and cornea. Articular cartilage thickness was reduced and the bone density and trabecular pattern were improved. Degenerative joint changes were neither prevented nor delayed. Bone-marrow transplantation is a potential treatment but has not been reported.

Other lysosomal storage diseases

Several of these conditions have been described in the cat, all characterised by an inherited deficiency of enzymes necessary for hydrolysis of proteins, polysaccharides and complex lipids. These enzymes are present in lysosomes and when deficient there is an intracellular accumulation of the substrate. Neurons are preferentially affected by some of these diseases (neuronal storage diseases, lipodystrophies), whereas others principally affect white matter (leucodystrophies). The clinical signs are due to the deleterious effects on cell function that result from the intracellular substrate accumulation. Most are inherited as autosomal recessive traits and result from mutation in the coding sequence of one of the acid hydrolases in the lysosomes. Although these diseases can affect many different tissues, most affect the CNS and are considered in Chapter 7. A summary of the main lysosomal storage diseases is given in Table 8.4.

Patellar luxation

Congenital medial patellar instability has been reported in the cat (Flecknell & Gruffydd-Jones, 1979). It has been suggested that instability may not be uncommon, although clinical lameness is rare. The Devon Rex may show a susceptibility, but the condition has been seen in other breeds, including the domestic shorthair. Lateral patellar luxation has also been recognised, but is less common (Schrader & Sherding, 1989).

The clinical features include intermittent 'locking' of the stifle, followed by extension of the joint to release the patella, and an abnormal 'crouched' hindleg gait and carriage of the limb. Some cases show deformity of the stifle, with a shallow trochlear groove and rotation of the tibial tuberosity, although the severe angular and torsional deformities of the femur and tibia seen in the dog are very rare in the cat. Cats can also suffer a traumatic luxation of the patella, and the femoropatellar joint can luxate or subluxate secondary to a hip dislocation. Traumatic patellar luxation may be more likely to occur if there is an underlying congenital instability of the femoropatellar joint, insufficient to cause a clinical problem until trauma, which may be comparatively mild, aggravates the joint. Patellar luxation/subluxation will cause secondary osteoarthritis in time. Surgical correction of congenital patellar luxation is indicated if the lameness is severe. Similar techniques are used as described in the dog, including relocation of the tibial tuberosity, recession sulcoplasty of the trochlear groove and capsular tightening.

Proximal femoral metaphyseal osteopathy

This occurs mainly in young adult castrate cats, although it is reported in entire males and in kittens (Queen *et al.*, 1998). The condition is characterised by necrosis of the femoral neck resulting in a pathological fracture. There is often a history of a vague hindleg lameness which can suddenly worsen when the pathological fracture occurs. Pain on flexion and extension of the hip joint is a feature, although is often mild or moderate until the fracture occurs.

Radiography of the pelvis shows loss of bone within the femoral neck; in some cases a fracture is obvious, although there is usually minimal displacement at the fracture site (Figure 8.42). Over half the cases show bilateral disease and a few cases are complicated by developmental medial patellar luxation. In one cat, multiple metaphyses were affected.

The aetiology of the condition is unknown, although a metaphyseal bone necrosis has been produced in experimental cats by the intravenous inoculation of feline herpes virus (Hoover & Griesemer, 1971). To date, no inclusion bodies typical of herpes virus have been found in bone cells of material removed at the time of surgery, and only in the minority of cases have inflammatory cells been reported consistent with an osteomyelitis. However, when surgical treatment is carried out the disease has already been present for some considerable time and earlier pathology may have resolved. Treatment is by a femoral head and neck resection with a good prognosis. The high incidence in male-castrate cats is interesting since castration is known to delay growth plate closure in the male (May *et al.*, 1991) and this might

Table 8.4 Inherited metabolic disorders (lysosomal storage disorders)

Disorder	Enzyme defect	Material accumulating	Cells involved	Breed, age, etc.	Presenting clinical signs
GM1 gangliosidois	β-Galactosidase	GM1 ganglioside	Neurons	Siamese, Korat and other cats 3–6 months	Ataxia, head tremors, spastic quadriparesis
GM2 gangliosidosis	Hexosaminidase A and B	GM2 ganglioside	Neurons	Cats 6–12 months	Dementia, blindness, seizures
Sphingomyelinosis (Niemann–Pick disease)	Sphingomyelinase (phosphocholine hydrolase)	Sphingomyelin	Neurons	Siamese and DSH	Ataxia, head tremors, hypermetria
Ceroid lipofuscinosis (amaurotic familial idiocy)	P-phenylenediamine-mediated peroxidase	Ceroid and lipofuscin	Neurons	Siamese cats 6–12 months	Dementia, blindness, seizures
Globoid cell leucodystrophy (Krabbe's disease)	β-Galactocerebrosidase	Galactocerebrosidase	Macrophages (globoid cells) in white matter	Cats 6–12 months	Rear limb ataxia or paresis, quadriparesis
Glycogen storage disease type II (Pompe's disease)	α-Glucosidase	Type II glycogen	Neurons, neuroglia	Cats 12 months	Generalised muscle weakness, seizures
Alpha mannosidosis	α-Mannosidase	Oligosaccharides	Neurons, neuroglia	Persians 2–4 months, DLH and DSH 6–12 months	Generalised tremors, ataxia, head tremors, spastic paraplegia, opisthotonus
Mucopolysaccharidosis type I	α_1-Iduronidase	Glycosaminoglycans	Connective tissue	White DSH 4–12 months	Deformed skull, crouched gait, wheelbarrow posture, RTI, corneal clouding, etc.
Mucopolysaccharidosis type VI	Aryl-sulfatase B	Glycosaminoglycans	Connective tissue	Siamese, Siamese-cross 4–9 months	Deformed skull, abnormal gait, corneal clouding, ataxia, paraparesis
Glycogen storage disease type IV	α_1,4-D-glucan	Glycogen	CNS, PNS, skeletal muscle, cardiac muscle, liver	Norwegian forest cats 5–8 months	Tremors, weakness, tetraplegia, bunny hopping

CNS: central nervous system; PNS: peripheral nervous system; DSH: domestic shorthair; DLH: domestic longhair; RTI: respiratory tract infection.

Figure 8.42 Ventrodorsal view of the hip joint of a 2-year-old male neutered domestic shorthaired cat with proximal femoral metaphyseal osteopathy. There is extensive bone resorption from the femoral neck of both hip joints complicated by pathological fractures.

predispose these animals to microbial agents localising from the bloodstream to the metaphysis.

Feline capital physeal dysplasia syndrome

This condition was recently reported by Forrest *et al.* (1999) and it is likely that it refers to the same disease process identified as proximal femoral metaphyseal osteopathy by the author. Ten cases were reported, of which nine were neutered males. The ages ranged from 12 to 21 months and in all cases there was fracture of the capital physis with varying degrees of femoral neck resorption. The disease was bilateral in nine cases. Femoral head and neck resection was performed in five cats and histopathology was reported in two cases, from which there was 'a suggestion of epiphyseal dysplasia'. It is not clear what the authors mean by epiphyseal dysplasia, although chronic physeal fibrosis, sclerosis and necrosis centred at the physis was described. The authors state that feline capital physeal dysplasia syndrome is distinct from proximal femoral metaphyseal osteopathy since a slipped physis is the first radiographic sign, although it is not clear from the case details whether this conclusion is valid or not. Craig *et al.* (2001) reported another 13 cases, of which 10 were male castrates.

Hip dysplasia

Radiographical features of hip dysplasia are often seen in the cat (Figure 8.43), but they are usually incidental findings, not associated with a hindleg lameness. The disease can produce secondary osteoarthritis. The radiographical features have been reported by several authors (Riser, 1964; Carlson, 1967; Kolde, 1974; Peiffer *et al.*, 1974; Holt, 1978) and are similar to those of the dog; for example, widening of the lateral and medial joint space, subluxation of the femoral head, shallow acetabulum and osteophyte development.

Figure 8.43 Ventrodorsal view of the pelvis of an 8-year-old domestic shorthaired cat showing obvious hip dysplasia and secondary osteoarthritis.

Clinical signs can sometimes be severe, and include a crouching hindleg gait, howling with pain, inability to climb stairs, reluctance to defecate, and pain and crepitus in the hip joints. The condition is said to be more common in the Siamese breed (Riser, 1964; Peiffer *et al.*, 1974).

Treatment has included resection of the pectineus muscle (Kolde, 1974; Peiffer *et al.*, 1974) and femoral head resection (Holt, 1978). Mild cases may respond to rest (confinement) and NSAIDs.

Osteochondrosis

Osteochondrosis is defined as an idiopathic disease characterised by a disturbed endochondral ossification in the young animal. Cases of osteochondrosis dissecans of the humeral head have been reported in a 9-month-old male Burmese kitten (Butcher & Beasley, 1986) and a 1-year old male neutered cat (Peterson, 1984); the author has seen a similar lesion in the stifle joint of a 8-month-old male-castrate domestic shorthaired cat. It is possible that these lesions were osteochondral fractures. All three cases responded to surgical excision of the lesion.

Neuromuscular diseases

These include those conditions which involve peripheral nerves or nerve roots (the neuropathies), the neuromuscular junction, and muscles themselves (the myopathies). The clinical feature common to all is weakness. Neuropathies are characterised by ataxia, paresis or paralysis with proprioceptive dysfunction, altered muscle tone, hyporeflexia or areflexia and muscle atrophy. Loss of sensation is variable. Myopathies typically show muscle weakness or stiffness, reduced exercise tolerance, gait abnormalities and often neck ventroflexion. Muscle atrophy is present in some myopathies, but hypertrophy can be a feature in others. Reflex activity is not severely impaired and sensation is present. Muscle pain may be present in some of the inflammatory myopathies. Neuromuscular diseases present with weakness during exercise or complete flaccid paralysis; regurgitation of food may be present. There is potential overlap between these diseases and diseases of the CNS; this section deals principally with those conditions that produce musculoskeletal signs. Excellent reviews of the feline neuromuscular diseases were recently provided by Jones (2000) and Le Couteur (2003).

Inherited myopathies

Feline X-linked muscular dystrophy

This has been reported in young (less than 2 years) male cats, which show a bunny-hopping gait, difficulty in walking and jumping, cervical rigidity, symmetrical muscle hypertrophy, tongue enlargement and tachypnoea/dyspnoea. There is an absence of the muscle protein dystrophin. Serum CPK levels are considerably increased and there are generalised electromyographic (EMG) changes. Muscle biopsies show gross muscle pallor and myofibre necrosis, phagocytosis, mineralisation and splitting. There is no treatment.

Nemaline myopathy

Diagnosis of this myopathy is based on the identification of nemaline rods within myofibres on biopsy examination. It has been reported in related 6–12-month-old cats. Affected animals show reluctance to walk and a forced rapid hypermetric gait with muscle atrophy, tremors and hyporeflexia. Electrophysiological assessments are normal and CPK is marginally elevated. There is no treatment.

Generalised ossifying myositis

This is a rare disorder of interstitial connective tissue, in which widespread muscle degeneration results from excessive fibrous tissue development with dystrophic calcification and ossification. Young cats with this disease show weakness, stiffness, decreased limb movement and muscle pain; calcified masses can be palpated within muscles. Radiography reveals extensive soft-tissue mineralisation, and histological examination of muscle biopsies demonstrates differentiated cartilage and bone without inflammation. There is no treatment. Case studies have been published (Norris *et al.*, 1980; Warren & Carpenter, 1984).

Myotonia

Myotonia is the continued active contraction of a muscle after the cessation of voluntary effort, and is characterised by muscle spasm, hypertrophy and stiffness; it is an inherited disease and is reported in domestic shorthaired cats. Affected kittens walk with an awkward, stiff gait, the limbs are abducted when walking owing to poor flexion of the proximal limb joints. The stiff gait is worse after rest and in colder

temperatures. When startled, the kittens will frequently fall into lateral recumbency with their legs stiff and extended. The jaws cannot be fully opened and sometimes there is dysphagia. Sometimes startling a kitten will result in spasm of the eyelids and/or orbicularis oculi muscle. Palpation of muscle groups will reveal widespread hypertrophy.

Under general anaesthetic, there is the very characteristic dimpling of the tongue and skeletal muscle after percussion, and EMG assessment reveals the spontaneous waxing and waning high-frequency discharge after insertion of the electrode (the 'dive-bomber' sound). No treatment is necessary for mildly affected cats, who can be kept as pets with a reasonable quality of life.

Hereditary myopathy of the Devon Rex

Muscle weakness and tremor, especially of the head, appear from 5 weeks to 4 months of age. Affected kittens walk with a high-stepping gait and develop ventroflexion of the head and neck. They rest often during exercise and frequently adopt an unusual 'dog-begging' posture when resting. Most have difficulty in eating and drinking from a bowl; the neck tends to remain flexed and this causes difficulty in chewing and swallowing food. Choking when eating is common and obstruction of the larynx can result in asphyxiation and death. Serum CPK is not elevated and there is no effective treatment.

Glycogen storage diseases (glycogenosis)

These are rare diseases in the cat; there is inadequate glycogen utilisation, with glycogen accumulation in various tissues including muscle. They are characterised by lack of activity of one of the enzymes involved in glycogen degradation or synthesis.

Glycogen storage disease type IV has been reported in young related Norwegian forest cats in the USA. It is an autosomal recessive disease caused by a deficiency of the glycogen branching enzyme α1,4,-D-glucan. Initial signs were fever, muscle tremor, bunny-hopping gait and weakness at 5 months of age, which developed to tetraplegia by 8 months. Severe muscle atrophy and contracture of the caudal antebrachial and cranial thigh muscles are seen. One cat showed ventricular hypertrophy and atrial fibrillation. Histological examination demonstrates the accumulation of abnormal glycogen, accompanied by severe degeneration of the CNS, peripheral nervous system, skeletal muscle and heart. Analysis of the glycogen in affected cats demonstrated less than 10% of normal levels of branching enzyme activity in liver and muscle.

Acquired myopathies

Myositis

Bacterial myositis can often result from bite and other wounds and local abscessation may occur. Treatment includes drainage, local antisepsis and systemic antibiotics. Occasionally, foreign bodies including teeth, claws and airgun pellets may be lodged in the tissues and require surgical removal. Foreign bodies are likely to be associated with non-healing sinuses and radiography can help in assessing these cases.

Other causes of myositis, such as parasitic (e.g. hepatozoonosis, babesiosis) and immune-based occur in the cat but are are not well documented. *Toxoplasma gondii* can cause polymyositis, often with respiratory and nervous signs. Suspected immune-based polymyositis has been reported in the cat, characterised by persistent ventroflexion of the neck, appendicular weakness, painful muscles and exercise intolerance. Serum CPK is elevated and EMG abnormalities are found. Histological abnormalities include myonecrosis with lymphocytic infiltrates. Some cats recover spontaneously, whereas others require glucocorticoid therapy (2 mg/kg prednisolone daily).

Cases of *Spirocerca lupi* infection of the oesophagus are reported in cats in Africa and the southern USA. Such lesions are nodular and cause vomiting and regurgitation; treatment is by surgical excision.

Hypokalaemic polymyopathy (muscle weakness syndrome; sporadic feline hypokalaemic polymyopathy)

This was widely reported in the USA in the mid-1980s, but seems rare in the UK (Hopkins, 1989). The presenting signs include acute onset of severe muscle weakness, characterised clinically by ventral flexion of the neck, reluctance to walk, stiff gait, easy fatigability and apparent muscle pain (Dow *et al.*, 1987a, b). There is a severe hypokalaemia associated with the clinical signs. Serum CPK levels are increased and EMG abnormalities are reported (e.g. excessive insertional

activity, spontaneous activity including positive sharp waves and fibrillation potentials, bizarre high-frequency discharges). Muscle biopsies most often show no abnormalities, although myonecrosis may be evident. Prolonged excessive urinary potassium losses were thought to have caused the potassium depletion, associated with renal dysfunction, and evidence of the latter was generally found on routine blood examination. The potassium loss was compounded by insufficient dietary potassium. It has been concluded that the potassium requirement for cats receiving a 33% protein diet is at least 0.3%; in kittens fed 0.2% potassium diets signs of potassium deficiency will occur (Hills *et al.*, 1982). The feeding of an acidifying diet may also increase potassium depletion (Dow *et al.*, 1987b) and certain drugs may accelerate renal potassium losses (e.g. diuretics, corticosteroids). The hypokalaemia, although secondary to renal disease, will itself cause further renal pathology. Most manufacturers have now increased the potassium content of their diets and levels of 0.5–0.7% are not uncommon. Muscle weakness and hypokalaemia have also been seen secondary to renal tubular acidosis (Drazner, 1980) and in a cat with primary hyperaldosteronism (Eger *et al.*, 1983).

Treatment is with oral potassium, preferably as potassium gluconate at a dose of 5–10 mmol/cat per day, given in two divided doses. Once clinical improvement has occurred and serum potassium levels are back to normal, the oral potassium supplement can be reduced; maintenance supplements of 2–6 mmol potassium/day may be necessary. Intravenous potassium therapy is best avoided, but is sometimes necessary if the hypokalaemia is severe. The potassium should be administered at a rate of 0.5–1.0 mmol/kg per hour. Potassium chloride should be diluted in a balanced electrolyte solution such as lactated Ringer's solution and administered via an infusion pump, since highly concentrated potassium-containing solutions must be infused carefully to avoid phlebitis and potentially fatal hyperkalaemia. During such infusion serum potassium must be monitored, together with electrocardiographic (ECG) recordings. Fluids that do not contain concentrations of potassium that are capable of replacing the deficit rapidly should not be used since they may actually worsen the hypokalaemia by a dilution effect. An alternative to administering highly concentrated potassium solutions is to infuse dopamine (0.5 μg/kg per minute), which causes translocation of potassium from the intracellular to the extracellular fluid.

Burmese sporadic myopathy

This was described as an inherited disease by Mason (1988). The age of onset of signs varied from 4 to 10 months, with an average of 7.4 months. Affected cats would develop ventroflexion of the neck with the lower jaw pressed on the cranial sternum; this could occur during rest or when walking. When walking, the head would rhythmically nod up and down as though co-ordinated with limb movement. The forelimbs were stiff, straight and hypermetric, while the hindlimbs would flex normally but were widespread and ataxic. Pupil dilation and claw protrusion occurred with handling, stress or fright. Affected animals could only walk short distances. Convulsions were also reported. The animals would improve and show complete normality before relapsing days or weeks later. The original problem was likened to thiamin deficiency and treatment of some cases with thiamin was thought to help reduce the severity of the signs. However, it is now known to be a congenital form of hypokalaemic polymyopathy and the Burmese breed has an inherited predisposition (Blaxter *et al.*, 1986; Jones & Alley, 1988). Treatment with potassium replacement as discussed above is generally successful.

Figure 8.44 Mediolateral radiograph of the stifle area of a cat with localised myositis ossificans. There are extensive bony deposits within the muscles and soft tissues around the joint.

Localised ossifying myositis

This is characterised by heterotopic non-neoplastic bone formation in a single muscle or group of muscles or other soft tissue (Dahlin, 1967). The ossification may be associated with trauma. Liu *et al.* (1974) described a case in a 2-year-old cat. The cat was presented with firm nodules, palpable on the medial aspect of both elbows. Radiography revealed a calcified mass proximal to each olecranon. The adjacent bones showed periosteal proliferation. Surgical resection of the lesions proved an effective treatment. The lesions consisted of proliferated fibrous and osteoid tissue in the muscle; there were well-formed calcified osseous trabeculae with more mature osseous tissue disposed peripherally. Another case was reported by Friend (2000); this was a 14-year-old cat with bilateral involvement of the soft tissues around the elbow joints. Figure 8.44 shows the radiographic appearance of myositis ossificans in a 6-year-old domestic shorthaired cat.

Neuromuscular junction diseases

Myasthenia gravis

This disease is associated with a failure of normal neuromuscular transmission associated with reduced numbers of functional acetylcholine receptors. Signs include generalised muscle weakness, dyspnoea, muscle tremor, ataxia and collapse when the animal is exercised (Dawson, 1970; Mason, 1976). A change in voice and difficulty in prehension and swallowing of food are also reported. The aetiology is unknown, although cases can be either congenital or acquired. Autoimmunity is thought to be involved in the latter type, where antibodies against acetylcholine receptors can be demonstrated. Both types have been described in the cat (Indrieri *et al.*, 1983). One case of autoimmune myasthenia gravis was associated with a thymoma (Scott-Moncrieff *et al.*, 1990) and another with drug administration (methimazole).

Three clinical forms are recognised: a focal form (oesophageal, laryngeal, facial muscle dysfunction), a generalised form with appendicular weakness with or without oesophageal dysfunction, and a severe form characterised by the sudden onset of severe appendicular weakness and respiratory muscle paralysis. Generalised muscle weakness is brought on by exercise; cats tire easily, show muscle tremors and are reluctant to exercise. They move with a crouching gait and then, often after only a few steps, flop onto their sides with the head resting on the paws. Other signs include dyspnoea, an altered meow, dysphagia and regurgitation of food because of megaoesophagus.

Diagnosis is based on a dramatic response to anticholinesterase drugs (e.g. edrophonium 2.5–5.0 mg i.v.). Electrophysiological investigation shows a decremental response to repeated electrical stimulation of muscle; circulating acetylcholine receptor antibodies are present in the acquired form. Treatment is with long-acting cholinesterase inhibitors (e.g. pyridostigimine 0.5–3.0 mg/kg p.o. daily). In acquired myaesthenia, prednisolone therapy (2–4 mg/kg p.o. daily) should be administered daily with a gradual reduction in dose over 6–8 weeks. Chemotherapy and possible surgical thymectomy should be considered if thymoma is diagnosed.

Organophosphate toxicity

A delayed form of neurotoxicity can occur in cats with prolonged exposure to organophosphate compounds or even days to weeks after minimal exposure. Affected cats are weak, tire easily with exercise and show ventroflexion of the head and hindlimb ataxia. Low serum cholinesterase values (less than 500 IU) can confirm a diagnosis. Most cats improve without treatment, although diphenhydramine (4 mg/kg every 8 h) can speed recovery.

Inherited neuropathies

Hyperoxaluric neuropathy

Cats with low concentrations of the enzyme D-glycerate dehydrogenase develop an axonopathy with lower motor neuron dysfunction. The cats excrete excessive L-glycerate in their urine, have an intermittent oxalaturia, and develop oxalate crystals in the kidneys and renal failure. Axons in the peripheral nerves, nerve roots and spinal cord are distended with neurofilaments. Young cats are affected and die, with renal failure, before 1 year of age.

Neuropathy associated with hyperchylomicronaemia

Monoparesis, Horner's syndrome, facial and masticatory muscle paralysis may occur in cats with primary inherited hyperchylomicronaemia owing to compression of peripheral nerves by lipid granulomas, as they exit the spinal foraminae or where they pass over bony prominences. The affected cats have

low lipoprotein lipase activity and elevated plasma triglyceride and cholesterol. Clinical signs will resolve if cats are fed a low-fat diet.

Neuropathy associated with sphingomyelinase deficiency

This has been reported in 2–5-month-old Siamese kittens and is an autosomal recessive inherited deficiency of the enzyme sphingomyelinase, which results in a demyelinating polyneuropathy. The affected cats have a progressive lower motor neuron paresis, muscle tremor and hepatosplenomegaly.

Distal axonopathy of Birman cats

These cats show a degenerative neuropathy of the sciatic nerves and several areas of the brain (cerebellum) and spinal cord (fasciculus, gracilis). A proximal–distal selectivity of the peripheral nerves as well as the spinal cord lesions define the disorder as a 'dying-back' disease. It occurs in 6–10-week-old male Birman cats and is characterised by a progressive hindlimb ataxia. An autosomal sex-linked mode of inheritance is suspected.

Acquired neuropathies

Ischaemic polyneuropathy (aortic thromboembolism)

Thromboembolism of the terminal aorta is a well-known syndrome in cats with hypertrophic cardiomyopathy, the animal presenting with an inability to stand on its hindlegs. There is an absence of femoral pulses and cold extremities and loss of sensation. There is evidence of concurrent cardiomyopathy. The resultant ischaemia of the hindlegs has an important effect on peripheral nerves and muscles (Griffiths & Duncan, 1979). In cases reported, motor function was markedly reduced distal to the stifle, particularly in the cranial tibial muscles. Improvement occurred in 2–3 weeks and complete recovery of motor function occurred in some cases. Affected muscles were often hard and painful on palpation. Part of the ischaemia is the result of vasoconstriction of the collateral circulation induced by serotonin and thromboxane A_2 from the platelets.

Many peripheral nerves had myelin defects to varying degrees; most demonstrated obvious degeneration but a few survived the ischaemia. Regeneration of damaged nerve fibres was demonstrated. Infarction of the cranial tibial muscles was common.

Some cats recover, but usually with some permanent disability, and there is a high chance of recurrence.

Treatment is based on prevention of extension of the clot and further primary thrombosis (heparin) and prevention of the effects of clot breakdown factors (5-hydroxytryptamine antagonists, e.g. cyproheptadine, and α blockade, e.g. acepromazine) and, in chronic cases, the use of drugs to reduce platelet aggregation (aspirin). Embolectomy is also possible. Treatment of the underlying cardiomyopathy is indicated.

Polyneuropathy associated with salinomycin

A primary axonopathy with secondary destruction of myelin was shown to be caused by contamination of cat food with salinomycin, an anticoccidial agent. The cases were reported in the Netherlands and Switzerland in 1995. The signs ranged from mild paresis to severe tetraparesis, respiratory signs (dysphonia, dyspnoea) and autonomic signs. Many cats recovered with supportive therapy.

Diabetic polyneuropathy

Cats with uncontrolled or poorly controlled diabetes mellitus may develop a distal polyneuropathy involving the hindlegs. There is a plantigrade posture, progressive paresis, hyporeflexia and muscle atrophy. The cats are polydipsic and polyuric, and have fasting hyperglycaemia and glycosuria. Blood fructosamine levels are increased. EMG and nerve conduction measurements show changes indicative of a combined axonal degeneration and demyelination. If treated early and the diabetes is well controlled the majority of cats will show significant improvement and may return to normal (Kramek *et al.*, 1984).

Traumatic neuropathy

Many injuries can result in nerve damage and the prognosis depends on the degree of axonal disruption. Some important examples include brachial plexus avulsion, ilial fractures with craniomedial displacement of the caudal fragment, sacroiliac fracture/luxation, injection of irritant substances into the caudal thigh muscles around the sciatic nerve, and pressure on nerve roots by vertebral exostoses in hypervitaminosis A. With stretch and compression injuries, recovery times vary from 1 week to

several months. Demyelination is rapidly repaired, but axonal disruption requires regeneration. Brachial plexus avulsions generally have a very poor prognosis.

Neoplasia

Peripheral nerves can be affected by primary neoplasms (neurofibroma, schwannoma), compressed by adjacent neoplasms or infiltrated by neoplastic cells (lymphoma). In addition to motor signs there may be paraesthesia and excessive licking at the site of the sensory dermatome.

Other myopathies

Tetanus

Although tetanus is really a disease of the CNS, it is typically associated with muscle signs. The cat is particularly resistant to tetanus because tetanus toxin is less able to penetrate the nervous system; even so, several case reports have appeared (e.g. Baker *et al.*, 1988). The tetanus or muscle rigidity may initially be localised to the area of the wound (if present). This can progress to generalised muscle stiffness and rigidity, and generalised tetanus is relatively easy to diagnosis because of the typical clinical features. The tonic contraction of the muscles may prevent ambulation; if the animal can walk it will have a very stiff gait. Severely affected animals lie on their sides with rigidly outstretched limbs and tails curved dorsally. Opisthotonus is common. Ears are drawn closely together, with wrinkling of the skin of the forehead. Spasms of the extraocular muscles cause intermittent enophthalmus and protrusion of the third eyelids. Spasms of facial and masticatory muscles result in narrowed palpebral fissures, curling of the lips (risus sardonicus) and inability to open the mouth (trismus).

Cats can show a localised form of tetanus which, because of the 'atypical features', is often misdiagnosed. Isolated muscles or muscle groups controlled by adjacent spinal cord segments may show spasm/contracture and the muscles involved may be close to the site of the wound, although localised tetanus has been reported following surgery (ovariohysterectomy). The criteria for diagnosing localised tetanus are:

- an alert, otherwise healthy cat
- spasticity of a limb or group of muscles innervated by the same or adjacent spinal nerves
- a wound (including surgical wounds) up to 3 weeks before the onset of signs
- a wound close to or distal to the spastic muscle groups
- the presence of clostridial organisms in Gram-stained smears from the contaminated wound
- elevated serum tetanus antibody concentrations.

Treatment is with tetanus antitoxin, antibiotics and supportive care, and recovery can occur. The muscle spasms can be controlled with phenothiazine, barbiturates and diazepam.

Fibrotic myopathy

Fibrous replacement of the semitendinosus muscle has been described in the cat (Lewis, 1988). The lameness was characterised by an abnormal gait, where there was marked flexion of the hip, stifle and hock as the leg was advanced, with an abruptly shortened anterior stride. The muscle was felt as a taut band on the caudomedial aspect of the thigh, which limited the extent of abduction. The cause, like fibrotic myopathies in other species, was not determined. Surgical lengthening of the muscle abolished the lameness immediately postoperatively, but the clinical signs returned later.

Contracture of the gastrocnemius muscle/tendon

A bilateral contracture of the gastrocnemius muscles and tendons with hyperextension of both tarsal joints was described in a 5-month-old kitten (Rengel *et al.*, 1977). The clinical signs were severe overextension of the hocks with heavy callus formation on the cranial surface of the tarsi, which were in contact with the ground. The case was treated successfully by surgical lengthening of the gastrocnemius tendons. A unilateral case in a 3-month-old kitten, seen by the author, had severe secondary bony changes within the hock joint. Two transarticular Kirschner wires were used to hold the hock joint in flexion. These were later removed and the kitten retained a normal foot posture.

Dystrophy-like myopathies

Vos *et al.* (1986) described two cases of feline myopathy characterised by varying muscle fibre diameter, internal nuclei, moderate degeneration and necrosis of solitary muscle fibres, and slight to moderate

endomysial and perimysial fibrosis. Very few regenerating muscle fibres were present. Only one of the cats showed a locomotor disorder, characterised by inability to jump and a kangaroo-like gait; chronic vomiting was also a feature. Hulland (1970) reported two young littermate Siamese cats with weakness ultimately resulting in an inability to support body weight. Muscle histology included irregular atrophy and hypertrophy of muscle fibres, individual muscle fibres showing degeneration and fragmentation, with aggregation of histiocyte cells and a lack of muscle fibre regeneration.

Others

Gershoff and Norkin (1962) described degenerative myopathy in cats fed vitamin E-deficient diets, not containing unsaturated fatty acids. A clinical case of vitamin E deficiency was described in a cat fed a very unusual diet (Dennis & Alexander, 1982). The animal presented with swollen muscles in its forelegs and hindlegs associated with difficult and painful movement. Histological examination of the muscle revealed several degenerative changes, including pale swollen myofibres, loss of cross-striations, hyaline degeneration and necrosis with flocculation granules, and myophagia by macrophages. Some swollen myofibres showed proliferation of sarcolemmal nuclei but no giant cell formation within myofibre cylinders. Chronic inflammatory change was also present.

A myopathy of unknown origin was reported by Joshua (1965). There was extensive myonecrosis, replacement fibrosis and muscle regeneration. The clinical signs included malaise, lameness and emaciation, with hardening and contracture of both triceps brachi muscles and biceps femoris in the right hindleg.

A histological myonecrosis in a cat was described by Gardner (1967). The affected muscle showed swelling, coagulation and fragmentation of the sarcoplasm in the necrotic fibres, which were interspersed with normal fibres. The cause of the myonecrosis was unknown and the cat showed other lesions such as ecchymoses, icterus and pulmonary oedema.

Diseases of the vertebral column

Intervertebral disc protrusions

King and Smith (1960a, b) found that dorsal disc protrusions occurred mainly in old cats over 15 years of age, where they were common and often multiple. These protrusions had occurred without noticeable clinical signs. Any part of the column could be affected, although the more severe varieties of protrusion were slightly more common in the cervical region. There are two types of disc degeneration reported, chondroid (calcified nucleus pulposus) and fibroid, and both Hansen's type I and type II disc protrusions have been described in the cat.

Cases of disc protrusion associated with clinical disease have been reported in the cat (Heavner, 1971; Hoerlein, 1978; Seim & Nafe, 1981; Gilmore, 1983; Littlewood *et al.*, 1984; Sparkes & Skerry, 1990; Bagley *et al.*, 1995), but such cases are rare; clinical disease is more often associated with protrusions in the thoracolumbar and lumbar regions and can occur in relatively young cats. Acute-onset or progressive paraparesis/paraplegia is the main presenting sign. The diagnosis and prognosis have largely depended on a detailed clinical examination. Plain radiography is seldom of help. Calcification of prolapsed intervertebral discs is rare in the cat (King *et al.*, 1958). A protruded disc should give a disc space that appears narrower than its neighbours, but King and his co-workers also found that disc spaces that appeared narrow on radiographs often contained normal discs, and protruded discs were often associated with normal-width disc spaces. Myelography will help to localise disc lesions.

Corticosteroids are often used for treatment where clinical signs are mild. Dorsal decompressive laminectomy and disc removal have been reported (Seim & Nafe, 1981).

Disc explosions do occur in the cat, and like the dog are associated with episodes of major trauma, such as a road traffic accident. The damage to the spinal cord is caused by an impact injury. Prognosis depends on the severity of clinical disease. Corticosteroids may be tried for treatment; decompression of the spine is seldom indicated.

Spondylosis deformans and ankylosing hyperostosis

Osteophyte development on the vertebral bodies of the spine has been described in the cat (Beadman *et al.*, 1964; Read & Smith, 1968) (Figure 8.45). Although it can be associated with pain, it is often an incidental finding, and its incidence increases with age (Read & Smith, 1968). Vertebral osteophytes are also seen in hypervitaminosis A and mucopolysaccharidosis.

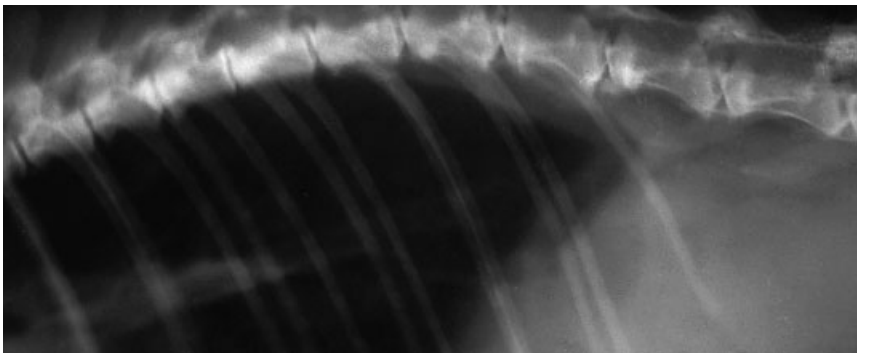

Figure 8.45 Lateral radiograph of the spine showing spondylosis.

Bacterial discospondylitis

Bacterial infections very occasionally localise to the spinal joints of the cat, particularly the intervertebral discs, where a discospondylitis results. The clinical signs are mainly stiffness and a painful back or neck. A neurological deficit may also result (Norsworthy, 1979). The infection is presumed to be blood-borne and the urinary tract is a possible source of infection.

Radiography may help in confirming the diagnosis, although the changes can be subtle. There may be destruction of vertebral bone on either side of the disc space, giving the space an irregular and widened appearance. Sclerosis of the vertebral bodies on either side of the lytic area may be seen and a spondylotic reaction may also be present. Alternatively, little more than a narrowing of the affected disc space will be apparent.

Treatment involves long-term systemic antibiotics, possibly in conjunction with surgical curettage of the lesion. In cases with obvious neurological deficits, more sophisticated spinal surgery may be required, such as decompressive laminectomy. Penetrating bite wounds at the tailbase have been associated with an infective spondylitis of the coccygeal vertebrae.

Atlantoaxial subluxation

Hypoplasia of the odontoid process with subluxation of the atlantoaxial joint has been described in an 11-month-old Siamese cat (Shelton *et al.*, 1991). The cat presented with progressive ataxia, tetraparesis and proprioceptive deficits. The atlantoaxial joint was stabilised by Kirschner wires inserted across the articular facets of C1 and C2.

Miscellaneous diseases

Hypertrophic pulmonary osteoarthropathy

This is very rare in the cat. It is a disease characterised by periosteal proliferation of new bone along the shafts of the limb bones. In most cases the disease is associated with an intrathoracic mass.

The aetiology of the conditions is not understood, but it is generally accepted that there is a rapid increase in peripheral blood flow in the extremities, which is followed by excessive formation of highly vascular connective tissue and subsequent periosteal bone formation. About seven cases have been reported in the domestic cat. Richards (1977) reported a case in a 1.5-year-old cat associated with a thymoma, and Roberg (1977) described a case in an 11-year-old cat associated with bronchiolar carcinoma. In both cases, the forelimbs were more affected than the hindlimbs and the phalanges were unaffected. The bony reaction was more extensive and less regular than seen in other species. Other cases have included pulmonary tuberculosis and a case with no intrathoracic abnormalities but with a renal papillary adenoma (Nafe *et al.*, 1981). Treatment is aimed at removal of the thoracic disease. Removal of solitary intrathoracic masses may result in regression of the bony changes. If neoplastic disease is involved then the prognosis is often poor owing to recurrence or metastatic spread. There is always the possibility that the thoracic mass is itself a metastatic spread from a primary focus elsewhere in the body. Unilateral intrathoracic vagotomy (on the side of the lesion), incision of periosteal pleura, subperiosteal rib resection and bilateral cervical vagotomy have been associated with resolution of the bony lesion

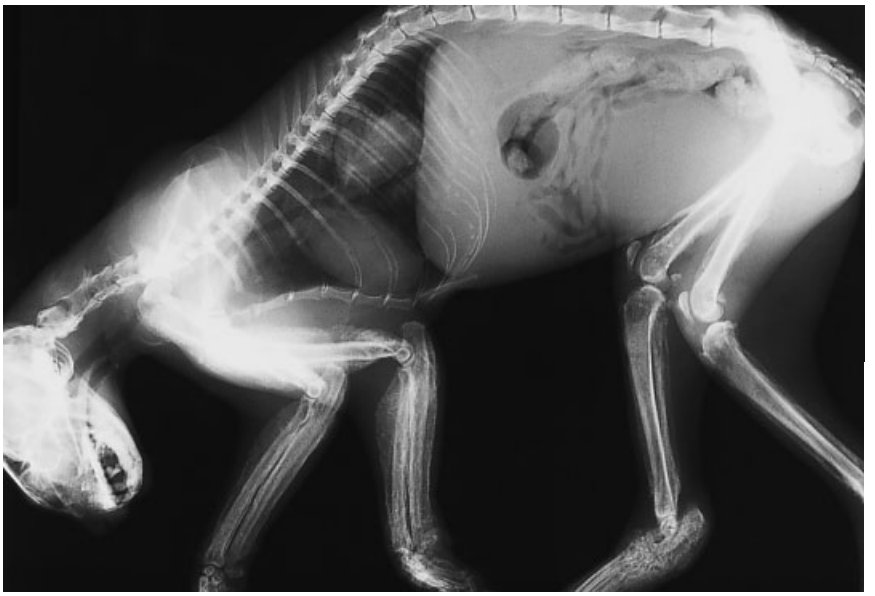

Figure 8.46 Lateral survey radiograph of a cat with Marie's disease. There is an obvious radiodense mass within the thoracic cavity and a periosteal reaction can be seen on several of the limb bones.

in other species (Brodey, 1980). Analgesics may also help.

Clinically, the animals are presented with lameness, which may be shifting, associated with swollen painful limbs. Radiography is a helpful aid to diagnosis (Figure 8.46).

Disuse osteopenia

This is a bony loss in an individual bone or limb or in the entire skeleton, caused by a lack of weight-bearing and normal body stress. It is most often seen in a limb not being used because of fracture healing. External support of a limb by, for example, a resin cast will cause bone loss over a period of time. Radiograph-ically, the affected bones appear obviously osteopenic. Pathological fracture is always a possible untoward sequela.

The aetiology is unknown, although reduced blood supply through the bone owing to muscular inactivity, for instance, will cause blood stagnation and increase carbon dioxide levels, which will stimulate osteoclastosis (Little, 1973). Affected animals may show elevated blood calcium and phosphorus, and may excrete increased levels of urinary calcium. The process is reversible and normal bone will be reformed when the normal stresses are reapplied to the bone.

Osteopetrosis

Osteopetrosis is a descriptive term and refers to a generalised skeletal sclerosis or a generalised increase in skeletal mass. It has been seen by the author as a congenital problem and as an acquired problem, and presumably reflects an imbalance in bone turnover. The difference between the terms osteosclerosis and osteopetrosis is not precisely defined. However, osteopetrosis is a generalised condition and the radiographic increase in skeletal density is always striking. Two acquired cases, one in a 3-year-old and the other in an 8-year-old cat, were reported by Kramers *et al.* (1988). Radiography of both cats showed a generalised massive increase in bone density in the vertebrae, a marked cortical thickening in the long bones with loss of normal trabecular structure, especially in the subchondral areas, and additional irregular osseous structures within the medullary cavity of the long bones. One cat was severely anaemic. Vari-ous aetiopathogenetic mechanisms are incriminated in acquired osteopetrosis, although many cases go unexplained.

Congenital (possibly inherited) osteopetrosis has been seen in one kitten by the author. The whole skeleton was affected and pathological fractures were seen (although the bone is very dense it is brittle and susceptible to fracture). Skeletal pain, stunted growth and poor appetite were all features. Some cases of

Table 8.5 Differential diagnosis of the feline hyperaesthesia syndrome

Trauma (e.g. fracture pelvis, fracture/dislocation coccyx)	Bite wounds
Osteomyelitis	Myositis
Dermatitis	Steatitis
Feline infectious peritonitis	Abdominal pain
Aortic thromboembolism	Polyarthritis
Myeloproliferative disease	Hip dysplasia
Osteopetrosis	Hyperparathyroidism
Intervertebral disc disease	Discospondylitis
Spondylosis deformans	Ankylosing hyperostosis
Spinal tumours (e.g. lymphosarcoma)	Idiopathic

congenital osteopetrosis can be cured by transplantation of spleen or bone-marrow cells from normal littermates to provide a population of functionally competent osteoclasts.

Myelofibrosis/osteosclerosis syndrome

Myelofibrosis is characterised by fibroblastic proliferation and varying degrees of collagen deposition in the marrow cavity. Primary (idiopathic) myelofibrosis is defined as a chronic myeloproliferative disease associated with myeloid metaplasia of the liver, spleen and lymph nodes, and abnormal growth of haematopoietic cells in bone marrow. Secondary myelofibrosis occurs as a non-specific, reactive change following prolonged bone-marrow damage (Weiss & Armstrong, 1985). Osteosclerosis may occur in some cases of myelofibrosis, although it may not be apparent radiographically. Hoover and Kociba (1974) reported varying degrees of medullary osteosclerosis in neonate cats with anaemia induced by inoculation of FeLV. Both bone formation and resorption were inhibited, but the latter more so. Flecknell *et al.* (1978) similarly reported osteosclerosis associated with FeLV infection and Ward *et al.* (1969) described osteosclerosis as a terminal development in cats with naturally occurring erythroleukaemias.

Feline hyperaesthesia syndrome

This syndrome refers to those cats which present with apparent pain or hyperaesthesia on handling, especially over the lumbar spine (Wilkinson, 1984b). Several possible diagnoses need to be considered (Table 8.5), but there are many cases of 'idiopathic hyperaesthesia' where no diagnosis is established. Such cases may respond to corticosteroid therapy, although some require euthanasia.

References

Anon. (1982) Craniofacial malformation in Burmese kittens. *Feline Pract* **12**(6), 32–33.

Arnone B., Labanti G. & Bolletino T. (1984) Extraskeletal osteosarcoma in cat: clinical and histopathological aspects. *Associazione Italiano Veterinari per Piccoli Animal* **23**(4), 217–220.

Bagley R.S., Tucker R.L., Moore M.P. & Harrington M.L. (1995) Intervertebral disk extrusion in a cat. *Vet Radiol Ultrasound* **36**, 380–382.

Baker J.L., Waters D.J. & de LaHunta A. (1988) Tetanus in two cats. *J Am Anim Hosp Assoc* **24**, 159–164.

Baker J.R. & Hughes I.B. (1968) A case of deforming cervical spondylosis in a cat associated with a diet rich in liver. *Vet Rec* **83**, 44–45.

Banks W.C. (1971) Parosteal osteosarcoma in a dog and a cat. *J Am Vet Med Assoc* **158**, 1412–1415.

Barclay S.M. (1979) Lymphosarcoma in tarsi of a cat. *J Am Vet Med Assoc* **175**, 582–583.

Beadman R.M., Smith R.N. & King A.S. (1964) Vertebral osteophytes in the cat. *Vet Rec* **76**, 1005–1007.

Bennett D. (1973) Successful surgical correction of pectus excavatum in a cat. *Vet Med Small Anim Clin* **68**, 936–937.

Bennett D. (1975) Orthopaedic disease affecting the pelvic region of the cat. *J Small Anim Pract* **16**, 723–738.

Bennett D. (1976a) Nutrition and bone disease in the dog and cat. *Vet Rec* **98**, 313–320.

Bennett D. (1976b) Nutrition and bone disease in the cat. *Feline Advisory Bureau Bulletin* **25**(4), 5–7.

Bennett D. & Campbell J.R. (1976) Mechanical interference with lower jaw movement as a complication of skull fractures. *J Small Anim Pract* **17**, 747–751.

Bennett D. & Duff S.I.R. (1980) Transarticular pinning as a treatment for hip luxation in the dog and cat. *J Small Anim Pract* **21**, 373–379.

Bennett D. & Duff S.I.R. (1983) Giant cell tumour of the ulna in a cat. *J Small Anim Pract* **24**, 341–345.

Bennett D. & Nash A.S. (1988) Feline immune-based polyarthritis – a study of 31 cases. *J Small Anim Pract* **29**, 501–523.

Bennett D., Campbell J.R. & Brown P. (1979) Osteosarcoma associated with healed fractures. *J Small Anim Pract* **20**, 13–18.

Bennett D., Gaskell R.M., Mills A., *et al.* (1989) Detection of feline calicivirus antigens in the joins of infected cats. *Vet Rec* **124**, 329–332.

Bennett D., May C. & Carter S.D. (1992) Lyme disease. In *Veterinary Annual*, Vol. 32 (eds Raw M.-E. & Parkinson T.J.). Butterworth Scientific, Guildford.

Berg J.N., Fales W.H. & Scanlan C.H. (1979) Occurrence of anaerobic bacteria in diseases of the dog and cat. *Am J Vet Res* **40**, 876–881.

Biller D.S., Johnston G.C., Birchard S.S. & Fingland R.B. (1987) Aneurysmal bone cyst in a rib of a cat. *J Am Vet Med Assoc* **190**, 1192–1195.

Bitetto W.V., Patnaik A.K., Schraeder S.C. & Mooney S.G. (1987) Osteosarcoma in cats: 22 cases (1974–1984). *J Am Vet Med Assoc* **190**, 91–93.

Blaxter A.C., Lieverley P., Gruffydd-Jones T. & Wotton P. (1986) Periodic weakness in Burmese kittens. *Vet Rec* **118**, 619–620.

Blunden A.S., Wheeler S.J. & Davies J.V. (1986) Hyperparathyroidism in the cat of probable primary origin. *J Small Anim Pract* **23**, 791–798.

Boehringer B.T. (1975) Foot deformity in a cat. *Feline Pract* **5**(3), 50.

Brodey R.S. (1979) Hypertrophic osteoarthropathy. In *Spontaneous Animal Models of Human Disease*, Vol. II (eds Andrews E.J., Ward B.C. & Altman N.H.). Academic Press, New York, pp. 241–246

Brown N.O., Patnaik A.K., Mooney S., *et al.* (1978) Soft tissue sarcomas in the cat. *J Am Vet Med Assoc* **173**, 744–749.

Brown P.J., Hoare C.M. & Rochlitz I. (1985) Multiple squamous cell carcinoma of the digits in two cats. *J Small Anim Pract* **26**, 323–328.

Brown R.J., Trevethan W.P. & Henry V.L. (1972) Multiple osteochondroma in a Siamese cat. *J Am Vet Med Assoc* **160**, 433–435.

Bunge M.M., Foil C.S., Taylor H.W. & Glaze M.B. (1992) Relapsing polychondritis in a cat. *J Am Anim Hosp Assoc* **28**, 203–206.

Burgess E.C. (1992) Experimentally induced infection of cats with *Borrelia burgdoferi*. *Am J Vet Rec* **53**, 1507–1511.

Butcher R. & Beasley K. (1986) Osteochondritis dissecans in a cat. *Vet Rec* **118**, 646.

Carlson W.D. (1967) *Veterinary Radiology*. Baillière Tindall, London, p. 429.

Carro T., Pederson N.C., Beaman B.L. & Munn R. (1989) Subcutaneous abscesses and arthritis caused by a probable bacterial L-form in cats. *J Am Vet Med Assoc* **194**, 1583–1588.

Carter H.E. (1964) The clinical approach to fractures in small animals. *Vet Rec* **76**, 1412–1417.

Catcott E.J. (1964) *Feline Medicine and Surgery*. American Veterinary Publications, Wheaton, IL.

Chapman V. & Zeiner F.N. (1961) The anatomy of polydactylism in cats with observations on genetic control. *Anat Rec* **141**, 205–217.

Clark L. (1970) The effect of excess vitamin A on long bone growth in kittens. *J Comp Pathol* **80**, 625–634.

Clark L. (1971a) Mid-diaphyseal bone turnover during and after vitamin A toxicosis in kittens. *J Comp Pathol* **81**, 365–371.

Clark L. (1971b) Hypervitaminosis A: a review. *Aust Vet J* **47**, 568–571.

Clark L. & Seawright A.A. (1968) Skeletal abnormalities in the hindlimbs of young cats as a result of hypervitaminosis A. *Nature* **217**, 1174–1176.

Clark L., Seawright A. & Hrdlicka J. (1970) Exostosis in hypervitaminosis A cats with optimal calciumphosphorus intakes. *J Small Anim Pract* **11**, 553–561.

Cohn L.A. & Meuten D.J. (1990) Bone fragility in a kitten: an osteogenesis impefecta-like syndrome. *J Am Vet Med Assoc* **197**, 98–100.

Cotchin E. (1956) Further examples of spontaneous neoplasms in the domestic cat. *Br Vet J* **122**, 263–272.

Cotchin E. (1957) Neoplasia in the cat. *Vet Rec* **69**, 425–436.

Cotchin E. (1984) Neoplasia. In *Diseases of the Cat and Their Management* (ed. Wilkinson G.T.). Blackwell Science, Oxford, Chapter 15.

Cottrill N.B., Cater J.D., Pechman R.D., *et al.* (1987) Bilateral orbital parosteal osteoma in a cat. *J Am Anim Hosp Assoc* **23**, 405–408.

Cowell K.R., Jezyk P.F., Haskins M.E. & Patterson D.F. (1976) Mucopolysaccharidosis in a cat. *J Am Vet Med Assoc* **169**, 334–339.

Craig L.E. (2001) Physeal dysplasia with slipped capital femoral epiphysia in 13 cats. *Vet Pathol* **38**, 92–97.

Crawley A.C., Niedzielski K.H., Issac E.L., *et al.* (1997) Enzyme replacement therapy from birth in a felune model of mucoplysaccharidosis type IV. *J Clin Invest* **99**, 651–662.

Crocker W. (1919) Osteoclastoma in cat foreleg. *Cornell Vet* **9**, 142.

Dahlin D.C. (1967) *Bone Tumors*. 2nd edn. CC Thomas, Springfield, IL.

Danforth C.H. (1947a) Heredity of polydactyly in the cat. *J Hered* **38**, 107–112.

Danforth C.H. (1947b) Morphology of the feet in polydactyl cats. *J Anat* **80**, 143–171.

Davies J.D. & Little N.R.F. (1972) Synovioma in a cat. *J Small Anim Pract* **13**, 127–133.

Dawson J.R.B. (1970) Myasthenia gravis in a cat. *Vet Rec* **86**, 562–563.

Dawson S., McArdle F., Bennett D., *et al.* (1992) Investigation of vaccine reactions and breakdowns following feline calicivirus vaccination. *Vet Res* **132**, 346–350.

Dawson S., Bennett D., Carter S.D., *et al.* (1993) Acute arthritis of cats associated with feline calicivirus infection. *Res Vet Sci* 56, 133–143.

Dennis J.M. & Alexander R.W. (1982) Nutritional myopathy in a cat. *Vet Rec* **111**, 195–196.

Dow S.W., Fettman M.J., Le Couteur R.A. & Hamar D.W. (1987a) Potassium depletion in cats: renal and dietary influence. *J Am Vet Med Assoc* **191**, 1569–1575.

Dow S.W., Le Couteur R.A., Fettman M.J. & Spurgeon T.L. (1987b) Potassium depletion in cats: hypokalaemic polymyopathy. *J Am Vet Med Assoc* **191**, 1563–1568.

Drazner F.H. (1980) Distal renal tubular acidosis associated with chronic pyelonephritis in a cat. *Calif Vet* **34**, 15–21.

Dubielzig A.R., Adams W.M. & Brodey R.S. (1979) Inductive fibroblastoma – an unusul dental tumor of young cats. *J Am Vet Med Assoc* **174**, 720–722.

Eger C.E., Robinson W.R. & Huxtable C.R.R. (1983) Pituitary aldosteronism (Con's syndrome) in a cat: a case report and review of comparative aspects. *J Small Anim Pract* **24**, 293–307.

Emms S.G. & Harvey C.E. (1986) Preliminary results of maxillectomy in the dog and cat. *J Small Anim Pract* **27**, 291–306.

Engle G.C. & Brodey R.S. (1969) A retrospective study of 395 feline neoplasms. *J Am Anim Hosp Assoc* **5**, 21–31.

Flecknell P.A. & Gruffydd-Jones T.J. (1979) Congenital luxation of the patellae in the cat. *Feline Pract* **9**(3), 18–20.

Flecknell P.A., Gibbs C. & Kelly D.F. (1978) Myelosclerosis in a cat. *J Comp Pathol* **88**, 627–631.

Forbes S., Nelson R.W. & Guptill L. (1990) Primary hypoparathyroidism in a cat. *J Am Vet Med Assoc* **196**, 1285–1287.

Forrest L.J., O'Brien R.T. & Manley P.A. (1999) Feline capital physeal dysplasia syndrome. *Veterinary Radiology and Ultrasound* **40**, 672.

Fox S.M., Cooke M.M. & Beban H.J. (1995) Primary intraosseous fibrosarcoma in a cat. *N Z Vet J* **43**, 197–200.

Freund E. (1937) Chondromatosis of joints. *Arch Surg* **34**, 670.

Friend E.F. (2000) Myositis ossificans in a cat. In *Conference Notes, Feline Orthopaedics and Traumatology, Proceedings BVOA Autumn Meeting*, 11–12 November, University of Cambridge, Cambridge, UK, p. 117.

Fry P.D. (1968) Cervical spondylosis in the cat. *J Small Anim Pract* **9**, 59–61.

Fry P.D. & Jukes H.F. (1995) Fracture associated sarcoma in the cat. *J Small Anim Pract* **36**, 124–126.

Gardner D.E. (1967) Skeletal myonecrosis in a cat. *N Z Vet J* **15**, 211–213.

Gehring V.H. (1975) Osteogenesis imperfecta bei der katze. *Kleintierpraxis* **20**, 205.

Gerber B., Crottaz M., vonTscharner C. & Scharer V. (2001) Feline relapsing polychondritis: two cases and a review of the literature. *J Feline Med Surg* **4**, 189–194.

Gershoff S.N. & Norkin S.A. (1962) Vitamin E deficiency in cats. *J Nutr* **77**, 303–308.

Gershoff S.N., Andrus S.B., Hegsted D.M. & Lentini E.A. (1957) Vitamin A deficiency in the cat. *Lab Invest* **6**, 227–240.

Gibson MD (1998) *Borrelia burgdorferi* infection of cats. *J Am Vet Med Ass* **202**, 1786.

Gilmore D.R. (1983) Extrusion of a feline intervertebral disk. *Vet Med Small Anim Clin* **78**, 207–209.

Gleiser C.A., Rawlston R.L., Jardine J.H. & Gray K.N. (1979) Malignant fibrous histiocytoma in dogs and cats. *Vet Pathol* **16**(2), 199–208.

Goad M.E.P. & Roenick W.J. (1983) Osseous histoplasmosis in a cat. *Feline Pract* **13**(2), 32–36.

Gottfried S.D., Popovitch C.A., Goldschmidt M.H. & Schelling C. (2000) Metastatic digital carcinoma in the cat: a retrospective study of 36 cats (1992–1998). *J Am Anim Hosp Assoc* **36**, 501–509.

Green H.H. & Lindo D.E. (1968) Pectus excavatum (funnel chest) in a feline. *Can Vet J* **9**, 279–292.

Gresti A. (1975) Occurrence of bilateral articular synoviomas in two cats. *Clin Vet* **98**, 156.

Griffiths I.R. & Duncan I.D. (1979) Ischaemic neuromyopathy in cats. *Vet Rec* **104**, 518–522.

Gunn-Moore D.A., Jenkins P.A. & Lucke V.M. (1996) Feline tuberculosis. *Vet Rec* **138**, 53–58.

Gustafsson P. & Wolfe D. (1968) Bone-metastasizing lung carcinoma in a cat. *Cornell Vet* **58**, 425–430.

Hardy W.D. (1976) The aetiology of canine and feline tumours. *J Am Anim Hosp Assoc* **12**, 313–334.

Haskins M.E., Jezyk P.F., Desnick R.J., *et al.* (1979) Mucopolysaccharidosis in a domestic short-haired cat – a disease distinct from that seen in the Siamese cat. *J Am Vet Med Assoc* **175**, 384–387.

Hays G.P. (1917–1918) A case of syndactylous cat. *Morphology* **30**, 65–82.

Heavner J.E. (1971) Intervertebral disc syndrome in the cat. *J Am Vet Med Assoc* **159**, 425–427.

Hegreberg G.A. & Norby D.E. (1973) An inherited storage disease of cats. *Fed Proc* **32**, 821.

Hegreberg G.A., Norby D.E. & Hamilton M.J. (1974) Lysosomal enzyme changes in an inherited dwarfism of cats. *Fed Proc* **33**, 598.

Heldmann E., Anderson M.A. & Wagner-Mann C. (2000) Feline osteosarcoma: 145 cases (1990–1995). *J Am Anim Hosp Assoc* **36**, 518–521.

Herron M.R. (1983) The musculoskeletal system. In *Feline Medicine* (ed. Pratt P.W.). American Veterinary Publications, Drawer K K, Santa Barbara, CA, Chapter 13.

Hill F.W.G. (1977) A survey of bone fractures in the cat. *J Small Anim Pract* **18**, 457–463.

Hills D.L., Morris J.G. & Rogers Q.R. (1982) Potassium requirement of kittens as affected by dietary protein. *J Nutr* **112**, 216–622.

Hoerlein B.F. (1978) *Canine Neurology*. WB Saunders, Philadelphia, PA, p. 551.

Holt E. (1978) Hip dysplasia in a cat. *J Small Anim Pract* **19**, 273–276.

Hooper P.T., Ireland L.A. & Carter A. (1985) Mycoplasma polyarthritis in a cat with probable severe immune deficiency. *Aust Vet J* **62**, 352.

Hoover E.A. & Griesemer R.A. (1971) Bone lesions produced by feline herpes virus. *Lab Invest* **25**, 457–464.

Hoover E.A. & Kociba G.J. (1974) Bone lesions in cats with anaemia induced by feline leukaemia virus. *J Natl Cancer Inst* **53**, 1277–1284.

Hopkins A.L. (1989) Sporadic feline hypokalaemic polymyopathy. *Vet Rec* **125**, 17.

Horne R. (1964) Feline systemic mycoses: an up to date review. *Mod Vet Pract* **45**(1), 39–46.

Howard E.B. & Kenyon E.B. (1967) Malignant osteoclastoma (giant cell tumour) in the cat with associated mast cell response. *Cornell Vet* **57**, 398–409.

Hubler M., Johnston K.A., Burling R.T., *et al.* (1986) Lesions resembling osteochondromatosis in two cats. *J Small Anim Pract* **27**(3), 181–187.

Hulland T.J. (1970) Muscle. In *Pathology of Domestic Animals*, Vol. II. 2nd edn (eds Jubb K.V.F. & Kennedy P.C.). Academic Press, New York, pp. 453–474.

Hulse E.V. (1966) A benign giant-cell synovioma in a cat. *J Pathol Bact* **91**, 269–271.

Indrieri R.J., Creighton S.R., Lambert E.H. & Lennon V.A. (1983) Myasthenia gravis in two cats. *J Am Vet Med Assoc* **182**, 57–60.

Ingham B. (1970) Dysplasia of a ramus of the mandible in a cat. *Br Vet J* **126**, iii–iv.

Jackson O.F. (1975) Congenital bone lesions in cats with fold-ears. *Bulletin Feline Advisory Bureau* **14**(4), 2–4.

Jacobsen R.H. & Saidla J.E. (1990) Update on feline Lyme disease. In *Feline Health Topics for Veterinarians*, Vol. 5. Cornell University, Ithaca, pp. 1–8.

Jacobson S.A. (1971) *Comparative Pathology of the Tumors of Bone*. CC Thomas, Springfield, IL.

Jaffe H.L. (1958) *Tumors and Tumorous Conditions of the Bones and Joints*. Lea & Febiger, Philadelphia, PA.

Janssens L.A.A., Janssens G.O. & Janssens D.L. (1991) Anterior cruciate ligament rupture associated with cardiomyopathy in three cats. *Vet Comp Orthoped Traumatol* **4**, 35–37.

Jezyk P.E. (1985) Constitutional disorders of the skeleton in dogs and cats. In *Textbook of Small Animal Orthopaedics* (eds Newton C.D. & Nunamaker D.J.). JB Lippincott, Philadelphia, PA, Chapter 57.

Jezyk P.F., Haskins M.E., Patterson D.F., *et al.* (1977) Mucopolysaccharidosis in a cat with arylsulfatase B deficiency: a model of Martoeaux–Lamy syndrome. *Science* **198**, 834–836.

Jobora A.G. & Paton J.S. (1984) Extraskeletal osteoma in a cat. *Aust Vet J* **61**, 405–407.

Jones B.R. (2000) Feline neuromuscular diseases. In *Conference Notes, Feline Orthopaedics and Traumatology. Proceedings BVOA Autumn Meeting*, 11–12 November, University of Cambridge, Cambridge, UK, pp. 105–114.

Jones B.R. & Alley M.R. (1988) Hypokalaemic myopathy in Burmese kittens. *N Z Vet J* **36**, 150–151.

Joshua J.O. (1965) *The Clinical Aspects of some Diseases of Cats*. William Heinemann Medical Books, London.

Jubb K.J.F. & Kennedy P.C. (1963) *Pathology of Domesticated Animals*. Academic Press, New York, pp. 12, 56.

Kas N.P., Van der Heul R.O. & Misdorp W. (1970) Metastatic bone neoplasms in dogs, cats and a lion (with some comparative remarks on the situation in man). *Zentralbl Vet Med* **17**, 909–919.

Kessler M., Tassani-Prell M., Bombard D. & Matis U. (1997) Feline osteosarcoma; epidemiological, clinical and radiographic findings in 78 cases. *Tierarztliche Praxis* **25**, 275–283.

King A.S. & Smith R.N. (1960a) Disc protrusion in the cat: distribution of dorsal protrusions along the vertebral column. *Vet Rec* **72**, 335–337.

King A.S. & Smith R.N. (1960b) Disc protrusion in the cat: age incidence of dorsal protrusion. *Vet Rec* **72**, 381–383.

King A.S., Smith R.N. & Kon V.M. (1958) Protrusion of the intervertebral disc in the cat. *Vet Rec* **70**, 509–512.

Knecht C.D. (1978) Fractures in cats; a survey of 100 cases. *Feline Pract* **8**(3), 43–46.

Knecht C.D. & Greene J.A. (1977) Osteoma of the zygomatic arch in a cat. *J Am Vet Med Assoc* **171**, 1077–1078.

Kolde D.L. (1974) Pectineus tenectomy for treatment of hip dysplasia in a domestic cat: a case report. *J Am Anim Hosp Assoc* **10**, 564–565.

Kramek B.A., Moise S., Cooper B. & Raffe M.R. (1984) Neuropathy associated with diabetes mellitus in the cat. *J Am Vet Med Assoc* **184**, 42–45.

Kramers P., Fluckiger M.A., Rahn B.A. & Cordey J. (1988) Osteopetrosis in cats. *J Small Anim Pract* **29**, 153–164.

Krook L. (1971) In *Current Veterinary Therapy*. 4th edn (ed. Kirk R.W.). WB Saunders, Philadelphia, PA.

Krook L., Barrett R.B., Usui K. & Woolke R.E. (1963) Nutritional secondary hyperparathyroidism in the cat. *Cornell Vet* **53**, 224–240.

Langley-Hobbs S.J., Carmichael S. & McCartney W.T. (1997) External skeletal fixation for stabilisation of comminuted humeral fractures in cats. *J Small Anim Pract* **38**, 280–285.

Langweiler M., Haskins M.E. & Jezyk P.F. (1978) Mucopolysaccharidosis in a litter of cats. *J Am Anim Hosp Assoc* **14**, 748–751.

Lees P. & Taylor P.M. (1991) Pharmacodynamics and pharmacokinetics of flunixin in the cat. *Br Vet J* **147**, 298–305.

Le Couteur R.A. (2003) Update on feline neuromuscular diseases. *J Feline Med Surg* **5**, 109–115.

Levitt L. & Doige C.E. (1989) Pulmonary intraosseus fibrosarcoma in a cat. *J Am Vet Med Assoc* **194**, 1601–1603.

Lewis D.D. (1988) Fibrotic myopathy of the semitendinosus muscle in a cat. *J Am Vet Med Assoc* **193**, 240–241.

Lewis G.E., Fidler W.J. & Crumrine M.H. (1972) Mycetoma in a cat. *J Am Vet Med Assoc* **161**, 500–503.

Lewis R.E. & Van Sickle D.C. (1970) Congenital hemimelia (agenesis) of the radius in a dog and cat. *J Am Vet Med Assoc* **156**, 1892–1897.

Li A., Bennett D., Gibson N. & Carmichael S (1999) Thirteen pancarpal arthrodeses using 2.7–3.5 mm hybrid dynamic compression plate. *Vet Comp Orthop Traumatol* **12**, 102–107.

Lindsay F.E.F. (1968) Skeletal abnormalities of a cat thorax. *Br Vet J* **124**, 306–308.

Little K. (1973) *Bone Behaviour*. Academic Press, London.

Littlewood J.D., Herrtage M.E. & Palmer A.C. (1984) Intervertebral disc protrusion in a cat. *J Small Anim Pract* **25**, 119–127.

Liu S.-K., Dorfman H.D. & Patnaik A.K. (1974) Primary and secondary bone tumors in the cat. *J Small Anim Pract* **15**, 141–156.

Lucke V.M., Baskerville A., Bardgett P.L., *et al.* (1968) Deforming cervical spondylosis in the cat associated with hypervitaminosis A. *Vet Rec* **82**, 141–142.

McClelland R.B. (1941) A giant cell tumor of the tibia in a cat. *Cornell Vet* **31**, 86–87.

Magnarelli L.A., Anderson J.F., Levine H.R. & Levy S.A. (1990) Tick parasitism and antibodies to *Borrelia burgdorferi* in cats. *J Am Vet Med Assoc* **197**, 63–66.

Mahaffey E., Fabbert N., Johnson D. & Guffey M. (1977) Disseminated histoplasmosis in three cats. *J Am Anim Hosp Assoc* **13**, 46–51.

Mason K. (1988) A hereditary disease in Burmese cats manifested as an episodic weakness with head nodding and neck ventroflexion. *J Am Anim Hosp Assoc* **24**, 147–151.

Mason K.V. (1976) A case of myasthenia gravis in a cat. *J Small Anim Pract* **17**, 467–472.

May C., Carter S.D., Barnes A., McLean C., Bennett D., Coults A. & Grant C.K. (1994) *Borrelia burgdorferi* infection in UK cats. *J Small Anim Pract* **35**, 517–520.

May C. & Newsholme S.J. (1989) Metastasis of feline pulmonary carcinoma presenting as multiple digital swelling. *J Small Anim Pract* **30**, 302–310.

May C., Bennett D. & Downham D.Y. (1991) Delayed physeal closure associated with castration in cats. *J Small Anim Pract* **32**, 326–328.

Mellanby E. (1941) Skeletal changes affecting the nervous system produced in young dogs by diets deficient in vitamin A. *J Physiol* **99**, 467–486.

Mellanby E. (1950) *A Story of Nutritional Research: The Effect of Some Dietary Factors on Bones and the Nervous System*. Williams & Wilkins. Baltimore, MA.

Miller A.S., McCrae M. & Rhodes W.H. (1969) Mandibular epidermoid carcinoma with reactive bone proliferation in a cat. *Am J Vet Res* **30**, 1465–1468.

Miller R.M. (1969) Nutritional secondary hyperparathyroidism. *Vet Med Small Anim Clin* **64**, 400–408.

Moise N.S. & Crissman J.W. (1982) Chronic progressive polyarthritis in a cat. *J Am Anim Hosp Assoc* **18**, 965–969.

Moise N.S., Crissman J.W., Fairbrother J.F. & Baldwin C. (1983) *Mycoplasma gateae* arthritis and tenosynovitis in cats: case report and experimental reproduction of the disease. *Am J Vet Res* **44**, 16–21.

Moore T., Sharman I.M. & Scott P.P. (1963) Vitamin A in the kidney of the cat. *Res Vet Sci* **4**, 397–403.

Morton D. (1985) Chondrosarcoma arising in a multilobular chondroma in a cat. *J Am Vet Med Assoc* **186**, 804–806.

Nafe L.A., Herron A.J. & Burke R.L. (1981) Hypertrophic osteopathy in a cat associated with renal papillary adenoma. *J Am Anim Hosp Assoc* **17**, 659.

Nielson S.W. (1952) Extraskeletal giant cell tumour in a cat. *Cornell Vet* **42**, 304–311.

Norris A.M., Pallett L. & Wilcock B. (1980) Generalised myositis ossificans in a cat. *J Am Anim Hosp Assoc* **16**, 659–663.

Norsworthy G.D. (1979) Discospondylitis as cause of posterior paresis. *Feline Pract* **9**(1), 39–40.

Pedersen N.C., Pool R.R. & O'Brien T. (1980) Feline chronic progressive polyarthritis. *Am J Vet Res* **41**, 522–535.

Pedersen N.C., Laliberte L. & Ekman S. (1983a) A transient febrile limping syndrome of kittens caused by two different stains of feline calici virus. *Feline Pract* **13**(1), 26–35.

Pedersen N.C., Pool R.R. & Morgan J.P. (1983b) Joint disease of dogs and cats. In *Textbook of Veterinary Internal Medicine, Diseases of the Dog and Cat*. 2nd edn (ed. Ettinger S.J.). WB Saunders, Philadelphia, PA, Chapter 84.

Peiffer R.L. Jr, Young W.O. Jr & Blevins W.E. (1974) Hip dysplasia and pectineus resection in the cat. *Feline Pract* **4**(3), 40–43.

Penwick R.C. & Nunamaker D.M. (1987) Rostral mandibulectomy: a treatment for oral neoplasia in the dog and cat. *J Am Anim Hosp Assoc* **23**, 19–25.

Peterson C.J. (1984) Osteochondritis dissecans of the humeral head of a cat. *N Z Vet J* **32**, 115–116.

Peterson M.E., Taylor S., Greco D.S., *et al.* (1990) Acromegaly in 14 cats. *J Vet Intern Med* **4**, 192–201.

Pollack M., Martin R.A. & Diters R.W. (1984) Metastatic squamous cell carcinoma in multiple digits of a cat: case report. *J Am Anim Hosp Assoc* **20**, 835–839.

Pool R.R. (1981) Osteochondromatosis. In *Pathology in Small Animal Surgery* (ed. Bojrab M.J.). Lea & Febiger, Philadelphia, PA, pp. 641–649.

Pool R.R. & Carrig C.B. (1972) Multiple cartilaginous exostoses in a cat. *Vet Pathol* **9**, 350–359.

Pool R.R. & Harris J.M. (1975) Feline osteochondromatosis. *Feline Pract* **5**(2), 24–30.

Pool R.R., Bodle J.E., Mantos J.J. & Ticer J.W. (1974) Primary lung carcinoma with skeletal metastases in the cat. *Feline Pract* **4**(4), 36–41.

Prymak C. & Goldschmidt M.H. (1991) Synovial cysts in five dogs and one cat. *J Am Anim Hosp Assoc* **27**, 151–154.

Purdy J.G. (1961) Osteogenic sarcoma in a cat. *Can Vet J* **2**, 156.

Queen J., Bennett D., Carmichael S, Gibson N., Li A., Payne-Johnson C.E. & Kelly D.F. (1998) Femoral neck metaphyseal osteopathy in the cat. *Vet Rec* **142**, 159–162.

Quigley P.J. & Leedale A.H. (1983) Tumours involving bone in the domestic cat: a review of fifty-eight cases. *Vet Pathol* **20**, 670–686.

Read R.M. & Smith R.N. (1968) A comparison on spondylosis deformans in the English and Swedish cat and in the English dog. *J Small Anim Pract* **9**, 159–166.

Reed R.R., Hoger R.S. & Trautman R.J. (1963) Coccidioidomycosis in two cats. *J Am Vet Med Assoc* **143**, 953–956.

Rengel M.J., Farrow C.S., Leighton R.L. & Rose R.L. (1977) Contracted gastrocnemius tendons: a surgical approach toward correction. *Feline Pract* **7**(1), 14–23.

Richards C.D. (1977) Hypertrophic osteoarthropathy in a cat. *Feline Pract* **7**(2), 41–43.

Riddle W.E. & Leighton R.L. (1970) Osteochondromatosis in a cat. *J Am Vet Med Assoc* **156**, 1428–1430.

Riser W.H. (1964) In *Feline Medicine and Surgery* (ed. Catcott E.J.). American Veterinary Publications, Wheaton, IL, p. 296.

Riser W.H., Brodey R.S. & Shirer J.F. (1968) Osteodystrophy in mature cats: a nutritional disease. *J Am Vet Radiol Sol* **9**, 37–46.

Roberg J. (1977) Hypertrophic pulmonary osteoarthropathy in a cat. *Feline Pract* **7**(6), 18–22.

Robertson J.L. (1982) Chronic progressive polyarthritis in a cat. *Carnation Research Digest* **18**, 8–15.

Robinson R. (1971) *Genetics for Cat Breeders.* Pergamon Press, Oxford, p. 170.

Russell R.G. & Walker M. (1983) Metastatic and invasive tumors of bone in dogs and cats. *Vet Clin North Am* **13**(1), 163–180.

Rutman M.A., Richards D.A. & Chandler F.W. (1975) Feline cryptococcosis. *Feline Pract* **5**(3), 36–43.

Salisbury S.K., Richardson D.C. & Lantz G.C. (1986) Partial maxillectomy and premaxillectomy in the treatment of oral neoplasia in the dog and cat. *Vet Surg* **15**, 16–26.

Saperstein G., Harris S. & Leipold H.W. (1976) Congenital defects in domestic cats. *Feline Pract* **6**(4), 18–43.

Schmidt R.E. & Langham R.F. (1967) A survey of feline neoplasms. *J Am Vet Med Assoc* **151**, 1325–1333.

Schmitz J.A. (1978) Bronchogenic carcinoma in a cat presenting as rear leg lameness. *Feline Pract* **8**(3), 18–22.

Schneck G.W. (1974a) A case of ectrodactylia in a cat. *Bulletin Feline Advisory Bureau* **14**(1), 27.

Schneck G.W. (1974b) Two cases of congenital malformation (peromelus ascelus and ectrodactyly) in cats. *Vet Med Small Anim Clin* **69**, 1025–1026.

Schrader S.C. & Sherding R.G. (1989) Disorders of the skeletal system. In *The Cat, Disease and Clinical Management* (ed. Sherding R.G.). Churchill Livingstone, New York, Chapter 46, pp. 1247–1292.

Schrauwers E. & Appeldoorn A. (1991) Anterior cruciate ligament rupture associated with cardiomyopathy in three cats. *Vet Comp Orthoped Traumatol* **4**, 158.

Scott P.P. (1964) Nutritional requirements and deficiencies. In *Feline Medicine and Surgery* (ed. Catcott E.J.). American Veterinary Publications, Wheaton, IL.

Scott-Moncrieff J.C., Cook J.R. & Lant Z. (1990) Acquired myasthenia gravis in a cat with thymoma. *J Am Vet Med Assoc* **196**, 1291–1293.

Scott-Moncrieff J.C., Elliott G.S., Radovsky A. & Blevins W.E. (1989) Pulmonary squamous cell carcinoma with multiple digital metastases in a cat. *J Small Anim Pract* **30**, 696–699.

Searle A.G. (1952–1953) Hereditary 'split-hand' in the domestic cat. *Annals of Eugenics* **17**, 274–282.

Seawright A.A., English P.B. & Gartner R.J.W. (1967) Hypervitaminosis A and deforming cervical spondylosis of the cat. *J Comp Pathol* **77**, 29–39.

Seim H.B. & Nafe L.A. (1981) Spontaneous intervertebral disc extrusion with associated myelopathy in a cat. *J Am Anim Hosp Assoc* **17**, 201–204.

Shelton S.B., Bellah J., Chrisman C. & McMullen D. (1991) Hypoplasia of the odontoid process and secondary atlantoaxial luxation in a Siamese cat. *Prog Vet Neurol* **2**, 209–211.

Silva-Krott L.U., Tucker R.I. & Meeks J.C. (1993) Synovial sarcoris in a cat. *J Am Vet Med Ass* **203**, 1430–1431.

Simon MM, Schaible U.E., Wallich R. & Kramer M.D. (1991) A mouse model for *B. burgdorferi* infection: approach to a vaccine against Lyme disease. *Immunol Today* **12**, 11–16.

Sis R.F. & Getty R. (1968) Polydactylism in cats. *Vet Med Small Anim Clin* **63**, 948–951.

Sparkes A.H. & Skerry T.M. (1990) Successful management of a prolapsed intervertebral disc in a Siamese cat. *Feline Pract* **18**, 7–9.

Spjut H.J., Dorfman H.D., Fechner R.E. & Ackerman L.V. (1971) *Tumors of Bone and Cartilage*. Armed Forces Institute of Pathology, Washington, DC.

Stead A.C., Else R.W. & Stead M.C.P. (1995) Synovial cysts in cats. *J Small Anim Pract* **36**, 450–454.

Straw R.C., Withrow S.J., Gillette E.L. & McChesney A.E. (1986) Use of radiotherapy for the treatment of intra-nasal tumours in cats: six cases (1980–1985). *J Am Vet Med Assoc* **189**, 927–929.

Sullivan M. (1989) Temporomandibular ankylosis in the cat. *J Small Anim Pract* **30**, 401–405.

Susanek S.J. (1983) Feline skin tumours. *Compend Contin Educ Pract Vet* **5**, 251–258.

Tacke S. & Schimke E. (1995) Rupture of the cruciate ligaments in cats. *Kleintierpraxis* **40**, 341–350.

Thoday K.L. & Evans J.G. (1972) Synovioma in a cat. *J Small Anim Pract* **13**, 399–402.

Tischler S.A. & Owens J.M. (1986) Ulnar fibrosarcoma in a cat. *Mod Vet Pract* **67**, 39.

Tomsa K., Glaus T., Hauser B., Fluckiger M., Arnold P., Wess G. & Reusch C. (1999) Nutritional secondary hyperparathyroidism in six cats. *J Small Anim Pract* **40**, 533–539.

Turrel J.M. & Pool R.R. (1982) Primary bone tumour in the cat. A retrospective study of 15 cats and a literature review. *Vet Radiol* **23**, 152–166.

Vos J.H., van der Linde-Sipman J.S. & Goedegebrurure S.A. (1986) Dystrophy-like myopathy in the cat. *J Comp Pathol* **96**, 335–341.

Walker M.A., Duncan R., Shaw J.W. & Chapman W.W. (1975) Aneurysmal bone cyst in a cat. *J Am Vet Med Assoc* **167**, 933–934.

Walker R.W., Richardson D.C., Bryant M.J. & Draper C.S. (1983) Anaerobic bacteria associated with osteomyelitis in domestic animals. *J Am Vet Med Assoc* **182**, 814–816.

Ward J.M., Sidikoff C.H. & Schalm I.W. (1969) Myeloproliferative disease and abnormal erythrogenesis in the cat. *J Am Vet Med Assoc* **155**, 879–888.

Warren H.B. & Carpenter J.L. (1984) Fibrodysplasia ossificans in three cats. *Vet Pathol* **21**, 495–499.

Waters D.J., Honeckman A., Cooley A. & DeNicola D. (1998) Skeletal metastasis in feline mammary carcinoma: case report and literature review. *J Am Anim Hosp Assoc* **34**, 104–108.

Weiss D.S. & Armstrong P.F. (1985) Secondary myelofibrosis in three dogs. *J Am Vet Med Assoc* **197**, 423–425.

Wilkinson G.T. (1984a) Mycotic disease. In *Diseases of the Cat and Their Management*. 2nd edn (ed. Wilkinson G.T.). Blackwell Science, Oxford, Chapter 18.

Wilkinson G.T. (1984b) Diseases of the locomotor system. In *Diseases of the Cat and Their Management*. 2nd edn (ed. Wilkinson G.T.). Blackwell Science, Oxford, Chapter 8.

Wilkinson G.T. (1984c) Disease of the reproductive system. In *Diseases of the Cat and Their Management*. 2nd edn (ed. Wilkinson G.T.). Blackwell Science, Oxford, Chapter 10.

Wilkinson G.T. & Robins G.M. (1979) Polyarthritis in a young cat. *J Small Anim Pract* **20**, 293–297.

Williams-Jones H.E. (1944) Arrested development of the long bones of the forelimbs in a female cat. *Vet Rec* **56**, 449.

Wills J.M., Howard P.G., Gruffydd-Jones T.J. & Wathes C.M. (1988) Prevalence of *Chlamydia psittaci* in different cat populations in Britain. *J Small Anim Pract* **29**, 327–339.

Withrow S.J. & Holmberg O.L. (1983) Mandibulectomy in the treatment of oral cancer. *J Am Anim Hosp Assoc* **19**, 273–286.

Chapter 9

THE BLOOD

C.M. Knottenbelt and L. Blackwood

Introduction

Disorders of the blood and haematopoietic system are common in the cat. The high incidence is attributed to infection with feline leukaemia virus (FeLV), feline immunodeficiency virus (FIV) and *Haemobartonella felis*. These infections are discussed in Chapters 23, 24 and 29. The aim of this chapter is to provide an overview of the major blood disorders of the cat.

Bone marrow and haematopoiesis

Haematopoiesis is the process by which blood cells are formed. In neonates and immature cats, the marrow of all bones is actively involved in blood cell production. As maturity is reached, active haematopoiesis becomes restricted to the flat bones and the proximal ends of the marrow cavity of long bones, especially the humerus and femur. This must be taken into account when collecting bone marrow from adult cats. All blood cell types are produced in the marrow, but the peripheral lymphoid tissues also produce lymphocytes. The liver and spleen retain the capacity to produce blood cells in circumstances in which demand outstrips the marrow's ability to produce blood cells [extramedullary haematopoiesis (EMH)].

There are two types of bone marrow: red marrow and yellow marrow. Red marrow is haematopoietically active, while yellow does little other than store fat. As the animal matures, yellow marrow is substituted for red except in selected sites, but can be reactivated when demand for erythrocyte production increases.

Red marrow consists of a mixed population of cells directly involved in haematopoiesis, and a supportive connective tissue stroma. The stromal elements include fibroblasts, endothelial cells and acrophages supported by a meshwork of collagen and reticular fibres. The microenvironment created by these cells supports blood cell production.

The haematopoietic cells in the bone marrow can be divided into three groups: pluripotent stem cells, differentiating progenitor cells and fully functional mature blood cells. Pluripotent stem cells are capable of self-renewal. As cells become committed to a certain cell lineage, their ability to proliferate is reduced and eventually lost. Thus, the marrow has a pyramidal structure, in which one stem cell gives rise to many daughter cells (Figures 9.1–9.3). Specific information concerning production of all cell lines in cats is lacking, so the following description draws from available information in other mammalian studies.

Erythropoiesis

Erythropoiesis has been well studied in the cat owing to the effects of retroviral infections on red cell production. Erythrocytes are normally produced in the bone marrow. This development occurs in islets around central ('nurse') macrophages, which phagocytose debris, store iron and contribute to local control of the microenvironment. EMH in the liver and spleen is stimulated only if marrow is unable to match the demand. In erythropoiesis, the pluripotent stem cell in the marrow is influenced by factors called 'burst-promoting activity' (BPA) to form colonies of cells called erythroid burst forming units (BFU-E). BPA is probably the cytokine interleukin-3 (IL-3, produced by T-lymphocytes). BFU-E then differentiate into erythroid colony-forming units (CFU-E) in response to erythropoietin. Erythropoietin also causes differentiation of CFU-E into the first morphologically recognisable erythroid precursor, the proerythroblast. This cell continues to differentiate through the

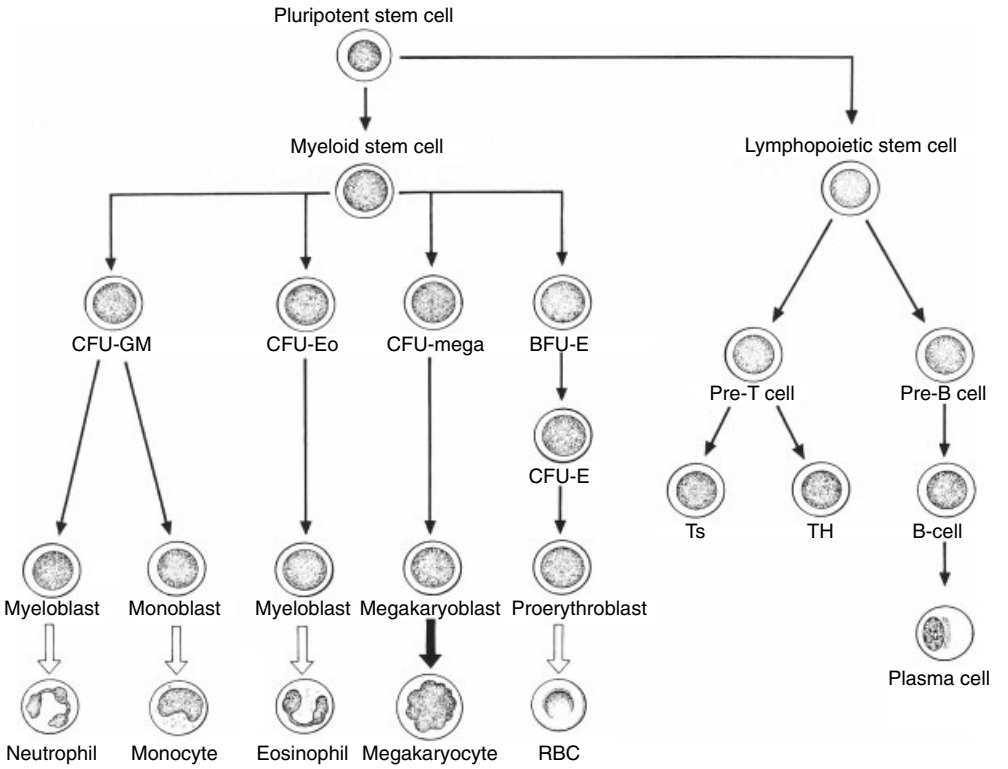

Figure 9.1 Diagrammatic representation of haematopoiesis showing the differentiation of the various cell lineages.

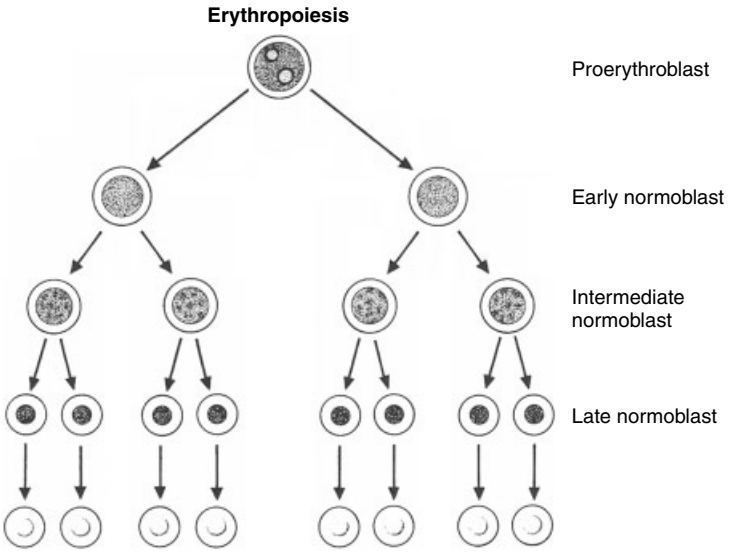

Figure 9.2 Diagrammatic representation of erythrocyte differentiation from the first morphologically recognisable precursor, the proerythroblast, to mature red cells. Note the pyramidal arrangement of cells, i.e. increasing numbers or progeny from a single proerythroblast.

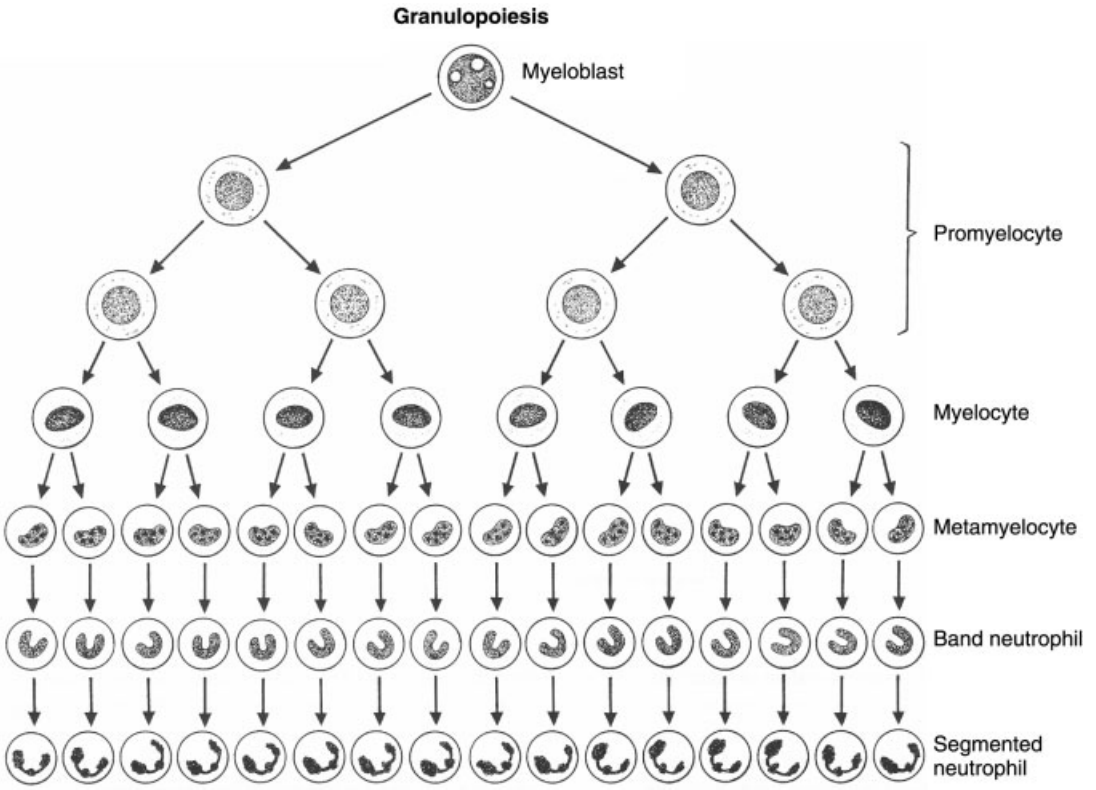

Figure 9.3 Diagrammatic representation of neutrophil maturation from the first morphologically recognisable precursor, the myeloblast. The capacity to divide is lost at the metamyelocyte stage.

Table 9.1 British and American nomenclature of the erythroid series

British nomenclature	American nomenclature
Proerythroblast	Rubriblast
Early normoblast	Prorubriblast
Intermediate normoblast	Rubricyte (basophilic)
	Rubricyte (polychromatophilic)
Late normoblast	Metarubricyte
Reticulocyte	Reticulocyte
Erythrocyte	Erythrocyte

early, intermediate and late normoblast stages to the reticulocyte and then mature erythrocyte. (British and American nomenclature for the erythroid series differ: see Table 9.1.) It takes approximately 7 days for red cells to differentiate in the marrow, and after release they continue to mature for 24–48 h in the circulation or spleen. The average lifespan of red cells in the feline circulation is 68–80 days, and most effete red cells are phagocytosed by splenic macrophages.

The glycoprotein hormone erythropoietin is the main regulator of erythropoiesis and is produced in the kidney in response to lowered oxygen tension. Other hormones such as thyroid hormone and androgens may affect the production or release of erythropoietin, but have no intrinsic erythropoietin activity. (Although the liver can produce erythropoietin in humans, this is not the case in cats.)

Granulopoiesis and lymphopoiesis

The factors controlling granulopoiesis are less well defined than is erythropoietin in erythropoiesis. CFU-C (so called because they were first described in colony-forming units in culture) are the multipotent stem cells for the granulocyte series. These stem cells are morphologically similar to small lymphocytes.

In the presence of colony-stimulating activity (CSA) these will proliferate and differentiate into the cells of the granulocyte–monocyte lineages. CFU-GM (granulocyte–monocyte colony-forming unit) has been identified as the particular CFU-C progenitor which gives rise to both granulocytes and monocytes.

CSA is not a single hormone, and there is probably a colony-stimulating factor for each cell lineage. In addition to colony-stimulating factors, macrophages, activated lymphocytes and endothelial cells produce local factors (mainly cytokines), which stimulate granulopoiesis. Regulation of production is partly achieved by a negative feedback effect mediated by inhibitory substances from mature neutrophils and prostaglandin E from macrophages, unless there is continued stimulation for granulocyte release.

The first morphologically recognisable granulocyte is the myeloblast. These cells differentiate through the progranulocyte, myelocyte, metamyelocyte and band forms to become mature neutrophils. The capacity for cell division is lost at the metamyelocyte stage, by which time 16–32 myelocytes have arisen from each myeloblast.

Neutrophils

Within the marrow there is a maturation pool of neutrophils, consisting of metamyelocytes, band cells and segmented neutrophils. This pool acts as a reserve should there be a sudden demand for neutrophils, and contains approximately 5 days' supply of cells. The marrow transit time for a neutrophil (from inception to entering the pool) is approximately 4 days. In contrast to red blood cells (RBCs), the half-life of circulating neutrophils is hours, and is shortened in acute infections as most of the neutrophils migrate to the tissue pool. In the normal animal, there is no significant pool of neutrophils in the tissue. The neutrophils in the blood pool are divided into the circulating and marginating pools. Cats have a marginating pool almost three times as large as the circulating pool. Neutrophil distribution is illustrated in Figure 9.4.

Monocytes

Monocytes share a common precursor with neutrophils and are produced from monoblasts with fewer maturation steps than neutrophils. There is no storage pool. They circulate in the blood for a variable period (usually hours), then enter the tissues, where they mature into macrophages.

Eosinophils and basophils

The progenitor cell for eosinophils is CFU-Eo (Young *et al.*, 1997). Division and differentiation occur in response to stimulation by T-lymphocytes (especially via IL-2) and undefined humoral factors. Basophils are thought to arise from CFU-C (the myeloid precursor) or a precursor derived from this cell, which is also thought to give rise to mast cells.

Lymphocytes

Within the bone marrow, lymphoid cells arise from the pluripotent stem cells and diverge from this common precursor at a very early stage. The progeny from the stem cells will differentiate into T-, B- and null lymphocytes (which can be identified using surface markers) depending on microenvironmental control. Null cells can be divided into two subsets: one set comprises haematopoietic precursors, and the other has cytolytic capabilities.

Lymphopoiesis occurs within the bone marrow and peripheral lymphoid tissue. The marrow stem cells can differentiate into either B- or T-cells. Pre-T-cells migrate from the marrow to the thymus, where they proliferate and differentiate into T-lymphocytes owing to the influence of local microenvironmental factors including thymosin, produced by thymic epithelial cells. Following initial maturation, T-cells migrate to the peripheral lymphoid tissues. Populations of T-cells perform a myriad of functions in the regulation of haematopoiesis and orchestration of the immune response. These effects are mediated by cytokines, and include induction of B-cell proliferation, differentiation and antibody synthesis, modulation of the activity of other T-lymphocytes, production of memory cells for specific antigens, and regulation of haematopoiesis. Populations of lymphocytes also have cytolytic activity against pathogen-infected cells.

An equivalent to the avian bursa has not been identified in mammals, and pre-B-lymphocytes mature to B-lymphocytes within the marrow. These cells then migrate to the peripheral lymphoid tissues, where they mature and proliferate, developing into plasma cells and memory B-cells in response to antigenic stimulation. Conversely, much of the lymphopoiesis in normal marrow is independent of antigenic stimulation, although a few B-cells will undergo antigen-dependent stimulation into plasma cells.

Circulating lymphocytes consist of various populations with different life spans, but most are long-lived (months to years) recirculating memory T-cells.

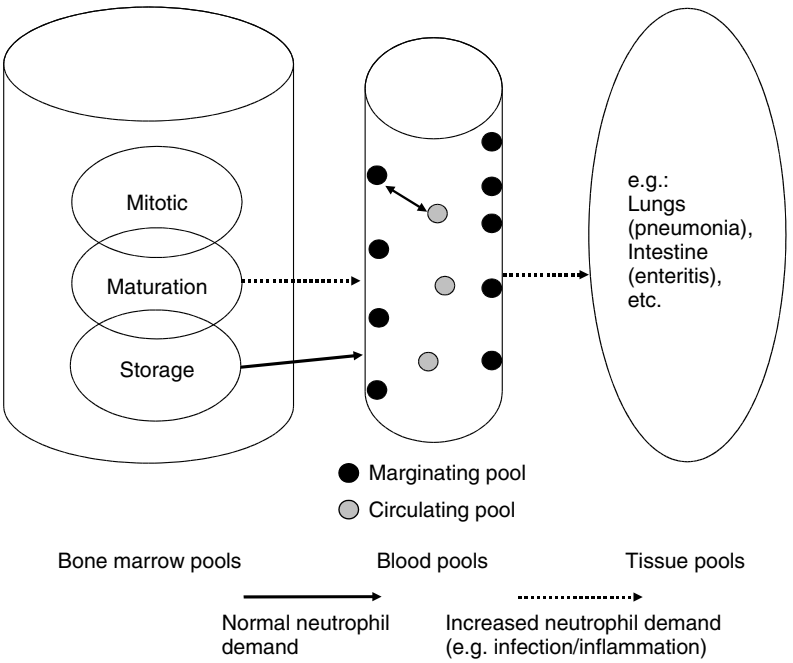

Figure 9.4 Neutrophil distribution. In the normal cat, segmented neutrophils are released from the storage pool to replace those lost from the bloodstream. When this storage pool is insufficient to meet demand, immature neutrophils are released from the maturation pool (which consists of metamyelocytes and band cells) and a left shift results. The storage and maturation pools contain about 4–5 days' supply of neutrophils, and act as a reserve should demand increase. The blood pool consists of marginating and circulating pools. In the cat, the marginating pool, which consists of cells stuck to or rolling along the small blood vessels, is almost three times as large as the circulating pool. Neutrophils may pass between the marginating and circulating pools. Neutrophils spend about 8 h in the blood before migrating to the tissue pool, from which they are rapidly cleared. In healthy animals there are very few neutrophils in the tissue pool.

It should be remembered that the blood is only a transport system allowing lymphocyte redistribution and recirculation, and contains less than 5% of the total body lymphocyte pool in health.

Megakaryopoiesis

Megakaryocyte colony-forming units (CFU-mega) are the committed precursor cells derived from the pluripotent stem cells, which give rise to platelets. The major haematopoietic growth factor for platelets is thrombopoietin, which has been characterised in the cat (Matsushiro *et al.*, 1998). These cells undergo nuclear division without accompanying cytoplasmic division, resulting in a multinucleated cell with copious cytoplasm: the megakaryocyte. During platelet production, megakaryocytes protrude cytoplasmic processes close to or into marrow sinusoids, and platelets break off from these processes as the vesicles around small regions of cytoplasm unite. The vast majority of platelets arise in the bone marrow, but some may arise from megakaryocytes that become fixed in the pulmonary parenchyma.

Therapeutic application of haematopoietic growth factors

Many of the growth factors and cytokines required for the control of blood cell production, differentiation and survival have been identified, and the feline proteins characterised. Unfortunately, recombinant feline proteins are not commercially available. However, recombinant DNA technology has been used to produce these factors for human patients, and the human recombinant proteins have been used with some success in feline patients. It must be remembered that these are foreign proteins that are not licensed for feline use, and may produce adverse reactions.

In addition, repeated exposure often leads to the development of a clinically significant antibody response, which limits the duration of useful therapy.

Erythropoietin

Recombinant human erythropoietin (rHu-EPO) has been used successfully in the treatment of feline anaemia secondary to failure of erythropoietin production in renal failure (Cowgill *et al.*, 1998). Despite the high homology of the feline and human proteins, a percentage of cats will produce anti-rHu-EPO antibodies, resulting in reappearance of the anaemia after a period of weeks to months. Inconsistently, other adverse effects including seizures, systemic hypertension and iron deficiency may be seen. Recently, experimental gene therapy in which the gene for feline erythropoietin was introduced into muscle cells using an adeno-associated vector (Beall *et al.*, 2000) has been successful in maintaining haematocrit, and similar technology may eventually be available for clinical patients.

Colony-stimulating factors

Human recombinant G- and GM-colony-stimulating factors will stimulate granulopoiesis in cats (Fulton *et al.,* 1991; Arai *et al.,* 2000). Again, rapid production of anti-rHu factors may limit clinical efficacy and this is especially problematic in the treatment of retrovirally mediated disease as chronic therapy is required (see Chapters 3 and 23). Rapid development of anti-rHU-GM-colony-stimulating factor antibodies has been reported and, in FIV-infected cats, therapy was associated with increased FIV load (Arai *et al.*, 2000). rHuG-colony-stimulating factor has been used to ameliorate myelosuppression after chemotherapy and in the treatment of other drug-induced neutropenias. No benefit was seen when rHuG-CSF was used in cats with panleucopenia, probably because the infected marrow cannot respond (London, 2000).

Cytokines

Although several feline cytokines have been characterised, none is yet available for clinical use. Cytokines have a myriad of potential applications from immune enhancement in cancer therapy to potentiation of DNA vaccination. Recombinant human interferon-α (2b) has been used to reduce viral load cats with FeLV (Zeidner *et al.*, 1990, 1995; Weiss *et al.*, 1991; Kolbl *et al.*, 2000) (see Chapter 23). However, its efficacy has been hampered by the formation of neutralising antibodies within weeks.

Sample collection

Blood sampling

Blood samples should routinely be collected from the jugular vein in the cat, since flow from a cephalic vein can be slow. Cats rarely resent collection from this site and a large volume of blood can be collected over a relatively short period. A fresh blood smear should be made immediately and submitted to the laboratory with the blood sample: this allows accurate examination of cell morphology and identification of red cell parasites. Blood sampling should be considered an adjunct to history and clinical examination, and diagnoses made using blood parameters should take into account the clinical condition and history. Blood results must always be interpreted using the reference ranges provided by the laboratory.

Bone-marrow sampling

Bone marrow should be evaluated in conjunction with haematological assessment, and a blood sample should be submitted with the bone-marrow samples. Indications for sampling the bone marrow are:

- unexplained cytopenias
  - non-regenerative anaemia
  - neutropenia
  - thrombocytopenia
  - pancytopenia
- abnormal/immature lymphocytes or granulocytes in the peripheral blood
- inexplicably high numbers of any cell line
- lymphoma
- hyperproteinaemia
- hypercalcaemia of unknown origin
- pyrexia of unknown origin
- detection of FeLV in discordant cats.

Bone marrow may be harvested either by aspiration, and the sample evaluated by cytology, or by biopsy, and the sample evaluated by histopathology. Histopathological assessment of core biopsies allows evaluation of architecture and stromal elements as well as haematopoietic cells. Ideally, both samples should be taken in all cases.

Bone-marrow aspirates in the cat may be taken from either the proximal femur via the trochanteric fossa or

Table 9.2 Bone-marrow aspiration from the humerus

(1) Preposition several clean glass slides near vertically, e.g. against a sandbag on the bench. Have further slides ready for smearing.
(2) Place the cat in left lateral recumbency.
(3) Clip over the cranial and lateral aspects of the proximal humerus. Aseptically prepare and drape the area.
(4) Infiltrate the skin and subcutis with local anaesthetic, then advance the needle onto the periosteum and infiltrate with anaesthetic. This is imperative in sedated patients.
(5) Make a small stab incision over the craniolateral aspect of the humerus, on the flat surface distal to the greater tubercle.
(6) Grasp the humerus (through the drape) and advance the Klima (15 G) needle through the subcutis onto the bone.
(7) Advance the needle through the cortical bone in a lateral to medial direction by applying FIRM pressure and twisting to and fro.
(8) Once through the cortex, the needle will be firmly lodged and you will be able to move the leg 'skewered' on the needle.
(9) Remove the central stylet. Attach a 10 or 20 ml syringe, and apply fairly vigorous suction. As soon as bloody material appears in the syringe release the negative pressure.
(10) Remove the needle and syringe as one unit. Apply a drop of marrow to the top of each slide. Marrow spicules will remain stuck to the top of the slide as blood flows down.
(11) Make smears: place a second slide over the first at right angles, LIGHTLY crushing the marrow spicules. The upper slide is then drawn across the lower, creating a smear on the underside of the upper slide. SMEARS MUST BE MADE RAPIDLY BEFORE CLOTTING OCCURS.
(12) Close the wound with a single suture.

Table 9.3a Bone-marrow aspiration from the femur

(1) Preposition several clean glass slides near vertically, e.g. against a sandbag on the bench. Have further slides ready for smearing.
(2) Place the cat in right lateral recumbency (if right-handed).
(3) Clip over the trochanteric fossa and head of the femur. Aseptically prepare and drape the area.
(4) Infiltrate the skin and subcutis with local anaesthetic, then advance the needle onto the periosteum and infiltrate with anaesthetic.
(5) Make a small stab incision in the skin over the trochanteric fossa.
(6) Grasp the femur (through the drape) and advance the Klima (15 G) needle through the subcutis onto the bone medial to the greater trochanter, directing it parallel to the femur.
(7) Advance the needle through the cortical bone down the shaft of the femur by applying FIRM pressure and twisting to and fro (like placing a pin).
(8–12) See Table 9.2.

Table 9.3b Bone-marrow biopsy from the femur

(1) Position and prepare the cat as above.
(2) Insert the Jamshidi (12–14 G) needle through the cortex medial to the greater trochanter as for aspirate.
(3) Once firmly lodged in the proximal femur, remove the central stylet and advance the needle a further 2 cm or so into the marrow cavity.
(4) Rotate the needle briskly in one direction to section off the biopsy at its base.
(5) Remove the needle.
(6) Using the blunt probe (not the stylet) push the sample from the tip of the needle back up the shaft and out through the proximal end (this prevents crush artefact due to tapering of the needle distally).
(7) Close the skin with a single suture.

the craniolateral aspect of the proximal humerus, just distal to the greater tubercle (Plate 9.1). The ilium is not suitable for sampling in the cat owing to the narrow marrow space. The femur is the preferred site for collection of core biopsies. Sedation and local anaesthesia are adequate for aspiration from the humerus, but general anaesthesia is usually required for aspiration from the femur and harvesting of core biopsies. Specialised Klima or Jamshidi needles are required (Plate 9.2).

The collection of bone-marrow samples is described in Tables 9.2 and 9.3. It is imperative that slides are positioned ready to receive the marrow and there are adequate personnel available to assist in the rapid making of smears. If this cannot be achieved, bone marrow can be collected into an EDTA-primed syringe.

Failure to aspirate marrow may occur if the needle has not been advanced fully through the near cortex, if the stylet is lodged in the far cortex (humerus only), for other reasons of poor technique, or if there is myelophthesis or myelofibrosis (which should be suspected on repeated dry taps).

A bone-marrow core biopsy is indicated if there is failure to harvest an aspirate, if the aspirate is of non-diagnostic quality, or if myelofibrosis/osteosclerosis or marrow necrosis is suspected. The technique for bone-marrow core biopsy is outlined in Table 9.3b.

Red blood cells

Pathophysiology

RBCs are responsible for the delivery of oxygen to body tissues and, in the normal cat, production and removal are balanced to ensure that tissue oxygenation is maintained. The cat is unique in its ability to modulate oxygen affinity in response to anaemia. Normal cats have two types of haemoglobin, HbA and HbB. In addition, they have small quantities of HbB subtypes. Compared with other species, feline haemoglobins (except for the HbB subtypes) have a relatively low oxygen affinity (and low 2,3-diphosphoglycerate concentrations), facilitating oxygen delivery at tissue sites. This explains why the normal feline red cell counts, packed cell volume and haemoglobin concentration are lower than those in normal dogs. It is hypothesised that erythrocytes produced in response to anaemia have considerably increased 2,3-diphosphoglycerate and adenosine triphosphate (ATP), which decrease the oxygen affinity of HbA. In addition, these cells have normal levels of HbA, reduced levels of HbB and increased levels of high-affinity HbB subtypes. This would seem disadvantageous, but the presence of a mixture of haemoglobins with different oxygen affinities at different tissue oxygen tensions may improve adaptation to a wider range of oxygenation conditions in anaemia (Weiser, 1995a).

Laboratory assessment of red blood cells

Erythrocyte reference ranges may vary between laboratories (Table 9.4).

Table 9.4 Erythrocyte reference ranges

Parameter	Normal range
Red blood cell count	5–10 × 10^{12}/l
Packed cell volume (PCV) or haematocrit (Ht)	30–45% (PCV) or 0.30–0.45 l/l (Ht)
Haemoglobin concentration (Hb)	10–15 g/dl
Mean corpuscular volume (MCV)	39–55 fl
Mean corpuscular haemoglobin (MCH)	12.5–17.5 fl
Mean corpuscular haemoglobin concentration (MCHC)	30–36 g/dl

Source: Veterinary Clinical Diagnostic Services, University of Glasgow.

Table 9.5 Causes of macrocytosis and microcytosis

Increased mean cell volume (macrocytosis)	Decreased mean cell volume (microcytosis)
Regenerative anaemia	Iron-deficiency anaemia
Feline leukaemia virus-related macrocytic anaemia	Congenital portosystemic shunts (PSS)
Artefact due to aged sample	Acquired PSS in liver disease
Other rare causes, e.g. myeloproliferative diseases, vitamin B_{12}/folate deficiency	Artefactual due to not enough blood and excess EDTA

Quantitative parameters

Red cell count

Feline red cells and platelets have a considerable size overlap resulting in a variable, but considerable, proportion of platelets being included in the red cell count. As there are far fewer platelets than red cells this only becomes significant in severely anaemic cats, when the automated counter creates a haematocrit from a falsely elevated red cell count. In these cases, haematocrit should be verified by a spun packed cell volume.

Packed cell volume (PCV)

PCV can be measured in-house, using a microcentrifuge and microhaematocrit reader. In addition to the PCV, examination of the microhaematocrit tube may reveal plasma icterus, haemolysis or lipaemia, or changes in the buffy coat. It is useful to measure total protein with PCV. More complete analysis of other red cell parameters requires a haematology analyser.

Mean cell volume (MCV)

MCV indicates the average size of red cells. The red cell distribution width describes the variability in red cell size and thus considers the entire population of red cells. This is likely to be distorted by platelet overlap in cats, and it has been suggested that reference values of MCV are too high. However, cats tend to produce large reticulocytes when the marrow is fully stimulated and this degree of macrocytosis is likely to be detected. Table 9.5 lists the causes of macrocytosis and microcytosis.

Mean corpuscular haemoglobin (MCH)

MCH is the amount of haemoglobin per average red cell.

Table 9.6 Common red blood cell (RBC) abnormalities seen on examination of feline blood smears

RBC morphology	Appearance	Associated conditions
Rouleux	Stacked coins	Normal (thought to be related to serum protein concentrations); may be marked in hyperproteinaemia
Autoagglutination	Irregular clumps of RBCs	Immune-mediated haemolytic anaemia
Anisocytosis (Plate 9.3)	Variation in RBC size	Regenerative response; iron deficiency
Polychromasia (Plate 9.3)	Variation in RBC colour	Regenerative response; iron deficiency
Nucleated RBCs	Small cell similar to a reticulocyte with pale blue–grey cytoplasm and small dark eccentric nucleus	Regenerative anaemia; splenic disease (failure to remove nuclei)
Schistocytes (Plate 9.3)	Cleaved/fragmented RBCs	Microangiopathic change; disseminated intravascular coagulation, congestive heart failure, congenital cardiac disease glomerulonephritis, haemangiosarcoma, etc.
Heinz bodies (Plate 9.5)	Round, refractile bodies lying along the inner surface of the cell membrane which look like unstained projections of the cell membrane on standard stains	May be present in 10% or more of red cells in normal cats; increased owing to oxidative damage
Acanthocytes (Plate 9.3)	Cells with irregular projections from the cell contour	Severe hepatic lipidosis, glomerulonephritis, porstosystemic shunts, haemangiosarcoma, etc.
Haemoparasites	Very small coccoid organisms singly or in chains on the edge of or within the cells	*Haemobartonella felis*
Spherocytes	Cannot be identified in cats owing to reduced central pallor in normal RBC	

Mean corpuscular haemoglobin concentration (MCHC)

MCHC is more useful than MCH as it gives the average concentration of haemoglobin in each cell. Decreased MCHC means hypochromasia, but hypochromasia is not readily observed in cats. (Note that hyperchromasia does not exist, and elevated MCHC is generally artefactual and caused by lipaemia or haemolysis, for example.)

Qualitative parameters

Red cell morphology should be routinely assessed by examination of an air-dried blood smear under high power. The more common red cell abnormalities seen on examination of feline blood smears are summarised in Table 9.6, and some are illustrated in Plate 9.3.

Reticulocytes

Reticulocytes are immature RBCs released prematurely from the bone marrow into the circulation. In cats, red cells remain in the marrow until they are only weakly polychromatic, so although virtually all polychromatophilc cells are reticulocytes, not all reticulocytes are polychromatophilic. Thus, polychromasia is a relatively insensitive indicator of regeneration in cats.

Two forms of reticulocyte exist in the cat: punctate and reticulate, or aggregate. Aggregate reticulocytes mature into punctate reticulcytes after 12–24 h in the circulation. Aggregate reticulocytes are thus more immature and therefore reflect recent marrow release. Punctate reticulocytes have undergone a degree of maturation and can remain in the bloodstream for up to 4 weeks after the anaemia has resolved. For this reason, only aggregate reticulocytes are considered evidence of ongoing regeneration and punctate reticulocytes are not included in the reticulocyte count. In acute anaemia it can take 3–4 days before the reticulocyte count increases significantly. In the early stages of acute anaemia the condition may be incorrectly categorised as non-regenerative. (In mild anaemias, reticulocytes may not be released from the marrow

Table 9.7 Guidelines for the reticulocyte response

Degree of regeneration	Feline aggregate reticulocytes ($\times 10^9$/l)
None	<15 (0.5%)
Slight	50 (2%)
Moderate	100 (4%)
Marked	200 (5%)

until they mature to punctate, and in these cases the punctate reticulocyte count is useful.)

Reticulocytes are readily identified following incubation of whole blood in EDTA anticoagulant with new methylene blue (NMB) stain, which stains clumped ribosomal material as dark dots (Plate 9.4). There are several ways of quantifying reticulocyte response (Table 9.7). The absolute number of reticulocytes is more accurate than the reticulocyte percentage, as percentage is affected by the number of mature RBCs (i.e. with profound anaemia the percentage of reticulocytes will be increased because of the relative reduction in RBC numbers). In the cat, absolute number is also more reliable than corrected reticulocyte percentage and reticulocyte production index, because of the variable lifespan of feline reticulocytes.

Absolute reticulocyte count ($\times 10^9$/l)
= Observed % reticulocytes
$\times$ RBC count ($\times 10^{12}$/l) $\times$ 10

An absolute aggregate (or reticulate) reticulocyte response of greater than 50×10^9/l is evidence of regeneration.

Kittens

Kittens are born with a haematocrit of approximately 35%. Haematocrit declines over the first 3–4 weeks to 25%, but then gradually increases to adult values by 16 weeks. At birth, the erythroid population is macrocytic, but this is replaced by cells of normal size by 4 or 5 weeks (Meyers-Wallen *et al.*, 1984). If there is restricted iron availability, usually due to late weaning onto adequate solid foods, kittens may develop a more marked anaemia and microcytosis between 4 and 8 weeks of age. Kittens also have high lymphocyte counts.

Table 9.8 Classification of the degree of anaemia in cats

Severity of anaemia	Haematocrit (%)
Mild	20–24%
Moderate	14–19%
Severe	10–13%
Very severe	<10%

Anaemia

Anaemia is characterised by a decreased haemoglobin concentration, which is most commonly accompanied by a reduction in the number of erythrocytes. Tissue oxygenation is therefore reduced, resulting in stimulation of erythropoietin and increased sympathetic tone. The clinical signs associated with anaemia reflect reduced tissue oxygenation and the associated physiological adjustments.

Mucous membrane pallor provides a rough guide to the degree of anaemia, but can be deceptive in cats. Tachycardia and poor tolerance of stress reflect the increase in sympathetic tone. Cardiac auscultation may reveal the presence of a soft systolic murmur due to increased blood turbulence and/or gallop sounds. Tachypnoea and dyspnoea due to oxygen deficiency may only be recorded in cats with severe anaemia, during exercise or when stressed. The cat's ability to tolerate severe anaemia is due its unique red cell physiology (see above) and altered lifestyle in response to reduced tissue oxygenation.

The severity of clinical signs recorded in anaemic cats is related more closely to the chronicity than to the degree of anaemia (the classification of degree of anaemia is summarised in Table 9.8). Chronic anaemia, such as that associated with non-regenerative anaemia, is tolerated better than acute anaemia, such as that associated with severe haemolysis. Clinical signs may not become apparent in cats with chronic anaemia until the haematocrit is as low as 10–15%. The severity of the anaemia can only be determined by assessment of PCV.

Investigation of anaemia

The nature, duration and severity of anaemia can be defined using a number of readily available tests:

- packed cell volume/haematocrit
- total serum protein (normal 60–80 g/l)
- examination of a direct smear (see above)
- reticulocyte count.

Further tests are required to establish the cause of the anaemia and include:

- Coombs' test (see section on haemolytic anaemia)
- erythropoietin assay
- assessment of iron metabolism (see section on iron deficiency)
- bone-marrow aspirate/biopsy (see above).

Erythropoietin assay

Plasma erythropoietin concentrations can be of value in evaluating anaemia in cats. Erythropoietin is generally increased in cats with anaemia due to diseases (including FeLV-related anaemias) other than chronic renal failure (CRF). Erythropoietin is normal or moderately reduced in cats with CRF (Kociba *et al.*, 1983; Wardrop *et al.*, 1986; Pechereau *et al.*, 1997). In cats with primary polycythaemia, erythropoietin values are generally low to normal (Cook & Lothrop, 1994; Hasler & Giger, 1996). However, there is overlap between groups and a low or normal serum erythropoietin does not exclude secondary polycythaemia.

Classification of anaemia

Anaemia is classified as regenerative or non-regenerative depending on the degree of bone-marrow response. The bone-marrow response can be determined by performing a reticulocyte count or assessing a blood smear for evidence of regeneration (macrocytosis, polychromasia), but it should be remembered that most reticulocytes in the cat are not markedly polychromatophilic so polychromasia is a poor indicator of regenerative response. Regenerative anaemias can be further divided into those due to blood loss and those due to haemolysis.

Regenerative anaemia

Haemolytic anaemia

Haemolytic anaemia is associated with excessive breakdown of red cells. When haemolysis is rapid or occurs intravascularly, it can be associated with jaundice, bilirubinuria and haemoglobinuria. Haemolytic anaemias are usually strongly regenerative with a marked reticulocytosis, anisocytosis, polychromasia and increased MCV once the haemolysis is established. Neutrophilia with a left shift is common: this may reflect either generalised stimulation of the bone marrow, or a response to the tissue damage and systemic inflammatory response induced by the causes or effects of immune-mediated haemolytic anaemia. Table 9.9 lists the mechanisms by which haemolysis can occur in the cat.

Table 9.9 Common causes of haemolytic anaemia in cats

Mechanism of haemolysis	
Immune-mediated	*Haemobartonella felis*
	Feline leukaemia virus associated
	Autoimmune (primary or associated with systemic lupus erythematosus)
	Neonatal isoerythrolysis
	Cold agglutinin disease
	Drug associated
Heinz body associated	Oxidative damage
Congenital	Congenital erythrocyte enzyme deficiencies
	Congenital erythropoietic porphyria
	Increased erythrocyte osmotic fragility

Immune-mediated haemolytic anaemia Haemolysis destroys only erythrocytes, so blood volume, leucocytes, platelets and serum protein remain normal. Acute haemolytic anaemia will appear non-regenerative until the marrow responds in 3–5 days, and during this period a neutrophilia with left shift may also develop. Iron-deficiency anaemia does not occur because there is no external blood loss. Haemoglobin released from haemolysed red cells is eventually metabolised by the tissues into unconjugated bilirubin (which circulates bound to plasma proteins), and is then very efficiently taken up by hepatocytes, conjugated and excreted into bile. Only massive, acute haemolysis overwhelms this process to produce jaundice.

Immune-mediated haemolytic anaemia is usually diagnosed on the basis of a positive slide agglutination test or a positive Coombs' test. Once a positive diagnosis has been made it is important to establish any underlying cause, as primary (autoimmune) immune-mediated haemolytic anaemia is uncommon in the cat. A diagnosis of primary immune-mediated haemolytic anaemia can only be made once all other possible causes have been thoroughly investigated and ruled out (Table 9.9).

Slide agglutination test A slide agglutination test is performed by mixing one drop of blood in EDTA with two drops of saline on a glass slide. Clumping of the red cells either grossly or microscopically is consistent with

a diagnosis of immune-mediated haemolytic anaemia. Rouleaux, which can mimic autoagglutinates, should be completely dispersed by the addition of saline.

Coombs' test The Coombs' test is used to identify the presence of antibodies attached to the surface of the patient's red cells by the addition of a second antibody. Coombs' tests can be used to identify the class of antibody involved and the severity of the immune-mediated process. Coombs' test does not confirm a diagnosis of primary (autoimmune) haemolytic anaemia as the test may be positive in a number of diseases that cause secondary immune-mediated haemolysis (Table 9.9). The slide agglutination test is a crude method of assessing antibody–red cell binding and the Coombs' test is likely to be positive in patients with a positive slide agglutination test.

Haemobartonella felis (*feline infectious anaemia*, Mycoplasma haemofelis, Mycoplasma *spp*.) Feline infectious anaemia has been reported as a common cause of anaemia among young cats and those infected with FeLV and/or FIV or otherwise immunosuppressed. Cats with a concurrent immunosuppressive disease have a poorer prognosis, and all cats with *H. felis* should be tested for FeLV and FIV infections to ensure that an appropriate prognosis can be provided. *Haemobartonella felis* has been renamed as *Mycoplasma*, and two forms recognised in the UK are *M. haemofelis* and *M. haemominutum*. The pathogenesis of these organisms is still under investigation and is discussed more fully in Chapter 29.

Feline leukaemia virus-associated haemolytic anaemia

FeLV can result in anaemia via both myeloproliferative and lymphoproliferative disease mechanisms, by action on erythroid precursors and by immune-mediated haemolysis. Cats with immune-mediated haemolysis associated with FeLV will often be positive on Coombs' testing and this cannot therefore be used to confirm a diagnosis of autoimmune haemolysis. FeLV infection is discussed more fully in Chapter 23.

Systemic lupus erythematosus

Autoimmune haemolytic anaemia, leucopenia and thrombocytopenia can occur in cats with systemic lupus erythematosus (SLE). Other clinical signs, including skin lesions, glomerulonephritis (resulting in proteinuria), polyarthropathy and neurological disturbances (due to meningeal involvement), are required before SLE is suspected. Diagnosis is dependent on appropriate clinical signs, haematological findings and a positive antinuclear antibody (ANA) test, or lupus erythematosus (LE) cell test. SLE is very rare, and positive ANA and LE tests can also occur in cats infected with FeLV.

Neonatal isoerythrolysis

Neonatal isoerythrolysis (NI) is the destruction of a neonate's red cells by maternal antibodies. In cats this can occur when a type A or AB kitten is born to a type B queen (Cain & Suzuki, 1985; Gandolfi, 1988; Jonsson *et al.*, 1990; Griot-Wenk *et al.*, 1996). High levels of anti-A antibodies present in the colostrum and milk are ingested and absorbed during the first 16 h of life (Casal *et al.*, 1996). Affected kittens develop marked haemoglobinuria, lethargy and sometimes icterus within 24 h of birth. Many kittens die within a few days and surviving kittens may develop tail-tip necrosis (Bridle & Littlewood, 1998). NI can be prevented by avoiding mating type B queens with type A or AB toms or by ensuring that at-risk kittens are fostered onto a type A queen for the first 24 h of life. After 24 h the kittens are no longer able to absorb colostral antibodies and can be safely returned to their mother.

Cold agglutinin disease

Cold agglutinin disease has been reported in the cat (Schrader & Hurvitz, 1983). It is a rare disease caused by immunoglobulin M (IgM) antibodies, which result in agglutination of RBCs in peripheral vessels. The resultant microvascular occlusion and poor perfusion will cause cyanosis and gangrene of the digits, pinnae, tail, eyelids or nose. Anaemia is usually mild and significant haemolysis is rare.

Oxidative damage

Oxidative damage affects feline red cells in two ways: the induction of methaemoglobinaemia and Heinz body formation (Plate 9.5). Methaemoglobinaemia occurs within the first 1–2 h of an oxidative insult, but is reversible. Methaemoglobin is not capable of oxygen carriage and therefore signs of acute hypoxia are seen when more than 20–40% haemoglobin has been affected. Congenital methaemoglobin reductase deficiency causing persistent methaemoglobinaemia and cyanotic mucous membranes has been reported in a domestic shorthaired cat (Harvey *et al.*, 1994), but is not usually associated with anaemia (Harvey, 1996).

Heinz body formation is an irreversible change resulting in increased fragility of RBCs. Feline haemoglobins are more sensitive to oxidative damage than

those of other species because of their relatively high concentration of oxidisable sulfhydryl groups. In other species, Heinz bodies can be removed from the cell by the spleen ('pitting') or the affected RBCs can be cleared. The feline spleen (which is non-sinusoidal) is inefficient at pitting or removing affected red cells. Large numbers of Heinz bodies can therefore occur in normal cats.

Multiple cellular abnormalities develop in association with Heinz bodies that reduce RBC survival and make cells more prone to haemolysis. The size and number of Heinz bodies can be used to predict the degree of haemolysis (Ewing *et al.*, 1997). The severity of the anaemia induced depends on the ability of the marrow to replace damaged cells. The causes of Heinz body formation are (Ewing *et al.*, 1997):

- paracetamol (toxic dose is 50–60 mg/kg)
- lymphoma
- diabetes mellitus
- hyperthyroidism
- propylene glycol
- hypophosphataemia
- methionine
- methylene blue
- onions (>28 g/kg).

Cats are much less likely than dogs to ingest toxins inadvertently and toxicity is usually associated with owner medication (paracetamol) or consumption of toxins in a disguised form, such as onion powder in baby foods (which may be present in relatively high concentrations) or cooked onions in onion soup.

Erythrocyte osmotic fragility

Chronic, severe, intermittent haemolytic anaemia has recently been reported in Abyssinian and Somali cats and appears to be associated with increased erythrocyte osmotic fragility (Kohn *et al.*, 2000). Affected cats develop significant anaemia (5–25%) at a range of ages (6 months to 5 years). Other common laboratory findings include hyperglobulinaemia, lymphocytosis, mild hyperbilirubinaemia and elevated hepatic enzyme activities. It has been proposed that a novel hereditary erythrocyte defect may be responsible for the development of haemolytic anaemia in these cats (Kohn *et al.*, 2000).

Congenital erythrocyte enzyme deficiencies associated with haemolysis

Congenital disorders are usually identified in young cats; however, some erythrocyte enzyme deficiencies may not be identified for several years. Haemolytic anaemia can result from severe deficiencies of pyruvate kinase, one of the rate-controlling enzymes in glycolysis (Harvey, 1996). Pyruvate kinase deficiency has been reported in Abyssinian and Somali cats, as well as a domestic cat (Ford *et al.*, 1992).

Congenital erythropoietic porphyria is an autosomal dominant inherited condition (Glenn *et al.*, 1968; Giddens *et al.*, 1975). Partial deficiency of the enzyme, which synthesises the porphyrin precursors of haeme, results in a build-up of porphyrins. Tissues, urine and faeces become discoloured and affected animals may develop photosensitivity, renal failure and haemolytic anaemia. The anaemia is macrocytic and hypochromic owing to reduced haemoglobin synthesis.

Treatment of haemolytic anaemia The underlying cause of the haemolytic anaemia should be identified and treated appropriately. In the case of suspected primary immune-mediated haemolytic anaemia, drug and vaccination history should be studied to determine a predisposing cause. Any drug given 7–10 days before onset of haemolysis should be suspected of inducing an immune-mediated haemolysis and should be withdrawn. Immunosuppressive doses of prednisolone (2–4 mg/kg per day in divided doses) remain the mainstay of treatment for haemolytic anaemia and are often required to prevent red cell haemolysis, despite the presence of a primary disease such as *H. felis*. The small size of the feline patient makes long-term use of other immunosuppressive agents difficult, as most preparations are not available at appropriate doses. However, bolus doses of cyclophosphamide (100–150 mg/m^2) may be given orally or intravenously at initiation of therapy to help try to achieve remission. Azathioprine at a dose of 0.3 mg/kg p.o. daily can be used in patients refractory to prednisolone alone, although appropriate preparations are difficult to come by and may have to be made up by a pharmacist on an individual basis. Azathioprine hepatotoxicity and myelosuppression can be significant and cats should therefore be monitored frequently while receiving treatment.

Cage rest and standard therapy alone are successful in most patients with haemolytic anaemia. Patients showing severe symptoms (weakness or dyspnoea) may require transfusion. Transfused red cells, however, have a short lifespan in patients with haemolytic anaemia, and blood transfusions may often actually increase the rate of erythrocyte haemolysis. Since patients with haemolytic anaemia have a normal blood volume, fluid therapy is of no benefit and may contribute to volume

Table 9.10 Investigation of blood-loss anaemia

Cause of blood loss	Tests required
Coagulopathy	Platelet count, PT, PTT, ACT, BMBT
Gastrointestinal	Faecal occult blood (false positives common), endoparasitic flotation
Urinary	Urine dipstick, urine sedimentation
Body cavity	Thoracic and abdominal radiographs, ultrasonography
External parasites	Check and treat for fleas

PT: prothrombin time; PTT: partial thromboplastin time; ACT: activated clotting time; BMBT: buccal mucosal bleeding time.

overload. Oxygen supplementation is also of minimal benefit. Transfusions and the use of haemoglobin component oxygen-carrying fluids will be discussed in greater detail later in this chapter.

Haemorrhagic anaemia

Table 9.10 summarises the approach to localisation of blood-loss anaemia.

Acute blood loss Acute, severe blood loss causes hypovolaemic shock rather than anaemia. Proportional loss of all blood components means that initially PCV and total protein (TP) remain normal. Volume expansion during recovery then progressively dilutes PCV and TP. Loss of over 30% of blood volume in a single episode of haemorrhage can cause death due to hypovolaemic shock. Patients that survive are therefore unlikely to have lost more than 30% of circulating red cells, and will not be severely anaemic unless bleeding continues at a slower rate. Erythrocyte regeneration is not evident for 3–4 days. Acute blood loss can therefore initially mimic non-regenerative anaemia. Subsequent regenerative responses peak at 1 week, although PCV may take up to 2–3 weeks to normalise. TP returns to normal more rapidly (1 week). Persistent anaemia and hypoproteinaemia suggest ongoing blood loss.

Chronic blood loss Typically chronic blood-loss anaemia is initially very regenerative, featuring anisocytosis, polychromasia, reticulocytosis, Howell–Jolly bodies and nucleated RBCs. Chronic external haemorrhage, especially gastrointestinal losses, may eventually cause iron deficiency and a microcytic anaemia, which may become poorly regenerative or apparently non-regenerative over time. Iron deficiency in the adult cat is much less common than in other species, and hypochromasia is not observed (Weiser, 1995b).

Treatment of acute and chronic blood loss The most effective means of treating anaemia due to haemorrhage is to identify and remove the underlying cause. Since hypovolaemic shock is the major consequence of severe haemorrhage, vigorous volume replacement (usually with isotonic crystalloid fluids) is the initial supportive treatment of choice. Refractory cases may benefit from synthetic colloids, plasma or haemoglobin component-carrying solutions, although these must be used with care (see section on transfusion medicine). Whole blood is indicated for patients with moderate to severe anaemia without hypovolaemia (e.g. patients with acute severe haemorrhage that have received fluid therapy) and in patients with chronic ongoing blood loss.

Non-regenerative anaemia

The lifespan of a feline erythrocyte is approximately 70 days. Non-regenerative anaemia therefore develops gradually as the diseased marrow fails to replace ageing erythrocytes. Compensatory mechanisms are well established, enabling patients to cope despite severe anaemia. Typical non-regenerative anaemia features minimal anisocytosis or polychromasia, and has a low reticulocyte count (1%). Erythrocytes usually appear normal (normocytic, normochromic anaemia). Serum protein is usually normal, but may be reduced in iron-deficiency anaemia, which is often microcytic. Many of the systemic disorders that cause non-regenerative anaemia only produce mild subclinical anaemia, whereas primary bone-marrow disorders typically cause moderate to severe anaemia. Bone-marrow disorders often cause concurrent leucopenia and thrombocytopenia, which may be more marked than the anaemia in acute marrow disease.

Investigation of non-regenerative anaemia

Systemic illnesses can usually be identified by history, physical examination and haematology and/or biochemistry results. Mild to moderate non-regenerative anaemia is most commonly anaemia of chronic disease (anaemia of inflammatory disease), associated with such processes as chronic inflammatory diseases, infection and neoplasia. Serological testing for retroviruses (FIV and FeLV) should be performed in all cats with non-regenerative anaemia. Bone-marrow aspiration cytology and/or core biopsy histopathology is essential for establishing a definitive diagnosis in patients with non-regenerative anaemia due to primary marrow disorders. The causes of non-regenerative anaemia are summarised in Table 9.11.

Table 9.11 Causes of non-regenerative anaemia

Cause of anaemia	Severity	Effects
Systemic disease	Moderate to severe	Iron-deficiency anaemia (chronic blood loss)
		Chronic renal failure (erythropoietin deficiency)
		Feline leukaemia virus-associated non-regenerative anaemia
		Drug-induced marrow failure (e.g. griseofulvin)
	Mild (subclinical)	Anaemia of chronic disease/anaemia of inflammatory disease
		Lead poisoning
		Chronic liver disease
		Hypoadrenocorticism
Primary bone marrow	Usually severe	Aplastic anaemia
		Pure red cell aplasia
		Myelophthisis (marrow infiltration, e.g. leukaemia)
		Myelofibrosis
		Myelodysplasia
	Variable	Myelonecrosis

Iron-deficiency anaemia Suspected iron deficiency should be investigated by measuring serum iron, total iron-binding capacity and ferritin (when available) and, ideally, bone-marrow iron stores. Serum iron concentrations may be low in iron deficiency, inflammatory diseases and renal disease, and may be increased in response to glucocorticoid therapy, parenteral iron therapy, haemolytic anaemia and liver disease. Total iron-binding capacity (TIBC) is an indirect measurement of transferrin, since transferrin is the major iron-carrying protein. Iron deficiency causes serum iron and TIBC/transferrin saturation to fall. Erythrocyte protoporphyrin and serum ferritin levels can be measured in cats (Hawke *et al.*, 1992; Andrews *et al.*, 1994), but the diagnostic value of these tests has not been evaluated in a range of disease states. The most accurate assessment of body stores of iron is evaluation of marrow iron stores; however, this is difficult in cats as bone marrow may not contain stainable iron even in a normal state (Harvey, 1997).

Treatment of iron deficiency involves removing the underlying cause of blood loss and giving oral ferrous sulfate at 4–6 mg of iron/kg daily for several months.

Lead poisoning Lead poisoning rarely causes anaemia in the cat (Evans, 1994). Diagnosis is based on blood lead concentrations. Affected cats should be treated with calcium edetate.

Anaemia of chronic disease Mild normocytic, normochromic anaemia is commonly seen in association with chronic disease. This is thought to be due to a shortened erythrocyte lifespan coupled with reduced red cell production and disordered iron metabolism and storage (Weiss & Krehbiel, 1983; Waner & Harrus, 2000). Cats rarely show clinical signs attributable to the anaemia.

Anaemia of chronic renal failure Normocytic, normochromic anaemia is common in renal failure (see Chapter 10). Anaemia in these patients is attributed to reduced renal erythropoietin production (the major contributing factor), reduced red cell survival, reduced erythropoiesis (due to secondary hyperparathyroidism), and haemorrhage associated with thrombopathies and gastrointestinal ulceration. Increased gastrin (due to reduced renal metabolism) causes increased gastric acid production, leading to mucosal irritation, ulceration and haemorrhage. Uraemic toxins can induce platelet dysfunction, thereby resulting in inadequate primary haemostasis.

Treatment should be directed at minimising blood loss (gut protectants, H_2 blockers) and increasing erythropoietin concentrations. rHu-EPO is indicated when the PCV falls below 15%. rHu-EPO should be administered at a dose of 50–100 IU/kg by subcutaneous injection three times weekly until the PCV is greater than 25%. The frequency and dose can then be reduced and titrated to effect (changing the dose every 3 weeks). The PCV should not be allowed to increase further or polycythaemia may develop. Iron supplementation may be of benefit as rHu-EPO-stimulated erythropoiesis puts a high demand on iron stores, and is indicated where there is suspected or documented iron deficiency. A significant number of cats will develop antibodies to recombinant erythropoietin and it has been suggested that these antibodies not only inactivate the rHu-EPO, but may cross-react with endogenous erythropoietin, thereby exacerbating the anaemia (Cowgill, 1995; Cowgill *et al.*, 1998). Other adverse effects are uncommon, but hypertension may be seen in cats treated with erythropoietin, which have no prior history of blood pressure problems. A small proportion of cats may be genuinely erythropoietin resistant and, as with insulin resistance, this may be associated with other diseases. Anabolic steroids (androgens) are often administered to cats with chronic renal failure. They

must be given for several months before an increase in PCV is detected, and are often ineffective.

Feline leukaemia virus-associated non-regenerative anaemia FeLV infection may result in anaemia, leucopenia, thrombocytopenia or pancytopenia. The anaemia may be macrocytic (often associated with marrow dysplasia), normocytic or normochromic. Cats presenting with macrocytosis and no increase in reticulocytes should be tested for FeLV (Cotter, 2000). FeLV is thought to cause anaemia by a number of mechanisms: direct marrow suppression, anaemia of chronic disease (due to concurrent infections associated with immunosuppression), or secondary to marrow dysplasia or malignancy (Cotter, 2000). It is therefore important to identify and treat any concurrent infections that may be causing the anaemia. FeLV infection is discussed in greater detail in Chapter 23.

Feline immunodeficiency virus-associated non-regenerative anaemia Erythroid dysplasia or myelodysplastic syndromes with erythroid maturation arrest have been reported to occur in cats infected with FIV. However, granulocytic progenitors are more commonly suppressed than erythroid progenitors in marrow cultures (Linenberger *et al.*, 1995).

Primary bone-marrow disorders Pure red cell aplasia and aplastic anaemia are forms of marrow failure that have been regarded as incurable without marrow transplantation. Immunosuppressive therapy may be helpful if an underlying immune-mediated aetiology is suspected. Immunological diseases with antibodies directed against haematopoietic precursors in the marrow have not been shown to occur in the cat. However, occasional cats improve in response to steroid and symptomatic therapy. Unfortunately, with FeLV-associated marrow suppression this response is usually transient.

Cats with myelodysplastic disease often present with a non-regenerative anaemia accompanied by other haematological abnormalities and morphological changes in the erythroid series in the blood and marrow suggestive of disturbed cellular maturation. Blasts may be increased in the marrow, and some cats will progress to overt leukaemia. Myelodysplastic and overtly neoplastic myeloproliferative diseases can be considered as different variants in a continuum of stem cell disease. Recent research in FeLV-infected cats has shown clonal proliferation in myelodysplastic disease, which supports the theory that this is a preleukaemic state (Hisasue *et al.*, 2000). The prognosis for cats with myelodysplastic syndromes is poor.

Myeloproliferative diseases, where there is overt neoplastic change in one or more cell lines in the marrow, may often present due to neutropenia or thrombocytopenia before the non-regenerative anaemia is clinically significant. Haematology may reveal a leukaemic blood picture in addition to cytopenias, but definitive diagnosis and classification require bone-marrow sampling. The prognosis for these conditions is poor (see Chapter 23).

Myelofibrosis results from the proliferation of connective tissue elements within the marrow. In some cases there may be cortical thickening and bone deposition within the marrow cavity. These lesions crowd out normal haematopoiesis and may suppress this process by release of inhibitory factors. Myelofibrosis and osteosclerosis have been reported in association with FeLV infection, where changes may be seen in association with myelodysplasia. Myelonecrosis is also reported in FeLV and FIV infection. The prognosis for these conditions is poor. There are no reports of idiopathic myelofibrosis in cats, as seen in dogs.

Treatment of non-regenerative anaemia

The best method of treating non-regenerative anaemia secondary to systemic disorders is to eliminate the underlying aetiology. Specific therapies are discussed in each section.

Transfusion in patients with non-regenerative anaemia

Since recipient erythrocytes typically have a normal circulating lifespan in animals with non-regenerative anaemia, transfusion is an effective method of supportive treatment, and a single matched blood transfusion may stabilise an anaemic patient for up to 4 weeks.

The ideal transfusion endpoint is probably the conversion from severe anaemia to a mild to moderate anaemia (PCV of 20–25%). If the post-transfusion PCV is over 25%, endogenous erythropoietin release may fail to be stimulated, with a consequent delay in the recovery of normal haematopoiesis.

Refractory non-regenerative anaemia may necessitate repeat blood transfusions. Multiple transfusions over a prolonged period greatly increase the risk of transfusion reactions. Even subtle incompatibilities will decrease the circulating lifespan of donor erythrocytes, necessitating progressively more frequent transfusions to maintain an adequate PCV. Cross-matching and blood typing should always be performed before transfusion in patients receiving

additional blood transfusions more than 1 week after the initial transfusion was administered.

Polycythaemia

Polycythaemia is an increase in circulating red blood cells. Secondary polycythaemia can be associated with relative tissue anoxia (due to cardiopulmonary disease or high altitude) or due to excessive erythropoietin production (erythropoietin-producing renal tumours have been reported in cats) (Cook & Lothrop, 1994; Hasler & Giger, 1996). Polycythaemia vera is a myeloproliferative disorder of the erythroid line, and is rare in cats (Evans, 1994). Patients present with symptoms of hyperviscosity (muddy mucous membranes, variable neurological signs) and an elevated PCV (70–85%). Diagnosis is based on ruling out secondary causes of polycythaemia, bone-marrow aspirate or biopsy, and erythropoietin levels.

Initial treatment with phlebotomy will minimise the signs of hyperviscosity. Hydroxurea is the drug of choice for the treatment of polycythaemia, and has been used successfully in cats (Evans & Caylor, 1995), but is not currently available in the UK in an appropriate preparation. Bolus dosage of hydroxyurea is associated with acute methaemoglobinaemia, and Heinz body formation in some cases. An escalating dose regimen has been described which requires splitting of capsules, which can only be carried out in institutions with suitable biohazard protection (Watson *et al.*, 1994). In addition, hospitalisation to allow monitoring for acute side-effects is recommended. Care must be taken with chronic use to avoid severe myelosuppression.

Radioactive phosphorus has been used to treat primary polycythaemia in humans and a small number of dogs (long-term control was achieved in approximately 40% of cases). This treatment is not currently available because of the requirement for specialised isolation facilities. There are no reports of its use in cats.

White blood cells

Laboratory assessment of white blood cells

Leucocyte reference ranges vary between laboratories (Table 9.12). The morphological features of feline white blood cells (WBCs) are summarised in Table 9.13.

Neutrophils

The neutrophil (Plate 9.6) is a vital component in defence against pathogens, and can kill or inactivate bacteria, yeasts, fungi and parasites. It is able to eliminate infected or transformed cells, to amplify or modulate the immune response, and is involved in the regulation of granulopoiesis.

Neutrophil kinetics have been discussed in the section on haematopoiesis.

Table 9.12 Leucocyte reference ranges

Parameter	Normal range
White blood cell count	$5.5–15.5 \times 10^9$/l
Neutrophils	$2.5–12.5 \times 10^9$/l
Band neutrophils	0×10^9/l
Monocytes	$0–0.85 \times 10^9$/l
Lymphocytes	$1.5–7 \times 10^9$/l
Eosinophils	$0–1.5 \times 10^9$/l
Basophils	Rare

Source: Veterinary Clinical Diagnostic Services, University of Glasgow.

Table 9.13 Morphological description of leucocytes

White blood cell morphology	Appearance of nucleus	Appearance of cytoplasm
Neutrophil	Large, irregular, less pronounced lobulation than in the dog	Pale with fine pink granulation
Band neutrophil	Smooth U-shaped or sigmoid nucleus	Pale with fine pink granulation
Monocyte	Angular or irregular bilobed, occasionally round or bean-shaped	Dull, blue–grey with ground-glass appearance
Lymphocyte	Round, dark nucleus	Narrow rim of cytoplasm, intensely blue
Eosinophil	Bilobed nucleus	Rod-shaped red–orange granules throughout
Basophil	Weakly lobulated	Grey with small grey–purple granules

Table 9.14 Causes of neutrophilia in cats

Mechanism	Causes
Acute inflammatory response	Bacterial infection (localised or generalised) Other infections (viral rhinotracheitis, fungal infections, toxoplasmosis) Immune-mediated disease Neoplasia Tissue necrosis (e.g. pancreatitis)
Physiological response	Adrenaline induced Emotional stress, fear, excitement (Exercise induced)
Stress or corticosteroid response	
Others	Chronic granulocytic leukaemia Neutrophil dysfunction Paraneoplastic syndromes (leukaemoid reaction)

Neutrophilia

The causes of neutrophilia are listed in Table 9.14.

Physiological neutrophilia Redistribution of neutrophils from the marginating pool to the circulating pool can produce a significant increase in neutrophil count in response to stress or exercise, as approximately three times as many neutrophils are maintained in the marginating pool as are in the circulating pool (Figure 9.4). This does not reflect a real increase in the total blood neutrophil count, merely a shift of cells into the circulating pool from which they are sampled; therefore, no left shift (band neutrophils) is seen. The neutrophilia may be accompanied by lymphocytosis.

Stress/steroid-induced neutrophilia A mature neutrophilia is produced by an initial release of cells from the marrow storage pool, shifting cells from the marginating to the circulating pool, and by reducing endothelial adherence so that neutrophil circulation time is prolonged. The stress response in the cat is less marked than in the dog. It may not be accompanied by a monocytosis; however, the eosinophil count is typically low to absent. This 'stress leucogram' may be produced by exogenous steroid administration, prolonged 'medical' stress or hyperadrenocorticism. A stress leucogram is also often found in association with inflammatory responses, where there will be a combination of a left-shifted neutrophilia (and possibly monocytosis) with lymphopenia and eosinopenia (see below).

Acute inflammatory response An acute inflammatory response is characterised by a neutrophilia with a left shift, as a result of increased release of cells from the marrow storage pool. Myelopoiesis increases to meet increased demand, but as the storage pool becomes depleted, bands or metamyelocytes are released into the circulation, resulting in a left shift (Plate 9.7). In general, the degree of left shift is proportional to the inflammatory stimulus. This left shift may be either regenerative or degenerative.

A regenerative left shift is characterised by an absolute increase in neutrophil numbers with immature cells in the circulation, and indicates an adequate response. A degenerative left shift arises when the bone marrow is unable to maintain an adequate response. The storage pool becomes exhausted, but the left shift persists as increasingly immature bands and metamyelocytes are released into the circulation. The total neutrophil count is reduced or normal, with low numbers of mature neutrophils. The most dramatic example of this is in feline panleucopenia infection.

Chronic inflammation Chronic inflammation may not result in significant changes on the haemogram: neutrophil numbers may be normal or increased. In most cases, where neutrophilia is secondary, history, clinical findings and further investigations indicate the initiating cause. Illusive inflammatory foci can sometimes be identified by labelling patient WBCs with gamma-emitting radioisotopes such as technetium and performing scintigraphy (a 'white cell scan').

Chronic granulocytic leukaemia Extreme neutrophilia may be due to chronic granulocytic leukaemia (CGL), but this is extremely rare in the cat. Hepatosplenomegaly, mild anaemia and thrombocytopenia may be suggestive of CGL if no underlying cause is found. There are no reports of treatment of CGL in the cat.

Leukaemoid reaction In the cat, a leukaemoid reaction is arbitrarily defined as a white blood cell count (WCC) of greater than 75×10^9/l. Similarly, extreme neutrophilic leucocytosis has been arbitrarily defined as a total WCC of greater than 50×10^9/l with greater than 50% neutrophils (Lucroy & Madewell, 2001). Neutrophilias of this magnitude are associated with a wide spectrum of infectious, immune-mediated, inflammatory and neoplastic processes, and also with

tissue necrosis secondary to these processes, trauma or thrombosis. Unfortunately, extreme neutrophilia is generally a poor prognostic indicator (Lucroy & Madewell, 2001).

Toxic change

'Toxic changes' occur when there is an enhanced turnover rate of neutrophils, due to incomplete maturation in the bone marrow as a result of intense marrow stimulation and shortened maturation times in the marrow (Kociba, 2000). Any severe inflammatory disease can produce toxic changes, although they are most frequently seen in severe localised or systemic bacterial infections. Toxic changes include increased cytoplasmic basophilia, cytoplasmic vacuolations, Döhle bodies (round blue cytoplasmic structures) and, less commonly, toxic granulation and giant neutrophils (Plate 9.8). As 'toxicity' becomes severe, nuclear swelling and a ragged appearance to the nuclear envelope may develop.

Cytoplasmic basophilia is due to increased residual cytoplasmic RNA, reflecting enhanced neutrophil turnover. Cytoplasmic vacuolation is due to loss of granule and membrane integrity associated with disturbed cell maturation in the marrow. Döhle bodies are aggregates of endoplasmic reticulum within the cytoplasm and are of less significance in cats than in other species, as they are commonly seen in normal cats and those with minor inflammation (Kociba, 2000). Atypical neutrophil granulation has been reported in Birman cats, but does not appear to be associated with abnormal neutrophil function (Hirsch & Cunningham, 1984).

Neutropenia

Neutropenia is the result of either failure of bone-marrow production or excessive neutrophil consumption. Concurrent abnormalities in other cell lines (e.g. thrombocytopenia, anaemia) suggest that bone-marrow disease is responsible and a bone-marrow biopsy or aspirate should be performed to confirm the diagnosis. Neutrophils have a short lifespan and are therefore often the first cell line to be affected by marrow disease. Excessive neutrophil consumption is usually associated with a septic focus, and may produce a degenerative left shift if consumption exceeds production. Clinical signs will be much more acute, and circulating neutrophils may show evidence of toxic change and a left shift with reduced numbers of mature neutrophils (Tvedten, 1994a). The causes of neutropenia are listed in Table 9.15.

Table 9.15 Causes of neutropenia in cats

Mechanism	Causes
Overwhelming demand/ decreased survival	Peracute bacterial infections (especially endotoxic or septic shock) Peritonitis Aspiration pneumonia Acute salmonellosis
Reduced or ineffective granulopoiesis	Retroviral infection (FeLV/FIV) Feline panleucopenia virus
Bone marrow disease	Leukaemia Myelophthesis Myelodysplasia
Cytotoxic drug therapy Idiosyncratic drug reactions (Immune-mediated destruction) (Cyclic neutropenia)	

FeLV: feline leukaemia virus; FIV: feline immunodeficiency virus.

Panleucopenia virus Panleucopenia virus infection (see Chapter 21) causes a dramatic neutropenia and leucopenia (Tvedten, 1994a). As the bone marrow repopulates, there is a dramatic increase in the numbers of immature myeloid cells. This extreme degenerate left shift can be mistaken for a myeloid leukaemia. Giant and atypical neutrophils can be seen in the peripheral blood, although normal cells are seen within a few days, thus allowing differentiation from leukaemia.

Chemotherapy-associated neutropenia Neutropenia associated with anticancer chemotherapy is usually most severe 5–7 days after drug administration (see Chapter 3). Cats with neutrophil counts of $<2 \times 10^9$/l should be monitored for sepsis. Cats with neutrophil counts of $<0.5 \times 10^9$/l and pyrexia are assumed to have sepsis (Tvedten, 1994a). Myelosuppressive chemotherapy should be withheld if the neutrophil count is $<2.5 \times 10^9$/l or the platelet count falls below 50×10^9/l (i.e. <3 platelets per high-power field), and the offending drugs reinstituted at an appropriate lower dose on recovery.

Feline leukaemia virus-associated bone-marrow disease FeLV infection causes ineffective granulopoiesis (see Chapter 23). The virus can cause either myeloid hypoplasia or granulocytic hyperplasia (Prasse, 1983). Cyclic neutropenia has been reported in two cats with FeLV. Prednisolone therapy appeared to stop this cycling (Kociba, 2000).

Drug-induced marrow failure Myelotoxicoses may occur as a result of exposure to toxins, hormones and drugs. Drug toxicity may be either a predictable response to drugs such as chemotherapeutic agents (see Chapters 1 and 3) or an idiosyncratic toxicity, that is, an adverse reaction to other drugs in an individual patient. The bone-marrow toxicity of azathioprine, which can be profound in cats, is a species-specific toxicity, which may be due to low levels of thiopurine methyltransferase, an enzyme important in azathioprine metabolism, in feline RBCs (Beale *et al.*, 1992; White *et al.*, 2000).

In addition to cytotoxic drugs, some other medications have been associated with bone-marrow toxicoses in cats. A dose-dependent reversible bone-marrow toxicity is reported with chloramphenicol (Penny *et al.*, 1970), which is reflected in the recommended dose for the species. Zidovudine [azidothymidine (AZT)], a deoxythymidine analogue antiviral drug that has been used to treat FeLV and FIV, also causes a dose-related anaemia and neutropenia (Haschek *et al.*, 1990). Similarly, bone-marrow toxicity is seen with the antiherpetic agents acyclovir and valacyclovir, and is likely to occur with the analogous drug gancyclovir (Owens *et al.*, 1996; Nasisse *et al.*, 1997).

Reports of idiosyncratic bone-marrow toxicoses in cats are sparse. However, neutropenia and pancytopenia have been reported after griseofulvin administration (Helton *et al.*, 1986; Rottman *et al.*, 1991; Baeufils *et al.*, 1993). This is thought to be essentially idiosyncratic but Siamese, Abyssinian and Himalayan breeds may be predisposed, as are cats that are FIV positive (Kunkle & Meyer, 1987; Shelton *et al.*, 1990; Baeufils *et al.*, 1993). Bone-marrow hypoplasia and pancytopenia has also been reported after albendazole administration (Stokol *et al.*, 1997). Thrombocytopenia and agranulocytosis have also been reported in cats receiving methimazole (Peterson *et al.*, 1988). Cats are apparently resistant to the haematological toxicity seen with oestrogens in other species. Drug-induced immune-mediated haemolytic anaemia and/or thrombocytopenia may be seen as an idiosyncratic reaction to almost any drug, but have been commonly associated with the use of propylthiouracil (Peterson *et al.*, 1984).

Congenital abnormalities of neutrophils

Chédiak–Higashi syndrome This syndrome is an inherited disorder of the microtubules and granules present in leucocytes and other cells (Kociba, 2000). It has been reported in smoke-blue Persian cats with yellow–green irises. Affected cats have an increased bleeding tendency (due to abnormal platelet function) and low-normal neutrophil counts (Prier & Collier, 1987).

Table 9.16 Causes of lymphocytosis and lymphopenia

Causes of lymphocytosis	Causes of lymphopenia
Physiological (common in cats)	Corticosteroids (endogenous or exogenous)
Lymphoid leukaemia	Viral disease (FeLV, FIV, feline panleucopaenia)
Prolonged immune stimulation (FeLV)	Loss of lymphocyte-rich lymph (chylothorax, lymphangiectasia, other enteric disease)
Hypoadrenocorticism (very rare in cats, lymphocytosis inconsistent)	Lymphoma
Age: young animals have high lymphocyte counts	

FeLV: feline leukaemia virus; FIV: feline immunodeficiency virus.

Pelger–Hüet anomaly Pelger–Hüet anomaly is an autosomal dominant inherited disorder reported in domestic shorthaired cats. The homozygous form is lethal, but heterozygote cats show granulocyte hypo-segmentation (Latimer *et al.*, 1985). Cells are usually classified as immature or band neutrophils, but appear to have normal function (Kociba, 2000).

Neutrophil dysfunction

Functional neutrophil abnormalities occur in a number of conditions, and as yet are not fully described in the cat. Reduced adherence capacity has been demonstrated in dogs with diabetes mellitus, but as yet not in cats. Defective chemotaxis has been reported in cats with Chédiak–Higashi syndrome, FeLV infection and feline infectious peritonitis (FIP). FeLV infection also causes reduced bacterial killing capacity.

Lymphocytes

The causes of lymphocytosis and lymphopenia are listed in Table 9.16.

Lymphocytosis

Physiological lymphocytosis Physiological lymphocytosis in the cat may be dramatic. As this is thought to be due to adrenaline release, every effort should be

made to minimise anxiety in the patient when blood samples are taken.

Inflammatory lymphocytosis Lymphocytosis secondary to antigenic stimulation may be seen in response to chronic infectious diseases or chronic inflammation, and is a consequence of lymphocyte proliferation and expansion of the blood lymphocyte pool. Reactive lymphocytes may be seen transiently in any immune-stimulated state. These cells must be differentiated from lymphoblasts that have undergone neoplastic transformation and care should be taken that a presumptive diagnosis of lymphoproliferative disease is not made in error.

Lymphoid leukaemia Leukaemia is defined as a haematopoietic neoplasm that originates in the bone marrow. Leukaemia is not always associated with the presence of abnormal cells in the peripheral blood. Leukaemias are usually divided into acute and chronic on the basis of the degree of differentiation and maturity of the affected cells. Acute lymphocytic leukaemia (ALL) involves lymphoblast cells, whereas chronic lymphocytic leukaemia (CLL) involves mature populations of lymphocytes. The chronic leukaemias generally have a more favourable prognosis. Small to medium-sized lymphocytes counts in excess of 20×10^9/l are consistent with CLL. Evaluation of a case of suspected CLL must include bone-marrow biopsy, to rule out a more aggressive leukaemia. Confirmation of clonality (i.e. demonstrating the clonal origin of the vast majority of cells) is helpful in differentiating CLL from other forms of lymphocytosis (see section on lymphoproliferative diseases).

Lymphoma Lymphocytosis is seen in only a small minority of cats with lymphoma. Atypical cells are also more frequently seen in lymphoma patients with normal or reduced lymphocyte counts (Gabor *et al.*, 2000).

Lymphopenia

Lymphopenia is usually associated with lymphocyte apoptosis or redistribution due to glucocorticoid exposure. Panleukopenia virus infects lymphocytes and may therefore cause direct injury and subsequent lymphopenia (Kociba, 2000). Both FeLV and FIV are thought to cause lymphopenia by induction of apoptosis. Chylothorax and lymphangiectasia are associated with altered sequestration or drainage of lymphocytes within lymph, resulting in lymphopenia. Lymphopenia is also a common finding in cats with lymphoma (Gabor *et al.*, 2000).

Table 9.17 Causes of eosinophilia in cats

Mechanism	Causes
Parasitic	Ectoparasites
	Pulmonary (aleurostronglyus)
	Enteric (*Giardia*, coccidia, ascarids)
Allergic	Asthma
	Flea-allergic dermatitis
	Eosinophilic granuloma complex
	Atopy
	Food hypersensitivity
Inflammatory	Inflammatory bowel disease (eosinophilic enteritis)
	Focal inflammation
	Lower urinary tract disease
	Rhinitis/sinusitis
	Eosinophilic granuloma complex
	Steatitis
Neoplastic	Mast cell tumour (disseminated/intestinal)
	Lymphoma
	Myeloproliferative disease (eosinophilic leukaemia and others)
	Miscellaneous tumours
Infectious	Feline panleukopenia virus
	Feline infectious peritonitis
	Toxoplasmosis
	Upper respiratory tract infection
	Pyometra
Miscellaneous	Chronic renal failure
	Cardiac disease
	Immune-mediated skin disease
	Hypereosinophilic syndrome
	Others

Eosinophils

Eosinophilia

The causes of eosinophilia are listed in Table 9.17.

Hypereosinophilic syndrome

Hypereosinophilic syndrome is an uncommon disorder. It is characterised by persistent, marked predominantly mature eosinophilia, and tissue infiltration with mature eosinophils in multiple organs, which lacks a recognised cause. The most commonly affected tissues are the bone marrow, small intestine and mesenteric lymph nodes. Cardiac involvement is reported but has most often been an incidental necropsy finding. Middle-aged domestic shorthaired cats are most frequently affected, and there may be a female predisposition, although reported case numbers are small. In cats, the most common clinical signs are diarrhoea, weight loss, vomiting and anorexia. Physical

abnormalities may include thickened loops of intestine, lymphadenopathy, hepatomegaly or splenomegaly, erythroderma, pruritus and other skin lesions, and pyrexia (Neer, 1991). Diagnosis relies on exclusion of causes of secondary eosinophilia (see Table 9.17). Differentiation of hypereosinophilic syndrome from rarer cases of eosinophilic leukaemia is difficult, if not impossible. In any case, the two syndromes may represent different presentations of one infiltrative eosinophilic disease, or a CGL, and the prognosis for the two diseases is unfortunately similarly poor (Huibregtse & Turner, 1994). Bone-marrow myeloid hyperplasia and a varying population of mature and immature cells may be seen infiltrating other organs in either disease. Treatment of hypereosinophilic syndrome has relied predominantly on corticosteroids (prednisolone 0.25–4 mg/kg twice daily), which produces survival times of weeks to months (Neer, 1991). The use of cytotoxic drugs in these cats has not been fully investigated.

Eosinopenia

Eosinopenia can be difficult to define since most normal ranges extend to zero (Kociba, 2000). Eosinophils decrease in many acute infections, owing to the release of corticosteroids. Similarly, exogenous steroids can cause eosinopenia.

Basophils

Normal cats have low numbers of basophils. However, basophils play an important role in hypersensitivity reactions and basophilia is often seen in association with eosinophilia.

Monocytes

The monocyte is the circulating precursor of the macrophage. Both monocytes and macrophages are involved in the scavenging damaged cells and debris. Macrophages have an important role in the immune system and regulate inflammation and haematopoiesis. Monocytosis occurs in chronic inflammation and may be seen without neutrophilia.

Mast cells

Mast cells are not seen in blood smears from the normal cats. The frequency with which mast cells may be identified on buffy coat smears in feline patients with inflammatory conditions has not been evaluated. Systemic mastocytosis is a mast cell neoplasia associated with mast cell leukaemia, which most commonly presents with splenomegaly and vomiting. The haemogram reveals mastocytaemia and anaemia (Liska *et al.*, 1979). Unfortunately, the prognosis for these cats is poor. Mast cell tumours affecting only the spleen, conversely, carry a favourable prognosis.

Platelets

Because of feline platelet–RBC overlap, platelet numbers cannot be assessed by automatic analysers. The platelet count must therefore be determined by manual examination of a blood smear. Platelets are discussed in detail below.

Bleeding disorders

Normal haemostasis

Vascular constriction, platelet aggregation and activation of the clotting cascade normally control bleeding. Vascular constriction reduces blood pressure while a stable clot is formed and prevents ongoing blood loss.

Primary haemostasis

Primary haemostasis involves vasoconstriction and formation of the platelet plug, thereby restoring vessel integrity and preventing further blood loss. Platelet adherence is normally inhibited by endothelial production of prostacyclin. Vessel injury and exposed subendothelium cause platelet adherence (via collagen and von Willebrand's factor) and activation. The release of platelet granules results in recruitment of other platelets, activation of the coagulation cascade and the stimulation of fibrin, fibroblasts, and so on. Serotonin released from platelets further enhances vascular constriction.

Secondary haemostasis

Secondary haemostasis involves activation of the coagulation cascade (Figure 9.5) to create a fibrin mesh, which stabilises the platelet plug, thereby forming a more stable clot. Secondary haemostasis is dependent on circulating coagulation proteins that become activated by exposure to damaged vascular endothelium and/or platelet aggregation. All coagulation proteins are manufactured in the liver except for factor VIII, which is produced by megakaryocytes and vascular endothelial cells. The common pathway is responsible for the conversion of fibrinogen into

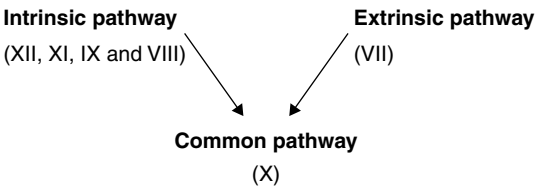

Figure 9.5 Diagram showing the division of the coagulation factors in the clotting cascade.

fibrin, which then bonds to create a mesh of fibrin throughout the platelet plug.

Investigation of bleeding disorders

Clinical findings

Disorders of primary and secondary haemostasis are characterised by different clinical presentations. Failure of the primary platelet plug results in multiple small haemorrhages detected as petechial and ecchymotic haemorrhages on the mucous membranes and hairless parts of the skin. Gastrointestinal or respiratory haemorrhage may result in melaena. Once the clot is stabilised by normal secondary haemostasis, haemorrhage stops, limiting bleeding.

Failure of secondary haemostasis causes failure of stabilisation after formation of a normal clot. This results in rebleeding, producing large bleeds into cavities including joint spaces, thoracic and abdominal cavities and, occasionally, obvious haematomas. Following trauma the bleeding may appear to stop due to formation of a normal platelet plug; however, further bleeding occurs minutes to hours later when secondary haemostatic mechanisms have failed.

Primary haemostasis testing

Platelet count

The simplest, most reliable method of estimating platelet counts is from a blood smear. Each platelet per oil immersion field (×1000 total magnification) represents a circulating platelet count of 20×10^9/l (Tasker *et al.*, 1999a). Counting the number of platelets in 10 oil immersion fields and multiplying the final total by 2 therefore gives the estimated platelet count $\times 10^9$/l. Spontaneous bleeding can occur at platelet counts of less than 30×10^9/l. It is important to establish that the platelet count is greater than 30×10^9/l before tests of platelet function are performed. Smears must be carefully examined for platelet aggregates (Plate 9.6) (especially towards the feathered edge and tail of the smear) before thrombocytopenia is declared. The normal platelet count in the cat is 300–800 $\times 10^9$/l.

Buccal mucosal bleeding time

Buccal mucosal bleeding time (BMBT) allows assessment of platelet and vessel function. Thrombocytopenia can also prolong BMBT since inadequate platelet numbers hinder normal development of the platelet plug. Since BMBT usually requires sedation or anaesthesia in cats, care should be taken to avoid administration of drugs that cause peripheral vasodilatation. Acepromazine, however, has not been shown to prolong BMBT or induce a clinical bleeding tendency in the cat (Callan *et al.*, 2000). BMBT is measured by making a standardised small incision in the buccal mucosa of the upper lip. The time taken for bleeding to stop is recorded and is the BMBT. If blood is mopped away during the procedure, care must be taken to avoid disrupting the clot in any way. Damage to the clot causes prolongation of the BMBT in normal patients. The normal BMBT in the cat is 1–2.4 min (Parker *et al.*, 1988).

Clot retraction

Platelets are responsible for clot retraction. This test therefore assesses platelet function and number, albeit crudely. Since platelet number can be accurately assessed on a blood smear, this test should be used to identify thrombocytopathies, once thrombocytopenia has been excluded. Whole blood is placed into a glass tube and kept at 37℃ for up to 5 h. Once a blood clot has formed the size of the clot should be marked on the tube. When platelet function is normal, the blood clot should shrink to 50% of its original size within 2–4 h.

Von Willebrand's factor

Von Willebrand's factor is also known as factor VIII-related antigen and plays a vital role in adhesion of the platelet to the vessel wall during primary clot formation. Deficiency of this factor is associated with von Willebrand's disease and can be quantified using an electroimmunoassay (EIA) or enzyme-linked immunosorbent (ELISA) assay. Von Willebrand's disease has been reported only rarely in the cat (French *et al.*, 1987; Thomas, 1996).

Secondary haemostasis testing

The interpretation of tests of secondary haemostasis is summarised in Table 9.18.

Table 9.18 Interpretation of clotting tests

APTT or ACT	PT	Factors potentially affected	Potential diagnoses
Prolonged	Normal	XII, XI, IX, VIII	DIC, haemophilia, vWD, vitamin K deficiency, Hageman factor deficiency
Normal	Prolonged	VII	Vitamin K deficiency (VII has the shortest half-life so PT increased first)
Normal	Normal	No single factor at <30% of normal	Normal
Prolonged	Prolonged	X, V or combinations of XII, XI, IX, VII, VII	Vitamin K deficiency, DIC

APTT: activated partial thromboplastin time; ACT: activated clotting time; PT: prothrombin time; DIC: disseminated intravascular coagulation; vWD: von Willebrand's disease.

Whole blood clotting time

Whole blood clotting time (WBCT) provides a crude but readily available test of both primary and secondary haemostasis. Whole blood is placed into a glass tube and kept at 37℃. The tube is checked every 30 s for evidence of clot formation. The WBCT will be prolonged if there is severe thrombocytopenia, a severe single factor deficiency (<5% of normal activity) or hypofibrinogenaemia. The results of this test will be affected by the PCV of the blood and the size and temperature of the tube. A WBCT of less than 6 min is considered normal.

Activated clotting time

Activated clotting time (ACT) assesses the intrinsic and common clotting pathways (all factors except for factor VII). To perform the test, 2 ml of blood is placed into an ACT tube warmed to body temperature. The time taken for clot formation is assessed visually. Single clotting factors must be reduced to less than 5% of normal to prolong the ACT, and severe thrombocytopenia ($<10 \times 10^9$/l) or hypofibrinogenaemia will also prolong the ACT. This test is therefore less sensitive than the APTT (see below) (Tvedten, 1994b). The normal ACT is 50–75 s in cats (McConnell, 2000).

Activated partial thromboplastin time

Activated partial thromboplastin time (APTT) assesses the intrinsic and common clotting pathway (high molecular weight kininogen, prekallikrein, and factors XII, XI, IX and VIII). Blood must be collected in citrate anticoagulant and submitted to a laboratory. Some laboratories may require control samples from a cat without clotting abnormalities to be submitted at the same time. Single clotting factors must be reduced to less than 30% of normal before prolongation of APTT is recorded; however, thrombocytopenia does not affect the results (Tvedten, 1994b).

Prothrombin time

Prothrombin time (PT) assesses the extrinsic and common clotting pathway (factors VII, V and X and fibrinogen). Blood must be collected in citrate anticoagulant and submitted to a laboratory. Some laboratories may require control samples from a cat without clotting abnormalities to be submitted at the same time. Single clotting factors must be reduced to less than 30% of normal before prolongation of PT is recorded (Tvedten, 1994b).

Specific factor analysis

Diagnosis of a deficiency in a specific factor can only be made once the likely abnormality has been identified. Citrated plasma can then be mixed with plasma from animals with known factor deficiencies and the APTT repeated. This test can therefore identify a cat with a single factor deficiency.

Fibrinogen

Fibrinogen levels will decline when there is widespread activation of the clotting cascade (e.g. disseminated intravascular coagulation). Fibrinogen levels are measured in citrated plasma.

Tests of clot inhibition

Antithrombin III

Antithrombin III (AT3) limits fibrin formation and therefore acts as a natural anticoagulant in the circulation. Its activity is markedly enhanced by heparin. Feline AT3 can be measured using a commercially

available human kit. Subnormal AT3 levels may be associated with disseminated intravascular coagulation (DIC), a failure of hepatic AT3 metabolism or loss of AT3 via the gastrointestinal tract or renal glomeruli (in protein-losing diseases) (Thomas & Green, 1998). Cats with experimentally induced FIP and cats with acquired heart disease have been shown to have normal-high concentrations of AT3 (Boudreaux *et al.*, 1989; Welles *et al.*, 1994); this may be due to AT3 acting as an acute-phase protein in the cat (Welles *et al.*, 1993). AT3 may not therefore be a useful indicator of DIC in cats with FIP (Boudreaux *et al.*, 1989).

Proteins induced by vitamin K absence (PIVKA)

A cage-side test has been developed which is uniquely sensitive to PIVKA. This test has been shown to identify accurately cats with bleeding tendencies, which will subsequently normalise within 3–5 days of parenteral vitamin K administration (Center *et al.*, 2000). PIVKA clotting time has been shown to be more sensitive than routinely used coagulation assessments in the detection of cats with coagulopathies (Center *et al.*, 2000).

Circulating inhibitors

Circulating anticoagulants, which inhibit coagulation, have been reported. Their presence is identified by a failure to correct coagulation tests when the patient's plasma is mixed with normal plasma or by progressive increases in a coagulation times over a 1–2 h period (Feldman *et al.*, 1983).

Tests of fibrinolysis

Fibrin degradation products

Fibrin degradation products (FDPs) are formed during fibrinolysis and are therefore used in the diagnosis of DIC. Blood must be collected into special tubes that prevent the activation of the fibrinolytic system after collection. The presence of increased FDPs indicates increased breakdown of fibrin and/or fibrinogen, or reduced hepatic clearance, or a combination of these mechanisms. Elevations in FDPs have been associated with DIC cats, but have also been recorded in clinically normal cats (O'Rourke *et al.*, 1982; Thomas & Green, 1998).

D-Dimer

D-Dimer is a fragment of fibrin formed when fibrin is degraded. It can be detected in plasma using a monoclonal antibody. Elevations of D-dimer have proved useful in the diagnosis of DIC in dogs (Stokol *et al.*, 2000). There are no published reports of its use in cats.

Platelet disorders

Thrombocytopenia

Thrombocytopenia can be associated with a failure of platelet production (due to bone marrow disease), or excessive use or destruction of platelets. Immune-mediated platelet destruction is usually secondary to FeLV (most commonly), drugs, vaccination, neoplasia or infections such as *Ehrlichia*. Primary immune-mediated (or autoimmune) thrombocytopenia is rare (Tasker *et al.*, 1999b). Immune-mediated thrombocytopenia has been reported in association with immune-mediated haemolytic anaemia (Tyler *et al.*, 1991) and SLE (Gabbert, 1983). A diagnosis of primary immune-mediated thrombocytopenia can only be made once all potential underlying causes have been excluded (Table 9.19) and there has been a response to sustained immunosuppressive therapy (Tasker *et al.*, 1999b).

Management of immune-mediated thrombocytopenia

Immunosuppressive agents

All potential underlying causes (Table 9.19) should be ruled out or treated before the use of immunosuppressive agents. Immunosuppressive therapy is reserved for cases where no underlying cause can be identified or when the presence of antibodies directed against platelets or bone-marrow megakaryocytes has been shown. Prednisolone at a dose of 2–4 mg/kg is usually the agent of choice. Azathioprine at a dose of 0.3 mg/kg p.o. daily has been used in patients refractory to prednisolone alone, although appropriate preparations may have to be made up by a pharmacist on an individual basis, and idiosyncratic myelosuppression and hepatotoxicity can occur. One report showed a dramatic increase in platelet numbers following substitution of prednisolone with dexamethasone at a dose of 0.64 mg/kg p.o. daily, used in combination with azathioprine (Tasker *et al.*, 1999b). Once a normal platelet count has been obtained, immunosuppressive agents are gradually tapered and the platelet count is monitored at regular intervals.

Table 9.19 Causes of thrombocytopenia in cats

	Causes	Diagnostic tests
Secondary	FeLV/FIV	FeLV/FIV testing
	Ehrlichia canis or *Risticii morulae*	Serology
	Neoplasia	Survey radiographs; abdominal and cardiac ultrasound
	Bone-marrow disease	Bone-marrow aspirate and core
	Drug associated	History of drug exposure 10 days before onset of thrombocytopenia
Primary	Autoimmune	Rule out all secondary causes; demonstrate antiplatelet antibodies or antibodies on megakaryocytes; response to immunosuppressive therapy

FeLV: feline leukaemia virus; FIV: feline immunodeficiency virus.

Vincristine

Vincristine has been used to increase megakaryocyte platelet release. Although there is no established dose for this purpose in the cat, 0.5 mg/m^2 or 0.025 mg/kg given by intravenous injection is unlikely to result in any toxicity (see also Chapter 3). If, however, platelet destruction has not been halted before vincristine administration, the increase in platelet release may have no significant effect on platelet numbers in the long term.

Platelet-rich plasma or whole blood

Administration of whole blood or platelet-rich plasma (PRP) rarely results in a significant increase in platelet numbers unless multiple units of PRP are given. Whole blood is indicated if there is concurrent anaemia due to blood loss or immune-mediated haemolytic anaemia. This is discussed in the section on transfusion medicine.

Thrombocytopathy

Thrombocytopathy results in inadequate platelet function. Platelet numbers may be normal or even increased, but the patient exhibits clinical signs of inadequate primary haemostasis. Many drugs have been suggested to interfere with platelet function; however, thrombocytopathy associated with drug administration is poorly documented except in the case of non-steroidal anti-inflammatory drugs (NSAIDs). Hyperthyroid cats have large platelets compared with euthyroid cats on smear examination, but an associated thrombocytopathy has not been documented (Sullivan *et al.*, 1993). The causes of thrombocytopathies in cats are summarised in Table 9.20.

Von Willebrand's disease

Von Willebrand's disease has rarely been reported in the cat (Thomas, 1996). It is associated with subnormal factor VII concentrations, which cause prolongation of APTT and an absence of von Willebrand's factor (French *et al.*, 1987).

Thrombocytosis

The platelet count may increase transiently following haemorrhage or resolution of any thrombocytopenia (rebound thrombocytosis). The presence of large platelets generally indicates increased bone-marrow release of shift (immature) platelets. Reactive thrombocytosis may also be seen due to non-specific stimulation of thrombopoiesis associated with increased concentrations of stimulatory cytokines in a variety of inflammatory, infectious and neoplastic conditions. This physiological response must be differentiated from rare essential thrombocythaemia (neoplastic platelet proliferation) (Evans *et al.*, 1982; Hammer *et al.*, 1990).

Vascular disorders

Cutaneous asthenia (Ehlers–Danlos syndrome)

This syndrome has been reported in Persian, Himalayan and domestic shorthaired cats. Bleeding occurs as a result of defective collagen synthesis, but is rarely the predominant clinical sign.

Vasculitis

Vasculitis, present in cats with FIP, may precipitate coagulation abnormalities by causing DIC.

Table 9.20 Causes of thyrombocytopathies in cats

	Causes	Mechanism
Hereditary	von Willebrand factor deficiency	Platelets fail to adhere to vessel, causing failure of primary platelet plug
	Chédiak–Higashi syndrome	Deficiency of the constituents of platelet storage granules
	Poorly characterised thrombocytopathy	Secretion or signal transduction disorder (Callan *et al*., 2000)
Acquired	Uraemia	Inhibition of platelet aggregation
	Hepatic disease	Multiple mechanisms: platelet dysfunction due to accumulation of FDPs, alteration in membrane lipids, persistence of aged platelets, all leading to reduced aggregation
	Non-steroidal anti-inflammatory drugs	Inhibition of thromboxane A_2 formation, causing inhibition of platelet adhesion
	Disseminated intravascular coagulation	Platelet dysfunction due to accumulation of FDPs
	Myeloproliferative disorders	Defective adhesion and aggregation
	Dysproteinaemia	Interferes with platelet adhesion, aggregation and platelet factor 3 exposure
	Immune-mediated thrombocytopenia	Antiplatelet antibody-associated interference with function
	Ehrlichiosis	Decreased adhesion, aggregation, hyperproteinaemia (*Ehrlichia* species dependent)
	Drug associated	Aspirin: cyclo-oxygenase inhibition and prevention of formation of thromboxane A_2. Potentially many others by other mechanisms

FDP: fibrin degradation product.

Clotting factor disorders

Congenital clotting factor deficiencies

Haemophilia (A and B)

Haemophilia A and B are caused by hereditary deficiencies of factors VIII and IX, respectively. Haemophilia B is also known as Christmas disease. They are both inherited via a sex-linked recessive gene. The condition is most common in male cats as the majority of females will only be carriers of the defect (unless they are homozygous for the haemophilia gene). Affected cats will have prolongation of the APTT; however, carriers of haemophilia A or B will not be detected by the APTT as factors are only reduced to 40–60% of normal in these animals (Tvedten, 1994b). Both haemophilia A and B have been reported in domestic mixed-breed cats (Brooks & Dodds, 1989; Baldwin & Cowell, 1997). Haemophilia B has also been reported in British shorthaired and Siamese cats (Maggio-Price & Dodds, 1993; Baldwin & Cowell, 1997). Haemophilia B has also been reported in association with Hageman factor deficiency (Dillon & Boudreaux, 1988) and with a contact activation defect (Littlewood & Evans, 1990).

Hageman factor (XII) deficiency

Hageman factor deficiency is the most common coagulation disorder in domestic shorthaired cats. The disorder is inherited by an autosomal recessive mechanism and affected cats have extreme prolongation of APTT and ACT. Affected cats do not haemorrhage despite this defect and the abnormality is usually detected on routine coagulation screening.

Vitamin K-dependent multifactor coagulopathy

A multifactor coagulopathy has been reported in Devon Rex cats, which is thought to be inherited by an autosomal recessive gene. Both PT and APTT are prolonged owing to a failure of activation of vitamin-K dependent factors (Maddison *et al*., 1990; Littlewood *et al*., 1995). There are no reports of the use of the PIVKA test in these patients.

Factor X deficiency

Factor X deficiency has been reported in a single cat (Gookin *et al*., 1997). Both PT and APTT are prolonged.

Acquired clotting factor deficiencies

Vitamin K antagonists (coumarin, warfarin)

Vitamin K antagonists are used in rat poisons. They interfere with the enzyme responsible for returning vitamin K to an active form (vitamin K epoxide reductase), thereby causing a functional vitamin K deficiency. This results in deficiency of factors II, VII, IX and X. Since factor VII has the shortest half-life, prolongation of the PT is usually the first coagulation abnormality detected. The PIVKA test may be more sensitive in the early stages of vitamin K antagonism.

Hepatic disease

Coagulation abnormalities appear to be common in cats with hepatic disease (Lisciandro *et al.*, 1998; Thomas & Green, 1998; Center *et al.*, 2000). Forty-five per cent of cats with hepatic lipidosis have abnormal results on one or more tests in a coagulation profile, although few show clinical bleeding tendencies (Center *et al.*, 1993). Prolongation of PT or APTT and PT are the most common abnormalities reported (Center *et al.*, 1993; Thomas & Green, 1998); however, PIVKA tests may prove more sensitive at detecting coagulation abnormalities (Center *et al.*, 2000). The abnormalities in hepatic disease are usually attributable to vitamin K deficiency (associated with a failure to absorb vitamin K); however, failure of hepatic synthesis of clotting factors, and DIC are involved in some cats with hepatic disease. Coagulation abnormalities may be more likely in cats with marked increases in alkaline phosphatase activity (Lisciandro *et al.*, 1998).

Other diseases

Malabsorption and maldigestion (due to severe inflammatory bowel disease or exocrine pancreatic insufficiency) can result in coagulation abnormalities owing to failure of uptake of fat-soluble vitamin K (Edwards & Russell, 1987; Perry *et al.*, 1991; Center *et al.*, 2000). PIVKA tests may be the most sensitive method of detecting these abnormalities (Center *et al.*, 2000), which appear to respond to parenteral vitamin K administration. FIV infection has been associated with an unexplained defect in the intrinsic pathway (Hart & Nolte, 1994).

Neoplasia can also result in coagulation abnormalities via release of heparin (mast cell tumours) (Rogers, 1992) or inhibition of fibrin clot formation (Rogers, 1992; Thomas & Green, 1998). Other causes of coagulation abnormalities include snakebites (Peterson *et al.*, 1995), production of circulating inhibitors, phenobarbitone administration (via decreased activities of factors II and VII) (Feldman *et al.*, 1983) and heparin therapy for thrombotic disease.

Management of coagulation disorders

Restrict activity

Since primary clot formation remains intact, rebleeding will be the major problem in patients with coagulation disorders. It is therefore vital that activity is restricted and trauma is minimised.

Vitamin K therapy

Treatment with vitamin K_1 is indicated in any patient where ingestion of anticoagulant rodenticides is suspected or known to have occurred (Table 9.21). Vitamin K_1 administration is also indicated in cats with hepatic disease or other diseases thought to impair vitamin K absorption (see above). Vitamin K_1 should be administered by subcutaneous injection at a dose of 0.5 mg/kg every 12 h for 3 days. Devon Rex vitamin K-dependent multifactor coagulopathy can be treated with oral vitamin K administration at a dose of 5 mg/kg daily, but may require parenteral vitamin K_1 during initial management.

Blood transfusion

Transfusion of fresh-frozen plasma or whole blood is indicated in patients with severe depletion of coagulation factors. Since factors remain active for only a few hours it is vital that plasma is harvested and frozen as soon as possible after collection. Once frozen, plasma can be stored for up to 6 months without deterioration of clotting factors. This is discussed in greater detail in the section on blood transfusion.

Disseminated intravascular coagulation

DIC is a disorder characterised by widespread activation of the coagulation cascade resulting in thrombosis of microvasculature. Patients develop widespread haemorrhagic disease due to a consumptive coagulopathy (Slappendel, 1988). A diagnosis of DIC is usually made by the identification of three or more haemostatic abnormalities on a clotting profile (depleted fibrinogen, prolongation of APTT and

Table 9.21 Treatment of anticoagulant toxicity in cats

Toxin ingested	Initial vitamin K_1 therapy	Follow-up oral therapy
Warfarin or other first generation coumarin	2.5 mg/kg by s.c. injection (several sites)	0.25–2.5 mg/kg divided every 8–12 h for 5–7 days
Second generation coumarins or inandione	5 mg/kg by s.c. injection (several sites)	5 mg/kg divided every 8–12 h for 2 weeks Re-evaluate coagulation at end of treatment and 3 weeks after treatment withdrawn
Unknown anticoagulant	2.5 mg/kg by s.c. injection (several sites)	2.5 mg/kg divided every 8–12 h for 7 days Re-evaluate coagulation at 2 days after treatment withdrawn If PT normal retest after further 2 days and again 1 week after therapy withdrawn If PT prolonged continue therapy for further 2 weeks

PT: prothrombin time.

thrombocytopenia) (Feldman *et al.*, 1981; Peterson *et al.*, 1995). In cats, DIC is most commonly associated with hepatic disease, neoplasia or infectious diseases such as FIP (Peterson *et al.*, 1995; Thomas & Green, 1998), although it may also be associated with trauma, cardiac disease or toxicity (Thomas & Green, 1998).

Management

The most important factor in the treatment of DIC is prompt treatment of the underlying cause, to remove the procoagulant stimulus. Secondary hypovolaemia, hypoxaemia, endotoxaemia and acidaemia will also contribute to the development of DIC, so aggressive supportive therapy is required as indicated on an individual basis. As thrombosis is more likely to be life-threatening than haemorrhage in patients with DIC, heparin or low molecular weight heparin analogues are the mainstay of therapy. However, heparin may worsen haemorrhage where there is factor depletion. Conversely, factor replacement using plasma or whole blood may potentiate thrombosis and the generation of FDPs. If fulminant DIC or haemorrhage is present then factor replacement is probably necessary, and should ideally be given simultaneously with heparin. This is not without risk, as rapid degradation of fibrinogen in whole blood or plasma occurs, generating FDPs, which may further exacerbate haemorrhage, and the formation of fibrin thrombi may further compromise the microvascular circulation. Antithrombin III is not currently available for veterinary use, but is widely used instead of plasma or whole blood in human medicine as it avoids these complications.

Thrombosis

Pathophysiology

Thrombosis occurs when there is a disturbance to the normal balance between fibrin formation and degradation. This can be caused by alterations in the vessel wall, blood flow or the composition of the blood. Damage to a thrombus through turbulent blood flow can result in thromboembolic disease.

Vascular defects

Damage to vessel walls through venipuncture, intravenous catheter placement, vasculitis or neoplastic invasion results in exposure of subendothelial collagen. This predisposes to fibrin formation and eventual thrombosis.

Alterations in blood flow

Reductions in blood flow can precipitate fibrin formation. Atrial enlargement results in a dramatic reduction in blood flow and sludging. This explains why cats with cardiac disease are prone to atrial thrombus formation and thromboembolism (see Chapter 19). Obstruction to flow due to the presence of foreign bodies, neoplasms or aneurysms will produce a similar effect.

Alterations in anticoagulant factors

In humans congenital deficiencies of the quantity or function of inhibitory factors are responsible for the majority of thrombotic disease. Congenital deficiencies

Table 9.22 Important anticoagulant factors in the cat

Factor	Site of synthesis	Mechanism
Protein C	Liver (vitamin K dependent)	Activated by thrombin bound to thrombomodulin. Activated protein C inactivates membrane-bound Va and VIIIa and encourages fibrinolysis
Protein S	Liver and megakaryocytes (vitamin K dependent)	Enhances actions of protein C
Antithrombin III	Liver and endothelial cells	Inactivates IIa, IXa, Xa, XIa and XIIa. Heparin binding is required to make this effect physiologically relevant
Heparin cofactor II		Thrombin inhibitor, action accelerated by heparin

have not been reported in veterinary patients. Deficiencies in cats are usually due to consumption (DIC) or excessive loss in protein-losing nephropathies and enteropathies. The important anticoagulant factors in the cat are summarised in Table 9.22.

Treatment

Treatment of thromboembolic disease is discussed in Chapter 19.

Transfusion medicine

Blood groups in cats

One blood group system with three types (A, B and AB) has been identified in the cat (Auer & Bell, 1981). The frequency of type B cats varies dramatically in different breeds (Table 9.23). Even within the non-pedigreed domestic shorthair and domestic longhair populations, the frequency of type B cats varies markedly with geographical location (Table 9.24). Type AB cats are rare (Auer & Bell, 1981; Giger *et al.*, 1991a, b; Griot-Wenk *et al.*, 1996; Knottenbelt *et al.*, 1999a).

Inheritance of blood types

The type A allele is completely dominant over the type B allele. Therefore, cats with phenotype A may have the genotype A/A or A/B, whereas only cats homozygous for the B allele express significant amounts of the type B erythrocyte antigen (Giger *et al.*, 1991a) and none of the type A antigen. Type AB is separately inherited in the feline blood group system since type AB cats are rarely the offspring of matings between type A and type B cats (Griot-Wenk *et al.*, 1996). Griot-Wenk *et al.* (1996) therefore suggested that a second mechanism of inheritance may be involved in production of the type AB phenotype. The AB allele appears to be recessive to the A allele, but dominant over the B allele (Griot-Wenk *et al.*, 1996). Type AB cats are only found in breeds in which type B cats have been identified (Griot-Wenk *et al.*, 1996).

Blood group antigens

Auer and Bell (1981) demonstrated that feline type A and type B antigens are expressed by foetal erythrocytes before 38 days of gestation. Cats with type A blood express both the type A and B antigens in varying proportions, the variability perhaps being due to the homozygous or heterozygous nature of cats with type A blood (Griot-Wenk *et al.*, 1993). Cats with type B blood however, express no type A antigen. Type B erythrocytes are therefore characterised by the presence of type B and a lack of detectable type A antigen (Andrews *et al.*, 1992).

Type AB blood shows coexpression of both type A and type B antigens (Andrews *et al.*, 1992; Griot-Wenk *et al.*, 1996). The proportions of each antigen vary between different type AB individuals (Andrews *et al.*, 1992) and intermediate forms have been recovered from type AB red cells (Griot-Wenk *et al.*, 1996). No cats without either type A or B red cell antigens (analogous to the human blood group O) have as yet been reported.

Alloantibodies

Naturally occurring antibodies against foreign blood types in the cat are clinically important as they are responsible for the premature destruction of transfused red cells, potentially fatal transfusion reactions and neonatal isoerythrolysis.

All type B cats possess high-titred, naturally occurring alloantibodies against type A antigens. Low-titred

Table 9.23 Frequency of feline blood types in different breeds

Breed	Country	*n*	Type A (%)	Type B (%)	Type AB (%)
Abyssinian	USA	194	79.9	20.1	
American shorthair	USA	15	100.0		
Birman	USA	216	82.4	17.6	
	UK	24	62.5	29.2	8.3
British shorthair	USA	85	41.2	58.8	
	UK	121	39.7	58.7	1.6
Burmese	USA	25	100.0		
	UK	10	90.0	10.0	
Devon Rex	USA	100	57.0	43.0	
Himalayan	USA	35	80.0	20.0	
Norwegian forest	USA	20	100.0		
Oriental shorthair	USA	15	100.0		
Persian	USA	170	75.9	24.1	
	UK	88.2	11.8		
	Italy	38	97.4	2.6	
	Germany	25	84.0	16.0	
Scottish fold	USA	27	85.2	14.8	
Siamese	USA	99	100.0		
Somali	USA	27	77.8	22.2	
Tonkinese	USA	31	100.0		

Data from Von Haarer and Grunbaum (1990), Giger *et al*. (1991a,b), Continenza *et al*. (1992) and Knottenbelt *et al*. (1999a).
n: number of cats tested; %: percentage of cats.

Table 9.24 Frequency of blood types in domestic shorthaired and longhaired cats worldwide

Country	*n*	Type A (%)	Type B (%)	Type AB (%)
Australia	1895	73.3	26.3	0.4
Austria	101	97	3	0
England	477	97.1	2.9	0
Finland	61	100	0	0
France	350	85.1	14.9	0
Germany	600	94.0	6.0	0
Holland	95	95.8	3.1	1.1
Italy	401	88.8	11.2	0
Japan	265	89.3	1.0	9.7
Scotland and northern England	139	87.1	7.9	5.0
Switzerland	1018	99.6	0.4	0
USA	1072	99.7	0.3	0

Data from Auer and Bell (1981), Giger *et al*. (1989, 1991a,b, 1992) and Knottenbelt *et al*. (1999a).
n: number of cats tested; %: percentage of cats.

anti-B antibodies are detectable in many, but not all, type A cats (Auer & Bell, 1981; Giger *et al*., 1989; Bucheler & Giger, 1993; Knottenbelt *et al*., 1999b). The presence of the type B antigen in variable proportions on type A cells (Griot-Wenk *et al*., 1993) may account for this variation.

The naturally occurring anti-B antibodies of type A cats are weak IgM agglutinins and weak haemolysins comprising equal proportions of IgM and IgG (Bucheler & Giger, 1993). Type B cat alloantibodies appear to be strong anti-A haemolysins and haemagglutinins predominantly of the IgM class (Wilkerson

et al., 1991b; Bucheler & Giger, 1993), although some isoagglutinating activity has also been associated with IgG (Wilkerson *et al.*, 1991a).

Main indications for blood transfusions

Blood transfusion will stabilise an anaemic patient; however, the most benefit is seen when cats with blood loss or non-regenerative anaemias are transfused. Transfused red blood cells should have a normal lifespan (70 days) in cats with non-regenerative anaemia, but may be rapidly destroyed in patients with haemolytic anaemia. Blood should, however, be administered to cats with haemolytic anaemia if clinical signs associated with the anaemia are severe, as the cat may die before the haemolytic process can be controlled with appropriate therapy. Fresh plasma or fresh-frozen plasma contains clotting factors, which are beneficial to cats with congenital or acquired coagulopathies.

The clinical condition of the patient is the single most important factor in determining the need for transfusion. Clinical compromise such as weakness, dyspnoea and ataxia in an anaemic patient necessitates a transfusion. Cats often show few signs of anaemia until their PCV falls below 10–15% and will tolerate a low PCV for a number of days provided they remain unstressed (Knottenbelt & Mackin, 1998b). Transfusion is therefore indicated if the PCV is less than 10%, the PCV has fallen rapidly to less than 15% or the bone-marrow response is minimal (Knottenbelt & Mackin, 1998b). Samples for all diagnostic tests (such as blood smears, FeLV/FIV testing, Coombs' test and blood typing) should be collected before blood is administered.

The volume of blood to be transfused is calculated using the following equation (Pichler & Turnwald, 1985):

$$66 \times \text{Weight (kg)} \times \frac{(\text{Required PCV} - \text{Recipient PCV})}{\text{PCV of donated blood}}$$

The aim of transfusion should be to increase the PCV sufficiently to minimise clinical signs of the anaemia, while not inhibiting the normal mechanisms for stimulating red cell production. In cats it is usual to aim for a post-transfusion PCV of 18–20% (Knottenbelt & Mackin, 1998b). Even a small increase in the recipient PCV will often alleviate a life-threatening crisis.

Donor selection and safety

Donor cats should be clinically healthy, fully vaccinated indoor cats with a lean body weight of 4 kg or more. Blood volume is approximately 66 ml/kg lean body weight in cats (Turnwald & Pichler, 1985; Boothe, 1990). Therefore, a 4 kg cat can donate up to 50 ml of blood (i.e. no more than 20% of blood volume) provided fluid therapy is administered (Hartmann's or normal saline 100–150 ml to be administered over 1 h). Donors should be regularly tested for FeLV, FIV and *H. felis* to reduce the risk of disease transmission. To maximise the benefit to the recipient and to minimise the risk of making the donor anaemic, blood should only be collected from donors with a PCV of >35% or in the top half of the normal range. Donors should be identified and blood typed in advance of requirement, thereby ensuring that donors of all types are available. Blood can be collected from a donor every 4–6 weeks, provided the donor's PCV is routinely checked before each blood collection.

Donor recipient matching

The transfusion of type A or AB blood to type B cats can result in a fatal reaction which can occur with as little as 1 ml of incompatible blood. The transfusion of incompatible blood to type A cats results in a mild, subclinical reaction but a dramatic reduction in red cell lifespan (Callan & Giger, 1994). Type AB cats should be transfused with type AB blood when possible. If no type AB donors can be identified type A blood can be given. Type B blood should not be used unless the red cells are separated from the plasma before transfusion, as high titres of anti-A antibody in type B donated blood can result in the destruction of recipient red cells. Administration of a compatible blood transfusion should increase the PCV for up to 4 weeks.

Cross-matching

Cross-matching does not rule out minor incompatibilities, and may fail to type accurately cats that do not possess alloantibodies. Cross-matching should always be performed if blood typing is not available and on any occasion when a donor requires a second transfusion.

Blood typing

Desk-top blood-typing kits providing a rapid and reliable typing result are available. Autoagglutination should be ruled out before typing.

Collection and storage of blood

Blood should always be collected from the jugular vein to avoid the slow flow rates associated with peripheral veins (Plate 9.9). Most cats require a sedation combination such as ketamine and midazolam or diazepam before blood collection (acepromazine and medetomidine should not be used) (Knottenbelt & Mackin, 1998a). Feline blood is usually collected into a 60 ml syringe containing anticoagulant (citrate phosphate dextrose or heparin) and can then be transferred into a blood bag for storage or administration. Blood collected into citrate phosphate dextrose can be stored for up to 4 weeks at 4–5℃ (Wardrop, 1995). Heparinised blood must be used immediately.

Blood administration

Blood should be given via intravenous catheter into the cephalic or jugular vein. If the patient is severely hypotensive or a kitten, the proximal femur provides the best alternative (since uptake from bone marrow is very efficient). Intraperitoneal administration of blood achieves only a 40% extraction of blood and should therefore be done only when no other route is available (Turnwald & Pichler, 1985). Administration of blood through a filtered blood product giving set minimises the risk of microthrombi entering the circulation. Stored blood must be administered through a blood product giving set as cellular aggregates and microthrombi can lead to pulmonary capillary damage and pulmonary oedema. Stored blood must be gently warmed to reduce blood viscosity, prevent patient chilling and minimise vasoconstriction. The rate of blood administration should be adjusted according to the patient's condition (Table 9.25).

Table 9.25 Recommended blood transfusion rates for cats

Patient category	Blood flow rate (ml/kg per hour)
Hypovolaemic	20
Normovolaemic	5–10
Cardiovascular dysfunction	2
Renal failure	2

Transfusion reactions

All patients receiving blood or blood products should be monitored during the transfusion period. Clinical signs of a transfusion reaction include vocalisation, vomiting, pruritus, depression, dyspnoea, tachypnoea or coughing, tachycardia or bradycardia, and tremors or convulsions. If the reaction is severe the cat may show signs of anaphylactic shock and may develop cardiopulmonary arrest. Anorexia and jaundice may be seen in more chronic transfusion reactions.

Haemolysis

Type A cats that are given type B blood will sometimes develop a mild transfusion reaction that may not be apparent clinically; however, the recipient's PCV will typically fall to pretransfusion levels within days of the transfusion (Giger & Bucheler, 1991). Type B cats that are transfused with type A blood invariably develop rapid and often fatal transfusion reactions following even a single transfusion of very small volumes of blood (Auer & Bell, 1981). Bacterial contamination, overheating or freezing of the blood bag or syringe can result in a similar transfusion reaction owing to red cell haemolysis occurring before transfusion.

If a haemolytic transfusion reaction is suspected the transfusion should be stopped and crystalloids administered. The cat should be monitored for evidence of shock or disseminated intravascular coagulation, haemaglobinaemia and haemaglobinuria. Shock therapy in the form of intravenous corticosteroids and aggressive fluid therapy should be given if required. Oxygen supplementation, antihistamines and adrenaline may also be required. Once the patient is stable the cause of haemolysis can be determined by ensuring that matched blood was administered, checking that typing or cross-matching results are correct, and checking that the remaining blood has not haemolysed within the syringe or blood bag.

Pyrexia

An increase in body temperature of 1℃ or more within 4 h of transfusion is common (Turnwald & Pichler, 1985). Pyrexia can be caused by bacterial contamination of blood, or an acute reaction caused by antibodies to platelets, WBCs or plasma proteins. These antibodies cannot be detected by cross-matching or blood typing red cells. If pyrexia is recorded haemolysis should be ruled out and the bag assessed for bacterial contamination. Pyrexia is, however, usually transient and is rarely associated with bacterial infections or haemolysis.

Bacterial contamination of blood bag

Bacterial contamination of blood before administration can occur during collection and storage. Refrigeration does not eliminate bacteria, which will start to multiply when blood is warmed. Transfusion of contaminated blood will cause the patient to become pyrexic within 15 min. Other signs such as shock, abdominal pain, vomiting and diarrhoea may also occur. Antibiotics and supportive therapy should be administered. Confirmation of bacterial contamination can be obtained by examining the blood bag for haemolysis and submitting blood for bacterial culture and sensitivity.

Hypocalcaemia

Citrate anticoagulant chelates calcium and can cause hypocalcaemia when large volumes are administered rapidly (Turnwald & Pichler, 1985). This is rarely a problem unless inappropriate volumes of anticoagulant are used or when citrate metabolism is impaired (e.g. severe liver disease). Hypocalcaemia is associated with ear twitching, vocalisation, tremors, vomiting and cardiac arrhythmia.

Vomiting

Vomiting is commonly associated with rapid administration of blood or feeding around the time of transfusion. It can occur during blood administration or soon afterwards. The transfusion should be stopped for a minimum of 15 min and other causes of transfusion reactions excluded. The transfusion can usually be continued at a slower rate without further adverse effects. Cats should not be fed before or during transfusion administration.

Circulatory overload

Circulatory overload is a common complication associated with rapid administration of whole blood (Turnwald & Pichler, 1985), and can result in pulmonary oedema (tachypnoea, dyspnoea and coughing) and tachycardia. If this occurs, the transfusion must be stopped. Frusemide and oxygen may be required to control the symptoms. Blood should always be administered at a flow rate appropriate for the clinical condition of the patient.

Infectious diseases

The risk of transmission of infectious disease can be minimised by using indoor cats tested for FeLV, FIV and *H. felis*. This risk can never be eliminated completely.

Haemoglobin-based oxygen-carrying fluids

Oxyglobin® is a bovine haemoglobin product containing polymerised bovine haemoglobin tetramers (bovine haemoglobin glutamer-200). Oxyglobin is potentially indicated in situations where an increase in oxygen-carrying capacity is urgently required and whole blood or packed red cells are unavailable or contraindicated. Oxyglobin is a colloid and will expand plasma volume, so has also been recommended for hypovolaemic shock. However, its use in cats is currently controversial.

There are limited data on the use of Oxyglobin in cats and the product is currently not licensed for use in this species. There are many anecdotal reports of cats receiving Oxyglobin and although some are favourable, there are also several reports of acute-onset respiratory distress soon after administration of Oxyglobin had begun, which was fatal in some cats. A recent study reported adverse effects in 44 of 72 cats receiving the solution, with 35% of cats developing pulmonary oedema or pleural effusion (Gibson *et al.*, 2002). As yet, the pathophysiology of this reaction has not been elucidated. Administration of Oxyglobin results in increased central venous pressure, which can produce pulmonary oedema, although this does not appear to be the only mechanism involved. Oxyglobin should therefore be used with extreme caution, especially in cases with pre-existing cardiac disease, and following the informed written consent of the patient's owner. It is also contraindicated where there is renal failure, oliguria or anuria.

In other species, the vasoactive effects of free haemoglobin increase mean arterial and pulmonary artery pressures, resulting in increased vascular resistance, reduced cardiac output and disappointing oxygen delivery to tissues (Meyer, 2001). This may limit the beneficial effects of administration in animals with acute haemorrhagic hypovolaemic shock.

Lymphoproliferative disease

Lymphoproliferative diseases include lymphoma, lymphoid leukaemia and myeloma. Lymphoid neoplasia accounts for up to 25% of feline tumours, and lymphoma is the most common form of lymphoproliferative disease. Lymphoma is a solid tumour which

arises in the peripheral lymphoid tissue (Plate 9.10), whereas in leukaemia the neoplastic transformation occurs in the bone marrow. Myeloma is a tumour of plasma cells, most often associated with the production of paraproteins.

Lymphoma

Lymphoma (lymphosarcoma) is discussed in many sections throughout this book; what follows is a brief overview.

Cats of any age or breed may be affected by lymphoma. Multicentric disease is less common in the cat than the dog, affects cats of all ages and is often regional in distribution. Cranial mediastinal (thymic) lymphoma is common in younger cats, while the alimentary and extranodal forms affect predominantly middle-aged to older cats. Extranodal forms such as renal, spinal, nasal or ocular lymphoma are also more common in the cat than the dog, although cutaneous lymphoma is less common. Reports vary as to which anatomical form is most common overall. Recent data suggest that, in the USA, the alimentary form is now the most common (Mauldin *et al.*, 1995; Vail *et al.*, 1998). This may reflect a reduction in the number of FeLV-associated lymphomas in other sites as a consequence of widespread FeLV vaccination.

Retroviruses have an important role to play in lymphoid tumorigenesis, and this is discussed in Chapter 23. Fewer cats now presenting with lymphoma are FeLV positive, based on p27 ELISA, than was previously reported. In some centres this appears to reflect an overall reduction in presentation of FeLV-positive cats with cranial mediastinal lymphoma, but a continued association between FeLV positivity and lymphoma in this site (Vail, 2000a). However, it is the authors' experience that most cats presenting in the UK with cranial mediastinal disease are also FeLV negative, and that far fewer cats with any form of lymphoma are FeLV positive, based on the p27 ELISA, than is historically reported. Some serologically negative cats may have been exposed to FeLV, but may have persistent retroviral elements integrated into their genome or persistent virus in the bone marrow. Polymerase chain reaction (PCR)-based techniques have identified FeLV elements in tumour tissue from ELISA-negative cats with lymphoma, and this supports the 'hit and run' theory of FeLV-related lymphomagenesis, where exposure to FeLV can initiate tumorigenesis even if persistent infection does not occur. Compared with cats not exposed to FeLV, cats that have been exposed to the virus but have recovered are five times as likely to develop lymphoma, while cats persistently infected with FeLV are 50 times as likely to develop lymphoma. Recent work in a small number of cats also supports the theory that some cats develop lymphoma independently of FeLV infection (Wang *et al.*, 2001). FIV may be important in B-cell lymphomagenesis in some cats, although this is not widely accepted.

Presentation

Primary disease

Most cats with lymphoma are systemically unwell. Cats with multicentric or regional lymphoma generally present with non-painful lymph-node enlargement and are often depressed. Mild to moderate pyrexia may be seen. Hepatosplenomegaly is less common than in the dog. Cases with cranial mediastinal disease present with depression, respiratory distress (which may be very severe), exercise intolerance, or regurgitation and dysphagia. In most cases the compressibility of the cranial thorax is reduced. Cats with alimentary lymphoma may present with either signs referable to malabsorption (weight loss, diarrhoea), anorexia, or signs of intestinal obstruction where there is a mass lesion. Colonic lymphoma tends to present with signs referable to the obstruction caused. Extranodal lymphoma produces clinical signs dependent on the site involved.

Paraneoplastic syndromes

Hypercalcaemia is uncommon in cats with lymphoma, but may be more common in cats with myeloma. Presentation due to secondary immune-mediated disease (anaemia or thrombocytopenia) is also uncommon.

Diagnosis

The diagnosis of lymphoma must be confirmed by cytological or histological evaluation.

Cytology

In the cat, aspirates from nodes are often non-diagnostic, owing to the difficulty in differentiating lymphoma from benign hyperplasia. Renal lymphoma is also difficult to diagnose on the basis of fine-needle aspirates. In these situations, biopsy is frequently required. Cytological examination of fine-needle aspirates from extranodal masses or effusions is more often diagnostic. Cytological evaluation of cerebrospinal fluid (CSF) may be of value, but many spinal lymphomas in cats are extradural (Spodnick *et al.*, 1992;

Lane *et al.*, 1994) so cells will not exfoliate into the CSF unless there is disruption of the dura.

It is especially important to choose a skilled cytologist when submitting feline samples. Cats often have many normal or reactive lymphocytes in thoracic and, to a lesser extent, abdominal effusions due to a wide variety of disease processes, so care is required in interpretation. A marked lymphocytosis with reactive cells may also be seen in CSF from patients with toxoplasmosis.

Histopathology

A complete lymph node should be submitted for histopathological evaluation, and if possible the mandibular nodes should be avoided. Where mycobacterial disease is a potential differential diagnosis, a small piece of fresh tissue from the unfixed node should be placed in a sealed universal for submission for mycobacterial culture. This can be stored or frozen and submitted should the histopathology be suggestive. Trucut biopsies of nodes should be avoided as they do not allow enough appreciation of lymph-node architecture. Alimentary and extranodal lymphoma (depending on the site) may require biopsy for diagnosis; this is especially true of renal lymphoma.

Investigation

Clinical pathology

Haematology Haematology is rarely of any value in diagnosis, as only a minority of cats with lymphoma have a leukaemic blood picture. It is, however, imperative for staging, treatment planning and monitoring while on myelosuppressive drugs. Typical findings at presentation are a non-regenerative anaemia, neutrophilia, commonly associated with lymphopenia, eosinopenia and monocytosis (Gabor *et al.*, 2000).

Biochemistry Assessment should include renal and hepatic parameters, calcium, electrolytes, albumin and globulin or total protein. Abnormalities tend to reflect specific tissue involvement. This may assist in tumour staging and identification of intercurrent diseases that affect treatment or prognosis.

FeLV/FIV testing See also Chapters 23 and 24. The virus status of the cat may affect case management (see prognostic indicators). Treatment is not contraindicated per se in FeLV antigen- or FIV antibody-positive cats: each case should be approached as an individual, the risk to other cats being taken into account.

Bone-marrow sampling Ideally, all cases should have bone-marrow samples taken to allow more accurate clinical staging. Sampling is recommended if there are any cytopenias or if there are abnormal cells in the circulation.

Immunophenotyping

Feline lymphomas may be B-cell or T-cell in origin (Jackson *et al.*, 1996; Gabor *et al.*, 1999). This is influenced by site: most cranial mediastinal tumours are T-cell lymphomas. Very small numbers of null cell tumours (which do not stain with either marker) and T-cell-rich B-cell tumours are also reported (Steele *et al.*, 1997). The latter tend to be restricted to a mandibular or cranial cervical lymph node in older cats, and represent a specific subset of low-grade lymphomas that are not retrovirus associated (Steele *et al.*, 1997; Day *et al.*, 1999). FeLV-induced tumours may be either B- or T-cell (Jackson *et al.*, 1996). FIV may have a role in B-lymphomagenesis, and it is suggested this is caused by immune dysfunction (Beatty *et al.*, 1998; Callanan *et al.*, 1996), although the mechanism is unproven and other authors have suggested that FIV may not have a direct role in lymphomagenesis (Endo *et al.*, 1997).

Diagnostic imaging

Radiography Thoracic radiography may be very suggestive of cranial mediastinal lymphoma, although cardiac disease and pyothorax can appear similar. In alimentary lymphoma, contrast studies often allow recognition of abnormalities (see Plate 9.10).

Ultrasonography Ultrasonography is especially valuable in confirming cranial mediastinal lymphoma and ruling out cardiac disease, and in the evaluation of suspected alimentary lymphoma. Examination of parenchymatous organs may show changes consistent with lymphomatous infiltrate. Ultrasonography is valuable in guiding fine-needle aspiration and biopsy of internal nodes and other organs, especially splenic, renal, hepatic and intestinal lesions.

Clinical staging

It has been suggested that clinical staging is of prognostic relevance in cats (Mooney *et al.*, 1989). However, there is a large range of survival times in each stage group and long-term survival can be achieved by animals with advanced disease. In addition, the World Health Organisation staging system

Table 9.26 World Health Organisation clinical staging system for domestic animals with lymphosarcoma

	Criteria
Stage	
I	Single lymph node
II	Multiple lymph nodes in a regional area
III	Generalised lymphadenopathy
IV	Involvement of liver and/or spleen (±III)
V	Bone marrow or blood involvement and/or involvement of any non-lymphoid organ.
Substage	
a	Without systemic clinical signs
b	With systemic clinical signs

(Table 9.26) is essentially unsuitable for clinical staging of feline lymphoma as it is designed for multicentric disease. However, clinical substages a and b are relevant: cats that have systemic clinical signs of disease at presentation have a poorer prognosis than those that present essentially asymptomatically with a mass lesion.

Prognostic indicators

In the cat, there are few proven prognostic indicators. The strongest prognostic indicator is response to therapy, which cannot be evaluated before treatment. Cats that achieve complete remission are much more likely to achieve long-term survival than those that do not respond fully, as these animals usually relapse rapidly (Zwahlen *et al.*, 1998). Inclusion of doxorubicin in the treatment protocol is thought to be associated with longer remission and survival times (see below).

Cats with substage b disease, which show systemic signs, may also carry a poorer prognosis (Vail *et al.*, 1998), while cats with shorter clinical histories may have a better prognosis (Link & Hirschberger, 2000; Vail, 2000a). FeLV-positive cats have a poorer prognosis overall owing to the risk of other FeLV-related disease. It is unclear whether these cats respond less well to chemotherapy than FeLV-negative cats; some studies report shorter remission and survival (Mooney *et al.*, 1989; Vail *et al.*, 1998), whereas other studies, in alimentary lymphoma, found no difference (Mahony *et al.*, 1995). Animals with lymphoma and FIV are likely to have a poorer prognosis owing to the direct effects of infection on marrow, intercurrent disease and reduced tolerance to chemotherapy, but this has not been documented.

As yet, no difference in prognosis between T- and B-cell lymphoma has been demonstrated in cats. However, the diversity of feline lymphoma (histological type, anatomical site, retroviral association) may mean that other variables are masking significant differences in some subsets of lymphoma. Proliferative indicators such as argyrophilic nucleolar organiser regions are not of prognostic value in the cat (Rassnick *et al.*, 1999).

In alimentary lymphoma, tumours that are lymphocytic rather than lymphoblastic may respond more favourably to chemotherapy, even with a regimen containing only prednisolone and chlorambucil (Fondacaro *et al.*, 1999). It is important that these cases are differentiated from lymphocytic–plasmacytic enteritis.

Treatment

Cats that receive no therapy have median survival times of approximately 4 weeks. Overall, with combination chemotherapy, reported median remission and survival times are as short as 4 and 6 months, respectively (Vail, 2000b). This is affected by the relatively low rate of complete remission in cats (50–70%). However, a significant proportion of cats that do achieve complete remission experience a durable remission and prolonged survival (more than 2 years).

Surgery/radiotherapy

In cases where lymphoma is apparently restricted to a single site, surgical excision or local radiotherapy may be carried out. However, it should always be remembered that lymphoma has a propensity to affect multiple sites, and in the vast majority of cases follow-up chemotherapy should be considered. For example, radiation therapy alone has been recommended for the treatment of nasal and retrobulbar tumours, but has been associated with progression to involve the kidneys (Morris *et al.*, 1996), and most cats with central nervous system (CNS) lymphoma have lymphoma in other sites (Spodnick *et al.*, 1992; Lane *et al.*, 1994). Radiation therapy may be of benefit in rescue therapy for localised disease.

Standard chemotherapeutic regimens

A detailed discussion of these regimens, including drug dosage calculations, adverse effects and safe handling, is given in Chapter 3.

There is a great deal of apprehension about treating cats with cytotoxic drugs. While it is undoubtedly true that more individual adjustments are required for feline patients, in general most cats tolerate chemotherapy well. Most standard chemotherapeutic regimens

involve a relatively intense induction protocol, then a less intense maintenance protocol. Maintenance is thought to be necessary in veterinary oncology because the doses used are such that significant residual disease remains after induction, even when clinical remission appears complete.

The main regimens used are the vincristine, cyclophosphamide and prednisolone-based COP regimens (low and high dose), and doxorubicin-containing protocols such as modified COP or Madison–Wisconsin. The role of doxorubicin in the management of feline lymphoma is controversial as the drug has been disappointing both as a single agent (Peatson & Maddison, 1999) and in rescue therapy for cats relapsing after COP therapy. However, the addition of doxorubicin may increase remission and survival times over those achieved with COP alone (Moore *et al.*, 1996; Vail *et al.*, 1998). Recent results suggest COP is an excellent protocol for cats, and achieves a higher response rate than has previously been suggested (Teske *et al.*, 2002).

Special considerations

Central nervous system/renal lymphoma

For cats with CNS lymphoma, cytosine arabinoside is recommended during induction, as this drug can cross the blood–brain barrier. Similarly, cats with renal lymphoma have an increased risk of meningeal or other CNS involvement, so it is prudent to include cytosine arabinoside in their treatment.

Alimentary lymphoma

Where there is a mass lesion that is amenable to surgery, this should be resected. In the presence of any residual disease, combination chemotherapy should also be given. Even if no other disease is detected, there is a high risk of subclinical disease elsewhere and chemotherapy should be considered. Where there is extensive intestinal infiltrate or in a postoperative setting, chemotherapy should be instigated in a staggered manner to reduce the risk of tumour lysis resulting in intestinal perforation. One method of doing this with the COP protocol is to initiate prednisolone therapy, give vincristine on day 3 and give cyclophosphamide on day 5.

Myeloma

Myeloma (multiple myeloma, plasma cell myeloma) is a tumour of B-cell origin in which neoplastic plasma cells in the marrow produce gammaglobulins. Functional, gammaglobulin-producing, extramedullary plasma cell tumours are also reported. Both types of malignancy are very rare in the cat.

Clinical signs

Cats with myeloma may present with a variety of symptoms, referable to the biological behaviour of the tumour. Bone lesions may result in pain, lameness and ultimately pathological fractures. Collapse of affected vertebrae can result in neurological signs due to cord compression (Jacobs, 1994; Bienzle *et al.*, 2000). Bone-marrow infiltration with plasma cells may result in a mild, non-regenerative anaemia and mild to moderate cytopenias. Presentation owing to the symptoms of the paraneoplastic syndromes associated with myeloma is also common.

Paraneoplastic syndromes

Hypergammaglobulinaemia

Hypergammaglobulinaemia results in hyperviscosity syndrome. IgA- and IgM-producing tumours result in more severe hyperviscosity than IgG as these are multimeric molecules. IgA- and IgG-producing tumours have been reported in cats (Hawkins *et al.*, 1986; McDonald *et al.*, 1994; Bienzle *et al.*, 2000; Hickford *et al.*, 2000). Hyperviscosity results in a myriad of clinical signs, including ocular signs (retinal detachment, haemorrhage, vessel dilatation and tortuosity), neurological signs due to poor CNS perfusion, polyuria/polydipsia secondary to poor renal perfusion and renal tubular and glomerular damage, cardiac signs, bleeding diathesis and thromboembolism.

Hypercalcaemia

Hypercalcaemia is a relatively common paraneoplastic syndrome in cats with multiple myeloma, leading to presentation with anorexia, polyuria and polydispia, renal compromise, gastrointestinal signs and other systemic signs (Sheafor *et al.*, 1996; Bienzle *et al.*, 2000).

Investigation

Haematology

Haematology may reveal a non-regenerative anaemia, and possibly mild neutropenia and thrombocytopenia. Very rarely, plasma cells may be seen in the circulation. There is often increased rouleaux formation due to hyperproteinaemia.

Biochemistry
Biochemistry usually reveals elevated globulin or total protein concentrations, accompanied by any combination of hypercalcaemia, elevated liver enzymes and azotaemia. Serum protein electrophoresis is required to confirm whether the hyperglobulinaemia is monoclonal. A monoclonal gammopathy is not pathognomonic for myeloma, and is occasionally associated with other B-cell lymphoid tumours. In addition, infectious diseases such as FIP may occasionally produce a monoclonal gammopathy.

Urinalysis
Urinalysis may reveal low specific gravity and the presence of Bence Jones proteins on specific testing (these proteins are not detected by urine dipstick analysis).

Bone-marrow aspirate
A diagnosis of myeloma can only be made on the basis of bone-marrow aspiration and biopsy, and more than one sample may have to be taken owing to regional distribution of plasma cells in the marrow. Increased numbers of morphologically normal plasma cells are seen, often clumped together.

Treatment

Melphalan and prednisolone are the mainstay of myeloma therapy (see Chapter 3). Response to chemotherapy in cats is highly variable, although long-term remission can be achieved in some cases. Radiation therapy may be of benefit in treating individual problematic or solitary bone lesions.

Leukaemia

Leukaemia is a neoplastic condition arising in the marrow as a result of neoplastic transformation of either lymphoid or myeloid haematopoietic cells and their progeny. In most but not all cases, abnormal cells are released from the bone marrow into the circulation. Leukaemias account for 15–35% of haemolymphatic neoplasms in the cat.

An extensive discussion of the role of retroviruses in feline leukaemogenesis is given in Chapter 23. Most acute leukaemias have a retroviral aetiology, but most reported cases of eosinophilic leukaemia and chronic lymphocytis leukaemia have been FeLV negative. Chemotherapy is discussed in Chapter 3. The following is a brief overview.

Acute leukaemias

Acute leukaemias are those in which the neoplastic transformation occurs at the level of the stem cell or committed blast cell, so the neoplastic cells are poorly differentiated. Proliferation is rapid and uncontrolled, with arrested or defective maturation. Poorly differentiated, functionally abnormal cells overcrowd the marrow and spill out into the circulation. The clinical course is rapid and signs are severe. Both acute lymphoblastic and acute myeloid leukaemias occur in the cat, with myeloid leukaemias predominating. This has only become apparent as morphological classification has been superseded by cytochemical staining to identify the cell of origin; without the use of special stains, many myeloid leukaemias will be falsely classified as lymphoid (Grindem *et al.*, 1985; Facklam & Kociba, 1986). In myeloid leukaemias any cell line may be affected, and mixed forms are also reported (Winter, 1980; Colbatzky & Herrmanns, 1993; Bounous *et al.*, 1994). In addition, the predominant cell type may alter during the course of the disease.

Presenting signs are acute-onset lethargy, malaise, anorexia and weakness. Neutropenia and thrombocytopenia develop rapidly, so signs referable to these cytopenias may be evident (e.g. pyrexia, sepsis, petechiation). The occasional cat presents with anaemia. Mild to moderate lymphadenopathy and hepatosplenomegaly may be seen. Hyperviscosity may occur when abnormal cells are present in vast numbers. Diagnosis is based on bone-marrow evaluation. Special stains are often required to differentiate lymphoid and myeloid leukaemia.

The prognosis for acute leukaemias is poor. Treatment in these cases is fraught with difficulty as many cytotoxic drugs exacerbate cytopenias in the short term. Death during induction is not uncommon. The reasons for treatment failure are:

- failure to induce remission due to intrinsic drug resistance
- failure to maintain remission due to rapid development of acquired drug resistance
- organ failure due to leukaemic infiltration
- fatal haemorrhage/sepsis secondary to cytopenias.

Long-term survival has, however, been reported in a few cats with lymphoblastic leukaemia treated with COP (Cotter, 1983), and short-term survival in response to low-dose cytosine arabinoside has been reported (Helfand, 1987). Cytosine has also produced a survival of approximately 4 months in a case of acute megakaryocytic leukaemia (Hamilton *et al.*,

1991). Successful allogeneic bone-marrow transplantation has been reported in a cat with acute myeloid leukaemia which was not associated with retroviral infection (Gasper *et al.*, 1996). However, the prognosis for the majority of cats with acute myeloid leukaemia remains grave.

Chronic leukaemia

In chronic leukaemia, the uncontrolled proliferation affects well-differentiated cells. Morphologically, the cells appear well differentiated but may be functionally abnormal. These conditions have a more insidious onset and a protracted progression of less severe clinical signs. Unfortunately, chronic lymphoid and myeloid leukaemia is much less common in the cat than acute leukaemia.

CLL has been reported in seven cats (Holzworth, 1960; Thrall, 1981; Facklam & Kociba, 1986; Cotter & Holzworth, 1987; Couto, 1988). Most cats were FeLV negative. The condition is characterised by high lymphocyte count consisting mostly of morphologically mature lymphocytes in both blood and bone marrow without significant neutropenia or thrombocytopenia. Diagnosis is confirmed by finding that more than 30% of marrow nucleated cells are lymphocytes and ideally clonality should be confirmed. Clonality is determined by demonstrating identical gene rearrangements within the suspected neoplastic cell population using molecular biology techniques such as PCR (Helfand & Modiano, 2000).

Treatments for CLL in cats have included chlorambucil, melphalan, prednisolone and vincristine, either in combination or alone. Survival times of up to 4 years have been reported in cats treated with alkylating agents and prednisolone; chorambucil and prednisolone are recommended.

Hypereosinophilic syndrome, eosinophilic leukaemia and polycythaemia are chronic leukaemias or myeloproliferative diseases and are discussed above. Definitive diagnostic criteria for chronic myeloid leukaemias in cats are currently lacking. It is suggested that myeloid leukaemia can be differentiated from myelodysplastic syndromes by the lack of bone-marrow dysplasia and the presence of profound, predominantly mature leucocytosis. There are no reports on the treatment of chronic granulocytic leukaemia in the cat.

References

Andrews G.A., Chavey P.S., Smith J.E. & Rich L. (1992) *N*-Glycolylneuraminic acid and *N*-acetylneuraminic acid define feline blood group A and B antigens. *Blood* **79**, 2485–2491.

Andrews G.A., Chavey P.S. & Smith J.E. (1994) Enzyme-linked immunosorbent assay to measure serum ferritin and the relationship between serum ferritin and nonheme iron stores in cats. *Vet Pathol* **31**, 674–678.

Arai M., Darmen J., Lewis A. & Yamamoto J.K. (2000) The use of human haemopoietic growth factors (rhGM-CSF and rhEPO) as a supportive therapy for FIV-infected cats. *Vet Immunol Immunopathol* **77**, 71–92.

Auer L. & Bell K. (1981) The AB blood group system of cats. *Anim Blood Groups Biochem Genet* **12**, 287–297.

Auer L. & Bell K. (1983) Transfusion reactions in cats due to AB blood group incompatibility. *Res Vet Sci* **35**, 145–152.

Auer L., Bell K. & Coates S. (1982) Blood transfusion reactions in the cat. *J Am Vet Med Assoc* **180**, 729–730.

Baeufils J.P., Martin-Granell J. & Bertrand F. (1993) Severe neutropenia in a female cat treated with griseofulvin. *Pratique Medicale et Chirurgicale de L'Animal de Compagnie* **28**, 405–407.

Baldwin C.J. & Cowell R.L. (1997) Inherited coagulopathies. In *Consultations in Feline Internal Medicine*. 3rd edn (ed. August J.R.). WB Saunders, Philadelphia, PA, pp. 488–498.

Beale K.M., Altman D., Clemmons R.R. & Bolon B. (1992) Systemic toxicosis associated with azathioprine administration in domestic cats. *Am J Vet Res* **53**, 1236–1240.

Beall C.J., Phipps A.J., Mathes L.E., *et al.* (2000) Transfer of the feline erythropoietin gene to cats using a recombinant adeno-associated virus vector. *Gene Ther* **7**, 534–549.

Beatty J.A., Callanan J.J., Terry A., *et al.* (1998) Molecular and immunophenotypical characterisation of a feline immunodeficiency virus (FIV)-associated lymphoma: a direct role for FIV in B lymphocyte transformation. *J Virol* **72**, 767–771.

Bienzle D., Silverstein D.C. & Chaffin K. (2000) Multiple myeloma in cats: variable presentation with different immunoglobulin isotypes in two cats. *Vet Pathol* **37**, 364–369.

Boothe D.M. (1990) Drug therapy in cats: mechanisms and avoidance of adverse drug reactions. *J Am Vet Med Assoc* **196**, 1297–1305.

Boudreaux M.K., Weiss R.C., Cox N. & Spano J.S. (1989) Evaluation of antithrombin-III activity as a coindicator of disseminated intravascular coagulation in cats with induced feline infectious peritonitis virus infection. *Am J Vet Res* **50**, 1910–1913.

Bounous D.I., Latimer K.S., Campagnoil R.P. & Hynes P.F. (1994) Acute myeloid leukaemia with basophilic differentiation (AML, M-2B) in a cat. *Vet Clin Pathol* **23**, 15–18.

Breuer W., Hermanns W. & Thiele J. (1999) Myelodysplastic syndrome (MDS), acute myeloid leukaemia (AML) and chronic myeloproliferative disorder (CMPD) in cats. *J Comp Pathol* **121**, 203–216.

Bridle K.H. & Littlewood J.D. (1998) Tail tip necrosis in two litters of Birman kittens. *J Small Anim Pract* **39**, 88–89.

Brooks M.B. & Dodds W.J. (1989) Factor IX deficiency (haemophilia B) in two male domestic short-hair cats. *J Am Anim Hosp Assoc* **25**, 153–155.

Bucheler J. & Giger U. (1993) Alloantibodies against A and B blood types in cats. *Vet Immunol Immunopathol* **38**, 283–295.

Cain G.R. & Suzuki Y. (1985) Presumptive neonatal isoerythrolysis in cats. *J Am Vet Med Assoc* **187**, 46–48.

Callan M.B. & Giger U. (1994) Transfusion medicine. In *Consultations in Feline Medicine*. 2nd edn (ed. August J.R.). WB Saunders, Philadelphia, PA, pp. 525–532.

Callan M.B., Griot-Wenk M.E., Hackner S.G. & Giger U. (2000) Persistent thrombopathy causing bleeding in 2 domestic shorthaired cats. *J Vet Intern Med* **14**, 217–220.

Callanan J.J., Jones B.A., Irvine J., *et al.* (1996) Histologic classification and immunophenotype of lymphosarcoma in cats with naturally and experimentally acquired feline immunodeficiency virus. *Vet Pathol* **33**, 264–272.

Casal M.L., Jezyk P.F. & Giger U. (1996) Transfer of colostral antibodies from queens to their kittens. *Am J Vet Res* **57**, 1653–1658.

Center S.A., Randolph J.F., Erb H.N. & Reiter S. (1990) Eosinophilia in the cat: a retrospective study of 312 cases (1975–1986). *J Am Anim Hosp Assoc* **26**, 349–358.

Center S.A., Crawford M.A., Guida L., *et al.* (1993) A retrospective study of 77 cats with severe hepatic lipidosis: 1975–1990. *J Vet Intern Med* **7**, 349–359.

Center S.A., Warner K., Corbett J., *et al.* (2000) Proteins invoked by vitamin K absence and clotting times in clinically ill cats. *J Vet Intern Med* **14**, 292–297.

Colbatzky F. & Hermanns W. (1993) Acute megakaryoblastic leukaemia in one cat and two dogs. *Vet Pathol* **30**, 186–194.

Continenza R., Lubas G. & Gugliucci B. (1992) Indagini prelimisul sistema di gruppo sanguigno AB nel gatto allevato in Italia. *Atti Societa Italiana Scienze Veterinarie* **XLVI**, 1470–1477.

Cook S.M. & Lothrop C.D. (1994) Serum erythropoietin concentrations measured by immunoassay in normal, polycythemic and anemic dogs and cats. *J Vet Intern Med* **8**, 18–25.

Cotter S.M. (1983) Treatment of lymphoma and leukaemia with cyclophosphamide, vincristine and prednisolone. II. Treatment of cats. *J Am Anim Hosp Asso* **19**, 166–172.

Cotter S.M. (2000) Nonregenerative anemia. In *Textbook of Veterinary Internal Medicine*. 5th edn (eds Ettinger S.J. & Feldman E.C.). WB Saunders, Philadelphia, PA, pp. 1804–1816.

Cotter S.M. & Holzworth J. (1987) Disorders of the hematopoietic system. In *Diseases of the Cat*. WB Saunders, Philadelphia, PA, pp. 755–807.

Couto C.G. (1988) Oncology. In *The Cat. Diseases and Clinical Management.* 1st edn. (ed. Sherding R.G.). Churchill Livingstone, New York, pp. 589–647.

Couto C.G. & Hammer A.S. (1994) Disorders of hemostasis. In *The Cat: Diseases and Clinical Management* (ed. Sherding R.G.). Churchill Livingstone, New York, pp. 739–753.

Cowgill L.D. (1995) CVT update: use of recombinant human erythropoietin. In *Kirk's Current Veterinary Therapy.* XII. *Small Animal Practice* (eds Bonagura J.D. & Kirk R.W.). WB Saunders, Philadelphia, PA, pp. 961–962.

Cowgill L.D., James K.M., Levy J.K., *et al.* (1998) Use of recombinant human erythropoietin for management of anaemia in dogs and cats with renal failure. *J Am Vet Med Assoc* **212**, 521–528.

Day M.J., Kyaw-Tanner M., Silkstone M.A., *et al.* (1999) T-cell-rich B-cell lymphoma in the cat. *J Comp Pathol* **120**, 155–167.

Dillon A.R. & Boudreaux M.K. (1988) Combined factors IX and XII deficiencies in a family of British shorthair cats. *J Am Vet Med Assoc* **193**, 833–834.

Edwards D.F. & Russell R.G. (1987) Probable vitamin K-deficient bleeding in two cats with malabsorption syndrome secondary to lymphocytic–plasmacytic enteritis. *J Vet Intern Med* **1**, 97–101.

Endo Y., Cho KyuWoan, Nishigaki K., *et al.* (1997) Molecular characteristics of malignant lymphomas in cats naturally infected with feline immunodeficiency virus. *Vet Immunol Immunopathol* **57**, 153–167.

Evans L.M. & Caylor K.B. (1995) Polycythemia vera in a cat and management with hydroxurea. *J Am Anim Hosp Assoc* **31**, 434–438.

Evans R.J. (1994) The blood and haematopoietic system. In *Feline Medicine and Therapeutics*. 2nd edn (eds Chandler E.A., Gaskell C.J. & Gaskell R.M.). Blackwell Science, Oxford, pp. 192–226.

Evans R.J., Jones D.R.E. & Gruffydd-Jones T.J. (1982) Essential thrombocythaemia in the dog and cat: a report of four cases. *J Small Anim Pract* **23**, 457–467.

Ewing P.J., Cowell R.L. & Morgan S.J. (1997) Heinz bodies. In *Consultations in Feline Internal Medicine*. 3rd edn (ed. August J.R.). WB Saunders, Philadelphia, PA, pp. 469–473.

Facklam N.R. & Kociba G.J. (1986) Cytochemical characterization of feline leukemic cells. *Vet Pathol* **23**, 155–161.

Feldman B.F., Madewell B.R. & O'Neill S. (1981) Disseminated intravascular coagulation: antithrombin, plasminogen and circulation abnormalities in 41 dogs. *J Am Vet Med Assoc* **179**, 151–154.

Feldman B.F., Soares C.J., Kitchell B.E., *et al.* (1983) Haemorrhage in a cat caused by inhibition of factor XI (plasma thromboplastin antecedent). *J Am Vet Med Assoc* **182**, 589–591.

Fondacaro J.V., Richter K.P., Carpenter J.L., *et al.* (1999) Feline gastrointestinal lymphoma: 67 cases. *Eur J Comp Gastroenterol* **4**, 5–11.

Ford S., Giger U., Deusberg C., *et al.* (1992) Inherited erythrocyte pyruvate kinase deficiency causing haemolytic anaemia in an Abyssinian cat. *J Vet Intern Med* **6**, 123.

French T.W., Fox L.E., Randolph J.F. & Dodds, W.J. (1987) A bleeding disorder (von Willebrand's disease) in a Himalayan cat. *J Am Vet Med Assoc* **190**, 437–439.

Fulton R., Gasper P.W., Ogilvie G.K., *et al.* (1991) Effect of recombinant human colony stimulating factor on haematopoiesis in normal cats. *Exp Haematol* **19**, 759–767.

Gabbert N.H. (1983) Systemic lupus erythrematosus in a cat with thrombocytopenia. *Vet Med Small Anim Clin* **1**, 77–79.

Gabor L.J., Canfield P.J. & Malik R. (1999) Immunophenotypic and histological characterisation of 109 cases of feline lymphosarcoma. *Aust Vet J* **77**, 436–441.

Gabor L.J., Canfield P.J. & Malik R. (2000) Haematological and biochemical findings in cats in Australia with lymphosarcoma. *Aust Vet J* **78**, 456–461.

Gandolfi R.C. (1988) Feline neonatal isoerythrolysis: a case report. *Calif Vet* **3**, 9–11.

Gasper P.W., Rosen D.K. & Fulton R. (1996) Allogenic marrow transplantation in a cat with acute myeloid leukaemia. *J Am Vet Med Assoc* **208**, 1280–1284.

Gibson G.R., Callan M.B., Hoffman V. & Giger U. (2002) Use of hemoglobin-based oxygen carrying solution in cats. *J Am Vet Med Assoc* **221**, 96–102.

Giger U. (1991) Feline neonatal isoerythrolysis – a major cause of fading kitten syndrome. *Proc Am Coll Vet Intern Med* **9**, 347–350.

Giger U. (1992) Erythropoietin and its clinical use. *The Compendium of Continuing Education for the Practising Veterinarian* **14**, 25–33.

Giger U. & Bucheler J. (1991) Transfusion of type-A and type-B blood to cats. *J Am Vet Med Assoc* **198**, 411–418.

Giger U., Kilrain C.G., Filippich L.J. & Bell K. (1989) Frequencies of feline blood groups in the United States. *J Am Vet Med Assoc* **195**, 1230–1232.

Giger U., Bucheler J. & Patterson D.F. (1991a) Frequency and inheritance of A and B blood types in feline breeds of the United States. *J Hered* **82**, 15–20.

Giger U., Griot-Wenk M., Bucheler J., *et al.* (1991b) Geographical variation of the feline blood type frequencies in the United States. *Feline Pract* **19**, 21–27.

Giger U., Gorman N.T., Hubler M., *et al.* (1992) Frequencies of feline A and B blood types in Europe. *Proceedings of the International Society of Animal Genetics Conference* **23** (Suppl. I), 17–18.

Giddens W.E., Labbe R.F., Swango J.L. & Padgett G.A. (1975) Feline congenital erythropoietic porphyria associated with severe anaemia and renal disease. Clinical morphologic and biochemical studies. *Am J Pathol* **80**, 367–386.

Glenn B.L., Glenn H.G. & Omtvedt I.T. (1968) Congenital porphyria in the domestic cat (*Felis catus*); preliminary investigation on inheritance pattern. *Am J Vet Res* **29**, 1653–1657.

Gookin J., Brooks M.B., Catalfamo J.L., *et al.* (1997) Factor X deficiency in a cat. *J Am Vet Med Assoc* **211**, 576–579.

Grindem C.B. (1989) Bone marrow biopsy and evaluation. *Vet Clin North Am Small Anim Pract* **19**, 669–696.

Grindem C.B., Perman V. & Stevens J.B. (1985) Morphological classification and clinical and pathological characteristics of spontaneous leukemia in 10 cats. *J Am Anim Hosp Assoc* **21**, 227–236.

Griot-Wenk M., Pahlsson P., Chisholm-Chait A., *et al.* (1993) Biochemical characterisation of the feline AB blood group system. *Anim Genet* **24**, 401–407.

Griot-Wenk M.E., Callan M.B., Casal M.L., *et al.* (1996) Blood type AB in the feline AB blood group system. *Am J Vet Res* **57**, 1438–1442.

Hamilton T.A., Morrison W.B. & DeNicola D.B. (1991) Cytosine arabinoside chemotherapy for acute megakaryocytic leukaemia in a cat. *J Am Vet Med Assoc* **199**, 359–361.

Hammer A.S. (1991) Thrombocytosis in dogs and cats: a retrospective study. *Comp Haematol Int* **1**, 181–186.

Hammer A.S. & Wellman M. (1999) Leukoerythroblastosis and normoblastaemia in the cat. *J Am Anim Hosp Assoc* **35**, 471–473.

Hammer A.S., Couto C.G., Getzy D. & Bailey M.Q. (1990) Essential thrombocythemia in a cat. *J Vet Intern Med* **4**, 87–91.

Hart S.W. & Nolte I. (1994) Hemostatic disorders in feline immunodeficiency virus-seropositive cats. *J Vet Intern Med* **8**, 355–362.

Harvey J.W. (1996) Congenital erythrocyte enzyme deficiencies. *Vet Clin North Am Small Anim Pract* **26**, 1003–1111.

Harvey J.W. (1997) Bone marrow evaluation. In *Proceedings of the 15th Annual College of Veterinary Internal Medicine Forum* 12.

Harvey J.W., Dahl M. & High M.E. (1994) Methemoglobin reductase deficiency in a cat. *J Am Vet Med Assoc* **205**, 1290–1291.

Haschek W.M., Weigel R.M., Scherba G., *et al.* (1990) Zidovudine toxicity to cats infected with feline leukaemia virus. *Fundam Appl Toxicol* **14**, 764–775.

Hasler A.H. & Giger U. (1996) Serum erythropoietin values in polycythemic cats. *J Am Anim Hosp Assoc* **32**, 294–301.

Hawke C.G., Maddison J.E., Poulos V. & Watson A.D.J. (1992) Erythrocyte protoporphyrin concentrations in clinically normal cats and cats with lead toxicity. *Res Vet Sci* **53**, 260–263.

Hawkins E.C., Feldman B.F. & Blanchard P.C. (1986) Immunoglobulin A myeloma in a cat with pleural effusion and serum hyperviscosity. *J Am Vet Med Assoc* **188**, 876–878.

Helfand S.C. (1987) Low-dose cytosine arabinoside-induced remission of lymphoblastic leukemia in a cat. *J Am Vet Med Assoc* **191**, 707–710.

Helfand S.C. & Modiano J.F. (2000) Chronic lymphocytic leukemia. In *Schalm's Veterinary Hematology*. 5th edn. Lippincott Williams & Wilkins, Philadelphia, PA, pp. 638–641.

Helton K.A., Nesbitt G.H. & Caciolo P.L. (1986) Griseofulvin toxicity in cats: literature review and report of seven cases. *J Am Anim Hosp Assoc* **22**, 453–458.

Hickford F.H., Stokol T., van Gessel Y.A., *et al.* (2000) Monoclonal immunoglobulin G cryoglobulinaemia and multiple myeloma in a domestic shorthair cat. *J Am Vet Med Assoc* **217**, 1029–1033.

Hirsch V.M. & Cunningham T.A. (1984) Hereditary anomaly of neutrophil granulation in Birman cats. *Am J Vet Res* **45**, 2170–2174.

Hisasue M., Nishigaki K., Katae H., *et al.* (2000) Clonality analysis of various haematopoietic disorders in cats naturally infected with feline leukaemia virus. *J Vet Med Sci* **62**, 1059–1065.

Holzworth J. (1960) Leukemia in the cat: I. Lymphoid malignancies. *J Am Vet Med Assoc* **136**, 47–69.

Hubler M., Kaelin S., Hagen A., *et al.* (1987) Feline neonatal isoerythrolysis in two litters. *J Small Anim Pract* **28**, 833–838.

Huibregtse B.A. & Turner J.L. (1994) Hypereosinophilic syndrome and eosinophilic leukaemia: a comparison of 22 hypereosinophilic cats. *J Am Anim Hosp Assoc* **30**, 591–599.

Jackson M.L., Wood S.L., Vikram M. & Haines D.M. (1996) Immunohistochemical identification of B and T lymphocytes in formalin fixed, paraffin embedded feline lymphosarcomas: relation to feline leukaemia virus status, tumor site, and patient age. *Can J Vet Res* **60**, 199–204.

Jacobs T. (1994) Multiple myeloma in a cat with paraparesis. *Feline Pract* **22**, 28–32.

Jonsson N.N., Pullen C. & Watson A.D.J. (1990) Neonatal isoerythrolysis in Himalayan kittens. *Aust Vet J* **67**, 416–417.

Kolbl S., Skolec R., Hirt R., *et al.* (2000) Effects of long term low dose interferon alpha in cats persistently infected with FeLV. *Kleintierpraxis* **45**, 497–510.

Knottenbelt C.M. & Mackin A.J. (1998a) Blood transfusions in the dog and cat. Part 1: Blood collection techniques. *In Practice* **20**, 110–114.

Knottenbelt C.M. & Mackin A.J. (1998b) Blood transfusions in the dog and cat. Part 2: Indications and safe administration. *In Practice* **20**, 191–199.

Knottenbelt C.M., Addie D.D., Day M.J. & Mackin A.J. (1999a) Determination of the prevalence of feline blood types in the UK. *J Small Anim Pract* **40**, 115–118.

Knottenbelt C.M., Day M.J., Cripps P.J. & Mackin A.J. (1999b) Measurement of titres of naturally-occurring alloantibodies against feline blood group antigens in the United Kingdom. *J Small Anim Pract* **40**, 365–370.

Kociba G.J. (2000) Leukocyte changes in disease. In *Textbook of Veterinary Internal Medicine: Diseases of the Dog and Cat.* 5th edn (eds Ettinger S.J. & Feldman E.C.). WB Saunders, Philadelphia, PA, pp. 1842–1857.

Kociba G.J., Lange R.D., Dunn C.D. & Hoover E.A. (1983) Serum erythropoietin changes in cats with feline leukaemia virus-induced erythroid aplasia. *Vet Pathol* **20**, 548–552.

Kohn B., Goldschmidt M.H., Hohenhaus A.E. & Giger U. (2000) Anemia, splenomegaly, and increased osmotic fragility of erythrocytes in Abyssinian and Somali cats. *J Am Vet Med Assoc* **217**, 1483–1491.

Kraje A.C., Mears E.A., Hahn K.A., *et al.* (1999) Unusual metastatic behaviour and clinicopathologic findings in eight cats with cutaneous or visceral haemangiosarcoma. *J Am Vet Med Assoc* **214**, 670–672.

Kunkle G.A. & Meyer D.J. (1987) Toxicity of high doses of griseofulvin in cats. *J Am Vet Med Assoc* **191**, 322–323.

Lane S.B., Kornegay J.N., Duncan J.R. & Oliver J.E. (1994) Feline spinal lymphosarcoma: a retrospective evaluation of 23 cats. *J Vet Intern Med* **8**, 99–104.

Latimer K.S., Raakich P.M. & Thompson D.F. (1985) Pelger–Hët anomaly in cats. *Vet Pathol* **20**, 370.

Linenberger M.L., Shelton G.H., Persik M.T. & Abkowitz J.L. (1991) Hematopoiesis in asymptomatic cats infected with feline immunodeficiency virus. *Blood* **78**, 1963–1968.

Linenberger M.L., Beebe A.M., Pedersen N.C., *et al.* (1995) Marrow accessory cell infection and alterations in haematopoiesis accompany severe neutropenia during experimental acute infection with feline immunodeficiency virus. *Blood* **85**, 94.

Link M. & Hirshberger J. (2000) Feline lymphoma: treatment results and prognostic factors: 18 cats. *Tierarztliche Praxis* **28**, 87–93.

Lisciandro S.C., Hohenhaus A. & Brooks M. (1998) Coagulation abnormalities in 22 cats with naturally occurring liver disease. *J Vet Intern Med* **12**, 71–75.

Liska W.D., MacEwen E.G., Zaki F.A., *et al.* (1979) Feline systemic mastocytosis: a review and results of splenectomy in seven cats. *J Am Anim Hosp Assoc* **15**, 589.

Littlewood J.D. & Evans R.J. (1990) A combined deficiency of factor VIII and contact activation defect in a family of cats. *Br Vet J* **146**, 30–35.

Littlewood J.D., Shaw S.C. & Coombes L.M. (1995) Vitamin-K dependent coagulopathy in a British Devon rex cat. *J Small Anim Pract* **36**, 115–118.

London C (2000) Hematopoietic cytokines: the myeloproliferative factors. In *Kirk's Current Veterinary Therapy*. XIII. *Small Animal Practice* (ed. Bonagura J.D). WB Saunders, Philadelphia, PA, pp. 403–408.

Lucroy M.D. & Madewell B.R. (2001) Clinical outcome and diseases associated with extreme neutrophilic leukocytosis in cats: 104 cases (1991–1999). *J Am Vet Med Assoc* **218**, 736–739.

McConnell M.F. (2000) Haemostatic diagnostic techniques. In *Manual of Canine and Feline Haematology and Transfusion Medicine* (eds Day M.J., Mackin A. & Littlewood J.D.). BSAVA, Cheltenham, pp. 173–181.

McDonald W.J., Burton S.A. & Fuentealba I.C. (1994) Plasma cell myeloma producing an immunoglobulin a paraprotein in a cat. *Vet Clin Pathol* **35**, 157.

Maddison J.E., Watson A.D.J., Eade I.G. & Exner T. (1990) Vitamin K-dependent multifactor coagulopathy in Devon rex cats. *J Am Vet Med Assoc* **197**, 1495–1497.

Maggio-Price L. & Dodds W.J. (1993) Factor IX deficiency (haemophilia B) in a family of British shorthair cats. *J Am Vet Med Assoc* **203**, 1702–1704.

Mahony O.M., Moore A.S., Cotter S.M., *et al.* (1995) Alimentary lymphoma in cats: 28 cases. *J Am Vet Med Assoc* **207**, 1593–1598.

Matsushiro H., Kato H., Tahara T., *et al.* (1998) Molecular cloning an functional expression of feline thrombopoietin. *Vet Immunol Immunopathol* **66**, 225–236.

Mauldin G.E., Mooney S.C., Meleo K.A., *et al.* (1995) Chemotherapy in 132 cats with lymphoma: 1988–1994. *Proceedings of the 15th Annual Conference of the Veterinary Cancer Society*, pp. 35–36.

Meyer R. (2001) Current topics in fluid therapy: oxyglobin. In *Recent Advances in Veterinary Anesthesia and Analgesia* (eds Gleed R.D. & Ludders J.W.). International Veterinary Information Service, New York, Document No. A1407.0501 (www.ivivs.org).

Meyers-Wallen V.N., Haskins M.E. & Patterson D.F. (1984) Hematologic values in healthy neonatal, weanling and juvenile kittens. *Am J Vet Res* **45**, 1322–1327.

Mooney S.C., Hayes A.A., MacEwen E.G., *et al.* (1989) Treatment and prognostic factors in lymphoma in cats: 103 cases (1977–1981). *J Am Vet Med Assoc* **194**, 696–699.

Moore A.S., Cotter S.M., Frimberger A.E., *et al.* (1996) A comparison of doxorubicin and COP for maintenance of remission in cats with lymphoma. *J Vet Intern Med* **10**, 372–375.

Morris J.S., Blackwood L., Dobson J.M. & Villiers E.J. (1996) Association between nasal and renal lymphoma in cats. Clinical Research Abstract, *Br Small Anim Vet Assoc Cong* p. 241.

Nasisse M.P., Dorman D.C., Jamison K.C.M., *et al.* (1997) Effects of valacyclovir in cats infected with feline herpesvirus1. *Am J Vet Res* **58**, 1141–1144.

Neer M. (1991) Hypereosinophilic syndrome in cats. *The Compendium of Continuing Education for the Practising Veterinarian* **13**, 549–555.

O'Rourke L., Feldman B.F. & Ito R.K. (1982) Coagulation, fibrinolysis and kinin generation in adult cats. *Am J Vet Res* **43**, 1478–1480.

Owens J.G., Nasisse M.P., Tadepalli S.M. & Dorman D.C. (1996) Pharmacokinetics of acyclovir in the cat. *J Vet Pharmacol Ther* **19**, 488–490.

Parker M.T., Collier L.L., Kier A.B. & Johnson G.S. (1988) Oral mucosal bleeding times of normal cats and cats with Chediak–Higashi syndrome or Hageman trait (factor XII deficiency). *Vet Clin Pathol* **17**, 9–12.

Peatson A.E. & Maddison J.E. (1999) Efficacy of doxorubicin as an induction agent for cats with lymphosarcoma. *Aust Vet J* **77**, 442–444.

Pechereau D., Martel P. & Braun J.P. (1997) Plasma erythropoietin concentrations in dogs and cats: reference values and changes in anaemia or chronic renal failure. *Res Vet Sci* **62**, 185–188.

Penny R.H.C., Carlisle C.H., Prescott C.W. & Davidson H.A. (1970) Further observations on the effect of chloramphenicol on the haemopoietic system of the cat. *Br Vet J* **126**, 453–458.

Perry L.A., Williams D.A., Pidgeon G.L. & Boosinger T.R. (1991) Exocrine pancreatic insufficiency with associated coagulopathy in a cat. *J Am Anim Hosp Assoc* **27**, 109–114.

Peterson J.L., Couto C.G. & Wellman M.L. (1995) Haemostatic disorders in cats: a retrospective study and review of the literature. *J Vet Intern Med* **9**, 298–303.

Peterson M.E., Hurvitz A.I., Leib M.S., *et al.* (1984) Propylthiouracil-associated hemolytic anaemia, thrombocytopenia, and antinuclear antibodies in cats with hyperthyroidism. *J Am Vet Med Assoc* **184**, 806–808.

Peterson M.E., Kintzer P.P. & Hurvitz A.I. (1988) Methimazole treatment of 262 cats with hyperthyroidism. *J Vet Intern Med* **2**, 150–157.

Pichler M.E. & Turnwald G.H. (1985) Blood transfusion in dogs and cats Part I. Physiology, collection, storage and indications for whole blood therapy. *The Compendium of Continuing Education for the Practising Veterinarian* **7**, 64–71.

Prasse K.W. (1983) White blood cell disorders. In *Textbook of Veterinary Internal Medicine*. 2nd edn (ed. Ettinger S.J.). WB Saunders, Philadelphia, PA, pp. 2001–2045.

Prier D.J. & Collier L.L. (1987) Neutropenia in cats with the Chédiak–Higashi syndrome. *Can J Vet Res* **51**, 407.

Rassnick K.M., Mauldin G.N., Moroff S.D., *et al.* (1999) Prognostic value of argyrophilic nucleolar organizer region (AgNOR) staining in feline intestinal lymphoma. *J Vet Intern Med* **13**, 187–190.

Rogers K.S. (1992) Coagulation disorders associated with neoplasia in the dog. *Vet Med* **87**, 55–61.

Rottman J.B., English R.V., Breitschwerdt E.B. & Duncan D.E. (1991) Bone marrow hypoplasia in a cat treated with griseofulvin. *J Am Vet Med Assoc* **198**, 429–432.

Schrader L.A. & Hurvitz A.I. (1983) Cold agglutinin disease in a cat. *J Am Vet Med Assoc* **183**, 121–122.

Sheafor S.E., Gamblin R.M. & Couto C.G. (1996) Hypercalcaemia in two cats with multiple myeloma. *J Am Anim Hosp Assoc* **32**, 503–508.

Shelton G.H., Grant C.K., Linenberger M.L. & Abkowitz J.L. (1990) Severe neutropenia associated with griseofulvin therapy in cats with feline immunodeficiency virus. *J Vet Intern Med* **4**, 317–319.

Shimoda T., Shiranga N., Mashita T. & Hasegawa A. (2000) Bone marrow necrosis in a cat affected with feline leukaemia virus. *J Vet Med Sci* **62**, 113–115.

Slappendel R.J. (1988) Disseminated intravascular coagulation. *Vet Clin North Am Small Anim Pract* **18**, 169–184.

Spodnick G.J., Berg J., Moore F.M. & Cotter S.M. (1992) Spinal lymphoma in cats: 21 cases (1976–1989). *J Am Vet Med Assoc* **200**, 373–376.

Steele K.E., Saunders G.K. & Coleman G.D. (1997) T-cell-rich B-cell lymphoma in a cat. *Vet Pathol* **34**, 47–49.

Stokol T., Randolf J.F., Nachbar S., *et al.* (1997) Development of bone marrow toxicosis after albendazole administration in a dog and cat. *J Am Vet Med Assoc* **210**, 1753–1756.

Stokol T., Brooks M.B., Erb H.N. & Mauldin G.E. (2000) D-Dimer concentrations in healthy dogs and dogs with disseminated intravascular coagulation. *Am J Vet Res* **61**, 393–398.

Sullivan P., Gompf R., Schmeitzel L., *et al.* (1993) Altered platelet indices in dogs with hypothyroidism and cats with hyperthyroidism. *Am J Vet Res* **54**, 2004–2009.

Tasker S., Cripps P.J. & Mackin A.J. (1999a) Estimation of platelet counts on feline blood smears. *Vet Clin Pathol* **28**, 42–45.

Tasker S., Mackin A.J. & Day M.J. (1999b) Primary immune-mediated thrombocytopaenia in a cat. *J Small Anim Pract* **40**, 127–131.

Teske E., van Straten G., van Noort R. & Rutteman G.R. (2002) Chemotherapy with cyclophosphamide, vincristine and prednisolone (COP) in cats with malignant lymphoma: new results with an old protocol. *J Vet Intern Med* **16**, 176–186.

Thomas J.S. (1996) Von Willebrand's disease in the dog and cat. *Vet Clin North Am* **26**, 1089–1110.

Thomas J.S. & Green R.A. (1998) Clotting times and antithrombin III activity in cats with naturally developing diseases: 85 cases (1984–1994). *J Am Anim Med Assoc* **213**, 1290–1295.

Thrall M.A. (1981) Lymphoproliferative disorders: lymphocytic leukemia and plasma cell myeloma. *Vet Clin North Am Small Anim Pract* **11**, 321–347.

Turnwald G.H. & Pichler M.E. (1985) Blood transfusion in dogs and cats. Part II. Administration, adverse effects and component therapy. *The Compendium on Continuing Education for the Practising Veterinarian* **7**, 115–122.

Tvedten H. (1994a) Leukocyte disorders. In *Small Animal Clinical Diagnosis by Laboratory Methods*. 2nd edn (eds Willard M.D., Tvedten H. & Turnwald G.H.). WB Saunders, Philadelphia, PA, pp. 53–79.

Tvedten H. (1994b) Haemostatic abnormalities. In *Small Animal Clinical Diagnosis by Laboratory Methods*. 2nd edn (eds Willard M.D., Tvedten H. & Turnwald G.H.). WB Saunders, Philadelphia, PA, pp. 81–95.

Tyler R.D., Cowell R.L. & Loar A.S. (1991) Tests for autoimmune diseases. In *Consultations in Feline Internal Medicine* (ed. August J.R.). WB Saunders, Philadelphia, PA, pp. 359–365.

Vail D.M. (2000a) Lymphoma. In *Schalm's Veterinary Hematology*. 5th edn. Lippincott Williams & Wilkins, Philadelphia, PA, pp. 620–625.

Vail D.M. (2000b) Lymphoma: principles of management. In *Schalm's Veterinary Hematology*. 5th edn. Lippincott Williams & Wilkins, Philadelphia, PA, pp. 626–630.

Vail D.M., Moore A.S., Ogilvie G.K. & Volk L.M. (1998) Feline lymphoma (145 cases): proliferation indices, cluster of differentiation 3 immunoreactivity, and their association with prognosis in 90 cats. *J Vet Intern Med* **12**, 349–354.

Von Haarer M. & Grunbaum E.G. (1990) Zur klinischen bendentung der blutgruppen bei katzen. *Die Edelkatze* **1**, 12–14.

Waner R. & Harrus S. (2000) Anaemia of inflammatory disease. In *Schalm's Veterinary Haematology*. 5th edn (eds Feldman B.F., Zinkl J. & Jain N.). Lippincott, Williams & Wilkins, Philadelphia, PA, pp. 205–209.

Wang J., Kyaw-tanner M., Lee C. & Robinson W.F. (2001) Characterisation of lymphosarcomas in Australian cats using polymerase chain reaction and immunohistochemical examination. *Aust Vet J* **79**, 41–46.

Wardrop K.J. (1995) Selection of anticoagulant-preservatives for canine and feline blood storage. *Vet Clin North Am Small Anim Pract* **25**, 1263–1276.

Wardrop K.J., Kramer J.W., Abkowitz J.L., *et al.* (1986) Quantitative studies of erythropoiesis in the clinically normal, phlebotomized and feline leukaemia virus infected cats. *Am J Vet Res* **47**, 2274–2277.

Watson A.D.J., Moore A.S. & Helfand S.C. (1994) Primary erythrocytosis in the cat: treatment with hydroxurea. *J Small Anim Pract* **35**, 320–325.

Weiser G. (1995a) Erythrocyte responses and disorders. In *Textbook of Veterinary Internal Medicine*. 4th edn (eds Ettinger S.J. & Feldman E.C.). WB Saunders, Philadelphia, PA, pp. 1864–1891.

Weiser G. (1995b) Hematologic technology for diagnosing anemia. In *Kirk's Current Veterinary therapy*. XII. *Small Animal Practice* (ed. Bonagura J.D.). WB Saunders, Philadelphia, PA, pp. 437–442.

Weiss D.J. & Krehbiel J.D. (1983) Studies on the pathogenesis of anemia of inflammation: erythrocyte survival. *Am J Vet Res* **44**, 1830.

Weiss R.C., Cummins J.M. & Richards A.B. (1991) Low-dose orally administered alpha interferon treatment for feline leukaemia virus infection. *J Am Vet Med Assoc* **199**, 1477–1481.

Welles E.G., Boudreaux M.K. & Tyler J.W. (1993) Platelet, antithrombin, and fibrinolytic activities in taurine-deficient and taurine-replete cats. *Am J Vet Res* **54**, 1235–1243.

Welles E.G., Boudreaux M.K., Crager C.S. & Tyler J.W. (1994) Platelet function and antithrombin, plasminogen and fibrinolytic activities in cats with heart disease. *Am J Vet Res* **55**, 619–627.

White S.D., Rosychuk R.A.W., Outerbridge C.A., *et al.* (2000) Thiopurine methyltransferase in red blood cells of dogs, cats and horses. *J Vet Intern Med* **14**, 499–502.

Wilkerson M.J., Meyers K.M. & Wardrop K.J. (1991a) Anti-A isoagglutinins in two type B cats are IgG and IgM. *Vet Clin Pathol* **20**, 10–14.

Wilkerson M.J., Wardrop K.J., Meyers K.M. & Giger U. (1991b) Two cat colonies with A and B blood type and a clinical transfusion reaction. *Feline Pract* **19**, 22–26.

Winter H. (1980) Pathomorphology of feline myeloproliferative diseases with emphasis on erythropoietic neoplasms. *Kleinterpraxis* **25**, 203–216.

Young K.M., Moriello K.A. & Peickert H. (1997) Characterisation of eosinophil progenitor cells in feline bone marrow. *Am J Vet Res* **58**, 348–353.

Zeidner N.S., Myles M.H., Mathiason-DuBard C.K., *et al.* (1990) Alpha interferon (2b) in combination with zidovudine for the treatment of presymptomatic feline leukaemia virus induced immunodeficiency syndrome. *Antimicrob Agents Chemother* **34**, 1749–1756.

Zeidner N.S., Myles M.H., Mathiason-DuBard C.K. & Hoover E.A. (1995) reversal of feline leukaemia virus infection by adoptive transfer of activated T lymphocytes, interferon alpha, and zidovudine. *Semin Vet Med Surg Small Anim* **10**, 256–266.

Zwahlen C.H., Lucroy M.D., Kraegel S.A. & Madewell B.R. (1998) Results of chemotherapy for cats with alimentary malignant lymphoma: 21 cases (1993–1997). *J Am Vet Med Assoc* **213**, 1144–1149.

Further reading

Ahn A.H. & Cotter S.M. (1995) Approach to the anemic patient. In *Kirk's Current Veterinary Therapy*. XII. *Small Animal Practice* (ed. Bonagura J.D.). WB Saunders, Philadelphia, PA, pp. 447–451.

Baldwin C.J. & Ledet A.E. (1994) Pancytopenia. In *Consultations in Feline Internal Medicine*. 2nd edn (ed. August J.R.). WB Saunders, Philadelphia, PA, pp. 495–502.

Boudreaux M.K. (1996) Platelets and coagulation: an update. *Vet Clin North Am* **26**, 1065–1087.

Day M.J. (1998) Disorders of haemostasis. *Vet Q* **20**, S40–S41.

Day M.J. (1998) Immune-mediated thrombocytopaenia. *Vet Q* **20**, S43–S44.

Garon C.L., Scott M.A., Selting K.A. & Cohn L.A. (1999) Idiopathic thrombocytopenic purpura in a cat. *J Am Anim Hosp Assoc* **35**, 464–470.

Giger U. (2000) Regenerative anemias caused by blood loss or hemolysis. In *Textbook of Veterinary Internal Medicine*. 5th edn (eds Ettinger S.J. & Feldman E.C.). WB Saunders, Philadelphia, PA, pp. 1784–1804.

Giger U. & Akol K.G. (1990) Acute hemolytic transfusion reaction in an Abyssinian cat with blood type B. *J Vet Intern Med* **4**, 315–316.

de Gopegui R.R. & Feldman B.F. (1995) Use of blood and blood components in canine and feline patients with haemostatic disorders. *Vet Clin North Am Small Anim Pract* **25**, 1387–1402.

Green C.E. & Meriwether B.A. (1982) Activated partial thromboplastin time and activated coagulation time in monitoring heparinized cats. *Am J Vet Res* **43**, 1473–1477.

Grindem C.B. (1997) Classification of myeloproliferative disease. In *Consultations in Feline Internal Medicine*. 3rd edn (ed. August J.R.). WB Saunders, Philadelphia, PA, pp. 499–508.

Griot-Wenk M. & Giger U. (1991) Cats with type AB blood in the United States. *J Vet Intern Med* **5**, 139.

Griot-Wenk M. & Giger U. (1995) Feline transfusion medicine. Blood types and their clinical importance. *Vet Clin North Am Small Anim Pract* **25**, 1305–1322.

Hall R.L. (1994) Interpreting the leukogram. In *Consultations in Feline Internal Medicine*. 2nd edn (ed. August J.R.). WB Saunders, Philadelphia, PA, pp. 489–494.

Harvey J.W. (1995) Methemoglobinemia and Heinz body hemolytic anemia. In *Kirk's Current Veterinary Therapy*. XII. *Small Animal Practice* (ed. Bonagura J.D.). WB Saunders, Philadelphia, PA, pp. 443–446.

Jain N.C. (1994) Examination of the blood and bone marrow. In *Essentials of Veterinary Haematology* (ed. Jain N.C.). Lea and Febiger, Philadelphia, PA, pp. 1–18.

Jordan H.L., Grindem C.B. & Breitschwerdt E.B. (1993) Thrombocytopenia in cats: a retrospective study of 41 cases. *J Vet Intern Med* **7**, 261–265.

Joshi B.C., Raplee R.G., Powell A.L. & Hancock F. (1979) Autoimmune thrombocytopenia in a cat. *J Am Anim Hosp Assoc* **15**, 585–588.

Loar A.S. (1994) Anaemia: Diagnosis and treatment. In *Consultations in Feline Internal Medicine*. 2nd edn (ed. August J.R.). WB Saunders, Philadelphia, PA, pp. 469–487.

Peterson J.L. & Couto C.G. (1994) Lymphoid leukemias. In *Consultations in Feline Internal Medicine*. 2nd edn (ed. August J.R.). WB Saunders, Philadelphia, PA, pp. 509–513.

Raskin R.E. (1996) Myelopoiesis and myeloproliferative disorders. *Vet Clin North Am Small Anim Pract* **26**, 1023–1042.

Raskin R.E. & Krehbiel J.D. (1985) Myelodysplastic changes in a cat with myelomonocytic leukemia. *J Am Vet Med Assoc* **187**, 171–174.

Tvedten H. (1994) Erythrocyte disorders. In *Small Animal Clinical Diagnosis by Laboratory Methods*. 2nd edn (eds Willard M.D., Tvedten H. & Turnwald G.H.). WB Saunders, Philadelphia, PA, pp. 31–51.

Tyler R.D. & Cowell R.L. (1997) Normoblastaemia. In *Consultations in Feline Internal Medicine*. 3rd edn (ed. August J.R.). WB Saunders, Philadelphia, PA, pp. 483–487.

Tyler R.D., Cowell R.L. & Meader V. (1994) Bone marrow evaluation. In *Consultations in Feline Internal Medicine*. 2nd edn (ed. August J.R.). WB Saunders, Philadelphia, PA, pp. 515–523.

Ward H. & Couto C.G. (1997) Myeloid leukaemias. In *Consultations in Feline Internal Medicine*. 3rd edn (ed. August J.R.). WB Saunders, Philadelphia, PA, pp. 509–513.

Chapter 10

THE KIDNEY

P.J. Barber

Introduction

There are relatively few specific diseases recognised to affect the feline kidney; however, a large and increasing (Lulich *et al*., 1992) number of cats are diagnosed with chronic renal failure (CRF). Renal disease is a common and important condition, particularly in the geriatric cat.

Renal function

The principal function of the kidney is to maintain the extracellular fluid constant in both composition and volume. This is achieved by ultrafiltration of plasma at the glomerulus, followed by modification of the composition of the ultrafiltrate by tubular secretion and reabsorption to produce urine, which is then excreted. Renal functions may be broadly categorised as:

- *excretory*: excretion of metabolic waste products, drugs and toxins
- *regulatory*: maintenance of fluid, acid–base and electrolyte homeostasis
- *endocrine*: production of erythropoietin, vitamin D metabolites and renin.

Renal disease (definitions)

Renal disease refers to any pathology affecting the kidneys, which may, if mild, not necessarily cause renal dysfunction. The term renal failure could be used to describe the failure of the kidneys to perform any one of their normal functions; however, renal disease generally affects multiple functions in a graded manner, with progressive loss of all functions as the disease advances in severity. Clinically, the term renal failure is generally used to describe the syndrome of decreased glomerular filtration causing azotaemia. Azotaemia is an abnormal increase in the concentration of non-protein nitrogenous waste products in the blood, detected biochemically as an increase in creatinine and urea concentrations. Uraemia is the syndrome of clinical signs that develops as a consequence of urinary excretory failure and azotaemia. Although all uraemic patients are azotaemic, the presence of clinical signs depends on the severity and rate of onset of the azotaemia. The term renal insufficiency is used if renal function is impaired sufficiently to cause loss of renal reserve without azotaemia.

Clinical approach to the patient

As with all medical conditions, a detailed history and thorough clinical examination are essential to the development of a logical diagnostic investigation. In the normal cat the kidneys have considerable functional reserve; therefore, renal disease, if mild, may be silent or only produce clinical signs relating to the urinary system. Failure of renal function is thought to occur when at least two-thirds to three-quarters of the functional capacity of both kidneys is impaired. Unlike renal disease, uraemia is characterised by multiple physiological and metabolic alterations producing a polysystemic, diverse range of clinical signs. These clinical signs are similar whatever the initiating cause of the uraemia (Box 10.1).

Box 10.1 Clinical signs and biochemical changes of uraemia

The spectrum and severity of clinical signs will vary with the severity and duration of the uraemia and the nature and rate of progression of the underlying renal disease.

Fluid and electrolyte disturbances
- Fluid balance: primary polyuria and secondary polydipsia
- Dehydration
- Reduced ability to adapt to changes in dietary sodium intake
- Metabolic acidosis
- Phosphate retention and hyperphosphataemia
- Hypokalaemia or hyperkalaemia

Metabolic and endocrine disturbances
- Azotaemia
- Abnormal insulin metabolism and insulin resistance
- Deranged carbohydrate and lipid metabolism (hypertriglyceridaemia)
- Negative nitrogen balance, protein catabolism and weight loss
- Secondary renal hyperparathyroidism and renal osteodystrophy
- Decreased erythropoietin production
- Euthyroid sick syndrome

Gastrointestinal signs
- Anorexia and consequent weight loss
- Oral ulceration, stomatitis, tongue-tip necrosis and halitosis
- Uraemic gastropathy with glandular atrophy, gastritis and ulceration
- Vomiting
- Gastrointestinal haemorrhage
- Increased amylase and lipase concentrations
- Constipation, occasionally diarrhoea

Neuromuscular disturbances
- Uraemic encephalopathy: dullness, lethargy, altered behaviour, seizures
- Peripheral polyneuropathy
- Muscle wasting and weakness
- Hypokalaemic myopathy

Cardiovascular and pulmonary disturbances
- Systemic arterial hypertension (ocular lesions)
- Left ventricular hypertrophy
- Murmurs, tachycardia, dysrhythmias and gallop rhythms
- Uraemic pneumonitis and pericarditis (rare)
- Pulmonary mineralisation

Haematopoietic and immune disturbances
- Normocytic, normochromic, non-regenerative anaemia
- Platelet dysfunction: haemorrhagic tendency
- Neutrophil dysfunction, decreased cell-mediated immunity
- Increased susceptibility to infection

Box 10.2 Sources of azotaemia

Prerenal
Factors that decrease renal blood flow
- Urine specific gravity usually >1.030
- Good prognosis
- Should resolve rapidly once volume deficits and renal perfusion restored

Renal
Abnormalities of the kidneys, including glomeruli, tubules, interstitium
- Urine specific gravity usually <1.030
- Variable prognosis dependent on cause

Postrenal
Factors that decrease urine output, usually trauma or obstruction
- Frequently oliguria or anuria, clinical presentation helpful
- Good prognosis
- Should resolve rapidly once urine output restored

When presented with a cat with suspected renal disease it is important to achieve a specific diagnosis to enable an accurate prognosis to be given and to optimise therapy. The vast majority of cases of renal disease are only identified once azotaemia is present; however, not all azotaemic cats have renal disease. In approaching a case of suspected renal disease the clinician should attempt to determine:

- the presence and nature of the renal disease
- the degree of renal functional impairment (presence of azotaemia or uraemia).

If azotaemia is present the source of the azotaemia must be established (Box 10.2):

- *prerenal azotaemia*: inadequate renal perfusion
- *renal azotaemia*: intrinsic or primary renal failure
- *postrenal azotaemia*: obstruction to urine flow or rupture of the urinary tract.

If intrinsic renal failure is present the initial investigation should be aimed at determining whether the case is acute or chronic.

Investigation

The diagnosis of renal failure is usually based on the demonstration of decreased excretory function. Additional diagnostic procedures may then be used to evaluate the nature of the primary renal insult and the presence of other abnormalities secondary to renal dysfunction. Only a few techniques are used in the diagnosis of renal disease, although a wide variety of tests may be used in the investigation of the complications of renal failure, particularly CRF. Accurate identification of a specific cause of renal disease is imperative to optimise therapy to slow or stop the development of further renal lesions. Detection of any pre- or postrenal element to the azotaemia is important as early correction may prevent the development of intrinsic renal damage. Recognition of pre- and postrenal disease is relatively easy, based on history and clinical examination combined with a small number of diagnostic investigations.

Routine haematology and biochemistry

Samples for serum biochemistry should be obtained before and after the administration of fluid therapy if indicated, to allow the effect of treatment to be followed and to establish the degree of prerenal azotaemia. A complete biochemistry and haematology profile, including electrolytes, calcium and phosphate, as well as creatinine and urea is required to assess the degree of dysfunction and the complications of renal failure.

Laboratory assessment of renal function

Currently, routine assessment of renal function is made by determination of plasma concentrations of endogenous substances normally excreted by the kidney, usually urea and creatinine. Although very practical tests, the use of fasting plasma urea and creatinine concentrations as measures of renal function has severe limitations. Both are relatively insensitive indicators of renal dysfunction, increasing above the reference range only after renal function is reduced by approximately 75%, and both are influenced by non-renal factors affecting their production or excretion (Box 10.3). Neither concentration of creatinine or urea nor the relationship between the two parameters is useful in distinguishing chronic from acute renal failure (ARF) or pre- or postrenal failure from intrinsic renal failure.

The ideal assessment of renal excretory function is by the measurement of glomerular filtration rate (GFR). Clearance of inulin and endogenous and exogenous creatinine have been used to measure GFR in the cat (Ross & Finco, 1981; Brown *et al.*, 1996b). All of these techniques have disadvantages when considered for use in the clinical situation, perhaps the most important of which is the need for accurate

Box 10.3 Assessment of azotaemia

Both plasma urea and creatinine are insensitive markers of renal dysfunction and neither distinguishes renal from extrarenal causes of azotaemia.

Plasma urea concentrations
- Synthesised in the liver from ammonia (production reduced in hepatic disease)
- Excretion is almost exclusively renal, freely filtered at glomerulus
- Increases with protein intake, high-protein diet, recent meal
- Increased in intestinal haemorrhage
- Increased in protein catabolic states: fever, corticosteroids, etc.
- Reabsorption from urine increased in dehydration
- Clinical signs may better correlate with urea than creatinine

Plasma creatinine concentrations
- Formed in muscle from non-enzymic degradation of creatine
- Production rate determined by muscle mass (decreased in emaciated animals)
- Freely filtered at glomerulus
- Small amount of intestinal degradation
- Minimally affected by protein ingestion or urine flow rate
- Probably better indicator of glomerular filtration rate than urea

collection of urine. More recently, plasma clearance tests using radiolabelled filtration markers such as technetium-99m diethylene-triaminepentacetic acid (Russo *et al.*, 1986; Rogers *et al.*, 1991) and iohexol (Brown *et al.*, 1996a) have been used to evaluate GFR, obviating the need for timed urine collections.

Routine urinalysis

The laboratory analysis of urine is an important but underutilised diagnostic tool. A basic in-house urinalysis consists of macroscopic examination, measurement of specific gravity, semiquantitative chemistry (usually by dipstick) and microscopic sediment examination. Further analysis such as bacterial culture and quantitative urine chemistry may be carried out as required.

When analysing a urine sample, the aim is to obtain a sample with *in vitro* characteristics the same as those of the urine *in vivo*, in the bladder. Therefore, when interpreting the results of urinalysis, factors relating to the collection and storage of the sample need to be considered. Obtaining a urine sample by cystocentesis is a relatively simple and atraumatic procedure in the cat, particularly if the bladder is easily palpable, making this the collection technique of choice in this species. Of prime importance is the need to obtain a sample before the initiation of treatment, particularly fluid therapy, antibiotics, diuretics, glucocorticoids and radiographic contrast media.

Urine solute concentration

The measurement of urine solute concentration has two purposes. First, it provides an assessment of renal function, the ability of the renal tubules to dilute or concentrate the glomerular filtrate. Secondly, knowledge of the urine concentration is required to aid the interpretation of the semiquantitative tests of urine analysis (dipstick chemistries and microscopic sediment examination). Osmolality is the 'purest' measurement of urine solute concentration, being a measure of the number of solute particles dissolved in water. Although specific gravity approximates to osmolality, the measurements are not identical. The specific gravity is a measure of the density of a liquid relative to pure water and is affected by both the number of dissolved solutes and the nature of these solutes (molecular size and weight), as well as by temperature. In practice, the solute concentration of urine is measured by assessing the refractive index of urine using a refractometer, which is calibrated to measure specific gravity. Urine specific gravity should not be measured using reagent strips.

The specific gravity of normal cats is very variable, depending on the fluid and electrolyte status (Box 10.4). The ancestors of the domestic cat originated from the desert regions of North Africa, and cats have retained the capability to produce highly concentrated urine [up to a maximum urine concentration of 2984 mOsm/kg and specific gravity of 1.087 under conditions of water deprivation (Ross & Finco, 1981)]. The low frequency of bacterial urinary tract infection in the cat may be related to the high osmolality of feline urine (Demetriou *et al.*, 1997).

Isosthenuria is urine with a specific gravity similar to that of the glomerular filtrate (1.008–1.012). Any values above or below this imply a degree of function of the renal tubules. It is possible that the ability to dilute urine may require fewer functioning nephrons than the ability to concentrate.

Semiquantitative urine chemistry

True quantitation of the excretion of any substance in urine requires accurate measurement of that sub-

Box 10.4 Assessment of urine solute concentration

The urine solute concentration will vary widely with the hydration status of the cat.

Normal range for urine specific gravity (SG)
- Range of normal SG 1.001–1.080+
- Usual range of SG in hydrated cat 1.035–1.060

Clinical implications for urine specific gravity (SG)
- Isosthenuria is urine with an SG 1.008–1.012
  Isosthenuria is urine with an SG similar to that of the glomerular filtrate
  Values above or below this imply a degree of function of the renal tubules
- In normal hydration, SG outside the usual range does not imply an abnormality
- Urine SG of >1.030 implies adequate concentrating ability
- A concentrated urine sample with high serum creatinine and urea concentrations indicates that the animal has adequate tubular function and is attempting to compensate for dehydration, implying a prerenal azotaemia
- A low urine specific gravity in a dehydrated animal is abnormal. A persistently low urine SG in an azotaemic animal suggests primary renal failure

Factors influencing measurement of specific gravity (SG)
- Diseases outside the kidneys affecting tubular function (hypercalcaemia, hyperadrenocortism)
- Preservative boric acid increases urine SG
- SG altered by temperature: urine must be at room temperature
- Affected by drug therapy including diuretics, fluid therapy and corticosteroids
- Affected by both number and nature of solute molecules

stance in urine and collection of a 24 h urine sample to eliminate any effect of diurnal variation in excretion. The combination of dipstick measurement and consideration of urine specific gravity provides a crude semiquantitative biochemical analysis.

Dipsticks are simple to use but can easily give erroneous results. It is also important to remember that these sticks are optimised for use on human urine and therefore not all the tests are accurate in feline urine. Reagent pads for leucocytes, nitrite, specific gravity and urobilinogen are considered unreliable in the cat. It is preferable to carry out a microscopic urine sediment examination to detect the presence of white blood cells and bacteria. The presence of bilirubinuria is an abnormal finding in the cat, unlike the dog which has a lower renal threshold for bilirubin excretion. As these are chemical and enzymic reactions, the urine should be at room temperature and uncontaminated with disinfectants, and the reagent pads must be read at the correct time intervals. Extreme discoloration of urine may preclude accurate assessment of these colorimetric reactions.

Quantitative urine chemistry

Abnormalities of renal tubular function may cause alteration of renal tubular solute handling and so excretion. Accurate quantitation of excreted solutes, particularly electrolytes, relative to filtered load, is assessed by measuring fractional excretion. Fractional excretion represents the excretion per unit GFR. This requires concurrent measurement of GFR and plasma concentration (to calculate the quantity filtered) along with urinary excretion, usually over at least 24 h. Alternatively, spot determinations may be made, without the need for GFR measurement, by using the ratio of urine to plasma creatinine to eliminate the effect of water reabsorption (Box 10.5).

Fractional excretions of electrolytes are influenced by the electrolyte load to be excreted, which is determined principally by dietary intake, with a superimposed circadian rhythm. Therefore, spot values are not generally considered a reliable indicator of fractional excretion (Finco *et al.*, 1997). Equally, fractional excretion rates can only be compared for animals on similar diets, limiting their use in the clinical situation.

Box 10.5 Fractional excretion (FE) of electrolytes

The FE of an electrolyte is the excretion of that electrolyte per unit glomerular filtration rate
May be measured on a 'spot' urine sample using the formula:

$$\text{FE electrolyte (\%)} = \frac{\text{Urine [electrolyte]} \times \text{Plasma [creatinine]}}{\text{Urine [creatinine]} \times \text{Plasma [electrolyte]}} \times 100$$

- Assumes no diurnal variation in electrolyte excretion
- Affected by dietary intake of electrolyte

Urine pH

Urine pH is measured as an indicator of acid–base balance (crude), presence of urinary tract infection (UTI) and predisposition to crystaluria and urolith formation. The consumption of protein lowers urine pH, such that cats, like other carnivores, tend to have acidic urine. There may also be a postprandial increase in urine pH, known as the 'alkaline tide', for up to 4 h after a meal. The normal range of pH values in cat urine is approximately 5.0–9.0. Urine pH can be measured using a pH meter or dipstick reagent pads. Studies comparing dipsticks and pH meters for assessment of urine pH have shown the dipsticks to be inherently inaccurate (Heuter *et al.*, 1998).

Urine protein

A small amount of protein is normally present in the urine of healthy animals. A urine protein excretion of up to 30 mg/kg per day is considered normal in cats (Russo *et al.*, 1986; Adams *et al.*, 1992). Proteinuria is defined as an abnormally high concentration of protein in the urine. It is a relatively common laboratory finding, usually detected during screening using urine dipstick strips. The results of urine protein analysis should be assessed alongside urine sediment examination and specific gravity measurement.

Dipstick reagent strips are generally based on the reagent tetrabromophenol blue. Although this is extremely sensitive to albumin it is relatively insensitive to a number of pathological urinary proteins, producing false-negative results in the presence of globulin, Bence-Jones proteins and other non-albumin proteins. False positives occur in very alkaline samples. Urine samples should not be taken in the 24 h following the use of radiographic contrast media, as these may cause a true transient proteinuria and can also produce false-positive results in a number of tests used in the detection of proteinuria.

Quantitative laboratory evaluation of urine protein concentration depends not only on the amount of protein filtered but also on the degree of concentration of the filtrate by the renal tubules; therefore, total 24 h protein excretion is more useful in quantifying protein losses. The urine protein:creatinine ratio is a unitless ratio calculated by dividing the urine protein concentration by the urine creatinine concentration (Box 10.6). It has been shown that the urine protein:creatinine ratio in a randomly collected urine sample correlates well with measured 24 h urinary protein excretion in cats (Adams *et al.*, 1992). The sample submitted for laboratory evaluation of protein and creatinine concentrations should be centrifuged to remove particulate and cellular matter. A protein:creatinine ratio of less than 1.0 is considered to be normal; however, as most normal cats have a ratio of less than 0.7 (Adams *et al.*, 1992), a ratio of between 0.7 and 1.0 should be considered suspect.

Box 10.6 Urine protein:creatinine ratio

Protein:creatinine ratio measured on a 'spot' urine sample correlates well with 24 h urine protein excretion

$$\text{Urine protein:creatinine ratio} = \frac{\text{Urine protein concentration (mg/dl)}}{\text{Urine creatinine concentration (mg/dl)}}$$

Conversion factors

Total protein from g/l to mg/dl	multiply by 100
Creatinine from μmol/l to mg/dl	divide by 88.4

Only correlates to 24 h protein excretion in cases where:

- Glomerular filtration rate is stable
  - therefore may be inaccurate in acute renal failure
- Protein loss during a 24 h period is constant
- Glomerular filtration and tubular concentration of urine affect creatinine and protein in a similar manner
- There is no significant urinary tract inflammatory disease or urine sediment
  - probably still valid in sediment showing 5–20 red blood cells/high-power field
- Protein:creatinine ratio is <1
  - the predictive value of the ratio decreases as the ratio exceeds the normal range
  - in these cases it should be used only as an estimate of 24 h protein excretion

Urine sediment examination

Microscopic sediment examination is a fundamental part of the routine urinalysis. This examination is essential to interpret fully the results obtained from the remainder of the analysis. It is a semiquantitative technique, making estimations of the quantity of sediment present, and must always be considered in light of the urine concentration and collection technique. Normal feline urine may contain some red and white blood cells, lipid droplets, sperm and occasionally some casts or crystals. Owing to the adverse osmotic and pH environment of urine, sediment should be examined as soon as possible, ideally within 2 h, to minimise the degenerative cellular changes. Urine sediment examination is particularly useful to identify inflammatory conditions of the urinary tract and bacterial infections. The presence of renal epithelial cells or increased numbers of tubular casts indicates the presence of active renal pathology; however, a normal urine sediment does not rule out kidney disease.

The lining of the urinary tract is composed of an epithelial layer, cells of which may exfoliate into the urine. Cuboidal epithelial cells originate from the renal tubules, but can only be reliably identified if incorporated into casts. Transitional epithelial cells originate from the renal pelvis, ureters, urinary bladder and urethra, and show a great deal of variability in morphology, depending on the depth of origin within the epithelium and the anatomical site. Increased numbers of epithelial cells occur in response to inflammation, urolithiasis or neoplasia. Differentiating neoplastic cells in urine sediment is extremely difficult as changes characteristic of neoplasia may also occur as a response to severe inflammation. The diagnosis of a neoplastic lesion of the urinary tract requires further diagnostic procedures (usually including biopsy).

The presence of casts in the urine is known as cylinduria (Figure 10.1) and generally indicates tubular pathology. Normal urine may contain a few casts, usually hyaline. Cellular casts are considered abnormal. Depending on the stage of degeneration it may be difficult to identify definitively the type of cells present in a cast. Epithelial cell casts occur as a result of severe damage to the renal tubule leading to sloughing of the cells. White blood cell casts usually only occur in upper UTIs. Hyaline casts are often found in animals with glomerular proteinuria. All casts are relatively fragile and so are very prone to degeneration and fragmentation, especially at high pH or low urine specific gravity, and if centrifuged too quickly.

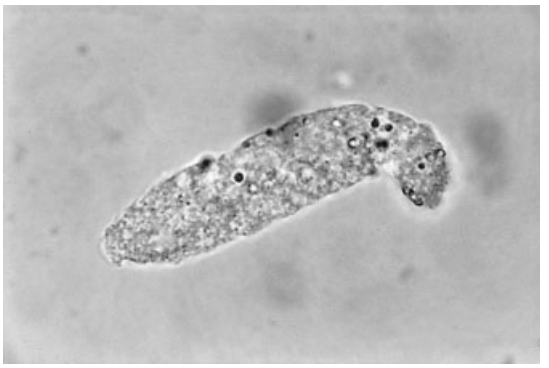

Figure 10.1 A feline urine sediment (unstained) containing a granular cast. Granular casts are thought to result from the degeneration of cellular casts. This cast also contains a number of lipid droplets.

Urine culture

Bacterial culture and sensitivity testing is required for definitive diagnosis of UTI and ideally should be carried out whenever a UTI is suspected from either sediment examination or clinical signs. Care must be taken in the collection and handling of urine samples to prevent bacterial contamination or proliferation or death of significant bacteria.

Samples obtained by catheterisation or voiding may contain bacteria commensal to the lower urinary tract; therefore, a cystocentesis sample is the ideal (Lees *et al.*, 1984). Urine culture should be carried out as soon as possible (ideally within 12 h) or preservative, such as 1% boric acid, used. The first stage of bacterial culture is qualitative to identify the species of bacteria. A single species is unlikely to represent contamination, as the majority of infections causing urinary tract disease are due to a single species of bacterium.

Quantitative bacterial culture is required to determine whether the bacteria are significant or merely contaminants. Quantitative bacterial counts are generally expressed as colony forming units per millilitre, each colony being derived from a single bacterium. In humans and dogs counts of greater than 10 000 organisms/ml are significant in catheterised samples and greater than 100 000/ml in voided samples. Owing to the inherent antibacterial nature of feline urine it has been suggested that the number of bacteria indicating significant bacteriuria should be lower than the values quoted for humans and dogs. Until these values have been accurately determined suspicious samples should be confirmed by repeat culture of a cystocentesis sample. A cystocentesis sample should

usually be sterile and a culture from such a sample is nearly always significant.

The final part of a culture is antimicrobial sensitivity or susceptibility testing. Many antibiotics are concentrated in the urine to much higher levels than present in plasma; therefore, the use of normal sensitivity discs is inappropriate and will underestimate the sensitivity of many microbes. Ideally, the laboratory should be using discs specifically designed for use with urine or use a broth culture technique to determine minimum inhibitory concentrations (MICs). In upper UTI, the infection may also involve the tissues and so plasma concentrations of antibiotic are also important.

Systemic arterial blood pressure

Systemic hypertension is both a consequence and a potential cause of renal disease, and so measurement of systemic arterial blood pressure should be an integral part of the assessment of the feline renal failure patient.

Blood pressure may be measured by direct or indirect techniques. Direct techniques, although considered the gold standard, involve arterial catheterisation and therefore less invasive indirect techniques are more applicable to the clinical setting. Indirect methods of measurement evaluated in the cat include oscillometric, Doppler and photoplethysmographic techniques (Binns *et al.*, 1995).

All techniques utilise a cuff placed around an extremity and inflated to occlude blood flow in the artery under examination. The size of the cuff will affect the reading obtained, large cuffs tending to underestimate blood pressure. The cuff width used should be 30–40% of the circumference of the extremity. As the cuff is deflated the flow of blood through the artery is detected, the method of detection varying with the technique used.

The Doppler flowmeter device (Doppler ultrasonic sphygmomanometry) is a relatively cheap, simple to use device. The Doppler technique has been validated in the cat and has superior accuracy and reliability to the oscillometric (Binns *et al.*, 1995). The Doppler system detects blood flow by emiting an ultrasound signal and then producing an auditory signal based on the change in frequency of the reflected ultrasound due to the movement of the red blood cells (Doppler shift). The main limitation of the technique is that assessment of diastolic pressures is subjective and so tends to be inaccurate.

The brachial, median, cranial tibial or coccygeal arteries are used for blood pressure measurement. The median artery is usually occluded when using the Doppler technique by placing the cuff around the antebrachium. The transducer is then placed between the carpal and metacarpal pads until a pulse is located. Clipping the hair and the use of coupling gel will improve the ease with which a signal is obtained and reduce the amount of adventitious noise. Ideally, the cat should be positioned such that the occluding cuff is at the level of the aortic valve. The cuff is inflated to 30 mmHg higher than the pressure required to obliterate the pulse, and then slowly deflated. The first sound heard as blood flow returns through the artery is the systolic blood pressure. It is important to note details of the technique, such as cuff size, in the animal's record to facilitate consistency.

Attendance at the veterinary practice and the procedure of taking blood pressure measurements have been shown to increase both heart rate and blood pressure. Ideally, serial measurements should form the basis of an assessment of blood pressure owing to day-to-day variability in this 'white-coat' effect (Belew *et al.*, 1999). Cats with renal insufficiency have a greater white-coat effect than healthy cats (Belew *et al.*, 1999). The animal should be allowed to settle in a quiet examination room for approximately 10 min before the reading is taken; this should be completed before the clinical examination. It is preferable for the owner to be present to reassure the cat. It is important to measure blood pressure in a standard manner, gaining between five and 10 measurements each time and making serial measurements to confirm the diagnosis. A normal range should be set up on healthy cats for the technique, within each practice.

Examination of the retina is an important part of the clinical examination of the cat. In practices without blood pressure measuring equipment it is the only method to identify suspect hypertensive cats. If blood pressure is routinely measured assessment of the retina assists in the determination of the significance of pressure readings. Although most practitioners use direct ophthalmoscopy for fundic examination the use of indirect ophthalmoscopy should be considered. This technique gives an inverted and reversed image with less magnification. The greater field of view permits a more rapid assessment of a large area of the fundus, ideal for screening cats for hypertensive retinopathy.

Imaging the kidneys

Abdominal radiography and ultrasound are useful techniques in the investigation of renal disease. Both

techniques have advantages and ideally should be used in conjunction to assess fully any patient suspected of having renal disease.

Survey abdominal radiography is primarily useful for the assessment of renal size, as unlike ultrasound examination, renal size can be related to body size. Standard lateral and ventrodorsal abdominal radiographs should be taken, permitting assessment of the kidneys along with their relationship to other abdominal viscera and the reminder of the urinary tract. The kidneys are usually seen more clearly in the lateral view, especially if there is abundant retroperitoneal fat. There is generally superimposition of the two kidneys, which is minimised by positioning in right lateral recumbancy. Renal size is assessed on the ventrodorsal view and related to the length of the second lumbar vertebra (L2). The kidneys should be of similar size and are usually reported to be 2.4–3.0 × L2 in length. However, in older cats despite normal renal function renal length may be between 2.0 and 2.4 × L2 (Feeney & Johnston, 1998). It is possible that this is evidence of renal disease sufficiently mild to leave renal function unaffected. Kidneys of very young kittens and entire cats may be larger than those of other normal cats. Renomegaly may be pathological but may also be physiological owing to compensatory hypertrophy (Box 10.7).

Excretory urography may be used to confirm the size, shape and position of the kidneys, and also provides crude information regarding renal function and architecture. Intravenous urography is not a benign procedure and therefore careful consideration should be given to patient selection. Administration of iodinated contrast media may elicit a systemic adverse reaction or be the cause of further renal damage. Contrast-induced nephropathy includes hypotension and tubular toxicity, and intravenous fluid therapy to induce volume expansion for at least 12 h before and after the study would seem appropriate. Equally, the contrast study may be non-diagnostic if the cat has severely compromised renal function. For these reasons intravenous urography should be avoided in anuric, oliguric and dehydrated cats.

Box 10.7 Renal enlargement

Physiological
- Compensatory physiological hypertrophy
  - after unilateral nephrectomy
  - unilateral renal agenesis
  - portosystemic shunts
- Kittens and large male cats

Pathological
- Polycystic renal disease
- Hydronephrosis
- Feline infectious peritonitis
- Pyelonephritis (bacterial upper urinary tract infection)
- Renal neoplasia (primary or metastatic)
  - renal lymphoma
- Acute renal failure
- Perinephric pseudocysts
- Acromegaly

Renal ultrasound examination is complementary to radiography. The advantages of ultrasonography are that it is non-invasive and rapid, usually requiring no or minimal sedation. Unlike radiography, ultrasonography allows some assessment of renal architecture and can identify the presence of intrarenal abnormalities. Ultrasound examination is particularly useful in cases with impaired renal function or poor abdominal contrast preventing radiographic visualisation of the kidneys.

In the cat sonographic measurement of renal size is useful owing to the relatively uniform body size. However, true sagittal scans are vital to accurate measurement. The kidney length is usually 3.0–4.3 cm (Walter *et al.*, 1987). A hyperechoic medullary line paralleling the corticomedullary junction (the 'medullary rim sign') may be seen as a normal finding in cats (Figure 10.2) and has been associated with the presence of microscopic focal mineral deposits within the tubular lumen (Yeager & Anderson, 1989).

Ultrasonographic patterns are rarely useful in the diagnosis of specific renal diseases, although they are helpful in narrowing the potential differential diagnoses. Ultrasonography is particularly useful defining the anatomical location, extent and distribution (focal, multifocal or diffuse) of disease, and in cases of focal disease, in differentiating solid from cavitating lesions. Diffuse disease is most frequently hyperechoic, but may have normal echogenicity. Perinephric pseudocysts and polycystic renal disease produce relatively specific sonographic patterns.

More advanced imaging techniques including renal scintigraphy and duplex Doppler sonography are currently being appraised in the cat.

Renal cytology and biopsy

Renal cytology and biopsy are usually required to obtain a definitive diagnosis in cases of renal disease. However, renal biopsy is not a diagnostic test to be undertaken lightly. Before considering biopsy a thorough diagnostic investigation should have been carried

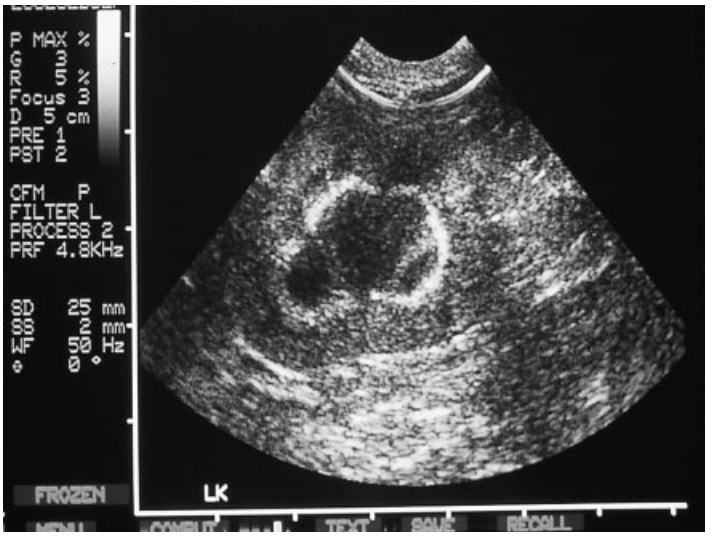

Figure 10.2 Ultrasound image of the kidney of a normal cat showing a prominent 'medullary rim' sign which may be seen as a normal finding.

out to assess for renal disease. The clinician should have in mind a differential list and biopsy is only indicated in cases where the result of histopathology will influence the treatment options and, therefore, the outcome of the case. Renal biopsy is rarely indicated in feline CRF without significant proteinuria.

Having established that biopsy is indicated, it is important to stabilise the patient before the procedure. As haemorrhage is a potential complication of the procedure and haemostatic disorders are complications of renal disease, the documentation of normal primary and secondary haemostasis is necessary before attempting biopsy. It would seem prudent to control systemic hypertension. Although fine-needle aspiration techniques may be possible in some cats without sedation, sedation or general anaesthesia with analgesia is required in most biopsy cases to prevent sudden movements of the patient.

Three biopsy techniques have been described:

- fine-needle aspiration (using a 21–25 G hypodermic needle or spinal needle)
- core biopsy (manual or automated biopsy devices)
- surgical biopsy (wedge biopsy, partial or total nephrectomy).

In general, core biopsy using automated biopsy needles is the technique of choice for diagnostic renal biopsy (Osborne *et al.*, 1996), but the preferred technique will depend on the details of the individual case.

Biopsies may be taken using the following methods:

- blind percutaneous
- ultrasound guided percutaneous (with or without a biopsy guide attached to the transducer)
- keyhole technique
- direct visualisation via laporoscopy or celiotomy.

The ease of palpation of the feline kidneys makes percutaneous biopsy, in which the kidney is immobilised by abdominal palpation, relatively simple. The use of ultrasound guidance facilitates monitoring of the position of the needle, localisation in the case of a focal lesion and observation postbiopsy for evidence of haemorrhage. The availability of ultrasound improves the safety and accuracy of renal biopsy. Optimal biopsy technique involves positioning the biopsy needle path such that the needle enters the renal cortex only and avoids the renal pelvis, artery and vein, and also the large arcuate arteries at the corticomedullary junction.

Fine-needle aspiration of the kidneys permits a cytological examination only and is rarely diagnostic. The primary advantages of this technique are the technical ease and a lower incidence and severity of postbiopsy complications. Fine-needle aspiration is indicated when a diagnosis is likely to be made on the basis of cytology or to obtain material for bacterial culture. Samples consist of fluid or easily exfoliated cells. Hence, fine-needle aspiration is most useful for the diagnosis of lymphosarcoma and other neoplastic or inflammatory disease (including feline infectious peritonitis). It is probably the technique of choice in the investigation of cavitary lesions. Differential diagnoses should not be excluded on the basis of negative results from fine-needle aspirates.

One of the most common complications of renal biopsy is haemorrhage, of varying severity. Perirenal

haemorrhage and subcapsular haemorrhage with haematoma formation are common after biopsy. The subcapsular renal veins in the cat may theoretically predispose the cat to subcapsular haemorrhage. Post-biopsy macroscopic haematuria has been reported in 16% of cats and microscopic haematuria in all cases (Minkus *et al.*, 1994). Close monitoring of the cat after biopsy is essential (both packed cell volume and urinalysis for haematuria). Manipulation of the kidney (such as palpation) should be avoided and cage rest instituted to reduce disturbance of the clot at the biopsy site. More severe haematuria may cause the formation of blood clots within the renal pelvis, leading to outflow obstruction and hydronephrosis. Intravenous fluid administration during and after the procedure induces a diuresis and reduces the risk of clot formation. The incidence of hydronephrosis after renal biopsy has been reported to be as high as 4% (Jeraj *et al.*, 1982).

Renal biopsy may also cause renal damage, usually via damage to renal vessels resulting in ischaemia and infarction. This damage may be significant in a cat with already compromised renal function. Biopsy paths that cross the corticomedullary junction result in more severe renal damage, and biopsies that contain large vessels or renal medulla are therefore likely to be associated with renal infarction. Biopsy of small kidneys therefore carries an increased risk of renal damage and is unlikely to be rewarding in achieving a diagnosis. Biopsy of neoplastic tissue has the potential to cause seeding of the neoplasm along the needle track, the risk being more significant with core biopsies and minimal with fine-needle aspiration. The rate and severity of complications are dependent on the experience of the operator.

Acute renal failure

ARF is a clinical syndrome characterised by an abrupt and severe decline in GFR. Unlike CRF, in which animals tend to have a slow, progressive decline in renal function, allowing time for compensatory mechanisms to evolve, the sudden nature of ARF leads to severe metabolic derangements and clinical signs, with a generally poor prognosis. In contrast to chronic disease, in ARF the damage to nephrons, although severe, is, at least in the early stages, reversible and normal renal function may be restored. ARF is relatively rare in the cat and there is little published information on optimum treatment protocols.

Classification

It is important to distinguish between the four presentations of ARF, as this will affect the management and prognosis of the case (see Box 10.2):

- prerenal
- primary intrinsic (renal)
- postrenal
- (decompensated CRF – acute on chronic).

The term ARF is usually restricted to those conditions caused by intrinsic or primary renal disease (as opposed to pre- or postrenal renal failure). However, both pre- and postrenal causes of renal failure will eventually, if untreated, lead to actual renal damage and may be a cause of intrinsic ARF. With early recognition of pre- or postrenal causes of azotaemia, supportive therapy and prompt correction of the underlying defect, intrinsic renal damage can be prevented and the prognosis for return to normal renal function is good. ARF may also occur in cats with pre-existing CRF (so-called acute on chronic), and it is important, although difficult, to distinguish this from decompensated end-stage CRF.

Aetiology of intrinsic acute renal failure

The principal causes of intrinsic ARF are nephrotoxins and ischaemia leading to acute tubular necrosis. The large renal blood flow (20% of cardiac output), combined with a high metabolic rate and transport functions of the kidney, make it uniquely susceptible to both ischaemic and nephrotoxicant injury. However, ARF may result from a wide number of causes (Box 10.8).

ARF is relatively commonly acquired while an animal is hospitalised, particularly in the critical care situation. Multiple factors are present in many cases of ARF, a number of minor renal insults summating to cause renal damage. A common example would be the use of non-steroidal anti-inflammatory drugs (NSAIDs) in the hypotensive cat. During hypotension, for example after blood loss due to trauma, renal blood flow is maintained by the action of locally produced prostaglandin. The kidney then corrects the hypotension by the retention of water and sodium. The administration of NSAIDs prevents the protective production of prostaglandin and exposes the kidney to the effects of hypotension. Such a cat is at risk for ARF and in addition has reduced means to correct the hypotension. Given the

Box 10.8 Aetiology of acute renal failure

Ischaemic injury
- Shock
  - hypovolaemic
  - hypotensive
  - septic
- Decreased cardiac output
  - congestive cardiac failure
  - arrhythmia
  - cardiac tamponade
- Anaesthesia
- Renal vessel thrombosis
  - arterial thrombosis associated with cardiomyopathy
  - disseminated intravascular coagulation
- Non-steroidal anti-inflammatory drugs
- Polycythaemia and hyperviscosity syndromes

Nephrotoxic injury
- Therapeutic agents
  - aminoglycosides, sulfonamides, tetracyclines
  - non-steroidal anti-inflammatory drugs
  - doxorubicin, methotrexate, gold salts, cyclosporin
- Intravenous radiographic contrast agents
- Organic compounds
  - ethylene glycol
  - carbon tetrachloride
- Endogenous compounds
  - myoglobin
  - haemoglobin
- Heavy metals
- Snake bite, bee sting

Miscellaneous conditions
- Hypercalcaemia
- Upper urinary tract infection
- Urinary tract obstruction
- Glomerulonephritis
- Hypokalaemia

Risk factors for acute renal failure
- Preexisting renal disease
- Age
- Fever or sepsis
- Other organ dysfunction

severe consequences and poor prognosis of ARF, clinicians should be aware of the potential for renal damage and actively intervene to prevent renal insult.

There are three phases in the course of ARF. The induction phase is the time from the initial renal insult to the point when renal function starts to decline. Intervention at this stage to prevent further renal injury may halt progression to ARF. The maintenance phase is characterised by damage to a critical number of nephrons, the presence of tubular lesions and a decline in GFR, with oliguria developing in those patients most severely affected. If the patient survives the maintenance phase healing may occur and the animal enters the recovery phase when the azotaemia begins to resolve.

Clinical signs

Clinical signs of ARF are those of severe uraemia and are therefore relatively non-specific, including lethargy, vomiting, anorexia and dehydration. Halitosis, oral ulceration and tongue-tip necrosis may also be noted.

Diagnosis

Diagnosis relies on laboratory evidence of a sudden elevation in creatinine and urea, although in many cases previous evidence of prior normal renal function is not available. In such cases historical and clinical features must be used to distinguish ARF from CRF (Box 10.9).

Oliguria (urine production of <0.5 ml/kg per hour) was considered an essential characteristic of ARF, but it is now recognised that non-oliguric ARF can occur. In general, isosthenuria is indicative of intrinsic renal failure, with concentrated urine implying the presence of a prerenal element to the azotaemia. Exceptions to this are cats with diseases such as hypoadrenocorticism and hypercalcaemia, where a low urine specific gravity may be present in the face of dehydration, despite normal tubular function. Although an active urine sediment may provide additional confirmation of ongoing renal damage, cylindruria is relatively uncommon in ARF. Definitive differentiation of ARF from CRF may require renal biopsy, but the procedure is not without risk and should not be under-taken lightly. Detection of lesions of ARF is difficult, particularly in the cat, owing to the frequency of vacuoles in normal tubular cells. In many cases histopathological change is minimal and changes relating to the presence of chronic disease are much easier to identify.

Once ARF is suspected diagnostic investigations should pursue the possibility of pre- or postrenal causes and correctable renal or underlying diseases. A full assessment of the systemic complications of ARF should then be made.

Box 10.9 Differentiation of acute and chronic renal failure

Acute renal failure (ARF)	Chronic renal failure (CRF)
Historical findings	
• Healthy until recently	• Previous history illness (polydipsia etc.)
• Cause of ARF (e.g. nephrotoxic drug)	
Physical examination	
• Good body condition	• Poor condition, weight loss
• Kidneys painful and enlarged or normal	• Kidneys small, non-painful and scarred
• Severe signs for degree of azotaemia	• Milder signs for degree of azotaemia
Biochemical and haematological findings	
• Hyperkalaemia	• Hypokalaemia or normokalaemia
• Severe metabolic acidosis	• Mild metabolic acidosis
	• Non-regenerative anaemia
Urinalysis	
• Anuria or oliguria	• Polyuria until end-stage CRF
• Proteinuria	• Benign sediment
• Cylinduria and cell debris	

Management

The aim of treatment is to prevent further renal damage and provide adequate time and supportive care for renal healing to occur. There are no specific treatments for ARF other than dialysis. In the hospital setting prevention of ARF is better than cure and at-risk cats should have close monitoring of renal function. Once ARF has occurred serial monitoring is essential if supportive therapy is to be effective. This should include full clinical examination, accurate measurement of body weight (to assess the effect of fluid therapy), measurement of urine output, assessment of packed cell volume, serum biochemistry, including total protein, creatinine, urea, calcium, phosphorus and ideally electrolytes, and acid–base status.

Conversion of oliguria to non-oliguria is usually recommended. It is not certain whether this changes the course of the disease, indeed it may merely provide prognostic information that the cat had less severe ARF. However, conversion of oliguria to non-oliguria simplifies the treatment of the metabolic consequences of ARF.

Prevention of further renal insult

When ARF is suspected initial management should aim to identify and correct any reversible disorders that may cause ongoing renal injury. Identification of pre- and postrenal factors contributing to renal dysfunction is paramount. If these conditions are promptly corrected before the development of intrinsic renal damage, return to normal renal function is rapid. Initial fluid therapy in ARF aims to replace any fluid deficits to restore renal perfusion, eliminating any prerenal component to the ARF.

Immediately on recognition of ARF any potentially nephrotoxic drug treatment should be halted. When nephrotoxic injury is suspected non-specific therapy to halt the absorption of the agent, such as induction of vomiting or gastric lavage, should be started, if appropriate. Any specific antidote should also be administered.

If intrinsic ARF is the cause of azotaemia, then the initial diagnostic investigation should aim to identify any treatable renal disease. In most cases the cause of intrinsic ARF remains unknown, or if known cannot be reversed. However, treatable conditions such as UTI should not be overlooked.

Fluid, acid–base and electrolyte imbalances

Initial fluid therapy should aim to replace fluid deficits, and cover maintenance requirements and ongoing losses over 4–8 h. The nature of the fluid administered is dependent on the electrolyte status of the cat, but as these cases are usually hyperkalaemic normal saline (0.9% sodium chloride) is often the initial fluid of choice. During rehydration the cat should be closely monitored for evidence of overhydration (Box 10.10).

Throughout rehydration urine output should be closely monitored (using an indwelling catheter and closed collection system). Once rehydration has been achieved the cat may remain oliguric or become polyuric. If oliguria persists fluid administration should be dramatically reduced to replace insensible

Box 10.10 Assessment of overhydration

Baseline parameters should be assessed and changes in the following parameters monitored closely:

- Physical examination
  - tachycardia
  - restlessness
  - chemosis and serous nasal discharge
  - increased bronchovesicular respiratory sounds
  - overt crackles and wheezes on auscultation
- Body weight
- Packed cell volume and total protein
- Central venous pressure

losses (20 ml/kg per day) and estimated contemporary fluid losses from vomiting and diarrhoea.

If urine output is restored (1–2 ml/kg per hour or greater), the aim of subsequent therapy is to maintain hydration and replace insensible and urinary losses. This is usually done retrospectively, the fluid rate being adjusted to replace urinary and insensible losses of the preceding 4–8 h ('ins and outs'). Restoration of urine output is frequently followed by a polyuric phase in which there is a tendency for dehydration, and urinary electrolyte losses can be great.

Animals with primary renal failure cannot excrete high sodium loads and therefore once the cat is rehydrated hypotonic, low-sodium fluids (0.45% sodium chloride and 2.5% dextrose) should be considered for long-term maintenance. Potassium supplementation will probably be required at this stage and supplementation should be based on plasma potassium concentrations. Fluid therapy should be withdrawn gradually once the animal is taking food and water and the azotaemia is stable.

Serum potassium concentrations are dependent on renal excretion, oral intake and the acid–base status of the patient. Hyperkalaemia most commonly occurs in ARF in cats with severe oliguria, particularly if caused by urethral obstruction (Drobatz & Hughes, 1997). Profound hyperkalaemia induces cardiac conduction disturbances and is therefore life threatening, requiring immediate intervention (Box 10.11). In the longer term

Box 10.11 Treatment of hyperkalaemia

Assessment of the severity of hyperkalaemia should be based on **both** measurement of plasma potassium concentrations **and** presence of electrocardiographic (ECG) changes

Rescue therapy of severe and moderate hyperkalaemia is temporary and therapy to initiate diuresis is required to facilitate potassium excretion

Severe life-threatening hyperkalaemia

- Calcium gluconate 10% 0.5–1.0 ml/kg
  - slow intravenous injection over 15 min
  - monitor ECG, can cause arrhythmia
  - provides immediate but short-duration protection of myocardium
  - does not lower potassium concentrations

Moderate to severe hyperkalaemia

- Sodium bicarbonate
  - use if concurrent acidosis (see Box 10.12)
  - contraindicated in hypocalcaemia
  - exchanging intracellular hydrogen for potassium
- Glucose 5–10% solution at constant rate infusion or 20–50% glucose 1–2 ml/kg i.v.
  - hypertonic glucose solutions should be administered slowly into a large vein
  - stimulates endogenous insulin release, causing cellular uptake of glucose and potassium
- Regular insulin 0.1–0.25 IU/kg i.v. followed by 1–2 g glucose per unit insulin administered
  - monitor blood glucose levels carefully for hypoglycaemia
  - stimulates cellular uptake of glucose and potassium

Asymptomatic hyperkalaemia

- Fluid therapy (potassium free fluids)
- Restoration of urine output
- Peritoneal dialysis

conversion from oliguria to non-oliguria will allow control of potassium concentrations via fluid therapy.

Failure of renal excretion of fixed acid in ARF may lead to metabolic acidosis. Mild to moderate acidosis will correct with appropriate fluid therapy, once urine output is increased. Severe metabolic acidosis may cause life-threatening cardiovascular complications and so judicious treatment is usually recommended when blood pH is less than 7.1–7.2 (Box 10.12). If in-house blood gas analysis is not available, empirical doses of sodium bicarbonate may be used, although overcorrection of metabolic acidosis can result in ionised hypocalcaemia, hypernatraemia and paradoxical cerebrospinal fluid acidosis.

Restoring urine output

If the initial rehydration fails to restore urine output a number of techniques may be used to reverse the oliguria (Box 10.13). Persistence of oliguria may be due to inadequate correction of hypovolaemia, as a dehydration of less than 5% of body weight is undetectable on clinical examination. A fluid challenge of 3–5% of body weight is usually used to ensure that there is not clinically undetected dehydration. Close monitoring of the patient for clinical signs of overhydration and ideally the measurement of central venous pressure are required. If oliguria persists after fluid challenge, fluid therapy should be reduced until urine output increases. Current recommendations to restore urine output suggest the administration of the loop diuretic frusemide, either alone or in combination with dopamine or mannitol. A synergistic effect of the combination of frusemide with dopamine has been shown in experimentally induced ARF in dogs. Although this combination has been used safely in cats (Chew, 2000) its efficacy is unproven. Unlike the dog, the cat does not have renal dopamine receptors and although dopamine causes a diuresis and natriuresis, it is thought that this is due to a systemic adrenergic response (Clark *et al.*, 1991). There is currently little evidence to support the use of either mannitol or dopamine in human ARF patients (Star, 1998).

Box 10.12 Treatment of metabolic acidosis

Mild to moderate acidosis resolves with fluid therapy
Specific treatment only required if blood pH falls below 7.1–7.15
Aim of therapy to raise blood pH to 7.2

Calculated dose
- Sodium bicarbonate dose (mmol) = 0.3 × body weight × base deficit
  - administer half total dose slowly by intravenous injection over 15–30 min
  - reassess after initial therapy
  - give remainder in maintenance fluids

Complications of therapy
- Hypernatraemia
- Hyperosmolality
- Metaobolic alkalosis
- Hypocalcaemia
- Paradoxical cerebrospinal fluid acidosis

Box 10.13 Restoration of urine output

Conversion of oliguric to non-oliguric acute renal failure (ARF) facilitates the management of ARF

- Fluid therapy
  - replace fluid deficicts
  - fluid challenge with 3–5% body weight
  - monitor closely for overhydration
- Frusemide 2–6 mg/kg
  - intravenous injection every 6–8 h
  - incrementally increase dose hourly (three doses) until diuresis achieved
  - exacerbates aminoglycoside toxicity
  - may be combined with mannitol or dopamine therapy
- Mannitol (10–20% solution) 0.25–0.5 g/kg
  - slow intravenous injection, may repeat once
  - effect seen within 1 h, if no response halt treatment
  - may cause severe overhydration
  - repeat bolus every 4–6 h if effective
  - alternatively give continuous infusion of 2–5 ml/min of 5–10% solution
  - maximum daily dose 2 g/kg
- Dopamine infusion 1–3 μg/kg per minute
  - 'low-dose renal', dilute in 5% dextrose or saline
  - monitor electrocardiogram for tachycardia or arrhythmia
  - possible synergistic effect with frusemide (1 mg/kg per hour by i.v. bolus)

Peritoneal dialysis

If oliguria persists despite aggressive medical management, severe azotaemia and metabolic derangements will ensue. Peritoneal dialysis may be necessary to maintain life in these cases. Peritoneal dialysis may also be used in cases of dialysable intoxication (e.g. barbiturates or early ethylene glycol toxicity) or over-

hydration. Peritoneal dialysis is extremely labour intensive, requiring close monitoring, and if contemplated it should ideally be initiated early in the course of the condition.

Dialysis is the transfer of solutes and water from one compartment to another across a semipermeable membrane, which in the case of peritoneal dialysis is the peritoneum, the two compartments being the peritoneal cavity and the extracellular fluid. The dialysate is infused into the peritoneal cavity and left in place for a variable period, referred to as the dwell time, while equilibration occurs, after which the fluid is drained. Transfer of solutes may occur in both directions, but the principal aim of peritoneal dialysis is to substitute for renal excretory function. Peritoneal dialysis may be continuous or, more typically in veterinary patients, intermittent. Modification of the composition of the dialysate and duration of dwell time influence the exchange of solutes and water.

In its simplest form peritoneal dialysis may be carried out using large-gauge needles; however, commercially available fenestrated catheters are preferable. The procedure for peritoneal dialysis has been described in the literature (Chew *et al.*, 2000). Complications of the technique include catheter occlusion, hypoalbuminaemia and most seriously peritonitis.

Systemic complications

Systemic complications of uraemia are relatively common (see Box 10.1), particularly in ARF because of the relatively high concentrations of uraemic toxins that rapidly accumulate in the circulation. Gastrointestinal signs, anorexia, vasculitis and coagulation abnormalities and neurological dysfunction are all potential complications. Reduction in the degree of uraemia is the ideal method of management, but supportive therapy is usually required until this can be achieved.

Uraemia has been associated with depressed immunological function, especially cellular immunity, and this is exacerbated in critically ill ARF patients, particularly as concurrent disease is frequently present. Therefore, ARF cats are highly susceptible to infection and all indwelling catheters (intravenous and urinary) should be handled aseptically. Indwelling urinary catheters should be attached to closed collection systems and collected urine monitored closely for the presence of infection.

The duration of therapy must be judged on an individual case basis. Failure to establish a diuresis or persistence of severe metabolic derangements has a poorer prognosis. Euthanasia should be considered if dialysis is not available and there is no clinical improvement after 3–5 days of treatment.

Chronic renal failure

CRF is renal failure that has persisted for an extended period. The phrase is usually restricted to those conditions caused by intrinsic or primary renal disease (as opposed to pre- or postrenal renal failure). The duration of renal failure necessary to warrant the description chronic is a debatable point; however, CRF may be defined as the presence of azotaemia or uraemia of renal origin, of more than 2 weeks' duration (Brown, 1996).

The prevalence of spontaneous CRF in the aged cat is estimated to be three times higher than in the aged dog (Polzin *et al.*, 1992). Many reports of the prevalence of CRF originate from university teaching hospitals in the USA, CRF representing between 1.2 and 2.4% of feline cases seen (Krawiec & Gelberg, 1989; Lulich *et al.*, 1992). The prevalence appears to be increasing, with a four-fold increase in diagnosed cases of feline CRF between 1980 and 1990 (Lulich *et al.*, 1992). This apparent increase in prevalence must be considered in light of the increased willingness of owners to seek veterinary attention, particularly for their ageing cats, alongside improved efforts by veterinary surgeons to diagnose renal disease.

Aetiology of intrinsic chronic renal failure

Several pathological surveys of renal lesions in cats with CRF have been conducted, most involving postmortem studies of renal pathology (DiBartola *et al.*, 1987; Lulich *et al.*, 1992), which will emphasise the lesions found in cats with severe renal functional impairment. However, similar histopathological results have been obtained using biopsy techniques (Jeraj *et al.*, 1982; Minkus *et al.*, 1994). Although many specific pathological entities have been recognised as causing CRF in cats, in a large percentage of cases the pathological lesions give little indication of the underlying aetiology.

The inability to determine the primary causes of feline renal disease relates to a number of characteristics of renal pathophysiology. The various anatomical components of the kidney are functionally interdependent, such that damage to one portion of the nephron will invariably lead to progressive damage to other structures. Similarly, the tissues of the kidney

have a limited repertoire of response to injury and disease. Both of these attributes result in a common renal pathology, irrespective of the inciting cause, especially in advanced or generalised disease. The term chronic generalised nephropathy has been used to describe such primary renal disease that results in diffuse pathology of the renal parenchyma (Polzin *et al.*, 1995). There is some confusion over the nomenclature among the studies of feline renal pathology, with some reports using the term chronic tubulointerstitial nephritis, probably reflecting the impression that glomerular lesions in these cases are less significant or secondary to the tubulointerstitial pathology (DiBartola *et al.*, 1987; Minkus *et al.*, 1994). Overall, however, these studies reveal that in 29–66% of CRF cats, no specific pathological diagnosis could be determined (DiBartola *et al.*, 1987; Lulich *et al.*, 1992; Minkus *et al.*, 1994).

Clinical signs

Although recognised in all ages of cat, CRF is more common in older cats (DiBartola *et al.*, 1987; Lulich *et al.*, 1992; Polzin *et al.*, 1992). No conclusive sex predisposition has been found (DiBartola *et al.*, 1987). Maine coon, Abyssinian, Siamese, Burmese and Persian breeds of cat have been identified to be at significantly increased risk of CRF (Lulich *et al.*, 1992).

Clinical signs of CRF vary dependent on the degree of renal dysfunction, with many cats being asymptomatic in the early stages of the disease. The common historical and clinical findings in cats with CRF are those of uraemia.

Diagnosis

The diagnosis of CRF is based on the demonstration of persistently decreased renal excretory function. For practical purposes (in the absence of pre- or post-renal causes of azotaemia), demonstration of elevated plasma urea and creatinine concentrations provides evidence of decreased renal excretory function. Demonstration of chronicity should be based on two assessments, ideally at a 2–4 week interval.

A diagnosis of CRF is further supported by the presence of a persistently low urine specific gravity. Cats with experimentally induced reductions in renal functional mass demonstrate a considerable ability to concentrate urine (Ross & Finco, 1981). Despite this finding, renal concentrating ability appears to be lost at a relatively early stage of naturally occurring CRF (Elliott & Barber, 1998).

If CRF is suspected the clinician should:

- determine the presence and extent of renal failure
- determine the chronicity and stability of the renal failure (requires multiple samples over time)
- attempt to identify the renal disease initiating the failure, as this may be amenable to specific therapy
- identify any factors contributing to the progression of CRF (this may include some of the systemic complications of renal failure)
- identify the systemic complications resulting from renal dysfunction.

All CRF cases should receive regular monitoring, involving full clinical examination (including assessment of body weight), the measurement of systemic arterial blood pressure, and analysis of blood and urine samples. This permits the early detection of problems and allows tailoring of treatment to the individual animal. Valuable information regarding the efficacy of therapy can only be gained if these examinations are made when the cat is stable. Although investigations may be required when there is an acute deterioration, parameters assessed at this time are influenced by the degree of dehydration and anorexia and may not be representative.

Management

There are two broad aims to the treatment of CRF:

- to enhance the quality of life
- to extend the duration of life.

Management is approached using two strategies. First, to ameliorate the clinical signs and systemic complications associated with renal dysfunction. Secondly, to prevent further deterioration in renal function, which may involve treating the initiating cause of the renal damage, if this is still present, and halting or slowing the intrinsic progression of CRF that is thought to occur in some individuals. Prevention of the progression of renal failure is pivotal to the treatment of feline CRF because management of end-stage renal failure (by dialysis or transplant) is generally inappropriate owing to cost, technical and ethical considerations.

Progression

The aim of treatment must be to maintain the animal in stable CRF, with GFR at a level where clinical signs of renal dysfunction are tolerable or can be ameliorated using conservative medical management. Therefore, the prevention of progression of renal damage is

vital to the management of these cases. Deterioration in renal function is not necessarily linear and frequently many cats are stable for long periods with intermittent acute decrements.

The postulated causes of progression of renal dysfunction in CRF are many but can be broadly categorised into three groups:

- The primary disease process itself; failure to identify and eliminate the inciting cause of renal failure may lead to ongoing renal damage.
- Loss of renal function leads to derangements of systemic and metabolic homeostasis, including systemic hypertension, hyperphosphataemia, metabolic acidosis, dyslipoproteinaemias, proteinuria and hyperparathyroidism, which may perpetuate the renal injury.
- The kidney attempts to heal and compensate for injury, by glomerular hypertrophy, hypertension and hyperfiltration and interstitial fibrosis, all of which have been implicated in the temporal deterioration of renal function.

After experimental partial ablation, the feline kidney demonstrates compensatory increases in the GFR in each individual nephron [the single-nephron glomerular filtration rate (SNGFR)]. These adaptive mechanisms may be considered beneficial, in that increasing each SNGFR compensates for the loss of nephrons and so minimises the overall decrease in GFR. The hypothesis is that these adaptive changes are a potentially adverse response that represents a final common pathway for the progression of CRF to eventual glomerular sclerosis and end-stage renal failure (Hostetter *et al.*, 1981). In the cat glomerular hyperfiltration is associated with glomerular hypertension, hypertrophy, mesangial expansion and proteinuria (Brown & Brown, 1995). Despite these adaptations, experimental studies of feline CRF using nephrectomy models of renal insufficiency have shown that the cat appears to have comparatively stable renal function for at least 12 months after marked reductions in renal mass, despite the presence of renal changes on histology (Ross *et al.*, 1982; Adams *et al.*, 1993).

After diagnosis of CRF, attempts should be made to identify, and if amenable, treat any primary renal disease that is causing renal damage. The systemic complications of renal failure should also be evaluated and where possible corrected. Although glomerular hyperfiltration, hypertension and hypertrophy are difficult to diagnose clinically, a number of therapeutic manoeuvres may be effective in reducing these potentially maladaptive processes and slowing the intrinsic progression of CRF. These include dietary protein restriction, angiotensin-converting enzyme (ACE) inhibitors, modification of dietary lipid intake and phosphate restriction. Evidence for a beneficial effect on survival for each of these treatments is limited and therefore currently each case should be assessed on an individual basis.

Dietary management

Dietary modification has long been recommended for the management of CRF in cats and the use of commercially available 'renal diets' (in conjunction with dietary phosphate restriction) has been proven to increase survival significantly (Elliott *et al.*, 2000).

Dietary protein restriction is frequently advocated for the management of CRF. In moderate to severe CRF, the controlled restriction of non-essential protein will reduce the accumulation of nitrogenous waste products that are believed to contribute considerably to the clinical signs of the uraemic syndrome. More controversially, the use of a restricted protein diet in early CRF may slow the rate of progression to end-stage renal failure by preventing the maladaptive changes in surviving nephrons. However, evidence for a beneficial effect of protein restriction on renal function is not available in the cat (Adams *et al.*, 1993; Finco *et al.*, 1998).

The use of dietary protein restriction in animals with clinical signs of uraemia is not disputed, although the point at which restriction should be instigated is debatable. If conclusive evidence of an effect on renal progression becomes available then early introduction of low-protein diets would be advisable. Changing the diet is notoriously difficult in cats and such difficulties are exacerbated in animals with a poor appetite. A restricted protein diet introduced before the onset of clinical signs may be more readily accepted than one introduced once uraemia intervenes. Poor appetite and the decreased palatability of restricted protein diets make malnutrition a serious problem in renal failure patients. Cases should be monitored carefully for weight loss and decreasing muscle mass. Malnutrition will lead to catabolism of body protein for energy and a detrimental increase in the production of uraemic toxins.

Other dietary components that have been studied for their effect to modify the rate of progression of CRF include calorie intake and fatty acid composition. Dietary phosphate restriction is discussed under the section on renal secondary hyperparathyroidism.

Angiotensin-converting enzyme inhibitors

ACE inhibitors have been shown to have a renoprotective effect, which is independent of any effect on systemic blood pressure. ACE inhibitor administration in the partially nephrectomised cat reduced glomerular capillary pressure, while sustaining or increasing renal plasma flow and GFR (Brown *et al.*, 2001). ACE inhibitor therapy may be particularly useful in reducing the degree of proteinuria in cats with CRF (Watanabe *et al.*, 1999). The mechanisms of these effects are unclear, but may be haemodynamically mediated by causing renal vasodilatation (especially of the efferent arteriole) and a direct effect of the drug on the glomerular basement membrane. Similar, well-controlled studies in naturally occurring CRF in cats have not yet been reported.

The beneficial effect of an ACE inhibitor, by reducing glomerular pressure, would be expected to cause a decrease in GFR and so may increase azotaemia. A rise in creatinine of more than 50% warrants withdrawal of the drug. As the beneficial effects are not yet fully proven, use of an ACE inhibitor should be on the basis of a therapeutic trial with close monitoring of plasma creatinine, proteinuria and systemic blood pressure.

Complications of chronic renal failure

The multiple functions of the kidney, combined with the widespread effects of uraemic toxins, lead to a number of clinical signs and metabolic disorders – the complications of CRF. These complications may severely affect the quality of life in CRF patients. Equally, these complications may also contribute to the progressive decline in renal function. Effective treatment is available for many of these complications and so frequent monitoring to identify, treat or even prevent these complications is essential. As individual patient responses to therapies vary, monitoring is also vital to ensure efficacy and compliance.

Systemic hypertension

In the cat systemic hypertension usually occurs secondary to other diseases, including CRF. The prevalence of hypertension in CRF varies between studies, presumably due to differences in measurement techniques, animal populations and the cut-off point chosen for the diagnosis of hypertension. For example, hypertension is reported in between 19 and 61% of cats with CRF (Kobayashi *et al.*, 1990; Syme *et al.*, 2002).

In the cat, systemic hypertension has been associated with ocular, renal, neurological and cardiovascular pathology. The main effect of systemic hypertension is on the small arteries and arterioles, which undergo hypertrophy and hyperplasia of the tunica media, loss of the elastic lamina and eventual arteriosclerosis. Arteriolar damage then leads to ischaemia, infarcts and capillary haemorrhage or leakage of plasma proteins in the target tissue.

Under normal circumstances the autoregulatory ability of the kidney protects the sensitive glomerulus from transient increases in blood pressure. However, with renal insufficiency the afferent arterioles are dilated and elevations in blood pressure are transmitted directly to the glomerulus. The resultant glomerular hypertension may initially manifest as proteinuria, but if untreated may progress to glomerular sclerosis and a decline in renal function.

Ideally, serial measurements of blood pressure, as part of regular monitoring, should form the basis of an assessment of blood pressure. As the normal range for blood pressure is technique dependent, it is not possible to give definitive information as to what constitutes hypertension and when therapy is required. The following are broad guidelines for instituting treatment:

- markedly elevated blood pressure (systolic >200 mmHg)
- moderate elevations in blood pressure (systolic >175 mmHg) and evidence of end-organ damage due to hypertension
- persistent moderate hypertension without end-organ damage.

Treatment is usually carried out on a trial basis, monitoring for a decrease in blood pressure without adverse effects or the development of hypotension. In general, a period of about 2 weeks is sufficient to document a response, although if severe clinical signs are present therapy may need to be more aggressive. Classically, a staged therapeutic response is recommended, starting with dietary sodium restriction, followed by the use of various pharmacological agents. Most animals with renal failure are already eating a sodium-restricted diet and in most cases this is not sufficient to reduce hypertension. The current treatment of choice for the cat is amlodipine besylate, a long-acting dihydropyridine, calcium channel antagonist (Snyder, 1998; Elliott *et al.*, 2001). An initial dose of 0.625 mg p.o. per cat once daily is used and may be increased cautiously if the response is poor, to 1.25 mg daily. Combination therapy is required in some cases, with the addition of an ACE inhibitor or

a β-blocker. The use of amlodipine has been shown to decrease the risk of ocular injury and neurological complications in experimentally induced hypertensive renal insufficiency (Mathur *et al*., 2002). Although this same study demonstrated a correlation between albuminuria and systemic arterial blood pressure, antihypertensive therapy has not yet been demonstrated to improve survival in hypertensive cats with CRF.

Renal secondary hyperparathyroidism

Renal secondary hyperparathyroidism (RHPTH) is characterised by excess circulating concentrations of parathyroid hormone (PTH) resulting from altered mineral homeostasis due to decreased renal function. The factors currently thought to be important in the pathogenesis of RHPTH are phosphate retention, due to decreased renal excretion, and decreased synthesis of 1,25-dihydroxycholecalciferol (calcitriol, the active form of vitamin D) by the proximal tubules. Both phosphate retention and decreased concentrations of calcitriol influence PTH secretion indirectly by decreasing ionised calcium concentrations, and also by a direct effect on the parathyroid gland, leading to increased PTH synthesis and eventual parathyroid hyperplasia.

RHPTH is implicated as a cause of intrinsic progression as well as contributing to the uraemic complications of CRF. Excess circulating PTH causes the demineralisation of bone, leading to the various changes termed renal osteodystrophy. Clinical signs of renal osteodystrophy may vary from chronic low-grade bone pain that is not easily localised but may affect the quality of life, to pathological fractures and rubber jaw, both of which are relatively rare in the cat. More widespread uraemic signs have also been attributed, at least in part, to excess PTH. Soft-tissue calcification is a more common manifestation of feline RHPTH that may frequently be noted radiographically. Nephrocalcinosis has been hypothesised as a mechanism whereby RHPTH may be a cause of ongoing renal damage; however, the significance of RHPTH as a cause of progression is controversial.

At the time of diagnosis of CRF approximately three-quarters of cats will have elevated plasma PTH concentrations. The prevalence and severity of RHPTH increases as renal function declines, making RHPTH an inevitable consequence of end-stage renal disease (Barber & Elliott, 1998).

Definitive diagnosis of RHPTH can only be made on demonstration of elevated circulating concentrations of PTH. As intact PTH is heat labile the precise details of sample handling should be confirmed with the laboratory to which the sample is being sent before sampling. In CRF cases, PTH assay is required to assess the degree of RHPTH at the start of treatment and then subsequently to assess the response to treatment, particularly after any changes in therapy. However, when plasma phosphate is elevated above the laboratory normal range, the PTH concentration will also be elevated. There are no controlled clinical studies that suggest that PTH measurement is of value prognostically. In addition, at present, the level to which PTH secretion should be reduced is not known. Nevertheless, serial assay of plasma PTH is often the only objective way of monitoring response to therapy. The PTH concentration in plasma should always be interpreted in conjunction with simultaneous plasma biochemistry results, particularly calcium, phosphate and renal values. Ideally, calcium should be assessed as the ionised fraction, but if this facility is not available, total calcium concentration should be examined.

Therapy for RHPTH should be instituted in a staged manner (Box 10.14). The cornerstone of therapy for RHPTH is dietary phosphate restriction. After initiation of phosphate restriction plasma phosphate levels usually stabilise at a lower level by 2–8 weeks; however, PTH concentrations may continue to decline without additional intervention. Proteinacious foods are the main source of phosphate in the diet, so phosphate restriction is generally combined with protein restriction. The aim of dietary phosphate restriction is not merely to prevent or normalise hyperphosphataemia, but to reduce plasma phosphorus to the lower limit of the reference range, the point at which the most effective control of PTH secretion is usually attained. If dietary management alone is not achieving this or if PTH concentrations are not decreasing, then intestinal phosphate binding agents should be introduced to restrict phosphate intake further.

Intestinal phosphate binding agents form non-absorbable salts of phosphate, binding phosphate in both the diet and intestinal secretions. In all cases dosage should be individualised for each patient and titrated to effect, based on plasma phosphate concentrations. High dietary phosphate limits the effectiveness of phosphate binding agents, so preferably these should be used in combination with a low-phosphate diet. To achieve efficient phosphate binding, the medication should ideally be given mixed through the food or immediately before feeding, and because of this mixing factor, gels and liquids are generally more effective than capsules and tablets.

Phosphate restriction is the most important aspect of treatment of RHPTH. If effective control of phos-

Box 10.14 Management of renal secondary hyperparathyroidism

Dietary phosphate restriction
- Optimum control by reducing dietary phosphate in proportion to reduction in glomerular filtration rate
- Gradual introduction over 1–2 weeks
- Monitor plasma phosphate and parathyroid hormone (PTH) concentrations
- Aim to reduce plasma phosphate to lower limit of reference range
- If limited response after 2–8 weeks consider phosphate binders
- Using commercial or homemade diets

Intestinal phosphate-binding agents
- Form non-absorbable salts of phosphate (both dietary and in intestinal secretions)
- Titrate dosage to effect
- Ideally combine with low-phosphate diet, as high dietary phosphate limits effectiveness
- Give mixed into food or immediately before meal
- Avoid calcium salts in hypercalcaemia or hyperphosphataemia
- Adverse effects: unpalatable, nausea/anorexia, constipation and hypophosphataemia
- Toxicity may be caused by calcium or aluminium (not reported in the cat) absorption
- Aluminium hydroxide 30–100 mg/kg per day, divided doses with each meal
- Calcium carbonate 30–100 mg/kg per day, divided doses with each meal
- Calcium acetate 20–60 mg/kg per day, divided doses with each meal

Vitamin D therapy
- Directly inhibits PTH secretion
- Only use once phosphate controlled and no further reduction in PTH occurs
- Narrow therapeutic index and beneficial effects not proven
- Enhances intestinal absorption of calcium and phosphorus
- Contraindicated in hypercalcaemia and hyperphosphataemia
- Monitor calcium (initially weekly) and titrate dosage to maintain normocalcaemia
- Monitor for beneficial effect, if not seen halt treatment
- Calcitriol 1.5–3.5 ng/kg per day (maximum 10 ng/kg per day)
- Alphacalcidol 1.5–3.5 ng/kg per day (maximum 10 ng/kg per day)

phate intake can be achieved, PTH concentrations can be normalised (Barber *et al.*, 1999). A beneficial effect of dietary phosphate restriction alone has been demonstrated in experimental studies (Ross *et al.*, 1982) and in combination with conventional dietary management in naturally occurring feline CRF (Elliott *et al.*, 2000).

Treatment with an active form of vitamin D has been recommended, to inhibit PTH secretion directly. This group of drugs has a very narrow therapeutic index and as such their use should be restricted to those cases where calcitriol production is limited by structural renal damage, such that no degree of phosphate restriction will normalise calcitriol concentrations. Measurement of calcitriol is expensive and not readily available, and it is therefore assumed that deficiency exists once plasma phosphate is well controlled and no further reduction in PTH occurs. All active vitamin D preparations enhance intestinal absorption of calcium and phosphorus and so are contraindicated unless plasma concentrations of calcium and phosphate are normal. Plasma calcium must be closely monitored, initially weekly, and ideally as ionised calcium rather than total calcium. The dosage should be titrated to maintain normocalcaemia, not merely to decrease PTH concentrations, and therapy discontinued if hypercalcaemia occurs. The long-term advantages of this form of therapy are as yet unproven and if no appreciable clinical benefit is seen (not merely a reduction in PTH concentrations) then the therapy should be discontinued.

Anaemia of chronic renal failure

A normochromic, normocytic, non-regenerative anaemia is often associated with feline CRF. The aetiology of this anaemia is multifactorial, with postulated causes including:

- a relative deficiency of erythropoietin (Cook & Lothrop, 1994) (the kidney is the principal site of production of erythropoietin)

- decreased red blood cell lifespan
- inhibition of erythropoiesis by uraemic toxins
- bleeding tendency due to platelet dysfunction
- blood loss, especially from the gastrointestinal tract.

Management of the anaemia of CRF should include an initial assessment of the cat to rule out and treat other potential causes of anaemia, such as flea infestation and gastrointestinal ulceration. Nutritional and iron deficiencies will impair the erythropoietic potential and should be corrected before initiating treatment. Blood transfusions, androgen and recombinant erythropoietin therapy have all been used to treat the anaemia of CRF. Unfortunately, the limited availability of donor blood and poor efficacy of androgen therapy limit their use.

Recombinant human erythropoietin (rHuEPO) is the most effective therapy for anaemia of CRF (Cowgill *et al.*, 1998), producing a rapid reticulocytosis and increase in haematocrit. Therapy should be started only if clinical signs relating to the anaemia are present, usually when the packed cell volume (PCV) is less than 20%. Initial dosage is 50–100 U/kg injected subcutaneously three times weekly, with PCV monitored at least twice weekly. Once the PCV has increased to the lower end of the reference range, the dosage is usually reduced to once or twice weekly. Adverse effects of rHuEPO include polycythaemia, seizures, hypersensitivity reactions and systemic hypertension. Absolute failure to respond to rHuEPO is usually due to iron deficiency.

After an initial response many cats treated develop antibodies to rHuEPO, which leads to a severe refractory anaemia greater than that present before treatment. This suggests that anti-rHuEPO antibodies interfere with both rHuEPO and endogenous erythropoietin. This anaemia is usually reversible when therapy is discontinued. For this reason rHuEPO should not be initiated too early in the course of progressive CRF.

Box 10.15 Classification of proteinuria

Prerenal
Occurs when the filtered load of a low molecular weight protein exceeds the tubular resorptive capacity

- haemoglobin in haemolytic anaemia
- myoglobin in rhabdomyolysis
- immunoglobulin (Bence Jones proteins) in multiple myeloma
- immunoglobulin in paraproteinaemia (chronic infections, leukaemia)

Renal
- *Glomerular proteinuria*

Results from damage to the glomerular filtration barrier, allowing serum proteins to pass more easily into the filtrate, usually predominantly albumin loss

- glomerulonephritis
- amyloidosis

- *Tubular proteinuria*

Primary tubular proteinuria is characterised by incomplete tubular resorption of proteins in the presence of normal glomerular permeability, typically mild proteinuria

- acute tubular necrosis
- acute and chronic renal failure
- polycystic kidney disease
- Fanconi's syndrome

- *Renal parenchymal inflammation*

Any cause of inflammation within the kidney parenchyma (pyelonephritis) will lead to exudation of inflammatory proteins into the filtrate and hence proteinuria

- pyelonephritis

Postrenal
Inflammatory and degenerative lesions of the urogenital tract distal to the kidneys, proteinuria is mild to moderate and associated with an active urine sediment

- urinary tract infection
- prostatitis, vaginitis
- neoplasia
- urolithiasis

Proteinuria

Proteinuria is defined as an abnormally high concentration of protein in the urine. Proteinuric disorders may be classified as prerenal, renal and postrenal (Box 10.15). Those associated with postrenal conditions are relatively easy to diagnose, animals frequently presenting with clinical signs relating to lower urinary tract or genital disease. With prerenal proteinuria the protein is usually detected as part of the routine screening of the urine of sick patients and clinical signs reflect the underlying disorder. Proteinuria associated with renal lesions is more problematic to diagnose and frequently asymptomatic in the early stages if the protein loss is mild. As this loss increases non-specific clinical signs such as weight loss and lethargy may be noted.

Diagnostic approach to proteinuria

Proteinuria is usually detected on semiquantitative screening tests, such as urine dipstick reagent strips, and the initial objective should be to assess whether this is within the limits of normal urinary protein loss. To determine the significance of proteinuria both the magnitude and persistence of the excess protein loss must be established. The quantity, nature and source of the urinary protein will then aid in reaching a diagnosis. A second sample, preferably obtained by cystocentesis, will allow confirmation of the persistence of the proteinuria and may aid in anatomical localisation of the source of the protein. A negative result implies transient proteinuria or a disease distal to the bladder.

Proteinuria due to inflammatory exudate may be detected by microscopic examination of the urine sediment. The presence of leucocyte or red blood cell casts would confirm a renal involvement; however, these casts are rarely seen and tend to disintegrate in dilute urine. Casts are often present in the urine of animals with moderate to severe proteinuria, most typically hyaline casts, although granular casts are also reported. Although the presence of an active urine sediment does not definitively diagnose lower urinary tract disease, the presence of significant proteinuria with a benign sediment excludes this possibility. In this situation the protein:creatinine ratio should be evaluated to quantify further the urinary protein loss.

Although the magnitude of the proteinuria can be used to predict the site of protein loss, there is great variability in ratios with different diseases. The quantity of protein loss in glomerular disease is massive compared with that in prerenal and postrenal proteinuria. Protein:creatinine ratios of greater than 13 commonly occur in glomerular proteinuria (glomerulonephritis or amyloidosis), animals with amyliodosis tending to have the highest values. Prerenal proteinuria is frequently mild, with a ratio of less than 5, whereas postrenal proteinuria may be mild to moderate.

Results of routine haematology and serum biochemistry may be helpful in cases of prerenal and renal proteinuria. The presence of a hyperproteinaemia or evidence of haemolysis or leukaemia may suggest a prerenal cause. Plasma protein concentration in glomerular disease is variable, hypoalbuminaemia occurring if the protein loss is severe but conversely, especially in cats, hyperglobulinaemia may be associated with the chronic inflammatory focus initiating the lesion. Biochemistry results in cases of renal proteinuria allow the assessment of renal function.

Other diagnostic tests may be used as necessary to elucidate the cause of proteinuria. Protein electrophoresis allows the quantitative estimation of the proteins in the urine and comparison with serum electrophoresis may be used to confirm the presence of a prerenal proteinuria. Assay of proteins such as lysozyme and ribonuclease in the urine would confirm the diagnosis of specific tubular proteinuria. However, these techniques are not widely used in small animal medicine and so are poorly characterised. The main indication for renal biopsy is to distinguish between renal amyliodosis and glomerulonephritis.

Nephrotic syndrome

The nephrotic syndrome is characterised by massive proteinuria, hypoalbuminaemia, hyperlipidaemia and subcutaneous oedema and/or ascites. The proteinuria leads to hypoalbuminaemia, a loss of plasma oncotic pressure and subsequent development of oedema. The pathophysiology of the hyperlipidaemia is complex and not fully understood. The severity of protein loss required to produce the nephrotic syndrome only occurs in renal amyloidosis or glomerulonephritis.

Upper urinary tract infection

A bacterial UTI exists when any portion of the urinary tract that would normally be sterile is colonised by bacteria. In the normal cat the tract distal to the mid-urethra is not sterile but has a commensal bacterial population. The proximal urinary tract is maintained in a sterile state, despite direct communication with the external environment, by a series of anatomical and physiological defence mechanisms. Pathogenesis of UTI is a balance between the virulence of the bacterial agent and these host defences. Treatment involves the use of appropriate antimicrobial agents and consideration of any predisposing factor that may impair these host mechanisms. The major bacterial threat is from ascending colonisation of bacteria from the external environment. Bacterial infections may also result from haematogenous or lymphatic spread.

Infections are unlikely to be localised to one single anatomical site in the urinary tract. It is most likely that the infection will extend to affect other local structures; therefore, it is probably appropriate to avoid strict anatomically based terms such as pyelonephritis and use the phrases lower and upper UTI. Indeed, it is important to realise that once one

part of the system is infected, the whole of the urinary tract is at risk of colonisation.

This consideration of host defences versus microbial virulence leads to the classification of UTIs as being simple or complicated. In simple or uncomplicated UTI there is transient, self-limiting and frequently undetected abnormality of the host defence mechanisms. In complicated UTI there are predisposing abnormalities in the host defences. Consequently, complicated UTIs frequently result in recurrent bacterial infections and the underlying cause must be resolved to prevent these:

- *relapse*: infection persists, is never completely cured, so clinical signs recur
- *reinfection*: recurrent infection due to a different pathogen
- *superinfection*: infection with an additional pathogen during treatment.

Diagnostic investigation of urinary tract infection

Significant bacteriuria must be identified to confirm the diagnosis of bacterial UTI. Full urinalysis allows the detection of bacteria and also permits the detection of factors that may indicate impaired host defence mechanisms.

Localisation of a UTI is important because of the potential serious consequences and differing treatment regimen for an upper UTI. Localisation of an infection within the urinary tract can be a diagnostic challenge. Clinical signs may help to localise the disease, but signs of upper urinary tract disease may be subtle. Palpable abnormalities or pain associated with the kidneys or the presence of systemic illness may be indicative of upper UTI. The presence of casts, particularly white blood cell casts, which eventually degenerate to granular casts, indicates renal involvement. Biochemical evidence of renal dysfunction may point to renal involvement, but pre-existing renal failure could also exist as a predisposing factor to UTI. Upper UTI is often accompanied by a leucocytosis. Diagnostic imaging such as radiography or ultrasound may also be useful. Diagnostic imaging may also detect anatomical abnormalities predisposing to infection.

Treatment of upper urinary tract infection

A limited number of bacterial species causes bacterial UTI in the cat. Commonly isolated species include *Escherichia coli*, *Streptococcus*, *Staphylococcus*, *Proteus*, *Klebsiella*, *Pasteurella*, *Enterobacter* and *Enterococcus*. The treatment for upper UTI needs to be aggressive to ensure that permanent renal damage does not ensue. Bacterial culture is essential to confirm the diagnosis, aid in the antibiotic selection and ensure that a cure has been achieved. Drugs should be chosen that are concentrated in the urine and bacteriocidal antibiotics should be used in preference to bacteriostatic. To confirm the *in vivo* efficacy of treatment, examination of sediment should indicate no bacteria by 4 days following the start of treatment and the cure should be confirmed by repeat culture 1 week to 10 days after completing the course of treatment. Antimicrobial therapy should be continued for at least 3–6 weeks.

If infection recurs then the animal should be considered to have a defective host defence mechanism and a careful diagnostic search for predisposing factors should be made. If a relapsing infection is suspected it suggests that the infection is not being cleared fully. Without the use of serotyping or biotyping techniques, distinguishing a relapse from a reinfection is difficult if the same species of bacterium is isolated. Relapsing infections tend to recur more quickly than reinfections. In this situation a nidus of infection that therapeutic levels of antibiotics do not reach is the most likely cause.

Asymptomatic urinary tract infection

A UTI may be symptomatic or asymptomatic (sometimes termed covert). In asymptomatic infections there are, by definition, no clinical signs referable to the urinary tract. Asymptomatic infections are often found in cats with low urine specific gravity, such as those with CRF or hyperthyroidism. Approximately one-third of cats with CRF will have a UTI at some stage during the course of their disease (Demetriou *et al.*, 1997). Therefore, at-risk animals should have urinalysis and culture as part of their diagnostic investigation and monitoring.

Specific renal diseases

Congenital renal malformations

Congenital renal anomalies such as renal agenesis, renal ectopia and renal fusion have been described in the cat. Under most circumstances, if there is sufficient functional renal mass, there are no clinical signs and the condition is generally found incidentally

either at post-mortem examination or during celiotomy for unrelated reasons.

Unilateral renal agenesis is of note as it is often accompanied by absence of the ipsilateral uterine horn or vas deferens and epididymis, as both organs are embryonically derived from the Müllerian ducts. The ovary and testis are generally unaffected.

Hydronephrosis

Hydronephrosis is defined as dilation of the renal pelvis due to obstructed urine outflow. If the obstruction is severe and prolonged, destruction of the surrounding renal parenchyma will occur. Bilateral disease is usually recognised earlier than unilateral disease owing to the presence of postrenal azotaemia. In unilateral hydronephrosis complete destruction of the renal parenchyma may go unrecognised, as renal excretory function is maintained by the contralateral kidney.

Hydronephrosis is relatively easily recognised on renal ultrasound examination; the renal pelvis is dilated by anechoic fluid and there may be variable loss of renal parenchyma. If sufficiently severe, hydronephrosis may lead to renomegaly. Contrast radiography may be useful to identify the cause of the urinary tract obstruction. In cases where renal damage is severe, renal filtration of contrast will be poor and visualisation of the dilated outflow tract may be difficult.

Glomerulonephritis

In glomerulonephritis glomerular injury is caused by an immune-mediated mechanism. Initially, the glomerular injury is characterised by proteinuria, but as the condition progresses glomerular sclerosis and irreversible damage to the glomerulus may occur, rendering the entire nephron non-functional, decreasing the GFR and causing azotaemia. Clinical signs may relate to either the protein loss, filtration failure or both.

Glomerulonephritits is caused by antibody–antigen complexes present in the glomerulus which cause a localised type III hypersensitivity response, activating complement and leading to glomerular damage. There are three mechanisms whereby such complexes may originate:

- preformed circulating antigen–antibody complexes become trapped in the glomerulus
- *in situ* immune complex formation due to 'planted' antigens of non-glomerular origin
- autoimmune glomerulonephritis, in which antibodies are directed against intrinsic glomerular antigens.

Autoimmune glomerulonephritis has not been recorded as a cause of naturally occurring glomerulonephritis in the cat. The propensity for circulating immune complexes to cause glomerulonephritis is determined by their composition. In the presence of antibody excess the complexes tend to be large and insoluble, and are rapidly removed and destroyed by the reticuloendothelial system. If there is marked antigen excess the complexes do not readily bind complement and so do not induce immune-mediated injury. Mild antigen excess or antigen antibody equivalence produce soluble complexes that are capable of inducing glomerulonephritis.

Glomerulonephritis may be further classified morphologically into minimal change, membranous, proliferative, membranoproliferative and sclerotic. The majority of cases of feline glomerular disease are membranous, although proliferative glomerulonephritis has also been reported. Glomerular sclerosis is probably an end-stage of glomerulonephritis and of more general renal disease. In humans this classification is used to aid the formulation of therapy and prognosis, but such correlations have not been validated in the cat.

Glomerulonephritis may be found in association with any chronic antigenic stimulus, including infectious, inflammatory and neoplastic diseases. Metabolic disorders and administration of various drugs and vaccines may also lead to glomerulonephritis. In the cat, glomerulonephritis has been particularly associated with infectious diseases [including feline leukaemia virus (FeLV), feline immunodeficiency virus (FIV) and feline infectious peritonitis (FIP)] and haemolymphatic neoplasia. There may also be a genetic predisposition to glomerulonephritis, as the condition has been reported in sibling cats (Nash & Wright, 1983). However, in the majority of cases an underlying antigen source is not identified and the disease is classed as idiopathic.

Although a number of case series has been reported, the condition now appears to be relatively rare in the UK. Glomerulonephritis usually affects young adult cats (average age 3–4 years), with males being predisposed (Nash *et al.*, 1979; Arthur *et al.*, 1986). There is no reported breed predilection. Glomerular proteinuria caused by glomerulonephritis is characteristically massive and in many cases may lead to clinical signs related to protein loss, such as weight loss, lethargy and eventually the nephrotic syndrome. Initially, proteinuria may be the sole clinical finding; however, glomerulonephritis will eventually lead to renal damage and if unresolved eventual CRF, with its associated clinical signs.

Urinalysis typically reveals proteinuria with a benign sediment. The severity of the urinary protein loss should be assessed and monitored using the protein:creatinine ratio, and generally ranges from mild to severe (protein:creatinine ratio of 5–13). In the early stages of disease, before the development of renal failure, urine concentrating ability may be retained. Plasma protein concentrations may be variable, hypoalbuminaemia occurring if the protein loss is severe, but conversely hyperglobulinaemia may be associated with the chronic inflammatory focus initiating the lesion. Hypercholesterolaemia is reported as a characteristic feature of the nephrotic syndrome; however, it is a common, non-specific finding in cats with any form of renal disease. Biochemistry results in glomerulonephritis allow the assessment of renal function.

Renal biopsy is the only definitive method of identifying the type of glomerular disease present and distinguishing between glomerulonephritis and amyloidosis. Complete morphological classification of glomerular lesions may require light, electron and immunofluorescence microscopy, and it is important to liaise with the pathologist regarding the preservation of biopsy samples. If glomerulonephritis is suspected a thorough investigation for diseases associated with glomerulonephritis should be done.

Various treatment protocols have been suggested for the management of glomerulonephritis in cats; however, few objective data are available on efficacy. Glomerulonephritis frequently has a waxing and waning course, making interpretation of the efficacy of treatment difficult. Monitoring the urine protein:creatinine ratio (at least two measurements separated by at least 2 days to avoid day-to-day variation), serum albumin, creatinine and urea is essential to evaluate response to therapy.

The principal treatment involves identification and removal of the underlying antigenic stimulus. In apparently idiopathic cases or cases where this stimulus cannot be removed immunosuppressive drugs have been advocated, although the value of this therapy is dubious (Arthur *et al.*, 1986). Immunosuppressive doses of prednisolone (2–4 mg/kg per day) should be used on a trial basis monitoring for efficacy, as alteration of the balance of antibody to antigen may exacerbate the potential for immune complexes to cause glomerular injury. Moderate dietary protein restriction has been suggested to limit the degree of proteinuria and may in addition provide benefits in azotaemic patients. More recently, a beneficial effect including a reduction in proteinuria has been demonstrated in dogs treated with ACE inhibitors (Grauer *et al.*, 2000) and such therapy may be applicable in cats. In cats with clinically significant ascites or oedema cautious use of frusemide may be beneficial to promote removal of excess fluid; however, great care must be taken to avoid dehydration and exacerbation of azotaemia. Cats with concurrent azotaemia should also receive management for CRF.

The prognosis is variable, but the condition tends to be slowly progressive, with approximately half of the affected cats having reasonable survival times (2.5–6 years) (Arthur *et al.*, 1986). Cats presenting in CRF tend to have a poorer prognosis than those presenting with the nephrotic syndrome alone. The severity of glomerular lesions on light microscopy does not correlate well with outcome, but ultrastructural changes and immunohistological findings are of prognostic value (Arthur *et al.*, 1986).

Renal amyloidosis

Renal amyloidosis is characterised by the extracellular deposition of fibrillar proteins arranged in a β-pleated sheet configuration. This biophysical configuration gives these proteins their properties of insolubility and resistance to proteolysis *in vivo*, as well as their specific staining characteristics. A number of classes of amyloidosis are defined in humans, but only reactive (secondary) systemic amyloidosis is of significance in small animal medicine. Reactive systemic amyloidosis occurs secondary to inflammatory, neoplastic and chronic infectious disease, although in many cases the predisposing disease is not found. These amyloid deposits are amino-terminal fragments of serum amyloid A protein, which is an acute-phase protein present in increased concentrations in chronic inflammatory conditions. Only a small percentage of cats with such inflammatory disease develop amyloid deposits, and it is thought that other inherited and acquired factors are likely to be important in these individuals. Familial amyloidosis occurs in Abyssinian cats and is also a reactive systemic amyloidosis.

Severe proteinuria occurs when amyloid deposits present in the glomerulus cause glomerular damage. However, most domestic cats with amyloidosis and at least 25% of Abyssinian cats with familial amyloidosis have medullary amyloid deposits without significant glomerular deposits (DiBartola, 1995). Medullary deposition may result in fibrosis and interference with the blood supply to the inner portion of the medulla causing papillary necrosis. In such cases of medullary amyloidosis proteinuria may be mild or

absent, although the deposits will interfere with renal concentrating ability.

Most cats with spontaneous systemic amyloidosis are middle-aged to older cats. Abyssinian cats first show renal amyloid deposits between 9 and 24 months of age, although these cases usually present with clinical signs from 1 to 5 years of age, with females being slightly overrepresented (DiBartola, 1995). The disease appears to have variable penetrance, and amyloid deposition may be mild and asymptomatic. Renal amyloid deposits lead to progressive renal disease, with the degree of proteinuria reflecting the severity of glomerular involvement. Cats usually present with signs of CRF and weight loss. The kidneys are usually small, firm and irregular on palpation. Laboratory evaluation reveals evidence of renal failure, with a low urine specific gravity occurring early in the course of the disease. In most cases the degree of proteinuria is insufficient to cause hypoalbuminaemia, indeed many cats are hyperglobulinaemic, presumably relating to the underlying inflammatory condition. Amyloid deposition is also found in other tissues in Abyssinian and other cats with systemic amyloidosis. These deposits tend not to cause clinical signs, although acute hepatic haemorrhage has been reported as the presenting sign in a number of Oriental shorthair and Siamese cats with systemic reactive amyloidosis (Zuber, 1997).

Definitive diagnosis is by demonstration of amyloid deposits in the kidneys of affected cats. Amyloid deposits demonstrate characteristic green birefringence after Congo red staining when viewed under polarised light. The diagnosis is frequently difficult to achieve if glomerular involvement is minimal or absent, requiring medullary biopsies.

In contrast to glomerulonephritis, systemic amyloidosis is generally a progressive, fatal condition. Treatment involves identification and removal of any underlying inflammatory or neoplastic condition. General management of CRF should be instituted as required. If the condition is identified before the development of CRF, therapy aimed at preventing further deposition of amyloid and causing the dissociation of existing amyloid fibrils has been suggested, using colchicine or dimethylsulfoxide (DMSO). However, neither drug has been evaluated in the treatment of feline amyloidosis.

Polycystic kidney disease

Renal cysts may be congenital or acquired, and may affect one or both kidneys. Polycystic kidney disease is characterised by multiple cysts occurring in both kidneys. Polycystic kidney disease occurs as an autosomal dominant inherited renal disease of Persian and Persian-related cats, with a prevalence of 45% in some Persian populations (Beck & Lavelle, 2001) and 49% in Persian cats in the UK (Cannon *et al.*, 2001).

The pathophysiology of cystic disease is incompletely understood. Renal cysts are fluid-filled sacs lined with epithelium, which generally originate in existing nephrons and may therefore occur in the renal cortex or medulla. Cystic structures have also been noted in other organs, such as the liver, in cats with polycystic kidney disease. Cysts vary in size from 1 mm to greater than 1 cm and tend to increase in number and size with time. Eventually, progressive cyst enlargement compresses the adjacent renal parenchyma and if sufficient renal mass is affected renal failure will develop.

Clinical signs may be absent if the condition is unilateral or not severe, or cats may present with varying signs of CRF. Renal failure may occur at any age; however, affected Persian cats typically present at approximately 7 years. Renomegaly may be obvious, with the kidneys being irregular in outline. Laboratory evaluation is necessary to determine the extent of the renal dysfunction. Excretory urography may be used to demonstrate the cystic lesions, which appear as radiolucent areas within the renal parenchyma. However, ultrasonographic examination is non-invasive and a very sensitive diagnostic technique for this condition. Cysts are seen as multiple, round, anechoic regions (Figure 10.3).

The autosomal dominant inheritance of polycystic kidney disease in the Persian should make it relatively easy to eliminate from the feline population and several ultrasound-based screening programmes have been established. Potential complications of polycystic kidney disease in humans include hypertension, haemorrhage and infection. Owing to the possible inherited nature of all polycystic renal disease, affected cats should not be used for breeding. There is no specific therapy for polycystic renal disease and treatment is aimed at managing the resultant CRF.

Ethylene glycol toxicity

See also Chapter 4.

Ethylene glycol (EG) toxicity is a relatively common cause of ARF in the cat. EG is colourless and odourless and most often encountered in antifreeze or as an industrial solvent. The lethal dose of EG is 1.5 ml/kg in the cat (Gaynor & Dhupa, 1999). The

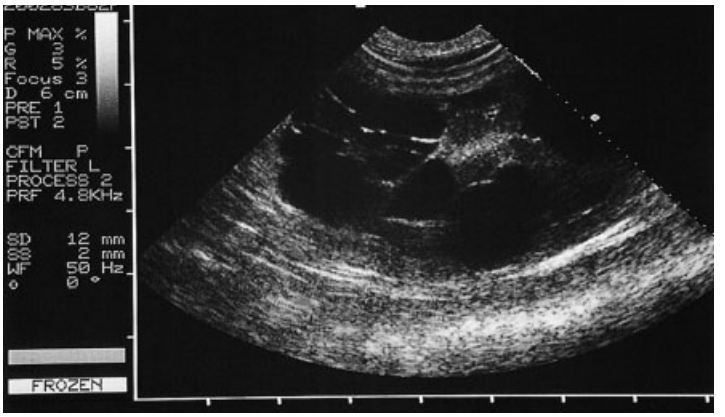

Figure 10.3 Ultrasound image of the kidney of a Persian with polycystic kidney disease. Multiple large anechoic cysts have replaced the normal renal structure.

main toxic effects are caused by the metabolites of EG, although EG itself will cause central nervous system (CNS) depression, serum hyperosmolality and an osmotic diuresis. After rapid absorbtion from the digestive tract, EG is primarily metabolised by hepatic alcohol dehydrogenase to glycoaldehyde. Glycoaldehyde is in turn metabolised to glycolate, glycoxylate and then oxalate.

Initial clinical signs of EG intoxication are CNS depression, ataxia, paresis and eventual seizures, coma and death if sufficiently large volumes have been ingested. Vomiting may also be seen. A severe normochloraemic metabolic acidosis with a high anion gap and serum hyperosmolality occurs. After 12–24 h cardiac and pulmonary signs may be noted, including tachypnoea, tachycardia and non-cardiogenic pulmonary oedema. Finally, oliguric ARF occurs between 12 and 24 h after ingestion (Dial *et al.*, 1994).

Early diagnosis of EG intoxication is important if treatment is to be successful. Biochemical findings reflect the ARF, although in addition hyperglycaemia and hypocalcaemia may be seen. Hypocalcaemia is thought to be caused by chelation of serum calcium by oxalic acid. Urinalysis shows calcium oxalate monohydrate crystalluria from 3 h postingestion (Dial *et al.*, 1994). Hyperechogenicity is often seen on ultrasound examination of affected kidneys. Renal pathology shows acute tubular necrosis with numerous intratubular calcium oxalate crystals.

Gastric lavage or induction of vomiting may be useful to prevent further absorption of EG if ingestion has occurred within 1–2 h of presentation. Specific therapy involves blocking the metabolism of EG by alcohol dehydrogenase to its more toxic metabolites. Ethanol acts as a competitive inhibitor of alcohol dehydrogenase, but causes severe CNS and respiratory depression, usually requiring intensive monitoring. Ethanol is given as a 20% solution at a dose of 5.0 ml/kg i.v. every 6 h for five treatments then every 8 h for four treatments, or alternatively the same total dose may be given as a continuous-rate infusion. 4-Methylpyrazole, which has been used successfully in the dog, is not effective in EG toxicity in the cat (Dial *et al.*, 1994). Supportive therapy with intensive monitoring and management is usually required in these cases, as well as treatment for ARF. Treatment is more successful if initiated before the establishment of ARF. Cats presented in ARF due to EG toxicity have a grave prognosis. Reported fatality rates in cats are between 78 and 100% (Gaynor & Dhupa, 1999).

Hypokalaemic nephropathy

Hypokalaemia is a common finding in cats with stable CRF, occurring in approximately 18% of cases (Elliott & Barber, 1998). Potassium depletion results in morphological and functional abnormalities in the kidney, resulting in a decreased GFR, polyuria and polydipsia (primary polydipsia combined with an impaired tubular response to antidiuretic hormone) and lymphoplasmacytic tubulointerstitial nephritis (DiBartola *et al.*, 1993). In addition, severe hypokalaemia can cause muscle weakness in the cat, characterised by a plantigrade hindlimb stance, stiff gait and cervical ventroflexion. A syndrome of polymyopathy and nephropathy has been induced in cats fed long term on an acidifying diet, high in protein but marginally replete in potassium (DiBartola *et al.*, 1993). Therefore, all cats with renal disease should have regular monitoring of plasma potassium concentrations. Moderate hypokalaemia can be treated with oral potassium gluconate, the exact quantity required being based on serial potassium measurements and the response to therapy. Severe hypokalaemia will require

more aggressive treatment with a combination of oral and intravenous potassium supplementation.

Renal neoplasia

Primary renal neoplasia is relatively rare in the cat and is usually malignant and often unilateral. Metastatic renal neoplasia is more common because of the high blood flow and large capillary network. The most common neoplasm of the feline kidney is lymphoma.

Renal lymphoma is generally a bilateral condition. Affected cats are usually middle-aged to older cats and present with renomegaly and clinical signs compatible with CRF. Renal lymphoma is associated with FeLV infection in approximately half of the cases (Mooney *et al*., 1987), although there is considerable variation in the prevalence of the various anatomical forms of lymphoma and their association with FeLV. Renal lymphoma is often associated with concurrent lymphoma in other tissues such as the nose, eye and CNS. Diagnosis can usually be made based on fine-needle aspiration cytology. Treatment with various chemotherapy protocols has been reported. Survival times are decreased in cats with more marked renal failure, but this should not preclude treatment.

Perinephric pseudocysts

Perinephric pseudocyst (PNP) formation is a relatively uncommon condition of the cat characterised by the accumulation of a variable amount of fluid in a fibrous sac surrounding the kidney. The fluid usually accumulates between the parenchyma and the surrounding capsule, but occasionally may be extracapsular, often being attached at the renal hilus. The PNP is generally composed of fibrous connective tissue with no epithelial lining (therefore the lesion does not represent a true cyst). In the majority of cases the fluid within the PNP is a transudate or modified transudate (Ochoa *et al*., 1999). The pathogenesis of these lesions is uncertain. In a small number of cases the PNP is uriniferous and it is speculated that in these cases urinary tract trauma or obstruction has caused perirenal extravasation of urine, inflammation and the formation of a fibrous sac. The condition may be unilateral or bilateral.

The condition generally affects older cats. The cats are usually presented owing to the presence of abdominal enlargement, or alternatively renomegaly is palpated incidentally on routine examination. The majority of cats have a degree of renal dysfunction, with some cats having clinical signs relating to uraemia. In some cases CRF has been diagnosed before the development of PNP (Ochoa *et al*., 1999). Findings on abdominal ultrasound are very characteristic, with the PNP appearing as a cyst-like structure, filled with anechoic fluid surrounding the kidney. Radiographic findings show renomegaly but excretory urography is required to determine true renal size and the presence of the PNP. However, the study may be of poor quality if renal function is sufficiently compromised. Aspiration and analysis of the fluid will aid the diagnosis and differentiate a PNP from a perirenal haematoma or abscess, which tend to have a mixed rather than an anechoic ultrasound pattern. A uriniferous PNP may be diagnosed by concurrent measurement of fluid and serum creatinine.

The success of treatment will depend on the remaining renal function. Ultrasound-guided drainage of the PNP may provide some relief of clinical signs, but the PNP usually refills, with varying rapidity. This technique is probably best used where CRF precludes surgical management. Surgical resection of the PNP is generally recommended. Combined removal and nephrectomy has tended to result in a poor prognosis with a rapid deterioration in renal function and so should be avoided. Successful omentalisation of a PNP has also been described (Hill & Odesnik, 2000).

References

Adams L.G., Polzin D.J., Osborne C.A. & O'Brien T.D. (1992) Correlation of urine protein/creatinine ratio and twenty-four-hour urinary protein excretion in normal cats and cats with surgically induced chronic renal failure. *J Vet Intern Med* **6**, 36–40.

Adams L.G., Polzin D.J., Osborne C.A. & O'Brien T.D. (1993) Effect of dietary protein and calorie restriction in clinically normal cats and in cats with surgically induced chronic renal failure. *Am J Vet Res* **54**, 1653–1662.

Arthur J.E., Lucke V.M., Newby T.J. & Bourne F.J. (1986) The long-term prognosis of feline idiopathic membranous glomerulonephropathy. *J Am Anim Hosp Assoc* **22**, 731–737.

Barber P.J. & Elliott J. (1998) Feline chronic renal failure: calcium homeostasis in 80 cases diagnosed between 1992 and 1995. *J Small Anim Pract* **39**, 108–116.

Barber P.J., Rawlings J.M., Markwell P.J. & Elliott J. (1999) Effect of dietary phosphate restriction on renal secondary hyperparathyroidism in the cat. *J Small Anim Pract* **40**, 62–70.

Beck C. & Lavelle R.B. (2001) Feline polycystic kidney disease in Persian and other cats: a prospective study using ultrasonography. *Aust Vet J* **79**, 181–184.

Belew A.M., Barlett T. & Brown S.A. (1999) Evaluation of the white-coat effect in cats. *J Vet Intern Med* **13**, 134–142.

Binns S.H., Sisson D.D., Buoscio D.A. & Schaeffer D.J. (1995) Doppler ultrasonographic, oscillometric sphygmomanometric, and photoplethysmographic techniques for non-invasive blood pressure measurement in anesthetized cats. *J Vet Intern Med* **9**, 405–414.

Brown S.A. (1996) Chronic renal failure: recent developments in medical management. In *BSAVA Manual of Canine and Feline Nephrology and Urology* (eds Bainbridge J. & Elliott J.). BSAVA, Cheltenham, pp. 195–208.

Brown S.A. & Brown C.A. (1995) Single-nephron adaptations to partial renal ablation in cats. *Am J Physiol* **269**, R1002–R1008.

Brown S.A., Finco D.R., Boudinot D., *et al.* (1996a) Evaluation of a single injection method, using iohexol, for estimating glomerular filtration rate in cats and dogs. *Am J Vet Res* **57**, 105–110.

Brown S.A., Haberman C. & Finco D.R. (1996b) Use of plasma clearance of inulin for estimating glomerular filtration rate in cats. *Am J Vet Res* **57**, 1702–1705.

Brown S.A., Brown C.A., Jacobs G., *et al.* (2001) Effects of the angiotensin converting enzyme inhibitor benazepril in cats with induced renal insufficiency. *Am J Vet Res* **62**, 375–383.

Cannon M.J., MacKay A.D., Barr F.J., *et al.* (2001) Prevalence of polycystic kidney disease in Persian cats in the United Kingdom. *Vet Rec* **149**, 409–411.

Chew D.J. (2000) Fluid therapy during intrinsic renal failure. In *Fluid Therapy in Small Animal Practice*. 2nd edn (ed. DiBartola S.P.). WB Saunders, Philadelphia, PA, pp. 410–427.

Chew D.J., DiBartola S.P. & Crisp M.S. (2000) Peritoneal dialysis. In *Fluid Therapy in Small Animal Practice*. 2nd edn (ed. DiBartola S. P.). WB Saunders, Philadelphia, PA, pp. 507–527.

Clark K.L., Robertson M.J. & Drew G.M. (1991) Do renal tubular dopamine receptors mediate dopamine-induced diuresis in the anesthetized cat? *J Cardiovasc Pharmacol* **17**, 267–276.

Cook S.M. & Lothrop C.D. Jr (1994) Serum erythropoietin concentrations measured by radioimmunoassay in normal, polycythemic, and anemic dogs and cats. *J Vet Intern Med* **8**, 18–25.

Cowgill L.D., James K.M., Levy J.K., *et al.* (1998) Use of recombinant human erythropoietin for management of anemia in dogs and cats with renal failure. *J Am Vet Med Assoc* **212**, 521–528.

Demetriou J., Barber P.J. & Elliott J. (1997) Influence of urine concentration on growth of bacteria in feline urine. *Proceedings of the World Small Animal Veterinary Association Congress*, Birmingham, UK, April 1997, p. 241.

Dial S.M., Thrall M.A.H. & Hamar D.W. (1994) Comparison of ethanol and 4-methylpyrazole as treatments for ethylene glycol intoxication in cats. *Am J Vet Res* **55**, 1771–1782.

DiBartola S.P. (1995) Renal amyloidosis. In *Canine and Feline Nephrology and Urology*. 1st edn (eds Osborne C.A. & Finco D.R.). Williams & Wilkins, Baltimore, MD, pp. 400–415.

DiBartola S.P., Rutgers H.C., Zack P.M. & Tarr M.J. (1987) Clinicopathologic findings associated with chronic renal disease in cats: 74 cases (1973–1984). *J Am Vet Med Assoc* **190**, 1196–1202.

DiBartola S.P., Buffington C.A., Chew D.J., *et al.* (1993) Development of chronic renal disease in cats fed a commercial diet. *J Am Vet Med Assoc* **202**, 744–751.

Drobatz K.J. & Hughes D. (1997) Concentration of ionized calcium in plasma from cats with urethral obstruction. *J Am Vet Med Assoc* **211**, 1392–1395.

Elliott J. & Barber P.J. (1998) Feline chronic renal failure: clinical findings in 80 cases diagnosed between 1992 and 1995. *J Small Anim Pract* **39**, 78–85.

Elliott J., Rawlings J.M., Markwell P.J. & Barber P.J. (2000) Survival of cats with naturally occurring chronic renal failure: effect of dietary management. *J Small Anim Pract* **41**, 235–242.

Elliott J., Barber P.J., Syme H.M., *et al.* (2001) Feline hypertension: clinical findings and response to antihypertensive treatment in 30 cases. *J Small Anim Pract* **42**, 122–129.

Feeney D.A. & Johnston G.R. (1998) The kidneys and ureters. In *Textbook of Veterinary Diagnostic Radiology*. 3rd edn (ed. Thrall D.E.). WB Saunders, Philadelphia, PA, pp. 466–479.

Finco D.R., Brown S.A., Barsanti J.A., *et al.* (1997) Reliability of using random urine samples for 'spot' determination of fractional excretion of electrolytes in cats. *Am J Vet Res* **58**, 1184–1187.

Finco D.R., Brown S.A., Brown C.A., *et al.* (1998) Protein and calorie effects on progression of induced chronic renal failure in cats. *Am J Vet Res* **59**, 575–582.

Gaynor A.R. & Dhupa N. (1999) Acute ethylene glycol intoxication. Part I. *Compendium for Continuing Education for the Practicing Veterinarian (NA)* **21**, 1014–1023.

Grauer G.F., Greco D.S., Getzy D.M., *et al.* (2000) Effects of enalapril versus placebo as a treatment for canine idiopathic glomerulonephritis. *J Vet Intern Med* **14**, 526–533.

Heuter K.J., Buffington C.A. & Chew D.J. (1998) Agreement between two methods for measuring urine pH in cats and dogs. *J Am Vet Med Assoc* **213**, 996–998.

Hill T.P. & Odesnik B.J. (2000) Omentalisation of perinephric pseudocysts in a cat. *J Small Anim Pract* **41**, 115–118.

Hostetter T.H., Olsen J.L., Rennke H.G., *et al.* (1981) Hyperfiltration in remnant nephrons: a potentially adverse response to renal ablation. *Am J Physiol* **241**, F85–F93.

Jeraj K., Osborne C.A. & Stevens J.B. (1982) Evaluation of renal biopsy in 197 dogs and cats. *J Am Vet Med Assoc* **181**, 367–369.

Kobayashi D.L., Peterson M.E., Graves T.K., *et al.* (1990) Hypertension in cats with chronic renal failure or hyperthyroidism. *J Vet Intern Med* **4**, 58–62.

Krawiec D.R. & Gelberg H.B. (1989) Chronic renal disease in cats. In *Kirk's Current Veterinary Therapy* X (ed. Kirk R.W.). WB Saunders, Philadelphia, PA, pp. 1170–1173.

Lees G.E., Simpson R.B. & Green R.A. (1984) Results of analyses and bacterial cultures of urine specimens obtained from clinically normal cats by three methods. *J Am Vet Med Assoc* **184**, 449–454.

Lulich J.P., O'Brien T.D., Osborne C.A. & Polzin D.J. (1992) Feline renal failure: questions, answers, questions. *Compendium for Continuing Education for the Practicing Veterinarian (NA)* **14**, 127–152.

Mather S., Syme H., Brown C.A., *et al.* (2002) Effects of the calcium channel antagonist amlodipine in cats with surgically induced hypertensive renal insufficiency. *Am J Vet Res* **63**, 833–839.

Minkus G., Reusch C., Häuf A., *et al.* (1994) Evaluation of renal biopsies in cats and dogs – histopathology in comparison with clinical data. *J Small Anim Pract* **35**, 465–472.

Mooney S.C., Hayes A.A., Matus R.E. & Macewen E.G. (1987) Renal lymphoma in cats: 28 cases (1977–1984). *J Am Vet Med Assoc* **191**, 1473–1477.

Nash A.S. & Wright N.G. (1983) Membranous nephropathy in sibling cats. *Vet Rec* **113**, 180–182.

Nash A.S., Wright N.G., Spencer A.J., *et al.* (1979) Membranous nephropathy in the cat: a clinical and pathological study. *Vet Rec* **105**, 71–77.

Ochoa V.B., Dibartola S.P., Chew D.J., *et al.* (1999) Perinephric pseudocysts in the cat: a retrospective study and review of the literature. *J Vet Intern Med* **13**, 47–55.

Osborne C.A., Bartges J.W., Polzin D.J., *et al.* (1996) Percutaneous needle biopsy of the kidney. *Vet Clin North Am Small Anim Pract* **26**, 1461–1504.

Polzin D.J., Osborne C.A., Adams L.G. & Lulich J.P. (1992) Medical management of feline chronic renal failure. In *Kirk's Current Veterinary Therapy* XI (eds Kirk R.W. & Bonagura J.D.). WB Saunders, Philadelphia, PA, pp. 848–853.

Polzin D.J., Osborne C.A., Bartges J.W., *et al.* (1995) Chronic renal failure. In *Textbook of Veterinary Internal Medicine*. 4th edn (eds Ettinger S.J. & Feldman E.C.). WB Saunders, Philadelphia, PA, pp. 1743–1760.

Rogers K.S., Komkov A., Brown S.A., *et al.* (1991) Comparison of four methods of estimating glomerular filtration rate in cats. *Am J Vet Res* **52**, 961–964.

Ross L.A. & Finco D.R. (1981) Relationship of selected clinical renal function tests to glomerular filtration rate and renal blood flow in cats. *Am J Vet Res* **42**, 1704–1710.

Ross L.A., Finco D.R. & Crowell W.A. (1982) Effect of dietary phosphorus restriction on the kidneys of cats with reduced renal mass. *Am J Vet Res* **43**, 1023–1026.

Russo E.A., Lees G.E. & Hightower D. (1986) Evaluation of renal function in cats, using quantitative urinalysis. *Am J Vet Res* **47**, 1308–1312.

Snyder P.S. (1998) Amlodipine: a randomized, blinded clinical trial in 9 cats with systemic hypertension. *J Vet Intern Med* **12**, 157–162.

Star R.A. (1998) Treatment of acute renal failure. *Kidney Int* **54**, 1817–1831.

Syme H.M., Barker P.J., Markwell P.J. & Elliott J. (2002) Prevalence of systematic hypertension in cats with chronic renal failure at initial evaluation. *J Am Vet Med Assoc* **220**, 1799–1804.

Walter P.A., Feeney D.A., Johnston G.R. & Fletcher T.F. (1987) Feline renal ultrasonography: quantitative analyses of imaged anatomy. *Am J Vet Res* **48**, 596–599.

Watanabe T., Mishina M. & Wakao Y. (1999) Studies with the ACE inhibitor benazepril in an experimental model and in clinical cases of renal insufficiency in cats (Abstract 106). *J Vet Intern Med* **13**, 252.

Yeager A.E. & Anderson W.I. (1989) Study of association between histologic features and echogenicity of architecturally normal cat kidneys. *Am J Vet Res* **50**, 860–863.

Zuber R.M. (1997) Amyloidosis in oriental shorthair cats. In *Consultations in Feline Internal Medicine* 3 (ed. August J.R.). WB Saunders, Philadelphia, PA, pp. 337–340.

Further reading

Lane I.F., Grauer G.F. & Fettman M.J. (1994) Acute renal failure. Part II. Diagnosis, management and prognosis. *Compendium for Continuing Education for the Practicing Veterinarian (NA)* **16**, 625–645.

Osborne C.A., Stevens J.B., Lulich J.P., *et al.* (1995) A clinician's analysis of urinalysis. In *Canine and Feline Nephrology and Urology*. 1st edn (eds Osborne C.A. & Finco D.R.). Williams & Wilkins, Baltimore, MD, pp. 136–205.

Polzin D.J. & Osborne C.A. (1995) Pathophysiology of renal failure and uraemia. In *Canine and Feline Nephrology and Urology*. 1st edn (eds Osborne C.A. & Finco D.R.). Williams & Wilkins, Baltimore, MD, pp. 335–367.

Chapter 11

THE LOWER URINARY TRACT

C.J. Gaskell

Introduction

Feline lower urinary tract disease (LUTD) is a common reason for presentation in general veterinary practice. The all-embracing term brings together those clinical cases which show signs of haematuria, increased frequency of urination, straining and difficulty in urination, partial and complete obstruction of the urethra, and rarely urinary incontinence. While numerous specific conditions are recognised, the majority of cases of feline LUTD are of unknown aetiology and are referred to as idiopathic feline lower urinary tract disease (IFLUTD). This is a useful clinical grouping, but it has been rightly argued that this may well include a number of aetiologically distinct entities and the designation should not be used as a diagnostic dustbin or preclude proper investigation (Osborne *et al*., 1999). Full evaluation of all cases is essential for correct diagnosis.

Investigation

History and clinical examination

The investigation of cases of LUTD requires, as in all clinical cases, a thorough history and clinical examination. The history should include full details of the presenting complaint and any evidence of previous episodes. Male cats, specifically neutered male cats, are overrepresented in surveys of LUTD. Some causes of LUTD, for example neoplasia, tend to occur in older cats, while IFLUTD is recognised more frequently in younger adults. The potential for owner confusion between straining to pass faeces and urine should be appreciated. Recurrence is common in certain types of LUTD.

Cases of LUTD are frequently unremarkable on clinical examination. Important exceptions are those animals with urethral obstruction where palpation of a distended and painful urinary bladder should alert the clinician. Care should be taken not to rupture the bladder. Such cats may be depressed or even collapsed as a result of postrenal failure, a potentially life-threatening situation that requires immediate recognition and management.

Laboratory tests

Urinalysis is a routine and basic aid to the examination of cases of LUTD. The technique used for obtaining a urine sample depends to some extent on the tests to be applied. A fresh sample obtained from a clean box with no litter, or non-absorbent litter, is satisfactory for basic urine analysis, i.e. specific gravity, pH and crude assessment of protein levels, but not for sediment or bacteriological assessment.

Urine caught midstream provides a better sample and can be obtained from most cats by the application of steady, but not excessive, pressure on the bladder through the abdominal wall. There is little point, and some danger, in increasing the pressure in a cat that is unwilling to release urine. Such cats may urinate naturally as soon as they are returned to the cage.

Urethral catheterisation in the cat requires heavy sedation or general anaesthesia if damage to the urethral wall as a result of spasm or struggling is to be avoided. A 'tom-cat' catheter with a stylet can be used in both sexes. In the male the penis is extruded manually and the well-lubricated catheter introduced into

the urethral orifice. The catheter will pass easily for the first 2 cm or so, but resistance is frequently encountered at the brim of the pelvis; release of the extruded penis will allow the urethra and catheter to move cranially into the pelvic cavity and the catheter can be advanced. In the female the urethral orifice does not protrude above the floor of the vagina and may be catheterised by running the tip of the catheter blind along the floor of the vagina. If this is not successful, an auroscope may be useful to identify the urethral opening. Urine obtained by catheterisation may be contaminated by bacteria from the external genitalia.

Cystocentesis, that is the direct puncture of the bladder through the abdominal wall, provides the most satisfactory sample for urine analysis and represents a sterile technique for obtaining a sample for bacterial culture. The procedure is no more stressful than routine blood sampling and provided restraint is adequate to prevent sudden movement, can be done without sedation or anaesthesia. The cat is restrained in lateral recumbency and a small area of the ventral midline just cranial to the pubis shaved and cleaned. The bladder is held against the ventral abdominal wall, a needle (23 G) introduced through the abdominal wall into the bladder and urine removed. If the bladder is not palpable the cat is caged until sufficient urine has been formed. The slight trauma to the bladder wall may lead to the presence of a few red blood cells (RBCs) in the sample.

The concentration of urine in normal cats, as assessed by specific gravity (SG), is variable, but may be high (>1045) in animals fed low-moisture or dry foods. It is best measured using a refractometer. Urine in cases of LUTD is often concentrated, but SG is not specifically affected in uncomplicated disease. Urinary pH is also variable and, while typically acidic on a meat-based diet, is influenced by dietary composition. Urine produced in the hours following a meal is alkaline (the postprandial alkaline tide), although such fluctuations in pH level out within the bladder in most cats that urinate only infrequently. Urine retained for a long time in the bladder also tends to become more alkaline. Lower urinary tract bacterial infection may be associated with a rise in urinary pH, due to breakdown of urea in the urine by urease-producing organisms. The use of pH meters is preferred to the use of urine dipsticks.

Urinary protein levels are generally higher in the cat than in the dog and the presence of slight or moderate proteinuria, as assessed by dipstick techniques, does not itself indicate significant urinary tract disease. In the context of LUTD, findings of urinary protein must be interpreted in conjunction with examination of the urinary sediment. Inflammation of the lower urinary tract will inevitably be associated with some proteinuria. The presence of lipid droplets in feline urine is a normal finding and is related to the large amount of lipid present in normal renal tubules of all members of the Felidae.

Phosphate, or struvite, crystals are also a normal component of feline urinary sediment, particularly in alkaline urine. Whether such crystalluria is an accurate reflection of bladder urine composition is debatable, as crystals precipitate in cooling urine and may be seen forming in freshly voided urine on a microscope slide. The tendency for cats to show stress hyperglycaemia is sometimes reflected in glycosuria in otherwise normal animals.

Microscopic examination of urinary sediment is a crucial part of urinalysis in cases of LUTD. The presence of inflammatory cells (pyuria) and RBCs, and crystalluria are frequent findings in a range of conditions. Haematuria (the presence of RBCs in the urine), together with crystalluria, is a frequent finding in IFLUTD, often in the absence of pyuria. In some cases haemorrhage from the lower urinary tract may be considerable. Some RBCs may be seen in cystocentesis samples as a consequence of the technique. Cytological examination of urine sediment may reveal evidence of neoplastic disease of the bladder but is unreliable. Further discussion of urinalysis in the context of renal disease is found in Chapter 10. Davies (1998) provides useful further reading on clinical pathology in LUTD.

Urine bacterial culture, with parallel or subsequent antibiotic sensitivity, should be carried out where urinalysis suggests the presence of bacterial infection. This should ideally be attempted before any use of antibiotics or after a period of withdrawal of treatment. The attempted culture of viruses from feline urine is not currently a routine diagnostic procedure and the significance of any isolate is, in any case, unclear.

Routine haematology and blood biochemistry are frequently normal in uncomplicated cases of LUTD. Cats with urethral obstruction will show marked elevations in blood levels of urea and creatinine, together with hyperkalaemia where obstruction has been present for some time.

Diagnostic imaging

Imaging of the lower urinary tract using either radiography or ultrasound can be a useful adjunct to diagnosis. Radiographs of the urinary tract should be

preceded by 12 h of starvation and an enema should be given to ensure the removal of overlying faeces. Contrast studies of the lower urinary tract necessitate urethral catheterisation and heavy sedation or anaesthesia is required. Plain, or survey, radiographs of the caudal abdomen will usually show the urinary bladder in a well-nourished cat with good abdominal contrast. Plain radiographs of non-obstructed cases of IFLUTD are generally normal. Radiopaque cystic calculi above a certain size (3–5 mm) may be seen on plain films, but contrast studies are necessary to demonstrate radiolucent or soft-tissue structures in the lumen of the bladder, to reveal thickening or irregularities of the bladder wall, or to identify an unseen bladder.

Contrast studies are also of value in demonstrating the presence of vesicourachal or other diverticulae, not uncommon complications of LUTD in cats. Contrast agents, negative (air to create a pneumocystogram) or positive (generally iodine-based water-soluble agents), can be introduced via a urethral catheter after the bladder has first been emptied of urine; 30 ml is usually adequate for bladder distension. Where bladder rupture is suspected air is generally avoided because of the albeit slight risk of air embolism. Double-contrast studies of the bladder are of most use where irregular or ulcerating lesions of the wall are suspected (e.g. in bladder neoplasia); an initial 5 ml of positive contrast is followed by distension of the bladder with air. Although not essential, it is good practice to remove the contrast agents from the bladder after cystography.

Radiographic examination of the ureters may be carried out using intravenous urography. Iodine-based contrast agent is excreted by the kidneys and can be seen radiographically delineating the ureters. The procedure is of most potential value in investigating cases of suspected ectopic ureters. Radiography of the urethra by, for example, retrograde introduction of positive contrast, is not frequently carried out. Scrivani *et al.* (1997) described experience of retrograde urethrography in cats with non-obstructive LUTD and found it generally unrewarding, although it may be of value in the investigation of repeated obstruction in male cats.

The use of ultrasound to obtain images of the lower urinary tract, specifically the bladder, can be valuable (Voros *et al.*, 1997). The advantages over radiography include safety, the ability to carry out the procedure in a conscious patient and the ability to investigate fluid spaces without the use of contrast agents. Assessment of the density of cystic calculi is better made radiographically.

Cystoscopy, or uroendoscopy, which is of value in the investigation of bladder disease in the bitch, is less practicable in cats owing to their small size. However, recent advances in technology are making it more feasible and its application has been recently reviewed (Cannizzo *et al.*, 2001)

Biopsy

The taking of a biopsy from the bladder at exploratory cystotomy may be helpful in confirming some diseases of the lower urinary tract, such as neoplasia, but findings in the majority of cases are non-specific.

Idiopathic feline lower urinary tract disease

IFLUTD is a grouping of cases that present with similar clinical signs for which no clear aetiology can be demonstrated. Numerically, this is an important condition or group of conditions, for it is probable that within IFLUTD there are several different entities. These cases are characterised by haematuria and dysuria, with or without urethral obstruction, and have been variously referred to over the years as feline urolithiasis or urological syndrome (FUS), or on the basis of different clinical presentations, such as urethral obstruction (urethral plugs, 'blocked cat') or idiopathic, 'sterile' or interstitial cystitis. These clinical signs may be seen with any condition of the lower urinary tract, and this makes it important to rule out other, albeit less common, causes of disease. The incidence of IFIUTD has been assessed by a number of surveys in Britain and the USA as between 0.5 and 1% of the general cat population per annum, although up-to-date data are not available. The incidence within referral veterinary populations is much higher (Osborne *et al.*, 2000). It is a clinical impression in the UK that the incidence has fallen in recent years, and objective evidence to this effect is available for feline urethral obstruction in North America (Osborne *et al.*, 2000).

Urethral obstruction with a mixture of struvite crystals and a proteinaceous matrix occurs, for purely anatomical reasons, almost invariably in the male: cystitis is seen with equal frequency in both sexes. Despite initially conflicting data, neutered cats appear to be at greater risk. There is no clear explanation for this; it does not appear to be related in the male cat to urethral development and diameter. IFLUTD is

uncommon in cats less than 1 year of age and shows no marked breed incidence, although it may be seen relatively more frequently in longhaired cats. Recurrence is common in unmanaged cats, varying between 30 and 50% in different series.

Pathogenesis and aetiology

The pathogenesis of the 'clinical' stages of IFLUTD is fairly clear, although the sequence of events before the development of signs is poorly understood. The urethral obstruction seen in the male is due to the accumulation of struvite ($MgNH_4PO_4 \cdot 6H_2O$) crystals in a proteinaceous matrix in the urethra, typically at the tip of the penis or at the level of the bulbourethral glands. Occasionally, the obstructing material may be predominantly crystalline, and less commonly it may be sabulous (a purely proteinaceous or matrix plug) in nature. Similar material may be found in the bladder. The effect of the urethral obstruction is to reduce, and eventually stop, glomerular filtration, leading to a rapid build-up of waste metabolites such as urea, and a failure of kidneys to maintain ionic and acid–base balance. Failure of renal function, and particularly the development of hyperkalaemia, leads to coma and death in 48–92 h (Burrows & Bovee, 1978).

The bacteriologically sterile cystitis recognised as part of IFLUTD is seen in both sexes. Recent literature has drawn attention to the possible similarities between this clinical presentation in cats and interstitial cystitis (IC), an idiopathic condition of people (Clasper, 1990; Buffington *et al.*, 1996; Westropp & Buffington, 2002). The term feline interstitial cystitis (FIC) has been coined, and the condition in cats proposed by some as a useful model for human disease.

The aetiology of IFLUTD is not known, although it is clear that various factors may predispose an individual cat to the condition. Several of these factors were identified in epidemiological studies carried out in Europe and the USA in the 1970s (Dorn *et al.*, 1973; Willeberg, 1975, 1981; Reif *et al.*, 1977; Walker *et al.*, 1977) and confirmed in later surveys (Buffington *et al.*, 1997; Lekcharoensuk *et al.*, 2001); they included inactivity, as assessed by access to and time spent out-of-doors, neutering, being overweight, eating dry food and having a low fluid intake. These and other factors may also act synergistically, the possession of more than one predisposing factor giving more than additive risk value (Willeberg & Priestler, 1976).

A number of these factors had been identified as early as the 1920s (Kirk, 1925): some have been the subject of very considerable investigation. Suggestions that diet may have a crucial role in IFLUTD through its effect on urinary environment have been frequently made: possible factors have included the level of ash in the diet and dietary magnesium concentrations, the feeding of low-moisture or dry cat foods (DCF), and the influence of diet on urinary pH. However, the feeding of high-ash diets does not in itself appear to be important. While the disease can be produced by feeding high levels of dietary magnesium, such levels are considerably higher than those found in commercial cat foods and the effect is influenced significantly by other dietary ions and urine pH.

An increased risk of IFLUTD has been associated with the feeding of low-moisture or DCF, most marked when these foods form a high proportion of the diet. The increased risk of IFLUTD on DCF compared with other types of diet (e.g. canned) may be associated in part with the effect on the cat's total fluid intake and hence urinary concentration. The related factor of extra-food fluid intake has also been shown to influence the risk of disease, those cats drinking 'less than a saucer-full' of fluid daily being significantly more likely to develop FUS (Walker *et al.*, 1977). It has been shown that cats have a lower total fluid intake, lower urinary volume and more concentrated urine when fed an experimental diet in a dry form (i.e. 90% dry matter) than when the same food is fed in a higher moisture form (i.e. 10% dry matter) (Gaskell, 1979). The manner of feeding may also influence the effect, for the kinetics of fluid balance in cats fed specific meals of DCF may differ considerably from those in animals fed on an *ad libitum* basis.

Feeding patterns, as well as the composition of the diet, will also influence urinary pH, an important role for which has been identified in IFLUTD. Urine of low pH (<6.8) reduces the incidence of struvite crystalluria and hence the risk of urethral obstruction. This observation, together with the role of dietary ionic composition, has formed the basis of the dietary recommendations for the management of the condition that have been developed in recent years.

These various factors, while important, are clearly not the cause of IFLUTD, since they are present in many healthy cats and absent in some cases of the disease. Indeed some, such as the impact of dietary composition, will have changed as formulations of commercial diets have been changed in the light of the findings of epidemiological and other studies.

A role for viral agents in the aetiology of IFLUTD was suggested in the early 1970s following the isolation of a calicivirus (Manx strain) and subsequently a second, cell-associated feline herpes virus, which

was shown to induce disease in susceptible cats (Fabricant, 1977). Other workers have been unable to confirm these findings and it seems unlikely that the primary cause of IFLUTD is viral (Gaskell *et al.*, 1979), although some hypothesise a role for calicivirus infection in some cases (Osborne *et al.*, 2000). Subsequent work with the original North American herpesvirus isolate has not been conclusive, but has shown a close relationship between the virus and a bovine herpesvirus (BHV4) (Kruger *et al.*, 1989). While a number of cases may be secondarily infected with bacteria, it is generally accepted that such infection has no primary role in IFLUTD (Shechter, 1970).

The demonstration of bladder diverticulae, usually at the site of the foetal urachus, is not uncommon in cases of IFLUTD and particularly in cases of urethral obstruction where intraluminal pressure has been high. They are not considered primary and are self-limiting once the LUTD is controlled.

IFLUTD almost certainly includes a number of different entities and each in turn may be multifactorial in origin. Notwithstanding the inconsistencies and difficulties of disease definition, various epidemiological studies have produced a profile of the cat most likely to develop the clinical condition, and thereby suggested logical approaches to management. The increased ability to manipulate the pathogenesis of the condition by altering the urinary environment through commercially available diets is valuable, particularly for cats known to be predisposed, but a lack of understanding of the underlying aetiology of the condition remains. The role and importance of the protein component of the obstructing material, which may be crucial for the development of the condition, are particularly poorly understood.

Clinical signs

The clinical signs associated with IFLUTD are haematuria, increased frequency of urination, and dysuria or anuria. Within the broad description, the syndrome can be divided into cats with cystitis/urethritis and no obstruction to urine flow, and those with partial or complete urethral obstruction. In the latter group, the presence of obstruction leads to increasing attempts to urinate, abdominal discomfort, licking of the perineum and progression to depression, coma and death from renal failure within 36–92 h. In the early stages, owners may confuse the signs with those of constipation. On clinical examination the bladder of obstructed cats is large, tense and painful: care should be taken to prevent bladder rupture, which may occasionally occur spontaneously. In cases of cystitis the bladder is small, firm and painful, but the cat is generally systemically well.

Diagnosis

Diagnosis of IFLUTD is usually uncomplicated and based on clinical signs, but the lack of a definitive diagnostic test makes possible potential confusion with other causes of LUTD. This makes the use of urinalysis and culture/sensitivity and, on occasions, radiography or other diagnostic techniques, essential in those cases that are not typical or fail to respond as expected to treatment. Haematology and blood biochemistry are not helpful diagnostically, although in cases of urethral obstruction will show changes consistent with impairment of renal function.

Management

The management of cases of IFLUTD is best considered under two categories, those cases with urethral obstruction and those cases that are not obstructed.

Urethral obstruction

The treatment of cats with urethral obstruction should be regarded as an emergency. Management is based on an understanding of the pathogenesis of the clinical signs and consists of not only the relief of the obstruction, but also the correction of the systemic effects of the renal failure. While in many cases of recent obstruction the systemic effects are limited, in some cats their correction is the priority. In such cases immediate relief of bladder pressure by cystocentesis should be followed by stabilisation of the patient before clearance of the obstruction is attempted. The prevention of recurrence, both in the immediate post-obstruction period and in the long term, is also an important consideration.

Relief of the obstruction

The aim of the treatment is to clear the obstruction with a minimum of additional trauma to the urethra, and hence the lowest risk of subsequent scarring and narrowing. Treatment with antispasmodics, for example acepromazine, is rarely successful, although it has the advantage of being atraumatic. Occasionally, and where the obstruction is at the tip of the penis, the white gritty material may be milked from the urethra by gentle massage of the lubricated penis. The use of

manual pressure on the bladder to force the obstructing material out is rarely helpful and carries the considerable risk of rupturing the bladder.

In a large number of cases, urethral irrigation and catheterisation are necessary to clear the obstruction. This should be carried out under general anaesthesia in all but the most depressed animals to avoid iatrogenic damage to the urethra. The choice of anaesthetic agent should acknowledge the compromised state of the cat and in particular the impairment to renal excretion. Decompressive cystocentesis is often indicated before catheterisation to relieve both backpressure on the upper urinary tract and forward pressure on the obstructing material in the urethra. It also provides a pretreatment urine sample for analysis and culture. Care should be taken not to introduce the needle from a position too far cranially, as the bladder may slip off the end of the needle as it reduces in size.

Following extrusion and cleaning of the penis, initial irrigation is best achieved using a suitably lubricated blunt-ended lacrimal duct or similar needle. Sterile water or saline should be used repeatedly to flush and dilate the urethra in an attempt to break down or allow the passage of the obstructing material. Once the penile urethra has been cleared, a plastic tom-cat catheter may be passed and irrigation continued where a higher obstruction is present. Some difficulty in the passage of the catheter will usually be appreciated in the normal cat with the penis extruded as the urethra passes over the ischium, and this should not be confused with pathological obstruction; release of the penis and caudal traction on the prepuce will allow the urethra to straighten and the catheter to pass into the pelvic urethra.

Repeated lavage of the urethra is often required before the obstructing material is removed. The material should be flushed clear; forcing the catheter past the obstructing plug will traumatise the urethral wall and predispose to later stricture formation. Reintroduction of the metal stylet with the catheter in the urethra should also be avoided as the stylet may well pass through the side-holes and damage the urethra. Once the catheter has been passed, the bladder is emptied by syringe using gentle suction; lavage of the bladder with sterile water or saline to remove crystalline or other debris may be of value, but should be weighed up against potential trauma to the bladder wall. The installation of antibacterial agents is of doubtful value, unless a bacterial cystitis is present. Systemic antibiotics are preferable if indicated (see below).

Failure to relieve the obstruction is an indication for urethrostomy, although this technique, if needed at all, is better carried out as an elective procedure when the urethra and the cat have recovered from the acute obstructive episode.

Correction of systemic effects of obstruction

The depression seen in cats with complete obstruction for longer than 24 h is associated with acidosis, raised plasma potassium levels and azotaemia. Blood urea levels, often greater than 60 mmol/l, may indicate the severity of the renal failure, which becomes life threatening but is invariably reversible. Together with the restoration of urine flow, treatment should include intravenous fluid therapy with a balanced electrolyte solution such as lactated Ringer's; the small amount of potassium in these fluids is probably insignificant. In the absence of immediate laboratory results or blood gas analysis as a basis for treatment, an electrocardiographic trace is of value. The loss of P waves and spiked T waves are useful markers of hyperkalaemia and imply an associated acidosis. Blood gas analysis will quantify the bicarbonate deficit, but in the absence of such measurements, sodium bicarbonate is indicated in depressed animals at a rate of 1–3 mEq/kg body weight, by slow intravenous injection and by the addition of a similar amount to the intravenous fluid. This dose of bicarbonate may be repeated as necessary. Such cats are frequently hypothermic, and warmth and general nursing are important. The use of intravenous insulin together with glucose to reduce hyperkalaemia rapidly has been described (Schaer, 1975) but is rarely indicated, particularly if sodium bicarbonate is used.

Management in the postobstruction period

The maintenance of urine flow immediately following relief of the obstruction is important both to maintain urethral patency and to monitor urine production. The placement of an indwelling urinary catheter will achieve this for those cats where urine flow is still restricted by, for example, severe mucosal swelling or the presence of residual debris, or where overdistension of the bladder has led to a degree of atony. However, indwelling catheters tend to cause further damage to the lower urinary tract and may well facilitate ascending bacterial infection, and the decision on whether to use one is based on the particular circumstances in an individual case. In cases where relief of obstruction is straightforward and the cat is systemically well, the use of an indwelling catheter is rarely indicated. Where an indwelling catheter is used, it should be for as short a time as possible.

A catheter is secured to the prepuce by three or four loose stitches and the resultant incontinence may be controlled in severely depressed cats by attaching tubing, for example from an intravenous administration set, to the catheter, carrying the urine away to a bottle. The tubing may be bandaged to the tail to take any tension off the urethral catheter. An Elizabethan collar is often necessary to prevent the cat interfering with the catheter or tubing. The patency of the indwelling catheter should be checked regularly and any obstruction of the catheter cleared by retrograde flushing. The use of antibiotics to prevent secondary bacterial infection is controversial, and should ideally only follow demonstration of infection, culture and sensitivity. Prophylactic use in the presence of an indwelling catheter may merely encourage resistant infections. Antibiotics should be chosen on the basis of their known value in urinary tract infections, and nephrotoxic drugs should be avoided. Urinary antiseptics containing methylene blue cause haemolytic anaemia in cats and should be avoided. Cats that have recently been obstructed should not be given urinary acidifiers.

Some cats undergo a marked diuresis following the relief of the obstruction; this may last for 2 or 3 days, or in some cases up to 10 days, and is believed to be due both to the clearance of accumulated metabolites, and to a temporary inability of the renal tubules to concentrate urine effectively. Fluid therapy, either subcutaneous or intravenous, is necessary to maintain hydration in these animals. Initially, a balanced electrolyte solution is appropriate, but in a small number of cats continued diuresis may lead to excessive loss of ions, and supplementation, particularly with potassium, may be necessary. The potential for both dehydration and hypokalaemia in these cats should be recognised and monitored for if diuresis is prolonged.

The use of antispasmodics, such as prazosin, phenoxybenzamine or dantrolene, is advocated by some following the relief of obstruction for their action on the muscle of the urethra. However, little objective evidence exists for their efficacy and all may lead to side-effects. Similarly, the use of drugs such as bethanacol to improve detrusor muscle contractility has not been shown to have a benefit over the bladder rest provided by catheterisation, and may also be associated with side-effects.

Long-term management

Recurrence of urethral obstruction is common in obstructive IFLUTD; in one series in the UK some 30% of cats surviving the obstructive episode had further episodes within 6 months (Walker *et al.*, 1977). Owners should be made aware of this and warned to look for the early signs of obstruction. While prevention of recurrence is hampered by a poor understanding of the underlying cause or causes, it is logical to attempt to control those factors that have been recognised as predisposing to IFLUTD and to the development of struvite crystalluria. Commercial diets are available that are low in magnesium and that produce a urinary environment of low pH. Low fluid intake is known to be associated with the condition; thus, DCF should be avoided and the cat may be encouraged to take in more fluid by adding water to the food. Fresh water should always be available. A cat that is overweight and has low levels of activity is also at greater risk of developing IFLUTD, but these factors are less easy to manipulate. A clean litter tray or ready access to outside should always be provided. If non-acidifying diets are used, urinary acidifiers may be valuable in the long term; not all are useful in consistently reducing pH, but methionine and ammonium chloride have been shown to be effective. Acidifiers are best given with food to offset the effect of the alkaline tide.

Recurrence of urethral obstruction in the male cat may be prevented by the surgical removal of the distal, narrow portion of the urethra, the most commonly used techniques being perineal or prepubic urethrostomy. Of these two techniques, the former is favoured by most, and has been adequately described in the literature (Johnston, 1974; Gaskell *et al.*, 1978). Prepubic urethrostomy is indicated where the damage to the urethra is proximal, or as a salvage procedure following failure of perineal urethrostomy. Such surgery should be reserved for those cases where repeated obstruction occurs despite the use of dietary and other management measures. Recurrence in these cases is often associated with a degree of urethral stricture. Careful examination is indicated to identify the site of stricture and to rule out other causes of urethral obstruction. The prognosis following urethrostomy is good, although surgery does not control the underlying problem of IFLUTD and recurrent sterile cystitis may occur. It has also been well demonstrated that ascending bacterial cystitis is common following perineal urethrostomy. Further urethral stricture and urinary incontinence have both been recorded as postoperative problems, but are not common following uncomplicated surgery.

Cystitis

Cases of idiopathic cystitis usually resolve spontaneously over a few days; traditionally, management has

included urinary acidifiers, the feeding of a high-fluid ('wet') diet and, although there is no evidence to support a primary role for bacterial infection, antibiotics. The demonstration of bladder diverticulae, usually at the site of the foetal urachus, is not uncommon in cases of IFLUTD. They are not considered as primary factors in the development of the condition, and are self-limiting once LUTD is controlled.

Comparisons of feline cystitis with human IC, where defects in the protective uroepithelial glycosaminoglycans (GAG) lining of the bladder and an association with stress have been identified as factors in the condition, have led to further suggestions for treatment. The use of oral supplements of GAGs (e.g. pentosan polysulfate; Cartrophen, Arthopharm) or GAG precursors (e.g. *N*-acetyl glucosamine; Cystease, Ceva Animal Health) have been suggested to improve the GAG layer: they may be helpful but there is as yet no published evidence for their efficacy. Side-effects may include inappetence and prolonged bleeding time. Amytriptyline, a tricyclic antidepressant with anti-inflammatory and analgesic properties, has also been recommended for the treatment of severe, recurrent cases of idiopathic cystitis on the basis of experience in human patients with IC and anecdotal experience in cats. The dose recommended is between 5 and 10 mg/cat per day, usually given at night, to produce a slight calming effect on the cat (Chew *et al.*, 1998). Liver function should be checked before and after treatment. In the absence of properly evaluated trials of the use of amitriptyline, its true value is difficult to assess.

As with other presentations of IFLUTD, advice should also be aimed at increasing fluid intake and reducing environmental stress. Moist, or canned, food should be fed, and fresh water and a clean litter tray should be readily available. A consistent diet, most usefully of a diet designed for use in LUTD, may be helpful. Corticosteroids do not appear to be of value. Analgesia may be indicated in acute episodes. Care must be taken, particularly in view of the sometimes recurrent nature of the condition, to distinguish idiopathic cystitis from the haematuria and dysuria associated with bacterial cystitis, the presence of true calculi, or the rare cases of neoplasia of the urinary bladder. Cystitis may also be associated with the use of the cytotoxic drug cyclophosphamide and this is well recognised in a number of species, including cats (Stanton & Legrende, 1986). Administration of the drug should be ceased immediately clinical signs are noticed and diuresis initiated.

Lower urinary tract infection

Bacterial infection of the lower urinary tract is recognised in cats, although less commonly than in dogs. The reasons for this are not clear but may include the higher osmolarity of feline urine and other effective local defence mechanisms such as glycosaminoglycans (Lees, 1996). Bacterial infection is uncommon as a primary entity, occurring almost invariably as a secondary phenomenon following other forms of LUTD, or in cats that have been catheterised, especially those where a catheter is left indwelling. Indeed, identification of bacterial infection of the lower urinary tract should always prompt identification of a possible predisposing cause. The clinical signs are increased frequency of urination, dysuria and/or haematuria; the cat is rarely systemically unwell and mild infections may cause no clinical signs at all.

Diagnosis is based on the presence of RBCs, epithelial and inflammatory cells, and bacteria in the urine. Bacterial culture is best carried out on urine obtained by cystocentesis and should demonstrate significant numbers of organisms ($>1 \times 10^4$/ml). Samples obtained at catheterisation or from voided urine may be useful diagnostically but are of less value for culture. Bacterial sensitivity will indicate the appropriate therapy, and treatment for up to 10–14 days is usually advisable, with longer courses necessary in cases of chronic cystitis. Penicillins or potentiated sulfonamides are the most useful drugs in the first instance. A diagnosis of bacterial cystitis, particularly if there is a failure to respond to treatment or there is a rapid recurrence of signs, should prompt further investigations into a possible underlying cause. Fungal infection of the lower urinary tract is rare but has been reported, usually due to *Candida albicans*, after repeated antibacterial therapy. It appears to be difficult to eradicate.

Viral infection of the urinary tract, specifically with a herpes virus, has been proposed as a possible cause of IFLUTD but has not found support (see above). Feline calicivirus (FCV) and feline syncytium-forming virus (FeFSV) may be isolated from the urine of cats (Gaskell *et al.*, 1979). No clinical significance is normally associated with their presence, although a role for FCV in IFLUTD has been suggested by Osborne *et al.* (2000).

Parasitic infestation of the feline bladder due to *Capillaria feliscati* occurs in certain parts of the world, such as Australia (Waddell, 1968). Infection is not usually associated with clinical signs; diagnosis is based on the demonstration of eggs in the urine, and

fenbendazole (25 mg/kg body weight twice daily for 3–10 days) is suggested as treatment (Brown & Prestwood, 1986).

Calculus disease

The formation of discrete urinary calculi (uroliths, urinary stones) is less common in cats than idiopathic LUTD. The majority of such calculi, which occur most frequently in the bladder and only occasionally in the renal pelvis, are composed of either struvite (magnesium ammonium phosphate) or calcium oxalate (Thumchai *et al.*, 1996; Osborne *et al.*, 2000). In North America the increased number of cases involving calcium oxalate and the reduction in struvite calculi in recent years is attributed in part to the modifications in proprietary foods to minimise struvite crystalluria and the use of calculolytic diets to dissolve struvite calculi (Buffington & Chew, 1999; Osborne *et al.*, 2000). Other calculi types are recognised, although with much less frequency. Ammonium urate calculi may be associated with liver disease (e.g. portosystemic shunts).

Calculi form as crystalloids are deposited around an initial nidus, the rate of growth and composition of the calculus depending on the urinary environment. Calculi may be clinically silent or may cause inflammation and haematuria and dysuria. Occasionally calculi may lodge in the urethra, particularly of male cats, to cause obstruction. Secondary urinary tract infection may occur as a consequence of the damage caused by calculi. A small proportion of feline struvite calculi is associated at the outset with urinary tract infection with urease-producing bacteria that cause a rise in urinary pH and struvite crystal formation. The majority of cats with calculus disease are over 1 year of age, with the average age at presentation being about 7 years. There is no breed predisposition for struvite calculi, although Burmese, Himalayan and Persian are said to be predisposed to calcium oxalate calculi. Classic calculi differ in composition from typical urethral plugs, recognised as part of IFLUTD, in their low protein or matrix content.

The diagnosis of calculus disease is rarely made by palpation; radiographic or ultrasonographic examinations are more valuable. Urinalysis may reveal crystalluria, and there are frequently signs of urinary tract inflammation. Urinary pH is also useful in predicting calculus type; struvite calculi are more likely in alkaline, and calcium oxalate in acid, urine. Haematology and blood biochemistry are not often helpful in diagnosis, although the uncommon presence of hypercalcaemia may predispose an individual cat to calcium oxalate calculus disease. Urine culture may reveal the presence of bacterial infection. In some cases where the calculi are small they may be obtained for analysis, and also removed, by urohydropropulsion (Lulich *et al.*, 1993). This involves the forced, but steady, manual expression of urine from a full, or filled, bladder of the anaesthetised cat held upright so that the calculi fall to the bladder neck.

Knowledge of the composition of the calculi is important, as the approach to treatment and attempted prevention of recurrence is in the main related to the type of calculi present. For struvite calculi, surgical removal may be appropriate, but resolution and prevention can be achieved through the feeding of a calculolytic diet (Osborne *et al.*, 1996) that is low in magnesium and produces acidic urine, together with the use of antibiotics to control primary (in the case of infection-induced calculi) or secondary bacterial infection. Given the tendency for cats fed a dry diet to produce more concentrated urine, it is logical to feed high-moisture foods and/or to add water to the food. By definition, dilute urine will have lower concentrations of calculogenic compounds. The use of commercially available acidifying, low-magnesium diets has been shown to result in the dissolution of struvite calculi within an average of 1 month and to be effective in preventing recurrence (Osborne *et al.*, 1996). These foods should make up the complete diet. If non-acidifying diets are fed, urinary acidifiers may be used. Acidifiers such as methionine (1 g/day) or ammonium chloride (0.8 g/day) may be given at mealtimes to control the normal postprandial alkaline tide in urine. Failure to dissolve may be due to incorrect identification of calculi type, or a calculus of mixed type, or failure to control bacterial infection. In the case of infection-related struvite calculi, antibacterial therapy may need to be maintained until complete dissolution of the calculi, which may be a source of infection, has been achieved. Eradication of infection is crucial for the prevention of recurrence. The long-term use of acidifying diets is indicated to prevent recurrence, although uncommonly they may lead to acidaemia in immature cats or cats with renal insufficiency. Urinary acidifiers should not be used in addition to acidifying diets. The creation of a urinary environment that reduces the risk of struvite crystalluria may produce urine appropriate for calcium oxalate crystal formation, and the periodic examination of urine samples is indicated.

Surgical removal is the treatment of choice for calcium oxalate calculi in the bladder. Dietary modification has not been shown to produce dissolution, but is of value in reducing the risk of recurrence. Such diets aim to produce urine that is undersaturated in calcium and oxalate through dietary control of these components, together with modifications of dietary protein, phosphorus, magnesium, potassium and vitamin B_6. Water intake, and thus less concentrated urine, should be encouraged through the feeding of high-moisture foods. Commercially available diets are available that meet these objectives. Modification of urinary pH is not thought to affect recurrence; the initial association of the majority of calcium oxalate calculi with acid urine may be due to other predisposing metabolic changes. In the uncommon cases where the calculus disease is associated with hypercalcaemia and resultant hypercaluria, its cause must be identified and managed.

Other types of urinary calculi, such as calcium phosphate, urate and cystine, have been recorded in cats but are rare. Treatment is usually surgical and through the management of any identified predisposing condition. Regular follow-up is indicated to identify recurrence. As in all cases of urinary calculus disease the encouragement of high fluid intake and ample opportunity to urinate frequently are important in the management of potential recurrence.

Neoplasia

Tumours of the feline bladder are rare, and those of the ureters and urethra very rare (Schwarz *et al.*, 1985; Brearley *et al.*, 1986). Several tumour types have been reported, but transitional cell carcinoma is the most frequent, accounting for some 50% of cases. Benign tumours occur very infrequently. Malignant bladder tumours are seen typically in older animals (two-thirds are aged between 8 and 13 years) and cause haematuria and dysuria that is unresponsive to treatment for cystitis. Secondary bacterial infection may be present. Diagnosis may be made on contrast cystography, either a pneumocystogram or double-contrast study, or ultrasonography, and confirmed by laparotomy and biopsy. Cytology of urine sediment is not often diagnostic. Surgical treatment may be attempted but is rarely successful, or even feasible, owing to the infiltrative nature of the tumours and the frequently late presentation and recognition. Cystectomy, with translocation of the trigone or ureters into portions of the gastrointestinal tract, has not proved a successful technique.

Trauma

Rupture of the bladder may occur as the result of trauma, or iatrogenically owing to overzealous palpation of a distended bladder in cases of urethral obstruction. Inability to palpate the bladder after some hours without urination suggests bladder rupture, which may be confirmed by positive contrast radiography. Unmanaged cases may develop post-renal azotaemia associated with the passage of urine into the peritoneal cavity and the resorption of waste products. Treatment may be by surgical repair when the cat has recovered from the immediate effects of the trauma, although some cases may heal spontaneously if the bladder is kept empty by means of an indwelling urethral catheter. The decision whether to use prophylactic antibiotics if an indwelling catheter is placed is made on a case-by-case basis.

Trauma to the urethra may result from pelvic fracture, but is seen less commonly than in dogs. The most frequent cause of urethral injury arises from attempts to clear urethral obstruction due to crystalline or proteinaceous deposits (see IFLUTD, above). Such damage may lead to urethral stricture, and severe urethral trauma or rupture is an indication for urethrostomy.

Urinary incontinence

Urinary incontinence, defined as the unconscious passage of urine, is uncommon in the cat.

Congenital ectopic ureter is rare in the cat, but recorded cases have been reviewed by Holt and Gibbs (1992). Male and female cats are affected with equal frequency. A history of incontinence noticed since an early age may be accompanied by perineal scalding with urine. Individuals with unilateral ectopia may also urinate normally. Diagnosis is made by intravenous urography and simultaneous pneumocystography, with the course and site of emptying of the ureters assessed under fluoroscopy. Surgical relocation of the ectopic ureter(s) is the treatment of choice. Ureteronephrectomy can be carried out if only one ureter is ectopic, and is indicated in the presence of hydroureter/hydronephrosis, the most common complication of ectopic ureter. Iatrogenic vaginoureteral fistulae have been described as a complication of

abdominal surgery (Allen & Webbon, 1980). Congenital urethral sphincter mechanism incompetence has also been described in a few cases, most commonly associated with hypoplasia of the urethra (Holt & Gibbs, 1992). Congenital dysfunction of the lower urinary tract, along with faecal incontinence, may also be associated with spinal abnormalities such as those seen in Manx kittens.

An equivalent of the hormone-responsive incontinence that is recognised in neutered bitches does appear to be seen in cats (Barsanti & Downey, 1984), but is much less common. The use of phenylpropanolamine, an adrenergic agonist, has been described in such cases, at doses of 12.5 mg p.o. twice daily or 7 mg p.o. three times daily. Acquired urinary incontinence, associated with overflow of urine from a distended bladder, is seen occasionally with fractures of the sacrococcygeal region, where the tail is often also flaccid, and as a feature of some cases of feline dysautonomia (Key–Gaskell syndrome) (see Chapter 7). In both, faecal incontinence and/or constipation may also be present. Treatment consists of manual emptying of the bladder and the use of bethanechol (1.25–2.5 mg p.o. twice daily), although care should be taken with the use of such parasympathomimetics, and any side-effects such as lacrimation, salivation and abdominal cramps managed with atropine and treatment modified or stopped. The prognosis for neurologically induced bladder dysfunction is guarded. Prolonged distension of the bladder due to urethral obstruction (IFLUTD) may leave a bladder with poor tone and overflow incontinence in the immediate postobstruction period. An indwelling urethral catheter, and the associated incontinence, may help the bladder to recover tone.

Inappropriate urination, sometimes referred to as periuria, may be seen in a range of LUTDs and as a behavioural problem. Owners may report this as 'incontinence' and a careful history is necessary to distinguish between the two. Behavioural periuria is discussed in Chapter 5.

Accessory sex gland disease

Diseases of the prostate in cats are rarely recognised, almost certainly because the majority of male cats, and certainly the majority of vet-visiting cats, are neutered at a young age. Adenocarcinoma of the prostate has been reported, causing dysuria (Hubbard *et al.*, 1990). The bulbourethral glands, while often being the site of urethral obstruction in IFLUTD, are very rarely involved in other disease.

References

Allen W.E. & Webbon P.M. (1980) Two cases of urinary incontinence in cats associated with acquired vagino-ureteral fistula. *J Small Anim Pract* **21**, 367–371.

Barsanti J.A. & Downey R. (1984) Urinary incontinence in cats. *J Am Anim Hosp Assoc* **20**, 979.

Brearley M.J., Thatcher C. & Cooper J.E. (1986) Three cases of transitional cell carcinoma in the cat and a review of the literature. *Vet Rec* **118**, 91–94.

Brown S.A. & Prestwood A.K. (1986) Parasites of the urinary tract. In *Current Veterinary Therapy*, Vol. IX (ed. Kirk R.W.). WB Saunders, Philadelphia, PA.

Buffington C.A. & Chew D.J. (1999) Calcium oxalate urolithiasis in cats. *J Endourol* **13**, 659–663.

Buffington C.A., Chew D.J. & DiBartoli S.P. (1996) Interstitial cystitis in cats. *Vet Clin North Am Small Anim Pract* **26**, 317–326.

Buffington C.A., Chew D.J., Kendall M.S., *et al.* (1997) Clinical evaluation of cats with non-obstructive urinary tract diseases. *J Am Vet Med Assoc* **210**, 46–50.

Burrows C.F. & Bovee K.C. (1978) Characterisation and treatment of acid–base and renal defects due to urethral obstruction in cats. *J Am Vet Med Assoc* **172**, 801–805.

Cannizzo K.L., McLoughlin M.A., Chew D.J. & DiBartola S.P. (2001) Uroendoscopy. Evaluation of the lower urinary tract. *Vet Clin North Am Small Anim Pract* **31**, 789–801.

Chew D.J., Buffington C.A.T. & Kendall M.S. (1998) Amytriptylline treatment for severe recurrent idiopathic cystitis in cats. *J Am Vet Med Assoc* **213**, 1282–1286.

Clasper M. (1990) A case of interstitial cystitis and Hunner's ulcer in a domestic shorthaired cat. *N Z Vet J* **38**, 158–160.

Davies M. (1998) Urinary system. In *Manual of Small Animal Clinical Pathology* (eds Davidson M., Else R. & Lumsden J.). BSAVA, Cheltenham.

Dorn C.R., Sayeressig S. & Schmidt D.A. (1973) Factors affecting risk of urolithiasis–cystitis–urethritis in cats. *Am J Vet Res* **34**, 433–436.

Fabricant C. (1977) Herpesvirus-induced urolithiasis in specific pathogen-free male cats. *Am J Vet Res* **38**, 1837–1842.

Gaskell C.J. (1979) Studies on the feline urological syndrome. PhD Thesis, University of Bristol.

Gaskell C.J., Denny H.R., Jackson O.F. & Weaver A.D. (1978) Clinical management of the feline urological syndrome. *J Small Anim Pract* **19**, 301–314.

Gaskell R.M., Gaskell C.J., Page W., *et al.* (1979) Studies on a possible viral aetiology for the feline urological syndrome. *Vet Rec* **105**, 243–247.

Holt P.E. & Gibbs C. (1992) Congenital urinary incontinence in cats: a review of 19 cases. *Vet Rec* **130**, 437–442.

Hubbard B.S., Vulgamott J.C. & Liska W.D. (1990) Prostatic carcinoma in a cat. *J Am Vet Med Assoc* **197**, 1493–1494.

Johnston D.E. (1974) Feline urethrostomy – a critique and new method. *J Small Anim Pract* **15**, 421.

Kirk H. (1925) *The Diseases of the Cat*. Bailliere, Tindall and Cox, London, p. 261.

Kruger J.M., Osborne C.A. & Whetstone C.A. (1989) Genetic and serologic analysis of cell-associated herpesvirus infection of the urinary tract in conventionally reared cats. *Am J Vet Res* **50**, 2023–2027.

Lees G.E. (1996) Bacterial urinary infections. *Vet Clin North Am* **26**, 297.

Lekcharoensuk C., Osborne C.A. & Lulich J.P. (2001) Epidemiologic study of risk factors for lower urinary tract diseases in cats. *J Am Vet Med Assoc* **218**, 1429–1435.

Lulich J.P., Osborne C.A. & Carlson M. (1993) Nonsurgical removal of urocystoliths in dogs and cats by voiding urohydropropulsion. *J Am Vet Med Assoc* **23**, 660–663.

Osborne C.A., Lulich J.P. & Thumchai R. (1996) Diagnosis, medical treatment and prognosis of feline urolithiasis. *Vet Clin North Am* **26**, 589–627.

Osborne C.A., Kruger J.M., Lulich J.P. & Polzin D.J. (1999) Feline urologic syndrome, feline lower urinary tract disease, feline interstitial cystitis: what's in a name? *J Am Vet Med Assoc* **214**, 1470–1480.

Osborne C.A., Kruger J.M., Lulich J.P., *et al*. (2000) Feline lower urinary tract diseases. In *Textbook of Veterinary Internal Medicine* (eds Ettinger S.J. & Feldman E.C.). WB Saunders, Philadelphia, PA.

Reif J.S., Bovee K., Gaskell C.J., *et al*. (1977) Feline urethral obstruction; a case–control study. *J Am Vet Med Assoc* **170**, 1320–1324.

Schaer M. (1975) The use of regular insulin in the treatment of hyperkalaemia in cats with urethral obstruction. *J Am Anim Hosp Assoc* **11**, 106.

Schechter R.D. (1970) The significance of bacteria in feline cystitis and urolithiasis. *J Am Vet Med Assoc* **156**, 1567–1573.

Schwarz P.D., Greene R.W. & Patnaik A.K. (1985) Urinary bladder tumours in the cat; a review of 27 cases. *J Am Anim Hosp Assoc* **21**, 237.

Scrivani P.V., Chew D.J., Buffington C.A., *et al*. (1997) Results of retrograde urethrography in cats with idiopathic, nonobstructive lower urinary tract disease and their association with pathogenesis: 53 cases (1993–1995). *J Am Vet Med Assoc* **211**, 741–748.

Stanton M.E. & Legrende A.M. (1986) Effects of cyclophosphamide in dogs and cats. *J Am Vet Med Assoc* **188**, 1319.

Thumchai R., Lulich J.P. & Osborne C.A. (1996) Epizootiology evaluation of 3498 feline uroliths: 1982–1992. *J Am Vet Med Assoc* **208**, 547–551.

Voros K., Wladar S., Marsi A., *et al*. (1997) Ultrasonographic study of feline lower urinary tract disease: 32 cases. *Acta Vet Hung* **45**, 387–395.

Waddell A.H. (1968) Further observation on *Capillaria felis-cati* infections in the cat. *Aust Vet J* **44**, 33.

Walker A.D., Weaver A.D., Anderson R.S., *et al*. (1977) An epidemiological survey of the feline urological syndrome. *J Small Anim Pract* **18**, 283.

Westropp J.L. & Buffington C.A. (2002) *In vivo* models for interstitial cystitis. *J Urol* **167**, 694–702.

Willeberg P. (1975) Diets and the feline urological syndrome; a retrospective case–control study. *Nord Vet Med* **27**, 1.

Willeberg P. (1981) Epidemiology of the feline urological syndrome. *Adv Vet Sci Comp Med* **25**, 311–344.

Willeberg P. & Priestler W.A. (1976) Feline urological syndrome: associations with some time, space, and individual patient factors. *Am J Vet Res* **37**, 975–978.

Chapter 12

THE RESPIRATORY SYSTEM

A.M. Kerins and R. Breathnach

Introduction

Diseases of the feline respiratory tract are frequently encountered in companion animal practice. They range from acute to chronic and from mild to severe, with both infectious and non-infectious aetiologies being commonly reported. Efforts to reach an accurate diagnosis are frequently impaired by the limited array of clinical signs seen in response to injury or insult to the respiratory tract. In addition, diseases that are not primarily of respiratory origin may, at least in part, manifest themselves through abnormal respiration. It is intended that this chapter will give the veterinarian a review of diseases of the feline respiratory system by anatomical region. Descriptions of the most up-to-date diagnostic and therapeutic protocols are included in an effort to provide the reader with a useful practical resource.

The reader is referred to Chapter 22 for a comprehensive review of infectious causes of respiratory tract disease.

Diagnosis

The principal functions of the respiratory system are to maintain sufficient oxygenation of the blood and help to maintain acid–base balance of the body by the removal of carbon dioxide. Therefore, non-respiratory diseases that interfere with these systems will lead to compensatory changes in respiratory pattern (e.g. cardiac disease, anaemia, shock and acidosis). A thorough physical examination and a problem-orientated approach are therefore essential to allow an accurate diagnosis to be reached.

To facilitate the localisation of lesions within the respiratory tract, it is important to characterise the type and nature of the respiratory signs. For example, sneezing is normally associated with the presence of nasal disease. Inspiratory dyspnoea, with or without stridor, may suggest upper respiratory tract or pleural space disease, respectively. Conversely, expiratory dyspnoea is frequently encountered with lower respiratory tract (particularly bronchial) disease.

Radiography can provide useful information on all regions of the respiratory tract. To obtain radiographs of diagnostic value, appropriate chemical restraint is recommended in the absence of any contraindications. The nasal chambers are best viewed using intraoral non-screen film, as this avoids superimposition of mandibular structures. To assess the lower respiratory tract, right and left lateral and ventrodorsal inflated chest views are necessary. In cats where pleural effusion is suspected, a dorsoventral view should be taken in preference to the ventrodorsal view. It is important that such cats are not rotated to take both left and right lateral views, as this may lead to collapse of the newly dependent lung and a rapid deterioration in the respiratory status. An expiratory film may be of value in trying to determine the presence of overinflation or air-trapping, particularly in those cases characterised by expiratory dyspnoea (e.g. feline asthma syndrome).

Despite the limitations imposed by normal aerated lung tissue, ultrasound may provide useful information in relation to the pleural cavity and soft-tissue structures in the mediastinum. This technique also allows for an assessment of cardiac disease, which is a common differential for respiratory tract signs in the cat. Its non-invasive nature makes it particularly useful in the acute case and, in the hands of an experienced

operator, can act as guidance for needle biopsy and aspiration procedures.

Specialist diagnostic techniques are usually required to collect samples for microbiology and pathology from relatively inaccessible regions of the respiratory tract. Nasal flushing, broncheoalveolar lavage (BAL) and thoracocentesis are commonly used in the authors' hospitals for sample collection from the nasal cavity, lower airways and lung parenchyma, and pleural space, respectively. Suggested techniques for these are included in the text. Endoscopy of the upper and lower airways may provide invaluable information (e.g. foreign body or neoplasia), but requires a scope of sufficiently narrow diameter. Other diagnostic techniques to investigate feline respiratory diseases have been described but are outside the scope of this chapter.

Diseases of the nasal planum and nares

While ulceration is the most common condition that affects the nasal planum, it often arises secondary to contact with caustic chemicals or as part of feline calicivirus (FCV)-related disease. In both cases it may be accompanied by ulceration in the mouth (particularly the tongue) (Plates 12.1 and 12.2). An important differential for ulceration at this site is a squamous cell carcinoma (SCC), the most common tumour of this region, which particularly affects older cats with a non-pigmented nasal planum and excessive exposure to sunlight (Cox *et al.*, 1991; Miller *et al.*, 1991; Lana *et al.*, 1997). The early stage in SCC development is characterised by erythema and crusting ulceration (actinic dermatitis). If left untreated, malignant transformation may follow, leading to a locally invasive SCC that rarely metastasises. Diagnosis is based on the signalment, history and histopathology. Early cases of actinic dermatitis may respond to conservative treatment, including reduced sunlight exposure and the use of sunblocks. Treatment of overt SCC, if considered appropriate, should be aggressive and is likely to include wide surgical excision. Where available, radiation therapy, cryotherapy and phototherapy may also be useful (Cox *et al.*, 1991; Thón *et al.*, 1995; Lana *et al.*, 1997). The client should be advised that recurrence of the lesion is common. The use of topical antineoplastic agents has largely fallen out of favour owing to safety considerations.

Other rare conditions affecting the nasal planum include autoimmune dermatoses (pemphigus complex), mycotic disease (especially cryptococcus, although uncommon in Europe), idiopathic depigmentation (vitiligo) and hyperpigmentation in orange cats (lentigo simplex) (White, 1994). Stenotic nares have been reported rarely in Persian cats with marked inspiratory noise. The treatment is surgical (Harvey, 1986).

Diseases of the nasal cavity (including nasal sinuses)

Inflammation of the nasal cavity (rhinitis) is a relatively common condition in the cat. The involvement of FCV, feline herpesvirus (FHV) and *Bordetella bronchiseptica* is discussed in detail in Chapter 22. Diseases of the feline sinuses are rarely of primary origin, and usually represent extension of disease from the nasal cavity. If both regions are involved, the condition is more correctly termed rhinosinusitis. The clinical signs of nasal disease typically include sneezing, increased inspiratory noise and nasal discharge (Plate 12.3). In more severe cases, there may be a blood-tinged discharge or overt nasal haemorrhage (epistaxis), and even facial distortion.

On the basis of clinical signs, it is usually possible to localise disease to the nasal cavity. However, the differential diagnosis of feline nasal disease is rendered difficult by the relatively inaccessible nature of the compartment and its ability to respond in a limited way to a wide variety of insults. Signalment and history may be particularly relevant. Nasopharyngeal polyps and congenital abnormalities typically affect young cats, whereas nasal tumours and dental disease are more commonly encountered in older cats. Acute disease of short duration is most often associated with the 'cat flu' complex, particularly if the vaccination history is incomplete or the animal has been in contact with infected cats.

Physical examination must be thorough and include visualisation of the face, the hard and soft palates, tongue, upper teeth and pharynx. The eyes should be examined for evidence of conjunctivitis and keratitis or other pathology. Otic examination may reveal otitis media often associated with nasopharyngeal polyps. Otitis media may also lead to facial nerve dysfunction and Horner's syndrome. Nasal discharges should be characterised according to their location (unilateral or bilateral) and type (serous, mucoid, mucopurulent), and the presence or absence of blood.

When the course of disease is prolonged, other diagnostic tests may be required to characterise the extent, location and type of pathology involved before an

Box 12.1 Technique for nasal flush

- The patient is anaesthetised with a short-acting agent and intubated using a cuffed endotracheal tube.
- A feline male urinary catheter or wide-gauge intravenous catheter is gently introduced into the nasal cavity.
- Approximately 2 ml of prewarmed phosphate-buffered saline is flushed down the catheter using a syringe.
- Suction is immediately applied to the syringe. Usually no more than half of the instilled fluid is collected.
- Samples should be stored in EDTA bottles and sterile tubes for cytology and culture.

aetiology, treatment and prognosis can be determined (Willoughby & Coutts, 1995). Radiography should include the nasal cavity, nasal sinuses and temporal bullae, and should also attempt to determine any spread to surrounding bony tissue (Coulson, 1988). Rhinoscopy may allow direct visualisation of the nasal chambers either through the nares (auroscope or rigid arthroscope) or from the nasopharynx (flexible paediatric bronchoscope). The inaccessibility of the nasal cavity has led to the development of several techniques for the collection of material suitable for microbiological and cytological evaluation, including nasal flushing (Box 12.1) and swabbing. Samples for histology may be collected by vigorous flushing or blunt forceps-grab biopsy (Willoughby & Coutts, 1995).

Bacterial rhinitis and idiopathic chronic rhinosinusitis

Primary bacterial rhinitis is relatively uncommon in the cat, but infection with *Bordetella bronchiseptica* has been reported (see Chapter 22). However, in most cases of rhinitis, and irrespective of the initial insult, secondary opportunistic bacterial infections contribute significantly to clinical disease. Although treatment of secondary bacterial infection is normally warranted and will frequently improve the patient's clinical signs, overall resolution of the condition is often incomplete or transient while the primary underlying cause remains.

For those cases in which the primary disease remains undetermined, the term idiopathic chronic rhinosinusitis (chronic snuffles) is usually applied. Such cases are often believed to represent an end-stage of severe viral rhinitis (Cape, 1992). This is particularly true of FHV infection, where extensive mucosal and bony injury to the turbinates may predispose the nasal cavities to chronic disease.

Idiopathic chronic rhinosinusitis is often a diagnosis of exclusion. Radiographs often demonstrate soft-tissue opacities in the nasal cavity and destruction of the bony turbinates. Soft-tissue opacities may also be observed in the frontal sinuses. Nasal cytology is non-specific and is frequently characterised by the presence of degenerative neutrophils with phagocytosed bacteria. The results of culture vary from case to case, but aerobic bacteria are commonly isolated (Cape, 1992). Results of virus isolation must be interpreted with caution. Individual test results may not always be reliable as the FHV carrier-state is common in the field and reactivation of shedding may occur without clinical signs. Furthermore, the shedding of FHV is intermittent, such that false negatives may occur. It is prudent to determine the feline leukaemia virus (FeLV) and feline immunodeficiency virus (FIV) status of cats with chronic rhinitis, although the precise role of these agents in idiopathic chronic rhinosinusitis remains uncertain.

Once a diagnosis has been made, treatment is aimed at controlling infection during clinical episodes of disease. It is recommended that antibacterial therapy should be based on the results of culture and sensitivity testing. In all cases, treatment should continue for 3–6 weeks. The use of mucolytics such as bromhexine may ease the clinical signs. However, in a large number of cases, clinical resolution remains incomplete and/or temporary.

Surgical techniques to remove diseased tissue, relieve nasal obstruction and facilitate drainage of the affected cavity have been described (Birchard & Bradley, 1989). In extreme cases, sinus obliteration by autogenous fat graft implantation has been performed (Anderson, 1987). However, this surgery is not well tolerated and should only be reserved for severe, refractory cases.

Mycotic rhinitis

Fungal infection of the nasal cavity is less common in the cat than in the dog, and most frequently associated with *Cryptococcus neoformans*. *Aspergillus*, *Penicillium* and *Trichosporon* species have also been isolated from individual cases. Cats with mycotic rhinitis frequently display a nasal discharge and sneezing, and may additionally show skin lesions, a proliferative growth extruding from the nares, nasal deformity and neurological signs (Flatland *et al.*, 1996). Definitive diagnosis

is based on demonstration of the causative agent by cytology and culture. In the case of *Cryptococcus* species a serological test to detect serum cryptococcal antigens is available and may be used to monitor response to treatment (Pentlarge & Martin, 1986; Flatland *et al.*, 1996). However, false negatives are possible and probably reflect localised disease. Several treatment regimens have been described for nasal cryptococcosis, including fluconazole, itraconazole and combinations of amphotericin B with either ketoconazole or flucytosine (Van Pelt & Lappin, 1994). Oral ketoconazole at a dose rate of 10 to 20 mg/kg per day (divided, twice daily) has been recommended (Pentlarge & Martin, 1986), but side-effects such as anorexia and vomiting have been reported. With this in mind, the authors now prefer to use fluconazole and itraconazole whenever possible.

Nasopharyngeal polyps

The problem of nasopharyngeal polyps is primarily observed in young cats (1 month to 5 years of age) (Parker & Binnington, 1985; Ford, 1989). They are composed of granulation tissue covered by a variable epithelial lining. Although their origin is uncertain, it is believed that they derive from the mucosal lining of the auditory tube or the middle ear. As such, they are frequently associated with otitis media, although sometimes subclinically. When they grow rostrally down the eustachian tube, they normally locate in the nasopharynx, above the soft palate. Associated clinical signs include sneezing, nasal discharge and stertorous respiration, with or without concurrent signs of otitis media and externa. Episodes of acute respiratory distress with cyanosis and syncopal attacks can be attributed to upper airway obstruction (Brownlie & Bedford, 1985). Diagnosis may be possible by the radiographic demonstration of a soft-tissue pharyngeal density or evidence of changes in the middle ear. Visualisation of the polyp may be possible in the anaesthetised cat by displacing the soft palate ventrally, and subsequently retracting it rostrally. Surgical removal of the polyp by oral traction is the treatment of choice. This may be facilitated by midline incision of the soft palate. Postsurgical complications can include Horner's syndrome, persistent otitis media and polyp regrowth (Parker & Binnington, 1985; Ford, 1989). Where radiographs indicate a soft-tissue density in the tympanic cavity, bulla osteotomy has been advocated as a means of reducing polyp regrowth (Trevor & Martin, 1993). Indeed, some authors advocate this approach even in the absence of radiographic evidence of tympanic involvement (Kapatkin *et al.*, 1990).

Neoplasia

Intranasal tumours are an uncommon occurrence in the cat, with the vast majority being reported in older animals. Tumour types include adenocarcinoma, undifferentiated carcinomas, olfactory neuroblastoma (also called esthesioneuroblastomas) and lymphomas. Presenting signs include chronic and progressive sneezing, an initially unilateral nasal discharge (frequently bloody), intermittent epistaxis and inspiratory dyspnoea (Cox *et al.*, 1991). Facial distortion and bony lysis are also reported. The majority of intranasal tumours are locally invasive; however, metastasis to distant sites (e.g. lungs) is uncommon. Affected cats may also display neurological signs including seizures, owing to localised tumour invasion of the cranium. Some cats with intranasal tumours display only neurological signs (Smith *et al.*, 1989). Initial suspicions are based on the presence of soft-tissue opacities or bone destruction within the nasal cavity. Definitive diagnosis is by cytological and/or histopathological identification of tumour cells. The treatment of choice for lymphomas is chemotherapy (see Chapter 3). For other tumours, treatment by surgical debulking and radiotherapy, or radiotherapy alone, is generally indicated (Straw *et al.*, 1986; Cox *et al.*, 1991). The response to such treatment strategies is generally quite good, particularly when disease is not advanced, but the overall prognosis is usually guarded to poor. A very poor prognosis is associated with olfactory neuroblastomas or advanced disease with bone lysis. In such cases, euthanasia on humane grounds is recommended (Cox *et al.*, 1991).

Palate defects

Defects of the hard and soft palates are usually either congenital in kittens or traumatically acquired in later life. Most affected kittens present in the first few days of life, with a history of ill-thrift or the presence of milk emanating from the nostrils. Aspiration pneumonia and sudden death are other possible sequelae. Defects of the hard palate in older cats are usually associated with a history of recent trauma, and may be accompanied by other injuries. Affected cats may be inappetant and food may exit the nostrils. Corrective surgery is often indicated, although some authors advocate that traumatic palate defects less than 2 mm in width may be treated conservatively.

Oronasal fistulae are an uncommon cause of unilateral nasal discharge in the cat and usually arise secondary to periodontal abscessation (particularly of the

upper canines) or neoplasia (Ford, 1989). In the case of dental disease the prognosis is good, with removal of the affected tooth normally being curative. In the case of neoplasia, the prognosis is guarded to poor.

Other causes of rhinitis

Foreign bodies represent a rare cause of unilateral rhinitis in the cat. Treatment is by flushing and antibacterial therapy. Regurgitation of food material secondary to megaoesophagus may also be associated with rhinitis. *Haemophilus felis* has been isolated from some cases of rhinitis, but its pathogenic significance is uncertain.

Diseases of the larynx

Diseases of the larynx are relatively uncommon in the cat. The most commonly observed clinical condition is iatrogenic spasm induced during attempted intubation of the anaesthetised cat. The condition may be routinely prevented by the application of topical local anaesthetic before intubation. Some authors describe an idiopathic spontaneous laryngeal spasm in the conscious cat (Ford, 1989). Affected cats usually display sudden-onset respiratory distress that may last for up to 1 min. Treatment is aimed at promoting swallowing during such attacks by syringing a small amount of water into the mouth, while also addressing any possible predisposing factors. The mechanism of this idiopathic spasm is presumed to involve contact of irritant material such as hair and pharyngeal secretions with the sensitive laryngeal mucosa.

Laryngeal paralysis is reported in the cat, but appears to be much rarer than in the dog. Affected cats exhibit signs of stridor, exercise-related respiratory compromise and altered vocalisation (White *et al.*, 1986). Diagnosis is based on demonstration with a laryngoscope or an endoscope of paradoxical movement of the vocal folds when viewed in the lightly anaesthetised cat (abduction on expiration, adduction on inspiration). Dyspnoea and stridor are relieved upon intubation. Surgical treatment is by arytenoid lateralisation or partial laryngectomy. There is some evidence to suggest that in cats that acquire the condition in later life, laryngeal paralysis may represent the preliminary stages of a more generalised and progressive form of neuromuscular disease, with such cases warranting further diagnostic work-up and a more guarded prognosis.

Laryngeal neoplasia is very rare in the cat. The most commonly reported tumours are lymphosarcoma and SCC (Carlisle *et al.*, 1991). The condition tends to affect older cats, although one case of lymphosarcoma has been reported in a 2-year-old. Presenting signs are similar to laryngeal paralysis and include dyspnoea, stridor, altered vocalisation and coughing. Prognosis is poor and treatment is primarily palliative, including the possible placement of a tracheostomy tube to relieve respiratory compromise.

Chronic granulomatous inflammation of the larynx has a similar clinical presentation to neoplasia, and should be considered as part of the differential diagnosis for any soft-tissue mass at this site. However, the prognosis for inflammatory disease is significantly better. The condition is usually controlled by a combination of medical (corticosteroid and antibiotic) and surgical treatment (permanent tracheostomy or excision of excess tissue). The diagnosis is confirmed on biopsy.

Laryngeal trauma and foreign bodies are rare causes of acute respiratory distress in the cat.

Diseases of the trachea

Specific disorders of the feline trachea appear to be uncommon. Unlike in the dog, overt tracheitis is rarely diagnosed and is most likely to be secondary to viral upper respiratory tract infection. *Bordetella bronchiseptica* has been implicated as a cause of tracheitis in the cat, although the incidence is lower than in the dog (see Chapter 22).

Parasitic causes of upper airway disease include the nematode *Capillaria aerophila*, adults of which live under the tracheal epithelium. While most cases remain asymptomatic, some cats develop a persistent dry cough which may be elicited on tracheal palpation. Diagnosis is confirmed by demonstrating parasitic ova in the faeces, or fluid obtained by tracheobronchial washing techniques. Fenbendazole is the current treatment of choice.

Tracheitis may also arise secondary to inhalation of food material, but the clinical picture in such cases is dominated by the inhalation pneumonia that frequently accompanies such an event (see below).

Tracheal trauma in the cat may follow penetrating wounds in the neck area (e.g. fight injuries) and are frequently associated with anasarca (subcutaneous emphysema). Surgical intervention may be required to correct obvious tracheal defects. Tracheal rupture may follow blunt chest trauma, but episodes of dyspnoea

may only become evident some time after the initial trauma. Although anasarca and pneumomediastinum are often present, they are not consistent and their absence can make radiological diagnosis difficult. Surgical repair of such defects may be possible (Berkwitt & Berzon, 1985).

Iatrogenic tracheal stenosis is a reported complication of endotracheal tubes that are excessively inflated, with affected cats developing progressive dyspnoea after surgery (McMillan, 1985). Treatment involves attempts at surgical resection and anastamosis. However, the prognosis is poor, with many cats dying from complications of the surgical procedure.

Tracheal neoplasia is rare in the cat, but should be part of the differential diagnosis of any upper airway distress. The most frequently reported tumours include lymphosarcoma and various carcinomas (Beaumont, 1982; Carlisle *et al.*, 1991). Attempts at surgical resection carry a poor prognosis in advanced cases. Tracheal compression secondary to anterior mediastinal lymphosarcoma and thymoma is commonly encountered in practice (Gruffydd-Jones *et al.*, 1979; Carpenter & Holzworth, 1982). Such tumours are frequently accompanied by pleural effusion which further aggravates any dyspnoea (see below).

Although tracheal foreign bodies and tracheal collapse are reported, they would be considered to be rare causes of dyspnoea in the cat.

Diseases of the bronchi and lower airways

Disorders of the feline bronchi are not uncommon, but remain largely of undefined aetiology. Individual cases may be difficult to characterise definitively, largely because specific markers for disease are not available. Although diagnostic aids such as radiography, BAL or transtracheal washing may localise pathology to the bronchial tree, they rarely allow for a definitive diagnosis to be established. Such difficulties have led to a confusing nomenclature to describe feline bronchial disease, and a diagnosis may only be confirmed retrospectively based on the animal's response to treatment.

Bronchoalveolar lavage

BAL is a relatively simple technique that allows the collection of fluid and cells from the lower airways for subsequent microbiological and cytological examination. It is particularly indicated in those cases of suspected bronchopulmonary disease in which empirical treatment has proven unsatisfactory and/or the duration of disease is prolonged. The technique is relatively simple to perform but requires general anaesthesia (Box 12.2).

Box 12.2 Technique for bronchoalveolar lavage (BAL)

- The patient is anaesthetised with a short-acting agent and intubated using a cuffed (preferably sterile) endotracheal (ET) tube. A surgical plane of anaesthesia is not required. Indeed, it is advantageous if the cough reflex is maintained.
- The cat is placed in lateral recumbency. Since BAL largely collects from the dependent lung, when a disease process is predominantly unilateral, the more affected lung is placed downwards.
- A 4–6 Fr sterile urinary catheter is passed down the ET tube using sterile technique and advanced just out of the ET tube (premeasure the catheter against the ET tube). Lightly anaesthetised cats may cough.
- 5–10 ml of prewarmed sterile phosphate-buffered saline is flushed down the catheter using a syringe.
- Suction is immediately applied to the syringe. Usually no more than half of the instilled fluid is collected.
- If necessary, the process may be repeated several times.
- Samples should be stored in EDTA bottles and sterile tubes for cytology and culture.

Feline asthma syndrome

Feline asthma syndrome (FAS) is a respiratory disease of proposed allergic aetiology typically characterised by recurrent episodes of dyspnoea, wheezing and coughing (Plate 12.4). In severe acute cases, cyanosis is frequently evident. When disease is longstanding, the periods of respite in between episodes may be unduly short or even absent. Because the pathology often involves significant narrowing of the lumen of the smaller bronchi and airways, dyspnoea tends to be most marked during expiration. There is no one diagnostic test that allows for a definitive diagnosis of FAS to be established. Radiographic changes often vary with the extent of clinical disease. They may be absent, mild or severe and may include increased bronchial and/or interstitial patterns (Corcoran *et al.*, 1995). Lung overinflation (increased lung radiolucency and flattening and caudal displacement of the diaphragm)

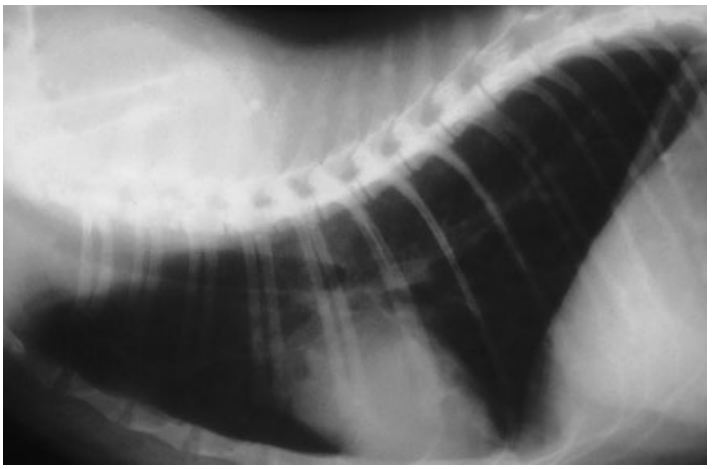

Figure 12.1 Feline asthma. Lateral thoracic radiograph revealing hyperlucent lung fields with slight widening of the trachea and flattening of the diaphragm.

may be apparent during episodes of clinical disease (Figure 12.1). A peripheral eosinophilia and an increased percentage of eosinophils in bronchial secretions have both been reported (Plate 12.5). However, these latter findings are neither consistent nor unique to this syndrome, as surprisingly high numbers of eosinophils have been found in bronchial secretions of apparently healthy cats (Padrid *et al.*, 1991). Thus, eosinophil numbers must be interpreted in conjunction with the clinical picture. It should be noted that a diagnosis of FAS is often suspected by the exclusion of other recognised causes of respiratory signs. A diagnosis of FAS is most strongly supported by the rapid resolution of clinical signs upon institution of appropriate treatment. In the acute cyanotic patient, oxygen therapy along with parenteral aminophylline (5 mg/kg i.v.) and dexamethasone (0.2–2.2 mg/kg i.v. or i.m.) is indicated. In less severe cases, oral medication with corticosteroids (prednisolone 0.5–1 mg/kg p.o. every 12 h) and/or bronchodilators (aminophylline 6.6 mg/kg p.o. every 12 h) is suitable. Terbutaline (a selective bronchodilator) has also been used at a dose rate of 0.625 mg/cat p.o. twice daily. Since relapses are common, treatment may need to be maintained longer term or repeated at intermittent intervals. Corticosteroids and bronchodilators may also be given by inhalation to compliant cats, using adapted metered-dose inhalers (Padrid, 2000b). Occasionally, inciting allergens may be identified, such as feathers, smoke, aerosol sprays or the introduction of new cat litter. In such cases, removal of the proposed allergen may reduce or abolish the need for longer term therapy. Some people have tried cyproheptadine (antihistamine and antiserotonin) and leukotriene receptor antagonists as adjunctive therapy in asthmatic cats, but there is nothing in the literature to support their use, nor are they licensed for this purpose (Padrid, 2000b).

Acute bronchitis

Cats presenting with acute bronchitis tend to have a recent history of acute-onset coughing. Radiography may reveal a bronchial pattern and BAL often indicates the presence of a non-specific inflammatory condition. Large numbers of macrophages may be evident in the BAL. Results of microbiological examination are inconsistent, and no correlation has been established between the disease and specific microbial organisms. Treatment is largely symptomatic and the diagnosis of acute bronchitis is often made retrospectively. Many cats make a complete recovery, with no recurrence of clinical signs.

Chronic bronchitis

Chronic bronchitis is a progressive condition characterised by idiopathic airway inflammation that leads to excessive mucous production and chronic coughing. Diagnosis is largely based on the exclusion of other causes of chronic coughing such as pulmonary neoplasia and bronchopneumonia. Again, the results of radiography and BAL are non-specific. The term chronic asthmatic bronchitis has been used to describe cases in which wheezing is also a prominent feature. In severe cases, particularly those of prolonged duration, bullous emphysema may also develop secondary to chronic hyperinflation. Chronic bronchitis is often associated with fibrosis leading to a

Figure 12.2 Pneumonia. Dorsoventral thoracic radiograph showing a patchy alveolar infiltrate in the caudal lung lobes of a 4-year-old feline leukaemia virus-positive domestic shorthaired cat. The results of a bronchoalveolar lavage were consistent with bacterial pneumonia.

less favourable response to treatment. Recommended treatments include combined corticosteroid and bronchodilator therapy. Antimicrobial therapy, either empirical or on the basis of culture and susceptibility testing, may also be indicated.

Diseases of the pulmonary parenchyma

Pneumonia, or inflammation of the lung parenchyma, is a relatively uncommon condition in the cat which has been associated with a number of different aetiologies (Figure 12.2). Although bacterial involvement is an important feature of the disease, such involvement is usually secondary to other inciting causes. Pathogens commonly isolated from the lungs of cats with pneumonia include *Escherichia coli*, *Klebsiella*, *Pasteurella*, *Pseudomonas*, *Bordetella* and streptococci. Identification of the bacterial pathogens present in suspected cases allows for an assessment of their likely pathogenic significance and the selection of appropriate antibacterial agents with which to treat.

Bordetella bronchiseptica (see also Chapter 22)

Although primary bacterial pneumonia is rare in the cat, it seems likely that *B. bronchiseptica* plays a primary role in some cases of feline pneumonia. This assumption is largely based on the isolation of almost pure cultures of *B. bronchiseptica* from the lungs of kittens with severe and often fatal bronchopneumonia (Willoughby *et al*., 1991; Welsh, 1996). Affected animals are usually less than 10 weeks of age and exhibit signs of depression, dyspnoea and cyanosis. Infection can prove fatal in some cases. At post-mortem examination, the lungs of affected kittens often contain firm grey nodules scattered throughout consolidated lung tissue. Cut surfaces usually reveal a purulent exudate that on histopathology is shown to block the smaller airways. Diagnosis is often possible from culture of fluid obtained by BAL or transtracheal wash (Welsh, 1996). Since *Bordetella* species are relatively fastidious organisms that grow best on selective media (at the authors' laboratory, charcoal–cephalexin medium is routinely used), it is recommended to request specifically *Bordetella* isolation from the test laboratory. Antimicrobial therapy is preferably based on the results of culture and susceptibility testing. However, the majority of feline *B. bronchiseptica* isolates appear to be sensitive to oxytetracycline, doxycycline and enrofloxacin, but resistant to trimethoprim and ampicillin (Speakman *et al*., 1997). Since bronchopneumonia has not been reproduced experimentally with *B. bronchiseptica*, attention should also focus on environmental and husbandry factors that may contribute to the development of disease.

Viral pneumonia

Severe and sometimes fatal pneumonia in young kittens has been reported secondary to FCV and FHV infections, particularly under experimental challenge conditions. It seems likely that pneumonia is a rare complication of virus infection in cats in the field, and may reflect large challenge doses or, in the case of FCV, particularly virulent strains of virus. The pattern of pneumonia is typically interstitial.

Mycotic pneumonias

Fungal infections of the feline lung, as with the nasal mycoses, represent a rare group of conditions, predominantly reported in the USA. Organisms involved

include *Cryptococcus*, *Blastomyces*, *Aspergillus* and *Coccidoides* species. Thoracic radiographs normally reveal a diffuse interstitial pattern. In some cases, serological tests are available which help to confirm a diagnosis (e.g. *Cryptococcus*; Barrs *et al.*, 2000). Treatment with systemic antifungals such as ketoconazole has proved effective. However, the newer imidazole drugs such as fluconazole and itraconazole are gaining in popularity, as they are often safer and more effective. Since fungal diseases are more common in immunocompromised patients, it is pertinent to determine the FeLV and FIV status of cats suspected of having a mycotic pneumonia (Barrs *et al.*, 2000) (Plate 12.6)

Aspiration pneumonia

Many conditions predispose to the inhalation of particulate and liquid substances into the respiratory tract. These include pre-existing causes such as cleft palate, megaoesophagus, persistent vomiting or seizures, and iatrogenic causes such as emetics, general anaesthesia, forced feeding or the long-term administration of liquid medication (de Souzza *et al.*, 1998). An early diagnosis can have a significant influence on the success of treatment. A patent airway must be maintained and, if necessary, the cat should be intubated. Material still present in the oropharynx should be removed to minimise the risk of further inhalation. The provision of additional oxygen support (e.g. intranasal tube or oxygen tent) should help to correct hypoxaemia. Where facilities permit, particulate matter may be removed from the larger airways using a bronchoscope. The use of corticosteroids in these patients is controversial owing to their immunosuppressive properties, and is best limited to the treatment of shock if present. Antimicrobial therapy is an important part of the therapeutic strategy and should be based on the results of culture and susceptibility testing whenever possible. For those cases in which intestinal contents have been inhaled, the authors routinely use combined aminoglycoside and cephalosporin therapy (Tams, 1985). As therapy is often required for 1–3 weeks, the cat must be monitored carefully for signs related to aminoglycoside toxicity.

Smoke inhalation

Inhalation of smoke may be associated with clinical disease at several levels (Tams, 1985). Carbon monoxide poisoning leads to effective tissue hypoxia. Thermal damage may also occur, usually when hot particulate materials such as soot are inhaled. Finally, the combustion process produces many toxic by-products that ultimately end up in the lungs. Pulmonary function may be further compromised by oedema formation secondary to tissue damage and the increased incidence of bronchopneumonia that arises secondary to reduced alveolar macrophage function in the damaged lung. Treatment is aimed at reversing the initial hypoxia by oxygen supplementation, treating bronchopneumonia if present and relieving any bronchospasm by the use of bronchodilators. As in aspiration pneumonia, the use of steroids is controversial, with decisions being made on a risk–benefit basis.

Parasitic lung disease

Toxoplasma gondii (see also Chapter 28)

Cats play a key role in the epidemiology of *T. gondii* since they are the only animals known to excrete the oocyst stage. Many cases of *T. gondii* infection in the cat remain subclinical. However, clinical signs of disease may be seen in cats of almost any age (Dubey & Carpenter, 1993). Affected cats are often pyrexic and lethargic. Signs of respiratory tract involvement commonly include dyspnoea and tachypnoea. Other clinical signs attributable to infection of other body systems may also be apparent. These include central nervous system signs (e.g. varying degrees of blindness, locomotor deficiencies and seizures), abdominal discomfort and jaundice. A detailed examination of the eyes is recommended, as many cats will display evidence of ocular changes.

Thoracic radiographs usually reveal a diffuse interstitial and alveolar pattern. Ante-mortem diagnosis may be aided by the demonstration of tachyzoites in BAL fluid samples (Hawkins *et al.*, 1997; Brownlee & Sellon, 2001). Several serological tests are currently available for aiding a diagnosis, with the most reliable being based on immunoglobulin M (IgM) titres. However, interpretation of serological results can be fraught with error. Cats with clinical disease may have a low IgM titre if the class switch to IgG has already occurred. Furthermore, asymptomatic cats may remain IgG seropositive for prolonged periods, certainly well beyond the time of clinical cure. The identification of *T. gondii* oocysts in the faeces is unreliable, as shedding of oocysts has often ceased by the time clinical signs are evident. *Toxoplasma* organisms may be found in impression smears from tissue aspirates. Histopathology and specialised immunohistochemical techniques can also aid in confirming a diagnosis.

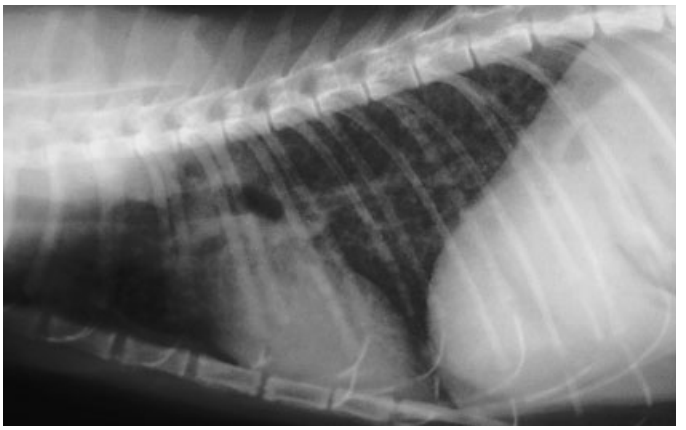

Figure 12.3 *Aelurostrongylus abstrusus* infection. Lateral thoracic radiograph revealing a widespread bronchial interstitial pattern throughout the lung fields. Faecal examination confirmed the presence of *A. abstrusus* larvae.

In severe cases of clinical *T. gondii* infection, the prognosis is poor. Treatment should be instigated once signs are recognised or a diagnosis is confirmed. Both potentiated sulfonamides and clindamycin have been advocated for the treatment of clinical toxoplasmosis in the cat.

Aelurostrongylus abstrusus (see also Chapter 31)

Adult worms of *A. abstrusus* live in the terminal bronchioles and alveolar ducts of infected cats. Most cases are probably asymptomatic, although chronic coughing and dyspnoea have been reported. In the most severe cases, infection may prove fatal. Thoracic radiographs may reveal a peribronchial and/or patchy alveolar pattern (Figure 12.3). Definitive diagnosis is based on demonstration of first stage larvae in faecal samples, usually by the modified Baermann technique. Most cases are self-limiting and only require conservative use of antibiotics, corticosteroids and possibly bronchodilators. The FeLV and FIV status may require checking in cases that are not self-limiting. Fenbendazole is a suitable agent for killing adult worms.

Paragonimus kellicotti is a rare fluke infection of the feline lung that occurs in localised regions of the USA. Its pattern of occurrence is determined by the distribution of the parasite's intermediate hosts (crustaceans).

Signs of pulmonary artery enlargement and parenchymal lung changes may be observed in cases of feline heartworm disease (see Chapter 31).

Pulmonary neoplasia

Primary lung tumours are uncommon in the cat (Mehlhaff & Mooney, 1985; Hahn & McEntee, 1997). Early clinical signs are usually non-specific and include inappatence, weight loss, lethargy and pyrexia. Subsequent signs of respiratory embarrassment include dyspnoea, coughing and tachypnoea. Most primary lung tumours in cats are malignant and frequently metastasise both locally (intrathoracic) and more distantly (extrathoracic). Some primary lung carcinomas are characterised by metastasis to one or more of the cat's digits, with lameness being a common presenting sign (Jacobs, 1997).

Many tumour types may metastasise to the lung; however, mammary gland adenocarcinomas are overrepresented, probably underpinning the high rate of malignancy of this tumour type in cats (Plate 12.7). Reported clinical signs include coughing and dyspnoea.

Radiographic diagnosis of pulmonary neoplasia is not always reliable, with many reports of false negatives in the early stage of disease (nodules must be at least 3 mm in diameter to be visualised radiographically). Primary tumours may present as solitary or multiple nodules. In pulmonary metastasis, poorly circumscribed interstitial nodules or a diffuse pulmonary pattern may be observed in addition to a better-defined nodular pattern (Forrest & Graybush, 1998). In both cases, pleural effusion may also be present.

Diagnosis may be facilitated by cytological examination of bronchial or pleural fluid, if present. Ultrasound-guided fine-needle aspirates of both diffuse disease and accessible discrete masses may also prove diagnostic. Surgical treatment by lobectomy should only be considered where disease appears to be localised. The prognosis for most cases of pulmonary neoplasia is poor.

Figure 12.4 Mediastinal mass. Dorsoventral thoracic radiograph showing a soft-tissue opacity in the cranial thorax with collapse of the cranial lung lobes. A small volume of pleural fluid is also present. Post-mortem examination revealed the mediastinal mass to be a thymic lymphoma.

Other causes of pulmonary disease

Clinical signs of respiratory disease are less frequently encountered than alimentary signs in *Mycobacterium tuberculosis* infection in the cat. However, the zoonotic importance of this agent demands that it be con-sidered as part of the differential diagnosis of feline respiratory disease. Pulmonary oedema is frequently associated with cardiac disease, particularly cardiomyopathy. Paraquat toxicity is rare in cats, but the proliferative bronchiolitis and alveolitis encountered in this condition may be associated with pulmonary oedema, tachypnoea and dyspnoea in the later stages of disease. *Yersinia pestis* may cause pneumonic forms of plague in certain regions of the world (Eidson *et al.*, 1991). The lungs are also sensitive to barotrauma during anaesthesia (Manning & Brunson, 1994).

Diseases of the mediastinum

The most common condition of the feline mediastinum is mediastinal (thymic) lymphosarcoma. This tumour is most common in young adult cats and is associated with a high carriage rate of FeLV. Thymomas are less common than lymphosarcomas, are usually benign and tend to occur in older cats (Carpenter & Holzworth, 1982). In both cases, clinical signs may include cachexia, dyspnoea, tachypnoea and regurgitation. A pleural effusion is also commonly encountered (see below). In the case of thymomas, some cats may also exhibit paraneoplastic signs including myositis and dermatitis (Carpenter & Holzworth, 1982). The FeLV status of all cats with anterior mediastinal masses should be determined.

The presence of an anterior mediastinal mass may be suspected by demonstrating reduced compliance of the cranial thorax on digital palpation. Radiographic findings include a soft-tissue density in the cranial thorax, tracheal elevation, caudal displacement of the heart, loss of the cardiac silhouette and pleural effusion (Gruffydd-Jones *et al.*, 1979; Carpenter & Holzworth, 1982) (Figure 12.4). In some cases, mediastinal lymphosarcomas may also occur in the posterior mediastinum. Cytology of fine-needle aspirates and pleural effusion should allow confirmation of the presence of tumour cells, and a differentiation between thymoma and lymphosarcoma. Such a differentiation is highly relevant, as surgical removal of benign thymomas is often curative, whereas chemotherapy is the treatment of choice for mediastinal lymphosarcoma.

Other rare conditions of the feline mediastinum include pneumomediastinum, usually secondary to tracheal trauma (see above) or gas-forming mediastinitis.

Disorders of the chest wall

Damage to the thoracic cage is a frequent occurrence following episodes of trauma in cats, with common sequelae including haemothorax, pneumothorax (see below) and underlying pulmonary contusion. Individually fractured ribs (one fracture per rib) usually respond to conservative treatment. Flail chest represents a specific, life-threatening condition associated with fracture of individual ribs in more than one place, allowing paradoxical motion of the fractured segments during respiration and ventilation–perfusion

Box 12.3 Technique for thoracocentesis

Unless there is specific indication to do otherwise, thoracocentesis is performed through the right chest wall.

Equipment needed:
- 20/21 G over-the needle catheter or butterfly catheter
- three-way stopcock, extension tubing and 20 ml syringe
- sample tubes: EDTA tube, clot tube, anaerobic culture vehicle for inoculation, swab for aerobic culture, polished slides for direct smears
- graduated collecting dish
- 1–2 ml local anaesthetic.

Procedure:
- For pleural effusion, the needle is inserted one-third from the ventral thorax. For pneumothorax, the needle is inserted in the mid-thorax.
- Clip the chest wall from the fifth to the tenth intercostal space.
- Infiltrate the skin and deeper tissues of the seventh intercostal space, down to the pleura, with local anaesthetic.
- Aseptically prepare the shaven site.
- Advance the catheter into the pleural space at an angle directed cranially, but avoiding the vessels that course along the caudal border of the rib in front.
- Apply suction via the syringe while advancing to allow prompt recognition of the appropriate depth of needle placement.
- A 'pop' sensation should be appreciable as the needle enters the pleural space.
- Remove the stylet once in the correct place.
- Orientate the catheter in various directions to aspirate any pockets of fluid or air.

mismatching. Treatment of severe chest trauma is initially aimed at correcting any shock, hypoxia and pleural space abnormalities. Internal surgical stabilisation of flail chest should only be attempted when the underlying disease process has been corrected or resolved. A method for the external stabilisation of flail chest segments without the requirement for general anaesthesia has been described. This method uses splints secured by single circumcostal sutures around each of the affected rib segments (McAnulty, 1995).

Thoracic wall tumours including fibrosarcoma and osteosarcoma are uncommon. Pectus excavatum is a rare congenital abnormality associated with dorsal displacement of the sternum and an associated flattening of the chest wall.

Disorders of the diaphragm

The diaphragm plays a key role in normal respiration and functions as an effective barrier between the thoracic and abdominal cavities. Although compromise of this barrier may be congenital in origin (peritoneo-pericardial diaphragmatic hernia), most of the cases seen in practice are acquired following an episode of blunt abdominal trauma. Congenital hernias are often asymptomatic. Signs of respiratory embarrassment are usually observed if the extent of traumatic rupture and subsequent herniation is large or complicated by gas accumulation in the displaced organs. However, cats may exhibit no respiratory signs for many months, particularly if the defect and herniation are relatively minor. Clinical signs ultimately develop secondary to the accumulation of a modified pleural transudate (Plate 12.8) (see below) and include weight loss, innappatence, moderate tachypnoea and abdominal breathing.

Suspected cats should be handled carefully to avoid increasing the pressure in the abdomen and promoting further herniation of organs. Auscultation may reveal reduced lung sounds and muffled or displaced heart sounds. The presence of borborygmi is not consistent and such sounds may also be referred from the abdomen. Thoracic radiography is usually diagnostic, but may require the administration of oral barium for confirmation. In chronic cases, radiographic changes may be moderate and the diagnosis is aided by positive contrast celiography, fluoroscopy and ultrasound examination.

Surgical repair of the diaphragmatic defect and replacement of abdominal organs is the treatment of choice. Cases in which the stomach has prolapsed and is tympanic may require thoracocentesis (Box 12.3) to relieve the tympany and improve respiratory function prior to anaesthesia. Anaesthesia is complicated by the requirement for positive pressure ventilation on entering the abdomen and the necessity to minimise pneumothorax before wound closure.

Diseases of the pleural space

The pleura is a continuous serous membrane which surrounds the pulmonary parenchyma on one side (visceral pleura) and reflects to form the lining of the thoracic wall (parietal pleura) on the other. Ordinarily, the space between the parietal and visceral pleura (the pleural space) is occupied by a thin film of capillary fluid of no more than 2–3 ml. However, this space has

the potential to expand if air or fluid collects within. This results in an increased resistance to maximum lung inflation.

As discussed under the section dealing with diagnosis, the classification of respiratory signs helps to localise to some extent the area of most concern in a respiratory case. Cats with pleural disease frequently present with inspiratory dyspnoea without stridor, or a 'restrictive' respiratory pattern characterised by rapid, shallow breathing. The inspiratory phase often has a marked abdominal component. Respiratory signs are usually accompanied by depression, a reluctance to move and inappatence. Coughing is an infrequent clinical finding. Other features such as weight loss, pyrexia, dysphagia, regurgitation, dehydration, cyanosis, open-mouthed breathing and collapse may be noted. Auscultation of the chest frequently reveals muffled heart sounds and increased bronchial sounds. Percussion of the chest wall may be altered owing to the presence of fluid in the pleural space. Conversely, the accumulation of gas would be associated with greater resonance. The severity and progression of clinical signs are influenced by both the rate of accumulation and the overall volume of fluid or air present in the pleural space. Diseases of the pleural space can present as life-threatening emergencies (see Thoracocentesis, below).

There are two major categories of pleural space pathology. These are the pleural effusions, where fluid accumulates in the pleural space, and pneumothorax, where air or gas accumulates in the pleural cavity. Soft-tissue tumours of the pleural lining are possible, although rare. In cats, the four most common conditions are associated with the accumulation of purulent exudate (pyothorax), blood (haemothorax), chyle (chlyothorax) and air (pneumothorax). There are several other conditions of the cat in which pleural effusions may be observed (e.g. feline infectious peritonitis and congestive heart failure). However, since the pleural effusion is a secondary feature of such diseases, they are not considered in detail in this chapter.

Pleural effusions

Pleural space homoeostasis is governed by a combination of capillary hydrostatic pressure, capillary colloidal osmotic pressure, capillary permeability and lymphatic function. The combined effect of these pressures is a continual net flow of fluid through the pleural space. Any alteration or disruption to these individual forces may predispose to pleural effusion. Since the majority of companion animals, including cats, have a single contiguous pleural space owing to fenestrations of the mediastinum, most pleural effusions tend to become bilateral.

The diagnosis of a pleural effusion is based on clinical signs, thoracic radiographs and ultrasound examination, with differentiation being aided by laboratory evaluation of any fluid present. Radiographic findings may vary in individual cases, but include interlobar fissure lines, rounding of lung margins at the costophrenic angles and separation of lung borders away from the thoracic wall. Other features that may be observed on radiographs include scalloping of lung margins dorsal to the sternum, blurring of the cardiac silhouette and widening of the mediastinal space.

Relatively small quantities of pleural fluid can be appreciated on lateral recumbent or ventrodorsal views of the chest, especially when the films are taken on expiration. Radiography may also provide valuable information as to the likely cause of the pleural effusion, particularly when views are taken post-thoracocentesis. For example, a loss of lucency in the anterior thorax with caudal displacement of the heart and dorsal displacement of the trachea is suggestive of an anterior mediastinal mass. Cardiomegaly may be seen with acquired heart disease. Rupture of the diaphragm is often accompanied by a loss of the crural lines and cranial displacement of abdominal contents. Multiple small opacities in lung parenchyma may be seen with pulmonary carcinoma, and peritoneal fluid may also be visible in suspected cases of feline infectious peritonitis.

Ultrasonography, where available, should be performed before large quantities of fluid are drained, because the fluid can act as an 'acoustic window', thereby allowing a better visualisation of the various thoracic structures.

Definitive diagnosis of the nature of the pleural effusion requires thoracocentesis (see later). Gross visual examination of the fluid allows for an assessment of colour, smell, turbidity, and the presence or absence of particulate matter. Two to four millilitres collected in an EDTA blood tube will allow for estimation of total protein content, specific gravity and nucleated cell counts. Cytological evaluation of direct smears allows for the identification of individual cell types (Plate 12.9) and may indicate the presence of bacterial or fungal pathogens (special stains may be required). Aerobic and anaerobic cultures should allow such pathogens to be identified and their antibiotic susceptibility determined. Knowledge of the results of the above-mentioned tests allows pleural effusions to be divided into either transudates or exudates. The latter category may be further subdivided into inflam-

matory and non-inflammatory exudates. An alternative strategy for distinguishing between transudates and exudates is based on the measurements of lactate dehydrogenase, pH, glucose and red cell numbers in the pleural fluid (Padrid, 2000a).

Confusion can arise in interpreting the characteristics of pleural effusions resulting from some neoplastic conditions, as these can range from modified transudates to inflammatory and non-inflammatory exudates. Cytological evaluation of pleural fluid can be further complicated by the presence of benign reactive mesothelial cells, which may appear malignant. This is particularly common when the excess pleural fluid has been present for some time. If a neoplastic condition is suspected, it should be confirmed by radiography and fine-needle aspiration or biopsy of any intrathoracic, mediastinal or pulmonary masses. Mediastinal lymphosarcoma is the most common cause of feline neoplastic pleural effusion (Forrester, 1988).

In addition to pleural fluid analysis, it is important to screen cats with pleural effusion for general organ system dysfunction. This should include a complete blood count, serum biochemistry profile and urinalysis. It is also advisable to test cats with pleural effusion for FeLV and FIV, as the presence of these viruses may influence the management of the case.

Thoracocentesis (see Box 12.3)

Thoracocentesis is defined as the surgical puncture and drainage of the pleural space. The removal of abnormal accumulations of fluid or air leads to improved ventilation and reduced respiratory distress, and promotes safer manipulation of the patient. Even the removal of small volumes of air or fluid may significantly improve respiratory function. Thoracocentesis is therefore the first procedure to be performed in extremely dyspnoeic animals with confirmed pleural space disease.

As well as its therapeutic value, thoracocentesis is of significant diagnostic value, giving an indication of the cause of the effusion (e.g. pus) and providing fluid for analysis. Further diagnostic procedures should not be performed until the cat is judged to be clinically stable.

Where thoracocentesis is indicated, general anaesthesia is frequently contraindicated. When the cat's temperament mitigates against handling or restraint, sedation can be used if deemed absolutely necessary. However, the favoured approach is by the infiltration of local anaesthetic. Indeed, in many cases, cats will tolerate the procedure even without the use of local anaesthetic.

Since cats with pleural space disease have a limited respiratory reserve, minimal stress and restraint beforehand, and preoxygenation via a face-mask or enclosed chamber, are recommended. Ideally, the animal should be in sternal recumbency. Unless there is a specific indication to enter the left-hand side or both sides, the right-hand side is generally chosen. The equipment needed and technique are outlined in Box 12.3. A pneumothorax is drained at midthoracic level through the seventh or eight intercostal space, whereas pleural effusions are preferentially drained at the slightly lower level of the ventral third of the chest, through the same intercostal space.

The procedure can be repeated at intervals and from side to side. If the tap yields nothing of significance or the cat has obtained no relief, the presence of loculated pockets of fluid or the possibility of parenchymal disease should be considered. The presence of haemothorax provides a particularly difficult choice for the practitioner. Thoracocentesis is generally contraindicated in the presence of a bleeding disorder caused by anticoagulant toxicity, severe thrombocytopenia or a heritable coagulopathy. However, the risks involved are acceptable if the volume of blood present is causing a potentially fatal degree of respiratory compromise.

Pyothorax

Pyothorax (exudative pleurisy) is defined as a suppurative inflammation of the thoracic cavity with the resultant accumulation of inflammatory exudate within the pleural space. Although the route of infection is not always evident, pyothorax may arise due to haematogenous or lymphatic spread, tracking foreign bodies, penetrating chest wounds, oesophageal perforation or iatrogenic (often postoperative) causes (Plate 12.10). It may also result from pulmonary neoplasia, abscessation or pneumonia (parapneumonic effusion) and extension from diskospondylitis. Young male cats that fight may be at increased risk of traumatically acquired infections. Most cases of pyothorax are associated with a moderate to severe bilateral effusion, although cases with a unilateral distribution are also reported. A combined picture of air and effusion in the thorax (pneumohydrothorax) may occur in those cases in which the causative organism is a gas-producing anaerobe or in which the infection arises from a necrotising pneumonia. However, caution should be exercised as the presence of air may

Box 12.4 Anaesthetic protocol for chest tube placement

Preoperative considerations:
- conscious radiographs to establish the degree and location of pleural effusion
- drain effusion in severely compromised patients by thoracocentesis
- minimise handling of the patient if causing distress.

Premedication:
- midazolam (0.2 mg/kg) and ketamine (5 mg/kg) intramuscularly.

Induction:
- preoxygenation for 5 min using a face-mask
- propofol (6 mg/kg) slowly intravenously to effect **OR** diazepam (0.3 mg/kg) combined with ketamine (3 mg/kg) slowly intravenously
- endotracheal intubation with a cuffed tube.

Maintenance:
- isofluorane or halothane in 100% oxygen delivered by Ayre's T-piece
- intermittent positive pressure ventilation as necessary
- maintain in sternal recumbency or with the compromised lung more dependent
- local anaesthetic (lignocaine/bupivicaine) infiltrated around site of chest tube placement.

Box 12.5 Technique for chest tube placement

Equipment needed:
- 10–16 Fr rubber feeding tube or commercially available trochar chest tube. If using a feeding tube, three to five fenestrations should be cut into the distal 5–6 cm to promote chest drainage and minimise the risk of tube blockage
- two tube gate-clamps or suitable tube cap
- pair of curved haemostats
- scalpel blade
- non-absorbable suture material
- bandaging materials with or without Elizabethan collar.

Procedure:
- Unless indicated by a right-sided unilateral effusion, chest drains are usually placed in the left thorax.
- The surgical site is aseptically prepared.
- A small stab incision is made approximately one-third of the way down the 10th intercostal space (ICS).
- A small subcutaneous tunnel is advanced in a cranioventral direction to the eighth ICS using haemostats.
- If the chest tube has no stylet, it is clamped with haemostats at the fenestrated end to aid tube placement.
- The chest drain is then pushed through the muscles and parietal pleura of the eighth ICS, being careful to avoid the intercostal vessels that run along the caudal aspect of the eighth rib. If using a tube and trochar, place the lower hand about 3 cm from the chest wall while advancing the tube to prevent 'follow-through' on entering the chest cavity.
- The drain is advanced cranioventrally for 10–15 cm and until all fenestrations are in the chest cavity.
- The tube must be capped or clamped at all times when not in use.
- Chest tube placement may be verified radiographically. It should gently curve to rest on the thoracic floor.
- The tube is secured in place using a Chinese purse-string suture. For further security, tape may be placed around the tube and sutured to the skin.
- Antibacterial ointment is placed around the skin incision.
- The tube is loosely bandaged to the cat's flank using a body stocking or equivalent.

also indicate iatrogenic introduction following thoracocentesis.

Many pathogens have been cultured from pleural taps in cases of pyothorax, including *Bacteroides* and *Fusobacterium* species, and *Pasteurella multocida* (Fooshee, 1988). Other organisms isolated less frequently include streptococci, staphylococci, *Corynebacterium* species, *Clostridium* species, *Actinomyces* and *Nocardia* species, *Enterobacteriacae*, *Mycoplasma* species and even some fungi (Plate 12.11). This range of potential aetiological agents underpins the importance of acquiring samples for both aerobic and anaerobic culture, and if suspected, fungal culture. Despite this, false-negative cultures are often encountered, especially if anaerobic organisms are involved. Although precise identification of the causal organism allows for the selection of appropriate chemotherapeutic agents, it is generally of little prognostic value.

It is advisable that the analyses and interpretation of the pleural aspirate should be performed in conjunction with a complete blood count. Pyothorax cases are characterised by a turbid or an opaque cream-coloured viscous fluid aspirate, which may or may not contain loculated material. A pungent smell is a variable finding. A Gram stain (or similar) is a simple procedure to perform and allows for rapid assessment of microorganisms in pleural fluid. The smears of puru-

lent effusions are frequently dominated by degenerate neutrophils. Macrophages and mesothelial cells are usually present in variable numbers, depending on the cause and chronicity of the fluid. In some cases of pyothorax, the exudate may be dominated by non-degenerate neutrophils and macrophages (often those caused by *Actinomyces* species, *Nocardia* species or fungi). The protein level in this type of exudate is generally in excess of 3.5 g/dl. In some cases of pyothorax due to *Actinomyces* or *Nocardia* species, the exudate may contain small, yellow–grey particles consisting of tissue debris and bacteria, called sulfur granules. Systemic signs of pyothorax often include a peripheral leucocytosis, neutrophilia with a left shift and possible evidence of toxic changes to circulating neutrophils.

Initial stabilisation of pyothorax patients is based on therapeutic thoracocentesis. Successful longer term resolution requires chest tube placement and aggressive medical management focused on fluid and electrolyte balance, appropriate analgesia and nutritional requirements. Chest tubes may be introduced under local anaesthesia (with or without sedation) or preferably under general anaesthesia. A recommended anaesthetic protocol is included in Box 12.4. Chest tube placement is aided by intermittent positive pressure ventilation and oxygen supplementation. Only a small number of patients will require bilateral chest tube placement, and unless otherwise indicated, the left-hand side is preferentially used for tube placement. Box 12.5 provides guidance on a suitable technique for chest tube placement in the cat.

Lavage and drainage are essential components to the successful management and treatment of pyothorax. Intensive care must be provided for these patients because of the potential for problems to arise. The frequency with which the chest needs to be drained and lavaged varies between cases, and is largely governed by the rate of fluid formation. Drainage three or four times daily is adequate in most cases, but this may need to be increased to six to eight times daily in severely affected cats. If fluid accumulation is so rapid that intermittent drainage is not sufficient or practical then continuous, closed, underwater suction is indicated. The lavage technique involves instilling 10–20 ml/kg body weight of an isotonic fluid such as saline or lactated Ringer's solution, at body temperature, into the pleural space through a chest drain. The fluid is left *in situ* for up to 1 h, and then drained. If dyspnoea occurs during lavage, then smaller volumes should be used. If the cat's temperament permits, mild coupage or rocking of the patient from side to side may facilitate the retrieval of fibrinous debris. The above procedures may need to be repeated for 5–10 days to obtain clinical resolution. The benefits of adding antibiotics or proteolytic enzymes to the lavage fluid are controversial. Some authors recommend the addition of heparin to the lavage fluid (1500 u/100 ml of fluid) (Fossum, 1997).

It is important to realise that some of the administered fluid will invariably be lost owing to resorption during the lavage process (approx. 25% or less). The aspirated fluid can also be used for periodic cytological evaluation to assess any therapeutic progress. The thorax should be re-evaluated radiographically every 2–3 days. This also facilitates assessment of current tube placement. Serum electrolyte concentrations should also be evaluated periodically, as depletion of certain electrolytes is a recognised complication of repetitive lavage therapy. The tube may finally be removed when the lavage fluid is clear and bacteria are no longer evident on cytological or microbiological examination. It should be remembered that the presence of the tube alone will provoke an effusion equivalent to 2–3 ml/kg per day (Noone, 1985). Surgical intervention is an option in those cases that fail to respond to aggressive medical therapy. Such cases are usually associated with underlying disease (e.g. pulmonary abscess).

Appropriate antimicrobial therapy should be based on susceptibility results following pleural fluid culture. In the absence of such information initially, agents such as penicillin G, ampicillin, amoxycillin, clavulanate-potentiated amoxycillin, clindamycin and metronidazole have proved beneficial in practice. Aminoglycosides, sulfonamides and tetracyclines are generally regarded as inappropriate because of their poor efficacy against anaerobes. In severe cases, antibacterial therapy should initially be given intravenously if suitable preparations are available. In all cases, antibacterial therapy should be continued for 2 weeks beyond the resolution of clinical signs (usually 4–6 weeks in total). Adhesions within the pleural space and pleuritis are two potential sequelae to pyothorax, either one of which would have a negative effect on the prognosis for a full recovery.

Haemothorax

Haemothorax is defined as the accumulation of blood in the pleural space. This is usually due to haemorrhage as a result of trauma to the chest wall (the animal may have concurrent pneumothorax), diaphragm, heart wall, lung parenchyma or mediastinal structures. Other potential differentials in the diagnosis of cats presenting with haemothorax include iatrogenic, pul-

monary infarction, lung lobe torsion and neoplasia. The presence of an underlying coagulopathy must also be considered. The potential dangers involved in performing thoracocentesis on such patients have already been alluded to above. The clinical signs observed in such cases can range from mild to rapidly fatal, depending on the volume of blood present within the pleural space and the rate of accumulation.

The effusion in these cases is typically red. The presence of a clot is largely governed by the length of time the blood has been present within the pleural space (Sherding, 1994). Analysis of any sample obtained confirms the large number of red blood cells present in the fluid, with values for packed cell volume, total protein and specific gravity typically being approximately 25% of the peripheral blood values (Forrester, 1988). The possibility of a coagulopathy should be investigated by obtaining a detailed history and by performing appropriate tests for blood clotting function.

The treatment of haemothorax requires a combined approach to address the separate problems of reduced circulating blood volume and impaired ventilation. Many cats can be successfully managed with a conservative approach incorporating cage rest (preferably an oxygen-enriched chamber), frequent observation of vital signs and sequential monitoring of packed cell volume and plasma proteins. Provision of a source of heat and fluid therapy for circulatory support are often beneficial for a more rapid recovery. Red blood cells in the pleural space are resorbed to a degree and therefore, if left *in situ*, can be viewed as a method of autotransfusion for the cat. Thoracocentesis should only be performed if considered necessary to relieve respiratory distress and, in such cases, it may prove necessary to replace lost red blood cells by transfusion from a donor. Chest tube placement is rarely indicated in cases of haemothorax. If significant bleeding continues to occur, an emergency thoracotomy is indicated to control the bleeding. Constrictive pleuritis, because of organisation of a clot within the pleural space, is a rare complication of haemothorax.

Table 12.1 Causes of chylothorax

Congenital	Congenital abnormalities of the thoracic duct Tetralogy of Fallot Other congenital defects
Traumatic	Surgical perforation/laceration/ligation Other chest traumas resulting in similar injuries
Inflammatory	Granulomatous lesions
Neoplastic	Mediastinal lymphosarcoma/thymoma obstructing lymphatic drainage Erosion of the thoracic duct by tumours
Cardiogenic	Cardiomyopathy Congestive heart failure Pericardial effusion Tricuspid dysplasia
Idiopathic	Cause undetermined
Other	Diffuse lymphatic abnormalities involving the thoracic duct (e.g. lymphangiectasia) Venous thrombosis Possible association with pancreatic disease and parasitism

Chylothorax

Chylothorax represents the accumulation of chyle within the pleural space. Determination of the precise cause of this type of effusion is often frustrating in practice. It is usually the result of an alteration in the dynamics of lymph flow through the thoracic duct, due to pressure either within (increased lymph flow) or outside the thoracic duct (obstruction to flow). The possible causes can be subdivided into different groups using a broad classification system (Table 12.1).

One study reported that older cats were more prone to developing chylothorax than were young cats, although the condition has been reported in virtually all ages. There is no age predisposition for chylothorax in the cat. The clinical signs are generally similar to any other pleural effusion, although coughing may be a particular feature of the disease. Proteins, fats, fat-soluble vitamins, antibodies and lymphocytes are carried in the lymphatics and can be rapidly lost from the general circulation. Thus, related systemic signs such as weight loss and a decline in the general health are often observed, and must be taken into consideration when deciding on the treatment and longer term management of the cat.

Chylous effusions are characterised by a milky-white, pink-tinged appearance, and they generally separate out to form a creamy top if allowed to stand. Concentrations of cholesterol and triglycerides within the effusion should be assayed and compared with those in the peripheral circulation. Chylous fluid has a higher triglyceride content than serum and a normal or low cholesterol content. A pleural fluid cholesterol: triglyceride ratio of less than 1 is also suggestive of a

chylous effusion. Effusions that appear to be chylous, but do not fit the criteria mentioned above, have traditionally been referred to by the term 'pseudochylous' effusions. However, there is currently no evidence to prove that such effusions actually occur in cats (Fossum, 1988). Degenerate neutrophils and sepsis are uncommon findings with chylothorax owing to the bacteriostatic nature of the fatty acids present in the fluid.

Because the treatment of chylothorax varies considerably according to the underlying cause, it is imperative that related disease processes are identified before commencing definitive therapy (Table 12.1). If the underlying disease is effectively treated, then the effusion will often resolve, although complete resolution may take several months. Effective treatment for any mediastinal masses will quickly remove the physical obstruction predisposing to fluid accumulation. In those cases with a cardiogenic origin, attention should focus on improving the dynamics of general circulation. In traumatic cases, surgery is generally not indicated unless conservative therapy has proved unsuccessful over a period of at least 2 weeks. Chest tubes are only indicated in those animals with suspected chylothorax secondary to trauma, with rapid fluid accumulation or following surgery. In most other cases, intermittent thoracocentesis, combined with treatment of any underlying related disease process, should be sufficient. One potential complication that has been recorded in cases of chronic chylothorax in cats is the development of a fibrosing or constrictive pleuritis that can lead to a permanent reduction of respiratory function (Fossum *et al.*, 1992; Suess *et al.*, 1994).

The treatment of idiopathic chylothorax in the cat poses specific challenges for the clinician. Medical management, including the placement of chest tubes and the feeding of a low-fat diet, may not be sufficient to control the condition adequately, forcing consideration of other surgical options. The choices of procedures available include thoracic duct ligation, shunting and pleurodesis. Thoracic duct ligation is facilitated by lymphangiography, both to choose the location and to check the placement of ligatures. Shunting techniques may be passive or active, and aim at diverting the effusion into the peritoneal cavity. Pleurodesis is the creation of adhesions between the visceral and parietal pleura caused by the instillation of irritating agents into the pleural cavity. The same result can also be achieved by inducing mechanical damage to the pleural lining at surgery. It should be emphasised that the success rates for the various surgical procedures can often be disappointing. No data derived from controlled trials are currently available to decide on the efficacy of benzopyrone drugs such as rutin in the resolution of chylous effusions in the cat.

Pneumothorax

Pneumothorax is the accumulation of air or gas within the pleural space. Air can enter the space by a variety of means, including disruption to the chest wall or diaphragm, puncture of the pulmonary visceral pleura or the entry of mediastinal air. Trauma is probably the single most common cause of pneumothorax and can be subdivided into open (i.e. with a connection to the outside) or closed cases (i.e. due to disruption of the integrity of the thoracic space or structures from within). Rare cases of pneumothorax related to rupture of large pulmonary cysts creating bronchopleural fistulae have also been reported. Some cases of pneumothorax appear to be spontaneous or idiopathic in origin. Traumatic and spontaneous pneumothorax must be differentiated because the former usually responds to medical management, whereas the latter often requires surgical intervention. A combination of air and pus may be present in the pleural cavity if purulent material leaks into the space from an adjacent abscess. Many cats presenting with pneumothorax may have a concurrent pneumomediastinum.

Pneumothorax may also occur under tension if the lung or pleura acts as a one-way valve. In this situation, inspired air becomes trapped in the pleural space, leading to increasing intrapleural pressure and decreasing the efficiency of gaseous exchange; so-called tension pneumothorax. This situation constitutes a life-threatening emergency and prompt intervention with thoracocentesis is necessary to avoid a fatal outcome. The placement of a chest drain may be deemed necessary at a later stage (see below).

Sucking chest wounds are a relatively common occurrence and are an important cause of respiratory embarrassment in some cases of pneumothorax. These wounds suck air in from the outside during the inspiratory phase of respiration when the chest is maximally expanded. This phenomenon can lead to lung collapse, as the differential pressure gradient is lost, thereby allowing equilibration of the atmospheric air surrounding the lungs with the air within the lungs themselves.

Diagnosis of pneumothorax is initially suspected on the grounds of clinical signs compatible with the loss of functional lung volume, and is subsequently confirmed by radiography and thoracocentesis. There are diminished breath sounds on auscultation and hyperreso-

nance on percussion. In cases that result from trauma, the cat usually presents with acute dyspnoea and some degree of cyanosis due to hypoventilation and hypoxia.

Radiography reveals poorly expanded lungs that are retracted from the chest wall. One feature that is almost considered pathognomic is the separation of the cardiac silhouette from the sternum by a gas opacity. The radiographs must be carefully assessed for the presence of any related abnormalities (e.g. fractured ribs). Treatment should be aimed at re-establishing the appropriate pressure in the thoracic cavity. Management of pneumothorax is dictated by the context in which it occurs and the presence or absence of complications. In the case of severe traumatic pneumothorax or large 'open' causes, surgery may be necessary to reconstruct the thoracic wall. A thoracotomy may be necessary in the case of large oesophageal perforations, lung lobe torsions and some cases of lung abscessation. In mild cases, cage rest may be all that is required. Thoracocentesis is often indicated to remove excess air and relieve the dyspnoea. Small visceral pleural tears will often seal following removal of air from the thorax. Chest tube placement is only usually necessary if thoracocentesis has to be repeated more than twice in a 24 h period, if tension pneumothorax develops or in cases of spontaneous pneumothorax. As with pyothorax, follow-up and monitoring of these patients necessitate repeat radiographs and the quantification of the amount of air aspirated each time. The prognosis is generally good in most cases of pneumothorax.

References

Anderson G.I. (1987) The treatment of chronic sinusitis in six cats by ethmoid conchal curettage and autogenous fat graft sinus ablation. *Vet Surg* **16**, 131–134.

Barrs V.R., Martin P., Nicoll R.G., *et al.* (2000) Pulmonary cryptococcosis and *Capillaria aerophila* infection in an FIV-positive cat. *Aust Vet J* **78**, 154–158.

Beaumont P.R. (1982) Intratracheal neoplasia in two cats. *J Small Anim Pract* **23**, 29–35.

Berkwitt L. & Berzon J.L. (1985) Thoracic trauma. Newer concepts. *Vet Clin North Am Small Anim Pract* **15**, 1031–1039.

Birchard S.J. & Bradley R.L. (1989) Surgery of the upper respiratory tract. In *The Cat: Diseases and Clinical Management* (ed. Sherding R.G.). Churchill Livingstone, New York, pp. 851–874.

Brownlee L. & Sellon R.K. (2001) Diagnosis of naturally occurring toxoplasmosis by bronchoalveolar lavage in a cat. *J Am Anim Hosp Assoc* **37**, 251–255.

Brownlie S.E. & Bedford P.G. (1985) Nasopharyngeal polyp in a kitten. *Vet Rec* **117**, 668–669.

Cape L. (1992) Feline idiopathic chronic rhinosinusitis: a retrospective study of 30 cases. *J Am Anim Hosp Assoc* **28**, 149–155.

Carlisle C.H., Biery D.N. & Thrall D.E. (1991) Tracheal and laryngeal tumours in the dog and cat: literature review and 13 additional patients. *Vet Radiol* **32**, 229–235.

Carpenter J.L. & Holzworth J. (1982) Thymoma in 11 cats. *J Am Vet Med Assoc* **181**, 248–251.

Corcoran B.M., Foster D.J. & Fuentes V.L. (1995) Feline asthma syndrome: a retrospective study of the clinical presentation in 29 cats. *J Small Anim Pract* **36**, 481–488.

Coulson A. (1988) Radiography as an aid to diagnosis of nasal disorders in the cat. *Vet Annu* **28**, 150–158.

Cox N.R., Brawner J.R., Powers R.D. & Wright J.C. (1991) Tumours of the nose and paranasal sinuses in cats: 32 cases with comparison to a national database (1977 through 1987). *J Am Anim Hosp Assoc* **27**, 339–347.

Dubey J.P. & Carpenter J.L. (1993) Histologically confirmed clinical toxoplasmosis in cats: 100 cases (1952–1990). *J Am Vet Med Assoc* **203**, 1556–1566.

Eidson M., Thilsted J.P. & Rollag O.J. (1991) Clinical, clinicopathologic, and pathologic features of plague in cats: 119 cases (1977–1988). *J Am Vet Med Assoc* **199**, 1191–1197.

Flatland B., Greene R.T. & Lappin M.R. (1996) Clinical and serologic evaluation of cats with cryptococcosis. *J Am Vet Med Assoc* **209**, 1110–1113.

Fooshee S.K. (1988) Managing the cat with septic pleural effusion. *Vet Med* **83**, 907–913.

Ford R.B. (1989) Noninfectious diseases of the upper respiratory tract. In *The Cat: Diseases and Clinical Management* (ed. Sherding R.G.). Churchill Livingstone, New York, pp. 755–772.

Forrest L.J. & Graybush C.A. (1998) Radiographic patterns of pulmonary metastasis in 25 cats. *Vet Radiol Ultrasound* **39**, 4–8.

Forrester S.D. (1988) The categories and causes of pleural effusion in cats. *Vet Med* **83**, 894.

Fossum T.W. (1988) The characteristics and treatments of feline chylothorax. *Vet Med* **83**, 914.

Fossum T.W. (1997) Surgery of the lower respiratory system: pleural cavity and diaphragm. In *Small Animal Surgery* (ed. Fossum T.W.). Mosby, St. Louis, MO, pp. 675–704.

Fossum T.W., Evering W.N., Miller M.W., *et al.* (1992) Severe bilateral fibrosing pleuritis associated with chronic chylothorax in five cats and two dogs. *J Am Vet Med Assoc* **201**, 317–324.

Gruffydd-Jones T.J., Gaskell C.J. & Gibbs C. (1979) Clinical and radiological features of anterior mediastinal lymphosarcoma in the cat: a review of 30 cases. *Vet Rec* **104**, 304–307.

Hahn K.A. & McEntee M.F. (1997) Primary lung tumors in cats: 86 cases (1979–1994). *J Am Vet Med Assoc* **211**, 1257–1260.

Harvey C.E. (1986) Surgical correction of stenotic nares in a cat. *J Am Anim Hosp Assoc* **22**, 31–32.

Hawkins E.C., Davidson M.G., Meuten D.J., *et al.* (1997) Cytologic identification of Toxoplasma gondii in bronchoalveolar lavage fluid of experimentally infected cats. *J Am Vet Med Assoc* **210**, 648–650.

Jacobs T.M. (1997) The lung-digit syndrome in a cat. *Feline Pract* **25**, 31–36.

Kapatkin A.S., Matthiesen D.T., Noone K.E., *et al.* (1990) Results of surgery and long-term follow-up in 31 cats with nasopharyngeal polyps. *J Am Anim Hosp Assoc* **26**, 387–392.

Lana S.E., Ogilvie G.K., Withrow S.J., *et al.* (1997) Feline cutaneous squamous cell carcinoma of the nasal planum and the pinnae: 61 cases. *J Am Anim Hosp Assoc* **33**, 329–332.

McAnulty J.F. (1995) A simplified method for stabilization of flail chest injuries in small animals. *J Am Anim Hosp Assoc* **31**, 137–141.

McMillan F.D. (1985) Iatrogenic tracheal stenosis in a cat. *J Am Anim Hosp Assoc* **21**, 747–750.

Manning M.M. & Brunson D.B. (1994) Barotrauma in a cat. *J Am Vet Med Assoc* **205**, 62–64.

Mehlhaff C.J. & Mooney S. (1985) Primary pulmonary neoplasia in the dog and cat. *Vet Clin North Am Small Anim Pract* **15**, 1061–1067.

Miller M.A., Nelson S.L., Turk J.R., *et al.* (1991) Cutaneous neoplasia in 340 cats. *Vet Pathol* **28**, 389–395.

Noone K.E. (1985) Pleural effusions and diseases of the pleura. *Vet Clin North Am Small Anim Pract* **15**, 1069–1084.

Padrid P. (2000a) Canine and feline pleural disease. *Vet Clin North Am Small Anim Pract* **30**, 1295–1307, vii.

Padrid P. (2000b) Feline asthma. Diagnosis and treatment. *Vet Clin North Am Small Anim Pract* **30**, 1279–1293.

Padrid P.A., Feldman B.F., Funk K., *et al.* (1991) Cytologic, microbiologic, and biochemical analysis of bronchoalveolar lavage fluid obtained from 24 healthy cats. *Am J Vet Res* **52**, 1300–1307.

Parker N.R. & Binnington A.G. (1985) Nasopharyngeal polyps in cats: three case reports and a review of the literature. *J Am Anim Hosp Assoc* **21**, 473–478.

Pentlarge V.W. & Martin R.A. (1986) Treatment of cryptococcosis in three cats, using ketoconazole. *J Am Vet Med Assoc* **188**, 536–538.

Sherding R.G. (1994) Diseases of the pleural cavity. In *The Cat: Diseases and Clinical Management* (ed. Sherding R.G.). Churchill Livingstone, New York, pp. 1053–1091.

Smith M.O., Turrel J.M., Bailey C.S. & Cain G.R. (1989) Neurologic abnormalities as the predominant signs of neoplasia of the nasal cavity in dogs and cats: seven cases (1973–1986). *J Am Vet Med Assoc* **195**, 242–245.

de Souzza H.J., dos Santos A.E., Ferreira A.M.R. & da Cruz J.B. (1998) Chronic lipidic pneumonia in a cat. *Feline Pract* **26**, 16–19.

Speakman A.J., Binns S.H., Dawson S., *et al.* (1997) Antimicrobial susceptibility of *Bordetella bronchiseptica* isolates from cats and a comparison of the agar dilution and E-test methods. *Vet Microbiol* **54**, 63–72.

Straw R.C., Withrow S.J., Gillette E.L. & McChesney A.E. (1986) Use of radiotherapy for the treatment of intranasal tumors in cats: six cases (1980–1985). *J Am Vet Med Assoc* **189**, 927–929.

Suess R.P., Flanders J.A., Beck K.A. & Earnest-Koons K. (1994) Constrictive pleuritis in cats with chylothorax: 10 cases (1983–1991). *J Am Anim Hosp Assoc* **30**, 70–77.

Tams T.R. (1985) Aspiration pneumonia and complications of inhalation of smoke and toxic gases. *Vet Clin North Am Small Anim Pract* **15**, 971–989.

Thén A.P., Madewell B.R., Shearn V.I. & Moulton J.E. (1995) Prognostic factors associated with radiotherapy of squamous cell carcinoma of the nasal plane in cats. *J Am Vet Med Assoc* **206**, 991–996.

Trevor P.B. & Martin R.A. (1993) Tympanic bulla osteotomy for treatment of middle-ear disease in cats: 19 cases (1984–1991). *J Am Vet Med Assoc* **202**, 123–128.

Van Pelt D.R. & Lappin M.R. (1994) Pathogenesis and treatment of feline rhinitis. *Vet Clin North Am Small Anim Pract* **24**, 807–823.

Welsh R.D. (1996) *Bordetella bronchiseptica* infections in cats. *J Am Anim Hosp Assoc* **32**, 153–158.

White R.A.S., Littlewood J.D., Herrtage M.E. & Clarke D.D. (1986) Outcome of surgery for laryngeal paralysis in four cats. *Vet Rec* **118**, 103–104.

White S.D. (1994) Diseases of the nasal planum. *Vet Clin North Am Small Anim Pract* **24**, 887–895.

Willoughby K. & Coutts A. (1995) Differential diagnosis of nasal disease in cats. *In Practice* **17,** 154–161.

Chapter 13

THE REPRODUCTIVE SYSTEM

T.J. Gruffydd-Jones

Introduction

The tremendous increase in the number of cats kept as pets in the UK has been accompanied by an increased interest in pedigree cats and their breeding. This, together with the increasing emphasis on feline medicine and expectations of owners, has led to greater demands on the veterinary surgeon to advise on breeding management and to investigate reproductive failure. Requests of this type are now commonplace, but there is relatively little information on reproduction in cats, particularly with respect to infertility, on which to base such advice.

Normal reproduction

Cats living under natural conditions are seasonally polyoestrous. However, provision of artificial lighting will abolish the anoestrous period, which normally occurs from September to December, and most cats confined indoors will display sexual activity throughout the year. There is considerable variation in the age of puberty and oestrous cycle patterns within breeds of cats, but particularly between breeds (Jemmett & Evans, 1977; Povey, 1978). In general, the Oriental cats (Siamese, Burmese and foreign shorthaired cats) tend to mature much earlier than other breeds. They may first display oestrus well before 6 months of age, whereas longhaired and British shorthaired cats may not mature until over 1 year of age. Longhaired cats may cycle only once or twice in a year and the period of oestrus may last for only a few days. In contrast, oestrus in Oriental cats may last for 10 days or more and the interoestrus interval may be as short as 1 week. Oriental queens may sometimes develop a permanent display of oestrous behaviour if not mated. Oestrus is termed 'calling' by cat breeders. It is characterised by restlessness, continual squirming and rubbing, increased sociability, vocalisation and adoption of the oestrous posture. In adopting the true oestrous posture, the queen crouches on her front legs, and extends and paddles with her hindlegs causing spinal lordosis, while deflecting her tail to one side. She presents herself in this way to other cats or humans. There is considerable individual variation in the extent of the oestrous display in individual cats, but it is generally more marked in Oriental queens. In some queens behavioural changes associated with oestrus are subtle and their recognition may depend on close familiarity with the usual behaviour of the queen. Changes in the external genitalia are unusual during oestrus, although occasionally a scant mucoid discharge may be observed. In most cats no distinctive period of proestrus can be recognised and oestrus is characterised by a sudden adoption of oestrous behaviour, followed by an equally abrupt cessation. This is associated with very rapid changes in oestrogen concentrations. Oestradiol concentrations may change two-fold within 24 h. Queens will continue to display oestrus and accept mating after ovulation has occurred and the corpora lutea have begun to secrete significant amounts of progesterone.

One of the unusual features of reproduction in cats is the phenomenon of induced ovulation. Mating is generally required for successful ovulation. In unmated cycles the follicles fail to ovulate and form corpora lutea, but simply undergo atresia. The mechanism of induced ovulation depends on vaginal receptors that are stimulated by the male (tom) cat's penis during coitus. These cause the hypothalamus to release gonadotrophin-releasing factor, which in turn causes the pituitary gland to release luteinising hormone (LH). The mechanism of LH release in cats has been

a subject of considerable interest in recent years and there is now a good understanding of the factors that influence this process (Gruffydd-Jones, 1989).

- **Number of matings:** a single mating may not be adequate to induce ovulation and the critical factor appears to be overcoming a threshold for stimulation of the pituitary gland to release LH. In queens that fail to ovulate a barely detectable increase in LH occurs after mating, but if any significant increase has been achieved ovulation will be triggered. Ovulation is generally an 'all or nothing' phenomenon, with all ripe follicles ovulating together. The time-course for LH release is quite short, with peak concentrations being achieved within 90 min after mating, and therefore it is important that the multiple matings take place in quick succession. If cats are allowed to mate at will this usually occurs, several matings usually occurring within the first 30 min.
- **Day of oestrus:** oestrogens are thought to be important in priming the release of LH and queens may not be fully primed early in oestrus. The optimum day for mating is probably around days 2–4 of oestrus.
- **Individual variability:** the receptivity of queens to mating-induced ovulation may show some individual variability. There are many instances in which ovulation has been demonstrated in queens that have had no opportunity to mate. This is not true spontaneous ovulation, but ovulation induced by stimuli other than mating. Receptors similar to those found in the vagina are also found in the lumbar area; in particularly receptive queens it is possible that stroking over this area or mounting by another queen (which is not unusual behaviour in groups of breeding queens) may provide sufficient stimulation to induce LH release.

These factors clearly have practical implications in breeding management at mating to optimise the chances of ovulation occurring at the appropriate time.

During mating the tom mounts the queen and grabs the scruff of her neck with his teeth. The actual period of coitus lasts for only a few seconds and as the tom's penis enters her vagina, the queen will cry out. Immediately after coitus the tom dismounts and retires a short distance while the queen displays her postcoital 'rage reaction'. This frequently involves lashing out at the tom, followed by frantic rolling and licking at the vulva. The absence of this typical postcoital reaction suggests that coitus has not occurred.

Ovulation occurs 24–36 h after mating and the eggs spend a further 4 days travelling down the oviduct. Implantation begins approximately 2 weeks after mating. The corpora lutea are not essential for the maintenance of pregnancy during its latter stages and ovariectomy after 50 days will not cause abortion. The factors involved in controlling luteal lifespan are not fully understood. The role of prostaglandins is uncertain, but they do not appear to have a straightforward luteolytic action in cats. The duration of gestation is very variable. Most pregnancies last for 63–65 days, but parturition before 60 days or after 70 days is not considered abnormal. It is also not uncommon to encounter split births, with some kittens being born on one day and the remainder being born 24–48 h later.

There is also considerable variation in litter size. Oriental queens tend to have large litters, occasionally in excess of 10, whereas Persian cats may average only two or three kittens in each litter. A small proportion of queens will display oestrous behaviour during pregnancy. Some of these will mate and ovulate successfully, giving rise to the phenomenon of superfetation – the simultaneous development of two sets of foetuses of differing ages within the same uterus.

Some queens will display a postpartum oestrus within 2 weeks of parturition. However, this will usually only occur if the litter is removed at birth and the queen is not allowed to feed her kittens.

Passage of 'liver-like' pieces of tissue at parturition along with normal litters is common and these represent partially resorbed or mummified foetuses that have died *in utero*. They are particularly common in large litters and probably result from overcrowding in the uterus.

Unsuccessful, sterile matings will lead to the formation of corpora lutea and pseudopregnancy. This does not usually result in lactation and nesting behaviour, as in the bitch, but more subtle changes in behaviour suggestive of pregnancy and weight gain may be noted. The duration of pseudopregnancy is variable, but usually lasts for approximately 6 weeks, which leads to an extended interoestrus interval.

Pregnancy diagnosis

Pregnancy diagnosis is vital in the assessment of reproductive failure. It is most successfully performed by abdominal palpation from 3 to 4 weeks after mating, when each conceptus is palpable as a tense, spherical swelling. Care must be taken not to confuse faecal boluses or kidneys with the conceptuses, particularly

in the event of a small litter. Repeated abdominal palpation on successive days is valuable in doubtful cases. The conceptual swellings become softer, elongate and merge from 5 weeks onwards. They are then difficult to palpate until the last week or so of pregnancy, when foetal heads can be identified. Abdominal distension usually becomes prominent from about 5 weeks onwards.

Cat breeders use the phenomenon of 'pinking up' as an indication of pregnancies. This refers to a hyperaemia of the teats, which occurs 3–4 weeks after mating. It is a progesterone-dependent change and also occurs in pseudopregnancy.

Radiography and ultrasound may also be used for pregnancy diagnosis. Ultrasonography is now more widely available in practice and has the advantage over manual palpation of indicating foetal viability, which may be of particular value in assessing queens with a history of gestational failure. Foetal skeletal calcification does not become readily recognised on radiography until the last 2 weeks of pregnancy, by which time the presence of foetuses can generally be detected readily by other means. It may be of value after parturition to check for retained foetuses if foetal maceration is suspected. Pregnancy diagnosis can be performed by radiography early in pregnancy, but identifying the presence of uterine swellings by radiographic exposure is probably best avoided at this stage.

Mismating

No treatments for mismating have been assessed and reported as being reliably effective, safe and free of side-effects. Oestrogens given shortly after mating will block oviductal transport and oestradiol administered at a dosage of 0.25 mg 40 h after mating has been used for mismating (Herron & Sis, 1974). However, such high dosage with oestrogens may lead to subsequent reproductive complications. Cats are also very sensitive to toxic effects of marrow suppression and hepatoxicity with oestrogens. Their use is therefore questionable.

High doses of progestagens (e.g. megoestrol acetate 2 mg) soon after mismating have been used to prevent implantation, but neither their efficacy nor their potential side-effects have been evaluated.

Prostaglandins have been used later in pregnancy for termination, with variable results. As mentioned previously, there is controversy over the potential luteolytic action of prostaglandins in cats. Prostaglandins appear to be more effective later in pregnancy, that is, after 40 days (Baldwin *et al.*, 2000). The efficacy of prostaglandins in terminating pregnancy may be increased by concurrent use of corticosteroids (Wyckoff & Ganjam, 1979) or cabergoline, an antiprolactin drug (Verstegen *et al.*, 1993). There have been marked variations in the dosage regimens used, but generally around 0.2 mg/kg is given daily for up to 5 days. Side-effects of prostaglandin therapy are considered later (treatment for endometritis), but some owners may find termination so late in pregnancy unacceptable.

The best policy following mismating is either to spay the cat 2–3 weeks later if the queen is not required for future breeding or to allow her to carry the litter to term.

Oestrus suppression

Surgical ovariohysterectomy is the most suitable method of contraception for cats not intended for breeding.

Temporary contraception may be required for queens that are intended for breeding at a later date. Particular indications are:

- in queens that have reached puberty at an early age and are not considered sufficiently mature to breed
- for planning and spacing litters throughout the year
- to enable queens to regain condition after their litters have been weaned.

In addition to contraception, suppression of the oestrous cycle is desirable in some circumstances to avoid potential complications of oestrus. Queens in oestrus will often show a reduction in appetite and if allowed to call incessantly they may lose condition. Some breeders also report difficulty in breeding from queens that have been allowed to call repeatedly without mating.

Progestagens are most often used for oestrus suppression and megoestrol acetate is the most widely used drug. It can be used to prevent a single oestrous period by administering 5 mg for 3 consecutive days starting on the first day that oestrous behaviour is noted. However, it is much more often used to postpone oestrus indefinitely. Most breeders use lower dosages than the recommended dose of 2.5 mg weekly, frequently as little as 1.25 mg weekly or even less frequently. There is individual variation in response to this drug and it is advisable to determine the minimum effective dosage for each queen that will reduce the likelihood of side-effects. Breeders may find that

the dosage required varies depending on the time of year and season.

The two other progestagens most commonly used for oestrus control in cats are medroxyprogesterone acetate and proligesterone. They are usually used in injectable form for more prolonged suppression of oestrous. Their major disadvantage is the lack of flexibility compared with oral preparations.

Certain side-effects may arise with the use of these drugs through their inherent progestational action. They may modify behaviour and increase appetite, leading to weight gain. More serious side-effects are predisposition to endometritis, adrenal suppression and the development of diabetes mellitus (see Chapter 20). Mammary hyperplasia is an uncommon but serious side-effect (see below). The pathogenesis of endometritis (discussed below) is complex, but the key factor is that progestagens will increase the risk of endometritis developing in queens with a predisposition to this disorder. The diabetogenic potential of progestagens has only recently been recognised. This may be partly dose related, the risk increasing with prolonged usage. Certain individuals appear to have a predisposition for showing this side-effect and overt diabetes mellitus may develop after only a relatively short period of treatment. The underlying mechanism by which the progestagens induce diabetes mellitus is complex and it has been suggested that the different progestagens vary in their diabetogenic potential. In some cases diabetes mellitus will resolve if progestagen therapy is withdrawn (which creates a significant disadvantage in the use of depot preparations), but in others the condition persists despite withdrawal of the drug.

The glucocorticoid action of some progestagens is recognised and these drugs are sometimes used for their anti-inflammatory action. This can lead to adrenal suppression, which can create a problem through induction of iatrogenic hypoadrenocorticism if higher dosages have been used and treatment is withdrawn suddenly. This is unlikely to be a problem if the lower dosages recommended for oestrus prevention are used.

Andogens such as mibolerone have been used for oestrus suppression in bitches, but do not appear to be suitable for cats, partly because of the risk of side-effects but also because of variable efficacy.

Alternative methods to pharmacological suppression of oestrus are available. Vaginal swabbing or mating with a vasectomised tom will induce pseudopregnancy, although care must be taken to prevent a fertile mating during the same oestrous period. This will extend the interoestrus interval to around 5–9 weeks. It is also possible to use human chorionic gonadotrophin (hCG) to induce ovulation and hence pseudopregnancy (see later).

Reproductive failure

Queens

Reproductive failure in queens can be divided into several types, according to the stage at which the problem arises and following a practical approach to their differentiation and diagnosis.

Failure to call

Sufficient time should be allowed for a young queen to mature, bearing in mind her breed, before considering a failure of puberty. Weight is an important determinant of puberty and small queens may mature relatively late. In addition, the season at the time of birth influences puberty. Queens born in the autumn will usually mature the following spring, but kittens born in the spring may not call until the following year.

Social contacts with other cats have an important effect on oestrous behaviour in queens. Failure of puberty frequently occurs in a single pet queen denied contact with other cats. Such queens may display oestrus if housed either with other breeding queens or in close proximity to a stud tom. In contrast, oestrus may occasionally be suppressed in timid queens maintained in a group. Determination of serum oestradiol concentrations generally shows that normal follicular activity is taking place but that oestrous behaviour is inhibited (Shille *et al.*, 1979). These individuals will generally call if housed alone.

If failure of oestrus develops in previously proven queens the possibility of pseudopregnancy should be investigated. This is a common occurrence if neutered toms are housed with the breeding queens. Neutered toms, even if castrated prepubertally, will frequently mount and mate breeding queens. They do not have penile spines, which develop as a testosterone-dependent secondary male characteristic, but these are not essential to stimulate the vagina adequately to induce ovulation. If queens are introduced to the tom (or neutered toms) during the interoestrus period, oestrous behaviour is often not observed, although a subsequent pregnancy confirms that oestrus has taken place. It is possible that mating early in oestrus, and the opportunity to mate at will, may inhibit development of the oestrous display. A similar situation may

arise if neutered toms are housed with the queens. Serum progesterone estimations will readily identify whether pseudopregnancy is occurring and the problem is easily rectified by separating breeding queens and neutered toms.

Hormonal induction of oestrus is possible as regimens using either pregnant mare serum gonadotrophin (PMSG; 100 IU daily for 2 days, then 50 IU daily for 3 days) or follicle-stimulating hormone (FSH; 2 mg daily for up to 5 days or until signs of oestrus develop).

The response to treatment is variable (Wildt *et al.*, 1978), particularly in pedigree queens, and hence there is a danger of underdosing or overdosing. Underdosing will be ineffectual and overdosing may cause superovulation or development of ovarian cysts. This approach to failure of oestrus should therefore be kept as a final resort.

Failure to mate

This is not a common problem in cats. Occasionally, oestrus is inhibited in nervous queens that travel to the stud tom for mating. These queens may mate successfully if they are moved some time before oestrus to allow them to become familiar with their new surroundings.

Vaginal cytology can be used to monitor the oestrous cycle and identify periods of oestrus if oestrous behaviour is not prominent. Oestrus is associated with clearing of the vaginal smear and an increase in anuclear superficial cells. However, vaginal cytology has some disadvantages in cats. The appearance of clearing and anuclear cells is more difficult to recognise in cats than in dogs. In addition, there is the potential for prematurely inducing ovulation while collecting samples for vaginal cytology.

Failure to produce live kittens after mating

Ovulation failure

Pregnancy failure is the most likely explanation of failure to produce kittens once mating has occurred; however, ovulation failure is occasionally encountered. The latter can be identified by the collection of a blood sample within 3–10 days of mating for progesterone assay. Progesterone concentrations will not rise above baseline level of 3–4 nmol/l in queens failing to ovulate, but will be considerably higher following successful ovulation.

In cases of apparent ovulation failure the first step should be to investigate the mating management. It is important to establish that coitus is occurring and that the tom is not simply mounting the queen. Failure of the queen to display the typical postcoital behaviour should be considered as an indication that coitus has not taken place. It is also important to ensure that the mating management is arranged to optimise the chances of mating-induced ovulation, that is, that multiple matings are taking place in quick succession on each day of oestrus.

Hormonal induction of ovulation can be achieved using hCG. This should be given at a dosage of 200 IU intravenously or subcutaneously as close to mating as possible. Although this treatment may be successful the advisability of using a queen that can ovulate successfully only after exogenous hormonal manipulation in a breeding programme should be considered carefully.

Fertilisation failure and preimplantation loss

Fertilisation is very efficient in cats and this largely reflects the phenomenon of induced ovulation, which ensures that fresh sperm will be awaiting the ova following ovulation. Preimplantation losses are also generally minimal in cats. Fertilisation failure and preimplantation loss are therefore relatively unimportant causes of reproductive failure in cats. Their investigation is complex and generally necessitates attempted recovery of the eggs at laparotomy within the first 6 days of mating. The procedure for egg collection requires specialised techniques and is not usually feasible in practice.

Pregnancy failure

Abortion and particularly resorption are the most important forms of pregnancy failure in cats. These occur after implantation and can therefore be differentiated from earlier problems of fertilisation failure and preimplantation loss by positive pregnancy diagnosis. Resorption is often accompanied by a sudden reduction in abdominal size with a bloody vaginal discharge and may be mistaken for abortion.

Nutritional deficiencies

Although various experimentally induced nutritional deficiencies have been shown to cause reproductive failure these are unlikely to arise in practice, with the possible exception of taurine deficiency. The

importance of taurine as an essential component of the diet of cats has been recognised only relatively recently and previous minimum requirements for taurine are now considered to have been too low. The association of taurine deficiency with retinal disease and dilated cardiomyopathy is well established. However, in experimentally induced studies of taurine deficiency, various reproductive problems have been encountered including the birth of stillborn kittens and reductions in litter size (Sturman *et al.*, 1986). The importance of taurine deficiency as a cause of naturally occurring resorptions is not known. Reputable pet food manufacturers now ensure that the taurine content of their feline diets allows a considerable margin of safety and deficiency is unlikely to occur if such foods constitute a major part of the diet. However, a deficiency is possible if breeders compile their own diets and the dietary management should be investigated in all cases of reproductive failure.

Hormonal factors

No convincing evidence exists that hormonal imbalances are a significant cause of reproductive failure in cats. There are anecdotal reports of progesterone deficiency causing habitual resorption or abortion, which can be rectified by progesterone supplementation. The postulated mechanism in this disorder is premature regression of the corpora lutea leading to a critical drop in progesterone levels. This would therefore be expected to occur before around day 40–45 of pregnancy, after which pregnancy can be maintained by fetoplacental production of progesterone. Serial estimations of serum progesterone concentrations to demonstrate abnormally low levels in the first two-thirds of pregnancy would be the only reliable method of diagnosing this problem. Abnormally low concentrations of progesterone have rarely been demonstrated in queens at the author's clinic. In one queen progesterone supplementation with a progesterone implant resulted in a successful pregnancy despite a history of habitual resorptions, although the progesterone deficiency occurred late in pregnancy and probably resulted from inadequate fetoplacental production of progesterone, since only one or two kittens were ever subsequently produced.

Ovarian cysts are common in cats but these are of a simple histological appearance and there is no evidence that they are endocrinologically active or cause reproductive failure. Most of them probably represent developmental abnormalities.

Infectious diseases

Feline leukaemia virus (see Chapter 23)

Feline leukaemia virus (FeLV) has been considered an important cause of pregnancy failure in the past. However, the prevalence of this virus in pedigree cats has been dramatically reduced by breeders using the test and removal system, and FeLV infection is now uncommon in pedigree breeding catteries.

FeLV-related reproductive failure most often appears as resorption at around 5–7 weeks of pregnancy with passage of a pink vaginal discharge. Abortion is seen less frequently and if infected cats are rebred, reproductive failure may occur progressively earlier with each subsequent pregnancy. The underlying mechanism of the reproductive failure is not known. Although most FeLV-infected queens are likely to be infertile, if they do breed successfully, the kittens are likely to be infected at birth. However, genetic transfer of FeLV does not appear to occur and this implies that there is transplacental infection of the foetuses. This has led in turn to the suggestion that resorption results from the foetal death induced by the virus. However, chronic endometritis is common in FeLV-infected infertile queens and this, which may be predisposed by FeLV-related immunosuppression, may account for the reproductive failure.

Chlamydia psittaci *(see Chapter 27)*

Chlamydia species cause infertility in other species and there is strong circumstantial evidence to incriminate *Chlamydia psittaci* feline strain in reproductive failure in cats. *Chlamydia* species are frequently isolated from infertile cats, or high antibody titres are found indicating recent or active infection. There may also be a history of conjunctivitis suggestive of chlamydial infection in catteries with infertility problems. In addition, the organism can be readily isolated from the vagina of infected queens and occasionally from aborted foetuses. Despite this strong circumstantial evidence, no direct cause and effect has been demonstrated.

The reproductive failure appears as abortion around the 5th to 7th week of pregnancy. Serology is usually the most suitable method for investigation. If chlamydial infection is suspected to be responsible for the infertility, a prolonged course of tetracycline is indicated to eliminate infection. This may lead to a successful return to breeding.

Feline panleucopenia virus (see Chapter 21)

Feline panleucopenia virus (feline infectious enteritis virus) has a trophism for rapidly developing cells and

if a pregnant queen is infected, transplacental spread of the virus occurs, leading to foetal infection and death. However, most breeding cats are regularly vaccinated and in practice this is a rare cause of infertility.

Other infectious agents

The role of other infectious agents in infertility is unclear. Any infection that causes significant illness, particularly if associated with pyrexia, may lead to abortion as a non-specific result. The respiratory viruses may therefore be associated with abortion in the acute stage of infection and transplacental infection associated with abortion has been reported (Van Vuuren *et al.*, 1999). However, there is no evidence that carrier status is associated with any reproductive problems. Feline immunodeficiency virus (FIV) infection has been demonstrated in some cats with a history of recent abortion, but since the virus is so prevalent this may be a coincidental finding. Abortion has been observed in some experimentally infected cats in the primary phase of FIV infection.

Reproductive failure has been linked with feline infectious peritonitis (FIP). This is difficult to substantiate in view of the problems in diagnosing FIP virus infection and the uncertainty in identifying carrier status. It is possible that concurrent infection with FeLV may be the explanation for infertility in some catteries with endemic FIP.

Toxoplasmosis causes abortion in some species. However, there is little evidence to incriminate this as a cause of infertility in cats and attempts to induce reproductive failure by challenge of pregnant queens have been unsuccessful (Dubey & Hoover, 1977).

Mycoplasma species have been reported as a relatively common isolate from vaginal swabs, but are generally not considered to be significant pathogens in cats.

Chronic endometritis

Chronic endometritis is one of the most common causes of reproductive failure in cats and can occur in a variety of different forms. In mild cases the problem may be manifested as the birth of stillborn kittens, but as the severity increases it progresses to resorption and eventually early embryonic death.

The cause of chronic endometritis is complex and multifactorial, although the primary factor is the hormonal milieu that leads to endometrial changes of cystic hyperplasia and leaves the uterus vulnerable to secondary infection. Repeated and prolonged progesterone dominance is the key factor and this may arise through successive luteal phases in the absence of pregnancy (i.e. pseudopregnancy, which may be influenced by management factors) or the use of progestagens. A variety of opportunist bacteria may cause secondary infection, including *Escherichia coli*, β-haemolytic streptococci, *Staphylococcus aureus*, *Proteus* species and occasionally anaerobes. These bacteria are part of the normal vaginal flora in cats and therefore the significance of their isolation from vaginal swabs collected from queens with suspected endometritis is difficult to assess.

Endometritis should be suspected in any queen with a history of a vaginal discharge unrelated to parturition or abortion. However, by no means every queen with endometritis will have shown a vaginal discharge and diagnosis in these cases is difficult, depending on histological examination of uterine biopsies. Full-thickness wedge biopsies are obtained at laparotomy and this also provides the opportunity to examine the uterus grossly. If the uterus is severely thickened the prospects for future breeding are poor and spaying should be considered.

Histological examination allows assessment of the severity of endometrial changes and it is important in prognosis. Severe changes are likely to be irreversible, but milder cases may respond to treatment.

Prostaglandins are the most useful drugs in the treatment of endometritis. Their beneficial effect seems to depend on their ecbolic effect rather than any luteolytic action, which is questionable in cats. The use of prostaglandins has been recommended particularly for cats with discharges associated with an open cervix, but they may also have some dilatory effect on the cervix. Various prostaglandin preparations are available, none of which is licensed for use in cats, but dinoprost has been the most widely used. This is a synthetic form of naturally occurring prostaglandin F2α which has an ecbolic action. A wide range of treatment regimens has been used. A dosage of 0.05–0.2 mg/kg is usually administered from twice daily to alternate days for around 5–10 days. Adverse effects are common and occur within the first 10 min of injection. The most common side-effect is vocalisation, but urination, defecation, panting and mydriasis are also frequently seen. Hyperaemia, particularly evident on the pinnae if examined closely, is common and is presumed to be associated with vasodilatory effects. These side-effects resolve quickly within 30 min, but may appear quite distressing to the cat and disturbing to the owner. It is sometimes recommended that if a lower dosage is given initially this may minimise side-effects when the dosage is subsequently increased,

although a recent study suggests that this may identify which cats are more likely to show side-effects and that development of side-effects is consistent in individual cats. Antibiotics are frequently given in combination with prostaglandins, but their value is questionable. Subsequent breeding management is crucial and it is important to avoid a progestational influence unless associated with pregnancy. In queens that ovulate readily during oestrus without the need for the stimulus of mating, there may be an advantage in breeding at the next cycle. However, the increased blood supply and opening of the cervix associated with oestrus may be beneficial in combating endometritis if this is not then followed by a progestational phase.

Failure of parturition

Dystocia and problems associated with parturition are uncommon in non-pedigree cats, but are more commonly encountered in pedigree breeding catteries. An incidence of dystocia of around 5% has been reported for most pedigree cats (Gunn-Moore & Thrusfield, 1995), but a higher incidence of up to 10% is seen in some breeds such as Siamese and possibly Rex cats. Functional dystocia associated with uterine inertia is the most common cause of dystocia in cats (Ekstrand & Linde-Forsberg, 1994). Old age, stress, obesity and concurrent disease can contribute to the development of primary uterine inertia. It is suggested that extremes of litter size may increase the incidence of dystocia, particularly through large litters leading to secondary uterine inertia and small litters predisposing to foeto-maternal oversize, although this has not been evident in some studies. Malpresentation sometimes associated with a small pelvic canal or death of the kittens is more common in Persian cats.

Recognition of dystocia and the need for intervention is complicated by the marked variation that can occur in the normal process of parturition. In most cats stages 2 and 3 of parturition, involving uterine contractions, expulsion of the kittens and passage of the placentae, are completed within as little as 30 min to several hours. However, occasionally stage 2 can be very protracted, sometimes as much as 24 h between the birth of kittens. Unproductive straining, the presence of a kitten in the pelvic canal for more than 20–30 min without any progress, malodorous vaginal discharges and any distress in the queen are indications for intervention. Radiography and ultrasonography can be useful diagnostic aids and may identify more serious problems such as uterine torsion or deformed kittens which indicate the need for a Caesarean section. If a kitten is partly visible, gentle digital manipulation may assist its delivery but is usually ineffective. Medical management may be appropriate if primary uterine inertia has been diagnosed. Administration of oxytocin is usually the first step, at 2–4 units. Supplementation with calcium using slow intravenous infusion of 2–4 ml of 2.5% calcium gluconate may increase uterine contractions. If medical management fails or an obstructive dystocia is diagnosed, Caesarean section will be required.

Toms

Requests to investigate reproductive failure in toms are less common. In most cases the problem appears as a lack of libido or failure to produce kittens after apparently normal matings.

Lack of libido

Lack of libido may appear as a disinclination to mate or a total disinterest in queens.

Toms disinclined to mate may initially appear keen but withdraw from the queen at the last moment before mounting. This is most often seen in toms who have first been used at a very young age and it may be possible to trace the problem to an attempted mating with an uncooperative queen who has displayed a particularly marked postcoital rage reaction. Attempts to improve the tom's confidence by selecting tractable queens may prove successful. It may also help to try to familiarise the tom with the environment and management used for mating, which may be a factor in inhibiting libido. The tom should also be examined for any physical factors that may prevent mating, such as persistence of the 'penile' frenulum causing deviation of the penis or the presence of a scrotal hair ring which can prevent extrusion of the penis.

Total disinterest in queens, in toms that have previously bred successfully, is most likely to be associated with some concurrent disease and full clinical evaluation should be undertaken. Most toms presented for disinterest in females have never bred previously. The testicles should be assessed for their position, size and consistency. Determination of serum testosterone concentrations is often the first step in investigation of such cases, but is seldom diagnostically useful. A stimulation test using hCG is more likely to be productive than a single basal testosterone and should lead to an increase in testosterone over basal levels of six-fold or more, reaching at least 4 ng/ml or more.

If an inherent endocrine disorder is present, treatment is unlikely to be effective and it may be inadvisable

to use such a tom as a breeding stud. Cytogenetic assessment to identify chromosomal abnormalities is more likely to be productive and karyotyping is now more readily available at specialist centres. Testicular biopsy may be useful, but is seldom undertaken in cats.

Failure to produce kittens

It is important to establish that several queens of proven fertility have been mated and that the absence of foetuses has been documented by pregnancy diagnosis before considering a diagnosis of infertility in a tom.

The first step in investigation is to ensure that the tom is truly mating the queen and that mating management is such that the possibility of ovulation is not compromised (see earlier). Mating should be observed and the absence of the typical postcoital reaction in the queen suggests that coitus has not taken place. The external genitalia of the tom should be carefully examined in such cases to check for physical abnormalities that may be preventing coitus.

If normal mating has been confirmed, semen evaluation is the next logical step in investigation, but is not usually feasible. Semen can be collected from toms by use of an artificial vagina or electroejaculation, but these techniques are not readily available in referral centres. A cruder approach is based on collection of a vaginal smear from an oestrous queen immediately after she has been mated by the tom. Sperm can be identified after staining air-dried smears with Leishman's or methylene blue. This can establish the presence of sperm. It may reveal a significant proportion of abnormal sperm and the presence of inflammatory cells may be identified. Infertility that develops in a tom who has previously bred successfully may reflect temporary aspermia possibly related to recent illness. Investigation is concentrated on identifying any subclinical problems and such toms may eventually regain normal spermatogenesis if the underlying illness is resolved. If the tom has never bred the future prospects for breeding are poor. Cytogenetic analysis and testicular biopsy are possible methods of further investigation.

Other conditions of the genital tract

Neoplasia

Tumours of the testicles, ovaries and uterus are rare in cats. Occasionally, uterine tumours may cause a persistent bloody vaginal discharge.

Uterine prolapse

This is a rare sequela to parturition. It may be possible to reduce the prolapse, but hysterectomy may be required. The prognosis is guarded since affected queens are usually in severe shock.

Uterine torsion

This condition is also rare in cats. It is notable for two reasons. First, it is one of the few causes of genuinely sudden death in previously healthy adult cats. Secondly, it may lead to uterine rupture and a possible explanation for some of the occasional bizarre cases of extrauterine foetuses. Uterine torsion is also a potential complication of parturition and cause of dystocia.

Conditions of the mammary glands

Neoplasia

Tumours of the mammary glands are quite common in old cats and a large proportion of these is malignant. Mammary tumours tend to metastasise, particularly to the lungs. Surgical excision should therefore not be undertaken unless chest radiographs are clear.

Mammary hyperplasia

This condition is seen either as an uncommon complication following the use of progestagens in cats of both sexes, whether entire or neutered, or occasionally in pregnant queens (Hinton & Gaskell, 1977). It is characterised by massive hypertrophy of one or all of the mammary glands. All the mammae may usually be involved and there may be considerable oedema of the overlying skin. Ulceration may occur in time. The main importance of this condition is in its similarity of appearance to neoplasia. However, it can be readily differentiated on histological examination of a biopsy. In cats receiving progestagens, the condition resolves following withdrawal of the drug. It may necessitate ovariohysterectomy in pregnant cats.

Various drugs, mainly antiprolactin agents, have been used in an attempt to treat this disorder, with disappointing results and often limited by side-effects. There has been recent interest in the possible value of antiprogesterone agents. These drugs are not licensed in the UK, but are available and have been used with some reported success elsewhere in Europe. Mifepristone and agleprisone have been used.

Mastitis

Mastitis occasionally occurs during lactation. In acute cases the queen will be severely depressed, inappetent, dehydrated and pyrexic. One or more mammary glands are swollen, hot and painful. Occasionally they may abscessate. There is a good response to antibiotics and poulticing of the affected glands. It is vital to remove the litter, both to prevent further spread of infection and trauma of the mammary glands and to prevent the kittens from ingesting the infected milk.

In cases of chronic or mild mastitis, the queen may show no clinical signs, with the condition manifesting itself as gastrointestinal disturbances and death in the kittens.

Other conditions

Lactational tetany (eclampsia)

Lactational tetany is an uncommon complication following parturition in cats. Despite its name, it may occasionally occur during pregnancy. It is characterised by ataxia, tremors and twitching of the muscles. This will progress to fits if untreated. The condition responds rapidly to slow intravenous injection of 2.0–5.0 ml/kg of 2.5% calcium borogluconate. A 2.5% solution may be administered subcutaneously and the diet should be supplemented with a suitable source of calcium.

References

Baldwin C., Evans L.E. & Peter A.T. (2000) Evaluation of natural prostaglandin therapy for pregnancy termination in the domestic cats. *Feline Pract* **28** (3), 16.

Cline E.J., Jennings L.L. & Sojka N.J. (1980) Breeding laboratory cats during artificially induced oestrus. *Lab Anim Sci* **29**, 338.

Dubey J.P. & Hoover E.A. (1977) Attempted transmission of *Toxoplasma gondii* infection from pregnant cats to their kittens. *J Am Vet Med Assoc* **170**, 538.

Ekstrand C. & Linde-Forsberg C. (1994) Dystocia in the cat: a retrospective study of 155 cases. *J Small Animl Pract* **35**, 459.

Gruffydd-Jones T.J. (1989) Some aspects of reproduction in cats. *Adv Small Anim Pract* **1**, 79.

Gruffydd-Jones T.J. (1990) Reproductive endocrinology of the cat. In *Manual of Small Animal Endocrinology* (ed. Hutchinson M.). BSAVA, Cheltenham.

Gunn-Moore D.A. & Thrusfield M.V. (1995) Feline dystocia: prevalence, and association with cranial conformation and breed. *Vet Rec* **136**, 350.

Herron M.A. & Sis R.F. (1974) Ovum transport in the cat and the effect of estrogen administration. *Am J Vet Res* **35**, 1277.

Hinton M. & Gaskell C.J. (1977) Non-neoplastic mammary hypertrophy in the cat associated either with pregnancy or with oral progestagen therapy. *Vet Rec* **100**, 277.

Jemmett J.E. & Evans J.M. (1977) A survey of sexual behaviour and reproduction of female cats. *J Small Anim Pract* **18**, 31.

Povey R.C. (1978) Reproduction in the female cat. A study of breeders. *Can Vet J* **19**, 207.

Shille V.M., Lundstrom K. & Stabenfeldt G.H. (1979) Follicular function in the domestic cat as determined by levels of estradiol-17β in plasma and related to oestrous behaviour and cornification of exfoliated vaginal epithelium. *Biol Reprod* **21**, 953.

Sturman J.A., Gargano A.D., Messing J.M. & Imaki H. (1986) Feline maternal taurine deficiency: effect on mother and offspring. *J Nutr* **116**, 655.

Van Vuuren M., Geissler K., Gerber D., *et al.* (1999) Characterisation of a potentially abortigenic strain of feline calicivirus isolated from a domestic cat. *Vet Rec* **144**, 636.

Verstegen J., Onclin K., Silva L.D.M. & Donnay I. (1993) Abortion induction in the cat using prostaglandin $F_2\alpha$ and a new anti-prolactinic agent Carberoline. *J Reprod Fertil* **47**, 411.

Wildt D.E., Kinney G.M. & Seager S.W.J. (1978) Gonadotrophin induced reproductive cyclicity in the domestic cat. *Lab Anim Sci* **28**, 301.

Wyckoff J.T. & Ganjam V.K. (1979) Successful termination of pregnancy in cats by the administration of a combination of adrenocorticotropin (ACTH) and prostaglandin $F_2\alpha$–THAM salt (PCF). *Fedn Proc* **38**, 1189.

Chapter 14

PAEDIATRICS AND INHERITED DISEASES

K. Willoughby

Paediatrics is a challenging area of veterinary medicine. One sick kitten can look very much like another, although widely varied pathological processes may be going on. This chapter will describe the normal neonate and developmental milestones, before going on to consider the sick neonate and the general approach to these small patients. In the second section, inherited diseases of cats are described and the principles of differentiating hereditary from non-hereditary disease explained.

The normal kitten

Most non-pedigree kittens have a birth weight between 100 and 120 g (Festing & Bleby, 1970). Pedigree kittens can vary in birth weight between 80 and 140 g, dependent on breed (Sparkes *et al.*, 2000). Kittens should usually be expected to grow at a rate of 50–100 g per week; this is dependent on both sex and breed–male kittens and those of larger breeds grow more rapidly. Failure to gain weight or weight loss may be the first reported sign by a breeder or an owner. Some developmental milestones and normal clinical findings for kittens are shown in Table 14.1 and Box 14.1, respectively (Gruffydd-Jones, 1994; Murtaugh, 1994; Hosgood & Hoskins, 1998; Hotson-Moore & Sturgess, 1998).

Susceptibility of the neonate to disease due to immaturity

The major body systems are immature in young kittens and this is reflected in their inability to withstand insult in the same way as an adult cat. Specific factors involved are described below (Boothe & Tannert, 1992; Gruffydd-Jones, 1994; Murtaugh, 1994; Hosgood & Hoskins, 1998; Hotson-Moore & Sturgess, 1998).

Table 14.1 Developmental milestones in kittens

2–3 days	Umbilical cord falls off
6–14 days	Eyelids and ear canals open
3 weeks	Pupiliary light response present
3–4 weeks	Menace response present
3–4 weeks	Kitten can move about out of the nest
4–6 weeks	Solid food can be taken
6 weeks	Hearing present and can be tested

Data from Hoskins (1990) and Hosgood & Hoskins (1998).

Thermoregulation

For the first few weeks of life, kittens are unable to maintain their body temperature and hypothermia will result if they are unable to stay close to the queen or other heat source. Shivering is present from 6–8 days of age and from that age thermoregulatory ability improves. The rectal temperature of 1-day-old kittens is 34.7–36.3°C and rises over the first 7 days to approximately 37.5°C, reaching adult levels by 4 weeks old. Kittens are very susceptible to cooling, having high surface area and low body weight; they should be examined on a heated pad or a warm blanket, rather than a cold table. It is important for the queen to accompany small kittens to the consulting room as a source of heat as well as security; it is in any case advisable to examine the queen for any evidence of disease.

Hepatic function and glucoregulation

The liver is immature in neonatal period. Liver microsomal enzymes are probably largely functional by 8 weeks of age, although do not reach adult levels until 4–5 months. Glycogen stores in newborns are low and fall rapidly when fasted; gluconeogenesis is required to maintain normal blood glucose. However,

Box 14.1 Normal clinical findings in kittens (Hoskins, 1990; Hosgood & Hoskins, 1998)

NB. It is always advisable to also examine the queen thoroughly for any evidence of disease, especially metritis or mastitis.

- Heart rate: approximately ⩾220 beats/min (<4 weeks old)
- Respiratory rate: 15–35 breaths/min (<4 weeks old)
- Auscultation: breath sounds should be present and symmetrical, although very quiet owing to small tidal volume. Heart sounds should have regular sinus rhythm. No murmur should be present. Even with a paediatric/neonatal stethoscope accurate localisation of murmurs is difficult
- Rectal temperature:
  - <2 weeks old 35.5–36°C
  - >4 weeks old 37.7°C
- Abdominal palpation: both kidneys should be palpable, left caudal to right. The spleen should not be palpable and the caudal margin of the liver should not extend beyond the ribs, although it is more easily palpable than for the adult. The stomach may feel very large and fluid filled, extending into the mid abdomen if full. Urine can be expressed from the bladder if full. Urine colour should be assessed for evidence of haemolysis (neonatal isoerythrolysis)
- Neurological examination:
  - assess mentation
  - should be nursing/sleeping until ~21 days and walking by 23–40 days
  - flexor dominance is normal, with transient extensor dominance at 15–40 days (i.e. extends when picked up, then flexor dominance reasserts)
  - raking of litter tray by 30 days
  - postural reflexes not mature until 8 weeks:
    righting response: from birth
    vestibular nystagmus: from 21 days
    non-visual placing: from 5 days
    visual placing: from 21days
    extensor postural thrust: from 14–16 days
    hemi-walking: from 4–6 weeks
- External examination:
  - weigh (daily, or as often as seen)
  - assess hydration: at <6 weeks adult indicators, such as skin tenting, presence of sunken eyes and heart rate, are not reliable and moistness of mucous membranes and quantity and colour of urine are the best indicators
  - examine for injury or defects:
    - head: cleft palate, stenotic nares, bulging of closed eyelids (suggestive of infection), nasal discharge, skull deformity, overshot or undershot jaw, etc.
    - eyes: discharge, pupiliary light reflex (PLR), blink reflex (>21 days), menace reflex (>21 days), ophthalmological examination may be indicated
    - ears: external canals open at 6–14 days. Check surrounding skin for parasites, trauma, defects and skin lesions
    - thorax: flat chested kitten syndrome (dorsoventral flattening), pectus excavatum, fractures, etc., auscultate
    - abdomen: check umbilicus for swelling (hernia, infection), urine staining (persistent urachus, urethral defects), patency of anus and urethra, presence and position of testes or vulva
    - skin: wounds, pyoderma, bruising, presence of fleas, lice, mites, ringworm, condition and type of hair coat (altered in hypothyroidism, pituitary dwarfism and hypotrichosis)
    - limbs and tail: check long bones and joints for deformities or restriction of movement, count toes, check tail for kinks, check spine for bony or soft-tissue defects
    - neurological examination: can be very limited. Ensure sucking reflex, menace reflex (>4 weeks old), walking and posture (>4 weeks old). History of seizures, presence of house-training (>6 weeks old)

the immature liver has a poor gluconeogenic response to hypoglycaemia. Kittens must not be fasted (e.g. before anaesthesia) or hypoglycaemia is likely, complicating recovery and subsequent management. Low albumin due to reduced liver function can cause problems with highly protein-bound drugs; these considerations mean that drug dosages should be altered appropriately (Boothe & Tannert, 1992).

Renal function

Nephrogenesis is incomplete at birth and adult renal function is not achieved until at least 8–12 weeks old. Hypotension, low glomerular filtration rate (GFR) and immature tubular secretion comprise the limiting factors on the renal function of the neonate. Low urine specific gravity, glycosuria and proteinuria are common in kittens of less than 8 weeks of age. Renal factors may predispose to drug toxicity owing to prolongation of excretion; therefore, dose rates and intervals should be prolonged.

Cardiovascular function

The immature heart is easily compromised for a number of reasons. There is a low myocardial contractile element and low ventricular compliance, which results in a fixed stroke output and poor reserve. Output is dependent on heart rate (HR) and there is poor tolerance of volume loading. A decline in foetal HR can signify hypoxia (unlike the tachycardia expected in response to hypoxia in adults). Vasomotor control via baroreceptors is poor, allowing the development of hypotension. The parasympathetic dominance gives a predisposition to bradycardia. Blood sampling of small kittens should not exceed volumes of 5–6 ml/kg (approximately 10% total blood volume) or shock may occur.

Respiratory function

Stimulation by rubbing or licking causes reflex respiration in kittens until 2–3 days old. The respiratory rate is slow (see Box 14.1) for the first week of life but high thereafter. Immature animals have a high oxygen demand (approximately two to three times that of adults) and are very susceptible to hypoxia. The small diameter of the airways increases air resistance and the small alveoli give little respiratory reserve. The thoracic wall is poorly supported owing to bony immaturity, which can lead to failure to achieve adequate lowering of intrathoracic pressure and maintenance of a functional airway. Apparent respiratory failure/dyspnoea is a common presenting sign in sick kittens and may be primary or secondary to other disease (Hoskins, 1999).

Neurological function

The nervous system undergoes considerable maturation after birth. The central nervous system (CNS) and peripheral nervous system (PNS) are immature at birth and the primitive reflexes give way to adult ones over the first 11–12 weeks of life (Bradshaw, 1992). Immature animals have a dominant parasympathetic system and an immature sympathetic system (see Cardiovascular function, above). The blood–brain barrier is also more permeable than in adults. These differences must be taken into account when calculating drug dosages, especially anaesthetic or analgesic agents (Boothe & Tannert, 1992; Hosgood & Hoskins, 1998).

Gastrointestinal function

The gastrointestinal tract is well developed at birth, as not only important is it for the continued nutrition of the kitten but also has a crucial role in the absorption of maternally derived antibody. Sterile at birth, the gastrointestinal tract acquires a normal flora within a few days. Diarrhoea is, however, a common presenting sign in sick kittens and can rapidly lead to dehydration.

Immune system

There is limited immune competence from birth, dominated by immunoglobulin M (IgM). Until the thymus is mature (approximately 12 weeks) the T-cell response to pathogens is reduced. There has been little work on non-specific immunity in the cat, but in other species this is less efficient in neonates. Passive immunity [maternally derived antibody (MDA)] is therefore crucial for neonatal kittens. At least 90% of a kitten's passive immunity is gained from adequate intake of colostrum. The uptake of antibodies from the gut starts to reduce after 8 h and is minimal by 48 h. However, IgA secreted in the milk continues to provide passive protection to the gut as long as the kitten suckles. The quality of this passive transfer of immunity depends on the immune experience of the queen, so it is important that queens are housed in the same environment in which they were brought up; this ensures that kittens receive colostral immunity to the 'household pathogens' present. Moving the queen to a new environment while pregnant or when the kittens are very young might leave kittens unprotected if she has not been herself exposed. Some colostrum replacement products are available for cats, but their efficacy is currently unproven.

Fluid homoeostasis

Dehydration occurs easily in kittens. The fluid requirement is approximately twice that of adults, and is variously estimated at 120–180 ml/kg per day. Although

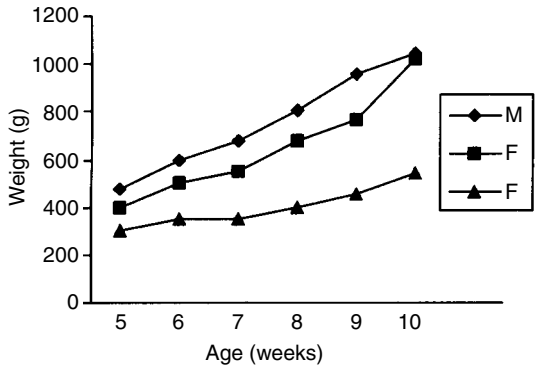

Figure 14.1 Weight-gain chart of a litter of kittens. One kitten (▲) lags behind its siblings owing to pectus excavatum.

due mostly to the reduced renal concentrating ability, other factors involved in these increased fluid needs include greater body surface area to weight ratio, comparative lack of body fat and higher metabolic rate.

Sick kittens

Kittens have a limited way in which they can respond to illness, regardless of the primary cause (Gruffydd-Jones, 1994). Signs suggestive of a sick kitten include:

- crying and agitation
- cessation of suckling
- failure to gain weight or weight loss
- inactivity, weakness and coma
- respiratory difficulty with or without cyanosis
- diarrhoea
- sudden death.

Cat breeders frequently weigh kittens daily, or every few days, for the first few weeks of life. These measurements can be important in identifying sick kittens (Figure 14.1). Clinical examination of kittens should be as thorough as for adults (see Box 14.1). With kittens, it is important to look carefully for any sign of congenital or hereditary disease; all areas of the kitten must be carefully examined and any abnormality noted. History taking is also very important when considering the possibility of infectious, nutritional, toxicity, hereditary or congenital disease (Box 14.2).

Kittenhood diseases

Diseases occurring in kittenhood can have a large number of causes and can be multifactorial. The broad areas are listed below.

Box 14.2 Historical factors important in the examination of a sick kitten

- Breed
- Age
- Sex
- Weight (compared with littermates of same sex)
- Owner complaint
- Number of kittens affected
- Pregnancy history of queen: nutrition, drugs administration, other events, problems at kittening, e.g. Caesarean section:
  - this pregnancy
  - previous pregnancies
- Litter history: suckling, weaning age, growth curves
  - this litter
  - previous litters
- Relevant or similar disease in close relatives or in-contact cats?

Data from Hoskins (1990) and Hosgood & Hoskins (1998).

Subnormal birth weight

Risk factors for a subnormal birthweight include the age, health and nutritional status of the queen, and also kitten factors such as congenital or hereditary disease. Low birth weight is not associated with maternal size, number in litter or sex of kittens (Festing & Bleby, 1970). Kittens with a low birth weight have a higher mortality in the first 6 weeks of life (which includes stillbirth) and an increased tendency to succumb to other diseases or be 'poor doers' (Lawler & Monti, 1984).

Hereditary/congenital disease

Hereditary disease is a genetic fault, transmitted from one generation to the next. The actual mode of heredity (dominant, autosomal, sex-linked, polygenic, etc.) may take considerable time and effort to elucidate, in many diseases is not clear-cut and can be complicated by incomplete penetrance. Congenital defects are not necessarily hereditary; they are simply present at birth and may be due to a teratogenic effect. For cat breeders, it is important to be able to differentiate between hereditary and congenital disease. Hereditary disease and its control are discussed in greater detail later in this chapter.

Nutritional

Inadequate or excessive nutrition can play a role in kitten illness or losses (Remillard *et al.*, 1993; Lawler

& Evans, 1995). Starvation or a low-quality diet in pregnant queens can lead to poor maternal body condition during pregnancy and low-birthweight kittens. Intrauterine malnutrition may result from placental inadequacy, perhaps due to overcrowding. The role of intrauterine growth retardation in subsequent development in humans has been widely studied and linked to a number of problems, but has not been researched in the cat. A few deficiencies are specific to kittens, whereas other nutritional diseases may occur in cats of any age.

Taurine

Taurine deficiency in the queen can cause reproductive failure in addition to the well known ocular and cardiac effects (Dieter *et al.*, 1993). If taurine-deficient queens do achieve pregnancy, this is likely to result in stillbirth, birth of low-birth-weight kittens or kittens with neurological problems (Sturman *et al.*, 1986).

Nutritional hyperparathyroidism (see also Chapter 10)

The use of all-meat diets is associated with secondary nutritional hyperparathyroidism (Bray, 1984; Crager & Nachreiner, 1993). Affected kittens are usually presented reluctant to move or with sudden-onset lameness. On radiography, multiple fractures may be evident. Vertebral compression fractures can cause neurological deficits. Therapy consists of feeding an adequate diet and cage rest for up to 4 weeks to minimise further trauma. Providing an adequate diet can be provided, mineral supplementation is not usually necessary. Surgical intervention may be considered, but should normally be reserved until better skeletal materialisation is achieved.

Trauma

Traumatic incidents for very young kittens (at a few days of age) are usually a result of queen-related or owner-related factors. Dystocia is a common cause of trauma or hypoxia at birth and may not result in immediate death: some kittens may linger for a few days just 'not doing well'. Queens may neglect, inadvertently suffocate or cannibalise kittens. Maternal neglect of a sickly kitten is a programmed response, which can be difficult to differentiate from poor mothering of normal kittens. Owners or their children may drop, squeeze or step on kittens by accident (and be naturally reluctant to confess).

Box 14.3 Potentially teratogenic agents

- Antibiotics: quinolones and tetracyclines
- Antifungals: griseofulvin
- Anti-inflammatories: DMSO
- Anaesthetics: pentobarbitone
- Gastrointestinal drugs: misoprostol
- Anticonvulsants: phenytoin
- Organophosphorus compounds
- Antineoplastic chemotherapeutic agents
- Live vaccines
- Steroids: testosterone, oestrogens, corticosteroids
- Phenolic disinfectants
- Exhaust or solvent fumes
- Ionising radiation
- Environmental toxins: PCBs, dioxins, etc.

Data from Papich (1989) and Lawler & Evans (1995).

Toxins

Many substances are toxic to the pregnant cat or growing kitten (Papich, 1989; Lawler & Evans, 1995). It is always advisable to avoid treatment of pregnant animals with any drug or externally applied chemical during pregnancy, unless either the company can supply safety data for use in pregnancy, or the queen's life or quality of life is at risk. Where specific data on cats are not available, drugs known to be teratogenic in other species should also be avoided. A list of potential teratogens is given in Box 14.3.

Infectious diseases

Many neonatal diseases and postweaning deaths are attributed to infectious disease (Gruffydd-Jones, 1994; Sturgess, 1998). The postweaning period is the most common time for infectious diseases to cause problems, probably owing to waning maternally derived immunity and increased exposure of kittens to potential sources of infection. Infectious agents can also, however, be involved in neonatal kitten deaths. Infectious agents can gain access to the kitten from the queen, from other animals or from the environment. A variety of routes of infection is possible, but particular risks for kittens are infections acquired at birth or via the umbilicus, in addition to the more usual routes of infection (oronasal, etc.).

Bacterial infections

Neonatal sepsis is probably the most significant bacterial infection of young kittens and can be caused by

a number of species, including *Staphylococcus, Streptococcus, Salmonella, Escherichia coli, Klebsiella, Campylobacter, Enterobacter, Enterococcus, Pseudomonas, Clostridia, Bacteroides, Fusobacterium* and *Pasturella* species (Hoskins, 1993). Gram-negative organisms are most frequently isolated, which probably reflects their prevalence as commensals in the respiratory and gastrointestinal tracts of healthy adult animals. Mastitis in the queen can lead to the ingestion of large quantities of bacteria. In all cases the queen should be examined as well as the kittens. Clinical signs of overwhelming neonatal bacterial infection are rather non-specific, frequently including hypothermia, diarrhoea, crying, restlessness, failure to suckle, dyspnoea and cyanosis. In some cases sudden death may be the first sign noted. Chronic cases may occur, with the production of microabscesses in internal organs; such kittens frequently fail to thrive or gain weight properly. While blood cultures are required to confirm the diagnosis, frequently treatment cannot be withheld for long and non-specific therapy must be initiated immediately after the retrieval of sample material, which may be useful for the remaining kittens in the litter. Samples that should be taken in kittens with suspected bacterial infection/septicaemia are:

- whole blood (if possible): 1 ml into suitable liquid medium
- urine: by cystocentesis
- any exudates present: by swab or collection of exudates as appropriate into suitable transport medium
- faeces: a faeces sample is preferred. A rectal swab may miss significant organisms.

If specific infections are suspected, they should be specified on the submission form so that suitable selective media are used or culture techniques performed (e.g. for *Salmonella* spp., *Campylobacter* spp., *Clostridia* spp.). In case of suspected neonatal sepsis the whole litter should be treated with a broad-spectrum antibacterial such as amoxycillin/clavulanate in addition to standard management of hypothermia and hypoglycaemia (see below).

Bordetella bronchiseptica (see also Chapter 22) can cause acute respiratory failure due to bacterial bronchopneumonia in young kittens, usually reported in conjunction with feline calicivirus (FCV) or feline herpesvirus (FHV) infection (Willoughby *et al.*, 1991; Speakman *et al.*, 1998). Affected kittens show acute dyspnoea and cyanosis and die within hours. Culture of *B. bronchiseptica* requires selective medium and should be performed on lung tissue or exudates. Unlike canine isolates, feline isolates of *B. bronchiseptica* are frequently resistant to amoxycillin/clavulanate and trimethoprim/sulfonamide; doxycyline is considered the drug of choice in feline bordetellosis (Speakman *et al.*, 1997).

Viral infections

Many viral infections have been associated with fading kittens (Sturgess, 1998). The retroviruses **feline leukaemia virus** (FeLV) and **feline immunodeficiency virus** (FIV) can both be transmitted transplacentally, but while this is inevitable for FeLV, it is rarer with FIV and the main route of transmission from dam to kitten is considered to be via the milk or other body fluid (e.g. at parturition). FeLV can cause infertility, abortion, stillbirth, or birth of weak or fading kittens. Surviving kittens born to a FeLV viraemic queen are persistently infected and usually succumb to FeLV-related disease within 2 years. Queens infected with FIV do not always transmit infection to their kittens, but will pass on MDA, which will result in positive in-house tests. For this reason, kittens born to infected queens cannot be positively diagnosed as infected (on antibody testing) until MDA can be assumed to have waned, usually by 4–6 months of age. The outlook for FIV-positive kittens is better than for FeLV-infected kittens, but the long-term prognosis is guarded. These infections are further discussed in Chapters 23 and 24.

Infection with the upper respiratory tract viruses FCV and FHV is uncommon below 6 weeks of age, as MDA is usually protective, owing to the background of vaccination and exposure in the general population. Where kittens are colostrum deprived or immunosuppressed for other reasons, or in colonies with high levels of disease or infected with virulent strains, disease can occur in young kittens, causing high morbidity and also some mortality (Dawson & Willoughby, 1999; Hoskins, 1999). Ocular lesions are particularly common in the younger age group, including ophthalmia neonatorum and deep corneal ulcerations, which may require surgical intervention. These viruses are further discussed in Chapter 22.

Feline panleukopenia virus (FPV, feline infectious enteritis) is best known in young kittens for its role in producing cerebellar ataxia owing to hypoplasia of the cerebellum, when the kitten is infected either *in utero* (by wild-type or live vaccine virus) or in the first 3 weeks of life. These 'wobbly kittens' are usually noted to be ataxic when they first start to walk, and though ataxia can be severe, it is not progressive and can be consistent with a good quality of life as a pet. Where

Table 14.2 Some drugs indicated for use in kittens (Boothe & Tannert, 1992; Sturgess, 1998)

Drug	Dose	Comments
Amoxycillin/clavulanic acid	12.5–25 mg/kg twicy daily	Renal excretion but wide therapeutic index
Cephalexin		Renal excretion but wide therapeutic index
Doxycyline	10 mg/kg once daily	Intestinal excretion. Lipid soluble. Absorption reduced by milk ingestion. Risk of discoloration of teeth. Agent of choice for *Haemobartonella felis, Bordetella bronchiseptica, Mycoplasma* spp.
Metronidazole	25 mg/kg twice daily for 5 days, then 10 mg/kg twice daily	Renal excretion, half-life prolonged. Toxicity is CNS signs; dose should be reduced and dosing interval prolonged. Used for *Giardia.*
Trimethoprim–sulfonamide	30 mg/kg once daily	Accurate oral dosing may be achieved with paediatric preparations, although such use is not licensed. Used for coccidial infection
Fenbendazole	50 mg/kg once daily for 3 days	This dose is recommended for routine worming and *Giardia* in young kittens

adequate MDA is not present, infection with FPV can cause devastating disease in young kittens, frequently resulting in per-acute death, acute enteritis or severe secondary infections due to immunosuppression (see Chapter 21).

Feline coronavirus (FCoV) has been implicated in the fading kitten syndrome by some authors, but is not now currently thought to be an important cause (Addie & Toth, 1993). Although FeCoV is probably usually transmitted to susceptible neonates/juveniles from in-contact adults, feline infectious peritonitis is unusual in kittens less than 12 weeks of age and is further discussed in Chapter 25.

Other viruses, such as rotavirus, astrovirus, reovirus and torovirus, are occasionally reported from diseased neonates, but such infections are considered rare.

Parasitic infestations

The ectoparasites that may infest kittens are fleas (*Ctenocephalides felis*), lice (*Felicola subrostrasa*) and ear mites (*Otodectes cyanotis*). Notoedric mange (due to *Notoedres cati*) is considered very rare in cats in the UK. These parasites rarely cause problems, although significant blood loss can occur with heavy flea infestations, leading to haemorrhagic anaemia. Routine flea control is usually all that is required, and topical preparations are available with product licences for young kittens. Note that owners frequently inadvertently overdose kittens with the widely available pyrethrins or pyrethroids. Under normal circumstances, to avoid hypothermia, kittens should not be bathed in ectoparasitacide shampoos.

The ascarid *Toxocara cati* is transmitted via the milk, or through a transport (usually rodent) host. Following transmammary infection, there is no liver and lung migratory phase. *Toxascaris leonina* has no migratory phase and is transmitted either directly or via a transport host. There is no transplacental transmission with either of the feline ascarids (Dunn, 1978). Infestation is widespread but usually subclinical. Rarely, heavy infestations may cause a pot-bellied appearance, diarrhoea and general failure to thrive. The migratory stage may cause mild hepatic or pulmonary lesions, including pulmonary artery hyperplasia; these lesions are of unknown clinical significance. Piperazine is best avoided in small kittens, as neurotoxicity due to inadvertent overdosage is not uncommon, and efficacy is variable. The benzimidazoles and pyrantel-based anthelmintics are preferred and accurate dosing is easier with these products. Owing to the migration of *T. cati*, at least two doses should be given.

Haemobartonella felis can be transmitted from the queen to newborn kittens, but the route of this transmission (*in utero*, during parturition, via the milk) is not known. Infection with *H. felis* causes haemolytic anaemia in cats of all ages and is discussed in detail elsewhere (see Chapter 29). Tetracyclines are the recommended therapy, notwithstanding the risk of tooth discoloration. This risk may be less with doxycyline (Table 14.2).

The intestinal coccidian parasites most frequently demonstrated infecting cats are *Isospora felis* and *I. rivolta*. Other species may be seen occasionally or in countries other than the UK (*Toxoplasma, Cryptosporidium, Hammondia, Besnoitia, Sarcocystis*). Transmission may be direct or via an intermediate or paratenic (usually rodent) host. Clinical signs are not common in adults, but these parasites can become endemic in catteries, causing diarrhoea (with or without blood), weight loss and dehydration in neonatal kittens. Infection may be fatal. Diagnosis is on faecal floatation and the recommended therapy is trimethoprim–sulfonamide (see Table 14.2). Coccidiosis is further discussed in Chapter 31.

Acute infection with *Toxoplasma gondii* during pregnancy has been shown to cause the birth of small, lethargic kittens, which have a higher than expected mortality rate (Dubey & Carpenter, 1993; Dubey *et al.*, 1995). These congenitally infected kittens can shed oocysts from birth. *In utero* or neonatal infections may also be implicated in ocular disease in the absence of other clinical findings (Powell & Lappin, 2001). *In utero* infections are probably unusual in the field, where most cats are exposed to *T. gondii* at an early age through the ingestion of prey species. Postnatal infection is associated with many and varied signs. Anorexia, lethargy and dyspnoea are commonly reported, but neurological, ocular, enteric, hepatic and vague signs of pyrexia, inappetance and weight loss may also be seen. Diagnosis is frequently not straightforward; toxoplasmosis is discussed further in Chapter 28. Therapy is with potentiated sulfonamides or clindamycin.

Another protozoan, *Giardia*, can cause acute diarrhoea in young kittens, which is frequently mucoid and may be pale and steatorrhoeic. It can be difficult to diagnose and in suspected cases either multiple samples must be examined by the zinc sulfate concentration technique, or a therapeutic trial may be undertaken. Both metronidazole and fenbendazole are effective (see Table 14.2). *Giardia* infection is discussed further in Chapter 31.

Neonatal isoerythrolysis

This disease is probably more common than is recognised in practice. It occurs infrequently among the non-pedigree cat population, but can be rather common in specific breeds. The disease occurs owing to the existence of at least three different blood groups in cats, A, B and AB, and the spontaneous production of alloantibodies targeted against the 'other' blood type (Knottenbelt *et al.*, 1999a, b). Cats with blood group A produce small amounts of anti-B antibody. Cats with blood group B produce large amounts of anti-A antibody. Cats with blood group AB do not generally produce alloantibodies in significant amounts. In particular, kittens born to group B queens are at risk, as these queens produce high titres of anti-A antibodies in the colostrum. Suckling of group A or AB kittens results in intravascular and extravascular haemolysis, while group B kittens are unaffected. Clinical signs occur within hours of suckling and include sudden death, failure to thrive or suckle, the presence of red–brown urine due to haemoglobinuria, and severe pallor and/or icterus. Many cases are fatal as a result of renal or other (multiple) organ failure and disseminated intravascular coagulation (DIC). If the kitten survives, tail or ear-tip necrosis may occur at 7–14 days of age.

Table 14.3 Distribution of feline blood groups (as percentage of total sample) in non-pedigree cats on a geographical basis

Country	Type A	Type B	Type AB
USA	95–99.7	0.3–5.0	(rare)
UK	87.1	7.9	5.0
Europe	85–100	3–15	(rare)
Australia	73.7	26.3	(rare)

Data from Holmes (1950), Giger *et al*. (1991a, b), Haarer & Grunbaum (1993), Leidinger *et al*. (1993), Jensen *et al*. (1994) and Knottenbelt *et al*. (1999a).

The incidence of this disease varies with the prevalence of group B cats in any given population, and there are marked geographical variations (Table 14.3) and breed variations, which can also vary geographically. The breeds with the highest reported incidence of type B blood are Persian, Devon and Cornish Rex, British shorthair, Birman and Persian: breeds with an apparently low incidence of type B include Siamese and Burmese (Giger *et al.*, 1991a; Knottenbelt *et al.*, 1999a, b). Some breeders have their stud or queens tested to ensure that only compatible matings are carried out. Any pedigree litter exhibiting signs suggestive of neonatal isoerythrolysis should have sire and dam blood typing performed to attempt to prevent unsuitable matings. Kittens may be typed at birth and the access of type A kittens to a type B queen restricted for 24 h. The kittens may be cross-suckled on a type A queen and then returned to the original queen when the period of colostrum absorption is over (see also Chapter 9).

Table 14.4 Haematological parameters for normal neonatal and juvenile kittens

(a) Red blood cell parameters

Age	PCV (%)	Hb (g/dl)	RBC ($\times 10^{12}$/l)	MCV[c] (fl)	MCH[c] (pg)	MCHC[c] (g/dl)
0–6 h[a]	44.7	12.2	4.95	90.3	24.6	27.3
12–48 h[a]	41.7	11.3	5.11	81.6	22.1	27.1
0–2 weeks[b]	33.8–37.0	11.5–12.7	5.05–5.53	65.5–69.3	22.4–23.6	33.7–35.3
2–4 weeks[b]	25.7–27.3	8.5–8.9	4.57–4.77	52.7–55.1	18.0–19.6	32.5–33.5
4–6 weeks[b]	26.3–27.9	8.3–8.9	5.66–6.12	44.3–46.9	14.2–15.4	31.3–32.5
6–8 weeks[b]	28.5–31.2	8.8–9.4	6.31–6.86	44.6–46.6	13.6–14.1	30.4–31.4
8–9 weeks[b]	32.6–34.0	9.6–10.0	6.84–7.04	46.9–48.7	13.9–14.3	29.1–29.9
12–13 weeks[b]	31.5–34.7	9.8–10.4	7.20–7.66	42.7–46.3	13.4–14.1	30.4–32.2
16–17 weeks[b]	33.8–36.0	10.6–11.4	7.87–8.41	41.6–44.6	13.1–13.9	30.8–32.4

(b) White blood cell parameters ($\times 10^9$/l)

Age	WBC	Segmented neutro	Non-segmented neutro	Lymph	Mono	Eosino	Baso
0–6 h[a]	7.55						
12–48 h[a]	10.18						
0–2 weeks[b]	9.1–10.24	5.28–6.64	0.04–0.08	3.21–4.25	0–0.02	0.51–1.39	0.01–0.03
2–4 weeks[b]	14.21–16.51	6.15–7.69	0.07–0.15	5.97–7.15	0–0.4	1.24–1.56	0
4–6 weeks[b]	16.08–18.82	7.92–11.22	0.14–0.26	5.64–7.18	0	1.22–1.72	0
6–8 weeks[b]	16.13–20.01	5.74–7.78	0.14–0.3	8.02–11.16	0–0.02	0.88–1.28	0–0.04
8–9 weeks[b]	21.79–25.57	9.59–12.41	0.03–0.21	8.46–11.88	0.07–0.18	1.97–2.59	0
12–13 weeks[b]	19.84–26.56	9.23–12.77	0.08–0.22	7.85–13.7	0	1.2–1.9	0–0.06
16–17 weeks[b]	18.58–20.82	8.82–10.66	0.09–0.23	7.72–9.84	0–0.04	0.81–1.19	0

Data from [a] Jain (1996) and [b] Meyers-Waller *et al*. (1984).
Where a range is shown, these values are calculated from mean value ±1 SEM, otherwise a mean value is shown. The packed cell volume (PCV) was calculated by microhaematocrit; other values were obtained using an automated cell counter (Coulter) and [c] by calculation from those values. Different methods or laboratories may give different results.
Hb: haemoglobin; RBC: red blood cells; MCV: mean corpuscular volume; MCH: mean corpuscular haemoglobin; MCHC: mean corpuscular haemoglobin concentration; WBC: white blood cells; Neutro: neutrophils; Lymph: lymphocytes; Mono: monocytes; Eosino: eosinophils; Baso: basophils.

Investigative approach to the sick kitten

Clinical pathology

After careful history taking and clinical examination, further investigation, including laboratory tests, may be necessary. It is possible to obtain adequate jugular blood samples from kittens to perform key tests. Important parameters, which can be tested for on small blood samples, are packed cell volume (PCV), blood smear, autoagglutination, blood glucose (stick), blood urea (stick) and total protein (refractometer). Urinalysis (stick and refractometer) and sediment examination are also possible. The results of these examinations are often sufficient to assist with diagnosis and management of the sick kitten (Hoskins, 1990; Miller, 1995). After 4 weeks of age, larger samples can be taken with care (no more than 5–6 ml/kg body weight). Some haematological and biochemical values reported for normal kittens (Meyers-Wallen *et al*., 1984; Jain, 1986; Earle *et al*., 1990; Chandler, 1992; Miller, 1995) are shown in Tables 14.4 and 14.5.

Infectious disease screening

Infectious disease screening may be necessary. It is wise to test the queen (the most likely source of infection) for evidence of FeLV and FIV, and kittens for evidence of upper respiratory tract viruses (FHV and FCV), *Chlamydophilia*, or potentially pathogenic

Table 14.5 Serum biochemical parameters for normal kittens

	Age (weeks)					
	0–2	2–4	4–6	7–12	12–20	Adult
Glucose (mmol/l)	4.22–7.16	5.50–6.22	ND	ND	3.27–5.60	3.7–6.9
BUN (nmol/l)	7.85–19.28	6.07–10.71	5.36–12.85	8.93–13.57	6.78–13.14	6.07–12.14
Creatinine (μmol/l)	17.7–53.0	26.5–44.2	17.7–106.8	35.4–88.4	35.4–79.6	79.7–185.6
Calcium (mmol/l)	ND	ND	2.09–2.74	2.20–2.79	2.22–2.72	2.22–2.72
Phosphorus (mmol/l)	2.23–3.00	2.42–3.07	2.45–3.16	2.23–3.62	2.87–3.52	2.87–3.52
Total protein (g/l)	35–47	41–47	41–59	51–57	54–68	59–81
Albumin (g/l)	20–24	22–24	ND	ND	25–36	23–39
Cholesterol (mmol/l)	4.23–11.4	5.73–11.20	ND	ND	1.63–3.40	1.55–6.97
Bilirubin (μmol/l)	1.71–17.1	1.71–3.42	ND	ND	6.84–20.54	<10.26
Alkaline phosphatase (IU/l)	68–269	90–135	ND	ND	39–124	11–210
Alanine aminotransferase (IU/l)	10–38	10–18	9–41	23–50	18–58	30–100
Sodium (mmol/l)	134–145	142–148	143–151	147–152	143–162	146–160
Potassium (mmol/l)	4.0–5.4	4.7–6.1	4.7–5.9	5.0–6.2	4.1–5.9	3.7–5.4
Chloride (mmol/l)	ND	ND	118–127	113–128	107–121	112–129

Data from Chandler *et al*. (1992). Where necessary the data are converted from North American units to SI units as used in the UK. Adult values reported by the same authors are quoted to allow comparison. Biochemical values may vary between laboratories owing to variation in methods.
BUN: blood urea nitrogen; ND: not determined.

bacteria, such as *Bordetella bronchiseptica, Campylobacter* or *Salmonella* species. Where septicaemia is suspected, blood culture may be attempted (see Neonatal sepsis, above).

Diagnostic imaging

Radiography is challenging in small kittens and is infrequently performed. Sedation or anaesthesia should be used to achieve good positioning. Interpretation of radiographs of small kittens requires experience. It is necessary to reduce the kilovoltage greatly owing to poor mineralisation and thinness of small kittens (Hoskins, 1990). Suitable techniques are described in radiography texts. Radiological differences between young kittens and adults include (Hosgood & Hoskins, 1998):

- *thorax*: decreased alveolar volume (especially at <2weeks old) leads to generalised increased interstitial markings; the thymus may be visible
- *abdomen*: detail is generally poor owing to lack of fat; the liver is usually proportionally larger than for adult animals
- *skeleton*: bone poorly mineralised, presence of open growth plates and secondary ossification centres.

Ultrasonography may be useful for the assessment of abdominal organs and for cardiac abnormalities, and is considered safer than radiography for both the neonatal patient and the operator. To achieve good image resolution in small kittens, a 7.5 MHz transducer is required and a skilled imager is essential to interpret ultrasonographic examination of small kittens. It should be possible to detect effusions, intussusceptions, foreign bodies, soft-tissue masses, portosystemic shunts and disease of abdominal organs (kidney, liver, bladder, spleen, intestine), and congenital cardiac defects.

Other techniques

Electrocardiography is not as useful in small kittens as in adults, and does not usually allow the calculation of mean electrical axis and right- or left-sided enlargement. It may be helpful for cardiac disease where arrhythmias are present and to establish the presence or otherwise of P waves and QRS complexes (Hoskins, 1990; Hosgood & Hoskins, 1998).

Deafness testing is available at a few specialist centres and may be indicated where congenital deafness is suspected (e.g. white cats). The brainstem auditory-evoked response (BAER) is considered suitable for use in cats and kittens from 6 weeks of age (Strain, 1999).

Therapeutic approach to the sick kitten

Regardless of the primary cause, hypothermia, dehydration and hypoglycaemia occur rapidly in sick kittens and frequently lead to death unless dealt with in conjunction with specific therapy for any identified underlying disease (Macintire, 1999).

Hypothermia

Hypothermia is best managed by placing the kitten in a warm environment, such as an incubator (temperature 29.4–32.2℃, humidity 55 –60%) and warming gradually. The kitten should not be placed directly on a heat source or put under a heat lamp unless it is able to move away voluntarily. Environmental warming is more efficient and incubators can be improvised using available heat sources (warm water bottles, microwave heat bags, hot water blanket) and humidification achieved by placing a pan of warm water in the pen (ensuring the kitten cannot fall into it). Room thermometers available for babies can be used to monitor the environment within such improvised incubators. If a suitable incubator or similar is not immediately available, the kitten should be wrapped in or surrounded by an insulating blanket or pad. It is important to insulate the limbs and tail: bandages or cotton wool may be used to wrap these lightly. In addition, warm fluid therapy should be given (see below) and the use of warm water enemas has been suggested. The kitten should preferably be in sternal recumbancy. If this is not possible it should be turned every 30 min to reduce pooling of blood in the dependent lung. Rectal temperature should also be taken every 30 min. The kitten should not be fed by mouth until rewarmed.

Dehydration

Fluid therapy is vital in dehydrated kittens (Boothe & Tannert, 1992; Hoskins, 1995; Macintire, 1999). For kittens of less than 6 weeks of age, the jugular vein may be the only peripheral vein it is possible to catheterise. If the intravenous route is not accessible, the intraosseous route can be used. An 18 or 20 G needle is usually used for intraosseous fluid administration, inserted aseptically into the femur via the trochanteric fossa (or the humerus at the greater tubercle). The potential risks of using the intraosseous route include osteomyelitis, so a good standard of needle care is required. Although the subcutaneous route is easy, it is far from ideal; absorption may not occur owing to peripheral vasoconstriction secondary to hypothermia and dehydration. If neither the intravenous nor intraosseous route is feasible, then fluids should be given intraperitoneally. This route also suffers from potentially poor absorption but is more reliable than the subcutaneous route. The risk of puncturing or damage to abdominal organs is low, but should be remembered, and aseptic technique is required. The calculated fluid need (see below) is divided into two or three boluses spaced throughout the day. The intraperitoneal route is not suitable for continuous therapy.

Ideally, a syringe driver of fluid pump should be used to give fluids to neonates. If this is not available it is essential that a paediatric giving set with a burette chamber is used to prevent overrapid infusion and compromise of cardiorespiratory function. These chambers can be filled with a suitable small volume and the infusion rate accurately assessed; the drip rate is 60 drops/ml rather than the 10–15 drops/ml of a conventional giving set.

Fluids given to paediatric patients should be warmed. The low rates of infusion needed mean that fluids can cool rapidly in the giving set; a warm water bath (or surgical gloves filled with warm water), through which the giving set passes close to the kitten, can be helpful. The rate of administration recommended varies: although maintenance is widely reported in kittens to be approximately twice adult needs, the risk of overhydration during fluid therapy may require caution in the early stages of rehydration. Rates of 40–60 ml/kg per day are frequently recommended, increasing the rate as appropriate depending on the kitten's clinical condition (see below).

The choice of fluids should be based on the clinical disease present, and losses should be replaced with a similar fluid, as for an adult animal. It should be noted that lactated Ringer's solution is usually contraindicated in kittens less than 6 weeks of age owing to their inability to metabolise lactate to bicarbonate (reduced liver function). Solutions with antimicrobial preservatives should also be avoided, as these can be toxic. General recommendations (Boothe & Tannert, 1992; Hoskins, 1995; Macintire, 1999) are to:

- use a multiple electrolyte solution
- supplement with 5% dextrose to correct hypoglycaemia (see below)
- add potassium if confirmed hypokalaemia present
- give warmed fluids
- set fluid rates dependent on the degree of loss:
  - maintenance: start at 40–50 ml/kg per day

  - moderate: give 40–50 ml/kg over 4–8 h, then reduce to 4–50 ml/day
  - shock: can increase rate to 40–50 ml/kg per hour with careful monitoring
- monitor carefully for continued dehydration or overhydration:
  - general condition
  - dyspnoea, tachycardia, cough, pulmonary crackles, ascites, chemosis (overhydration)
  - weigh three or four times daily (excessive gain may indicate overhydration)
  - check urine output, colour and specific gravity
  - check mucous membrane moistness
- ensure catheter and needle care to prevent infection: aseptic technique at insertion, cover with bandage
- encourage eating and drinking when rehydrated, warm and not hypoglycaemic.

As the kitten improves and can maintain hydration electrolyte balance and hypoglycaemia by drinking and food/milk intake, fluid therapy should be reduced and then discontinued. During the reduction stage, non-dextrose-containing fluids may be given by the subcutaneous route.

Hypoglycaemia

Most sick neonates are hypoglycaemic owing to anorexia, low glycogen stores and poor gluconeogenesis. Signs of hypoglycaemia are weakness, tremors, seizures, stupor and coma. A blood glucose stick or in-house glucose meter can quickly and simply be used to confirm clinical suspicion (Macintire, 1999).

- Hypoglycaemic, not dehydrated, not hypothermic: give 1–2 ml of 10–15% dextrose by mouth.
- Hypoglycaemic with mild dehydration: give 2.5% dextrose in 0.45% sodium chloride subcutaneously. This relies on adequate circulation to allow absorption.
- Severe hypoglycaemia: give 5% dextrose solution slowly intravenously (or intraosseously) to effect.
- In profound hypoglycaemia: a bolus of 1–2 ml/kg of 25% dextrose can be given by slow intravenous injection and followed by a controlled rate of isotonic fluid fluids with added 2.5–5% dextrose.

When the kitten is warm, rehydrated and no longer hypoglycaemic, oral feeding may start with kitten milk replacer by bottle, syringe or stomach tube. The stomach capacity is ~50 ml/kg, so a newborn kitten (average 100 g) is given 5 ml every 4–6 h. After illness in neonates, the dose should start at 5 ml and increase by approximately 1 ml/feed until the calculated volume required is reached.

Blood transfusion is possible, and is indicated for anaemia, bleeding disorders, haemorrhage and non-immune-mediated haemolysis. Transfusion may be given intravenously, intraosseously or intraperitoneally. With intravenous or intraosseous transfusion, 95% of the erythrocytes are in the circulation within 5 min. With intraperitoneal transfusion, roughly 70% are in the circulation within 72 h. Whole citrated blood (1:8–1:10 parts citrate:blood) should be cross-matched and given over 2 h. Administration of vitamin K (0.5–2.5 mg/kg s.c. or i.m.) is usually recommended for kittens of less than 2 days old or with bleeding tendency. The considerations around blood transfusion in cats are discussed in Chapter 9.

Specific therapy

See Boothe & Tannert (1992) and Sturgess (1998). Few products have veterinary product licences for neonatal kittens. Antimicrobials, anthelmintics and analgesics are the agents most commonly required. Drug distribution in kittens is different to that in adults, and this requires modification of dose rates and dosing intervals to avoid either failure to achieve therapeutic levels or overdosage (Table 14.6). Other factors also interact with immaturity to complicate drug therapy of paediatric patients. Ingestion of milk may bind some drugs or slow gastric emptying. In addition, kittens may be exposed to drugs through the queen's milk; this must be considered when treating nursing queens.

Antimicrobials

The penicillins and cephalosporins are the most commonly used antimicrobials in kittens. Although affected by decreased renal excretion (which prolongs the half-life), they tend to be safe because of the wide therapeutic index. These drugs are frequently available in suitable, licensed presentations to allow accurate dosing, and are generally the drugs of choice in young kittens.

Tetracyclines are generally contraindicated in young animals owing to their potential to discolour teeth. Tetracycline or doxycycline is, however, the drug of choice for both *Haemobartonella* and *B. bronchiseptica* infections in kittens. Doxycycline is more lipid soluble than tetracycline and can be given at a less frequent

Table 14.6 Therapeutic considerations for young kittens

Factors causing therapeutic failure	Factors causing potential toxicity
Reduced gastric emptying and peristalsis: slower oral absorption and lower plasma concentration	Increased intestinal permeability: faster absorption and higher peak drug concentration
Higher proportion of total body water, especially extracellular fluid: increased drug distribution with lower peak concentration, but longer half-life	Increased gastric pH: enhanced absorption of acid drugs Increased absorption of volatile gases: sensitivity to inhaled agents
Reduced hepatic function: failure to activate pro-drugs	Increased absorption of topical agents or environmental toxins
Reduced hepatic function: decreased clearance of metabolised drugs	Low serum proteins: reduced binding of protein-bound drugs, causing higher concentrations and potentially longer half-life Decreased body fat: reduced accumulation of fat-soluble agents causing higher plasma concentrations Reduced renal function: decreased clearance of drugs by the kidneys

From Boothe & Tannert (1992).

dosing interval. It is also excreted by the intestine rather than the kidneys and undergoes enterohepatic circulation. Doxycycline is also less likely to cause tooth discoloration owing to a lower calcium affinity.

Metronidazole is the drug of choice for *Giardia* infections. Decreased clearance leads to a prolonged half-life. Toxicity causes CNS signs; the dose should be reduced and the interval prolonged if this occurs.

The sulfonamides have a very prolonged half-life in kittens owing to reduced hepatic metabolism and reduced renal excretion. In combination with trimethoprim, they are generally safe, however, although the dosing interval may need to be prolonged.

The aminoglycoside drugs (streptomycin, gentamycin, etc.) carry a significant risk of nephrotoxicity and should be used only where absolutely necessary, for example in *Pseudomonas* or *Proteus* species infections resistant to other agents.

The quinolones (enrofloxacin, ciprofloxacin) are contraindicated in kittens owing to the possibility of production of erosions of articular cartilage. They may also cause crystaluria.

Anthelmintic drugs

The benzimidazole drugs, such as fenbendazole, have a high therapeutic index and are available in a wide number of preparations, including suspensions suitable for young kittens. With activity against all the major internal parasites and *Giardia*, they are widely used.

Ectoparasitacides

Fipronil spray may be used from 2 days of age.

Imidacloprid spot-on should not be used before 8 weeks of age. The dam may be treated and migration of the product is claimed to treat the nursing kittens.

Approach to the cattery with increased kitten losses

Neonatal mortality rates

Kitten deaths are often defined as neonatal at <14 days old, suckling at 2–6 weeks and weaned at up to 12 weeks. In studies of specific pathogen-free (SPF) colonies of domestic shorthaired cats the vast majority of kitten deaths (>90%) occurred in the immediate postbirth period (less than 7 days old), and slightly more than half of these were due to stillbirth (Festing & Bleby, 1970; Young, 1973; Lawler & Monti, 1984). Risk factors for death included low birth weight, single kitten or more than seven kittens in litter, anatomical abnormality of kitten, first or second pregnancy, more than seventh pregnancy and maternal obesity. In these SPF colonies, the low rate of deaths in older kittens

are considered most likely to be due to the strict disease-control measures in force. In a studies of less restrictive colonies, although the majority of deaths (>50%) were in the first week of life, more deaths occurred at an older age. Both infectious respiratory tract disease and enteric infections were noted in these studies. A survey of pedigree cat breeders in the USA (Scott *et al*., 1978) reported that 10% of kittens were stillborn and that by 7 days of age a further 15% mortality was found. By 6 weeks of age the total mortality of liveborn kittens was 22%. A total of 27% mortality was reported within the first year of life. A recent British survey of pedigree cats, carried out by the Feline Advisory Bureau in 1995/1996, showed an average 5% stillbirths, and an 8% death rate to 1 week old, rising to 10% by 8 weeks (Sparkes *et al*., 2000). The improved figures in this study may reflect a number of factors, not least improved husbandry conditions with regard to disease control and selection of breeding stock in more recent times.

In general terms, only cat breeders are likely to seek advice on problems with disease or increased mortality in their colony. Breeders frequently keep good records, which may span many generations of cats and can often be relied upon to give very detailed histories. The investigation of problems within a breeding cattery frequently depends as much on history as on investigation, and the collection and organisation of good historical data are very important. The breeder frequently wants to ascertain whether some infectious or hereditary disease is occurring in the colony, to be able to instigate control measures. After careful history taking (see Box 14.2), the mainstay of investigation into increased kitten losses is careful examination of sick kittens and, frequently, post-mortem examination of dead kittens (Lawler, 1994; Haskins & Casal, 1997). To obtain as much information as possible from dead kittens, it is essential that post-mortem examination is carried out by a veterinary pathologist. If this is not possible, extensive samples should be taken from all the major organs, whether or not they appear grossly normal, for histopathological, virological and bacteriological examination. Samples should include neurological tissue and bone-marrow core biopsy or aspirate.

Inherited diseases

Hereditary and congenital disease

See Patterson *et al*. (1989), Robinson (1991), Blunden (1998), and Malik (2001). The breeder will often wish to know if there is a hereditary defect present. It can be very hard to establish whether a defect is hereditary (i.e. transmitted from parent(s) to offspring) or congenital (i.e. present at birth but may or may not be hereditary). A list of defects reported in cats is shown in Table 14.7. In some of these heredity is known, whereas in others a teratogenic effect may produce the same defect (e.g. cleft palate is hereditary in some cases, but may also be caused by treatment with griseofulvin during pregnancy).

Approach to suspected hereditary diseases: is this disease hereditary?

Background

The different forms of a gene that can occur at a specific site (locus) on a chromosome are called alleles. Any animal with a normal chromosome number can have only two alleles, which may be the same (homozygous) or different (heterozygous). Within a population, there may be more than two alleles possible at any given locus; this is known as multiple alleles.

Modes of inheritance

See Robinson (1991) and Blunden (1998). The majority of hereditary defects are simple autosomal recessive traits, where the homozygote dominant is normal, the heterozygote is an unaffected carrier and the homozygote recessive is affected. Recessive traits can lie hidden for many generations until two unaffected carriers are mated to produce an affected kitten. The elimination of affected kittens, by the defect being fatal at an early age or by failure of recognition of a hereditary disease by the breeder, means that the gene can become a problem for some lines or small breeds if a carrier becomes a widely used breeding animal. The impact of the males in a small breed is particularly high.

Some hereditary defects are dominant traits, such as Manx taillessness, dominant white and polycystic kidney disease. The homozygote dominant is affected and can produce only affected kittens. The heterozygote is affected, but can produce both normal and affected kittens if bred to another heterozygote or homozygote recessive. The homozygote recessive is normal. In some dominant traits, the homozygote dominant is fatal *in utero* (e.g. Manx taillessness), which leads to small litter size and altered ratio of affected to unaffected. These diseases can be simply eliminated from the breeding population, providing a suitable screening test is available, by removing all affected individuals.

Table 14.7 Congenital defects of cats (Saperstein *et al*., 1976; Blunden, 1998; Hosgood & Hoskins, 1998; Robinson, 1991; Malik, 2001). Where hereditary disease is known or suspected, breed(s) affected are given

Midline defects	
Schistosoma	Rare. Abdomen not closed, rudimentary or absent hindlimbs
Exencephaly	Common cause of stillbirth. Combination of facial and skull defects
Spinal dysraphism/spina bifida	Failure of closure of the dorsal vertebrae. May also have protrusion of spinal cord or meninges (meningocoele). May be surgically correctable depending on severity. Breed incidence in Manx and Siamese cross
Vertebral body anomalies	Hemivertebrae: leading to scoliosis, kyphosis or lordosis. Block vertebrae. Kinked tail. Siamese and foreign may be predisposed
Cleft plate, harelip	Common defect. Breed incidence and suspected hereditary in Siamese, but also associated with teratogens (especially griseofulvin, hypervitaminosis A)
Caudal dysgenesis	Dysgenesis of sacral and coccygeal region, with abnormal development of caudal equina. Causes bunny-hopping and incontinence. Selected for in Manx
Pectus excavatum	Common. Deformed sternebrae deviate dorsally into the thorax. Can cause respiratory and cardiac disease. Breed predisposition in Siamese, Burmese and related breeds
Flat-chested kitten syndrome	Common. Affected kittens have dorsoventrally flattened chests and 'swim'. Severely affected kittens may die. Can grow out of problem but some remain barrel-chested. Almost certainly hereditary in Burmese and related breeds
Facial deformities (Lobprise *et al*., 1999)	
Brachycephalic syndrome	Stenotic nares, elongated soft palate, everted laryngeal saccules. Breed incidence in Persian and related breeds
Overshot jaw	Upper teeth protrude over lower. Overshot jaw is occasionally seen and may require dental work to allow closure of mouth
Undershot jaw	Lower teeth protrude over upper teeth. 'Normal' in Persians and some related breeds (British, exotics)
Rostral displacement of maxillary canines ('lance tooth')	Canine impinges on incisors. Seen in some breeds of cats but hereditary unknown (familial in some breeds of dog)
Other dental problems	Malpositioned canines, twisted jaw, arching of the upper dental arcade, retained deciduous teeth. Seen in many breeds. Enamel hypoplasia; speculated due to teratogenic factor
Craniofacial anomaly	Exencephaly, anophthalmia, hydrocephaly, double whisker pads, cleft palate and rotated ears. Seen in Burmese, thought to be due to autosomal dominant gene with variable expression. Not seen in UK
Four ears	Possessing a small extra pair of 'ears', associated with microphthalmia and micrognathia. Recessive trait
Limb deformities	
Amelia	Total lack of limbs
Peromelus ascelus	Lack of hindlimbs only
Micromelia	Shortened forelimbs
Ectrodactyly	Split foot, at the level of the metacarpals. Demonstrated as dominant gene
Polydactyly	Extra toes. Dominant gene
Syndactyly	Fusion of the toes
Patellar luxation	Same lesion as is seen in the dog: Devon Rex, Chartreux, Maine Coon, DSH
Hip dysplasia (Keller *et al*., 1999)	Is described but not as well defined in cats as it is for dogs

(continued)

Table 14.7 *(continued)*

Twinning abnormalities	
Siamese twins	Diprosopus (two faces, one body), posterior twinning, etc. Mirrored organs (i.e. on the 'wrong side'). Associated in humans and dogs with primary ciliary dyskinesia
Hernias	
Umbilical	Inherited as threshold traits in some breeds of dog. Can occur in some lines of many cat breeds, suggesting hereditary factor. May occur in conjunction with other abnormalities, especially ventral body wall defects, peritoneo-pericardial hernia, failure of caudal sternal fusion
Inguinal	Uncommon in cats but described in DSH.
Peritoneo-pericardial	Rare defect. Has been described in Persian and Siamese. Can be associated with other (usually ventral midline) defects: see umbilical hernia above
Hiatial	Rare defect, usually considered congenital
Cardiac defects (Stepien & DeMorais, 2000)	
Patent ductus arteriosis (PDA)	Siamese, Persian, other breeds
Endocardial fibroelastosis	Proliferation of elastic and collagen fibres. Siamese and Burmese predisposition, young age at onset
Familial hypertrophic cardiomyopathy (Kittleson *et al*., 1999)	Maine Coons
Congenital rhythm disorders	Persistent atrial standstill in Burmese and DSH; suspected familial
Other developmental defects which occur but have no established breed predispositions	Ventricular septal defect, atrial septal defect, subaortic, pulmonic, tricuspid stenosis/dysplasia, tetralogy of Fallot, vascular ring anomalies
Respiratory tract (Hoskins, 1999)	
Few general developmental abnormalities are reported in cats	Agenesis of lung lobes, bullous cysts
Urinary tract (Greco, 2001)	
Polycystic kidney disease	Autosomal dominant in Persians and related breeds. Can also be associated with hepatic and pancreatic cysts
Amyloidosis (Neiwold *et al*., 1999)	Causes protein-losing nephropathy. Abyssinians
Primary hyperoxaluria	Acute renal failure develops at 5–9 months of age owing to deposition of oxalate crystals. Reported as autosomal recessive in DSH
Other renal developmental defects, unknown hereditary in cat	Renal ectopia, fusion of kidneys, unilateral renal agenesis, perirenal pseudocyst
Tubular tract developmental defects, unknown hereditary in cat	Ectopic ureters, persistant urachus, rectovaginal fistula, ectopic urethra
Hepatic	
Portosystemic shunts	Breed predisposition in Birman, perhaps others (Burmese)
Biliary atresia	
Hepatic cysts	
Amyloidosis (Van der Linde-Sipman *et al*., 1997; Neiwold *et al*., 1999)	Oriental, Devon Rex
Storage disorders	Many have hepatic involvement but clinical signs usually neurological. See Metabolic (below)
Gastrointestinal	
Megaoesophagus	Rare in cats, known hereditary in certain dog breeds

(continued)

Table 14.7 *(continued)*

Oesophageal achalasia	Uncommon disorder, where caudal oesophagus fails to relax on swallowing. Leads to cranial megaoesophagus. Considered probably inherited
Pyloric stenosis	Siamese
Agenesis of small or large intestine	Causes death early in life
Atresia ani	Seen in many breeds
Megacolon	Rare, may be due to absence of myenteric plexus. Surgical correction required, guarded prognosis
Reproductive (Meyers-Wallen, 2000)	
Failure of testicular descent	Cryptorchidism, monorchidism. Sex-limited trait, considered hereditary in many breeds
Ovarian abnormalities	Ovarian hypoplasia, supernumery ovaries
Tubular defects	Fusion, disjoint of uterine body and horns. Uterus unicornus: may be associated with agenesis of ovary, kidney or ureters
Hermaphroditism, pseudohermaphroditism	May be hereditary or teratogen (e.g. progestagen) induced
Hypospadias	Incomplete closure of urethra
Chromosomal abnormalities	May be spontaneous, inherited or teratogen induced. Most are fatal *in utero*. Tortoiseshell male (XXY, XX/XY, etc.) is the best known. Many others are possible, but rarely diagnosed
Neurological and neuromuscular abnormalities (Chrisman, 2000; Sheldon & Engval, 2002)	
Cerebellar hypoplasia	Almost always considered due to FPV infection
Hydrocephalus	May have Siamese predisposition, perhaps others.
Familial neuraxonal dystrophy	Progressive ataxia and shaking at 4–6 weeks of age
Tremor ('shaking kitten')	Whole body tremor at 2–4 weeks of age. Seen in Birmans. Usually outgrown. Underlying defect unknown
Cerebellar abiotrophy	Autosomal recessive in DSH
Deafness	White-coated cats. Associated with the dominant white gene in any breed. In DSH, 38% reported deaf bilaterally, 12% unilaterally. More common, but not exclusively, in blue-eyed cats
'Spasticity' (Robinson, 1992)	Devon Rex
Hypokalaemia (Blaxter *et al*., 1986)	Burmese
Ocular defects (Narfstrom, 1999)	
Globe defects	
Microphthalmia	Teratogenic, especially griseofulvin. Hereditary in dogs but unknown in cats
Convergent squint	Due to misrouting of visual pathways in Siamese
Spontaneous nystagmus	Siamese and other colour-pointed cats
Others	Cyclops
Eyelid defects	
Entropion	Inversion of eyelids. Persians
Ectropion	Eversion of eyelids. Rare in cats
Agenesis	More commonly upper than lower. DSH and Persian
Nictitating membrane cartilage eversion	Rolling of the third eyelid: Burmese
Imperforate lacrimal puncta	Usually secondary to infection in cats
Corneal defects	
Epibulbar or corneal dermoids	Cysts containing normal skin structures. Birmans, Burmese, DSH
Aberrant canthal dermis	Long hairs extend from the medial canthus onto the cornea, causing irritation. Persian

(continued)

Table 14.7 *(continued)*

Corneal opacity/dystrophy	Suggested inherited in Manx cats, from 4 months old. Progressive bilateral, symmetrical clouding of cornea in absence of other ocular disease. May also be seen in some lysosomal storage diseases (see Metabolic disease)
Uveal tract and lens	
Heterochromia (odd eyes)	Specified by some breeds. Occurs with dominant white (and deafness)
Coloboma	Notch in pupil. May be associated with other defects
Congenital cataracts	DSH, Persian, Birman and colour-pointed breeds. Present at birth, usually observed only at >6 weeks of age
Juvenile cataracts	Inherited (probably autosomal recessive) in British shorthaired, colour-point. Progressive opacification, starting at up to 6 years of age
Retina	
Progressive retinal atrophy (PRA)	Persian (early onset): possible autosomal recessive. Abyssinian (early onset): rod/cone dysplasia, autosomal dominant. Abyssinian (late onset). Siamese (early onset). DSH (possibly dominant). British shorthair
Optic nerve hypoplasia	Unilateral or bilateral. Causes poor vision. Any breed
Retinal dysplasia	Retina develops until around 6 weeks of age. Infectious diseases, especially FPV and FeLV, may cause dysplasia
Skin disorders	
Curly coat (rexing)	Devon, Cornish, other Rex breeds. Dominant gene.
Hypotrichosis	Variable alopecia from birth. May occur with other defects, especially of ectodermal tissues (teeth, skin). Reported in Sphynx, Cornish Rex, Devon Rex, Siamese and Birman
Cutaneous asthenia (Ehlers–Danlos syndrome)	Collagen defect causing excessive stretching of skin. Burmese, other breeds. May be hereditary (autosomal dominant) but can arise from spontaneous mutation
Epitheliogenesis imperfecta	Very rare
Cartilaginous ear defects (specified in some breed standards)	Scottish fold (autosomal dominant): has folded ears from around 4 weeks of age. In the heterozygote usually only the ears are folded. In the homozygote, cartilage problems in the long bones cause deformity and loss of function. A few heterozygotes may also be affected in this way. American curl (autosomal dominant): swept back ears, no known deleterious affect of homozygote
Metabolic diseases	
Storage diseases	Usually progressive neurological signs, some have white cell abnormalities, skeletal abnormalities and corneal clouding. All are hereditary. Most are diagnosed on post mortem. Specialist research laboratories may offer enzyme assays or genetic testing.
GM1 and GM2 gangliosidosis	Korat, Siamese, DSH. Genetic testing available for Korat and Siamese form
Mannosidosis	DSH
Mucopolysaccharoidosis I and VI	Siamese and DSH. Excess glycosaminoglycans may be detected in urine; skeletal deformities, especially spinal, observed on radiographs
Sphingomyelinosis	Siamese, Balinese, DSH
Globoid cell leucodystrophy	Onset from 2 weeks old in DSH
Ceroid lipofuscinosis	Siamese
Glycogen storage diseases	Norwegian forest

(continued)

Table 14.7 *(continued)*

Osteogenesis imperfecta	Excessive bone fragility
Hyperchylomicronaemia (Jones *et al*., 1983; Ginzinger *et al*., 1996)	Persistant lipaemia, PNS paralysis (onset 8–9 months old)
Haematological diseases	
Coagulopathies	
Haemophilia A	X-linked recessive factor VIII deficiency, usually mild disease in cats
Haemophilia B	X-linked recessive factor IX deficiency. Reported in British shorthair, Siamese and DSH
von Willebrand's disease	Deficiency of factor VIIIR, which is important in platelet adhesion. Hereditary in dogs, but extremely rare in the cat, with few cases reported
Hageman factor deficiency	Autosomal recessive deficiency in factor XII. Clinically inapparent, but causes prolonged APTT.
Vitamin K-dependent factor deficiency	Presumed autosomal recessive disease described in Devon Rex, where factors II, VII, IX and X were affected by a suggested failure in correct absorption or processing of vitamin K. Responded to supplemental vitamin K_1
Combined deficiencies	Some combinations of factor deficiencies have also been reported (VIII and XII; IX and XII). As these genes are present on different chromosomes the nature of their heredity or otherwise remains obscure
Chediak–Higashi syndrome	Autosomal recessive. Reported in Persian. Causes partial albinism, large eosinophilic granulation of neutrophils and melanocytes, bleeding tendency and cataract. Neutrophil function is abnormal
Pelger–Huet anomaly	Suggested autosomal dominant. Clinically inapparent failure of normal nuclear segmentation in granulocytes, monocytes and megakaryocytes
Neutrophil granulation	Small eosinophilic granules in neutrophils, seen in Birman. Neutrophil function is not affected and there are no clinical signs
Porphyria	Rare, autosomal dominant defect in haem synthesis, causing accumulation of porphrin metabolites in tissues and excretion in urine and faeces. Teeth and bones have brownish coloration, fluorescing in ultraviolet light. Reported in DSH and Siamese. In the Siamese report, signs of photosensitisation and anaemia were also present
Endocrine diseases	
Congenital hypothyroidism	Cretinism, poor growth. DSH, Abyssinian (autosomal recessive)
Pituitary dwarfism	Very rare in the cat

DSH:domestic shorthair; FPV: feline panleukoperia virus; FeLV: feline leukaemia virus; PNS: peripheral nervous system; APTT: activated partial thromboplastin time.

Incompletely dominant traits can occur. In such cases, there are multiple alleles without the usual dominant/recessive nature and the heterozygote can show the effect of both alleles. Homozygotes may be normal or severely affected and elimination of all affected animals is required to control the disease.

Incomplete penetrance can occur with some genes. It would be anticipated that the homozygote CC and heterozygote Cc should appear (phenotypically) similar, and that the homozygote cc is different. This straightforward dominance demonstrates complete (100%) penetrance. In some cases, however, incomplete penetrance occurs and the heterozygote Aa is phenotypically aa. The reasons for incomplete penetrance are unknown, but unless genetic screening is available, incomplete penetrance can complicate the control of hereditary disease.

Polygenic traits are controlled by a number of genes, each of which may have a relatively small effect. Conformational attributes, such as face shape in Persians, are frequently considered polygenic.

Threshold traits are those where a large number of genes is involved in the control of a particular feature, such as descent of the testes. Depending on the number of genes involved, there is a threshold at which the feature alters from normal to abnormal.

Sex-linked traits are usually carried on the X chromosome (e.g. haemophilia A, orange coat colour). As males have only one X chromosome they are either affected or unaffected and can only pass the allele onto their daughters; their sons inherit the Y chromosome. Females can be homozygotes or heterozygotes and can pass the allele on to both sexes.

Sex-limited traits are demonstrated by only one sex but can be passed on by both; e.g. cryptorchidism, milk yield, mothering ability.

The different modes of inheritance can complicate the establishment of whether a hereditary disease is occurring. Any sudden increase in congenital defects or increased mortalities in a breeding colony should be investigated to assess the possibility of a hereditary cause. It is essential to assess the information provided in the context of that particular cattery. Many catteries run at a mortality rate of around 10%, but this can vary among breeds. A complete pedigree history and breeding history is needed, which requires a degree of co-operation between breeders that can be hard to achieve.

Signs suggestive of a hereditary disease

Diseases proven to be hereditary in some breeds are shown in Table 14.7. Where a disease is not known to be hereditary, a number of factors may suggest that it may be (Patterson *et al.*, 1989):

- The abnormality occurs at a higher frequency in a group of related cats than in the general population.
- There is evidence of a breed predisposition to a specific abnormality.
- The same abnormality is observed in several related kittens or kittens born to related cats.
- The defect increases in frequency with inbreeding; especially with recessive or polygenic traits.
- A defect involves the same anatomical site in a group of related animals.
- The defect can be traced to a specific metabolic abnormality, e.g. enzyme deficiencies.
- A disease has a consistent age of onset and clinical course, suggesting genetic control, e.g. storage diseases, retinal atrophy.
- The disease is associated with a chromosomal abnormality, e.g. male tortoiseshell. Little work has been done on these diseases in small animals.

The typical pattern of appearance of hereditary disease is therefore one that occurs in a group of related cats and increases in incidence as the prevalence of the gene in the population increases.

Factors suggesting a non-hereditary disease include:

- the presence of more than one abnormality in a kitten or in its littermates
- a known history of exposure to teratogens (see Box 14.3)
- the presence of abnormalities against a background of no previous problems with several previous matings of the same sire and dam (see Test matings, below).

Control of hereditary disease

Until recently, it has been necessary to rely on testing mating and pedigree analysis to detect carriers, or potential carriers, of deleterious genes. However, with the advent of highly sensitive and specific molecular genetic techniques, it is now possible for certain specific defects to detect homozygotes and heterozygotes by genetic testing.

Test matings

If hereditary disease is suspected, but it is not possible to decide from mating history or previously published data on the heredity of a defect, there are two main alternatives. The breeder may remove affected or suspected carrier cats from the breeding population, usually by neutering both parents and their kittens. It must be remembered that all other related cats (i.e. progenitors and sibs of both parents, and their offspring) should be considered potential carriers. The other possibility is to carry out test matings. Test matings will prove heredity or eliminate it to a specified degree, but do carry certain risks and limitations.

- They can produce affected kittens, which may be unacceptable to the breeder.
- They can take a long time, unless the defect is obvious at an early stage.
- Test mating programmes are not usually suitable to clear queens, requiring a large number of unaffected kittens to be born.

A variety of test mating programmes can be designed (Robinson, 1991). The simplest involves mating a parent to an affected offspring, if this is possible. The predicted outcome for an autosomal recessive hereditary defect is 50% affected kittens, 50% non-affected. If seven or more normal kittens are produced (with no abnormal kittens), the defect is considered unlikely to be hereditary, with a confidence limit of 99%. Where mating of an affected cat is not possible, either successive repeat matings, or matings with known carriers must be performed. The predicted outcome in this case for an autosomal recessive hereditary defect is 25% affected kittens and 75% non-affected (some of which will be carriers). For this programme 16 normal kittens (and no abnormal ones) must be produced to achieve the confidence limit of 99%. In any test mating programme, the production of a kitten showing the specified defect is usually taken as proof of heredity.

Genetic testing

Genetic testing is currently available for a few defects in cats, but as more information about the cat genome becomes available it may be more widely offered. As an example of genetic testing , a disease for which this is available in the cat is GM1 and GM2 gangliosidosis of Korat cats (Baker, H., Scott-Richey Research Centre, College of Veterinary Medicine, Auburn, USA, personal communication). The defect in this breed has been detected in the specific genes for β-galactosidase (GM) and *N*-acetylhexosaminidase B (GM). Blood samples from breeding cats can be tested for the presence of normal or abnormal alleles using the polymerase chain reaction to amplify the relevant DNA fragments for sequencing. In this way, genetically sound (homozygous normal:normal) or carrier cats (heterozygous normal:abnormal) can be identified and removed from the population without the need for a test mating programme. Further, it is possible to mate carrier cats to known genetically sound cats and to screen their kittens, retaining those of normal genotype for breeding. In this way the diversity of the gene pool in this small breed can be maintained.

References

Addie D.D. & Toth S. (1993) Feline coronavirus is not a major cause of neonatal kitten mortality. *Feline Pract* **21**(5), 13–18.

Blaxter A., Lievesley P., Gruffydd-Jones T.J. & Wotton P. (1986) Periodic muscle weakness in Burmese kittens. *Vet Rec* **118**, 619–620.

Blunden T.S. (1998) The neonate: congenital defects and fading puppies. In *Manual of Small Animal Reproduction and Neonatology* (eds Simpson G.M., England G.C.W. & Harvey M.). BSAVA Publications, Cheltenham, pp. 143–152.

Boothe D.M. & Tannert K. (1992) Special considerations for drug and fluid therapy in the pediatric patient. *Compendium on Continuing Education for the Practicing Veterinarian (North American Edition)* **14**, 313–329.

Bradshaw J.W.S. (1992) *Behaviour of the Domestic Cat*. CAB International, Wallingford.

Bray N.C. (1984) Nutritional secondary hyperparathyroidism in a kitten. *Feline Pract* **14**(4), 31–35.

Chandler M.L. (1992) Pediatric normal blood values. In *Current Veterinary Therapy*, vol. XI (eds Kirk R.W. & Bonagura J.D.). WB Saunders, Philadelphia, PA, pp. 981–984.

Chrisman C.C. (2000) Polyneuropathies of cats. *J Small Anim Pract* **41**, 384–389.

Crager C.S. & Nachreiner R.F. (1993) Increased parathyroid hormone concentration in a Siamese kitten with nutritional secondary hyperparathyroidism. *J Am Anim Hosp Assoc* **29**, 331–336.

Dawson S. & Willoughby K. (1999) Feline infectious upper respiratory tract disease – an update. *In Practice* **21**, 232–243.

Dieter J.A., Stewart D.R., Haggarty M.A., *et al.* (1993) Pregnancy failure in cats associated with long term dietary taurine insufficiency. *J Reprod Fertil*, Suppl **47**, 457–463.

Dubey J.P. & Carpenter J.L. (1993) Neonatal toxoplasmosis in littermate cats. *J Am Vet Med Assoc* **203**, 1546–1549.

Dubey J.P., Lappin M.R. & Thulliez P. (1995) Diagnosis of induced toxoplasmosis in neonatal cats. *J Am Vet Med Assoc* **207**, 179–185.

Dunn A.M. (1978) *Veterinary Helminthology*. 2nd edn. William Heinemann Medical Books, London.

Earle K.E., Smith P.M., Gillott W.M. & Poore D.W. (1990) Haematology of the weanling, juvenile and adult cat. *J Small Anim Pract* **31**, 225–228.

Festing M.F.W. & Bleby J. (1970) Breeding and performance and growth of SPF cats (*Felis catus*). *J Small Anim Pract* **11**, 533–542.

Giger U., Bücheler J. & Patterson D.F (1991a) Frequency and inheritance of A and B blood types in feline breeds in the United States. *J Hered* **82**, 15–20.

Giger U., Bücheler J. & Patterson D.F (1991b) Geographical variation of the feline blood type frequencies in the United States. *Feline Pract* **19**, 21–27.

Giger U., Gorman N.T., Hubler M., *et al.* (1992) Frequencies of the feline A and B blood types in Europe. *Proceedings of the International Society of Animal Genetics Conference* **23**, (Suppl I), 17–18.

Ginzinger D.G., Lewis M.E.S., Ma Y.H., *et al.* (1996) A mutation in the lipoprotein lipase gene is the molecular basis of chylomicronaemia in a colony of domestic cats. *J Clin Invest* **97**, 1257–1266.

Greco D.S. (2001) Congenital and inherited renal diseases of small animals. *Vet Clin North Am Small Anim Pract* **31**, 393–399.

Gruffydd-Jones T.J. (1994) The genital system and paediatrics. In *Feline Medicine and Therapeutics*. 2nd edn (eds Chandler E.A., Gaskell C.J. & Gaskell R.M.). Blackwell Science, Oxford, pp. 269–286.

Haarer M. & Grunbaum E.G. (1993) Blood group serological examinations in cats in Germany. *Kleinterpraxis*, **38,** 195–208.

Haskins M.E. & Casal M.L. (1997) Interpreting gross necropsy observations in neonatal and pediatric kittens. In *Consultations in Feline Internal Medicine*, vol. 3 (ed. August J.R.). WB Saunders, Philadelphia, PA, pp. 587–594.

Holmes R. (1950) Blood groups in cats. *J Physiol* **111**, 61.

Hosgood G. & Hoskins J.D. (1998) *Small Animal Pediatric Medicine and Surgery*. Butterworth Heinemann, Oxford.

Hoskins J.D. (1990) Clinical evaluation of the kitten: from birth to eight weeks of age. *Compendium on Continuing Education for the Practicing Veterinarian (North American Edition)* **12**, 1215–1225.

Hoskins J. (1993) Feline neonatal sepsis. *Vet Clin North Am Small Anim Pract* **23**, 91–100.

Hoskins J.D. (1995) Fluid therapy in the puppy and kitten. In *Current Veterinary Therapy*, vol. XII (ed. Bonagura J.D.). WB Saunders, Philadelphia, PA, pp. 34–37.

Hoskins J.D. (1999) Feline respiratory diseases. *Vet Clin North Am Small Anim Pract* **29**, 945–959.

Hotson-Moore P. & Sturgess K. (1998) Care of neonates and young animals. In *Manual of Small Animal Reproduction and Neonatology* (eds Simpson G.M., England G.C.W. & Harvey M.). BSAVA Publications, Cheltenham, pp. 153–170.

Jain N.C. (1996) *Essentials of Veterinary Haematology*. Lea and Fabinger, Philadelphia, PA.

Jensen A.L., Olesen A.B. & Arnbjerg J. (1994) Distribution of feline blood types detected in the Copenhagen area of Denmark. *Acta Vet Scand* **35**, 121–124.

Jones B.R., Wallace A., Harding D.R.K., *et al*. (1983) Occurrence of ideopathic, familial hyperchylomicronaemia in a cat. *Vet Rec* **112**, 543–547.

Keller G.G., Reed A.L., Lattimer J.C. & Corley E.A. (1999) Hip dysplasia: a feline population study. *Vet Radiol Ultrasound* **40**, 460–464.

Kittleson M.D., Meurs K.M., Munroe M.J., *et al*. (1999) Familial hypertrophic cardiomyopathy in Maine Coon cats–an animal model of a human disease. *Circulation* **99**, 3172–3180.

Knottenbelt C.M., Addie D.D., Day M.J. & Mackin A.J. (1999a) Determination of the prevalence of feline blood groups in the UK. *J Small Anim Pract* **40**, 115–118.

Knottenbelt C.M., Day M.J., Cripps P.J. & Mackin A.J. (1999b) Measurement of titres of naturally occurring alloantibodies against feline blood group antigens in the UK. *J Small Anim Pract* **40**, 365–370.

Lawler D.F. (1994) Investigating kitten deaths in catteries. In *Consultations in Feline Internal Medicine*, vol. 1 (ed. August J.R.). WB Saunders, Philadelphia, PA, pp. 47–54.

Lawler D.F. & Evans R.H. (1995) Nutritional and environmental considerations in neonatal medicine. In *Current Veterinary Therapy*, vol. XII (ed. Bonagura J.D.). WB Saunders, Philadelphia, PA, pp. 37–40.

Lawler D.F. & Monti K.L. (1984) Morbidity and mortality in neonatal kittens. *Am J Vet Res* **45**, 1455–1459.

Leidinger J., Leidinger E. & Giger U. (1993) Distribution and importance of feline blood type-A and type-B in Austria. *Weiner Tierartztliche Monatsschrift* **80**, 10–14.

Lobprise H.B., Wiggs R.B. & Peak R.M. (1999) Dental diseases of puppies and kittens. *Vet Clin North Am Small Anim Pract* **29**, 871–893.

Macintire D.C. (1999) Pediatric intensive care. *Vet Clin North Am Small Anim Pract* **29**, 971–988.

Malik R. (2001) Genetic diseases of cats. *J Feline Med Surg* **3**, 109–113.

Meyers-Wallen V.N. (2000) Inherited disorders of the reproductive tract in dogs and cats. In *Current Veterinary Therapy*, vol. XIII (ed. Bonagura J.D.). WB Saunders, Philadelphia, PA, pp. 904–908.

Meyers-Wallen V.N., Haskins M.E. & Patterson D.F. (1984) Hematologic values in healthy neonatal, weanling and juvenile kittens. *Am J Vet Res* **45**, 1322–1327.

Miller E. (1995) Diagnostic studies and sample collection in neonatal dogs and cats. In *Current Veterinary Therapy*, vol. XII (ed. Bonagura J.D.). WB Saunders, Philadelphia, PA, pp. 26–30.

Murtaugh R.J. (1994) Pediatrics: the kitten from birth to eight weeks. In *The Cat: Diseases and Clinical Management* (ed. Sherding R.G.). Churchill Livingstone, New York, pp. 1877–1892.

Narfstrom K. (1999) Hereditary and congenital ocular disease in the cat. *J Feline Med Surg* **1**, 135–142.

Neiwold T.A., Van der Linde-Sipman J.S., Murphy C., *et al*. (1999) Familial amyloidosis in cats: Siamese and Abyssinian AA proteins differ in primary sequence and pattern of deposition. *Int J Exp Clin Invest* **6**, 205–209.

Papich M.G. (1989) Effects of drugs on pregnancy. In *Current Veterinary Therapy*, vol. X (eds Kirk R.W. & Bonagura J.D.). WB Saunders, Philadelphia, PA, pp. 1291–1299.

Patterson D.F., Aguirre G.A., Fyfe J.C., *et al*. (1989) Is this a genetic disease? *J Small Anim Pract* **B30**, 127–139.

Powell C.C. & Lappin M.R. (2001) Clinical ocular toxoplasmosis in neonatal kittens. *Vet Ophthalmol* **4**, 87–92.

Remillard R.L., Pickett J.P. Thatcher C.D. & Davenport D.J. (1993) Comparison of kittens fed queen's milk with those fed milk replacers. *Am J Vet Res* **54**, 901–907.

Robinson R. (1991) *Genetics for Cat Breeders*. 3rd edn. Butterworth Heinemann, Oxford.

Robinson R. (1992) Spasticity in the Devon Rex cat. *Vet Rec* **130**, 302–302.

Saperstein G., Harris S. & Leipold H.W. (1976) Congenital defects in domestic cats. *Feline Pract* **6**(4), 18–43.

Scott F.W., Geissinger C. & Peltz R. (1978) Kitten mortality survey. *Feline Pract* **8**(6), 31–34.

Sheldon G.D. & Engval E. (2002) Muscular dystrophies and other inherited myopathies. *Vet Clin North Am Small Anim Pract* **32**, 103–124.

Sparkes A.H., Bessant C., Gunn-Moore D., *et al.* (2000) Results of a questionnaire-based study of pedigree cat breeding in the UK (Abstract). *European Society of Veterinary Internal Medicine Congress*, Neufchatel, Switzerland. [This abstract may be found in the Feline Focus section of *J Feline Med Surg* **2**(3), v–vi.]

Speakman A.J., Binns S.H., Dawson S., *et al.* (1997) Antimicrobial susceptibility of *Bordetella bronchiseptica* isolates from cats and a comparison of the agar dilution and E-test methods. *Vet Microbiol* **54**, 63–72.

Speakman A.J., Dawson S., Binns S.H., *et al.* (1998) *Bordetella bronchiseptica* infection in the cat: a review. *J Small Anim Pract* **40**, 252–256.

Stepien R.L. & DeMorais R.L. (2000) Feline congenital heart disease. In *Current Veterinary Therapy*, vol. XIII (ed. Bonagura J.D.). WB Saunders, Philadelphia, PA, pp. 738–741.

Strain G.M. (1999) Congenital deafness and its recognition. *Vet Clin North Am Small Anim Med* **29**, 895–907.

Sturgess K. (1998) Infectious diseases of young puppies and kittens. In *BSAVA Manual of Small Animal Reproduction and Neonatology*. BSAVA Publications, Cheltenham, pp. 159–166.

Sturman J.A., Gargano A.D., Messing J.M. & Ikami H. (1986) Feline maternal taurine deficiency: effect on mother and offspring. *J Nutr* **116**, 655–667.

Van der Linde-Sipman J.S., Neiwold T.A., Tooten P.C.J., *et al.* (1997) Generalised AA-amyloidosis in Siamese and Oriental cats. *Vet Immunol Immunopathol* **56**, 1–10.

Willoughby K., Dawson S., Jones R.C., *et al.* (1991) Isolation of *Bordetella bronchiseptica* from kittens with pneumonia in a breeding cattery. *Vet Rec* **129**, 407–408.

Young C. (1973) Preweaning mortality in specific pathogen free kittens. *J Small Animal Pract* **14**, 391–397.

Further reading

Bäheler J. (1999) Fading kitten syndrome and neonatal isoerythrolysis. *Vet Clin North Am Small Anim Pract* **29**, 853–870.

Gelens H.C. & Ihle S.L. (1999) Failure to Grow. *Vet Clin North Am Small Anim Pract* **29**, 989–1001.

Hoskins J.D. (1993) Fading puppy and kitten syndromes. *Feline Pract* **21**(5), 19–22.

Hoskins J.D. (1999) Pediatric health care and management. *Vet Clin North Am Small Anim Pract* **29**, 837–852.

Hotson-Moore P. & Sturgess K. (1998) Care of neonates and young animals. In *Manual of Small Animal Reproduction and Neonatology* (eds Simpson G.M., England G.C.W. & Harvey M). BSAVA Publications, Cheltenham, pp. 153–170.

Kirk C.A. (2001) New concepts in pediatric nutrition. *Vet Clin North Am Small Anim Pract* **31**, 69–92.

Lawler D.F (1989) Care and diseases of neonatal puppies and kittens. In *Current Veterinary Therapy*, vol. X (eds Kirk R.W. & Bonagura J.D). WB Saunders, Philadelphia, PA, pp. 1325–1333.

Moon P.F., Masset B.J. & Pacoe P.J. (2001) Neonatal critical care. *Vet Clin North Am Small Anim Pract* **31**, 343–365.

Chapter 15

THE ORAL CAVITY

C.E. Harvey

Introduction

Nutritionally, cats are obligate carnivores. They do not have 'chewing' teeth. The mouth opens wide to permit food material to be passed to the carnassial teeth, which cut it into swallowable pieces. The nutritional requirements of cats are now well established; however, diets that meet the published nutritional requirements may contribute to the development of periodontal disease because they do not provide the dietary abrasion that results from a natural diet (Watson, 1994). The salivary pH of cats is slightly alkaline (Zetner, 1992), which makes dental caries unlikely but promotes deposition of dental calculus.

In this chapter, the convention of naming the teeth based on the prototypical carnivore mouth is used; thus, there are no upper first premolar or lower first or second premolar teeth in the cat, and only a small functionless upper first molar tooth. The lower first molar tooth is unlike that of dogs or most other non-felid carnivores: it has a double-cusped crown and a large mesial (rostral) and small distal (caudal) root.

Oral tissues are the most readily available 'window' into the body. The oral mucosa will reflect pyrexia, anaemia or specific system malfunction (such as immunological, cardiorespiratory, renal or hepatic abnormalities).

Oral and dental conditions in cats are very common and can be frustrating to treat. Some basic tenets for management of feline oral diseases are:

- Any abnormality will coexist with, and may be exacerbated by, plaque-induced inflammation.
- Asymmetrical lesions demand attention.
- The pragmatic approach to management of conditions involving teeth or gingiva in cats is to divide them into those that do and those that do not require extraction (Carmichael, 2000).
- Our understanding of the feline immune system, and in particular local (mucosal) protection, is imperfect, and thus we are often left with empirical treatment as the only currently available option. This is slowly changing (Dunham, 1999).

In a recent study of several thousand cats in the USA, oral disease was second only to healthy as the primary diagnosis in cats aged 0–7 years, and was by far the most common diagnosis in the older animals (Lund, 1996). A more detailed examination of these data listed dental calculus as being present in 24% and gingivitis in 13% of 15 226 cats; only 9.5% were diagnosed as healthy (Lund *et al.*, 1999). Every cat should be considered to be a potential dental patient: one should 'lift the lip' every time the cat is presented, for whatever reason. Because periodontal disease (plaque-induced inflammation and tissue resorption) is ubiquitous in middle-aged and ageing cats, it is easy to fall into the trap of assuming that, in a cat with extensive calculus accumulation, any pathology present is periodontal in origin. There are several conditions that may present as gingival inflammation or gingival irregularity and that are not plaque-induced periodontal disease. For these patients, a dental scale/polish or extraction may be inappropriate or insufficient treatment.

Oral health is an important contributor to the growing interest in geriatric care and of wellness as a concept. Recently, there has been frequent mention of the oral–systemic disease connection. Systemic abnormalities such as severe renal failure may cause oral ulceration (ammonia resulting from breakdown of urea in saliva causes a chemical burn) and will exacerbate periodontal disease. Whether oral disease can cause systemic disease has proved to be difficult to determine. Dental procedures cause bacteraemia in cats (Harari *et al.*, 1991), although this is of unknown

significance. Bacteraemia is a common occurrence (a daily event during mastication and tooth-brushing) and is cleared rapidly by the reticuloendothelial system in a healthy animal. There is proof of an association between oral/dental disease (specifically periodontal disease) and systemic or distant organ abnormalities in dogs and humans, but there is no proof of a cause and effect relationship in these species (DeBowes *et al.*, 1996; Slots, 1998). Although there is no proof even of an association in cats (because this has not been studied), there is no reason to believe that cats are different in this respect from other species. Early dental awareness and prevention are strongly recommended.

The full range of pathologies can occur in the oral tissues: infection, inflammatory and immune-mediated diseases, and degenerative, genetic, neoplastic, traumatic and metabolic conditions. When the epithelial protection mechanisms (salivary and cellular) are malfunctioning and the epithelial surface has been breached, the exposed oral tissues are bathed in a fluid rich in bacteria, and they react to the bacteria. Thus, inflammatory changes are almost universal in oral lesions.

The challenge is to recognise the patients with disease that merits additional diagnostic work-up or treatment. First, every patient with clinically obvious oral disease deserves a general physical examination and history. Secondly, there are some indicators that require particular attention:

- asymmetrical oral disease, even if it appears to be inflammatory and centred on the gingival tissues
- swelling of oral tissues
- if the extent of inflammation is greater than seems appropriate for the extent of dental plaque and calculus present: the periodontium (the tissues surrounding the teeth) should be examined in every cat
- ulceration, whether of the gingiva or of any other oral tissue
- exposure of bone: normally, periodontal disease develops sufficiently slowly that the soft tissues can maintain coverage of bone as the tissues recede
- inflammation that extends beyond the mucogingival junction
- poor response to periodontal treatment.

Swellings should be aspirated, and asymmetrical lesions or lesions extending beyond the mucocutaneous junction (except in very obvious situations such as acute ulcerations on the tongue resulting from an acute viral infection in a young cat) should be biopsied if they do not contain fluid. Oral radiographs can be very useful, particularly for lesions centred on the jaws; the contrast between root canal, dentine, periodontal ligament and alveolar bone forms a very recognisable pattern. Bacterial culture is very rarely of any specific assistance in the management of a clinical case.

Clinical signs

Clinical signs should be regarded as a reason for careful examination and not taken as indicative of a specific diagnosis. They include halitosis, drooling or bleeding from the mouth, dropping food from the mouth and pawing at the mouth. Oral conditions also often cause clinical signs, such as inappetance, or hiding or other behavioural changes, which are very general; these signs may result from dental pain.

Oral examination

Any reason for presentation of a feline patient is an opportunity for an oral examination. Lifting the lip to examine the buccal surfaces of the teeth, and then rotating the head back to cause the mouth to open, takes but a few seconds and may reveal a treasure trove of disease awaiting management. While the head is rotated back, pushing down on the lower incisor teeth will reveal the palate and palatal surfaces of teeth and, while the mandible is still pulled ventrally, pushing up with the thumb between the mandibles will reveal the tongue and sublingual furrows. Pushing down on the tongue reveals the pharynx and tonsils.

Detailed periodontal examination typically requires sedation or anaesthesia. Each tooth should be examined for mobility, pocketing and resorptive lesions, and the extent of plaque and calculus deposition assessed. While the cat is chemically restrained, radiographs may be taken. Routine use of whole-mouth radiographs in feline dental patients often reveals conditions that were not apparent on clinical examination (Verstraete *et al.*, 1998). Use of specific technique and small dental films is essential (Lommer *et al.*, 2000b).

Other relevant examinations include biopsy (of swellings and asymmetrical lesions or of stomatitis cases that have not responded to treatment as expected), cytology [to differentiate squamous cell carcinoma (SCC) from eosinophilic granuloma or stomatitis], and a review of systemic health (to evaluate systemic disease that may contribute to the oral condition, or to evaluate the anaesthetic risk for that

patient). Tests for feline immunodeficiency virus (FIV) and feline leukaemia virus (FeLV) are indicated in many cats with oral diseases.

Differentiation of oral diseases

There are some very typical locations and appearances of specific oral conditions, which are described below. As noted above, these often coexist with or are exacerbated by plaque-induced periodontal disease. There is a typical pattern in periodontal disease cases (see below), and differences from this pattern should be investigated so that concurrent conditions are recognised.

Periodontal disease

Periodontal disease results from accumulation of dental plaque. In the wild state, dietary abrasion retards (but does not prevent) accumulation of plaque and development of periodontal disease; however, some feline convenience foods enhance accumulation of plaque (Watson, 1994). The extent of retardation resulting from a natural diet, compared with commercially available diets, was questioned recently (Clarke & Cameron, 1998). Overall, dry diets tend to retard plaque accumulation more than soft-food diets; diets specifically formulated for plaque control (e.g. Hill's Prescription Diet Feline t/d, and Friskies Feline Dental Diet) are even more effective than standard extruded dry food. Plaque is a soft deposit that can be wiped off teeth readily; it consists primarily of bacteria in a complex biofilm (DuPont, 1997). Minerals in saliva precipitate in plaque to form hard dental calculus, which promotes further plaque accumulation and maturation by providing a rough surface that cannot be readily wiped off by dental abrasion.

It is generally accepted that plaque maturation to an anaerobic-predominant flora is critical to the disease process. Specific bacteria identified as periodontopathogens include the black-pigmented *Bacteroides* group, particularly *Porphyromonas* and *Prevotella* spp. Bacteria present in gingival pockets of cats with gingivitis are very similar to those found in dogs and humans (Mallonnee *et al*., 1988; Norris & Love, 1999; Reiter & Mendoza, 2002), although some feline-specific subspecies of *Porphyromonas gingivalis*-like bacteria have been identified (Norris & Love, 2000b). Spirochaetes have also been identified, including members of a category called pathogen-related oral spirochaetes (Valdez *et al*., 2000). We are only beginning to understand the interaction of dental plaque with local and systemic immunological responses that result in disease and, in particular, the periodontal immunological peculiarities of cats compared with dogs and humans.

Pasteurella multocida is isolated in such frequency from the mouth of cats that are clinically normal and from those with oral disease that it should be presumed to be present in any cat. Whether this is a significant cause of oral disease in cats is unknown; however, it is significant in bite wounds (of cats, dogs or humans) caused by cats.

Bacteria are present in overwhelming numbers as plaque increases. Inflammation results, and neutrophils, attracted by the inflammation, engulf some of the bacteria and retreat into connective tissue. There the neutrophils burst, releasing cytokines that stimulate additional inflammation and tissue resorption. The extent of the inflammatory response and the rate of tissue destruction depend on the inflammatory and immunological responses of the patient, as well as on the extent of plaque accumulation and specific bacterial population.

Plaque and calculus are deposited most extensively on the buccal surface of the upper fourth premolar tooth; there is generally little calculus on the canine or lower first molar teeth (Harvey, 2001). Compared with humans and dogs, gingival inflammation in cats tends to correlate less clearly with calculus deposition.

Periodontal disease consists of gingivitis (the initial stage) and periodontitis (the irreversible stage).

Gingivitis

The gingiva is the tissue forming the abrasion-resistant cuff around the crowns of the teeth; it varies from about 1 cm (over the upper canine teeth) to about 1–2 mm (over the buccal surface of the upper fourth premolar teeth). Gingivitis (inflammation of the gingiva) is reversible if plaque is removed, provided that the animal's immune responses are normal. Resolution of gingivitis following plaque removal will be only partial or short term, even in an immunologically competent cat, if oral hygiene is not excellent; this is difficult to attain in cats. Gingivitis is common in young cats and it is not known whether juvenile gingivitis is an indicator of subsequent more severe oral disease such as stomatitis; it may also be a stage in immunological development, similar to the severe tonsillitis seen in maturing humans and some dogs. Gingivitis is very common; depending on the definition and means of

detection, up to 80% of mature cats have at least mild gingivitis around some teeth.

Periodontitis

The tooth is held in the jaw by connective tissue fibres (the periodontal ligament) that originate in the cortex of the alveolar bone and insert in the cementum lining the root. Connective tissue inflammation weakens the strength of the ligament, and subsequent resorption of bone eliminates some of the bone surface area available for attachment. This combination of soft-tissue and bone pathology is known as periodontitis.

Sometimes, bone loss and gingival loss occur at a similar rate, producing gingival recession, and sometimes bone is resorbed more rapidly, producing a pocket between the tooth and the gingiva (0–1 mm is considered normal pocket depth in cats). A deep pocket enhances retention of anaerobic bacteria and exacerbation of disease. Again, depending on the definition and method of examination, periodontitis is present to some extent in one or more teeth in about 50% of cats aged 4 years or more, increasing on average with increasing age until the teeth are lost. Loss of attachment of itself indicates past disease; 2–3 mm of attachment loss in a tooth that no longer has significant periodontal inflammation is compatible with long-term retention of the tooth, if excellent oral hygiene is provided. With continuing inflammation resulting in additional periodontitis, the tooth becomes loose and is eventually lost.

Extensive periodontal bone abnormality is sometimes seen around the upper canine teeth of cats: the normal alveolar/trabecular radiographic pattern is missing or is replaced with irregular patchy calcification, and the juga (the bony prominence housing the root) may bulge buccally (Lommer & Verstraete, 2001). The canine tooth itself may be extruded into the mouth (supereruption), even though at least initially it is not mobile. The canine tooth may also be resorbed. It is not known whether these changes around the upper canine teeth are the result of plaque-induced periodontitis.

Treatment

Scaling/polishing and extraction are by far the most commonly used options for the management of feline periodontal disease. Scaling and polishing should be accompanied by detailed examination of the tooth. Pocket depth can be measured by gently probing the periodontal pockets with a blunt-tipped periodontal probe and mobility assessed by pressing against the tooth. A sharp-pointed dental explorer is used to examine the surface of the tooth (including the unattached root within the pocket) for areas of irregularity that indicate incompletely removed calculus or presence of a resorptive lesion. Because of the shape and size of feline teeth, treatment of severe periodontal disease other than by extraction usually is impractical or inappropriate; this is particularly the case given that, for treatment of severe periodontal disease to be successful, excellent life-long frequent home care is required. Thus, teeth that are loose, and those with extensive periodontal pockets, should be extracted. Detailed information on dental examination, scaling, polishing, extraction and pocket management techniques are available in veterinary dental textbooks.

A 'dental' is often considered a routine procedure, assigned to a veterinary nurse in many practices. Veterinary nurses can become very competent at scaling of teeth provided they have the requisite skills and provided they have been trained thoroughly. No matter who scales the teeth, every feline dental patient deserves to have its mouth examined by a veterinarian while under anaesthesia.

Complications of dental scaling procedures

Overinflation of the endotracheal tube resulting in rupture of the trachea occurs most commonly in cats undergoing dental procedures (Hardie *et al.*, 1999; Mitchell *et al.*, 2000). No more than 2.5 ml of air is necessary to provide a seal. Injection of 6 ml caused rupture in seven of 10 feline cadaver specimens (Hardie *et al.*, 1999).

Because ultrasonic dental scalers and high-speed dental units produce a chilling mist, feline patients should be protected from hypothermia during dental procedures by wrapping them in a plastic bag and hot water blanket (Hale & Anthony, 1997).

Prevention

Prevention is a very important part of management of periodontal disease, and is best practised from a young age rather than waiting until professional treatment is required. Some cats will tolerate tooth-brushing and it is effective if practised consistently (Richardson, 1965). Having the cat do the oral hygiene work is more attractive to many owners. Two maintenance-formulation diets that are effective in retarding accumulation of

plaque and calculus compared with the usual dry food formulation are now marketed (Hill's Prescription Diet Feline t/d and Friskies Feline Dental Diet). Chlorhexidine, the most effective chemical antiplaque agent, is available as a palatable gel or rinse. Chlorhexidine maintains its effectiveness even after years of daily use. These rinses or gels can be used as dentifrices, applied with a brush. Daily use is more effective than less frequent use. An effective feline-specific antiplaque enzymic chew product is available (Gorrel *et al.*, 1998) and may be more palatable to some cats than a chlorhexidine product.

The differentiation between periodontal disease (gingivitis) and stomatitis (see below) in cats is often unclear, and the first step in management of a stomatitis case often includes dental scaling. Thus, the response to periodontal treatment should be evaluated 2–4 weeks after treatment; this is an excellent opportunity to review compliance with instructions for oral hygiene.

Use of antibiotic drugs in cats with oral diseases

Antibiotics are not routinely required during periodontal procedures. As noted above, bacteraemia is a daily phenomenon, and an otherwise healthy animal is at very little risk during a scaling and polishing procedure, even when there is some gingivitis present.

Use of an antibiotic is recommended:

- when the oral disease is extensive enough to require antimicrobial treatment: the major criterion is extent of inflammation, as in cats with severe stomatitis; gingivitis is not of itself an indication for systemic antibiotic treatment
- when the procedure will involve extensive contact with connective tissue or bone (e.g. when gingival flaps, extractions or similar procedures will be performed)
- in cats undergoing any dental procedure if the cat is systemically ill (e.g. cardiorespiratory, hepatic, renal or immune system disease).

Antibiotic drugs recommended for use in cats to combat bacterial contamination of oral tissues or to prevent bacteraemia include amoxicillin–clavulanic acid (Synulox, Pfizer, 11–22 mg/kg three times daily), clindamycin (Antirobe, Pharmacia, 5–10 mg/kg twice daily) and spiramycin–metronidazole (Stomorgyl, Merial, 12.5 mg/kg metronidazole once daily). Amoxicillin–clavulanic acid provides very broad-spectrum activity, including anaerobes; clindaymycin has excellent anaerobic activity and penetrates into bone readily; and metronidazole has excellent anaerobic activity and works well in combination with spiramycin, which is concentrated in saliva. These recommendations are based on published antimicrobial susceptibility data (Hennet, 1991; Zetner & Thiemann, 1993b; Harvey, 2001); however, recent data suggest that *in vitro* susceptibility patterns may not match well with clinical results, at least in cats (Norris & Love, 2000a).

Ideally, when extensive inflammation is present, antibiotic administration is commenced several days before the procedure to reduce the bacterial load and extent of inflammation in the mouth, and should be continued for 1 or 2 days after the procedure if flaps or extractions have been performed. If prevention of bacteraemia is the only consideration, a single dose of the antibiotic is given, timed so that it is at peak serum concentration at the time of the procedure.

Stomatitis

Stomatitis is inflammation of any oral epithelial surface (stoma = mouth). In feline practice, the term stomatitis is used to refer to inflammation that is non-gingival; that is, it extends beyond the mucogingival margin or is entirely non-gingival. This continues to be a very frustrating syndrome, but fortunately it is less common than periodontal disease. Fire-engine-red areas of inflammation and ulceration in the mouth are painful.

The use of the term stomatitis is questionable because its use implies the existence of a single disease. The condition may be a single result of multiple causes, exacerbated by bacteria and perhaps viruses that contribute to the severity of disease even though they may not be the primary aetiological factor. The area of involvement varies widely, as does the type of lesion (inflammatory, ulcerative, necrotising, granulomatous) (Pedersen, 1992). Although 'chronic' is often used to describe the condition, the appearance and severity of the inflammation in many cats suggest that there may be a combination of chronic and continuing acute pathology.

Several immunological aspects have been investigated (Harley *et al.*, 1999a); however, immunological work often is not matched with detailed clinical oral examination, which means that interpreting the results of studies is complicated because the role of bacterial plaque is not factored into the studies.

Hypergammaglobulinaemia usually is present in affected cats. Serum immunoglobulin G (IgG) and IgM are increased (Zetner *et al.*, 1993; Harley *et al.*, 1999b); serum IgA was also found to be increased in one study (Zetner *et al.*, 1993). The secretory index suggests that salivary IgA and IgM are significantly decreased compared with normal cats (Harley *et al.*, 1999b). A monoclonal gammopathy has been observed in occasional patients (Lyon, 1994). Serum IgE concentration, which may indicate a hypersensitivity response, was found to be elevated only in about one-third of affected cats (Zetner *et al.*, 1996b). The increased serum immunoglobulin consists primarily of antibodies to specific oral bacteria (Sims *et al.*, 1990). *Actinobacillus actinomycetemcomitans*, which causes severe juvenile periodontitis in humans, has not been identified by culture or DNA probe testing in cats (Harvey *et al.*, 1994); high serum *A. actinomycetemcomitans* antibody concentrations reported in cats with stomatitis but not in clinically normal cats (Sims *et al.*, 1990) may be *Pasteurella* species antibodies, as these bacteria are known to cross-react with *A. actinomycetemcomitans*, and *Pasteurella* species are very common in the mouths of cats.

On biopsy of affected tissue, large numbers of acute inflammatory cells (neutrophils) and lymphocytes and plasma cells are seen (hence the use of the term lymphocytic–plasmacytic stomatitis or LP gingivitis–stomatitis in the literature). The lymphocytic and plasma cell infiltration is to be expected in any connective tissue that is chronically exposed to bacteria, and does not represent a specific condition. CD4:CD8 lymphocyte ratios in affected cats do not differ from those in normal cats (Anderson & Pedersen, 1996; DeBowes, 1996).

Interleukin-6 (IL-6) expression is seen early on in biopsies of affected cats, and IL-4 expression occurs late in the process; IL-2, IL-4, IL-6, IL-10, IL-12 (p35 and p40) and interferon-γ are all significantly increased with increasing severity of disease (Harley *et al.*, 1999a). The similarity of the cytokine expression in affected cats compared with clinically normal cats suggests that the pathogenesis is similar in all affected cats, and is roughly similar to those changes seen with development of chronic periodontal diseases in humans (Harley *et al.*, 1999a). Although a local cell-mediated immunopathy seems a very likely primary contributor, it is still not clear whether any of the reported observations indicate a specific immunopathy as the cause of the oral pathology, whether the response to bacteria is a primary contributor, or both. Neutrophil function was found to be normal compared with age-matched controls in one study (Harvey & Campbell, 1989). The serum melatonin concentration in cats with gingivitis was found to be lower than that of a (non-aged-matched) control group, leading these authors to suggest that melatonin may have an influence on the immune system (Zetner *et al.*, 1998). The main conclusion that can be reached from the immunological and related studies of cats with chronic stomatitis reported to date is that cause cannot yet be separated from effect. Immunological response testing may be helpful in defining specific causes or directing treatment in the future, but is not yet perfected (Dunham, 1999).

Viruses may play a critical role (Pedersen, 1992). Any condition that suppresses immune responses may trigger severe disease in locations, such as the mouth, where bacteria come into contact with reactive cells. Gingival inflammation is the most common manifestation of FIV infection (Yamamoto *et al.*, 1989). In a study of 1996 cats, 55% of those with a combination of fever and gingivitis were FIV or FeLV positive (Scarlett, 1995). A recent study questioned the accepted relationship between FIV and periodontal inflammation, suggesting that this may be a function of age, because older cats are more likely both to be FIV positive and to have severe periodontal disease than younger cats (Norris *et al.*, 1999). FIV and FeLV tests should be performed on any cat with stomatitis or non-responsive periodontal disease or on any non-thriving cat with any periodontal inflammation. Many cats with chronic non-responsive stomatitis are FIV and FeLV negative.

Acutely, feline calicivirus (FCV) and feline herpesvirus (FHV) both cause lingual and palatal ulceration, and FCV is very commonly isolated from oral fluids of cats with chronic stomatitis (Knowles *et al.*, 1989, 1991); specific-pathogen-free cats infected with FCV or FHV do not tend to go on to develop chronic disease (Reubel *et al.*, 1992), and the location of the lesions in chronic stomatitis (gingiva, buccal mucosa, glossopalatine folds) is not the same as that seen in acute viral infection (primarily the tongue and palate). There is some evidence that specific FCV serotypes are present in chronic stomatitis (Poulet *et al.*, 2000), and stomatitis lesions are more severe in FIV-infected cats if FCV is also present (Tenorio *et al.*, 1991). Stomatitis occurs in cats vaccinated against FCV and FHV. For more information on viral infections, see Chapters 21–23.

Very recently, there has been considerable interest in *Bartonella* species as an associative or causative factor in stomatitis in cats. Surveys using a recently

introduced serological test (FeBart®Test, National Veterinary Laboratory, Franklin Lakes, NJ, USA) suggest that some stomatitis patients are infected with *Bartonella* species (Hardy, 2002a).

Clinical features

Affected cats often are in pain and may be very reluctant to permit their mouths to be opened. The lesions typically are symmetrical, and consist of either bright red areas of inflamed oral mucosa or areas of granulation and/or ulceration surrounded by a zone of inflamed mucosa. Lesions on the tongue or palate are very unusual in cats with the classic stomatitis condition.

Periodontal inflammation

This is very common in stomatitis cases. It may seem more acute than would seem appropriate for the extent of visible plaque and calculus present. Periodontal inflammation in stomatitis cases does not respond normally to standard periodontal treatment; it may abate somewhat but rapidly returns. Severe gingivitis is seen in some young cats, often with little or no evident plaque or calculus accumulation. It is not known whether severe juvenile gingivitis is an indicator of an increased likelihood of severe stomatitis subsequently; as noted above, juvenile gingivitis may be an immunological maturational stage, which some cats do not complete.

Periodontally centred stomatitis

The non-gingival inflammation is continuous with areas of gingival inflammation.

Glossopalatine fold stomatitis (faucitis)

Typically large red traffic-light-like lesions caudal and lateral to the teeth are seen on each side rostral to the pharyngeal opening. These lesions are often, although not always, seen in conjunction with gingivitis. They seem to be particularly painful, perhaps because the lesions are pulled apart and compressed as the cat opens and closes its mouth.

Pharyngitis

Lesions are present in the pharyngeal wall and may surround the tonsillar crypts.

Various combinations of or all of these forms can be present in a particular patient.

Management

One of the features of feline stomatitis is that, even though it is often unresponsive and thus frustrating to manage, the condition remains limited to stomatitis (except in FIV- and FeLV-positive cats). Thus, there is no reason to give up on treatment because of concern about non-oral complications or the development of more widespread immunological abnormality.

Acute cases require nursing care (gentle oral cleaning with a chlorhexidine oral rinse or gel and nutritional support) and antimicrobial treatment (see Periodontal disease, above); waiting for 7–10 days will determine whether there will be failure to respond before proceeding with more specific steps. The extent of plaque and calculus accumulation are assessed and the teeth scaled as soon as is practical.

Young cats with lesions limited to juvenile gingivitis

Any periodontal disease should be treated. Scaling is performed if necessary or, if there is no calculus apparent (i.e. no skipping when a periodontal probe is run across the surfaces of the teeth), the surface of teeth may be rubbed thoroughly with a gauze sponge without sedation if the cat will tolerate it, then daily chlorhexidine provided as an oral gel and re-examine in 1 month.

Chronic periodontally centred stomatitis

A serum sample is submitted for FIV and FeLV testing. The general history and physical examination should be reviewed to rule out coexisting systemic disease. Any periodontal disease should be treated (scaling and polishing, with extractions as needed), along with antibiotic treatment and daily chlorhexidine oral hygiene follow-up (see Periodontal disease, above), and then await results. If treatment of the periodontal disease by scaling, antimicrobial treatment and oral hygiene with chlorhexidine is unsuccessful, the chlorhexidine treatment should be continued and anti-inflammatory treatment begun (see below). As noted above, there is little reason routinely to biopsy symmetrical stomatitis: the presence of chronic inflammatory cells will be confirmed, but

the results of the biopsy will not determine more specific therapy. Biopsy is indicated if the lesions are asymmetrical or are non-responsive to anti-inflammatory therapy. Samples are taken from ulcerated areas. The purpose of biopsy is to rule out squamous cell carcinoma, pemphigus vulgaris and severe primary gingival hyperplasia, conditions that could be confused with stomatitis, or if the owner is reluctant to accept extensive extractions and wants assurance that multiple extractions are essential.

Short of extensive extractions, we are left at present with antibacterial therapy and anti-inflammatory or immunosuppressant treatment as the only practical medical treatment options beyond periodontal therapy and oral hygiene.

Anti-inflammatory treatment

Treatment comprises oral prednisolone (2 mg/kg twice daily for 3–5 days, then once daily for 2–3 weeks) or subcutaneous repository steroid (triamcinolone, up to 10 mg). If there is some initial success and then recurrence, the anti-inflammatory treatment can be repeated. Although it may be effective for management of the oral lesions, use of megestrol as an anti-inflammatory drug is not recommended because of side-effects. If the cat needs continuous prednisolone or monthly (or more frequent) repository steroid injections after 4–6 months, full-mouth extraction may be considered as a means of avoiding continuing use of corticosteroid medication. As an alternative to corticosteroid anti-inflammatory therapy, sodium salicylate was used to treat a group of cats; it was tolerated well and it was determined that treatment every third day is sufficient to maintain therapeutic serum concentration; in the short term, oral inflammation was not eliminated but the cats were more comfortable (Eriksen *et al.*, 1992).

One report of results of treatment with metronidazole–spiromycin and triamcinolone described excellent results in 90% of treated cats, but it is not clear to what extent the results were due to periodontal therapy and/or extractions that were also performed in the 18 cats (Pfeifer *et al.*, 1988). In another report, following dental scaling and 1 week of metronidazole–spiramycin treatment postscaling, 23 cats with chronic gingivostomatitis were assigned to one of four groups: oral hygiene (chlorhexidine and glucose oxidase–lactoperoxidase) alone; metronidazole–spiramycin antibacterial treatment weekly on alternate weeks; 1 mg/kg methylprednisolone daily for 6 weeks followed by 0.5 mg/kg daily therapy; or 1 mg/kg sodium aurothiomalate once weekly. Three months after scaling, clinical results were poor in all four groups and cytokine expression within the oral tissues did not change (Harley *et al.*, 1999b).

Cases that are not responsive to or recur frequently following anti-inflammatory and antimicrobial treatment

If there is poor success with periodontal/antibiotic and anti-inflammatory treatment, and the owner wishes to retain the teeth in the mouth, the next level of treatment is immunosuppressive medications, such as aurothioglucose or aurothiomalate (1 mg/kg once weekly). Although these medications are often successful in controlling clinical signs of oral disease in severely affected cats (White *et al.*, 1992), side-effects preclude recommending these drugs as the primary treatment.

Very recently, in response to the observation that some feline stomatitis patients are *Bartonella* species positive, treatment with azithromycin (10 mg/kg once daily for 10 days) resulted in clinical improvement and a reduction in *Bartonella* antibodies (Hardy, 2002b) in some of the affected cats. The *Bartonella* diagnostic test and the clinical response to azithromycin treatment both indicate that *Bartonella* species are not the only cause of feline stomatitis. Given that the response to established medical therapy generally is mixed, submission of a serum sample for *Bartonella* antibody analysis (see above), followed by a course of azithromycin treatment if the serological test is positive, seems a reasonable intermediate step before full-mouth extraction.

As is the case with any condition that does not respond well to standard therapy, many alternatives have been tried or recommended. There have occasional flurries of interest in laser therapy, but with no well-documented results to demonstrate that laser treatment is any better than scaling and medical treatment. Radiation treatment does not provide effective long-term results (Goldstein *et al.*, 1991). Other therapies mentioned include oral administration of bovine lactoferrin (Sato *et al.*, 1996), preactivated merocyanine 540 (Wiggs *et al.*, 1993), homoeopathic treatment (Bellows, 1998), and 'paramunity-inducing drugs' (Block *et al.*, 1997). Cyclosporine has been suggested, to be used locally as ointment (0.5%) smeared on the gingiva or lips, or as tablets (3 mg/kg twice daily for a maximum of 3 months or until lesions resolve, if earlier). Although the results of some of these regimens have been reported, the studies often are of short

duration, include scaling and extraction of some teeth, involve few patients, poorly define inclusion and exclusion criteria, may be limited to FeLV- or FIV-infected cats, and do not include control groups. One double-blind study of a paramunity-inducing drug (Baypamun® HK) failed to show any difference compared with placebo in FeLV-infected cats (Block *et al.*, 1997). Experience with some of these medical or alternative treatments on a compassionate use basis by this author has not suggested particular benefit compared with standard regimens. Thus, the use of any of these treatments at this time is not recommended. For the welfare of the cat, extensive extractions should be considered if several attempts at medical and periodontal management have been unsuccessful.

Targeted feline immunospecific therapies hold promise (Harley *et al.*, 1999b), but feline-specific agents will be expensive and time-consuming to develop and test (Dunham, 1999).

For a description of the management of FeLV- and FIV-infected cats, see Chapters 23 and 24.

Extraction

The only consistently successful treatment of stomatitis (long-term resolution or control of oral inflammation in 80% of affected cats) is extensive (all premolar/molar teeth) or full-mouth extraction (Hennet, 1997). The great advantage of extensive extraction is that no further medical treatment is required in most cases, and there is no need for daily oral hygiene either. Domestic cats manage well without teeth; some still prefer dry food fed dry. Extraction of teeth of cats can be frustrating and challenging, particularly in cats with stomatitis, where the gingiva may be easily damaged but the attachment of the roots is still healthy. When multiple teeth in a single quadrant are to be extracted, the clinician should incise along the buccal gingival margins, flap back the gingiva, burr away alveolar bone on the buccal side to expose the root, separate the teeth into single root sections, and then elevate the roots using the small size dental elevators now available. Teeth of cats are small and fracture easily if mishandled during extraction. If a root does fracture, a fine root elevator may be used to loosen it, or additional buccal alveolar bone removed with the burr to expose the fragment. Atomisation (removal of a root fragment by burring it away within the alveolus) is no longer recommended by this author; in the mandible, the mandibular canal may be penetrated, resulting in significant haemorrhage. Once the teeth have been extracted bony projections are smoothed off with a burr, and the gingiva sutured across the alveoli (using 4-0 or 5-0 absorbable suture material in a simple interrupted pattern). The gingiva should be under no tension when sutured, to avoid dehiscence. Use of alveolectomy (removal of buccal bone to expose the root) is quicker and kinder to the tissue than attempting closed extraction with the use of elevators alone, and fracture and retention of root fragments is much less likely. An analgesic medication (e.g. butorphanol, 0.5 mg every 6–12 h) is required for 2–3 days after extraction, as the condition and procedure are both painful (Zetner *et al.*, 1996a).

Other forms of chronic oral inflammation or ulceration are described in Miscellaneous oral lesions (see below).

Feline odontoclastic resorptive lesions

Teeth of domestic cats often are destroyed by a process of active odontoclastic resorption. This is not caries (Schneck, 1976; von Schlup & Stich, 1982; Berger *et al.*, 1996). The lesion seen most typically is an irregular cavitation at the gingival margin (the neck of the tooth, where the enamel of the crown narrows to meet the cementum of the root; hence the commonly used but inappropriately narrow term 'neck lesion'). Localised soft-tissue inflammation or granulation covering the dental defect and extending onto the crown is commonly seen. The crown may be extensively missing or completely absent.

One or more feline odontoclastic resorptive lesions (FORLs) are found in about 50% of the domestic cat population aged 5 years or more (Reiter & Mendoza, 2002). The prevalence increases with increasing age, and many teeth may be affected in any one cat. FORLs most often affect the buccal surfaces of the premolar or lower first molar teeth at the gingival margin or neck of the tooth. Canine teeth also are affected, with lesions typically occurring in the roots, often in a tooth with a crown and gingival margin that appears to be normal. These lesions can occur anywhere on the surface of the root (Harvey *et al.*, 2000) and occasionally appear to be limited to the crown.

At the time of writing, the cause is not known, although very recent studies described in the next paragraph suggest a possible aetiology. The pathophysiology has been determined. Stem cells are attracted to a periodontal site and are transformed into clastic cells that attack cementum, erode into dentine and may go

on to undermine the enamel of the crowns in many cases (von Schlup & Stich, 1982; Okuda & Harvey, 1992a). Inflammatory cytokines that stimulate clastic activity are found in areas of active dental resorption (Okuda & Harvey, 1992b; Shigeyama *et al.*, 1996). A reparative process occurs in some lesions, resulting in 'bone-cementum tissue' (Okuda & Harvey, 1992a). Endodontic necrosis is not part of the pathophysiology of this condition (Okuda & Harvey, 1992a; Lommer & Verstraete, 2000a). Although plaque-induced inflammation is a possible cause of the stem-cell attraction, it is unclear whether the localised gingival inflammation commonly associated with FORLs results from accumulation of plaque in the irregular dental tissue at the gingival margin, was present coincidentally before development of the lesion, or is the cause. There are many root resorption lesions with normal gingival margins. A long-term study of a small number of cats suggested that there is poor correlation of plaque and calculus accumulation, development of gingival inflammation and subsequent development of FORLs (Harvey, 1999), and no correlation could be found between periodontitis and FORL in a detailed radiographic examination of 81 mandibles (Gengler *et al.*, 1995). Microfracture of the cemental surface (abfraction), perhaps as a result of occlusal stress, has been proposed (Burke *et al.*, 2000); this could be a cause of local inflammation and stem-cell attraction. Dietary abnormalities in affected cats (low calcium, low magnesium) have been described (Zetner 1990; Lund *et al.*, 1998), although the results of these studies are inconsistent. Abnormalities in factors controlling calcium homoeostasis are also under investigation (Reiter, 1998). A study that concluded that FIV infection increases the likelihood of development of FORLs (Hoffman-Lehmann *et al.*, 1998) in fact showed only that FIV and gingival inflammation are related, which is well known. Lack of access to the external environment has been identified as a risk factor (Scarlett *et al.*, 1999); evidence is mixed as to whether FORLs are less common in wild cats (Van Wessum *et al.*, 1992; Verstraete *et al.*, 1996).

Dental resorptive lesions are much more common in cats than in dogs or in humans, for unknown reasons. What is it that causes the cementum to be attacked, whereas in other species there is often very extensive resorption of alveolar bone (resulting from periodontal disease) adjacent to an intact cemental surface? This is another mystery of the feline inflamatory system waiting to be solved. Very recent studies suggest an answer to this question. Examining groups of cats with and without clinically and radiographically evident FORLs, Reiter (2003) found that serum calcitonin and 25-OH vitamin D were increased in the FORL group; examination of dietary information in these two groups of cats suggested that the vitamin D concentration was significantly greater in the affected cats, and vitamin D levels in many diets greatly exceed the maximum recommended concentration. Although these observations require confirmation by feeding trials in cats starting from a young age, Reiter (2003) noted the similarity between previously described lesions of vitamin D toxicosis in other species and the clinical condition in cats.

An extensive microscopic study by Gorrel and Larsson (2002), of feline teeth with no clinically or radiographically evident resorptive lesions, showed that the cementum of cats that did have resorptive lesions in other teeth was not normal. Both groups of cats had evidence of microscopic non-inflammatory resorption on the cementum. The resorption remained confined to the cementum and either had repaired or was repairing in the cats with no teeth with resorptive lesions in their mouths, whereas in the cats with teeth elsewhere in the mouth that had clinically or radiographically evident resorptive lesions, the microscopic resorption on macroscopically normal teeth was more severe and in many instances had contacted dentine and resulted in microscopic ankylosis. These results are compatible with the findings in the Reiter (2003) study.

Treatment

Although retaining a tooth in the mouth seems like a noble objective, studies of the results of restoration of FORLs (Lyon, 1992; Wiggs, 1993; Zetner & Steurer, 1995; Roes, 1996; Schweighart-Banzhaf & Benz, 1997), using a variety of restorative materials and techniques, have shown that the long-term likelihood of retaining an intact tooth is very poor. Retention of the restoration and no recurrence of the FORL typically is $<25\%$ in 2–3 years. The cause of failure is continued resorption, often around the restoration itself. If restoration is to be considered, dental radiographs are critical in treatment planning, because clinical examination alone often underestimates the extent of the lesion. No studies have identified specific circumstances under which restoration is more likely to be successful (e.g. extent of the lesion, particular teeth, types of restorative material or cavity preparation technique). Osteoplasty to leave the restored lesion in a permanently supragingival position has been proposed as a way of reducing the likelihood of further resorption (Okuda *et al.*, 1995). Since a second

anaesthesia may be necessary to extract a tooth that was previously restored, and teeth are not required for normal health or function of domestic cats, it seems that for the welfare of the cat, extraction is the logical treatment for gingivally involved lesions at this time. Where there is no gingival involvement (i.e. the lesion is entirely confined to the unexposed root), and is found only on radiographic examination, treatment is unnecessary in the absence of specific clinical signs of oral discomfort. The owner should be informed that additional lesions may develop in other teeth.

Recently, the first report of neodymium:yttrium aluminium garnet (Nd:YAG) laser treatment of FORLs appeared (Anthony, 2001). Five years after treatment, 79% of 71 teeth showed no further FORL development. Laser retreatment (without sedation) was required in some cats, and oral hygiene recommended at home consisted of daily brushing and rinsing with zinc-ascorbate gel. Whether the laser treatment, the extent of home care, or both, were critical to the much improved results in this report compared with restorative treatment is not known.

Prevention of the development of resorptive lesions in other teeth, or of further development of resorption around a restored lesion in an affected tooth, may be possible by using a biphosphonate medication such as alendronate (Harvey, 2001); further investigation is needed before this approach can be recommended clinically.

Extraction was described above. Although it has been generally accepted for many years that all of a tooth targeted for extraction must be removed, this has been questioned recently for FORLs. When there is well-attached root structure, in a tooth that has no deep periodontal pockets and no evidence clinically or radiographically of endodontic necrosis, and the gingiva surrounding the tooth is not severely inflamed, (except in the area of the lesion itself), crown amputation has been demonstrated to provide satisfactory long-term results (DuPont, 1995). This means reflecting the gingival tissue, burring away the tooth to below the level of the attachment and then suturing the gingiva over the remaining root segment. Some of these deliberately retained roots will be resorbed and some will simply stay in place for the life of the animal, without clinical consequence.

Mass lesions

Swellings in the mouth are quite common in cats. The site of the swelling is of primary importance.

Swellings of the jaws

Although neoplasms are unfortunately common in the mouths of cats, not every mass lesion in the jaw of cats is neoplastic (Kapatkin *et al.*, 1991). Some feline oral neoplasms appear more ulcerative than protuberant; biopsy is the only definitive way to rule out neoplasia.

Neoplasia

Although many types of neoplasm have been found in the jaws of cats, by far the most common type is squamous cell carcinoma (SCC) (Vos & van der Gaag, 1987). This can occur in two clinical forms, as either a protuberant mass or as an ulcerating mass. The ulcerative lesions will be surrounded by firm swelling of adjacent tissue, but the central ulcerated area may be packed with food and may appear superficially as a severe periodontal abscess with bone necrosis. When biopsying these unilateral ulcerative lesions, some viable tissue must be removed from the walls of the ulcerated area.

Gingival/jaw squamous cell carcinomas

These SCCs invade bone but metastasise late in the disease process, either to mandibular lymph nodes or to the lungs (Quigley & Leedale, 1983). Aggressive surgical treatment (unilateral mandibulectomy or partial bilateral mandibulectomy) can be curative for mandibular lesions, although often the lesion has grown beyond the point of manageable surgical resection, given the small size of the head in cats. Cats manage well following removal of the mandible on one side or partially on both, after a period of several days to adjust to the changed circumstances in their mouth; an oesophageal feeding tube may be indicated for several days if the cat is in poor condition before surgery. Maxillary lesions rarely are completely resectable. Other forms of treatment (radiation, potentiated radiation, photodynamic therapy, hyperthermia, chemotherapy) provide mixed results, similar at best to those achieved by radical surgery (Grier *et al.*, 1980; Roberts *et al.*, 1991; Hutson *et al.*, 1992; Mauldin *et al.*, 1992; Posterino-Reeves *et al.*, 1993).

Fibrosarcoma, osteosarcoma (Heldmann *et al.*, 2000), inductive fibroameloblastoma in young cats (Dubielzig *et al.*, 1974) and even less commonly other tumours also occur occasionally in the jaws of cats. Treatment options generally are very limited although, as noted above, cats tolerate removal of major sections of jaws well. Confusion exists over the exact nature and

appropriate nomenclature of the various proliferative lesions on the gingiva of cats (Dubielzig, 1982).

Gingival hyperplasia

This occurs occasionally in cats, much less commonly than in dogs. This generally affects all of the gingival tissue, rather than appearing as a distinct mass in only one area of the mouth. The hyperplastic tissue has an even surface colour unless traumatised by the teeth of the occluding jaw, and often an evenly rough surface. Drugs that can cause gingival hyperplasia in cats include diphenylhydantoin and cyclosporine. Treatment is surgical removal of the protuberant tissue to re-form a natural gingival contour; some gingiva must be left to form the protective cuff around the crown. Recurrence is common.

A normal feature of the mouth of the cat is a 0.5 cm diameter mass medial (lingual) to the lower first molar tooth, in the sublingual furrow between the jaw and the tongue; this is a small salivary gland. Also normal, and particularly prominent in male cats, are the jugae, the bony external protuberances housing the alveoli that contain the roots of the upper canine teeth; these remain following loss of the tooth, and may be prominent enough to be mistaken for an abnormal mass.

Swellings on and in the tongue

Masses on the dorsal surface of the tongue tend to be non-neoplastic in cats. Eosinophilic granuloma is the most common diagnosis. Typically, this is a firm raised lesion, often with a flat surface with small white spots or streaks. Diagnosis and treatment are discussed under Miscellaneous oral lesions (see below).

Far more serious are lesions that arise in the substance of the tongue, specifically SCC. This aggressive tumour arises typically in the root of the tongue or in the area of the frenulum. It may be embedded mainly within the tongue, with little or occasionally no apparent epithelial irregularity. It is firm. Clinical signs may not be obvious until the lesion is large, at which time the tongue may have lost much of its flexibility. Any firm mass in the tongue of a middle-aged or an old cat should be presumed to be an SCC until proven otherwise by biopsy. One possible differential diagnosis for a lesion in the frenulum is a granuloma resulting from a linear foreign body sawing its way through the epithelium. Surgery is not a practical treatment for lingual SCC, unless the tongue is to be completely removed and a permanent oesophagostomy or gastrostomy feeding access is created, because prehension and swallowing of food would be impossible. Radiation and chemotherapy regimens available to date have also proved to be ineffective.

Ranula

Saliva leaking into tissue from an injured gland or duct collects into a swelling. Depending on the location of the leak, the saliva may accumulate in the sublingual tissue as a ranula. The swelling is translucent and mucoid fluid is aspirated. Recurrence is likely following simple drainage; definitive treatment is removal of the mandibular and sublingual salivary glands on that side. Pitting oedema of the sublingual tissues as a result of a foreign body that has penetrated the ventral pharynx could be confused with a ranula, although a ranula is not oedematous.

Miscellaneous oral lesions

Eosinophilic granuloma

Single, and occasionally multiple, raised lesions occur on the dorsal surface of the tongue or on the hard palate. These lesions are a chronic inflammatory response of unknown cause, exacerbated or continued by the action of the tongue. Similar lesions are seen on the mucocutaneous junction of the lip, typically at the midline philtrum area, again associated with licking. They may have small irregular white areas visible on the surface, which are probably areas of dystrophic calcification. Usually, they can be diagnosed by cytological examination of a scraping, although some irregular eosinophilic granuloma lesions are similar to SCC in gross appearance; biopsy is recommended to differentiate them. Treatment is by injection of repository anti-inflammatory steroid medication into the mass (up to 2 mg triamcinolone initially, repeated at an increased dose 4 weeks later if necessary), or several weeks of oral prednisolone therapy (1–2 mg/kg daily). Lesions occasionally recur and can be retreated. Surgery, cryosurgery and radiation therapy have been used with moderate success, but rarely need to be considered because medical treatment is sufficient in almost all cases.

Endodontic periapical abscessation or fistulation

When a tooth is fractured, the pulp tissues are exposed and become necrotic. Necrotic fluid leaks

out through the apex to cause a periapical reaction. This may present as a mass in the jaw or as a fistula, typically opening onto the mucogingival junction or alveolar mucosa. The fractured tooth usually is obvious on inspection, and a dental radiograph shows a radiolucency centred on the apex of the involved tooth. Root canal therapy or extraction provides satisfactory treatment; the periapical swelling resolves once the inciting agent has been eliminated.

Oral trauma

Compared with dogs, cats tend to injure their maxilla, mandibular symphysis and/or their temporomandibular joint (TMJ), rather than fracture the body of the mandible. These injuries typically result from falling from a height. An uncomplicated mandibular symphyseal separation is held in correct alignment with a simple circlage wire; this is not a fracture, and the fixation should not be twisted maximally tight, as this will disrupt the fibrous healing that needs to take place.

TMJ injury may be a luxation (dorsocranially) or a fracture, or both. The fibrous articular disc may fold on itself, enlarging the joint space. The result is malocclusion, typically sufficient to cause the upper and lower canine teeth on the injured side to hit against each other when the cat attempts to close its mouth. Radiographs must be well-positioned and interpreted correctly to be of value. A luxation is reduced by forcefully closing the jaws together while a pencil is in position between the upper and lower premolar teeth on that side, until the condyle can slide into place. Condylar fractures cannot be surgically reduced in cats, and are best treated conservatively initially. Malocclusion resulting from maxillary fracture, or from TMJ condylar fracture or chronic luxation, can be managed by occlusal adjustment (reducing the height of one of the maloccluding teeth, or splitting the symphysis and placing it in fixation so as to permit 'normal' occlusion (Buchet & Boudrieau, 1999). If reluctance to open or close the mouth persists or worsens, condylectomy is performed, with excellent results provided that no sharp bony fragments remain to irritate the articular facet. A false joint forms.

Jaw fractures that require stabilisation can be held in fixation by using the canine teeth as fixation points, using dental composite materials (Zetner & Steurer, 1992; Bennett *et al.*, 1994). This avoids the need to invade the bone itself: the bone fragments typically are too small to permit the use of more common orthopaedic fixation techniques. Another benefit of dental fixation is that it avoids damage to the roots. Use of parapulpar pins to stabilise further the acid-etched composite fixation is unnecessary (Roecken & Gerlach, 1996).

Another injury sometimes seen in association with mandibular symphyseal separation and/or TMJ luxation/fracture is midline splitting of the hard palate; soft-tissue closure within 2–3 days of the injury usually is sufficient treatment. If a symptomatic longitudinal fistula occurs long term, carefully planned palatal flap surgery will successfully close the defect.

Tongue injuries include electric cord burns and lacerations. Both should be treated conservatively, using minimal or no débridement, and fresh laceration sutured. Linear foreign bodies can become caught beneath the tongue, and may saw their way deep into the frenulum. Removal of the foreign body is all that is necessary; it may not be visible unless the body of the tongue is pushed dorsally, allowing a clear view of the sublingual furrow.

Other oral injuries

Biting an electric cord also may cause necrosis of part of the palate, resulting in a fistula between the oral and nasal cavities. Once the initial injured tissue has healed to form a well-defined fistula, surgery or placement of a custom-made acrylic plug is necessary to close the fistula.

Autoimmune disease

Pemphigus vulgaris has been reported occasionally in cats. Generalised or randomly scattered blebs or ulcerations are seen on the palate and lining of the cheek, or on the mucocutaneous junction area of the lips. Lesions may also be found on other mucocutaneous junction or skin areas. Diagnosis is confirmed by immunofluorescence testing of a biopsy of the affected tissue. Treatment is prednisolone (see above).

Chronic palatal ulceration

This is seen occasionally, sometimes accompanied by severe haemorrhage and apparently unassociated with any other oral condition. Lesions are surrounded by normal palatal epithelium. The ulcerations may be round, oval or linear, single or multiple, and symmetrical or asymmetrical. Biopsy has been unrewarding and the cause is unknown. Very occasionally, the haemorrhage is sufficiently severe to necessitate ligation of the palatine artery on one or both sides.

Inherited and congenital abnormalities

In addition to occasional congenital palate defects (which can usually be closed using a well-planned and carefully performed surgical procedure), a wide variety of dental occlusal abnormalities is seen in cats. Some of these malocclusions are the result of bone length or bone width mismatch (such as are typically seen in severely brachycephalic cats in which the lower canine teeth irritate the upper lip) or tooth position abnormalities (such as the rostrally displaced upper canine teeth seen in some long-faced cats). Almost all of these 'abnormalities' are compatible with comfortable use of the mouth. Orthodontic treatment is indicated only if incapacitating malocclusion is present; extraction or crown shortening (partial pulpectomy) of affected teeth is a practical alternative to orthodontic movement.

Abnormalities of the structure of specific teeth also occur, ranging from absence of the tooth (and less often, impaction) to mis-shapen crowns and supernumerary roots. These conditions rarely require treatment.

Many dental treatments adapted from those used in humans and dogs are possible in cats. They are described in any of the current veterinary dental texts.

References

Anderson J.G. & Pedersen N.C. (1996) Characterization of T-lymphocyte subsets in cats with chronic lymphocytic plasmacytic stomatitis. *Proceedings of the Veterinary Dental Forum* **113**.

Anthony J. (2001) Use of a Nd:Yag laser for treatment of feline osteoclastic resorptive lesions. *J Am Anim Hosp Assoc* **37**, 17–20.

Bellows J. (1998) Homeopathic treatment for feline gingivitis. *Vet Forum*, 30 April 1998.

Bennett J.W., Kapatkin A.S. & Marretta S.M. (1994) Dental composite for the fixation of mandibular fractures and luxations in 11 cats and 6 dogs. *Vet Surg* **23**, 190–194.

Berger M., Shawalder P., Stich H. & Lussi A. (1996) Differentialdiagnose von Resorptiven Zahnekrankungen (FORL) und karies. *Schweiz Arch Tierheilkund* **138**, 546–551.

Block A., Hartmann K., Lutz H. & Kraft W. (1997) Plazebokontrollierte Doppelblindstudie uber die Wirksamkeit eines Paramunitatsinducers bei naturlich FeLV-infizierten Katzen. *Teriarzt Prax* **25**, 261–266.

Buchet M. & Boudrieau R.J. (1999) Correction of malocclusion secondary to maxillary impaction fractures using a mandibular symphyseal realignment in eight cats. *J Am Anim Hosp Assoc* **35**, 68–76.

Burke F.J.T., Johnston N., Wiggs R.B. & Hall A.F. (2000) An alternate hypothesis from veterinary science for the pathogenesis of non-carious cervical lesions. *Quintess Int* **31**, 475–482.

Carmichael D.T. (2000) Recent advances in small animal dentistry. www.IVIS.org/advances (accessed November 2000).

Clarke D.E. & Cameron A. (1998) Relationship between diet, dental calculus and periodontal disease in domestic and feral cats in Australia. *Aust Vet J* **76**, 690–693.

DeBowes L. (1996) T-lymphocytes in cats with chronic stomatitis. Presentation at the *Veterinary Dental Forum*, 1996.

DeBowes L.J., Mosier D., Logan E., *et al.* (1996) Association with periodontal disease and histologic lesions in multiple organs from 45 dogs. *J Vet Dent* **13**, 57–60.

Dubielzig R.R. (1982) Proliferative dental and gingival diseases of dogs and cats. *J Am Anim Hosp Assoc* **18**, 577–584.

Dubielzig R.R., Adams W.M. & Brodey R.S. (1974) Inductive fibroameloblastoma, an unusual dental tumor of young cats. *J Am Vet Med Assoc* **174**, 720–722.

Dunham S.P. (1999) Cytokines and anti-cytokine therapy: clinical potential for treatment of feline disease. *J Feline Med Surg* **1**, 7–14.

DuPont G. (1995) Crown amputation with intentional root retention for advanced feline resorptive lesions – a clinical study. *J Vet Dent* **12**, 9–13.

DuPont G. (1997) Understanding dental plaque: biofilm dynamics. *J Vet Dent* **14**, 91–94.

Eriksen T., Harvey C.E. & Venner M. (1992) Palliativ behandling af felin paradontal syndrom. *Dansk Vet* **75**, 429–431.

Gengler W., Dubielzig R. & Ramer J. (1995) Physical examination and radiographic analysis to detect dental and mandibular bone resorption in cats: a study of 81 cases from necropsy. *J Vet Dent* **12**, 97–100.

Goldstein G.S., King G. & Venner M. (1991) Radiation as adjunct therapy in treating plasmacytic lymphocytic stomatitis in cats. *Proceedings of the World Veterinary Dental Congress*.

Gorrel C. & Larsson A. (2002) Feline odontoclastic resorptive lesions: Unveiling the early lesion. *J Small Anim Pract* **43**, 482–488.

Gorrel C., Inskeep G. & Inskeep T. (1998) Benefits of a 'dental hygiene chew' on the periodontal health of cats. *J Vet Dent* **15**, 135–138.

Grier R.L., Brewer W.G. & Theilen G.N. (1980) Hyperthermic treatment of superficial tumors in cats and dogs. *J Am Vet Med Assoc* **177**, 227–233.

Hale F.A. & Anthony J.M. (1997) Prevention of hypothermia in cats during routine oral hygiene procedures. *Can Vet J* **38**, 297–299.

Harari J., Gustafson S. & Mienoth K. (1991) Dental bacteremia in cats. *Feline Pract* **19**, 27.

Hardie E.M., Spodnick G.J., Gilson S.D., *et al.* (1999) Tracheal rupture in cats: 16 cases. *J Am Vet Med Assoc* **214**, 508–512.

Harley R., Helps C.R., Harbour D.A., *et al.* (1999a) Cytokine mRNA expression in lesions in cats with chronic gingivstomatitis. *Clin Diag Lab Immunol* **6**, 471–478.

Harley R., Helps C.R., Gruffydd-Jones T.J., *et al.* (1999b) Clinical and immunological findings in feline chronic gingivstomatitis. *Proceedings of the British Veterinary Dental Association* pp. 2–6.

Harvey C.E. (1999) Longitudinal study of emergence of FORLs in cats. *Proceedings of the British Veterinary Dental Association*, Addendum.

Harvey C.E. (2001) Periodontal disease in cats – comparison with dogs. *Proceedings of the British Veterinary Dental Association*, Addendum, Birmingham, 2001.

Harvey C.E. (2003) Alendronate retards progression of feline odontoclastic responsive lesions. *Proc World Vet Dent Cong*, Kyoto, 2003.

Harvey C.E. & Campbell D. (1989) Neutrophil function in cats with chronic gingivostomatitis. *Proceedings of the Veterinary Dental Forum* pp. 12–13.

Harvey C.E., Hammond B.F. & Whitaker E.J. (1994) Is there an association between dental resorptive lesions and *Actinobacillus actionomycetemcomitans. Proceedings of the Veterinary Dental Forum* p. 48.

Harvey C.E., Orsini P., Mclahan C. & Schuster C. (2000) Mapping the central point of feline odontoclastic lesions. *Proceedings of the Veterinary Dental Forum* pp. 142–144.

Harvey C.E., Thornsberry C. & Miller B. (1995a) Subgingival bacteria: comparison of culture results in dogs and cats with gingivitis. *J Vet Dent* **12**, 147–150.

Harvey C.E., Thornsberry C., Miller B. & Shofer F.S. (1995b) Antimicrobial susceptibility of subgingival bacterial flora in cats with gingivitis. *J Vet Dent* **12**, 157–160.

Harvey C.E., Shofer F. & Laster L. (2001a) Prevalence of feline odontoclastic resorptive lesions. Review and additional data. *J Vet Dent* (submitted).

Harvey C.E., Shofer F. & Laster L. (2001b) Epidemiological study of periodontal disease in cats. *J Vet Dent* (submitted).

Heldmann E., Anderson M.A. & Wagner-Mann C. (2000) Feline osteosarcoma; 145 cases (1990–1995). *J Am Anim Hosp Assoc* **36**, 518–521.

Hennet P. (1991) Utilisation de la spiromycine et du metronidazole lors de malade paradontale chez le chien. *Rec Med Vet* **167**, 1029–1036.

Hennet P. (1997) Chronic gingivo-stomatitis in cats: long-term follow-up of 30 cases treated by dental extractions. *J Vet Dent* **14**, 15–21.

Hoffmann-Lehmann R., Berger M., Sigrist B., *et al.* (1998) Feline immunodeficiency virus infection leads to increased incidence of feline odontoclastic resorptive lesions. *Vet Immunol Immonopathol* **65**, 299–308.

Hutson C.A., Willauer C.C., Walder E.J., *et al.* (1992) Treatment of mandibular squamous cell carcinoma in cats by use of mandibulectomy and radiotherapy: seven cases (1987–1989). *J Am Vet Med Assoc* **201**, 777–781.

Kapatkin A.S., Marretta S.M., Patnaik A.K., *et al.* (1991) Mandibular swellings in cats: prospective study of 24 cats. *J Am Anim Hosp Assoc* **27**, 575–580.

Knowles J.O., Gaskell R.M., Gaskell C.J., *et al.* (1989) Prevalence of feline calicivirus, feline leukaemia virus and antibodies to FIV in cats with chronic stomatitis. *Vet Rec* **124**, 336–338.

Knowles J.O., McArdle F., Dawson S., *et al.* (1991) Studies on the role of feline calicivirus in chronic stomatitis in cats. *Vet Microbiol* **27**, 205–219.

Lommer M. & Verstraete F.J.M. (2000a) Prevalence of odontoclastic resorption lesions and periapical radiographic lucencies in cats; 265 cases (1995–1998). *J Am Vet Med Assoc* **217**, 1866–1869.

Lommer M.J., Verstraete F.J.M. & Terpak C.H. (2000b) Dental radiographic technique in cats. *Compendium of Continuing Education for the Practicing Veterinarian* **22**, 107–117.

Lommer M. & Verstraete F.J.M. (2001) Radiographic patterns of periodontitis in cats; 147 cases (1998–1999). *J Am Vet Med Assoc* **218**, 230–234.

Lund E.M. (1996) Preliminary data, National Companion Animal Study. Quoted in *J Vet Dent* **13**, 56.

Lund E.M., Bohacek L.K., Dahle J.L., *et al.* (1998) Prevalence and risk factors for odontoclastic resorptive lesions in cats. *J Am Vet Med Assoc* **212**, 392–395.

Lund E.M., Armstrong P.J., Kirk C.A., *et al.* (1999) Health status and population characteristics of dogs and cats examined at private veterinary practices in the United States. *J Am Vet Med Assoc* **214**, 1336–1341.

Lyon K. (1992) Subgingival odontoclastic resorptive lesions: classification, treatment and results in 58 cats. *Vet Clin North Am Small Anim Pract* **22**, 1417–1432.

Lyon K. (1994) Feline lymphoplasmacytic stomatitis associated with monoclonal gammopathy and Bence-Jones proteinuria. *J Vet Dent* **11**, 25–27.

Mallonnee D.H., Harvey C.E., Venner M. & Hammond B.F. (1988) Bacteriology of periodontal disease in the cat. *Arch Oral Biol* **33**, 677–683.

Mauldin G.N., Mauldin G.E. & Meleo K.A. (1992) Treatment of feline oral squamous cell carcinoma with radiation therapy alone or radiation therapy and hyperthermia. *Vet Cancer Soc Newslett* **16**, 4–5.

Mitchell S.L., McCarthy R., Rudloff E. & Pernell R.T. (2000) Tracheal rupture associated with intubation in cats: 20 cases (1996–1998). *J Am Vet Med Assoc* **216**, 1592–1595.

Norris J.M. & Love D.N. (1999) Associations among three feline *Porphyromonas* species from the gingival margin of cats during periodontal health and disease. *Vet Microbiol* **65**, 195–207.

Norris J.M., Packiarajah M.J.D., Malik R. & Love D.N. (1999) Associations among age, feline immunodeficiency viral status and periodontal disease in domestic cats in Australia. *Aust Vet Pract* **29**, 79–83.

Norris J.M. & Love D.N. (2000a) *In vitro* antimicrobial susceptibilities of three *Porphyromonas* spp. and *in vivo* responses in the oral cavity of cats to selected antimicrobial agents. *Aust Vet J* **78**, 533–537.

Norris J.M. & Love D.N. (2000b) Serum antibody responses of cats to soluble whole cell antigens of feline *Porphyromonas gingivalis. Vet Microbiol* **73**, 37–49.

Okuda A. & Harvey C.E. (1992a) Etiopathogenesis of dental resorptive lesions. *Vet Clin North Am Small Anim Clin* **22**, 1385–1404.

Okuda A. & Harvey C.E. (1992b) Immunohistochemical distribution of interleukins as possible stimulators of odontoclastic resorption activity in feline dental resorptive lesions. *Proceedings of the Veterinary Dental Forum* pp. 41–44.

Okuda A., Harvey C.E. & Asari M. (1995) Challenges in treatment of external odontoclastic resorptive lesions in cats. *Compendium of Continuing Education for the Practicing Veterinarian* **17**, 1461–1469.

Pedersen N.C. (1992) Inflammatory oral cavity diseases of the cat. *Vet Clin North Am Small Anim Pract* **22**, 1323–1346.

Pfeifer E.G., Kampfer M. & Neu H. (1988) Die behandlung der chronischen Gingivitis der Katze. *Prak Tierarzt* **2**, 29–32.

Posterino-Reeves N.C., Turrel J.W. & Withrow S.J. (1993) Oral squamous cell carcinoma in the cat. *J Am Anim Hosp Assoc* **29**, 438–441.

Poulet H., Brunet S., Soulier M., *et al.* (2000) Comparison between acute oral/respiratory and chronic stomatitis/gingivitis isolates of feline calicivirus: pathogenicity, antigenic profile and cross-neutralization studies. *Arch Virol* **145**, 243–261.

Quigley P.J. & Leedale L.H. (1983) Tumors involving bone in the domestic cat: a review of fifty-eight cases. *Vet Pathol* **20**, 670–686.

Reiter A. (2003) Calciotropic factors in feline odontoclastic lesions. *Proc Vet Dent Congress*, Kyoto, 2003.

Reiter A. & Mendoza K.A. (2002) Feline odontoclastic resorptive lesions. An unsolved enigma in veterinary dentistry. *Vet Clin North Am* **32**, 791–837.

Reubel G.H., Hoffmann D.E. & Pedersen N.C. (1992) Acute and chronic faucitis of domestic cats: a feline calicivirus-induced disease. *Vet Clin North Am Small Anim Pract* **22**, 1347–1360.

Richardson R.L. (1965) Dental calculi in the cat. *Arch Oral Biol* **10**, 245.

Roberts W.G., Klein M.K., Loomis M., *et al.* (1991) Photodynamic therapy of spontaneous cancers in felines, canines and snakes with chloroaluminum sulfonated phthalocyanine. *J Natl Cancer Inst* **83**, 18–23.

Roecken F.E. & Gerlach K.F. (1996) Die Verblockung der Ober- und Unterkiefercanini mit der Composite-Adhasivtechnik zur Behandlung von Kieferfrakturen bei der Katze. *Praktische Tierarzt* **77**, 712–722.

Roes F. (1996) Pathogenese, diagnostik und therapie bei 'neck lesions' der Katze unter Verwendung von Glas-Ionomer-Zementen. Thesis, Freie Universitat, Berlin.

Sato R., Osamu I., Tanaka Y., *et al.* (1996) Oral administration of bovine lactoferrin for treatment of intractable stomatitis in feline immunodeficiency virus positive and negative cats. *Am J Vet Res* **57**, 1443–1446.

Scarlett J.M. (1995) Data reported by IDEXX Laboratories, Westbrook, Maine, USA.

Scarlett J.M., Saidla J. & Hess J. (1999) Risk factors for odontoclastic resorptive lesions in cats. *J Am Anim Hosp Assoc* **35**, 188–192.

von Schlup D. & Stich H. (1982) Epidemiologische und morphologische untersuchungen am katzengebiss. II: Mittelung: Morphologische untersuchungen der 'neck lesions'. *Kleintier Prax* **27**, 179.

Schneck G.W. (1976) Neck lesions in teeth of cats. *Vet Rec* **99**, 100.

Schweigart-Banzhaf D. & Benz D. (1997) Resorptive lesions bei der katze. Eine klinische Untersuchung zur versorgung mit Dyract. *Kleintier Prax* **42**, 97–108.

Shigeyama Y., Grove T.K., Strayhorn C. & Somerman M.J. (1996) Expression of adhesion molecules during tooth resorption in feline teeth: a model system for aggressive osteoclastic activity. *J Dent Res* **75**, 1650–1657.

Sims T.J., Moncla B.J. & Page R.C. (1990) Serum antibody response to antigens of oral Gram-negative bacteria by cats with plasma-cell gingivitis. *J Dent Res* **69**, 877–882.

Slots J. (1998) Causal or casual relationship between periodontal infection and non-oral disease. *J Dent Res* **77**, 1764–1765.

Tenorio A.P., Franti C.E., Madewell B.R. & Pedersen N.C. (1991) Chronic oral infections of cats and their relationship to persistent oral carriage of feline calici-, immunodeficiency, or leukemia viruses. *Vet Immunol Immunopathol* **29**, 1–14.

Valdez M., Haines R., Riviere K.H., *et al.* (2000) Isolation of oral spirochetes from dogs and cats and provisional identification using polymerase chain reaction analysis specific for human plaque *Treponema* spp. *J Vet Dent* **17**, 23–26.

Van Wessum R., Harvey C.E. & Hennet P. (1992) Feline dental resorptive lesions: prevalence patterns. *Vet Clin North Am Small Anim Pract* **22**, 1405–1416.

Verstraete F.J.M., van Aarde R.J., Nieuwoudt B.A., *et al.* (1996) The dental pathology of feral cats on Marion Island. Part II: Periodontitis, external odontoclastic resorption lesions and mandibular thickening. *J Comp Pathol* **115**, 283–297.

Verstraete F.J.M., Kass P.H. & Terpak C.H. (1998) Diagnostic value of full-mouth radiography in cats. *Am J Vet Res* **59**, 692–695.

Vos J.H. & van der Gaag I. (1987) Canine and feline oral-pharyngeal tumours. *J Vet Med A* **34**, 420–427.

Watson A.D.J. (1994) Diet and periodontal disease in dogs and cats. *Aust Vet J* **71**, 313–318.

White S.D., Rosychuk R.A.W., Janik J.A., *et al.* (1992) Plasma cell stomatitis–pharyngitis in cats: 40 cases (1973–1991). *J Am Vet Med Assoc* **200**, 1377–1380.

Wiggs R.B. (1993) Presentation at the *Veterinary Dental Forum*, Auburn University, AL, USA.

Wiggs R.B., Lobprise H.B., Mattews J.L. & Gulliya K.S. (1993) Effects of preactivated MC540 in the treatment of lymphocytic plasmacytic stomatitis in feline leukemia virus and feline immunodeficiency virus positive cats. *J Vet Dent* **10**, 9–13.

Yamamoto J.K., Hansen H., Ho E.W., *et al.* (1989) Epidemiologic and clinical aspects of feline immunodeficiency virus infection in cats from the continental United States and Canada and possible modes of transmission. *J Am Vet Med Assoc* **194**, 213–220.

Zetner K. (1990) Neck lesions bei der Katze: Diagnostich – atiologisch Untersuchungen uber zussamenhange zuschen Roentgenbefund und Futterung. *Waltham Report* **30**, 15–23.

Zetner K. (1992) Treatment of jaw fractures in small animals with parapulpar pin composite bridges. *Vet Clin North Am Small Anim Pract* **22**, 1461–1467.

Zetner K. & Steurer I. (1992) Influence of dry food on the development of feline neck lesions. *J Vet Dent* **9**, 4–6.

Zetner K. & Steurer I. (1995) Long-term results of restoration of feline resorptive lesions with microglass composite. *J Vet Dent* **12**, 15–17.

Zetner K. & Thiemann G. (1993) The antimicrobial effectiveness of clindamycin in diseases of the oral cavity. *J Vet Dent* **10**, 6–9.

Zetner K., Kampfer P., Lutz H. & Harvey C.E. (1993) Comparative immunological and virological studies of chronic oral diseases in cats. *Eur J Companion Anim Pract* **3**, 57–61.

Zetner K., Rausch W.D., Weissensteiner J., *et al.* (1996a) Schmerzbeseitigung nach Zahnbehandlung bei der Katze. *Prakt Tierarzt* **77**, 678–682.

Zetner K., Bigler B., Kolbl S., *et al.* (1996b) Die Bedeuting von IgE im Serum von Katzen mit chronsicher Gingititis/ Parodontitis. *Prakt Tierarzt* **77**, 188–194.

Zetner K., Steurer I., Kampfer P.H. & Maier H. (1998) Malatonin und chronisch-entzundliche erkrankungen in der Mundhohle bei Katzen. *Praktische Tierarzt* **79**, 410–416.

Chapter 16

THE GASTROINTESTINAL TRACT

C.G. Ruaux, J.M. Steiner and D.A. Williams

Introduction

The gastrointestinal tract is the point of entry of all metabolic energy into the animal and represents a major interface between the organism and the external environment. The processes of digestion, absorption and elimination of food are highly complex, involving the co-ordinated regulation of mechanical and chemical degradation of food, enzymic processing, mucosal absorption and transport of nutrients, and the regulation of transmucosal electrolyte flux and water flow.

The correct functioning of the gastrointestinal tract relies on the presence and function of other organs such as the liver and exocrine pancreas; however, this chapter discusses the clinical approach to the hollow organs of digestion.

The hallmark signs of gastrointestinal disease are vomiting or regurgitation for the upper tract and diarrhoea or constipation for the lower tract. In the early stages of gastrointestinal disease clinical signs of disease may be vague. The fastidious nature of cats complicates the approach to gastrointestinal disease. Clinical signs of gastrointestinal disease may pass unnoticed by many cat owners until the disease process is well advanced.

The cat is an obligate carnivore. The minimum requirement for dietary protein in cats is approximately 19% of the daily caloric intake. This differs markedly from dogs and humans. Dogs have a minimum requirement of approximately 4% protein of the daily caloric intake. The cat is primarily a hunter, rather than showing the opportunistic omnivore/scavenging feeding behaviour of dogs. The digestive tract of cats has evolved to handle a diet different to dogs, and areas of gastrointestinal anatomy, physiology and pathology differ markedly between cats and dogs.

The oesophagus

Dysphagia, regurgitation and vomiting

Owners often describe an animal as 'vomiting' in any situation involving the ejection of food. True vomiting is the ejection of gastric contents and is a hallmark sign of gastric disease. In constrast, oesophageal disorders are associated with regurgitation or dysphagia. There is a marked difference in approach to animals with isolated oesophageal disease versus gastric disease, and the differential diagnoses considered for oesophageal disorders often differ from those considered for gastric disease.

Selected differences between vomiting and regurgitation are outlined in Table 16.1. True vomiting is a highly co-ordinated reflex involving the synchronous contraction of abdominal and diaphragmatic muscles, culminating in a final productive contraction with ejection of gastric content. While this is true of

Table 16.1 Characteristics of vomiting and regurgitation in cats that may aid in the differentiation of vomiting and regurgitation in the clinical history

Characteristic	Vomiting	Regurgitation
Premonitory nausea	Common	Absent
Abdominal 'heaves'	Common	Absent
Formation of tubular cast	Occasional	Common
Bile staining	Common	Absent
pH	Acidic	Neutral
Reconsumption of ejected material	Rare/absent	Rare

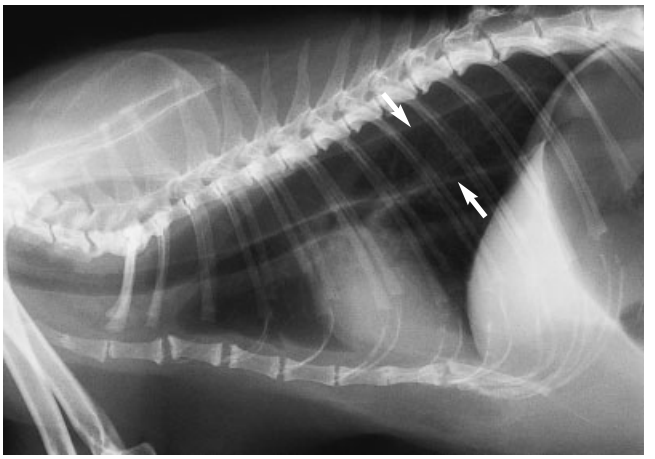

Figure 16.1 Plain thoracic radiograph of megaoesophagus in a cat. Note the distended, gas-filled oesophagus, particularly visible in the caudal thorax (arrows). The stomach contains excess free gas secondary to aerophagia.

all species that can vomit, the cat has a distinctive premonitory retching behaviour, which is usually easy to identify on questioning of the owner. Regurgitation is a more passive process entirely due to muscular action of the oesophagus. There are usually no premonitory signs such as retching. The muscles of the abdomen and diaphragm are not involved in pure regurgitation.

The nature of the ejected material often aids differentiation between vomiting and regurgitation. Material regurgitated from the oesophagus has not reached the stomach and will not have been exposed to acid or the proteolytic enzymes of the stomach. Regurgitated material is undigested, and the pH of the material is near neutral, while food that had an appreciable residence time in the stomach has an acid pH, appearing partially degraded.

In dogs, the formation of material into a tubular cast may be suggestive of oesophageal disease. The vomiting behaviour of cats, with a rapid withdrawal of the head as vomiting occurs, often results in the deposition of tubular or partly formed vomitus. The appearance of a cast is consequently not as suggestive of oesophageal disease in cats as it is in dogs. Isolated disease of the oesophagus is rare in the cat.

Clinical examination and evaluation of the oesophagus

Much of the oesophagus is not available for direct examination or palpation. Complete and thorough physical examination is important in cases of suspected oesophageal disease to identify signs of systemic illness that may be complicating the clinical presentation of the cat. Weight loss, poor growth and respiratory signs secondary to aspiration pneumonia may all be observed. While these signs are not specific, they may increase a clinician's suspicion of oesophageal disease.

Once oesophageal disease is suspected, further assessment of the oesophagus may proceed by direct endoscopic examination or radiography.

Oesophageal radiography

The use of deep sedation should be avoided during the radiographic examination of the feline oesophagus. Deep sedation can lead to relaxation of oesophageal musculature, yielding false-positive findings of decreased oesophageal motility or increased oesophageal gas.

Plain thoracic radiographs commonly allow detection of radiopaque oesophageal foreign bodies, the presence of free oesophageal gas (Figure 16.1) and the presence of developmental anomalies such as oesophageal diverticula.

Static contrast studies may demonstrate the presence of oesophageal diverticula, radiolucent foreign bodies and segmental disorders of oesophageal motility. If an oesophageal motility disorder is suspected, functional assessment of the oesophagus may be performed using contrast radiographic techniques, which are reviewed in detail elsewhere. The presence of annular smooth muscle in the distal oesophagus generates a herringbone pattern in the oesophageal mucosa, which may be visible after administration of liquid contrast media.

Oesophageal endoscopy

The oesophagus is readily examined endoscopically, and suitable endoscopic equipment is now available in many veterinary practices, reducing the use of radiographic contrast studies. The oesophagus is disten-sible and the linear nature of the oesophageal lumen makes the use of rigid endoscopic equipment feasible. Ideally, the endoscope should have air insufflation, saline flush and a biopsy channel to allow mucosal biopsy or the retrieval of foreign bodies. For simple visualisation of the oesophageal mucosa, however, less complex endoscopes without multiple channels are practicable.

The normal oesophageal mucosa in the cat is a light salmon-pink color. The normal mucosa is thrown up into annular ridges in the distal oesophagus (Plate 16.1).

Endoscopic examination allows direct assessment of the oesophageal mucosa for friability, colour and bleeding. Foreign bodies may be visualised and their removal may be feasible. Caution should be exercised when attempting the removal of sharp, bony foreign bodies to avoid oesophageal perforation or severe damage to the oesophageal mucosa.

Diseases of the oesophagus

Disorders of oesophageal motility

Megaoesophagus

Severe, diffuse loss of normal oesophageal motility results in megaoesophagus, the oesophagus losing normal muscular tone, becoming flaccid and highly distensible. Megaoesophagus may be primary or secondary, with secondary disease more commonly encountered in veterinary medicine. Most cases of primary megaoesophagus are idiopathic, reflecting a diffuse loss of normal neuromuscular function in the oesophagus. Congenital megaoesophagus, typically due to congenital neuromyopathy, anatomical anomalies or a variety of lysosomal storage diseases, may occasionally be encountered. Clinical signs of regurgitation and poor growth are usually first noticed at the time of weaning. Most cases of both idiopathic primary and secondary megaoesophagus occur in adult cats.

Although isolated primary and secondary megaoesophagus are rare in cats, megaoesophagus as a component of feline dysautonomia has been important in feline medicine in recent years. Feline dysautonomia is described in more detail in Chapter 7.

Secondary megaoesophagus has been described arising from numerous primary diseases in dogs, but most of these diseases are rare in cats, and insufficient cases have been described to define the typical involvement of the oesophagus in cats affected by these diseases. Unusual diseases that can be associated with megaoesophagus and may need to be ruled out in the clinical approach to isolated megaoesophagus in cats are listed in Table 16.2.

Table 16.2 Diseases occasionally associated with secondary megaoesophagus

Disease	Diagnostic assessment
Systemic lupus erythematosus	Antinuclear antibodies, presence of RBC phagocytosis
Hypoadrenocorticism	ACTH stimulation test, alterations in serum electrolytes
Oesophageal hiatal hernia	Contrast radiography ± endoscopy
Lead toxicity	Presence of nucleated RBCs, blood lead levels
Oesophagitis	Endoscopy

RBC: red blood cell; ACTH: adrenocorticotropic hormone.

Oesophageal diverticula

Diverticula are sac-like, flaccid evaginations of one or more layers of the oesophagus, lacking in normal motility. Oesophageal diverticula are rarely encountered in the cat. Oesophageal diverticula may be either primary, due to congenital disorders of oesophageal anatomy, or secondary to other oesophageal diseases.

The clinical signs and symptoms of oesophageal diverticula are related to impaction of foodstuffs within the diverticulum. There may be local ulceration of the oesophageal mucosa, and typical clinical signs are regurgitation, dysphagia, reduced appetite and weight loss. Dyspnoea may be noted if the diverticulum impinges upon the trachea or major bronchi. Regurgitation of food from the diverticulum may occur at any time after feeding.

Diagnosis of oesophageal diverticula is usually established with radiographic studies. Plain radiography may demonstrate an abnormal soft-tissue density within the thorax. Retention of barium mixed with food or fluid confirms the diagnosis.

Management of oesophageal diverticula is usually only supportive, and is similar to the management of oesophagitis. Large diverticula may require resection of redundant tissue to achieve adequate control of clinical signs.

Oesophageal strictures

Oesophageal stricture formation may occur secondary to either severe mucosal trauma or ulceration resulting from gastro-oesophageal reflux, which occurs most frequently as a complication of general anaesthesia. Subsequent fibrosis and shrinkage reduces the diameter of the oesophagus and prohibits dilatation to allow passage of food. If oesophageal strictures are longstanding, a proximal dilatation of the oesophagus may develop, with subsequent clinical signs of dysphagia and regurgitation.

Development of an oesophageal stricture requires damage to extend into the submucosa and muscularis. Healing of these deeper layers involves fibroblastic proliferation, with subsequent scar shrinkage and remodelling leading to the development of the stricture.

Primary oesophageal strictures most commonly occur as a result of developmental anomalies of the great vessels leading from the heart. Persistent right aortic arch has been described in the cat. The classical clinical presentation of persistent right aortic arch involves onset of regurgitation and poor growth soon after weaning. Some cats tolerate the presence of the persistent right aortic arch into adulthood, and show signs only after impaction of the oesophagus with a foreign body. Radiography will usually demonstrate oesophageal dilatation proximal to the retained vessel and stricture. Surgical resection of the constricting structure is required. Longstanding oesophageal dilatation may be a sequela to persistent right aortic arch, requiring further long-term medical management after surgery.

Oesophagitis

Oesophageal inflammation is usually due to exposure of the oesophageal mucosa to irritants or caustic substances. Gastro-oesophageal reflux is the most common cause of oesophagitis in cats. Rarely, oesophageal inflammation may be caused by calicivirus infection or by exposure to irritants on the coat, which are ingested during grooming.

Oesophagitis commonly occurs secondary to oesophageal motility disorders. Oesophageal hypomotility allows pooling of food, fluids and any gastric reflux, prolonging the exposure of the mucosa to irritation. Oesophagitis may become self-perpetuating as inflammation of the oesophagus is associated with reduced tone in the lower oesophageal sphincter, which may then promote gastro-oesophageal reflux and further inflammation.

Clinical signs of oesophagitis are typical of oesophageal disease in general, including dysphagia, inappetance, regurgitation and ptyalism (excessive salivation). Cats with oesophagitis often resent palpation of the cervical portion of the oesophagus, and may demonstrate exaggerated swallowing in response to this palpation. Diagnosis of oesophagitis is typic-ally made during endoscopic examination. The oesophageal mucosa is typically reddened and friable, and there may be patches of mucosal haemorrhage, erosion and ulceration. The mucosa may be more easily damaged by contact with the endoscope than normal. As oesophagitis is a common sequela of oesophageal motility disorders, it is usually warranted to treat for oesophagitis as part of the therapy of these disorders.

Oesophageal foreign bodies

Various foreign bodies have been described in the oesophagus of the cat, and are commonly acquired during play behaviour. String, bone, trichobezoars (hairballs), needles and fishhooks may all be seen, depending on the environment of the cat. In some areas, seasonal grasses may be consumed by the cat and may lodge in the oesophagus and retropharynx. Clinical signs of oesophageal foreign bodies are those of oesophageal disease in general, but are notable for their acute nature. Retching, gagging, ptyalism and pawing at the mouth may be observed. Affected cats are anorexic, and may be dyspnoeic or febrile if aspiration pneumonia has developed.

The diagnosis of oesophageal foreign body is usually established from radiography. Contrast radiography may be necessary to distinguish trichobezoars from soft-tissue masses, and some objects may only be visible during endoscopy. Thin, linear foreign bodies such as string and grasses usually require direct examination, and it is important to examine closely the oral cavity and base of the tongue for string foreign bodies. Grasses may be partially regurgitated into the retropharynx, and are often best observed by gentle retraction of the soft palate under anaesthesia. It is important to diagnose and remove oesophageal foreign bodies rapidly, as prolonged impaction of foreign bodies and the subsequent mucosal damage and oesophagitis are risk factors for stricture formation.

Oesophageal neoplasia

The oesophagus is an uncommon site of primary neoplastic disease in the cat, accounting for less than

0.5% of primary neoplasms in this species. Squamous cell carcinoma (SCC), usually seen in older cats, is the most common oesophageal neoplasm. SCCs are typically observed in the distal oesophagus. Cats present with a history of progressive anorexia, dysphagia and regurgitation, weight loss and depression. Plain radiographs usually demonstrate a soft-tissue mass in the distal oesophagus, while contrast studies demonstrate mucosal filling defects. Confirmation of the diagnosis requires endoscopic evaluation (Plate 16.2) and biopsy; the prognosis is poor to grave.

Compression of the oesophagus by mediastinal lymphoma or thymoma will result in dysphagia and regurgitation. Mediastinal lymphoma is usually seen in younger cats, and may be accompanied by dyspnoea secondary to pleural effusion and findings of an incompressible cranial thorax. Diagnosis is based on radiographic findings of a soft-tissue mass in the cranial thorax and cytological analysis of pleural fluid (see also Chapter 23).

Medical therapy of oesophageal disease

While the diseases of the oesophagus are varied in their aetiologies, the clinical signs and resulting abnormal-ities requiring management are common among most of the diseases. If the primary cause of oesophageal disease has been established, specific therapy may be indicated.

The therapy of oesophageal disease requires consideration of oesophageal motility, oesophageal mucosal inflammation and protection of the oesophageal mucosa from further damage. All oesophageal diseases typically involve compromise in all three areas, with the relative importance varying from disease to disease. Drugs that are used for the treatment of oesophageal disease in cats are outlined in Table 16.3.

Motility disorders

Oesophageal motility is commonly compromised in oesophageal disease. Reduced muscular activity of the oesophagus compromises the ability of the oeso-phagus to deliver food boluses to the stomach.

Oesophageal motility may be assisted by simple mechanical means in many cases. Some animals are able to handle liquids better than solids, so liquefaction of the diet may allow food to enter the stomach. Normal canned cat foods, mixed with approximately one-third volume of warm water and thoroughly processed in a typical food processor, can often be given to cats with mild oesophageal motility disorders.

As cats are relatively small animals, feeding of the diet from an elevated posture is usually straightforward, with one person holding the cat over a shoulder while another administers small boluses of food. The cat should be held over the shoulder after feeding for approximately 30 min, to give the maximum gravitational assistance to food passage into the stomach.

The feline oesophagus is composed of smooth-muscle layers, and is more amenable to pharmacological manipulation than the canine oesophagus, which contains a large proportion of skeletal muscle. Metoclopramide may be useful in the management of decreased oesophageal motility in cats (see Table 16.3). Other anticholinergic agents such as bethanechol may be useful in rare cases, but should be used with care.

Oesophagitis

Oesophageal motility disorders will commonly induce a secondary oesophagitis, and oesophagitis itself may contribute to decreased oesophageal motility. Mild oesophagitis, such as that induced by uncomplicated removal of foreign bodies, will usually resolve with 24–36 h of oesophageal rest. Severe oesophagitis will require complete oesophageal rest for several days and pharmacological intervention (see Table 16.3). If severe oesophagitis is present it may be necessary to place a gastrostomy tube to provide nutritional support during oesophageal healing. The gastrostomy tube may be passed endoscopically or surgically, or by blind, non-endoscopic techniques.

The inflamed oesophageal mucosa is more delicate than normal, and is susceptible to physical damage as well as reflux damage. Mucosal protection may be valuable in many cases of oesophagitis, particularly if pre-existing ulcers or mucosal abrasions have been documented endoscopically. Sucralfate, a compound of sucrose and aluminium, forms a gel that binds to ulcerated and abraded gastrointestinal mucosa, protecting the mucosa from further damage.

Oesophagitis secondary to gastro-oesophageal reflux may be controlled by reduction of gastric acid output. Since damaged oesophageal mucosa is highly susceptible to acid damage, successful resolution of oesophageal mucosal disease often requires more aggressive suppression of gastric acid output than is necessary for the therapy of gastric disease. In many cases of oesophagitis due to oesophageal reflux it is necessary to use proton pump inhibitors to allow healing of the oesophageal mucosa.

Table 16.3 Drugs used for the treatment of gastrointestinal disease in cats

Indication	Drug	Mode of action	Dose range
Motility modification	Metoclopramide	Not fully defined, probably procholinergic, increases oesophageal peristalsis and lowers oesophageal sphincter tone	0.2–0.5 mg/kg p.o. 30 min before a meal
	Bethanechol	Cholinergic agonist	2.5–5.0 mg per cat p.o. twice daily
Anti-inflammatory	Prednisolone Prednisone	Glucocorticoid	0.5–2.0 mg/kg p.o. twice daily, withdraw with gradual taper
	Dexamethasone	Glucocorticoid	0.1–0.5 mg/kg s.c. or i.m. once daily
Anti-neoplastic and immunosuppressive	Azathioprine	Purine antimetabolite, has a glucocorticoid-sparing effect, allows lower doses to achieve similar effect	0.3 mg/kg every other day, monitor white cell counts for leucopenia. Has a narrow therapeutic margin in cats
	Chlorambucil	Cell-cycle non-specific DNA alkylating agent, useful for both severe inflammation and and lymphosarcoma	Use in combination with prednisone/prednisolone at 15 mg/m^2 once daily for 4–5 days, repeated every 3 weeks. Monitor white cell counts for leucopenia
Mucosal protection	Sucralfate	Sucrose/aluminium gel, couples to ulcerated/abraded tissues, forms physical barrier	300–500 mg ($\frac{1}{3}$–$\frac{1}{2}$ tablet) crushed to form a suspension if necessary, p.o. twice daily Administer 30–60 min after antacid medications
	Misoprostol	Prostaglandin E_2 analogue, may improve gastric mucosal barrier function	3.0–5.0 μg/kg p.o. twice daily
Antacids	Cimetidine	Histamine H_2-receptor blocker	5–10 mg/kg p.o. three times daily, can be given by slow i.v. infusion
	Omeprazole	Proton pump inhibitor	0.7 mg/kg p.o. once daily
Antibacterial	Amoxycillin	β-Lactam antibiotic	20 mg/kg twice daily as part of triple therapy for GSOs
	Metronidazole	Heterocyclic antibiotic, effective against fastidious anaerobes and protozoa	25 mg/kg twice daily for giardiasis 10–20 mg/kg twice daily as part of triple therapy for GSOs or as adjunctive immunomodulator in IBD Many cats find oral metronidazole offensive
	Enrofloxacin	Fluoroquinolone antibiotic	5 mg/kg i.v. once daily for systemic/septic salmonellosis
	Clarithromycin	Macrolide antibiotic	7.5 mg/kg p.o. twice daily as part of triple therapy for GSOs
Anthelminthic	Fenbendazole		50 mg/kg p.o. once daily for 3 days for giardiasis

GSO: gastric spiral organism; IBD: inflammatory bowel disease.

Oesophageal strictures

Oesophageal strictures are typically treated by dilatation of the affected area. Two main techniques have been described, bougienage and balloon-catheter dilatation. Bougienage involves the passage of solid rods of increasing diameter through the stricture, gradually stretching and breaking down the fibrous tissue of the stricture. Bougienage applies shearing forces to the affected oesophageal segment, which may predispose to further tearing of the mucosa/submucosa and relapse of the stricture. Balloon-catheter dilatation utilises radially applied forces to stretch the stricture, which is believed by some authors to decrease the recurrence of strictures. Postoperative use of mucosal protectants and corticosteroids is indicated to reduce scarring and recurrence of the stricture, regardless of the method used. Strictures will often require repeated dilatations at 2–3 week intervals to obtain complete resolution. Dilatation of oesophageal strictures has a high potential for complications and requires careful postoperative management. Surgical resection of stenotic lesions is rarely successful unless the abnormal segment is located in the cervical region or distal thoracic region, when an abdominal approach is feasible.

The stomach

The stomach is a muscular and glandular organ, representing the first major organ of digestion in the cat, and has numerous functions. The muscular action of the stomach causes mechanical breakdown of food boluses to progressively smaller particles before duodenal digestion and absorption. Meanwhile, the glandular portion of the stomach produces gastric acid, a family of proteinase precursors, the pepsinogens, and gastric lipase.

Protection of the gastric mucosa from the damaging effects of gastric acid, proteinases and lipase relies on the gastric mucosal barrier, which is made up of a layer of mucus, the epithelial cell membranes and a specialised local circulation. Rapid epithelial cell turnover, secretion of bicarbonate ions, rapid clearance of hydrogen ions that have back-diffused into the mucosa and the synthesis of prostaglandins are important in the regulation and normal function of the gastric mucosal barrier.

Gastric acid production and motility are controlled by paracrine and endocrine mechanisms and the autonomic nervous system (Figure 16.2). Disorders of acid production, loss of the protective mucous layer, disturbed gastric motility or dysfunction of the autonomic nervous system may all be associated with a risk of gastric mucosal damage.

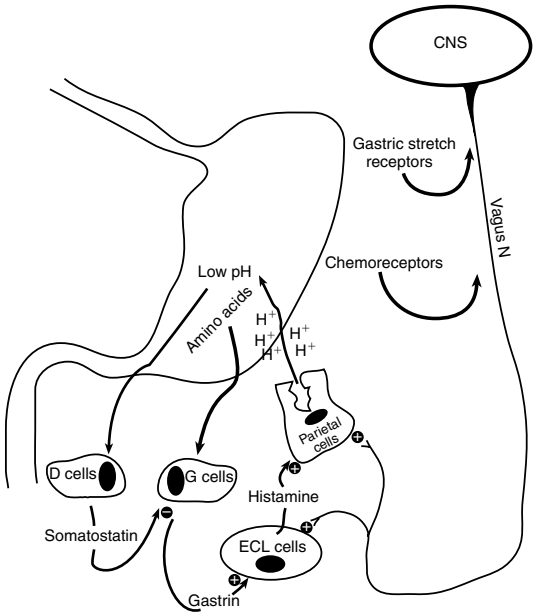

Figure 16.2 Diagrammatic representation of endocrine, paracrine and neural control mechanisms regulating gastric acid production. The presence of food, particularly amino acids, in the antrum and pylorus stimulates G cells to produce gastrin, up-regulating the production of histamine by enterochromaffin-like (ECL) cells. Stomach fill is detected by stretch receptors, and the presence of food by chemoreceptors, which signal the CNS via vagal afferents to increase cholinergic output. Parietal cells secrete hydrogen ions into the stomach lumen under the influence of histamine, gastrin and cholinergic input from the vagus nerve. Low pH in the antrum and pylorus stimulates D cells to produce somatostatin, which down-regulates G cell gastrin production.

The hallmark sign of gastric disease, particularly gastric mucosal disease, is vomiting. Vomiting, typically caused by acute disease in younger cats or chronic disease in mature animals, is an extremely common presenting complaint in clinical practice. Although vomiting is a hallmark sign of gastric disease, it is not specific to gastric disease, and numerous other medical disorders are associated with vomiting in the cat. It is important to consider other extragastric and extragastrointestinal disease processes in cats presented for vomiting.

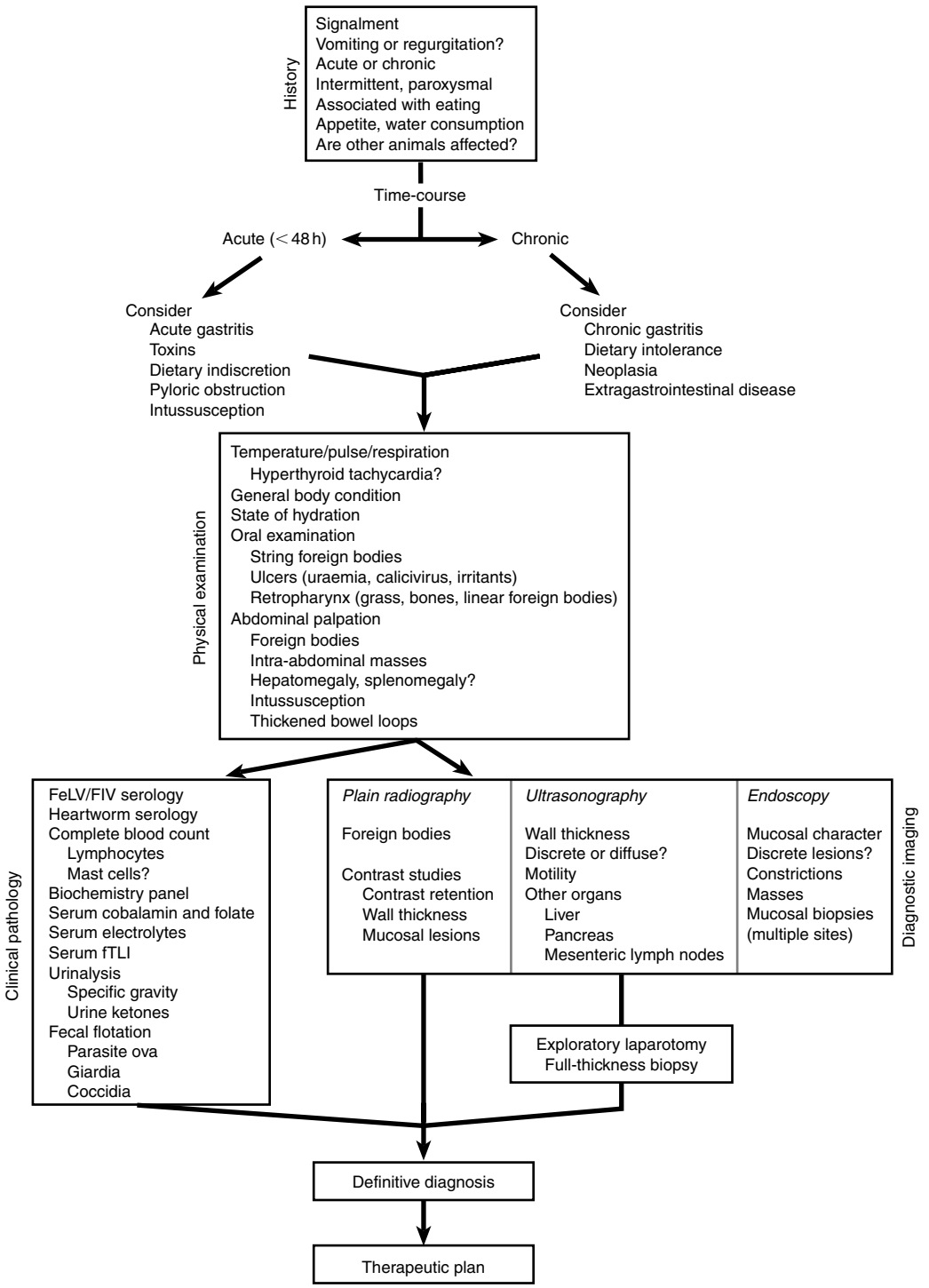

Figure 16.3 Algorithm detailing a rational clinical approach to the vomiting cat. FeLV: feline leukaemia virus; FIV: feline immunodeficiency virus; fTLI: feline trypsin-like immunoreactivity.

Vomiting is a complex, centrally mediated sequence of reflex events, culminating in the forceful ejection of gastric contents. The vomiting reflex is mediated by the chemoreceptor trigger zone (CRTZ), located in the brainstem at the base of the lateral ventricle. The CRTZ is distinguished from most other areas of central nervous system (CNS) tissue by the absence of the blood–brain barrier. The CRTZ is thus exposed to circulating substances, such as toxins and mediators released from the gut or other organs, which may alter the threshold of the vomiting reflex.

A clinical approach to the vomiting cat

An algorithm detailing clinical considerations in the approach to a vomiting cat is illustrated in Figure 16.3. It is important to make an early distinction between acute and chronic vomiting, as the aetiologies of the two are typically different. In general, acute vomiting will have been occurring for less than a week, and cats with acute vomiting disorders are often presented within the first 24–48 h of the disease. Acute vomiting typically results from a single, isolated insult to the stomach, small intestine or pancreas. Chronic vomiting will often have been present for a week or more and tends to be more intermittent in character.

Many cases of acute vomiting in cats are self-limiting and resolve with conservative therapy. Chronic vomiting requires a definitive diagnosis of the underlying disease process to allow the development of an effective therapeutic plan. Many owners (and, presumably, cats) become frustrated by ongoing conservative treatment of chronic vomiting, particularly if each episode is treated as an isolated incident of acute vomiting. Young cats are more commonly presented with infectious, parasitic and toxic causes of acute vomiting (Table 16.4).

Most acutely vomiting cats are anorectic, while chronically vomiting cats typically have a variable appetite. Important information in the history includes the type and quantity of food typically eaten, history of recent changes in diet or appetite, and history of recent changes in the environment of the cat. Depending on the age of the residences in the area of the practice, or prior use of local land, consideration should be given to the possibility of environmental exposure to toxins such as lead, mercury and pesticides. Acute exposure to large amounts of lead paint dust can cause an acute onset of vomiting and diarrhoea in some cats.

The presence of diarrhoea in combination with vomiting, and the timing of onset of the two symptoms, may shed light on possible aetiologies. If vomiting is observed first, followed by diarrhoea, it is suggestive of an initial insult to the upper gastrointestinal tract with subsequent effects on the more distal gastrointestinal tract. This is commonly encountered

Table 16.4 Potential causes of vomiting in cats, categorised by age

Young cats	Mature cats	Old cats
Dietary	Gastrointestinal parasites	Chronic renal failure
Indiscretion	Gastritis	Gastric tumours
Sudden diet change	Pancreatitis	Hyperthyroidism
Overeating	Gastric tumours	Pancreatitis
Gastritis	Enteritis	Enteritis
Ingestion of grass or other plants	Inflammatory bowel disease	Inflammatory bowel disease
	Intestinal tumours	Megacolon
	Toxicoses (drug side-effects?)	Feline infectious peritonitis
Infectious disease	Gastric outflow obstruction	Gastric outflow obstruction
Feline enteritis	Foreign body	Drugs or toxins
Feline infectious peritonitis	Trichobezoars	Heartworm disease (in endemic areas)
Coronavirus	Peritonitis	
Gastrointestinal parasites	Liver disease	
Foreign body	Hyperthyroidism	
Toys	Heartworm disease (in endemic areas)	
String	Chronic renal failure	
Toxicoses		
Enteritis		

Modified from Burrows (1996), data reproduced with permission.

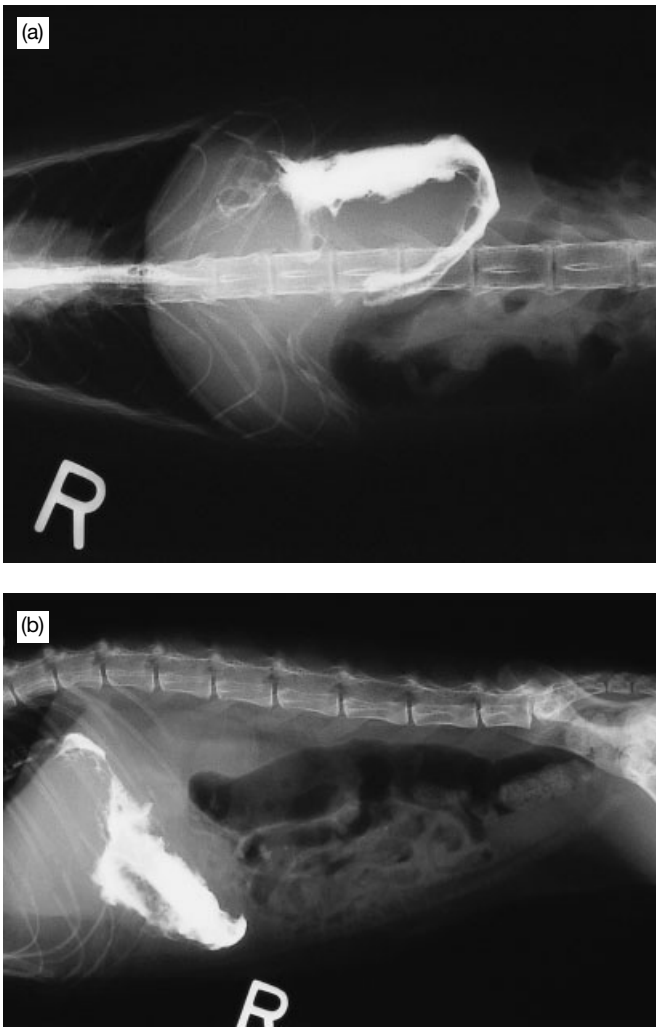

Figure 16.4 (a) Dorsoventral and (b) lateral positive-contrast radiographs of the stomach in a cat with gastric neoplastic masses. Note the filling defects and irregular retention of constrast in the mucosa, suggestive of mucosal disease and mucosal or intramural masses. The final diagnosis was lymphosarcoma of the gastric wall (see also Plate 16.5).

in hunting or scavenging cats, presenting with a history of acute vomiting and inappetance followed by diarrhoea. Physical examination and plain radiography may reveal skeletal remains in the small intestine, presumably the remains of prey animals or carcasses scavenged by the cat. If diarrhoea precedes chronic vomiting, it suggests a distal gastrointestinal disease, with vomiting as a secondary symptom.

Physical examination should be thorough and methodical, including oral examination, abdominal palpation and thoracic auscultation. Frequently, clinical signs of underlying disease processes will be detected on physical examination. Oral examination may reveal ulceration of the mucous membranes and uraemic halitosis, or the presence of linear foreign bodies trapped around the tongue base. It is usually difficult to visualise entrapped string or wool foreign bodies in a cat without deep sedation or anaesthesia.

Abdominal palpation is often unrewarding in cats with acute vomiting, except when large foreign bodies or intussusceptions are detected. Abdominal palpation may reveal masses, changes in size and character of other organs such as the liver, spleen and kidneys, or thickening of small intestine in chronically vomiting cats. Another potential cause of secondary vomiting in cats, which is usually readily detected on palpation of the abdomen, is constipation or megacolon, as discussed in a later section.

Consideration of history and physical examination findings allows the clinician to decide whether the cat is presenting with acute or chronic vomiting. Cats with acute vomiting are often managed symptomati-

Table 16.5 Gastric emptying times of a variety of radiopaque markers in cats

Marker type	Total gastric emptying time (h)
Liquid barium	0.25–2.0
Food/barium mixture	4–17
Small BIPS (1.5 mm diameter)	6–27

Adapted from Lamb (1999).
BIPS: barium-impregnated polyethylene spheres.

cally, or surgically if indicated (i.e. foreign bodies, intussusceptions). Cats with chronic vomiting will require add-itional assessment to establish a definitive diagnosis.

Further diagnostic work-up of chronically vomiting cats should include serology for feline leukaemia virus (FeLV) and feline immunodeficiency virus (FIV) status, heartworm status in areas with endemic canine heartworm, complete blood count with differential white cell count, and assessment of blood urea, creatinine and liver enzymes. Urinalysis should be performed, particularly assessing the urine concentrating ability and the presence of ketonuria, as diabetic/ketoacidotic cats will often vomit. In cases with suspected hepatic disease, preprandial and postprandial serum bile acid concentrations should be measured.

Measurement of serum concentrations of cobalamin, folate and feline trypsin-like immunoreactivity is useful in many chronically vomiting cats, screening for the presence of more diffuse gastrointestinal diseases.

Clinical examination and evaluation of the stomach

The normal stomach is almost entirely inaccessible to routine physical examination by palpation, as it is located directly caudal to the liver and generally enclosed within the abdominal portion of the ribcage. Some foreign bodies, gastric neoplastic masses or a stomach heavily laden with food may be detectable on palpation. In the majority of cases of suspected chronic gastric disease, however, the examination and evaluation of the stomach proceed through any or all of abdominal radiography, endoscopy and ultrasonography.

Gastric radiography

Plain abdominal radiographs allow assessment of the positioning of the stomach and other abdominal organs. Radiopaque gastric foreign bodies are usually readily detected on plain radiography.

Radiographic studies using contrast media yield information regarding gastric mucosal thickness, the presence of masses or radiolucent foreign bodies (Figure 16.4). The increasing availability of endoscopic equipment has largely superseded the use of contrast studies of the upper gastrointestinal tract of the cat.

Numerous methods for the assessment of gastric motility which are feasible for use in general clinical practice have been described in cats. These include the use of barium mixed with a test meal, barium-impregnated polyethylene spheres (BIPS; Arnolds Veterinary Products) and 3-mm-long sections of radiopaque polyethylene tubing. The gold standard method of assessing gastric emptying is scintigraphy, requiring the use of radioisotopes and subsequent isolation of the animal. Scintigraphy is only performed at specialist referral centres or in a research setting. Table 16.5 summarises the reported gastric emptying times for various radiopaque markers in cats. The total emptying times vary widely and it is important to consider the expected emptying time for the marker being used when assessing gastric outflow.

Gastric endoscopy

Endoscopic evaluation of the stomach can yield a large amount of information when assessing gastric disease in cats. Endoscopy allows direct visualisation of gastric ulcers and intraluminal masses, biopsy of both diseased and normal gastric mucosa, and the retrieval of foreign bodies. Endoscopic equipment for the examination of the stomach should allow control of the endoscope tip in three dimensions; flexible fibre-optic endoscopes of 12 mm diameter or less with an integrated biopsy channel are ideal.

The endoscopic appearance of normal gastric mucosa in the cat is illustrated in Plate 16.3, while the appearance of the gastric mucosa in a cat with severe gastritis is illustrated in Plate 16.4. It is important to visualise the entire gastric mucosa when conducting an endoscopic examination, and to biopsy apparently normal gastric mucosa in addition to any areas of grossly visible pathology. The sensitivity of endoscopic examination in detecting mucosal changes consistent with inflammatory bowel disease in the stomach or small intestine was only 50% in one study (Baez *et al.*, 1999). Normal appearance of the mucosal surface on endoscopic examination does not rule out inflammatory or infiltrative disease of the stomach. It is important to biopsy several sites in the stomach and upper

duodenum during the examination, regardless of the appearance of the mucosa on visual examination.

Gastric ultrasonography

Ultrasonography of the cranial abdomen can yield useful information in cats with gastric disease, if proper preparation has taken place. The best conditions for ultrasonographic examination of the stomach occur in a fasted animal, with the stomach filled with water. Failure to distend the stomach slightly may produce artefactual thickening of the stomach wall, and visualisation of folded mucosa may produce the appearance of masses. The presence of gas in the stomach will also interfere with effective imaging. Although ultrasonographic examination and detection of gastric disease has been described in cats, a greater yield of information will usually be obtained from endoscopic examination and biopsy.

Gastric mucosal permeability testing

Assessment of gastric mucosal permeability may be a valuable diagnostic tool in the work-up of gastric diseases in cats. This approach is based on the administration of a marker compound that only permeates the gastric mucosa, then assessing the recovery of the marker in urine or serum following administration. The disaccharide sucrose can be used to measure gastric mucosal permeability in cats. Sucrose in its native form can only be absorbed from the stomach, as it is immediately cleaved to glucose and fructose on entry to the duodenum. An increase in urinary recovery of sucrose is evidence of increased gastric mucosal permeability, as may occur with gastritis, gastric ulceration and inflammatory bowel disease (IBD) of the stomach. At the time of writing, the utility of this technique for the diagnosis of gastric diseases in cats is being assessed in the authors' laboratory.

Diseases of the stomach

Gastritis

The history and presentation of gastritis in cats may be acute or chronic. Of the two, chronic gastritis is the more important clinically, acute gastritis being relatively uncommon in adult cats. With the exception of hunting and scavenging cats, acute gastritis due to dietary indiscretion is much less common in cats than dogs. Kittens, however, are not infrequently presented with a history of the acute onset of vomiting. The differential diagnoses of acute vomiting in kittens are outlined in Table 16.4. The diagnosis of acute gastritis is usually made by consideration of the history, and ruling out other causes of vomiting in the patient.

Chronic gastritis is an important cause of chronic vomiting in adult and elderly cats, and may occur as an isolated primary disease process, a component of more generalised gastrointestinal disease such as IBD, or secondary to other chronic disease processes.

History and physical examination findings in cats with chronic gastritis are often vague and non-specific. Vomiting is a common presenting complaint in cats with gastritis; however, many cats present with infrequent vomiting, inappetance or anorexia. Gastritis impairs gastric motility, which may result in vomiting of virtually undigested food some hours after eating. In some cats with longstanding gastritis, vomiting behaviour and premonitory signs may be subtle, making it difficult to distinguish vomiting from regurgitation in these cases.

Clinical suspicion of chronic gastritis is based on ruling out other causes of chronic vomiting and inappetance. Definitive diagnosis of chronic gastritis is based on histopathological examination of gastric mucosal biopsies. Various methods of histopathological description and grading of the severity of gastritis have been described. The correlation between endoscopic appearance and histopathological grade in gastric biopsy specimens is frequently poor. Correlations between severity of clinical signs, histopathological grading and response to therapy are also poor.

Most cases of chronic primary gastritis in cats are idiopathic. The pathophysiology of chronic inflammatory disease in the gastrointestinal tract is not well understood. Presumably, there is an underlying defect in immune system regulation and modulation of inflammatory mediators. Dietary intolerance, allergies, autoimmune disease and repeated exposure to dietary and bacterial antigens may all be involved in the inception and progression of chronic gastritis.

Trichobezoars

Trichobezoars, or hairballs, are commonly encountered gastric foreign bodies in cats. While accumulation of excessive hair in the stomach is pathological, the normal grooming behaviour of cats invariably involves consumption of large amounts of hair, suggesting that the accumulation of hair in the stomach is due more to disturbed gastric function or motility than to the excessive consumption of hair. Cats with trichobezoars are commonly presented with chronic

vomiting, which is typically attributed to the presence of the trichobezoar. Gastric biposies often show evidence of lymphocytic/plasmacytic gastritis in cats with trichobezoars. As chronic gastritis will interfere with normal gastric motility, many trichobezoars may be secondary to chronic gastritis. The formation of trichobezoars in severely affected cats may be greatly reduced by anti-inflammatory and antacid therapy, or by feeding fibre-rich hairball-control diets.

Helicobacter *and other gastric spiral organisms*

It is now generally accepted in human gastroenterology that a large proportion (90% or more in some estimates) of cases of gastritis and gastric ulcer disease is attributable to infection with the spiral microorganism *Helicobacter pylori*. With this observation has come an increasing interest in the presence and possible role of *Helicobacter* species and other gastric spiral organisms (GSOs) in gastrointestinal disease of companion animals. The actual role of GSOs in gastrointestinal disease of cats is far from clear, although experimental infection does cause gastric inflammation. The presence of GSOs as part of the normal flora of the stomach in humans, cats, dogs and rodents has been well known to histopathologists since the late nineteenth century. There was no significant difference in frequency of detection of GSOs in cats with IBD compared with normal controls (Yamasaki *et al.*, 1998). This does not, however, rule out GSOs as pathogenic organisms in gastrointestinal disease of cats. Although it is impossible to determine from histopathological examination whether GSOs are pathogenic or not, the response to antibacterial therapy of some cats with chronic gastritis suggests that, in some cases, GSOs at least contribute to the disease. Cats can be asymptomatically infected with *H. pylori*; this is likely to be an anthropozoonosis, that is, infection of the cat is more likely to derive from the owner than vice versa. Infected cats do not realistically represent a health risk to their owners.

Gastric ulcer disease

Gastric ulcers are the result of damage to the gastric mucosae, followed by perpetuation of the damage in underlying submucosa and muscularis layers caused by exposure to gastric acid and pepsins. Primary gastric ulcer disease is relatively uncommon in the cat.

Ulcer disease may arise from excess gastric acid production. This may be observed as a paraneoplastic syndrome in cats with mast cell tumours or systemic mastocytosis, due to excessive histamine release from the neoplastic mast cells. Zollinger–Ellison syndrome, hypergastrinaemia secondary to gastrinoma with subsequent gastric hyperacidity and ulcerative disease, has also been reported in cats. This disease is apparently rare, with only three cases described in the literature.

Gastric neoplastic masses may become ulcerated (Plate 16.5) and the appearance of ulceration can complicate endoscopic examination and diagnosis. It is important to biopsy the edge of ulcerative lesions in the stomach to rule out gastric neoplasia.

Gastric motility disorders

Although gastric motility disorders undoubtedly occur in cats, the relative rarity of the facilities necessary to assess and diagnose accurately gastric motility dis-orders in veterinary medicine is reflected in the infrequent reporting of these disorders. Gastric motility disorders associated with prominent clinical signs are usually associated with delayed or impaired gastric emptying, and the clinical signs are vomiting of either undigested or partially digested food some time after eating. While excessively rapid gastric emptying is also a gastric motility disorder, the consequences of rapid gastric emptying are usually compensated by the small and large intestine, and do not usually result in clin-ical signs.

Gastric motility disorders will arise secondary to chronic gastritis, and chronic motility disorders will result in a secondary gastritis due to increased mucosal contact with food, all of which can complicate the diagnosis of the underlying cause of the disease. The clinical signs of primary motility disorders often mimic those of chronic gastritis.

A definitive diagnosis of gastric motility disorders requires facilities that are not usually available to the typical veterinary practice; however, plain abdominal radiographs and contrast studies may give evidence of decreased gastric emptying and increase the suspicion of a primary gastric motility disorder. A simple rule of thumb is that a meal containing half the daily calorific allowance of the cat should be completely emptied from the stomach within 10–12 h of feeding. If retention of food is noted beyond 12 h, with strictly enforced fasting, gastric emptying is probably delayed and disorders associated with delayed gastric emptying should be considered.

Most disorders resulting in delayed gastric emptying result from either functional or anatomical dis-

orders of the pylorus or antrum. Hypertrophy of the antral mucosa has been reported in cats (Dennis *et al.*, 1987). Pyloric dysfunction with no visible anatomical lesions has been described in Siamese cats (Pearson *et al.*, 1974). Delayed gastric emptying may also be associated with metabolic disorders such as diabetes mellitus, hypokalaemia, uraemia and inflammatory disease of the abdominal organs such as pancreatitis or peritonitis.

If a primary gastric motility disorder is suspected, pharmacological manipulation of gastric motility may be worthwhile. Response to therapy retrospectively supports the provisional diagnosis.

Gastric neoplasia

The stomach is an uncommon site of primary neoplasia in the cat, accounting for less than 2% of all primary neoplasms in this species. Clinical signs of gastric neoplasia are vague and non-specific, and the disease is typically well progressed at the time of diagnosis. Typical clinical signs of gastric neoplasia include inappetance, weight loss, chronic vomiting of grad-ually increasing frequency or severity, and occasional haematemesis. The most common gastric neoplasm of cats is gastric lymphoma, while the stomach is the least frequent site of gastrointestinal adenocarcinoma in the cat.

The prognosis for most gastric neoplastic lesions is poor to grave, as the disease is usually extensive at the time of diagnosis, making surgical resection difficult or impossible. Treatment of alimentary lymphoma involving the stomach may be attempted with chemotherapy and surgical debulking of extensive masses. Alimentary lymphoma is less susceptible to chemotherapy than other forms of lymphoma (see also Chapter 3).

Gastric foreign bodies

Cats, by virtue of their more fastidious dietary habits, are presented with gastric foreign bodies far less frequently than dogs, but this remains an important differential diagnosis in the assessment of acute vomiting in the cat.

The stomach normally breaks down solid food to particles of less than 2 mm diameter, before emptying into the duodenum. Larger, indigestible or acid-resistant objects tend to remain in the stomach until the digestible matter has been processed. Objects that have a small enough diameter to enter the small intestine are cleared from the stomach by a series of 'house- keeping' contractions during the inter-digestive period.

If an indigestible object enters the small intestine, it may pass through the intestine to the colon and rectum and be passed in faeces, or it may lodge at some point to become an intestinal or, less commonly, a rectal foreign body.

Objects that are too large to pass through the pylorus tend to be retained in the stomach. In this position they may cause acute pyloric obstruction. The continued presence of the foreign body is also an irritant that will result in mucosal inflammation and ulceration.

The clinical signs of gastric foreign bodies are usually an acute onset of vomiting, anorexia, lethargy and, in some cases, polydipsia and abdominal pain. Haematemesis may be observed if the foreign body has damaged the mucosa.

In some cases, the cat will be presented with a history that includes the owner observing the cat eating the foreign body, or noticing the absence of a toy or another small item. Some foreign bodies can remain *in situ* for prolonged periods, causing only occasional vomiting or anorexia.

Clinical biochemistry and haematology are usually unrewarding. Some animals will demonstrate mild hyponatraemia, hypochloraemia and hypokalaemia as a consequence of vomiting. In these cases there is usually a history of severe or persistent vomiting and these electrolyte abnormalities are not unexpected.

Foreign bodies may be palpable on clinical examination, but this is not a reliable finding and the diagnosis is typically made radiographically or endoscopically. Plain radiographs are often normal, unless the foreign body is very large or radiodense, or of a distinctive shape. Contrast radiographic techniques often reveal filling defects in the stomach, or possibly the retention of contrast material by a fibrous or porous foreign body after liquid contrast has emptied from the stomach.

Endoscopic retrieval of foreign bodies may be attempted following observation of the foreign body either directly or via radiography. Alternatively, surgical removal at gastrotomy surgery may be required. It is prudent to radiograph the patient just before surgery, to confirm that the gastric foreign body is still within the stomach.

Gastric parasites

Parasitism of the stomach is relatively rare in cats. Several species of nematode have been described infesting the stomachs of domestic cats, mainly in tropical areas, but the total number of reports of

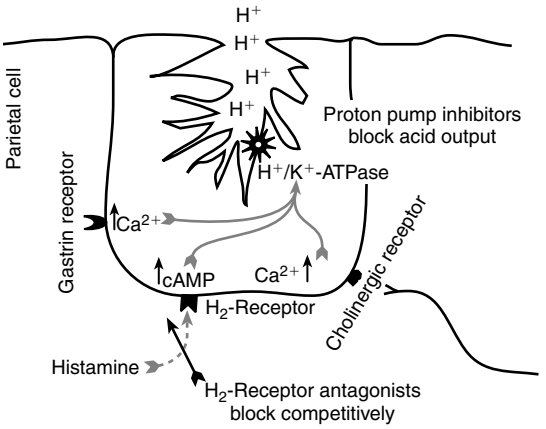

Figure 16.5 Diagrammatic representation of the modes of action of antacid medication in the suppression of gastric acid production by parietal cells. Histamine H_2-receptor blockers competitively inhibit the receptor, decreasing but not eliminating cyclic adenosine monophosphate (cAMP) release in the parietal cell. Proton pump inhibitors block proton release non-competitively, and are more effective than the histamine receptor blockers at reducing gastric acid production.

these nematodes is low. In most cases, the cat is an aberrant host for these nematodes. Infestation may be associated with clinical signs such as chronic vomiting and weight loss; however, many infestations are asymptomatic. Many of the available broad-spectrum anthelmintics are effective against these parasites.

Of the gastric nematode parasites reported in cats, *Ollulanus tricupsis* may be the most important clinically, and may well be underdiagnosed in cats presenting with chronic vomiting and/or weight loss. *Ollulanus tricuspis* is a very small worm, less than 1 mm in length, and is not readily observed during gastric endoscopy. Neither eggs nor infective larvae are passed in faeces, and diagnosis requires microscopic exam-ination of gastric biopsies or fresh vomitus, using either a Baermann concentration technique or direct examination of smears. Transmission of this parasite is via a direct oral–oral route. Cats become infected through contact with or consumption of vomitus containing the infective third stage larvae. *Ollulanus tricuspis* is most typically a problem of catteries, or in stray or feral cat populations. Single pet cats, receiving regular prophylactic anthelmintics, are unlikely to develop disease as a result of this nematode.

General principles of the medical therapy of gastric disease

The stomach produces several substances that are potentially damaging to its own mucosa, including gastric acid and proteinases. Medical therapy of gastric disease will typically involve the use of antacid medications, gastric mucosal protectants and agents to modify gastric motility.

Regulation of gastric acid production

In general, pharmacological control of gastric acidity is exerted via one of two drug classes, histamine H_2-receptor blockers such as cimetidine or ranitidine, or proton pump inhibitors such as omeprazole (see Table 16.3). The mode of action, and resulting potency with respect to inhibition of gastric acid production, differ markedly between these two classes of drugs.

Histamine H_2-receptor blockers are competitive inhibitors of the receptor, and act to decrease the production of cyclic adenosine monophosphate (cAMP) which acts as a secondary messenger within the parietal cell (Figure 16.5). cAMP within the cytoplasm triggers a signal cascade, which culminates in activation of the H^+/K^+-ATPase pump. cAMP acts in combination with intracellular calcium: cytosolic concentrations of calcium increase as a result of cholinergic activity of the autonomic nervous system and direct action of gastrin on parietal cell receptors. As H_2-receptor blockers act competitively, they never completely abolish histamine-mediated increases in intracellular cAMP, and cannot completely eliminate gastric acid production.

H_2-receptor blockers differ in their relative potency. In the dog cimetidine exerts a maximal reduction in acid production of approximately 75%, with duration of action of approximately 5 h (Daly *et al.*, 1980). Ranitidine is a more potent inhibitor of histamine-mediated gastric acid production, with maximal reduction of approximately 90% in the dog. Similar data are not available in the cat.

Proton pump inhibitors, as the name implies, inhibit the H^+/K^+-ATPase proton pump. As this is the final stage in gastric acid secretion, the relative efficacy of proton pump inhibitors is much greater than that of H_2-receptor blockers. These drugs are non-competitive inhibitors of the proton pump; it is possible to abolish gastric acid production completely with proton pump inhibitors.

The gastric mucosa is remarkably resistant to acid damage, and in many cases of isolated gastric disease

the moderate reductions in gastric acidity afforded by H_2-receptor blockers are sufficient to allow healing. When ulceration is severe, or there is concurrent oesophageal ulceration, it is usually necessary to use a proton pump inhibitor to allow healing.

Mucosal protectants

In most cases of acute gastritis the disease is self-limiting and does not involve significant damage to the mucosa. In cases with gastric ulceration or erosions, however, the gastric mucosa needs to be protected from further damage.

Sucralfate, an aluminium salt of sucrose octasulfate, affords good protection of exposed or damaged mucosa in the distal oesophagus, stomach and duodenum. This compound forms a gel on exposure to acidic conditions, which binds strongly to damaged mucosa in the stomach, reducing access of gastric acid and pepsins to the ulcerated tissues. Sucralfate may also bind bile acids and pepsins directly, and may stimulate the production of beneficial prostaglandins in the gastric mucosa.

Sucralfate must be administered orally and some cats find this medication unpalatable. It is a potent binder of some drugs and careful consideration of the timing of administration relative to other medications must be made. Sucralfate will reduce the uptake of most H_2-receptor blockers by 10–30% and also reduces the absorption of fluoroquinolones. Although sucralfate requires an acid environment for activity, it is not necessary for the stomach to be at physiological pH, and mildly acid conditions are sufficient to allow sucralfate to become active. To avoid a loss of efficacy of H_2-receptor blockers when used in combination with sucralfate, the receptor blocker should be administered first, followed by sucralfate 30–60 min later.

Prostaglandin analogues

Certain endogenous prostaglandins, particularly pros-taglandin E_2, are important regulators of gastric mucous production. The use of non-specific cyclooxygenase inhibitors, such as non-steroidal anti-inflammatory drugs (NSAIDs) and corticosteroids, may be associated with decreased production of these beneficial prostaglandins and reduced function of the gastric mucosal barrier. This can leave the stomach prone to ulceration, and complicates the use of these drugs in some cases. Misoprostol is a prostaglandin E_2 analogue which stimulates gastric mucous production and may be useful in the therapy of gastropathies secondary to NSAID use, and in the management of chronic gastric ulceration.

Medical therapy for specific gastric diseases

Acute gastritis

Acute gastritis is the result of an isolated insult to the gastric mucosa, with subsequent vomiting and fluid losses. Acute gastritis is most commonly encountered in kittens and younger cats. The history is usually one of acute-onset vomiting, nausea or inappetance, and possibly polydipsia or lethargy. Often, by the time the cat is presented to a veterinarian the vomiting has abated. Clinical examination is often unremarkable. A thorough examination is important, however, to screen for other conditions or signs of systemic disease that may result in acute-onset vomiting. Differential diagnoses that are particularly relevant in the age group most commonly presented with acute gastritis include foreign bodies, intussusception and infectious gastrointestinal diseases.

In most cases clinical biochemistry and haematology are unrewarding, as it is unusual for uncomplicated acute gastritis to produce significant biochemical abnormalities. Assessment of blood urea nitrogen, glucose, total protein and packed cell volume (PCV) is useful in most cases to screen for dehydration or hypovolaemia, manifesting as an increased packed cell volume and total protein, and in more severe cases an increase in blood urea nitrogen. It is possible to obtain all of the above information in a matter of minutes at comparatively low cost and from a very small quantity of blood.

If no specific cause for the acute gastritis is discovered on examination, the management of acute gastritis is supportive or symptomatic in nature. The most important element of therapy in most cases of acute gastritis is gastric rest, allowing the inflammation to resolve and the mucosa to heal. Gastric rest, achieved by giving nothing by mouth, is typically applied for 24 h, followed by the gradual reintroduction of water, then bland food fed in small amounts, and finally a return to the normal diet if there is no subsequent vomiting. If vomiting persists after presentation, and after the beginning of gastric rest, this typically indicates a more serious underlying disease process such as gastric foreign body or intussusception, and warrants a more aggressive investigation.

In general, with no evidence of metabolic compromise, acute gastritis resolves without drug intervention. If PCV and total protein are increased, parenteral replacement of fluid deficits and maintenance on polyionic crystalloid fluids are worthwhile.

There is no evidence of any benefit from the administration of broad-spectrum antibiotics to uncompli-

cated cases of acute gastritis. Antiemetic drugs may be useful in some cases, although these are usually reserved for cases with incessant or incapacitating vomiting, and are used to control vomiting during further diagnostic assessment and the formulation of a logical therapeutic plan.

Chronic gastritis

Chronic gastritis, which may be either primary or secondary to other disease processes, is the most common cause of chronic vomiting in adult cats. The approach to chronic gastritis requires more emphasis on the medical evaluation of the patient and arrival at a definitive diagnosis wherever possible. Chronic gastritis commonly coexists with inflammation of the small intestine.

Most cases of isolated chronic gastritis in cats are idiopathic. The diagnosis is established by exclusion of other disorders associated with chronic vomiting and histopathological examination of gastric mucosal biopsies. Endoscopic examination and mucosal biopsy are very useful in the medical work-up of chronic gastritis in cats. Endoscopy yields information on the presence of gastric ulceration, erosions or masses. Endoscopically obtained mucosal biopsies establish the predominant cell type involved in idiopathic gastritis and can be used to rule out lymphoma.

Mild, relatively superficial gastritis will typically respond to antacid medications such as cimetidine or rantitidine in combination with frequent small meals. It is often useful to change the diet to a novel protein source, using either a homemade diet or one of the numerous proprietary formulations available. Sucralfate can be useful in some cases.

Moderate or severe lymphocytic/plasmacytic gastritis usually requires some form of anti-inflammatory or immunomodulatory therapy, in addition to antacid medications and sucralfate. Prednisolone/prednisone is the usual first line of anti-inflammatory medication in these cats. Assuming that the gastric mucosa has been fully assessed, either by endoscopic examination and biopsy or by surgical biopsy, early aggressive glucocorticoid therapy usually gives the best treatment results. Doses of 1–2 mg/kg twice daily are a typical starting dose for prednisolone in cats; the dose is maintained at this level for a minimum of 2 weeks, even if clinical signs abate immediately. The dose is subsequently tapered over 8–10 weeks, aiming for complete withdrawal if possible. In many cases, the complete withdrawal of steroid medication is associated with relapse, in which case the lowest dose providing adequate control of clinical signs is used.

Most cases of moderate to severe idiopathic gastritis benefit from the use of antacid medications. Omeprazole may be necessary in some cases. Sucralfate may be used if there is any evidence of mucosal abrasion or ulceration, particularly in the first 7–10 days after diagnosis.

Severe cases of chronic gastritis occasionally require a more aggressive immunosuppressive protocol using additional medications such as azathioprine or chlorambucil. The use of these medications is discussed in more detail in the section on inflammatory bowel disease.

Cats that are difficult to handle and dose with oral medications may be treated with depot injectable prednisolone, using a dose of 20 mg/5 kg cat given subcutaneously every 3 weeks. The injectable depot prednisolone treatment does not usually give as great a benefit as daily oral dosing. If a cat that is being treated for moderate to severe gastritis with high doses of corticosteroids develops haematemesis, misoprostol is indicated.

While the basic immunopathology of IBD, including chronic gastritis, is poorly understood, it is possible that dietary antigens may play a major role in this disease. Dietary modification may be beneficial in the management of these cases. Dietary modification in IBD is discussed in more detail in a later section of this chapter.

Chronic gastritis associated with gastric spiral organisms

Gastric spiral organisms are commonly observed in mucosal biopsy specimens from cats with chronic gastritis. The importance of these organisms in the induction of chronic gastritis of cats is highly controversial, as the asymptomatic infection rate of healthy cats with GSOs is not significantly different to that of diseased cats. While it is extremely difficult to decide whether GSOs are an aetiological agent in most cases of chronic gastritis of cats, this does not rule out the possibility that GSOs are important in some cases. Some cats with GSOs and clinical signs of chronic gastritis will improve with antimicrobial therapy. The difficulty lies in determining which cases are likely to respond before starting therapy. Experimentally, the complete eradication of GSOs from cat stomachs has been achieved using 'triple therapy' with clarithromycin, 7.5 mg/kg p.o. twice daily, amoxicillin, 20 mg/kg p.o. twice daily and metronidazole, 15 mg/kg p.o. bid twice daily. All medications are administered for a period of 2 weeks. This regime results in complete eradication of GSOs, and cats remain free of

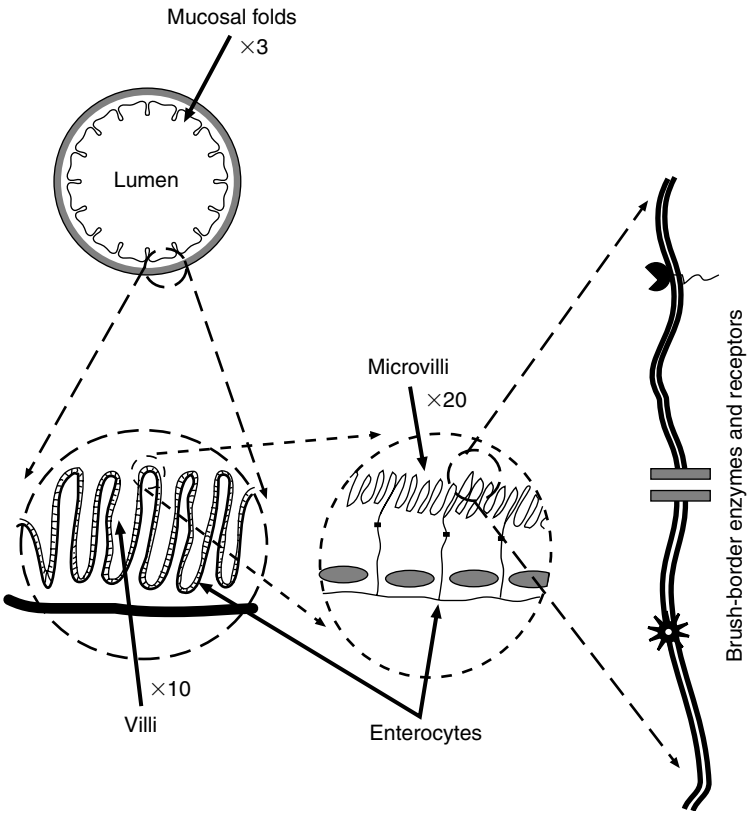

Figure 16.6 Diagrammatic representation of structural elements of the small intestine acting to increase the available surface area of the mucosa. Grossly visible folds of mucosa increase the surface area by a factor of approximately three, while the presence of villi and microvilli increases the surface area by a factor of 10 and 20, respectively.

GSO colonisation for at least 30 days after the cessation of treatment (Simpson K., Personal Communication). Many cats resent oral dosing with metronidazole, and excessive salivation is common. Oral dosing with metronidazole can be made easier by placing the medication in capsules.

The small intestine

The small intestine is the major site of nutrient digestion and absorption. The small intestine occupies a large portion of the abdominal cavity, while structural features of the small intestinal mucosa dramatically increase the surface area available for interaction with and absorption of both dietary nutrients and other environmental factors. The structural elements of the small intestine at the gross, microscopic and ultrastructural levels which increase available surface area are illustrated in Figure 16.6.

Inward folding of the mucosa in grossly visible folds increases the available surface area by a factor of approximately three over a plain tube of equivalent diameter. The mucosa is arranged into finger-like structures called villi, which increase the surface area by an additional factor of 10. The villus is the functional unit of the small intestinal mucosa. Enterocytes arise from division of stem cells in crypts at the base of the villus, then migrate and mature along the length of the villus and are finally shed from the villous tip into the lumen. As enterocytes migrate along the villus their function alters, starting from a mainly secretory function in the crypt and lower villus, maturing to a mostly absorptive function in the upper part of the villus.

Enterocytes have a microscopic brush-border modification of the luminal cell membrane. These microvilli increase the available surface area for digestion and absorption of nutrients by a factor of nearly 20 over the surface area of the villous projections.

In combination, the three structural elements of rugae, villi and microvilli increase the effective surface area of the intestinal mucosa by a factor of 600. The loss of one element, for instance villous shortening as may occur in some viral enteropathies or IBD, will dramatically alter the function of the small intestine.

The small intestine contains a complex population of normal microorganisms that play a role in maintaining the normal structure and function of the intestine. The normal bacterial content in the feline small intestine has not been thoroughly explored, but it appears that total numbers of bacteria in the small intestine and the proportion of obligate anaerobic bacteria are greater in the cat than in the dog. The small intestine is also in direct, if circuitous, contact with the external environment of the animal, and thus represents a major potential point of entry for bacteria, viruses and allergens.

The feline small intestine is approximately 50 cm long. The small intestine is divided into three anatomical and functional areas, the duodenum, jejunum and ileum. Structural and functional characteristics distinguish these three areas, with decreasing villus to crypt length ratios progressively down the small intestine. The ileum has been demonstrated to be the only site of cobalamin absorption in the cat, while it is presumed, but has not been demonstrated conclusively, that folate is absorbed in the jejunum. Knowledge of the absorption sites of these vitamins can aid in localisation of small intestinal lesions.

As the function of the small intestine is heavily reliant on the secretion of large quantities of fluids and enzymes, followed by reabsorption of the majority of these fluids, disturbance of small intestinal function is usually manifested as diarrhoea. Other clinical signs, such as vomiting, inappetance and weight loss are commonly encountered, and indeed may be the only clinical sign of small intestinal disease in some cases. Although diarrhoea is generally considered to be the hallmark sign of small intestinal disease, it is often not present.

Diarrhoea is not pathognomonic for small intestinal disease, as numerous metabolic disorders and extragastrointestinal diseases can induce diarrhoea.

The clinical signs of isolated small intestinal disease are often subtle or vague and it may be difficult to isolate the disease process to the small intestine. In some cases, weight loss or poor appetite may be the only complaint, and the diagnosis of small intestinal disease is based on elimination of other disease processes. The fastidious nature of cats and their typical elimination behaviour decrease the likelihood that cats will be presented for chronic small intestinal disease with a complaint of diarrhoea. In many cases cats are presented to a veterinary surgeon because of owner concerns with inappetance, weight loss or the onset of vomiting.

A clinical approach to diarrhoea in the cat

An algorithmic approach to diarrhoea in the cat is illustrated in Figure 16.7. The causes of acute diarrhoea are quite different to the typical causes of chronic diarrhoea in cats, and the approach to diagnosis and therapy is markedly different for the two conditions. In general, acute disease is managed in a supportive or symptomatic fashion, with the emphasis on support of the patient's fluid balance and electrolyte status. Chronic diarrhoea, by contrast, is not responsive to symptomatic or supportive therapy, requiring a diligent assessment of the patient to arrive at a definitive diagnosis and rational therapy.

Common to the approach to diarrhoea and vomiting disorders is the importance of attempts to isolate the disease to a specific organ. In cases with diarrhoea, the distinction is between small intestinal and large intestinal disease. This distinction is often not clear-cut, as many disease processes feature diffuse involvement of the gastrointestinal tract. Longstanding disease of the small intestine results in increased fluid input into the large intestine, and can eventually lead to large intestinal disease. Delivery of undigested or unabsorbed food into the large intestine can result in alterations of the bacterial flora in the large intestine and compromised large intestinal absorptive function.

Although it may not be feasible to isolate definitively the cause of diarrhoea to the small or large intestine on historical grounds, it is generally possible to gauge which organ is the major contributor to the diarrhoea, which helps to focus diagnostic testing. Historical characteristics tending to differentiate between small and large intestinal disease are listed in Table 16.6. Pure large intestinal disease is relatively uncommon in the cat.

Acute diarrhoea is more typically encountered in younger cats, and is usually the result of an isolated insult or incident. Most cases of acute diarrhoea in cats are self-limiting, but some, such as feline panleucopenia virus infection, are life-threatening. Dietary intolerance may also play a role in acute diarrhoea, particularly if there is a history of recent diet change. Many adult cats are lactose intolerant and exposure to cow's milk may result in diarrhoea.

The emphasis during physical examination of cats with acute diarrhoea is on the assessment of the state of hydration, and screening for other disorders that

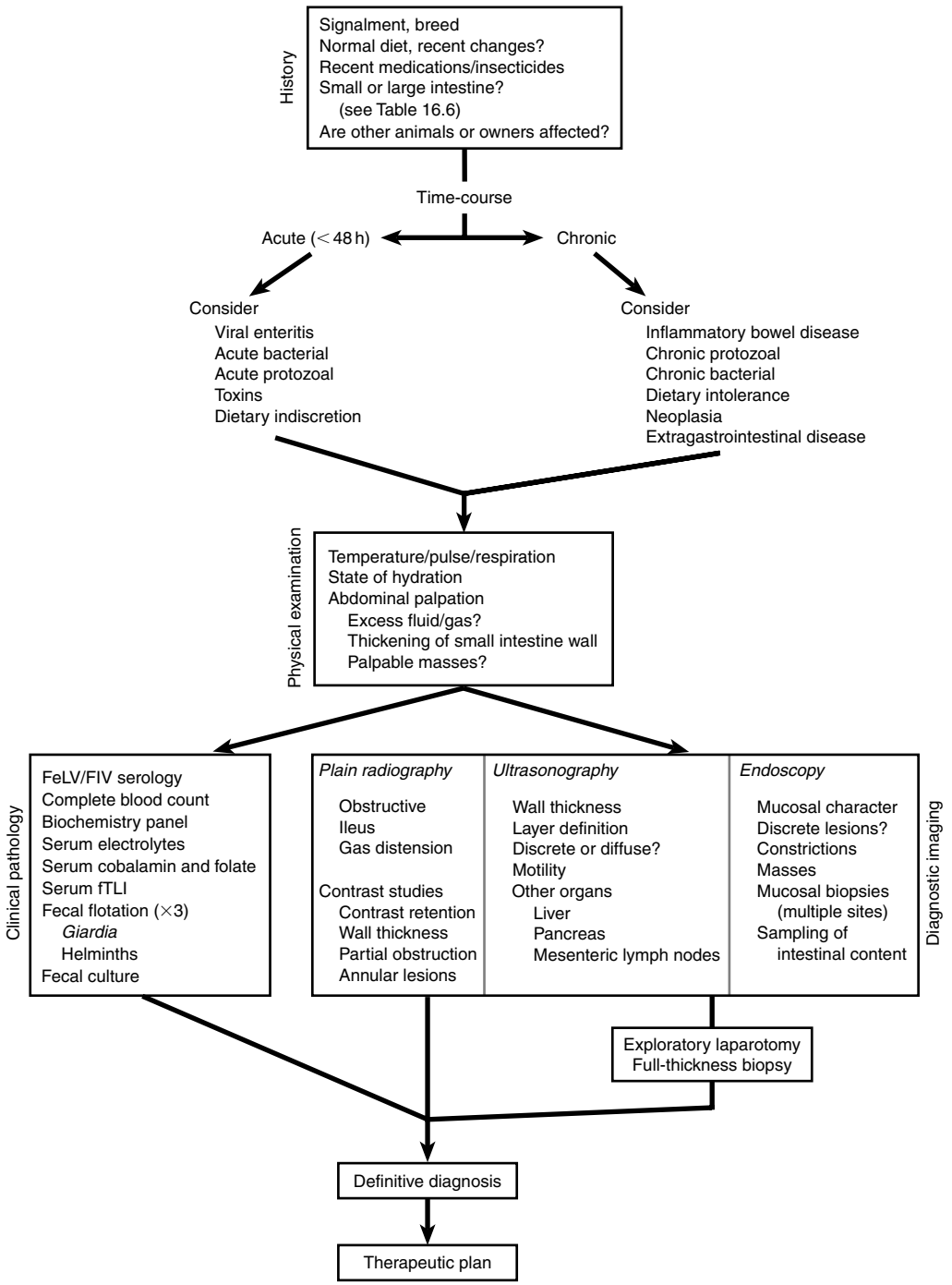

Figure 16.7 Algorithm detailing a rational clinical approach to the cat with diarrhoea. FeLV: feline leukaemia virus; FIV: feline immunodeficiency virus; fTLI: feline trypsin-like immunoreactivity.

Table 16.6 Characteristics of small intestinal and large intestinal diarrhoea in cats that may aid in the differentiation of small intestinal from large intestinal disease in the clinical history

Characteristic	Small intestine	Large intestine
Frequency of defecation	Usually no, or a very small, increase	Frequent (more than three times/day) to almost continuous in some cases
Faecal volume	Increased total volume passed in 24 h, each motion is usually large	Each motion is usually smaller than normal
Faecal continence/urgency	Usually normal, no increase in urgency	Faecal continence may be lost
Tenesmus	Rare	Common
Haematochezia	Rare/absent	Occasionally observed
Melaena	Occasional	Absent
Presence of mucus	Rare	Common
Inappetance	Variable	Rare
Weight loss	Common	Rare

may complicate the management of the patient. Typically, a conclusive aetiological diagnosis is not made.

Some topical parasiticides used for flea and helminth control in cats are occasionally ($<1\%$ of treated cats) associated with acute diarrhoea within 24 h of application. These cases are usually mild and self-limiting, and the history of recent application suggests the cause. This is usually a transient phenomenon and is not repeated at subsequent applications.

While acute diarrhoea is typically a result of an isolated infectious or toxic insult, chronic diarrhoea is typically associated with longstanding changes in the structure of the intestine. Chronic diarrhoea is usually a disease of adult or elderly cats; in these patients it is important to consider extraintestinal diseases that may cause secondary diarrhoea. Thorough physical examination is important to screen for clinical signs associated with extraintestinal disorders. Various metabolic disorders and extraintestinal diseases may cause diarrhoea in cats:

- exocrine pancreatic insufficiency
- chronic pancreatitis
- hyperthyroidism
- hepatopathy
- hypoadrenocorticism
- heart failure
- hyperadrenocorticism
- toxicoses
- chronic renal disease.

With the exception of exocrine pancreatic insufficiency, other clinical signs tend to dominate the history and physical examination of these cats.

Clinical examination and evaluation of the small intestine

The normal small intestine occupies a large proportion of the abdominal cavity, and is readily available to physical examination by palpation. While accessibility of the small intestine to palpation increases the ability of the clinician to assess the normality or otherwise of small intestinal anatomy, many small intestinal diseases involve relatively subtle changes in physical structure of the intestine. Examination and assessment of the small intestine usually involves a combination of physical examination, clinical pathology and function testing, diagnostic imaging, direct visualisation and histopathological assessment.

Physical examination and palpation

Physical examination and abdominal palpation are frequently helpful in the diagnosis of small intestinal disease in the cat. Palpation may detect foreign bodies, intussusception, plication and bunching of the intestine, as will occur with linear foreign bodies, discrete masses in the intestinal wall and diffuse thickening of the intestinal wall. The small intestine of the cat is relatively easy to palpate, and is easier to assess than the small intestine of the dog. In most average-sized cats the intestine is palpated with a single hand, the loops of intestine being allowed to slip through the fingers as the hand is drawn down the abdomen. It is often useful to elevate the thorax of the cat with the non-palpating hand, while allowing the cat to stand on its hindlegs. Infiltrative diseases such as intestinal lymphoma and IBD often cause a thickening or stiffening of the intestinal wall. This is often discernible on palpation, as the intestinal loops feel more hose-like. Acute diseases, such as viral enteritides or bacterial infection, are often associated with ileus, increased gas and fluid in the small intestine, and abdominal discomfort on palpation. The presence of excessive intestinal gas and fluid produces a bubbly sensation on palpation. Often, auscultation of the abdomen will reveal frequent loud borborygmi in cats with acute intestinal disease.

If a discrete mass is detected on palpation of the abdomen, it is often possible to sample the mass by percutaneous fine-needle aspiration.

Palpation of an intestinal foreign body or an intussusception is an indication for further radiographic examination and possible exploratory laparotomy and corrective surgery.

Clinical biochemistry

Screening clinical biochemistry and haematology is useful in the diagnostic work-up of suspected chronic small intestinal disease. As most cases of chronic diarrhoea are in middle-aged to elderly cats, clinical biochemistry and haematology will establish the metabolic state of the patient before further diagnostic interventions and therapy are planned.

Biochemistry may reveal elevations in liver enzyme activities indicating potential hepatic disease, while blood urea and creatinine concentrations may be increased if there is pre-existing renal disease. Disturbed gastrointestinal permeability and absorptive function may result in electrolyte disturbances. Protein-losing enteropathies are only rarely associated with either hypoproteinaemia or hypoalbuminaemia in cats.

Serum cobalamin and folate concentrations

In dogs, the measurement of serum folate and cobalamin concentrations has been described in the diagnosis of several disorders of the gastrointestinal tract. The usefulness of these measures arises from the sites of absorption of these two vitamins and the observation that, in most cases where a properly balanced diet is being fed, dietary deficiency of these vitamins is extremely unlikely. Methods for the assay of both cobalamin and folate have been validated for use with feline serum in the authors' laboratory.

Consideration of the normal physiology of cobalamin and folate absorption allows the use of serum cobalamin and folate concentrations as a screening tool for intestinal dysfunction and, in some cases, localisation of the disease to a specific area of the small intestine. Although the strength of the relationship between changes in serum vitamin concentrations and changes in bacterial flora has not been extensively investigated in the cat, this does not reduce the value of these measures in screening for intestinal disease.

Cobalamin and folate are both water-soluble vitamins, which are absorbed in specific sections of the small intestine, the jejunum for folate (extrapolated from other species) and the ileum for cobalamin.

Table 16.7 Disease conditions and factors that may result in alterations in the serum concentrations of cobalamin and folate in cats

Decreased cobalamin	Normal cobalamin
Decreased folate	
Diffuse small intestinal disease, particularly infiltrative disorders such as inflammatory bowel disease and intestinal lymphosarcoma	Disease affecting the proximal small intestine only, cobalamin may be normal or increased
Disease affecting the proximal small intestine (jejunum), and increased bacterial numbers	Consumption of a diet deficient in folates (a pure tuna diet has been reported to cause folate deficiency), cobalamin may be normal or increased
Normal folate	
Disease involving the distal small intestine (ileum)	Does not rule in or rule out intestinal disease
Excessive bacterial consumption of cobalamin	

Serum concentrations of cobalamin and folate are influenced by a large number of factors. These include bacterial absorption of cobalamin in the small intestine, bacterial synthesis of folates in the small intestine, excessive dietary consumption if the animal is receiving supplements, and decreased absorption due to mucosal disease. Numerous factors may contribute to an increased serum concentration of either cobalamin or folate; however, the likely causes of decreased serum concentrations are fewer in number, and generally indicate some form of intestinal pathology (Table 16.7).

Assuming that, as in other species studied, folates are absorbed in the more proximal small intestine, a subnormal serum folate concentration is consistent with disease affecting this section of the bowel. Often, low serum folate concentration is due to infiltrative disease of the mucosa or partial villous atrophy. Low serum folate in combination with normal cobalamin suggests localisation of the disease to the jejunum.

Folates may also be synthesised by intestinal bacteria. A higher than normal serum folate concentration may thus suggest the presence of increased bacterial numbers in the small intestine. In dogs, high serum folate is suggestive of small intestinal bacterial overgrowth; however, the occurrence of small intestinal bacterial overgrowth in the cat has not been documented at this time.

Cobalamin can only be absorbed when complexed with a protein called intrinsic factor, which is produced by the exocrine pancreas in the cat. The intrinsic factor–cobalamin complex is absorbed by specific receptors in the ileum. Decreased serum cobalamin concentration, in isolation, suggests a disease process affecting the ileum or exocrine pancreatic insufficiency. A complicating factor is that some intestinal bacteria will consume cobalamin, and thus increased numbers of intestinal bacteria may also reduce serum cobalamin concentrations. As previously discussed, small intestinal bacterial overgrowth has not been well docu- mented in the cat.

The combination of low serum cobalamin and folate in the cat is consistent with diffuse small intestinal disease, as would be expected with infiltrative disorders such as inflammatory bowel disease or lymph- oma. Some aggressive cases of alimentary lymphoma may develop too rapidly to deplete body stores of cobalamin.

Serum trypsin-like immunoreactivity

Serum feline trypsin-like immunoreactivity (fTLI) represents circulating trypsinogen, the inactive precursor of trypsin released from the acinar cells of the exocrine pancreas. Low serum trypsin-like immunoreactivity is a reliable indicator of exocrine pancreatic insufficiency in dogs, and measurement of circulating trypsin-like immunoreactivity has become the diagnostic test of choice for this disorder in dogs. Immunoassays for trypsin-like immunoreactivity are species specific: feline trypsinogen and trypsins are not detected by assays for canine TLI. An fTLI enzyme-linked immunosorbent assay (ELISA) has been developed in the authors' laboratory, and is offered as a clinical service. Using this assay, the definitive diagnosis of exocrine pancreatic insufficiency in cats has been greatly simplified. An fTLI concentration of <8 μg/l is considered indicative of exocrine pancreatic insufficiency, and this test should be used to rule out exocrine pancreatic insufficiency in cats with chronic gastrointestinal signs before more invasive diagnostic tests are considered.

Abdominal radiography

Plain abdominal radiography is usually of greatest usefulness in the diagnostic assessment of acute abdominal disease. Plain abdominal radiography rarely reveals a diagnosis in cats with chronic diarrhoea; however, plain radiography is usually performed in these cases as a screening procedure, and to assess the state of other abdominal organs such as the liver or kidneys.

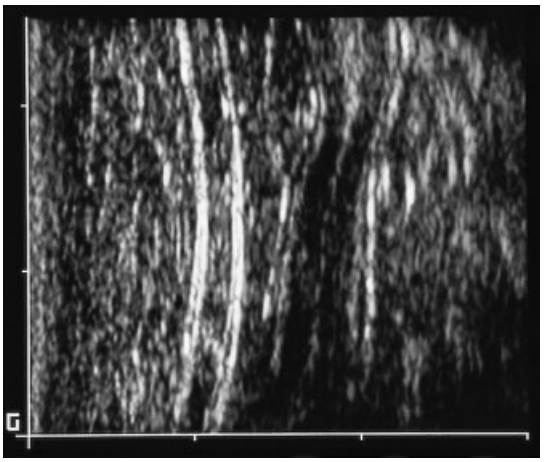

Figure 16.8 Normal ultrasonographic appearance of feline small intestine. This is a longitudinal view of small intestine. The lumen is relatively empty; five layers are visible. From the lumen outwards, the layers visible are mucosal surface (very thin, hyperechoic), mucosa (thickest layer, hypoechoic), submucosa (thin, slightly hyperechoic), muscularis (similar thickness to submucosa, hypoechoic) and serosa (approximately half as thin as muscularis, brightly hyperechoic).

Plain abdominal radiographs allow detection of radiopaque foreign bodies, intussusceptions and plication of the intestines, as can occur with linear foreign bodies. An obstructive pattern, with proximal fluid accumulation and gas distal to the obstruction, may be observed when radiolucent foreign bodies are causing obstruction. Functional ileus is associated with a mixed pattern of fluid pooling and gas retention.

The use of BIPS in cats with partial or functional obstruction of the small intestine has been described. Contrast radiographic techniques using liquid barium may demonstrate irregular wall thickening, irregular diameter of the lumen and prolonged retention of contrast medium in some cases of small intestinal lymphoma. Some cases of lymphoma will exhibit a 'string of pearls' pattern, with retention of contrast in lobulated areas of the diseased small intestine. As it is possible for normal peristaltic contractions of the small intestine to produce a very similar pattern, it is important to document persistence of this pattern to support the diagnosis of small intestinal infiltrative disease. Although barium contrast series studies have traditionally been used to investigate and diagnose small intestinal motility disorders and wall thickness, the use of abdominal ultrasonography tends to supplant this technique.

Abdominal ultrasonography

In the hands of an experienced operator, modern high-resolution ultrasound equipment has the potential to yield a wealth of information on small intestinal structure. As the individual structural layers of the small intestine differ in echogenicity, it is possible to visualise and measure the thickness of these layers non-invasively, and to assess differences in relative echogenicity, as can occur with infiltration by inflammatory or neoplastic cells. The normal ultrasonographic appearance of the feline small intestine is illustrated in Figure 16.8. The normal small intestine has five layers visible on ultrasonography, corresponding to the mucosal surface, mucosa, submucosa, muscularis and serosa. With the combination of high-resolution real-time imaging and guided biopsy, ultrasound-guided fine-needle aspiration of intestinal lesions is often feasible. Abdominal ultrasonography can also yield information on pancreatic anatomy and structural changes that can occur with pancreatic disease. Mesenteric lymph nodes can be assessed and fine-needle aspirates can be obtained, which may allow non-invasive staging of intestinal neoplasia.

Endoscopic examination and biopsy

Direct endoscopic examination and visualisation of the mucosa is an excellent diagnostic modality for many small intestinal diseases in the cat. In many cases discrete mucosal lesions are detected more readily by endoscopy than by plain radiography, and the use of endoscopic biopsy equipment allows the direct sampling of diseased mucosa. Strictures and partial obstructions are readily observed in the proximal intestine, and foreign body retrieval may be feasible. The duodenum is readily accessible to experienced endoscopists, and it may be feasible to enter the ileum during a retrograde, colonoscopic examination. The jejunum is usually inaccessible to endoscopic examination in the cat.

On endoscopic examination of the normal feline small intestine the mucosa has a velvety appearance owing to the presence of massed villi, and is typically a light pink colour. Infiltrative diseases of the small intestinal mucosa tend to reduce the velvety appearance, with the loss of villous structure (Plate 16.6). The mucosa tends to be more friable when inflamed and contact with the endoscope tip will readily lead to bleeding in many cases.

Many cases of inflammation or neoplastic infiltration of the small intestinal mucosa result in only subtle changes in the grossly visible structure of the mucosa. It is important to obtain biopsies of several areas of the intestine during an endoscopic examination, and to obtain biopsies of apparently normal mucosa as well as grossly diseased tissues.

Endoscopic biopsies usually only yield mucosa and fragments of submucosa, and the biopsy samples are small and prone to crushing artefacts. As a consequence, in some cases, exploratory laparotomy and full-thickness biopsy of the small intestine may be necessary to establish a diagnosis.

Exploratory laparotomy and biopsy

Surgical exploration and full-thickness biopsy may be the only feasible approach to a definitive diagnosis of small intestinal diseases. Localised lesions of the jejunum, for instance, are often difficult to sample through non-invasive techniques such as fine-needle aspiration or endoscopic biopsy. Diseases that are isolated in the muscularis or serosa are not readily detectable with endoscopic biopsy.

Full metabolic screening of the patient is import-ant before undertaking exploratory surgery and full-thickness biopsy. Biopsy specimens should be obtained from several areas of the stomach, duodenum, jejunum, ileum and colon. At a minimum, a trained pathologist with experience in interpreting intestinal pathology should carry out histopathological assessment of haematoxylin and eosin-stained sections of intestine.

Histopathological grading systems for the presence and severity of IBD in haematoxylin and eosin-stained sections of small intestine have been proposed by various authors. Unfortunately, none of these systems shows a particularly good correlation with the clinical signs and severity of disease or response to therapy. The main importance of histopathological assessment is to establish a diagnosis, and to differentiate idiopathic inflammatory disease from neoplastic or infectious disease. In some cases, specialised immunohistochemical techniques may be necessary to distinguish IBD from intestinal lymphoma.

Intestinal permeability and function testing

The clinical signs of small intestinal disease, particularly diarrhoea and weight loss, result from loss of function of the small intestinal mucosa. Disturbances in fluid and electrolyte flux, and the loss of circulating proteins as a result of mucosal disease, result in increased fluid losses, decreased efficiency of nutrient digestion and absorption, and secondary disorders

such as intestinal bacterial overgrowth and inflammation.

Some gastrointestinal disorders do not lead to morphological abnormalities, while others cause only subtle changes that can easily be misinterpreted by the histopathologist. As histopathological assessment of the intestinal mucosa does not give a reliable indication of mucosal function, techniques are needed that measure intestinal mucosal surface area, permeability and absorptive function.

Inert monosaccharides and disaccharides can be used to assess intestinal permeability and mucosal function. By administering a mixture of sugars with different mechanisms of absorption it is possible to assess changes in the permeability of the mucosa, the surface area present for passive diffusion, the integrity of intracellular connections and the presence of carrier molecules. It is possible to use five sugars simultaneously to measure gastric permeability, small intestinal permeability and small intestinal mucosal function with a single test procedure (Steiner *et al.*, 2000a). Urinary recovery of mixtures of sugars has been used as a diagnostic and monitoring tool in humans, and a few studies have been reported in the veterinary literature. With the establishment of reference values for urinary recovery of sugars and normal recovery ratios in cats, this may also become a valuable diagnostic test of small intestinal function.

Diseases of the small intestine

Infectious disease

The small intestine is the first of the hollow organs of the gastrointestinal tract where microorganisms play a major role in the development of some disease processes. Bacterial involvement in small intestinal disease, particularly in the onset of some forms of acute diarrhoea, is frequently assumed. It is likely that a disturbance of the normal bacterial flora in the intestine is more common than disease due to specific pathogens. With some exceptions, as detailed below, the clinician is generally ill-advised to use broad-spectrum antibiotics indiscriminately in the treatment of small intestinal disease and diarrhoea. This could lead to further disturbance in the bacterial flora present in the intestine, which may perpetuate clinical signs. It may also select for antibiotic resistance in any pathogens that are present and may ultimately contribute to a public health hazard. Antibiotic therapy should only be used when faecal or duodenal juice culture documents the presence of a known enteric pathogen, and antibiotic choice should be guided by the sensitivity of the organism isolated.

Viral disorders of the small intestine

Numerous viral infections have been associated with acute to subacute or chronic diarrhoea in cats, with the severity of the clinical signs reflecting the different areas of the small intestinal villi affected.

Feline panleucopenia, or feline parvovirus, is a highly contagious viral infection of the small intestinal mucosa. This virus infects and destroys rapidly dividing cells, such as the stem cells in the villous crypts and proliferating white blood cell precursors in the bone marrow (hence the panleucopenia). Loss of the crypt stem cells results in the rapid loss of intestinal mucosal integrity, loss of control of fluid secretion and impairment of fluid resorption. Feline panleucopenia typically causes severe acute diarrhoea, with marked dehydration, blood loss from intestinal mucosal damage, fever, sepsis and death in many cases. The aims of therapy are to replace lost fluid volumes and compensate for the increased fluid requirements caused by the diarrhoea and to minimise the consequences of bacterial translocation from the gut. Intravenous fluid therapy and high-dose, broad-spectrum bacteriocidal antibiotics are usually necessary. Vaccination has reduced the frequency of panleucopenia infection markedly, but occasional cases are still encountered, particularly in unvaccinated cats, feral or wild cat populations and occasionally in catteries (see Chapter 21).

Feline enteric coronavirus (FECoV) is another cause of acute diarrhoea in young cats. Clinical signs are usually less dramatic than those encountered with panleucopenia, but include diarrhoea, mild fever, dehydration and inappetance. In some cases intravenous fluid therapy may be necessary; however, most cases recover with conservative therapy, as described later. FECoV infects cells at the tips of the villi, redu-cing the resorptive capacity of the small intestine, but does not lead to dramatic fluid losses as seen with feline panleucopenia. Asymptomatic infections are apparently common in adult cats, as many normal cats shed FECoV particles in the faeces. The main importance of FECoV infection is the close relationship between FECoV and feline infectious peritonitis (FIP)-inducing strains of feline coronavirus. The presence of antibodies to FECoV will result in a positive titre to FIP, which complicates the diagnosis of FIP (see Chapter 25).

FIP virus itself, in the 'dry' granulomatous form of the disease, may cause diarrhoea as a result of granulomatous enteritis and serositis.

FIV-positive cats may develop chronic enteritis in up to 15% of cases (Yamamoto *et al.*, 1989). These cats present with diarrhoea, inappetance or anorexia, weight loss and dehydration. Enteritis in cats with FIV may be a direct result of the viral infection, or may be secondary to compromised immune function in the intestine (see Chapter 24).

Rotavirus and astrovirus infections have been described as causes of mild, self-limiting diarrhoea in young kittens, but do not represent a major clinical problem.

Torovirus-like particles have been isolated from the faeces of cats presenting with a syndrome of mild diarrhoea and nictitating membrane prolapse (Muir, 1990). This is a very mild disorder and, in general clinical practice, cats with this syndrome are often not presented to veterinarians, or are presented only for nictitating membrane prolapse without the owners being aware of the mild diarrhoea.

FeLV infection may also be associated with gastrointestinal disease, both as a result of chronic immune suppression and as part of the FeLV–panleucopenia syndrome in stressed or debilitated cats (see Chapter 23).

Bacterial disorders of the small intestine

Numerous enteric pathogens have been isolated from faecal cultures of cats with chronic diarrhoea, but the importance of these organisms is often far from clear. Some organisms, considered pathogenic in humans, can be isolated from faecal cultures of apparently healthy cats. The small intestine possesses a complex normal bacterial flora, with bacteria present in steadily increasing numbers down the length of the small intestine towards the ileocaecocolic valve. Bacterial causes of acute small intestinal disease are possible, but viral infections probably account for a greater proportion of the cases of acute enteritis in cats presented to veterinary practitioners.

Although the importance of enteric pathogens in acute small intestinal disease is often overestimated, some bacterial infections are associated with both significant acute disease and some chronic diarrhoeal states in cats, and may also represent a public health issue. It is important to consider the possibility of these infections, and rule them out by faecal culture, in cats with chronic small intestinal disease.

Salmonella species are an important potential enteric pathogen of cats. Cats with enteric salmonellosis are usually presented with vomiting and diarrhoea, with the diarrhoea typically mucoid or haemorrhagic in nature. Birds, particularly domestic fowl, appear to be the main source of infection of domestic cats. Hunting cats may become infected from wild birds carrying *Salmonella* species. The owner should be questioned closely regarding potential exposure to wild birds and domestic poultry. Exposure to raw poultry carcasses represents another potential source of infection; the consumption of raw carcass trimmings and off-cuts may explain infections in otherwise isolated indoor cats.

Salmonellosis should be suspected in any cat with chronic, relapsing mucoid diarrhoea, particularly if the diarrhoea is accompanied by febrile or septic incidents. Diagnosis is based on isolation of Salmon-ellae from faecal cultures. *Salmonella* species can be isolated from the faeces of normal cats; however, the reported rates of isolation are relatively low (0.5–2.5%).

Therapy of enteric salmonellosis is usually supportive and most cats recover spontaneously. Infected cats shed Salmonellae for several weeks, during which time they should be handled carefully and with scrupulous attention to hygiene as zoonotic infection is possible. The use of probiotics, such as live *Acidophilus* yoghurts, may aid recovery in some cats, but such use is entirely empirical.

Cats with systemic salmonellosis, diagnosed on the basis of recurring bouts of septic illness and positive blood cultures for Salmonellae, will require antibiotic therapy. High-dose intravenous fluoroquinolones may be the best choice. Many strains of *Salmonella* are resistant to β-lactam antibiotics. Aminoglycosides, while showing a favourable *in vitro* effect, show poor penetration of the cell types typically infected in cats with systemic salmonellosis.

Campylobacter jejuni has been isolated from faeces of cats with acute enteritis, characterised by watery to mucoid stools, which may then progress to a chronic diarrhoea. In common with salmonellosis, *Campylobacter* is probably contracted from exposure to poultry in most cases. Cat-to-cat transmission is possible, particularly in environments with large numbers of cats such as catteries and humane society shelters. Campylobacteriosis should be suspected in any cat with a history of acute to chronic, mucoid diarrhoea, recent exposure to poultry or wild birds, or a compatible history of recent exposure to a large number of cats, for instance in a shelter.

Diagnosis of campylobacteriosis relies on the presence of compatible clinical signs and the demonstration of the organism in faecal cultures. In some cases, it may be possible to recognise the organism on Gram-stained faecal smears, the characteristic morphology of the organism being either a comma- or seagull-shaped rod.

Table 16.8 Helminth and cestode parasites of the feline small intestine

Parasite	Characteristics	Diagnosis
Helminths		
Toxacara cati	The most prevalent helminth parasite of cats; lactating queens infect kittens	Slightly oval, rough-coated egg, non-embryonated, 75 × 65 μm; dark-coloured ovum
Toxascaris leonina	Much less common than *Toxacara*; no transmammary infection	Egg is larger than that of *Toxocara*, (82 × 70 μm), smooth shelled, non-embryonated; light-coloured ovum
Uncinaria stenocephala	Uncommon hookworm, occasionally infects cats; resistant to cold temperatures; clinical disease not recorded in UK	Oval, thin and clear-shelled egg with multicelled ovum, 72 × 45 μm
Capillaria putorii	Occasional parasite of the stomach and small intestine in cats, usually seen in rural cats; eggs may be confused with *C. aerophila*	Lemon-shaped egg with two plugs at the poles, non-embryonated, 70 × 35 μm
Cestodes		
Dipylidium caninum	Most common tapeworm in cats, transmission is via flea intermediate hosts	Commonly diagnosed from finding segments in faeces or on perianal hair coat; eggs passed in large, thin-shelled packets (>200 μm) containing numerous encapsulated scoleces
Taenia taeniaeformis	Transmission by consumption of small rodent intermediate hosts; encountered in hunting or rural cats	Single encapsulated scoleces may be found on faecal flotation; scoleces are roughly circular (32–37 μm); segments may be found in faeces or on perianal hair coat

Either erythromycin or neomycin is effective for the treatment of chronic campylobacteriosis. Owners should be warned of the potential for zoonotic infection and all handlers of the cat should maintain scrupulous hygiene.

The occurrence and importance of small intestinal bacterial overgrowth in cats is an area of some controversy. It appears that cats have a relatively large resident population of anaerobic bacteria in the small intestine compared with dogs, but normal numbers are not well defined. Scrupulous attention to sampling and culture conditions is needed to yield accurate bacterial counts. Some cats with chronic diarrhoea show a response to antibacterial medications. The diagnosis and underlying pathology of this idiopathic antibiotic-responsive diarrhoea is an area of current research interest.

Helminths and cestodes

Several species of parasitic worm have the potential to infest the feline small intestine. Some common species are summarised in Table 16.8.

Toxocara cati is the most common small intestinal parasite of cats. Surveys of feral cat populations have found *T. cati* eggs in up to 30% of these cats in the USA. *Toxocara cati* can infect kittens through the queen's milk; this lactogenic infection represents the most common mode of infection. Adult cats remain susceptible to *T. cati* infection throughout life, and the worm can be contracted through ingestion of infective eggs, or ingestion of secondary hosts such as rodents, insects and birds.

Heavy *Toxocara* infestations in kittens may produce diarrhoea, weight loss, a pot-bellied appearance and poor hair coat. Rarely, extreme infestations can cause small intestinal obstruction or perforation.

Most modern anthelmintics are effective against the major intestinal parasites of cats. Hygiene is an important consideration in the control of *Toxocara* infestations in catteries or animal shelters. The infective eggs are able to survive for long periods in the environment, and the eggs possess a sticky coat that makes their removal from housing surfaces difficult. Scrupulous, rapid removal of faecal matter, bleaching of surfaces to remove the sticky coat from the eggs,

and use of flame guns to destroy the ova may all be necessary to gain adequate control in catteries.

Protozoa

The most commonly encountered protozoal parasites of the feline small intestine are coccidia, particularly members of the genus *Isospora*, *I. felis* and *I. rivolta*. Diagnosis is based on observation of unsporulated oocysts in fresh faecal floats. Coccidian oocysts sporulate to an infectious stage rapidly, in 1–2 days under ideal conditions. Coccidian oocysts are small and thin shelled, and may be easily missed on cursory examination.

Isospora is most frequently diagnosed in young kittens, where it may be associated with mild small intestinal diarrhoea. Occasionally, oocysts will be seen in faecal floats from adult cats. The clinical significance of *Isospora* is uncertain. Most kittens clear the infection readily, and appear to develop effective immunity early in life. Heavily populated catteries or animal shelters with high population densities of kittens may have clinically significant problems as a result of heavy and repeated *Isospora* infections in young animals, and in these situations improvement of hygiene is necessary. Coccidian oocysts are very resistant to the action of most disinfectants. Flame-gun treatment of surfaces, prolonged exposure to direct sunlight and thorough steam cleaning are all reasonably effective. Daily removal of faeces is necessary to avoid the development of infective sporocysts.

Toxoplasma gondii is another coccidian parasite of the small intestine in cats. This parasite is important clinically because of its ability to produce systemic illness in cats and other domestic animals, and as a zoonotic infection. The domestic cat is the definitive host of *T. gondii*, and uncomplicated infection generally produces only mild small intestinal disease in otherwise healthy, immunocompetent cats. Systemic infection has the potential to produce a plethora of clinical signs and differing disease processes, probably the most important clinically being infection of the CNS (see Chapter 28).

Toxoplasma oocysts can be observed in fresh faecal floats, but shedding may be intermittent. The oocysts are very small (12 μm diameter) and considerable skill is necessary to identify them and to differentiate *Toxoplasma* oocysts from other, non-pathogenic coccidia. Diagnosis of systemic toxoplasmosis is based on the detection of a rising *Toxoplasma* titre.

Cryptosporidium, another genus of coccidian parasites, has the potential to infect cats, along with numerous other animal species. Cryptosporidiosis is a serious condition in immunocompromised human patients, and zoonotic infection of human patients with *Cryptosporidium* has been documented (Bennett *et al*., 1985).

Giardia species, flagellate protozoan parasites, are an important and probably underdiagnosed cause of small intestinal disease in cats. *Giardia* reside free in the lumen of the small intestine and are motile. Infection may be asymptomatic, or clinical signs of diarrhoea and weight loss may be noted. With active disease caused by *Giardia*, mucoid, foul-smelling diarrhoea is passed, and there is usually evidence of steatorrhoea and malabsorption.

Diagnosis is by demonstration of the characteristic motile flagellate trophozoites. Trophozoities may be visible on direct smears of watery faeces; however, a concentration technique using zinc sulfate solution and centrifugal flotation is more reliable. Excretion of the parasite is intermittent and a single negative faecal floation does not rule out *Giardia* as a cause of small intestinal disease. It is generally recommended to repeat faecal flotation every other day with three repetitions. Duodenal juice obtained endoscopically or at laparotomy may also be examined; however, the sensitivity of duodenal juice examination does not tend to be greater than that of repeated faecal flotations.

Giardia infestations can be treated with metronidazole at a dose of 25 mg/kg twice daily. As metronidazole is a broad-spectrum antibiotic, and may also possess immunomodulatory activities, many practitioners use metronidazole empirically in the therapy of chronic small intestinal diarrhoea of cats. The doses used for immunomodulatory effect, however, are generally lower than those used to eliminate *Giardia*, and some authors consider metronidazole to be only 75% effective for elimination of *Giardia*. The use of metronidazole may therefore suppress the *Giardia* infection without eliminating the organism, and may actually perpetuate the clinical syndrome.

Fenbendazole, given orally at a dose of 50 mg/kg once daily for 3 days, has been found to be effective in the elimination of *Giardia* in dogs and, empirically, also in cats. As chronic giardiasis may be associated with IBD and a need for ongoing immunomodulation therapy, a useful approach may be to treat cats suspected of having giardiasis initially with fenbendazole, then, after assessing the response to therapy, to continue with metronidazole.

Intestinal foreign bodies and obstructions

Foreign body obstruction is an important differential diagnosis in any cat presented with acute onset of

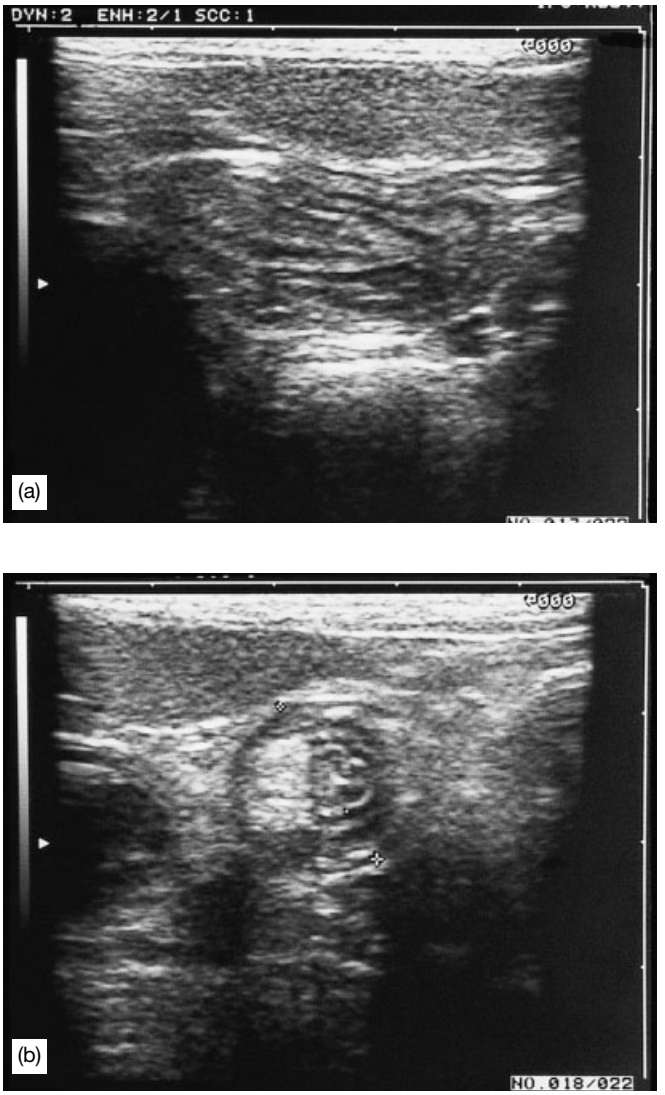

Figure 16.9 (a) Lateral and (b) transverse ultrasonographic views of a small intestinal intussusception in a cat. Note the multiple layered appearance of the small intestine.

vomiting. The clinical signs of small intestinal obstruction vary in severity depending on the level at which obstruction occurs. Obstruction of the small intestine may occur acutely as a result of intraluminal foreign bodies, accidents of intestinal motility such as intussusceptions and acute herniation following trauma. Chronic obstruction, which will generally have a more insidious clinical course, may result from the presence of neoplastic lesions, abscesses or strictures.

Acute high obstructions, such as in the pyloric antrum or cranial duodenum, will usually result in severe vomiting, which may be accompanied by hypovolaemia, dehydration and collapse. More chronic obstructions, and those occurring in the lower part of the small intestine, typically have a more chronic course, with the development of vomiting, inappetance and weight loss in some cases. Linear foreign bodies, such as a lingually entrapped string, tend to produce high small intestinal obstruction through plication of the intestinal loops. This may be further complicated by laceration of the mucosa and serosa, and peritonitis.

The diagnosis of small intestinal obstruction is usually suggested by history and physical examination findings. Abdominal palpation may reveal a foreign body, small intestinal plication, a characteristic sausage-shaped mass if an intussusception is present,

or the presence of a mixed fluid–gas intestinal content. Radiography and ultrasonography are commonly useful in establishing the diagnosis (Figure 16.9). Therapy is usually surgical, although the occasional case may be able to be managed conservatively if there is evidence on repeat radiographic examination that the obstruction is moving. Careful attention should be paid to replacement of lost fluid volume and normalisation of electrolyte status before surgery.

Inflammatory bowel disease

IBD is an infiltration of the gastrointestinal tract with inflammatory cells. Numerous conditions such as parasitism, dietary intolerance or allergy and bacterial disorders of the gastrointestinal tract are associated with the presence of inflammatory infiltrate into the gastrointestinal tract. It is important to distinguish between the presence of an appropriate immune system response to potential pathogens and the inappropriate presence of inflammatory infiltrate. The diagnostic approach to a cat with suspected IBD should rule out other disorders associated with chronic diarrhoea in cats (see A clinical approach to diarrhoea in the cat, page 415).

IBD is considered to be the most common histopathological diagnosis in animals with chronic vomiting and diarrhoea (Jergens, 1999). IBD has been recorded affecting the stomach, small intestine and large intestine, and may be isolated to one organ or diffuse throughout the entire gastrointestinal tract.

The clinical signs of IBD in cats are generally chronic diarrhoea, vomiting and weight loss. Vomiting may be the primary clinical sign even when only the small intestine is affected. The character of the diarrhoea in cats with IBD depends on the major organ involved. There may be pure small intestinal signs of large, bulky motions, pure large intestinal signs such as haematochezia and increased urgency, or a mixture of the two. Often, signs of small and large bowel disease are present simultaneously and cannot be distinguished. Even in cases with predominantly large bowel signs, lesions can be identified in the small intestine by biopsy in most cases.

Clinical biochemistry and haematology are often unrewarding in the work-up of IBD. There may be panhypoproteinaemia in severe diffuse disease, or serum cobalamin and folate concentrations may be altered, which may aid in lesion localisation or provide evidence of diffuse disease. Peripheral lymphocytosis or neutrophilia are rarely detected in cats with IBD; however, eosinophilia may be noted in cases of hypereosinophilic syndrome.

The definitive diagnosis of IBD is made via histopathological examination of biopsies of the intestinal wall and the absence of other known causes for intestinal inflammation. IBD is subclassified on the basis of the predominant cell type of the inflammatory infiltrate. Further description of the type and severity of the disease depends on the extent of inflammatory infiltration, alterations in the mucosal structure, changes in the villus to crypt ratio and epithelial cell maturity.

The relationship between the histopathological severity of IBD, clinical syndromes observed and response to therapy is relatively poor. In general, cats with a histopathological diagnosis of severe IBD will show severe signs of disease and require aggressive therapy. Cats with a relatively mild or moderate histopathological diagnosis, however, may also require aggressive or prolonged therapy to gain adequate control of clinical signs.

Lymphocytic/plasmacytic enteritis/enterocolitis

Lymphocytic/plasmacytic enteritis (LPE) is the most common form of IBD in cats. There is infiltration of the mucosa and submucosa by a mixed population of lymphocytes and plasma cells, accompanied by varying degrees of mucosal architectural distortion. Affected cats are usually middle-aged or older, although it is not unusual to encounter LPE in young adult cats. The most common clinical signs of LPE are chronic vomiting and weight loss; diarrhoea is variable and may not be present. Findings on physical examination are usually non-specific and vague, the most common finding being weight loss. Thickened bowel loops or mesenteric lymphadenopathy may be present in cats with more severe disease, but these changes are not routinely detected on abdominal palpation. There are no characteristic changes observed on clinical biochemistry and haematology; there may be elevations in liver enzyme activities and mild regenerative anaemia, but these findings are non-specific.

Diagnostic imaging using abdominal radiography generally does not reveal changes considered diagnostic for LPE. Contrast radiography may reveal changes in mucosal and wall thickness. Ultrasonographic examination of the small intestine can be valuable in the diagnosis of LPE. In general, the presence of marked wall thickening on abdominal ultrasound examination will correlate with marked changes on histopathological examination.

Endoscopic examination of cats with LPE may reveal increased mucosal friability, granularity and erosions. Since visual inspection by endoscopy is relatively insen-

sitive for the diagnosis of IBD in cats, it is essential to obtain multiple biopsies from several sites in the stomach and duodenum.

Eosinophilic enteritis/enterocolitis

Eosinophilic enteritis/enterocolitis (EE) is much less common than LPE in cats. There is infiltration of the lamina propria of affected sections of bowel with a mixed population of inflammatory cells, predominantly eosinophils. Eosinophilic enteritis/enterocolitis is typically a more severe disease than LPE, and requires more aggressive therapy.

Cats may present with either of two forms of EE, a form isolated to the intestine or as a manifestation of hypereosinophilic syndrome. Hypereosinophilic syndrome is a preneoplastic condition characterised by eosinophilic infiltration of multiple organs, including the liver, spleen and gastrointestinal tract. Cats with hypereosinophilic syndrome commonly have a peripheral eosinophilia. The long-term prognosis of cats with hypereosinophilic syndrome is poor and response to therapy is often minimal.

Cats with isolated EE usually have clinical signs of both small and large intestinal disease; haematochezia is common. It is more common with EE than LPE to detect a thickened section of intestinal wall on abdominal palpation or ultrasonographic examination.

Establishing the diagnosis of EE requires the clinician to rule out other potential causes of eosinophilic infiltration into the intestine. Eosinophilic infiltration of the gastrointestinal tract can be caused by parasitism, dietary intolerance and mast-cell disease, and may be idiopathic. The diagnosis is conclusively established by examination of histopathological samples from several sites. Initial therapeutic measures should include anthelmintic treatment and the use of a hypoallergenic diet. If these measures are unsuccessful, other therapeutic measures may include immunosuppressive therapies such as corticosteroids, azathioprine or chlorambucil. Eosinophilic enteritis isolated to the intestine is generally responsive to immunosuppressive doses of corticosteroids.

Neutrophilic inflammatory bowel disease

Idiopathic suppurative IBD is a rare diagnosis, with only a single case report in the literature (Leib *et al.*, 1986). While some neutrophils are usually present in the inflammatory infiltrate of cats with LPE, in suppurative IBD the neutrophil is the predominant cell type. As this is a rare disease it is not well characterised; however, bacterial involvement has been suggested and the use of broad-spectrum antibiotic therapy may be warranted.

Small intestinal neoplasia

The most common neoplastic condition of the feline small intestine is intestinal lymphoma. Other neoplasms commonly encountered in the feline gastrointestinal tract include adenocarcinoma and mast-cell tumors.

The clinical signs of small intestinal neoplasia are variable, depending on whether the neoplastic lesion forms a discrete tumour with subsequent partial obstruction of the intestine or the neoplastic process involves infiltration of the intestinal wall.

The most common clinical signs of alimentary lymphoma are anorexia and weight loss; there is commonly also chronic intermittent vomiting and sometimes pyrexia. These clinical signs and historical findings are essentially the same as those encountered with LPE, accentuating the importance of arriving at a definitive diagnosis in cases with chronic small intestinal diarrhoea, vomiting and weight loss.

Cats with intestinal lymphoma may present with discrete masses, but more commonly there is a diffuse neoplastic infiltrate of the intestinal wall, causing a thickening of the wall, disruption of the normal mucosal architecture and loss of effective absorptive surface area. Intestinal lymphoma may also spread to and involve the mesenteric lymph nodes, liver and spleen. Infection with FeLV is thought to be a major contributor to the development of intestinal lymphoma in cats in some regions, but at the time of presentation many cats are FeLV negative.

Intestinal adenocarcinoma is the second most common type of neoplastic lesion encountered in the feline intestine. There is a predisposition to this type of neoplasm in Siamese cats. This malignancy is usually well advanced and metastasis has commonly occurred at the time of diagnosis. Adenocarcinoma may be annular, involving 360 degrees of the intestinal wall, or may be intraluminal, with both infiltration of the intestinal wall and masses entering the lumen. Feline intestinal adenocarcinoma has been reported to be located most frequently in the jejunum, followed by the ileum and ileocaecal region (Cribb, 1988). The history and clinical signs of intestinal adenocarcinoma are common to lymphoma and IBD. Annular constrictions and neoplastic masses may be detected on abdominal palpation. The definitive diagnosis is by histopathological examination of sections of affected bowel.

The prognosis for cats with intestinal adenocarcinoma is poor, as metastasis has usually occurred at the time of diagnosis. Lymphoma of the intestine car-

ries a slightly better prognosis, as some intestinal lymphomas are susceptible to chemotherapy, as discussed elsewhere (see Chapters 3 and 23). Definitive diagnosis and staging of cats with chronic small intestinal disease is very important before starting prednisone/prednisolone therapy, as the use of glucocorticoids may induce multidrug resistance in the lymphoma cells, which may complicate subsequent management of small intestinal lymphoma.

Exocrine pancreatic insufficiency

Although the condition of exocrine pancreatic insufficiency is a disorder of the exocrine pancreas, the resulting clinical signs result from a loss of small intestinal function. Exocrine pancreatic insufficiency is a result of the loss of functional pancreatic acinar tissue and subsequent maldigestion and malabsorption of nutrients from the small intestine. Unabsorbed fats, polysaccharides and proteins increase the osmotic pull of the small intestinal content, resulting in loose stools or osmotic diarrhoea. The bowel motions of cats with exocrine pancreatic insufficiency are bulky and steatorrhoeic. Clinical signs include diarrhoea, weight loss or poor growth, and there may be a poor hair coat. In dogs, the most common cause of exocrine pancreatic insufficiency is pancreatic acinar atrophy, an idiopathic degenerative disorder. Although acinar atrophy can occur in cats, it is thought that as with humans, most cats develop exocrine pancreatic insufficiency as a result of chronic pancreatitis. The pancreas of the cat is the sole source of intrinsic factor in this species. This protein is essential for the absorption of cobalamin from the small intestine, and virtually all cats with exocrine pancreatic insufficiency have cobalamin deficiency.

The diagnosis of exocrine pancreatic insufficiency has previously relied on the demonstration of subnormal faecal proteolytic activity. Assay of faecal proteolytic activity, if done properly, is expensive, time consuming and lacking in specificity. The ability of veterinarians to diagnose this condition has been significantly advanced by the development of an ELISA specific for fTLI (Steiner *et al.*, 2000b). Using this assay, cats with a circulating serum fTLI concentration <8 μg/l are diagnosed as having exocrine insufficiency. TLI assays are species specific, and fTLI cannot be accurately measured by any immunoassay systems for the measurement of canine or human TLI. Serum fTLI is stable and easily shipped internationally for assay.

Although exocrine pancreatic insufficiency in cats is much easier to diagnose with access to a species-specific TLI assay, the disease is uncommon compared with the prevalence of IBD in the feline population. It has previously been observed that cats with IBD will often have concurrent cholangiohepatitis or pancreatitis (Weiss *et al.*, 1996). In the authors' experience, cats with clinical signs initially suggestive of exocrine insufficiency will often have increases in circulating fTLI, low serum cobalamin concentrations and either low or high serum folate concentrations. This is consistent with IBD as a primary disease process, with concurrent pancreatic inflammation.

The therapy for confirmed feline exocrine pancreatic insufficiency is by replacement of digestive enzymes with powdered supplements, accompanied by parenteral cobalamin supplementation, since nearly all patients are deficient. Clinical signs usually resolve readily and weight gains are noted. Pancreatic enzyme supplementation will be required for the remainder of the cat's life. Concurrent IBD may necessitate initial concurrent therapy with prednisolone, which may subsequently be able to be withdrawn.

General principles of the medical therapy of small intestinal disease

Acute diarrhoea

With the exception of acute obstructions due to foreign bodies or intussusceptions, which are generally surgical conditions, the medical therapy of acute small intestinal disease is supportive in nature. Acute small intestinal disease is associated with the rapid onset of dehydration and hypovolaemia as a result of diarrhoeal fluid losses, but is rare in cats. Acute small intestinal disease is usually due to a single, acute insult to the intestine, and is typically self-limiting. Therapy is usually by intestinal rest and replacement of circulating fluid volumes. If the cat is not vomiting, oral rehydration solutions are often useful for the replacement of circulating fluid volumes. In common with acute gastritis, many cats with an isolated acute disease of the small intestine are in recovery by the time they are presented to a veterinarian.

Severe acute disease, such as may be encountered with feline panleucopenia or acute salmonellosis, requires a more aggressive approach to therapy. A reasonable initial database includes PCV and total protein measurement, blood urea and serum glucose concentrations. This information can be obtained from less than a needle-hub full of blood and with inexpensive in-house equipment. Intravenous fluid therapy will be necessary, to replace fluid losses and meet main-

tenance requirements. In severe acute small intestinal disease there may be a loss of plasma proteins across the damaged mucosa. If total protein is declining during therapy, artificial colloid fluids or cross-matched plasma may be necessary to maintain adequate cardiac output and tissue perfusion.

Antibiotic therapy, as discussed previously, is typically contraindicated in the therapy of acute small intestinal disease. Most acute, infectious small intestinal diseases of cats are viral in origin. In severe enteritis, however, where there is evidence of severe mucosal compromise, the use of high-dose, broad-spectrum intravenous antibiotics is warranted to decrease the likelihood of mucosal translocation of bacteria and subsequent sepsis.

Motility-modifying drugs, such as anticholinergics or opioid derivatives, are generally not recommended for use in cats. Anticholinergic medications may potentiate ileus, while a lack of information on safe dosages and the potential for adverse reactions limits the use of opioid medications.

Intestinal rest is usually provided by withholding solid food for 24–48 h, during which time the diarrhoea will usually abate. Reintroduction of solid food starts with a bland, highly digestible diet such as boiled rice and cottage cheese, then gradual reintroduction of the animal's normal diet. A complete change to the animal's normal diet is generally not warranted; however, it is often useful to avoid high-fat foods in the first few days.

The concept of intestinal rest has been challenged recently by feed-through therapy, in which feeding of a readily digestible diet continues throughout the bout of acute diarrhoea. This has been shown in human children to be associated with a more rapid healing of the intestinal mucosa and return of normal function. The feed-through concept for acute diarrhoea has not been adequately explored in veterinary medicine; however, the relatively frequent occurrence of vomiting in veterinary patients with acute small intestinal disease is likely to reduce the applicability of this technique.

Chronic diarrhoea

Cats with chronic diarrhoea, in common with those presenting for chronic vomiting, will not respond to ongoing conservative or symptomatic therapy for the diarrhoea. Probably the most important element in the successful management of cats with chronic diarrhoea is the definitive diagnosis of the underlying disease process. In practice, many owners of cats with chronic diarrhoea are often unwilling or do not have the resources to allow definitive diagnosis by histopathology of intestinal biopsies. In this situation it is important to use as many non-invasive diagnostic tools as possible to narrow the differential diagnosis list, and emphasise that response to therapy may be limited or incomplete.

Cats with chronic IBD are generally treated with anti-inflammatory glucocorticoids. Early aggressive therapy appears to give the best response; typical starting doses should be in the range of 1–2 mg/kg twice daily with prednisone/prednisolone. This dose is maintained for at least 2 weeks, regardless of how rapidly clinical signs abate. After this induction period, a gradual tapering of the dose should be applied, over 8–10 weeks. It is not unusual for clinical signs to reappear during the tapering process; the dose is then raised to the lowest dose giving adequate control, and maintained at this point. If the cat has eosinophilic enteritis, higher doses of steroids, up to 5 mg/kg twice daily, may be required for control of clinical signs.

While the role of dietary antigens/allergens has not been fully defined in IBD, dietary management may be useful in the approach to some cats with IBD.

Some gastroenterologists recommend changing the diet to a novel protein source, to which the cat has not had previous exposure. This is a rapidly growing area of product development by commercial pet-food manufacturers, and numerous products are available. Alternatively, homemade diets may be used.

In some cases, an initial combination of medical and dietary therapy may be sufficient to gain control of clinical signs, and the anti-inflammatory therapy can be tapered entirely while maintaining the patient on the new diet. It is possible for the patient to develop intolerance or hypersensitivity to the new dietary proteins, with eventual return of clinical signs.

Another recent innovation is the use of partially hydrolysed proteins in commercial diets, with the underlying assumption that destruction of antigenic/allergenic epitopes will reduce responsiveness to the protein in the diet. This proposition is yet to be adequately tested in controlled clinical trials on IBD in cats.

Dietary therapy must be maintained for a minimum of 4 weeks before a positive benefit can be gauged, and should be maintained for at least 9–10 weeks before deciding that there is no benefit from a particu- lar diet.

Cats with a diagnosis of IBD that do not respond to glucocorticoid therapy may require more aggressive immunosuppressive therapy, using agents such as azathioprine or chlorambucil. If dietary modification has not been tried in these cats, however, it should be

attempted before adding increasing numbers of medications.

Some cats, particularly those with mild to moderate LPE, may benefit from the addition of metronidazole at a dose of 10–20 mg/kg twice daily. In this dose range the benefit, if any, of metronidazole may be due to an immunomodulatory effect, a suppressive effect on anaerobic bacteria in the intestine, or a combination of the two.

Cats with a history of chronic small intestinal disease should be screened for subnormal serum cobalamin concentrations. If the serum cobalamin is low, additional benefit may be gained by supplementation of cobalamin parenterally. There is no benefit from oral supplementation of cobalamin. The cat is cobalamin depleted either because intestinal bacteria have consumed the cobalamin, or because the ileum is unable to absorb the intrinsic factor–cobalamin complex. In either case, oral supplementation will have no effect on body cobalamin stores. Parenteral cobalamin supplementation is given by injection, generally at a dose of 250 μg/cat injected subcutaneously once weekly for 6 weeks, once every 2 weeks for 6 weeks, then once a month.

The large intestine

The large intestine extends from the ileocaecocolic junction through the ascending, transverse and descending colon to the rectum and anus. The hallmark sign of large intestinal disease is either diarrhoea or constipation.

The large intestine has two major functions. The first function of the colon is to absorb fluid presented to it from the small intestine. Little or no absorption of nutrients occurs in the large intestine. The daily input of fluid to the large intestine exceeds the circulating fluid volume of the body. Colonic absorption of this fluid is critical to normal homoeostasis. Normal absorption in the small intestine, and colonic fluid uptake, together account for 99% of the fluid presented to the gastrointestinal tract.

While the colon has to absorb large quantities of fluid as part of normal physiological processes, an additional colonic reserve allows additional fluid uptake from the colon to compensate in situations of increased small intestinal input, such as with chronic IBD. As the colon absorbs the majority of the excess fluid presented with marked small intestinal dysfunction, some cats with IBD may present with only mild signs of diarrhoea. Conversely, mild changes in large intestinal absorptive capacity on a percentage basis will cause a dramatic change in faecal water content, and hence lead to marked diarrhoea.

Fluid absorption from the colon is by passive diffusion; this diffusion is facilitated by the active uptake of salts from the colonic lumen, creating an ionic concentration gradient.

The second function of the colon, following absorption of fluids, is the formation and storage of faeces until the faecal matter is evacuated. The normal passage of faecal matter through the colon and rectum, and subsequent evacuation, relies on the presence of normal colonic motility. An absence or defect in colonic innervation or smooth-muscle function will result in decreased or absent colonic motility and subsequent loss of normal evacuation of the colon, resulting in constipation and eventually megacolon.

The large intestine possesses a large and complex bacterial flora, which may play a role in the normal physiology of the colon. In dogs, the fermentation of dietary fibre by colonic bacteria leads to the production of short-chain fatty acids which can be used as an energy substrate by colonocytes. The situation in cats is not clear; however, there is evidence that anaerobic bacteria are quantitatively more important in cats than in dogs. Infectious and contagious organisms will occasionally produce clinical signs of large intestinal disease in cats. *Campylobacter jejuni* and *Salmon- ella* species can produce large intestinal signs by overloading the fluid resorptive capacity of the colon secondary to small intestinal infection. The diagnosis and clinical management of these bacterial infections are discussed in the section on infectious disease of the small intestine.

Clinical examination and evaluation of the large intestine

In contrast to the small intestine, in which clinical signs of disease may be vague and localisation can be challenging, clinical signs of disease affecting the large intestine usually direct the clinician to this organ rapidly.

Historical findings in diarrhoea of large intestinal origin differ from small intestinal diarrhoea in several areas (see Table 16.6). The large intestine is the last line of defence against diarrhoea. Inflammation or irritation of the large intestine results in increased urgency for passage of bowel motions, and reduces the capacity of the large intestine to expand and accommodate faecal matter. Large intestinal diarrhoea is thus associated with the frequent passage of small quantities of soft to liquid faeces. The total volume of faeces passed in a 24 h period may be no greater than normal, or

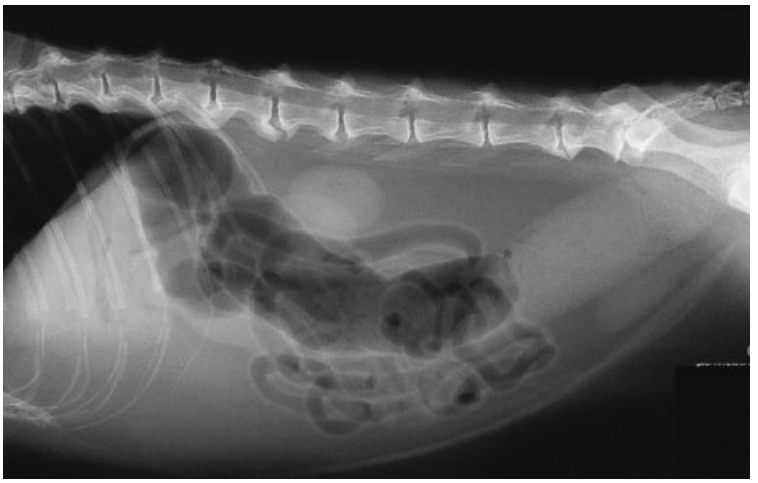

Figure 16.10 Lateral view plain radiographic study of the abdomen in a cat with constipation. Note the heavily laden large intestine extending cranially from the pelvic brim. This cat is markedly overweight; excessive intra-abdominal fat is increasing the contrast of the radiograph. Note also the spondylosis at several intervertebral spaces. Either the obesity or the spinal column disease, or a combination of both, may be contributing to the constipation in this cat.

slightly increased, but the total number of bowel motions will be dramatically increased.

Haematochezia and excess faecal mucus are common classical signs in large intestinal diarrhoea, while isolated streaks of fresh blood on faeces suggest mass lesions within the last 10 cm of the colon or in the perianal region.

The history in cats with constipation is usually straightforward. The owner presents the cat because it has failed to pass bowel motions. Tenesmus, a condition of unproductive straining, may also be reported. Outdoor cats may be presented for vomiting, lethargy or inappetance when constipated, if the owners are unaware of the lack of normal defecation. Tenesmus before passage of a bowel motion is consistent with constipation, while tenesmus continuing after passage of a motion is more suggestive of inflammation of the colon and rectum and subsequent increased contractile activity.

Physical examination and palpation

The large intestine in cats is amenable to direct palpation during the physical examination. Cats with large intestinal diarrhoea will usually have no gut content palpable in the descending colon, and may resent palpation of the distal abdomen and retroperitoneal area. Faecal staining, mucus and blood flecks may be noted in the perianal area. Constipation in cats is usually extremely easy to palpate; the heavily laden colon can be palpated from the pelvic brim cranially to the transverse colon. If the history and faecal character suggest that an isolated mass lesion is present in the distal rectum, gentle rectal palpation may be attempted with a gloved little finger. In general, it is advisable to administer sedation or anaesthesia before attempting rectal palpation of cats. Sedation and anaesthesia will also relax the abdominal muscles, making abdominal palpation more rewarding in some large or fractious cats.

Abdominal radiography

The normal colon, containing both gas and relatively radiodense faecal matter, is easily visualised on plain abdominal radiographs. Constipation in cats is easy to identify (Figure 16.10), with severe cases exhibiting a question-mark-shaped colon on a dorsoventral view. Constipation or reduced large intestinal motility may be revealed as isolated areas of faecal impaction, particularly if the impacted area does not appear to move on repeat examination.

Contrast radiography using barium enemas, or barium/air double-contrast techniques, has been described for use in veterinary patients. These techniques are useful in identifying strictures of the large intestine or filling defects caused by intraluminal masses. They are technically difficult and rely on scrupulous patient preparation to derive maximum information. Single-agent contrast radiography will often demonstrate filling defects or strictures simply by following the passage of a barium meal through the large intestine. Radiographic examination of cats with large intestinal diarrhoea rarely reveals a diagnosis.

Abdominal ultrasonography

The presence of free gas in the large intestine, which is one of the reasons for the ease of examination with plain radiography, can represent a problem in the ultrasonographic examination of the large intestine.

Ultrasound examination of this organ is possible, however, and information may be gained on wall thickness or the presence of discrete intramural masses.

Endoscopic examination and biopsy

The ready accessibility of the colon to endoscopic examination leads most clinicians to proceed to endoscopic examination directly from physical examination. Direct examination of the feline large intestine is relatively simple. Endoscopic examination can yield a large amount of information, from direct observation of the mucosa and of discrete lesions (Plate 16.7), and from histopathological examination of mucosal biopsies. Correct preparation of the patient is critical to obtain the maximum diagnostic benefit from endoscopic examination. Preparation for endoscopic examination, and details of endoscopic technique, are described in detail elsewhere.

It is important not to overdiagnose colitis on direct examination of the colonic mucosa, as enema solutions used in the preparation of the patient may cause hyperaemia. The entire length of the colon is accessible to examination, including the caecum. Entry of the endoscope into the ileum is usually not possible. The length of the colon should be examined for changes in mucosal integrity, masses, erosions and strictures. Numerous mucosal biopsy samples should be obtained, from apparently normal tissues and from grossly diseased mucosa.

Given the accessibility of the feline large intestine to endoscopic examination and palpation, it is unusual for exploratory laparotomy and surgical biopsy of the colon to be necessary to establish a diagnosis. The intent of colonic surgery is usually therapeutic rather than diagnostic.

Table 16.9 Potential aetiologies of constipation in the cat

Dietary factors	Low-residue diets Ingested foreign material Bones Wool Carpet (pica)
Environmental factors	Inactivity (hospitalisation, obesity) Change in routine (new house, etc.) Dirty litter tray
Painful defecation	Acute colitis Proctitis Anal/rectal stricture Pseudocoprostasis (in longhaired cats) Spinal disease or injury Pelvic, hip or limb disease
Colonic obstruction	Extraluminal Old pelvic fracture Intraluminal Stricture, tumour or foreign body
Neuromuscular	Megacolon Congenital or acquired Lumbosacral spinal cord disease Spinal lymphoma
Fluid or electrolyte imbalance	Dehydration Hypokalaemia Hypercalcaemia
Drug induced	Anticholinergics Phenothiazines Opiates Sucralfate

Modified from Murdoch (1996), data reproduced with permission.

Diseases of the large intestine

Inflammatory disease

Acute colitis

Acute colitis, in common with acute gastritis and enteritis, is usually due to an isolated insult to the colon, and is far less common in cats than in dogs. Occasional cases of acute colitis will be encountered in practice, particularly in hunting cats. Acute signs of large intestinal disease may also be encountered with acute salmonellosis or acute camplyobacteriosis. There is usually a small intestinal component to the disease in these infectious conditions and it is unusual for the cat to present with pure large intestinal symptoms.

Acute colitis is characterised by acute onset of frequent, urgent bowel emptying, often of profuse watery diarrhoea. There may be blood staining of the faeces and marked tenesmus. Usually there are no signs of systemic illness. Acute colitis is usually self-limiting and responds to conservative therapy.

The clinical approach to acute large intestinal diarrhoea is identical to the approach to small intestinal diarrhoea, and has been discussed in a previous section.

Chronic colitis

Chronic inflammation of the colon may be observed in isolation, or in combination with inflammation of any other part of the gastrointestinal tract. The aetiology of

chronic colitis remains unknown in most cases. The differential diagnoses, clinical approach to and management of chronic colitis are as previously described for IBD of the small intestine. Faecal flotation for parasites, particularly *Giardia* species, should be carried out.

Neoplastic disease

Both adenocarcinoma and lymphoma may occur in the large intestine of cats. Of the two, lymphoma occurs more commonly. Large intestinal lymphoma is more commonly seen in younger cats, while adenocarcinoma is more typically seen in cats older than 9 years of age.

Adenocarcinoma of the large intestine is usually slow growing, and the cat may show signs of mild constipation, occasional vomiting and haematochezia for some time before diagnosis. Adenocarcinoma of the large intestine is usually a discrete mass, which may be palpable on physical examination. Radio-graphic or endoscopic studies usually reveal the diagnosis. The actual clinical signs observed with large intestinal adenocarcinoma are variable, depending on the size and location of the tumour, and often the diagnosis is arrived at during the investigation of non- specific colonic disease.

Lymphoma of the large intestine may be discrete or diffuse. The diagnosis is established from histopathology of the affected section of the intestine. As with large intestinal adenocarcinoma, the clinical signs and history with large intestinal lymphoma are variable, depending on the presence or absence of discrete masses and the area and extent of large intestinal involvement. Management of lymphoma is described in more detail in Chapter 3.

Constipation

Constipation, the absence of defecation, and megacolon, the presence of persistent dilatation of the rectum and large intestine with loss of normal motility, are probably the most important clinical conditions of the large intestine in cats. These conditions have numerous potential aetiologies, which are summarised in Table 16.9.

Of the aetiologies described in Table 16.9, dietary and lifestyle factors are probably most important in initial development of constipation in most cats. The trend towards the feeding of highly palatable, low-residue diets and the relative inactivity of many indoor cats leave cats prone to obesity. The low-residue diets do not produce sizeable faecal bulk, decreasing the stretch on the rectum and stimulus to defecate. If faeces remain in the large intestine for a prolonged period they will become increasingly hard, as fluid resorption from the colon continues.

Healed pelvic fractures are another important cause of constipation in cats. Many pelvic fractures are treated conservatively in cats, which may result in malalignment of pelvic fragments and narrowing of the pelvic canal. This diagnosis is easily achieved through plain radiography, and should be immediately considered in any constipated cat with a history of pelvic injury.

Conditions decreasing the willingness of the cat to defecate will also promote constipation. These can range from dirty litter trays to orthopaedic disease of the hindlimbs, spinal cord disease or pseudocoprostasis, the impaction of perianal hair with faecal matter, which will lead to painful dermatitis and pulling of the hair coat if not removed. Obese and elderly cats are more prone to orthopaedic conditions and pseudocoprostasis, which increase the probability of constipation. Management of constipation is by attention to the inducing factor(s), dietary modification and the use of laxative medications, as described below.

Megacolon is a disease entity that may arise as a primary, idiopathic disorder or secondary to any of the causes of constipation listed in Table 16.9 if the condition is not corrected rapidly. Megacolon is a persistent enlargement of a flaccid, hypomotile large intestine and rectum. Megacolon is associated with obstipation, intractable constipation in which the affected cat simply cannot defecate. The pathogenesis of megacolon appears to involve a defect in the control of smooth-muscle contractility. Mucosal function remains apparently normal in this condition and fluid reabsorption from the large intestine continues as normal, rendering the faecal matter very hard and dry.

Medical management of megacolon is at best challenging and, in many cases, apparently without benefit. The initial therapy involves removal of the impacted faecal matter. This is achieved by the use of warm water and mild soap enemas. Often, cats with longstanding megacolon are elderly, frail and systemically ill, with dehydration and electrolyte disorders as a result of the failure to defecate. Attention must be given to pre-anaesthetic screening of these patients and restoration of circulating fluid volume and electrolyte balance. It is often prudent to hospitalise the cat, institute fluid therapy and then empty the colon with repeated short procedures rather than a longer, more aggressive single procedure. Phosphate retention enemas are toxic to cats and should not be used in this species.

After the colon is cleared of impacted faeces, medical management includes the use of low-residue diets with the addition of soluble fibre, such as pectin or guar gum. Prokinetic agents may be useful, although the most useful agent, cisapride, has recently been with-

drawn from the market in the USA, owing to adverse effects in human patients. Bethanechol (0.1–0.2 mg/kg three times daily) is a procholinergic drug that may be useful in cats with constipation, but may cause hypersalivation and should be used with care.

A variety of laxative preparations is available, including numerous 'hairball' medications based on paraffin waxes. Lactulose, an osmotic laxative, can be particularly useful in the management of constipated cats. A dose of approximately 5 ml twice daily usually produces soft stools in constipated cats that have not already developed megacolon and obstipation.

Longstanding megacolon is almost impossible to resolve medically. Owners should be warned of the need for anaesthetic procedures and repeated enemas, with the attendant risks of repeated anaesthetic procedures. For this reason, the prognosis for cats with megacolon that are treated medically is at best fair to guarded. In many cases, the best long-term outcome for the cat will be obtained with subtotal colectomy. Most cats tolerate this procedure well, and after an initial period of watery to soft stools, most cats will eventually produce a soft but formed stool, reducing or avoiding the need for repeated anaesthesia and evacuating enemas. The details of subtotal colectomy surgery are beyond the scope of this chapter, but can be found described in detail in most textbooks of small animal surgery.

References

Baez J.L., Hendrick M.J., Walker L.M. & Washabau R.J. (1999) Radiographic, ultrasonographic, and endoscopic findings in cats with inflammatory bowel disease of the stomach and small intestine: 33 cases (1990–1997). *J Am Vet Med Assoc* **215**, 349–354.

Bennett M., Baxby D., Blundell N., *et al.* (1985) Cryptosporidiosis in the domestic cat. *Vet Rec* **116**, 73–74.

Burrows C.F. (1996) Gastric disease. In *Manual of Canine and Feline Gastroenterology* (eds Thomas D.A., Simpson J.W. & Hall E.J.). British Small Animal Veterinary Association, Cheltenham.

Cribb A.E. (1988) Feline gastrointestinal adenocarcinoma: a review and retrospective study. *Can Vet J* **29**, 709–711.

Daly M.J., Humphrey J.M. & Stables R. (1980) Inhibition of gastric acid secretion in the dog by the H_2-receptor antagonists, ranitidine, cimetidine and metiamide. *Gut* **21**, 408–412.

Dennis R., Herrtage M.E., Jefferies A.R., *et al.* (1987) A case of hyperplastic gastropathy in a cat. *J Small Anim Pract* **28**, 491–504.

Jergens A.E. (1999) Inflammatory bowel disease: current perspectives. *Vet Clin North Am Small Anim Pract* **29**, 501–521.

Lamb C.R. (1999) Recent developments in diagnostic imaging of the gastrointestinal tract of the dog and cat. *Vet Clin North Am Small Anim Pract* **29**, 307–342.

Leib M.S., Sponenberg D.P., Wilcke J.R. & Loar A.S. (1986) Suppurative colitis in a cat. *J Am Vet Med Assoc* **188**, 739–741.

Muir P. (1990) Isolation of a novel virus from cats with nictitating membrane protrusion and diarrhoea. *Proceedings of the Annual Meeting of the American Animal Hospital Association*, p. 669.

Murdoch D. (1996) Large intestinal disease. In *Manual of Canine and Feline Gastroenterology* (eds Thomas D.A., Simpson J.W. & Hall E.J.). British Small Animal Veterinary Association, Cheltenham.

Pearson H., Gaskell C.J., Gibbs C. & Waterman A. (1974) Pyloric and oesophageal dysfunction in the cat. *J Small Anim Pract* **15**, 487–501.

Steiner J.M., Williams D.A. & Moeller E.M. (2000a) Development and validation of a method for simultaneous separation and quantification of 5 different sugars in canine urine. *Can J Vet Res* **64**, 164–170.

Steiner J.M., Williams D.A., Moeller E.M. & Melgarejo T.M. (2000b) Development and validation of an enzyme-linked immunosorbent assay for feline trypsin-like immunoreactivity. *Am J Vet Res* **61**, 620–623.

Weiss D.J., Gagne J.M. & Armstrong P.J. (1996) Relationship between inflammatory hepatic disease and inflammatory bowel disease, pancreatitis and nephritis in cats. *J Am Vet Med Assoc* **209**, 1114–1116.

Yamamoto J.K., Hansen H., Ho E.W., *et al.* (1989) Epidemiologic and clinical aspects of feline immunodeficiency virus infection in cats from the continental United States and Canada and possible mode of transmission. *J Am Vet Med Assoc* **194**, 213–225.

Yamasaki K., Suematsu H. & Takahashi T. (1998) Comparison of gastric lesions in dogs and cats with and without gastric spiral organisms. *J Am Vet Med Assoc* **212**, 529–533.

Further reading

Simpson J.W. (1996) Gastrointestinal endoscopy. In *Manual of Canine and Feline Gastroenterology* (eds Thomas D.A., Simpson J.W. & Hall E.J.). British Small Animal Veterinary Association, Cheltenham, Chapter 2.

Tams T.R. (ed.) (1990) *Small Animal Endoscopy*. 1st edn. C.V. Mosby, St. Louis, MO.

Willard M.D. (1991) Intestinal bacterial infections. In *Consultations in Feline Internal Medicine* (ed. August J.R.). WB Saunders, Philadelphia, PA.

Zoran D.L. (2000) Is it IBD? Managing inflammatory disease in the feline gastrointestinal tract. *Vet Med* **95**, 128–139.

Chapter 17

THE LIVER AND PANCREAS

J. Stonehewer

Diseases of the exocrine pancreas

The incidence of pancreatic disease in the cat has traditionally been considered low. However, it appears that although cats suffer from diseases of the exocrine pancreas frequently, these disorders often escape clinical diagnosis. A recent large retrospective study of post-mortem findings showed 1.3% of 6504 feline pancreata to have pathologically significant lesions (Steiner & Williams, 1999). Another study suggests an even higher rate of 35 per 1000 feline necropsies (Owens *et al.*, 1975). In contrast, of 180 648 cats entered into the Veterinary Medical Database at Purdue University over a 10-year period only 1027 (0.57%) were diagnosed with exocrine pancreatic disorders (Steiner & Williams, 1999). Other published rates on numbers of cats with pancreatic disorders vary from 1.5 (Strombeck & Guilford, 1991) to 4.6 (Kelly *et al.*, 1975) per 1000 cats. Although the cat appears to be susceptible to the same spectrum of pancreatic disorders as the dog, these disorders are much more difficult to recognise in cats than in dogs.

Most published reports suggest that the diagnosis is most often made at exploratory surgery (rarely) or post-mortem examination (most often) (Anderson & Strafuss, 1971; Duffell, 1975; Owens *et al.*, 1975; Garvey & Zawie, 1984; Strombeck & Guilford, 1991; Schaer & Holloway, 1991).

Pancreatitis

Classification

A variety of methods has been used when trying to classify feline inflammatory pancreatic disease. Some authors advocate the use of a purely histological classification (Swift *et al.*, 2000) categorising cases as acute necrotising pancreatitis, pancreatic fibrosis with active inflammation, pancreatic fibrosis without active inflammation or normal. Others suggest following the human classification scheme (Bradley, 1993), which is more clinically relevant. This scheme defines acute pancreatitis as an inflammatory condition of the pancreas after removal of the inciting cause. In contrast, chronic pancreatitis is defined by irreversible histopathological changes of exocrine pancreatic tissue, most notably fibrosis and atrophy. Both forms can be mild or severe. Mild forms of pancreatitis are associated with little or no pancreatic necrosis or systemic effects, and recuperation of the patient often occurs. Conversely, severe forms of pancreatitis are associated with extensive pancreatic necrosis and multiple organ involvement and often are associated with a poor prognosis.

Aetiopathogenesis

The aetiopathogenesis of feline pancreatitis is poorly understood. Extensive studies of experimental pancreatitis in cats and other species have led to the generally accepted hypothesis that pancreatic acinar cells ultimately respond in a common fashion to a variety of harmful stimuli. In brief, an initial decrease in secretion of pancreatic enzymes is followed by the formation of abnormal cytoplasmic vacuoles in which the contents of lysosomes and zymogen granules coalesce. This leads to an inappropriate intracellular activation of trypsin and subsequently of other digestive enzymes. These activated digestive enzymes cause local effects such as inflammation, haemorrhage, acinar cell necrosis and peripancreatic fat necrosis. Digestive enzymes released into the bloodstream may cause systemic effects, including systemic inflammatory changes, systemic vasodilation leading to hypotension, pulmonary oedema, disseminated intravascular coagulation, central nervous system deficits,

respiratory failure, renal failure and even multiorgan failure.

Published reports identify the following six main aetiological associations, although more than 90% of reported cases are idiopathic.

Coexisting cholangitis/cholangiohepatitis

There is no evidence to prove a causal link between pancreatitis and cholangitis and cholangiohepatitis although they may coexist (Kelly *et al.*, 1975; Garvey & Zawie, 1984). It is presumed that ascending bacterial infections of both the common bile duct and major pancreatic duct occur simultaneously (Hirsch & Doige, 1983). Since these two ducts enter the duodenum at a common papilla, this is plausible. It is also possible that cholangiohepatitis precedes the onset of pancreatitis and may be responsible for its initiation. Retrograde lymph flow may occur from the extrahepatic biliary system into pancreatic lymphatics, carrying bile acids to the pancreas, which are capable of initiating acute pancreatitis.

Pancreatic fluke infestation

In the long term this may lead to severe pancreatic ductular and acinar fibrosis and pancreatitis in cats; (Kelly *et al.*, 1975; Roudebush & Schmidt, 1982; Garvey & Zawie, 1984; Sheldon, 1966). Infection with the pancreatic trematode *Eurytrema procyonis* has not been reported to result in clinical signs of pancreatitis, but infection with the cat liver fluke *Amphimerus pseudofelineus* can result in chronic pancreatitis associated with chronic cholangitis. Flukes can also be identified within hepatic and pancreatic cysts. Feline liver flukes have not been reported in the UK. They are found in a number of areas around the USA and in tropical regions of the world.

Pancreatic trauma

Road traffic accidents and falls from heights causing pancreatic trauma have been reported as causes of acute pancreatitis in cats (Suter & Olsen, 1969; Ruwitch *et al.*, 1964; Schaer, 1979). All reported cases have been uniformly fatal, having a clinical course similar to haemorrhagic pancreatitis in dogs.

Toxoplasma gondii *infection*

This can be a cause of acute interstitial pancreatitis and has been reported to cause chronic pancreatitis in cats (Smart *et al.*, 1973).

Viral infections

Feline herpesvirus was isolated at necropsy from two kittens with necrotising pancreatitis (Van Pelt & Crandell, 1987). The primary clinical signs in these kittens were respiratory not gastrointestinal. Weaker evidence has been presented for feline parvovirus infection in kittens and feline infectious peritonitis.

Toxic agents

Two cases of feline pancreatitis after topical use of fenthion, an organophosphate cholinesterase inhibitor, have been reported.

Unlike dogs, cats do not appear to be predisposed to the development of pancreatitis in association with high-fat meals, obesity or the administration of many drugs, including glucocorticoids (Hardy, 1994).

The pathogenesis of pancreatitis in cats is generally insidious and much less severe than in dogs, and it rarely progresses to the death of the animal. In most published cases the diagnosis is established at post-mortem examination and the pancreatitis is generally subclinical and unexpected (Owens *et al.*, 1975). Exceptions include:

- traumatic acute pancreatitis where mortality is high
- cats with concurrent cholangitis/cholangiohepatitis in which liver disease is usually more severe than pancreatic disease
- cats with obstructive jaundice secondary to common bile-duct obstruction from pancreatic fibrosis
- rare cases that develop diabetes mellitus due to extensive islet cell destruction during the inflammatory process (a significant number of diabetic cats have evidence of chronic pancreatitis at necropsy).

Clinical signs

No apparent age, sex or breed predispositions exist for cats with pancreatitis. For cats with chronic pancreatitis the mean age at diagnosis is around 8 years (Duffell, 1975), but cases can be diagnosed in cats as young as 5 weeks or as old as 25 years (Owens *et al.*, 1975; Macy, 1989).

Clinical signs are non-specific. In a recent report of 40 cats with severe pancreatitis (Hill & Van Winkle, 1993) the following clinical signs were reported:

- lethargy 100%
- anorexia 97%
- dehydration 92%

- hypothermia 68%
- vomiting 35%
- abdominal pain 25%
- palpable abdominal mass 23%
- dyspnoea 20%
- ataxia 15%
- diarrhoea 15%

Especially remarkable is the low incidence of vomiting and abdominal pain, both of which are common clinical signs in human and canine pancreatic patients. Other clinical signs such as polyphagia, constipation, fever, icterus, polydipsia, polyuria and adipsia have been reported. Concurrent conditions, including hepatic lipidosis, inflammatory bowel disease (IBD), interstitial nephritis, diabetes mellitus and cholangiohepatitis occur frequently.

Physical examination findings are also usually non-specific. Depression and dehydration are common. Icterus may be present in cats with coexisting cholangitis/cholangiohepatitis or extrahepatic biliary obstruction. Occasionally, muffled heart and lung sounds are detected owing to pleural effusions associated with more acute cases (Owens *et al.*, 1975; Schaer & Holloway, 1991). Rarely, an abdominal effusion or hepatosplenomegaly may be detected during abdominal palpation. In cats with acute or subacute pancreatitis, and those with traumatic pancreatitis, a painful cranial abdominal mass may be palpated within 2–3 days following the injury (Suter & Olsen, 1969; Schaer & Holloway, 1991). A rare clinical finding associated with chronic pancreatitis is systemic lipodystrophy (Ryan & Howard, 1981). Cats present with multiple subcutaneous nodules that may drain an oily fluid onto the skin. Disseminated areas of fat necrosis are responsible for this manifestation.

Diagnosis

Establishing a diagnosis of pancreatitis in cats requires considerable clinical acumen. A thorough case history and complete physical examination must be carried out, followed by extensive laboratory and imaging examinations. It is important to remember that cats with pancreatitis often have subtle or absent clinical signs; exploratory laparotomies or necropsies have been required for definitive diagnosis in many cases. The clinical detection of feline pancreatitis is expected to increase as more sensitive and specific laboratory tests are developed, and as the technique of abdominal ultrasonography becomes more widely used in veterinary medicine. Laboratory and radiographic evaluations of cats with pancreatitis have provided highly variable data (Kitchell *et al.*, 1986). This probably reflects the low-grade chronic nature of most cases. A complete blood count and serum biochemistry profile often show mild and non-specific changes. In most cases the packed cell volume (PCV) is normal, although in experimental cases mild normocytic normochromic regenerative anaemias were occasionally observed. Total and differential white blood cell (WBC) counts range from normal to mature neutrophilia of 50 000 WBC/μl.

Serum concentrations of liver enzymes may be increased in some cases. Serum alkaline phosphatase concentration may be mildly increased, ranging from 1.5 to 15 times normal (Kelly *et al.*, 1975; Wilkins & Hurritz, 1975; Schaer, 1979), and serum alanine aminotransferase can also be increased from one to three times the upper limit of normal (Kelly *et al.*, 1975; Wilkins & Hurritz, 1975). Serum bilirubin may also be increased (Kelly *et al.*, 1975; Owens *et al.*, 1975; Wilkins & Hurritz, 1975). The cause of these elevations may be due to concurrent cholangitis/cholangiohepatitis or extrahepatic bile duct compression, or may be due to a toxic hepatitis secondary to release of toxic pancreatic enzymes into the bloodstream or lymphatics.

Blood urea and creatinine may be elevated secondary to concurrent renal failure or prerenal uraemia (in association with vomiting, diarrhoea and anorexia). Electrolyte abnormalities are common in cats with pancreatitis especially hypokalaemia and hypocalcaemia (Schaer, 1979; Macy, 1989; Schaer & Holloway, 1991). The hypocalcaemia is not enough to produce clinical signs, but may be an aid to diagnosis. Mild hypocholesterolaemia was noted in cats with experimentally induced pancreatitis (Kitchell *et al.*, 1986). Hyperglycaemia is commonly reported in cats with pancreatitis (Anderson & Strafuss, 1971; Duffell, 1975; Kelly *et al.*, 1975; Owens *et al.*, 1975; Wilkins & Hurritz, 1975; Schaer, 1979). This is rarely persistent or associated with glucosuria. It is therefore likely that the hyperglycaemia occurs secondary to stress or transient injury to β-cells during the episode of pancreatitis. Diabetes mellitus may occur as a result of chronic pancreatitis. Serum levels of amylase and lipase are generally within the reference range in most cases. When increases are seen they rarely exceed three times the upper limit of normal (Suter & Olsen, 1969; Kelly *et al.*, 1975; Wilkins & Hurritz, 1975; Schaer, 1979). In cats with experimentally induced pancreatitis the serum lipase was significantly increased in all cats (Kitchell *et al.*, 1986). It is worth

remembering that serum amylase concentration may be increased in cats with renal failure (Lulich *et al.*, 1992).

Abdominal and thoracic radiographs may be useful in the diagnosis of feline pancreatitis. The normal pancreas is not visible radiographically. In pancreatitis, radiographic changes seen include a decreased contrast in the cranial right quadrant of the abdomen, dorsal or dorsomedial displacement of the duodenum, and corrugation and spasticity of the duodenal wall. Left displacement of the stomach and caudal displacement of the transverse colon may also be seen. Pleural and abdominal effusions are occasionally seen in cats with severe pancreatitis (Owens *et al.*, 1975). Abdominocentesis generally yields a sterile exudate (Schaer & Holloway, 1991). Abdominal ultrasonography performed by a skilled operator is useful in the diagnosis of feline pancreatitis. Changes identified include pancreatic swelling, increased echogenicity of the pancreas, fluid accumulation around the pancreas and, less frequently, a mass effect in the area of the pancreas.

Abdominal computed tomography is commonly used in humans suspected of having pancreatitis, and although it would be of great benefit in the diagnosis of feline pancreatitis it is currently only rarely used.

A radioimmunoassay for the measurement of feline serum trypsin-like immunoreactivity (fTLI) in feline serum is being evaluated as a diagnostic tool for feline pancreatitis (Steiner & Williams, 1996). Some data suggest an increase in serum fTLI in many cats with pancreatitis (Steiner & Williams, 1996; Bruner *et al.*, 1997), whereas other data have found poor correlation between fTLI concentration and histopathological diagnosis (Swift *et al.*, 2000). Assays for trypsinogen activation peptide and for trypsin-α_1-protease inhibitor complexes may aid in the diagnosis of feline pancreatitis in the future (Steiner & Williams, 1999).

A definitive diagnosis of feline pancreatitis can be made by pancreatic biopsy at exploratory laparotomy or laparoscopy. This is expensive and may be contraindicated in some patients because of a high anaesthetic risk.

Therapy

Treatment of the underlying cause

Therapeutic efforts for cats with pancreatitis should be directed at reversing the aetiology, when known. Exposure to unnecessary drugs should be avoided. If cholangitis/cholangiohepatitis is identified by liver biopsy, appropriate antibiotic therapy with or without glucocorticoids should be given. Surgery is required in cases of pancreatic abscessation or bile duct obstruction secondary to pancreatic fibrosis. Flukes should be treated with fenbendazole (Duffell, 1975).

Supportive treatment

Aggressive fluid therapy is the mainstay of supportive therapy. Fluid, electrolyte (especially potassium) and acid–base imbalances must be assessed and corrected as needed.

Plasma

In rare cases of fulminant acute pancreatitis, whole blood or plasma transfusions may be of benefit to replace depleted α_2-macroglobulins. Studies in dogs suggest that when α_2-macroglobulin (one of the scavenging proteins for activated proteases in serum) is depleted, death ensues rapidly. A clinical trial did not show benefit in treating human pancreatitis patients with plasma, but anecdotally improvements have been seen in dogs and cats with severe disease.

Analgesia

Meperidine (1–2 mg/kg i.m. or s.c. every 2–4 h) and Butorphanol (0.2–0.4 mg/kg s.c. every 6 h) are two recommended analgesics to treat the abdominal pain sometimes associated with feline pancreatitis.

Alimentation

The traditional recommendation for any animal with pancreatitis was to withhold food and water for at least 3–4 days. This recommendation is justified in animals that vomit, but is contraindicated in cats that are not vomiting because of the likelihood of concurrent hepatic lipidosis (Akol *et al.*, 1993). The preferred route of alimentation is a jejunostomy tube, but as this is impractical in most cases a gastrostomy or naso-oesophageal tube may be used if the patient is not vomiting. If the cat is vomiting and there is no evidence of concurrent of hepatic lipidosis it should be given nil by mouth for 3–4 days. Water should be then reintroduced slowly, followed by small amounts of a low-fat diet. Small, frequent feedings are preferable to large, single meals.

Antibiotic therapy

Infectious complications are rare in cats with pancreatitis; therefore, antibiotics should only be given when

infection has been diagnosed. Efforts should be made to identify any organism involved and an appropriate antibiotic therapeutic agent chosen accordingly.

Anti-inflammatory agents
There are no data on the use of anti-inflammatory agents in cats with severe pancreatitis. Corticosteroids should only be used in cases of secondary cardiovascular shock or when concurrent conditions such as IBD require their use. They do not appear to be harmful in these patients (Steiner & Williams, 1999).

Dopamine
Dopamine cannot be recommended in the treatment of feline pancreatitis. Although its use has proven beneficial in the treatment of experimental pancreatitis if given within 12 h of induction, it can cause vomiting, seizures and cardiac arrhythmias and was no benefit when given more than 12 h after induction of disease.

Miscellaneous
Therapy for cats with chronic pancreatitis that become diabetic should be directed towards managing the diabetes mellitus. Occasionally these cats become non-insulin dependent, presumably because as pancreatic inflammation subsides, islet cell function improves.

Prognosis

The prognosis for cats with pancreatitis is directly related to severity of disease, extent of the pancreatic necrosis, occurrence of complications and presence of concurrent disease.

Exocrine pancreatic insufficiency

Exocrine pancreatic insufficiency (EPI) is a rare disease in cats (Williams, 1995). Few well-documented cases have been reported. The cat apparently has a large pancreatic functional reserve, as evidenced by the severe damage that can be induced by chronic pancreatic disease such as pancreatitis without producing signs of EPI.

Aetiology

Chronic pancreatitis is the most common cause of EPI in the cat. Other rare causes include pancreatic acinar atrophy (PAA), which is the most common cause of EPI in dogs, and pancreatic fluke (*E. procyonis*) infestation. Clinical signs of EPI may also occur as a result of obstruction of the pancreatic duct secondary to pancreatic adenocarcinoma (Garvey & Zawie, 1984) or complications associated with surgery of the proximal duodenum (Tanger *et al.*, 1982).

Pathophysiology

Most of the functional capacity of the exocrine pancreas must be lost before clinical signs develop. The lack of digestive enzymes in the duodenum leads to failure of intraluminal digestion. In addition, abnormalities of intestinal mucosal enzymes and abnormal intestinal mucosal transport mechanisms have also been found with or without concurrent morphological mucosal changes and overgrowth of bacteria. The cause of this is unknown, but the absence of the trophic influence of pancreatic secretions and nutritional factors may be contributory (Williams, 1995). The pancreas is also a major source of intrinsic factor in the cat (Fyfe, 1993).

Clinical signs

Cats with EPI often present with a chronic history of gradually worsening polyphagia, weight loss and diarrhoea, often with voluminous faeces or steatorrhoea. Greasy soiling of the perineal region or sometimes the entire haircoat may arise secondary to this steatorrhoea if it is severe. Affected animals are usually bright and active. Diabetes mellitus (Holzwirth & Coffin, 1953) and vitamin K-responsive coagulopathy (Perry *et al.*, 1991) have both been reported to coexist with EPI in rare cases.

Diagnosis

Routine laboratory tests and imaging are generally unhelpful in the diagnosis of feline EPI. The serum alkaline phosphatase and alanine aminotransferase may be mildly elevated, and the serum triglyceride and cholesterol levels may be mildly reduced, but the serum albumin and globulin levels are generally within normal limits. The complete blood count is usually normal.

Serum cobalamin (vitamin B_{12}) levels are usually low and may be undetectable in EPI, but it must be remembered that subnormal serum cobalamin is also a feature of small intestinal disease in the cat. Serum

folate levels may also be low. Assay of faecal proteolytic activity using a reproducible quantitative method such as radial immunodiffusion will identify most patients with EPI, but false positives can occur in cases of small intestinal disease (Williams *et al.*, 1990). The most reliable test for the diagnosis of EPI in the cat is the recently developed radioimmunoassay for fTLI (Steiner & Williams, 1996; Steiner *et al.*, 1996). The control range for this assay is 17–49 μg/l, and values of ≤8 μg/l are consistent with EPI.

The TLI test is species specific; the dog TLI test is not valid for diagnostic use on the cat. It is likely that loss of pancreatic acinar tissue must be extensive (>90%) before signs of EPI become apparent, so serum TLI may be subnormal in cats before the start of clinical signs of disease (Medinger *et al.*, 1993). Serum TLI concentrations are likely not to be quite as subnormal in cats with EPI as in affected dogs, since canine PAA is associated with essentially total loss of acinar tissue, whereas inflammation of residual acinar tissue in cats with chronic pancreatitis may lead to greater TLI concentrations than would otherwise be expected.

Treatment

Enzyme supplementation

Most cats with EPI can be managed successfully by simply supplementing each meal with pancreatic enzyme extracts. Enzyme replacement using a powdered non-enteric-coated pancreatic extract at an initial dose of one teaspoon per meal is usually effective. Tablets, capsules and enteric-coated preparations are likely to be less effective than powdered extracts and therefore are not recommended. Preincubation of the food with the enzymes or the addition of antacids does not increase the effectiveness of enzyme supplements given to dogs with EPI and is unlikely to do so in cats. Diarrhoea usually improves within 2–3 days of initial treatment. As soon as clinical improvement is seen, owners can determine a minimum effective dose of enzyme supplement that prevents return of clinical signs. This will vary from cat to cat and between different enzyme preparations.

Dietary modification

Fat digestion and absorption does not normalise even with appropriate treatment of EPI in dogs, probably because some of the supplemented lipase is denatured in the acid of the stomach. A very low-fat diet can further deprive the animal of essential fatty acids and fat-soluble vitamins, and should be avoided. A moderate fat restriction is necessary in some cats with EPI to avoid recurrence of clinical signs. These individuals may also benefit from supplementation with medium-chain triglyceride oil, which is readily digested and absorbed. Experimental studies also indicate that high levels of dietary fibre impair pancreatic enzyme activity, and high-fibre diets should therefore be avoided.

Vitamin supplementation

Most cats with EPI are deficient in cobalamin and some may not respond to enzyme supplementation alone. In these cases it is recommended to give subcutaneous injections of vitamin B_{12} 100–250 μg once weekly for 4 weeks, then less frequently depending on blood cobalamin levels. Vitamin K injections (5–20 mg s.c. every 12 h) should be given if a coagulopathy is present. Tocopherol (30–100 IU/day p.o. with food) can also be given if a deficiency is suspected.

Antibiotics

Small intestinal bacterial overgrowth is not reported in cats with EPI, but is a common complication in dogs with this condition. Antibiotic treatment should not be routinely given to cats with EPI, but may be recommended in cats that do not respond to enzyme supplementation alone. As obligate anaerobes are reported to be among the most common flora of the small intestine of the cat, metronidazole (25–100 mg p.o. every 12 h for 2 weeks) is the initial antibiotic of choice.

Treatment of concurrent conditions

IBD can complicate feline EPI, as with dogs. If patients do not respond to the above treatments, a biopsy of the small intestine should be obtained to confirm this possibility. Oral prednisolone is the treatment of choice for feline IBD.

Diabetes mellitus can occur concurrently with feline EPI and should be managed appropriately.

Pancreatic neoplasia

The most common tumours to affect the exocrine pancreas are benign adenomas and malignant adenocarcinomas. A few spindle cell sarcomas, lymphosarcomas and gastrinomas have also been reported (Andrews, 1987). Malignant neoplasms of the pancreas are uncommon in cats. Estimates of their

frequency are 1.1–1.8% of all feline cancers or 12.6 per 100 000 patient years for non-endocrine pancreatic tumours (Priester, 1974). Pancreatic adenomas are usually subclinical, but may lead to clinical signs because of the transposition of other abdominal organs. In addition, pancreatic adenocarcinomas can lead to obstruction of the pancreatic duct and acinar atrophy, tumour necrosis and pancreatitis, as well as dysfunction of other organs owing to metastatic disease.

The clinical signs of feline patients with exocrine pancreatic neoplasia are non-specific. In one case series of 58 (Priester, 1974), clinical signs were:

- anorexia 46%
- weight loss 37%
- lethargy 28%
- vomiting 23%
- icterus 14%
- constipation 9%
- diarrhoea 3%

Other less common clinical signs included polyuria, steathorrhoea, fever, dehydration and abdominal distension, as well as signs related to metastasis, including dyspnoea, lameness, bone pain and alopecia.

The mean age at time of diagnosis of pancreatic adenocarcinoma is 12 years, with cats over 15 years of age at a progressively increased risk. Pancreatic adenocarcinomas are highly malignant, with widespread metastasis usually occurring before diagnosis. The most frequent sites for metastasis are the regional lymphatics, liver, duodenum, peripancreatic fat, omentum, peritoneal cavity and lungs (Kircher & Nielson, 1976; Moulton, 1978). Routine blood tests and diagnostic imaging procedures are generally unrewarding in the diagnosis of pancreatic neoplasia, although a pancreatic mass may be found by careful abdominal ultrasound. In general, an exploratory laparotomy and biopsy are needed for a definitive pre-mortem diagnosis. Pancreatic adenomas are benign and theoretically do not need to be treated unless they cause clinical signs. However, the final distinction between adenoma and adenocarcinoma can only be made at exploratory laparotomy, at which time a partial pancreatectomy should be performed even in cases of pancreatic adenoma. The prognosis in these cases is excellent.

Even in the rare cases when pancreatic adenocarcinomas have not metastasised before diagnosis, attempts at surgical resection of the tumour rarely result in clean surgical margins. Chemotherapy and radiation therapy have shown very little success in human or veterinary patients with pancreatic adenocarcinomas; therefore, the prognosis for cats with this condition is grave.

Pancreatic cysts

Cystic dilatations of the pancreatic duct, known as pancreatic bladder, have been described in a few cats (Wolff, 1979; Garvey & Zawie, 1984). They may be found incidentally during abdominal palpation, radiography or ultrasound examinations, or may present with clinical signs compatible with bile-duct obstruction. A definitive diagnosis requires exploratory surgery, at which time the cysts can be drained or removed.

Pancreatic pseudocyst

One case of pancreatic pseudocyst in a cat has been described in the literature (Hines *et al.*, 1996). A cystic structure close to the left lobe of the pancreas was discovered during abdominal ultrasonography. Surgical intervention was successful in management of this cat. Pancreatic pseudocyst (a collection of sterile pancreatic juice enclosed by fibrous or granulation tissue) is a well-recognised complication of pancreatitis in human patients.

Diseases of the liver

The liver is a complex organ involved in numerous vital metabolic processes. It is central to the metabolism of protein, carbohydrate, lipids, vitamins and minerals, and has a very important role in detoxifying the contents of the portal blood, including many drugs.

The liver is the sole site of albumin synthesis. The half-life of serum albumin is about 7–10 days in the normal dog and cat (Dixon *et al.*, 1953). Hypoalbuminaemia rarely occurs in acute hepatic failure for this reason. As the normal hepatocyte operates at one-third its maximal capacity, when hypoalbuminaemia occurs with liver disease it is an indication of chronic end-stage disease and implies greater than 80% loss of functional hepatic mass (Schall, 1976; Feldman, 1980; Hall, 1985).

Some 75–90% of α-globulins and 50% of β-globulins are synthesised in the liver. Hyperglobulinaemia is often present in cats with liver disease (e.g. cholangiohepatitis), but the mechanism is not known (Schall, 1976).

Proposed mechanisms include:

- as a sequela to impairment of the mononuclear phagocyte system and its inability to clear toxins and infectious agents from the portal circulation

- in compensation for hypoalbuminaemia in an attempt to maintain plasma oncotic pressure (Feldman, 1980).

The liver is an important part of the mononuclear phagocyte system. Küpfer cells (which originate from monocytic stem cells in the bone marrow) line the hepatic sinusoids and prevent systemic absorption of bacteria and toxins from the portal system. Most clotting factors are synthesised in the liver; as a result, disorders of haemostasis can occur with severe liver disease. Bleeding tendencies associated with liver disease can occur owing to (Roberts & Cederbaum, 1972):

- inadequate synthesis of clotting factors
- increased destruction or utilisation of clotting factors (e.g. disseminated intravascular coagulation)
- platelet dysfunction
- increased rate of fibrinolysis
- vitamin K deficiency: in cats with complete bile-duct obstruction, fat and fat-soluble vitamin absorption is impaired. Vitamin K is not absorbed in adequate quantities; therefore, the cat becomes deficient. Factors II, VII, IX and X depend on vitamin K for normal structure and functional activity (Friedman, 1984). Abnormal coagulation tests [prothrombin time (PT) and activated partial thromboplastin time (APTT)] are often used to evaluate cats with bleeding tendencies before hepatic biopsy. A normal haemostasis screen does not, however, preclude serious haemorrhage at biopsy, as the tests are relatively insensitive and a normal test may be obtained with coagulation factors as low as 25–30% of normal (Roberts & Cederbaum, 1972).

Cats have some unique features of hepatic physiology and anatomy, which are important for the understanding of feline liver disorders:

- a constantly high use of protein in hepatic gluconeogenesis
- a relative deficiency of glucuronyl transferase, reducing the ability of the cat to metabolise drugs and toxins
- an inability to synthesise arginine, an important part of the hepatic urea cycle, which predisposes cats to hyperammonaemia during periods of prolonged fasting
- no steroid-induced isoenzyme of alkaline phosphatase (i.e. no elevation of this enzyme with steroid therapy in cats)
- the major pancreatic duct joins the common bile duct before its entry into the duodenum, which may help to explain the frequent coexistence of pancreatic and biliary tract disease in cats.

Diagnosis of liver disease

The diagnosis of liver disease in cats is difficult and must be based on case history, clinical, laboratory, radiographic, ultrasonographic and pathological findings.

History and clinical examination

Clinical signs of feline liver disease are typically chronic, vague and non-specific. They include anorexia, vomiting, diarrhoea and weight loss. More specific clinical signs such as jaundice and hepatomegaly may be observed, along with polydipsia, polyuria, abdominal effusion and bleeding.

Haematology

Haematology results are non-specific for hepatic disease (Rallis & Adamama-Moraitou, 1998). The most common finding is a moderate anaemia secondary to chronic disease or blood loss (gastrointestinal ulcers/coagulation disorders).

Biochemistry

Liver enzymes

Elevations in the serum concentration of liver enzymes frequently alert the clinician to the presence of liver disease or injury. Although these enzymes are useful indicators of hepatobiliary disease, enzyme abnormalities are non-specific and do not provide information about liver function, reversibility of lesions or prognosis.

Alanine aminotransferase (ALT) is the most specific of all the liver enzymes for hepatobiliary disease. It is normally found in the hepatic cytosol; therefore, increased levels of serum ALT indicate hepatocyte injury with increased membrane permeability and leakage of ALT from the cytosol. There is no correlation between the magnitude of enzyme elevation and the reversibility of disease, and elevations give no information about liver function. The half-life of ALT in the cat is less than 60 h (Dunn, 1992).

Aspartate aminotransferase (AST) is not liver specific (Nikumhang & Thornton, 1979). It is also found

in heart, skeletal muscle and brain, but may be more sensitive than ALT for the detection of liver disease in some cats (Day, 1994). There are cytosolic and mitochondrial forms of this enzyme (Schall, 1976), which explains why this enzyme is not consistently elevated with mild liver disease and/or with elevations of ALT.

Arginase is a liver-specific enzyme in the cat (Mia & Koger, 1978). Like ALT it increases immediately with hepatic necrosis, but unlike ALT it returns to normal after 2–3 days unless hepatic necrosis continues; thus, it may be of prognostic value when compared with ALT. Unfortunately, the test is not widely available.

Isoenzymes of alkaline phosphatase (AP) may be found in the intestine, liver, bone, placenta and kidney, but only the liver isoenzyme is clinically important in the cat because of the extremely short half-life of the other isoenzymes in serum. The serum concentration of liver AP may increase two to nine times in cats with cholestatic liver disease (McLain *et al.*, 1978). The greatest elevations are seen with complete bile-duct obstruction, but elevations may also be seen with hepatic lipidosis, inflammation or necrosis. The magnitude of increases in AP are usually less in cats than in the dog and, unlike in dogs, administration of phenobarbital or glucocorticoids does not induce AP activity in cats. Thus, even small increases in serum AP activity should be regarded as significant in cats (Hoffman *et al.*, 1977).

Gamma-glutamyltransferase (GGT) is regarded as an indicator of cholestasis rather than hepatocellular injury (Spano *et al.*, 1983). It is found in intestinal mucosa, renal cortex and pancreas, as well as in the liver; thus, it is not a liver-specific enzyme. Serum GGT activity appears to be a more sensitive but less specific indicator of cholestasis than serum AP in the cat, although both enzymes parallel each other in most cases (Center *et al.*, 1986a). One notable exception is that in hepatic lipidosis the serum AP tends to increase disproportionately compared with the GGT.

Bilirubin

Increased serum bilirubin concentrations result in jaundice. Eighty per cent of bilirubin is derived from destruction of senescent red blood cells in the liver, spleen and bone marrow. Unconjugated (free) bilirubin is transported in plasma tightly bound to albumin. Once taken up by hepatocytes it is conjugated primarily with glucuronic acid into a water-soluble form, which is excreted into the bile canaliculi. Most conjugated bilirubin in the intestine is converted to urobilinogen by intestinal microflora and excreted in the faeces as stercobilin (the source of the dark colour associated with faeces). A small proportion of urobolinogen (10%) is reabsorbed into portal blood and is either removed by hepatocytes or excreted in the urine.

The Van den Bergh test may be used to measure the unconjugated (free) and conjugated fractions of total serum bilirubin concentration. Unconjugated bilirubin is associated with prehepatic icterus caused by acute haemolysis, while conjugated bilirubin is associated with hepatic and posthepatic causes of icterus. Unfortunately, unconjugated and conjugated forms of bilirubin commonly are found together, and the performance of the van den Bergh test rarely adds any additional insights (Center, 1995). Hyperbilirubinuria may therefore be seen with haemolysis, hepatocellular disease and bile-duct obstruction. Bilirubinuria is an abnormal finding in the cat (unlike the dog) and its presence may be an early indicator of liver disease, but may also be found with fever, anorexia, diabetes mellitus, feline infections peritonitis (FIP), feline leukaemia virus (FeLV) and neoplasia.

Hepatic function tests

Serum bile acid concentrations Fasting serum bile acid concentrations are widely accepted as a sensitive and specific measure of hepatobiliary function in cats (Center *et al.*, 1986b). In some cats fasted serum bile acid concentrations will be normal even in the face of severe hepatobiliary disease; therefore, it is recommended also to collect a serum sample 2 h after a meal to measure postprandial serum bile acids. This is an endogenous challenge test of liver function that increases the sensitivity for detection of liver dysfunction over fasting serum bile acids alone. Bile acids are synthesised in the liver from cholesterol, conjugated primarily with taurine (and glycine) in cats and secreted as bile salts into bile. Ninety-five per cent of bile salts are recirculated: they are taken up from the gut (terminal ileum) and transported via the portal circulation to the liver, where they are cleared by hepatocytes and resecreted into the bile (enterohepatic circulation). Increases in fasted or postprandial circulating bile acid concentrations are indications of reduced liver function.

Blood ammonia concentration and ammonia tolerance test Most of the ammonia produced from protein catabolism in the intestinal tract is converted

to urea in the liver. When liver failure is present the conversion is insufficient, allowing ammonia concentrations in the systemic circulation to increase; thus, hyperammonaemia indicates hepatic dysfunction. Unfortunately, the correlation between fasting ammonia concentration and the presence of hepatic encephalopathy (HE) or hepatobiliary disease is inconsistent (Strombeck *et al.*, 1975). When plasma ammonia levels are increased, the correlation with liver disease is good, but a normal fasting ammonia level does not rule out a diagnosis of liver disease. A time-dependent oral or rectal ammonia tolerance test (ATT) improves the diagnostic reliability of plasma ammonia concentrations for evaluating liver function (Center, 1990). The test is performed by administering 100 mg/kg ammonium chloride after a 12-h fast and measuring ammonia levels before and 30 min after administration. Unfortunately, the ATT may be associated with vomiting or worsening HE and ammonia is labile; therefore, blood must be separated immediately and the plasma transported on ice to the laboratory for analysis. Bile acid concentrations (fasted and post prandial) must therefore be considered the test of choice for liver function.

Plasma proteins

- Albumin: hypoalbuminaemia is an indication of chronic end-stage liver disease and implies greater than 80% loss of functional hepatic tissue (Schall, 1976; Feldman, 1980; Hall, 1985)
- Globulins: hyperglobulinaemia is often present in cats with liver disease (e.g. cholangiohepatitis), but the mechanism is not known.

Clotting tests

The PT evaluates the extrinsic and common coagulation pathways. The activated clotting time (ACT) and the APTT evaluate the intrinsic and common coagulation pathways. At least one abnormal coagulation test is present in up to 66% dogs and 85% humans with liver disease, but severe clinical bleeding is uncommon. The incidence of coagulopathies in cats with liver disease is unknown. Screening tests are relatively insensitive, and a normal test may be obtained with coagulation factor concentrations as low as 25–30% of normal (Roberts & Cederbaum, 1972). Thus, fresh blood should be available for transfusion if needed, even when the results of coagulation tests are normal.

Imaging

Abdominal radiography is useful in determining the liver size. Hepatomegaly is most common and may be seen with some neoplasms and hepatitis. A small liver occurs commonly with portosystemic shunts. Radiopaque densities may be found with cholelithiasis or calcified lesions. Radiolucencies may be associated with gas-producing hepatobiliary infections (Wrigley, 1985).

Abdominal ultrasonography provides greater information about the hepatic parenchyma. Focal or diffuse changes in parenchymal echogenicity, vasculature, bile ducts and the gallbladder may be evaluated (Nyland & Hager, 1985; Wrigley, 1985; Biller *et al.*, 1992).

Hepatobiliary scintigraphy can be used to determine extrahepatic biliary obstruction (Boothe *et al.*, 1992) and other hepatobiliary disease (Newell *et al.*, 1996). Further work needs to be done to evaluate this technique.

Liver biopsy

The most important tool for the diagnosis of liver disease in cats is the hepatic biopsy. A definitive diagnosis cannot be made without evaluation of hepatic cells or tissue. Once a definitive diagnosis has been made, appropriate specific treatment can be commenced and an idea of prognosis can be given. Biopsies can be obtained at exploratory laparotomy, laparoscopy or percutaneously using ultrasound as a guide.

Diseases of the feline liver

The most common liver diseases affecting cats include inflammatory liver disease, hepatic lipidosis, neoplasia (mainly lymphosarcoma) and congenital portosystemic shunts (Zawie & Garvey, 1984; Gagne *et al.*, 1996; Weiss *et al.*, 2000). The incidence varies worldwide with, for example, hepatic lipidosis being much less common in the UK than in the USA.

Inflammatory liver disease (cholangiohepatitis complex)

The terminology used to describe the histopathological features of feline inflammatory liver disease is confusing. Recent retrospective studies have attempted to clarify the classification of inflammatory liver disease (Jones, 1989; Center & Rowland,

1994; Gagne *et al.*, 1996). The most recent study (Gagne *et al.*, 1996) evaluated 175 feline liver biopsy specimens. Results indicate that inflammatory liver disease can be divided into two types: cholangiohepatitis [acute (suppurative) or chronic] and lymphocytic portal hepatitis.

Acute (suppurative) cholangiohepatitis

The suspected aetiology of this condition is an ascending bacterial infection within the biliary tract. Abnormalities of the biliary system including choleliths and anatomical abnormalities of the gallbladder; and inflammation of the small intestine or pancreas may predispose cats to cholangiohepatitis. In one study (Weiss *et al.*, 1996), 83% of the cats with cholangiohepatitis had concurrent inflammatory infiltrates in the small intestine and 50% had pancreatic lesions.

Clinical signs associated with acute cholangiohepatitis are vague and non-specific (Gagne *et al.*, 1999). Almost three-quarters of all cases show a fever. Other clinical signs include anorexia, weight loss and ascites. Ninety per cent of cases have neutrophilia or left shift consistent with inflammation. Liver enzymes, bilirubin and bile acids are usually elevated. Histopathology reveals infiltration of large numbers of neutrophils into portal areas of the liver and cholangitis (inflammation of bile ducts).

Treatment includes restoration of fluid balance, antimicrobial therapy and surgical decompression of any extrahepatic bile duct obstruction. If possible, antibiotics should be chosen on the basis of culture and sensitivity of bile, liver aspirate or biopsy specimens. They should be excreted in the bile in active form, be active against aerobic and anaerobic intestinal coliform bacteria and should not be hepatotoxic. Combination antibiotic therapy using ampicillin (20–40 mg/kg p.o. every 8 h), chloramphenicol (50 mg p.o. every 12 h) and metronidazole (10–25 mg/kg, maximum dose 50 mg p.o. every 24 h) has been recommended (Zawie & Garvey, 1984). Treatment for 3 months or longer is required. Treatment with ursodeoxycholic acid and vitamin K may be useful, as well as management of any HE and correction of fluid and electrolyte deficits.

Chronic cholangiohepatitis

The aetiology of this form of cholangiohepatitis is unclear (Weiss *et al.*, 2000). It may be a chronic form of acute cholangiohepatitis, or a separate immune-mediated disease, possibly induced by the initial bacterial insult. Other agents that have been incriminated include feline coronavirus, FeLV, toxoplasma and liver flukes. Clinical signs are similar to acute cholangiohepatitis, but fever is rarely a feature. Histopathology reveals a mixed inflammatory infiltrate in portal areas and bile ducts consisting of neutrophils, lymphocytes and plasma cells. Periportal necrosis and moderate to severe bile-duct hypertrophy and portal fibrosis are also present (Gagne *et al.*, 1996). In terminal stages, chronic cholangiohepatitis may progress to biliary cirrhosis. Liver enzymes, bilirubin and bile acids are usually elevated.

The treatment of chronic cholangiohepatitis is similar to that of acute cholangiohepatitis, with the addition of glucocorticoids to the antibiotics, ursodeoxycholic acid, vitamin K and fluid therapy. An immunosuppressive dose of prednisolone (2–4 mg/kg p.o. every 12 h) should be given initially, then tapered down for long-term maintenance.

Long-term survival of cats with acute or chronic cholangiohepatitis can be expected if cats live longer than 3 months after diagnosis (Gagne *et al.*, 1999).

Lymphocytic portal hepatitis

This appears to be a distinct condition based on infiltration of lymphocytes and plasma cells but not neutrophils into portal areas, lack of cholangitis, and the presence at histopathology of an intact periportal limiting plate (Gagne *et al.*, 1996, 1999). Because the inflammatory infiltrate consists almost entirely of lymphocytes and plasma cells, several authors have speculated that this is an immune-mediated disease (Jones, 1989; Center & Rowland, 1994).

Clinical signs are non-specific and vague, the most common being anorexia and weight loss, although ascites may be seen (Gagne *et al.*, 1999). Liver enzymes and bile acids are usually elevated. Definitive diagnosis is with histopathology. Treatment of this condition is with immunosuppressive doses of corticosteroids. If this fails to control clinical signs and/or to bring the ALT and bilirubin within normal limits, azathioprine (0.3 mg/kg p.o. every 48h) or low-dose weekly methotrexate may be tried, but both drugs can be associated with side-effects that limit their use. The disease appears to be progressive, with 30% surviving less than 1 year in one study (Gagne *et al.*, 1999).

Hepatic lipidosis

Hepatic lipidosis (HL) is a disorder of cats characterised by extensive tryglyceride accumulation in hepatocytes, severe intrahepatic cholestasis and progressive

hepatic failure. The underlying cause and pathophysiology remain poorly understood. Although HL may occur secondary to other conditions such as diabetes mellitus, hyperthyroidism, neoplasia and pancreatitis and is often associated with anorexia or malnutrition in obese cats, the condition is usually idiopathic.

The pathophysiology remains poorly understood, but anorexia and its effects on protein and lipid metabolism seems to play an important role. Proposed mechanisms include:

- chronic anorexia:
  - results in reduction in plasma insulin levels to help to maintain blood glucose levels. Low insulin induces fat lipolysis resulting in increased synthesis of triglycerides in the liver
  - results in amino acid deficiency. Deficiency of arginine and carnitine results in failure of lipid metabolism which leads to hepatic lipid accumulation
  - results in protein-calorie malnutrition
- obesity:
  - promotes insulin resistance with release of fatty acids resulting in hepatic triglyceride accumulation
  - leads to increased tumour necrosis factor-α levels in adipose tissue, which increases the hormone leptin and leads to anorexia (Schwartz *et al.*, 1996)
- stress:
  - leads to catecholamine release, which may augment hormone-sensitive lipase and fatty acid mobilisation, leading to hepatic triglyceride accumulation.

Most affected cats are adult and there is no sex or breed predisposition. Affected cats are commonly obese, and have recently experienced a stressful event whereby they have become anorectic and lost weight rapidly. The initiating event is rarely known. Clinical signs include a decreased appetite, significant weight loss (often >25%, which may be obscured by continued obesity), depression, vomiting and jaundice. Mild hepatomegaly is a common finding. In the later stages signs of HE or clotting disorders may be found.

AP is commonly greatly increased, but surprisingly GGT may be normal or only slightly elevated (Center *et al.*, 1993). ALT and AST are often elevated, but not to the magnitude of AP. Hyperbilirubinaemia and increased serum bile acids are common. Definitive diagnosis is best accomplished with a liver biopsy, although cytological examination of a percutaneous fine-needle aspirate may allow a presumptive diagnosis of HL and is less invasive and therefore useful in evaluating critical patients.

Once a diagnosis of HL is made, the most important aspect of treatment is prompt and complete nutritional support (Griffin, 2000). Fluid and electrolyte imbalances should be corrected with intravenous fluid and electrolyte therapy. It is important to correct serum potassium and phosphorus abnormalities as anorexic cats are prone to developing hypokalaemia and HL cats are susceptible to hypophosphataemia, which can result in haemolytic anaemia. Imbalances can be corrected using intravenous potassium phosphate infused in 0.9% saline (Adams *et al.*, 1993).

Nutritional support should then be provided via a naso-oesophageal or gastrostomy tube. A high-protein, calorie-dense product should be chosen (e.g. Eukanuba Veterinary Diets High Calorie Formula). One-third of the daily requirement is given on day 1, two-thirds on day 2 and the full requirements on day 3, in each case split into three or four feeds per day. Tube feeding can be discontinued when the cat's appetite has returned (this may take 3–6 weeks). The use of diazepam as an appetite stimulant is not recommended (Center *et al.*, 1996).

The prognosis for feline HL remains guarded, but with early diagnosis and aggressive enteral nutritional support, most cats survive with no residual liver damage. Recurrence is unusual but it is advisable to not allow the cat to become obese again.

Hepatobiliary neoplasia

With the exception of lymphosarcoma, primary hepatobiliary neoplasia is rare in cats (Engle & Brodey, 1969; Patnaik, 1992). Hepatocellular carcinoma and bile-duct (cholangiocellular) carcinoma are reported most often (Engle & Brodey, 1969). There is no breed predisposition. Most affected cats are older than 10 years old, except for cats with FeLV-related disease. Clinical signs are non-specific. Diagnosis is made by hepatic biopsy. Treatment and prognosis depend on the type, site and degree of invasiveness of the tumour. Size of the neoplasm is less important in determining prognosis than degree of invasiveness and presence of metastases. A primary neoplasm confined to one liver lobe may be removed surgically by partial hepatectomy. Chemotherapy, radiotherapy and hyperthermia may be available at referral institutions.

Secondary neoplasia is common because of the liver's dual blood supply, lymphatic network and close proximity to other abdominal organs.

Toxic and drug-induced hepatopathy

A wide range of chemicals, drugs, insecticides and plant toxins has been implicated as causes of toxic injury to the liver (Beasley, 1990). Clinical signs are non-specific and elevated ALT is the most common laboratory abnormality. Acute hepatic necrosis is often found histologically. Because the offending toxic agent is rarely identified, treatment is supportive. Suggested treatment for paracetamol poisoning (St Omer & McKnight, 1980) is 140 mg/kg *N*-acetylcysteine p.o. or i.v. (20% solution as a loading dose, continue at 70 mg/kg 6 h later and four times per day thereafter for seven total treatments) and ascorbic acid 30 mg/kg p.o. four times per day.

Portosystemic shunts and hepatic encephalopathy

Portosystemic shunts (PSS) are less common in cats than in dogs. They are single or multiple vascular connections between the portal circulation and systemic circulation that bypass the liver. The most common types of PSS in cats are congenital (Blaxter *et al.*, 1988). These are usually single large vessels, which are either intrahepatic or extrahepatic. Intrahepatic PSS occur as a result of failure of closure of the ductus venosus at birth (Payne *et al.*, 1990). The most common type of PSS in cats is the single congenital extrahepatic shunt.

Acquired shunts, which are very rare, occur secondary to portal hypertension, which causes the formation of multiple extrahepatic vessels. This can occur in diseases such as cirrhosis, hepatic neoplasia and chronic cholangiohepatitis.

Shunting of the portal circulation prevents nutrients and hepatotrophic factors from reaching the liver, and precludes hepatic removal of toxins and bacteria from the portal circulation. As a result, most cats with PSS have a small liver and clinical signs of HE. HE is caused by derangement of neurotransmitter systems owing to defective metabolic processes in the liver. Inadequate metabolism of ammonia and aromatic amino acids by the liver may lead to these substances crossing the blood–brain barrier and reducing the excitatory glutamate and monoaminergic neurotransmitter systems. In addition, there is an increased tone of the inhibitory gamma-aminobutyric acid (GABA) system (Butterworth, 1994). PSS are the most common cause of HE in cats, but HE can also be seen with acute hepatic failure and chronic hepatic failure with associated acquired PSS.

The most common clinical signs are behavioural changes, ptyalism, depression, aggression, dementia, blindness and seizures. Signs may wax and wane and can worsen after a high-protein meal. Exaggerated response to sedatives and prolonged recovery from anaesthesia may be observed. Vague signs of liver disease such as anorexia, vomiting and polydipsia may also be seen. Cats with this condition may show a reduced growth rate. Copper-coloured irises have been associated with the presence of PSS in some cats (Center & Magne, 1990).

Haematology reveals microcytosis in 50% of cats with PSS. The pathogenesis is unknown, but iron deficiency is not involved. Serum biochemistry changes include mild increases in ALT, AST and AP, normal to decreased blood urea nitrogen, hypocholesterolaemia and occasional hypoalbuminaemia. Bilirubin is usually normal. Serum bile acids and ammonia are both usually elevated. Fasted bile acids can be normal, but postprandial bile acids are usually markedly elevated. Urine may be dilute and ammonium biurate crystals or calculi can be found in the urine of cats with PSS. Definitive diagnosis requires contrast portography, abdominal ultrasonography or rectal portal scintigraphy. The latter procedure is non-invasive, but does not provide reliable anatomical identification and localisation of the shunt.

Treatment involves managing the HE and surgically ligating the shunt.

Extrahepatic bile duct obstruction

Rather than being a specific disease, extrahepatic bile duct obstruction has a variety of causes which are classified as extraluminal or intraluminal. Intraluminal causes include choleliths, inspissated bile and liver flukes. Extraluminal causes include biliary, pancreatic or duodenal neoplasms, congenital abnormalities or strictures secondary to pancreatitis, duodenitis or trauma.

Diagnosis is usually made by a combination of physical findings, laboratory testing, imaging studies and exploratory laparotomy.

In addition to the non-specific clinical signs associated with liver disease, cats with complete obstruction of the bile duct may show acholic faeces and vitamin K-responsive coagulopathy, as well as absence of urobilinogen in the urine. Cats with extrahepatic bile duct obstruction show high serum AP, ALT, bilirubin and bile acid concentrations.

Treatment is medical stabilisation followed by immediate surgical relief of the obstruction.

Miscellaneous

Cholelithiasis

Uncommon in cats, the presence of choleliths is usually an incidental finding. Aetiology is unknown, but may be related to bile stasis and/or ascending infection of the biliary tree. Most feline choleliths consist predominantly of insoluble bile pigments, but cholesterol choleliths (the most common type in humans) have been reported (O'Brien & Mitchum, 1970; Jorgensen *et al.*, 1987). Clinical signs are vague and non-specific, but icterus is common. Diagnosis is by radiography and ultrasonography. Treatment is surgical.

Hepatic cysts

Congenital solitary or multiple cysts have been reported as a differential diagnosis for abdominal distension in cats, and can also be seen as an incidental finding (Black, 1983). Cystic dilatation of the intrahepatic bile ducts can be associated with polycystic renal disease in cats.

Hepatic arteriovenous fistula

A congenital intrahepatic communication between branches of the hepatic artery and portal vein has been reported in the cat (Legendre *et al.*, 1976). Signs are similar to PSS, except that portal hypertension and ascites are consistently seen.

Feline infectious peritonitis

Both the dry and wet forms of FIP can affect the liver, commonly causing jaundice (see also Chapter 25).

Management of feline liver disease

Arresting of further inflammation, reduction of fibrosis and removal of predisposing factors (e.g. infection)

Prednisolone

Glucocorticoid therapy may be considered when infectious causes have been ruled out and there is evidence of an autoimmune component to the problem (lymphocytic plasmacytic infiltrate). It should not be used when a liver biopsy has not been performed, and great care must be taken when the cat is showing signs of ascites, gastroduodenal ulceration or hepatic encephalopathy as steroids may worsen these clinical signs. In cats prednisolone is usually started at 2–4 mg/kg per day, tapered gradually to 1 mg/kg every second day.

Azathioprine

Azathioprine is an antimetabolite with anti-inflammatory and immune-modulating effects. It may be a valuable adjunct to glucocorticoid therapy, but is poorly tolerated by cats at doses greater than 0.3 mg/kg every other day. Even at this dose some cats may develop anorexia, vomiting, diarrhoea and severe leucopenia.

Ursodeoxycholic acid

Serum bile and hepatic concentrations of hydrophobic bile acids increase in patients with cholestatic liver disease. Studies show that hydrophobic bile acids interfere with hepatobiliary cell membranes and disrupt cellular function. The administration of ursodeoxycholic acid, a relatively hydrophobic bile acid, may result in clinical, biochemical and histological improvement. Its effect is to displace toxic bile acids by competing with them for absorption in the ileum, and it has an anti-inflammatory, immunomodulatory effect related to a decrease in the aberrant expression of major histocompatability class I antigens on hepatobiliary cells. The recommended dose is 15 mg/kg per day. The drug is contraindicated in obstructive jaundice.

Reduction of detoxification and excretion workload of the liver

Drugs that are metabolised by the liver should be avoided.

Provision of high-quality nutrition

Nutritional support is needed to prevent deleterious catabolic changes while providing optimal conditions for hepatic regeneration. The liver has tremendous capacity to regenerate, but needs adequate nutrition to regenerate hepatocytes. Immediate fluid and electrolyte imbalances must be corrected before moving on to dietary management. To monitor the effectiveness of nutritional support, it is important to look at the clinical response (i.e. reduction in clinical signs of HE) and regularly monitor body weight and total protein and albumin levels. Meals should be given little and often, and should be highly palatable as cats with hepatic disease are often anorexic.

Protein

Protein is the most important consideration. It should be high quality, highly digestible and given in

sufficient quantities to prevent catabolism while minimising ammonia production. If the protein is highly digestible it will not reach the colon to be fermented by bacteria and produce even more ammonia.

Severe protein restriction is only required in cases of severe HE. Usually moderate protein restriction is best. Recent evidence suggests that protein requirement may actually be increased in humans and rats with liver disease. Adequate protein is vital to allow hepatocellular regeneration.

It is also useful to avoid proteins that are high in aromatic amino acids as these can contribute to HE. The easiest way to feed high-quality protein is to feed a high-quality proprietary diet designed for patients with hepatic disease and adjust the protein level to the individual's clinical signs: more protein (e.g. cottage cheese or egg) can be added if blood albumin drops, or the diet can be diluted with carbohydrate (rice or pasta) if HE recurs.

Carbohydrate

This should be highly digestible so that the animal can use it as a primary calorie source, reducing the need for hepatic gluconeogenesis from fat and protein.

Fat

Fat is an important source of calories and palatability in liver disease. Previous advice to restrict fat in liver disease is flawed as steatorrhoea due to cholestasis is quite rare in cats with liver disease (fat restriction is only needed if steatorrhoea is observed), and short-chain fatty acids involved in HE result from colonic fibre metabolism and not from digestion of ingested fat.

Fibre

Moderately fermented fibres (such as beet pulp) have two beneficial effects in liver disease:

- *reduction of HE*: short-chain fatty acids from fibre fermentation in the colon help to trap ammonia as ammonium ions in the colon. They also increase nitrogen incorporation into bacteria and reduce ammonia production
- *reduction of constipation*: constipation contributes to HE since it increases the time available for colonic bacteria to act on faeces and produce ammonia.

Vitamins

- Vitamin B-water-soluble vitamins are lost in the polyuria associated with liver disease. The B vitamins should be supplemented in intravenous fluids and orally, using 1–2 ml/l fluids (protected from light) or doubling the recommended oral dose.
- Vitamin C is made in the liver therefore its production may be impaired in liver disease. It is also an antioxidant. The dose used is 30 mg/kg per day as ascorbic acid.
- Vitamin E is a natural antioxidant that protects the liver from injury by free radicals. The dose is 100–200 IU/day p.o. or i.m.
- Vitamin K_1 is needed for activation of clotting factors II, VII, IX and X, as well as proteins S and C. It should be supplemented if clotting times are prolonged. The dose is 1.5 mg/kg i.m., repeated every 5–21 days as needed. Overdose should be avoided as this may lead to Heinz body anaemia.
- Vitamins A and D must never be supplemented.

Miscellaneous

- Taurine: in jaundiced animals taurine is lost in the urine bound to bile acids. In cats with HL the taurine concentrations are very depleted compared with normal cats; therefore, supplementing with 250 mg/day p.o. is recommended
- L-Carnitine is an essential cofactor in normal mitochondrial fatty acid oxidation. It is speculated that a relative L-carnitine deficiency may augment 'bottle-necked' mitochondrial fatty acid oxidation in the cat with HL. A recommended dose for supplementation is 250–500 mg i.v. or p.o. per day until recovery.

Management of secondary complications of liver disease

Gastrointestinal ulceration

Bleeding ulcers may occur secondary to portal hypertension, decreased mucosal blood flow, reduced mucosal cell turnover and gastrointestinal hyperacidity as a result of reduced hepatic clearance of gastrin and histamine. Evidence of gastrointestinal ulceration includes haematemesis and melaena, but affected cats may present purely with anorexia and nausea evidenced by ptyalism.

Treatment is two-fold:

- Sucralphate (0.25 g/cat p.o. every 8–12 h) provides a physical barrier to acid and enzymes at the ulcer site, increases mucous production and viscosity, increases gastroduodenal bicarbonate production,

binds bile acids, acid and pepsin, and promotes epithelial repair.

- Famotidine (0.5–1 mg/kg p.o. per day, 0.5–1 mg/kg i.v. every 12 h) is an H_2 blocking agent. It should be used when there is evidence of gastric hyperacidity documented by measuring the pH of vomitus. Another H_2 blocker, cimetidine, should be avoided because of its inhibitory effect on hepatic P450 enzymes.

Ascites

Ascites can occur secondary to portal hypertension and/or severe hypoalbuminaemia. Treatment involves sodium restriction and strict cage rest to improve renal perfusion and thus promote water and electrolyte excretion. Diuretics are only given when ascites is refractory to these conservative measures. The aim is to move fluid slowly to avoid azotaemia and electrolyte imbalances.

Potassium-sparing diuretics are the best first choice as they help to avoid hypokalaemia (which can precipitate HE). Spironolactone (1–2 mg/kg p.o. every 12 h) is the best choice, but its diuretic effect is only moderate. Frusemide (0.25–0.5 mg/kg every 12 h) is more effective, but may result in hypokalaemia.

Hepatic encephalopathy

HE most commonly occurs secondary to congenital or acquired PSS. Treatment includes:

- intravenous fluid support (avoiding overloading as this may lead to cerebral oedema)
- avoiding hypokalaemia (adding potassium chloride to intravenous fluids if necessary, but taking great care not to overdose)
- avoiding hypoglycaemia (adding dextrose to intravenous fluids if necessary)
- following feeding recommendations
- removal of faeces and ammonia from the colon with warm enemas (lactulose is most effective)
- administering lactulose (0.1–0.5 ml/kg every 6–8 h) or lactitol (β-galactosidosorbitol: not licensed but less sweet tasting and therefore may be better tolerated by cats). These sugars interact favourably with the alimentary microflora to decrease the production of encephalopathic toxins. They are fermented by colonic bacteria to organic acids, which lower colonic pH and trap ammonia in the ionised form facilitating faecal excretion. They also optimise bacterial nitrogen fixation and decrease the number of ammonia-generating organisms. Lactulose also helps to prevent constipation. Excessive administration can result in diarrhoea. The dose can be titrated to obtain optimal clinical signs and a soft formed stool
- administering antibiotics. Neomycin (5.5–10 mg/kg p.o. every 12 h) will help to modify the alimentary environment, reducing the number of ammonia-generating bacteria. Amoxicillin has also been used, along with dietary management successfully to allay HE in cats with PSS (11 mg/kg p.o. twice daily).

HE can be exacerbated by gastrointestinal nitrogen loading from excessive protein intake, gastrointestinal bleeding, increased systemic mobilisation of protein with catabolism (infection, neoplasia, excess glucocorticoids), constipation, hypokalaemia and administration of sedatives or anaesthetic agents.

Bacterial infection

Bacterial infections may complicate hepatic disease. Cats with liver problems often have an increased susceptibility to infection, primarily as a consequence of the depressed hepatic reticuloendothelial system. The tendency to develop infection is aggravated by the increased translocation of intestinal bacteria into the portal circulation that occurs secondary to portal hypertension. Antibiotics should be chosen on the basis of culture and sensitivity of hepatic biopsies, but empiric therapy may be used while awaiting culture results. Such therapy should be guided by two considerations:

- The most common isolates in hepatobiliary disease are enteric bacteria.
- Drugs that rely on hepatic clearance should be avoided.

Good choices include amoxicillin, clavulanate-potentiated amoxicillin, cephalexin and enrofloxacin. Drugs to avoid include chloramphenicol, tetracyclines, sulfonamides and macrolides.

Coagulopathy

If coagulation deficits are diagnosed, supplementation with vitamin K_1 should be given at 1.5 mg/kg i.m. repeated every 5–21 days as needed. Overdosing should be avoided as this can lead to Heinz body anaemia. Before hepatic biopsy a matched full blood transfusion should be given and the patient monitored closely. If bleeding times are still abnormal after transfusion, biopsy should not be performed.

References

Adams L.G., Hardy R.M., Weiss D.J., *et al.* (1993) Hypophosphataemia and haemolytic anaemia associated with diabetes mellitus and hepatic lipidosis in cats. *J Vet Intern Med* **7**, 266–271.

Akol K.G., Washabau R.J. & Saunders H.M. (1993) Acute pancreatitis in cats with hepatic lipidosis. *J Vet Intern Med* **7**, 205–209.

Anderson N.V. & Strafuss A.C. (1971) Pancreatic disease in dogs and cats. *J Am Vet Med Assoc* **159**, 885–891.

Andrews L.K. (1987) Tumours of the exocrine pancreas. In *Diseases of the Cat* (ed. Holzworth J.). WB Saunders, Philadelphia, PA, p. 505–507.

Beasley V.R. (1990) Toxicology of selected pesticides, drugs, and chemicals. *Vet Clin North Am Small Anim Pract* **20**, 283–556.

Biller D.S., Kantrowitz B. & Miyabayashi T. (1992) Ultrasonography of diffuse liver disease disease. *J Vet Intern Med* **6**, 71–76.

Black A.P. (1983) A solitary congenital hepatic cyst in a cat. *Aust Vet Pract* **13**, 166–168.

Blaxter A.C., Holt P.E. & Pearson G.R. (1988) Congenital portosystemic shunts in the cat: a report of nine cases. *J Small Anim Pract* **29**, 631–645.

Boothe H.W., Boothe D.M., Komkov A. & Hightower D. (1992) Use of hepatobiliary scintigraphy in the diagnosis of extrahepatic biliary obstruction in dogs and cats: 25 cases (1982–1989). *J Am Vet Med Assoc* **201**, 134–141.

Bradley E.L. (1993) A clinically based classification system for acute pancreatitis. *Arch Surg* **128**, 586–590.

Bruner J.M., Steiner J.M., Williams D.A., *et al.* (1997) High feline trypsin-like immunoreactivity in a cat with pancreatitis and hepatic lipidosis. *J Am Vet Med Assoc* **210**, 1757–1760.

Butterworth R.F. (1994) Hepatic encephalopathy. In *Liver Biology and Pathobiology*. 3rd edn (ed. Arias I.M.). Raven Press, New York, pp. 1193–1208.

Center S.A. (1995) Pathophysiology, laboratory diagnosis and diseases of the liver. In *Textbook of Veterinary Internal Medicine*. 4th edn (ed. Ettinger S.J.). WB Saunders, Philadelphia, PA, pp. 1261–1312.

Center S.A. (1990) Liver function tests in diagnosis of portosystemic vascular abnormalities. *Semin Vet Med Surg* **5**, 94–99.

Center S.A. & Magne M.L. (1990) Historical, physical examination, and clinicopathological features of portosystemic vascular abnormalities in the dog and cat. *Semin Vet Med Surg* **5**, 83–93.

Center S.A. & Rowland P.H. (1994) The cholangitis/cholangiohepatitis complex in the cat. *Proceedings of the 12th Annual Veterinary Medical Forum*, Orlando, Florida, American College of Veterinary Internal Medicine, pp. 776–771.

Center S.A., Baldwin B.H., Dillingham S., *et al.* (1986a) Diagnostic value of serum γ-glutamyl transferase and alkaline phosphatase activities in hepatobiliary disease in the cat. *J Am Vet Med Assoc* **188**, 507–510.

Center S.A., Baldwin B.H., Erb H., *et al.* (1986b) Bile acid concentrations in the diagnosis of hepatobiliary disease in the cat. *J Am Vet Med Assoc* **189**, 891–896.

Center S.A., Crawford M.A., Guida L., *et al.* (1993) A retrospective study of 77 cats with severe hepatic lipidosis: 1975–1990. *J Vet Intern Med* **7**, 349–359.

Center S.A., Elston T.A., Rowland P.H., *et al.* (1996) Fulminant hepatic failure associated with oral administration of diazepam in 11 cats. *J Am Vet Med Assoc* **209**, 618–625.

Day D.G. (1994) Diseases of the liver. *The Cat Diseases and Clinical Management*, Vol. 2. 2nd edn (ed. Sherding R.G.). WB Saunders, Philadelphia, PA, pp. 1297–1340.

Dixon F.J., Maurer P.J. & Deichmuller M.P. (1953) Half lives of homologous serum albumins in several species. *Proc Soc Exp Biol Med* **83**, 287–288.

Duffell S. (1975) Some aspects of pancreatic disease in the cat. *J Small Anim Pract* **16**, 365–374.

Dunn J. (1992) Assessment of liver damage and dysfunction. *In Pract* (July), 193–200.

Engle G.C. & Brodey R.S. (1969) A retrospective study of 395 feline neoplasms. *J Am Anim Hosp Assoc* **5**, 21.

Feldman B.F. (1980) Clinical pathology of the liver. In *Current Veterinary Therapy*, Vol. VII (ed. Kirk R.W.). WB Saunders, Philadelphia, PA, pp. 875–885.

Friedman P.A. (1984) Vitamin K-dependent proteins. *N Engl J Med* **310**, 1458–1460.

Fyfe J.C. (1993) Feline intrinsic factor (IF) is pancreatic in origin and mediates ileal cobalamin (CBL) absorption. *J Vet Intern Med* **7**, 133–136.

Gagne J.M., Weiss D.J. & Armstrong P.J. (1996) Histopathologic evaluation of feline inflammatory liver disease. *Vet Pathol* **33**, 521–526.

Gagne J.M., Armstrong P.J., Weiss D.J., *et al.* (1999) Clinical features of inflammatory liver disease in cats: 41 cases (1983–1993). *J Am Vet Med Assoc* **214**, 513–516.

Garvey M.S. & Zawie D.A. (1984) Feline pancreatic disease. *Vet Clin North Am Small Anim Pract* **14**, 1231–1246.

Griffin B. (2000) Feline hepatic lipidosis: treatment recommendations. *Compendium of Continuing Education for the Practicing Veterinarian* **22**, 910–921.

Hall R.L. (1985) Laboratory evaluation of liver disease. *Vet Clin North Am Small Anim Pract* **15**, 3–19.

Hardy R.M. (1994) Diseases of the exocrine pancreas. In *The Cat – Diseases and Clinical Management*, Vol. 2. 2nd edn (ed. Sherding R.G.). WB Saunters, Philadelphia, PA, USA, pp. 1287–1292.

Hill R.C. & Van Winkle T.J. (1993) Acute necrotising pancreatitis and acute suppurative pancreatitis in the cat: a retrospective study of 40 cases (1976–1989). *J Vet Intern Med* **7**, 25–33.

Hines B.L., Salisbury S.K., Jakovljevic S., *et al.* (1996) Pancreatic pseudocyst associated with chronic-active necrotizing pancreatitis in a cat. *J Am Anim Hosp Assoc* **32**, 147–152.

Hirsch V.M. & Doige C.E. (1983) Suppurative cholangitis in cats. *J Am Vet Med Assoc* **182**, 1223–1226.

Hoffman W.E., Renegar W.E. & Dorner J.L. (1977) Serum half life of intravenously injected intestinal and hepatic alkaline phosphatase isoenzymes in the cat. *Am J Vet Res* **38**, 1637–1639.

Holzworth J. & Coffin D.L. (1953) Pancreatic insufficiency and diabetes mellitus in a cat. *Cornell Vet* **43**, 502–512.

Jones B.R. (1989) Feline liver disease. *Aust Vet Pract* **19**, 28–35.

Jorgensen L.S., Pentlarge V.W., Flanders J.A., *et al.* (1987) Recurrent cholelithiasis in a cat. *Compendium of Continuing Education for the Practicing Veterinarian* **9**, 265–269.

Kelly D.F., Baggott D.G. & Gaskell C.J. (1975) Jaundice in the cat associated with inflammation of the biliary tree and pancreas. *J Small Anim Pract* **16**, 163–172.

Kircher D. & Nielson S. (1976) Tumours of the pancreas. *Bull World Health Organ* **53**, 195–202.

Kitchell B.E., Strombeck D.R., Cullin J., *et al.* (1986) Clinical and pathological changes in experimentally induced acute pancreatitis in cats. *Am J Vet Res* **47**, 1170–1175.

Legendre A., Krahwinkel D., Carrig C., *et al.* (1976) Ascites associated with intrahepatic arteriovenous fistula in a cat. *J Am Vet Med Assoc* **168**, 589–591.

Lulich J.D., Osborne C.A., O'Brien T.D. & Polzin D.J. (1992) Feline renal failure: questions questions questions. *Compendium of Continuing Education for the Practicing Veterinarian* **14**, 157–160.

McLain D.L., Nagode L.A., Wilson G.P., *et al.* (1978) Alkaline phosphatase and its isoenzymes in normal cats and in cats with biliary obstruction. *J Am Anim Hosp Assoc* **14**, 94–99.

Macy D.W. (1989) Feline pancreatitis. In *Current Veterinary Therapy, Small Animal Practice*, Vol. X (ed. Kirk R.W.). WB Saunders, Philadelphia, PA, pp. 893–896.

Medinger T.L., Burchfield T. & Williams D.A. (1993) Assay of trypsin-like immunoreactivity (TLI) in feline serum. *Proceedings of the Eleventh American College of Veterinary Internal Medicine Forum*, Washington DC, p. 946.

Mia A.S. & Koger H.D. (1978) Direct colorimetric determination of serum arginase in various domestic animals. *Am J Vet Res* **39**, 1381–1383.

Moulton J. (1978) Tumours of the pancreas, liver, gallbladder and mesothelium. In *Tumours in Domestic Animals* (ed. Moulton J.). University of California Press, Berkeley, CA, pp. 273–286.

Newell S.M., Selcer B.A., Roberts R.E., *et al.* (1996) Hepatobiliary scintigraphy in the evaluation of feline liver disease. *J Vet Intern Med* **10**, 308–315.

Nikumhang P. & Thornton J.R. (1979) Plasma and tissue enzyme activities in the cat. *J Small Anim Pract* **20**, 169–174.

Nyland T.G. & Hager D.A. (1985) Sonography of the liver, gallbladder, spleen. *Vet Clin North Am Small Anim Pract* **15**, 1123–1148.

O'Brien T.R. & Mitchum G.D. (1970) Cholelithiasis in a cat. *J Am Vet Med Assoc* **156**, 1015–1017.

Owens J.M., Drazner F.H. & Gilbertson S.R. (1975) Pancreatic disease in the cat. *J Am Anim Hosp Assoc* **11**, 83–89.

Patnaik A.K. (1992) A morphologic and immunocytochemical study of hepatic neoplasms in cats. *Vet Pathol* **29**, 405.

Payne J.T., Martin R.A. & Constantinescu G.M. (1990) The anatomy and embryology of portosystemic shunts in dogs and cats. *Semin Vet Med Surg* **5**, 76–82.

Perry L.A., Williams D.A., Pidgeon G.L. & Bosinger T.R. (1991) Exocrine pancreatic insufficiency with associated coagulopathy in a cat. *J Am Anim Hosp Assoc* **27**, 109–114.

Priester W. (1974) Data from eleven United States and Canadian colleges of veterinary medicine on pancreatic carcinoma in domestic animals. *Cancer Res* **34**, 1372–1375.

Rallis T.S. & Adamama-Moraitou K.K. (1998) Diagnostic evaluation of liver diseases in dogs and cats. *European Journal of Companion Animal Practice* **VIII**, (2), 67–72.

Roberts H.R. & Cederbaum A.I. (1972) The liver and blood coagulation: physiology and pathology. *Gastroenterology* **63**, 297–320.

Roudebush P. & Schmidt D.A. (1982) Fenbendazole for treatment of pancreatic fluke infection in cats. *J Am Vet Med Assoc* **180**, 545–546.

Ruwitch J., Bonertz H.E. & Carlson R.E. (1964) Clinical aspects of pancreatic disease of dogs and cats. *J Am Vet Med Assoc* **145**, 21–24.

Ryan C.P. & Howard E.B. (1981) Systemic lipodystrophy associated with pancreatitis in a cat. *Feline Pract* **11**, 31.

Schaer M. & Holloway S. (1991) Diagnosing acute pancreatitis in the cat. *Vet Med* **86**, 782.

Schaer M.S. (1979) A clinicopathologic survey of acute pancreatitis in thirty dogs and five cats. *J Am Anim Hosp Assoc* **15**, 681–687.

Schall W.D. (1976) Laboratory diagnosis of hepatic disease. *Vet Clin North Am Small Anim Pract* **6**, 679–686.

Schwartz M.W., Baskin D.G., Bukowski T.R., *et al.* (1996) Specificity of leptin action on elevated blood glucose and hypothalamic neuropeptide Y gene expression in iblob mice. *Diabetes* **45**, 531–535.

Sheldon W.G. (1966) Pancreatic flukes (Eurotrema procyonis) in domestic cats. *J Am Vet Med Assoc* **148**, 251–253.

Smart M.E., Downey R.S. & Stockdale P.H.G. (1973) Toxoplasmosis in a cat associated with cholangitis and progressive pancreatitis. *Can Vet J* **14**, 313–316.

Spano J.S., August J.R., Henderson R.A., *et al.* (1983) Serum γ-glutamyl transpeptidase activity in healthy cats and cats with induced hepatic disease. *Am J Vet Res* **44**, 2049–2053.

St. Omer V.V. & McKnight ED. (1980) Acetylcysteine for treatment of acetaminophen toxicity in the cat. *Am J Vet Res* **179**, 911–913.

Steiner J.M. & Williams D.A. (1996) Feline trypsin-like immunoreactivity in feline exocrine pancreatic disease. *Compendium of Continuing Education for the Practicing Veterinarian* **18**, 543–547.

Steiner J.M. & Williams D.A. (1999) Feline exocrine pancreatic disorders. In *Current Veterinary Therapy, Small Animal Practice*, Vol. XIII (ed. Bonagura J.D. & Kirk R.W.). WB Saunders, Philadelphia, PA, pp. 701–705.

Steiner J.M., Medinger T.L. & Williams D.A. (1996) Development and validation of a radioimmunoassay for feline trypsin-like immunoreactivity (fTLI). *Am J Vet Res* **57**, 1417–1420.

Strombeck D.R. & Guilford W.G. (1991) *Small Animal Gastroenterology*. 2nd edn. Wolfe Publishing, London, pp. 429–458.

Strombeck D.R., Weiser M.G. & Kaneko J.J. (1975) Hyperammonaemia and hepatic encephalopathy in the dog. *J Am Vet Med Assoc* **166**, 1105–1108.

Suter P.F. & Olsen S.E. (1969) Traumatic haemorrhagic pancreatitis in the cat. *J Am Vet Radiol Soc* **10**, 4.

Swift N.C., Marks S.L., MacLachlan N.J. & Norris C.R. (2000) Evaluation of serum feline trypsin-like immunoreactivity for the diagnosis of pancreatitis in cats. *J Am Vet Med Assoc* **217**, 37–42.

Tanger C.H., Turrell J.M. & Hobson H.P. (1982) Complications associated with proximal duodenal resection and cholecystoduodenostomy in two cats. *Vet Surg* **11**, 60–66.

Van Pelt C.S. & Crandell R.A. (1987) Pancreatitis associated with a feline herpes virus infection. *Compan Anim Pract* **1**, 7–10.

Weiss D.J., Gagne J.M. & Armstrong P.J. (1996) Relationship between inflammatory hepatic disease and inflammatory bowel disease, pancreatitis and nephritis in cats. *J Am Vet Med Assoc* **209**, 1114–1116.

Weiss D.J., Armstrong P.J. & Gagne J.M. (2000) Feline cholangiohepatitis. In *Kirk's Current Veterinary Therapy*, Vol. XIII (ed. Bonagura J.D.). WB Saunders, Philadelphia, PA, pp. 672–674.

Wilkins R.J. & Hurritz A.I. (1975) Chemical profiles of feline diseases. *J Am Anim Hosp Assoc* **11**, 29–41.

Williams D.A. (1995) Feline exocrine pancreatic insufficiency. In *Current Veterinary Therapy, Small Animal Practice*, Vol. XII (eds Bonagura J.D. & Kirk R.W.). WB Saunders, Philadelphia, PA, pp. 732–735.

Williams D.A., Reed S.D. & Perry L. (1990) Fecal proteolytic activity in clinically normal cats and in a cat with exocrine pancreatic insufficiency. *J Am Vet Med Assoc* **197**, 210–212.

Wolff A. (1979) An unusual unidentified abdominal mass in a cat. *Vet Med* **74**, 162.

Wrigley R.H. (1985) Radiographic and ultrasonographic diagnosis of liver diseases in dogs and cats. *Vet Clin North Am Small Anim Pract* **15**, 21–38.

Zawie D.A. & Garvey M.S. (1984) Feline hepatic disease. *Vet Clin North Am Small Anim Pract* **2**, 1201–1230.

Chapter 18

THE EYE

L. Waters and K.C. Barnett

Introduction

To become a good ophthalmologist it is important to understand the principles of accurate history taking and a thorough clinical examination. To make a diagnosis the ability to interpret findings correctly is essential, mastering ophthalmic examination techniques is the key to this and can only be achieved by gaining as much experience as possible. A routine, which can be followed in every case, is extremely important and will ensure that other findings, perhaps more important than the obvious lesion, are not missed.

Take a history

During general history taking there are a few important points to bear in mind. The original source of the cat should be discovered, as many cats are obtained from rescue centres, with unknown illness and vaccination histories. Multicat households are common and may be particularly relevant when considering infectious diseases. The breed is not as important as it is in dogs, as there are fewer inherited eye diseases in the cat. There are, however, some inherited and breed-related eye conditions in feline patients. Age and sex of the individual should always be considered. General health is particularly relevant, as many feline ocular conditions are manifestations of systemic disease, and questions relating to appetite, general demeanour and concurrent illness should be asked. Previous or ongoing medication may be the cause of some ophthalmic conditions.

On questioning about the ophthalmic condition, discover the sign first noticed by the owner. Was it discharge, pain, redness, change in appearance, loss of vision or a combination of these? When did the problem start and has the situation has changed since then? Is the condition unilateral or bilateral and has this always been the case?

Clinical examination

While taking the history the animal should be allowed to wander around the consulting room. This is an ideal time to observe the cat without disturbing it. Before the patient is examined there should be a period of observation of its behaviour. In particular, bumping into objects, blepharospasm, photophobia, facial symmetry, head and adnexal conformation, along with any obvious discharges and tear staining, should all be noted.

A few essentials are required before starting the ocular examination. The first is a nurse who can hold the cat still. The owner is rarely the right person for the job. The cat's head can usually be adequately restrained by placing a gentle supporting hand underneath its mandible. Tougher measures may be required in some cases, but the temptation to sedate an uncooperative patient should be avoided, as ophthalmic examination of a sedated or anaesthetised patient is difficult and unrewarding. The consulting room should be well lit for general observation, but most importantly it should be possible to make it absolutely dark, for the use of focal illumination. The ideal is a room without windows, but if this is not possible there should be well-fitting blinds.

The order in which the different components of the examination are carried out is a personal decision, but it should always be in the same order and part of a routine, to avoid missing anything. A full physical examination is also essential.

The head should next be examined, paying particular attention to facial symmetry, lid position, and the presence and nature of any discharges. Using a focal

light source, such as a pen torch, ophthalmoscope or slit lamp on full beam, the eyelids, conjunctiva and nictitating membrane should be examined. Periorbital disease, obvious lesions and mucous membrane colour should all be noted. Both eyes should be retropulsed; they should move freely back into their sockets, without pain or resistance. The degree of backward movement will be restricted in short-nosed breeds. Touching the skin around the eye should cause the cat to blink; this is the palbebral reflex, and assesses both the skin sensation and ability to close the lids. The corneal reflex should then be checked. In a normal animal it should be difficult to touch the cornea without blinking occurring. In both these reflexes the sensation provided by cranial nerve V is being assessed along with the motor function of cranial nerve VII, which closes the lids. If the cat is unable to close its lids it will retract the globe and the third eyelid will move passively across the cornea. Both the room light and the focal light source should cast a clear bright reflection on the healthy corneal surface, dullness or disruption of this reflection indicates corneal disease.

Vision assessment

Assessing vision can often be difficult, particularly in nervous animals, but the information gained from the following simple tests should give a good indication. The menace reflex is fairly reliable, if care is taken not to cause air movement onto the cornea. The hand should be brought briskly up to the eye and the patient should blink; this tests cranial nerves II (afferent sensory pathway) and VII (motor pathway). The direction of the approach should be varied and results must be repeatable. The menace reflex is learnt and will not usually be present in young kittens. Next a very bright light should be quickly shone into the eye and the cat should blink bilaterally or flinch and have partial bilateral third eyelid protrusion. This is known as the dazzle reflex and is present in all patients including those with opacity in the anterior ocular media. A positive dazzle reflex indicates that the optic nerve is intact to the level of the midbrain and its associated fibres in the facial nucleus. Dropping cotton-wool balls is a cheap and easy test, as cats are keen to follow moving objects. They should be dropped into the animal's field of view and the cat should follow their path to the floor. Testing visual placing involves moving the animal towards the edge of the table and observing for appropriate placing of the thoracic limbs on the table. If there is still some uncertainty, an obstacle course should be made, using bins and chairs, for example, but not all the objects should be solid. The patient should negotiate the course when called by the owner.

The owner's perception of their pet's vision can be misleading. With slowly progressive disorders and in familiar surroundings, cats are quick to adapt to loss of vision and owners may be unaware of a deficit and take some convincing that there is a problem. Cases of sudden vision loss are usually much more obvious.

Pupillary light reflexes

Pupillary light reflex (PLR) testing should be carried out; this is not an assessment of vision but rather an indication of retinal and reflex pathway function. A strong focal light source such as the Finhoff transilluminator should be used to evaluate the eye and PLRs. The patient should be calm but alert during the assessment. A brief period may be required for the cat to acclimatise to the examination room because adrenaline responses may reduce the PLR.

PLRs are assessed with the swinging flashlight test. One eye is illuminated for 2–4 s before the light source is redirected towards the opposite eye for an equal amount of time. The examiner should note whether the pupil constricts, dilates or fails to respond. The test can be performed in light or dark conditions, but is more sensitive when performed in the dark, since pupillary excursions are greater. In the eye into which light is directed, constriction of the pupil is called the direct response. Simultaneous constriction of the opposite is called the indirect (consensual) response, which occurs via decussation of pupillomotor fibres in the optic chiasm. Each pupil should readily constrict in a direct and an indirect manner. Upon redirection of the light source to the next eye during the swinging flash light test, the newly illuminated pupil should already be in the semiconstricted position. If this pupil suddenly dilates under direct illumination, the eye is abnormal and said to have a positive swinging flashlight test or Marcus Gunn sign. This finding is considered pathognomonic of a prechiasmal lesion (i.e. affecting the retina or optic nerve).

Distant direct ophthalmoscopy

Before close examination of the eye, distant direct ophthalmoscopy should be performed. This an extremely easy and informative technique, which is underused. Using the direct ophthalmoscope, with the lens dial set at zero, the patient's eyes can be examined at arms'

length. Although a bright light is used, its distance from the eye means that it will be of low intensity when it reaches the eye and the pupils will tend to dilate. By directing the light beam through the pupils, the tapetal reflection can be seen, and tapetal reflectivity can be assessed, together with pupil size and symmetry, and opacities in the visual axis. This technique is of considerable value for establishing the presence of cataracts. It also allows the examiner to distinguish them from nuclear sclerosis, which will not cast a shadow on the fundic reflection. Nuclear rings can also be visualised. Using the phenomenon of parallax it is possible to determine the position of any observed opacity within the ocular media, relative to the plane of the pupil. The direction of movement of the opacity should be noted relative to the movement of the observer. Opacities in front of the anterior lens capsule and pupil appear to move in the opposite direction to the observer. In contrast, opacities located behind the plane of the pupil appear to move in the same direction as the observer, ultimately disappearing behind the iris.

Close direct ophthalmoscopy

The direct ophthalmoscope is probably the most widely used and familiar piece of veterinary ophthalmic equipment. There are many models available, differing in their level of sophistication and from a variety of different manufacturers. A relatively simple model is sufficient for veterinary use (Mould, 1993). The key features of a direct ophthalmoscope are:

- **on/off switch**: should incorporate a rheostat allowing light intensity to be varied
- **lens magazine**: a series of interchangeable lenses. The strength of the selected lens, in dioptres (D), is indicated in a window on the scope. This allows for compensation for the refractive error of the examiner [minus lenses (−D) for the short sighted and plus lenses (+D) for the long-sighted], along with compensation for the refractive error of the patient (designed for human patients and not as important in feline patients)
- **aperture/beam selector**: the largest beam width possible should be used (the narrowest beam should be reserved for tiny pupils, if mydriatics are inappropriate or elicit a poor response)
- **slit beam**: a useful and cheaper alternative to the slit-lamp biomicroscope. However, if used for this purpose, the beam should be directed onto the patient's eye at an angle and viewed from in front with the naked eye
- **red-free light** (i.e. green): for examining blood vessels and haemorrhages, as red structures appear black
- **cobalt blue filter**: for viewing fluorescein stain
- **graticule**: projects a pattern on the fundus, which helps to locate or measure lesions
- **detachable Finhoff illuminator**: a useful source of bright, relatively focused light.

Direct ophthalmoscopes have the advantage of containing a range of lens strengths, from −20 to +20 D in most cases. They provide an upright and magnified view of the fundus (×15 magnification), allowing detailed examination. Focusing on structures at different levels within the eye is possible. Plus lenses (+10 to +20 D) are used for more anterior structures such as the lens, and minus lenses for depressions such as colobomas.

One disadvantage of this instrument is that the examiner must be close to the eye (2–4 cm) and therefore close to the animal's teeth and claws. As a result of the magnification only a small but detailed field of view is provided and a mental image of the fundus must be created from the small pieces seen.

Using the direct ophthalmoscope

The initial examination should be performed through undilated pupils and then if necessary the pupils can be dilated with tropicamide (Mydriacyl; Alcon) and the examination reperformed. The instrument should be held as close to the observer's eye as possible. Spectacles, if worn, should be removed, and the lenses adjusted to take account of an individual refractive error. If the examiner has normal vision the lens should be initially set at 0 D. Only minor adjustments are likely to be required for examining the fundus of cats. The pupil should be located and the ophthalmoscope brought progressively closer to the patient's eye. This will maximise the field of view and reduce any distracting reflections. The view through the pupil may be likened to looking through a keyhole; the closer the observer's eye to the aperture, the more will be seen. It is sensible always to use the right eye to examine the patient's right eye and left eye to examine the patient's left eye. This keeps the examiner's face away from the cat's teeth. The optic disc should be located as a landmark and then the fundus mentally divided into four quadrants. Each segment should be examined in turn, using the patient's eye movements

to allow fuller exploration of the fundus. The ophthalmologist should concentrate on directing the light beam straight through the pupil. A mental picture or montage of the fundus should be created and any findings described or drawn immediately. The +D lenses should then be used to examine the more anterior structures.

Indirect ophthalmoscopy

Although this technique initially appears more difficult to master than direct ophthalmoscopy, it offers a number of advantages. Indirect methods provide a much wider view of the fundus, allowing thorough fundic examination to be carried out more rapidly than by direct ophthalmoscopy. Light penetration is better through partially opaque media, allowing a useful image to be obtained in eyes with nuclear sclerosis, immature cataract, anterior chamber or corneal opacity. The image is magnified four to five times, but has the disadvantage of being inverted and reversed. Although not used for this purpose very often, indirect ophthalmoscopy is also a very good way of examining the lens and anterior segment. By moving one's head close to the patient the lens can be used for magnification with the light source providing illumination.

Binocular indirect ophthalmoscopy

To perform binocular indirect requires a +20 D (+15 to +30) lens. The +20 D hand-held condensing lenses are the most useful and versatile for veterinary ophthalmoscopy; however, higher dioptre lenses give a wider field of view, albeit at lower magnification, and do not require such widely dilated pupils. Plastic ones are the cheapest option and are readily available, but glass lenses are preferable. The observer stands at arm's length from the cat and uses illumination to achieve a bright fundic reflection. The lens is then placed in the beam, held 5–10 cm in front of patient's cornea. The illumination can be provided by a head set and prism mounted on spectacles or headband. Moving the patient's head allows the observer to view different areas of the fundus while keeping the head and the lens in alignment.

Monocular indirect ophthalmoscopy

Using a +20 D lens and a focused light source such as the Finhoff illuminator or a pen torch, at arm's length, is a much cheaper form of indirect ophthalmoscopy. It provides a monocular view and is a very useful screening procedure. A specialist monocular indirect ophthalmoscope is available, from Welch-Allyn, which provides a correctly orientated, upright image. This instrument is slightly more expensive than a direct ophthalmoscope, but gives a wider field of view at lower magnification. Unlike the binocular it does not provide stereopsis.

Slit-lamp biomicroscopy

Using the slit-lamp biomicroscope allows detailed and magnified examination of ocular structures. The use of a narrow, slit beam of light produces an optical section through the transparent ocular media, which facilitates the localisation of lesions. It is invaluable for examination of the anterior segment, and both hand-held and table-mounted models are made. The hand-held models have the advantage of being cheaper, more readily available, portable and easier to use. However, it is difficult if not impossible to obtain good-quality photographs with these instruments. The rigid base of the table-mounted slit-lamps reduces movement and their photographic capabilities are superior to those of the hand-held slit-lamps; however, table-mounted models have a number of disadvantages, including being bulky and expensive, and consequently are not widely used in veterinary ophthalmology. Animals often resent the additional levels of restraint that may be required in holding them up to the device.

Every slit-lamp biomicroscope consists of an illumination system coupled with an examination system that provides variable levels of magnification. The illumination system typically consists of a light beam, which is variable from wide spot to narrow slit. In general, there is also a means of varying the intensity of illumination and the character of light may also be altered by means of filters, most commonly cobalt blue. The illumination beam is focused on the plane of the eye that is being examined. By altering the angle between the illuminating beam and the microscope portion of the slit-lamp, an optical section through the eye is obtained. By moving the light out of alignment with the examination system, it is also possible to use the slit-lamp for techniques such as retroillumination. In most models, the degree of magnification of the microscope portion may also be altered. Using the widest beam of light the adnexa, cornea and intraocular structures can be examined. With a goniolens in place, the slit-lamp can also be used to provide a magnified view of the opening of the

ciliary cleft. The slit beam can be directed obliquely into the eye, illuminating all opaque structures and providing an optical section through transparent structures. This allows visualisation of minute differences in optical characteristics to be detected, such as mild aqueous flare. Slit-lamp biomicroscopy also allows the depth of lesions to be judged, so that capsular opacities may be differentiated from subcapsular opacities within the lens, and the depth of corneal lesions can be accurately determined. If the beam of light is directed onto a structure behind the lesion of interest, the lesion is retroilluminated by light reflected from the more posterior structure. Retroillumination may be useful in detecting subtle changes such as lens vacuolation and iris atrophy, and in the demonstration of transillumination of uveal cysts. Although widely used in the examination of the posterior vitreous and fundus in human ophthalmology, slit-lamps are rarely used for this purpose in animals. To bring the fundic image within the focusing range of the slit-lamp biomicroscope, a 55 D Hruby lens must be applied to the cornea or a +90 D lens placed in front of the cornea.

Consulting room tests

These are simple and informative techniques that can be performed in the majority of patients while in the consulting room with the animal conscious.

The Schirmer tear test

The Schirmer tear test (STT) is a method of assessing the aqueous component of the tear film. The tear test strips should be placed into the ventral or dorsal conjunctival fornix, touching the cornea. This test should be performed before any discharges are cleaned from the eye or any solutions are placed into the eye. The strip should remain in place for 1 min without local anaesthetic; this is the Schirmer I tear test and measures basal and reflex tear production. In humans the Schirmer II test is used to measure basal tear production in the topically anaesthetised eye. In the dog the results are easy to interpret as under-production is indicated by values less than 10 mm of wetting and reduced production less than 15 mm. In the cat normal values are variable and may be low (Waters, 1994). Therefore, results should be interpreted in the light of clinical findings.

Fluorescein staining

Fluorescein is classically used to stain areas of corneal ulceration as this hydrophilic molecule attaches to exposed corneal stroma. Viewing the cornea using cobalt blue or ultraviolet light enhances detection. Descemet's membrane is lipid rich and will not stain with fluorescein. A disposable source, such as Flourets (impregnated strips) or Minims (single-dose vials) should be used to avoid cross-contamination of eyes. Flushing of the ocular surface should be performed following instillation, to remove dye trapped in surface irregularities. This dye can also be used to assess nasolacrimal patency, as it drains from the ocular surface to emerge at the external nares. While a positive result is useful, a negative result does not necessarily mean that the system is blocked, as in some individuals (usually short-nosed breeds) the tears may drain directly into the nasopharynx.

Rose Bengal staining

Rose Bengal can be used to stain devitalised and damaged epithelium, and is indicated for the detection of feline herpes virus (FHV)-induced dendritic ulcers. It can also be useful in dry eye cases, but should be used with caution, as it is irritating and epitheliotoxic. Applying local anaesthetic before instillation will reduce the irritation of rose Bengal.

Local anaesthetic

The use of local anaesthetic is an extremely useful part of the ocular examination. It aids examination by relieving ocular surface pain, and eases the discomfort of taking swabs and biopsies. It may eliminate spastic entropion, allowing more accurate assessment of the degree of surgical correction required. Both proxymetacaine and amethacaine are available as single-use vials, but amethacaine stings on application.

Tonometry

Accurate measurement of intraocular pressure (IOP) is vital for the diagnosis and appropriate management of glaucoma. Tonometry is the measurement of IOP and several types of tonometer are available for use in humans, some of which have been evaluated for use in animals. The Schiötz tonometer (an indentation tonometer) is a cheap and effective instrument for measuring IOP in practice. Indentation tonometry works on the principle that the degree to which the cornea is indented in response to an externally applied force is proportional to the IOP. This

economical tonometer has been evaluated for use in dogs and cats. The Schiötz tonometer consists of a concave base plate, designed to approximate the corneal curvature of humans. A smooth, weighted plunger penetrates the centre of the base plate, contacting the cornea. The other end of the plunger is in contact with a pivoted needle, which indicates the degree of indentation on a graduated scale. Following the administration of topical anaesthesia, the animal's nose is elevated so that the corneal surface is horizontal. The base plate is applied to the cornea and the degree of indentation is read from the graduated scale, the process being repeated until several similar readings are obtained. Weights of 7.5 g and 10 g can be applied to the device in addition to the standard 5.5 g weight. Low IOP allows greater indentation, and high IOP leads to lower readings on the indentation scale. Conversion tables (provided with the tonometer) can then be used to convert this reading to an IOP value (Miller & Pickett, 1992). Unfortunately, the Schiötz tonometer is not always easy to apply in uncooperative patients and is inherently not very accurate. There are several potential sources of error. For example, where excessive restraint is required, this may lead to artefactual elevations in IOP. In addition, there is considerable variation in the degree of ocular rigidity and corneal curvature between subjects. It is essential that this tonometer is dismantled and thoroughly cleaned after use, as dirty instruments may be highly inaccurate.

Although costly, applanation tonometers provide a relatively accurate means of IOP measurement. The Tonopen™ (BioRad) is readily available and extremely portable. The original Mackay–Marg electronic tonometer, which was widely evaluated for veterinary use, is no longer manufactured and is now only occasionally available for second-hand purchase. Applanation tonometers estimate IOP by measuring the force required to flatten a small area of the cornea. Both the Mackay–Marg and the Tonopen tonometers consist of probe-tips, which possess a central rod, contained within an outer sleeve. When gently pressed on the cornea, the end of the central rod bears the applied force until the cornea is flattened sufficiently for the outer sleeve to contact the cornea and bear the applied force. At this point the central rod recoils. A transducer records the pressure applied to the central rod and, in the case of the Mackay–Marg, these measurements are recorded on heat-sensitive paper as a hot-wire trace. The Tonopen also detects the point of recoil of the rod, but electronically converts this measurement into a digital IOP reading.

Although marked differences in IOP between eyes may be detected on digital palpation and indentation, this technique may be misleading and is not an acceptable means of IOP measurement in the management of glaucoma cases.

Gonioscopy

Examination of the opening of the ciliary cleft (iridocorneal drainage angle), known as gonioscopy, is also an important step in the assessment of glaucoma patients. Cats, unlike dogs, are unlikely to have goniodysgenesis predisposing them to primary glaucoma. Examination of the drainage angle is, however, useful in the investigation of uveal tract disease such as uveitis and neoplasia involving the iridocorneal angle. In the dog, the opening of the ciliary cleft cannot be directly visualised owing to the total internal reflection of light directed obliquely into this structure, within the anterior chamber. Specially made goniolenses are therefore required in dogs. In the cat, the opening of the ciliary cleft may be visualised directly owing to the relative depth of the feline anterior chamber. The opening of the ciliary cleft and structure of the pectinate ligaments may be examined using a direct ophthalmoscope, slit-lamp or hand-held fundus camera to provide magnification, looking directly across the anterior chamber.

Mydriasis

Dilation of the pupil is essential for a thorough examination of the lens and retina, particularly if using indirect ophthalmoscopy. The short-acting mydriatic tropicamide 1% (Mydriacyl; Alcon) is recommended for routine diagnostic use. Atropine 1% should not be used routinely as its effect is too long lasting. In addition, the use of atropine in cats should be avoided as its bitter taste makes them froth profusely at the mouth and using ointment may be better than drops. Mydriatics should not be applied to the eye until IOP measurement and gonioscopy have been completed. If glaucoma is suspected one should avoid dilating the pupil at all, as this will increase IOP. Congenitally microphthalmic eyes are often non-responsive to mydriatics.

Swabs, scrapes and smears

It may be useful to take a swab for bacteriology or viral identification at the beginning of the examination,

before discharges are cleaned away and any solutions are applied to the eye. It can then be discarded if not required. Special transport medium is required for viral and chlamydial isolation and can be obtained from the laboratory to which samples are sent. Oropharyngeal swabs can also be taken if viruses are suspected, to increase the chances of a positive diagnosis.

Cytology samples can be taken by scraping corneal and conjunctival lesions with a chimera spatula or a blunt scalpel blade, under topical anaesthesia. Special cytology brushes are also available (Willis *et al.*, 1997). These samples should be placed on a microscope slide and air-dried or fixed in methanol. They can either be sent to the laboratory or stained in-house for a rapid diagnosis.

Nasolacrimal flushing

Nasolacrimal flushing can be carried out under local anaesthesia in some co-operative cats, but most will require sedation or general anaesthesia. The nasolacrimal system can be flushed with sterile water or saline, to establish patency and dislodge foreign bodies. It should be possible to flush fluid from one punctum to the other, with the sac occluded, and from each punctum down the nasal opening.

Neuro-ophthalmic examination

This should also be carried out and a brief description can be found elsewhere in this chapter.

Hospital tests

These are further diagnostic aids which may require varying degrees of chemical restraint or anaesthesia.

Conjunctival biopsies can be easily obtained from the lower fornix or anterior third eyelid, under topical anaesthesia. A cotton bud soaked in local anaesthetic is held over the area to be biopsied, for 1–2 min. This allows penetration of the anaesthetic agent. The region of interest can then be picked up with forceps and snipped off with scissors. Pressure is applied to the region to stop local haemorrhage. Topical phenylephrine can also be used if bleeding does not stop within 5 min.

Fine-needle aspirate biopsies of periocular lesions can be performed.

Aqueocentesis is removal of fluid from the anterior chamber and may give useful information in cases of uveal disease. General anaesthesia and good magnification are required for it to be performed safely.

Retrobulbar access can be gained behind the last upper molar or occasionally by going in from an anterior approach. This approach can be used to help differentiate the causes of exophthalmos.

Excisional biopsies of lid lesions may be appropriate to make a diagnosis, and very occasionally enucleation and histopathological examination of the whole eye will be required to make a diagnosis.

As many ocular conditions in the cat may be manifestations of systemic disease, there are times when biopsy of other organs, such as lymph nodes, skin and bone marrow, may also be required to finalise a diagnosis.

Blood sampling should be performed in cases of bilateral disease, particularly retinal disease, uveitis and recurrent or unresponsive ocular conditions. As well as routine haematology and biochemistry, tests to look for feline leukaemia virus (FeLV), feline immunodeficiency virus (FIV), feline infectious peritonitis (FIP) and *Toxoplasma* infection should be performed.

Electroretinography uses the principle that when the eye is stimulated by light, a small electrical potential can be picked up at the surface of the globe, for example using a corneal electrode. When this is amplified and recorded it forms the electroretinogram (ERG). The ERG is a summation of several potential waves generated by different sites in the retina. Electroretinography is rarely used in the cat, but may be indicated in cases where the ocular media is opaque, for the diagnosis of sudden blindness and for precataract surgery assessment.

Ultrasound examination of the eye is extremely useful and can be used in the following situations: opacification of the ocular media, which precludes ophthalmoscopic examination (e.g. cataracts, haemorrhage, neoplasia), to determine the site and extent of tumours, retrobulbar and orbital disease, intraocular foreign bodies, lens luxations and measuring globe size.

Radiography is not very useful for imaging the globe itself, but may be useful in cases with bony orbit involvement. Contrast studies for dacryocystorhinography may also be informative.

Magnetic resonance imaging (MRI) and computed tomographic (CT) scans are extremely useful for imaging retrobulbar disease and in the visualisation of central lesions. CT is better for bone definition and MRI provides superior images of soft-tissue structures. Contrast media can be used in association with MRI to enhance lesions. These are only available in specialist centres and friendly local hospitals.

Equipment is extremely expensive, but the images are a valuable diagnostic aid, with superb detail and accurate localisation of lesions (Calia *et al.*, 1994; Dennis, 2000).

The globe and orbit

The orbit is the cavity within the bones of the skull, surrounding the eye and associated structures. The orbit separates the eye from the cranial cavity, but allows blood vessels and nerves to pass through the numerous foramina joining the two. The orbit is only partially bounded by bone, large areas being bounded by soft tissue. The floor of the orbit is incomplete, being formed by the sphenoid and palatine bones. The dorsal wall is formed by the dense collagenous orbital ligament, which runs between the zygomatic process of the frontal bone and the frontal process of the zygomatic bone. The rostral rim of the orbit consists of frontal, lacrimal and zygomatic bones. Dorsally, the orbit is largely bordered by the temporal muscle. The globe sits within the orbit and in the cat is particularly large, almost spherical and with a large cornea. It occupies a frontal position and provides good binocular vision. As the floor of the orbit is mainly soft tissue and the globe fits the orbit so well, any retrobulbar space-occupying condition quickly leads to exophthalmos (see Box 18.1).

An understanding of the anatomical relationships in this region is important when considering the clinical conditions that can affect the orbit. Disease processes affecting the caudal upper molar tooth roots, oropharynx, zygomatic salivary gland, masticatory muscles, frontal and maxillary sinuses may all extend into the orbit involving and displacing its contents. However, the extensive, if incomplete, bony case means that surgical access to the orbit and its contents is limited.

Box 18.1 Terminology involving the globe and orbit

- **Anophthalmos**: congenital absence of the eye
- **Microphthalmos**: a congenitally small eye, often accompanied by other changes (e.g. cataract)
- **Buphthalmos**: a congenitally enlarged eye, due to congenital glaucoma (see Plate 18.1)
- **Hydrophthalmos**: an enlarged globe, due to acquired glaucoma
- **Exophthalmos**: protrusion of the normal sized globe
- **Enophthalmos**: a sunken eye
- **Phthsis bulbi**: an acquired end-stage, irreversible shrunken eye, resulting from severe trauma or inflammation

Congenital anomalies

Feline congenital anomalies of the globe and orbit are rare, including multiple ocular defects. Anophthalmos and cyclopia have been recorded as teratogenic anomalies due to griseofulvin. Microphthalmos and cataract are also reported, but not as inherited conditions, and are often associated with other ocular anomalies.

Congenital strabismus and nystagmus both occur in the Siamese and other colour-dilute breeds, such as Birmans. These signs are a feature of albinism and subalbinism and are due to incomplete decussation of nerve fibres at the optic chiasm (Creel, 1971; Johnson, 1991).

Exophthalmos

Many of the conditions that involve the orbit are space-occupying lesions, which lead to exophthalmos. Exophthalmos is often best appreciated by observing the animal from above. Retropulsion of the globe should also be attempted. Secondary signs associated with exophthalmos include protrusion of the third eyelid, strabismus, conjunctivitis, ocular discharge, exposure keratitis and, in severe cases, neuropraxia of the optic nerve. A degree of exophthalmos is 'normal' in some bracycephalic breeds, in which the orbit tends to be shallow. Initially, vision in the exophthalmic globe may be retained but, with time, may be lost as secondary problems develop.

Causes include orbital cellulitis, or diffuse inflammation, which may be due to foreign bodies entering via either the mouth or conjunctiva, diseased upper molar teeth, frontal sinusitis and bite wounds. Exophthalmos due to orbital cellulitis is almost invariably unilateral, retropulsion of the globe frequently causes pain or discomfort and the cat may be pyrexic. Orbital cellulitis may lead to the formation of a retrobulbar abscess. Haematology may reveal a neutrophilia. Further investigation should include examination under anaesthesia, in particular to look for a reddened or discharging area behind the upper molar tooth. Radiography generally only demonstrates soft-tissue swelling; even if foreign bodies are present they are usually radiolucent. Ultrasonography may demonstrate a fluid-filled space behind the eye in cases of

abscessation. Drainage into the mouth should be attempted, through the pterygopalatine fossa behind the last molar tooth. This should be followed by systemic antibiotic and anti-inflammatory therapy.

Orbital neoplasia

Orbital neoplasia is not rare in the cat and is often malignant. The neoplasia may be primary from the orbital structures or secondary due to local extension (e.g. from the nasal cavity) (Peiffer *et al.*, 1978) or metastases. Orbital tumours are usually unilateral, presenting with gradual exophthalmos and commonly, but not invariably, in the older animal. The following have all been reported: adenocarcinoma, ameloblastoma, carcinoma, chondroma, fibosarcoma, haemangiosarcoma, lymphoma, melanoma, meningioma, osteoma, osteosarcoma, rhabdomyosarcoma, sarcoma and squamous cell carcinoma (SCC).

In contrast to retrobulbar abscess, the onset of clinical signs is generally gradual with slow progression and pain is not usually a feature. Depending on the position of the neoplasm, exophthalmos may be associated with deviation of the globe. Indentation of the globe may be evident on ophthalmoscopy. Imaging of the orbit radiographically, ultrasonographically, or by CT or MRI if available, is essential to determine the extent of involvement of orbital tissues. Fine-needle aspiration biopsy of the mass is best achieved with ultrasound guidance. A histopathological diagnosis is essential before treatment is contemplated. Only rarely is chemotherapeutic management indicated, for example in the case of lymphoma. Lateral orbitotomy is a complex surgical procedure and it is often not possible to resect the neoplasm while preserving the globe. Even with exenturation of the orbital contents the prognosis may be poor. The best results are gained when extensive surgery is combined with local radiation treatment. There have been several reports of intraocular sarcoma in older cats occurring months to years following trauma, infection or surgery (Dubielzig *et al.*, 1994). These tumours arise from proliferating lens epithelial cells, following rupture of the lens capsule. These cases are a good indication for enucleation of both hydrophthalmic and phthitic eyes in this species.

Orbital trauma

Retrobulbar haemorrhage may occur as a result of trauma (rarely due to bleeding disorders). Moderate haemorrhage may resolve spontaneously with symptomatic treatment. Care should be taken to prevent exposure keratitis, by the use of ointments or closure of the lids. Orbital fractures may also be associated with trauma (e.g. road traffic accidents or kicks) and may be difficult to demonstrate radiographically.

Proptosis of the globe

The proptosed globe is an ophthalmic emergency and requires immediate surgical intervention if any attempt at globe salvage is intended (Gilger *et al.*, 1995). Proptosis is the prolapse of the globe forwards and through the eyelids, which prevent its return to the orbit. The cause is trauma, which in this species must be severe and is often accompanied by fractures of the orbit. Proptosis is uncommon in the cat with its deep orbits, except in the Persian breeds with their more prominent eyes and flatter face. Treatment is surgical, with replacement of the globe as rapidly as possible, although vision loss is often permanent owing to optic nerve damage. Proptosed eyes should be repositioned under general anaesthesia as soon as possible. Until surgery can be carried out, the exposed globe must be kept moist with the help of ophthalmic ointments and/or cold compresses. Prognosis for salvage of vision is usually poor following proptosis and globe salvage is usually the first aim of surgery. Favourable prognostic indicators are a positive direct or consensual PLR, normal findings on posterior segment examination and vision present before surgical replacement. Unfavourable prognostic factors include proptosis in a non-brachycephalic breed, hyphaema, no visible pupil, facial fractures, optic nerve damage and avulsion of three or more extraocular muscles. The medial rectus muscle is usually the first muscle that ruptures and most eyes that are successfully repositioned retain a more or less marked lateral strabismus.

Other orbital lesions

Zygomatic salivary mucocoeles are uncommon and may be associated with trauma or neoplasia, but may also appear to occur spontaneously. They present as a space-occupying lesion of the ventral orbit and should be differentiated from neoplasia of the zygomatic salivary gland. Diagnosis is by aspiration of tenacious fluid suggestive of saliva and by zygomatic sialography. Treatment by extirpation of the gland carries a good prognosis; however, this is a difficult surgical procedure.

A rare cause of exophthalmos is orbital eosinophilic infiltrate in cats (Dziezyc *et al.*, 1992).

Hydrophthalmos

Hydrophthalmos is enlargement of the globe due to an increase in IOP and the eye is usually blind, often with conjunctival and episcleral congestion and severe corneal changes, together with retinal and optic atrophy. Although the eye may appear non-painful, enucleation is recommended.

Enophthalmos

Enophthalmos is the retraction of a normal-sized globe into the orbit, and must be differentiated from microphthalmos and phthisis bulbi. Enophthalmos, microphthalmos and phthisis bulbi are usually accompanied by prominence of the nictitating membrane. Enophthalmos may be caused by severe ocular pain; as part of Horner's syndrome, occasionally in cases of orbital tumour, and with loss of retrobulbar fat, when it is usually bilateral.

Enucleation of cats' eyes

A complication that may occur when enucleating cats' eyes, is blindness in the fellow eye. This loss of vision is believed to be due to damage to the optic chiasm. The optic nerve in the cat is very short, and when excessive traction is applied during enucleation it is easy to damage the chiasm and the opposite optic nerve. For this reason, great care should be taken not to pull on the globe that is being enucleated.

The eyelids

The upper and lower lids comprise three layers: The outer layer is composed of skin, eyelashes, hair and sebaceous glands; the middle layer of muscle, meibomian or tarsal glands and collagenous connective tissue known as the tarsal plate (which is less well developed than in humans). The bulk of the tarsal plate is made up of the meibomian gland tissue. These glands have their openings at the lid margin and the inner layer is the palpebral conjunctiva. The skin and conjunctiva meet at a mucocutaneous junction known as the lid margin or margointermarginalis.

The lids have a rich supply of blood vessels, nerves and lymphatics. The medial and lateral canthi are stabilised by the medial and lateral palpebral ligaments. Lid closure is effected by the orbicularis oculi muscle. Opening of the upper lid is controlled by the levator palpebrae superioris and the superciliaris muscles, while that of the lower lid is controlled by the palpebral fibres of the sphincter colli profundus muscle. All of these muscles except for the levator palpebrae superioris, which is supplied by the oculomotor nerve (cranial nerve III), are supplied by the facial nerve (VII). In addition there are elevating smooth-muscle fibres (Müller's muscle) in the upper lid with a sympathetic nerve supply. Sensory innervation to the lids is provided by the trigeminal nerve (V).

The upper, lower lids and third eyelids are vital for maintaining ocular surface health. The lids physically protect the eye from insult, distribute the tear film and help to remove debris from the surface of the eye during blinking. The upper and lower lids contribute mucins to the tear film from goblet cells within the palpebral conjunctiva. They also produce tear film lipid from the meibomian glands and assist in pumping tears down the nasolacrimal duct during blinking. The margins of the lids must be as smooth and free of defects as possible to carry out these functions efficiently and keep the eye comfortable.

The lids of normal kittens remain fused for 4–12 days. Occasionally infection behind the closed lids results in ophthalmia neonatorum, a condition that must be recognised and treated by premature opening of the lids. Affected individuals present with swelling and/or discharge, and the lids should be opened with tenotomy scissors or a scalpel blade to prevent sight-threatening complications. Frequent irrigation of the conjunctival sac and an appropriate topical medication can then be used to control the infection. This condition is often seen associated with FHV infection.

Fusion of the lids, known as **ankyloblepharon**, requires surgical opening.

Complete agenesis or partial absence (coloboma) of eyelid tissue is an uncommon congenital condition. In cats the upper lateral lid is generally affected and corneal changes may occur owing to contact from adjacent hairs and globe exposure (Plate 18.2). This condition has been reported not only in domestic cats but also in the snow leopard (Bellhorn *et al.*, 1971; Barnett, 1981). Small areas can be removed using a simple wedge resection to restore the lid margin. Severe cases require extensive surgical correction, using procedures such as the Mustardé technique.

Dermoids may involve the lids, but this form is not as common as lesions involving the cornea and conjunctiva (see later).

As well as being an essential component of the eye, the lids must also be seen as a part of the skin. They may be involved in generalised skin conditions

considered elsewhere in this book. Some skin diseases manifest primarily as lid conditions. It should also be remembered that the eyelid margin is a mucocutaneous junction and as such may be involved in some autoimmune diseases.

Eyelid trauma

Simple wounds to the lids should be dealt with using minimal débridement and primary repair. Very large areas of eyelid skin loss or severely infected/necrotic wounds may have to be managed medically initially and a secondary repair appropriate to the size and location of the defect used later. Where the lower canaliculus is involved this should be cannulated where possible and a stent left *in situ* for approximately 6 weeks so that the nasolacrimal duct might re-establish around the stent.

Cowpox (see Chapter 30)

Infection is most commonly seen in outdoor, hunting cats during the wetter seasons of autumn and spring. Small rodents are the reservoir hosts. Cases present initially with cutaneous lesions on the head and feet. These scabby lesions may be moist or dry. Ocular signs are associated with extensive lid involvement. More severe cases may have systemic involvement, with liver and kidney failure being possible sequelae (Bennett *et al.*, 1990).

Neoplasia

Eyelid tumours are less common but are more frequently malignant than in the dog, and the papilloma is rare. SCC is the most common tumour, and particularly affects white cats and cats with white fur around the eyes. Treatment with β-irradiation from a strontium-90 applicator can be very successful without surgical excision, which in most cases would be difficult owing to the loss of considerable portions of the eyelid margin. The following are also reported as lid tumours: adenoma, adenocarcinoma, basal cell carcinoma, fibroma/sarcoma, haemangiosarcoma, mast cell tumour, melanoma, neurofibroma/sarcoma, papilloma, sarcoma (viral associated) and lymphoma (McLaughlin *et al.*, 1993).

In many cases where less than one-third of the lid length requires removal, simple wedge resection with a small clear margin of excised tissue is curative. All lid tumours in the cat should be submitted for histopathology. Larger neoplasms or those requiring a large margin of excision may require more extensive plastic surgical procedures (e.g. the Mustardé technique or the lip-to-lid procedure, or possibly extensive cryotherapy. Rarely, radiotherapy may be undertaken. Chemotherapy is occasionally indicated (e.g. in cases of cutaneous lymphoma).

Extra lashes: distichiasis, trichiasis and ectopic cilia

Distichiasis is the presence of extra lashes on the lid margin. In trichiasis 'normal' cilia and facial hair are found to contact the cornea. Ectopic cilia are additional cilia emerging through the palpebral conjunctiva, directed towards the corneal surface. These disorders of the cilia are uncommon in the cat, with trichiasis from the lower medial lid in short-nosed breeds the most likely to be encountered. These conditions can result in epiphora, blepharospasm, chronic conjunctival hyperaemia and in some cases corneal ulceration. Although the presence of any of these lashes can be assessed more (distichia, trichiasis) or less easily (ectopic cilia), resulting clinical signs can be variable and it may be a considerable diagnostic challenge to assess, whether the extra or malpositioned lashes are the sole cause of the ocular disease. For this reason a very careful clinical examination should take place, including an assessment for ocular discomfort, epiphora and blink frequency, and the effect of topical anaesthesia on these clinical signs must be examined.

The third eyelid

The third eyelid (TEL), also known as the membrana nictitans, nictitating membrane or haw, is a triangular fold of conjunctiva originating from the ventromedial orbit, arising in the inferior conjunctival fornix. The conjunctival fold is structurally supported by a T-shaped piece of cartilage, the horizontal bar being parallel to the free edge of the third eyelid. The T-piece of elastic cartilage is curved to conform to the shape of the underlying globe. A serous gland produces 30–50% of the aqueous tear film component. The secretions of this gland reach the precorneal tear film via numerous duct openings on the posterior conjunctival surface of the third eyelid. The duct openings are typically located between lymphoid follicles and thus allow transport of immunoglobulins with the gland secretions onto the corneal surface. Aggregates of lymphoid tissue are present on both the inner and outer aspects of the TEL.

In the normal cat the leading edge of the TEL is unobtrusive, particularly if it is non-pigmented. A passive protective mechanism exists, which comes into play when the globe is retracted by the retractor oculi muscles, innervated by the abducens nerve (cranial nerve VI). Sympathetic nerve fibres innervate the smooth muscle that is responsible for maintaining tonic retraction. The cat is unique among common domestic animals in possessing a mechanism for active protrusion of the TEL. Active protrusion is effected by striated muscle fibres from the levator palpebrae superioris and lateral rectus muscles (supplied by cranial nerve VI) which attach to the TEL.

The TEL is essential for corneal health, as it distributes tears during each blink, and provides physical protection and immunological support to the ocular surface. It acts like a windscreen wiper, helping to remove particulate foreign body matter. For this reason, integrity of TEL and gland is of great importance, and only the presence of malignant neoplasia justifies removal of these structures.

Protrusion of the TEL is not unusual in the cat and is often associated with generalised clinical problems, in which case the prominence is likely to be bilateral. The cause is not always apparent. Various conditions may be associated with either unilateral or bilateral protrusion. Debility, weight loss and reduction in the amount of retrobulbar fat do not appear to be associated with TEL protrusion in the cat, as they are in the dog. Differentials of TEL protrusion in the cat are:

- Horner's syndrome
- retrobulbar space-occupying lesions
- microphthalmos and enophthalmos
- anterior segment pain
- conjunctival inflammation
- neoplasia
- trauma
- prolapse of the nictitans gland
- scrolling of the TEL cartilage
- symblepharon
- drug-induced
- dysautonomia
- chronic diarrhoea and TEL syndrome.

Horner's syndrome has a variety of causes, although the fundamental abnormality is sympathetic dennervation of the eye and adnexa. The clinical presentation is of TEL protrusion, miosis, enophthalmos, ptosis and narrowing of the palpebral fissure. Most cases are unilateral (Plate 18.3). See the Neuro-ophthalmology section, later, for more details.

Retrobulbar space-occupying lesions due to inflammation or neoplasia are frequently associated with unilateral TEL protrusion and with exophthalmos. Strabismus may be present and the direction of the squint can provide helpful clues as to the site of the tumour.

Microphthalmos and enophthalmos, either bilateral or unilateral, are associated with protrusion of the TEL. Phthisis bulbi is usually unilateral and is accompanied by TEL protrusion on the affected side.

Anterior segment pain produces globe retraction and consequent protrusion of the TEL. Blepharospasm may obscure the underlying structures. The condition may be unilateral or bilateral.

Conjunctival inflammation may be associated with TEL prominence, usually with more generalised conjunctival involvement, but sometimes just confined to the tissue covering the TEL.

TEL neoplasia is uncommon in cats. Both primary and secondary tumours are potential causes of TEL protrusion. They are usually unilateral when primary neoplasia is involved and may be unilateral or bilateral with secondary neoplasia. Chronic inflammation should be differentiated from neoplasia by biopsy. Fibrosarcoma, SCC, mast cell tumour, lymphosarcoma, adenoma and adenocarcinoma have all been reported (Buyukmichi, 1975; Williams *et al.*, 1981). Whereas fibrosarcoma and adenoma are primary tumours of the TEL, SCC and lymphosarcoma could have originated in the TEL or extended there from neighbouring tissues. Mast cell tumours may extend from upper or lower eyelids to involve the TEL.

Surgical excision is indicated for well-circumscribed isolated tumours and, on rare occasions, the whole TEL may need to be removed. It is important to emphasise that malignancy is the only indication for TEL removal, as absence of the TEL may seriously compromise corneal health.

Trauma may result from fighting, head trauma, foreign bodies and surgical intervention. Whenever the TEL is damaged an attempt should be made to retain or reconstruct a functional membrane and margin.

Symblepharon is a not uncommon reason for persistent prominence of the TEL in young cats and may be unilateral or bilateral.

Prolapse of the nictitans gland is a very uncommon condition in the cat that can give the spurious impression of a protruded TEL (Plate 18.4). It may occur in isolation, or in association with scrolling of the TEL cartilage. It is most frequently seen in Burmese cats.

Drug-induced protrusion is a potential temporary finding, after administration of, for example, phenothiazine tranquillisers.

Dysautonomia may be associated with bilateral TEL protrusion, and may even be the presenting sign, although absence of the pupillary light response with dilated pupils and normal vision is the most constant ocular feature.

Chronic diarrhoea is sometimes associated with a self-limiting, bilateral, TEL protrusion, particularly affecting young cats. Occasionally it may have a protracted time-course, but the cat is otherwise well and no treatment is required. A viral cause has been suggested (Muir *et al.*, 1990). Topical administration of a sympathomimetic drug such as phenylephrine produces retraction of the TELs within minutes, suggesting that postganglionic sympathetic dennervation is part of the problem.

TEL flaps can be used as a physiological bandage and adjunct to medical therapy in cases of superficial corneal ulceration or exposure keratitis caused by lagophthalmos. They are not indicated to replace conjunctival or corneal grafts in cases of more severe corneal ulceration. The major disadvantage of a TEL graft is that monitoring of the corneal disease is not possible. For this reason, consideration to the use of a bandage contact lens should be given before application of a TEL flap.

The lacrimal system

The lacrimal system consists of two components, a secretory component and an excretory component. The secretory component produces the preocular tear film (PTF). The tear film provides a clear refractive interface for the cornea, filling the depressions caused by the microvilli projecting from the anterior surface of the superficial epithelial cells. The tear film is composed of a thin anterior lipid layer, derived from meibomian gland secretions, which limits tear evaporation, a thick aqueous layer supplied predominantly by the lacrimal glands, and an inner layer of mucin provided by the conjunctival goblet cells (Carrington *et al.*, 1987). Mucin aids in lowering the tear surface tension, thereby facilitating the even spread of the preocular tear film, which occurs with blinking. The tear films covers the ocular surface and is distributed partly by blinking of the upper and lower lids and mainly by the TEL movement combined with globe retraction. Some loss of tears occurs because of evaporation and some from drainage into the excretory component of the lacrimal system.

The excretory component of the lacrimal system consists of an upper and a lower punctum, a cannaniculus running from each punctum to the lacrimal sac (poorly developed in the dog and cat) and a nasolacrimal duct running from the sac to the nasal opening (ostium). The nasolacrimal duct passes in the lacrimal bone via the lacrimal foramen and then passes along the medial surface of the maxilla. The tears drain into the vestibule of the nasal cavity. In brachycephalic cats the nasolacrimal duct often opens caudally into the nasopharynx. Investigations of the lacrimal apparatus consist of the assessment of the production, distribution and drainage of the PTF and careful inspection of the ocular surface.

Disorders of the lacrimal system are much less common in the cat than the dog. Such disorders fall into one of three categories:

- failure to produce a normal PTF or one of its components
- failure in distribution of the PTF on the ocular surface
- inability of the drainage system to remove the tears produced, owing to obstruction of the drainage system and/or overproduction of tears.

When lacrimal system abnormalities are suspected, the clinician should carefully assess blink rate, appearance of the ocular surface, the PTF, eyelid margin, meibomian gland openings, tear film quality and quantity.

Failures in preocular tear film production

These are more common in dogs than cats. Deficiencies in the lipid component are difficult to assess and may result from anatomical lid abnormalities such as coloboma and meibomitis. Mucin deficiencies are also difficult to assess, but may result from chronic conjunctivitis. Reduced levels of the aqueous tear film component are the most common tear film abnormality and are known as keratoconjunctivitis sicca (KCS). Causes of KCS include:

- aplasia or hypoplasia of the lacrimal gland
- immune-mediated destruction of the lacrimal gland
- drug-induced
- neurogenic

- chronic inflammation (Johnson *et al.*, 1990)
- FHV infection
- removal of the nictitans gland
- idiopathic.

Clinical signs of KCS include:

- reduced STT values
- increased blink rate
- enophthalmos
- conjunctival hyperaemia
- frank conjunctivitis
- dull, lack-lustre cornea
- mucoid ocular discharge
- corneal ulceration
- corneal neovascularisation
- corneal pigmentation
- dry ipsilateral nostril.

Medical treatment of KCS should involve identifying the underlying cause and treating it. Supportive treatment should consist of a combination of false tear preparations, topical cyclosporine, topical anti-inflammatories and antibiotics.

Failures in preocular tear film distribution

Inadequate spreading of the tear film can result from eyelid and TEL abnormalities, inadequate lid closure in brachycephalic cats, facial paralysis and trigeminal nerve palsy.

Failures of the drainage system

Obstruction of the excretory lacrimal system manifests as epiphora, with associated tear staining of the hair, chronic conjunctival inflammation, mild ocular discomfort and secondary infection. Causes of obstruction include lid/facial conformation in short-nosed cats and congenital absence of puncta, canniculi or duct. Acquired loss of puncta can occur following wounds or inflammation (e.g. in young cats with symblepharon). Foreign body obstruction occurs occasionally in cats. Overproduction of tears may also result in epiphora and this may be caused by ocular pain, adventitious cilia and conjunctivitis.

Neoplasia

Neoplasia of both the lacrimal and nictitans glands is rare, carcinomas being the most likely. Adenocarcinoma, lymphoma and SCC have all been reported at this site.

Episclera and sclera

The episclera consists of collagen, blood vessels, some elastic fibres, fibroblasts, melanocytes, some phagocytic cells and nerves (both myelinated and unmyelinated). The episclera is most developed between the limbus and the extraocular muscle insertions, where it blends superficially with the overlying Tenon's capsule. The sclera is relatively avascular and has a more compact arrangement of collagen than the overlying episclera. The cell types are similar but sparser. Conditions of the episclera and sclera, including inflammation and neoplasia, occur very rarely in cats.

The conjunctiva

The conjunctiva is a thin, semitransparent, variably pigmented mucous membrane. It runs from the lid margins to the limbus and is closely attached to the underlying tissues at these points. It is otherwise loosely attached and freely mobile, which means that both subconjunctival oedema and haemorrhage form readily. The conjunctiva can be anatomically divided as follows:

- nictitating conjunctiva: covering the inner and outer third eyelid
- palbebral conjunctiva: covering the posterior surface of the upper and lower eyelids
- bulbar conjunctiva: covering the anterior surface of the episclera and sclera
- fornix: the cul de sac between the palbebral and bulbar conjunctiva.

The conjunctival surface is covered by the PTF. Beneath this is a non-keratinised, stratified squamous epithelium, which contains mucin-producing goblet cells. The underlying stroma is divided into the superficial adenoid and deeper fibrous layers. The stroma contains the conjunctiva's rich vascular supply, derived from branches of the palbebral, malar and anterior ciliary arteries. There are sparse sensory nerve fibres, derived from the ophthalmic branch of the trigeminal nerve. The conjunctiva has a role in tear dynamics and provides immunological protection for the eye, with the involvement of conjunctiva-associated lymphoid tissue (CALT). These collections of lymphoid tissue and cells are the primary centres of lymphoid activity for the ocular surface and provide the only lymphatic drainage of the eye. These lymphoid nodules are found in the superficial substantia propria and receive antigens for presentation to circulating mononuclear cells.

Subconjunctival haemorrhage and oedema (chemosis) can be dramatic, owing to the loose arrangement of the connective tissue. It is important to determine the cause of subconjunctival haemorrhage. Local trauma is the most likely underlying problem, but systemic diseases with clotting abnormalities may be responsible. Conjunctival hyperaemia is a consistent feature of conjunctivitis in both acute and chronic cases, and it is important to differentiate this from episcleral congestion. The deeper vessel involvement of the episclera usually indicates primary episcleral or scleral disease, or intraocular problems, such as uveitis or glaucoma. The conjunctival vessels tend to be of smaller diameter and branching, and they blanch quickly following the application of topical 1–2% phenylephrine.

The TEL is covered in conjunctiva and should always be examined. Following the instillation of local anaesthetic, the TEL can easily be grasped with fine forceps and the underside examined.

Epibulbar dermoid

These congenital structures contain elements of normal hair and sometimes skin. They arise mainly in the region of the lateral limbus, but may extend to involve the cornea and/or lateral canthus (Hendy Ibbs, 1985). They may be unilateral or bilateral and can be found in any breed (Plate 18.5). There appears to be a genetic predisposition in Birmans, but no direct inheritance has been proven. In this breed dermoids can vary from small nodules in the conjunctiva to large, hairy lesions. Treatment of epibulbar dermoids is by surgical excision.

Conjunctival cysts

These cysts are rare and may be congenital or acquired and are most commonly seen in association with symblepharon. Proposed aetiologies include epithelial inclusion cysts, cystic neoplasms, parasitic cysts and lacrimal cysts. Surgical excision is the treatment of choice.

Conjunctivitis

The clinical signs of conjunctivitis are blepharospasm, ocular discharge, conjunctival hyperaemia and chemosis. Chemosis can be spectacular in some acute cases of conjunctivitis and it is not specific to any one aetiology (Plate 18.6). As the condition becomes more chronic cytology demonstrates the presence of multinucleated giant cells, keratinised epithelial cells and goblet cell proliferation, leading to reduced tear production. Follicle formation may also develop in long-standing cases of conjunctivitis, as a result of chronic antigenic stimulation.

Conjunctivitis in the cat is a common problem with a number of different aetiologies. As all of these causes present with very similar clinical signs it is important to make a diagnosis so that the appropriate treatment and prognosis can be given. Causes of conjunctivitis include:

- infectious
- immune-mediated
  - eosinophilic
  - hypersensitivity
- neoplasia
- trauma/foreign body
- keratoconjunctivitis sicca
- miscellaneous
- associated with other ocular disease.

Infectious conjunctivitis

In the cat the majority of conjunctivitis cases have an infectious aetiology. The most common cause is FHV in both its acute and chronic forms. Feline calicivirus may occasionally cause both acute and chronic conjunctivitis in the cat. Primary bacterial conjunctivitis is uncommon in the cat, except in the case of *Chlamydia psittaci* infection. *Mycoplasma* species have also been reported as a cause of feline conjunctivitis. Secondary infection following trauma is not uncommon and results from opportunistic invaders.

Feline herpes virus

FHV is by far the most common cause of feline conjunctivitis (Nasisse, 1982, 1990). Acute disease is associated with upper respiratory infection, primarily in younger cats. These animals usually have corneal ulceration and severe conjunctivitis. The condition is often compounded by secondary bacterial infection.

Common sequelae include symblepharon (Plate 18.7), corneal scaring, chronic rhinitis, KCS, abnormal tear drainage, recurrent conjunctivitis and keratitis. Chronic infection is seen as resistant or recurrent disease in older animals, primarily keratitis and conjunctivitis and is associated with the lifelong carrier status. These individuals harbour the virus in their

trigeminal nerve ganglia and recrudescence results in replication of the virus in the corneal epithelium.

Diagnosis is based on history and clinical signs. Many older cats will have a history of 'cat flu' as a kitten or have been obtained from multicat rescue centres. Dendritic ulcers in cases of keratitis are pathognomonic for FHV infection. Viral isolation can be performed by taking conjunctival and oropharyngeal swabs, but is often unsuccessful. Techniques now exist to identify viral DNA by performing a polymerase chain reaction (PCR) on corneal and conjunctival samples (Nasisse & Weigler, 1997).

Acute cases should receive systemic and topical antibiotics in association with supportive treatment. Tetracyclines are the drugs of choice. The use of topical antivirals in acute cases is often overlooked, but is logical as these animals have active viral replication. Their use in these cases may prevent many of the common sequelae of acute FHV infection. Tear replacement is helpful in many chronic cases that have marginal tear test values or overt secondary KCS. In chronic cases topical antivirals, topical antibiotic and occasionally corticosteroids (in cases of stromal keratitis) can be helpful. Caution should be applied when using topical steroids in these cases and concomitant antivirals are recommended. Topical antivirals used in FHV infection include:

- trifluorothymidine (Moorfields Hospital pharmacy)
- idoxuridine (imported)
- acyclovir (Zovirax; Wellcome).

More recently, some novel treatment options have been suggested and reports indicate that their use increases the interval between bouts of clinical disease and decreases their severity. New FHV treatment options include:

- L-lysine (125 mg p.o. twice daily): competes with arginine and inhibits FHV replication (Maggs *et al.*, 2003)
- interferon (20–50 IU/ml topically twice daily): stimulates local immunity
- cimetidine (50 mg p.o. once daily): stimulates cell-mediated immunity.

Chlamydia psittaci

Chlamydia psittaci as a cause of acute conjunctivitis in individuals is well recognised and responds to appropriate therapy. Chronic and recurrent conjunctivitis can be more of a problem (Wills, 1988). In multicat households a cycle of recurrent cases including upper respiratory tract disease in young cats can be a real problem. A presumptive diagnosis can be based on history and clinical signs, but definitive diagnosis requires isolation of the organism from conjunctival swabs. In longstanding cases this is rarely achieved and the demonstration of high antibody titres in unvaccinated individuals is helpful. PCR techniques are now available that will help considerably in the diagnosis of this infection.

The mainstay of treatment is the use of topical and systemic tetracyclines. All animals in a multicat household must be treated and 3–6 weeks of medication is recommended. Once-daily dosing with doxycline (Ronaxan, Rhone Merieux) 10 mg/kg is very useful in this situation. Vaccination is available as a preventive measure and all new cats entering an endemic household should be vaccinated.

Other infectious diseases

Fungal, rickettsial and parasitic organisms have all been reported, but are rare causes of conjunctivitis. In any longstanding cases FeLV and FIV testing should always be performed, as this may be an underlying problem.

Immune-mediated conjunctivitis

Eosinophilic conjunctivitis (**keratitis and keratoconjunctivtis**) is a condition unique to the cat, which is described in the section on the cornea.

Hypersensitivity reactions can occur locally to any topical ophthalmic preparation or inappropriate home remedy. In longstanding conjunctivitis cases it is often useful to stop topical treatments for a few days to ensure that they are not exacerbating the condition.

Neoplasia is an uncommon problem. Several tumours are possible, including SCC, but lymphosarcoma is the most common secondary neoplasm in this area. Occasionally, limbal melanomas occur, but these are usually benign, well circumscribed and slow growing. SCC can occur at the limbus and has been reported in cats.

Conjunctival trauma and foreign bodies are a common cause of conjunctivitis and subconjunctival haemorrhage. Conjunctival lacerations do not generally need suturing as this tissue heals rapidly. Most foreign bodies can be removed under local anaesthetic. Treatment with topical and/or systemic antibiotics and analgesia is appropriate.

KCS is not a common problem in the cat, but an STT must be performed in cases of conjunctivitis. There are occasional cases of primary dry eye, but more commonly tear production is decreased as a result of chronic conjunctivitis, whatever the cause. In these cases artificial tears are an essential part of the treatment.

Conjunctivitis associated with other ocular diseases

Even in what appear to be cases of minor conjunctivitis a full ophthalmic examination should always be performed. Many other ophthalmic diseases may present initially with signs of conjunctivitis, such as orbital disease, medial lower lid entropion, imperforate and micropuntum, keratitis, uveitis and glaucoma.

The cornea

The cornea is the transparent tissue comprising the central one-sixth of the outer tunic of the eye, in continuity with the surrounding white sclera. Its tensile strength and clarity provide a protective but clear refractive interface. The cornea's special function is to refract and transmit light through the lens and hence to the retina. The anterior surface of the cornea represents the major refractive component of the eye, contributing approximately 48 D of plus power towards the convergence of an image on the retina. Corneal avascularity is essential for optical clarity, but also demands that oxygen is derived predominantly from the tear film and that most nutritional requirements be fulfilled by the aqueous humour.

Anatomically, the cornea is divided into three layers, the epithelium, the stroma and the endothelium. Corneal epithelium is stratified, squamous, non-keratinised and non-secretory. The basal layer of columnar cells is tightly adhered to an underlying basement membrane. Two or three layers of interdigitating, wing or polygonal cells make up the intermediate layer; these are irregularly shaped cells with oval nuclei and termed wing cells. Above this are three to four layers of flattened, nucleated, squamous cells, called squames. They possess tight junctions that obliterate the intercellular space and afford a permeability barrier to the cornea. The anterior plasma membrane of the most superficial layer of cells shows numerous microvilli and microplicae, with a glycocalyx coat that interacts with and helps to stabilise the PTF (Carrington, 1985).

The corneal epithelium, like all stratified squamous epithelium, is self-renewing. Even in the unwounded cornea the surface is in a state of constant healing. Squamous epithelial cells are continually shed into the tear pool and simultaneously replenished by cells moving centrally from the limbus, the site of the stem cells, and anteriorly from the basal layers of the epithelium. When this equilibrium is disturbed, as occurs dramatically after an abrasion, the corneal epithelial wound healing response sets in, with increased cell replication at the peripheral cornea and rapid migration of cells to cover the defect.

The stroma is the middle connective tissue layer of the cornea. It is approximately 500 μm thick and is responsible for about 90% of the corneal thickness. It is the most highly organised and most transparent of any connective tissue in the body. The stroma meshes with the surrounding scleral connective tissue to form a rigid framework for maintaining IOP. The stroma is composed of lamellae, formed by flattened bundles of collagen fibrils orientated in a parallel manner. The resting stroma is in a constant state of maintenance remodelling, a task performed by the resident keratocytes (fibroblasts). The collagen molecules are broken down and re-formed as the cells move through the stroma. The keratocytes produce proteases, which enable this function. Overproduction of these enzymes by fibroblasts, inflammatory cells and bacteria facilitates corneal melting. Stromal fibroblasts regenerate the stroma after injury. Following re-epithelialisation new collagen is laid down, it has a different orientation to the normal lamellae and this results in scar formation.

The innermost layer of the stroma is the thickened basement membrane known as Descemet's membrane, which is secreted by the corneal endothelium. The cornea borders the anterior chamber with a low cuboidal, single-layered endothelium. These cells are regularly arranged and mainly hexagonal in shape. The corneal endothelium plays a major role in maintaining stromal hydration using a Na^+/K^+-activated adenosine triphosphatase (ATPase) pump. Unlike the corneal epithelium, the endothelium is not self-renewing and the number of cells decreases with age.

Corneal sensation is provided by the trigeminal nerve (cranial nerve V), the myelinated nerve endings of which pass through the anterior stroma. On penetration through the epithelial basement membrane, the myelin sheath is lost and the naked nerve ending terminates among the outermost squamous cells. The corneal epithelium is the most highly innervated of all epithelia, with approximately 300–400 more nerve

endings per unit than the epidermis. Superficial corneal ulcers are generally more painful than deep ones, because there is a greater density of sensory nerve endings in the epithelium and superficial stroma. Cats with descematocoeles may present with comfortable-looking eyes.

Congenital conditions

Dermoids

See Conjunctiva section, above.

Microcornea and megalocornea

Both are rare congenital conditions. By definition, no other associated ocular abnormalities are seen. They are usually bilateral and non-progressive. A small cornea may be seen in association with microphthalmos and a large one with buphthalmos. FHV may cause multiple ocular anomalies, which include corneal abnormalities, in litters of kittens. The cornea may look abnormally small when there are limbal and perilimbal abnormalities; for example, in some forms of anterior segment dysgenesis and inherited connective tissue disorders.

Persistent pupillary membranes

These may sometimes attach to the posterior cornea, producing localised or more generalised opacities at the point of contact.

Keratoconus and keratoglobus

Keratoconus occurs as a result of bilateral thinning of the central cornea. It has been reported sporadically in cats, as a possible corneal dystrophy or in association with other ocular defects such as lenticonus. Keratoglobus occurs as a result of limbal to limbal corneal thinning such that the cornea protrudes.

Lysosomal storage diseases

Specific enzyme deficiencies lead to the accumulation of abnormal products within the cell lysosomes and the disorders are classified according to the substrate that accumulates. Neurological abnormalities are the dominating feature but ocular involvement can include retinal changes, blindness and corneal clouding. Diffuse corneal clouding is a feature of these neurometabolic storage diseases; including mucopolysaccharidosis I, VI, VII, GM1 and GM2 gangliosidosis and mannosidosis.

Transient opacities

These may occur following eye opening. They clear rapidly and are of no clinical significance.

Acquired conditions

Feline herpes virus and the cornea

Acute FHV infection has been discussed in the context of conjunctivitis and in these cases corneal involvement is also commonly encountered. This usually takes the form of ulceration, which is sometimes severe. One of the possible consequences of this acute infection is the development of symblepharon. The corneal stem cells at the limbus are damaged and unable to restore and maintain a corneal epithelium. In response, the conjunctiva grows across the cornea to resurface it. If extensive this conjunctival growth can effectively blind the kitten. Surgical removal can be attempted but symblepharon re-forms a few weeks after surgery. This is a similar clinical situation to that seen in humans following alkali burns and until stem cells can be replenished no effective treatment is possible.

Other corneal problems are dendritic ulceration and stromal keratitis, both associated with FHV carrier status and recurrent or chronic disease. Dendritic ulceration is an indication of active viral replication within the corneal epithelium and responds well to topical antivirals. Affected cats present with intermittently sore, watery eyes. The ulcers are best demonstrated using rose Bengal. Stromal keratitis is perpetuated by the cat's own immune response to viral antigen and should be treated with a combination of antivirals and topical steroids.

Other corneal diseases have been attributed to FHV infection, including corneal sequestrum and eosinophilic keratoconjunctivitis, using PCR techniques to detect viral antigen in affected individuals. It may well be that FHV is the cause of these conditions or it may be just a reflection of the widespread presence of this virus in the cat population.

Corneal ulceration is a common problem in the cat and most ulcers will heal uneventfully in 7–10 days. Local trauma associated with fighting is the most frequent cause and covering with topical antibiotics and systemic analgesia is usually all that is required. If an ulcer fails to heal then another cause

should be suspected and a through ophthalmic examination performed. If the cause is found then it must be treated to enable the ulcer to heal.

Causes of corneal ulceration include:

- trauma:
  - fight injuries, road traffic accidents, foreign bodies, etc.
  - adnexal abnormalities: entropion, eyelid coloboma, hairs and lashes, neoplasia, etc.
  - brachycephalic cats with protruding eyes and decreased corneal sensitivity
  - burns: alkali and acid
- tear film abnormalities
- infection:
  - FHV
  - *Pseudomonas* spp.
  - secondary bacterial
- immune-mediated:
  - eosinophilic keratitis
- recurrent epithelial erosion:
  - older animals
  - FHV
- others:
  - sequestrum
  - neurotrophic
  - endothelial dysfunction.

Medical treatment of corneal ulceration relies on determining the underlying cause and addressing it. Medications that can be used are:

- topical antibiotics
- topical antiviral
- atropine ointment, for reflex uveitis
- collagenase inhibitors
- false tears
- systemic antibiotics
- analgesia.

Corticosteroids must not be used. Topical anaesthetic should not be used to control pain, as this would retard epithelial migration. Systemic analgesics may be used if pain is marked.

In cases of non-healing ulceration in the cat **phenol cautery or grid/punctate keratopathies** must not be performed as they predispose to sequestrum formation.

Non-ulcerative corneal disease

The cornea only has a limited number of responses to insult. The main three are oedema, vascularisation and pigmentation. Most corneal diseases will incorporate a combination of these signs. Other responses are cellular infiltration, degeneration and scarring. Corneal lipid deposition can occur as a primary or secondary problem but is extremely rare in the cat. Calcification can also occasionally be seen.

Endothelial dystrophy is a progressive, bilateral and severe endothelial dystrophy occasionally seen in domestic shorthairs. The mode of inheritance is unknown and the cats are normal in all other respects.

Stromal dystrophy, a progressive form of corneal dystrophy, inherited as a simple autosomal recessive, has been described in a group of Manx cats (Bistner *et al.*, 1976).

Eosinophilic keratoconjunctivitis is only seen in the cat and is characterised by white and pink deposits (resembling cottage cheese) in the superficial corneal stroma and epithelium (Plate 18.8). As its name suggests it can also involve the conjunctiva. There is no breed predisposition and it is most commonly seen in young to middle-aged cats (Paulsen *et al.*, 1987; Morgan *et al.*, 1996). Diagnosis is based on cytology from scrapings or biopsies. Mast cells and eosinophils predominate, with occasional mixed inflammatory cells. It has been suggested that this may be part of the eosinophilic granuloma complex, but there have been no reports of cats with concurrent ocular signs and skin lesions.

Treatment with topical steroids or cyclosporine will produce clinical remission, but many cases have a seasonal recurrence and require repeat treatments. In the past megoestrol acetate has been advocated as a treatment. It works well but because of its undesirable side-effects should be reserved for refractory cases or difficult cats.

Lipid keratopathy is the deposition of lipid within one or both corneas, and is not as common in the cat as in the dog (Carrington, 1983). The appearance is very variable, but vascularisation is a constant feature, which may precede or follow the predominantly stromal lipid deposition. Some affected animals, but by no means all, have plasma hyperlipoproteinemia. The condition is usually associated with, for example, anterior segment inflammation, localised corneal disease, previous corneal or ocular insult including surgery. The lipid and lipoprotein profile should be determined to check for systemic abnormalities, which should be addressed. Any local ocular disease should be identified and treated. If keratectomy or other treatment is contemplated in an attempt to remove or diminish dense opacities, it should only be performed when the lipoprotein profile is normal and any underlying local factors have been brought

under control. With suitable medical treatment (if indicated) or dietary manipulation, some lesions will regress, but it is pertinent to note that lipid removal is a slower process than lipid deposition.

Neurotrophic keratitis can result from cranial nerve V or VII palsy, owing to the absence of the blink reflex.

Corneal sequestrum is only seen in the cat and its other names include corneal necrosis, corneal nigrum and corneal sequestration. It can be seen in any breed, but there is predisposition in Persians, Birmans and Burmese (Startup, 1988; Morgan & Abrams, 1994). Corneal sequestrum is not a single disease entity but more likely to be the cornea's response to chronic damage. It can be seen associated with FHV infection, entropion, KCS and chronic exposure keratitis. The underlying defect in the commonly affected breeds is unknown. It may be an inherited problem such as a stromal dystrophy or it may be associated with a brachycephalic syndrome, similar to that seen in the dog; that is, protrusion of the globe, leading to incomplete blink and tear film spreading, with drying and exposure of the central cornea. Thorough ophthalmic examination is required in all cases to determine the presence of concurrent ocular disease.

Whatever the cause, the disease follows a similar pattern, with the lesion starting as brown stain deep within the stroma. The speed of progression is variable and in some cases extremely slow. The discoloured region increases in size, becomes darker and extends into the anterior stroma, eventually breaching the epithelium (Plate 18.9). At this stage a well-demarcated plaque is seen raised above the level of the epithelium. The lesion causes the cat no problems while confined to the stroma, but once ulceration occurs there is considerable ocular discomfort. In many chronic cases there is corneal oedema and vascularisation associated with the lesion. Some sequestra will slough spontaneously, but this can be a long process, during which the cat is very uncomfortable. The condition is usually unilateral, but the other eye may become affected at a later date (most likely in the pedigree cases).

Treatment involves determining the presence of an underlying cause and correcting it. Superficial keratectomy is the therapy of choice for removing the lesion and can be followed up with the use of supporting grafts and contact lenses. Topical tear replacement is useful in some cases. Recurrence is possible in some cases and can even occur under a conjunctival graft. More recently, topical interferon has been used to treat this condition, but the results of this are not yet available.

Neoplasia

Corneal neoplasia is extremely rare. Primary tumours have not been recorded. Secondary involvement may be seen with fibrosarcoma, lymphoma and melanoma.

Aqueous and glaucoma

The anterior chamber in the cat is deep, the cornea large and the iridocorneal angle wide. Gonioscopy, examination of the angle of filtration, is possible with the use of a goniolens (Plate 18.10). The pectinate ligament has fewer, finer and less branched fibres than in the dog, varying in colour from gold to blue according to the colour of the iris. The normal IOP of the cat is about 15–30 mmHg.

Glaucoma is defined as an increase in IOP associated with damage to the retina and optic nerve. Glaucoma may be subdivided into congenital, primary and secondary forms. Congenital glaucoma; does occur in the cat but is rare. Primary glaucoma, that is, glaucoma with no antecedent ocular disease, is considered to be hereditary, particularly in dogs and in humans, but no proven primary hereditary glaucoma has yet been recorded in any breed of cat and so glaucoma in cats must be considered to be secondary (Ridgway & Brightman, 1989; Wilcock *et al.*, 1990). The most common cause of glaucoma in the cat is chronic uveitis with or without lens luxation. It may also follow neoplasia, particularly uveal melanoma and lymphosarcoma.

The acute congestive glaucoma described in the dog, presenting with a blind and painful eye, is not usually seen in the cat. The clinical signs are usually more subtle and insidious in onset. Conjunctival and episcleral congestion, and occasionally chemosis, do occur. Corneal oedema is usually mild and corneal vascularisation, although sometimes present, does not show the intensity of the canine glaucomas. The cornea may appear clear and the eye apparently comfortable, such that the cat is not presented until late in the course of the disease. The pupil will be dilated in the affected eye and the resultant anisocoria may be the first obvious clinical sign. Hydrophthalmos often occurs and may lead to further corneal changes, but not to the typical fractures in Descemet's membrane seen in the dog. Ultimately, retinal and optic atrophy result from the increased IOP. Glaucoma in the cat may be unilateral or bilateral.

Treatment of glaucoma in the cat is difficult and often unsuccessful in either restoring or saving vision.

Cases are usually presented late with advanced and irreversible vision loss. However, of greater importance is the fact that the majority of cases are secondary to another eye condition and therefore the primary condition should be treated wherever possible. The cause of most glaucoma cases in the cat is anterior uveitis. The use of corticosteroids and other anti-inflammatory agents may therefore be of value, although some uveitis cases are poorly responsive to medical therapy. The use of miotics has proved to be of little or no value and might be contraindicated in the case of uvieits. Carbonic anhydrase inhibitors can be of some value, although they are not well tolerated in this species and dosage may have to be reduced. Topical antiglaucoma medications can be used in combination with these systemic medications.

Unfortunately, enucleation is the only possible treatment in some cases, particularly the painful eye. If neoplasia is suspected, then enucleation is the most appropriate treatment, except perhaps in the aged cat with a slow-growing tumour. Removal of the eye may be considered in trauma cases, especially where there may be lens rupture and the danger of the subsequent development of intraocular sarcoma.

Other conditions of the aqueous in the cat

The aqueous humour may be involved in other ocular conditions. Hypopyon and hyphaema accompany severe uveitis, which may often be a sign of systemic disease. Hypopyon may also indicate lymphoma. Hyphaema may also be present following trauma, associated with infections such as FIP and FeLV, in anaemia and thrombocytopenia, in cases of hypertension, and with blood dyscrasias. Hyphaema rarely requires treatment as the blood is readily cleared and a secondary glaucoma is unusual. Complete turbidity of the aqueous due to lipaemia is possible. Rare cases of parasitic larvae in the anterior chamber do occur.

The uveal tract

The uveal tract is the vascular and pigmented tunic of the eye consisting of the iris, ciliary body and choroid. The iris is the most anterior part of the uvea. It acts as a diaphragm in front of the lens and divides the anterior and posterior chambers of the anterior segment. The iris is divided into a central or pupillary part and an outer ciliary zone; the former is thinner and often darker in colour than the outer zone. The major arterial circle of the iris is distinguishable as a raised tortuous line around the periphery in most cats. The arteries which form this circle, and which represent terminations of the medial and lateral branches of the long posterior ciliary arteries, enter at the 9 and 3 o'clock positions. Venous drainage occurs via tortuous radial vessels, which empty directly into the anterior choroidal veins and subsequently the vortex veins.

Histologically, the iris is composed of a connective tissue stroma, nerves, blood vessels and muscles. The anterior border layer contains fibroblasts and the uveal melanocytes (but has no epithelium), and overlies the loosely arranged stroma. The sphincter muscle is found within the stroma and completely encircles the pupillary zone. The lack of epithelium means that diffusion can occur through the anterior stroma. Posterior to the stroma there are two layers of epithelium, apposed apex to apex, which form part of the blood–aqueous barrier. The anterior non-pigmented epithelium of the iris forms the dilator muscle and is continuous with the inner pigmented epithelium of the ciliary body. The posterior pigmented epithelium of the iris is continuous with the outer, non-pigmented ciliary epithelium.

Sensory and vasomotor nerves are derived from the trigeminal nerve and enter via the iris root, from the ciliary body. The nerve endings terminate, unmyelinated, diffusely in the stroma. Both sympathetic and parasympathetic fibres enter the iris. The sphincter muscle is supplied mainly with parasympathetic fibres, derived from the occulomotor nerve, via the ciliary ganglion and the long ciliary nerves, of which there are two in the cat. This muscle constricts the pupil and thereby regulates the amount of light entering the eye, in response to parasympathetic stimulation. The dilator muscle is arranged in a single layer of radially orientated fibres and supplied mainly by sympathetic fibres. These fibres derive from the superior cervical ganglion and travel via the posterior ciliary nerves.

Iris colour is determined by the amount of melanocytes (uveal melanocytes) in the stroma. A brown iris is due to dense diffuse pigmentation. A blue iris is seen when there is less pigment in the stromal melanocytes. An albino iris appears pink, as there is no pigment in the iris stroma or pigment epithelium, and the red glow of the fundus is reflected through the iris. The two eyes of some cats may be of different colours, one blue and one yellow (heterochromia iridum), and parts of the same iris may also differ in colour (heterochromia iridis). The pupil of the cat takes the form of a vertical slit in shape when constricted, but is circular when dilated.

The choroid lies between the retina and the sclera, and is highly vascularised and, in most cats, heavily pigmented. The choroid contains the choriocapillaris, commonly a cellular tapetum and a stroma containing large blood vessels.

The ciliary body is located posterior to the iris and anterior to the choroid. It has many functions, including secreting aqueous, nourishing the lens, containing the muscle power for accommodation, supporting the zonular fibres and forming part of the vitreous face. It consists of a thin stroma, ciliary muscles and blood vessels. It is covered with a non-pigmented epithelium, which is a direct continuation of the neuroretina. Beneath this lies a pigmented epithelium, an anterior extension of the retinal pigment epithelium. The non-pigmented epithelium secretes the aqueous. There is a potential space between the two epithelial layers, similar to that between the two layers of the retina, which is formed as the single layer of the optic cup inverts. However, the gap between the two ciliary epithelial layers is kept tightly closed by adhesion complexes between the cells.

The ciliary body is triangular in shape (thickest anteriorally), and divided into the anterior pars plicata and posterior pars plana. The surface of the pars plicata is thrown into multiple folds, known as the ciliary processes. These processes provide a large surface area for aqueous production. The ciliary processes also anchor the suspensory zonular fibres of the lens, although in contrast to primates, the degree of lens accommodation is limited in domestic animals as the underlying ciliary muscle is poorly developed. The most anterior portion of the ciliary body is the ciliary cleft of the iridocorneal angle.

Congenital anomalies

Uveal colobomas, both typical and atypical, are rare but have been recorded particularly in association with ocular colobomas elsewhere, including the eyelid and retina. Persistent pupillary membranes (PPMs) are remnants of the anterior portion of the mesodermal vascular membrane that surrounds and nourishes the lens during development *in utero* (Plate 18.11). This membrane usually regresses soon after birth, but in some cases may persist as web-like pigmented strands across the pupil, from iris to iris, iris to lens or iris to cornea. Lens and corneal attachments may be associated with focal opacities. The condition is congenital and non-progressive and can be distinguished from acquired synechiae by the origin of the strands. PPMs arise from the iris collarette, while synechiae generally arise from the pupil margin or periphery. PPMs are uncommon in the cat.

Changes in iris pigmentation

Benign melanosis are patches of brown–black pigment that occur on the surface of the iris in normal cats and slowly increase in size or multiply with age (Plate 18.12). They may be extremely difficult to differentiate from diffuse iris melanomas, a particularly malignant tumour in this species necessitating enucleation (Plate 18.13) (Bellhorn & Henkind, 1970; Acland *et al.*, 1980; Duncan & Peiffer, 1991). In the main, melanosis is slowly progressive, the pigment patches are not raised and the pupil is not distorted. While clinical signs may raise the suspicion of melanosis or melanoma, histopathological examination may be the only way to be certain. Melanosis does not require any treatment. Cats with melanosis should be regularly monitored. Thoracic radiography and abdominal ultrasound may be useful to rule out metastateses if there is a suspicion of a melanoma and enucleation should be considered.

Iris cysts, single or multiple, may be seen as an incidental findings in the anterior chamber or more rarely through the pupil. They may be of unknown cause or following a previous uveitis. Ectropion uvea, eversion of the posterior pigment epithelium through the pupil, may or may not be associated with iris cysts or again with iris inflammation. Iris atrophy, either following uveitis or with senility, may present as darker areas of the iris, which should be easily distinguishable from the above conditions by transillumination.

Uveitis

Uveitis in the cat is an important and not uncommon ocular disease (Davidson *et al.*, 1991). The inflammation may involve one part or the whole of the uvea. Anterior uveitis may primarily involve the iris (iritis) or both the iris and the anterior part of the ciliary body (iridocylitis). Intermediate uveitis primarily involves the posterior part of the ciliary body (par planitis). Posterior uveitis primarily involves the choroid (choroiditis), but close association of the retina means that inflammation of both choroid and retina is the usual situation. Panuveitis is inflammation of the entire uveal tract: iris, ciliary body and choroid. Endophthalmitis is inflammation of the entire globe contents.

Uveitis may occur in isolation or accompanying other ocular or systemic disease (Chavkin *et al.*, 1992;

Lappin *et al.*, 1992). In this species particularly, uveitis may be a sign of systemic disease in the presence or absence of other clinical signs. Also in this species, as in other species, recurrent uveitis often occurs. Many cases of uveitis remain of unknown aetiology.

Anterior uveitis presents classically as a red eye, which may or may not be painful; the pupil may be constricted (miosis) and the IOP low. One or both eyes may be affected to similar degree or, more usually, to differing degrees. Except in cases of traumatic uveitis, the condition in the cat is usually chronic and may be painless in such cases. Clinical signs also include hyperaemia of visible vessels, including those on the surface of the iris, which are often congested sufficient to produce a change in colour of the iris, sometimes the presenting sign to an owner. Aqueous flare, hypopyon and keratic precipitates on the posterior cornea are common, and there may be inflammatory debris on the anterior lens capsule. In severe cases hypopyon and/or hyphaema may be seen (Plate 18.14). Posterior synechiae with pigmentary adhesions on the anterior lens capsule and consequent irregularity of the pupil are not uncommon.

Choroiditis may present alone or together with anterior uveitis, and the involvement of the choroid usually also affects the retina producing a chorioretinitis. In the cat posterior segment changes occur less frequently than anterior segment changes and, in addition, may not be visible owing to the changes in the anterior segment. The clinical features of posterior uveitis will be discussed in more detail later in this chapter. The sequelae of uveitis include corneal opacity and neovascularisation, a permanently darker iris, pigment deposits on the anterior lens capsule, posterior synechiae, secondary glaucoma, cataract and lens luxation (Plate 18.15). and phthisis bulbi.

Causes of feline uveitis

The causes of uveitis are many and varied and include trauma; viruses, including FIP, FeLV–lymphoma complex and FIV; parasitic, particularly toxoplasmosis (see retina section, below, for more details); mycoses (cryptococcosis, histoplasmosis, blastomycosis, coccidiomycosis and candidiasis), rarely occurring in the UK; and occasionally bacteria, including tuberculosis. Many cases remain idiopathic.

Feline immunodeficiency virus

Uveitis is the most common ocular sign associated with FIV infection (Hopper *et al.*, 1989). The uveitis may result from immune complex deposition or localisation of FIV in uveal lymphoid tissue. In some cases there is secondary infection with *Toxoplasma gondii*. The signs tend to be those of chronic anterior uveitis, with aqueous flare, keratic precipitates, iridial hyperaemia and cortical cataracts as common findings. Secondary glaucoma, hydrophthalmos and lens luxation may be seen in longstanding cases. Localised 'intermediate' uveitis in the form of pars planitis has been described in several FIV-infected cats and may be due to a plasmocytic–lymphocytic infiltrate. This form of uveitis is also described in human patients with HIV-related disease. Affected eyes, even when glaucomatous, often appear to be non-painful. Other systemic signs attributable to FIV infection may also be present in affected patients, which tend to be middle-aged outdoor cats.

Feline leukaemia virus

FeLV-positive cats may present with ocular signs, primarily uveitis, but conjunctivitis, pupillary abnormalities, retinal haemorrhage and detachments have also been reported (Brightman *et al.*, 1991). Any cat with recurrent or refractory eye disease should be tested for FeLV and FIV, as underlying immunosuppression may be a problem. Uveitis is usually the result of FeLV-associated lymphoma, but may also be due to primary viral damage or immune complex deposition leading to breakdown of the blood–ocular barriers. The severity of uveitis varies and is often associated with intraocular haemorrhage as a result of anaemia and thrombocytopenia. Involvement of the cranial nerves with tumour invasion has been reported and can result in a D-shaped pupil. As with other FeLV-related conditions, affected cats tend to be young and usually have other clinical signs, such as pyrexia, lympadenopathy and weight loss.

Feline infectious peritonitis

It is not unusual for FIP cases to present initially with ocular signs. Uveitis can be seen with both the wet and dry forms of the disease. As with lesions elsewhere in the body, the ocular signs are attributed to a pyogranulomatous reaction and necrotising vasculitis. In this case the uveal vasculature is targeted and there is severe disruption to the blood–ocular barriers. Both anterior and posterior uveitis can be seen, but the anterior signs predominate. Aqueous flare, hypopyon and keratic precipitates are the most

common findings owing to the high protein levels in the aqueous. In FIP cases that do not appear to have anterior signs, more thorough examination may reveal choroidal exudation, retinal detachment and retinal perivascular exudates. Affected individuals tend to be young and develop other characteristic clinical signs, including pyrexia, ataxia, weight loss and effusions.

Diagnosis of uveitis

It is essential to try to identify a cause for uveitis, although there are many occasions where this remains unknown. Bilateral involvement usually indicates systemic disease, but one eye may be affected before the other.

Treatment

Treatment should be specific whenever possible (i.e. clindamycin for toxoplasmosis), but depends upon establishing the cause. However, symptomatic treatment is also necessary to reduce the intraocular inflammation and pain, and consists of mydriatics and anti-inflammatories (see Table 18.1). Moderate pupillary dilation is the aim and atropine should be used as frequently as is necessary to achieve and maintain this dilation. Of the corticosteroids, prednisolone acetate 1% is the most effective topically and oral prednisolone may be indicated for posterior uveitis. Care must be taken with long-term topical steroids as corneal ulceration may develop.

Since many FIV-infected cats live for several years following diagnosis it is important to keep the related uveitis under control and prevent the development of secondary problems. Lens luxations in FIV-positive cats can present an ethical treatment dilemma. Systemic essential fatty acids may be helpful as they have been shown to improve skin lesions and peripheral neuropathies in FIV-positive cats.

In cases of trauma-induced uveitis it is imperative to prevent infection by using systemic antibiotics. Topical and systemic non-steroidal anti-inflammatory drugs (NSAIDs) can be used in the cat, particularly where corticosteroids may be contraindicated, but this is not common.

Anterior uveal neoplasia is relatively common. Affected animals can present owing to abnormal ocular appearance or show signs of secondary glaucoma or uveitis. Neoplasia should always be considered in cases of refractory glaucoma and uveitis: in the case of a blind painful eye, 'if in doubt, take it out'. The following have all been recorded arising in either the iris or the ciliary body: adenoma, adenocarcinoma, fibrosarcoma, haemangiosarcoma, leiomyoma/sarcoma, lymphoma (Plate 18.17), plasma cell myeloma and SCC. Ciliary body adenoma/adenocarcinoma is usually pinkish in colour and can be seen distorting or protruding from behind the pupil. Prompt enucleation is advised and usually curative.

Anterior uveal melanoma, usually but not always pigmented, presents as a mass arising from the iris or ciliary body. Diffuse iris involvement can also occur, leading to iris thickening and increased pigmentation. In the cat, there is a high proportion of malignant lesions. It can be difficult to differentiate these from benign melanosis.

Cases of **metastatic neoplasia** present with similar signs regardless of the histological type and primary location of the tumour. Unlike primary ocular neoplasia, signs tend to be bilateral. Concurrent systemic

Table 18.1 Medical treatment of uveitis

Corticosteroids	Topical	Prednisolone acetate 1% (Pred Forte; Allergan) Dexamethasone 0.1% (Maxidex and Maxitrol; Alcon)
	Systemic	Prednisolone 1–2 mg/kg
NSAIDs	Topical	Ketorolac (Accular; Alcon) Flurbiprophen sodium 0.03% (Ocufen; Allergan) Diclofenac sodium 0.1% (Voltarol; CIBA vision)
	Systemic	Carprophen 4 mg/kg Metafenamic acid
Mydriatrics	Topical	Atropine 1% drops or ointment Tropicamide (Mydriacyl; Alcon) Phenylephrine 10%
Antibiotics	Systemic	Clindamycin 25 mg/kg (Antirobe; Upjohn) Oxytetracycline (may also have an immunosuppressive action) Broad spectrum following penetrating trauma

disease is not always obvious. Intraocular masses can be apparent or simply a uveitis from haematological spread. Lymphoma is the most common secondary neoplasia affecting the eye and can present as a solitary mass or generalised uveal tract infiltration (Corcoran *et al.*, 1995). Multiple myeloma and systemic histiocytosis may also present as cases of uveitis. Other metastases have been reported in the eye, including pulmonary adenocarcinoma.

The lens

The lens is a transparent, biconvex, avascular and refractive structure suspended by zonular fibres and situated behind the iris, which it supports. The lens arbitrarily divides the eye into anterior and posterior segments; the lens lies behind the posterior chamber, the anterior chamber being in front of the iris and behind the cornea. There is a firm attachment of the vitreous to the mid-periphery of the posterior lens capsule at the hyaloideocapsular ligament. Anteriorly, the posterior surface of the pupillary zone of the iris rests on the lens surface. The lens may be subdivided into a nucleus, cortex and capsule, which may be further subdivided into anterior and posterior portions. The suture lines occur where the lens fibres meet in the form of a Y anteriorly and an inverted Y posteriorly. The cat lens is particularly large and accommodation is poor.

The lens consists of a capsule, lens epithelium and lens fibres, which form throughout life. Primary lens fibres differentiate from the posterior lens epithelium at an early stage of eye development, this differentiation is induced by the embryological retina. These primary fibres elongate and fill the lens vesicle to form a solid sphere. In the adult these primary fibres form the central nucleus of the lens. No posterior epithelial cells are present in the adult lens and the posterior capsule is thin. Beneath the anterior lens capsule are actively dividing anterior epithelial cells. When these cells reach the equatorial region of the lens they start to elongate to form the secondary lens fibres, one arm of which stretches into the anterior cortex and the other into the posterior cortex. New secondary fibres are constantly produced throughout life, resulting in progressive compression of the nucleus of the lens. The anterior lens capsule is produced by the anterior epithelium throughout life and grows thicker as the animal ages. The secondary lens fibres are partially responsible for the normal ageing change of senile nuclear sclerosis, which is not as obvious in the cat as in the dog.

Disorders of the lens are uncommon in the cat and can be divided into congenital anomalies, cataract (simply defined as an opacity of the lens and/or its capsule) and luxation or subluxation of the lens (abnormal position due to partial or complete rupture of the zonular fibres).

Congenital anomalies

Congenital lens abnormalities may be caused by genetic or exogenous factors, and because proper lens development is crucial in the orchestration of intraocular embryogenesis, eyes with lens anomalies also often exhibit multiple ocular defects. The following abnormalities are all rare findings in the dog and cat: aphakia (absence of lens), microphakia (small lens), lenticonus (abnormally shaped lens) and lens coloboma.

Cataract

Cataract is rare in comparison to the dog, partially because there are very few proven reports of primary hereditary feline cataract. Both unilateral and bilateral congenital cataracts have been reported, but are usually isolated cases. Cataracts may develop secondary to any disease that affects the nutrition of the lens or damages it. Cataract in the cat is almost always secondary in form, the most common being postinflammatory following uveitis and often associated with posterior synechiae. Secondary cataract formation can also occur as a result of glaucoma and lens luxation. Trauma is another cause of cataract in this species, usually following a penetrating corneal injury. Diabetic cataract can occur in the cat, but is very rare. The only treatment for cataracts is surgical (Plate 18.18).

Persistent pupillary membranes arising from the iris may insert on the anterior lens capsule. These insertions are associated with capsular and subcapsular cataracts and may also be seen as a component of multiple ocular defects.

Senile nuclear sclerosis

This occurs in the cat, but is usually evident at a more advanced age than in the dog, often 10 years or older. There is an apparent greying of the nucleus and a change in its refractive index. Using distant direct ophthalmoscopy the denser nucleus appears as a dense sphere within the lens, against the tapetal reflection. Nuclear sclerosis has no notable effect on vision and

the fundus can still be clearly examined through it, using both direct and indirect ophthalmoscopy.

Lens luxation

In the cat, lens luxation, both unilateral and bilateral, occur less frequently than in the dog. Primary lens luxation has not been reported in the cat, although a breed predisposition in the Siamese has been noted (Olivero *et al*., 1991). Congenital lens luxation (with microphakia) is rare. Feline secondary lens luxation may follow trauma, anterior uveitis and glaucoma, particularly the latter when the zonular fibres have been stretched by increased IOP, hydrophthalmos and globe enlargement. Lens luxation is more commonly seen in aged cats, in which it presumably follows a degree of zonular degeneration. Probably for a similar reason, lens luxation of a total cataractous lens is not a rare occurrence and neither are secondary cataractous changes in an originally clear and dislocated lens. In the cat anterior lens luxation is the rule and posterior luxation is unusual. Glaucoma secondary to anterior lens luxation can occur, although not of the acute and severe type that is often seen in the dog. The removal of a dislocated lens is a rewarding surgical procedure in the cat and is indicated when secondary glaucoma is present or when cataract formation affects vision, provided always that underlying predisposing factors, such as uveitis, are also addressed.

The vitreous

The vitreous occupies the posterior segment of the eye and constitutes two-thirds of its volume. It is a transparent jelly-like substance, 99% water with collagen and hyaluronic acid and very few cells. Embryologically, the vitreous is derived from ectoderm and is divided into primary (hyaloid artery system), secondary (adult vitreous), which forms around the primary, and tertiary vitreous (lens zonular fibres). The vitreous is in contact with the lens, the zonules, the pars plana of the ciliary body, the retina and the optic disc. The cortex represents the outermost layer of the vitreous, and is firmly attached only at the vitreous base, to the pars plana and ora ciliaris retinae, the posterior lens capsule (hyloidocapsular ligament) and around the optic disc. The lens occupies an anterior depression in the vitreous body, known as the patella fossa. Its functions are to support the retina, to transmit light and to maintain the eyeball shape. Many of the vitreal conditions described in the dog are also seen in the cat but less commonly, except perhaps haemorrhage.

Congenital anomalies

Persistent hyaloid artery appears to be rare in the cat. Persistent hyperplastic primary vitreous (PHPV) has not been described in the cat.

Acquired diseases of the vitreous

Hyalitis usually represents an extension of an inflammatory process within the adjacent ocular structures (e.g. chorioretinitis or severe anterior uveitis), rather than true primary inflammation. This is manifest as haze within the vitreous. Important causes of hyalitis include FIP, toxoplasmosis, FIV and FeLV.

Haemorrhage into the vitreous is the most likely condition to be encountered clinically, and may result from inflammation, trauma, neoplasia, clotting disorders and, in particular, hypertension. In such cases vitreal haemorrhages may be accompanied by retinal haemorrhages. Haemorrhages into the vitreous may also occur in severe anaemia. Resolution of vitreal haemorrhage may be prolonged and formation of fibrous, contractile vitreoretinal membranes may lead to tractional retinal detachment.

Melanin and blood pigment products may be observed in the vitreous. These deposits result from intravitreal haemorrhage, penetrating ocular injuries with damage to the uveal tract and intraocular inflammation.

Gun pellets are not uncommon vitreous foreign bodies in cats. The site of ocular penetration is usually apparent as a lesion in the cornea or bulbar conjunctiva. An exit wound may also be observed ophthalmoscopically if the pellet has passed through the vitreous. Such injuries often result in formation of white fibrous membranes and granulomata within the vitreous body. In general, intraocular foreign bodies should be removed immediately, since they are frequently attended by severe endophthalmitis. However, sterile pieces of glass or lead, within the central vitreous, may incite little ocular reaction.

Uveal cysts, originating from the pigment epithelium of the ciliary body, may be an incidental finding in the vitreous. They are similar in appearance to those seen in the anterior segment. Cystic hyaloid remnants are very rare and appear as grey, transparent cysts suspended in the vitreous. Neither of these is of clinical significance.

Folds of detached retina may also be seen in the vitreous, particularly in cases of hypertension.

Vitreal degeneration can occur as a senile change, but is frequently associated with retinal degeneration, ocular inflammation, glaucoma and lens luxation. Affected eyes are predisposed to retinal detachment. Syneresis is irreversible liquefaction of the vitreous. Condensations and lytic areas may be observed within the framework of the vitreous as floating particles and strands. Asteroid hyalosis is an accumulation of numerous spherical white deposits of calcium/lipid suspended within the fibrillar network of the vitreous. The condition is not common but may be observed in older cats, with no other apparent ocular disease. Vision does not seem to be significantly affected. Synchisis scintillans is an uncommon condition which is associated with the formation of sparkling cholesterol crystals within a liquefied vitreous. This gives an ophthalmoscopic appearance similar to a 'snow scene' as crystals settle ventrally then swirl around in response to ocular movement. Visual impairment may be associated with this condition, as it may result from other diseases such as intraocular haemorrhage, retinal degeneration or chorioretinitis.

Several cases of cats with chronic low-grade hyalitis have been described (J. Mould, unpublished) that have a history of having dentals performed in the preceding 3–12 months. Several of these eyes have been enucleated and found to contain evidence of posterior penetrating injuries and vitreal abscessation. One should be aware when performing dentals in cats that instruments can easily migrate into the orbit when under pressure.

No primary neoplasia has been recorded. Secondary involvement because of extension from neighbouring structures, usually the uveal tract, is possible.

The fundus

The fundus is the posterior segment of the globe viewed ophthalmoscopically and consists of the retina over the underlying choroid and sclera, divided into tapetal (tapetum lucidum) and non-tapetal (tapetum nigrum) parts, the optic disc and the retinal blood vessels (Plate 18.19). The feline fundus shows much less variation than that of the dog. The tapetum is a large, well-developed, highly reflective and cellular layer. It is triangular in shape and usually yellow to green in colour, or occasionally blue. The tapetum may be absent in some blue-eyed white or colour-dilute cats and, in others with this coat and eye colour, the tapetum may be thin, showing the underlying choroidal vasculature. The area centralis (area of maximum cone density) is situated lateral to the optic disc, is an area devoid of retinal blood vessels and may appear darker in colour. In the cat the tapetal–non-tapetal junction is clearly defined, with only occasional tapetal islets visible.

The non-tapetal fundus is normally heavily pigmented and dark grey–brown in colour, except in breeds such as the Siamese and Himalayan in which, owing to a lack of ocular pigment, it appears tigroid with visible choroidal vessels (Plate 18.20).

The retinal blood vessels in the cat are described as holangiotic, as in the dog. There are three major pairs of cilioretinal arterioles and usually larger, less tortuous veins extending from the optic disc towards the periphery of the retina. The central portion of the disc is free from blood vessels and small vessels leave the periphery of the disc. Blood vessel tortuosity is rare in normal cats.

Histologically, the retina is usually considered to have 10 layers. The outermost is the retinal pigment epithelium (RPE), which lies next to the choroid and is derived from the outer layer of the optic cup. The remaining nine layers, which make up the neurosensory retina, develop from the inner layer of the optic cup, also ectodermal in origin. The nine layers, from the pigment epithelium inwards, are the receptors (rods and cones), the external limiting membrane, the outer nuclear layer, the outer plexiform layer, the inner nuclear layer, the inner plexiform layer, the ganglion cell layer, the nerve fibre layer and the internal limiting membrane.

Feline retinal disease can be classified in several ways and, although there are some specific forms of retinal degeneration, many cases presented may have an unknown aetiology and this is particularly seen in bilateral advanced retinal degeneration which presents as odd cases in all breeds. Furthermore, feline retinal disease is often associated with systemic disease and a full examination of the animal should be performed, in addition to the eye examination, before a definitive diagnosis is reached.

Congenital anomalies

Retinal dysplasia has been reported occasionally in the cat following infection with both panleucopenia virus and FeLV. It manifests as grey folds or rosettes in the tapetal fundus and white lesions in the non-tapetal fundus. Retinal dysplasia may occur as an isolated finding or with other ocular defects such as

microphthalmos and cataract. There are no reports of inherited retinal dysplasia in this species.

Coloboma of the fundus involving the disc peripapillary area and choroid is rare but has been recorded, sometimes with other congenital defects including eyelid agenesis.

Lysosomal storage diseases, in which multiple small spots occur in the fundus, together with neurological signs, have also been reported in kittens but are rare.

Acquired retinal disease: non-inherited

Non-inherited retinal disease covers a wide spectrum of conditions, including inflammatory, metabolic and cardiovascular disorders. Some of these diseases affect only the retina, but in others the retinal component is part of a more widespread problem. The retina is closely associated with the choroid and is therefore invariably involved in cases of posterior uveitis.

Several pathological changes can affect the fundus. These may be present alone or in combination, depending on the underlying disease process. The more common ones are listed below.

Retinal thickening due to infiltration with cells or fluid may occur in inflammatory or neoplastic conditions affecting the retina or in conditions such as hypertensive retinopathy. Over the tapetal area the thickened retinal layers reduce the reflection from the tapetum, giving a greyish appearance to the lesion. In the non-tapetal area lesions appear grey or whitish.

Retinal thinning due to degeneration may be the result of many conditions, including inflammatory retinal disease, inherited retinal degeneration and glaucoma. Thinning of the retina over the tapetal area is readily detected as it results in increased reflection from the underlying tapetum (tapetal hyperreflectivity). Retinal thinning is not easy to detect over the non-tapetal area.

In some conditions there may be **pigmentary changes** that affect the fundus, following inflammation, detachment or degeneration. These may be pigment proliferation and migration as a result of inflammatory conditions affecting the retinal pigment epithelium and choroid. Alternatively, destruction of the RPE may result in melanin loss, giving a mottled appearance. Pigmentary changes may be seen in both the tapetal and non-tapetal regions. Melanin is the pigment responsible for these changes.

A degenerate retina has a reduced requirement for blood supply and therefore the supplying blood vessels appear thinner or even become invisible, described as ***superficial retinal blood vessel attenuation***.

Haemorrhage, which can be preretinal, intraretinal or subretinal, may be a feature of some conditions such as chorioretinitis, hypertensive retinopathy and coagulopathies. Identification is usually straightforward, although haemorrhage involving the non-tapetal fundus may be more difficult to see. Haemorrhages will usually resorb in 1–2 weeks, except in the vitreous, which may take months.

The depth of the bleeding within the retina will alter its clinical appearance:

- fan-shaped or streak-like: within the nerve fibre layer
- punctate circular 'blot and dot': within the inner or outer plexiform layer
- tear-dropped or crescent-shaped: preretinal (i.e. between the inner limiting membrane and the nerve fibre layer)
- dull red with retina elevated: beneath the neurosensory retina or RPE.

Vitreal bleeding may gravitate ventrally or remain stationary. It obscures deeper structures and gives a red reflex.

Retinal detachment results when the neurosensory retina separates from the underlying retinal pigment epithelium. There are several types of detachment resulting from various different insults. The most common form seen in the cat is serous (bullous or exudative) detachments which occur when fluid accumulates beneath an intact retina (Plate 18.21). They can be partial or total. These are associated with either chorioretinitis or with vascular diseases such as hypertension or hyperviscosity syndrome. If the inciting cause can be controlled, the retina will usually reattach. In cats, eyes with reattached retinae usually remain blind.

Other forms of detachment, such as solid and rheumatogenous, rarely occur in the cat.

In optic nerve head atrophy, the affected optic nerve head becomes flatter and duller in appearance. This can occur not only following lesions involving the optic nerve, but also as a result of generalised retinal degeneration.

Inflammatory chorioretinal disease

The appearance of inflammatory chorioretinopathy varies depending on whether the lesions are active or inactive, which part of the fundus is affected and how extensive the affected area is. There are many known

potential causes of chorioretinitis, including infectious agents, immune-mediated disease and neoplasia. Fortunately, many of the potential infectious causes (e.g. fungal) are rarely identified in this country. Many of these conditions are ocular manifestations of systemic diseases and a full clinical examination should always be performed when signs of chorioretinal disease are detected.

Clinical presentation

Unless both eyes are affected there are usually few outward signs of a problem. Extensive chorioretinitis causes visual loss and reduced pupillary light responses. However, if the inflammation is a manifestation of a more widespread problem, other clinical signs may be noticed. With time there may be progressive retinal degeneration, even if the initial inflammation is controlled. Smaller focal lesions do not have an obvious effect on vision and are often only detected on routine fundoscopy. If the choroidal inflammation extends anteriorly then signs of anterior uveitis may also be present.

It is important to be aware that it is very difficult to tell from the clinical signs what the underlying cause might be. However it should be possible to differentiate between granulomatous and non-granulomatous disease. This is important as the aetiologies and therefore the prognoses for the two differ. Granulomatous disease carries a much poorer prognosis due to the nature of its causative agents (usually fungal).

Granulomatous disease usually has a characteristic dramatic appearance which depends somewhat on the region of the fundus involved. In the tapetal fundus a granulomatous infiltrate will often destroy the overlying tapetum and choroidal melanin will visible. The overlying retina will appear blurred owing to fluid and cellular infiltration. The lesions therefore appear as a circular blurred zone with a brown centre. In the non-tapetal fundus lesions appear as zones of lighter pigmentation within a normal colour background because the cellular exudate will dilute the melanin of the RPE and choroid. Extensive infiltration may be seen as fluffy white cotton-wool lesions. Blood vessels may appear congested and cuffed with inflammatory cells.

In non-granulomatous disease, active (acute) lesions appear as fuzzy, white or grey lesions in the retina, due to oedema, exudates and cellular infiltration. They are usually multifocal, patchy and distributed throughout the fundus. The lesions are rarely symmetrical, although they often occur in both eyes, reflecting underlying systemic disease. In the area of the tapetal fundus the exudates thicken the retina and therefore absorb incident light, which causes reduced tapetal reflection (hyporeflectivity). Excessive fluid production may result in retinal detachment. Haemorrhage, retinal detachment, vitreous haze and perivascular cuffing may also be seen. Visual impairment varies from slight to complete, depending on the severity of the lesions.

Chronic inflammatory or postinflammatory lesions are often more striking in appearance than active lesions. In the tapetal area the lesions may consist of a zone of tapetal hyperreflectivity (thinned retina) surrounding an area of pigmentary change. In other instances there may be patchy hyperreflectivity sometimes associated with mild pigmentary changes. Alterations in tapetal colour or even destruction of the affected tapetum may be seen in some cases. Non-tapetal postinflammatory lesions are often marked by patchy depigmentation. Gliosis (scarring) may be visible as grey lesions with distinct borders. Active and inactive lesions may be present in the same fundus.

Causes of inflammatory chorioretinal disease

As well as anterior segment changes, FeLV–lymphoma complex is sometimes associated with posterior segment manifestations as a consequence of neoplastic cellular infiltration. Pallor of retinal vessels may be seen as a result of FeLV-associated anaemia. Ophthalmoscopic manifestations include pigmentary disturbance, chorioretinal inflammation, retinal detachment, haemorrhages and optic neuritis.

Posterior segment signs are uncommon in cases of FIV. Uveitis is the most common ocular sign associated with FIV infection and results from immune complex deposition or localisation of FIV in uveal lymphoid tissue. In some cases there is secondary infection with *T. gondii*. The signs tend to be those of chronic anterior uveitis, with aqueous flare, keratic precipitates, iridial hyperaemia and cortical cataracts as common findings. Secondary glaucoma, hydrophthalmos and lens luxation may be seen in longstanding cases. Localised 'intermediate' uveitis in the form of pars planitis has been described in several FIV-infected cats and may be due to a plasmocytic–lymphocytic infiltrate. Affected eyes, even when glaucomatous, often appear to be non-painful. Other systemic signs attributable to FIV infection may also be present in affected patients.

FIP may cause inflammatory chorioretinal disease (see Uveitis section above).

The cat is the only definitive host for *T. gondii*, and dogs, along with other mammals, are intermediate hosts. It is important to rule out underlying immunosuppressive disease in affected cats, as the primary phase of infection is rarely associated with clinical signs. It is much more usual for cats to present with secondary toxoplasmosis following recrudesence of encysted organisms. Systemic signs may include pyrexia, weight loss, gastrointestinal disease, neurological or respiratory signs. Although the inflammation may affect any part or all of the uveal tract, the most common lesion is retinitis. This posterior segment change may be restricted initially to the retina, with focal retinitis, but the choroid soon becomes secondarily involved. Anterior uveitis is typically chronic in nature (Lappin *et al.*, 1989; Dubey & Carpenter, 1993).

Clindamycin and potentiated sulfonamides are the antibiotics of choice. They may have to be used in combination with topical and systemic steroids to alleviate the uveitis.

Isolated cases of uveitis associated with tuberculosis *Mycobacterium bovis* infection in cats have been reported. The predominant ocular signs are choroiditis with retinal detachment (Formston, 1994).

Disseminated mycotic infection with ocular involvement is seen commonly in endemic countries. Fortunately, such infections do not occur with any regularity in the UK. Initial infection is by inhalation of spores and haematogenous spread results in ocular involvement. Uveitis is the predominant ocular sign, starting with posterior inflammation and sometimes involving the anterior uvea. Multiple focal pyogranulomatous lesions may be observed on fundus examination. Other clinical signs may involve the central nervous system (CNS), respiratory system and skin. Potential infections include coccidiomycosis, histoplasmosis and blastomycosis.

Very occasionally, migrating parasitic larvae can cause clinical chorioretinal disease.

Occasionally, a definitive cause is not found and a diagnosis of immune-mediated or idiopathic chorioretinitis is made.

Treatment of inflammatory chorioretinal disease

It is very important to determine the primary cause and if possible to give specific therapy for it. In the main, treatment is aimed at reducing the damage caused by inflammation. Fortunately, not many fungal diseases are seen in the UK and therefore corticosteroid can be given safely. In other countries veternarians need to ensure that the condition is non-granulomatous before they can be administered. Steroids should be given in high doses for 2–3 weeks and then gradually withdrawn. Broad-spectrum antibiotics should be given for 1–2 weeks. In cases of fungal disease systemic antifungals should be started straight away.

Non-inflammatory retinal disease

Taurine deficiency (feline central retinal degeneration)

This unique fundic lesion was first described in the cat by Bellhorn & Fischer (1970). Ophthalmoscopically the abnormality was observed in the area centralis (the area with the highest cone and ganglion cell density), located primarily temporal to the optic nerve head. The lesions were bilaterally symmetrical, sharply outlined and varied from a small circular lesion to one that involved most of the area centralis (Plate 18.22). Histologically, the lesions were characterised by a focal loss of the outer retinal layers (i.e. the photoreceptors and their nuclei) and, in some cases, disorganisation of the inner retinal layers. After several years of study it was discovered that this lesion was the result of a deficiency in dietary taurine. These lesions had been described in both experimental and household cats, and although many of them had been fed unusual diets, including dog food, others were given proprietary diets. Once the cause of this problem had been elucidated the pet food manufacturers took steps to ensure a sufficient supply of dietary taurine in their products. In view of the awareness of the problem and the changes made in cat food production, it is now rare to see cases of feline central retinal degeneration. Occasional cases still occur in cats kept indoors and fed unusual diets.

Visual deficits are rarely associated with taurine deficiency retinopathy, even with extensive lesions. However, untreated cases can progress to total retinal degeneration and blindness. ERGs performed on affected cats show a loss of cone function with a normal rod (scotopic) ERG. These findings are backed up by electron microscopy, which shows structural abnormalities in the cones throughout the retina, with normal rod morphology. As the disease progresses, the ERG and electron-microscopic abnormalities include the rods. The rod changes can be reversed and function restored following dietary supplementation with taurine. The cone defects are irreversible, but correction of taurine levels prevents further progression of the disease.

Diabetic retinopathy

In humans, diabetes mellitus (DM) is the leading systemic disease involving the eye. In dogs the most common ocular complication of DM is the diabetic cataract, which is rare in the cat. Diabetic retinopathy is the main problem in humans and for many years it was thought that this sequela to DM did not occur in domestic animals. However, it is now known that it does indeed occur but is seen less commonly, as most diabetic animals do not live long enough to develop the retinopathy. The duration of the disease rather than the severity appears to determine the onset of retinal changes. Diabetic retinopathy tends to be seen more commonly in type 1 diabetics who are diagnosed in their teens and may develop ocular signs in their twenties. It is not as common in the elderly, diet-controlled diabetics. Early diabetic retinopathy may begin to be seen as improved treatment regimens mean that our patients live longer with the disease.

Cardiovascular disease and the eye

Systemic hypertension

Hypertension is defined as an increase in arterial blood pressure, above the normal for the population. This blood pressure is associated with increased morbidity and mortality. Diagnosis and treatment of this condition are dealt with in other chapters.

The first clinical signs of hypertension are very often those occurring in the eye (Sansom *et al.*, 1994). Ophthalmic screening of old cats will enable these cases to be picked up early and treatment initiated to prevent persistent hypertension and the inevitable loss of vision. The most common presenting ocular sign of hypertension in the cat is sudden-onset blindness due to extensive serous retinal detachment. This may be accompanied by retinal and/or intraocular haemorrhage (Plate 18.23). Partial detachments may also be seen, along with vitreal haemorrhage, hyphaema and the more subtle vascular anomalies involving the retinal blood vessels. Following detachments, even when the underlying hypertension is controlled, the retina will often reattach, but total retinal degeneration usually ensues and vision does not usually return.

Anaemia

Anaemia will result in pallor of the visible retinal vessels and the optic disc may appear paler than normal. It may be difficult to distinguish between the arteries and veins of the fundus. If the haematocrit and haemoglobin levels are sufficiently low, there may also be retinal haemorrhage. This is because anaemia causes a localised hypoxia, altering vascular dynamics and leading to vessel-wall fragility and haemorrhage. There may also be haemorrhages associated with a thrombocytopenia. This is a sign of a systemic problem, and a thorough clinical examination and work-up should be performed to determine the cause and institute treatment.

Hyperviscosity

The ocular manifestations of hyperviscosity are most apparent in the retinal vessels, which appear engorged and tortuous. There may also be a few small retinal haemorrhages and oedema of the optic disc. The two major causes of hyperviscosity are polycythaemia and hyperproteinaemia. Both will result in these characteristic retinal changes. Again, there is a systemic disease underlying these ocular changes and it is important to determine this before initiating treatment.

Lipaemia retinalis

Lipaemia retinalis is an ocular manifestation of chylomicronaemia (excessive quantities of large triglyceride-rich lipoproteins) and it may be seen in association with both primary and secondary hyperlipoproteinaemia (Crispin, 1993). Lipaemia retinalis is most readily observed against the dark background of the non-tapetal fundus and the lipaemia is easier to observe if the patient has a low packed cell volume (PCV), as there are fewer red blood cells to obscure the creamy plasma. The colour of the blood column within the retinal vessels varies from salmon-pink to creamy white. The underlying cause of the elevated lipid levels must be found and treated.

Acquired retinal disease: inherited

Generalised progressive retinal atrophy

Generalised progressive retinal atrophy (GPRA) is an inherited retinopathy and two distinct forms have been described, both in the Abyssinian breed. Other forms have been suspected in both the Persian and the Siamese (Plate 18.24). In the Abyssinian, one form occurs in the UK in kittens and is due to a simple autosomal dominant gene (Barnett & Curtis, 1985); the second form occurs in young adult cats, mainly in Scandinavia, and is due to a simple autosomal recessive gene (Narfstrom, 1983).

In the first form the retinal degeneration is bilateral, symmetrical and progressive, ending in total blindness. Young kittens are affected and the first observable clinical sign is a dilated pupil, recognised as early as 4 weeks of age. Nystagmus may also be noted. This form of retinal degeneration is a rod–cone dysplasia and ophthalmoscopically first appears at about 8 weeks of age and progresses rapidly. The classical signs of any retinal degeneration (i.e. hyperreflectivity in the tapetal region due to retinal thinning and attenuation of retinal blood vessels, together with loss of pigment in the non-tapetal region) occur (Plate 18.25). A poor pupillary light reflex is retained and secondary cataract does not occur.

The other form of GPRA in the Abyssinian occurs at 1–2 years of age, occasionally 3–4 years before clinical signs are apparent. This form is also bilateral and progressive, with advanced retinal degeneration varying from 3 to 6 years and with similar ophthalmoscopic signs to those described above.

There is no treatment for either form and both forms are currently rare in the UK; no cases of either form have been reported in recent years.

Neoplasia

Retinal neoplasia is uncommon, but the following have all been recorded: adenocarcinoma, astrocytoma, carcinoma, glioma, haemangiosarcoma, lymphoma, neuroblastoma, plasma cell myeloma, reticulosis and sarcoma.

The optic disc

The optic disc (papilla) is the only visible part of the optic nerve. The feline disc is small and roughly circular. It is cupped and has a well-defined edge. It is almost invariably totally within the tapetal region and is situated slightly lateral and ventral to the posterior pole of the eye. Occasionally, the tapetum may not extend to include the disc. The disc is grey and non-myelinated with a visible lamina cribrosa, myelination starting posterior to the lamina cribrosa. Occasionally, myelinated or opaque nerve fibres are visible ophthalmoscopically, but this normal variation is uncommon in the cat.

Abnormalities of the feline optic nerve are extremely rare. Possible conditions are the congenital findings of hypoplasia and coloboma. Acquired diseases include papilloedema, optic neuritis and optic atrophy. The following are all recorded as primary tumours of the optic nerve, but are uncommon: astrocytoma, glioma, lymphosarcoma, meningioma and SCC.

Neuro-ophthalmology

This section does not aim to provide a complete overview of neuro-ophthalmology, but illustrates some of the common problems encountered in the cat. Cranial nerves relating to the eye are listed in Table 18.2.

Pathways responsible for vision and initiation of the PLR have the same origin in the retina. Light stimulation of the retina is conveyed via the optic nerve to the optic chiasm. In mammalian species most axons within the optic nerve cross over, or decussate, within the optic chiasm to enter the optic tract of the opposite side. Decussating fibres arise in the nasal retina, whereas those arising from the far temporal retina remain ipsilateral. In cats 65% of these fibres decussate, whereas in dogs 75% of the fibres cross over. Pupillomotor fibres leave the optic tract to synapse with neurons in the midbrain (pretectal nucleus), thus completing the afferent portion of the PLR pathway. Nerve fibres remaining in the optic tracts are responsible for vision. These visual fibres proceed to the lateral geniculate body of the thalamus, where they are in turn relayed via the optic radiations to the visual (occipital) cortex for perception of vision. It is important to note that lesions in the lateral geniculate, optic radiations and visual cortex may affect vision but do not affect the PLR, since the pupillomotor fibres have already diverged from the optic tracts. Blindness with normal PLRs is typical of a central (cortical) lesion.

The efferent pathway for the PLR is mediated by the parasympathetic system. Preganglionic parasympathetic fibres that arise from parasympathetic nuclei (Edhinger–Westphal nucleus) exit the midbrain via the oculomotor nerve. They enter the orbit to synapse with postganglionic cell bodies in the ciliary ganglion temporal to the optic nerve. Postganglionic fibres travel via the short ciliary nerves, of which there are two in the cat, to innervate the ciliary body and iris musculature.

Pupillary abnormalitites

Changes in pupil size, shape and response to light stimulation may all indicate pupillary dysfunction. In mammals, pupil size and mobility are regulated predominantly by autonomic nerves that innervate the iris sphincter and dilator muscles. The iris sphincter

Table 18.2 Cranial nerves and the eye

Nerve	Function	Assessment	Dysfunction
Optic nerve (CN II)	Tract of the CNS; afferent pathway for vision and PLR	Vision testing and PLR	Blindness; no PLR
Oculomotor nerve (CN III)	Pupillary constriction: parasympathetic fibres supply intraocular smooth muscle; innervates dorsal, medial and ventral rectus muscles, the ventral oblique muscle and the levator palpebrae superioris; partial innervation of the upper eyelid	Pupil size; eye position and movement	Mydriasis; ventrolateral strabismus (down and out); ptosis
Trochlear (CN IV)	Innervates the dorsal oblique	Eye position and movement	Dorsolateral rotation; easier to detect in cats, owing to their pupil shape
Trigeminal nerve (CN V)	Sensory input from eye and lids (ophthalmic branch); motor function to the muscles of mastication; stimulates tear production	Palbebral reflex (afferent) in conjunction with CN VII; corneal reflex (afferent) in conjunction with CN VI; STTs	Motor function deficit; inability to close the mouth and masticatory muscle atrophy; loss of palpebral sensation deficits in the cornea sensation result in exposure keratopathy; reduced tear production
Abducens (VI)	Innervates the lateral rectus and retractor bulbi muscles	Eye position and movement	Medial strabismus and lack of corneal reflex
Facial nerve (CN VII)	Motor innervation to the muscles of facial expression, including orbicularis oculi (blinking); parasympathetic fibres to the lacrimal gland	Palpebral reflex (efferent) in conjunction with CN V; menace response (efferent) in conjunction with CN II; STTs; ear and facial movements	Facial paralysis; with inability to blink; reduced tear production; exposure keratopathy; unilateral deficits: facial asymmetry
Vestibulocochlear nerve (CN VIII)	Vestibular portion: equilibrium of posture, gait and co-ordination of eye movements	Eye position and movement	Nystagmus: horizontal, vertical or rotatory; vertical implies central disease

CN: Cranial nerve; PLR: pupillary light reflex; STT: Schirmer tear test.

muscle is predominantly under parasympathetic control and stimulation via the PLR intiates pupil constriction. The iris dilator muscle is predominantly under sympathetic innervation.

Pupillary changes may be present as unilateral or bilateral findings and may manifest in the following ways: persistent (static) miosis or mydriasis, abnormal pupil shape (dyscoria), inequality in pupil size (anisocoria), abnormal placement (corectopia), and decreased responsiveness to light. Pupil size and symmetry should be assessed in both ambient light and dark conditions. It is important to determine whether pupillary abnormalities are of neurological or non-neurological origin.

Anisocoria

Anisocoria may arise as a result of abnormalities of the eye, the oculosympathetic system, the light reflex pathways, the midbrain or the cerebellum. Anisocoria can be both neurological and non-neurological in origin (Neer & Carter, 1987; Bercovitch *et al.*, 1995). It is important to decide which is the abnormal eye. Pupil responses may remain intact with some causes of anisocoria (e.g. optic tract lesions and Horner's syndrome). Anisocoria may be more pronounced in the light (e.g. oculomotor paralysis). It may be more pronounced in dark conditions (e.g. Horner's syndrome). In cases of neurological anisocoria a negative

menace response in the affected eye usually implicates an afferent neurological lesion. Anisocoria is not observed if a lesion is bilateral and symmetrical.

Non-neurological causes of anisocoria include anterior uveitis, glaucoma, synechiae, iris atrophy, iris hypoplasia and pharmacological interference. Neurological causes of anisocoria include unilateral retinal or optic nerve disease, optic chiasmal lesions, unilateral optic tract lesions, Horner's syndrome, occulomotor nerve palsy, cerebellar syndrome, spastic pupil syndrome and dysautonomia.

Spastic pupil syndrome

This syndrome presents as fixed pupils that do not change in light or dark conditions. There is usually partial bilateral miosis. This is most often FeLV associated, with direct involvement of short ciliary nerves. Vision is unaffected.

D-shaped pupil (partial internal ophthalmoplegia)

This is effectively the same condition as above, but only one of the two short ciliary nerves supplying the iris constrictor muscle is paralysed. This results in a D-shape or reverse D-shape, depending on the branch involved and the eye involved (Plate 18.26).

Dysautonomia (Key–Gaskell syndrome)

This condition affects both the sympathetic and parasympathetic systems with the following ocular signs; persistent pupillary dilation (usually bilateral), decreased tear production, TEL protrusion and photophobia. Other clinical signs associated with a generalised dysautonomia will also be present. Pilocarpine testing is useful for making a diagnosis, as there is denervation hypersensitivity of the iris musculature. Fortunately, this is not seen as commonly as when it was first described, as even with intense nursing the prognosis is very poor.

Horner's syndrome

The ocular sympathetic tract is a three-neuron pathway. The central (or upper motor neuron) pathway begins in the hypothalamus and descends in the spinal cord to synapse on the lower motor neuron (LMN), located in the spinal cord segments T1–T3. Axons that arise from preganglionic cell bodies of the LMN exit the spinal cord and course cranially until they synapse with postganglionic cell bodies located in the cranial cervical ganglion, caudomedial to the tympanic bullae. Postganglionic fibres continue rostrally, through the middle ear, and enter the orbit with the ophthalmic branch of the trigeminal nerve. Sympathetic fibres are distributed to smooth muscle of the periorbita, eyelids, TEL and dilator muscle of the iris. This innervation is responsible for the tone in the smooth musculature, retraction of the upper lid and slight protrusion of the globe with opening of the palpebral fissure. Retraction of the TEL is also achieved via the tone in orbital musculature. If the innervation is lost, the parasympathetic influence on the iris sphincter dominates and the pupil remains constricted.

Ocular sympathetic denervation causes the clinical condition known as Horner's syndrome, with the following characteristic clinical signs: miosis, ptosis, narrowing of the palpebral fissure, enophthalmos, protrusion of the TEL and conjunctival hyperaemia due to local vasodilatation. Unilateral miosis is often the most prominent sign. The affected eye retains an intact PLR, but pupillary excursion is small. Vision is normal. Horner's syndrome may be a result of damage anywhere along the sympathetic pathway. Concurrent clinical signs are important to note and often help to localise the lesion (Neer, 1984; Van den Broek, 1987). The diseases caused by central, preganglionic and postganglionic lesions are referred to as first, second and third order Horner's syndrome, respectively. Full clinical and ophthalmic examination must be performed to pinpoint the lesion. Further diagnostic tests include pharmacological testing, radiography of the thorax, neck and skull, and MRI or CT scans. Idiopathic Horner's syndrome is uncommon in the cat, unlike the dog. Potential causes in the cat include trauma, ear disease and mediastinal neoplasia.

Brain tumours

Signs depend on both the tumour location and cell type, together with associated pathology such as peritumour oedema, acquired hydrocephalus, brain herniation and haemorrhage. Skull radiographs are of limited use and CT or MRI plus cerebrospinal fluid analysis are more useful. ERG is normal. Meningiomas are the most common intracranial tumour in cats, followed by astrocytomas. Tumours over the optic chiasm will present with sudden blindness in the absence of neurological or ophthalmo-

scopic abnormalities. Most other tumours are likely to cause other neurological signs before or along with visual disturbance.

Cat enucleations and blindness

Owing to the short optic nerve and therefore proximity of the chiasm, great care must be taken on enucleation. Tugging too hard on the globe will allow a retrograde inflammation to the chiasm and Wallerian degeneration of the fellow optic nerve, and hence a blind cat.

Strabismus

Strabismus (squints) may be due to a congenital abnormality, or result from lesions of extraocular muscles or their nerve supply. A common example is the bilateral convergent strabismus (esotropia) of some Siamese cats. This is often seen in association with nystagmus, as a result of misdirected axonal growth in the central visual pathways.

Traumatic proptosis of the globe can result in a strabismus due to tearing of the rectus muscles (usually the medial rectus). This results in a divergent strabismus or exotropia. Retrobulbar swelling (due to infection or neoplasia) may cause a deviation of the globe in addition to exophthalmos.

A full knowledge of the actions and innervations of the extraocular muscles is required to investigate the neurological aetiology of a squint (see Table 18.2). Surgery to correct squints in animals is possible but seldom necessary.

The co-ordination of eye movements is a complex mechanism, with inputs from the vestibular systems, cerebellum and higher centres. Communication between the nuclei of the nerves and the extraocular muscles occurs via the medial longitudinal fasciculus and helps to co-ordinate the extraocular muscles. The vestibular system is involved in controlling eye movements and position, as well as maintaining the position of the trunk and limbs with reference to the position or movement of the head.

Nystagmus

This is the involuntary repetitive to and fro movement of both eyes, and can be congenital (e.g. Siamese) or acquired (e.g. early vision loss and both central and peripheral vestibular disease). In general, the slow phase is away from the gaze and the fast phase brings the image back on the central retina. Inputs for nystagmus are a combination of visual, vestibular and cerebellar stimuli.

Normal nystagmus

The vestibulo-ocular reflex acts to steady retinal images during head movements by producing eye movements, which are equal and opposite. Sensory cells within the semicircular canals detect the motion, the vestibular nerve transmits the signal, and the motor control is effected via cranial nerves III, IV and VI.

Higher centres also influence the normal nystagmus induced by a change in velocity of head movements. The autonomic pursuit eye movements co-ordinated by the cerebral cortex allow fixation on a moving object in the surroundings, or a stationary object if the head is moving. This is the opticokinetic reflex and requires an intact visual pathway.

Abnormal nystagmus

Nystagmus occurring when the animal's head is unrestrained is called spontaneous nystagmus. Nystagmus occurring when the animal's head is held in an abnormal position by the examiner is called positional nystagmus. Abnormal nystagmus is usually a sign of vestibular disease, either peripheral or central.

Congenital blindness may result in continuous, almost random eye movements, described as searching or wandering nystagmus. If vision is later restored these movements will remain. This form of nystagmus is also seen in kittens with microphthalmos and congenital cataracts, even if the lesions do not render them totally blind. Nystagmus may also develop in animals that suffer vision loss at an early age.

Lysosomal storage diseases

Retinal changes occur in the form of multiple small spots, which represent the accumulation of glycolipid within the ganglion cells. A dull, grey, granularity in the area centralis has been described in α-mannosidosis. A more diffuse generalised retinal degeneration has also been described. Blindness is usually the result of central neuropathy and can occur, for example, in gangliosidosis and sphingomyelinosis. Although neurological signs are common to many of these diseases, their characterisation is neither complete nor precise.

Box 18.2 Tips for topical application of drugs to the eye

- Always clean the eye before treatment
- Only administer one drop
- Ointments: use 5 mm strip
- Minimise nozzle contact
- Ointments contraindicated with corneal penetrations
- If two treatments are given wait 10 min between them
- Give drops before ointments
- Allergic and irritant reactions may develop

Ocular pharmacology and therapeutics

Many different drugs are used in the treatment of ocular diseases and most of them are given topically. The most commonly used are antibiotics and anti-inflammatories, but many others are also available. Topical drugs are routinely given as drops or ointments or by subconjunctival injection (see Box 18.2). More recently, novel delivery systems, such as impregnated contact lenses, inserts and liposomes, have been developed. The method and frequency of administration vary depending on the drug formulation, the expected site of action and the disease being treated.

It is important that a correct diagnosis is made and its cause and pathology are understood. This will ensure that the most appropriate drug is used and it is given in an adequate dose, by the most effective route. It should always be remembered that some medications may have undesirable as well as beneficial effects on the eye. In some ocular diseases it may also be necessary to administer systemic medication to achieve high enough therapeutic levels in the eye. Clinical signs observed in the eye may be manifestations of systemic diseases; in these cases, the main complaint as well as its ophthalmic component must be dealt with. Once again, antibiotics and anti-inflammatories are the main drugs given systemically. They are usually given orally, but the subcutaneous, intramuscular and intravenous routes may also be used. Drugs given systemically for non-ocular conditions may have side-effects, which involve the eye.

General principles of ocular pharmacology and therapeutics

Choosing the correct drug is important. A specific diagnosis is required. The site of the problem and where the drug should act must be considered. Is there superficial disease, anterior chamber involvement or deeper posterior segment, or are there orbital lesions? Will the drug penetrate to the desired site of action? The duration of action of the compound will determine the frequency of dosing. Finally convenience is a factor. Is the drug readily available, what does it cost and will the owner and patient be compliant?

For each drug that is selected, the mode of action, the dosage regimen, possible adverse effects and any contraindications to its use must all be known.

The average dropper bottle will deliver a 50 μl drop and the feline conjunctival sac only has a 20–30 μl capacity. There is a tear turnover of 15% per minute which increases to 30% per minute following topical drug application. This means that the eye will be flooded with one drop of the compound: this drop has a 3 min residence time and will have completely disappeared within 5 min.

References

Acland G.M., McLean I.W., Aguirre G.D. & Trucksa R. (1980) Diffuse iris melanoma in cats. *J Am Anim Hosp Assoc* **176**, 52–56.

Barnett K.C. (1981) Ocular colobomata in the snow leopard *Panthera unica. J Jersey Wildlife Preservation Trust* **18**, 83–85.

Barnett K.C. & Curtis R. (1985) Autosomal dominant progressive retinal atrophy in Abyssinian cats. *J Hered* **76**, 168–170.

Bellhorn R.W. & Fischer C.A. (1970) Feline central retinal degeneration. *J Am Vet Med Assoc* **157**, 842–849.

Bellhorn R.W. & Henkind P. (1970) Intraocular malignant melanoma in domestic cats. *J Small Anim Pract* **10**, 631–637.

Bellhorn R.W., Barnett K.C. & Henkind P. (1971) Ocular colobomas in domestic cats. *J Am Vet Med Assoc* **159**, 1015–1021.

Bennett M., Gaskell C.J., Baxby D., *et al.* (1990) Feline cowpox virus infection. *J Small Anim Pract* **31**, 167–173.

Bercovitch M., Krohne S. & Lindley D. (1995) A diagnostic approach to anisocoria. *Compendium on Continuing Education for the Practicing Veterinarian* **17**, 661–673.

Bistner S.I., Aguirre G. & Shively J.N. (1976) Hereditary corneal dystrophy in the Manx cat. A preliminary report. *Invest Ophthalmol Vis Sci* **15**, 15–26.

Brightman A.H., Ogilvie G.K. & Tompkins M. (1991) Ocular disease in FeLV-positive cats: 11 cases (1981–1986). *J Am Anim Hosp Assoc* **198**, 1049–1051.

Buyukmichi N. (1975) Fibrosarcoma of the nictitating membrane in a cat. *J Am Vet Med Assoc* **167**, 934–935.

Calia C.M., Kirschner S.E., Baer K.E. & Stefanacci J.D. (1994) The use of computed tomography scan for the evaluation of orbital disease in cats and dogs. *Vet Comp Ophthalmol* **4**, 24–30.

Carrington S.D. (1983) Lipid keratopathy in a cat. *J Small Anim Pract* **24**, 495–505.

Carrington S.D. (1985) Observations on the structure and function of the feline cornea. Ph.D. Thesis, University of Liverpool, UK.

Carrington S.D., Bedford P.G.C., Guillon J.P. & Woodward E.G. (1987) Polarised light biomicroscope observations on the pre-corneal tear film III. The normal tear film of the cat. *J Small Anim Pract* **28**, 821–826.

Chavkin M.J., Lappin M.R., Powell C.C., *et al.* (1992) Seroepidemiologic evidence and clinical observations of 93 cases of uveitis in cats. *Prog Vet Comp Ophthalmol* **2**, 29–36.

Corcoran K.A., Peiffer R.L. & Koch S.A. (1995) Histological features of feline ocular lymphosarcoma: 49 cases (1978–1990). *J Am Vet Med Assoc* **158**, 191–199.

Creel D.J. (1971) Visual anomaly associated with albinism in the cat. *Nature* **231**, 465–466.

Crispin S.M. (1993) Ocular manifestations of hyperlipoproteinaemia. *J Small Anim Pract* **34**, 500–506.

Davidson M.G., Nasisse M.P., English R.V., *et al.* (1991) Feline anterior uveitis: a study of 53 cases. *J Am Anim Hosp Assoc* **27**, 77–83.

Dennis R. (2000) Use of magnetic resonance imaging for the investigation of orbital disease in small animals. *J Small Anim Pract* **41**, 145–155.

Dubey J.P. & Carpenter J.L. (1993) Histologically confirmed clinical toxoplasmosis in cats: 100 cases (1952–1990). *J Am Vet Med Assoc* **203**, 1556–1566.

Dubielzig R.R., Hawkins K.L., Toy K.A., *et al.* (1994) Morphological features of feline ocular sarcomas in 10 cats: light microscopy, ultrastructure and immunohistochemistry. *Vet Comp Ophthalmol* **4**, 7–12.

Duncan D.E. & Peiffer R.L. (1991) Morphology and prognostic indicators of anterior melanomas in cats. *Prog Vet Comp Ophthalmol* **1**, 25–32.

Dziezyc J., Barton C.L. & Santos A. (1992) Exophthalmia in a cat caused by eosinophilic infiltrate. *Prog Vet Comp Ophthalmol* **2**, 63–66.

Formston C. (1994) Retinal detachment and bovine tuberculosis in cats. *J Small Anim Pract* **35**, 5–8.

Gilger B.C., Hamilton H.L., Wilkie D.A., *et al.* (1995) Traumatic ocular proptoses in dogs and cats: 84 cases (1980–1993). *J Am Anim Hosp Assoc* **206**, 1186–1190.

Hendy Ibbs P.N. (1985) Familial epibulbar dermoids. *Vet Rec* **116**, 13–14.

Hopper C.D., Sparkes A.H., Gruffydd-Jones T.J., *et al.* (1989) Clinical and laboratory findings in cats infected with feline immunodeficiency virus. *Vet Rec* **125**, 341–346.

Johnson B.W. (1991) Congenitally abnormal visual pathways of Siamese cats. *Compendium on Continuing Education for the Practicing Veterinarian* **13**, 374–377.

Johnson B.W., Whitley H.E. & McLaughlin S.A. (1990) Effects of inflammation and aqueous tear film deficiency on conjunctival morphology and ocular mucus composition in cats. *Am J Vet Res* **51**, 820–824.

Lappin M.R., Greene C.E., Winston S., *et al.* (1989) Clinical feline toxoplasmosis. *J Vet Intern Med* **3**, 139–143.

Lappin M.R., Marks A., Greene G.E., *et al.* (1992) Serologic prevalance of selected infectious diseases in cats with uveitis. *J Am Vet Med Assoc* **201**, 1005–1009.

McLaughlin S.A., Whitley R.D., Gilger B.C., *et al.* (1993) Eyelid neoplasia in cats: a review of demographic data (1979–1989). *J Am Anim Hosp Assoc* **29**, 63–67.

Maggs D.J., Nasisse M.P. & Kass P.H. (2003) Efficacy of oral supplementation with L-lysine in cats latently infected with feline herpesvirus. *Am J Vet Res* **64**, 37–42.

Miller P.E. & Pickett J.P. (1992) Comparison of human and canine tonometry conversion tables in clinically normal cats. *J Am Vet Med Assoc* **201**, 1017–1020.

Morgan R.V. & Abrams K.L. (1994) Feline corneal sequestration: a retrospective study of 42 cases (1987–1991). *J Am Anim Hosp Assoc* **30**, 24–28.

Morgan R.V., Abrams K.L. & Kern T.J. (1996) Feline eosinophilic keratitis: a retrospective study of 54 cases (1989–1994). *Prog Vet Comp Ophthalmol* **6**, 131–134.

Mould J.R.B. (1993) The right ophthalmoscope for you? *In Practice* **15**(2), 73–76.

Muir P., Harbour D.A., Gruffydd-Jones T.J., *et al.* (1990) A clinical and microbiological study of cats with protruding nictitating membrane and diarrhoea: isolation of a novel virus. *Vet Rec* **127**, 324–330.

Narfstrom K. (1983) Hereditary progressive retinal atrophy in the Abyssinian cat. *J Hered* **74**, 273–276.

Nasisse M.P. (1982) Manifestations, diagnosis and treatment of ocular herpesvirus infection in the cat. *Compendium on Continuing Education for the Practicing Veterinarian* **4**, 962–970.

Nasisse M.P. (1990) Feline herpesvirus ocular disease. *Vet Clin North Am Small Anim Pract* **29**, 667–680.

Nasisse M.P. & Weigler B.J. (1997) The diagnosis of ocular feline herpesvirus infection. *Vet Comp Ophthalmol* **7**, 44–51.

Neer T.M. (1984) Horner's syndrome: anatomy, diagnosis and causes. *Compendium on Continuing Education for the Practicing Veterinarian* **6**, 740–746.

Neer T.M. & Carter J.D. (1987) Anisocoria in dogs and cats: ocular and neurologic causes. *Compendium on Continuing Education for the Practicing Veterinarian* **9**, 817–823.

Olivero D.K., Riis R.C., Dutton A.G., *et al.* (1991) Feline lens displacement. A retrospective analysis of 345 cases. *Prog Vet Comp Ophthalmol* **1**, 239–244.

Paulsen M.E., Lavach J.D., Severin G.A. & Eichenbaun J.D. (1987) Feline eosinophilic keratitis: a review of 15 clinical cases. *J Am Anim Hosp Assoc* **23**, 63–69.

Peiffer R.L., Spencer C. & Popp J.A. (1978) Nasal squamous cell carcinoma with periocular extension and metastasis in a cat. *Feline Pract* **8**, 43–46.

Ridgway M.D. & Brightman A.H. (1989) Feline glaucoma: a retrospective study of 29 clinical cases. *J Am Anim Hosp Assoc* **25**, 485–490.

Sansom J., Barnett K.C., Dunn K.A., *et al.* (1994) Ocular disease associated with hypertension in 16 cats. *J Small Anim Pract* **35**, 604–611.

Startup F.G. (1988) Corneal necrosis and sequestration in the cat: a review and record of 100 cases. *J Small Anim Pract* **29**, 476–486.

Van den Broek A.H.M. (1987) Horner's syndrome in cats and dogs: a review. *J Small Anim Pract* **28**, 929–940.

Waters L. (1994) The Schirmer II tear test in cats. In *Clinical Research Abstracts*. British Small Animal Veterinary Association, Cheltenham, p. 202.

Wilcock B.P., Peiffer R.L. & Davidson M.G. (1990) The causes of glaucoma in cats. *Vet Pathol* **27**, 35–40.

Williams L.W., Gelatt K.N. & Gwinn R.M. (1981) Ophthalmic neoplasms in the cat. *J Am Anim Hosp Assoc* **17**, 999–1008.

Willis M., Bounous D.I., Hirsh S., *et al.* (1997) Conjunctival brush cytology: evaluation of a new cytological collection technique in dogs and cats with a comparison to conjunctival scraping. *Vet Comp Ophthalmol* **7**, 74–81.

Wills J.M. (1988) Feline chlamydial infection (feline pneumonitis). *Adv Small Anim Pract* **1**, 182–190.

Chapter 19

THE CARDIOVASCULAR SYSTEM

A. French and P. Wotton

Introduction

Recent advances in knowledge have very much improved our understanding of the pathogenesis of cardiac disease in cats. At the same time the increasing use of diagnostic techniques such as ultrasonography and systemic blood pressure measurement, alongside more familiar techniques such as radiography and electrocardiography, has increased our ability to assess accurately abnormalities of cardiac function and anatomy, simply and non-invasively. Nevertheless, despite an increasing awareness of the importance of cardiovascular disease, in particular an increasing recognition of both primary and secondary myocardial diseases as major clinical problems, the diagnosis and treatment of cardiovascular disease in cats remain a challenge. This chapter will outline the methods of investigation used before considering the specific congenital and acquired conditions and their management.

Clinical history

A thorough history can provide a first indication of the possible presence of disease of the cardiovascular system, but it is important to realise that the presenting signs of cardiovascular disease and heart failure in cats may differ somewhat from those seen in other species. Signs in cats are often acute in onset, for example hindlimb pain and paresis due to aortic thromboembolism, or the sudden development of dyspnoea due to pulmonary oedema. Owners may attribute such signs to the effects of trauma. In other cases, vague and non-specific signs may provide the only evidence of cardiovascular disease. Cats often mask the presence of disease by markedly altering their level of activity. These early subtle signs may easily be overlooked by the owner until more obvious evidence of cardiovascular dysfunction develops. It is not uncommon for signs of heart disease to be discovered incidentally during the course of evaluation for another medical condition.

The usual presenting signs of cardiovascular disease in cats are listed below, in approximate order of frequency of occurrence:

- dyspnoea/tachypnoea/hyperpnoea (may be episodic)
- lethargy and/or weakness/collapse
- anorexia, weight loss
- episodic collapse/syncope
- stunted growth
- paresis, pain, lameness
- coughing
- abdominal enlargement.

Dyspnoea is the most commonly encountered and develops due to the presence of pulmonary oedema or pleural effusion in cases of congestive heart failure. Dyspnoea may also arise due to right-to-left shunting of blood in some (rare) congenital cardiac defects (e.g. tetralogy of Fallot). Dyspnoea due to pulmonary oedema can be episodic, and may mimic the clinical presentation of 'feline asthma' (see Chapter 12). Coughing is not common in cats with congestive cardiac failure, nor is ascites, two important differences from the clinical presentation of heart failure in dogs. The accumulation of a significant volume of ascitic fluid in a cat is much more likely to indicate a non-cardiac condition such as feline infectious peritonitis or lymphocytic cholangitis.

Severe congenital cardiac anomalies usually become symptomatic within the first year of life, often within the first few months. Owners may notice stunting of

growth, excessive tiring and dyspnoea or, less commonly, syncopal episodes or ascites. It is pertinent to obtain information about the progress of littermates, and any other progeny of the parents, if a hereditary defect is suspected. The breed and sex of the cat may also be relevant in this context as breed and sex predispositions are recognised for certain congenital anomalies and acquired diseases. Other important information includes dietary history and any other signs that could indicate the possibility of an underlying condition (e.g. an endocrinopathy or systemic hypertension) to which the cardiovascular disease may be secondary.

Clinical examination

A careful clinical examination is the most important part of the investigation. Clinical findings often provide objective evidence for the presence of cardiovascular disease or dysfunction, and can suggest the type of disease involved. They include:

- murmur, gallop sounds, arrhythmia
- altered respiration; abnormal lung sounds
- altered arterial pulse rate, rhythm or character
- altered intensity of apex beat
- paresis, lameness
- pyrexia or hypothermia
- jugular distension/abnormal pulsation
- hepatomegaly, ascites
- cyanosis.

Dyspnoeic cats should be handled carefully during examination and investigation, as their condition can be markedly exacerbated by stressful procedures. In some cases emergency therapy (e.g. thoracocentesis of a pleural effusion or management of acute pulmonary oedema with oxygen and intravenous frusemide) is required before diagnostic procedures can safely be carried out.

Particular attention should be paid to the rate and character of the respirations, the colour of the mucous membranes, and the rate, rhythm and character of the femoral arterial pulse. Cyanosis may accompany dyspnoea where pulmonary oedema or pleural effusion is severe, or can occur owing to a congenital right-to-left shunt. The pulse rate of the normal cat may vary widely from approximately 140 to 240 beats/min. Tachycardia can occur with stress and also in a number of non-cardiac disease states, such as pyrexia, anaemia, primary respiratory disorders or hyperthyroidism. The physiological response to heart failure is usually a sinus tachycardia, but sinus bradycardia, sometimes profound, is seen occasionally. Arrhythmias and conduction deficits are common in primary and secondary myocardial disease and may cause bradycardia (e.g. with complete atrioventricular block; Figure 19.1), tachycardia or an erratic rhythm (Figure 19.2), the latter often accompanied by a pulse deficit. Careful assessment of the quality of the pulse is also valuable, although the femoral artery may be difficult to palpate

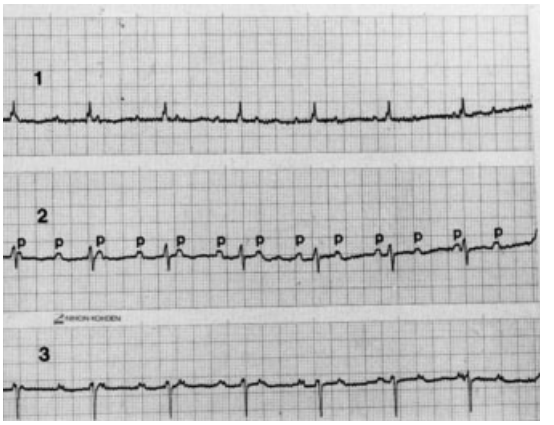

Figure 19.1 Third degree (complete) atrioventricular block. The P waves (marked in lead 2) are unrelated to the QRS complexes. Limb leads 1, 2 and 3 are shown. Paper speed: 50 mm/s; 1 cm = 1 mV.

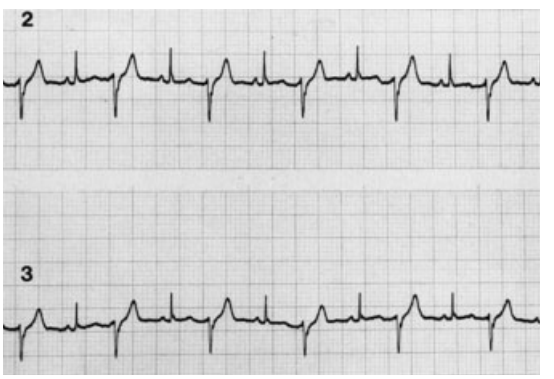

Figure 19.2 Ventricular bigeminy. Each alternate complex is a ventricular premature complex (negative polarity). Leads 2 and 3. Paper speed: 25 mm/s; 1 cm = 1 mV.

in some cats. The pulse becomes hyperkinetic (i.e. strength increased, volume usually reduced) with some congenital cardiac defects (e.g. patent ductus arteriosus) and in diseases characterised by high cardiac output (e.g. anaemia, hyperthyroidism). The pulse will be weak in dilated cardiomyopathy, may be variable in strength with arrhythmias and is markedly reduced in strength or absent with aortic thromboembolism, accompanied by cold, cyanosed and weak or paretic hindlimbs with pain and contracture of the muscles, particularly the gastrocnemius. Thromboembolism sometimes produces less dramatic signs, as discussed later.

Pyrexia, particularly if chronic or recurrent, might suggest a diagnosis of bacterial endocarditis, but this condition is very rare in cats. Pyrexia of any cause can lead to tachycardia and a functional systolic murmur, however, which should not be mistaken for evidence of primary cardiac disease. Hypothermia and bradycardia, accompanied by coldness of the extremities due to poor cardiac output (acute forward heart failure or cardiogenic shock), are sometimes seen in cases of dilated cardiomyopathy, and hypothermia may also occur with aortic thromboembolism.

Other important features to note during clinical examination include the presence or absence of a jugular pulse, alteration of thoracic resonance on percussion and the strength of the apex beat on palpation of the thorax. Jugular distension or abnormal jugular pulsation (more than a few centimetres above the thoracic inlet in the standing cat with the head elevated) may be seen in cases where right atrial pressure is elevated (e.g. right atrioventricular regurgitation, pericardial effusion). The fur over the jugular furrow must be clipped and/or moistened with surgical spirit to be able to see the jugular vein. The apex beat is normally most clearly palpable over the left fifth intercostal space. This may become more prominent if the left ventricle is hypertrophied (e.g. hypertrophic cardiomyopathy, hyperthyroidism) and its intensity is often reduced in dilated cardiomyopathy, or where there is pleural or pericardial effusion or an intrathoracic mass, when the ventral area of dullness on percussion is increased also. Where loud cardiac murmurs are present, palpation of the thorax may reveal a thrill. During the physical examination, careful attention should also be paid to the search for thyroid enlargement, the presence of ascites and hepatomegaly, and the size and contour of the kidneys. Where ascites is caused by right-sided congestive heart failure, there will usually also be hepatomegaly and jugular distension, and the jugular pulsation may be accentuated by palpation of the liver (hepatojugular reflux).

Auscultation

Auscultation of the heart and lungs plays a vital part in the investigation of cardiovascular disease, but may be hampered in cats by their purring. The small size of the cat's heart and its rapid rate of contraction also make the localisation and characterisation of murmurs more difficult. Auscultation should be carried out in a quiet environment. The cat's purring can sometimes be stopped by changing the animal's position, gently blowing on its face or distracting its attention, for example by running water. The whole cardiac area should be evaluated methodically, listening on both sides of the thorax at the apex, sternal border and base of the heart; both the bell and diaphragm of the stethoscope should be employed. The positions of the valve areas for auscultation are similar to those in the dog, and are discussed further in the section on congenital defects. Because of the small physical size of the heart it is much more difficult to define these areas clinically, although the use of a paediatric stethoscope, with a small chest piece, may help. The first and second heart sounds are usually clearly audible, the second often louder than the first, and these are the only heart sounds heard in normal cats. The heart and pulse rates should be compared simultaneously and should be the same; arrhythmias can produce a pulse deficit. The presence of pleural or pericardial effusions or intrathoracic masses often causes muffling of the heart and lung sounds. The heart may become louder on the right side of the thorax if displaced by fluid or a mass. In cats with heart failure of any cause, the third (early diastolic) or fourth (atrial) heart sounds often become audible as an extra, usually low-pitched diastolic sound termed a 'gallop sound'. This is generally best heard over the left apex region and may be heard more clearly with the bell of the stethoscope. The presence of gallop sounds is a useful indicator of heart disease, although they are occasionally heard in other situations, e.g. with sedation, or in hypertension.

Murmurs occur frequently in cats with various types of cardiac disease, both congenital and acquired. However, functional or physiological murmurs also occur in non-cardiac diseases, e.g. with anaemia and pyrexia and sometimes following sedation. Innocent murmurs (i.e. with no underlying cardiac disease or dysfunction) are encountered in kittens. A murmur can be produced by simply compressing the thoracic

wall during auscultation, especially in kittens. Thus, the presence of a murmur is not definitive evidence of cardiac disease. If possible, the murmur should be classified according to its timing within the cardiac cycle (systolic, diastolic), loudness, point of maximum intensity, radiation and acoustic profile (character). Auscultation of the thorax should be completed by assessing the loudness and character of the normal respiratory sounds and noting the presence of any adventitious lung sounds, for instance the crackles (or râles) that may occur with pulmonary oedema.

Diagnostic aids

While the history and clinical findings may strongly support a diagnosis of cardiovascular disease, further investigation is usually required before a definitive classification of the type of disease and its severity can be made. The most widely used aid to diagnosis is plain radiography, but other techniques of imaging, particularly ultrasonography, have become increasingly important. Electrocardiography is vital for the proper diagnosis and treatment of arrhythmias. The use and interpretation of these techniques can only be discussed briefly here; further details are available in several of the texts and papers cited.

Radiography

The care necessary in handling dyspnoeic cats, particularly for radiography, has already been stressed; in particular, a dyspnoeic cat should not be placed in dorsal recumbency, especially if the presence of a pleural effusion is suspected. It may be necessary to remove any significant accumulation of thoracic fluid before radiography can safely and usefully be completed, since an effusion obscures the cardiac silhouette as well as compromising respiratory function. However, before thoracocentesis is attempted it is helpful to take an initial dorsoventral radiograph to confirm the presence and distribution of the effusion.

Radiography allows an assessment to be made of the presence and degree of cardiomegaly and enlargement of specific cardiac chambers. It also allows evaluation of the pulmonary circulation, the great vessels (see Figures 19.7 and 19.11), the pulmonary parenchyma and pleural space, thus enabling the clinician to detect the common features of heart failure in cats, namely pulmonary oedema and pleural effusion. Pulmonary oedema in cats may have a very different radiographic appearance from the 'fluffy' perihilar infiltrate typically seen in dogs. It can have a very diffuse distribution in cats or may produce a mottled, patchy or more uniform infiltrate, sometimes resembling neoplasia (Figure 19.3).

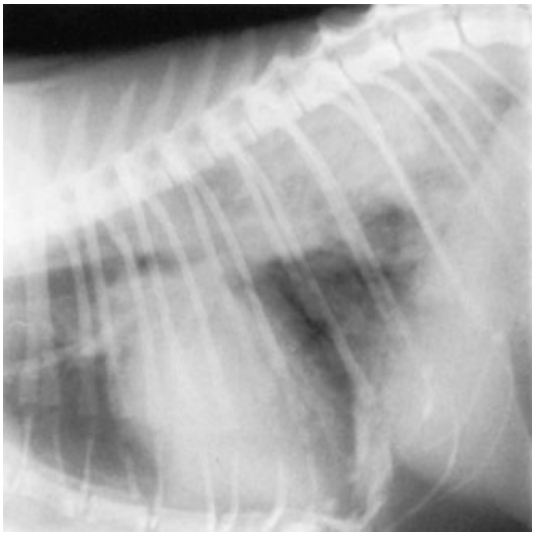

Figure 19.3 Pulmonary oedema and cardiomegaly. Lateral radiograph from a cat with unclassified cardiomyopathy, aortic thromboembolism and an acute onset of dyspnoea and cyanosis. The pulmonary oedema appears here as an area of intense infiltration.

The usual radiographic projections for the thorax in cases of cardiovascular disease are right lateral and dorsoventral. The conformation and relative shape and size of the thorax and heart are much less variable in cats than in the various breeds of dog. There is, however, some variation in the alignment of the longitudinal axis of the cat's heart, which may lie almost supine along the sternum in the lateral view in some normal individuals, especially older cats. The heart is more elongated and is smaller relative to the size of the thorax than in dogs. Because the cardiothoracic conformation of cats is relatively uniform, published guidelines and measurements for the detection of cardiomegaly are more useful than in dogs, where thoracic conformation varies widely between breeds. In the lateral projection the width of the normal heart, measured at its widest point and perpendicular to the longitudinal axis, should not exceed the distance between the fifth and seventh ribs at the same level (Van den Broek & Darke, 1987). In the dorsoventral projection the normal heart should not exceed two-thirds of the width of the thorax at its widest point. The vertebral scale system may also be

used to measure heart size in cats (Litster & Buchanan, 2000). In this system the long axis of the heart and the short axis of the heart are measured on the lateral film. These two distances are then transposed onto the vertebral column and recorded as the corresponding number of vertebrae as measured caudally from the cranial edge of T4. The sum of the two measurements should not exceed 8.2 vertebral bodies.

The positions of the cardiac chambers within the radiographic cardiac silhouette are shown in Figure 19.4. Enlargement of the left atrium and ventricle produces elongation of the heart in both projections. In the lateral view this results in elevation of the hilar structures (of which the trachea is most easily seen), which is a useful marker for cardiomegaly even when the heart itself is obscured by pleural effusion. However, intrathoracic masses may also elevate the heart and hilar structures. The apex may remain pointed in shape when the left ventricle is concentrically hypertrophied and may appear rounded when there is eccentric hypertrophy ('dilatation') of the left ventricle, but these features do not allow the reliable differentiation of concentric and eccentric hypertrophy. Enlargement of the left atrium may be seen as a caudodorsal bulge in the lateral view or may be more obvious as a left lateral bulge in the dorsoventral view. Enlargement of the right atrium and ventricle is best seen in the dorsoventral projection, producing rounding of the right cardiac border and sometimes craniocaudal widening of the heart in the lateral view. The dorsoventral view is particularly useful in cats, since atrial (especially left atrial) enlargement may produce very obvious widening of the heart and alteration of its shape in this projection, sometimes shifting the apex towards the midline when severe. The term 'valentine-shaped heart' is sometimes used to describe the appearance of a cardiac silhouette with broad 'shoulders' due to marked atrial enlargement, as seen in the dorsoventral view.

A widened aortic arch may be seen cranial to the heart in both projections with congenital defects such as aortic stenosis and patent ductus arteriosus, and may also occur normally in old cats and perhaps secondarily to conditions causing systemic arterial hypertension, such as chronic renal failure (Bonagura, 1994). Enlargement of the main pulmonary artery is not readily seen in cats as it is usually hidden within the cardiac silhouette. Inspection of the pulmonary vasculature can show evidence of pulmonary overcirculation in congenital defects with a left-to-right shunt, venous congestion where left atrial pressure is elevated and wide, and sometimes tortuous arteries in cases of pulmonary hypertension. Contrast radiography is sometimes necessary to gain additional information about internal cardiac anatomy in cases of both congenital and acquired cardiac disease. Although selective angiography (placing radiographic contrast material into a specific chamber of the heart using an intracardiac catheter) is rarely feasible in practice and has been superseded for many of its applications by ultrasonography, non-selective angiography (Figure 19.4) is still of value in some cases as an alternative to ultrasonography where the latter is not available (e.g. to distinguish between hypertrophic and dilated cardiomyopathy, to distinguish pericardial distension from cardiomegaly or to show a congenital right-to-left shunt). The procedure is generally well tolerated by cats and may be carried out with the use of sedative cocktails such as ketamine with midazolam, diazepam or acepromazine, following an overnight fast. The dose of ketamine for a healthy cat is 10 mg/kg (maximum 30 mg/cat) mixed in the same syringe with 0.2 mg/kg of midazolam and given intramuscularly. These doses should be reduced by 30–50% for cats with cardiac disease. Acepromazine may also be mixed with opioids such as buprenorphine or butorphanol, with smaller doses of ketamine if required. Atropine may be given if the heart rate is slow. The cat's medical condition (e.g. congestive heart failure, electrolyte imbalance) must be stabilised first and complications do occur occasionally, ranging from transient bradycardia or vomiting to cardiac arrest, particularly in cases of dilated cardiomyopathy. An intravenous catheter (20–22 G) should be inserted into a cephalic or jugular vein and intravenous radiographic contrast material is injected as quickly as possible, at a dose of approximately 450 mg of iodine/kg body weight (less in high-risk cases). A radiograph is taken immediately after injection and then several more as quickly as possible (e.g. 5, 10 and 15 s after injection). The construction of a 'cassette tunnel' may help in changing films rapidly (Fox & Bond, 1983).

Ultrasonography (echocardiography)

The use of ultrasonographic imaging has had a tremendous impact on the diagnosis of cardiac disease. In this technique very high-frequency sound waves (usually 5–10 MHz for echocardiography in cats) are used to generate images of the cross-sectional anatomy of the internal organs. When sound waves, generated by a piezoelectric crystal and transmitted through the soft tissues of the body, meet an interface between tissues of different acoustic impedance (e.g. myocardium and

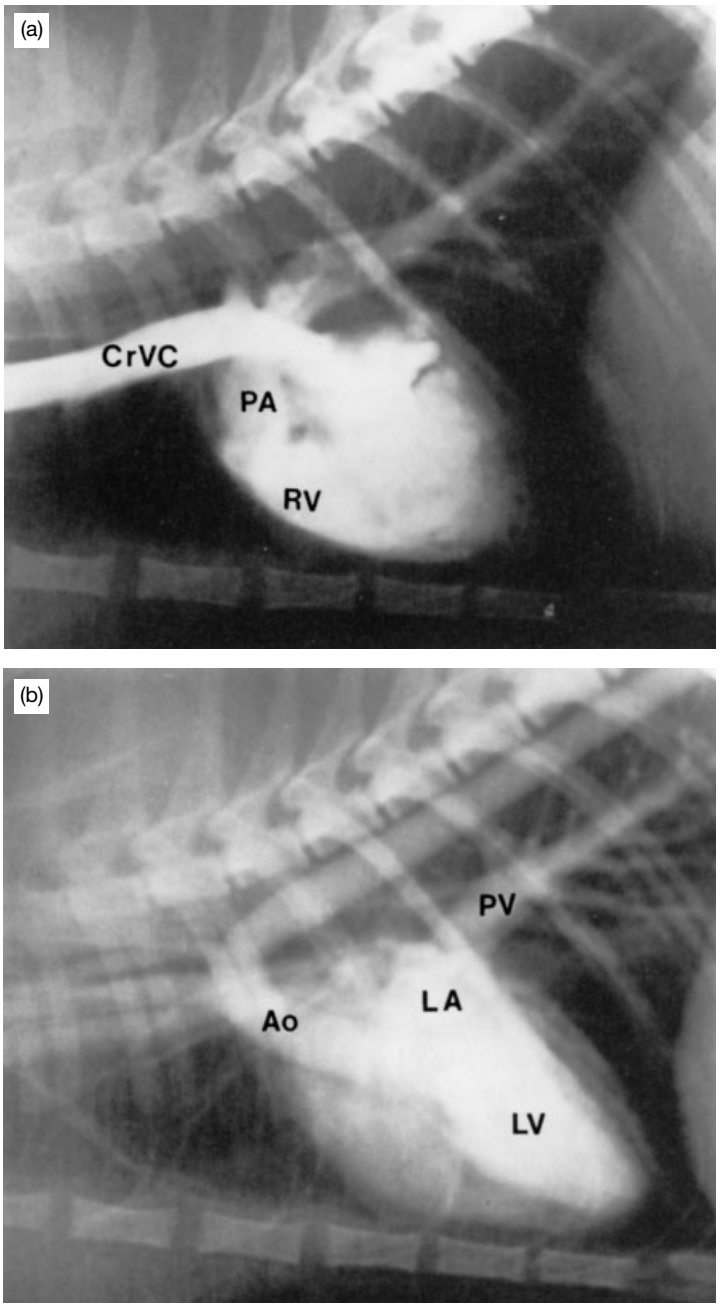

Figure 19.4 Non-selective angiogram from a healthy cat. (a) Initial right ventricular phase outlining the cranial vena cava (CrVC), right ventricle (RV, also partly overlying the left side here) and main pulmonary artery (PA). (b) Left ventricular phase showing the pulmonary veins (PV) emptying into the left atrium (LA) then left ventricle (LV) and aorta (Ao).

blood), a proportion of the sound is reflected and can be received by the same piezoelectric crystal. This echoed sound deforms the crystal, generating an electrical signal that is used to generate a two-dimensional (2D) image. Because this process happens in real time, it is possible to show movement and thus gain information on cardiac function as well as anatomy. Quantitative information on blood flow patterns and velocities can be derived by the technique of Doppler echocardiography, which makes use of the shift in frequency of sound reflected off moving red blood cells to determine blood flow velocity.

Information on blood flow may also be gained by the use of intravenous echocontrast agents (e.g. fluids such as agitated saline or colloids that contain microbubbles and thus strongly reflect ultrasound). This technique can be useful when looking for an intracardiac shunt or reverse-shunting patent ductus arteriosus (PDA). These techniques can be carried out safely and non-invasively, without the need for sedation or anaesthesia. It is beyond the scope of this chapter to discuss the theory, techniques or interpretation of echocardiography in any detail, and the reader is referred to the further reading listed (e.g. Kienle, 1998a; Moïse & Fox, 1999). Examples of the use of echocardiography are given in the sections on specific cardiac diseases. Figure 19.5 shows cardiac ultrasound images from a healthy cat, and some normal values for cardiac measurements determined by M-mode echocardiography are given in Table 19.1.

The most common indication for carrying out echocardiography in cats is to distinguish between the various forms of cardiomyopathy. Echocardiography is also valuable in determining the nature of congen-

Figure 19.5 Cardiac ultrasound images from a healthy cat from the right parasternal position. (a) Long-axis view in diastole; arrow shows open septal cusp of the left A-V valve. (b) Short-axis view at systole; arrowhead shows a chorda. (c) and (d) *Continued over page*.

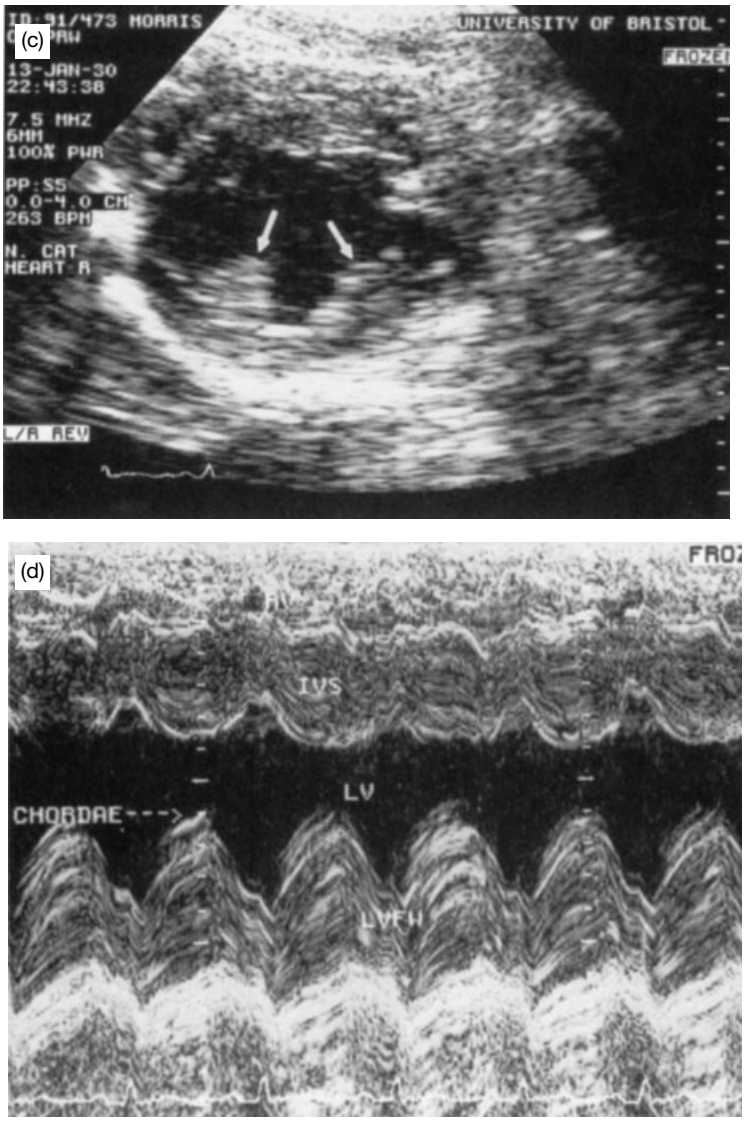

Figure 19.5 *Continued*. (c) Short-axis view at diastole; arrows show papillary muscles. (d) M-mode display at chordal level: the position used for making measurements of ventricular dimensions and wall thickness. Abbreviations as in Figure 19.4; also RA: right atrium; IVS: interventricular septum; LVFW: left ventricular free wall.

ital anatomical defects, particularly when used with Doppler techniques for detecting abnormal blood flow. Where pleural fluid is present, ultrasonography will also help to exclude non-cardiac causes such as thymic lymphoma and diaphragmatic rupture. Pleural fluid aids ultrasonographic examination, whereas it obscures radiographic detail.

Electrocardiography

Disturbances of cardiac electrical activity (impulse formation and conduction) are common in feline cardiovascular disease, especially primary and secondary cardiomyopathies. Electrocardiography is essential for defining arrhythmias and allowing decisions to be made about their significance, and may also give infor-

Table 19.1 Some normal values from M-mode echocardiography

Diastole	Left ventricular diameter	11.0–18.0 mm
	Left ventricular free wall	2.5–5.0 mm
	Interventricular septum	2.5–5.0 mm
Systole	Left ventricular diameter	5.0–10.0 mm
	Left ventricular free wall	5.0–9.0 mm
	Interventricular septum	5.0–9.0 mm
	Left ventricular fractional shortening (an indicator of systolic function)	35–65%

Adapted from Bonagura (1994).

mation on cardiac chamber enlargement and metabolic disturbances, but gives no direct indication of the contractile state of the myocardium. Again, it is beyond the scope of this chapter to discuss the theoretical basis, technique and interpretation of electrocardiography, and the reader is referred to the texts cited for a detailed discussion of these areas (e.g. Bonagura, 1994).

Most cats will tolerate the recording of an electrocardiogram (ECG) without the use of sedatives or tranquilisers, and as these may alter the ECG they should be avoided. Whether the patient is placed in right lateral (the position described in standard texts) or sternal recumbency makes little difference to the values recorded; P- and R-wave voltages are in fact slightly greater in sternal recumbency. As most cats tolerate sternal recumbency better, particularly if dyspnoeic, this position is often preferable. Where it is necessary to determine cardiac rhythm only, the cat may be placed in a cage, after attaching the electrodes, and allowed to take up any position that it finds comfortable. Some normal values are given in Table 19.2.

Other diagnostic aids

Thoracocentesis

The detection of a significant volume of pleural fluid on thoracic radiographs is an indication for thoracocentesis. This technique is described in Chapter 12. Removal of pleural fluid serves to reduce dyspnoea and aids diagnosis by allowing the intrathoracic viscera to be seen more clearly on radiographs. Fluid is also made available for laboratory examination. Both sides of the thorax can generally be drained from one site. The pleural effusion in congestive heart failure is often a transudate, relatively clear in appearance, low in protein (<30 g/l) and containing few cells. However modified transudates are also found and occasionally the fluid is chylous. Cytological examination of the fluid can help to rule out other causes of pleural effusion, such as thymic lymphoma. In congestive heart failure the fluid contains mainly erythrocytes, mesothelial cells and mature lymphocytes. Pleural effusion is seen most often in the dilated and restrictive forms of cardiomyopathy, although other forms of heart disease cannot be ruled out on that basis.

Table 19.2 Some normal electrocardiographic values (lead 2)

	Duration (ms)	Amplitude (mV)
P wave	Max. 40	Max. 0.25
P-R interval	50–100	–
QRS complex	Max. 40	Max. 1.0
Q-T interval	80–220	–
Heart rate	140–240 beats/min	

Laboratory tests

Laboratory investigations are of value in looking for underlying causes of cardiac disease and in assessing the effects of heart failure on the function of other organs, as well as any side-effects of therapy.

Haematology

A leucocytosis may be present in cases of endocarditis or myocarditis, but can be present in other forms of cardiomyopathy. Polycythaemia may occur where a congenital heart defect leads to right-to-left shunting of blood and cyanosis. Moderate or severe anaemia may give rise to a physiological murmur or may lead to signs of secondary cardiac disease.

Biochemistry

Assessment of renal function is valuable, as heart failure and the use of diuretics can both cause prerenal azotaemia and, conversely, chronic primary renal failure may give rise to signs of secondary cardiac disease. Renal dysfunction also affects digoxin excretion, and it can be valuable to determine the serum concentration of digoxin in cases where this of concern. Severe renal failure is seen occasionally owing to thromboembolic occlusion of the renal arteries. Electrolyte imbalance, particularly hyperkalaemia, is an important factor in initiating or exacerbating arrhythmias.

Hyperkalaemia and metabolic acidosis occur in cats with thromboembolic disease and renal failure. Hypokalaemia is seen in cats with chronic renal failure and sometimes following the prolonged use of diuretics. Serum alanine aminotransferase (ALT) is commonly elevated in hyperthyroid cats.

Other tests

Serum thyroxine levels should always be determined in older cats (>5–6 years) with heart disease to rule out underlying hyperthyroidism (see Chapter 20). Plasma or whole blood taurine levels should ideally be measured in cases of dilated cardiomyopathy; a plasma level of less than 20 nM/ml or a whole blood level of less than 100 nM/ml may be considered to indicate taurine deficiency. The laboratory to which the sample is being submitted should be consulted regarding sample type, conditions for transport and reference values. Blood culture is worthwhile if bacterial endocarditis is suspected.

Measurement of systemic arterial blood pressure

In cats with concentric hypertrophy of the left ventricle it is important to exclude systemic hypertension as an aetiological factor. Monitoring of systemic blood pressure is also important when vasodilator drugs are used in the treatment of cardiac disease. A number of systems is now available commercially for the indirect measurement of blood pressure in cats and the reader is referred to Chapter 9 for further discussion of these techniques and normal values.

Congenital heart disease

The prevalence of congenital heart disease in cats has been estimated to be approximately 2.8% in post-mortem surveys in the USA (Buchanan, 1999). The range of severity is very wide. In many cases (particularly atrioventricular valve malformations) the defect is mild and may go unrecognised until the cat reaches maturity or even old age. In others the defect is severe enough to cause death in the first few days or months of life. A male predominance has been reported for some defects.

The main features of the history and clinical examination associated with congenital heart disease are stunting of growth compared with unaffected litter mates, dyspnoea particularly on exertion, poor exercise tolerance, collapse, cyanosis and ascites. Where such signs occur the prognosis is often poor. Sometimes other members of the litter are also affected. Occasionally, the presenting signs may appear to be unrelated to the cardiovascular system (e.g. weakness/ataxia or seizures). Auscultation will usually reveal a murmur, which may be loud. However, the finding of a murmur in a kitten is not definitive evidence of the presence of a congenital cardiac anomaly. Innocent murmurs occur, for instance, where no abnormality of the heart can be found; these are usually quiet, occur during systole, and generally disappear by 4–6 months of age. Cardiomyopathy can give rise to a murmur through stretching or distortion of the atrioventricular valves, making them incompetent. Cardiomyopathy may occur in kittens as young as 5 or 6 months of age, and even kittens of a few weeks of age may be affected, particularly Burmese and Siamese. Conversely, a severe congenital defect may be present with no audible murmur, although this is uncommon. Further investigations, including radiography, ultrasonography, ECG, angiography, cardiac catheterisation and post-mortem examination, are often required to reach a definitive diagnosis.

Most of the congenital cardiac anomalies recognised in other species have been reported in cats, but many are rare. The relative prevalence of the more common defects is shown in Table 19.3. It should be noted that this is different from the frequency of occurrence of similar defects encountered in dogs. The more common defects are considered in more detail below. The medical treatment of congestive heart failure (CHF) of any cause is discussed later in the section on therapy for cardiomyopathy.

Table 19.3 Relative prevalence of the more common congenital anomalies

Defect	Prevalence (%)
Atrioventricular valve dysplasia	17
Ventricular septal defect	15
Patent ductus arteriosus	11
Vascular anomalies	8
Aortic stenosis	6
Tetralogy of Fallot	6
Atrial septal defect	4
Common atrioventricular canal	4
Pulmonary stenosis	3

Adapted from Buchanan (1999).

Atrioventricular valve malformations

Dysplasia of the left (mitral) or right (tricuspid) atrioventricular (A-V) valves is the most common form of congenital cardiac anomaly reported in cats. The range of severity is wide, and the anatomical defects seen include abnormalities of papillary muscle number or position (usually being upwardly displaced), abnormally long or short or fused chordae tendineae, and thickened valve leaflets, which may have notches or clefts. The result of these defects is to make the valve incompetent, producing a systolic murmur of A-V valvular insufficiency, although occasionally the valve may also be stenotic. Congenital anomalies may occur in combination; for example, tricuspid dysplasia has been associated with mitral dysplasia and with ventricular septal defects. If the A-V valvular incompetence is severe enough to be haemodynamically significant volume overload occurs, with enlargement of the atrium and ventricle of the affected side.

The clinical effects depend on the severity of the defect. A systolic murmur of A-V valvular insufficiency will usually be audible with maximum intensity over the left or right apex, depending on the side affected; this murmur may radiate widely. In many cases the defect is mild and the cat remains compensated and clinically normal, apart from the presence of a murmur. In more severe cases, volume overload and cardiomegaly of the affected side are detectable radiographically, by ECG and by ultrasonography, the latter being the most sensitive and specific. Ultrasonography shows the atrial and ventricular enlargement and may also demonstrate the anatomical defects of the left or right A-V valves, e.g. thickened or adherent valve leaflets, abnormal chordae and/or papillary muscles (Figure 19.6). Doppler techniques can be used to show the regurgitant blood flow.

Where CHF does develop, this happens over a variable period. Mitral dysplasia leads to pulmonary oedema, which causes dyspnoea, and in the most severe cases secondary right-sided CHF may follow on from this as a consequence of chronic pulmonary venous congestion and pulmonary hypertension. Tricuspid dysplasia primarily causes right-sided CHF with pleural effusion and/or ascites.

Ventricular and atrial septal defects

Abnormalities of formation of the interventricular and interatrial septa are not uncommon. Ventricular septal defects (VSDs) occur most often, either as isolated lesions or with other defects such as tricuspid dysplasia. Isolated atrial septal defects (ASDs) are infrequently identified, but an ASD may be seen complicating another defect, such as PDA. The embryology of cardiac septation is complex (the reader is referred to Bishop, 1999, for details) and septal defects are very variable in their size, position, association with other anomalies and haemodynamic effects. A very large subaortic VSD is seen as part of the tetralogy of Fallot (see below). A combination of a low (septum primum) ASD with a high VSD can occur forming one large defect, a common A-V canal, usually in association with abnormalities of the A-V valves. This complex anomaly results from abnormalities of development of the tissues arising from the embryonic endocardial cushions. It usually causes severe heart failure and carries a very poor prognosis.

The haemodynamic effects of these defects are dependent on the size of the lesion and the nature and severity of any associated anomalies. An ASD allows an abnormal shunting of blood from the left to the right atrium which, if of sufficient magnitude, results in volume overload and enlargement of the right atrium and ventricle and increased pulmonary blood flow. A quiet systolic murmur of relative pulmonic stenosis is audible at the left heart base owing to the larger than normal stroke volume of the right ventricle. A VSD also allows left-to-right shunting and pulmonary overcirculation. The effect here, because of the position of the defect, is predominantly one of increased pulmonary venous return and left-sided volume overload. The effect on the right ventricle is variable; it may be dilated or, if the VSD is large, hypertrophied. A loud holosystolic murmur is typically heard at the right sternal border, and again a murmur of relative pulmonic stenosis may be audible. If pulmonary hypertension develops, perhaps secondary to overperfusion, or if the right ventricle hypertrophies sufficiently, then a right-to-left shunt may occur, leading to cyanosis. This happens if right ventricular systolic pressure increases sufficiently to exceed the pressure on the left side. With a common A-V canal all four cardiac chambers are usually dilated owing to the large (usually left-to-right) shunt, A-V valvular incompetence and subsequent severe volume overload.

Clinical signs in cats with septal defects vary from an asymptomatic murmur to severe CHF, which may affect the left, right or both ventricles. Severe CHF generally develops in the first year of life, with large septal defects. Thoracic radiographs demonstrate cardiomegaly and pulmonary overcirculation, unless a right-to-left shunt has developed, when the lungs

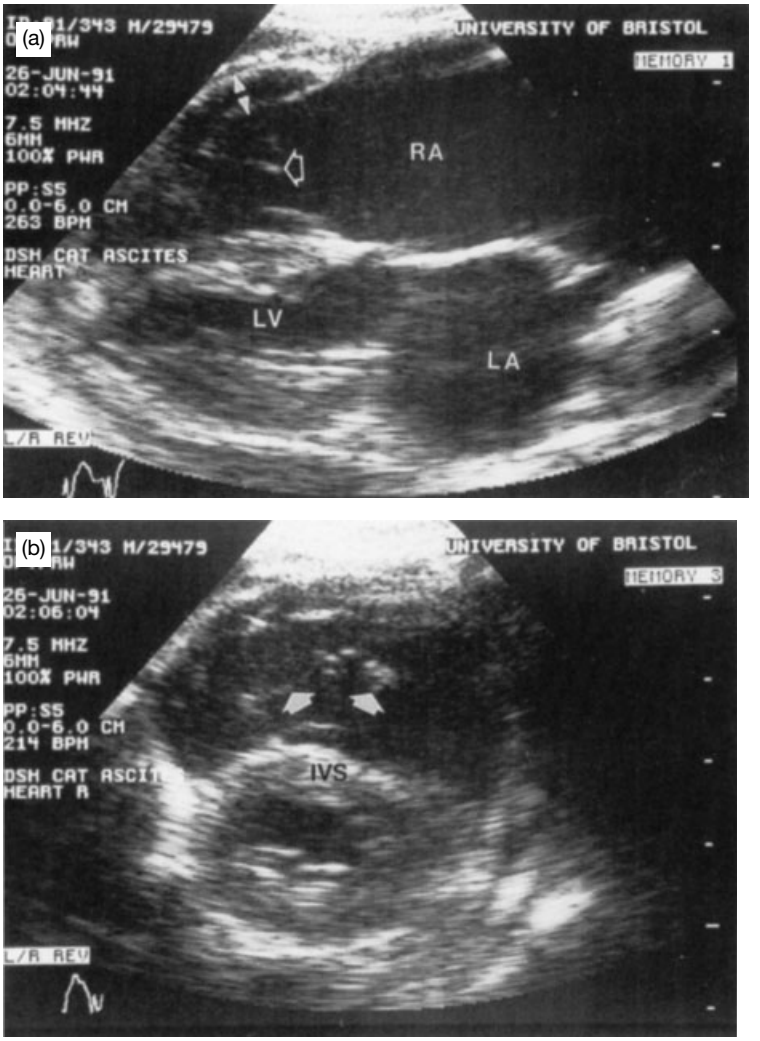

Figure 19.6 Cardiac ultrasound images of congenital right A-V valve dysplasia from the right (a–c) and left (d) parasternal positions. (a) Long-axis view; the right atrium is markedly dilated, the right ventricular free wall is hypertrophied (small arrowheads) and an abnormal, thick chorda is visible (open arrowhead). (b, c) Short-axis views at chordal and heart base levels, respectively; arrowheads indicate parts of the abnormal A-V valve and chordae. (d) Left apical (four-chamber) view; the right atrium is markedly dilated, the right ventricle less so. Abbreviations as in Figures 19.4 and 19.5. *(c) and (d) Continued opposite.*

appear underperfused. Evidence of CHF, if present, will also be apparent radiographically. Ultrasonography may show the septal defect if it is large enough and will show signs of right ventricular enlargement and volume overload, such as septal flattening or paradoxical septal motion. The ECG may show signs of right-sided enlargement, such as enlarged P-waves and deep S-waves in leads I, II, III and aVF. Occasionally a conduction deficit is seen owing to physical interruption of the conduction system by the septal defect.

Patent ductus arteriosus

PDA has not been described commonly in cats (in contrast to dogs, where it is one of the most common congenital cardiac anomalies), but it deserves mention because potentially it can be corrected surgically.

Figure 19.6 *Continued*. Cardiac ultrasound images of congenital right A-V valve dysplasia from the right (a–c) and left (d) parasternal positions. (a) Long-axis view; the right atrium is markedly dilated, the right ventricular free wall is hypertrophied (small arrowheads) and an abnormal, thick chorda is visible (open arrowhead). (b, c) Short-axis views at chordal and heart base levels, respectively; arrowheads indicate parts of the abnormal A-V valve and chordae. (d) Left apical (four-chamber) view; the right atrium is markedly dilated, the right ventricle less so. Abbreviations as in Figures 19.4 and 19.5.

There may be a predisposition in the Siamese breed, although it has not been shown to be hereditary. Associations with other congenital anomalies have been reported, including septal defects and tricuspid dysplasia.

Patency of the ductus arteriosus after birth results in a left-to-right shunt and pulmonary overperfusion with predominantly left-sided volume overload, the severity of which depends on the size of the ductus and pulmonary vascular resistance. A continuous murmur, loudest at the left heart base, and hyperkinetic femoral pulses are the classical clinical findings with PDA. Thoracic radiographs demonstrate varying degrees of left-sided cardiomegaly, pulmonary overperfusion and sometimes enlargement of the great vessels (Figure 19.7). The ECG may show evidence of left-

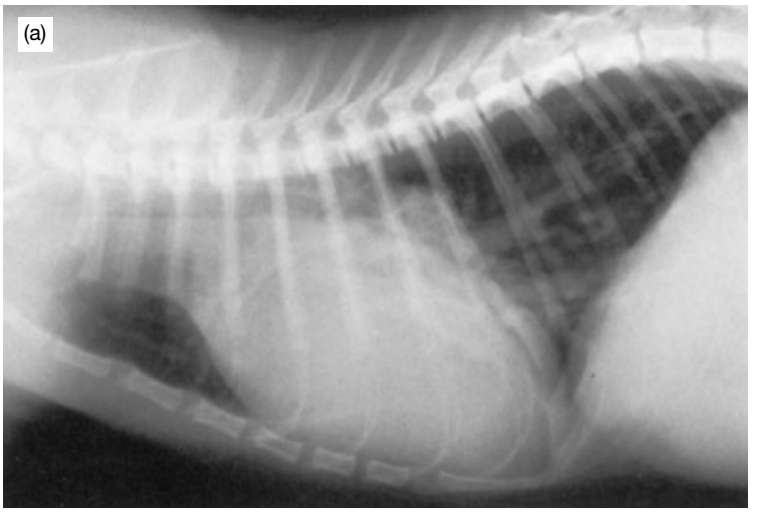

Figure 19.7 Patent ductus arteriosus. Radiographs from a 13-week-old Siamese kitten with a continuous murmur. (a) Lateral and (b) dorsoventral projections show marked generalised cardiomegaly, some patchy pulmonary oedema, a wide aortic arch and wide pulmonary arteries (arrowheads). (c) Injection of contrast material via a catheter in the aortic root outlines both the aorta and the pulmonary artery and a short, wide connection; a coronary artery is also opacified. A small ventricular septal defect was also found at post-mortem examination.

sided enlargement, e.g. tall R-waves in lead II, wide QRS complexes and wide P-waves. Ultrasonography shows enlargement of the left atrium and ventricle and may also reveal associated defects. If left untreated, PDA will progress to CHF, so surgical closure of the patent vessel is advisable; however, the prognosis should be guarded in cats, particularly if another defect is present. The occurrence of pulmonary hypertension,

right ventricular hypertrophy and right-to-left shunting with cyanosis is reported to be rarer in cats than in dogs (Bonagura, 1994).

Aortic stenosis

Aortic stenosis was previously reported to be one of the most common congenital defects in cats, but more recent surveys have not supported that conclusion. The obstruction to left ventricular outflow may occur at valvular level, or as a supravalvular or subvalvular fibrous ring. Associations with other congenital cardiac anomalies are reported. The effect of the obstruction is to produce concentric hypertrophy of the left ventricle with left atrial enlargement and poststenotic dilatation of the aorta, which is visible in the more severe cases on thoracic radiographs and with ultrasonography. Ultrasound can show the site of obstruction, and a pressure gradient and turbulent blood flow across the aortic valve can be demonstrated using Doppler ultrasound techniques. Clinically, a systolic ejection murmur is produced which is best heard at the left or right third to fourth intercostal space (Bonagura, 1994). The prognosis for this defect appears to be poor, with most cats developing left-sided CHF, but some cases remain asymptomatic. The clinical and echocardiographic findings in aortic stenosis can be very similar to those of hypertrophic cardiomyopathy, which may lead to some difficulty in diagnosis, particularly if the congenital defect is discovered in an adult cat. This factor may have led to some confusion in previous surveys of prevalence.

Cyanotic congenital heart defects

Cyanosis may arise in cases of congenital heart disease owing to right-to-left shunting of desaturated blood into the systemic circulation. This may occur, following the development of pulmonary hypertension and/or right ventricular hypertrophy, with anomalies that normally cause left-to-right shunting, such as septal defects or PDA, and also with other severe defects, but the most common in this rare category of conditions is the tetralogy of Fallot. This complex defect arises through abnormalities of development of the embryonic truncus arteriosus into an aorta and a pulmonary artery. This results in (i) a dextropositioned aorta, overriding the interventricular septum, (ii) a subaortic VSD, (iii) pulmonic stenosis (at the level of the valve or outflow tract), which may be severe to the extent of atresia and which causes (iv) secondary right ventricular hypertrophy. The resulting high right ventricular pressures cause a right-to-left shunt of blood through the VSD into the overriding aorta, and thus cyanosis.

Some cats with tetralogy of Fallot may survive to middle age, whereas others are severely affected in the first year of life. The history, apart from cyanosis, may include dyspnoea, severe exercise intolerance and seizure-like episodes. The latter are thought to be due to hypoxia and to blood hyperviscosity caused by secondary polycythaemia, which occurs as a response to the pulmonary underperfusion. CHF is unlikely to occur, but sudden death is a possible outcome. Clinical examination usually reveals a systolic murmur of pulmonic stenosis at the left heart base, and possibly a murmur from the VSD at the right sternal border; however, the murmurs may be subtle or absent. The cyanosis is often detectable clinically, and severe polycythaemia may produce visible reddening of the mucous membranes. The latter may also produce tortuosity of the retinal vessels. The ECG may show evidence of right ventricular hypertrophy, for example, a deviation of the mean electrical axis towards the right. Thoracic radiographs show right-sided enlargement and signs of pulmonary underperfusion. Echocardiography shows right ventricular hypertrophy and intravenous echocontrast can be used to show the right-to-left shunt, as can non-selective angiography.

The management of this serious condition is difficult. Palliative surgical procedures have been described (e.g. subclavian–pulmonary artery anastomosis). Periodic phlebotomy should control the polycythaemia, or this may be controlled medically with hydroxyurea (see Chapter 9). It has been suggested that β-adrenergic blockers may have some value in helping to limit the development of ventricular hypertrophy and perhaps also in suppressing arrhythmias, but there is no information as to their clinical value in this condition.

Other congenital conditions

Endocardial fibroelastosis

This condition has been described previously as a congenital anomaly with a strong predisposition in the Siamese and Burmese breeds, and was reported as being hereditary in Burmese. The lesions described were enlargement of the left atrium and ventricle with marked fibroelastic thickening of the endocardium. Signs of acute heart failure, with dyspnoea, cyanosis, arrhythmias and sudden death, were seen in

kittens from a few weeks up to a few months of age. However, it is now thought possible that the marked histological changes of fibroelastosis may, at least in some cases, merely be a non-specific response to other forms of congenital or acquired cardiac disease, such as taurine deficiency.

Vascular ring strictures

This anomaly is reported in kittens, causing regurgitation; it is discussed further in Chapter 16.

Excessive left ventricular moderator bands

Although increased numbers of left ventricular moderator bands are likely to be a congenital anomaly, this entity is discussed later under restrictive cardiomyopathy.

Pericardioperitoneal diaphragmatic hernia

This defect is not uncommon and occurs owing to incomplete separation of the abdominal and thoracic cavities, allowing abdominal viscera to lie within the pericardial sac. The condition appears to have a predisposition in longhaired cats. The defect may be asymptomatic and recognised incidentally, but dyspnoea is more likely and diarrhoea or vomiting is reported. Occasionally, affected kittens are simply found dead. There may be associated deformities of the sternebrae, although clinically insignificant deformities of the sternebrae are a common incidental radiographic finding in cats of all ages. Diagnosis is based on radiography, which shows abnormalities of the cardiac silhouette and soft-tissue densities within the pericardium. Confirmatory techniques such as barium contrast, non-selective angiography or ultrasonography can be helpful. This condition is treated by surgical reduction of the hernia and closure of the defect.

Acquired heart disease

Most cardiac disease of clinical significance in cats is acquired. The prevalence of acquired heart disease in cats has been reported as 8.5% in one large survey in the USA (Buchanan, 1999) and myocardial disease (cardiomyopathy) accounts for the majority of cases. Acquired valvular and pericardial diseases are recognised and will be mentioned briefly, but they are not diagnosed commonly.

Cardiomyopathy

Some authors restrict the use of the term 'cardiomyopathy' to myocardial conditions of unknown cause. In this chapter the broader definition of the word will be used; that is, the cardiomyopathies are a heterogeneous group of diseases characterised by dysfunction of the myocardium, unassociated with prior congenital heart disease, acquired disease of the heart valves, pericardium, vasculature or lungs.

Myocardial diseases may or may not, depending on their severity, lead to clinically significant impairment of myocardial function. A common effect of myocardial disease is to produce arrhythmias and/or conduction disturbances that may in themselves affect cardiac function.

Cardiomyopathies are generally classified under one or both of the following headings:

- aetiology, either primary/idiopathic, where no aetiology can be identified, or secondary (or specific) where there is a known cause
- by their effect on cardiac function or anatomy (e.g. dilated or hypertrophic).

This classification is summarised as follows:

- primary (idiopathic):
  - hypertrophic (obstructive and non-obstructive)
  - restrictive
  - dilated
  - unclassified
  - arrhythmogenic right ventricular cardiomyopathy
- secondary or specific (known aetiology)
  - metabolic (e.g. endocrine, nutritional)
  - infiltrative (e.g. neoplasia)
  - inflammatory (e.g. feline infectious peritonitis, feline immunodeficiency virus, protozoal or bacterial)
  - fibrotic (e.g. postinflammatory, secondary to other cardiac diseases)
  - toxic (e.g. anthracyclines)
  - excessive left ventricular moderator bands
  - others (e.g. trauma, infarction, systemic hypertension or severe anaemia).

Secondary cardiomyopathies of particular importance in cats are:

- hyperthyroidism
- systemic hypertension (secondary to chronic renal disease *or* idiopathic)

- dietary taurine deficiency
- acromegaly
- feline infectious peritonitis
- neoplasia (lymphoma).

An attempt should always be made to rule these out before categorising a case of cardiomyopathy as 'idiopathic' since, if an underlying cause can be identified and treated, the prognosis for the cardiomyopathy is much better. Most cases of cardiomyopathy in cats were previously thought to be primary. This situation has been changed by an increasing awareness of the effect of various systemic disease processes on myocardial function, and particularly with the discovery of the role of dietary taurine deficiency as a primary factor in the aetiology of dilated cardiomyopathy. Future research is likely to reduce further the number of cases described as -idiopathic.

Three main functional/anatomical classes of cardiomyopathy are recognised in cats. The pathophysiology and relative incidence of these will be described and then the clinical features, diagnosis and treatment of the cardiomyopathies as a whole will be discussed.

Hypertrophic cardiomyopathy

In hypertrophic cardiomyopathy (HCM) there is inappropriate hypertrophy of the left ventricle, papillary muscles and interventricular septum which reduces ventricular compliance (increases stiffness) and thus impairs ventricular diastolic function. Impaired relaxation has also been demonstrated (Golden & Bright, 1990). An increase in left atrial and pulmonary venous pressures is required to fill the stiff ventricle. Contractile (systolic) function is usually unimpaired and the shortening fraction may actually be increased. In some cases (the obstructive form of HCM) asymmetrical hypertrophy of the interventricular septum beneath the aortic valve causes a partial physical obstruction of outflow from the left ventricle during systole. Part of the obstruction to outflow is probably 'dynamic', owing to abnormal motion of the septal cusp of the left A-V valve towards the septum during systole (systolic anterior motion), which can be demonstrated by M-mode echocardiography. Doppler echocardiography will show a systolic pressure gradient across the outflow tract in hypertrophic obstructive cardiomyopathy (HOCM). Systolic anterior motion of the mitral valve causes mitral regurgitation, which if severe may contribute to congestive heart failure.

In the *classic* form of *primary* HCM, massive concentric hypertrophy results in marked reduction of the volume of the left ventricular lumen. In many cases, however, the degree and distribution of hypertrophy of the left ventricle may be quite variable and regional, and the ventricular lumen volume may remain normal (Bright *et al.*, 1992; Fox *et al.*, 1995). Because of the elevated filling pressures the left atrium becomes dilated and hypertrophied, and left atrial and pulmonary venous pressures may be markedly elevated, resulting in pulmonary oedema. Bouts of acute pulmonary oedema may occur if left ventricular filling is further compromised, for example by tachycardia, tachyarrhythmias or anaesthesia, or by further overload of the circulation such as the administration of intravenous fluids. Distortion of the mitral valve apparatus (owing to left ventricular hypertrophy or interference with closure caused by systolic anterior motion) leads to left A-V valvular incompetence and regurgitation, which further increases left atrial pressure and gives rise to a systolic murmur. A systolic murmur also arises from the area of outflow obstruction. Histological findings are variable, but there may be hypertrophy and cellular disorganisation of the myocardiocytes and some interstitial fibrosis. There may also be histological changes in the conduction system, especially the A-V node. Intramural coronary arteriosclerosis is present in a high percentage of cases (Fox *et al.*, 1995).

Most cases of HCM are classed as idiopathic. The most notable *systemic* cause in cats of concentric ventricular hypertrophy is hyperthyroidism, and the possibility of this very treatable condition should always be explored in older cats with signs of heart disease (see Chapter 20). Another condition that may cause mild to moderate ventricular hypertrophy is systemic hypertension, either secondary to chronic renal disease or idiopathic, although the importance of this as a potential cause of overt heart disease or failure is currently unknown. An association between 'primary' HCM and an elevated plasma level of growth hormone has been reported by Kittleson *et al.* (1992), but the significance of this finding is unknown. Peterson *et al.* (1990) have also noted cardiomegaly in cats with pituitary adenomas leading to acromegaly. Another suggested aetiology for HCM is an abnormal sensitivity of the myocardiocytes to circulating catecholamines, resulting in hypertrophy. Familial forms of HCM are described in humans and the more recent studies would suggest that the disease also has a genetic basis in cats. A heritable form of HCM with a suggested autosomal dominant mode of

inheritance has recently been reported in Maine Coone cats (Kittleson *et al.*, 1996) and American shorthaired cats (Meurs *et al.*, 1997).

The clinical and echocardiographic findings in congenital subaortic stenosis can be very similar to those in HCM, and as the latter can occur in young cats there is some potential for confusion between these two conditions. The possibility of infiltrative disease (e.g. lymphoma) should also be considered when the myocardium appears to be hypertrophied.

Dilated cardiomyopathy

The essential feature of dilated cardiomyopathy (DCM; previously termed 'congestive') is systolic failure owing to a decrease in the intrinsic inotropic function of the myocardiocytes. The cardiac chambers, especially the left ventricle, are dilated, which can be shown readily by echocardiography, and indicators of systolic function (e.g. fractional shortening, ejection fraction, ventricular diameter at end-systole, changes in ventricular wall thickness during systole and systolic time intervals) indicate reduced contractility. Ventricular compliance may also be reduced in DCM as in HCM, but the relative haemodynamic significance of this in DCM is not known. A-V valve stretching and valvular incompetence, secondary to ventricular enlargement, give rise to a systolic murmur. The histological findings in DCM are again variable, including myocardiocyte degeneration and focal fibrosis, and do not reflect the severity of the abnormalities of myocardial function (Liu, 1970).

The discovery of the role of dietary taurine deficiency as a prime factor in the aetiology of DCM (Pion *et al.*, 1989) and the subsequent supplementation of feline diets have almost eliminated this disorder. Cats with naturally occurring DCM were found to have low plasma levels of taurine, and the addition of supplementary taurine to their diet, and to the diet of cats with experimentally induced taurine deficiency, resulted in complete reversal of the condition, a unique situation among the 'primary' cardiomyopathies. Not all cats on the same diet will develop DCM, so it is likely that other factors (e.g. the bioavailability of the taurine in the food and its absorption or metabolism) are also involved. Taurine depletion has been linked to the feeding of a potassium-depleted, acidified diet (Dow *et al.*, 1992). The aetiology of DCM in cats with normal serum taurine levels is unknown. The myocardial failure may represent the end stage, perhaps after a latent period of months or years, of various possible insults to the myocardium, including viral or immune-mediated inflammation, toxins and myocardial failure secondary to infarction.

Restrictive cardiomyopathy

This heterogeneous form of cardiomyopathy is more difficult to define and to diagnose (Fox, 1999). Restrictive cardiomyopathy (RCM) is characterised by varying degrees of focal or diffuse fibrosis of the myocardium, subendocardium and endocardium. This primarily reduces ventricular compliance and restricts filling, thus leading to diastolic failure similar to that caused by HCM. The clinical diagnosis of RCM is made by observing clinically significant diastolic dysfunction without evidence of overt concentric hypertrophy. There is typically severe atrial enlargement in the absence of excessive mitral regurgitation.

The aetiology of RCM in cats is unknown, but one possibility is that it may follow a bout or bouts of myocarditis, perhaps after a variable period of latency between the initial insult to the myocardium and the development of clinical signs of diastolic failure (Wynne & Braunwald, 1997). Other types of infiltrative myocardial disease may also lead to diastolic dysfunction and may be referred to as secondary restrictive cardiomyopathies. Similar pathophysiology may result from pericardial fibrosis (constrictive pericarditis) or infiltrative, neoplastic and inflammatory diseases of the epicardium.

The entity of excessive left ventricular moderator bands is also included within the description of RCM, as these structures, which bridge the ventricular lumen, may limit ventricular filling, leading to diastolic failure and left atrial enlargement. The excessive moderator bands are probably the result of a congenital abnormality of ventricular development and may be an incidental finding. They may occur with other forms of congenital heart disease, and they have also been reported in association with other forms of acquired cardiomyopathy.

Unclassified cardiomyopathy

In recent years an increasing number of cats have been identified that do not fit into any recognised disease classification (Kienle, 1998b). Typically, these cats have severe biatrial enlargement, normal left ventricles or mild hypertrophy, and normal or slightly decreased systolic function, but they do not have the typical post-mortem findings of fibrosis seen in restrictive cardiomyopathy. Many cats have enlarge-

ment of the right ventricle. It is not known whether these cats represent a progressive or regressive form of other known cardiomyopathic states.

Arrhythmogenic right ventricular cardiomyopathy

Arrhythmogenic right ventricular cardiomyopathy (ARVC) has recently been described in cats (Fox, 1999). The aetiology is unknown; however, a familial form has been reported in humans. It is characterised by severe right atrial and ventricular enlargement and marked tricuspid regurgitation owing to distortion of the tricuspid valve; ventricular arrhythmias are common. It is possible that cases of ARVC have previously been misdiagnosed as tricuspid valve dysplasia. Cats tend to be presented with evidence of right-sided congestive heart failure or syncope.

Relative prevalence of the cardiomyopathies

The relative importance of the different types of cardiomyopathy in cats always seems to have shown some geographical variation. Previously, DCM was reported to be the most frequent form in the UK and in some areas of North America, whereas HCM appeared to be more frequent in eastern USA. However, since the discovery of the importance of taurine deficiency in cardiac disease, pet food manufacturers have increased the levels and bioavailability of taurine in commercial cat foods, and the frequency of occurrence of DCM in cats in the UK and the USA has decreased markedly. DCM due to taurine deficiency is only likely to be seen now in cats eating poorly prepared commercial or homemade diets, although DCM due to causes other than taurine deficiency is still encountered. Several other cardiac conditions may, particularly in their end stages, result in a dilated and hypokinetic heart that *resembles* DCM clinically and echocardiographically. These include:

- acquired valvular heart disease (advanced)
- severe/unrecognised congenital disease
- severe/advanced secondary cardiomyopathies (e.g. hyperthyroidism)
- pericardial effusion.

Pericardial disease leading to cardiac tamponade can be included here, as this produces a rounded cardiac silhouette on thoracic radiographs that can be difficult to differentiate from the generalised cardiomegaly of DCM if ultrasonography is not available (Figure 19.8).

With the declining prevalence of DCM, most cases of cardiomyopathy in cats fall into the hypertrophic or restrictive categories. Given the heterogeneous nature of both these forms of cardiomyopathy, however, it may be difficult to make a firm classification in some individuals, even with the aid of echocardiography. A small number of cats may have moderator band cardiomyopathy or ARVC. If the presentation is not typical of HCM, RCM or ARVC, then cats are

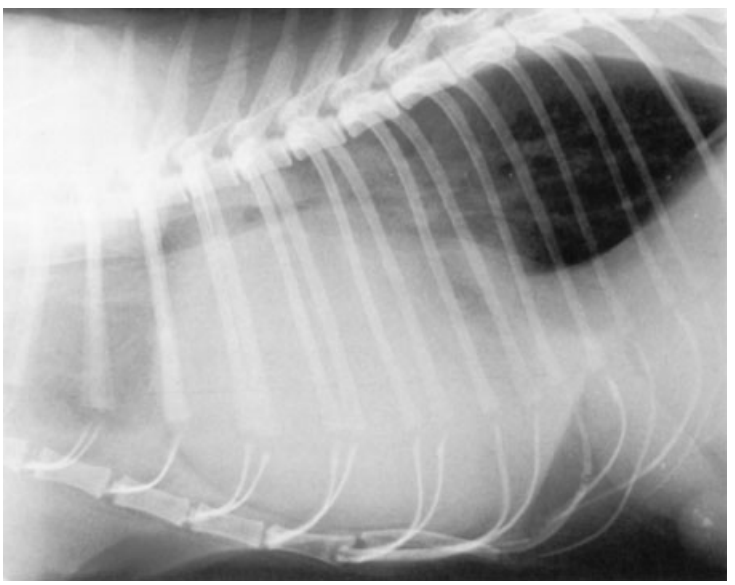

Figure 19.8 Lateral radiograph from a cat with restrictive cardiomyopathy and marked enlargement of the cardiac silhouette due to pericardial effusion. Some pleural effusion is also present.

placed in the unclassified group. However, it is likely that this group will (as mentioned above for DCM) include examples of other forms of cardiac disease, particularly in their more advanced stages, such as late recognised congenital disease, acquired valvular disease or secondary cardiomyopathies.

Although it may not be possible to classify an individual case of cardiomyopathy precisely, the most critical decisions to make from the point of view of prognosis and choosing appropriate therapy are:

- whether an individual case of cardiomyopathy is primary or secondary
- whether the disturbance of function is predominantly diastolic or systolic.

This second question is most easily answered by the use of echocardiography. With these questions in mind, the clinical features, diagnosis and treatment of the cardiomyopathies will now be discussed.

Diagnosis of the cardiomyopathies

The reader is referred back to the earlier sections on clinical history, clinical examination and diagnostic aids for a full discussion of these areas. This section will concentrate on the features that may help to distinguish the three main forms of cardiomyopathy, HCM, RCM and DCM.

Breed, sex and age

Cardiomyopathy occurs mainly in domestic cats of mixed breeding, but DCM has been associated with purebred cats, particularly the Oriental shorthaired breeds (Siamese, Burmese and Abyssinian). Whether this is associated with diet or is a true predisposition is not clear. HCM has been associated with longhaired cats. There is a marked male sex predisposition in HCM, with a reported frequency of occurrence of three to four times that of females. This predisposition is not reported in DCM and RCM. The age range for HCM and DCM is very wide, with kittens as young as 5 months or less being affected. RCM tends to occur in middle-aged and older cats.

Clinical features

The history and clinical findings are often similar in all three forms of cardiomyopathy. Abnormalities may range from mild to severe; some cases of HCM may remain asymptomatic for long periods, whereas signs of acute cardiac output failure ('cardiogenic shock') such as collapse, hypothermia and bradycardia may be seen, especially in DCM. The dietary history may indicate the possibility of taurine deficiency, and in such cases retinal degeneration may also be seen (Chapter 18).

Dyspnoea is usually the predominant feature in all forms of cardiomyopathy, although this may be episodic, particularly in HCM. Clinical examination may reveal adventitious lung sounds with pulmonary oedema, or muffling of heart and lung sounds and dullness on percussion where there is a pleural effusion. Pulmonary oedema tends to occur more frequently with HCM, pleural effusion with DCM and either with RCM. Other clinical features of cardiomyopathy include lethargy and anorexia, abnormalities on cardiac auscultation (murmurs, gallop sounds and arrhythmias), signs of thromboembolic disease and abdominal enlargement due to ascites. Ascites may occur more frequently with RCM and murmurs are reported more often in HCM. Unfortunately, *none* of the clinical trends given above is a reliable indicator of the form of cardiomyopathy present.

Radiography

Thoracic radiography is used to assess the presence and degree of cardiomegaly and to look for evidence of CHF (i.e. pulmonary oedema, pleural effusion or venous congestion). Some qualitative differences are reported between the plain radiographic features of the three major forms of cardiomyopathy that may help in distinguishing them. However, it must be stressed that, as with the clinical trends mentioned above, none of these is particularly reliable. Non-selective angiography is much more specific than plain radiography.

In HCM the cardiac silhouette in the dorsoventral projection is often described as valentine-shaped, owing to the retention of a pointed apex and the broad shoulders caused by atrial and auricular (especially left-sided) enlargement. The apex may be displaced towards the midline (Figure 19.9). Atrial enlargement is often particularly prominent in HCM and RCM because of the reduced compliance of the ventricle(s). Pulmonary oedema is said to be typical of HCM, although pleural and pericardial effusions are also seen, especially in longstanding cases. Non-selective angiography shows atrial enlargement and left ventricular hypertrophy, sometimes with very large papillary muscles, and may also indicate the presence of an obstruction in the left ventricular outflow tract. The circulation time from right ventricle to left

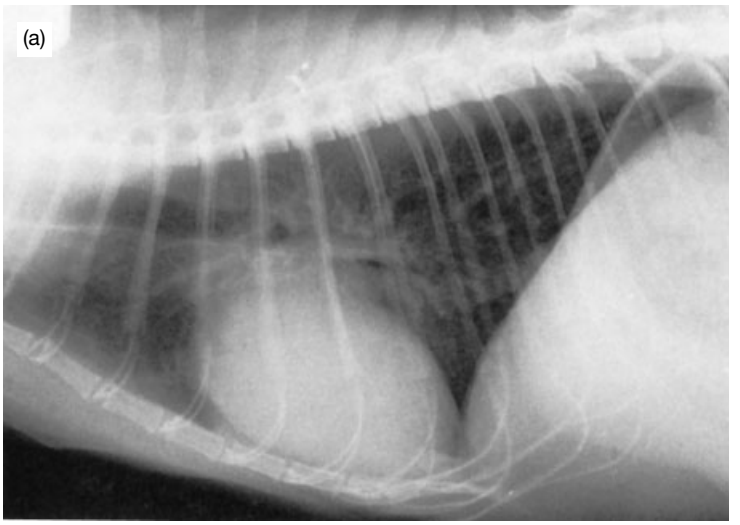

Figure 19.9 (a) Lateral and (b) dorsoventral radiographs from a cat with hypertrophic cardiomyopathy. The heart is enlarged and elongated, with an increase in sternal contact in the lateral projection. Left atrial enlargement is seen as a dorsal bulge on the lateral view, elevating the trachea, and a marked lateral bulge on the dorsoventral view; the apex is displaced to the right. Mild pulmonary oedema is seen as a hazy infiltrate.

atrium is generally normal (around 4–6 s post-injection). Non-selective angiography may, in *any* form of cardiomyopathy, demonstrate the presence of an atrial thrombus.

In DCM the typical description is of generalised cardiomegaly with a rounded cardiac apex. There may be pulmonary oedema, pleural effusion or both (Figure 19.10). Non-selective angiography shows biventricular and biatrial enlargement, and sometimes thin ventricular walls are apparent. Pulmonary circulation time is often prolonged and the aorta may appear narrow and poorly opacified.

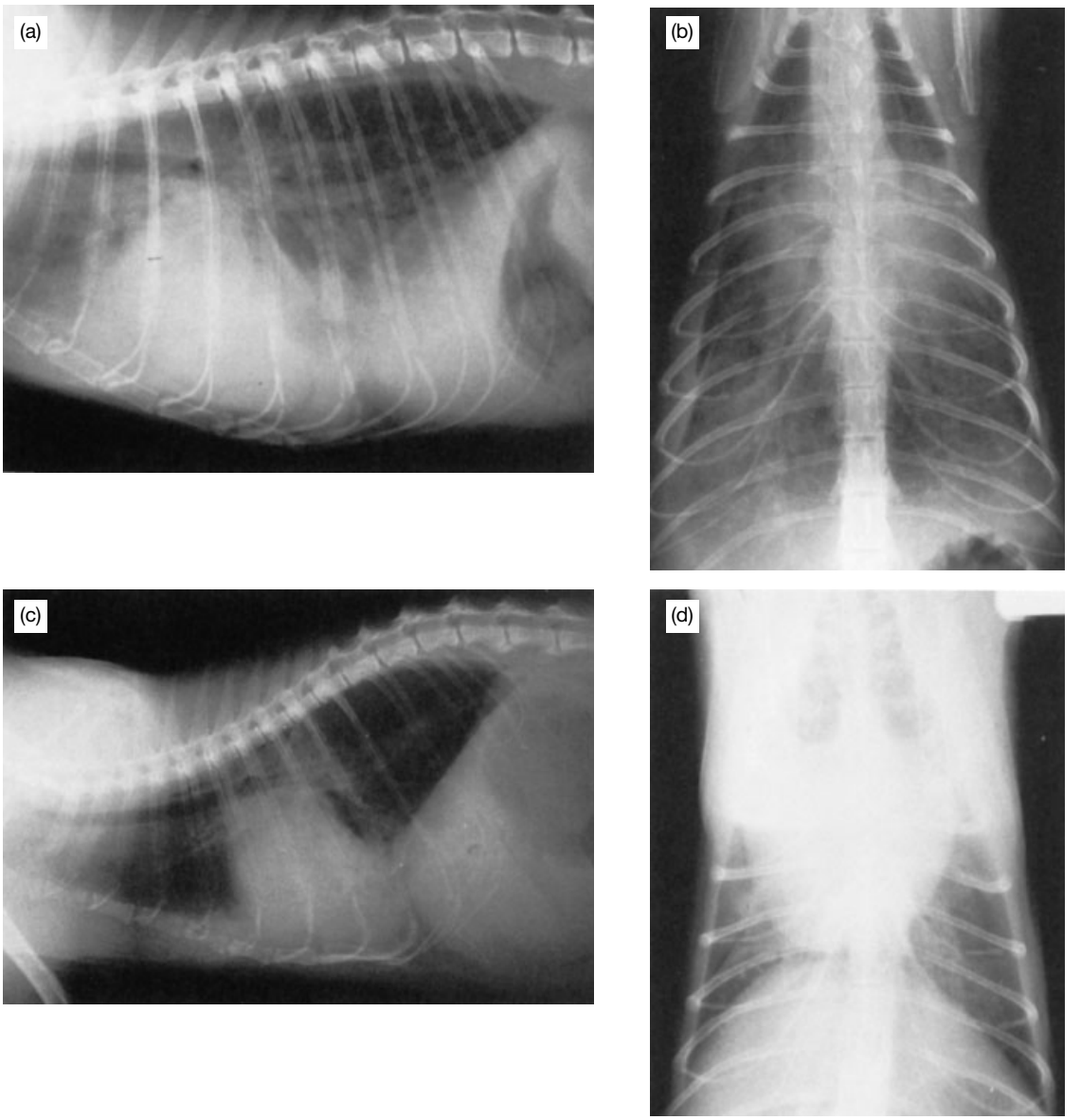

Figure 19.10 Radiographs from a cat with dilated cardiomyopathy, (a, b) before and (c, d) after removal of most of a pleural effusion by thoracocentesis and diuresis. In (a, lateral) and (b, dorsoventral) the cardiac silhouette is mainly obscured. Following drainage, generalised cardiomegaly can be seen; left atrial enlargement is seen as a dorsal bulge in the lateral view (c), elevating the trachea.

In RCM atrial enlargement may be marked and generalised cardiomegaly may be seen, especially if pericardial effusion is present. Pulmonary oedema, pleural effusion or ascites may be present (see Figures 19.3 and 19.11). Non-selective angiography may be the most reliable means of diagnosing RCM, showing marked atrial enlargement and an irregular outline to the left ventricular endocardium.

Echocardiography

This is the most sensitive and specific means of diagnosing and classifying cardiomyopathy, as it gives

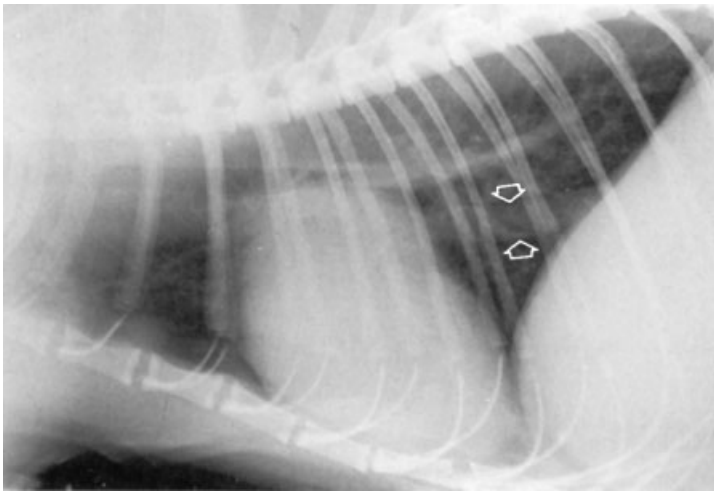

Figure 19.11 Lateral radiograph from a case of unclassified cardiomyopathy; there is cardiomegaly, widening of the caudal vena cava (arrowheads) and mild pulmonary oedema.

information on both the internal anatomy of the heart and its function. The echocardiographic features of the cardiomyopathies have been discussed above, but are summarised here.

In HCM there is hypertrophy of the ventricular (mainly left) free wall and interventricular septum (diastolic thickness greater than 6 mm). This may be marked and concentric (Figure 19.12) or variable and regional. There may be asymmetrical hypertrophy of the septum beneath the aortic valve (Figure 19.13a) leading to partial outflow obstruction. However, it should be noted that in older cats, or cats with systemic hypertension, the aortic root may be angled relative to the interventricular septum, giving the appearance of a subaortic obstruction. Papillary muscle hypertrophy may be marked. Systolic anterior motion of the mitral valve can be shown on M-mode or 2D echocardiography and spectral Doppler can be used to demonstrate the pressure gradient across the subaortic obstruction. Left ventricular systolic function (as assessed by fractional shortening, for instance) is normal or increased. Left ventricular diameter in diastole and systole tends to be normal or decreased. The left atrium is enlarged.

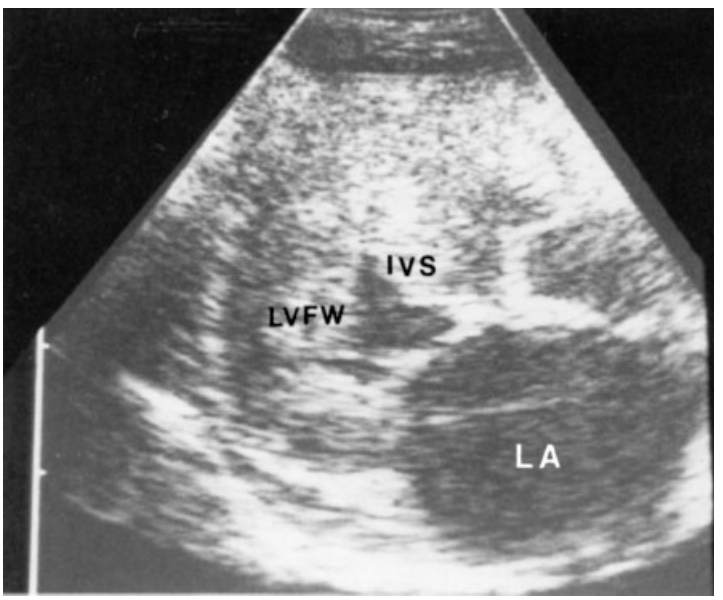

Figure 19.12 Cardiac ultrasound image of hypertrophic cardiomyopathy. The left atrium is markedly dilated and the left ventricle markedly hypertrophied. Abbreviations as in Figures 19.4 and 19.5.

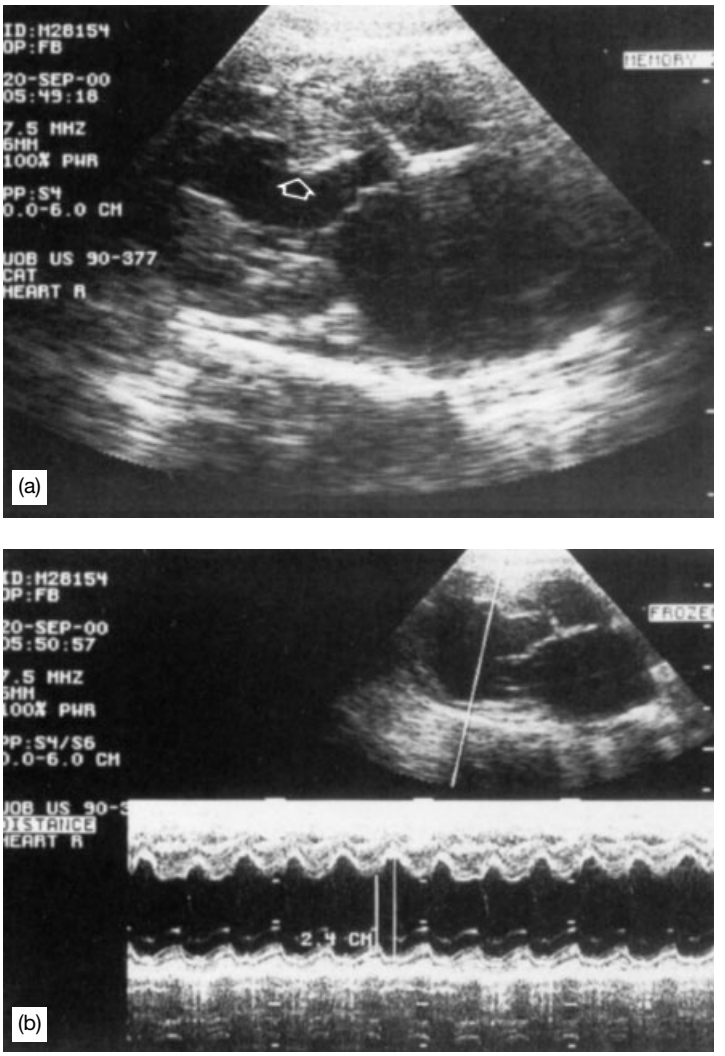

Figure 19.13 Unclassified cardiomyopathy. (a) Asymmetrical hypertrophy of the interventricular septum (arrowhead) beneath the aortic valve and marked left atrial dilatation. (b) An M-mode display shows poor free wall motion and left ventricular enlargement; the fractional shortening is 29% (same case as shown in Figure 19.11).

In RCM the interventricular septum and/or free wall may be mildly hypertrophied. There may be focal hyperechoic areas in the left ventricular free wall or areas of thinning. Left ventricular diameter in diastole and systole tends to be normal or decreased with normal contractility. Severe endocardial fibrosis may lead to obliteration of the left ventricular apical cavity and the endocardium may be notably thickened and irregular. Severe left or biatrial enlargement is common with mild A-V valve regurgitation. There may be mild dilation of the right ventricle.

Marked left atrial enlargement is suggestive of the presence of reduced left ventricular diastolic function; the largest left atria are generally seen in cases of HCM and RCM where ventricular compliance is reduced (Figure 19.14). This finding can be a helpful pointer in the diagnosis of diastolic dysfunction. The echocardiographic assessment of diastolic function is more difficult than that of systolic function. Values such as the rate of ventricular free wall thinning or the rate of change in ventricular volume during diastole (e.g. relaxation half-time) have been used in cats (Bright *et al.*, 1992). More recently, spectral Doppler transmitral and pulmonary venous flow patterns have been used in the evaluation of diastolic dysfunction in cats (Kienle, 1998a).

In DCM the major feature on ultrasonography is a reduction in systolic function (shortening fraction

Figure 19.14 Marked biatrial enlargement in a case of unclassified cardiomyopathy; left ventricular hypertrophy was patchy and systolic function was below normal (same case as shown in Figure 19.3).

usually less than 30%; Figure 19.13b). The diameter of the left ventricular lumen at diastole usually exceeds 16 mm, although this may be less marked or even normal in more acute cases or following diuresis or other therapy. Left ventricular wall thickness may be normal or reduced. The left atrium is usually dilated and the right atrium and ventricle may also be dilated.

Ultrasonography may, in *any* form of cardiomyopathy, demonstrate a pericardial effusion or an atrial thrombus (Figure 19.15).

Electrocardiography

Abnormalities of the ECG, both of rhythm and of impulse conduction, are common in cardiomyopathy, but the changes seen are non-specific for the form of cardiomyopathy involved. Abnormalities seen (see Table 19.2 for normal ECG values) include tall or wide P-waves indicating atrial enlargement, widening or, in particular, increased voltages of the QRS complex indicating ventricular enlargement (Figure 19.16), various supraventricular and ventricular tachyarrhythmias (see Figure 19.2), occasionally sinus bradycardia (e.g. in DCM) and conduction disturbances (Figure 19.17). Conduction disturbances are reported more frequently in HCM, particularly the abnormality described as left anterior fascicular block, but the latter is also seen in other forms of congenital and acquired cardiac disease (Figure 19.18).

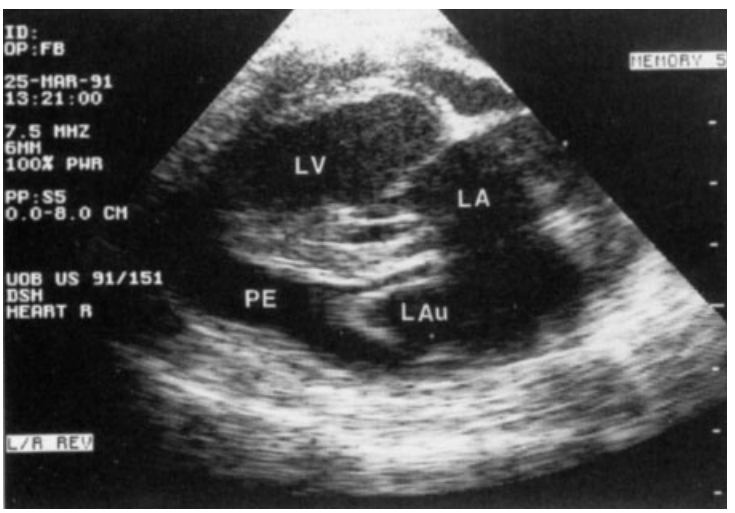

Figure 19.15 Pericardial effusion in a case of restrictive cardiomyopathy (same case as shown in Figure 19.8). A grossly dilated left auricular appendage (LAu) is seen within the distended, fluid-filled pericardial sac (PE); the outline of the left ventricle appears somewhat irregular.

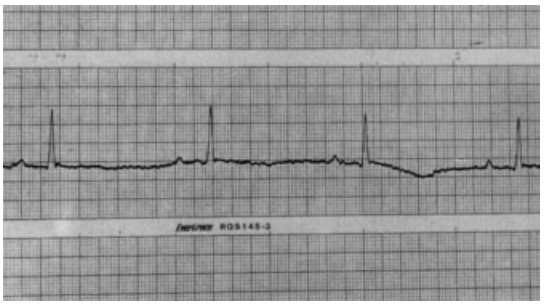

Figure 19.16 Lead 2 electrocardiogram from a cat with hyperthyroidism; R-wave voltage increased to 1.5 mV. Paper speed: 100 mm/s; 1 cm = 1 mV.

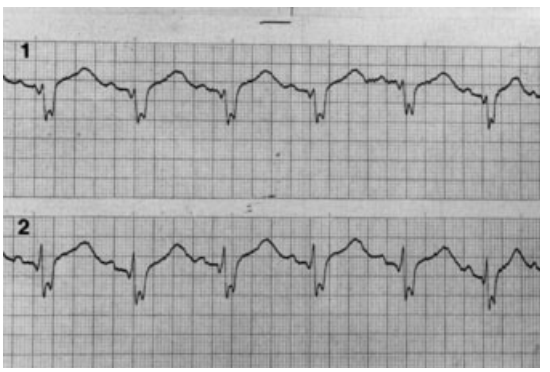

Figure 19.17 Right bundle branch block in a cat with hypertrophic cardiomyopathy; right axis deviation; QRS interval 60 ms. Leads 1 and 2. Paper speed: 100 mm/s; 1 cm = 1 mV.

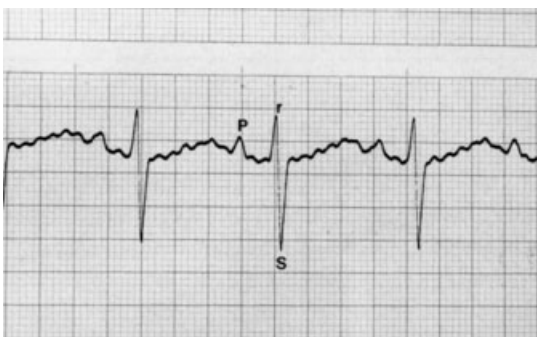

Figure 19.18 Left anterior fascicular block in a cat with hyperthyroidism; left cranial axis; QRS interval normal. Lead 2. Paper speed: 100 mm/s; 1 cm = 1 mV.

Prognosis for cardiomyopathy

The prognosis in cases of cardiomyopathy is dependent on factors such as the form of cardiomyopathy involved, its severity, whether any underlying aetiology can be identified and treated, the existence of other complicating related or unrelated conditions (e.g. renal failure, thromboembolic disease) and the response to treatment. The prognosis for HCM is generally better than for other forms of cardiomyopathy, and the occurrence of clinical signs may be very intermittent in HCM. The prognosis for taurine-responsive DCM is good, but poor for cases of DCM where taurine levels are normal. The prognosis is worse in any form of cardiomyopathy where there is a reduction in systolic function.

As mentioned above in the section on relative prevalence, it is very difficult, *from clinical and plain radiographic findings alone*, to determine the form of cardiomyopathy present in any individual case. If facilities for ultrasonography are not available, and if referral for ultrasonography is not possible, then in view of the apparent decline in the prevalence of DCM in the UK it is probably safest to assume that the case is one of *diastolic* failure when choosing a therapeutic regimen. However, *caution* should be exercised, particularly in the use of *negative inotropic* agents, if the functional status of the ventricles has not been determined.

Management of cardiomyopathy and cardiac failure

Key considerations in planning a therapeutic regimen are the major *presenting clinical signs* and the prognostic factors mentioned above, that is, the *pathophysiological form* of cardiac disease and any *underlying cause* if identified. Treatment of a primary or predisposing disease improves the prognosis, and it is possible that cardiac function may return to normal. The functional state of the ventricles determines whether inotropic support is indicated. The therapeutic principles covered in this section apply to the treatment of cardiac failure due to any form of cardiac disease, congenital or acquired. Options for treating cardiac failure, and the dose rates of many of the drugs used, are listed in Table 19.4. Table 19.5 summarises the therapeutic approaches used in specific forms of cardiac disease.

Before discussing therapy for heart failure it is helpful to describe the ways in which the heart and

Table 19.4 Therapeutic options in treating cardiac disease

	Examples
Diuretics	Frusemide 0.5–2.0 mg/kg p.o./i.v. every 8–12–24 h
Vasodilators	Glyceryl trinitrate 2% ointment ⅛–¼ inch p.c. every 6–8 h
	ACE inhibitors, e.g. enalapril 0.5 mg/kg p.o. every 24 h
	Ramipril 0.125–0.25 mg/kg every 24 h
	Benazepril 0.25–0.5 mg/kg every 24 h
	Hydralazine 0.5–1.0 mg/kg every 12 h
β-Adrenergic blockade	Propranolol 2.5–5.0 mg p.o. every 8–12 h
	Atenolol 6.25–12.5 mg every 12–24 h
Calcium channel blockade	Diltiazem 0.5–1.25 mg/kg p.o. every 8–12 h
Positive inotropes	Digoxin 0.005 mg/kg p.o. every 12–48 h
	Dobutamine/dopamine 1–5 μg/kg per minute i.v. CRI
Taurine supplementation	250–500 mg p.o. every 12 h
Diet change	Adequate taurine, low sodium
Aspirin	20–25 mg/kg p.o. two to three times weekly
Thoracocentesis	
Oxygen; bronchodilatation	Aminophylline 5–10 mg/kg p.o. every 8–12 h
Cage rest/sedation	Acepromazine 0.1 mg/kg s.c.
Nursing/warmth/intravenous fluids	
Treatment of primary cause (e.g. hyperthyroidism)	
Surgery for congenital defects (e.g. PDA)	

None of these drugs, apart from frusemide, is licensed for use in cats in the UK, benazepril is licenced for renal disease.
See text for further details of dose rates, indications, etc.
ACE: angiotensin-converting enzyme; CRI: constant rate infusion; PDA: patent ductus arteriosius.

circulation adapt to the presence of cardiac disease. If cardiac output is inadequate to meet the needs of the body, the circulatory system compensates through a series of neuroendocrine mechanisms. These include sympathetically mediated increases in heart rate, contractility and vascular tone, and sodium and water retention, mainly brought about by activation of the renin–angiotensin–aldosterone system (for a fuller discussion of this subject see Kittleson, 1998a). These adaptive responses (which result in selective vasoconstriction, increased cardiac work, eccentric ventricular myocardial hypertrophy and circulatory volume overload) support circulatory function and allow the cardiovascular system to compensate for the effects of cardiac disease for a variable period, but eventually progress to CHF in most cases. The clinical signs of heart failure (described earlier in the sections on clinical history and clinical examination) are due to a reduction in cardiac output (forward heart failure, or cardiogenic shock if severe and acute) and venous congestion (backward heart failure). The latter is produced by a combination of circulatory volume overload, venoconstriction and impaired cardiac diastolic function. The clinical signs of heart failure are often described as being predominantly left- or right-sided, reflecting which valve or chamber is primarily affected. This distinction is useful clinically, although in general the whole circulation is involved.

The treatment of cardiac failure will be discussed under the following headings:

- management of underlying disease
- management of volume overload, oedema and effusions
- vasodilatation and reduction of cardiac workload
- improving diastolic function
- improving systolic function
- management of arrhythmias
- management and/or prevention of thromboembolism.

Management of underlying disease

In view of the relative frequency of occurrence of secondary cardiomyopathies in cats, it is vital to search for and, if possible, treat any underlying disease. The most important of these are hyperthyroidism (see Chapter 20) and taurine deficiency.

In many cases of hyperthyroidism the cardiac effects are mild, causing only varying degrees of cardiomegaly

Table 19.5 Summary of therapeutic approach in specific forms of cardiac disease

Acute pulmonary oedema
- Frusemide (i.v. initially)
- Glyceryl trinitrate
- Cage rest; ? oxygen
- + Specific therapy (for type of disease)

Acute cardiac output failure (cardiogenic shock)
- Cage rest and intravenous fluids
- Dobutamine infusion
- Digoxin
- ? Diuresis later

Hypertrophic cardiomyopathy
- Frusemide
- Propranolol/atenolol/diltiazem
- Aspirin
- ACE inhibitor (if congestive heart failure present)

Dilated cardiomyopathy (systolic failure)
- Frusemide
- Taurine
- Digoxin or pimobendan
- Aspirin
- ACE inhibitor

Restrictive cardiomyopathy
- Frusemide
- Aspirin
- ACE inhibitor (if congestive heart failure present)
- ? Propranolol/atenolol/diltiazem ***or*** digoxin/pimobendan (depending on heart rate and on contractile function)

Thromboembolism
- Cage rest, fluids, analgesics, warmth
- ? Frusemide
- Heparin
- Aspirin
- Acepromazine

?: Optional, depending on requirements and the severity of the case; ACE: angiotensin-converting enzyme.

(which can be detected radiographically) and tachycardia, without overt heart failure. In such cases it is not necessary to treat for cardiac disease per se, except to control excessive tachycardia (>240 beats/min), if present, with a β-blocker (e.g. propranolol, atenolol) to reduce the heart rate to 150–200 beats/min before surgical or radioiodine thyroid ablation. Some of the clinical signs of hyperthyroidism are due in part to excessive adrenergic stimulation; thus, β-blockers are particularly useful in their control. As serum thyroxine levels fall, it may be possible to reduce or stop the β-blocker. Where there is overt cardiac failure, treatment for CHF (as described below) is required alongside antithyroid drugs, and surgery should be delayed until circulatory function is stabilised. The prognosis for cats with hyperthyroidism and CHF is guarded, and is poor where systolic function is reduced. However, in many cases it may be possible to reduce or withdraw cardiac medication following thyroid ablation.

Taurine deficiency should be suspected in all cases of dilated cardiomyopathy, particularly if the diet is poorly balanced or if there are lesions of central retinal degeneration (see Chapter 18). Taurine also has non-specific beneficial effects on myocardial function, and a clinical improvement may occur even when initial plasma taurine concentrations are in the normal range (Sisson *et al.*, 1991). The cat should be placed on a diet containing adequate levels of taurine, and extra taurine is added at the rate of 250–500 mg twice daily. The response to taurine may take several weeks, and treatment for dilated cardiomyopathy is required until cardiac function has returned to normal.

Management of volume overload, oedema and effusions

In all types of cardiac disease, diuretics are the major form of therapy used to control the effects of circulatory volume overload and venous congestion; that is, in treating the pulmonary oedema, pleural and pericardial effusion (and occasionally ascites) seen in CHF.

The most frequently used diuretic is frusemide, which can achieve significant diuresis and naturesis in cats. Other less potent diuretics (e.g. hydrochlorothiazide, 0.5–2.0 mg/kg body weight every 12–24 h) or potassium-sparing diuretics (e.g. spironolactone or amiloride) are also used occasionally, usually in combination with frusemide. These can be useful if effusions prove refractory to frusemide alone or if hypokalaemia is a problem. Frusemide may be administered by various routes and at a wide range of dose rates, depending on the severity of the condition. In cases of acute pulmonary oedema it is best to give it intravenously initially (1–2 mg/kg, two or three times daily, although up to 4 mg/kg may be used for short periods), along with a venodilator (see below), cage rest, oxygen supplementation if required and, if necessary, where the cat is markedly distressed, sedation (see below under thromboembolism). For maintenance therapy, once the oedema or effusion is controlled, then frusemide may be administered orally at about 1 mg/kg once or twice daily. Dosing as infrequently as once every 2–3 days may be sufficient,

for example in HCM. Conversely, in cases with refractory effusions, higher doses may be needed two or three times daily, or other diuretics or vasodilators (see below) may be used in combination with the frusemide. With pleural effusions, initial thoracocentesis is worthwhile to clear the chest of fluid quickly and thus to ease respiration. Periodic drainage of pleural and abdominal effusions may occasionally be necessary as an adjunct to diuresis. A low-sodium diet may be of value in the long-term management of refractory volume overload, but low-sodium diets may be unpalatable for some patients.

Care must be taken not to cause excessive diuresis, as dehydration, reduced cardiac output and prerenal azotaemia will result. This is a particular problem with cats, as they may not drink adequately to rehydrate themselves. Electrolyte depletion, particularly hypokalaemia, is a possible danger with high dose or chronic diuretic therapy, especially where the cat is inappetant, and routine monitoring of plasma sodium and potassium concentrations is advisable in such cases. Where hypokalaemia is identified, oral potassium supplements such as potassium gluconate can be used. A potassium-sparing diuretic or an angiotensin-converting enzyme (ACE) inhibitor would be a better alternative in this situation. If these are used in combination, serum potassium levels should be monitored carefully.

Vasodilatation and reduction of cardiac workload

Vasodilators are used increasingly to treat severe or refractory heart failure in cats and dogs. These agents act directly or indirectly to dilate arterioles and/or veins. The most frequently used vasodilators are glyceryl trinitrate (nitroglycerine), the ACE inhibitors (enalapril, benazepril and ramipril) and hydralazine.

Glyceryl trinitrate is a direct-acting venodilator, administered percutaneously as a 2% ointment applied to an area of hairless skin such as inside the pinnae. Gloves should be worn when applying this preparation. By reducing venous pressure and increasing systemic venous pooling of blood, the tendency to form oedema is reduced, thus assisting the action of diuretics. This is of particular value in the management of acute pulmonary oedema, usually in the first 24–48 h of treatment. More prolonged use results in the development of tolerance to the drug, unless it is used intermittently.

Hydralazine is a direct-acting arteriodilator, and has been advocated for use in refractory DCM and for mitral regurgitation. Hydralazine can produce hypotension and tachycardia, and the ACE inhibitors are easier to use in most circumstances in cats.

Inhibitors of ACE produce arteriolar and venous vasodilation *indirectly*, predominantly by inhibiting the formation of angiotensin II, which is a potent vasoconstrictor. In addition to causing vasoconstriction, angiotensin II stimulates aldosterone release from the adrenal cortex; thus, ACE inhibition will also reduce sodium and water retention. ACE inhibitors interfere at a number of levels with the development of CHF and they are the treatment of choice for chronic and refractory heart failure. This group of drugs is among the few to have been shown to prolong survival in human patients with chronic heart failure. Enalapril, benazepril and ramipril have all been used in cats; they seem to be equally effective and need only be given once daily. Benazepril and ramipril are only partially excreted by the kidneys and thus may be the ACE inhibitors of choice where concurrent chronic renal disease is present. ACE inhibitors may be used as an adjunct to frusemide in any case of refractory heart failure, although in the presence of hypotension vasodilators should be used with care, preferably monitoring systemic blood pressure. Hypotension may occur in some cases of DCM, in the obstructive form of severe HCM and in congenital outflow obstruction, such as aortic stenosis. Aldosterone levels may remain elevated even when ACE inhibitors are used. The aldosterone receptor antagonist spironolactone may be useful in this situation when used in addition to frusemide and an ACE inhibitor.

Vasodilators reduce cardiac workload by reducing afterload and/or preload. Another way of reducing the demands made on the heart, which is simple and effective, is to enforce rest by restricting the cat to a cage. This is particularly valuable in cases of acute pulmonary oedema or thromboembolism, where the cat may be markedly distressed. Drugs that reduce cardiac systolic function (negative inotropic agents) such as β-blockers and calcium channel blockers also serve to reduce myocardial work and oxygen demand. These are discussed further in the next section.

Improving diastolic function

Poor diastolic function of the ventricles is the hallmark of HCM and RCM, and may be important in DCM. Ventricular compliance is also reduced when

marked ventricular hypertrophy occurs with congenital defects such as aortic stenosis. β-Adrenergic blockers (e.g. propranolol, atenolol) and calcium channel blockers (e.g. diltiazem) have been used in these situations to *reduce* contractility and heart rate, thus increasing cardiac output by improving compliance and allowing more time for diastole. Lowering contractility may also reduce any dynamic component of outflow tract obstruction (conversely, arteriodilators may in theory worsen dynamic outflow obstruction).

β-Adrenergic receptor blockers have been the traditional negative inotropic agents used in cats with diastolic dysfunction, and propranolol and atenolol are the most commonly employed. Propranolol is a non-selective β-adrenergic blocker that requires frequent dosing (every 8 h). Atenolol has become more popular because it needs less frequent dosing (every 12–24 h) and is β_1 selective, which makes it safer for use in asthmatics and cats with uncontrolled pulmonary oedema. The use of non-selective β-blockers (i.e. they also block the β_2-receptors) may, in theory, lead to bronchospasm and vasoconstriction, although these potential side-effects do *not* seem to be a common problem. The β-adrenergic blockers also have useful antiarrhythmic properties and are the drugs of choice for ventricular tachyarrhythmias. They have greater negative chronotropic effects than calcium channel blockers. The short-acting β-blocker esmolol has been shown to decrease left ventricular outflow tract gradients in cats with the obstructive form of HCM (HOCM), which is a further potential advantage of β-blockers in this condition.

β-Blockers should be introduced gradually and the dose titrated slowly upwards, using the minimum effective dose to achieve the desired control of heart rate (the negative inotropic action is more difficult to quantify) while avoiding side-effects such as lethargy and excessive bradycardia.

The calcium channel blocker diltiazem is now widely used in the treatment of HCM in cats. Bright *et al.* (1991) showed that diltiazem reduced left ventricular hypertrophy and decreased oedema in cats with HCM. Diltiazem has the potential advantage that it is a coronary vasodilator and may improve myocardial blood flow. However, it is also a systemic arteriolar dilator, which may increase the left ventricular outflow tract gradient in the presence of HOCM. The calcium antagonists also have antiarrhythmic actions, especially against supraventricular tachyarrhythmias. The main disadvantage of diltiazem is that frequent dosing is required (every 8 h); long-acting preparations are not currently available in the UK.

A negative inotrope is generally recommended for routine use in HCM. However, negative inotropes should be used with caution, if at all, in cases where there is hypotension, bradycardia or A-V block. Their use in DCM is controversial. There is evidence that β-blockers prolong survival in humans with DCM, and that diastolic function is impaired in DCM. However, most clinicians avoid using negative inotropes, especially β-blockers, in cats with DCM.

Recently, ACE inhibitors have been used in the treatment of diastolic dysfunction. ACE inhibition reduces vascular remodelling by blocking the tropic effects of angiotensin II on myocytes. In one recent study in 19 cats with HCM, enalapril added to conventional therapy resulted in a decrease in diastolic left ventricular free wall and interventricular septal thickness and also a decrease in left atrial size (Rush *et al.*, 1998).

Improving systolic function

Where systolic function is impaired, in DCM or any other form of cardiac disease where contractility is reduced, attempts may be made to stimulate myocardial contractility using positive inotropic agents. The traditional positive inotrope for oral use is digoxin (and other digitalis glycosides). Digoxin acts on the myocardiocyte membrane sodium–potassium pump to increase the strength of contraction and also, by direct (central vagomimetic) and indirect actions, slows the heart rate, giving more time for diastole. Digoxin is thus also of value in treating supraventricular tachyarrhythmias by suppressing the rate of ventricular response. The digitalis glycosides have many systemic and cardiac toxic side-effects, particularly the induction of arrhythmias. Digitalis glycosides should be used with great caution in cats; cats seem especially sensitive to the toxic effects of the glycosides, and there is also much individual variation in susceptibility. If used, the serum concentration of digoxin should be monitored (Atkins *et al.*, 1990) (see Chapter 1). Changes in formulation or type of digoxin should be avoided, as this can lead to significant alterations in blood levels, sufficient to cause toxicity. Digitalis glycosides are not indicated in HCM, and may worsen any outflow obstruction.

In advanced cases of DCM and in acute cardiac output failure (cardiogenic shock), systolic function may be supported more effectively and immediately by the use of one of the sympathomimetic amines, dopamine or dobutamine. Dobutamine has less of a tendency to produce tachycardia and vasoconstriction; dopamine may be more effective in cardiogenic

shock. Both must be given by careful constant-rate intravenous infusion, preferably by means of an infusion pump or a microdrip set. Excessive infusion rates can result in seizures, although these stop if the infusion rate is reduced. Particular care must be taken not to overuse diuretics in such cases, and circulatory function may even have to be supported by the cautious use of intravenous fluids.

Pimobendan is a recently introduced positive inotrope and vasodilator licensed for use in dogs. There is currently little experience of its use in cats, but it may prove to be of value in some cases with myocardial failure. As mentioned above, taurine often improves systolic function, even where plasma taurine concentrations are in the normal range.

Management of arrhythmias

Most arrhythmias in cats are associated with primary or secondary cardiomyopathy, and management of the underlying myocardial disease and CHF, as discussed above, is often adequate for their control. Arrhythmias also occur secondarily to systemic disorders such as hyperthyroidism, renal failure, hyperkalaemia, shock, trauma and sepsis. Management is again generally aimed at the underlying problem, and many such arrhythmias are transient. Where specific therapy is required, the choice of drugs is limited. Many of the familiar antiarrhythmics, particularly the class I agents such as lignocaine and procainamide, produce toxic side-effects in cats, and must be used very cautiously. The drugs of choice for ventricular tachyarrhythmias are propranolol or atenolol. Supraventricular tachyarrhythmias may be managed with propranolol, atenolol, diltiazem or digoxin, depending on the underlying problem and the contractile function of the ventricles. Fortunately, cats seem to tolerate arrhythmias relatively well, without the need for specific therapy in many cases.

Symptomatic bradycardia ($<$100 beats/min), due to sinoatrial or A-V block, is encountered uncommonly in cats *without* evidence of underlying progressive myocardial disease. The treatment of choice in such cases would be the use of an artificial pacemaker, as anticholinergics and sympathomimetics are generally ineffective in increasing heart rate.

Management and/or prevention of thromboembolism

Thromboembolism is one of the most dramatic and potentially serious consequences of cardiomyopathy and, in a significant proportion of cases, is the first sign of disease. Most if not all cases of thromboembolism are associated with underlying cardiomyopathy, where the enlarged left atrium or ventricle allows blood stasis to occur, leading to platelet aggregation and thrombus formation. The exact pathogenesis is not known, and changes in the surface of the endocardium may be involved in activating coagulation. Thromboembolism has been particularly associated with HCM, where a *post-mortem* incidence (but not a clinical incidence) of approaching 50% has been recorded, and with RCM. Atrial enlargement is often greatest in these forms of cardiomyopathy. The incidence in DCM is, however, only slightly less than that in RCM. Thromboembolism is occasionally seen in cats with cardiomyopathy that have only mild cardiomegaly. A *rare* cause of thromboembolism is bacterial endocarditis. The clinical signs of thromboembolism arise owing to ischaemic neuromyopathy distal to the thrombus, and vary in severity depending on the degree of obstruction and the vessels involved. The ischaemia is caused partly by physical obstruction and partly by vasoconstriction of collateral vessels owing to the release of vasoactive substances from the thrombus (see Kittleson, 1998b, for a review of the pathogenesis and treatment of thromboembolism).

The most common form ($>$90%) in cats is aortic thromboembolism (also called saddle embolus), where an embolus blocks the terminal aorta and iliac trifurcation. The clinical signs are characteristic and distressing, with paresis and painful contracture of the muscles of the hindlimbs, especially the gastrocnemius muscles, marked reduction or absence of the femoral pulse, coldness and pallor of the extremities. Occasionally only one limb is affected. Thromboembolism to other sites, including the forelimbs (causing lameness, sometimes intermittent and often of a single limb), renal arteries (causing severe azotaemia), mesenteric, coronary, cerebral and other arteries is seen. Potentially fatal complications of thromboembolism include the development of gangrene, renal failure, disseminated intravascular coagulation, metabolic acidosis and hyperkalaemia.

Aspirin has been widely used prophylactically in cats for its ability to reduce platelet aggregation and thus to prevent or make less likely the development of thromboembolism. The dose given in Table 19.4 appears to be safe, although there is scant evidence that it is effective in reducing the risk of thromboembolism, especially in cases where thromboembolism has occurred before.

The prognosis for thromboembolism depends largely on the extent of ischaemic necrosis and the severity of the underlying cardiac disease, in particular whether systolic function is impaired, when the prognosis is much worse. Surgical embolectomy has largely been abandoned, in view of the high anaesthetic risk in these cases, the risks of reperfusion and the fact that recurrent thromboembolism may occur. If circulatory function can be supported then the pulse volume and limb function will often improve within a few days, although it may take 6–8 weeks for more complete recovery and sometimes permanent abnormalities of gait remain. If no improvement is seen after two to three days, then the prognosis becomes very poor. CHF should be managed by cage rest and cautious diuresis, with a slow intravenous fluid infusion (dextrose saline plus bicarbonate) if required for hypotension, warmth to combat hypothermia, analgesics (e.g. buprenorphine, morphine) and gentle physiotherapy. Metabolic acidosis and hyperkalaemia may be marked. The use of sodium heparin (200 IU/kg s.c. every 8 hours for 2–3 days) has been recommended to try to prevent further extension of the thrombus, and aspirin should be started and continued indefinitely. The coumarin anticoagulant warfarin has also been used prophylactically, but careful monitoring of clotting function is required when anticoagulants are used and they should not be used in outdoor cats. Acepromazine (approximately 0.1 mg/kg s.c., or more, to produce visible sedation and nictitating membrane prolapse) provides sedation for the distressed cat and may help by producing vasodilatation of the collateral arterial supply to the limbs. Hydralazine has also been used as an arteriodilator in this situation, but care must be taken to avoid hypotension if using vasodilators in these cases. Propranolol should be avoided at this stage as it may lead to vasoconstriction. It has also been suggested that propranolol may interfere with the antiplatelet effects of aspirin. Attempts have been made to produce clot lysis medically. Streptokinase appears to be of little benefit. Genetically engineered tissue plasminogen activator has been reported to be more effective. However, this is extremely expensive and has been associated with a high rate of mortality.

Other acquired cardiac diseases

Acquired valvular disease

Degenerative valvular heart disease appears to be of little clinical importance in cats (Buchanan, 1999), although it is an area that is poorly characterised and may be overlooked. The most frequent causes of A-V valvular incompetence in cats are mitral valve distortion due to hypertrophic or restrictive cardiomyopathy, ventricular enlargement secondary to dilated cardiomyopathy, and congenital valvular dysplasias. Pulmonary hypertension secondary to chronic left-sided heart failure of any cause is reported to be a significant cause of tricuspid regurgitation (Bonagura, 1994). The murmurs produced by acquired A-V valvular incompetence and their clinical effects are similar to those already described for congenital disease.

Bacterial endocarditis

This has been described in the cat, but appears to be rare. It may follow bacteraemia from an infected focus elsewhere, such as a subcutaneous abscess or a dental infection, or may occur in an immunosuppressed cat. The clinical signs of bacterial endocarditis are those of an infected focus, and resemble an immune-mediated disease such as polyarthropathy, namely chronic recurrent pyrexia and shifting lameness. A leucocytosis may be present on haematology and blood culture may be positive, allowing antibiotic sensitivity to be determined. Endocarditis may also be encountered in cats *without* clinical signs. Endocarditis affects the mitral valve, producing incompetence and a systolic murmur if of sufficient severity, and/or the aortic valve, here producing incompetence with a diastolic murmur and stenosis leading to a systolic murmur. Vegetations may be seen with ultrasonography. Endocarditis may also lead to myocardial damage, thromboembolism and sepsis in other organs. The response to antibiotic combinations, such as ampicillin or a cephalosporin plus an aminoglycoside (e.g. gentamycin), appears to be poor, and many affected cats die. Antibiotic therapy should ideally be based on blood culture and antibiotic sensitivity testing.

Pericardial disease

This occurs infrequently as a specific entity in cats. Fluid may accumulate in the pericardial sac secondary to cardiomyopathy (this is not uncommon, see Figure 19.15) and in conditions such as feline infectious peritonitis, congenital pericardioperitoneal diaphragmatic hernia and cardiac neoplasia. This can be readily detected by ultrasonography, and may be seen on thoracic radiographs as a rounded 'cardiomegaly'. However, it is uncommon for this accumulation to have any clinical significance for cardiac function (Rush *et al.*, 1990).

Neoplasia

Neoplasia of the heart is rare in cats. The most commonly encountered cardiac tumour is lymphoma, either as an isolated lesion or as part of more widespread neoplasia. Other forms reported include mesothelioma, chemodectoma, haemangiosarcoma and metastatic carcinoma.

Cor pulmonale

Infection by the heartworm *Dirofilaria immitis* is seen in cats in those parts of the world where this parasite is endemic, and is reported to have an increasing prevalence (Dillon, 1999) (see also Chapter 31). Mild right ventricular enlargement is reported in cats with chronic pulmonary disease (Bonagura, 1994), but in general the importance of chronic thoracic disease for cardiac function in cats is unknown.

Medial hyperplasia/hypertrophy of the pulmonary arteries

This is a common incidental finding at post-mortem examination. It is thought to be associated with pulmonary nematode migration and is not considered to be of any clinical significance.

Acknowledgements

The authors are grateful to former colleagues in the Department of Clinical Veterinary Science, University of Bristol, for permission to use some of the illustrative material from clinical cases included in this chapter, and to John Conibear for photography.

References

Atkins C.E., Snyder P.S., Keene B.W., *et al.* (1990) Efficacy of digoxin for treatment of cats with dilated cardiomyopathy. *J Am Vet Med Assoc* **196**, 1463–1469.

Bishop S.P. (1999) Embryological development: the heart and great vessels. In *Textbook of Canine and Feline Cardiology. Principles and Practice*. 2nd edn (eds Fox P.R., Sisson D.D. & Moše N.S.). WB Saunders, Philadelphia, PA, pp. 3 –12.

Bonagura J.D. (1994) Cardiovascular diseases. In *The Cat: Diseases and Clinical Management* (ed. Sherding R.G.). Churchill Livingstone, New York, pp. 819–946.

Bright J.M., Golden A.L., Gompf R.E., *et al.* (1991) Evaluation of the calcium channel blocking agents verapamil and diltiazem for treatment of hypertrophic cardiomyopathy. *J Vet Intern Med* **5**, 272–282.

Bright J.M., Golden A.L. & Daniel G.B. (1992) Feline hypertrophic cardiomyopathy: variations on a theme. *J Small Anim Pract* **33**, 266–274.

Buchanan J.W. (1999) Prevalence of cardiovascular disorders. In *Textbook of Canine and Feline Cardiology. Principles and Practice*. 2nd edn (eds Fox P.R., Sisson D.D. & Moše N.S.). WB Saunders, Philadelphia, PA, pp. 457–470.

Dillon R. (1999) Feline heartworm disease. In *Textbook of Canine and Feline Cardiology. Principles and Practice*. 2nd edn (eds Fox P.R., Sisson D.D. & Moše N.S.). WB Saunders, Philadelphia, PA, pp. 727–735.

Dow S.W., Fettman M.J., Smith K.R., *et al.* (1992) Taurine depletion and cardiovascular disease in adult cats fed a potassium-depleted acidified diet. *Am J Vet Res* **53**, 402–405.

Fox P.R. (1999) Feline cardiomyopathies. In *Textbook of Canine and Feline Cardiology. Principles and Practice*. 2nd edn (eds Fox P.R., Sisson D.D. & Moše N.S.). WB Saunders, Philadelphia, PA, pp. 621–678.

Fox P.R. & Bond B.R. (1983) Non-selective and selective angiography. *Vet Clin North Am Small Anim Pract* **13**, 259–272.

Fox P.R., Liu S.K. & Maron B.J. (1995) Echocardiographic assessment of spontaneously occurring feline hypertrophic cardiomyopathy: an animal model of human disease. *Circulation* **92**, 2645–2651.

Golden A.L. & Bright J.M. (1990) Use of relaxation half time as an index of ventricular relaxation in clinically normal cats and cats with hypertrophic cardiomyopathy. *Am J Vet Res* **51**, 1352–1356.

Kienle R.D. (1998a) Echocardiography. In *Small Animal Cardiovascular Medicine* (eds Kittleson M.D. & Kienle R.D.). Mosby, St Louis, MO, pp. 95–117.

Kienle R.D. (1998b) Feline unclassified and restrictive cardiomyopathy. In *Small Animal Cardiovascular Medicine* (eds Kittleson M.D. & Kienle R.D.). Mosby, St Louis, MO, pp. 363–369.

Kittleson M.D. (1998a) Pathophysiology of heart failure. In *Small Animal Cardiovascular Medicine* (eds Kittleson M.D. & Kienle R.D.). Mosby, St Louis, MO, pp. 136–148.

Kittleson M.D. (1998b) Thromboembolic disease. In *Small Animal Cardiovascular Medicine* (eds Kittleson M.D. & Kienle R.D.). Mosby, St Louis, MO, pp. 540–552.

Kittleson M.D., Pion P.D., De Lellis L.A., *et al.* (1992) Increased serum growth hormone in feline hypertrophic cardiomyopathy. *J Vet Intern Med* **6**, 320–324.

Kittleson M.D., Kittleson J.A. & Mekhamer Y. (1996). Development and progression of inherited hypertrophic cardiomyopathy in Maine Coon cats (Abstract). *J Vet Intern Med* **10**, 165.

Litster A.L. & Buchanan J.W. (2000) Vertebral scale system to measure heart size in radiographs of cats. *J Am Vet Med Assoc* **216**, 210–214.

Liu S.K. (1970) Acquired cardiac lesions leading to congestive heart failure in the cat. *Am J Vet Res* **31**, 2071–2088.

Meurs K.M., Kittleson M.D., Towbin J., *et al.* (1997) Familial systolic anterior motion of the mitral valve and/or hypertrophic cardiomyopathy is apparently inherited as an

autosomal dominant trait in a family of American short hair cats (Abstract). *J Vet Intern Med* **11**, 138.

Moše N.S. & Fox P.R. (1999) Echocardiography and Doppler imaging. In *Textbook of Canine and Feline Cardiology. Principles and Practice*. 2nd edn (eds Fox P.R., Sisson D.D. & Moše N.S.). WB Saunders, Philadelphia, PA, pp. 130 –172.

Peterson M.E., Taylor R.S., Greco D.S., *et al*. (1990) Acromegaly in 14 cats. *J Vet Intern Med* **4**, 192–201.

Pion P.D., Kittleson M.D. & Rogers Q.R. (1989) Cardiomyopathy in the cat and its relation to taurine deficiency. In *Current Veterinary Therapy*, vol. X (ed. Kirk R.W.). WB Saunders, Philadelphia, PA, pp. 251–262.

Rush J.E., Keene B.W. & Fox P.R. (1990) Pericardial disease in the cat: a retrospective evaluation of 66 cases. *J Am Anim Hosp Assoc* **26**, 39–46.

Rush J.E., Freeman L.M., Brown D.J. *et al*. (1998) The use of enalapril in the treatment of feline hypertrophic cardiomyopathy. *J Am Anim Hosp Assoc* **34**, 38–41.

Sisson D.D., Knight D.H., Helinski C., *et al*. (1991) Plasma taurine concentrations and M-mode echocardiographic measures in healthy cats and in cats with dilated cardiomyopathy. *J Vet Intern Med* **5**, 232–238.

Van den Broek A.H.M. & Darke P.G.G. (1987) Cardiac measurements on thoracic radiographs of cats. *J Small Anim Pract* **28**, 125–135.

Wynne J. & Braunwald E. (1997) The cardiomyopathies and myocarditides. In *Heart Disease: A Textbook of Cardiovascular Medicine*. 5th edn (ed. Braunwald E.). WB Saunders, Philadelphia, PA, pp. 1404–1463.

Chapter 20

THE ENDOCRINE SYSTEM

C.T. Mooney, J.S. Rand and L.M. Fleeman

Introduction

Hyperthyroidism and diabetes mellitus have emerged as relatively common disorders of older cats. As a consequence, and because of the similarities between human and feline hyperthyroidism and diabetes mellitus, there has been greater interest in feline endocrinology. Previously unrecognised disorders are being reported with increasing frequency and almost all endocrine diseases recognised in dogs have by now been diagnosed in cats. However, hyperthyroidism and diabetes mellitus remain the two most important endocrine diseases of cats, while the remainder are significantly less common. Disorders such as acromegaly, hyperadrenocorticism, hypoadrenocorticism, hyperaldosteronism, hypoparathyroidism and hyperparathyroidism are important because they are key differentials for a variety of problems and laboratory abnormalities commonly encountered in practice such as unstable diabetes mellitus, hypercalcaemia, hypocalcaemia, hyperkalaemia and hypokalaemia.

Feline hyperthyroidism

Hyperthyroidism (thyrotoxicosis) is the most common endocrine disorder of the cat. It was first definitively diagnosed in 1979 and its incidence has increased dramatically since. It is unclear whether this is because it is truly a new disease or because it is being diagnosed more frequently as a result of improved awareness, a growing cat population, increased longevity or a combination of these factors.

Increased thyroid hormone production by an abnormally functioning thyroid gland accounts for the majority of clinical features exhibited. Histopathologically, the normal thyroid follicular architecture is replaced by multiple well-defined hyperplastic nodules ranging from <1 mm to >2 cm in diameter. A well or partially defined capsule may be present and the changes are usually described as adenomatous hyperplasia (adenoma). This results in enlargement of either one ($<30\%$ of cases) or more commonly both ($>70\%$) thyroid lobes (goitre) such that they become easily palpable. Because of the benign nature of the lesions, the disease carries an excellent prognosis with effective therapy.

In humans, Graves' disease and toxic nodular goitre are the two most common forms of hyperthyroidism. In Graves' disease, autoantibodies are produced which bind to the thyroid-stimulating hormone (TSH) receptor, mimicking its activity. Similar autoantibodies have not been demonstrated in hyperthyroid cats (Mooney, 2002). Adenomatous thyroid tissue from affected cats retains its histological architecture and continues to grow and hyperfunction in tissue culture and when transplanted into nude mice, likening it to human toxic nodular goitre. In some human patients with this form of hyperthyroidism, a mutation of the gene for the TSH receptor has been suggested as a cause. Such mutations have not been identified in hyperthyroid cats, although the entire TSH receptor-coding sequence has yet to be examined. Other studies have demonstrated decreased expression of a G-protein in thyroid tissue from thyrotoxic cats. This protein is normally involved in the inhibition of a wide range of intracellular signalling processes, including the signal to secrete thyroid hormone. It is unclear whether this alteration is a cause or an effect of hyperthyroidism. Overexpression of the product of the cellular protooncogene c-Ras has also been demonstrated in thyroid tissue from hyperthyroid cats, but its significance is unclear (Mooney, 2002).

Epidemiologically, it appears that two genetically related breeds (Siamese and Himalayan) are at

decreased risk, and cats eating mainly canned cat food at increased risk of developing hyperthyroidism. In addition, there is an increased risk of hyperthyroidism in cats using cat litter and those that specifically prefer fish, liver or giblet-flavoured cat food (Mooney, 2002). Further investigation into the significance of these factors is warranted as their role in the aetiology or progression of the disorder is unknown.

Recognising hyperthyroidism

Hyperthyroidism is a disease seen almost exclusively in older animals. The average age at onset is 12–13 years. Almost all are in excess of 6 years and less than 5% are younger than 10 years at the time of diagnosis. There is no apparent sex predisposition.

Thyroid hormones are involved in numerous metabolic processes, including the regulation of heat production and carbohydrate, protein and lipid metabolism in virtually all organ systems. They also have a variety of indirect effects on other organs, most notably the sympathetic nervous system. As a consequence, the clinical features associated with thyroid hormone excess tend to be numerous and varied (Thoday & Mooney, 1992). The severity of the signs varies depending on the duration of the condition, the ability of the cat to cope with the demands of thyroid hormone excess and the presence or absence of concomitant abnormalities in other organ systems. Occasionally, clinical signs that reflect dysfunction of only one body system predominate. Thus, the presence or absence of any one sign does not confirm or exclude a diagnosis and hyperthyroidism will form part of the differential diagnosis for a large number of presenting complaints in the older cat. In addition, cats are generally less symptomatic today compared with 10 or 15 years ago, presumably because of increased awareness prompting earlier diagnosis (Broussard *et al.*, 1995). It is therefore not unusual to diagnose hyperthyroidism before owners have fully realised that their cats are ill.

Classically, affected cats are presented with a history of weight loss despite an increased appetite, polyuria/polydipsia and intermittent gastrointestinal signs of vomiting and/or diarrhoea.

- **Common features**
  - weight loss
  - polyphagia
  - polyuria/polydipsia
  - intermittent gastrointestinal signs (vomiting/diarrhoea)
  - tachycardia
  - systolic murmur
  - hyperactivity/irritability
  - palpable goitre
- **Other features**:
  - steatorrhoea
  - dermatological abnormalities (patchy or regional alopecia, unkempt coat)
  - tachypnoea/panting
  - increased temperature
- **Uncommon features**:
  - decreased activity
  - anorexia
  - gallop rhythm
  - arrhythmias
  - dyspnoea
  - hypokalaemic myopathy
  - hypertensive retinopathy/blindness.

Hyperthyroid cats are bright and alert and can often be hyperactive, difficult to examine and easily stressed. Notable findings on physical examination include tachycardia (heart rate in excess of 240 beats/min) with or without an audible systolic murmur. Most importantly, goitre is apparent in over 95% of affected patients. Goitre may not be immediately palpable because the enlarged lobe(s) have descended into the thoracic inlet, although this occurs infrequently. In rare cases, accessory or ectopic thyroid tissue, located anywhere from the tongue to the base of the heart, may be involved in the pathogenesis of the condition and consequently goitre may not be palpable.

A small proportion (<10%) of cases presents with apathetic hyperthyroidism, where anorexia and depression are the most significant features. In almost all cases this arises because of either hyperthyroid-induced overt congestive cardiac failure or the existence of a concurrent severe non-thyroidal disease. This carries a poorer prognosis and treatment is often limited by the severity of the secondary or concurrent complications.

Diagnosing hyperthyroidism

Routine clinicopathological screening tests are often performed in the investigation of hyperthyroidism and such results provide useful information to support a diagnosis or eliminate other diseases with similar clinical signs (Thoday & Mooney, 1992; Mooney, 2001a). Confirmation of the diagnosis relies on depicting abnormally elevated circulating thyroid hormone concentrations.

Screening for hyperthyroidism

Mild to moderate erythrocytosis and macrocytosis may be present in hyperthyroid cats, but often there are only minimal and insignificant changes in red cell parameters. Such changes presumably reflect increased erythropoitein production resulting from increased oxygen consumption or direct thyroid hormone-mediated β-adrenergic stimulation of erythroid marrow. A significantly higher incidence of Heinz body formation and larger mean platelet size have been reported in hyperthyroid cats, but the significance remains unclear. Not surprisingly, a stress leucogram, depicted by a mature neutrophilia and accompanying lymphopenia and eosinopenia, is common. Occasionally, lymphocytosis and eosinophilia are noted and potentially result from a relative decrease in available cortisol because of excess circulating thyroid hormone concentrations.

The most striking biochemical abnormalities are elevations in the hepatic enzymes, alkaline phosphatase (ALKP), alanine aminotransferase (ALT), aspartate aminotransferase (AST) or lactate dehydroganse (LDH). At least one of these enzymes is elevated in over 90% of hyperthyroid cats. The elevations can be dramatic (>500 IU/l), but the magnitude is proportional to the elevation in the thyroid hormones. The degree of elevation is therefore most subtle, if present at all, in early or mild cases of hyperthyroidism. In addition and as expected, liver enzyme concentrations decrease to within the reference range with successful management of hyperthyroidism. Hepatic damage resulting from malnutrition, congestive cardiac failure, hypoxia, infections and direct toxic effects of excess thyroid hormones have all been implicated as causative factors. However, histological examination of hyperthyroid cat livers reveals only modest and non-specific changes. Several recent reports have examined the possibility of other sources of these enzymes and have shown that both liver and bone contribute to increased ALKP activity in hyperthyroid cats.

Hyperphosphataemia, in the absence of azotaemia, appears to be common, occurring in up to 40% of cases. This, together with the elevation in the bone isoenzyme of ALKP, is suggestive of altered bone metabolism in hyperthyroidism. These changes are accompanied by decreased circulating ionised calcium concentration, hyperparathyroidism and a tendency towards elevated osteocalcin and 1,25-dihydroxycholecalciferol (calcitriol) concentrations. The clinical relevance is unclear.

Over 20% of hyperthyroid cats exhibit mild to moderate azotaemia. While this is not unexpected in a group of aged cats, thyrotoxicosis could also play a role by increasing protein catabolism and possibly, in a few cases, by reducing renal function because of decreased cardiac output. However, the effect of thyrotoxicosis on renal function is complicated because it can also be associated with an increased glomerular filtration rate (GFR) capable of masking renal dysfunction. Circulating creatinine concentration is significantly lower in hyperthyroid cats than in age-matched healthy animals. This may be related to reduced muscle mass rather than any direct effect of thyrotoxicosis on tubular secretion of creatinine and must be taken into consideration when interpreting individual values. As a consequence, renal disease must be carefully evaluated both before and after treatment of hyperthyroidism.

Hypokalaemia has been reported in a small number of cats, but the aetiology remains unclear. Blood glucose concentration may be mildly increased, presumably reflecting a stress response. Fructosamine concentration is significantly lower in hyperthyroid than in healthy cats, presumably as a result of increased protein turnover, and caution is advised in interpreting serum fructosamine concentration in hyperthyroid cats if concurrently diabetic. Other biochemical parameters such as cholesterol, sodium, chloride, bilirubin, albumin and globulin are largely unaffected by the hyperthyroid state.

Examination of urine is non-contributory as the only consistent abnormality detected is a variably low specific gravity.

Confirming the diagnosis

Confirming a diagnosis of hyperthyroidism is relatively straightforward. However, in a small number of cases equivocal results are found and eliminating or confirming a diagnosis may require more detailed investigation.

Thyroid hormone pathophysiology

The two active thyroid hormones are thyroxine (T4) and triiodothyronine (T3). T4 is the main secretory product of the thyroid gland. Within the circulation, over 99% of T4 is protein bound, with less than 1% free and metabolically active. The protein-bound portion serves to provide a hormone reservoir in plasma and to buffer hormone delivery to tissues. T3 is present in the serum at a much lower concentration than T4, but is three to five times more potent than T4. Up to

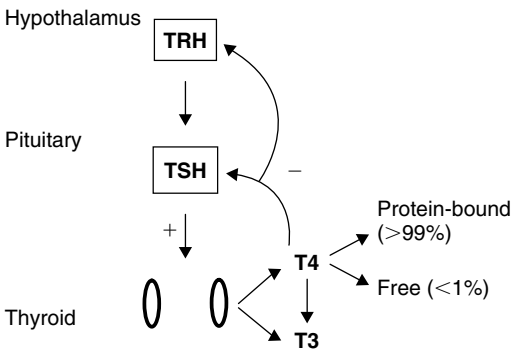

Figure 20.1 The hypothalamic–pituitary–thyroid axis. TRH: thyrotropin-releasing hormone; TSH: thyroid-stimulating hormone (thyrotropin); T4: thyroxine; T3: triiodothyronine; +/− : stimulation/inhibition (negative feedback).

60% of circulating T3 is produced by extrathyroidal peripheral monodeiodination of T4 and it is therefore often considered to be a prohormone with the possibility of autoregulation of production by individual tissues.

Overall control of thyroid function is via a negative feedback mechanism of circulating T4 and T3 on thyrotropin-releasing hormone (TRH) from the hypothalamus and TSH from the pituitary gland (Figure 20.1). In hyperthyroidism, there is excessive production of the thyroid hormones, T4 and T3, and consequently suppression of both TRH and TSH. Diagnostic tests generally exploit these changes, but neither feline TSH nor TRH can be accurately measured. Confirming a diagnosis of hyperthyroidism therefore relies on depicting an elevation in the free or total thyroid hormone concentration or manipulating the feedback mechanism through the use of various stimulatory or suppressive factors. Not all of these tests perform equally well in the diagnosis of hyperthyroidism, nor are they all required in individual cases (Mooney, 2001; Peterson *et al.*, 2001).

Total T3 and total T4

Elevated circulating concentrations of total (protein bound and free) T4 and T3 are the biochemical hallmarks of hyperthyroidism. Methods for their measurement are readily available, usually robust and relatively inexpensive. In cats the overall concentration and affinity of the binding proteins are lower and consequently the total hormone concentration is lower than in humans. Therefore, assays designed for human use, frequently used, must be modified to allow for the measurement of the lower circulating concentrations in cats and a feline specific reference range is required.

Concurrent elevations in circulating total T4 and T3 concentration are expected in hyperthyroid cats and it would therefore be unnecessary to measure both hormones in individual cases. However, in approximately 30% of hyperthyroid cats, the circulating total T3 concentration is within the reference range. These cases are generally mildly affected, the corresponding total T4 value is only just elevated and it is likely that the total T3 concentration would increase into the thyrotoxic range if the disorder were allowed to progress untreated. It is possible that this phenomenon reflects a compensatory decrease in peripheral conversion of T4 to the more active T3 as hyperthyroidism is developing, although in a small number of cases the suppressive effect of severe concurrent non-thyroidal illness may play a role. Owing to the poor diagnostic sensitivity of total T3 measurement, it is no longer recommended for the evaluation of hyperthyroidism.

Measurement of serum total T4 is a highly specific diagnostic test as elevated values do not develop in euthyroid cats. However, in approximately 10% of hyperthyroid cats, a single T4 value may be within the mid to high end of the reference range. In some of these cases, the disease is early and total T4 value may not yet have exceeded the reference range. Non-specific thyroid hormone fluctuation may also play a role. A circadian rhythm does not exist in cats, but circulating hormone concentrations vary both within and more pronouncedly between days. Increased thyroidal production and fluctuations in binding proteins or other undefined haemodynamic changes possibly account for these changes. If basal thyroid hormone concentrations are only mildly elevated, the degree of fluctuation can result in reference range values. In cats with markedly elevated circulating total T4 concentration, the degree of fluctuation is of little diagnostic significance.

Non-thyroidal illness has a suppressive effect on circulating total T4 concentration in cats, resulting in mid to high-end reference range values in mild hyperthyroidism. The mechanisms remain unclear, but are more likely to involve changes in peripheral thyroid hormone metabolism or protein binding rather than any effect on the hypothalamic–pituitary axis. Similarly to the phenomenon of fluctuation, the degree of suppression has little diagnostic significance in hyperthyroid cats with markedly elevated circulating total T4 concentration.

In early or mildly affected hyperthyroid cats, serum total T4 concentration would eventually increase into

Table 20.1 Interpretation of serum total thyroxine (T4) concentrations in clinical cases

Case	Total T4 (nmol/l)	Interpretation
Clinical signs of hyperthyroidism	>60	Hyperthyroidism confirmed
	30–60	Early/mild hyperthyroidism possible. Assess free T4 or retest in 3–6 weeks
Non-thyroidal illness present	<30	Euthyroid
	30–60	Hyperthyroidism likely particularly if concurrent illness severe

This is based on a guideline reference range of 15–60 nmol/l. Reference ranges are laboratory specific.

the diagnostic thyrotoxic range upon retesting 3–6 weeks later. Mildly affected hyperthyroid cats with concurrent illnesses usually do not pose a diagnostic dilemma. There are usually other clinical indicators of hyperthyroidism such as the existence of palpable goitre. In addition, the fact that serum total T4 concentration is within the mid to high end of the reference range is diagnostically significant (Table 20.1). Circulating total T4 concentration should be suppressed into the lower half or below the reference range in euthyroid individuals with similar illnesses. In euthyroid cats, the degree of suppression is correlated with the severity rather than the type of illness and has proved useful as a prognostic indicator. Circulating total T4 concentration will increase into the thyrotoxic range upon recovery or treatment of the concurrent disease in hyperthyroid cats.

Free T4

Assessment of circulating free T4 concentration is frequently recommended because it is less affected by the numerous factors capable of altering total T4 concentration. Unlike total T4, free T4 concentrations are generally similar between species and kits manufactured for human use can be adopted unmodified in cats. However, free T4 concentration is only accurately measured using equilibrium dialysis or ultrafiltration. Such methods are not widely available and are relatively expensive. In addition, free T4 analysis is less robust, as prolonged storage of the sample is associated with an increase over actual values. Circulating free and total T4 concentrations are highly correlated in hyperthyroidism and if total T4 is elevated, no further diagnostic information is obtained by measurement of free T4. However, circulating free T4 concentration is more consistently elevated in early or mildly affected cases and in those with concurrent non-thyroidal illness. The diagnostic performance of this test is complicated by a loss of specificity because up to 12% of euthyroid cats with non-thyroidal illness have an elevated free T4 concentration. Usually, such euthyroid cases have a low to mid reference range serum total T4 concentration. By contrast, cats with hyperthyroidism tend to have a mid to high reference range total T4 with an elevated free T4 value. Therefore, serum free T4 concentration should be interpreted with caution if used as the sole diagnostic criterion for hyperthyroidism and is best interpreted with a corresponding total T4 value.

Dynamic thyroid function tests

Although basal circulating thyroid hormone measurements eventually confirm the diagnosis in all hyperthyroid cats, there are occasions when a more immediate confirmation or elimination of hyperthyroidism is required. In such cases, any of the dynamic thyroid function tests could be used (Table 20.2).

The T3 suppression test relies on the ability of administered T3 to suppress TSH secretion from the pituitary and subsequently, through negative feedback, T4 production by the thyroid gland. In hyperthyroidism, TSH secretion is already chronically suppressed by persistently elevated circulating thyroid hormone concentrations and exogenous T3 therefore has little or no effect on endogenous T4 production. This test is not associated with any adverse effects, but is relatively prolonged and highly dependent on good owner compliance in reliably administering the tablets and adequate gastrointestinal absorption to increase circulating T3 concentration. This necessitates concomitant measurement of serum T3 concentration and significantly increases the cost of the test. It is often recommended as most useful in confirming euthyroidism and ruling out hyperthyroidism.

In hyperthyroid cats, there is a limited total T4 response to TRH administration because of chronic suppression of TSH. This test involves intravenous administration of TRH, is relatively rapid and only requires total T4 measurement. However, there tends to be an overlap in test results between euthyroid cats with severe non-thyroidal illness and hyperthyroid cats with markedly suppressed serum total T4 concentration. Adverse reactions, although transient, are

Table 20.2 Common protocols and methods of interpretation for the dynamic thyroid function tests

	T3 suppression	TRH response	TSH response
Drug	Liothyronine	TRH	TSH (bovine)
Dose	20 μg p.o. three times daily for 7 doses	0.5 IU/kg i.v.	0.1 mg/kg i.v.
Sample times	Basal and 2–4 h after last dose	Basal and 4 h	Basal and 6 h
Measurement	Total T4	Total T4	Total T4
Interpretation			
Euthyroid	<20 nmol/l + >50% suppression	>60% increase	>100% increase
Hyperthyroid	>20 nmol/l ± <50% suppression	<50% increase	Minimal/no increase
Precautions	Assess total T3 to ensure compliance and gastrointestinal absorption	Adverse reactions; subnormal responses with non-thyroidal illness	Bovine TSH potentially antigenic; recombinant human TSH not yet evaluated

The ranges quoted are guidelines only and are laboratory specific. T3: triiodothyronine; TRH: thyrotropin-releasing hormone; TSH: thyroid-stimulating hormone; T4: thyroxine.

also common, and include excess salivation, vomiting, tachypnoea and defecation.

As with the TRH response test, serum total T4 concentration shows little or no increase following exogenous TSH administration in hyperthyroid cats. Either the thyroid gland of affected cats is not capable of responding to TSH or T4 is already being produced at near maximal rate with limited reserve capacity. However, cats with equivocally elevated cicrculating total T4 concentration tend to exhibit results indistinguishable from those obtained from euthyroid animals. Because of this, coupled with the difficulty of and expense associated with obtaining exogenous TSH, the TSH response test is not recommended for investigating hyperthyroidism in cats.

Additional investigative procedures

Hyperthyroidism is associated with the development of hypertrophic cardiomyopathy, largely reversible following successful induction and maintenance of euthyroidism. Mild to severe cardiac enlargement may therefore be apparent on thoracic radiography. The most common abnormalities on cardiac ultrasound include left ventricular hypertrophy, increased left atrial and ventricular diameter, interventricular septum hypertrophy and enhanced contractility. Electrocardiographic changes include sinus tachycardia, prolongation of the QRS complex, right bundle branch block and, less frequently, increased R-wave amplitude and other atrial and ventricular arrhythmias.

The prevalence of overt cardiac changes has recently decreased, presumably reflecting earlier diagnosis and less severely affected cases. Neither radiography, electrocardiography nor ultrasonography is specifically indicated in uncomplicated hyperthyroid cases. However, a few cats exhibit clinical signs suggestive of congestive cardiac failure and such investigations may be required. The development of congestive cardiac failure usually indicates irreversible structural damage induced by the thyrotoxicosis, or exacerbation of a coexisting cardiomyopathy. Although hypertrophic cardiomyopathy predominates, a dilatative form of cardiomyopathy has occasionally been diagnosed. Hypertension may also be a feature of hyperthyroidism.

Hyperthyroid cats usually exhibit increased thyroidal uptake of radioactive iodine (^{123}I or ^{131}I) and while this confirms a diagnosis of hyperthyroidism, access to sophisticated computerised medical equipment is required. Technetium-99 m as pertechnetate ($TcMO_4^-$) can also be used and is preferred because of its short half-life, low radiation dose, wide availability and superior image quality. Percentage uptake is assessed quantitatively as for radioactive iodine or by comparison to salivary gland uptake (normally one-to-one ratio). However, thyroid imaging is more frequently used to delineate unilateral from bilateral involvement, alterations in the position of the thyroid lobes or involvement of accessory thyroid tissue, or to depict regional or distant metastases from the rare cases of functioning thyroid carcinoma.

Treating hyperthyroidism

Treatment is aimed at controlling the excessive production of the thyroid hormones either by medical inhibition of thyroid hormone synthesis, surgical removal of

Table 20.3 Drugs used in the medical management of feline hyperthyroidism

Drug	Mode of action	Indications	Daily dose	Precautions
Methimazole and carbimazole	Inhibits thyroid hormone production	Before surgery (2–3 weeks) Chronic management	5 mg two or three times daily 5 mg once or twice daily	Adverse reactions; avoid immediately before ^{131}I therapy
Propranolol	β_1/β_2-blocker	Symptomatic control	7.5–15 mg divided three times daily	Asthma, heart failure; chronic management
Atenolol	β_1-blocker		6.25–12.5 mg once or twice daily	Chronic management
Propranolol with potassium iodate	β_1/β_2-blocker	Before surgery (3 weeks)	7.5–15 mg divided three times days 1–21	Chronic management; immediately before ^{131}I therapy
	Inhibits thyroid hormone production and release		63.75 mg divided three times days 11–20	
Calcium ipodate	Inhibits T4–T3 conversion	Before surgery (up to 14 weeks)	100 mg divided twice daily	Chronic management

affected thyroid tissue or destruction through radioablation or local ethylene glycol administration. The former method is non-curative and because of this, medical management alone is not recommended in the rare cases of functioning thyroid carcinoma. There are numerous advantages and disadvantages associated with each form of therapy. There is no universally optimal therapy and considerations include age of the patient, severity of thyrotoxicosis, presence of concurrent illnesses, facilities available, potential complications, cost and the owners' willingness to accept the form of treatment advised (Mooney, 2001a, b).

Medical management

Many hyperthyroid cats can be managed long term with medical therapy. Medical treatment is also required before surgical thyroidectomy and may also be desirable to control clinical signs in affected cats while awaiting radioactive iodine therapy (Table 20.3).

Chronic medical management is a practical treatment option for hyperthyroidism that requires no special skills or facilities, is readily available, easy to implement, associated with few adverse reactions and reasonably inexpensive. Almost all cats are potential candidates because there are few specific contraindications. There is a rapid return to euthyroidism and hospitalisation is unnecessary. Anaesthesia is avoided, as are the perioperative and postoperative complications associated with surgical thyroidectomy. However, few drugs are available for long-term control, daily medication is necessary and there is a real risk of poor owner and/or cat compliance in regularly administering and accepting the medication. This ultimately impacts efficacy and cost because of the more frequent monitoring it necessitates. In addition, in a small number of cats, the development of certain adverse reactions may necessitate drug withdrawal. Thus, not all cats initially managed can be maintained chronically with this form of therapy.

Thioureylene antithyroid drugs

The thioureylene drugs include propylthiouracil, methimazole and carbimazole. These drugs are actively concentrated by the thyroid gland, where they act as general inhibitors of thyroid peroxidase-catalysed reactions involved in production of T4 and T3. They do not affect trapping of inorganic iodide or the release of preformed hormones by the thyroid gland.

Propylthiouracil is no longer recommended for use in cats because it is associated with a high incidence of adverse haematological reactions, including thrombocytopenia and immune-mediated haemolytic anaemia. Methimazole and carbimazole are therefore preferred; both potently and consistently induce euthyroidism and are the only drugs that can be used for long-term control of hyperthyroidism (Peterson *et al.*, 1988; Mooney *et al.*, 1992). Methimazole has recently been licensed for the preoperative long-term control of thyrotoxicosis in cats in the UK.

Carbimazole, a carbethoxy derivative of methimazole, was originally developed for human use in the hope of obtaining a drug with a longer duration of activity than methimazole. However, in both humans and cats, it is totally converted to methimazole soon after oral administration and only methimazole accumulates in the thyroid gland. A 5 mg dose of carbimazole is equivalent to approximately 3 mg of methimazole, reflecting the molar ratio of the two drugs (Peterson & Aucoin, 1993). The maximum serum concentration of methimazole achieved after carbimazole administration is therefore less than that achieved after administration of an equal weight of methimazole. This was suggested as a possible explanation for the slight variations in the dosages advocated for each drug and the overall lower prevalence of certain adverse reactions associated with carbimazole compared with methimazole. However, other possible explanations include a variation in the number and severity of cases treated with either drug in published reports and the fact that methimazole has a bitter taste, compared with carbimazole which is tasteless. Given that the active ingredient of both drugs is methimazole and that it is actively concentrated by the thyroid gland, it is probably reasonable to consider both drugs equipotent on a per gram basis with approximate equal risk of adverse reactions.

There are few contraindications to the use of methimazole in cats. It should be used with caution in cats with evidence of renal dysfunction and its administration before radioactive iodine ablation is controversial. Methimazole does not inhibit radioiodine uptake and may significantly enhance it after recent drug withdrawal, but it potentially shortens the overall residence time of iodine within the thyroid gland and thereby increases the risk of treatment failure. Reports in cats have variably suggested that prior antithyroid medication has no effect on treatment outcome, is a contributing factor in treatment failure or alternatively actually enhances its efficacy. Because of these conflicting reports, it is usually recommended that the drugs are withdrawn 1–2 weeks before radioiodine therapy.

Multiple daily dosing of methimazole is necessary in the initial stages of treatment at a dose of 5 mg administered either twice or three times daily depending on the severity of the thyrotoxic state. The return to biochemical euthyroidism is usually quite rapid, occurring within days. Not surprisingly, the length of therapy is correlated to the basal circulating total T4 concentration. However, a 2–3 week course is usually initially recommended, ensuring that the majority (approximately 90%) will have attained biochemical euthyroidism and allowing time for more obvious clinical improvement. If at this time, hyperthyroidism persists, a longer course of therapy or an increased dose (in 2.5–5.0 mg increments) is recommended, the choice depending on whether or not there has been any discernible decrease in circulating total T4 concentration. However, poor owner or cat compliance should first be excluded as a possibility. Once euthyroidism is achieved, surgical thyroidectomy can be performed, administering the last dose on the morning of surgery. In clinically severe cases, the dose is decreased and continued until the animal is considered to be a more reasonable surgical candidate.

For chronic management, the dose is decreased in 2.5–5 mg decrements, aiming for the lowest possible dose that maintains euthyroidism. Most cats stabilise on 5–10 mg of methimazole per day, although doses as high as 15–20 mg or as low as 2.5 mg may be required. Because of the relatively short plasma half-life of methimazole, dividing the dose twice daily is usually recommended. However, in humans the intrathyroidal residence time is up to 20 h and the same situation presumably exists in cats. For this reason, particularly if there are problems with owner and cat compliance, once-daily therapy may be attempted for chronic management. Failure to institute therapy every 24 h will result in increased thyroid hormone production and recurrent thyrotoxicosis.

Antithyroid drugs are routinely administered orally. Compliance can be problematic in fractious or inappetant cats, absorption may be adversely affected in the face of intestinal disease and there are difficulties in those cats that experience vomiting during treatment. Preliminary studies on the efficacy of topical administration and transdermal absorption of methimazole have been conflicting and this route is currently not recommended.

Most clinical adverse reactions associated with methimazole occur within the first 3 months of therapy. They include vomiting, with or without associated anorexia or depression, usually within the first 4 weeks of therapy, in 10–15% of patients. These reactions are usually mild and transient and rarely require drug withdrawal. Self-induced excoriations of the head and neck have been seen in a small number of cats. Drug withdrawal is required together with symptomatic glucocorticoid therapy and an alternative treatment for hyperthyroidism.

Several mild haematological complications have been associated with antithyroid drug therapy in cats. These include transient eosinophilia, lymphocytosis and lymphopenia occurring within the first few

weeks of therapy. Although they occur in 5–15% of cases, there is no apparent clinical effect. More serious haematological complications occur in less than 5% of treated cats and include granulocytopenia and thrombocytopenia, either alone or concurrently or, less frequently, immune-mediated haemolytic anaemia. It was previously recommended that complete blood and platelet counts be performed every 2 weeks at least for the first 3 months of therapy to depict these reactions. However, because of their unpredictable occurrence and low frequency this is not cost effective and is no longer recommended. Careful monitoring should be carried out if and when appropriate clinical signs (pyrexia, overt bleeding, etc.) occur. Hepatic toxicity as depicted by marked increases in liver enzyme and bilirubin concentrations has been described in a few rare (<2%) cases treated with methimazole. For these serious reactions, immediate drug withdrawal and symptomatic therapy are required. An alternative form of therapy for hyperthyroidism must be instituted.

Several other adverse reactions have been described, but their clinical significance remains unclear. Serum antinuclear antibodies develop in approximately 50% of cats treated with methimazole for longer than 6 months, particularly in those on high-dose (⩾15 mg/day) therapy. Although clinical signs of a lupus-like syndrome have not yet been described, decreasing the daily dosage is recommended. A bleeding tendency without thrombocytopenia has also been recognised. The mechanism remains unclear because methimazole therapy appears to have limited effect on clotting parameters and on the buccal mucosal bleeding time. Acquired myasthenia gravis has been associated with methimazole therapy in a few rare cases.

Assessment of circulating total T4 concentration provides the best means of monitoring therapeutic success. If therapy is successful, values are expected in the low end or below the reference range. Even if T4 is severely suppressed, clinical signs of hypothyroidism do not develop, presumably because corresponding total T3 concentrations tend to remain within the reference range. This is presumably because of preferential thyroidal secretion of T3, although increased peripheral production may play a role. Therapeutic monitoring is recommended 2–3 weeks after instituting treatment or after each dose adjustment, and every 3–6 months thereafter or as indicated clinically. Depicting a decline of previously elevated liver enzyme concentrations provides an alternative non-specific means of assessing therapeutic efficacy.

Alternative medical options

There are occasions when an alternative to methimazole is required, either because of the development of adverse reactions or because of specific contraindications. However, only short-term control of thyrotoxicosis can be achieved using alternative medication.

Propranolol is a non-selective β-adrenoceptor blocking agent usually used to symptomatically control the tachycardia, polypnoea, hypertension and hyperexcitability associated with hyperthyroidism. Propranolol has no direct effect on the thyroid gland but may inhibit peripheral conversion of T4 to T3 in cats as in humans. Because of this it is usually used in combination with methimazole when rapid control of the clinical effects is required or with stable iodine to ensure a more effective response. As it does not affect radioactive iodine treatment, it may be used alone while awaiting such therapy. Propranolol is contraindicated in cats with asthma or pre-existing congestive cardiac failure. Atenolol, a selective β_1-adrenoceptor blocking agent, is more useful in such situations and may only be required once daily. Hyperthyroidism affects the pharmacokinetic profile of propranolol and low doses are recommended initially with subsequent adjustments based on the cardiac response.

Large doses of stable iodine acutely decrease the rate of thyroid hormone synthesis (Wolff–Chaikoff effect) and release. Stable iodine is traditionally considered to have an inconsistent, short-lived and erratic effect in inducing euthyroidism, and carries the potential for rapid escape from inhibition and exacerbation of thyrotoxicosis. In addition, it is contraindicated before radioactive iodine administration and is associated with a high incidence of adverse reactions (salivation and partial to complete anorexia), purportedly because of its unpleasant brassy taste. If used, it is recommended as potassium iodate tablets together with propranolol (Foster & Thoday, 1999). Propranolol is administered for 20 days before surgery and potassium iodate is added to the regimen from day 10 to day 20. Serum total T4 concentration falls to within reference range in only one-third of cases, but serum total T3 concentration decreases in most cats, and therefore there is significant clinical improvement. Adverse reactions of potassium iodate are minimised by placing the tablets in a gelatin capsule before administration, and using as low a dose for as short a period as possible.

Calcium ipodate, an oral cholecystographic contrast agent, is the only other drug that has been assessed in hyperthyroid cats (Murray & Peterson, 1997). Its major effect is to inhibit peripheral T4 to T3

conversion. Although it is successful in reducing circulating total T3 concentration to within the reference range and it has no apparent adverse reactions, total T4 is largely unaffected. Its long-term effects have not yet been evaluated and further studies are unlikely because of its limited availability.

Surgical thyroidectomy

Surgical thyroidectomy is often considered the preferred treatment option in practice because it is a relatively simple, quick and curative procedure. However, prior control of the production or the effects of thyroid hormones is required to decrease the cardiac and metabolic complications associated with anaesthetising hyperthyroid cats.

Surgical technique

There are several techniques described and the choice is largely determined by the need for a unilateral or bilateral thyroidectomy. It is estimated that both thyroid lobes are affected in over 70% of cases and therefore the majority of cats require a bilateral thyroidectomy. In many of these cases both thyroid lobes are palpable and grossly abnormal on visual examination. Unfortunately, in up to 15% of bilateral cases, one thyroid lobe appears grossly normal, resulting in recurrent hyperthyroidism usually within 12 months if a unilateral thyroidectomy is initially carried out. Preoperative thyroid scintigraphy is useful in differentiating true unilateral from bilateral involvement, but access to nuclear imaging facilities is required. High-resolution ultrasonography, capable of assessing thyroid lobe size and parenchymal appearance, is useful, but not as accurate as scintigraphy. In the absence of imaging techniques, both thyroid lobes should be carefully examined at the time of surgery and removed if abnormal in any way. Routinely performing bilateral thyroidectomies irrespective of the gross appearance of the thyroid lobes is gaining popularity as it decreases the rate of recurrence and, as experience is gained, decreases the risk of surgical complications.

In true unilateral cases, the choice of technique is largely irrelevant, as only one parathyroid gland is necessary to maintain eucalcaemia, although methods that prevent recurrence are preferred. In bilateral cases, a technique is chosen that both minimises the risks of hypoparathyroidism and recurrence.

Thyroidectomy can be performed by extracapsular or intracapsular methods. During extracapsular thyroidectomy, the intact thyroid lobe and capsule is removed following ligation of the cranial thyroid artery while attempting to maintain blood supply to the cranial parathyroid gland. However, this technique is associated with a high risk of postoperative hypoparathyroidism. It has since been modified by using bipolar cautery instead of ligatures, which minimises blunt dissection around the cranial parathyroid gland. During intracapsular thyroidectomy, the thyroid capsule is incised and the thyroid lobe subsequently removed following blunt dissection, leaving the capsule *in situ*. This technique, while minimising the risk of parathyroid damage, is associated with a high rate of recurrence. Modification by removal of the majority of the capsule after removal of the thyroid lobe significantly decreases the risk of recurrence. It is generally agreed that there is no significant difference between the rate of postoperative hypocalcaemia and recurrence between modified extracapsular and modified intracapsular techniques, and these are therefore considered most appropriate for bilateral thyroidectomy (Welches *et al*., 1989).

Recovery and revascularisation of injured parathyroid tissue are possible even if it is surgically removed and subsequently implanted into a neck muscle (Flanders *et al*., 1991; Padgett *et al*., 1998). Staging bilateral thyroidectomies 3–4 weeks apart attempts to exploit this premise. A staged simplified complete thyroparathyroidectomy with parathyroid autotransplantation has been described with no associated postoperative hypocalcaemia (Norsworthy, 1995). This technique may be of benefit as a learning tool or if surgical experience is limited by a small throughput of cases, but may be limited by the increased costs and the risk of two anaesthetic procedures.

Hypoparathyroidism resulting in hypocalcaemia is the most significant potential postoperative complication, but there are other possibilities. Thyroid tissue is extremely vascular and is adjacent to numerous other vital structures within the cervical region, particularly the right recurrent laryngeal nerve which courses dorsally in close association with the right thyroid lobe. Other potential postoperative complications include haemorrhage, Horner's syndrome, laryngeal oedema or paralysis and voice change, although these appear to be infrequent.

Following thyroidectomy, circulating total T4 concentration usually falls below the reference range for weeks to months. Thyroxine supplementation is not required as there is eventual normalisation of thyroid hormone concentrations, because of activation of either the contralateral lobe in unilateral cases or accessory thyroid tissue in bilateral cases. Clinical

hypothyroidism is a rare sequela of bilateral thyroidectomy. Recurrence of hyperthyroidism is possible following both unilateral and bilateral thyroidectomy. Following unilateral thyroidectomy, development of lesions in the contralateral gland poses no additional surgical risk providing parathyroid function is maintained. In cases of recurrent hyperthyroidism following bilateral thyroidectomy, postoperative morbidity and mortality are significantly increased and an alternative treatment for the hyperthyroidism is indicated.

Administration of radioactive iodine

The administration of radioactive iodine as ^{131}I is considered to be the safest, simplest and most effective therapy for feline hyperthyroidism (Peterson & Becker, 1995). ^{131}I, like stable iodine, is actively concentrated by the thyroid gland, has a half-life of 8 days and emits both β-particles and γ-radiation. The β-particles cause over 80% of damage, but are locally destructive, travelling a maximum of 2 mm with an average pathlength of 400 μm. Therefore, there is minimal risk of damage to adjacent atrophic thyroid tissue, the parathyroid glands and other cervical structures.

The aim of therapy is to restore euthyroidism with the smallest possible single dose of ^{131}I, while avoiding the development of hypothyroidism. When initially evaluated, controversy surrounded the best method for calculating the optimum dose in individual cases. The use of fixed low or high doses results in the under treatment or overtreatment of a significant proportion of animals and while tracer kinetic studies more accurately estimate a therapeutic dose, access to sophisticated computerised nuclear medicine equipment is required. It is now recognised that markedly elevated pretreatment circulating T4 concentration, size of goitre as estimated by palpation and the severity of the clinical thyrotoxicosis all potentially adversely affect the eventual response to ^{131}I therapy. These factors are therefore considered when estimating a therapeutic dose, and using such a regimen euthyroidism is attained in over 90% of cases with a single dose.

Traditionally, ^{131}I is administered intravenously. Oral administration can be attempted but higher doses are generally required, the risks of radiation spillage are greater and vomiting is a potential risk. Subcutaneous is equally as effective as intravenous administration, but is preferred because it is simpler to administer, safer to personnel and less stressful to cats.

A small percentage of cats remain persistently hyperthyroid after ^{131}I therapy, but euthyroidism is eventually attained in some of these animals weeks to months later without further treatment. In these cases, there is a progressive decline in serum thyroid hormone concentration from pretreatment values. In a small number of cases, hyperthyroidism persists presumably because of an inadequate dose. These cats are generally successfully managed with a repeat injection of ^{131}I. Both hypothyroidism and recurrent hyperthyroidism can develop, but appear to be rare and other side-effects are minimal. The survival time for cats successfully treated with ^{131}I is excellent.

The main drawback to the widespread use of radioactive iodine is the requirement for special licensing and the paucity of facilities that can offer such treatment. In addition, cats must be hospitalised and isolated for variable periods after treatment. These can range from several days to several weeks depending on the dose used and local radiation regulations. Cats appear to tolerate these periods of hospitalisation well.

Percutaneous ethanol ablation

Intrathyroidal administration of ethanolol causes tissue necrosis and eventual induction of euthyroidism. Preliminary studies suggest that single injections in unilateral cases or staged injections in bilateral cases are effective in inducing euthyroidism in hyperthyroid cats. However, this treatment is associated with a high incidence of adverse reactions (transient dysphonia, Horner's syndrome, gagging and laryngeal paralysis) and specialised ultrasonographic equipment and advanced expertise are required.

Treatment of hyperthyroidism and renal disease

The presence of hyperthyroidism increases GFR, decreases circulating creatinine concentration and potentially masks underlying renal disease. Decreased GFR, increased serum urea and creatinine concentration and development of overt clinical signs of renal disease have all been reported after successful treatment of hyperthyroidism, irrespective of therapeutic modality. An inappropriately low pretreatment GFR value can accurately predict cats in which overt renal dysfunction will occur, but techniques for assessment of GFR are largely impractical and prohibitively expensive. In the absence of such estimations, careful evaluation of circulating urea and creatinine concentration and urine specific gravity is required before treatment. If both circulating parameters are appropriate

for that animal and the urine is concentrated, the risk of developing renal failure after therapy is low. If both concentrations are higher than expected and the urine is isosthenuric, then there is a risk of developing renal failure. In such cases, trial therapy using methimazole should be attempted and renal function reassessed once euthyroidism is achieved. If there is no deterioration in renal function as euthyroidism is achieved, then a more permanent therapeutic option may be selected. If renal function declines, therapy should be instituted for renal failure and the dose of antithyroid medication adjusted to maximise renal function while attempting to control the clinical signs of thyrotoxicosis. Maintenance of a mildly hyperthyroid state may be beneficial in these individuals.

Feline diabetes mellitus

Diabetes mellitus is the second most common endocrine disease of cats, with a reported incidence of between 1 in 100 and 1 in 400 (Panciera *et al.*, 1990). The single most significant risk factor for developing the condition is increasing age. Most cats are older than 6 years at the time of diagnosis, with a peak incidence between 10 and 13 years of age. Neutered cats, particularly males, are at greater risk, with male cats outnumbering female cats by 3 to 2. No breed association has been reported in the USA, but the Burmese breed in Australia and New Zealand has an increased prevalence, with certain families having more than 10% of offspring affected (Rand *et al.*, 1997). Obesity is also a significant risk factor (Scarlett & Donoghue, 1998). As the rate of feline obesity increases, a corresponding rise in the frequency of diabetes is likely, as is documented in humans.

Classifying diabetes mellitus

In humans, the current classification divides diabetes mellitus into type 1, type 2, other specific types and gestational diabetes (Expert Committee on the Diagnosis and Classification of Diabetes Mellitus, 1997). Based on this classification, the majority of diabetic cats is classified as type 2, which is characterised by β-cell dysfunction and insulin resistance (Rand, 1999).

Type 1 diabetes results from selective destruction of beta cells, usually via immune-mediated processes, but appears to be rare in cats (Goossens *et al.*, 1998). 'Other specific types of diabetes' constitute approximately 10–20% of feline cases. The most common of these reported by referral institutions is pancreatic destruction by pancreatic adenocarcinoma or less commonly pancreatitis (O'Brien *et al.*, 1985; Goossens *et al.*, 1998).

Diabetes secondary to other endocrinopathies, such as acromegaly and hyperadrenocorticism, is less frequent. Administration of megestrol acetate or long-acting corticosteroids is associated with diabetes in some cats. However, as relatively few cats develop diabetes after prolonged use of these drugs, it is likely that other predisposing factors pre-existed in affected cases.

Type 2 diabetes accounts for 80–90% of feline cases (O'Brien *et al.*, 1986; Goossens *et al.*, 1998). Type 2 diabetes is characterised by a combination of insulin resistance and inadequate insulin secretion, resulting in a relative or absolute deficiency of insulin. In humans, it is debated whether the initial primary defect is insulin resistance or impaired insulin secretion. This issue is unresolved and there is evidence that it varies between populations.

Insulin resistance

Diabetic cats are approximately six times less sensitive to insulin than normal cats, a situation similar to humans with type 2 diabetes. In non-diabetic cats, underlying low insulin sensitivity increases the risk of impaired glucose tolerance (Appleton *et al.*, 2001). When insulin sensitivity is reduced (insulin resistance), more insulin is required to produce the same glucose-lowering effect. This results in a compensatory increase of insulin secretion from β-cells. Once insulin secretion is no longer adequate to maintain normoglycaemia, hyperglycaemia ensues. Initially, impaired glucose tolerance occurs, and hyperglycaemia is either mild or is only evident subsequent to a glucose challenge. Further deterioration in the ability of β-cells to secrete insulin results in diabetes and moderate to marked hyperglycaemia. Hyperglycaemia occurs via increased glucose production by the liver and reduced glucose utilisation by peripheral tissues. Long-term demand for increased insulin secretion as a result of insulin resistance is believed to predispose β-cells to eventual failure.

Genetic factors

In humans, the basal level of insulin resistance is largely inherited and can be compounded by environmental and lifestyle factors such as obesity and physical inactivity. It is unknown whether there is also a genetic basis for the underlying low insulin sensitivity of some cats.

Obesity

Obesity is a risk factor for type 2 diabetes in both humans and cats, although not all diabetic people or cats are overweight. Obesity decreases insulin sensitivity in both species, resulting in chronic hyperinsulinaemia and, in the long term, β-cell failure. Insulin sensitivity was halved in adult cats when body weight increased by 44%, and this was accompanied by compensatory hyperinsulinaemia (Appleton *et al.*, 2001). Physical inactivity also increases the risk of type 2 diabetes in humans, both directly via decreased insulin sensitivity and indirectly by predisposing to obesity. Obesity and physical inactivity are increasing in both feline and human urban populations. Cats kept exclusively indoors are less active than outdoor cats and both are considerably less active than feral cats that must hunt to eat.

Glucose toxicity

Once overt diabetes develops, insulin resistance increases and insulin secretion is further decreased. This is part of the phenomenon termed glucose toxicity, which encompasses a variety of pathological effects resulting from chronic hyperglycaemia. It adds to the insulin resistance resulting from genetic and environmental factors.

Concurrent disease and medications

Hyperadrenocorticism, acromegaly, corticosteroid and megestrol acetate therapy are known to result in insulin resistance in cats. All may precipitate overt diabetes in predisposed cats. Acromegaly produces profound insulin resistance, and with time, likely induces diabetes in most cats. Other diseases that commonly affect older cats, such as hyperthyroidism, infections, renal failure and pancreatitis, occur as concurrent diseases in some diabetic cats and potentially may further decrease insulin sensitivity.

Gender

Neutered male cats are more predisposed to diabetes than are neutered female cats. Lower insulin sensitivity, hyperinsulinaemia and obesity are more common in neutered male cats than in females, and probably explain the increased risk.

Inadequate insulin secretion

The late age of onset for both feline diabetes and human type 2 diabetes lends support to the hypothesis that β-cell exhaustion, secondary to persistent hyperinsulinaemia, is an integral part of the disease process. Many researchers believe that the chronic hyperinsulinaemia is primarily secondary to insulin resistance. Other researchers postulate that hypersecretion of insulin is the primary abnormality, which in turn induces insulin resistance and β-cell exhaustion. Whatever the primary lesion, ultimately insulin secretion is inadequate to maintain normoglycaemia and hyperglycaemia ensues.

The progression of β-cell dysfunction occurs via a similar step-wise process in both feline diabetes and human type 2 diabetes (Lutz & Rand, 1996). Insulin resistance is initially associated with hypersecretion of β-cells and normoglycaemia is maintained. As β-cell dysfunction progresses, there is an abnormal pattern of insulin secretion, which is associated with impaired glucose tolerance. This is an intermediate stage between normal glucose tolerance and overt diabetes. The first phase of insulin secretion, which occurs in the initial 2–15 min after an increase in glucose, is significantly suppressed, while the second phase is delayed and exaggerated (Figure 20.2). As glucose tolerance progressively worsens, the second phase of insulin secretion is gradually decreased. In some diabetic cats it is no longer detectable (Figure

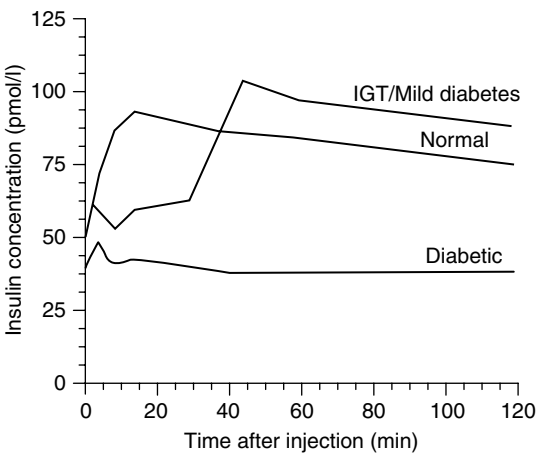

Figure 20.2 In cats with impaired glucose tolerance, the insulin secretion that occurs in the first 10 min (first phase secretion) after an increase in glucose is very reduced or absent compared with normal cats. Second phase insulin secretion is often exaggerated. Diabetic cats often have minimal insulin secretion in response to glucose. (Adapted from Lutz & Rand, 1995.)

20.2). The pattern of insulin secretion progresses from biphasic, through monophasic, to total failure (Lutz & Rand, 1995).

Glucose toxicity

Once persistent hyperglycaemia occurs, insulin secretion is further suppressed by glucose toxicity. Initially, the suppression of insulin secretion is functional and reversible. However, after 2 weeks of persistent hyperglycaemia, glycogen deposition and cell death become evident in β-cell islets. Insulin secretion is markedly suppressed in normal cats when they are infused with glucose to maintain glucose concentrations similar to those found in untreated diabetic cats. Within 3–7 days, insulin concentrations are similar to those found in insulin-dependent diabetic cats. Within 4 weeks, previously normal cats develop ketotic diabetes, which is reversible with insulin therapy. The exact mechanism of this hyperglycaemia-induced suppression of β-cell function is still unknown; however, the severity of the glucose toxic effect is dependent on the degree and the duration of hyperglycaemia. Loss of β-cells before the onset of hyperglycaemia appears to predispose the remaining β-cells to permanent damage from the effects of glucose toxicity, and increases the likelihood of permanent diabetes occurring. It is postulated that this increased susceptibility to glucose toxicity is associated with the hyperfunctioning state of the remaining β-cells.

Lipid toxicity

Elevated plasma levels of fatty acids have a similar effect on β-cells to glucose toxicity. This effect is termed lipid toxicity and it is also responsible for suppression of insulin secretion. It is difficult to determine individual mechanisms for glucose and lipid toxicity, because chronic hyperglycaemia results in hyperlipidaemia. It is possible that both may act through a common pathway to inhibit β-cell function. Multiple mechanisms may operate, with the causes of the initial reversible suppression of insulin secretion being different from those responsible for the death of β-cells.

β-Cell loss

β-Cell loss is the most serious component of the pathogenesis of feline diabetes. It compounds the underlying defect in insulin secretion and contributes to progression from relative to absolute insulin deficiency. Processes responsible for loss of β-cells include β-cell exhaustion and apoptosis, glucose and lipid toxicity, amyloid deposition and pancreatitis. It is important that therapy prevents further β-cell loss, because cats with residual endogenous insulin secretion are more likely to have better glycaemic control and may even achieve remission of their diabetes.

Amyloid deposition

Amyloid deposition in the pancreatic islets is the most consistent histological feature of type 2 diabetes and many diabetic cats and humans have substantial deposits that replace β-cells (Lutz *et al.*, 1994; Goossens *et al.*, 1998). Amyloid is toxic to β-cells and, in some cats, deposition is severe enough to be solely responsible for the development of diabetes (O'Brien *et al.*, 1995). However, it is not an essential component of type 2 diabetes in either humans or cats. In the majority of diabetic cats, it is one of the factors contributing to β-cell loss, but is not the sole cause of the failure of insulin secretion.

Amyloid is derived from the hormone amylin, which is secreted along with insulin from β-cells (Johnson *et al.*, 1986). Its deposition in the extracellular space of the pancreatic islets is probably secondary to β-cell dysfunction and appears to be dependent on a number of factors. The first is the amino acid sequence of the amylin molecule. Only a few species, including cats and humans, have an amino acid sequence in the critical portion of the amylin molecule which predisposes it to folding into sheets, allowing it to be deposited as amyloid. Another factor contributing to amyloid deposition is a high local concentration of amylin within the islets. As amylin is cosecreted with insulin, high local amylin concentrations may occur when there is hyperinsulinaemia associated with insulin resistance. Excessive amyloid deposition associated with a high plasma amylin concentration has been shown to be a feature of experimental feline diabetes induced by insulin resistance, causing initial hyperinsulinaemia. Recent evidence suggests that the amylin fibrils toxic to β-cells have a changed composition to secreted amylin.

Pancreatitis

Pancreatitis is a common histological finding in diabetic cats (Goossens *et al.*, 1998). The islet lesions are rarely severe enough to cause diabetes alone, but may contribute to β-cell loss. Pancreatitis may be triggered by the hyperlipidaemia that is associated with obesity and diabetes. In humans, pancreatitis is recognised as a major complication of diseases that

cause marked hyperlipidaemia, and many people with type 2 diabetes have histological evidence of pancreatitis. Severe necrotising pancreatitis is the most common cause of death during the first week of therapy of diabetic cats.

Recognising diabetes mellitus

The classic signs of diabetes in cats are polydipsia, polyuria and weight loss (Crenshaw & Peterson, 1996). Polydipsia and polyuria are typically present for weeks, or even months, before diagnosis. Weight loss is usually initially associated with a normal or increased appetite. A history of reduced appetite or anorexia is common just before diagnosis and may develop owing to concurrent disease or progression to ketoacidosis. About 30% of diabetic cats have a history of vomiting and the majority show a degree of lethargy. Poor coat condition is typical. Weakness, manifesting as a wobbly gait or an inability to jump, is common and electromyographic studies indicate that most cats have underlying peripheral neuropathy.

Ketoacidosis is present in approximately one-quarter of diabetic cats at the time of diagnosis, and results in depression, vomiting, anorexia and dehydration. It can be precipitated by concurrent disease, but may be inevitable once there is almost total failure of insulin secretion (Link, 2001). Ketosis and an acetone odour on the breath occur some days before ketonuria can be detected using a urine test strip and, if not treated, acidosis ensues. It is important to realise that small doses of insulin will usually correct ketosis and prevent life-threatening acidosis, even if marked hyperglycaemia persists.

Diabetes occurs in older cats and it is probably for this reason that concurrent disease is so common. Conditions commonly present at the time of diagnosis include hyperthyroidism, inflammatory bowel disease, eosinophilic granuloma complex, anaemia, neoplasia and renal failure. None of these has yet been causally related to diabetes mellitus.

Diagnosing diabetes mellitus

Diabetes is diagnosed if there are signs consistent with diabetes and evidence of persistent glucosuria and hyperglycaemia. Clinical signs of overt diabetes develop when the blood glucose level rises above the renal threshold, which is approximately 16 mmol/l (290 mg/dl) in healthy cats. Persistent hyperglycaemia can be confirmed by repeating the blood glucose measurement 4–12 h after the first sample. Glucosuria can be confirmed using urine test strips. If necessary, detection of glucose in urine-soaked cat litter can be achieved by adding one tablespoon of wet litter to 12–15 ml tap water, straining it through gauze and dipping the test strip in the filtrate. Commercial products for measuring urine glucose in cat litter are also available. Cats should be allowed to void urine at least once before repeat assessment of urine glucose.

Stress hyperglycaemia

Healthy pet cats sampled in a hospital environment usually have blood glucose values less than 9.5 mmol/l (170 mg/dl) and diabetic cats usually have values that exceed 16 mmol/l (Link & Rand, 1998). However, diagnosing diabetes is more complicated because of the effect of stress hyperglycaemia in both healthy and in sick non-diabetic cats which can lead to markedly elevated blood glucose concentrations. It results from acute stress associated with blood sampling or the more chronic stress of illness. Struggling is a predictor of acute stress hyperglycaemia, and probably causes hyperglycaemia via increased hepatic glucose production using lactate released from muscles. Blood glucose may increase as much as 10 mmol/l (180 mg/dl), resulting in values up to 16 mmol/l (290 mg/dl) in healthy cats that struggle. In sick, non-diabetic cats, blood glucose values as high as 34 mmol/l (620 mg/dl) have been reported. Such elevations can give rise to transient glucosuria. Stress hyperglycaemia also complicates the monitoring of glycaemic control in treated cats.

Fructosamine and glycated haemoglobin

The glycated proteins, fructosamine and glycated haemoglobin, are useful for differentiating non-diabetic hyperglycaemic cats from diabetic cats, especially when the typical clinical signs of diabetes have not been observed or reported (Hasegawa *et al.*, 1992; Lutz *et al.*, 1995; Crenshaw *et al.*, 1996; Thoresen & Bredal, 1996; Elliott *et al.*, 1997). However, neither test is fully sensitive or specific, as both are occasionally elevated in non-diabetic cats and some untreated diabetic cats have levels similar to those in healthy cats. Although individual laboratory reference ranges vary slightly, a fructosamine concentration in excess of 400 μmol/l strongly supports a diagnosis of diabetes. Glycated haemoglobin levels should be interpreted based on the reference range supplied by each individual laboratory.

Treating diabetes mellitus

Therapeutic considerations

The clinical implications of glucose and lipid toxicity are important. If maximum β-cell function is to be preserved once diabetes is diagnosed, it is vital that effective therapy is instituted as soon as possible to reduce hyperglycaemia and hyperlipidaemia. Lowering glucose and lipid levels will increase insulin sensitivity, improve the insulin secretory capacity of the remaining β-cells and reduce further loss of β-cells. It may also possibly reduce the risk of pancreatitis. A simple test measuring remaining β-cell function is not currently available for diabetic cats, and it is therefore impossible to predict those cats likely to achieve remission. Even if residual β-cell function is insufficient to allow clinical remission, cats with endogenous insulin are likely to have better glycaemic control than cats that have to rely totally on exogenous insulin. Therefore, therapy for all diabetic cats should aim for optimal glycaemic control as soon as possible, while avoiding hypoglycaemia.

Aims of therapy

The first aims of therapy are to treat ketoacidosis and dehydration if present. Subsequently, the goals are to achieve acceptable remission of all clinical signs while avoiding the development of hypoglycaemia.

Insulin is the most potent and efficacious drug currently available for the treatment of diabetes in cats. Insulin is more effective than oral hypoglycaemic agents in lowering blood glucose levels and, for this reason, is the first choice of therapy favoured by most clinicians. Therapy with insulin will prevent progression to ketoacidosis and will allow the earliest possible resolution of clinical signs. It will also achieve the most rapid reduction of glucose toxicity. Although oral hypoglycaemic agents are useful as sole agents in a minority of diabetic cats, in the future they are likely to be increasingly used in combination with insulin to achieve improved glycaemic control.

Although it is imperative that the effects of hyperglycaemia and glucose toxicity are reduced as soon as possible, it is not necessary to aim for euglycaemia. Pursuing tight glycaemic control is not advisable with current insulin preparations, because it makes clinical hypoglycaemia more likely (Whitley *et al.*, 1997). Fortunately, moderate hyperglycaemia in cats does not cause unacceptable clinical signs or risk of life-threatening complications.

Once good glycaemic control has been achieved, it usually takes 1–4 months for maximal recovery of β-cell function. It is at this stage that clinical hypoglycaemia and remission are most likely.

The sick diabetic cat with ketoacidosis

Depressed, dehydrated, hypothermic or pyrexic diabetic cats require hospitalisation and intensive supportive care. The treatment of ketoacidosis involves addressing underlying disease processes, correcting fluid, electrolyte and acid–base imbalances, and lowering blood glucose concentration. If there is evidence of sepsis, fever or leucocytosis, broad-spectrum antibiotics are indicated. In dehydrated diabetic cats, intravenous fluids are as important as insulin therapy. Balanced electrolyte or 0.9% saline solutions are suitable fluids to begin with, depending on the initial serum potassium concentration of the cat. Saline is preferred when there is hyperkalaemia. An initial fluid rate of 3–6 ml/kg per hour is appropriate in most cats. A slower infusion rate should be considered for cats with very high blood glucose concentrations (>33 mmol/l or >600 mg/dl) and severe hyperosmolality (>350 mOsm/kg). Cats with diabetes adapt over time to the hyperosmolality associated with hyperglycaemia, so it is important that care is taken to avoid a rapid fall in blood glucose concentration and subsequently osmolality.

Administration of exogenous insulin is required to move glucose into cells where it can be utilised for energy in preference to ketones. However, a more important goal is to halt ketogenesis, rather than to lower blood glucose concentrations. The aim is to decrease blood glucose concentration by 3–4 mmol/l per hour (55–70 mg/dl per hour), but not exceeding 6 mmol/l per hour (110 mg/dl per hour). If the blood glucose falls too rapidly or drops below 10 mmol/l (180 mg/dl), glucose or dextrose should be added to the intravenous fluids (see below). Most ketoacidotic cats have a total body deficit of potassium, although this may not be accurately reflected in the initial serum concentration. Because potassium moves into cells with glucose, hypokalaemia may become evident after commencing treatment for ketoacidosis. Intravenous potassium supplementation is therefore usually required within 12–24 h of instituting insulin therapy. Serum potassium concentrations should be closely monitored and supplementation administered accordingly. If this is not possible, the safest option is to supplement the intravenous fluids with 40 mmol/l potassium 6–12 h after commencing insulin therapy.

Serum phosphorus concentration may also decrease, resulting in haemolysis, paresis and neurological signs. Hypophosphataemia and hypokalaemia can be corrected concurrently by supplementing the intravenous fluids using a combination of 50% potassium chloride and 50% potassium dihydrophosphate.

Soluble, rapid-acting (neutral) insulin is used to treat sick diabetic cats, and is administered either as a constant rate intravenous infusion or by repeated intramuscular injections. For the intravenous infusion, 25 U of soluble insulin is added to a 500 ml bag of 0.9% saline, producing an insulin concentration of 0.05 U/ml. This is administered using an infusion pump into the main fluid line using a 'Y' junction. The line should first be flushed well as the plastic tubing adsorbs insulin. The recommended starting dose is 0.05 U/kg per hour, which equates to 1 ml/kg per hour. When the blood glucose is decreased to approximately 10 mmol/l (180 mg/dl), the insulin infusion is halved to 0.5 ml/kg per hour and the maintenance fluids are replaced with a solution containing 2.5% glucose or dextrose.

If an intravenous fluid pump is not available, the only practical option for administration of soluble insulin is repeated intramuscular injection. The recommended starting dose is 0.2 U/kg, followed by hourly doses of 0.05–0.2 U/kg, aiming for a decline in blood glucose concentration by 3–4 mmol/l per hour (55–70 mg/dl per hour) until a blood glucose of about 16 mmol/l (290 mg/dl) is attained. Soluble insulin can then be given at 0.1–0.4 U/kg every 4–6 h. Subcutaneous maintenance insulin therapy can commence as soon as the cat is rehydrated.

Maintenance insulin therapy

A wide variety of insulin preparations is available for maintenance therapy of diabetes in cats (Table 20.4). Acceptable glycaemic control can be achieved with isophane (NPH), lente, ultralente and protamine zinc insulin (PZI) in most cats, and the type of insulin chosen is often dependent on local availability. NPH and lente insulins have an intermediate duration of action and require twice-daily dosing. Ultralente and PZI are longer acting insulins and can sometimes be effective when administered on a once-daily basis (Moise & Reimers, 1983; Nelson *et al.*, 1992). The blood glucose response is often less predictable with longer acting insulins and in many cats they are better given twice daily.

Insulin is also classified according to species of origin: beef, pork or recombinant human. Although species of origin is an important consideration in dogs, duration of activity takes precedence in cats. Glargine is a new long-acting insulin analogue that is very useful in cats which have inadequate duration of insulin action using traditional insulins. It can be administered once or twice daily and has a concentration of 100 U/ml. However, it is not registered for veterinary use and there is the potential for prolonged hypoglycaemia if overdosed.

Table 20.4 Examples of insulin preparations for diabetic cats

Insulin	Advantages	Disadvantages	Trade names
Long acting			
PZI	Can be given once daily in many cats	May have an unpredictable onset and duration of action. 24 h blood glucose curves should be performed to ensure nocturnal hypoglycaemia is not occurring. Accurate dosing with 100 U/ml preparation. Prolonged hypoglycaemiamay occur	PZI insulin, 40 U/ml (USA)[a] Insuvet PZI, 100 U/ml (Europe)[b]
Human or porcine ultralente	Can be used successfully once daily in some cats	As for PZI, but fewer cats can be managed on once daily ultralente than PZI. The majority of cats will require twice-daily dosing. Some cats will have better control with lente insulin. Accurate dosing with 100 U/ml preparation may be a problem	Ultratard or Ultratard MC[c] (porcine) 100 U/ml Humulin UL[d] 100 U/ml

(continued)

Table 20.4 *(continued)*

Insulin	Advantages	Disadvantages	Trade names
Bovine ultralente	Can be given once daily in some cats	As for PZI, but may be so poorly absorbed in some cats that very high doses are needed to adequately lower blood glucose. Accurate dosing with 100 U/ml preparation may be a problem. Availability is a problem in many countries	Ultratard MC[c] (bovine) 100 U/ml
Insulin glargine	Can be given once daily in many cats, but some cats are better with twice daily administration Provides excellent duration of action in cats with inadequate duration of action using intermediate-acting insulins	Accurate dosing with 100 U/ml preparation may be a problem. Prolonged hypoglycaemia may occur	Lantus[e] 100 U/ml
Intermediate acting			
NPH (human or porcine)	More predictable onset and duration of action than long-acting insulins; 12 h blood glucose curves taken during the day should give an indication of blood glucose status during the night as well as the day	Requires twice-daily dosage. In many cats, duration of action may be too short (<3 h). Accurate dosing with 100 U/ml preparation may be a problem	Protophane[c] Humulin N[d] (human) 100 U/ml
Lente (human or bovine)	Similar to NPH above	Requires twice-daily dosing. Accurate dosing with 100 IU/ml preparation may be a problem	Monotard HM[c] Humulin L[d] (human) 100 U/ml Insuvet, lente[b] (bovine) 100 U/ml
40 U/ml porcine lente	As for lente, but the veterinary 40 U/ml preparation allows more accurate dosing of cats; predictable onset and duration of action in most cats	Requires twice-daily dosing. In a few cats, has too short a duration of action	Caninsulin[f]
Short acting			
Soluble insulin	Suitable for intravenous infusion	Not suitable for long-term management of diabetic cats owing to the short duration of action	Actrapid[c] Humulin R[d] (human) 100 U/ml Insuvet neutral[b] (bovine) 100 U/ml

Modified from Martin & Rand (2001), with permission from W.B. Saunders.
[a] Blue Ridge Pharmaceuticals (USA).
[b] Schering-Plough Animal Health.
[c] Novo Nordisk.
[d] Aza/Eli Lilly.
[e] Aventis Pharmaceuticals (Germany).
[f] Intervet (The Netherlands).

Most diabetic cats are eventually maintained on an insulin dose of 0.25–1 U/kg, calculated using non-obese body weight. Total doses of insulin in cats tend to be only 1–4 U. It is difficult to administer accurately less than 2 U of 100 U/ml insulin, even when using 0.3 ml insulin syringes. Therefore, there is likely to be substantial variability between each dose administered to diabetic cats by owners. Choosing an insulin preparation with a concentration of 40 U/ml, rather than 100 U/ml, helps to reduce dosing fluctuations. It is important to make the client aware of variations in dosing with different insulin syringes. The volume for 1 U on a 40 U/ml syringe is larger than on a 100 U/ml syringe. Also, 1 division on a 0.5 ml 100 U/ml syringe represents 1 unit, while on a 1 ml 100 U/ml syringe it represents 2 units. These differences can lead to underdosing and overdosing or confusion between the veterinarian and cat owner. Insulin dosing pens capable of administering a minimum dose of 1 U and increments of 0.5 U are an attractive option, but are only available with NPH insulin.

Choosing the initial insulin dose: where to start?

For most insulin preparations a safe starting dose is 0.25–0.5 U/kg of ideal body weight, rounded down to the nearest whole unit. The higher end of this dose range is reserved for cats with marked hyperglycaemia (blood glucose concentration ⩾20 mmol/l or 360 mg/dl). A starting dose of 1 U/cat is the safest option for all cats with blood glucose concentrations below 20 mmol/l (360 mg/dl), and for any cat when the initial blood glucose response to insulin cannot be monitored.

Twice-daily dosing is preferred for all insulins, even with long-acting insulins. Once-daily dosing of insulin, compared with twice-daily dosing, is associated with higher insulin doses and a greater risk of hypoglycaemia in humans and dogs, and the same is likely to be true for cats. Although insulin administration every 12 h is optimal, it is important that the insulin regime is flexible enough to suit the owner's lifestyle. Owners of diabetic cats should be aware that occasionally missing a single insulin injection will have negligible clinical consequences.

Monitoring the blood glucose response for several days following the initiation of insulin therapy is advisable (Figure 20.3). The principal goal is to ensure the lowest possible risk of hypoglycaemia when the cat is discharged. Serial blood glucose measurements are typically obtained before and every 2 h after insulin injection, until a nadir or minimum blood glucose reading is clearly apparent. The difference between the baseline and the nadir gives an indication of the responsiveness to insulin and hence the maximum dose of insulin that can be tolerated by the cat. Hypoglycaemic episodes are a risk if the blood glucose drops below 6 mmol/l (110 mg/dl), and subsequent doses should be reduced by 1–2 U. Cats with mild hyperglycaemia may have normoglycaemia or minimally elevated blood glucose concentrations after only 1–2 days of insulin treatment. If preinsulin blood glucose concentrations of 10–15 mmol/l (180–270 mg/dl) are achieved during the first week of therapy, control can often be achieved using oral hypoglycaemic agents alone. If the preinsulin blood glucose concentration is below 10 mmol/l (180 mg/dl), insulin therapy should be discontinued and the cat closely monitored for recurrence of hyperglycaemia. Some cats need only small doses of insulin (1 U once or twice daily) or oral hypoglycaemic drugs to maintain normoglycaemia, but without therapy hyperglycaemia recurs within several days.

The blood glucose response of a diabetic cat to a given dose of insulin tends to be quite variable from day to day. In addition, there may be gradual improvement of the response to insulin as glucose toxicity is reduced. Consequently, it is not advisable to increase the insulin dose for 1–2 weeks after initiation of therapy. The aim at this stage is to simply ensure that the cat is well enough to be discharged with minimal risk of hypoglycaemia.

Treatment of hyperglycaemic cats of unknown diabetic status

If a sick cat has a blood glucose of 15 mmol/l (270 mg/dl) or higher, it is advisable to immediately begin insulin therapy, even if stress hyperglycaemia or a transient increase in insulin resistance associated with another disease process is suspected. It is imperative that the effects of glucose toxicity are reduced as soon as possible to improve β-cell function, reduce insulin resistance and avoid permanent diabetes. Blood glucose concentrations can then be monitored over the next few days while concurrent disease status is investigated and treated.

Oral hypoglycaemic agents

Sole therapy using oral hypoglycaemic agents is only appropriate for diabetic cats without severe concurrent

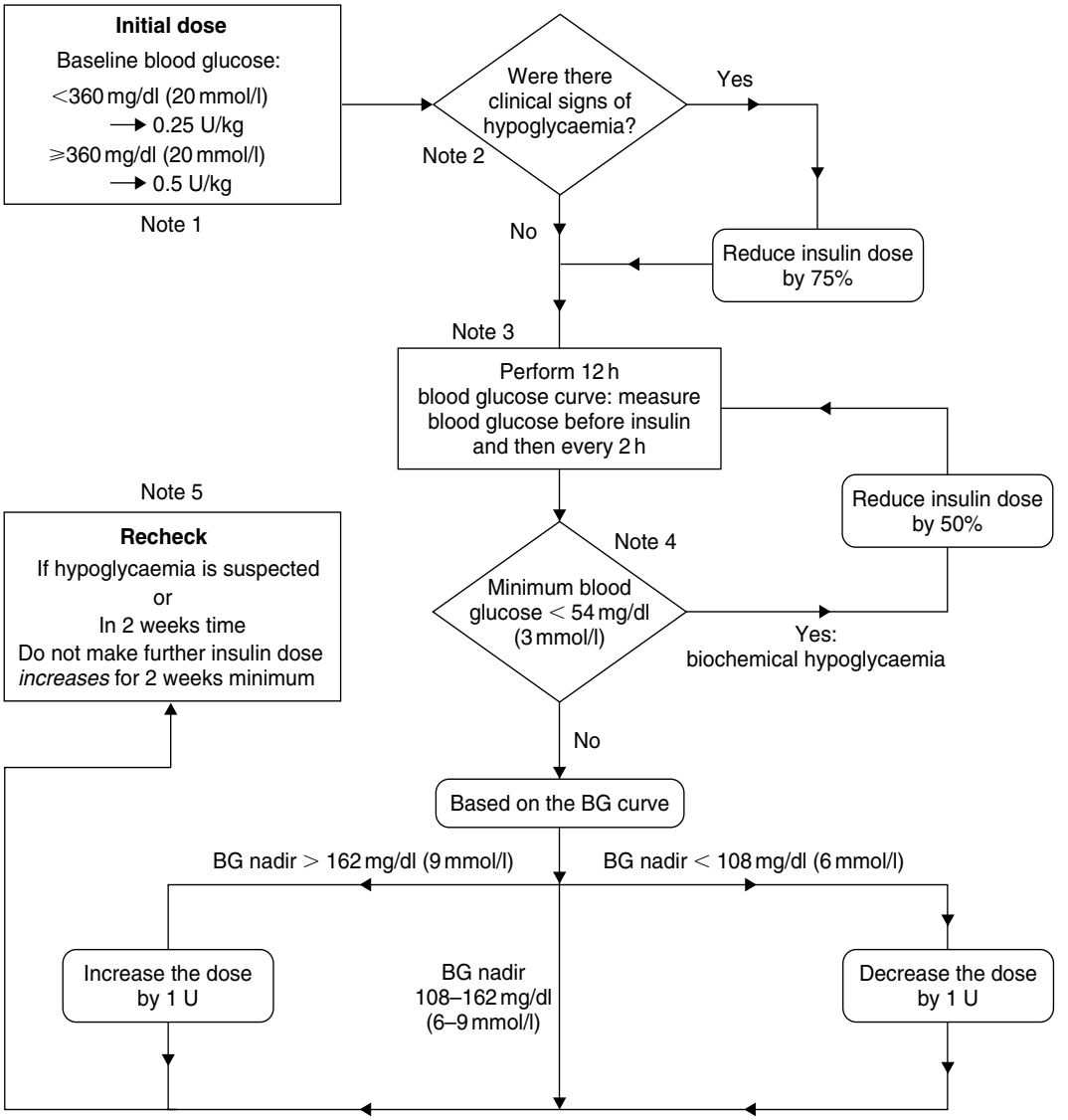

Figure 20.3 Algorithm for determining the initial insulin dose and the adjustment in dose during the first week of treatment. This protocol commences after diabetic ketoacidosis, dehydration, and/or electrolyte imbalances have been treated. Treatment with insulin is commenced at a conservative dose rate, given twice daily, with only one dose rate increase to be made (if indicated) in the first week of treatment. *Note 1*: dose rate should be rounded down to the nearest unit, or to a minimum of 1 U total dose. *Note 2*: clinical signs of hypoglycaemia include weakness, disorientation, ataxia, coma and convulsions. *Note 3*: The main focus of the blood glucose (BG) curve is to establish the lowest glucose concentration reached. If blood glucose approaches the low-normal range for blood glucose 108 mg/dl (<6 mmol/l), measurements should be made more frequently (every 0.5–1 h) until glucose increases. When obtaining a blood glucose curve, cats should be given their usual quantity and type of food. If indicated by the nadir glucose, insulin dose can be adjusted upward once during the first week, on day 3 or 4. Downward adjustments may be made on any day. *Note 4*: biochemical hypoglycaemia is a blood glucose below the normal range for blood glucose in cats 60 mg/dl (<3.3 mmol/l), as measured on a portable glucose meter, without clinical signs of hypoglycaemia being noted. *Note 5*: the insulin dose rate at home should remain the same as at discharge until a further blood glucose curve is performed, unless hypoglycaemia and/or diabetic remission are suspected.

disease, of normal or obese body weight and with a good appetite. It is not recommended for sick, ketotic or anorexic cats. Many owners object to the idea of giving subcutaneous insulin injections to their cat when they first learn of the diagnosis of diabetes. However, once they become familiar with the technique, most find it simpler and more reliable than administering life-long oral medication. Oral hypoglycaemic agents are sometimes life-saving for cats whose owners would choose to euthanise their pet rather than treat with insulin.

Glipizide is the only oral agent of well-known efficacy in diabetic cats (Feldman *et al.*, 1997). It is a sulphonylurea drug that acts to amplify insulin secretion from β-cells, providing functioning β-cells remain. Good control has been reported in about 35–40% of diabetic cats treated with glipizide. However, the success rate is dependent on the selection of appropriate cases and some practitioners report success in less than 5% of diabetic cats. Glipizide stimulates secretion of amylin along with insulin potentially accelerating amyloid deposition and further loss of β-cells. However, of greater concern is the marked hyperglycaemia that persists in many treated cats despite some improvement in clinical signs, resulting in continuing loss of β-cells via glucose and lipid toxicity. Potentially, this leads to the development of absolute insulin deficiency and deteriorating glycaemic control; sequelae that may have been avoided if insulin had been administered from the outset.

The recommended starting dose of glipizide is 2.5 mg per cat, administered twice daily. If this dose is well tolerated for the first 2 weeks, it may be increased to 5 mg twice daily. Adverse reactions include inappetence, vomiting, transient elevation of liver enzymes and icterus. Vomiting tends to occur within 1 h of administration and usually subsides after 2–5 days of therapy. Monitoring of liver enzymes is recommended before and during glipizide treatment and adds to the overall cost of this therapy. The drug should be discontinued if the cat becomes anorexic or lethargic, or if the serum alanine aminotransferase level exceeds 500 U/l. In cats that have successful glycaemic control despite adverse reactions, glipizide can be discontinued until signs resolve or liver enzymes return to normal, and then reinstituted at a lower dose. Although hypoglycaemia can occur in cats receiving glipizide, the risk is lower than it is with insulin therapy. Cats with mild hyperglycaemia or those attaining diabetic remission are most at risk for the development of hypoglycaemia while receiving glipizide therapy.

Improved glycaemic control may result if agents that reduce insulin resistance are administered along with exogenous insulin. Preliminary investigation of vanadium (45 mg orally once daily), metformin (2 mg/kg orally twice daily), and troglitazone (200 mg orally once daily) in cats has produced variable results. These insulin sensitisers may be useful adjuncts to insulin therapy but, as sole agents, are unlikely to be efficacious in the majority of diabetic cats.

Acarbose is an oral agent that, when administered with meals, decreases glucose absorption from the gastrointestinal tract. Cats on a high-protein, low-carbohydrate diet have minimal postprandial hyperglycaemia, reducing the usefulness of acarbose in diabetic cats (Martin & Rand, 1999). Cats on a high-carbohydrate diet with mild diabetes are more likely to benefit from acarbose, although data are limited. Acarbose may be most useful when combined with insulin or other oral hypoglycaemic agents rather than as a sole agent. Side-effects of acarbose include flatulence, loose stools and diarrhoea.

Studies are required in diabetic cats to determine whether oral hypoglycaemic agents in combination with insulin therapy result in more effective and safer glycaemic control, while remaining cost effective. Combination therapy of insulin given with a β-cell stimulator (e.g. glipizide), an insulin sensitiser (e.g. vanadium, metformin or troglitazone) and/or an agent that blocks glucose absorption (e.g. acarbose) may prove beneficial.

Dietary recommendations

Compared with dogs and humans, the postprandial increase in blood glucose concentration in cats is delayed and very prolonged, with the increase beginning 2–4 h after eating and persisting for 12–18 h. The magnitude of the increase is dependent on the pattern of eating and the composition of food ingested, with greater increases occurring after ingestion of high-carbohydrate diets and with once-daily feeding. The maximum increase in blood glucose after eating a typical commercial cat food is only 0.7–2 mmol/l (13–36 mg/dl), but may be over 3 mmol/l for a high-carbohydrate meal, fed once daily. Cats eating multiple small meals during the day of a moderate- or low-carbohydrate diet may have no detectable postprandial increase in blood glucose.

The optimal proportion of dietary protein, carbohydrate and fat for diabetic cats is still unknown. Consideration of the current understanding of the pathogenesis of feline diabetes has led to the theory

that diets with a higher protein and lower carbohydrate content may be preferable (Rand, 1999). Recently, it has been shown that a high-protein, low-carbohydrate diet resulted in better clinical control and lower insulin dose than a high-fibre, moderate-fat diet. High-protein, low-carbohydrate diets have also been shown to increase the frequency of diabetic remission. In healthy cats consuming a high-protein, low-carbohydrate diet, blood glucose concentrations are lower than in those fed a low-protein, high-carbohydrate diet. Based on these studies, it is advisable to avoid high-carbohydrate diets in diabetic cats. Selection of a high-protein, low-carbohydrate diet, ideally one designed for diabetic cats, is preferred, or if not available, a high-quality kitten diet. Canned food is generally lower in carbohydrate than dry food.

Because postprandial hyperglycaemia is so prolonged in cats, it is not feasible to match meals with insulin or glipizide administration, and there is usually no need to change the feeding regimen once diabetes has been diagnosed. If diabetic cats have a reduced appetite, food intake can often be increased by hand-feeding highly aromatic, palatable food.

Obesity is associated with marked insulin resistance which is reversible with weight loss. Calorie restriction should be conservative and weight loss should be no greater than 1–2% per week. Obese cats on a restricted calorie intake often consume most of the food soon after being fed, and it may be preferable to provide multiple small meals rather than one or two meals per day for these cats. It is unclear which diet is best for obese diabetic cats. Calorie restricted diets are typically high in carbohydrate. A low-carbohydrate, high-protein diet may provide better glycaemic control, but the higher calorie density of most of these diets makes weight loss more difficult.

Monitoring glycaemic control and changing insulin dose

One of the primary aims of therapy of diabetic cats is resolution of clinical signs and it is therefore important to monitor water intake and body weight regularly. In many cats, good clinical control can be attained even if there is still moderate hyperglycaemia (mean blood glucose concentration of 12–17 mmol/l or 215–306 mg/dl). Weight loss is a sign of inadequate glycaemic control and can be monitored by recording body weight every 1–2 weeks. Water intake can be measured at home or in the hospital, is better correlated with mean blood glucose than fructosamine concentration and is usually more cost effective. Although water intake can vary substantially from day to day, if measured for 1 or 2 days each week on a regular basis, it gives an overall indication of glycaemic control. Most cats with good clinical control that are eating a mix of canned and dry food drink less than 80 ml/kg per day. Those with exemplary control drink 20 ml/kg per day or less. Cats eating dry or canned food only have excellent clinical control if water intake is <60 ml/kg per day or <20 ml/kg per day, respectively. Cats consistently drinking more than 100 ml/kg per day are likely to have poor diabetic control (Figure 20.4).

The glycated proteins, fructosamine and glycated haemoglobin, are less useful indicators of glycaemic control in diabetic cats than clinical signs, are less cost effective, and results are not available at the time of consultation. Although mean values are significantly different when untreated diabetics, poorly controlled diabetics, well-controlled diabetics and normal cats are compared, there is overlap in individual cases (Crenshaw *et al.*, 1996; Elliott *et al.*, 1997, 1999). However, the glycated proteins are helpful in some situations, particularly where stress or fractiousness makes accurate serial blood glucose measurements unobtainable. They can be useful for the differentiation of a poorly controlled cat (marked hyperglycaemia) with an unobservant owner (polydipsia not reported) from a well-controlled cat (no evidence of polydipsia) with concurrent acute stress hyperglycaemia.

As the hyperglycaemia of diabetes is reduced by insulin treatment over time, the insulin requirement of the cat may decrease. This effect requires 2 or more weeks to occur, so a period of 2–4 weeks between increases in insulin dose is recommended and is probably due to the reversal of glucose toxicity, insulin resistance and increased hepatic glucose output. Owners should be encouraged to maintain a written log of clinical signs and this, together with results of a physical examination, should be reviewed approximately every 3 weeks during initial stabilisation. Once good control has been achieved, the frequency of assessment may be gradually reduced.

Monitoring clinical signs is vitally important for monitoring response to therapy. If a diabetic cat is losing weight, is polydipsic or is lethargic, then adjustment of the treatment regimen is probably required. If persistent negative glucosuria is recorded, it is also important to re-evaluate the dose. Serial blood glucose measurements are generally required to determine an appropriate adjustment to the

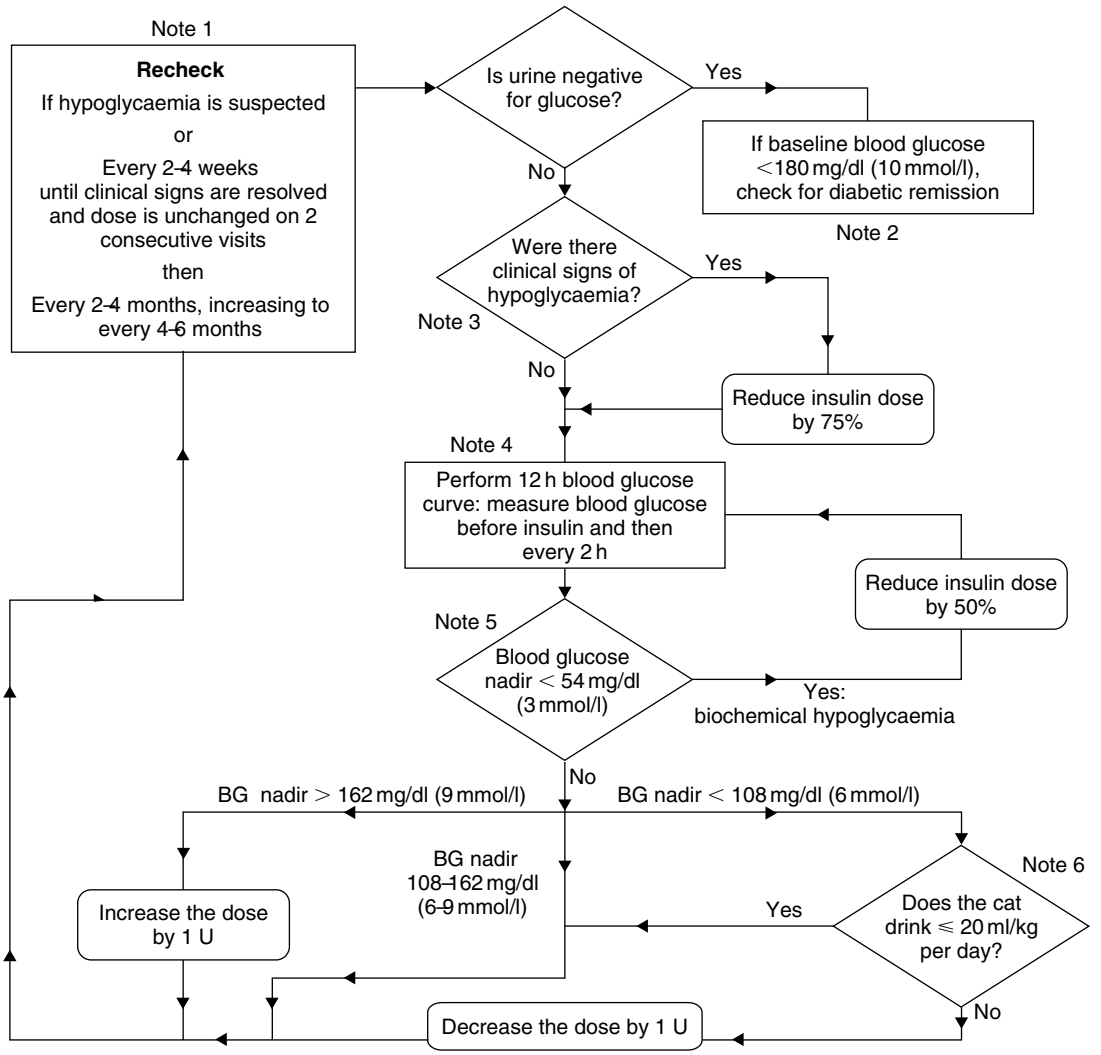

Figure 20.4 Algorithm for adjusting insulin dose subsequent to the first week of treatment. This figure gives a protocol for all revisits subsequent to the initial visit. Blood glucose (BG) responses to a given dose of insulin are generally more variable in the first few weeks or months of therapy; however, sudden changes in dose requirements or diabetic remission can occur even after several months. *Note 1*: rechecks are generally required more frequently until the insulin response and the clinical signs of diabetes are stabilised. With time, rechecks can be performed less frequently. *Note 2*: when diabetic remission is suspected, insulin should be withdrawn to determine whether hyperglycaemia and glycosuria recur. The cat should be monitored carefully by the owner and veterinarian, and insulin or oral hypoglycaemics reinstituted if glucose increases to ⩾234 mg/dl (13 mmol/l) or polydipsia returns. *Note 3*: clinical signs of hypoglycaemia include weakness, disorientation, ataxia, coma and convulsions. *Note 4*: the main focus of the blood glucose curve is to establish the lowest glucose concentration reached. If blood glucose approaches the low-normal range for blood glucose 108 mg/dl (<6 mmol/l), measurements should be made more frequently (every 0.5–1 h) until glucose increases. When obtaining a blood glucose curve, cats should be given their usual quantity and type of food. *Note 5*: biochemical hypoglycaemia is a blood glucose below the normal range for blood glucose in cats 60 mg/dl (<3.3 mmol/l), as measured on a portable glucose meter, without clinical signs of hypoglycaemia being noted. *Note 6*: a small group of diabetic cats which have very good control of diabetic clinical signs may have a mean blood glucose either within or only slightly above the normal range. One of the ways in which this is manifested is in the absence of polydipsia. These cats may be able to be maintained on a dose of insulin which leads to a blood glucose nadir of less than 5.0 mmol/l, without significant risk of hypoglycaemia.

insulin dose, but they should always be interpreted in the light of clinical signs, particularly water intake and demeanour.

Avoiding hypoglycaemia

A crucial therapeutic goal at all stages of treatment is to avoid hypoglycaemia. If an episode of clinical hypoglycaemia occurs, the cat should be evaluated before the next dose of insulin or glipizide is given. Some cats require a 50% reduction in the insulin dose, whereas others have achieved remission and require no further treatment.

Urine glucose measurements are an inexpensive and simple method for monitoring the risk of hypoglycaemia. It is advisable that owners record urine glucose once or twice weekly, particularly during the first 3–6 months of therapy. The majority of random urine samples from treated diabetic cats result in dipstick glucose readings of 2+ to 4. If persistently negative urine glucose readings are obtained, this often indicates diabetic remission or impending remission. Insulin or glipizide therapy can then be discontinued for several days while the urine glucose or blood glucose is monitored daily. If glucosuria or hyperglycaemia recurs, insulin therapy is reinstituted but the dose decreased by 1 U. Regular monitoring of urine glucose and water intake in cats that have achieved diabetic remission will help to alert the owner if the cat comes out of remission. Early institution of therapy is essential to maintain β-cell function. Some cats have several episodes of diabetic remission and relapse.

The serial blood glucose curve

Serial measurement of blood glucose every 1–2 h to generate a curve over 8–24 h is still the most accepted method to determine appropriate insulin dose adjustments. The curve should begin before insulin is administered and continue until one or two samples have been collected after recognition of a clear nadir, or continue until the next insulin injection is due. Either venous blood, from a central or peripheral vein, or capillary blood, from the pinna using a vacuum lancing device, is suitable for blood glucose measurement using a portable meter (Wess & Reusch, 2000). Serial blood glucose curves are usually performed in the veterinary hospital; however, the option of owners performing them at home using capillary blood glucose measurements has recently become available.

Cats should be allowed access to their usual food when obtaining a serial blood glucose curve. If the cat does not eat in hospital, blood glucose values may be lower than those obtained at home. Stress can substantially elevate blood glucose concentrations. If the cat struggles before or during blood collection, results are unlikely to reflect accurately the cat's glycaemic control, and the procedure should be repeated later. Some cats may need to be hospitalised for 12–24 h before a serial blood glucose curve to allow them to settle into a hospital environment; however, hospitalisation may increase stress in other cats and increases the cost to the client.

In diabetic cats, the glucose response to insulin can be frustratingly variable, both from day to day and over longer periods. It is not unusual for the nadir of serial blood glucose curves performed on consecutive days after the same dose of insulin to vary by 5 mmol/l (90 mg/dl) or more. Because of this, the results of these curves should be interpreted conservatively and only in the light of clinical findings before making insulin dose adjustments.

The nadir, or lowest blood glucose concentration obtained, indicates the maximum dose of insulin that can be tolerated by the cat. Mild to moderate hyperglycaemia in cats is well tolerated, whereas hypoglycaemia can be life threatening. Aiming for euglycaemia at most sample times increases the risk of hypoglycaemia at the nadir point and is likely to be achieved in only a minority of diabetic cats with currently available insulin preparations. Such cats probably have significant endogenous insulin secretion and may be managed with oral hypoglycaemic agents.

The recommended nadir to aim for in a serial blood glucose curve obtained in hospital is 5–9 mmol/l (90–160 mg/dl). If a lower nadir is obtained, the insulin dose should be reduced, usually by 1 U/cat. If a blood glucose reading less than 3 mmol/l (54 mg/dl) occurs, samples should be taken every 30–60 min until the blood glucose rises, and the cat should be closely observed for signs of hypoglycaemia. If signs of hypoglycaemia occur, intravenous administration of 1 ml of 50% dextrose solution may be required. If a nadir greater than the target range is obtained, the insulin dose should be increased, usually by 1 U/cat. A summary of the use and interpretation of serial blood glucose curves in diabetic cats is given in Table 20.5.

Problem solving when there is failure to achieve control of clinical signs

One of the most frequently encountered problems when treating diabetic cats is failure to achieve adequate

Table 20.5 Monitoring the diabetic cat: a summary of how to obtain blood glucose curves, interpretation and adjusting the insulin dose

Measuring blood glucose	Ensure that stress and struggle are minimised Use venous catheters, a 25–29 G needle or vacuum-assisted lances to obtain multiple samples atraumatically
	Portable blood glucose meters are suitable for performing blood glucose curves in a clinic or home setting
	Feed the cat as usual
	Measure blood glucose immediately before insulin is given, then every 2 h
	Preferably follow the blood glucose through to the next insulin dose (12 or 24 h later)
	If this is not possible, follow the blood glucose until it comes back close to baseline or until after a nadir is clearly evident
	If the blood glucose drops below 72 mg/dl (4.0 mmol/l) take more frequent samples to ensure hypoglycaemia is avoided. Administer oral or parenteral glucose if clinical signs occur
Interpreting blood glucose curves	Parameters that can be determined from the serial blood glucose curve include baseline blood glucose concentration, blood glucose concentration at nadir, time to reach nadir blood glucose and the mean blood glucose. The difference between baseline and nadir may be measured, as well as the time taken for the blood glucose to return to baseline concentration
	The nadir of blood glucose concentration is the most important parameter for determining insulin dose rate changes, as it determines whether the dose can be safely increased, or if the dose needs to be reduced
	The time taken to reach blood glucose nadir and the time taken to return to baseline blood glucose concentration are used to determine the dose frequency and the insulin type
	The difference between baseline and nadir of blood glucose concentration can be used to determine how responsive the cat is to given doses of insulin
	The mean blood glucose gives a measure of the overall diabetic control
Changes in insulin	Twice-daily administration is recommended in most cats.
	If the nadir of blood glucose is persistently occurring within 2 or 3 h of injection, and clinical signs are unresolved, a longer acting insulin should be used or more frequent dosing
	Insulin dose rate changes should be made conservatively. Where indicated, dose increases should be made at 2–4 week intervals and 1 U at a time
	The target for treatment is to achieve a blood glucose concentration of 90–160 mg/dl (5.0–9.0 mmol/l) at nadir. If the nadir is greater than 160 mg/dl (9.0 mmol/l), the insulin dose should be increased by 1 U, and if it is less than 90 mg/dl (5.0 mmol/l) the dose should be decreased by 1 U
	Daily changes in insulin dose based on food intake are not recommended
	If the cat shows a reduced or lack of appetite for more than 12–24 h at home, the veterinarian should examine the cat

From Rand & Martin (2001), with permission from W.B. Saunders.

control of clinical signs. Although it typically will take 1–4 months to achieve good glycaemic control, gradual clinical improvement should be evident soon after initiation of therapy. If this does not occur, the cat should be carefully evaluated before a decision is made to increase the insulin dose above 1 U/kg per injection. Possible reasons for failing to respond to therapy include insulin administration problems, concurrent disease, inadequate insulin dose, excessive insulin dose and the use of an insulin preparation with an inadequate duration of action for the dosing frequency.

The first step in the assessment of a cat showing a poor response to insulin therapy is to review the owner's injection technique. Confusion regarding dose calculation is common, particularly when 40 U/ml insulin is administered using a syringe designed for

measurement of 100 U/ml insulin. Inadequate mixing of insulin suspensions or inclusion of air bubbles in the syringe may also result in dosing errors. The storage conditions of the insulin bottle should also be reviewed, as heat-affected insulin will be less potent. Old bottles of insulin should be discarded and replaced with a new bottle.

The next step is careful evaluation for concurrent disease. Diabetic cats tend to be elderly and are prone to diseases that affect this age group. Infections, particularly of the urinary tract and oral cavity, and neoplasia may occur and be associated with poor glycaemic control. Water intake should be measured and a serial blood glucose curve obtained. Episodes of hypoglycaemia resulting from insulin overdose can be brief and may be followed by pronounced hyperglycaemia. It is possible to miss a period of hypoglycaemia if blood samples are collected every 2 h around the nadir. The curve may be mistakenly interpreted to indicate that the cat is receiving an inadequate insulin dose. To avoid this, blood samples should be collected every 30 min whenever the blood glucose concentration is falling rapidly. Stress hyperglycaemia may also cause problems with interpretation, and measurement of water intake or fructosamine concentration can be useful to identify suspected cats.

A more reliable response to therapy is achieved with most insulin preparations when they are administered on a twice-daily basis. Even longer-acting insulins, such as PZI or ultralente, may have an inadequate duration of action for once-daily dosing. Some cats may have poor absorption of longer acting insulins and show an improved response when they are changed to NPH or lente insulin. Some cats on NPH and a few on lente insulin have too short a duration of action to provide good clinical control. Hyperglycaemia is present much of the time, but increasing the insulin dose results in hypoglycaemia. Serial blood glucose curves will identify an early nadir at 2–3 h and changing to a longer acting insulin is often effective. An early nadir and short duration of action can also result from an excessive insulin dose. If the insulin dose is higher than 0.5 U/kg per injection, the dose should be decreased first and water intake or blood glucose measured after 7–10 days to determine whether control is better at a lower dose.

Prognosis

Although the majority of cats are insulin dependent, about one-third can achieve remission of their diabetes if good glycaemic control is achieved. Diabetic cats that do not achieve remission can be maintained with good quality of life on long-term insulin therapy. Nevertheless, a significant proportion of cats diagnosed with diabetes survive for less than 12 months (Kraus *et al.*, 1997; Goossens *et al.*, 1998). This is because many diabetic cats are elderly and have concurrent disease. Factors that reduce survival time include diabetic ketoacidosis at diagnosis, poor glycaemic control and the presence of concurrent disease, particularly renal failure.

Summary of key points

The majority of diabetic cats have a form of diabetes analogous to human type 2 diabetes. A minority have other specific types of diabetes, including diabetes secondary to pancreatic adenocarcinoma, hyperadrenocorticism and acromegaly. Type 2 diabetes is characterised by insulin resistance and inadequate insulin secretion. Insulin administration is the mainstay of therapy, and good clinical control can be achieved in most cats with NPH, lente, ultralente or PZI insulins. Problem cats with inadequate duration of insulin action may achieve better glycemic control with the new long-acting insulin analogue, glargine. The recommended starting dose for all insulins is 0.25–0.5 U/kg twice daily. It is recommended to aim for a nadir (lowest blood glucose after insulin administration) of 5–9 mmol/l (90–160 mg/dl). The insulin dose is increased by 1 U every 2 weeks until a nadir between 5 and 9 mmol/l (90–160 mg/dl) is achieved. If signs of hypoglycaemia occur, the cat should be re-evaluated. Some cats will have achieved remission and require no further insulin therapy. Others will require a lower insulin dose. It is important to monitor the cat's clinical signs at home, including water intake and urine glucose. Oral hypoglycaemic agents are successful as sole therapeutic agents in a minority of diabetic cats. Combination therapy, for example, insulin with an oral hypoglycaemic agent, may be used increasingly in the future to treat diabetic cats. Recent data suggest that a high-protein, low-carbohydrate diet results in increased frequency of diabetic remission, and that cats changed to this type of diet may need their insulin dose decreased.

Feline acromegaly

Acromegaly is a disease of growth hormone excess characterised by overgrowth of connective tissue, bone and viscera. Although an uncommon disease of cats, it is an important consideration in unregulated diabetic cats with marked insulin resistance. In cats, as in humans, acromegaly is caused by a growth

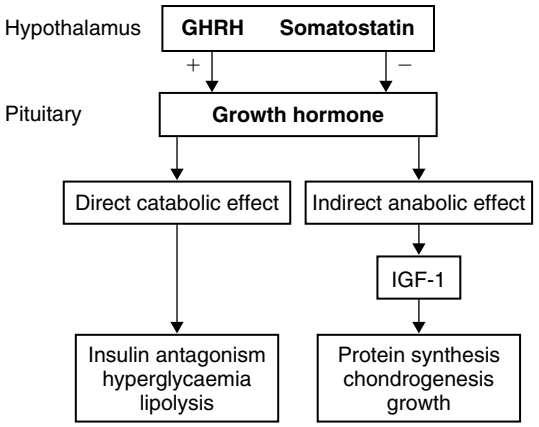

Figure 20.5 The hypothalamic–pituitary–growth hormone axis and its effects. GHRH: growth hormone-releasing hormone; IGF-1: insulin-like growth factor-1; +/−: stimulation/inhibition (negative feedback).

hormone-secreting pituitary tumour. Unlike the situation in dogs, progesterone and progestagens do not stimulate growth hormone overproduction in cats and the diabetogenic effect of these drugs is related to their inherent glucocorticoid effect.

Growth hormone has both anabolic and catabolic effects. The anabolic effects are presumably mediated through insulin-like growth factor 1 (IGF-1) and its catabolic effects are primarily attributed to insulin antagonism (Figure 20.5). In cases of growth hormone excess, the clinical features exhibited will reflect both of these effects.

Recognising acromegaly

Acromegaly is a disorder of middle-aged to ageing cats. Most reported cases are of mixed breed and the majority are male, suggesting a sex predisposition (Peterson *et al.*, 1990).

The most obvious and common clinical manifestation of acromegaly is insulin-resistant diabetes mellitus. Affected cats exhibit persistent polyuria and polydipsia despite the administration of often extremely high insulin doses (>20 IU/injection).

There are many other possible causes of insulin resistance in cats, but recognition of certain clinical features may provide supportive evidence of acromegaly. Excess growth hormone induces gross conformational change and can have marked effects on the skeletal, cardiac and renal systems. The underlying pituitary lesion may ultimately give rise to neurological signs.

Despite poor glycaemic control, affected cats tend to gain rather than lose weight and the development of ketoacidosis appears to be rare. Usually there is a combination of enlargement of the mandible leading to prognathism, tongue hypertrophy, increased dental spacing and eventual overall enlargement of the head, with gradual bowing of the hard palate. Radiographically, there is marked thickening of the bony ridges of the calvarium together with severe spondylosis in some affected cats. In a few cats with acromegaly, articular changes are severe and can be crippling. These initially result from fibrous thickening of the joint capsule and related structures and from bony and cartilaginous proliferation, and will eventually lead to degenerative joint disease.

Hypertrophic cardiomyopathy is another possible sequela to chronic growth hormone excess and results in systolic murmurs, gallop rhythms and eventually signs of overt congestive cardiac failure.

Renal hypertrophy may also develop and eventually leads to the development of azotaemia, proteinuria and clinical signs of renal failure. It is unclear whether this is a direct effect of chronic hormone excess, unregulated diabetes mellitus or a combination.

In cases where the pituitary tumour enlarges, neurological signs may develop because of compression and/or invasion of structures (usually hypothalamus and/or thalamus) dorsal to the pituitary gland. Resultant signs include somnolence, stupor, anorexia and less commonly circling, temperature deregulation, seizures and behavioural changes.

Diagnosing acromegaly

The most common routine clinicopathological abnormalities in acromegalic cats reflect insulin-resistant diabetes mellitus and include hyperglycaemia, glucosuria, hypercholesterolaemia, mild elevations in the liver enzymes ALKP and ALT, and increased circulating fructosamine concentration. Abnormalities specifically induced by growth hormone excess include hyperphosphataemia, hyperproteinaemia and mild erythrocytosis. The latter is presumably induced by the anabolic effects of growth hormone on bone marrow, while the former results from growth hormone-induced phosphate resorption by the kidneys. The mechanism of the hyperproteinaemia, of normal electrophoretic pattern, remains unclear. Azotaemia develops in cats with renal failure.

In the presence of appropriate clinical signs, a single elevated growth hormone concentration is adequate for a definitive diagnosis (Table 20.6).

Table 20.6 Interpretation of circulating growth hormone (GH) and insulin-like growth factor-1 (IGF-1) concentrations in acromegalic cats

	Reference range	Acromegaly	Precautions
GH (μg/l)	2–5	>6, usually >20	Occasional high values in non-acromegalic cats
IGF-1 (ng/ml)	200–800	>1000	Occasionally values <1000 in early cases

These are guideline ranges only. Reference ranges are laboratory specific.

In affected cats, basal circulating growth hormone concentrations are usually well above the reference range. However, analysis of growth hormone concentration can be problematic. A species-specific assay must be used, currently of limited availability. In addition, acromegalic cats may exhibit only mildly elevated or reference range growth hormone concentrations. Mildly elevated circulating concentrations are also reported in other illnesses, particularly hypertrophic cardiomyopathy, and may occur as a result of a secretory burst in healthy individuals. However, circulating IGF-1 concentrations are strongly correlated with non-pulsatile integrated 24 h growth hormone concentration and its measurement offers a useful alternative diagnostic test for acromegaly. IGF-1 assays are non-species specific and relatively freely available compared with growth hormone assays, and concentrations usually well exceed the reference range in acromegalic cats. Occasionally, reference range values are found in acromegalic cats despite elevated growth hormone concentrations. Such cases may be in the early stages without marked insulin resistance. IGF-1 values usually increase into the diagnostic range on retesting weeks to months later (Norman & Mooney, 2000).

Computed tomography (CT) or magnetic resonance imaging (MRI) can be employed to depict a pituitary mass. Although providing no information on the function of the tumour, its existence in an insulin-resistant diabetic cat with appropriate clinical signs is highly supportive of acromegaly.

Treating acromegaly

Acromegaly can be treated surgically, medically or by external beam radiotherapy. Because of the paucity of cases, none of these has been clearly evaluated. Hypophysectomy is a recognised treatment option for humans with acromegaly, but has not been investigated in cats. However, successful cryohypophysectomy has been described in one acromegalic cat, and repeated cobalt-60 irradiation has resulted in improved glycaemic control and reversal of the diabetic state in some cats. Octreotide, a somatostatin analogue, appears to have limited effect on growth hormone concentration in acromegalic cats.

Despite the limited availability of specific treatments, many acromegalic cats can survive for months to years with reasonable control of the diabetic state using high doses of insulin. The maximum dose of insulin used in an acromegalic cat is reported as 130 U/day, although some authors have suggested attempting to limit the maximum dose to approximately 15 U/injection to avoid hypoglycaemia from potential fluctuation of growth hormone. Death usually results from the development of uncompensated renal failure, cardiac failure or, less commonly, the development of progressive neurological signs because of expansion of the underlying pituitary tumour.

Feline hyperadrenocorticism

Hyperadrenocorticism is a disease of cortisol excess resulting from a functioning adrenal tumour or inappropriate adrenocorticotropic hormone (ACTH) production by an abnormal pituitary gland. Although less common in the cat than in the dog, the disease shares some similarities. The majority (>80%) result from an autonomously functioning pituitary tumour (usually adenoma) that in turn results in bilateral adrenal hyperplasia [pituitary-dependent hyperadrenocorticism (PDH)], while adrenal tumours (either adenoma or carcinoma) are less common (Duesberg & Peterson, 1997). The resultant excess cortisol production has a variety of consequences but in cats its diabetogenic effect predominates. Most (>80%) cats therefore present with diabetes mellitus that is often poorly regulated. However, unlike acromegaly, affected cats also present with signs of debilitation as manifested by weakness, weight loss and extreme skin fragility and its attendant complications.

Recognising hyperadrenocorticism

Hyperadrenocorticism is a disorder of middle-aged to ageing cats with no apparent breed predilection. There is an approximately equal distribution of females and males.

Table 20.7 Common protocols and methods of interpretation for the dynamic adrenal function tests used for investigating hyperadrenocorticism

	ACTH stimulation	Dexamethasone suppression	Combined tests
Drug	Tetracrosactrin	Dexamethasone	Dexamethasone and tetracosactrin
Dose	125 μg < 5 kg 250 μg < 5 kg i.v.	0.1 mg/kg i.v.	0.1 mg/kg and 125 μg at 2 h i.v.
Sample times	Basal and 1 h	Basal, 3–4 and 8 h	Basal, 2 and 3 h
Measurement	Cortisol	Cortisol	Cortisol
Interpretation for hyperadrenocorticism	1 h > 450 nmol/l	8 h < 30 nmol/l	2 h < 50% suppression and 3 h > 450 nmol/l

The ranges quoted are guidelines only and are laboratory specific. ACTH: adrenocorticotropic hormone.

The most common clinical features are polyuria, polydipsia and polyphagia. These signs are largely attributed to concurrent insulin-resistant diabetes mellitus. However, some cats are presented before the onset of diabetes mellitus and in others the diabetic state is well controlled. The existence of polyuria/polydipsia and polyphagia is variable in these animals and, when present, can precede the development of diabetes mellitus by several weeks to months (Watson & Herrtage, 1998). Obesity has been described, particularly in the early stages, but this is not always present nor is it persistent. However, most cats exhibit a marked pot belly as a result of muscle weakness, fat redistribution and in some hepatomegaly. Dermatological abnormalities in the cat are also common. These include truncal alopecia, hyperpigmentation and seborrhoea. However, more importantly, extremely thin and fragile skin develops in approximately half of affected cats. The skin tears easily during routine procedures such as injecting, restraint and clipping, and the skin is liable to severe secondary infection and repeated wound breakdown. These changes, together with a poorly regulated diabetic state, often prompt the investigation for hyperadrenocorticism.

Diagnosing hyperadrenocorticism

The classical haematological abnormalities (neutrophilia, lymphopenia, monocytosis and eosinopenia) associated with hyperadrenocorticism in the dog are not consistent in the cat. Hyperglycaemia, glucosuria, mild increases in circulating ALT concentration and hypercholesterolaemia are common, but presumably reflect the diabetic state. It has been suggested that that these abnormalities may reverse with insulin treatment alone, but some non-diabetic cats with hyperadrenocorticism have also been shown to have mild elevations in liver enzymes. However, the marked increase in ALKP concentration characteristic of hyperadrenocorticism in dogs does not occur in cats because a specific steroid-induced isoenzyme does not exist in this species. Urine specific gravity is usually greater than 1.020, but is complicated by the glucosuria found in many cases.

Demonstration of excess cortisol production is necessary to confirm a diagnosis of hyperadrenocorticism, but as in dogs adrenal function tests must be interpreted cautiously (Table 20.7). Measurement of basal circulating cortisol concentration is of no diagnostic value because of the overlap in test results between healthy cats and those with hyperadrenocorticism and non-adrenal illness. The urine cortisol:creatinine ratio (UCCR) is increased in cats with hyperadrenocorticism. However, clinical illness and hospitalisation also increase this ratio, limiting its diagnostic usefulness.

The ACTH stimulation test is easy to perform and relatively inexpensive. Blood samples are collected for cortisol estimation before and after synthetic ACTH (tetracosactrin) administration (Schoeman *et al.*, 2000). Tetracosactrin can be administered intravenously or intramuscularly, but the former is associated with a higher circulating ACTH concentration and is preferred. Although reports vary on when peak cortisol concentration occurs, there is general agreement that a 60 min sample is sufficient. A dose of 0.125 mg tetracosactrin is administered, but can be increased to 0.25 mg in larger cats. A post-ACTH cortisol concentration that is markedly above the reference range is expected. However, as in the dog, false-negative results may occur in some cats with hyperadrenocorticism and false-positive results are problematic in cats with non-adrenal illness.

Compared with dogs, cats appear to be more resistant to suppression of cortisol by dexamethasone. A low dose of dexamethasone (0.015 mg/kg) administered intravenously suppresses cortisol concentration for at least 8 h in healthy cats and fails to suppress cortisol concentration in cats with hyperadrenocorticism. However, higher doses (0.1 mg/kg) are required to suppress cortisol concentrations reliably in cats with non-adrenal illness. Most, but not all, cats with hyperadrenocorticism show inadequate cortisol suppression using this dose. A combination of dexamethasone suppression and ACTH stimulation testing has also been recommended. A blood sample for cortisol estimation is taken immediately before the intravenous injection of 0.1 mg/kg dexamethasone. A blood sample is obtained 2 h later, tetracosactrin immediately administered intravenously and a further sample obtained 1 h later. Most cats with hyperadrenocorticism will not exhibit cortisol suppression after dexamethasone and will exhibit an exaggerated response to tetracosactrin. Although useful in decreasing the number of tests performed and samples obtained from individual cats, the effects of non-adrenal illness on test results are similar to either test alone and as of yet large numbers of cats with hyperadrenocorticism have not been studied to assess clearly its diagnostic performance.

Extremely high doses of dexamethasone (1.0 mg/kg) have been suggested to be useful in differentiating PDH from adrenal tumours, but there are limited data to recommend widespread use. Measurement of endogenous ACTH concentration may provide more useful information. Cats with adrenal tumours have low to undetectable circulating ACTH concentration, whereas cats with PDH have inappropriately elevated values. Given the wide range of values found in healthy animals, plasma ACTH concentration can only be reliably interpreted after a diagnosis of hyperadrenocorticism has been confirmed. Endogenous ACTH is rapidly degraded after collection and special sampling handling procedures must be followed. These usually involve collection in cooled plastic EDTA tubes, chilled centrifugation and rapid freezing. Specific guidelines can be obtained from individual laboratories.

Diagnostic imaging is probably the most efficient means of differentiating adrenal tumours from PDH. Abdominal radiography is only capable of revealing extremely large adrenal tumours and as these tend to be rare, it has limited investigative value. Unlike in dogs, adrenal calcification is a normal age-associated feature in cats and should not be misinterpreted as evidence of adrenal neoplasia. However, radiography may be useful to depict distant metastatic spread from an adrenal carcinoma. Abdominal ultrasonography is a more useful tool for depicting overall size and shape of adrenal glands and both glands are reportedly easier to image in cats than in dogs. In cats with functioning adrenal tumours, a large mass on the affected side and a contralateral small, often undetectable, adrenal gland are expected. The normal shape, architecture and echogenicity of the affected gland may be disturbed and there may be evidence of local metastatic spread to the liver, kidney and/or great vessels. With PDH, both glands will be visible and relatively symmetrical. With PDH or adrenal tumours there may be marked and diffuse hyperechogenicity of the liver associated with steroid-induced hepatopathy.

Both CT and MRI can be used to depict pituitary masses but are expensive. MRI is associated with superior anatomical resolution and soft-tissue contrast compared with CT scans, and therefore is more useful for imaging adrenal glands. Like other imaging techniques, MRI cannot distinguish between adrenal adenomas and carcinomas in the absence of metastatic spread.

Treating hyperadrenocorticism

Effective treatment of cats with hyperadrenocorticism is complicated. Treatment has been attempted with unilateral and bilateral adrenalectomy, hypophysectomy, cobalt irradiation and various different drugs, all with varying success rates and adverse reactions. Untreated cats succumb to the deleterious effects of hypercortisolaemia within weeks to months. These effects primarily relate to open skin wounds and immunosuppression predisposing the cat to infections, insulin resistance and cardiovascular complications resulting in hypertension, congestive cardiac failure and thromboembolism.

Ketoconoazole, metyrapone and mitotane (o,p′-DDD) have all been attempted in affected cats but none has gained widespread acceptance. At appropriate doses, mitotane causes selective necrosis and atrophy of the zona fasciculata and reticularis of the adrenal cortex. In general, the use of mitotane has been discouraged because of the potential sensitivity of cats to the toxic effects of chlorinated hydrocarbons. However, adverse reactions have not been noted in healthy cats treated with between 25 and 50 mg/kg daily for 7 days. Despite this, it appears that this drug is not as effective as in dogs and that high doses may be required for prolonged periods before cortisol production is sufficiently suppressed. Ketoconazole, an imidazole antifungal agent, reversibly blocks steroid

synthesis in the adrenal gland and gonads but has unpredictable effects in healthy cats and those with hyperadrenocorticism. Metyrapone inhibits the 11-β-hydroxylase enzyme responsible for the conversion of 11-desoxycortisol to cortisol and appears to rapidly correct hypercortisolaemia in cats with hyperadrenocorticism. As such, it may be useful in the stabilisation period before surgery, but there are limited data on long-term efficacy, and availability of the drug is limited. Its effect may be short-lived as the ACTH concentration increases and overwhelms the enzymic block. Of the other drugs used in the treatment of canine hyperadrenocorticism, including levodeprenyl (monamine oxidase B inhibitor) and trilostane (3β-hydroxysteroid dehydrogenase inhibitor), neither has been clearly evaluated in cats. Cobalt-60 irradiation of pituitary lesions has also had limited success in treating cats with hyperadrenocorticism.

As a consequence of the variable efficacy of the treatment methods described above, surgical adrenalectomy is considered the treatment of choice for cats with hyperadrenocorticism. Unilateral adrenalectomy is usually successful in cats with adrenal adenomas or resectable carcinomas, whereas bilateral adrenalectomy is required in cats with PDH. In cats with PDH, both glucocorticoid and mineralocorticoid supplementation is initiated before surgery and continued for life. The prevalence of postoperative complications and mortality are high, and include electrolyte disturbances, hypoglycaemia, pancreatitis, sepsis, pneumonia and thromboembolism. Many of these complications are directly related to hypercortisolaemia and could be reduced by appropriate preoperative management. Long-term survival is highly dependent on good owner compliance in regularly administering mineralocorticoid replacement therapy.

Microsurgical transsphenoidal hypophysectomy has been attempted in a small number of cats with PDH (Meij *et al.*, 2001). Although technically difficult and requiring advanced imaging techniques, postoperative mortality may be less and long-term survival greater than for bilateral adrenalectomy. Desmopressin therapy is only required temporarily after surgery and thyroxine therapy is required long term.

Regardless of treatment modality, if cortisol production is sufficiently suppressed, insulin antagonism is reversed and insulin doses must be adjusted accordingly to prevent hypoglycaemia. In some cats, there is improved regulation of diabetes mellitus and in other cases insulin requirements resolve completely. Recurrence of the hyperadrenocorticism is possible and regular monitoring is required.

Unusual forms of hyperadrenocorticism

Iatrogenic hyperadrenocorticism is a potential complication of inappropriate glucocorticoid administration. However, cats appear to be more resistant than dogs to its development. Clinical signs are similar to the naturally occurring condition, although they tend to be less severe and the classical skin changes may not develop. Despite this, suppression of the pituitary–adrenal axis readily occurs in cats treated with glucocorticoids. Megestrol acetate, a progestagenic compound commonly used for a variety of dermatological and behavioural disorders in cats, produces more profound and marked suppression of the adrenal–pituitary axis than glucocorticoids. With both types of drug, clinical signs of hypocortisolaemia potentially develop if the drugs are rapidly withdrawn, particularly if the cat is stressed.

Hyperprogestonaemia, rather than hypercortisolaemia, has been described in a few rare cases of adrenal tumours. Affected cats have similar clinical signs to the classical hyperadrenocorticoid cat, but lack evidence of excess cortisol production in response to ACTH stimulation. Instead concentrations of cortisol precursors such as progesterone and 17α-hydroxyprogesterone may be increased. Although aminoglutethimide (inhibitor of the cholesterol side-chain cleavage enzyme necessary for steroid production) has been used with some short-term effect in one affected cat, its safety is unclear. Given that these cases have adrenal tumours, surgical adrenalectomy would appear to be a better choice.

Feline hypoadrenocorticism

Primary hypoadrenocorticism results from deficient adrenal production of glucocorticoids alone (atypical Addison's disease) or together with mineralocorticoids (Addison's disease). Glucocorticoid deficiency can also occur as a result of impaired secretion of ACTH from the pituitary gland. This is referred to as secondary hypoadrenocorticism and in clinical practice is most commonly associated with abrupt withdrawal from exogenous glucocorticoid or progestagen therapy.

Atypical Addison's disease has not yet been described in the cat and Addison's disease appears to be extremely rare, with fewer than 30 cases reported in the literature (Duesberg & Peterson, 1997; Peterson *et al.*, 1989). In only four cases there was a clearly defined cause (trauma and lymphoma in two cases each) and the

disorder is therefore usually referred to as idiopathic. However, lymphocytic infiltration of the adrenal gland has been noted, suggesting that there is an immune-mediated component in the cat as in the dog.

Recognising hypoadrenocorticism

Most affected cats are middle-aged to older, although hypoadrenocorticism has been recognised in cats as young as 1.5 years. It has been described in cats of mixed breed and one British shorthair, and in both sexes. Given the relative paucity of case reports, no firm conclusions can be drawn from these data.

Clinically, hypoadrenocorticism is difficult to recognise because of the poor specificity of the signs. The most common signs (>50% of cases) recognised by owners include lethargy, anorexia, weight loss and vomiting. Polyuria and polydipsia are recognised less frequently, and signs such as ataxia and dysphagia, presumably manifestations of muscle weakness, and muscle tremors are described infrequently. Diarrhoea has not been described in cats. The clinical signs may wax and wane and a temporary remission may occur with symptomatic therapy. On physical examination, the most commonly recognised features (>50% of cases) include depression, dehydration, weakness and hypothermia. Less frequently, a slow capillary refill time and weak pulse are recognised. Signs such as collapse, bradycardia, pallor and abdominal discomfort, often observed in dogs, are infrequent in cats.

Diagnosing hypoadrenocorticism

Thoracic radiography reveals microcardia and hypoperfusion of the lungs in over 50% of cases, resulting from dehydration, hypovolaemia and hypotension secondary to hypoadrenocorticism. Electrocardiographic changes are infrequent and only sinus bradycardia and atrial premature contractions have been described. The electrocardiographic changes commonly associated with hyperkalaemia in the dog, including peaking of the T waves, decreased R-wave amplitude, reduced or absent P wave and atrial standstill, have not been described in cats. This may be related to the milder hyperkalaemia noted in cats compared with dogs.

Hypoadrenocorticism is classically associated with a non-regenerative anaemia and a reverse stress leucogram characterised by absolute lymphocytosis and eosinophilia. However, in cats these changes are inconsistent. Approximately one-third develop a mild non-regenerative anaemia, but only a few exhibit absolute lymphocytosis and only rarely eosinophilia. Unfortunately, lymphocytosis may also occur in sick cats and it is therefore a non-specific marker of hypoadrenocorticism in this species. Maintenance of a normal eosinophil count in an extremely sick animal provides supportive evidence of hypoadrenocorticism in cats, as it does in dogs.

The majority of cats with hypoadrenocorticsm exhibit the classical electrolyte changes of hyperkalaemia, hyponatraemia and hypochloraemia. The sodium:potassium ratio is usually less than 23:1. However, the hyperkalaemia rarely exceeds 6.5–7.0 mmol/l. In addition to the electrolyte changes, hypoadrenocorticism is invariably associated with marked hypovolaemia and as a result most cats present with prerenal azotaemia and hyperphosphataemia. A few cats present with hypoglycaemia or mild acidosis, but hypercalcaemia appears to be less common in cats than in dogs.

The above combination of biochemical abnormalities has several differentials including both acute and terminal chronic renal failure. Potential causes of hyperkalaemia include:

- decreased renal elimination
  - renal failure (acute/chronic)
  - urethral obstruction
  - lower urinary tract rupture
  - hypoadrenocorticism
- diffuse cell death
- translocation
  - metabolic acidosis
- increased intake
  - potassium infusions
  - peritoneal effusion
- laboratory error.

Unfortunately, cats with hypoadrenocorticism exhibit reduced urine-concentrating ability, presumably resulting from sodium wasting. In only a few cases is concentrating ability maintained and estimation of urine specific gravity helpful in eliminating primary renal disease. In dogs, hyperkalaemia and hyponatraemia have also been associated with other disorders, including gastrointestinal disease (predominantly whipworm infestations), pregnancy, external blood loss and chylothorax with repeat drainage. In cats this phenomenon is infrequently recognised, although in a few cats with peritoneal effusion, hyperkalaemia and hyponatraemia have been described.

A definitive diagnosis of hypoadrenocorticism is dependent on depicting a low circulating cortisol concentration that fails to respond to exogenous ACTH administration. Typically, cortisol values both before

and after ACTH administration are undetectable. Plasma endogenous ACTH concentrations are usually extremely elevated (10–70 × reference range) in affected cats and although alone are not diagnostic of hypoadrenocorticism, they provide evidence of primary adrenocortical failure.

Treating hypoadrenocorticism

Initial therapy is aimed at restoring circulating fluid volume, correcting electrolyte disturbances, and providing glucocorticoid and mineralocorticoid replacement. Unless initially hypoglycaemic, 0.9% saline is the intravenous fluid of choice. Large volumes are initially administered (40 ml/kg per hour) for the first 1–2 h and the rate is subsequently decreased to account for dehydration and maintenance requirements. Intravenous fluid therapy is continued and then tapered once the azotaemia and the electrolyte imbalances are resolved and the cat is eating and drinking normally.

Rapid concurrent intravenous administration of a glucocorticoid preparation is usually recommended. Often dexamethasone is used (0.5–1.0 mg/kg every 6–12 h) as it does not interfere with ACTH response testing. However, it has minimal mineralocorticoid activity. Hydrocortisone as sodium succinate has increased mineralocorticoid activity and can be used once the ACTH response test has been completed. Although reports are limited, an infusion of 0.5–0.625 mg/kg as recommended in the dog should be sufficient. Once the cat is eating, oral supplementation commences using prednisolone (0.2 mg/kg per day) and fludrocortisone (0.1 mg/day). Alternatively, mineralocorticoid replacement can be achieved using repositol desoxycortisone pivalate (DOCP) at a dosage of 12.5 mg/cat i.m.

In dogs, the major clinical signs of hypoadrenocorticism resolve rapidly with appropriate treatment. In cats, weakness, lethargy and anorexia may persist for 3–5 days despite appropriate therapy.

Once stabilised, maintenance therapy consists of life-long mineralocorticoid supplementation using daily fludrocortisone (0.1 mg/cat) or monthly intramuscular administration of DOCP (12.5 mg/cat). Dosages are subsequently adjusted based on circulating electrolyte concentrations taken every 1–2 weeks initially and every 3–6 months thereafter. Concurrent glucocorticoid supplementation is usually recommended using prednisolone at a dose of 0.2 mg/kg per day. In cats difficult to pill, intramuscular methylprednisolone acetate can be used at a dose of 10 mg/month, although this increases the risk of iatrogenic hyperadrenocorticism. Glucocorticoid supplementation may not be required in all cases, but a source should be provided for use during times of stress. Providing treatment is maintained the long-term prognosis for affected cats is excellent.

Feline hyperaldosteronism

Primary hyperaldosteronism, or Conn's syndrome, is defined as an overproduction of the hormone aldosterone by the zona glomerulosa of the adrenal cortex (Figure 20.6). This leads to a number of electrolyte, cardiac and metabolic disturbances. These disturbances are not pathognomonic for primary hyperaldosteronism, but can potentially result from a variety of other disorders. Often considered rare, with less than a dozen well-documented cases, it may be more common than previously thought (Ahn, 1994; Duesberg & Peterson, 1997).

In humans hyperaldosteronism is usually caused by a solitary unilateral adenoma or idiopathic bilateral adrenal hyperplasia, while adrenal carcinoma appears to be rare. A unilateral adrenal mass has been identified in all affected cats and where histopathological diagnosis has been achieved, the prevalence of adrenal carcinoma has predominated.

Aldosterone excess results in sodium retention, expansion of the extracellular fluid volume, suppression of the renin–angiotensin system through negative feedback, potassium depletion and eventual metabolic alkalosis because of the resultant intracellular shift and increased renal excretion of hydrogen ions. Hypertension results from volume expansion together with increased vascular resistance. Hypokalaemia impairs renal concentrating ability and may eventually result in kaliopenic nephropathy.

Recognising hyperaldosteronism

Affected cats are of either sex and any breed, but tend to be older, most documented cases being in excess of 10 years of age.

The clinical manifestations tend to be related to either hypokalaemia or hypertension or both. Cats with hypokalaemia present with weakness and ataxia which progresses to dysphagia and the characteristic cervical ventroflexion. When hypertension is the primary complaint, cats present with blindness associated with retinal detachment, and cardiac murmurs are often auscultated. Polyuria and polydipsia may be a feature in all cases.

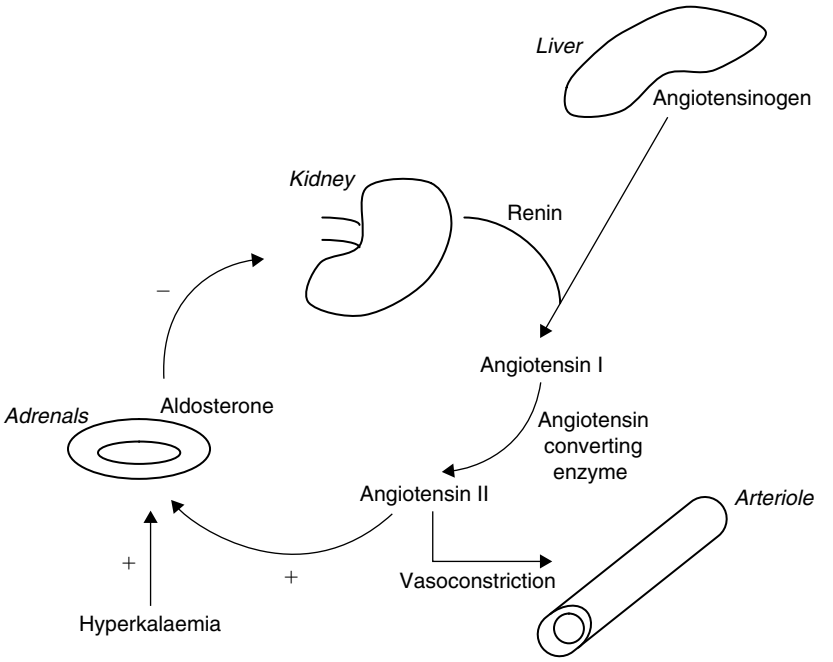

Figure 20.6 Control of aldosterone production (+/−; stimulation/inhibition (negative feedback)).

Diagnosing hyperaldosteronism

Cats exhibit marked hypokalaemia (circulating potassium <3.0 mmol/l) together with increased fractional excretion of potassium (kaliuresis). Circulating creatine kinase concentration is usually markedly elevated because of rhabdomyolyis and muscle cell membrane damage.

Hypertension, as assessed by indirect means, is mildly to severely elevated and left ventricular hypertrophy, presumably secondary to hypertension, may be evident on echocardiography. A variety of electrocardiographic abnormalities is possible with hypokalaemia, but relatively few (left anterior fascicular block and Mobitz type I second degree A-V block) have been described in cats.

Primary hyperaldosteronism is characterised by an elevated circulating concentration of aldosterone together with low or low-normal plasma renin activity. However, such hormone assays are not widely available and a presumptive diagnosis may have to rely on eliminating other causes of the presenting signs. Hypertension may be caused by a variety of other disorders, but usually these present in association with oedema. Hypokalaemia also has a number of differentials including renal disease which can be associated with hypertension. Potential causes of hypokalaemia include:

- decreased intake
  - prolonged anorexia
  - potassium poor intravenous fluids
- gastrointestinal loss
  - vomiting/diarrhoea
- translocation
  - metabolic alkalosis
  - insulin administration
- excessive renal loss
  - chronic renal failure
  - hyperaldosteronism
  - diabetic ketoacidosis
  - post lower urinary tract obstruction
  - excess glucocorticoid
  - diuretic therapy
- hyperthyroidism
- young Burmese cats
- laboratory error.

Many of these conditions are also associated with secondary hyperaldosteronism and variable plasma renin activity. However, in Conn's syndrome the hyperaldosteronism is usually extreme compared with

the moderate elevations associated with secondary processes and adrenal masses are usually easily found ultrasonographically in cats with this disorder.

Treating hyperaldosteronism

Surgical adrenalectomy is the treatment of choice, particularly if there is no evidence of metastatic spread in carcinoma cases. Medical management may be warranted for stabilisation before surgery and may be the treatment of choice for selected patients long term.

Initial treatment is aimed at alleviating hypokalaemia and this can be achieved using intravenous fluid therapy with potassium supplementation. Subsequently, oral potassium gluconate can be supplemented (2–6 mmol/cat per day) with adjustment depending on frequent, initially daily, potassium monitoring. Spironolactone, a powerful aldosterone receptor antagonist, may also be successful (2–4 mg/kg per day). Alternatively, amiloride, which inhibits the effects of aldosterone, may be used. Calcium channel blockers have been suggested to be useful in decreasing hypertension and aldosterone synthesis, but these effects have been variable in human patients. Specifically addressing metabolic alkalosis is not required as this is reversed upon adequate treatment of the hypokalaemia.

Feline hypoparathyroidism

Primary hypoparathyroidism is an extremely rare disorder in cats, with fewer than 10 cases described (Peterson *et al.*, 1991). The cause is unknown (idiopathic), but in a few cats parathyroid atrophy has been suggested. The young age at which some cats develop clinical signs suggests that parathyroid agenesis or dysgenesis may play a role.

Although the spontaneous condition is rare, hypoparathyroidism is an important disorder because it is a potential complication of bilateral thyroidectomy and occurs if all parathyroid tissue is injured, devascularised or inadvertently removed during the course of surgery. It is estimated that clinical hypoparathyroidism occurs in 10–30% of cats following bilateral thyroidectomy.

There are two parathyroid glands associated with each thyroid lobe: the internal (caudal) and external (cranial) glands. The parathyroid glands are principally concerned with calcium homoeostasis through the secretion of parathormone (PTH). PTH is secreted in response to hypocalcaemia and its actions serve to rapidly restore circulating calcium concentration. PTH performs its functions in three ways: stimulation of osteoclastic bone resorption of calcium and phosphorus, stimulation of increased calcium and decreased phosphorus reabsorption from the renal tubules, and activation of vitamin D, which in turn increases intestinal calcium absorption (Figure 20.7). Hypoparathyroidism therefore results in hypocalcaemia and hyperphosphataemia.

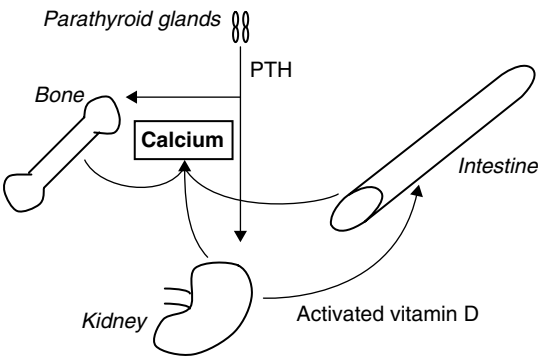

Figure 20.7 Schematic representation of the action of parathormone (PTH).

Recognising hypoparathyroidism

Idiopathic hypoparathyroidism is a disease of young adult cats from 6 months of any breed and either sex.

The disorder is characterised by an abrupt or gradual onset of intermittent neurological or neuromuscular disturbances including focal or generalised muscle tremors, weakness, ataxia and seizures. In addition, affected cats are generally anorexic, lethargic and dull or disorientated. Lenticular cataracts develop in over 50% of affected cases. These are recognised as small punctuate to linear opacities in the anterior or posterior subcapsular cortical region of the lens. While slowly progressive, visual impairment is rare because appropriate treatment of hypoparathyroidism halts their progression. Less common features include panting, pruritus, ptyalism, dysphagia, hypothermia and bradycardia.

Clinical signs of hypoparathyroidism are most likely to occur within 1–5 days of bilateral thyroidectomy. These signs include anorexia, vocalisation, irritability, muscle twitching, tetany and eventually generalised convulsions.

Diagnosing hypoparathyroidism

A variety of electrocardiographic changes is described with hypocalcaemia. However, in cats this is a crude way of estimating hypocalcaemia as relatively few exhibit any changes. Only sinus bradycardia and an increased Q-T interval have been described.

Confirmation of the diagnosis requires simultaneous measurement of circulating calcium, phosphate and PTH concentrations. Most laboratories measure total calcium concentration, which includes the ionised (50%), protein-bound (40%) and complex-bound (10%) fractions. Measurement of ionised calcium is preferred because it is not dependent on circulating protein concentration. However, providing the latter is not decreased, and particularly in the face of clinical signs, a definitive diagnosis of hypocalcaemia can be made with a total calcium estimation alone. In general, circulating total calcium concentration is extremely low once clinical signs are apparent (<1.5 mmol/l). However, because the effect of hypocalcaemia depends on both the severity and rate of change of calcium concentration, some cats with lower concentrations after bilateral thyroidectomy do not exhibit clinical signs and therefore do not require treatment. Concurrent phosphate concentration is generally within the high end of or above the reference range (>1.5 nmol/l).

There are few other conditions that cause clinical signs of hypocalcaemia and most of these are relatively easy to distinguish on clinical presentation alone:

- hypoalbuminaemia
- hypoparathyroidism
- ethylene glycol toxicity
- renal failure
- pancreatitis
- phosphate enema toxicosis
- eclampsia
- laboratory error.

However, if confirmation of hypoparathyroidism is required, circulating PTH concentration can be measured. It is important that a two-site intact assay is used. PTH is heat labile and special sample handling precautions are required. In both idiopathic and iatrogenic hypoparathyroidism, circulating PTH concentration is low or within the lower end of the reference range and inappropriate in the face of a low calcium concentration.

Treating hypoparathyroidism

The initial stage in therapy is to restore rapidly the circulating calcium concentration using the intravenous route (Table 20.8). Numerous parenteral calcium preparations are available. The calcium content is variable, but all are equally effective if doses are based on elemental calcium. Calcium chloride contains a greater calcium concentration than calcium gluconate, but

Table 20.8 Management of postoperative hypocalcaemia

	Acute	Subacute	Chronic	
Dose	10–15 mg/kg elemental calcium	60–90 mg/kg per day elemental calcium	50–75 mg/kg per day elemental calcium	Dihydrotachysterol
Route	Slow intravenous injection	Intravenous infusion	Oral	Oral
Directions	Equivalent to 1.0–1.5 ml/kg 10% calcium gluconate	25 ml of 10% calcium gluconate in 250 ml saline at 2.5 ml/kg per hour	Equivalent to 125–187 mg/kg per day calcium carbonate	0.03 mg/kg per day decreasing to 0.01 mg/kg per day or every other day
Alternatives	0.2–0.5 ml/kg 10% calcium chloride	Subcutaneous injection of acute dose diluted 1:1 in normal saline every 6–8 h	400–600 mg/kg per day calcium lactate	10–30 ng/kg per day of calcitriol or alfacalcidol
Precautions	Stop if bradycardia develops	Commence oral therapy concurrently	Measure serum calcium concentration regularly	

Reproduced with permission from Mooney (2001b).

tends to be extremely irritating if injected extravascularly and the latter is preferred. Calcium should be injected slowly over approximately 10–20 min to avoid cardiotoxicity. If bradycardia or electrocardiographic abnormalities (elevation of the S-T segment, shortening of the Q-T interval, premature ventricular contractions) develop, the infusion is slowed or discontinued. Tetany is rapidly corrected, but some clinical signs such as panting, nervousness, behavioural changes and hyperthermia may take longer to dissipate. Clinical signs are controlled variably for as little as 1 h or up to as long as 12 h. Oral supplementation is begun immediately but can take several days to increase circulating calcium concentration significantly. For this reason parenteral calcium administration is continued in the intervening period either through the use of a continuous infusion or through repeated subcutaneous injections of a diluted calcium gluconate solution. Normal saline is the diluting fluid of choice as precipitation of calcium salts occurs with fluids containing bicarbonate, lactate, acetate or phosphate. Frequent subcutaneous injections should be avoided as they increase the risk of iatrogenic calcinosis cutis.

Oral supplementation includes calcium and vitamin D. A more physiological treatment is administration of synthetic PTH, but this has not been attempted in cats and is unlikely to gain acceptance because of its high cost and requirement for repeated injections. Numerous calcium salts are available for oral use. Those with the highest calcium content are preferred, although calcium chloride is avoided because it tends to cause gastric irritation.

The most commonly recommended vitamin D preparations include ergocalciferol, dihydrotachsterol and calcitriol. Ergocalciferol is the cheapest and most readily available preparation, but extremely high pharmacological doses must be used in the absence of PTH for any effect. It is highly lipid soluble, requiring weeks to saturate body stores, and it has a long half-life, such that if hypercalcaemia occurs and the drug is withdrawn, several weeks are required before its effects dissipate. Dihydrotachysterol is a synthetic analogue of vitamin D, possessing both 1α and 25-hydroxy groups. It has a quicker onset of action and a shorter time for dissipation of effect in the event of toxicity. Calcitriol has a more immediate onset of action and a much shorter time for dissipation of effect. Alfacalcidol is a useful alternative which bypasses PTH activation by 25-hydroxylation in the liver. However, there are very few reports on its efficacy.

Monitoring of circulating calcium concentration is performed at least daily in the initial stages and then weekly until stable. The aim is to maintain concentrations at the low end or below the reference range in order to stimulate maximally any residual parathyroid tissue, if present, and avoid hypercalcaemia.

In cases of postoperative hypocalcaemia, once serum calcium concentrations are stable a gradual tapering of the dose of calcium first and then vitamin D is attempted. In most cases, parathyroid tissue recovers within 2–4 weeks. Even in the absence of parathyroid recovery, supplementation can usually be withdrawn after several months with maintenance of calcium concentration. This presumably reflects chronic adaptation to hypoparathyroidism through a PTH-independent pathway. In idiopathic cases, calcium but not vitamin D supplementation can be withdrawn as commercial rations contain adequate amounts.

Hypercalcaemia is a serious potential side-effect that can result in renal failure and death. All supplementation must be withdrawn and immediate treatment instituted.

Feline hyperparathyroidism

Primary hyperparathyroidism is a disorder resulting from excessive secretion of PTH from abnormal parathyroid glands. It is a rare disorder of cats, with only one large cases series describing seven cats (Kallet *et al.*, 1991). Unilateral adenoma or carcinoma predominates and bilateral lesions are rarely described. Through its action on bone, kidneys and indirectly on the gastrointestinal tract, excess PTH results in hypercalcaemia.

Recognising hyperparathyroidism

Affected cats are usually elderly (>8 years old) and the majority described are Siamese, suggesting a definite breed predisposition.

The clinical signs of hyperparathyroidism and hypercalcaemia are relatively non-specific and include, most commonly, anorexia, lethargy, weight loss, weakness and vomiting. Unlike in dogs, polyuria/polydipsia is not a consistent feature, but a cervical mass is often palpable. Urinary tract infections and calcium oxalate urolithiasis appear to be less common in affected cats than in dogs.

Diagnosing hyperparathyroidism

Hyperparathyroidism is associated with persistent hypercalcaemia, often marked (>4 mmol/l), together

with a low or low-normal circulating phosphate concentration. If renal function is impaired by the hypercalcaemia, hyperphosphataemia ensues and increases the risk of metastatic calcification. In the absence of renal failure, this risk is relatively low because of the phosphaturic effects of PTH.

Measurement of circulating total calcium concentration is usually used, but because of protein effects measurement of ionised calcium is preferred. Unfortunately, ionised calcium measurement is highly temperature and pH dependent and requires rapid analysis. Formulae have been derived to adjust total calcium for abnormalities in albumin, but these are primarily for use in dogs and have not been well defined in cats.

Although primary hyperparathyroidism is rare, it is an important differential for hypercalcaemia and as a possible predisposing cause of calcium oxalate urolithiasis. Often considered less common in cats than in dogs, hypercalcaemia has become increasingly recognised in this species (Midkiff *et al.*, 2000; Savary *et al.*, 2000). Most frequently affected cats are diagnosed with neoplasia, renal failure, hyperparathyroidism or idiopathic hypercalcaemia. Potential causes of hypercalcaemia include:

- hyperalbuminaemia
- neoplasia
  - lymphoma
  - squamous cell carcinoma
  - myeloproliferative disease
  - other tumours
- renal failure
- idiopathic
- primary hyperparathyroidism
- hypervitaminosis D
- nutritional secondary hyperparathyroidism
- granulomatous disease
- osteolytic/osteoporitic disease
- hypoadrenocorticism
- laboratory error.

In dogs, hypercalcaemia is a well-recognised phenomenon associated with neoplasia because of the production of compounds that stimulate resorption of bone adjacent to the tumour (local osteolysis) or, more commonly, of PTH-related peptides (humoral osteolysis) that have a similar action to PTH. Although described in cats with malignant lymphoma, squamous cell carcinoma and occasionally myeloproliferative diseases and other tumours, this phenomenon appears to be a less common feature of neoplasia than in dogs. Hypercalcaemia in association with hyperphosphataemia is well described in approximately 10–20% of cats with renal failure, but ionised calcium concentration is rarely abnormal and the hypercalcaemia is generally mild. Idiopathic hypercalcaemia describes a recently recognised condition characterised by persistent hypercalcaemia of unknown cause despite extensive medical evaluation. The hypercalcaemia is mild to moderate in severity, and circulating phosphate and PTH concentrations remain within the reference range. It has been associated with feeding acidified diets, administration of urinary acidifiers and calcium oxalate urolithiasis. Hypervitaminosis D, induced through either excess supplementation or ingestion of cholecalciferol-containing rodenticides, is also a well-recognised cause of hypercalcaemia in cats and tends to cause both marked hypercalcaemia and hyperphosphataemia. Less common causes of hypercalcaemia include nutritional secondary hyperparathyroidism caused by feeding kittens all-meat diets, granulomatous disease (cryptococcosis), and disorders associated with osteolysis and osteoporosis.

In primary hyperparathyroidism, circulating PTH values are within or above the reference range and are inappropriate in the presence of hypercalcaemia. Other causes of increased PTH concentration, such as renal and nutritional secondary hyperparathyroidism and hyperthyroidism, must be eliminated (Table 20.9). Further diagnostic information can be obtained from fine-needle aspiration or ultrasound examination of a cervical mass if present, but excisional biopsy is usually required for a more definitive diagnosis.

Treating hyperparathyroidism

Intravenous fluid therapy is helpful in decreasing circulating calcium concentration and has a renoprotective effect. However, surgical removal of abnormal tissue is the treatment of choice and will result in rapid regression of hypercalcaemia. Postoperative

Table 20.9 Interpreting the causes of hypercalcaemia

	Total calcium	Ionised calcium	Phosphate	PTH
Neoplasia	↑	↑	N/↓	↓
Hyperparathyroidism	↑	↑	N/↓	N/↑
Renal failure	↑	N/↓	↑	↑
Idiopathic	↑	↑ (mild)	N	N/↓
Hypervitaminosis D	↑	↑	↑	↓

N: within reference range; PTH: parathormone.

hypocalcaemia is a potential complication and cats should be carefully monitored until circulating calcium concentrations stabilise.

Miscellaneous endocrine disorders

Pituitary dwarfism

Congenital growth hormone deficiency, termed pituitary dwarfism, is a well-recognised disorder of dogs. It is rare in the cat, although a few isolated instances have been reported. It is characterised by proportional dwarfism and low circulating growth hormone and IGF-1 concentrations.

Diabetes insipidus

Diabetes insipidus is a disorder characterised by marked polyuria and secondary polydipsia, and is classified as either central or nephrogenic. Central diabetes insipidus refers to a complete or partial failure of the pituitary gland to produce antidiuretic hormone (ADH). In nephrogenic diabetes insipidus, the kidneys fail to respond to the actions of ADH.

Diabetes insipidus is an extremely rare disorder of cats. Possible causes include congenital ADH deficiency, neoplasia or trauma, but most cases are of unknown aetiology and classified as idiopathic.

Most cats present with profound polydipsia, polyuria and hyposthenuria (urine specific gravity <1.007), with no other abnormalities. As a general rule, other disorders associated with polyuria and polydipsia do not cause such severe signs or such dilute urine. However, as diabetes insipidus is rare, all other causes of polyuria and polydipsia must first be eliminated. Cats with diabetes insipidus fail to concentrate their urine after abrupt withdrawal of water, but subsequently respond to desmopressin (DDAVP), a synthetic ADH analogue. Close monitoring is required as cats can become severely dehydrated during water deprivation.

A partial response to hydrochlorthiazide at a dose of 12.5 mg twice daily may be obtained. This is a thiazide diuretic that paradoxically decreases urine production and alleviates the clinical signs, but hypokalaemia is a possible risk. Chlorpropramide, an oral hypoglycaemic agent that potentiates the action of ADH on the renal tubules, is generally ineffective, presumably because its effect is dependent on residual ADH secretion and it is associated with a high risk of hypoglycaemia. DDAVP, although expensive, is considered the treatment of choice in affected cats. It can be administered intranasally or instilled into the conjunctival sac at an approximate dose of 1–4 drops/day, adjusting the dose based on the response. Alternatively, DDAVP can be injected subcutaneously at a dose of 1–2 μg/day. DDAVP tablets are also available but have not yet been used in cats. Providing there is free access to water and owners cope with the clinical signs, treatment is not strictly necessary.

Feline hypothyroidism

Naturally occurring hypothyroidism is rare in the cat. It is also a rare complication following bilateral thyroidectomy or radioiodine treatment for feline hyperthyroidism.

Adult-onset primary hypothyroidism has only once been convincingly documented (Rand *et al.*, 1993). Congenital hypothyroidism has been recognised with greater frequency and has been suggested as a possible unrecognised cause of early death in kittens. Thyroid gland agenesis/dysgenesis, dyshormonogenesis, presumably related to defective thyroid peroxidase activity and an inability of the thyroid gland to respond to TSH, have been described and may be inherited as autosomal recessive traits. A breeding line of cats with spontaneous hypothyroidism resulting from thyroiditis has also been described.

Clinical signs in congenital cases vary depending on the type and severity of the underlying lesion. Affected kittens appear normal at birth, but by 4 weeks retarded growth is noted. Signs of disproportionate dwarfism develop, with an enlarged broad head, short limbs and short, rounded bodies. The kittens are generally lethargic and dull, and may become hypothermic and bradycardic. Teeth are frequently underdeveloped and replacement of deciduous teeth is often delayed until 18 months of age or older. In contrast to the dog, alopecia and obesity are not major features, the haircoat being predominantly undercoat with a few guardhairs. Many kittens develop severe constipation. Cats with TSH resistance usually die by 16 weeks of age, whereas the clinical signs with thyroid peroxidase defects become less pronounced with time. These kittens develop goitre, but this may not be evident until 6 months of age.

Extreme lethargy, apathy, seborrhoea and puffy facial features presumably related to myxoedema were predominant features in one hypothyroid adult cat with primary hypothyroidism. Marked weight gain, lethargy, alopecia of the pinnae and occasionally

hypothermia and bradycardia develop in iatrogenic cases of hypothyroidism.

A diagnosis is aided by demonstrating a mild anaemia and hypercholesterolaemia, although these features are not as consistent in naturally occurring as in iatrogenic cases. Circulating total T4 concentration is low, but care must be taken in its interpretation because of the unusually low values associated with non-thyroidal illness and in newborn kittens. A species-specific TSH assay is not yet available for the cat and a definitive diagnosis therefore usually relies on results of a TSH response test. The TRH response test has also been advocated. However, the total T4 increment is less than that following TSH administration and may complicate interpretation in cats with significant depression of thyroid hormones associated with non-thyroidal illness. In addition, temporary adverse reactions such as vomiting, salivation, tachypnoea and inappropriate defecation are common.

Treatment is relatively straightforward using l-thyroxine at a dose of 10–20 μg/kg per day, with any further adjustments depending on response. In kittens the response to treatment can be variable, with incomplete resolution of clinical signs. In adult cats the response to appropriate therapy is excellent.

Apudomas

Tumours arising from cells characterised by amine precursor uptake and decarboxylation (APUD) are often referred to as apudomas and comprise phaeochromocytomas, insulinomas and gastrinomas. Readers are referred to more detailed textbooks for further information.

Phaeochromocytomas are catecholamine-secreting (adrenaline, noradrenaline and less commonly dopamine) tumours derived from chromaffin cells of the adrenal medulla. Tumours of the adrenal medulla are rare in cats and only a few documented cases of functional phaeochromocytoma have been described.

Functional malignant tumours of the islet cells of the pancreas are a well-recognised cause of hypoglycaemia in dogs, but are rare in cats. Clinical signs are related to hypoglycaemia and a diagnosis is achieved by the demonstration of inappropriately high insulin concentrations in the face of hypoglycaemia, ultrasonographic demonstration of a pancreatic mass or localisation of a tumour at exploratory surgery.

Pancreatic gastrinomas (Zollinger–Ellison syndrome) have been described in a small number of cats. Clinical signs primarily relate to gastric acid hypersecretion causing gastrointestinal ulceration and vomiting.

References

Ahn A. (1994) Hyperaldosteronism in cats. *Semin Vet Med Surg Small Anim* **9**, 153–157.

Appleton D.J., Rand J.S. & Sunvold G.D. (2001) Insulin sensitivity decreases with obesity, and lean cats with low insulin sensitivity are at greatest risk of glucose intolerance with weight gain. *J Feline Med Surg* **3**, 211–228.

Broussard J.D., Peterson M.E. & Fox P.R. (1995) Changes in clinical and laboratory findings in cats with hyperthyroidism from 1983 to 1993. *J Am Vet Med Assoc* **206**, 302–305.

Crenshaw K.L. & Peterson M.E. (1996) Pretreatment clinical and laboratory evaluation of cats with diabetes mellitus: 104 cases (1992–1994). *J Am Vet Med Assoc* **209**, 943–949.

Crenshaw K.L., Peterson M.E., Heeb L.A., *et al.* (1996) Serum fructosamine concentration as an index of glycaemia in cats with diabetes mellitus and stress hyperglycaemia. *J Vet Intern Med* **10**, 943–949.

Duesberg C. & Peterson M.E. (1997) Adrenal disorders in cats. *Vet Clin North Am Small Anim Pract* **27**, 321–347.

Elliott D.A., Nelson R.W., Feldman E.C. & Neal L.A. (1997) Glycosylated haemoglobin concentration for assessment of glycaemic control in diabetic cats. *J Vet Intern Med* **11**, 161–165.

Elliott D.A., Nelson R.W., Reusch C.E., *et al.* (1999) Comparison of serum fructosamine and blood glycosylated haemoglobin concentrations for assessment of glycaemic control in cats with diabetes mellitus. *J Am Vet Med Assoc* **214**, 1794–1798.

Expert Committee on the Diagnosis and Classification of Diabetes Mellitus (1997) *Diabetes Care* **20**, 1183–1197.

Feldman E.C., Nelson R.W. & Feldman M.S. (1997) Intensive 50-week evaluation of glipizide administration in 50 cats with previously untreated diabetes mellitus. *J Am Vet Med Assoc* **210**, 772–777.

Flanders J.A., Neth S., Erb H.N. & Kallfelz F.A. (1991) Functional analysis of ectopic parathyroid activity in cats. *Am J Vet Res* **52**, 1336–1340.

Foster D.J. & Thoday K.L. (1999) Use of propranolol and potassium iodate in the presurgical management of hyperthyroid cats. *J Small Anim Pract* **40**, 307–315.

Goossens M.M., Nelson R.W., Feldman E.C. & Griffey S.M. (1998) Response to insulin treatment and survival in 104 cats with diabetes mellitus (1985–1995). *J Vet Intern Med* **12**, 1–6.

Hasegawa S., Sako T., Takemura N., *et al.* (1992) Glycated haemoglobin fractions in normal and diabetic cats measured by high performance liquid chromatography. *J Vet Med Sci* **54**, 789–790.

Johnson K.H., Hayden D.W., O'Brien T.D. & Westermark P. (1986) Spontaneous diabetes mellitus–islet amyloid complex in adult cats. *Am J Pathol* **125**, 416–419.

Kallet A.J., Richter K.P., Feldman E.C. & Brum D.E. (1991) Primary hyperparathyroidism in cats: seven cases (1984–1989). *J Am Vet Med Assoc* **199**, 1767–1771.

Kraus M.S., Calvert C.A., Jacobs G.J. & Brown J. (1997) Feline diabetes mellitus: a retrospective mortality of 55 cats (1982–1994). *J Am Anim Hosp Assoc* **33**, 107–111.

Link K.R.J. (2001) Feline diabetes: diagnostics and experimental modelling. In *Companion Animal Sciences*. The University of Queensland, Australia.

Link K.R. & Rand J.S. (1998) Reference values for glucose tolerance and glucose tolerance status in cats. *J Am Vet Med Assoc* **213**, 492–496.

Lutz T.A. & Rand J.S. (1995) Pathogenesis of feline diabetes mellitus. *Vet Clin North Am Small Anim Pract* **25**, 527–552.

Lutz T.A. & Rand J.S. (1996) Plasma amylin and insulin concentrations in normo- and hyperglycemic cats. *Can Vet J* **37**, 27–34.

Lutz T.A., Ainscow J. & Rand J.S. (1994) Frequency of pancreatic amyloid deposition in cats from south-eastern Queensland. *Aust Vet J* **71**, 254–255.

Lutz T.A., Rand J.S. & Ryan E. (1995) Fructosamine concentrations in hyperglycemic cats. *Can Vet J* **36**, 155–159.

Martin G. & Rand J.S. (1999) Food intake and blood glucose in normal and diabetic cats fed *ad libitum. J Feline Med Surg* **1**, 241–251.

Martin G.J. & Rand J.S. (2001) Pharmacology of a 40 IU/ml PZI preparation in diabetic cats: findings during the first week and after 5 or 9 weeks of treatment. *J Feline Med Surg* **3**, 23–30.

Meij B.P., Voorhout G., Van den Ingh T.S.G.A.M. & Rijnberk A. (2001) Transsphenoidal hypophysectomy for treatment of pituitary-dependent hyperadrenocorticism in 7 cats. *Vet Surg* **30**, 72–86.

Midkiff A.M., Chew D.J., Randolph J.F., *et al.* (2000) Idiopathic hypercalcaemia in cats. *J Vet Intern Med* **14**, 619–626.

Moise N.S. & Reimers T.J. (1983) Insulin therapy in cats with diabetes mellitus. *J Am Vet Med Assoc* **182**, 158–164.

Mooney C.T. (2001a) Feline hyperthyroidism: diagnostics and therapeutics. *Vet Clin North Am Small Anim Pract* **31**, 963–983.

Mooney C.T. (2001b) Feline hyperthyroidism: an update. *Waltham Focus* **11**, 18–23.

Mooney C.T. (2002) Pathogenesis of feline hyperthyroidism. *J Feline Med Surg* **4**, 167–169.

Mooney C.T., Thoday K.L. & Doxey D.L. (1992) Carbimazole therapy of feline hyperthyroidism. *J Small Anim Pract* **33**, 228–235.

Murray L.A.S. & Peterson M.E. (1997) Ipodate treatment of hyperthyroidism in cats. *J Am Vet Med Assoc* **211**, 63–67.

Nelson R.W., Feldman E.C. & DeVries S.E. (1992) Use of ultralente insulin in cats with diabetes mellitus. *J Am Vet Med Assoc* **200**, 1828–1829.

Norman E.J. & Mooney C.T. (2000) Diagnosis and management of diabetes mellitus in five cats with somatotropic abnormalities. *J Feline Med Surg* **1**, 183–190.

Norsworthy G.D. (1995) Feline thyroidectomy: a simplified technique that preserves parathyroid function. *Vet Med* November, 1055–1063.

O'Brien T.D., Hayden D.W., Johnson K.H. & Stevens J.B. (1985) High dose intravenous tolerance test and serum insulin and glucagons levels in diabetic and non-diabetic cats: relationships to insular amyloidosis. *Vet Pathol* **22**, 250–261.

O'Brien T.D., Hayden D.W., Johnson K.H. & Fletcher T.F. (1986) Immunohistochemical morphometry of pancreatic endocrine cells in diabetic, normoglycemic glucose intolerant and normal cats. *J Comp Pathol* **96**, 357–369.

O'Brien T.D., Butler P.C., Kreuffen D.K. *et al.* (1995) Human islet amyloid polypeptide expression in COS-1 cells: a model of intracellular amyloidogenesis. *Am J Pathol* **147**, 606–616.

Padgett S.L., Tobias K.M., Leathers C.W. & Wardrop K.J. (1998) Efficacy of parathyroid gland autotransplantation in maintaining serum calcium concentrations after bilateral thyroparathyroidectomy in cats. *J Am Anim Hosp Assoc* **34**, 219–224.

Panciera D.L., Thomas C.B., Eicker S.W. & Atkins C.E. (1990) Epizootiological patterns of diabetes mellitus in cats: 333 cases (1980–1986). *J Am Vet Med Assoc* **197**, 1504–1508.

Peterson M.E. & Aucoin D.P. (1993) Comparison of the disposition of carbimazole and methimazole in clinically normal cats. *Res Vet Sci* **54**, 351–355.

Peterson M.E. & Becker D.V. (1995) Radioiodine treatment of 524 cats with hyperthyroidism. *J Am Vet Med Assoc* **207**, 1422–1428.

Peterson M.E., Kintzer P.P. & Hurvitz, A.I. (1988) Methimazole treatment of 262 cats with hyperthyroidism. *J Vet Intern Med* **2**,150–157.

Peterson M.E., Greco D.S. & Orth D.N. (1989) Primary hypoadrenocorticism in ten cats. *J Vet Intern Med* **3**, 55–58.

Peterson M.E., Taylor S., Greco D.S., *et al.* (1990) Acromegaly in 14 cats. *J Vet Intern Med* **4**, 192–201.

Peterson M.E., James K.M., Wallace M. *et al.* (1991) Idiopathic hypoparathyroidism in five cats. *J Vet Intern Med* **5**, 47–51.

Peterson M.E., Melian C. & Nichols R. (2001) Measurement of serum concentrations of free thyroxine, total thyroxine, and total triiodothyronine in cats with hyperthyroidism and cats with nonthyroidal disease. *J Am Vet Med Assoc* **218**, 529–536.

Rand J.S. (1999) Current understanding of feline diabetes mellitus: part 1, pathogenesis. *J Feline Med Surg* **1**, 143–153.

Rand J.S. & Martin G.J. (2001) Management of feline diabetes mellitus. *Vet Clin North Am Small Anim Pract* **31**, 881–913.

Rand J.S., Levine J., Best S. & Parker W. (1993) Spontaneous adult-onset hypothyroidism in a cat. *J Vet Intern Med* **7**, 272–276.

Rand J.S., Bobbermien L.M., Hendrikz J.K. & Copland M. (1997) Over-representation of Burmese cats with diabetes mellitus. *Aust Vet J* **75**, 402–405.

Savary K.C.M., Price G.S. & Vaden S.L. (2000) Hypercalcemia in cats: a retrospective study of 71 cases (1991–1997). *J Vet Intern Med* **14**, 184–189.

Scarlett J.M. & Donoghue S. (1998) Associations between body condition and disease in cats. *J Am Vet Med Assoc* **212**, 1725–1731.

Schoeman J.P., Evans H.J., Childs D. & Herrtage M.E. (2000) Cortisol response to two different doses of intravenous synthetic ACTH (tetracosactrin) in overweight cats. *J Small Anim Pract* **41**, 552–557.

Thoday K.L. & Mooney C.T. (1992) Historical, clinical and laboratory features of 126 hyperthyroid cats. *Vet Rec* **131**, 257–264.

Thoresen S.I. & Bredal W.P. (1996) Clinical usefulness of fructosamine measurements in diagnosing and monitoring feline diabetes mellitus. *J Small Anim Pract* **37**, 64–88.

Watson P.J. & Herrtage M.E. (1998) Hyperadrenocorticism in six cats. *J Small Anim Pract* **39**, 175–184.

Welches C.D., Scavelli T.D., Matthiesen D.T. & Peterson M.E. (1989) Occurrence of problems after three techniques of bilateral thyroidectomy in cats. *Vet Surg* **18**, 392–396.

Wess G. & Reusch C. (2000) Capillary blood sampling from the ear of dogs and cats and use of portable meters to measure glucose concentration. *J Small Anim Pract* **41**, 60–66.

Whitley N.T., Drobatz K.J. & Panciera D.L. (1997) Insulin overdose in dogs and cats: 28 cases (1986–1993) *J Am Vet Med Assoc* **211**, 326–330.

Further reading

Feldman E.C. & Nelson R.W. (eds) (1996) *Canine and Feline Endocrinology and Reproduction*. 2nd edn. WB Saunders, Philadelphia, PA.

Peterson M.E., Randolph J.F. & Mooney C.T. (1994) The endocrine system. In *The Cat: Diseases and Clinical Management*, Vol. 2. 2nd edn (ed. Sherding R.G.). Churchill Livingstone, New York, pp. 1403–1506.

Rijnberk A. (ed.) (1996) *Clinical Endocrinology of Dogs and Cats. An Illustrated Text*. Kluwer Academic, Dordrecht.

Torrance A.G. & Mooney C.T. (eds) (1998) *Manual of Small Animal Endocrinology*. 2nd edn. BSAVA Publications, Cheltenham.

PART 3

INFECTIOUS DISEASES

Chapter 21

FELINE PANLEUCOPENIA/FELINE PARVOVIRUS INFECTION

D.D. Addie and H. Thompson

Introduction

It is tempting to assume that feline parvovirus (FPV; feline panleucopenia, feline infectious enteritis) is an infection of the past, which has been more or less eradicated by vaccination. However, outbreaks are still ubiquitous wherever there are groups of susceptible cats and often manifest as sudden death or acute illness.

FPV infects not only the domestic cat, but also other members of the Felidae (e.g. tigers, lions and leopards), Mustellidae (e.g. mink and ferret), Procyonidae (e.g. coatimundi and racoon) and Viverridae (e.g. civet cat) (Gaskell, 1994).

The virus

Like canine parvovirus (CPV), which causes a severe haemorrhagic enteritis in dogs, FPV is a small (18–26 nm in diameter), non-enveloped, resistant virus with single-stranded DNA genome of around 5 kilobases. Unlike FPV, which has been recognised in cats for at least 100 years, CPV type 2 emerged suddenly in the 1970s and it was suspected that rogue vaccines against FPV were responsible. CPV type 2 was subsequently replaced in nature by antigenically variant viruses (CPV type 2a and CPV type 2b), which now coexist in dog populations worldwide (Truyen *et al.*, 1996; Truyen, 2000). Only recently have vaccines been exonerated (Horiuchi *et al.*, 1998; Truyen *et al.*, 1998a, b; Truyen, 2000), and it is now thought that the sudden appearance of canine parvovirus in the domestic dog population may instead have involved the interspecies transmission between wild and domestic carnivores (Truyen *et al.*, 1998b). Based on the amino acid sequence of one fox isolate, Truyen *et al.* (1998b) concluded that the red fox parvovirus appears to be a true intermediate between feline and canine parvoviruses.

While CPV type 2 isolates did not replicate in cats, both CPV type 2a and CPV type 2b will do so (Mochizuki *et al.*, 1996). In a recent study in Japan, about 10% of the virus isolates from cats with feline enteritis were found to be CPV type 2a or type 2b (Truyen *et al.*, 1996). A third strain, CPV type 2c, isolated from leopard cats, can also infect domestic cats (Nakamura *et al.*, 2001). Surprisingly, only 30% of parvoviruses from cheetahs and other large cats in zoos were FPV; the others were CPV (Truyen, 2000).

Transmission

Transmission of parvoviruses is mainly indirect. Parvovirus is shed in faeces, but is also present in other secretions, and can survive for up to a year in the environment. Despite the good uptake of excellent vaccines by the British cat-owning community, parvovirus manages not to become extinct by subclinically infecting susceptible cats and kittens in which it replicates. These cats shed huge amounts of viral particles for a few days to possibly weeks, so that the environment becomes recontaminated. Virus can be transported on shoes, in cats' baskets, and so on, to contaminate new environments, so that even cats kept permanently indoors are not safe from infection. Transplacental transmission also occurs and can warrant caution when using live vaccines in pregnant queens.

Disinfection is difficult, with parvovirus resisting many disinfectants, but it is killed by sodium hypochlorite, formaldehyde and gluteraldehyde.

Pathogenesis

Parvovirus is ingested, or possibly inhaled. It replicates initially in the oropharyngeal tissues then spreads via the bloodstream to its main target organs: it is found in the tonsils, retropharyngeal lymph nodes, thymus and mesenteric lymph nodes after 1–3 days (Gaskell, 1994; Truyen, 2000). By 3 days postinfection virus can also be recovered from the intestinal-associated lymphoid tissues (Peyer's patches) (Truyen, 2000). A plasma phase viraemia occurs between 2 and 7 days postinfection (Greene, 1998). Intestinal crypt cells are infected from circulating virus, not from virus within the gut contents, which is why circulating antibody is protective (Truyen, 2000).

CPV binds to *N*-glycolyl-neuraminic acid and there is every reason to believe that FPV also binds to this sialic acid (Tresnan *et al*., 1995). The parvoviral genome is very small and lacks genes coding for certain enzymes necessary for the replication of the viral DNA; thus, the virus relies on the cell to provide such enzymes. These enzymes are only present in the cell just before division; therefore, parvoviruses require actively dividing cells to replicate, hence their predilection for the cells shown in Table 21.1.

A curious recent discovery was that FPV can persist in circulating lymphocytes for weeks despite high levels of virus-neutralising antibodies (Ikeda *et al*., 1998; Miyazawa *et al*., 1999). The incubation period from infection to the appearance of clinical signs is 5–9 days.

Table 21.1

Affected cells	Consequences	Clinical manifestation
Intestinal crypt epithelium	Villous collapse	Enteritis
Lymph node, thymus	Germinal centre depletion, apoptosis of lymphocytes, thymic atrophy	Lymphopenia
Bone marrow	Stem cell depletion	Panleucopenia
All cells in foetus	Foetal death	Loss of pregnancy
Developing cerebellum	Cerebellar hypoplasia	Ataxia

Clinical signs

Subclinical infection

Probably most cats that become infected with FPV are infected subclinically and show no signs of illness. The rate of mitosis of the cells of the intestinal crypt epithelium is important in the outcome of FPV infection: if the rate is slow, then intestinal lesions are minimal and clinically inapparent. However, if the cat is stressed, coinfected with bacteria or parasites which damage the villi and increase the mitotic rate, the combination can be lethal. Even a change of food can cause an increase in intestinal crypt cell mitotic rate which allows more FPV replication. This is why kittens sold into new homes can develop severe enteritis and die, while their littermates, still with the original owner, remain clinically well.

Sudden death: dying kittens

Sudden death, usually of kittens, but occasionally of adult cats is not a unusual presentation of FPV infection. FPV deaths typically occur in an environment with a large throughput of cats and kittens, especially unvaccinated animals; therefore such a problem is most often encountered in rescue catteries and pet shops. However, FPV has been reported to cause deaths of pedigree kittens (Addie *et al*., 1998) in spite of their queens being vaccinated. Kitten deaths can occur at any age, depending on when maternally derived antibody (MDA) wanes. As MDA wanes and before the kitten makes antibodies of its own, a window of susceptibility occurs during which parvovirus, if present, can infect the kitten. There ensues a race between the virus and the kitten's immune system. Typically, the whole litter dies, although occasionally one kitten is sold and becomes acutely ill or dies, while its littermates remain perfectly healthy (see Subclinical infection, above).

Classical feline enteritis

In classical feline enteritis, one is presented with an acutely ill cat, with a history of having been perfectly well the day before or earlier on the day of presentation. Such a history often gives rise in an owner's mind to suspicion of poisoning. Affected cats will seek out cool, isolated places and are attracted to water, but will not drink.

Usually, the cat will have a history of being unvaccinated, but vaccination, even at 8 and 12 weeks of age,

will not exclude a diagnosis of FPV as maternal immunity in some kittens will persist to 16 or even 20 weeks of age, rendering vaccinal virus inactive (Scott, 1971; Addie *et al.*, 1998) (see Advice for cat breeders, below).

Clinical examination reveals either pyrexia or a subnormal temperature (a grave prognostic sign), extreme depression, anorexia, dehydration and vomiting. Diarrhoea is less common, especially in the early stages, but if it occurs, it is profuse and watery and may contain blood. Abdominal palpation may reveal gas- and fluid-filled intestines, and may elicit pain (Gaskell, 1994). Haematology in early stages can reveal neutropenia as massive numbers of neutrophils flood into the gut and, later, cats infected with FPV will show panleucopenia owing to suppression of the bone marrow. Experimental infections of cats using CPV type 2b caused only a slight leucopenia but a marked lymphopenia, similar to CPV infection in dogs (Truyen, 2000). Without medical intervention, death is a result of severe dehydration and possibly overwhelming bacterial infection.

Feline ataxia, cerebellar hypoplasia and other central nervous system disorders

The predilection of FPV for dividing cells renders the foetus particularly vulnerable to infection if the pregnant queen has no protection herself. In the first trimester of pregnancy, FPV infection results in foetal death, resorption and/or abortion (Gaskell, 1994). Intrauterine parvovirus infection in the second trimester of pregnancy can cause cerebellar hypoplasia, hydrocephalus and hydranencephaly. Virus persists in mitotically active cells such as endothelial cells and the external germinal layer which normally gives rise to cerebellar granule cells (Sharp *et al.*, 1999). FPV has a separate cytopathic effect on Purkinje cells (Sharp *et al.*, 1999). FPV causes dysplasia of the cerebellum as it develops later in gestation and during the immediate postnatal period (Sharp *et al.*, 1999). Kittens begin to walk at 10–14 days of age and at this time kittens with cerebellar hypoplasia exhibit ataxia, dysmetria and intention tremor when they start to feed from a bowl. The developing cerebrum can also be infected, causing hydrocephalus and hydranencephaly. Forebrain lesions result in altered mentation; for example, one 8-week-old kitten showed aggression and persistent mewing while its littermate was inactive and dull (Sharp *et al.*, 1999). Sharp *et al.* (1999) also attributed arthrogryphosis and alopecia of a stillborn kitten to intrauterine FPV infection.

Pathology and histopathology

Gross post mortem may not reveal any obvious lesions in young kittens (5–8 weeks), except for thymic atrophy. In older kittens and cats, the surface of the small intestines will have a reddish blush (Plate 21.1) and the mesenteric lymph nodes will be enlarged and oedematous. Histopathological lesions are present in the small intestine, but their presence and severity will vary in time from level to level of the intestine: in early infection the duodenum will be more severely infected than the ileum, whereas in later infection it will be the other way around. Necrosis of the crypt epithelium, dilatation of the crypt lumen and collapse of the villi are the cardinal features. Intranuclear inclusions are more easily found in the crypt epithelium of the cat than in the dog. Secondary bacterial invasion of the damaged gut surface is common (Plate 21.2). There is lymphoid depletion of the thymus and the germinal centres of the nodes and Peyer's patches (Greene, 1998).

Diffuse bone marrow changes were found in 84% of 76 cases of FPV infection (Breuer *et al.*, 1998).

Diagnosis

Laboratory tests

FPV is notoriously difficult to isolate from faeces in cell culture, but it is a haemagglutinating virus and haemagglutination of porcine erythrocytes has been the method of detection for many years. FPV agglutinates erythrocytes at below pH 6.8 (Truyen & Parrish, 1992). Enzyme-linked immunosorbent assays (ELISAs) and rapid immunomigration tests have also been used, with varying results. Recently, polymerase chain reaction (PCR) has become useful in the detection of FPV DNA in faeces, gut contents (Truyen *et al.*, 1998b) and paraffin-embedded tissues (Sharp *et al.*, 1999), and seems to offer the most sensitive and practical means of detection.

Antibodies to FPV can be detected by haemagglutination inhibition and ELISAs. Since FPV may only be shed for a matter of hours (sometimes as little as 36 h) and the cat may have ceased to shed virus by the time it becomes ill, antibody testing of the sick cat can be more useful than detection of the virus itself.

Samples

From a living cat or kitten a sample of faeces and a sample of blood should be tested for virus and antibodies, respectively.

From a dead cat or kitten the contents of the colon or rectum should be sent in a clean receptacle for virus detection and three 1 cm sections of different levels of the small intestine (duodenum, jejunum and ileum) should be sent to a laboratory in 10% formol saline for histopathological examination.

Treatment

Treatment is largely supportive: intravenous fluids are essential to combat the massive dehydration. Suitable fluids include 5% dextrose saline, lactated Ringer's solution and other more complex balanced electrolyte solutions (Gaskell, 1994). Secondary bacterial infection can be dealt with using broad-spectrum antibiotics such as ampicillin or amoxycillin (15–20 mg/kg i.v. or s.c. every 6–8 h) (Greene, 1998). No food or fluid should be given by mouth for several days, so that there will be minimal cell division in the crypts of the villi. Antiemetics may be required if vomiting is persistent (e.g. metoclopramide 0.2–0.4 mg/kg p.o. or s.c. every 6–8 h) (Greene, 1998). Once the cat starts to improve, light food such as baby food, or liquidised fish or chicken can be given in tiny amounts four to six times a day. Low-dose diazepam (up to 2.5 mg total) can be given to stimulate the appetite of recovering cats (Greene, 1998).

Vitamin B compounds should be given parenterally because of the high requirement for B vitamins in repair of the intestinal mucosa and because the cat will not be eating.

Immune serum from a recovered cat, or one that has been vaccinated several times, may be useful in a cat that is known to have been exposed, but that has not yet developed clinical signs (Greene, 1998). However, serum from a blood type B cat should not be given to a blood type A cat as antibodies might lyse the erythrocytes of the recipient cat.

Prevention and control

Vaccination

Attenuated live and inactivated vaccines are available against FPV and protect against both FPV and CPV types 2a, b and c, but inactivated vaccines protect more weakly against CPV types than against FPV (Nakamura *et al.*, 2001). Most manufacturers recommend vaccination from 8 weeks of age onwards, with a final dose at 12 weeks. A booster at 1 year of age is essential to cover cats in which the initial course was ineffective owing to the presence of MDA. Annual boosters are recommended by the manufacturer, but are possibly not absolutely necessary, as there is evidence to suggest that immunity may persist: nine cats vaccinated with an inactivated FPV vaccine, kept in isolation and given no boosters, were challenged 7.5 years later and all still appeared to be immune (Scott & Geissinger, 1999). Scott and Geissinger concluded that feline herpes virus, calicivirus and panleucopenia virus boosters could be given at intervals of at least 3 years rather than annually.

Where colostrum is not available, vaccination of newborn kittens is possible and neutralising antibodies appear at 7–12 days of age, indicating protection (Greene, 1998). However, live vaccines should not be used in kittens under 4 weeks of age or in pregnant queens because of the risk of development of cerebellar hypoplasia.

Prevention in ordinary pet cats

Fortunately, vaccination against FPV is generally very effective. Keeping cats indoors is no protection against FPV as the virus can be taken inside on footwear.

Advice for cat rescue centres

Once parvovirus has occurred on a premises, the virus can be present for at least a year. Disinfection with sodium hypochlorite (household bleach, diluted 1:32) can reduce virus dose but will not eliminate virus from soft furnishings. Since bleach is inactivated by organic material, thorough cleaning beforehand is vital for the success of disinfection. It is important to realise that infection is maintained in premises by subclinical infection of susceptible animals which become infected, produce huge amounts of virus and then recover. Therefore, susceptible animals will be at risk if introduced within a year and any new animals should have had a full course of vaccination, completed at least a week before being introduced.

Advice for cat breeders

To establish whether a cattery has parvovirus, some of the breeding animals should be tested for antibodies: their titres will be much higher if they have been naturally exposed to FPV compared with postvaccinal levels. One option to prevent parvovirus is to stop breeding for a year, so that no susceptible kittens are introduced.

Kittens are protected by MDA. The time over which antibody will wane can be calculated by taking the mother's antibody titre and halving it every 9.5 days of the offspring's life (97% of the queen's titre is found in the kitten) (Greene, 1998). Thus, if a queen had an antibody titre of 1024, at 9.5 days old the kitten's titre would be approximately 512, at 19 days 256, at 28.5 days 128, and so on (providing the kitten had suckled colostrum adequately). In this example, the kitten's titre would be 32 at 47.5 days and so the kitten should be rehomed to a parvovirus-free environment at that stage and vaccinated when its titre had fallen to less than 10. The occurrence of MDA interfering with vaccination has long been recognised in dogs (e.g. Rottweilers) and modern vaccines often attempt to overcome this problem. What is less recognised is that MDA can persist up until almost 20 weeks of age in kittens, particularly those born to naturally exposed mothers, interfering with vaccination and leaving apparently vaccinated kittens susceptible to FPV (Addie *et al*., 1998).

Further vaccination of adult breeding stock is often pointless, since many cats will have a very high naturally acquired immunity, but it may be useful to screen all the breeding stock for antibodies and to boost any cats that have a very low antibody titre using a live vaccine (inactivated if the animal is pregnant).

References

Addie D.D., Toth S., Thompson H., *et al*. (1998) Detection of feline parvovirus in dying pedigree kittens. *Vet Rec* **142**, 353–356.

Breuer W., Stahr K., Majzoub M. & Hermanns W. (1998) Bone-marrow changes in infectious diseases and lymphohaemopoietic neoplasias in dogs and cats – a retrospective study. *J Comp Pathol* **119**, 57–66.

Gaskell R.M. (1994) Feline panleucopenia. In *Feline Medicine and Therapeutics*. 2nd edn (eds Chandler E.A., Gaskell C.J. & Gaskell R.M.). Blackwells, Oxford, pp. 445–452.

Greene C.E. (1998) Feline panleucopenia. In *Infectious Diseases of the Dog and Cat*. 2nd edn (ed. Greene C.E.). WB Saunders, Philadelphia, PA, pp. 52–57.

Horiuchi M., Yamaguchi Y., Gojobori T., *et al*. (1998) Differences in the evolutionary pattern of feline panleucopenia virus and canine parvovirus. *Virology* **249**, 440–452.

Ikeda Y., Shinozuka J., Miyazawa T., *et al*. (1998) Apoptosis in feline panleucopenia virus-infected lymphocytes. *J Virol* **72**, 6932–6936.

Miyazawa T., Ikeda Y., Nakamura K., *et al*. (1999) Isolation of feline parvovirus from peripheral blood mononuclear cells of cats in northern Vietnam. *Microbiol Immunol* **43**, 609–612.

Mochizuki M., Horiuchi M., Hiragi H., *et al*. (1996) Isolation of canine parvovirus from a cat manifesting clinical signs of feline panleukopenia. *J Clin Microbiol* **34**, 2101–2105.

Nakamura K., Ikeda Y., Miyazawa T., *et al*. (2001) Characterisation of cross-reactivity of virus neutralising antibodies induced by feline panleukopenia virus and canine parvoviruses. *Res Vet Sci* **71**, 219–222.

Scott F.W. (1971) Comments on feline panleukopenia biologics. *J Am Vet Med Assoc* **158**, 910–915.

Scott F.W. & Geissinger C.M. (1999) Long-term immunity in cats vaccinated with an inactivated trivalent vaccine (Published erratum appears in *Am J Vet Res* **60**, 763). *Am J Vet Res* **60**, 652–658.

Sharp N.J.H., Davis B.J., Guy J.S., *et al*. (1999) Hydranencephaly and cerebellar hypoplasia in two kittens attributed to intrauterine parvovirus infection. *J Comp Pathol* **121**, 39–53.

Tresnan D.B., Southard L., Weighert W., *et al*. (1995) Analysis of the cell and erythrocyte binding activities of the dimple and canyon regions of the canine parvovirus capsid. *Virology* **211**, 123–132.

Truyen U. (2000) Canine parvovirus. In *Recent Advances in Canine Infectious Diseases* (ed. Carmichael L.E.). International Veterinary Information Service (www.ivis.org).

Truyen U. & Parrish C.R. (1992) Canine and feline host ranges of canine parvovirus and feline panleukopenia virus: distinct host cell tropisms of each virus *in vitro* and *in vivo*. *J Virol* **66**, 5399–5408.

Truyen U., Evermann J.F., Vieler E. & Parrish C.R. (1996) Evolution of canine parvovirus involved loss and gain of feline host range. *Virology* **215**, 186–189.

Truyen U., Geissler K., Parrish C.R., *et al*. (1998a) No evidence for a role of modified live virus vaccines in the emergence of canine parvovirus. *J Gen Virol* **79**, 1153–1158.

Truyen U., Muller T., Heidrich R., *et al*. (1998b) Survey on viral pathogens in wild red foxes (*Vulpes vulpes*) in Germany with emphasis on parvoviruses and analysis of a DNA sequence from a red fox parvovirus. *Epidemiol Infect* **121**, 433–440.

Chapter 22

FELINE INFECTIOUS RESPIRATORY DISEASE

R.M. Gaskell, A.D. Radford and S. Dawson

Aetiology

Infectious respiratory disease in cats remains a significant clinical problem, despite the widespread use of vaccination over some 30 years. In general, the disease is most commonly seen where cats are grouped together, such as in boarding catteries or breeding establishments, particularly in young kittens as they lose their maternally derived antibody (MDA). The two main causes are feline herpesvirus (FHV; also called feline rhinotracheitis virus) and feline calicivirus (FCV) (Table 22.1). In the past, both viruses have been isolated from approximately equal numbers of cases of respiratory disease. In more recent surveys, however, FCV appears to be more common (Harbour *et al.*, 1991; Binns *et al.*, 2000). This may be due to the antigenic diversity amongst FCV isolates, compared with the single serotype of FHV, which may in turn affect the relative efficacy of the two vaccines.

In addition to these two viruses, there is increasing evidence that *Bordetella bronchiseptica* is an important cause of respiratory disease in cats. *Chlamydophila felis* (previously *Chlamydia psittaci var felis*) may also cause respiratory signs, although it is predominantly a conjunctival pathogen (see Chapter 27). Other agents may also be involved in feline respiratory disease, including feline reovirus, cowpox virus, and other bacteria and mycoplasmas (Table 22.1).

Table 22.1 Pathogens associated with feline respiratory disease

Agent	Significance
Feline herpesvirus (FHV) (also called feline rhinotracheitis)	One of the two main causes but may be becoming less common than FCV. Tends to be clinically more severe than FCV
Feline calicivirus (FCV)	One of the two main causes but may be becoming more common relative to FHV. Usually milder than FHV and typically characterised by mouth ulcers
Bordetella bronchiseptica	Tends to be associated with respiratory disease in rescue catteries, laboratory colonies and some breeding catteries. Individual cases may also occur. Transmission between dogs and cats may occur
Chlamydophila felis (formerly *Chlamydia psittaci*)	Predominantly conjunctivitis but some respiratory signs may occur
Feline reovirus	Mild disease experimentally
Cowpox virus	Occasional respiratory/ocular signs. Other skin signs also present
Other bacteria, e.g. *Staphylococcus*, *Streptococcus* and *Pasteurella* spp.; coliforms; *Haemophilus felis*	Mainly secondary pathogens
Mycoplasmas	Possibly primary but most likely secondary infection

Feline herpesvirus

FHV is an alphaherpesvirus whose host range is restricted to the Felidae. Alphaherpesviruses are one of three subfamilies within the herpesvirus family

and contain most of the herpesviruses that are of veterinary interest. Although the domestic cat appears to be the main host of FHV, isolates have also been obtained from exotic felids such as cheetahs. FHV is very closely related genetically and antigenically to canine herpesvirus-1 and phocine (seal) herpesvirus-1 (Lebich *et al.*, 1994; Harder *et al.*, 1996; Gaskell & Willoughby, 1999; Willoughby *et al.*, 1999).

Biologically, FHV isolates are generally similar with respect to pathogenicity. However, there may be slight differences between some biotypes, with the existence of attenuated vaccine strains and some apparently 'hot' challenge strains. Antigenically, all isolates of FHV are very similar and belong to one serotype. The virus also appears relatively homogeneous at the genetic level by restriction enzyme analysis, although some differences between isolates have been found (Grail & Harbour, 1990; Grail *et al.*, 1991; Horimoto *et al.*, 1992; Maeda *et al.*, 1995). There is therefore currently no easy method to study the role of individual isolates in disease.

FHV is a typical herpesvirus, containing double-stranded DNA, and with a glycoprotein–lipid envelope. Because of this envelope, FHV is highly susceptible to the effects of heat, acids and all common disinfectants, and can only survive for short periods outside its host (up to 18 h in a damp environment and up to 12 h in a dry environment).

Feline calicivirus

FCV is a member of the vesivirus genus in the calicivirus family. The virus is a small, non-enveloped, single-stranded RNA virus that infects both domestic cats and other members of the Felidae (Kadoi *et al.*, 1997). Although dogs have their own genetically distinct calicivirus (Roerink *et al.*, 1999), caliciviruses that are antigenically and genetically related to FCV have also been detected in dogs (Hashimoto *et al.*, 1999; Roerink *et al.*, 1999). However, the significance of these to either dogs or cats is largely uncertain.

Unlike FHV, there is a large number of different strains of FCV with varying antigenicity and pathogenicity. However, there is sufficient cross-reactivity between them to group all isolates in a single serotype and to allow some degree of cross-protection between the majority of strains. Similarly, on phylogenetic analysis, which uses genome sequence to compare isolates, FCVs also appear to represent one large group or genotype (Geissler *et al.*, 1997; Glenn *et al.*, 1999). Within this group, there is considerable genetic variability, particularly in those regions of the virus capsid gene that are responsible for viral antigenicity. This genetic diversity has led to the development of typing methods based largely on sequence analysis to differentiate FCV isolates and to explore, in depth, the epidemiology of the disease (Radford *et al.*, 1997, 2000; Sykes *et al.*, 1998).

Although both viruses are relatively short lived outside the cat, FCV is slightly more resistant than FHV, surviving for up to 1 week or possibly longer if the environment is damp. Fomite spread is therefore likely to be more significant for the transmission of FCV than of FHV. Similarly, FCV is not susceptible to as many disinfectants as FHV. However, both viruses are inactivated by a number of proprietary products, and also by bleach diluted 1:32 in water with washing-up liquid.

Bordetella bronchiseptica

Bordetella bronchiseptica is an aerobic, Gram-negative coccobacillus which is a well-known respiratory pathogen in many species including dogs, pigs and rabbits: it also causes occasional opportunistic infection in humans. It is closely related to *B. pertussis* and *B. parapertussis*, which cause whooping cough in humans. The pathogenicity of *B. bronchiseptica* is determined by the presence of several virulence factors such as surface fimbrae, which mediate adhesion to host cells, and flagellae, which make the organism motile.

In the past, *B. bronchiseptica* was considered to play only a secondary role in feline respiratory disease, but it is now established as a primary pathogen in this species. Respiratory disease has been reproduced in specific pathogen-free cats following both aerosol and nasal challenge (Jacobs *et al.*, 1993; Coutts *et al.*, 1996) and a number of field cases associated with *B. bronchiseptica* have also been reported (Willoughby *et al.*, 1991; Welsh, 1996; Turnquist & Ostlund, 1997). However, it is likely in the field that other factors may be involved in disease, including environmental factors such as stress or overcrowding, or in some cases, pre-existing viral infection. Such risk factors are discussed in more detail in the Epidemiology section below.

Other organisms

Reoviruses have occasionally been isolated from cats, and conjunctival and respiratory signs have been induced after experimental infection. However, they are not considered to be important pathogens in the field. Although cowpox virus infection in cats primarily causes skin lesions (Chapter 30), occasionally

respiratory or ocular signs may be seen. Cats are likely to become infected with cowpox virus while hunting, through contact with small rodents that act as reservoir hosts.

Infection with mycoplasmas is common in both colony cats and household pets, and the organisms have been isolated from the mucosal surfaces of both healthy and diseased cats. *Mycoplasma gateae* is probably a normal commensal, but a higher isolation rate of *M. felis* has been found in some studies of cats with conjunctivitis and respiratory disease compared with clinically healthy animals (Haesebrouck *et al.*, 1991). Although clinical signs have been reproduced experimentally, the implications are not clear, since specific pathogen-free cats were not used and other pathogens may have been involved.

Other bacteria such as *Staphylococcus* and *Streptococcus* species, *Pasteurella multocida*, and *Escherichia coli* are thought to play a role as secondary invaders. *Haemophilus felis* has been isolated from cats with rhinitis, conjunctivitis and lower respiratory tract disease. However, its significance as a pathogen is unclear as it may also be isolated from healthy animals (Inzana *et al.*, 1992; Olsson & Falsen, 1994).

Pathogenesis and pathology

Feline herpesvirus infection

Natural infection with FHV takes place via the nasal, oral or conjunctival routes. The virus primarily targets the mucosae of the upper respiratory tract including soft palate, tonsils and turbinates, and also the conjunctivae. The upper trachea may also sometimes be involved. Virus shedding can be detected in oropharyngeal and nasal swabs as early as 24 h after infection and generally persists for 1–3 weeks. Viraemia is rare because virus replication is normally restricted to areas of lower body temperature such as the respiratory tract. However, viraemia has occasionally been reported, and generalised disease has been seen, particularly in young kittens or immunosuppressed individuals.

Infection with FHV leads to areas of multifocal epithelial necrosis with neutrophilic infiltration and fibrin exudation. Intranuclear inclusion bodies are present in infected cells. Replication of the virus can also lead to osteolytic changes in the turbinate bones. Acute lesions normally take between 2 and 3 weeks to resolve, although turbinate destruction may be permanent, and may predispose affected cats to chronic rhinitis. Primary lung involvement may occur, but is rare. Although disease is not dependent on the presence of other organisms, secondary bacterial infection can enhance the pathology leading to, for example, bacterial pneumonia and sinusitis.

Feline calicivirus infection

As for FHV, the natural routes of infection for FCV are nasal, oral or conjunctival. Replication occurs mainly in the oral and respiratory tissues, although there are slight differences between strains of FCV in their tissue tropisms and pathogenicity. Thus, some strains have a predilection for the lung and others have been found within macrophages in the synovial membrane of joints (Bennett *et al.*, 1989; Dawson *et al.*, 1994). Virus has also been found in visceral tissues, faeces and occasionally in urine. The significance of this in transmission is unknown but is likely to be minimal.

Oral ulcers are a prominent pathological feature of FCV infection. They begin as vesicles that subsequently rupture, with necrosis of the overlying epithelium and infiltration of neutrophils at the periphery and base. These ulcers generally heal over a period of 2–3 weeks. Pulmonary lesions occur less frequently and appear to result from an initial focal alveolitis, leading to areas of acute exudative pneumonia and then to the development of a proliferative, interstitial pneumonia. Although primary interstitial pneumonia may occur with FCV, especially with the more virulent strains, it is possible that its importance has been over-emphasised in the past. This is because many early experimental studies used aerosol challenge to infect cats, rather than the more natural oronasal route of infection. Lesions seen in FCV-infected joints consist of an acute synovitis with thickening of the synovial membrane and an increase in quantity of synovial fluid within the joint (Dawson *et al.*, 1994).

Bordetella bronchiseptica

The primary route of infection is via the oronasal cavity where the organism colonises mucosal surfaces. The bacterium uses several virulence factors to adhere to the cilia of the respiratory epithelium. Once attached, ciliostasis and destruction of the cilia occur, resulting in the failure of the mucociliary clearance mechanism and facilitating further colonisation and persistence of bacteria. The release of toxins from *B. bronchiseptica* following colonisation is responsible for local and systemic inflammatory damage.

In other species such as dogs, the organism mainly appears to target the mucosa of the trachea and bronchii, leading to tracheobronchitis. Although the precise pathogenesis of the disease in cats is unclear, upper respiratory tract involvement appears to be more common. However, clearly in some instances the lower respiratory tract may also be targeted, since bronchopneumonia and coughing may occur.

Clinical signs

It is apparent that several organisms may cause respiratory disease in cats. Although there is considerable overlap between the clinical signs induced by each pathogen, some distinction between them on clinical grounds may be possible (Table 22.2; signs caused by *C. felis* (Chapter 27) are also included as a differential diagnosis).

Whatever the respiratory pathogens involved, the clinical signs seen will depend on a number of factors, including those associated with the agent (strain and infecting dose) and those associated with the host (e.g. general health, age and genetic make-up). Differences in microbial flora and husbandry conditions, and the presence of any pre-existing immunity may also affect the course of infection. Concurrent infections with immunosuppressive viruses such as feline immunodeficiency virus (FIV) (Chapter 24) and feline leukaemia virus (FeLV) (Chapter 23) may lead to more severe disease (Dawson *et al.*, 1991; Reubel *et al.*, 1992a, 1994).

Table 22.2 A guide to the typical clinical signs associated with infection with feline herpesvirus (FHV), feline calicivirus (FCV), *Bordetella bronchiseptica* and *Chlamydophila felis*

Clinical signs	FHV	FCV[a]	*B. bronchiseptica*	*C. felis*
Depression	+++	+	+	+
Sneezing	+++	+	+	+
Ptyalism	++	−	−	−
Conjunctivitis	++	+	−	+++
Ocular discharge	+++	+	−	+++
Nasal discharge	+++	+	++	+
Oral ulceration	(+)	+++	−	−
Keratitis	(+)	−	−	−
Coughing	(+)	−	++	−
Pneumonia	(+)	(+)	(+)	+/−
Limping	−	+	−	−

[a]Clinical signs following FCV infection may be more variable, reflecting the strain variability of FCV.
+++: marked; ++: moderate; +: mild; (+): less common; +/− : subclinical; − : absent.

Feline herpesvirus

FHV infection generally causes a severe upper respiratory disease, particularly in young, susceptible animals. The incubation period is usually 2–6 days, but may be longer. A lower challenge dose is generally associated with a longer incubation period and milder clinical signs.

Initial signs include depression, marked sneezing, inappetance and pyrexia, followed rapidly by serous ocular and nasal discharges (Plate 22.1). Sometimes in the early stages there is excessive salivation and ptyalism (drooling of saliva). Conjunctivitis typically develops and the ocular and nasal discharges change from serous to mucopurulent. In severe cases, dyspnoea and coughing may also occur. Oral ulceration can occur with FHV infection, but this is relatively rare compared with FCV where it is a characteristic feature. Occasionally, primary viral pneumonia or generalised disease may occur, particularly in young or debilitated animals. Other manifestations of infection include ocular disease such as ulcerative or interstitial keratitis. It is likely that improved diagnosis, for example using the polymerase chain reaction (PCR), will lead to greater recognition of such conditions (Nasisse *et al.*, 1992, 1998; Stiles *et al.*, 1997a, b). Skin ulcers and dermatitis syndrome in domestic cats and cheetahs (Flecknell *et al.*, 1979; Junge *et al.*, 1991; Hargis *et al.*, 1999; see also Chapter 6) and nervous signs have also been reported, but these are likely to be rare sequelae to FHV infection.

Unlike many other alphaherpesviruses such as canine herpesvirus-1, FHV does not appear to have a particular predilection for the reproductive tract. Experimental studies have suggested that abortion, when it occasionally occurs, is due to the severe systemic nature of the illness, rather than being a direct effect of the virus itself. Indeed, in an investigation of a natural outbreak of FHV in specific pathogen free cats, no cases of abortion were seen, even in severely affected pregnant queens (Hickman *et al.*, 1994).

The mortality rate with FHV infection is generally low, although in very young kittens or immunosuppressed cats the mortality rate may be higher owing to secondary bacterial infections, and more rarely, generalised viral infection. Clinical signs generally resolve within 10–20 days. However, in some cats the acute damage may have been severe enough to lead to permanent damage of the mucosae and turbinates,

leaving them prone to secondary bacterial infection and chronic rhinitis, sinusitis and/or conjunctivitis.

Feline calicivirus

Because of the large number of strains of FCV a range of different clinical signs may be seen. Most strains induce a fairly characteristic, mild upper respiratory tract syndrome with pyrexia, oral ulceration and mild respiratory and conjunctival signs. In contrast, some strains appear to be non-pathogenic, whereas other strains are more virulent and capable of inducing more severe disease. Recently, an outbreak of severe haemorrhagic fever has been described, caused by a highly virulent strain of FCV (Pedersen *et al.*, 2000). Although this is a potentially worrying development in FCV pathogenesis, such severe disease currently appears to be very rare.

Early signs of infection are usually depression and pyrexia, although cats generally appear brighter than those infected with FHV. Sneezing, conjunctivitis and ocular and nasal discharges typically occur, but are generally less prominent than following FHV infection. The most consistent and characteristic clinical sign associated with FCV infection is ulceration of the tongue (Plate 22.2). Ulcers may also be seen on the lips or the nose. Cats with ulcerated mouths may show excessive salivation with wetness round the mouth. However, affected cats often show few other clinical signs and it is likely that many such cases go unrecognised or undiagnosed. Skin ulceration on other parts of the body may be seen, but occurs more rarely. Some of the more virulent strains of FCV may cause pneumonia with associated dyspnoea. FCV has also been reported in occasional cases of abortion (Ellis, 1981; van Vuuren *et al.*, 1999).

A feature of some FCV strains is a lameness and pyrexia syndrome (Pedersen *et al.*, 1983; Dawson *et al.*, 1994; TerWee *et al.*, 1997). This lameness, which may or may not be associated with respiratory disease, is commonly seen as a shifting lameness accompanied by pyrexia. Affected cats are often dull and anorexic. In most cases there is full recovery within 24–48 h and there are no known long-term effects on the joints. It is likely that lameness and respiratory disease are not entirely distinct clinical entities, with most 'limping' strains of FCV causing some degree of respiratory disease and vice versa (TerWee *et al.*, 1997). Lameness, with or without respiratory disease, has also been seen after vaccination (Church, 1989; Dawson *et al.*, 1993a, b). In most cases, such lameness appears to be due to coincidental infection with field virus in young kittens as they lose their MDA. However, in some cases, vaccine virus appears to be involved (Radford *et al.*, 1997, 2000).

FCV has also been implicated in chronic stomatitis/gingivitis. In some studies, approximately 80% of cats with lymphoplasmacytic gingivitis stomatitis complex have been shown to be shedding FCV compared with 20% of control cats (Thompson *et al.*, 1984; Knowles *et al.*, 1989). However, these shedding rates may depend on the criteria used for the selection of clinical cases (Tenorio *et al.*, 1991). In one colony of cats, chronic stomatitis developed following the accidental introduction of FCV into the colony, further suggesting a role for the FCV in this disease (Waters *et al.*, 1993). However, although some isolates of FCV may be able to induce acute faucitis (Reubel *et al.*, 1992b), chronic oral disease has not been reproduced experimentally in cats following infection with FCV either alone or in combination with FIV, another known risk factor for this disease (Dawson *et al.*, 1991; Knowles *et al.*, 1991). It is therefore likely that other pathogens and host factors may also play a role in this complex and serious syndrome.

Bordetella bronchiseptica (see also Chapter 12)

In the field a range of clinical signs has been reported in cats infected with *B. bronchiseptica*, varying from severe dyspnoea, cyanosis and death due to bronchopneumonia (Willoughby *et al.*, 1991; Welsh, 1996; Turnquist & Ostlund, 1997) to milder signs of sneezing, oculonasal discharge and coughing (Welsh, 1996; Binns *et al.*, 1999; Dawson *et al.*, 2000). In general, coughing appears to be less marked in cats than in dogs infected with *B. bronchiseptica*.

Young kittens appear to be most susceptible to *B. bronchiseptica*-induced respiratory disease, particularly bronchopneumonia. In the field it is likely that other factors such as poor hygiene and overcrowding may lead to higher challenge doses and greater host susceptibility, leading to increased severity of clinical disease.

In experimental studies using specific pathogen-free cats the main clinical signs of *B. bronchiseptica* infection are pyrexia, lethargy, coughing, sneezing, oculonasal discharge and submandibular lymphadenopathy which resolve after about 10 days (Jacobs *et al.*, 1993; Coutts *et al.*, 1996).

Diagnosis

In general, it is not always necessary to determine the precise cause of infectious respiratory disease in

individual cats; however, in some circumstances it is particularly advised:

- in colony cats where specific control measures will be required
- in vaccinated cats
- where *B. bronchiseptica* or *C. felis* infection is suspected, to enable the rational choice of antibacterial treatment.

Although there is considerable overlap between the diseases seen with each of the aetiological agents, a presumptive diagnosis can sometimes be made on the basis of clinical signs alone (see Table 22.2). For example, FCV would be suspected where oral ulceration is a predominant feature. Where there is marked sneezing with a more severe respiratory disease and conjunctivitis, then FHV would be more likely. *Bordetella bronchiseptica* may be associated in some cases with coughing, and *C. felis* is primarily associated with marked and persistent conjunctivitis.

Laboratory diagnosis of FHV and FCV has generally been by isolation of the viruses in feline cell cultures. A plain oropharyngeal swab should be taken from the cat, placed into suitable viral transport medium and sent within 24 h to an appropriate laboratory. For viral culture, results may take up to 2 weeks to confirm, particularly if no virus is isolated. Serology is generally not helpful in the diagnosis of FHV or FCV infection owing to widespread immunity from vaccination. Recently, the PCR has been used for the diagnosis of both FHV and *C. felis* (Stiles *et al.*, 1997a, b; Weigler *et al.*, 1997; Sykes *et al.*, 1999). PCR and sequencing have also been used to distinguish between FCV isolates, where they have been particularly useful in the investigation of vaccine failures (Radford *et al.*, 1997, 2000) and in dissecting the epidemiology of the disease (Radford *et al.*, 2001a, b).

Diagnosis of *B. bronchiseptica* infection is also made from oropharyngeal swabs, and if a nasal discharge is present, a nasal swab may also be taken. Swabs should be placed into charcoal Amies transport medium, although ordinary Amies transport medium can also be used. *Bordetella bronchiseptica* should be cultured on an appropriate selective medium such as charcoal/cephalexin agar, which reduces overgrowth by other respiratory flora. Transtracheal washing has been used for the isolation of *Bordetella* from clinical cases (Welsh, 1996), although in the authors' experience this has not proved to be necessary (Speakman *et al.*, 1999).

When diagnosing acute disease, results of isolation must be interpreted with care. False positives may occur owing to the presence of clinically normal carriers in the population (see below). False negatives may also occur, particularly when only low levels of the infecting organism are shed, such as may occur in the later stages of acute disease.

Other bacteria such as *Staphylococcus* and *Streptococcus* species may also be cultured from oropharyngeal and nasal swabs, and it may be helpful to carry out antibacterial sensitivity testing, particularly in more severe cases.

For the diagnosis of infection with *C. felis*, a vigorous conjunctival swab should be taken and sent to the laboratory in appropriate transport medium. Isolation in cell culture, PCR and enzyme-linked immunosorbent assay (ELISA) techniques have all been used to detect infection with this agent (Chapter 27).

Treatment

At present there are no antiviral drugs in widespread use for the treatment of FHV or FCV. Drugs such as acyclovir, given in human herpesvirus infection, do not seem to have good activity against FHV (Nasisse *et al.*, 1989, 1997). However, antiviral treatments are available for cases of ulcerative keratitis associated with FHV infection (see Chapter 18). Interferon has been suggested to be useful for acute viral infections, although there is little documented evidence for its success in cats.

In cases of viral respiratory disease, broad-spectrum antibiotic cover is generally given to help to control secondary bacterial infection. As swallowing may be painful, antibiotics can be given either as syrups or parenterally. Cats should be re-examined after 4–5 days and, if necessary, bacterial culture and sensitivity carried out. Good nursing care, with regular cleaning of discharges, is essential and is generally best done at home if the owner is conscientious. The cat should be encouraged to eat by offering strongly flavoured aromatic foods. If eating is painful, liquidised or specialised proprietary foods may be of some help. It has been suggested that diazepam administered just before feeding can be useful to stimulate appetite, although the cat's general condition may preclude this. Some severe cases may require fluid therapy, and where anorexia is prolonged, a nasogastric or gastrotomy tube may be indicated (Tennant & Willoughby, 1993).

Although not licensed for cats in the UK, nasal decongestants (e.g. phenylephrine) have been recommended in the acute phase of disease. Mucolytic drugs such as bromhexine hydrochloride may help to

clear mucus from airways, especially in the more chronic phase. However, conventional steam inhalation (e.g. placing the cat in a steamy room) is probably more useful.

Almost all isolates of *B. bronchiseptica* from cats are sensitive to tetracycline and doxycycline and the majority to enrofloxacin. Tetracycline and doxycycline are also the antimicrobials of choice for treating *C. felis*. Feline isolates of *B. bronchiseptica* are less susceptible to clavulanate-potentiated amoxycillin (CPA), and a high level of resistance has been detected to ampicillin and trimethoprim (Speakman *et al*., 1997). Although it probably depends on the source of the samples tested, canine *B. bronchiseptica* isolates appear to be more sensitive than those from cats to CPA and ampicillin (Angus *et al*., 1997; Speakman *et al*., 2000). Although antimicrobial therapy should help to alleviate clinical disease, antibiotic treatment of clinically recovered carrier cats may not lead to the elimination of the organism (Coutts *et al*., 1996).

Epidemiology

Both FHV and FCV are fairly widespread in the general cat population, with an increased prevalence where cats are kept grouped together. The viruses circulate and maintain themselves in the cat population in the following ways.

- First, they can spread directly between acutely infected and susceptible cats. Clearly, there must be sufficient susceptible animals within the population and opportunities for contact between them for the virus to persist in this way.
- Secondly, the virus can survive in the environment, but only for relatively short periods. However, indirect transmission can occur, especially within the close confines of a cattery where secretions may contaminate cages, feeding and cleaning utensils or personnel.
- Thirdly, as with many cat infections, both FCV and FHV can persist in the cat population because recovered animals may become carriers.

There are no known reservoir or alternative hosts for FCV and FHV, and *in utero* transmission does not generally seem to occur.

Despite vaccination, carriers are common in the population and are probably the main reason why these viruses are so widespread. An understanding of the FHV and FCV carrier states is important to help to determine strategies for control.

The feline herpesvirus carrier state

The FHV carrier state is the normal sequel to infection (Figure 22.1). It is characterised by periods

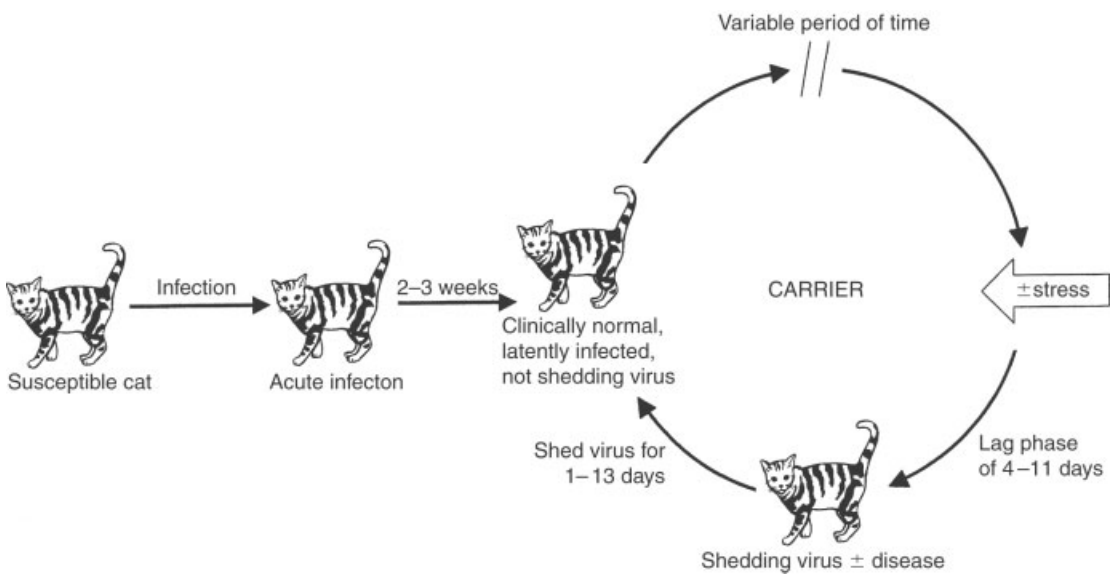

Figure 22.1 Feline herpesvirus carrier state.

of latency where no infectious virus is detectable, interspersed by episodes of virus shedding where infectious virus is present in oronasal, ocular and conjunctival secretions (reactivation). In some cases, carriers show mild clinical signs while they are shedding (recrudescence), which may act as a useful indicator that such individuals are likely to be infectious to other cats.

Although virtually all FHV-recovered cats become carriers, only a proportion of these are likely to be of epidemiological importance and shed virus under natural conditions. Reactivation may occur spontaneously, but is most likely to occur following stress, for example after a change of housing such as going into a boarding cattery, to a cat show or to stud (Gaskell & Povey, 1977). Shedding does not occur immediately after stress: there is a lag period of approximately 1 week, followed by a shedding episode of up to 2 weeks. Thus, carrier cats are most likely to be infectious from 1 to 3 weeks following a stress. Corticosteroid treatment can also induce shedding and care should be taken when using these drugs in carriers as some of these cats may develop severe recrudescent disease.

There is some evidence that the stress of parturition and lactation may precipitate virus shedding in queens, but the clinical outcome in the kittens will depend on their levels of MDA present at that time (Gaskell & Povey, 1982). In some cases, kittens may become infected subclinically under protection of MDA and thereby become latent carriers without ever having shown clinical disease. Such a mechanism favours virus spread to the next generation without harming its host.

As with some other herpesvirus infections, FHV remains latent in carriers in trigeminal ganglia, although there is evidence to show that other tissues may also be involved (Gaskell *et al.*, 1985; Reubel *et al.*, 1993; Weigler *et al.*, 1997). The latent carrier state is almost certainly life-long, but there is a refractory phase of several months after a period of shedding when animals are less likely to experience another episode.

In practical terms, any animal with a known history of respiratory disease, or with persistent or recurrent respiratory disease, should be suspected of being a carrier. Similarly, any queen that repeatedly produces litters that develop respiratory disease is probably a carrier and it may be advisable not to use such queens for breeding.

As with MDA, vaccine-induced immunity does not prevent infection or the development of the carrier state. Therefore, vaccinated cats should be regarded as potential carriers, even though they may have no history of clinical disease. There is no evidence that vaccination will eliminate an existing latent infection. However, it is possible, although as yet unproven, that vaccination may reduce episodes of virus shedding.

The feline calicivirus carrier state

For FCV, a carrier is generally defined as a cat that continues to shed virus for more than 30 days following infection (Figure 22.2). In some experimental studies, it has been shown that most cats still shed FCV in oropharyngeal secretions 30 days after infection. Subsequently, there is an exponential decline in

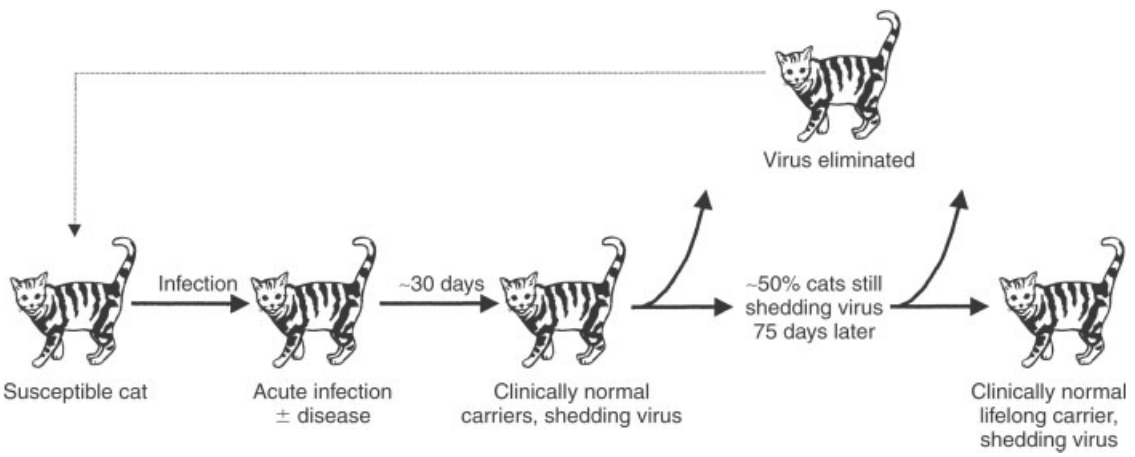

Figure 22.2 Feline calicivirus carrier state.

the proportion of animals that remain as carriers, with approximately 50% of the cats still shedding FCV 75 days later (Wardley & Povey, 1977). While this probably represents an oversimplification of the true dynamics of the FCV carrier state, it is a useful guide. It follows that although individual FCV carriers may shed virus for life, most cats appear to eliminate the virus spontaneously. However, it is likely that in the field, reinfection is common. There is some evidence that pre-existing FIV infection may potentiate FCV shedding in terms of either the duration of shedding (Dawson *et al.*, 1991) or the titre of virus shed (Reubel *et al.*, 1994).

Unlike FHV, the carrier state for FCV is characterised by more-or-less continuous virus shedding and such animals are likely to represent a constant source of infection to susceptible cats. The site of persistence of FCV is not fully characterised. Although virus has been identified in the tonsillar tissue of carriers, other sites are likely to be involved since tonsillectomy does not terminate the carrier state. Similarly, the mechanism of persistence for FCV is not fully elucidated, although it is probable that viral evolution leading to antigenic variation plays a role (Johnson, 1992; Kreutz *et al.*, 1998; Radford *et al.*, 1998; Poulet *et al.,* 2000).

FCV carriers have been arbitrarily divided into high-, medium- and low-level shedders, each shedding a fairly constant amount of virus that fluctuates round a mean for that individual cat (Wardley, 1976). High-level excretors are likely to have greater epidemiological significance in that they may more easily, following only brief contact, infect susceptible individuals. Low-level shedders are probably not as infectious and may also be more difficult to detect since the level of virus shed may sometimes fall below the sensitivity of virus isolation. Therefore, when trying to detect FCV carriers it is advisable to take a series of swabs over several weeks before an individual is believed to be FCV negative.

FCV infection is still very common in the general cat population, despite vaccination. Before vaccines were introduced in the 1970s, surveys showed that approximately 8% of household pets, 25% of cats attending cat shows and 40% of colony cats were shedding the virus. Younger cats had a higher isolation rate than older cats, probably reflecting their high susceptibility to infection once passive immunity has waned. However, despite many years of vaccination, it has been found recently that approximately 20–25% of cats in a variety of husbandry situations still shed FCV (Harbour *et al.*, 1991; Coutts *et al.*, 1994; Binns *et al.*, 2000).

In one rescue shelter, FCV prevalence was approximately 25% despite the regular use of vaccination to control clinical disease (Radford *et al.*, 2001b). Recent molecular epidemiology studies have shown that within this particular shelter, most isolates were distinct, unless the isolates were obtained from cats that were housed in the same pen. This suggests that hygiene measures undertaken in this particular cattery were sufficient to prevent cross-infection. In contrast, in breeding colonies, it appears that in general, only one isolate predominates, although evolution of the individual colony isolates may occur over time (A.D. Radford *et al.*, unpublished observations). Such molecular techniques will hopefully allow us in the near future to develop a clearer understanding of the epidemiology of FCV, and the role of the carrier state in the continued high prevalence of this virus.

As with FHV, pre-existing immunity, acquired either naturally as MDA or artificially following systemic FCV vaccination, does not prevent infection and such animals may become carriers following subclinical infection with field virus. There is no evidence that vaccination will 'cure' an existing carrier state.

Bordetella bronchiseptica

Bordetella bronchiseptica appears to be widespread in the general cat population. Surveys in the UK, mainland Europe and the USA have shown seroprevalences of 24–79% and isolation rates of 3–11%, depending on the population tested (McArdle *et al.*, 1994; Bergman *et al.*, 1997; Hoskins *et al.*, 1998; Binns *et al.*, 1999; Speakman *et al.*, 1999). Seroconversion occurred in young kittens between 5 and 10 weeks of age (McArdle *et al.*, 1994).

A large-scale, cross-sectional epidemiological study of cats with and without respiratory disease found that although 11% of 740 cats were shedding *B. bronchiseptica* overall, the prevalence of infection varied with the type of household sampled (Binns *et al.*, 1999). Thus, 0% of household pets, 9% of cats in breeding catteries, 19.5% of cats in rescue catteries and 13% of cats in other colonies were positive for *B. bronchiseptica*. Statistical analysis showed that living in rescue shelters or large multicat households was a risk factor associated with a higher prevalence of the organism. Separate analysis of the rescue shelter subpopulation showed a highly significant association of *B. bronchiseptica* with current respiratory disease, suggesting that different risk factors for infection may operate in this type of environment. Interestingly, there was no association between the isolation of

Bordetella and the two respiratory viruses, supporting the experimental evidence that *B. bronchiseptica* may be able to cause disease independently.

This study also suggested that, as for FCV and FHV, there appears to be a carrier state with *B. bronchiseptica*, with 9% of healthy cats shedding the organism (Binns *et al.*, 1999). In one experimental study, the organism was shed from the oropharynx of clinically recovered cats for at least 19 weeks following infection (Coutts *et al.*, 1996). In the same study, two seropositive queens started to shed *B. bronchiseptica* following parturition, although the organism was not detected beforehand. This suggests that, as with FHV latency, the stress of parturition may induce shedding.

Bordetella bronchiseptica can infect other species commonly kept in contact with cats, such as dogs and rabbits. Humans may occasionally be affected, particularly if immunosuppressed. It is therefore possible that interspecies transmission, in particular between dogs and cats, may play a role in the epidemiology of this disease. The epidemiological study referred to above found that contact with dogs with recent respiratory disease was a highly significant risk factor for the presence of the organism in cats (Binns *et al.*, 1999). In addition, molecular epidemiological studies have suggested that isolates from dogs and cats on the same premises may in some cases look similar, suggesting that there may be transmission between the two species (Binns *et al.*, 1998). There is also evidence that some isolates may cause respiratory disease in both species: in a recent outbreak of respiratory disease affecting two dogs and two cats in the same household, all four animals appeared to be infected with the same strain of *Bordetella* (Dawson *et al.*, 2000). This has implications for disease control where dogs and cats are kept together.

Transmission

Both FCV and FHV are shed primarily in ocular, nasal and oral secretions. Transmission of FCV and FHV occurs mainly by direct cat-to-cat contact via infectious discharges between acutely infected or carrier cats and susceptible individuals. Indirect transmission via contaminated secretions on cages, feed bowls, cleaning utensils, personnel, etc., may also occur, particularly within the close confines of a cattery. However, since both viruses are relatively short lived outside the cat, the environment is usually not a long-term source of infection.

True aerosol transmission is not thought to be of major importance for the spread of feline respiratory pathogens. Cats have a small tidal volume and do not appear to produce an infectious aerosol for the respiratory viruses during normal respiration. However, sneezed macrodroplets may travel over a distance of 1–2 m, allowing virus transmission to occur.

Transmission is affected by the duration and intimacy of contact between the cats, and for all of these agents it is likely that transmission is more successful in overcrowded conditions. Poor ventilation and hygiene will also lead to a build-up of pathogens in the environment. Transmission is thought to be achieved more easily from acutely infected cats than from carrier cats as the discharges are more copious and the amount of virus is higher. However, carriers are undoubtedly important sources of virus, particularly in transmission between queens and kittens and in the close contact seen between cats in multicat colonies.

Bordetella is shed in oral and nasal secretions of infected cats. It is therefore likely that direct or indirect contact with such discharges is the main route of transmission, although no detailed studies have been carried out to confirm this. Some cats may shed higher levels of *B. bronchiseptica* and therefore be more likely to transmit it to other animals. As with the FCV and FHV, overcrowding and poor management may predispose to infection and disease.

Immunity

Following primary infection with FHV, most cats are generally resistant to subsequent reinfection. However, protection is not necessarily complete in all animals and may only be of relatively short duration. By 6 months after infection, cats may only be partially protected following subsequent challenge, and carrier cats may also develop recrudescent disease. Only low levels of virus-neutralising antibody develop following initial infection or vaccination, suggesting that, as for other alphaherpesviruses, cell-mediated and local immunity play a significant role in protection. However, after reactivation or field virus challenge, virus neutralising antibody titres generally rise to more moderate levels and thereafter remain reasonably stable, independent of virus shedding episodes.

Similarly, most cats are protected following the use of modified live or inactivated FHV vaccines. Again however, immunity is not necessarily complete in all animals, even if challenge takes place within 3 months of the initial vaccination (Scott, 1977; Orr *et al.*, 1978;

Povey & Wilson, 1978). Similar levels of protection have been reported after a year (Bittle & Rubic, 1974). More recent studies have shown that the relative efficacy of an inactivated vaccine decreased from 83% shortly after primary vaccination to 52% after 7.5 years (Scott & Geissinger, 1999).

Most cats develop some degree of immunity following natural FCV infection. However, as with FHV, it is not complete in all animals, and again, may not be of very long duration. In addition, the many different strains of FCV may show varying degrees of cross-protection. The immunity following the use of modified live or inactivated vaccine is similarly incomplete, even shortly after vaccination, although this may depend on the strains or challenge system used (Scott, 1977; Povey *et al.*, 1980; Gaskell *et al.*, 1982; Pedersen & Hawkins, 1995).

For FCV, protection has also been reported to last for 10–12 months after vaccination (Bittle & Rubic, 1975). Virus-neutralising antibody levels tend to be higher than with FHV and in general there is a better correlation with protection: levels of 1:16 are said to be protective (Povey & Ingersoll, 1975). However, protection has also been seen with lower levels of virus-neutralising antibody, suggesting that cell-mediated and possible local immunity may also play a role (Tham & Studdert, 1987; Knowles *et al.*, 1991; Pedersen & Hawkins, 1995). In more recent studies, moderate levels of virus-neutralising antibody have been shown to persist in a group of vaccinated cats for at least 4 years, although after 7.5 years, titres had declined to low or non-detectable levels (Scott & Geissinger, 1997, 1999). Protection against FCV challenge decreased from 85% 3 weeks after vaccination to 63% after 7.5 years.

MDA (which is essentially colostral) in kittens may persist for 2–10 weeks for FHV, with mean levels falling below detectable levels (less than 1:2) by 9 weeks of age (Gaskell & Povey, 1982). For FCV, MDA persists for 10–14 weeks in most kittens (Johnson & Povey, 1983). However, for both viruses, low levels of MDA do not necessarily protect against subclinical infection and kittens infected at this time may become carriers without showing clinical disease. In addition, in FHV infection, some animals with no detectable MDA appear to be protected against disease but not infection (Gaskell & Povey, 1982).

Studies on immunity in *B. bronchiseptica* infection have concentrated on the measurement of immunoglobulin G levels in serum as measured by ELISA (Jacobs *et al.*, 1993; McArdle *et al.*, 1994; Coutts *et al.*, 1996). Following primary infection, antibody levels rise within 1 month to reasonably high levels, and a duration of immunity studies of at least a year has been reported following intranasal vaccination (Williams *et al.*, 2002). MDA for *B. bronchiseptica* has been detected in experimental cats, although this appears to be fairly short lived, lasting for only 2–6 weeks (Jacobs *et al.*, 1993; Coutts *et al.*, 1996).

Prevention and control

Vaccination has now been available for many years against FHV and FCV and it has been relatively successful in controlling disease. Recently, vaccines against *B. bronchiseptica* have also become available for cats. Despite vaccination, respiratory disease can still be a problem, particularly in groups of cats such as in rescue or boarding catteries, and in breeding colonies where there are young kittens.

Carriers of these pathogens are widespread in the cat population, providing a plentiful source of infection for susceptible individuals. Certain husbandry situations, such as stress and overcrowding, can also potentiate disease. Therefore, prevention and control are best achieved by a combination of vaccination and management. For *B. bronchiseptica*, the possibility of transmission between dogs and cats should also be considered.

Vaccination

Several different types of FHV and FCV vaccine are available. Most vaccines are either modified live or inactivated adjuvanted, and are given systemically. Modified live intranasal vaccines are currently not available in the UK but are marketed elsewhere, particularly in the USA. In addition, the potential use of genetically engineered vaccines is being explored for both viruses (Sussman *et al.*, 1995; Willemse *et al.*, 1996; Yokoyama *et al.*, 1996, 1998; DeSilver *et al.*, 1997; Gaskell & Willoughby, 1999; Sommerville *et al.*, 2002). It is likely that future vaccines for feline respiratory disease will consist of recombinant viruses, giving a better immune response as well as improved safety.

Most vaccines are suitable for routine vaccination programmes, and in previously unexposed cats, most induce reasonable protection against disease. However, as stated previously, it should be emphasised that vaccination does not in general protect against infection and the development of the carrier state, and vaccinated animals remain potential sources of field virus to other cats.

For FHV there is only one serotype, and therefore it is likely that vaccines protect against all FHV field isolates. In contrast, although all FCV isolates belong to a single diverse serotype, important antigenic differences between FCV isolates mean that no single vaccine strain is likely to protect equally well against all field viruses. Nevertheless, several strains of FCV have been selected for use in vaccines on the basis that they are considered broadly cross-reactive. FCV F9 was the first strain shown in the early 1970s and again in the 1990s to neutralise 50% or more of current FCV isolates (Dawson *et al.*, 1993b; Pedersen & Hawkins, 1995). Subsequently, other strains such as FCV 255 have also been used in vaccines. Recently, companies have sought to achieve market advantage through claims of broader cross-reactivity for their vaccine strains. It is likely that the ability to neutralise a high proportion of current field isolates will play an increasingly important role in marketing these vaccines. However, it is probable, at least for the foreseeable future, that strains of FCV will always exist in the field that are either poorly protected or not protected against by individual vaccines. Indeed, there is some limited evidence that widespread vaccine usage may be driving FCV towards the evolution of such vaccine-resistant strains (Pedersen & Hawkins, 1995; Lauritzen *et al.*, 1997). It would therefore be desirable for the efficacy of commercially available vaccines to be regularly monitored against panels of contemporary field viruses. However, this is not something that is currently routinely performed.

In some groups of cats, FCV-related disease may still occur despite regular vaccination. This is likely to reflect the antigenic diversity of FCV isolates. In this situation, it may be appropriate to consider changing the vaccine to one based on a different strain. However, this should be done with care as any new vaccine may show either increased or reduced protection against the predominant colony virus. Any decision to change vaccine may be informed by determining the neutralisation profile of vaccine-induced antisera against the predominant colony virus. However, this is only available at specialist laboratories, is neither cheap nor rapid, and may be difficult to interpret.

Although modified live vaccines are in general safe, clinical signs have been reported following their use, particularly in young kittens following their first vaccination (Church, 1989; Dawson *et al.*, 1993a). In most cases this is likely to be due to a coincident field virus infection at a time of declining MDA levels in the kitten. However, in other cases, such signs may be due to vaccine virus. Clinical signs may be induced with some vaccines if the vaccine reaches the oral or respiratory mucosa (e.g. if the cat or a littermate licks the injection site, or if an aerosol is made at the time of injection). In addition, although vaccine virus should not generalise following parenteral administration, spread of the modified live FCV component to the oropharynx has been shown to occur occasionally (Bennett *et al.*, 1989; Pedersen & Hawkins, 1995). This raises the possibility of disease in the individual, and cat-to-cat spread of vaccine virus.

For FCV, the recent development of a molecular typing system has confirmed that the majority of vaccine reactions (clinical disease within 21 days of the last vaccine) are associated with field virus. However, in some cases, vaccine virus does seem to be involved (Radford *et al.*, 1997, 2000). This method of molecular typing is based on sequence analysis of a hypervariable region of the FCV capsid gene, where distinct differences can be found between unrelated isolates. Isolates that share a strong epidemiological link are usually less than 5% different from one another, whereas unrelated isolates are generally 20–40% different in this region.

It is interesting to speculate what happens to FCV vaccine viruses once individual cats start shedding them. Vaccine safety studies required before live vaccines are marketed suggest that they are unlikely to spread and persist in the population and, until recently, it has been the authors' experience that vaccine-type viruses have only been identified in recently vaccinated animals. However, we have recently identified a single colony of cats that appears to be endemically infected with an FCV vaccine-like virus, raising the possibility that in rare cases, vaccine virus may persist in individual cat populations, possibly causing disease (Radford *et al.*, 2001a).

In contrast to live vaccines, inactivated vaccines have the advantage of not being able to spread or revert to virulence, and are therefore particularly useful in virus-free colonies. Some inactivated vaccines have also been used during pregnancy in queens as a useful control measure aimed at prolonging the duration of MDA in their kittens (Iglauer *et al.*, 1989). However, individual data sheets should be checked for this indication. Although inactivated vaccines are classically considered less efficacious than live vaccines, modern adjuvants have led to improvements in immunogenicity. Indeed, a long duration of immunity and reasonable levels of protection in most cats have recently been shown for an adjuvanted, inactivated FHV and FCV vaccine (Scott & Geissinger, 1997, 1999).

Adjuvants may, however, cause problems in individual cats. Local injection site reactions following vaccination may sometimes occur, and in some cases systemic reactions including pyrexia and lethargy may also be observed. Most of these signs are usually transient, but local reactions may persist for several weeks. In recent years, it has become apparent that in rare cases, such reactions may progress to sarcomas (see Chapter 2). Although adjuvants, particularly those based on aluminium, have been implicated in the aetiology of vaccine-associated sarcomas, their precise role in the process is currently unclear.

Live intranasal vaccines probably give marginally better protection than systemic vaccines, but at the expense of greater side-effects. Following intranasal vaccine some mild sneezing can be seen several days later, although in some cats the side-effects may be more severe. Intranasal vaccines, however, can be of use where a rapid onset of protection is required, for example for a cat going into a boarding cattery or in the face of an outbreak of disease. Only one dose of intranasal vaccine is required to induce immunity during primary vaccination, and specific immunity develops very rapidly. Complete protection has been shown 4 days after intranasal vaccination and partial protection after 2 days. Live intranasal vaccines may also overcome MDA better than parenteral vaccines. However, at the time of writing, no live intranasal vaccines are marketed in the UK, although they are used to some extent in the USA owing to concerns about the role of adjuvants in vaccine-associated sarcomas.

Most vaccine manufacturers recommend annual revaccination, although the necessity for this has recently been questioned. Although there is some evidence that duration of immunity for FCV and FHV may be longer (see Immunity section, above), it is important that an individual risk–benefit assessment is carried out, in terms of both safety and efficacy, to determine the most appropriate vaccination strategy for each individual animal (Gaskell *et al.*, 2002a, b).

For *B. bronchiseptica*, intranasal modified live vaccines have recently been marketed in the UK and elsewhere, and show good efficacy (Williams *et al.*, 2002). An inactivated fimbrial subunit vaccine has also been licensed for use in some countries (Jacobs *et al.*, 1993).

Possible reasons for vaccine failures associated with respiratory disease signs are summarised in Table 22.3.

Table 22.3 Major reasons for vaccine failures

(a) ***Vaccine reactions*** (clinical signs occurring within 3 weeks of vaccination)

Operator factors
- Vaccine virus gains access to the respiratory mucosa from modified live systemic vaccines through incorrect administration (e.g. aerosolisation, licking the injection site)

Vaccine factors
- Incomplete attenuation: spread of vaccine virus to the respiratory mucosa from modified live systemic vaccines through generalisation of vaccine virus from the site of injection
- Intranasal vaccines may cause mild clinical symptoms in some individuals

Host and viral factors
- Infection with field virus before the development of complete vaccine-induced protection. Most frequently seen after the first kitten vaccine
- Respiratory disease due to pathogens not vaccinated against
- Recrudescent disease in carrier cats associated with stress of vaccination (FHV)

(b) ***Vaccine breakdowns*** (clinical signs occurring 3 weeks or more following vaccination)

Vaccine/operator factors
- Incorrect storage, handling or administration of vaccine

Host factors
- Failure to respond to vaccine owing to immunosuppression (e.g. infection with feline leukaemia or immunodeficiency virus, corticosteroid treatment)
- Non-specific factors that may either reduce the response to vaccine or increase an individual's disease susceptibility (e.g. age, genotype, general health and intercurrent disease)
- Failure to respond to vaccine due to maternally derived antibody
- Respiratory disease due to pathogens not vaccinated against
- Recrudescent disease in carrier cats (FHV)

Viral factors
- Infection with strains of virus not protected against by the vaccine (FCV)
- Overwhelming challenge dose due to overcrowding, poor hygiene

Disease control in different situations

The following recommendations are based largely on the control of viral respiratory disease in cats. However, it is likely that similar measures will also be effective against *B. bronchiseptica*. Routine vaccination for FHV and FCV is recommended, and in certain high-risk situations *B. bronchiseptica* vaccines may also be indicated. The possibility of transmission of *Bordetella* between dogs and cats should also be considered.

Household pets

All household pets should be regularly vaccinated with any of the available vaccines. They are most likely to be exposed to respiratory pathogens when entering a high-risk situation such as a boarding cattery or veterinary hospital. Exposure is less likely to occur between neighbouring household pets, except in an urban environment with a high-density cat population. Cats are mainly territorial animals and with neutered animals, once their territory is established, any contact with other cats is usually too brief to encourage extensive transmission of pathogens. In addition, the respiratory viruses are relatively fragile outside the cat and, therefore, indirect transmission will be a rare event. Thus, individual cats should, if possible, be routinely vaccinated and should avoid stress and social contact as far as possible. From the point of view of infectious disease, ideally a friend or neighbour should feed the cat while the owner is on holiday, but if the cat does go into a boarding cattery, then it should be fully vaccinated.

Boarding catteries

All cats admitted to a boarding cattery should have an up-to-date vaccination record for FHV and FCV. This means that young kittens should have completed the full vaccination course (i.e. two vaccines 3–4 weeks apart at least 7 days before admission) and adult cats should have had their annual booster at least 7 days before admission. Where vaccination has lapsed for longer than 18 months and an animal is to enter a high-risk situation such as a boarding cattery, it might be advisable to give a full vaccine course. In situations where rapid protection is required, intranasal vaccination may be used in countries where this is available. However, clients should be aware that such vaccines may induce mild clinical signs.

However, cattery owners should not rely solely on adequate vaccination for disease control, for respiratory pathogens will inevitably be present in the cattery either from the occasional animal incubating disease or, more likely, from carriers. Indeed, even fully vaccinated animals may succumb to disease if the viral challenge is high enough. Therefore, precautions should be taken to prevent any possible cross-infection and to reduce the concentration of such agents in the environment. Such measures are outlined in Table 22.4. Although at first sight they may appear complicated, in practice they are not difficult to implement, and in the authors' experience, can actually increase efficiency within a cattery. In addition, they will reduce the spread of other pathogens.

Table 22.4 Recommendations to prevent the spread of respiratory viruses in a boarding cattery

(1) Make sure all incoming cats are fully vaccinated.
(2) House cats individually unless they are from the same household.
(3) Build the cattery with solid partitions between pens. Ensure frontages are at least 1 m apart and the surface of the pen is made of non-porous material that is easily washable.
(4) Arrange the pen so the food and water bowls and the litter tray are easily accessible without having to enter the pen.
(5) Either wash hands in a disinfectant bucket between visiting each pen, or have a set of rubber gloves on a peg by each pen, dedicated for use in that pen only. These can be disposed of or disinfected thoroughly before use with a new boarder.
(6) Wear rubber boots, and if it is necessary to enter the pen, step into a disinfectant bath before and after entering.
(7) Either use disposable food trays or have two sets of feed bowls used on alternate days. Soak the used set in a recommended disinfectant for several hours, rinse thoroughly and leave to dry until reuse.
(8) Prepare food in a central area.
(9) If it is necessary to replace a badly soiled litter tray, follow a similar system to the feed bowls.
(10) Between residents, thoroughly disinfectant the pen, allow to dry and preferably leave empty for 2 days before reusing.
(11) Put those cats that either have signs of respiratory disease or are known to have had respiratory disease, or are suspected from previous experience of being carriers, in a separate section or at one end of the cattery, and feed/clean last.
(12) Feed cats in the same order every day, and attend to each pen completely before moving to the next.
(13) Reduce the concentration of infectious diseases in the environment by adequate ventilation, low relative humidity and optimal environmental temperature.
(14) In mixed boarding catteries and kennels, be aware of possible transmission of *Bordetella bronchiseptica* between cats and dogs. Disinfect between areas, use separate staff if possible and avoid visiting coughing dogs before cats (and vice versa).

Shelter facilities

In general, the same measures apply as with boarding catteries, but it is often impossible to separate animals to the same extent. However, animals should be

segregated or batched and quarantined as far as possible, and those with clinical signs isolated. Unless animals can be quarantined on arrival for 3–4 weeks, systemic vaccines may not have time to become effective. In these circumstances it may be advisable to use intranasal vaccines if available.

Breeding catteries

In disease-free colonies, cats should be vaccinated routinely if there is any contact at all with other cats. For FCV and FHV, inactivated vaccines are perhaps preferable. Great care should be taken to avoid bringing respiratory pathogens into the colony: any cat with a history of respiratory disease or from a household with a history of respiratory disease may be a carrier. It should be remembered that cats may become infected subclinically under cover of MDA or vaccine-induced immunity. The greatest risk of infection to disease-free households is likely to be from stud cats and new breeding stock, where exposure is prolonged. Such animals should come from a colony free from respiratory disease. There is also a slight risk of infection from cat shows, where approximately 25% of cats are shedding FCV (Coutts *et al.*, 1994). However, direct contact between cats at shows is limited and hygiene measures are usually good.

Cats entering the colony should be quarantined for 3 weeks to identify animals incubating disease and, if appropriate, screened virologically at least twice a week during this time. This increases the probability of detecting FHV re-excretion and low-level FCV carriers. Even so, there is still the risk of importing both latent FHV carriers and low-level FCV carriers. With unvaccinated cats, this risk can be minimised by not accepting cats that have seroconverted to FHV or FCV. Since FIV infection seems to potentiate FCV infection, it is probably wise to test for FIV and indeed FeLV as well. The necessity to screen for *B. bronchiseptica* and *C. felis* may also be considered.

In breeding colonies where the disease is endemic, in some circumstances it may be feasible to restock the colony with virus-free cats and to use a barrier system to keep the viruses out. A commercial or an institutional colony could achieve this by using specific pathogen-free animals. A pedigree cat breeding unit could hand-rear kittens of existing stock in isolation, bearing in mind that the viruses are very widespread and that it might be difficult to ensure that the colony remains virus free, even with vaccination. Cats free of *B. bronchiseptica* are difficult to obtain because the organism appears to be widespread, even in otherwise specific pathogen-free cats, but this can be achieved through careful monitoring (Coutts *et al.*, 1996).

For most situations, however, the only reasonable course in breeding colonies with endemic disease is to attempt disease control. This may be done by:

- regular vaccination programmes against FHV and FCV. *Bordetella bronchiseptica* vaccination should be considered where this pathogen is shown to be a problem
- giving booster vaccinations to queens either before mating or during pregnancy to boost levels of MDA in kittens (if the latter, by using an inactivated vaccine, and only if it has a data sheet supporting such use)
- keeping cats as stress free as possible while employing good management practices to reduce the spread of pathogens within the colony
- avoiding the use of particular queens with a history of respiratory disease in their kittens
- moving queens into isolation at least 3 weeks before term, so that the kittens are not exposed to carriers in the colony, and any FHV shedding episode from the queen induced by the move will be over before parturition
- moving early weaning kittens into isolation away from the mother as soon as it is feasible (ideally at 4–5 weeks) if it is likely that she is a carrier
- vaccinating all kittens as soon as MDA is at a non-interfering level (normally 9+ weeks) and keeping them in strict isolation until 1 week after the second dose (normally at 12 weeks)
- earlier vaccination schedules, the starting age depending on the age in that particular colony that kittens first become affected. A recent field study has shown that kittens may respond to systemic vaccination against FCV and FHV given at 3 weekly intervals from 6 weeks of age (Dawson *et al.*, 2001). Intranasal vaccines have also been advocated 7–10 days before disease normally occurs in a colony, and then again at 12 weeks of age. However, it should be borne in mind that such vaccines are neither currently available in the UK nor generally licensed for such early use.

References

Angus J.C., Jang S.S. & Hirsh D.C. (1997) Microbiological study of transtracheal aspirates from dogs with suspected lower

respiratory tract disease: 264 cases (1989–1995). *J Am Vet Med Assoc* **210**, 55–58.

Bennett D., Gaskell R.M., Mills A., *et al.* (1989) Detection of feline calicivirus antigens in the joints of infected cats. *Vet Rec* **124**, 329–332.

Bergman J.G.H.E., Vernooij J. & Zegers E.M. (1997) Prevalence of antibodies against *Bordetella bronchiseptica* in cats with a history of respiratory disease. *Vet Q* **19** (Suppl 1), S50.

Binns S.H., Speakman A.J., Dawson S., *et al.* (1998) The use of pulse-field electrophoresis to examine the epidemiology of *Bordetella bronchiseptica* isolated from cats and other species. *Epidemiol Infect* **120**, 201–208.

Binns S.H., Dawson S., Speakman A.J., *et al.* (1999) Prevalence and risk factors for feline *Bordetella bronchiseptica* infection. *Vet Rec* **144**, 575–580.

Binns S.H., Dawson S., Speakman A.J., *et al.* (2000) A study of feline upper respiratory tract disease with reference to prevalence and risk factors for infection with feline calicivirus and feline herpesvirus. *J Feline Med Surg* **2**, 123–133.

Bittle J.L. & Rubic W.J. (1974) Studies of feline viral rhinotracheitis vaccine. *Vet Med Small Anim Clin* **69**, 1503–1505.

Bittle J.L. & Rubic W.J. (1975) A feline calicivirus vaccine combined with feline viral rhinotracheitis and feline panleukopenia vaccine. *Feline Pract* **5** (6), 13–15.

Church R.E. (1989) Lameness in kittens after vaccination. *Vet Rec* **125**, 609.

Coutts A.J., Dawson S., Willoughby K. & Gaskell R.M. (1994) Isolation of feline respiratory viruses from clinically healthy cats at UK cat shows. *Vet Rec* **135**, 555–556.

Coutts A.J., Dawson S., Binns S., *et al.* (1996) Studies on natural transmission of *Bordetella bronchiseptica* in cats. *Vet Microbiol* **48**, 19–27.

Dawson S., Smyth N.R., Bennett M., *et al.* (1991) Effect of primary-stage feline immunodeficiency virus infection on subsequent feline calicivirus vaccination and challenge in cats. *AIDS* **5**, 747–750.

Dawson S., McArdle F., Bennett D., *et al.* (1993a) Investigation of vaccine reactions and breakdowns after feline calicivirus vaccination. *Vet Rec* **132**, 346–350.

Dawson S., McArdle F., Bennett M., *et al.* (1993b) Typing of feline calicivirus isolates from different clinical groups by virus neutralisation tests. *Vet Rec* **133**, 13–17.

Dawson S., Bennett D., Carter S.D., *et al.* (1994) Acute arthritis of cats associated with feline calicivirus infection. *Res Vet Sci* **56**, 133–143.

Dawson S., Jones D., McCracken C.M., *et al.* (2000) Bordetella bronchiseptica infection in cats following contact with infected dogs. *Vet Rec* **146**, 46–48.

Dawson S., Willoughby K., Gaskell R.M., *et al.* (2001) A field trial to assess the effect of vaccination against feline herpesvirus, feline calicivirus and feline panleucopenia virus in 6-week-old kittens. *J Feline Med Surg* **3**, 17–22.

DeSilver D.A., Guimond P.M., Gibson J.K., *et al.* (1997) Expression of the complete capsid and the hypervariable region of feline calicivirus in the baculovirus expression system. In *First International Symposium on Caliciviruses. Proceedings of a European Society for Veterinary Virology (ESVV) Symposium, Reading.* (eds Chasey D., Gaskell R.M. & Clarke I.N.). ESVV and Central Veterinary Laboratory, pp. 131–143.

Ellis T.M. (1981) Jaundice in a Siamese cat with *in utero* feline calicivirus infection. *Aust Vet J* **57**, 383–385.

Flecknell P.A., Orr C.M., Wright A.I., *et al.* (1979) Skin ulceration associated with herpesvirus infection in cats. *Vet Rec* **104**, 313–315.

Gaskell R.M. & Povey R.C. (1977) Experimental induction of feline viral rhinotracheitis (FVR) virus re-excretion in FVR-recovered cats. *Vet Rec* **100**, 128–133.

Gaskell R.M. & Povey R.C. (1982) Transmission of feline viral rhinotracheitis. *Vet Rec* **111**, 359–362.

Gaskell R. & Willoughby K. (1999) Herpesviruses of carnivores. *Vet Microbiol* **69**, 73–88.

Gaskell C.J., Gaskell R.M., Dennis P.E. & Woolridge M.J.A. (1982) Efficacy of an inactivated feline calicivirus (FCV) vaccine against challenge with United Kingdom field strains and its interaction with the FCV carrier state. *Res Vet Sci* **32**, 23–26.

Gaskell R.M., Dennis P.E., Goddard L.E., *et al.* (1985) Isolation of felid herpesvirus 1 from the trigeminal ganglia of latently infected cells. *J Gen Virol* **66**, 391–394.

Gaskell R.M., Gettinby G., Graham S.J. & Skilton D. (2002a) *Veterinary Products Committee (VPC) Working Group on Feline and Canine Vaccination. Final Report to the VPC.* Report no. PB 6432. Department for Environmental, Food and Rural Affairs, London.

Gaskell R.M., Gettinby G., Graham S.J. & Skilton D. (2002b) Veterinary Products Committee working group report on feline and canine vaccination. *Vet Rec* **150**, 126–134.

Geissler K., Schneider K., Platzer G., *et al.* (1997) Genetic and antigenic heterogeneity among feline calicivirus isolates from distinct disease manifestations. *Virus Res* **48**, 193–206.

Glenn M., Radford A.D., Turner P.C., *et al.* (1999) Nucleotide sequence of UK and Australian isolates of feline calicivirus (FCV) and phylogenetic analysis of FCVs. *Vet Microbiol* **67**, 175–193.

Grail A. & Harbour D.A. (1990) Restriction endonuclease analysis of DNA from isolates of feline herpesvirus type 1. *Nippon Juigaku Zasshi* **52** (5), 1007–1013.

Grail A., Harbour D.A. & Chia W. (1991) Restriction endonuclease mapping of the genome of feline herpesvirus type 1. *Arch Virol* **116**, 209–220.

Haesebrouck F., Devriese L.A., van Rijssen B. & Cox E. (1991) Incidence and significance of isolation of *Mycoplasma felis* from conjunctival swabs of cats. *Vet Microbiol* **26**, 95–101.

Harbour D.A., Howard P.E. & Gaskell R.M. (1991) Isolation of feline calicivirus and feline herpesvirus from domestic cats 1980 to 1989. *Vet Rec* **128**, 77–80.

Harder T.C., Harder M., Vos H., *et al.* (1996) Characterization of phocid herpesvirus-1 and -2 as putative alpha- and gammaherpesviruses of North American and European pinnipeds. *J Gen Virol* **77**, 27–35.

Hargis A.M., Ginn P.E., Mansell J.E.K.L. & Garber R.L. (1999) Ulcerative facial and nasal dermatitis and stomatitis in cats associated with feline herpesvirus 1. *Vet Dermatol* **10**, 267–274.

Hashimoto M., Roerink F., Tohya Y. & Mochizuki M. (1999) Genetic analysis of the RNA polymerase gene of caliciviruses from dogs and cats. *J Vet Med Sci* **61**, 603–608.

Hickman M.A., Reubel G.H., Hoffman D.E., *et al.* (1994) An epizootic of feline herpesvirus, type 1 in a large specific pathogen-free cat colony and attempts to eradicate the infection by identification and culling of carriers. *Lab Anim* **28**, 320–329.

Horimoto T., Limcumpao J.A., Xuan X., *et al.* (1992) Heterogeneity of feline herpesvirus type 1 strains. *Arch Virol* **126**, 283–292.

Hoskins J.D., Williams J., Roy A.F., *et al.* (1998) Isolation and characterization of *Bordetella bronchiseptica* from cats in southern Louisiana. *Vet Immunol Immunopathol* **65**, 173–176.

Iglauer F., Gartner K. & Morstedt R. (1989) Maternal protection against feline respiratory disease by means of booster vaccinations during pregnancy – a retrospective clinical study. *Kleintierpraxis* **34**, 235.

Inzana T.J., Johnson J.L., Shell L., *et al.* (1992) Isolation and characterization of a newly identified *Haemophilus* species from cats: *'Haemophilus felis'. J Clin Microbiol* **30**, 2108–2112.

Jacobs A.A.C., Chalmers W.S.K. & Pasman J. (1993) Feline bordetellosis: challenge and vaccine studies. *Vet Rec* **133**, 260–263.

Johnson R.P. (1992) Antigenic change in feline calicivirus during persistent infection. *Can J Vet Res* **56**, 326–330.

Johnson R.P. & Povey R.C. (1983) Transfer and decline of maternal antibody to feline calicivirus. *Can Vet J* **24**, 6–9.

Junge R.E., Miller R.E., Boever W.J., *et al.* (1991) Persistent cutaneous ulcers associated with feline herpesvirus type 1 infection in a cheetah. *J Am Vet Med Assoc* **198**, 1057–1058.

Kadoi K., Kiryu M., Iwabuchi M., *et al.* (1997) A strain of calicivirus isolated from lions with vesicular lesions on tongue and snout. *New Microbiol* **20**, 141–148.

Knowles J.O., Gaskell R.M., Gaskell C.J., *et al.* (1989) Prevalence of feline calicivirus, feline leukaemia virus and antibodies to FIV in cats with chronic stomatitis. *Vet Rec* **124**, 336–338.

Knowles J.O., McArdle F., Dawson S., *et al.* (1991) Studies on the role of feline calicivirus in chronic stomatitis in cats. *Vet Microbiol* **27**, 205–219.

Kreutz L.C., Johnson R.P. & Seal B.S. (1998) Phenotypic and genotypic variation of feline calicivirus during persistent infection of cats. *Vet Microbiol* **59**, 229–236.

Lauritzen A., Jarrett O. & Sabara M. (1997) Serological analysis of feline calicivirus isolates from the United States and United Kingdom. *Vet Microbiol* **56**, 55–63.

Lebich M., Harder T.C., Frey H.R., *et al.* (1994) Comparative immunological characterization of type-specific and conserved B-cell epitopes of pinniped, felid and canid herpesviruses. *Arch Virol* **136**, 335–347.

McArdle H.C., Dawson S., Coutts A.J., *et al.* (1994) Seroprevalence and isolation rate of *Bordetella bronchiseptica* in cats in the UK. *Vet Rec* **135**, 506–507.

Maeda K., Kawaguchi Y., Ono M., *et al.* (1995) Comparisons among feline herpesvirus type 1 isolates by immunoblot analysis. *J Vet Med Sci* **57**, 147–150.

Nasisse M.P., Guy J.S., Davidson M.G., *et al.* (1989) *In vitro* susceptibility of feline herpesvirus-1 to vidarabine, idoxuridine, trifluridine, acyclovir, or bromovinyldeoxyuridine. *Am J Vet Res* **50**, 158–160.

Nasisse M.P., Davis B.J., Guy J.S., *et al.* (1992) Isolation of feline herpesvirus 1 from the trigeminal ganglia of acutely and chronically infected cats. *J Vet Intern Med* **6**, 102–103.

Nasisse M.P., Dorman D.C., Jamison K.C., *et al.* (1997) Effects of valacyclovir in cats infected with feline herpesvirus 1. *Am J Vet Res* **58**, 1141–1144.

Nasisse M.P., Glover T.L., Moore C.P. & Weigler B.J. (1998) Detection of feline herpesvirus 1 DNA in corneas of cats with eosinophilic keratitis or corneal sequestration. *Am J Vet Res* **59**, 856–858.

Olsson E. & Falsen E. (1994) '*Haemophilus felis*': a potential pathogen for cats? (Letter; Comment). *J Clin Microbiol* **32**, 858–859.

Orr C.M., Gaskell C.J. & Gaskell R.M. (1978) Interaction of a combined feline viral rhinotracheitis–feline calicivirus vaccine and the FVR carrier state. *Vet Rec* **103**, 200–202.

Pedersen N.C. & Hawkins K.F. (1995) Mechanisms of persistence of acute and chronic feline calicivirus infections in the face of vaccination. *Vet Microbiol* **47**, 141–156.

Pedersen N.C., Laliberte L. & Ekman S. (1983) A transient febrile 'limping' syndrome of kittens caused by two different strains of feline calicivirus. *Feline Pract* **13** (1), 26–35.

Pedersen N.C., Elliott J.B., Glasgow A., *et al.* (2000) An isolated epizootic of hemorrhagic-like fever in cats caused by a novel and highly virulent strain of feline calicivirus. *Vet Microbiol* **73**, 281–300.

Poulet H., Brunet S., Soulier M., *et al.* (2000) Comparison between acute oral/respiratory and chronic stomatitis/gingivitis isolates of feline calicivirus: pathogenicity, antigenic profile and cross-neutralisation studies. *Arch Virol* **145**, 243–261.

Povey C. & Ingersoll J. (1975) Cross-protection among feline calicviruses. *Infect Immun* **11**, 877–885.

Povey R.C. & Wilson M.R. (1978) A comparison of inactivated feline viral rhinotracheitis and feline caliciviral disease vaccines with live-modified viral vaccines. *Feline Pract* **8** (3), 35–42.

Povey R.C., Koonse H. & Hays M.B. (1980) Immunogenicity and safety of an inactivated vaccine for the prevention of rhinotracheitis, caliciviral disease, and panleukopenia in cats. *J Am Vet Med Assoc* **177**, 347–350.

Radford A.D., Bennett M., McArdle F., *et al.* (1997) The use of sequence analysis of a feline calicivirus (FCV) hypervariable

region in the epidemiological investigation of FCV related disease and vaccine failures. *Vaccine* **15**, 1451–1458.

Radford A.D., Turner P.C., Bennett M., *et al.* (1998) Quasi-species evolution of a hypervariable region of the feline calicivirus capsid gene in cell culture and in persistently infected cats. *J Gen Virol* **79**, 1–10.

Radford A.D., Dawson S., Wharmby C., *et al.* (2000) Comparison of serological and sequence-based methods for typing feline calicivirus isolates from vaccine failures. *Vet Rec* **146**, 117–123.

Radford A.D., Sommerville L., Ryvar R., *et al.* (2001a) Endemic infection of a cat colony with a feline calicivirus closely related to an isolate used in live attenuated vaccines. *Vaccine* **19**, 4358–4362.

Radford A.D., Sommerville L.M., Dawson S., *et al.* (2001b) Molecular analysis of isolates of feline calicivirus from a population of cats in a rescue shelter. *Vet Rec* **149**, 477–481.

Reubel G.H., George J.W., Barlough J.E., *et al.* (1992a) Interaction of acute feline herpesvirus-1 and chronic feline immunodeficiency virus infections in experimentally infected specific pathogen free cats. *Vet Immunol Immunopathol* **35**, 95–119.

Reubel G.H., Hoffmann D.E. & Pedersen N.C. (1992b) Acute and chronic faucitis of domestic cats: a feline calicivirus induced disease. *Vet Clin North Am Small Anim Pract* **22**, 1347–1360.

Reubel G.H., Ramos R.A., Hickman M.A., *et al.* (1993) Detection of active and latent feline herpesvirus 1 infections using the polymerase chain reaction. *Arch Virol* **132**, 409–420.

Reubel G.H., George J.W., Higgins J. & Pedersen N.C. (1994) Effect of chronic feline immunodeficiency virus infection on experimental feline calicivirus-induced disease. *Vet Microbiol* **39**, 335–351.

Roerink F., Hashimoto M., Tohya Y. & Mochizuki M. (1999) Genetic analysis of a canine calicivirus: evidence for a new clade of animal caliciviruses. *Vet Microbiol* **69**, 69–72.

Scott F.W. (1977) Evaluation of a feline viral rhinotracheitis-feline calicivirus disease vaccine. *Am J Vet Res* **38**, 229–234.

Scott F.W. & Geissinger C.M. (1997) Duration of immunity in cats vaccinated with an inactivated feline panleukopenia, herpesvirus and calicivirus vaccine. *Feline Pract* **25** (4), 12–19.

Scott F.W. & Geissinger C.M. (1999) Long-term immunity in cats vaccinated with an inactivated trivalent vaccine. *Am J Vet Res* **60**, 652–658.

Sommerville L.M., Radford A.D., Glenn M., *et al.* (2002) DNA vaccination against feline calicivirus infection using a plasmid encoding the mature capsid protein. *Vaccine* **20**, 1787–1796

Speakman A.J., Binns S.H., Dawson S., *et al.* (1997) Antimicrobial susceptibility of *Bordetella bronchiseptica* isolates from cats and a comparison of the agar dilution and E-test methods. *Vet Microbiol* **54**, 63–72.

Speakman A.J., Dawson S., Binns S.H., *et al.* (1999) *Bordetella bronchiseptica* infection in the cat. *J Small Anim Pract* **40**, 252–256.

Speakman A.J., Dawson S., Corkill J.E., *et al.* (2000) Antibiotic susceptibility of canine *Bordetella bronchiseptica* isolates. *Vet Microbiol* **71**, 193–200.

Stiles J., McDermott M., Bigsby D., *et al.* (1997a) Use of nested polymerase chain reaction to identify feline herpesvirus in ocular tissue from clinically normal cats and cats with corneal sequestra or conjunctivitis. *Am J Vet Res* **58**, 338–342.

Stiles J., McDermott M., Willis M., *et al.* (1997b) Comparison of nested polymerase chain reaction, virus isolation, and fluorescent antibody testing for identifying feline herpesvirus in cats with conjunctivitis. *Am J Vet Res* **58**, 804–807.

Sussman M.D., Maes R.K., Kruger J.M., *et al.* (1995) A feline herpesvirus-1 recombinant with a deletion in the genes for glycoproteins gI and gE is effective as a vaccine for feline rhinotracheitis. *Virology* **214**, 12–20.

Sykes J.E., Studdert V.P. & Browning G.F. (1998) Detection and strain differentiation of feline calicivirus in conjunctival swabs by RT-PCR of the hypervariable region of the capsid protein gene. *Arch Virol* **143**, 1321–1334.

Sykes J.E., Anderson G.A., Studdert V.P. & Browning G.F. (1999) Prevalence of feline *Chlamydia psittaci* and feline herpesvirus 1 in cats with upper respiratory tract disease. *J Vet Intern Med* **13**, 153–162.

Tennant B. & Willoughby K. (1993) The use of enteral nutrition in small animal medicine. *Compendium of Continuing Education for the Practicing Veterinarian* **15**, 1054.

Tenorio A.P., Franti C.E., Madewell B.R. & Pedersen N.C. (1991) Chronic oral infections of cats and their relationship to persistent oral carriage of feline calici-, immunodeficiency, or leukemia viruses. *Vet Immunol Immunopathol* **29**, 1–14.

TerWee T., Lauritzen A., Sabara M., *et al.* (1997) Comparison of the primary signs induced by experimental exposure to either a pneumotrophic or a 'limping' strain of feline calicivirus. *Vet Microbiol* **56**, 33–45.

Tham K.M. & Studdert M.J. (1987) Antibody and cell-mediated immune responses to feline calicivirus following inactivated vaccine and challenge. *J Vet Med B* **34**, 640–654.

Thompson R.R., Wilcox G.E., Clark W.T. & Jansen K.L. (1984) Association of calicivirus infection with chronic gingivitis and pharyngitis in cats. *J Small Anim Pract* **25**, 207–210.

Turnquist S.E. & Ostlund E. (1997) Calicivirus outbreak with high mortality in a Missouri feline colony. *J Vet Diag Invest* **9**, 195–198.

Vuuren M. van, Geissler K., Gerber D., *et al.* (1999) Characterisation of a potentially abortigenic strain of feline calicivirus isolated from a domestic cat. *Vet Rec* **144**, 636–638.

Wardley R.C. (1976) Feline calicivirus carrier state: a study of the host/virus relationship. *Arch Virol* **52**, 243–249.

Wardley R.C. & Povey R.C. (1977) The clinical disease and patterns of excretion associated with three different strains of feline calicivirus. *Res Vet Sci* **23**, 7–14.

Waters L., Hopper C.D., Gruffydd-Jones T.J. & Harbour D.A. (1993) Chronic gingivitis in a colony of cats infected with

feline immunodeficiency virus and feline calicivirus. *Vet Rec* **132**, 340–342.

Weigler B.J., Babineau C.A., Sherry B. & Nasisse M.P. (1997) High sensitivity polymerase chain reaction assay for active and latent feline herpesvirus-1 infections in domestic cats. *Vet Rec* **140**, 335–338.

Welsh R.D. (1996) *Bordetella bronchiseptica* infections in cats. *J Am Anim Hosp Assoc* **32**, 153–158.

Willemse M.J., Chalmers W.S. & Sondermeijer P.J. (1996) *In vivo* properties of a feline herpesvirus type 1 mutant carrying a lacZ insertion at the gI locus of the unique short segment. *Vaccine* **14**, 1–5.

Williams J., Laris R., Gray A.W. & Jacobs A.A. (2002) Studies on the efficacy of a novel intranasal vaccine against feline bordetellosis. *Vet Rec* **150**, 439–442.

Willoughby K., Dawson S., Jones R.C., *et al.* (1991) Isolation of *Bordetella bronchiseptica* from kittens with pneumonia in a breeding cattery. *Vet Rec* **129**, 407–408.

Willoughby K., Bennett M., McCracken C.M. & Gaskell R.M. (1999) Molecular phylogenetic analysis of felid herpesvirus 1. *Vet Microbiol* **69**, 93–97.

Yokoyama N., Maeda K., Tohya Y., *et al.* (1996) Pathogenecity and vaccine efficacy of a thymidine kinase-deficient mutant of feline herpesvirus type I in cats. *Arch Virol* **141**, 481–494.

Yokoyama N., Fujita K., Damiani A., *et al.* (1998) Further development of a recombinant feline herpesvirus type 1 vector expressing feline calicivirus immunogenic antigen. *J Vet Med Sci* **60**, 717–723.

Chapter 23

FELINE LEUKAEMIA VIRUS INFECTION

O. Jarrett and M.J. Hosie

Introduction

Feline leukaemia virus (FeLV) is a retrovirus of domestic cats that occurs throughout the world. Like all retroviruses, FeLV may establish a persistent infection in its host. A persistently infected (viraemic) cat is at very high risk of developing a fatal disease within 2–4 years of becoming infected. Many diseases caused by FeLV involve the lymphoid or haematopoietic tissues and include tumours, particularly lymphomas and leukaemias, as well as degenerative conditions such as anaemia and immunodeficiency. Some forms of chemotherapy are successful in treating lymphomas, but there is no specific treatment for the viral infection. During the prolonged incubation period before disease develops, the viraemic cat is generally in good health, but can transmit the virus to other cats. Fortunately, most cats that are exposed to the virus do not become viraemic but recover and are immune. Susceptible animals can be protected from infection by the detection and isolation of viraemic cats, and by vaccination. Diagnostic tests are available for the rapid diagnosis of FeLV infection.

Structure, replication and persistence of feline leukaemia virus

Some knowledge of the structure and molecular biology of FeLV is helpful in understanding the basis of virus transmission, diagnosis and vaccination (Jarrett, 2000). After the virus infects cells, a DNA copy of the RNA genome is made by the viral enzyme, reverse transcriptase, and is integrated into the cellular chromosomal DNA as a provirus. The provirus remains there during the life of the cell, which is the molecular basis of the persistence of FeLV in cats. Upon cellular division, the provirus is expressed and progeny virus is released without harming the cell. Consequently, virus is produced only in those tissues that contain dividing cells.

There are two components of the viral particle that are of particular interest: the major internal capsid protein, p27, and the surface glycoprotein, gp70. The p27 protein is the antigen that is detected in the plasma of viraemic cats by in-practice diagnostic tests. The gp70 molecule, encoded by the viral *env* gene, contains antigens that are important in the induction of immunity to FeLV, both following recovery from natural infection and after vaccination.

The gp70 molecule also contains sites that attach to cell receptors and thus determines the subgroup of the virus. There are three subgroups: A, B and C. FeLV-A is the common form that is responsible for transmission of the virus in nature, and is present in all isolates of FeLV (Jarrett *et al.*, 1978). The two other subgroups arise *de novo* from FeLV-A in individual viraemic cats. FeLV-B, which is found in about half of isolates together with FeLV-A, is generated by recombination between the *env* genes of FeLV-A and endogenous, defective FeLV-like proviruses that are present in all cat cells (Stewart *et al.*, 1986). These endogenous proviruses are the remnants of ancient retroviruses, and although they are no longer transmitted between cats, they can donate parts of their *env* genes to form recombinants with FeLV-A, which are recognised as FeLV-B. FeLV-B can be transmitted naturally between cats, but only in a mixture with FeLV-A. Cats that are viraemic with FeLV-A and FeLV-B are at higher risk of developing lymphoma than cats with FeLV-A alone. FeLV-C, which occurs in about 1% of isolates, is a mutant in the *env* gene of FeLV-A (Rigby *et al.*, 1992) and is not transmitted in nature from the cat in which it arises. Following the generation of FeLV-C in a viraemic cat, a severe, fatal anaemia may occur within

a few weeks. Since viruses of subgroups B and C depend on FeLV-A for their generation and/or transmission between cats, it follows that immunity to FeLV-A will protect cats against infection with any subgroup. This is another factor that is relevant to vaccination since some FeLV vaccines contain only antigens of subgroup A.

It is a common misconception that FeLV subgroups are also serotypes. This is not so, for while FeLV-A isolates are antigenically identical in virus neutralisation tests, isolates of FeLV-B and FeLV-C are more diverse and many cannot be distinguished readily from FeLV-A.

Transmission and pathogenesis

Transmission

The source of FeLV is the persistently viraemic cat which excretes virus from all epithelial surfaces, and most significantly from the nose and mouth. The virus is frequently spread by the transfer of contaminated saliva during mutual grooming, but can also be transmitted across the placenta and in the milk. Several host and viral factors determine whether a cat exposed to FeLV will become viraemic or recover. The most important host factors affecting the outcome of infection include the age at which the cat becomes infected (Hoover *et al.*, 1976) and its immune status. Kittens infected within the first 4–5 months of life have a high risk of becoming permanently infected. After this period, resistance to infection develops rapidly, so that by 6 months of age only about 15% of cats develop persistent viraemia following natural exposure. Cats that have recovered from FeLV infection and have virus-neutralising antibodies, or kittens that have maternally derived antibody (MDA), are resistant to infection.

The dose of virus to which the cat is exposed is also important, and the effect of this is seen dramatically in the contrast between the prevalence of infection in closed multicat households in which the virus is enzootic and in free-ranging cats, generally from single-cat households. In multicat households the dose is high, owing to continuous exposure from viraemic cats. Consequently, these populations are often found to have a prevalence of 30–40% of viraemic cats, which consequently have a high risk of developing FeLV-associated diseases. In contrast, free-ranging cats have a low prevalence of FeLV viraemia of approximately 1%, and therefore their incidence of FeLV-related disease is very low. However, about 40% of cats in this population have antiviral antibodies, indicating that they have been exposed to virus. This observation suggests that free-ranging cats are exposed to low doses of virus, reflecting the intermittent nature of cat-to-cat contact in this population.

Congenital infection is uncommon, since the majority of FeLV-infected queens have reproductive problems and *in utero* infection results in neonatal or foetal death in over three-quarters of infected queens. Some kittens may become immune, but the majority have a persistant infection. Kittens born to queens that have recovered from FeLV infection usually acquire MDAs that protect against infection for the first 2–3 months of life.

Spread of the virus *in vivo*

The virus that is transmitted into the oropharynx of susceptible cats grows in local lymphoid tissue and within a few days the progeny is carried by a cell-associated viraemia to the bone marrow and lymphoid organs, where it grows extensively in dividing cells (Rojko *et al.*, 1979). From these sites, infectious virus spreads all over the body in the plasma, and infects epithelial cells in many organs, including the salivary glands, nasal mucosa and the oropharynx, from which it is excreted. This cycle, from exposure to excretion, occupies about 3 weeks.

At any time during this period, viral growth may be blocked by an antiviral immune response (Hardy *et al.*, 1976a; Flynn *et al.*, 2002). If immunity develops rapidly, the virus may not reach the bone marrow and the infection may be eliminated without the appearance of a viraemia. If the immune response is delayed a little longer, until after the virus begins to grow in the marrow, the infection is also controlled and only a transient viraemia may occur, lasting for some days or weeks. In fact, in most of these cases the virus persists for a further few weeks or months in a hidden, or latent state, in the marrow. When the immune response is further delayed, permitting the virus to infect epithelial cells, the virus may not be cleared and a persistent viraemia ensues.

'Latent' infection

Virus in the latent infections that occur in the bone marrow, and probably in other tissues, appears to be eliminated from most cats within a few months, although some infections can persist for years (Pacitti & Jarrett, 1985). Although virus is not demonstrable

in the plasma of latently infected cats, and does not appear to be excreted from the oropharynx, infectious virus may be isolated by culture of bone-marrow cells obtained from aspirates. Following natural infection, about half of cats exposed to FeLV have a latent infection in the bone marrow 6 months after exposure, and 10% still harbour latent virus after 3 years. Indeed, it may be that no cat ever really recovers completely from FeLV infection and that proviral DNA, at least, may persist in the cat for life. This might explain why virus-neutralising antibodies persist in recovered cats for many years in the absence of overt infection or exposure to viraemic cats. If this is the case, the risk of such latent persistence leading to re-excretion of virus or the development of disease must be extremely low, since recovered cats have the same life expectancy as cats that have never been exposed to FeLV. However, as discussed below, proviral DNA has been found in the tumours of ostensibly FeLV-free cats, suggesting that the virus may be involved in an early event in the pathogenesis of the tumour and then persists only as a provirus, possibly in a defective form. Latent virus or provirus may also be the source of the FeLV p27 antigen that is sometimes found in the plasma of cats from which infectious virus cannot be isolated, the so-called 'discordant' cats.

Immunity

The other major factor that allows FeLV to persist in its host is the selective immunological tolerance to viral antigens that is induced in viraemic cats. The major consequence of tolerance is that there is no effective immune response against the virus, allowing it to grow unhindered. Another important effect of tolerance is that there is no immune selection pressure on the virus to undergo antigenic change. Presumably this is why FeLV-A is genetically and antigenically stable, and exists in a single antigenic type, as noted above. This conservation is a positive factor for the success of vaccination.

Fortunately, most cats that are exposed to FeLV recover from the infection, develop an antiviral immune response and are resistant to reinfection. The immune response that controls FeLV infection involves both antibody (Russell & Jarrett, 1978) and T-cell killing (Flynn *et al.*, 2002). Cell-mediated immunity is probably responsible for the rapid clearance of virus-infected cells, as cytotoxic T-cells appear in the blood of cats within 1–2 weeks following infection. After the virus disappears from the plasma, virus-neutralising antibodies are found in the serum. Cats that have virus-neutralising antibodies are then resistant to reinfection, although a minority of recovered cats do not have antibodies. MDA passively transferred in the colostrum protects young kittens from infection (Jarrett *et al.*, 1977). Therefore, the presence of virus-neutralising antibodies in the serum is a useful diagnostic indicator of an immune cat.

FeLV is unlikely to survive for long outside the host as it is destroyed readily by disinfectants, soap, heating and drying. Hence, transmission via fomites is unlikely. The virus will survive, however, if it is kept moist and at room temperature, so that there is potential for iatrogenic transmission to occur via contaminated needles, surgical instruments or blood transfusions.

Clinical features of related diseases

The consequence of persistent infection is the development of FeLV-related diseases. These conditions occur in cats over a wide range of ages, but particularly in 2–4-year-old animals. The reasons for this distribution are that many cats are infected during the first few weeks of life when kittens are most susceptible, and that an incubation period of 2–4 years is then required for the sequence of genetic events to occur that lead to the development of particular diseases. However, a few viraemic cats have been known to survive for periods of 10 years or more.

FeLV causes both malignant and non-malignant diseases, all of which are serious and potentially fatal. The most frequent conditions caused by the virus are lymphoma (lymphosarcoma), lymphoid and myeloid leukaemias, anaemia, immunosuppression, enteritis, bone-marrow suppression and reproductive disorders. Table 23.1 lists some of the characteristics of the diseases associated with FeLV infection.

Lymphoma and leukaemia

FeLV was discovered in cats with lymphoid tumours (Jarrett *et al.*, 1964). A summary of the more important clinical and diagnostic features of the lymphoid tumours associated with FeLV is given in Box 23.1. Lymphoma is among the most common tumours of the cat, no doubt because FeLV is the cause of many cases. FeLV is found in about 80–90% of cats with thymic lymphoma, in 60% of cases of multicentric lymphoma, but in only 30% of cats with alimentary lymphoma. A common form, thymic or mediastinal

Table 23.1 Common diseases caused by feline leukaemia virus (FeLV)

		% of cases associated with FeLV
Malignant diseases		
Lymphoma		
Thymic	Mass of malignant T-lymphoblasts at the site of the thymus	80
Multicentric	Malignant T-cells throughout the lymphoid tissues	60
Alimentary	Malignant B-cells in the gut wall	30
Miscellaneous	Malignant cells, often B-cells, in e.g. the kidney, liver, CNS, skin	60
Lymphoid leukaemia	Malignant lymphoblasts from the bone marrow in the blood	
Myeloid leukaemia	Range of malignant myeloid cells from the bone marrow	90
Erythroleukaemia	Proliferation of malignant cells of both erythroid and myeloid series	
Non-malignant diseases		
Anaemia	Range of conditions from haemolytic anaemia to pure red cell aplasia	
Immunodeficiency	Susceptibility to opportunistic infections; thymic atrophy	
Enteritis	Degeneration of epithelial cells of villous crypts	
Marrow aplasia	Hypoplasia of myeloid cells of the bone marrow	
Reproductive failure	Early foetal death	

Box 23.1 Diagnostic features in lymphoma

Thymic lymphoma
- Younger cats
- Weight loss
- Tachypnoea, dyspnoea, exercise intolerance
- Regurgitation
- Loss of cranial thoracic compressibility
- Radiography: mass in anterior mediastinum; displacement of the trachea
- Cytology on pleural effusion: malignant lymphoblasts
- FeLV test positive in 80%
- Young animal (average 2.5 years)

Multicentric lymphoma
- Bilateral enlargement of peripheral lymph nodes
- Splenomegaly
- Histology of lymph-node biopsy: malignant cells
- FeLV test positive in 60%

Alimentary lymphoma
- Older cats
- Tumour masses palpable in abdomen
- Weight loss, inappetance/anorexia
- Wasting, vomiting or diarrhoea
- Pallor of mucous membranes
- Anaemia
- FeLV test positive in only 30%

Miscellaneous lymphomas
- Lymphomas in kidney, liver, CNS, eye or skin

Lymphatic leukaemia
- Intermittent pyrexia
- Weakness, inappetance
- Pallor of mucous membranes
- Petechial haemorrhages in mucous membranes and skin
- Haematology: raised white cell count and malignant cells, anaemia
- FeLV test positive in 60%

lymphoma, is illustrated in Plate 23.1 and the multicentric form in Plate 23.2.

From the observation that there was an association between the occurrence of FeLV-negative lymphoma and exposure to FeLV in multicat households, it was suggested that the virus may be involved in the aetiology of these tumours but had disappeared as an infectious entity. It remains unresolved whether this relationship was really due to FeLV infection or exposure to some other risk factor in the same environment, for example infection with feline immunodeficiency virus (FIV), which is now known to predispose to the development of lymphomas. Some evidence that FeLV is involved in such cases was the amplification of FeLV DNA by the polymerase chain reaction (PCR) from the tumours of cats that were negative in conventional diagnostic tests for the virus (Jackson *et al.*, 1996). However, these findings have yet to be confirmed.

Lymphomas that do not fit into any of these well-defined categories occur in extranodal sites, particularly in the kidney, spinal cord, eye or skin. The clinical signs in these cases are related to the particular tissues affected. Renal lymphomas are relatively common, either as primary tumours or associated with alimentary tract lymphomas. Likewise, ocular tumours may be primary or part of the multicentric form. Spinal lymphoma occurs mainly in younger cats, with a median age of 24 months (Lane *et al.*, 1994). The position of spinal lymphoma is usually reflected in the presenting neurological signs. Over 80% of cases present with hindlimb paresis and the majority test positive for FeLV. The tumour consists of high-grade lymphoblastic or immunoblastic cells, and in most cases is a single tumour restricted to the epidural space. There is a predilection for the thoracic and lumbar vertebral canal. However, the majority of cases have multicentric disease, with about two-thirds having a leukaemic bone marrow.

Myeloid leukaemia is also common in cats and FeLV is associated with most cases. Some of the diagnostic features of myeloid leukaemias are summarised in Box 23.2.

Box 23.2 Diagnostic features in myeloid leukaemias

Myeloid leukaemia
- Tumour cells may be poorly differentiated with very few mature neutrophils, or well differentiated with late members of the neutrophil or (rarely) eosinophil series in the blood
- White cell count varies considerably
- Anaemia is macrocytic and normochromic with reticulocytosis
- Extramedullary haematopoiesis invariably occurs

Erythroleukaemia
- Proliferation of malignant cells of both the erythroid and granulocytic series
- In the blood, granulocytic cells are usually well differentiated, while cells of the erythroid series are often primitive with many aberrant blast forms

Acute erythraemia
- Malignant cells are erythroid
- The blood contains large numbers of malignant erythroblasts and normoblasts

Anaemia

Cats are more susceptible to anaemia than other species of domestic animal, partly because their erythrocytes have a lifespan of only 70–80 days. FeLV induces both regenerative and non-regenerative anaemia. One common form of the latter is erythroid hypoplasia (pure red cell aplasia), a progressive and fatal degenerative disease caused by an impairment in the differentiation of erythroid precursor cells in the bone marrow, which is associated with FeLV-C infection (Mackey *et al.*, 1975; Onions *et al.*, 1982). In this condition there is frequently a macrocytic anaemia with no reticulocyte response. If the anaemia is severe, a bone-marrow aspirate or core biopsy should be taken to rule out leukaemia as a cause, and to assess the numbers of erythroid precursors. Plate 23.3 illustrates the effects of FeLV-C on bone marrow. The bone marrow is usually normocellular, but may be hypocellular with an increased myeloid to erythroid ratio. Myelofibrosis is common in chronically anaemic cats. *Haemobartonella felis* occurs frequently as a secondary infection in viraemic cats and is susceptible to treatment with doxycycline.

Therapy

Cats with lymphoma, if left untreated, have a poor prognosis, with the condition being fatal within 1 or 2 months. However, many cats with lymphoma, particularly thymic lymphoma, respond well to chemotherapy using combinations of drugs such as cyclophosphamide, vincristine, prednisolone and doxorubicin. Detailed regimens are described in Chapter 3 and in Couto (2001). Overall survival periods of 6–9 months

may be obtained, and the outcome depends to some extent on the FeLV status of the cat. Survival times for FeLV-negative cats are reported to be 9–18 months, compared with only 3–4 months for FeLV-positive animals (Couto, 2001). Therefore, the two essential facts that must be established before therapy is considered are an accurate clinical pathological diagnosis, usually on a fine-needle biopsy of affected tissue or biopsy, and the FeLV status of the cat.

Treatment of the virus infection has been attempted using antiretroviral drugs or non-specific 'stimulants of immunity', but these have not provided any real benefit. Elimination of the virus in a proportion of viraemic cats has been achieved through immunotherapy by the adoptive transfer of autologous or allogeneic immune lymphocytes, expanded by activation and growth *ex vivo* (Zeidner *et al*., 1993; Blakeslee *et al*., 1998; Flynn *et al*., 2002). This treatment is not available routinely, but its limited success holds out the hope that simpler and more effective therapies may be developed in future that will reverse the state of immunotolerance to the virus and lead to its elimination from the host.

Diagnosis

Two approaches are used to control FeLV infection in pet cats: the removal of the source of infection by the identification and isolation of viraemic cats, and the removal of susceptible cats by vaccination. The first method relies on the demonstration of virus in the blood. Diagnostic tests detect either free p27 antigen in the plasma, infectious virus or antigen in white blood cells. Plate 23.4 illustrates three different formats by which FeLV may be detected in the blood. Plasma antigen is readily detected by enzyme-linked immunosorbent assays or immunomigration (chromatographic) tests. In-practice tests, which permit rapid diagnosis, are based on these technologies. Further confirmatory tests are available from specialist laboratories. Infectious virus is demonstrated by virus isolation from the plasma, whereas antigen in the cytoplasm of neutrophils, lymphocytes and platelets on blood smears is detected by immunofluorescence. Proviral DNA in blood leucocytes may be amplified by a PCR, but this test is expensive and so far offers little advantage over conventional methods (Miyazawa & Jarrett, 1997). It should be emphasised that the test for FeLV-neutralising antibodies detects immune cats and not viraemic cats, so is not appropriate for control programmes. However, the test may be very useful as an aid in the management of households in which FeLV infection is being controlled, as discussed below.

There has been considerable debate about the reliability of in-practice tests in distinguishing between FeLV-positive and -negative cats. Possible errors in results may occur because of the inherent characteristics of a test, including the physical nature of the device, and its specificity and sensitivity. In addition, operator errors may result if the manufacturer's instructions are not adhered to stringently. Even with the high levels of specificity and sensitivity claimed by most manufacturers, the predictive values of these tests are such that in a population in which the prevalence of infection is very low, as in the general cat population, a considerable proportion of positive results will be false. Likewise, for populations in which the prevalence is high, as in cats with lymphoma, false-negative results may be encountered.

A prudent course of action in diagnostic testing for FeLV is to seek confirmation of the results of tests, particularly those that give an unexpected result. Examples of this are a healthy cat that tests positive, or a cat with clinical signs consistent with FeLV infection that is found to be negative. Retesting immediately using a device of the same batch or with another brand of in-practice test may help to resolve the dilemma. By far the most reliable method, however, is to have the blood sample tested by a laboratory that uses an alternative technology such as virus isolation or immunofluorescence.

Some professional authorities have made useful recommendations about diagnostic testing for FeLV, and indeed FIV. For example, the American Association of Feline Practitioners recommends that all cats should be tested for these viruses and that positive cats should not be allowed to mix with susceptible cats. Adherence to this advice would undoubtedly lead to a greatly reduced incidence of the infection, as has occurred in countries such as The Netherlands and Switzerland. In many circumstances, however, it may be difficult to afford to test all cats, and only animals considered to be at high risk of infection are tested. This compromise is often applied by rescue shelters to cats before rehoming, or by veterinary surgeons to kittens and cats before vaccination. Cats at high risk include those whose origins are unknown or who are strays, feral cats and cats with clinical signs that may be attributable to FeLV infection.

Discordance in test results

Around 10% of cats that test positive for plasma antigen are found to be negative by virus isolation or immunofluorescence (Jarrett *et al*., 1991). One reason for this discordant state is that the cat may have been recently exposed to FeLV and may be either at the

beginning of an infection or in the course of recovery. In either of these phases there may be sufficient antigen in the blood to be detected, but insufficient virus. In this case the discordant state is transient and on retesting 4–12 weeks later the cat is found to be negative by both tests. A second reason may be that the virus infection is contained in a particular tissue from which only antigen, but not virus, is released into the blood. A known example is the localisation of virus to the mammary gland. In this case, a cat may remain in a discordant state for many months or even years. The danger in this situation is that at any time the virus may be reactivated and the cat may become viraemic, so that it excretes virus and has a high risk of subsequently developing a serious FeLV-related disease. It is not known whether cats in the discordant state pose a risk to others by horizontal transmission of virus, or develop FeLV-related diseases themselves. Therefore, they should be monitored at intervals for their virus status.

Control programmes

Accurate and rapid diagnosis allows the implementation of a test and removal programme in multicat households. When a cat within a household is found to be positive for FeLV, all of the cats in contact should be tested. The household should be quarantined and the positive and negative cats separated from each other for a period of 3 months and then retested. This interval allows cats that may have been transiently infected at the time of the first test to recover and subsequently to test negative. Also, during this period, any negative cats that were incubating the infection at the first test will become viraemic and subsequently test positive. Such a process of testing and removal or isolation should be continued until all of the cats are consistently positive or negative in two consecutive tests performed 3 months apart. Using this programme, a virus-free household can be derived and maintained by subsequent monitoring of cats before they enter the house, either as new residents or for breeding. In this way FeLV has been successfully eradicated from very large numbers of cat households, particularly households of pedigree breeding cats (Hardy *et al.*, 1976b).

Management of healthy viraemic cats

Healthy viraemic cats may continue in good health for many months or years. These cats should be afforded the same health care as uninfected cats, including vaccination, although it is pointless to administer a FeLV vaccine. Health checks every 6 months should be advised. Ideally, viraemic cats should not be allowed to mix with susceptible cats either indoors or outdoors, and should not be bred. In closed multicat households, recovered or non-infected cats will outlive the viraemic cats so that after 3–5 years the household will become FeLV free (Addie *et al.*, 2000). If FeLV-positive and FeLV-negative cats have already been in contact with each other for 6 months or more, it is very likely that the negative cats will be solidly immune. Their immune status may be confirmed by an assay for virus-neutralising antibodies. There is then little risk to seropositive cats from mixing with viraemic cats.

Owners of free-ranging cats should be advised of the danger that their cat poses to susceptible cats and should be strongly encouraged to keep their cat indoors.

Vaccination

The second means of control is by vaccination. Several different types of FeLV vaccine are available (Sparkes, 1997). The first, of which there are several examples, comprises inactivated virions or viral products derived from FeLV-infected cells. The second type consists of the recombinant protein part of the envelope gp70, produced in bacteria. A third type is a live canarypox–FeLV recombinant virus that expresses FeLV genes in infected cells (Poulet *et al.*, 2003). It is recommended that the vaccines be administered in two doses, 3 weeks apart, beginning when kittens are 8–9 weeks old, and that an annual booster dose should be given. Each vaccine is claimed to provide substantial, although not necessarily complete, protection against FeLV challenge. There is variation in this regard between products, although all of the vaccines available in the UK are of high efficacy.

Ideally, all cats that are to be vaccinated should be tested for FeLV before immunisation. Infected cats should be isolated and only uninfected cats should be vaccinated, as FeLV vaccination will not reverse FeLV infection in a viraemic cat. In practice, the prevalence of viraemia is generally so low in cats to be vaccinated (0.5–1.0%) that many veterinarians choose to test only kittens or cats from populations that may be at high risk of infection, as discussed above.

As a result of test and removal programmes, in conjunction with the vaccination of uninfected cats, the prevalence of FeLV infection has been markedly reduced and the spread of infection within multicat households prevented.

Vaccine-associated sarcomas

The development of soft-tissue sarcomas at vaccine injection sites in cats was first recognised in the USA. The occurrence of these tumours has been attributed to the inoculation of inactivated FeLV or rabies vaccines (reviewed in McEntee & Page, 2001). Microscopic examination of injection sites has revealed macrophages containing aluminium, although it is unclear whether this residual adjuvant was tumorigenic or merely a marker of the neoplastic process. It has been suggested that persistent inflammation induced by adjuvants or other vaccine components may lead to cell transformation in predisposed cats. However, any factor that induces local inflammation at an injection site has the potential to induce a sarcoma at that site. To date, epidemiological studies have not identified specific brands of FeLV or rabies vaccines that are associated with an increased risk for sarcoma development, perhaps because the prevalence of sarcomas in cats is relatively low and numerous brands of vaccines have been administered to cats in the USA. In the UK, the Suspected Adverse Reaction Surveillance Scheme of the Veterinary Products Committee has reported annual rises in the incidence of vaccine-associated sarcomas over the period 1996–2000 (Gaskell *et al.*, 2002). However, the numbers are still low and it remains to be established whether these tumours will become a major source of concern in the UK.

Vaccine-associated sarcomas are characterised by rapid growth, ulceration and necrosis, and often infiltrate along fascial planes so that complete surgical excision is often difficult and consequently local recurrences are common. Radical surgical excision of the sarcoma increases the median survival time and appendicular tumours are treated most effectively by amputation. Therefore, some US authorities have suggested that vaccines should be administered to the distal portion of the limbs or tail since this permits radical excision of tumours developing at vaccination sites. Another important recommendation for preventing vaccine-associated sarcomas is to avoid overvaccination, since the risk of vaccine-associated sarcomas increases with the number of vaccines administered.

Public-health considerations

It has been suggested that close contact between people and their FeLV-infected pet cats could lead to transmission of the virus to humans via licking, scratching or biting. Indeed, it is known that in the laboratory FeLV-B and FeLV-C can grow in some cell lines of human origin. Clusters of cancers in patients and their pets aroused concern that leukaemias in humans and cats may share a common aetiology. However, epidemiological surveys have not confirmed any association between cat ownership and leukaemia and there is no serological evidence that FeLV may be transmitted from cats to humans. Furthermore, no evidence has been found for FeLV antigen or antibodies in leukaemia patients who were also owners of cats that died of FeLV-positive lymphoma. Detailed studies using PCR have investigated bone-marrow aspirates or peripheral blood mononuclear cells from patients with different haematological tumours and no FeLV DNA sequences were detected (Nowotny *et al.*, 1995). However, until the aetiology of leukaemia is resolved, there will remain doubts as to the risks to the developing foetus, children and immunosuppressed individuals from FeLV-infected pet cats. Therefore, it has been recommended that individuals in these categories should have limited contact with infected cats (Donaldson *et al.*, 1994).

References

Addie D.D., Dennis J.M., Toth S., *et al.* (2000) Long-term impact on a closed household of pet cats of natural infection with feline coronavirus, feline leukaemia virus and feline immunodeficiency virus. *Vet Rec* **146**, 419–424.

Blakeslee J., Noll G., Olsen R. & Triozzi P.L. (1998) Adoptive immunotherapy of feline leukemia virus infection using autologous lymph node lymphocytes. *J AIDS Hum Retrovirol* **18**, 1–6.

Couto C.G. (2001) What is new in feline lymphoma? *J Feline Med Surg* **3**, 171–176.

Donaldson L.J., Rankin J. & Proctor S. (1994) Is it possible to catch leukaemia from a cat? *Lancet* **344**, 971–972.

Flynn J.N., Dunham S.P., Watson V. & Jarrett O. (2002) Longitudinal analysis of feline leukemia virus-specific cytotoxic T lymphocytes: correlation with recovery from infection. *J Virol* **76**, 2306–2315.

Gaskell R., Gettinby G., Graham S. & Skilton D. (2002) *Veterinary Products Committee (VPC) Working Group on Feline and Canine Vaccination. Final Report to the VPC.* DEFRA Publications, London.

Hardy W.D. Jr, Hess P.W., MacEwen E.G., *et al.* (1976a) Biology of feline leukemia virus in the natural environment. *Cancer Res* **36**, 582–588.

Hardy W.D. Jr, McClelland A.J., Zuckermann E.E., *et al.* (1976b) Prevention of contagious spread of FeLV and the development of leukaemia in pet cats. *Nature* **263**, 326–328.

Hoover E.A., Olsen R.G., Hardy W.D. Jr, *et al.* (1976) Feline leukemia virus infection: age-related variation in response of cats to experimental infection. *J Nat Cancer Inst* **57**, 365–369.

Jackson M.L., Haines D.M. & Misra V. (1996) Sequence analysis of the putative viral enhancer in tissues from 33 cats with various feline leukemia virus-related diseases. *Vet Microbiol* **53**, 213–225.

Jarrett O. (2000) Feline leukaemia virus. In *Nature Encyclopaedia of Life Sciences*. London: Nature Publishing Group. http://www.els.net/ [doi:10.1038/npg.els.0001021]

Jarrett O., Russell P.H. & Stewart M.F. (1977) Protection of kittens from feline leukaemia virus infection by maternally-derived antibody. *Vet Rec* **101**, 304–305.

Jarrett O., Hardy W.D. Jr, Golder M.C. & Hay D. (1978) The frequency of occurrence of feline leukaemia virus subgroups in cats. *Int J Cancer* **21**, 334–337.

Jarrett O., Pacitti A.M., Hosie M.J. & Reid G. (1991) A comparison of diagnostic methods for feline leukemia virus and feline immunodeficiency virus. *J Am Vet Med Assoc* **199**, 1362–1364.

Jarrett W.F.H., Crawford E., Martin W.B. & Davie F. (1964) Leukaemia in the cat. A virus-like particle associated with leukaemia (lymphosarcoma). *Nature* **202**, 567.

Lane S.B., Kornegay J.N., Duncan J.R. & Oliver J.E. Jr (1994) Feline spinal lymphosarcoma: a retrospective evaluation of 23 cats. *J Vet Intern Med* **8**, 99–104.

McEntee M.C. & Page R.L. (2001) Feline vaccine-associated sarcomas. *J Vet Intern Med* **15**, 176–182.

Mackey L., Jarrett W., Jarrett O. & Laird H. (1975) Anemia associated with feline leukemia virus infection in cats. *J Nat Cancer Inst* **54**, 209–217.

Miyazawa T. & Jarrett O. (1997) Feline leukaemia virus proviral DNA detected by polymerase chain reaction in antigenaemic but non-viraemic ('discordant') cats. *Arch Virol* **142**, 323–332.

Nowotny N., Ulthman A., Hass O.A., *et al*. (1995) Is it possible to catch leukaemia from a cat? *Lancet* **346**, 252–253.

Onions D., Jarrett O., Testa N., *et al*. (1982) Selective effect of feline leukaemia virus on early erythroid precursors. *Nature* **296**, 156–158.

Pacitti A.M. & Jarrett O. (1985) Duration of the latent state in feline leukaemia virus infections. *Vet Rec* **117**, 472–474.

Poulet H., Brunet S., Boularand C. *et al*. (2003) Efficacy of a canarypox virus-vectored vaccine against feline leukaemia. *Vet Rec* **153**, 141–145.

Rigby M.A., Rojko J.L., Stewart M.A., *et al*. (1992) Partial dissociation of subgroup C phenotype and *in vivo* behaviour in feline leukaemia viruses with chimeric envelope genes. *J Gen Virol* **73**, 2839–2847.

Rojko J.L., Hoover E.A., Mathes L.E., *et al*. (1979) Pathogenesis of experimental feline leukemia virus infection. *J Nat Cancer Inst* **63**, 59–68.

Russell P.H. & Jarrett O. (1978) The specificity of neutralizing antibodies to feline leukaemia viruses. *Int J Cancer* **21**, 768–778.

Sparkes A.H. (1997) Feline leukaemia virus: a review of immunity and vaccination. *J Small Anim Pract* **38**, 187–194.

Stewart M.A., Warnock M., Wheeler A., *et al*. (1986) Nucleotide sequences of a feline leukemia virus subgroup A envelope gene and long terminal repeat and evidence for the recombinational origin of subgroup B viruses. *J Virol* **58**, 825–834.

Zeidner N.S., Mathiason-DuBard C.K. & Hoover E.A. (1993) Reversal of feline leukemia virus infection by adoptive transfer of lectin/interleukin-2-activated lymphocytes, interferon-alpha, and zidovudine. *J Immunotherapy* **14**, 22–32.

Further reading

Cotter S.M. (1998) Feline viral neoplasia. In *Infectious Diseases of the Dog and Cat*, 2nd edn (ed. Greene, C.E.) WB Saunders Company, Philadelphia.

Jarrett O. (2000) Feline leukaemia virus. In *Nature Encyclopaedia of Life Sciences*. London: Nature Publishing Group. http://www.els.net/ [doi:10.1038/npg.els.0001021]

Neil J.C., Fulton R., Rigby M. & Stewart M. (1991) Feline leukaemia virus: generation of pathogenic and oncogenic variants. *Current Topics in Microbiology and Immunology* **171**, 68–93. Springer-Verlag, Berlin.

Chapter 24

FELINE IMMUNODEFICIENCY VIRUS INFECTION

D.A. Harbour, S.M.A. Caney and A.H. Sparkes

Introduction

In 1986, investigation of an outbreak of disease in a previously healthy colony of rescued cats in Northern California by workers at the University of California (Davis) Veterinary School resulted in the isolation of a new retrovirus from the affected cats (Pedersen *et al.*, 1987). These cats exhibited a variety of clinical signs suggestive of an immunodeficiency disorder, but the colony was, and had been, kept free of feline leukaemia virus (FeLV) infection by a rigorously applied screening programme. The new virus was shown to belong to the lentivirus genus of retroviruses and was tentatively named the feline T-lymphotropic lentivirus (FTLV). By international agreement, and to bring the nomenclature into line with that of other T-lymphotropic lentiviruses [including human immunodeficiency virus (HIV), the cause of the acquired immunodeficiency syndrome (AIDS) in people] the name was changed to feline immunodeficiency virus (FIV). FIV has been shown to be a significant cause of disease in cats worldwide.

The agent

FIV virions are similar to other lentiviruses but are slightly smaller, 100–110 nm in diameter. They consist of a cylindrical core, containing a helical ribonucleoprotein strand, surrounded by a membrane that is derived from the outer membrane of the infected cell as the virus particle is externalised by budding. Projecting from the membrane are short spikes composed of molecules of two proteins, a transmembrane protein of about 40 kDa and a surface protein of about 95 kDa, against which neutralising antibodies are directed. There is considerable heterogeneity in the surface protein among FIV isolates and they can be divided into five subgroups based on the antigenicity of this protein.

Like other lentiviruses, FIV possesses a Mg^{2+}-dependent reverse transcriptase, which distinguishes it from the Mn^{2+}-dependent reverse transcriptase of FeLV. When the virus enters a cell, following uncoating, the reverse transcriptase (which is an integral component of the virion structure) makes a double-stranded DNA copy of the virion RNA genome. The double-stranded DNA copy is integrated into the chromosomal DNA of the host cell. The integrated DNA is known as a provirus, and is essential for further replication of the virus; replication can only take place once the provirus is integrated. Transcription of the provirus leads to the manufacture of virus proteins. Apart from the reverse transcriptase and membrane glycoproteins, there are core (gag) proteins of about 24, 15 and 10 kDa molecular weight.

Epidemiology

Testing of stored serum has shown that antibodies to FIV were present in samples collected in the UK in 1975 (Gruffydd-Jones *et al.*, 1988) and in the USA in 1968 (Shelton *et al.*, 1990a). The worldwide distribution of FIV indicates that the virus has almost certainly existed for many years prior to 1968, and therefore this is a newly recognised (rather than a newly evolved) virus that is endemic in the general cat population.

A survey of exotic cats (Barr *et al.*, 1989) showed evidence of FIV infection in several zoo populations, including snow leopards, lions, tigers and jaguars, and also in free-roaming populations of Florida panthers and bobcats. It is now known that these viruses differ sufficiently from the FIV in domestic cats to warrant

Table 24.1 Distribution breakdown of cats in the 59 surveys analysed by Courchamp and Pontier (1994)

Distribution parameter	No. of cats tested	No. of cats FIV positive	% cats FIV positive
Health status			
Healthy	35 474	1,847	5.21
Sick	43 941	7026	15.99
Not reported	5964	562	9.43
Sex and neutering status			
Intact males	13 455	1739	12.92
Neutered males	12 577	1954	15.54
Intact females	10 931	559	5.12
Neutered females	8544	568	6.65
Age distribution			
<1 year	12 057	213	1.77
1–3 years	14 668	1230	8.39
4–6 years	6738	1129	16.76
>6 years	8462	1625	19.20
Roaming habits			
Indoor	12 166	550	4.52
Indoor/outdoor	27 166	3346	12.32
Feral	6818	1071	15.71
Breed distribution			
Non-pedigree	40 477	5240	12.95
Pure-bred pedigree	8155	566	6.94
Mixed pedigree	8319	683	8.21
Household size distribution			
1 cat	23 498	2423	10.31
2–5 cats	18 286	1708	9.34
>5 cats	4177	468	11.20
Total study	85 529	9441	11.04

separate classification as puma lentivirus and lion lentivirus (Brown *et al.*, 1994; Langley *et al.*, 1994; VandeWoude *et al.*, 1997). FIV has been divided into five subtypes (A–E) on the basis of differences in their envelope protein genes, and this division is supported by analysis of the genes encoding other virus proteins (Carpenter *et al.*, 1998; Kurosawa *et al.*, 1999) and, to some extent, by virus cross-neutralisation (Inoshima *et al.*, 1998), although some antisera are broadly cross-reactive (Hohdatsu *et al.*, 1997). Subtypes A, B and C are found on more than one continent, but only subtype A has been reported in the UK to date. Recombinant viruses generated from subtypes A/B, B/D and A/C envelope gene sequences have been reported (Bachmann *et al.*, 1997). FIV subtype B appears to be an older virus group and is possibly more host adapted (less pathogenic) than FIV subtype A.

Serological surveys have been conducted in several countries to determine the prevalence of FIV infection in various cat populations. Courchamp and Pontier (1994) analysed 59 serosurveys for the influence of several parameters on FIV infection. The worldwide infection rate estimated from 85 529 cats tested was high, 11.04% (Table 24.1), but this was not uniform between countries or even continents, with a higher prevalence in Oceania and Asia than in Europe and North America (Table 24.2). Parameters influencing FIV infection were sex, age and roaming habits. Neutering, breed and group size effects seemed to be rather indirect. In most surveys, the prevalence of FIV infection is much greater among sick cats (i.e. those with clinical problems) than among healthy cats. However, in Switzerland, The Netherlands and Australia there was little difference between sick and healthy cats. If pathogenicity does vary between strains of FIV, it may be that the strains occurring in these three countries are less pathogenic than those found elsewhere. Additional serological findings in specific populations of cats such as pedigree show cats, farm and feral cats highlight the strong association of FIV infection with free access to the outdoor environment.

Table 24.2 Seroprevalence of feline immunodeficiency virus (FIV)

Continent/country (overall % positive)	FIV seroprevalence (%)		
	Sick cats	Healthy cats	Other cats
North America (8.06%)			
USA	11.8	4	21.2[a] 5.0[b] 9.8[c]
USA + Canada	14	1.2	
Europe (12.71%)			
Austria	3.5		3.2[a]
Denmark	19.4	4.8	18.4[b]
Finland			6.6[b]
France	24.1	6.9	32[b]
Germany	12.3	3.2	9.5[a]
Greece	8.5	1.4	
Hungary	30.7	0	
Italy	23.8	8.8	64.3[d] 10.0[b] 15.3[c]
Netherlands	5.0	2.2	
Norway	10.1	5.9	
Switzerland	3.5	1.2	
Turkey (Istanbul)	25.8	16.2	22.2[b]
UK	14.8	6.9	27.0[b]
Asia (23.12%)			
Japan	36.5	10.7	
Taiwan	0	1.4	12.5[b]
Oceania (23.30%)			
Australia	25.7	26.7	14.2[c]
New Zealand	27.3	6.8	

Adapted from Courchamp and Pontier (1994).
[a] Health status not reported.
[b] Feral cats.
[c] Cats suspected to be infected on clinicopathological grounds.
[d] In contact with FIV-positive cat.

In another study, Courchamp *et al.* (1998) showed that FIV prevalence rates in a given population did not statistically change between years, after controlling for changes in the age structure of the samples. FIV infection was characterised by risk factors linked to aggressive behaviour: old mature male adults with large territories are more likely to be infected. In cats less than 1 year of age FIV infection was rare, but the prevalence increased steadily with age, being highest in middle-aged and older cats. This is in contrast to FeLV infection, since cats usually become infected with FeLV at an early age. In almost all cases the highest prevalence of FIV infection occurs in those cats that most often meet and have contact with other cats. One exceptional finding was that, overall, the prevalence of infection was lower in entire males than in neutered males, even though entire tom cats would be expected to encounter other cats outdoors more frequently than neutered toms. However, neutered cats tended to be older than entire cats, so the difference in infection prevalence may simply be due to differences in longevity. Neutered female cats also had a higher prevalence of FIV infection than entire females. Thus, FIV infection spreads, with low contagiousness, mainly between particularly aggressive individuals, and the virus is endemic in this population.

Courchamp *et al.* (1997) presented a deterministic model of the dynamics of FIV and FeLV simultaneously infecting a single host population. The model has been tested with data generated by a long-term study of several natural cat populations. Stability analysis and simulations show that, once introduced in a population, FIV spreads and is maintained, while FeLV can either disappear or persist. Moreover, introduction of both viruses into the population induces an equilibrium state for individuals with or without

disease. The viruses never induce the extinction of the population. Furthermore, whatever the outcome for the host population (persistence of FIV only, or of both viruses), the global population size at the equilibrium state is only slightly lower than it would have been in the absence of the infections (i.e. at the carrying capacity), indicating a low impact of the viruses on the population. Finally, the impact of the diseases examined simultaneously is higher than the sum of the impact of the two diseases examined separately. This seems to be due to a higher mortality rate when both viruses infect a single individual.

Pathogenesis

Unlike HIV, which uses the CD4 molecule as its primary receptor, FIV uses primarily a chemokine receptor, CXCR4 (Willett & Hosie, 1999), but may also be able to utilise other chemokine receptors such as CCR3 (Johnston & Power, 1999) and CCR5 (Kovacs *et al.*, 1999). This explains why FIV is able to infect a number of cell types that do not express CD4. Plasma and peripheral blood mononuclear cell (PBMC)-associated viraemia peaks at 6–8 weeks following infection and decreases abruptly thereafter.

Proviral DNA is detectable as early as 5 days after infection in blood leucocytes and after 10 days in other organs. The central nervous system (CNS), lungs, thymus, tonsils and mesenteric lymph nodes are the earliest sites of virus localisation (Dua *et al.*, 1994). FIV does not appear to infect myeloid or erythroid precursors directly, and the mechanisms of marrow suppression are likely to involve virus, viral antigen and/or infected accessory cells in the marrow microenvironment (Linenberger & Abkowitz, 1995).

FIV causes a disease in cats similar in clinical presentation and disease progression to that of HIV and AIDS. The primary stage of illness occurs 6–8 weeks following infection in cats of all ages, but it differs in severity and clinical signs. Generalised lymphadenopathy, starting about 10 days after infection, persists in neonatally infected cats, is transient in young adults, but is normally inapparent in aged cats. Neutropenia appears 6–8 weeks after infection in cats of all ages, and a persistent decrease in $CD4^+/CD8^+$ T-lymphocyte ratios, starting around 28 days, due solely to decreased $CD4^+$ T-lymphocytes or to both increased $CD8^+$ and decreased $CD4^+$ T-lymphocytes, is seen (George *et al.*, 1993).

FIV is present in many follicular dendritic cells (FDCs) and sparsely in $CD4^+$ T-cells in the paracortical area of lymph nodes (Bach *et al.*, 1994). Since the distributions of FIV gag antigens are mainly in the FDCs, the FDCs may play an important role as a major reservoir and may be a primary target of FIV at early stages of infection (Toyosaki *et al.*, 1993). The thymic cortex is also a major site of early infection. During the ensuing acute illness, the proportion of FIV-infected macrophages in tissues increases dramatically. This early shift in the predominant cellular localisation of FIV from T-lymphocytes to macrophages may be important for establishing viral persistence (Beebe *et al.*, 1994).

Regression of FIV infection has been observed in kittens born to chronically infected mothers (O'Neil *et al.*, 1997). Both provirus and non-maternal FIV antibody were detected in all kittens by 4 weeks of age; by 10–14 months of age their PBMCs became polymerase chain reaction (PCR) negative, but FIV infection was detected in biopsied lymph node or bone marrow. Despite this evidence of persistent tissue provirus, antibody production did not persist in any of the cats beyond 1 year of age. Thus, FIV infection can be suppressed to extremely low levels barely detectable with the assays available, although absolute clearance of virus may not occur (O'Neil *et al.*, 1997). Suppression of FIV replication appears to be a function of $CD8^+$ T-lymphocytes and is mediated by a soluble factor or factors (Flynn *et al.*, 1999).

Under natural conditions, following the primary phase of infection, there is probably a prolonged period (perhaps months to years) of asymptomatic infection in most, if not all, infected cats. It is uncertain precisely how long this period lasts, but it probably varies greatly between individuals. Eventually, however, as the FIV-induced immune dysfunction progresses, the majority of infected cats are thought to develop clinical signs in association with this.

The development of the immunodeficiency (feline AIDS) phase of infection may depend in part on exposure to additional pathogens (Bendinelli *et al.*, 1995). Specific pathogen-free cats experimentally infected with FIV have been subsequently exposed to common infectious pathogens and immune stimuli over several years. Cats with pre-existing FIV infection showed signs of disease after exposure to *Haemobartonella felis* (now renamed *Mycoplasma haemofelis*), *Toxoplasma gondii*, feline herpesvirus (FHV) and feline calicivirus (FCV) similar to signs in non-FIV-infected cats, although they were more severe (Reubel *et al.*, 1994). Further studies have demonstrated that chronic clinical signs can be induced when cats with FIV are coinfected with *Chlamydia psittaci* (O'Dair *et al.*, 1994).

In addition, Pedersen *et al.* (1990) showed that pre-existing FeLV infection in cats enhanced the severity of both the acute and chronic stages of subsequent FIV infection. Other factors may also be relevant to the development of disease, such as the age of the cat at the time of infection, exposure dose, route of infection and potential variation in viral pathogenicity.

FIV infection of the brain results in glial activation accompanied by enhanced glutamatergic activity. Neurological signs observed in infected cats include ataxia, aggression and reduced motor activity. Neuropathological changes include gliosis, perivascular cuffing and neuronal loss in the brains of infected cats, but not in uninfected cats. FIV antigen and genome is detected in the brains of most infected cats (Power *et al.*, 1997). Cerebrospinal fluid from FIV-infected cats has a significantly increased albumin quotient, indicating a disrupted blood–brain barrier (Podell *et al.*, 1997). Infection of the CNS is from the bloodstream, although how the virus crosses the blood–brain barrier is unknown. It may occur through migration of infected monocytes and/or lymphocytes into the brain or free virus may enter the CNS, either directly or through infection of endothelial cells. The lesion pattern at least in initial stages is similar, consisting of meningitis, perivascular infiltrations, especially of the deep white matter, and inflammation of the choroid plexus (Georgsson, 1994).

FIV-associated tumours can occur in the absence of FeLV, which suggests that the role of FIV in lymphomagenesis is generally indirect (Terry *et al.*, 1995).

Transmission

Experimental work has shown that FIV can be readily transmitted by intravenous, subcutaneous or intraperitoneal inoculation. Subcutaneous inoculation is successful even in cats with high levels of maternal antibody. Infection by mucosal routes is also successful, but much higher doses of virus are required. Less is known about the natural modes of FIV transmission. Biting, often as a result of territorial fighting, is the primary route of transmission. Virus is shed in the saliva of infected cats (Yamamoto *et al.*, 1988) and efficient transmission was shown to occur under experimental conditions when the skin of an uninfected cat was punctured by the canine teeth of an infected cat (Yamamoto *et al.*, 1989). Epidemiological studies consistently demonstrate that FIV infection is most common among free-roaming, mature male cats, that is, those which are most likely to fight and bite. Clinically ill cats, particularly those with mouth lesions, will probably be most infective as much greater quantities of virus are shed in the saliva of these cats (Yamamoto *et al.*, 1988; Park *et al.*, 1995).

Vertical transmission of FIV has been demonstrated in cats infected before breeding and conception (O'Neil *et al.*, 1996). Pregnant cats acutely infected with FIV transmit the virus to their offspring via both prenatal and postnatal routes. Queens infected 4–30 months before conception transmitted FIV to 71% of their kittens; 51% were virus positive on the day of birth. Low maternal $CD4^+$ cell count, longer duration of maternal infection (>15 months) and maternal symptoms of clinical immunodeficiency correlate with increased rates of mother-to-kitten FIV transmission (O'Neil *et al.*, 1996). *In utero* transmission led to several pathogenic consequences, including arrested foetal development, abortion, stillbirth, subnormal birth weights, and birth of viable, virus-infected and asymptomatic but T-cell-deficient kittens. Foetal and/or placental maturation may determine the timing of lentivirus transmission (Rogers & Hoover, 1998).

Infectious FIV has been recovered from the milk of acutely infected mothers (Sellon *et al.*, 1994) and postnatal milk-borne transmission has been demonstrated by foster-nursing experiments (O'Neil *et al.*, 1995).

A potential route of indirect FIV transmission is through salivary contamination of food and food bowls. If it does occur this would probably not be an efficient means of transmission, since FIV appears to be relatively labile in the environment and cats would only be exposed to very low levels of virus. Therefore, a considerable period of contact would be necessary before infection occurred. Urine and faeces are highly unlikely to be major sources of FIV and hence the shared use of litter trays is probably not significant in transmission. Prolonged periods of intimate contact may facilitate direct transmission through mutual grooming and the licking of scratches and wounds. However, in studies of transmission in which infected and uninfected cats were housed together for several years, transmission rates were low, so direct and indirect contact are considered to be relatively unimportant.

Among related viruses in the lentivirus and other retrovirus genera there are several modes of transmission. For instance, visna virus (VV) and FeLV may be spread by prolonged close contact. FeLV may also be transmitted by indirect contact. Sexual contact is the principal route of transmission of HIV. Caprine arthritis encephalitis virus, VV and FeLV are passed vertically in the colostrum, while VV and FeLV can

also be transmitted *in utero* and equine infectious anaemia virus is spread by arthropod vectors. Epidemiological evidence suggests that FIV transmission by blood-sucking insects such as fleas is not significant, but iatrogenic infection resulting from the use of surgical instruments contaminated with infected blood is a possibility.

There has been no success to date in demonstrating venereal transmission, either from male to female, or from female to male, and epidemiological evidence indicates that sexual activity bears little or no relationship to the transmission of FIV. However, replication-competent FIV has been detected in cell-free and cell-associated forms in semen obtained by electroejaculation from infected cats, and cats have been infected by artificial insemination (Jordan *et al.*, 1998), so venereal transmission remains a possibility (Jordan *et al.*, 1995), although transmission by naturally infected males during mating has not been reported.

Clinical signs

Clinical signs associated with FIV infection may arise either as a direct result of the viral infection, or as a consequence of the immunodeficiency syndrome that is associated with infection. Information regarding these signs has come both through the observation of natural clinical cases and from experimental studies of FIV infection. Many clinical cases have a history of chronic illness. Often this appears to start as episodes of sporadic or recurrent illness, which are frequently interspersed with (sometimes prolonged) periods of clinical normality. Some cats have shown a rapid advancement of clinical signs, whereas others have shown little indication of deterioration in clinical condition, even over prolonged periods. In most cats, however, as the disease progresses, the clinical signs become more persistent and more severe. Characteristically, and especially in advanced cases, the clinical signs may be multiple, and cats may become severely ill such that death occurs or euthanasia is required on humane grounds. Because the clinical signs arise largely from secondary diseases or opportunistic infections, none is in any way diagnostic of FIV infection. However, underlying FIV infection should be suspected in cats with a history of chronic illness, in cats with severe, unexplained clinical signs, in individuals that do not respond as expected to normal therapeutic measures, and in cats that have a combination of several clinical signs. Clinicopathological abnormalities may also arouse suspicion (see Laboratory findings below).

There is a distinct primary phase of FIV infection occurring shortly after infection with the virus and, in the majority of infected cats, this is followed by a long subclinical phase before the development of a progressive immunodeficiency syndrome. The main clinical signs associated with the primary phase are pyrexia and generalised lymphadenopathy but, in many cats, these signs are mild and may not be noticed by the owner. Opportunistic infections (e.g. pyodermas) have also been observed in some cats, probably arising as a result of the neutropenia and leucopenia that are frequently seen during the primary phase. Specific neurological changes, including anisocoria, delayed righting reflex and delayed pupillary light reflex, as well as delayed visual- and auditory-evoked potentials and marked alterations in sleep patterns, have been seen, indicating that FIV may cause an acute neurological disease. FIV-infected cats spend 50% more time awake than uninfected cats and exhibit 40% more sleep–waking stage shifts. However, such cats show no overt signs of systemic morbidity, such as pyrexia or body-weight loss (Prospero-Garcia *et al.*, 1994).

Following the primary phase of infection most cats are thought to undergo a prolonged period when they are free of clinical signs attributable to FIV infection. Nevertheless, during this period, experimentally infected cats have been shown to develop a progressive deterioration in immune function, and probably in the majority of naturally infected cats this eventually leads to the development of clinical signs.

The later stages of FIV infection are characterised by the development of clinical signs related to a progressive immunodeficiency syndrome (Table 24.3). The signs that develop have frequently been likened to the non-neoplastic findings that occur in association with FeLV infection. Clinical signs during this stage of the disease are frequently associated with secondary opportunistic infections or inappropriate immune responses to antigens. The course of infection and range of clinical signs shown in any individual case are very variable, but from the information available certain common trends can be seen. The most frequent findings are diseases of the oral cavity, respiratory tract and gastrointestinal tract. Often, no opportunistic infections can be identified and the mechanism of disease development is unknown. Non-specific signs such as lethargy, malaise, weight loss, lymphadenopathy and pyrexia are also very common. Oral cavity diseases are encountered most frequently and include chronic gingivitis, stomatitis and periodontitis of varying severity. In some cases, extremely severe purulent and necrotising gingivitis has been seen.

Table 24.3 Common clinical signs associated with feline immunodeficiency virus infection

Common signs	Other reported signs
Malaise/lethargy/depression	Otitis externa
Chronic gingivitis/stomatitis	Chronic abscessation
Inappetence/anorexia	Vomiting
Weight loss/emaciation	Recurrent cystitis
Chronic upper respiratory tract infection	Renal disease/failure
Pyrexia	Neurological disorders
Chronic diarrhoea	Behavioural abnormalities
Lymphadenopathy	Reproductive failure/abortion
Chronic dermatoses, including	Neoplasia, including
Demodicosis	Lymphoma
Notoedric mange	Myeloproliferative disorders
Pustular dermatitis	
Miliary dermatitis	
Alopecia	
Chronic ocular signs, including	
Conjunctivitis	
Keratitis	
Uveitis	
Ocular discharge/epiphora	

Neurological abnormalities have been observed in a small proportion of infected cats. The signs seen are very variable, but are sometimes dramatic and have included psychomotor abnormalities, aggression, anisocoria and convulsions. Behavioural function and cognition were quantitatively impaired in FIV-infected cats tested on several behavioural measures (Steigerwald *et al.*, 1999). These measures included an open-field observation, locomotion tests, traversing planks of various widths for food reinforcement and a spatial learning task. No group differences were observed on any measure of locomotion. Differences were present with exploratory and stationary activity in the open-field observation, with infected cats exhibiting higher levels of exploratory activity and less stationary activity compared with control cats. In the plank-walking experiment, infected cats were less able successfully to cross progressively narrower planks compared with control animals. As a group, FIV-infected cats committed more reference and working memory errors than control cats. The main difference demonstrated was a higher activity level and associated distractibility in FIV-infected cats that appears to be related to their overall deficient performance when learning new tasks.

In addition, specific concurrent or opportunistic infections have often been identified in FIV-infected cats (Bendinelli *et al.*, 1995). These have included conditions such as cowpox, demodicosis, notoedric mange, bacterial cystitis, toxoplasmosis, haemobartonellosis, FCV infection, FHV infection, bacterial pneumonia, systemic candidiasis, coccidiosis, pyothorax and feline infectious peritonitis. *Bartonella henselae* may induce clinical disorders in cats infected with FIV. Incidence of lymphadenopathy was significantly higher in cats infected with both *B. henselae* and FIV compared with the incidence in cats negative for either or both agents. The same relation was also observed for the incidence of gingivitis among the four cat groups, suggesting that coinfection of *B. henselae* and FIV may be associated with gingivitis and lymphadenopathy in cats (Ueno *et al.*, 1996). Some of these infections are unusual and would immediately suggest the possibility of an underlying immunosuppression, whereas the role of FIV infection in others is uncertain. The inadvertent introduction of FCV into a colony of 19 experimental cats, 13 of which were infected with FIV, resulted in the development of chronic gingivitis in nine animals. The gingivitis was generally more severe in the cats infected with both viruses, suggesting that FIV may make cats infected with FCV more susceptible to chronic gingivitis (Waters *et al.*, 1993).

Some workers have noted an unexpectedly high incidence of neoplasia in FIV-infected cats, and a retrospective study has demonstrated a significant

correlation between FIV infection and lymphoid malignancies independent of FeLV infection (Shelton *et al.*, 1990a). Since FIV is not an oncogenic virus, it is likely that the high incidence of neoplasia is related to the immunosuppressive properties of the virus.

Laboratory findings

Clinicopathological abnormalities occur in most cats infected with FIV. However, the number and severity of these abnormalities will vary greatly between individuals, and will depend on a number of factors, including the stage of disease.

Haematological abnormalities are common and the changes seen are often both diverse and multiple. The abnormalities seen during the investigation of FIV infection in a series of 90 cats referred to the authors' clinic are shown in Table 24.4. Forty-nine (54%) of the cats showed multiple haematological abnormalities, and a further 24 (17%) had a single abnormality. The most consistent changes in serum protein electrophoretic patterns were increases in the concentrations of α_2-globulin and gammaglobulin subfractions. Although there is no established system for staging the degree of immunosuppression in cats infected with FIV, cytopenias appeared to be more common in cats with advanced clinical signs of disease. In particular, lymphopenia is a hallmark of chronic, symptomatic FIV infection.

In some cases there are obvious explanations for the observed changes, for example hypersensitivity disorders (e.g. flea-bite hypersensitivity) in cats with eosinophilia and/or basophilia, and concurrent infections or stress in some cats showing neutrophilia and leucocytosis. However, the reasons for many of these abnormalities remain unclear, and are probably multifactorial. The factors involved are likely to include direct and indirect effects of FIV on circulating cells or bone marrow, concurrent or opportunistic diseases, immune-mediated mechanisms and effects of drug therapy. As in HIV infection, a reduction in the $CD4^+$ subset of lymphocytes is seen in FIV-infected cats. Neutropenia is not commonly seen in feline diseases, but has been observed in a substantial proportion of FIV cases. An inhibitory substance present in the serum and directed at the granulocyte–macrophage lineage of cells in the bone marrow has been shown to occur in at least one infected cat (Shelton *et al.*, 1989), and may be an important cause of neutropenia. It appears that in general the cytopenias (anaemia, neutropenia, lymphopenia and leucopenia) are both more common and more severe in cats with clinically advanced immunosuppression (Shelton *et al.*, 1990b; Sparkes *et al.*, 1993). Progressive anaemia has been observed in several cats that were terminally ill. Where the haematology of infected cats has been monitored over a prolonged period, abnormalities have become more frequent and often more profound as the disease progresses.

In addition to the haematological changes, serum biochemical abnormalities may be seen in infected cats. In the cases of FIV infection seen at the authors' clinic, the most commonly observed changes appear to be elevations in serum proteins (see Table 24.4). The hyperproteinaemia and hyperglobulinaemia may be profound on occasions, and it appears that elevated levels of immunoglobulin G (IgG) may be partly responsible for this in many cases. Other serum biochemical abnormalities have been seen with FIV infection, but generally appear to reflect the involvement of disease with specific organs.

Table 24.4 Common haematological and serum biochemical abnormalities in a series of 90 feline immunodeficiency virus-infected cats

Abnormality	% Affected
Leucocytosis	13
Neutrophilia	27
Lymphocytosis	4
Monocytosis	23
Eosinophilia	11
Basophilia	16
Leucopenia	13
Neutropenia	11
Lymphopenia	29
Anaemia	18
Hyperproteinaemia	38
Hyperglobulinaemia	25
Hypergammaglobulinaemia	67
Hyperalpha2globulinaemia	91
Hypoalbuminaemia	12

Pathology

Acute phase of infection

The principal pathological finding in the early or acute phase of FIV infection, which may last for 10–40 weeks, is peripheral generalised lymphadenopathy (Yamamoto *et al.*, 1988). Microscopically, there is enlargement of the cortical zone of the lymph node as a result of follicular hyperplasia. Disruption of the

mantle zone of the follicles occurs. The germinal centres are increased in size, as well as number, and are often irregularly shaped; as a result, they may extend into the paracortex and also the medulla. In addition, there is widespread erythrophagocytosis in the medullary sinuses. Other lesions that have been found at this stage of infection in experimental cats include the expansion of lymphoid tissue in the lung and intestine, and expansion of the B-cell compartment of the splenic white pulp. The splenic red pulp may also be hypercellular. The feline thymus is another target organ and site of viral replication during the acute stage of FIV infection. Thymic lesions develop about 4 weeks after infection and include thymitis, premature cortical involution and medullary B-cell hyperplasia with germinal centre formation and epithelial distortion. Morphological alterations, productive viral infection and altered thymocyte subpopulations suggest that thymic function is compromised, thus contributing to the inability of FIV- infected cats to replenish the peripheral T-cell pool (Woo *et al.*, 1997).

Asymptomatic phase

During the intermediate stage of infection the lymph nodes may show either hyperplasia or involution. Some nodes have both lesions concurrently (known as a mixed pattern). There is evidence that chronic inflammatory lesions may be present in the intestine of some cats at this stage. The brains of asymptomatic cats show a small decrease, compared with age-matched uninfected cats, in neuronal density in the frontal cortex, parietal cortex and striatum. The only other indications of pathology within these regions are a mild diffuse astrogliosis, occasional microglial nodules and the accumulation of satellite cells around selected neurons. There is no significant large neuron loss in asymptomatic FIV-infected cats.

Immunodeficiency phase

In the terminal stages of FIV infection, gross pathological findings are often unspectacular, which is surprising, considering that cats have usually become severely ill. Those changes that do occur tend to be directly related to the presenting clinical signs, and because of the wide range of clinical problems associated with FIV, the pathological findings in chronic infection are very variable and none is pathognomonic.

Microscopic lesions are more consistent, but again are not specific for FIV. In general, there are inflammatory lesions in a variety of tissues and organs, together with abnormalities in the lymph nodes. Histological examination of the lungs of FIV-infected cats reveals the occurrence of alveolitis, parenchymatous lymphoplasmocytic infiltration and myomatosis. Lymphocytic infiltration of the liver is also known to occur.

In lymph nodes, follicular hyperplasia is prominent and later they show either generalised atrophy or a mixed pattern. In the atrophic nodes the follicles appear either small and indistinct or have a burned-out appearance because of the loss of cells and the aggregation of hyaline material. The lymph nodes in terminally ill cats show considerable destruction of the nodal architecture, with involution and depletion of lymphoid follicles. In severely involuted nodes the connective tissue and vascular skeleton are very prominent. In this terminal stage, viral antigen is seen prominently in histiocytes and macrophages of the sinus (Matsumura *et al.*, 1994).

The alimentary tract is commonly affected. The lesions accompanying gingivitis, stomatitis and periodontitis usually involve diffuse infiltration by lymphocytes and plasma cells. In the small intestine and colon, foci of chronic inflammation are not uncommon, even in cats that have not shown signs of enteritis. In some cases mucosal ulceration occurs at these sites, with additional infiltration by inflammatory cells through the thickness of the gut wall. Irregularity and dilatation of the crypts have been seen in the small intestine of some cats. There are no reports of specific aetiological agents associated with any of these lesions.

Perivascular mononuclear infiltration of the brain is seen in cats with mild neurological signs. Other cats have been found to have meningioencephalitis involving lymphocytic–plasmacytic infiltration, even though neurological signs had not been observed (Brown *et al.*, 1991). On average, half of the large neurons in the cortex are lost. In one cat, lesions were identified throughout the brain, affecting the cerebrum, medulla and cervical spinal cord (Gunn-Moore *et al.*, 1996). Perivascular lymphocytic cuffing, gliosis and white-matter vacuolation were most severe in the cerebrum, affecting the white matter and the deep laminae of the grey matter. Gemistocytes were prominent, and many bizarre cells with large, sometimes multinucleate, hyperchromatic nuclei were evident. Although the cat was serologically negative for FIV, active FIV infection was demonstrated within the cerebrum. This pathological picture resembled that seen in human patients with HIV dementia, but was unlike

that reported before for FIV. This may have been due to the fact that this animal had longstanding neurological signs, and may therefore have represented a later stage in the pathological process than normally seen in cats.

In a series of FIV-infected cats showing an anterior uveitis, no accumulation of retinal lesions was found compared with uninfected cats examined (Loesenbeck *et al.*, 1996). In addition, there were no indications of lesions caused by opportunistic infections. In the posterior segments of the eyes, immunohistochemical examinations proved the plasma proteins C3 and IgG to be predominantly intravascular. In all cats at least one of the plasma proteins C3 or IgG could be detected in the extravascular tissue of the anterior uvea. The extravascular presence of plasma proteins within the tissue seemed to be caused by an increased permeability of the vessels due to inflammation. Furthermore, the similar extravascular distribution patterns of IgG and complement component C3 in some of the cases indicated that immune complexes may play a role in the anterior uveitis of FIV-infected cats.

Kidney abnormalities are commonly found in FIV-infected cats, characterised by mesangial widening with segmental to diffuse glomerulosclerosis and presence of IgM and C3, and scanty IgG deposits in the mesangium. Tubulointerstitial lesions are also present. In some cats the lesions were severe enough to cause a marked increase in blood urea nitrogen and creatinine, and heavy glomerular non-selective proteinuria (Poli *et al.*, 1993).

Epidemiological and experimental data suggest that FIV may have a role in lymphomagenesis. Histopathological and immunophenotypic analysis using a panel of anti-cat and cross-reactive anti-human monoclonal and polyclonal antibodies identified most of these tumours as high-grade B-cell lymphomas of the centroblastic or immunoblastic subtypes. B-cell lymphosarcomas were comparable to those observed in HIV infections. The role of FIV in lymphomagenesis is indirect and related to the potential for malignant transformation during polyclonal B-cell activation (Callanan *et al.*, 1996).

Diagnosis

Diagnostic tests for use in practice

It is not possible to make a diagnosis of FIV infection on clinical grounds and so diagnosis is based predominantly on serological tests. It is important to note that the presence of antibody indicates persistent FIV infection since, in contrast to most viral infections, the immune response to FIV does not eliminate the virus. However, kittens born to FIV-infected queens usually have maternally derived antibodies (MDAs) that will be detected by the diagnostic kits, so kittens under 16 weeks old that test positive should be retested about 4 months later, when MDAs will have disappeared.

In recent years, a number of commercial kits designed to be used in veterinary practices for the rapid diagnosis of FIV infection (often coupled with FeLV diagnosis) have been introduced. These kits detect antibodies to the virus in serum or plasma (their use with whole blood is not recommended owing to a greater chance of false-positive results) and most are based on the technique of rapid immuno-migration. Such kits (e.g. Witness; Synbiotics) incorporate a synthetic peptide, corresponding to a part of the FIV transmembrane envelope protein (gp40) to which cats' immune systems respond early and vigorously, bound to gold particles. When FIV-positive cat serum is added, specific antibody binds to the synthetic peptide–gold, and migrates to a reaction zone where the complex is captured, forming a coloured band. Excess, unreacted synthetic peptide–gold particles migrate further to a validation zone, where they are captured and form a second coloured band that shows that the test has worked. Snap Combo Plus (IDEXX) is an enzyme-linked immunosorbent assay (ELISA) kit that detects gp40 together with FIV gag proteins. This may increase sensitivity since a small proportion of cats do not seroconvert to both envelope and gag proteins. Since all such diagnostic kits compromise between specificity (probability of a negative test result on an uninfected cat) and sensitivity (probability of a positive test result on an infected cat), their use can result in false-positive or false-negative results. It is desirable, therefore, to carry out a confirmatory test using another technique on any serum testing positive (particularly if weakly positive), or any negative serum where FIV infection is strongly suspected.

Diagnostic tests used in diagnostic laboratories

Other methods of diagnosis include virus isolation, detection of the retroviral enzyme reverse transcriptase and detection of the viral genome in infected cells by either *in situ* hybridisation or PCR. These latter diagnostic methods have their principal use as

research tools. The development of serological tests to detect viral antigen (the routine method of FeLV diagnosis) has been hampered by the fact that there appears to be very little free FIV antigen present in the blood. However, an assay is available that can be carried out by culturing small amounts of whole blood and is based on the detection of FIV gag protein, which is released into the culture supernatants. The amount of core antigen produced is measured with an ELISA using specific monoclonal antibodies. This test is a useful alternative to serological techniques for diagnostic purposes in circumstances such as early preseroconversion viraemia or the presence of maternal antibodies in kittens (Guiot *et al.*, 1995).

Indirect immunofluorescence was the first test used for the detection of FIV antibodies. However, this technique is time consuming and so once an ELISA had been developed, the introduction of commercial ELISA kits into the UK in April 1988 enabled large-scale FIV testing to begin. ELISA kits based on a 96-well microtitre plate format (e.g. PetChek Plus Anti-FIV; IDEXX) are often used by most diagnostic laboratories for initial screening of sera. Confirmation may then be made by Western blotting (immunoblotting) and radioimmunoprecipitation assay (RIPA) to detect antibodies, present in serum or plasma, which are directed against specific viral proteins.

The isolation of FIV, and other related immunodeficiency viruses, was made possible by the information and technological advances gained from the study of HIV. Thus, the procedure for isolation of FIV from peripheral blood lymphocytes closely resembles that used for the isolation of HIV and is given in detail elsewhere (Harbour *et al.*, 1988). If the lymphocytes are infected then cytopathic effects, including ballooning degeneration, syncytium formation and increased cell death, occur, usually after 5–14 days of culturing. The presence of virus in the culture can be confirmed by immunofluorescence, electron microscopy and reverse transcriptase assay, or with a commercial antigen ELISA. Virus isolation is not suitable for large-scale testing because it is expensive and labour intensive and does not give a rapid result. A highly sensitive commercial kit (Cavidi HS kit Lenti RT) is available for the detection of Mg^{2+}-dependent reverse transcriptase in lymphocyte culture fluid, which indicates the active replication of a lentivirus. Although this test is not specific for FIV, it distinguishes the lentivirus from the other two feline retroviruses, FeLV and feline foamy virus (FeFV). It is not, however recommended for direct detection of FIV in plasma.

PCR, a method for amplification of specific sequences of DNA in the FIV provirus, is even more sensitive for detecting very low levels of virus in blood or tissues, but great care must be taken to avoid cross-contamination of samples which can lead to false-positive results. A recent development, real-time PCR, reduces the risk of cross-contamination, but the equipment required is expensive. *In situ* hybridisation involves the use of a labelled FIV RNA or DNA probe to detect viral mRNA in fixed peripheral blood lymphocytes or tissues, and the sensitivity can be increased by incorporating a PCR step to amplify FIV sequences before the hybridisation.

Treatment and prognosis

Specific therapy

Currently, there are no specific antiviral agents effective against FIV that can be recommended for use in cats. However, because of the importance of FIV as a comparative model for HIV studies, considerable attention has been devoted to the efficacy of chemotherapeutic agents against FIV. Many of the drugs known to inhibit HIV replication are also effective against FIV, at least *in vitro*. One such drug, 9-(2-phosphono-methoxyethyl)adenine (PMEA), has been shown to be effective *in vivo*, producing clinical improvement in field cases of FIV infection in which secondary infections were apparent (Egberink *et al.*, 1990). Two related drugs, (R)-PMPDAP and FPMPA, proved effective in ameliorating the clinical symptoms of FIV-infected cats as measured by several clinical parameters, including the incidence and severity of stomatitis, immunological parameters such as relative and absolute $CD4^+$ lymphocyte counts, and virological parameters including proviral DNA levels in PBMCs of drug-treated animals. In comparison with PMEA, these drugs are more potent and less toxic inhibitors of FIV replication, and treated cats showed no haematological side-effects at higher doses than PMEA. Azidothymidine (AZT, Zidovudine) is much less effective in cats than might have been expected from the results of *in vitro* studies, and is fairly toxic, frequently causing anaemia. However, a dose of 5 mg/kg three times daily has been reported to be beneficial in FIV-positive cats with chronic gingivostomatitis. Future clinical trials will determine the safety of other antiviral agents for use in FIV-infected cats. Unfortunately, in the immediate future, even if agents are shown to be safe and effective *in vivo*, it is unlikely that treatment with these drugs will be

economically viable for most cats. As with HIV, these agents may slow down the progression of disease, but are unlikely to be able to eliminate infection. Vaccination will probably be the most successful method of preventing FIV infection.

Although antiviral therapy may play an important role in the treatment of HIV-infected humans, treatment of specific or concurrent infections is also considered to be of great importance, and it is on this aspect of therapy that we must focus for cats. Numerous specific concurrent infectious and non-infectious diseases have been identified in FIV-infected cats, and establishing a diagnosis of FIV should not preclude further investigation of a sick cat. It is important to try to establish what, if any, other disease processes are ongoing, and to institute appropriate treatment for these. It is perhaps also relevant to consider ways of reducing exposure of an infected cat to potential pathogens, by maintaining vaccination and perhaps by attempting to minimise contact with other cats, especially free-roaming cats.

No difference in FeLV vaccine efficacy was found between FIV-negative and FIV-positive animals. The whole group of cats was observed for over 3 years. Prevention of coinfection by immunising FIV-positive cats against FeLV infection improved the clinical outcome and prolonged the cats' life expectancy (Hofmann-Lehmann *et al.*, 1995). By contrast (Buonavoglia *et al.*, 1993), vaccination of cats in the primary stage of FIV infection with a modified live feline panleucopenia virus (FPV) vaccine produced severe clinical signs, similar to those typically observed in cats naturally infected with field strains of FPV (fever, diarrhoea, leucopenia), so it is important to select vaccines for use in FIV-infected cats carefully. Where possible, it is advisable to use inactivated vaccines in potentially immunosuppressed cats.

Symptomatic therapy

Despite further investigations, it is not always possible to find specific concurrent diseases, and in these cases symptomatic therapy based on clinical signs is always justified. Many such cases have shown a favourable response to the use of antibiotics (presumably indicating that secondary bacterial infections are common in FIV-infected cats, although not always immediately apparent). If antibiotics are to be used empirically it is probably sensible to use a broad-spectrum bactericidal agent.

This group has also found a (perhaps surprising) value in the use of corticosteroids in some infected cats. In a number of cases, particularly of pyrexia, inappetence or stomatitis/gingivitis that have failed to show response to conventional therapy, there has often been a dramatic response to the use of corticosteroids. In most cases a good response has been achieved by the use of daily or alternate-day prednisolone, often at quite low doses (0.5–1 mg/kg), although higher doses may be necessary. Part of the benefit of corticosteroids appears to be derived from their potent anti-inflammatory activity; however, these agents are known to be immunosuppressive and therefore the long-term consequences of their use may be deleterious. This does not preclude their use, although caution should be exercised and, before embarking on corticosteroid therapy, other lines of treatment should be attempted (where appropriate). If there is any suspicion of involvement of bacterial pathogens, it is clearly essential to use antibiotics. Use of methylprednisolone acetate in acutely infected cats was found to have no effect on the humoral immune response to FIV, but suppressed $CD8^+$ cell antiviral activity, leading to higher plasma viral RNA levels than in untreated cats (Barr *et al.*, 2000). By contrast, methylprednisolone treatment of cats with established FIV infections appeared to reverse neurophysiological changes, emphasising the complexity of host–lentivirus interactions.

Other supportive and symptomatic measures may be of value in certain cases, including fluid therapy, anabolic steroids in cases of severe weight loss, and possibly blood transfusions. Attention should also be paid to the diet, to ensure that cats are consuming a balance of food meeting their nutritional requirements, and again where weight loss is a problem, provision of a palatable high-calorie food may be valuable.

Progress in vaccine development

Since the early 1990s, there have been numerous trials of experimental FIV vaccines (see reviews by Elyar *et al.*, 1997; Willett *et al.*, 1997) with various outcomes (protection, partial protection, no protection or enhancement). Protection has only been achieved against the homologous virus used for vaccination or closely related strains of FIV. Moreover, in trials where protection has been demonstrated, the challenge viruses used have been those that do not lead to high plasma virus loads, which correlates with low pathogenicity. It is likely, therefore, that these experimental vaccines would be ineffective against the majority of field strains of FIV. Nevertheless, in March 2002, the first commercial FIV vaccine was licensed by Fort

Dodge Animal Health. This is a killed vaccine containing two strains of FIV (one each from the USA and Asia). It is administered in three doses, and the preventable fraction achieved in trials was 55.4%. The preventable fraction is the proportion of cats protected that, without vaccination, would have become infected. It is calculated thus:

$$\frac{\text{\% Unvaccinated cats not protected} - \text{\% Vaccinated cats cat not protected}}{\text{\% Unvaccinated cats not protected}} \times 100$$

Protection lasted for at least 12 months. One disadvantage with the vaccine is that the antibodies produced to it interfere with the diagnostic tests based on detection of FIV antibody.

Research continues in the search for a more effective vaccine, with the use of DNA vaccines and cytokine adjuvants showing some promise (Hosie *et al.*, 1998).

Prognosis

The prognosis for FIV-infected cats must be guarded. If the diagnosis of FIV infection is made early in the course of the disease, there may be a long period during which the cat is free of clinical signs related to FIV and so the outlook may be less bleak. Although it is not certain that all infected cats go on to develop an immunodeficiency syndrome, the evidence available suggests that the majority do, and in all cats, the infection appears to be permanent (in common with other lentivirus infections in other species). The prognosis for a cat infected with FIV and showing clinical signs suggestive of an immunodeficiency syndrome is poor. It is difficult to give any reliable estimate of the mortality rate among FIV-infected cats. Surveys have given different results, ranging from around 15% (Ishida *et al.*, 1989) to over 45% (Hopper *et al.*, 1989) during a 6–12 month follow-up period. The mortality rate will vary according to which population of cats is studied (e.g. referral cases or first opinion cases) and the picture is further complicated by the fact that in some cases owners choose euthanasia for their cats for reasons other than the severity of clinical signs. Nevertheless, FIV infection is undoubtedly a major cause of disease in cats and is frequently associated with mortality. Owners should be made aware of these facts, and while many cats initially show a good response to supportive and symptomatic therapy, in most cases deterioration will eventually occur, necessitating euthanasia on humane grounds.

In humans with HIV infection, a careful and precise system has been developed to stage the progress of the infection. Although a similar system has been suggested for staging FIV infection (Ishida & Tomoda, 1990), it has not become established because many of the criteria for staging HIV infection have proved to be unreliable when applied to FIV-infected cats, owing to a much greater diversity in the range and course of clinical signs than is seen in HIV infection in humans (Bendinelli *et al.*, 1995). However, plasma virus load is 1–2 logs higher in cats with rapidly progressive FIV disease than in long-term survivors. Differences in plasma FIV RNA levels are evident by 1–2 weeks after infection and are consistent throughout infection, so have some prognostic value (Diehl *et al.*, 1996).

Control

At present, control measures relating to FIV are restricted to details of management, since the only commercial vaccine available (see above) is not licensed for use in the UK and the prospects for successful antiviral chemotherapy are also limited.

Management of uninfected cats

To achieve minimal risk of FIV infection, there should be as little contact with cats outside the house as possible, and in particular it is important to avoid contact with stray and feral cats. However, once a cat has begun to venture away from home and establishes its territory, it is very difficult to prevent wandering without taking drastic measures. Often a cat must be left to live with the risk, and the best compromise is to keep it in at night, since this is when most cat fights take place. It is also possible to reduce the tendency for a cat to roam (and therefore to socialise and fight with other cats) by ensuring that it is neutered. This is best done at the earliest opportunity, but is likely to be beneficial at any age.

Management of infected cats

Decisions regarding the management of an infected cat depend largely on individual circumstances and the views and conscience of the owner. In view of the low risk of transmission other than by aggression, euthanasia need not be recommended, except in the case of the very aggressive cat that could not be confined indoors. Otherwise, euthanasia of an FIV-infected cat is recommended only on humane grounds when the cat is severely ill. In most cases, the recommendations

given above for management of uninfected cats can be followed so as to minimise the risk of transmission of FIV to other cats and to reduce the risk of contact with other infectious agents that may cause more severe disease in an immunosuppressed FIV-infected cat.

If there are infected and uninfected cats within a household then the owner will face a dilemma: should the infected cats be kept separately or should they remain in contact with the other cats? Separation of cats is often very difficult and totally impractical in some cases. In addition, since FIV does not appear to be readily transmitted by close contact between cats, the risk avoided by keeping infected cats separately may not justify the difficulty and stress that can arise from such measures. Finally, it is worthwhile remembering that if the uninfected cats have outdoor access then there is probably a greater risk of infection from neighbouring cats than from those within the household, provided that there is no fighting among the cats in the household. Given these considerations, most owners decide to keep their cats together. Another alternative is to rehome the infected or uninfected cat(s), whichever proves easier. If all cats within a household are infected, then considerations are limited to the confinement of the cats.

Advice for breeding colonies

To minimise the risk of introducing FIV into the colony, breeders are advised to prevent their breeding cats having free access outdoors, or having contact with any cats that are allowed outdoors. Regular testing of breeding cats (e.g. annually) and of new cats before introduction, is sensible. If an infected cat is identified then appropriate measures must be taken: stop breeding, test all other cats and remove, or completely separate, infected ones. All cats should be retested in 3–6 months and, if still negative, breeding can resume. It is wise to avoid overcrowding and to isolate each queen before and after kittening. Retesting all cats 6 months after resumption of breeding is strongly advised. Although it is probable that sexual transmission rarely occurs, it is nevertheless strongly recommended that FIV-infected toms are not used at stud.

Advice for cat rescue centres and organisations

Special consideration must be given to rescue cats and in some instances the advice will differ from that given to owners of pet cats infected with FIV.

Financial constraints are likely to prevent the routine screening for FIV in all cats. If this is not possible, it is suggested that testing is reserved for those cats that are showing clinical signs. In addition, it would be wise to test cats that are obviously aggressive and bite other cats – often the adult entire males. If financial provisions allow, the testing of stray and feral cats would also be sensible, since these are the cats most likely to be infected with FIV.

Careful consideration is necessary before a cat rescue society knowingly rehomes a cat with FIV, since an infected cat (particularly if ill when the diagnosis of FIV infection was made) has a poor prognosis and is likely to need regular veterinary attention. Infected cats should not remain for a lengthy period in the foster home or shelter, so the most realistic and responsible option may be euthanasia, even if the cat is relatively healthy.

It is recommended that aggressive cats are housed alone while at the centre, and tested for FIV if possible. It is also advisable to keep cats in the smallest groups possible; this is an important measure in preventing the spread of any infectious agent. A policy of neutering cats before rehoming should also be effective in reducing the transmission of FIV, since neutered cats are less likely to fight and bite.

References

Bach J.M., Hurtrel M., Chakrabarti L., *et al.* (1994) Early stages of feline immunodeficiency virus infection in lymph nodes and spleen. *AIDS Res Hum Retroviruses* **10**, 1731–1738.

Bachmann M.H., Mathiason-Dubard C., Learn G.H., *et al.* (1997) Genetic diversity of feline immunodeficiency virus: dual infection, recombination, and distinct evolutionary rates among envelope sequence clades. *J Virol* **71**, 4241–4253.

Barr M.C., Calle P.P., Roelke M.E. & Scott F.W. (1989) Feline immunodeficiency virus infection in non-domestic felids. *J Zoo Wildl Med* **20**, 265–272.

Barr M.C., Huitron-Resendiz S., Selway D.R., *et al.* (2000) Exogenous glucocorticoids alter parameters of early feline immunodeficiency virus infection. *J Infect Dis* **181**, 576–586.

Beebe A.M., Dua N., Faith T.G., *et al.* (1994) Primary stage of feline immunodeficiency virus infection: viral dissemination and cellular targets. *J Virol* **68**, 3080–3091.

Bendinelli M., Pistello M., Lombardi S., *et al.* (1995) Feline immunodeficiency virus: an interesting model for AIDS studies and an important cat pathogen. *Clin Microbiol Rev* **8**, 87–112.

Brown E.W., Yuhki N., Packer C. & O'Brien S.J. (1994) A lion lentivirus related to feline immunodeficiency virus: epidemiologic and phylogenetic aspects. *J Virol* **68**, 5953–5968.

Brown P.J., Hopper C.D. & Harbour D.A. (1991) Pathological features of lymphoid tissues in cats with natural feline immunodeficiency virus (FIV) infection. *J Comp Pathol* **104**, 345–355.

Buonavoglia C., Marsilio F., Tempesta M., *et al.* (1993) Use of a feline panleukopenia modified live virus vaccine in cats in the primary-stage of feline immunodeficiency virus infection. *Zentralbl Veterinarmed (B)* **40**, 343–346.

Callanan J.J., Jones B.A., Irvine J., *et al.* (1996) Histologic classification and immunophenotype of lymphosarcomas in cats with naturally and experimentally acquired feline immunodeficiency virus infections. *Vet Pathol* **33**, 264–272.

Carpenter M.A., Brown E.W., MacDonald D.W. & O'Brien S.J. (1998) Phylogeographic patterns of feline immunodeficiency virus genetic diversity in the domestic cat. *Virology* **251**, 234–243.

Courchamp F. & Pontier D. (1994) Feline immunodeficiency virus: an epidemiological review. *C R Acad Sci III* **317**, 1123–1134.

Courchamp F., Suppo C., Fromont E. & Bouloux C. (1997) Dynamics of two feline retroviruses (FIV and FeLV) within one population of cats. *Proc R Soc Lond B Biol Sci* **264**, 785–794.

Courchamp F., Yoccoz N.G., Artois M. & Pontier D. (1998) At-risk individuals in feline immunodeficiency virus epidemiology: evidence from a multivariate approach in a natural population of domestic cats (*Felis catus*). *Epidemiol Infect* **121**, 227–236.

Diehl L.J., Mathiason-Dubard C.K., O'Neil L.L. & Hoover E.A. (1996) Plasma viral RNA load predicts disease progression in accelerated feline immunodeficiency virus infection. *J Virol* **70**, 2503–2507.

Dua N., Reubel G., Moorem P.F., *et al.*, (1994) An experimental study of primary feline immunodeficiency virus infection in cats and a historical comparison to acute simian and human immunodeficiency virus diseases. *Vet Immunol Immunopathol* **43**, 337–355.

Egberink H., Borst M., Niphuis H., *et al.* (1990) Suppression of feline immunodeficiency virus infection *in vivo* by 9-(2-phosphonomethoxyethyl)adenine. *Proc Nat Acad Sci USA* **87**, 3087–3091.

Elyar J.S., Tellier M.C., Soos J.M. & Yamamoto J.K. (1997) Perspectives on FIV vaccine development. *Vaccine* **15**, 1437–1444.

Flynn J.N., Cannon C.A., Sloan D., *et al.* (1999) Suppression of feline immunodeficiency virus replication *in vitro* by a soluble factor secreted by $CD8^+$ T lymphocytes. *Immunology* **96**, 220–229.

George J.W., Pedersen N.C. & Higgins J. (1993) The effect of age on the course of experimental feline immunodeficiency virus infection in cats. *AIDS Res Hum Retroviruses* **9**, 897–905.

Georgsson G. (1994) Neuropathologic aspects of lentiviral infections. *Ann N Y Acad Sci* **724**, 50–67.

Gruffydd-Jones T.J., Hopper C.D., Harbour D.A. & Lutz H. (1988) Serological evidence of feline immunodeficiency virus infection in UK cats from 1975–76. *Vet Rec* **123**, 569–570.

Guiot A.L., Rigal D., Pialot D. & Chappuis G. (1995) Development of a simple, rapid and accurate *in vitro* whole blood technique for the detection and semi-quantification of FIV cellular viremia. *Vet Microbiol* **47**, 331–342.

Gunn-Moore D.A., Pearson G.R., Harbour D.A. & Whiting C.V. (1996) Encephalitis associated with giant cells in a cat with naturally occurring feline immunodeficiency virus infection demonstrated by *in situ* hybridization. *Vet Pathol* **33**, 699–703.

Harbour D.A., Williams P.D., Gruffydd-Jones T.J., *et al.* (1988) Isolation of a T-lymphotropic lentivirus from a persistently leucopenic domestic cat. *Vet Rec* **122**, 84–86.

Hofmann-Lehmann R., Holznagel E., Aubert A., *et al.* (1995) Recombinant FeLV vaccine: long-term protection and effect on course and outcome of FIV infection. *Vet Immunol Immunopathol* **46**, 127–137.

Hohdatsu T., Fujimori S., Maeki M., *et al.* (1997) Virus neutralizing antibody titer to feline immunodeficiency virus isolates of subtypes A, B and D in experimentally or naturally infected cats. *J Vet Med Sci* **59**, 377–381.

Hopper C.D., Sparkes A.H., Gruffydd-Jones T.J., *et al.* (1989) Clinical and laboratory findings in cats infected with feline immunodeficiency virus. *Vet Rec* **125**, 341–346.

Hosie M.J., Flynn J.N., Rigby M.A., *et al.* (1998) DNA vaccination affords significant protection against feline immunodeficiency virus infection without inducing detectable antiviral antibodies. *J Virol* **72**, 7310–7319.

Inoshima Y., Miyazawa T., Kohmoto M., *et al.* (1998) Cross virus neutralizing antibodies against feline immunodeficiency virus genotypes A, B, C, D and E. *Arch Virol* **143**, 157–162.

Ishida T. & Tomoda I. (1990) Clinical staging of feline immunodeficiency virus infection. *Nippon Juigaku Zasshi* **52**, 645–648.

Ishida T., Washizu T., Toriyabe K., *et al.* (1989) Feline immunodeficiency virus infection in cats of Japan. *J Am Vet Med Assoc* **194**, 221–225.

Johnston J. & Power C. (1999) Productive infection of human peripheral blood mononuclear cells by feline immunodeficiency virus: implications for vector development. *J Virol* **73**, 2491–2498.

Jordan H.L., Howard J., Tompkins W.A. & Kennedy-Stoskopf S. (1995) Detection of feline immunodeficiency virus in semen from seropositive domestic cats (*Felis catus*). *J Virol* **69**, 7328–7333.

Jordan H.L., Howard J., Barr M.C., *et al.* (1998) Feline immunodeficiency virus is shed in semen from experimentally and naturally infected cats. *AIDS Res Hum Retroviruses* **14**, 1087–1092.

Kovacs E.M., Baxter G.D. & Robinson W.F. (1999) Feline peripheral blood mononuclear cells express message for both CXC and CC type chemokine receptors. *Arch Virol* **144**, 273–285.

Kurosawa K., Ikeda Y., Miyazawa T., *et al.* (1999) Development of restriction fragment-length polymorphism method to differentiate five subtypes of feline immunodeficiency virus. *Microbiol Immunol* **43**, 817–820.

Langley R.J., Hirsch V.M., O'Brien S.J., *et al.* (1994) Nucleotide sequence analysis of puma lentivirus (PLV-14): genomic organization and relationship to other lentiviruses. *Virology* **202**, 853–864.

Linenberger M.L. & Abkowitz J.L. (1995) Haematological disorders associated with feline retrovirus infections. *Baillieres Clin Haematol* **8**, 73–112.

Loesenbeck G., Drommer W., Egberink H.F. & Heider H.J. (1996) Immunohistochemical findings in eyes of cats serologically positive for feline immunodeficiency virus (FIV). *Zentralbl Veterinarmed (B)* **43**, 305–311.

Matsumura S., Ishida T., Washizu T. & Tomoda I. (1994) Histopathology and viral antigen distribution in lymph nodes of cats naturally infected with feline immunodeficiency virus. *J Vet Med Sci* **56**, 523–528.

O'Dair H.A., Hopper C.D., Gruffydd-Jones T.J., *et al.* (1994) Clinical aspects of *Chlamydia psittaci* infection in cats infected with feline immunodeficiency virus. *Vet Rec* **134**, 365–368.

O'Neil L.L., Burkhard M.J., Diehl L.J. & Hoover E.A. (1995) Vertical transmission of feline immunodeficiency virus. *AIDS Res Hum Retroviruses* **11**, 171–182.

O'Neil L.L., Burkhard M.J. & Hoover E.A. (1996) Frequent perinatal transmission of feline immunodeficiency virus by chronically infected cats. *J Virol* **70**, 2894–2901.

O'Neil L.L., Burkhard M.J., Obert L.A. & Hoover E.A. (1997) Regression of feline immunodeficiency virus infection. *AIDS Res Hum Retroviruses* **13**, 713–718.

Park H.S., Kyaw-Tanner M., Thomas J. & Robinson W.F. (1995) Feline immunodeficiency virus replicates in salivary gland ductular epithelium during the initial phase of infection. *Vet Microbiol* **46**, 257–267.

Pedersen N.C., Ho E.W., Brown M.L. & Yamamoto J.K. (1987) Isolation of a T-lymphotropic virus from domestic cats with an immunodeficiency-like syndrome. *Science* **235**, 790–793.

Pedersen N.C., Torten M., Rideout B., *et al.* (1990) Feline leukemia virus infection as a potentiating cofactor for the primary and secondary stages of experimentally induced feline immunodeficiency virus infection. *J Virol* **64**, 598–606.

Podell M., Hayes K., Oglesbee M. & Mathes L. (1997) Progressive encephalopathy associated with CD4/CD8 inversion in adult FIV-infected cats. *J Acquir Immune Defic Syndr Hum Retrovirol* **15**, 332–340.

Poli A., Abramo F., Taccini E., *et al.* (1993) Renal involvement in feline immunodeficiency virus infection: a clinicopathological study. *Nephron* **64**, 282–288.

Power C., Moench T., Peeling J., *et al.* (1997) Feline immunodeficiency virus causes increased glutamate levels and neuronal loss in brain. *Neuroscience* **77**, 1175–1185.

Prospero-Garcia O., Herold N., Phillips T.R., *et al.* (1994) Sleep patterns are disturbed in cats infected with feline immunodeficiency virus. *Proc Natl Acad Sci USA* **91**, 12947–12951.

Reubel G.H., Dean G.A., George J.W., *et al.* (1994) Effects of incidental infections and immune activation on disease progression in experimentally feline immunodeficiency virus-infected cats. *J Acquir Immune Defic Syndr* **7**, 1003–1015.

Rogers A.B. & Hoover E.A. (1998) Maternal–fetal feline immunodeficiency virus transmission: timing and tissue tropisms. *J Infect Dis* **178**, 960–967.

Sellon R.K., Jordan H.L., Kennedy-Stoskopf S., *et al.* (1994) Feline immunodeficiency virus can be experimentally transmitted via milk during acute maternal infection. *J Virol* **68**, 3380–3385.

Shelton G.H., Abkowitz J.L., Linenberger M.L., *et al.* (1989) Chronic leukopenia associated with feline immunodeficiency virus in a cat. *J Am Vet Med Assoc* **194**, 253–255.

Shelton G.H., Grant C.K., Cotter S.M., *et al.* (1990a) Feline immunodeficiency virus and feline leukemia virus infections and their relationships to lymphoid malignancies in cats: a retrospective study (1968–1988). *J Acquir Immune Defic Syndr* **3**, 623–630.

Shelton G.H., Linenberger M.L., Grant C.K. & Abkowitz J.L. (1990b) Hematologic manifestations of feline immunodeficiency virus infection. *Blood* **76**, 1104–1109.

Sparkes A.H., Hopper C.D., Millard W., *et al.* (1993) Feline immunodeficiency virus infection: clinicopathologic findings in 90 naturally occurring cases. *J Vet Intern Med* **7**, 85–90.

Steigerwald E.S., Sarter M., March P. & Podell M. (1999) Effects of feline immunodeficiency virus on cognition and behavioral function in cats. *J Acquir Immune Defic Syndr Hum Retrovirol* **20**, 411–419.

Terry A., Callanan J.J., Fulton R., *et al.* (1995) Molecular analysis of tumours from feline immunodeficiency virus (FIV)-infected cats: an indirect role for FIV? *Int J Cancer* **61**, 227–232.

Toyosaki T., Miyazawa T., Furuya T., *et al.* (1993) Localization of the viral antigen of feline immunodeficiency virus in the lymph nodes of cats at the early stage of infection. *Arch Virol* **131**, 335–347.

Ueno H., Hohdatsu T., Muramatsu Y., *et al.* (1996) Does coinfection of *Bartonella henselae* and FIV induce clinical disorders in cats? *Microbiol Immunol* **40**, 617–620.

VandeWoude S., O'Brien S.J., Langelier K., *et al.* (1997) Growth of lion and puma lentiviruses in domestic cat cells and comparisons with FIV. *Virology* **233**, 185–192.

Waters L., Hopper C.D., Gruffydd-Jones T.J. & Harbour D.A. (1993) Chronic gingivitis in a colony of cats infected with feline immunodeficiency virus and feline calicivirus. *Vet Rec* **132**, 340–342.

Willett B.J. & Hosie M.J. (1999) The role of the chemokine receptor CXCR4 in infection with feline immunodeficiency virus. *Mol Membr Biol* **16**, 67–72.

Willett B.J., Flynn J.N. & Hosie M.J. (1997) FIV infection of the domestic cat: an animal model for AIDS. *Immunol Today* **18**, 182–189.

Woo J.C., Dean G.A., Pedersen N.C. & Moore P.F. (1997) Immunopathologic changes in the thymus during the acute stage of experimentally induced feline immunodeficiency virus infection in juvenile cats. *J Virol* **71**, 8632–8641.

Yamamoto J.K., Sparger E., Ho E.W., *et al.* (1988) Pathogenesis of experimentally induced feline immunodeficiency virus infection in cats. *Am J Vet Res* **49**, 1246–1258.

Yamamoto J.K., Hansen H., Ho E.W., *et al.* (1989) Epidemiologic and clinical aspects of feline immunodeficiency virus infection in cats from the continental United States and Canada and possible modes of transmission. *J Am Vet Med Assoc* **194**, 213–220.

Chapter 25

FELINE CORONAVIRUS INFECTION

A.H. Sparkes

Introduction

Feline coronavirus (FCoV) infections are prevalent throughout the world. Infection with FCoV can result in a diverse range of signs from no clinical disease at all to the progressive fatal manifestation of infection known as feline infectious peritonitis (FIP). Despite the ubiquitous nature of infection with FCoV in most domestic cat populations, FIP remains a relatively rare disease. However, FIP is one of the most serious of the viral infections of cats, not only because of its fatal nature, but also because of the difficulties in achieving an ante-mortem diagnosis and the problems associated with control of this disease.

Aetiology

Feline coronaviruses belong to a group of very closely related coronaviruses including transmissible gastroenteritis virus (TGEV) of pigs, the recently emerged porcine respiratory coronavirus, canine coronavirus (CCV) and a human coronavirus (HCV-229E). Interspecies transmission has been demonstrated for at least some of these coronaviruses, and they are regarded as host-range mutants of a single virus.

Coronaviruses are enveloped RNA viruses containing the largest known RNA genome, making them highly susceptible to spontaneous mutation during replication. This has led to the concept of quasispecies: during normal replication the high rate of mutations leads to a 'cloud' of viruses that differ slightly genetically and ultimately this can lead to antigenic variations (Herrewegh *et al.*, 1997). Another source of genomic and antigenic variation between coronavirus isolates comes from recombination events between different coronavirus strains, and this may occur between different species-adapted strains (such as between CCV and FCoV).

Two serotypes of FCoV exist, referred to as types I and II, which are defined by neutralisation assays. Type II FCoVs are thought to have arisen by recombination with CCV, resulting in incorporation of the CCV spike gene (the gene encoding the membrane spike protein) in the FCoV genome. The prevalence of type I and II infections appears to vary between different countries; however, type I viruses are generally more prevalent although more difficult to cultivate *in vitro*, whereas the less common type II infections are more readily grown in tissue culture (Vennema *et al.*, 1995). The full range of clinical disease can be seen with both serotypes of FCoV.

The serotypes of FCoV are interesting from an evolutionary perspective, but from a clinical perspective it is more valuable to recognise that two biotypes of FCoV exist, unrelated to the serotypes. This recognises the fact that certain mutations within FCoV isolates result in a dramatic shift in the pathogenicity of the virus, such that certain variants develop a tropism for macrophages and have the capacity to cause fatal FIP. In contrast, the majority of FCoV strains are of much lower virulence and are more adapted to replication in enterocytes lining the gastrointestinal tract, generally causing no more than mild diarrhoea. These two biotypes of FCoV are frequently referred to as feline infectious peritonitis virus (FIPV) and feline enteric coronavirus (FECV), but it is clear that these are not two different viruses but simply strains of a single virus with markedly different virulence resulting from small mutations in their genomes. Thus, the two biotypes of FCoV, while exhibiting diversely different biological behaviour, are indistinguishable antigenically and serologically. Indeed, as the mutations associated with

virulence vary between different FIP-producing strains of the virus (Vennema *et al.*, 1998), even sophisticated molecular diagnostic tests such as reverse transcriptase–polymerase chain reaction (RT-PCR) assays are unable to distinguish between the different biotypes (Herrewegh *et al.*, 1997).

Epidemiology

Infection with FCoV is ubiquitous in domestic cat populations throughout the world. Serological surveys have demonstrated that typically 25–40% of household pet cats are FCoV seropositive, while this figure generally rises to 80–100% for cats from breeding catteries and other large catteries (Loeffler *et al.*, 1978; Horzinek & Osterhaus, 1979; Pedersen *et al.*, 1981; Sparkes *et al.*, 1992). Despite this high level of exposure to FCoV infection in cat populations, FIP remains a relatively uncommon disease. This fact, along with other observations, suggests that the majority of natural FCoV infections are likely to be with FECV biotypes, and that FIPV variants are relatively uncommon.

Infection with enteritis-producing strains of FCoV is thus endemic in cat populations, and highly prevalent in large colonies of cats and catteries. Kittens born in an environment where FCoV is prevalent are likely to be protected initially from maternally derived immunity. Maternally derived antibody (MDA) titres typically wane to undetectable levels at 6–8 weeks of age, and then titres rise again at 8–14 weeks of age, indicating natural infection with FCoV (Pedersen *et al.*, 1981). Studies performed using PCR to detect viral shedding in the faeces have demonstrated that kittens typically start shedding between 5 and 11 weeks of age and viral shedding usually precedes seroconversion (Harpold *et al.*, 1999).

Commonly, kittens will be infected from asymptomatic adult cats that shed virus in their faeces. Most, if not all cats from an infected household will shed FCoV in their faeces. For some cats the shedding appears to be intermittent, presumably associated with recurrent infections, whereas for others the shedding is persistent (for at least many months) and is associated with persistent productive infection in the ileum, colon and rectum (Herrewegh *et al.*, 1997; Foley *et al.*, 1997a; Harpold *et al.*, 1999; Addie & Jarrett, 2001). However, shedding of virus in the faeces is not correlated with the magnitude of the FCoV antibody titre in the serum. Long-term carriers of FCoV which remain asymptomatic and shed virus in their faeces for many months thus appear common and although most of these cats are probably infected with a low-virulence enteritis-producing strain of virus, early studies also showed that infection with virulent FIP-producing strains of coronavirus can also lead to a long-term carrier status if the cat resisted development of clinical disease.

Direct transmission of FCoV via the faecal–oral route (largely from asymptomatic cats) is probably the most common source of infection. However, FCoV may also be transmitted through environmental contamination. Although coronaviruses are relatively labile and susceptible to most commonly used disinfectants, studies have demonstrated that FCoV may remain viable in the environment for between 2 and 7 weeks, suggesting that this is a further potential source of infection, especially where normal hygiene precautions are not maintained.

Most infected kittens remain asymptomatic following infection, but some develop mild to moderate self-limiting vomiting and diarrhoea of a few days' duration (Pedersen *et al.*, 1981; Pedersen, 1983a). However, wherever FCoV infections occur, there is a risk of virulent viral mutation occurring and the emergence of a FIP-producing strain of the virus along with subsequent development of clinical disease.

FIP is predominantly a disease of young cats. Clinical cases typically first appear during the postweaning period, but the peak age for development of FIP is between 6 months and 2 years (Pedersen, 1995). There is a markedly higher prevalence of disease in cats from breeding catteries and other large multicat households, presumably largely reflecting the fact that these are environments where exposure to FCoV is difficult to avoid. Indeed, the proportion of cats in a cattery chronically shedding coronavirus in their faeces and the frequency of coronavirus shedding have been shown to be linked to the risk of FIP cases developing (Foley *et al.*, 1997b). However, other factors may also be involved as breed predilections for development of FIP have been identified and in one study a polygenic inherited susceptibility to the development of FIP was proposed (Foley & Pedersen, 1996). Other studies have demonstrated an increase in the risk of FIP cases developing in catteries with increasingly larger numbers of cats (greater than seven) and where cats are permanently introduced from other catteries (Kass & Dent, 1995).

It has been suggested that the overall mortality due to FIP in mature household cats kept in low numbers (one or two individuals) is approximately 1 in 5000, whereas in colonies of cats it is generally about 5% (Pedersen, 1995). Typically, in colony situations the disease is sporadic, with outbreaks occurring where

mortality rates may reach around 10%, following which a lower rate of disease is seen. Occasionally, small epidemics of disease are seen where up to 40% of high-risk (young) cats may die, but these are relatively rare. Commonly, FIP will be observed in several or all kittens from an individual litter over a period of time. Stress factors also appear to be important in the development of FIP: it is well recognised that FIP frequently develops after one or a number of stressors in a young cat, including rehoming, elective surgery (neutering), vaccination and intercurrent infections (e.g. feline leukaemia virus and feline immunodeficiency virus infection).

Pathogenesis

Infection with FCoV is spread mainly via the faecal–oral route. Once a cat has been infected, as already noted, some will be persistent shedders of virus in their faeces while others will shed for only a limited period, and some may shed intermittently (possibly associated with reinfection). The virus replicates within mature enterocytes in the small and large intestine, with resultant diarrhoea and vomiting in a proportion of infected cats. Those with most severe signs apparently have most severe lesions in the ileum with villous atrophy, fusion of villi, sloughing of villous tips and mild inflammatory infiltrates (Pedersen *et al.*, 1981).

There is evidence that one of the major differences between enteritis-producing strains of FCoV and FIP-producing strains is the ability of the latter to replicate to high titres in macrophages (Stoddart & Scott, 1989). It used to be thought, therefore, that infection with enteritis-producing strains was limited and essentially confined to the epithelium of the intestinal tract, and that the crucial difference with FIP-producing strains was the ability to cross this barrier and to establish systemic infection associated with replication in macrophages. However, recent studies have shown that this hypothesis is too simplistic. By the use of sensitive molecular biological assays such as RT-PCR, the presence of FCoV genomic material can be demonstrated at extraintestinal sites in many healthy FCoV-seropositive cats as well as some seronegative cats from catteries where infection is endemic (see later under Diagnosis). Nevertheless, although enteritis-producing strains of FCoV are not necessarily confined to the intestine, it does appear that productive infection is mainly limited to this site in comparison to FIP-producing strains that are able to disseminate and replicate widely throughout the body.

Clinical FIP occurs when a cat is exposed to and infected with a virulent mutant of FCoV, and where the infection is unable to be contained by the host's immune response. The potential sources of virulent FIP-producing strains of FCoV include asymptomatic carrier cats shedding virus, clinical cases of FIP which may be shedding virus, and environmental contamination (see under Epidemiology above). There have also been occasional reports suggesting the possibility of transplacental transmission of FIP, but if this does occur it appears to be exceptionally rare. However, it is now believed that the majority of clinical cases arise through spontaneous *in situ* mutation of an existing FCoV infection leading to the emergence of a virulent FIP-producing variant (Vennema *et al.*, 1998). Infection with FCoV is often prolonged, and other factors may encourage increased viral replication, such as infection in younger cats (with a poorer immune response), and stress factors such as rehoming, neutering, vaccination and intercurrent disease. With increased viral replication, spontaneous mutations lead to the development of quasispecies (see under Aetiology above) and eventually a mutation may occur that results in the emergence of an FIP-producing strain. There is little doubt that horizontal transmission of virulent FCoV strains also occurs, but it is likely that spontaneous mutations in a cat already infected with FCoV account for the majority of clinical cases. The outcome of infection in an individual thus depends on the result of complex interactions between the strain and dose of virus; and the age, genotype, immune competence and immune status of the cat.

The emergence of an FIP-producing strain of FCoV will allow efficient replication of the virus in macrophages and if this is not controlled by a good immune response this will lead to rapid dissemination of infection and a monocyte/macrophage cell-associated viraemia. Infected macrophages eventually die, leading to release of virions, which in turn may infect more macrophages, leading to an exponential expansion of the infection.

Many studies have documented the involvement of the immune system in the development of FIP. Humoral immunity is clearly not protective and, indeed, under experimental conditions pre-existing FCoV antibodies in a cat may lead to an enhanced or accelerated form of disease on subsequent exposure to a FIP-producing strain of the virus: the antibody-dependent enhancement (ADE) of infection (Pedersen, 1987), although this may not necessarily occur under natural conditions (Addie *et al.*, 1995). However, passive immunity cannot be transferred through the

serum of immune cats, and a humoral immune response is seen both in cats that succumb to FIP and in those that resist challenge with virulent virus. This suggests that cell-mediated immunity is crucial in determining the outcome of infection. Antibody production is important in the pathogenesis of FIP as, through the development of immune complexes, it enhances uptake of viral particles by the phagocytic cells in which the virus will replicate. In addition, the appearance of immune complexes is associated with fluctuating levels of complement and an immune-mediated vasculitis (type III hypersensitivity reaction) contributing to the clinical signs that develop in effusive FIP (Pedersen, 1983b; Paltrinieri *et al*., 1998). Pyogranulomatous lesions are typically seen on serosal surfaces of cats affected with effusive disease, whereas granulomatous lesions are typical of the non-effusive form of the disease. There is evidence that these lesions represent a combination of type III and type IV (cell-mediated) hypersensitivity to FCoV antigens (Pedersen, 1983b; Paltrinieri *et al*., 1998).

It is believed that in effusive cases of FIP there is poor cell-mediated immunity and the dominant lesion is type III hypersensitivity-induced vasculitis, mainly associated with serosal surfaces leading to effusions accumulating in body cavities. Lesions are characterised by the focal accumulation of viral antigen, immunoglobulin G (IgG) and complement. Non-effusive pyogranulomatous lesions are typically perivascular (necrotising vasculitis and perivasculitis) and probably represent the development of partial or incomplete cell-mediated immunity to the virus (there are fewer macrophages and there is less virus present in comparison to the lesions found in effusive disease). Under this hypothesis, protection against challenge with virulent FIP-producing strains of FCoV is dependent mainly on the development of strong cell-mediated immunity (Pedersen, 1983b).

FIP lesions can occur in a wide variety of tissues. In effusive disease they typically consist of fibrinous deposits and small pyogranulomas on the omentum and serosal surfaces of most abdominal organs and also the pleural surfaces. In non-effusive disease the granulomatous lesions are usually much larger and surrounded by more fibrosis; they are often found within the abdomen (surface-orientated granulomas are most commonly seen in the liver, kidneys and mesenteric lymph nodes) and thorax, and also in other tissues, particularly the central nervous system (CNS; meninges and ependyma) and eye (especially in uveal tissue). A characteristic feature of FIP is perivascular cuffing, where infected macrophages and other inflammatory cells tend to congregate around small venules in the target tissues.

Clinical signs

Enteritis-inducing strains of FCoV are usually associated with mild disease at most. Many cases remain completely asymptomatic, but in young kittens mild, transient diarrhoea of several days' duration is generally the only sign. Vomiting occurs in a smaller proportion of cases and is not usually a dominant feature. Clinical signs may be exacerbated by concomitant infection with other enteric pathogens (viruses, bacteria, parasites), but on only one occasion has FCoV-induced enteritis been reported to be fatal (in the absence of FIP).

FIP is a disease with extremely diverse clinical manifestations. There are no clinical signs that are pathognomonic for this disease, and the diverse nature of the signs means that FIP has to be considered in the differential diagnosis of many clinical presentations. The disease takes on one of two broad forms: effusive (or 'wet') FIP and non-effusive (or 'dry') FIP. In effusive disease, lesions are focused on the serosal surfaces of body cavities and the vasculitis present results in the outpouring of a protein-rich fluid into the cavity (most commonly the abdomen). In non-effusive disease lesions are still most common in the abdominal cavity, but granulomas develop within organs and other structures (usually towards the serosal surfaces), leading to more diverse and often more vague clinical signs. Other sites are also commonly affected, particularly the eyes and the CNS. Effusive disease is more common than non-effusive and in general probably accounts for around 60–70% of cases.

The clinical course of FIP varies from several days at one end of the extreme, to several months at the other. Effusive disease tends to have a somewhat shorter duration than non-effusive disease and most cases have a course of a few weeks. The early signs in FIP are non-specific and common to both forms of the disease. These include fluctuating pyrexia, lethargy, inappetence, weight loss and diarrhoea. Mild upper respiratory tract signs have also been reported early in the course of disease in some cats. The severity and duration of these signs vary, but in some cases these early signs will be so mild that they may not be recognised by owners, who may only be aware of disease when more overt signs develop. In other cases the signs may be more severe, prompting owners to seek veterinary attention, but the vague nature of the signs make early

diagnosis of FIP extremely difficult. As the disease progresses, more overt signs of either effusive or non-effusive disease usually develop, although in some cases this may take many weeks or months to occur.

Pedersen (1995) reported the distribution of gross lesions in over 200 cases of FIP. In this series he found that the effusive disease affected the peritoneal cavity in over 80% of cases, and in nearly 60% gross lesions were confined to the abdomen. Pleural disease occurred in around 35% of cases, but gross lesions were confined to the pleural cavity in only 11%. Sites of other lesions included the CNS and eyes. In non-effusive cases, gross lesions were most commonly seen in the abdominal cavity (seen in approximately 50% of cases), but lesions were also found in the eyes and/or CNS in around 50% of the cases, and the pleural cavity was less frequently affected.

With the peritoneal and pleural cavities being most commonly affected in effusive disease, it is not surprising that the most common presenting signs are abdominal distension (due to the presence of gross ascites) and/or dyspnoea (due to a pleural effusion and/or extensive ascites causing pressure on the diaphragm). These signs are often accompanied by a waxing and waning non-responsive pyrexia and the other non-specific signs seen early in the course of disease, but some cats remain remarkably bright despite the presence of severe disease. In male cats, the effusion may affect the scrotum, with gross visible swelling of the scrotal sac, and in some cats there is also a pericardial effusion. Occasionally, pericardial effusions and cardiac tamponade have been the main presenting signs in cases of FIP. The presence of a pleural effusion and/or a pericardial effusion may lead to muffling of heart and/or lung sounds on thoracic auscultation. Other signs may also be seen in cats with effusive FIP. Hepatic involvement in the disease process may lead to the presence of jaundice, and in some cases there may be the ocular or CNS signs more typically seen with non-effusive disease.

In non-effusive disease, granulomas develop in a variety of body organs and the clinical signs are extremely variable, generally reflecting the organs involved. The most common site for the lesions is the abdominal cavity, with lesions commonly found in the liver, mesenteric lymph nodes, kidneys, spleen and omentum. Enlarged mesenteric lymph nodes may be felt on abdominal palpation, and renomegaly may also be present in some cases. In around 50% of cases of non-effusive disease, lesions are also found in the CNS and/or eyes. Ocular lesions typically consist of a uveitis; again, the lesions are predominantly vascular and perivascular, with inflammation affecting the iris (which may lead to a change in colour of the pupil), ciliary body, choroids and retina. Anterior uveitis may lead to clouding of the aqueous humour, and sometimes protein deposits on the posterior surface of the cornea (keratitic precipitates). Hyphaema may also be present. In the absence of significant neurological or ocular involvement, the signs of non-effusive disease may remain vague and non-specific. Persistent pyrexia, progressive weight loss and lethargy are often dominant signs. Jaundice is also a relatively common finding.

With CNS involvement, multifocal or diffuse lesions are common, with lesions (pyogranulomatous menin goencephalomyelitis) typically affecting the choroid plexus, meninges and ependyma. Inflammation and local accumulation of exudate may result in obstruction to the flow of cerebrospinal fluid (CSF) and the development of secondary hydrocephalus. As in the other forms of FIP, lesions are commonly perivascular (often centred around venules), and even in cases where clinical signs of neurological disease are absent, lesions may still be found histologically. Although analysis of CSF can be helpful in the diagnosis of FIP, it is not uncommon for lesions to be present around the brainstem and high cervical cord, which may make collection of fluid from a cisternal puncture difficult. Where neurological signs are observed, they are variable in nature. Ataxia, affecting primarily the hindlimbs, is probably the single most common neurological manifestation of FIP, but other signs include generalised ataxia, quadriparesis, nystagmus, seizures, personality changes, vestibular signs and cerebellar ataxia. With FIP, clinical signs tend to be progressive over a relatively short period (a few weeks), although there may be some fluctuation in severity of signs, especially early in the disease.

A more unusual manifestation of non-effusive FIP is the development of a focal intestinal granuloma, which may lead to the development of clinical signs relating to partial intestinal obstruction (Harvey *et al.*, 1996). These discrete granulomas have to be differentiated from other diseases such as intestinal intussusceptions and neoplasia.

Although clinical disease with FIP is often divided into effusive and non-effusive forms, it is important to understand that these are not two entirely separate entities. Rather, there tends to be a spectrum of disease, with many effusive cases having some lesions typical of the non-effusive form, and many non-effusive cases still having some small effusion in one of more cavities. This can be helpful from a diagnostic standpoint (e.g. where ocular lesions are present in effusive cases, and where fluid can be analysed in non-effusive

cases). Some cases of non-effusive disease may have a prolonged course of disease and develop more typical effusive disease in the later stages, associated with a terminal decline in the immune response.

Diagnosis

Infection with enteritis-producing strains of FCoV is rarely severe enough to require specific diagnosis of the underlying aetiological agent. Mild and transient enteritis in kittens can be due to many different agents and investigation is generally undertaken only when the signs are more persistent or particularly severe. In both situations, FCoV is unlikely to be a primary pathogen. Nevertheless, FCoV can be demonstrated in the faeces of infected kittens by electron-microscopic examination of the faeces, or by RT-PCR. However, the clinical value of this is questionable, as many healthy cats and kittens will also shed FCoV in their faeces. Thus, other than for detection of carriers or demonstrating the presence of FCoV infection in a colony of cats, such investigations have limited value.

FIP remains a difficult disease in which to make an ante-mortem diagnosis. One of the difficulties is the wide range of clinical presentations with this disease, making it a consideration in the differential diagnosis of a very wide range of signs. However, this difficulty is compounded by the lack of specific, routine laboratory tests to confirm the clinical suspicions of a diagnosis. In deciding whether FIP is a likely or probable diagnosis in any individual case, consideration needs to be given to the background of the cat and historical features, to the clinical signs that the cat is showing and to the results of a variety of routine laboratory tests. These may lead to sufficient evidence for a presumptive diagnosis of FIP to be made, but if significant doubt exists confirmatory testing may be necessary.

Making a presumptive diagnosis of feline infectious peritonitis

As routine laboratory tests will not confirm a suspected diagnosis of FIP it is important that the complete clinical picture is considered before assuming that a cat is suffering from this disease. Cases of FIP are far more common in young cats (less than 2 years of age), in pedigree cats and in other cats from multicat households. Older cats and cats from single cat households also develop FIP, but these cases are less common, and with appropriate clinical signs and supportive laboratory data, the index of suspicion will be higher in cats known to have come from a higher risk background.

In cases of suspected FIP, a thorough clinical examination is mandatory to try to identify any signs that are consistent with the diagnosis. This should include both a thorough ocular and neurological examination, whether effusive or non-effusive disease is suspected. If non-effusive disease is suspected, careful examination for the presence of small amounts of effusion (e.g. screening thoracic and abdominal radiographs) is prudent. If an effusion is present, laboratory analysis of the fluid is one of the most useful of the routine laboratory tests. Similarly, if abdominal effusive disease is suspected, thoracic radiographs to detect a pleural effusion can be valuable, as few other diseases would produce an effusion characteristic of FIP in both the abdominal and thoracic cavities.

As FIP is a progressive disease, the clinical manifestations will change over time. Reaching a diagnosis in the early stages when clinical signs are vague may be extremely challenging, but in most cases, as time goes by, more classical signs of FIP will develop. However, this means that repeat and thorough clinical examinations will be required in ongoing cases to detect the development of these signs.

Routine laboratory tests

Results of routine laboratory tests are useful in either supporting a presumptive diagnosis of FIP or suggesting that some other cause for the signs is more likely. On routine haematology, the most consistent features are a lymphopenia, a neutrophilic leucocytosis that may be accompanied by a left shift, and a mild to moderate non-regenerative anaemia. The anaemia tends to be progressive as the disease advances, and in some cases may be exacerbated by concurrent *Haemobartonella felis* infection.

Results of routine serum biochemistry, as with haematology, are non-specific. The most commonly observed changes are hyperproteinaemia due to hyperglobulinaemia, often accompanied by low or low-normal serum albumin concentrations. These changes result in a low albumin:globulin ratio. The prevalence and severity of the hyperproteinaemia seen in FIP vary. It has been reported to occur in between 50 and 80% of FIP cases, and varies from mild to very marked elevations in globulin concentrations, producing total protein concentrations sometimes in excess of 100 g/l. Results of protein electrophoresis show that the elevated globulin levels are usually due to a combination of elevated α_2- and γ-globulins and sometimes also β-globulins. There is usually a polyclonal gammopathy

present, but occasionally monoclonal spikes have been reported. The elevated gammaglobulin concentrations do not correlate with FCoV antibody titres, suggesting that proteins such as complement fractions which have the same mobility as immunoglobulins may be responsible for some of this elevation and/or that there is non-specific polyclonal antibody production in some cases (Paltrinieri *et al.*, 1998).

The elevated α_2-globulins seen in FIP represent elevated acute-phase inflammatory proteins, and more detailed studies have shown that both α_1-acid glycoprotein and haptoglobin are typically elevated in cases of FIP. However, these proteins are simply markers of inflammation, and therefore elevated concentrations are not specific for cases of FIP.

Other biochemical changes seen with FIP include hyperbilirubinaemia in approximately 25% of cases, elevated liver enzymes (e.g. alanine aminotransferase and alkaline phosphatase) and mild to moderate azotaemia. The latter may be due to renal involvement in some cases of FIP, but in others will be due to prerenal azotaemia resulting from the debilitation and dehydration that occurs with the disease. Although histological evidence of glomerulonephritis is not uncommon in FIP cases, results of urinalysis are generally unremarkable (other than bilirubinuria in a proportion) and significant proteinuria is rare.

Although all the haematological and biochemical changes seen in association with FIP are non-specific and can occur with many other diseases, they are still valuable in making a presumptive diagnosis of the disease. In a cat showing appropriate clinical signs, if there are multiple haematological and biochemical abnormalities typical of the changes seen with FIP, the positive predictive value of these observations (the likelihood that FIP is the underlying cause) is high, whereas if few or none of the typical changes are observed, FIP is an unlikely underlying cause (Sparkes *et al.*, 1994). Thus, although a diagnosis of FIP cannot be made or excluded on the basis of routine laboratory tests, they are valuable in supporting a presumptive diagnosis or in suggesting that FIP is unlikely. Results of these tests can be misleading, however, as occasionally cases of confirmed FIP show no abnormalities on routine haematology and biochemistry, whereas other diseases may at times lead to all of the changes classically associated with FIP.

Coronavirus serology

Coronavirus serology is frequently performed as part of the routine screening of cats with suspected FIP. Although potentially useful in the diagnostic evaluation of these cases, excessive reliance should not be placed on this test, and it is of no more value than results of routine haematology and biochemistry.

Coronavirus serology is usually based on immunofluorescence tests or enzyme-linked immunosorbent assays (ELISAs). None of the assays can distinguish between the different virulence strains of FCoV and thus a positive titre simply shows that a cat has been exposed to a strain of FCoV, to which it has mounted a humoral immune response. The titre cannot distinguish the type of FCoV strain, whether the infection is current or previous, or whether the cat is susceptible to the development of FIP. Interpretation of coronavirus titres thus requires great care, and a positive titre has to be seen in the background of a high prevalence of seropositivity in the general pet cat population (typically 25–40% are seropositive) and a very high prevalence of seropositivity in multicat households, where typically 80–100% are seropositive (Loeffler *et al.*, 1978; Horzinek & Osterhaus, 1979; Pedersen *et al.*, 1981; Sparkes *et al.*, 1992).

In general, cats with clinical FIP tend to have higher FCoV antibody titres than healthy cats or cats with non-FIP diseases, but there is complete overlap in the magnitude of titres between these different populations (Sparkes *et al.*, 1992), such that even very high antibody titres cannot be taken as evidence of clinical FIP. A minority of cats with confirmed, clinical FIP also have a lack of detectable FCoV antibodies. This is unusual, and probably occurs as a result of immune complexing of antibodies in the terminal stages of disease. The situation is further complicated by the fact that titres reported from different laboratories vary widely, even where the same test methodology is used.

When FCoV serology is performed, overinterpretation of the results should be avoided. A positive titre, especially of moderate to high magnitude, is supportive of a diagnosis of FIP, especially if accompanied by other clinicopathological changes typical of FIP (see above; Richards, 1995). However, negative titres do not exclude a diagnosis, and even high antibody titres are frequently encountered in healthy cats and cats suffering from diseases other than FIP. Euthanasia should never be performed simply on the basis of a positive FCoV antibody titre.

Fluid analysis

The analysis of effusions remains one of the most valuable routine tests for the diagnosis of FIP. This is the reason why even in suspected cases of non-effusive disease, it is worthwhile undertaking investigations to assess whether a small amount of effusion is present

and can be aspirated. The fluid in cases of FIP is typically straw-coloured, and viscous due to its high protein content, and may form a fibrin clot if left standing. Physical appearance can be variable, however, and in some cases the fluid will be almost colourless and appear less viscous, although unless complicated by a second disease process, the fluid will invariably have a high protein content.

Studies have shown that in FIP effusions, the total protein content of the fluid is in excess of 35 g/l, with levels of around 60 g/l being typical (Sparkes *et al.*, 1991). In addition to total protein, the albumin:globulin ratio should always be determined as FIP cases invariably have a globulin concentration greater than or equal to 50% of the total protein content (Shelley *et al.*, 1988; Sparkes *et al.*, 1994). The total cell count of FIP effusions is usually less than 20×10^6/ml, with a predominance of non-degenerate neutrophils and macrophages. Other diseases (e.g. neoplasia and lymphocytic cholangitis) may sometimes yield effusions indistinguishable from those seen in FIP, but this is uncommon and the finding of an effusion fulfilling the criteria typical of FIP, along with other supportive evidence (clinical signs and clinicopathological data) provides strong evidence for a presumptive diagnosis. The finding of this type of effusion in more than one body cavity (e.g. thorax and abdomen) provides even more compelling evidence.

Polymerase chain reaction

Advances in molecular biology have led to the development of sensitive techniques to detect the nucleic acid sequences of specific microorganisms in clinical material. PCR assays have been applied to the detection of FCoV sequences in infected cats, and these are now offered as a commercial diagnostic assay by several laboratories. Initially, it was hoped that these assays would prove of great value in the diagnosis of FIP. If enteritis-producing strains of FCoV were confined to the intestinal tract, demonstration of the virus at extraintestinal sites (e.g. in a blood sample) would be indicative of infection with a FIP-producing strain and thus (with appropriate clinical signs) be highly supportive of a diagnosis. However, rather than provide a simple diagnostic test for FIP, the advent of RT-PCR has enabled a better understanding of the complexity of infection with FCoV in the cat.

Studies have shown that in cases of confirmed FIP, the RT-PCR test to detect genomic FCoV material from blood samples is typically positive in 80–90% of cases. However, when the same test is applied to healthy cats from FCoV-endemic catteries, studies have shown many of these are also RT-PCR positive; generally in the order of 30–80% (Herrewegh *et al.*, 1995; Gunn-Moore *et al.*, 1998). Indeed, some healthy cats test positive by RT-PCR but are seronegative (Herrewegh *et al.*, 1997; Gunn-Moore *et al.*, 1998).

Thus, the RT-PCR assays currently available cannot distinguish between virulent FIP-producing strains of FCoV and the less virulent enteritis-producing strains, and the high rate of positive results from blood samples of healthy cats suggests that this test has little, if any, value in the routine diagnosis of FIP and at best has no more value than serology.

Cerebrospinal fluid analysis

In cats with CNS manifestations relating to FIP, analysis of CSF can give valuable additional information, both to support the diagnosis of FIP and to rule out other potential causes of the clinical signs. With FIP, CSF samples typically have marked elevations in both total white cell counts (with a predominance of neutrophils) and total protein levels.

Towards a definitive diagnosis

The results of the investigations already outlined may, in many cases, give sufficient grounds for a presumptive diagnosis of FIP to be made. However, in many situations a definitive diagnosis is desirable before a decision on whether euthanasia should be performed, and where the presence of disease has implications for other in-contact animals. Definitive diagnosis of FIP is possible, and several tests are potentially helpful.

Additional tests on effusions: RT-PCR and immunofluorescence

Studies have shown that whilst RT-PCR analysis of blood is of little value as a diagnostic tool, analysis of effusions is potentially very useful. Although not providing 100% sensitivity or 100% specificity, the results of RT-PCR on effusions appears to be a useful diagnostic tool. Gamble *et al.* (1997) reported that 11 of 12 cats with effusive FIP tested RT-PCR positive on fluid analysis, whereas 10 of 11 cats with effusions due to causes other than FIP tested negative on fluid analysis. RT-PCR analysis of effusions thus provides strong additional evidence to support or rule out a diagnosis of FIP, although occasional false-positive or false-negative results can occur. Similarly, other authors have reported on the use of direct immunofluorescence

staining of cytological preparations of effusions to detect FCoV antigens (Paltrinieri *et al*., 1999). As with RT-PCR, this technique appears reasonably reliable for the confirmation of effusive FIP and could be used to support a diagnosis of FIP.

However, in the majority of cases of effusive FIP, the diagnosis is relatively straightforward and the list of differential diagnoses well defined. Thus, although RT-PCR and immunofluorescence may be useful in some cases, in many the presence of the characteristic effusion coupled with other clinical signs and clinicopathological changes may be adequate to make a presumptive diagnosis. Of more concern are the cases of non-effusive disease, where clinical signs and routine laboratory tests may be compatible with a diagnosis of FIP, but many other differential diagnoses remain real possibilities. Here, histopathology and immunostaining are the only ways to confirm a diagnosis. These tests can also be applied to effusive cases.

Histopathology and immunohistopathology

The only way of making a definitive diagnosis of FIP is by histopathological examination of affected tissues either collected at post-mortem examination or collected ante-mortem from appropriate sites. Where significant doubts occur over the diagnosis of effusive FIP (e.g. where lymphocytic cholangitis or neoplasia remains a possibility), exploratory laparotomy may be indicated with collection of grossly affected tissue for histological analysis. Similarly, in suspected non-effusive disease, evidence can be sought for the involvement of disease at sites where biopsy collection of material would be possible, by surgery or by percutaneous needle biopsy using ultrasound guidance if necessary. Ultrasound examination of the abdomen can be particularly useful in this instance, for detecting granulomas in the liver, kidneys or spleen, or for detection of mesenteric lymphadenomegaly.

Histological examination of tissues affected by FIP yields characteristic signs of granulomatous and/or pyogranulomatous inflammation. Although the histological nature of the lesions is not pathognomonic for FIP (other infectious agents may also cause similar lesions), together with the clinical, clinicopathological and historical information, this is usually taken as evidence of a definitive diagnosis. For absolute confirmation (which may be required in some cases), it is possible to detect the presence of FCoV within the lesions by immunohistochemical means, thus demonstrating the presence of FCoV antigen within the typical histological lesions.

Treatment

Once clinical signs of FIP develop, it is generally an incurable and fatal disease. Although exceptional cases of spontaneous recovery do occur, these are extremely rare and the disease is usually both progressive and fatal. This does not mean that infection with virulent FCoV invariably results in death, as the majority of cats probably resist the development of disease or at least overt clinical disease, and do recover from infection (Pedersen, 1995).

Treatment of cats affected with FIP is generally supportive and symptomatic as specific antiviral therapy is currently not feasible. Fluid therapy, nutritional support and symptomatic treatment with corticosteroids are probably the most common therapeutic interventions used, and this may produce temporary alleviation of clinical signs. However, concerns exist in multicat households as a cat with clinical disease has the potential to be shedding virulent strains of FCoV, thus posing a potential risk to other in-contact cats. In severely affected cats, euthanasia is usually the most humane course of action to avoid suffering.

Attempts have been made to treat FIP-diseased cats with a combination of immunomodulating and antiviral drugs in the hope of inhibiting viral replication while stimulating a cell-mediated immune response (Weiss, 1995). Such an approach is attractive, but has not actually proved to be beneficial so far. The antiviral agent ribavarin and recombinant human α-interferon have both been demonstrated to have antiviral activity against FIPV *in vitro* and indeed their activities appear synergistic. However, experience with these agents *in vivo* has resulted in severe toxicity (bone-marrow suppression, gastrointestinal signs) associated with the use of ribavarin in cats, even at low doses (Weiss, 1995), precluding its clinical use.

Immunomodulating therapy has been attempted with a variety of agents. Under experimental conditions, the use of high doses of recombinant human α-interferon (10^6 U/kg daily then every other day for 2–3 weeks) prolongs the survival in cats infected with FIPV at the time of drug administration, suggesting an antiviral or immunomodulating effect (Weiss, 1995). However, as this effect was seen by administration of the drug at the time of viral challenge, this is not relevant to the treatment of naturally occurring disease. Similarly, studies with the immunomodulators

Propionibacterium acnes and thioproline have not suggested any sustained benefit in cases of FIP (Weiss, 1995). Glucocorticoids and cyclophosphamide have also been used for immunosuppression in clinical cases of FIP, and while temporary improvement in clinical signs has been reported to occur in some cases, again, no sustained benefit is seen (Pedersen, 1995).

It may therefore be possible to prolong the life of an FIP-diseased cat and/or to increase the quality of life for a period of time by the use of some of these agents. Their use may therefore be justifiable in selected circumstances (e.g. glucocorticoids alone or in combination with α-interferon and/or cyclophosphamide), but at best, only temporary amelioration of the clinical condition should be expected. Further progress in this area will rely on a more complete understanding of the immunopathogenesis of FIP, the development of more reliable diagnostic tests for the early diagnosis of the disease and the development of less toxic antiviral agents.

Prevention and control

Management strategies to prevent cats developing FIP are hampered in many respects. The strains of virus causing FIP are uncommon mutants of a ubiquitous virus present in virtually all cat populations. Infection with pathogenic strains of the virus and differentiation from non-pathogenic strains are impossible in the clinical situation, and making a definitive diagnosis of the disease is problematic. Nevertheless, management strategies have been developed to help to prevent the likelihood of FIP developing, or of spread of FCoV infection to cats, and these combined with vaccination in certain circumstances may help in the prevention of the disease.

Vaccination

Vaccination against FIP has been attempted by various methods, including administration of sublethal doses of virulent FIPV, avirulent viruses, inactivated preparations, antigenically related coronaviruses from other species and genetically engineered vaccinia recombinants expressing the structural genes of FIPV. The results of these experiments were diverse, protection often being unpredictable, and in some studies ADE was seen after challenge.

A commercial FIP vaccine has been developed based on the intranasal administration of a temperature-sensitive mutant FIPV isolate, derived from strain DF2 (serotype II). This vaccine is now widely available in many parts of the world. The vaccine virus, being temperature sensitive, only replicates in the tissues of the upper respiratory tract. It is reported to induce both a local mucosal IgA response and a systemic cell-mediated immune response (Gerber, 1995).

This vaccine has been the subject of a number of different field trials and laboratory-based efficacy studies, conducted both by the manufacturer and by independent scientists. As is often the case, these studies have yielded some conflicting results, making it difficult to assess the true efficacy of the vaccine. Although some experimental studies have documented ADE in vaccinated cats subsequently challenged with FIPV (McArdle *et al.*, 1995; Scott *et al.*, 1995), this was observed following single challenge with relatively high doses of virus, thus not mimicking the natural situation. Indeed, most studies, including some field studies together with extensive use of the vaccine in the field, have failed to identify ADE following the use of this vaccine, and this is not considered to be a problem in clinical use.

Although some experimental studies have failed to demonstrate vaccine efficacy, several have shown a reasonable degree of protection induced by vaccination. Under field conditions, there is evidence of efficacy when administered to seronegative cats or cats with low FCoV antibody titres (Fehr *et al.*, 1995, 1997; Reeves, 1995), but not when used in catteries where FIP is endemic (Fehr *et al.*, 1995). Even when efficacy has been demonstrated, it is clear that this is considerably less than 100% protection.

In addition to these limitations, the vaccine is currently only licensed for use in kittens over 16 weeks of age, and in endemic situations most kittens of this age will already be infected with FCoV. Nevertheless, there are situations in which the vaccine may be of value: if kittens have been reared under conditions to prevent exposure to FCoV, they could be vaccinated before introduction to a high-risk environment, and similarly if other seronegative (or low-titre) cats are being introduced to a high-risk environment (e.g. where FIP is endemic) these too may benefit from vaccination. However, as FIP is not a common disease (estimated to affect no more than 1 in 5000 pet cats), and the vaccine is considerably less than 100% efficacious, routine vaccination of cats cannot be recommended.

Management strategies

Husbandry practices can be altered to minimise the risk of cats developing FIP, particularly in colony situations,

but these are to a large extent aimed at preventing or reducing the prevalence of the underlying infection with enteritis-producing strains of FCoV. The general approach to disease management given below is based on that described by Gaskell and Dawson (2000).

Household pets

In general, FIP is uncommon to rare in household pets, except where a new kitten has been obtained from a colony where FCoV infection is endemic, and sometimes the stress of weaning, rehoming, vaccination, and so on will precipitate the development of FIP. Ideally, to minimise the risk of this occurrence, household pets should be obtained from a source where there are relatively few cats and where there is no history of the disease. If there is a particular concern, it may be possible to obtain kittens known to be seronegative to FCoV.

If household pets are kept singly or in small, stable groups, the risk of developing FIP is very low. As transmission of the virus is by the faecal–oral route, this risk is even lower in cats confined indoors. Although studies suggest that 25–40% of pet cats are FCoV seropositive, it is likely that many of these seropositive cats have been exposed to relatively low levels of the virus (so that an effective immune response is more likely to limit viral replication). In addition, many of these cats may have been exposed to the virus later in life than cats from FCoV-endemic catteries (where infection usually occurs in the first few weeks of life), again giving the opportunity for a better protective immune response to develop.

Other than choosing the source of new kittens with some care, and avoiding having large numbers of cats sharing one living space, specific measures to reduce the risk of FIP in household pet cats are difficult to recommend and probably not warranted.

Catteries with endemic feline infectious peritonitis

In catteries with a history of FIP, two management approaches have been advocated: either eradication of infection or taking measures to try to reduce the incidence of disease.

Eradication of infection is laborious and time consuming, and requires a considerable commitment on the part of the owner. Furthermore, given the ubiquitous nature of FCoV infections, maintaining a virus-free colony can be extremely challenging. This system is thus unsuitable for use in most household or breeding cattery situations. Segregation of cats into small groups (or even better individually) based on either the magnitude of their FCoV titre (which may correlate somewhat with FCoV faecal shedding) or results of RT-PCR testing of faeces to identify cats shedding virus, can be valuable. Repeat testing of the cats in each group every month can result, over time, in the identification of small numbers of cats that may be persistently shedding virus or have persistently elevated FCoV antibody titres (and therefore would need eliminating from the colony), while the majority of cats will have waning antibody titres over time and will stop shedding FCoV in faeces. Such an eradication programme would be extremely expensive and laborious to undertake, however, and RT-PCR testing of faeces would be a more reliable way of detecting shedders than serology (Hickman *et al.*, 1995; Pedersen, 1995; Foley *et al.*, 1997b).

A more practical approach is to consider elimination of FCoV infection in kittens born in an FCoV-endemic environment, thus providing the opportunity of selling or rehoming kittens free of FCoV infection. This approach has been shown to work well in studies by Addie and Jarrett (1992, 1995). These studies have shown that if pregnant queens are isolated when they are 1–2 weeks prepartum, and if the queen is subsequently kept isolated with her kittens (while employing good hygiene procedures to prevent fomite or environmental spread of infection to the kittens), a substantial proportion of these kittens will remain FCoV antibody negative once any MDA has waned. Following weaning, the queen is removed and the kittens are kept isolated and tested at 12–16 weeks of age for FCoV antibodies, and if the litter is negative, the isolation procedure will have been successful and they can be rehomed as FCoV-negative kittens. This procedure sometimes fails if the queen herself is shedding FCoV and thus passes it on to the kittens. This is less likely if an older (greater than 2 years of age) queen is used, but can further be prevented by early weaning of the kittens (at 5–6 weeks of age when maternally derived immunity is still protective) and removing the queen from the environment. Good hygiene is also an important part of the control of spread of FCoV to the kittens in these situations. Although these procedures have been proven to be successful, they too require considerable commitment from breeders, and there are some concerns about the behavioural development of kittens when they are reared in isolation up to the age of 4 months.

As eradication of FCoV infection, or even just eradication of infection in the kittens is difficult, often it may be more appropriate to accept that there is endemic FCoV infection, and to institute measures to try to minimise both the prevalence of this infection and its impact. Practical control measures have been recommended (Pedersen *et al.*, 1995), bearing in mind that the faecal–oral route is the major way in which the virus is spread:

- At least one litterbox should be provided for every two cats, located in areas that are easy to clean and disinfect.
- Litterboxes should be kept away from food and water bowls to prevent cross-contamination.
- Faeces should be removed from litterboxes at least once daily, and litter should be completely changed as often as possible (at least weekly), accompanied by disinfection of the trays.
- Cats should be kept in small stable groups of four or less, minimising cross-contamination within a household.
- Ordinary households should have a maximum of eight to 10 cats for a breeding programme. Larger numbers require some purpose-built facilities to enable proper hygiene and care to be maintained.
- Regular brushing of the coat, particularly of long-haired cats, is desirable to reduce contamination with faeces and litter.
- Isolation of queens and their kittens can be recommended as a means of controlling the spread of FCoV to the kittens.

Minimising other recognised risk factors for development of FIP is also indicated (see Epidemiology, above).

New entrants to a colony of cats pose a potential risk, as they may be FCoV shedders. Short-term quarantine is probably not helpful as virus shedding may persist for many weeks to months. Introducing such a cat to a small, stable group of mature cats (see above) is likely to carry the lowest risk. If an individual cat is to enter a high-risk household, it would be sensible to perform FCoV serology first, and if the cat has a low or negative titre to undertake vaccination before its introduction.

Cat shows and stud cats are also possible sources of infection, although hygiene at cat shows is probably sufficient to minimise this. Similarly, the risk can be reduced for stud cats and visiting queens by limiting the time spent together and not allowing them to share food, water and littertrays; however, this may not always be practical.

Catteries with no history of feline infectious peritonitis

In most cases, the FCoV status of cats in a cattery will be unknown. Serotesting of cats, in the absence of disease, is not generally encouraged and, even in the absence of cases of FIP, most cattery situations will still have endemic FCoV infection and thus most cats would test seropositive. Nevertheless, there are some exceptions to this and some catteries may contain cats known to be seronegative. In such situations efforts should be made to maintain the colony free of infection (through hygiene precautions and testing cats before admitting them to the colony), while recognising that long-term maintenance of a FCoV-negative status is extremely difficult (Addie & Jarrett, 1995).

Rescue catteries

Control of FIP in rescue catteries should follow similar lines to the control in catteries where FIP is endemic. Adequate hygiene and avoiding overcrowding are essential strategies for minimising the risk of FIP in such situations. Cats should be housed individually or, if this is not possible, batched on arrival and kept in small, stable groups. Vaccination before or on arrival is a consideration, although ideally this should be done only after serotesting as the vaccine appears to be of little value in cats with moderate to high titres.

References

Addie D.D. & Jarrett O. (1992) A study of naturally occurring feline coronavirus infections in kittens. *Vet Rec* **130**, 133–137.

Addie D.D. & Jarrett O. (1995) Control of feline coronavirus infections in breeding catteries by serotesting, isolation and early weaning. *Feline Pract* **23**, 92–95.

Addie D.D. & Jarrett O. (2001) Use of reverse-transcriptase polymerase chain reaction for monitoring shedding of feline coronavirus by healthy cats. *Vet Rec* **148**, 649–653.

Addie D.D., Toth S., Murray G. & Jarrett O. (1995) The risk of typical and antibody-enhanced feline infectious peritonitis among cats from feline coronavirus endemic households. *Feline Pract* **23**, 24–26.

Fehr D., Holzngel E., Bolla S., *et al.* (1995) Evaluation of the safety and efficacy of a modified live FIPV vaccine under field conditions. *Feline Pract* **23**, 83–88.

Fehr D., Holzngel E., Bolla S., *et al.* (1997) Placebo-controlled evaluation of a modified life virus vaccine against feline infectious peritonitis: safety and efficacy under field conditions. *Vaccine* **15**, 1101–1109.

Foley J.E. & Pedersen N.C. (1996) The inheritance of susceptibility to feline infectious peritonitis in purebred catteries. *Feline Pract* **24**, 14–22.

Foley J.E., Poland A., Carlson J. & Pedersen N.C. (1997a) Patterns of feline coronavirus infection and fecal shedding from cats in multiple-cat environments. *J Am Vet Med Assoc* **210**, 1307–1312.

Foley J.E., Poland A., Carlson J. & Pedersen N.C. (1997b) Risk factors for feline infectious peritonitis among cats in multiple-cat environments with endemic feline enteric coronavirus. *J Am Vet Med Assoc* **210**, 1313–1318.

Gamble D.A., Lobbiani A., Gramegna M., *et al.* (1997) Development of a nested PCR assay for detection of feline infectious peritonitis virus in clinical specimens. *J Clin Microbiol* **35**, 673–675.

Gaskell R. & Dawson S. (2000) FIP-related disease. In *Textbook of Veterinary Internal Medicine*. 5th edn (eds Ettinger S.J. & Feldman E.C.). WB Saunders, Philadelphia, PA, pp. 438–444.

Gerber J.D. (1995) Overview of the development of a modified live temperature-sensitive FIP virus vaccine. *Feline Pract* **23**, 62–66.

Gunn-Moore D.A., Gruffydd-Jones T.J. & Harbour D.A. (1998) Detection of feline coronaviruses by culture and reverse transcriptase–polymerase chain reaction of blood samples from healthy cats and cats with clinical feline infectious peritonitis. *Vet Microbiol* **62**, 193–205.

Harpold L.M., Legendre A.M., Kennedy M.A., *et al.* (1999) Fecal shedding of feline coronavirus in adult cats and kittens in an Abyssinian cattery. *J Am Vet Med Assoc* **215**, 948–951.

Harvey C.J., Lopez J.W. & Hendrick M.J. (1996) An uncommon intestinal manifestation of feline infectious peritonitis: 26 cases (1986–1993). *J Am Vet Med Assoc* **209**, 1117–1120.

Herrewegh A.A.P.M., Egberink H.F., Horzinek M.C., *et al.* (1995) Polymerase chain reaction (PCR) for the diagnosis of naturally occurring feline coronavirus infections. *Feline Pract* **23**, 56–60.

Herrewegh A.A., Mahler M., Hedrich H.J., *et al.* (1997) Persistence and evolution of feline coronavirus in a closed cat-breeding colony. *Virology* **234**, 349–363.

Hickman M.A., Morris J.G. & Rogers Q.R. (1995) Elimination of feline coronavirus infection from a large experimental specific pathogen-free cat breeding colony by serologic testing and isolation. *Feline Pract* **23**, 96–102.

Horzinek M.C. & Osterhaus A.D. (1979) Feline infectious peritonitis: a worldwide serosurvey. *Am J Vet Res* **40**, 1487–1492.

Kass P. & Dent T. (1995) The epidemiology of FIP in catteries. *Feline Pract* **23**, 27–32.

Loeffler D.G., Ott R.L., Evermann J.F. & Alexander J.E. (1978) The incidence of naturally occurring antibodies against feline infectious peritonitis in selected cat populations. *Feline Pract* **81**, 43–47.

McArdle F., Tennant B., Bennett M., *et al.* (1995) Independent evaluation of a modified live FIPV vaccine under experimental conditions (Universtiy of Liverpool experience). *Feline Pract* **23**, 67–71.

Paltrinieri S., Cammarata M.P., Cammarata G. & Comazzi S. (1998) Some aspects of humoral and cellular immunity in naturally occuring feline infectious peritonitis. *Vet Immunol Immunopathol* **65**, 205–220.

Paltrinieri S., Parodi M.C. & Cammarata G. (1999) *In vivo* diagnosis of feline infectious peritonitis by comparison of protein content, cytology, and direct immunofluorescence test on peritoneal and pleural effusions. *J Vet Diagn Invest* **11**, 358–361.

Pedersen N.C. (1983a) Feline infectious peritonitis and feline enteric coronavirus infections. Part 1: Feline enteric coronavirus. *Feline Pract* **13** (4), 13–19.

Pedersen N.C. (1983b) Feline infectious peritonitis and feline enteric coronavirus infections. Part 2: Feline infectious peritonitis. *Feline Pract* **13** (5), 5–20.

Pedersen N.C. (1995) An overview of feline enteric coronavirus and feline infectious peritonitis infections. *Feline Pract* **23**, 7–20.

Pedersen N.C. (1987) Virologic and immunologic aspects of feline infectious peritonitis virus infection. *Adv Exp Med Biol* **218**, 529–550.

Pedersen N.C., Boyle J.F., Floyd K., *et al.* (1981) An enteric coronavirus infection of cats and its relationship to feline infectious peritonitis. *Am J Vet Res* **42**, 368–377.

Pedersen N.C., Addie D. & Wolf A. (1995) Recommendations from working groups of the International Feline Enteric Coronavirus and Feline Infectious Peritonitis workshop. *Feline Pract* **23**, 108–111.

Reeves N.P. (1995) Vaccination against naturally occurring FIP in a single large cat shelter. *Feline Pract* **23**, 81–82.

Richards J.R. (1995) Problems in the interpretation of feline coronavirus serology (specificity vs. sensitivity of test procedures). *Feline Pract* **23**, 52–55.

Scott F.W., Corapi W.V. & Olsen C.W. (1995) Independent evaluation of a modified live FIPV vaccine under experimental conditions (Cornell experience). *Feline Pract* **23**, 74–76.

Shelley S.M., Scarlett-Kranz J. & Blue J.T. (1988) Protein electrophoresis on effusions from cats as a diagnostic test for feline infectious peritonitis. *J Am Anim Hosp Assoc* **24**, 495–500.

Sparkes A.H., Gruffydd-Jones T.J. & Harbour D.A. (1991) Feline infectious peritonitis: a review of clinicopathological changes in 65 cases, and a critical assessment of their diagnostic value. *Vet Rec* **129**, 209–212.

Sparkes A.H., Gruffydd-Jones T.J., Howard P.E. & Harbour D.A. (1992) Coronavirus serology in healthy pedigree cats. *Vet Rec* **131**, 35–36.

Sparkes A.H., Gruffydd-Jones T.J. & Harbour D.A. (1994) An appraisal of the value of laboratory tests in the diagnosis of feline infectious peritonitis. *J Am Anim Hosp Assoc* **30**, 345–350.

Stoddart C.A. & Scott F.W. (1989) Intrinsic resistance of feline peritoneal macrophages to coronavirus infection correlates with *in vivo* virulence. *J Virol* **63**, 436–440.

Vennema H., Poland A., Hawkins K.F. & Pedersen N.C. (1995) A comparison between the genomes of FECVs and FIPVs and what they tell us about the relationships between feline coronaviruses and their evolution. *Feline Pract* **23**, 40–44.

Vennema H., Poland A., Foley J. & Pedersen N.C. (1998) Feline infectious peritonitis viruses arise by mutation from endemic feline enteric coronaviruses. *Virology* **243**, 150–157.

Weiss R.C. (1995) Treatment of feline infectious peritonitis with immunomodulating agents and anti-viral drugs: a review. *Feline Pract* **23**, 103–106.

Chapter 26

RABIES VIRUS INFECTION

P.P. Pastoret, B. Brochier and R.M. Gaskell

Introduction and history

Terrestrial rabies is a neurotropic disease of virtually all mammals. It exists worldwide, except in places such as Australia and New Zealand, and terrestrial rabies has been eradicated from the British isles by quarantine and other measures.

The disease has been recognised since antiquity. The Latin word *rabies* comes from an old Sanskrit word *Rabhas*, which means 'to do violence' (Steele, 1975). In Britain, the earliest mention of the disease was in 1026, but is was not until the late eighteenth and nineteenth centuries that it became frequent. Dogs were recognised as the major source of infection (urban rabies) and the first attempt to deal with it on a national basis was made in 1831 when a Bill was drafted to 'prevent the spreading of canine madness' (Waterhouse, 1971). The Bill did not become law, but local authorities were later given the power to require muzzling, to restrict the movement of dogs and to destroy strays. These methods were only partly successful when left to local authorities, but when the Board of Agriculture assumed overall responsibility and introduced quarantine, among other measures, there was a marked decline in the number of rabies cases each year. The disease appeared to have been eradicated in 1903, was reintroduced in 1918, but was finally eliminated by 1922.

The absence of records of terrestrial rabies in wildlife in Britain, and the success of the straightforward measures by which the disease was eventually eliminated through the control of dogs, suggest that it was never established in the United Kingdom in a permanent and widespread form. Between 1886 and 1903 in the whole of Great Britain, 3056 animals are known to have died of rabies, but of these, the only wild animals affected were a herd of deer, and it is presumed that this outbreak originated from attacks by a stray, rabid dog (Waterhouse, 1971).

Since the final eradication of terrestrial rabies from Great Britain in 1922, although several cases have occurred in animals while in quarantine, only two cases have occurred in dogs that had passed through the specified 6 month quarantine period (Morgan-Jones, 1969; Peace & Hopes, 1970). Fortunately, in both cases, the disease was contained, but as a result of this, quarantine procedures were changed and animals entering quarantine were later required to be vaccinated; only two deaths from rabies have since occurred in quarantine (King *et al.*, 1985; Department of Health Memorandum, 2000). However, more recently, rabies control measures in the UK have changed again with the introduction of the Pet Travel Scheme (PETS). This scheme allows pet dogs and cats from certain countries to enter the UK without quarantine as long as they meet certain conditions (see below).

The causative agent

Rabies virus is a bullet-shaped virus, a member of the Rhabdoviridae. The Rhabdoviridae are enveloped RNA viruses characterised by their shape (Greek *rhabdos*, rod) and by the presence of helical ribonucleocapsids enclosed in a lipid envelope bearing surface projections. The genome is a single molecule of negative sense single-stranded RNA which is non-infectious and is transcribed into five mRNAs, each of which codes for a single protein. The gene order is 3′-N-NS-M-G-L-5′, representing the nucleocapsid protein (N), the non-structural protein (NS), the matrix protein (M), the envelope glycoprotein (G) and a large protein (L), the RNA-dependent RNA polymerase (Tordo *et al.*, 1988; Wunner *et al.*, 1988; Pastoret & Brochier, 1992).

Rabies virus belongs to the genus *Lyssavirus*, named after rabies in Greek (Greek *Lyssa*, madness). For many years rabies virus was thought to be unique. It is now clear that antigenic variation exists within the rabies virus (Schneider, 1982) and the existence of several distinct rabies-related viruses is now recognised (King *et al.*, 1990; Pastoret & Brochier, 1992; Bourhy *et al.*, 1993). These viruses can be distinguished from rabies virus using conventional sera or monoclonal antibodies and sequence-based phylogeny. The exact significance of rabies-related viruses in the epidemiology of classical rabies is not well understood, but some rabies-related viruses may infect cats (Foggin, 1982; King & Crick, 1988). Of special interest are lyssaviruses isolated from insectivorous bats which can be occasionally transmitted to terrestrial mammals (Office International des Epizooties, 1998; McColl *et al.*, 2000).

The biological behaviour of conventional isolates of rabies virus also varies in that there are differences in pathogenicity between strains, depending on their species of origin or on their passage history in the laboratory; the dose and route of exposure also influence the outcome of infection (Charlton, 1988). There is also an intrinsic difference in species susceptibility to rabies virus infection in that the amount of infectious virus needed to induce the disease experimentally differs markedly between species (Sikes, 1962; Parker & Wilsnack, 1966; Smith & Baer, 1988). The level of virus excretion and the percentage of virus excretors within an infected group also vary according to the species and the infecting virus strain (Blancou & Barrat, 1988). In some species a paradox has been observed when a high dose of virus has been used for infecting animals; such animals seem to be more resistant to challenge than animals given a lower infecting dose (Blancou *et al.*, 1983).

Rabies virus is sensitive to lipid solvents and emulsifying agents and thus is quickly inactivated by a number of disinfectants, including formalin, soap and quaternary ammonium compounds (Waterhouse, 1971; Dean, 1975). The virus is easily inactivated by heat and sunlight, but stable at low temperatures. Under normal environmental conditions, therefore, it does not remain infective for long outside the host in contaminated secretions.

Pathogenesis and pathology

Rabies virus is excreted in the saliva of infected animals and is mainly transmitted by biting, or less frequently, by contamination of mucosa or a superficial wound (Afshar, 1979). In the USA, airborne transmission has also been recorded in humans, coyotes and foxes following exposure to caves heavily populated by infected bats (Constantine, 1962; Winkler, 1975). However, several dogs and cats exposed in the same way did not become infected. Experimentally, rabies has been transmitted by the oral route to various laboratory animals, foxes, skunks and cats, and infection of dogs from eating rabid fox carcases has been reported from the Arctic (Soave, 1966; Bell & Moore, 1971; Charlton, 1988). An important sequela to the demonstration of oral infection is the development of oral rabies vaccines for wildlife.

On gaining entry to the body, the virus multiplies locally within myocytes at the site of exposure before moving up the axon of the associated nerve to the central nervous system (CNS) to produce an encephalitis; there is also evidence that in some cases virus may enter peripheral nerves directly, without preliminary replication in non-nervous tissue (Murphy *et al.*, 1973a, b; Baer, 1975a; Charlton, 1988). During the spread of virus through the CNS, virus moves centrifugally into the peripheral nerves, viral antigens appearing in nerve endings in salivary glands, skin, mucosal surfaces, gut and most other organs. Thus saliva may be infective for a few days before clinical signs appear.

As in other species, infection of the salivary glands is important in the spread of the disease: at least 70% of rabid cats have virus in their saliva and are able to transmit infection (Vaughn *et al.*, 1963; Chantal & Blancou, 1985; Blancou & Pastoret, 1990), and this may vary according to the virus strain.

Gross pathological findings are minimal in rabies. The carcass may be emaciated and there may be evidence of self-trauma. Although in dogs there may be foreign bodies in the alimentary tract as a result of pica, this is less common in cats. Histologically, there is diffuse encephalitis with mononuclear cell perivascular cuffing and focal gliosis, constituting an inflammatory response typical of any non-suppurative infection of the brain (Jubb *et al.*, 1985). Spongiform lesions in the brains of rabid animals have also been reported (Charlton, 1988).

There may also be a ganglioneuritis in the paravertebral ganglia and degenerative changes in the salivary gland. Neuronal degeneration in rabies is usually relatively severe compared with some other viral infections of the CNS, and in carnivores in particular it is often quite extensive. In addition, the neurons may contain characteristic intracytoplasmic inclusions containing viral antigen, called Negri bodies. These can

occur in several areas of the brain, but are usually most prominent in the hippocampus; they are pathognomonic for rabies in most species (Atanasiu, 1975). In cats, however, some confusion may arise, in that even in normal cats inclusions that resemble Negri bodies may be found in the cytoplasm of some nerve cells (Szlachta & Habel, 1953).

Although Negri bodies are found in the majority of cases of rabies (McQueen, 1960; Tustin & Smit, 1962) and have in the past been used extensively in diagnosis, their absence does not exclude the disease. In addition, when identification of Negri bodies was used as the predominant method of rabies diagnosis, it was usually considered necessary to keep the animal alive until it died naturally, to increase the sensitivity of the test (Tierkel, 1959). The technique has therefore now been superseded in most countries by more reliable techniques in terms of specificity, sensitivity and speed of diagnosis (see below).

As already mentioned, the susceptibility of animals to rabies virus varies a great deal, depending on the animal species, the virus dose and the virus strain (biotype). For example, foxes are highly susceptible to their own virus, but humans seem to be fairly resistant to this biotype. In general, cats are probably of intermediate susceptibility (Jaeger & Barth, 1979; Soulebot *et al.*, 1981). Cats appear to be more susceptible than dogs to attenuated strains of vaccines (Dean & Guevin, 1963; Vaughn, 1975; Pastoret *et al.*, 1985). Other factors significant in determining an individual's susceptibility to the disease include the age of the animal, and the nature and site of the wound. Thus, a young cat suffering a deep wound in the head region, heavily contaminated with saliva, is more likely to develop the disease, with a shorter incubation period, than an older animal with a superficial wound on the extremities. In mice, resistance to rabies virus infection has been shown to be under genetic control (Lodmell, 1988).

Experimentally in cats the incubation period has been shown to range from 9 to 51 days (median 18 days), while the periods of clinical illness until death ranged from 1 to 8 days (median 5 days) (Vaughn *et al.*, 1963). Virus was first detected in the saliva of these cats, by conventional virological techniques, 1 day before the appearance of clinical signs, and virus shedding usually then continued until the cat died. Under natural conditions, the incubation period is generally similar, although in occasional cases it may be much longer, probably up to 6 months or more. In dogs, for example, cases have occasionally been recorded beyond this time (Waterhouse, 1971).

Clinical signs

The clinical course of rabies is classically described as three, often overlapping, phases: the prodromal period, the excitative phase ('furious' rabies; Figure 26.1) and the paralytic stage ('dumb' rabies; Figure 26.2). In cats, the prodromal phase usually lasts for only 1 day and is manifested by a marked change in behaviour (Vaughn, 1975). Sullen cats may become more alert, restless and friendly, whereas amicable cats may scratch or bite without provocation, or become depressed and withdrawn, hiding in dark places. Aggression is more commonly observed in the cat than in the dog (Tierkel, 1959). During this initial period, there may be slight pyrexia and some dilatation of the pupils, with an impaired corneal reflex.

Gradually, the excitement phase predominates, and it is in this form that rabies is most easily recognised and the animals are at their most hazardous to others. The cat becomes increasingly nervous, irritable and vicious, and may show muscle tremors, flaccidity or

Figure 26.1 'Furious' rabies.



Figure 26.2 'Dumb' rabies.

incoordination. As in humans, there is difficulty in swallowing owing to spasm, and eventual paralysis of the muscles of deglutition. This in turn leads to the accumulation of saliva, and drooling or frothing. As the cat enters the paralytic stage, muscular incoordination and convulsions gradually lead to generalised paralysis, coma and death. The excitement phase may last for up to 7 days, but sometimes it is virtually nonexistent and cats progress directly from the prodromal phase to the paralytic stage.

Although in classical rabies there is undelayed progression of the characteristic clinical signs through to death, in some cases infection may lead to a more variable outcome. Thus, in dogs in Ethiopia a carrier state has been reported, which may or may not be associated with a period of clinical signs (Andral & Serie, 1965; Fekadu, 1975; Carey & McLean, 1983; Charlton, 1988). Chronic recrudescent rabies has also been observed experimentally in a cat (Perl *et al.*, 1977). Recovery from CNS infection in both animals and humans has also been reported, albeit rarely (Bell, 1975; Fedaku *et al.*, 1981; Charlton, 1988). A serological survey in South America showed that 1% of the cats included in the study had antirabies neutralising antibodies (Diaz *et al.*, 1975). However, this may have been only as a result of the peripheral infection and its significance is not clear.

Since most animals die from rabies and no serological response can be detected before the onset of clinical signs, most information on protective immune mechanisms in rabies has been obtained from vaccination studies. There is a good correlation between antibody titres obtained after vaccination and protection (Blancou *et al.*, 1986a), and protection against rabies can be obtained through passive transfer of specific antibodies. However, vaccinated animals without detectable neutralising antibodies can still resist challenge, and undoubtedly other immunological mechanisms, particularly cell-mediated immunity, are involved in protection.

Diagnosis and action in suspect cases

In Britain, where rabies is not endemic, most veterinary surgeons are inexperienced in dealing with the disease. Nevertheless, because of the public health risk and the great danger that the disease may become established in the terrestrial wildlife of the country, a diagnosis of rabies should always be considered when certain clinical signs are present. The furious form of rabies, where the cat shows unprovoked aggression, is probably most easily recognisable, but should be distinguished from pseudorabies (Aujeszky's disease; see Chapter 30). However, it is when an incoordinated, paralytic or moribund animal is presented that there may be most difficulty. The differential diagnosis includes toxoplasmosis, CNS infection, neoplasia or trauma, thiamin deficiency, oral and pharyngeal foreign bodies, and poisoning with substances such as lead, organochlorine compounds, benzoic acid and strychnine. The syndrome of spongiform encephalopathy should also be considered (Wyatt *et al.*, 1990, 1991). The severe weakness seen in animals moribund from infectious diseases such as panleucopenia and feline leukaemia virus infection may also on occasion simulate paralytic or terminal rabies.

A detailed account of the action to be taken in Britain in a case of suspected rabies has been given by members of the State Veterinary Service (Anon, 1987; Department of Health Memorandum, 2000). In brief, a suspect case should be detained in isolation on the premises on which it has been examined and the Divisional Veterinary Manager (DVM) of the Department for Environment, Food and Rural Affairs (DEFRA) must be notified immediately. The veterinary surgeon and any other handler should carry out a thorough personal disinfection in soap or detergent and water and any contaminated clothing should be changed. If anyone is bitten or scratched, it is imperative to wash and flush the wound immediately with soap or detergent (not both, as soap inhibits quaternary ammonium

compounds) and water, then water alone, followed by the application of 40–70% alcohol, tincture or aqueous solutions of iodine, or 0.1% quaternary ammonium compounds (e.g. cetrimide BP). No further animals should enter the consulting room until the case is diagnosed as negative or the premises have been satisfactorily cleaned and disinfected under the supervision of the DVM. The names and addresses of any contacts (e.g. those in the waiting room) should be recorded. The Veterinary Officer will inform the public health authorities of any necessary further action.

If the animal dies or is killed, the head and neck should be removed by a DEFRA veterinary officer and transported fresh and intact to an appropriate diagnostic laboratory (in the UK, the Veterinary Laboratories Agency, Weybridge). It should be packed in a sealed container, held at a low temperature, but must not be frozen.

A combination of several laboratory techniques is generally used to diagnose rabies.

- Fluorescent antibody test on brain smears to demonstrate viral antigen: results are available within 2–3 hours and the test has a high degree of accuracy, correlating well with mouse inoculation.
- Histological examination of brain material, usually from the hippocampus, for the specific Negri body inclusions: results are available within 2 days, but are only 40–50% accurate, especially if the animal is killed (Kissling, 1975). Formalin-fixed brain tissue may also be examined by the fluorescent antibody test, if the tissues are trypsin treated (Webster & Casey, 1988). Immunochemical techniques have also been developed.
- Mouse inoculation: mice are inoculated intracerebrally with a suspension of brain tissue, and observed for up to 28 days for mortality. If sufficient mice are inoculated the observation time may be reduced by killing mice at intervals and examining their brains by the fluorescent antibody test (Koprowski, 1973; Webster & Casey, 1988).
- Cell culture isolation: it has been found that some cell cultures [e.g. BHK-21 cells and a murine neuroblastoma (NA) cell line] appear to be at least as sensitive as mouse inoculation for isolation of virus, and this has largely replaced the mouse inoculation test in several laboratories (Crick & King, 1988; Webster & Casey, 1988).
- Panels of monoclonal antibodies may be used in fluorescent antibody tests on brain smears or infected cell cultures, to determine the origin of the rabies virus, e.g. vaccine or field virus (Esh *et al.*, 1982; Bellinger *et al.*, 1983; Whetstone *et al.*, 1984), or rabies or rabies-related virus (Webster & Casey, 1988), or for epidemiological typing, e.g. skunk versus fox rabies (Smith & Baer, 1988).
- Detection of rabies virus nucleic acid after gene amplification is also increasingly being used (Bourhy & Sureau, 1990); followed by sequencing, it allows precise typing of the strain.

Epidemiology

Although virtually every mammal is susceptible to rabies, the natural disease occurs predominantly in carnivores. Thus, in Europe, the red fox is the most important species affected, whereas in Asia it is the domestic dog (Blancou, 1988). In the USA and Canada, rabies is enzootic in several species of animals, such as skunks, foxes and racoons (Smith & Baer, 1988). Monoclonal antibody studies and sequencing studies have shown that although each strain of rabies virus has the potential to infect many species, in different geographical areas usually only one or two vectors predominate.

In many parts of the world, including Europe and the Americas, bats also harbour rabies. Bat rabies seems to be endemic in the UK (McColl *et al.*, 2000). However, bat rabies exists largely as an independent cycle and is not generally linked to terrestrial rabies, although spill-over can and does occur (Smith & Baer, 1988). In contrast, in Latin America, vampire bats are a frequent source of infection for cattle, although the dog is the major vector for humans. In Latin America, therefore, sylvatic rabies (i.e. in wildlife) and urban rabies (i.e. in dogs) coexist. Sylvatic and urban rabies also coexist in parts of Eastern Europe, Africa and Asia, but here a number of wildlife species, including wolves, jackals and mongooses, also act as reservoir hosts; these animals fill the same ecological niche as foxes in other countries (Winkler, 1975; Pastoret *et al.*, 1988b).

Fox rabies in Europe

In continental Europe, epizootics of fox rabies have occurred several times in the past, but the disease then appeared to terminate without specific control measures around the end of the nineteenth century (Winkler, 1975; Blancou, 1988). In 1939,

however, a new, stable, epizootic began, with numerous cases of rabies being reported in foxes and badgers in Poland, and since then it has become an increasing and important problem (Pastoret *et al.*, 1989).

The present European epizootic of rabies has spread some 1400 km westward from Poland since 1939. For several years the front of the epizootic advanced by 20–60 km/year (Toma & Andral, 1977; Macdonald, 1988). This epizootic is sylvatic: the reservoir of infection is in wildlife. While it involves all susceptible species, both wild and domestic, the red fox (*Vulpes vulpes*) is involved in more than 75% of cases. The red fox is both the vector of the disease and its reservoir. It plays a key role in the maintenance of the disease, but usually it does not transmit it directly to humans. People are mainly at risk from affected domestic animals such as cattle and cats, although human deaths in Europe from rabies are now very rare (Blancou, 1988).

The percentage of rabid foxes is almost certainly underestimated, for several reasons (Braunschweig, 1982). For example, the occurrence of the disease in cubs in the den is always neglected but may be relatively frequent (Thiriart *et al.*, 1985). The fox seems to be the only species to play a role in the maintenance of the present epizootic; it has been shown that where rabies has been eliminated from the fox population in certain areas of Europe, the disease then disappears from all other species, except for bats (Wandeler, 1988).

The prevailing hypothesis is that the virus originated in dogs and became adapted, by successive passages, for foxes (Winkler, 1975). This virus is classified as lyssavirus serotype 1. The virus is highly pathogenic for the fox: a dose of 0.3 mouse intracerebral LD50 is sufficient to kill one in two foxes, whereas domestic carnivores require a dose 100 000 times greater to produce the same effect (Blancou, 1985). When the disease front penetrates a new area the foxes within the area suffer an epizootic of rabies. When the fox population is heavily decimated, the incidence of the disease decreases and remains low for a 'silent' period of some 2–3 years. After the initial epizootic, secondary enzootic outbreaks recur, often at intervals of 3–5 years (Aguilar-Setién *et al.*, 1985; Macdonald & Voigt, 1985).

Superimposed upon the annual variation in the incidence of reported cases of vulpine rabies is a seasonal pattern. Cases tend to peak in late winter and reach a trough in mid-summer. The late winter/early spring peak of rabies seems to be linked to the mating season of foxes. In recent years the advance of the rabies epizootic seemed to have stopped, as exemplified by the situation in France (Blancou *et al.*, 1988a), before its elimination by fox vaccination. France is now rabies free, having met the World Health Organisation (WHO) criteria of rabies freedom, that is, not having a case of rabies in humans or terrestrial mammals acquired indigenously for 2 years. The last case of terrestrial rabies in France was in December 1998 (Rabies Bulletin Europe, 2000).

In Europe, the fox is the animal that is most susceptible to rabies. The proportion of rabid foxes that excrete the virus is very high: 93–100% of rabid foxes harbour the virus in the salivary glands and excrete it in large quantities in saliva. Furthermore, virus may be excreted for 5 days or more before the onset of the disease (Blancou *et al.*, 1979a, b; Aubert *et al.*, 1991). The incubation period of the disease in foxes depends mainly on the dose of virus with which the animal has been infected and varies from 10 to 41 days. The clinical disease lasts for 3–5 days. The symptoms are variable (George *et al.*, 1980). The furious form is relatively rare; instead, most animals become apathetic and develop paralysis (Steck & Wandeler, 1980).

Rabies virus is transmitted by biting. Since the dumb or apathetic form of the disease predominates in the fox, rabid foxes usually do not wander far from their original territory (Artois & Aubert, 1985). This may explain why the front of a fox rabies epizootic progresses slowly.

In continental Europe, rabies in domestic animals tends to follow the pattern of disease seen in wildlife (Blancou & Barrat, 1988). Thus, when the incidence of rabies increases in foxes, it also increases in domestic species such as cattle, sheep, cats and dogs. Human exposure occurs through contact with infected domestic species. Cats become infected relatively often, possibly because they tend to have regular contact with wildlife and vaccines are used less frequently in this species (Wachendörfer, 1962; Diesch *et al.*, 1982). There is no evidence, however, that rabies persists among cats in areas where canine (urban) and wildlife (sylvatic) rabies have been eliminated.

In other areas of the world where urban rabies occurs, stray dogs are common and these animals are one of the reservoirs of infection. Human exposure tends to reflect contact between people and animals, and the control of the disease in the dog population by vaccination leads to a marked drop in human exposure rates (Larghi *et al.*, 1988).

Prevention and control

Introduction

There are two aspects to be considered with respect to rabies vaccination: preventive vaccination and postexposure treatment. The first human vaccination by Louis Pasteur in 1885 was for postexposure treatment. Nowadays, human postexposure treatment requires several vaccinations, together with an injection of specific immunoglobulin if the exposure was severe. Veterinarians and others exposed to an increased risk of infection should be protected by preventive vaccination. In animals only preventive vaccination is generally carried out. In some countries, postexposure vaccination of domestic animals may be allowed, but only if the animal has previously been vaccinated.

Whether current vaccines based on serotype 1 (classical rabies virus) confer adequate protection against the rabies-related viruses is still not clear; some studies have demonstrated adequate protection whereas others have not, and it has been suggested there may be a case for producing polyvalent vaccines in some parts of the world (King & Crick, 1988).

Conventional vaccines for human use

Only inactivated vaccines have been licensed for human use. Inactivated vaccines prepared in the nervous systems of adult animals have been used for protection against rabies. However, their use has led to problems because of postvaccinal nervous system reactions. Such reactions are due to the myelin content of nervous tissues; foreign myelin may be responsible for the induction of hypersensitivity reactions in the recipient, leading to paralysis. Because myelination is delayed in neonatal mice, the use of suckling mouse brain reduces this risk, but reactions have still occurred, and thus such vaccines are best avoided.

Since rabies virus can nowadays be grown in cell culture, current vaccines in developed countries are derived from cell culture and are perfectly safe. They can be used for preventive vaccination or for postexposure treatment in conjunction with specific immunoglobulin therapy. In some parts of the world, however, cost precludes the use of such improved vaccines. New cell culture vaccines (Vero cells) or new vaccination procedures (intradermal) may reduce the cost. Vectored vaccines (canarypox) have also been developed for both human and veterinary use (Pastoret *et al.*, 1993).

Vaccines for domestic animals

Attenuated virus vaccines have been widely used in the past for immunisation of domestic animals. However, all of them still had some residual pathogenicity for some species, and cases of vaccine-induced rabies occasionally occurred, often in cats (Dean & Guevin, 1963; Esh *et al.*, 1982; Bellinger *et al.*, 1983; Whetstone *et al.*, 1984; Pastoret *et al.*, 1985). The use of monoclonal antibodies and sequencing studies has made it much easier to distinguish such cases from infection with wild-type virus. Humans exposed to attenuated vaccine strain for veterinary use have been treated in the same way as after wild-type virus exposure.

In the past few years, safe and potent inactivated vaccines have been developed for veterinary use, and these have now essentially superseded injectable attenuated vaccines. However, live oral vaccines are used in foxes, and in some parts of the world where street rabies occurs they are also used in free-roaming dogs. Rabies virus strains have been adapted to cell cultures so that large amounts of virus can be produced without the hazards associated with vaccines prepared in nervous tissue, and newer adjuvants have also increased the immunogenicity of modern inactivated vaccines. A recombinant vaccinia–rabies glycoprotein vaccine has been developed, which has been shown to be both safe and efficacious for the cat (Kieny *et al.*, 1984; Blancou *et al.*, 1989), and also a recombinant canarypox–rabies vaccine (Taylor *et al.*,1994).

Control measures for rabies in Britain

The presence of rabies in continental Europe posed a threat to Britain (Wright, 1977) and for a long time control measures for rabies in Britain relied exclusively on a rigorously enforced 6 month quarantine period for all mammals, except for farm stock and some other herbivores which are subject to other controls (Anon, 1976). Animals entering quarantine are required to be vaccinated with an authorised vaccine. All quarantine kennels are under veterinary supervision. Details of quarantine procedures, including the code of practice for the welfare of dogs and cats in quarantine, are available from DEFRA (Box 26.1).

However, as an alternative to quarantine, following publication of the Kennedy Report (Kennedy, 1998), the UK Government has now introduced PETS (http://www.defra.gov.uk/animalh/quarantine). This was initiated as a pilot scheme in February 2000, allowing pet cats and dogs to enter the UK without quarantine from certain European countries under certain

Box 26.1 Sources of information for the Pet Travel Scheme.

Post:	Pet Travel Scheme Department for Environment, Food and Rural Affairs, Area 201, 1a Page Street London SW1P 4PQ UK
Tel.:	+44 (0)870 241 1710
Fax:	+44 (0)207 904 6834
E-mail:	pets.helpline@defra.gsi.gov.uk
Website:	http://www.defra.gov.uk/animalh/quarantine

Box 26.2 European countries eligible for the Pet Travel Scheme (PETS) (http://www.defra.gov.uk/animalh/quarantine)

Andorra	Gibraltar	Netherlands
Austria	Greece	Norway
Belgium	Iceland	Portugal
Cyprus	Italy	San Marino
Denmark	Liechtenstein	Spain
Finland	Luxembourg	Sweden
France	Malta	Switzerland
Germany	Monaco	Vatican

France excludes French Guyana and St Pierre and Miquelon.
Norway excludes Svalbard.
Portugal includes the Azores and Madeira.
Spain includes the Canary Islands, but excludes Ceuta and Melilla.

Under PETS, pets from the Channel Islands, Isle of Man and the Republic of Ireland can, having travelled to any qualifying country, return to the UK as long as they are accompanied by proper official certification.
Jersey, Guernsey, the Isle of Man and the Republic of Ireland have each produced their own official PETS certificate.

Box 26.3 Long-haul countries eligible for the Pet Travel Scheme (PETS) (http://www.defra.gov.uk/animalh/quarantine).

PETS was extended on 31 January 2001 to include certain long-haul (i.e. non-European) countries and territories. These are:

Antigua and Barbuda	Martinique
Ascension Island	Mauritius
Australia	Mayotte
Barbados	Montserrat
Bermuda	New Caledonia
Cayman Islands	New Zealand
Falkland Islands	Réunion
Fiji	Singapore
French Polynesia	St Helena
Guadaloupe	St Kitts & Nevis
Hawaii	St Vincent
Jamaica	Vanuatu
Japan	Wallis and Futuna

There is a slightly different procedure for bringing pets to the UK from these countries or territories.

Other countries being considered which may be included in the future are:

Cape Verde Islands	St Lucia
Cook Islands	Taiwan
Seychelles	

conditions, and was extended to Cyprus, Malta and certain long-haul countries and territories in January 2001 (Boxes 26.2 and 26.3). The scheme only operates on certain sea, air or mail routes to England. A full, up-to-date list of countries eligible for the scheme, and details of approved routes and transport companies, are available from DEFRA (see Box 26.1).

Although all cats and dogs imported into the UK that do not meet the requirements of PETS must spend 6 months in quarantine, under certain conditions an animal may become eligible for early release from quarantine from the date that it can be shown to comply with the rules of the scheme.

To be eligible to enter the UK under PETS, animals must be fitted with a microchip, vaccinated against rabies and test seropositive following the vaccination. There is a slightly different procedure for France. A list of laboratories currently recognised for serological analysis after vaccination within the European Union is given in Box 26.4. The optimum time for a blood sample to be taken for blood testing is 30 days after the last vaccine injection. A small proportion of vaccinated animals may not show the 0.5 IU antibody titre on blood testing required by PETS, and these animals have to be vaccinated and blood tested again.

Once the animal has been microchipped, vaccinated and blood tested, a government-authorised veterinarian will need to issue an official PETS certificate to the owner to verify that these procedures have been carried out. However, a 6-month interval is required between the date of the blood sample with a successful test result and the day of travel. Before pets are allowed to enter or re-enter the UK under the scheme they must also be treated 24–48 h before re-entry against the fox tapeworm (*Echinococcus multilocularis*) and ticks to

Box 26.4 Laboratories within the European Union recognised for serological analysis after rabies vaccination.

Austria	Federal Institute for the Control of Viral Infection in Animals Department for Equine, Pets and Vaccine Control – Virology Unit Robert Kochgasse 17 2340 Mödling Tel.: +43 2236 46640 902
Belgium	Pasteur Institute of Brussels Department of Rabies Rue Engeland 642 BE-1180 Brussels Tel.: +32 2 373 31 55
Denmark	Danish Veterinary Institute for Virus Research Lindholm DK-4771 Kalvehave Tel.: +45 55 86 02 00
Finland	National Veterinary and Food Research Institute PL 368 (Heimeentie 57) FI-231 Helsinki Tel.: +358 9 393 101
France	Agence française de sécurité sanitaire des aliments de Nancy Domaine de Pixérécourt BP 9 FR-54220 Malzéville Tel.: +333 83 29 89 50
Germany	Institut für Virologie Frankfurter Strasse 107 D-35392 Giessen Tel.: +49 641 99 38350
	Eurovir Hygiene Institut Biotechnologiepark D-14943 Luckenwalde Tel.: +49 3371 681 269
Greece	Ministry of Agriculture Centre of Athens Virus Department Neapoleos Street 25 GR-15310 Ag. Paraskevi Athens Tel.: +30 1 6010903
Italy	Instituto Zooprofilattico Sperimentale delle Venezie Via Romea 14/A I-35020 Legnaro (PD) Tel.: +39 049 8084261
Spain	Laboratorio de Sanidad y Produccion Animal del Estado Direccion General de Sanidad de la Produccion Agaria Camino del Jau, S/N ES-18320 Santa Fé (Granada)
Sweden	National Veterinary Institute Commission of Diagnostics Section of Diagnostics Department of Virology PO Box 585 SE-751 23 Uppsala Tel.: +46 1867 4000
Switzerland	Institute of Veterinary Virology Schweizerische Tollwutzentrale Langgass-Strasse 122 CH-3012 Bern Tel.: +41 31 631 23 78
UK	Veterinary Laboratories Agency (Weybridge) New Haw, Addlestone Surrey KT15 3NB Tel.: +44 01 932 357 345
	BioBest Pentlands Science Park Bush Loan Penicuik Midlothian EH26 0PZ Tel.: +44 0131 445 6101

prevent potentially serious zoonotic diseases entering the UK. The animal must be accompanied by an official PETS certificate issued by the veterinary surgeon who carried out this treatment.

Details of the scheme for pet owners and procedures for veterinary surgeons (including microchipping, vaccination, blood testing, treatment against ticks and a tapeworm, and certification) are available from DEFRA (see Box 26.1). Further practical details of pet travel outside the UK are also given. It should also be noted that some countries require their own export health certificate or other documentation.

Control measures in countries where rabies is endemic

In countries where rabies is endemic, apart from measures aimed at wildlife control, the incidence of the disease in cats and dogs may be reduced by the elimination of stray animals, by licensing, by restriction of movement and by vaccination. Several vaccines are available for use in dogs and cats (e.g. for the USA, see vaccines listed under the Compendium of Animal Rabies, Prevention and Control, 2001). Since the use of any live vaccine carries an inherent risk, the newer, potent inactivated vaccines have now essentially

superseded the use of live injectable vaccines, although live oral vaccines are used in free-roaming dogs in some countries where street rabies occurs.

In cats and dogs, primary vaccination is generally not recommended before 3 months of age, followed by a booster 1 year later; thereafter, 1–3 year boosters are recommended, depending on the vaccine. At least 1 month should be allowed for the development of immunity. It should be remembered, however, that although available vaccines confer reasonable protection, fully vaccinated cats may in some cases still develop rabies.

Veterinarians and others exposed to an increased risk of infection should also be protected by prophylactic vaccination.

Control of rabies in wildlife

In Western Europe, prophylactic measures taken in the past (Taylor, 1976; Bögel *et al.*, 1981), such as the destruction of foxes, did not prevent the spread of the epizootic, for although such measures may be temporarily effective, the fox population rapidly recovers and rabies then recurs. However in recent years, fox rabies has nearly been eliminated in most of continental Western Europe, by oral vaccination of foxes (Blancou *et al.*, 1988a; Brochier *et al.*, 2000).

Thus, during recent years, most of the research on the control of fox rabies has concentrated on the development of methods of vaccination of the fox by the oral route (Mayr *et al.*, 1972; Baer, 1975b; Steck *et al.*, 1982a, b). After an initial trial, this method has now been used extensively in most European countries (Kappeler *et al.*, 1988; Schneider & Cox, 1988; Brochier *et al.*, 1988c, 2000) under the control of the WHO (Blancou *et al.*, 1988b).

One of the vaccines used (SADB19 attenuated strain of rabies virus) consists of 1.8 ml of virus suspension in a hermetically sealed capsule contained in a bait (Schneider & Cox, 1988). Initially chicken head baits were used, but baits now consist of a machine-made mixture of fat, bone and fish meal. When a fox chews the bait, the vaccine capsule bursts and the virus suspension spreads over the oral mucosa. Each bait contains 150 mg of tetracycline, which is used as a marker of bait uptake.

Attempts to control rabies by vaccinating wild carnivores have been very successful, and many areas of Europe are now free from rabies as a result of this (Wandeler, 1988; Brochier *et al.*, 2000). However, the use of attenuated rabies virus remains controversial as far as safety and stability are concerned (Leblois & Flamand, 1988), since these vaccine strains are pathogenic for some non-target species, such as rodents. There is no evidence, though, that they can become established in the small mammals in the wild (Wandeler, 1988).

To improve both the safety and the stability of the vaccine, a recombinant vaccinia virus (VVTGgRAB 187 XP-26D3 strain) expressing the immunising glycoprotein of rabies virus has been developed (Kieny *et al.*, 1984; Wiktor *et al.*, 1984). The ability of this VVTGgRAB strain to protect foxes against rabies has been demonstrated (Blancou *et al.*, 1986b; Brochier *et al.*, 1988a).

The safety of this recombinant virus for non-target species has been tested in many laboratory animals, domestic animals and wild animals. In addition, horizontal transmission of the recombinant virus did not occur in foxes, badgers, wild boars, cattle, dogs and ferrets (Brochier *et al.*, 1988b, 1989b). The site as well as the degree of multiplication of the recombinant virus in the fox was also studied. The virus multiplied for a short time only in the same organs as the vector vaccinia strain without any modification of its tissue specificity (Thomas *et al.*, 1990). Under experimental conditions, vaccination of rabid foxes during the incubation period with the recombinant virus did not produce asymptomatic carriers of the virus (Brochier *et al.*, 1989a).

An initial, restricted trial was carried out with this recombinant vaccine in foxes in October 1987 in Belgium (Pastoret *et al.*, 1988a). Larger trials were then carried out in 1988, 1989 and 1990, and the vaccine used in all rabies-infected areas of Belgium (Newmark, 1988; Brochier *et al.*, 1990, 1991) was leading to the elimination of wildlife rabies (Brochier *et al.*, 2001). The recombinant vaccinia–rabies glycoprotein vaccine has also been shown to be efficacious and safe for the oral immunisation of the main vectors in North America (Rupprecht *et al.*, 1986; Tolson *et al.*, 1987). Because of its high thermostability it should also be tested for the control of wildlife rabies in Africa.

The use of this recombinant vaccine has allowed the elimination of fox rabies in Belgium, France and the Grand Duchy of Luxembourg (Brochier *et al.*, 2000).

Acknowledgement

The authors would like to thank the UK Government Department for Environment, Food and Rural Affairs, for very helpful advice in preparing this chapter, particularly the section on handling a suspect case.

References

Afshar A. (1979) A review of non-bite transmission of rabies virus infection. *Br Vet J* **135**, 142.

Aguilar-Setién A., Thomas I., Brochier B., *et al.* (1985) La rage vulpine. *Cahiers d'Ethologie Appliquée* **5**, 51–70.

Andral L. & Serie C. (1965) Etudes expérimentales sur la rage en Ethiopie. *Ann Inst Pasteur* **108**, 442–450.

Anon (1987) *Rabies Guidance Notes for Practising Veterinary Surgeons*. Ministry of Agriculture, Fisheries & Food, UK.

Artois M. & Aubert M.F.A. (1985) Behaviour of rabid foxes. In *Ecology and Epidemiology of Wild and Feral Canids in the Paleartic Zone. Revue D'Ecologie (La Terre et la Vie)*, Vol. 40 (eds Artois M., Blancou J. & Kempf C). pp. 171–176.

Atanasiu P. (1975) Animal inoculation and the Negri body. In *The Natural History of Rabies*, Vol. I (ed. Baer G.M.). Academic Press, New York, pp. 374–400.

Aubert M.F.A., Blancou J., Barrat J., *et al.* (1991) Transmission et pathogénie chez le renard roux de deux isolats à dix ans d'intervalle du virus de la rage vulpine. *Ann Rech Vet* **22**, 77–93.

Baer G.M. (1975a) Pathogenesis to the central nervous system. In *The Natural History of Rabies*, Vol. I (ed. Baer G.M.). Academic Press, New York, pp. 181–198.

Baer G.M. (1975b) Wildlife vaccination. In *The Natural History of Rabies*, Vol. II (ed. Baer G.M.). Academic Press, New York, pp. 261–266.

Bell J.F. (1975) Latency and abortive rabies. In *The Natural History of Rabies*, Vol. II (ed. Baer G.M.). Academic Press, New York, pp. 331–355.

Bell J.F. & Moore G.J. (1971) Susceptibility of carnivora to rabies virus administered orally. *Am J Epidemiol* **93**, 176.

Bellinger D.A., Chang J., Bunn T.O., *et al.* (1983) Rabies induced in cats by high-egg-passage Flury strain vaccine. *J Am Vet Med Assoc* **183**, 997–998.

Blancou J. (1985) La rage du renard. *Ann Med Vet* **129**, 293–307.

Blancou J. (1988) Epizootiology of rabies: Eurasia and Africa. In *Rabies, Developments in Veterinary Virology* (eds Campbell J.B. & Charlton K.M.). Kluwer Academic, Boston, MA.

Blancou J. & Barrat J. (1988) Rôle épidémiologique des diverses espèces animales dans la contamination rabique de l'homme en Europe. *Bull Acad Vét France* **61**, 497–512.

Blancou J. & Pastoret P.P. (1990) La rage du chat et sa prophylaxie. *Ann Méd Vét* **134**, 315–324.

Blancou J., Aubert M.F.A., Andral L. & Artois M. (1979a) Rage expérimentale du renard roux (*Vulpes vulpes*). I. Sensibilité selon la voie d'infection et la dose infectante. *Rev Méd Vét* **130**, 1001–1015.

Blancou J., Andral L., Samudio & Silva-Crispin L.S. (1979b) Rage expérimentale du renard roux (*Vulpes vulpes*). II. Excrétion du virus rabique après infection. *Rev Méd Vét* **130**, 1473–1482.

Blancou J., Aubert M.F.A. & Soulebot J.P. (1983) Différences dans le pouvoir pathogène des souches de virus rabique adaptées au renard ou au chien. *Ann Virol (Inst Pasteur)* **134E**, 523–531.

Blancou J., Artois M., Barrat J. & Prave M. (1986a) Vaccination du chat contre la rage; taux d'anticorps et résistance à l'épreuve un an après la vaccination. *Rev Méd Vét* **137**, 29–36.

Blancou J., Kieny M.P., Lathe R., *et al.* (1986b) Oral vaccination of the fox against rabies using a live recombinant vaccinia virus. *Nature* **322**, 373–375.

Blancou J., Aubert M.F.A. & Artois M. (1988a) La rage sylvatique en Europe. In *Vaccination to Control Rabies in Foxes. La Vaccination Antirabique du Renard*. (eds Pastoret P.P., Brochier B., Thomas I. & Blancou J.) Commission of the European Communities, EUR 11439 EN-FR, pp. 14–21.

Blancou J., Pastoret P.P., Brochier B., *et al.* (1988b) Vaccinating wild animals against rabies. *Rev Sci Tech Off Int Epiz* **7**, 1005–1013.

Blancou J., Artois M., Brochier B., *et al.* (1989) Innocuité et efficacité d'un vaccin antirabique recombinant des virus de la vaccine et de la rage administré par voie orale au renard, au chien et au chat. *Ann Rech Vét* **20**, 195–204.

Bögel K., Moegle H., Steck F., *et al.* (1981) Assessment of control in areas of wildlife rabies. *Bull World Health Organ* **59**, 269–279.

Bourhy H. & Sureau P. (1990) *Laboratory Methods for Rabies Diagnosis*. Institut Pasteur, Paris.

Bourhy H., Kissi B. & Tordo N. (1993) Molecular diversity of the *Lyssavirus* genus. *Virology* **194**, 70–81.

Braunschweig A. (1982) Ein modell für die Fuchspopulationsdynamik in der Bundesrepublik Deutschland. In *The Red Fox: Behaviour and Ecology*. Zimen Junk, The Hague, pp. 97–106.

Brochier B., Languet B., Blancou J., *et al.* (1988a) Use of recombinant vaccinia–rabies virus for oral vaccination of fox cubs (*Vulpes vulpes*) against rabies. *Vet Microbiol* **18**, 103–108.

Brochier B., Languet B., Blancou J., *et al.* (1988b) Innocuité du virus recombinant vaccine-rage chez quelques espèces non-cibles. In *Vaccination to Control Rabies in Foxes. La Vaccination Antirabique du Renard* (eds Pastoret P.P., Brochier B., Thomas I. & Blancou J.). Commission of the European Communities, EUR 11439 EN-FR, pp. 118–123.

Brochier B., Thomas I., Iokem A., *et al.* (1988c) A field trial in Belgium to control fox rabies by oral immunization. *Vet Rec* **123**, 618–621.

Brochier B., Blancou J., Aubert M.F.A., *et al.* (1989a) Interaction between rabies infection and oral administration of vaccinia–rabies recombinant virus to foxes (*Vulpes vulpes*). *J Gen Virol* **70**, 1601–1604.

Brochier B., Blancou J., Thomas I., *et al.* (1989b) Use of recombinant vaccinia–rabies glycoprotein virus for oral vaccination of wildlife against rabies: innocuity to several non-target bait consuming species. *J Wildl Dis* **25**, 540–547.

Brochier B., Thomas I., Bauduin B., *et al.* (1990) Use of a vaccinia–rabies recombinant virus for the oral vaccination of foxes against rabies. *Vaccine* **8**, 101–104.

Brochier B., Kieny M.P., Costy F., *et al.* (1991) Large scale eradication of rabies using recombinant vaccinia–rabies vaccine. *Nature* **354**, 520–522.

Brochier B., Dechamps P., Costy F., *et al.* (2000) Deux ans d'absence de rage chez le renard en Belgique. Bilan de

l'épidémiosurveillance de la rage en 1999. *Ann Méd Vét* **144**, 247–254.

Brochier B., Dechamps P., Costy F., *et al.* (2001) Elimination de la rage en Belgique pour la vaccination du renard roux (*Vulpes vulpes*). Ann Méd Vét **145**, 293–305.

Carey A.B. & McLean R.G. (1983) The ecology of rabies: evidence of co-adaptation. *J Appl Ecol* **20**, 777–800.

Chantal J. & Blancou J. (1985) Le virus rabique. In *Pasteur et la Rage. Inf Tech Serv Vét*, No. 92–95, pp. 281–292.

Charlton K.M. (1988) The pathogenesis of rabies. In *Rabies, Developments in Veterinary Virology* (eds Campbell J.B. & Charlton K.M.). Kluwer Academic, Boston, MA, pp. 101–150.

Compendium of Animal Rabies, Prevention and Control (2001) *J Am Vet Med Assoc* **218**, 26–31.

Constantine D.G. (1962) Rabies transmission by non-bite route. *Publ Health Rep Wash* **77**, 287.

Crick J. & King A. (1988) Culture of rabies virus *in vitro*. In *Rabies, Developments in Veterinary Virology* (eds Campbell J.B. & Charlton K.M.). Kluwer Academic, Boston, MA, pp. 47–66.

Dean D.J. (1975) Local wound treatment. In *The Natural History of Rabies*, Vol. II (ed. Baer G.M.). Academic Press, New York, pp. 305–317.

Dean D.J. & Guevin V.H. (1963) Rabies vaccination of cats. *J Am Vet Med Assoc* **142**, 367.

Department of Health Memorandum on Rabies Prevention and Control (2000) http://www.doh.gov.uk/memorandumrabies/index.htm (February 2000).

Diaz A.M.O. de, Fuenzalida E. & Bell J.F. (1975) Non fatal rabies in dogs and cats. *Ann Microbiol (Inst Pasteur)* **126B**, 503–509.

Diesch S.L., Hendrickx S.L. & Currier R.W. (1982) The role of cats in human rabies exposures. *J Am Vet Med Assoc* **181**, 1510.

Esh J.B., Cunningham J.G. & Wiktor T.J. (1982) Vaccine-induced rabies in four cats. *J Am Vet Med Assoc* **180**, 1336.

Fekadu M. (1975) Asymptomatic non-fatal canine rabies. *Lancet* **i**, 569.

Fekadu M., Shaddock J.H. & Baer G.M. (1981) Intermittent excretion of rabies virus in the saliva of a dog two and six months after it had recovered from experimental rabies. *Am J Trop Med Hyg* **30**, 1113.

Foggin C.M. (1982) Atypical rabies in cats and a dog in Zimbabwe. *Vet Rec* **110**, 338.

George J.P., George J., Blancou J. & Aubert M.F.A. (1980) Description clinique de la rage du renard. Étude expérimentale. *Rev Méd Vét* **131**, 153–160.

Jaeger D. & Barth R. (1979) Experimental infection of cats with rabies street virus strain NYC. *Berliner und Münchener Tierärzliche Wochenschrift* **92**, 27.

Jubb K.V.F., Kennedy P.C. & Palmer N. (1985) Viral infections of the nervous system. In *Pathology of Domestic Animals*, Vol. 1. 3rd edn. Academic Press, Orlando, FL, pp. 293–296.

Kappeler A., Wandeler A.I. & Capt S. (1988) Ten years of rabies control by oral vaccination of foxes in Switzerland. In *Vaccination to Control Rabies in Foxes. La Vaccination Antirabique du Renard* (eds Pastoret P.P., Brochier B., Thomas I. & Blancou J.). Commission of the European Communities, EUR 11439 EN-FR, pp. 55–60.

Kennedy J. (1998) Quarantine and rabies: a reappraisal. Report by the Advisory Group on Quarantine to the Rt Hon. Nick Brown MP, Minister of Agriculture, Fisheries and Food. MAFF Publications, London.

Kieny M.P., Lathe R., Drillien R., *et al.* (1984) Expression of rabies virus glycoprotein from a recombinant vaccinia virus. *Nature* **312**, 163–166.

King A. & Crick J. (1988) Rabies-related viruses. In *Rabies, Developments in Veterinary Virology* (eds Campbell J.B. & Charlton K.M.). Kluwer Academic, Boston, MA, pp. 177–179.

King A., Davies P. & Crick J. (1985) Rabies in a quarantine kennel in the UK: the Irish wolfhound from Florida. *State Vet J* **39**, 42–44.

King A., Davies P. & Lawrie A. (1990) The rabies viruses of bats. *Vet Microbiol* **23**, 165–174.

Kissling R.E. (1975) The fluorescent antibody test in rabies. In *The Natural History of Rabies*, Vol. I (ed. Baer G.M.). Academic Press, New York, pp. 401–416.

Koprowski H. (1973) The mouse inoculation test. In *Laboratory Techniques in Rabies* (eds Campbell J.B. & Koprowski H.). World Health Organization, Geneva, pp. 85–93.

Larghi O.P., Arrosi J.C., Nakajata A.J. & Villa-Nova A. (1988) Control of urban rabies. In *Rabies, Developments in Veterinary Virology* (eds Campbell J.B. & Charlton K.M.). Kluwer Academic, Boston, MA, pp. 407–422.

Leblois H. & Flamand A. (1988) Studies on pathogenicity in mice of rabies virus strains used for oral vaccination of foxes in Europe. In *Vaccination to Control Rabies in Foxes. La Vaccination Antirabique du Renard* (eds Pastoret P.P., Brochier B., Thomas I. & Blancou J.). Commission of the European Communities, EUR 11439 EN-FR, pp. 101–104.

Lodmell P.L. (1988) Genetic control of resistance to rabies. In *Rabies, Developments in Veterinary Virology* (eds Campbell J.B. & Charlton K.M.). Kluwer Academic, Boston, MA, pp. 151–161.

McColl K.A., Tordo N. & Aguilar-Séten A. (2000) Bat lyssavirus infections. *Rev Sci Tech Off Int Epiz* **19**, 177–196.

Macdonald D.W. (1988) Rabies and foxes: the social life of a solitary carnivore. In *Vaccination to Control Rabies in Foxes. La Vaccination Antirabique du Renard* (eds Pastoret P.P., Brochier B., Thomas I. & Blancou J.). Commission of the European Communities, EUR 11439 EN-FR, pp. 5–13.

Macdonald D.W. & Voigt D.R (1985) The biological basis of rabies models. In *Population Dynamics of Rabies in Wildlife*, pp. 71–108.

McQueen J.L. (1960) Rabies diagnosis. Special application of fluorescent antibody techniques. *Proceedings of the 63rd Meeting of the US Livestock Sanit. Assoc*, San Francisco, 1959, pp. 356–363.

Mayr A., Kraft H., Jaeger O. & Haacke H. (1972) Orale immunisierung von fuschsen gegen tollwut. *Zentbl Vet Med* **B19**, 615–625.

Morgan-Jones K.R. (1969) The case of rabies in Surrey. *Vet Rec* **85**, 476.

Murphy F.A., Bauer S.P., Harrison A.K. & Winn W.C. Jr (1973a) Comparative pathogenesis of rabies and rabies-like viruses.

Viral infection and transit from inoculation site to the central nervous system. *Lab Invest* **28**, 361.

Murphy F.A., Harrison A.K., Winn W.C. & Bauer S.P. (1973b) Comparative pathogenesis of rabies and rabies-like viruses. Infection of the central nervous system and centrifugal spread of virus to peripheral tissues. *Lab Invest* **29**, 1.

Newmark P. (1988) New vaccine and initiative mean end of rabies in sight for Europe? *Nature* **336**n, 416.

Office International des Epizooties (1998) Rabies in Denmark in sheep. *Dis Info* **11** (34), 116.

Parker R.L. & Wilsnack R.E. (1966) Pathogenesis of skunk rabies virus: quantitation in skunks and foxes. *Am J Vet Res* **27**, 33.

Pastoret P.P. & Brochier B. (1992) Rhabdovirus, infection and immunity. In *Encyclopedia of Immunology* (eds Roitt I.M. & Delves P.J.). Academic Press, Orlando, FL, pp. 1329–1332.

Pastoret P.P., Thomas I., Brochier B. & Schwers A. (1985) Les problèmes associés à la vaccination antirabique des animaux domestiques. *Ann Méd Vét* **129**, 361–374.

Pastoret P.P., Brochier B., Languet B., *et al.* (1988a) First field trial of fox vaccination against rabies using a vaccinia–rabies recombinant virus. *Vet Rec* **123**, 481–483.

Pastoret P.P., Thiry E., Brochier B., *et al.* (1988b) Diseases of wild animals transmissible to domestic animals. *Rev Sci Tech Off Int Epiz* **7**, 705–736.

Pastoret P.P., Brochier B., Thomas I., *et al.* (1989) Fox rabies in Europe. *Ir Vet J* **42**, 93–95.

Pastoret P.P., Brochier B., Chappuis G. & Desmettre P. (1993) Vaccines against rabies virus. In *Progress in Vaccinology*, Vol. 4, *Veterinary Vaccines* (eds Hoglund S. & Pausley R.). Springer, Berlin, pp. 139–162.

Peace C.K. & Hopes R. (1970) The case of rabies at Newmarket. *Vet Rec* **86**, 299.

Perl D.P., Bell J.F., Moore G.J. & Stewart S.J. (1977) Chronic recrudescent rabies in a cat. *Proc Soc Exp Biol Med* **155**, 540–548.

Rabies Bulletin Europe (2000) http://www.who-rabies-bulletin.org (April 2000).

Rupprecht C.E., Wiktor T.J., Johnston D.H., *et al.* (1986) Oral immunization and protection of raccoons (*Procyon lotor*) with a vaccinia-rabies glycoprotein recombinant virus. *Proc Natl Acad Sci USA* **83**, 7947–7950.

Schneider L.G. (1982) Antigenic variants of rabies virus. *Comp Immunol Microbiol Infect Dis* **5**, 101.

Schneider L.G. & Cox J.H. (1988) Eradication of rabies through oral vaccination: the German field trial. In *Vaccination to Control Rabies in Foxes. La Vaccination Antirabique du Renard* (eds Pastoret P.P., Brochier B., Thomas I. & Blancou J.). Commission of the European Communities, EUR 11439, EN-FR, pp. 22–38.

Sikes R.K. (1962) Pathogenesis of rabies in wildlife 1. Comparative effect of varying doses of rabies virus inoculated into fox and skunks. *Am J Vet Res* **23**, 1041–1047.

Smith J.S. & Baer G.M. (1988) Epizootiology of rabies: the Americas. In *Rabies, Developments in Veterinary Virology* (eds Campbell J.B. & Charlton K.M.). Kluwer Academic, Boston, MA, pp. 267–299.

Soave OA. (1966) Transmission of rabies to mice by ingestion of infected tissue. *Am J Vet Res* **27**, 44.

Soulebot J.P., Brun A., Chappuis G., *et al.* (1981) Experimental rabies in cats: immune response and persistence of immunity. *Cornell Vet* **71**, 311.

Steck F. &Wandeler A.I. (1980) The epidemiology of fox rabies in Europe. *Epidemiol Rev* **2**, 71–96.

Steck F., Wandeler A.I., Bichsel P., *et al.* (1982a) Oral immunisation of foxes against rabies. A field study. *Zentralbl Veterinär Med* **29**, 372.

Steck F., Wandeler A.I., Bichsel P., *et al.* (1982b) Oral immunisation of foxes against rabies: laboratory and field studies. *Comp Immun Microbiol Infect Dis* **5**, 165–171.

Steele J.H. (1975) History of rabies. In *The Natural History of Rabies*, Vol. I (ed. Baer G.M.). Academic Press, New York, pp. 1–29.

Szlachta H.L. & Habel R.E. (1953) Inclusions resembling Negri bodies in the brains of non-rabid cats. *Cornell Vet* **43**, 207.

Taylor D. (1976) Rabies: epizootic aspects. *Vet Rec* **99**, 157.

Taylor J., Tartaglia J., Riviere M., *et al.* (1994) *Dev Biol Stand* **82**, 131–135.

Thiriart C., Iokem A., Costy F., *et al.* (1985) Immunization of young foxes against rabies: interaction between vaccination and natural infection. *Ann Rech Vet* **16**, 289–292.

Thomas I., Brochier B., Languet B., *et al.* (1990) Primary multiplication site of the vaccinia-rabies glycoprotein recombinant virus administered to foxes by the oral route. *J Gen Virol* **72**, 37–42.

Tierkel E.S. (1959) Rabies. *Adv Vet Sci* **v**, 183.

Tolson N.D., Charlton K.M., Stewart R.B., *et al.* (1987) Immune response in skunks to a vaccinia virus recombinant expressing the rabies virus glycoprotein. *Can J Vet Res* **51**, 363–366.

Toma B. & Andral L. (1977) Epidemiology of fox rabies. In *Advances in Virus Research*, Vol. 21 (eds Lauffer M.A., Bang F.B., Maramorosch K. & Smith K.M.). Academic Press, New York, pp. 1–36.

Tordo N., Poch O., Ermine A., *et al.* (1988) Génétique moléculaire du virus de la rage, un siècle après Pasteur. In *Molecular Biology and Infectious Diseases*. Elsevier, Paris, pp. 31–40.

Tustin R.C. & Smit J.D. (1962) Rabies in South Africa. An analysis of histological examinations. *J South Afr Vet Med Assoc* **33**, 295.

Vaughn J.B. (1975) Cat rabies. In *The Natural History of Rabies*, Vol. II (ed. Baer G.M.). Academic Press, New York, pp. 139–154.

Vaughn J.B., Gerhardt P. & Paterson J.C.S. (1963) Excretion of street rabies virus in saliva of cats. *J Am Vet Med Assoc* **184**, 705.

Wachendörfer G. (1962) Role of cats in the present rabies epidemic in Germany. *Dtsch Tierärz Wsch* **69**, 555.

Wandeler A.I. (1988) Control of wildlife rabies: Europe. In *Rabies, Developments in Veterinary Virology* (eds Campbell J.B. & Charlton K.M.). Kluwer Academic, Boston, MA, pp. 365–380.

Waterhouse R. (Chairman) (1971) Rabies in Europe with particular reference to Great Britain. Report of the Committee

of Inquiry on Rabies. Final Report. Cmnd 4696. HMSO, London.

Webster W.A. & Casey G.A. (1988) Diagnosis of rabies infection. In *Rabies, Developments in Veterinary Virology* (eds Campbell J.B. & Charlton K.M.). Kluwer Academic, Boston, MA, pp. 201–222.

Whetstone C.A., Bunn T.O., Emmons R.W. & Wiktor T.J. (1984) Use of monoclonal antibodies to confirm rabies in ten dogs, two cats, and one fox. *J Am Vet Med Assoc* **185**, 285–288.

Wiktor T.J., McFarlan R.J., Reagan K.J., *et al.* (1984) Protection from rabies by a vaccinia virus recombinant containing the rabies virus glycoprotein gene. *Proc Natl Acad Sci USA* **81**, 7194–7198.

Winkler W.G. (1975) Fox rabies. In *The Natural History of Rabies*, Vol. II (ed. Baer G.M.). Academic Press, New York, pp. 3–22.

Wright A.I. (1977) Waiting for rabies. In *The Medical Annual* (eds Bodley-Scott R. & Fraser J.). John Wright & Sons, Bristol, pp. 347–353.

Wunner W.H., Larson J.K., Dietzschold B. & Smith C.L. (1988) The molecular biology of rabies viruses. *Rev Infect Dis* **10**, S771–S784.

Wyatt J.M., Pearson G.R., Smerdon T., *et al.* (1990) Spongiform encephalopathy in a cat. *Vet Rec* **126**, 513.

Wyatt J.M., Pearson G.R., Smerdon T., *et al.* (1991) Naturally occurring scrapie-like spongiform encephalopathy in five domestic cats. *Vet Rec* **129**, 233–236.

Chapter 27

CHLAMYDIAL INFECTIONS

J.E. Sykes

Introduction

Chlamydophila felis (previously feline *Chlamydia psittaci*) was first isolated in hens' eggs in the USA from cats with respiratory disease in 1942 (Baker, 1942). Because *C. felis* was the first feline respiratory pathogen to be identified, it was initially believed that most cases of feline upper respiratory tract disease (URTD) were the result of chlamydial infection. With the isolation of feline calicivirus (FCV) and feline herpesvirus-1 (FHV-1) in the late 1950s, the importance of *C. felis* was questioned. In the late 1970s, however, a number of studies re-emphasised its importance as a conjunctival pathogen of cats. There is some evidence that *C. felis* may occasionally be associated with other clinical signs, such as vaginal discharge, although much remains to be learned about the importance of these conditions.

Aetiology

Chlamydiae are obligately intracellular Gram-negative bacteria. Unlike viruses, they possess both DNA and RNA, their replication cycle involves binary fission and they are susceptible to certain antimicrobial drugs. Unlike Rickettsiae, they lack a cytochrome system for electron transport and cannot synthesise adenosine triphosphate (ATP) and guanosine triphosphate (GTP). Their cell walls show similarity to those of Gram-negative bacteria, and their DNA is also contained within nucleoids that are not separated from the cytoplasm by a membrane. The genome sizes of *Chlamydia psittaci* and *Chlamydia trachomatis* have been estimated to be around 1450 kb (Frutos *et al.*, 1989).

Chlamydiae are placed within the order Chlamydiales and family Chlamydiaceae. Until recently, a single genus, *Chlamydia*, was recognised, containing the four species *C. trachomatis, C. psittaci, C. pneumoniae* and *C. pecorum*. However, results of 23S rRNA gene analysis have shown that chlamydiae can be divided into nine groups, which correlate with the host species infected. Therefore, Chlamydiae have now been reclassified into nine species belonging to two genera, *Chlamydia* and *Chlamydophila* (Everett *et al.*, 1999). The genus *Chlamydia* includes *Chlamydia trachomatis*, infecting humans, *Chlamydia muridarum*, infecting rodents, and *Chlamydia suis*, infecting swine. *Chlamydophila* comprises *Chlamydophila pecorum* (previously *Chlamydia pecorum*), which infects cattle and sheep, *Chlamydophila pneumoniae* (previously *Chlamydia pneumoniae*), as well as four new species derived from *Chlamydia psittaci: Chlamydophila psittaci, Chlamydophila abortus, Chlamydophila caviae* and *Chlamydophila felis*, which generally infect birds, sheep, guinea-pigs and cats, respectively.

Chlamydia trachomatis is a well-characterised species. In humans, certain serovars of *C. trachomatis* are responsible for a chronic keratoconjunctivitis known as trachoma, a major public health problem in developing regions such as North Africa and south-east Asia (Stamm, 1998). Other serovars cause mainly ocular, genital, or both ocular and genital infections in humans, which are spread mainly by sexual transmission with occasional ocular transfer. *Chlamydia pneumoniae* is a major cause of pneumonia in humans, and has also been associated with acute to chronic bronchitis, sinusitis, pharyngitis, coronary artery disease, asthma, cerebrovascular disease, sarcoidosis and reactive arthritis. *Chlamydophilia psittaci* and *C. abortus* are zoonoses, causing respiratory and reproductive disease, respectively.

Serological studies suggest that multiple strains of *C. felis* exist, which may differ in virulence (Yerasimides, 1960; Kuroda-Kitogawa *et al.*, 1993). Random

amplification of polymorphic DNA fingerprinting has demonstrated the existence of at least two feline strains (Pudjiatmoko *et al.*, 1997). Although the major site of antigenic variation in *C. trachomatis* is in the major outer membrane protein gene (*ompA*), DNA analysis has shown that *ompA* is highly conserved between different *C. felis* isolates (Sayada *et al.*, 1994; May *et al.*, 1996; Sykes, 1997).

The chlamydial developmental cycle involves an alternation between the predominantly extracellular, infectious elementary body (EB), measuring 0.3 μm in diameter, and the intracellular, metabolically active reticulate body (RB), measuring 0.5–1.5 μm in diameter. Only the RB can divide, which occurs in an intracellular vacuole called an inclusion. The length of the cycle in cell culture varies from 48 to 72 h. The RBs then reorganise into EBs, which are subsequently released from the host cell and may enter a new, uninfected host cell, where they reorganise into RBs.

Chlamydial EBs survive for only a few days at room temperature. Survival for up to 1 month at 4°C may be possible (Baker, 1942). They are inactivated by lipid solvents and detergents, but are somewhat resistant to acids and alkalis.

Pathogenesis

Much remains unknown regarding the pathogenesis of chlamydial infections in cats. The organism appears to have a predilection for the conjunctival epithelial cell. Natural transmission of *C. felis*, as for the other respiratory pathogens, presumably occurs by close contact with other infected cats and their aerosols, and via fomites. Mutual grooming and self-grooming are probably important means of natural inoculation. It is unclear whether natural transmission by the venereal route occurs in cats. The incubation period in experimentally infected cats is approximately 3–5 days.

Infections caused by chlamydiae tend to follow a chronic, insidious course, often progressing through asymptomatic stages. chlamydiae may be capable of passing through periods of delayed development interspersed with production of new crops of infectious EBs. Human chlamydial infections of up to 20 years' duration have been reported in the literature. It is unclear whether chronic disease is the result of repeated reinfection or the presence of persistent chlamydiae. Persistent chlamydiae in the form of atypical RBs have been identified in the joints of humans with reactive arthritis. Localisation of persistent Chlamydiae to deeper tissues, such as the subsynovial layer in patients with arthritis (Beutler *et al.*, 1995), may afford protection from the continual rapid cell turnover characteristic of epithelial tissues.

Chlamydophilia felis may also be capable of entering a persistent state within tissues. Conjunctivitis associated with *C. felis* may persist for several months. Organisms have been isolated from the conjunctiva for up to 215 days after experimental infection, although most cats cease conjunctival shedding at around 60 days after infection (Wills, 1986; O'Dair *et al.*, 1994). Persistent elevations in serum titres to *C. felis*, despite apparent cessation of shedding, also suggest that some cats may be capable of harbouring persistent chlamydiae. The intestinal tract may be a site of persistent infection in cats, as has been shown in birds and ruminants. Prolonged rectal and vaginal excretion by cats with experimentally induced chlamydial conjunctivitis has been documented (Wills, 1986). The occasional finding of *C. felis* in the spleen, liver and peritoneum of cats has not been consistent, and the significance of the presence of organisms in these locations remains unclear (Baker, 1944; Dickie & Sniff, 1980; Hoover, 1980).

Chlamydial disease may be exacerbated by superinfection with other microorganisms. In one study, 8% of cats had both chlamydial and either FCV or FHV-1 infection (Wills *et al.*, 1988a). Cats with concurrent FCV infection had additional signs, such as oral ulceration, in addition to conjunctivitis. Dual infection with FCV appears to be more common than with FHV-1, although this may relate to the ease of detection of FCV compared with FHV-1. Coinfections with feline immunodeficiency virus (FIV) prolong the duration of conjunctivitis and chlamydial shedding and, in cats with existing FIV infection, superinfection with *C. felis* may accelerate the clinical progression of FIV infection (O'Dair *et al.*, 1994). Both *Mycoplasma* species and *Bordetella bronchiseptica* can complicate *C. felis* infections (Shewen *et al.*, 1980; Sykes, 1997). Other bacteria, including those that normally colonise the healthy conjunctival sac, can also act as secondary invaders and worsen disease.

Clinical signs

Respiratory and ocular disease

Since the discovery of *C. felis*, there has been much controversy regarding the extent of disease attributable to the organism. *Chlamydophilia felis* is primarily a

conjunctival pathogen, capable of causing acute to chronic conjunctivitis, with blepharospasm, chemosis and congestion and a serous to mucopurulent ocular discharge, but no dyspnoea or coughing (Plates 27.1 and 27.2). Mild pulmonary lesions may result from aerosol exposure (Hoover *et al.*, 1978), but as these are clinically insignificant, *C. felis* is no longer known as the 'feline pneumonitis agent'. Transient pyrexia, reduced appetite and weight loss may occur shortly after infection, although many cats remain well and continue to eat. An acute-phase reactant response was shown to accompany pyrexia in experimentally infected cats (TerWee *et al.*, 1998). Clinical signs improve after a few weeks, but mild conjunctivitis frequently persists for several months. Nasal discharge and sneezing may occur in some cats. The strain and/or the route of infection may influence the extent of respiratory tract involvement. Sneezing and nasal discharge without concurrent ocular involvement is highly unlikely to be associated with *C. felis* infection (Sykes *et al.*, 1999b).

In contrast to ocular chlamydial infections of other host species, *C. felis* infection is rarely associated with corneal damage. Reported cases of corneal involvement, including punctate keratitis and scarring, did not exclude the possibility that corneal disease was attributable to dual infection with other pathogens, such as FHV-1 (El-Sheikh, 1978; Tabatabayi & Rad, 1981). One study showed that simultaneous inoculation of a *Streptococcus* species isolate with *C. felis* was more likely to be associated with keratoconjunctivitis. Corneal ulceration occurred in half of the cats infected (Darougar *et al.*, 1977). The ability of the organism to cause corneal disease may also be dependent on strain and/or host factors.

Chlamydophilia felis has occasionally been isolated from cases of neonatal conjunctivitis in kittens (Sykes, 1997; Wills & Gaskell, 1994), although most kittens appear to be protected by maternally derived antibody (MDA; see below) (Plate 27.3). Whether or not such cases are associated with genital infection in the queen, as occurs in humans infected with *C. trachomatis*, is unclear.

Reproductive tract disease

Causal relationships between chlamydial infections and reproductive disease have been recognised in many host species. *Chlamydophilia felis* has been suspected as a cause of abortion, neonatal mortality and infertility in catteries, but a definite causative link has not been reported. Infertility and abortion have been equally distributed between infected and uninfected colonies (Pointon *et al.*, 1991) and many chlamydia-infected colonies do not have reproductive problems. FHV-1 may be responsible for a number of suspected cases of *C. felis*-induced genital and perinatal disease. FHV-1 was detected in four of eight cats with combined reproductive and URTD in a large epidemiological survey of cats with URTD, whereas *C. felis* was not detected (Sykes *et al.*, 1999b).

In experimentally infected cats, isolation of chlamydiae from the vagina has been associated with a vaginal discharge (Wills, 1986; O'Dair *et al.*, 1994; Sykes *et al.*, 1999a). Intravaginal and intraurethral inoculation has been associated with vaginal discharge, bleeding and swelling in females; urethritis and urethral discharge in males, and proctitis in both sexes (Darougar *et al.*, 1977; El-Sheikh, 1978). Other investigators have been less successful in their attempts to isolate chlamydia from the rectum or vagina. One report suggested that vaginal shedding of chlamydia may be affected by the age of the cat, with kittens less than 13 weeks of age failing to shed organisms from the vagina (TerWee *et al.*, 1998). Direct inoculation of *C. felis* into the oviducts led to salpingitis and growth of the organism in this location for weeks, with minimal systemic signs (Kane *et al.*, 1985). Although the valvular structures in the feline reproductive tract may prevent chlamydial infection ascending from the vagina, haematogenous dissemination may allow the agent to relocate to the reproductive tract. Although *C. felis* DNA could not be detected using the polymerase chain reaction (PCR) in serial blood samples collected from experimentally infected cats (Sykes *et al.*, 1999a), infection has been transmitted experimentally by blood transfusion (TerWee *et al.*, 1998). Systemic signs and conjunctivitis developed 7 and 35 days later, respectively. Failure to detect *C. felis* in the blood using PCR may reflect the presence of extremely low numbers of organisms in the blood, or a very short period of chlamydaemia that was undetected.

Infection of placental tissues using PCR has been demonstrated in a cat experimentally infected with *C. felis* during gestation (Sykes, 1997). Placentitis was not observed histologically and no evidence of infection was detected in the neonates. The queen experienced apparently normal parturition, but vaginal shedding of *C. felis* began immediately afterwards and continued for at least 12 days. This is similar to observations in ewes following abortion or birth of weak lambs. It is possible that *C. felis* infection may be influenced by the host's endocrine environment, as has been shown for other host species.

For *C. felis* to cause infertility or abortion, certain criteria may need to be met. In other species, the ability of Chlamydiae to cause reproductive disease can depend on the stage of pregnancy at which infection occurs, coinfection with other organisms, concurrent immunosuppression, route of infection and the strain involved.

Other manifestations

Chlamydial infection has been associated with peritonitis in a mature female cat (Dickie & Sniff, 1980). Squamous cells and macrophages in the peritoneal exudate and intestine contained chlamydial inclusions, although the authors were unable to transmit the infection to kittens. Peracute illness and death associated with systemic chlamydiosis has been reported in a fishing cat housed at a zoological park in The Netherlands (Kik *et al.*, 1997).

Chlamydiae were observed in the gastric mucosa of 12 young cats from five related research or commercial breeding colonies (Hargis *et al.*, 1983). Four of the cats showed signs of weight loss of undetermined cause. Administration of the organism to cats by aerosol and oral inoculation resulted in conjunctivitis, rhinitis and, in some, mild gastritis.

Recently, an association between chlamydial infection and lameness in cats has been reported (TerWee *et al.*, 1997, 1998). Lameness occurred 2 weeks after the onset of conjunctivitis in 10 of 19 experimentally infected cats, and only in cats receiving a high dose of inoculum. Transient lameness was also noted in one of the author's experimentally infected cats. Further studies are required to determine whether lameness may be associated with *C. felis* infection in the field situation, and whether the lameness reflects predominantly immune-mediated phenomena, as occurs in humans with Reiter's syndrome, or direct damage resulting from intrasynovial chlamydial replication.

Epidemiology

The prevalence of *C. felis* infection has been examined using a variety of different assays in several different geographical locations. Using the complement fixation test (CFT), the prevalence of anti-chlamydial antibodies in cats has ranged from 0 to 32%. Serological studies in the USA and from 1991 onwards in the UK are confounded by the effects of vaccination. Also, recent infection with *C. felis* correlates poorly with the presence of CFT antibodies. The prevalence of *C. felis* in cats with URTD as determined using culture has ranged from 23 to 31% (Wills *et al.*, 1988a; Hanselaer *et al.*, 1989). The author recently used PCR on conjunctival swabs to obtain a prevalence of 66/462 (14.3%) in cats with URTD (Sykes *et al.*, 1999b).

Studies using both culture (Wills *et al.*, 1988a) and PCR (Sykes *et al.*, 1999b) have shown that cats in the 2–6 month age group are most likely to be infected with *C. felis*. In the author's study, the prevalence was also high in cats aged 7–11 months. The next most frequently affected group was cats less than 8 weeks of age. However, in another study, cats 5 weeks of age or younger were relatively protected from chlamydial infection, presumably owing to passive immunity (Wills *et al.*, 1988a). Cats older than 5 years of age were least likely to be infected with *C. felis*. There does not appear to be a strong predilection for any particular breed or sex.

The prevalence of *C. felis* in asymptomatic cats is low. None of 50 cats was positive using culture (Shewen *et al.*, 1980) and one of 95 cats was positive using PCR (Sykes *et al.*, 1999b). Persistent chlamydial shedding after resolution of clinical signs may explain positive results in some asymptomatic cats (see Pathogenesis, above). The one asymptomatic cat that was positive using PCR had recovered from an episode of URTD, which included conjunctivitis, 2 months previously.

Zoonotic potential

Another area of controversy surrounding feline chlamydiosis is its zoonotic potential. *Chlamydophilia felis* has been implicated in conjunctivitis in humans, but evidence to support this association has not been strong. One report involved a man with unilateral follicular conjunctivitis. His 12-week-old kitten, which slept on his bed, also had a unilateral ocular discharge (Ostler *et al.*, 1969; Schachter *et al.*, 1969). The man lived in a crowded boarding house with several other humans, cats, dogs and monkeys. Chlamydiae were isolated from the kitten and the affected human, and distinguished from *C. trachomatis* by their failure to uptake iodine. Most recently, a non-trachomatis chlamydia was isolated from a human immunodeficiency virus (HIV)-positive man with chronic conjunctivitis, who had recently acquired a stray queen and its kittens. A chlamydia was subsequently isolated from one of the kittens, which was shown to be identical to that isolated from the man, using restriction

digestion and partial sequencing of the *omp2* gene (Hartley *et al.*, 2001). The *omp2* gene sequence matched that of *C. felis*. However, only four of 21 owners of cats with chlamydial conjunctivitis complained of recent itchy or sore eyes, compared with two of eight owners of cats that were negative for *C. felis* (Wills, 1986). *Chlamydophilia felis* has also been incriminated as a cause of other disease in humans, including hepatosplenomegaly, glomerulonephitis and endocarditis (Griffiths *et al.*, 1978; Regan *et al.*, 1979). However, in all these cases, associations were made on the basis of serology, which is not species specific. It is possible that the pathogen involved in some or all of these cases was the more recently discovered *C. pneumoniae*, which also fails to stain with iodine. If *C. felis* is zoonotic, maintenance of hygienic conditions and prompt treatment of affected cats is recommended to prevent human disease, although further investigation of the zoonotic potential of this organism is needed. Adherence to guidelines for people with immunodeficiencies to reduce public health risk of their pets should also minimise the risk of infection by *C. felis* (Greene, 1998a).

Chlamydia has also been implicated in cat scratch disease (CSD) in humans (Emmons *et al.*, 1976), which is now known to be caused by the Gram-negative bacteria *Bartonella henselae* and *B. clarridgeiae*. These implications were made primarily on the basis of serology. Recent studies have described serological cross-reactions between *Bartonella* and *Chlamydia* species (Maurin *et al.*, 1997), and these may be responsible for the erroneous interpretations of *Chlamydia* in CSD.

Diagnosis

Chlamydial infection needs to be differentiated from other infectious and non-infectious causes of feline URTD. It is not possible to differentiate infections caused by the three major respiratory pathogens on the basis of clinical signs and, because mixed infections may also occur, accurate diagnosis requires some form of microbiological assay.

Examination of Giemsa-stained conjunctival smears for chlamydial inclusions is not currently recommended as a reliable means of diagnosis of feline chlamydial infection. Inclusions are generally only visible early in the course of infection, and sometimes not at all (Wills, 1986). False positives may occur as a result of confusion with melanin granules in the cytoplasm of conjunctival cells.

Serum antibody titres detected using indirect immunofluorescence correlate well with recent infection. Ninety-six per cent of cats infected with *C. felis* have titres >32, compared with only 7.5% of uninfected cats (Wills *et al.*, 1988a). Unfortunately, a diagnosis is often required before there is an appreciable rise in antibody titre. The CFT is unreliable in detecting recent *C. felis* infection (Cello, 1971).

Various enzyme-linked immunosorbent assay (ELISA) antigen kits are available for the diagnosis of human *C. trachomatis* infection, which have variable sensitivities and specificities for detecting *C. felis.* For example, one assay was found to have a specificity of 90% and a sensitivity of 79% compared with cell culture (Wills *et al.*, 1988b), whereas another had a sensitivity of 25% and specificity of 84% compared with direct fluorescent antibody (Pointon *et al.*, 1991). These assays may be of some benefit where other, more sensitive assays are not available.

The gold standard for chlamydial diagnosis is cell culture, which most commonly uses fluorescent antibodies to detect intracytoplasmic chlamydial inclusions following inoculation of cell monolayers (Plate 27.4). This is more sensitive than direct application of fluorescent antibody to smears of affected tissues. Special transport media containing appropriate antimicrobials are required to preserve chlamydial viability. Isolation in cell culture is technically demanding, time consuming and expensive. Transportation and storage problems can affect the sensitivity of cell culture, and some samples may be toxic for cell culture monolayers. The sensitivity of culture may vary from laboratory to laboratory depending on equipment and technical expertise.

Diagnostic PCR assays are now used routinely for diagnosis of human chlamydial infections, and assays for *C. felis* are becoming increasingly available. PCR has been shown to have good sensitivity and specificity with proper sample collection and storage (McDonald *et al.*, 1998; Sykes *et al.*, 1999a). Nucleic acid amplification techniques are more rapid, less expensive and in many cases more sensitive than traditional techniques such as culture and ELISA. Use of a real-time PCR assay to detect *C. felis* has also been reported, which is capable of quantifying the number of organisms within a clinical sample down to 10 genomic copies (Helps *et al.*, 2001). The biggest problem with all nucleic acid amplification techniques is false positives resulting from contamination, which may occur before sample submission or after submission to the laboratory. Veterinarians collecting samples for PCR should contact the laboratory for sample

collection and handling guidelines to minimise contamination occurring outside the laboratory.

Treatment

Chlamydiae are susceptible to tetracyclines, erythromycin, rifampin, fluoroquinolones and the newer macrolide azithromycin (Stamm, 1998). Clinically significant antimicrobial resistance has not been reported for Chlamydiae.

Sulfonamides and chloramphenicol are ineffective against *C. felis*. Penicillin is inhibitory at high doses, but does not eliminate the organism. Tetracyclines are most efficacious, although recurrences have been noted with treatment durations anywhere from 4 days to 7 weeks. In experimentally infected cats, *C. felis* infection was successfully eradicated using systemic doxycycline alone for 3 weeks (5 mg/kg every 12 h) (Sykes *et al.*, 1999a). Rapid clinical improvement and elimination of the organism occurred by day 2 after institution of treatment when culture was used as a test-of-cure, and by day 6 after institution of treatment when PCR was used as a test-of-cure. All cats remained negative until the end of the study (2 additional weeks beyond cessation of treatment). Because of the long half-life of doxycycline, once-daily administration at 10 mg/kg is likely to be equally effective and more convenient to pet owners. Systemic treatment with doxycycline has been shown to be superior to twice-daily topical treatment with 1% chlortetracycline ointment (Sparkes *et al.*, 1999).

Despite these results, in some cases, periods of treatment longer than 3 weeks have been necessary to eliminate natural infections with *C. felis*. Some have recommended combining systemic therapy with topical tetracycline ointments every 6–8 h (Gaskell & Bennett, 1996; Greene, 1998b). A minimum of 6–8 weeks of treatment, especially for cattery cats, has also been suggested (Gruffydd-Jones *et al.*, 1995; Greene, 1998b). Continuing treatment for 2 weeks after resolution of clinical signs is generally recommended. Two catteries were successfully treated with in-feed lincomycin–spectinomycin (55 mg and 111 mg/cat per day, respectively), which was given for 8 weeks (Pointon *et al.*, 1991).

It is possible that in chronic infections, in which the organism has entered a persistent state (if this truly occurs in cats), the organism may be more difficult to eliminate, as occurs in humans with chlamydial arthritis (Leirisalo-Repo, 1993). However, recurring cases often involve large numbers of cats and poor compliance; often not all cats are treated and the owner fails to administer all doses. All cats must be treated with the full course of antimicrobials and proper hygiene and quarantine must be maintained. This may be difficult to achieve when large numbers of cats must be treated. It is also important to consider the concurrent presence of viral causes of URTD, which may show initial response with antimicrobial therapy owing to resolution of secondary bacterial infections. Use of a 1:32 bleach to detergent solution is recommended for general disinfection where undiagnosed FCV infection remains a possibility.

There is a risk of permanent teeth discoloration in kittens if tetracyclines are used in pregnant queens in the last 2–3 weeks of pregnancy or in kittens in the first few months of life. Doxycycline has reduced calcium-binding avidity compared with other tetracyclines, and therefore produces only minor discoloration. There is little evidence to suggest the occurrence of such side-effects in cats using doxycycline, but owners should be made aware of the possibility. In humans, erythromycin is substituted, but there have been no studies of the effect of erythromycin in cats with chlamydiosis. Recently, a 4 week course of amoxycillin–clavulanic acid was shown to eliminate *C. felis* in experimentally infected cats, with no recurrence 6 months after discontinuing therapy (Sturgess *et al.*, 2001), although a 19 day course was followed by recurrence of infection. This may be a safe alternative to tetracyclines for the treatment of chlamydiosis in young kittens.

Vaccination and immunity

Immunity to chlamydial infection is generally weak or short lived. Although protection from rechallenge occurs 3 months after initial challenge, protection beyond this period is only partial (Wills, 1986). However, the apparent age-related resistance of cats to *C. felis* infection suggests that some form of protective immunity must eventually develop. In human chlamydial infections, antibody alone does not appear to be sufficient for protection or recovery from infection, probably because of the protected intracellular location of chlamydiae. The humoral immune response to *C. felis* has been examined, and appears similar to that for other chlamydial species (TerWee *et al.*, 1998). Cell-mediated immunity, particularly that effected by T-helper cells, appears essential for resolution of infection.

Most kittens acquiring colostrum from previously exposed queens appear to be protected by MDA until

9 weeks of age; some may be protected as late as 12 weeks of age (Wills *et al*., 1988c).

Both modified live and inactivated cell culture vaccines have been used in the USA and the UK, either alone or in combination with feline panleucopenia, FCV and FHV-1 components. *Chlamydophilia felis* vaccines have been associated with atypical reactions in about 3% of cats, consisting of fever, lethargy, anorexia and lameness 7–21 days after vaccination. In addition, the chlamydial vaccine does not prevent infection or clinical signs, although the latter are generally reduced in severity. Vaccines may be of most benefit as part of a control programme in catteries with endemic chlamydiosis.

References

Baker J.A. (1942) A virus obtained from a pneumonia of cats and its possible relation to the cause of atypical pneumonia in man. *Science* **96**, 475–476.

Baker J.A. (1944) A virus causing pneumonia in cats and producing elementary bodies. *J Exp Med* **79**, 159–171.

Beutler A.M., Schumacher H.R. Jr, Whittum-Hudson J.A., *et al*. (1995) Case report: *in situ* hybridization for detection of inapparent infection with *Chlamydia trachomatis* in synovial tissue of a patient with Reiter's syndrome. *Am J Med Sci* **310**, 206–213.

Cello R.M. (1971) Microbiological and immunological aspects of feline pneumonitis. *J Am Vet Med Assoc* **158**.

Darougar S., Monnickendam M.A., El-Sheikh H., *et al*. (1977) Animal Models for the study of chlamydial infections. In *Non-gonococcal Urethritis and Related Infections* (eds Hobson D. & Holmes K.K.). American Society for Microbiology, Washington, DC, pp. 186–198.

Dickie C.W. & Sniff E.S. (1980) Chlamydia infection associated with peritonitis in a cat. *J Am Vet Med Assoc* **176**, 1256–1259.

El-Sheikh E.H.A. (1978) Feline chlamydial keratoconjunctivitis as an analogue of trachoma. Ph.D. Thesis, University of London.

Emmons R.W., Riggs J. L. & Schachter J. (1976) Continuing search for the aetiology of cat scratch disease. *J Clin Microbiol* **4**, 112–114.

Everett K.D., Bush R.M. & Andersen A.A. (1999) Emended description of the order Chlamydiales, proposal of Parachlamydiaceae fam. nov. and Simkaniaceae fam. nov., each containing one monotypic genus, revised taxonomy of the family Chlamydiaceae, including a new genus and five new species, and standards for the identification of organisms. *Int J Syst Bacteriol* **49 Pt 2**, 415–440.

Frutos R., Pages M., Bellis M., *et al*. (1989) Pulsed-field gel electrophoresis determination of the genome size of obligate intracellular bacteria belonging to the genera *Chlamydia*, *Rickettsiella*, and *Porochlamydia*. *J Bacteriol* **171**, 4511–4513.

Gaskell R.M. & Bennett M. (1996) Feline *Chlamydia psittaci* infection. In *Feline and Canine Infectious Diseases*. Blackwell Science, Oxford, pp. 21–25.

Greene C.E. (1998a) Immunocompromised people and pets. In *Infectious Diseases of the Dog and Cat*. 2nd edn (ed. Greene C.E.). WB Saunders, Philadelphia, PA, pp. 710–717.

Greene C.E. (1998b) Chlamydial infections. In *Infectious Diseases of the Dog and Cat*. 2nd edn (ed. Greene C.E.). WB Saunders, Philadelphia, PA, pp. 172–174.

Griffiths P.D., Lechler R.I. & Treharne J.D. (1978) Unusual chlamydial infection in a human renal allograft recipient. *BMJ* **ii**, 1264–1265.

Gruffydd-Jones T.J., Jones B.R., Hodge H., *et al*. (1995) *Chlamydia* infection in cats in New Zealand. *NZ Vet J* **43**, 201–203.

Hanselaer J.R., Derore A., Boucherie P. & Mattheeuws D. (1989) Demonstration of *Chlamydia psittaci* in feline conjunctivitis cases in Belgium. *Vlaams Diergeneeskd Tijdschr* **58**, 165–168.

Hargis A.M., Prieur D.J. & Gaillard E.T. (1983) Chlamydial infection of the gastric mucosa in twelve cats. *Vet Pathol* **20**, 170–178.

Hartley J.C., Stevenson S., Robinson A.J., *et al*. (2001) Conjunctivitis due to *Chlamydophila felis* (*Chlamydia psittaci* feline pneumonitis agent) acquired from a cat: case report with molecular characterization of isolates from the patient and cat. *J Infect* **43**, 7–11.

Helps C., Reeves N., Tasker S. & Harbour D. (2001) Use of real-time quantitative PCR to detect *Chlamydophila felis* infection. *J Clin Microbiol* **39**, 2675–2676.

Hoover E.A. (1980) Feline pneumonitis. In *Current Veterinary Therapy*, Vol. VII, *Small Animal Practice* (ed. Kirk R.W.). WB Saunders, Philadelphia, PA, pp. 1299–1302.

Hoover E.A., Kahn D.E. & Langloss J.M. (1978) Experimentally induced feline chlamydial infection (feline pneumonitis). *Am J Vet Res* **39**, 541–547.

Kane J.L., Woodland R.M., Elder M.G. & Darougar S. (1985) Chlamydial pelvic infection in cats: a model for the study of human pelvic inflammatory disease. *Genitourin Med* **61**, 311–318.

Kuroda-Kitogawa Y., Suzuki-Muramatsu C., Yamaguchi T., *et al*. (1993) Antigenic analysis of *Chlamydia pecorum* and mammalian *Chlamydia psittaci* by use of monoclonal antibodies to the major outer membrane protein and a 56- to 64-kd protein. *Am J Vet Res* **54**, 709–712.

Leirisalo-Repo M. (1993) Are antibiotics of any use in reactive arthritis? *APMIS* **101**, 575–581.

McDonald M., Willett B.J., Jarrett O. & Addie, D.D. (1998) A comparison of DNA amplification, isolation and serology for the detection of *Chlamydia psittaci* infection in cats. *Vet Rec* **143**, 97–101.

Maurin M., Eb F., Etienne J. & Raoult D. (1997) Serological cross-reactions between *Bartonella* and *Chlamydia* species: implications for diagnosis. *J Clin Microbiol* **35**, 2283–2287.

May S.W., Kelling C.L., Sabara M. & Sandbulte J. (1996) Virulence of feline *Chlamydia psittaci* in mice is not a function of the major outer membrane protein (MOMP). *Vet Microbiol* **53**, 355–368.

O'Dair H.A., Hopper C.D., Gruffydd-Jones T.J., *et al.* (1994) Clinical aspects of *Chlamydia psittaci* infection in cats infected with feline immunodeficiency virus. *Vet Rec* **134**, 365–368.

Ostler H.B., Schachter J. & Dawson C.R. (1969) Acute follicular conjunctivitis of epizootic origin. *Arch Ophthalmol* **82**, 587–591.

Pointon A.M., Nicholls J.M., Neville S., *et al.* (1991) *Chlamydia* infection among breeding catteries in South Australia. *Aust Vet Pract* **21**, 58–63.

Pudjiatmoko, Fukushi H., Ochiai Y., *et al.* (1997) Diversity of feline *Chlamydia psittaci* revealed by random amplification of polymorphic DNA. *Vet Microbiol* **54**, 73–83.

Regan R.J., Dathan J.R.E. & Treharne J.D. (1979) Infective endocarditis with glomerulonephritis associated with cat chlamydia (*Chlamydia psittaci*) infection. *Br Heart J* **42**, 349–352.

Sayada C., Andersen A., Rodriguez P., *et al.* (1994) Homogeneity of the major outer membrane protein gene of feline *Chlamydia psittaci. Res Vet Sci* **56**, 116–118.

Schachter J., Ostler H.B. & Meyer K.F. (1969) Human infection with the agent of feline pneumonitis. *Lancet* **i**, 1063–1065.

Shewen P.E., Povey R.C. & Wilson M.R. (1980) A survey of the conjunctival flora of clinically normal cats and cats with conjunctivitis. *Can Vet J* **21**, 231–233.

Sparkes A.H., Caney S.M.A., Sturgess C.P. & Gruffydd-Jones T.J. (1999) The clinical efficacy of topical and systemic therapy for treatment of feline ocular chlamydiosis. *J Feline Med Surg* **1**, 31–35.

Stamm W.E. (1998) Chlamydial infections. In *Harrison's Principles of Internal Medicine* (eds Fauci A.S., Braunwald E., Isselbacher K.J., *et al.*). McGraw-Hill, New York.

Stamm W.E., Tam M., Koester M. & Cles L. (1983) Detection of *Chlamydia trachomatis* inclusions in McCoy cell cultures with fluorescein-conjugated monoclonal antibodies. *J Clin Microbiol* **17**, 666–668.

Sturgess C.P., Gruffydd-Jones T.J., Harbour D.A. & Jones R.L. (2001) Controlled study of the efficacy of clavulanic acid-potentiated amoxycillin in the treatment of *Chlamydia psittaci* in cats. *Vet Rec* **149**, 73–76.

Sykes J.E. (1997) Improvements in diagnosis and understanding of feline upper respiratory tract pathogens. Ph.D. Thesis, University of Melbourne.

Sykes J.E., Studdert V.P. & Browning G.F. (1999a) Polymerase chain reaction detection of *Chlamydia psittaci* in untreated and doxycycline-treated experimentally-infected cats. *J Vet Intern Med* **13**, 146–152.

Sykes J.E., Anderson G.A., Studdert V.P. & Browning G.F. (1999b) Prevalence of feline *Chlamydia psittaci* and feline herpesvirus 1 in cats with upper respiratory tract disease. *J Vet Intern Med* **13**, 153–162.

Tabatabayi A.H. & Rad M.A. (1981) First isolation of feline *C. psittaci* from a cat in Iran. *Feline Pract* **11**, 35–38.

TerWee J., Lauritzen A.Y., Sabara M., *et al.* (1997) Comparison of the primary signs induced by experimental exposure to either a pneumotrophic or a 'limping' strain of feline calicivirus. *Vet Microbiol* **56**, 33–45.

TerWee J., Sabara M., Kokjohn K., *et al.* (1998) Characterization of the systemic disease and ocular signs induced by experimental infection with *Chlamydia psittaci* in cats. *Vet Microbiol* **59**, 259–281.

Wills J.M. (1986) Chlamydial infection in the cat. Ph.D. Thesis, University of Bristol.

Wills J.M., Howard P.E., Gruffydd-Jones T.J. & Wathes C.M. (1988a) Prevalence of *Chlamydia psittaci* in different cat populations in Britain. *J Small Anim Pract* **29**, 327–339.

Wills J.M., Millards W.G. & Howard P.E. (1988b) Evaluation of a monoclonal antibody based ELISA for detection of feline *Chlamydia psittaci. Vet Rec* **119**, 418–420.

Wills J.M., Roberts K., Richmond J.S. & Gruffydd-Jones T.J. (1988c) Transmission of feline *Chlamydia psittaci* from dam to kittens. In *Proceedings of the European Society for Chlamydia Research*, Bologna, Italy, p. 61.

Yerasimides T.G. (1960) Isolation of a new strain of feline pneumonitis virus from a domestic cat. *J Infect Dis* **106**, 290–296.

Chapter 28

FELINE TOXOPLASMOSIS

M.R. Lappin

Introduction

Toxoplasma gondii infection is extremely common in cats and people throughout the world. The seroprevalence in cats and people varies by the region and country, but is commonly 30–40% (Dubey & Beattie, 1988). Once a cat or human has been infected with *T. gondii*, the organism probably remains in the tissues for life. Cats are the only definitive host of *T. gondii* and pass oocysts of the organism in stools. Oocysts are infectious after sporulation, which occurs after 1–5 days in the environment. Humans are infected by the ingestion of sporulated oocysts or tissue cysts. Clinical toxoplasmosis can be severe in transplacentally infected children and in other immunosuppressed people. Most cats are subclinically infected by *T. gondii*, but clinical disease potentially resulting in death occurs in some. The clinical manifestations of toxoplasmosis are diverse and most diagnostic test results are not pathognomonic. Feline toxoplasmosis has been extensively reviewed (Dubey, 1985). This chapter is an updated version of previously reported work (Lappin, 1999) and presents an overview of the current clinical and zoonotic issues associated with feline toxoplasmosis.

Aetiology

Toxoplasma gondii is a tissue protozoan with three primary life stages. Tachyzoites are the rapidly dividing stage of the organism that disseminates in blood or lymph during active infection. Tachyzoites replicate intracellularly until the infected cell is destroyed, releasing the organism. Clinical signs develop as inflammation of infected organs occurs. If immune responses are inadequate, overwhelming infection occurs, resulting in death.

If appropriate immune responses attenuate organism replication, tissue cysts develop that contain the slowly dividing bradyzoites. Tissue cysts form readily in the central nervous system (CNS), muscles and visceral organs. Bradyzoites are alive and can be reactivated by immunosuppression to divide rapidly as tachyzoites. Following infection of cats and people, it is likely that bradyzoites persist in tissues for life. Bradyzoites are likely the source of intermittent antigenaemia and immune complex formation in cats (Lappin *et al.*, 1989a,b, 1992d, 1993).

Only cats complete the coccidian life cycle in the intestinal tract. After a cat ingests bradyzoites, epithelial cells are infected and a series of asexual replications occurs, followed by the sexual cycle. The male gamete fertilises the female gamete and oocysts are formed. Oocysts are passed in faeces and are unsporulated and non-infectious (Plate 28.1). Sporozoites (four in each of two sporocysts) develop in oocysts after 1–5 days of exposure to oxygen and appropriate environmental temperature and humidity (Plate 28.2). When faeces is buried by the cat, sporulated oocysts commonly survive for 18 months, even in areas with high temperature, freezing temperatures, and low humidity (Lindsay *et al.*, 1997).

Transmission

Ingesting of any of the three life stages of *T. gondii* can infect warm-blooded vertebrates, including cats and people. Since cats are usually not coprophagic, ingesting *T. gondii* bradyzoites during carnivorous feeding infects most cats; oocysts can generally be detected in faeces starting 3 days after infection. Oocyst shedding is usually completed by 10–21 days after infection. If cats are infected by ingestion of sporulated oocysts,

onset of oocyst shedding is between 18 and 44 days after infection and the patent period lasts for 6–10 days (Dubey, 1996). It appears that tachyzoite ingestion can result in infection of some cats and people (Bonametti *et al.*, 1997). Kittens allowed to nurse infected queens were more likely to develop toxoplasmosis than those that did not nurse (Dubey *et al.*, 1995), and the organism has been detected in the milk of queens (Powell *et al.*, 2001).

Transplacental infection occurs if a *T. gondii*-naïve woman or queen ingests *T. gondii* during gestation. It is difficult to infect the foetus during the first trimester, but if infection occurs, sequelae are generally severe. In people, stillbirth, abortion and severe CNS disease are common. In neonatally infected kittens, interstitial pneumonia, necrotising hepatitis, myocarditis, non-suppurative encephalitis and uveitis are commonly detected after necropsy and histological examination (Dubey *et al.*, 1996). In people, the foetus is more likely to be infected if exposed during the second and third trimesters, but resultant disease is usually milder than that associated with first trimester infections. This appears to be true for cats as well (Sato *et al.*, 1993; Powell & Lappin, 2001). Previously infected women are unlikely to transmit *T. gondii* to the fetus even if exposed during gestation; it is unknown whether this is true for queens.

Pathogenesis

Fatal toxoplasmosis can result from overwhelming primary infection or bradyzoites in tissue cysts can be induced to replicate rapidly and disseminate again as tachyzoites (Dubey & Carpenter, 1993b). Primary infection resulting in death generally occurs in immunodeficient individuals such as transplacentally infected foetuses; clinical signs are usually mild or not detected during primary infection of immunocompetent individuals. Activation of bradyzoites occurs during severe immunodeficiency. For example, disseminated fatal toxoplasmosis can be induced in healthy, experimentally infected cats by administration of extremely high doses of glucocorticoids (Dubey & Frenkel, 1974). In addition, immune suppression induced by cyclosporine has resulted in fatal toxoplasmosis in cats undergoing renal transplantation (Bernsteen *et al.*, 1999). People with chronic toxoplasmosis and the acquired immune deficiency syndrome (AIDS) commonly develop activated cerebral toxoplasmosis as $CD4^+$ lymphocyte counts diminish (Oksenhendler *et al.*, 1994).

The mechanism of disease is unknown in chronic, subfatal toxoplasmosis. Disease may be related in part to low-level tachyzoite replication. Intermittent antigenaemia (Lappin *et al.*, 1989a) and parasitaemia (Burney *et al.*, 1999) have been detected in experimentally inoculated cats. *Toxoplasma gondii*-specific antigens (Lappin *et al.*, 1992d) and DNA (Lappin *et al.*, 1996a), are detected in aqueous humour from more cats with uveitis than without uveitis, suggesting that organism replication in ocular tissues is occurring. However, not all cats with *T. gondii* in aqueous humour are diseased, and the organism is rarely documented in ocular tissues of cats without fatal disease. Most cats with uveitis have lymphocytes and plasma cells in the ciliary body (Davidson *et al.*, 1991; Peiffer & Wilcock, 1991). Pathogenesis of disease may relate to immunological reactions against the organism; immune complex formation and deposition in tissues and delayed hypersensitivity reactions may be involved. Cats with uveitis were more likely to have detectable *T. gondii*-specific serum immune complexes than healthy cats (Lappin *et al.*, 1993). Interleukin-6 is likely to be a mediator of inflammation in ocular toxoplasmosis (Lappin *et al.*, 1997). It is possible that *in utero* infection or infection in the neonatal period influences the development of ocular toxoplasmosis. In one study, ocular disease was detected in 15 of 21 kittens born to queens infected during gestation (Powell & Lappin, 2001). It was hypothesized that ocular toxoplasmosis was reactivated by coinfection with other pathogens, but activated disease was not detected in *T. gondii*-infected cats sequentially infected with *Bartonella henselae* and feline herpesvirus-1 (Powell *et al.*, 2002).

Clinical considerations

Intestinal toxoplasmosis

Following ingestion of *T. gondii* bradyzoites, the intestinal cycle is completed in 21 days or less. Some experimentally inoculated cats develop self-limiting, small bowel diarrhoea; this is presumed to result from enteroepithelial replication of the organism. However, detection of *T. gondii* oocysts in faeces is rarely reported in studies of naturally exposed cats with or without clinical disease (Dubey & Beattie, 1988; Dubey *et al.*, 1990). In a recent study of 203 client-owned or shelter-source cats with diarrhoea or without diarrhoea, 23.6% were seropositive but none had *T. gondii* oocysts detected in faeces (Hill *et al.*, 1998). In a study

of 263 kittens less than 1 year of age, three (1.1%) were shedding oocysts morphologically consistent with *T. gondii* (Spain *et al.*, 2001). Protozoal agents morphologically consistent with *T. gondii* enteroepithelial stages were found in intestinal tissues from two cats with inflammatory bowel disease (Peterson *et al.*, 1991). The positive response to anti-*Toxoplasma* drugs in these two cats suggests that toxoplasmosis may occasionally induce inflammatory bowel disease.

Extraintestinal toxoplasmosis

Overwhelming tachyzoite replication

Toxoplasmosis induced transplacentally or by suckling in kittens is often clinically severe, resulting from overwhelming tachyzoite replication (Dubey & Johnstone, 1982; Dubey *et al.*, 1989, 1996; Dubey & Carpenter, 1993a,b; Sato *et al.*, 1993; Powell & Lappin, 2001). Anorexia, vocalisation, signs of depression, lethargy, hypothermia, dyspnoea and sudden death are common clinical abnormalities in kittens born alive. Clinical signs developed within 2 days of birth and as late as 25 days after birth. Necrosis with infiltrates of macrophages in lung, liver, cardiac, muscle, CNS, ocular, adrenal and renal tissues are characteristic and are likely to relate to the cause of death (Dubey *et al.*, 1996).

Clinical findings for 100 cats with histologically confirmed extraintestinal toxoplasmosis diagnosed between 1952 and 1990 were reported (Dubey & Carpenter, 1993a). Clinically, 36 cats were thought to have generalised toxoplasmosis; for the remainder the principal lesions were considered pulmonary in 26, abdominal in 16, hepatic in 12, pancreatic in one, cardiac in 12, neurological in seven and neonatal in nine. Histological examination revealed inflammation resulting from replication of tachyzoites that resulted in fatal disease or euthanasia. Tissues with lesions consistent with toxoplasmosis included lungs (84 of 86; 97.7%), brain (53 of 55; 96.4%), liver (84 of 90; 93.3%), heart (51 of 59; 86.4%), pancreas (38 of 45; 84.4%), eyes (22 of 27; 81.5%) and adrenals (18 of 30; 60%). The organism was detected concurrently in most tissues. The clinical course was known for 60 cats; it varied from 1 day to 3 months with a mean of 14 days (Dubey & Carpenter, 1993a). Only 11 of the cats were purebred and 65 of 99 for which sex was known were male. The median and mean ages were 2 and 4 years, respectively, and the majority were aged less than 1 year. Fever (73%), dyspnoea, polypnoea, anorexia, lethargy, icterus (24%), signs of abdominal discomfort, CNS signs and signs of ocular inflammation were common.

Chronic toxoplasmosis

Clinical extraintestinal toxoplasmosis has been suspected in a number of other cats with a more chronic course. Since these cats did not die and the organism was not demonstrated, a presumptive diagnosis was made based on appropriate serological findings, exclusion of other potential causes of the clinical syndrome and response to anti-*Toxoplasma* drugs (see section on clinical diagnosis, below). The primary clinical findings include anterior uveitis, posterior uveitis, fever, muscle hyperaesthesia, weight loss, anorexia, seizures and ataxia (Lappin *et al.*, 1989c, 1992c,d; O'Neil *et al.*, 1991; Chavkin *et al.*, 1992). Fever and muscle hyperaesthesia usually resolve quickly following administration of anti-*Toxoplasma* drugs (see Treatment, below) and are rarely recurrent.

Uveitis can be unilateral or bilateral (Lappin *et al.*, 1989c, 1992c,d; Chavkin *et al.*, 1992). Severe anterior segment inflammation (Plate 28.3) can occur; hypopyon, flare and keratic precipitates may make visualisation of the posterior segment difficult. Chorioretinitis can be unifocal or multifocal, punctate or diffuse (Plate 28.4). Lens luxation and secondary glaucoma are common sequelae (Chavkin *et al.*, 1992). Cats with uveitis are commonly seropositive for *T. gondii* and other potential ocular pathogens such as feline leukaemia virus (FeLV), feline immunodeficiency virus (FIV) and feline infectious peritonitis virus, making serological diagnosis difficult (see Diagnosis section, below) (Lappin *et al.*, 1989c, 1994; Chavkin *et al.*, 1992). Ocular disease and CNS disease occur alone or concurrently and can be detected in cats without polysystemic signs of disease such as fever.

Chronic subfatal toxoplasmosis has been detected in cats with and without coinfection by FeLV or FIV (Lappin *et al.*, 1989c; O'Neil *et al.*, 1991).

The clinical syndromes reported in retrovirus-infected cats are similar to those from retrovirus-naïve cats. It is possible that the cats with coinfections had not developed immunodeficiency severe enough to cause overwhelming tachyzoite replication and death.

Diagnostic tests

Haematological, biochemical and urinalysis findings

There are no pathognomonic laboratory findings associated with clinical toxoplasmosis (Lappin *et al.*, 1989c; Dubey & Carpenter, 1993a). However, if the clinical history is consistent with toxoplasmosis, the

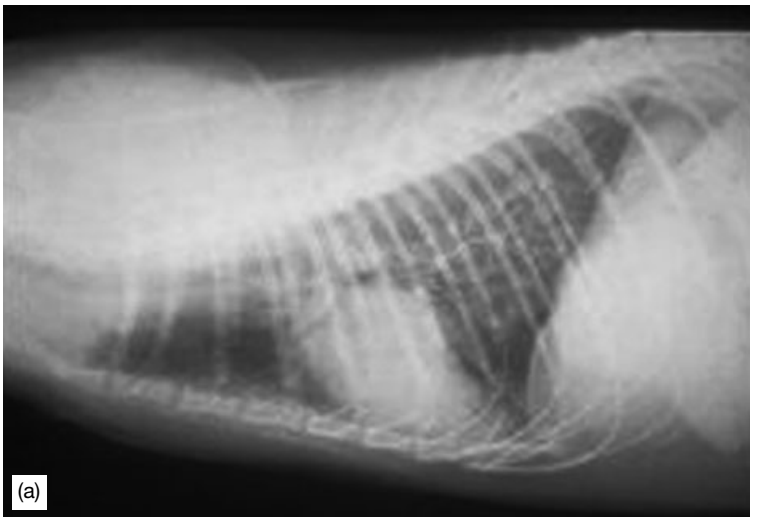

Figure 28.1 Radiographs from a cat with disseminated toxoplasmosis. Note the mixed interstitial and alveolar pattern.

following laboratory abnormalities raise the clinical suspicion: non-regenerative anemia, neutrophilic leucocytosis, lymphocytosis, monocytosis, neutropenia, eosinophilia, increased activities of creatinine kinase, alanine aminotransferase, alkaline phosphatase and lipase, hyperbilirubinaemia, hyperproteinaemia, proteinuria and bilirubinuria.

Radiographic findings

Interstitial and alveolar patterns are detected with pulmonic toxoplasmosis; pleural effusion is rarely detected (Figure 28.1). Abdominal radiographic findings are non-specific but can include homogeneous increased density due to peritoneal effusion, hepatomegaly, lymphadenopathy, intestinal masses or loss of contrast in the cranial right quadrant of the abdomen due to pancreatitis. In cats with CNS involvement, mass lesions are potentially detected by myelography, computed tomographic (CT) scan or magnetic resonance image (MRI).

Cytology and cerebrospinal fluid analyses

In a series of cats with suspected CNS toxoplasmosis, cerebrospinal fluid (CSF) protein levels ranged from normal to 149 mg/% and nucleated cell counts ranged from <5 to 28 cells/mm^3 (Lappin M.R. unpublished data). Small mononuclear cells were the predominant white blood cells. Tachyzoites can be detected cytologically in blood, CSF, transtracheal wash fluids, peritoneal effusions and pleural effusions from clinically ill animals (see Plate 28.1).

Faecal examination

Toxoplasma gondii oocysts measure 10 × 12 μm and can be microscopically demonstrated in feline faeces following flotation using solutions with a specific gravity of 1.18 (see Plates 28.1 and 2) (Dubey & Beattie, 1988). Oocysts of the non-pathogenic coccidians *Hammondia hammondi* or *Besnoitia darlingi* cannot be distinguished microscopically from those of *T. gondii*; definitive diagnosis can be made with laboratory animal inoculation or documentation of *T. gondii* antibodies in the suspect cat. Most cats with clinical toxoplasmosis have completed the oocyst shedding period and so the diagnostic utility of faecal examination is limited. However, owing to the potential zoonotic risk, cats with clinical signs referable to toxoplasmosis should have their faeces examined.

Serology

Toxoplasma gondii-specific antibodies, antigens and immune complexes have been detected in the serum of cats. Tests for antigens and immune complexes are currently only available in research laboratories and so will not be discussed further (Lappin *et al.*, 1989a, 1993).

Antibodies can be detected with multiple techniques that are commercially available, including enzyme-linked immunosorbent assay (ELISA), immunofluorescent antibody, Western blot immunoassay, Sabin Feldman dye test and a variety of agglutination tests. ELISA, immunofluorescent antibody assay and Western blot immunoassay have been adapted to detect immunoglobulin M (IgM), IgG and IgA antibody responses (Figure 28.2) (Burney *et al.*, 1995; Lappin *et al.*, 1989b, 1994; Cannizzo *et al.*, 1996; Lappin, 1996).

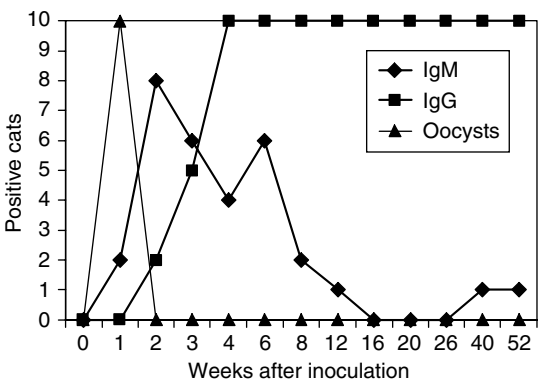

Figure 28.2 Temporal appearance of *Toxoplasma gondii*-specific IgM, IgG and IgA antibodies in serum of experimentally inoculated cats.

A latex agglutination assay and an indirect hemagglutination assay are available commercially. These assays can be used with serum from multiple species and theoretically detect all classes of immunoglobulin directed against *T. gondii*. However, these assays rarely detect antibody in feline serum samples positive only for IgM (Lappin & Powell, 1991). Combining modified agglutination tests using formalin-fixed and acetone-fixed tachyzoites can be used to predict recent infection accurately, but the assays are not commercially available (Dubey & Thulliez, 1989).

Using ELISA, approximately 80% of healthy, experimentally infected cats have detectable *T. gondii*-specific IgM in serum within 2–4 weeks following inoculation with *T. gondii*; these titres generally are negative within 16 weeks after infection (Lappin *et al.*, 1989b). Persistent IgM titres (>16 weeks) have been documented commonly in cats coinfected with FIV and in cats with ocular toxoplasmosis. In some chronically infected cats, IgM can be detected again after repeat inoculation with *T. gondii*, primary inoculation with the Petaluma isolate of FIV (Lappin *et al.*, 1992b) and administration of glucocorticoids (Lappin *et al.*, 1992a). Because of these findings, IgM titres cannot accurately predict when a cat shed oocysts or whether a cat has clinical toxoplasmosis. However, detectable IgM titres were present in the serum of 93.3% of the cats in one study of clinical toxoplasmosis; IgG titres were detected in 60% and so the IgM antibody class appears to correlate with clinical disease better than IgG (Lappin *et al.*, 1989c).

Toxoplasma gondii-specific IgG can be detected by ELISA in serum in the majority of healthy experimentally inoculated cats within 3–4 weeks after infection (Lappin, 1996). IgG antibody titres can be detected for at least 6 years after infection (Dubey, 1995); since the organism probably persists for life, IgG antibodies probably do so as well. Single, high IgG titres do not necessarily suggest recent or active infection; healthy cats commonly have titres over 10 000, 6 years after experimental induction of toxoplasmosis (Dubey, 1995). The demonstration of an increasing IgG titre can document recent or active disease, but in experimentally infected cats the time-span from the first detectable positive IgG titre to the maximal IgG titre is approximately 2–3 weeks. Many cats with subfatal clinical toxoplasmosis have chronic, mild clinical signs and may not be evaluated serologically until their IgG antibody titres have reached their maximal values. In humans and cats with reactivation of chronic toxoplasmosis, IgG titres only rarely increase.

Western blot immunoassay can be used to determine the *T. gondii* antigens recognised by humoral immune responses (Lappin *et al.*, 1994). Transplacentally infected kittens could be distinguished from *T. gondii*-naïve kittens with antibodies in serum from colostrum ingestion by comparing antigen recognition patterns between the queen and kittens (Cannizzo *et al.*, 1996).

Aqueous humour and cerebrospinal fluid antibody and DNA measurement

Detection of *T. gondii*-specific antibodies produced by the eyes or CNS can be used to document clinical toxoplasmosis. Whereas IgG and IgA class antibodies are produced transiently by the eyes and CNS of healthy cats after experimental inoculation (Chavkin *et al.*, 1994; Lappin *et al.*, 1995; Munana *et al.*, 1995), IgM has only been detected in the aqueous humour or CSF of cats with clinical disease (Lappin *et al.*, 1992d). Most cats with local production of *T. gondii*-specific antibodies in aqueous humour have responded to the administration of anti-*Toxoplasma* drugs, suggesting that aqueous humour antibody testing can aid in the diagnosis of clinical ocular toxoplasmosis in cats (Lappin *et al.*, 1992d). *Toxoplasma gondii* DNA has been detected in the aqueous humour of cats with uveitis by polymerase chain reaction (PCR) (Lappin *et al.*, 1996a). However, the organism is also detected occasionally in the aqueous humour of cats without uveitis and so positive results do not definitively document clinical toxoplasmosis (Lappin *et al.*, 1996a; Burney *et al.*, 1998).

Demonstration of *Toxoplasma gondii* in tissues

In addition to cytological demonstration of *T. gondii* tachyzoites, PCR, tissue culture or animal inoculation can detect the organism in whole blood, aqueous humour or CSF. Tissue biopsy sections can be assessed for the presence of *T. gondii* by haematoxylin and eosin (H&E) staining, immunohistochemical staining, PCR, cell culture or animal inoculation. Immunohistochemical staining procedures are superior to H&E staining because they are specific for *T. gondii*. It may be difficult to document the organism in the tissues of some clinically ill cats because of the small sections of tissue evaluated histopathologically and because the pathogenesis of disease in some may be immune mediated. This appears to be particularly true for the ophthalmic form of the disease in cats.

Diagnosis of clinical feline toxoplasmosis

Definitive diagnosis of clinical feline toxoplasmosis requires documentation of the organism in tissues in association with inflammation. This is usually achieved at necropsy in cats with overwhelming tachyzoite replication (Dubey & Carpenter, 1993). Ante-mortem definitive diagnosis of clinical feline toxoplasmosis is rarely made by demonstrating bradyzoites or tachyzoites in tissues or effusions.

Since *T. gondii*-specific antibodies can be detected in the serum, CSF and aqueous humour of normal animals as well as those with clinical signs of disease, it is impossible to make an ante-mortem diagnosis of clinical toxoplasmosis based on these tests alone. The following combination can be used to make a presumptive ante-mortem diagnosis of clinical feline toxoplasmosis:

- demonstration of antibodies in serum, aqueous humour or CSF which document exposure to *T. gondii*
- demonstration of an IgM titre >1:64, a four-fold or greater increase in IgG titre, or the documentation of local antibody production or DNA in aqueous humour or CSF which suggests recent or active infection
- clinical signs of disease referable to toxoplasmosis
- exclusion of other common aetiologies
- positive response to appropriate treatment.

Treatment

Cats with suspected clinical toxoplasmosis should be administered supportive care as needed. Clindamycin hydrochloride (12 mg/kg p.o. every 12 h for 4 weeks) or trimethoprim–sulfonamide combination (15 mg/kg p.o. every 12 h for 4 weeks) has been used most frequently by the author for the treatment of clinical feline toxoplasmosis.

Administration of clindamycin to research cats for up to 6 weeks has been shown to be safe (Jacobs *et al.*, 1989; Greene *et al.*, 1993). In one study of cats given *T. gondii* by carotid artery inoculation, some clindamycin-treated cats died, while untreated cats did not (Davidson *et al.*, 1996). However, this was apparently related to the route of inoculation; cats infected by *T. gondii* using the naturally occurring oral route did not have complications induced by clindamycin administration (Lappin, M.R., PhD dissertation, 1988,

University of Georgia). Vomiting and small bowel diarrhoea occur with administration of clindamycin in some cats. These clinical signs usually develop acutely; if the drug is stopped for 1–2 days and then reinstituted it is usually tolerated. Clindamycin has also been used successfully for the treatment of CNS toxoplasmosis in cats. Some cats with CNS toxoplasmosis require continual treatment.

Cats that cannot tolerate clindamycin can be administered trimethoprim–sulfonamide combinations. Owing to good penetration into the CNS, trimethoprim–sulfonamide therapy is also indicated for cats with CNS toxoplasmosis and poor response to clindamycin. If trimethoprim–sulfonamide combinations are used, a complete blood cell count should be performed every 2 weeks to monitor for the development of macrocytic anaemia.

Pyrimethamine combined with sulfa drugs is effective for the treatment of human toxoplasmosis, but commonly results in toxicity in cats. The macrolide antibiotics azithromycin, spiramycin and clarithromycin may be effective alternative anti-*Toxoplasma* drugs, but have not been evaluated for the treatment of clinical feline toxoplasmosis. Minocycline is effective for the treatment of ocular toxoplasmosis in rabbits. It is possible that the related synthetic tetracycline, doxycycline (5 mg/kg p.o. twice daily for 4 weeks) may also be effective for the treatment of clinical feline toxoplasmosis.

Cats with toxoplasmic uveitis have intense intraocular inflammatory reactions that commonly leads to lens luxations and glaucoma (Chavkin *et al.*, 1992). Otherwise subclinically infected cats often can be managed with topical glucocorticoids alone (Davidson & English, 1998). If topical glucocorticoid therapy fails or if systemic signs such as fever and muscle pain occur, cats with suspected toxoplasmic uveitis should be treated with anti-*Toxoplasma* drugs in combination with either topical, oral or parenteral glucocorticoids. The author generally prescribes clindamycin and topical 1% prednisolone acetate (one drop, four to six times daily), unless there are concurrent corneal ulcers. Recheck evaluation is performed on days 3 and 7. If there is poor response by day 7, oral prednisolone (1.1 mg/kg p.o. every 12 h) is added to the treatment regimen. Alterative anti-*Toxoplasma* therapy can also be considered in cats with poor response by day 7. Anti-*Toxoplasma* therapy is usually discontinued after 4 weeks. Glucocorticoid treatment is continued as needed to control inflammation. Occasionally, parenteral administration of glucocorticoids is required.

Prognosis

Fever and muscle hyperaesthesia commonly begin to respond within the first 2–3 days of clindamycin or trimethoprim–sulfonamide administration, whereas ocular and CNS toxoplasmosis respond more slowly to therapy. If fever or muscle hyperesthaesia is not lessening after 3 days of treatment, one should administer an alternative anti-*Toxoplasma* drug or consider other causes for the clinical syndrome. Recurrences of clinical signs appear to be more common in cats treated for less than 4 weeks. It is unlikely that currently available anti-*Toxoplasma* drugs can totally clear the body of the organism and so recurrences are common. Cats with fever or muscle hyperaesthesia generally have a good prognosis. Cats with ocular or CNS toxoplasmosis have a guarded prognosis. The prognosis is poor for cats with hepatic or pulmonary disease from organism replication, particularly in immunocompromised cats. For example, cats with activated toxoplasmosis resulting from immunosuppressive drug therapy prescribed for renal transplantation died in spite of clindamycin administration (Bernsteen *et al.*, 1999).

Zoonotic considerations

Toxoplasma gondii is one of the most common small animal zoonoses; approximately 30–40% of adult humans in the world are seropositive, suggesting previous or current infection by *T. gondii*. Fortunately, clinical disease is generally mild following primary infection of immunocompetent people. Self-limiting fever, malaise and lymphadenopathy are the most common clinical abnormalities and the majority never realise when their first *T. gondii* infection occurred. The disease is potentially confused with infectious mononucleosis. Clinical disease can be much more severe in immunosuppressed individuals, particularly the foetus, people with AIDS, and people treated with immunosuppressive agents for the treatment of cancer and to prevent organ transplant rejection. *Toxoplasma gondii* is a common opportunistic CNS infection of people with AIDS; as T-helper cells counts decline, toxoplasmic encephalitis from activation of bradyzoites in tissue cysts can result (Oskenhendler *et al.*, 1994). If a mother has her first *T. gondii* infection during gestation, stillbirth, CNS disease and ocular disease are common clinical manifestations in the foetus (Dubey & Beattie, 1988). The importance of *T. gondii* as a zoonotic disease should not be underestimated.

However, cat owners with potentially immunosuppressive diseases are commonly counselled by human health-care providers to give away their pet cats, or consider euthanasia, owing to the risk of acquiring toxoplasmosis (Spencer, 1992; Glaser *et al.*, 1994).

As discussed previously, people are most commonly infected by *T. gondii* after ingestion of sporulated oocysts or ingestion of tissue cysts. Thus, prevention of toxoplasmosis in people can be achieved by avoiding those two life stages.

Sporulated oocyst transmission

Once passed into the environment, sporulated oocysts survive for months to years and so it is likely that many people acquire toxoplasmosis when working with soil or drinking contaminated water. Clinical toxoplasmosis developed in a group of people following a common exposure in a riding stable (Teutsch *et al.*, 1979), in a group of soldiers drinking contaminated water in Panama (Beneson *et al.*, 1982) and from an oocyst-contaminated municipal water supply (Aramini *et al.*, 1999). All water collected from the environment should be boiled or filtered before drinking. Care should be taken to wash hands carefully after working with soil, or gloves should be worn. Produce from the garden should be washed carefully before ingestion. Children's sandpits should be covered when not in use. If cats are owned, a litterbox liner should be used and the litterbox should be cleaned daily; oocysts require 1–5 days to sporulate. Immunosuppressed or pregnant cat owners should not clean the litterbox. Sporulated oocysts are extremely resistant to most disinfectants; exposure to 10% ammonia for 10 min is required to inactivate this stage of the parasite. Thus, cleaning with scalding water or steam is most practical.

Veterinarians are commonly consulted concerning the risk of individual cats for the zoonotic transfer of *T. gondii*. Although it cannot be stated definitively that a person will not acquire toxoplasmosis from their personal cat, it is probably unlikely. It is true that cats are the only definitive host for toxoplasmosis, but oocysts are only shed for days to several weeks following primary inoculation. Thus, an individual cat will be passing oocysts into the human environment for only a small fraction of its entire lifespan. Following primary inoculation of cats, it is difficult to induce repeat oocyst shedding. Prednisolone (10–80 mg/kg p.o.) or methylprednisolone (10–80 mg/kg i.m.) will induce repeat oocyst shedding in some cats with toxoplasmosis (Dubey & Frenkel, 1974). However, these doses are not routinely used in clinical practice. Administration of methyprednisolone acetate (5 mg/kg weekly for 4–6 weeks) to cats infected with *T. gondii* for 14 weeks or 14 months failed to induce oocyst shedding (Lappin *et al.*, 1992a).

Cats infected with *T. gondii* were given FIV followed by FeLV and shown to develop immunodeficiency-associated syndromes (unpublished data); however, repeat *T. gondii* oocyst shedding could not be demonstrated. Cats with FIV (Plate 28.4) (Lin *et al.*, 1992; Lappin *et al.*, 1996b) or FeLV (Patton *et al.*, 1991) infections have been inoculated with *T. gondii*; oocyst shedding periods and the number of oocysts shed were similar to those for cats without FIV or FeLV infections. It has been shown that gut immunity to *T. gondii* in cats is not permanent; four of nine cats inoculated 6 years after primary inoculation shed oocysts even though each had high serum antibody titres (Dubey, 1995). However, *T. gondii* infected cats with and without FIV infection failed to repeat oocyst shedding when reinfected with *T. gondii* 16 months after primary inoculation (Lappin *et al.*, 1996b). Thus, cats that are exposed to *T. gondii* frequently probably do not shed large numbers of oocysts after the first infection.

Toxoplasma gondii oocysts are not infectious when passed by cats; sporulation requires 1–5 days in the environment (Dubey & Beattie, 1988). Most cats are fastidious and do not leave faeces on their fur for this length of time. Bioassay failed to detect oocysts on the fur of cats 7 days after they were shedding millions of oocysts in faeces (Dubey, 1995). These findings suggest that touching individual cats is an unlikely way to acquire toxoplasmosis, and this hypothesis is supported by epidemiological studies. In one study, veterinary health-care providers were no more likely than the general population to be seropositive for *T. gondii* infection (Behymer *et al.*, 1973). Since oocysts are passed in an unsporulated and non-infectious form, working with fresh feline faeces (<1 day old) is not a risk for veterinary health-care personnel. People with human immunodeficiency virus (HIV) infection who owned cats were no more likely to acquire toxoplasmosis during their illness than people with HIV infection who did not have cat contact (Wallace *et al.*, 1993).

Oocysts measuring $10 \times 12\ \mu m$ in a cat faecal sample could be *T. gondii*. *Hammondia hammondi* and *Besnoitia darlingi* are morphologically similar coccidians passed by cats, but are not human pathogens. The faeces should be collected daily until the oocyst shedding period is complete; administration of clindamycin (25–50 mg/kg p.o. daily), sulfonamides (100 mg/kg p.o. daily) or pyrimethamine (2.0 mg/kg p.o. daily) can reduce levels of oocyst shedding.

There is no serological assay to predict accurately when a cat shed *T. gondii* oocysts in the past, and most cats that are shedding oocysts are seronegative. Most seropositive cats have completed the oocyst shedding period and are unlikely to repeat shedding; most seronegative cats would shed the organism if infected. However, since humans are probably not commonly infected with *T. gondii* from contact with individual cats and since serological test results cannot accurately predict the oocyst shedding status of seropositive cats, testing healthy cats for toxoplasmosis is of little clinical use (Angulo *et al.*, 1994). Faecal examination is an adequate procedure to determine when cats are actively shedding oocysts, but cannot predict when a cat has shed oocysts in the past. If an owner is concerned that they may have toxoplasmosis, they should see their doctor for testing.

Tissue cyst transmission

Ingestion of *T. gondii* in tissues can result in human toxoplasmosis (Dubey & Beattie, 1988). Meats (particularly pork in the USA) should be cooked to medium to well done to inactivate tissue cysts. Gloves should be worn when handling raw meats (including field dressing) for cooking, or hands should be cleaned thoroughly afterwards. Freezing meat at −20°C for several days will kill most, but not all tissue cysts. Ingestion of raw goat's milk can also result in human toxoplasmosis.

References

Angulo F.J., Glaser C.A., Juranek D.D., *et al.* (1994) Caring for pets of immunocompromised persons. *J Am Vet Med Assoc* **205**, 1711–1718.

Aramini J.J., Stephen C., Dubey J.P., *et al.* (1999) Potential contamination of drinking water with *Toxoplasma gondii* oocysts. *Epidemiol Infect* **122**, 305–315.

Behymer R.D., Harlow D.R., Behymer D.E., *et al.* (1973) Serologic diagnosis of toxoplasmosis and prevalence of *Toxoplasma gondii* antibodies in selected feline, canine, and human populations. *J Am Vet Med Assoc* **162**, 959–963.

Beneson M.W., *et al.* (1982) Oocyst-transmitted toxoplasmosis associated with ingestion of contaminated water. *N Engl J Med* **307**, 666–669.

Bernsteen L., Gregory C.R., Aronson L.R., *et al.* (1999) Acute toxoplasmosis following renal transplantation in three cats and a dog. *J Am Vet Med Assoc* **215**, 1123–1126.

Bonametti A.M., Passos J.N., Doga da Silva E.M. & Macedo Z.S. (1997) Probable transmission of acute toxoplasmosis through breast feeding. *J Trop Pediatr* **43**, 116.

Burney D.P., Lappin M.R., Cooper C.M., *et al.* (1995) Detection of *Toxoplasma gondii*-specific IgA in the serum of cats. *Am J Vet Res* **56**, 769–773.

Burney D.P., Lappin M.R., Dow S.W., *et al.* (1998) Polymerase chain reaction for the detection of *Toxoplasma gondii* within aqueous humor of experimentally inoculated cats. *Vet Parasitol* **79**, 181–186.

Burney D.P., Lappin M.R., Spilker M., *et al.* (1999) Detection of *Toxoplasma gondii* parasitemia in experimentally inoculated cats. *J Parasitol* **5**, 947–951.

Cannizzo K.P., Lappin M.R., Cooper C.M., *et al.* (1996) *Toxoplasma gondii* antigen recognition by serum IgM, IgG, and IgA of queens and their neonatally infected kittens. *Am J Vet Res* **57**, 1327–1330.

Chavkin M.J., Lappin M.R., Powell C.C., *et al.* (1992) Seroepidemiologic and clinical observations of 93 cases of uveitis in cats. *Prog Vet Comp Ophthalmol* **2**, 29–36.

Chavkin M.J., Lappin M.R., Powell C.C., *et al.* (1994) *Toxoplasma gondii*-specific antibodies in the aqueous humor of cats with toxoplasmosis. *Am J Vet Res* **55**, 1244–1249.

Davidson M.G. & English R.V. (1998) Feline ocular toxoplasmosis. *Vet Ophthalmol* **1**, 71–80.

Davidson M.G., Nasisse M.P., English R.V., *et al.* (1991) Feline anterior uveitis: a study of 53 cases. *J Am Anim Hosp Assoc* **27**, 77–83.

Davidson M.G., Lappin M.R., Rottman J.R., *et al.* (1996) Paradoxical effect of clindamycin in experimental, acute toxoplasmosis in cats. *Antimicrobial Agents Chemother* **40**, 1352–1359.

Dubey J.P. (1985) Toxoplasmosis in cats. *Feline Pract* **16**, 12–45.

Dubey J.P. (1995) Duration of immunity to shedding *Toxoplasma gondii* oocysts by cats. *J Parasitol* **81**, 410–415.

Dubey J.P. (1996) Infectivity and pathogenicity of *Toxoplasma gondii* oocysts for cats. *J Parasitol* **82**, 957–961.

Dubey J.P. & Beattie C.P. (1988) *Toxoplasmosis of Animals and Man*. CRC Press, Boca Raton, FL, pp. 1–220.

Dubey J.P. & Carpenter J.L. (1993a) Histologically confirmed clinical toxoplasmosis in cats: 100 cases (1952–1990). *J Am Vet Med Assoc* **203**, 1556–1566.

Dubey J.P. & Carpenter J.L. (1993b) Neonatal toxoplasmosis in littermate cats. *J Am Vet Med Assoc* **203**, 1546–1549.

Dubey J.P. & Frenkel J.K. (1974) Immunity to feline toxoplasmosis: modification by administration of corticosteroids. *Vet Pathol* **11**, 350–379.

Dubey J.P, & Johnstone I. (1982) Fatal neonatal toxoplasmosis in cats. *J Am Anim Hosp Assoc* **170**, 538–540.

Dubey J.P. & Thulliez P. (1989) Serologic diagnosis of toxoplasmosis in cats fed *Toxoplasma gondii* tissue cysts. *J Am Vet Med Assoc* **194**, 1297–1299.

Dubey J.P., Johnstone I., Menrath V.H., *et al.* (1989) Congenital toxoplasmosis in Abyssinian cats. *Vet Parasitol* **32**, 261–264.

Dubey J.P., Zajac A., Osofsky S.A., *et al.* (1990) Acute primary toxoplasmic hepatitis in an adult cat shedding *Toxoplasma gondii* oocysts. *J Am Vet Med Assoc* **197**, 1616–1618.

Dubey J.P., Lappin M.R. & Thulliez P. (1995) Diagnosis of induced toxoplasmosis in neonatal cats. *J Am Vet Med Assoc* **207**, 179–185.

Dubey J.P., Mattiz M.E. & Lipscomb T.P. (1996) Lesions of neonatally induced toxoplasmosis in cats. *Vet Pathol* **33**, 290–295.

Glaser C.A., Angulo F.J. & Rooney J.A. (1994) Animal associated opportunistic infections among persons infected with the human immunodeficiency virus. *Clin Infect Dis* **18**, 14–24.

Greene C.E., Lappin M.R. & Marks A. (1993) Effect of clindamycin on clinical, hematologic, and biochemical parameters in healthy cats. *J Am Anim Hosp Assoc* **28**, 323–326.

Hill S., Lappin M.R., Reif J.S., *et al.* (2000) Prevalence of enteric zoonoses in cats. *J Am Vet Med Assoc* **216**, 687–692.

Jacobs G., Lappin M.R., Marks A. & Greene C.E. (1989) Effect of clindamycin on feline factor-VII activity. *Am J Vet Res* **50**, 393–395.

Lappin M.R. (1996) Feline toxoplasmosis: interpretation of diagnostic test results. *Semin Vet Med Surg* **11**, 154–160.

Lappin M.R. (1999) Feline toxoplasmosis. *In Practice* **6**, 578–589.

Lappin M.R. & Powell C.C. (1991) Comparison of latex agglutination, indirect hemagglutination, and ELISA techniques for the detection of *Toxoplasma gondii*-specific antibodies in the serum of cats. *J Vet Intern Med* **5**, 299–301.

Lappin M.R., Greene C.E., Prestwood A.K., *et al.* (1989a) Enzyme-linked immunosorbent assay for the detection of circulating antigens of *Toxoplasma gondii* in the serum of cats. *Am J Vet Res* **50**, 1586–1590.

Lappin M.R., Greene C.E., Prestwood A.K., *et al.* (1989b) Diagnosis of recent *Toxoplasma gondii* infection in cats by use of an enzyme-linked immunosorbent assay for immunoglobulin M. *Am J Vet Res* **50**, 1580–1585.

Lappin M.R., Greene C.E., Winston S., *et al.* (1989c) Clinical feline toxoplasmosis: serologic diagnosis and therapeutic management of 15 cases. *J Vet Int Med* **3**, 139–143.

Lappin M.R., Dawe D.L., Lindl P.A., *et al.* (1992a) The effect of glucocorticoid administration on oocyst shedding, serology, and cell mediated immune responses of cats with recent or chronic toxoplasmosis. *J Am Anim Hosp Assoc* **27**, 625–632.

Lappin M.R., Gasper P.W., Rose B.J., *et al.* (1992b) Effect of primary phase feline immunodeficiency virus infection on cats with chronic toxoplasmosis. *Vet Immunol Immunopathol* **35**, 121–131.

Lappin M.R., Marks A., Greene C.E., *et al.* (1992c) Serologic prevalence of select infectious diseases in cats with uveitis. *J Am Vet Med Assoc* **201**, 1005–1010.

Lappin M.R., Roberts S.M., Davidson M.G., *et al.* (1992d) Enzyme-linked immunosorbent assays for the detection of *Toxoplasma gondii*-specific antibodies and antigens in the aqueous humor of cats. *J Am Vet Med Assoc* **201**, 1010–1016.

Lappin M.R., Cayatte S., Powell C.C., *et al.* (1993) Detection of *Toxoplasma gondii* antigen containing immune complexes in the serum of cats. *Am J Vet Res* **54**, 415–419.

Lappin M.R., Bush D.J. & Reduker D.W. (1994) Feline serum antibody responses to *Toxoplasma gondii* and characterization of target antigens. *J Parasitol* **80**, 73–80.

Lappin M.R., Burney D.P., Hill S.A. & Chavkin M.J. (1995) Demonstration of *Toxoplasma gondii*-specific IgA in the aqueous humor of cats. *Am J Vet Res* **56**, 774–778.

Lappin M.R., Burney D.P., Dow S.W., *et al.* (1996a) Polymerase chain reaction for the detection of *Toxoplasma gondii* in aqueous humor of cats. *Am J Vet Res* **57**, 1589–1593.

Lappin M.R., George J.W., Pedersen N.C., *et al.* (1996b) Primary and secondary *Toxoplasma gondii* infection in normal and feline immunodeficiency virus-infected cats. *J Parasitol* **82**, 733–742.

Lappin M.R., Dow S. & Reif J.S. (1997) Elevated interleukin 6 activity in aqueous humor of cats with uveitis. *Vet Immunol Immunopathol* **58**, 17–26.

Lin D.S., Bowman D.D. & Jacobson R.H. (1992) Immunological changes in cats with concurrent *Toxoplasma gondii* and feline immunodeficiency virus infections. *J Clin Microbiol* **30**, 17–24.

Lindsay D.S., Blagburn D.L. & Dubey J.P. (1997) Feline toxoplasmosis and the importance of the *Toxoplasma gondii* oocyst. *Compendium of Continuing Education for the Practicing Veterinarian* **19**, 448–461.

Munana K.R., Lappin M.R., Powell C.C., *et al.* (1995) Sequential measurement of *Toxoplasma gondii*-specific antibodies in the cerebrospinal fluid of cats with experimentally induced toxoplasmosis. *Prog Vet Neurol* **15**, 627–631.

Oksenhendler E., Charreau I., Tournerie C., *et al.* (1994) *Toxoplasma gondii* infection in advanced HIV infection. *AIDS* **8**, 483–487.

O'Neil S.A., Lappin M.R., Reif J.S., *et al.* (1991) Clinical and epidemiologic aspects of feline immunodeficiency virus and *Toxoplasma gondii* coinfections in cats. *J Am Anim Hosp Assoc* **27**, 211–220.

Patton S., Legendre A.M., McGavin M.D., *et al.* (1991) Concurrent infection with *Toxoplasma gondii* and feline leukemia virus. *J Vet Intern Med* **5**, 199–201.

Peiffer R.L. & Wilcock B.P. (1991) Histopathologic study of uveitis in cats: 139 cases (1978–1988). *J Am Vet Med Assoc* **198**, 135–138.

Peterson J.L., Willard M.D., Lees G.E., *et al.* (1991) Toxoplasmosis in two cats with inflammatory intestinal disease. *J Am Vet Med Assoc* **199**, 473–476.

Powell C.C. & Lappin M.R. (2001) Ocular toxoplasmosis in neonatal kittens. *Vet Ophthalmol* **4**, 87–92.

Powell C.C., Brewer M. & Lappin M.R. (2001) Detection of *Toxoplasma gondii* in the milk of experimentally infected lactating queens. *J Vet Parasitol* **102**, 29–33.

Powell C.C., Kordick D. & Lappin M.R. (2002) Inoculation with *Bartonella henselae* followed by feline herpesvirus 1 fails to activate ocular toxoplasmosis in chronically infected cats. *J Feline Med Surg* **4**, 107–110.

Sato K., Iwamoto I. & Yoshiki K. (1993) Experimental toxoplasmosis in pregnant cats. *Jpn J Vet Sci* **55**, 1005–1009.

Spain C.V., Scarlett J.M., Wade S.E. & McDonough P. (2001) Prevalence of enteric zoonotic agents in cats less than 1 year old in central New York State. *J Vet Intern Med* **15**, 33–38.

Spencer L. (1992) Study explores health risks and the human/animal bond. *J Am Vet Med Assoc* **201**, 1669.

Teutsch S.M., *et al.* (1979) Epidemic toxoplasmosis associated with infected cats. *N Engl J Med* **300**, 695–699.

Wallace M.R., Rossetti R.J. & Olson P.E. (1993) Cats and toxoplasmosis risk in HIV-infected adults. *J Am Med Assoc* **269**, 76–77.

Chapter 29

FELINE INFECTIOUS ANAEMIA

S. Tasker

Introduction

Feline infectious anaemia (FIA) can arise as a result of a number of parasitic infections of erythrocytes. A haemolytic form of anaemia usually results. Rare causes of infectious anaemia include *Cytauxzoon felis* and *Babesia felis*. However, the most common cause of FIA is *Haemobartonella felis*, which is now recognised worldwide and is the only known cause of FIA reported in the UK.

Haemobartonella felis

Haemobartonella felis was first recognised in South Africa in 1942 by Clark (1942), who described the presence of *Eperythrozoon felis* on erythrocytes from an anaemic cat. Some years later Flint and McKelvie (1955) proposed that the agent should be called *Haemobartonella felis*.

Renaming and reclassification of the causative agent

Haemobartonella felis is a Gram-negative and non-acid-fast bacterium (Weiss & Moulder, 1984). It has not been successfully cultivated outside the host (Harvey, 1998). The organism is an obligate parasite (Small & Ristic, 1971) and until recently was classified as a rickettsial organism (Weiss & Moulder, 1984). However, recent data regarding the DNA sequence of *Haemobartonella* isolates have revealed that they are closely related to the genus *Mycoplasma* (Rikihisa *et al*., 1997; Johansson *et al*., 1999) and the existence of two morphologically and genetically distinct genotypes of *H. felis* has been documented. These genotypes have been named by some as the large/Ohio and small/California forms (Rikihisa *et al*., 1997; Berent *et al*., 1998; Foley *et al*., 1998; Messick *et al*., 1998) and are actually likely to represent distinct species. Reclassification and renaming of these species as mycoplasmal organisms has recently occurred (Foley & Pedersen, 2001; Neimark *et al*., 2001, 2002), with renaming of *H. felis* species as *Mycoplasma haemofelis* (for the large form) and '*Candidatus* Mycoplasma haemominutum' (for the small form) (see sections on Morphology and Pathogenesis, below). These two species are collectively referred to as the feline haemoplasmas. This chapter will use the name *H. felis* when describing work published before the reclassification and known existence of the two distinct species.

Morphology

Electron microscopy

It has been shown by electron microscopy that *H. felis* has a pleiomorphic appearance with coccoid, rod and ring forms being identified as epicellular solitary organisms, in groups or in chains (Demaree & Nessmith, 1972; Jain & Keeton, 1973) on the surface of erythrocytes (Figure 29.1). The organisms appear to be partially buried in the erythrocytic surface and adhere to the erythrocytic membrane at intermittent contact points (Demaree & Nessmith, 1972). Infected erythrocytes are more spherical than non-infected erythrocytes (Jain & Keeton, 1973), maybe reflecting erythrocytic osmotic changes as a result of *H. felis* infection.

Light microscopy

In polychrome-stained blood smears *H. felis* appears as coccoid, rod or ring forms (Flint *et al*., 1958;

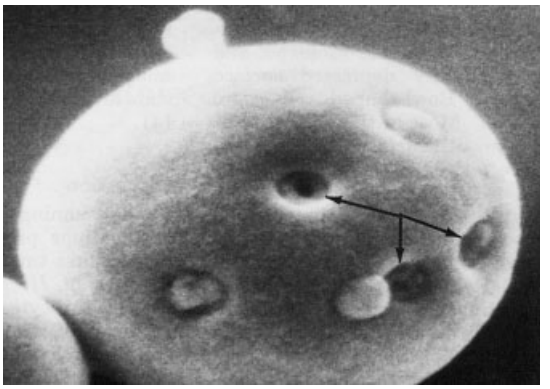

Figure 29.1 Scanning electron-microscopic image of an erythrocyte infected with *Haemobartonella felis* (×18 500). Coccoid *H. felis* bodies are visible, lying within indentations on the erythrocyte cell surface. Surface lesions (arrows) apparently produced by parasitic adhesions can be seen (Reproduced with permission from Jain & Keeton, 1973.).

Schalm & Splitter, 1968; Nash & Bobade, 1986) (Plates 29.1 and 29.2). The thickness of a blood smear and position of the parasite on the erythrocyte may influence the morphology of the observed *H. felis* (Schalm & Splitter, 1968; Harvey & Gaskin, 1977), but the coccoid form is most commonly recognised. The coccoid forms range from 0.2 to 0.8 μm in diameter (Flint *et al.*, 1958; Foley *et al.*, 1998). A difference in morphology between the *M. haemofelis* and '*Candidatus* M. haemominutum' species has been reported (Foley *et al.*, 1998), with *M. haemofelis* (the so-called large form) having larger bodies than '*Candidatus* M. haemominutum' (the so-called small form).

Pathogenesis

Organisms appear in the blood an average of 7–8 days (range of 2–20 days) after experimental inoculation of cats with *H. felis* (Splitter *et al.*, 1956; Harvey & Gaskin, 1977). Cycles of parasitaemia then occur at non-random intervals with an average duration of 6 days between parasitaemic episodes which last for just 1–2 days. The packed cell volume (PCV) tends to fall in association with the appearance of *H. felis* and may continue to fall for a few days following the disappearance of parasites from the circulation. The clearance of parasites from the blood can be rapid with reports of a high level of parasitaemia disappearing within hours (Harvey & Gaskin, 1977). Although the PCV may remain low for a few days, in some cases the PCV rises dramatically following clearance of *H. felis* from the blood.

Recent experimental and prevalence studies have shown differences in pathogenicity between the two feline haemoplasmas. Experimental infection of cats with two different isolates of '*Candidatus* M. haemominutum' (Foley *et al.*, 1998; Westfall *et al.*, 2001) did not result in significant clinical signs and anaemia was not induced, although it has been suggested that coinfection with '*Candidatus* M. haemominutum' and feline retroviruses [particularly feline leukaemia virus (FeLV)] may result in anaemia (George *et al.*, 2002). Conversely, experimental infection with *M. haemofelis* usually results in a severe, sometimes fatal, haemolytic anaemia (Berent *et al.*, 1998; Foley *et al.*, 1998; Westfall *et al.*, 2001). Experimental inoculation of *M. haemofelis* to cats already infected with '*Candidatus* M. haemominutum' may result in more severe clinical disease than *M. haemofelis* alone (Westfall *et al.*, 2001). A prevalence study in the USA (Jensen *et al.*, 2001) found that anaemic cats were more likely than non-anaemic cats to be infected with either *M. haemofelis* or both '*Candidatus* M. haemominutum' and *M. haemofelis* supporting the experimental study results that *M. haemofelis* is more pathogenic.

Haemobartonella felis induces anaemia by haemolysis and sequestration (Carney & England, 1993). The attachment of *H. felis* to erythrocytes results in direct damage to the erythrocytic membrane, leading to a shortened erythrocyte lifespan (Maede, 1975) and haemolysis. Erythrocyte damage may also expose hidden, or change existing, erythrocytic antigens, causing the production of antierythrocytic antibodies. Antibodies may also be directed against the organism itself, resulting in erythrocytic destruction as an 'innocent bystander' effect (Harvey, 1998). Although intravascular haemolysis may occur by direct damage to erythrocytes, the majority of haemolysis is extravascular in nature. Macrophage erythrophagocytosis occurs in the spleen, liver, lungs and bone marrow (Maede, 1978; Simpson *et al.*, 1978). The splenic macrophages can also remove *H. felis* organisms from the surface of the erythrocytes (a process called pitting), returning unparasitised cells into the circulation (Maede & Murata, 1978). This may explain the rapid increase in PCV seen in some cases following the clearance of *H. felis* from the circulation.

In animals other than the cat, splenectomy is usually required before clinical disease is produced by *Haemobartonella* organisms. In cats, it has been

shown that splenectomy has little effect on the incubation period or severity of disease induced by *H. felis* (Flint & Moss, 1953; Splitter *et al.*, 1956), although the parasitaemia may last longer than in intact cats (Harvey & Gaskin, 1978b).

Cats that recover from infection remain chronically infected with *H. felis* for an undetermined period, which may be lifelong. Previously, the carrier status was believed to occur when cats were allowed to recover from *H. felis* infection without antibiotic treatment (Harvey & Gaskin, 1978b), but a recent study has detected chronic infection by polymerase chain reaction (PCR) assays in cats up to 6 months after initial infection, despite doxycycline treatment (Berent *et al.*, 1998). Parasitaemia is not generally visible on blood smears during this period and such cats are clinically normal, with a normal PCV or a mild regenerative anaemia. These cats appear to be in a balanced state in which replication of organisms is balanced by phagocytosis and removal (Harvey, 1998), although reactivation of infection can occur and may result in clinical disease (Foley *et al.*, 1998). An increase in the level of parasitaemia has been documented in carrier cats given corticosteroids (Harvey & Gaskin, 1978b; Berent *et al.*, 1998), but clinical disease was not seen.

Epidemiology

Mode of transmission

The epidemiology of *H. felis* is poorly understood. Experimental transmission has been demonstrated via the intravenous, intraperitoneal and oral routes using blood from infected cats (Flint *et al.*, 1959). Vertical transmission from dam to offspring has been implicated (Harbutt, 1963; Fisher *et al.*, 1983) although it is not known whether this occurs transplacentally, during parturition and/or via the milk. It has been noted that uninfected and infected cats housed together for several months show no evidence of horizontal spread of infection (Splitter *et al.*, 1956; Flint *et al.*, 1959) and saliva and urine are not thought to be infective. Many believe that infection can be spread between cats by blood-sucking arthropods (in particular fleas) (Nash & Bobade, 1986), although this is not proven. Transmission can also occur via infected blood transfusions.

Prevalence and risk factors

Reports of the prevalence of *H. felis* in different cat populations, based on cytological diagnosis, vary greatly, from 3.6 to 28% (Nash & Bobade, 1986; Turner *et al.*, 1986; Grindem *et al.*, 1990). Some studies have reported that males and young cats are more likely to be infected (Grindem *et al.*, 1990), although others have found no evidence of a sex or age predisposition (Nash & Bobade, 1986; Yamaguchi *et al.*, 1996). A recent study looking at UK cats (Tasker *et al.*, 2003a) found that older male cats were more likely to be infected with '*Candidatus* M. haemominutum', so reports are conflicting. The increased incidence in male cats in some studies, together with reports that cat-bite abscesses and outdoor roaming are risk factors for *H. felis* (Flint *et al.*, 1958; Grindem *et al.*, 1990), suggest that horizontal transmission may occur via fighting. Other risk factors identified include lack of vaccinations, FeLV-positive status and the presence of anaemia (Grindem *et al.*, 1990). Such risk factors are in line with the belief that *H. felis* is an opportunistic pathogen where stress or illness contributes to the development of disease. *Haemobartonella felis* infection has been reported in combination with toxoplasmosis, FeLV, feline infectious peritonitis, *Babesia felis* and upper respiratory tract infections (Hoskins & Barta, 1984; Schoeman *et al.*, 2001). However, in a significant number of cats a precipitating stress factor cannot be identified and in these cases *H. felis* appears to be a primary pathogen.

Recent prevalence studies using a PCR assay for diagnosis of feline haemoplasma infection in the USA (Jensen *et al.*, 2001) and the UK (Tasker *et al.*, 2003a), summarised in Table 29.1, found a relatively high prevalence of infection with '*Candidatus* M. haemominutum' in both countries, whereas *M. haemofelis* was more commonly detected in the USA than in the UK. It

Table 29.1 Results of feline haemoplasma prevalence studies in the USA and the UK using a polymerase chain reaction for diagnosis

	USA (Jensen *et al.*, 2001)	UK (Tasker *et al.*, 2003a)
Total no. of cats in study	220	426
Cats positive for '*Candidatus* Mycoplasma haemominutum'	12.7%	16.9%
Cats positive for *Mycoplasma haemofelis*	4.5%	1.4%
Cats positive for both '*Candidatus* M. haemominutum' and *M. haemofelis*	2.3%	0.2%

may be that geographical variation in the prevalence of the feline haemoplasma species exists worldwide.

Association with feline leukaemia and feline immunodeficiency virus infection

As mentioned above, FeLV infection is a risk factor for *H. felis* infection; up to 47.2% of *H. felis*-infected cats are FeLV positive (Cotter *et al.*, 1975; Nash & Bobade, 1986). This association may be because cats with *H. felis* are more susceptible to FeLV infection or because the FeLV infection activates latent *H. felis* infection. It has been shown that concurrent *H. felis* infection increased the susceptibility of cats to experimental FeLV infection (Kociba *et al.*, 1983). An association between feline immunodeficiency virus (FIV) and *H. felis* infection has also been proposed; in one study 40% of anaemic FIV-positive cats were infected with *H. felis* (Hopper *et al.*, 1989). Coinfection with '*Candidatus* M. haemominutum', which is usually relatively apathogenic, and FeLV has been associated with anaemia (George *et al.*, 2002), suggesting that FeLV may influence the development of anaemia in cats infected with '*Candidatus* M. haemominutum'.

Clinical signs

The clinical signs seen with *H. felis* infection depend on a number of factors, such as the species involved (see Pathogenesis, above), stage of infection, whether the *H. felis* infection is primary or secondary to another disease process or stress, and the degree and speed of development of the anaemia. Naturally infected cases often show vague and non-specific clinical signs, which usually reflect the presence of anaemia rather than *H. felis* per se.

Previous reports that uncomplicated *H. felis* infection caused few or no clinical signs (Seamer & Douglas, 1959; Bobade *et al.*, 1988) may have reflected infection with an *H. felis* form of low pathogenicity such as '*Candidatus* M. haemominutum' (Foley *et al.*, 1998). Chronically infected cats are also usually clinically normal (Berent *et al.*, 1998). In other studies, severe anaemia was shown to occur in all infected cats (Flint *et al.*, 1958; Foley *et al.*, 1998), most probably due to a pathogenic form such as *M. haemofelis*. Common clinical signs seen in ill cats include anorexia, lethargy, weight loss and depression. Intermittent pyrexia is often seen, particularly in the acute stages of the disease, as well as splenomegaly and lymphadenopathy. These latter findings may reflect extramedullary haematopoiesis. Icterus is occasionally seen.

The FeLV and FIV status of infected cats also influences the clinical picture. The clinical signs and the degree of anaemia are more severe in those cats coinfected with both *H. felis* and FeLV than in those infected with *H. felis* alone (Kociba *et al.*, 1983; Bobade *et al.*, 1988; George *et al.*, 2002). In an experimental study it was found that FIV-positive cats showed more severe clinical signs associated with *H. felis* infection than did non-FIV-infected cats (Reubel *et al.*, 1994).

Laboratory features

Haemobartonella felis infection typically causes a regenerative anaemia. The severity of anaemia depends on the stage of infection, but the PCV usually falls to an average of 15–18% (VanSteenhouse *et al.*, 1993; Foley *et al.*, 1998). Regeneration is characterised by the presence of an adequate reticulocyte response for the degree of anaemia present. Because cats have two morphological forms of reticulocyte, it is important to know the criteria that a laboratory uses to count feline reticulocytes. In addition, reticulocyte counts on blood heavily parasitised with *H. felis* are unlikely to be reliable because the supravital stains used to identify reticulocytes will also stain the organisms. Raised reticulocyte counts are the hallmark of a regenerative anaemia, but other features of regeneration that may be seen on blood smears include anisocytosis, macrocytosis and polychromasia. The nature of *H. felis* anaemia is often macrocytic and normochromic (Flint *et al.*, 1959; Foley *et al.*, 1998), although in one study it was found that macrocytosis usually reflected FeLV-positive status (Bobade *et al.*, 1988). Normoblasts may be present and, although these can be a feature of diseases that are not associated with regenerative anaemias, *H. felis* was found to be the most common cause of normoblastaemia in a recent retrospective study (Hammer & Wellman, 1999). The degree of normoblastaemia associated with *H. felis* infection can be severe (VanSteenhouse *et al.*, 1995). In one review of haemobartonellosis cases, 44% of cats had significant anaemias that were non-regenerative in type (VanSteenhouse *et al.*, 1993). It is known that concurrent disease can reduce regenerative responses to anaemia and in this review two of the five cats tested for FeLV were found to be positive, which may explain the non-regenerative response in these cats. Blood samples taken from cats during the early stage of anaemia will also appear to be non-regenerative because of inadequate time for bone-marrow response. There are, however, some cases for

which the non-regenerative nature of the anaemia seen with *H. felis* cannot be explained.

White blood cell parameters are too variable to be of diagnostic use (Maede & Hata, 1975; VanSteenhouse *et al.*, 1993) and platelet counts are usually normal. Erythrophagocytosis, where erythrocytes are ingested by mononuclear cells, or more rarely neutrophils, is sometimes visible on blood smears (Maede & Hata, 1975; Espada *et al.*, 1991).

Bone-marrow samples from affected cats tend to reflect the regenerative form of the anaemia, with a decreased myeloid to erythroid ratio, and erythrophagocytosis may be visible on bone-marrow aspirate smears (Harvey & Gaskin, 1977; Espada *et al.*, 1991).

Positive Coombs' tests and autoagglutination have been reported in acute haemobartonellosis cases (Maede & Hata, 1975; Harvey & Gaskin, 1978a; Alleman *et al.*, 1999), indicating the presence of erythrocyte-bound antibodies. Cold reacting (immunoglobulin M) antibodies have been documented (Zulty & Kociba, 1990) with *H. felis* infection, but the significance of these is not known, and it has been suggested that many normal cats have low titres of cold reacting antibodies (Dunn *et al.*, 1984).

Hyperbilirubinaemia may result from haemolysis and can be a feature of both extravascular and intravascular haemolysis. In severe cases clinical jaundice is seen. Haemoglobinaemia and haemoglobinuria only occur with intravascular haemolysis, which has occasionally been reported with *H. felis* (Maede *et al.*, 1974; Hoskins & Barta, 1984). Raised serum liver enzymes may result from anaemia-induced hypoxic damage.

Diagnosis

Examination of blood smears

The most traditional means of diagnosis of *H. felis* is demonstration of organisms on a good-quality blood smear. The preparation and staining of diagnostic blood smears have been reviewed previously (Butt, 1990).

A number of Romanowsky-type blood stains can be used for *H. felis* staining (Plates 29.1 and 29.2). Giemsa staining is favoured by some authors (Evans & Gruffydd-Jones, 1984), although May–Grunwald–Giemsa, which is more technically demanding, may be more successful in demonstrating the organism (Bobade & Nash, 1987). The organism stains an intense red with a bluish tinge with Giemsa staining. Wright's stain has also been used. *Haemobartonella felis* appears on the surface of the erythrocyte, and may be found singly, in pairs or in chains with severe infestation. Very occasionally organisms may lie free of the erythrocytes because of detachment from cells. New methylene blue staining and other reticulocyte stains should not be used for the diagnosis of *H. felis* because it is difficult to distinguish precipitated ribosomal material from organisms.

To avoid false-positive diagnoses it is imperative that artefacts caused by improper drying or fixation and stain precipitation are avoided. The use of fresh filtered stain solutions is recommended (Bobade & Nash, 1987). Stain precipitate is usually found above the plane of focus of the erythrocytes and is more densely staining and larger than *H. felis* organisms. Refractile artefacts occur when moisture adheres to the cells on the film, and these tend to have irregular borders and appear colourless when the erythrocytes are in focus. Howell–Jolly bodies are erythrocytic nuclear remnants and can be differentiated from *H. felis* by their larger size (around 1–2 μm in diameter).

Acridine orange (AO) and direct fluorescent antibody staining methods are reported to be more sensitive than standard Romanowsky stains for demonstrating *H. felis* (Small & Ristic, 1967; Bobade & Nash, 1987). However, both techniques are limited by the need for a fluorescent microscope. AO combines specifically with nucleic acids and organisms appear as bright orange with an undertone of yellow green. Non-specific fluorescence can give false-positive results, and Howell–Jolly bodies, which also stain with AO, must be differentiated from *H. felis* (Harvey & Gaskin, 1977).

The phenomenon of cyclical parasitaemias means that the absence of *H. felis* organisms on blood smears does not rule out a diagnosis of haemobartonellosis. The preparation of multiple fresh blood smears during the course of a day or over a period of a few days may increase the chances of obtaining a positive diagnosis. Sample handing may also have an effect on the identification of organisms on blood smears. It has been shown that ethylenediaminetetraacetic acid (EDTA) anticoagulant dislodges the organism from the erythrocyte cell surface (Alleman *et al.*, 1999), making identification on blood smears extremely difficult. However, the concentration of EDTA present in blood collection tubes is much lower than that used in the studies showing dislodgement. As a precaution, it is probably prudent to avoid making blood smears using blood that has been incubated in EDTA for more than 30 min.

Serology

An indirect immunofluorescent antibody assay has shown that the immune response to *H. felis* occurs in most cats by 21 days postinfection, and lasts for at least 6 months (Foley *et al.*, 1998). The immune response to specific *H. felis* antigens, demonstrated by Western immunoblotting (Alleman *et al.*, 1999), found that some antigens are recognised as early as 14 days after infection. However, it is not known whether such antigens are conserved between different *H. felis* forms, which would be necessary for a serological test to be of diagnostic value. Indeed, it has been proposed that antigenic variation may play a role in the development of cyclical parasitaemia in cats infected with *H. felis*. Since antibodies can be demonstrated in asymptomatic carrier cats as well as in anaemic cats, a positive serological test does not equate with the presence of disease. Serological testing is not currently available commercially.

Polymerase chain reaction

The PCR assay is a technique whereby specific lengths of DNA are amplified so that previously undetectable amounts become detectable. The PCR method is therefore an extremely sensitive test, which has been successfully applied to the diagnosis of feline haemoplasma infection (Tasker & Lappin, 2002). PCR assays are also very specific and assays have been developed that can detect and distinguish both '*Candidatus* M. haemominutum' and *M. haemofelis* (Jensen *et al.*, 2001). A real-time PCR assay to quantify '*Candidatus* M. haemominutum' and *M. haemofelis* DNA in blood samples has also recently been described (Tasker *et al.*, 2003b) and is now commercially available in the UK. PCR has been shown to be more sensitive than the examination of blood smears in the detection of *H. felis* in several studies (Berent *et al.*, 1998; Foley *et al.*, 1998; Jensen *et al.*, 2001; Westfall *et al.*, 2001; Tasker *et al.*, 2003a) and may now be considered as the diagnostic test of choice for feline haemoplasma infection (Tasker & Lappin, 2002). *Haemobartonella felis* can be detected by PCR as early as 3 days postinfection and cats remain PCR positive until antibiotic treatment is started. Cats can then become negative on PCR during antibiotic treatment, but may become positive again between 3 days and 5 weeks after completion of the antibiotic course. Accordingly, it is recommended that blood samples for *H. felis* PCR should not be collected while a cat is undergoing antibiotic treatment, although a positive result may occur if the therapy is ineffective. Asymptomatic cats remain PCR positive for at least 6 months, indicating the ability of PCR to detect chronically infected cats (Berent *et al.*, 1998; Foley *et al.*, 1998). In a recent study it was found that 10% of healthy cats were infected with feline haemoplasma species (Tasker *et al.*, 2003a), confirming that a positive PCR result does not always correlate with the presence of clinical haemoplasmal disease.

Treatment

In view of the recognised problems that exist with the diagnosis of haemobartonellosis, it has been recommended that if a regenerative haemolytic anaemia is found with no other known underlying cause (such as FeLV or a drug-induced haemolytic anaemia), trial treatment for *H. felis* may be warranted.

Tetracycline derivatives are most commonly used to treat *H. felis* infection. Tetracycline and oxytetracycline can both cause drug-induced fevers in cats and require dosing three times a day, which may be problematic for owner compliance. The preferred tetracycline derivative used is doxycycline because this is associated with fewer side-effects and requires less frequent dosing than other tetracyclines. The recommended doxycycline dose is 10 mg/kg p.o. per day. Therapy should be continued for 14–21 days depending on the response to treatment. It should be noted that there have been reports of oesophageal strictures secondary to oral doxycycline treatment (Melendez *et al.*, 2000; McGrotty & Knottenbelt, 2002). As a precaution it has been recommended that oral doxycycline dosing be followed by the administration of a small amount of water by syringe, or food, to encourage passage of the drug into the stomach. It has been shown with PCR that, despite being effective for the treatment of anaemia, doxycycline does not usually eliminate infection (Berent *et al.*, 1998; Foley *et al.*, 1998; Dowers *et al.*, 2002). Since *Haemobartonella* species are now reclassified as *Mycoplasma* organisms (Foley & Pedersen, 2001; Neimark *et al.*, 2001), there has been a focus of attention on drugs with potent anti-mycoplasmal activity. However, the macrolide azithromycin, effective for the treatment of several *Mycoplasma*-associated syndromes in humans, was not found to be effective in the treatment of haemobartonellosis in a recent study (Westfall *et al.*, 2001). Enrofloxacin has been recommended for the treatment of haemobartonellosis (Winter, 1993). A recent study (Dowers *et al.*, 2002) found that both 5 and 10 mg/kg p.o. per day doses of enrofloxacin were

associated with clinical improvement in cats inoculated with *M. haemofelis*, but clearance of the organism, as indicated by a negative PCR result, did not always result. Diffuse retinal degeneration and acute blindness have been reported following enrofloxacin treatment in cats (Gelatt *et al.*, 2001). Although this is said to be a rare and idiosyncratic reaction, doses higher than the 5 mg/kg per day dose recommended by the manufacturers should not be used. Imidocarb dipropionate, an antiprotozoal agent, has been suggested as a potential treatment for feline haemoplasma infection (Lappin *et al.*, 2002). However, this drug is not licensed for use in cats. Further studies are warranted before firm recommendations can be made.

The anaemia induced by *H. felis* is in part immune mediated and corticosteroids have been recommended as adjunct therapy (VanSteenhouse *et al.*, 1993), although their value in treatment is not proven at present. Concurrent diseases that could be exacerbated by the use of corticosteroids must be ruled out first (Hoskins & Barta, 1984). Some advocate corticosteroids only if the anaemia is pronounced or acute in onset and/or when the blood smear shows autoagglutination (Carney & England, 1993). The recommended dose is 2–4 mg/kg p.o. per day, alongside antibiotic therapy, with a tapering of dosage towards the end of therapy.

Supportive care may be required. Cats are able to tolerate anaemia very well, but if the anaemia is severe (PCV $<$ 12%) or if the PCV has dropped rapidly, a blood transfusion may become necessary. Feline blood transfusions should only be performed with typed or cross-matched recipient and donor blood to avoid potentially fatal blood transfusion reactions.

Post-mortem findings

Abnormalities found on necropsy are variable and in some cases minimal. Gross findings include pallor and emaciation in most cases, variable splenomegaly, jaundice and lymphadenopathy (Holzworth, 1956; Flint *et al.*, 1959). Histological changes include bone-marrow hyperplasia, although in chronic cases bone-marrow exhaustion may be seen (Holzworth, 1956; Flint *et al.*, 1958). Splenic passive congestion, extramedullary hyperplasia and erythrophagocytosis are reported, and the liver may show centrilobular necrosis, degeneration and/or extramedullary hyperplasia (Holzworth, 1956; Splitter *et al.*, 1956; Hatakka, 1972).

Prognosis

The long-term prognosis of cats after recovery from uncomplicated haemobartonellosis appears to be good if a definitive diagnosis is made and therapy instituted (Harvey, 1998). Recovered cats become chronic carriers for an undetermined period, possibly lifelong, and such cats are believed to be prone to relapse of clinical disease after periods of illness or stress (see Pathogenesis section above).

Prevention

It is difficult to advise on the prevention of infection because the epidemiology of *H. felis* is poorly understood. Considering the possible methods of transmission of *H. felis* together with the known risk factors, it seems prudent to recommend elimination of blood-sucking arthropods, maintenance of routine vaccination against other infectious diseases and a reduction in intercat aggression. In addition, cats with a history of *H. felis* infection should not be used as blood donors.

Cytauxzoon felis

Cytauxzoon felis is a usually fatal tick-borne protozoal disease of cats seen in several south-central and south-eastern states in the USA (Kier & Greene, 1998), although recently the existence of a less virulent form of *C. felis* has been suggested (Meinkoth *et al.*, 2000). Affected cats develop anorexia, depression, pallor, fever and jaundice, and usually die within 5 days. Diagnosis is made by identification of round 'signet-ring'-shaped bodies or bipolar ovoid 'safety-pin' forms on Romanowsky-stained blood smears (Butt, 1990). In contrast to *Haemobartonella* and *Babesia* species, *C. felis* also has a tissue phase, so identification of organisms is possible within macrophages from samples of bone marrow, spleen or lymph node. Recently, successful treatment of *C. felis* has been reported with diminazene aceturate or imidocarb dipropionate together with supportive care (Greene *et al.*, 1999).

Babesia felis

Babesia felis is a tick-borne protozoal disease of young cats reported only in Africa and southern Asia

(Taboada, 1998; Schoeman *et al*., 2001). Affected cats show lethargy, anorexia, weakness or diarrhoea. Fever and jaundice are rarely observed. Intravascular and extravascular haemolysis causes a severe chronic anaemia. Diagnosis is based on the recognition of the erythrocytic organisms on Romanowsky-stained blood smears. Treatment of feline babesiosis has not been critically evaluated, but primaquine phosphate, an antimalarial compound, has been reported to be effective, although the therapeutic dose is very close to the lethal dose (Potgieter, 1981).

References

Alleman A.R., Pate M.G., Harvey J.W., *et al*. (1999) Western immunoblot analysis of the antigens of *Haemobartonella felis* with sera from experimentally infected cats. *J Clin Microbiol* **37**, 1474–1479.

Berent L.M., Messick J.B. & Cooper S.K. (1998) Detection of *Haemobartonella felis* in cats with experimentally induced acute and chronic infections, using a polymerase chain reaction assay. *Am J Vet Res* **59**, 1215–1220.

Bobade P.A. & Nash A.S. (1987) A comparative study of the efficiency of acridine orange and some Romanowsky staining procedures in the demonstration of *Haemobartonella felis* in feline blood. *Vet Parasitol* **26**, 169–172.

Bobade P.A., Nash A.S. & Rogerson P. (1988) Feline haemobartonellosis: clinical, haematological and pathological studies in natural infections and the relationship to infection with feline leukaemia virus. *Vet Rec* **122**, 32–36.

Butt M.T. (1990) Diagnosing erythrocytic parasitic diseases in cats. *Compendium of Continuing Education for the Practicing Veterinarian* **12**, 628–638.

Carney H.C. & England J.J. (1993) Feline hemobartonellosis. *Vet Clin North Am Small Anim Pract* **23**, 79–90.

Clark R. (1942) *Eperythrozoon felis* (sp. Nov) in a cat. *J South Afr Vet Med Assoc* **13**, 15–16.

Cotter S.M., Hardy W.D. Jr & Essex M. (1975) Association of feline leukemia virus with lymphosarcoma and other disorders in the cat. *J Am Vet Med Assoc* **166**, 449–454.

Demaree R.S. Jr & Nessmith W.B. (1972) Ultrastructure of *Haemobartonella felis* from a naturally infected cat. *Am J Vet Res* **33**, 1303–1308.

Dowers K.L., Olver C., Radecki S.V. & Lappin M.R. (2002) Use of enrofloxacin for treatment of large-form *Haemobartonella felis* in experimentally infected cats. *J Am Vet Med Assoc* **221**, 250–253.

Dunn J.K., Searcy G.P. & Hirsch V.M. (1984) The diagnostic significance of a positive direct antiglobulin test in anaemic cats. *Can J Comp Med* **48**, 349–353.

Espada Y., Prats A. & Albo F. (1991) Feline haemobartonellosis. *Vet Int* **3**, 35–40.

Evans R. & Gruffydd-Jones T. (1984) Anaemia in cats. *In Practice* **6**, 168–177.

Fisher E.W., Toth S. & Collier W.O. (1983) Anaemia in a litter of Siamese kittens. *J Small Anim Pract* **24**, 214–219.

Flint J.C. & McKelvie D.H. (1955) *Feline infectious anaemia – diagnosis and treatment*. In *92nd Annual Meeting of the American Veterinary Medical Association*, Minneapolis, MN, pp. 240–242.

Flint J.C. & Moss L.C. (1953) Infectious anaemia in cats. *J Am Vet Med Assoc* **122**, 45–48.

Flint J.C., Roepke M.H. & Jensen R. (1958) Feline infectious anaemia. I. Clinical aspects. *Am J Vet Res* **19**, 164–168.

Flint J.C., Roepke M.H. & Jensen R. (1959) Feline infectious anaemia. II. Experimental cases. *Am J Vet Res* **20**, 33–40.

Foley J.E. & Pedersen N.C. (2001) '*Candidatus* Mycoplasma haemominutum', a low-virulence epierythrocytic parasite of cats. *Int J Syst Evol Microbiol* **51**, 815–817.

Foley J.E., Harrus S., Poland A., *et al*. (1998) Molecular, clinical, and pathologic comparison of two distinct strains of *Haemobartonella felis* in domestic cats. *Am J Vet Res* **59**, 1581–1588.

Gelatt K.N., van der Woerdt A., Ketring K.L., *et al*. (2001) Enrofloxacin-associated retinal degeneration in cats. *Vet Ophthalmol* **4**, 99–106.

George J.W., Rideout B.A., Griffey S.M. & Pedersen N.C. (2002) Effect of preexisting FeLV infection or FeLV and feline immunodeficiency virus coinfection on pathogenicity of the small variant of *Haemobartonella felis* in cats. *Am J Vet Res* **63**, 1172–1178.

Greene C.E., Latimer K., Hopper E., *et al*. (1999) Administration of diminazene aceturate or imidocarb dipropionate for treatment of cytauxzoonosis in cats. *J Am Vet Med Assoc* **215**, 497–500.

Grindem C.B., Corbett W.T. & Tomkins M.T. (1990) Risk factors for *Haemobartonella felis* infection in cats. *J Am Vet Med Assoc* **196**, 96–99.

Hammer A.S. & Wellman M. (1999) Leukoerythroblastosis and normoblastemia in the cat. *J Am Anim Hosp Assoc* **35**, 471–473.

Harbutt P.R. (1963) A clinical appraisal of feline infectious anaemia and its transmission under natural conditions. *Aust Vet J* **39**, 401–404.

Harvey J.W. (1998) Haemobartonellosis. In *Infectious Diseases of the Dog and Cat* (ed. Greene C.E.). WB Saunders, Philadelphia, PA, pp. 166–171.

Harvey J.W. & Gaskin J.M. (1977) Experimental feline haemobartonellosis. *J Am Anim Hosp Assoc* **13**, 28–38.

Harvey J.W. & Gaskin J.M. (1978a) Feline haemobartonellosis. In *45th Annual Meeting of the American Animal Hospital Association*, Salt Lake City, UT, pp. 117–123.

Harvey J.W. & Gaskin J.M. (1978b) Feline haemobartonellosis: attempts to induce relapses of clinical disease in chronically infected cats. *J Am Anim Hosp Assoc* **14**, 453–456.

Hatakka M. (1972) Haemobartonellosis in the domestic cat. *Acta Vet Scand* **13**, 323–331.

Holzworth J. (1956) Anaemia in the cat. *J Am Vet Med Assoc* **128**, 471–488.

Hopper C.D., Sparkes A.H., Gruffydd-Jones T.J., *et al.* (1989) Clinical and laboratory findings in cats infected with feline immunodeficiency virus. *Vet Rec* **125**, 341–346.

Hoskins J.D. & Barta O. (1984) Concurrent *Haemobartonella felis* and *Toxoplasma gondii* infections in a cat. *Vet Med Small Anim Clin* **79**, 633–637.

Jain N.C. & Keeton K.S. (1973) Scanning electron microscopic features of *Haemobartonella felis. Am J Vet Res* **34**, 697–700.

Jensen W.A., Lappin M.R., Kamkar S. & Reagen W.J. (2001) Use of a polymerase chain reaction assay to detect and differentiate two strains of *Haemobartonella felis* infection in naturally infected cats. *Am J Vet Res* **62**, 604–608.

Johansson K.E., Tully J.G., Bolske G. & Pettersson B. (1999) *Mycoplasma cavipharyngis* and *Mycoplasma fastidiosum*, the closest relatives to *Eperythrozoon* spp. and *Haemobartonella* spp. *FEMS Microbiol Lett* **174**, 321–326.

Kier A.B. & Greene C.E. (1998) Cytauxzoonosis. In *Infectious Diseases of the Dog and Cat* (ed. Greene C.E.). WB Saunders, Philadelphia, PA, pp. 470–473.

Kociba G.J., Weiser M.G. & Olsen R.G. (1983) Enhanced susceptibility to feline leukaemia virus in cats with *Haemobartonella felis* infection. *Leukaemia Rev Int* **1**, 88–89.

Lappin M.R., Brewer M. & Radecki S. (2002) Effects of imidocarb dipropionate in cats with chronic haemobartonellosis. *Vet Ther* **2**, 144–149.

McGrotty Y.L. & Knottenbelt C.M. (2002) Oesophageal stricture in a cat due to oral administration of tetracyclines. *J Small Anim Pract* **43**, 221–223.

Maede Y. (1975) Studies on feline haemobartonellosis. IV. Lifespan of erythrocytes of cats infected with *Haemobartonella felis. Jpn J Vet Sci* **37**, 269–272.

Maede Y. (1978) Studies on feline haemobartonellosis. V. Role of the spleen in cats infected with *Haemobartonella felis. Jpn J Vet Sci* **40**, 141–146.

Maede Y. & Hata R. (1975) Studies on feline haemobartonellosis. II. The mechanism of anemia produced by infection with *Haemobartonella felis. Jpn J Vet Sci* **37**, 49–54.

Maede Y. & Murata H. (1978) Ultrastructural observation on the removal of *Haemobartonella felis* from erythrocytes in the spleen of a cat. *Jpn J Vet Sci* **40**, 203–205.

Maede Y., Hata R., Shibata H., *et al.* (1974) Clinical observation on six cases of feline infectious anaemia. *J Jpn Vet Med Assoc* **27**, 267–272.

Meinkoth J., Kocan A.A., Whitworth L., *et al.* (2000) Cats surviving natural infection with *Cytauxzoon felis*: 18 cases (1997–1998). *J Vet Intern Med* **14**, 521–525.

Melendez L.D., Twedt D.C. & Wright M. (2000) Suspected doxycycline-induced oesophagitis with oesophageal stricture formation in three cats. *Feline Pract* **28**, 10–12.

Messick J.B., Berent L.M. & Cooper S.K. (1998) Development and evaluation of a PCR-based assay for detection of *Haemobartonella felis* in cats and differentiation of *H. felis* from related bacteria by restriction fragment length polymorphism analysis. *J Clin Microbiol* **36**, 462–466.

Nash A.S. & Bobade P.A. (1986) *Haemobartonella felis* infection in cats from the Glasgow area. *Vet Rec* **119**, 373–375.

Neimark H., Johansson K.E., Rikihisa Y. & Tully J.G. (2001) Proposal to transfer some members of the genera *Haemobartonella* and *Eperythrozoon* to the genus *Mycoplasma* with descriptions of '*Candidatus* Mycoplasma haemofelis', '*Candidatus* Mycoplasma haemomuris', '*Candidatus* Mycoplasma haemosuis' and '*Candidatus* Mycoplasma wenyonii'. *Int J Syst Evol Microbiol* **51**, 891–899.

Neimark H., Johansson K.E., Rikihisa Y. & Tully J.G. (2002) Revision of haemotrophic *Mycoplasma* species names. *Int J Syst Evol Microbiol* **52**, 683.

Potgieter F.T. (1981) Chemotherapy of *Babesia felis* infection: efficacy of certain drugs. *J South Afr Vet Assoc* **52**, 289–293.

Reubel G.H., Dean G.A., George J.W., *et al.* (1994) Effects of incidental infections and immune activation on disease progression in experimentally feline immunodeficiency virus-infected cats. *J Acquir Immune Defic Syndr* **7**, 1003–1015.

Rikihisa Y., Kawahara M., Wen B., *et al.* (1997) Western immunoblot analysis of *Haemobartonella muris* and comparison of 16S rRNA gene sequences of *H. muris, H. felis*, and *Eperythrozoon suis. J Clin Microbiol* **35**, 823–829.

Schalm O.W. & Splitter J.W. (1968) Feline infectious anaemia. *Calif Vet* **22**, 24–28.

Schoeman T., Lobetti R.G., Jacobson L.S. & Penzhorn B.L. (2001) Feline babesiosis: signalment, clinical pathology and concurrent infections. *J South Afr Vet Assoc* **72**, 4–11.

Seamer J. & Douglas S.W. (1959) A new blood parasite of British cats. *Vet Rec* **71**, 405–408.

Simpson C.F., Gaskin J.M. & Harvey J.W. (1978) Ultrastructure of erythrocytes parasitized by *Haemobartonella felis. J Parasitol* **64**, 504–511.

Small E. & Ristic M. (1967) Morphologic features of *Haemobartonella felis. Am J Vet Res* **28**, 845–851.

Small E. & Ristic M. (1971) Haemobartonellosis. *Vet Clin North Am* **1**, 225–230.

Splitter E.J., Castro E.R. & Kanawyer W.L. (1956) Feline infectious anaemia. *Vet Med* **51**, 17–22.

Taboada J. (1998) Babesiosis. In *Infectious Diseases of the Dog and Cat* (ed. Greene C.E.), WB Saunders, Philadelphia, PA, pp. 473–481.

Tasker S. & Lappin M.R. (2002) *Haemobartonella felis*: recent developments in diagnosis and treatment. *J Feline Med Surg* **4**, 3–11.

Tasker S., Binns S.H., Day M.J., *et al.* (2003a) Use of a PCR assay to assess prevalence and risk factors for *Mycoplasma haemofelis* and '*Candidatus* Mycoplasma haemominutum' in cats in the United Kingdom. *Vet Rec* **152**, 193–198.

Tasker S., Helps C.R., Day M.J., *et al.* (2003b) Use of Real-Time PCR to detect and quantify *Mycoplasma haemofelis* and '*Candidatus* Mycoplasma haemominutum' DNA. *J Clin Microbiol* **41**, 439–441.

Turner C.M., Bloxham P.A., Cox F.E. & Turner C.B. (1986) Unreliable diagnosis of *Haemobartonella felis. Vet Rec* **119**, 534–535.

VanSteenhouse J.L., Millard J.R. & Taboada J. (1993) Feline haemobartonellosis. *Compendium of Continuing Education for the Practicing Veterinarian* **15**, 535–545.

VanSteenhouse J.L., Taboada J. & Dorfman M.I. (1995) *Haemobartonella felis* infection with atypical haematological abnormalities. *J Am Anim Hosp Assoc* **31**, 165–169.

Weiss E. & Moulder J.W. (1984) Order I: Rickettsiales. In *Bergey's Manual of Systematic Bacteriology*, Vol. 1 (eds Krieg N.R. & Holt J.G.). Williams and Wilkins, Baltimore, MD, pp. 687–729.

Westfall D.S., Jensen W.A., Reagan W.J., *et al*. (2001) Inoculation of two genotypes of *Haemobartonella felis* (California and Ohio variants) to induce infection in cats and the response to treatment with azithromycin. *Am J Vet Res* **62**, 687–691.

Winter R.B. (1993) Using quinolones to treat haemobartonellosis. *Vet Med* 306–308.

Yamaguchi N., Macdonald D.W., Passanisi W.C., *et al*. (1996) Parasite prevalence in free-ranging farm cats, *Felis silvestris catus*. *Epidemiol Infect* **116**, 217–223.

Zulty J.C. & Kociba G.J. (1990) Cold agglutinins in cats with haemobartonellosis. *J Am Vet Med Assoc* **196**, 907–910.

Chapter 30

OTHER INFECTIONS

K. Willoughby and M. Bennett

Introduction

Many of the agents and diseases included in this chapter are covered elsewhere in Part 2 of this book: in these cases a summary is provided here and the reader is cross-referenced to the appropriate chapter. Other infections are rare, but can affect multiple and diverse systems, while others still cause no disease in cats, but are proven or potential zoonoses. Some agents are considered more likely to cause disease only in immunosuppressed cats. Cats at risk of immunosuppression include those infected with feline leukaemia virus (FeLV), feline immunodeficiency virus (FIV), feline panleucopenia virus (FPLV), those on long-term or high-dose corticosteroids or cytotoxic agents, cats with diabetes mellitus, hyperadrenocorticism (Cushing's syndrome), or other chronic debilitating disease or stress. Where unusual infectious agents are detected, a diligent search for any underlying disease should always be undertaken before commencing therapy.

Feline abscess and cellulitis

Feline abscesses and cellulitis are probably the most common infections encountered in cats. A wide variety of organisms may be isolated from these lesions (Table 30.1), often introduced through scratches and bites received when fighting with other cats (Love *et al*., 1989, 1990). Cat-fight abscesses are also covered in Chapter 6 'The skin'. The majority of abscesses are caused by organisms sensitive to first line antibacterial therapy, such as penicillin group antibiotics (Dow *et al*., 1986; Jang *et al*., 1997) and this, combined with the provision of appropriate drainage, is usually sufficient to resolve most lesions. Chronic cases should be investigated further; such investigations should include:

- examination to detect foreign bodies, such as tooth fragments, grass seed-heads or airgun pellets. In contrast to the dog, foreign bodies are unusual

Table 30.1 Agents isolated from cat-bite abscesses or which can be involved in chronic or non-healing lesions[a]

Bacteria	*Actinomyces* spp.
	Dermatophilus congolensis
	Enterobacteriaceae including *Escherichia coli*
	Enterococcus spp.
	Fusobacterium spp.[a]
	Mycobacterium spp.
	Mycoplasma spp.
	Nocardia asteroides
	Pasteurella multocida (many subspecies)
	Peptostreptococcus spp.[a]
	Porphyromonas spp.[a]
	Propionibacterium spp.[a]
	Rhodococcus equi
	Staphylococcus spp.
	Streptococcus spp.
Fungi	*Candida* spp.
	Hyphomycetes
	Microsporum spp.
	Sporothrix schenki
	Trichophyton spp.
	Trichosporon spp.
Viruses	Cowpox virus
	Feline calicivirus (FCV)
	Feline herpesvirus-1 (FHV-1)

Data from Love *et al*. (1979, 1980, 1981, 1982, 2000), Kanoe *et al*. (1984), Dow *et al*. (1986), Beale (1995), Dobbinson & Tannock (1995), Hoshuyama *et al*. (1996), Greene (1998) and Norris and Love (1999).
[a] Anaerobes.

complicating factors in cats (Brennan & Ihrke, 1983), but they should still be sought
- screening for FIV and FeLV
- culture and sensitivity of lesional material (after at least 48 h off antibacterial therapy)
- careful, perhaps repeated examination for mycobacterial or fungal infections (Beale, 1995).

Where more unusual agents are detected, special therapy may be required.

Actinomycosis and nocardiosis

Actinomyces and *Nocardia* species are Gram-positive, pleiomorphic branching rods and filaments. The two organisms are difficult to distinguish except by culture. They are both facultative anaerobes, but whereas *Actinomyces* species are part of the normal flora of the oral cavity and respiratory tract of cats and dogs, *Nocardia* are common soil saprophytes. Clinically, both are uncommon infections in cats, causing chronic granulomatous lesions, which can be invasive into underlying tissues.

Actinomycosis

Infection with *Actinomyces* species, although rare, is more common than nocardial infection and is usually assumed to be acquired by bite wounds or infection of previous wound by contamination with saliva. *Actinomyces* species are most frequently associated with localised abscesses, cellulitis and pyothorax (Bestetti *et al*., 1977; Murakami *et al*., 1997; Stowater, 1978; Yovich & Read, 1995; Greene, 1998; Pascual *et al*., 1999).

This organism is always found in mixed infections; the presence of other organisms is considered to increase the pathogenicity of *Actinomyces* species. The pus characteristically contains 'sulfur granules'. Diagnosis of involvement of *Actinomyces* species can be problematic as culture frequently gives negative results. Most species are facultative anaerobes, and some grow only on anaerobic culture. In most cases 5–7 days' incubation is required, and the presence of other organisms complicates culture. Effusion cytology can be helpful as branching, filamentous rods may be seen. Treatment can be difficult and requires the establishment of adequate drainage combined with antibacterial therapy. Actinomycosis is usually treated with a prolonged course of penicillin, but poor drug penetration into the lesions may cause therapeutic failure. Other drugs that can be used include clindamycin, erythromycin, tetracyclines and chloramphenicol. *Actinomyces* species are generally resistant to cephalexin, metronidazole and aminoglycosides. Actinomycosis has not been reported in humans following contact with an infected animal, but can occur following bite wounds. When treating an animal with clinical actinomycosis, suitable precautions should be taken to prevent accidental contamination of skin wounds (e.g. by wearing gloves).

Nocardiosis

Nocardiosis is rarer in cats than actinomycosis. In humans nocardial infections are frequently associated with immunosuppression, and this would seem also to be the case in cats. Feline nocardiosis most commonly presents as cutaneous abcesses/mycetoma, draining tracts or pyothorax, although pulmonary and systemic forms are sometimes reported (Armstrong, 1980; Wilkinson, 1983; Davenport & Johnson, 1986; Tilgner & Anstey, 1996; Greene, 1998). Sulfur granules are not common in nocardial infections but are occasionally observed. The organism is usually present in pure culture, and may be observed in cytological preparations as beaded, branching, filamentous organisms. *Nocardia* species are Gram-positive and weakly acid fast. Anaerobic cultures may require 2–4 weeks' incubation to confirm the diagnosis, so therapy usually starts following cytological examination. Sulfonamides are the usual drugs used in nocardiosis and therapy may need to be prolonged (at least 3–6 months, sometimes longer). Other drugs may be used: amikacin, penicillins, erythromycin and tetracyclines have all been suggested. The usual second line antibacterials (amoxycillin–clavulanate and cephalosporins) may be less effective; when culture results are available antibacterial therapy can be altered as appropriate (Hirsh & Jang, 1999). Antibacterial therapy should ideally be combined with establishment of surgical drainage. Further details of clinical signs, differential diagnoses and treatment can be found in the appropriate systems chapters (Chapters 12, Respiratory disease, and 6, The skin). As with actinomycosis, transmission to humans has not been reported from an infected animal, but has been reported from bite or scratch wounds, presumably owing to soil contamination.

Streptococcal infections

β-Haemolytic streptococci of Lancefield group G are part of the normal flora of the upper respiratory

tract, oropharynx, lower genital tract and skin of cats (Reitmeyer *et al.*, 1991). They can be responsible for a number of clinical syndromes, including fading kitten syndrome (FKS), wound infections, lymphadenitis and arthritis, as well as being involved in opportunistic infections (Greene, 1998).

Neonatal kittens probably become infected at birth from their mother's genital tract, with infection entering through the umbilicus and then spreading to various sites around the body via the liver. Septicaemia and embolic disease may result, leading to a variety of clinical signs, but often culminating in death. Kittens may also die acutely in the septicaemia phase; others survive and progress to FKS. Occasionally, the umbilicus is enlarged or obviously infected on clinical examination, but this is not always the case. Mostly kittens have non-specific signs, fail to gain weight and die around 7–10 days of age. Infection is most common in litters born to younger queens (under 2 years old), or if the litter or the queen are immunocompromised (e.g. by FeLV or FIV infection); prevalence is low in mature or experienced queens, possibly owing to elimination of the organism. If the disease is endemic in a colony, older cats become immune and maternally derived antibody (MDA) is then passed on to their kittens.

In older kittens, up to 6 months old, subclinical infection in tonsils may develop into clinical tonsillitis and cervical lymphadenopathy (Swindle *et al.*, 1980). Infection may also occur at distant sites owing to localised streptococcal infections: arthritis, osteomyelitis, discospondylitis and pneumonia are reported and other sites can also be involved (Iglauer *et al.*, 1991). Signs are dependent on the site affected, and embolic disease may occur in any case, complicating the clinical picture. All cats presenting with apparent streptococcal infection should be checked for underlying immunosuppressive disease (e.g. FeLV, FIV, other chronic diseases and diabetes mellitus). Therapy with penicillin group antibacterials should be instituted, as should surgical drainage and flushing of wounds or abscesses.

Group B, C and G and other streptococci are also frequently isolated from wounds and abscesses in adult cats (Devriese & Haesebrouck, 1992) and as opportunist pathogens, secondary to upper respiratory and other mucosal infections, in which case antibiotics, particularly penicillins, may be used in treatment.

Cats can also harbour asymptomatic infections of group A streptococci in their oropharynx (Crowder *et al.*, 1978). Group A streptococci are more often associated with human disease. Hence, the family pet may become a reservoir for human infection and the source of recurrent tonsillitis or pharyngitis in a family. A more recent study (Wilson *et al.*, 1995) examined 26 households in which clinical disease due to infection with group A streptococci was confirmed in children, but failed to demonstrate any evidence of concurrent infection of cats (or dogs) in these households. However, isolation of streptococci from such cases can be difficult, and if a family pet is suspected of being the source of human infection it may be advisable to treat it with penicillin or a cephalosporin, even in the absence of isolation.

Tuberculosis, leprosy and atypical mycobacterial infections

Cats can be infected with a number of mycobacterial species (Greene, 1998). These can be broadly broken down into four groups:

- members of the closely related *Mycobacterium tuberculosis* complex of organisms, *M. tuberculosis, M. bovis* or *M. microti* and an *M. microti*-like variant, all of which can cause tuberculosis
- *M. avium* complex (MAC) bacteria, saprophytes which can also cause a tuberculosis-like disease or more local lesions
- *M. lepraemurium*, a rodent agent and the cause of feline leprosy (see Chapter 6, The skin)
- various other mycobacteria, normally found in the environment, may be involved in chronic wounds and abscesses (see Chapter 6).

Tuberculosis

Tuberculosis is an infrequent infection of cats, and many cases are subclinical so disease is rare. The majority of clinical cases are due to *M. bovis*, with some due to *M. microti*; cats appear relatively resistant to infection with *M. tuberculosis. Mycobacterium bovis* and *M. tuberculosis* infections are most often contracted from humans, although cattle and wild mammals might be alternative sources of infection in some areas. The main source of *M. microti* is wild rodents and insectivores (Cavanagh *et al.*, 2002). Although *M. microti* infections are very common in wildlife, they appear to be rare in cats. *Mycobacterium microti* can be more difficult to culture in the laboratory than other members of the *M. tuberculosis* complex, so misdiagnoses may have occurred in the past. Recently, a *M. microti*-like variant has been isolated from cats

which may have previously been misidentified as either *M. bovis* or *M. tuberculosis* (Blunden & Smith, 1996; Gunn-Moore *et al.*, 1996; Monies *et al.*, 2000).

Mycobacterium avium is a saprophyte found in soil and water, and only an opportunist pathogen of animals and humans. This organism can form deep granulomata that can be hard to differentiate from true tuberculosis (Jordan *et al.*, 1994; Malik *et al.*, 1998).

The clinical signs seen reflect the route of infection, which can be respiratory, oral or percutaneous, and the site of granuloma formation. In cats, signs are usually alimentary and rather non-specific, such as anorexia, wasting, pyrexia, vomiting or diarrhoea (owing to malabsorption). The alimentary form often causes palpably enlarged mesenteric lymph nodes. When the respiratory tract is affected, pulmonary granuloma may produce retching and a variable non-productive cough accompanied by non-specific signs of anorexia, pyrexia and weight loss. Dysphagia or hypersalivation may occur, reflecting chronic ulceration of the oropharynx, tonsils and draining lymph nodes. With both intestinal and respiratory forms, a pleural and/or peritoneal effusion may be present. Clinical pathology investigation also produces rather non-specific results, although hyperglobulinaemia is often present, as is hypercalcaemia. There is usually a low-grade leucocytosis and a non-regenerative anaemia consistent with chronic disease. Diagnostic imaging techniques may be helpful to assess organ involvement and allow collection of biopsy/aspirate material. The acid-fast organisms can be detected in leucocytes, aspirates, effusions or biopsies in most affected animals; biopsy gives the most consistent results. Isolation may be possible on special media, but can be a lengthy process. Specialist laboratories may be able to offer rapid polymerase chain reaction (PCR) diagnosis, which combined with 'spoligotyping' (a molecular method of typing based on the detection of insertion sequences) can also rapidly identify the agent to species and even strain level (Aranaz *et al.*, 1996, 1998; Rodriguez-Ferri *et al.*, 1996). Intradermal testing is unreliable and not suitable as a screening test in the cat. Unless specifically sought, the diagnosis is often missed and may be made only at necropsy.

Improvement of clinical signs following treatment of cats with either isoniazid or streptomycin has been reported, but did not produce bacteriological cure, and single drug therapy is therefore not recommended. The current recommended treatment is a prolonged course of a combination of therapies. The first 3 months should comprise at least three drugs (clarithromycin, rifampicin and enrofloxacin are considered the least toxic combination for cats), followed by further therapy for at least 4–6 months with rifampicin and either clarithromycin or enrofloxacin. Therapy is both prolonged and expensive and the prognosis is poor. In addition, the decision on whether to treat cats with tuberculosis must take account of the potential risk of zoonotic transmission. Although zoonotic spread from cats has not been reported, the bacteria are excreted in exudates and possibly faeces of cats. Elderly or immunosuppressed owners are usually considered particularly at risk. As a bacteriological cure is rare, and antibiotic resistance is already a problem in human medicine, euthanasia is therefore often recommended on public health grounds.

Non-tubercular mycobacterial infections

Skin and ocular forms of mycobacterial infection can also occur in the cat. The skin form can be associated with the tubercular species above or with the *M. microti*-like variant and MAC organisms (Stevenson *et al.*, 1998; Malik *et al.*, 1998; Lemarie, 1999; Miller *et al.*, 1999). Although frequently associated with ulcerated, non-healing lesions or with draining sinus tracts, cutaneous tuberculosis can present as raised firm nodules or loss of pigmentation. The granulomata can invade underlying tissues. Systemic involvement may occur, and the non-specific signs described above may include uveitis and central nervous system (CNS) signs. Diagnosis rests with cytological examination, culture and species identification (see tuberculosis above), which is required to assess the zoonotic risk and to make decisions on therapy. Zoonotic transmission of *M. avium* has not been reported; infection from common sources is probably as likely as transmission between owners and their cats. The zoonotic potential of the *M. microti*-like variant is not known. Therapy, if considered, is as for tuberculosis above. Surgery is sometimes suggested as an adjunct to therapy for isolated lesions, but the risk remains of poor wound healing and severe recurrence. In severe cases, or where there is systemic involvement, euthanasia is frequently the best course of action.

Atypical mycobacterial infections

Occasionally, various saprophytic *Mycobacteria* including *M. fortuitum–M. chelonei* complex, *M. smegmatis, M. xenopi* and *M. phlei* have been isolated from superficial or, rarely, deeper, persistent abscesses or ulcerative or granulomatous lesions of cats (Foster *et al.*,

1999; Paulsen *et al*., 2000). Sinus formation is common, but lymphatic involvement is rare in cats. Cats are usually well, although there may be a low-grade or intermittent pyrexia, but the lesions may persist for years. Occasionally, a pyogranulomatous panniculitis is associated with these agents. Thorough and repeated sampling may be needed to detect the organisms: culture of multiple pieces of biopsy material is most likely to yield a diagnosis, although PCR might also be expected to be useful if it becomes available. In humans, such infections are often associated with immunosuppression. Treatment is by surgical removal/debulking or drainage combined with antibacterials. Gentamicin or potentiated sulfonamides are sometimes useful, as the usual anti-tuberculous antibiotics are usually ineffective. Enrofloxacin, tetracyclines, chloramphenicol and erythromycin can also be considered. Ideally, sensitivity testing should be performed on isolates, as these opportunistic agents differ widely in their sensitivities. Treatment is usually recommended for 6–8 weeks, but may require some months; even after this, visceral lesions or recurrence may develop. The outlook is guarded, and treatment is apparently more likely to be successful in dogs than in cats.

Feline leprosy

Feline leprosy is caused by *Mycobacterium lepraemurium* ('rat leprosy'). It is an uncommon condition thought to be contracted from rat (or other rodent) bites. The clinical signs are of single or multiple, fleshy, sometimes ulcerated but non-painful nodules on the head or limbs, which develop between 2 weeks and several months following injury. Unlike other mycobacterial infections, caseation is not a feature of feline leprosy. The spread of the infection may be accompanied by lymphangitis and regional lymphadenopathy.

Diagnosis is based on finding acid-fast organisms in cytological preparations or biopsy material. M*ycobacterium lepraemurium* is very difficult to grow *in vitro*, so isolation is not usually attempted. The authors do not know of any laboratories offering PCR-based diagnosis routinely (Hughes *et al*., 1997), although this may be the best approach to obtaining a definitive diagnosis.

The usual treatment is surgical removal, but local infiltration with streptomycin, oral dapsone or clofazamine may be considered if complete excision is not possible. Haemolytic anaemia and neurotoxicity have been reported with dapsone in cats. Clofazamine appears to be better tolerated and has been used successfully. Even after apparently successful surgical treatment, recurrence of lesions at the same or other sites often occurs. Spontaneous remission may occasionally take place (Roccabianca *et al*., 1996).

Tyzzer's disease

This is an uncommon disease of cats and dogs caused by *Clostridium piliforme*, part of the normal intestinal flora of many rodents. Cats are therefore thought to become infected through contact with rodents, and they may be more susceptible to disease if immunosuppressed or stressed in some way, for example as a result of panleucopenia infection (Ikegami *et al*., 1999). The bacteria replicate inside intestinal epithelial cells, may cause iliocolitis and may spread to cause focal periportal hepatitis. The clinical signs include rapid-onset anorexia, depression, abdominal pain and distension, hepatomegaly and, possibly, jaundice (Kovatchh & Zebarth, 1973; Kubokawa *et al*., 1973; Schneck, 1975; Nimmo-Wilkie & Barker, 1985; Ikegami *et al*., 1999). Death often ensues within 2 days, so the diagnosis is usually made post mortem, based on gross and microscopic lesions of gastrointestinal tract, liver or occasionally other organs (e.g. heart) and isolation of *C. piliformis*. The efficacy of therapy is unknown as the diagnosis is usually made at post-mortem examination.

Mycoplasma infections

The role of mycoplasma in feline disease is not clear. Several species have been isolated from cats, in particular *M. felis* and *M. gatae*. Infection is common both in colony cats and household pets, and the organisms have been isolated from both diseased and healthy cats.

Mycoplasma gatae is probably a normal commensal of the conjunctivae and upper respiratory tract of cats and probably has little pathogenic potential for these sites. *Mycoplasma felis*, however, may be a cause of conjunctivitis and respiratory disease (Crisp *et al*., 1987; Haesebrouck *et al*., 1991; Foster *et al*., 1998). In addition, in contrast to the dog, *Mycoplasma* species are not isolated from bronchoalveolar lavage of healthy cats; however, they are isolated from approximately 25% of cats with chronic bronchial disease (Padrid *et al*., 1991; Randolph *et al*., 1993). Feline pulmonary mycoplasmal infection is also associated with the development of bronchietasis, so antibacterial therapy is

advisable. For a discussion of the main causes of feline infectious respiratory disease, see Chapter 22.

Mycoplasma gatae and *M. felis* have both also been implicated in arthritis in cats (Moise *et al.*, 1983; Hooper *et al.*, 1985) and with subcutaneous abscesses. Ureaplasmas have been implicated in one experimental study in spontaneous abortions and kitten mortality, but there is no evidence that this occurs in the field.

Lyme disease (borreliosis)

Borrelia burgdorferi is spread by ticks (usually *Ixodes* species) during their feeding activity on a host species. Hosts can include domestic animals and humans, and the dog is the best known veterinary species in terms of clinical disease. There is evidence of seropositivity to *B. burgdorferi* in cats (4.2% in the UK, ~13% in North America), but there seems to be no specific disease association (May *et al.*, 1994); infection is therefore frequently considered to be subclinical in cats. Some authors, however, describe non-specific clinical signs associated with natural infection, which include lameness, neurological signs, hepatic dysfunction and (chronic) colitis. In experimental infection, using arthropod-maintained *B. burgdorferi*, signs of lameness were detected and lymphoid, lung, CNS and joint pathology was demonstrated at post-mortem examination. Where disease is suspected, serology, or possibly PCR, could be used to confirm exposure.

Q-fever

Q-fever is caused by the rickettsia *Coxiella burnetii* (see Greene, 1998, for a thorough review). Although, like other Rickettsiae, *C. burnetii* can be transmitted between and from ticks, it can also be maintained in wild and domestic animal populations by ingestion and inhalation of infectious material such as placentas, urine and faeces. In most species, infection causes no disease, but in humans the outcome of infection can be severe: the clinical signs can include general malaise, pyrexia, pneumonia, myalgia, vomiting and diarrhoea.

Antibody to Q-fever is apparently quite common in domestic cats; up to 40% cats may have been infected at some time. Although most feline infections appear to cause no disease, they can occasionally result in abortion or premature parturition. In North America there have been several reports of human Q-fever contracted from parturient and aborting cats.

As infection in cats is often subclinical, or diagnosed only retrospectively, there is little information available on treatment. Tetracyclines, potentiated sulfonamides and quinolones have all been suggested.

Listeria

Listeriosis is a rare syndrome in cats, although *L. monocytogenes* has been detected occasionally in faeces from healthy cats (and dogs). When disease occurs it is usually due to consumption of infected dairy products or meat and may occur at the same time as human cases in the same household, owing to a common source. Clinical signs are usually restricted to non-specific vomiting, diarrhoea and pyrexia, although neurological signs are seen sporadically. Signs reflect the localisation of embolic microabcesses. Many antibacterials are effective against *L. monocytogenes*, including trimethoprim–sulfonamides, ampicillin, erythromycin, tetracyclines, rifampin and chloramhenicol.

Anthrax

Anthrax is extremely rare in cats (and dogs), and when it does occur is usually due to consumption of infected meat. The oedematous form of the disease occurs in cats, with swelling of the head and neck and of the tissues of the upper gastrointestinal tract, usually spreading to involve of the mesenteric lymph nodes, liver and spleen. Diagnosis rests on isolation or detection of *Bacillus anthracis* in infected tissues. Therapy with penicillin group antibiotics can be successful if started early enough in infection. Post-mortem examination of infected animals is a zoonotic risk and should not be performed except in licensed facilities.

Yersiniosis, pseudotuberculosis and plague

Yersinia enterocolitica and *Y. pseudotuberculosis* can be isolated from the soil and from the faeces of many animals, including cats and dogs. Infection usually causes no clinical signs in cats, although *Y. pseudotuberculosis* has been reported to cause gastroenteritis, abdominal lymphadenitis and multiple caseous abscesses in liver, kidneys and spleen.

In humans, particularly young children, both can cause severe disease, and children have been known

to acquire clinical pseudotuberculosis from cat faeces while playing in sandpits. If a cat is shown to be shedding *Y. enterocolitica* or *Y. pseudotuberculosis* in its faeces, then treatment with tetracyclines or potentiated sulfonamides may be considered appropriate on public health grounds.

In areas of the world where plague is endemic in wild rodents (e.g. parts of North America, Central Asia and parts of East Africa), cats can become infected with the plague organism, *Yersinia pestis*, through contact with rodents or their fleas. Cats (or their fleas) may in turn pass the infection on to humans, with veterinary surgeons being particularly at risk (Gage *et al.*, 2000).

Feline plague has been mainly described in North America, where the most common form of the disease in cats is bubonic plague, clinical signs of which include pyrexia, dehydration and lymphadenopathy (Eidson *et al.*, 1991; Chomel *et al.*, 1994; Carlsson, 1996). Septicaemic plague is often fatal within several days, with few signs other than collapse and shock. Pneumonic plague is apparently rare in cats.

Should treatment be considered necessary, then drainage and lavage of buboes and intramuscular aminoglycoside injections (streptomycin at 5 mg/kg twice daily or gentamicin at 2 mg/kg twice daily) for 3 weeks have reported as being successful. However, on public health grounds, euthanasia might be a preferred option.

Tularaemia

Tularaemia is caused by *Francisella tularensis*, a Gram-negative, pleiomorphic rod, endemic in wild rabbits and rodents, among which it is transmitted by various ticks. Type A is found in North America and is the more virulent form, whereas type B rarely causes disease in any host and occurs in the rest of the northern hemisphere.

Cats usually become infected either by tick bites or by ingestion of infected rabbits, rodents or contaminated water. Cats appear to be more susceptible to tularaemia than dogs, but the disease is still rare. Clinical signs include depression, anorexia and pyrexia, lymphadenopathy, splenomegaly and hepatomegaly. Oral and tongue ulceration, abscesses and jaundice have also been reported. Infection is often fatal. Diagnosis is based on antibody detection or by isolation of *F. tularensis*, which can be carried out at specialist laboratories only. Treatment of cats and dogs is rarely successful, and on public health grounds should probably not be attempted.

Tularaemia is a zoonotic disease, and cat to human transmission has been reported. The clinical signs in humans are similar to those in the cat and often fatal.

Candidiasis

Candida albicans is commonly isolated from the ears, nose, oral cavity and anus of dogs, where it is part of the normal flora. It is a rare opportunist pathogen in immunosuppressed or debilitated cats where it causes chronic, non-healing ulcerative lesions (e.g. in chronic otitis externa). Lesions are typically greyish mucoid plaques with a foul-smelling odour, although systemic and intestinal candidiasis, causing chronic diarrhoea, also occasionally occur.

A diagnosis is made by the detection of yeast-like organisms in stained smears of lesions and biopsy material, or isolation colonies on Sabaraud's agar.

Topical therapy with gentian violet or nystatin has been recommended, and systemic ketoconazole (5–10 mg/kg p.o. two or three times daily) may be used. However, most important is treatment of the predisposing cause.

Blastomycosis

Blastomyces dermatitidis is a soil saprophyte, mainly seen in North America. Infection is by inhalation, which may cause primary lung disease and allow widespread dissemination to other organs. Pyrexia, lethargy, pulmonary, skin and ocular lesions are most common, but the site and severity of the lesions determine the clinical signs seen. Diagnosis is usually by identification of yeast-like organisms in cytological preparations or on histopathology. Treatment is with amphotericin B, sometimes followed by ketoconazole.

Histoplasmosis

Found in soil worldwide, *Histoplasma capsulatum* infections are mainly a clinical problem in North America, where they cause pulmonary and systemic disease in cats. In cats in particular histoplasmosis present as respiratory distress, dyspnoea and tachypnoea. Coughing is not a common feature. Diagnosis is usually by cytology of respiratory wash samples or histopathological examination, and detection of yeast-like organisms within phagocytes. Treatment is with ketoconazole.

Cryptococcosis

Cryptococcosis occurs worldwide and has been reported, but is rarely diagnosed, in Britain. *Cryptococcus neoformans* is a saprophytic yeast-like fungus, frequently associated with pigeon droppings (Greene, 1998). In humans, infection is associated with immunosuppression and this may also be the case in the domestic cats. Many organ systems can be involved (Pal, 1991; Gerds-Grogan & Dayrell-Hart, 1997; Malik *et al.*, 1998; Barrs *et al.*, 2000; Beatty *et al.*, 2000; Foster *et al.*, 2000; Zaisser *et al.*, 2001), but the upper respiratory tract is the most common site of infection in cats. Cryptococcus usually presents as a chronic nasal disease, with chronic nasal discharge, deformity of the nasal bones and on occasion a polyp-like lesion protruding from the nostril. Cryptococcus can also cause CNS, ocular and skin lesions. Weight loss and lethargy are also usually pre-sent, reflecting the chronicity of the disease.

Diagnosis is based on demonstration of the characteristic yeast-like budding organisms in cytological preparations or in lesions, or detection of antigen or antibody in sera (Flatland *et al.*, 1996; Malik *et al.*, 1999). Treatment can be attempted with ketoconazole or a combination of amphotericin B and 5-fluorocytosine, but the prognosis is always guarded (Kano *et al.*, 1997; Jacobs *et al.*, 1997).

Although cryptococcus can affect humans, it is not known whether zoonotic spread can occur from the cat. Sensible precautions should, however, be taken when handling or treating affected animals.

Coccidiomycosis

Coccidioides immitis is a soil saprophyte found mainly in desert areas of the south-western USA. Feline infection is very rare, but may be associated with skin lesions, or even more rarely with respiratory signs or serious disseminated disease. Diagnosis is by cytology, serology or culture, but owing to high exposure rates can be difficult to confirm. The treatment of choice is long-term ketoconazole.

Feline cowpox

Cowpox virus is, as its name suggests, a poxvirus (Baxby & Bennett, 1994). Within the family Poxviridae, it belongs to the genus *Orthopoxvirus* and as such is closely related to smallpox virus (now eradicated), vaccinia virus (the modern smallpox vaccine, the origins of which are unknown), infectious ectromelia ('mousepox') virus and a number of other viruses of domestic and wild mammals. It is found mainly in western Eurasia. Despite its name, cowpox virus circulates mainly in wild rodents, and domestic cats are the species in which clinical disease is most often diagnosed (Figure 30.1). Human infection, although uncommon, can often be traced to contact with an infected cat, or sometimes direct contact with rodents.

Cowpox in the wild

Cowpox virus probably circulates in different rodent species in different areas of its geographical range, and generally causes no overt disease in its endemic hosts (Chantrey *et al.*, 1999). In western Europe, bank voles (*Clethrionomys glareolus*), field voles (*Microtus agrestis*) and woodmice (*Apodemus sylvaticus*) are the main reservoir hosts. In northern Europe, the virus has been isolated from root voles (*Microtus oeconomus*) and antibody detected in voles, lemmings and possibly shrews. In Turkmenia, both antibody and virus infection have been detected in suslicks (*Citellus fulvus*) and great gerbils (*Rhombomys opimus*) and antibody, possibly due to cowpox virus infection, has also been detected in gerbils (*Meriones libicus*) and, at low prevalence, rats (*Rattus norvegicus*) in Georgia. However, rats are unlikely to be reservoir hosts or the virus would be found worldwide, and small-scale surveys have not detected antibody in British rats.

The dynamics of cowpox virus infection have been studied in British populations of wild bank voles and wood mice (Begon *et al.*, 1998, 1999), and were found to reflect the population dynamics of each of these two hosts. Bank vole and wood mouse populations in Great Britain generally undergo seasonal (i.e. within-year) fluctuations in size: bank vole populations typically peak in early summer and fall in the autumn, while wood mouse populations peak later in the year and fall in the following spring. The incidence of infection (as measured by seroconversion) in both species follows closely the host population dynamics, and can be predicted from the number of susceptible and infected animals in the population the previous month.

No obvious clinical signs of infection are seen either in naturally infected or experimentally infected voles and mice (Bennett *et al.*, 1997). A marked reduction in fecundity has been observed in experimentally infected bank voles and wood mice, but it is not known whether this occurs in naturally infected

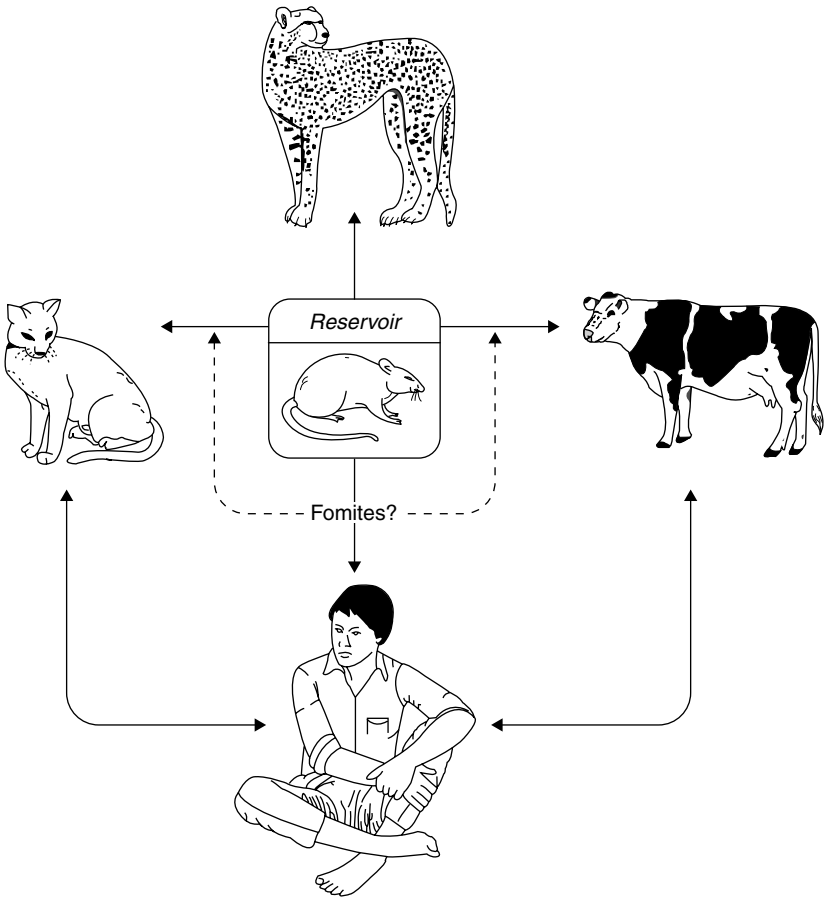

Figure 30.1 Epidemiology of cowpox.

animals in wild populations (Feore *et al.*, 1997). Indeed, under some circumstances, infected wild rodents may have an apparently higher survival rate than uninfected animals (Telfer *et al.*, 2002).

Clinical signs in cats

The domestic cat is the species in which cowpox is most frequently diagnosed in western Europe and, unlike rodents, cats generally develop systemic disease (Bennett *et al.*, 1990a; Bomhard *et al.*, 1992; Nowotny *et al.*, 1994). Cats probably become infected by direct contact with infected wild rodents, perhaps when hunting. The usual route of infection appears to be through a break in the skin, although oronasal infection is also possible. Most feline cases are seen in the autumn, reflecting the population and infection dynamics of rodents. Cat-to-cat transmission can occur, but is rare and seldom leads to clinical disease. Thus, cats are not endemic hosts and serological surveys generally detect only a low prevalence of infection.

The pathogenesis of feline cowpox follows the typical pattern of a systemic poxvirus infection. A single primary skin lesion develops at the site of inoculation, usually the head or a forelimb, within a few days of inoculation (Figure 30.2). It may be simply a small, ulcerated lesion or, if secondary bacterial infection occurs, abscessation or cellulitis may develop. A white cell-mediated viraemia develops, with virus replication in lymphoid tissue, the lungs and turbinates. The viraemic phase lasts for about 5 days, and may be accompanied by mild systemic clinical signs such as pyrexia, inappetance, depression, and occasionally mild diarrhoea or conjunctivitis. Clinical pneumonia, associated with virus replication in the lungs, is unusual, and usually indicates a poor prognosis.

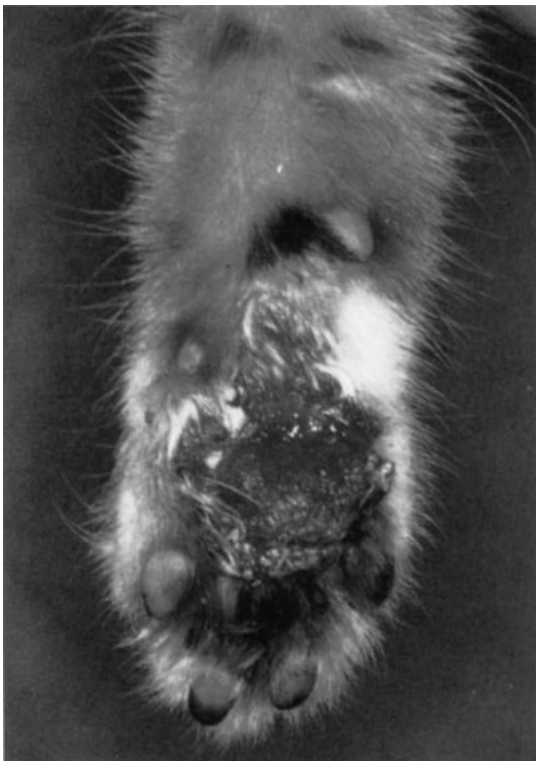

Figure 30.2 Ulcerated cowpox virus lesion on paw.

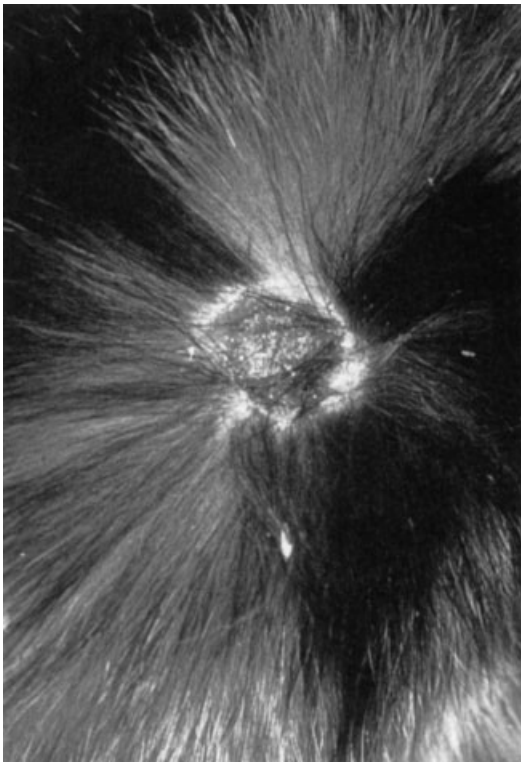

Figure 30.3 Hairless scabbed lesion on dorsum.

Secondary, widespread skin lesions appear just over a week after the primary lesion, as small erythematous nodules that increase in size over 2–3 days to become scabbed ulcers approximately 0.5–1 cm across (Figure 30.3). The secondary lesions are not pruritic and gradually heal, so that by 4–6 weeks the dried scabs separate leaving small, bald patches. New hair growth soon hides the lesion sites, although the scars may remain for life and can be easily seen if the hair is clipped, for example for surgery. More severe disease, such as pneumonia or large or non-healing lesions, is often associated with immunosuppression, and may result from coinfection with FeLV or FIV, or some other concurrent illness.

Human cowpox

In many cases the source of human infection cannot be traced, but more than half of cases are associated with contact with infected cats (Baxby *et al.*, 1994). As in cats, the incidence of human infection is greatest in autumn, probably reflecting the underlying infection dynamic in rodents. The incidence of human cowpox is not known, but is probably very low: only one or two cases are reported each year in Great Britain, and serological surveys have found only a very low prevalence of antibody. Although it has been suggested that immunosuppression caused by HIV infection might lead to an increased incidence of human cowpox, there is no evidence that this has happened.

The usual route of infection is through a break in the skin and, in most cases, lesions are limited to the site(s) of inoculation, most often the hands or face, including the eyes. There is no overall age or sex predisposition to human infection, although possible trends towards girls less than 12 years old and adolescent males have been reported. The lesions can vary in size and severity, and are often very painful. Local lymphadenopathy and systemic signs such as pyrexia and nausea are common, and many cases require hospitalisation. More severe cowpox, with multiple lesions and, rarely, death, has been reported, usually associated with immunosuppression.

Diagnosis

With experience, many veterinary surgeons can accurately diagnose most cases of cowpox in cats on clinical signs alone. Differential diagnoses might include cat-bite abscesses, neoplasia, eosinophilic granuloma and miliary eczema, although the discrete, widespread lesions of cowpox are quite characteristic.

Fixed biopsy material can be examined microscopically for the characteristic eosinophilic, intracytoplasmic inclusion bodies of cowpox virus. However, these are not always easily found and immunostaining may be necessary for confirmation.

Virus isolation can be attempted on dry, unfixed scab material. This can be sent by mail without need for special transport medium. Electron microscopy of scab material enables rapid diagnosis in many cases, but virus isolation is more sensitive. However, isolation may take up to 10 days. Some laboratories now offer diagnosis by PCR.

Serum can be tested for antibody using several assays. An immunofluorescence test is now routinely used as it is both sensitive and relatively rapid. Because cowpox virus is not endemic in cats, detection of antibody is almost diagnostic of present infection. However, using class-specific monoclonal antibodies, the immunofluorescence test can be modified to detect only immunoglobulin M, indicative of present infection.

Treatment and prevention

There is no specific treatment for cowpox, so treatment usually consists of broad-spectrum antibiotics to control secondary and concurrent bacterial infection. Large lesions may be cleaned with antiseptics, and an Elizabethan collar or paw bandaging may be necessary to prevent scratching. Corticosteroids should be avoided as they may exacerbate the condition.

There is no vaccine available. Vaccinia virus does not grow well in cats and is itself zoonotic.

Feline parapoxvirus infection

Occasional reports exist of feline parapoxvirus (possibly orf) infection (Hamblet, 1993). The condition appears to be much less common than feline cowpox. In the best recorded case, the infected cat had multiple, crusty and scabbed skin lesions which healed after several weeks, and the cat had been in contact with goats. Diagnosis depends on electron microscopy of scabs as parapoxviruses are difficult to grow in cell culture and few laboratories undertake parapoxvirus serology.

Other zoonotic agents

This section contains some brief overviews of agents that generally cause little or no disease in cats, but may be zoonotic and therefore pose a public health risk.

Leptospirosis

Clinical leptospirosis is rare in cats, despite the presence of antibodies in some populations of cats; cats are therefore considered generally resistant to infection (Larsson *et al.*, 1984, 1985; Agunloye & Nash, 1996), although leptospirosis and salmonellosis have been associated with feline stillbirths (Reilly *et al.*, 1994). Surveys from many countries, including the UK, have suggested an antibody prevalence of 5–20%, with various serovars being detected, including *icterohaemorrhagiae*, *pomona* and *bratislava*. Experimentally, the pathogenesis of feline leptospirosis is similar to that of the canine infection, but clinical signs rarely develop in cats despite the development of histological lesions in the kidneys and liver. It is important to be aware, however, that cats can excrete potentially zoonotic leptospires in their urine for up to 3 months following experimental infection.

Hantavirus infection

Hantaviruses are enzootic worldwide in wild and laboratory rodent populations (Escutenaire *et al.*, 1997). Different strains of differ in their pathogenicity in humans. The hantavirus pulmonary syndrome in North America and haemorrhagic fever with renal syndrome in Asia both cause high mortality. However, most European strains usually induce only subclinical or mild disease. *Hantavirus* antibody in cats has been detected in laboratory-housed cats and dogs in Belgium and virus has been isolated from a cat in China (Luo, 1985). Surveys in Britain and Austria found antibody reactive to *Hantavirus* in 5–10% of cats from a variety of disease and environmental backgrounds, but a similar survey in The Netherlands did not detect any antibody (Bennett *et al.*, 1990b; Nowotny, 1996).

The clinical significance of *Hantavirus* infection in cats is not known, and there is little evidence to suggest that cats are a source of human infection; the overall prevalence of antibody in humans in the UK is only 0.5%, with higher prevalence found in those whose work or recreation exposes them to rodents. However, there is little evidence of infection in British

wild rodents, so the source(s) of human infections in Great Britain are generally not known.

Bartonellosis: cat-scratch disease and bacillary angiomatosis

The *Bartonella* species (previously known as *Rochalimaea* and including *Grahamella*) are Gram-negative bacteria, transmitted between hosts by arthropod vectors, mostly fleas. The species *Bartonella henselae* (most common) and *B. clarridgeiae* can be isoated from cats and cause cat-scratch disease (CSD), baciliary angiomatosis and other diseases of immunocompromised people (Bonilla *et al.*, 2000; Maruyama *et al.*, 2000, 2001; Gurfield *et al.*, 2001). In the USA, estimates range from 6000 to over 20 000 cases of CSD each year, 2000 of which require hospitalisation, but the incidence in Europe, and particularly in Great Britain, appears to be much lower, despite surveys of cat blood samples showing infection in cats to be common just about worldwide. The variation in prevalence of infection has been suggested to be due to climatic factors and their influence on the population of fleas. Older cats, feral cats and cats with current flea infestations are more likely to be seropositive.

Transmission of *B. henselae* between cats or cats and humans may be via cat fleas, or more specifically the inoculation (by scratching) of flea faeces which contains large amounts of the organism. Experimentally, infection of naïve cats can be achieved by intravenous or intramuscular blood inoculation or by infestation with infected fleas. Direct contact between cats without the presence of fleas, even for a prolonged period, has not resulted in transmission. In experimental infections, signs reported are both vague and mild, including low-grade pyrexia, lymphadenopathy and occasionally non-specific, minor neurological signs. Although *B. henselae* in cats has been linked to hepatic disease and possibly reproductive disorders, in natural infections subclinical disease seems most likely, and it is known that cats may remain infected for many years. Diagnosis is unlikely to be required outside research facilities, but may be requested to investigate cats when CSD or other manifestations of human infection occur. Culture can be difficult, as it requires sterile blood collection (technique as for diagnosis of bacterial endocarditis) and culture for several weeks. PCR may be a more useful tool and is used in an increasing number of laboratories. Serology apparently does not correlate well with recent or active infection.

Bartonella species have been associated with several clinical syndromes in humans, from CSD in the relatively immunocompetent to serious life-threatening illness of immunocompromised people, including baciliary angiomatosis, peliosis hepatica, bacteraemia and relapsing fever, endocarditis, granulomatous disease and neurological dysfunction.

CSD is a generally a benign, self-limiting disease, usually seen in children. A primary skin lesion, usually at the site of a recent scratch or wound, first appears as a non-pruritic, erythematous papule, develops into a vesicle, then a pustule that ruptures, scabs over and heals. Regional lymphadenitis develops about a week after the skin lesion and may last for several months. By the time the patient seeks medical help, lymphadenitis is often the only clinical sign.

Atypical CSD (5–10% cases) may include Perinaud's oculoglandular syndrome (after conjunctival inoculation), encephalitis (especially in adults), recurrent or suppurative lymphadenitis retinitis, arthralgia/arthritis and systemic lesions (e.g. in the spleen).

Bacillary angiomatosis (BA) is a disease mainly associated with human immunodeficiency virus (HIV) infection and characterised by multiple subcutaneous nodules, which are blood-filled cystic tumours. The disease may also produce systemic lesions or localised lesions, for example on the spleen or liver (when it is known as peliosis) or in CNS, bone, heart or elsewhere.

Antibiotic therapy of human CSD and BA has not generally proved useful, although some workers have had some success with intravenous gentamicin in severe cases. Other suggested agents include rifampin and doxycyline. In CSD, surgical drainage may be helpful. Relapses may occur even after prolonged therapy (>6 weeks). *Bartonella henselae* appeared to be eliminated from three cats treated with either doxycycline (25–50 mg p.o. twice daily) or lincomycin (100 mg p.o. twice daily).

Prevention of infection in humans (and other cats) relies on adequate ectoparasite control.

Other agents associated with bites and scratches

- *Capnocytophaga canimorsus* and *C. cynodegmi*, also known as dysgonic fermenter type 2 (DF-2) and DF-2-like organisms: these bacteria are part of the normal oral flora of many animal species, including cats. They are pleiomorphic Gram-negative bacteria that can be difficult to grow in culture. *Capnocytophaga* species are frequently transmitted through bites and scratches, but usually

cause no or little disease in humans. However, in immunosuppressed and splenoctomised individuals they can cause severe disease including septicaemia, septic endocarditis, arthritis, meningoencephalitis and death. Even in immunologically competent normal children, inoculation by a scratch of the eye can cause severe keratitis.

It can take up to 10 days to detect *Capnocytophaga* species in culture, so treatment is usually begun as soon as infection is suspected. Although most isolates are susceptible to penicillin, some are not, leading to further delays in onset of effective treatment.

- *Pasteurella* species are the most commonly isolated organisms from human wounds caused by cat bites (up to 75%) and can cause severe systemic infections in humans.
- Eugonic fermenter type 4 (EF-4) is a Gram-negative bacterium, with cultural properties similar to those of *Pasteurella* species, and is part of the normal commensal flora of the oral cavity of cats and many other carnivores (Corboz *et al.*, 1993). It has been isolated from purulent bite wounds, and septicaemia in animals and humans. It has also been associated with fatal pneumonia in cats, causing sudden death. The stress of recent transportation may have been a predisposing factor.
- *Pseudomonas* species, *Actinobacillus* species, streptococci, staphylococci, *Corynebacterium* species and a variety of anaerobes are also commonly isolated from human wounds caused by cat bites.

Toxoplasmosis

See Chapter 28.

Influenza virus

Influenza virus can infect cats following experimental inoculation, and there is some serological evidence of infection in the field. However, there is no evidence that cat to human transmission might occur, the reverse being more likely during human influenza epidemics.

Anaerobiospirillum species infection

Anaerobiospirillum species are spiral bacteria that have been isolated from the faeces of children with diarrhoea but not from normal human faeces (Malnick *et al.*, 1989; Goddard *et al.*, 1998). However, *Anaerobiospirillum* species is a normal finding in cat and dog faeces, and transmission from a puppy to a baby has been reported, so transmission from cats is also likely to be possible.

Other enteric agents with zoonotic potential include *Campylobacter, Salmonella* and *Helicobacter* species. These agents are further discussed in Chapter 16 (The gastrointestinal tract).

Aujeszky's disease (pseudorabies)

Aujeszky's disease (also known as pseudorabies and mad itch) is caused by a herpesvirus, suid herpesvirus-1 (pseudorabies virus) (Hara *et al.*, 1991a,b). The disease only occurs in areas where Aujeszky's disease is endemic in pigs. Although pigs are the reservoir host, other animals, for example cattle, sheep, dogs, cats and rats, can also be infected. These species are usually 'dead-end' hosts, and although they may shed virus in their oral and nasal secretions, do not generally transmit the disease themselves (Henderson *et al.*, 1995).

Infection in cats is usually associated with contact with infected pigs or eating uncooked, infected pig meat, including wild pig meat (e.g. wild boars), although infection by ingestion of other incidental hosts (e.g. rats) is also possible.

Infection in cats is almost always fatal, and often rapidly so. Although behavioural changes (restlessness, anorexia and hypersalivation) may be seen in dogs, often in cats no clinical signs are seen as they run off to hide early in disease development.

The intense pruritus, commonly localised around the face or mouth and often described as a characteristic sign of Aujeszky's disease in dogs, is generally absent in cats. Terminal signs usually develop within 48 h of the onset of clinical signs, include paralysis and coma, and some cats may die suddenly without showing any prior clinical signs (Egberink, 1990; Hara *et al.*, 1991a, b; Henderson *et al.*, 1995).

Diagnosis is usually made at necropsy, as progression of disease is so fast that antibody has not developed by time of death. Virus can sometimes be isolated from tonsil, spleen or brain. The demonstration of virus antigen in frozen sections of tonsil or brain is more sensitive, however.

Feline reovirus infection

Reoviruses are found in many mammalian and avian species and can be divided into three serotypes

regardless of their species of origin. The clinical importance of infection in cats is unknown, although serological surveys show that infection is widespread (Mochizuki *et al.*, 1992; Mochizuki & Uchizono, 1993).

Reoviruses have been isolated from the faeces and oropharyngeal secretions of cats showing a variety of clinical signs and also from healthy cats. Experimentally, the inoculation of newborn kittens with reovirus type 1 caused death in 2 days and necropsy revealed signs of respiratory infection. Inoculation of kittens with reovirus type 2, however, caused only mild diarrhoea, and inoculation of kittens with reovirus type 3 induced mild conjunctivitis and respiratory signs. Diagnosis is by detection of virus from faeces or oropharyngeal swabs by electron microscopy or isolation in cell culture.

Feline torovirus infection

Toroviruses are a group of viruses similar to the coronaviruses, but with a characteristic rod or doughnut-shaped core. They include Berne virus isolated from a horse, Breda virus isolated from cattle and several torovirus-like isolates from humans. Torovirus-like particles and antibody reacting with Breda virus types 1 and 2 have been also detected in cats, and infection has been linked with a self-limiting clinical syndrome involving persistent diarrhoea and protrusion of the nictitating membrane (Muir *et al.*, 1990).

Feline foamy virus infection

Feline foamy virus, or feline syncytium-forming virus (FeSFV), is a member of the foamy virus group (the genus *Spumavirus*) in the family Retroviridae. Foamy virus infection is extremely common in cats. The virus infects many cell types in many organs of the body, and is excreted in saliva.

Spumaviruses have been isolated from many species but, unlike many other retroviruses, they do not appear to be pathogenic, although an involvement in feline polyarthritis has been suggested. Their main importance at present lies not in clinical medicine but as potential contaminants of cell cultures used in diagnosis and research and for vaccine production.

Feline 'staggering disease'

A neurological syndrome of cats characterised by unsteady, staggering gait, depression, and progressive hindlimb ataxia and paresis has been described from several European countries, and possibly other parts of the world including North America, Japan and Australia (Lundgren *et al.*, 1995, 1997; Nowotny & Weissenbock, 1995; Berg & Berg, 1998; Reeves *et al.*, 1998; Berg *et al.*, 1999; Nakamura *et al.*, 1999; Nishino *et al.*, 1999; Billaud *et al.*, 2000; Ludwig & Bode, 2000, Horii *et al.*, 2001). Post-mortem examination reveals a very characteristic non-suppurative meningoencephalomyelitis mainly in the grey matter of the cortex, brainstem and spinal cord. The histopathology is consistent with a viral infection, and Borna disease virus (BDV) is considered to be the cause. BDV causes a progressive encephalopathy of horses and sheep in central Europe, and BDV or a related virus may also be associated with certain psychiatric disorders in humans. Several serological studies have shown that cats with 'staggering disease' are more commonly seropositive for BDV than are unaffected cats. However, success in isolation of the virus from affected cats has been limited, although detection by *in situ* hybridisation of brain sections is described. More recently, the use of PCR has improved sensitivity in detection of BDV and it has been detected in brain tissue from cats with a variety of poorly localised neurological signs and histopathological findings. Experimentally, it has recently been shown that the virus can establish a non-lytic infection in feline brain cells in primary cell culture, and it is speculated that the interaction between the virus and the immune system may account for the variety of neurological signs encountered.

Canine distemper virus

Canine distemper virus (CDV) can infect domestic cats both experimentally and in the field, but generally causes no clinical signs. In big cats, however, natural CDV infection has been associated with encephalitis.

Feline spongiform encephalopathy

Feline spongiform encephalopathy (FSE) is, one hopes, a new disease that has already been eradicated. There is little doubt that FSE was caused by bovine spongiform encephalopathy (BSE)-contaminated material being fed to cats. Retrospective surveys of feline CNS material taken at necropsy suggested that FSE is a relatively new disease of cats, and the first

cases were reported in 1990, soon after the emergence of BSE in cattle.

The clinical signs include ataxia, incoordination, hyperaesthesia, dysmetria or hypermetria, hypersalivation, muscle tremors and changes in behaviour (Wyatt *et al*., 1991; Gruffydd-Jones *et al*., 1992). The majority of cases occur in adult cats, although a few cases in cats under 2 years of age are reported. The disease may be suspected on narrowing down the differential diagnoses with investigative procedures (see Chapter 7, The nervous system), but the definitive diagnosis can only be made at post mortem, by the demonstration of characteristic histopathology of the brain at necropsy, and the demonstration of fibrils in CNS tissue by electron microscopy and modified prion protein by immunostaining (Wyatt *et al*., 1991; Gruffydd-Jones *et al*., 1992; Ryder *et al*., 2001). The risk of human infection from affected live cats is not known, but likely to be small. However, tissues, particularly lymphoid and CNS material, taken post-mortem from suspected cases (or from cats with neurological disease of unknown aetiology) should be handled with extreme care.

References

Agunloye C.A. & Nash A.S. (1996) Investigation of possible leptospiral infection of cats in Scotland. *J Small Anim Pract* **37**, 126–129.

Aranaz A., Liebana E., Pickering X., *et al.* (1996) Use of polymerase chain reaction in the diagnosis of tuberculosis in cats and dogs. *Vet Rec* **138**, 276–280.

Aranaz A., Liebana E., Mateos A., *et al.* (1998) Restriction fragment length polymorphism and spacer oligonucleotide typing: a comparative analysis of fingerprinting strategies for *Mycobacterium bovis. Vet Microbiol* **61**, 311–324.

Armstrong P.J. (1980) Nocardial pleuritis in a cat. *CanVet J* **21**, 189–191.

Bakerspigel A. (1973) An unusual strain of *Nocardia* isolated from an infected cat. *Can J Microbiol* **19**, 1361–1365.

Barrs V.R., Martin P., Nicoll R.G., *et al.* (2000) Pulmonary cryptococcosis and *Capillaria aerophila* infection in an FIV-positive cat. *Aust Vet J* **78**, 154–158.

Baxby D. & Bennett M. (1994) Cowpox virus. In *Encyclopedia of Virology* (eds Webster R.G. & Granoff A.). Academic Press, London, pp. 261–267.

Baxby D., Bennett M. & Getty B. (1994) Human cowpox; a review based on 54 cases, 1969–1993. *Br J Dermatol* **131**, 598–607.

Beale K.M. (1995) Nodules and draining tracts. *Vet Clin North Am Small Anim Pract* **25**, 887–900.

Beatty J.A., Barrs V.R., Swinney G.R., *et al.* (2000) Peripheral vestibular disease associated with cryptococcosis in three cats. *J Feline Med Surg* **2**, 29–34.

Begon M., Feore S., Bown K., *et al.* (1998) The population dynamics of cowpox virus infection in bank voles: testing fundamental assumptions. *Ecol Lett* **1**, 82–86.

Begon M., Hazel S.M., Baxby D, *et al.* (1999) Transmission dynamics of a zoonotic pathogen within and between wildlife host species. *Proc R Soc B* **266**, 1–7.

Bennett M., Gaskell C.J., Baxby D., *et al.* (1990a) Feline cowpox virus infection. *J Small Anim Pract* **31**, 167–173.

Bennett M., Lloyd G., Jones N., *et al.* (1990b) Prevalence of antibody to hantavirus in some cat populations in Britain. *Vet Rec* **127**, 548–549.

Bennett M., Crouch A., Begon M., *et al.* (1997) Cowpox in British voles and mice. *J Comp Pathol* **116**, 35–44.

Berg A.L. & Berg M. (1998) A variant form of feline Borna disease. *J Comp Pathol* **119**, 323–331.

Berg A.L., Johannisson A., Johansson M., *et al.* (1999) Peripheral and intracerebral T cell immune response in cats naturally infected with Borna disease virus. *Vet Immunol Immunopathol* **68**, 241–253.

Bestetti G., Buhlmann V., Nicolet J. & Fankhauser R. (1977) Paraplegia due to *Actinomyces viscosus* infection in the cat. *Acta Neuropathol (Berl)* **39**, 231–235.

Billaud J.N., Ly C., Phillips T.R. & de la Torre J.C. (2000) Borna disease virus persistence causes inhibition of glutamate uptake by feline primary cortical astrocytes. *J Virol* **74**, 10438–10446.

Blunden A.S. & Smith K.C. (1996) A pathological study of a mycobacterial infection in a cat caused by a variant with cultural characteristics between *Mycobacterium tuberculosis* and *M. bovis*. *Vet Rec* **138**, 87–88.

Bomhard D., Pfleghaar S. von & Mahnel H. (1992) Zur Epidemiologie, Klinik, Pathologie und Virologie der Katzen-Pocken-Infektion. *Kleintierpraxis* **37**, 219–230.

Bonilla H.F., Chenoweth C.E., Tully J.G., *et al.* (2000) Bartonella infection in animals: carriership, reservoir potential, pathogenicity, and zoonotic potential for human infection. *Clin Microbiol Rev* **13**, 428–432.

Brennan K.E. & Ihrke P.J. (1983) Grass awn migration in dogs and cats: retrospective study of 182 cases. *J Am Vet Med Assoc* **182**, 1201–1204.

Carlsson M.E. (1996) *Yersinia pestis* infection in cats. *Feline Pract* **24**, 22–33.

Cavanagh R., Begon M., Bennett M., *et al.* (2002) *Mycobacterium microti* infection (vole tuberculosis) in wild rodent populations: a potential reservoir for punlmonary tuberculosis in humans. *J Clin Microbiol* **40**, 3281–3285.

Chantrey J., Meyer H., Baxby D., *et al.* (1999) Cowpox – reservoir hosts and geographic distribution. *Epidemiol Infect* **122**, 455–460.

Chomel B.B., Jay M.T., Smith C.R., *et al.* (1994) Serological surveillance of plague in dogs and cats, California, 1979–1991. *Comp Immunol Microbiol Infect Dis* **17**, 111–123.

Corboz L., Ossent P. & Gruber H. (1993) Lokale und sytemische Infektionen mit Bakterien der Gruppe EF-4 bei Hundeen, Katzen und bei einem Dachs: Bakeriologische und Pathologisch-anatomische Befunde. *Schweiz Arch Tierheilkd* **135**, 96–102.

Crisp M.S., Birchard S.J., Lawrence A.E. & Fingeroth J. (1987) Pulmonary abscess caused by a *Mycoplasma* sp. in a cat. *J Am Vet Med Assoc* **191**, 340–342.

Crowder D.R., Dorn C.R. & Smith R.E. (1978) Group A *Streptococcus* in pets and group. A streptococcal disease in man. *Int J Zoon* **5**, 45–54.

Davenport D.J. & Johnson G.C. (1986) Cutaneous nocardiosis in a cat. *J Am Vet Med Assoc* **188**, 728–729.

Devriese L.A. & Haesebrouck F. (1992) *Streptococcus suis* infections in horses and cats. *Vet Rec* **130**, 380.

Dobbinson S.S. & Tannock G.W. (1995) A bacteriological investigation of subcutaneous abscesses in cats. *NZ Vet J* **B33**, 27–29.

Dow S.W., Jones R.L. & Adney W.S. (1986) Anaerobic bacterial infections and response to treatment in dogs and cats: 36 cases (1983–1985). *J Am Vet Med Assoc* **189**, 930–934.

Egberink H.F. (1990) Aujeszky's disease in dogs and cats. *Tijdschr Diergeneeskd* **115**, 349–353.

Eidson M., Thilsted J.P. & Rollag O.J. (1991) Clinical, clinipathologic and pathological features of plague in cats: 119 cases (1977–1988) *J Am Vet Med Assoc* **119**, 1191–1197.

Escutenaire S., Thomas I., Clement J., *et al.* (1997) Hantavirus epidemiology in red bank voles (*Clethrionomys glareolus*). *Ann Med Vet* **141**, 471–476.

Feore S.M., Bennett M., Chantrey J., *et al.* (1997) The effect of cowpox virus infection on fecundity in bank voles and wood mice. *Proc R Soc B* **264**, 1–5.

Flatland B., Greene R.T. & Lappin M.R. (1996) Clinical and serologic evaluation of cats with cryptococcosis. *J Am Vet Med Assoc* **209**, 1110–1113.

Foster S.F., Barrs V.R., Martin P. & Malik R. (1998) Pneumonia associated with *Mycoplasma* spp. in three cats. *Aust Vet J* **76**, 460–464.

Foster S.F., Martin P., Davis W., *et al.* (1999) Chronic pneumonia caused by *Mycobacterium thermoresistibile* in a cat. *J Small Anim Pract* **4**, 433–438.

Foster S.F., Charles J.A., Parjker G., *et al.* (2000) Cerebral cryptococcal granuloma in a cat. *J Feline Med Surg* **2**, 201–206.

Gage K.L., Dennis D.T., Orloski K.A., *et al.* (2000) Cases of cat-associated human plague in the western US, 1977–1998. *Clin Infect Dis* **30**, 893–900.

Gerds-Grogan S. & Dayrell-Hart B. (1997) Feline cryptococcosis: a retrospective evaluation. *J Am Anim Hosp Assoc* **33**, 118–122.

Goddard W.W., Bennett S.A. & Parkinson C. (1998) *Anaerobiospirillum succiniciproducens* septicaemia: important aspects of diagnosis and management. *J Infect* **37**, 68–70.

Greene C.E. (1998) *Infectious Diseases of the Dog and Cat*. 2nd edn. WB Saunders, Philadelphia, PA.

Gruffydd-Jones T.J., Galloway P.E. & Pearson G.R. (1992) Feline spongiform encephalopathy. *J Small Anim Pract* **33**, 471–476.

Gunn-Moore D.A., Jenkins P.A. & Lucke V.M. (1996) Feline tuberculosis: a literature review and discussion of 19 cases caused by an unusual mycobacterial variant. *Vet Rec* **138**, 53–58.

Gurfield A.N., Boulouis H.J., Chomel B.B., *et al.* (2001) Epidemiology of *Bartonella* infection in domestic cats in France. *Vet Microbiol* **80**, 185–198.

Haesebrouck F., Devriese L.A., Rijssen B. van & Cox E. (1991) Incidence and significance of isolation of *Mycoplasma felis* from conjunctival swabs of cats. *Vet Microbiol* **26**, 95–101.

Hamblet C.N. (1993) Parapoxvirus in a cat. *Vet Rec* **132**, 144.

Hara M., Shimizu T., Nemoto S., *et al.* (1991a) The genome type of Aujeszky's disease virus isolated from a cat in Japan. *J Vet Med Sci* **53**, 1087–1089.

Hara M., Shimizu T., Nemoto S., *et al.* (1991b) A natural case of Aujeszky's disease in the cat in Japan. *J Vet Med Sci* **53**, 947–949.

Henderson J.P., Graham D.A. & Stewart D. (1995) An outbreak of Aujeszky's disease in sheep in Northern Ireland. *Vet Rec* **136**, 555–557.

Hirsh D.C. & Jang S.S. (1999) Antimicrobial susceptibility of *Nocardia nova* isolated from five cats with nocardiosis. *J Am Vet Med Assoc* **215**, 815–817, 795–796.

Hooper P.T., Ireland L.A. & Carter A. (1985) Mycoplasma polyarthritis in a cat with probable severe immune deficiency. *Aust Vet J* **62**, 352.

Horii Y., Garcia J.N.P., Noviana D., *et al.* (2001) Detection of anti-borna disease virus antibodies from cats in Asian countries, Japan, Philippines and Indonesia using electrochemiluminescence immunoassay. *J Vet Med Sci* **63**, 921–923.

Hoshuyama S., Kanoe M. & Amimoto A. (1996) Isolation of obligate and facultative anaerobic bacteria from feline subcutaneous abscesses. *J Vet Med Sci* **58**, 273–274.

Hughes M.S., Ball N.W., Beck L.A., *et al.* (1997) Determination of the etiology of presumptive feline leprosy by 16S rRNA gene analysis. *J Clin Microbiol* **35**, 2464–2471.

Iglauer F., Kunster I., Moerstedt R., *et al.* (1991). *Streptococcus canis* arthritis in a cat breeding colony. *J Exp Anim Sci* **34**, 59–65.

Ikegami T., Shirota K., Goto K., *et al.* (1999) Enterocolitis associated with dual infection by *Clostridium piliforme* and feline panleukopenia virus in three kittens. *Vet Pathol* **36**, 613–615.

Jacobs G.J., Medleau L., Calvert C. & Brown J. (1997) Cryptococcal infection in cats: factors influencing treatment outcome, and results of sequential serum antigen titers in 35 cats. *J Vet Intern Med* **11**, 1–4.

Jang S.S., Breher J.E., Debaco L.A., Hirsch D.C. (1997) Organisms isolated from dogs and cats with anaerobic infections and susceptibility to selected antimicrobial agents. *J Am Vet Med Assoc* **210**, 1610–1614.

Jordan H.L., Cohn L.A. & Armstrong P.J. (1994) Disseminated *Mycobacterium avium* complex infection in three Siamese cats. *J Am Vet Med Assoc* **204**, 90.

Kano R., Nakamura Y., Watari T., *et al.* (1997) A case of feline cryptococcosis treated with itraconazole. *Mycoses* **40**, 381–383.

Kanoe M., Kido M. & Toda M. (1984) Obligate anaerobic bacteria found in canine and feline purulent lesions. *Br Vet J* **140**, 257–262.

Kovatch R.M. & Zebarth G. (1973) Naturally occurring Tyzzer's disease in a cat. *J Am Vet Med Assoc* **162**, 136–138.

Kubokawa K., Kubo M., Takasaki Y., *et al.* (1973) Two cases of feline Tyzzer's disease. *Jpn J Exp Med* **43**, 413–421.

Larsson C.E., Santa Rosa C.A., Hagiwara M.K., *et al.* (1984) Prevalence of feline leptospirosis – serologic survey and attempts of isolation and demonstration of the agent. *Int J Zoonoses* **11**, 161–169.

Larsson C.E., Santa Rosa C.A., Larsson M.H., *et al.* (1985) Laboratory and clinical features of experimental feline lepto - spirosis. *Int J Zoonoses* **12**, 111–119.

Lemarie S.L. (1999) Mycobacterial dermatitis. *Vet Clin North Am Small Anim Pract* **29**, 1291–1301.

Love D.N., Jones R.F., Bailey M. & Johnson R.S. (1979) Isolation and characterisation of bacteria from abscesses in the subcutis of cats. *J Med Microbiol* **12**, 207–212.

Love D.N., Jones R.F. & Bailey M. (1980) Characterization of *Fusobacterium* species isolated from soft tissue infections in cats. *J Appl Bacteriol* **48**, 325–331.

Love D.N., Jones F.R. & Bailey N. (1981) Characteristics of *Bacteroides* spp. isolated from soft tissue infections of cats. *J Appl Bacteriol* **48**, 325–321.

Love D.N., Jones R.F., Bailey M., *et al.* (1982) Isolation and characterisation of bacteria from pyothorax (empyaemia) in cats. *Vet Microbiol* **7**, 455–461.

Love D.N., Johnson J.L. & Moore L.V. (1989) Bacteroides species from the oral cavity and oral-associated diseases of cats. *Vet Microbiol* **19**, 275–281.

Love D.N., Vekselstein R. & Collings S. (1990) The obligate and facultatively anaerobic bacterial flora of the normal feline gingival margin. *Vet Microbiol* **22**, 267–275.

Love D.N., Malik R. & Norris J.M. (2000) Bacteriological warfare amongst cats: what have we learned about cat bite infections? *Vet Microbiol* **74**, 179–193.

Ludwig H. & Bode L. (2000) Borna disease virus: new aspects on infection, disease, diagnosis and epidemiology. *Rev Sci Tech* **19**, 259–288.

Lundgren A.L., Zimmermann W., Bode L., *et al.* (1995) Staggering disease in cats: isolation and characterization of the feline Borna disease virus. *J Gen Virol* **76**, 2215–2222.

Lundgren A.L., Johannisson A., Zimmermann W., *et al.* (1997) Neurological disease and encephalitis in cats experimentally infected with Borna disease virus. *Acta Neuropathol* **93**, 391–401.

Luo Z.Z. (1985) Isolation of epidemic haemorrhagic fever virus from a cat. *Clin J Microbiol Immunol* **5**, 79–81.

Malik R., Wigney D.I., Muir D.B., *et al.* (1992) Cryptococcosis in cats: clinical and mycological assessment of 29 cases and evaluation of treatment using orally administered fluconazole. *J Med Vet Mycol* **30**, 133–144.

Malik R., Gabor L., Martin P., *et al.* (1998) Subcutaneous granuloma caused by *Mycobacterium avium* complex infection in a cat. *Aust Vet J* **76**, 604–607.

Malik R., Speed B.R., Kaldor J., *et al.* (1999) Serum antibody response to *Cryptococcus neoformans* in cats, dogs and koalas with and without active infection. *Med Mycol* **37**, 43–51.

Malnick H., Jones A. & Vickers J.C. (1989) Anaerobiospirillum: cause of a new zoonosis? *Lancet* **i**, 1145.

Maruyama S., Nakamura Y., Kabeya H., *et al.* (2000) Prevalence of *Bartonella henselae, Bartonella clarridgeiae* and the 16S rRNA gene types of *Bartonella henselae* among pet cats in Japan. *J Vet Med Sci* **62**, 273–279.

Maruyama S., Kasten R.W., Boulouis H.J., *et al.* (2001) Genomic diversity of *Bartonella henselae* isolates from domestic cats from Japan, the USA and France by pulsed-field gel electrophoresis. *Vet Microbiol* **79**, 337–349.

May C., Carter S.D., Barnes A., *et al.* (1994) *Borrelia burgdorferi* infection in cats in the UK. *J Small Anim Pract* **35**, 517–520.

Miller M.A., Fales W.H., McCracken W.S., *et al.* (1999) Inflammatory pseudotumor in a cat with cutaneous mycobacteriosis. *Vet Pathol* **36**, 161–163.

Mochizuki M. & Uchizono S. (1993) Experimental infections of feline reovirus serotype-2 isolates. *J Vet Med Sci* **55**, 469–470.

Mochizuki M., Tamazumi T., Kawanishi A., *et al.* (1992). Serotype-2 reoviruses from the feces of cats with and without diarrhea. *J Vet Med Sci* **54**, 963–968.

Moise N.S., Crissman J.W., Fairbrother J.F. & Baldwin C. (1983) *Mycoplasma gateae* arthritis and tenosynovitis in cats: case report and experimental reproduction of the disease. *Am J Vet Res* **44**, 16–21.

Monies R.J., Cranwell M.P., Palmer N., *et al.* (2000) Bovine tuberculosis in domestic cats. *Vet Rec* **146**, 407–408.

Muir P., Harbour D.A., Gruffydd-Jones T.J. *et al.* (1990) A clinical and microbiological study of cats with nictitating membrane protrusion and diarrhoea; isolation of a novel virus. *Vet Rec* **127**, 324–330.

Murakami S., Yamanishi M.W. & Azuma R. (1997) Lymph node abscess due to *Actinomyces viscosus* in a cat. *J Vet Med Sci* **59**, 1079–1080.

Nakamura Y., Watanabe M., Kamitani W., *et al.* (1999) High prevalence of Borna disease virus in domestic cats with neurological disorders in Japan.*Vet Microbiol* **70**, 153–169.

Nimmo-Wilkie J.S. & Barker I.K. (1985) Colitis due to *Bacillus piliformis* in two kittens. *Vet Pathol* **22**, 649–652.

Nishino Y., Funaba M., Fukushima R., *et al.* (1999) Borna disease virus infection in domestic cats: evaluation by RNA and antibody detection. *J Vet Med Sci* **61**, 1167–1170.

Norris J.M. & Love D.N. (1999) The isolation and enumeration of three feline oral *Porphyromonas* species from subcutaneous abscesses in cats. *Vet Microbiol* **65**, 115–122.

Nowotny N. (1996) Serological examinations in domestic cats for virus infections of wild rodents with potential human pathogenicity. *Zentralblatt fur Hygiene und Umweltmedizin* **198**, 452–461.

Nowotny N. & Weissenbock H. (1995) Description of feline nonsuppurative meningoencephalomyelitis (staggering disease) and studies of its etiology. *J Clin Microbiol* **33**, 1668–1669.

Nowotny N., Fischer O.W., Schilcher F., *et al.* (1994) Pockenvirusinfektionen bei Hauskatzen: klinische, pathohistologische, virologische und epizootiologische Untersuchungen. *Wien Tierarztl Mschr.* **81**, 362–369.

Padrid P.A., Feldman B.F., Funk K., *et al.* (1991) Cytologic, microbiologic, and biochemical analysis of bronchoalveolar lavage fluid obtained from 24 healthy cats. *Am J Vet Res* **52**, 1300–1307.

Pal M. (1991) Feline meningitis due to *Cryptococcus neoformans* var. *neoformans* and review of feline cryptococcosis. *Mycoses* **34**, 313–316.

Pascual C., Foster G., Falsen E., *et al*. (1999) Actinomyces *bowdenii sp. nov*., isolated from canine and feline clinical specimens. *Int J Syst Bacteriol* **49**, 1873–1877.

Paulsen D.B., Kern M.R. & Weigand C.M. (2000) Mycobacterial neuritis in a cat. *J Am Vet Med Assoc* **216**, 1589–1591, 1569.

Randolph J.F., Moise N.S., Scarlett J.M., *et al*. (1993) Prevalence of mycoplasmal and ureaplasmal recovery from tracheobronchial lavages and of mycoplasmal recovery from pharyngeal swab specimens in cats with or without pulmonary disease. *Am J Vet Res* **54**, 897–900.

Reeves N.A., Helps C.R., Gunn-Moore D.A., *et al*. (1998) Natural Borna disease virus infection in cats in the United Kingdom. *Vet Rec* **143**, 523–526.

Reilly G.A., Bailie N.C., Morrow W.T., *et al*. (1994) Feline stillbirths associated with mixed *Salmonella typhimurium* and leptospira infection. *Vet Rec* **135**, 608.

Reitmeyer J.C., Guthrie R.K. & Steele J.H. (1991) Biochemical properties of group G streptococci isolated from cats and man. *J Med Microbiol* **35**, 148–151.

Roccabianca P., Caniatti M., Scanziani E. & Penati V. (1996) Feline leprosy: spontaneous remission in a cat. *J Am Anim Hosp Assoc* **32**, 189–193.

Rodriguez-Ferri E.F., Bunschoten A.E., Van Embden J.D. & Cousins D. (1996) Spacer oligonucleotide typing of *Mycobacterium bovis* strains from cattle and other animals: a tool for studying epidemiology of tuberculosis. *J Clin Microbiol* **34**, 2734–2740.

Ryder S.J., Wells G.A.H., Bradshaw J.M. & Pearson G.R. (2001) Inconsistent detection of PrP in extraneural tissues of cats, with feline spongiform encephalopathy. *Vet Rec* **148**, 437–441.

Schneck G. (1975) Tyzzer's disease in an adult cat. *Vet Med Small Anim Clin* **70**, 155–156.

Stevenson K., Howie F.E., Low J.C., *et al*. (1998) Feline skin granuloma associated with *Mycobacterium avium*. *Vet Rec* **143**, 109–110.

Stowater J.L. (1978) Actinomycosis in the spinal canal of a cat. *Feline Pract* **8**, 26–27.

Swindle M.M., Narayan O., Luzarraga M. & Bobbie D.L. (1980) Contagious streptococcal lymphadenitis in cats. *J Am Vet Med Assoc* **177**, 829–830.

Telfer S., Bennett M., Bown K.J., *et al*. (2002) The effects of cowpox on survival in natural rodent populations: increases and decreases. *J Anim Ecol* **71**, 558–568.

Tilgner S.L. & Anstey S.I. (1996) Nocardial peritonitis in a cat. *Aust Vet J* **74**, 430–432.

Wilkinson G.T. (1983) Cutaneous *Nocardia* infection in a cat. *Feline Pract* **13**, 32–34.

Wilson K.S., Maroney S.A. & Gander R.M. (1995) The family pet as an unlikely source of group A beta-hemolytic streptococcal infection in humans. *Pediatr Infect Dis J* **14**, 372–375.

Wyatt J.M., Pearson G.R., Smerdon T.N., *et al*. (1991) Naturally occurring scrapie-like encephalopathy in five domestic cats. *Vet Rec* **129**, 233–236.

Yovich J.C. & Read R.A. (1995) Nasal *Actinomyces* infection in a cat. *Aust Vet Pract* **25**, 114–117.

Zaisser A., Kresken J.G., Weber A., *et al*. (2001) A case report to cryptococcosis in cat. *Kleintierpraxis* **46**, 581.

Further reading

General sources

August J.R. (1997) *Consultations in Feline Medicine*, Vol. 3. WB Saunders, Philadelphia, PA.

Gorman N. (1996) *Canine Medicine and Therapeutics*. 3rd edn. Blackwell Science, Oxford.

Greene C.E. (1998) *Infectious Diseases of the Dog and Cat*. 2nd edn. WB Saunders, Philadelphia, PA.

Ramsey I. & Tennant B. (2001) *Manual of Canine and Feline Infectious Diseases*. BSAVA, Cheltenham.

Tennant B. (2000) *Small Animal Formulary*. 4th edn. BSAVA, Cheltenham.

Normal bacterial flora of cats

Allaker R.P., Langlois T. & Hardie J.M. (1994) Prevalence of *Eikenella corrodens* and *Actinobacillus actinomycetemcomitans* in dental plaque of dogs. *Vet Rec* **134**, 519.

Devriese L.A., Cruz Colque J.I., De Herdt P. & Haesebrouck F. (1992) Identification and composition of the tonsillar and anal enterococcal and streptococcal flora of dogs and cats. *J Appl Bacteriol* **73**, 421–425.

Chapter 31

ENDOPARASITES

A.J. Trees

Introduction

The endoparasites of the cat comprise a variety of species which are found in each of the major taxonomic groups. With a few exceptions, they are seldom a cause of more than mild clinical disease and their incidence depends entirely on the lifestyle of the individual cat. Unlike the dog, whose diet is usually strictly controlled by the owner, a cat allowed to roam freely may supplement its food from the wild and, as a consequence, acquires more parasites from this source than directly from other cats. Most cat parasites have an indirect life cycle involving infection of intermediate hosts which enable the parasites to be concentrated, protected and dispersed in the environment to a degree that virtually guarantees successful transmission. The intermediate hosts include arthropods, molluscs, amphibians, reptiles, birds and mammals, and more than one may be involved in transmission. They can act as true intermediate hosts, which are essential for successful development of larval stages of the parasite, or as transport hosts, which simply carry the parasite passively, as when an earthworm ingests parasite eggs or larvae, disseminating them by passage through the gut. The term 'paratenic host' is used in those instances where the immature stage of a parasite is trapped permanently in the tissues, depending on predation by cats for completion of development. Even well-fed cats will hunt if allowed and this is important in parasite transmission. One study, for example, found that an average of 11 animals a year were taken by cats and reported by their owners (Churcher & Lawton, 1987). This is undoubtedly an underestimate. It is particularly significant in the context of toxoplasmosis (see Chapter 28). Cats that are housed throughout their lives and fed entirely on cooked or tinned meat can be protected from parasites which utilise intermediate hosts. However, other ingenious modes of transmission evolved by parasites still defy effective control: the common roundworm *Toxocara cati*, for example, passes from dam to offspring via the milk, thus ensuring establishment of a worm burden in very young kittens.

Without doubt, the most important aspects of cat parasites, both external as well as internal, are the problems they pose as zoonoses. Toxocaral infection of humans resulting in the disease visceral larva migrans is believed to be caused almost entirely by the dog ascarid *Toxocara canis*, but *T. cati* and *Toxascaris leonina*, both found in cats, are potentially able to infest humans and should not be entirely dismissed as a possible cause of the disease. A more serious threat from the cat is toxoplasmosis, an infestation by a protozoan parasite which depends on the cat for development of its sexual stages. Asexually reproducing forms are able to develop in the tissues of all warm-blooded animals and such infestations are widespread, but fortunately only an occasional cause of disease. Human toxoplasmosis may be a congenital infection or acquired later in life, either directly from cat faeces or from meat contaminated with the parasite. In humans, the disease can cause severe damage to central nervous tissues with involvement of the eye and the lymphatic system. Toxoplasmosis can be of considerable economic importance in some farm livestock: in Britain, for example, it is one of the most common causes of ovine abortion. Cryptosporidiosis and giardiasis, both occurring in cats, are now frequently diagnosed human infections. There will be an increasing demand for the small animal practitioner to prove or disprove the presence of these infections in family pets.

The remarkable extent to which some cat parasites succeed in contaminating the environment is because of their ability to survive outside the primary

feline host. The eggs of *Toxocara* and the oocysts of *Toxoplasma* remain viable for months or even years under suitable conditions, and the tissue forms of these parasites remain dormant in many cases for the lifetime of their respective intermediate hosts. The prevention of infection of cats by parasites necessitates restriction of freedom to a degree that most owners would be unable to impose and indeed would regard as undesirable. It must be assumed that the average household pet cat allowed to roam and forage at random will acquire some of the parasites described here, and it is important, therefore, that their nature and potential pathogenicity for all their hosts be fully appreciated.

Common helminth parasites

Tapeworms

Dipylidium caninum

Despite its name, this tapeworm is common in cats. Fleas are the usual intermediate hosts, but the biting louse *Felicola subrostratus* is another source of infection. Adult worms live in the small intestine attached by the scolex, which bears four suckers and a retractable rostellum armed with five or six rows of rose-thorn-shaped hooks. The scolex is pinhead sized and the slender strobila has a narrow 'neck' region and numerous segments, which assume a characteristic cucumber-seed shape as they mature. These tapeworms may grow up to 40–50 cm in length, but most specimens rarely exceed 25 cm in the cat. The greater the number present, the shorter in length individual worms tend to be. They are often found in considerable numbers, several hundred having been recorded on occasions.

Each mature segment has a double set of male and female reproductive organs and a genital opening on either side, visible in the gravid segment as opaque indentations. The gravid segments contain egg capsules, each encompassing a cluster of from 10 to 20 eggs. For completion of the life cycle, the eggs must be ingested by larval fleas, which have chewing mouthparts and feed on organic debris in the host's bedding. The onchosphere released from the egg migrates into the body cavity of the larval flea and forms a cysticercoid, which persists through the pupal to the adult stage of the flea. Infestation of the cat occurs when fleas are accidentally swallowed while grooming. All stages of biting lice can ingest the egg, and cysticercoids develop as in fleas.

Gravid segments are shed in the faeces and also pass from the rectum independently of bowel movement to contaminate the perineal hair and the bedding. Most cats remove perineal contamination, but desiccated segments may be found on the longhaired breeds. Fresh segments are 1 cm in length and cream-coloured with a reddish-brown centre formed by the mass of dark egg capsules. Egg capsules are about 200 μm in length and are best seen by teasing apart the segment under a dissecting microscope. Segments move sluggishly for a time but soon rupture to release the egg capsules. Absence of egg capsules in segments may be a cause of confusion in identification. When completely desiccated, the segments are brittle, amber-coloured flakes no more than 3–4 mm in length. Soaking for several minutes in normal saline will restore their shape, but egg capsules are unlikely to be present.

Surveys of the incidence of intestinal parasites of cats based on observations at autopsy show *D. caninum* to be common in Britain: an infection rate of over 50% was recorded at Aberystwyth and Glasgow, 44.5% in London, 12.7% in Liverpool, and 13.0% in Swansea. From these surveys and others reviewed by Nichol *et al.* (1981), it is apparent that faecal examination for the detection of tapeworms is unreliable since segments, egg capsules and free eggs appear intermittently in the faeces and can easily be missed. The incidence of tapeworms is always much higher by autopsy examination.

Of the intermediate hosts of *D. caninum*, cat and dog fleas are more likely to transmit infestation than lice, as the latter have become scarce following the introduction of modern insecticides to which they are so vulnerable.

Taenia taeniaeformis

The above-mentioned review of the incidence of endoparasites of cats (Nichol *et al.*, 1981) indicates that *T. taeniaeformis* is recorded much less frequently than *Dipylidium caninum* in all surveys. The highest incidence of 15% was recorded in Glasgow and Swansea. All other surveys based on autopsy findings give a figure below 10%. This tapeworm occurs in low numbers in the small intestine; it is unusual to find more than three or four in an individual. Morphologically, this species is easily distinguished from *D. caninum* by being much larger and stouter. Individuals grow to 50 cm in length and have a relatively large head with four suckers and a double row of hooks on the rostellum. There is no narrow 'neck' region behind the scolex and the mature segments have a posterior

margin wider than the anterior end, giving strobila a distinctive serrated appearance and the gravid segments a flattened bell-shape. Each segment has a single set of male and female reproductive organs and the genital openings are irregularly unilateral.

The intermediate stage of *T. taeniaeformis* is called *Cysticercus fasciolaris* and develops in the liver of rats, mice, voles and squirrels. This larval stage differs from that of other taeniid tapeworms in having, in addition to the scolex, a short strobila of segments terminating with a small bladder. It is tightly packed into a pea-sized cyst formed by a host tissue reaction. The cystic stage is infective for cats in about 60 days and after ingestion the adult tapeworm is mature in 16–18 days. Gravid segments are shed in the faeces and, like *Dipylidium*, may migrate from the rectum independently of bowel movement. They can be distinguished easily from those of *Dipylidium* by their different shape and unilateral genital pore. When broken open in water, large numbers of dark-brown eggs are released, measuring 40 μm in diameter and not enclosed in egg capsules. It is important to distinguish between the two tapeworms because treatment must be accompanied by measures to prevent reinfestation, the epidemiology of each being entirely different. Both species of tapeworm may occur together and tend to infest cats over 1 year of age.

Species of *Taenia* tapeworms other than *T. taeniaeformis* are extremely uncommon in cats.

Echinococcus

Echinococcus granulosus does not reach sexual maturity in the cat and experimental infections are short lived; cats, therefore, can be disregarded as a source of hyatid disease. *Echinococcus multilocularis*, which, does not occur in Britain, can infect cats, although less frequently and at lower intensity than dogs. Prevalences of 0.4–3.4% have been found in cats in Europe (Eckert & Deplazes, 1999). Although *Echinococcus* is harmless to the cat, because this is a dangerous zoonosis, cats imported to the UK are required to be treated to eliminate this infection. Treatment must be given between 24 and 48 h before import and be certified by a veterinarian.

Clinical signs

The majority of tapeworm infestations are symptomless and often remain undetected in cats that bury their faeces outdoors. Occasionally, however, and more especially in the finer breeds of cat such as Siamese and Burmese, obvious abdominal discomfort is sometimes seen. The shedding of segments may cause anal irritation and excessive attention to the perineal region. Diarrhoea and weight loss, despite popular belief, are not features of tapeworm infestations. The most unpleasant aspect of tapeworms is the aesthetic objection by the owner to the constant shedding of gravid segments about the house.

Treatment and control

The drug of choice is praziquantel. This is specifically active against tapeworms and has no effect on roundworms. Tapeworms disintegrate before they are voided. Apparent failure to treat successfully is nearly always because of reinfestation; this is certain to occur if no measures are taken to break the tapeworm's life cycle. When *Dipylidium* infestation is diagnosed, the cat in question and all other cats and dogs in contact must be treated for ectoparasites, and likely flea habitats in the environment destroyed. In most cases, it is not possible to prevent free-roaming cats from hunting rodents, and owners must be warned that reinfestation with *T. taeniaeformis* after treatment should be expected. Because of the short prepatent period, segments may appear as early as 3 weeks after treatment owing to reinfection. Thus, frequent treatment may be necessary to keep cats free from tapeworms, but it should be stressed that they are relatively harmless and, with the exception of a few records of human infection with *Dipylidium* (acquired by inadvertently swallowing an infected flea or louse), the tapeworms of the cat are of no public health significance.

Roundworms

Ascarids

Two ascarids are found in the small intestine of the cat worldwide, *Toxocara cati* (= *T. mystax*) and *Toxocaris leonina*, the former being much the more common species. The majority of surveys (e.g. Nichol *et al.*, 1981) show *T. cati* to be the most prevalent of all endoparasites, the incidence decreasing with age from a 30% infection rate in kittens under 3 months of age to below 10% in adult and aged cats. *Toxocaris leonina* is much less common and in surveys is usually found in less than 5% of the cat population. The difference in life cycles and epidemiology of the two worms explains this disparity in incidence. Recently, a third

species, *Toxocara malaysiensis*, has been described from the small intestine of cats in Malaysia (Gibbons *et al.*, 2001). It superficially resembles *T. canis* but has been distinguished both morphologically and by ribosomal RNA gene sequence analysis (Zhu *et al.*, 1998; Gibbons *et al.*, 2001). It has been found in 11% of cats in Kuala Lumpur (Lee *et al.*, 1993) and may occur in many other countries where it may have been assumed to be *T. canis*. Its life cycle and pathological significance are unknown but assumed to resemble *T. cati*. Its zoonotic significance is unknown.

Toxocara cati is a large white worm, with the male measuring about 10 cm and the female up to 15 cm, but they are often much shorter in length. At the anterior end there is a pair of cervical alae which give the worms an arrow-headed appearance, and the male caudal region ends in a short finger-like process barely perceptible to the naked eye. *Toxocaris leonina* is similar in appearance but usually smaller and has lanceolate cervical alae and no finger-like appendage in the male. The egg of *T. cati* is subspherical, measuring about 75 μm with a thick, pitted shell stained a light-brown colour. The egg of *T. leonina* is about the same size, but the shell is smooth and colourless. In both species the egg contains an ensegmented ovum when passed in the faeces.

Life cycle of Toxocara cati

The life cycle of *T. cati* is less complicated than that of *T. canis* in the dog. There are three modes of infestation: by ingestion of embryonated eggs, from larvae in the milk of suckling queens and from larvae in paratenic hosts. Embryonation of the eggs to the infective L_2 stage takes at least 4 weeks and considerably longer at outdoor winter temperatures. When embryonated eggs are ingested, the larvae undergo a liver-to-lung migration and eventually return to the small intestine, where they grow to maturity and start laying eggs about 6–7 weeks after infestation. This route, however, is probably of little importance in kittens where the most potent source of infestation is via the milk; larvae are present in the milk throughout lactation. These larvae are derived from the tissues of the queen, especially mammary tissues, where they have been stored as L_2 larvae acquired both before and during pregnancy and throughout lactation. It should be noted that intrauterine infection, which invariably occurs in dogs infected with *T. canis*, does not occur in *T. cati* infections. When the embryonated eggs of *T. cati* are ingested by earthworms, beetles, rodents or birds, the L_2 migrates into the tissues of these paratenic hosts and remains there until eaten by a cat. An interesting feature of *T. cati* is that when larvae are acquired from the milk or from paratenic hosts, there is no liver-to-lung migration, development to maturity occurring entirely in the gut. Virtually all kittens become infected when they suckle; a low level of infestation is maintained in adult cats by ingestion of embryonated eggs and the predation of paratenic hosts.

Life cycle of Toxocaris leonina

This ascarid is acquired by ingestion of the embryonated egg containing the L_2 larvae or by the predation of the same species of hosts that harbour the L_2 of *T. cati*. There is, however, a slight difference in that *T. leonina* develops from L_2 to L_3 in these hosts, which must therefore be regarded as true intermediate rather than as paratenic hosts. Whichever is the source of infestation, there is no liver-to-lung migration and the prepatent period is at least 8 weeks. Because there is neither intrauterine nor transmammary infection, *T. leonina* is seldom seen in cats under 6 months of age and it always tends to be present in smaller numbers than *T. cati*.

Clinical signs

Clinical disease due to ascarids is less frequent in cats than in dogs and occurs mainly in kittens less than 8 weeks old that have acquired a heavy infestation of *T. cati* while suckling. As there is no liver-to-lung migration following infestation via this route, the pathogenic effects are confined to the gut. A burden comprising several dozen worms can cause unthriftiness, diarrhoea, a poor coat and an accumulation of gas in the intestines, which gives kittens a characteristic wormy, pot-bellied appearance.

Diagnosis, treatment and control

Often the most conspicuous evidence of infestation is the presence of worms in vomit or faeces. The distinctive eggs of the two species of ascarids can be detected in faeces by the standard McMaster slide technique, but they are unlikely to be present in kittens before 8 weeks of age.

Of the benzimidazoles, both mebendazole and fenbendazole given orally are highly efficient against ascarids, but may have to be given daily for a number of days depending on circumstances. Selamectin as a single topically applied dose is also effective.

A suitable regimen of treatment for kittens would be a routine dose at 4–6 weeks of age, followed by treatment every 3 weeks up to 4 months of age. Subsequent treatments depend on the degree of access to infestation from a contaminated environment, or the availability of paratenic hosts. Free-roaming cats and cats kept in catteries with outside soil and grass runs are likely to carry a low burden of ascarids all their lives and should therefore be routinely treated at least twice a year. There is at present no way to destroy larvae in the body tissues and so to prevent transmammary infection, but pregnant queens should be treated and prevented from acquiring infestation throughout pregnancy and lactation.

Soil in gardens contaminated by faeces containing ascarid eggs is likely to become a permanent source of infection. The eggs are extremely resistant and can remain viable for 2 or 3 years if protected from sunlight and desiccation. The feline habit of burying faeces, although to some extent reducing the amount of contamination, is likely to favour longevity of ascarid eggs. The destruction of eggs contaminating cages, pens and concrete runs is best achieved by heat treatment using boiling water containing a detergent, or by steam sterilisation.

Human visceral larva migrans

This disease is acquired by the accidental ingestion by humans of the embryonated eggs of the ascarids of the dog and cat. The larvae of all three species migrate in the tissues in a wide variety of mammals and birds, including humans, who act as yet another paratenic host. By far the most important for humans is the dog ascarid *T. canis*, which is believed to be responsible for the majority of human visceral larva migrans. There is serological, histopathological and epidemiological evidence to suggest that *T. cati* is unlikely to be implicated, although it should not be completely disregarded as a possible cause. The opportunity for human infection from cats is less than from dogs because cats bury their faeces.

A survey by Woodruff and de Savigny (1982) highlights the difference between dogs and cats as a source of larva migrans. Using the enzyme-linked immunosorbent assay (ELISA) technique they showed that 15.7% of dog breeders exhibiting at shows had significant toxocaral serum antibodies indicating present or past infestation, compared with only 1.5% positive in a similar group of cat breeders and 2.6% positive in healthy adults in the general population. Moreover, in Iceland, where dogs have long been prohibited to control hydatidosis, the human population showed no serological evidence of toxocaral infestation despite a large population of cats. There can be no doubt that cats are capable of contaminating the environment with faecal-borne infections because the incidence of toxoplasmal antibodies in Iceland is similar to that of humans in Britain.

The authors conclude that cats clearly constitute a much lower risk to the general population than do dogs in respect of toxocaral infestation, but not in respect of toxoplasmal infestation.

Aelurostrongylus abstrusus

The lungworm of the cat is recognised as a common infestation in most parts of the world. It is a typical metastrongyloid nematode living in the lungs as an adult and utilising a range of molluscan intermediate hosts, and an even greater variety of paratenic hosts which preserve and concentrate the parasite and aid its dispersal. Most infestations are benign, and there is evidence that in the absence of superinfestation the burden is spontaneously shed after 3–4 months, after which the cat is strongly resistant to reinfestation. Occasionally, however, the worms may cause quite severe respiratory signs, although it is not certain whether this is because of heavy infestation or decreased resistance (see Chapter 12).

The adult worms live in the terminal bronchioles, alveolar ducts and the smaller branches of the pulmonary artery. They are very small, slender worms, the males measuring about 5 mm and the females 9 mm in length, but they are difficult to recover intact as they lie embedded in lung tissues. Eggs are laid embryonated into the alveoli, where the L_1 hatches and ascends the air passages to be coughed up and swallowed, appearing in the faeces as a small 0.36 mm-long sluggish larva possessing a characteristic S-shaped kink in the tail. The L_1 can survive for several months and further development takes place only in the intermediate host. Most of the common species of slugs and snails are suitable, and the larvae actively penetrate the integument and undergo two ecdyses in the muscle of the foot to the L_3 stage, which is infective for cats. The molluscan intermediate host may be eaten by various paratenic hosts, in which the larvae are found unchanged in many tissues such as the gastrointestinal tract, submucosa and subserosa, lungs, diaphragm and adipose tissue. After ingestion of the infected intermediate or paratenic host by a cat, the L_3 penetrates the intestinal tract and travels to the lungs via the lymphatics and bloodstream. The prepatent period is from 34 to 42 days.

The only aspect of the life cycle that is imperfectly understood is whether infestation of cats occurs by ingestion of the molluscan intermediate host or one of the paratenic hosts. Cats are not known to eat slugs and snails, and when molluscs are experimentally fed they tend to provoke vomiting. The paratenic hosts include amphibians, reptiles, rodents and birds. In Britain, birds are probably the principal source of infection for cats; small rodents such as mice and voles are vegetarian, and the insectivorous shrews appear to be unpalatable to cats. The slow-worm is another possible paratenic host. As many as 600 infective larvae have been found in an individual snail; larvae can survive in this host for at least 2 years and for an indefinite period in the paratenic host.

The course of experimental infestation of cats and the histopathology of lungworms have been studied in detail by Hamilton (1966a, 1967). He found that as few as 50 infective larvae caused lung lesions, but in the region of 800 were necessary to produce respiratory signs. When an infecting dose of 1600–3200 was given, severe signs developed which were potentially lethal. Dyspnoea and coughing, even at rest but especially on exertion, were the most common signs. In severe infestations, a chronic cough developed with increasing dyspnoea, inanation, anorexia and fever. Harsh lung sounds or moist râles may be heard on auscultation, and occasionally sneezing and oculonasal discharge occurs. Severity of infestation reaches a peak at 6–12 weeks, after which the signs subside and the disease spontaneously resolves. Larvae first appear in the faeces at about 5 weeks after infestation and increase to a peak at 10–14 weeks; they then gradually decline and eventually disappear altogether by week 24. Small numbers of adults may persist in the lungs for many months, although they do not produce larvae unless the cat is stressed.

Pathology

Lesions are confined to the thoracic cavity. In the mildest cases, which can result from as few as 50 infective larvae, pinpoint-sized greyish nodules occur throughout the lungs. In more severe infestations nodules up to 10 mm in diameter are seen, especially beneath the pleura, giving it an irregular surface. They are firm greyish-yellow lesions which tend to coalesce when numerous. The pleural cavity may contain thick milky fluid, rich in eggs and larvae. In most cases, the bronchial lymph nodes are enlarged. These lesions form 2–4 weeks after infestation, reach maximum size at 6–14 weeks and almost completely regress by week 24.

Histopathological changes have been followed chronologically by Hamilton (1966a). The earliest lesions are formed by aggregates of eosinophils, lymphocytes and macrophages in bronchioles and alveoli, with hypertrophy of the smooth muscle of the walls of bronchioles, alveolar ducts and the media layer of branches of the pulmonary artery. Adult worms and eggs in various stages of development are seen in section and in time these provoke a marked cellular reaction, often with central necroses and calcification of the nodular mass. Epithelialisation of the surrounding lung tissue is a feature. As the parasitic colonies decline 4–6 months after infestation, numerous masses of hypertrophied bronchiolar and smooth muscle, and marked medial hypertrophy and hyperplasia of the pulmonary artery branches are characteristic features of the lungs. Residual lesions may persist for several years and even a lifetime. In 34.7% of 256 randomly selected cats, Hamilton (1966b) found hypertrophy and hyperplasia of pulmonary arteries indistinguishable from those produced by experimental lungworm infestation. He concludes that lungworms are probably the cause of this common lesion of cat lungs. Hamilton (1968a) also showed that a good acquired immunity developed to infestation, reinfestation causing respiratory signs but no shedding of larvae in the faeces. Immunity seems to be related to the presence of a small residual population of adults.

Diagnosis, treatment and control

The only reliable method of diagnosing infestation is the demonstration of the characteristic larvae in faeces, best recovered from fresh samples by Baermann apparatus. Larvae, however, may appear intermittently and are completely absent in the early and later stages of infestation. Hamilton (1968b) reported using an indirect fluorescent antibody test on cat serum and found it to be highly specific for *A. abstrusus*, but the test did not differentiate between active and past infestation. Lesions are visible radiologically but they are probably not specific enough to be diagnostic.

Fenbendazole given daily for 3–5 days is effective for treatment. In the hunting cat which has free access to the intermediate and paratenic hosts, there is no way of preventing infestation. It must be stressed,

however, that infestations are self-limiting and most are symptomless.

Ollulanus tricuspis

This minute nematode is found coiled on the stomach wall under a layer of mucus; the males measure 0.7 mm and the females 1.0 mm in length. The life cycle is direct, infestation passing from cat to cat by infective L_3 in the vomit, but larvae may also develop to adults endogenously without leaving the stomach. A review of this worm in the cat is given by Hasslinger (1984). Although generally regarded as non-pathogenic, there are several reports from the USA of chronic fibrosing gastritis associated with *Ollulanus* infestation (e.g. Hargis *et al.*, 1983). Its presence can be detected by examination of vomit or stomach washings for L_3, which are generally absent from the faeces. When it is suspected of causing gastritis, treatment with mebendazole or fenbendazole is recommended.

Unusual helminth parasites

Uncinaria stenocephala

The common hookworm of dogs does not seem capable of establishing itself in cats and there is no record of this worm from cats in Britain. There is only one record of hookworm eggs in cat faeces in the UK (Else *et al.*, 1977), but it cannot be assumed that the eggs came from a hookworm infestation in the cat in question.

Capillaria aerophila

These nematodes live in the trachea and bronchi of the dog, cat and fox. They are fine slender worms measuring 25–30 mm in length, lying closely adherent to the mucous membrane of the air passages. The life cycle is direct and the characteristic bipolar eggs containing an unsegmented ovum are coughed up and swallowed, to pass in the faeces. The parasite is rare and most likely to be found in cats sharing the same habitat as foxes.

It is important to remember that, when examining the faeces of hunting cats, the presence of strongyle-type or bipolar eggs may constitute spurious parasitism, the eggs having been derived from nematodes of wild animals.

Toxoplasmosis and other coccidial infections

Toxoplasma gondii

This coccidian protozoan parasite is one of the most important endoparasites of cats because of its potential to cause clinical disease in cats, its zoonotic importance and its common and widespread prevalence. Although the parasite infects any warm-blooded animal, it is only in felids that oocysts are excreted in faeces to contaminate the environment, so the domestic cat plays a pivotal role in the maintenance and dissemination of this ubiquitous parasite. Feline toxoplasmosis is dealt with elsewhere in this volume (Chapter 28).

Neosporosis

Infection with the *Toxoplasma*-like protozoan *Neospora caninum* is common in dogs. Although cats have been experimentally infected, to date no natural infection in the cat has been reported. Neurological signs with negative *Toxoplasma* serology should alert the clinician to the possibility of neosporosis, although this possibility seems very unlikely.

Isospora infection (*Isospora felis* and *I. rivolta*)

Isospora species of cats and dogs have evolved a more elaborate life cycle than the familiar *Eimeria* species of ruminants and birds; in addition to the normal intestinal coccidian life cycle, they utilise rodent paratenic hosts in which sporozoites derived from oocysts are found encysted in extraintestinal tissues. *Isospora* oocysts sporulate to form two sporocysts each with four sporozoites. Cats therefore become infected from two sources: oocysts shed by cats, and tissue forms in rodents. The parasite resembles *Toxoplasma*, but differs in having a strictly limited range of paratenic hosts (Dubey & Frenkel, 1972).

Although a common and widespread infection, coccidiosis is seldom a cause of clinical disease in cats, probably because their fastidious nature precludes the possibility of ingestion of food grossly contaminated by faeces containing oocysts. Most infections are symptomless and probably derive from paratenic hosts, but heavy infections have been reported as a cause of diarrhoea with the passage of blood and mucus, tenesmus, and scalding of the perineum and

tail. Such severe signs are only likely to be seen in kittens kept in very unhygienic conditions.

Oocysts may be found during routine faecal examination and require differentiation from those of *Toxoplasma*, *Sarcocystis* and *Cryptosporidium*. The surveys of endoparasites of cats mentioned in the sections on tapeworms and roundworms show a variable incidence of cats shedding *Isospora* oocysts, with *I. felis* apparently more prevalent than *I. rivolta* and both confined to cats below the ages of 3 and 5 years, respectively (Nichol *et al.*, 1981), suggesting that a strong immunity to infection develops with age.

Diagnosis, treatment and control

Oocysts can be demonstrated by direct microscopic examination of faecal smear or by the standard flotation technique used for nematode eggs. *Isospora felis* measures $30 \times 40\,\mu m$ and *I. rivolta* $20 \times 25\,\mu m$ (*T. gondii* $= 10 \times 12\,\mu m$). In the absence of reinfection, coccidiosis is a self-limiting disease, but treatment with sulfadimidine at a dosage rate of 0.25 g daily for 4 days would effect a cure.

Strict attention to hygiene will prevent clinical disease, but light infections are to be expected, especially in young cats allowed to hunt rodents.

Sarcocystis infection

Sarcocystis infects the mucosal cells of the intestine of the definitive cat host, undergoing a coccidian-type life cycle with the production of oocysts which infect the intermediate host species. There are several *Sarcocystis* species in the cat, each with an obligatory indirect cycle involving one species of intermediate host. For example, two species, *S. tenella* and *S. medusiformis*, infect sheep as intermediate hosts, producing different types of tissue cysts in the ovine musculature, and other *Sarcocystis* species of cats infect cattle, pigs, rabbits and so on. Infection of the definitive host is usually symptomless, but multiplication by schizogamy in the intermediate host and subsequent invasion of skeletal and cardiac muscle and also viscera may produce a systemic reaction. The life cycle is completed when the definitive host consumes the tissues of the intermediate host in which the parasite has entered a resting cystic stage.

The oocysts of *Sarcocystis* are sporulated when passed in the faeces of the predator host, having formed two sporocysts each containing four sporozoites. The sporocysts, however, are usually free in the faeces and, having an average measurement of $12 \times 9\,\mu m$, resemble in size the oocysts of *Toxoplasma*. Levine (1985) gives a comprehensive account of the genus *Sarcocystis* and related coccidia.

Cryptosporidiosis

Cryptosporidium is a genus containing species of coccidia that tend to infect young animals with a poorly developed immune system, or individuals with compromised immunity, as in feline leukaemia virus infection. The life cycle is similar to that of other coccidia, with a prepatent period of about 3 days. There are, however, some important aspects of development that are not seen in other enteric coccidial infections: no invasion of intestinal mucosal cells occurs; and two types of oocyst are produced, a resistant oocyst that is found in the faeces and becomes immediately infective, and oocysts that release infective stages (sporozoites) in the intestine to cause autoinfection.

The taxonomy of *Cryptosporidium* species has been a matter of uncertainty and debate, especially in view of its zoonotic potential. There is now evidence that the *Cryptosporidium* in cats is distinct enough from that in other mammals as to warrant species status, *C. felis* (Xiao *et al.*, 2000). The oocysts are smaller than those of *C. parvum* and there are nucleotide sequence divergencies in several areas of the genome that support species status based on molecular phylogeny. *Cryptosporidium parvum* also infects cats, although the relative prevalences of *C. parvum* and *C. felis* are not known.

Prevalences of infection have ranged from 5.4 to 8.1% in faecal surveys (Mtambo *et al.*, 1991; Hill *et al.*, 2000), with oocysts found in cats both with and without diarrhoea. Clinical signs associated with infection include persistent diarrhoea, weight loss and anorexia (Poochna & Pippin, 1982; Bennett *et al.*, 1985). Diagnosis is supported by demonstration of oocysts in faecal smears stained with modified Ziehl–Nielsen stain (Henriksen & Pohlenz, 1981). Because of the small size of oocysts (4–5 μm diameter), faecal smears should be examined at high power.

Molecular epidemiological methods have demonstrated feline *Cryptosporidium* infecting several human immunodeficiency virus (HIV)-positive humans (Xiao *et al.*, 2000). Bennett *et al.* (1985) described a non-clinical feline infection in a household where a child was infected. It thus appears that cats can be responsible for sporadic cases of human cryptosporidiosis, especially in immunocompromised individuals.

There is as yet no specific treatment for cryptosporidiosis other than symptomatic. Oocysts are very resistant, but can be destroyed by 5% ammonium hydroxide, 4% sodium hypochlorite, 10% formalin, freezing, and by heating to 60℃ for 30 min. With increasing awareness of human cryptosporidiosis, the zoonotic nature of this parasite will focus attention on infections in cats, whether symptomless or associated with diarrhoea.

Giardiosis

These protozoans live in the small intestine as motile, pear-shaped flagellated trophozoites about 13 × 7 μm in size. Each trophozoite has two nuclei, and one surface is a concave adhesive disc enabling it to attach to intestinal microvilli. There is no evidence of sexual reproduction, and multiplication is by binary fission. The *Giardia* parasite is excreted in the faeces as an elongated oval cyst, 8–14 μm long. Trophozoites also appear unencysted in faeces but soon die in this form.

The *Giardia duodenalis* morphological group is a species complex and molecular phylogeny is elucidating the relationships of a number of biological and morphologically indistinguishable types. This is important in the context of the zoonotic implications of feline giardiasis, since *Giardia* is one of the most common human parasitic infections. Current evidence suggests that while there are many feline and human isolates that are similar, indicating possible zoonotic transmission, there is also a distinctive cat genotype. It appears likely that, like *Cryptosporidium*, some sporadic human giardiasis infections may be contracted from cats, notably in immunocompromised humans.

The excretion of *Giardia* cysts is not uncommon even in healthy cats and surveys have reported prevalences of 2–4% (Kirkpatrick, 1988; Nolan & Smith, 1995; Hill *et al.*, 2000).

Clinical signs

Overcrowding and high humidity favour the transmission of infection, which may or may not be accompanied by clinical signs. Diarrhoea, either intermittent or continuous, with weight loss, is the principal feature of disease. Faeces are mucoid and have a strong odour, and there is evidence of steatorrhoea as a consequence of malabsorption. Pyrexia and vomiting may or may not be evident. For a general review, see Dubey (1993). Detailed descriptions of feline giardiasis are given by Brightman and Slonka (1976), Kirkpatrick and Farrell (1984) and Kirkpatrick and Laczak (1985). The signs are probably largely due to malabsorption following physical and biochemical changes in the gut mucosa. Immunological responses of the host appear to play a part, together with host–parasite competition for nutrients and gross alterations in gut flora.

The demonstration of trophozoites or cysts in the faeces is the standard method of diagnosis. A centrifugal flotation technique for cysts using zinc sulfate yields the best results (Kirkpatrick & Farrell, 1982). In fresh watery faeces, trophozoites may be seen in a direct smear, but they must not be confused with commensal protozoa; staining with iodine will reveal structural details. Examination every other day on three occasions is recommended because excretion of the parasites is intermittent. The use of a fibre-optic endoscope or gelatin capsule to retrieve material directly from the duodenum has been advocated as a more reliable method of recovering *Giardia*, although a major retrospective study did not recommend this (Leib *et al.*, 1999).

Treatment

Oral metronidazole at a dosage rate of 22 mg/kg body weight twice daily for 5 days is an effective treatment for cats (Zimmer, 1987). The trophozoites found in faeces soon perish, but the more persistent ones are destroyed by freezing, boiling or desiccation. Sodium hypochlorite 1% is an effective surface disinfectant.

Exotic parasites

Cats entering Britain from the European Union and some other rabies-free countries are no longer required to be quarantined. Under the Pet Travel Scheme, imported cats must be treated for ticks and tapeworms (to exclude *E. multilocularis*). It is likely that some parasites regarded as exotic to Britain will be encountered occasionally in imported cats.

Ancylostoma tubaeforme

This feline hookworm lives in the small intestine and lays a strongyloid egg containing an ovum in an early stage of segmentation, measuring 75 μm in length. *Ancylostoma braziliense*, the canine hookworm, has been recorded in cats. Selamectin is an effective treatment.

Strongyloides stercoralis and *Strongyloides cati*

These minute nematodes live in the small intestine and lay eggs measuring 40 μm and containing an L_1 larva. *Strongyloides stercoralis* is important because the L_3 can infect humans by skin penetration.

Trichuris serrata

The whipworm of the cat lives in the caecum and lays distinctive eggs with bipolar plugs similar to those of *Capillaria*.

Spirocerca lupi

Spirocercosis is much more likely to be encountered in the dog than the cat. The adult worms live in the oesophagus and stomach, where they provoke the development of fibrous nodules. The eggs passed in the faeces are elongate and thick walled, measuring 40 μm in length. Beetles act as intermediate hosts and paratenic hosts play an important part in transmission.

Capillaria feliscati

This small, hair-like nematode lives in the bladder of cats, and bipolar eggs are passed in the urine.

Dirofilaria immitis

Infestation with heartworm used to be regarded as uncommon in cats but, in endemic areas, it is now recognised that cats may frequently be infected. However, the number of worms establishing is fewer than in the dog, reproductive females are rare and, hence, microfilariae are absent from the blood of most infected cats. Clinical signs may not necessarily be simi-lar to those seen in dogs, but coughing, dyspnoea, vomiting, weight loss and lethargy are the usual presenting signs, and sudden death without warning as a result of heart failure or respiratory failure is not uncommon. Adult worms may die following a short-lived infestation and cause severe pulmonary thrombo-embolism. Haematological examination of infected cats reveals anaemia, eosinophilia, basophilia and hyperglobulinaemia. With microfilariae frequently absent from the blood, diagnosis is based on clinical and radiological examination coupled with immuno-assay. Antibody detection tests may be more useful than antigen detection tests since, although not definitive, they will indicate exposure. Since antigen tests detect antigens released by reproductive female worms, they are usually negative in cats. Heartworm is best controlled by chemoprophylaxis. In endemic areas, infection can be prevented safely and easily by monthly administration of avermectin/milbemycin drugs, such as selamectin. Treatment with thiacetarsamide to kill the adult worms is usually successful and well tolerated, but sudden deaths have occurred from thromboembolism 1–2 weeks after administration. For fuller details of this disease readers should refer to Rawlings (1986).

Joyeuxiella pasqualei

This tapeworm resembles *Dipylidium* and is especially common in Africa and the Middle East. The life cycle involves both beetles and lizards acting as intermediate hosts. Unlike *Dipylidium*, the egg capsules contain only a single egg.

Diphyllobothrium latum

This and species of the related genus *Spirometra* may be encountered in cats. The eggs are operculate and yellow in colour, measuring about 75 μm in length.

Other operculate eggs in cat faeces could be those of flukes belonging to one of several genera and readers are referred to standard textbooks of veterinary parasitology for their identification.

Leishmaniosis

Leishmania infantum is a flagellated protozoan, transmitted by *Phlebotomus* species flies in endemic areas of southern Europe and elsewhere in warm climates. Predominantly an infection in dogs, rare infections in cats have been described in endemic areas. The infection is not endemic in the UK, but cats imported from endemic areas may be infected and the disease may have a very long incubation period. In cats the disease usually presents as cutaneous lesions with or without dissemination (see Ozon *et al.*, 1998, for a description of a recent case). Diagnosis is based on detection of parasites in biopsies from lesions (skin or nodules) or bone marrow or lymph nodes, and serology and polymerase chain reaction (PCR) detection in blood are also helpful. The disease is rare and only about 40 cases have been reported between 1911 and 1996 (see review by Laruelle-Magalon & Toga, 1996). Although disease appears to be rare, infection in cats in endemic areas may be more common than is currently presumed. Thus, in Sicily, 61% of cats were found to be infected, by PCR examination of blood (Pennisi *et al.*, 2000).

References

Bennett M., Baxby D., Blundell N., *et al.* (1985) Cryptosporidiosis in the domestic cat. *Vet Rec* **116**, 73–74.

Brightman A.H. & Slonka G.F. (1976) A review of five clinical cases of giardiasis in cats. *J Am Anim Hosp Assoc* **12**, 492–497.

Churcher P.B. & Lawton J.H. (1987) Predation by domestic cats in an English village. *J Zool* **212**, 439–455.

Dubey J.P. (1993) Intestinal protozoa infections. *Vet Clin North Am Small Anim Pract* **23**, 37–55.

Dubey J.P. & Frenkel J.K. (1972) Extra-intestinal stages of *Isospora felis* and *I. rivolta* (Protozoa: Eimeriidae) in cats. *J Protozool* **19**, 89–92.

Eckert J. & Deplazes P. (1999) Alveolar echinococcosis in humans: the current situation in central Europe and the need for countermeasures. *Parasitol Today* **15**, 315–319.

Else R.W., Bagnall B.G., Phaff J.J.G. & Potter C. (1977) Endo- and ecto-parasites of dogs and cats: a survey from practices in the East Anglian Region, BSAVA *J Small Anim Pract* **18**, 731–737.

Gibbons L.M., Jacobs D.E. & Sani R.A. (2001) *Toxocara malaysiensis* n.sp. (Nematoda: Ascaridoidea) from the domestic cat (*Felis catus* Linnaeus, 1758). *J Parasitol* **87**, 660–665.

Hamilton J.M. (1966a) Experimental lungworm disease of the cat. *J Comp Pathol* **76**, 147–157.

Hamilton J.M. (1966b) Pulmonary arterial disease of the cat. *J Comp Pathol* **76**, 133–145.

Hamilton J.M. (1967) The number of *Aelurostrongylus abstrusus* larvae required to produce pulmonary disease in the cat. *J Comp Pathol* **77**, 343–346.

Hamilton J.M. (1968a) Passive immunization in lungworm infection of the cat. *J Comp Pathol* **78**, 331–333.

Hamilton J.M. (1968b) Immunofluorescence as a diagnostic procedure in lungworm disease of the cat. *Vet Rec* **83**, 401–403.

Hargis A.M., Prieur D.J. & Blanchard J.L. (1983) Prevalence, lesions and differential diagnosis of *Ollulanus tricuspis* infection in cats. *Vet Pathol* **20**, 71–79.

Hasslinger M.A. (1984) *Ollulanus tricuspis*, the stomach worm of the cat. *Feline Pract* **14**(5), 32–35.

Henriksen S.Aa. & Pohlenz J.F.C. (1981) Staining of *Cryptosporidium* by a modified Ziehl–Nielsen technique. *Acta Vet Scand* **22**, 594–596.

Hill S.L., Cheney J.M., Taton-Allen G.F., *et al.* (2000) Prevalence of enteric zoonotic organisms in cats. *J Am Vet Med Assoc* **216**, 687–692.

Kirkpatrick C.E. (1988) Epizootiology of endoparasitic infections in pet dogs and cats presented to a veterinary teaching hospital. *Vet Parasitol* **30**, 113–124.

Kirkpatrick C.E. & Farrell J.P. (1982) Giardiasis. *Compendium on Continuing Education for the Practicing Veterinarian* **4**, 367–378.

Kirkpatrick C.E. & Farrell J.P. (1984) Feline giardiasis. Observations on natural and induced infections. *Am J Vet Res* **45**, 2182–2188.

Kirkpatrick C.E. & Laczak J.P. (1985) Giardiasis in a cattery. *J Am Vet Med Assoc* **187**, 161–162.

Laruelle-Magalon C. & Toga I. (1996) Un cas de leishmaniose féline. *Prat Méd Chir Anim Comp* **31**, 255–261.

Lee C.C., Cheng N.A.B.Y. & Bohari Y. (1993) *Toxacara canis* from domestic cats in Kuala Lumpur. *Trop Biomed* **10**, 79–80.

Leib M.S., Dalton M.N., King S.E. & Zajac A.M. (1999) Endoscopic aspiration of intestinal contents in dogs and cats: 394 cases. *J Vet Intern Med* **13**, 191–193.

Levine N.D. (1985) *Veterinary Protozoology*. Iowa State University Press, Ames, IA.

Mtambo M.M.A., Nash A.S., Blewett D.A., *et al.* (1991) *Cryptosporidium* infection in cats: infection in domestic and feral cats in the Glasgow area. *Vet Rec* **129**, 502–504.

Nichol S., Ball S.J. & Snow K.R. (1981) Prevalence of intestinal parasites in domestic cats from the London area. *Vet Rec* **109**, 252–253.

Nolan T.J. & Smith G. (1995) Time series analysis of the prevalence of endoparasitic infections in cats and dogs presented to a veterinary teaching hospital. *Vet Parasitol* **59**, 87–96.

Ozon C., Marty P., Pratlong F., *et al.* (1998) Disseminated feline leishmaniosis due to *Leishmania infantum* in southern France. *Vet Parasitol* **75**, 273–277.

Pennisi M.G., Maxia I., Vitale F., *et al.* (2000) Studio dell'infezione de *Leishmania* medianta PCR in gatti che vivono in zona endemica. *Alti della Società Italiana delle Scienze Veterinarie* **56**, 215–216.

Poochna K.B. & Pippin C. (1982) Intestinal cryptosporidiosis in the cat. *Vet Pathol* **19**, 708–710.

Rawlings C.A. (1986) *Heartworm Disease in Dogs and Cats*. WB Saunders, Philadelphia, PA.

Woodruff A.W. & Savigny D.H. de (1982) Toxocaral and toxoplasmal antibodies in cat breeders and in Icelanders exposed to cats but not to dogs. *BMJ* **i**, 309.

Xiao L., Morgan U.M., Fayer R., *et al.* (2000) *Cryptosporidium* systematics and implications for public health. *Parasitol Today* **16**, 287–292.

Zhu X.A., Jacobs D.E., Chilton N.B., *et al.* (1998) Molecular characterisation of a *Toxocara* variant from cats in Kuala Lumpur, Malaysia. *Parasitology* **117**, 155–164.

Zimmer J.F. (1987) Treatment of feline giardiasis with metronidazole. *Cornell Vet* **77**, 383–388.

Further reading

Dunn A.M. (1978) *Veterinary Helminthology*. 2nd edn. William Heinemann, London.

Soulsby E.J.L. (1982) *Helminths, Arthropods and Protozoa of Domesticated Animals*. 3rd edn. Baillière Tindall & Cassell, London.

Urquhart G.M., Armour J., Duncan J.L., *et al.* (1987) *Veterinary Parasitology*. Longman Scientific and Technical, London.

INDEX

Note: page numbers in *italics* refer to figures, those in **bold** refer to tables and boxes. The abbreviation FeLV is used in subentries for feline leukaemia virus, and FIV for feline immunodeficiency virus

abducens nerve **487**
abortion 349, 350, 351
abscess 679–80
  cat-fight 91–2, 679
  endodontic periapical 390–1
  nocardia 93
  periodontal 328–9
acanthocytes **243,** Plate 9.3
acarbose 547
acepromazine 524
acetominophen *see* paracetamol
N-acetylcysteine 6, 48, 447
achondroplasia 213
acid–base imbalance 293, 294
acids, corrosive 47
acne 117, Plate 6.20
acromegaly 539, 552–4
actinic keratosis 106
Actinobacillus 691
Actinomyces (actinomycosis) 92–3, 680
activated clotting time (ACT) 258
activated partial thromboplastin time (APTT) 258
acute inflammatory response 252, Plate 9.7
acute renal failure (ARF) 283, 291–6, 308
Addison's disease 557
adjuvants 16–17, 589, 604
adrenal cortex, aldosterone overproduction 559, *560*
adrenal tumour 554, 556
adrenalectomy, surgical 557, 561
adrenocorticotrophic hormone (ACTH) 558–9
  stimulation test 555, 556
Aelurostrongylus abstrusus (lungworm) *334,* 701–3
age
  constipation 433
  drug disposition 4–5
  fear onset 61
  toileting problems 59–60
aggression 64–7
  cat-to-cat 51, 52, 66–8
  cats in same household 67–8
  defensive 61, 64
  fear-related 64–5
  frustration-related 64, 65–6
  rabies 640
  territorial 66–7
  towards people 51, 52, 64
  urine spraying 55
albendazole toxicity 254
aldosterone overproduction 559, 560, *560*
alfacalcidol 563
alkalis, corrosive 47
alkylating agents 20, **21**
allergens 84, 90, 105
  see also food, allergy
alloantibodies 264–6
alopecia 74, 77, 90–1, 116, 119–20, Plate 6.1
amelia 213
amiloride 561
aminoglycosides 367
aminophylline 331
amitraz 81, 82
amitriptyline 91
amlopidine 299
ammonia 56, 443–4
amoxycillin 413
amoxycillin/clavulanic acid **361**
Amphimerus pseudofelineus (pancreatic fluke) 436
amylin 540
amyloid deposits 306–7, 540
amyloidosis, renal 306–7
anaemia 9, 244–51
  chronic renal failure 249–50, 301–2
  feline infectious 669–76
    see also Haemobartonella felis (feline infectious anaemia)
  FeLV 250, 601, **602,** 603, Plate 23.3
  FIV 250
  haemolytic 245, 246, 247–8, 259
  haemorrhagic 248
  Heinz body formation 246–7, Plate 9.5
  infectious 246
  innocent bystander effect 670
  iron-deficiency 249
  non-regenerative 248–51, 558
  ocular signs 485
  regenerative 245–8
Anaerobiospirillum 691
anaesthetic agents, cutaneous reactions **104**
anal reflex 135
anaphylaxis in chemotherapy 27
Ancylostoma tubaeforme (hookworm) 705
angiotensin converting enzyme (ACE) inhibitors 298, 299, 306, 521, 522
anisocoria 132, 487–8
anisocytosis **243,** Plate 9.3
ankyloblepharon 464
ankylosing hyperostosis 226
ankylosis 183
  temporomandibular 176
anorexia 5, 26–7, 405, 446
anthelmintic drugs 367
anthrax 684
antibiotics
  antitumour 20, **22**
  bacterial osteomyelitis 178
  bacterial skin infections 92, 93, 94
  compound fractures 178
  cutaneous reactions **104**
  eosinophilic ulcer 89
  exocrine pancreatic insufficiency 440
  infective arthritis 194
  kittens 366–7
  oral disease 383
  pyothorax 340
  resistance 583
  respiratory disease 582, 583
  sensitivity testing 287
  stomatitis 386
anticholinesterase 44
anticholinesterase drugs 170, 223
anticoagulant factors 264
anticoagulants, rodenticide 42, 262, **263**
anticonvulsants, cutaneous reactions **104**
antidepressants, tricyclic 57, 63, 91
antidiuretic hormone 565
antiemetics 26
antifungal drugs 94–5, **104**
  cryptococcosis 99, 179
  dermatophytosis 96–7
  mycetoma 98

antifungal drugs (*cont'd*)
non-suppurative osteomyelitis 179
phaeohyphomycosis 98
antihistamines 86, **104**
antimetabolites 20, **21**
antinuclear antibody 198, 246
antiretroviral drugs 602
antithrombin III (AT3) 258–9
antithyroid drugs **104,** 533–5
antiviral drugs 470, 631
anus **128,** 129, 136–7, 429
anxiety, urine marking 56
aortic arch 497
aortic stenosis 507
aortic thromboembolism 223
apomorphine contraindication **5**
appetite stimulants 26
apudomas 566
aqueous humour 474–5, 662, 663–4
arrhythmia management 523
arsenic toxicosis 46
arthritis **173,** 185–7, **188–9,** 190–203
babesiosis **188,** 196
bacterial **188,** 193–5
calicivirus **188,** 195
chlamydia 199
Hepatozoon canis 196
immune-based **188–9,** 195, 196–204
infective **188,** 193–6
Leishmania donovani **188,** 196
Lyme disease **188,** 195–6
mycoplasma **188,** 194–5, 684
rickettsia **188,** 196
septic 193–5
systemic lupus erythematosus **189,** 198, 199
toxoplasmosis 196
traumatic 185, **188**
tubercular 195
arthrodesis 193
arthrogryposis 213
arthroplasty 192
ascarids 699–701
ascites 450
L-asparaginase–crisantaspase **23**
Aspergillus (aspergillosis) 179, 327, 332
aspirin 4, 7, **8,** 47, 523
Association of Pet Behaviour Counsellors (APBC) 51
asthenia, cutaneous 260
asthma syndrome, feline 330–1, Plate 12.4, Plate 12.5
astrocytoma 151
astrovirus 421
ataxia 133, 573
atlantoaxial subluxation 227
atopic disease 84–6
atrial septal defect 503–4
atrioventricular valve malformations 503, *504, 505*
atropine 44, 45
Aujesky's disease 144–5, 640, 691
aurothioglucose (gold salt) therapy 101–2, **104,** 386
aurothiomalate (gold salt) therapy 386
autoimmune disease, oral 391
avermectin 79–80, 81
axonopathy, distal of Birman cats 158, 223
azathioprine 5–6, 102, 254, 448
azithromycin 386, 664
azotemia **283,** 293, 529, 553
AZT *see* zidovudine

β-blockers 299, 522, 535
B cells 238
β-cells 539, 540
Babesia felis (feline infectious anaemia) 671, 675–6
babesiosis, arthritis **188,** 196
bacillary angiomatosis 690
Bacillus anthracis (anthrax) 684
bacteraemia, oral 380, 383
bacterial endocarditis 524
bacterial infections
arthritis **188,** 193–5
blood transfusion 268
chronic endometritis 351
encephalitis 146–7
kittens 359–60
liver disease 450
periodontal 381
pneumonia 332
pyothorax 338
rhinitis 327
small intestine 422
upper urinary tract infection 304
barrier systems 591
Bartonella (cat-scratch disease) 384–5, 386, 690
Bartonella henselae 613, 690
basal cell tumour **107,** 115, Plate 6.18
basophilia, cytoplasmic 253
basophils 238, 256
bats 641
behaviour/behavioural problems 51–68
avoidance 59
clinical disease links 52–3
faeces deposit location 54
fearful 52
grooming 4, 62
house soiling 53
misdirected predatory behaviour 64, 66
posture 53–4
security 59
urine deposit location 54
see also aggression
behavioural therapy 52, 62–3
benzene hexachloride 44
benzocaine, contraindication **5**
benzoic acid, toxicity risk 4, 48
benzoyl peroxide 117
Berne virus 692
biceps reflex 135
bile acids, serum concentrations 443
bile duct, extrahepatic obstruction 447
bile duct carcinoma 446
bilirubin 443
Biot's breathing 148
Birman cats 144, 158, 223
birth weight, subnormal 358, 359
bites 690–1
bladder 136–7, 317, 322
see also lower urinary tract disease (FLUTD)
Blastomyces (blastomycosis) 179, 332
Blastomyces dermatitidis (blastomycosis) 685
bleeding 42
disorders 256–64
bleomycin **22**
blindness 9, 489
blood 240, 244
clotting tests 258–9
loss 248
volume 3
blood cells 235
see also leucocytes; red blood cells
blood groups 264, **265,** 362
blood pressure 288, 299, 502
see also hypertension
blood transfusion 250–1, 262, 264–8, 366
blood–brain barrier, neonatal 357
boarding catteries, respiratory disease prevention 590
bone
arrested development of forelimbs 213–14
density 180, *181, 182*
fibrous dysplasia 209–10
infections **173,** 176–9
metabolic disease **173,** 179–85
metastases 210
neoplasm direct extension 210–11
periosteal new 177
bone cyst, aneurysmal 209
bone marrow 235, 240–1, 250, Plate 9.1, Plate 9.2
drug-induced failure 254
FeLV-associated disease 253, 601, Plate 23.3
griseofulvin-induced suppression 10
Bordetella bronchiseptica 360, 586, 587
respiratory disease 577, 578, 581, 582, 583, 587–91
epidemiology 585–6
pathogenesis/pathology 579–80
pneumonia 332
rhinitis 327
tracheitis 329
vaccine 13, 16, 589, 591
Borna disease 144, 692
Borrelia burgdorferi (borreliosis) **188,** 195–6, 684
bougienage 401, 403
bovine spongiform encephalopathy (BSE) 692–3
Bowen's disease 100, 106
brachial plexus avulsion 162
brain 125–6, *129,* 139
feline parvovirus 573
FIV infection 611, 615–16
neoplasia 488–9
supratentorial structures 125, *126*
trauma 147–9
brainstem 126

Breda virus 692
bromadiolone 42
bromhexine hydrochloride 582–3
bronchial diseases 330–2
bronchoalveloar lavage 330
bronchopleural fistulae 342
buccal mucosal bleeding time (BMBT) 257
bulbourethral gland disease 323
bullous pemphigoid 102
Burmese cats 214, 221
buspirone 57

Caesarean section 352
calcium
  deficiency 180, 181, 268
  hyperparathyroidism 184, 185, 563, 564
  supplementation 180–1, 185, 212, 562–3
  see also hypercalcaemia
calcium channel blockers 522
calcium ipodate 535–6
calcium oxalate calculi *see* struvite crystals
calcium–EDTA, lead toxicosis 46
Campylobacter jejuni (campylobacteriosis) 422
Candida (candidiasis) 320, 613, 685
Candidatus Mycoplasma haemominutum 669, 670, 671–2, 674
canine distemper virus 692
canine parvovirus 571, 572, 573
Capillaria aerophila (nematode) 329, 703
Capillaria feliscati (nematode) 706
capital physeal dysplasia syndrome, feline 218
Capnocytophaga 690–1
carbamate toxicosis 44
carbaryl 82
carbimazole 533, 534
carbohydrate, dietary 449
carboplatin **23,** 27
cardiac chambers 496, 497
cardiac disturbance in toxicoses 41
cardiac silhouette 497, *498*
cardiac tamponade 511
cardiac workload reduction 521
cardiomegaly 496, 511, *515,* 524
cardiomyopathy 499, 502, 508–18
  arrhythmogenic right ventricular 511
  diastolic function improvement 521–3
  dilated 510, 511, 513, *514,* 516–18, 522
    taurine deficiency 520
    thromboembolism 523
  hypertrophic 509–10, 512, *513,* 515–18, 522
    acromegaly 553
    hyperthyroidism 532
    obstructive 522
    thromboembolism 523
  management 518–24
  restrictive 510, *511,* 512, 514, 516, 523
cardiovascular disease 485
cardiovascular function, neonatal 357
cardiovascular system 493–525
  clinical examination 494–6
  diagnostic aids 496–502
L-carnitine 449
carnivores, wild 646
carpi radialis, extensor reflex 135
cat breeders, disease prevention 574–5, 591, 620, 633
cat-fight abscess 91–2, 679
cat-scratch disease 384–5, 386, 690
cataract 462, 479, 561, Plate 18.18
cathartics 41
cauda equina malformations 140–1, 212–13
cell cycle 20
cellulitis 679–80
central nervous system (CNS) 125
  conditions 144–57
  congenital/developmental defects 139–44
  encephalopathies 144–7
  ethylene glycol toxicosis 307–8
  feline parvovirus 573
  FIP 626, 630
  FIV infection 611
  lymphoma 272
  neonatal 357
  neoplasias 150–2
  neurochemical balance alteration 53
  rabies 638
  signs in toxicoses 41
  toxoplasmosis 662, 663–4, 665
  trauma 147–9
  vestibular disease 154–7
  see also seizures
cephalexin **361**
cephalosporins 366
cerebellar hypoplasia 573
cerebellum 126, 140
cerebral oedema 147
cerebrospinal fluid (CSF) 138, 662, 663–4
cervical pain 128
cestodes 423–4
charcoal, activated 43
Chédiak–Higashi syndrome 254
chemoreceptor trigger zone (CRTZ) 403
chemotherapy 19–36, Plate 3.2
  carcinoma 33
  CNS tumours 152
  haemangiosarcoma 33
  leukaemia 33, **34,** 273, 274
  lymphoma 28–31, 271–2, 601–2
  mammary carcinoma 33
  mast cell tumours 33–4
  myeloma 31–2
  neutropenia 253
  principles 19–20, **21–3,** 24–7
  protective clothing 36
  rescue therapy 24, 31
  sarcoma 33, **35**
  see also cytotoxic drugs
chest tube placement 339
chest wall diseases 335–6
Cheyletiella (cheyletiellosis) 80, Plate 6.5
Cheyne–Stokes respiration 148
chlamydia, arthritis 199
Chlamydia psittaci see Chlamydophila felis
Chlamydophila felis 350, 469, 470, 577, 583
  vaccine 13, 16
α-chloralose toxicosis 43
chlorambucil 5–6, **21,** 33, 89, 101
chloramphenicol 7–9
chlorhexidine 117
chloride, hypoadrenocorticism 558
chlorpyrophos toxicity 160
cholangiohepatitis complex 444–5
cholangitis/cholangiohepatitis 436
cholecalciferol toxicosis 43
cholelithiasis 448
chondrodysplasia 214
chondroma, multilobular 207
chondrosarcoma 206–7
chorioretinal disease, inflammatory 482–4
choroid 475, 476
choroiditis 476, 477
chronic renal failure (CRF) 281, 296–302
  acute renal failure differential diagnosis 292
  anaemia 249–50, 301–2
  asymptomatic urinary tract infection 304
  hypokalaemia 308
  perinephric pseudocysts 309
  polycystic kidney disease 307
  renal amyloidosis 306, 307
chylomicronaemia 485
chylothorax 341–2
cilia, ectopic 465
ciliary body 475, 476
cimetidine 6–7, 26, 410, 470
circling, compulsive 126
circulatory overload, blood transfusion 268
cisplatin contraindications **5,** 27
clarithromycin 664, 682
cleaning products, ammonia-based 56, 60
clindamycin 665
clomipramine 57, 91
Clostridium piliforme (Tyzzer's disease) 683
clot inhibition testing 258–9
clot retraction 257
clothing, protective 36
clotting factors 442
  disorders 261–2, 442, 444, 450
clotting tests 444
coagulation cascade 256, *257*
coagulation inhibitors, circulating 259
coagulation proteins 256
coagulopathy 450
coat 25, 74
  see also hair
cobalamin 418–19, 425, 427, 429, 439
Coccidioides immitis (coccidiomycosis) 178–9, 332, 686
coccidiosis 362, 423–4, 613
Codman's triangle 205
cold agglutinin disease 246
colitis 431–2
coloboma 464, 476, 482
colon 429–30

colony-stimulating activity (CSA) 238
colony-stimulating factors 240
colostrum 357
coma 147
comb, flea 76
communication, feline 52, 55
compulsive disorders, feline 53
congenital defects 139–44, 368, **369–73**
  corneal 472
  duplication 214
  eye 462
  heart 499–500, 502–8
  kittens 358
  lens 479
  musculoskeletal **174,** 212–17, **218,** 219
  oral 392
  retinal 481–2
  uveal tract 476
  vestibular disease 156
  vitreous 480
  see also developmental defects
conjunctiva 461, 466, 468–71
conjunctiva-associated lymphoid tissue (CALT) 468
conjunctivitis 469–71, Plate 18.6, Plate 18.7
Conn's syndrome 559–61
consciousness alteration 147
constipation 433–4
contraception 347–8
Coombs' test 246
cor pulmonale 525
cornea 471–4, Plate 18.9
  clouding 472, 489
  reflex 132
  scarring 469
corpus luteum 346
corticosteroids *see* steroids
cortisol 555
  suppression 556, 557
Corynebacterium 691
coumarin rodenticides 42, 262, **263**
counterconditioning 63
cowpox 73, 74, 99, 686–9
  eyelid 465
  respiratory disease 578–9
Coxiella burnetii (Q-fever) 684
cranial nerves 129–33, **487**
craniofacial malformation of Burmese kittens 213
cryohypophysectomy 554
Cryptococcus neoformans (cryptococcosis) 99, 146, 179, 327, 328, 332, 686
Cryptosporidium (cryptosporidiosis) 424, 697, 704–5
Ctenocephalides felis (flea) 77, 361
culture, casts 287
CXCR4 chemokine receptor 610
cyanosis 507
cyclo-oxygenase (COX) inhibition 6, 7
cyclophosphamide **21,** 27, 33, **35**
  FIP 632
  immune-based arthritis 203
  lymphoma therapy 272, 601
cyclosporine 88
cylinduria 287
cyproheptadine 26
cystitis 316, 317, 319–20
cystocentesis 314
cytarabine **21**
Cytauxzoon felis (infectious anaemia) 675
cytochrome P450-mediated oxidation 6
cytokines 240
cytology, exfoliative 76
cytotoxic drugs 19, 24, 27, 35–6
  mechanism of action 20, **21–3**
  see also chemotherapy

DDT 44
deafness 154, 364
decontamination, toxicoses 41
defecation 137
  see also constipation
defence strategies 62, 64
dehydration 357–8, 365–6, 574
dementia, old age 61
Demodex gatoi (demodicosis) 81–2, 100, Plate 6.7
dental conditions 379
  see also periodontal disease
dental extraction 387
dental scaling 382
Dermanyssus gallinae (poultry mite) 82–3, Plate 6.8
dermatitis
  contact 105
  exfoliative 116–17
  idiopathic facial of Persian cats 117, Plate 6.21
  lichenoid 105
  papulocrusting (miliary) 77, 90, Plate 6.11
  superficial necrolytic 116
dermatophytosis 73, 76, 95–7, Plate 6.12
  griseofulvin 9–10
  mural folliculitis 120
  retrovirus infection 95, 100
dermatoses, pedal 118–19
Descemet's membrane 471
desensitisation, systematic 63
desmopressin 565
developmental defects 139–44
  musculoskeletal **174,** 212–17, **218,** 219
  see also congenital defects
Devon Rex cats 168–9, 217, 220, 261
dexamethasone 88, 331, 556
diabetes insipidus 565
diabetes mellitus 538–52
  acromegaly 553
  diet 547–8
  failure to achieve control 550–2
  glycaemic control monitoring 548, *549,* 550
  hyperadrenocorticism 554
  hypoglycaemia avoidance 550
  indoor house soiling 53
  insulin resistance 538–9
  megestrol acetate-induced 10
  pancreatitis 437
  polyneuropathy 223
  serial blood glucose curve 550, **551**
  sick cat with ketoacidosis 542–3
  treatment 542–3, **544,** 545, *546,* 547–8, *549,* 550–2
  type 1 538
  type 2 538, 539
diabetic neuropathy 158–9
diabetic retinopathy 485
dialysis 295
diaphragm disorders 335–6, 508, Plate 12.8
diarrhoea 415, *416,* **417,** 428–30
  feline coronavirus 421
  inflammatory bowel disease 426
  large intestine **417,** 430
  third eyelid protrusion 467
  with vomiting 405
diascopy 76
diastolic function improvement 521–2
diazepam **8,** 153, **154**
  α-chloralose toxicosis 43
  depth perception impairment 63
  indoor spraying treatment 57–8
  insecticide toxicosis 44, 45
  strychnine toxicosis 43
dieldrin 44
diet
  calcium-deficient 180
  calorie-restricted 548
  chronic renal failure 298
  diabetes mellitus 547–8
  elimination 84
  essential fatty acids 86–7
  exocrine pancreatic insufficiency 427
  hyperthryoidism 528
  idiopathic lower urinary tract disease 316
  low-residue 433
  meat 359
  nutritional secondary hyperparathyroidism 179–80
  taurine levels 511
dietary toxins/contaminants 48, 74
digitalis glycosides 4, 9
digoxin 9
dihydrotachysterol 563
diltiazem 522
D-dimer 259
dimercaprol 46
diphenhydramine 223
diphenylhydantoin teratogenicity **139**
Dipylidium caninum (tapeworm) 698
dipyridal toxicosis 45
diquat toxicosis 45
Dirofilaria immitis (heartworm) 525, 706
dirty face syndrome 117, Plate 6.21
discoid lupus erythematosus 102–3
discospondylitis 157, 193, 226
disseminated intravascular coagulation (DIC) 259, 260, 262–3
distichiasis 465
diuresis stimulation in toxicosis 41
diuretics 9, 450, 520–1, 565
dobutamine 522–3
Döhle bodies 253

dopamine 222, 295
Doppler flowmeter device 288
doramectin 81
doxorubicin 20, **22,** 33, **35**
lymphoma therapy 31, 601
toxicity **8,** 9, 25, 27
doxycycline 102, **361,** 366–7, 583
drug receptors 4, 40
drugs 3–11
cutaneous reactions **104,** 105
dosage 25
fear indications 63
liver disease 447
resistance 20
toxicoses 47–8, 156–7
vestibular disease 156–7
ductus arteriosus, patent 499, 504–7
dwarfism, pituitary 565
dysautonomia 467, 488
dysautonomia syndrome, feline 160–1
dysgonic fermenter type 2 (DF-2) 690–1
dysmetria 133
dysphagia 397–8, 401
dystocia 352

ear canal 118
ear cleaning 118
Echinococcus (tapeworm) 699
Echinococcus multilocularis (fox tapeworm) 644, 645, 705
echocardiography 497–500, 514–17
eclampsia 354
ectoparasitacides 367
ectrodactylia 213
ectropion uvea 476
Ehlers–Danlos syndrome 260
elbow
infective arthritis *193*
osteoarthritis 185
synovial cysts 211
electrocardiography 500–1
cardiomyopathy 517, *518*
hypoparathyroidism 562, 563
kittens 364
electrodiagnostic testing 139
electrolyte imbalance 293–4
electromyographic signals 139
electroretinography 461
elimination, inappropriate 58–60
emetics 40–1
encephalitis
bacterial 146–7
protozoal 146
rabies 144, 638
toxoplasmosis 146
encephalomyelitis, mycotic 146
encephalomyelopathy of Birmans 144
encephalopathy 144–7
feline ischaemic 149
FIV 145
hepatic 149, 444, 447, 450
endocardial fibroelastosis 507–8
endometritis, chronic 350, 351–2
endoparasites 697–707
endophthalmitis 476
endoscopy
large intestine 431, Plate 16.7
oesophagus 398–9, Plate 16.1
small intestine 419–20, Plate 16.6
stomach 407, 410, Plate 16.3
enophthalmos 464, 466
enrofloxacin 9, 583, 674–5, 682
enteritis
classical feline 572–3
lymphocytic/plasmacytic 426, 429
enteritis/enterocolitis, eosinophilic 426
enterocytes 413
environment of cat 74
environmental allergens 90
enzyme replacement therapy 216
eosinopenia 256
eosinophil(s) 238, 255–6, Plate 12.5
eosinophilia 558
eosinophilic conjunctivitis 470
eosinophilic enteritis/enterocolitis 426
eosinophilic furunculosis 81
eosinophilic granuloma 77, 81, 88–90, 390, Plate 6.10
eosinophilic keratoconjunctivitis 473, Plate 18.8
eosinophilic plaque 88, 89, Plate 6.10
eosinophilic ulcer 88, 89, Plate 6.10
epibulbar dermoid 469, Plate 18.5
epidermal necrosis, metabolic 116
episclera 468
ergocalciferol 563
erythema multiforme 103, 105
erythrocytes
congenital enzyme deficiencies 247
differentiation *236*
osmotic fragility 247
parasitic infection 669
erythrocytosis
hyperthryoidism 529
primary **34**
erythroid hyperplasia 601
erythrophagocytosis 673
erythropoiesis 235, 237
erythropoietin 237
assay 245
recombinant human 240, 301–2
ethanol
ethylene glycol toxicosis 46, 308
percutaneous ablation of thyroid 537
ethylene glycol toxicosis 46–7, 307–8
eugonic fermenter type 4 (EF-4) 691
exophthalmos 462–3
exostoses
hypervitaminosis A 182, 183
osteocartilaginous 204
exposure, controlled 63
extensor reflex, crossed 134, 135, 137
eye/eye disease
anterior segment pain 466
blood sampling 461
cardiovascular disease 485
clinical examination 455–6
congenital anomalies 462
cranial nerves **487**
enucleation 464, 474, 489
fine-needle aspirate biopsy 461
FIV infection 616
fluorescein staining 459
globe 462–4
enophthalmos 464
fundus 481–6, Plate 18.19, Plate 18.20
hydrophthalmos 464
proptosis 463
gonioscopy 460
history taking 455
local anaesthetic 459
movements 127
mycobacterial infection 682
mydriasis 460
orbit 462–4
retrobulbar access 461
retrobulbar space-occupying lesions 466
Rose Bengal staining 459
scrapes/smears/swabs 460–1
sympathetic innervation *163*
tests 459–62
therapy 490
tonometry 459–60
toxoplasmosis 663–4, 665
eyelashes 465
eyelid 464–5
agenesis 464
cowpox 465
dermoids 464
excisional biopsy 461
fusion 464
neoplasia 465
third 465–7, Plate 18.3
flaps 467
neoplasia 466
protrusion 466, 467
trauma 466
trauma 465

facial nerve 131, **487**
paralysis 155
factor X deficiency 261
factor XII deficiency 261
faeces
inappropriate elimination 58–60
indoor deposition 55
familiarisation pheromone 57
famotidine 450
fat, dietary 449
fatty acids, essential 86–7
faucitis 385
fears 60–3
aggression 64–5
febantel 4
feeding, tube during chemotherapy 27
Felicola subrostratus (biting louse) 82, 361
Felifriend 67
feline calicivirus
arthritis **188,** 195, 199
carrier state 584–5
FIV infection 613
idiopathic lower urinary tract disease 316–17

feline calicivirus (*cont'd*)
immunity 587
kittens 360
respiratory disease 577, 578
clinical signs 581, Plate 22.2
control 587–91
diagnosis 582
epidemiology 583, 584–5
pathogenesis/pathology 579
prevention 587–91
treatment 582–3
stomatitis 384
transmission 586
vaccination 13, 15, **189,** 195, 199, 587–9, 591
lack of efficacy 17
feline coronavirus 421, 623–34
aetiology 623–4
antibody-dependent enhancement (ADE) of infection 625–6
clinical signs 626–8
diagnosis 627–31
elimination in kittens 633–4
enteritis-producing strains 625, 626
epidemiology 624–5
FIP-producing strains 625
kittens 361
pathogenesis 625–6
serology 629
transmission 624
see also peritonitis, feline infectious
feline foamy virus 692
feline herpesvirus
carrier state 583–4
chronic rhinitis 327
conjunctivitis 469, Plate 18.7
cornea 472–3
FIV infection 613
idiopathic lower urinary tract disease 316–17
immunity 586–7
kittens 360
pancreatitis 436
respiratory disease 577–8
clinical signs 580–1, Plate 22.1
control 587–91
diagnosis 582
epidemiology 583–4
pathogenesis/pathology 579
prevention 587–91
treatment 582–3
skin disease 99–100
transmission 586
vaccination 13, 15, 586–7, 587–9, 591
feline immunodeficiency virus (FIV) 10, 607–20
anaemia 250
chronic rhinitis 327
clinical signs 612–14
concurrent infections 618
control 619–20
dermatitis 100
dermatophytic mycetoma 98
diagnosis 616–17
encephalopathy 145
enteritis 421
epidemiology 607–10
FeLV concurrent infection 609–10, 611
Haemobartonella felis infection 672
iatrogenic infection 612
immunodeficiency phase 610–11, 615–16
kittens 360
laboratory findings 614
lymphoma 28, 31
neoplasia 613–14
opportunistic infections 613
pathogenicity 608
pathology/pathogenesis 610–11, 614–16
prevalence 609
prognosis 619
stomatitis 384
subtypes 608
toxoplasmosis 666, Plate 28.4
transmission 611–12
treatment 616–17
uveitis 477, 478, 483
vaccine development 618–19
feline infectious enteritis *see* feline parvovirus
feline ischaemic encephalopathy (FIE) 149
feline leukaemia virus (FeLV) 597–604
anaemia 250
bone marrow disease 253
chronic rhinitis 327
clinical features of disease 599, **600,** 601
control 603
dermatitis 100
diagnosis 602–3, Plate 32.4
fibrosarcoma association 115
FIV concurrent infection 609–10, 611
gastrointestinal disease 421
Haemobartonella felis infection 671, 672
haemolytic anaemia 246
healthy viraemic cats 603
immunity 599
kittens 360
latent infection 598–9
leukaemia 33
lymphoma 28, 31
malignant disease 599, **600,** 601
periosteal proliferative polyarthritis 198
persistence 597–8
public health 604
renal lymphoma association 272
replication 597–8
reproductive failure 350
retinal dysplasia 481
spread 598
stomatitis 384
structure 597–8
therapy 601–2
transmission 598, 611–12
uveitis 477
vaccine-associated sarcoma 17, 604
vaccine/vaccination 13, 603, 618
feline leukaemia virus (FeLV)–lymphoma complex 483
feline leukaemia virus (FeLV)–panleucopenia syndrome 421
feline panleucopenia 253, 421, 566
kittens 360–1
reproductive failure 350–1
retinal dysplasia 481
teratogenicity 139
vaccine 13, 15
see also feline parvovirus
feline parapoxvirus 689
feline parvovirus 571–5
clinical signs 572–3
control 574
diagnosis 573–4
laboratory tests 573–4
pathogenesis 572
pathology 573, Plate 21.1, Plate 21.2
prevention 574
subclinical infection 572
sudden death 572
transmission 571–2
treatment 574
vaccination 574
see also feline panleucopenia
feline rhinotracheitis virus 577
feline sarcoma virus 115, 211
feline syncytium-forming virus 692
feline torovirus 692
Feliway 57, 67
femoral metaphysis, osteopathy of proximal 217
fenbendazole **361,** 424, 700, 702, 703
fenthion 436
fertilisation failure 349
fetal resorption 349
fibre, dietary 449
fibrin degradation products 259
fibrinogen 258
fibrinolysis tests 259
fibrosarcoma **109,** 115–16, 208, 210–11
fibrotic myopathy 225
fibrous dysplasia 209–10
fipronil 79, 80, 81, 82
fistula
bronchopleural 342
endodontic periapical 390–1
hepatic arteriovenous 448
oronasal 328–9, 391
flail chest 335
flea-bite hypersensitivity 77, 90, 614
fleas
allergic dermatitis 62
allergy 73, 78
control 77–9
environmental control 78–9
kittens 361
management 77–9
product formulation 78
rabbit 79, Plate 6.2
flexor reflex 134, **135**
flight 62, 65
flooding 63

fluid homeostasis 357–8
fluid imbalance 293
fluid therapy 365–6
  ethylene glycol toxicosis 46
  feline parvovirus 574
fluke
  lung 334
  pancreatic infestation 436
fluorescein staining 459
5-fluorouracil contraindication 27
folate, serum levels 418–19, 425, 427, 440
food
  allergy 73, 83–4, 90, Plate 6.9
  hypersensitivity 62
  intolerance 83–4
foot, dermatoses 118–19
foreign bodies
  conjunctiva 470
  gastric 408, 409–10
  oesophageal 400
  rhinitis 328–9
  small intestine 424–5
  tongue 391
  vitreous 480
forelimbs
  arrested development of long bones 213–14
  evaluation 128, 134–6
L-form infections 93
FPMPA 617
fractional cell kill hypothesis 24
fractures 173–4
  compound 178
  jaw 391
  pathological 181
  pelvic 432
Francisella tularensis (tularaemia) 685
fructosamine 541, 548
frusemide 9, 295, 520–1
frustration, indoor marking 56
fundus 481, Plate 18.19, Plate 18.20
fungal infections
  chorioretinal 484
  encephalomyelitis 146
  pneumonia 332, Plate 12.6
  pyothorax 338
  rhinitis 327–8
  superficial 94–7
furosemide toxicity risk **8**
furunculosis, eosinophilic 81

gait evaluation 127, 133–4
ganglioneuritis 638
gangliosidosis 489
gastric acid 403, 411–12
gastric disease 403, *404,* 405–13
gastric lavage 41, 43, 45
gastric mucosal permeability testing 407
gastric mucosal protectants 411
gastric mucous production regulation 411–12
gastric spiral organisms (GSO) 408, 413
gastric ulceration 26, 407, 409, Plate 16.5
gastrinomas 566
gastritis 408, 412–13, Plate 16.4
gastro-oesophageal reflux 400
gastrocnemius muscle/tendon contracture 225
gastrointestinal tract 397–433
  chemotherapy toxicity 26–7
  disease **402**
  feline parvovirus 573, Plate 21.1, Plate 21.2
  FIV 615
  neonatal 357
  ulceration 449–50
Gastrospirillum (gastric spiral organism) 408, 413
gastrostomy tube feeding 27
genetic testing 375
genital tract neoplasia 353
geriatric cats, toileting 59–60
gestation period 346
Giardia duodenalis (giardiasis) 705
Giardia lamblia (giardiasis) 424, 432, 705
  kittens 362
  vaccine 13
  zoonosis 697
gingival hyperplasia 390
gingivitis 381–2, 383, 385, 581
glaucoma 474–5, 480
glipizide 547
glomerular filtration rate 283
  acute renal failure 290, 292
  hyperthyroidism 537
  single-nephron 297
glomerulonephritis 305–6
glossopalatine fold stomatitis 385
glossopharyngeal nerve 131
glucocorticoids 87–8, 559, 632
gluconeogenesis 355–6
glucoregulation in neonates 355–6
glucose
  serial blood curve 550, **551**
  toxicity 539, 540
glucuronidation 4, 6, 40
glucuronyl transferase 4, 6, 40
glycaemic control monitoring 548, *549,* 550
D-glycerate dehydrogenase deficiency 223
glyceryl trinitrate 521
glycogen storage diseases 167, **217,** 220
glycogen stores 355
glycosuria 541
goniolens 474, Plate 18.10
gonioscopy 460, 474, Plate 18.10
granulomas 626
  eosinophilic 77, 81, 88–90, Plate 6.10
  FIP 631
  mycobacterial 682
granulopoiesis 237–8, *239*
griseofulvin 97
  teratogenicity 139, 462
  toxicity risk **8,** 9–10, 254
grooming problems 62
growth factors, haematopoietic 239–40
growth hormone (GH) 553
  acromegaly 552, 553, 554
  congenital deficiency 565
  excess 552
habituation 60–1, 63
haemagglutination, feline parvovirus 573
haemangiosarcoma chemotherapy 33
haematopoiesis 235, *236,* 237–40
haematopoietic growth factors 239–40
Haemobartonella felis (feline infectious anaemia) 246, 361, 669–75
  chronic infection 671
  clinical signs 672
  diagnosis 673–4, Plate 29.1, Plate 29.2
  epidemiology 671–2
  FIP concurrent infection 628
  laboratory features 672–3
  morphology 669–70
  pathogenesis 670–1
  post-mortem findings 675
  prevalence 671–2
  prevention 675
  prognosis 675
  reclassification/renaming 669
  risk factors 671
  transmission 671
  treatment 674–5
haemoglobin
  glycated 541, 548
  oxidation susceptibility 4
haemolysis, transfusion reaction 267
haemoparasites **243,** Plate 9.3
haemophilia 261
haemostasis 256–8
haemothorax 340–1
Hageman factor deficiency 261
hair 75–6
  loss 25, 62, Plate 3.1
  pulling 90
hairballs 408, 433
haloperidol 91
hantavirus 689–90
head 126–7
  movements 127
  neurological evaluation 132–3
  ventroflexion 150
health, general 74
heart
  auscultation 495–6
  cyanotic congenital defects 507
  neoplasia 525
heart disease
  acquired 508–18, 524
  congenital 502–8
  effusion/oedema management 520–1
heart failure, congestive 502, 503, 504, 518–24
heartworm 525, 706
Heinz bodies 6, 40, **243,** Plate 9.3, Plate 9.5
Helicobacter pyloris 409, 413
helminths, small intestine 423–4
hemimelia 213
hemistanding/hemiwalking 133
heparin 524
hepatic arteriovenous fistula 448
hepatic encephalopathy 149, 444, 447, 450
hepatitis, lymphocytic portal 445
hepatobiliary neoplasia 446

hepatobiliary scintigraphy 444
hepatocellular carcinoma 446
hepatocutaneous syndrome 116
Hepatozoon canis arthritis **188,** 196
herbicides, toxicoses 45
hereditary diseases 358, 368, **369–73,** 373–5, 392
herpesvirus 691
see also feline herpesvirus
heterochromia iridum/iridis 475
hexachlorophene toxicity risk 4
hindlimbs, evaluation 134–6
hip dysplasia 218–9
histamine H_2-receptor blockers 410, 411
Histoplasma capsulatum (histoplasmosis) 179, 685
HIV infection 690
home range 66–7
hookworm 705
hopping 133–4
Horner's syndrome 132, 155, 162, 162, **163**, 466, 488, Plate 18.3
enophthalmos 464
hyperchylomicronaemia 223
nasopharyngeal polyp surgery 328
house soiling 53–60
house-training problems 51, 52–60
household products
ammonia-based 56, 60
toxicoses 46–7
Howell–Jolly bodies 673
humans *see* zoonoses
hyaloid artery, persistent 480
hydralazine 521, 524
hydrocephalus 140
hydrochlorthiazide 565
hydronephrosis 305
hydrophthalmos 464
hydroxyurea **23, 139**
hyperadrenocorticism 106, 539, 554–7
hyperaesthesia syndrome, feline 53, 91, 228
hyperaldosteronism 559–61
hypercalcaemia 563, 564
myeloma 269, 272
hyperchylomicronaemia 158, 223
hypereosinophilic syndrome 103, 255–6, 274
hypergammaglobulinaemia 272, 384
hyperglobulinaemia 441–2
hyperglycaemia 540
postprandial 547, 548
stress 541
treatment 545
hyperostosis 181
hyperoxaluric neuropathy 158, 223
hyperparathyroidism 563–5
nutritional secondary in kittens 179–81, *182,* 359
primary 184–5
renal secondary 184, 300–301
hyperphosphataemia 529
hyperprogestonaemia 557
hyperreflexia 137
hypersensitivity reactions
chemotherapy 27
delayed type IV 105
immune-mediated conjunctivitis 470
type I 83
type III 305, 626
see also flea-bite hypersensitivity
hypertension
hyperaldosteronism 560
ocular signs 485, Plate 18.23
systemic 287, 299
hyperthyroidism 519–20, 527–38
asymptomatic urinary tract infection 304
diagnosis 528–32
electrocardiogram 518
hypertrophic cardiomyopathy 532
recognition 528
renal disease 537–8
screening 529
skin disorders 106
treatment 7, 532–8
hyperviscosity, ocular signs 485
hypervitaminosis A 48, 163, 181–3
hyphaema 475, 477, Plate 18.14
hypoadrenocorticism 557–9
hypocalcaemia 268
hypocortisolaemia 557
hypoglycaemia 150, 366, 550
hypokalaemia 169
hypokalaemic nephropathy 308
hypokalaemic polymyopathy 169, 221–2
hypoparathyroidism 185, 561–3
hypophysectomy, microsurgical transsphenoidal 557
hypopyon 475, 477, Plate 18.14
hypothermia in kittens 355, 365
hypothyroidism 105–6, 213, 565–6
hypovitaminosis A 183–4

idarubicin **22**
ileum 414
imidazoles 97
immune serum 574
immune system
FIP 625–6
neonatal 357
immunity gap 15
immunoglobulin E (IgE) 83, 84, 85–6
immunoglobulin G (IgG) 384
immunoglobulin M (IgM) 357, 384
immunomodulation 631–2
immunosuppression
eosinophilic enteritis/enterocolitis 426
eosinophilic ulcer 89
FIP 632
gastritis 413
unresponsive stomatitis 386–7
immunotherapy 86, 602
inappetance 5
incontinence 60, 322–3
infections
arthritis 193–6
blood transfusion 268
bone **173,** 176–9
corneal ulceration 473
kittens 359–62
lower urinary tract 320–1
opportunistic 613
reproductive failure 350–1
small intestine 421–4
see also bacterial infections; parasitic infections; protozoal infections; viral infections
inflammation, chronic 252
inflammatory bowel disease 407, 413, 426–7
exocrine pancreatic insufficiency 440
grading systems 420
medical therapy 428–9
neutrophilic 427
toxoplasmosis 661
influenza virus 691
innocent bystander effect 670
insect growth inhibitors 79
insecticides, toxicoses 44–5
insects, bite allergy 80–1
insulin
administration 542–3
acromegaly 554
hyperadrenocorticism 557
with oral hypoglycaemic agents 547
dosage 545, *546,* 548, *549,* 550
maintenance therapy 543, 545
preparations **543–4,** 552
resistance 538–9, 548, 553
secretion 539–40
insulin-like growth factor I (IGF-I) 554
insulinomas 566
interferon 470, 631
intervertebral discs 157, 226
intracardiac shunt 499
intracranial pressure, increased 147–8
intradermal testing 85, 86
intraocular pressure
measurement 459–60
raised 464, 474
intrauterine infection, feline parvovirus 573
intussusception 425, 428
iodine 535
radioactive 532, 537
iris 475
atrophy 476
cysts 476
melanoma 476, Plate 18.13
pigmentation change 476, Plate 18.12, Plate 18.13
sphincter muscle 486–7
iron deficiency 249
isoerythrolysis, neonatal 246, 362
isoniazid 682
Isospora (coccidian) 362, 423–4, 703–4
itraconazole 10, 97
ivermectin 79, 80, 81, 82
Ixodes (ticks) 82

jaundice 448
jaw
fractures 391
neoplasia/swellings 389–90
tone 133

joints
  lavage 192
  metastases 210
Joyeuxiella pasqualei (tapeworm) 706

kangaroo cats 214
keratitis
  dendritic ulcers 470
  stromal 472
keratoconjunctivitis, eosinophilic 473, Plate 18.8
keratoconjunctivitis sicca 467–8, 471
keratoconus/keratoglobus 472
ketoacidosis 541, 542–3
ketoconazole **8,** 10, 556–7
Key–Gaskell syndrome 160–1, 488
kidney
  biopsy 289–90, 305
  FIV infection 616
  function 281, 283, 357
  imaging 288–9
  lymphoma 272, 308, 601
  oxalate crystals 223
  see also renal *entries*
kittens
  antibiotics 366–7
  behavioural weaning 65–6
  blood transfusion 366
  Bordetella bronchiseptica 581
  clinical pathology 363
  congenital disease 358, 368, **369–73**
  dehydration 357–8, 365–6
  diagnostic imaging 364
  diseases 358–62
  early weaning 591
  failure to produce 349, 353
  feline coronavirus elimination 633–4
  feline parvovirus 572, 574, 575
  flea control 79
  haematocrit 244
  hand rearing 65–6
  hereditary disease 358, 368, **369–73,** 373–5
  hereditary primary seborrhoea oleosa 118
  hypoglycaemia 366
  infections 359–62
    screening 363–4
  losses 367–8
  neonatal isoerythrolysis 246
  normal 355, **356**
  nutrition 358–9
  nutritional secondary hyperparathyroidism 179–81
  sick 358, 363–7
  socialisation period 61
  streptococcal infection 681
  sudden death 572
  therapeutic approach 365–7
  toileting learning failure 58
  toxins 359
  toxoplasmosis 661
  trauma 359
  vaccination 15–16, 17, 591
  see also neonates
Klippel–Feil anomaly 214

lacrimal gland neoplasia 468
lacrimal system 467–8, 468
lactational tetany 354
lameness, feline calicivirus 581
laminin α_2 deficiency 167
Langerhans' cells 83
large intestine 429–33
  bacterial flora 430
  clinical examination/evaluation 430–1
  constipation 432–3
  diarrhoea **417,** 430
  diseases 431–3
  endoscopy 431, Plate 16.7
  functions 429–30
  inflammatory disease 431–2
  neoplasia 432
larva migrans, human visceral 701
larynx diseases 329
laser therapy, odontoclastic resorptive lesions 389
laxatives 433
lead poisoning 45–6, 249
Leishmania donovani (leishmaniasis) **188,** 196
Leishmania infantum (leishmaniasis) 706–7
leishmaniasis 100
lens 479–80
  luxation 477, 480, Plate 18.15
leprosy, feline 93, 94, 683
leptospirosis 689
leucocytes 251–6
leukaemia 273–4
  acute 273–4
    lymphoblastic 33, **34**
    lymphocytic 255
    myeloid 33, **34**
  chemotherapy 33, **34**
  chronic 274
    granulocytic 252
    lymphocytic 33, **34,** 255, 274
    myeloid 33, **34,** 274
  eosinophilic 274
  FeLV 599, **600,** 601
  lymphoid 33
  myeloid 33, **34,** 274, 601
  red cell **34**
leukaemoid reaction 252–3
libido, lack 352–3
ligament damage in infective arthritis 194
lignocaine toxicity risk **8,** 10
limbs
  rear 128
  see also forelimbs
lime sulphur 80, 81, 82, 85
lipaemia retinalis 485
lipid keratopathy 473–4
lipid toxicity 540
lipidosis, hepatic 444, 445–6
lipoprotein lipase 223
Listeria monocytogenes (listeriosis) 684
litter/litter trays 58–9
liver 444
  enzymes 442–3, 446, 447, 529
  function in neonates 355–6
  function tests 443–4
  see also hepatic *entries*
liver disease 262, 441–50
  bacterial infections 450
  cysts 448
  diagnosis 442–4
  drug-induced 447
  inflammatory 444–5
  management 448–50
  neoplasia 446
  nutrition 448–9
  secondary complications 449–50
  toxin-induced 447
local anaesthetic, eye 459
louse, biting 82, 361
lower urinary tract disease (FLUTD) 313–23
  accessory sex gland 323
  calculus 321–2
  diagnostic imaging 314–15
  hair loss 62
  idiopathic 315–20
  indoor house soiling 53, 54, 58, 59
  infection 320–1
lufenuron 97
lung digit syndrome 119
lung fluke 334
lungs
  auscultation 495–6
  collapse 342
  disease 331–4, Plate 12.7
  hypoperfusion 558
  tumour metastases 119
lungworm 333, *334,* 701–3
lupus erythematosus (LE) cell test 246
luteinizing hormone (LH) 345–6
luxations 174–6
Lyme disease **188,** 195–6, 684
lymphocytes 238–9
lymphocytosis 254–5, 558
lymphoma 269–72
  alimentary 31, 272, 409, 427, 432, 601
  chemotherapy 28–31
  clinical staging 270–1
  CNS 272
  COAP protocol 29
  COP protocol 29–30, 31
  diagnosis 269–70
  epitheliotropic 119
  FeLV 599, **600,** 601, Plate 23.1, Plate 23.2
  gastric 409
  investigations 270
  lymphocytosis 255
  mediastinal *29,* 31, 401
  nasal *30*
  ocular 601
  prednisolone 29
  presentation 269
  prognostic indicators 271
  renal 272, 308, 601
  spinal 601
  treatment 29–31, 271–2
  uveal 478–9, Plate 18.16, Plate 18.17

lymphomagenesis 611, 616
lymphopenia 255
lymphopoiesis 238–9
lymphoproliferative disease 268–73
lymphosarcoma
  laryngeal 329
  mediastinal 334–5
  stomach wall *406,* Plate 16.5
  tracheal 330
Lynxacarus radovskyi (cat fur mite) 82
L-lysine 470
lysosomal storage diseases 141, **142, 143,** 215–17, **218,** 489
  corneal clouding 472, 489
  retinal dysplasia 482
lyssaviruses 638

macrocytosis 529
malabsorption 262
Malassezia 94–5
malignancy 19
  carcinoma chemotherapy 33
  FeLV 599, **600,** 601
  see also metastases; neoplasia
malnutrition, intrauterine 359
malocclusion 392
mammary carcinoma 33
mammary glands
  FeLV localisation 603
  hyperplasia 353
  neoplasia 353
mandible, ramus aplasia 214
mange
  notoedric 81, 361
  otodectic 79–80, 361, Plate 6.3
mannosidosis 489
Manx cats, sacrocaudal dysgenesis 140–1, 212
Marcus Gunn sign 456
marking, indoor 51, 52, 54–8
mast cell tumours 33–4, **111,** 115
mast cells 256
mastitis 354
mastocytosis, cutaneous 115
maternally-derived antibody (MDA) 15, 357, 360, 361
  feline parvovirus in kittens 572, 575
  FIV infection 616
  infectious respiratory tract disease 577, 587, 588, 591
  streptococcal infection 681
mating 346
  failure 349
  test in hereditary disease 374–5
  vasectomised tom 348
matrix supplements in osteoarthritis 192
maxillofacial compression 213
mean cell volume (MCV) 242
mean corpuscular haemoglobin (MCH) 242
mean corpuscular haemoglobin concentration (MCHC) 243
mebendazole 700, 703
mediastinal disease 335
  neoplasia *29,* 31, 401
megacolon 433
megakaryopoiesis 239
megalocornea 472
megaoesophagus *398,* 399
megestrol acetate 26–7, 91, 347–8
  iatrogenic hyperadrenocorticism 557
  indoor spraying treatment 57–8
  insulin resistance 539
  toxicity risk **8,** 10
melanoma
  anterior uveal 478, Plate 18.13
  iris 476, Plate 18.13
melanosis, benign of iris 476, Plate 18.12
melphalan **21,** 32, 273
membrane P-glycoprotein pump 20
menace response 132
meningiomas 150–1, 151–2
meningocoele 213
meningoencephalitis, FIV 615
mercury toxicosis 46
merosin deficiency 168
metabolic acidosis 46, 294
metabolic disease, bone **173,** 179–85
metabolic epidermal necrosis 116
metabolism, phases 3–4, 40
metal toxicoses 45–6
metaldehyde toxicosis 45
metastases
  bone 210
  CNS 151
  joints 210
  lung tumour 119, 334
  osteoclastoma 208
  osteosarcoma 205
  renal 308
  synovial sarcoma 209
methaemoglobinaemia 4, 40, 246–7
methaemoglobinurina 6
methimazole 7, 254, 533, 534, 535
methionine 6
methotrexate **21**
methylmercury teratogenicity **139**
methylphenidate sodium succinate 148
methylprednisolone 88, 160
metoclopramide 26
metronidazole **8, 361,** 367, 413, 429, 705
metyrapone 556, 557
microcardia 558
microchipping 644, 645
microcornea 472
microphthalmos 462, 464, 466
Microsporum canis 13, 95, 97
Microsporum gypseum 95
middening 55
minocycline 665
mismating 347
misoprostol 412
mites 79–80
  cat fur 82
  cheyletiellosis 80, Plate 6.5
  ear 361
  harvest 80, Plate 6.4
  poultry 82–3, Plate 6.8
  sarcoptes 81, Plate 6.6
mitotane 556
mitoxantrone **22**
  carcinoma treatment 33
  sarcoma treatment 33, **35**
  tissue necrosis 27
molluscicide toxicoses 45
monocytes 238, 256
morphine
  excitation 40
  pharmacodynamics 4
  toxicity risk 4, **8,** 10
mosquito bites 89, 90
motor neurons 133, *136*
mouth *see* oral cavity
moxidectin 81
mucolytic drugs 582–3
mucopolysaccharidosis 141–4, 215–16, **218,** 489
multidrug resistance 20
mupirocin 117
mural folliculitis 119–20
muscle biopsy 139
muscle weakness syndrome *see* hypokalaemic polymyopathy
muscular dystrophy 166–7, 220, 225
myasthenia gravis 170, 222–3
mycetoma 93, 98
mycobacteria 93–4, 100, 682–3
Mycobacterium avium (tuberculosis) 682
Mycobacterium bovis (tuberculosis) 484, 681–2
Mycobacterium lepraemurium (rat leprosy) 683
Mycobacterium microti (tuberculosis) 681–2
Mycobacterium tuberculosis (tuberculosis) 334, 681–2
Mycoplasma felis 579, 683–4
Mycoplasma gatae 579, 683–4
Mycoplasma haemofelis (feline infectious anaemia) 246, 669, 670
mycoplasmas, arthritis **188,** 195
mycosis 97–9
mydriasis 460
myelodysplastic disease 250
myelofibrosis 250
myelofibrosis/osteosclerosis syndrome 228
myeloma 32–3, 269, 272–3
myeloproliferative disease 250
myelosuppression, cytotoxic drugs 25–6
myelotoxicoses 254
myopathies 164–71, **174**
  acquired 169, 221–2
  Burmese sporadic 222
  dystrophin-deficient 165–6
  dystrophy-like 225
  fibrotic 225
  hereditary non-inflammatory 165–9
  hereditary of Devon Rex cats 167–8, 220–1
  inherited 220–1
  nemaline 169, 220
myositis 168, 169, 170, 220, 221, 222
myotonia 166–7, 220

nares diseases 326
nasal cavity diseases 326–9, Plate 12.3
nasal decongestants 582
nasal flushing 327
nasal planum diseases 326
nasal sinus disease 326–9
nasogastric tube feeding 27
nasolacrimal flushing 461
nasopharyngeal polyps 118, 156, 328, Plate 6.22
neck evaluation 128
Negri bodies 638–9
nemaline myopathy 168, 220
nematodes 410, 703, 706
neonates
  immaturity 355–8
  isoerythrolysis 246
  mortality rates 367–8
  sepsis 359–60
neoplasia
  bladder 322
  brain 488–9
  cornea 474
  direct extension to bone 210–11
  eyelid 465
  FIV 611, 613–14
  genital tract 353
  heart 525
  hepatobiliary 446
  immune-mediated conjunctivitis 470
  intranasal 328
  iris melanoma 476, Plate 18.13
  jaw 389–90
  lacrimal gland 468
  large intestine 432
  larynx 329
  lung disease Plate 12.7
  mammary glands 353
  mediastinal disease *29,* 31, 401
  musculoskeletal **173–4,** 204–12
  nictitans gland 468
  oesophageal 400–1, Plate 16.2
  orbital 463
  pancreas 440–1
  peripheral nervous system 159
  polyneuropathy 224
  pulmonary 334
  renal 308
  retinal 486
  skin tumours 106, **107–14,** 115–17
  small intestine 427–8
  stomach *406,* 409, Plate 16.5
  third eyelid 466
  thoracic wall 335
  tracheal 330
  tumour biology 19–20, 28
  uvea 478–9, Plate 18.16, Plate 18.17
    metastatic 478–9
  vestibular disease 156, 157
  see also malignancy; metastases
Neospora caninum 146, 703
nephrotic syndrome 303
nerve biopsy 139
nervous system 125–9
  see also central nervous system (CNS); peripheral nervous system
neurilemmoma 159
neuro-ophthalmology 461, 486–9
neurofibromas 159
neurological examination 131–9
neuromuscular disease **174,** 220–6
neuromuscular junction disorders 169–70, 222–3
neuropathy
  acquired 223–4
  hyperchylomicronaemia 223
  hyperoxaluric 158, 223
  inherited **174,** 223
  sphingomyelinase deficiency 158, 223
neutering, territory effects 67
neutropenia 253–4
  chemotherapy 25, **26**
  chemotherapy-associated 253
  griseofulvin-induced 10
neutrophilia 252–3, Plate 9.7, Plate 9.8
neutrophils 238, *239,* 251–4, Plate 9.6
nictitans gland 466, 468, Plate 18.4
nictitating membrane *see* eyelid, third
nitrofurans 4
Nocardia (nocardiosis) 93
non-steroidal anti-inflammatory drugs (NSAIDs) 190–1, **192,** 291, 412
Notoedres cati (notoedric mange) 81, 361
nuclear sclerosis, senile 479–80
nutrition 358–9, 448–9
  deficiencies in reproductive failure 349–50
nystagmus 132–3, 155, 462, 489

obesity 432, 433, 446, 539, 548
ocular pharmacology 490
oculocardiac reflex 133
oculocephalic reflex 133
oculomotor nerve 130, **487**
odontoclastic resorptive lesions 387–9
odours, social 55, 57
oesophageal diverticular 399
oesophageal motility disorders 399–400
oesophageal strictures 400, 401, **402,** 403
oesophagitis 400, 401, **402**
oesophagus 397–401, 403
  balloon-catheter dilatation 401, 403
  clinical examination/evaluation 398–9
  diseases 399–401, **402,** 403
  endoscopy 398–9, Plate 16.1
  foreign bodies 400
  motility disorders 401, **402**
  neoplasia 400–1, Plate 16.2
oestrogens 347
oestrus 345, 346
  control 10
  induction 348–9
  suppression 347–8
oestrus cycle 345
olfactory nerve 130
Ollulanus tricuspis (nematode) 410, 703
omeprazole 410, 413
oncornavirus, C-type 211
ondansetron 26
onion toxicity 247
ophthalmia neonatorum 464
ophthalmoplegia, partial internal 488, Plate 18.26
ophthalmoscopy 456–8
opioids, toxicity risk **8,** 10
optic disc 486
optic nerve 130, 464, 486, **487,** 489
optic nerve head atrophy 482
oral cavity 379–92
  squamous cell carcinoma 326
  trauma 391
  ulceration 326, 391, Plate 12.1, Plate 12.2
    feline calicivirus 579, 581
  see also palate; teeth; tongue
oral disease 380, 381, 389–92
oral hypoglycaemic agents 545, 547
oral–systemic disease 379
orf 689
organ of Corti degeneration 154
organochlorine insecticides 44
organophosphate toxicity **8,** 10–11, 44, 165, 170, 222
oronasal fistulae 328–9, 391
osteoarthritis 185–7, **188,** 189, 190–3
osteoarthropathy, hypertrophic pulmonary 227
osteoblastosis 183
osteocartilaginous exostoses 203–4
osteochondromatosis 203–4, 212
osteochondrometaplasia, synovial 211
osteochondrosis 219
osteoclastoma 207–8
osteoclastosis 183
osteodystrophy 181
  renal 299
osteogenesis imperfecta 211–12
osteoma 204–6, 207
osteomalacia 181, 184
osteomyelitis 176–9
osteopathy, proximal femoral metaphyseal 216
osteopenia 179–81, *182,* 212, 227
osteopetrosis 227–8
osteoporosis, juvenile idiopathic 212
osteosarcoma 204–5, *206*
osteosclerosis 228
otitis externa 118, Plate 9
otitis interna 156
otitis media 156, 328
Otodectes cyanotis (otodectic mange) 79–80, 361, Plate 6.3
ovarian cysts 350
ovariohysterectomy, surgical 347
overgrooming 62, 90
ovulation 346
  failure 349
  induced 345–6, 348–9
owners
  cooperation in neighbourhood 67
  fear reinforcement 61, 62, 63
oxalate crystals 223
oxime compounds 44

oxygen-carrying fluids, haemoglobin-based 268
Oxyglobin® 268

pacing, compulsive 126
packed cell volume (PCV) 242, 266
paediatrics 355–68
  see also kittens; neonates
palate defects/disease 328–9, 391
palpebral reflex 132
pancreas
  diseases 435–41
  exocrine insufficiency 428, 439–40
  neoplasia 440–1, 566
  paraneoplastic alopecia 116
  trauma 436
pancreatic enzyme supplementation 427, 428
pancreatitis 435–9, 540–1
panniculus reflex 135–6
panuveitis 476
paracetamol
  contraindication **5,** 6
  toxicity 4, 6–7, 47–8, 247, 447
Paragonimus kellicotti (lung fluke) 334
paraneoplastic syndromes 269, 272
paraquat toxicosis 45, 334
parasitic infections
  erythrocytes 669
  kittens 361–2
  lower urinary tract infection 320–1
  lung disease 333–4
  skin 77–83, 85
  small intestine 422–8
  stomach 410
  tracheal 329
parasiticides, cutaneous reactions **104**
parathyroid 563
  agenesis/dysgenesis 561
parathyroid hormone (PTH) 299, 301, 561, 562, 563
  excess 300, 563–4
paresis 133
parturition failure 352
Pasteurella 691
patellar luxation 216
patellar reflex 134, 135
pathogen-free animals 591
pectus excavatum *214,* 335
Pelger–Huët anomaly 254
pelvis
  dislocation 174, *175*
  fractures 173, 432
pemphigus foliaceus 101, 105, Plate 6.16
pemphigus vulgaris 391
D-penicillamine 46
penicillins 366
Penicillium rhinitis 327
pericardial disease 511, 524
Perinaud's oculoglandular syndrome 690
perinephric pseudocysts 308–9
periodontal abscess 328–9
periodontal disease 381–3
periodontal examination 380
periodontal inflammation 385
periodontitis 382
periosteal proliferative polyarthritis **189,** 197, 200, 201, *202,* 203
peripheral nerves 126
peripheral nervous system
  disease diagnosis 157–8
  myopathies 164–71
  neonatal 357
  neuropathies 157–64
peritoneal dialysis 295
peritonitis, feline infectious (FIP) 145, 351, 421
  control 632–4
  diagnosis 627–31
  dry form 626
  effusion analysis 629–30
  effusive 626–7
  FIV infection 613
  Haemobartonella felis infection 671
  histopathology 631
  immune system 625–6
  jaundice 448
  lesions 626
  management 632–4
  non-effusive 626–7
  prevention 632–4
  treatment 631–2
  uveitis 477–8
  vaccination 632
  wet form 626
  see also feline coronavirus
permethrin 4, 80, 82
personality of cat 54–5, 61
Pet Travel Scheme (PETS) 13, 637, 643–5, 705
pets, household
  FIP 633
  streptococcal infection 681
  vaccination against respiratory disease 590
phaeochromocytomas 566
phaeohyphomycosis 98, Plate 6.14
pharyngitis 385
phenobarbitone 63, 153, **154**
phenol toxicosis 47
phenylephrine 582
phenytoin contraindication **5,** 7, 153
pheromonotherapy 57, 67
phobias 60–3
phosphate binding 301
phosphate crystals 314
phosphorus
  deficiency 181
  diabetes mellitus 543
  hyperparathyroidism 564
  restriction 301
  supplementation 180, 212
phthisis bulbi 464, 466
pimobendan 523
pituitary, inappropriate ACTH production 554
pituitary dwarfism 565
pituitary tumour 553, 554
placing reactions 134
plague 685
plaque 381
plasma cell pododermatitis 102, Plate 6.17
platelet-rich plasma 260
platelets 239, 256, 257
  disorders 259–60
pleural effusions 337, Plate 12.1, Plate 12.9
pleural space disease 336–40
pleurisy, exudative 338–40
pleurodesis 342
(R)-PMPDAP 617
pneumonia 332–3
  aspiration 333
  bacterial 332
  FIV infection 613
  mycotic 332–3, Plate 12.6
  viral 332
pneumothorax 342
poison exposures *see* toxicoses
polioencephalomyelitis, feline 145
polyarthritis
  idiopathic **189,** 199, *202,* 203
  periosteal proliferative **189,** 197–8, 200, 201, *202*
polyarthritis/meningitis syndrome **189,** 198, 199
polychondritis, feline relapsing 203
polychromasia **243,** Plate 9.3
polycystic kidney disease 307
polycythaemia 251, 274
polydactylia 212–13
polydipsia 541
polymyopathy, hypokalaemic 168, 169, 221–2
polymyositis 169
polyneuropathy
  acute idiopathic 160–1
  diabetes mellitus 224
  hypertrophic 158
  ischaemic 159, 223–4
  neoplasia 224
  salinomycin-induced 48, 160, 224
  toxic 159–60
  traumatic 224
polyradiculoneuropathy, chronic relapsing 160
polyuria 541
porphyria, congenital erythropoietic 247
portosystemic shunts 447, 450
postural thrust reaction, extensor 134
posture
  evaluation 133–4
  urine marking 53–4
potassium
  depletion in CRF 308
  diabetes mellitus 542
  hyperaldosteronism 560, 561
  hypoadrenocorticism 558
  hypokalaemic polymyopathy 169, 221
  potassium-depletion polymyopathy 169
  supplementation 221–2, 308, 561
potassium bromide toxicity **154**
potassium chloride 43
pralidoxime chloride 44

praziquantel 699
predatory behaviour, misdirected 64, 66
prednisolone **23, 30,** 32, 33, 88
  FIV 618
  gastritis 413
  inflammatory bowel disease 429
  liver disease 448
  lymphoma therapy 272, 601
  myeloma therapy 273
  stomatitis 386
  toxoplasmosis 666
pregnancy 346
  diagnosis 346–7
  failure 349
  feline parvovirus 573
  FIV 611
  lactational tetany 354
  preimplantation loss 349
  termination 347
  toxoplasmosis 660
primaquine phosphate 676
progenitor cells, differentiating 235
progestagens, contraception 347–8
progesterone deficiency 350
propranolol 63, 535
proprioception 134
proptosis 463
propylene glycol toxicity 48
propylthiouracil **5,** 7, 254, 533
prostaglandin analogues 411–12
prostaglandins 347, 351–2
prostate disease 323
protein
  plasma 444
  urinary 314
protein, dietary
  liver disease 448–9
  novel source 429
  requirement 397
  restriction in CRF 298
proteins invoked by vitamin K absence (PIVKA) 42, 259, 262
proteinuria 302–3, 306, 553
prothrombin time (PT) 42, 258
proton pump inhibitors 410, 411
protozoal infections 146, 424
pruritis 73, 74
  flea-bite hypersensitivity 77
  food allergy 84–5, Plate 6.9
Prussian blue 43
Pseudomonas 177, 691
pseudopelade 120
pseudopregnancy 346, 348
pseudorabies 144–5, 640, 691
pseudotuberculosis 684–5
psychoactive medication 52
puberty 345
pulmonary arteries, medial hyperplasia/hypertrophy 525
pulmonary circulation 496, 497
pulmonary osteoarthropathy, hypertrophic 226–7
pupil
  abnormalities 486–8
  D-shaped 488, Plate 18.26
pupillary light reflex 132, 456, 486
pupillary membrane, persistent 472, 476, 479, Plate 18.11
pyloric obstruction, gastric foreign bodies 410
pyoderma, superficial 92
pyothorax 338–40, Plate 12.10, Plate 12.11
pyrethrins/pyrethroids, toxicosis 44–5
pyruvate kinase deficiency 247
Pythium insidiosum (pythiosis) 98–9

Q-fever 684
quarantine 591, 603, 637, 643
queens, breeding 345–6
  oestrus suppression 347–8
  reproductive failure 348–52
  vaccination 15–16, 591
quinolones 367

rabies 637–46
  carrier state 640
  clinical signs 639–40
  control 643–6
  diagnosis 640–1
  dumb 639, *640*
  elimination 637
  encephalitis 144
  endemic 645–6
  epidemiology 641
  fox 641–2
  furious 639
  incubation 639
  pathogenesis/pathology 638–9
  prevention 643–5
  quarantine 637, 643
  susceptibility 639
  suspect cases 640–1
  sylvatic 641
  transmission 642
  urban 641, 642
  vaccination 13, 17, 640, 643, 645–6
  virus 637–8
radial nerve injury 162
radiation therapy 152, 271, 554
ranitidine 26, 410
ranula 390
rectum 429
red blood cells 242–51
  abnormalities 243, Plate 9.3
  count 242
  differentiation 237
  laboratory assessment 242–4
  morphology 243, Plate 9.3
  nucleated **243,** Plate 9.3
  oxidative damage 246–7
  pathophysiology 242
  see also anaemia
reflexes 132–3, 134–6, 137
regurgitation 397–8, 401, 508
renal agenesis 304
renal amyloidosis 306–7
renal cysts 307
renal cytology 289–90
  see also kidney
renal disease 281, 304–9
  clinical signs 281–2
  congenital malformations 304
  cystic 307
  hyperthyroidism 537–8
  imaging 288–9
  investigation 283–7
  lymphoma 272, 308
  neoplasia 308
  perinephric pseudocysts 308–9
  secondary hyperparathyroidism 184–5, 299–301
  ultrasound *289*
  see also acute renal failure (ARF); chronic renal failure (CRF)
renal failure, acromegaly 553
renal osteodystrophy 299
renin–angiotensin–aldosterone system 519
reoviruses 578, 691–2
repositol desoxycortisone pivalate (DOCP) 559
reproduction 345–7
reproductive failure 348–53
  nutritional deficiencies 349–50
  queens 348–52
  toms 352–3
rescue centres 574, 620, 634
resorption 349
respiration 357
  intracranial pressure increase 148
  toxicoses 41
respiratory tract disease 325–42
  bronchial 330–1
  chest wall 335
  clinical signs 580–1, Plate 22.1, Plate 22.2
  diagnosis 325–6, 581–2
  diaphragm disorders 335–6
  infectious 577–91
  larynx 329
  lower airways 330–1
  mediastinal 334–5
  nasal cavity 326–9
  nasal planum/nares 326
  pathology/pathogeneis 579–80
  pleural space 336–40
  pulmonary parenchyma 331–4
  trachea 329–30
  treatment 582–3
  upper 671
reticulocytes 243–4, Plate 9.4
retina 288, 481–2
  degeneration 9, 482, 484, 485, Plate 18.22
  detachment 482, Plate 18.21
  disease 481–6
  neoplasia 486
retinal atrophy, generalised progressive 485–6, Plate 18.24, Plate 18.25
retinal blood vessels 481, 482, Plate 18.19
retinal pigment epithelium 481, 482
retrovirus infection 95, 100
rheumatoid arthritis **188,** 196–7, 200, 201, 203
rhinitis 327–8

rhinoscopy 327
rhinosinusitis, idiopathic chronic 327
ribavirin 631
rickets 181
rickettsia **188,** 196, 684
rifampicin 682
righting reactions 134
rodent ulcer 89
rodenticide toxicoses 42–3, 42–8
rodents, cowpox reservoir 579, 686–9
Rose Bengal staining 459
rotavirus 421
roundworms 699–701

sacrocaudal dysgenesis, Manx cats 140–1, 212–13
sacrococcygeal fractures 161–2
salicylates 7, 47
salinomycin-induced polyneuropathy 48, 160, 223
salivary mucocoele, zygomatic 463
Salmonella (salmonellosis) 422
Sarcocystis (coccidian) 704
sarcoma 33, **35,** 207, 208, 209
  vaccine-associated 16–17, 115, 589, 604
Sarcoptes 81, Plate 6.6
Schiff–Sherrington phenomenon 137
Schirmer tear test 459
schistocytes **243,** Plate 9.3
schwannoma 159
sciatic nerve injury 162
sclera 468
scopolamine contraindication **5**
scratches 690–1
scratching 55
sebaceous adenitis 119, 120
sebaceous gland atrophy 119
seborrhoea oleosa, hereditary primary in Persian cats 117–18
security, signals 57
seizures 152–4
  feline ischaemic encephalopathy 149
  psychomotor 126
  strychnine toxicosis 43
  thiamin deficiency 150
  toxicoses 41
selamectin 79, 80, 81, 82, 705
selegiline 63, 65
selenium sulphide 80, 81, 82
self-licking 90
self-mutilation 62, 77
semen evaluation 353
semitendinosus muscle, fibrous replacement 225
sensation evaluation 133, 136
sepsis
  neonatal 359–60
  neutropenia cancer patient 25–6
serology testing 137
shelter facilities 590–1
shiny cat syndrome 116
shock 41
  hypovolaemic 248
shoulder
  osteoarthritis 185
  synovial cysts 211
Siamese cats 142, 179, 215
skin
  biopsy 76–7
  colour 74
  condition 73–4
  cowpox lesions 688
  cutaneous asthenia 260
  debris 75
  mast cell tumours 33
  mycobacterial infection 682
  paraneoplastic syndromes **113–14,** 116–17
  scraping 75
skin disease 73–7
  acne 117, Plate 6.20
  allergic 83–8
  atopic disease 84–6
  diagnostic techniques 75–7
  endocrine disorders 105–6
  immune-mediated 100–5
  infectious 91–100
    bacterial 91–4
    fungal 94–9
    viral 99–100
  metabolic disorders 106
  subcutaneous mycosis 97–9
  terminology **75**
skin tumours 106, **107–12,** 115–17
slide agglutination test 245–6
slit-lamp biomicroscopy 458–9
small intestine 414–15, *416,* 417–29
  adenocarcinoma 427
  clinical examination/evaluation 417–21
  diseases 421–2, 428–9
  feline parvovirus 573, Plate 21.1
  foreign bodies 424–5
  function 414–15, 420–1
  infections 421–4
  laparotomy 420
  mucosa 413
  mucosal disease 420, Plate 16.6
  neoplasia 426–7
smears, impression 76
smoke inhalation 333
snuffles, chronic 327
social systems, feline 52
socialisation 60–1
sodium 558, 559
  dietary restriction 299
sodium pentobarbitone 43, 45
sodium phosphate enemas **5,** 7
sodium polyborate 79
sodium sulphate 41
sorbitol 41
spastic pupil syndrome 488
spherocytes **243,** Plate 9.3
sphingomyelinase deficiency 158, 223
Spilopsylus cuniculi (rabbit flea) 79, Plate 6.2
spinal cord 126
  damage *136,* 137
  malformations in tailless cats 140–1, 212–13
  sacrococcygeal lesions 129
  trauma 147–9
spinal reflexes 134, **135**
spinal shock 137
spiramycin 664
Spirocerca lupi (spirocercosis) 706
spironolactone 561
Splendore–Hoeppli reaction 98
spondylosis deformans 226
spongiform encephalopathy, feline 146, 640, 692–3
Sporothrix schenckii (sporotrichosis) 98
spumaviruses 692
squamous cell carcinoma 106, **107,** 115
  extension to bone 211
  eyelid 465
  gingival 389–90
  jaw 389–90
  laryngeal 329
  mouth 326
  multiple *in situ* 106
  oesophageal 400, Plate 16.2
  third eyelid 466
staggering disease 144, 692
Staphylococcus 93, 177, 582
stem cells 235, 237
steroids 88, 91
  chemotherapy **23**
  cutaneous reactions **104**
  discoid lupus erythematosus 103
  FIV 618
  gastric mucous production 412
  immune-based arthritis 201–2
  immune-mediated skin disease 101
  infectious anaemia 675
  insulin resistance 539
  osteoarthritis 190–1
  systemic lupus erythematosus 103
  vasculitis 103
stifle joint
  injuries 175
  locking 217
  polyarthritis *202*
  synovial cysts 211
stomach 403, *404,* 405–13
  endoscopy 407, Plate 16.3
  foreign bodies 408, 409–10
  motility 403, 407
    disorders 409
  neoplasia *406,* 409, Plate 16.5
  parasitic infection 410
  see also gastric *entries*
stomatitis 383–7
  anti-inflammatory treatment 386
  dental extraction 387
  feline calicivirus 581
  glossopalatine fold 385
  periodontally-centred 385–6
strabismus 462, 489
strength evaluation 127, 133–4
Streptococcus 177, 582, 680–1
streptomycetes, non-suppurative osteomyelitis 179
streptomycin 682
stress 591
  coping strategies 61

feline coronavirus 625
grooming 62
hepatic lipidosis 446
Stronglyloides (nematodes) 706
struvite crystals 314, 315–16, 321
strychnine toxicosis 42–3
subluxations 174–6
atlantoaxial 227
succinylcholine 4
sucralfate 26, 412, 413, 449–50
sulphate 5, 40
sulphation 6
sulphonamides 4, 367
sulphones 4
swinging flashlight test 456
symblepharon 466, 469, Plate 18.7
synchisis scintillans 481
syndactylia 213
synovial cysts 211
synovial fluid 190, 194, 195
synovioma 208
synovitis 185, 196, *197*
syringomyelia 213
systemic lupus erythematosus (SLE) 103, 201, 246
arthritis **189,** 197–8, 199

T cells 238
Taenia taeniaeformis (tapeworm) 698–9
tail 128, 136–7
kinked 212
tailless cats, malformations 140–1, 212–13
tapeworms 698–703, 706
fox 644, 645, 705
taste deterrents 66
taurine 5
deficiency 349–50, 359, 449
cardiomyopathy 511, 519, 520
dilated cardiomyopathy 510
retinal disease 484, Plate 18.22
tear film, preocular 467–8, 473
teeth 379, 387–9, 390–1, 392
see also periodontal disease
temporomandibular joint 175, 176, 391
tendon injuries 176
teratogens 139, **359**
terbinafine 10, 97
territory
aggression 66–7
core 57, 59, 62
sexual determination of size 67
time-share systems 68
urine marking 56
tetanus 160–1, 224
tetracosactrin 555, 556
tetracyclines 366–7, 470, 583, 674
toxicity risk **8,** 11
tetralogy of Fallot 507
thallium toxicosis 43
thermoregulation, neonatal 355
thiacetarsamide toxicity risk **8**
thiamin deficiency 48, 149–50, 157
6-thioguanine **21**
thioureylene drugs 533–5
thoracic duct ligation 342
thoracocentesis 336, 337–8, 340, 501
thorax
drainage 339–40
trauma 335, 340
thrombocytopathy 260, **261**
thrombocytopenia 25, 259–60
thrombocytosis 260
thromboembolism 223–4, 523–4
thrombopoietin 239
thrombosis 263–4
thymoma 223, 334, 335, 401
and exfoliative dermatitis 116–17
thyroglobulin 7
thyroid
dynamic function tests 531–2
percutaneous ethanol ablation 537
thyroid hormones 529–30
thyroid-stimulating hormone (TSH) 531–2, 565, 566
thyroid-stimulating hormone (TSH) receptor 527
thyroidectomy, surgical 536–7
thyrotoxicosis *see* hyperthyroidism
thyrotrophin-releasing hormone (TRH) response test 566
L-thyroxine 566
thyroxine (T_4) 7, 529–31, 566
ticks 82, 644, 645, 675–6
borreliosis 684
imported cats 705
TLI test 427, 440
toileting, indoor 58–60
toms, reproductive failure 352–3
tongue 390, 391, 581
tonometry 459–60
torovirus 421
toxic epidermal necrolysis 103–5
toxic polyneuropathy 159–60
toxicoses 39–41
dietary toxins/contaminants 48
household products 46–7
insecticides 44–5
medicinal preparations 47–8
metals 45–6
rodenticides 42–3
toxins 156–7, 359, 436, 447
Toxocara cati (ascarid) 361, 423, 697, 698, 699–701
Toxocara malayensis (ascarid) 700
Toxocaris leonina (ascarid) 697, 699–701
Toxoplasma gondii (toxoplasmosis) 659–67, 703
abortion 351
aetiology 659, Plate 28.1, Plate 28.2
arthritis 196
chronic subfatal 660, 661
clinical considerations 660–1
diagnosis 661–4
encephalitis 146
extraintestinal 661
FIV concurrent infection 666, Plate 28.4
Haemobartonella felis infection 671
immunoglobulins 663
intestinal 660–1
kittens 362
lung disease 333–4
myositis 221
oocysts 662, 698, Plate 28.3
pancreatitis 436
pathogenesis 660
prognosis 665
protozoal myositis 170
serology 662–3
small intestine 424
tachyzoites 661, 662
transmission 659–60, 665–7, Plate 28.4
transplacental infection 660
treatment 664–5
uveitis 484
zoonosis 665–7
trachea diseases/trauma 329–30
tracheitis 329
transferases 3, 4
trauma 61
bladder 322
conjunctival 470
corneal ulceration 473
eyelid 465
kittens 359
musculoskeletal 173–6
neurological 147–9
oral cavity 391
orbital 463
pancreas 436
peripheral nervous system 161–2
pneumothorax 342
polyneuropathy 223–4
skull and vestibular disease 156
temporomandibular joint 391
third eyelid 466
thorax 335, 340
trachea 329–30
uveitis 478
triceps reflex 135
trichiasis 465
trichobezoars 408–9, 433
trichogram 76
Trichophyton mentagrophytes 95
Trichosporon rhinitis 327
Trichuris serrata (whipworm) 706
trigeminal nerve **129,** 131, 471, 475, **487**
triiodothyronine (T_3) 7, 529–31
trimethoprim–sulfonamide 665
trimethoprim–sulphonamide **361**
trochlear nerve 130, **487**
Trombicula autumnalis (harvest mite) 80, Plate 6.4
trypsin-like immunoreactivity, serum feline 418–19, 438
tuberculosis 93, 195, 334, 484, 681–2
tularaemia 685
tumours *see* malignancy; metastases; neoplasia
Tyzzer's disease 683

ulceration
cornea 472–3
dendritic 470, 472
gastric 26, 407, 409, Plate 16.5

ulceration (*cont'd*)
gastrointestinal tract 449–50
mouth 326, 391, 579, 581, Plate 12.1, Plate 12.2
nasal planum 326
tongue 581
Uncinaria stenocephala (dog hookworm) 703
uraemia 295–6, 298, 299, 300
ureters, congenital ectopic 322–3
urethral catheterisation 313–14, 318–19, 323
urethral obstruction 315–16, 317–19, 323
urinalysis 284–7, 313–14
urinary calculi 321–2
see also struvite crystals
urinary catheters, indwelling 296
urinary incontinence 60, 322–3
urinary tract infection 285, 287, 303–4
see also lower urinary tract disease (FLUTD)
urination behaviour 53–5
urine
composition 55
concentration 314
culture 287–8
electrolytes **285**
output restoration 293, 295
pH 286
protein 286
protein:creatinine ratio 286
sediment examination 287
solute concentration 284, 285
spraying 54–5
see also marking, indoor
urography, excretory 288–9
ursodeoxycholic acid 448
uterus prolapse/torsion 353
uvea
cysts 480
neoplasia 478–9, Plate 18.16, Plate 18.17
uveal tract 475–9
uveitis 476–9
anterior 477, 616
disseminated mycotic 484
FIV 477, 478, 483
toxoplasmosis 665
trauma 478

Vaccine-Associated Feline Sarcoma Task Force (VAFSTF; US) 17
vaccine/vaccination 13–18
adjuvants 17, 589, 604
cutaneous reactions **104**
failure **589**
injection site reactions 17, 115, 589, 604
intranasal 589
see also named diseases
vaccine virus persistence 588
vaccinia–rabies glycoprotein vaccine 643
vaginal swabbing 348
vascular disorders 260
vascular ring strictures 507–8
vasculitis 103, 105, 260
vasodilators 521
ventricle, left, excessive moderator bands 508
ventricular cardiomyopathy, right, arrhythmogenic 511
ventricular compliance 521–2
ventricular septal defect 503–4
vertebral bodies, osteophyte formation 226
vertebral column disease **174,** 225–6
vestibular disease 154–7
vestibular system anatomy *155*
vestibulocochlear nerve **487**
vinblastine **22,** 27
vinca alkaloids 20, **22**
vincristine **22,** 25, 27, 33, **35**
lymphoma therapy 272, 601
platelet release 260
polyneuropathy induction 160
viral infections
kittens 360–1
lower urinary tract infection 320
pancreatitis 436
pneumonia 332
small intestine 421
stomatitis 384
viscosupplements 192
vision 132, 456
brain tumours 488–9
visna virus 611–12
visual pathways, central *130*
vitamin(s), supplementation 449
vitamin A
deficiency 183–4
excess 48, 164, 181, 182–3
vitamin B supplementation 449, 574
vitamin B_1 *see* thiamin
vitamin B_{12} supplementation 440
vitamin C supplementation 449
vitamin D
deficiency 181
renal secondary hyperparathyroidism 184, 185, 301
supplementation 181, 185, 563
vitamin D_3 43
vitamin E
deficiency 225
supplementation 449
vitamin K
antagonists 262, **263**
clotting factor disorders 262
deficiency 262, 442
rodenticide toxicosis 42
supplementation 440, 449, 450
vitamin K-dependent multifactor coagulopathy 261
vitreous 480–1
vocalisation 55, 65
volume overload 520–1
vomiting 397–8, 403, *404,* 405–6
blood transfusion 268
gastric foreign bodies 410
gastritis 408
inflammatory bowel disease 425
intestinal foreign bodies 424
reflex 403
von Willebrand's disease 257, 260
von Willebrand's factor 257

warfarin 42, 262, **263,** 524
waste disposal 36
weaning 65–6
wheelbarrowing 133
whipworm 706
whiskers, loss with chemotherapy 25, Plate 3.1
white blood cells *see* leucocytes
whole blood clotting time (WBCT) 258
wildlife, rabies control 646
Wolff–Chaikoff effect 535

xanthomas 106
xylazine 4

Yersinia (yersiniosis) 684–5

zidovudine 254, 617
Zollinger–Ellison syndrome 409, 566
zoonoses 83, 689–91
cowpox 688
endoparasites 697–8
FeLV risks 604
streptococcal infection 681
toxoplasmosis 665–7, 703

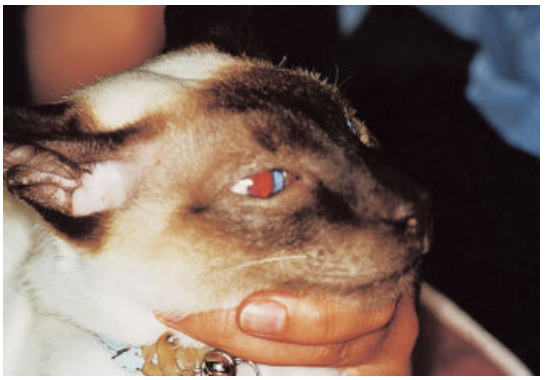

Plate 3.1 Cat showing loss of most of its whiskers following COP chemotherapy.

Plate 3.3 Post-mortem specimen from a cat which was suffering from diffuse alimentary lymphoma. Note that the small intestine is grossly thickened; mesenteric lymph-node involvement is also evident.

Plate 3.2 Intravenous catheter placement to ensure safe administration of vesicant or irritant injectable cytotoxic drugs.

Plate 3.4 Multicentric lymphoma. Cat showing marked submandibular lymphadenopathy (other lymph nodes were also enlarged).

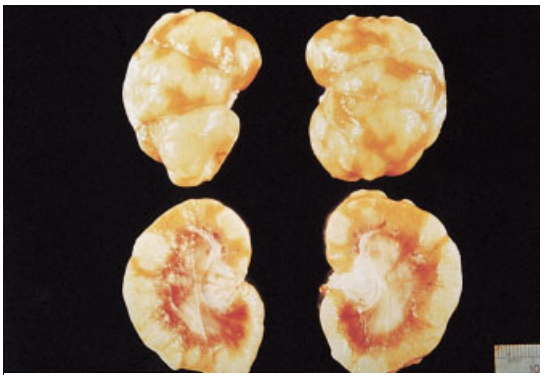

Plate 3.5 Kidneys from a cat suffering from renal lymphoma.

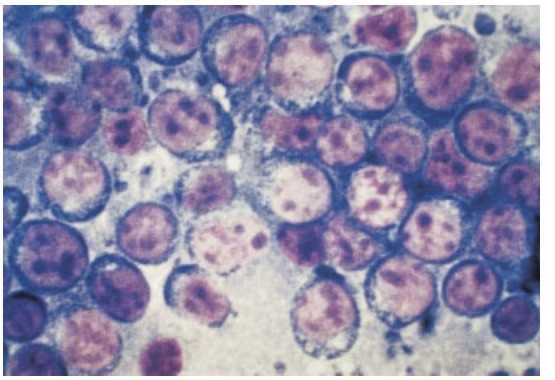

Plate 3.7 Cytological preparation of a fine-needle aspirate from a lymph node affected by lymphoma showing large numbers of neoplastic lymphoblasts. The nuclei possess multiple prominent nucleoli which vary in size and shape. Variation in nuclear size is also present. (High power, oil immersion, ×100 objective.)

Plate 3.6 Ocular lymphoma. Note the lymphoid infiltrate into the anterior chamber of the eye and anterior uveitis.

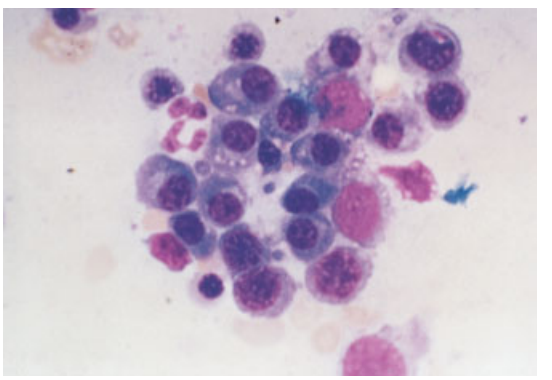

Plate 3.8 Bone-marrow aspirate from a case of myeloma. Diagnosis of myeloma depends on the demonstration of neoplastic plasma cells in the bone marrow. Note the Golgi apparatus that appears as a pale crescent adjacent to the nucleus. (High power, oil immersion, ×50 objective.)

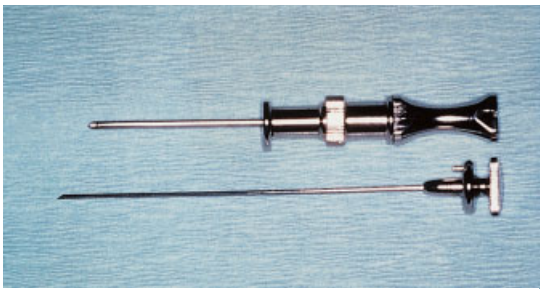

Plate 3.9 Klima needle suitable for bone-marrow aspiration in cases of suspected leukaemia.

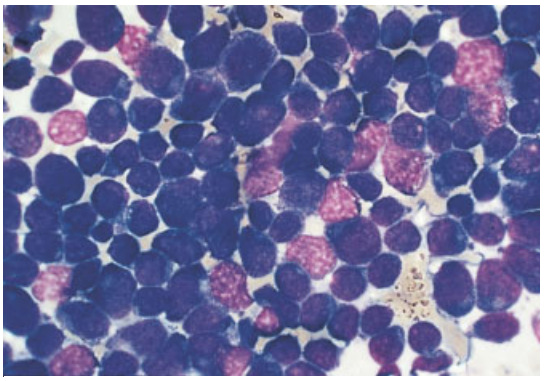

Plate 3.11 Bone-marrow aspirate from a case of acute lymphoblastic leukaemia. The bone marrow is crowded out by a population of immature neoplastic lymphoid cells. Other cell lines are severely depleted. (High power, oil immersion, ×100 objective.)

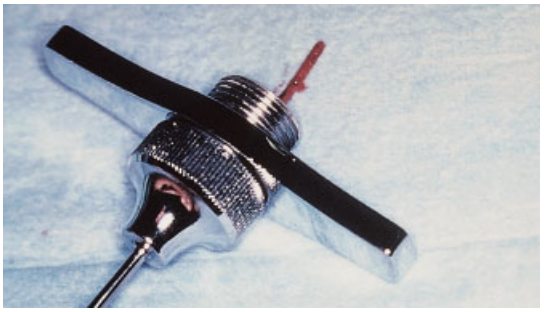

Plate 3.10 Jamshidi needle suitable for bone-marrow core biopsy.

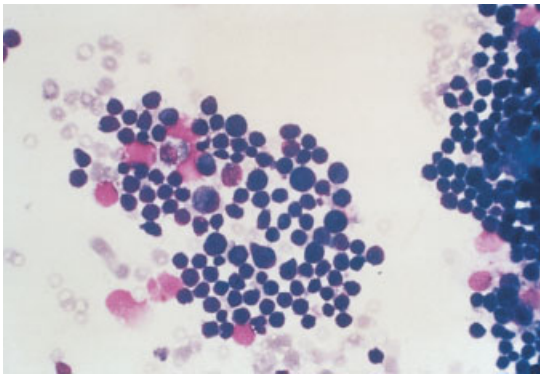

Plate 3.12 Bone-marrow aspirate from a case of chronic lymphocytic leukaemia. The majority of cells present are mature lymphocytes. (Low power, ×20 objective.)

Plate 3.13 Multiple cutaneous mast cell tumours in a cat. In some cases these will regress spontaneously; if not, prednisolone can be used.

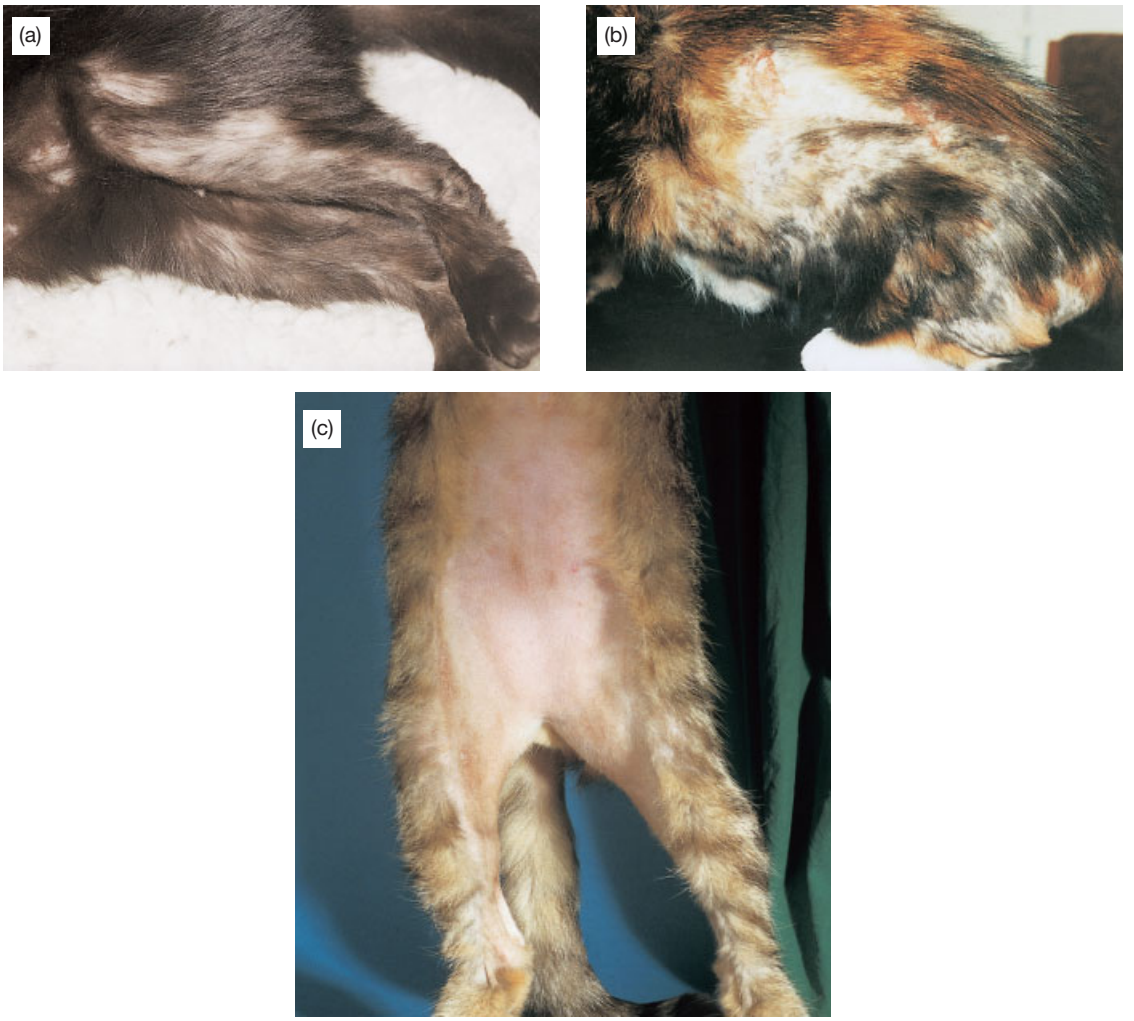

Plate 6.1 (a) Symmetric alopecia of the hindlegs and trunk associated with flea allergy; (b) trunkal alopecia and focal crusting associated with flea allergy; (c) ventral abdominal alopecia associated with flea allergy and atopy.

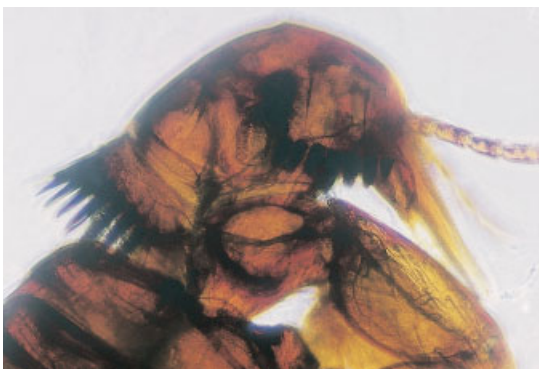

Plate 6.2 Rabbit flea, *Spilopsyllus cuniculi*.

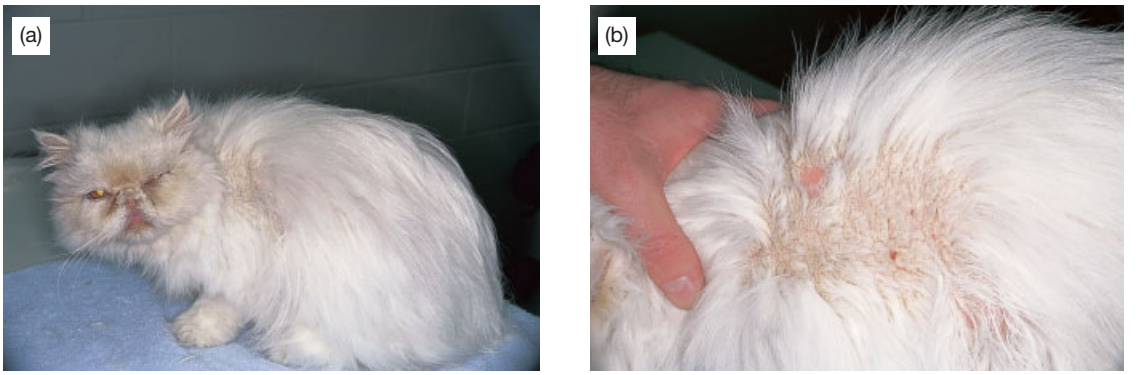

Plate 6.19 Exfoliative dermatitis in a cat with thymoma. (a) view of the whole cat; (b) dorsal trunk alopecia, erythema and profuse scaling.

Plate 6.20 Feline acne with numerous keratinous follicular casts on the chin.

Plate 6.21 Persian facial dermatitis syndrome with severe facial dermatitis and waxy exudate.

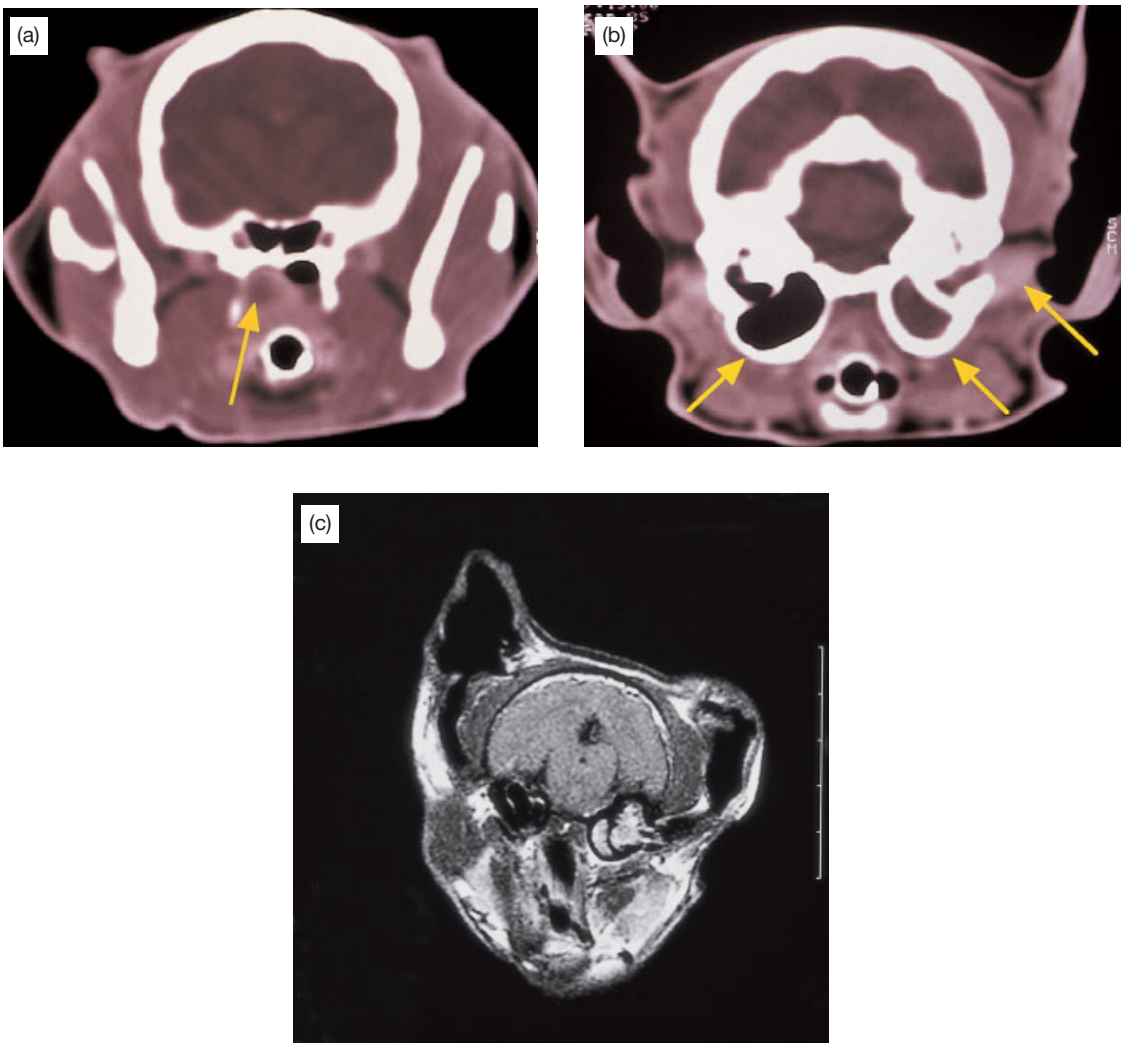

Plate 6.22 (a) CT scan of a cat with a nasopharyngeal polyp (arrow) (courtesy of L. Forrest); (b) CT scan of the same cat with evidence of the external ear canal containing polyp tissue (arrow) (courtesy of L. Forrest); (c) MRI scan of a cats head with a neoplasm in the external to middle ear canal (courtesy of R. Nicoll).

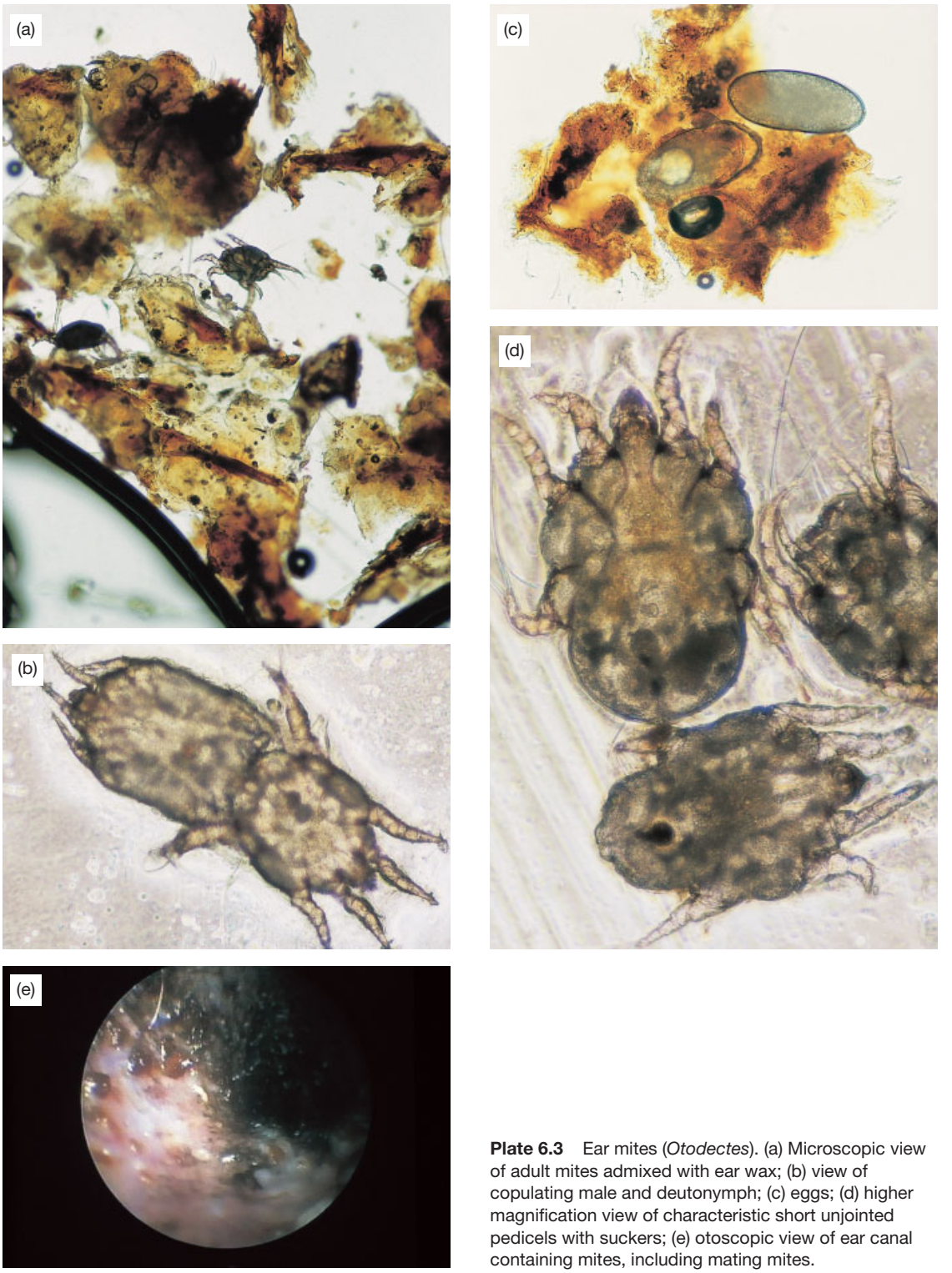

Plate 6.3 Ear mites (*Otodectes*). (a) Microscopic view of adult mites admixed with ear wax; (b) view of copulating male and deutonymph; (c) eggs; (d) higher magnification view of characteristic short unjointed pedicels with suckers; (e) otoscopic view of ear canal containing mites, including mating mites.

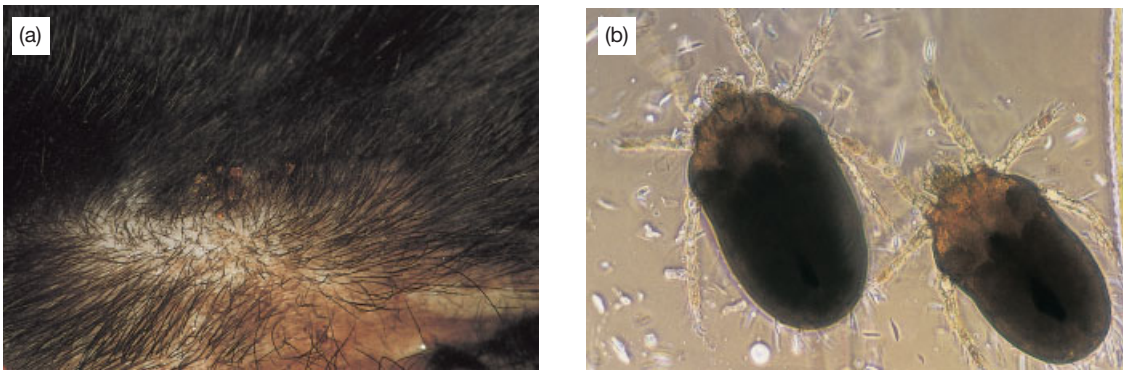

Plate 6.4 Trombiculids. (a) Harvest mites on the trunk of a cat; (b) microscopic view of larval trombiculids.

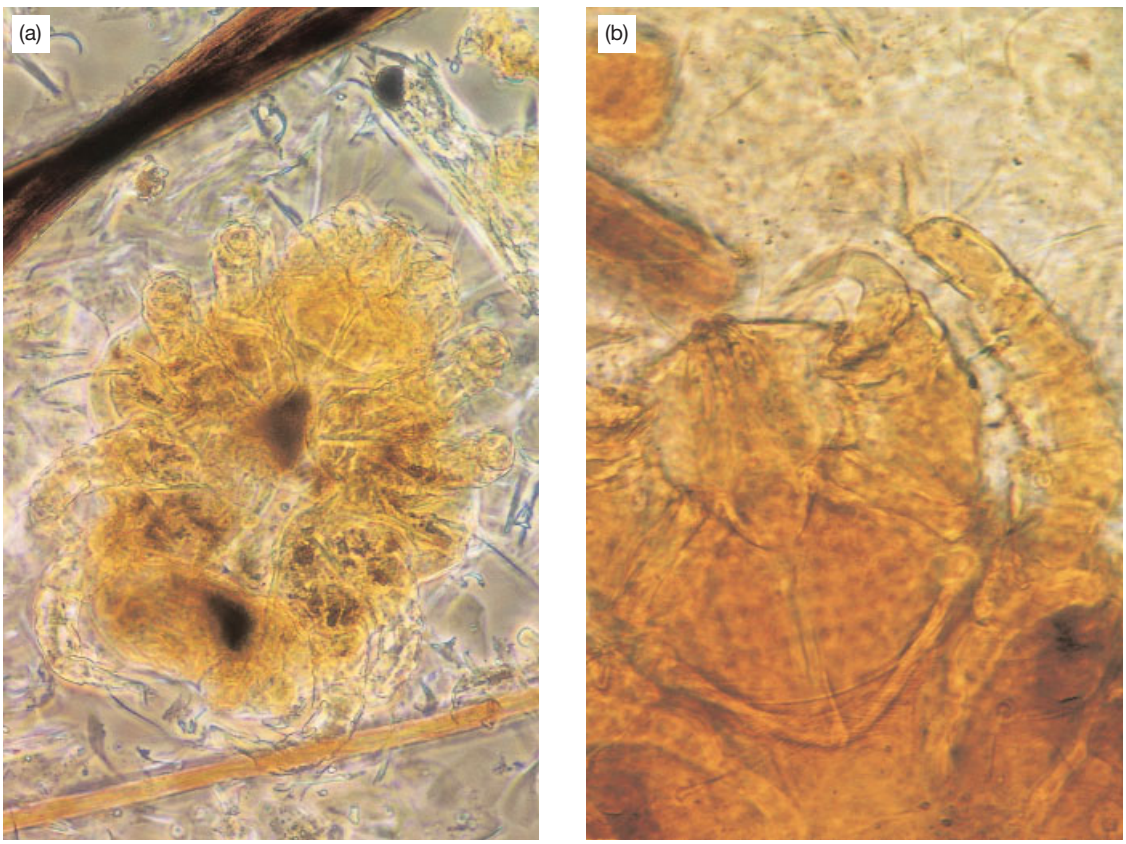

Plate 6.5 (a) Microscopic view of *Cheyletiella* mite, including (b) a close up of the large hooks of the accessory mouthparts.

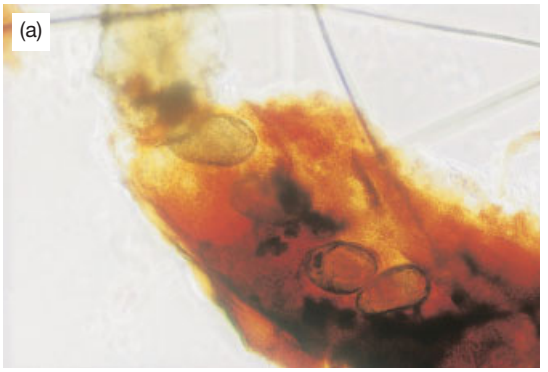

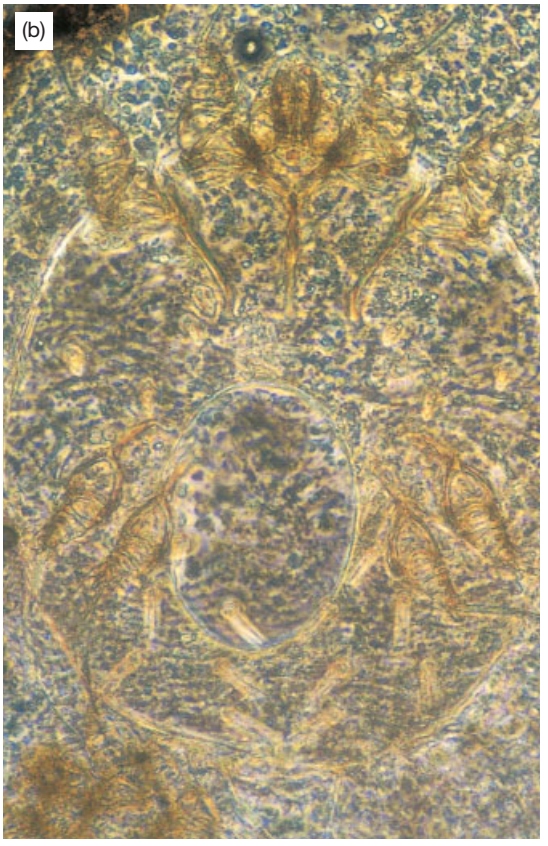

Plate 6.6 (a) *Sarcoptes* mite with several eggs and faecal pellets from a tiger (courtesy of Susan E. Shaw); (b) gravid female sarcoptid mite from an infested cat with papulocrusting dermatitis.

Plate 6.7 Demodicosis. (a) Facial ulceration and alopecia due to *Demodex cati*; (b) *Demodex cati* (long form); (c) *Demodex gatoi* (short form).

Plate 6.11 Facial papulocrusting dermatitis in an allergic cat with suspected food allergy.

Plate 6.12 Dermatophytosis in a Persian cat (generalised and chronic) due to *Microsporum canis*. (Courtesy of A. Robinson and S. Shaw)



Plate 6.13 (a) Macroconidia of *Microsporum canis* (courtesy of A. Robinson); (b) fluorescence with calcofluor white of *M. canis*-infected hairs.

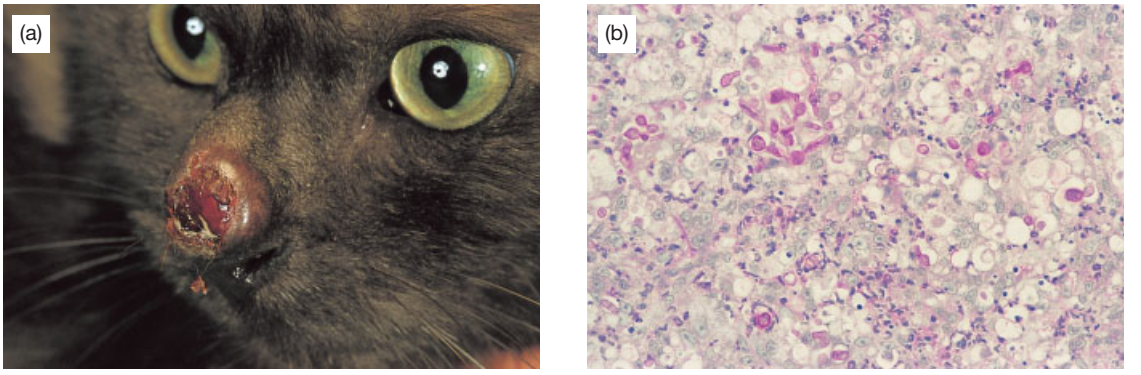

Plate 6.14 (a) *Alternaria alternata* granulomatous infection in a domestic shorthair cat; (b) periodic acid–Schiff-positive staining for fungal elements within a histological section of the granuloma in (a).

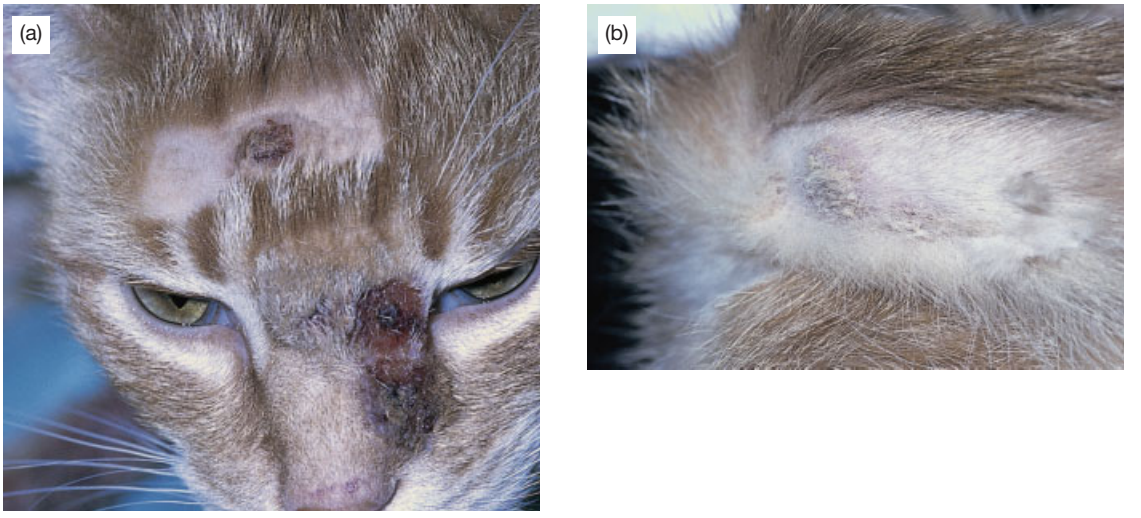

Plate 6.15 (a) Cutaneous crusted plaques of pox infection; (b) plaque lesions of pox on the tail.

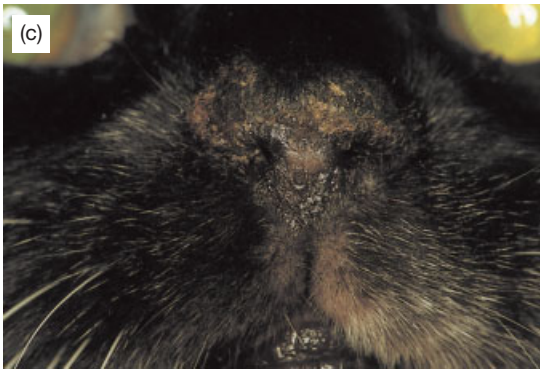

Plate 6.16 (a,b) Paronychia of multiple claw folds with purulent discharge of pemphigus foliaceus and (c) crusting of the nose.

Plate 6.17 Ulcerative form of plasma cell pododermatitis.

Plate 6.18 Basal cell tumour on the dorsal trunk of a Siamese cat. (Courtesy of M. Van de Stadt.)

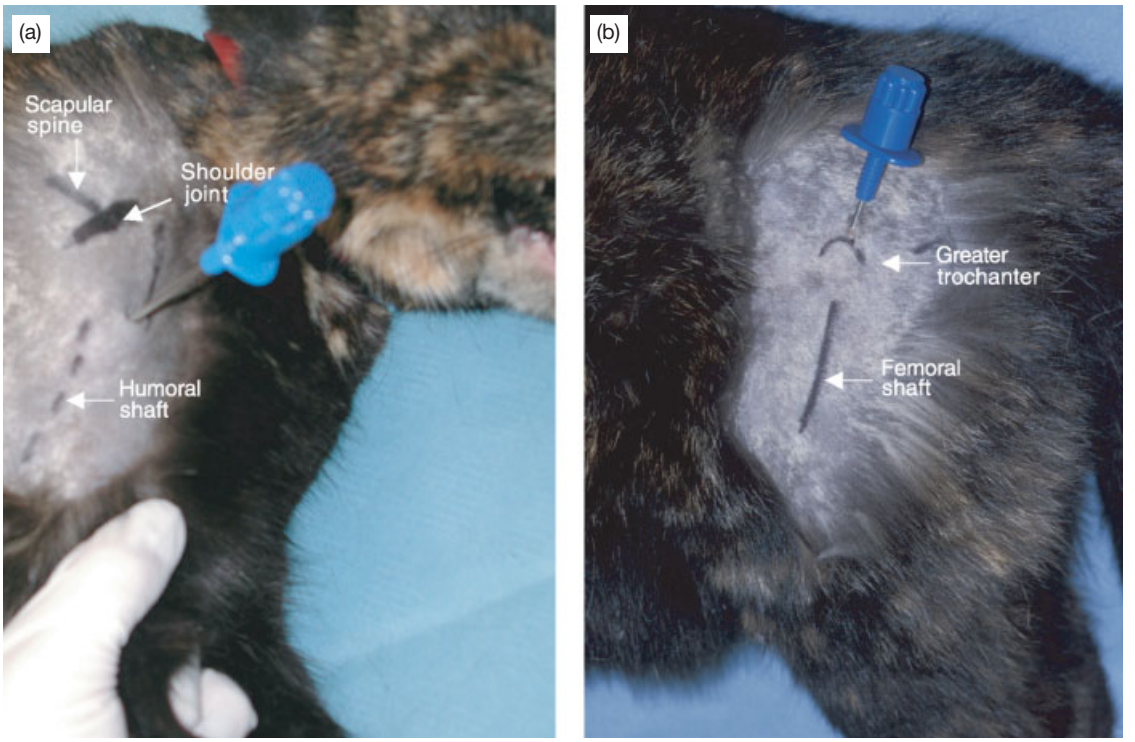

Plate 9.1 Bone-marrow aspiration sites in the cat (illustrated on cadavers, to allow black line labelling of landmarks). (a) Proximal humerus; (b) femur.

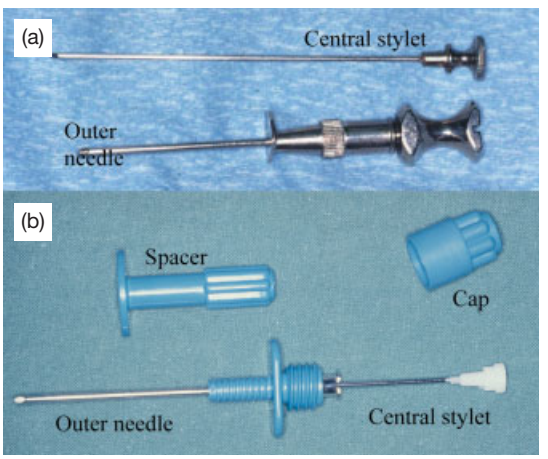

Plate 9.2 Bone-marrow aspirate needles. (a) Klima needle; (b) disposable modified Illinois sternal iliac bone marrow aspiration needle (Baxter's Healthcare, Thetford, UK).

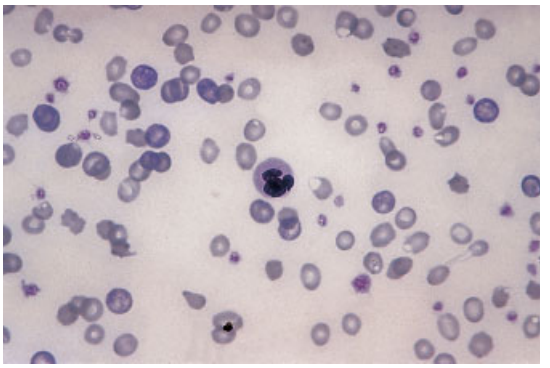

Plate 9.3 Blood smear from a cat with glomerulonephritis. There is marked anisocytosis and moderate polychromasia. There is poikilocytosis, with acanthocytes and occasional schistocytes (May–Grunwald–Giemsa). (Photomicrograph courtesy of R. Barron, University of Glasgow.)

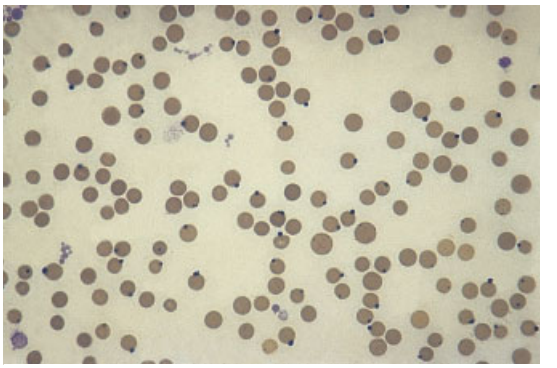

Plate 9.5 Blood smear from a cat, showing increased numbers of Heinz bodies (blue projections) (new methylene blue). (Photomicrograph courtesy of R. Barron, University of Glasgow.)

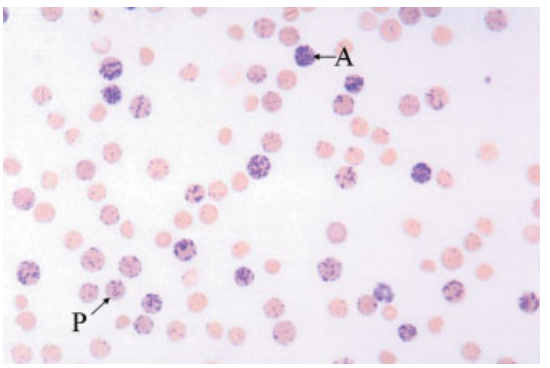

Plate 9.4 Photograph showing the appearance of feline reticulocytes following incubation with new methylene blue stain. Increased numbers of aggregate (A) and punctate (P) reticulocytes are present. Only aggregate reticulocyte count reflects ongoing regenerative response. In normal cats, aggregate reticulocytes account for less than 1% and punctate reticulocytes for up to 10% of red blood cells. (Photomicrograph courtesy of R. Barron, University of Glasgow.)

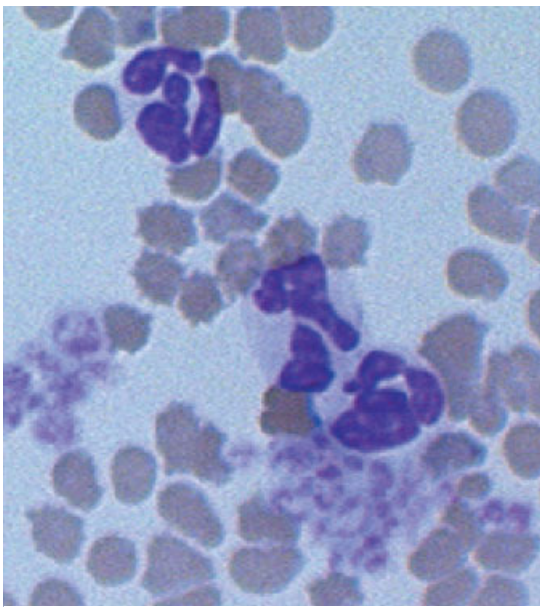

Plate 9.6 Blood smear from a cat. Three neutrophils are seen with multilobulated nuclei. Platelet aggregates are also seen (May–Grunwald–Giemsa). (Photomicrograph courtesy of R. Barron, University of Glasgow.)

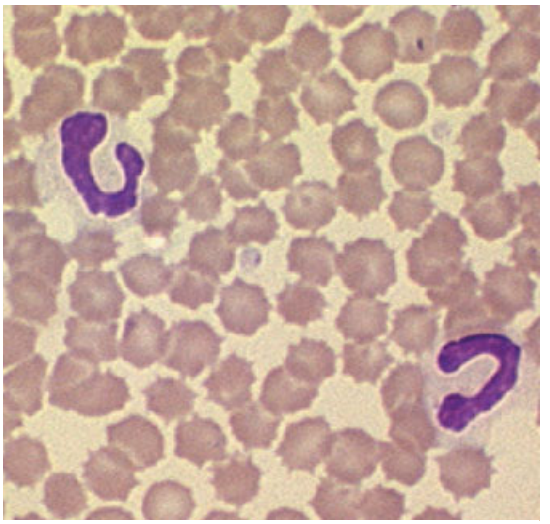

Plate 9.7 Blood smear from a cat. Two band neutrophils are seen with U-shaped nuclei (May–Grunwald–Giemsa). (Photomicrograph courtesy of R. Barron, University of Glasgow.)

Plate 9.9 Blood collection from a sedated donor cat in dorsal recumbency.

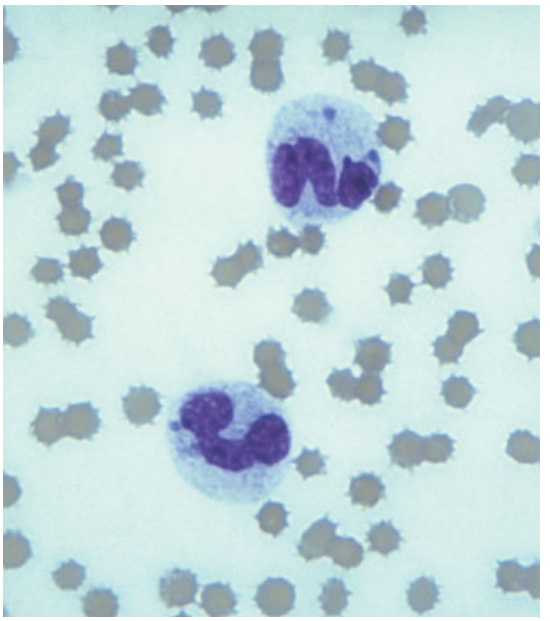

Plate 9.8 Blood smear from a cat. Neutrophils show toxic change: increased cytoplasmic basophilia, cytoplasmic vacuolation and mild nuclear swelling. Döhle bodies are also seen (May–Grunwald–Giemsa). (Photomicrograph courtesy of R. Barron, University of Glasgow.)

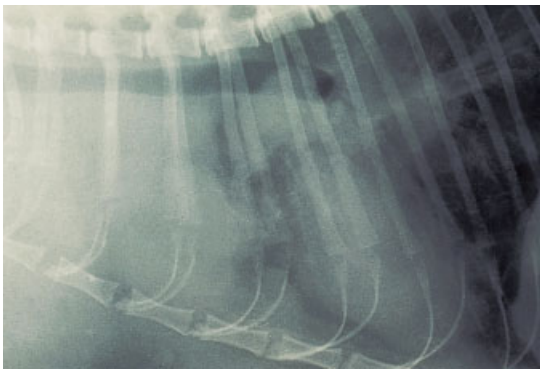

Plate 9.10 Lateral thoracic radiograph of a cat with lymphoma, showing enlargement of the suprasternal, cranial mediastinal and tracheobronchial lymph nodes.

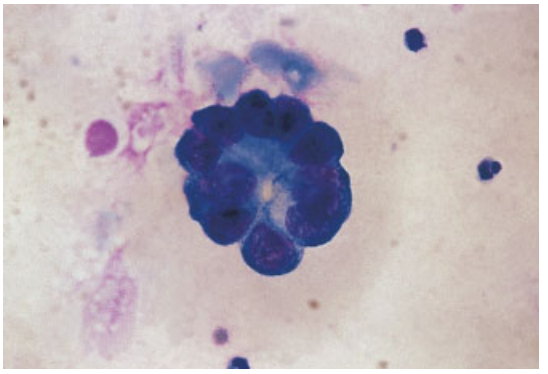

Plate 12.9 Pleural effusion (neoplasia). Adenocarcinomatous cells in pleural fluid of a 12-year-old Persian cat. Note the ring of large cells with a central 'lumen' exhibiting variable nuclear size, nuclear and cellular moulding, cytoplasmic basophilia and variable nuclear to cytoplasmic ratio. The ring or acinar form suggests a glandular origin to the tumour. (Wright–Giemsa ×2000.)

Plate 12.10 Pyothorax. Diffuse purulent effusion in the pleural cavity of a 7-year-old cat following a traumatic wound to the chest wall.

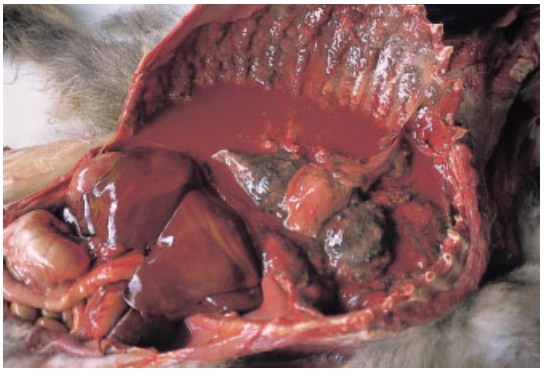

Plate 12.11 Nocardiosis. Sanguinous pleural effusion due to *Nocardia* spp. infection in the chest cavity of a 4-year-old domestic shorthaired cat with concomitant feline leukaemia virus infection.

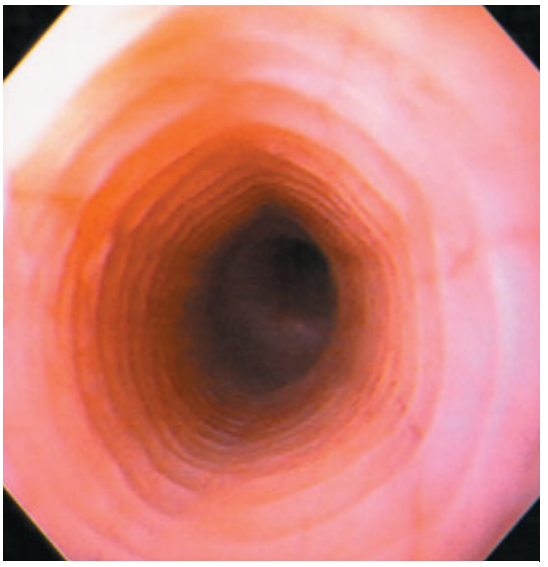

Plate 16.1 Endoscopic view of normal feline oesophagus. Note the light pink mucosa, visible submucosal blood vessels, and striated 'ribbing' caused by annular smooth muscle in the submucosa. The lower oesophageal sphincter is just visible at the distal oesophagus. (Courtesy of Dr M. Willard, Texas A&M University.)

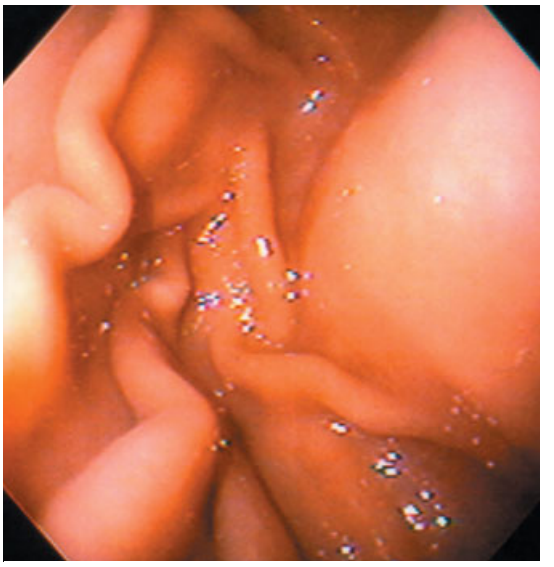

Plate 16.3 Endoscopic appearance of normal gastric mucosa in a cat. The view is of the greater curvature of the stomach, with the stomach partly inflated; note the rugal folds. (Courtesy of Dr M. Willard, Texas A&M University.)

Plate 16.2 Endoscopic view of a squamous cell carcinoma in the distal oesophagus of a cat. Note the distortion of the mucosa, and shallow crater-like ulceration. (Courtesy of Dr M. Willard, Texas A&M University.)

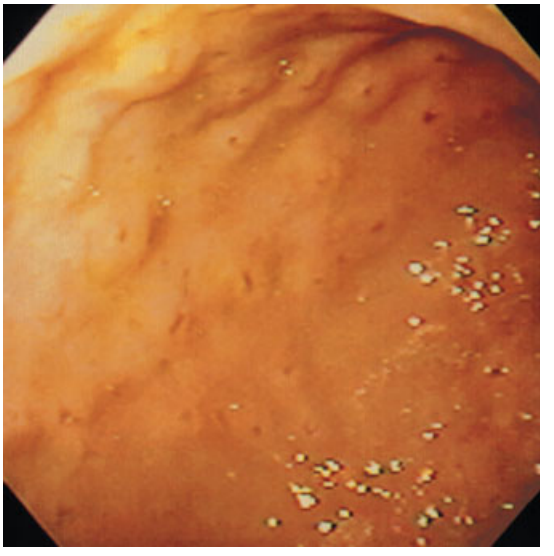

Plate 16.4 Endoscopic appearance of gastritis in a cat. Note the roughened, 'thicker' appearance of the mucosa relative to normal mucosa (Plate 16.3) and the presence of submucosal petechial haemorrhages. (Courtesy of Dr M. Willard, Texas A&M University.)

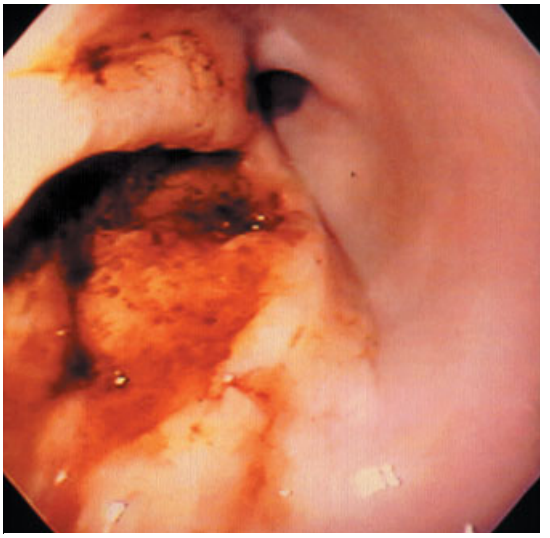

Plate 16.5 Endoscopic view of gastric lymphosarcoma in a cat. Note the large, ulcerated lesion with free blood on the surface. The gastric mucosa is paler than normal; this may be due to anaemia or infiltration with neoplastic cells. (Courtesy of Dr M. Willard, Texas A&M University.)

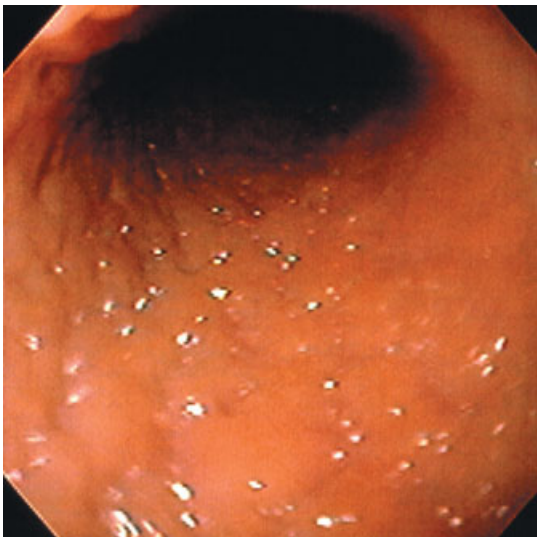

Plate 16.6 Endoscopic view of the duodenum in a cat with inflammatory bowel disease. There is a loss of normal mucosal appearance; the mucosa appears 'thickened' and hyperaemic. This cat has pronounced changes on endoscopic assessment. It is possible to have significant mucosal/submucosal disease without such prominent changes in gross appearance. (Courtesy of Dr M. Willard, Texas A&M University.)

Plate 16.7 Endoscopic view of lymphocytic/plasmacytic colitis in a cat. The mucosa shows areas of diffuse reddening and submucosal haemorrhage. The mucosa was more fragile than normal. (Courtesy of Dr M. Willard, Texas A&M University.)

Plate 18.1 Buphthalmos in a kitten.

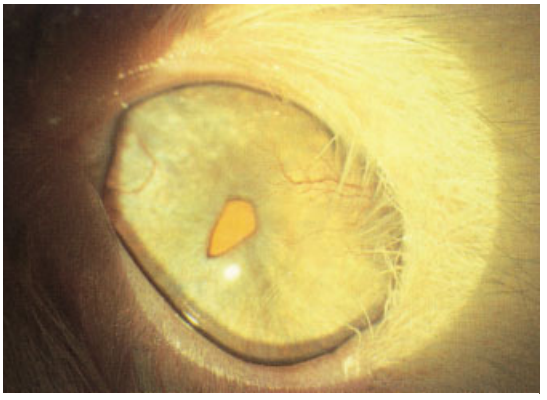

Plate 18.2 Lateral canthal upper lid coloboma resulting in trichiasis and a secondary keratitis.

Plate 18.3 Horner's syndrome (left eye).

Plate 18.4 Prolapse of the nictitans glands.

Plate 18.5 Epibulbar dermoid in a Birman cat.

Plate 18.6 Conjunctival chemosis.

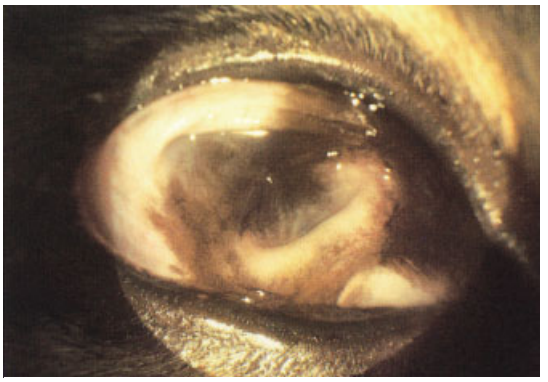

Plate 18.7 Symblepharon.

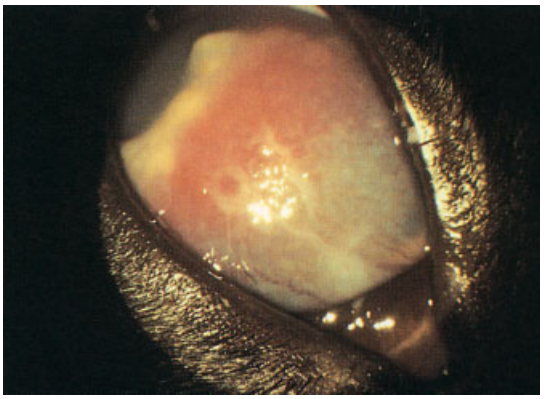

Plate 18.8 Proliferative keratitis. Note the creamy white surface deposit.

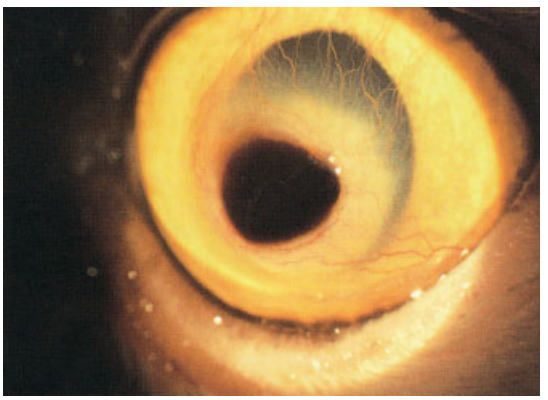

Plate 18.9 Corneal sequestrum in association with extensive corneal vascularisation.

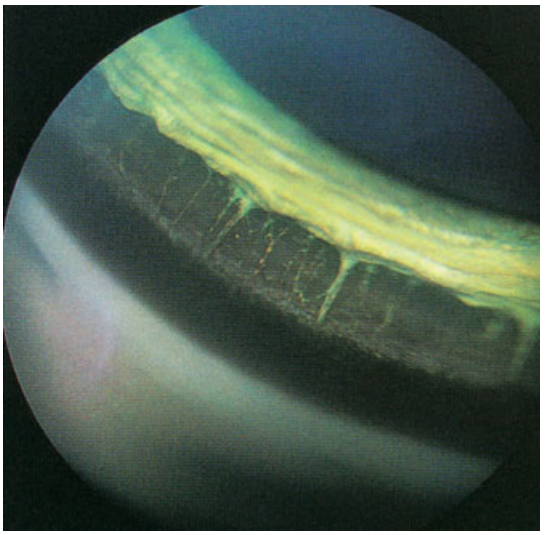

Plate 18.10 Goniophotograph of a normal irido-corneal angle.

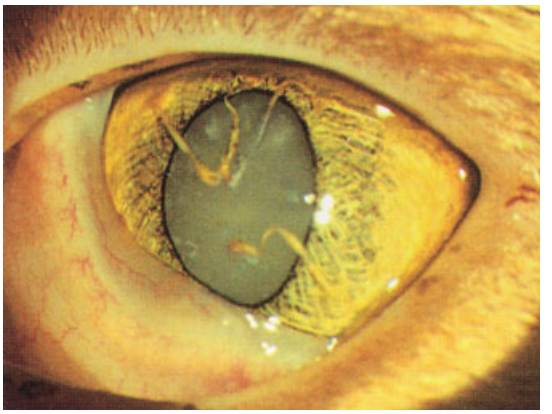

Plate 18.11 Persistent pupillary membranes and cataract.

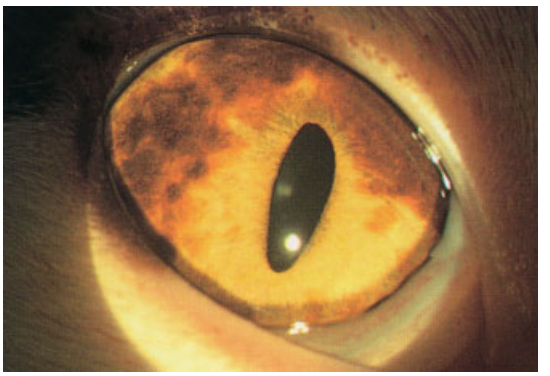

Plate 18.12 Iris pigmentation (normal).

Plate 18.13 Diffuse iris melanoma and secondary glaucoma.

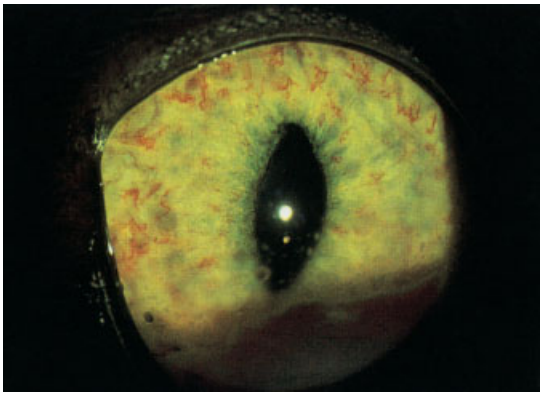

Plate 18.14 Anterior uveitis. Note keratic precipitates and hyphaema.

Plate 18.15 Anterior lens luxation in association with uveitis.

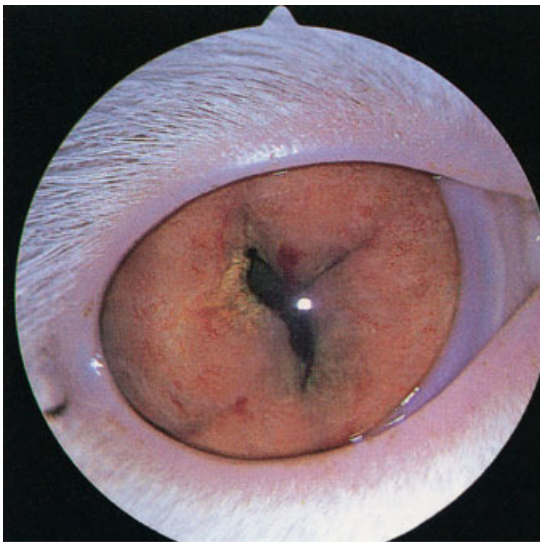

Plate 18.16 Lymphosarcoma (diffuse).

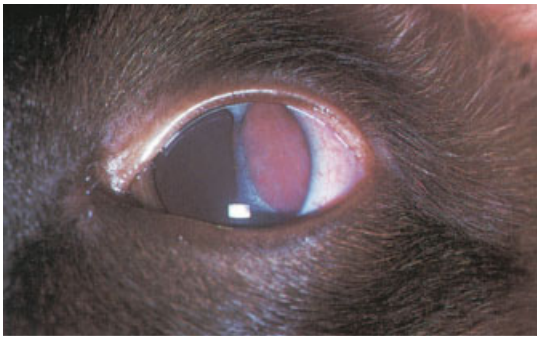

Plate 18.17 Lymphoma (anterior chamber mass).

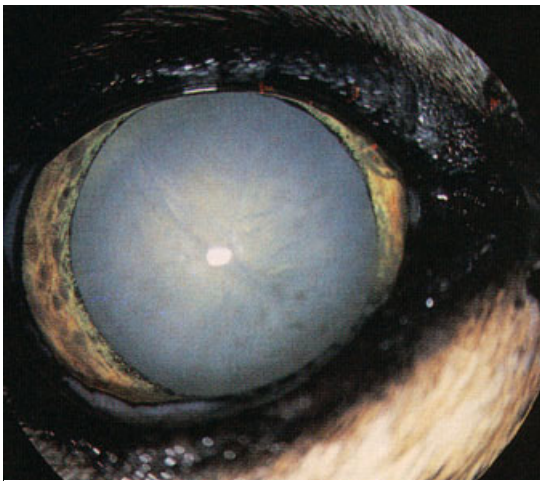

Plate 18.18 Cataract (total).

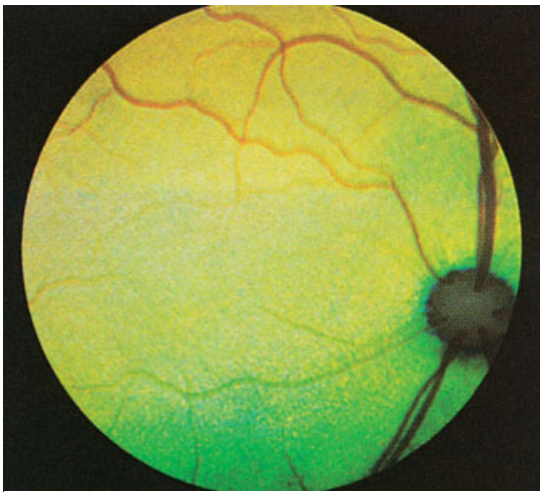

Plate 18.19 Normal ocular fundus (yellow-green) of the cat.

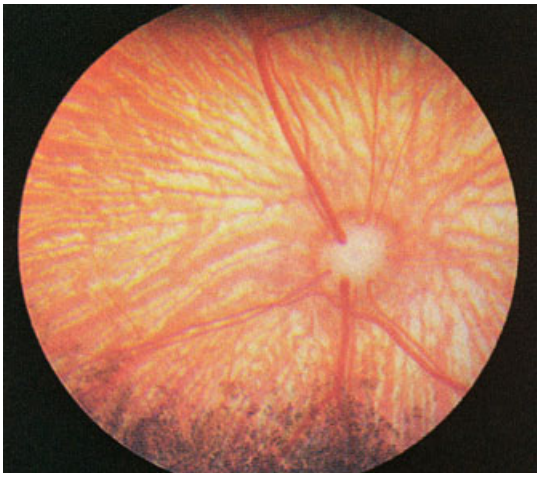

Plate 18.20 Subalbinotic fundus of a blue-eyed white cat.

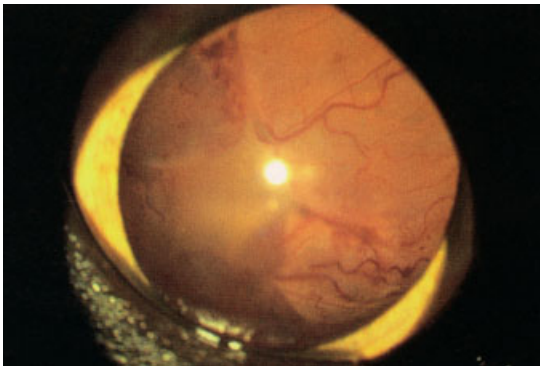

Plate 18.21 Retinal detachment.

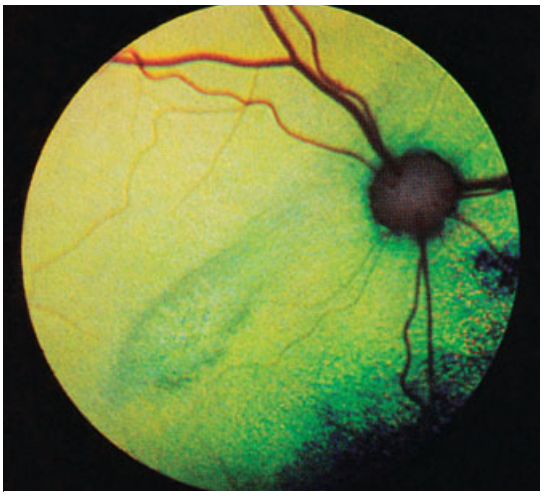

Plate 18.22 Taurine deficiency retinopathy.

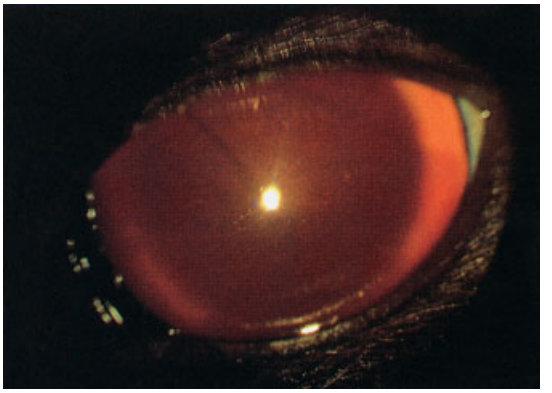

Plate 18.23 Hyphaema in association with retinal detachment.

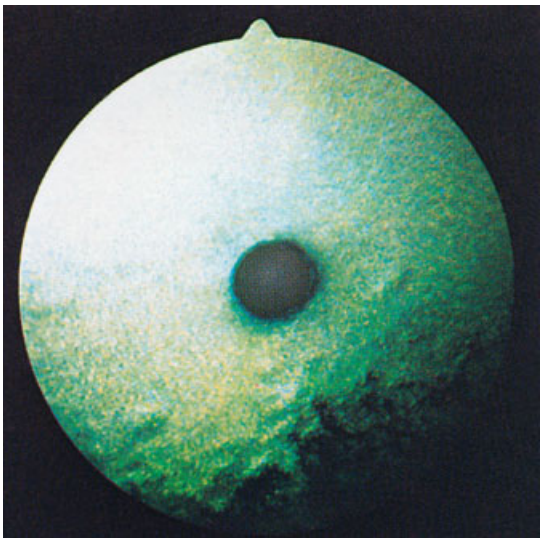

Plate 18.24 Advanced generalised retinopathy in siamese cat.

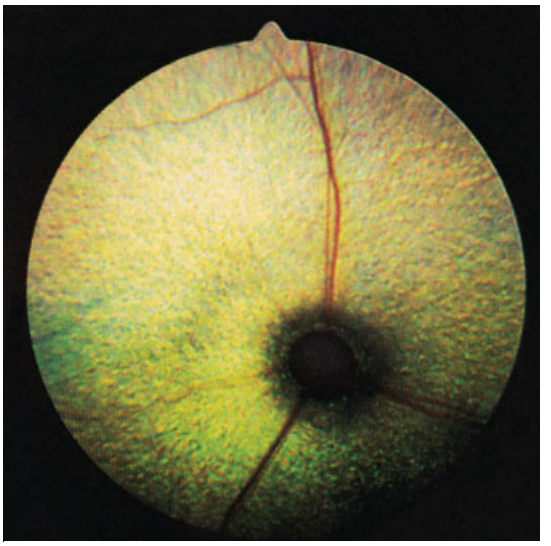

Plate 18.25 Hereditary PRA in Abyssinian cat. (Note increased tapetal reflectivity and narrowed blood vessels.)

Plate 18.26 'D' shaped pupil (in association with uveitis; this cat was FIV positive).

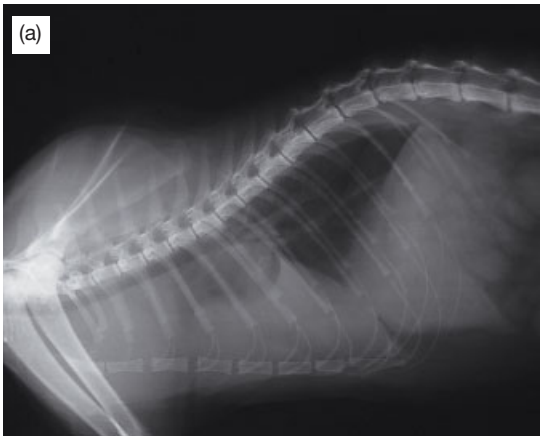

Plate 23.1 Thymic lymphoma. (a) Radiograph showing the dorsal displacement of the trachea by a mass in the anterior thorax. (b) Post-mortem finding of a large tumour mass in the anterior mediastinum.

Plate 23.2 Multicentric lymphoma. Post-mortem finding of gross, bilateral enlargement of peripheral lymph nodes.

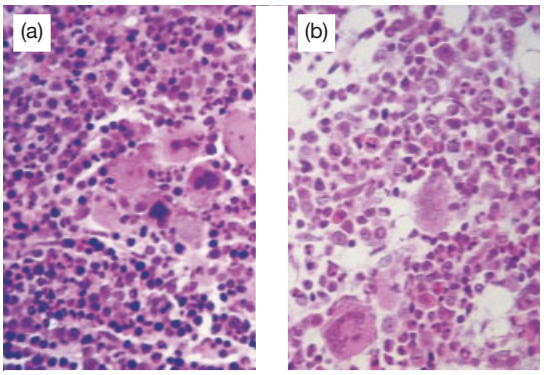

Plate 23.3 Anaemia caused by feline leukaemia virus-C (FeLV-C). (a) Normal bone marrow with active erythropoiesis and production of erythroblasts. (b) Bone marrow from a cat infected with FeLV-C showing severe depletion of erythroblasts caused by a block in erythropoiesis.

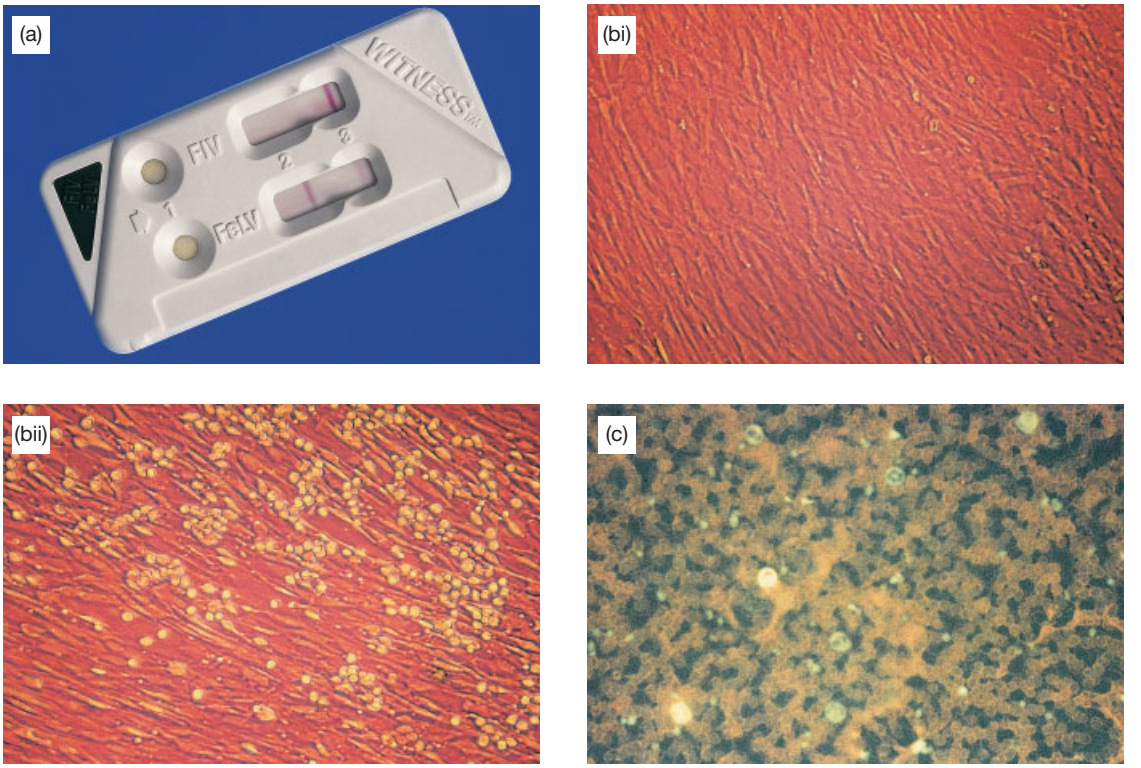

Plate 23.4 Diagnosis of feline leukaemia virus (FeLV) infection. (a) In-practice rapid immunomigration test. This test is for FeLV antigen and anti-feline immunodeficiency virus (FIV) antibodies in plasma. The pink band on the left denotes a positive result, while the band on the right indicates that the test is valid. This cat is FeLV positive and FIV negative. (b) Virus isolation. Specific transformation of cell cultures by FeLV: (i) uninfected cells; (ii) infected cells in which the presence of FeLV is shown by the rounding of cells after infection with plasma from a viraemic cat (interference microscopy). (c) Immunofluorescence. An air-dried blood smear from a viraemic cat stained with anti-FeLV antibody. FeLV antigen in the cytoplasm of neutrophils, lymphocytes and platelets fluoresces green.

Plate 27.1 Acute conjunctivitis with chemosis in a cat infected with *Chlamydophila felis*.

Plate 27.3 Eyelids sealed with mucopurulent ocular discharge in 6 week old Persian kittens infected with *Chlamydophila felis*.

Plate 27.2 Chronic conjunctivitis with mucopurulent ocular discharge in a cat infected with *Chlamydophila felis*.

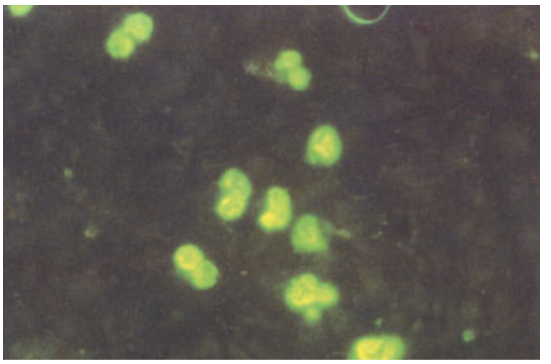

Plate 27.4 Green intracytoplasmic inclusions of *Chlamydophila felis* in McCoy cells stained by indirect immunofluorescence.

Plate 28.1 Unsporulated oocysts (10 × 12 μm) from a faecal flotation.

Plate 28.3 Iritis and aqueous humour flare consistent with toxoplasmosis in a 3-year-old cat. (Courtesy of Dr C. Powell, Colorado State University.)

Plate 28.2 Sporulated oocysts (10 × 12 μm) from a faecal flotation.

Plate 28.4 Punctate chorioretinitis consistent with toxoplasmosis in a 5-year-old cat. (Courtesy of Dr C. Powell, Colorado State University.)

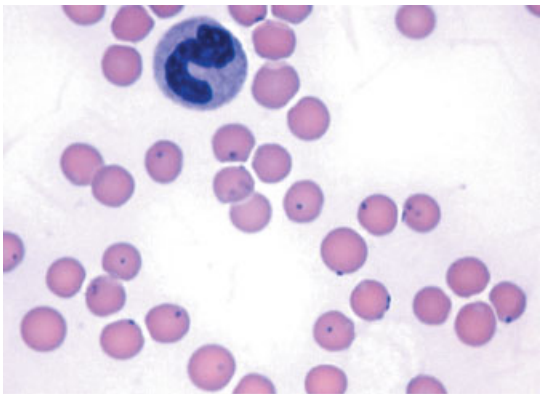

Plate 29.1 Wright–Geimsa blood smear (original magnification ×1000) from a non-anaemic cat with '*Candidatus* Mycoplasm haemominutum' infection. The organisms are most easily identified by those lying on the surface of the erythrocyte, showing their epicellular location.

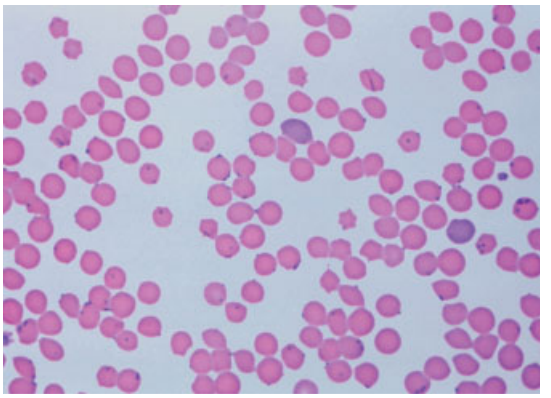

Plate 29.2 Wright–Geimsa blood smear (original magnification ×400) from an anaemic cat with *Mycoplasma haemofelis* infection. Organisms are present on erythrocytes either singly or in multiple numbers. Anisocytosis and polychromasia are evident.