

FELINE MEDICINE REVIEW & TEST

SAMANTHA TAYLOR
ANDREA HARVEY



SAUNDERS
ELSEVIER

Access on desktop, laptop, tablet or
smartphone for on-the-go review

FELINE

MEDICINE

REVIEW & TEST

Content Strategist: Robert Edwards
Content Development Specialists: Clive Hewat, Veronika Watkins
Project Manager: Sukanthi Sukumar
Designer: Miles Hitchen
Illustration Manager: Amy Naylor

FELINE MEDICINE

REVIEW & TEST

Edited by

Samantha Taylor BVetMed(Hons) CertSAM DipECVIM-CA MRCVS

European Veterinary Specialist in Internal Medicine
RCVS Recognized Specialist in Feline Medicine
Distance Education Coordinator
International Cat Care
Tisbury
UK

Andrea Harvey BVSc DSAM(Feline) DipECVIM-CA MRCVS

MANZCVS(Associate)

Registered Feline Specialist (NSW)
RCVS Recognized Specialist in Feline Medicine
Small Animal Specialist Hospital (SASH)
Sydney, NSW
Australia



Edinburgh London New York Oxford Philadelphia St Louis Sydney Toronto 2015

SAUNDERS
ELSEVIER

© 2015 Elsevier Ltd. All rights reserved.

No part of this publication may be reproduced or transmitted in any form or by any means, electronic or mechanical, including photocopying, recording, or any information storage and retrieval system, without permission in writing from the publisher. Details on how to seek permission, further information about the Publisher's permissions policies and our arrangements with organizations such as the Copyright Clearance Center and the Copyright Licensing Agency, can be found at our website: www.elsevier.com/permissions.

This book and the individual contributions contained in it are protected under copyright by the Publisher (other than as may be noted herein).

ISBN: 978-0-7020-4587-5

British Library Cataloguing in Publication Data

A catalogue record for this book is available from the British Library

Library of Congress Cataloging in Publication Data

A catalog record for this book is available from the Library of Congress

Notices

Knowledge and best practice in this field are constantly changing. As new research and experience broaden our understanding, changes in research methods, professional practices, or medical treatment may become necessary.

Practitioners and researchers must always rely on their own experience and knowledge in evaluating and using any information, methods, compounds, or experiments described herein. In using such information or methods they should be mindful of their own safety and the safety of others, including parties for whom they have a professional responsibility.

With respect to any drug or pharmaceutical products identified, readers are advised to check the most current information provided (i) on procedures featured or (ii) by the manufacturer of each product to be administered, to verify the recommended dose or formula, the method and duration of administration, and contraindications. It is the responsibility of practitioners, relying on their own experience and knowledge of their patients, to make diagnoses, to determine dosages and the best treatment for each individual patient, and to take all appropriate safety precautions.

To the fullest extent of the law, neither the Publisher nor the authors, contributors, or editors, assume any liability for any injury and/or damage to persons or property as a matter of products liability, negligence or otherwise, or from any use or operation of any methods, products, instructions, or ideas contained in the material herein.

ELSEVIER

your source for books,
journals and multimedia
in the health sciences

www.elsevierhealth.com



Working together
to grow libraries in
developing countries

www.elsevier.com • www.bookaid.org

The
Publisher's
policy is to use
paper manufactured
from sustainable forests

Printed in Germany

Contents

Contributors	vii
Acknowledgements	ix
Dedication	xi
Prefacexiii
Abbreviationsxv
Chapter 1 Dermatological disorders	1
Chapter 2 Gastrointestinal and hepatic disorders	52
Chapter 3 Haematological disorders	120
Chapter 4 Respiratory disorders	143
Chapter 5 Urinary tract disorders	189
Chapter 6 Endocrinological disorders	215
Chapter 7 Neurological disorders	249
Chapter 8 Toxicity and trauma	274
Chapter 9 Miscellaneous disorders	300

This page intentionally left blank

Contributors

Dominic Barfield, BSc BVSc
MVetMed DACVECC MRCVS

Lecturer in Veterinary Emergency
and Critical Care
Royal Veterinary College
London
UK

Cases: 6.5, 8.1, 8.2, 8.3, 8.4

Caroline J. Blundell, BVetMed
CertSAM MANZCVSc MRCVS

Co-Director
The Oxford Cat Clinic
Oxford
UK

Cases: 2.14, 3.4

Lara Boland, BVSc(Hons) MANZCVS
(Feline Medicine)

Senior Clinical Registrar in Small
Animal Medicine
University of Sydney
New South Wales
Australia

Cases: 2.11, 3.1, 4.2, 7.1, 9.8

Martha J. Cannon, BA VetMB
DSAM(Fel) MRCVS

Director
The Oxford Cat Clinic
Oxford
UK

Cases: 2.14, 3.5, 5.3, 6.6, 6.7, 9.9, 9.10,
9.11, 9.12

Anne Fawcett, BA(Hons) BSc(Vet)
(Hons) BVSc(Hons) MVetStud GradCertEduc
(Higher Ed)

Lecturer
Faculty of Veterinary Science
University of Sydney
Camperdown
Australia

Cases: 1.9, 1.10, 1.11, 1.12, 2.2, 2.3,
4.6, 5.2, 8.6, 9.13

Nikki C. Gaut, BVetMed MANZCVS
(Feline Medicine) MRCVS

Veterinary Surgeon
London
UK

Cases: 1.2, 2.12, 2.13, 6.1, 9.3, 9.4

Andrea M. Harvey, BVSc
DSAM(Feline) DipECVIM-CA MRCVS
MANZCVS(Associate)

Registered Feline Specialist (NSW)
RCVS Recognized Specialist in Feline
Medicine
Small Animal Specialist Hospital (SASH)
Sydney, NSW
Australia
Case: 4.9

Natasha Hetzel, BSc BVSc CertSAM
MRCVS

Clinical Teaching Fellow in Small
Animal Internal Medicine
University of Bristol
Bristol
UK

Cases: 2.6, 2.7, 4.1, 6.2, 7.3

Contributors

Roshan M. Jungalwalla,
BVSc (Hons) MACVS

Small Animal Veterinarian
North Hobart Veterinary Hospital
Hobart
Australia
Cases: 1.8, 2.4, 4.5, 7.4, 9.7

Amy L. Lam, BVSc(Hons)
GradCertVetStud MANZCVS MRCVS

Senior Registrar, Small Animal
Medicine
Small Animal Specialist Hospital
Sydney
Australia
Cases: 1.1, 3.3, 7.5, 7.6, 9.1

Carolyn R. O'Brien, BVSc(Hons)
MVetClinStud FACVSc(Feline Medicine) PhD

The University of Melbourne
Melbourne
Australia
Cases: 1.4, 1.5, 1.6, 1.7, 2.5, 3.2, 4.4,
5.1, 9.6

Rachel Perry, BSc BVM&S MANZCVS
(Small Animal Dentistry & Oral Surgery) MRCVS

Director
Perrydentalvet Ltd
East Sussex
UK
Cases: 9.3, 9.4

Elise E. Robertson, BS BVetMed
MACVSc(Feline) DipABVP(Feline) MRCVS

Director
Feline Vet Ltd
Feline Specialist Referrals &
Endoscopy Veterinary Referrals
Brighton
UK
Cases: 1.3, 2.8, 2.9, 4.3, 8.5
and editorial support

Kirsty A.M. Roe, BVSc CertSAM
DipACVIM DipECVIM-Ca

American and European Specialist in
Small Animal Internal Medicine
Willows Veterinary Centre and Referral
Service
Solihull
UK
Cases: 2.10, 6.4, 7.2, 9.2, 9.5

Anita M. Schwartz, MRCVS

Staff Clinician
Langford Veterinary Services
University of Bristol
UK
Cases: 2.1, 4.7, 4.8, 4.10, 5.4

Samantha Taylor, BVetMed(Hons)
CertSAM DipECVIM-CA MRCVS

Distance Education Coordinator
RCVS Recognized Specialist in Feline
Medicine
International Cat Care
Tisbury
UK
Cases: 5.5, 5.6, 6.3

Acknowledgements



The Editors would like to acknowledge the International Society of Feline Medicine (ISFM) and Centre of Veterinary Education (University of Sydney) Feline Distance Education course, as many of the authors of the book were course participants, contributing cases that they had written for course assignments. As tutors of the ISFM/CVE Feline distance education course, the Editors are also particularly proud of these authors in what they were able to achieve through having completed this course. Without the contributing authors this book could never have come about and we appreciate their hard work and effort. In addition we would like to thank the other clinicians, nurses and technicians involved in the care of the cats in this book. The Editors would also like to express their ongoing gratitude to International Cat Care who have supported them both during and after their specialist training. Special thanks also go to Elise Robertson for editorial assistance and support.

This page intentionally left blank

Dedication

For my boys: Brett, Alex and Leo. Thank you for your constant support and for always making me laugh.

Samantha Taylor

To my partner, Richard, for constantly inspiring me to be a better clinician, and to my many animals and patients who continue to teach me so much.

Andrea Harvey

This page intentionally left blank

Preface



Samantha Taylor and Andrea Harvey are both experienced clinicians and internationally recognized Specialists in Feline Medicine and have treated a large variety of feline medicine cases both in the United Kingdom and Australia. Having worked together for some years, their writing a book which collects together examples of some of the types of cases they have seen, from the more common to the unusual, was a challenging but rewarding task.

During their specialist training the editors have consulted many texts during revision and when tackling challenging cases. They wanted to write a new type of textbook that was highly practical, user friendly and provides the reader with access to useful information at the turn of a page.

Their aim has been to provide veterinary students and practitioners with real, and as such not always straightforward, cases covering a wide variety of disciplines, giving readers of *Feline Medicine: Test and Review* a useful resource with which to test their knowledge and learn a bit more about cats.

The editors hope they have achieved their aim and that readers of this book feel better able to handle the challenges that this complex and interesting species presents to them in their clinics.

This page intentionally left blank

Abbreviations

ACE	Angiotensin converting enzyme
ACEi	Angiotensin-converting enzyme inhibitor
AChRAB	Acetylcholine receptor antibody
ACP	Acepromazine
ACT	Activated clotting time
ACTH	Adrenocorticotrophic hormone
ADH	Alcohol dehydrogenase
AFB	Acid-fast bacilli
AGP	Acid glycoprotein
AKI	Acute kidney injury
ALP	Alkaline phosphatase
ALT	Alanine transaminase
Ao	Aorta
APTT	Activated partial thromboplastin time
ARB	Angiotensin receptor blocker
AST	Aspartate aminotransferase
ATE	Arterial thromboembolism
BAL	Bronchoalveolar lavage
BCS	Body condition score
BID	Twice daily
BP	Blood pressure
bpm	Beats per minute
brpm	Breaths per minute
BUN	Blood urea nitrogen
CBC	Complete blood count
CHF	Congestive heart failure
CHOP	Cyclophosphamide/hydroxydaunomycin (doxorubicin)/Oncovin (vincristine)/prednisolone
CK	Creatine kinase
CKD	Chronic kidney disease
CN	Cranial nerve
CNS	Central nervous system
COP	Cyclophosphamide/oncovin (vincristine)/prednisolone
COX	Cyclo-oxygenase
CPDA-1	Citrate-phosphate-dextrose-adenine-1
CPP	Cerebral perfusion pressure
CRI	Constant rate infusion
CRT	Capillary refill time
CSF	Cerebrospinal fluid
CSL	Compound sodium lactate
CT	Computed tomography

Abbreviations

CVC	Caudal vena cava
DCM	Dilated cardiomyopathy
DI	Diabetes insipidus
DIC	Disseminated intravascular coagulation
DKA	Diabetic ketoacidosis
DLH	Domestic long-haired
DM	Diabetes mellitus
DNA	Deoxyribonucleic acid
DSH	Domestic short-haired
DTM	Dermatophytosis test medium
DV	Dorsoventral
ECG	Electrocardiography/electrocardiogram
EDTA	Ethylene diamine tetra acetic acid
EFA	Essential fatty acid
EG	Ethylene glycol
ELISA	Enzyme linked immunosorbent assay
EMG	Electromyography
EOD	Every other day
EPI	Exocrine pancreatic insufficiency
EPO	Erythropoietin
ET	Endotracheal
FCV	Feline calici virus
FCoV	Feline corona virus
FE	Female entire
FeLV	Feline leukaemia virus
FHV	Feline herpes virus
FIC	Feline idiopathic cystitis
FIP	Feline infectious peritonitis
FIV	Feline immunodeficiency virus
FLUTD	Feline lower urinary tract disease
FN	Female neutered
FNA	Fine needle aspiration/aspirate
FOPS	Feline orofacial pain syndrome
FORL	Feline odontoclastic resorptive lesion
fPLI	Feline pancreatic lipase immunoreactivity
FPV	Feline panleucopenia virus/feline parvovirus
FR	French
fTLI	Feline trypsin-like immunoreactivity
GGT	Gamma-glutamyl transferase
HCM	Hypertrophic cardiomyopathy
HCT	Haematocrit
HL	Hepatic lipidosis
HPA	Hypothalamic-pituitary-adrenal
HR	Heart rate
HUC	Histiocytic ulcerative colitis
IBD	Inflammatory bowel disease
ICP	Intracranial pressure
IFA	Immunofluorescence assay
IGF	Insulin-like growth factor-1
IM	Intramuscular

Abbreviations

IMHA	Immune-mediated haemolytic anaemia
IRIS	International Renal Interest Society
IU	International units
IV	Intravenous
IVF	Intravenous fluids
LA	Left atrium/atrial
LA: Ao	Left atrium:aortic root ratio
LCAT	Latex cryptococcal antigen test
LDDS	Low dose dexamethasone suppression
LV	Left ventricle/ventricular
LVFW	Left ventricular free wall
MAP	Mean arterial pressure
MCH	Mean corpuscular haemoglobin
MCHC	Mean corpuscular haemoglobin concentration
MCV	Mean corpuscular volume
ME	Male entire
MN	Male neutered
MRI	Magnetic resonance imaging
mRNA	Messenger RNA
MST	Mean survival time
NPH	Neutral protamine hagedorn (insulin)
NPS	Nasopharyngeal stenosis
NSAID	Non-steroidal anti-inflammatory drug
PAS	Periodic acid-schiff
PCR	Polymerase chain reaction
PCV	Packed cell volume
PD	Polydipsia
PKD	Polycystic kidney disease
PLE	Protein losing enteropathy
PLN	Protein losing nephropathy
PMI	Point of maximal intensity
PO	Per os
PPDH	Peritoneopericardial diaphragmatic hernia
PR	Per rectum
PSO	Permethrin spot-on
PSS	Portosystemic shunt
PT	Prothrombin time
PTH	Parathyroid hormone
PTHrp	Parathyroid hormone related peptide
PU	Polyuria
PZI	Protamine zinc insulin
q	Each, every
QDS	Four times a day
RAAS	Renin-angiotensin-aldosterone system
RI	Reference interval
RGM	Rapidly growing mycobacteria
RR	Respiratory rate
RT	Rectal temperature
RTA	Road traffic accident
RT-PCR	Reverse transcriptase polymerase chain reaction

Abbreviations

RVC	Royal Veterinary College, UK
SAM	Systolic anterior motion of the mitral valve
SAMe	S-Adenosylmethionine
SC	Subcutaneous
SCC	Squamous cell carcinoma
SG	Specific gravity
SID	Once daily
SpO ₂	Oxygen saturation
TID	Three times daily
TLI	Trypsin-like immunoreactivity
TP	Total protein
TS	Total solids
T4	Thyroxine
U	Unit(s)
UK	United Kingdom
UPC	Urine protein:creatinine ratio
USG	Urine specific gravity
UTI	Urinary tract infection
UV	Ultraviolet
VD	Ventrodorsal
WBC	White blood cells
WCC	White cell count
ZN	Ziehl-Neelsen

Dermatological Disorders

Case 1.1

Signalment and Clinical History

A 5-year-old FN DSH presented with chronic (>6 weeks) skin changes to her nasal planum extending up the nasal bridge and down to the upper and lower lips. There was no known nasal discharge. The cat was an indoor/outdoor cat resident in Australia. Twelve months prior to this, similar less severe changes were noted on her nose, which resolved. The cat was on a regular commercial diet, with up-to-date preventative health care.

Clinical Examination Findings

Physical examination was otherwise unremarkable (Figure 1.1).

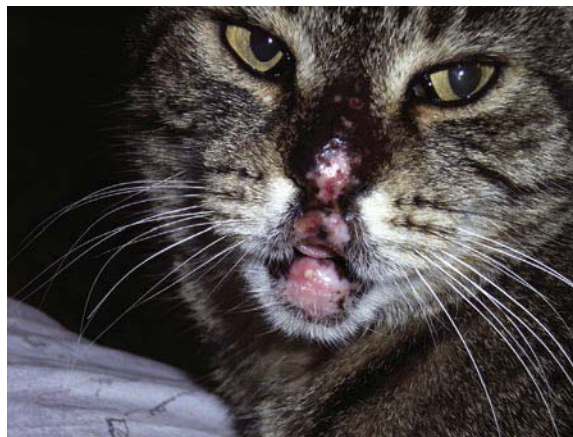

Figure 1.1. Nasal lesions prior to treatment.

Q 1. How would you describe these lesions?

Punctate depigmented alopecic, ulcerated and excoriated lesions are evident on the nasal planum, upper and lower lip.

Q 2. *Formulate a list of differential diagnoses for these lesions.*

- Inflammatory/immune mediated disease
 - Eosinophilic folliculitis secondary to acute hypersensitivity to insect envenomation – mosquitoes, fleas
 - Food hypersensitivity
 - Pemphigus foliaceus or pemphigus erythematosus
 - Sterile eosinophilic pustulosis
 - Subcorneal pustular dermatosis
- Infectious disease
 - Viral dermatitis – herpes
 - Cryptococcosis
 - Dermatophytosis
 - Demodicosis
- Neoplasia
 - Squamous cell carcinoma (SCC)
 - Basal cell carcinoma
 - Cutaneous lymphoma (mycosis fungoides)
 - Mast cell tumour
- Miscellaneous
 - Solar contact dermatitis
 - Dermatitis secondary to a contact irritant

Q 3. *How would you manage this case?*

Both further diagnostics and trial therapeutics can be considered.

Any diagnostic should start with the most cost-effective and least invasive investigations, and may include some of the following:

- Scan area with Wood's lamp
- Skin scrapes (superficial and deep) for assessment for mites
- Oropharyngeal swab for herpes virus polymerase chain reaction (PCR)
- Impression smears for cytology (e.g. acanthocytes indicating pemphigus)
- LCAT (latex cryptococcal antigen test)
- Biopsy for histopathology +/- additional tests such as herpes virus PCR or immunohistochemistry
- CBC (complete blood count)/biochemistry and FIV (feline immunodeficiency virus)/FeLV (feline leukaemia virus) for assessment of general health

Therapeutic trials may be used to evaluate the possibility of some disorders, particularly:

- Flea bite hypersensitivity – rigorous flea treatment
- Mosquito bite hypersensitivity – avoidance of mosquitoes by keeping indoors +/- doxycycline treatment
- Food hypersensitivity – diet trial (novel protein or hydrolysed protein diet)
- Herpes dermatitis – famciclovir trial

Results of Further Diagnostics

Examination of the nose under a Wood's lamp was negative, but does not completely exclude dermatophytosis. Superficial and deep skin scrapes were negative for mites. Impression smears showed numerous eosinophils and no fungal elements (including cryptococcosis). LCAT was negative. Herpes virus PCR (oropharyngeal swab) was negative, but this does not completely exclude herpes dermatitis.

CBC and routine biochemistry can be assessed for marked peripheral eosinophilia that can be seen in hypereosinophilic syndrome, and for indication of multiple organ involvement from conditions such as neoplasia. In this case, the results were unremarkable. FeLV and FIV enzyme-linked immunosorbent assay (ELISA) were negative.

Results of Therapeutic Trials

Initial treatment commenced with broad spectrum antibacterials with good skin penetration: amoxicillin clavulanate 15 mg/kg PO BID. A diet trial using a hydrolysed protein diet was started and selamectin was applied topically as a spot-on. It was advised for the cat to be kept indoors at dusk and dawn to reduce exposure to mosquitoes.

The owner was not able to keep the cat indoors, and the lesions became progressively worse, with more pronounced erythema and ulceration over the following 3 weeks.

Further Diagnostic Testing

A punch skin biopsy was performed with the cat under general anaesthesia. Histopathology showing marked eosinophilic perifollicular reaction and neutrophilic infiltrate of the dermis. Fungal culture of the lesion was negative.

Q 4. Considering this information, what is your diagnosis for the patient?

A diagnosis of facial eosinophilic furunculosis with high suspicion of insect bite hypersensitivity is made on the basis of histopathology and lesion localization. Cats can also display lesions on the pinna, flank, or extremities. These reactions are classically associated with insect bite hypersensitivity (particularly mosquitoes); however, they can also be seen with drug reactions and Herpes virus dermatitis which is not fully excluded.

Q 5. How would you treat this cat?

Various treatments have been described in the literature to treat this condition. The most important step is to reduce exposure to mosquitoes. Keeping cats indoors during dusk and dawn, and reducing exposure to breeding grounds (swamps, etc.) is important. Non-toxic insect repellants can also be applied to the fur near the head, not the skin.

Immunomodulatory control is usually required short term. Doxycycline (5 mg/kg PO BID), followed by corticosteroids are the most commonly required treatments.

- Prednisolone can be used at 1–2 mg/kg PO SID
- For cats that will not tolerate daily oral treatment, methylprednisolone 5 mg/kg IM monthly can be used. It should be noted that there is an increased risk for cats treated with corticosteroids to develop diabetes.

Other immunosuppressive treatments can be used as steroid-sparing agents. In this case the author used ciclosporin 8.8 mg/kg (25 mg) SID for 3 weeks before a marked change in the nose was appreciated. The dose was reduced to 8.8 mg/kg EOD for 2 weeks, then 8.8 mg/kg every third day for 2 weeks, 8.8 mg/kg every fourth day for 2 weeks, the 8.8 mg/kg once a week for 2 weeks before discontinuing.

Outcome of This Case

The nose markedly improved and was no longer ulcerated/crusting or painful 1 month (Figure 1.2) after starting therapy. Reduced pigment (leucoderma) and scarring alopecia were evident.

The cat restarted ciclosporin during episodes of recurrence (seasonal pattern noted), as keeping the cat indoors was not an option (Figure 1.3).



Figure 1.2. Three months after initial presentation.

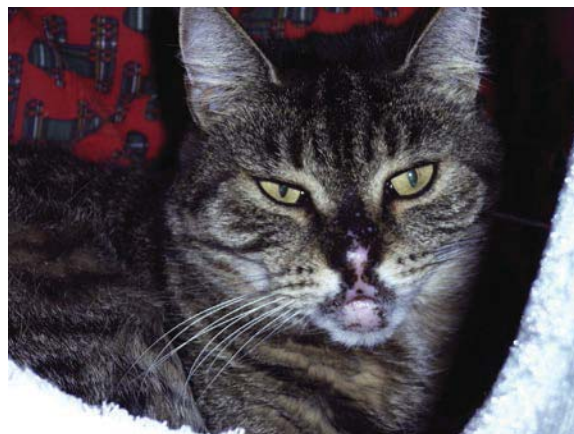

Figure 1.3. Fifteen months after initial presentation.

Discussion

Mosquito bite hypersensitivity is a hypersensitivity reaction with late phase reactions. There may be involvement of cellular immunity or an hereditary abnormality. Lesions are commonly noticed on the nasal planum, ears, and foot pads, occasionally on the nipple skin or pre-aural skin. Punctate lesions are noticed where insects bite and then inject saliva – to which the cat is allergic.

Mosquito bite hypersensitivity can be controlled without immune-modulating drugs by keeping the cat inside, especially during dusk and dawn and/or using insect repellants. Finding and eliminating the source of mosquitoes is important.

Ciclosporin is a potent immunosuppressive therapy that been used in feline eosinophilic dermatitis complexes at 2.5–10 mg/kg SID. Infectious diseases such as toxoplasmosis and herpes virus infection may recrudescence, or new unusual infectious diseases arise (e.g. mycobacterial infections) when cats are immunosuppressed with ciclosporin. The use of ciclosporin in mosquito bite hypersensitivity is not well documented.

Other alternatives to immunosuppressive corticosteroids include chlorambucil and gold therapy. In many milder cases, doxycycline treatment is effective (thought to be due to its immunomodulatory properties) without any additional immunosuppressive agents.

Further Reading

- Mason, K.V., Evans, A.G., 1991. Mosquito bite-caused eosinophilic dermatitis in cats. *Journal of the American Veterinary Medical Association* 198 (12), 2086–2088.
- Morris, D.M., 2004. Feline eosinophilic dermatoses. *Conference Proceedings: Western Veterinary Conference* 2004.
- Nagata, M., Ishida, T., 1997. Cutaneous reactivity to mosquito bites and its antigens in cats. *Veterinary Dermatology* 8, 19–26.

Case 1.2

Signalment and History

A 4-month-old FE indoor-only Persian kitten from a single-cat household was presented with multiple patches of erythematous, dry, scurfy skin with some alopecia. Lesions were present on the cat's nose and ear tips. The owner described that the lesions were present since she had purchased the cat from the breeder and that she had never seemed to be pruritic.

The kitten was otherwise well and had been vaccinated, wormed, and treated for fleas.

Clinical Examination

Lesions similar to those seen in [Figure 1.4](#) were visible on presentation. The kitten was in good body condition with no other abnormal findings.

Q 1. *Formulate a list of differential diagnoses for the skin lesions in this cat.*

- Dermatophytosis
- Flea bite hypersensitivity
- Mosquito bite hypersensitivity

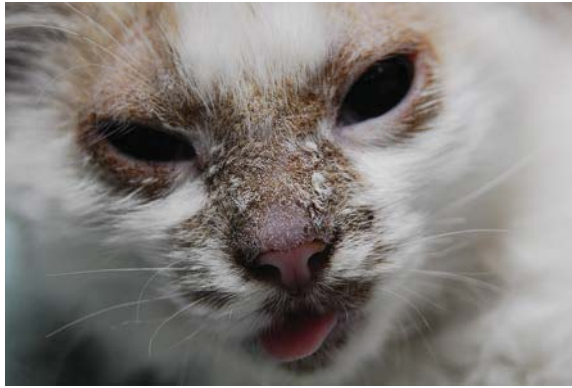

Figure 1.4. A kitten with similar facial lesions to the kitten in this Case. Courtesy of Anne Fawcett.

- Ectoparasites (e.g. *Demodex*, *Otodectes*, *Cheyletiella*, *Sarcoptes*)
- Food hypersensitivity
- Herpes dermatitis

Q 2. How would you investigate this case in the first instance?

- Wood's lamp: to look for fluorescence indicating dermatophytes (*Microsporum canis*)
- Coat brushings: to look for flea dirt
- Tape strip: looking for ectoparasites such as *Cheyletiella* and *Otodectes*
- Skin scrape: to look for deeper ectoparasites such as *Demodex*
- Trichogram: a microscopic examination of 20–30 hairs can determine if the alopecia is self-induced. A normal telogen:anagen ratio is a positive indicator.



Tip Box

Always make sure the Wood's lamp has been switched on and warmed up for at least 3 min before using, and then is held over the hair shafts for 3 min, as some strains are slow to fluoresce.

In this case a Wood's lamp was used in the initial consultation and confirmed the presence of the apple-green fluorescence that is associated with *M. canis* (Figure 1.5).

Q 3. How would you confirm the diagnosis?

Fungal culture is the only reliable method for confirming the diagnosis. Damaged hairs, fluorescing hairs, or hairs closely associated with skin lesions are plucked, or lesions brushed with a sterile toothbrush, and inoculated onto Sabouraud's dextrose agar (where they will grow colonies that can be identified via direct microscopy within days to weeks) or placed into dermatophytosis test medium (DTM), which glows red if positive.



Figure 1.5. Fluorescence under the Wood's lamp consistent with the dermatophytosis.

Hairs are collected from cats that look completely normal by whole body brushing using a sterile toothbrush or massage brush, which can then be spread across an agar plate.

The fungal culture in this case returned positive for *M. canis*.

Q 4. How would you manage this case and evaluate response to treatment?

- Eliminate infection from host
 - Systemic antifungal medication should be administered to the patient (e.g. itraconazole at 5–10 mg/kg SID PO).
 - Therapy should be 1 week on and 1 week off as itraconazole has a slow breakdown and can accumulate, leading to a depot effect. Three treatments are given initially before retesting.
 - Itraconazole should not be used on pregnant queens (due to being teratogenic), kittens of less than 10 days old, or in cats with concurrent liver disease (due to toxicity).
- Prevent dissemination of spores
 - Clipping the coat of long-haired cats and topical application of antifungal shampoos can reduce environmental contamination and reinfection.
 - Cats should ideally be sedated for clipping to minimize stress; the procedure is then repeated again several weeks after systemic treatment. Care is needed during clipping to prevent minor skin trauma.
 - Infected hair should be disposed of by burning, and clippers should be disinfected.

- Shampooing with chlorhexidine and miconazole can be carried out twice weekly. Warm water should cover the coat before the shampoo is lathered, left for 10 min and then rinsed thoroughly. A lime-sulphur shampoo could also be used.

➤ Decontaminate environment

- Infected cats should be restricted to one room and any objects that cannot be disinfected should be disposed of via burning.
- Vigorous vacuuming to remove fungal spores on shed hairs and chemical agents such as bleach 1:10 should be applied to all surfaces.

Response to treatment is determined by at least 2 negative dermatophyte cultures and may take up to 20 weeks to resolve in some cases.

Treatment and Outcome

The kitten was started on itraconazole orally at a dose of 5 mg/kg once daily for 1 week on/1 week off treatment for a total of 3 treatment weeks. After 3 weeks of treatment there was still fluorescence under the Wood's lamp so treatment was continued, and twice weekly bathing with miconazole and chlorhexidine shampoo was advised. Although the skin lesions appeared to improve, hair plucks and dermatophyte cultures continued to return positive at the end of the 3-week treatment intervals over the next couple of months.

Although initially reluctant, the owner finally agreed to the kitten being hospitalized and sedated with medetomidine 0.05 mg/kg SC and butorphanol 0.4 mg/kg SC to have a full coat clip and shampoo. Six weeks later the fungal culture was negative.

Q 5. *What further advice would you give if this cat came from a multi-cat household?*

- Transmission can occur through direct contact with the infected cat or through contact with an infected environment.
- All in-contact cats should have hair plucks for dermatophyte culture and if negative should be quarantined from the infected individual. However, in a large multi-cat household (or a cattery) this can be time consuming and expensive, and it is likely all cats are culture positive, so it is prudent to treat all cats in the household.
- Treatment should be as above: topical, systemic, and environmental.
- Clothing may act as a fomite and should be changed between infected and non-infected cats (fomites can survive 12–24 months in the environment).
- The owner should be made aware that complete resolution may take months to years.

Discussion

Dermatophytosis is common in young cats of less than a year old, and is thought to be due to immature immunity allowing infection. Long-haired cats, especially Persians, are overrepresented, and this is thought to be due to inefficient self-grooming and lack of sunlight to the skin (which dermatophytes favour).

The clinical picture of dermatophytosis is variable and can mimic many other feline dermatoses. Pruritus is variable and may have been a reason why the owner did not describe this as a feature in her history.

Treatment can be frustrating, expensive, and prolonged, and good client communication at the beginning will ensure commitment and compliance to reach a favourable outcome.

Further Reading

Frymus, T., Gruffydd-Jones, T., Pennisi, M.G., et al., 2013. Dermatophytosis in cats: ABCD guidelines on prevention and management. *Journal of Feline Medicine and Surgery* 15, 598–604.

Case 1.3**Signalment and History**

A 2-year-old MN British Shorthair cat presented with a large swelling of the nasal bridge (Figures 1.6 and 1.7) and another swelling at the tail base. No sneezing or nasal discharge had been reported. Minimal improvement was noted with either swelling following treatment with amoxicillin-clavulanate and meloxicam. Vaccination and

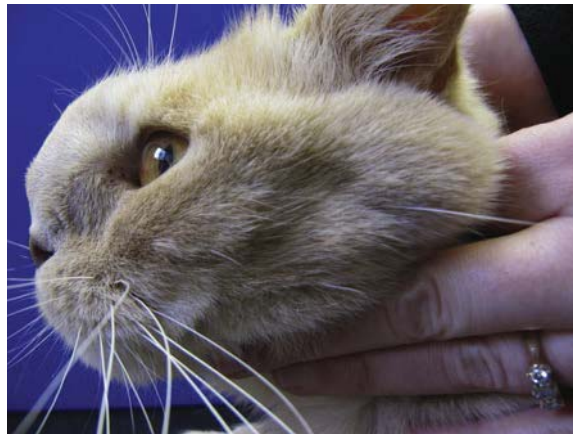

Figure 1.6. Nasal swelling, side view.



Figure 1.7. Large swelling affecting entire nasal bridge.

endo/ectoparasite control was current. The cat was a regular hunter with free access outdoors.

Clinical Examination

Examination demonstrated a large, hard/non-fluctuant, non-painful swelling affecting the nasal bridge. The skin over the swelling was normal. There was also a firm nodule approximately 2 cm in diameter over the tail base. The cat was also pyrexia (39.7 °C) and had mandibular and prescapular lymphadenopathy (right larger than left).

Q 1. *Formulate a list of differential diagnoses for the nasal swelling.*

- Traumatic injury/nasal bone fracture/haematoma
- Bacterial infection (e.g. *Nocardia*, mycobacteria)
- Fungal infection (e.g. *Cryptococcus*, *Aspergillus*, *Alternaria*, phaeohyphomycosis)
- Neoplasia (e.g. SCC, lymphoma, fibrosarcoma, chondrosarcoma, osteosarcoma)

Q 2. *Do the signalment and the other clinical findings help to narrow down the differential diagnoses?*

Neoplasia would be less likely in this age of cat and would not explain the concurrent tail base swelling and prescapular lymphadenopathy. An infectious aetiology would be more likely given the different locations involved. Fungal infection would be less likely to explain the lymphadenopathy and tail base mass but cannot be excluded.

Q 3. *What are the options for further investigating this case?*

- Fine-needle aspiration (FNA) of the nasal swelling, tail base swelling, and enlarged lymph nodes for cytological assessment +/- bacterial and fungal culture
- Nasal swab for fungal culture
- LCAT
- *Aspergillus* serology
- Imaging of the nose (radiographs/CT (computed tomography)/MRI (magnetic resonance imaging))
- Nasal biopsies (both intranasal and the external swelling) for histopathology and culture
- Biopsy/removal of the tail base mass and an enlarged lymph node for histopathology and culture
- Assessment of general health may also include CBC/biochemistry, thoracic imaging, and FeLV/FIV ELISA

Further Case Information

- Cytology of FNA from nasal and tail base swelling: mixed inflammation, mainly degenerate neutrophils with scattered lymphocytes and macrophages. No infectious agents were identified. Ziehl-Neelsen (ZN) stains were performed and were negative for acid-fast bacilli (AFB).
- LCAT: negative.

- *Aspergillus* serology: negative for *A. terreus*, *A. nidulans*, *A. niger*, *A. flavus*, and *A. fumigatus*.
- Skull radiographs: a soft tissue density above the nasal bone with no obvious infiltration or communication with the associated sinus/nasal cavity, and no evidence of pathology within surrounding bones was noted.
- Chest/abdominal survey radiographs: unremarkable.
- Haematology/biochemistry: within normal limits.
- FIV/FelV ELISA: negative.

Q 4. Given these results, what differential diagnoses would you consider most likely?

The clinical history, examination, and investigations so far would indicate that an unusual bacterial cause, such as mycobacterial disease, was the most likely differential diagnosis. This was supported by the cat being a hunter, and the locations involved being common bite locations from small wild rodents. *M. microti*, *M. lepraemurium*, *M. bovis*, *M. avium*, and non-tuberculous mycobacteria would all be possibilities.

Q 5. What samples would you want to collect in order to look for infectious aetiologies?

Tissue samples can be taken from the nasal swelling, lymph nodes, and tail base mass. It is usually easiest to excise a whole lymph node in order to obtain enough tissue, and in this case also excising the tail base mass would be prudent. It is vital that not all the tissue is placed in formalin, as fresh tissue samples are required for culture +/- PCR if histopathology is suggestive of any infectious aetiology.

Further Case Information

One of the enlarged prescapular lymph nodes and the tail base mass were excised. The nasal swelling was not biopsied in this case due to concerns regarding wound healing. They were each divided into four pieces; one was submitted in formalin for histopathology and ZN staining. The second was submitted to a mycobacterial reference laboratory for mycobacterial culture, the third to a microbiology laboratory for routine bacterial and fungal culture; the fourth piece was kept in a plain container and frozen in case of further requirements for analysis.

Q 6. What are the treatment options for this cat pending results?

Where mycobacterial infection is suspected, appropriate antibiotic treatment usually consists of a combination of three antibiotics for at least 2 months, and two of the antibiotics for at least a further 4 months. Specific treatments will depend on the type of mycobacteria present, and response to treatment. First-line treatments for the tuberculous group of mycobacteria are usually a combination of a fluoroquinolone, rifampicin, and clarithromycin or azithromycin. It is reasonable to start treatment with two or three of these antibiotics whilst pending results in suspect cases.

Further Case Information

Histopathology of both the lymph node and tail base mass revealed granulomatous inflammation. The tail base mass had inflammation extending to the margins. No

AFB were seen with ZN staining. Culture for *M. bovis* and *M. microti* was negative. Routine bacterial and fungal cultures were negative.

Q 7. Do these results exclude mycobacterial infection?

No, tuberculous mycobacteria are extremely difficult to culture, and over 50% of cases may be negative on culture. Furthermore, the samples were only cultured for *M. bovis* and *M. microti* because this was performed at a reference laboratory (Veterinary Laboratory Agency, UK) that monitors for *M. bovis* since it is a notifiable disease in the UK. Their main concern is identifying *M. bovis* and so they do not routinely culture for other mycobacterial species. In addition, in some cases, very few organisms are found in tissues and therefore the AFB are not always found on histopathology.

Q 8. What are the options for further management of this case regarding investigations and treatment?

► Further investigation could include:

- Mycobacterial PCR on fresh (frozen) tissue, paraffin embedded tissue or Romanowsky-stained cytology slides
- Interferon gamma blood test for *M. bovis* and *M. microti*

Further treatment could include continuation of two to three of the appropriate antibiotic treatments for first-line treatment of tuberculous mycobacteria with ongoing assessment of response to treatment.

Further Case Information

In this case, further investigations were not performed and treatment was instigated with ibafloxacin 3% oral gel 15 mg/kg PO SID, azithromycin 10 mg/kg PO SID, and rifampicin 10 mg/kg PO SID. Within 4 weeks, the nasal bridge had reduced in size (Figures 1.8 and 1.9), the mandibular lymph nodes and remaining prescapular

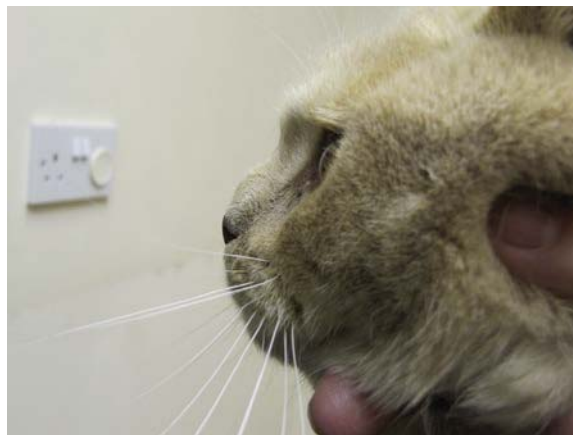

Figure 1.8. Normal profile view on completion of treatment.

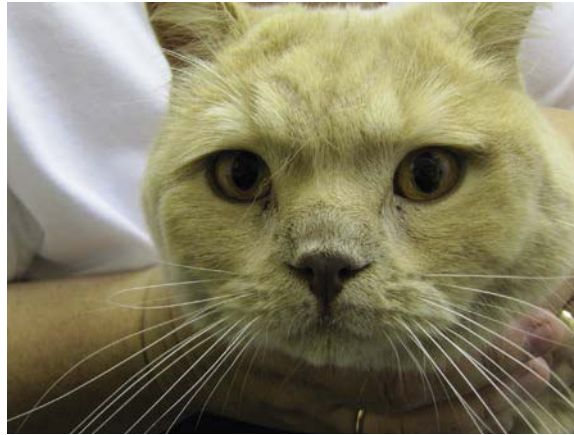

Figure 1.9. Nasal swelling no longer evident and indicating clinical remission.

lymph node had reduced in size, and there was no recurrence of the tail base mass. After 6 months of this treatment, complete clinical remission was achieved. Treatment was then stopped, and the cat still remains in clinical remission 2 years after initial presentation.

Discussion

This is an example of a case of suspected mycobacterial infection that was not proven but responded to triple combination therapy. Mycobacteria can cause various clinical syndromes in a cat, ranging from localized cutaneous nodules to disseminated, and often fatal, infections.

There are many different types of mycobacteria, which for simplicity can be divided into three groups:

1. Tuberculous: *M. tuberculosis*, *M. microti*, *M. bovis*
2. Saprophytic, opportunistic non-tuberculous: *M. avium-intracellulare* complex, *M. genavense*, *M. terrae* complex, *M. chelonae-abscessus*, *M. smegmatis*
3. Lepromatous (cannot be cultured by routine methods): *M. leprae*, *M. lepraemurium*

Each group is associated with different syndromes and differs in ease of diagnosis, treatment, and prognosis. Treatment for all, however, is required long term, and this is important to discuss with the owners prior to embarking on treatment to ensure that they are committed to medicating both practically and financially. There are also many other aspects of mycobacterial disease that are also important to discuss with owners before embarking on treatment, such as zoonotic risk.

For further information on aspects to consider when discussing treatment of confirmed or suspected mycobacterial disease with owners, see Case 4.7.

Further Reading

Greene, C.E., Gunn-Moore, D.A., 2012. Mycobacterial infections. In: Greene, C.E. (Ed.). *Infectious Diseases of the Dog & Cat*, fourth ed. W.B. Saunders Co., Philadelphia, PA, pp. 495–521.

Gunn-Moore, D.A., Jenkins, P.A., Lucke, V.M., 1996. Feline tuberculosis: a literature review and discussion of 19 cases caused by an unusual mycobacterial variant. *Veterinary Record* 138, 53–58.

Lloret, A., Hartmann, K., Pennisi, M.G., et al., 2013. Mycobacterioses in cats: ABCD guidelines on prevention and management. *Journal of Feline Medicine and Surgery* 15 (7), 591–597.

Case 1.4

Signalment, Clinical History, and Clinical Examination

A 6-year-old FN DSH was presented because of a chronic wound involving the skin and subcutaneous tissue of the inguinal area, which had not improved following 10 days of amoxicillin-clavulanate. The cat was otherwise in good health.

Physical examination showed the cat to be bright and interactive. She was slightly overweight (body condition score (BCS) 7/9). In the inguinal region of the ventral abdomen there was an area of approximately 10 cm² where the skin was discoloured, with numerous ulcerations and draining tracts that exuded scant amounts of serosanguinous fluid (Figure 1.10). The subcutaneous tissue had a nodular, thickened feel. The cat did not seem to resent palpation of the area. Examination was otherwise unremarkable with normal vital parameters.

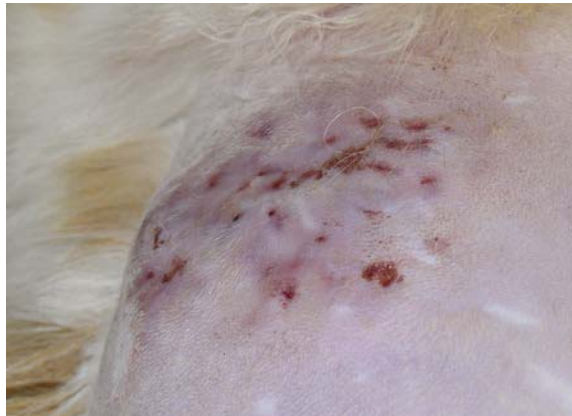

Figure 1.10. Ulcerations and draining tracts involving the skin and subcutaneous tissue of the inguinal area.

Q 1. Formulate a differential diagnosis list for this skin lesion.

- Infectious
 - Mycobacteria
 - *Nocardia*
 - *Actinomyces*
 - *Rhodococcus*

- Saprophytic fungi
- Pseudomycetoma
- Neoplastic
 - Lymphangiosarcoma
 - Haemangiosarcoma
 - Lymphoma
 - Ulcerative mammary carcinoma
- Inflammatory
 - Sterile panniculitis

Q 2. *How would you investigate this case?*

- FNA and cytology/microbiology
- Tissue biopsy with collection into formalin for histopathology and plain tissue for microbiology
- Haematology/CBC/biochemistry, urinalysis and retroviral testing to assess for possible underlying immunosuppressive conditions

Results

FNA was performed through intact skin that had been disinfected with 70% ethanol to eliminate skin surface bacteria. Cytological examination revealed marked pyogranulomatous inflammation. No infectious organisms were observed but 'special stains' were planned. Blood and urine tests were normal apart from a mild mature neutrophilia. FIV antibody and FeLV antigen ELISAs were negative.

Q 3. *How would you interpret the cytology results in this case so far? Which 'special stains' might the cytopathologist employ and what would they be looking for?*

The presence of pyogranulomatous inflammation is highly suggestive of an infection with an intracellular organism such as a *Mycobacterium* spp. or other saprophytic organism. Acid-fast (such as ZN) and periodic acid-Schiff (PAS) staining would be appropriate to look for AFB and fungal organisms, respectively.

Q 4. *What other tests could be performed to help with the diagnosis?*

Aerobic culture (including the utilization of mycobacterial media and Sabouraud dextrose agar for fungi) would be appropriate. Not all mycobacterial organisms that cause disease in cats can be cultured in the laboratory; however, the 'rapidly growing mycobacteria' (RGM) can be cultured within 7–10 days, although care needs to be taken to avoid contaminating the sample with skin surface contaminants that can quickly overgrow these organisms.

Where available, PCR can be performed on clinical samples (including Romanowsky-stained cytology slides, fresh and paraffin-embedded tissue) to identify a variety of organisms within samples; however, this is best performed in instances where the presence of AFB or fungal organisms has already been confirmed. Negative PCR results do not exclude the diagnosis.

Q 5. What treatments might you initiate pending results?

Ideally, treatment should begin with one or two oral antimicrobials (doxycycline, a fluoroquinolone, and/or clarithromycin). These are usually chosen empirically until results of culture and susceptibilities are known (in Australia, doxycycline and/or a fluoroquinolone are best, whereas in the United States clarithromycin is the drug of choice initially). *M. smegmatis* group tends to be inherently resistant to clarithromycin, *M. fortuitum* group isolates are often resistant to one or several agents, and *M. chelonae-abscessus* group isolates tend to be resistant to all drugs available for oral dosing apart from clarithromycin and linezolid. It is recommended to commence treatment at standard dose rates increased slowly to the high end of the dose range unless adverse effects are observed.

Treatment and Results

The cat had been prescribed a combination of doxycycline (10 mg/kg PO SID) and marbofloxacin (2 mg/kg PO SID) pending results.

Small numbers of AFB were identified within macrophages on ZN-stained cytology slides. The remainder of the material was plated onto Lowenstein-Jensen agar and incubated at 37 °C. A pure growth of *M. goodii* was detected after 6 days, confirming the diagnosis of a RGM panniculitis. The organism was sensitive to doxycycline, ciprofloxacin, moxifloxacin, amikacin, linezolid, and imipenem but resistant to clarithromycin.

Q 6. What advice would you give to the owner regarding zoonotic risk or transmission of infection to their other animals?

RGM are not known to be transmissible between individuals, nor do they represent a zoonotic risk, so no precautions need to be taken in this regard.

Q 7. How long would you advise treating for?

Typically 3–12 months of medical therapy is sufficient to cure the cat; however, surgical resection of residual infection is sometimes necessary. Medical therapy should be administered for at least 1–2 months after affected tissues look and feel completely normal.

Outcome

The lesion had reduced in diameter by approximately 5 cm after 1 month of therapy and was completely resolved after a further 2 months of treatment. The medications were continued for 1 month after the resolution of clinical signs, and the cat was disease-free after 12 months of follow-up.

Discussion

RGM form colonies on solid media within 7 days of incubation. RGM are ubiquitous environmental saprophytes and include a variety of organisms that cause

opportunistic disease in both healthy and immunocompromised animals and people. In healthy animals the infection tends to be localized (such as panniculitis or lymphadenitis) and usually occurs after a breach in the integument through which the organism is inoculated. Disseminated disease and/or pneumonia caused by RGM are very rare in cats.

Panniculitis is the most common clinical presentation of RGM in cats and the infection often begins in the inguinal region, although the axillae, flanks, or dorsum may be affected, particularly if the cat is overweight. The disease may subsequently spread to contiguous areas of the lateral and ventral abdominal wall, perineum, and tail base. RGM have a preference for fat, which offers a favourable environment for survival and proliferation of RGM by providing triglycerides for growth of organisms or protecting them from the phagocytic or immune responses of the host, and this is a key factor in the pathogenesis of these infections. The condition usually remains localized, and spread to internal organs or lymph nodes is rare; cats typically do not show signs of systemic illness unless the disease is very extensive or secondarily infected.

Further Reading

- Horne, K.S., Kunkle, G.A., 2009. Clinical outcome of cutaneous rapidly growing mycobacterial infections in cats in the south-eastern United States: a review of 10 cases (1996–2006). *Journal of Feline Medicine and Surgery* 11, 627–632.
- Malik, R., Wigney, D.I., Dawson, D., et al., 2000. Infection of the subcutis and skin of cats with rapidly growing mycobacteria: a review of microbiological and clinical findings. *Journal of Feline Medicine and Surgery* 2, 35–48.
- O'Brien, C.R., Fyfe, J., Malik, R., 2012. Infections caused by rapidly growing mycobacteria. In: Greene, C.E. (Ed.), *Infectious Diseases of the Dog and Cat*. Elsevier, St. Louis, pp. 515–521.

Case 1.5

Signalment, Clinical History, and Clinical Examination

An 11-year-old MN DSH cat presented with a non-painful swelling of the dorsal nasal bridge (Figure 1.11) that had been slowly enlarging for the past few years. The cat was domiciled in a suburban area of Australia, but had free-range access to the outdoors.

The cat was otherwise in good health and had no evidence of intranasal involvement or regional lymphadenopathy. The rest of his physical examination, including fundoscopy, was normal.

Q 1. Formulate a differential diagnosis list for localized nodular lesions of the nasal bridge, with or without concurrent nasal cavity signs in cats.

► Infectious

- Bacterial
 - *Mycobacterium* spp. (including the causative agents of feline leprosy, *M. avium* complex, *M. tuberculosis* complex, and *M. ulcerans*)
 - *Nocardia* spp.

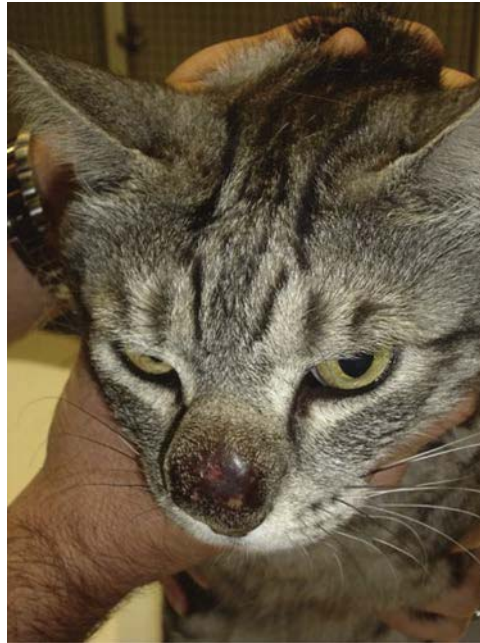

Figure 1.11. Appearance of Case 1.5 on initial presentation.

- *Actinomyces* spp.
- *Corynebacterium pseudotuberculosis*
- Fungal
 - *Cryptococcus neoformans* or *C. gattii*
 - *Aspergillus* spp. or *Penicillium* spp.
 - *Sporothrix schenckii*
 - Dematiaceous (pigmented) hyphomycosis (also known as phaeohyphomycosis) (e.g. *Exophiala* spp., *Alternaria* spp.)
 - Hyaline (non-pigmented) hyphomycosis (e.g. *Paecilomyces* spp.)
 - Zygomycosis
 - Pythiosis
 - Eumycotic mycetoma (e.g. *Staphylotrichum coccosporum*)
 - Pseudomycetoma
- Neoplastic
 - Nasal lymphoma
 - Nasal carcinoma
 - Sarcoma

Q 2. How would you further investigate this case?

Obtaining a diagnosis depends on the procurement of representative material for cytology, histopathology, and microbiology from the affected site.

Cytological and histopathological samples are initially prepared with Romanowski-type stains (e.g. Diff Quik®) or haematoxylin/eosin, and if an infectious agent is suspected (typically hallmarked by pyogenic or pyogranulomatous inflammation), special stains such as Gram, ZN, PAS, or silver stains are then employed to help identify the presence of particular organisms. In some cases, 'negatively staining' organisms (e.g. mycobacteria, *Nocardia*, or fungi) may be observed in the initial cytological or histopathological samples.

Fresh tissue samples should also be submitted to the laboratory so that culture can be attempted in the case of an infectious aetiology. Often, in the case of saprophytes, special culture media or growth requirements (e.g. temperature, CO₂ levels, prolonged incubation periods) may be necessary, so the laboratory should be advised of the suspected aetiological agents, and an appropriate laboratory chosen that utilizes the specific culture media required. In the case where the organism is not able to be cultured, referral of the sample to a specialist reference laboratory may be necessary, where advanced culture techniques and/or molecular methods such as PCR and sequence analysis may be employed in an attempt to identify the causative organism. PCR can be performed on ethanol-fixed cytology slides, fresh tissue, lesion swabs, and paraffin-embedded tissue sections (provided that the sample has not been fixed for longer than 48 h, as the formalin tends to degrade DNA after this period).

If regional lymphadenopathy is detected, FNA or biopsy may be attempted, particularly if metastatic neoplasia is suspected. Ideally, in most cases a minimum database of haematology/biochemistry, urinalysis, and retroviral testing should be obtained before treatment is attempted. Further imaging such as nasal CT, thoracic radiographs/CT, and abdominal ultrasound may also be considered if systemic involvement or concurrent disease is suspected or if tumour staging is required.

Diagnostic Test Results

An FNA was obtained from the lesion in this case and cytological examination of a Diff Quik® stained slide revealed the presence of pyogranulomatous inflammation with pleomorphic fungal organisms. The cat was anaesthetized and the lesion was debulked (Figure 1.12), and fresh and formalin-fixed tissue was submitted to the laboratory. A mycotic dermal granuloma was confirmed on histopathology and the organism was cultured and identified at a specialist reference laboratory as an *Alternaria* spp. Routine haematology, serum biochemistries, and urinalysis were within normal limits, and retroviral testing was negative.

Q 3. What treatment options are available for this case?

The mainstay of treatment for localized phaeohyphomycosis is surgical resection of as much grossly affected tissue as possible, followed by a prolonged course of systemic antifungal therapy (ideally determined by in vitro susceptibility testing, although this can be unreliable for moulds). Suitable antimicrobials include itraconazole and posaconazole. Moulds are not susceptible to fluconazole, and voriconazole has been reported to cause neurological side effects in cats. As itraconazole has been observed to cause a dose-dependent hepatotoxicity, routine monitoring of alanine transferase is recommended on at least a monthly basis during therapy.



Figure 1.12. Appearance of Case 1.5, 10 days after surgery.

Further Case Information

The cat in this case report was initially treated with 50 mg of itraconazole PO SID with food, then the treatment regimen was changed to 32 mg posaconazole PO SID for 3 months. There had been no recurrence of disease at 1 year post diagnosis, and the cat was subsequently lost to follow-up.

Discussion

Localized infections of the nasal bridge by saprophytic organisms are occasionally reported in the cat, and cases with no evidence of concurrent nasal involvement are thought to arise from penetrative injuries from plant thorns or cat scratches, where the spores are likely to be inoculated directly into the subcutaneous tissue. Infections tend to be confined to the skin and/or subcutis; however, cerebral phaeohyphomycosis has been reported in the cat.

Alternaria spp. are routinely found in soil. The fungal spores distribute over a wide range and are found ubiquitously on household surfaces. These organisms have been cultured from the skin of animals including cats, thus it is important that the diagnosis is not made from culture alone, but is accompanied by clinical and pathological evidence of invasive fungal disease. A serosurvey of cats from the United Kingdom demonstrated widespread exposure to the organism that tended to increase with age, and there appeared to be no difference in antibody levels between cats housed indoors or with access to the outdoors, or in individuals domiciled in urban or non-urban environments. Frustratingly, there also appeared to be no difference in antibody titres between uninfected controls and cats with confirmed alternariosis, thus precluding this as a clinical test for the disease.

Although infections with saprobes are often associated with immunosuppression in people, the vast majority of cats are apparently immunocompetent, although all patients should routinely undergo testing to rule out concurrent disease, including retroviral infection.

Further Reading

- Dye, C., Johnson, E.M., Gruffyd-Jones, T.J., 2009. *Alternaria* spp. infection in nine domestic cats. *Journal of Feline Medicine and Surgery* 11, 332–336.
- Malik, R., Vogelnest, L., O'Brien, C.R., et al., 2004. Infections and some other conditions affecting the skin and subcutis of the naso-ocular region of cats – clinical experience 1987–2003. *Journal of Feline Medicine and Surgery* 6, 383–390.
- Malik, R., Norris, J., White, J., Jantulik, B., 2006. Wound cat. *Journal of Feline Medicine and Surgery* 8, 135–140.
- Miller, R.I., 2009. Nodular granulomatous fungal skin disease of cats in the United Kingdom: a retrospective review. *Veterinary Dermatology* 21, 130–135.

Case 1.6

Signalment, Clinical History, and Clinical Examination

A 15-year-old FN DSH cat was presented with a history of suspected inflammatory bowel disease and recurrent pancreatitis over the past 2 years. The cat had been treated with low-dose oral prednisolone and metronidazole, plus dietary modification; however, persistently elevated serum glucose and fructosamine concentrations as well as the clinical finding of polyuria and polydipsia prompted a diagnosis of diabetes mellitus, thought to be likely due to the effects of recurrent acute or chronic pancreatitis and the long-term use of glucocorticoids. Glargine insulin BID therapy was commenced. Oral metronidazole (50 mg PO BID) was continued, but the prednisolone was changed to budesonide (1 mg PO SID).

The cat responded well to the treatment regimen, with body weight increasing from 3.2 to 4.8 kg. The cat remained relatively well for the next 12 months but began to require an increased dose of glargine, and her owner noted inappropriate urination and coat changes (dry flaky skin with ventral (Figure 1.13) and bilaterally symmetrical trunk and flank alopecia).

Q 1. What are the possible differential diagnoses for bilaterally symmetrical alopecia in this case?

- Infectious/parasitic
 - Dermatophytosis
 - Demodicosis (*Demodex cati*, *D. gatoi*)
 - Sarcoptic mange
 - *Cheyletiella* spp. mites
- Endocrine
 - Hyperadrenocorticism (pituitary dependent, adrenal cortex adenoma/carcinoma, iatrogenic)

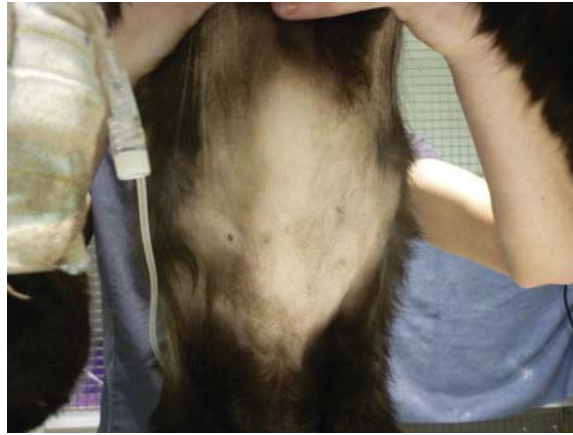

Figure 1.13. Alopecia was evident on the ventral abdomen.

- Paraneoplastic
 - Pancreatic/hepatic adenocarcinoma
- Allergic
 - Flea allergy dermatitis
 - Food allergy
 - Atopy
- Inflammatory
 - Lymphocytic mural folliculitis
 - Sebaceous adenitis
- Psychogenic
- Telogen effluvium
- Alopecia areata

Q 2. *How would you investigate the alopecia further at this stage?*

Further historical information should be obtained from the owner, such as the presence of behaviours indicating pruritus (e.g. excessive grooming, rubbing, or chewing of the affected areas). Also, it should be noted whether the hair can be epilated easily.

Initial diagnostic tests might include:

- Examination of skin scrapings to look for parasites (superficial scrapings are required for *D. gatoi*, deep scrapings for *D. cati*)
- Flea combing
- Adhesive (acetate) tape preparations (unstained for *Cheyletiella* mites, stained for skin cytology)
- Wood's lamp examination/dermatophyte culture
- Hair trichogram to examine for evidence of fungal infection, overgrooming, stage of growth, and possibly evidence of *Demodex* infestation (around the hair bulb)

- Abdominal ultrasonography looking for evidence of pancreatic or hepatic neoplasia
- Skin biopsy

Diagnostic Test Results

The results of the skin tests listed above were all negative for the cat in this case. There was no evidence of hair shaft trauma on the trichogram that would indicate overgrooming. Abdominal ultrasonography revealed that the kidneys were normal in size and shape; however, the corticomedullary distinction was reduced. The liver had a diffusely coarse echotexture. There was mild regional thickening of the duodenum with no loss of layering. The pancreas was somewhat hypoechoic with homogeneous echotexture. The rest of the abdominal organs, including the adrenal glands, were within normal limits. Skin biopsies were not performed.

Q 3. *What are the possible differential diagnoses for inappropriate urination in this case?*

- Cystitis
 - Bacterial
 - Fungal
 - Sterile/idiopathic
- Neoplastic
 - Transitional cell carcinoma
 - Other (e.g. lymphoma)
- Urolithiasis (struvite, calcium oxalate, other)
- Polyuria/polydipsia
 - Poorly controlled diabetes mellitus
 - Chronic kidney disease
 - Hyperadrenocorticism
 - Diabetes insipidus (nephrogenic or central)
 - Hyperthyroidism
- Behavioural
 - Stress response (note that stress also plays an important role in the development of feline idiopathic cystitis)
 - Neurological disease (cerebral)

Further Information

A neurological examination was within normal limits. Urinalysis revealed a urine specific gravity of 1.015, trace protein, negative glucose, and inactive urine sediment. A blood glucose curve was performed that showed adequate control of the diabetes mellitus on the current dose of glargine insulin (4 IU SC BID). At this point it was noted that the cat had developed hyperpigmentation and comedones on the skin of the lateral thorax (Figure 1.14).

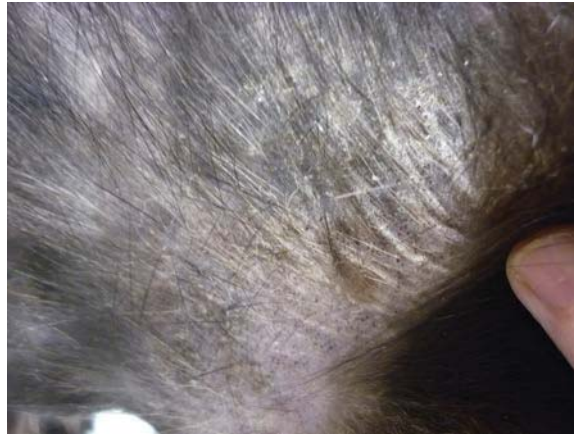

Figure 1.14. Hyperpigmentation and comedones were present on the skin of the lateral thorax.

Q 4. *What is the likely diagnosis?*

The most likely diagnosis is iatrogenic hyperadrenocorticism secondary to systemic absorption of budesonide. Concurrent chronic kidney disease should also be considered.

Q 5. *How could you confirm the diagnosis?*

An adrenocorticotrophic hormone (ACTH) stimulation test is used to confirm iatrogenic hyperadrenocorticism. Serum is collected for a resting cortisol level, and a second sample is taken 1 h after the intravenous or intramuscular administration of 125 µg of tetracosactrin.



Tip Box

Cortisol concentrations have a much more variable peak in cats than dogs after administration of tetracosactrin, thus some authors recommend that two samples be collected, and the recommended time interval varies from 30 to 180 min.

In the face of excessive exogenous glucocorticosteroid administration, the hypothalamic-pituitary-adrenal (HPA) axis is suppressed, resulting in atrophy of the cortisol-producing cells in the zona fasciculata and zona reticularis of the adrenal cortex, resulting in a reduced release of endogenous cortisol in response to the administration of a synthetic ACTH analogue.

The results of the ACTH stimulation test for this case are shown in [Table 1.1](#).

Although only the 60-min post-stimulation blood sample was collected in this case, the results unequivocally support the diagnosis of iatrogenic hyperadrenocorticism.

Table 1.1 ACTH Stimulation Test Results

	Result	Reference Interval (nmol/L)
Resting cortisol	<8	28–138
Cortisol 1 h post stimulation	<8	55–220

Discussion

Spontaneous hyperadrenocorticism (due to either overproduction of ACTH by a pituitary adenoma or excessive cortisol excretion due to an adrenal tumour) is rare in the cat, and iatrogenic hyperadrenocorticism due to excessive administration of exogenous corticosteroids is also relatively uncommon. Feline iatrogenic hyperadrenocorticism has been reported secondary to parenteral methylprednisolone, dexamethasone, topical triamcinolone 0.1% ointment, inhalational fluticasone, and oral prednisolone.

Affected animals typically display the hallmark clinical features of hyperadrenocorticism, such as polyuria/polydipsia, lethargy, and muscle wastage, a pot-bellied appearance, and skin and coat changes (thin, fragile skin, and/or generalized alopecia). Typically, clinicopathological abnormalities include an elevation in alanine transferase (presumably due to a steroid hepatopathy or hepatic lipidosis). It is important to note that, unlike dogs or people, cats typically do not display elevated alkaline phosphatase levels with this disease, as they lack a steroid-induced isoenzyme of alkaline phosphatase. As with naturally occurring hyperadrenocorticism, insulin resistance leading to diabetes mellitus is frequently a sequel to increased circulating glucocorticosteroid levels.

Budesonide is a potent corticosteroid and the enteric-coated oral formulation is used to treat Crohn's disease in people, where it causes negligible suppression of the HPA axis due to an extensive first-pass effect in the liver. There is evidence that some HPA suppression does occur in dogs given the drug; however, the effects are less than an equivalent dose of prednisolone. Budesonide is recommended by many authors as a useful adjunct to the treatment of inflammatory bowel disease in cats that are experiencing significant side effects due to prednisolone, or have a comorbidity that mandates the minimization of steroid doses (e.g. diabetes mellitus). The HPA-suppressive effects of this drug have not been studied in the cat, and although it usually appears well tolerated in most patients, iatrogenic hyperadrenocorticism has been anecdotally reported in the cat.

Further Reading

- Lien, Y., Huang, H., Chang, P., 2006. Iatrogenic hyperadrenocorticism in 12 cats. *Journal of the American Animal Hospital Association* 42, 414–423.
- Sparkes, A., Adams, D.T., Douthwaite, J.A., Gruffydd-Jones, T.J., 1990. Assessment of adrenal function in cats: response to intravenous synthetic ACTH. *Journal of Small Animal Practice* 31, 2–5.

Case 1.7

Signalment, Clinical History, and Clinical Examination

A 12-year-old MN Birman cat was presented because of lethargy and non-pruritic crusting skin lesions on the eyelid and lip margins, nasal planum (Figure 1.15), ventral chin, and ear pinnae (Figure 1.16). There were similar lesions on the skin of the dorsal spinal region and tail base, interdigital spaces of all four feet (Figure 1.17), as well as paronychia of multiple nail beds. There was evidence of mild flea infestation. Rectal temperature was recorded as 39.5 °C, but the rest of the physical examination was normal.

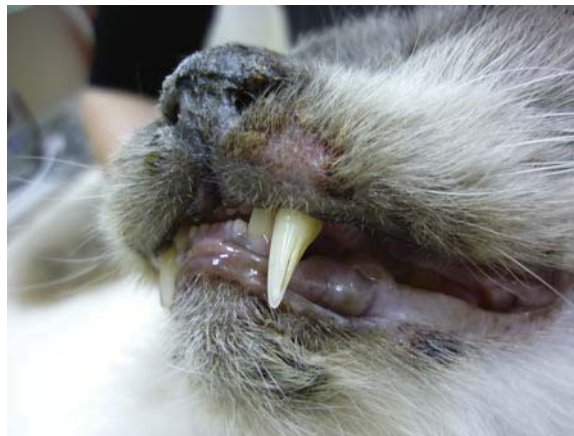

Figure 1.15. Appearance of Case 1.7 on initial presentation. Note the crusting lesions on the lip margins and nasal planum.

Q 1. What are the possible differential diagnoses for the skin lesions in this case?

- Dermatophytosis
- Parasitic skin disease
 - Demodicosis
 - Sarcoptic mange
 - *Notoedres cati*
- Immune mediated
 - Flea allergy dermatitis
 - Pemphigus foliaceus
 - Pemphigus erythematosus
 - Discoid lupus erythematosus
 - Systemic lupus erythematosus
 - Cutaneous drug reaction

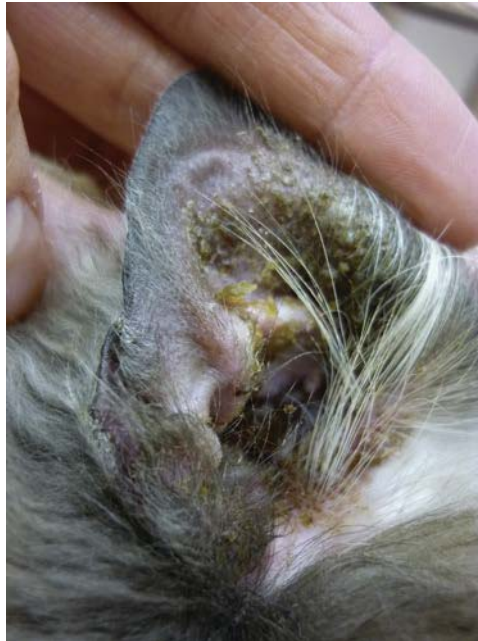

Figure 1.16. Crusting dermatitis on the inner surface of the pinnae of Case 1.7.



Figure 1.17. Crusting interdigital dermatitis was evident in Case 1.7.

- Cutaneous T-cell lymphoma
- SCC in situ
- Paraneoplastic exfoliative dermatitis (e.g. thymoma related)
- Bacterial folliculitis
- Herpes virus dermatitis

Q 2. How would you investigate this case further?

Cytology of the lesions should be performed to assess for the presence of secondary infection and to look for acantholytic keratinocytes (although their presence is not pathognomonic for pemphigus foliaceus).



Tip Box

Samples for cytology are best collected by one of three methods: (1) clear adhesive tape, (2) impression smears, or (3) gentle skin scraping with a blunt spatula.

In this case, impression smears were collected by gently but firmly pressing a clean glass slide over the affected areas. Samples can then be methanol fixed and stained with a Romanowsky-type stain such as Diff Quik® or similar.

Samples can be collected for dermatophyte culture by either plucking hairs and/or skin scales at the margins of lesions with a clean pair of forceps. Broken or frayed hairs, or those that fluoresce under Wood's lamp illumination, should be preferentially selected. The plucked hairs are then firmly pressed into the surface of a DTM tube. The cap of the tube should be loosely replaced and the tube incubated at room temperature for 10–14 days, checking for a red colour indicator change directly beneath the developing fungal colony (this may appear any time from 48 h after inoculation). Ideally, a suspected positive result is confirmed by identifying the morphology of developed conidia as either *Microsporum* or *Trichophyton* spp. under microscopic examination.

Deeper skin scrapings can help to rule out parasites. If there is evidence of bacterial pyoderma on cytology, samples can be submitted for aerobic culture (and/or the cat should be given an empirical course of antibiotics suitable for the treatment of superficial pyoderma). A skin biopsy is also warranted in this case.

A minimum database consisting of haematology, serum biochemistry, and urinalysis should be performed to assess for systemic disease.

Diagnostic Test Results

Cytological examination of a Diff Quik®-stained impression smear of a nail-bed lesion showed large numbers of often degenerate neutrophils with extracellular and occasionally intracellular bacteria. Intermixed with these were individual and aggregated parabasal, intermediate, and cornified nucleated squamous cells, indicative of acantholysis (Figure 1.18).

Interpretation: likely pemphigus foliaceus with secondary bacterial pyoderma.

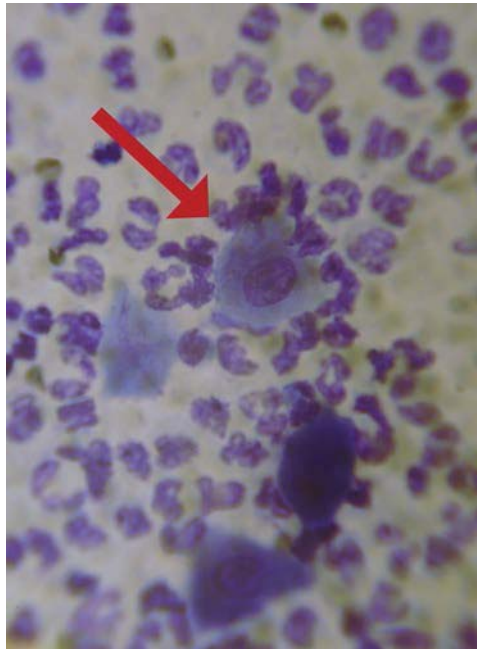


Figure 1.18. Diff Quik®-stained cytology of the exudate obtained from the nail bed in this case. Note the individual nucleated keratinocyte (red arrow) amongst the numerous degenerate neutrophils ($\times 1000$).

Blood and urine were collected for routine analysis and were within normal limits, apart from a mild mature neutrophilia, mild eosinophilia, and mild increase in serum gamma globulins.

Skin biopsies were obtained after 2 weeks of oral cephalexin therapy (75 mg PO BID). These revealed an acanthotic and hyperplastic epidermis with diffuse neutrophilic infiltration into the superficial dermis. Some areas appeared to have superficial crusts and others appeared ulcerated; however, there were still remnants of subcorneal pustules that contained non-degenerate neutrophils and acantholytic keratinocytes. No microorganisms were identified visually. The likely histopathological diagnosis was pemphigus foliaceus.

Q 3. *How would you manage this case?*

Antibiotics were used in this case to treat the secondary pyoderma. Ideally antibiotic selection is based on the results of culture and susceptibility testing; however, amoxicillin-clavulanate or a first-generation cephalosporin are appropriate empirical choices for pyoderma. Likewise, a strict flea control regimen such as monthly selamectin would be recommended for this cat.

Treatment for pemphigus foliaceus is usually initiated with immunosuppressive doses of glucocorticosteroids. Oral prednisolone is often the initial choice; however, some animals respond more favourably to triamcinolone or dexamethasone. Recently, the successful use of topical glucocorticoids (e.g. hydrocortisone aceponate) has been reported. These drugs may also be combined with chlorambucil or ciclosporin,

although glucocorticoid monotherapy is usually adequate. Management of any concurrent pyoderma is important, and gentle medicated shampooing (often under mild sedation) may help to lift the crusts and make the cat more comfortable in the initial stages of treatment. Ideally, owners should be advised to avoid sun exposure in affected cats.

Anecdotally, due to its presumed immunomodulatory effects, doxycycline at 5 mg/kg PO SID or BID may be helpful as an adjunct to glucocorticoids in mildly affected cases.



Tip Box

Oesophageal strictures have been associated with the use of the hydrochloride formulations of doxycycline; thus the monohydrate formulations should be chosen, liquid formulations used, or 5 mL water given PO after tableting.

Q 4. Are there any predispositions or exacerbating factors for pemphigus foliaceus in cats?

The condition does not appear to have an age, breed, or sex predisposition in cats. Stress and UV light exposure may exacerbate the condition, and some cases appear to be triggered by previous or concurrent illnesses such as infections or neoplastic processes (especially thymoma). There is speculation that some cases may be triggered by prior or current drug therapy, although evidence for this association is weak in cats.

Discussion

Although infrequently reported, pemphigus foliaceus is the most common autoimmune dermatopathy in cats. It is likely caused by the production of autoantibodies directed against the intracellular adhesions (desmosomes) between the keratinocytes of the superficial epidermis, although the exact immunological pathogenesis of the disease in cats has not been investigated at this stage.

It tends to have a waxing and waning clinical course that often starts on the head and/or feet, and then spreads to other areas, occasionally becoming generalized. Affected cats may be systemically unwell with anorexia, lethargy, and pyrexia (perhaps due to secondary bacterial infection of the lesions).

The finding of acantholytic keratinocytes on cytological examination of pustule exudate is suggestive of, but not pathognomonic for, pemphigus foliaceus. The diagnosis requires confirmation with the finding of pustules and acanthocytes within the stratum corneum.

If an identifying trigger can be identified and removed, the cat may eventually be able to be weaned off immunosuppressive treatment; however, most animals require treatment for life. The response to treatment is usually favourable, and most cats have a good prognosis with regards to disease control even if the condition cannot be cured in most cases.

Further Reading

- Neuber, A., Shaw, S.C., 2011. Topical application of hydrocortisone aceponate spray (Cortavance) for the treatment of pemphigus foliaceus in a cat. *Wiener Tierärztliche Monatsschrift* 98, 156–159.
- Olivry, T., 2006. A review of autoimmune skin diseases in domestic animals: I – Superficial pemphigus. *Veterinary Dermatology* 17, 291–305.

Case 1.8

Signalment and History

A 10-month-old MN Burmese presented with a swelling over the point of his right shoulder of 4 days' duration. No other clinical signs were present. The cat was a mixed indoor/outdoor cat and had possibly fallen off the garage roof a few days previously. The cat had been seen by a veterinarian a week previously for faucitis (caudal stomatitis), and a long-acting cefovecin injection had been administered.

Clinical Examination

Vital parameters were within normal limits: the cat weighed 5 kg with a BCS of 5/9. Faucitis (caudal stomatitis) was still present. There was a semifluctuant 3-cm-diameter non-painful swelling over the point of the right shoulder. The central area of the swelling was alopecic and slightly black in colour, with a hard/brittle surface.

Q 1. Formulate a list of differential diagnoses for the swelling.

- Seroma post trauma
- Abscess
- Foreign body reaction (e.g. to microchip)
- Atypical bacterial/fungal infection
- Haematoma
- Injection site reaction pattern (e.g. from previous cefovecin injection)
- Chemical/heat burn/insect bite
- Connective tissue disorder
- Neoplasia
- Synovial cyst

Q 2. How would you manage this case?

Aspirating the mass and collecting material for cytology and culture is likely to be most useful diagnostically. In this case 5 mL of clear serosanguinous fluid was aspirated and this resolved the swelling. In-house cytology revealed a mix of red blood cells and non-degenerate neutrophils. The fluid was not cultured.

The cat re-presented 1 day later with another identical swelling at the same site.

Q 3. How would you further investigate this case?

Options for further investigation include:

- Aspiration of the new swelling for further cytology +/- culture
- Imaging of the shoulder joint as synovial cysts, although rare in this location, are often associated with joint pathology
- Further investigation to look for a foreign body (e.g. imaging) and determining microchip location
- Coagulation tests (e.g. buccal mucosal bleeding time, prothrombin time [PT] and activated partial thromboplastin time [APTT]) to exclude a coagulopathy that could be causing recurrent haematomas

- Collection of samples of the mass and overlying skin for histopathology and fungal/bacterial culture

Further Case Information

Packed cell volume (PCV) and coagulation times were normal: PCV 43%, APTT 11 s, PT 10 s and platelet count normal.

No abnormalities of the shoulder joint were noted on radiography and the microchip was located 15 cm away from the mass. Surgical biopsy of the mass and overlying skin was elected as the next course of action.

It was decided to proceed to surgery to remove affected tissue and obtain samples for pathology. During surgery the dermis cut normally; however, the subcutis came apart in stringy stands of sticky white connective tissue. Strict haemostasis was observed (cautery and ligature where indicated) to reduce the chance of seroma formation. Closure of the wound was difficult; the subcutis was closed with a simple continuous pattern (4-0 polyglycolic acid) with many of the sutures pulling through. Tacking sutures were placed from subcutis to the muscle layer. Dermal closure was without concern and a cruciate pattern of 3-0 monofilament nylon was used. A torso body bandage was placed postoperatively to reduce the chance of seroma formation. It was decided not to place a drain since if the connective tissue was abnormal a drain might delay healing. The cat was discharged with transmucosal buprenorphine analgesia. The wound healed uneventfully.

The skin over the affected area was biopsied and sent for histopathology, and a small sample was kept in a saline swab in case culture was indicated.

On further examination it was noted that large flaps of skin (5–6 cm) could be pulled up (Figures 1.19–1.21).

Q 4. Can you refine your differential diagnosis list at this stage?

Given the findings at surgery, the recurrent nature of the swelling, absence of foreign body or coagulopathy, it seemed most likely that there was a reaction to the previously injected antibiotic or a connective tissue disorder.

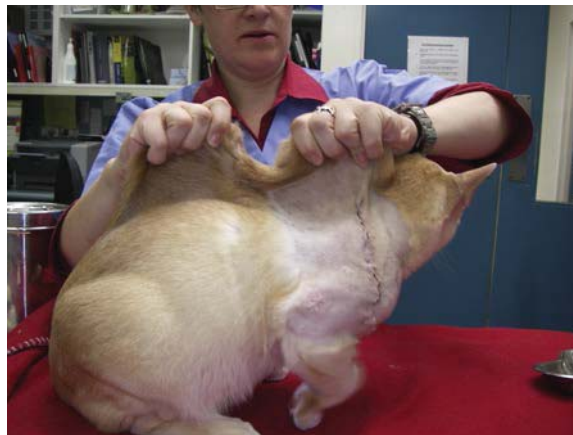

Figure 1.19. Case 1.8 showing a lack of skin elasticity.

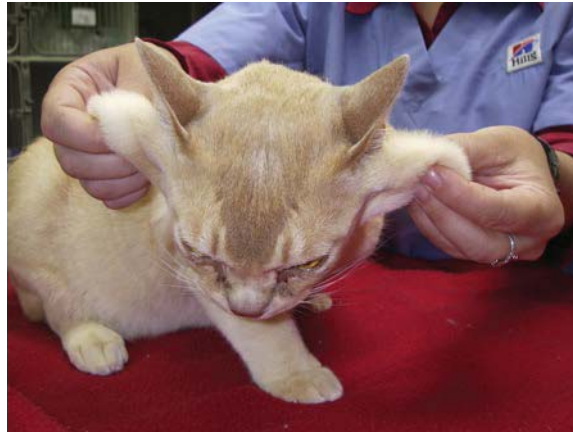

Figure 1.20. Case 1.8 with exaggerated skin distension.

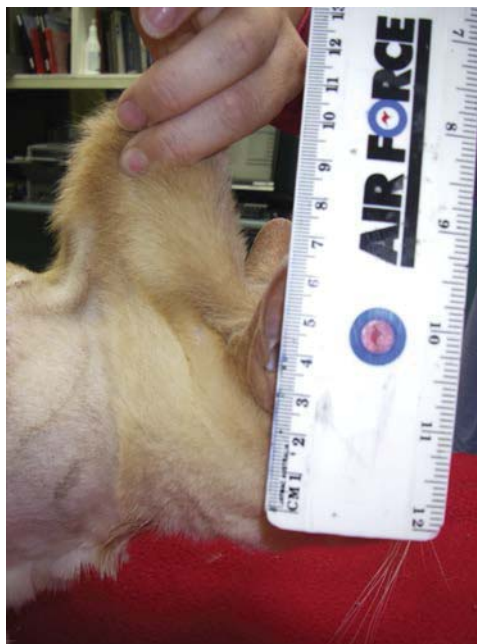

Figure 1.21. Hyperextensibility of the skin in Case 1.8.

Further Case Information

Histopathology revealed the presence of a collagen disorder. Special stains demonstrated that quite a few of the collagen bundles contained a red core surrounded by normal blue-staining collagen using Masson's trichrome stains. This change is said to be highly suggestive of altered collagen in Ehlers-Danlos-like syndrome (feline cutaneous aesthenia).

Q 5. *What advice would you give to the owner?*

This is an inherited disorder and therefore affected cats should not be bred.

Cats should be housed indoors and measures taken to prevent accidental or self-trauma as skin is easily torn, difficult to suture, and areas of dermal necrosis may develop. Despite the difficulty in suturing wounds, the skin does tend to heal normally.

As cats age skin tuck procedures may be required to remove excess skin.

If there is indication of joint laxity and associated pain, suitable analgesia should be commenced.

There has been some experimental use of pentoxifylline due to its ability to reduce platelet adhesion to damaged vessel walls and increase oxygen release, thereby reducing clot formation and ischemia. There are limited studies evaluating the drug's efficacy.

Cats can be expected to have a near normal life expectancy provided skin lesions can be managed.

Discussion

Ehlers-Danlos syndrome is a rare connective tissue disorder reported in humans, and a similar syndrome is reported in dogs, cats and occasionally other species. Affected cats have a defect in the structure, function or production of collagen. In Ehlers-Danlos-like syndrome (feline cutaneous aesthenia) syndrome the weak collagen allows shearing of the blood vessels that supply the dermis, leading to infarction of the skin and necrosis, as occurred in this case. Hereditary collagen dysplasia in cats encompasses a group of rare connective tissue disorders with slight variance in the exact genetic mutation involved. Both autosomal dominant and recessive traits have been found. Cats are usually normal as kittens with clinical signs becoming more overt as they age and the weak collagen allows skin distension. Clinical signs are somewhat varied but include:

- Hyperextensibility of cutaneous tissue: quantified by the skin elasticity test: height of the skin when elevated from the dorsal midline/length of animal $\times 100$. Average values are 19% in cats; values higher than this are consistent with collagen abnormalities.
- Development of areas of dermal necrosis
- Easily torn skin
- Joint laxity
- Seroma formation
- In humans the condition is associated with cardiovascular and gastrointestinal complications

Diagnosis is based on clinical signs and histopathology with altered distribution, length, and staining of collagen fibres. Not all animals with this syndrome demonstrate sufficient changes under light microscopy, and electron microscopy

may be required for diagnosis. These conditions are different to fragile skin syndrome associated with some neoplastic and endocrine conditions in older cats.

Further Reading

Sequeira, L.J., Rocha, N.S., Bandarra, E.P., Figueiredo, L.M.A., Eugenio, F.R., 1999. Collagen dysplasia (cutaneous asthenia) in a cat. *Veterinary Pathology* 36, 603–606.

Case 1.9

Signalment and Clinical History

A 7-year-old MN Ragdoll presented for investigation of cutaneous nodules on the bridge of the nose and cranial to the base of the left ear, similar to those shown in [Figure 1.22](#). The cat had lost approximately 400 g over a 12-month period. The cat lived in Sydney, Australia, and was primarily indoors with access to a large courtyard garden. It was fed a premium commercial wet and dry diet. Vaccination, worming, and flea control were up to date.

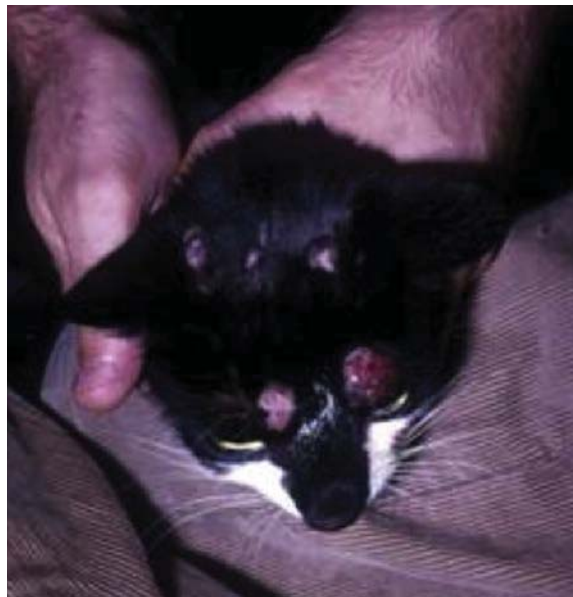

Figure 1.22. Case 1.9 presented with lesions similar to those seen in this image.

Clinical Examination

The cat was slightly underweight (BCS 2.5/5), weighing 3.6 kg, and normothermic (rectal temperature 38.1 °C). There were four erythematous, firm cutaneous nodules

on the head: two proximal to the nose and two at the base of the right ear. Mandibular lymph nodes were bilaterally enlarged. No other significant abnormalities were noted.

Q 1. *Formulate a differential diagnosis list for cutaneous nodules in the cat (for all geographic locations).*

- Bacterial infection
 - Actinomycosis
 - *Actinobacillus*
 - Nocardiosis
 - Mycobacteria (particularly feline leprosy syndrome)
 - Bacterial pseudomycetoma
 - Miscellaneous (e.g. melioidosis)
- Fungal infection
 - Aspergillosis
 - Blastomycosis
 - Coccidioidomycosis
 - Cryptococcosis
 - Dermatophytosis
 - Eumycotic mycetoma
 - Histoplasmosis
 - Phaeohyphomycosis
 - Sporotrichosis
 - Trichosporonosis
- Other infectious causes
 - Algal infection (e.g. protothecosis)
 - Nematode infection (e.g. cutaneous habronemiasis)
 - Protozoal infection (e.g. leishmaniasis)
- Neoplasias
 - Basal cell tumour
 - Fibrosarcoma
 - Mast cell tumour
 - SCC
- Miscellaneous
 - Foreign body
 - Cellulitis
 - Cutaneous histiocytosis
 - Sterile nodular panniculitis

Q 2. *How would you further investigate this case?*

Cytological evaluation of impression smears or FNAs of nodules stained with Diff Quik® is a minimally invasive, inexpensive first step that frequently allows for direct visualization of causative organisms (e.g. *Cryptococcus* spp., *Nocardia* spp., mycobacterial infections) and some neoplasms (e.g. cutaneous mast cell tumour, SCC).

Biopsy and histopathological evaluation allows definitive diagnosis and exclusion of neoplastic disease. Ideally, multiple biopsies are taken so that some can be submitted in formalin while some can be stored at 5 °C for cultures and susceptibility testing as required.

Systemic health is evaluated with a minimum database including a CBC, biochemistry panel (including total thyroxine (T4)), and urinalysis (which may indicate a metabolic cause of weight loss), as well as viral studies including FeLV antigen and FIV antibody testing.

Specific tests can be ordered on the basis of preliminary results.

Diagnostic Test Results

- Cytological evaluation of a Diff Quik® smear revealed numerous round to oval extracellular yeasts characterized by a clear capsule or halo and narrow-based budding.
- Histopathological evaluation revealed pyogranulomatous inflammation consisting of activated macrophages and neutrophils, and incorporating numerous organisms. On this basis a diagnosis of cryptococcosis was made.
- Cryptococcal antigen latex agglutination serology returned a titre of >2048 (an antigen titre of >2 is positive and indicates active infection).
- FIV antibody ELISA and FeLV antigen ELISA were both negative.

Q 3. *In what countries is cryptococcal infection commonly seen?*

It is most common in Australia, the United States, and Canada, but can occasionally be seen in the United Kingdom and other European countries, and would be lower on the list of differential diagnoses in these countries. Other regions in which this infection occurs include sub-Saharan Africa and South America.

Q 4. *List possible clinical signs associated with feline cryptococcosis.*

- Solitary to multiple cutaneous nodules or ulcerated plaques on the face, trunk, or limbs.
- Mass lesions associated with the nasal cavity, bridge of nose, and frontal sinuses, often associated with unilateral to bilateral serous, mucopurulent or haemorrhagic nasal discharge, and upper respiratory signs (sneezing, snuffling, stertor). Nasopharyngeal granulomas may develop.



Tip Box

Cats with cryptococcosis may present with a variety of clinical signs affecting the skin and subcutis, central nervous system (CNS) and respiratory tract (particularly the nose).

- Pulmonary and pleural space disease leading to dyspnoea or tachypnoea, reflecting the presence of cryptococcal pneumonia, pleuritis, or a cryptococcal mediastinal mass (rare in Australia, but seen in California).
- CNS involvement: cryptococcal meningitis, multifocal granulomatous encephalomyelitis, often leading to obtundation, behavioural changes, hyperaesthesia,

seizures, vestibular signs, anisocoria, and blindness (due to retinal or optic nerve involvement).

- Less frequently, infection is identified in bone, gingiva, liver, mediastinum, myocardium, spleen, thyroid gland, or tongue.

Q 5. What is the current recommended treatment?

Treatment with an azole, such as fluconazole or itraconazole, is recommended often in combination with flucytosine, depending on the degree of systemic involvement. For nasal cavity involvement alone, monotherapy with fluconazole may be adequate. Fungal culture of a nasal swab and susceptibility testing should be performed to direct optimal treatment. Cats with CNS involvement or disseminated disease should also be treated with amphotericin B. A recommended protocol is 0.5–0.75 mg/kg amphotericin B in 400 mL of 0.45% NaCl with 2.5% dextrose SC twice a week, to a cumulative dose of at least 16 mg/kg. Fractious cats may require sedation.

Further Information on Response to Treatment, Diagnosis, and Outcome

The multiple cutaneous nodules in this case are suggestive of disseminated disease following nasal cavity infection. The cat was treated with flucytosine (125 mg PO TID for 30 days) and fluconazole 50 mg PO BID ongoing. At 6 months, the cryptococcal antigen latex agglutination serology had decreased to 16. Treatment was continued for another 12 months, at which point the cryptococcal antigen latex agglutination serology was zero and treatment was ceased. The owner was advised to repeat serology every 6 months due to the risk of recurrence.

Discussion

Cryptococcosis is the most common systemic mycosis of cats worldwide, predominantly caused by *C. neoformans* and *C. gattii* (formerly *C. neoformans* var. *gattii*). Inoculation is typically via inhalation of infected spores from environmental sources including pigeon excrement and decaying plant matter in the hollows of particular trees. In this case, landscaping may have liberated cryptococcal organisms from an environmental niche leading to infection of this patient. Nonetheless the disease is also reported in exclusively indoor-dwelling cats.

Siamese, Birman, and Ragdoll cats were overrepresented in an Australian study. Anecdotal reports suggest that these breeds may require prolonged, occasionally life-long treatment. The median age of affected cats is 6 years.

Cryptococcal species and molecular type vary with geographic location, potentially impacting presentation and antifungal susceptibility.

Recent studies suggest that retroviral status does not appear to be a risk factor for cryptococcosis, although FeLV-positive cats may be more likely to relapse and respond slowly to treatment than FeLV-negative cats.

In one study, 60% of cats were cured with an initial course of therapy, but one-third relapsed. Cats with CNS involvement, particularly those with altered mental status, had a less favourable prognosis. Neurological signs often worsened within the first 3 days of treatment with amphotericin B, possibly due to an inflammatory

response to dying *Cryptococcus* organisms. Short-term anti-inflammatory doses of glucocorticoids may improve survival in the first 10 days in cats with CNS involvement.

Treatment should be continued until a zero titre is achieved. Thereafter cats should be monitored regularly to detect relapse. There is no correlation between pretreatment cryptococcal antigen titre and outcome. Owners should be warned about the likelihood of relapse.

If Finances Are Limited

Monotherapy with fluconazole is relatively cheap, but may not be effective, particularly with CNS or other disseminated infection. If there is good response to monotherapy with fluconazole, then it should be continued lifelong, as this treatment alone is unlikely to be curative. Monotherapy with flucytosine is not recommended as organisms rapidly develop resistance.

Further Reading

O'Brien, C.R., Krockenberger, M.B., Wigney, D.I., et al., 2004. Retrospective study of feline and canine cryptococcosis in Australia from 1981 to 2001: 195 cases. *Medical Mycology* 42, 449–460.

Trivedi, S.M., Malik, R., Meyer, W., Sykes, J.E., 2011. Feline cryptococcosis: impact of current research on clinical management. *Journal of Feline Medicine and Surgery* 13, 163–172.

Case 1.10

Signalment and Clinical History

A 1-year-old MN DSH presented with mildly pruritic cutaneous lesions (Figure 1.23) on the face refractory to treatment with a 14-day course of cephalexin (20 mg/kg PO BID). Vaccination, worming, and flea control were up to date.

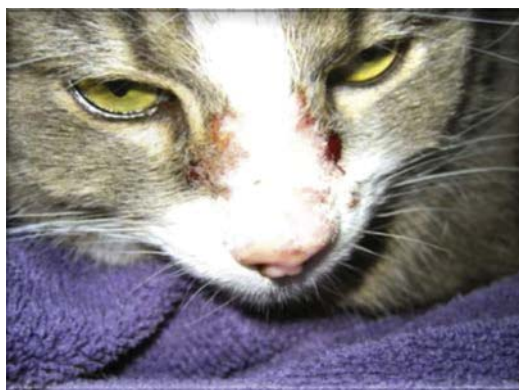

Figure 1.23. Erythema and erosions on the face of Case 1.10.

Clinical Examination

The cat was in good body condition (BCS 3/5). The facial lesions consisted of erythema and erosions extending from the medial canthus of the eyes onto the bridge of the nose. No other significant abnormalities were noted.

Q 1. List your key differential diagnoses for ulcerating and crusting dermatitis in cats.

- Bacterial
 - *Staphylococcus* spp.
- Fungal
 - Dermatophytosis
- Viral
 - Feline cowpox virus infection
 - Herpetic dermatitis
- Neoplastic
 - SCC
- Immune mediated
 - Eosinophilic granuloma complex
 - Mosquito bite hypersensitivity
 - Cutaneous adverse food reaction
 - Pemphigus foliaceus

Q 2. How would you further investigate this case?

Cytologic evaluation of Diff Quik® impression smears may be helpful in characterizing the local inflammatory response.

Fungal culture is required to definitively diagnose dermatophytosis and identify aetiologic agents; however, it may be possible to directly visualize fungal hyphae based on microscopic examination of hair-pluck samples.

Biopsy and histopathological examination typically allow for definitive diagnosis, with characterization of inflammatory response, visualization of neoplastic cells, viral inclusion bodies (FHV-1), and aetiologic agents in situ.

Diagnostic Test Results

Cytology of impression smears of the lesions revealed predominantly neutrophils, erythrocytes, and moderate eosinophils.

Histopathological examination of several punch biopsies revealed a predominantly eosinophilic inflammation, with the presence of viral inclusion bodies confirming a diagnosis of feline herpes virus (FHV-1).

Q 3. What other clinical signs can be associated with FHV-1 infection?

- Rhinitis (acute or chronic) and rhinosinusitis
- Conjunctivitis (most commonly bilateral but can be unilateral)

- Superficial and/or deep corneal ulcers, especially dendritic ulcers
- Less typically, acute disease may be associated with viraemia and pneumonia, particularly in kittens
- Chronic FHV infection may lead to stromal keratitis associated with corneal oedema, vascularization, and scarring
- FHV has also been associated with uveitis, corneal sequestra, and neurological disease

Q 4. How can FHV-1 as a cause of upper respiratory or ocular signs be diagnosed?

PCR on conjunctival, corneal, or oropharyngeal swabs is the diagnostic method of choice. Latent infection can also produce positive results, and so results need to be interpreted together with clinical signs.

Virus isolation, where available, can be helpful, but false negative results are common due to fragility of the virus.

FHV-specific antigen can be detected by immunofluorescence assay (IFA) on conjunctival or corneal smears or biopsies.

Serology is unreliable as antibody detection does not distinguish between active and latent infection, nor does it allow differentiation between naturally infected and vaccinated cats.

Q 5. How would you treat this case?

Famciclovir has been used for the treatment of FHV-1-associated disease, including chronic rhinitis and dermatitis, with a current dose recommendation of 30–40 mg/kg PO TID-BID. The rationale for using a systemic antiviral in these cases is that it reaches the superficial cornea and conjunctiva as well as the deeper tissues harbouring FHV-1, including the anterior uvea and neural tissues.



Tip Box

Famciclovir is an antiviral drug that has been evaluated in the treatment of FHV infection with a dose recommendation of 30–40 mg/kg PO BID-TID. Further clinical trials are required but promising results have been noticed in cats with ocular disease, rhinosinusitis and dermatitis associated with FHV.

Recombinant feline interferon omega has antiviral and immunomodulatory properties, and is licensed for use in cats. It has been shown to have a dose-dependent inhibitory effect on in vitro replication of FHV-1. It is typically injected on days 0, 2, and 4 at a dose of 1 MU/kg with another series of injections repeated in 7–14 days. Perilesional intradermal injection was associated with marked improvement in one cat.

Human interferon alpha has also been used at 5–35 U daily (the lower dose for oral administration, a higher dose for subcutaneous administration) but is less bioactive than feline interferon and does not reduce FHV-1 shedding.

Topical aciclovir has been used in some cases, but this drug should not be administered systemically as it is toxic to cats.

Further Information on Response to Treatment, Diagnosis, and Outcome

The cat was treated with famciclovir monotherapy for 21 days, and the lesions resolved almost completely. Eight months later the cat presented with the same symptoms and was treated again.

Discussion

FHV-1 can cause ulcerative and crusting facial dermatitis in cats, albeit not as commonly as upper respiratory tract and ocular signs. It should be suspected in cats with ulcerative dermatoses on the face and nasal planum, especially where there is a history of upper respiratory tract disease.

Histologically, FHV-1 dermatitis is characterized by epidermal necrosis with variable eosinophilic and neutrophilic infiltrate. Definitive histological diagnosis requires detection of intranuclear inclusion bodies, but these may be overlooked, leading to misdiagnosis as eosinophilic plaque or hypersensitivity.

To ensure biopsy samples are appropriate, samples of ulcerative lesions should include marginal epithelium, and nasal planum biopsies should include dermis. In the absence of inclusion bodies, a diagnosis can be confirmed using immunohistochemistry to detect viral protein.

Owners should be counselled about the risk of recurrence due to FHV-1 recrudescence. To this end, it may be useful to administer famciclovir during known stressful events (e.g. boarding the cat or moving house).

If Finances Are Limited

The least costly treatment options include topical aciclovir and/or orally administered famciclovir. Where herpes dermatitis is suspected based on the nature and distribution of lesions, a treatment trial prior to taking biopsies is a reasonable approach.

Further Reading

- Gutzwiller, M.E.R., Brachelente, C., Taglinger, K., et al., 2007. Feline herpes dermatitis treated with interferon omega. *Veterinary Dermatology* 18 (1), 50–54.
- Malik, R., Lessels, N.S., Webb, S., et al., 2008. Treatment of feline herpesvirus-1 associated disease in cats with famciclovir and related drugs. *Journal of Feline Medicine and Surgery* 11, 40–48.

Case 1.11

Signalment and Clinical History

An 11-year-old MN DSH cat presented for investigation of a non-healing wound at the base of the right ear. The wound had been present for several weeks, despite a course of amoxicillin-clavulanic acid, topical wound cleaning with dilute chlorhexidine, and application of an Elizabethan collar to prevent self-trauma.

The cat was in otherwise good health. Vaccination, worming, and flea control were sporadic. The cat had both indoor and outdoor access and was a known fighter.

Clinical Examination

The cat was in good body condition (BCS 3/5), and normothermic (rectal temperature 37.5 °C). There was an open, ulcerated wound, measuring approximately 1.5 cm long by 1 cm wide, with suppurative discharge (see [Figure 1.24](#)). Granulation tissue was present sporadically. A mass effect corresponding to the wound could be palpated to approximately 1 cm below the skin.

Q 1. Formulate a differential diagnosis list for non-healing wounds in the cat.

Both localized and systemic factors may contribute to non-healing wounds in the cat.

► Localized

- Infection (e.g. infection with mycobacteria or atypical bacteria such as *Nocardia* or *Actinomyces* spp.)
- Foreign body (e.g. a remnant of a claw or tooth embedded in the wound)
- Neoplasia (e.g. SCC, mast cell tumour, basal cell tumour, fibrosarcoma)
- Ischaemia
- Self-trauma
- Ongoing irritation (e.g. the owner may be applying a topical phenol)

► Systemic

- Metabolic disease (e.g. diabetes mellitus, chronic kidney disease, hypoalbuminaemia, malnutrition, hyperadrenocorticism, hyperthyroidism)
- Viral disease (e.g. FIV or FeLV)
- Systemic infection
- Neoplasia
- Administration of drugs affecting wound healing (e.g. corticosteroids)

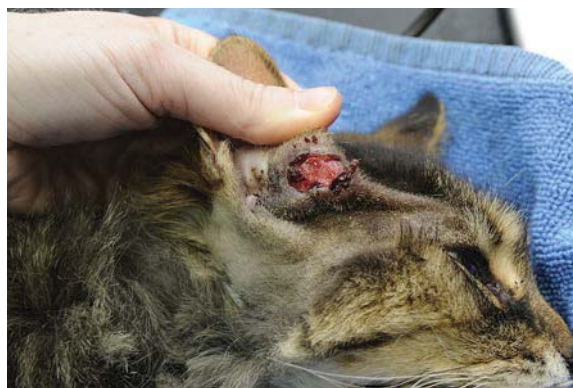

Figure 1.24. A close-up image of the wound at the base of the right ear.

Q 2. *How would you further investigate this case?*

Cytology of impression smears or FNAs can be a useful initial non-invasive investigation, and may reveal bacteria (including mycobacteria with ZN staining), neoplastic cells, or non-specific inflammatory changes. However, it will often not lead to a definitive diagnosis.

Biopsy allows histopathological evaluation, and in the case of delayed wound healing is the most definitive way to distinguish granulation tissue from neoplasia. Fresh tissue samples should be obtained in addition to formalin-fixed samples, in case special tissue cultures are required if histopathology is suggestive of unusual infectious agents such as mycobacteria.

A CBC and biochemistry panel, including total T4 and urinalysis, is useful in ruling out metabolic disease such as chronic kidney disease or diabetes mellitus, which may delay wound healing.

FIV/FelV ELISAs are also indicated.

Diagnostic Test Results

A complete blood count revealed a mild neutrophilia ($14.1 \times 10^9/L$, reference interval (RI) 2–13) and monocytosis ($0.9 \times 10^9/L$, RI <0.7), consistent with mild inflammation. The biochemistry panel including total T4 was unremarkable.

Histopathology of an excisional biopsy (Figure 1.25) was consistent with SCC with incomplete margins.

Q 3. *What are the risk factors for feline SCC?*

- Solar exposure leads to actinic changes that progress to carcinoma in situ and eventually invasive carcinoma. Outdoor cats are at an increased risk of developing SCC.
- White cats are 13 times more likely to develop solar-induced SCC than other coloured cats. Similarly, cats with unpigmented nasal planums or pinnae are at increased risk.

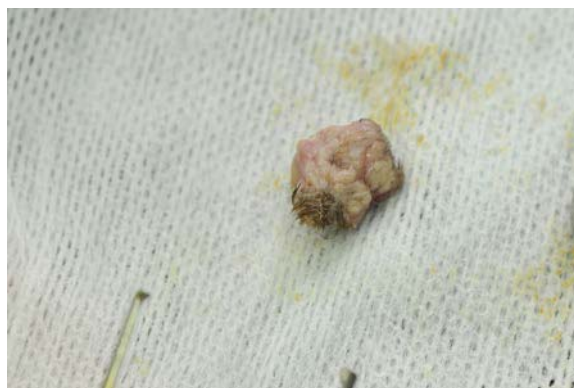

Figure 1.25. The mass following excisional biopsy. Margins were incomplete.

- Mutations of the tumour suppressor gene *p53* are found in >50% of cats with nasal planar SCC.
- The mean age for diagnosis of SCC is 12 years, suggesting age (and long-term exposure to ultraviolet (UV) light) is a risk factor. In the author's experience, SCC also occurs in relatively young cats.

Q 4. *What is the potential for metastases with this neoplasm, and would you undertake further investigations to stage neoplastic disease in this patient?*

SCC very rarely metastasize, and therefore thorough staging is not necessarily required, particularly if finances are limited. If they do metastasize, the most likely site is local lymph nodes.

- Assess size of regional lymph nodes, and FNA for cytology
- Thoracic radiographs (left lateral, right lateral, and ventrodorsal views) can be performed to assess for pulmonary metastases

Diagnostic Test Results

Cytologic evaluation of aspirates of submandibular lymph nodes revealed non-specific inflammatory changes.

Thoracic radiographs were taken (Figures 1.26 and 1.27).

Q 5. *What is your interpretation of the radiographs?*

There is an approximately 1.5×2 cm soft tissue smooth-edged mass containing multiple mineralized densities in the left cranial lung field at the level of the fourth intercostal space. The remainder of the lungs is unremarkable.

Care should be taken in the interpretation of this mass, since it may easily be assumed that this represents metastatic spread. However, this is not the typical appearance of pulmonary metastases. A single mass of this size, particularly with the

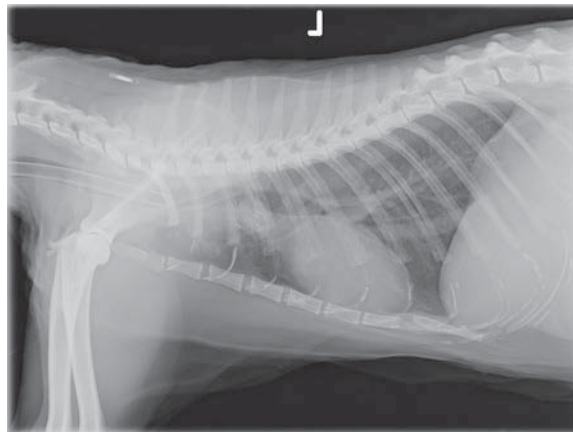


Figure 1.26. Left lateral radiograph revealing a pulmonary mass in the cranial thorax.

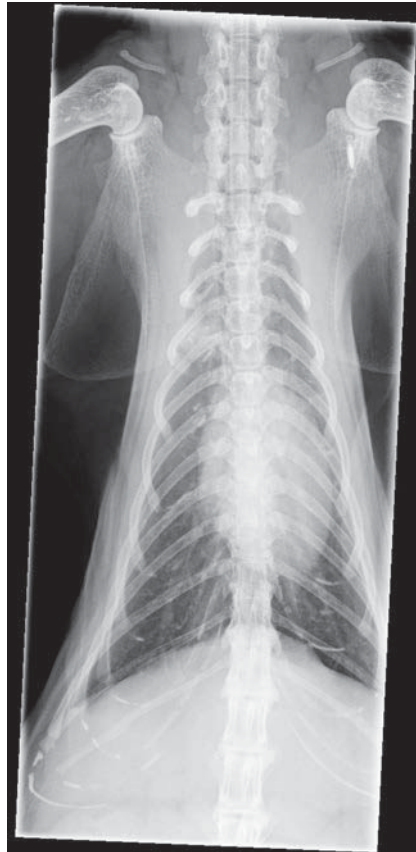


Figure 1.27. Ventrodorsal thoracic radiograph revealing the same mass in the left cranial thorax.

mineralization, is more likely to represent another disease process and be an incidental finding. An inflammatory granuloma may be most likely, but a primary pulmonary neoplasm (benign or malignant) is also possible.



Tip Box

Commonly incidental lung masses may be found in older cats, and their presence is therefore often difficult to interpret and may present a therapeutic dilemma. In cases of uncertainty, consultation with an imaging specialist is advisable.

Q 6. What treatment options would you give the owner?

As SCCs are typically locally aggressive and slow to metastasize, surgical excision is the treatment of choice in this case. Wide surgical excision with a skin flap may be necessary in this case, and consultation with a specialist surgeon may be advisable.

Other treatment options in the early stages of disease include cryosurgery, radiation therapy, strontium-90 plesiotherapy, photodynamic therapy, and intralesional carboplatin. For early nasal planar SCC, complete resection of the nasal planum is typically curative. Adjunct cryosurgery or radiotherapy is necessary if margins are incomplete.

Recent studies suggest that treatment with a dual cyclo-oxygenase (COX) and 5-lipoxygenase inhibitor such as tepoxalin, particularly in cases of oral SCC where 5-lipoxygenase expression was more common, may be worth evaluating in cats.

Further Information on Response to Treatment, Diagnosis, and Outcome

In this case, the owner declined further treatment or referral to an oncologist and elected for palliative therapy with a COX inhibitor (piroxicam 0.3 mg/kg PO three times per week). COX inhibitors may not reduce neoplastic cell proliferation but may decrease tumour angiogenesis and reduce the rate of metastasis. Monitoring of renal parameters monthly was recommended due to potential nephrotoxicity of the drug. After 1 week the piroxicam was withdrawn and replaced with meloxicam. Four weeks later, the cat was euthanized due to marked loss of condition and reduced quality of life.

Discussion

SCC is the most common epithelial tumour of the skin and oral cavity of cats. Most skin lesions are found on the face or head (e.g. the nasal planum, pinnae, and eyelids). UV-induced SCCs are the most common. A high index of suspicion for SCC is based on appearance and location of the lesion, particularly in sparsely haired areas around the face and head. The most economic and efficacious treatment depends on the extent and location of the lesion. For example, excisional biopsy with adequate margins is often curative if SCC is detected early.

Further Reading

Murphy, S., 2013. Cutaneous squamous cell carcinoma in the cat: current understanding and treatment approaches. *Journal of Feline Medicine and Surgery* 15 (5), 401–407.

Case 1.12

Signalment and Clinical History

A 5-year-old MN DSH cat with a history of marked halitosis was admitted for a routine dental scale and polish. The cat had been seen previously for episodes of over-grooming that resolved with prednisolone at anti-inflammatory doses. Vaccinations were up to date; worming and flea control were sporadic.

Clinical Examination

The cat was overweight (BCS 4/5). The upper lip and chin were erythematous and the upper lip was ulcerated (Figure 1.28). There was a region of alopecia on the ventral neck associated with an exudative dermatitis (Figure 1.29). No other significant abnormalities were noted.

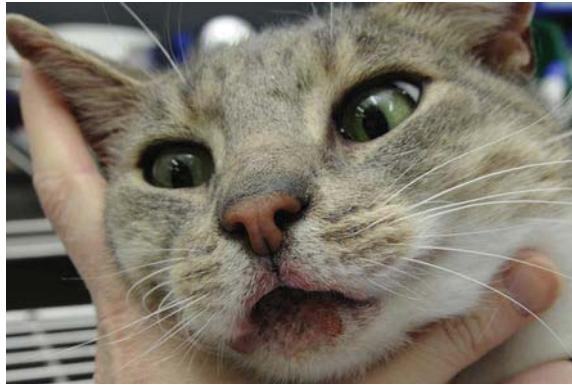

Figure 1.28. A close-up of the bilaterally ulcerated, erythematous upper lip.

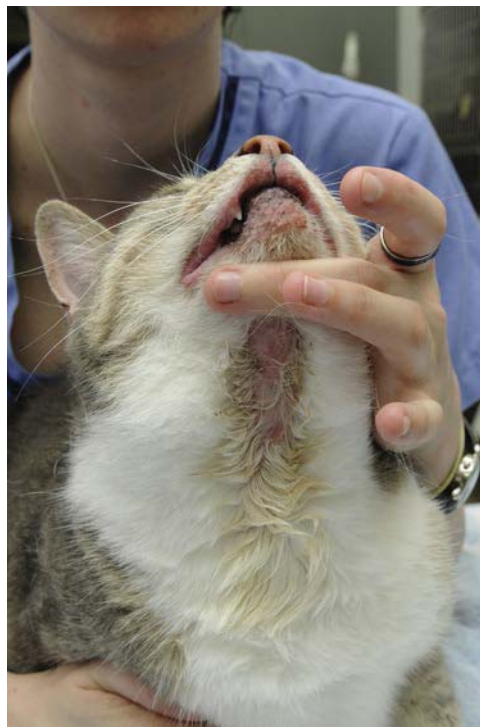


Figure 1.29. A pruritic, raised, exudative cutaneous lesion on the ventral neck.

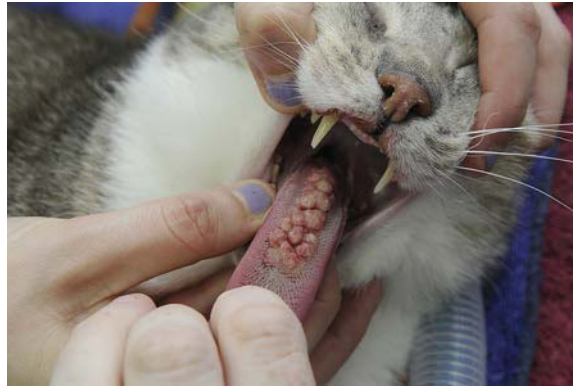

Figure 1.30. A multilobulated, vegetative, exudative lesion observed in the central region of the caudal tongue.

Q 1. What are the key differential diagnoses for these dermatological lesions?

- Eosinophilic granuloma
- Neoplasia (e.g. SCC, mast cell tumour, cutaneous lymphoma)
- Focal inflammation due to trauma, contact with a caustic substance or an infectious agent

On intubation of the cat during routine anaesthetic induction a lesion was observed on the caudal tongue ([Figure 1.30](#)).

Q 2. How would you further investigate this lesion?

Biopsy and histopathology is the diagnostic method of choice for neoplasia and eosinophilic granuloma complex. Cytology is not reliable for diagnosis of the latter, but cytology of impression smears can be useful for looking for secondary bacterial or yeast infection.

Where neoplasia is suspected, a CBC, biochemistry panel, and urinalysis are useful for staging, as are thoracic radiographs and aspiration of regional lymph nodes to detect metastatic spread.

In cats with eosinophilic granuloma complex, peripheral lymphadenopathy is common. Peripheral eosinophilia is reported in one- to two-thirds of cases. As this condition is often associated with flea hypersensitivity, a flea comb can be used to detect occult flea infestation. In cases where fleas are not detected, a flea treatment trial is recommended. Flea antigen testing may be used to detect hypersensitivity. A large number were found on this cat ([Figure 1.31](#)).

FeLV testing may be indicated as there was a high incidence of FeLV infection in one study of eosinophilic granulomas in cats, but significant geographical variation can be expected.

In another study, over 6% of cats with severe ulcerative cutaneous or oral lesions had FHV-1 as detected via immunohistochemistry. Testing may be indicated in refractory cases of eosinophilic granuloma.



Figure 1.31. A flea comb test was positive for cat fleas (*Ctenocephalides f. felis*).

Diagnostic Test Results

Histopathological evaluation of multiple biopsies revealed extensive ulceration, regions of eosinophilic necrosis surrounded by epithelioid macrophages, and widespread infiltration of tissue by eosinophils mixed with mast cells consistent with eosinophilic granuloma.

Q 3. How would you treat this condition?

Treatment is aimed at suppressing the exuberant inflammatory response. The mainstay of treatment is prednisolone (1–2 mg/kg PO BID for 7–10 days, then tapered to the lowest effective dosage). If adverse effects of prednisolone are unacceptable, ciclosporin may be used at a dose of 7 mg/kg PO SID, tapering to QID as required.

Methylprednisolone may be preferred if owners cannot orally medicate cats. This can be given by SC injection every 14–21 days for up to three doses.

Treat secondary bacterial infection based on culture and sensitivity of tissue, or with a broad-spectrum antimicrobial such as amoxicillin trihydrate-clavulanate potassium. Subgingival scaling may aid in reducing residual bacterial load in the oral cavity.

Eliminate triggering allergens. Affected cats should be placed on a flea trial consisting of a reliable feline flea treatment such as selamectin, imidacloprid, fipronil or indoxacarb applied at fortnightly intervals, for three consecutive doses. It may be necessary to supplement this with an insect growth inhibitor such as lufenuron every 6 months to break the flea life cycle, or the orally administered monthly flea treatment spinosad, which effectively kills fleas before they lay eggs.

Owners should be counselled on environmental decontamination to break the flea life cycle and reduce the risk of re-infestation. Other pets in the house should also be treated for fleas.

Cats with suspected food hypersensitivity should be placed on an elimination diet consisting of a novel protein or commercial hydrolysed diet for a period of 8 weeks. Diagnosis of food allergy is only definitively made following rechallenge.

Intradermal testing can be used to determine hypersensitivity to other agents including house dust mites and pollens. Allergen-specific immunotherapy may be used in such cases.

Surgical removal of localized or linear eosinophilic granulomas may be considered but was not recommended in the above case due to the location of the lesions.

Radiotherapy, cryotherapy, laser therapy, and immunomodulating drugs (e.g. levamisole, thiabendazole, and interferon alpha) have been used with mixed success.

A small number of cases are idiopathic with a heritable dysfunction of eosinophilic regulation believed to be responsible.

If treated early and aggressively, complete regression of the lesion is possible. In this case, with flea control and prednisolone treatment, the lesions resolved completely within 6 weeks. Unfortunately the cat returned 6 months later with recurrent lesions and a heavy flea burden.

Discussion

There are three reported forms of eosinophilic granuloma complex: eosinophilic plaque (commonly on the ventral abdomen and medial thighs but also on the ventral neck as in this case), eosinophilic granuloma (the nodular and linear form), and indolent ulcer (often found on the upper lip and also known as 'rodent ulcer'). Successful treatment requires identification and elimination of the inciting cause. Glucocorticoids should only be used to provide temporary relief of symptoms until the underlying cause is addressed.

If Finances Are Limited

Clinical diagnosis of eosinophilic plaque and lip ulcers is adequate unless lesions are atypical or poorly responsive to therapy. Biopsy of tongue lesions is always recommended as it is clinically impossible to distinguish eosinophilic granuloma from SCC. However, in a cat with concurrent lesions (such as ulcerated lips and exudative dermatitis with obvious flea infestation), a tentative diagnosis of eosinophilic granuloma is made. Prednisolone and methylprednisolone are inexpensive, but owners should be counselled on adverse effects, including polyuria, polydipsia, polyphagia, and potential metabolic sequelae such as induction of diabetes mellitus.

Spontaneous regression is reported. Monotherapy with an antimicrobial such as amoxicillin trihydrate-clavulanate potassium may be adequate, particularly in cases of eosinophilic plaque.

Further Reading

- Lee, M., Bosward, K.L., Norris, J.M., 2010. Immunohistological evaluation of feline herpesvirus-1 infection in feline eosinophilic dermatoses or stomatitis. *Journal of Feline Medicine and Surgery* 12, 72–79.
- Wildermuth, B.E., Griffin, C.E., Rosenkrantz, W.S., 2011. Response of feline eosinophilic plaques and lip ulcers to amoxicillin trihydrate-clavulanate potassium therapy: a randomised, double-blind placebo-controlled prospective study. *Veterinary Dermatology* 23, 110–118, e24–25.

CHAPTER

2

Gastrointestinal and Hepatic Disorders

Case 2.1

Signalment and Clinical History

An 11-year-old MN DSH cat presented for investigation of reduced appetite, lethargy, and weight loss of 6–8 weeks' duration. Diarrhoea (normal volume, passed with increased frequency) and occasional haematochezia were reported. No response to broad-spectrum antibiotic or antiparasitic treatment was noted. The cat was fed a normal commercial diet and routine preventative health care was up to date.

Clinical Examination

The cat was bright, alert, responsive, and in fair body condition (body condition score (BCS) 3–4/9). Abdominal palpation revealed a suspicion of thickened intestinal loops. Examination was otherwise unremarkable.

Q 1. Based on the information provided, are you able to differentiate between small and large intestinal diarrhoea?

Haematochezia and increased frequency of defecation is indicative of large intestinal disease, but weight loss is indicative of small intestinal disease, suggesting involvement of both locations, which is common in cats.

Q 2. What are the options for further investigation of chronic diarrhoea and weight loss?

- Faecal parasitology +/- culture
- Polymerase chain reaction (PCR) for *Giardia*, *Trichomonas foetus*, and *Cryptosporidium*, and *Giardia* enzyme-linked immunosorbent assay (ELISA)



Tip Box

A positive faecal culture result for a known pathogen such as *Salmonella*, *Campylobacter*, or *Clostridium difficile* must be considered carefully, as these pathogens can be cultured from the faeces of healthy cats and may not be the cause of the current diarrhoea.

- Routine biochemistry and haematology should be performed and serum total thyroxine (T4) included in older cats to exclude non-intestinal disease and identify consequences of diarrhoea (e.g. dehydration or electrolyte derangements)
- Serum cobalamin and folate concentrations can be measured, reduced serum concentrations indicating chronic small intestinal disease or exocrine pancreatic insufficiency

- Decreased serum feline trypsin-like immunoreactivity (TLI) indicates exocrine pancreatic insufficiency (EPI) and increased feline pancreatic lipase immunoreactivity (fPLI) suggests pancreatitis
- Rectal cytology may show inflammatory or neoplastic cells
- FIV (feline immunodeficiency virus) and FeLV (feline leukaemia virus) ELISAs are indicated in chronic disease since retroviral infections can be associated with gastrointestinal signs either as a result of secondary gastrointestinal pathogens or due to virus-induced enteritis
- Abdominal radiography to assess for evidence of obstructive disease or masses
- Abdominal ultrasonography to look for masses, lymphadenopathy, measure intestinal wall thickness and identify abnormal layering, assess for presence of free abdominal fluid. Ultrasound-guided fine needle aspiration (FNA) of masses, enlarged lymph nodes, or focally thickened intestinal walls can be performed to provide samples for cytology
- Gastrointestinal endoscopy or exploratory laparotomy to obtain intestinal biopsies, dependent on results of other investigations

Diagnostic Test Results

- Faecal parasitology and culture: negative
- *Giardia* and *T. foetus* PCR: negative
- Haematology: moderate mature neutrophilia ($21.7 \times 10^9/L$; RI (reference interval): 2.5–12.8) and mild monocytosis ($1.06 \times 10^9/L$; RI: 0.07–0.85). Serum biochemistry including total T4 was unremarkable
- Serum cobalamin (186.0 $\mu g/L$; RI: 270–1000) and folate (4.2 $\mu g/L$; RI: 9.5–20.2) concentrations: both subnormal
- TLI (22.5 $\mu g/L$; RI: 12–82) and fPLI (1.2 $\mu g/L$; RI: 0.1–3.5): within normal limits
- FIV antibodies ELISA positive, FIV PCR positive; FeLV ELISA negative
- Abdominal ultrasonography: markedly thickened large intestinal mucosal layer (7 mm; RI colonic wall: <1.7 mm) with loss of normal wall layering (Figure 2.1)

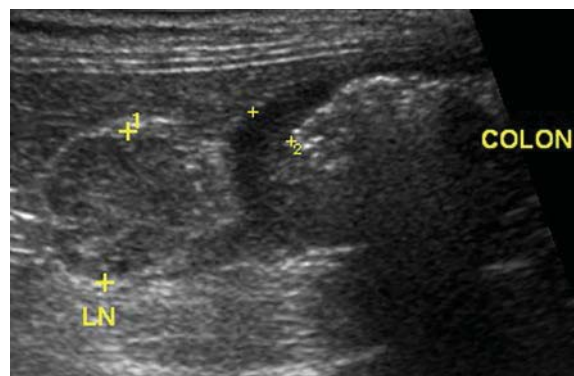


Figure 2.1. Ultrasound image showing enlarged and irregular colonic lymph node and increased colonic wall thickness with loss of normal wall layering. Courtesy of the University of Edinburgh.

The colonic and jejunal lymph nodes were enlarged and hyperechoic with an irregular contour. The duodenum and jejunum showed a prominent muscularis layer with increased jejunal wall thickness (3.3 mm; RI: <2.8 mm) (Figure 2.2).

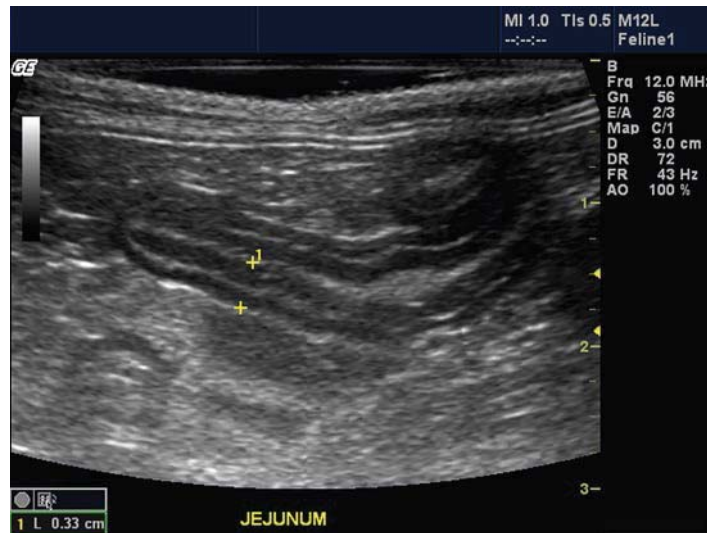


Figure 2.2. Ultrasound image showing jejunal loop with prominent muscularis layer and increased overall wall thickness. Courtesy of the University of Edinburgh.

Q 3. What are the main advantages and disadvantages of obtaining biopsies endoscopically or via exploratory laparotomy?

Endoscopy

- Advantages
 - Less invasive technique with minimal risk
 - No wound to heal before instigating treatment
 - Allows visualisation of the intestinal lumen
- Disadvantages
 - Biopsies may be superficial, which could lead to incorrect diagnosis or be non-diagnostic samples
 - Other abdominal organs not examined or able to be biopsied (e.g. lymph nodes)

Exploratory Laparotomy

- Advantages
 - Full thickness biopsy improves accuracy of diagnosis
 - Examination +/- biopsy of entire length of small intestine plus other organs
- Disadvantages
 - More invasive: wound healing to be considered, longer anaesthesia
 - Risk of biopsy site dehiscence and peritonitis

- Unable to visualize large area of intestinal lumen
- Biopsy of large intestine considered to increase risk of peritonitis, so generally not recommended

Diagnostic Test Results

In this case, it was chosen to perform upper and lower gastrointestinal endoscopy. The stomach and small intestine were grossly normal, but the colonic mucosa appeared diffusely thickened. Biopsies were collected from all areas. Histopathology revealed evidence of mild, diffuse chronic enteritis and severe multifocal, granulomatous ulcerative colitis (Figure 2.3). There was no evidence of any aetiological agents. Ziehl-Neelsen stains of the colonic biopsies were negative.

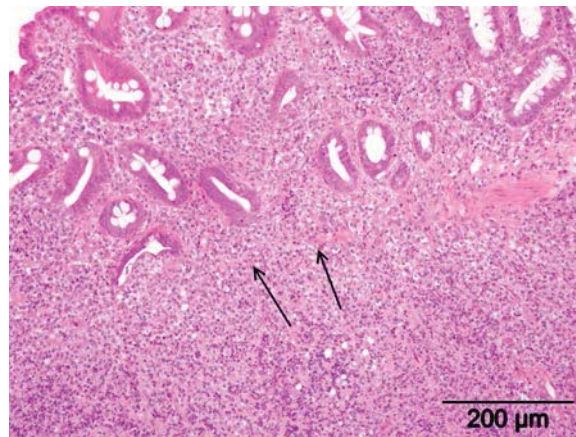


Figure 2.3. Histopathology of colonic biopsies showing granulomatous inflammation.

Q 4. Considering as many possible causes as you can, outline what you think the most likely cause of the granulomatous colitis is, and why.

Parasitic disease may cause granulomatous inflammation; however, the negative faecal parasitology makes this unlikely. Fungal enteritis/colitis is a differential diagnosis but is rare in cats and no fungal organisms were seen on histopathology. Mycobacterial infection should be a consideration, but intestinal involvement is rare in cats and no acid-fast bacteria were identified; however, further diagnostic tests (culture, PCR) could be performed. Feline infectious peritonitis (FIP) should always be considered when there is pyogranulomatous inflammation but rarely results in such diffuse mural pathology in the colon, and there was no other evidence of FIP, although this cannot be completely excluded. Immunohistochemistry can be performed to look for coronavirus. In dogs, granulomatous colitis has been associated with *Escherichia coli* infection and that would be a possibility.

In this case it was considered likely that the severe granulomatous colitis was either related to the FIV infection or a form of unrelated inflammatory bowel disease (IBD). Granulomatous enteritis and pyogranulomatous colitis have been described in FIV-infected cats.

Q 5. How would you manage this patient?

The exact cause-and-effect relationship between FIV infection and the enteritis and colitis is not known, but treatment focuses on management of the gastrointestinal disease as a form of IBD.

Treatment options include dietary trial (single-source protein/carbohydrate diet, novel protein/carbohydrate or hydrolysed diet) followed by immunosuppressive therapy if this is ineffective. Fluoroquinolones in case of potential *E. coli* involvement should also be considered.

Further Information on Treatment and Outcome

In this case due to severity of signs medical treatment was started immediately without performing a diet trial. However, severity is not a predictor of response to diet. Prednisolone 1 mg/kg SID and marbofloxacin were initiated. Parenteral cobalamin and oral folate supplementation was initiated.

Within 3 weeks of treatment the cat's appetite improved and he gained 500 g of weight. Faecal consistency normalized, and haematochezia resolved. Marbofloxacin was withdrawn after 8 weeks and a week later the diarrhoea recurred. Recommencing marbofloxacin and later increasing the prednisolone dose failed to improve the diarrhoea, and the cat was euthanized without postmortem.

Discussion

Histiocytic ulcerative colitis (HUC; also known as granulomatous colitis) is seen in young dogs; it is associated with invasive *E. coli* infection and is responsive to treatment with fluoroquinolones. It is possible that a similar pathogenesis exists in cases of feline granulomatous colitis. The treatment with prednisolone might have resulted in worsening of the FIV viraemia, which in turn might have been responsible for the condition becoming refractory to treatment, but this is purely speculative and the cause of treatment failure is unknown.

Case 2.2**Signalment and Clinical History**

A 1-year-old MN DSH cat presented with a history of vomiting approximately four times in 12 h. Prior to that, the cat was seen chewing on a toy attached to a cord. The toy was recovered, without the cord. The cat vomited up a small amount (approximately 3 cm) of cord. The cat was in otherwise good health, living exclusively indoors on a premium commercial diet. Vaccination, worming, and flea control were up to date.

Clinical Examination

The cat was overweight (BCS 3.5–4/5) and pyrexia (rectal temperature 39.4 °C). The abdomen was slightly tense on palpation but not remarkably so. No other significant abnormalities were noted.

Q 1. Formulate a differential diagnosis list for cranial abdominal pain in cats.

- Gastrointestinal disease
 - Gastric foreign body
 - Gastritis
 - Gastric ulceration
 - Enteritis
 - Small intestinal foreign body
- Hepatobiliary disease
 - Cholangitis
 - Cholecystitis
 - Cholelithiasis
 - Hepatitis
- Pancreatic disease
 - Pancreatitis
 - Pancreatic abscess
- Peritoneal disease
 - Feline infectious peritonitis
 - Septic peritonitis
- Mesenteric disease
 - Abscess
 - Intussusception
 - Neoplasia
 - Intestinal volvulus
- Musculoskeletal
 - Trauma
 - Referred pain (spinal, renal)

Q 2. What are the most common sites for a linear foreign body to anchor in the cat?

The base of the tongue and the pylorus.

Thus a thorough oral examination, paying particular attention to the base of the tongue, should be undertaken in any cat presented with acute vomiting. The base of the tongue was easily examined and there was no indication of a foreign body anchored at this site.

Q 3. What are the potential sequelae of a gastrointestinal linear foreign body?

Intestinal peristalsis propels the linear foreign body through the gastrointestinal tract. If this is anchored at any site, the intestine becomes plicated. The linear foreign body becomes taut as peristalsis continues and effectively acts as a saw through the mesenteric wall of the intestine. This leads to full-thickness laceration of the intestine, followed by peritoneal contamination and peritonitis. Non-anchored linear foreign bodies may bunch up or knot up within the intestine, leading to a partial or full obstruction.

Q 4. *How would you further investigate this case?*

Given the history of foreign body ingestion, coupled with the condition and clinical signs of the cat, the presence of a gastrointestinal foreign body should be excluded.

- Abdominal palpation under sedation or general anaesthesia can be helpful in establishing the presence of a foreign body, abdominal mass, or organomegaly.
- Plain radiographs are a minimally invasive first step that may reveal the presence of a foreign body or characteristic changes (plication of intestines in the case of a linear foreign body, the presence of tapered enteric gas bubbles or an obstructive gas pattern) associated with the presence of a foreign body. Peritonitis, indicated by loss of serosal detail, may be visible on plain radiographs.
- Contrast studies are more valuable in determining the presence of non-linear foreign bodies.
- Ultrasound may be suggestive if a hyperechoic linear structure is seen within the intestines or echogenic free fluid observed consistent with peritonitis.
- Results of laboratory testing (complete blood count (CBC), biochemistry panel including fPLI and urinalysis) are non-specific but may aid in ruling in or out other differentials such as pancreatitis or cholangiohepatopathy.
- Definitive diagnosis is via exploratory laparotomy.

Diagnostic Test Results

A right lateral abdominal radiograph was taken to assess for a foreign body (Figure 2.4).

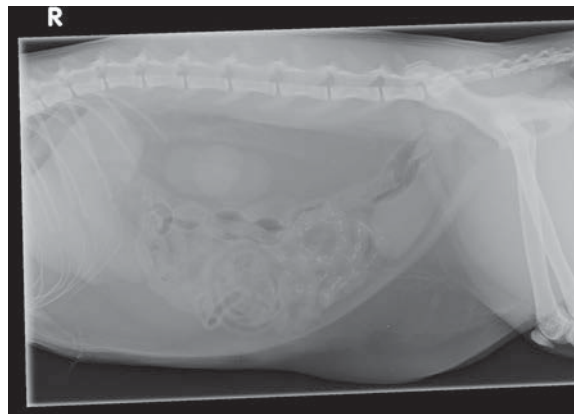

Figure 2.4. Right lateral abdominal radiograph.

Q 5. *What are the key radiographic abnormalities?*

A linear coil of metallic radiolucent objects is visible. Plication of the small intestine is evident, supporting the clinical suspicion of a linear foreign body. There are no radiographic signs of peritonitis.

Further Information on Response to Treatment, Diagnosis, and Outcome

The cat was placed on intravenous Hartmann's solution and given cephalixin IV (30 mg/kg) before being anaesthetized.

A ventral midline celiotomy was performed. The jejunum was plicated, congested, and hyperaemic (Figure 2.5) with a nodular linear foreign body palpable through the intestinal wall. The proximal end of the linear foreign body was located in the mid jejunum. A 7 mm enterotomy was made in the antemesenteric border of the jejunum, exposing the foreign body (Figure 2.6). The cord was pulled gently through the incision, with care taken to place minimal tension on the foreign body. The foreign body was removed entirely via this incision. It measured over 40 cm (Figure 2.7).

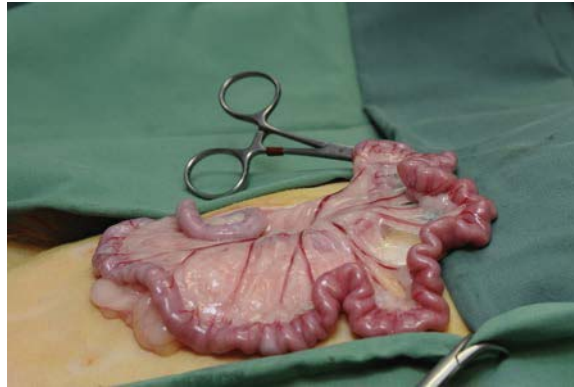

Figure 2.5. Exploratory laparotomy revealed plication of the small intestine with congestion and hyperaemia evident.

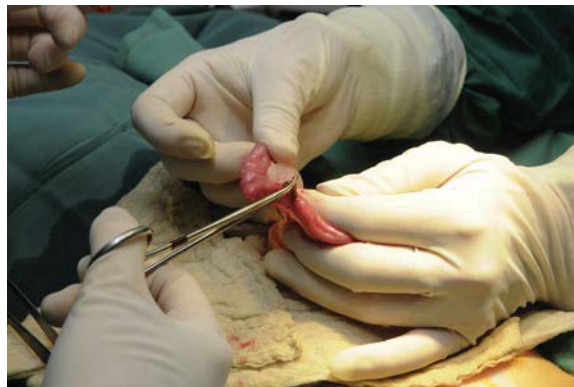

Figure 2.6. The foreign body was exposed through an enterotomy in the anti-mesenteric border of the jejunum.



Figure 2.7. The foreign body following removal.

The enterotomy was closed in a simple interrupted pattern using a 3.0 absorbable monofilament suture. The site was covered with omentum and the abdomen lavaged with several litres of warmed saline. A routine three-layer closure was performed.

The cat was treated with buprenorphine analgesia postoperatively, and small amounts of food slowly introduced. He was discharged 3 days after surgery and made a full recovery.

Q 6. *What other techniques are available for removing a linear foreign body in a cat?*

An alternative single enterotomy technique has been described. After an enterotomy is made in the antemesenteric border of the proximal duodenum, the linear foreign body is located and anchored to a syringe cap or rubber catheter. The enterotomy is then closed and the syringe cap or catheter milked aborally along the intestine and into the colon. It can then be removed by an assistant via the anus. This technique is contraindicated in cases of severe plication or intestinal compromise, or where the foreign body is knotted or matted, or of variable diameter.

Discussion

Linear foreign bodies can be challenging to diagnose, unless the owner observes a pattern of attraction to this kind of foreign body or infers its ingestion from circumstantial evidence. The most common reported signs of linear foreign bodies are vomiting, anorexia, and depression.

In the author's experience, many cat toys (often manufactured overseas) contain string with metallic components that show up on radiographs.

Linear foreign bodies often require multiple enterotomies/gastrotomies to remove, as pulling the foreign body can cause friction against the mesenteric border of the intestine, leading to occult perforations. In the above case, there was minimal tension on the foreign body, which enabled removal via a single enterotomy. This may be because it was removed relatively soon after ingestion.

If Finances Are Limited

As the pathogenesis of obstruction and peritonitis secondary to linear foreign body in a number of cases is due to anchoring of the foreign body around the tongue, it is argued that some cats may be managed conservatively. If the foreign body is lodged sublingually, this involves cutting the foreign body at this site, allowing it to pass down the oesophagus and through the gastrointestinal tract. Continued vomiting, severe abdominal pain with pyrexia, or severe or degenerative left shift are indications for surgical intervention. Persistent proximal fixation was a major reason for failure of conservative treatment in one case series. Where anchoring of the foreign body at the pylorus is detected, surgical intervention is indicated.

Owners electing conservative treatment must be fully informed of the risks to their cat.

Further Reading

- Anderson, S., Lippincott, C.L., Gill, P.J., 1992. Single enterotomy removal of gastrointestinal linear foreign bodies. *Journal of the American Animal Hospital Association* 28, 487–490.
- Cimino Brown, D., 2003. Small intestines. In: Slatter, D. (Ed.), *Textbook of Small Animal Surgery*, third ed. Saunders Elsevier, Philadelphia, PA.
- Muir, P., Rosin, E., 1995. Failure of the single enterotomy technique to remove a linear intestinal foreign body from a cat. *Veterinary Record* 136 (3), 75.

Case 2.3**Signalment and Clinical History**

A 14-year-old old MN Burmese cat presented with a history of dyschezia, vomiting, and weight loss. The cat had been treated successfully for obstipation with a warm water enema 6 months previously.

The cat had not produced a stool for at least 5 days, but the owner reported the cat appeared to strain to defecate, only to produce small amounts of liquid faeces. The cat was fed a commercial diet designed for senior indoor cats. Vaccination, worming, and flea control were up to date.

Clinical Examination

The cat was underweight (BCS 2/5), with tacky mucous membranes and marked skin tenting. Abdominal palpation revealed a column of firm faeces in the colon. No other significant abnormalities were noted.



1. List factors that may contribute to constipation or obstipation in cats.

- Pelvic deformities
- Sacral spinal cord deformities (Manx pedigree)
- Lumbosacral disease

- Cauda equina syndrome
- Intestinal foreign bodies
- Ileus
- Dysautonomia
- Aganglionosis
- Neoplasia (intraluminal versus extraluminal)
- Hypokalaemia
- Hypercalcaemia
- Nutritional secondary hyperparathyroidism
- Hypothyroidism
- Dehydration
- Dietary factors
- Inflammation of the anorectum
- Pharmacologic agents (e.g. opiates, anticholinergic drugs, phenothiazines)
- Environmental/behavioural (e.g. litter box change, hospitalization)
- Idiopathic megacolon

Q 2. List differentials for dyschezia in the cat.

- Pelvic narrowing
 - Trauma
 - Fracture healing
- Colorectal disease
 - Perineal hernia
 - Perianal fistula
 - Colonic impaction
 - Idiopathic megacolon
- Anal sac disease
 - Anal sac abscess
 - Neoplasia
- Pseudocoprastasis (more common in long-haired cats)
- Prostate disease (rare)
 - Prostatic abscess
 - Benign prostatic hyperplasia
 - Prostatic neoplasia

Q 3. How would you further investigate this case?

Survey radiographs of the abdomen allow assessment of colon diameter and content, and may reveal causes of constipation and obstipation in the cat, including pelvic fractures.

A recent study found that a ratio of the maximal diameter of the colon to the length of L5 was a repeatable and accurate measurement, with a value of >1.48 being suggestive of megacolon. In this study, all cats with a ratio of >1.62 had megacolon, which required subtotal colectomy.

Rectal examination under sedation or general anaesthesia is useful in identifying pelvic narrowing, perineal hernias, perianal fistulae, anorectal strictures, and anorectal masses.

A CBC, serum biochemistry panel including total thyroxine (T4) and urinalysis may be performed to rule out systemic disturbances (such as dehydration and electrolyte abnormalities) that may contribute to or cause constipation and obstipation.

Diagnostic Test Results

A right lateral abdominal radiograph was taken (Figure 2.8). The ratio of maximal diameter of the colon (3.4 cm) to the length of L5 (2.2 cm) was 1.6, consistent with megacolon. There are no obvious intraluminal or extraluminal obstructions. Lateral and ventrodorsal views of the pelvis and spine are required to rule out abnormalities such as narrowing of the pelvic canal, but as there was no history of trauma in this case, a lateral radiograph sufficed.

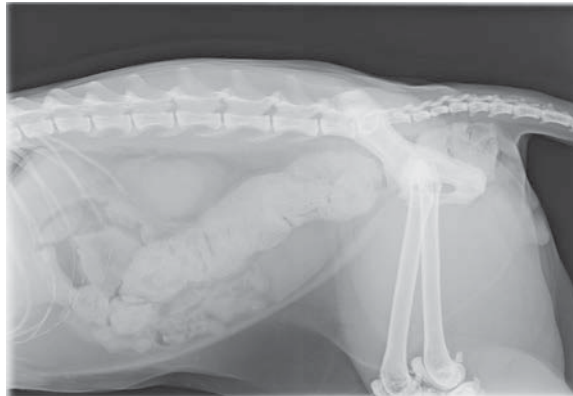


Figure 2.8. Right lateral abdominal radiograph demonstrating a large column of faecal material distending the colon.

Q 4. *What is the difference between constipation, obstipation, and megacolon in the cat?*

The difference is of degree and chronicity of faecal retention.

- Constipation is defined as infrequent or incomplete defecation associated with retention of faeces.
- Obstipation is associated with permanent loss of colonic motility.
- Megacolon occurs when obstipation leads to irreversible dilation and hypertrophy of the colon.

Q 5. *How would you treat this case initially?*

Hospitalization for intravenous fluid therapy is recommended to correct dehydration and electrolyte derangements and to assist in evacuation of impacted faeces. In such cases, a gentle, warm water enema and manual evacuation under a general anaesthetic may be necessary once the patient is rehydrated.

Pre-anaesthetic administration of an antibiotic (e.g. metronidazole) should be considered as colonic manipulation can lead to bacterial translocation. The airway should be maintained with a cuffed endotracheal tube to prevent aspiration in case colonic manipulation triggers vomiting via stimulation of stretch receptors in the colon. The author infuses the colon with a combination of warm water and a sterile, water-based lubricant while gently reducing the faecal mass by abdominal palpation and digital disimpaction.

Patients should then be continued on a combination of laxatives, prokinetics, and dietary therapy, such as discussed below, in order to prevent recurrence.

Q 6. *How would you treat refractory cases?*

Medical therapy consists of combinations of dietary management, laxatives, and prokinetics (e.g. cisapride).

There are different classes of laxatives, which all work in different ways, and in refractory cases a combination of a laxative from each class is advisable, together with both dietary management and cisapride.

The different laxatives available are:

- Osmotic laxative (e.g. lactulose, polyethylene glycol)
- Emollient laxative (e.g. docusate)
- Stimulant laxative (e.g. bisacodyl, danthron)

With dietary management, there are broadly two schools of thought: the first is feeding a high fibre diet, which acts as a bulk-forming laxative, aiming to improve colonic motility, but at the risk that it can simply add to the bulk of faeces. The second is feeding an easily digestible low residue diet to reduce faecal bulk. The right balance between insoluble/soluble fibre is likely to be important, and adding psyllium, sterculia, or ispaghula may be helpful in some cases.

With cases that are refractory to aggressive medical management, then the treatment of choice is subtotal colectomy, through which 90–95% of the colon is removed, regardless of gross appearance. A short, distal segment is spared to facilitate anastomosis. Presurgical enema is not recommended as this liquefies faeces and increases the risk of bacterial contamination at surgery.

Q 7. *List possible postoperative complications.*

- Peritonitis due to surgical contamination or dehiscence of anastomosis
- Sepsis secondary to contamination, bacterial translocation
- Colorectal stricture
- Wound infection/breakdown
- Loose stool and increased frequency of defecation is common and may persist for months postoperatively

Further Information on Response to Treatment, Diagnosis, and Outcome

Subtotal colectomy was recommended but the owner declined due to the age of the cat. The cat was anaesthetized routinely and a warm water enema performed as described above. Following the procedure, the cat was kept on intravenous fluids for

24 h before being discharged on lactulose (2–3 mL PO BID) and cisapride (5 mg PO BID). One week later the owner reported that the cat was bright, eating, and defecating well. Four months later the cat re-presented with the same signs and required another enema. More aggressive medical management as discussed above may prevent these recurrences.

Discussion

Megacolon is an irreversible increase in colon diameter. Clinical signs include dyschezia, vomiting, anorexia, and weight loss. Diagnosis is based on a history of chronic or recurrent constipation that is refractory to medical treatment, abdominal palpation of a distended colon, and radiographic evidence of an impacted, enlarged colon.

Idiopathic megacolon accounts for approximately two-thirds of cases and is believed to be due to a generalized dysfunction of colonic smooth muscle. Diagnosis is based on exclusion of mechanical obstruction, systemic derangements, and other functional abnormalities that may lead to constipation and obstipation (Figure 2.9).

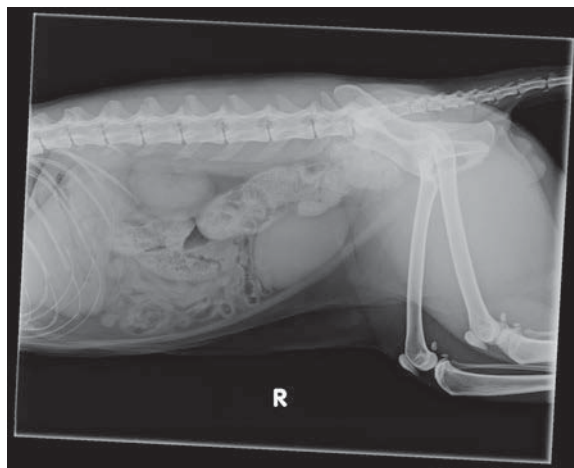


Figure 2.9. Right lateral abdominal radiograph of a different cat demonstrating obstipation secondary to an extraluminal mass (in this case an osteochondroma emerging from the lumbosacral junction, impinging on the L1-S1 nerve root). The ovoid mass measured approximately 2.5×2 cm, and recurred after surgical excision. It was easily palpated on digital rectal examination. The ratio of maximal diameter of the colon (3 cm) to the length of L5 (2.3 cm) was 1.3.

Further Reading

- Byers, C.G., Leasure, C.S., Sanders, N.A., 2006. Feline idiopathic megacolon. *Compendium on Continuing Education for the Practicing Veterinarian*, 28, 658–665.
- Trevail, T., Gunn-Moore, D., Carrera, I., et al., 2011. Radiographic diameter of the colon in normal and constipated cats and in cats with megacolon. *Veterinary Radiology and Ultrasound* 52 (5), 516–520.

Case 2.4

Signalment and History, and Clinical Examination

A 5-year-old, indoor-only, FN Russian Blue cat presented with a chronic waxing-waning history of reduced appetite, intermittent small intestinal diarrhoea, and flatulence. She was fully vaccinated but not wormed. Her diet consisted of a mix of commercial wet and dry food.

Clinical Examination

The cat was in poor body condition (BCS 2.5/9) and weighed 2.05 kg. She had a poor quality hair coat, but examination was otherwise largely unremarkable.

Q 1. *Formulate a differential diagnosis list for chronic small intestinal diarrhoea in cats.*

- Extra-intestinal causes
 - Metabolic: hyperthyroidism, hypoadrenocorticism (rare)
 - Abdominal extra-intestinal: hepatobiliary disease, pancreatitis
- Intestinal causes
 - Obstruction
 - Intussusception, foreign body, neoplasia
 - Maldigestion
 - EPI
 - Malabsorption
 - Inflammatory bowel disease (lymphoplasmacytic, neutrophilic, eosinophilic)
 - Infiltrative neoplasia (e.g. gastrointestinal lymphoma)
 - Nutritional
 - Dietary hypersensitivity
 - Dietary intolerance
 - Dietary indiscretion
 - Infectious
 - Bacterial (more often a cause of acute diarrhoea)
 - *Campylobacter*, *Salmonella*, *E. coli*, *Clostridium perfringens*
 - Protozoal
 - *Giardia*, *T. foetus* (usually large intestinal)
 - Coccidia
 - *Isospora*, cryptosporidia
 - Parasitic
 - Roundworm, whipworm, hookworm
 - Viral
 - FIV-associated disease

Q 2. *How would you initially manage this case?*

Appropriate options for initial management would include:

- Dietary trial with either an easily digestible bland diet, single-source carbohydrate/protein diet, or hydrolysed protein diet

- Worming +/- dietary trial
- Trial treatment for *Giardia* (50 mg/kg fenbendazole SID for 5 consecutive days) +/- dietary trial
- Faecal parasitology and culture, faecal PCR panel +/- CBC, and biochemistry prior to further diagnostics or treatment

Further Case Information

- In this case a diet trial using a hydrolysed protein diet was performed together with worming using milbemyacin.
- The cat's appetite improved but diarrhoea persisted.
- At this stage, CBC, biochemistry (including T4), FeLV/FIV ELISA, and faecal analysis, culture, and PCR were performed (see Tables 2.1–2.3 for results).
- Faecal culture: negative for *Salmonella*, *Campylobacter*, *Clostridia*, and *E. coli*

Table 2.1 CBC/Biochemistry Results

Test	Result	Reference Interval
RBC ($\times 10^{12}/L$)	8.0	4.9–10.0
Haemoglobin (g/L)	135	77–156
HCT	0.45	0.25–0.48
MCV (fL)	55	43–55
MCH (pg)	17	13–17
MCHC (g/L)	300	282–333
Platelets ($\times 10^9/L$)	244	300–800
WBC ($\times 10^9/L$)	10.7	5.5–19.0
Neutrophil (%)	67	%
Neutrophils ($\times 10^9/L$)	7.2	2.0–13.0
Lymphocyte (%)	21	%
Lymphocytes ($\times 10^9/L$)	2.2	0.9–7.0
Monocyte (%)	2	%
Monocytes ($\times 10^9/L$)	0.2	0–0.7
Eosinophil (%)	10	%
Eosinophils ($\times 10^9/L$)	1.1	0–1.1
Basophil (%)	0	%
Basophils ($\times 10^9/L$)	<0.1	
Sodium (mmol/L)	158	144–158
Potassium (mmol/L)	4.3	3.7–5.4
Chloride (mmol/L)	129	106–123
Bicarbonate (mmol/L)	7	12–24
Na:K ratio	36.7	29.0 to +
Anion gap (mmol/L)	26.3	15.0–31.0

Continued

Table 2.1 CBC/Biochemistry Results—cont'd

Test	Result	Reference Interval
Glucose, serum (mmol/L)	5.6	3.2–7.5
Urea (mmol/L)	9.9	5.0–15.0
Creatinine (mmol/L)	0.10	0.08–0.20
Calcium (mmol/L)	2.6	2.1–2.8
Phosphate (mmol/L)	1.3	1.0–2.3
Ca:P ratio	2.0	1.1–2.3
Protein, total (g/L)	68	60–84
Albumin (g/L)	32	25–38
Globulin (g/L)	36	31–52
Total bilirubin (μmol/L)	3	0–7
ALP (IU/L)	37	5–50
AST (IU/L)	84	2–62
ALT (IU/L)	324	19–100
CK (IU/L)	122	64–400
Cholesterol (mmol/L)	3.3	2.2–5.5
Gamma GT (IU/L)	<3	0–6
Pancreatic lipase (μg/L)	2.6	0.1–3.5
FeLV	Negative	
FIV	Negative	
Platelets	Clumped but adequate	
Total T4 (nmol/L)	18	10–60

ALP, alkaline phosphatase; ALT, alanine transaminase; AST, aspartate aminotransferase; CK, creatine kinase; gamma GT, gamma glutamyl transferase; HCT, haematocrit; MCH, mean corpuscular haemoglobin; MCHC, mean corpuscular haemoglobin concentration; MCV, mean corpuscular volume; RBC, red blood cells; WBC, white blood cells. Bold type denotes abnormal result.

Table 2.2 Faecal Analysis Results

Variable	Result
Colour	Brown
Consistency	Formed
Starch	Moderately increased
Muscle	Normal
Neutral fat	Slightly increased
Fatty acids	Slightly increased
Trypsin	Negative
Faecal	Occult blood positive
Flotation	Nil eggs/cysts

Table 2.3 Faecal PCR Results

Organism	Result
<i>Tritrichomonas foetus</i>	Negative
<i>Cryptosporidium</i> spp.	Negative
<i>Giardia</i>	Negative
<i>Toxoplasma gondii</i>	Negative
<i>Salmonella</i> spp.	Negative
<i>C. perfringens</i> (CPEA gene)	Negative
Coronavirus	Negative
Panleucopenia virus	Negative

Q 3. Can you refine your differential diagnoses further given these results?

- Metabolic causes are excluded, although atypical hypoadrenocorticism could still be possible but is extremely rare in cats.
- Infectious causes are much less likely, although negative parasitology does not completely exclude isospora infection.
- Nutritional causes are less likely given the lack of response to a hydrolysed protein diet, although there could still be a positive response with alternative diet trials.
- Inflammatory bowel disease, EPI, neoplasia, and causes of partial obstruction such as intussusception remain possibilities.

Q 4. How would you further investigate this case?

Abdominal radiographs and abdominal ultrasound would further evaluate the possibility of causes of partial intestinal obstruction, assess for intestinal masses, diffuse intestinal wall thickening, mesenteric lymphadenopathy, and further evaluate the liver and pancreas.

Further Case Information

In this case abdominal ultrasound only was performed. There was a large amount of fluid present within the large intestine, but no other ultrasonographic abnormalities were evident. Intestinal wall thickness and layering were normal.

Q 5. What are the most likely remaining differential diagnoses in this case and how would you further distinguish between them?

There is no evidence of partial intestinal obstruction, or neoplastic disease. Most likely remaining differential diagnoses are therefore inflammatory bowel disease +/- pancreatitis +/- inflammatory liver disease (these often occur together in cats) and EPI.

Measurement of TLI, folate, and cobalamin should be performed to further investigate the possibility of EPI and small intestinal disease, prior to considering intestinal biopsies.

Further Case Information

- B12 injections, metronidazole, psyllium, and probiotics were initiated pending TLI results.
- A hydrolysed diet was continued.
- TLI was 1.2 µg/L (RI: 12–84 µg/L), confirming the presence of EPI.

Q 6. How would you manage this case?

- Pancreatic enzyme supplementation: given with meals for life, although the amount of enzyme supplement required can vary with time. There is no need to incubate the food with powder before feeding. The recommended dose of enzyme supplementation is broad from 'one teaspoon per meal' to '1250 IU protease, 22,500 amylase, 25,000 lipase total SID'. Some sources recommend feeding bovine, porcine or game pancreas (raw) to animals that will not tolerate the powder/capsule supplement.
- Cobalamin (vitamin B12) injections: cats with EPI are usually cobalamin deficient and should be supplemented with 250 µg SC weekly for 6 weeks, every 14 days for 6 weeks, and then monthly 6 months. Ideally serum B12 levels should be measured periodically and 6 months after commencing treatment to see if ongoing supplementation is required.
- Diet: a highly digestible nutritionally complete diet should be fed.
- Management of concurrent disease: cats may have secondary intestinal infections due to the altered micro-environment, inflammatory bowel disease, fat soluble vitamin deficiencies (e.g. vitamin K), or cholangiohepatitis. EPI in cats is often a consequence of chronic pancreatitis, and diabetes mellitus can sometimes also be present. If any concurrent conditions are not addressed, clinical symptoms may persist.

Case Outcome and Follow-up

The cat responded well to the above management. Her weight improved (3.1 kg), stools formed, and defecation reduced in frequency to 1–2 times per day.

If Finances Are Limited

If finances are limited careful consideration should be taken to focus on treating the most easily treatable disorders and focusing investigations on those that are most likely to substantially alter the management of the case. For example, dietary trials, worming, trial treatment for *Giardia*, vitamin B12, and metronidazole treatment (for its immunomodulatory effects) are good initial options that are not costly. Although EPI is rare in cats, it should be considered and excluded if there are no other significant laboratory and imaging abnormalities, prior to consideration of intestinal biopsies.

Discussion

EPI is a syndrome caused by insufficient synthesis of pancreatic digestive enzymes, resulting in maldigestion. EPI is uncommon in cats and is thought to most often

be a consequence of chronic pancreatitis. Clinical signs include weight loss, loose voluminous stools, and steatorrhoea. The marked polyphagia with voluminous stools often seen in dogs with EPI is not so commonly appreciated in cats. Serum TLI is sub-normal in affected cats, and this is highly sensitive and specific. Many cats with EPI have concurrent small intestinal disease and also severely decreased serum cobalamin concentrations. It is also not uncommon for cats with EPI to have concurrent diabetes mellitus and/or cholangiohepatitis.

Further Reading

Steiner, J.M., Williams, D.A., 1999. The Veterinary Clinics of North America: Small Animal Practice 29 (2), 551–575.

Steiner, J.M., Williams, D.A., 2000. Serum feline trypsin-like immunoreactivity in cats with exocrine pancreatic insufficiency. Journal of Veterinary Internal Medicine 14 (6), 627–629.

Case 2.5

Signalment, Clinical History, and Clinical Examination

A 12-month-old MN Bengal cat (3.7 kg) was presented for chronic weight loss, malaise, inappetence, and a history of 'bringing up' undigested food shortly after eating, once or twice a day for several weeks. He was also observed to make exaggerated swallowing movements several times a day. There was no history of recent general anaesthesia or administration of oral medications.

The cat was slightly underweight (BCS 3/9), but physical examination was otherwise unremarkable.

Q 1. *What historical and/or physical examination findings would help you differentiate vomiting from regurgitation in cats?*

Typically, regurgitation has no prodromal stage that would indicate the presence of nausea, although this can be difficult to differentiate from the discomfort induced by oesophageal inflammation and/or distension. Also, the material (food and/or saliva) is expelled with relatively little effort (often suddenly and apparently unexpectedly) and there is usually no retching. Likewise, the material will not contain bile or digested food and/or blood if regurgitating is the sole problem. Palpable dilation of the cervical oesophagus may occasionally be present on the physical examination of a regurgitating animal.

Q 2. *Formulate a differential diagnoses list for regurgitation in cats.*

- Oesophagitis (e.g. secondary to gastro-oesophageal reflux, chronic vomiting, or drug administration – e.g. doxycycline hydrochloride, clindamycin)
- Oesophageal stricture
- Oesophageal hypomotility/mega-oesophagus (idiopathic, secondary to dysautonomia, myasthenia gravis, general or localized myopathy)
- Oesophageal foreign body

- Vascular ring anomaly
- Intramural or intraluminal mass (e.g. carcinoma)
- Extraluminal compression (e.g. mediastinal lymphadenopathy or cyst, thymoma, thymic lymphoma)

Q 3. What diagnostic procedures would you employ to investigate this case? Outline also what you might expect to find out with each investigation and any other advantages of each diagnostic procedure.

Plain and contrast thoracic radiography

Thoracic radiography (ideally conscious initially) may show evidence of oesophageal disease/dysfunction, such as food or fluid retained in the oesophagus, a radio-opaque oesophageal foreign body, oesophageal mass or gas dilation of the oesophagus (either proximal to an intramural or extraluminal constriction or involving the entire length in the case of mega-oesophagus). There may also be evidence of structural abnormalities such as hiatal hernia. Thoracic radiographs may also reveal the aetiology of an extraluminal compression (e.g. mediastinal mass) or evidence of complications, such as aspiration pneumonia or mediastinitis.

Contrast oesophagram

This procedure may reveal obstructive conditions (strictures, vascular ring anomalies, foreign bodies, mass lesions) and/or irregularities of the mucosa. Care should be taken to avoid aspiration when administering liquid barium and a water-soluble iodinated contrast medium should be used if there is any suspicion of oesophageal perforation.

Barium fluoroscopy

The availability of this diagnostic modality is often limited; however, it provides excellent information regarding motility disorders and may provide evidence of gastro-oesophageal reflux and/or dynamic hiatus hernia. Typically, the procedure is performed on an unsedated animal. The cat is fasted overnight (to increase the chances of compliance) and a small amount of barium is mixed with tinned food. The cat is then placed in a Perspex box with the barium-impregnated food, and the fluoroscopy beam is angled horizontally so the animal remains in a normal position. The food bolus can then be observed moving from the oral cavity to the stomach (Figure 2.10).

Upper gastrointestinal endoscopy

Endoscopy is used to visualise the internal surface of the oesophagus; this is especially useful for the diagnosis of oesophagitis, ulcerations, oesophageal strictures, intraluminal and intramural mass lesions, and foreign bodies (although the finding of normal-appearing oesophageal mucosa does not exclude the diagnosis). It also allows intervention, such as the collection of material for pathology (and microbiology, if required), the retrieval of foreign bodies, and the dilation of strictures. An assessment of the motility of the oesophagus cannot be made under general anaesthesia, nor can an appraisal of the tone of the lower oesophageal sphincter be made. If barium contrast radiography has already been utilized, this procedure should ideally be performed after a 24-h period, otherwise adherent barium may impede visualisation of the mucosal surface of the oesophagus. A gastrostomy tube may also be useful in the management of the oesophageal condition and can be placed via endoscopic guidance once the diagnostic investigations are complete.

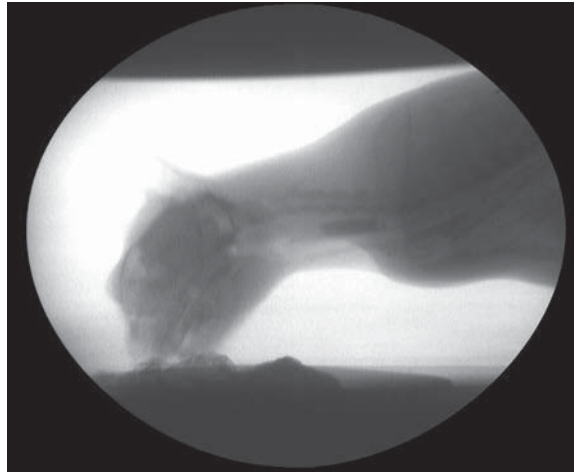


Figure 2.10. Fluoroscopic image of a cat ingesting a barium-impregnated meal.

Results of Diagnostic Tests

Plain thoracic radiography did not reveal mega-oesophagus; however, there were several patchy gas densities within the oesophageal lumen (no sedative drugs were administered for this procedure). There was no evidence of a vascular ring anomaly or hiatal hernia.

The cat was anaesthetized and upper gastrointestinal endoscopy was performed. This showed roughened and erythematous mucosa with some ulcerations and areas of hyperplasia in the distal part of the oesophagus. There was no evidence of stricture formation. The stomach and upper duodenum appeared normal. Biopsies of the oesophagus, stomach, and small intestine were obtained.

Q 4. *What is your interpretation of the imaging findings and oesophagoscopy?*

The findings of the diagnostic investigation are consistent with oesophagitis of unknown origin. The histopathological findings of the biopsies were consistent with this diagnosis.

Q 5. *What treatments would be appropriate in this case and why?*

1. Reduction of gastric acid secretion. Acid reflux into the distal oesophagus causes mucosal irritation and dysfunction of the lower oesophageal sphincter, resulting in a self-perpetuating problem. Increasing the pH of stomach secretions helps to mitigate this cycle. H₂-receptor antagonists (ranitidine, cimetidine, famotidine) decrease gastric acid secretion by competitive inhibition and are only suitable for the treatment of mild to moderate oesophagitis. Proton-pump inhibitors (omeprazole) have a more potent action than H₂-receptor antagonists and the advantage of SID administration. They function by non-competitive inhibition of the H⁺, K⁺-ATP pump, which supplies the hydrogen component of stomach (hydrochloric) acid.

2. Increasing lower oesophageal tone. The utility of prokinetics (metoclopramide, cisapride) in the management of feline oesophagitis has not been extensively investigated; however, they are thought to also enhance the rate of gastric emptying and may improve overall oesophageal motility.
3. Providing a physical barrier against gastric acid. Sucralfate (polyaluminium sucrose-sulfate complex) is a cytoprotective agent that creates a protective layer over the damaged epithelium of the oesophagus. It is also thought to function by inactivating pepsin and absorbing bile acids. The actions of this drug are optimized if it is administered as an oral slurry in an acidic environment.

The benefit of using glucocorticosteroids to reduce oesophageal inflammation and/or stricture formation has not been established in cats, and may be deleterious in the event of aspiration pneumonia; their use in this setting is controversial.

Severe cases may require gastrostomy tube placement for the provision of nutrition while the oesophagus is healing. Pre-existing conditions leading to oesophagitis, such as hiatal hernia, may require surgical correction, and medically resistant cases of gastro-oesophageal reflux-induced oesophagitis may benefit from antireflux cardioplasty.

Treatment and Outcome

The cat was prescribed omeprazole (0.5 mg/kg PO SID), metoclopramide (0.3 mg/kg PO QDS initially), and sucralfate (0.25 g PO TID, mixed in a small amount of water and given as a slurry approximately 1 h before food and other medications). It was recommended that he receive small frequent wet-food meals. The cat responded well to the medications, and the owners reported a resolution of the regurgitation and odynophagia over several days. The medications were discontinued after 2 weeks and the cat did not have a return of any clinical signs consistent with oesophagitis over a follow-up period of 6 months.

Discussion

Oesophagitis (especially that related to the provision of irritating oral tablet or capsule formulations, such as doxycycline hydrochloride and clindamycin) has become a significant entity in feline practice. Studies have shown that the transit time of capsules and tablets administered without subsequent food or water ('dry swallow') can be up to 4–5 min. It is therefore good practice to routinely administer food or water following any tablet or capsule administration. Untreated oesophagitis can progress to stricture formation, which requires repeated balloon dilation, and strictures can be recurrent. In cases where the oesophagitis is uncomplicated by strictures, the prognosis is good, providing any underlying causes can be resolved.

Further Reading

- Frowde, P.E., Battersby, I.A., Whitley, N.T., et al., 2011. Oesophageal disease in 33 cats. *Journal of Feline Medicine and Surgery* 13, 564–569.
- Glazer, A., Walters, P., 2008. Esophagitis and esophageal strictures. *Compendium on Continuing Education of Veterinary Practitioners* 30, 281–291.

- Han, E., Broussard, J., Baer, K.E., 2003. Feline esophagitis secondary to gastroesophageal reflux disease: clinical signs and radiographic, endoscopic, and histopathological findings. *Journal of the American Animal Hospital Association* 39, 161–167.
- Melendez, L.D., Twedt, D.C., Wright, M., 2000. Suspected doxycycline-induced esophagitis with esophageal stricture formation in three cats. *Feline Practice* 28, 10–12.

Case 2.6

Signalment and History

A 5-year-old FN Siamese presented with a 5-day history of progressive inappetence, lethargy, and vomiting, and a 2-day history of jaundice.

The patient was an indoor/outdoor cat, fed on dry commercial cat food. Vaccination, flea, and worming treatment were current.

Clinical Examination

The cat was in slightly reduced body condition (BCS 4/9, weight 4.4 kg). She was quiet but alert and responsive and estimated to be 7% dehydrated with tacky, jaundiced mucous membranes (capillary refill time (CRT) 2 s). The remainder of the examination and vital parameters were unremarkable.

- Q** 1. Formulate differential diagnoses lists for jaundice and vomiting (which are the major problems identified in this case) and highlight which differentials you would consider to be most likely.

Differential Diagnoses for Jaundice

- Pre-hepatic
 - Haemolysis (e.g. *Haemoplasma* spp., oxidative damage, FeLV, primary or secondary immune-mediated haemolytic anaemia)
- Hepatic
 - Inflammatory liver disease (neutrophilic/lymphocytic cholangitis)
 - Hepatic lipidosis
 - Infectious disease (FIP, toxoplasmosis)
 - Neoplasia (primary or metastatic)
 - Sepsis
 - Hepatotoxicity (drugs, e.g. diazepam, paracetamol, methimazole; toxins, e.g. phenols, lead, copper)
- Post-hepatic
 - Pancreatitis
 - Cholangitis
 - Cholecystitis
 - Neoplasia (biliary cystadenoma, carcinoma, pancreatic adenocarcinoma, adenoma, duodenal papilla carcinoma)
 - Gall bladder/bile duct rupture
 - Cholelithiasis

Differential Diagnoses for Vomiting

- Gastrointestinal disease (e.g. gastritis/enteritis, neoplasia, pyloric or intestinal obstruction such as foreign body or neoplasia, inflammatory bowel disease, motility disorder, infectious disease (e.g. *Helicobacter* spp.), obstipation)
- Dietary indiscretion/intolerance/allergy
- Intra-abdominal, extra-intestinal disease (e.g. pancreatitis, hepatic disease, renal disease, peritonitis)
- Metabolic disease (e.g. sepsis, acid-base disorders, hypercalcaemia, diabetic keto-acidosis, hyperthyroidism)
- Drugs (e.g. NSAIDs (non-steroidal anti-inflammatory drugs), erythromycin, tetracycline)
- Toxins (e.g. ethylene glycol, lead)
- Neurologic disorders (e.g. vestibular disease, neoplasia, raised intracranial pressure)

In light of the signalment, history, and clinical signs, pancreatitis, cholangitis (acute neutrophilic) or a combination of pancreatitis/cholangitis +/- inflammatory bowel disease ('triaditis') are considered the most likely differential diagnoses.

Q 2. What investigations would you perform next?

- Haematology (Table 2.4) should be performed to exclude haemolysis and to assess for evidence of inflammation/infection.
- Serum biochemistry should be assessed (Table 2.5) for evidence of hepatic disease, to evaluate serum proteins, to determine the degree of hyperbilirubinaemia, and to assess the renal parameters and electrolytes.

Table 2.4 Haematology Results at Presentation

Parameter	Patient Result	Reference Interval
Haemoglobin (g/dL)	9.70	8.00–15.00
HCT (%)	28.5	25.00–45.00
RBC ($\times 10^{12}/L$)	6.03	5.50–10.00
MCV (fL)	47.2	40.0–55.0
MCH (pg)	16.1	12.5–17.0
MCHC (g/dL)	34.0	30.0–35.0
Platelets ($\times 10^9/L$)	671	200–700
WBC ($\times 10^9/L$)	6.60	4.90–19.0
Neutrophils ($\times 10^9/L$)	4.36	2.40–12.5
Lymphocytes ($\times 10^9/L$)	0.99	1.40–6.00
Monocytes ($\times 10^9/L$)	0.66	0.10–0.70
Eosinophils ($\times 10^9/L$)	0.07	0.10–1.60
Basophils ($\times 10^9/L$)	0.00	0.00–0.10

Smear examination was unremarkable. Bold type denotes abnormal result. For abbreviations, see the footnote to Table 2.1 and the List of Abbreviations.

Table 2.5 Biochemistry Results at Presentation

Parameter	Patient Result	Reference Interval
Urea (mmol/L)	5.8	6.5–10.5
Creatinine (μmol/L)	64	44–175
Total protein (g/L)	56.4	77–91
Albumin (g/L)	19.8	24–35
Globulin (g/L)	36.6	21–51
Albumin:globulin ratio	0.54	0.4–1.3
ALT (IU/L)	72	15–45
ALP (IU/L)	21	15–60
Total bilirubin (μmol/L)	173.7	0–10
GGT (IU/L)	11	0–2
Sodium (mmol/L)	153.1	149–157
Potassium (mmol/L)	2.33	4–5
Chloride (mmol/L)	115	115–130
Calcium (mmol/L)	2.08	2.3–2.5
Phosphate (mmol/L)	0.97	0.95–1.55
Glucose (mmol/L)	8.5	3.5–7.5

Bold type denotes abnormal result. For abbreviations, see the footnote to Table 2.1 and the List of Abbreviations.

FIV and FeLV ELISA may also be performed to evaluate retroviral status (Table 2.6). Given that the cat is depressed and dehydrated, blood pressure (BP) (Table 2.7) should also ideally be measured to assess for hypotension secondary to hypovolaemia.

Table 2.6 Retroviral Testing

Parameter	Patient Result
FIV (ELISA)	Negative
FeLV (ELISA)	Negative

Table 2.7 Systolic Blood Pressure (Doppler Method)

Parameter	Patient Result	Reference Interval
Systolic BP (mmHg)	95	120–160

Q 3. What is your interpretation of these results?

Pre-hepatic jaundice can be excluded. Lymphopenia and eosinopenia are consistent with a stress leucogram. There is no evidence of neutrophilia/neutropenia, left shift, or toxic change to suggest sepsis.

The mildly decreased urea may reflect hepatic insufficiency. Hypoalbuminaemia could be due to decreased hepatic production, or renal or gastrointestinal loss. The mildly elevated alanine transaminase (ALT) could reflect early/mild hepatocyte damage due to a primary or secondary hepatopathy. Elevated gamma-glutamyl transferase (GGT) is indicative of cholestatic disease. Marked hyperbilirubinaemia in the absence of significantly elevated hepatic enzymes is not consistent with hepatic jaundice. The jaundice is therefore most likely to be post-hepatic. Hypokalaemia could be attributed to anorexia or gastrointestinal loss. Hyperglycaemia could be stress induced or consistent with pancreatitis. The hypocalcaemia could be attributed to hypoalbuminaemia or could reflect a genuine hypocalcaemia that could be associated with pancreatitis.

Q 4. Are there any further investigations that you would like to perform?

Further indicated clinical pathology tests are urinalysis (Table 2.8) to exclude protein losing nephropathy and, given the clinical suspicion of pancreatitis, a SNAP™ fPL in-house test and/or fPLI should be assessed (Table 2.9). TLI could be assessed but is an insensitive marker of pancreatitis. Amylase and lipase are of no clinical value in the diagnosis of feline pancreatitis.

Table 2.8 Urinalysis Results at Presentation

Parameter	Patient Result	Reference Interval
pH	7.8	
Blood	Negative	N/A
Glucose	Negative	N/A
Ketones	Negative	N/A
Protein	43.4	N/A
Specific gravity	1.032	>1.035
Protein:creatinine ratio	0.24	<0.4
Creatinine	16.0	N/A
Sediment examination	Scant WBC and epithelia	
Aerobic and anaerobic culture	Negative	

Bold type denotes abnormal result.

Table 2.9 Further Tests

Parameter	Patient Result	Reference Interval
fPLI (µg/L)	101.0	2.0–7.0
SNAP fPL test	Abnormal	

Bold type denotes abnormal result.

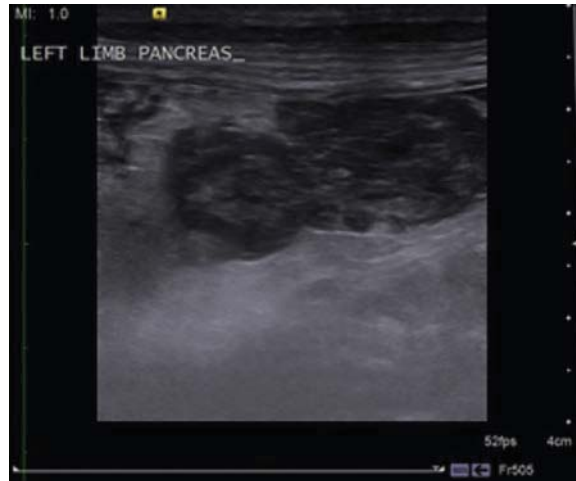


Figure 2.11. Ultrasonographic image of an enlarged, hypoechoic pancreas surrounded by hyperechoic mesentery. No other abnormalities were detected.

The hypocalcaemia is mild and likely affected by hypoalbuminaemia. This could be further investigated by assessing ionized calcium if available, but in this case it is unlikely to affect treatment and is thus not necessary.

Abdominal ultrasound should be performed to assess the liver, gall bladder, biliary tree, pancreas, and gastrointestinal tract as primary areas of interest. However, the rest of the abdomen should also be examined thoroughly to evaluate the other organs and to exclude free abdominal fluid (Figure 2.11).

Q 5. What is the most likely diagnosis?

Pancreatitis is the most likely diagnosis, and this is supported by the abnormal SNAP fPL and fPLI results. Histopathology is the only method of obtaining a definitive diagnosis of pancreatitis. Biopsies are not, however, frequently obtained due to surgical risk, the fact that disease is often patchy or localised, biopsies may not be representative, and a more definitive diagnosis is unlikely to change the management.

Q 6. How would you treat this case?

Correction of hypotension, fluid deficit, and electrolyte disturbances

1. A 5 mL/kg bolus of Hartmann's was administered intravenously over 20 min to address the hypotension, and systolic BP improved to 110 mmHg. This was repeated, and BP normalized (124 mmHg).
2. The dehydration, which was estimated at 7%, was then corrected over 24 h:

$$\begin{aligned}
 \text{Fluid deficit (L)} &= \text{Body weight (kg)} \times \% \text{ dehydration} / 100 \\
 &= 4.4 \text{ kg} \times 7 / 100 \\
 &= 0.3 \text{ L} \\
 &= 300 \text{ mL}
 \end{aligned}$$

3. The daily maintenance requirement was added to this (approximates to 50 mL/kg/day or 2 mL/kg/h):

$$\begin{aligned}\text{Maintenance fluid requirement (mL)} &= 50 \text{ mL/kg/day} \times 4.4 \text{ kg} \\ &= 220 \text{ mL}\end{aligned}$$

4. The total volume from 2 and 3 should then be administered over 24 h

$$\begin{aligned}\text{Total volume of crystalloid fluid required} &= 300 \text{ mL} + 220 \text{ mL} \\ &= 520 \text{ mL}\end{aligned}$$

$$\begin{aligned}\text{Minus the two boluses given to correct hypotension} &= 2 (5 \text{ mL} \times 4.4 \text{ kg}) \\ &= 44 \text{ mL}\end{aligned}$$

$$\begin{aligned}\text{Total volume of crystalloid fluid required} &= 520 \text{ mL} - 44 \text{ mL} \\ &= 476 \text{ mL}\end{aligned}$$

6. Rate of administration = 476 mL/24 h
= 19.8 mL/h

The response of the patient to the fluid administration should be monitored closely so the fluid plan can be increased or decreased as required.

In this case potassium (KCl) supplementation was provided to correct the hypokalaemia (27.5 mmol KCl in 500 mL Hartmann's). The rate of KCl administration must not exceed 0.5 mmol/kg/h so this was not included in the bolus administration.

The hypocalcaemia was mild and the cat was asymptomatic so parenteral calcium supplementation was not required at this stage. This was, however, closely monitored.

Anti-emetic Therapy

Maropitant (1 mg/kg SC SID) and metoclopramide (1–2 mg/kg SID continuous rate infusion (CRI)) were administered.

Nutritional Support

Once vomiting was controlled, a naso-oesophageal tube was placed to provide nutrition as the patient would not eat voluntarily. The patient was tempted with oral food prior to tube feeding and an appetite stimulant (mirtazapine 3.75 mg PO every third day) was administered.

Analgesia

Pain was not apparent on abdominal palpation. However, as pain can be difficult to recognize in cats, manifesting only as lethargy and/or anorexia, buprenorphine (0.02 mg/kg IV TID) was administered.

Outcome

There was a marked improvement in the biochemical parameters by day 4, and all parameters were normal by day 25. The patient recovered fully and has had no further episodes of pancreatitis.

Discussion

The cause of pancreatitis is usually unknown, but it can be caused by ischaemia, infection (toxoplasmosis, feline herpes virus (FHV), FIP), pancreatic duct obstruction, and trauma. The initiating event is the premature activation of digestive zymogens within the acinar cell causing necrosis and pancreatic autodigestion. In cats it is often associated with cholangitis and/or inflammatory bowel disease. The severity of disease and clinical signs are very variable. Most cases respond well to supportive and symptomatic treatment, but prognosis is dependent on severity of disease with ionized hypocalcaemia, a negative prognostic factor.

Further Reading

- Warman, S., Harvey, A., 2007. Feline pancreatitis: current concepts and treatment guidelines. In Practice 29, 470–477.
- Washabau, R.J., 2010. Feline pancreatic disease. In: Ettinger, S.J., Feldman, E.C. (Eds.), Textbook of Veterinary Internal Medicine, seventh ed. Elsevier Saunders, pp. 1704–1709.
- Xenoulis, P.G., 2008. Current concepts in feline pancreatitis. Topics in Companion Animal Medicine 23, 185–192.

Case 2.7

Signalment and Clinical History

A 7-year-old FN DSH cat presented for investigation of a 3-week history of inappetence progressing to anorexia, weight loss, and lethargy. There was no prior medical history. The patient was an indoor/outdoor cat, fed a commercial wet diet, and with no history of travel outside the United Kingdom. Vaccination, flea, and worming treatment were current.

Physical Examination

Physical examination revealed the patient to be quiet but alert and responsive, jaundiced, and mildly dehydrated (7%), but examination was otherwise unremarkable. The patient was in good body condition (BCS 5/9, weight 4.4 kg) but had lost 0.5 kg since weight was recorded at routine vaccination 6 months previously. (See Case 2.6 for differentials for jaundice.)

Q 1. How would you investigate this case further?

- CBC to exclude anaemia (and thus pre-hepatic causes of jaundice) and to evaluate for evidence of an inflammatory leucogram
- Serum biochemistry to evaluate for evidence of hepatocellular damage, cholestasis, degree of hyperbilirubinaemia, and other indicators of functional hepatic injury (e.g. hypoalbuminaemia, hypoglycaemia, decreased urea, and hyperammoniaemia). Electrolyte abnormalities and other concurrent disease processes (e.g. renal disease) may also be evaluated.
- fPLI to look for evidence of pancreatitis

- Blood pressure should ideally be assessed in any ill, dehydrated cat
- Abdominal ultrasonography to evaluate the liver, pancreas, and gastrointestinal tract in particular
- Abdominal and thoracic radiography to exclude concurrent or metastatic disease may also be considered but should not be prioritized if sedation is required in an unstable patient

Diagnostic Test Results

See Tables 2.10 and 2.11.

- BP was normal (125 mmHg, reference interval 120–160 mmHg)
 - fPLI was within reference interval
 - Abdominal ultrasound revealed a diffusely hyperechoic and slightly enlarged liver. The biliary tree appeared normal (Figure 2.12)

Table 2.10 Biochemistry Results at Presentation

Parameter	Patient Result	Reference Interval
Urea (mmol/L)	5.0	6.5–10.5
Creatinine (μmol/L)	63	44–175
Total protein (g/L)	67.2	77–91
Albumin (g/L)	28.7	24–35
Globulin (g/L)	38.5	21–51
Albumin:globulin ratio	0.75	0.4–1.3
ALT (IU/L)	130	15–45
ALP (IU/L)	706	15–60
Total bilirubin (μmol/L)	84.1	0–10
Gamma GT (IU/L)	2	0–2
Sodium (mmol/L)	155.0	149–157
Potassium (mmol/L)	4.75	4–5
Chloride (mmol/L)	116	115–130
Calcium (mmol/L)	2.45	2.3–2.5
Phosphate (mmol/L)	0.99	0.95–1.55
Glucose (mmol/L)	7.5	3.5–7.5

Bold type denotes abnormal result. For abbreviations, see the footnote to Table 2.1 and the List of Abbreviations.

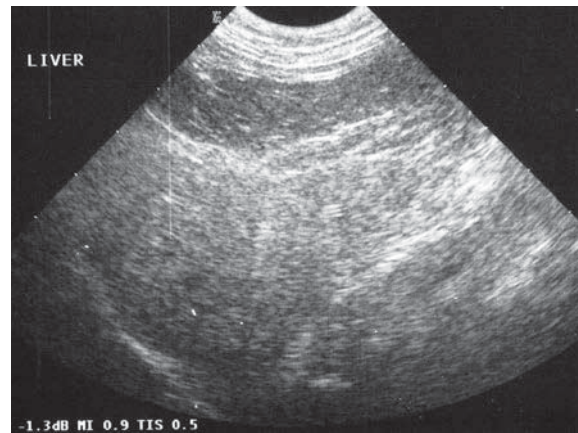
Q 2. Outline the possible differential diagnoses in this case in view of the laboratory and imaging results.

- The lack of anaemia in the CBC makes pre-hepatic jaundice unlikely.
- There is no evidence of sepsis (left shift, neutrophilia or toxic neutrophils).

Table 2.11 Haematology Results at Presentation

Parameter	Patient Result	Reference Interval
Haemoglobin (g/dL)	8.42	8.00–15.00
HCT (%)	30.9	25.00–45.00
RBC ($\times 10^{12}/L$)	8.28	5.50–10.00
MCV (fL)	47.8	40.0–55.0
MCH (pg)	15.0	12.5–17.0
MCHC (g/dL)	31.4	30.0–35.0
Platelets ($\times 10^9/L$)	48	200–700
WBC ($\times 10^9/L$)	4.57	4.90–19.0
Neutrophils ($\times 10^9/L$)	3.16	2.40–12.5
Lymphocytes ($\times 10^9/L$)	0.98	1.40–6.00
Monocytes ($\times 10^9/L$)	0.41	0.10–0.70
Eosinophils ($\times 10^9/L$)	0.00	0.10–1.60
Basophils ($\times 10^9/L$)	0.10	0.00–0.10

Smear examination revealed platelet clumps, machine count falsely low, platelet count normal. Bold type denotes abnormal result. For abbreviations, see the footnote to Table 2.1 and the List of Abbreviations.


Figure 2.12. Ultrasonographic image of the diffusely hyperechoic and enlarged liver.

- The elevated liver parameters support a hepatic cause. Elevations in alkaline phosphatase (ALP), ALT, and bilirubin with GGT within reference interval is a pattern seen typically in hepatic lipidosis.
- The normal fPLI result makes pancreatitis less likely but does not exclude it.
- The ultrasonographic findings are most suggestive of hepatic lipidosis or possibly infiltrative disease (e.g. lymphoma).

Q 3. *How would you confirm your suspicion of hepatic lipidosis?*

FNA of the liver can be performed in a conscious patient and will confirm hepatic lipidosis. It may also be useful in the diagnosis of lymphoma. A tissue biopsy would be required to evaluate for cholangitis or neoplasia that may be present concurrently.

Diagnostic Test Results

Cytology ([Figure 2.13](#)) revealed a marked vacuolar hepatopathy consistent with hepatic lipidosis (HL).

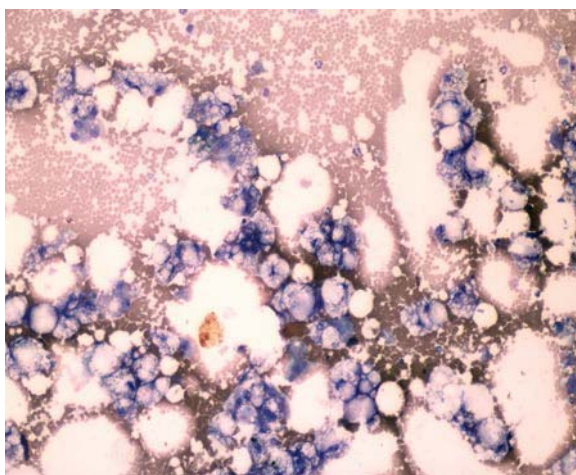


Figure 2.13. Cytology of liver showing extensive vacuolation of hepatocytes.

Q 4. *List the main treatment considerations for a cat with hepatic lipidosis.*

1. Correct fluid and electrolyte abnormalities
2. Instigate enteral feeding as soon as possible (cautiously at first to avoid re-feeding syndrome)
3. Administer anti-emetic therapy if required and to facilitate feeding
 - Maropitant (1 mg/kg SC SID)
 - Metoclopramide (1–2 mg/kg SID CRI)
4. Measure and supplement vitamin B12
 - Decreased in up to 40% of cats with HL (all cats with concurrent gastrointestinal disease)
 - Measure (for monitoring) and empirically supplement (0.125–0.5 mg SC weekly for 4–6 weeks, then as required to maintain normal levels)
5. Assess and correct any coagulation disturbances
 - Assess APTT (activated partial thromboplastin time) and PT (prothrombin time)
 - Supplement vitamin K (1 mg/kg SC BID)

6. Consider supplementation with additional nutrients
 - Supplementation with taurine, arginine, thiamine, S-adenosylmethionine (SAMe), and vitamin E are of unproven benefit but are recommended by some authors
 - Most evidence for L-carnitine (250–500 mg/cat SID) supplementation
7. Treat hepatic encephalopathy if applicable
 - Lactulose (0.3–0.5 mL/kg PO TID)
 - Ampicillin (10–20 mg/kg IV, SC, or PO TID).

Q 5. *What are the options for enteral feeding? Outline the characteristics of an appropriate food type and feeding plan for this patient.*

Syringe feeding should not be employed as it is stressful to cats and leads to food aversion.

Tube feeding can be provided via a naso-oesophageal tube, oesophagostomy tube, or gastrostomy tube (either percutaneous endoscopic or surgical placement). As anaesthesia is to be avoided until the patient has been stabilized and enteral nutrition has been instigated, a naso-oesophageal tube should be placed initially. This can be replaced by an oesophagostomy or gastrostomy tube when the patient is more stable. An oesophagostomy tube is ideal as it can be placed under a very brief anaesthesia, can be used immediately, and is less invasive than a gastrostomy tube. Patients that require enteral tube feeding over a longer periods of time can be discharged with an oesophagostomy or gastrostomy tube.

A balanced diet designed for cats (energy provided as 30–40% protein, 50% lipids, 20% carbohydrate) can be used in liquid form (if available) or tinned diets can be liquidized and diluted to facilitate naso-oesophageal feeding as required. A high protein diet is ideal, but this can exacerbate encephalopathy in severe cases necessitating a restricted protein diet initially, which is changed to a higher protein diet once tolerated.

For cats with HL it is recommended to feed 60–80 kcal/kg/day, so this patient would require 264–352 kcal per day.

One-third of the calorie requirement should be fed on day 1, two-thirds on day 2, and the total requirement on day 3. This should be divided into at least four to five daily meals, but smaller, more frequent meals are often required due to gastric stasis and ileus. Alternatively it may be fed as a CRI via a syringe driver. The patient should be monitored for evidence of refeeding syndrome, with particular monitoring of serum phosphate concentration.

Discussion

Hepatic lipidosis is seen in debilitated cats after a period of reduced calorie intake/anorexia, or secondary to concurrent diseases. The development of a catabolic state leads to increased mobilization of peripheral fat stores to the liver in conjunction with reduced removal of lipid from the liver. This causes excessive lipid accumulation in hepatocytes and can lead to severe hepatic dysfunction or death. It is either a primary (idiopathic) condition or occurs secondary to an underlying disease process, most commonly inflammatory liver disease, small intestinal diseases, pancreatitis, neoplasia, kidney disease, and endocrine disorders such as diabetes mellitus and hyperthyroidism.

Outcome

The patient responded well to initial treatment with fluid therapy, anti-emetics and n/o tube feeding. An oesophagostomy tube was later placed. L-carnitine, vitamin B12, and SAME were supplemented. Liver biopsy was not obtained as the serum biochemistry and clinical signs improved as expected with treatment. The patient was discharged after 14 days and the oesophagostomy tube was removed on day 23. The patient was assumed to have idiopathic HL as no underlying disease process was identified, although pancreatitis is always difficult to exclude.

Further Reading

Armstrong, P.J., Blanchard, G., 2009. Hepatic lipidosis in cats. *Veterinary Clinics of North America: Small Animal Practice* 39, 599–616.

Holan, K.M., 2009. Feline hepatic lipidosis. In: Bonagura, J.D., Twedt, D.C. (Eds.), *Kirk's Current Veterinary Therapy XIV*, Elsevier Saunders, pp. 570–575.

Case 2.8

Signalment and History

A 1-year-old FN DSH cat presented with a 1-month history of chronic vomiting. The cat had also lost weight despite a ravenous appetite. The cat was fed a complete wet and dry diet, but there was little improvement following various dietary trials. Vaccination and parasite control were current.

Clinical Examination

Clinical examination was within normal limits except:

- Unkempt hair coat
- Poor BCS (1.5/5)

Q 1. *Formulate a Problem List.*

- Chronic vomiting
- Weight loss
- Polyphagia

Q 2. *How can you differentiate between vomiting and regurgitation based on clinical signs?*

- Vomiting involves active abdominal effort and tends to be preceded by prodromal signs of nausea (salivation, lip licking). Partially digested, bile-stained food may be ejected.
- Regurgitation can be described as the passive expulsion of undigested food without active abdominal force or prodromal signs.

In this case the cat showed abdominal effort, retching, and food was violently ejected, consistent with vomiting.

(See Cases 2.6 and 2.13 for information on differential diagnoses for vomiting.)

Q 3. Considering your differential diagnoses, what are the options for further investigation of this cat?

- Haematology and biochemistry to exclude extra-gastrointestinal causes of vomiting such as hepatic and renal disease
- fPLI to investigate the possibility of pancreatitis
- Serum cobalamin and folate concentrations to further investigate the possibility of small intestinal disease
- Abdominal radiographs to assess for gastrointestinal foreign bodies, abdominal masses, and evidence of partial small intestinal obstruction
- Abdominal ultrasound to further evaluate abdominal organs, particularly the gastrointestinal tract, to assess for evidence of gastric outflow obstruction, partial small intestinal obstruction, and intestinal wall thickness and layering

Further case information is shown in [Tables 2.12–2.14](#).

Table 2.12 Case Information

Test	Laboratory Value	Normal Reference Interval
Serum Chemistry		
Total protein (g/L)	63.0	60.0–80.0
Albumin (A) (g/L)	29.0	25.0–45.0
Globulin (G) (g/L)	34.0	25.0–45.0
Albumin:globulin ratio	0.85	0.6–1.50
Urea (mmol/L)	5.7	2.5–9.9
Creatinine (μmol/L)	142.8	20.0–177.0
ALT (IU/L)	17.0	5.0–60.0
ALP (IU/L)	11.3	<60.0
Gamma GT (IU/L)	2.2	0.1–9.0
Total bilirubin (μmol/L)	0.1	0.1–5.1
CK (IU/L)	193.2	20.0–225.0
Bile acids (fasting) (μmol/L)	1.5	0.1–5.0
Sodium (mmol/L)	146.9	145–157
Potassium (mmol/L)	4.40	3.5–5.5
Sodium:potassium ratio	33.39	28.0–40.0
Chloride (mmol/L)	118.7	100–124
Inorganic phosphorus (mmol/L)	1.51	0.9–2.2
Total calcium (mmol/L)	2.00	2.00–2.50
Glucose (mmol/L)	4.9	2.8–4.9

Continued

Table 2.12 Case Information—cont'd

Test	Laboratory Value	Normal Reference Interval
Haematology		
White cells ($\times 10^9/L$)	12.0	6.0–15.0
Neutrophils ($\times 10^9/L$)	10.20	2.5–12.5
Lymphocytes ($\times 10^9/L$)	2.08	2.0–7.0
Monocytes ($\times 10^9/L$)	0.48	<0.6
Eosinophils ($\times 10^9/L$)	0.24	0.05–0.7
Red cells ($\times 10^{12}/L$)	4.75	5.0–10.0
Haemoglobin (g/dL)	11.0	9.0–15.0
HCT (l/L)	0.34	0.26–0.47
MCV (fL)	45.0	42.0–57.0
MCH (pg)	15.6	13.0–17.5
Platelets ($\times 10^9/L$)	380	150–550

For abbreviations, see the footnote to Table 2.1 and the List of Abbreviations.

Table 2.13

FelV antigen test	Negative	
FIV antibody test	Negative	

Table 2.14 External Laboratory Results

	Patient Value	Reference Interval
fPLI ($\mu g/L$)	0.8	0.1–3.5
Cobalamin (ng/L)	200	≥ 275
Folate ($\mu g/L$)	15	9.5–20.2

Bold type denotes abnormal result.

Q 4. What is your interpretation of the laboratory results?

- The laboratory results are all within normal limits, making renal and liver disease an unlikely cause of the vomiting.
- There are no electrolyte derangements as a result of the chronic vomiting.
- Serum protein concentrations are normal excluding a protein losing enteropathy.
- There is no evidence on haematology of chronic gastrointestinal blood loss.
- fPLI is normal although this does not exclude the possibility of pancreatitis.
- Hypocobalaminaemia is present, suggestive of intestinal malabsorption.

Further Case Information

Abdominal radiography demonstrated ingesta within the stomach, suggestive of delayed gastric outflow since the cat had not been fed for 10 h prior to taking radiographs.

On abdominal ultrasound no evidence of physical gastric or intestinal obstruction could be identified. However, there was evidence of gastrointestinal ileus: the stomach contained ingesta, and the duodenum was mildly dilated with evidence of retroperistalsis, other areas of small intestine contained ingesta and, although there were no distended loops of small intestine evident, few peristaltic waves were seen during the scan. Intestinal wall thickness and layering was within normal limits. All other abdominal organs were ultrasonographically normal, and there were no enlarged mesenteric lymph nodes or free abdominal fluid identified.

Q 5. *Given the results so far, what are your remaining most likely differential diagnoses?*

- Partial gastric or intestinal obstruction (e.g. foreign body, intermittent intussusception, pyloric stenosis)
- Gastrointestinal dysmotility
 - Infiltrative gastrointestinal disease (e.g. IBD, lymphoma (less likely))
 - Dysautonomia (unlikely with no other suggestive signs)
 - Visceral myopathy
 - Pancreatitis

Q 6. *What are the options for further investigation of this case?*

- A barium or barium impregnated spheres study to further evaluate gastric outflow obstruction
- Laparotomy to assess the gastrointestinal tract for foreign bodies and obtain full thickness gastrointestinal biopsies
- Upper gastrointestinal endoscopy to evaluate for gastric foreign bodies and obtain endoscopic gastrointestinal biopsies

Further Case Information

In this case, upper gastrointestinal endoscopy was performed, revealing a trichobezoar (Figures 2.14 and 2.15) within the pyloric antrum. This was able to be removed endoscopically. Duodenoscopy was then performed and multiple endoscopic biopsies taken from the duodenum, jejunum, and then the stomach.

Histopathology demonstrated low-grade lymphoplasmacytic gastritis and a moderate to severe lymphoplasmacytic enteritis.

Diagnosis: pyloric trichobezoar and lymphoplasmacytic enteritis.

Q 7. *What are the options for further managing this case?*

Therapeutic options include:

- Dietary trials
 - Hydrolysed protein diet
 - Single-source protein/carbohydrate diet

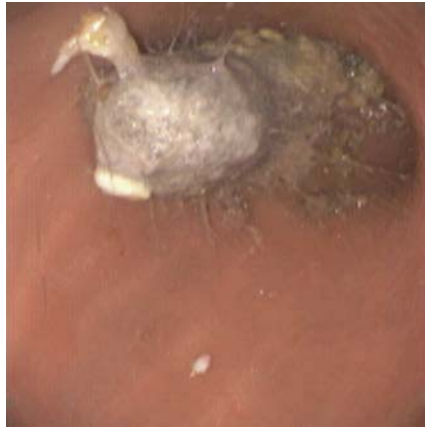

Figure 2.14. Endoscopic view of the pyloric antrum showing the trichobezoar obstructing the pylorus.

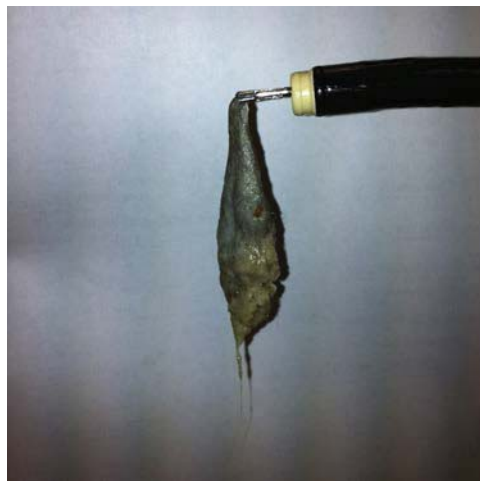

Figure 2.15. The trichobezoar was able to be removed in its entirety with endoscopic forceps, and was approximately 5 × 3 cm in size.

- Novel protein/carbohydrate diet
- Easily digestible diet
- Corticosteroids
 - Systemic prednisolone
 - Budenoside
- Metronidazole for immunomodulatory effects
- Vitamin B12 250 µg weekly until serum concentrations have normalized

Further Case Information

Despite an initial response to dietary management, the cat in this case did relapse, requiring the addition of the anti-inflammatory prednisolone (1 mg/kg) for approximately 2 months, gradually weaning down to lowest effective dose. This cat is currently in clinical remission and doing extremely well on prescription hypoallergenic diet alone.

Discussion

Vomiting can be one of the most frequent clinical signs of IBD in cats. Affected cats are frequently misdiagnosed as having hairballs as the primary problem. It is still uncertain why cats appear prone to trichobezoars but may be due to poor gastrointestinal motility, either as a primary idiopathic condition, or secondary to inflammatory bowel disease as was likely in this case.

Case 2.9

Signalment, History, and Clinical Examination

An 8-month-old FN Bengal cross was examined for a 10-day history of tenesmus and passing small, frequent amounts of mucoid diarrhoea and haematochezia. The cat was acquired from a local breeder when she was 12 weeks old and preventative health care was current. She was an indoor cat in a single cat household.

The cat was quiet but responsive. She was pyrexia (39.7 °C), in thin body condition (1.5/5) (Figure 2.16), and had an unkempt hair coat. A mucoid discharge was noted coming from her anus (Figure 2.17). Her anal tone was normal. A large, firm



Figure 2.16. Patient in kennel showing signs of depression and unkempt hair coat.

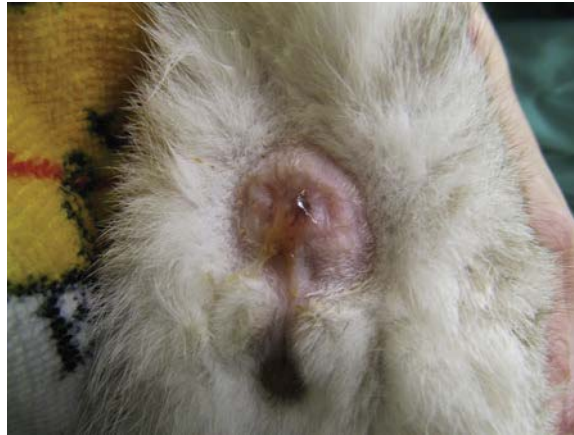

Figure 2.17. Mucoid faeces with streaks of fresh blood leaking from anus.

abdominal mass was palpable in the mid-caudal abdomen, palpation of which elicited a strong pain response and subsequent straining.

Q 1. Would you describe the diarrhoea as small or large intestinal in origin, and why?

The nature of the diarrhoea is consistent with large intestinal diarrhoea due to the tenesmus, passage of small amounts of frequent mucoid diarrhoea, and haematochezia. However, the poor body condition cannot be related to large intestinal diarrhoea alone, and another disease process would be expected to be causing this, likely related to the abdominal mass.

Q 2. Formulate a list of differential diagnoses for large intestinal diarrhoea.

- Dietary indiscretion
- Dietary hypersensitivity
- Colitis
- Infectious
 - Bacterial (e.g. *Campylobacter*, *Clostridia*)
 - Coccidial (e.g. *Cryptosporidium*, *Isospora*)
 - Protozoal (e.g. *Giardia*, *T. foetus*)
- Neoplasia (e.g. lymphoma)
- Partial colonic obstruction (e.g. intussusception), foreign body, neoplasm, extra-intestinal obstruction (e.g. enlarged lymph nodes)

Q 3. Formulate a list of differential diagnoses for the mid-caudal abdominal mass.

- Intussusception
- Foreign body
- Neoplasm

- Granuloma
- Enlarged lymph node: neoplasia (e.g. lymphoma), FIP, eosinophilic sclerosing fibroplasia

Q 4. What are the options for further investigation of this case?

- Abdominal imaging (radiographs and ultrasound to further investigate the abdominal mass). Thoracic radiographs to further assess for systemic disease (e.g. FIP, neoplasia)
- CBC and serum biochemistry to further assess for systemic disease
- FeLV antigen ELISA
- Faecal culture, parasitology, and *Tritrichomonas* PCR to further investigate the large intestinal diarrhoea although this may be related to the abdominal mass
- A right lateral abdominal radiograph was taken (Figure 2.18).

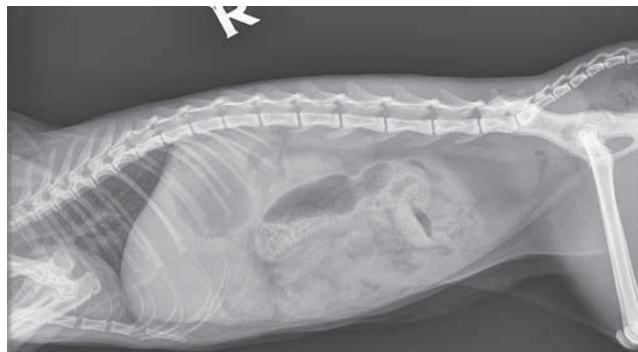

Figure 2.18. Conscious right lateral abdominal radiograph.

Q 5. What is your interpretation of the radiograph and differential diagnoses for the abnormalities seen?

There is an approximately 4 × 2 cm mid-abdominal soft tissue mass with mild accumulation of colonic gas and noticeable 'gravel sign' suggestive of partial obstruction. This indicates that the mass is likely associated with intestinal wall or mesenteric lymph node causing an extra-intestinal partial obstruction. Differential diagnoses would include granuloma (e.g. associated with foreign body, mycobacteria, FIP), lymphoma, eosinophilic sclerosing fibroplasia.

Q 6. What is your interpretation of the laboratory results and differential diagnoses for the abnormalities?

There is a mild hypoalbuminaemia, hyperglobulinaemia, and decreased A:G ratio (0.22). The CBC shows a moderate hypochromic and microcytic anaemia with a moderate lymphopenia. The rest of the laboratory results are within normal limits and ELISA negative for FIV/FeLV (see Tables 2.15 and 2.16).

Table 2.15 CBC and Serum Biochemistry Results

Test	Laboratory Value	Normal Reference Interval
Serum Chemistry		
Total protein (g/L)	94.3	60.0–80.0
Albumin (g/L)	17.2	25.0–45.0
Globulin (g/L)	76.9	25.0–45.0
Albumin:globulin ratio	0.22	0.6–1.50
Urea (mol/L)	8.7	2.5–9.9
Creatinine (μmol/L)	107.8	20.0–177.0
ALT (IU/L)	17.0	5.0–60.0
ALP (IU/L)	11.3	<60.0
GGT (IU/L)	2.2	0.1–9.0
Total bilirubin (μmol/L)	0.1	0.1–5.1
CK (IU/L)	135.9	20.0–225.0
Bile acids (fasting) (μmol/L)	1.5	0.1–5.0
Sodium (mmol/L)	146.9	145–157
Potassium (mmol/L)	4.40	3.5–5.5
Sodium:potassium ratio	33.39	28.0–40.0
Chloride (mmol/L)	118.7	100–124
Inorganic phosphorus (mmol/L)	1.51	0.9–2.2
Total calcium (mmol/L)	2.00	2.00–2.50
Glucose (mmol/L)	4.9	2.8–4.9
Haematology		
White cells ($\times 10^9/L$)	12.0	6.0–15.0
Neutrophils ($\times 10^9/L$)	10.20	2.5–12.5
Lymphocytes ($\times 10^9/L$)	0.97	2.0–7.0
Monocytes ($\times 10^9/L$)	0.48	<0.6
Eosinophils ($\times 10^9/L$)	0.24	0.05–0.7
Red cells ($\times 10^{12}/L$)	4.75	5.0–10.0
Haemoglobin (g/dL)	4.0	9.0–15.0
Haematocrit (l/L)	0.167	0.26–0.47
MCV (fL)	33.6	42.0–57.0
MCH (pg)	11.5	13.0–17.5
Platelets ($\times 10^9/L$)	380	150–550

Bold type denotes abnormal result.

For abbreviations, see the footnote to Table 2.1 and the List of Abbreviations.

Table 2.16 Retroviral Antibody/Antigen Test

FeLV antigen test	Negative
FIV antibody test	Negative

Hyperglobulinaemia can be associated with any inflammatory/infectious disease or neoplasia. However, a hyperglobulinaemia of this degree in this age of cat would raise suspicions of the possibility of FIP.

A microcytic hypochromic anaemia could indicate chronic blood loss (likely gastrointestinal given the history) and iron deficiency. Other causes of anaemia (e.g. bone marrow disease) are not excluded without further investigation (e.g. reticulocyte count).

Further Information

In this case abdominal ultrasound was not available. This may have provided more information on the location of the abdominal mass and the presence of any other intra-abdominal abnormalities, which may have helped to further guide the most appropriate next investigations. In this case laparotomy was performed.

The laparotomy revealed a moderate amount of yellow viscous free abdominal fluid. There were multifocal nodules covering the serosa of the ascending colon, omentum, and associated mesenteric lymph nodes. There was a large 4 × 5 cm colonic mass causing luminal obstruction.

Q 7. Does this information help to further narrow down differential diagnoses?

The presence of free abdominal fluid and the gross nature of that fluid further raise concerns about the possibility of FIP. However, other inflammatory or neoplastic disease can still not be excluded.

Q 8. What would be the next diagnostic steps in helping to provide more evidence of FIP, and how would you make a definitive diagnosis?

- The Rivalta test is a quick and useful way of diagnosing that the fluid is an exudate. FIP is unlikely if the Rivalta test is negative. It is highly likely if it is positive; however, is not a definitive diagnosis, as other diseases causing an exudate (e.g. bacterial peritonitis, lymphocytic cholangitis, lymphoma) can also result in a positive Rivalta test (Box 2.1).

Box 2.1 Rivalta Test

1. Test tube filled with distilled water
2. Add one drop of 98% acetic acid
3. Add one drop of effusion
4. If the drop dissipates = negative = transudate
5. If drop precipitates = positive = exudate

- Fluid protein analysis: FIP typically causes a proteinaceous effusion with a high globulin concentration, the albumin:globulin ratio typically < 0.45 . Other diseases rarely result in an effusion with such a low A:G ratio, but this is not always the case, and a higher A:G ratio does not exclude FIP.
- Fluid cytology: in FIP there is usually mixed inflammation often with non-degenerative neutrophils and macrophages.
- Immunofluorescence can be performed on effusions to look for FCoV (feline corona virus) antigen within macrophages. If positive this provides a definitive diagnosis, but a negative result does not exclude FIP.
- Histopathology of affected tissues shows a pyogranulomatous inflammation and immunohistochemistry can be performed on tissues to look for FCoV antigen within tissue macrophages, which if positive provides a definitive diagnosis.

Other tests in a young pedigree cat that may be considered when FIP is a differential diagnosis are FCoV antibody titres and α_1 -acid glycoprotein – a serum acute phase protein that can be significantly elevated in cats with FIP. FCoV antibody titres in serum can contribute to the diagnosis but should be interpreted with care as they are not conclusive for diagnosing FIP. A high percentage of healthy asymptomatic cats that can be FCoV antibody positive will never develop FIP.

Further Case Information

The Rivalta test was positive.

Cytological evaluation of the fluid revealed a moderately cellular effusion containing non-degenerative neutrophils and macrophages without signs of extracellular bacterial colonies. Further fluid analysis confirmed protein concentration >35 g/L (43 g/L), cell count $>5.0 \times 10^9$ (9.0×10^9) consisting mainly of mononuclear cells and neutrophils and thus consistent with a non-septic exudate.

Abdominal tissue samples were submitted for histopathology and confirmed pyogranulomatous inflammation, consistent with FIP. Immunohistochemistry staining for FCoV antigen definitively confirmed FIP. Interestingly, this cat also tested positive for *T. foetus*.

Q 9. *Given that FIP was a differential diagnosis, is there anything else that might have been helpful in further increasing the index of suspicion of diagnosis prior to laparotomy?*

- If abdominal ultrasound had been available, the presence of free abdominal fluid would have been diagnosed and fluid could have been sampled without the need for laparotomy.
- Thoracic radiographs/ultrasound would have identified whether there was any pleural effusion present as well. This firstly narrows down the differential diagnoses as fewer diseases can result in a bi-cavitary effusion of that nature, and it would have allowed an alternative or additional method of collecting fluid for analysis.
- A thorough ophthalmic examination could have been performed to look for presence of uveitis or chorioretinitis that may be seen with FIP.

Further Case Information

In this case the owners opted for euthanasia once a diagnosis had been confirmed.

Discussion

Once clinical signs develop, deterioration and death usually occur within weeks to months despite various treatments attempted and reported in the literature. FIP unfortunately still retains its reputation of a disease with a grave prognosis. To date, all proposed treatment protocols for both effusive and non-effusive forms of FIP have been ineffective in producing a cure. Patients definitively diagnosed with FIP have a mortality rate of virtually 100%. Immunosuppressive drugs such as prednisolone may slow disease progression and minimize clinical signs, but they do not establish a cure. Some practitioners may prescribe immune modulators alone or in combination with prednisolone (e.g. feline recombinant interferon omega) to treat cats with FIP. To date, evidence of their true efficacy is still lacking. Polyprenyl immunostimulant, another immunomodulating agent, is currently being evaluated for its ability to restore compromised immune function in FIP patients.

Further Reading

- Ishida, T., Shibantai, A., Tanaka, S., Uchida, K., et al., 2004. Use of recombinant feline interferon and glucocorticoid in the treatment of feline infectious peritonitis. *Journal of Feline Medicine and Surgery* 6 (2), 107–109.
- Legendre, A.M., Bartges, J.W., 2009. Effect of polyprenyl immunostimulant on the survival times of three cats with the dry form of feline infectious peritonitis. *Journal of Feline Medicine and Surgery* 11, 624–626.
- Pederson, N.C., 2009. A review of feline infectious peritonitis virus infection, 1963–2008. *Journal of Feline Medicine and Surgery* 11, 225–258.

Case 2.10

Signalment and History

An 8-year-old MN DSH cat presented with a 6-month history of weight loss and intermittent haematemesis despite a normal appetite. The cat was indoor only, fully vaccinated, wormed, and fed a chicken-based dry commercial diet.

Clinical Examination

The cat was in poor body condition (BCS 2/9), and abdominal palpation revealed thickened intestines.



1. Construct a list of differential diagnoses for haematemesis.

- Gastric ulceration secondary to IBD, neoplasia, or NSAID treatment
- Foreign body

- Excessive histamine release from mast cell tumour
- Gastrinoma
- Uraemic gastritis
- Coagulopathy

Blood can originate from the nasopharynx, oral cavity, oesophagus, stomach, or swallowed from the respiratory tract. Given the abnormal abdominal palpation, it was suspected to be gastrointestinal in origin. Haematology and biochemistry were performed to investigate underlying systemic disease as a cause of weight loss and vomiting (Tables 2.17 and 2.18).

Table 2.17 Haematology Results at Presentation

	Patient Result	Reference Interval
RBC ($\times 10^{12}/L$)	8.17	5.00–10.00
Haemoglobin (g/dL)	13.8	9.0–15.0
HCT (l/L)	0.45	0.260–0.470
MCV (fL)	44.9	35.1–53.9
MCH (pg)	14.6	13.0–17.5
MCHC (g/dL)	32.6	28.0–36.0
White cells ($\times 10^9/L$)	17.2	6.0–15.0
Neutrophils ($\times 10^9/L$)	8.91	2.50–12.50
Lymphocytes ($\times 10^9/L$)	2.79	2.00–7.00
Monocytes ($\times 10^9/L$)	0.4	≤ 0.60
Eosinophils ($\times 10^9/L$)	5.1	0.00–0.70
Platelet count ($\times 10^9/L$)	392	150–550

Blood smear (Figure 2.19); Bold type denotes abnormal result. For abbreviations, see the footnote to Table 2.1 and the List of Abbreviations.

Q 2. Identify the three blood cells with pink staining granules on the blood smear (Figure 2.19). What further differentials would you consider based upon the blood results, and describe how you would investigate this case further.

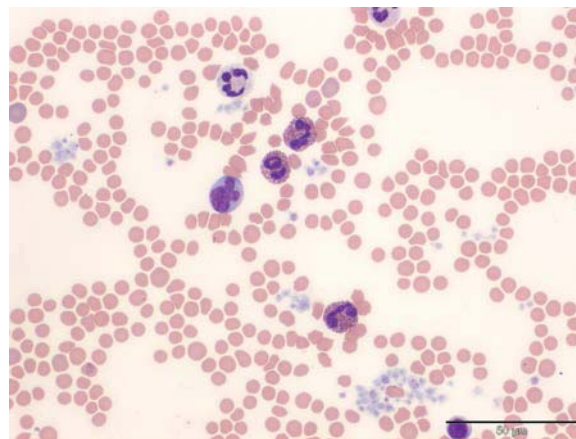
The cells are eosinophils, characterized by a segmented nucleus and numerous orange-pink granules. Common differentials for eosinophilia include allergy (atopy, food allergy, airway disease), eosinophilic granuloma complex, parasitism, eosinophilic enteritis, and hypereosinophilic syndrome. Hypoadrenocorticism and eosinophilic leukaemia are both rare in cats. Panhypoproteinaemia is consistent with blood loss, protein losing enteropathy (most likely given the history and physical examination), or rarely severe protein losing nephropathy. Hypocalcaemia is due to a reduction in the protein-bound calcium fraction.

Further investigations would include faecal flotation for endoparasites, urinalysis to look for proteinuria, folate and cobalamin measurement, as deficiency in these

Table 2.18 Biochemistry Results at Presentation

	Patient Result	Reference Interval
Albumin (g/L)	16.7	25.0–45.0
Globulin (g/L)	23.7	25.0–45.0
Urea (mmol/L)	7.0	2.5–9.9
Creatinine (μmol/L)	96.4	20.0–177.0
ALT (u/L)	18.4	5.0–60.0
ALP (u/L)	9.7	≤60.0
Total bilirubin (μmol/L)	0.5	0.1–5.1
Cholesterol (mmol/L)	2.7	2.20–4.00
Sodium (mmol/L)	150.5	145.0–157.0
Potassium (mmol/L)	4.5	3.50–5.50
Chloride (mmol/L)	122.3	100.0–124.0
Inorganic phosphorus (mmol/L)	1.65	0.90–2.20
Calcium (mmol/L)	1.87	2.05–2.95
Glucose (mmol/L)	4.3	2.8–4.9

Bold type denotes abnormal result. For abbreviations, see the footnote to Table 2.1 and the List of Abbreviations.


Figure 2.19. Blood smear at ×400 magnification.

vitamins (in the absence of dietary deficiency) indicates proximal and distal small intestinal disease, respectively, and measurement of fPLI as chronic pancreatitis can occur concurrently with inflammatory gastrointestinal disease. Imaging including abdominal ultrasound to assess the gastrointestinal tract and survey thoracic radiographs to detect pulmonary metastases is advised.

Faecal flotation was unremarkable and urinalysis was negative for protein. Both folate and cobalamin were low (folate 6.3 µg/L, RI: 9.5–20.2; cobalamin <100 ng/L, RI: 270–1200) but fPLI was within normal limits, making pancreatitis unlikely. Thoracic radiographs were unremarkable. Abdominal ultrasound revealed generalized thickening of the muscularis layer of the small intestine (Figure 2.20).

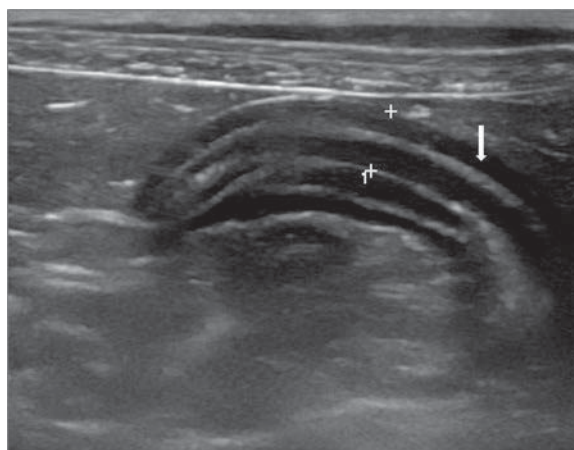


Figure 2.20. Ultrasound image showing thickening of the muscularis layer of the small intestine (arrow). The crosses denote the thickness of the wall at 4 mm.



Tip Box

The most common cause of hypocobalaminaemia in cats is small intestinal malabsorption due to mucosal disease such as IBD. Cobalamin deficiency contributes to poor health and supplementation in cats with IBD and has been suggested to increase weight gain and decrease gastrointestinal signs; parenteral supplementation in addition to treating the underlying disease is therefore advised.



3. Given these findings, what options would you discuss with the owners next?

Generalized small intestinal thickening ultrasonographically is often seen with IBD but can also be present with intestinal lymphoma, therefore further investigations are aimed at obtaining a histopathological diagnosis via endoscopic biopsies or at exploratory coeliotomy. Endoscopy is less invasive although only samples the mucosal layers of the stomach and duodenum, therefore risks missing disease deeper in the tissue. Some studies have suggested that endoscopic biopsies of the mucosa do not allow for accurate differentiation between IBD and small cell lymphoma in cats. Surgical biopsies are full thickness and allow exploration of the whole abdomen but risk dehiscence, particularly in a hypoalbuminaemic patient. Endoscopy was therefore chosen in this case.

No gross abnormalities were seen in the stomach at endoscopy, but increased granularity of the duodenal mucosa was noted (Figure 2.21) and multiple gastric and duodenal biopsies were taken. Histopathology revealed marked lymphoplasmacytic gastritis and lymphoplasmacytic and eosinophilic enteritis with significant villous atrophy consistent with severe IBD.

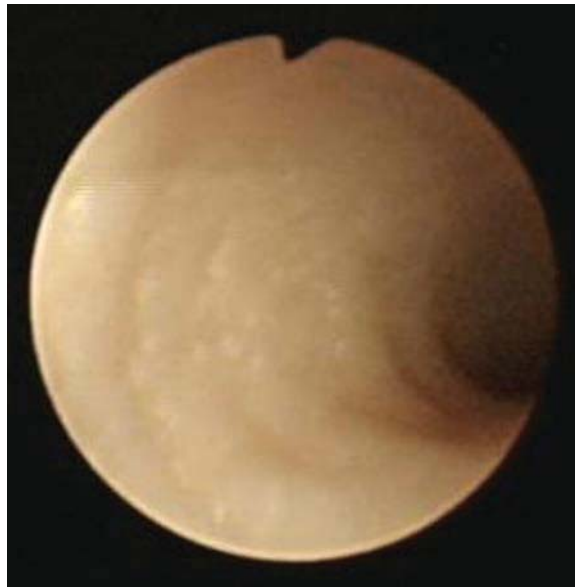

Figure 2.21. Endoscopic image of the duodenum showing increased granularity of the mucosa.

Q 4. What are the treatment options for this case?

Treatment of IBD involves dietary modification, feeding a hypoallergenic or novel protein exclusion diet for around 2 months initially. Some cats will respond to dietary management alone, and those that do usually improve in the first 2–3 weeks. Cases refractory to diet require immunosuppression with prednisolone 1–2 mg/kg PO BID, decreasing the dose by 25% every 3 weeks over several months. Metronidazole (10 mg/kg BID) can be used alone or in combination with prednisolone for 4 weeks for its immunomodulatory effect. Chlorambucil 1–2 mg/m² PO every 48 h can be prescribed to cases that don't improve with corticosteroids. Hypocobalaminaemia should be corrected.

Treatment and Outcome

In this case due to the eosinophilic component to the disease and possible dietary hypersensitivity, a prescription hypoallergenic diet was commenced in addition to parenteral cobalamin supplementation. Eosinophilic forms of IBD generally are more refractory to treatment, therefore a combination of prednisolone and chlorambucil was prescribed for immunosuppression.

One month following the diagnosis, the cat had gained weight and serum albumin was normal. After 6 months maintenance treatment consisted of hypoallergenic diet and chlorambucil. Haematology was performed every 2 months to monitor for myelosuppression as a possible side effect of chlorambucil.

Discussion

IBD is one of the most common causes of chronic vomiting and/or diarrhoea in cats. The aetiology is unknown, and it is considered to be a multifactorial disorder as a result of dietary allergy or intolerance, parasites, bacteria, genetics, and inappropriate immune responses to intestinal microflora.

Case 2.11

Signalment and Clinical History

A 7-year-old FN DSH cat presented with a 2-month history of weight loss and inappetence. Vaccination, worming, and flea control were up to date.

Clinical Examination

Abdominal palpation revealed a large, firm, cranial abdominal mass. No other significant abnormalities were noted.

Q 1. *Formulate a differential diagnosis list for a cranial abdominal mass in a cat.*

- Neoplasia involving cranial abdominal organs (e.g. hepatic, pancreatic, gastric, duodenal, lymph nodes)
- Non-neoplastic lymphadenopathy (e.g. reactive lymph nodes secondary to gastrointestinal inflammation or infection)
- Gastric or duodenal foreign body (e.g. trichobezoar)
- Intestinal intussusception
- Inflammatory (e.g. granulomatous) disease involving cranial abdominal organs/lymph nodes (e.g. mycobacterial, toxoplasma, fungal infection, FIP)

Q 2. *How would you investigate this case?*

Abdominal radiographs and ultrasound would be useful to provide further information about the abdominal mass. Ultrasound is likely to be of most diagnostic value. Haematology and serum biochemistry are indicated to further evaluate systemic health. As many of the differential diagnoses can be associated with FeLV/FIV infection, retroviral testing is also indicated.

Diagnostic Test Results

- Abdominal ultrasound revealed severe thickening of approximately 50% of the gastric wall (1.5–2 cm thickness) with complete loss of normal gastric layering.

Adjacent lymph nodes (gastric and hepatic) were enlarged (8 mm in length). No other abdominal abnormalities were identified.

- Serum biochemistry revealed a moderate hypercalcaemia: total calcium 3.17 mmol/L (RI: 2.3–2.5 mmol/L) and a moderate hyperphosphataemia of 2.24 mmol/L (RI: 0.95–1.55).
- Haematology was unremarkable and retroviral serology was negative.
- To confirm hypercalcaemia, it is useful to measure ionized calcium, which in this case was elevated at 1.61 mmol/L (RI: 1.1–1.4 mmol/L).

**Tip Box**

Ionized calcium is the physiologically active form of calcium and accounts for approximately 50–60% of total calcium concentration.

Q 3. Formulate a differential diagnosis list for hypercalcaemia in a cat.

- Artifactual
- Paraneoplastic hypercalcaemia (e.g. lymphoma, multiple myeloma, squamous cell carcinoma)
- Idiopathic hypercalcaemia
- Kidney disease
- Hypervitaminosis D (e.g. cholecalciferol toxicity, granulomatous disease)
- Primary hyperparathyroidism (rare)
- Hypoadrenocorticism (rare)

Q 4. What differential diagnosis would you consider most likely given the combination of the ultrasound and laboratory findings?

Gastric lymphoma would be considered most likely.

Q 5. What additional diagnostic tests could you perform?

To investigate the gastric wall thickening the following investigations could be performed:

- Gastroscopy and biopsy of stomach wall
- Exploratory laparotomy and biopsy (stomach wall and lymph nodes)
- Ultrasound guided fine needle biopsy (stomach wall and lymph nodes).

Further Case Information

In this case, the cat was sedated (ketamine 5 mg/kg and midazolam 0.25 mg/kg IM) and ultrasound guided FNAs of the gastric wall and abdominal lymph nodes were performed. Cytology revealed large cell lymphoma at both sites (Figure 2.22). The hypercalcaemia was therefore likely paraneoplastic.

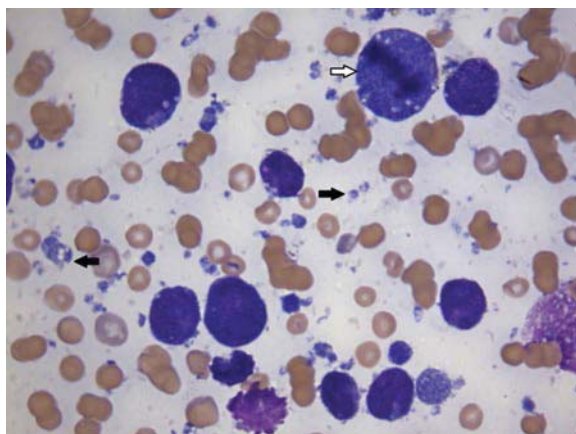


Figure 2.22. Modified Wright's stain cytology of gastric wall fine needle aspirates depicting large atypical lymphoid cells with large nucleoli, a mitotic figure (white arrow) and lymphoglandular bodies (black arrows) in the background ($\times 1000$). Image courtesy of Kostas Papasoulitis, University of Bristol.



Tip Box

Hypercalcaemia is an uncommon finding in cats with lymphoma in comparison to dogs in which approximately 15% of cases of lymphoma may have hypercalcaemia of malignancy.



6. How would you manage this case following the diagnosis of lymphoma?

In this case the hypercalcaemia was not severe (i.e. ionized calcium < 1.8 mmol/L) and the cat non-azotaemic, therefore aggressive treatment of the hypercalcaemia with furosemide for example (to increase renal calcium excretion) was not required. However, the hypercalcaemia was addressed with fluid therapy (0.9% sodium chloride 4 mL/kg/h for volume expansion and diuresis) and prednisolone treatment was commenced as part of a lymphoma chemotherapy protocol. Paraneoplastic hypercalcaemia usually rapidly resolves with treatment of the neoplasia. Prednisolone will also reduce bone resorption of calcium, decrease intestinal calcium absorption, and increase renal calcium excretion. In this case the calcium concentration started to reduce rapidly and the hypercalcaemia resolved over 48–72 h.

Treatment options for lymphoma include prednisolone alone, which can induce remission but only for a short period, and multi-agent chemotherapy. Protocols studied include COP (cyclophosphamide, vincristine [Oncovin], and prednisolone) and protocols containing doxorubicin.

The cat may require analgesia, anti-emetics and nutritional support during the initial treatment period.

This cat was treated with a COP lymphoma chemotherapy protocol (see [Box 2.2](#)). This protocol consists of a 6-week induction period followed by a maintenance regime.

Box 2.2 COP Chemotherapy Protocol for Feline Lymphoma

- Vincristine 0.5–0.7 mg/m² IV once weekly for 6 weeks and then once every 3 weeks
- Cyclophosphamide 150 mg/m² PO per week (frequency of dosing adjusted to an equivalent weekly dose as tablets should not be split)
- Prednisolone 40 mg/m² PO SID for 6 weeks then 20 mg/m² PO EOD

The cat was also treated with gastroprotectants, sucralfate (0.5 g PO TID) and famotidine (5 mg PO SID), to reduce the risk of gastrointestinal ulceration and haemorrhage (secondary to lymphoma and also the use of a high dose of prednisolone) during the first 2 weeks of treatment.

In this case complete remission was documented by repeat abdominal ultrasound at the end of the induction period. Maintenance chemotherapy was discontinued after 12 months as the cat remained in complete remission. No recurrence was present 6 months later.

Q 7. *What side effects should be discussed with clients when using a COP chemotherapy protocol?*

- Vincristine may cause myelosuppression, extravasation injury, gastrointestinal side effects (e.g. inappetence), and rarely peripheral neuropathies.
- Cyclophosphamide may cause myelosuppression, gastrointestinal side effects (e.g. inappetence, vomiting), slow fur regrowth, hepatotoxicity, and nephrotoxicity. Sterile haemorrhagic cystitis is rare in cats compared to dogs.
- Prednisolone may cause polydipsia, polyuria, polyphagia, weight gain, muscle atrophy, hepatomegaly, cutaneous atrophy, slow fur regrowth, insulin resistance (increased risk of diabetes mellitus), immunosuppression, and gastrointestinal ulceration.

**Tip Box**

The neutrophil nadir of vincristine and cyclophosphamide is approximately 7–10 days after treatment. Cyclophosphamide has a greater potential for myelosuppression in comparison to vincristine. Haematology should be monitored regularly during chemotherapy (initially weekly) to check for myelosuppression, and drug doses adjusted accordingly.

Anti-emetics (e.g. maropitant 1 mg/kg SC or PO SID) may be used if gastrointestinal side effects occur during chemotherapy or prophylactically just before a chemotherapy treatment.

Discussion

In this case, gastric lymphoma was diagnosed via FNA cytology, which was possible due to the marked thickening of the gastric wall. If ultrasound is not available then

endoscopy or exploratory laparotomy could be used to obtain biopsies if the patient is stable enough for anaesthesia.

There are few clearly recognized prognostic indicators in cases of feline lymphoma. Poor prognostic indicators include systemic illness at diagnosis, poor initial response to chemotherapy (partial or lack of remission), and FeLV positive status. Gastrointestinal lymphoma (excluding small cell intestinal lymphoma) is generally considered to have a poorer prognosis than other anatomic forms in cats; however, the range of survival times is often wide, and occasional cats can have long clinical remission, as in this case.

Further Reading

Barrs, V., Beatty, J., 2012. Feline alimentary lymphoma: 2. Further diagnostics, therapy and prognosis. *Journal of Feline Medicine and Surgery*, 14 (3), 191–201.

Case 2.12

Signalment, Clinical History, and Clinical Examination Findings

A 7-year-old FN indoor-only Havana presented with a 7-day history of inappetence and lethargy. A hunched posture and stilted gait had also been noted. The cat had a 5-year history of chronic intermittent vomiting. Worming and vaccinations were up to date, and the cat was fed a high quality commercial diet.

On physical examination, the cat was in poor body condition (BCS 1.5/5) with 300 g weight loss in 2 months. Mucous membranes were tacky and the cranial abdomen appeared very uncomfortable on palpation. No other abnormalities were detected.

Q 1. *Formulate a problem list, prioritizing the most significant problems.*

- Weight loss
- Cranial abdominal pain – possibly leading to stilted gait
- Chronic vomiting
- Mild (approximately 5%) dehydration

Q 2. *Formulate a list of differential diagnoses for weight loss in cats.*

- Low dietary intake
 - Quality of food
 - Quantity of food: anorexia/inappetence/oral dysphagia/vomiting/regurgitation
- Malabsorption or maldigestion
 - Intestinal: IBD/neoplasia
 - Exocrine pancreatic disease: EPI/pancreatitis
- Excessive catabolism/ineffective metabolism
 - Renal: chronic kidney disease, polycystic kidney disease
 - Hepatic: cholangiohepatitis/hepatic lipidosis/neoplasia

- Cardiac failure: hypertrophic cardiomyopathy
- Parasitic infections: roundworms/hookworms/whipworms
- Endocrinopathies: hyperthyroidism/hyperadrenocorticism/diabetes mellitus/hyperaldosteronism
- Neuromuscular disease

Q 3. *With the concurrent abdominal pain and vomiting what are the major differential diagnoses?*

- Intestinal: IBD/lymphoma
- Pancreatitis

Q 4. *What initial diagnostic investigations would you perform in this case?*

- Haematology, biochemistry, and urinalysis to investigate the possibility of renal or hepatic disease, to look for evidence of infection/inflammation, electrolyte imbalances, and to assess serum proteins for evidence of protein loss
- Serum folate and cobalamin concentrations could be assessed to investigate small intestinal disease
- fPLI could be assessed to look for laboratory evidence of pancreatic inflammation
- Abdominal ultrasound to assess in particular the pancreas, gastrointestinal tract (particularly evaluating gastric and intestinal wall thickness and layering), assessing for enlarged mesenteric lymph nodes, presence of any abdominal masses or free fluid

Diagnostic Test Results and Management

Hartmann's IV fluids were initiated to correct the dehydration with metoclopramide as an anti-emetic added as a constant rate infusion (1 mg/kg IV over 24 h). Maropitant was administered subcutaneously at a dose of 1 mg/kg as an anti-emetic and buprenorphine analgesic administered sublingually at a dose of 0.02 mg/kg every 6–8 h. For biochemistry, haematology, and urinalysis results, see [Tables 2.19–2.21](#).

Q 5. *What are the significant laboratory findings?*

- Hypoalbuminaemia
- Normal urine protein:creatinine ratio (UPC) excludes protein-losing nephropathy as a cause of the hypoalbuminaemia
- Significant renal and hepatic disease is excluded
- fPLI is normal, reducing the likelihood of pancreatitis, although it cannot be excluded
- Mildly elevated globulins suggestive of inflammation

Table 2.19 Biochemistry Results

	Patient Result	Reference Interval
Albumin (g/L)	18	22–44
ALP (u/L)	9	10–90
ALT (u/L)	51	20–100
Bilirubin (μmol/L)	10	2–10
Urea (mmol/L)	5.8	3.6–10.7
Calcium (mmol/L)	2.31	2.00–2.95
Phosphorus (mmol/L)	1.52	1.10–2.74
Creatinine (μmol/L)	100	27–186
Glucose (mmol/L)	8.3	3.9–8.3
Sodium (mmol/L)	142	142–164
Potassium (mmol/L)	4.2	3.7–5.8
Globulin (g/L)	60	15–57
Spec fPLI (μg/L)	1.1	0.1–3.5
Folate (μg/L)	18.3	9.5–20.2
Cobalamin (ng/L)	480.0	>270

For abbreviations, see the footnote to Table 2.1 and the List of Abbreviations.

Bold type denotes abnormal result.

Table 2.20 Haematology Results

	Patient Result	Reference Interval
Haemoglobin (g/dL)	9.6	9.0–15.0
HCT (l/L)	0.33	0.260–0.470
MCV (fL)	53.8	35.1–53.9
MCH (pg)	15.7	13.0–17.5
MCHC (g/dL)	29.1	28.0–36.0
White cells ($\times 10^9/L$)	7.5	6.0–15.0
Neutrophils ($\times 10^9/L$)	5.78	2.50–12.50
Lymphocytes ($\times 10^9/L$)	1.35	2.00–7.00
Monocytes ($\times 10^9/L$)	0.30	≤ 0.60
Eosinophils ($\times 10^9/L$)	0.08	0.00–0.70
Platelet count ($\times 10^9/L$)	176	150–550

For abbreviations, see the footnote to Table 2.1 and the List of Abbreviations.

Bold type denotes abnormal result.

Table 2.21 Urinalysis Results

Urine specific gravity	>1.050
pH	6
Protein	+
Glucose	Negative
Ketones	Negative
Bilirubin	Negative
Blood/haemoglobin	Negative
Protein:creatinine ratio	0.1 (non-proteinuric <0.2)

Q 6. What are the causes of hypoalbuminaemia and what is the most likely cause in this case?

- Gastrointestinal loss (protein-losing enteropathy)
- Renal loss (protein-losing nephropathy)
- Insufficient synthesis (malnutrition or liver failure)

The most likely cause in this case is gastrointestinal loss. This may be due to any infiltrative gastrointestinal disease, such as IBD or gastrointestinal lymphoma.

Further Case Information

- Abdominal ultrasound showed no identifiable abnormalities in the liver, biliary tract, stomach, spleen, and pancreas.
- The small intestinal wall was diffusely thickened, measuring up to 4.6 mm in places (normal jejunum and ileum should be less than 4 mm) with disruption of intestinal layering.
- Mild mesenteric lymph node enlargement.
- There was no evidence of free abdominal fluid.

Q 7. What differential diagnoses would you consider for these ultrasonographic abnormalities?

- Inflammatory bowel disease.
- Intestinal lymphoma: high grade (lymphoblastic) or low grade (lymphocytic). The latter is more common when changes are mild and diffuse throughout the intestine.

Q 8. What are the options for further investigation or management?

- Investigation
 - Endoscopic small intestinal biopsies
 - Ultrasound-guided FNA of enlarged mesenteric lymph nodes

- Surgical or laparoscopic full-thickness biopsies of small intestine and mesenteric lymph nodes (+/- liver, pancreas)
- Management
 - Treat for presumptive inflammatory bowel disease to begin with and monitor response
 - Dietary management: hypoallergenic hydrolysed diet, or single-source protein/carbohydrate diet
 - Corticosteroids: prednisolone starting at anti-inflammatory dose, increasing to immunosuppressive dose if inadequate response (accepting this may compromise further diagnostic tests and possibly the effectiveness of chemotherapy for neoplasia)
 - Metronidazole for potential anti-inflammatory properties in IBD

A week later the cat had only vomited once and gained 100 g in weight, but diarrhoea with fresh blood was reported. Metronidazole was started at 10 mg/kg BID, and the consistency of the faeces improved. However, the poor body condition persisted, and so surgical intestinal biopsies were scheduled. At surgery there was marked mesenteric lymphadenopathy present (Figure 2.23). Biopsies were taken from the small intestine, pancreas, and mesenteric lymph nodes.

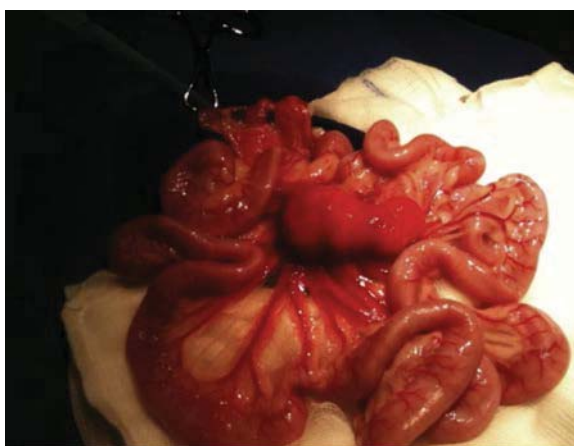

Figure 2.23. Note the marked mesenteric lymphadenopathy evident at laparotomy.

Whilst under the general anaesthetic an oesophagostomy feeding tube was placed to maintain nutrition postsurgery.

The histopathology report was suggestive of IBD, but low grade (small cell) lymphocytic lymphoma could not be excluded. Following laparotomy wound healing (12 days post surgery), the cat was started on immunosuppressive therapy with prednisolone 2 mg/kg BID and chlorambucil 2 mg every 3 days in order to treat the refractory IBD or suspected small cell lymphoma.

Q 9. What side effects can be associated with prednisolone and chlorambucil?

- Prednisolone can cause polyuria, polydipsia, polyphagia, and by antagonizing the actions of insulin can lead to diabetes mellitus.
- Chlorambucil can cause anorexia, vomiting, nausea, myelosuppression (rare), and very rarely neurotoxicity. Haematology should be monitored initially monthly during treatment.

Follow-up Information

Four weeks later the cat's faeces were normal, she was eating well, and displaying normal behaviour for the first time in 3 months. Her weight and body condition had significantly improved. Intermittent episodes of diarrhoea were controlled with 10-day courses of metronidazole. The cat continued to do well for 12 months before recurrence of the clinical signs of weight loss, vomiting, and inappetence at which point the cat was euthanized.

Discussion

This case demonstrates the difficulty distinguishing between low grade lymphocytic (small cell) intestinal lymphoma and lymphoplasmacytic inflammatory bowel disease. It has been proposed that IBD may precede intestinal lymphoma. The distinction between the two may be academic since treatment for severe IBD and low grade intestinal lymphoma is essentially the same, consisting of dietary management and immunosuppressive therapy with prednisolone and chlorambucil if required. The prognosis for low grade lymphocytic intestinal lymphoma treated with prednisolone and chlorambucil can be very good with 76% of cats achieving complete remission with median remission times of 18.9 months (range 3.5–73) reported in one study.

**Tip Box**

Further tests on the tissue to distinguish between IBD and small-cell lymphoma can include:

- Immunophenotyping: a monomorphic population of lymphocytes supports a diagnosis of lymphoma, whilst a mixed population supports inflammation. Classification of T-cell or B-cell lymphoma is possible.
- Clonality testing is then used to examine the clonality of neoplastic infiltrates.

Further Reading

- Fondacaro, J.V., Richter, K.P., Carpenter, J.L., et al., 1999. Feline gastrointestinal lymphoma: 67 cases (1988–1996). *European Journal of Gastroenterology* 4 (2), 5–11.
- Lingard, A.E., Briscoe, K., Beatty, J.A., et al., 2009. Low-grade alimentary lymphoma: clinico-pathological findings and response to treatment in 17 cases. *Journal of Feline Medicine and Surgery* 11, 692–700.

Case 2.13

Signalment, Clinical History, and Examination Findings

A 10-year-old, MN DLH cat presented with a history of reducing appetite over the past few months. No other clinical signs were noted. On physical examination he had lost 400 g in 2 months and had moderate dental disease with feline odontoclastic resorptive lesions. Vital parameters were all within normal limits, and the remainder of the physical examination was normal. There was no palpable thyroid goitre.

Q 1. Outline your approach to this case.

- Routine haematology and biochemistry to assess for systemic disease (Table 2.22)
- Total T4 to exclude hyperthyroidism
- If these are normal then consideration of dental treatment
- Other considerations could include abdominal ultrasound to further assess for intra-abdominal disease, and/or a short analgesic +/- anti-emetic trial to help establish whether pain and/or nausea are contributing to inappetence.

Urinalysis demonstrated a specific gravity of 1.042, suggesting that the mildly elevated urea was pre-renal, and was otherwise unremarkable. Total T4 was normal.

The cat was placed onto intravenous fluids and dental radiographs and extractions were performed under general anaesthesia. Although the cat's weight stabilized the cat's appetite did not improve and a few weeks later the cat started to vomit and pass foul-smelling diarrhoea. Physical examination demonstrated some abdominal discomfort and moderate dehydration.

Q 2. Formulate a list of differential diagnoses for vomiting and diarrhoea in this cat.

- Intestinal disease
 - Intestinal obstruction, e.g. foreign body/intussusception/neoplasia
 - Infectious causes
 - Viral (e.g. FIP)
 - Protozoal (e.g. *Giardia*)
 - Bacterial (e.g. *Campylobacter*)
 - IBD
 - Motility disorders
 - Neoplasia (e.g. lymphoma, adenocarcinoma)
- Extraintestinal
 - Pancreatitis
 - Peritonitis
 - Liver disease
 - Renal disease
 - Drugs/toxins
- Dietary
 - Indiscretion
 - Intolerance
 - Hypersensitivity

Table 2.22 Investigations and Management

	Patient Result	Reference Interval
Albumin (g/L)	31	22–44
ALP (U/L)	8	10–90
ALT (U/L)	39	20–100
Amylase (U/L)	1053	300–1100
Bilirubin (μmol/L)	4	2–10
Urea (mmol/L)	10.6	6–10
Calcium (mmol/L)	2.11	2.00–2.95
Phosphorus (mmol/L)	1.25	1.10–2.74
Creatinine (μmol/L)	121	27–186
Glucose (mmol/L)	6.3	3.9–8.3
Sodium (mmol/L)	141	142–164
Potassium (mmol/L)	4.2	3.7–5.8
Total protein (g/L)	62	54–82
Globulin (g/L)	31	15–57
Haemoglobin (g/dL)	11.9	9.0–15.0
HCT (l/L)	0.347	0.260–0.470
MCV (fL)	42.0	35.1–53.9
MCH (pg)	14.4	13.0–17.5
MCHC (g/dL)	34.3	28.0–36.0
WBC (× 10 ⁹ /L)	9.4	6.0–15.0
Neutrophils (× 10 ⁹ /L)	7.24	2.50–12.50
Lymphocytes (× 10 ⁹ /L)	0.85	2.00–7.00
Monocytes (× 10 ⁹ /L)	0.38	≤0.60
Eosinophils (× 10 ⁹ /L)	0.94	0.00–0.70
Platelets (× 10 ⁹ /L)	82	150–550

For abbreviations, see the footnote to Table 2.1 and the List of Abbreviations.
 Bold type denotes abnormal result.

Q 3. How would you further investigate this case?

- Abdominal radiographs and ultrasound would be appropriate next diagnostic steps to further assess the gastrointestinal tract, pancreas, and liver
- fPLI could be performed to investigate the possibility of pancreatitis

Further Case Information

This case had abdominal ultrasound performed revealing the pancreas to have a mixed echogenicity with hypoechoic foci throughout. The intestinal tract and liver were ultrasonographically normal, and there were no enlarged mesenteric lymph

nodes or free abdominal fluid. These findings increased the suspicion of pancreatitis. fPLI was found to be very mildly elevated (3.9 µg/L; RI: 0.1–3.5).

Q 4. *How would you manage this case?*

- Opioid analgesia, e.g. buprenorphine (0.01–0.02 mg/kg IM/IV/SC or sublingually TID).
- Anti-emetics, e.g. maropitant (1 mg/kg/24 h SC or PO). If further anti-emetics required, metoclopramide can be added as a CRI (1–2 mg/kg per day).
- Antacids, e.g. omeprazole, ranitidine, may be considered if there is persistent vomiting or any evidence of gastrointestinal ulceration (e.g. haematemesis, melaena, anaemia).
- Correct and maintain fluid and electrolyte imbalances via intravenous fluids (IVF).
- Nutritional support: once vomiting is controlled frequent small amounts of a highly digestible diet should be introduced. If anorexic, enteral nutrition via a naso-oesophageal or oesophagostomy tube should be provided.
- Appetite stimulants can be used in mildly inappetent cats. Mirtazapine (1/8–1/4 of 15 mg tablet per cat q48–72 h PO) or cyproheptadine (0.1–0.5 mg/kg BID–SID PO). These should only be introduced after adequate analgesic and anti-emetic therapy.
- Antibiotics with Gram-negative activity (e.g. amoxicillin-clavulanate, marbofloxacin) can be considered if clinical signs are recurrent or non-responsive to other therapies, in case of ascending bacterial infection.
- Metronidazole (10 mg/kg BID PO/IV) would be warranted in this case given the foul-smelling diarrhoea.

Further Case Information

This cat was hospitalized for IVF and given buprenorphine IV, maropitant SC, metoclopramide CRI, and cyproheptadine. The vomiting and diarrhoea resolved; however, the appetite did not improve and so an oesophagostomy tube was placed under general anaesthesia and a 4-week course of vitamin B12 injections started at 250 µg/cat weekly. A week later the cat's appetite had returned to normal and the oesophagostomy tube was removed.

Follow-up

The cat re-presented 1 year later with acute inappetence, vomiting, and diarrhoea. On physical examination he had a painful abdomen with a cranial abdominal thickening. On ultrasound similar pancreatic abnormalities were present to those seen previously, and in addition there was thickening of the gall bladder wall with projections of soft tissue echogenicity into the lumen. No evidence of cholestasis was present. Exploratory laparotomy was performed due to concerns of gall bladder neoplasia. Cholecystocentesis was performed. The gall bladder wall was thickened but no masses were located. Bile was aspirated for culture but the gall bladder was deemed too friable for biopsy at surgery. Some bile was inspissated and this was thought to be responsible for the ultrasound findings. The pancreas was macroscopically oedematous and abnormal with suspected microabscesses

(later confirmed on histopathology) running through the corresponding mesentery and mesenteric lymph nodes (Figures 2.24 and 2.25). The intestines appeared grossly normal. Biopsies were taken from the pancreas. Histopathology revealed severe chronic active interstitial pancreatitis with lobular hyperplasia. Bile culture was negative.

The cat was managed in the same way as previously, with the addition of marbofloxacin (2 mg/kg SID PO) for 21 days. The cat responded well and made a full and continued recovery.

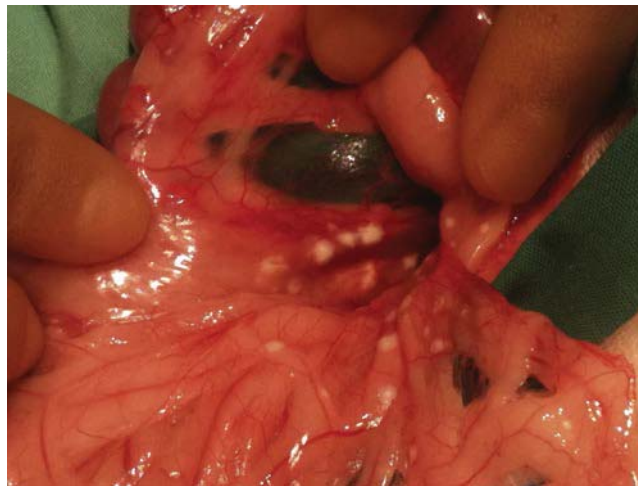


Figure 2.24. Microabscessation of the mesentery was evident at laparotomy.

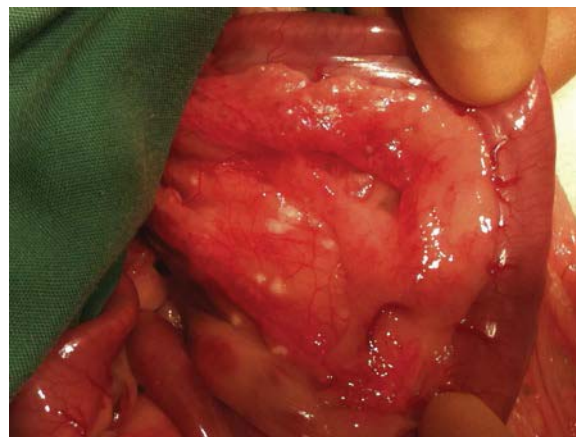


Figure 2.25. The pancreas was erythematous and thickened at laparotomy.

Discussion

This case demonstrates the often non-specific clinical presentation of pancreatitis, some of the difficulties in diagnosis, and its ability to be a waxing and waning chronic disease. With early and aggressive nutritional support, analgesia, and good supportive nursing care, these cases usually respond well to treatment. In hindsight surgical intervention was not of benefit in this case, and the risks of hypotension and exacerbation of acute pancreatitis should have been balanced against the benefits of taking pancreatic tissue for bacterial culture and biopsies of gall bladder wall, liver, and intestine to rule out concurrent IBD and liver disease or the presence of neoplasia. Medical management with reassessment of ultrasonographic changes would have been a less invasive option.

Case 2.14

History

A 10-week-old male Chinchilla kitten was introduced to an existing indoor household of two 18-month-old sibling Chinchilla cats. Two weeks later the kitten developed soft stools that quickly progressed to liquid diarrhoea with no blood or mucus. The kitten remained lively with a good appetite. The older cats appeared unaffected. There was no exposure to plants or toxins.

Physical Examination

Unremarkable other than lean BCS (2/5) and gas and fluid faeces within the small intestines on abdominal palpation.

Q 1. What are the main differential diagnoses for acute diarrhoea in a young kitten and which do you consider most likely?

- Diet: intolerance (common) or allergy (rare)
- Inflammatory bowel disease
- Infection
 - Bacterial (*Salmonella*, *Campylobacter*)
 - Viral (FIV, FeLV, panleukopenia, coronavirus, rotavirus)
 - Protozoal (*Giardia*, *Cryptosporidium*, *Tritrichomonas*)
 - Parasitic (e.g. roundworm, hookworms)
- Toxins: drugs, plants, poisons
- Partial intestinal obstruction: foreign body, intussusception

Absent vomiting, bright demeanour, with physical examination, and the quantity of faeces still being passed made a diagnosis of obstruction unlikely. IBD can occur in any age but in such a young cat dietary sensitivity and infectious causes are much more likely.

Further Case Information

A single-source protein diet (chicken and rice) was prescribed alongside probiotics with instructions to collect 3 days of stool samples to increase the chance of detecting any intermittently shed organism. Samples were stored at 4 °C and then pooled. Faecal culture and parasitology were negative.

The diarrhoea initially resolved with the change in diet and so no further treatment was given, but 3 weeks later the diarrhoea recurred with stools now sticky, and containing blood and mucus, suggestive of acute large bowel diarrhoea.

Q 2. How would you further evaluate the case?

Trichomonas foetus would be high on the differential diagnoses list and can be further evaluated with a faecal PCR for *T. foetus*. This was performed in this case and found to be positive.

Q 3. What are typical features of *T. foetus* infection?

Trichomonas foetus most commonly causes a waxing and waning colitis with increased frequency of defecation, semiformal-to-liquid faeces, and sometimes fresh blood or mucus in the faeces. The diarrhoea often has a strong smell. With severe diarrhoea the anus may become inflamed and painful, and in some cases faecal incontinence may be seen. Affected cats usually remain well in themselves. The diarrhoea may respond to antibiotic treatment initially but then recurs when treatment ceases. Although cats of all ages can be affected with diarrhoea due to *T. foetus*, it is most commonly seen in young cats and kittens, the majority being under 12 months of age. Affected cats frequently come from rescue shelters and pedigree breeding colonies.

Q 4. What are the different diagnostic options for *T. foetus* and what are their benefits and disadvantages?

- Looking for moving parasites in fresh faecal smears (see Further Reading for details). Inexpensive but may be many false negatives.
- Using a specific culture (pouch) system. Cost moderate, sensitivity approx. 55%. May be helpful as an affordable screening test in group situations where cost is an issue.
- Detection of *T. foetus* DNA using PCR. More costly but by far the most sensitive test. Even this test can be hampered by intermittent shedding of the parasite, recent use of antibiotics, or heavy contamination of the faecal sample with litter, so samples should be selected with care. Even so, sensitivity usually exceeds 90%.

Q 5. How would you treat this case?

Ronidazole at a dose of 30 mg/kg SID for 2 weeks is the recommended treatment (see [Box 2.3](#)).

Box 2.3 Ronidazole

Ronidazole is bitter and has to be re-compounded into suitable size capsules for each cat. They should be given whole to avoid any human exposure. A lower dose should be used for young kittens (or cats with hepatopathy). From limited studies its use appears to be relatively safe in cats, although a small number of patients have developed neurological signs (e.g. twitching and seizures), which have resolved on stopping the drug. *Ronidazole should not be used in pregnant or lactating queens, nor in kittens of less than 12 weeks of age. Ronidazole is not licensed for use in cats; it should only be used with caution and with informed, signed, owner consent.*

Ronidazole is very teratogenic and may result in a number of different and severe birth defects. Anyone handling Ronidazole should wear gloves (especially if they are a woman of reproductive age). Ideally owners should sign a consent form indicating they are aware of human health implications.

Q 6. What additional advice would you give to an owner in a multi-cat household and the management of asymptomatic cats?

Spread is by direct contact with infected faeces. Although mutual grooming may transfer the parasite, the primary infection source of *T. foetus* is usually the litter box. *T. foetus* can live for several days in a wet stool. Attention should be paid to having sufficient litter. Asymptomatic carriers are common and so all cats in the household should be treated to prevent cross-contamination and re-infection.

Further Case Information

Ronidazole was compounded into sufficient appropriate-sized capsules to provide 14 days of treatment for each animal at a dose rate of 30 mg/kg given SID PO for the adult cats and 25 mg/kg for the 12-week-old kitten. On day 6 of treatment one of the in-contact adult cats was seen to twitch his leg abnormally and veterinary advice was sought. Examination was unremarkable. On day 10 the other adult cat presented to the out-of-hours clinic with rapidly self-limiting vomiting and pyrexia.

Q 7. How would you advise the owner regarding treatment with ronidazole at this stage?

Owners should closely observe cats being treated with ronidazole for any sign of weakness or ataxia and cease dosing straight away if these signs occur as these are recognized side effects. It is likely that the pyrexia implies infection and not a ronidazole reaction, but ronidazole should still be withdrawn until the cat is well since it should not be used in any unwell cat. Ronidazole can be continued in other cats in the household if they remain unaffected.

If Finances Are Limited

The long-term prognosis even for untreated cats is good. Studies suggest that some cats will resolve their diarrhoea within 2 months and all will eventually overcome the infection. However, in one study resolution of the clinical signs took an average of 9 months, and some cases have been recorded where diarrhoea persisted for

over 2 years. However, using a simple, highly digestible diet frequently results in an improved faecal consistency, and this alone may allow sufficient control in some affected cats. Removing cats from a multi-cat environment will also aid recovery.

Further Reading

- Gookin, J., Copple, C., Papich, M., et al., 2005. Efficacy of ronidazole in vitro and in vivo for the treatment of feline *Tricrichomonas foetus* infection (abstract). Journal of Veterinary Internal Medicine 19, 436.
- Gookin, J.L., Copple, C.N., Papich, M.G., et al., 2006. Efficacy of ronidazole for treatment of feline *Tricrichomonas foetus* infection. Journal of Veterinary Internal Medicine 20 (3), 536.
- http://www.cvm.ncsu.edu/docs/personnel/gookin_jody.html. This website provides detailed up-to-date information on diagnosis and treatment of *T. foetus*.

CHAPTER

3

Haematological Disorders

Case 3.1

Signalment and Clinical History

An 8-year-old MN DSH cat presented with a 1-week history of lethargy. Vaccination, worming and flea control were up to date. The cat had both indoor and outdoor access.

Clinical Examination

The cat was lethargic, in sternal recumbency, had very pale pink mucous membranes (Figures 3.1 and 3.2), mild to moderate tachypnoea (respiratory rate (RR) 35–40 brpm), and a grade I/VI left systolic cardiac murmur. No other significant abnormalities were noted.

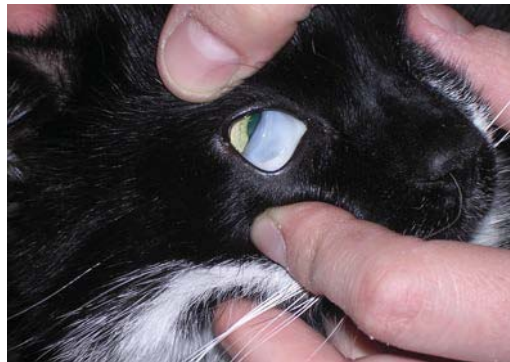

Figure 3.1. Image illustrating the very pale ocular conjunctiva. Image courtesy of Catherine Bovens.

Q 1. What emergency treatment and investigations would you perform on this cat?

- Emergency database: packed cell volume (PCV), total protein (TP), blood glucose, electrolytes, urea
- Place in oxygen cage with minimal handling
- Place an intravenous catheter if handling possible without worsening dyspnoea to allow further treatment

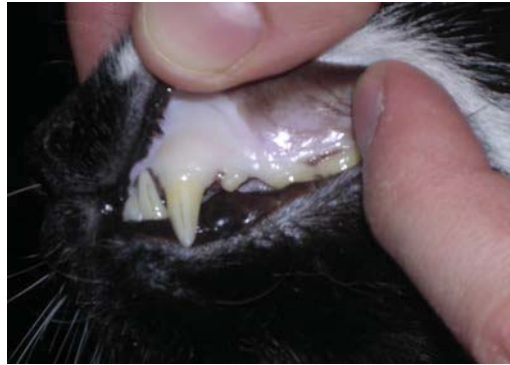

Figure 3.2. Image illustrating the very pale mucous membranes.

Further Case Information

The cat was found to have a severe anaemia (PCV 8%; RI (reference interval): 25–45%). Other emergency database parameters were normal. Blood typing was then performed and the cat was found to be blood type A.

Q 2. *What are the blood types found in cats and their significance to blood transfusion?*

Cats can be type A, B, or AB. Recent research has also identified an additional red cell antigen called the 'Mik' antigen that may also be responsible for transfusion reactions. Type B cats have high levels of naturally occurring anti-A antibodies and so must not receive type A blood as a severe haemolytic crisis may result. If a type A cat receives type B blood the reaction is milder but still significant. Type AB cats ideally receive type AB blood but may be given type B or preferably type A blood in an emergency. Close monitoring of cats during all transfusions is recommended.

Q 3. *What factors should be considered prior to performing a blood transfusion and why?*

There is not a specific PCV at which a transfusion should automatically be given. Instead the following should be considered:

- Blood type and availability of suitable donors/blood products
- Clinical condition of cat: RR, heart rate (HR), exercise/handling tolerance (i.e. is the cat 'coping' with the anaemia or in acute need of oxygen carrying support)
- Blood volume and cardiac output (i.e. blood loss versus haemolysis)
- Acute versus chronic anaemia (chronic anaemia tolerated much better)
- Regenerative or non-regenerative anaemia (degree of regenerative response, assessment of bone marrow regenerative function)
- Differential diagnoses for the cause of the anaemia and predicted trends in haematocrit or PCV level (e.g. acute or ongoing haemorrhage, presence of a coagulopathy, chronic anaemia)
- Presence of comorbid disease (e.g. cardiac disease may increase risk of fluid overload)
- Transfusion history and need for cross-matching

Treatment and Further Investigation

The cat deteriorated clinically (increasing tachypnoea and collapse) and was given a transfusion of 50 mL of whole type A blood (packed cells not available).

No transfusion reaction was observed and posttransfusion PCV was measured at 14%.



Tip Box

As a rough guide, 2 mL/kg of whole blood increases a patient's PCV by approximately 1%. RR, HR, rectal temperature, and demeanour should be closely monitored during a transfusion to identify a transfusion reaction.

Diagnostic testing (on blood collected prior to transfusion) was directed at further characterizing the anaemia and identifying an underlying cause.

- Haematology revealed a strongly regenerative anaemia (Figure 3.3) with a reticulocyte count of $200 \times 10^9/L$ (a reticulocyte count of $>50 \times 10^9/L$ is considered regenerative).
- Serum biochemistry was unremarkable apart from a mild elevation in bilirubin.
- FIV (feline immunodeficiency virus)/FeLV (feline leukaemia virus) ELISA (enzyme-linked immunosorbent assay) was negative.
- Thoracic radiographs were unremarkable and abdominal ultrasound revealed a moderate splenomegaly (considered likely secondary to extramedullary haematopoiesis).

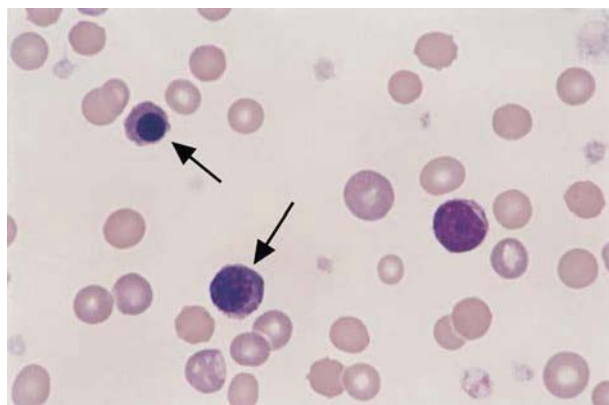


Figure 3.3. Modified Wright's x100 blood smear showing a regenerative anaemia (polychromasia and anisocytosis) with nucleated red blood cells (arrows).



4. List differential diagnoses for regenerative anaemia in cats.

- Haemolysis
 - Primary immune-mediated haemolytic anaemia (IMHA)

- Secondary immune-mediated haemolytic anaemia (e.g. lymphoma, haemoplasma infection, drug induced, FeLV infection)
- Heinz body haemolytic anaemia (e.g. onion toxicity, paracetamol toxicity, diabetic ketoacidosis)
- Hypophosphataemia
- Inherited erythrocyte defects (e.g. pyruvate kinase deficiency)
- Microangiopathic haemolytic anaemia
- Haemorrhage
 - Trauma
 - Gastrointestinal haemorrhage
 - Urogenital haemorrhage
 - Coagulopathy

Further Case Information

Blood was submitted for haemoplasma DNA polymerase chain reaction (PCR) and treatment with doxycycline (10 mg/kg SID PO) was commenced while awaiting results (not available for several days). A Coombs test was performed to investigate primary IMHA. The cat's HR and RR stabilized following the transfusion but the PCV remained static over the next 48 h and the cat remained lethargic.

Haemoplasma DNA PCR was positive at high levels for '*Candidatus Mycoplasma haemominutum*'. A Coombs test was positive.

Q 5. What is the significance of the positive '*Candidatus M. haemominutum*' test result and how would you treat this cat?

'*Candidatus M. haemominutum*' is considered less pathogenic than *Mycoplasma haemofelis* and less likely to be associated with clinical anaemia. In this case it is difficult to be certain if the cat has haemoplasma-induced haemolytic anaemia or if it has a primary IMHA with an incidental haemoplasma infection, or both. '*Candidatus M. haemominutum*' infection alone does not usually result in Coombs positive status, although *M. haemofelis* infection will.

So far the cat had not responded to antibiotic treatment alone, although the PCV had stabilized. Further treatment options therefore include:

- Give the cat longer on doxycycline treatment and continue close monitoring
- Consider primary IMHA and add immunosuppressive treatment

Further Information on Response to Treatment, Diagnosis, and Outcome

With consideration of owner finances, the cat was treated with immunosuppressive prednisolone (1 mg/kg PO BID) and antibiotics changed to pradofloxacin (see Discussion; 5 mg/kg PO SID). Response to treatment was monitored with weekly haematology and fortnightly '*Ca. M. haemominutum*' PCR initially. The haematocrit normalized after 2 weeks of treatment and prednisolone was reduced at 15% increments every 2–3 weeks over a total of 5 months. The pradofloxacin was continued until a negative '*Candidatus M. haemominutum*' PCR test was obtained (after 2 months). '*Candidatus M. haemominutum*' PCR remained negative 2 weeks after discontinuing pradofloxacin.

Discussion

'*Candidatus M. haemominutum*' infection rarely results in significant anaemia, unless concurrent retroviral infection is present. In this case the cat was retrovirus negative and although '*Candidatus M. haemominutum*' infection may alone explain the anaemia, the lack of response to antibiotic treatment but response to prednisolone may suggest an immune-mediated component. Given that cats may be asymptotically infected with '*Candidatus M. haemominutum*' and the Coombs positivity, primary IMHA with concurrent '*Candidatus M. haemominutum*' infection was suspected although the haemotrophic mycoplasma infection may have played a role in the haemolysis; treatment is therefore still indicated, especially in view of the immunosuppressive effects of prednisolone.

In this case pradofloxacin was selected for ongoing treatment of '*Candidatus M. haemominutum*' for several reasons, including ease of administration of a liquid antibiotic to the cat and evidence to suggest that this antibiotic may be more effective at clearing haemoplasma infections than doxycycline, although at increased cost. '*Candidatus M. haemominutum*' infections can be very difficult to resolve completely and chronic carrier states can occur.

Further Reading

Tasker, S., 2010. Haemotropic mycoplasmas: what's their real significance in cats? *Journal of Feline Medicine and Surgery* 12, 369–381.

Case 3.2

Signalment, Clinical History, and Clinical Examination

A 9-month-old MN Burmese cat (3.2 kg) was presented because of acute collapse. He had been vaguely unwell for approximately 1 month prior to presentation, becoming progressively inappetent and lethargic.

Physical examination revealed pale, icteric mucous membranes, tachycardia (>200 bpm), tachypnoea, and pyrexia (39.8 °C). He was in thin body condition and estimated to be 5% dehydrated. PCV was 10% and total protein was 65 g/L.



1. What is your assessment of the case at this stage?

There are three major problems that have been identified: anaemia, jaundice, and pyrexia.

The cat has severe anaemia with a normal serum protein level. Anaemia can be caused by haemolysis, decreased red blood cell production or blood loss, although the absence of low serum protein levels would make significant external haemorrhage less likely. Jaundice may be due to pre-hepatic, hepatic, and/or post-hepatic causes; however, the combination of severe anaemia and icterus is suggestive of haemolysis. Pyrexia can be due to infectious, inflammatory, and immune-mediated processes or neoplasia.

The tachycardia and tachypnoea are most likely a response to tissue hypoxia secondary to anaemia, and the acute collapse is also most likely attributable to the severe anaemia.

Q 2. List the specific causes of haemolytic anaemia in cats.

- Haemoplasmas (e.g. *M. haemofelis*, *Ca. M. haemominutum*, *Candidatus Mycoplasma turicensis*)
- Oxidative (Heinz body) anaemia
 - Allium family ingestion (e.g. onion, garlic, etc), paracetamol (acetaminophen), repeated propofol administration (consecutive days), other drug toxicities
- Hereditary red blood cell (RBC) defects
 - Pyruvate kinase deficiency (Abyssinian, Somali, Bengal, Singapura, DSH, Egyptian Mau, La Perm, Maine Coon, Norwegian Forest, Savannah, Siberian)
 - Increased erythrocyte osmotic fragility (Abyssinian, Somali)
 - Porphyria (Siamese, DSH)
- Hypophosphataemia (usually secondary to treatment for diabetic ketoacidosis or re-feeding syndrome)
- Primary immune-mediated
- Secondary immune-mediated (lymphoma and other lymphoproliferative or myeloproliferative neoplasms, feline infectious peritonitis, retroviral infections, other inflammatory conditions, e.g. abscesses, pyothorax, nephritis, enteritis, polyarthritis, etc.)
- Neonatal isoerythrolysis
- Acute haemolytic transfusion reactions
- Microangiopathic (fragmentation injury) anaemia (disseminated intravascular coagulation (DIC); though not as commonly seen as in dogs, haemangiosarcoma)
- Gram-negative sepsis
- Feline leukaemia virus infection
- Other infectious agents (*Cytauxzoon felis* (North America/Europe), *Babesia* spp. (South Africa/Middle East))

Q 3. Which further tests should be performed at this stage?

A haemogram, including reticulocyte count and blood smear specifically looking for evidence of regenerative response, unusual red and white blood cell morphology, Heinz bodies, and/or haemoplasmosis, and a serum biochemistry profile (especially liver enzyme activities and quantifying the hyperbilirubinaemia) should be performed.

A slide agglutination test can be performed to look for evidence of RBC auto-agglutination. If not apparent, a direct Coombs test using feline-specific reagents to detect erythrocyte-bound immunoglobulin or complement can be performed. (NB: a positive test in either case does not differentiate primary from secondary IMHA.)

A coagulation profile (activated partial thromboplastin time/prothrombin (APTT/PT)) may be considered to rule out a coagulopathy, especially if invasive tests are likely to be performed subsequently (although evidence of an overt coagulopathy in this case is lacking), and imaging of the chest and abdomen may be useful to look for evidence of internal haemorrhage and/or underlying infectious, inflammatory, or neoplastic disease.

FeLV/FIV ELISAs and haemoplasma PCR should be performed.

Given the likelihood that the cat will need a blood transfusion, preliminary blood typing and/or the sourcing of a blood donor should also be a priority in this case.

Q 4. How would you manage this case pending results?

- A blood transfusion or oxyglobin transfusion (if available) is required in this case to provide oxygen-carrying capacity, given the degree of anaemia in combination with evidence of cardiovascular compromise
- Doxycycline or fluorquinolone should be initiated (5 mg/kg BID or 10 mg/kg SID) in case of haemoplasma infection
- Supportive treatment with intravenous fluids (IVF) to maintain perfusion, and an oxygen enriched environment, are also advised (NB: Take care with fluid therapy and blood product administration; the cat should be monitored closely for volume overload)

Preliminary Results

Blood was collected and submitted to an external laboratory for a full haemogram, serum biochemistry profile, and haemoplasma PCR.

- In-house activated clotting time was within normal limits
- FeLV/FIV ELISAs were negative
- Slide agglutination test revealed strong auto-agglutination of RBCs, confirming the presence of primary or secondary immune-mediated haemolysis
- Preliminary thoracic and abdominal imaging showed no evidence of free body cavity fluid

Treatment and Outcome

A type A blood transfusion was administered resulting in a posttransfusion PCV of 17%. Doxycycline and corticosteroids were initiated, and the cat was placed on IVF and in an oxygen-enriched environment, with close monitoring of vital parameters. Unfortunately, despite this, the cat deteriorated and died over the next 12 h. The external laboratory blood test results, which were received after the cat had died, confirmed the presence of severe, poorly (or pre-) regenerative anaemia, with marked RBC agglutination. Serum biochemistry profile showed moderate elevations of alanine aminotransferase (ALT) and alkaline phosphatase (ALP), as well as total bilirubin. Haemoplasma PCR was negative.

Necropsy revealed widespread fibrinous lesions throughout the abdominal cavity. Histopathological examination of numerous abdominal organs, including the liver and kidneys, revealed widespread pyogranulomatous vasculitis, consistent with feline infectious peritonitis (FIP), which was later confirmed via immunohistopathology (Figure 3.4).

Discussion

Immune-mediated haemolytic anaemia in cats is usually secondary (e.g. haemotropic mycoplasmas, lymphoproliferative or myeloproliferative neoplasms, retroviral infection, etc.) and a thorough investigation should be conducted in all cases to look for an underlying cause.

Primary IMHA has been documented in cats and may be more common than once thought. A small proportion of feline patients have been reported with Evans syndrome (concurrent IMHA and immune-mediated thrombocytopenia).

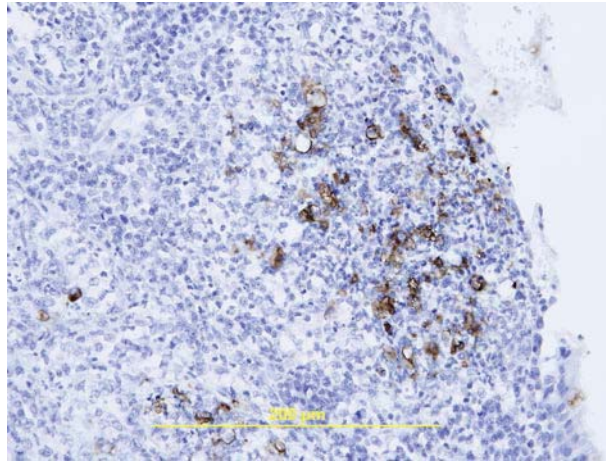


Figure 3.4. Photomicrograph showing feline coronavirus antigen within macrophages on immunohistochemical staining (brown), confirming the diagnosis of feline infectious peritonitis.

The immune reaction may be targeted against normal RBCs or erythrocytes that have been antigenically altered, for example by an antigenic epitope supplied by an infectious agent (e.g. *M. haemofelis*). In some cases, the immune-mediated attack is directed towards RBC precursors, giving rise to a non-regenerative anaemia (this clinicopathological picture may also occur in 'classic' IMHA that is relatively recent in onset before the bone marrow has had time to react).

Treatment of secondary IMHA should be aimed at the underlying disorder (e.g. appropriate antibiotic therapy for haemoplasmas, chemotherapy, or surgical removal of neoplasms, and withdrawal of non-essential drugs). Likewise, supportive measures such as fluid therapy and blood transfusions should be used as necessary and stress should also be kept to a minimum.

Prednisolone is the initial therapy of choice for immune-mediated destruction of erythrocytes, given at 2–4 mg/kg PO SID (or divided if the cat experiences gastrointestinal irritation). If necessary, dexamethasone can be administered at 0.25–1 mg/kg SID parenterally, if oral medication is contraindicated. Once the PCV has stabilized in the low normal range for at least a week, the dose of prednisolone can be tapered, usually by reducing by 25% every 3–4 weeks.

Chlorambucil or ciclosporin can be added to the regimen if the animal requires very high doses of prednisolone to maintain remission or has a comorbidity (e.g. diabetes mellitus) that mandates that the dose of glucocorticoids be kept at a minimum.

Further Reading

- Kohn, B., 2010. Immune-mediated haemolytic anemia. In: August, J.R. (Ed.), *Consultations in Feline Medicine*, vol. 6. Saunders Elsevier, St Louis, pp. 617–627.
- Kohn, B., Weingart, C., Eckmann, V., et al., 2006. Primary immune-mediated haemolytic anaemia in 19 cats: diagnosis, therapy and outcome. *Journal of Veterinary Internal Medicine* 20, 159–166.
- Norris, J.M., Bosward, K.L., White, J.D., et al., 2005. Clinicopathological findings associated with feline infectious peritonitis in Sydney, Australia: 42 cases (1990–2002). *Australian Veterinary Journal* 83, 666–673.

Case 3.3

Signalment and Clinical History

A 4-year-old MN Tonkinese presented with lethargy and reduced appetite over a few days, and more acute onset tachypnoea with a soft 'non-productive' cough. The cat was an indoor/outdoor cat living in rural Australia. There were no known toxins in the immediate environment, but red-bellied black snakes had been seen on the property.

Clinical Examination

On examination the cat was dyspnoeic, with orthopnoea. Petechiae were noted on pale gums (Figure 3.5). During examination the cat became more markedly dyspnoeic, and epistaxis and haemoptysis began. Further examination was aborted and the cat was immediately placed in an oxygen cage (Figure 3.6).

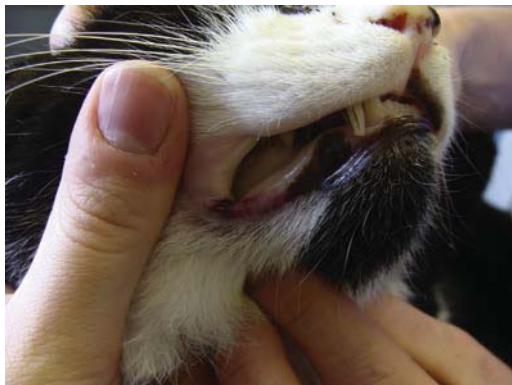


Figure 3.5. Petechiation and ecchymoses on the mucous membranes similar to that seen in the cat in Case 3.3.

Q 1. Outline how you would initially manage this case.

Reduce stress, keep in a quiet room in an oxygen cage, initial hands-off approach.

Have an endotracheal tube, suction kit, and anaesthetic agents ready in case intubation is required.

Once stable enough:

- PCV/TP to assess blood volume status and effect of haemorrhage, blood smear to assess platelet numbers. Collect blood for complete blood count to assess severity and nature of anaemia
- Coagulation parameters. In-house activated clotting time (ACT) can be performed, but a PT and APTT should also be performed (in house or external laboratory)
- Blood typing in case blood transfusion is required (see Case 3.1 for more details on cat blood types)
- Further investigations will be dependent on assessment but may include serum biochemistry and FeLV/FIV testing
- Thoracic radiographs may be indicated once the cat is stable



Figure 3.6. The cat within an oxygen box, exhibiting haemoptysis.

Diagnostic Test Results

- APTT: 66 (reference interval (RI): 65–119) s
- PT: 100 (RI: 15–22) s
- PCV: 0.15 (RI: 0.33–0.52)
- Total solids (TS): 60 (RI: 57–89) g/L
- Blood smear: polychromasia, reticulocytosis. Eight platelets per high-power field and some platelet clumping
- FeLV/FIV ELISA negative
- Blood type A
- Serum biochemistry unremarkable
- Thoracic radiographs were not performed

Q 2. What is your interpretation of these blood test results and most likely diagnosis?

There is a severe anaemia, with a regenerative response.

There is prolongation of the PT with a normal APTT indicative of an abnormality in the extrinsic coagulation pathway that involves predominantly factor VII. Factor VII is a vitamin K-dependent clotting factor (along with factors II, IX, X). With vitamin K deficiency, prolongation of PT occurs first since factor VII has the shortest half-life

of the vitamin K-dependent factors. Therefore a prolonged PT with normal APTT is indication of inadequate vitamin K, which is most commonly seen with anticoagulant rodenticide toxicity or liver failure.

There is a slightly reduced platelet number; however, there is clumping of platelets (common phenomenon in cats), thus the count is expected to be higher than seen.

Anticoagulant rodenticide toxicity with subsequent pulmonary haemorrhage and blood loss anaemia is therefore most likely in this case.

Q 3. How would you manage this cat?

- A blood transfusion (fresh whole blood) is required from a cat with a compatible blood type (type A (see [Box 3.1](#)).
- Vitamin K1 treatment for a minimum of 30 days, ensuring that coagulation times remain normal a few days after ceasing treatment.
- Strict rest to minimize further haemorrhage until coagulation times have normalized.

Box 3.1 Performing a Blood Transfusion Blood Collection

Equipment: 60 mL syringe, 3 × 20 mL syringes or 6 × 10 mL syringes, 21G butterfly catheter, in-line microthrombi filter, citrate-phosphate-dextrose-adenine (CPDA-1) anticoagulant (9.4 mL), blood collection bag and microthrombi filter administration set, sedatives (for donor), replacement fluids for the donor.

1. Sedate the donor (if required) (NB: sedatives administered to the donor will potentially sedate the recipient. The author prefers ketamine/midazolam protocols over inhaled anaesthetic agents due to the risk of hypotension). Check the donor's PCV is >35%. Weigh the donor. No more than 10 mL/kg blood should be collected from the donor.
2. Prepare the donor's jugular aseptically. Using butterfly needle attached to 60 mL syringe containing 1 mL of CPDA-1 for 9 mL of blood, remove predetermined donation volume of blood from the donor. Gently rock the syringe as you withdraw the blood to ensure anticoagulant is evenly dispersed (and prevent clotting).
3. Inject blood into blood collection bag, and apply filter.
4. Administer to recipient at 0.5–1 mL/kg/h for 15 min (monitoring closely for transfusion reactions), then at 5–10 mL/kg/h until the unit of blood is given. Cats with cardiovascular disease should be given the blood at 4 mL/kg/h to reduce the likelihood of fluid overload. No other medications or fluids (other than 0.9% NaCl) should be given at the same time as a blood transfusion. Blood should be administered within 4 h of collection for maximal effect of clotting factors and platelets, and to minimize bacteraemia. Blood should be given at room temperature.
Monitor lung sounds for indications of pulmonary oedema, respiratory rate (assess for tachypnoea), heart rate (assess for tachycardia), blood pressure (assess for hypotension), and body temperature (assess for pyrexia) for evidence of transfusion reactions and fluid overload every 30 min during a transfusion.
5. The donor should receive twice the volume donated in crystalloids given intravenously over an hour.

Further Case Information

Fifty-five mL of packed red blood cells was collected into 6.1 mL of CPDA-1. This was then administered over 4 h to the recipient.

The cat was also started on vitamin K1, initially 5 mg/kg SC and then 5 mg/kg PO SID for 30 days.

The patient was kept confined for the first 3 days of therapy, with minimal venepuncture, and soft food only given.

Q 4. *What prognosis would you discuss with the owners?*

In an otherwise healthy cat, the prognosis for cats treated for rodenticide toxicity is excellent if the cat survives beyond the first 48 h. However, some cats may require more than one blood transfusion.

The owner should be asked to investigate the source of rodenticide in the environment, as re-exposure poses a serious problem.

Second-generation anticoagulants are the most common agents in modern rodenticides and include brodifacoum, bromadiolone, diphacinone, and chlorophacinone. They are generally more toxic and have a much longer half-life than first-generation products, and therefore treatment with vitamin K1 should be continued for at least 30 days and coagulation times assessed again 3 days after ceasing treatment.

Further Information on Response to Treatment

This cat made a full recovery and repeated coagulation times 3 days after stopping vitamin K1 treatment (after 30 days) were within normal range. As the owners could not find a source of the toxicity, they opted to keep the cat as an indoor-only cat.

Discussion

Other aspects of treatment that are sometimes appropriate in suspected rodenticide toxicity include emesis and administration of adsorbents. Emetics may be administered to appropriate patients if exposure is within 1–2 h. However, inducing emesis in cats is more problematic than in dogs. Activated charcoal administered as an adsorbent may be combined with a cathartic.

Rodenticide anticoagulants block the production of vitamin K through antagonism of vitamin K epoxide reductase. Factor VII is the first coagulation factor affected by depletion of vitamin K, hence a prolonged PT occurs before APTT. The animal can be still normal in early stages of toxicity, as the other clotting pathways are still effective. Seventy-two hours after factor IX becomes depleted, the intrinsic pathway is also blocked, therefore the APTT usually also becomes prolonged.

The bioavailability of oral vitamin K1 is increased by feeding with a small amount of fat. Vitamin K1 should not be given intravenously as there is a risk of anaphylaxis. Vitamin K3 is not effective.

Further Reading

Barfield, D., Adamantos, S., 2011. Feline blood transfusions: a pinker shade of pale. *Journal of Feline Medicine and Surgery* 13 (1), 11–23.

Kohn, B., Weingart, C., Giger, U., 2003. Haemorrhage in seven cats with suspected anticoagulant rodenticide intoxication. *Journal of Feline Medicine and Surgery* 5, 295–304.

Case 3.4**Presenting History**

A 6-year-old MN DSH presented with a 24-h history of twitching and drooling associated with 10–15 s periods of spastic hyperextension of the head. Between episodes the cat behaved normally. Vaccinations and worming were up to date.

Physical Examination

On presentation the cat was in good body condition (body condition score (BCS) 3/5, weight 5.1 kg) despite having lost 10% of his body weight in the previous 10 months. An intermittent facial twitch was observed but neurological and ophthalmic examination was otherwise unremarkable. However, two brief episodes of hyperextension of the head occurred during examination, followed by rapid recovery. No other significant abnormalities were noted.

The nature of the neurological signs observed in this case suggested a focal seizure. Seizure disorders are divided into primary idiopathic seizures with no identifiable underlying cause (idiopathic epilepsy), and secondary disorders, which can have intracranial or extracranial causes.

Q 1. *What are the major differentials for secondary seizures (both intracranial and extracranial causes)?*

- Vascular: ischaemic encephalopathy, hypertension, thromboembolic disease, polycythaemia
- Inflammatory: non-suppurative meningoencephalitis
- Infectious: toxoplasmosis, cryptococcosis, FIP, FeLV, FIV, rabies, aberrant parasitic migration
- Toxins: lead, organophosphate, ethylene glycol
- Metabolic: hepatic or renal encephalopathy, hypoglycaemia, hypocalcaemia, hyperthyroidism
- Neoplastic: tumours affecting the cerebral cortex
- Nutritional: thiamine deficiency
- Degenerative: storage diseases

Q 2. *How would you further investigate and manage this case?*

Initial investigations would include blood pressure measurement and a minimum database of PCV, TP, urea/creatinine, electrolytes, and blood glucose to immediately identify any extracranial causes that would require specific treatment.

Alongside performing these, placing an IV catheter and administering diazepam and initiation of phenobarbitone or levetiracetam may be required to stop and prevent further seizure activity.

More complete haematology/biochemistry and FeLV/FIV serology may then be performed.

Diagnostic Test Results

- Systolic blood pressure 200 mmHg (Doppler method)
- FeLV antigen ELISA negative
- FIV antibody ELISA positive

Serum Biochemistry and Haematology

	Patient Result	Reference Interval
Albumin (g/L)	37	22–44
ALP (U/L)	55	10–90
ALT (U/L)	140	20–100
Amylase (U/L)	645	300–1100
Total bilirubin (μmol/L)	7	2–10
Blood urea nitrogen (mmol/L)	9	4–11
Calcium (mmol/L)	2.49	2.00–2.95
Phosphorus (mmol/L)	1.59	1.09–2.74
Creatinine (μmol/L)	90	27–186
Glucose (mmol/L)	4.8	3.9–8.3
Na ⁺ (mmol/L)	145	142–164
K ⁺ (mmol/L)	4.0	3.7–5.8
Total protein (g/L)	72	54–82
Globulin (g/L)	35	15–57
Reticulocytes (%)	0.5	0.0–1.0
Haemoglobin (g/dL)	22.40	8–15
HCT (%)	61.6	25–45
RBC (× 10 ¹²)	18.30	5.5–10
MCV (fL)	33.7	40–55
MCH (pg)	12.3	12.5–17
MCHC (g/dL)	36.4	30–35
Platelets (× 10 ⁹ /L)	n/a	200–700
WBC	6.45	4.9–19
Neutrophils	4.84	2.4–12.5
Lymphocytes	1.36	1.4–6.0
Monocytes	0.19	0.1–0.7
Eosinophils	0.07	0.1–1.6
Basophils	0.00	0–0.1

Bold type denotes abnormal results.

Blood film evaluation: microcytosis ++, platelets clumped, adequate numbers.

ALP, alkaline phosphatase; ALT, alanine transaminase; HCT, haematocrit; MCH, mean corpuscular haemoglobin; MCHC, mean corpuscular haemoglobin concentration; MCV, mean corpuscular volume; RBC, red blood cells; WBC, white blood cells.

Q 3. *What are the most significant abnormalities?*

- Hypertension
- A marked erythrocytosis (polycythaemia)
- Microcytosis
- FIV positive ELISA

Q 4. *What is your interpretation of these results?*

The erythrocytosis is severe and is the most likely cause of the seizures. Hypertension can also cause seizures and is most likely to be secondary to the erythrocytosis in this case but should be re-evaluated once the erythrocytosis has been addressed. The FIV positive status may be an incidental finding and unrelated to the cat's clinical signs, or may be a predisposing factor to development of the underlying disease responsible for the erythrocytosis. Although FIV is a neurotropic virus and infection can itself cause neurological signs, in this case the severe erythrocytosis is much more likely to be the cause of this cat's clinical signs.

Q 5. *What are the possible causes of erythrocytosis?*

Erythrocytosis/polycythaemia can be due to an absolute increase in the number of RBCs (absolute polycythaemia) or to a decrease in the volume of plasma as in dehydration (relative polycythaemia). The normal biochemistry and total protein together with a lack of clinical evidence of dehydration helps to exclude relative polycythaemia in this case.

Absolute erythrocytosis/polycythaemia can be primary or secondary. Primary polycythaemia rubra vera is a myeloproliferative disease where the bone marrow spontaneously produces excessive numbers of red blood cells. Secondary polycythaemia is caused by an increase in erythropoietin.

Secondary polycythaemia can be appropriate to a physiologic response:

- Hypoxia associated (e.g. cyanotic heart disease or hypoxic lung disease)
- Altitude related: adaptation to living at high altitudes and low oxygen tensions
- Genetic: heritable causes associated with abnormalities in haemoglobin oxygen release

Or an inappropriate increase in erythropoietin (EPO) production:

- Renal cell carcinoma
- Other (e.g. liver) tumours that release proteins that mimic EPO
- Endocrine abnormalities (e.g. adrenal adenoma)

Q 6. *What other investigations might you consider to further differentiate the cause of the erythrocytosis?*

- Measurement of EPO to distinguish between primary and secondary erythrocytosis
 - If EPO is high then further investigation of causes of secondary erythrocytosis is required
 - If EPO is low then primary polycythaemia vera is diagnosed
- For secondary erythrocytosis
 - Appropriate erythrocytosis can be investigated by arterial blood gas analysis, echocardiography, and thoracic radiographs to look for the presence of, and causes of, hypoxia

- Inappropriate erythrocytosis requires identification of a neoplasm that may be secreting EPO or EPO-like substances, and can be investigated with imaging, starting with abdominal radiographs and ultrasound. Often the EPO-secreting renal neoplasms can be very small and advanced imaging such as computed tomography (CT) or magnetic resonance imaging (MRI) can be required to identify them.

Further Case Information

In this case EPO measurement was not performed. Thoracic radiography and echocardiography were unremarkable. Abdominal ultrasonography revealed a spherical hypoechoic mass within the pole of the left kidney. All other findings were unremarkable. Fine needle aspirates of the mass were suggestive of a renal carcinoma.

Q 7. What are the treatment options for this case?

- Initial phlebotomy removing 10–20 mL/kg of blood and replacing with crystalloids to try to reduce the packed cell volume (PCV) to <50% (NB: phlebotomy in these cases can be challenging due to the increased viscosity of the blood)
- Palliative repeat phlebotomy as required, or nephrectomy to remove the presumed underlying cause (the use of medicinal leeches to manage polycythaemia has been reported)

Further Case Information

The cat was sedated and 90 mL of blood removed from the jugular vein (Figure 3.7); then 180 mL of crystalloids were administered through a second IV catheter. The cat was clinically stable following phlebotomy, with all neurological signs resolved. Post-phlebotomy the PCV was 55%. A further phlebotomy removing 80 mL of blood was performed the following day, achieving a PCV of 48%.

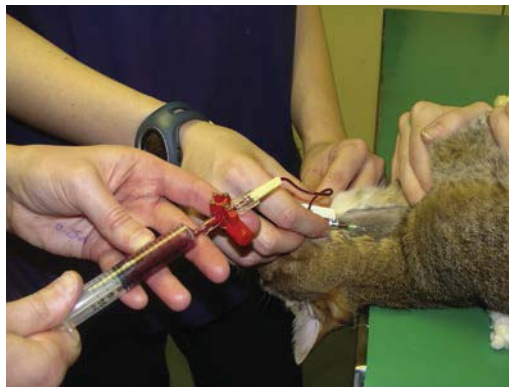

Figure 3.7. Phlebotomy can be challenging in patients with erythrocytosis due to increased blood viscosity.

Two weeks later the PCV had again increased to above 50%. Nephrectomy was performed 3 weeks after initial presentation. Pre-operative coagulation times, renal parameters, and urine specific gravity were unremarkable.

A grossly abnormal left kidney was removed (Figures 3.8 and 3.9), and histopathology indicated a well-differentiated renal carcinoma.

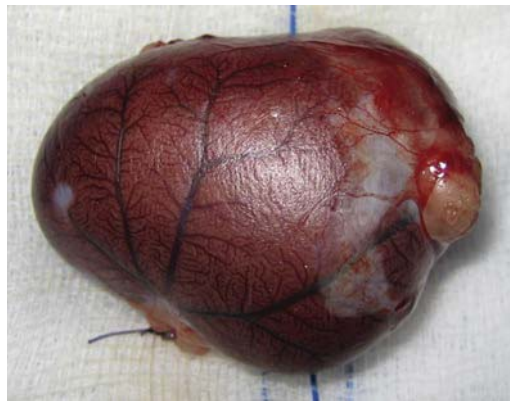

Figure 3.8. The left kidney was removed.

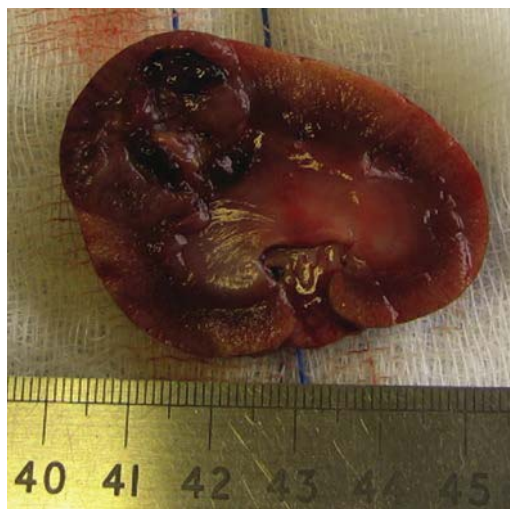

Figure 3.9. Left kidney in cut-section showing the mass later diagnosed as a renal carcinoma.

The cat responded well to nephrectomy and 3 months later was clinically normal with a normal PCV. The cat remained well for 2 years before developing a refractory leucopenia and concurrent episodes of pyrexia despite antibiotics resulting in euthanasia.

Further Reading

Nett, C.S., Arnold, P., Glaus, T.M., 2001. Leeching as initial treatment in a cat with polycythaemia vera. *Journal of Small Animal Practice* 42 (11), 554–556.

Case 3.5

Case Description

A 4-year-old FN Siamese cat presented with a 12 h history of acute onset lethargy and weakness. The cat had access outdoors and was a hunter. A similar but less severe episode of lethargy and weakness that occurred 3 months previously had resolved without treatment.

Physical Examination and Initial Investigations

On examination the cat was quiet but responsive with mild resting tachypnoea (RR 40 brpm) and pale mucous membranes. Femoral pulses were weak and HR 220 bpm. RT was 37.2 °C. Abdominal palpation revealed mild cranial abdominal discomfort.

Blood was taken for haematology and biochemistry (Tables 3.1 and 3.2).

Table 3.1 Haematology Results

Haematology	Patient Result	Reference Interval
RBC ($\times 10^{12}/L$)	3.69	5.5–7.5
Haemoglobin (g/dL)	4.8	9–14
PCV (%)	16	27–42
MCV (fL)	39.3	40–55
MCH (pg)	12.6	13–17.5
MCHC (g/dL)	32.0	30–35
Reticulocytes ($\times 10^9/L$)	4.3	
Reticulocyte index	0.05	<0.4
WBC ($\times 10^9/L$)	9.4	7.5–20
Neutrophils ($\times 10^9/L$)	7.71	2.5–12.5
Lymphocytes ($\times 10^9/L$)	1.32	1.5–6.5
Monocytes ($\times 10^9/L$)	0.38	0–1.0
Eosinophils ($\times 10^9/L$)	0.00	0–1.5
Basophils ($\times 10^9/L$)	0.00	0–1.0
Platelets ($\times 10^9/L$)	46	300–700

Bold type denotes abnormal results.

PCV, packed cell volume. For other abbreviations, see footnote to table on p. 132 and the List of Abbreviations.

Table 3.2 Serum Biochemistry Results

Serum Biochemistry	Patient Result	Reference Interval
ALT (IU/L)	95	<60
ALP (IU/L)	49	<60
Total bilirubin (µmol/L)	8	0–12
Total protein (g/L)	62	54–82
Albumin (g/L)	21	25–39
Globulin (g/L)	41	15–57
Creatinine (µmol/L)	139	0–190
Urea (mmol/L)	7	2.8–11
Calcium (mmol/L)	2.7	2–3
Phosphorus (mmol/L)	0.9	0.8–2.5
Glucose (mmol/L)	10	3–7.5

Bold type denotes abnormal results.

For abbreviations, see the footnote to the table on p. 132 and the List of Abbreviations.

Q 1. How would you categorize the anaemia in this case?

Moderate anaemia, which is normocytic and normochromic with low reticulocyte count and low reticulocyte index. This indicates either a non-regenerative anaemia or a 'pre-regenerative anaemia' in which acute red cell loss is so recent that there has not been time for regeneration to develop.

Q 2. List the possible explanations for a low platelet count.

- Laboratory anomaly
 - Blood clot in sample
 - Platelet clumping
 - Macrothrombocytes miscounted as erythrocytes on an automated cell count
- Excessive consumption
 - Recent haemorrhage
 - Vasculitis
 - DIC
- Reduced production
 - Myeloproliferative disease: FeLV/FIV, lymphosarcoma
 - Myelofibrosis
 - Myelodysplasia
 - Aplastic anaemia
- Increased destruction
 - Primary: immune-mediated thrombocytopenia
 - Secondary: drug-induced (e.g. anti-thyroid medications), paraneoplastic response, etc.

In cats erroneously low automated platelet counts are common and examination of a fresh blood smear is essential.

In this case platelet numbers on a fresh blood smear were markedly reduced indicating that the thrombocytopenia was genuine.

Q 3. *What are the indications for a blood transfusion? Is a transfusion indicated in this case?*

There are no hard-and-fast rules to dictate when a blood transfusion should be provided. The two factors to consider are the severity of the anaemia and its speed of onset; in general, cats will cope better with anaemia that has been chronic and gradually progressive.

As a rule of thumb a blood transfusion should be considered when:

- Anaemia is severe enough to cause clinical signs (e.g. weakness, dyspnoea)
- There is acute anaemia with PCV <15%
- There is chronic anaemia with PCV <10%

In this case there are clinical signs that appear to be attributable to anaemia (lethargy, weakness, tachycardia, tachypnoea, weak and thready pulses). The PCV is just above 15%. However, if the PCV remains stable the cat may respond to more conservative management.

If a blood transfusion is not supplied, close monitoring of PCV, circulation, and respiration will be required.

Further Investigations

Thoracic radiographs were unremarkable. Abdominal radiographs showed a generalized loss of detail in the cranial abdomen.

Abdominal ultrasonography revealed a small amount of free fluid within the abdomen. All abdominal organs appeared normal other than the liver, which was diffusely heterogeneous with small hyperechoic foci throughout.

Q 4. *List the feline liver diseases that could produce these diffuse ultrasound changes.*

- Inflammatory liver disease
 - Chronic neutrophilic cholangitis (acute and chronic)
 - Lymphocytic cholangitis
- Hepatic lipidosis
- Hepatic amyloidosis
- Neoplastic diseases may produce focal changes, but some may also present with diffuse changes that make them more difficult to identify ultrasonographically
 - Lymphosarcoma
 - Haemangiosarcoma
 - Mast cell tumour

Q 5. *How would you further investigate this case?*

Paracentesis for fluid analysis will be helpful in characterizing the fluid. Fine needle aspirates of the liver would be contraindicated given the thrombocytopenia.

Further Case Information

Ultrasound-guided paracentesis yielded a dark red sample that did not clot when in contact with air.

Fluid Analysis

Red cells/ μL	4,760,000
Nucleated cells/ μL	26,460
Total protein g/L	66

Smears contained blood with low numbers of associated leucocytes. No infectious organisms were seen.

Coagulation Profile	Patient Result	Reference Interval
Prothrombin time (s)	8.6	9.0–13.0
Partial thromboplastin time (s)	24.0	10.0–25.0
Fibrinogen (citrate)	<0.5	1.0–4.0

Bold type denotes abnormal results.

Q 6. What are the most likely causes of haemoabdomen in the cat?

- Abdominal neoplasia: most commonly associated with haemangiosarcoma or other neoplasias of the spleen or liver
- Non-neoplastic causes
 - Hepatic bleeding secondary to hepatic necrosis, amyloidosis, inflammatory liver disease, hepatic haematoma, or coagulopathy
 - Blunt trauma (e.g. ruptured bladder)
 - Gastrointestinal ulceration

Further Case Information

Initial treatment was with:

- Cage rest to reduce the cat's oxygen demand
- Minimal handling for further procedures to minimize risk of further bleeding
- Blood transfusion: a type-matched and cross-matched blood transfusion was given to improve RBC counts

The cat responded well to emergency treatment and there was no evidence of ongoing intra-abdominal bleeding.

Q 7. A liver biopsy will be required to reach a definitive diagnosis in this case. When and how would you recommend collecting a biopsy?

Collection of a biopsy should be postponed until the cat has recovered fully from the effects of the recent blood loss and red cell and platelet counts have returned to normal.

Options for collection of liver tissue samples include:

- Fine needle aspiration: not recommended in this case
 - Potential for non-diagnostic samples if the cat has amyloidosis, haemangiosarcoma, or inflammatory liver disease
 - Moderate risk of causing haemorrhage
- Ultrasound-guided Tru-Cut biopsy: not recommended in this case
 - Potential for non-diagnostic samples if the cat has inflammatory liver disease
 - Very high risk of causing haemorrhage
- Surgical biopsy: recommended in this case
 - Although a more invasive procedure, collection of a surgical biopsy at exploratory laparotomy will provide a definitively diagnostic sample and allows full control of intra-operative haemorrhage
 - Exploratory laparotomy will also allow examination and biopsy of other abdominal organs as appropriate

Outcome

In this case the owner declined further investigations.

Medical management with ursodeoxycholic acid and antioxidants (vitamin E and SAMe) was maintained and the cat remained well for 6 months before suffering another episode of abdominal bleeding, at which time the cat was euthanized.

Postmortem examination revealed a mildly enlarged liver with multiple blood clots adhering to its surface (Figure 3.10). Histopathology revealed widespread deposition of amyloid protein throughout the liver parenchyma.

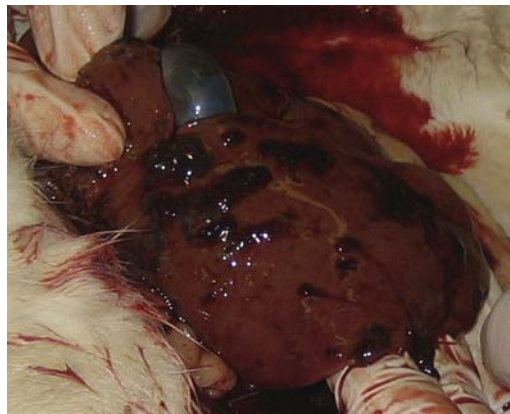


Figure 3.10. At postmortem examination the liver was enlarged with multiple blood clots adhering to its surface.

Discussion

Primary hepatic amyloidosis is a familial disorder that occurs with increased frequency in Siamese and Oriental breeds. The mode of inheritance is unknown and there is currently no genetic test available to identify affected cats or carrier cats.

It is a gradually progressive condition that is usually associated with minimal clinical signs until the disease is advanced. Spontaneous haemorrhage from the liver is a common presenting sign, and as in this case liver enzymes may be normal or only mildly elevated at times, although they will be markedly elevated at other times. Thrombocytopenia occurs as a consequence of haemorrhage but is not an effect of the amyloidosis itself.

There is no specific treatment; deposition of hepatic amyloid is irreversible, progressive, and ultimately fatal.

Further Reading

Beatty, J.A., Barrs, V.R., Martin, P.A., et al., 2002. Spontaneous hepatic rupture in six cats with systemic amyloidosis. *Journal of Small Animal Practice* 43 (8), 355–363.

Respiratory Disorders

Case 4.1

Signalment and History

A 4-year-old MN DSH cat presented with an acute history of tachypnoea. Two previous episodes of tachypnoea had occurred after play. The cat was fed a commercial dry diet. Vaccination, worming, and flea control were current.

Physical Examination

The cat was in good body condition, bright, alert, and responsive. Mucous membranes were pale pink and moist (capillary refill time (CRT) 1.5 s). The patient was tachycardic (220 bpm) and mildly tachypnoeic (40 brpm). Thoracic auscultation revealed a grade III/VI systolic murmur, point of maximal intensity (PMI) left base, and increased respiratory sounds. Thoracic percussion was unremarkable.

Q 1. *What can you infer from the history and physical examination?*

Episodic tachypnoea could be associated with respiratory disease, such as feline asthma (although there is no history of cough that might support this), or cardiac disease causing cardiogenic pulmonary oedema or pleural space disease. Metabolic causes, such as hyperthyroidism, are less likely in this age of cat, and with no other clinical signs. Cardiomyopathy can occur in cats of any age. The murmur may suggest a cardiac cause, but up to 50% of cats with audible murmurs do not have discernible cardiac disease. A gallop sound or arrhythmia is a very specific finding for cardiac disease, but neither was present in this case. The absence of stertor, stridor, or increased inspiratory effort make an upper respiratory tract lesion less likely, and upper respiratory disease is more likely to be associated with dyspnoea rather than tachypnoea.

Q 2. *List the most likely causes of tachypnoea and a systolic heart murmur at the left base in this case.*

- Lower respiratory tract
 - Pulmonary oedema (cardiogenic or non-cardiogenic)
 - Feline asthma
 - Pulmonary contusions

- Pneumonia (bacterial, viral, fungal, parasitic)
- Neoplasia: primary or metastatic
- Intrathoracic tracheal disease (foreign body, neoplasia, trauma, extraluminal compression)
- Pleural space disease
 - Transudate (hypoalbuminaemia)
 - Modified transudate (congestive heart failure, neoplasia, diaphragmatic hernia, mediastinal mass)
 - Exudate
 - Septic (pyothorax)
 - Non-septic (feline infectious peritonitis (FIP), neoplasia, mediastinal mass)
 - Chylothorax (congestive heart failure (CHF), neoplasia, mediastinal neoplasia, thoracic duct rupture, idiopathic, lung lobe torsion, diaphragmatic hernia)
 - Haemothorax (trauma, coagulopathy)
 - Pneumothorax
- Extra thoracic causes of tachypnoea
 - Pain/stress/anxiety
 - Metabolic disease (hyperthyroidism, metabolic acidosis, anaemia, erythrocytosis)
 - Neuromuscular disease (central nervous system (CNS) disease, myopathy or neuropathy, e.g. tick paralysis)
 - Toxicity (smoke inhalation, petroleum products)
 - Abdominal distension
- Systolic heart murmur (left base)
 - Left ventricular (LV) outflow tract obstruction
 - Interventricular septal hypertrophy (e.g. hypertrophic cardiomyopathy (HCM), hyperthyroidism, hypertension)
 - Systolic anterior motion of the mitral valve (SAM) (HCM, catecholamine excess)
 - Aortic outflow obstruction (e.g. fixed sub-aortic stenosis or endocarditis)
 - Dynamic right ventricular outflow tract obstruction (e.g. incidental finding, hyperdynamic state, catecholamine excess)
 - Flow/innocent murmur (e.g. catecholamine excess or anatomic variation)

Q 3. *How would you initially manage this case?*

This patient was stable so oxygen therapy was not required and preliminary investigations could be performed. There is a risk of decompensation, and such patients should be handled carefully and constantly reassessed. Procedures should be abandoned, and oxygen and other medications (e.g. light sedation such as butorphanol to minimize distress, bronchodilators, furosemide) administered if required.

Thoracic radiography to evaluate for evidence of pulmonary oedema and lower airway disease and echocardiography to investigate the cause of the murmur are indicated initially.

In this case, the patient remained stable, and echocardiography followed by thoracic radiographs (Figures 4.1 and 4.2) obtained under light sedation (acepromazine 0.01 mg/kg, butorphanol 0.2 mg/kg IM) were performed.

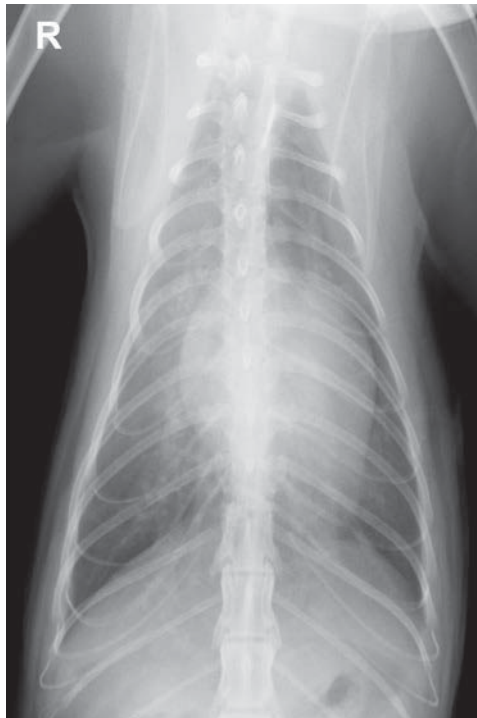


Figure 4.1. Dorsoventral thoracic radiograph.

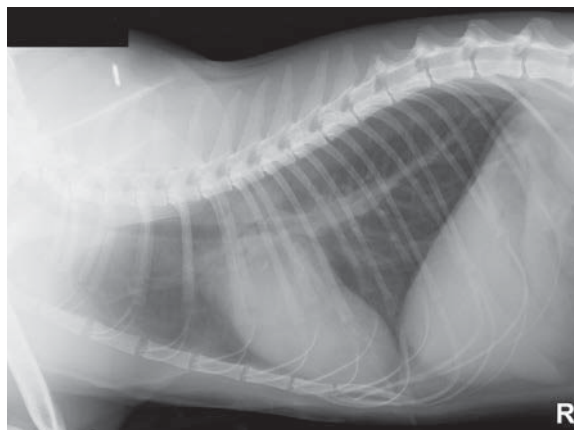


Figure 4.2. Right lateral thoracic radiograph.

Q 4. Discuss the radiographic findings (Figures 4.1 and 4.2).

There is cardiomegaly (cardiac silhouette $>2/3$ width of thorax in dorsoventral (DV) view and >2 rib spaces wide in lateral view) and caudal tracheal elevation secondary to left atrial enlargement. Pulmonary vascular distension is evident (cranial lobar vessels $>$ proximal aspect of fourth rib in lateral view and caudal lobar vessels $>$ thickness of ninth rib in DV view). There is a patchy alveolar pattern throughout the lung fields, effacing the caudal vena cava and some pulmonary vasculature. It is worse on the right side. This is most likely due to cardiogenic oedema. These findings suggest left-sided CHF secondary to HCM.

Further Case Information

Echocardiography (Figures 4.3–4.5) demonstrated concentric LV hypertrophy, more pronounced on the free wall than the interventricular septum. There was left atrial dilation and SAM. Simultaneous electrocardiography (ECG) showed a sinus tachycardia. There was no evidence of pleural or pericardial effusion. These findings were consistent with HCM, with elevated left atrial pressure suggestive of left-sided CHF.

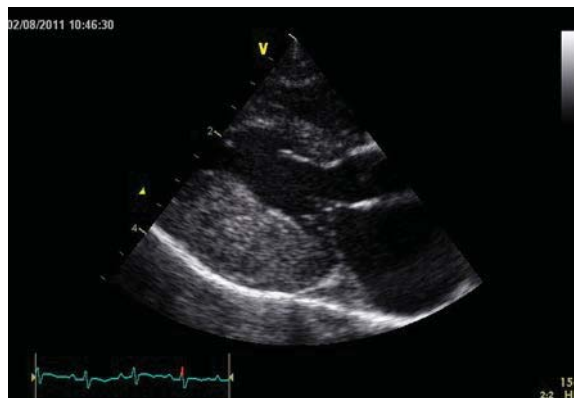

Figure 4.3. Right parasternal long axis view, optimized for the left ventricular outflow tract. Significant left ventricular free wall hypertrophy can be seen, with a rounded-appearing left atrium.

Q 5. How would you further manage this case?

Administration of furosemide (use lowest dose necessary to control signs, 1–2 mg/kg IV/SC/IM q 2–6 h) is indicated to resolve the oedema and normalize respiration prior to further investigations.

Further investigations should include systolic blood pressure (BP) to exclude hypertension as a potential cause of left ventricular hypertrophy, and to assess for hypotension prior to using medications that might induce hypotension.

A complete blood count (CBC), serum biochemistry, and urinalysis may also be performed to identify any additional problems; for example, azotaemia that might affect treatment. Total T4 (thyroxine) could also be assessed to exclude hyperthyroidism.

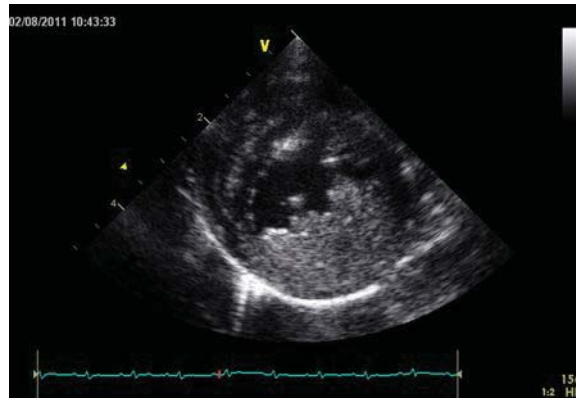

Figure 4.4. Right parasternal short axis view, at the level of the papillary muscles. Severe, asymmetric, left ventricular free wall and papillary muscle hypertrophy is present.

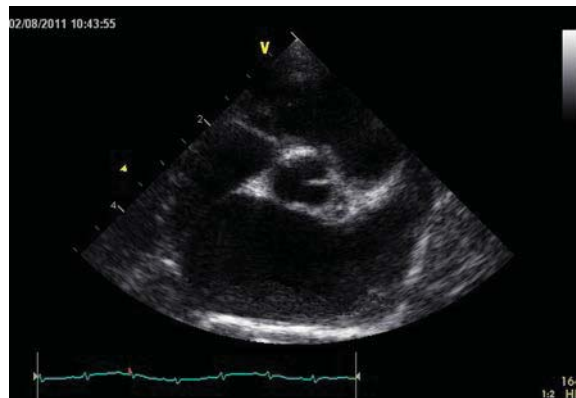


Figure 4.5. Right parasternal short axis view, at the level of the heart base. Severe left atrial (LA) and auricular dilation can be seen. LA:Ao ratio is approximately 2.5 (normal <1.5). Ao, aorta.

An ECG should be considered if the tachycardia persists after stabilization or an arrhythmia is detected.

Further Diagnostic Test Results

CBC and biochemistry were unremarkable. Systolic BP was 140 mmHg (reference interval (RI) 120–160).

Q 6. What is your ongoing treatment plan for this case?

Furosemide (1–2 mg/kg SC/IM/IV q 2–6 h as required) to control pulmonary oedema. An angiotensin converting enzyme (ACE) inhibitor (ACEi) (e.g. benazepril 0.25–0.5 mg/kg

PO SID) should be instigated to control RAAS (renin-angiotensin-aldosterone system) activation. Antithrombotic therapy (clopidogrel 4.5 mg/kg SID +/- aspirin 4.5 mg/kg PO q 3 days) is indicated, as HCM is a well-established risk factor for arterial thromboembolism (ATE). Due to the cardiovascular effects of sympathetic drive, stress should be minimized in patients with HCM at risk of CHF. Home monitoring of respiratory rate with a cut-off value of 40 brpm or a progressive increase in respiratory rate is a sensitive way to assess control of CHF. Titration of the oral furosemide dose to effect may be performed by owners in conjunction with telephone communication with the veterinary clinic.

Follow-up

The cat remained well on treatment (furosemide, benazepril, and aspirin) but died suddenly after 6 months.

Discussion

HCM is a primary, idiopathic myocardial disease, resulting in reduced ventricular relaxation, elevated diastolic filling pressure, and eventually CHF. Diagnosis relies on echocardiographic identification of LV myocardial thickness >6 mm.

Many cats remain asymptomatic for years; median survival time was >3617 days in one study, compared to 194 days for cats presenting with CHF. No treatment is proven to slow the progression of asymptomatic HCM. Cats with significant outflow tract obstruction caused by SAM may benefit from a beta-blocker (atenolol 1–2 mg/cat SID titrated up to a maximum dose of 6.25 mg/cat PO BID if tolerated). There is, however, currently no evidence base for this treatment or consensus amongst cardiologists. A beta-blocker is contraindicated in patients with CHF. HCM increases the risk of ATE.

If Finances Are Limited

Physical examination findings can provide a great deal of information. If pulmonary oedema is suspected, a response to furosemide is highly supportive. Thoracocentesis, rather than imaging, can be performed if pleural effusion is suspected. Echocardiography is required for diagnosis of HCM, but precise echocardiographic findings do not often alter the management of the case once CHF has been diagnosed, apart from in cases of dilated cardiomyopathy (DCM), which are much less common. Thoracic radiographs provide more information regarding the presence of CHF, but this may be inferred from the examination and treatment response.

Further Reading

- Macdonald, K., 2010. Myocardial disease: feline. In: Ettinger, S.J., Feldman, E.C. (Eds.), seventh ed. Textbook of Veterinary Internal Medicine, vol. 2. Elsevier Saunders, pp. 1328–1341.
- Payne, J.R., Luis Fuentes, V., Boswood, A., et al., 2010. Population characteristics and survival in 127 referred cats with hypertrophic cardiomyopathy (1997 to 2005). *Journal of Small Animal Practice* 51, 540–547.
- Wagner, T., Luis Fuentes, V., Payne, J.R., et al., 2010. Comparison of auscultatory and echocardiographic findings in healthy adult cats. *Journal of Veterinary Cardiology* 12, 171–182.

Case 4.2

Signalment and Clinical History

A 6-month-old FN British Shorthair cat presented with a 10-day history of inappetence, lethargy, and progressively worsening dyspnoea. Vaccination, worming, and flea control were up to date. The cat had both indoor and outdoor access.

Clinical Examination

The cat had tacky mucous membranes, moderate skin tenting, and was pyrexic (rectal temperature (RT) 40 °C), with a rapid, shallow (restrictive) respiratory pattern (respiratory rate 50 brpm). Thoracic auscultation revealed reduced lung sounds in the ventral thorax bilaterally. SpO₂ was 88% on room air.

Q 1. *Formulate a differential diagnosis list for a restrictive respiratory pattern in a cat.*

- Pleural space disease
- Pulmonary parenchymal disease
- Thoracic wall disease
- Diaphragmatic disease
- Peritoneal cavity disease (abdominal distension)
- Peripheral nerve or neuromuscular disease

The restrictive respiratory pattern and reduced lung sounds in the ventral thorax bilaterally are all suggestive of pleural space disease.

Q 2. *How would you initially manage this cat?*

Emergency management involved oxygen supplementation (cage oxygen) and placement of an intravenous catheter. In this case a brief thoracic ultrasound was performed, which revealed bilateral pleural fluid, and bilateral thoracocentesis was performed (150 mL of fluid removed in total).

Q 3. *List causes of pleural effusion in cats.*

- Transudate: hypoalbuminaemia
- Modified transudate: CHF, neoplasia, lung lobe torsion
- Exudate: feline infectious peritonitis (aseptic), pyothorax (septic)
- Chyle: CHF, neoplasia, trauma, lung lobe torsion, idiopathic
- Haemorrhage: coagulopathy, trauma, neoplasia

Diagnostic Test Results

- The pleural fluid was grossly flocculent and purulent in appearance. Cytology of the fluid revealed septic neutrophilic inflammation (intracellular bacteria present) consistent with a pyothorax (Figure 4.6).

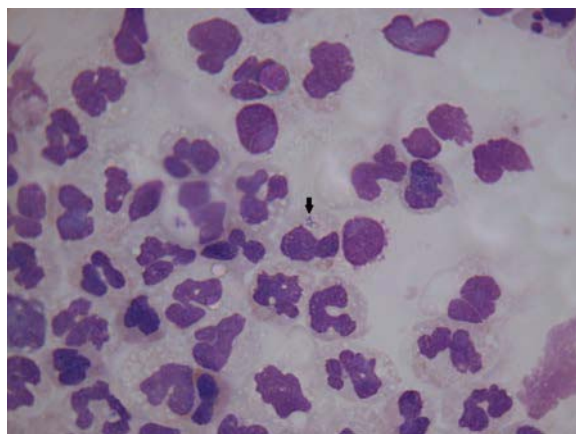


Figure 4.6. Modified Wright's stain cytology of a pleural effusion in a cat depicting septic neutrophilic inflammation with intracellular bacteria (arrow). Image courtesy of Kostas Papasouliotis.

- Haematology revealed a moderate leucopenia ($3.46 \times 10^9/\text{L}$, RI: $4.9\text{--}19 \times 10^9/\text{L}$) and a moderate neutropenia ($1.63 \times 10^9/\text{L}$, RI: $2.4\text{--}12.5 \times 10^9/\text{L}$) with a left shift and marked toxicity of neutrophils.
- Serum biochemistry revealed a mild increase in urea (11 mmol/L, RI: 6.5–10.5 mmol/L), marked hypoalbuminaemia (12.9 g/L, RI: 24–35 g/L) and moderate hyperbilirubinaemia ($23.5 \mu\text{mol/L}$, RI: 0–10 $\mu\text{mol/L}$).

Q 4. What are possible explanations for the neutropenia, increased urea, hypoalbuminaemia, and hyperbilirubinaemia in this case in light of the pyothorax diagnosis?

The increased urea is likely pre-renal in origin given the evidence of dehydration (tacky mucous membranes, skin tenting) on initial physical examination. The neutropenia is likely secondary to consumption as a result of the pyothorax. The hypoalbuminaemia is likely secondary to the marked inflammatory effusion in the pleural space. The hyperbilirubinaemia may be secondary to sepsis.

Q 5. How would you further manage this case?

- Once stable, consideration should be given to thoracic imaging and placement of a chest drain to allow more complete fluid drainage +/- pleural space lavage. Lavage can be useful when the fluid is very viscous and flocculent, which is often the case with pyothorax.
- Repeated thoracocentesis without thoracic drain placement can be effective in some cases if the fluid drains readily. Common problems associated with this include incomplete emptying of the pleural space due to the presence of flocculent, thick purulent fluid, and an inability to lavage the thorax.
- Antibiotics based on culture and sensitivity of the pleural fluid
- Analgesia
- Intravenous fluids
- Nutritional support if the cat is not eating

Q 6. Describe the correct location for thoracic drain placement in a cat.

The site of thoracic drain entry into the thorax is the seventh or eighth intercostal space. The drain should enter the skin at the level of the 11th to 13th intercostal space to create a subcutaneous tunnel to avoid pneumothorax development. The intercostal vessels and nerves are located caudal to each rib, and care should be taken to avoid them during drain placement. In cases of pleural effusion the aim is to have the drain end in a ventral position (fluid will accumulate ventrally) to allow for optimal drainage. In cases of pneumothorax the aim is to have the drain end in a more dorsal position (air will accumulate dorsally).

Further Case Information

Thoracic radiographs (Figure 4.7) revealed that the pleural effusion was worse on the left side. A left-sided thoracic drain was placed under general anaesthesia (Figure 4.8) and another 100 mL of purulent fluid was drained. The pleural space was lavaged with warm, sterile saline (10–15 mL/kg over 10 min) and drained three times a day for 5 days. Analgesia was provided with buprenorphine (0.015 mg/kg IV TID) followed by oral meloxicam (0.05 mg/kg PO SID) once the cat was well hydrated and eating. On day 5, less than 2 mL/kg/day of fluid was retrieved via the thoracic drain; radiographs confirmed minimal pleural effusion, and the thoracic drain was removed.

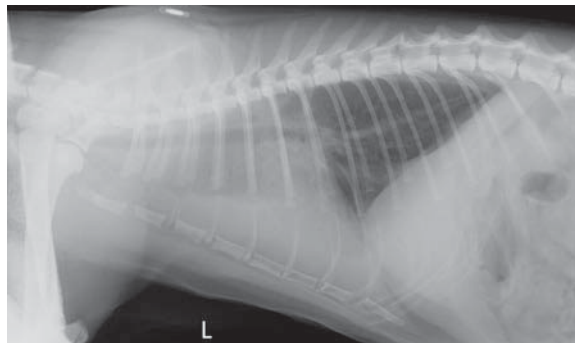


Figure 4.7. Left lateral thoracic radiograph demonstrating pleural effusion.

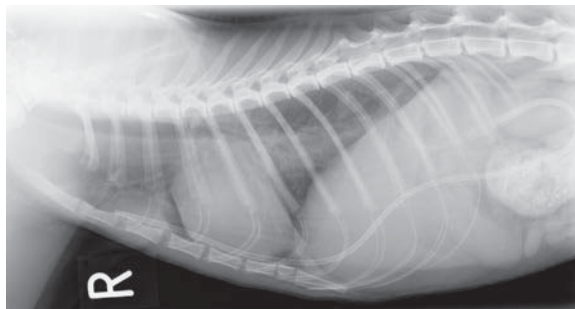


Figure 4.8. Right lateral thoracic radiograph showing thoracic drain in situ. Radiographs should always be taken following chest drain placement to assess the location of the chest drain.

Intravenous amoxicillin-clavulanate (20 mg/kg IV TID) was initiated pending culture results. These revealed a profuse growth of *Pasteurella multocida* and mixed anaerobes; a 5-week course of marbofloxacin 2 mg/kg PO SID and metronidazole 10 mg/kg PO BID was then initiated. Repeat thoracic radiographs at the end of the 5-week course revealed no radiographic abnormalities.

Discussion

Feline pyothorax usually involves infection with multiple types of obligate and facultatively anaerobic bacteria similar to feline oral bacterial flora. The cause of feline pyothorax is usually not identified; however, the aetiopathogenesis may include haematogenous spread of bacteria, extension of infection into the pleural space from other organs (e.g. secondary to bacterial pneumonia), or direct bacterial inoculation (e.g. cat bite wound). In the current case the cause was unknown.

Feline pyothorax usually carries a good prognosis if diagnosed early in the course of disease. Bilateral thoracic drain placement is recommended ideally in cases of bilateral pyothorax to allow effective drainage and lavage of the entire thorax, and especially if the material being removed is tenacious and/or if thoracocentesis on one side fails to effectively drain both sides. In this case the effusion was more pronounced on the left side and a single drain was used.

Further Reading

- Barrs, V.R., et al., 2004. Feline pyothorax: a retrospective study of 27 cases in Australia. *Journal of Feline Medicine and Surgery* 7, 211–222.
- Beatty, J., Barrs, V., 2010. Pleural effusion in the cat: a practical approach to determining aetiology. *Journal of Feline Medicine and Surgery* 12, 693–707.

Case 4.3

Signalment and History

A 13-year-old, FN, Burmese cat presented with a 2-month history of progressive inspiratory stertor. The cat had a previous 12-year history of chronic, bilateral, purulent nasal discharge. Vaccination, ecto/endo-parasite control was current and the cat was kept indoors. Treatment with antibiotics intermittently over several years resulted in intermittent, temporary improvement of the nasal discharge.

Clinical Examination

Bilateral purulent nasal discharge with occasional streaks of fresh blood (Figure 4.9) and marked inspiratory stertor and mouth breathing were noted.

See Case 4.11 for differential diagnoses for nasal discharge and stertor.



1. Considering the differential diagnoses for nasal discharge and stertor, putting all the clinical history together, which do you think would be most likely in this case?

The cat has a history consistent with chronic rhinitis. The new signs of progressive stertor may be related to worsening rhinitis, or to further complications associated with chronic rhinitis such as polyps, nasopharyngeal stenosis, or progression to neoplasia.

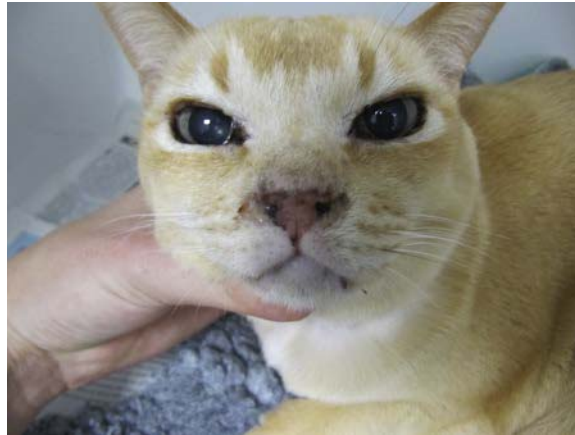

Figure 4.9. Dried, purulent, bilateral nasal discharge was present.

Q 2. *How would you investigate this cat?*

Nasal imaging and/or rhinoscopy are likely to be the most useful diagnostic procedures in this case.

Given that these procedures would involve general anaesthesia, BP assessment, haematology, and serum biochemistry prior to anaesthesia are advisable. Assessing coagulation times prior to taking nasal biopsies is also advised.

Options for further investigation include:

- Investigation of fungal disease; however, this cat was in an area with low geographical prevalence for fungal disease, therefore tests such as latex cryptococcal antigen testing (LCAT) and aspergillosis serology were not performed.
- A thorough oral examination including dental charting and use of a periodontal probe should be performed, and if probing depths exceed 0.5 mm, the tooth should be radiographed using dental radiography (bisecting angle technique) and high definition dental films assessing for periapical disease.
- Diagnostic imaging under general anaesthesia should be pursued in this case. Imaging options include radiography, magnetic resonance imaging (MRI) or computed tomography (CT). If CT or MRI are not available, conventional radiography, although less sensitive than cross-sectional imaging, may be sufficient to help localize and identify the extent of disease.
- Depending on imaging results, rhinoscopy, nasal flushing and biopsy can be performed. Nasal flush samples may be submitted for cytology and biopsy samples for histology and culture.

Q 3. *What radiographic views are useful in the investigation of nasal disease?*

Radiographic views should include:

1. Lateral skull
2. Dorsoventral intraoral view (with high definition dental film)
3. Rostro 10° ventro-caudodorsal view
4. Lateral oblique skull views

These views should be assessed for signs of middle ear disease, nasopharyngeal soft tissue densities, sinus density, nasal cavity symmetry, and integrity of nasal septum. If neoplastic, fungal, or other infectious pulmonary disease is suspected, survey thoracic radiographs should also be performed.

Further Case Information

Haematology and serum biochemistry were unremarkable. Systolic BP (Doppler) was the upper end of normal at 160 mmHg. Coagulation times (prothrombin time (PT) and activated partial thromboplastin time (APTT)) were within normal limits.

CT imaging was chosen for this case due to its increased sensitivity and specificity compared to radiographic evaluation. In addition, it allowed for a cross-sectional evaluation of the thorax assessing for signs of pulmonary neoplasia. The images showed bilateral destruction of turbinate tissue surrounding the ventral meatus and ethmoturbinates (Figure 4.10). A circular narrowing of the nasopharynx to a diameter of approximately 2 mm was also noted (Figure 4.11). Cranial to the narrowing was marked contrast enhancement of the soft palate, suggesting both thickening and dorsal displacement. This most likely suggested soft palate adhesion to the dorsal nasopharyngeal compartment.

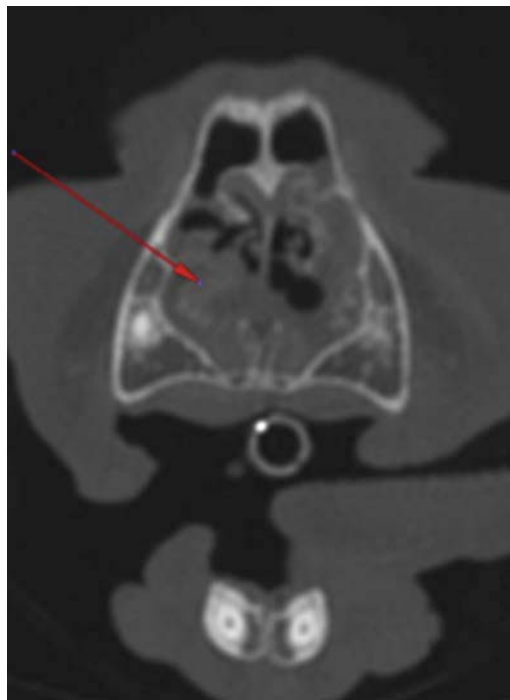

Figure 4.10. CT image illustrating destruction of the ventral concha and fluid accumulation. Courtesy of Andrew Denning, New Priory Veterinary Clinic, Brighton, UK.

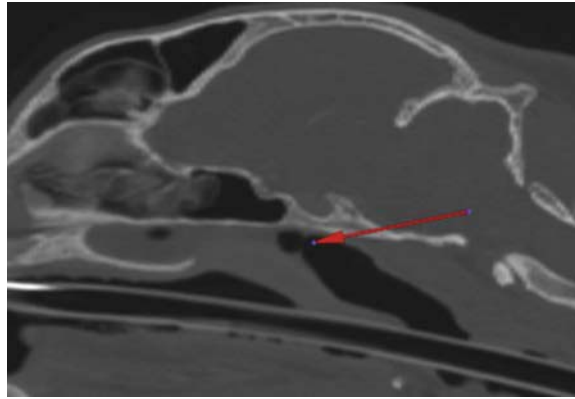


Figure 4.11. CT image illustrating a thin band of tissue across nasopharynx. Courtesy of Andrew Denning, New Priory Veterinary Clinic, Brighton, UK.

After advanced imaging, a thorough oral examination was performed and no evidence of dental disease was noted. CT, although less sensitive than dental radiography, did not support evidence of oronasal fistula(e).

- Q** 4. See [Figure 4.12](#) (retrograde view of nasopharyngeal region) and [Figure 4.13](#) (anterograde view of caudal nasal cavity). Combining these findings with the CT results, what is the likely diagnosis?

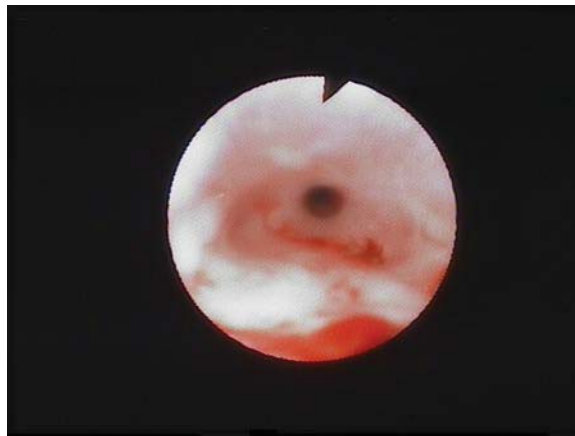


Figure 4.12. Retrograde view of nasopharyngeal stenosis using flexible endoscope.

In this case, retroflexed pharyngoscopy confirmed the CT finding of nasopharyngeal stenosis, in which the aperture measured just 1 mm in diameter.

The CT findings also suggested pathology within the nose with turbinate destruction that could be due to neoplasia, inflammation, or infection.

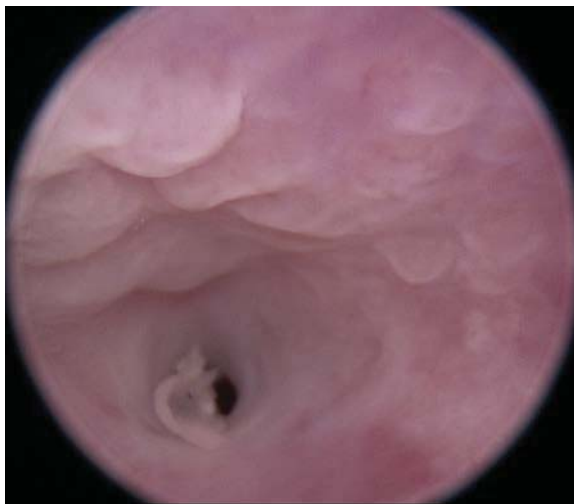

Figure 4.13. Anterograde view of nasopharyngeal stenosis using 1.9 mm 30° oblique rigid rhinoscope.

Further Case Information

Histopathology from nasal biopsy samples showed mild to moderate bilateral lymphoplasmacytic rhinitis. There were no signs of viral inclusion bodies suggestive of active feline herpes virus (FHV-1) infection.

Diagnosis: chronic rhinitis and nasopharyngeal stenosis.

Q 5. What are the treatment options for this cat?

Treating both the lymphoplasmacytic rhinitis and nasopharyngeal stenosis will increase the chances of improving the cat's clinical signs.

Nasopharyngeal stenosis treatment options include:

- Vascular forceps dilation
- Balloon dilation
- Balloon dilation + temporary stent placement
- Balloon dilation + laser ablation
- Transpalatal resection and reconstruction

Treatment of lymphoplasmacytic rhinitis options include:

- Antibiosis for secondary bacterial infection
- Famciclovir as an antiviral for FHV-1 involvement
- Meloxicam as an anti-inflammatory
- Nebulization
- Mucolytics
- Topical corticosteroids: prednisolone nasal drops or inhalational fluticasone
- Systemic prednisolone as an anti-inflammatory (also important post correction of stenosis to reduce inflammation and prevent re-stenosis)

NB: Remember not to use NSAIDs (non-steroidal anti-inflammatory drugs) and corticosteroids at the same time.

Treatment and Outcome

In this case balloon dilation + diode laser ablation was chosen for its ability to ablate/resect the obstructing tissue and provide additional haemostasis. Medical therapy continued with pradofloxacin (for its spectrum against *Mycoplasma*, *Chlamydophila felis*, *Bordetella bronchiseptica*, Gram positive and anaerobic bacteria), and famciclovir (40 mg/kg PO q 12 h) post-operatively for approximately 6 weeks to reduce the risk of FHV-1 recrudescence associated with immunosuppressive doses of prednisolone. Oral prednisolone therapy was initiated at 2 mg/kg SID for 10 days and gradually reduced to 0.5 mg/kg PO q 48 h over 8 weeks.

Stertor resolved in this case, but 5 months post ablation, minor inspiratory sterter returned suggesting some degree of stricture re-formation. Further investigations/treatment was declined at this stage.

Discussion

Nasopharyngeal stenosis should be considered an important differential in cats presenting with chronic and progressive upper respiratory tract disease, when significant sterter is present. It is a relatively uncommon condition that involves the narrowing of the choanae where little air can pass. Stenosis can be a result of chronic infection, aspiration rhinitis, or a congenital malformation.

Diagnosis is typically made during retroflexed rhinoscopy when a smooth membrane is seen in the nasopharynx obscuring the view to the choanae.

The treatment for nasopharyngeal stenosis is traditionally dilation with forceps or a balloon catheter. Restricturing can be common and frustrating for owners. More recently, diode laser ablation and fluoroscopic-guided placement of balloon expandable metallic stents have been evaluated.

Further Reading

- Berent, A.C., Weisse, C., Todd, K., et al., 2008. Use of a balloon-expandable metallic stent for treatment of nasopharyngeal stenosis in dogs and cats: six cases (2005–2007). *Journal of the American Veterinary Medical Association* 233, 1432–1440.
- Scherk, M., 2010. Snots and snuffles: rational approach to chronic feline upper respiratory syndromes. *Journal of Feline Medicine and Surgery* 12 (7), 548–557.

Case 4.4

Signalment, Clinical History, and Clinical Examination

A 10-month-old FN DSH cat was presented because of a progressive cough of several months' duration. The owner had noticed that the cat had become somewhat more lethargic over that period.

The cat had a mild inspiratory dyspnoea. HR was 140 bpm. Physical examination was otherwise unremarkable.

The cat was an indoor-only cat in a single-cat household. Preventative health care was up to date.

Q 1. What differential diagnoses would you consider in this cat?

Coughing is typically associated with disease of the lower respiratory tract in cats. Unlike in dogs, this sign does not typically occur with CHF in cats.

One would need to consider inflammatory or infectious conditions of the bronchi or pulmonary parenchyma, such as allergic airway disease, parasitic disease (e.g. *Aelurostrongylus abstrusus*, heartworm pneumonitis), bacterial infections (e.g. *Mycoplasma*, *Bordetella bronchiseptica*, or organisms inhaled from the oronasal and pharyngeal areas), viral infections (e.g. FHV-1, feline calicivirus (FCV), influenza viruses, etc.), and protozoa (e.g. *Toxoplasma*). In appropriate geographical areas, invasive fungal infections such as histoplasmosis or coccidioidomycosis would also be a consideration. Neoplastic aetiologies would be unlikely, although lymphoma has been diagnosed in this age group.

Occasionally, pleural space disease is associated with coughing in cats, and the inspiratory dyspnoea in the absence of obvious upper respiratory tract signs (such as stridor) in this case would be suggestive of this aetiology. Space-occupying lesions within the thoracic cavity would include mediastinal/perihilar lymphadenopathy of either infectious or haemolympathic neoplastic aetiology; thymic neoplasia or cysts; diaphragmatic herniation (of either traumatic or congenital origin); peritoneopericardial herniation or diseases that lead to pleural effusion (e.g. pyothorax, congestive heart failure, feline infectious peritonitis, or the various causes of chylothorax).

Q 2. How would you investigate this case further?

Thoracic radiographs are likely to be the most useful initial investigation, with further investigations being determined by the findings on radiographs.

Further Case Information

The cat was sedated with butorphanol and acepromazine IM, and lateral and DV plain thoracic radiographs were obtained (Figures 4.14 and 4.15).

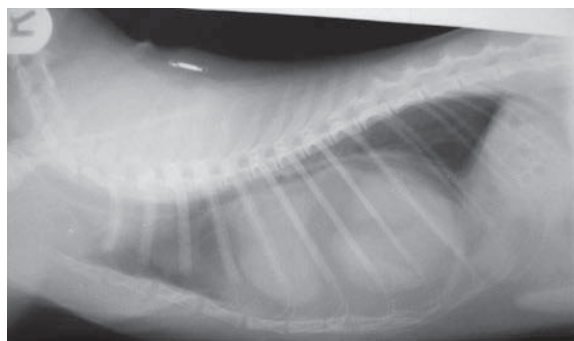


Figure 4.14. Lateral thoracic radiograph.

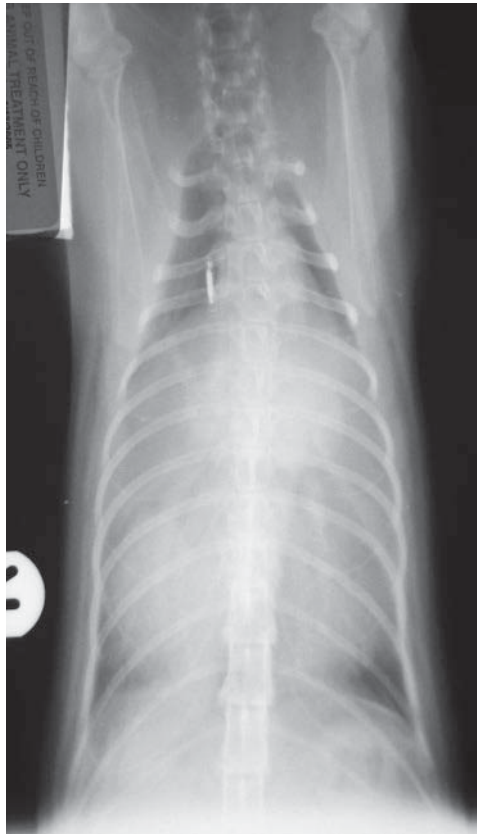


Figure 4.15. Ventrodorsal thoracic radiograph.

Q 3. What is your interpretation of the thoracic radiographs?

There is dorsal displacement of the trachea due to enlargement of the cardiac silhouette, with overlapping of the caudal cardiac silhouette and the diaphragm ventrally. Heterogeneous soft tissue densities are suggestive of abdominal viscera (likely liver) within the pericardial space.

Q 4. What is the most likely diagnosis?

Congenital peritoneopericardial diaphragmatic hernia.

Q 5. When might radiography not be diagnostic for this condition, and what other imaging modalities can be helpful in confirming the diagnosis?

Thoracic radiography is usually suggestive of the diagnosis, especially if there is significant abdominal visceral herniation, often resulting in visualization of the dorsal

mesothelial remnant. When only the omentum is herniated, however, the radiographic appearance of the chest may be normal.

Two-dimensional echocardiography is often used to confirm the location of the liver within the pericardial space, often with displacement of the heart. Care needs to be taken not to mistake a consolidated accessory lung lobe for hepatic tissue. Gas within the lumen of herniated bowel loops may impede ultrasonographic visualization of the heart.

If ultrasonography is not available, upper intestinal barium studies, pneumopericardiography, non-selective angiocardiology, and/or positive contrast peritoneography may be helpful in confirming the diagnosis.

Q 6. *How would you manage this case?*

The presence of clinical signs suggests the need for herniorrhaphy in this case.

Q 7. *What are the possible complications with surgery and are there any precautions that can be taken?*

Care needs to be taken to allow slow re-expansion of the lungs if atelectasis is present, as non-cardiogenic oedema has been reported during and after surgery in some cases.

Some authors advocate a pre-operative assessment of clotting status, as postoperative bleeding diatheses have also been reported (presumably due to compromised liver function due to organ entrapment and compromised blood supply).

Other complications are rare but may include hypotension and arrhythmias, particularly during reduction of the abdominal viscera from the pericardial space, and transient hyperthermia.

Q 8. *Is surgery always indicated in these cases?*

Asymptomatic cats are generally treated conservatively, as many will live a normal, healthy life. Deaths due to cardiac tamponade have been reported, although this seems to be rare.

Treatment and Outcome

The cat underwent a routine repair of the peritoneopericardial diaphragmatic hernia via an abdominal approach. A large amount of intra-abdominal fat (falciform ligament) and the entire liver were located within the pericardial space. There were no intra- or post-operative complications.

Discussion

Although peritoneopericardial diaphragmatic hernias (PPDH) result from an abnormal communication between the pericardial and peritoneal spaces, these are always the result of a congenital abnormality in cats rather than the result of trauma (which may occur in people) as there is normally no connection between the pericardium and the diaphragm. PPDH is the most common defect of the pericardium in cats, and occasionally concurrent defects such as pectus excavatum may also be noted.

In many cats the condition is discovered as an incidental finding. Often the condition results in the physical finding of displaced or muffled heart sounds and/or an 'empty' abdomen on palpation. A significant number of cats present with respiratory or gastrointestinal signs that vary with the degree of abdominal viscera herniation. Affected cats may also have non-specific signs, such as intermittent anorexia, lethargy, exercise intolerance, and collapse.

Further Reading

- Evans, S.M., Biery, D.N., 1980. Congenital peritoneopericardial diaphragmatic hernia in the dog and cat: a literature review and 17 additional case histories. *Veterinary Radiology* 21, 108–116.
- Reimer, S.B., Kyles, A.E., Filipowicz, D.E., Gregory, C.R., 2004. Long-term outcome of cats treated conservatively or surgically for peritoneopericardial diaphragmatic hernia: 66 cases (1987–2002). *Journal of the American Veterinary Medical Association* 224, 728–732.

Case 4.5

Signalment and History

A 12-year-old FN DSH cat presented with dyspnoea. The owner noted that she had been in a cat fight a week earlier and had since been inappetent, lame on the left fore, and had some scabs in her left ear with a smelly discharge. In the preceding 48 h she had also lost her meow.

Clinical Examination

On presentation the cat had markedly increased inspiratory effort and stridor. There was a mild painful palpable swelling over the region of the larynx, pain on palpation of the left elbow, and a tear in the left pinnae with purulent discharge. She was estimated to be 3% dehydrated as indicated by mild skin tenting and tacky mucous membranes.

Vital parameters were as follows:

- Heart rate 180 bpm
- Respiration rate 24 brpm
- Temperature 38.3 °C
- Weight 4.1 kg
- Body condition score (BCS) 5/9

Q 1. What clinical signs assist in the localization of the site of the respiratory distress?

An increase in inspiratory effort can be due to either upper airway obstruction or to pleural space disease. With pleural space disease rapid shallow breaths are expected, whereas with upper airway obstruction slow deep breaths are usually expected. Stridor is generally indicative of laryngeal disease. In this case the inspiratory effort, with a normal respiratory rate, and presence of stridor localizes disease to the larynx.

Q 2. Formulate a list of differential diagnoses for laryngeal disease in this cat.

- Abscess/cellulitis/laryngeal oedema secondary to the cat bite
- Laryngeal foreign body
- Laryngeal spasm
- Laryngeal paralysis
- Laryngeal neoplasia
- Laryngeal oedema
- Inflammatory laryngeal disease

Q 3. What are your initial priorities in managing this case?

- Minimize stress
- Oxygen supplementation
- Mild sedation (e.g. butorphanol) is required

Further Case Information

Together with the above measures, amoxicillin-clavulanate was administered SC due to the presence of bite wounds. The cat gradually deteriorated over a 48-h period, developing worsening inspiratory effort, open mouth breathing, and also mild expiratory effort. Thoracic radiographs were taken at this stage.

Q 4. What is your interpretation of the radiographs shown in [Figures 4.16–4.18](#)?

On both the lateral and VD views there is evidence of aerophagia (green arrow). There is no evidence of pulmonary or pleural space abnormalities. There is gas within a dilated oesophagus (red arrow), which may indicate mega-oesophagus or be due to aerophagia. There is mild increase in soft tissue at the heart base (blue arrow); this may reflect enlargement of the hilar lymph nodes but is difficult to interpret. On the lateral laryngeal view there appears to be a soft tissue opacity in the proximal oesophagus (blue arrow) and in the trachea just caudal to the larynx (red arrow). This may be soft tissue, foreign body, or fluid/mucous accumulation.

Q 5. Outline your next diagnostic and therapeutic steps.

A patent airway needs to be established, which requires general anaesthesia and placement of an endotracheal (ET) tube.

If it is not possible to pass an ET tube, then a tracheostomy tube or permanent tracheotomy would be required, and so preparation for this is required prior to anaesthetizing the cat.

Further diagnostics would include ultrasound of the swollen laryngeal area, visualization of the larynx and examination of the larynx and pharynx, upper airway endoscopy, and fine needle aspiration (FNA) and/or biopsy of any abnormal tissue for cytology and histopathology.

Q 6. Outline the approach you would take in anaesthetizing this cat.

- Pre-oxygenate (flow by or intranasal if tolerated) and obtain baseline SpO₂ values with pulse oximetry if tolerated by the cat

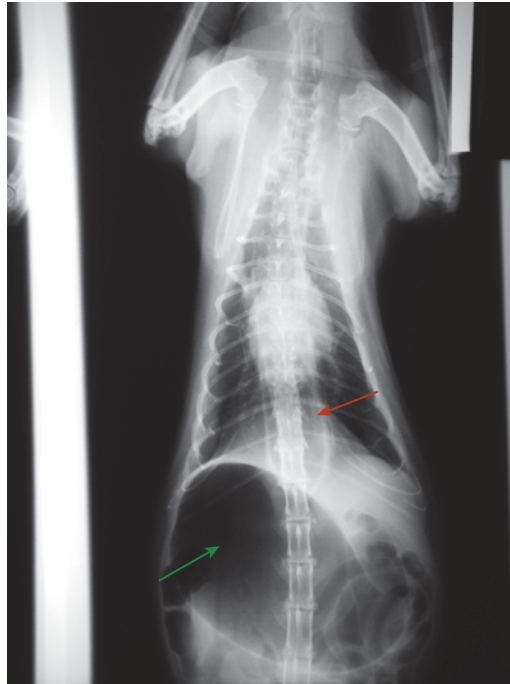


Figure 4.16. Ventrordorsal thoracic radiograph.

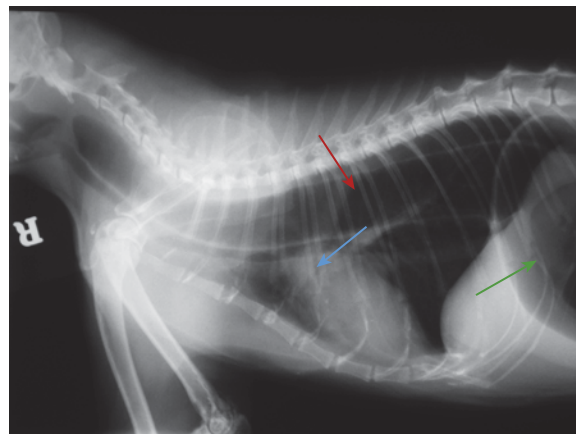


Figure 4.17. Right lateral thoracic radiograph.

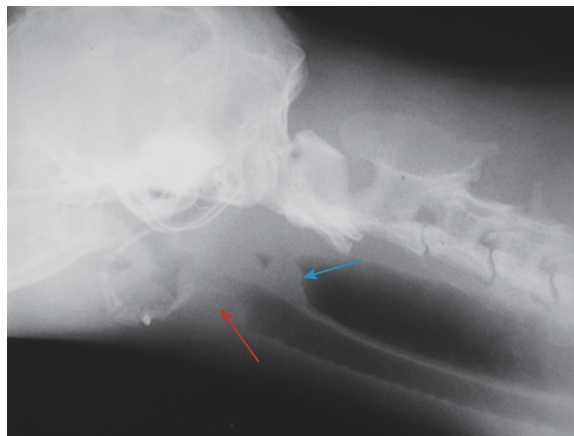


Figure 4.18. Right lateral laryngeal radiograph.

- Pre-medicate to calm the patient prior to anaesthesia
- Ensure all equipment that may be required is ready, including various sized ET tubes, smaller feeding tubes/urinary catheters in case an ET tube cannot be passed, equipment for performing a tracheotomy, suction equipment for suctioning the airways, intravenous anaesthetic agent, and fully equipped anaesthetic machine
- Place an IV catheter
- Induce anaesthesia with an IV agent such as propofol or alphaxan
- Once anaesthetized, visualize the larynx, apply lignocaine, and intubate
- If an ET cannot be passed an infant feeding tube (8 FR), dog urinary catheter or an over the needle 22 g intravenous catheter with stylet removed can be used to obtain access to the airway. It is often possible to then feed an ET tube over the smaller tube and through the larynx. Be prepared to perform tracheotomy if needed to establish an airway.

Further Case Information

On evaluation the larynx appeared erythematous and oedematous and markedly obscured the airway. No foreign body was observed. Respiration and oxygen saturation improved markedly post intubation and the ET tube passed easily once past the laryngeal swelling. An FNA and/or biopsy could have been taken at this stage but was not performed in this case due to the risk of exacerbating further swelling and worsening airway obstruction. A tracheotomy was, however, performed anyway in this case, and therefore there would have been less risk with taking FNAs or biopsies.

Q 7. Outline how you would manage this case postoperatively.

- Close monitoring is required during anaesthetic recovery with suction equipment to hand in case airways become obstructed with mucus
- Continue flow by oxygen until respirations and SpO₂ remain stable
- Continuation of broad-spectrum antibiotics

- Opioid analgesia (also providing mild sedation)
- Suctioning of the proximal trachea and moistening with sterile saline to prevent build-up of mucoid material in the airway, every 1–2 h initially
- Regular cleaning of the tracheotomy site (every 1–4 h depending on mucus production) with saline and cotton tips to prevent obstruction
- Continuous monitoring of patients with a tracheotomy is initially required since obstruction of the site with mucus can result in respiratory arrest and death

As time progresses the amount of secretions produced tend to reduce and frequency of cleaning can be reduced also. The tracheotomy site should be closed once upper airway swelling has resolved. The patency of upper airway can be checked by occluding the tracheotomy site; if the cat can still breathe normally, the airway is patent. If the cat is discharged it is important that the owner keep the cat indoors and is fully aware of the dangers associated with an open tracheotomy site. Possible complications include occlusion of the tracheotomy site (and respiratory arrest), pneumonia, infection at tracheotomy site, and foreign body introduced into the trachea.

Discussion and Follow-up

The cat improved markedly post surgery and was discharged 48 h later. One month later she was anaesthetized for closure of the tracheotomy; the larynx was examined and noted to be mildly thickened with a roughed texture (Figure 4.19). A biopsy was taken with histopathology revealing presence of lymphoplasmacytic laryngitis. In hindsight, if biopsy was to be performed it would have been more advisable while the tracheotomy was patent in case of postoperative swelling, and was only worthwhile doing if the results would change the way in which the cat was managed. It is difficult to speculate whether this inflammation was a consequence of direct laryngeal trauma associated with a cat bite, laryngeal paralysis associated with trauma with secondary laryngeal oedema and inflammation, or whether inflammatory laryngitis was a pre-existing underlying condition. In this case as inflammation was mild, and there were no clinical signs at this stage, no further treatment was commenced. In more severe symptomatic cases, prednisolone can be required.

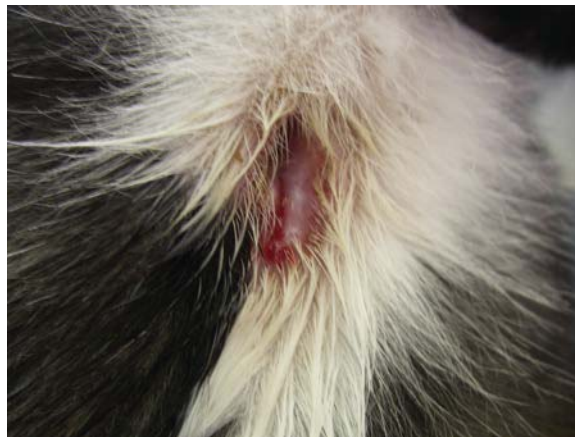

Figure 4.19. Tracheotomy site 1 month after initial surgery.

Further Reading

- Tasker, S., Foster, D.J., Corcoran, B.M., et al., 1999. Obstructive inflammatory laryngeal disease in three cats. *Journal of Feline Medicine and Surgery* 1 (1), 53–59.
- Taylor, S.S., Harvey, A.M., Barr, F.J., et al., 2009. Laryngeal disease in cats: a retrospective study of 35 cases. *Journal of Feline Medicine and Surgery* 11 (12), 954–962.

Case 4.6

Signalment and Clinical History

A 1-year-old MN DSH presented for investigation of acute, profound lethargy and inappetence.

The cat had been adopted from a shelter the previous day. At the time of adoption the cat had a weepy eye, suspected due to FHV-1. It was prescribed 250 mg lysine PO BID. Upon arrival at the new home the cat ate two bowls of food without hesitation.

When the owners contacted the shelter to report their cat's sudden change in demeanour, they were informed that several other cats were showing similar signs and some had developed a cough.

At the shelter the cat had been fed a premium commercial diet for indoor cats. The cat had been vaccinated with a killed vaccine against FHV-1, FCV, and feline panleucopenia virus 2 weeks prior.

Clinical Examination

The cat was in good body condition (BCS 3/5), with tacky mucous membranes and mild skin tenting suggesting dehydration. RT was normal (39 °C). The cat had a mild mixed inspiratory/expiratory dyspnoea with tachypnoea (44 brpm) and a restrictive pattern. Lung fields sounded harsh on the left-hand side. Serous ocular discharge was present bilaterally, a marked mucoid nasal discharge bilaterally, and there was sub-mandibular lymphadenomegaly.

Q 1. What are the most likely differential diagnoses that you would consider in this cat?

The history and combination of clinical signs make an infectious upper respiratory tract disease most likely. Infectious agents that could be involved include:

- FHV-1
- Feline calici virus (FCV)
- *Chlamydomydia felis*
- *Bordetella bronchiseptica*
- *Mycoplasma* spp.
- Less likely:
- *Toxoplasma gondii*
- Cryptococcal pneumonia

FHV-1 and *C. felis* are the most common pathogens causing ocular signs, whilst these and FCV are the most common pathogens causing rhinitis. Both calici virus

and herpes virus can cause secondary bronchopneumonia with secondary bacterial infections including possible involvement of *Mycoplasma* and *Bordetella*, any of which could account for lower respiratory tract signs.

Q 2. How would you stabilize this patient prior to investigation?

Mild sedation with butorphanol may reduce dyspnoea without depressing the patient's cardiorespiratory systems. Depending on oxygen saturation, mask or chamber administration of oxygen may be required. Intravenous fluids may be required to restore hydration, but care should be taken not to overload the patient. Minimal handling/restraint should be employed until the patient is stable.

After initial stabilization, thoracic radiographs were taken (Figures 4.20 and 4.21).

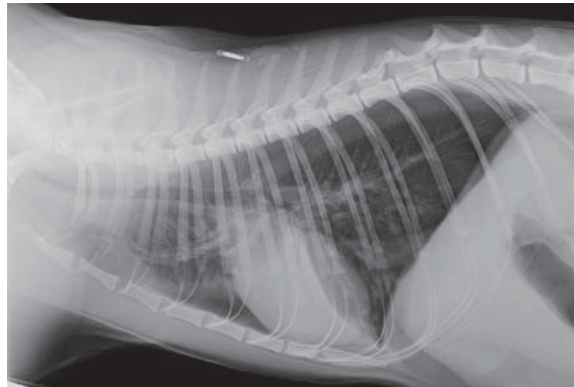


Figure 4.20. A conscious left lateral thoracic radiograph.

Q 3. What is your interpretation of the thoracic radiographs?

There is a diffuse bronchoalveolar pattern particularly in the cranial lung fields and right caudal lung fields. These changes are consistent with bronchopneumonia.

Q 4. How would you further manage this case?

There are several aspects of management to consider:

- Further investigation to identify the aetiological agent
- Treatment of the individual patient
- Preventing further spread of disease

Further investigation to identify the aetiological agent

- Conjunctival swab for *C. felis* and FHV-1 polymerase chain reaction (PCR)
- Oropharyngeal swab for FHV-1, FCV, *Bordetella bronchiseptica* PCR
- Bronchoalveolar lavage can be used to obtain samples for cytology, bacterial culture, and PCR (FHV-1, FCV, *Bordetella bronchiseptica*, and *Mycoplasma*); however,

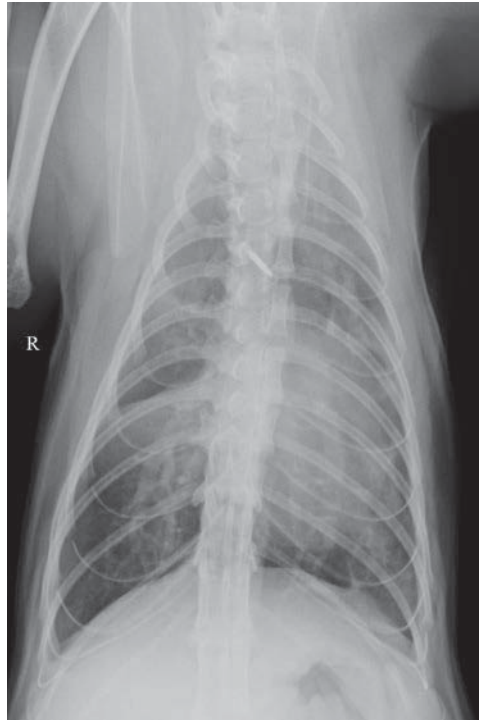


Figure 4.21. A conscious dorsoventral thoracic radiograph.

the risk of general anaesthesia in a patient with unstable respiratory tract disease may outweigh the benefits in a case such as this

- A CBC, serum biochemistry panel, and urinalysis may be performed to assess systemic health

Treatment of the individual patient

- Antibiotic therapy such as amoxicillin-clavulanate or doxycycline should be instigated to treat secondary bacterial infection. Intravenous fluid therapy is important to maintain hydration
- Nebulization and coughage, with or without mucolytic agents such as bromhexine, can be useful
- Famciclovir can be initiated if FHV-1 is suspected
- Supportive care including cleaning discharges to prevent excoriations, grooming, and nutritional support are prudent. Warming food can help increase palatability but a feeding tube (e.g. naso-oesophageal) may be needed.

Preventing further spread of disease

- Strict isolation, barrier nursing, and hygiene are critical

Diagnostic Test Results

The CBC revealed neutropenia ($1.2 \times 10^9/L$, RI 2.0–13), most likely to be secondary to overwhelming demand.

In this case an oropharyngeal swab was taken for complete respiratory pathogen PCR panel with negative results for *C. felis*, FCV and FHV-1, and positive for *Bordetella bronchiseptica* and *Mycoplasma felis*.

Q 5. Given these results would you change anything regarding treatment?

Treatment of choice for *Bordetella bronchiseptica* is doxycycline (5 mg/kg BID) for 10–14 days. Longer treatment is required to clear *M. felis* infection; however, the significance of a positive PCR from the oropharynx is uncertain, and therefore longer treatment would only be advised if there were persistent clinical signs.

Q 6. What advice would you give the shelter?

Because destocking was not an option, the shelter was advised to close for a minimum 7-day period during which cats were not re-homed and new cats were not received. Volunteers and non-essential staff were asked to take leave during this time to minimize fomite transmission. The premises were disinfected thoroughly and all cats commenced on a 14-day course of doxycycline. New cats were isolated for a period of 7 days. Vaccination using a modified live intranasal vaccine may be used in this situation but should be used judiciously as this can lead to bacterial shedding and clinical disease in some cats.

Discussion

Bordetella is considered a primary pathogen in cats. It is susceptible to common disinfectants but can persist in the environment for over 10 days, so fomite transmission is likely. Like other respiratory pathogens it can be shed in nasal and oral secretions, but cats can contract *Bordetella* from infected dogs. Clinical signs include pyrexia, coughing, sneezing, ocular discharge, lymphadenomegaly, severe pneumonia, and in severe cases cyanosis and death.

Diagnosis is typically via bacterial culture or PCR but both of these lack sensitivity. The significance of positive PCR for *M. felis* from the oropharynx is unknown, as it can be found as a commensal organism.

If Finances Are Limited

Suspect cases may be treated empirically with doxycycline and supportive care as required.

Further Reading

Egberink, H., Addie, D., Belak, S., et al., 2009. *Bordetella bronchiseptica* infection in cats: ABCD guidelines on prevention and management. *Journal of Feline Medicine and Surgery* 11, 610–614.

Case 4.7**Signalment and Clinical History**

An 8-year-old MN Burmilla cat was presented with a 1-month history of weight loss, reduced appetite, and an intermittent soft cough. The cat was a keen hunter. Vaccination, worming, and ectoparasite control were current.

Clinical Examination

The cat was underweight (BCS 3/9) and abdominal palpation revealed thickened nodular areas in the mid-abdominal region. Mild tachypnoea was present (48 bpm) and thoracic auscultation revealed bilaterally harsh lung sounds.

Q 1. *Formulate a list of the most common differential diagnoses for coughing.*

- Tracheal disorder
 - Foreign body
 - Tracheitis
 - External compression (e.g. enlarged lymph nodes, mediastinal mass)
 - Collapse (rare in cats)
 - Trauma
 - Neoplasia (intramural, mural, extramural)
- Bronchial disorder
 - Chronic bronchitis
 - Asthma
 - Bronchopneumonia (bacterial, upper respiratory tract (URT) viruses)
 - *Aelurostrongylus abstrusus*
 - Neoplasia (intramural, mural, extramural)
 - External compression (e.g. enlarged tracheobronchial lymph nodes)
- Pulmonary parenchyma
 - Pneumonia
 - Pulmonary oedema (rarely causes coughing)
 - Pulmonary fibrosis
 - Heartworm

Q 2. *How would you further investigate this case?*

- Thoracic radiographs and abdominal imaging
- Complete haematology and serum biochemistry to further investigate for systemic disease
- FeLV/FIV status

Diagnostic Test Results

Haematology revealed a moderate neutrophilia ($17.6 \times 10^9/L$; RI: 2.5–12.8) with a mild left shift. Serum biochemistry was unremarkable. Retroviral serology was negative.

- Q** 3. Interpret the thoracic radiograph (Figure 4.22) and suggest differential diagnoses for the abnormalities seen.

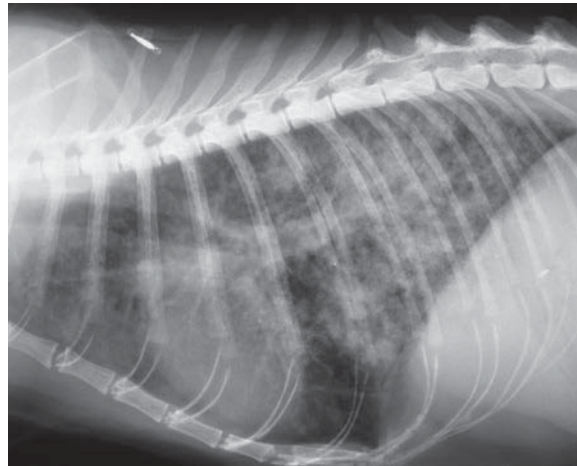


Figure 4.22. Right lateral thoracic radiograph showing a marked generalized nodular interstitial lung pattern. Courtesy of the University of Edinburgh.

The lateral thoracic radiograph reveals a severe, generalized nodular alveolar-interstitial lung pattern.

Differential diagnoses would include:

- Neoplasia (e.g. lymphoma or metastatic disease)
- Pulmonary haemorrhage (secondary to trauma, coagulopathy, or neoplasia)
- Pulmonary oedema (cardiogenic or non-cardiogenic)
- Infectious disease: bacterial, viral, lungworm, toxoplasmosis, heartworm, fungal disease

Diagnostic Test Results

Abdominal ultrasound was also performed to assess the abnormalities present on palpation. This revealed lymphadenomegaly of medial iliac, colic, and mesenteric lymph nodes with rounded hypoechoic nodes of up to 2 cm diameter (Figure 4.23). FNAs were taken from two enlarged lymph nodes for cytological examination. Unfortunately these were non-diagnostic.

- Q** 4. What most likely differential diagnoses would you consider at this stage?

- Neoplasia: lymphoma, widespread metastatic disease
- Lymphadenitis: bacterial, FIP, mycobacteria, toxoplasmosis, fungal infection

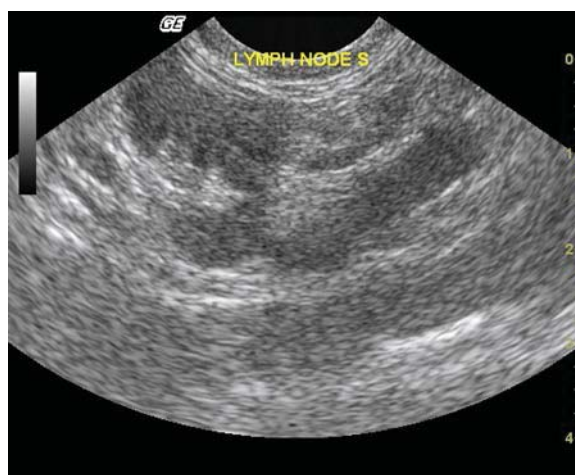

Figure 4.23. Markedly enlarged and irregular mesenteric lymph nodes. Courtesy of the University of Edinburgh.

Q 5. What are the options for further investigation?

- Retinal examination to look for signs of chorioretinitis, which might be associated with lymphoma or an infectious aetiology
- *Toxoplasma gondii* serology
- Latex cryptococcal antigen titre
- Bronchoalveolar lavage (BAL) for cytology and culture
- Biopsy of the enlarged abdominal lymph nodes (Tru-Cut under ultrasound guidance or at exploratory laparotomy)

Diagnostic Test Results

- The retinal examination showed no abnormalities. *Toxoplasma* titres (IgG: 50; IgM: <20) were consistent with previous exposure.
- Bacterial (including *Mycoplasma*) culture of the BAL fluid was negative. Cytology showed evidence of severe chronic-active inflammation with a neutrophil and macrophage predominance. Further tests on the BAL fluid (Gram stain, PAS, and Ziehl-Neelsen (ZN)) were negative.
- Histopathological examination of the enlarged mesenteric lymph nodes, removed during laparotomy, showed severe diffuse granulomatous and pyogranulomatous lymphadenitis and a single acid-fast *Bacillus* was identified in the cytoplasm of one macrophage. Together with the other changes, this was considered sufficient for a diagnosis of mycobacteriosis.
- A lymph node biopsy was submitted for mycobacterial culture, and colonies typical of *Mycobacterium microti* were isolated after approximately 5 weeks.

**Tip Box**

If mycobacterial disease is suspected, a total of four samples should be obtained:

- o Formalin fixed for histology and ZN staining
- o Unfixed for routine bacterial culture
- o A further two samples should be frozen. If ZN-positive organisms are detected, one of the frozen pieces can be submitted for mycobacterial culture and the last one retained, in case further tests are required.

This should be considered for any case where enlarged lymph nodes or cutaneous or subcutaneous nodules are detected.



6. What would you discuss with the owners regarding treatment of mycobacteria and if treating what drugs would you use?

**Tip Box**

Factors to be considered when discussing treatment of mycobacterial infection with owners:

- o All Mycobacteria, which are members of the tuberculosis complex (*M. tuberculosis*, *Mycobacterium bovis*, *M. microti*) pose a potential zoonotic risk, although rare
- o Treatment is discouraged if there are immune-suppressed persons in the household who might come into contact with the infected cat
- o Treatment of a cat with generalized disease, pulmonary involvement, or large draining skin lesions should also be considered very carefully as the risk of disease transmission to humans might be increased
- o Costs may be significant due to the drug protocols required
- o Commitment to compliance is required as lengthy (6 months) treatment daily or twice daily may be needed
- o Medication side effects are possible
- o The prognosis for any mycobacterial infection is guarded

Treatment should consist of an initial phase and a continuation phase. The initial phase typically lasts for 2 months and consists of three antibiotics (usually rifampicin, fluoroquinolone, and clarithromycin/azithromycin) and the continuation phase lasts for a further 4 months with two antibiotics (usually rifampicin and fluoroquinolone or clarithromycin/azithromycin). Combination therapy is necessary to prevent the development of antibiotic-resistant mutants.

Further Information on Response to Treatment, Diagnosis, and Outcome

Triple antibiotic therapy (as above) was initiated. The cat responded well with clinical signs rapidly resolving. At reassessment after 4 months of treatment (now receiving marbofloxacin and azithromycin) thoracic radiographs showed a significant improvement in the radiographic abnormalities (Figure 4.24) and normal abdominal palpation.

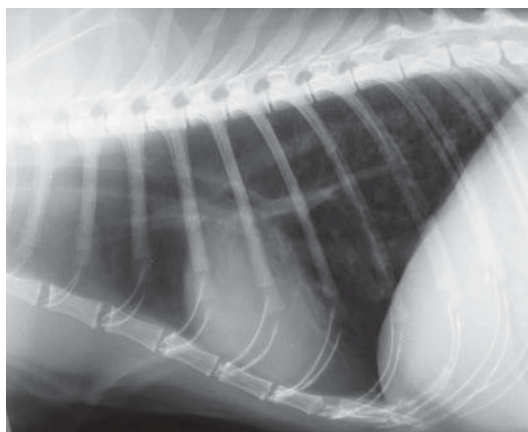


Figure 4.24. Right lateral thoracic radiograph taken 4 months after initiation of therapy. There is significant improvement of the lung pattern. Courtesy of the University of Edinburgh.

Discussion

Several mycobacterial spp. can cause disease, including *M. microti* (the vole 'bacillus'). In the UK it has been shown that several wild rodents can be naturally infected with *M. microti*, therefore hunting is considered a likely source of infection. Most commonly, this leads to non-healing skin lesions at the site of rodent bite wounds. Cases like the one presented here where the lower respiratory tract, intestinal tract, and/or mesenteric lymph nodes are affected are seen less commonly. Prognosis is guarded, but treatment may be successful in some cases.

Further Reading

Rüfenacht, S., Bogli-Stubler, K., Bodmer, T., et al., 2011. *Mycobacterium microti* infection in the cat: a case report, literature review and recent clinical experience. *Journal of Feline Medicine and Surgery* 13, 195–204.

Case 4.8

Signalment and Clinical History

A 1-year-old FN Oriental shorthair cat was presented with a 2-day history of laboured breathing and reduced appetite and activity level. The cat was indoor only, and worming and vaccination were up to date.

Clinical Examination

On presentation, the cat showed significant dyspnoea and tachypnoea (RR 60 brpm). Abdominal effort and a restrictive breathing pattern were evident. On thoracic auscultation normal lung sounds were absent or decreased bilaterally in the cranial thorax,

and inspiratory wheezes were audible caudodorsally. Thoracic percussion was dull over the cranial lung fields and compression of the rib cage was reduced.

Q 1. *Given the clinical examination findings, what differential diagnoses for dyspnoea do you consider to be most likely?*

- Pleural effusion
 - Transudate: hypoalbuminaemia
 - Modified transudate: cardiac disease, intrathoracic neoplasia
 - Exudate
 - Septic: pyothorax
 - Non-septic: FIP
- Haemothorax: neoplasia, coagulopathy, trauma
- Chylothorax: cardiac disease, diaphragmatic hernia, intrathoracic neoplasia, lung lobe torsion, idiopathic heartworm (*D. immitis*)

Reduced cranial rib spring is suggestive of the presence of a mediastinal mass, so a mediastinal mass with pleural effusion is most likely. The most common mediastinal masses in the cat are thymoma and lymphoma, with lymphoma being most common in young cats.

Q 2. *What other clinical signs might you see with a mediastinal mass?*

Difficulty swallowing, dysphagia, and regurgitation are most common. Horner syndrome and caval syndrome can also occur less commonly.

Q 3. *How would you further investigate this case?*

Either thoracic radiography or ultrasound would be appropriate.

However, cats in respiratory distress must be handled with great care, as decompensation can occur very rapidly, which could lead to the sudden death of the patient. Minimal handling, and keeping the cat quiet and in an oxygen-enriched environment are paramount.

Ultrasound can be performed with more minimal restraint than radiography and so is preferable if available. Since pleural effusion is strongly suggested by examination findings, thoracocentesis to stabilize the patient prior to imaging may be appropriate. Any collected fluid should be submitted for measurement of protein concentrations and cytology.

Diagnostic Tests

In this case, following stabilization, thoracic radiographs were performed (Figure 4.25).

Q 4. *Describe the radiographic findings.*

There is a large soft tissue opacity filling the entire cranial thorax, displacing the trachea dorsally and the carina dorsocaudally. The cardiac silhouette is obscured suggesting the additional presence of pleural fluid. Only a small portion of lung caudodorsally is air filled. Suspected cranial mediastinal mass and pleural effusion.

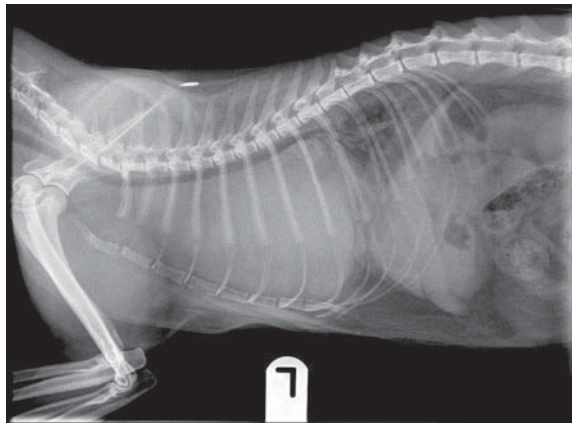


Figure 4.25. Lateral thoracic radiograph showing a large cranial mediastinal mass displacing the trachea dorsally. Courtesy of Companion Care, Fort Kinnaird (Edinburgh).

Q 5. Which diagnostic tests would you perform next?

- Thoracic ultrasonography
- FNA of the mass under ultrasound guidance, for cytology
- Aspiration of pleural fluid for cytology
- If cytological examination is not conclusive, ultrasound-guided Tru-Cut biopsy of the mass could be considered
- FeLV testing (mediastinal lymphoma can be associated with FeLV)
- Routine haematology and serum biochemistry are ideally performed to assess for multi-organ involvement and general health prior to treatment

Diagnostic Test Results

- Thoracic ultrasound demonstrated a large (approximately 5 cm diameter), heterogeneous, poorly vascularized mass in the cranial thorax, which displaced the heart and the brachiocephalic trunk to the right side. A small amount of pleural fluid was also present.
- Cytology of pleural fluid and FNAs from the mass showed presence of many large lymphoid cells consistent with mediastinal lymphoma.
- Routine haematology and biochemistry were unremarkable.
- FeLV and FIV enzyme-linked immunosorbent assays (ELISAs) were negative.

Q 6. How would you treat this condition?

- Combination chemotherapy such as COP (cyclophosphamide, vincristine, prednisolone) or CHOP (cyclophosphamide, vincristine, doxorubicin, prednisolone) protocols with or without L-asparaginase would be appropriate.
- Radiation therapy may also be an option in some cases, particularly those that have relapsed after chemotherapy.

Treatment and Outcome

The cat was maintained in an oxygen-enriched environment after starting a CHOP chemotherapy protocol including L-asparaginase. After the initial 36 h, the respiratory distress had improved significantly and the cat was moved to room air. Forty-eight hours later the cat was breathing normally and was discharged. One month after initiation of chemotherapy, repeat thoracic radiographs demonstrated complete resolution of the mediastinal mass (Figure 4.26). The cat remains in complete remission (CR) after 6 months of treatment.

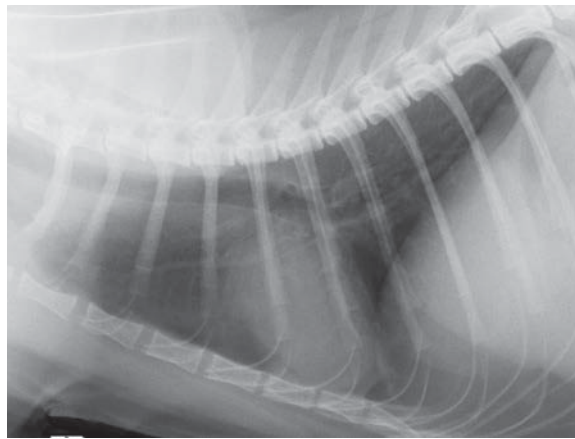


Figure 4.26. Lateral thoracic radiograph showing complete resolution of the mediastinal mass. Courtesy of the University of Edinburgh.

Discussion

Mediastinal lymphoma, together with the multicentric form, used to be the most common anatomic type of lymphoma in the cat as these forms are strongly associated with FeLV infection. With the decreasing prevalence of FeLV infection over the last 20 years, these forms have become rarer and intestinal lymphoma is the most common. Typically, cats with mediastinal lymphoma were young (often under 2 years) and FeLV positive. However, mediastinal lymphoma can also be seen in older FeLV-negative cats and young FeLV-negative Siamese and Oriental cats are overrepresented. Several studies suggest that there might be a genetic predisposition for mediastinal lymphoma in these breeds. One study showed that young Siamese cats with lymphoma have a more favourable prognosis for CR and survival than other breeds with prolonged survival times and even cure. Those cats that have localized disease and achieve CR have the best prognosis.

Further Reading

Fabrizio, F., Calam, A.E., Dobson, J.M., et al., 2014. Feline mediastinal lymphoma: a retrospective study of signalment, retroviral status, response to chemotherapy and prognostic indicators. *Journal of Feline Medicine and Surgery* 16 (8), 637–644.

Case 4.9

Signalment and History

A 7-year-old, FN DSH cat presented with a 1-week history of lethargy, inappetence, and dyspnoea. No previous problems were reported. She was an outdoor, fully vaccinated (FCV, FHV-1, FPV, FeLV) cat, fed a commercial dry diet, and regularly wormed. There was no access to toxins and the cat had never been outside the United Kingdom.

Clinical Examination

On observation the cat was weak, tachypnoeic (80 brpm) and dyspnoeic with increased inspiratory and abdominal effort. The cat was in good body condition (BCS 2.5/5) and weighed 4.1 kg. Mucous membranes were dry and pale pink with CRT 3 s. Femoral pulses were regular with no pulse deficits; peripheral pulses were weak. Jugular vein distension and pulsation was evident. On auscultation heart and lung sounds were muffled with bilateral ventral dullness on thoracic percussion. The cat was mildly tachycardic (220 bpm); no murmurs were audible. Rectal temperature was 37.6 °C.

Q 1. Create a problem list and consider the most important differential diagnoses for the cat's problems.

- This cat's problems are inappetence, lethargy, dyspnoea/tachypnoea, poor pulse quality, delayed CRT, jugular vein distension, and pulsation and mild dehydration.
- Tachypnoea/dyspnoea is the most significant problem and can be the consequence of airway (upper or lower), pulmonary parenchymal (e.g. oedema), pleural space (e.g. effusion, pneumothorax), body wall or mediastinal disease, abdominal cavity disorders (e.g. ascites), or miscellaneous causes (e.g. pain, acidaemia, anaemia).
- The combination of tachypnoea/dyspnoea with increased inspiratory and abdominal effort, muffled lung sounds, and dullness on percussion was suggestive of pleural space disease.
- Reduced pulse quality and delayed CRT indicates hypotension, which can be caused by hypovolaemia, reduced cardiac output, or peripheral vasodilation. Jugular distension and pulsation is indicative of right-sided heart failure.
- The respiratory signs, reduced pulse quality, and jugular pulsation together suggested that cardiac disease was the most likely cause of the cat's problems. The weakness, inappetence, and dehydration could also be a consequence of cardiac disease.

Q 2. How would you initially manage this cat?

- Minimization of stress and oxygen supplementation are initial priorities
- Blood pressure assessment is also warranted if this can be performed without resulting in stress to the cat
- Given the suspicion of pleural space disease on examination, thoracocentesis, thoracic ultrasound, or thoracic radiographs would be the next options, depending on how stable the cat was at this stage

Further Case Information

The cat was put in an oxygen cage in a quiet room prior to further assessment. Systolic BP was measured by Doppler to investigate the reduced pulse quality confirming hypotension (80 mmHg; normal range 120–160 mmHg).

The cat was stable enough for radiographs to be taken, so conscious thoracic radiographs were obtained (Figures 4.27 and 4.28).

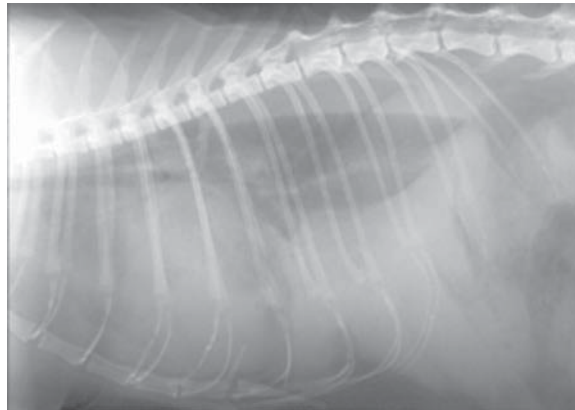


Figure 4.27. Right lateral thoracic radiograph.

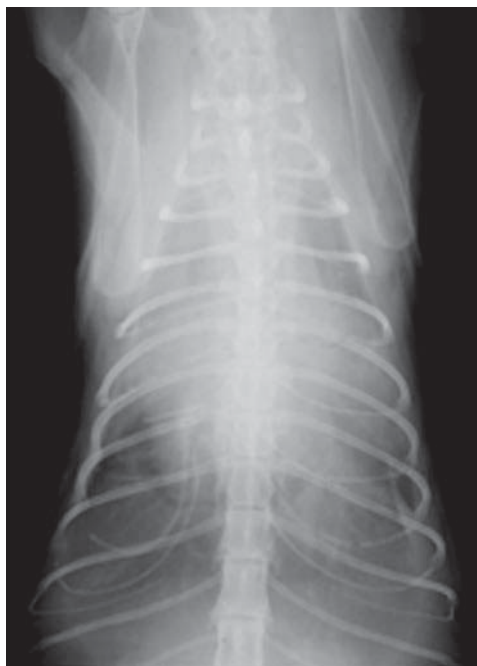

Figure 4.28. Dorsoventral thoracic radiograph.

Q 3. What is your interpretation of the radiographs?

On the lateral view the lung lobes are retracted away from the thoracic wall and the cardiac silhouette is obscured by an increased opacity throughout the ventral thorax, indicating the presence of a pleural effusion. On the dorsoventral view the cardiac silhouette and lung fields were bilaterally obscured by increased opacity, indicating the presence of a bilateral pleural effusion.

Q 4. What are your differential diagnoses for a pleural effusion and which do you think is most likely in this case?

Pleural effusion can comprise a pure transudate (e.g. hypoalbuminaemia), modified transudate (e.g. CHF), septic exudate (pyothorax), non-septic exudate (e.g. FIP), chylous (e.g. CHF, idiopathic), haemorrhagic (e.g. trauma, coagulopathy).

CHF was considered the most likely cause of the effusion, with hypotension present due to reduced cardiac output.

Further Case Information

Thoracocentesis yielded 250 mL of a clear fluid, later confirmed to be a modified transudate on pleural fluid analysis. The dyspnoea resolved following thoracocentesis. ECG (Figure 4.29) and echocardiography (Figures 4.30 and 4.31) were performed to further investigate the possibility of cardiac disease.

Q 5. Evaluate the ECG shown in Figure 4.29, including measuring the complexes. What is your interpretation of the ECG?**Answer**

► See Table 4.1

Table 4.1 ECG Evaluation

Parameter	Measurement	Reference Interval
Average heart rate (bpm)	180	120–240
P wave duration (s)	— ¹	<0.04
P wave amplitude (mV)	— ¹	<0.2
PQ interval (s)	— ¹	0.05–0.09
QRS duration (s)	0.05	<0.04
R wave amplitude (mV)	0.2	<0.9
ST depression (mV)	0	0
ST elevation (mV)	0	0
QT interval (s)	0.16	0.12–0.18
Mean electrical axis	30	0–160°

¹P waves values not obtained as P waves too small to measure.

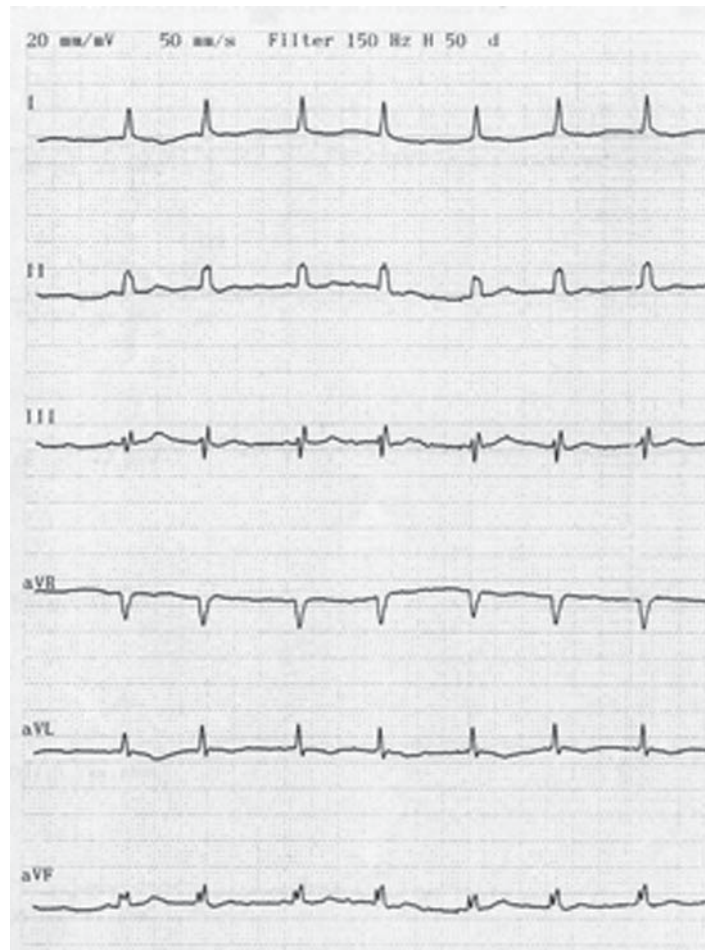


Figure 4.29. Standard 6-lead ECG recording.

Comments

- Predominant sinus rhythm 180 bpm
- Prolonged QRS duration is suggestive of left ventricular enlargement or left bundle branch block; notched R waves may indicate the presence of intramyocardial infarction or can be associated with bundle branch block

Q 6. Evaluating the echocardiographic images shown in Figures 4.30 and 4.31, together with the measurements in Table 4.2, what is your interpretation of the echocardiographic findings? What is your diagnosis?

Answer

- Echocardiography reveals left atrial dilation, reduced left ventricular free wall thickness in systole, and significantly reduced fractional shortening, all consistent

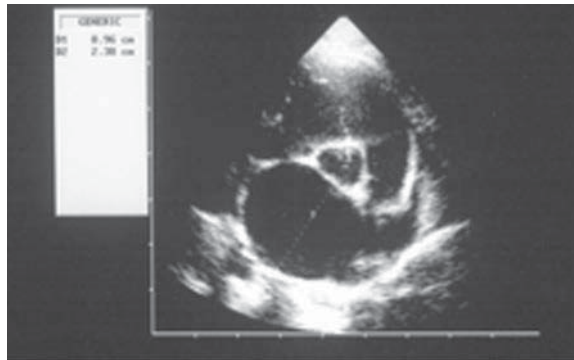


Figure 4.30. Right parasternal short axis view at the level of the base of the heart, demonstrating left atrial enlargement. There is no evidence of 'smoke' or thrombi.

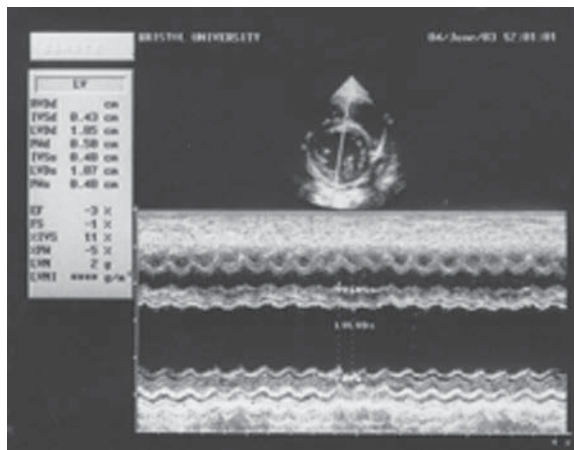


Figure 4.31. Right parasternal short axis view at the level of the papillary muscles just below the chordae tendinae: left ventricular (LV) M-mode study, demonstrating LV dilation and thinning of LV free wall.

with DCM. Aortic outflow velocity is also significantly reduced, consistent with reduced cardiac output (CO) secondary to myocardial failure.

- Other echocardiographic findings that aren't shown on the images and measurements included biventricular and biatrial dilation, and a mild pericardial effusion.

Diagnosis

- DCM, which can occur secondary to taurine deficiency, be it idiopathic or genetic

Q 7. How would you manage this cat?

- Assessment of diet and serum taurine concentrations and supplementation with taurine

Table 4.2 Echocardiographic Measurements (M-mode)

	Values	Reference Values
IVS diastole (cm)	0.46	0.42 ± 0.7
IVS systole (cm)	0.46	0.67 ± 0.12
LVD diastole (cm)	1.88	1.5 ± 0.2
LVD systole (cm)	1.76	0.72 ± 0.15
LVFW diastole (cm)	0.46	0.41 ± 0.07
LVFW systole (cm)	0.49	0.68 ± 0.11
Fractional shortening (%)	6.38	52 ± 7
LA:Ao (cm)	2.95	1.25 ± 0.18
Combined mitral E and A wave (cm/s)	34	87 ± 9
Aortic outflow (m/s)	31	109 ± 19

Ao, aorta; IVS, interventricular septum; LA, left atrium; LVD, left ventricular diameter; LVFW, left ventricular free wall.

- Haematology and biochemistry to assess systemic health, particularly renal parameters and electrolytes to obtain baseline values prior to starting any treatments, and total T4 to exclude hyperthyroidism
- Furosemide for diuresis
- Further thoracocentesis as required
- Inotropic support: dobutamine in the short term, pimobendan or digoxin longer term
- Other therapeutic options include benazepril (for its effect on reducing the neuroendocrine response to heart failure and potential modulation of ventricular remodelling), and aspirin +/- or clopidogrel as antithrombotic agents

Further Case Information

- The cat had received a commercial diet so taurine deficiency was considered unlikely, but serum was submitted to assess taurine concentration, which was normal. Taurine (250 mg PO BID) was initiated while awaiting serum taurine results
- Haematology, biochemistry, and total T4 were all within reference interval
- Furosemide was initiated (1 mg/kg IV TID)
- Dobutamine, for inotropic support, was initiated as a constant rate infusion of 2 µg/kg/min

Over the next few hours, continuous ECG recording was used to monitor heart rate and rhythm, and the cat was observed for seizures, since tachycardia, dysrhythmias, and seizures can occur as side effects of dobutamine. Respiration, pulse quality, CRT, and systolic BP were also monitored closely.

Systolic BP increased to 100 mmHg over the following 4 h, peripheral pulse quality improved, and CRT normalized. Respiratory and heart rates remained unchanged. By day 2, the cat's demeanour had improved, normal appetite returned and the systolic BP increased to 110 mmHg. However, respiratory rate increased to 60 brpm and recurrence of pleural effusion was identified. Thoracocentesis was repeated, and as renal parameters and electrolytes remained normal and the cat was eating well, it was considered safe to initiate digoxin at 7 µg/kg PO SID to start longer-term inotropic support.

The cat's demeanour and respiration continued to improve. The respiratory rate remained at 28–36 brpm. Systolic BP increased to 120 mmHg. The dobutamine infusion was reduced by 50% every 2 h for 4 h and then discontinued. Benazepril (0.6 mg/kg PO SID) was also initiated. Serum electrolyte and urea/creatinine concentrations were assessed daily to monitor for dehydration and electrolyte disturbances, which are risks associated with furosemide treatment, and if occurred would induce/potentiate digoxin intoxication. They remained within normal ranges, and serum digoxin concentration measured on day 4 was just below the therapeutic range. The cat was discharged on day 6 continuing on oral furosemide (1 mg/kg BID), digoxin (7 µg/kg SID), and benazepril (2.5 mg SID). The cat required further thoracocentesis on day 20, and frusemide was then increased to 2 mg/kg BID PO since renal parameters and electrolytes remained normal. The cat remained well until recurrence of dyspnoea again on day 110 post diagnosis, and was euthanized at this stage.

Discussion

DCM is characterized by LV or biventricular dilation and impaired contractility, resulting in systolic dysfunction. There are limited data on the use of digoxin in cats; however, it does appear that efficacious and correct dosing and careful monitoring significantly reduce risks of intoxication. No side effects were seen in this case, and the survival time greatly exceeds reported median survival times of 11–13 days. Other treatments that could be considered are pimobendan, as an alternative inodilator; and aspirin or clopidogrel, for potential prophylaxis against thromboembolic disease.

Further Reading

- Ferasin, L., 2009a. Feline myocardial disease 1: Classification, pathophysiology and clinical presentation. *Journal of Feline Medicine and Surgery* 11 (1), 3–13.
- Ferasin, L., 2009b. Feline myocardial disease 2: Diagnosis, prognosis and clinical management. *Journal of Feline Medicine and Surgery* 11 (3), 183–194.

Case 4.10

Signalment and Clinical History

A 12-year-old FN DSH presented for investigation of progressively worsening upper respiratory noise and unilateral nasal discharge of 3 months' duration. The discharge was serous in nature and occasionally contained blood. Routine preventative health care was up to date.

Clinical Examination

The cat was bright, alert, responsive, and in good body condition (BCS 4/9). A loud inspiratory upper respiratory noise (stertor) was audible and mild tachypnoea was present (34 brpm). A small amount of left-sided serous to mucoid nasal discharge was present. There was no evidence of facial asymmetry or pain, and retropulsion of both globes was normal. Oral examination revealed many missing teeth but was otherwise unremarkable. There was no peripheral lymphadenopathy.

Q 1. *Formulate a list of differential diagnoses for nasal discharge and/or stertor.*

- Viral infection (FHV, FCV)
- Chronic rhinosinusitis
- Nasal foreign body
- Nasal neoplasia (e.g. lymphoma, adenocarcinoma)
- Fungal infection (e.g. *Cryptococcus* spp., *Aspergillus* spp.)
- Nasopharyngeal polyp
- Nasopharyngeal stenosis
- Tooth root abscess
- Oronasal fistula
- Nasal trauma

Q 2. *Which of these differential diagnoses most commonly (at least initially) cause a unilateral discharge?*

- Nasal foreign body
- Nasal neoplasia
- Tooth root abscess
- Oronasal fistula

Q 3. *What does the presence of stertor suggest?*

The fact that the cat has a loud stertorous respiratory noise suggests that the disease process has led to a significant degree of upper airway obstruction. This is commonly seen with nasopharyngeal stenosis, polyps, neoplasias, and fungal granulomas.

Q 4. *What are the options for further investigation of nasal discharge and stertor in the cat?*

- A retinal examination to check for lesions suggestive of systemic lymphoma or *Cryptococcus neoformans* infection (unusual with nasal disease)
- Systolic BP can be measured to rule out hypertension as a possible cause for the intermittent presence of haemorrhagic nasal discharge

- Oropharyngeal or nasal swabs for FHV, FCV, *Mycoplasma* spp., and *Bordetella bronchiseptica* PCRs. However, a positive test result does not prove a disease association as cats can be asymptomatic carriers of these agents. Recently vaccinated cats may also test positive.
- Depending on geographical location, a latex *Cryptococcus* antigen test is recommended and nasal swab cytology and fungal culture can be performed.
- Routine biochemistry and haematology may be considered to assess general health. FeLV/FIV ELISAs should be considered in high risk cats and those with chronic disease. If epistaxis is present, particularly without concurrent nasal discharge, coagulation times (APTT and PT), platelet numbers, and buccal mucosal bleeding time should be performed to assess for coagulopathy.
- Diagnostic imaging (CT or radiographs) of the nose, sinuses, bullae, and pharynx are particularly indicated when neoplasia, foreign body, fungal infection, or polyps are suspected. Thoracic imaging should be performed to assess for pulmonary metastasis or disseminated fungal disease where these are likely differential diagnoses.
- Retroflexed rhinoscopy allows visual assessment of the nasopharynx. Visualization of the ventral and dorsal nasal meatus is achieved by anterograde rhinoscopy with a rigid endoscope. Biopsies can be collected from both locations. With anterograde rhinoscopy the scope should not be advanced further than the level of the medial canthus of the eyes in order to avoid damaging the cribriform plate.

Results of Initial Investigations

In this case the following investigations were performed:

- Retinal examination: unremarkable
- Systolic BP: within normal limits (140 mmHg, Doppler method)
- CBC and serum biochemistry showed no significant abnormalities, and retroviral serology was negative; APTT/PT were normal
- Dorsoventral intra-oral radiographs of the nasal cavity were taken (Figure 4.32)

Q 5. What are the significant abnormalities shown on the radiographs and your differential diagnoses for these?

- Deviation of the nasal septum towards the left side
- Loss of the nasal turbinate structure on the left side with increased soft tissue density and areas of radiolucency

Nasal radiographic findings in cats are usually quite non-specific. These abnormalities would raise the suspicion as to the possibility of neoplasia; however, rhinitis and fungal disease can also cause similar radiographic abnormalities.

Results of Further Investigations

- Thoracic radiographs: unremarkable
- Retroflexed rhinoscopy: a large, smooth soft tissue mass was identified in the rostral nasopharynx, which appeared to obstruct the choanae. After cuffing the ET

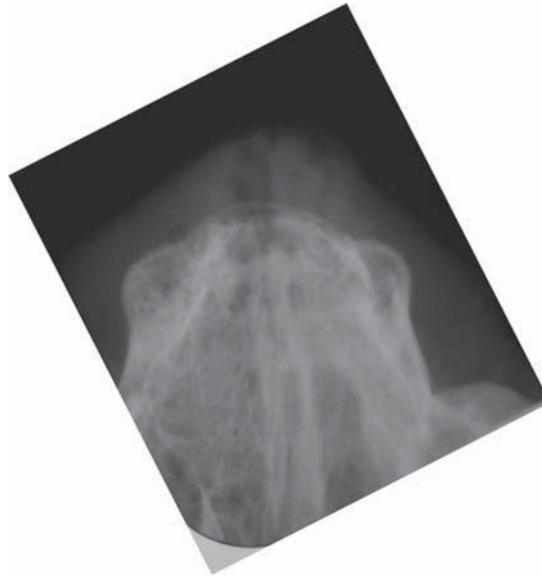


Figure 4.32. Dorsoventral intra-oral radiograph. Courtesy of the University of Edinburgh.

tube gently and packing the caudal oropharynx with gauze sponges, both nostrils were flushed with sterile saline rostrocaudally resulting in the mass becoming dislodged (Figure 4.33). The tissue was submitted for histopathology. On recovery from anaesthesia all upper respiratory noise had resolved.



Tip Box

It is relatively common in cases of nasal lymphoma to be able to dislodge tissue using rostrocaudal vigorous flushing. If this had not achieved a reasonable sample, then biopsies should be taken from the mass; this can sometimes be achieved in the absence of a rhinoscope by placing the cat in dorsal recumbency and pulling the soft palate rostrally with forceps to visualize the caudal nasopharynx.

Diagnosis

Histopathology confirmed nasopharyngeal lymphoma.

Q 6. What are the treatment options for nasal lymphoma?

- Definitive treatment
 - Radiation therapy
 - Chemotherapy: COP protocol or other protocols such as CHOP and modified Wisconsin-Madison
- Palliative treatment
 - Corticosteroids

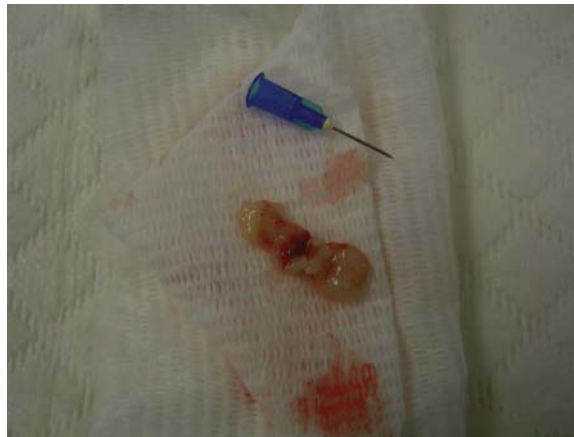

Figure 4.33. Nasopharyngeal mass removed by forced flushing.

Q 7. What would you advise the owner regarding prognosis?

The prognosis for nasal lymphoma is generally good with treatment. One study reports a median survival time of 749 days for cats that achieve complete remission when treated with chemotherapy alone. Radiation therapy as a sole treatment modality can result in a good response, with reported median survival times (MST) of 40.8 months in one study and 536 days in another. The combination of multi-agent chemotherapy and radiation therapy does not appear to provide an advantage. The prognosis for cats receiving no treatment or prednisolone alone is poor (MST of 22 days).

Discussion

Lymphoma is the most common nasal neoplasm in cats and is usually found in middle-aged to older cats. Other nasal neoplasms in the cat are adenocarcinoma, squamous cell carcinoma, and various sarcomas. Nasal lymphoma is typically thought to be an isolated form of lymphoma, although involvement of other organ systems has been reported (67% of cats that underwent postmortem examination), including kidneys. Nasal lymphoma is usually not associated with FeLV infection and in most cases is of B-cell immunotype. Lymphoid neoplasms are sensitive to both chemotherapy and radiation, and nasal lymphoma has the potential for a good long-term prognosis.

Further Reading

- Reed, N., Gunn-Moore, D., 2012a. Nasopharyngeal disease in cats: 1. Diagnostic investigation. *Journal of Feline Medicine and Surgery* 14 (5), 306–315.
- Reed, N., Gunn-Moore, D., 2012b. Nasopharyngeal disease in cats: 2. Specific conditions and their management. *Journal of Feline Medicine and Surgery* 14 (5), 317–326.

Urinary Tract Disorders

Case 5.1

Signalment, Clinical History, and Clinical Examination

A 3-year-old MN DSH cat was presented because of mild weight loss and a vague history of being 'off colour'. Physical examination was unremarkable. Blood and urine were collected for analysis, which revealed a moderate azotaemia (urea 19.1 mmol/L, reference interval: 5–15, creatinine 0.42 mmol/L, reference interval: 0.08–0.21), with a mild elevation in serum potassium (6.4 mmol/L, reference interval: 3.7–5.4), a urine specific gravity of 1.028, urine dipstick 3+ haemoglobin, 1+ protein, and sediment exam 3–5 white blood cells per high powered field and occasional bacteria. Urine culture was negative.

The cat was admitted and administered intravenous fluid therapy for 24 h, which resulted in some, but not complete, improvement of the azotaemia. An abdominal ultrasound was performed, which showed mild hydronephrosis of both kidneys (renal pelvis 4–5 mm diameter bilaterally), and a mildly dilated ureter could be followed a short distance on both sides; however, no obvious cause of the condition could be ascertained. The rest of the abdominal ultrasound, including the lower urinary tract, was within normal limits. Fine needle aspirates and cytology of the renal cortices did not reveal any abnormalities.

Q 1. *What is your interpretation of the clinical pathology tests and imaging?*

This cat is likely to be suffering postrenal azotaemia caused by partial bilateral ureteral obstruction; however, some degree of intrinsic renal dysfunction in one or both kidneys cannot be ruled out. If only one ureter is obstructed, the contralateral kidney is functioning normally, and there is no significant renal hypoperfusion, one would not expect to observe significant azotaemia.

Q 2. *Formulate a differential diagnosis list for this condition.*

- Intraluminal obstruction
 - Ureterolithiasis (>97% is calcium oxalate in cats)
 - Ureteral obstruction due to dried solidified blood calculi
 - Proteinaceous/inflammatory sediment within the ureters
- Mural lesions
 - Ureteral strictures (congenital or acquired)
 - Ureteritis

► Extraluminal compression

- Tumours of the trigone region of the bladder or structures surrounding the ureters, e.g. retroperitoneal leiomyosarcoma (not likely in this case due to the negative imaging findings)
- Retroperitoneal fibrosis following renal transplantation (not applicable in this case)
- Surgical trauma, e.g. inadvertent ligation of the ureter during ovariohysterectomy (not applicable in this case)

Any of the conditions listed above could be complicated by concurrent intrinsic renal disease; however, there is no historical or clinicopathological evidence of chronic kidney disease at this stage.

Q 3. *What further investigations could be performed in this case?*

1. Plain abdominal radiography. In some cases radiopaque calculi may be visualized along the course of one or both ureters, or there may be evidence of nephrolithiasis and/or cystoliths. If there is a significant amount of faecal material in the distal colon, an enema may assist in optimizing radiographic detection of calculi in the ureters. That being said, feline ureteral calculi may be too small to adequately visualize via plain radiographs, so their absence does not exclude this diagnosis.
2. Intravenous excretory pyelography. Generally the visualization of the kidney and ureter is poor and there is a risk of contrast-induced nephrotoxicity.
3. Percutaneous antegrade pyelography. The cat is anaesthetized, and under ultrasound guidance a spinal needle is placed into the renal pelvis through the greater curvature of the kidney. Urine is withdrawn until the size of the renal pelvis has reduced by half (this urine can be submitted for analysis and/or culture) and is replaced by an equal volume of iodinated contrast media. The passage of the contrast media is then observed either by immediate and repeat plain abdominal radiographs performed 15 min later or observed in real time via fluoroscopy.
4. Retrograde ureteropyelography. This technique involves the injection of contrast media against the flow of urine into the ureter via a catheter introduced either during surgery or endoscopy of the bladder.
5. Helical computed tomography (CT). CT provides a good indication of the number and position of ureteral calculi, as well as the ability to be combined with intravenous excretory or antegrade pyelography for the detection of other causes of ureteral obstruction.

Results

The cat underwent an abdominal CT scan (Figure 5.1), which revealed bilateral ureteroliths, approximately mid-length of the right ureter and in the distal part of the left. No contrast studies were performed.

Q 4. *What are the options for treating this cat?*

1. Medical management
 - a. Aggressive management with IV fluids and diuretics to promote diuresis; care must be taken to monitor for adequate urine output and signs of overhydration

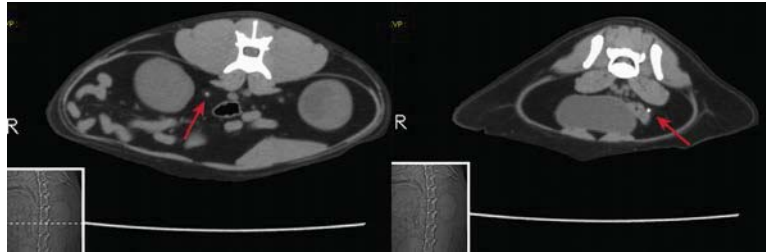


Figure 5.1. Abdominal CT sections. Ureteroliths can be observed in both the right and left ureters (red arrows).

- b. Antispasmodic agents such as prazosin can also be used in an attempt to reduce ureteral spasm, although their effectiveness is unproven
2. Surgical management to remove ureteroliths from one of both ureters
3. Ureteral stenting
4. Subcutaneous urethral bypass

Treatment and Further Testing

In this case, medical management was initially attempted with some improvement in azotaemia, but on repeat ultrasound 7 days later there was more marked dilation of the left renal pelvis (increased from 5 mm to 16 mm; [Figure 5.2](#)). A repeat CT scan showed little change in the position of the ureteroliths. The right renal pelvis was measured at 4–5 mm on ultrasound, indicating that the degree of obstruction had not changed.

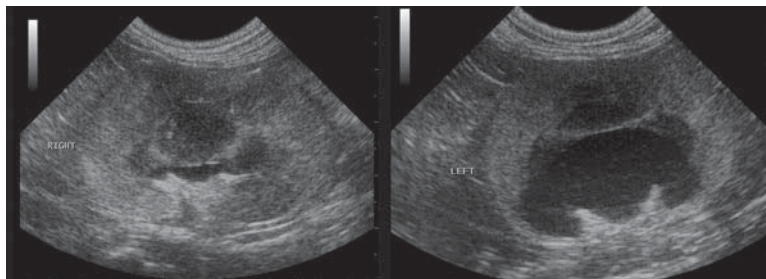


Figure 5.2. Ultrasound of the kidneys showed marked dilation of the left renal pelvis (16 mm). The right renal pelvis is also moderately dilated (5 mm).

The cat was referred for surgery and the decision was made to remove the left ureterolith. Given the risk of ureteral stricture formation, it was considered too much of a risk to attempt to remove both ureteroliths at the same time. A ureterolith was located 20 mm proximal to the trigone in the left ureter. Ureterotomy was performed and a 2 × 1 mm urolith was removed, sent for analysis and confirmed to be calcium oxalate. A ureteroneocystotomy was performed using the 'drop in' technique. The cat made a slow but uneventful recovery from the surgery and at 4 weeks post surgery the azotaemia had resolved. Over time the right kidney became small and fibrotic, with the left kidney increasing in size.

Q 5. What is your explanation for the changes in the sizes of the kidneys?

This scenario, labelled 'big kidney-little kidney', is commonly seen in cats with ureterolithiasis. Frequently, the initial ureteral obstruction is clinically silent, given that many cats are affected unilaterally at first. It is not until the cat develops a ureterolith in the contralateral ureter, and is presented in an acute renal crisis (due to a chronically dysfunctional kidney on one side and an obstructed ureter on the other), that the evidence of previous obstruction becomes apparent.

Discussion

Calcium oxalate uroliths cannot be dissolved medically and therefore either need to be passed spontaneously or removed surgically. Medical management often involves IV fluids (ideally monitoring central venous pressure, urinary output, body weight, and other indicators of hydration status), an osmotic diuretic (e.g. mannitol constant rate infusion), adrenergic agonists, amitriptyline, or glucagon in an attempt to relax the ureter.

The risk of leaving partially obstructed ureters needs to be balanced against the risk of surgical complications. If medical management fails, ideally surgical relief of the obstructions should be performed within 48–72 h of obstruction to avoid permanent renal damage. Immediate relief of the obstruction can be performed if specialist interventional endoscopic techniques are available.

Surgically placed 5 French nephrostomy tubes can be used to relieve the obstruction while the cat is being stabilized for surgery. Haemodialysis has been used in the pre-operative setting to relieve postrenal azotaemia; however, this does not mitigate further nephron loss due to the increased ureteral pressures.

Recently the use of ureteral stents or subcutaneous ureteral bypass systems have come into favour for the management of feline ureteral obstruction. Although the use of these devices has not been investigated extensively, they appear to be a viable option for the short- and long-term management of ureteral obstruction.

Further Reading

- Berent, A.C., 2011. Ureteral obstructions in dogs and cats: a review of traditional and new interventional diagnostic and therapeutic options. *Journal of Veterinary Emergency and Critical Care* 21, 86–103.
- Hardie, E., Kyles, A.E., 2004. Management of ureteral obstruction. *Veterinary Clinics Small Animal Practice* 34, 989–1010.
- Kyles, A., Hardie, E., Wooden, E., et al., 2005. Clinical, clinicopathologic, radiographic, and ultrasonographic abnormalities in cats with ureteral calculi: 163 cases (1984–2002). *Journal of the American Veterinary Medical Association* 226, 932–936.

Case 5.2**Signalment and Clinical History**

A 6-year-old MN Burmese cat presented with a history of stranguria, pollakiuria, and gross haematuria (Figure 5.3). The cat had been treated for urinary tract obstruction with urethral catheterization 8 months earlier. The owners reported that the cat was



Figure 5.3. A voided urine sample from the patient.

otherwise well, lived entirely indoors, and had no history of exposure to rodenticides or other potential toxins. Vaccination, worming, and flea control were up to date.

Clinical Examination

The cat was in good body condition (body condition score (BCS) 3) and normothermic (rectal temperature 38.8 °C). The bladder wall was thickened and painful on palpation. No other significant abnormalities were noted.

Q 1. *Differential diagnoses for haematuria are included in Case 5.4. What differential diagnoses for haematuria may also cause stranguria and pollakiuria?*

- Idiopathic cystitis with urethritis, urethral plugs, and/or spasm
- Urethral stricture (as a consequence of traumatic catheterization)
- Urethral trauma
- Urolithiasis
- Neoplasia (e.g. transitional cell carcinoma)
- Prostatic disease (rare): prostatitis, neoplasia, abscess, cyst

Q 2. *How would you investigate this case?*

Obtain a sterile urine sample via cystocentesis.

- A dipstick can be used to confirm haematuria, rule out glycosuria and ketonuria that may occur in the case of diabetes mellitus and associated secondary bacterial urinary tract infection (UTI), and to determine urine pH.

Table 5.1 Urinalysis Results at Presentation

	Patient Result
Specific gravity	1.033
Glucose	Negative
Bilirubin	Negative
Ketones	Negative
pH	6.5
Urobilinogen	Normal (<20 µmol/L)
Red blood cells	Marked (++++)
White blood cells	Marked (++++)
Protein	Large (+++) 3 g/L
Casts, type	Negative
Bacteria	Negative
Fat	Few
Epithelial cells, type	Squamous
Epithelial cells, number	Few
Sperm	Negative
Crystals, type	Negative
Debris	Occasional

- A refractometer can be used to determine urine specific gravity (see [Table 5.1](#)).
- Sediment examination facilitates detection of inflammation and bacteria, as well as any other cells (e.g. neoplastic cells), and to characterize crystalluria if present.
- Culture and sensitivity should be performed to rule out urinary tract infection, particularly where signs are recurrent, as this may be due to bacterial resistance to antimicrobial therapy.

Q 3. *What additional tests would you use to rule in/out urolithiasis as a cause of recurrent signs of urinary tract disease?*

The absence of crystalluria does not rule out urolithiasis. Survey abdominal radiographs allow detection of the most common uroliths in cats (struvite and calcium oxalate) as these are radio-opaque. Double contrast cystography may improve detection of urocystoliths.

Ultrasonography may help determine the presence of uroliths but does not give an accurate indication of the number of uroliths present.

Additional laboratory testing is recommended in animals with predisposing metabolic disease such as hyperadrenocorticism and hypercalcaemia.

Where finances are limited and signs are recurrent, one option is to progress to exploratory cystotomy as this allows direct visualization and removal of uroliths from the lower urinary tract, as well as an opportunity to evaluate and biopsy the bladder wall if required.

Diagnostic Test Results

Ultrasonographic examination revealed a cystic calculus measuring 5 × 10 mm within the lumen of the bladder. The bladder wall appeared thickened. The kidneys had well-defined corticomedullary architecture and appeared similar in size, with no evidence of renal calculi. Ultrasound of the entire abdomen revealed no other significant abnormalities.

Further Information on Response to Treatment, Diagnosis, and Outcome

The cat was anaesthetized routinely for ventral midline celiotomy. The urinary bladder was exteriorized and packed off with moistened laparotomy sponges. Stay sutures were placed to minimize surgical trauma to the bladder. The bladder was drained via cystocentesis. A stab incision was made in the ventral bladder wall and extended 1 cm to facilitate exploratory cystotomy. A single, rosette-shaped cystolith was located and removed from the trigone of the bladder using mosquito haemostats (Figure 5.4). The bladder was flushed copiously with sterile saline.

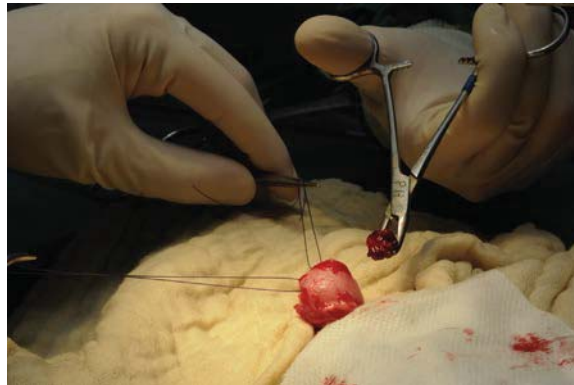


Figure 5.4. The cystolith is removed via cystotomy. Note the use of stay sutures to minimize trauma to the bladder.

A urinary catheter was placed to facilitate retrograde flushing of the bladder to dislodge any uroliths in the urethra. The incision was closed in a simple interrupted pattern using a 3.0 absorbable monofilament (Figure 5.5).

The suture line was tested for leakage by insufflating the bladder with sterile saline using a syringe and 22-gauge needle. No fluid leakage was detected. The abdomen was lavaged with warmed, sterile saline and suctioned prior to routine closure.

The patient received buprenorphine and meloxicam postoperatively for pain relief. The cystolith (Figure 5.6) was submitted to the Minnesota Urolith Center for analysis.

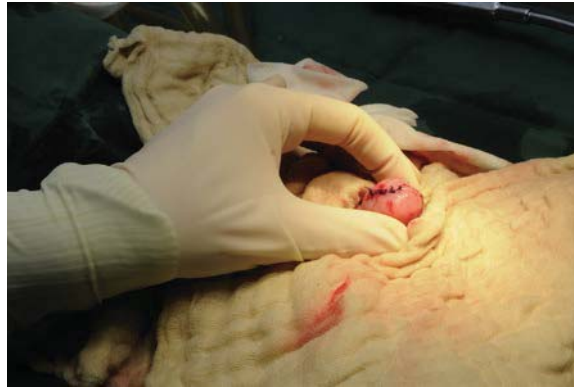

Figure 5.5. The cystotomy is closed with a synthetic, absorbable monofilament in a simple interrupted pattern.

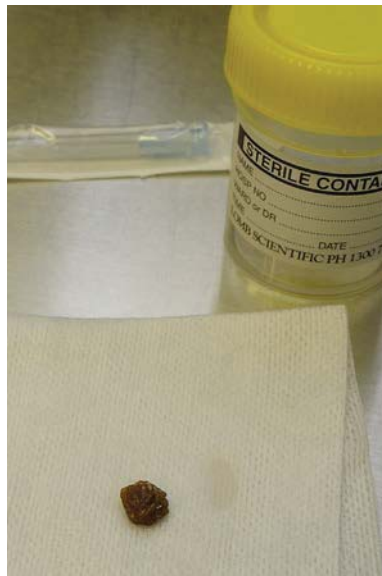

Figure 5.6. The cystolith following surgical removal.

Diagnostic Test Results

- Urine bacterial culture was negative
- The cystolith was identified as calcium oxalate monohydrate

Q 4. *What is the likelihood of recurrence and how is recurrence of calcium oxalate urolithiasis prevented?*

Recurrence of calcium oxalate uroliths is more common than recurrence of struvite uroliths, recurring once in just over 7% of affected cats in one study, with less than 1% experiencing second and third recurrences.

No treatment is completely effective in preventing recurrence of calcium oxalate uroliths in feline patients; however, recurrence within weeks of cystotomy is likely due to incomplete removal of uroliths at the time of surgery rather than true recurrence.

An appropriate therapeutic diet should reduce urine calcium and oxalic acid concentration, promote inhibitors of calcium oxalate crystals, and produce dilute urine with a pH in the neutral to alkaline range. A wet diet and increasing water intake will help to reduce urine supersaturation and therefore help to reduce risk of urolith formation.

Assessing for underlying hypercalcaemia is important, and managing any identifiable causes of hypercalcaemia is paramount. In cats with idiopathic hypercalcaemia, a high fibre diet with supplemental potassium citrate (75 mg/kg PO BID, adjusted to induce a pH of 7.0–7.5) is recommended.

Survey abdominal radiographs should be performed every 6 months to detect uroliths early.

Discussion

The epidemiology of feline uroliths has changed markedly, likely in response to changes made to commercial diets. In the early 1980s, calcium oxalate was detected in only 2% of feline uroliths, with struvite accounting for 78%. By 2002, more than half of the uroliths submitted to the Minnesota Urolith Center were calcium oxalate, possibly due to widespread feeding of diets designed to prevent struvite crystalluria. At present, it appears that the proportion of struvite uroliths is gradually overtaking that of calcium oxalate uroliths. This may be due to reformulation of commercial feline diets to reduce the risk of calcium oxalate formation. Similar trends have been documented through the Canadian Veterinary Urolith Centre. Male cats, particularly Himalayan, Persian, Burmese, and Siamese cats, are at an increased risk of developing calcium oxalate uroliths.

Surgical removal is the treatment of choice as there is no medical protocol for the dissolution of calcium oxalate uroliths. Urohydropulsion techniques are only applicable for uroliths less than 1 mm in diameter in males and less than 5 mm diameter in females. This procedure will be unsuccessful if uroliths adhere to the urethral mucosa or in the presence of strictures.

Postoperative radiographs are essential as calcium oxalate uroliths are incompletely removed via cystotomy in up to 20% of cases.

Further Reading

Albasan, H., Osborne, C.A., Lulich, J.P., et al., 2009. Rate and frequency of recurrence of uroliths after an initial ammonium urate, calcium oxalate or struvite uroliths in cats. *Journal of the American Veterinary Medical Association* 235 (12), 1450–1455.

Dijcker, J.C., Plantinga, E.A., van Baal, J., Hendriks, W.H., 2011. Influence of nutrition on feline calcium oxalate urolithiasis with emphasis on endogenous oxalate synthesis. *Nutritional Research Review* 24, 96–110.

McLoughlin, M.A., 2011. Complications of lower urinary tract surgery in animals. *Veterinary Clinics of North America Small Animal Practice* 41, 889–913.

Case 5.3

Case Description

A 3-year-old MN Siamese cat was presented for a booster vaccination and weight loss was noted (3.5 kg body weight, from 3.8 kg). There was moderate non-painful irregular renomegaly. No other physical abnormalities were detected.

Q 1. What are the major differential diagnoses for bilateral renomegaly in the cat?

- Feline infectious peritonitis (FIP): can cause renomegaly due to renal granulomas that typically protrude from the surface producing an irregular outline
- Bacterial pyelonephritis may cause renomegaly but it is usually less marked than the changes caused by other differential diagnoses listed here
- Neoplasia
 - Renal lymphosarcoma
 - Primary renal neoplasia: often unilateral but may be bilateral. Renal carcinoma is the most common primary renal neoplasm in the cat; others include transitional cell carcinoma, sarcoma, haemangiosarcoma, malignant nephroblastoma, etc.
 - Metastatic disease
- Polycystic kidney disease (PKD): an inherited disease most commonly seen in Persian cats and related breeds
- Renal amyloidosis
 - Primary amyloidosis: an inherited disease most associated with the Abyssinian breed
 - Secondary amyloidosis: amyloid deposition as a consequence of chronic pyelonephritis or glomerulonephritis
- Perinephric pseudocysts cause accumulations of large amounts of fluid under the renal capsule producing marked renomegaly, but the outline is smooth on palpation.
- Hydronephrosis is more usually unilateral (secondary to ureteral obstruction) and again produces a smooth renal outline.

Q 2. How would you further investigate this case?

Haematology and biochemistry are useful to evaluate systemic health, particularly to assess renal function and to look for other abnormalities that could be suggestive of FIP.

Abdominal ultrasound will be most useful in further characterizing the renal changes, to differentiate between infiltrative disease, perinephric pseudocysts, and PKD. If there is evidence of infiltrative disease, then fine needle aspirates will be helpful to look for evidence of inflammation or neoplasia.

Renal lymphosarcoma can be associated with feline leukaemia virus (FeLV), and therefore retroviral testing may be warranted.

Further Case Information

- Blood tests and urinalysis: serum biochemistry, urine analysis, and full blood count were all unremarkable and retrovirus tests were negative.
- Abdominal ultrasound: both kidneys were of similar appearance. Renal architecture was preserved with normal appearance to the renal pelvis, medulla, and cortex. Surrounding the renal parenchyma there was a well-defined hypoechoic rim of tissue that varied in depth from 0.2 to 0.9 cm (Figure 5.7). An enlarged lymph node (2.5×2 cm) was identified in the mid-cranial abdomen, but no other abnormalities were detected.

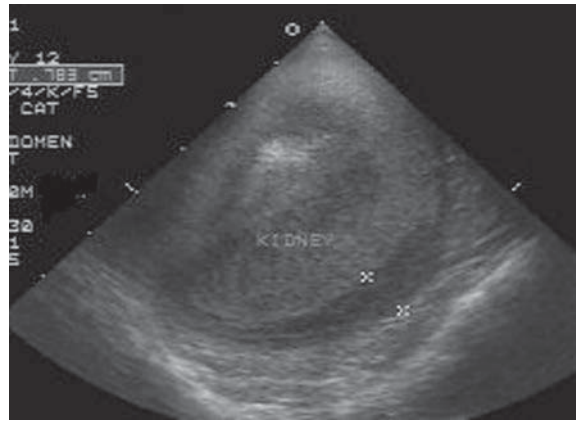

Figure 5.7. Ultrasound appearance of the kidneys showing the hypoechoic rim of tissue just below the renal capsule.

- Thoracic radiographs: unremarkable.
- Fine needle aspirates: samples collected from the hypoechoic renal lesions revealed a monomorphic population of lymphoblastic lymphocytes admixed with low to moderate numbers of mildly dysplastic epithelial cells interpreted to be renal cells.

Diagnosis

The ultrasound appearance and the cytology findings were consistent with a diagnosis of renal lymphosarcoma.

Q 3. *When discussing whether to start chemotherapy for a cat with lymphosarcoma, what prognostic indicators can be used to help to inform the owner's decision?*

One of the most important prognostic considerations is the anatomical location of the tumour.

- Gastrointestinal tumours
 - Diffuse, low grade, lymphocytic alimentary lymphosarcoma tends to respond very well to treatment with prednisolone and chlorambucil. The medium- to long-term prognosis is good.

- Focal, high grade, lymphoblastic alimentary lymphosarcoma is more aggressive and there is high metastatic potential. Surgical excision of the mass followed by chemotherapy with COP (cyclophosphamide/Oncovin (vincristine)/prednisolone) or other multidrug protocols is recommended. The prognosis is variable; some tumours recur within months, while other cats remain in complete remission for a number of years.
- Nasal lymphosarcomas generally respond very well to chemotherapy with COP or other multidrug protocols, with reported median survival time of 749 days. Lifelong cure can be achieved in some cases.
- Mediastinal lymphosarcoma usually responds well to treatment; complete remission is often maintained for several years and lifelong cure can occur.
- Renal lymphosarcoma is generally associated with a poor prognosis especially if the cat is in renal failure at the time of diagnosis. Published case series are lacking, but predicted survival time is measured in months rather than years.
- Laryngeal and central nervous system lymphosarcomas tend to respond less well to treatment.
- Lymphosarcomas that involve the bone marrow and/or spleen have a poor prognosis.
- Other sites: cutaneous, pulmonary, bladder, trachea, etc. Lymphosarcomas in these sites are reported in small numbers making interpretation of their responses to treatment difficult. A guarded prognosis is required.

Other factors to consider include:

- Lymphoblastic versus lymphocytic: high grade, large cell, lymphoblastic tumours are more aggressive than low grade, small cell, lymphocytic tumours.
- Cats that achieve complete remission early in the course of treatment have a significantly better prognosis than those that are slower to respond.
- For solid tumours, prior use of corticosteroids reduces the length of remission achieved by subsequent chemotherapy.
- In cats with lymphoblastic lymphoma, weight loss during the first month of treatment appears to be associated with significantly shorter survival time.



Tip Box

Lymphosarcomas may be of B cell or T cell, but to date feline studies have not been able to attribute any prognostic significance to the cell type. This is in contrast to the situation in canine lymphosarcoma where T cell tumours generally have a less favourable prognosis than B cell tumours.

In the past FeLV positive cats appeared to have a less favourable prognosis than those that were FeLV negative, but some recent studies have not shown any difference in survival time. Similarly, clinical staging of the tumour has not been shown to have a significant bearing on the prognosis.

Q 4. *What common adverse effects of treatment should be discussed with the owner prior to starting chemotherapy?*

- Gastrointestinal side effects: nausea and inappetence are common in the days following dosing with a cytotoxic drug. Concurrent treatment with maropitant may help to palliate this.

- Bone marrow suppression: all cytotoxic agents have the potential to cause varying degrees of myelosuppression. Regular monitoring of white cell counts is essential. If the neutrophil count falls below $1.5 \times 10^9/L$, treatment should be ceased until the cell count has recovered, and thereafter the dosing interval should be extended to prevent recurrence of neutropenia.
- Alopecia: hair growth at sites that have been clipped will be slow or absent. Most cats will lose their whiskers while on COP or other multidrug protocols (Figure 5.8); the coat over the rest of the body is also often affected by loss of the coarser longer hairs, leaving a shorter softer coat.

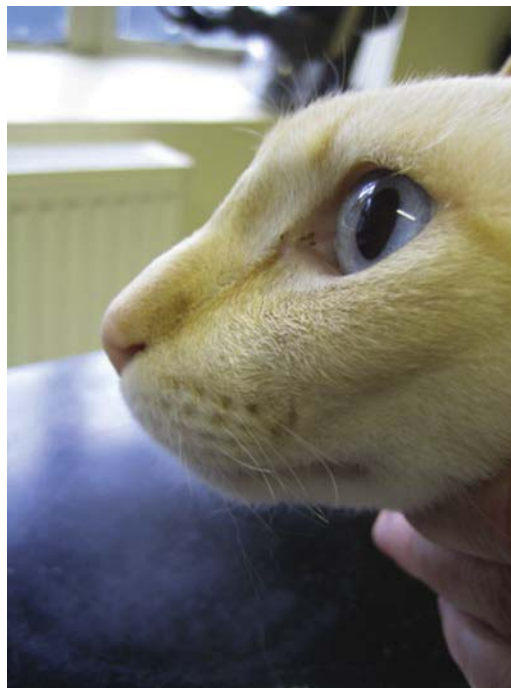

Figure 5.8. Loss of whiskers is a common adverse effect of cytotoxic drug treatment.

Other side effects are rare and are specific to individual drugs. For example, vincristine can cause a peripheral neuropathy; cumulative doses of doxorubicin can become nephrotoxic; cyclophosphamide may cause sterile cystitis, although this is much less common in cats than in dogs.

Treatment and Outcome

The prognosis for a cat with renal lymphosarcoma is guarded, but in this case the disease was identified prior to the onset of renal failure and the cat remained well.

The cat was treated with a combination of vincristine, cyclophosphamide, and prednisolone using a weekly cycle of treatment for the first 6 weeks. He tolerated treatment

well with minimal loss of appetite and no leucopenia, but he did lose most of his whiskers (Figure 5.8). He remained active and regained some of the weight he had lost and his kidneys became palpably smaller. Renal ultrasound after 6 weeks of treatment indicated significant reduction in the amount of neoplastic tissue (maximum depth now 0.18 cm).

Treatment was continued at a slightly reduced intensity, using a 2-weekly cycle of treatment with the same drugs. The cat remained well with no evidence of renal failure or bone marrow suppression. Renal ultrasonography after a further 3 months revealed no visible abnormal tissue and the frequency of treatment was reduced to a 4-weekly cycle for a further 2 months before treatment was stopped.

Re-evaluation 3 months after ceasing treatment revealed no ultrasonographic evidence of tumour recurrence and the cat remains well at the time of writing, 11 months after initial diagnosis.

This case is unusual in that the renal lymphosarcoma was fortuitously diagnosed early in its course, prior to the onset of renal failure; no doubt this has been a significant factor in this cat's good medium-term survival.

Further Reading

- Henry, C.J., Turnquist, S.E., Smith, A., et al., 1999. Primary renal tumours in cats: 19 cases (1992–1998). *Journal of Feline Medicine and Surgery* 1, 165–170.
- Krick, E.L., Moore, R.H., Cohen, R.B., Sorenmo, K.U., 2011. Prognostic significance of weight changes during treatment of feline lymphoma. *Journal of Feline Medicine and Surgery* 13 (12), 976–983.
- Simon, D., Eberle, N., Laacke-Singer, L., Nolte, I., 2008. Combination chemotherapy in feline lymphoma: treatment outcome, tolerability, and duration in 23 cats. *Journal of Veterinary Internal Medicine* 22 (2), 394–400.
- Taylor, S.S., Goodfellow, M.R., Browne, W.J., et al., 2009. Feline extranodal lymphoma: response to chemotherapy and survival in 110 cats. *Journal of Small Animal Practice* 50 (11), 584–592.

Case 5.4

Signalment and Clinical History

A 1-year-old MN Ragdoll cat was presented with an 11-month history of intermittent haematuria. Episodes of haematuria lasted 2–3 days and resolved without treatment. No dysuria was noted. The cat was otherwise well, and vaccination, worming, and ectoparasite control were current.

Clinical Examination

Physical examination was unremarkable, including palpation of both kidneys and the urinary bladder and examination of the penis.

Q 1. What are the key differential diagnoses for haematuria?

- Systemic disease
 - Coagulopathy: primary or secondary haemostasis

➤ Local disease

- Kidneys
 - Nephro-ureterolithiasis
 - Trauma
 - Neoplasia
 - Acute pyelonephritis
 - Glomerulopathy
 - PKD
 - Infarction
 - Vascular anomalies
 - Idiopathic renal haematuria
- Lower urinary tract
 - Feline idiopathic cystitis
 - Cystic calculi
 - Bacterial cystitis
 - Trauma
 - Transitional cell carcinoma
 - Polyps or diverticuli
- Genital tract
 - Prostatic abscess, prostatitis, prostatic neoplasia
 - Penile inflammation, trauma, neoplasia
 - Vaginal inflammation, trauma, neoplasia

In this case, given the cat's age, and the intermittent and self-resolving nature, feline idiopathic cystitis was considered likely, but other causes such as urolithiasis or bacterial urinary tract infection are not excluded.

Q 2. Which diagnostic test might be useful as an initial, relatively non-invasive way of localizing the origin of the haematuria?

Collecting a free-catch urine sample followed by collection of a cystocentesis sample (Table 5.2).

Table 5.2 Urinalysis Results for both Cystocentesis (Clinic) and Free-catch Samples (Home)

	Free-catch Sample	Cystocentesis Sample
Appearance	Gross haematuria	Gross haematuria
pH	6.5	6.0
SG	>1.055	>1.055
Dipstick results	Positive for blood and protein (+++)	Positive for blood and protein (+++)
Sediment examination	Numerous red cells and occasional white cells	Numerous red cells and occasional white cells

SG, specific gravity.

If red blood cells are present only in the free-catch sample but not in the cystocentesis sample, it indicates bleeding distal to the urinary bladder, i.e. urethra or genital tract. If both samples contain blood, a distinction cannot be made.

Urinalysis Results

Q 3. Which further diagnostic tests could you perform in this case?

- Urine culture, although bacterial infection is unlikely in highly concentrated urine
- Biochemistry (to assess renal parameters) and haematology (to look for anaemia and assess platelet count) as well as a coagulation profile (APTT (activated partial thromboplastin time)/PT (prothrombin time))
- Imaging studies of the urogenital tract including plain radiography, negative and/or positive contrast cystography, double contrast cystography and/or retrograde positive contrast, and excretory urography and ultrasonography. Antegrade pyelography and CT are less commonly indicated
- Cystoscopy (for female cats weighing at least 3 kg) can be considered dependent on other results

Diagnostic Test Results

- Haematology and serum biochemistry were unremarkable
- Urine bacterial culture was negative
- Ultrasonography of the urogenital tract revealed three small (0.15–0.22 cm diameter) ureteroliths located in the proximal portion of the left ureter (Figure 5.9). The right ureter contained two ureteroliths (0.15 and 0.14 cm

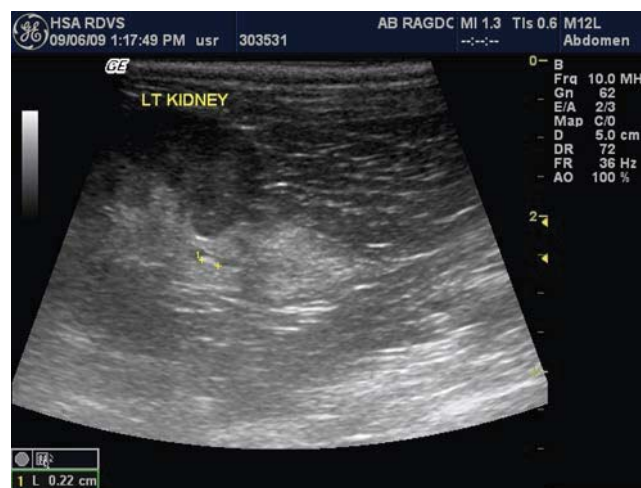

Figure 5.9. Ultrasound image showing the largest of the three calculi located within the proximal portion of the left ureter. Courtesy of the University of Edinburgh.

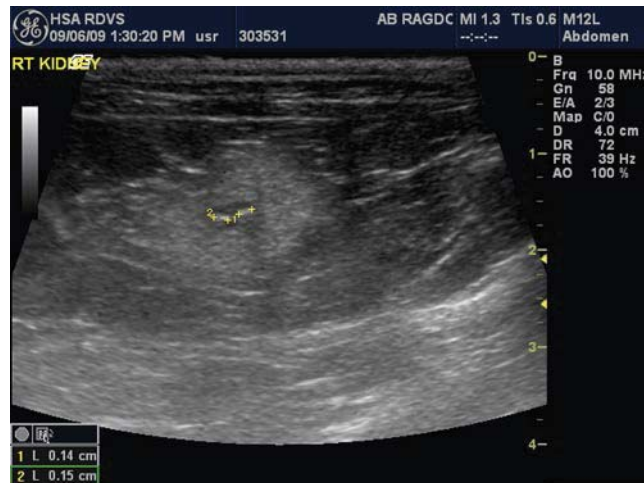


Figure 5.10. Ultrasound image showing both calculi located within the right ureter. Courtesy of the University of Edinburgh.

diameter) (Figure 5.10), and a cystolith (0.1 cm diameter) was also present. Neither the ureters nor the renal pelvises were dilated, and both kidneys were of normal shape, size, and echogenicity.

The ultrasound findings of urolithiasis explained the cat's clinical signs. Given the cat's general good health and the lack of ultrasonographic evidence of ureteral obstruction (i.e. ureteral dilation, renal pelvis dilation) no further investigations were performed.

Q 4. What information may suggest what types of uroliths are most likely, and what further investigations may provide more information?

Ragdoll cats are predisposed to both calcium oxalate and struvite urolithiasis. The vast majority of stones located in the upper urinary tract of cats (i.e. renoliths and ureteroliths) are composed of calcium oxalate. Calcium oxalate uroliths form in acidic urine, as found in this case.

Further tests helpful in distinguishing stone type include:

- Plain radiography: calcium oxalate stones are typically very radiodense
- Repeat urinalysis in case crystalluria was intermittent (note crystals present may not always be consistent with stone type)

Q 5. What are the treatment options for this case?

1. Medical management. Assuming the uroliths are calcium oxalate, there are no protocols for medical dissolution. The goal of medical management is to promote the passage of the ureteroliths to the bladder. This may be achieved by increasing urine output through administration of intravenous fluids with or without concurrent administration of diuretics. Smooth muscle relaxants and

analgesics should be used to reduce ureteral spasm. A number of other drugs, which may augment the movement of ureteroliths, such as anti-inflammatory agents (corticosteroids or non-steroidal anti-inflammatory drugs (NSAIDs)), glucagon, and amitriptyline, have been used, but further studies are needed to establish efficacy. It is crucial to monitor renal parameters and hydration status carefully during conservative management.

2. Dietary modification. This is used in an attempt to prevent recurrence of calcium oxalate uroliths or limit the growth of existing stones. Water intake should be increased to reduce urine specific gravity (SG) and urine supersaturation for calculogenic minerals. There are also several commercially available prescription diets marketed for the prevention of calcium oxalate stones.
3. Surgical management. Ureteral surgery is associated with significant post-operative complications (approximately 25–30% of patients) and mortality rates of up to 18–39% so should only be performed by an experienced surgeon.
4. Minimally invasive procedures. Minimally invasive alternatives such as extracorporeal shock wave lithotripsy, laser lithotripsy, and ureteral stents or subcutaneous ureteral bypass systems are becoming increasingly more available.



Tip Box

Approximately 20–30% of patients with ureteral obstruction experience spontaneous resolution of the obstruction with medical management. Depending on whether the uroliths continue to cause a problem once in the urinary bladder, they may or may not be removed by cystotomy, or, if small in size (<3–5 mm in female, <1 mm in male cat), by voiding urohydropropulsion. Cystoscopic retrieval is also possible in females for stones smaller than 5 mm.

Given the invasive nature of surgical removal and the possible associated complications, partially obstructing ureteroliths are often left in place and monitored carefully if medical management fails. However, if the stones cause clinical signs, such as haematuria in this case, ideally they should be removed.

Discussion

Ureterolithiasis has been diagnosed increasingly frequently in cats in the last 10–15 years and is regarded as an important cause of acute and chronic kidney disease. Therefore, cats presenting with haematuria and/or azotaemia (especially in the absence of lower urinary tract signs) should be evaluated for the presence of upper urinary tract calculi. Combining radiography and ultrasonography achieves a sensitivity of 90% in detection of ureteroliths.

Further Reading

Horowitz, C., Berent, A., Weisse, C., et al., 2013. Predictors of outcome for cats with ureteral obstructions after interventional management using ureteral stents or a subcutaneous ureteral bypass device. *Journal of Feline Medicine and Surgery* 15 (12), 1052–1062.

Case 5.5

Signalment and History

A 3-year-old MN Persian cat was presented with a 2-day history of haematuria, stranguria, and pollakiuria and inappropriate urination. A similar episode occurred 3 months ago. The cat was kept exclusively indoors, fed a dry commercial diet, and lived with three other unrelated cats. Vaccination and parasite control were current.

Physical Examination

The cat was in slightly excessive body condition (BCS 3.5/5). Abdominal palpation demonstrated a small bladder. No other abnormalities were noted. A cystocentesis urine sample was obtained (Figure 5.11).




Figure 5.11. A urine sample can provide useful further information and is vital in the investigation of FLUTD.

Urine Sample Results

A cystocentesis sample revealed moderate amounts of red and white blood cells and the SG was >1.050 . Scant crystals were noted.

Q 1. What type of crystals are these and what is the significance in this case?

Struvite crystals: crystalluria is a normal finding in feline urine due to supersaturation, and given the urine SG and dry diet of this cat scant struvite crystals would not be a cause for concern. Specific treatment is not required unless a urolith is present, or a urethral plug with crystalline material within it.



Tip Box

Sample handling dramatically influences crystal precipitation; urine should be examined within 2 h and ideally 30 min of collection and at room temperature. Samples stored for longer (or sent in the post/refrigerated) are likely to show artifactual crystalluria.

- Q** 2. List the causes of feline lower urinary tract disease (FLUTD) in order from most to least common.

Feline idiopathic cystitis (FIC) is the most common cause (around 60% of cases) followed by urolithiasis and urethral plugs. Despite the common use of antimicrobial agents in the treatment of FLUTD, bacterial infection makes up only a very small proportion of cases (around 2%). Urinary tract neoplasia and anatomic defects are also very uncommon.



Tip Box

Bacterial UTI is an uncommon cause of FLUTD in cats, due to the cat's intrinsic resistance to infection (high urine SG, long urethra, high urine osmolality, low urine pH), and therefore antibiotics are overused in the treatment of FLUTD. Certain patient groups are more likely to be affected (cats with lower urine SG due to concurrent disease, older cats, cats post urethral surgery or urethral catheterization), and urine bacterial culture is indicated in these cases. The majority of cats with FLUTD will have FIC, and antibiotic treatment is therefore not indicated unless a bacterial culture is positive.

- Q** 3. Considering the cat's age and urinalysis results, FIC is likely in this case. Assuming this is the diagnosis, what treatment options are available?

The management of FIC should be 'multimodel' and encompass medical, dietary, and behavioural aspects to prevent recurrence and include:

1. Increasing water intake: to reduce urine SG (change to a wet diet and other techniques to increase drinking, e.g. water fountain, adding water to food)
2. Provide appropriate litter facilities: substrate favoured by cat at adequate depth, adequate number (one per cat plus one), tray type preferred by cat (open, closed), regular cleaning, private, quiet location
3. Stress reduction (see Q6)
4. Medical treatment
 - a. FIC is a self-limiting condition, so the effect of medication is often over-interpreted
 - b. Analgesics and anti-inflammatory drugs reduce the discomfort associated with FIC and can reduce the urethral spasm that contributes to urethral obstruction in some cases
 - c. Several drugs have been shown to be of no benefit, including prednisolone, pentosan polysulphate, glucosamine, amitriptyline, and synthetic pheromones



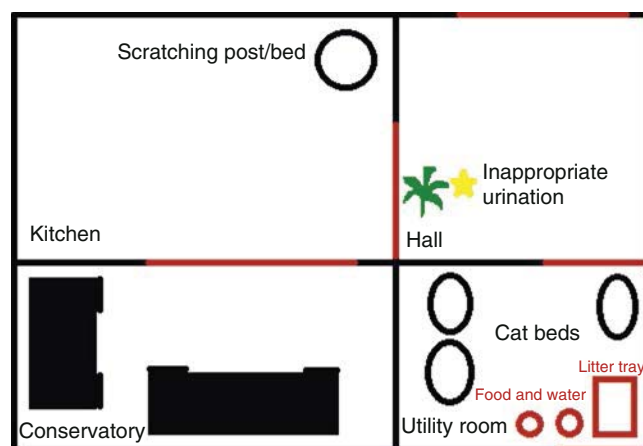
Tip Box

Amitriptyline may be useful in severe, recurrent cases (with other management), and in studies individual cats have benefited from glucosamine and pentosan but the difference was not significant.

- Q** 4. Stress is thought to play a role in the development of FIC. What questions should you ask the owner about the cat's lifestyle to investigate further?

- Further information regarding the cat's background: how long has the owner had the cat, i.e. from a kitten? Was the cat from a breeder or rescue?

- 



*
*
*
*
*
*
*
*
*
*
*
*

•
•
•
•
•
•
•
•
•
•
•
•
•



Tip Box

Multimodel environmental modification (MEMO): important management technique for FLUTD.

A large scale study of FIC used a multimodel approach of owner education, stress management, and environmental modification to treat cats with recurrent FIC and noted a good response with over 75% of cats having no return of urinary signs. See Further Reading: Buffington et al. (2006).

A large scale study of FIC used a multimodel approach of owner education, stress management, and environmental modification to treat cats with recurrent FIC and noted a good response with over 75% of cats having no return of urinary signs. See Further Reading: Buffington et al. (2006).

Box 5.1 Specific Treatment Plan

- Initially provide analgesia using a NSAID (following routine biochemical analysis, in this case to exclude renal disease as the cat's PKD status was unknown).
- Alter the cat's diet to a wet diet and increase water intake using a water fountain and placing water sources in other locations frequented by the cat (e.g. upstairs) and away from food.
- Provide additional litter trays including one in another room, perhaps in the conservatory (the hall and kitchen being busy traffic areas).
- Clean the trays daily (instead of a 'deep litter' system).
- Make use of three-dimensional space and provide beds on the windowsill in the conservatory where the affected cat was seen to sit and watch the birds. Provide 'passing places' around small passing areas such as the door to the utility room to allow the nervous cat to pass without conflict, e.g. a shelf above the ground.
- Provide additional food and water resources away from the litter trays and in two locations. The affected cat liked to spend times upstairs so a feeding station was put on the first floor.
- An additional scratching post and bed could be placed in the conservatory again to prevent blocking/guarding by other cats.
- Environmental enrichment was recommended for the benefit of all the cats as they were kept exclusively indoors. Examples include playing with the cats, providing more toys, more hiding places on elevated surfaces, and consideration to outdoor access by installing a pen or cat fencing to prevent escape. Note that exposure to strange cats in the local area may increase stress.
- Desensitization and counter-conditioning to reduce fear of household noises, e.g. gradual exposure and reward.

Q 5. *What initial advice will you give the owner to try and reduce the cat's stress?*

The owner needs to provide the cat with easy access to all resources. See [Box 5.1](#) for specific recommendations in this case.

Outcome: the owner made recommended changes, including allowing limited outdoor access. The cat only suffered one further episode of FIC when housed in a boarding cattery.

Discussion

FIC is commonly encountered in first opinion practice. Current research supports the hypothesis that FIC occurs when a 'susceptible cat is placed in a provocative environment', i.e. genetic predisposition to stress, early life experiences, and stressful living environment act together to cause FIC. The cat in this case was not well socialized as a kitten and not part of the other resident cats' social group. Resource access was limited for the cat and stress combined with highly concentrated urine may have resulted in FIC. Management must therefore address all aspects including behavioural modification.

Further Reading

- Buffington, C.A., Westropp, J.L., Chew, D.J., et al., 2006. Clinical evaluation of multimodal environmental modification (MEMO) in the management of cats with idiopathic cystitis. *Journal of Feline Medicine and Surgery* 8, 261.
- Ellis, S.L.H., Rodan, I., Carney, H.C., et al., 2013. AAFP and ISFM Feline environmental needs guidelines. *Journal of Feline Medicine and Surgery* 15, 219.

Case 5.6

Signalment and History

A 19-year-old FN DSH cat presented with a history of gradual weight loss, reduced appetite over the last year, and recent polyuria/polydipsia. The cat had started vocalizing overnight and was less willing to interact with the owners. The cat was kept indoors, fed a commercial dry diet, and vaccination/parasite control was current.

Physical Examination

The cat was in reduced body condition (BCS 2/5) with a poor haircoat. Abdominal palpation revealed small, firm, non-painful kidneys.

Investigations

- Blood samples: biochemistry (see below Table 5.3). Haematology unremarkable.
- Urinalysis: see Table 5.4

Table 5.3 Biochemistry and Electrolyte Results at Presentation

	Patient Result	Reference Interval
Sodium (mmol/L)	156.0	145.0–157.0
Potassium (mmol/L)	3.1	3.5–5.5
Chloride (mmol/L)	114.0	100.0–124.0
Na:K	47.5	28.0–40.0
Urea (mmol/L)	22.2	2.5–9.9
Creatinine (μmol/L)	306.2	20.0–177.0
Glucose (mmol/L)	6.8	3.4–5.3
Total protein (g/L)	74.5	60.0–80.0
Albumin (g/L)	33.6	25.0–45.0
Globulin (g/L)	40.9	25.0–45.0
Albumin:globulin	0.82	0.60–1.50
Calcium (mmol/L)	2.48	2.00–2.50
Phosphate (mmol/L)	1.2	0.9–1.45
ALT (IU/L)	62	5–60
ALP (IU/L)	45.9	<60.0
Total bilirubin (μmol/L)	0.5	0.1–5.1
Cholesterol (mmol/L)	4.0	2.2–4.0

Bold type indicates an abnormal result.

ALT, alanine aminotransferase; ALP, alkaline phosphatase.

Table 5.4 Urinalysis Results at Original Presentation (Cystocentesis Sample)

Test	Result
Specific gravity	1.016
Glucose	Negative
Ketones	Negative
Blood	Negative
Protein	Trace
pH	6.0
Bilirubin	Negative
Sediment examination	Unremarkable

- Q** 1. *The results are consistent with chronic kidney disease (CKD). What stage is the disease (according to the International Renal Interest Society (IRIS) staging system), and what further tests would you perform to complete the substaging process?*

The IRIS staging system is initially based on serum creatinine (ideally on a starved sample in a hydrated patient). This cat is stage 3. Sub-staging should be performed by measuring systolic blood pressure (BP) and urine protein:creatinine ratio (UPC).

Investigations

- Systolic BP was recorded (indirect Doppler method) at 215 mmHg repeatedly.
- Retinal examination revealed several small areas of bullous retinal detachment in both eyes.



Tip Box

Around 20% of cats with CKD will be hypertensive, so cats with CKD should have systolic blood pressure measured regularly.

- UPC was normal at 0.16 (reference interval <0.2).
- This cat is therefore in IRIS stage 3 CKD, sub-stage non-proteinuric, hypertensive with evidence of end-organ complications (retinal detachment).

- Q** 2. *Describe any further investigations you could perform and your approach to management of this case. Justify your treatment choices.*

Further investigations

Although CKD is usually the result of interstitial nephritis, other causes of CKD should be excluded such as pyelonephritis, hypercalcaemia, and urolithiasis with urine bacterial culture, full biochemistry, and imaging, respectively. In the majority of cases extensive diagnostics are not required as the signalment, clinical signs, and biochemical (including urinalysis) results are consistent with CKD as in this case.

**Tip Box**

Urine bacterial culture is recommended in all cats with CKD, at diagnosis and during monitoring of the condition as pyelonephritis can cause CKD, but also cats with CKD are more likely to develop a urinary tract infection, which can be occult. The majority of cases will have an active sediment (87% in a recent study – see Further Reading) meaning sediment examination can be used as a screening test in cases of limited finance.

Geriatric cats with CKD often have comorbid disease such as hyperthyroidism, diabetes mellitus, osteoarthritis, and dental disease, and failure to manage these conditions may reduce the effectiveness of strategies to manage CKD. Therefore, additional investigations may depend on thorough clinical examination and biochemical results and include measurement of total thyroxine (T₄), fructosamine, or echocardiography, for example.

Management of stage 3 CKD

- Dietary management: a reduced phosphate diet has been shown to prolong life expectancy in cats with CKD and is appropriate for IRIS stage 2 and upwards. The diet should be introduced gradually and during a period of reasonable appetite.
- Management of hypokalaemia: the cat is hypokalaemic and this may reduce appetite and cause weakness. Supplementation should be started with potassium gluconate orally at 2–6 mEq SID in divided doses.
- Management of hypertension: calcium channel blockers are the treatment of choice in feline hypertension. The retinal changes are consistent with end-organ damage due to hypertension, meaning treatment should be started immediately with amlodipine at 0.625 mg SID and systolic BP rechecked after 7 days.
- Management of inappetence: an appetite stimulant could be used such as mirtazapine (which also has an anti-emetic effect). The dose should be reduced to 3.75 mg per cat q 72 h as the cat is in higher stage CKD. Alternative treatments could include antacids such as H₂ blockers or omeprazole.
- Maintenance of hydration: increasing water intake at home should be encouraged with a wet diet, multiple available water sources, and if necessary subcutaneous fluids can be administered in the home environment by motivated owners. Dehydration may reduce the cat's appetite and quality of life and if severe may progress to hypovolaemia and contribute to acute kidney injury.

Further Information

Urine bacterial culture was negative at diagnosis and the cat improved clinically on treatment, readily accepting the renal diet, gaining a small amount of weight, and systolic BP reducing to 150 mmHg.

Re-examination Six Months Post Diagnosis

The cat's weight was stable and appetite remained normal (eating renal diet exclusively). The owner reported a reluctance to jump onto higher surfaces and hesitation when using stairs. Systolic BP remained at 150 mmHg. Biochemistry showed no significant change in urea or creatinine, but serum phosphate had increased to 1.60 mmol/L.

(RI: 0.9–1.45) and urinalysis showed the UPC was elevated at 0.45; sediment was inactive so bacterial culture was not submitted.

Q 3. *What, if any, changes would you make to the treatment regime and why?*

The cat is now hyperphosphataemic and proteinuric (IRIS sub-stage proteinuric). Hyperphosphataemia results in hyperparathyroidism and likely progression of renal disease. The phosphate-restricted diet is no longer controlling phosphate in this case, so addition of a phosphate binder (e.g. chitosan/calcium carbonate, lanthanum carbonate) is indicated.

Ideally urine bacterial culture would be performed in proteinuric cats to exclude UTI as a cause of post-renal proteinuria, but the inactive sediment makes this unlikely (although not impossible). Reassessment of UPC to confirm persistence of proteinuria is desirable. If persistently proteinuric (UPC >0.4), then treatment with an angiotensin-converting enzyme (ACE) inhibitor or angiotensin receptor blocker (ARB) should be commenced.

The mobility issues reported likely indicate osteoarthritis, a common comorbidity in geriatric cats. Treatment may include analgesia and management changes (e.g. resources placed on lower levels). Ideally, radiography would be performed but is rarely necessary, and response to treatment often used to confirm diagnosis.



Tip Box

- o CKD and osteoarthritis are common comorbidities
- o NSAIDs have previously been contraindicated in CKD; however, recent research on meloxicam use in cats with CKD has not shown a detectable detrimental effect on renal function
- o Hydration must be maintained and the lowest dose to control clinical signs used
- o Owner consent must be obtained if using off-licence

Outcome

Treatment was altered as described and meloxicam administered at 0.01 mg/kg PO SID to good effect. The UPC reduced to 0.2 on treatment with an ARB. The cat remained stable for a further 6 months and then it was euthanized following an acute clinical deterioration.

Discussion

With appropriate management cats with CKD can achieve reasonable survival times and quality of life. Complicating conditions (e.g. hypertension, hypokalaemia, dehydration) and factors associated with progression (e.g. hyperphosphataemia, proteinuria) should be investigated and managed if indicated.

Further Reading

- Gowan, R.A., Lingard, A.E., Johnston, L., 2011. Retrospective case-control study of the effects of long-term dosing with meloxicam on renal function in aged cats with degenerative joint disease. *Journal of Feline Medicine and Surgery* 13, 752–761.
- White, J.D., Stevenson, M., Malik, R., et al., 2013. Urinary tract infections in cats with chronic kidney disease. *Journal of Feline Medicine and Surgery* 15 (6), 459–465.

Endocrinological Disorders

Case 6.1

Signalment, Clinical History, and Clinical Examination Findings

A 9-year-old MN DLH cat presented with a history of polyuria (PU), polydipsia (PD), marked polyphagia, and weight loss.

The cat was in thin body condition (body condition score (BCS) 2/5) and his coat was unkempt. A thyroid goitre was palpable on the right side of his neck, and the cat was tachycardic with a heart rate (HR) of 200 bpm. Hyperthyroidism was therefore suspected.

Q 1. What initial investigations would you consider performing?

- Total thyroxine (T4): to confirm/exclude hyperthyroidism
- Haematology and biochemistry: to evaluate for other systemic diseases that could be contributing to the clinical signs (e.g. diabetes mellitus and chronic kidney disease (CKD)) and to obtain baseline values prior to treatment
- Blood pressure (BP): to assess for hypertension, which commonly occurs in older cats and often secondarily to hyperthyroidism
- Urinalysis: in particular to assess urine specific gravity (USG), glucose, and urine protein

Diagnostic Test Results

- Haematology and biochemistry were unremarkable (Table 6.1) apart from a persistent hypokalaemia (2.3–2.9 mmol/L, reference interval (RI) 3.5–5.9)
- Serum total T4 concentration was high at 60 nmol/L
- Systolic BP (Doppler) was 200 mmHg on several readings
- Urinalysis, including culture and sensitivity, was within normal limits. USG was 1.034 (the mild dilution suspected due to the polydipsia)

Table 6.1 Haematology and Biochemistry

PCV %	K ⁺ mmol/L (3.5–5.8)	Urea mmol/L (5.7–12.8)	Crea μmol/L (71–212)	T4 nmol/L (15–40)	USG	UPC <0.2	BP mmHg
44	2.3	6.7	142	60	1.034	0.21	200

Bold type denotes abnormal result.

Q 2. Formulate a list of differential diagnoses for hypokalaemia.

- Reduced intake
 - Anorexia
 - Intravenous fluids (IVF) with inadequate potassium supplementation
- Increased loss
 - Gastrointestinal (vomiting, diarrhoea)
 - Urinary
 - Renal disease
 - Diuresis (diuretic administration, diabetes mellitus, post-obstructive diuresis)
 - Primary hyperaldosteronism
- Intracellular translocation
 - Hyperthyroidism
 - Metabolic alkalosis
 - Insulin therapy
 - Burmese hypokalaemic polymyopathy



Tip Box

Hypertension is a relatively common finding in cats over the age of 8 years and is easily diagnosed with the use of a Doppler BP monitor. Fundic examination can also be helpful in demonstrating hypertensive retinopathy, suggested by the presence of retinal oedema/bullae, retinal haemorrhage, and/or retinal detachment.

Q 3. What are the most common causes of hypertension in cats?

- Chronic kidney disease
- Hyperthyroidism
- Hyperaldosteronism
- Chronic anaemia
- Other possible but not proven causes: obesity, diabetes mellitus, hyperadrenocorticism, idiopathic hypertension

Q 4. Considering that this cat is both hypokalaemic and hypertensive, what are the most likely differential diagnoses, and what investigations would confirm a diagnosis?

- Primary hyperaldosteronism: would be confirmed by demonstrating an elevated plasma aldosterone concentration. Abdominal ultrasound would confirm whether an adrenal mass was present.
- Hyperthyroidism: already confirmed but concurrent disorders are common in older cats and concurrent hyperaldosteronism may often be missed if not investigated.
- CKD: International Renal Interest Society (IRIS) stage 1 kidney disease cannot be excluded as a cause of the hypertension, but, as above, hyperaldosteronism may often be missed if hypokalaemia/hypertension are assumed to be secondary to renal disease.

Further Case Information

- Plasma aldosterone concentration was 3179 pmol/L (RI: 195–390), confirming hyperaldosteronism
 - Ultrasound demonstrated a large left adrenal mass (Figure 6.1), consistent with primary hyperaldosteronism; the right adrenal was normal (Figure 6.2)
- Diagnosis: primary hyperaldosteronism due to an adrenal tumour with concurrent hyperthyroidism

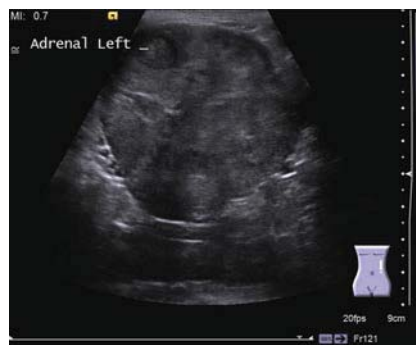

Figure 6.1. Ultrasound image of left adrenal mass.

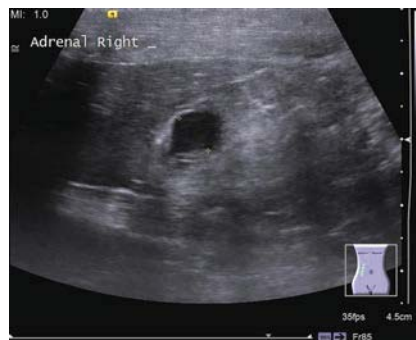

Figure 6.2. Ultrasound image of right adrenal gland (normal).

Q 5. *What are the treatment options for this cat?*

Hyperthyroidism can be treated with radioactive iodine therapy, surgical thyroidectomy, antithyroidal medication or diet.

Primary hyperaldosteronism can be treated medically with oral potassium gluconate supplementation, spironolactone (a potassium-sparing diuretic that acts as an aldosterone antagonist), and amlodipine besylate to treat the hypertension. Primary hyperaldosteronism due to an adrenal tumour can be managed by surgical adrenalectomy.

Further Case Information

This cat was treated with 4 mEq potassium gluconate, 10 mg spironolactone, 1.25 mg amlodipine besylate, and 10 mg carbimazole SID.

On re-examination a month later the PD had resolved and there was no further weight loss or clinical signs of hyperthyroidism. The total T4 concentration had reduced to 18 nmol/L (RI: 15–40) and the potassium concentration was now normal. Systolic BP was within normal limits at 150 mmHg.

Nine months later the cat re-presented with recurrence of weight loss, polyphagia, and PU/PD. On clinical examination the coat was unkempt and the cat was tachycardic (200 bpm) with a grade 3/6 systolic heart murmur. Systolic BP was still within normal limits at 160 mmHg. Hypokalaemia had recurred: serum potassium concentration was 2.2 mmol/L (RI: 3.5–5.8) and total T4 concentration was mildly elevated (42.1 nmol/L; RI: 15–40).

The cat was now refusing to take any medication in food and so alternative treatment options for the hyperthyroidism were considered. Radioactive iodine would be contraindicated in this case, in the United Kingdom, due to the prolonged hospitalization time in isolation that is required, making ongoing treatment and monitoring of the hyperaldosteronism problematic.

Surgical thyroidectomy was therefore chosen. Sadly, the cat suffered a cardiac arrest on induction of anaesthesia and was unable to be resuscitated. A postmortem was not carried out and so cause of death was undetermined.

Discussion

Primary hyperaldosteronism may be caused by an aldosterone-secreting neoplasm (adenoma or carcinoma) of the adrenal gland, or less commonly by bilateral adrenal hyperplasia. Once considered a rare disease, it is now becoming more commonly recognized. Surgical adrenalectomy is a potentially curative treatment but has been associated with a high risk of fatal haemorrhage.

The case demonstrates the importance of measuring blood pressure in older cats and being aware of the possibility of comorbid diseases in this patient group, which may influence diagnosis, treatment, and prognosis.

Further Reading

- Ash, R.A., Harvey, A.M., Tasker, S., 2005. Primary hyperaldosteronism in the cat: a series of 13 cases. *Journal of Feline Medicine and Surgery* 7 (3), 173–182.
- Schulman, R.L., 2010. Feline primary hyperaldosteronism. *Veterinary Clinics of North America: Small Animal Practice* 40 (2), 353–359.

Case 6.2**Signalment and History**

A 13-year-old FN DSH cat presented with a 7-month history of weight gain (2 kg), PU/PD, and severe polyphagia. The patient was indoor/outdoor and fed a commercial diet. Vaccination, flea, and worming were current.

Clinical Examination

The patient was bright, alert, and responsive, overweight (BCS 4/5) with a pot-bellied appearance and unkempt, greasy haircoat that had not regrown at previously clipped sites (Figure 6.3). No other abnormalities were detected. The patient was normothermic. Respiratory rate (RR), HR, and pulse quality were normal.

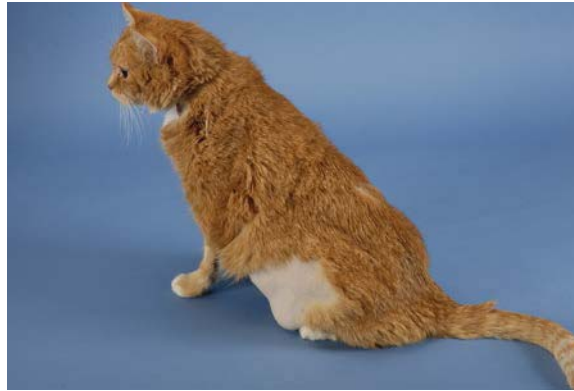

Figure 6.3. Case 6.2 presenting with pot-bellied appearance, unkempt and greasy haircoat.

Q 1. *Formulate a problem list.*

- PU/PD
- Polyphagia
- Weight gain
- Pot-bellied appearance
- Lack of hair regrowth
- Unkempt greasy coat

Q 2. *Taking all the problems into consideration, what differential diagnoses would you consider most likely?*

- Collectively, the clinical signs are most suggestive of hyperadrenocorticism.
- Acromegaly, diabetes mellitus and neoplasia (with paraneoplastic dermatological changes) are also possible differentials.
- Obesity with concurrent renal, hepatic, endocrine, or dermatological disease cannot be excluded.

Q 3. How would you investigate this case?

- Haematology, biochemistry, and urinalysis should be assessed to exclude electrolyte disturbances, renal/hepatic disease, DM, urinary tract infection (UTI), and evaluate USG.
- Total T4 should be assessed to exclude hyperthyroidism.
- Abdominal ultrasound should be performed to evaluate the adrenal glands, liver, pancreas and kidneys in particular.
- Dependent on these results an ACTH stimulation test may be performed to evaluate for hyperadrenocorticism.

Laboratory Results (Tables 6.2–6.5)

Abdominal ultrasonography revealed mild hepatomegaly and a left adrenal mass (13 mm diameter). No other abnormalities were detected (Figure 6.4).

Table 6.2 Haematology Results at Presentation

Parameter	Patient Result	Reference Interval
Haemoglobin (g/dL)	14.30	8.00–15.00
HCT (%)	41.30	25.00–45.00
RBC ($\times 10^{12}/L$)	8.30	5.50–10.00
MCV (fL)	49.80	40.0–55.0
MCH (pg)	17.00	12.5–17.0
MCHC (g/dL)	34.60	30.0–35.0
Platelets ($\times 10^9/L$)	54.00	200.0–700.0
WBC ($\times 10^9/L$)	14.90	4.90–19.0
Neutrophils ($\times 10^9/L$)	12.52	2.40–12.5
Lymphocytes ($\times 10^9/L$)	1.34	1.40–6.00
Monocytes ($\times 10^9/L$)	0.89	0.10–0.70
Eosinophils ($\times 10^9/L$)	0.15	0.10–1.60
Basophils ($\times 10^9/L$)	0.00	0.00–0.10

Smear examination: platelets appear clumped on film. Platelet count may be falsely low, platelets plentiful. Bold type denotes abnormal result.

HCT, haematocrit; MCH, mean corpuscular haemoglobin; MCHC, mean corpuscular haemoglobin concentration; MCV, mean corpuscular volume; RBC, red blood cells; WBC, white blood cells.

Table 6.3 Biochemistry Results at Presentation

Parameter	Patient Result	Reference Interval
Urea (mmol/L)	10.30	6.5–10.5
Creatinine ($\mu\text{mol/L}$)	156.00	133.0–175.0

Continued

Table 6.3 Biochemistry Results at Presentation—cont'd

Parameter	Patient Result	Reference Interval
Total protein (g/L)	73.70	77.0–91.0
Albumin (g/L)	29.20	24.0–35.0
Globulin (g/L)	44.50	21.0–51.0
Albumin:globulin ratio	0.66	0.4–1.3
ALT (IU/L)	154.00	15.0–45.0
ALP (IU/L)	55.00	15.0–60.0
Total bilirubin (μmol/L)	8.00	0.0–10.0
Sodium (mmol/L)	155.50	149.0–157.0
Potassium (mmol/L)	4.51	4.0–5.0
Chloride (mmol/L)	126.00	115.0–130.0
Calcium (mmol/L)	2.50	2.3–2.5
Phosphate (mmol/L)	1.28	0.95–1.55
Glucose (mmol/L)	8.40	3.5–7.5
Total T4	15.20	15.00–40.00

Bold type denotes abnormal result.

ALP, alkaline phosphatase; ALT, alanine transaminase.

Table 6.4 Urinalysis Results at Presentation (Cystocentesis)

Parameter	Patient Result	Reference Interval
pH	7.1	6–7.5
Blood	Negative	N/A
Glucose	Negative	N/A
Ketones	Negative	N/A
Protein	21.6	N/A
Specific gravity	1.016	>1.035
Protein:creatinine ratio	0.35	<0.4
Creatinine	5.5	N/A
Sediment examination	Scant fat droplets and epithelia	
Urine culture	Negative	

Bold type denotes abnormal result.

Table 6.5 ACTH Stimulation Test

Parameter	Patient Result	Reference Interval
Basal cortisol (nmol/L)	54.00	25–75
Cortisol 1 h post ACTH (nmol/L)	190.00	200–400
Cortisol 3 h post ACTH (nmol/L)	194.00	200–400

Bold type denotes abnormal result.

ACTH, adrenocorticotrophic hormone.

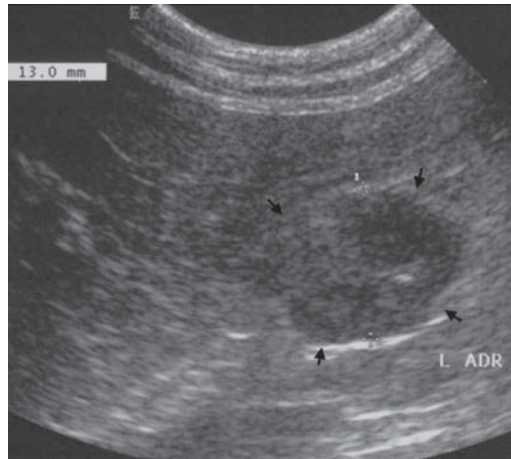


Figure 6.4. Ultrasonographic image of the left adrenal gland in long axis.

Q 4. What is your interpretation of these results?

Hyperthyroidism can be excluded as a potential cause of polyphagia. DM, hypercalcaemia and hypokalaemia can be excluded as potential causes of PU/PD. The mildly elevated alanine transaminase (ALT) could be due to metabolic (hepatic lipidosis, hyperadrenocorticism), neoplastic (lymphoma, metastatic), or degenerative (hypoxia secondary to congestion) hepatocellular injury. Mild hyperglycaemia without glycosuria is most likely due to stress.

Neutrophilia, lymphopenia, and monocytosis are most likely due to a stress leucogram or hyperadrenocorticism.

Differentials for USG 1.016 with polyuria are hyperadrenocorticism, non-azotaemic CKD (IRIS stage 1), pyelonephritis, or partial central diabetes insipidus (DI).

The ACTH stimulation test is not suggestive of hyperadrenocorticism, but it is not a very sensitive test for hyperadrenocorticism in cats.

Unilateral adrenomegaly may be a functional adrenal neoplasm (hyperadrenocorticism, hyperaldosteronism, hyperprogesteronism, or pheochromocytoma) or may be a non-functional incidentaloma. In this case clinical findings are not consistent with hyperaldosteronism or pheochromocytoma.

The presence of an adrenal mass and the clinical signs are most suggestive of a hormone secreting adrenal tumour; but further testing is required.

Q 5. How would you further investigate this case?

- Low dose dexamethasone (0.1 mg/kg IV) suppression (LDDS) test
- Systolic BP looking for evidence of hypertension which could indicate other adrenal pathology, e.g. hyperaldosteronism or pheochromocytoma.

Results are shown in Table 6.6. Systolic BP was 155 mmHg (Doppler method).

Table 6.6 Low Dose Dexamethasone Suppression Test

Parameter	Patient Result	Reference Interval
Basal cortisol (nmol/L)	124.00	0–137.9
Cortisol 4 h post dexamethasone (nmol/L)	38.00	<38.6
Cortisol 8 h post dexamethasone (nmol/L)	<11.00	<38.6

Q 6. What is your interpretation of these results, and how would you further manage the case?

The LDDST test is not supportive of hyperadrenocorticism as the serum cortisol concentration is suppressed below 38.6 nmol/L at 4 h and 8 h post dexamethasone administration. Systolic BP is normal, making an aldosterone or catecholamine secreting adrenal neoplasm less likely.

Other adrenal steroids in the adrenal steroid pathways may be produced to excess and thus cause clinical signs similar to hyperadrenocorticism without an increase in serum cortisol. Progesterone, 17-OH-progesterone, oestradiol, and testosterone could be measured to investigate for other adrenal steroid excess.

Results are shown in Table 6.7.

Table 6.7 Additional Adrenal Steroid Assays

Parameter	Patient Result	Reference Interval
Progesterone (nmol/L)	11.00	0.19–2.2
17-OH-Progesterone (nmol/L)	<1.00	<1.2
Testosterone (nmol/L)	<0.05	0.69–1.73
Oestradiol (pmol/L)	9.50	0–10
Aldosterone (pmol/L)	197.00	195.00–390.00

Bold type denotes abnormal result.

Q 7. What is your diagnosis?

Hyperprogesteronism associated with a left adrenal mass.

Q 8. Outline the options for management of this case.

Thoracic radiographs should be taken to exclude pulmonary metastasis. Adrenalectomy is the definitive treatment for functional adrenal tumours. It is unsuitable for debilitated patients and those with evidence of caudal vena cava (CVC) invasion. Medical therapy (aminogluthiamide or trilostane) has been used in poor surgical candidates or to decrease progesterone production prior to surgery, but efficacy has not been well reported.

Q 9. What are the likely complications associated with adrenalectomy?

Adrenalectomy has a high (30%) reported peri-operative mortality. Severe, acute haemorrhage from the CVC is the most common cause of death. It is advised that adrenalectomy is performed by an experienced surgeon, with involvement of an experienced anaesthetist. The patient should be blood typed and a suitable donor readily available.

As the remaining adrenal gland is usually atrophied there is a risk of hypocortisolaemia following surgery. Dexamethasone (0.2 mg/kg IV) should be administered at commencement of adrenalectomy. Prednisolone (0.2 mg/kg PO BID) should then be given for 5 days postoperatively, then on alternate days for 2 weeks. The patient should be monitored for evidence of hypoadrenocorticism (e.g. electrolyte disturbance) and an ACTH stimulation test should be performed after cessation of prednisolone.

Although potentially more of a risk in hypercortisolaemia, sepsis may occur due to the adverse effects of excess steroids on immune function. Postoperative prophylactic, broad-spectrum antibiotics (e.g. amoxicillin-clavulanate) is thus recommended.

Follow-up

Thoracic radiographs revealed no evidence of pulmonary metastasis. Adrenalectomy was performed without complications. Histopathology revealed an adrenocortical carcinoma. Clinical signs had resolved 5 months postoperatively. ACTH stimulation testing and serum progesterone were normal 4 weeks after prednisolone was discontinued.

Discussion

Defective biosynthetic pathways, enzyme deficiencies, and abnormal behaviour of neoplastic cells within the adrenal gland tumour cause excessive production and secretion of adrenal hormones. Progesterone is produced in the zona fasciculata and reticularis and is a precursor of androgens, oestrogens, and cortisol. Increased circulating progesterone simulates the actions of glucocorticoids and the clinical signs of hyperadrenocorticism via both direct binding of progesterone to cortisol binding proteins and competitive binding, which results in increased unbound, active cortisol.

As in this case, post-ACTH cortisol levels were decreased in many of the previously reported cases, thought to be due to suppression of the hypothalamic-pituitary-adrenal axis by progesterone. DM has been reported in the majority of cases of hyperprogesteronism.

Adrenalectomy has a high complication rate, but reported cats with hyperprogesteronism who survive to discharge post adrenalectomy have a good prognosis. Metastatic rate is not established.

Further Reading

- Nelson, R.N., 2004. Primary progesterone secreting adrenal tumors in cats, 3rd ed. In: Feldman, E., Nelson, R. (Eds.), *Canine and Feline Endocrinology and Reproduction*. Saunders, St Louis, Missouri, pp. 391–392.
- Refsal, K.R., Harvey, A.M., 2010. Primary hyperaldosteronism, 6th ed. In: August, R. (Ed.), *Consultations in Feline Medicine*. Saunders, St Louis, Missouri, pp. 258–259.
- Rossmeisl, J.H., Scott-Moncrieff, J.C., Siems, J., et al., 2000. Hyperadrenocorticism and hyperprogesteronemia in a cat with an adrenocortical adenocarcinoma. *Journal of the American Animal Hospital Association* 36 (6), 512–517.

Case 6.3

Signalment and History

A 7-year-old MN DSH cat presented with a history of PU, PD, marked polyphagia, and weight loss. A diagnosis of DM was made on the basis of persistent hyperglycaemia, glycosuria, and elevated serum fructosamine. Treatment with lente insulin was commenced at 0.5 IU/kg BID, but no improvement in clinical signs was noted, and despite gradual dose increases up to 2 IU/kg BID the cat remained markedly polyuric/polydipsic and persistently hyperglycaemic with a rising serum fructosamine level. A recently performed glucose curve is shown in Figure 6.5 and illustrates the effect on blood glucose of insulin administration. The cat was fed a commercial diet designed for diabetic cats, supplemented with cooked chicken. Vaccination, worming, and flea control were up to date.

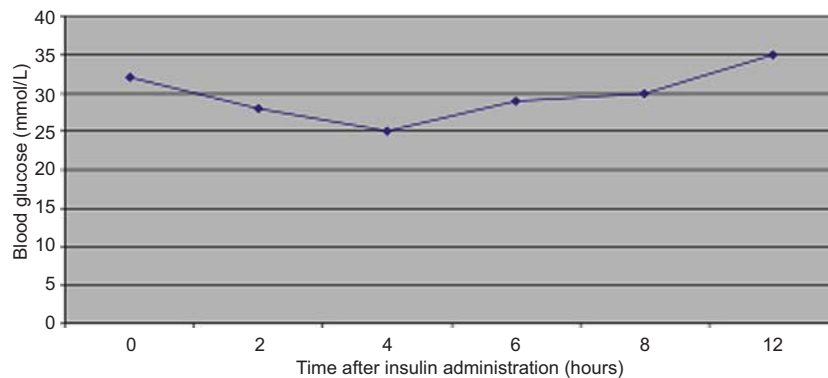


Figure 6.5. Blood glucose curve performed 1 week after the insulin dose was increased to 2 IU/kg BID.

Clinical Examination

The cat was in thin body condition (BCS 1/5) and exhibited a bilateral plantigrade stance. No other significant abnormalities were noted.

Q 1. Formulate a differential diagnosis list of causes of diabetic instability in cats.

Causes of diabetic instability include:

- Insulin factors
 - Handling: freezing, overheating, violent agitation of bottle, expired insulin
 - Choice of insulin: inappropriate duration of action
 - Dosing regimen: inappropriate dosage interval, inappropriate dose
 - Administration: poor injection technique, inaccurate dosage, incorrect syringe
- Monitoring
 - Monitoring: effects of stress, timing, using single blood glucose results, using urine glucose, Somogyi overswing

- Dose adjustment: too frequent, too large dose increases (>20%)
- Cat factors
 - Underlying disease
 - Inflammatory disease: pancreatitis, inflammatory bowel disease (IBD), respiratory disease
 - Infectious disease: viral infection, UTI, dental disease
 - Organ failure: CKD, hepatic disease, cardiac disease
 - Endocrine disease: hyperthyroidism, hyperadrenocorticism, acromegaly
- Drug treatment: corticosteroids, progestogens

Q 2. How would you further investigate this case?

Common causes of diabetic instability should be investigated, beginning by excluding insulin factors by discussion with the owner and, if necessary, observation of the owner drawing up and administering the insulin. Insulin storage and frequency of replacement should be assessed.

A thorough review of the case history should be performed, including initial diagnosis, insulin dose, pattern/frequency of dose increases, monitoring technique, and results. This may identify overlooked causes of instability and can be rewarding when more than one veterinary surgeon has been involved with the case. The effect of treatment on clinical signs should also be discussed with the owner, as this can be easily ignored when reviewing multiple glucose curves. Fair control is acceptable in cases where the cat's clinical signs have resolved and body weight is stable.

In this case the owner was storing and administering insulin correctly (plus the glucose curve in [Figure 6.5](#) was performed following administration of insulin by a veterinary nurse), insulin dose had been increased appropriately, and clinical signs remained severe and unchanged.

Following these steps basic biochemistry, haematology, and urinalysis (including bacterial culture) were performed to investigate underlying disease as a cause of poor glycaemic control (see [Table 6.8](#)). Serum fructosamine was measured to provide a measure of current glycaemic control. Viral testing was also performed to exclude feline leukaemia virus (FeLV) and feline immunodeficiency virus (FIV).

Haematology was unremarkable, retroviral serology was negative, and urinalysis revealed glycosuria but was negative for ketones. Urine bacterial culture was negative.

Table 6.8 Biochemistry Results at Presentation

	Patient Result	Reference Interval
Urea (mmol/L)	22.4	6.5–10.5
Creatinine (μmol/L)	146	133–175
Total protein (g/L)	78.6	77.0–91.0
Albumin (g/L)	32.7	24.0–35.0
Globulin (g/L)	45.5	21.0–51.0
ALT (IU/L)	94	15–45
ALP (IU/L)	45	15–60
Total bilirubin (μmol/L)	6.3	0.0–10.0

Continued

Table 6.8 Biochemistry Results at Presentation—cont'd

Sodium (mmol/L)	149.9	149.0–157.0
Potassium (mmol/L)	4.6	4.0–5.0
Chloride (mmol/L)	115	115–130
Calcium (total) (mmol/L)	2.41	2.30–2.50
Phosphate (mmol/L)	1.54	0.95–1.55
Glucose (mmol/L)	28 (4 h post insulin and feeding)	3.5–5.5
Fasting bile acids (μmol/L)	4.8	0.0–15.0
Fructosamine (μmol/L)	700	175–400

Bold type denotes abnormal result.

For abbreviations, see footnote to Table 6.3.

Q 3. Consider the significance of the above results and describe how you would further investigate this case.



Tip Box

Urine bacterial infection is common in diabetic cats (12%) and is a significant cause of diabetic instability. Samples should ideally be obtained for culture via cystocentesis. Although lower urinary tract signs and an active sediment are predictors of a UTI, absence of these signs does not exclude infection, and bacterial culture should always be performed.

Urine bacterial infection is excluded in this case by the negative bacterial culture.

The moderate elevation in urea with normal creatinine may represent dehydration (although this was not clinically evident), early renal disease, or gastrointestinal haemorrhage. Assessment of urine specific gravity would be helpful in the differentiation of pre-renal and renal causes of an elevated urea, but in this case the presence of glycosuria and PU/PD complicates this distinction. The mildly elevated ALT is consistent with the unstable diabetes but may indicate underlying hepatocellular damage. The cat is severely hyperglycaemic as expected, and the severely elevated fructosamine indicates chronic hyperglycaemia and very poor diabetic control.

At this point no clear cause of diabetic instability has been identified and further screening for underlying disease is appropriate.

Further investigation would include measurement of feline pancreatic lipase immunoreactivity (fPLI) as an indication of active pancreatic inflammation, and measurement of serum T4 would allow exclusion of hyperthyroidism as a complicating endocrine disease. Imaging including survey radiography and abdominal ultrasound to look for occult neoplasia and inflammatory disease is appropriate.

In this case T4 and fPLI were within normal reference intervals. Although chronic pancreatitis can wax and wane, given the severity of the cat's clinical signs and diabetic instability an elevated result would be expected.

Thoracic radiography demonstrated cardiomegaly (Figure 6.6), which was confirmed on echocardiography as mild hypertrophic cardiomyopathy (HCM). Abdominal radiography and ultrasonography showed bilateral renomegaly with normal renal echogenicity and architecture. No other abnormalities were identified.

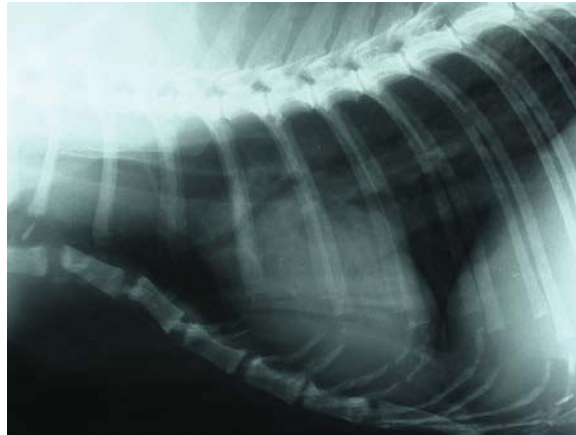


Figure 6.6. Right lateral thoracic radiograph.

- Q** 4. *Given the results so far in this case and conditions excluded, refine your differential diagnosis list for this case.*

Insulin factors have been excluded. The test results above exclude the common cat factors including UTI, dental disease, pancreatitis, and organ failure. The mild HCM is unlikely to explain the insulin resistance observed. Bilateral renomegaly may be an incidental and irrelevant finding or may indicate underlying renal infiltrative disease, less likely given the normal renal architecture. Undocumented Somogyi overswing is not excluded as hypoglycaemia can be missed on a 2 hourly glucose curve, however this was not noted on other curves with hourly sampling. Less common causes of insulin resistance remain as differential diagnoses including hyperadrenocorticism and acromegaly, as well as occult neoplasia not yet discovered.

- Q** 5. *What clinical features may suggest hyperadrenocorticism or acromegaly, and how would you test for these endocrine conditions?*

Hyperadrenocorticism causes severe skin fragility in cats, along with other dermatological changes including alopecia, pyoderma, seborrhoea, and comedones. A pot-bellied appearance due to obesity and hepatomegaly is also often observed. Acromegaly can result in an increase in head size, prognathism, and hypertrophy of soft tissues.

The diagnosis of hyperadrenocorticism in cats is based on clinical signs, biochemical results, imaging findings, and finally endocrine testing using urine cortisol:creatinine ratio, ACTH stimulation tests, and the LDDS test. Acromegaly is diagnosed on the basis of an elevated insulin-like growth factor-1 (IGF-1), appropriate clinical signs, and imaging findings.

The cat in the current case is a large cat, with large paws, but the owner is not aware of a change in appearance ([Figure 6.7](#)). However, the clinical signs and organomegaly, along with the lack of dermatological changes consistent with hyperadrenocorticism are consistent with acromegaly, and therefore IGF-1 measurement is appropriate.

IGF-1 was measured and revealed a result of >2000 ng/mL, consistent with a diagnosis of acromegaly.



Figure 6.7. The cat was large but physical examination was generally unremarkable.

Q 6. What are the treatment options for this cat?

Ideally, treatment is directed at the cause of the acromegaly, i.e. the pituitary tumour. Treatment options therefore consist of hypophysectomy, radiotherapy, and medical management. Medical treatments include long-acting somatostatin analogues, including octreotide. Clinical signs in some cats can be controlled with high doses of insulin.



Tip Box

There is not currently an 'ideal' treatment for acromegaly in cats. The efficacy of medical treatments has not been demonstrated. Radiation treatment is the most available treatment targeting the pituitary tumour, but this treatment is not a cure in the majority of cases and rather just improves diabetic control and reduces the insulin requirement.

Treatment and Outcome

An MRI (magnetic resonance imaging) scan was performed to facilitate radiotherapy planning (Figure 6.8) and revealed a large pituitary mass. The cat in this case received 10 fractions of radiotherapy spaced over a 3-week period, which were well tolerated. Insulin requirements decreased after 3 weeks and insulin therapy was withdrawn 7 weeks later. The cat remained well 1 year after the diagnosis of acromegaly.

Discussion

Acromegaly is likely an underdiagnosed endocrinopathy in cats. However, more common causes of diabetic instability should be excluded before endocrine testing is performed. Interpretation of IGF-1 results can be complicated by overlap with diabetic cats without acromegaly and therefore should be measured only following thorough investigation and with compatible clinical signs.

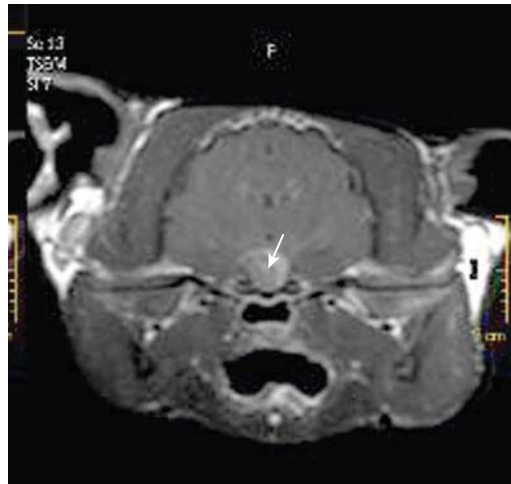


Figure 6.8. Transverse T1 weighted image post gadolinium showing a large, contrast enhancing pituitary mass (arrow).

If Finances Are Limited

Before embarking on expensive endocrine testing, owners should be counselled regarding the likely underlying condition. If further diagnostic tests and treatment such as MRI and radiotherapy are not possible (owner wishes/finances), then the clinician's focus should be on excluding any other conditions that would contribute to diabetic instability (e.g. UTI, dental disease, undiagnosed Somogyi overswing) and increasing the dose of insulin gradually to try and control the clinical signs.

Further Reading

Niessen, S.J., 2010. Feline acromegaly: an essential differential diagnosis for the difficult diabetic. *Journal of Feline Medicine and Surgery* 12, 15–23.

Case 6.4

Signalment and History

A 7-year-old MN Maine Coon presented with a history of persistent PU/PD, polyphagia, and weight loss following a diagnosis of DM 4 months previously. Lente insulin was prescribed at a dose of 0.5 IU/kg BID, and despite a gradual increase in dose to 1.5 IU/kg BID, the clinical signs did not improve. Chronic small intestinal diarrhoea was also reported. The owner's insulin storage and injection technique were appropriate. The cat was fully vaccinated and wormed and had been fed a prescription hypoallergenic diet for 6 weeks. A blood glucose curve revealed no response to insulin with persistent hyperglycaemia over a 24 h period.

Clinical Examination

The cat was in poor body condition (BCS 2.5/9) and mild hepatomegaly was present on abdominal palpation.

Haematology, biochemistry (Table 6.9), and urinalysis were performed to look for a possible underlying cause of diabetic instability.

Haematology was unremarkable. Urinalysis revealed glucosuria, and bacterial culture was negative.

Table 6.9 Biochemistry Results at Presentation

	Patient Result	Reference Interval
Albumin (g/L)	30.2	25.0–45.0
Globulin (g/L)	32.5	25.0–45.0
Urea (mmol/L)	5.6	2.5–9.9
Creatinine (μ mol/L)	53.9	20.0–177.0
ALT (U/L)	75.6	5.0–60.0
ALP (U/L)	109	≤ 60.0
Total bilirubin (μ mol/L)	5.1	0.1–5.1
Cholesterol (mmol/L)	6.8	2.20–4.00
Sodium (mmol/L)	146.7	145.0–157.0
Potassium (mmol/L)	5.4	3.50–5.50
Chloride (mmol/L)	107.8	100.0–124.0
Inorganic phosphorus (mmol/L)	1.52	0.90–2.20
Calcium (mmol/L)	2.33	2.05–2.95
Glucose (mmol/L)	25.4	2.8–4.9

Bold type denotes abnormal result.

For abbreviations, see footnote to Table 6.3.

Q 1. How would you interpret these results and investigate this case further?

Although hepatocellular damage can't be excluded, the mild increases in ALT and ALP are consistent with hepatic lipidosis due to unstable diabetes. The mild hypercholesterolaemia and severe hyperglycaemia are also consistent with unstable diabetes.



Tip Box

Hepatic lipidosis commonly causes increased ALP activity with lesser increases in ALT and AST. Gamma-glutamyl transferase (GGT) is usually normal.

Further investigation of both the unstable DM and chronic diarrhoea would include measurement of serum T4 (as hyperthyroidism could cause insulin resistance) and measurement of fPLI as an indicator of active pancreatic inflammation due to pancreatitis (a common cause of diabetic instability). Chronic pancreatitis where destruction of both islet and acinar cells occurs can result in DM and exocrine pancreatic

insufficiency (EPI), and, as EPI can cause diarrhoea, trypsin-like immunoreactivity (TLI) should also be measured. Measurement of serum folate and cobalamin is advisable as deficiencies can occur with malabsorptive small intestinal disease. Faecal flotation is recommended to check for endoparasites, along with abdominal ultrasound to look for abnormalities causing diabetic instability (e.g. neoplasia) and/or chronic small bowel disease (e.g. increased intestinal wall thickness). Thoracic radiographs to look for metastases are also recommended.

Further Case Information

In this case T4 and TLI were within normal limits fPLI was increased (14.1 µg/L; RI: 0.1–3.5 µg/L), serum folate was normal, and cobalamin was low (197 ng/L; RI: >270 ng/L). Abdominal ultrasound revealed the liver was hyperechoic and enlarged. There was mild thickening of the small intestines secondary to muscularis hypertrophy (Figure 6.9).

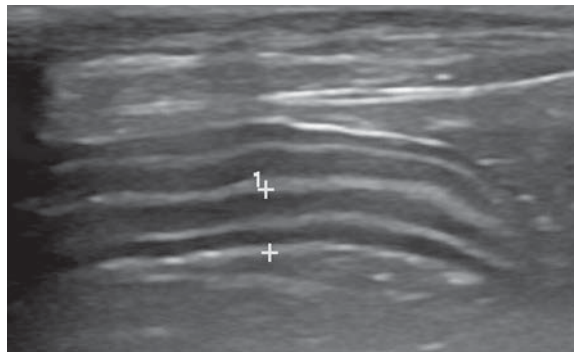


Figure 6.9. Ultrasound image showing thickening of the muscularis layer of the small intestine. The crosses denote the thickness of the wall at 3.5 mm.

Q 2. Given these findings, what are your differentials?

- The increased fPLI is consistent with pancreatitis.
- Hypocobalaminaemia is consistent with distal small intestinal malabsorption (due to inflammatory bowel disease or lymphoma), which is also compatible with the ultrasound findings. Hypocobalaminaemia can occur due to EPI but this has been excluded.
- Hepatomegaly could occur with infiltrative disease such as hepatic lipidosis, lymphoma, amyloidosis, or inflammatory liver disease.

Q 3. What would you do next?

Exploratory laparotomy to obtain biopsies from the liver, gastrointestinal tract (stomach, duodenum, jejunum, ileum), and pancreas is advised. As the muscularis layer of

the small intestine is abnormal, full thickness surgical biopsies may be preferable to superficial endoscopic biopsies.

An exploratory laparotomy was performed and multiple biopsies were taken as above. Histopathology revealed mild hepatic lipidosis, severe lymphoplasmacytic enteritis with villus atrophy in the duodenum, jejunum, and ileum consistent with IBD and islet cell vacuolation in the pancreas, with no evidence of pancreatitis. Pancreatic inflammation can be patchy, so pathology may have been missed on biopsy, explaining the elevated fPLI (a false positive result is also possible).

Q 4. *How would you treat this patient?*

Treatment of IBD involves feeding a novel protein or hypoallergenic diet, metronidazole for its immunomodulatory properties, and immune suppression with prednisolone +/- chlorambucil in severely affected cases. A hypoallergenic diet has already been used in this case without improvement, therefore a novel protein diet is advised. Corticosteroids contribute to insulin resistance and are contraindicated in a diabetic cat, therefore metronidazole is recommended initially followed by chlorambucil if there is no improvement. Parenteral cobalamin supplementation is advised.

Case Outcome

Feeding a low carbohydrate, high protein diet may help glycaemic control in poorly regulated diabetic cats; therefore a prescription diabetic diet containing pork as a novel protein was initiated, in addition to metronidazole 10 mg/kg PO BID for 4 weeks. Although there was some improvement in the diarrhoea, the cat failed to gain weight, and therefore chlorambucil 2 mg PO every other day was also prescribed after 2 weeks. The cat gained weight and diarrhoea resolved but remained PU/PD with persistent hyperglycaemia, and as the IBD was considered to be under control, the decision was made to change to a different type of insulin.

Q 5. *What classes of insulin (other than lente) are available to use for long-term therapy in diabetic cats?*

Neutral protamine hagedorn (NPH) insulin, protamine zinc insulin (PZI), and long-acting insulin analogues such as glargine (Lantus, Sanofi Aventis) or detemir (Levemir, Novo Nordisk) are available with licensing laws differing globally (products currently off-licensed for use in cats in the United Kingdom).



Tip Box

- o NPH insulin has a duration of action less than 12 h, which is too short for adequate glucose control in most cats, and PZI isn't readily available in some countries
- o Glargine is a synthetic insulin analogue that develops microprecipitates in the subcutaneous tissues following injection; insulin is released slowly, which results in a relatively constant insulin concentration over 24 h
- o Detemir is a synthetic insulin analogue where the insulin molecule reversibly binds to albumin, resulting in slow release into the plasma and a prolonged duration of action

Good diabetic control was achieved in this case following a change to insulin glargine.

Further Reading

Jergens, A.E., 2012. Feline Idiopathic Inflammatory Bowel Disease: What we know and what remains to be unraveled. *Journal of Feline Medicine and Surgery* 14 (7), 445–458.

Case 6.5

Signalment and Clinical History

A 7-year-old MN DSH cat was presented with a history of lethargy and inappetence. He had been diagnosed 14 months ago as a diabetic and treated with porcine lente insulin injections BID, as well as dietary modification to a high protein, low carbohydrate diet. Glucose control was unknown.

Clinical Examination

On presentation the cat was recumbent and obtunded. HR was 200 bpm with poor peripheral pulses and no deficits. Respiratory rate was 28 brpm. Mucous membranes were pale yellow with a capillary refill time (CRT) of <2 s. Rectal temperature (RT) was 36.5 °C and the cat's BCS was poor (2/9).

Q 1. *What is your initial assessment of this patient from the physical examination, and what treatments could you instigate prior to any further investigation?*

An approach in the emergency patient is to use the major body system assessment: neurological, cardiovascular, and respiratory systems.

- Neurological: the cat has decreased/inappropriate mentation. There are many causes for this (degenerative, inflammatory, neoplastic, toxic, metabolic, nutritional, etc.).
- Cardiovascular: although the HR might be within the normal range, the other physical examination findings indicate hypoperfusion. Cats can have tachycardia or bradycardia associated with this.
- Respiratory: mildly tachypnoeic with no abnormalities on thoracic auscultation.

Treatment

Hypoperfusion is the main abnormality on examination, therefore intravenous access and administration of isotonic (replacement) crystalloid fluid to be given as a bolus is an appropriate initial treatment. A typical bolus is 5–20 mL/kg over 10–20 min with regular patient reassessment (HR, pulse profile, mucous membrane colour, CRT, etc.).

Q 2. *If a blood gas machine was made available to you and the cat was found to have a metabolic acidosis, would that change your initial management and why?*

Sodium chloride 0.9% with its high chloride makes it an acidic fluid (pH 5.4) and could in theory make the acidosis worse. Therefore, compound sodium lactate (lactated Ringer solution or Hartmann's) with a buffer (lactate) acts as a bicarbonate precursor and would be a better choice and most likely correct the acidosis faster. Sodium bicarbonate use in diabetic ketoacidosis (DKA) is controversial and might even delay

resolution of the ketosis (from central nervous system (CNS) acidosis, affecting oxygen delivery to the tissues, hyperosmolality, etc.).

Further Case Information

Abnormal biochemistry results were as follows: hyperglycaemia, glucose 17.2 mmol/L (4.11–8.83), mild increase in cholesterol 8.39 mmol/L (1.68–5.81), ALT 352 U/L (20–100), phosphorus 0.39 mmol/L (1.6–2.75), and hyperbilirubinaemia 60 µmol/L (2–10).

A urine sample was taken (via cystocentesis) to submit for culture and sensitivity. In-house urinalysis showed USG 1.009, glucose +++, ketones +++, bilirubin+++, pH 5.0; sediment was unremarkable.

Q 3. What is your working diagnosis in this case?

The history, presentation, hyperglycaemia, and ketonuria indicate DKA (although measurement of blood pH needed to confirm acidosis).

Q 4. How would you further manage this patient's fluid requirements over the next few days? Provide not only the type of fluid but any supplementation.

Fluid requirements

Fluid requirements in DKA are often high; they are calculated from maintenance fluid requirement (approx. 2 mL/kg/h, depending on age, energy requirement, etc.), percentage dehydration (from physical examination), and ongoing losses (diarrhoea and vomiting). It is important to note that glucose is an effective osmole and therefore will cause an osmotic diuresis (hyperglycaemia creates the polyuria which drives the polydipsia).

Electrolytes should be checked at least once a day, preferably q 12 h.



Tip Box

Hypotonic fluids (e.g. 0.18% NaCl with 4% dextrose, 5% glucose, 0.45% NaCl) are often referred to as maintenance fluids; however, they are likely to result in hyponatraemia, hypochloraemia, and hypokalaemia. These fluids often have glucose in them, which can complicate matters as well; the glucose is present to prevent erythrocyte lysis and not impart any nutritional benefit. These fluids should not be used in these patients.

Supplementation

Potassium should be supplemented in any inappetent patient on IVF, especially if they are receiving potassium-free fluids. Potassium supplementation should not exceed 0.5 mmol/kg/h, for risk of effects on the myocardium. Cats with DKA often become rapidly hypokalaemic once receiving insulin therapy.

Phosphorus supplementation is required in this case, as either sodium phosphate or potassium phosphate. It could be added to the IVF or as a separate continuous rate infusion (0.01–0.06 mmol/kg/h), and regular checking is prudent as hyperphosphataemia can lead to further problems.

A solution to the difficulty with supplementing multiple fluid types, insulin, and obtaining multiple blood samples is to place a central line (Figure 6.10).

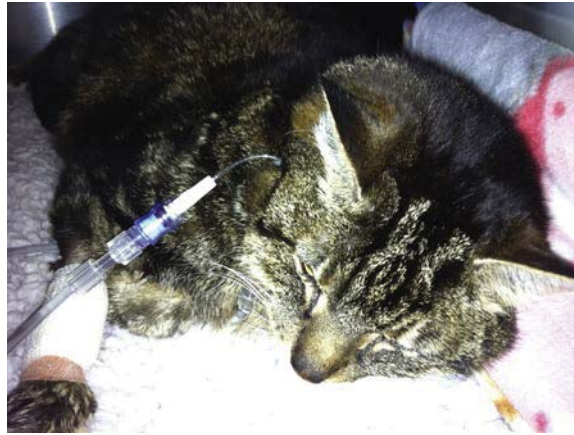

Figure 6.10. Cat with a central venous catheter, useful for not only delivering fluids but also for blood sampling.

Q 5. Describe an insulin therapy protocol for this case.

There are many ways to provide exogenous insulin, though in management of DKA neutral insulin would be preferred. The protocol in [Box 6.1](#) was used in this case.

Insulin infusions are excellent at gradually decreasing the glucose level of the patient; however, 24 h monitoring is required.

Box 6.1 Insulin Therapy Protocol

- o Firstly, make an infusion solution using soluble (regular) insulin in normal saline (0.9% NaCl) to a concentration of 50 mU/mL (0.05 IU/mL; e.g. 25 IU regular insulin in a 500 mL bag or 2.5 IU in a 50-mL syringe). Then run approximately 50–100 mL through line to adsorb to plastic.
- o The solution should be infused at 1 mL/kg/h until the blood glucose is in the range of 10–15 mmol/L (in most cases this infusion rate should cause a predictable fall of glucose by 1–3 mmol/L/h).
- o When the glucose is in the desired range, decrease the insulin infusion rate to 0.5 mL/kg/h and, using a separate fluid bag, supplement dextrose at 120–180 mg/kg/h to hold the glucose at a normal level.
- o Generally, if on IVF at 6–7 mL/kg/h, a 2.5% dextrose-supplemented litre bag of compound sodium lactate (CSL) (or equivalent) will achieve the desired glucose rate.

Protocol with permission from Professor David Church, RVC.

Alternative protocols

- Neutral insulin given as intermittent (hourly) injections, once the patient has been adequately hydrated
- Glargine has different effects depending on its administration, acting more like a neutral insulin if given intramuscularly compared to subcutaneously; however, further research is needed into its use in the treatment of DKA

Further Case Information

The cat was treated with isotonic crystalloids supplemented with potassium phosphate and potassium chloride along with an insulin infusion. After 4 h the cat was more alert, pulse quality was normal, and electrolytes improving.

Q 6. What further imaging, blood tests, or procedures might be prudent and why?

The onset of DKA often has a trigger, or concurrent disorder, commonly pancreatitis (both acute and chronic), infections (both viral and bacterial, especially UTIs with the latter), hepatic lipidosis, cholangiohepatitis, neoplasia, and acromegaly. The cat in this case was jaundiced, requiring further investigation including imaging (thoracic radiographs and abdominal ultrasound) and measurement of fPLI (see Table 6.10). Urinalysis and culture are advisable for every unstable diabetic.

Table 6.10 Further Investigation Results

Investigation	Result
Urine culture and sensitivity	Negative
Thoracic radiographs	No abnormalities
Abdominal ultrasound	Liver was diffusely slightly hyperechoic, and both adrenals were enlarged (>6 mm) and hypoechoic. (Bilateral adrenal enlargement on abdominal ultrasound is reported to be a normal finding in some DKA cats.) Pancreas bulky
fPLI (µg/L)	35.0 (RI: 2.0–7.0)

Bold type denotes abnormal result.

Q 7. What is your diagnosis in this case at this point?

The cat has DKA and pancreatitis. The liver has an abnormal appearance on ultrasound, which could indicate pathology (e.g. neutrophilic cholangitis or hepatic lipidosis), but biopsy would be required to confirm this diagnosis.

Q 8. How would you further manage this case?

Fluid therapy, correction and monitoring of electrolytes, and insulin supplementation are the mainstay of management of DKA.

The elevated fPLI indicates pancreatitis, which is a painful condition, so analgesia (opioids) should be provided. Nausea and vomiting are also likely so an anti-emetic may be helpful (e.g. metoclopramide, maropitant).

Nutrition should be addressed in these patients as soon as possible. A naso-oesophageal tube can be placed consciously and is well tolerated, although an oesophagostomy tube if the patient is stable enough would be ideal. This can be left in place with minimal owner care when the cat goes home, to provide the cat's resting energy requirement or to supplement feeding/water if required.

Antibiotic therapy is generally not indicated in the management of pancreatitis; however, as infectious processes can trigger DKA, and neutrophilic cholangitis may

be a comorbidity associated with pancreatitis, use of a broad-spectrum antibiotic is appropriate.

Further Case Information

The cat responded well to treatment and was changed from an insulin infusion to lente insulin after 24 h treatment.

Discussion

What do I do if I don't have 24 h monitoring?

A cat can have diabetic ketosis (DK) or DKA and still be bright and eating, in which case they would not require such a protocol to reduce their blood glucose, although they will require hospitalization and IVF. These cases can be very difficult to manage, in particular in the acute phase. It is therefore important to advise the owners of this and that the hospitalization might be prolonged. It can be prudent if you are in an area where there is a 24 h hospital or referral centre and that the clients can afford that these patients are managed there initially. Continual blood sampling might benefit from placement of a central venous catheter, and if the continuous insulin protocol is followed, it can lead to a 'dance' of often changing fluids, which will happen at any time day or night. There is also the iatrogenic risk of hypoglycaemia in these patients, especially on a continuous rate infusion of insulin. Therefore if these patients are going to be managed in facilities that do not have the ability of 24 h care, then intermittent neutral insulin therapy would be more desirable.

What do I do if I only have glargine?

Glargine has been shown to work in a similar fashion to neutral insulin if given intramuscularly (1–2 U/cat, followed by intermittent glargine every 2 or more hours), so a dose given intramuscularly and subcutaneously at the same time will give both immediate and longer-lasting action.

Further Reading

- Chan, D.L. 2009. The inappetent hospitalized cat: clinical approach to maximizing nutritional support. *Journal of Feline Medicine and Surgery* 11, 925–933.
- Marshall, R.D., Rand, J.S., Gunew, M.N., Menrath V.H. 2013. Intramuscular glargine with or without concurrent subcutaneous administration for treatment of feline diabetic ketoacidosis. *Journal of Veterinary Emergency and Critical Care* 23 (3), 286–290.

Case 6.6

Signalment and Clinical History

A 12-year-old MN DSH was presented for annual vaccination and health check. The owners had noticed a recent reduction in appetite but no other abnormalities.

Physical Examination

Abnormal findings were:

- Weight loss (3.8 kg from 4 kg 1 year previously) and poor body condition (BCS 2/5)
- Poor coat condition

- Mild tachycardia (200 bpm); regular heart rhythm, no audible heart murmur, good pulse pressure, and normal mucous membrane colour
- Soft mobile, well-defined mass in the right cervical region, approximately 1 × 0.5 cm in size

Initial investigations were as outlined in Table 6.11.

Table 6.11 Initial Investigations

Serum biochemistry		
ALT (IU/L)	55	<60
ALP (IU/L)	35	<60
Total protein (g/L)	79	54–82
Creatinine (μmol/L)	124	0–190
Urea (mmol/L)	10.5	2.8–11
Glucose (mmol/L)	6.0	3–7.5
Endocrinology		
Total T4 (nmol/L)	46.5	19–60
Urinalysis		
Specific gravity	1.028	
pH	6.5	
Protein	++	
Blood	Negative	
Glucose	Negative	
Bilirubin	Negative	
Sediment analysis	Inactive	

For abbreviations, see footnote to Table 6.3.

Q 1. Given the initial blood and urine test results, what are the potential explanations for the mass in the right cervical region?

- Mass is an enlarged thyroid gland, but total T4 is normal because:
 - Concurrent unrelated disease is causing suppression of total T4
 - The enlarged thyroid gland is not producing excess T4:
 - Thyroid cyst
 - Thyroid carcinoma
 - Non-functional thyroid adenoma
- Mass is an enlarged parathyroid gland: parathyroid adenoma, carcinoma, or cyst
- Mass is an enlarged lymph node
- Mass is an abscess or a neoplasm of non-endocrine origin

Q 2. What further tests would you recommend in this case?

- Initial tests could include:
 - Further investigation of hyperthyroidism: comparison of free T4 and total T4, measured in the same sample

- Further investigation of parathyroid function: a more extensive serum biochemistry, with particular reference to serum calcium, phosphate, and ionized calcium
- Investigation of subnormal USG as above, wider biochemistry panel, bacterial urine culture, renal imaging
- Depending on further findings, other investigations might include:
 - Fine needle aspirates from the mass
 - Ultrasonography of the mass
 - Thoracic radiographs
 - Parathyroid hormone (PTH) assay

Further Investigations

Results of further investigations are outlined in [Table 6.12](#).

Table 6.12 Further Investigations

Serum biochemistry		
ALT (IU/L)	53	<60
Alkaline phosphatase (IU/L)	38	<60
Total bilirubin ($\mu\text{mol/L}$)	8	0–12
Total protein (g/L)	76	54–82
Albumin (g/L)	35	25–39
Globulin (g/L)	41	15–57
Creatinine ($\mu\text{mol/L}$)	168	0–190
Urea (mmol/L)	11.0	2.8–11
Calcium (mmol/L)	3.23	2–3
Phosphorus (mmol/L)	0.67	0.8–2.5
Glucose (mmol/L)	10.0	3–7.5
Na (mmol/L)	162	50–165
K (mmol/L)	3.9	3.5–5.8
Ionized Ca (mmol/L)	1.6	1.0–1.4
Haematology		
RBC ($\times 10^{12}/\text{L}$)	7.16	5.5–7.5
Haemoglobin (g/dL)	12.6	9–14
PCV (%)	37	27–42
MCV (fL)	51.5	40–55
MCH (pg)	17.3	13–17.5
MCHC (g/dL)	34.5	30–35
WBC ($\times 10^9/\text{L}$)	11.99	7.5–20
Neutrophils ($\times 10^9/\text{L}$)	7.38	2.5–12.5
Lymphocytes ($\times 10^9/\text{L}$)	2.16	1.5–6.5

Table 6.12 Further Investigations—cont'd

Monocytes ($\times 10^9/L$)	0.99	0–1.0
Eosinophils ($\times 10^9/L$)	1.30	0–1.5
Platelets ($\times 10^9/L$)	575	300–700
Endocrinology		
Total T4 (nmol/L)	53.8	19–60
Free T4 (pmol/L)	21.4	10–50
PTH (pg/mL)	40.7	<40
PTH-rp (pmol/L)	<0.1	<0.5
Thoracic radiographs	Unremarkable	

Bold type denotes abnormal result.

PCV, packed cell volume; PTH, parathyroid hormone.

For full list of abbreviations, see footnotes to Tables 6.2 and 6.3.

Q 3. List the potential causes of hypercalcaemia in the cat.

- Idiopathic hypercalcaemia
- Secondary to CKD
- Hypercalcaemia of malignancy
- Primary hyperparathyroidism
- Vitamin D toxicosis
- Increased bone turnover (e.g. osteomyelitis, osteosarcoma)
- Granulomatous disease (e.g. mycobacterial infection, fungal infection)
- Hypoadrenocorticism
- Artefact (e.g. due to lipaemia or haemolysis)

Q 4. How does assessing serum phosphate help to differentiate possible causes of hypercalcaemia?

Cats with primary hyperparathyroidism or hypercalcaemia of malignancy are likely to have low serum phosphate, or normal serum phosphate but within the lower end of the reference interval. In all other conditions serum phosphate is likely to be elevated or in the upper half of the reference interval.

Q 5. How do you interpret the parathyroid hormone level?

This cat is hypercalcaemic, which should cause suppression of PTH secretion; however, in this case the PTH level is just above the reference interval, indicating an inappropriately high level and supporting a diagnosis of primary hyperparathyroidism.

Q 6. What treatment options exist for this condition?

Surgical excision of the enlarged parathyroid gland is the treatment of choice. Prior to surgery fluid therapy may encourage calciuresis to moderate the hypercalcaemia.

If surgery is not possible, palliative treatments for hypercalcaemia include:

- Furosemide: increases urine calcium excretion. Best used with concurrent administration of intravenous or subcutaneous saline to avoid dehydration.
- Prednisolone: decreases intestinal calcium absorption, increases urine calcium excretion, and reduces calcium mobilization from bone. Only appropriate for use once a definitive diagnosis has been achieved.
- Bisphosphonates: reduce osteoclast activity.

Further Information

Parathyroidectomy may result in a period of postoperative hypocalcaemia. Mild hypocalcaemia may not require treatment, but if serum calcium falls below 1.8 mmol/L, or if there are any clinical signs of hypocalcaemia, immediate treatment is required.

Q 7. How would you manage postoperative hypocalcaemia?

- Initial treatment is with IV calcium supplementation:
 - 10% calcium gluconate solution: diluted at least 1:1 into normal saline
 - Administer 1–1.5 mL/kg, diluted in at least the same volume of saline and given very slowly over a period of 20 min, monitoring continuously for bradycardia
 - Repeat every 6–8 h as needed
- Maintenance therapy should also be initiated as soon as possible:
 - Oral vitamin D supplementation is essential to allow absorption of calcium from food until normal parathyroid function returns
 - In the United Kingdom a liquid formulation of vitamin D3 is available (One-Alpha suspension 2 µg/mL; Leo Pharmaceuticals), which allows practical dosing for cats. Dose: 0.03–0.06 µg/kg SID (equivalent to one drop per 2–3 kg body weight)
 - Oral calcium supplementation is usually required in the initial treatment period but, once the cat is eating well, normocalcaemia can usually be maintained with vitamin D3 supplementation and a good quality commercial diet
 - Suggested doses for oral calcium supplementation depend on the calcium salt used. Carbonate: approx. 200 mg/kg SID. Gluconate: approx. 1 g/kg SID. Lactate: approx. 700 mg/kg SID



Tip Box

When treating hypocalcaemia due to temporary postoperative hypoparathyroidism, the aim should be to maintain serum calcium close to the low end of the reference interval in order to stimulate PTH secretion and encourage more rapid return to normal function of the atrophied parathyroid glands.

Treatment and Outcome

Surgical exploration of the mass revealed an enlarged parathyroid gland embedded in the right thyroid gland. A unilateral thyroid/parathyroidectomy was performed,

and subsequent histopathology confirmed the presence of a parathyroid adenoma. The cat made an uneventful recovery from surgery and did not develop postoperative hypocalcaemia; he remains well at the time of writing, 14 months after the parathyroidectomy.

Discussion

Primary hyperparathyroidism is a rare condition in cats. In the majority of cases it is caused by a unilateral functional parathyroid adenoma, and the enlarged parathyroid gland is usually palpable. Parathyroid cystadenomas and parathyroid carcinomas are reported but are even less common than functional parathyroid adenomas.

Clinical signs are mild and referable to hypercalcaemia (anorexia, lethargy, gastrointestinal signs, PU/PD, occasionally neurological signs if hypercalcaemia is marked). Confirmation of diagnosis is based on finding hypercalcaemia with elevated ionized calcium, low or low-normal serum phosphate and high-normal to elevated serum PTH concentrations.

Surgical excision of the affected gland is usually curative in cats with unilateral parathyroid adenoma.

Serum calcium should be monitored once or twice daily for the first 7 days. Clinical signs of hypocalcaemia include anxiety, ear tremor, facial pruritus, muscle tremor/fasciculations, weakness, and eventually seizures.

Case 6.7

Signalment, History, and Clinical Examination

A 6-year-old FN DSH cat developed pruritic skin lesions on her face, hocks, and dorsum, with areas of alopecia and broken hairs (Figures 6.11 and 6.12). The cat was the only



Figure 6.11. Alopecia and secondary excoriation around the face.

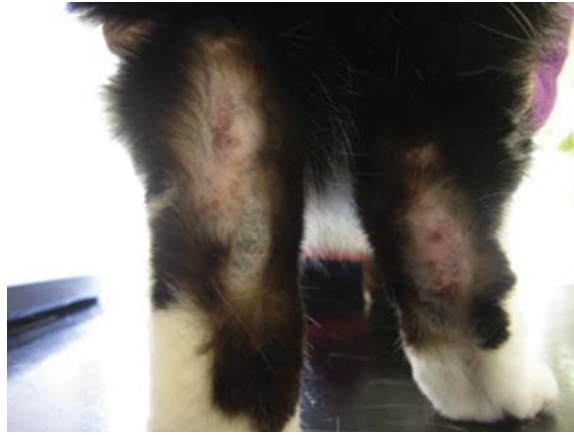

Figure 6.12. Alopecia and secondary excoriation around the hocks.

pet in the household and was restricted to the indoors. Flea control was current. There were no other clinical signs, and physical examination was otherwise unremarkable.

Q 1. List your major differential diagnoses for multifocal pruritic skin lesions in the cat.

- Flea allergy dermatitis
- Atopy
- Food allergy
- Dermatophytosis
- Insect bite hypersensitivity
- *Malassezia* dermatitis
- Pyoderma
- Other parasites: mites and lice (*Cheyletiella*, *Felicola*, *Notoedres* demodicosis, etc.)

Q 2. How would you further investigate this case?

Tape tests, skin scrapes, and hair plucks will be useful to look for mites, bacteria, dermatophytes, and *Malassezia*. Wood's lamp and hair plucks/coat brushings will be useful to further investigate for dermatophytosis. Treatment trials with flea treatment and food trials will help to rule out flea allergic dermatitis and food allergy. Ultimately, skin biopsies may also be required.

Further Case Information

Further investigations were as follows:

- Wet paper test: no evidence of fleas
- Skin scrape and acetate tape test: negative for mites and *Malassezia*
- Bacterial culture and sensitivity: heavy pure growth of *Staphylococcus intermedius*, sensitive to all common antibiotics

- Dermatophyte microscopy and culture: negative
- Skin biopsies: subcorneal pustular dermatitis and folliculitis

Comment: Chronic dermatitis, cause unidentified, with some bacterial pyoderma/folliculitis.

Q 3. *How do you interpret the presence of bacterial folliculitis in this case?*

Primary pyoderma/folliculitis is rare in cats. Secondary bacterial infections are very common in cats with pruritic skin disease, and this is the most likely explanation here. The presence of pyoderma contributes to further inflammation, pruritus, and self-excoriation so treatment is indicated, but treatment of the primary condition will also be required.

Q 4. *What is the most likely diagnosis?*

Atopic dermatitis is the most likely remaining diagnosis, although a food allergy has not been excluded.

Q 5. *What are the options for management of this case?*

Management of atopy includes treatment of complicating factors (pyoderma, parasite infestation, *Malassezia* overgrowth), avoidance of the allergen (if known), and/or treatment with essential fatty acids, antihistamines, glucocorticoids, ciclosporin, and immunotherapy.

Further Case Information

Initial treatment was with essential fatty acids (EFA; evening primrose oil 500 mg SID), amoxicillin-clavulanate (50 mg BID) to treat the pyoderma, and prednisolone (5 mg SID, equivalent to approximately 1.4 mg/kg SID).

After 3 weeks the skin lesions were markedly improved and the cat appeared well with no side effects reported. Amoxicillin-clavulanate was ceased, EFAs continued, and the dose of prednisolone was reduced to 2.5 mg SID, but this led to a rapid recurrence of pruritus.

Treatment with 5 mg prednisolone SID was continued over subsequent months. Adjunctive treatment with an antihistamine (clemastine 0.5 mg BID) was well tolerated but did not have significant effect in that further attempts to reduce the prednisolone dose again resulted in rapid recurrence of pruritus. Treatment with clemastine was discontinued.

Three months later the pruritus remained well controlled by 5 mg prednisolone SID, but the owner noted a marked increase in appetite, thirst, and urine output. The cat had lost weight but physical examination was otherwise unremarkable. Results of blood tests and urinalysis indicated DM.

Q 6. *What would be your initial approach to managing the diabetes in this case?*

Ceasing prednisolone and feeding a low carbohydrate/high protein diet may resolve the diabetes. In the short term insulin injections can be used to encourage more rapid control of clinical signs, but careful monitoring will be required to ensure that the

dose of insulin meets the cat's need but does not become excessive as the insulin antagonistic effect of the prednisolone wears off. Home monitoring of blood glucose can be very useful in this circumstance.

Q 7. *What alternative treatments might be effective in managing the atopy while avoiding the use of systemic corticosteroids?*

- Antihistamines: effective in a minority of cases
- Ciclosporin
- Topical hydrocortisone aceponate spray
- Allergen-specific immunotherapy treatment based on results of specific allergen testing (intradermal skin tests, or ELISA (enzyme-linked immunosorbent assay) serology tests)
- Sodium aurothiomalate (gold salts) injections: not recommended due to the high risk of severe adverse effects

Q 8. *What adverse effects are associated with ciclosporin and what precautions should be taken prior to/during treatment?*

- Gastrointestinal side effects
Gastrointestinal adverse effects including transient inappetence, diarrhoea, and/or vomiting are reported in 25% of cases. In around 10% of cats these signs persist more chronically, most often exhibited as ongoing poor appetite and weight loss. In these cases treatment should be ceased and an alternative treatment will be required to control the atopy.
- Immunosuppression
 - Ciclosporin should not be used in cats that are FeLV or FIV positive
 - There are a small number of reported cases of clinical toxoplasmosis developing in cats on long-term treatment with ciclosporin. This has led to a recommendation that toxoplasma titres should be assessed prior to starting treatment. It is therefore prudent to discuss the risk of toxoplasmosis with the owner and to take steps to reduce the risk of the cat being exposed to new infections:
 - Avoid feeding raw meat
 - Avoid unpasteurized milk
 - Take steps to reduce hunting behaviour: keep the cat indoors at all times, or at least during the early evening and early morning when hunting behaviour tends to be at its most active. If the cat is allowed outdoors, apply a collar with a bell or ultrasonic warning device since this appears to significantly reduce successful hunting
 - Reactivation of other latent infections, e.g. herpes virus infection, may also be a potential concern
 - Ciclosporin may reduce the response to vaccination, and it is therefore recommended to cease its use for 2 weeks before and after vaccination.
 - Concurrent use of both prednisolone and ciclosporin is not recommended.
 - Ciclosporin is a T-lymphocyte suppressor and T-lymphocytes have a role in identifying and removing neoplastic cells. Ciclosporin therefore has the potential to allow more rapid progression of tumours.

- Ciclosporin has some insulin antagonizing effects and must be used with care in diabetic cats. However, since ciclosporin is significantly less diabetogenic than are glucocorticoids, it may still be a rational treatment choice for cats with corticosteroid-induced diabetes once prednisolone treatment has been withdrawn.

Further Treatment and Outcome

In this case treatment was as follows:

- Reduce and then cease prednisolone over a period of 3 weeks
- Feed a canned low carbohydrate/high protein diet
- Treat with ciclosporin (7 mg/kg SID once prednisolone has been ceased)

Pruritic skin lesions recurred as the prednisolone dose was reduced and then ceased (see [Figures 6.13 and 6.14](#)), but treatment with ciclosporin was well tolerated and

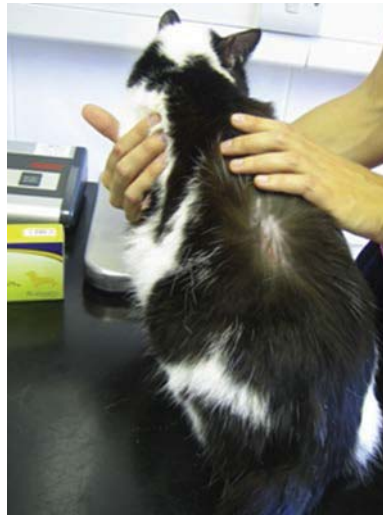

Figure 6.13. On ceasing prednisolone pruritic lesions recurred – pictured here a lesion on the dorsal midline.

within 2 weeks the pruritus was well controlled. After 4 weeks on treatment the lesions were markedly improved (see [Figure 6.15](#)) and dosing was reduced to a frequency of once every other day. Attempts to reduce the ciclosporin dose further were not successful, but the cat's signs remained well controlled on a dose of 7 mg/kg every other day.

The diabetes resolved within 2 months; the owner continued to feed the low carbohydrate diet, and normal glucose metabolism was maintained thereafter.

Discussion

Atopic dermatitis is a type 1 hypersensitivity to environmental allergens and typically presents as a pruritic dermatitis that responds to prednisolone treatment. Diagnosis

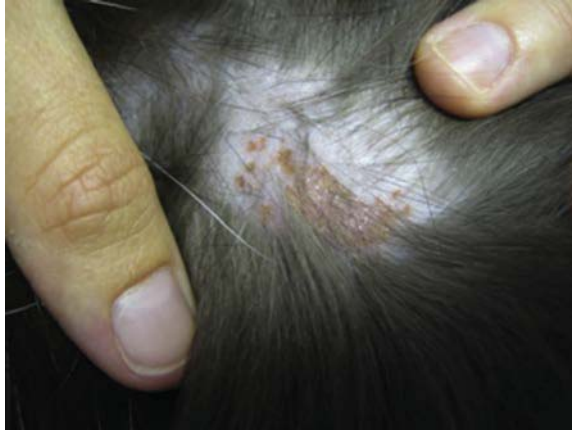

Figure 6.14. On ceasing prednisolone pruritic lesions recurred – pictured here a close-up of a lesion on the dorsal midline.

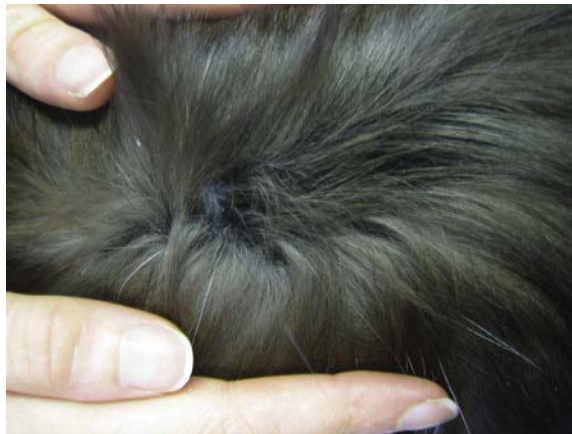

Figure 6.15. Marked improvement in the skin lesions after 4 weeks of treatment with ciclosporin.

is made by exclusion of other causes of pruritus (see above) and compatible clinical signs. Allergen identification can be performed with a blood or intradermal skin test.

Prednisolone can predispose to development of diabetes mellitus in cats, and as in the case of this report further complicates the management. An alternative treatment for atopy such as ciclosporin can be very useful in such cases, but owners need to be aware of potential adverse effects and precautions that should be taken to minimize these.

Neurological Disorders

Case 7.1

Signalment, Clinical History, and Clinical Examination Findings

A 3-year-old MN DSH cat presented with a history of acute onset ataxia and a left-sided head tilt (Figure 7.1). The cat had both indoor and outdoor access and no other significant previous history. Vaccination and parasite control were current.

On examination there was positional vertical nystagmus. External ear canal otoscopic examination was unremarkable. No other significant abnormalities were noted on general or neurological examination.



Figure 7.1. Case 7.1 presented with a left-sided head tilt.

Q 1. List differential diagnoses for peripheral vestibular disease in a cat.

- Idiopathic vestibular disease
- Otitis interna/media
- Nasopharyngeal polyps
- Neoplasia (e.g. squamous cell carcinoma or adenocarcinoma of the ear canal with inner ear involvement)

- Toxicity (e.g. aminoglycosides, loop diuretics, and topical ear preparations such as chlorhexidine)
- Trauma to the inner ear
- Congenital peripheral vestibular disease (Siamese and Burmese)

Q 2. List differential diagnoses for central vestibular disease in a cat.

- Infectious (e.g. feline infectious peritonitis (FIP), cryptococcosis, toxoplasmosis)
- Extension of otitis media/interna into the brain/meninges
- Neoplasia (e.g. lymphoma, meningioma with involvement of the vestibular nuclei in the brainstem or the cerebellum)
- Vascular accident
- Trauma (i.e. with involvement of the vestibular nuclei in the brainstem or the cerebellum)
- Thiamine deficiency
- Metronidazole toxicity

Q 3. How can you differentiate central from peripheral vestibular disease by neurological examination findings?

Peripheral vestibular disease is usually unilateral and associated with asymmetrical ataxia without deficits in postural reactions (i.e. proprioception normal), spontaneous horizontal or rotary nystagmus, which is not positional in nature, normal mental status and no paresis. Horner's syndrome may be seen with peripheral vestibular disease.

Central vestibular disease should be suspected in the presence of altered mentation, ipsilateral postural reaction deficits, loss of conscious proprioception, and/or paresis. The nystagmus can be spontaneous, or positional in nature, varying in direction with head position. Vertical nystagmus in any head position is most consistent with central vestibular disease.

In this case the cat had positional vertical nystagmus suggesting that central vestibular disease was more likely.

Q 4. How would you further investigate this case?

Options for further investigation include:

- Haematology and biochemistry to look for markers of inflammation or indications of disease such as FIP (e.g. hyperglobulinaemia)
- Bulla and nasopharyngeal radiography to look for indications of otitis media or polyps/neoplasia
- Examination under general anaesthesia to allow full examination of ear canals and nasopharynx
- Advanced imaging (magnetic resonance imaging (MRI)) to examine the peripheral and central vestibular systems

Given that central vestibular disease was suspected based on neurological (positional vertical nystagmus) and physical examination findings (unremarkable external ear canals), an MRI scan of the brain was performed (Figure 7.2).

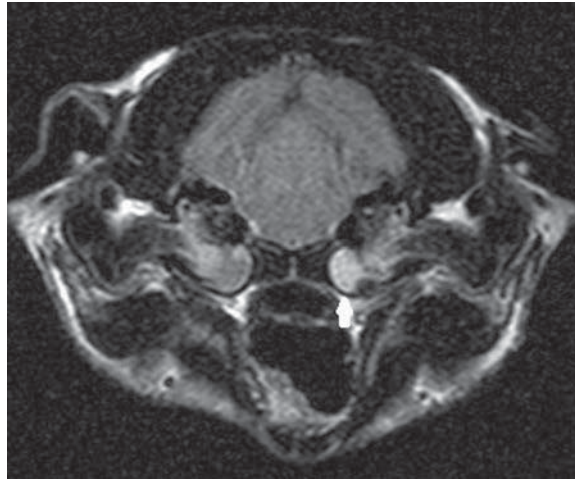


Figure 7.2. Transverse flair MRI scan of the cat's head.

Q 5. What are the key MRI scan abnormalities and your interpretation of them?

Both bullae are filled with soft tissue/fluid (arrow) consistent with bilateral chronic otitis media/interna. This was associated with focal meningitis (meningeal enhancement dorsomedial to both bulla) localized around cranial nerves (CN) VII and VIII bilaterally, but worse on the left side.

It was suspected that chronic otitis media, resulting from ear mite infestations as a kitten, had progressed to otitis media/interna with associated extension to focal meningitis.

Further Information on Response to Treatment, Diagnosis, and Outcome

Myringotomy and aspiration of the middle ear contents were performed via the left tympanic membrane (intact), and cytology revealed neutrophilic inflammation (unable to collect adequate sample for bacterial culture).

Q 6. What are the treatment options for this case and the pros and cons of each?

- Prolonged antibiotic treatment (broad spectrum to include anaerobic cover): the cheapest and least invasive option but infection may persist in inspissated pus, and in this and many cases information on sensitivity to chosen antibiotic is unavailable.
- Bilateral myringotomy/middle ear flushing: less invasive than ventral bulla osteotomy but complete removal of infected material is less likely to occur and infection may persist. This procedure may also result in worsening of vestibular signs.
- Bilateral ventral bulla osteotomy: greatest chance of resolution of infection; however, risks include possible facial nerve paralysis (may be temporary or permanent due to trauma or resection of the facial nerve), Horner's syndrome

(may be temporary or permanent due to trauma or resection of the sympathetic nerve supply to the eye) or worsening of vestibular signs secondary to trauma to the ear. Also the most expensive option.

Outcome

In this case the owner elected a prolonged antimicrobial course in the first instance.

The cat responded well to treatment with amoxicillin-clavulanate with gradual improvement of the severity of the head tilt and ataxia over the next week. By 4 weeks post MRI no neurological signs were noted.

Discussion

The underlying cause in this case was peripheral vestibular disease due to otitis media, although the original neurolocalization had been suggestive of a central vestibular lesion. It is possible that there was central vestibular involvement secondary to the meningitis due to extension from the inner ear infection. Vertical nystagmus is usually but not always associated with central vestibular disease. Otitis media/interna is a relatively common cause of feline peripheral vestibular disease and is not always associated with external ear canal disease at the time of diagnosis.

In this case the otitis was bilateral but only unilateral signs of vestibular disease were apparent, suggesting that the left side was more severely affected.

Further Reading

Negrin, A., Cherubini, G.B., Lamb, C., 2010. Clinical signs, magnetic resonance imaging findings and outcome in 77 cats with vestibular disease: A retrospective study. *Journal of Feline Medicine and Surgery* 12 (4), 291–299.

Case 7.2

Signalment and Clinical History

A 5-month-old FE DSH cat presented with a 2-month history of lethargy and inappetence. Four generalized tonic-clonic seizures lasting around 10 min had occurred in the last week. The cat was indoor only and fed a commercial diet for growing cats. Vaccination and flea and worming control were up to date. No toxin exposure was reported.

Clinical Examination

The cat was in poor body condition (BCS 3/9) and small in stature with copper-coloured irises (Figure 7.3). Neurological examination was normal.

Q 1. Formulate a problem list and differential diagnoses for each problem.

Problem list

- Lethargy
- Inappetence



Figure 7.3. The cat at presentation showing copper-coloured irises.

- Seizures
- Poor body condition and small stature

Lethargy, inappetence, poor body condition, and small stature are relatively non-specific and likely secondary to the underlying disease process. The primary problem is therefore seizures.

Causes of seizures

- Extracranial
 - Metabolic: hepatic encephalopathy, hypoglycaemia, hypocalcaemia, severe azotaemia, hypophosphataemia, hyperthyroidism
 - Toxins: organophosphates/carbamates, organochlorides, lead, ethylene glycol, bromethalin, metaldehyde
 - Nutritional: thiamine deficiency
 - Hypertension
 - Hyperviscosity: polycythaemia, multiple myeloma
- Intracranial
 - Idiopathic epilepsy
 - Neoplasia: meningioma, lymphoma, glioma, pituitary adenoma/adenocarcinoma, choroid plexus tumour, ependymoma, neuroblastoma, skull osteosarcoma, metastatic tumours
 - Infectious/inflammatory: FIP, toxoplasma, cryptococcus, feline immunodeficiency virus (FIV), feline leukaemia virus (FeLV), bartonellosis, rabies
 - Cerebrovascular accident: ischaemia/infarction, haemorrhage

- Bacterial meningitis
- Non-suppurative meningoencephalitis
- Trauma
- Hydrocephalus
- Lysosomal storage disease

Q 2. How would you investigate this case further?

Initially it is important to confirm the patient is seizing by reviewing the history, as collapse, syncope (uncommon in cats), behavioural disorders, and vestibular disease can be confused with seizures. In this case the owner had video recorded one of the events; this can be a helpful way to determine whether seizure activity is occurring.



Tip Box

Seizures can be classified as partial or generalized. Cats commonly exhibit partial seizures, and the focal nature of this type of seizure is associated with a higher incidence of focal intracranial pathology. Generalized seizures are more common with idiopathic epilepsy than partial seizures; however, primary (or idiopathic) epilepsy is less common in cats compared to dogs.

The next step is to rule out extracranial causes of seizures. Haematology (Table 7.1) and biochemistry (Table 7.2) were performed to investigate for metabolic disease. Testing for FeLV and FIV was performed to rule out retroviruses as a cause of seizures. Retroviral testing was negative.

Table 7.1 Haematology Results at Presentation

	Patient Result	Reference Interval
RBC ($\times 10^{12}/L$)	8.10	5.00–10.00
Haemoglobin (g/dL)	10.1	9.0–15.0
HCT (L/L)	0.332	0.260–0.470
MCV (fL)	40.7	42.0–57.0
MCH (pg)	13.0	13.0–17.5
MCHC (g/dL)	30.4	28.0–36.0
WBC ($\times 10^9/L$)	8.24	6.0–15.0
Neutrophils ($\times 10^9/L$)	4.53	2.50–12.50
Lymphocytes ($\times 10^9/L$)	3.38	2.00–7.00
Monocytes ($\times 10^9/L$)	0.33	≤ 0.60
Eosinophils ($\times 10^9/L$)	0.00	0.00–0.70
Platelets ($\times 10^9/L$)	340	150–550

Bold type denotes abnormal result.

HCT, haematocrit; MCH, mean corpuscular haemoglobin; MCHC, mean corpuscular haemoglobin concentration; MCV, mean corpuscular volume; RBC, red blood cells; WBC, white blood cells.

Table 7.2 Biochemistry Results at Presentation

	Patient Result	Reference Interval
Albumin (g/L)	23.3	25.0–45.0
Globulin (g/L)	30.9	25.0–45.0
Urea (mmol/L)	2.2	2.5–9.9
Creatinine (μmol/L)	64.6	20.0–177.0
ALT (U/L)	65.4	5.0–60.0
ALP (U/L)	84.9	≤60.0
Total bilirubin (μmol/L)	0.7	0.1–5.1
Cholesterol (mmol/L)	3.60	2.20–4.00
Sodium (mmol/L)	152.7	145.0–157.0
Potassium (mmol/L)	4.80	3.50–5.50
Chloride (mmol/L)	123.2	100.0–124.0
Inorganic phosphorus (mmol/L)	2.65	0.90–2.20
Calcium (mmol/L)	2.35	2.05–2.95
Glucose (mmol/L)	4.9	2.8–4.9

Bold type denotes abnormal result.

ALP, alkaline phosphatase; ALT, alanine transaminase.

Q 3. How would you interpret these results and what would you do next?

Microcytosis can occur with iron deficiency, portosystemic shunts (PSSs), and uncommonly chronic inflammatory disease. As the cat wasn't anaemic, iron deficiency was unlikely. Mild hypoalbuminaemia and low urea are consistent with hepatic dysfunction. There was no history of malnutrition or feeding a protein-restricted diet that could also cause these abnormalities. Hypoalbuminaemia can also occur with protein-losing nephropathy or enteropathy but with the microcytosis, mildly increased liver enzymes and low urea, liver dysfunction; specifically PSS was suspected. Arteriovenous fistula and portal vein hypoplasia are other differentials but are very rare in cats. Because the cat is growing, the alkaline phosphatase (ALP) bone isoenzyme is likely contributing to its increased value and hyperphosphataemia is due to bone release of phosphorus.



Tip Box

Increases in liver enzymes such as ALT and ALP are indicators of hepatobiliary disease and not abnormal liver function.

A bile acid stimulation test is advised as the next step (see [Table 7.3](#)).

Q 4. Explain the significance of these results and what you would do next.

Both pre- and postprandial bile acids are very high, indicative of liver dysfunction, and given the age of the patient, a PSS is most likely (rather than acquired liver disease).

Table 7.3 Bile Acid Stimulation Test Results

	Patient Result	Reference Interval
Pre-prandial bile acid ($\mu\text{mol/l}$)	124.8	0.1–5.0
Postprandial bile acid ($\mu\text{mol/L}$)	95.8	0.5–10.0

Bold type denotes abnormal result.

Higher fasting than postprandial bile acids may be secondary to interdigestive gall bladder contraction or as a result of variations in gastric emptying, intestinal transit, or response to cholecystokinin release (which stimulates gall bladder contraction).

Where access to specialized imaging modalities is limited, abdominal radiographs could be performed to look for microhepatica (present in 50% of cats) and bilateral renomegaly; however, radiographs cannot be used to confirm the diagnosis of PSS. Abdominal ultrasound is therefore advised next.

Abdominal ultrasound revealed an anomalous vessel connecting the left gastric vein to the caudal vena cava (Figure 7.4) consistent with an extra-hepatic PSS. Ultrasound is relatively inexpensive and non-invasive, but accuracy is highly operator dependent for the diagnosis of a PSS, and failure to identify a shunt does not exclude it. Abdominal computed tomography (CT) provides a definitive diagnosis and information on shunt morphology where finances allow (Figure 7.5).

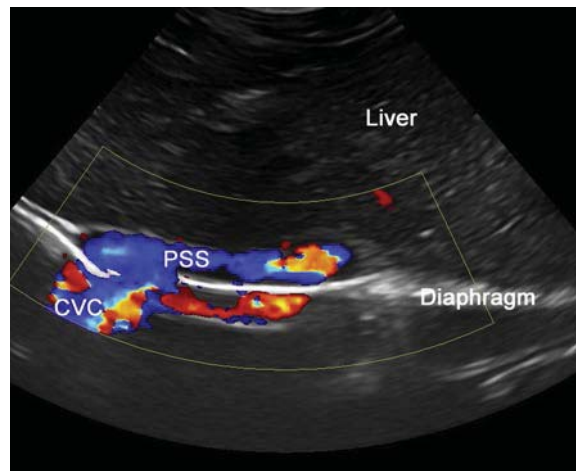


Figure 7.4. Colour Doppler abdominal ultrasound image of the extra-hepatic portosystemic shunt (PSS). CVC, caudal vena cava.

Q 5. What are the treatment options for this cat?

Surgical shunt attenuation is the treatment of choice, but an initial period of medical management is advised to try to control the signs of hepatic encephalopathy, including: feeding a low protein diet (to reduce substrates for ammonia formation by colonic bacteria), oral lactulose (to reduce intestinal transit time decreasing time for

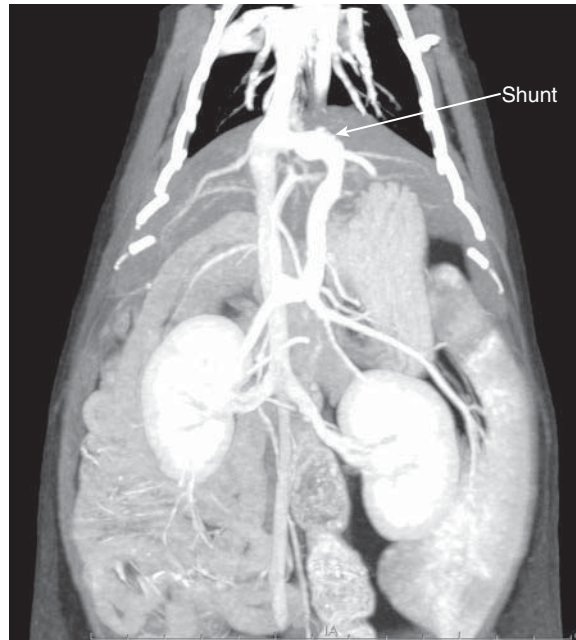


Figure 7.5. CT image post contrast showing an extra-hepatic gastrocaaval shunt (arrow).

ammonia production and absorption and to produce an acidic environment trapping ammonium in the colon), and oral antibiotics (to reduce the number of urease-producing bacteria in the intestine). Where seizures or neurological signs are uncontrolled with hepatic encephalopathy management, low dose phenobarbitone or levetiracetam can be prescribed. Surgical shunt attenuation can be performed when stable.

Treatment and Outcome

Following 4 weeks of medical management (including levetiracetam), surgical shunt attenuation with a cellophane band was performed. Two months later the cat's post-prandial bile acids were normal and no further seizures occurred.

Discussion

Neurological abnormalities are common in cats with PSS, and hypersalivation is also reported in 67–84% of cases. Copper coloured irises are reported in 13–64% of cats with PSS. Medical management is important to stabilize patients prior to surgery (in particular cats that have seizures) for a minimum of 2–4 weeks.

Further Reading

Lipscomb, V.J., Jones, H.J., Brockman, D.J., 2007. Complications and long-term outcomes of the ligation of congenital portosystemic shunts in 49 cats. *Veterinary Record* 160 (14), 465–470.

Case 7.3

Signalment and Clinical History

A 12-year-old MN DSH cat presented with a 5-day history of progressive neurological signs (depression and left-sided hemiparesis). There was no significant previous clinical history. Vaccinations and flea and worming treatment were current. The cat was indoor/outdoor, fed a commercial, dry diet, and had not travelled outside the United Kingdom.

Physical Examination

On presentation the cat was obtunded. He was in good body condition (BCS 5/9).

Neurological examination revealed reduced hopping on all four limbs, but this was most noticeable on the left hind. There was reduced tactile placing in both hind limbs, but again this was more pronounced on the left hind. The menace and response to nares stimulation were reduced on the left side. Examination was otherwise unremarkable apart from a scab on the skin overlying the left frontal sinus region. This was non-painful and there was no evidence of pus or inflammation when the scab was removed.

Q 1. How would you interpret these neurological findings?

- Reduced left menace localizes to CN II, R forebrain, L cerebellum, CN VII
- Reduced left nares stimulation localizes to R forebrain, CN V
- Depression/obtundation localizes to forebrain or brainstem (in the absence of additional cranial nerve deficits the latter is less likely)
- Hopping and tactile placing deficits L > R indicate neurological dysfunction. The lesion may be anywhere in the nervous system but could localize to the R forebrain

If possible the signs should be explained by one lesion. In this case they can all be localized to the right forebrain. Left cerebellar disease cannot be completely excluded, but there were no cerebellar ataxia or hypermetria signs to support this.

Q 2. What are the most likely differential diagnoses in this case?

- Neoplasia
 - Primary: meningioma, lymphoma, glioma, ependymoma, pituitary tumour
 - Metastatic: lymphoma, carcinoma, haemangiosarcoma
- Abscess
- Cyst
- Infectious encephalitis/meningitis
 - Bacterial: bite wound
 - Viral: FeLV, FIV, FIP
 - Protozoal: toxoplasmosis
 - Fungal: cryptococcosis
 - Parasitic: cerebral larval migrans

- Trauma
 - Head trauma, intracranial haemorrhage, subdural haematoma
- Toxic
 - Lead
- Vascular
 - Infarct, haemorrhage, hypertension
- Metabolic
 - Hepatic encephalopathy, renal encephalopathy, hypoglycaemia, hypo/hypernatraemia

Although this patient had a bite wound on the skin over his left frontal sinus region, this was non-painful and inconsistent with the neurolocalization (multifocal signs would be expected), bacterial encephalitis was thus considered unlikely. In a cat of this age, neoplastic disease was considered the most likely cause of the clinical signs. Meningioma is the most common feline intracranial neoplasm and was thus considered most likely.

Q 3. *How would you further investigate this case?*

Serum biochemistry, complete blood count, and urinalysis should be performed to exclude metabolic disease. FIV/FelV status should be established due to the possibility of neoplasia and the presence of forebrain signs that can be associated with FIV infection. BP should also be assessed to exclude both hypertension as a vascular cause of neurological signs and hypotension in an obtunded patient. Fundic examination can provide useful information such as evidence of increased intracranial pressure or chorioretinitis as seen in infectious causes such as FIP, toxoplasmosis and cryptococcosis. MRI is indicated to investigate intracranial disease. Cerebrospinal fluid (CSF) analysis may be indicated dependent on the results of this. Thoracic radiographs and abdominal ultrasound may be considered to exclude metastatic or concurrent disease.

Diagnostic Test Results

- Serum biochemistry, haematology, and urinalysis were all unremarkable
- The patient was FIV enzyme linked immunosorbent assay (ELISA) and polymerase chain reaction (PCR) positive, FeLV negative
- Systolic BP (BP) was normal (130 mmHg; reference interval (RI): 120–160)
- Brain MRI revealed an extra-axial mass compressing the right hemisphere in the fronto-parietal region. Its appearance (hyperintense on T2-weighted images, broad based, and strongly enhancing with gadolinium contrast) was consistent with a meningioma. There was also evidence of peri-tumour oedema (Figure 7.6)
- Thoracic and abdominal imaging were unremarkable

Q 4. *What are the treatment options and associated prognoses in this case?*

The treatment of choice is surgery. Age, location of tumour, and multiple tumours have not been shown to affect outcome. Median survival time after surgical resection has been reported to be between 22 and 27 months, with another study demonstrating 71% survival at 6 months, 66% at 1 year, and 50% at 2 years. Recurrence occurs in approximately 20% of cases with a median time to recurrence of 9.5 months in these cases. The most common complications of surgery are central blindness,

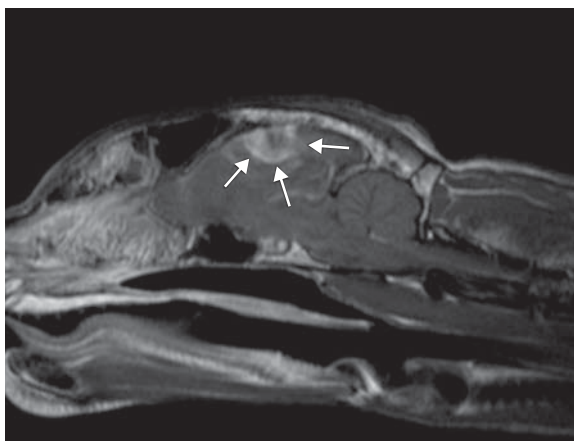

Figure 7.6. Sagittal, T1-weighted MRI scan demonstrating the meningeoma (white mass, arrows) compressing the underlying brain tissue.

anaemia, and acute kidney injury. The peri-operative mortality rate is reported as between 17% and 19%.

Radiotherapy is less commonly employed for the treatment of meningeoma in cats, but survival of 240 days was reported in one cat treated with radiotherapy.

Medical management with chemotherapy (hydroxyurea, lomustine) has also been reported less commonly and with less success (80-day survival for a cat treated with an unspecified chemotherapy protocol in one study).

Prednisolone therapy (at anti-inflammatory doses) to reduce peri-tumour oedema is indicated prior to surgery or in cases where definitive treatment will not be pursued. Mannitol (1–2 g/kg IV infusion over 30 min) may be used to reduce intracranial pressure if indicated. Anti-epileptic medications may be used in cases with seizures, although seizures only occur in approximately 20% of cats with meningeoma.

If Finances Are Limited

Palliative therapy with an anti-inflammatory dose of prednisolone will reduce peri-tumour oedema and CSF (cerebrospinal fluid) production and will thus temporarily reduce the clinical signs associated with the tumour. Anti-epileptic therapy (e.g. phenobarbitone) may be used to control seizures if present.

Q 5. What is the significance of the positive FIV results?

Given that both ELISA and PCR are positive, this is considered to be a true positive result indicative of FIV infection. FIV causes immunodeficiency, making cats more susceptible to infection, neoplasia, or immune-mediated disease but has not been shown to be associated with intracranial neoplasia. No other signs attributable to FIV infection were present, and therefore this was considered to be an incidental finding, with the cat assumed to be in the asymptomatic phase of infection, which can last for many years.

FIV infection was thus not considered a contraindication for surgery, but the client was advised that the patient may be more susceptible to peri/postoperative infection.

The owner was also advised that this cat should be kept indoors to minimize his exposure to infections and prevent transmission to other cats via fighting.

Further Information on Diagnosis, Response to Treatment, and Outcome

The mass was surgically removed in its entirety without any complications. It was histologically confirmed as a meningioma. The patient remains well with no clinical signs 18 months later.

Discussion

Meningiomas are extra-axial neoplasms that arise from the arachnoid cells of the meninges, most commonly occurring in older cats. They are usually benign, well-encapsulated masses, and displace the surrounding brain tissue rather than invading it. Surgical resection is thus usually successful provided they are in an accessible location. Meningiomas are slow growing and signs are often insidious, most commonly involving altered consciousness, circling, decreased vision, ataxia, paresis, and seizures. Meningiomas have been found incidentally in cats with no clinical signs or cats presenting with vague signs such as anorexia and lethargy.

Further Reading

- Hosie, M.J., Addie, D., Belak, S., et al. 2009. Feline immunodeficiency ABCD guidelines on prevention and management. *Journal of Feline Medicine and Surgery* 11, 575–584.
- Sessums, K., Mariani, C., 2009. Intracranial meningioma in dogs and cats: a comparative review. *Compendium Continuing Education for Veterinarians* 330–339.
- Troxel, M.T., Vite, C.H., Van Winkle, T.J., et al. 2003. Feline intracranial neoplasia: retrospective review of 160 cases (1985–2001). *Journal of Veterinary Internal Medicine* 17, 850–859.

Case 7.4

Signalment and History

An 18-month-old MN DSH cat presented with a 24 h history of progressive weakness. He was an inside/outside cat living in a 'bushy' area of southern Tasmania, Australia. The cat was fed a normal commercial diet.

Clinical Examination

The cat was mentally alert and responsive but had generalized flaccid paralysis. Patella and withdrawal reflexes were absent and deep pain response to all limbs was present. Menace reflex was absent and gag reflex was reduced.

The cat was mildly bradycardic (heart rate (HR) 120 bpm) and hypothermic (36.5 °C). Respiratory rate (RR) was 32 brpm, with an increase in inspiratory effort and occasional expiratory grunt. The remainder of the examination was unremarkable.

Q 1. Summarize the problems in this case and provide neurolocalization.

Problem list

- Sudden onset, progressive generalized flaccid paralysis
- Hypothermia
- Bradycardia
- Respiratory compromise

Neurolocalization

There is generalized (forelimb, hindlimb, and cranial nerve), bilateral, flaccid paresis/paralysis (reduced muscle tone, reduced spinal reflexes, flaccid paralysis). These changes may be seen with diseases that affect peripheral nerves (lower motor neuron signs), neuromuscular transmission, or muscular function.

Q 2. Formulate a differential diagnosis list for weakness in the cat.

Neurolocalization

- Degenerative: degenerative myopathy/neuropathy, lysosomal storage disease
- Metabolic: hypoglycaemia, hypernatraemia, hypocalcaemia, hypokalaemia, diabetic neuropathy, hyperlipidaemia, reduced tissue oxygenation (cardiac, respiratory disease, or dysfunction with oxygen carrying capacity of red blood cells)
- Neoplasia: paraneoplastic neuropathy/myopathy
- Nutritional: thiamine deficiency
- Infectious/inflammatory: toxoplasmosis, botulism, polymyositis
- Immune-mediated: myasthenia gravis
- Idiopathic: idiopathic polyneuropathy
- Toxic: tick envenomation, snake envenomation, redback spider envenomation, organophosphate toxicity

Q 3. Are you able to highlight what the most likely differential diagnoses are given the other presenting signs in the above case together with consideration of the geographical region?

In the above case the onset was sudden, paresis progressive, and the cat also exhibited hypothermia, mild bradycardia, and increased inspiratory effort with expiratory grunt. The most likely differentials for these clinical signs in this geographical region are:

- Snake bite
- Tick bite

Stabilization

The cat was hospitalized, maintained in sternal recumbency with 100% flow-by oxygen, actively warmed, and ocular lubrication applied. Attempts were made when handling him to induce as little stress as possible. An intravenous catheter was placed and IVF (intravenous fluids) initiated.

Q 4. How would you definitively refine your differential diagnoses?

A full body search was negative for a tick or tick crater. This involved examining all orifices, feeling the cat all over for scabs/ticks; in cats with long or matted hair a full body clip may be required. While not always located in cases of tick paralysis their presence can be a helpful diagnostic. A search for snake bite was unrewarding (snake bite sites are rarely located).

A minimum database and activated clotting time (Table 7.4), urinalysis (dip stick and specific gravity) (Table 7.5), and in-house snake venom detection test (Figure 7.7) were performed. The test for snake envenomation in this case was performed on urine and returned a positive result. Coagulation times are usually elevated with snake bite envenomation so this can also aid diagnosis.

Table 7.4 Blood Test Results

Variable	Result	Reference Interval
Urea (mmol/L)	5.7	5.7–12.9
Creatinine (μmol/L)	71	71–212
Total protein (g/L)	74	57–89
ALT (U/L)	111	12–130
ALP (U/L)	78	14–111
Glucose (mmol/L)	16.29	4.17–9.22
CK (U/L)	1065	10–200
PCV (%)	46	30–45
ACT (s)	90	(<60–90)

Bold type denotes abnormal result.

ACT, activated clotting time; CK, creatine kinase; PCV, packed cell volume. For further abbreviations, see footnote to Table 6.2.

Table 7.5 Urinalysis

Variable	Result	Reference Interval
Specific gravity	1050	n/a
Glucose	4+	Nil
Blood	4+ haemolysed	Nil
pH	6.5	n/a
Protein	+	Nil

Bold type denotes abnormal result.

Q 5. What is your interpretation of the laboratory results?

The positive test for tiger snake envenomation confirms the diagnosis of snake bite. Elevated creatine kinase (CK) is often seen in snake envenomation due to the action

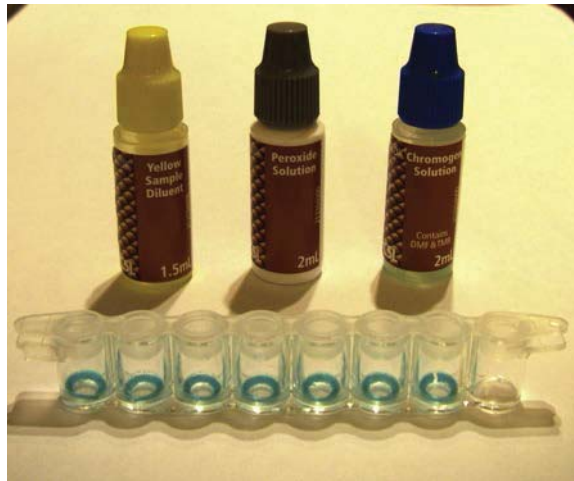

Figure 7.7. Commonwealth serum laboratories (CSL) snake venom detection kit (SVDK): detection of tiger, brown, black, death adder, and taipan envenomation with +ve and –ve controls and blank well. The SVDK available in Australia enables the detection of snake envenomation using blood, urine, or a swab from the bite site. It also allows identification of the type of snake (which may influence treatment and prognosis). It is advised to perform test on cat heparinized blood or plasma (preferable) if envenomation occurred less than 8 h prior to presentation and to use urine if the time post envenomation is greater than 8 h or unknown.

of myotoxins. The elevated blood and urine glucose is likely due to stress; blood and urine glucose should be checked prior to discharge to exclude diabetes. The '4+ haemolysed blood' noted on urine dip stick is likely due to envenomation (myotoxins and haemolysins) and indicates the presence of haemoglobinuria and/or myoglobinuria.

Q 6. What are the possible consequences of snake bite envenomation?

Post-envenomation signs may include vomiting, acute collapse, salivation, trembling, defecation, tachypnoea followed by temporary recovery. Occasionally there is swelling/pain located at the bite wound. Signs relating to the liberation of toxin vary with each snake species. Australian snakes have neurotoxins (flaccid paralysis), myolysins (destruction of muscle tissue, resultant elevated CK and myoglobinuria), haemolysins (anaemia and bilirubinuria), pro-coagulant toxins (disseminated intravascular coagulation), and anticoagulants (coagulopathies). Acute kidney injury may develop due to the direct effect of toxins or secondary to circulatory pigment build-up. Other complications can include mega-oesophagus, aspiration pneumonia, and respiratory failure.

Q 7. How would you manage this case?

Supportive treatments

- Ensure airway patent, intubate and ventilate if needed, provide oxygen
- Secure intravenous access and commence fluid therapy at 2–3 times maintenance rates to promote diuresis

- Pre-medicate (to reduce risk of anaphylaxis) with chlorpheniramine prior to administering antivenom (have adrenaline (epinephrine) to hand in case of anaphylactic reaction)
- Buprenorphine analgesia as required
- Ocular lubrication
- Assistance with thermoregulation

Snake antivenom

- Polyvalent and monovalent antivenoms available dependent on whether the type of snake was known. In this instance tiger snake antivenom was the treatment of choice as it cross-neutralizes all venomous snakes in Tasmania.
- Each vial of antivenom should be diluted with five times the volume of saline and given by slow intravenous injection over 30 min. Patients need to be monitored (HR, RR, BP, temperature, SpO₂, signs of agitation/swelling/discomfort) for signs of anaphylaxis. If signs develop, antivenom administration should be halted, adrenaline administered if needed, and then the administration recommenced at a slower rate.

Follow-up

Twenty-four hours post admission the cat's gag had returned and he was able to eat. He was still weak and had slightly incomplete pupillary light reflex at this stage, but by 48 h post admission he was clinically normal.

If Finances Are Limited

In Australia cats have a much more favourable outcome post snake bite than dogs, and many may recover without the administration of antivenom, which is very expensive. If antivenom is not administered, supportive treatment should be implemented with intravenous fluids, temperature regulation, frequent turning, and ocular lubrication. Some owners may decide to nurse the animal at home and some will recover, however, the risk of death and secondary complications is high.

Case 7.5**Signalment and Clinical History**

A 3-year-old MN DSH cat presented with a 24 h history of progressively worsening inappetence, lethargy, and weakness. He was retching prior to presentation and presented in respiratory distress. He was an indoor/outdoor cat living in an urban environment in the coastal northern suburbs of Sydney, Australia. He was fed a regular commercial diet and was up to date with vaccinations and intestinal parasite control, but not with flea control.

Clinical Examination

On examination the cat was generally weak, with paresis of all four limbs, and fatigued rapidly. An engorged tick was found adjacent to the left pinna. There was a fatigable

palpebral reflex and weak withdrawal and patella reflexes. He was tachypnoeic with marked inspiratory effort. Thoracic auscultation revealed crackles and muffled heart sounds. Mild pyrexia of 39.4 °C was present.

Q 1. Formulate a problem list with differential diagnoses for each problem.

- Generalized progressive paresis with weak withdrawals and patella reflexes
 - Polyneuropathy
 - Myopathy
 - Junctionopathy
- Engorged tick
 - *Ixodes* (causing clinical signs of tick paralysis)
 - 'Bush' tick (not all ticks are *Ixodes* and capable of causing paralysis)
- Increased inspiratory effort
 - Upper respiratory tract obstruction, e.g. laryngeal paralysis
 - Respiratory muscle paresis (intercostal/diaphragmatic)
 - Pleural space disease
- Crackles on thoracic auscultation
 - Interbronchial/alveolar fluid
 - Pneumonia
 - Oedema (e.g. congestive heart failure)
 - Interstitial restrictive disease (e.g. pulmonary fibrosis)
- Pyrexia
 - Inflammation
 - Infection
 - Neoplasia

Q 2. What is the most likely diagnosis and how would you manage this case?

The patient has signs consistent with tick paralysis from *Ixodes holocyclus*. With respiratory distress, it is best to minimize potential stressors to the patient and quickly identify the species of tick (see Figure 7.8). The tick is confirmed to be a paralysis tick (four legs each side: front to back: one dark, two light, one dark).

Identification and removal of any further ticks is also required (see Figure 7.9). Clipping cats may allow identification of further ticks. However, most cats find this distressing and therefore any readily identified ticks should be promptly removed and the patient stabilized first.

Light sedation (e.g. butorphanol 0.2 mg/kg ± acepromazine (ACP) 0.02 mg/kg) is sometimes required to reduce respiratory effort and reduce exertion. Strict cage rest is important.

Tick antiserum is required to reduce the risk of further deterioration. In this case 1 mL/kg tick antitoxin was given IV over 30 min with close monitoring for signs of anaphylaxis (because it is dog serum) such as tachycardia, hypotension, vomiting, dyspnoea, pallor, or Bezold-Jarisch reaction (bradycardia/hypotension). If bradycardia occurs, the rate of administration should be slowed. If signs of anaphylaxis occur, the infusion should be discontinued and adrenaline administered.



Figure 7.8. Paralysis tick.

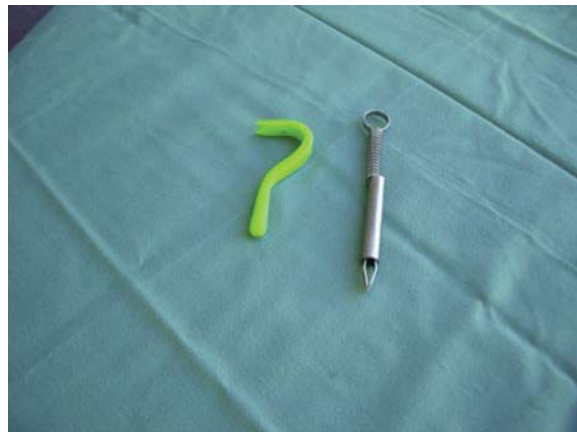

Figure 7.9. Tick removers. Courtesy Justin Wimpole, Small Animal Specialist Hospital, NSW, Australia.

Applying an acaricidal product suitable for cats such as fipronil is beneficial in killing other ticks (including nymphs) that haven't been identified.

If tachypnoea and abnormalities on thoracic auscultation persist, thoracic radiographs are indicated. Stress should be minimized and flow-by oxygen provided.

Further Information on Progression of the Case

The cat remained pyrexia, with increased RR and crackles. Thoracic radiographs were performed under sedation as described above.

The radiographs show a diffuse alveolar pattern with air bronchograms. There is border effacement of the heart. There is a prominent lobar sign in the cranial lung lobes.

Q 3. What are your differential diagnoses for the described radiographic changes?

Differential diagnoses include aspiration pneumonia (most likely), bronchopneumonia, cardiogenic and non-cardiogenic pulmonary oedema, neoplasia, haemorrhage, and smoke inhalation.

Q 4. What are the options for further management of this case?

CT- or ultrasound-guided aspiration of affected lung, bronchoscopy, and bronchoalveolar lavage could be performed to provide further information. In this case, further diagnostics were not performed due to the risk of patient morbidity and the fact that aspiration pneumonia was most likely.

Cats with aspiration pneumonia, particularly secondary to a polyneuropathy (such as tick paralysis), can develop respiratory fatigue quickly and are challenging to manage.

- Sedation is usually required to keep the patient relaxed:
 - Butorphanol 0.1–0.2 mg/kg or buprenorphine 0.01–0.02 mg/kg TID, +/- ACP 0.02 mg/kg q 4–6 h
 - Heavier sedation: ketamine 5 mg/kg + midazolam 0.2 mg/kg + butorphanol 0.2 mg/kg IM
- Placement of nasal catheters for oxygen administration if SpO₂ is not adequately maintained
- Anaesthesia can be required for:
 - Intubation: if the patient has temporary respiratory fatigue
 - Artificial ventilation if the patient has longer-term hypoventilation (endotracheal (ET) CO₂ > 55 mmHg, venous CO₂ > 55, arterial CO₂ > 40)
- Intravenous fluids 2 mL/kg/h, 0.45% NaCl + 2.5% glucose + KCl supplementation as required
- Intravenous antibiotics to cover Gram negative and anaerobic bacteria
 - If culture and sensitivity has not been performed, then empiric antibiotics such as a combination of amoxicillin-clavulanate or clindamycin and a fluoroquinolone (+/- metronidazole) are advised
- Nil PO until a swallow reflex has been observed
- Nursing care is also vital:
 - Ocular lubricant QID both eyes to prevent corneal ulceration
 - Nebulization and coupage TID to assist mucociliary clearance
 - Suction of airways and vigilant ET tube care is essential if intubation is required
 - Turning q 2 h to reduce atelectasis and hypoventilation
 - Check and express bladder as required
 - Thermoregulation: warm bedding if required.
- Tracheostomy tubes can be placed if there is significant laryngeal paralysis and prolonged treatment is anticipated

Follow-up Information

The patient slowly improved with supportive treatments and treatment of pneumonia as outlined above. Intubation and ventilation were not required. He was discharged from hospital after 5 days and received a further 2 weeks of antibiotics at home. Repeat radiographs 4 weeks after initial diagnosis showed resolution of pneumonia.

Discussion

Tick paralysis causes a generalized polyneuropathy. Aspiration pneumonia is a common consequence of the associated laryngeal and oesophageal dysfunction, which can be further exacerbated by sedation/anaesthesia, which also inhibits swallowing, cough reflex, and mucociliary transport. Non-cardiogenic pulmonary oedema has also been reported in severe cases of aspiration pneumonia.

Further Reading

Musca, F., Gunew, M., 2004. Tick Paralysis in Cats: A Retrospective Review. Control and Therapy. Post Graduate Foundation in Veterinary Science. The University of Sydney (Perspective #40).
Schull, D., Litster, A., Atwell, R., 2007. Tick toxicity in cats caused by *Ixodes* spp. in Australia: a review of published literature. Journal of Feline Medicine and Surgery 9, 487–493.

Case 7.6

Signalment and Clinical History

A 14-year-old MN DSH cat presented with a 4-day history of tachypnoea and progressive weakness.

Examination Findings

The cat was in good body condition (BCS 5/9), with normal muscle mass. He had increased inspiratory effort, cervical ventroflexion, and appeared generally weak with a crouched gait, which was exacerbated by exercise. Conscious proprioception was reduced, and spinal and postural reflexes were normal. A fatigable palpebral reflex was present; all other cranial nerve examinations were unremarkable. Cranial rib spring was reduced.

Q 1. Formulate a list of differential diagnoses for generalized weakness.

- Metabolic disease
 - Hypoglycaemia
 - Hypokalaemia
 - Thiamine deficiency
- Haematopoietic disease
 - Anaemia
 - Polycythaemia: hyperviscosity

- Neuromuscular disease
 - Junctionopathies (e.g. myasthenia gravis)
 - Myopathies (e.g. polymyositis, hypokalaemic polymyopathy)
 - Polyneuropathies (e.g. tick paralysis, snake envenomation, Guillain-Barre-like syndrome, idiopathic, paraneoplastic conditions, botulism, organophosphate toxicity)
- Cardiorespiratory disease
- Endocrine disease
 - Hypo/hyperthyroidism
 - Diabetes mellitus
 - Hyperaldosteronism

Q 2. Remembering to consider the other presenting problems as well, what further diagnostic investigations would you perform?

- Blood pressure assessment
- Serum biochemistry, to particularly include electrolytes, glucose, aspartate aminotransferase (AST), CK
- Routine haematology to assess for anaemia or polycythaemia
- Total thyroxine (T4) concentration
- Thoracic radiographs and/or ultrasound to assess the tachypnoea, increased inspiratory effort, and reduced cranial rib spring

Diagnostic Test Results

- Systolic BP was normal at 130 mmHg
 - Haematology was unremarkable except for a stress leucogram
 - CK was 6231 U/L (RI: < 200)
 - ALT was mildly elevated 157 U/L (<60)
 - Total T4 was within the RI at 15 (10–45 nmol/L)
- A right lateral thoracic radiograph was taken (Figure 7.10).

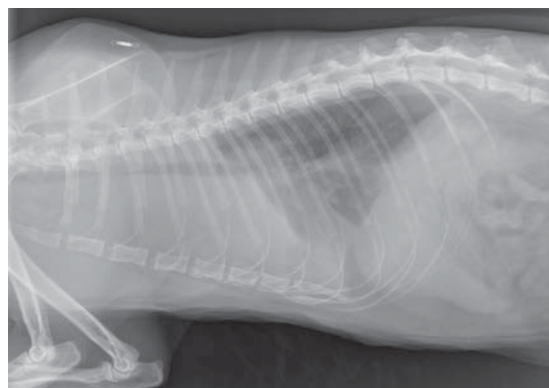


Figure 7.10. Right thoracic radiograph.

Q 3. What are the key radiographic abnormalities?

- Pleural effusion
- Mild dorsal tracheal elevation

The mild dorsal tracheal elevation may be suggestive of the presence of a cranial mediastinal mass, but this is not definitive on the radiographs. No evidence of mega-oesophagus, pneumonia, or pulmonary oedema was noted.

Cranial thoracic ultrasonography confirmed the presence of a 27 × 40 mm hypoechoic cystic cranial mediastinal mass.

Q 4. What are the differential diagnoses for a cranial mediastinal mass in cats?

Thymoma and mediastinal lymphoma are by far the most common, and thymoma would be the most common in an older cat. Other possibilities include:

- Thymic carcinoma
- Idiopathic mediastinal cyst
- Ectopic thyroid tumour
- Haemangiosarcoma
- Mesothelioma
- Granuloma
- Chronic inflammation
- Pulmonary abscessation

Q 5. How would you further manage and investigate this case?

Options for further investigation include:

- Thoracocentesis and cytology of pleural fluid
- Ultrasound-guided fine needle aspiration of the cranial mediastinal mass
- More advanced investigations of neuromuscular disease include:
 - Edrophonium chloride response test
 - Electrodiagnostics: electromyograms and nerve condition studies
 - Acetylcholine receptor antibody (AChRAb) titre (<http://vetneuromuscular.ucsd.edu>)
 - Muscle and nerve biopsy
- Thoracotomy and resection of cranial mediastinal mass (once patient is stable, presence of the mass is confirmed and lymphoma excluded)

Further Information about the Case

Thoracocentesis was performed yielding 130 mL of a modified transudate with unremarkable cytology. The cat's breathing improved, but he remained very weak.

An ultrasound-guided fine needle aspirate of the mass revealed a predominance of small lymphocytes on cytology. This does not provide a definitive diagnosis: lymphoma, thymoma, or a thymic cyst remain possible, with histology required to confirm a diagnosis.

The weakness is not completely explained by the presence of a cranial mediastinal mass or pleural effusion, and therefore further diagnostics were performed. Myasthenia

gravis has been associated with thymomas, and therefore this was considered the most likely possibility.

An edrophonium response test was performed with a positive response.



Tip Box

The edrophonium response test requires administration of edrophonium chloride IV. This is a short-acting cholinesterase, increasing levels of acetylcholine at the neuromuscular junction and temporarily ameliorating clinical signs in cases with myasthenia gravis.

Blood was simultaneously submitted for anticholinesterase antibodies, which were found to be elevated at 0.5 nmol/L (RI: <0.3 nmol/L), confirming a diagnosis of myasthenia gravis.

Q 6. How would you manage this case?

Considering the severity of weakness in this patient and concerns regarding anaesthesia, acetylcholinesterase drugs are recommended. Pyridostigmine and neostigmine are the most commonly used drugs. Recommended therapeutic dose ranges for pyridostigmine vary, generally 0.25–3 mg/kg SID to TID. Pyridostigmine at 3.3 mg PO TID was used in this case. Atropine (0.05 mg/kg IM) was available to reduce cholinergic effects (ptyalism, mild nystagmus, muscle twitching) if required.

Once stable for anaesthesia, thoracotomy and surgical removal of the mass were performed. It was an encapsulated, well-circumscribed mass that was confirmed to be a thymoma on histopathology.

Myasthenia gravis associated with thymoma is immune-mediated and may resolve with removal of the primary cause alone without the need for immunosuppressant medication. In this case, immunosuppressants were used and tapered over a 6-month period postoperatively. Prednisolone is the most commonly used immunosuppressant treatment in cats. It was initially started at 2 mg/kg PO SID 10 days postoperatively. It was not effective in resolving myasthenic signs within 2 weeks. Ciclosporin was therefore used at an initial total dose of 2 mg/kg PO BID.

Case Outcome

Postoperatively pyridostigmine was administered at 5 mg PO BID. Five days postoperatively bilateral pupillary miosis and twitching were encountered without ptyalism or bradycardia. Pyridostigmine was stopped and restarted 3 days later at 2.5 mg PO EOD for 3 months, then discontinued. The patient was reassessed 6 months after surgery. There was no recurrence of the cranial mediastinal mass and no recurrence of muscle weakness. AChRabs were repeated and were <0.3 nmol/L prior to discontinuing ciclosporin.

Discussion

Cats presenting with neuromuscular weakness typically display signs of respiratory distress, mega-oesophagus, dysphagia, and regurgitation or inappetence. Myasthenia

gravis is a differential diagnosis for progressive generalized weakness, particularly when exacerbated with exercise.

The condition can be congenital or acquired. The acquired form results from autoantibodies directed at acetylcholine receptor or MuSK protein at the postsynaptic neuromuscular junction. An increase in serum ACh receptor autoantibodies is confirmatory. However, 10% of patients may not have an elevated AChRab at initial presentation.

In comparison to canine myasthenia gravis, acquired feline myasthenia is uncommon. The link between thymic disease and myasthenia gravis is complex, involving immune dysfunction and loss of self-tolerance.

Myasthenia gravis may not resolve despite adequate resection of a thymoma, for reasons that are unclear. In some cases long-term treatment with pyridostigmine and/or immunosuppressive agents may be required. AChRabs may be used to guide therapy in these situations.

Further Reading

Shelton, G.D., 2000. Risk factors for acquired myasthenia gravis in cats: 105 cases (1986–1998). *Journal of the American Veterinary Medical Association* 216 (1), 55–57.

CHAPTER

8

Toxicity and Trauma

Case 8.1

Signalment and Clinical History

A 5-year-old FN DSH cat has vomited after spending time in a garage, where the owner thinks it could have ingested either car oil or anti-freeze. The owner's other cat was also shut in but is now missing.

Clinical Examination

On presentation the cat is slightly obtunded but responsive, with a heart rate (HR) of 210 bpm and weak femoral pulses with no deficits. The cat had a respiration rate (RR) of 30 brpm with normal thoracic auscultation. The bladder is very small.

Q 1. *You suspect from the history that the cat has ethylene glycol (EG) toxicity. What is the toxic dose for a cat, and what laboratory tests can be performed both on blood and urine that could confirm your diagnosis?*

- Toxic dose: 1.5 mL/kg.
- Laboratory tests: classically cats have a metabolic acidosis from the EG metabolites, an increased anion gap, hypocalcaemia, hyperglycaemia, and azotaemia.
- EG detection kits are available: they take approximately 30 min to run. False positives are seen if propylene glycol or glycerol is in the cat's blood. False negatives are also seen with lower EG concentrations.
- Urinalysis: depending on timing (can take 3–6 h), decreased urine specific gravity (SG) and the presence of crystalluria, both calcium oxalate monohydrate or dihydrate crystals. Renal casts are also often present. Urine (and vomitus) can be examined with a blue light (or Wood's lamp) to detect fluorescent dyes in the anti-freeze preparations.

Q 2. *Why is EG toxic?*

EG itself is not significantly toxic and is renally excreted; however, EG is metabolized in the liver via alcohol dehydrogenase (ADH) to glycoaldehyde and via the same enzyme to glycolic acid, which itself is converted to glyoxylic acid and then oxalic acid (the latter in the blood). Calcium binds to the oxalic acid and precipitates crystals (calcium oxalate monohydrate crystals) in the kidneys. The crystalluria can be seen 3–6 h after ingestion. The glycolate and glycoxylate are thought to be the main cause of the toxic effects, which result in acute kidney injury (AKI).

Further Case Information

You have placed a peripheral IV catheter and started giving intravenous fluids (IVF). At the same time you have run an emergency database that shows the cat has a packed cell volume (PCV) of 35%, total solids 80 g/L, mild hyperkalaemia (5.8 mmol/L), mild azotaemia (creatinine 280 μ mol/L and urea 22 mmol/L), and moderate hyperglycaemia (glucose 12 mmol/L). You are unable to measure anion gap or ionized calcium and the bladder is empty so urinalysis is not possible.

Q 3. *Should treatment be started for EG intoxication without a definitive diagnosis?*

When there has been a known or suspected ingestion of EG, it is imperative not to delay treatment, especially if the patient has been presented <2–3 h from ingestion.

Q 4. *You decide to treat the cat for EG toxicity on the assumption of clinical signs and supportive tests. What treatments are available and how do they work?*

There are two main treatments available specifically for EG toxicity: ethanol and fomepizole. They are not antidotes, but both aim to reduce EG from being metabolized.

1. Ethanol competitively and preferentially binds to ADH, leaving the unconverted EG to be renally excreted. Although medical ethanol should be used, in these cases any alcohol would be preferential as time is of the essence (i.e. vodka NOT surgical spirit or methylated spirit as these contain methanol). Ethanol itself causes central nervous system (CNS) depression, which can be profound.
2. Fomepizole (4-methylpyrazole) is a competitive ADH inhibitor. It has fewer side effects than ethanol. It has been shown to be effective in cats used at a higher dose rate than in dogs (125 mg/kg IV initially, then 31.25 mg/kg at 12, 24, and 36 h).

The cat was treated with ethanol as well as IVF therapy and supportive care and is showing signs of improvement.

The owner has now found the other cat (MN DSH 6 years old) 24 h later. This cat is obtunded, HR 150 bpm, RR 30 brpm, rectal temperature (RT) 36.5 °C with a small bladder. A wet preparation of the urine shows many crystals (Figure 8.1).

Q 5. *What treatment would you recommend based upon these findings?*

If the patient has been showing signs for >24 h and you have documented calcium oxalate crystals, then the renal damage has been done. Check that the cat is indeed oliguric or anuric, and check the renal analytes and electrolytes. Experimentally, if cats were treated with fomepizole >3 h after EG administration they had 100% mortality. Renal replacement therapy might buy time for the kidney to have a chance of recovery (can take 4 weeks) though permanent damage is likely, and unless in a country where renal transplantation is available, treatment may be futile.

The owner is adamant you treat their second cat. An emergency database shows that this cat has a PCV 35%, TP 90%, and marked azotaemia (urea >50 mmol/L and creatinine 1284 μ mol/L). You have placed a urinary catheter to measure urine output.

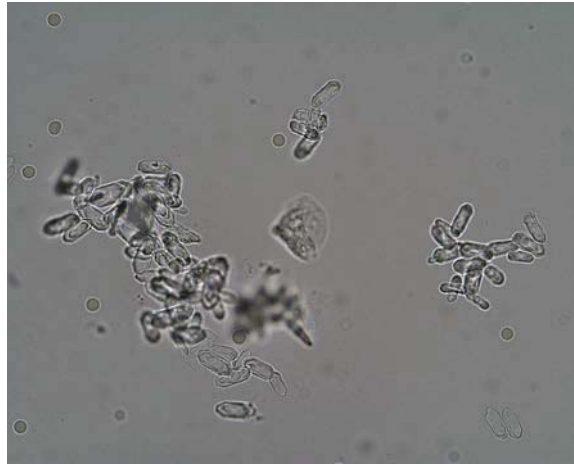

Figure 8.1. Calcium oxalate monohydrate crystals. Photo courtesy of Anne Leuschner, Royal Veterinary College.

Q 6. *How would you manage this case? What fluids would you give, how would you monitor the patient, and are there any treatments that could be given?*

Fluids

An isotonic crystalloid replacement fluid should be primarily used. Supplementation with potassium might be required (especially if they are in the polyuric phase).

Monitoring

Fluid balance (calculated 'ins and outs') is useful with any AKI; therefore a urinary catheter should be placed to accurately measure the urine production. If this is impossible, then bladder palpation or ultrasound can indicate urine production or a non-absorbable litter can be used and the urine volume measured. With oliguric or anuric cats overhydration is a distinct possibility, and therefore measuring the body weight q 6 h might provide you with a trend. Electrolytes (in particular potassium) should be measured at least BID. Long-stay jugular catheters are appropriate to use in these cases to minimize the vascular damage and potential stress involved in multiple blood samples being taken (Figure 8.2).

Further treatments

Although there are no specific treatments that have been shown to be effective in treating AKI, furosemide, mannitol, dopamine, diltiazem, and fenoldopam have all been used in an attempt to restore urine output. Furosemide, either as a bolus or continuous rate infusion, might have a renoprotective effect by decreasing the oxygen consumption of the kidney. Hyperkalaemia is managed mainly with fluid therapy and restoration of urine output, but further management may be needed (e.g. calcium gluconate, glucose/insulin, sodium bicarbonate). Time is required to see if there is going to be a return of renal function, and that can take >4 weeks. Therefore, renal replacement therapy might be the only option remaining; either

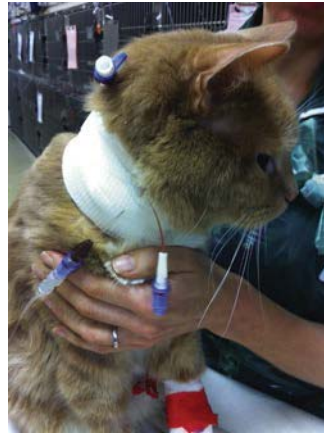

Figure 8.2. Cat with central line (long-stay jugular catheter) and urinary catheter, to monitor urinary output.

peritoneal dialysis, intermittent haemodialysis, or continuous renal replacement therapy. Although technically peritoneal dialysis can be achieved in general practice, it is labour intensive and 24-h care is required.

Comments

The goal is to convert to a polyuric state, and care should be maintained in assessing their 'ins and outs' at least four times a day. The majority of patients that reach a polyuric state should survive to hospital discharge, though obviously they might have chronic kidney disease.

Case Outcome

The first cat made a full recovery with no lasting chronic kidney damage, but the second cat was euthanized after 24 h of treatment as it remained anuric.

Further Reading

Connally, H.E., Thrall, M.A., Harmar, D.W., 2010. Safety and efficacy of high-dose fomepizole compared with ethanol as therapy for ethylene glycol intoxication in cats. *Journal of Veterinary Emergency and Critical Care* 20, 191–206.

Lunn, K.F., 2011. The kidney in critically ill small animals. *Veterinary Clinics of North America: Small Animal Practice* 41, 727–744.

www.iris-kidney.com, the International Renal Interest Society.

Case 8.2

Signalment and Clinical History

A 7-year-old MN DSH cat is presented after having been found in the garden panting, with wet hind limbs, and cried when the owners picked it up in a towel. Moments earlier a dog was seen running from the garden; a dog attack is suspected.

Clinical Examination

On presentation the cat is tachypnoeic with an RR of 70 brpm, with lung sounds evident on thoracic auscultation bilaterally. Mucous membranes were pale pink with a CRT (capillary refill time) of 1 s. The HR was 240 bpm, with absent peripheral pulses. There was saliva staining to the thorax and hind quarters and a couple of puncture wounds evident on the limbs, though the cat was too sore during initial examination for a detailed examination. Neurologically the cat was quiet, but responsive. RT was 37.5 °C. Systolic blood pressure (BP) was measured at 70 mmHg (Doppler).

Q 1. What is the definition of shock, and what forms of shock have been described? Which is likely in this case?

Definition: global tissue hypoxia (imbalance between delivery and consumption of oxygen on a cellular level).

Types of shock

- Hypovolaemic shock (e.g. haemorrhage, vomiting, and diarrhoea)
 - Cardiogenic shock (e.g. hypertrophic cardiomyopathy leading to congestive heart failure)
 - Obstructive shock from failure of blood returning to the circulation (e.g. gastric dilatation and volvulus)
 - Distributive shock, which is commonly seen with sepsis and anaphylaxis
- Some texts refer also to *hypoxic* (e.g. anaemia) and *metabolic* (e.g. hypoglycaemia) as additional forms of shock.
- Hypovolaemia is most likely the cause of shock in this cat.

Q 2. Describe how you would initially assess and stabilize this patient.

Assessment

Major body systems (cardiovascular, respiratory, neurological) need to be assessed.

- Neurological: the cat appears neurologically intact from initial examination. The quiet demeanour could be related to pain, hypoperfusion (hypovolaemia and hypotension), although a neurological injury could not totally be excluded.
- Cardiovascular: clinical examination signs are consistent with hypovolaemic shock.
- Respiratory: as lung sounds are evident throughout, significant pleural space disease is less likely. The tachypnoea is most likely related to pain, although bite injuries could also cause pulmonary contusions, and thoracic radiography is needed to fully exclude traumatic conditions such as pneumothorax and ruptured diaphragm.

Stabilization

- Intravenous catheter placement (with concurrent sampling for minimum database, including PCV, TP, glucose, electrolytes, and some metabolites, e.g. renal parameters).
- IVF resuscitation using isotonic crystalloids (using a bolus of the percentage of blood volume over a period of time, i.e. 10 mL/kg over 15 min). Colloids could also be used in this case (however, currently starches have been withdrawn from use in the UK).
- Analgesia with opioids preferential (e.g. methadone, buprenorphine).

Further Case Information

The cat (Figure 8.3) was given two 10 mL/kg boluses of compound sodium lactate (CSL) each over a 15 min period. Concurrently, he was supported with flow-by oxygen. He was also given analgesia (methadone 0.2 mg/kg slow IV). His heart rate decreased (200 bpm), peripheral pulses returned, and systolic BP improved to 95 mmHg. His RR improved and once he was stable a lateral thoracic radiograph was taken and shown to be unremarkable.

Q 3. What, if any, antibiotics should be used?

In this case bacterial contamination is highly likely in the bite wounds, so antibiotic cover is appropriate. Antibiotic spectrum should cover those organisms commonly associated with bite wounds (e.g. Gram positive aerobes *Staphylococcus* and *Streptococcus* spp., and gram negative facultative anaerobes *Escherichia coli*, *Enterococcus* spp., and *Pasteurella* spp.). An appropriate first choice is amoxicillin-clavulanate; others could include first or second generation cephalosporins. Swabs can be taken from cleaned wounds to assist a change in antibiotics if required.

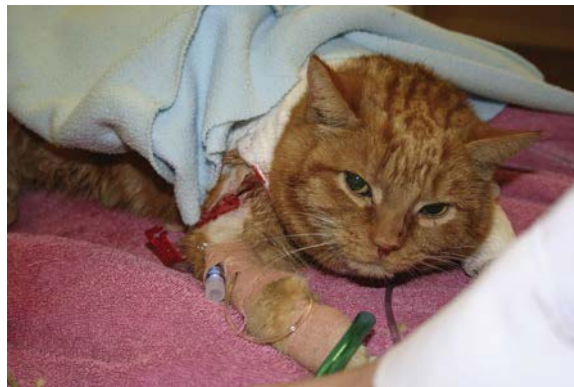

Figure 8.3. Initial stabilization of patient; note intravenous catheter and flow-by oxygen. Photo courtesy of Zoë Halfacree.

Further Case Information

The cat received intravenous antibiotics (potentiated amoxicillin, 20 mg/kg TID IV).

Although the cat has initially responded to fluid therapy and supportive care, you plan to anaesthetize the cat once it is more stable to clip and explore the wounds. General anaesthesia and potentially a prolonged procedure will have additional impact on the patient. Maintenance of good perfusion (e.g. BP, HR, pulse profile, serum lactate) is imperative prior to any further investigation or treatment.

Four hours later you anaesthetize the cat and clip the wounds (Figures 8.4 and 8.5).

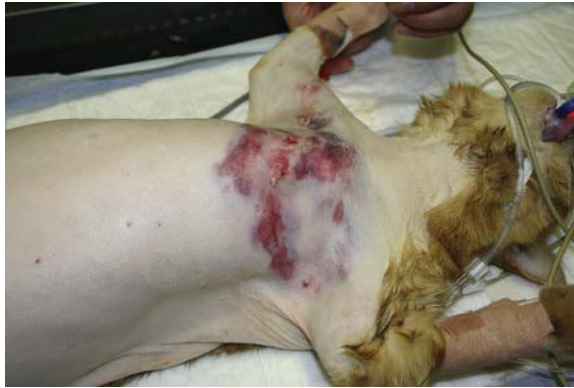

Figure 8.4. Thoracic bite wounds: 'what lies beneath'. Photo courtesy of Zoë Halfacree.

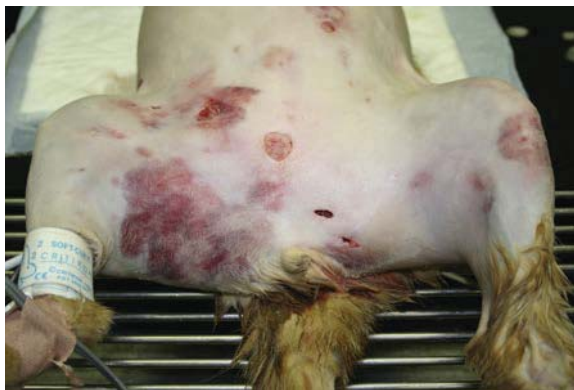

Figure 8.5. Extensive soft tissue injuries from bite wounds. Photo courtesy of Zoë Halfacree.

Q 4. *How do you treat these wounds and determine how far the wounds are explored?*

The risk is not being prepared for 'what lies beneath' these puncture wounds. Radiographs can be used to see if there is obvious penetration to a body cavity (e.g. pneumothorax, pneumoperitoneum), and these cavities should then be explored. Puncture wounds should be probed (and sometimes opened) to determine their extent. If there is uncertainty about their communication with a cavity, then positive contrast can be used.

The affected area should be clipped and cleaned, sterile water-soluble lubrication should be put into areas where the skin is not complete to avoid contamination. Once free of hair the wound can be flushed: sterile Hartmann's-CSL is potentially less damaging to fibroblasts than normal saline (0.9% NaCl). The ideal pressure (8–10 psi) for this can be generated by using any needle on a pressurized bag of fluids with an extension set. By using a 20–30 mL syringe with a 19-gauge needle, the pressure has been reported to exceed 10 psi. Dilute chlorhexidine (0.05%) has also been used, but at a

low concentration (0.05%) to avoid toxicity to granulation tissue. Any necrotic tissue and foreign material should be removed (debridement).

The use of dressings and bandages (e.g. wet/dry) and types of drainage if required are dependent on the extent of the wounds and the individual preference of the veterinarian.

Further Case Information

This patient recovered well after surgical exploration of the puncture wounds. Penrose drains were placed and covered. The drains were removed after 4 days and the wounds left to heal by secondary intention. Antibiotic treatment was continued for 10 days.

Discussion

Although there is a 'golden period' where wounds should be explored if possible, this should always be dependent on the extent of the injuries and the stability of the patient. Cases such as this can be challenging to treat as small wounds can conceal deeper injury to body cavities. Sepsis is also a potential complication. Patients should be stabilized prior to extensive investigation and attending clinicians be prepared for any deterioration. In these cases it is important not to rush into 'fixing' the wounds if the patient is not stable.

Further Reading

Baines, S., Lipscomb, V., Hutchinson, T., 2012. BSAVA Manual of Canine and Feline Surgical Principles. BSAVA Press.

Case 8.3

Signalment and Clinical History

A 2-year-old MN DSH cat presented with a 1-week history of lethargy and inappetence. A week earlier the cat had been hit by a car and sustained superficial injuries on his hind quarters that were clipped and cleaned. The cat was treated with cefovecin and non-steroidal anti-inflammatory drugs (NSAIDs).

On presentation the cat was in lateral recumbency and poorly responsive. HR was 140 bpm and RR 20 brpm with no abnormalities on cardiac or thoracic auscultation. Mucous membranes were white with undetectable CRT. Femoral pulses were weak. Abdominal palpation elicited pain and a fluid wave was palpable. RT was 34.2 °C.

An emergency database showed a PCV of 20% and total solids 58 g/L. Blood glucose was 2.1 mmol/L.

Systolic BP (Doppler sphygmomanometry) was 60 mmHg.



1. Describe how you would initially manage this case.

Intravenous access is imperative. It can be difficult to obtain in cold, hypotensive patients. A cut down could be made to facilitate intravascular access, or the intraosseous route used (Figure 8.6) until the intravascular volume is increased. The humeral head or tibial crest can be used most readily.

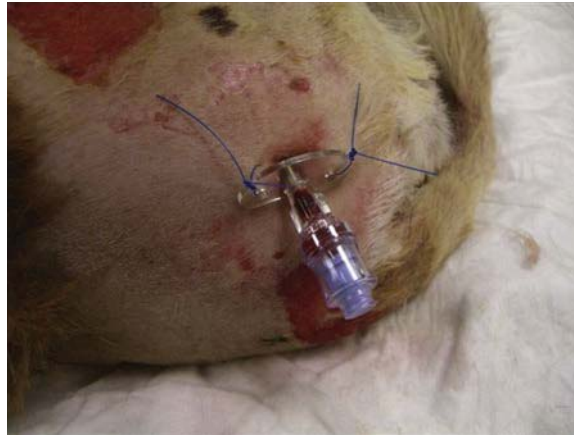

Figure 8.6. Intraosseus needle in the ischium. Photo courtesy of Sophie Adamantos, Royal Veterinary College.

Box 8.1 Glucose Supplementation

- o Initially a bolus of 50% dextrose (0.5–1 mL/kg diluted in 5× volume of isotonic crystalloid) should be given as a ‘slow push’ over 5–10 min. Recheck the plasma glucose level once this has been given as an additional bolus might be required.
- o Maintenance: a fluid bag (0.9% NaCl or CSL) should be made up to 2.5% or 5% glucose and run at 1–2 mL/kg/h. This should not be used to bolus the patient or run at higher rates as this can lead to hyperglycaemia. Glucose concentrations above 10% can lead to phlebitis and should only be given in a central/long-term catheter.

Rapid administration of intravenous crystalloid fluid boluses (e.g. 10 mL/kg over 15 min) should be given to improve perfusion. A concurrent ‘slow push’ of glucose would be advisable in this patient (see [Box 8.1](#)).

BP should be monitored as well as HR, pulse character, and CRT to monitor volume resuscitation. Active warming should also be started (e.g. using a forced air warming device or warm water blankets).

Further Case Information

- The cat’s HR improved to 180 bpm and systolic BP increased to 75 mmHg with three fluid boluses of 10 mL/kg.
- The blood glucose was 6.8 mmol/L, after the initial glucose bolus, and he was placed on a 2.5% glucose in CSL at 2 mL/kg/h, and an additional bag of CSL was running (without glucose supplementation) at 4 mL/kg/h.
- A warming blanket was placed over the cat.

You suspect that this cat has sepsis, most likely from injuries related to the initial trauma. You are concerned that there could be free peritoneal fluid.

Q 2. Describe three methods to obtain a sample of abdominal fluid.

1. Blind tap: if there is obvious free abdominal fluid in the abdomen a blind tap can be used. For a diagnostic tap, a 22G needle and 3-ml syringe can be used. The skin should be prepared sterilely. If the cat is in lateral recumbency, then the tap can be around the umbilicus, though any area can be used. Care should be taken to avoid internal organs and accidental bladder sampling.
2. Diagnostic peritoneal lavage can be performed when there is inadequate fluid in the peritoneum to be sampled: 10–20 mL/kg of warm saline can be introduced into the abdomen via a catheter aseptically placed. The patient is rolled and fluid collected from the same catheter.
3. Ultrasound guidance allows sampling of small pockets of fluid. A high level of experience of ultrasound is not necessary. It is useful to have the animal standing and ultrasounding from below, because fluid tends to run to the dependent part of the abdomen. Areas where fluid accumulates and also might be easier to see (depending on volume) are around the bladder and liver.

Further Case Information

In this case you find a small pocket of fluid adjacent to the bladder using ultrasound, obtain a sample and make a direct smear of the fluid (Figures 8.7 and 8.8).

Q 3. How can you identify in-house if the effusion is septic?

Examination of effusion in-house is vital. By definition, the presence of intracellular bacteria in the sampled fluid is a septic effusion (Figures 8.7 and 8.8). Free bacteria can be hard to identify, and there is always the possibility of skin contamination as well as some stain precipitation which might have the appearance of bacteria.

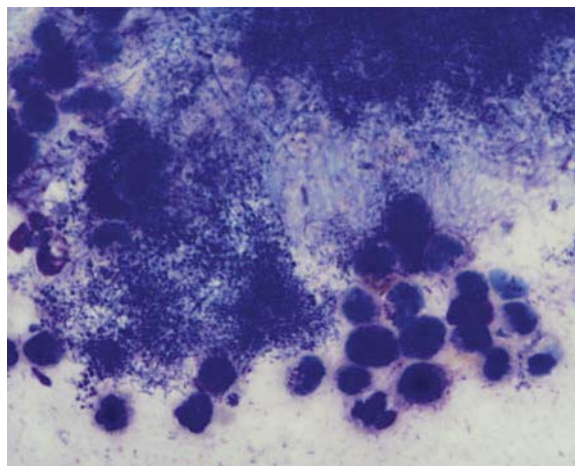


Figure 8.7. Effusion: note the proteinaceous background with abundance of extracellular rods and cocci. Courtesy of Kate English, Royal Veterinary College.

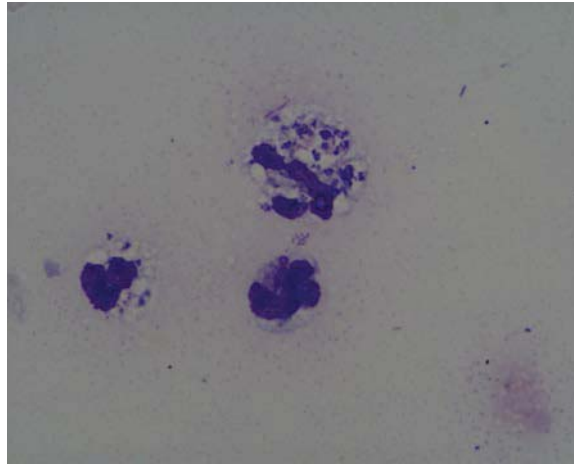


Figure 8.8. Neutrophils with intracellular bacteria in the septic effusion. Courtesy of Kate English, Royal Veterinary College.

An alternative is to measure the glucose of the abdominal fluid and compare it to the peripheral circulation. A glucose difference of 1.1 mmol/L is consistent with a septic effusion (86% sensitive, 100% specific). Many septic effusions also have a pungent odour, especially when anaerobes are involved.

Q 4. *What antibiotics would be prudent to start this cat on? And why?*

A broad-spectrum antibiotic protocol should be used: amoxicillin-clavulanate, marbofloxacin and clindamycin, or ampicillin and gentamicin, or amikacin (after preliminary fluid therapy and adequate BP). Ideally, choose agents that can be given intravenously to obtain effective (high) therapeutic levels rapidly and a drug combination that covers normal intestinal flora (i.e. aerobes, anaerobes, Gram positive and Gram negative, the so-called four quadrant therapy).



Tip Box

A 'four quadrant approach' is the use of antibiotics against four groups of bacteria: Gram +ve, Gram -ve, aerobic, and anaerobic bacteria. This approach is reserved for patients suspected of sepsis or based on bacterial culture results.

Q 5. *What is the next step in management of this case?*

Surgery is the next step once a septic process has been identified. Most septic abdominal cases like this have a tear in the bowel, damage to the urinary tract, or less commonly damage to the biliary system. Septic peritonitis as the result of haematogenous spread of infection (i.e. no anatomical abnormalities detected on exploratory surgery) is much less common. External abdominal wounds can also introduce infection. The

history of this case (road traffic accident (RTA)) warrants further surgical investigation, and regardless of the cause the inflammatory fluid requires removal from the peritoneum. Medical management alone is highly unlikely to be successful.

Prior to surgery the patient should be stabilized by maintaining normal blood glucose, maintaining BP as high as possible (which might require a vasopressor), restoring fluid volume as much as possible and minimizing the length of anaesthesia (e.g. clipping prior to anaesthetic induction) as well as maintaining the cat's temperature.

Further Case Information

Sadly this patient died prior to surgery. A postmortem revealed a rupture of the small intestine, likely due to the RTA.

Discussion

Hypotension, hypothermia, and hypoglycaemia are unfavourable prognostic indicators in cats on presentation and are associated with a high mortality. Focus should be on major body systems and initial resuscitation efforts prior to any further diagnostics. Injuries to cats, such as in this case, are not necessarily as effusive as the equivalent in dogs, so any small pockets of free fluid should be sampled. Trauma is the most common cause of septic peritonitis, consisting of bite wounds, gunshot wounds, and RTAs, as in this case.

Further Reading

Bonczynski, J.L., Ludwid, L.L., Barton, L.J., et al., 2003. Comparison of peritoneal fluid and peripheral blood, pH, bicarbonate, glucose and lactate concentration as a diagnostic tool for septic peritonitis in dogs and cats. *Veterinary Surgery* 32 (2), 161–166.

Case 8.4

Signalment and Clinical History

An approximately 2-year-old MN DSH cat is presented to you following an RTA. Patient history is unknown.

Clinical Examination

On presentation the cat is in sternal recumbency and tachypnoeic (RR 80 brpm) with obvious facial trauma, haemorrhage from the nares and mouth, and proptosis of the right eye (which was severely damaged) (Figures 8.9 and 8.10). The cat's HR was 140 bpm and lung sounds were audible bilaterally throughout his thorax. Systolic BP was 170 mmHg.

Q 1. What should be your first step in managing this case?

Acute trauma patients should be approached the same way when presented to you, focusing on the major body systems (neurological, cardiovascular, and respiratory status).

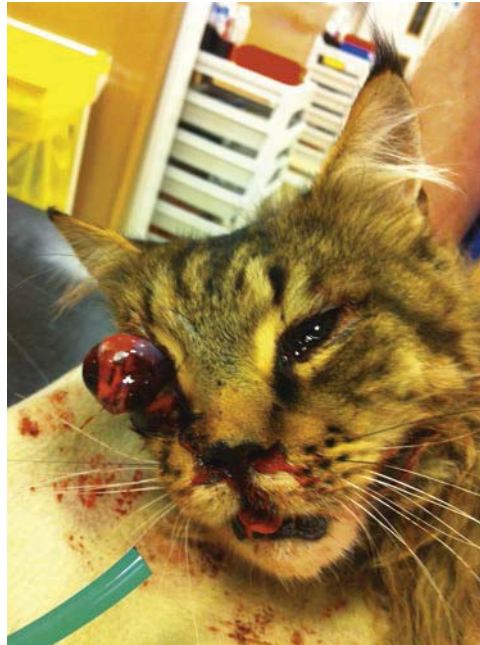

Figure 8.9. Patient with extensive facial trauma.

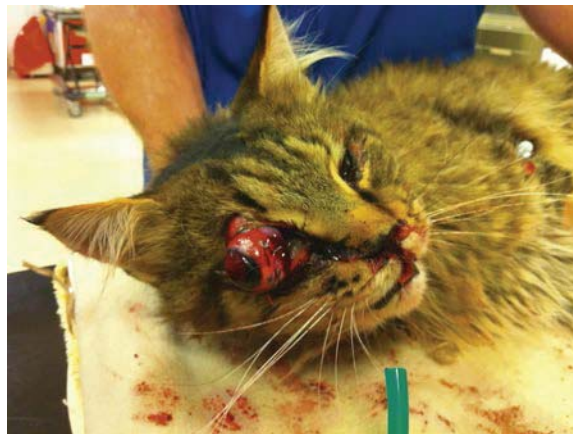

Figure 8.10. Proptosis right eye.

When managing a head trauma case, initially a rapid physical examination should be performed specifically considering major body systems: HR, pulses, thoracic and cardiac auscultation, as well as neurological examination (including mentation assessment). Oxygen should be given; flow-by may be adequate if the patient is still but oxygen delivery could be enhanced by using a mask if tolerated. Although oxygen

might be delivered to a higher concentration in an oxygen-rich environment (e.g. oxygen cage), these patients are not stable enough to be left alone.

Vascular access should be gained, though may be challenging if the cat is hypovolaemic and/or hypotensive.

Thoracic examination in trauma should focus on the auscultation of lung sounds in all quadrants. Blind thoracocentesis might be required if lung sounds are not audible dorsally. When the patient is stable a thoracic radiograph should be taken to assess for any evidence of a diaphragmatic rupture, as well as pulmonary contusions and subclinical pneumothorax/pleural effusion.

Analgesia should be provided with opioids, the best choice to minimize any effects on the cardiovascular system.

Further Case Information

The cat was initially stabilized with flow by oxygen, and intravenous access was obtained by placing a 22G catheter in the cephalic vein. A minimum database was obtained: PCV 30% and TP 65 g/L, blood glucose 10.6 mmol/L. The cat was given a 10 mL/kg bolus of CSL. Buprenorphine (0.02 mg/kg IV) was administered, and a lateral thoracic radiograph was unremarkable. The right globe was considered too badly damaged to be replaced and enucleation would be needed once the cat was stable.

Q 2. What is the next step in managing a head trauma case?

The main concern, in addition to the major body systems, is the risk of secondary brain injury. The primary brain injury is a result of the trauma; the secondary brain injury is a result of hypoxia and decreased perfusion. To maintain adequate perfusion to the brain (cerebral perfusion pressure (CPP)) the mean arterial pressure (MAP) needs to be maintained as well as limiting a potential rise in the intracranial pressure (ICP) (see [Box 8.2](#)): $CPP = MAP - ICP$.

Fluids are incompressible and in a fixed-volume space, such as the calvarium, an increase in ICP (e.g. haemorrhage) physically limits cerebral perfusion.

The goal is to maintain adequate cerebral perfusion and to achieve this the systolic BP should be ≥ 90 mmHg.

Box 8.2 Signs of Increased Intracranial Pressure

A full neurological exam is not appropriate until your patient is more stable, and may be limited by facial/ocular injury/swelling. Indications of increased ICP include:

- o Cushing reflex: systemic hypertension and reflex bradycardia (the bradycardia might be difficult to assess in cats, e.g. from high vagal tone, electrolyte changes, hypothermia).
- o Respiratory pattern: from hyperventilation to apnoea, including Cheyne-Stokes.
- o Mental status: any deterioration (with adequate perfusion).
- o Ocular examination: mydriatic pupils (might indicate a diencephalic lesion). Absent light response could indicate irreversible mid-brain damage or cerebellum herniation. Increased optic nerve sheath diameter is used in people as an indicator of raised ICP, and recently an abstract has appeared for its use in dogs, though to date there have been no clinical studies in cats.
- o Posture: decerebrate (this posture, four limb extensor rigidity with opisthotonus, with marked changes in mentation carries a grave prognosis) or decerebellate (can have normal mentation).

Further Case Information

In this case it was considered from the cat's decreased mentation, obvious head injuries, relative bradycardia, and hypertension that he had raised ICP.

Q 3. *How should the cat be treated for increased ICP?*

- **Mannitol:** osmotic diuretic, thought to have additional neuroprotective benefits as well as reducing cerebral oedema. For it to be effective it needs to be given over 10–20 min (0.5–2 g/kg); it should not be given in hypovolaemic patients.
- **Hypertonic saline:** 2–4 mL/kg as a one-off bolus can be given if hypovolaemic and thought to have additional benefits. See tip box.

**Tip Box**

Hypertonic saline (e.g. 7.5% NaCl) causes movement of fluid from intracellular and interstitial compartments to intravascular compartment. It is thought to improve cerebral perfusion by dehydration of cerebral endothelial cells. It may also reduce secondary brain injury by increasing re-uptake of damaging excitatory amino acids into cells and decreasing neutrophil adhesion.

- **Hyperventilation:** should only be used as a temporary measure to decrease ICP in the intubated patient. Hyperventilation causes vasoconstriction (decreased intracranial blood volume) and therefore can significantly decrease perfusion and oxygenation of the brain. The goal should be to decrease the PaCO₂ and maintain at 35–38 mmHg.

If concerned about raised ICP, avoid jugular blood samples (will decrease vascular drainage and increase ICP), keep the patient's head 30°–45° above the body (to improve venous drainage), and make sure the patient is adequately oxygenated.

Further Case Information

As the cat was thought to be hypovolaemic on presentation with suspected increased ICP, a catheter was placed and 3 mL/kg of hypertonic saline (7.5% NaCl) administered over 5 min. The cat became more responsive, HR increased to 180 bpm, and pulse profile improved.

Q 4. *What should you look out for on a minimum database?*

Changes in PCV and TPP might not be apparent in the acute stages of haemorrhage. Attempts should be made to stop obvious external haemorrhage, although it is difficult to stop any internal haemorrhage. Calvarian fractures can be significant but are not predictive of outcome. Hyperglycaemia is proportional to severity of head trauma, with median blood glucose for mild head trauma (8.3 mmol/L) being significantly lower than moderate or severe (12.3 mmol/L and 12.2 mmol/L, respectively). Hyperglycaemia is thought to increase free radical production, release of excitatory amino acids, and lead to cerebral oedema. There have been no studies looking into control of blood glucose and outcome in people with head trauma.

Q 5. *Should steroids be given to the cat in this case (or any cat/dog with head trauma)?*

In a word: *no*. Although we cannot always compare different spp., in people the CRASH (corticosteroid randomization after significant head injury) trial showed compelling evidence that the risk of death was significantly higher in people receiving corticosteroids.

Further Case Information

The cat responded to supportive care (analgesia, fluids) and had his proptosed eye removed 36 h later; it was discharged from hospital a further 48 h later. Although computed tomography (CT) (Figure 8.11) showed obvious fractures, no surgery was required for stabilization.

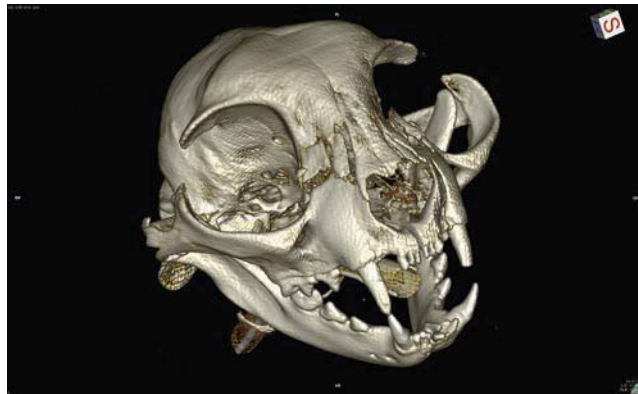

Figure 8.11. Reconstructed skull CT image of the patient showing obvious skull fractures.

Discussion

The key points in managing head injury include initial assessment of the major body systems. Priorities include providing oxygen supplementation and ensuring tissue perfusion (e.g. IVF, maintaining adequate BP ≥ 90 mmHg); in addition, monitoring neurological status (mentation, pupil size, modified Glasgow coma scale, etc.) and treating for raised ICP if required (e.g. mannitol if normovolaemic or hypertonic saline if hypovolaemic). Avoid jugular compression (e.g. venipuncture), and elevate the head and thorax 15° – 30° .

Further Reading

- Adamantos, S., Garosi, L., 2011a. Head trauma in the cat: 1. Assessment and management of craniofacial injury. *Journal of Feline Medicine and Surgery* 13, 806–814.
- Adamantos, S., Garosi, L., 2011b. Head trauma in the cat: 2. Diagnosis and management of traumatic brain injury. *Journal of Feline Medicine and Surgery* 13, 815–823.

Case 8.5**Signalment, History, and Clinical Examination**

A 2-year-old FN DSH cat presented as an emergency following ingestion of 11 × 200 mg ibuprofen tablets. Time of ingestion was estimated to be 6 h prior to emergency presentation. The cat was mildly tachypnoeic and tachycardic. The bladder was large and non-painful. No other examination abnormalities were present.

Q 1. *What is the toxic ibuprofen dose for a cat?*

A dose of 25 mg/kg has potential for gastrointestinal ulcers, while 85 mg/kg can cause acute kidney injury (AKI). Neurological signs can be seen at 200 mg/kg.

The toxic dose may be lower in younger cats or older cats with pre-existing renal disease. Cats are considered to be twice as sensitive as dogs because they have a limited glucuronyl conjugating capacity. This patient had consumed 488 mg/kg.

Q 2. *What are the consequences of ibuprofen toxicity in the cat?*

Ibuprofen is an NSAID that inhibits prostaglandin synthesis. It blocks the conversion of arachidonic acid to various prostaglandins, including 'protective' prostaglandins. Certain NSAIDs can affect prostaglandin synthesis and the secretion of the protective mucous layer and blood flow within the stomach and small intestine. They can also alter renal blood flow, glomerular filtration rate, tubular ion transport, renin release, and water homeostasis. NSAIDs may also affect platelet function by inhibiting aggregation.

Q 3. *What further evaluations would you want to perform on this patient?*

Due to these known effects, the general health and associated consequences of ibuprofen toxicosis should be assessed. These can include:

- Haematology and biochemistry
- Electrolytes
- Blood gases
- Urinalysis
- Systolic BP

Further Case Information (Table 8.1 and 8.2)

- Full urinalysis confirmed adequate urine concentration (USG 1.040)
- The systolic BP was 150 mmHg (normal)

Table 8.1 Biochemistry Results at Presentation

Biochemistry	Patient Results	Reference Interval
Albumin (g/L)	35.0	22.0–44.0
ALP (u/L)	62	10–90
ALT (u/L)	77	20–100
Amylase (u/L)	829	300–1100
Total bilirubin (μmol/L)	2.0	2.0–10.0
Urea (mmol/L)	9.0	4.0–11.0
Calcium (mmol/L)	2.45	2.00–2.95
Phosphate (mmol/L)	1.49	1.09–2.74
Creatinine (mmol/L)	90	27–186
Glucose (mmol/L)	16.0	3.9–8.3
Sodium (mmol/L)	140	142–164
Potassium (mmol/L)	3.80	3.70–5.80
Total protein (g/L)	57.0	54.0–82.0
Total globulin (g/L)	22.0	15.0–57.0

Bold type denotes abnormal result.

ALP, alkaline phosphatase; ALT, alanine transaminase.

Table 8.2 Haematology Results at Presentation

	Patient Results	Reference Interval
WBC ($\times 10^9/L$)	8.0	4.0–15.0
RBC ($\times 10^{12}/L$)	10.03	5.50–10.00
Haemoglobin (g/dL)	15.3	8.0–15.0
PCV (%)	51	27.0–50
MCV (fL)	52.0	40.0–55.0
MCH (pg)	16.3	13.0–17.0
MCHC (g/dL)	31.2	31.0–34.0
Platelets ($\times 10^9/L$)	298	200–600
Neutrophils ($\times 10^9/L$)	4.3	2.5–12.5
Band Neutrophils ($\times 10^9/L$)	0.0	0.0–0.3
Lymphocytes ($\times 10^9/L$)	3.6	1.5–7.0
Monocytes ($\times 10^9/L$)	0.1	0.0–0.8
Eosinophils ($\times 10^9/L$)	0.0	0.0–1.5
Basophils ($\times 10^9/L$)	0.0	

Bold type denotes abnormal result.

Q 4. What is your interpretation of the results?

The blood results suggest a mild erythrocytosis, hyperglycaemia, and hyponatraemia.

Q 5. What are the primary goals and treatment options available for this patient?

The primary goal of treatment is to prevent gastric ulceration, renal injury, CNS effects, and possible hepatic effects associated with ibuprofen toxicosis. Unfortunately, there are no specific antidotes. Initial treatment included:

- Intravenous fluid therapy to encourage diuresis
 - AKI often occurs within the first 12 h after massive exposure, but may be delayed for 3–5 days
- Placement of indwelling urinary catheter to quantify 'ins and outs'
 - Alternatively, weigh pad or litter that the cat uses to urinate and subtract the dry weight (1 mL urine = 1 g)

**Tip Box**

One should not be discouraged from placing an indwelling urinary catheter in either a male or female patient. The author prefers using a soft polyurethane catheter for long-term placement. This can then be attached to a 'closed' urine collection system to minimize bacterial contamination.

Q 6. When is pharmacological diuresis indicated to enhance urine output?

Diuretics are only indicated if it is uncertain, or documented, that the cat is not producing enough urine. Oliguria has been defined as urine production <0.3 mL/kg/h, but urine production in a rehydrated patient with AKI of 0.5–1.0 mL/kg/h is considered inappropriate. Furosemide, mannitol, and hypertonic dextrose can be used as diuretics.

This cat was initially placed on a balanced isotonic IV solution (Hartmann's) at the rate of 5 mL/kg/h using an infusion pump. Vital parameters including respiratory rate/effort and systolic BP were monitored closely for signs of overperfusion. A soft polyurethane urinary catheter was placed using sterile procedure and connected to a closed collection system. This would help quantify 'ins and outs' and would allow for more refined adjustments in IVF rates to ensure adequate diuresis.

Q 7. What other treatments should be considered in this case?**Initiation of gastroprotectants**

The onset of gastrointestinal upset occurs within the first 2–6 h post ingestion, and gastrointestinal haemorrhage and ulceration occur 12 h to 4 days post ingestion.

- Treatment options: a combination of misoprostol, H₂ blockers, sucralfate, and/or omeprazole. In this case, sucralfate was used to bind to any potential mucosal erosions and ulcers, and protect them from exposure to gastric acid, bile acids, and pepsin. Sucralfate was given at 0.25 g every 8–12 h PO in cats. As the cat was still eating, omeprazole was administered at 1 mg/kg PO SID.

Nutritional support

Animals with AKI are in a state of negative nutritional balance at a time when protein and energy are needed to support regeneration of damaged renal tissue. If the

cat is not vomiting, an oesophagostomy or gastrostomy tube can be placed if the cat is stable enough for the short anaesthesia required to place the tube. If not, a naso-oesophageal tube can be used.

Further Case Information

Within 24 h, this patient was considered extremely bright, alert, and responsive. Blood parameters indicated mild azotaemia and hyperphosphataemia; however systolic BP remained normal. Within 96 h of intensive treatment with IVF, gastro-protectants, phosphate binding agents, and activated charcoal, the patient gradually became anorexic. A naso-oesophageal tube was placed to help facilitate daily caloric requirement and for continued administration of activated charcoal. In addition, maropitant was administered to combat nausea due to worsening azotaemia and hypergastrinaemic state. At this point, urine output was considered inadequate (<1 mL/kg/h), even with the assistance of pharmacological diuresis. Sadly, this patient was euthanized 6 days post admission due to AKI.

Discussion

Cats are relatively intolerant of large doses of NSAIDs. Any suspect toxicity case should be promptly and aggressively treated in an attempt to achieve a more favourable prognosis.

Further Reading

Jones, R.D., Baynes, R.E., Nimitz, C.T., 1992. Nonsteroidal anti-inflammatory drug toxicosis in dogs and cats: 240 cases (1989–1990). *Journal of the American Veterinary Medical Association* 201, 475–477.

Case 8.6

Signalment, Clinical History, and Clinical Examination Findings

A 9-year-old old MN DSH cat presented with a history of behavioural changes following topical application of a spot-on flea product purchased from the supermarket (Figure 8.12). The product was a permethrin-based flea product labelled for canine use only.

Following application, the cat became agitated and exhibited mild twitching. The owners reported that cat had not experienced seizures or loss of consciousness. After learning of the potential toxicity of this product to cats via the Internet, the owners bathed the cat in dishwashing liquid.

There was no history of exposure to other potential toxins. Vaccination and worming were up to date.

Physical Examination

The cat was in good condition (body condition score (BCS) 3/5) and normothermic (39 °C). The entire coat was damp, consistent with bathing. The cat exhibited bilateral mydriasis and marked ptialism. Mild muscle fasciculations were noted. No other significant abnormalities were noted.

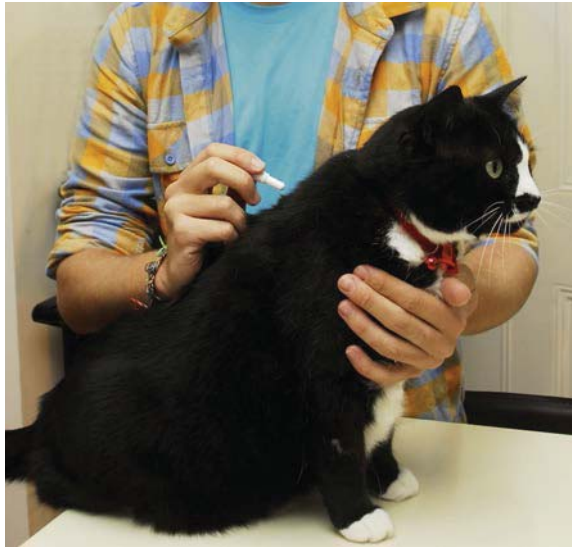

Figure 8.12. Warning on the front of a canine flea and tick product designed to alert owners about the risks of toxicity in cats. This label change was the result of collaboration between pharmaceutical companies and veterinarians following reports of high mortality due to misuse of permethrin spot-on (PSO) products in Australia.

Q 1. *Permethrin intoxication causes tremors and seizures in cats. List other possible differential diagnoses for tremors and seizures in cats.*

Intracranial

- Idiopathic epilepsy
- Degenerative disease
- Congenital, e.g. hydrocephalus
- Infectious: bacterial (e.g. nocardiosis), fungal (e.g. cryptococcosis), parasitic (e.g. dirofilariasis), protozoal (e.g. toxoplasmosis), viral (e.g. feline infectious peritonitis, feline immunodeficiency virus)
- Inflammatory/immune mediated disease: encephalitis
- Trauma
- Neoplasia
 - Primary intracranial (e.g. meningioma, lymphoma)
 - Local extension (e.g. extension of middle ear, nasal, or skull neoplasm)
 - Metastatic
- Vascular
 - Haemorrhage (e.g. coagulopathy, hypertension)
 - Infarct (e.g. thromboembolism)

Extracranial

- Metabolic

- Electrolyte derangements (e.g. hypernatraemia, hyponatraemia, hypocalcaemia)
- Hypoglycaemia
- Hepatic encephalopathy
- Uraemic syndrome
- Polycythaemia
- Nutritional: thiamine deficiency
- Drugs/toxins
 - Lead
 - Metaldehyde
 - Metronidazole
 - Organophosphates
 - Piperazine
 - Strychnine
 - Pseudoephedrine
 - Amphetamines
 - Bromethalin rodenticides
 - Mycotoxins

A diagnosis of permethrin intoxication was made on the basis of history and clinical signs.

Q 2. *What clinical signs may be associated with permethrin intoxication?*

- Seizures
- Muscle fasciculations/tremors (e.g. repeated contraction of cutaneous muscles)
- Twitching/shaking/shivering (e.g. ear flicking, paw shaking)
- Ptyalism
- Hyperaesthesia
- Ataxia/incoordination
- Pyrexia
- Tachypnoea
- Dyspnoea
- Hypothermia
- Mydriasis
- Gastrointestinal signs (e.g. anorexia, vomiting, diarrhoea)
- Transient blindness
- Urinary retention
- Cyanosis
- Collapse
- Cardiac arrhythmia/cardiac arrest

Q 3. *What is the expected onset and duration of clinical signs?*

Onset of clinical signs is typically within hours of exposure to a permethrin spot-on (PSO) but may be delayed 24–72 h. There is no reported correlation between amount of permethrin applied and the severity of clinical signs, possibly due to variation in

dose rate, absorption, route of administration (e.g. dermal absorption via secondary ingestion through grooming) and host factors. In the majority of cats that made a full recovery, clinical signs resolved within 24–72 h of treatment, but some required hospitalization for weeks.

Q 4. *How would you treat this patient?*

1. Decontamination. Although the owners have bathed the cat it is important to ensure that as much of the toxin is removed as possible. A warm bath with mild detergent, followed by towel drying, is suggested. It may be useful to apply an Elizabethan collar to prevent grooming. If recent oral exposure is suspected, administration of activated charcoal may bind toxins in the gastrointestinal tract and help prevent further absorption.
2. Muscle fasciculations can be controlled with methocarbamol (55–200 mg/kg IV, up to a maximum dose of 330 mg/kg SID); diazepam (0.25–1 mg/kg IV) or midazolam (0.3 mg/kg IV or IM).
3. Temperature monitoring and control. Muscle fasciculations can lead to hyperthermia; bathing and sedation may lead to hypothermia.
4. Supportive therapy including IVF, ocular lubrication, and urinary catheterization or bladder expression as needed. Affected cats should be placed in a quiet, dark environment to limit auditory and visual stimulation.
5. Recently use of an intravenous lipid emulsion infusion combined with methocarbamol has been described for the treatment of permethrin toxicity, single word space only with favorable outcomes.

Further Information

An IV catheter was placed, and a bolus of diazepam (1 mg/kg) was administered IV. The cat was then bathed in a warm bath and washed thoroughly with detergent that was rinsed off with lukewarm water, and then the cat gently towel dried. After being initially stable, the following morning the cat began seizing and progressed to status epilepticus.

Q 5. *How would you control seizures in this patient?*

Initially:

- Diazepam 0.25–1 mg/kg IV, IM, or per rectum (PR) (up to three doses)
or
- Midazolam 0.3 mg/kg IV, IM (up to three doses)

These drugs have a short half-life, and, if given alone, seizures will likely continue as soon as the drug has worn off. Given that phenobarbitone does not take immediate effect, in a patient in status epilepticus, this should be initiated immediately after diazepam, to prevent further seizing.

- Phenobarbitone 2–4 mg/kg diluted 1:10 with 0.9% NaCl slow IV as a bolus. To administer a loading dose this should be repeated every half an hour up to a total dose of 15–20 mg/kg, and then 2–4 mg/kg continued twice daily.

If seizures continue:

- Propofol (initial bolus of 4–6 mg/kg followed by 0.05–0.3 mg/kg per minute IV as constant rate infusion (CRI)) (Figure 8.13).

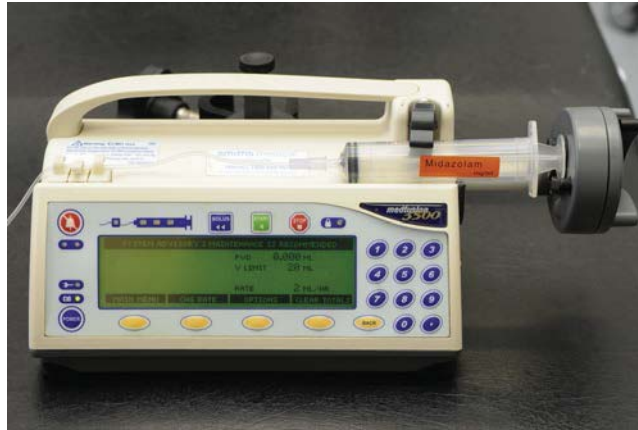

Figure 8.13. A constant-rate infusion of drugs such as midazolam, propofol, or phenobarbitone may be required to control seizures in affected cats.

Q 6. List possible complications associated with PSO toxicity and treatment.

- Hypothermia (secondary to bathing and/or sedation)
- Hyperthermia due to muscle fasciculations/seizures
- Rebound hyperthermia
- Cerebral oedema
- Aspiration pneumonia
- Hypoproteinaemia
- Anaemia
- Apnoea
- Pleural effusion
- Cardiac arrest
- Respiratory arrest
- Urinary retention
- Urinary tract infection
- Corneal ulcer
- Transient blindness

Further Information on Response to Treatment, Diagnosis, and Outcome

Seizures continued despite two boluses of diazepam PR. Seizure activity was reduced following an IV bolus of phenobarbitone as above. This dose was repeated three times, and no further seizure activity occurred. IVF (Hartmann's solution at 2× maintenance) were administered throughout treatment. The cat was discharged after 3 days with only a mild ear twitch and a corneal ulcer. This resolved within 5 days with application of antibiotic ointment BID.

Discussion

Permethrin is a synthetic pyrethroid that is toxic to insects as well as mammals. The primary mode of action is disruption of voltage-dependent sodium channels, leading to depolarization and repetitive firing of neurons in the CNS. It is a common ingredient in over-the-counter flea and tick products for pets, and the most commonly reported cause of intoxication in pet cats in both the United States and the United Kingdom, despite warnings on product labels (Figure 8.14).

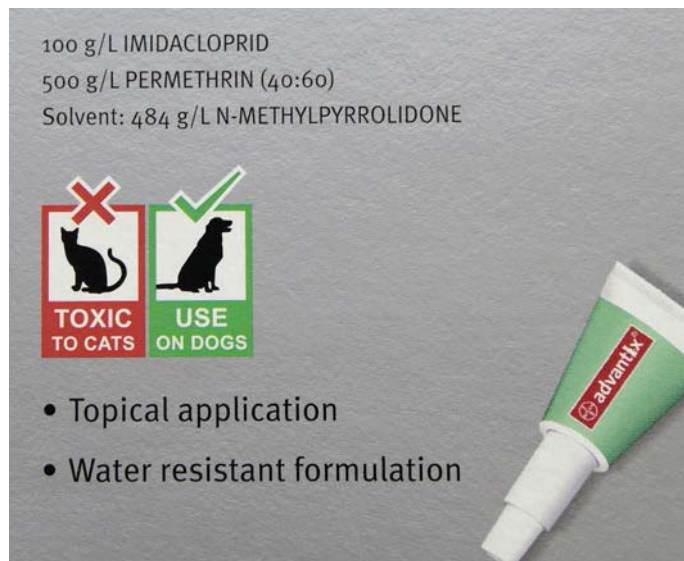

Figure 8.14. Warning label for spot-on products containing permethrin.

A recent study suggests that mortality associated with permethrin intoxication may be grossly underestimated due to under-reporting and failure of owners to present affected animals to the veterinarian.

To reduce the risk of toxicity, pet owners should be counselled about the potential toxicity of permethrin-containing products at point of sale, and educated that dog flea products should never be applied to cats. Owners should avoid storing dog and cat flea products together to ensure the products are not confused and prevent contact between recently treated dogs and cats in the same home.

If Finances Are Limited

Finances are often limited in such cases as permethrin-containing products are often applied to cats because they are inexpensive, or when owners try to save money by dosing a dog and cat with the same product. Animals with a history of exposure should be bathed and observed carefully. Animals with muscle fasciculations or seizures may respond to diazepam and, if refractory, repeat doses of phenobarbitone. Owners should be warned that animals left unattended may develop seizures and fatal complications.

Further Reading

- Boland, L.A., Angles, J.M., 2010. Feline permethrin toxicity: retrospective study of 42 cases. *Journal of Feline Medicine and Surgery* 12, 61–71.
- Malik, R., Ward, M.P., Seavers, A., et al., 2010. Permethrin spot-on intoxication of cats: literature review and survey of veterinary practitioners in Australia. *Journal of Feline Medicine and Surgery* 12, 5–14.
- Kuo, K., Odunayo, A., 2013. Adjunctive therapy with intravenous lipid emulsion and methocarbamol for permethrin toxicity in 2 cats. *Journal of Veterinary Emergency and Critical Care (San Antonio)* 23 (4), 436–441.

CHAPTER

9

Miscellaneous Disorders

Case 9.1

Signalment and Clinical History

A 7-year-old MN Burmese cat presented with a history of acute pain and lameness in the right forelimb. For 1 month, he had been less energetic. His weight was stable, and he was otherwise in good health. He was mostly indoors and fed a commercial dry diet. Routine preventative health care was up to date.

Clinical Examination Findings

The cat was in a reasonable body condition (body condition score (BCS) 4/9), mildly hypothermic (rectal temperature (RT) 37.0 °C) and monoparetic with complete loss of conscious proprioception in the right forelimb (Figure 9.1), which was diffusely painful. The patient was mildly tachycardic (heart rate (HR) 200 bpm) without a murmur and mildly tachypnoeic (respiratory rate (RR) 30 brpm). Pulmonary auscultation was otherwise unremarkable.

Q 1. Formulate a problem list.

- Acute right forelimb lameness and loss of proprioception
- Tachypnoea
- Tachycardia
- Hypothermia
- Reduced exercise tolerance

Q 2. Formulate a differential diagnostic list for forelimb lameness in cats.

- Musculoskeletal disorder
 - Fracture
 - Myopathy
 - Joint disease: dislocation/subluxation
 - Ligamentous strain/rupture
- Neurological disorder
 - Brachial plexus avulsion
- Embolic disease: arterial/venous
 - Thromboembolism

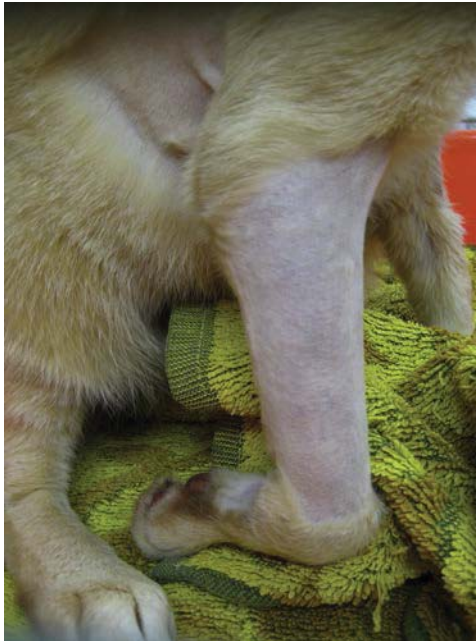

Figure 9.1. The cat with right forelimb monoparesis (clipped for investigations).

- Septic embolism
- Neoplastic embolism (distal to site)
- Vascular occlusion
- Soft tissue disorder
 - Wound
 - Abscess/cellulitis
 - Neoplasia

Q 3. *What would be your initial diagnostic and therapeutic approach in this case?*

- Further examination of the right fore particularly assessing pad colour, temperature, pulse, any evidence of injury, instability, crepitus, swelling
- Using a Doppler probe on the right and left palmar arteries for comparison of blood flow
- Opioid analgesia
- Depending on results of further evaluation:
 - Thoracic radiographs to assess the cardiac silhouette, vessels, and pulmonary parenchyma
 - Radiographs of the right and left forelimb to assess for skeletal injuries
 - Echocardiography to investigate cardiovascular disease and possible embolic disease

Further Case Information

- Further examination of the right fore revealed mild pain with no evidence of soft tissue or musculoskeletal injury. The right paw was cold, and the pad cyanotic in comparison to the left paw (can be seen in figure 9.1)
- The Doppler signal was absent from the right median palmar artery, signal was present on the left fore, and the patient was normotensive
- Buprenorphine 0.02 mg/kg was administered IM
- A right lateral thoracic radiograph was taken (Figure 9.2)

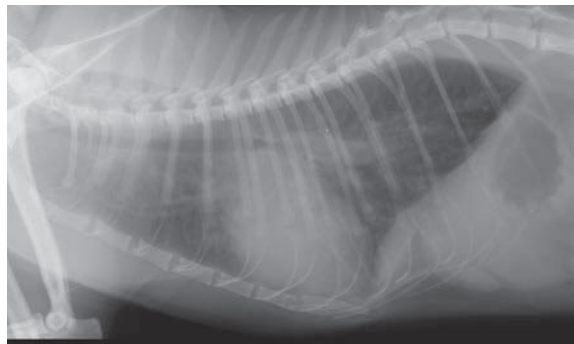

Figure 9.2. Right lateral thoracic radiograph.

Q 4. What are the key radiographic abnormalities?

- Pulmonary venous and arterial dilation
- Cardiomegaly
- Pulmonary oedema
- Small volume pleural effusion

An echocardiogram was performed. Figure 9.3 is an M-mode image showing a comparison between the left atrial and aortic diameters (LA:Ao).

Q 5. What are the significant findings on this echocardiographic image?

- Severe left atrial dilation (LA:Ao > 2)
- Spontaneous echocontrast in left atrium

Considering these findings, radiographs were not performed of the right or left forelimb.

Q 6. Given these results, what are the most likely diagnoses for this patient?

- Right branchial arterial embolism, most likely thromboembolic
- Cardiomyopathy (hypertrophic most common)
- Congestive heart failure

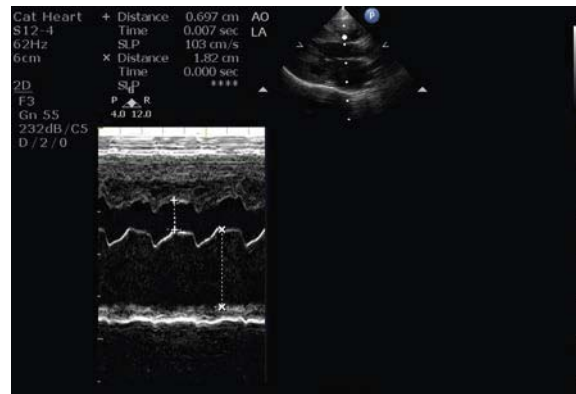

Figure 9.3. LA-Ao M-mode.

Q 7. What other investigations might you want to perform?

- Full echocardiography to confirm the type of heart disease (e.g. hypertrophic cardiomyopathy (HCM), less commonly restrictive cardiomyopathy (RCM) or dilated cardiomyopathy (DCM))
- Ultrasonography or angiography can be used to demonstrate the location of the thrombus
- Routine blood database to assess renal parameters, and possible causes of clots including thrombocytosis, or sepsis.

Q 8. How would you initially manage this case?

The cat's guarded short- and especially long-term prognosis should be discussed with the owners.

Further treatments

- Manage any overt congestive heart failure
 - Loop diuretic: furosemide: crisis 2–4 mg/kg IV, then 1–2 mg/kg PO SID to BID as needed
 - Oxygen therapy
 - +/- Thoracocentesis
- Reduce the likelihood of further clot formation (there are no clinical studies to prove efficacy of these drugs at this time)
 - Clopidogrel 18.75 mg PO SID
 - Aspirin 5 mg/kg PO every 72 h
 - Low molecular weight heparin, i.e. Daltaparin 100–300 IU/kg SC SID to BID
 - Warfarin has been used in the management of thromboembolism but consideration should be given to the risk of haemorrhage and frequent monitoring of coagulation times required.

Supplementary care

- Promote collateral circulation
 - Massage several times a day

- Analgesia: opioids, i.e. buprenorphine 0.01–0.02 mg/kg buccal/SC/IV BID to TID or fentanyl transdermal patch 3–5 µg/kg. Analgesia can be reduced after 48–72 h when the patient is more comfortable.

Controversial treatments

- Thrombolytic therapy (streptokinase, urokinase, and tissue plasminogen activator): expensive, with significant risk of haemorrhage and mortality. There is also risk of reperfusion injury.
- Intravascular thrombectomy has been described for saddle thrombi, but not branchial artery embolic disease.
- Vasodilation: (acepromazine) not recommended in congestive heart failure and unlikely to improve collateral circulation.

Q 9. What parameters would you monitor to assess for response to treatment?

- Improvement in HR, RR, blood pressure (BP), and return of Doppler signal to the affected limb
- Return of function of the affected limb
- Monitor for hyperkalaemia from reperfusion

Q 10. What is the prognosis for this cat?

Of cats with aortic thromboembolism 50–60% survive acute congestive heart failure and thromboembolic crisis. There is little reported about cats with brachial thromboembolism. Cats with aortic thromboembolism commonly die within the first 6–36 h, as a result of heart failure, systemic thromboembolic formation, or euthanasia. A lack of improvement during the first 48 h indicates a grave prognosis. Most cats have underlying heart disease, and there is a high risk (43%) of recurrent thromboembolism.

Further Information on Response to Treatment, Diagnosis, and Outcome

HCM was confirmed on echocardiography. The blood supply to the right fore improved within 4 days. The cat was ambulatory and comfortable. The cat was discharged on furosemide, ACEi (angiotensin-converting enzyme inhibitor), and clopidogrel. The patient returned 2 months later with pulmonary oedema and did not respond to increased doses of furosemide and addition of spironolactone and was therefore euthanized.

Discussion

Thromboembolism is common in cats with heart disease. Cats with a left atrium of >20 mm are at greatest risk. Typically clots form in the aortic trifurcation ('saddle' thrombus). Thromboemboli can also affect the kidney, brain, and lung. Platelets release vasoactive substances that reduce collateral circulation and cause vasoconstriction, which is the main target for therapy.

This is a classic presentation of thromboembolic disease. Doppler provides a rapid diagnosis. Further investigations into the cause of the thrombi are indicated. If a patient has intractable pain, or lack of improvement of circulation within 24–48 h of treatment, euthanasia is strongly recommended.

Further Reading

- Fuentes, V.L., 2012. Arterial thromboembolism: Risks, realities and a rational first-line approach. *Journal of Feline Medicine and Surgery* 14 (7), 459–470.
- Smith, S.A., Tobias, A.H., Jacob, K.A., et al., 2003. Arterial thromboembolism in cats: acute crisis in 127 cases (1992–2001) and long-term management with low-dose aspirin in 24 cases. *Journal of Veterinary Internal Medicine* 17 (1), 78–83.

Case 9.2

Signalment, History, and Clinical Examination

An 8-month-old MN DSH cat presented with a history of weight loss, inappetence, and lethargy for 3 months (Figure 9.4). The cat was indoor only, fully vaccinated, and wormed. The cat was dull and in poor body condition (BCS 3/9). A fluid thrill and approximately 3-cm-diameter mass were present on abdominal palpation.

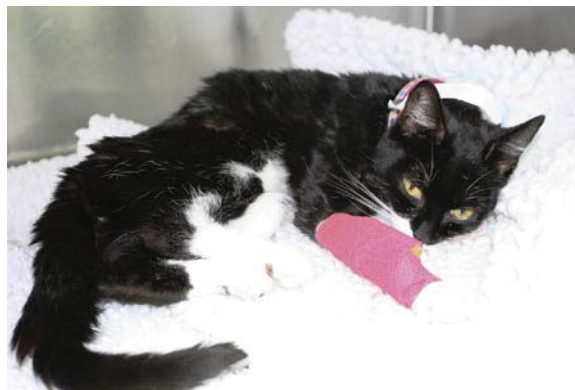

Figure 9.4. Patient at presentation.

The cat tested negative for feline immunodeficiency virus (FIV) and feline leukaemia virus (FeLV). Haematology and biochemistry profiles were performed (Tables 9.1 and 9.2). Blood smear examination revealed no evidence of red cell regeneration.

Table 9.1 Haematology Results at Presentation

	Patient Result	Reference Interval
RBC ($\times 10^{12}/L$)	3.68	5.00–10.00
Haemoglobin (g/dL)	5.5	9.0–15.0
HCT (l/L)	0.19	0.260–0.470
MCV (fL)	52.0	35.1–53.9
MCH (pg)	15.0	13.0–17.5
MCHC (g/dL)	28.6	28.0–36.0
WBC ($\times 10^9/L$)	13.9	6.0–15.0

Continued

Table 9.1 Haematology Results at Presentation—cont'd

	Patient Result	Reference Interval
Neutrophils ($\times 10^9/L$)	12.4	2.50–12.50
Lymphocytes ($\times 10^9/L$)	1.22	2.00–7.00
Monocytes ($\times 10^9/L$)	0.14	≤ 0.60
Eosinophils ($\times 10^9/L$)	0.14	0.00–0.70
Platelets ($\times 10^9/L$)	168	150–550

Bold type denotes abnormal result.

HCT, haematocrit; MCH, mean corpuscular haemoglobin; MCHC, mean corpuscular haemoglobin concentration; MCV, mean corpuscular volume; RBC, red blood cells; WBC, white blood cells.

Table 9.2 Biochemistry Results at Presentation

	Patient Result	Reference Interval
Albumin (g/L)	18	25.0–45.0
Globulin (g/L)	58	25.0–45.0
Urea (mmol/L)	2.6	2.5–9.9
Creatinine ($\mu\text{mol/L}$)	48	20.0–177.0
ALT (U/L)	72	5.0–60.0
ALP (U/L)	38	≤ 60.0
Total bilirubin ($\mu\text{mol/L}$)	25	0.1–5.1
Cholesterol (mmol/L)	2.9	2.20–4.00
Sodium (mmol/L)	146.3	145.0–157.0
Potassium (mmol/L)	3.5	3.50–5.50
Chloride (mmol/L)	116.7	100.0–124.0
Inorganic phosphorus (mmol/L)	1.69	0.90–2.20
Calcium (mmol/L)	1.79	2.05–2.95
Glucose (mmol/L)	4.1	2.8–4.9

Bold type denotes abnormal result.

ALP, alkaline phosphatase; ALT, alanine transaminase.

Q 1. How would you interpret the above results and what would you do next?

The moderate non-regenerative normocytic, normochromic anaemia is likely due to chronic inflammation. Hyperglobulinaemia can be caused by chronic infection, inflammation, neoplasia (multiple myeloma, plasmacytoma, and lymphoma), or immune-mediated disease. The hypoalbuminaemia could be compensatory due to hyperglobulinaemia, due to third-space loss in the suspected abdominal effusion or due to protein losing nephropathy (PLN) or enteropathy. Increased alanine transaminase (ALT) is consistent with hepatocellular damage and hyperbilirubinaemia due to decreased hepatic uptake and conjugation of bilirubin secondary to liver disease.

Serum protein electrophoresis to determine whether a monoclonal or polyclonal gammopathy is present, urinalysis to look for proteinuria as a result of PLN, and abdominal ultrasound to investigate the origin of the abdominal mass and abdominocentesis are advised. Abdominocentesis can also be performed blindly by elevating the cat horizontally and inserting a needle into the lowest point of the abdomen if ultrasound is not available.

In this case the gammopathy was confirmed to be polyclonal and no proteinuria was detected. Abdominal ultrasound revealed markedly enlarged mesenteric lymph nodes and a moderate volume of ascites (Figure 9.5). Abdominocentesis revealed a clear yellow viscous fluid (Figure 9.6). The total protein of the fluid was 40 g/dL and white blood cell (WBC) count was $2.26 \times 10^9/L$. Cytology revealed 53% neutrophils and 47% macrophages.

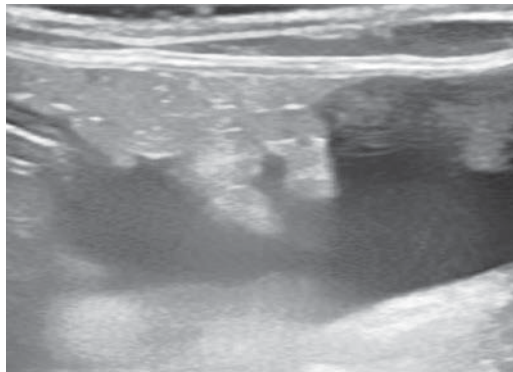


Figure 9.5. Abdominal ultrasound image showing ascites.



Figure 9.6. Abdominocentesis sample of ascites.

Q 2. Do these results help to refine the differentials and what further investigations would you perform?

Neoplasia can result in a monoclonal gammopathy but also a polyclonal gammopathy. The polyclonal result is also consistent with chronic antigenic stimulation such as feline infectious peritonitis (FIP), inflammation, and immune-mediated disease (NB: FIP can rarely cause a monoclonal gammopathy). The biochemistry, effusion characteristics (high protein content and low cell count), and ultrasound findings are highly suspicious for FIP. Further investigations are therefore aimed at trying to confirm the diagnosis. Lymphocytic cholangitis can cause ascites, raised liver enzymes,

hyperbilirubinaemia, and hyperglobulinaemia but would not cause mesenteric lymphadenopathy. Lymphoma remains a possibility.

Measurement of serum feline coronavirus (FCoV) antibodies, serum alpha-1 acid glycoprotein (AGP) levels (an acute phase protein), and FCoV reverse transcriptase polymerase chain reaction (RT-PCR) was performed on serum and effusion (Table 9.3). Thoracic imaging could be performed to look for pleural effusion but was not performed.

Table 9.3 Further Results

Sample	FCoV Antibody Titre	Alpha-1 AGP	FCoV RT-PCR
Serum	>1280	2.02 mg/mL	Positive
Effusion	–	–	Positive

Q 3. How would you interpret these results?

The high serum FCoV antibody titre indicates exposure to FCoV and seroconversion. High levels of alpha-1 AGP are consistent with inflammation and are not therefore specific for FIP; however, alpha-1 AGP is often markedly elevated in FIP (>1.5 mg/mL). Alpha-1 AGP may also be high in asymptomatic cats infected with FCoV. RT-PCR measures messenger RNA (mRNA) with the theory that levels of mRNA may correlate with the level of FCoV replication and thus be correlated with the presence of FIP. This can be performed in blood, faeces, effusions, and tissue samples; however, it is not specific for FIP, and further work is required before the true diagnostic value of this test is known.



Tip Box

FCoV antibodies are present in up to 90% of cats in catteries and up to 50% of cats in single-cat households; only around 5% of cats infected with FCoV will develop FIP. The presence of antibodies does not indicate FIP (only FCoV exposure), and the absence of antibodies does not exclude FIP as large amounts of virus in the body can bind to antibodies rendering them unavailable to bind to antigen in the test or antibodies can be lost in effusions.

Q 4. Are there any other tests to try to confirm a diagnosis of FIP that could have been performed?

Looking for other evidence of FIP such as presence of pleural fluid and ocular changes can be helpful. Ultrasound guided percutaneous Tru-Cut biopsy of the mesenteric lymph node could have been performed. Histopathology typically shows pyogranulomatous parenchymal foci, perivascular mononuclear infiltrates, and fibrinous polyserositis in cats with FIP; however, lesions can be multifocal and therefore might be missed with Tru-Cut biopsies. Immunohistochemistry to detect FCoV antigen within tissue macrophages is very specific but may not be detected in some cats with FIP due to varied distribution within lesions. Immunofluorescence can be performed to look for FCoV antigen in macrophages in effusion, but low numbers of macrophages on effusion smears can result in negative staining.

Treatment and Outcome

There is no proven effective treatment for FIP, and due to the poor prognosis the cat was euthanized.

Discussion

FIP remains a challenging diagnosis. The patient's history, examination, and laboratory findings can increase suspicion of a diagnosis of FIP. Positive immunostaining of effusion (if present) or tissue is very specific for FIP, but false negative results can occur.

Case 9.3

Signalment, History, and Clinical Examination

A 7-year-old MN DSH cat was presented with a history of abnormal behaviours associated with food prehension, and occasional vocalization during mastication. General physical examination was unremarkable. Oral examination demonstrated intense ulcerative inflammation of the gingival tissues, extending onto the alveolar and buccal mucosa (Figure 9.7). In addition, there was moderate symmetrical caudal stomatitis.

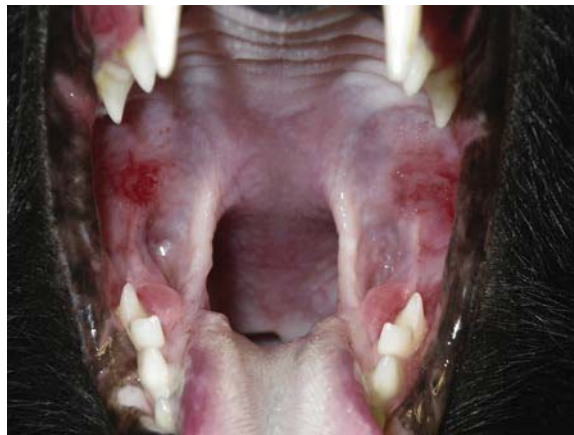

Figure 9.7. Oral examination showed severe inflammation of the gingival tissues and caudal stomatitis.

Conscious oral examination provoked an intense pain reaction upon opening the mouth. A small ulcer was noted on the dorsal surface of the tongue. Body temperature was 38.8°C and the cat was in good body condition. Mandibular lymph nodes were subjectively enlarged bilaterally.

Q 1. What is the current problem list for this cat and what differential diagnoses should be included?

- Oral inflammation including gingivitis and stomatitis, mandibular lymphadenopathy, lingual ulceration

- Differential diagnoses in this case include feline chronic gingivostomatitis (FCGS), uraemic stomatitis, eosinophilic granuloma complex, trauma, toxin ingestion and neoplasia such as squamous cell carcinoma



Tip Box

The cat in this case has caudal stomatitis/mucositis (as well as gingivitis). This area of the mouth does not have a specific anatomical term. The term 'faucitis' is commonly misused nomenclature for inflammation in this area – the fauces are the lateral walls of the oropharynx (where the tonsils are located).

Q 2. What further diagnostic tests would you like to perform and why?

- Blood tests for a biochemistry profile and haematology would be appropriate in this case to rule out underlying systemic disease such as chronic kidney disease (azotaemia can be associated with oral ulceration).
- Viral testing for FIV should be considered.
- Swabs for feline calici virus (FCV) PCR should be considered, but are not imperative. The role of FCV in FCGS remains unclear (see Q3).
- Further examination under general anaesthesia would allow thorough dental examination including periodontal probing, full mouth dental radiography, and the collection of biopsy samples if warranted (e.g. the inflammation seen with FCGS is typically symmetrical, so any asymmetrical inflammation should be biopsied to rule out neoplasia).

Further Case Information

- Biochemistry revealed hyperglobulinaemia (mild) but no azotaemia
- Haematology was unremarkable
- FeLV/FIV ELISA was negative
- FCV PCR was positive

Q 3. How do we interpret the blood test results? Does this help us establish the most likely diagnosis?

The hyperglobulinaemia is consistent with a chronic inflammatory process. This, in association with clinical findings, makes a diagnosis of FCGS most likely.

The positive FCV PCR is of unknown significance in cases like this. While it has been shown that 98–100% cases of FCGS may test positive for FCV, its presence has not been correlated with the causation of disease. Inoculation of the virus has been shown to induce acute signs of the disease, but not the chronic form seen in FCGS. It is possible that the ulcerative glossitis in this case may have been attributable to an acute FCV infection.

Q 4. What medical treatment could be considered in this case?

FCGS is a disease of unclear aetiology, but is thought to be an inappropriate immune reaction to oral antigens (bacterial, viral, and/or food). Attempting to control the

oral bacteria with antibiotics seems logical, but it must be remembered that plaque bacteria within a biofilm are not a single species, but number several hundred species. Furthermore, bacteria in the form of a biofilm are much more resistant to standard antibiotic doses which may therefore exert a limited effect. Chemical control of plaque bacteria could be considered using an oral chlorhexidine rinse or gel. However, this requires direct administration into the cat's mouth and may not be considered ethical if the patient is experiencing extreme levels of oral pain.

As this cat is in pain, analgesia is imperative. The systemic administration of a non-steroidal anti-inflammatory drug (NSAID) is encouraged if otherwise clinically safe. Oral administration of the opioid buprenorphine could also be considered in addition, or if the cat is anorectic.

Further Case Information

- The cat was prescribed clindamycin (5.5 mg/kg BID PO) and meloxicam (0.05 mg/kg SID PO)
- The cat was more comfortable, but re-examination 3 weeks later revealed further weight loss (150 g)
- Oral examination showed similar levels of oral inflammation

Q 5. *What would you recommend as the next step in treatment?*

Oral examination under general anaesthesia should be performed. This should include peri-odontal probing and full mouth dental radiography. The extent and severity of oral inflammation should also be precisely documented, preferably with photographic support. At this stage, any teeth affected by peri-odontitis or tooth resorption should be treated by extraction as necessary, and all teeth scaled and polished. Sub-gingival deposits of calculus should be removed mechanically or by hand. Treatment of diseased teeth and a continued medical approach may provide improvement in cases which have either milder or less chronic forms of the disease.

In this case, due to the severity of the inflammation surrounding the premolars and molar teeth, a more radical extraction approach was warranted to remove these teeth. The gingival inflammation surrounding the canine and incisor teeth was minimal, with no evidence of peri-odontitis or tooth resorption in these teeth and hence they were not extracted.

Q 6. *What is the best way to ensure success during extraction of these teeth?*

Pre-operative dental radiographs are mandatory. This not only allows assessment of any other underlying dental disease (periodontitis or tooth resorption), but also allows identification of any anatomical variations which could affect the extraction technique. In this case, a third root on the maxillary third pre-molar (107 & 207) was identified bilaterally (Figure 9.8). This tooth usually has two roots, but can have a third root in 10% of cats.

An open (surgical) approach is recommended. Teeth should be sectioned if multi-rooted, sharp instruments of an appropriate size should be used, and a delicate technique employed, combined with patience. Adequate time should be set aside for this surgical procedure. Post-operative radiographs are essential to ensure entire root removal. Any root substance left behind may potentially contribute to ongoing oral inflammation.

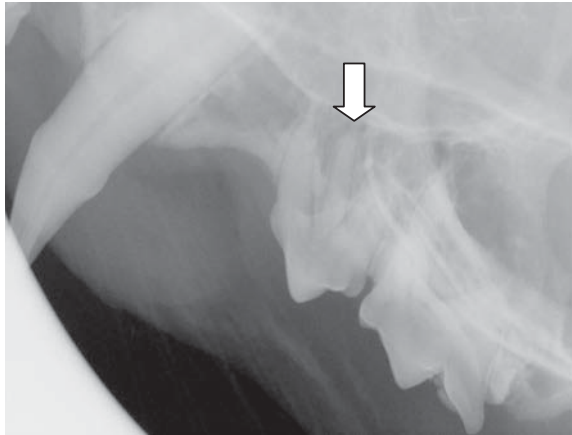


Figure 9.8. Dental radiographs showed a third root on the maxillary third premolar bilaterally (arrow) – useful information when planning extractions.

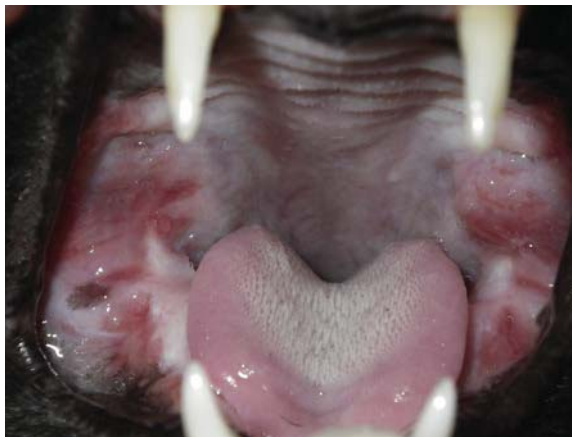

Figure 9.9. The cat in Case 9.3, 12 weeks after dental treatment.

Outcome

The patient recovered well and showed immediate improvements in comfort levels. At the 6 week re-examination, the cat had gained weight (550 g) and was eating wet and dry food comfortably. By 12 weeks pain on opening the mouth had resolved. [Figure 9.9](#) shows some remaining caudal inflammation, but it is very much reduced from the initial presentation. The inflammation in some cases can take as long as 6 months to completely resolve. In this case, the cat was clinically acceptable and no further treatment was required as the inflammation continued to resolve over the following months.

Q 7. If this cat had not improved, and continued to show marked levels of pain and inflammation, what approach would you subsequently offer the client?

An immunomodulatory approach may be helpful for refractory cases, assuming that extractions have been performed entirely, without root remnants left in situ. Recombinant feline interferon omega given by topical oromucosal administration has been shown to be helpful in these cases, and is particularly beneficial in reducing the pain associated with the inflammation. Alternatively, ciclosporin has also been shown to be effective in improving refractory cases. Corticosteroids, such as prednisolone, may be considered if all other approaches have failed. These are potent anti-inflammatory drugs, and the side effects of their use should be carefully considered. Anecdotally, a dietary change has been helpful for some cats, using a diet devoid of preservatives and additives.

Further Reading

- Hennet, P., Camy, G., Privat, V., McGahie, D., 2011. Comparative efficacy of a feline recombinant interferon omega in refractory cases of calicivirus positive cats with caudal stomatitis: a randomised multicentre controlled double blinded study of 39 cats. *Journal of Feline Medicine and Surgery* 13 (8), 577–587.
- Reiter, A.M., Soltero-Rivera, M.M., 2014. Applied feline oral anatomy and tooth extraction techniques: an illustrated guide. *Journal of Feline Medicine and Surgery* 16 (11), 900–913.

Case 9.4

Signalment, History, and Clinical Examination

A 17.5 year-old FN DSH cat was presented for routine monitoring on treatment with meloxicam for osteoarthritis. The cat has started to select wet food over dry food but is otherwise well. Clinical examination revealed a lean cat (BCS 2.5/5).

Oral examination showed moderate generalized gingivitis, marked plaque and calculus deposits, some missing teeth, and evidence of partially missing crowns. On some teeth there are hard dental tissue defects at the gingival margin, raising concerns regarding tooth resorption (previously known as feline odontoclastic resorptive lesions). Dental treatment under general anaesthesia is suggested.

Q 1. The client is concerned about the prospect of general anaesthesia in a geriatric cat. What pre-operative tests would you recommend?

- Pre-operative blood tests, to include assessment of renal and hepatic parameters, blood glucose, electrolytes, total proteins, pack cell volume (PCV) and total thyroxine (T4), provide valuable information prior to anaesthesia and can help to identify underlying systemic diseases not readily identifiable on clinical examination
- Urinalysis, including specific gravity (SG), can give vital additional information regarding renal function
- Blood pressure determination is advised in senior and geriatric cats

Further Case Information

Pre-anaesthetic test results were:

- Systolic blood pressure (Doppler technique) was 160 mmHg

- Routine biochemistry parameters and total T4 were within normal limits and the PCV was 40%
- Urinalysis was unremarkable, with a SG of 1.040

Q 2. *What factors should be considered when planning this cat's anaesthetic protocol?*

Geriatric cats have a poor ability for compensation during general anaesthesia with limited homeostatic reserves, and so a balanced anaesthetic protocol should be employed, incorporating multi-modal analgesia wherever possible and considering:

- The cat's reduced body mass: predisposing to hypothermia, potentiated by the patient becoming wet during dental procedures. The cat should be kept warm with devices such as heat pads, Bair huggers and blankets, and excessive wetting avoided. Care must be taken to avoid thermal burns when using devices without thermostatic controls.
- Fluid therapy: IV fluids should be given during anaesthesia to maintain blood pressure; however, cats are more sensitive than dogs to fluid overload due to their lower relative circulating blood volume and a syringe driver or fluid pump should be employed to ensure accuracy. Occult cardiac and renal disease in an older cat may also reduce tolerance of fluid overload.
- Regional anaesthesia (nerve blocks): given the anticipated extractions, local nerve blocks can reduce the amount of inhaled anaesthesia required. Bupivacaine was chosen in this case due to its duration of action and ability to provide analgesia into the post-operative period.
- The cat in this case is already receiving meloxicam so no intra-operative additional NSAIDs should be given unless the meloxicam was withheld prior to anaesthesia.
- Due to this cat's geriatric status, and the expectation of multiple extractions of a surgical nature, a prophylactic dose of antibiotic was given pre-operatively at the time of the pre-medication. Cefuroxime (20 mg/kg) was given by slow IV injection.
- Pre-medication with methadone and co-induction using midazolam and propofol enabled a reduced dose of propofol to be utilized, thus reducing cardiovascular depression.
- Tracheal rupture has been reported to be associated with dental treatment in the cat. Risk factors include using an over-long endotracheal tube (resulting in bronchial intubation), over-inflating the cuff or failing to deflate it during repositioning or extubation, and rotating the patient around a fixed endotracheal tube.
- Preventing aspiration of fluids and debris can be achieved by lubricating the endotracheal tube, correctly inflating it, and placing an additional retrievable absorbant pack within the oropharynx.
- Avoid post-operative blindness. A case report series linked post-operative blindness in cats to the use of spring-loaded mouth gags. Their use can severely limit blood supply to the cerebral cortex causing cortical blindness, and so should be avoided. If the mouth needs to be propped open for short periods, the operator's non-dominant hand may be used, or a needle cap cut to the appropriate size and placed between the canine teeth.

Further Case Information

The cat was anaesthetized and examined; the abnormalities found are shown in Figures 9.10 and 9.11.

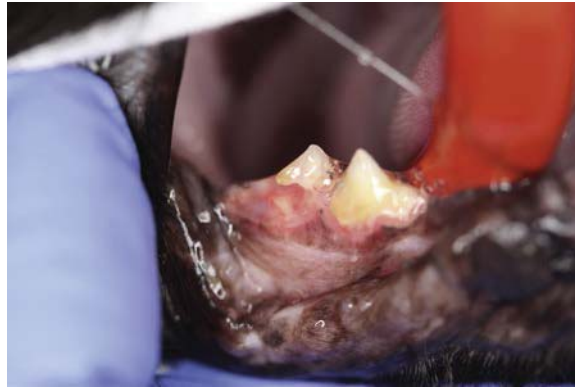

Figure 9.10. The right mandible of Case 9.4.

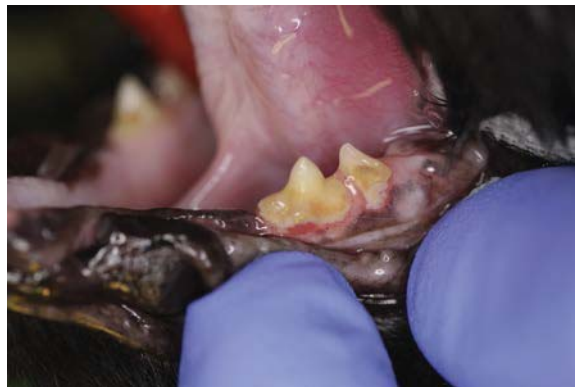

Figure 9.11. The left mandible of Case 9.4.

Q 3. *Looking at the left and right mandibular premolars and molars, which teeth are missing, and which are present?*

- On the right side, the third premolar is missing (407), the fourth is present (408), and half of the molar crown is present (409)
- On the left, a symmetrical pattern is observed with a missing 307, present 308, and half of 309

Q 4. *What are your next diagnostic steps?*

- The teeth should be scaled to remove calculus deposits enabling an accurate assessment of the hard dental tissues. If necessary, a sharp explorer probe can be used on the hard tissues to palpate for irregular or subtle defects.
- Intra-oral dental radiography is obligatory.

Q 5. What are the main types of tooth resorption (previously known as feline odontoclastic resorptive lesions) noted clinically in cats?

Two main types are identified with significance for the clinical approach, and only radiography can distinguish the two:

- Type 1 is typically associated with an inflammatory process (such as peri-odontal disease). Destruction of the hard dental tissues occurs, with obvious lesions at the cemento-enamel junction (neck). Radiographically, the peri-odontal ligament remains intact, and is visible around each root. The radiodensity of affected roots remains the same as unaffected teeth. The pulp is visible within the tooth root.
- Type 2 is truly idiopathic. The peri-odontal ligament becomes lost as the tooth substance is resorbed and replaced by alveolar bone. It therefore becomes indistinguishable on radiographs. Furthermore, the radiodensity of the root becomes reduced, and is more similar to surrounding bone. The pulp space is no longer visible.

Further Case Information

Results of the dental radiography are shown in [Figures 9.12 and 9.13](#).

Q 6. What type of tooth resorption can be seen in the radiographs, in which teeth?

- In the mandibular third premolars (307 & 407) there are no visible crowns. 'Ghost roots' are noted with radiodensity similar to surrounding bone. This is typical of the end stage of type 2 resorption.
- In the mandibular molar (309 & 409) (red arrow) extensive destruction of the crown is noted. However, the peri-odontal ligament spaces remain visible, with root radiodensities not reduced. This is typical for type 1 resorption.
- In the mandibular fourth premolars (308 & 408) (black arrow) more subtle resorption is noted within the crown noted by radiolucent areas. The peri-odontal ligaments are visible and the radiodensity of the root is not reduced. This is consistent with type 1 resorption.

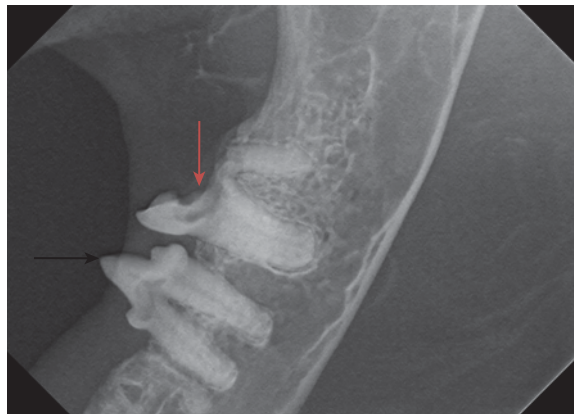


Figure 9.12. Radiograph of the left mandible. See answer to Q6 for more information.

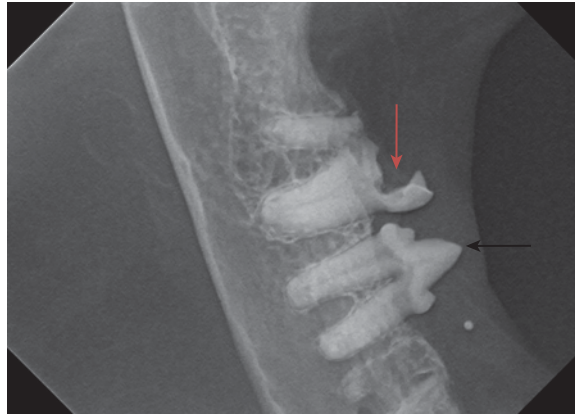


Figure 9.13. Radiograph of the right mandible. See answer to Q6 for more information.

Q 7. *What treatment approach is recommended?*

No treatment is required for 307 & 407. The crown is lost, and the gingiva has healed over the lost crown, showing no inflammation.

The remaining teeth should be completely extracted, and are not suitable for crown amputation.

All teeth were scaled, and the mouth rinsed with a chlorhexidine solution before starting the extractions. An open approach was used, creating a small gingivoperiosteal envelope flap. The teeth were sectioned, and then extracted using appropriate sized hand instruments. The alveolar bone was subsequently smoothed with a fine diamond burr on a water-cooled high-speed hand piece, and the flaps sutured using a fine gauge (1M/5-0) monofilament, absorbable suture material.

Post-extraction radiographs were taken to confirm complete extraction of root material.

Outcome

The cat made a swift, uneventful recovery. The owner reported an improvement in demeanour and expressed satisfaction with the procedure despite the cat's age.

Further Reading

Clarke, D.E., Caiafa, A., 2014. Oral examination in the cat: a systematic approach. *Journal of Feline Medicine and Surgery* 16 (11), 873–886.

Case 9.5

Signalment, History, and Clinical Examination

A 5-year-old MN DSH cat presented with a history of weight loss and abdominal distension for 4 weeks. On presentation the cat was in poor body condition (BCS 3/9), and abdominal palpation revealed ascites.

Q 1. Formulate a differential diagnosis list for ascites.

- Transudate: hypoalbuminaemia (NB: any chronic transudate will become a modified transudate with time, due to mesothelial irritation)
- Modified transudate: portal hypertension/obstruction of caudal vena cava, abdominal neoplasia, right-sided congestive heart failure, inflammatory disease, pancreatitis
- Exudate:
 - Non-septic: FIP, lymphocytic cholangitis, amyloidosis, pancreatitis, steatitis, neoplasia
 - Septic: penetrating wound, intestinal perforation, ruptured abscess, migrating foreign body
- Uroperitoneum
- Bile peritonitis
- Chyloperitoneum: neoplasia, congestive heart failure, steatitis, ruptured lymphatic vessel or obstructed lymphatic drainage, also reported rarely with FIP
- Haemoperitoneum: ruptured vessel or organ secondary to trauma or neoplasia, ruptured liver secondary to amyloidosis, coagulopathy

**Tip Box**

Congestive heart failure cannot be ruled out in the absence of any abnormalities on cardiac auscultation, although ascites is an unusual presentation of congestive heart failure in a cat.

Q 2. How would you investigate this case?

Abdominocentesis to collect a diagnostic sample of peritoneal fluid is the most useful initial investigation to characterize the fluid type and refine the differential diagnoses.

Haematology, biochemistry, and urinalysis are advised to evaluate protein levels and liver parameters. Hyperglobulinaemia may be present with FIP, and hypoalbuminaemia could result in transudate formation. Viral testing for FeLV and FIV is advised as immune dysfunction and neoplasia can occur secondarily to infection with either/both viruses.

Further Case Information

- Two mL of a clear, colourless fluid were obtained by abdominocentesis with a protein level of 10 g/L and a nucleated cell count of less than $1 \times 10^9/L$ (Figure 9.14), consistent with a transudate
- Haematology was unremarkable, and retroviral serology was negative (see Tables 9.4 and 9.5)

Q 3. How does interpretation of the blood, fluid, and urine results help refine the differential diagnosis?

The marked hypoalbuminaemia is consistent with severe protein loss, which could be due to protein-losing enteropathy (PLE), protein-losing nephropathy (PLN), or



Figure 9.14. Abdominocentesis fluid sample.

Table 9.4 Biochemistry Results at Presentation

	Patient Result	Reference Interval
Albumin (g/L)	16.6	28–42
Globulin (g/L)	30.1	28–42
Sodium (mmol/L)	157.7	153–162
Potassium (mmol/L)	5.00	3.8–5.3
Chloride (mmol/L)	121	110–121
Calcium (mmol/L)	1.93	2.07–2.80
Phosphorus (mmol/L)	1.75	0.92–2.16
Urea (mmol/L)	11.1	6.1–12
Creatinine (umol/L)	158	107–193
Cholesterol (mmol/L)	5.1	2.2–6.7
Bilirubin (mmol/L)	0.2	0–3
ALT (U/L)	40	25–130
CK (U/L)	149	52–506
ALP (U/L)	22	11–58
Glucose (mmol/L)	5	3–5

Bold type denotes abnormal result.

CK, creatine kinase. For further abbreviations, see footnote to Table 9.2.

Table 9.5 Urinalysis Results at Presentation

Urinalysis	
Specific gravity	1.020
pH	6.5
Nitrite	Negative
Protein	+++
Glucose	Negative
Ketones	Negative
Bilirubin	Negative
Blood	Negative
Sediment	Unremarkable

decreased production (liver failure). It is too severe to be due to decreased protein intake or secondary to chronic effusion. Liver failure is unlikely as other biochemical markers of decreased liver function such as hypoglycaemia or hypocholesterolaemia are not present, therefore PLE and PLN are most likely. Hypocalcaemia (total calcium) is likely secondary to the hypoalbuminaemia. The ascitic fluid is a transudate secondary to hypoalbuminaemia and is consistent with the biochemistry results.

Significant proteinuria is present with poorly concentrated urine and needs to be quantified further. Proteinuria can be due to pre-renal, intrinsic renal, or post-renal disease. Pre-renal proteinuria is unlikely with a normal globulin level, and the degree of proteinuria is too severe to be functional such as following exercise or stress. As the urine sediment is inactive, a post-renal cause such as a urinary tract infection (UTI) is unlikely, so the proteinuria is most likely secondary to intrinsic kidney disease resulting in PLN.

Q 4. What further investigations may be helpful at this stage?

A urine protein:creatinine (UPC) ratio and urine culture to quantify the proteinuria and rule out occult UTI should be performed.

Further Case Information

The UPC ratio was 12.28 (reference interval (RI): <0.4) and urine culture was negative.

Q 5. What is your interpretation of the UPC ratio, and how would you further investigate the case?

The UPC ratio is significantly elevated, consistent with PLN. PLN can be triggered by infectious, inflammatory, or neoplastic disease; therefore thoracic radiographs and abdominal ultrasound should be performed to look for evidence of underlying disease.

Further Case Information

Thoracic radiographs were unremarkable. Abdominal ultrasound revealed a hypoechoic, enlarged left limb of the pancreas with a hyperechoic appearance to the surrounding fat. The kidneys were of normal ultrasonographic appearance.

Q 6. *What are the most likely differential diagnoses considering all the results so far?*

PLN and pancreatitis are the most likely differential diagnoses. PLN is likely caused by glomerulonephritis (primary/idiopathic or secondary). Proteinuria can occur with defective renal tubular resorption or glomerular capillary hypertension in the absence of classic primary glomerular disease; however, typically this results in only low level proteinuria (UPC ratio 0.4–2). Pancreatitis could be triggering PLN or could be a concurrent and unrelated disorder.

Q 7. *Are there any other investigations that should be considered?*

Feline pancreatic lipase (FPL) measurement is helpful to confirm the diagnosis of pancreatitis and was increased at 30.6 µg/L (RI: 4.1–12.9 µg/L) in this case. Systemic hypertension may occur as a consequence of glomerular disease, therefore BP should be measured. Systolic BP was normal (140 mmHg, Doppler technique). Thromboembolism can occur as a consequence of urinary loss of antithrombin III (which is approximately the same size as albumin), therefore serum or urinary levels of antithrombin III can be measured; however, the results may not affect case management as antithrombotic treatment is advised regardless. Serum antithrombin was 100%.

Q 8. *What are the treatment options for this case?*

Treatment of pancreatitis includes IVF therapy to maintain hydration, analgesia, and anti-emetics. PLN management includes treating any underlying disease trigger, ACEi to decrease proteinuria (e.g. benazepril 0.5 mg/kg SID PO), and low dose aspirin (0.5 mg/kg PO SID) to decrease glomerular inflammation and inhibit platelet aggregation. Clopidogrel can be used as an alternative to aspirin to decrease platelet activation and try to decrease the risk of thromboembolic disease, but this does not inhibit thromboxane therefore has no anti-inflammatory properties, making aspirin the treatment of choice. A protein-restricted renal diet may be useful to decrease proteinuria, although protein restriction should be assessed on an individual case basis as hypoalbuminaemia may deteriorate. Omega-3 fatty acid supplementation is advised due to the anti-inflammatory, anti-thrombotic, and anti-oxidant effects.

Discussion

It is important to investigate thoroughly for underlying disease that can trigger glomerulonephritis, and a definitive diagnosis requires histologic examination with immunofluorescence microscopy and electron microscopy of the glomeruli from a biopsy of the renal cortex. Biopsies may suggest the underlying cause of glomerular disease and allow institution of a more directed treatment plan: immunosuppressive

therapy may be indicated in non-azotaemic cats with primary/idiopathic membranous nephropathy diagnosed by histopathology. However, biopsy carries a risk of bleeding, and since a potential underlying trigger of glomerulonephritis had been found, a biopsy was not performed in this case.

Further Reading

Littman, M.P., 2011. Protein-losing nephropathy in small animals. *Veterinary Clinics of North America Small Animal Practice* 41 (1), 31–62.

Case 9.6

Signalment, Clinical History, and Clinical Examination

A 3-year-old MN DSH cat was presented with a few weeks' history of weight loss, mild lethargy, and polydipsia. The cat was in reasonable body condition, and apart from a 4-5/6 systolic heart murmur, the physical examination was unremarkable.

Blood and urine were collected for in-house analysis; the significant findings are presented in [Table 9.6](#).

Table 9.6 Significant Findings on Serum Biochemistry Analysis

Analyte	Patient Result	Reference Interval
Urea (mmol/L)	16.7	5.7–12.9
Creatinine (umol/L)	501	71–212
Total calcium (mmol/L)	3.74	1.95–2.83

All other values were within the normal range, including PCV (32.1%), total plasma protein (79 g/L), serum phosphorus (2.35 mmol/L), and total thyroxine (T4) (40 mmol/L). Urine specific gravity was recorded as 1.012.

Echocardiography demonstrated normal cardiac chamber dimensions. The cat's systolic BP was also determined to be normal by Doppler sphygmomanometry.

Q 1. What is your interpretation of the clinical pathology tests?

The most significant clinicopathological finding is total hypercalcaemia. Azotaemia is also present with a low urine specific gravity, suggestive of chronic kidney disease (CKD). The hypercalcaemia may be the cause or result of CKD.

Q 2. Formulate a differential diagnosis list for hypercalcaemia in cats.

- Hypercalcaemia of malignancy (associated with elevated parathyroid hormone related peptide (PTHrp), or due to primary or metastatic bone neoplasia)
- Acute or chronic kidney disease
- Primary hyperparathyroidism
- Feline idiopathic hypercalcaemia
- Granulomatous disease

- Vitamin D toxicosis (rodenticides, plants, psoriasis medication, excessive supplementation)
- Administration of acidifying diets or urinary acidifiers (e.g. D,L-methionine)
- Hyperthyroidism (associated with mild elevations of total calcium but normal ionized calcium) and parathyroid hormone levels that normalize once euthyroidism has been achieved)
- Hypoadrenocorticism (elevations of calcium have been uncommonly recognized in cats with this condition, and is usually mild and clinically insignificant)
- Non-pathological causes (hyperproteinaemia, lipaemia, post-prandial, laboratory error)

Q 3. *What are the options for further investigation in this case?*

Further historical information should be sought from the owner regarding access to potential sources of vitamin D toxicity (e.g. outdoor access, hunting activity, exposure to specific plants, use of psoriasis ointment by human cohabitants).

Detailed physical examination, specifically checking for palpable cervical masses (parathyroid neoplasia or hyperplasia) or evidence of neoplasia (carcinomas in the mouth, anal sac adenocarcinoma, mammary adenocarcinoma, lymphoproliferative neoplasia) or infectious diseases (enlarged lymph nodes, chronic wounds, etc.).

Diagnostic imaging: thoracic radiographs and abdominal ultrasound to further look for evidence of neoplasia.

Serum ionized calcium: although testing of the serum total calcium is more readily available in clinical practice, it may not accurately reflect the physiologically significant calcium levels. Ionized calcium is the biologically active form and regulates the body's PTH and calcitonin levels, as well as its own reabsorption rate within the kidney tubules.

PTH: plasma collected with EDTA (ethylene diamine tetra acetic acid) or whole blood serum should be separated and immediately frozen and remain so until they reach the laboratory.

Parathyroid hormone related peptide (PTHrp): elevations in this analyte should prompt a more thorough search for underlying neoplasia. Positive retroviral tests may indicate an increased risk of lymphoma. Normal values do not rule out humoral hypercalcaemia of malignancy.

Vitamin D metabolites: these compounds are chemically identical across species, thus tests developed for humans are also appropriate for use in veterinary medicine:

- 25-Hydroxyvitamin D (25(OH) vitamin D3/calcidiol): this is a pre-hormone produced by hydroxylation of cholecalciferol in the liver. The concentration of this metabolite gives a good indication of vitamin D ingestion in cats.
- 1,25-Dihydroxyvitamin D (1,25(OH)₂ vitamin D3/calcitriol): calcidiol is converted to calcitriol in the kidneys and is the biologically active form of vitamin D in the body.

NB: Careful attention should be paid to the assessment of abdominal imaging studies for any evidence of calcium oxalate uroliths, as hypercalcaemia is a known risk factor for this condition in cats.

Q 4. *How should you treat the hypercalcaemia assuming it is a repeatable finding and/or confirmed by documenting ionized hypercalcaemia, pending other results?*

- 0.9% sodium chloride fluids to promote diuresis

- If there is inadequate reduction in serum calcium with fluid therapy alone, furosemide can be initiated (providing the cat is adequately hydrated) to further promote diuresis and increase urinary calcium excretion
- Treatment with calcitonin and/or bisphosphonates is sometimes employed if diuresis alone is ineffective
- Glucocorticoids can be effective in further reducing serum calcium via reduction in bone resorption, intestinal absorption, and increased renal excretion of calcium, but should not be initiated until lymphoma has been excluded as it may mask lymphoma and delay diagnosis as well as potentially reduce responsiveness to chemotherapy

Further Results

There was no suggestion of vitamin D toxicity from the history. No evidence of neoplasia was identified on physical examination, thoracic radiographs, and abdominal ultrasound. Blood was taken for endocrine analysis (Table 9.7).

Table 9.7 Endocrine Data

Analyte	Patient Result	Reference Interval
Ionized calcium (mmol/L)	2.3	1.2–1.8
Parathyroid hormone (PTH) (pg/mL)	0	22–122
Parathyroid hormone-related peptide (PTHrp) (pg/mL)	Not measured	<1.0
25(OH) vitamin D3 (calcidiol) (nmol/L)	355	48–148
1,25(OH) ₂ vitamin D3 (calcitriol) (pmol/L)	Not measured	200–500
Phosphate (mmol/L)	1.4	0.9–1.45

Bold type denotes abnormal result.

Q 5. How would you interpret the results in this case?

Neoplasia is less likely but not fully excluded.

PTH concentration is low, excluding primary hyperparathyroidism and renal secondary hyperparathyroidism.

Elevated 25(OH) vitamin D levels suggest ergocalciferol (vitamin D2) or cholecalciferol (vitamin D3) toxicity (1,25(OH)₂ vitamin D3 levels may be normal, depressed, or elevated), either due to rodenticide ingestion (typically via the consumption of an intoxicated rodent in cats) or via over-supplementation of calcitriol (usually during the treatment of spontaneous or iatrogenic hypoparathyroidism).

The normal phosphate concentration is unusual in this case, as hyperphosphataemia usually also occurs with vitamin D toxicoses.

Treatment and Outcome

Following initial fluid therapy the cat was treated with furosemide and prednisolone for several weeks. Repeated blood testing revealed that the serum total calcium level had reduced (2.99 mmol/L) and serum creatinine was now 313 μ mol/L, although

the urea was still elevated (18.9 mmol/L). Treatment was continued for several more weeks following which time renal parameters and calcium concentrations had normalized. The cat remained well, and several months later 25(OH) vitamin D3 levels had returned to normal and all treatment was tapered and finally stopped.

Discussion

Hypercalcaemia in cats is most frequently idiopathic, but can be related to neoplasia (e.g. carcinoma, lymphoma, multiple myeloma), CKD, and primary hyperparathyroidism.

With CKD total hypercalcaemia is usually mild, and ionized calcium is usually normal. A diagnosis of primary hyperparathyroidism can be difficult to establish in cats that do not have a palpable or ultrasonographically detectable cervical mass or elevations in PTH; however, a PTH level in the upper two-thirds of the reference range in the face of elevated serum ionized calcium is considered highly suggestive of the disease.

Feline idiopathic hypercalcaemia has been an emerging entity since the early 1990s. This entity is characterized by elevations in serum ionized calcium of unknown origin (after an extensive investigation to rule out other causes of hypercalcaemia).

A number of infectious diseases associated with a granulomatous inflammatory response (e.g. mycobacteriosis, cryptococcosis, or nocardiosis) are associated with hypercalcaemia in cats. This is thought to be due to excessive production of calcitriol-like metabolites by mononuclear cells.

Vitamin D toxicosis can occur with cholecalciferol rodenticide poisoning, over-supplementation of vitamin D, ingestion of plants containing high levels of 1,25(OH)₂ vitamin D3 (e.g. *Cestrum diurnum* (day-blooming jessamine)), or the ingestion of human psoriasis ointments containing calcipotriene. Recently vitamin D intoxication due to contamination of commercial cat food has been reported. In this case vitamin D toxicosis was suspected but no confirmed source of vitamin D was discovered.

Further Reading

- Morita, T., Awakura, T., Shimada, A., et al., 1995. Vitamin D toxicoses in cats: natural outbreak and experimental study. *Journal of Veterinary Medical Science* 57, 831–837.
- Savary, K.C.M., Price, G.S., Vaden, S.L., 2001. Hypercalcemia in cats: a retrospective study of 71 cases. *Journal of Veterinary Internal Medicine* 14, 184–189.
- Wehner, A., Katzenberger, J., Groth, A., et al., 2013. Vitamin D intoxication caused by ingestion of commercial cat food in three kittens. *Journal of Feline Medicine and Surgery* 15 (8), 730–736.

Case 9.7

Signalment and History

A 14-year-old FN DSH cat presented for evaluation of a small mass on her dorsum. In the past 1–2 weeks she had also developed small intestinal diarrhoea and was losing weight (110 g lost in 2 weeks) despite a normal appetite. She had a mixed indoor/outdoor lifestyle, was fed a commercial wet diet, and preventative health care was current. She had previously been diagnosed with hyperthyroidism, which was well controlled with oral carbimazole treatment. She had also had a well-differentiated dermal mast cell tumour removed from the right side of her face 2 years ago, with clean margins.

Clinical Examination

On examination she was in reasonable body condition with a BCS of 4/9 and weighed 2.9 kg. Vital parameters were all within normal limits. She had palpably thickened intestinal loops and splenomegaly. There was a 4 mm slightly pink, alopecic, semi-pedunculated mass on the dorsum.

Q 1. *Formulate a problem and differential diagnoses list.*

- Weight loss despite a good appetite
 - Maldigestion: EPI
 - Malabsorption: inflammatory or neoplastic infiltrative intestinal disease
 - Increased nutrient utilization: hyperthyroidism, diabetes mellitus, neoplasia
 - Miscellaneous: lymphocytic cholangitis
- Cutaneous mass
 - Neoplasia: e.g. basal cell tumour, mast cell tumour
 - Benign: inflammatory, granuloma, papilloma
 - Small intestinal diarrhoea (see Case 2.4 for differential diagnoses)
- Splenomegaly
 - Extramedullary haematopoiesis
 - Splenitis
 - Splenic neoplasia

Q 2. *What diagnostic investigations would you perform?*

- Fine needle aspirates of the cutaneous mass.
- Complete blood count (CBC) and biochemistry, including thyroxine (T4), and urinalysis would be a prudent first step in further evaluating for systemic diseases given the weight loss, and to ensure good control of the hyperthyroidism.

Further Case Information

Cytology of fine needle aspirates revealed a large number of mast cells and occasional eosinophils, suggestive of a cutaneous mast cell tumour. See [Tables 9.8 and 9.9](#) for biochemistry, haematology and urinalysis results.

Table 9.8 Urinalysis Results

Volume (mL)	1.0
Colour	Yellow
Transparency	Clear
Specific gravity	1.017
Glucose	Negative
Billirubin	Negative
Ketones	Negative

Table 9.8 Urinalysis Results—cont'd

Haemoglobin	Negative
pH	5.5
Protein	Negative
Urobilinogen	Normal (less than 20 umol/L)
RBC/hpf	Less than 5
WBC/hpf	Less than 5
Casts, number	Negative
Casts, type	N/A
Bacteria, number	Negative
Bacteria, type	N/A
Fat	Occasional
Epithelial cells, number	Occasional
Epithelial cells, type	Squamous
Sperm	Negative
Crystals, number	Negative
Crystals, type	N/A
Debris	Negative

hpf, high power field; RBC, red blood cells; WBC, white blood cells

Table 9.9 Blood Test Results

Parameter	Patient Result	Reference Interval
T4, total (nmol/L)	25	10–60
RBC ($\times 10^{12}/L$)	7.5	4.9–10.0
Haemoglobin (g/L)	91	77–156
Haematocrit (L/L)	0.38	0.25–0.48
MCV (fL)	51	43–55
MCH (pg)	12	13–17
MCHC (g/L)	239	282–333
Platelets ($\times 10^9/L$)	280 (clumped and adequate)	300–800
WBC ($\times 10^9/L$)	7.9	5.5–19.0
Neutrophil (%)	75	
Neutrophil ($\times 10^9/L$)	5.9	2.0–13.0
Lymphocyte (%)	17	
Lymphocyte ($\times 10^9/L$)	1.3	0.9–7.0
Monocyte (%)	4	
Monocyte ($\times 10^9/L$)	0.3	0–0.7
Eosinophil (%)	4	
Eosinophil ($\times 10^9/L$)	0.3	0–1.1

Continued

Table 9.9 Blood Test Results—cont'd

Parameter	Patient Result	Reference Interval
Sodium (mmol/L)	152	144–158
Potassium (mmol/L)	4.6	3.7–5.4
Chloride (mmol/L)	120	106–123
Bicarbonate (mmol/L)	16	12–24
Na:K ratio	33.0	29.0–+
Anion gap (mmol/L)	20.6	15.0–31.0
Glucose, serum (mmol/L)	5.4	3.2–7.5
Urea (mmol/L)	7.8	5.0–15.0
Creatinine (mmol/L)	0.13	0.08–0.20
Calcium (mmol/L)	2.4	2.1–2.8
Phosphate (mmol/L)	1.5	1.0–2.3
Ca:P ratio	1.6	1.1–2.3
Protein, total (g/L)	65	60–84
Albumin (g/L)	30	25–38
Globulin (g/L)	35	31–52
Bilirubin, total (umol/L)	4	0–7
ALP (IU/L)	22	5–50
AST (IU/L)	13	2–62
ALT (IU/L)	95	19–100
CK (IU/L)	100	64–400
Cholesterol (mmol/L)	7.2	2.2–5.5
Gamma GT (IU/L)	<3	0–6
Feline pancreatic lipase (µg/L)	7.8	0.1–3.5 normal 3.6–5.3 equivocal elevation >5.4 consistent with pancreatitis

Bold type denotes abnormal result.

ALP, alkaline phosphatase; ALT, alanine transaminase; AST, aspartate aminotransferase; CK, creatine kinase; gamma GT, gamma glutamyl transferase; MCH, mean corpuscular haemoglobin; MCV, mean corpuscular volume; MCHC, mean corpuscular haemoglobin concentration; RBC, red blood cells; T4, thyroxine; WBC, white blood cells.

Q 3. What is your interpretation of the blood results?

- Urine specific gravity is suboptimal in the low end of the isosthenuric range, which, in the light of no other abnormalities that may account for this, may be consistent with International Renal Interest Society (IRIS) stage 1 CKD
- Total T4 is well controlled making this unlikely to be the cause of the weight loss
- Haematology and biochemistry are largely unremarkable excluding diabetes mellitus and cholangitis
- FPL is mildly elevated suggestive of pancreatitis. This is likely to reflect concurrent/secondary pancreatic inflammation since pancreatitis alone would not explain all the clinical signs

Q 4. *How would you further investigate this case?*

An abdominal ultrasound would be indicated to further evaluate in particular the palpable splenomegaly and the palpably thickened small intestines. In this scenario it is always prudent to discuss with the owners prior to ultrasound about the possibility of taking fine needle aspirates from abnormal organs (e.g. the spleen) if any enlarged lymph nodes are identified, etc.

Further Case Information

Abdominal ultrasound revealed patchy mild small intestinal thickening with wall thickness measuring up to 3.7 mm (normal <3 mm) but with no loss of layering. Splenomegaly was confirmed, with the spleen also having irregular margins and being mildly heterogeneous. Mesenteric lymph nodes caudal to the spleen were also enlarged with irregular margins. Other abdominal organs were ultrasonographically normal.

Q 5. *Do the ultrasound findings help to further narrow down your differential diagnoses, and what are the options for further investigation?*

The splenomegaly and enlarged mesenteric lymph nodes raise the suspicion of neoplastic disease, which could account for the clinical signs. Given the presence of a cutaneous mast cell tumour, systemic mastocytosis would be a possibility. Alternatively, the cutaneous mast cell tumour could be low grade and incidental with a different disease process, such as lymphoma affecting the spleen. The diffuse thickening of the small intestines could be consistent with inflammatory bowel disease (IBD), or may also represent gastrointestinal lymphoma or intestinal mast cell neoplasia.

Options for further investigation would include:

- Fine needle aspirate of the spleen, liver +/- enlarged mesenteric lymph nodes to further investigate the possibility of systemic mastocytosis or lymphoma. This may be the easiest, least invasive initial option, results of which may be enough to further direct management of the cat
- Inflated thoracic radiographs to further assess for metastatic disease
- Laparotomy to remove the spleen, biopsy the mesenteric lymph nodes and small intestine, and remove the cutaneous mast cell tumour at the same time

The benefits of laparotomy are that it allows removal of the spleen, which may be required for the treatment of splenic mast cell neoplasia. Laparotomy also allows more thorough assessment of the extent of the disease, allowing biopsies of the liver, intestines, and mesenteric lymph nodes as well. However, fine needle aspirates may provide enough information to reach a diagnosis and assess extent of the disease, and potentially avoid a more invasive surgery if there is widespread neoplastic disease that surgery might not be helpful with (e.g. lymphoma). There is also the benefit of being able to start treatment with corticosteroids if required, earlier than if laparotomy has been performed. There are more risks with performing laparotomy, but a higher chance of yielding definitive diagnoses.

Further Case Information

In this case it was opted to perform laparotomy. A coagulation profile (APPT (activated partial thromboplastin time)/PT (prothrombin time)) was performed first, which was

normal. Inflated chest radiographs (three views) were also taken with no significant abnormalities. Anti-histamine (chlorpheniramine) and H2 blocker (ranitidine) were included in pre-medication to reduce potential effects of histamine release from mast cell tumours.

On gross examination the spleen was firm, enlarged, and mottled; the liver was enlarged, mottled, and had rounded margins; and the small intestine was diffusely thickened and mesenteric lymph nodes markedly enlarged. The stomach, duodenum, ileum, mesenteric lymph nodes, and liver were biopsied, and the spleen was removed. At the time of surgery, two further dermal masses were noted on the right hindlimb and were removed along with the mass on the dorsum.

Histopathology results revealed all three dermal masses to be well-differentiated mast cell tumours. The spleen was consistent with mast cell neoplasia with evidence of metastases to the mesenteric lymph nodes and liver. There was no evidence of mast cell neoplasia within the intestines, which were all consistent with chronic lymphoplasmacytic enteritis and gastritis.

Q 6. *What are the options for managing this case?*

The options for chemotherapeutic treatment include tyrosine kinase inhibitors, lomustine (CCNU), and vinblastine. Chlorambucil may also have some beneficial effects. Most of these treatments would be used in combination with prednisolone. Palliative prednisolone therapy alone can also be required when the owner does not wish to use any chemotherapeutic agents. In this case prednisolone would also be indicated for the inflammatory bowel disease that may also be contributing to clinical signs.

Other supportive treatments include anti-histamines and H2 blockers to reduce the effect of histamine release and gastrointestinal ulceration.

Q 7. *What prognosis would you give to the owner?*

Prognosis can be very difficult to predict as there is significant variability in behaviour depending on anatomic location and no relevant grading system exists in cats, in difference to canine mast cell tumours. Cats with splenic mast cell neoplasia generally have a median survival time of 10–16 months with splenectomy and less than 6 months without. The prognosis may be worse in this case given that there is already presence of metastatic disease, but performing splenectomy in this situation is still likely to increase survival time.

Further Case Information

In this case, the owners opted against any chemotherapeutic treatments and even against prednisolone treatments, as she was very difficult to medicate. Given that her hyperthyroidism was stable, they opted to simply continue with carbimazole therapy for this and to allow her to enjoy as much quality of life as possible and not to add in any further medications. The cat gained weight following surgery and survived for a further 10 months post-operatively, with a good quality of life during this time.

Discussion

Feline mast cell tumours are frequently encountered in general practice, being the most common splenic tumour, second most common skin tumour, and third most common intestinal tumour in cats. Mast cell tumours in cats are generally classified into

cutaneous, visceral, or intestinal disease. Cutaneous mast cell tumours in cats are often well differentiated and have a benign clinical course, with complete resection usually being curative, although there are always exceptions to this. Visceral and intestinal mast cell tumours carry a much less favourable prognosis. Common metastatic sites include liver, abdominal lymph nodes, bone marrow, lung, and intestinal tract. Clinical signs associated with visceral and intestinal mast cell tumour disease are due both to the effects of the primary neoplasm and mast cell degranulation. Findings may include mastocytæmia, anaemia (due to bone marrow involvement, gastric ulceration, or anaemia of chronic disease), coagulation disorders, anorexia, vomiting, anaphylactoid reactions, dyspnoea, weight loss, pleural and peritoneal effusion, and pruritus.

Treatment and prognosis vary dramatically with location and histologic classification. Historically, there has been limited clinical evidence upon which to determine optimal treatment for mast cell tumours in cats, but there has been development of new treatments such as tyrosine kinase inhibitors that provide new treatment avenues.

Further Reading

- Henry, C., Herrera, C., 2013. Mast cell tumours in cats: clinical update and possible new treatment avenues. *Journal of Feline Medicine and Surgery* 15 (1), 41–47.
- Litster, A.L., Sorenmo, K.U., 2006. Characterisation of the signalment, clinical and survival characteristics of 41 cats with mast cell neoplasia. *Journal of Feline Medicine and Surgery* 8 (3), 177–183.

Case 9.8

Signalment, Clinical History, and Clinical Examination Findings

A 3-year-old FN DLH cat presented with a 3-day history of ataxia, inappetence, and lethargy progressing to collapse. Vaccination, worming, and flea control were up to date. The cat was indoor/outdoor and known to hunt.

The following abnormalities were noted on examination:

- Obtunded mentation
- Dehydration (skin tenting and dry mucous membranes)
- Jaundice and pallor
- Hypotension (weak peripheral pulses and systolic BP 65 mmHg)
- Tachycardia (250 bpm)
- Tachypnoea (45 brpm, with reduced lung sounds ventrally bilaterally)
- Severe hypothermia (RT 32.5 °C)
- Abdominal pain

Q 1. What treatments would you instigate initially to try and stabilize this cat?

- Provision of oxygen and minimization of stress (given the tachypnoea and reduced lung sounds).
- Gain IV access and initiate IV fluid therapy (given the hypotension and evidence of dehydration); a bolus of 10 mL/kg of crystalloids could be given following reassessment of blood pressure.
- Active warming: in this case performed using an air-filled heated blanket initially, followed by placement in a paediatric incubator.

Q 2. What initial investigations would you perform on this cat?

Body systems requiring further investigation include:

- Respiratory system: based on the exam, pleural effusion was suspected so thoracocentesis was performed (radiography or ultrasonography could be used to confirm the presence of fluid if available)
- Abdominal cavity: based on the finding of abdominal pain the abdomen was imaged with ultrasound; radiography could also be used
- Neurological system: the obtunded mentation and weakness may suggest underlying central nervous system (CNS) disease or reflect the severe hypothermia or metabolic or cardiovascular disease. An emergency database ideally including biochemistry (to also investigate the jaundice) and haematology should be performed

Further Case Information

Thoracocentesis removed 100 mL of clear, non-viscous yellow fluid. Following this, the cat's respiratory rate improved to 30–35 brpm. Brief emergency ultrasound of the abdomen revealed a mild to moderate amount of free peritoneal fluid and a mildly hyperechoic appearance to the liver. A peritoneal fluid sample was collected for analysis, and this was similar in gross appearance to the pleural fluid.

Haematology abnormalities

- Marked leucopenia ($1.86 \times 10^9/\text{L}$; RI: $4.9\text{--}19 \times 10^9/\text{L}$)
- Marked neutropenia ($0.82 \times 10^9/\text{L}$; RI: $2.4\text{--}12.5 \times 10^9/\text{L}$) with toxic changes to neutrophils (2+)

Biochemistry abnormalities

- Moderate increase of urea (18.6 mmol/L ; RI: $6.5\text{--}10.5 \text{ mmol/L}$)
- Marked hypoalbuminaemia (12 g/L ; RI: $24\text{--}35 \text{ g/L}$) (TP 33 g/L ; RI: $77\text{--}91 \text{ g/L}$)
- Marked elevation in ALT (1220 IU/L ; RI: $15\text{--}45 \text{ IU/L}$)
- Hyperbilirubinaemia ($78 \mu\text{mol/L}$; RI: $0\text{--}10 \mu\text{mol/L}$)
- Marked hypoglycaemia (1.5 mmol/L ; RI: $3.5\text{--}5 \text{ mmol/L}$)

Q 3. What is your interpretation of these findings?

The appearance of the fluid is consistent with a transudate or modified transudate and fluid analysis will further characterize this. Biventricular effusions are most typically seen with severe hypoalbuminaemia, congestive heart failure, neoplasia, FIP, and vasculitis.

The hyperechoic liver is a relatively non-specific finding and can be consistent with infection/inflammation, hepatic lipidosis, and infiltrative neoplasia.

Neutropenia with toxic changes is suggestive of sepsis.

The moderate increase of urea was most likely pre-renal resulting from fluid deficits, although renal causes cannot be excluded. Urinalysis to assess urine specific gravity would have clarified this.

The marked hypoalbuminaemia may have been due to decreased production (hepatic insufficiency) or increased loss (protein-losing enteropathy or protein-losing nephropathy). Loss into the effusions may have been a contributing factor along with systemic vasculitis.

The marked elevation of ALT is consistent with hepatocellular damage and the hyperbilirubinaemia is likely hepatic in origin (primary hepatic disease), although pancreatitis and sepsis cannot be excluded as causes.

The hypoglycaemia may be due to decreased glucose production (e.g. hepatic insufficiency, hypoadrenocorticism), increased glucose consumption (e.g. sepsis), or to excess secretion of insulin or insulin-like factors (e.g. insulinoma). In this case hepatic insufficiency and sepsis were considered the most likely causes.

Further Case Information

The cat developed a large haematoma following jugular venipuncture; coagulation times (PT, APTT) were measured and were both markedly increased.

Q 4. What is your interpretation of the coagulation abnormalities?

Prolonged PT and APTT indicate multiple coagulation factor deficiencies (intrinsic, extrinsic, and/or common coagulation pathways). This may occur in hepatic insufficiency or disseminated intravascular coagulation (either or both of which may have been present in this case) and vitamin K deficiency or antagonism (e.g. rodenticide toxicity), which was considered less likely given the cat's presentation and other laboratory findings.

Further Case Information

In light of the bicavitary effusions, tachycardia, and hypotension, brief echocardiography was also performed and was unremarkable.

Pleural and peritoneal fluid analysis revealed very low cellularity (cell count of $0 \times 10^9/L$; just one to two cells were noted in each fluid sample: non-degenerate neutrophils and/or mononuclear cells) and total protein levels of 25 g/L with albumin:globulin ratios of 0.67.

Q 5. Classify the body cavity effusions, and suggest likely differential diagnoses.

The body cavity effusions are of very low cellularity, but the protein level suggests a modified transudate. Modified transudates arise due to congestive heart failure, vasculitis, neoplasia, and infectious diseases (e.g. FIP, mycobacteria, toxoplasmosis). Pure transudates may be caused by increased hydrostatic pressure (e.g. congestive heart failure), decreased oncotic pressure (e.g. hypoalbuminaemia), or vasculitis.

Case Outcome

The cat was treated with repeated IV glucose boluses (0.25–0.5 g/kg) and further crystalloid and colloid (5 mL/kg over 20 min) boluses as well as IV broad spectrum antibiotics in view of suspected sepsis. Unfortunately the cat's condition continued to deteriorate and euthanasia was elected. On post-mortem examination histopathology (Figure 9.15) of the brain and liver revealed multifocal necrosis and inflammation associated with protozoal tissue cysts (appearance consistent with *Toxoplasma gondii*), and protozoal tissue cysts were also identified in the spleen.

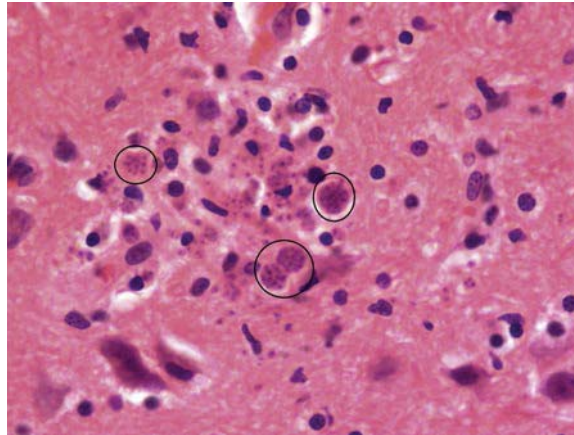


Figure 9.15. H&E $\times 80$. Brain demonstrating toxoplasma tissue cysts (in black circles) and an associated glial reaction. Image courtesy of Debra Fewes.

Q 6. What tests are available for antemortem diagnosis of toxoplasmosis, and what are their limitations?

Diagnosis of toxoplasmosis can be difficult antemortem. Definitive diagnosis requires identification of the organism within tissues on histopathology. Tachyzoites can often be identified on cytology of body cavity effusions (but were not present in this case), cerebrospinal fluid (CSF), aqueous humour, or bronchoalveolar lavage (BAL) fluid.

Serological testing (IgG and IgM immunoglobulins) can aid diagnosis antemortem. A four-fold rise in IgG titre over a 2–4 week period would be suggestive of recent infection, and an IgM titre of $>1:64$ is considered consistent with active toxoplasmosis. However, toxoplasmosis may present acutely before seroconversion occurs. In this case, the cat's clinical deterioration and euthanasia meant that serological testing or further tests such as tissue biopsy or therapeutic trials to reach a diagnosis were not possible.

Discussion

This was an unusual case of peracute toxoplasmosis. The cause of the body cavity effusions was likely multifactorial (hypoalbuminaemia, vasculitis). The presentation of clinical toxoplasmosis varies depending on the organs involved, but common clinical signs include inappetence, weight loss, lethargy, pyrexia, ocular inflammation, and dyspnoea (pulmonary involvement). Other clinical signs may include neurological changes, jaundice, myositis, and gastrointestinal signs. Clindamycin (25 mg/kg/day) for 2–4 weeks is commonly recommended for treatment.

Further Reading

Hartmann, K., Addie, D., Belák, S., 2013. Toxoplasma Gondii Infection in Cats: ABCD guidelines on prevention and management. *Journal of Feline Medicine and Surgery* 15 (7), 631–637.

Case 9.9**Signalment and History**

A 10-year-old MN DSH presented with a 2-day history of progressive lethargy and abnormal head carriage. Further questioning of his owners indicated that over the previous month they had become aware of a reduction in appetite and polydipsia, and of some weight loss. No other signs had been noted.

Clinical Examination

The cat was in good body condition (BCS 3/5). When placed on the floor and encouraged to move he could only walk a few paces, with his head held low ([Figure 9.16](#)), before sinking into sternal recumbency.

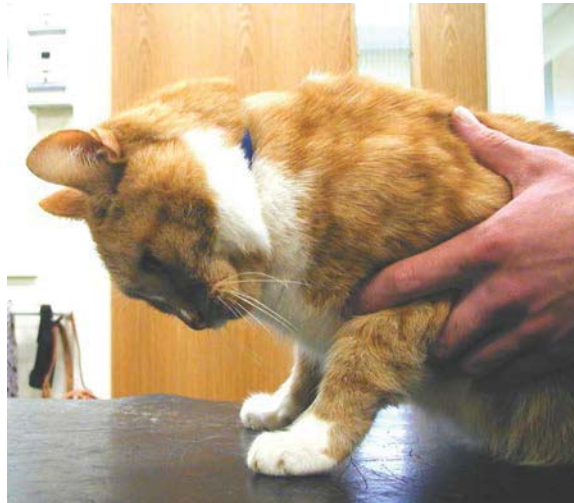

Figure 9.16. Abnormal head carriage at the time of presentation.

Abdominal palpation revealed that both kidneys were enlarged with an irregular outline; the right kidney was larger than the left kidney. Neurological examination and ophthalmic examinations were unremarkable.

Q 1. *What is your interpretation of the presenting findings in this cat and most likely differential diagnosis?*

The abnormal head carriage is due to ventroflexion of the neck, which is typically a sign of muscle weakness.

The pre-existing poor appetite, polydipsia, and weight loss, coupled with the palpably irregular and enlarged kidneys, suggests that there is renal disease. Hypokalaemia is a common consequence of CKD in the cat, and can lead to muscle weakness and cervical ventroflexion, although other causes of muscle weakness cannot be excluded.

Q 2. *How can neurological deficits be distinguished from muscle weakness based on physical examination findings?*

Careful interpretation of the results of neurological examination are required to differentiate muscle weakness from neuropathy.

Upper motor neuron disorders are associated with increased tone and exaggerated reflexes and should be readily distinguishable from muscle weakness. Lower motor neuron disorders and peripheral neuropathies cause loss of muscle tone and weak or absent reflex responses that can be more difficult to differentiate from muscle weakness. The latter leaves neurological reflexes intact but responses may appear blunted due to inability of the muscle to contract in response to the nerve impulse. Responses may also be lost on repeated testing due to tiring of the muscle or, in the case of myasthenia gravis, due to loss of response to acetylcholine in the neuromuscular junction.

In this case reflexes appeared weak but present consistent with muscle weakness. No other neurological abnormalities were noted.



Tip Box

When conducting a neurological examination in a cat with loss of muscle tone and weakness it is important to:

- o Support the cat's weight when testing proprioceptive reflexes
- o Look for subtle indications that the cat is *trying* to respond to the test, e.g. with a limb placing response, whisker twitch, or blink reflex, even if the movement is not successfully completed
- o Conduct the neurological tests after a period of rest, and if results are equivocal allow a further period of rest to allow the muscle fibres or neuromuscular junctions to recover before repeating the test

Q 3. *List the major causes of unilateral or bilateral renomegaly in the cat.*

- Neoplasia: lymphosarcoma, renal carcinoma, metastatic disease
- Polycystic kidney disease (PKD)
- FIP
- Hydronephrosis
- Amyloidosis
- Perinephric pseudocysts
- Pyelonephritis
- Renal trauma and haemorrhage

Q 4. *How would you further investigate this case?*

- Serum biochemistry to assess for presence of hypokalaemia and azotaemia
- Urinalysis and haematology to further evaluate renal function
- Blood pressure measurement would be recommended if blood and urine tests confirm the presence of chronic kidney disease
- Renal ultrasound will be useful to further characterize the abnormal kidneys

Further Investigations

See [Tables 9.10–9.12](#) for blood and urine test results.

- Systolic blood pressure: 148 mmHg (RI: 120–180 mmHg)
- Total T4: 12 nmol/L (RI: 10–55 nmol/L)
- Renal ultrasound ([Figure 9.17](#)): both kidneys showed similar lesions and were significantly enlarged at approx. 5 cm × 8 cm.

Q 5. Describe the ultrasonographic changes shown in [Figure 9.17](#). What diagnosis is this consistent with?

There are multiple hypoechoic lesions throughout the kidney parenchyma with no discernible normal renal architecture. The ultrasound findings are characteristic of PKD.

Table 9.10 Serum Biochemistry

Parameter	Patient Result	Reference Interval
Total protein (g/L)	77.8	60–80
Albumin (g/L)	31.2	25–45
Globulin (g/L)	46.6	25–45
Urea (mmol/L)	31.1	2.5–9.9
Creatinine (μmol/L)	292.4	20–177
Inorganic phosphorus (mmol/L)	2.45	0.9–2.2
ALT (IU/L)	50.0	<60
AlkP (IU/L)	23.4	<60
Na (mmol/L)	153.0	145–157
K (mmol/L)	2.69	3.5–4.5
CK (IU/L)	576.8	20–225

Bold type denotes abnormal result.

For further abbreviations, see footnote to [Table 9.9](#).

Table 9.11 Urinalysis

Specific gravity	1.015
pH	6.0
Protein	++
Blood	Negative
Glucose	Negative
Bilirubin	Negative
Sediment analysis	Inactive
Urine culture	Negative
Protein:creatinine ratio	1.8

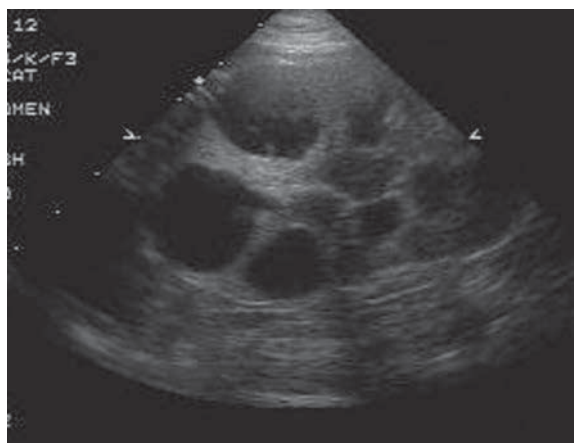
Bold type denotes abnormal result.

Table 9.12 Haematology

Parameter	Patient Result	Reference Interval
PCV (%)	23	25–45
RBC ($\times 10^{12}/L$)	5.11	5.0–10.0
Haemoglobin (g/dL)	7.5	9–15
MCHC (g/dL)	32.5	28–36
MCV (fL)	45.2	40–55
Film comment	No evidence of regeneration	
WBC ($\times 10^9/L$)	12.5	6.0–15.0
Neutrophils ($\times 10^9/L$)	10.5	2.5–12.5
Lymphocytes ($\times 10^9/L$)	1.88	2.0–7.0
Monocytes	0	<0.9
Eosinophils ($\times 10^9/L$)	0.13	<0.7

Bold type denotes abnormal result.

PCV, packed cell volume. For further abbreviations, see footnote to Table 9.1.

**Figure 9.17.** Ultrasound appearance of an affected kidney.

Q 6. Use the IRIS classification system to stage this cat's CKD.

This cat is in IRIS stage 3 CKD (creatinine in the range 251–439 $\mu\text{mol}/L$). He is proteinuric (UPC ratio > 0.4) and hyperphosphataemic, but his arterial blood pressure falls within the range of 'minimal risk of end organ disease' (substage AP0).

(The International Renal Interest Society (IRIS) is an international group of veterinary nephrologists that have produced consensus guidelines covering the staging and approach to treatment of cats and dogs with CKD (www.iris-kidney.com).)

Q 7. What are the options for treatment of the hypokalaemia?

Potassium can be given by intravenous infusion or as an oral supplement. Either route is appropriate in a cat that is well hydrated and not off its food.

- IV supplementation requires careful monitoring; insufficient supplementation of IVF will further contribute to hypokalaemia, but over-aggressive supplementation too rapidly can lead to potentially fatal dysrhythmias. When supplying IV potassium, follow the published guidelines for supplementation (Table 9.13) and do not exceed 0.5 mmol/kg/h.

Table 9.13 Suggested Potassium Supplement Rates for Intravenous Use

Serum Potassium	Amount of K ⁺ to Add to a 500-mL Bag of 0.9% Saline
<2 mmol/L	40 mmol
2–2.5 mmol/L	30 mmol
2.5–3 mmol	20 mmol
3–3.5 mmol/L	14 mmol
Rate of infusion must not exceed 0.5 mmol/kg/h	

- Oral supplementation is safe, effective, and at adequate doses can produce a rapid response with no risk of hyperkalaemia since oral potassium in excess of requirements will not be absorbed from the gastrointestinal tract.

In this case the cat was not dehydrated and although eating less than normal still consuming an adequate amount of food, therefore oral potassium supplementation (2 mEq PO TID initially) was provided.

Q 8. What are the remaining priorities of treatment for the longer-term management of CKD in this case?

Hyperphosphataemia and proteinuria have been associated with a poorer prognosis in cats with CKD and warrant treatment.

The hyperphosphataemia should be managed initially with a low phosphate diet, and if this fails to reduce the serum phosphate or is poorly accepted, then phosphate binders (e.g. lanthanum carbonate) can be added.

The proteinuria should be managed with an ACEi or an angiotensin receptor blocker, although this may encourage potassium retention so care is essential when concurrent potassium supplementation is required. In this case benazepril (2.5 mg PO SID) was used and was well tolerated.

Outcome

Within 24 h there was a marked improvement in the cat's muscle strength and activity. The potassium supplementation was titrated down to a maintenance level of 2 mEq per day. The low protein, low phosphate diet was well accepted, and the proteinuria improved with ACE inhibition.

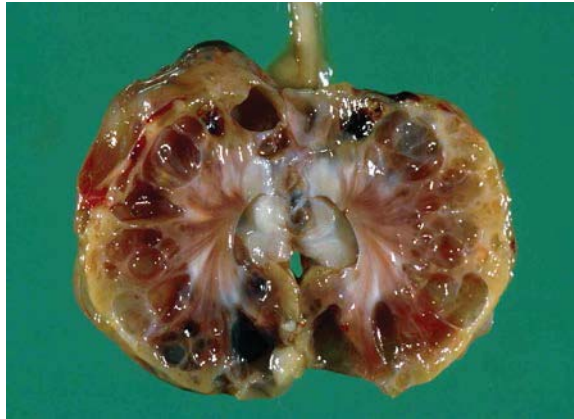

Figure 9.18. Gross appearance of an affected kidney at postmortem.

The cat remained well for a further 4 months before being euthanized due to progression of CKD.

Discussion

PKD is an inherited disorder more common in Persian-related breeds and British Short-hair cats but is occasionally seen in DSH and DLH cats. Multiple renal cysts are present from birth, but are initially small and have no detectable effect on renal function. As time goes on the cysts enlarge until they eventually compromise kidney function (see [Figure 9.18](#)). The rate at which the cysts enlarge is variable and unpredictable; most affected cats do not show signs of renal disease until relatively late in life, but some severely affected individuals will succumb to progressive azotaemia as young as 2 or 3 years old.

In this case the PKD was advanced at the time of diagnosis, the long-term prognosis was therefore guarded especially in view of the marked proteinuria and hyperphosphataemia, both of which tend to be associated with more rapid progression of CKD. In view of this the owners opted for a relatively conservative approach to treatment to which the cat responded for a short time.

Further Reading

Korman, R.M., White, J.D., 2013. Feline CKD: Current therapies - what is achievable? *Journal of Feline Medicine Surgery* 15 (Suppl 1), 29–44.

Case 9.10

Signalment and History

An 8-month-old FE DSH cat was presented with a 7-day history of progressive mammary gland enlargement. The cat had been in her owners' possession since she was a kitten and had been fully vaccinated and regularly wormed. She had always been in good health and remained well in herself despite the mammary swelling. She had come into oestrus for the first time at around 6 months of age, and her owners had

been undecided as to whether to have a litter of kittens from her so they had requested treatment to temporarily inhibit oestrus. A subcutaneous injection of 100 mg proligestone had been administered approximately 3 weeks prior to the current presentation.

Q 1. What are the possible causes of mammary enlargement in a female cat?

- Lactation
- Mastitis
- Mammary fibroadenomatous hyperplasia
- Neoplasia

Q 2. What are the options for temporary oestrus control in the cat? What is their duration of effect, and what are the potential adverse effects?

- Progestogens: e.g. proligestone, megestrol acetate
 - Duration of effect
 - Proligestone: variable, usually around 5 months
 - Megestrol acetate: more predictable control, suppresses oestrus for as long as treatment is continued. Oestrus usually occurs within 2 weeks of ceasing treatment
 - Potential adverse effects:
 - Dose-related adverse effects include lethargy, increased appetite, weight gain, and adrenocortical insufficiency
 - Increased risk of diabetes mellitus, chronic endometrial hyperplasia/pyometra, and mammary fibroadenomatous hyperplasia
 - Additional potential adverse effects of injectable preparations: transient pain at the time of injection; local skin thinning, discolouration and loss of hair; local or systemic allergic-anaphylactic reactions
- Manual stimulation of ovulation: cats are reflex ovulators, and in some cases ovulation can be induced by manual stimulation of the vagina using a cotton bud
 - Duration of effect: variable, but usually short-term effect – 1–2 weeks
 - Potential adverse effects: none
- GnRH agonist implant, e.g. suprelorin implant: licensed for induction of temporary infertility in male dogs but also effective as a means of oestrus suppression in queens
 - Duration of effect: unpredictable – average 11 months
 - Potential adverse effects: none reported
- Melatonin supplement:
 - Daily oral supplementation appears to maintain oestrus suppression for as long as treatment is continued. Melatonin implants can suppress oestrus for 2–4 months
 - Potential adverse effects: not yet documented

Physical Examination

General physical examination was unremarkable. All the mammary glands were markedly enlarged (Figure 9.19) but were not painful on palpation, milk could not be expressed from any of the nipples, and there was no evidence of erythema or inflammation.



Figure 9.19. Marked enlargement of multiple mammary glands.

Q 3. *What is the most likely diagnosis in this case?*

Mammary fibroadenomatous hyperplasia.

Q 4. *What are the treatment options for this condition?*

- Ovariohysterectomy
- Aglepristone injections (not licensed for use in cats in UK)
- Other suggested treatments include use of cabergoline or dinoprost (neither is licensed for use in cats in UK).

Diagnosis, Treatment, and Outcome

The diagnosis of mammary fibroadenomatous hyperplasia was based on the signalment, physical findings, and recent history of progestogen use. Confirmation of the diagnosis would require surgical biopsy, but this is rarely indicated due to the pathognomonic appearance of the condition.

The cat was treated with aglepristone at a dose of 10 mg/kg by SC injection, on days 1, 2, 7, and 14. The cat remained well, and at the time of the third injection the mammary glands were softer and smaller in size. There was continued marked improvement by day 14, and all of the hyperplasia had resolved within 3 weeks of starting treatment.

The owners elected not to breed from the cat, and she underwent routine ovariohysterectomy 1 week later.

Discussion

Mammary fibroadenomatous hyperplasia is a benign condition of the feline mammary glands. Affected cats develop dramatic firm non-painful swelling of one or, more commonly, many of the mammary glands. If the glands become excessively enlarged, there may be ulceration and excoriation of the skin causing pain, inflammation, and a risk of secondary infection. The mammary swelling is progesterone dependent; the condition is most common in young, intact female cats, but can also occur in neutered females and occasionally in males. It is recognized as a rare adverse effect of progestogens.

The condition resolves within a few weeks of a reduction in serum progesterone levels, so in non-pregnant entire females ovariohysterectomy is usually the treatment of choice. However, proligestone injections induce high serum progesterone levels for about 4–6 weeks, so in this case it was unlikely that ovariohysterectomy would resolve the condition until after the effects of the progestagen had subsided. Aglepristone is a progesterone receptor antagonist that is effective in the management of mammary hyperplasia, and although not licensed for use in cats, it appears to be well tolerated in this species. Reported dosing protocols vary somewhat; for example:

- 10 mg/kg SID for 4 or 5 days
- 10 mg/kg on 2 consecutive days, repeated weekly for 1–4 weeks
- 20 mg/kg once a week for 1–4 weeks

In this case only short-term treatment was required as the hyperplasia resolved rapidly. Ovariohysterectomy is recommended for long-term prevention of recurrence.

Further Reading

Görlinger, S., Kooistra, H.S., van den Broek, A., Okkens, A.C., 2002. Treatment of fibroadenomatous hyperplasia in cats with aglepristone. *Journal of Veterinary Internal Medicine* 16 (6), 710–713.

Wehrend, A., Hospes, R., Gruber, A.D., 2001. Treatment of feline mammary fibroadenomatous hyperplasia with a progesterone-antagonist. *Veterinary Record* 148, 346–347.

Case 9.11

Signalment and History

An 8-year-old FN Burmese cat was presented with a 48-h history of self-trauma to the tongue. The cat's owner initially noticed blood from the mouth, and when attempting to look into the mouth the cat scratched frantically at the tongue. Vaccination, flea, and worm treatment were current, and no other significant health problems were reported. Initial treatment with cefovecin, dexamethasone, and subsequently meloxicam had failed to improve the cat's condition.

Q 1. List your major differential diagnoses for sudden onset oral pain in this cat.

- Foreign body lodged in mouth or around tongue
- Trauma or wound in mouth
 - Licking or chewing a sharp object
 - Wasp or bee sting
 - Electric shock damage (e.g. from chewing a cable)
 - Acid, caustic or thermal burn
 - Fight wound
- Dental pain
- Feline orofacial pain syndrome
- Painful neoplastic lesion

Physical Examination

On presentation the cat was slim (weight 3.3 kg, BCS 2/5) but otherwise in good condition. Physical examination was unremarkable other than abnormalities in the mouth. There was severe self-inflicted damage to the tongue (Figure 9.20) and also mild-to-moderate dental disease.

Q 2. As the cat had recently been treated with meloxicam to no effect, what alternative and/or adjunctive analgesics could be considered in this case? (Box 9.1)

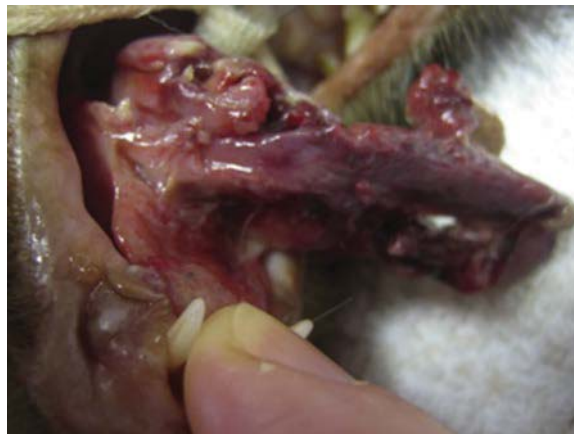

Figure 9.20. Severe damage to the tongue caused by self-mutilation.

Q 3. What is the likely diagnosis, and how would you confirm this?

The signalment, history, and clinical presentation are typical of feline orofacial pain syndrome (FOPS). Confirmation of the diagnosis is by elimination of other possible causes of oral pain (see above question), which may involve:

- Examination of the face, mouth, and throat under anaesthesia

Box 9.1 Alternative Analgesics for Use in This Case

- o Opioids
 - Morphine
 - 0.2–0.5 mg/kg IM every 3–4 h
 - Constant rate infusion 0.12 mg/kg/h
 - Buprenorphine
 - 0.02–0.03 mg/kg IV, IM, SC or dosed into the mouth for transmucosal absorption
 - Duration of effect depends on the dose and the severity of the pain – repeat every 6–12 h as needed
 - Fentanyl
 - Transdermal administration via a fentanyl patch – 25 µg/h
 - Slow and unpredictable onset of effect. Use an alternative opioid concurrently with the fentanyl patch for the first 12–24 h as required
 - Tramadol
 - 2–4 mg/kg PO BID
 - Tablets are bitter tasting so dosing can be difficult
- o Ketamine: little analgesic effect if used alone, but useful as an antihyperalgesic when given with an opioid and delivered by constant rate infusion:
 - Dose range 2–20 µg/kg/min – starting at the lower dose and titrating up to effect
- o Gabapentin: 3–5 mg/kg SID or BID
- o Amitriptyline: 1–2 mg/kg SID or BID

- Radiography of the head, neck, and dental arcades
- Biopsy of any soft tissue lesions identified during the investigation
- Treatment of dental disease

Q 4. *How would you initially manage this case?*

- Provide adequate analgesia. This is a severely painful condition that requires a multimodal approach to analgesia using combinations of the previously listed analgesics. NSAIDs are also indicated, but in this case care will be needed due to the recent use of dexamethasone.
- Provide fluid and nutritional support. The cat will not be able to eat comfortably for some weeks:
 - Fluid therapy (provided IV) may be needed initially if the cat is dehydrated
 - A naso-oesophageal feeding tube will allow immediate liquid feeding, but may not be well tolerated in cats with FOPS.
- Prevent further attempts at self-mutilation. In the short term the cat will need to be physically prevented from attacking the mouth while other forms of analgesia and medical management take effect:
 - Bandaging the front paws
 - Use of an Elizabethan collar (poorly tolerated by many cats). A soft collar (Figure 9.21) will be more comfortable than a plastic collar
 - Provision of multimodal analgesia will usually help to settle the cat, but where needed additional mild sedation (e.g. acepromazine, 0.01–0.03 mg/kg IM or SC) may be helpful initially (once any fluid deficits have been corrected)

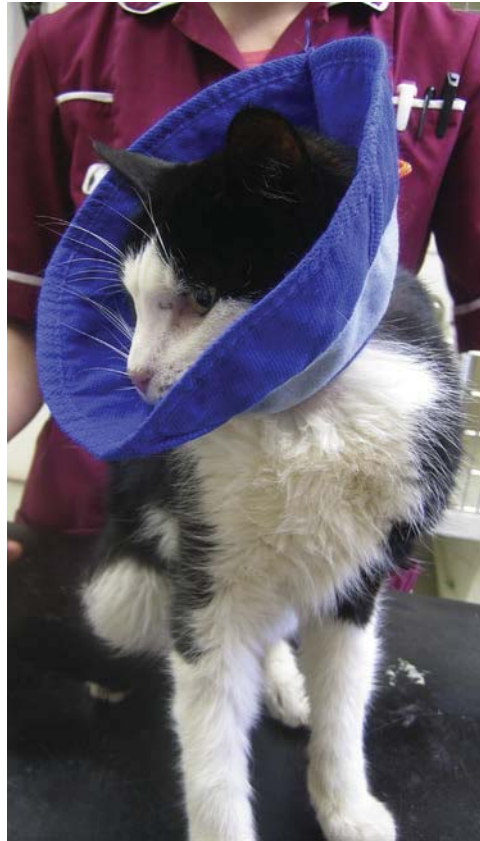

Figure 9.21. An example of a cat wearing a soft Elizabethan collar; often better tolerated than a hard plastic collar.

- Once the most acute risk of self-mutilation has been controlled, less restrictive measures may suffice:
 - Trim the claws to maintain blunt tips
 - Apply soft plastic nail sheaths that can be glued over the front claws
 - Attend to the damaged tongue. Non-viable and necrotic tissue can be trimmed away, but attempts to suture the remaining wounds may not be helpful and the presence of foreign suture material in the mouth may encourage further attempts at self-excoriation in the days and weeks to come.
 - Provide adequate antibiotic cover. Broad-spectrum antibiotic cover is indicated. Oral dosing will be painful for the cat, so injectable antibiotics are indicated initially, followed by dosing via the feeding tube.
- For the cat in this case immediate management was as follows:
- Ongoing analgesia:
 - Buprenorphine 0.03 mg/kg IV TID daily

- Gabapentin 3 mg/kg PO BID for the first 4 days, then meloxicam to be re-introduced thereafter (allowing a further 4-day wash-out period from the date of administration of dexadreson)
- Naso-oesophageal feeding
- Nursing care, facial cleaning, etc. as required
- The cefovecin injection given previously provided adequate antibiosis as there was no gross evidence of infection in the mouth
- All claws were clipped short and bandages were applied to both forelimbs

Investigations

Haematology and biochemistry were unremarkable and oral radiographs were normal. No evidence of caustic injury or neoplasia were seen. Mild dental disease only was noted and was addressed while the cat was anaesthetized.

Diagnosis

As investigation failed to reveal an underlying cause of the oral pain, the cat was likely suffering from FOPS.

Q 5. How would you manage a case of FOPS?

As FOPS is considered neurogenic; in addition to analgesia treatment for neuropathic pain is required using anti-epileptic drugs for their anti-allodynic effect. Options include phenobarbitone, carbamazepine, levetiracetam, or gabapentin. Any dental disease should also be treated, and depending on the severity of the injury longer-term feeding tubes inserted. Advanced diagnostics such as CT (computed tomography) or MRI (magnetic resonance imaging) can be performed to exclude other causes of trigeminal nerve pain (e.g. trigeminal nerve neoplasia) but were not performed in this case. As FOPS may be linked to stress, the cat's environment/lifestyle should be assessed and improved if indicated.

Further Case Information

The cat in this case was treated with ongoing analgesia (described above) and phenobarbitone (2 mg/kg BID), and after an encouraging initial response the cat was anaesthetized 48 h after admission.

On examination the viable parts of the tongue were less swollen and showed voluntary movement, but the rostral third and the right side of the tongue were devitalized with a large central deficit (Figure 9.22).

The necrotic areas were excised and damaged viable tissue allowed to heal by secondary intention. While under anaesthetic, dental treatment was undertaken to extract all abnormal teeth and to scale and polish all healthy teeth. An oesophagostomy tube was placed and the naso-oesophageal tube was removed. No causes of stress could be identified.

The cat recovered well and was discharged 24 h later with soft nail covers and a soft Elizabethan collar. Ongoing treatment was with oral buprenorphine, meloxicam, and phenobarbitone. Cefovecin cover was still active.

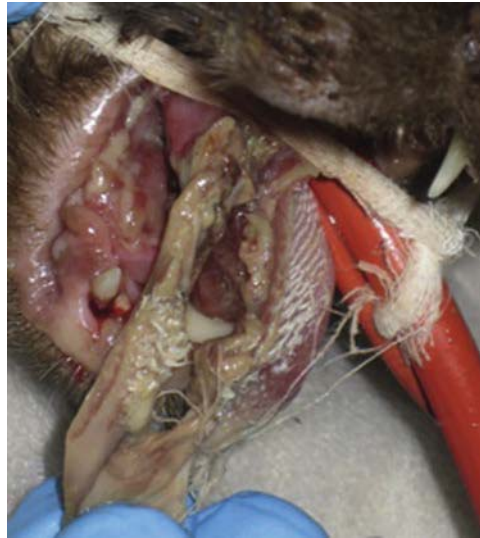

Figure 9.22. Appearance of the tongue 4 days after the onset of signs, showing the large deficit in the centre of the tongue and the necrotic remains of the right side and rostral third of the tongue.

One week later no further episodes of orofacial pain had been seen; the cat was not yet able to eat for herself but she was taking tube feeding well. Phenobarbitone level was within the therapeutic range.

During the following week the cat started to eat. Buprenorphine was ceased and the oesophagostomy tube was removed once oral food intake was adequate. Phenobarbitone treatment was maintained in the long term, but meloxicam was ceased once the tongue had completely healed.

The cat made a complete recovery and was left with a significantly shortened tongue (Figure 9.23) but with normal function for both eating and grooming.

Discussion

Feline orofacial pain syndrome is characterized by intermittent episodes of acute onset severe orofacial pain, thought to be neurogenic in origin, possibly analogous to trigeminal neuralgia or glossodynia in humans. Dental disease is a common finding in affected cats and stress appears to be a contributing factor in around 20% of cases. Currently anti-epileptic drugs appear to be the most effective treatment probably due to their allodynic effect rather than any anti-convulsant properties. Burmese cats are most commonly affected.

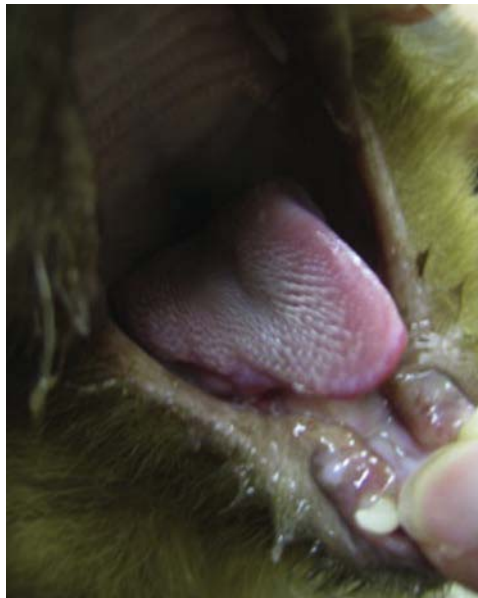


Figure 9.23. Appearance of the tongue 6 months later.

Further Reading

- Rusbridge, C., Heath, S.E., Johnson, N.W., Gunn-Moore, D.A., 2002. Feline orofacial pain syndrome. Proceedings of the 15th Annual Symposium of the European Society of Veterinary Neurology, vol. 17, Journal of Veterinary Internal Medicine, Philadelphia. 246.
- Rusbridge, C., Heath, S.E., Gunn-Moore, D.A., et al., 2010. Feline orofacial pain syndrome (FOPS): a retrospective study of 113 cases. Journal of Feline Medicine and Surgery 12, 498–508.
- Sparkes, A.H., Heiene, R., Lascelles, B.D.X., et al., 2010. ISFM and AAFP consensus guidelines: long-term use of NSAIDs in cats. Journal of Feline Medicine and Surgery 12, 521–538.

Case 9.12

Case Description

A 13-year-old MN Maine Coon cat was presented with a 10-day history of sudden onset right forelimb lameness. The cat was a solo pet, fed on a commercial brand of maintenance cat food. He had free access to the outdoors and was occasionally involved in fights with neighbouring cats. He was regularly vaccinated, treated for fleas, and wormed occasionally.

Physical Examination

On presentation the cat was non-weight-bearing on the affected limb. The third digit was painful and markedly swollen. The nail was absent and there was mucopurulent discharge from the nail bed and ventral aspect of the digit. The second and fourth

digits were also swollen and painful with some crusting between the toes and around the nail bed of the fourth digit.

No other significant abnormalities were detected on general physical examination including thoracic auscultation and abdominal palpation.

Q 1. *List the potential causes of a painful and swollen forelimb digit in a cat.*

- Bacterial infection secondary to:
 - Cat bite injury
 - Overgrown claw impinging on foot pad
 - Foreign body
 - Infected wound
- Trauma
 - Fractured metacarpal or phalanges
 - Hyper-extension injury causing ligament strain or rupture
- Neoplasia
 - Primary:
 - Squamous cell carcinoma
 - Fibrosarcoma
 - Osteosarcoma
 - Metastatic
 - Digital metastases from a primary pulmonary or bronchial carcinoma or adenocarcinoma
- Other infectious causes
 - Fungal infection
 - Mycobacterial infection

Further Clinical History

This cat had previously been examined 2 days after the onset of lameness at which time the third digit had been swollen and painful and the nail although still present had shown lateral deviation. No other significant abnormalities were identified on physical examination at that time.

Initial treatment had been with a 7-day course of amoxycillin-clavulanic acid (12.5 mg/kg PO BID) and a single subcutaneous injection of ketoprofen (2 mg/kg). There was no evidence of improvement during this course of treatment.

Q 2. *What are the potential causes of lack of response to antibiotic in this case?*

- Primary cause is a bacterial infection that has not responded to treatment
 - Infection is secondary to foreign body that is still in situ
 - Poor compliance in dosing the tablets
 - Infection is in a compartment that has poor antibiotic penetration: joint space, tendon sheath, etc.
 - Underlying immunosuppression is compromising the response to treatment: e.g. due to retroviral infection
 - Bacterial infection is resistant to amoxicillin-clavulanate: e.g. penicillinase-producing *Staphylococcus*, L-form bacteria, mycobacterial infection

- Primary cause is not bacterial: trauma, neoplasia, fungal infection

Q 3. *What further investigations would you recommend?*

Closer inspection of the area under sedation or anaesthetic, allowing the fur to be clipped from the affected areas. Pre-anaesthetic blood and urine tests should be recommended to evaluate kidney and liver function in this older cat.

If no bite wound or foreign body is evident, further investigations might involve:

- Full blood count and retrovirus tests
- Samples of exudate for cytology and bacterial culture
- Radiography of the affected limb and thorax (to look for neoplasia)

Depending on the initial findings definitive diagnosis may require:

- Tissue biopsies for histopathology and potentially for further investigation of infectious causes: bacterial culture, fungal culture, mycobacterial testing

Further Investigations

A pre-anaesthetic blood screen revealed no significant biochemical abnormalities, and in-house tests for FeLV and FIV were negative.

The cat was anaesthetized for further investigation and the right forefoot was clipped and cleaned (Figures 9.24 and 9.25). Radiographs of the right forepaw and thorax were taken (see Figures 9.26 and 9.27).

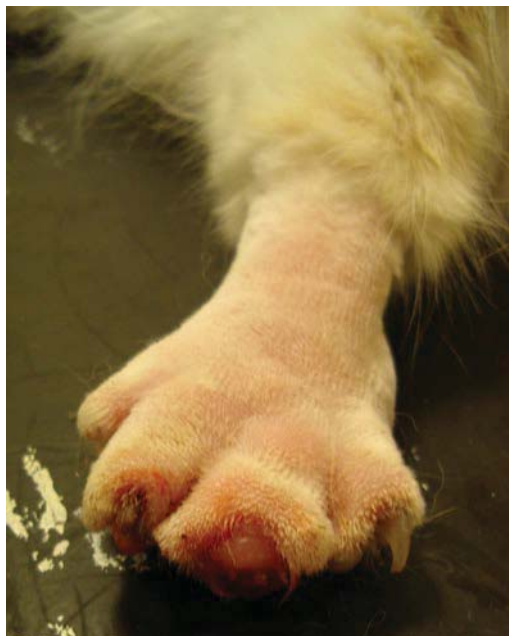

Figure 9.24. Marked swelling of the third digit, with less severe swelling of the second and fourth digits.

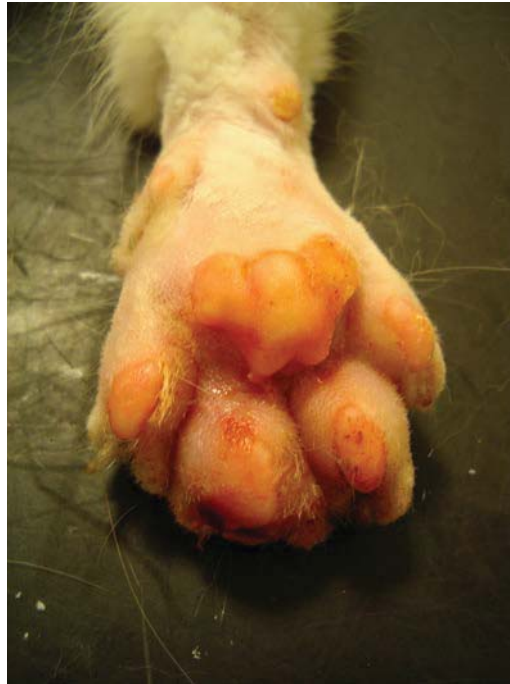

Figure 9.25. Mucopurulent discharge from the nail bed and the ventral aspect of the third digit.

Q 4. Describe the radiographic changes.

The dorsopalmar radiograph of the right forepaw reveals complete lysis of all the phalanges of the third digit and partial osteolysis of the proximal phalanx of the fourth digit.

The lateral thoracic radiograph reveals a large, well-defined soft tissue density in the caudodorsal lung field.

Q 5. What is the likely diagnosis?

These findings are suggestive of the presence of a primary pulmonary neoplasia with metastatic spread to the digits, a condition sometimes termed 'lung-digit syndrome'.

Outcome

In view of the strength of the presumptive diagnosis and the poor prognosis associated with this condition, the owners declined further invasive interventions but they did consent to the collection of fine needle aspirate samples. Aspirates were collected from the third digit and from the region of the pulmonary lesion; the results were suggestive of carcinoma, considered most likely to be of pulmonary origin.

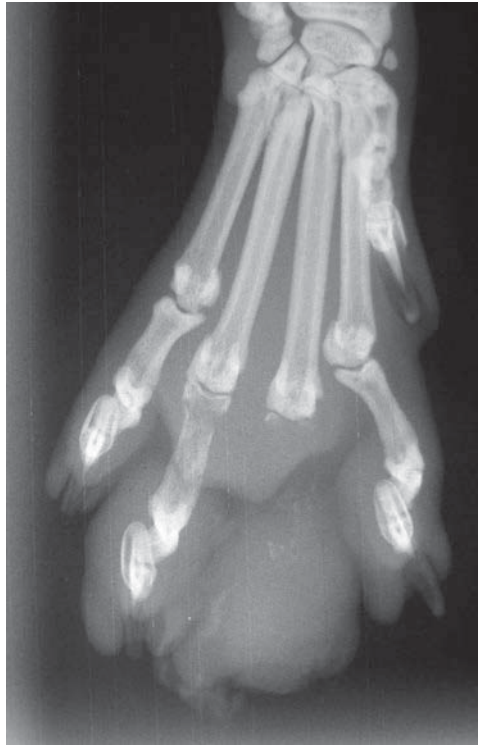

Figure 9.26. Dorsopalmar radiograph of the affected foot.

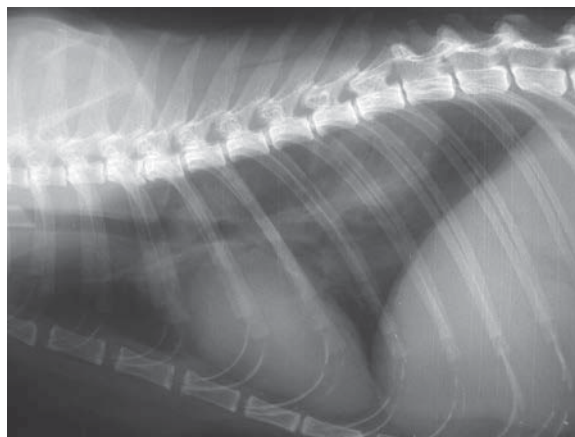


Figure 9.27. Left lateral inflated thoracic radiograph.

The cat made an uneventful recovery from anaesthesia. Analgesia was maintained using oral buprenorphine (0.02 mg/kg TID) and meloxicam (0.3 mg/kg by SC injection, then 0.1 mg/kg PO SID). Antibiotic cover was maintained as before.

The cat remained non-weight-bearing on the affected limb despite the use of buprenorphine and meloxicam, and on confirmation of the diagnosis the cat was euthanized without postmortem.

Discussion

Metastatic digital carcinoma arising from a primary pulmonary carcinoma is a condition sometimes referred to as 'lung-digit syndrome'. As illustrated here, the majority of cases have no clinical signs referable to the primary lung tumour, and the presenting features are lameness and digital swelling.

In a review of 64 cats with digital carcinoma, 87.5% were due to metastasis from a primary pulmonary carcinoma, and most cases had multiple affected digits on different limbs. The eight cats that did not have pulmonary carcinoma had primary squamous cell carcinoma involving one digit or two adjacent digits in one foot. The prognosis for the cats with metastatic pulmonary carcinoma was significantly less good than for those with primary squamous cell carcinoma, with average survival time of 4.9 and 29.5 weeks, respectively.

In another retrospective study of 36 cats with digital metastasis of primary pulmonary neoplasia, average survival time was 67 days (range 12–122 days). In this study the average age of affected cats was 12.7 years (range 5–20 years) and the primary presenting signs were lameness, digital swelling, ulceration of the skin or purulent discharge, and deviation of the nail or loss of the nail. Forelimb and hindlimb digits were equally affected, and 17% of cases (6 out of 36) had multiple digit involvement at first presentation.

Intractable pain and lameness is a characteristic feature of the condition and multimodal analgesia should be employed, but even so pain may persist. Amputation of the affected digit(s) can be considered as a palliative treatment to relieve pain, but the poor medium-term prognosis suggests that euthanasia is often a more appropriate option.

Further Reading

- Goldfinch, N., Argyle, D.J., 2012. Feline lung-digit syndrome: unusual metastatic patterns of primary lung tumours in cats. *Journal of Feline Medicine and Surgery* 14 (3), 202–208.
- Gottfried, S.D., Popovitch, C.A., Goldschmidt, M.H., Schelling, C., 2000. Metastatic digital carcinoma in the cat: a retrospective study of 36 cats (1992–1998). *Journal of the American Animal Hospital Association* 36 (6), 501–509.
- van der Linde-Sipman, J.S., van den Ingh, T.S., 2000. Primary and metastatic carcinomas in the digits of cats. *Veterinary Quarterly* 22 (3), 141–145.

Case 9.13

Signalment and Clinical History

A 6-month-old female Devon Rex cat was admitted for a routine ovariohysterectomy. The cat lived exclusively indoors with a littermate. Vaccination, worming, and flea control were up to date.

Clinical Examination and Further Information

The cat was in good body condition (BCS 3/5, at 2.45 kg) and normothermic (RT 39.0 °C) but became fractious on physical examination, which was limited while the cat was conscious.

Examination following anaesthetic induction revealed a subtle fluid wave in the abdomen, with multiple palpable abdominal nodules, suspected to be enlarged mesenteric lymph nodes. On surgical exploration, the abdomen contained a viscous yellow-to-golden fluid (total protein 97 g/L with sparse macrophages and neutrophils).

The cat recovered uneventfully from the spey.

Q 1. List key differentials for high-protein abdominal effusion in a young cat. How might you differentiate these?

- Effusive FIP
- Lymphocytic cholangitis
- Neoplastic effusion (particularly associated with lymphoma)
- Bacterial peritonitis

Cytologic examination can be used to identify neoplastic cells, such as neoplastic lymphocytes, and degenerative neutrophils with bacteria in the case of bacterial peritonitis. The albumin to globulin ratio can also be helpful, since it is often <0.4 in FIP and would be unusual to be <0.4 with the other differential diagnoses. With lymphocytic cholangitis other hepatic abnormalities would be expected to be present. Other suggestive findings of FIP can also be evaluated for (see below).

Q 2. How is a diagnosis of FIP confirmed?

Definitive diagnosis of FIP in cats with suggestive clinicopathological findings is based on detection of FCoV antigen within the macrophages (Figure 9.28) of tissue or fluid samples via immunohistochemistry or direct immunofluorescence,

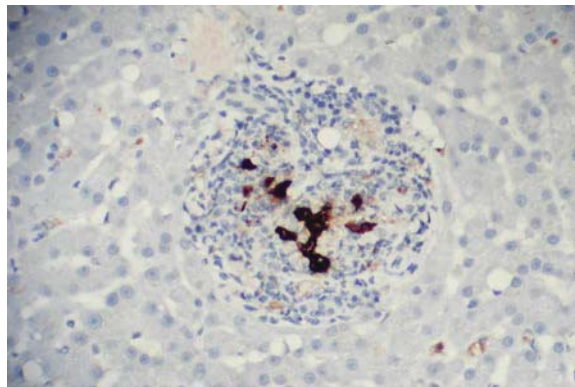


Figure 9.28. Immunohistochemistry detects feline coronavirus antigen (stained brown) within macrophages.

respectively. However, a negative result does not exclude FIP. In cases of 'wet' FIP, histopathology typically reveals fibrinous-granulomatous serositis with high-protein cavity effusions, granulomatous necrotizing phlebitis, and pyogranulomatous inflammatory lesions. In cases of 'dry' FIP, perivascular macrophages may be surrounded by heavy infiltrates of B lymphocytes and plasma cells within surrounding tissue.

Serum protein electrophoresis may be supportive, with most cats with FIP having elevated gamma globulin, but this is seen with other conditions. Serum albumin:globulin ratios of <0.8 and effusion albumin:globulin ratios of <0.4 are also highly suggestive, but not pathognomonic, for FIP.

The more consistent clinicopathological findings that are present for FIP (e.g. young purebred cat, body cavity effusions especially if bicavitary effusions present with low albumin:globulin ratio, mild non-regenerative anaemia, elevated bilirubin, enlarged mesenteric lymph nodes, evidence of uveitis or chorioretinitis), the more likely the diagnosis, and the less likely that the combination of findings can be explained by another disease process.

Other tests, including PCR and serology, must be interpreted with caution as genetic differences between enteric FCoV and FIP virus remain contentious and enteric FCoV is serologically indistinguishable from FIP virus.

Diagnostic Test Results

Direct immunofluorescence on the abdominal fluid using a fluorescein-labelled antibody against FCoV types I and II to identify the virus within macrophages was positive, confirming a diagnosis of FIP.

Q 3. List the risk factors for development of FIP in cats.

- Exposure to feline enteric coronavirus (FCoV)
- Exposure to a higher viral load of FCoV (e.g. in a multi-cat household or cattery)
- Purebreds are more likely to suffer from FIP, which may signify breed or individual line genetic susceptibility
- Stress (surgery, stay in a cattery, environmental change such as moving house, concurrent FeLV infection)

Q 4. What is the prognosis and current recommended treatment for FIP?

The prognosis for cats with FIP is poor, with a median survival time after diagnosis of 9 days. Shorter survival times are reported in cats with lower lymphocyte counts, high bilirubin, and voluminous effusions. Some cats with dry FIP may remain clinically well for much longer periods of time.

Treatments that have been tried with limited reported and some anecdotal success include Virbagen Omega interferon, and polyprenyl immunostimulants, often combined with prednisolone. Further work, however, needs to be performed with these treatments.

Anti-inflammatory doses of prednisolone (0.5–1 mg/kg SID) can be helpful as a palliative treatment.

Q 5. *What is the likelihood of the other cat in the household developing FIP?*

It is highly likely that the other cat in the household has been exposed to FCoV, and, being of the same breed and line, may have an individual line genetic susceptibility that predisposed the first cat to developing FIP. It is thought that horizontal transmission of FIP is rare, but reports of more than one cat in a household developing FIP in the same time frame cannot completely exclude this. In summary, there is always the chance that the other cat could develop FIP, but it is unlikely. Assessing a CBC and biochemistry would be worthwhile to look for any early clinicopathological indicators.

Owners should be counselled to maintain a high plane of nutrition and minimize stress for the surviving cat. It is unlikely that the intranasal FIP vaccination, available in the United States and some European countries, will be effective since the cat will already have been exposed to FCoV. Even in unexposed cats the efficacy of the vaccine is questionable.

Further Information on Response to Treatment, Diagnosis, and Outcome

Due to difficulty in administering oral medication, and the cat's low tolerance for injections, the owners elected to monitor and euthanize once the cat's quality of life deteriorated. She became increasingly hyperaesthetic and withdrawn and was euthanized 1 month after diagnosis. The other cat did not develop FIP.

Discussion

A high index of suspicion for FIP should be maintained when presented with a young, purebred cat with a high-protein, low-cellularity abdominal effusion. Diagnosis of effusive FIP is typically more straightforward than diagnosis of the non-effusive form (Figures 9.29–9.31). Clinical signs vary with organs affected and may include: CNS signs such as from hyperaesthesia and behavioural changes to ataxia, nystagmus, and seizures; ocular signs such as uveitis, chorioretinitis, and retinal detachment; renal involvement; pneumonia and intestinal lesions that may be associated with vomiting and diarrhoea. Fever, anorexia, lethargy, and weight loss or failure to thrive may be the only signs. FIP should always be considered a differential diagnosis of fever of unknown origin in young cats, particularly those from a multi-cat environment.

If Finances Are Limited

Diagnosis of FIP is based on ruling out other, treatable causes of clinical signs and can be costly. If clinicopathologic findings including effusion analysis are consistent with FIP, affected cats may be treated with palliative prednisolone prior to euthanasia when their quality of life declines.



Figure 9.29. Feline infectious peritonitis (FIP) should be suspected in young cats, particularly purebreds but also DSH cats as depicted in this image, present with abdominal effusion. This kitten was euthanized and a diagnosis of FIP was confirmed using immunohistochemistry on postmortem biopsies.

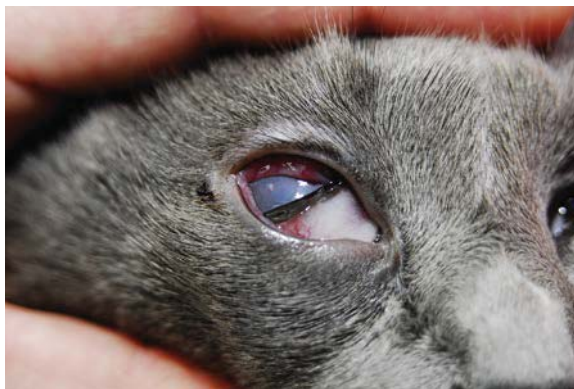

Figure 9.30. Dry feline infectious peritonitis (FIP) is more challenging to diagnose. This kitten's eye was enucleated. It later developed neurological signs and effusive FIP. Histopathology of the eye was performed and revealed extensive pyogranulomatous inflammation, consistent with FIP.

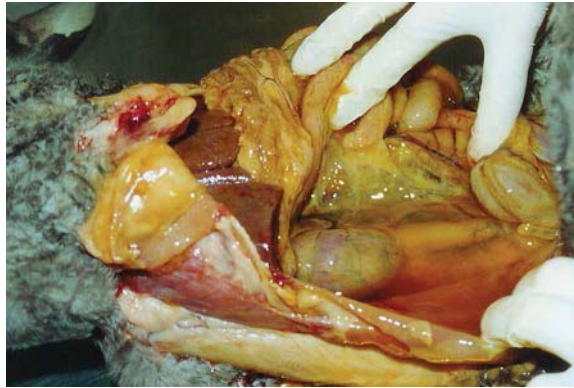


Figure 9.31. Postmortem of a cat euthanized due to effusive feline infectious peritonitis (FIP). Voluminous, viscous effusion is characteristic of FIP.

Further Reading

- Addie, D., Belak, S., Boucraut-Baralon, C., et al., 2009. Feline infectious peritonitis: ABCD guidelines on prevention and management. *Journal of Feline Medicine and Surgery* 11, 594–604.
- Ishida, Y., Shibantai, A., Tanaka, S., et al., 2004. Use of recombinant feline interferon and glucocorticoid in the treatment of feline infectious peritonitis. *Journal of Feline Medicine and Surgery* 6, 107–109.
- Legendre, A.M., Bartages, J.W., 2009. Effect of polyprenyl immunostimulant on the survival times of three cats with the dry form of feline infectious peritonitis. *Journal of Feline Medicine and Surgery* 11, 624–626.
- Norris, J.M., 2011. Updates on the diagnosis of feline infectious peritonitis. In: *ANZCVSc Science Week Proceedings*, pp. 57–58.

Index

A

- Abdominal computed tomography (CT)
 - for calcium oxalate uroliths, 190, 191f
 - for portosystemic shunt, 256, 257f
- Abdominal distention, 317
- Abdominal effusion, 305
 - high-protein, differentials for, 355
- Abdominal palpation, in investigation for
 - linear foreign bodies, 58
- Abdominal ultrasound
 - for adrenal gland tumour, 220, 222f
 - for gastric lymphoma diagnosis, 102
 - for histiocytic ulcerative colitis, 53–54, 53f
 - for PSS, 256, 256f
 - for renal lymphosarcoma investigation, 198, 199, 199f
- Abdominocentesis, 280, 305–306, 318
 - fluid sample, 319f
- Absolute polycythaemia, 134
- Acepromazine, 304
- Aciclovir, for feline herpesvirus 1, 41–42
- Acid reflux, into distal oesophagus, 73
- Acidifying diets, 323
- Acromegaly
 - clinical examination of, 225–229
 - clinical signs of, 228, 229f
 - discussion of, 229
 - investigation for, 226, 227t, 228f
 - signalment and history of, 225, 225f
 - treatment of, 229, 229b
 - and outcome, 229, 230f
- Active warming, 331
- Acute kidney injury (AKI), 274, 293
 - fluid balance in, 276
- Acute pain, 300
- Adrenal gland tumour, 224
 - clinical examination of, 219–220, 219f
 - primary hyperaldosteronism due to, 217
 - discussion of, 224
 - follow-up for, 224
 - investigation for, 220, 222, 223t
 - laboratory results of, 220–224, 220t–221t, 222f
 - management of, 223, 223t
 - signalment and history of, 219
- Adrenal steroid assays, for investigation of
 - adrenal gland tumour, 223t
- Adrenalectomy
 - for adrenal gland tumour, 223
 - complications associated with, 224
 - surgical, for primary hyperaldosteronism, 218
- Adrenocorticotropin hormone (ACTH)
 - stimulation test, for iatrogenic hyperadrenocorticism, 24, 25t
- Adrenomegaly, unilateral, 222
- Aerophagia, lymphoplasmacytic laryngitis and, 162
- Aglepristone injections, 342–343
- Alanine transaminase (ALT),
 - elevated, 333
- Alopecia, 243f–244f
 - bilaterally symmetrical
 - differential diagnoses for, 21
 - investigation for, 22
 - and chemotherapy, 201, 201f
- Alternaria* sp., 19–20
- Aminogluthiamide, for adrenal gland tumour, 223

Page numbers followed by *b*, *t*, and *f* indicate boxes, tables, and figures, respectively.

- Amitriptyline, 345b
 - for feline idiopathic cystitis, 208b
 - Amlodipine besylate, for primary hyperaldosteronism, 218
 - Amoxicillin-clavulanate
 - for *Bordetella* infection, 168
 - intravenous, for feline pyothorax, 152
 - for lymphoplasmacytic laryngitis, 162
 - for mosquito bite hypersensitivity, 3
 - for mycobacterial infection, 9–10
 - for peripheral vestibular disease, 252
 - for pyoderma, 29, 245
 - Amoxicillin trihydrate-clavulanate potassium, for eosinophilic granuloma complex, 50–51
 - Ampicillin, for hepatic encephalopathy, 85
 - Anaemia
 - blood loss, 130
 - haemolytic, 125
 - preliminary results, 126
 - signalment, clinical history, and clinical examination, 124–126
 - moderate, 137t–138t, 138
 - normocytic and normochromic, 305
 - regenerative, 122, 122f
 - differential diagnosis for, 122
 - severe, 121, 124
 - with regenerative response, 129
 - Anaesthesia, for tick paralysis, 268
 - Analgesia, 287
 - multimodal and perioperative, during dental procedure, 314
 - Analgesics, for feline idiopathic cystitis, 208
 - Antacids, for pancreatitis, 114
 - Anti-coagulant
 - rodenticide toxicity, 130
 - Anti-epileptic drugs, 348
 - Anti-inflammatory drugs, for feline idiopathic cystitis, 208
 - Antibiotics, 279
 - for *Bordetella* infection, 168
 - for central and peripheral vestibular disease, 251
 - with gram-negative activity, for pancreatitis, 114
 - lack of response to, potential causes of, 350
 - preanaesthetic administration of, for megacolon, 64
 - Antibiotics (*Continued*)
 - for pyoderma, 29
 - for tick paralysis, 268
 - Antiemetics
 - for gastric lymphoma, 105
 - for hepatic lipidosis, 84
 - for pancreatitis, 80, 114
 - Antiepileptic medications, for meningioma, 260
 - Antispasmodic agents, for calcium oxalate uroliths, 191
 - Antithrombotic therapy, for hypertrophic cardiomyopathy, 147–148
 - Antivenom, for snake bite envenomation, 265
 - Aortic thromboembolism (ATE), 304
 - Aortic trifurcation, 304
 - Ascites, 307, 307f, 317
 - abdominocentesis sample of, 307f
 - differential diagnosis for, 318
 - investigation for, 318
 - Aspiration during dental procedure, 314
 - Aspiration pneumonia, tick paralysis and, 269
 - Aspirin, 303, 321
 - for dilated cardiomyopathy (DCM), 182
 - Atopic dermatitis, 248
 - case information, 245–247
 - discussion of, 248
 - investigations for, 244
 - signalment, history and clinical examination of, 243–244, 243f–244f
 - treatment and outcome of, 247, 247f–248f
 - Azithromycin, for mycobacterial infection, 11–13
 - Azotaemia, 211, 293
 - mild, 275
- ## B
- Bacterial folliculitis, atopic dermatitis and, 245
 - Bacterial pyelonephritis, and bilateral renomegaly, 198
 - Bacterial urinary tract infection (UTI), and feline lower urinary tract disease (FLUTD), 208b
 - Balloon dilation with diode laser ablation, for nasopharyngeal stenosis, 157

Index

- Barium fluoroscopy, for investigation of oesophagitis, 72, 73f
- Benazepril
 - for DCM, 182, 184
 - for hypertrophic cardiomyopathy, 147–148
- Bicavitary effusion, 332
- 'Big kidney-little kidney' scenario, in ureterolithiasis, 192
- Bilateral myringotomy/middle ear flushing, for central and peripheral vestibular disease, 251
- Bilateral renomegaly, differential diagnoses for, 198
- Bilateral ventral bulla osteotomy, for central and peripheral vestibular disease, 251–252
- Bilaterally symmetrical alopecia
 - differential diagnoses for, 21
 - investigation for, 22
- Bile acid stimulation test, for PSS, 255, 256t
- Biopsy
 - for eosinophilic granuloma complex, 49
 - punch, skin, for mosquito bite hypersensitivity, 3
 - for squamous cell carcinoma, 44
- Bisphosphonates, 324
 - for hypercalcaemia, 242
- Bite wounds, 280f
- Blood smear, 125
- Blood test, for snake bite investigation, 263t
- Blood transfusion, 130, 121, 126
 - factors to be considered prior to, 121, 122b
 - indications for, 139
 - performing blood collection for, 130b
- Blood types, 121
- Bone marrow suppression, chemotherapy and, 201
- Bordetella* infection, 169
 - clinical examination of, 166–168
 - diagnostic test results of, 169
 - discussion of, 169
 - investigation for, 167–168
 - management of, 167
 - preventing spread of, 168
 - radiographs of, 167f–168f
 - interpretation of, 167
 - signalment, clinical history, and clinical examination findings on, 166
- Bordetella* infection (Continued)
 - stabilization of patient prior to investigation, 167
 - treatment of, 168
- Brain injury
 - primary, 287
 - secondary, 287
- Broad-spectrum antibiotic protocol, 284
- Budesonide, 25
- Buprenorphine, 287, 302, 304, 311, 345b, 346–348, 354
 - analgesia, after removal of linear foreign bodies, 60
 - for feline pyothorax, 151
 - for pain relief after surgical removal of cystolith, 195
- Butorphanol
 - in *Bordetella* infection investigation, 167
- C**
 - C. felis*, 166–167
 - C. gattii*, 38
 - C. neoformans*, 38
 - Calcitonin, 324
 - Calcium oxalate crystals, 275, 276f
 - Calcium oxalate monohydrate, as cystolith, 196
 - Calcium oxalate uroliths, 192, 205
 - differential diagnosis for, 189
 - discussion of, 192
 - epidemiology of, 197
 - investigations for, 190, 191f
 - recurrence of, 197
 - signalment, clinical history, and clinical examination of, 189–190
 - treatment
 - options for, 190
 - and testing for, 191–192, 191f
 - Calcium supplementation, oral, for postoperative hypocalcaemia, 242
 - Calicivirus, 314
 - Candidatus Mycoplasma haemominutum*, 123
 - infection, 124
 - case information, 121, 123
 - clinical examination, 120
 - response to treatment, diagnosis, and outcome, 123

- Candidatus Mycoplasma haemominutum*
(Continued)
 signalment, clinical history/clinical examination findings on, 120
 treatment/further investigation for, 122–123, 122b
- Carbimazole, 325, 329–330
- Cardiogenic shock, 278
- Cardiomegaly, 227, 228f
- Cardiomyopathy
 dilated
 case information, 179–184, 179f, 181f–182f, 183t
 clinical examination of, 178
 differential diagnosis for, 178
 discussion of, 184
 management of, 178, 181
 radiographs on, 179f
 signalment and history of, 178
 hypertrophic, 148
 case information, 146–147, 146f–147f
 diagnostic test results of, 147–148
 discussion of, 148
 follow-up for, 148
 management of, 144, 146
 physical examination of, 143–146, 148
 radiographic findings on, 145f, 146
 signalment and history of, 143
 treatment plan for, 147
- Cavity effusion, classifying of, and differential diagnoses, 333
- Celiotomy, in linear foreign body diagnosis, 59
- Central vestibular disease
 differential diagnoses for, 250
 versus peripheral vestibular disease, 250
- Cephalosporin, for pyoderma, 29
- Cervical region, right, mass in, 239
- Cheek teeth
 extraction of, 312f, 311
 management of, 329
- Chemotherapy, for lymphosarcoma
 adverse effects of, 200
 indications for, 199
- Chlorambucil, 127
 for IBD, 101, 232
 for mosquito bite hypersensitivity, 5
 side effects of, 111
- Chlorhexidine, 310–311
- Chlorpheniramine, 329–330
- CHOP (cyclophosphamide, vincristine, doxorubicin, prednisolone)
 chemotherapy, for mediastinal lymphoma, 176
- Chronic diarrhoea, small intestinal, differential diagnosis for, 66
- Chronic feline gingivostomatitis, 176, 310
 aetiology of, 310–311
 dental radiographs of, 312f
 diagnostic evaluations for, 318
- Chronic kidney disease (CKD), 216
 discussion of, 214
 investigations for, 211–212, 211t–212t, 212b
 IRIS classification system, in staging for, 338
 longer-term management of, treatment for, 339
 management of, 213
 and osteoarthritis, 214b
 outcome of case, 214
 physical examination of, 211
 signalment and history of, 211
- Chronic pancreatitis, 231–232
- Chyloperitoneum, 318
- Cisapride, for oesophagitis, 74
- Clarithromycin
 for mycobacterial infection, 11
 for panniculitis, 16
- Clindamycin, 334
 as a cause of oesophagitis, 74
- Clopidogrel, 303, 321
 for DCM, 182
 for hypertrophic cardiomyopathy, 147–148
- Coagulation profile, 125, 140t
- Coat brushings, for dermatophytosis investigation, 6
- Cobalamin
 deficiency, 100b
 injections, for exocrine pancreatic insufficiency (EPI) management, 70
 supplementation, parenteral, for inflammatory bowel disease, 233
- Collagen dysplasia, hereditary, 34
- Colonic lymph node, enlarged and irregular, 53f

Index

- Colour Doppler abdominal ultrasound, for PSS, 256f
 - Congestive heart failure, 318b
 - Constipation, 63
 - factors that may contribute to, 61
 - Coombs' test, 123
 - direct, 125
 - COP (cyclophosphamide, vincristine [oncovin], and prednisolone) chemotherapy protocol for feline lymphoma, 105b
 - for gastric lymphoma, 104
 - Copper coloured irises, 253f
 - PSS and, 257
 - Corticosteroids, 313, 126
 - for low grade lymphocytic intestinal lymphoma, 110
 - for mosquito bite hypersensitivity, 3
 - Coughing, 158
 - differential diagnosis for, 170
 - COX inhibitors, squamous cell carcinoma and, 47
 - Cranial abdominal mass, differential diagnosis for, 102
 - Cranial abdominal pain, differential diagnosis for, 57
 - Cranial mediastinal mass, differential diagnoses for, 271
 - CRASH trial, 289
 - Cryptococcosis, 38
 - clinical examination of, 35–37
 - clinical signs of, 37
 - diagnostic test results of, 37–38
 - discussion of, 38–39
 - investigation for, 36
 - signalment, clinical history, and clinical examination findings on, 35, 35f
 - treatment of, 38
 - CSL snake venom detection kit (SVDK), 264f
 - CT imaging, for nasopharyngeal stenosis, 154, 154f–155f
 - Culture and sensitivity, in investigation for feline uroliths, 194
 - Cutaneous nodules, in cryptococcosis, differential diagnosis for, 36
 - Cutaneous tissue, hyperextensibility of, 34
 - Cyclophosphamide, 105b
 - for renal lymphosarcoma, 201–202
 - side effects of, 105
 - Ciclosporin, 127
 - adverse effects associated with, 246
 - for eosinophilic granuloma complex, 50
 - for mosquito bite hypersensitivity, 4–5
 - for myasthenia gravis, 272
 - Cystic calculus, and investigation for feline uroliths, 195
 - Cystocentesis, in investigation for feline uroliths, 193
 - Cystolith
 - calcium oxalate monohydrate as, 196
 - removal via cystotomy, 195f–196f
 - Cystoscopy, for ureterolithiasis, 204
 - Cystotomy, for removal of cystolith, 195f–196f
- ## D
- Daltaparin, 303
 - Decontamination, 296
 - Dental disease, 309–317, 348
 - treatment of, 311
 - Dental procedure
 - anaesthesia for, 311
 - Dermal granuloma, mycotic, 19
 - Dermatitis
 - atopic, 248
 - nasal, 1f
 - ulcerating and crusting, in FHV-1 infection, differential diagnoses for, 40
 - Dermatological disorders, 1–51
 - cryptococcosis, 35–39
 - dermatophytosis, 5–9
 - Ehlers-Danlos syndrome, 31–35
 - eosinophilic granuloma complex, 47–51
 - feline herpesvirus 1 (FHV-1) infection, 39–42, 166
 - iatrogenic hyperadrenocorticism, 21–25
 - mosquito bite hypersensitivity, 1–5
 - mycobacterial infection, 9–14
 - panniculitis, 14–17
 - pemphigus foliaceus, 26–30
 - phaeohyphomycosis, 17–21
 - squamous cell carcinoma, 42–47
 - Dermatophytosis, 8
 - clinical examination of, 5–8, 6f
 - confirmation of diagnosis for, 6
 - differential diagnoses for, 5

- Dermatophytosis (*Continued*)
 discussion of, 8
 management of, 7
 signalment and clinical history of, 5
 treatment and outcome of, 8
- Detemir, 233, 233b
- Dexamethasone
 administration, after adrenalectomy, 224
 for pemphigus foliaceus, 29–30
- Dextrose, hypertonic, 292
- Diabetes mellitus (DM)
 case information, 232–233
 case outcome of, 233–234
 clinical examination of, 231–232, 231t
 signalment and history of, 230
- Diabetic instability
 causes of, 225
 investigation for, 226, 227t
 and urine bacterial infection, 226b
- Diabetic ketoacidosis (DKA)
 case information, 237–238, 237t
 clinical examination of, 234–235
 discussion of, 238
 fluid requirements in, 235–236, 235b
 insulin therapy protocol for, 236b
 management of, 237
 signalment, clinical history of, 234
 supplementation for, 235–236, 236f
- Diagnostic peritoneal lavage, 283
- Diarrhoea, 52b
 differential diagnoses for, in cat with pancreatitis, 112
 intestinal, 325
 nature of, in feline infectious peritonitis (FIP), 92
- Diazepam, 132, 296
- Diet, for EPI management, 70
- Dietary management, for low grade lymphocytic intestinal lymphoma, 110
- Dietary modification
 for stage 3 chronic kidney disease, 211–213
 for ureterolithiasis, 206
- Digoxin, for DCM, 184
- 1,25-Dihydroxyvitamin D (1,25(OH)₂ vitamin D₃/calcitriol), 323
- DCM
 case information, 179–184, 179f, 181f–182f, 183t
 clinical examination of, 178
- DCM (*Continued*)
 differential diagnosis for, 178
 discussion of, 184
 management of, 178, 181
 radiographs of, 179f
 interpretation of, 180
 signalment and history of, 178
- Diode laser ablation, balloon dilation with, for nasopharyngeal stenosis, 157
- Dipstick, in investigation for feline uroliths, 193
- Distributive shock, 278
- Diuresis, pharmacological, 292
- Diuretics, 292
 for calcium oxalate uroliths, 190
- DKA. *see* Diabetic ketoacidosis (DKA).
- Dobutamine, for DCM, 183
- Dog attack, 277
- Doppler ultrasound, in thromboembolic disease, 304
- Double contrast cystography, in investigation for feline uroliths, 194
- Doxycycline, 123, 126
 for *Bordetella* infection, 168, 169
 for mosquito bite hypersensitivity, 3, 5
 for panniculitis, 16
 for pemphigus foliaceus, 30
- Doxycycline hydrochloride as a cause of oesophagitis, 74
- Dyschezia, differentials for, 62
- Dysplasia, collagen, hereditary, 34
- Dyspnoea, 178
 in mediastinal lymphoma, differential diagnosis for, 175
- E
- ECG, in DCM, 181f, 183t
- Echocardiography
 in DCM, 182f, 183t
 interpretation of, 180
 in hypertrophic cardiomyopathy, 146, 146f–147f
 two-dimensional, in peritoneopericardial diaphragmatic hernia, 160
- Edrophonium response test, 272b
- Effusion
 abdominal, 305
 bicavitary, 332
 septic, 283, 283f–284f

Index

- Ehlers-Danlos syndrome, 34
 - clinical examination of, 31–32
 - discussion of, 34–35
 - examination of, 32f–33f
 - management of, 31
 - signalment and history of, 31
 - Elizabethan collar, 345, 346f
 - Emetics, 131
 - Endocrinological disorders, 215–248
 - acromegaly, 225–230
 - adrenal gland tumour, 219–224
 - diabetes mellitus, 230–234
 - diabetic ketoacidosis, 234–238
 - primary hyperaldosteronism, 215–218
 - primary hyperparathyroidism, 238–243
 - Endoscopy
 - advantages of, 54
 - disadvantages of, 54
 - for IBD, 100, 101f
 - Engorged tick, and tick paralysis, 266
 - Enteropathy, 305
 - Enterotomy, alternate single technique, for
 - removing linear foreign bodies, 60
 - Eosinophilic furunculosis, facial, 3
 - Eosinophilic granuloma complex, 51
 - clinical examination of, 47–49, 48f–49f
 - diagnostic test results of, 50–51
 - differential diagnoses for, 49
 - discussion of, 51
 - investigation of, 49
 - signalment, clinical history, and clinical examination findings on, 47
 - treatment of, 50
 - Eosinophils, in IBD, 98
 - EPI. *see* Exocrine pancreatic insufficiency (EPI).
 - Epistaxis, 128
 - Erythrocytosis, 134, 135f
 - appropriate, 134
 - inappropriate, 135
 - Erythropoietin (EPO), 134
 - Oesophagus, dilated, in lymphoplasmacytic laryngitis, 162
 - Essential fatty acids, for atopic dermatitis, 245
 - Ethanol, 275
 - Ethylene glycol (EG) toxicity, 274
 - case information, 275, 277f
 - clinical examination, 274
 - signalment/clinical history, 274
 - urinalysis in, 274
 - Exocrine pancreatic insufficiency (EPI), 70–71, 231–232
 - case information on, 67–69, 67t–69t
 - case outcome and follow-up for, 70
 - clinical examination of, 66–67
 - discussion of, 70–71
 - management of, 66, 70
 - signalment and history of, 66
 - Exploratory cystotomy, in investigation for
 - feline uroliths, 194
 - Exploratory laparotomy
 - advantages of, 54
 - disadvantages of, 54–55
 - in linear foreign body diagnosis, 59f
 - Extracranial causes of seizures, 253
- ## F
- Facial eosinophilic furunculosis, 3
 - Facial trauma, 285, 286f
 - Factor VII, 129–131
 - Faecal flotation
 - in IBD diagnosis, 100
 - in investigation for unstable diabetes mellitus and chronic diarrhoea, 231–232
 - Faecal retention, degree and chronicity of, 63
 - Famciclovir
 - for feline herpesvirus 1, 41–42
 - for nasopharyngeal stenosis, 157
 - Feline coronavirus (FCoV)
 - antibodies, 308t, 308b
 - antigen, with macrophages, 355–356
 - immunohistochemistry for antigen, 354f
 - Feline herpesvirus 1 (FHV-1) infection, 42
 - as cause of upper respiratory or ocular signs, 41
 - clinical examination of, 40
 - clinical signs of, 40
 - diagnostic test results of, 40–41
 - discussion of, 42
 - investigation for, 40
 - signalment, clinical history, and clinical examination findings on, 39, 39f
 - treatment of, 41
 - Feline idiopathic cystitis (FIC), 210
 - discussion of, 210
 - and FLUTD, 208
 - physical examination of, 207

- Feline idiopathic cystitis (FIC) (*Continued*)
 signalment and history of, 207
 treatment options for, 208
 treatment plan for, 210b
 urine sample for, 207–210, 207f, 207b
- Feline idiopathic hypercalcaemia, 325
- FIP, 358f
 and bilateral renomegaly, 198
 case information, 95–96
 clinical examination and information, 355–356
 clinicopathological findings for, 356
 development of, 357
 diagnosis of, 308
 diagnostic test results, 356–357
 discussion of, 97
 ‘dry,’ 355–356, 358f
 effusive, 359f
 investigations for, 93, 93f
 laboratory results for, 93, 94t–95t
 prognosis and treatment for, 356
 risk factors for development of, 356
 Rivalta test for, 95, 95b
 signalment, history, and clinical examination of, 305–308, 305f, 355
 biochemistry results, 306t
 differentials and investigations, 307, 308t
 haematology results, 306t
 interpretation on, 305
 signalment and history of, 91–95, 91f–92f
 treatment and outcome, 309, 357
 ‘wet,’ 355–356
- Feline interferon omega, 313
 recombinant, for feline herpesvirus 1, 41
- Feline liver disease, 139
- FLUTD, causes of, 208, 208b
- Feline odontoclastic resorptive lesions (FORLs)
 outcome, 312–313
 signalment, history, and clinical examination of, 313
 types of, 316
- Feline oro-facial pain syndrome (FOPS), 344, 348
 analgesics for, 345b
 case information, 347–348, 348f–349f
 confirmation of diagnosis, 344
 diagnosis and, 347
- Feline oro-facial pain syndrome (FOPS) (*Continued*)
 initial management of, 345
 investigations for, 347
 physical examination, 344–347, 344f
 signalment and history, 343–344
- Feline pancreatic lipase immunoreactivity (fPLI), measurement of, in investigation of acromegaly, 227
- Feline pyothorax
 case information, 151–152, 151f
 clinical examination of, 149
 diagnostic test results of, 149–151, 150f
 discussion of, 152
 management of, 149–150
 signalment, clinical history, and clinical examination findings on, 149
- Feline uroliths
 clinical examination of, 193–194, 194t
 diagnostic test results of, 195–197
 epidemiology of, 197
 investigation for, 193
 signalment, clinical history, and clinical examination findings on, 192–193, 193f
 treatment, diagnosis and outcome of, 195, 195f–196f
- Feline leukaemia virus (FeLV) infection, mediastinal lymphoma and, 177
- Fentanyl, 345b
 transdermal patch, 304
- Fine-needle aspiration, 141, 329
 for panniculitis, 15
- Fipronil
 for flea hypersensitivity, 50
- Flea antigen testing, for flea hypersensitivity, 49
- Flea comb test, for flea hypersensitivity, 49, 50f
- Flea hypersensitivity, 49
- Fluconazole, for cryptococcosis, 38–39
- Flucytosine, for cryptococcosis, 38
- Fluid analysis, 140t
- Fluid requirements, in diabetic ketoacidosis, 235–236
- Fluoroquinolone
 for mycobacterial infection, 11
 for panniculitis, 16
- Focal seizure, 132
- Fomepizole, 275

Index

- Forelimb
 - digit, potential causes of painful and swollen, 350
 - lameness, differential diagnostic list for, 300
- 'Four quadrant approach,' 284b
- fPLI. *see* Feline pancreatic lipase immunoreactivity (fPLI).
- Fungal culture
 - for cryptococcosis, 38
 - for dermatophytosis diagnosis, 6–7, 40
- Furosemide, 276, 292, 303, 324–325
 - for DCM, 184
 - for hypercalcaemia, 242
 - for hypertrophic cardiomyopathy, 146–148
- G**
- Gabapentin, 345b, 347
- Gastric acid secretion, reduction of, for oesophagitis, 73
- Gastric lymphoma
 - case information, 103–105, 104f
 - clinical examination of, 102
 - diagnostic test results of, 102–103
 - discussion of, 105–106
 - investigation for, 102
 - signalment and clinical history of, 102
- Gastrointestinal and hepatic disorders, 52–119
 - exocrine pancreatic insufficiency (EPI), 66–71
 - FIP, 91–97
 - gastric lymphoma, 102–106
 - hepatic lipidosis, 81–86
 - histiocytic ulcerative colitis, 52–56
 - inflammatory bowel disease, 97–102
 - linear foreign bodies, 56–61
 - low grade lymphocytic (small cell) intestinal lymphoma, 106–111
 - megacolon, 61–65
 - oesophagitis, 71–75
 - pancreatitis, 75–81
 - nonspecific clinical presentation of, 112–116
 - Tritrichomonas foetus* infection, 116–119
 - vomiting, 86–91
- Gastrointestinal endoscopy, upper, for investigation of oesophagitis, 72
- Gastrointestinal lymphoma, 106
- Gastrointestinal side effects, of chemotherapy, 200
- Gastrointestinal tumours, 199–200
- Gastroprotectants, initiation of, 292
- Generalized nodular alveolar-interstitial lung pattern, 171f
 - differential diagnosis for, 171
- Generalized seizures, 254b
- Gingivitis, 309
 - dental radiographs of, 312f, 312f
 - interpretation of, 318–320
- Glargine, 233, 233b
 - for diabetic ketoacidosis, 238
- Global tissue hypoxia, 278
- Glomerulonephritis, 321–322
- Glucocorticoids, 324
- Glucocorticosteroids
 - for oesophagitis, 74
 - for pemphigus foliaceus, 29–30
- Glucose supplementation, 282b
- Glucuronyl conjugating capacity, 290
- Gold therapy, for mosquito bite hypersensitivity, 5
- Gonadotropin-releasing hormone (GnRH), agonist implant, 341
- Granuloma, mycotic dermal, 19
- Granulomatous colitis. *see* Histiocytic ulcerative colitis (HUC).
- Granulomatous inflammation, and parasitic disease, 55, 55f
- H**
- Haematemesis, differential diagnoses for, 97
- Haematological disorders, 120–142
 - Candidatus M. haemominutum* infection, 120–124
 - immune-mediated haemolytic anaemia, 124–127
 - primary hepatic amyloidosis, 137–142
 - renal carcinoma, 131–137
 - rodenticide toxicity, 128–131
- Haematoma, 333
- Haematuria
 - diagnostic test for, 203, 203t
 - differential diagnoses for, 202
 - causing stranguria and pollakiuria, 193
- Haemoabdomen, 140

- Haemolysis, 121
- Haemoperitoneum, 318
- Haemoptysis, 128, 129f
- Haemorrhage, 123
- Head carriage, abnormal, 335, 335f
- Head trauma, 286–287
- Helical computed tomography, for calcium oxalate uroliths, 190
- Heparin, 303
- Hepatic encephalopathy, treatment of, 85
- Hepatic lipidosis, 85, 231, 231b
 - diagnostic test results of, 82–85, 82t–83t, 83f–84f
 - discussion of, 85
 - enteral feeding options for, 85
 - investigation for, 81
 - outcome of, 86
 - signalment and clinical history of, 81
 - treatment considerations for, 84
- Hepatobiliary disease, 255b
- Hepatocytes, vacuolation of, 84f
- Hepatomegaly, 232
- Hereditary collagen dysplasia, 34
- Histiocytic ulcerative colitis (HUC), 56
 - clinical examination of, 52–53
 - diagnostic test results of, 53, 53f–55f, 55–56
 - discussion of, 56
 - signalment and clinical history of, 52, 52b
 - treatment and outcome of, 56
- Horner syndrome, peripheral vestibular disease and, 250
- Hydration, management of, in chronic kidney disease, 213
- Hydrolyzed protein diet, for mosquito bite hypersensitivity, 3
- 25-Hydroxyvitamin D (25(OH) vitamin D₃/calcidiol), 323
- Hyperadrenocorticism, 228
 - diagnosis of, 228
 - iatrogenic, 25
 - case information, 23–24, 24f
 - diagnostic test results of, 23
 - discussion of, 25
 - signalment, clinical history, and clinical examination of, 21–23, 22f
 - spontaneous, 25
- Hyperaldosteronism, primary, 216, 218
- Hypercalcaemia, 104b
 - in cats, 325
 - with chronic kidney disease, 325
 - clinical pathology tests, 322t
 - interpretation, 322
 - differential diagnosis for, 103, 322
 - investigation for, 323
 - possible causes of, 241
 - serum phosphate assessment to differentiate, 241
 - results of, 324, 324t
 - interpretation of, 324
 - signalment, clinical history, and clinical examination, 322–324
 - treatment and outcome, 324–325
 - treatment of, 323
- Hyperglobulinaemia, 305
- Hyperkalaemia
 - management for, 276
 - mild, 275
- Hyperparathyroidism, primary, 243
- Hyperphosphataemia, 293
- Hypertension, 134, 216b
 - common causes of, 216
 - management of, in chronic kidney disease, 213
 - systemic, 321
- Hyperthyroidism, 216, 325
 - treatment of, 218
- Hypertonic dextrose, 292
- Hypertonic saline, 288, 288b
- Hypertrophic cardiomyopathy (HCM), 148
 - case information, 146–147, 146f–147f
 - diagnostic test results of, 147–148
 - discussion of, 148
 - follow-up for, 148
 - management of, 144, 146
 - physical examination of, 143–146, 148
 - radiographic findings on, 145f, 146
 - signalment and history of, 143
 - treatment plan for, 147
- Hyperventilation, 288
- Hypoalbuminaemia, 305, 332
 - feline pyothorax and, 150
- Hypocalcaemia, postoperative, management of, 242
- Hypocobalaminaemia, common
 - cause of, 100b
- Hypoglycaemia, 333

Index

- Hypokalaemia
 - differential diagnoses for, 216
 - management of, in chronic kidney disease, 213
 - options for treatment of, 339
- Hypophosphataemia, in chronic kidney disease, 339
- Hypotension, 331
- Hypothermia, during dental procedure, 300
- Hypotonic fluids, for diabetic ketoacidosis, 235b
- Hypovolaemia, 278
- I
- Ibafloxacin, for mycobacterial infection, 12–13
- IBD. *see* Inflammatory bowel disease (IBD).
- Ibuprofen, 290
 - toxicity, consequences of, 290, 291t
- Idiopathic epilepsy, 132
- Idiopathic hypercalcaemia, in cats, 197
- Imaging studies, for ureterolithiasis, 204
- Imidacloprid, for flea hypersensitivity, 50
- Immune-mediated haemolytic anaemia, 126
 - primary, 126
 - secondary, 127
- In-house snake venom detection test, 263, 264f
- Inappetence, 281
 - management of, in chronic kidney disease, 213
- Inflammation, pyogranulomatous, 15
- Inflammatory bowel disease (IBD), 102
 - clinical exam of, 97–101, 98t–99t
 - discussion of, 102
 - investigation for, 98, 99f–101f
 - signalment and history of, 97
 - and small-cell lymphoma, 111b
 - treatment of, 101, 233
 - and outcome, 101–102
- Insect repellants, for mosquito bite hypersensitivity, 3
- Inspiratory effort, increased, in lymphoplasmacytic laryngitis, 161
- Insulin, classes of, for long-term therapy in diabetic cats, 233
- Insulin-like growth factor (IGF), elevated, in diagnosis of acromegaly, 228
- Insulin therapy protocol, for DKA management, 236b
- Intermittent facial twitch, 132
- International Renal Interest Society (IRIS), 338
 - staging system for chronic kidney disease, 212
- Intestinal peristalsis, 57
- Intestine, thickened, loops of, 326
- Intracranial pressure, increased, signs of, 287b
- Intracranial causes of seizures, 253–254
- Intravascular thrombectomy, 304
- Intravenous access, 281, 282f
- Intravenous antibiotics, for tick paralysis, 268
- Intravenous catheter placement, 278, 279f
- Intravenous crystalloid fluid boluses, 282
- Intravenous excretory pyelography, for calcium oxalate uroliths, 190
- Ionized calcium, 103b, 323
- Itraconazole
 - for cryptococcosis, 38
 - for dermatophytosis, 7–8
 - for phaeohyphomycosis, 19
- Ixodes holocyclus*, 266, 267f
- J
- Jaundice, 124
 - differential diagnoses for, 75–76
- K
- Ketamine, 345b
- Kidney disease, chronic, 216
 - discussion of, 214
 - investigations for, 211–212, 211t–212t, 212b
 - IRIS classification system, in staging for, 338
 - longer-term management of, treatment for, 339
 - management of, 213
 - and osteoarthritis, 214b
 - outcome of case, 214
 - physical examination of, 211

- Kidney disease, chronic (*Continued*)
 re-examination six months post
 diagnosis of, 213–214
 signalment and history of, 211
- Kidneys, change in sizes of, in calcium
 oxalate uroliths, 192
- L**
- Lactulose, for hepatic encephalopathy, 85
- Lameness, 354
- Lantus. *see* Glargine.
- Laparotomy
 benefits of, 329
 mesenteric lymphadenopathy at, 110f
- Large intestinal diarrhoea, differential
 diagnoses for, 92
- Laryngeal and central nervous system
 lymphosarcomas, chemotherapy
 for, 200
- Laryngeal disease, differential diagnoses
 for, 162
- Leptoid or tuberculous species, in
 mycobacterial infection, 13
- Lethargy, 120, 128, 281
 acute onset, 137
 treatment/further investigation for,
 122–123
- Levemir. *see* Detemir.
- Levetiracetam, for PSS, 257
- Light sedation, for tick paralysis, 266
- Linear foreign bodies, 60
 clinical examination for, 56–58
 common sites for, 57
 diagnostic test results of, 58, 58f
 discussion of, 60
 investigation for, 58
 potential sequelae of, 57
 response to treatment, diagnosis and
 outcome of, 59–60, 59f–60f
 signalment, clinical history and clinical
 examination findings on, 56
- Lipidosis, hepatic, 85, 231, 231b
 diagnostic test results of, 82–85,
 82t–83t, 83f–84f
 discussion of, 85
 enteral feeding options for, 85
 investigation for, 81
 outcome of, 86
- Lipidosis, hepatic (*Continued*)
 signalment and clinical history of, 81
 treatment considerations for, 84
- Liver
 cytology of, 83f
 enlarged, 141f
 fine needle aspirate of, 84
- Liver biopsy, 140
- Liver failure, 318–320
- Local anaesthetic blocks, during dental
 procedure, 314
- Long-stay jugular catheters, 276
- Low dose dexamethasone suppression test,
 for investigation of adrenal gland
 tumour, 223t
- Low grade lymphocytic (small cell)
 intestinal lymphoma, 111, 111b
 case information, 109–111, 110f
 diagnostic test results and management
 of, 107–109, 108t–109t
 discussion for, 111
 follow-up information for, 111
 signalment, clinical history and
 clinical examination findings
 on, 106–107
- Lower motor neurone disorders, 336
- Lower respiratory tract diseases,
 tachypnoea and systolic heart
 murmur and, 143–144
- Lufenuron, for flea hypersensitivity, 50
- 'Lung-digit syndrome,' 352, 354
 case description, 349
 clinical history, 350–351
 investigations for, 351–352, 351f–352f
 physical examination, 349–350
 radiographs, 312f, 353f
 description of, 352
- Lymphadenopathy, peripheral, in
 eosinophilic granuloma
 complex, 49
- Lymphocytic cholangitis, 307
- Lymphoma
 feline, COP chemotherapy protocol for,
 105b
 gastric
 case information, 103–105, 104f
 clinical examination of, 102
 diagnostic test results of, 102–103
 discussion of, 105–106

Index

- Lymphoma (*Continued*)
 - investigation for, 102
 - signalment and clinical history of, 102
 - gastrointestinal, 106
 - low grade lymphocytic (small cell)
 - intestinal, 111, 111b
 - case information, 109–111, 110f
 - diagnostic test results and management of, 107–109, 108t–109t
 - discussion for, 111
 - follow-up information for, 111
 - signalment, clinical history and clinical examination findings on, 106–107
 - mediastinal
 - clinical examination of, 174–175
 - diagnostic tests for, 175–176, 176f
 - discussion of, 177
 - signalment and clinical history of, 174
 - treatment and outcome of, 176–177, 177f
 - nasal, 187b
 - clinical examination of, 185–186
 - diagnosis of, 187–188
 - discussion of, 188
 - investigations for, results of, 186, 188f
 - prognosis for, 188
 - radiographs of, 186, 187f
 - signalment and clinical history of, 184
 - treatment options for, 187
 - small-cell, 111b
 - treatment options for, 104
 - Lymphoplasmacytic inflammatory bowel disease, 111
 - Lymphoplasmacytic laryngitis, 165
 - anaesthesia for, 162
 - case information, 162–165
 - clinical examination of, 161–162
 - discussion and follow-up for, 165, 165f
 - initial priorities for management of, 162
 - postoperative management of, 164
 - radiographs of, 162, 163f–164f
 - signalment and history of, 161
 - Lymphoplasmacytic rhinitis, treatment options for, 156
 - Lymphosarcoma, 200b
 - chemotherapy for
 - adverse effects of, 200
 - indications for, 199
 - renal, 199
 - case description, 198
 - chemotherapy for, 200
 - diagnosis of, 199–201
 - investigation for, 198, 199f
 - treatment and outcome of, 201–202, 201f
- ## M
- Magnetic resonance imaging (MRI)
 - for acromegaly, 229, 230f
 - for central and peripheral vestibular disease, 250–251, 251f
 - for meningioma, 259, 260f
 - Mammary enlargement, possible causes of, 341
 - Mammary fibroadenomatous hyperplasia, 342
 - diagnosis, treatment, and outcome, 342–343
 - physical examination, 341–342, 342f
 - signalment and history, 340–341
 - Mannitol, 288, 292
 - for meningioma, 260
 - Marbofloxacin
 - for pancreatitis, 115
 - for panniculitis, 16
 - Maropitant, 293
 - for hepatic lipidosis, 84
 - for low grade lymphocytic intestinal lymphoma, 107
 - Mass
 - abdominal, 305
 - on dorsum, 325
 - Masson's trichrome stains, in Ehlers-Danlos syndrome, 34
 - Mast cell tumour
 - abdominal ultrasound of, 329
 - blood results, 327t–328t
 - interpretation of, 326
 - clinical examination, 326
 - cutaneous, 326
 - dermal, well-differentiated, 325
 - differential diagnosis for, 326
 - investigations for, 326, 329

- Mast cell tumour (*Continued*)
 management of, 330
 signalment and history and, 325
 urinalysis results, 327t
- Mediastinal lymphoma
 clinical examination of, 174–175
 diagnostic tests for, 175–176, 176f
 results of, 176
 discussion of, 177
 signalment and clinical history
 of, 174
 treatment of, 176
 and outcome, 177, 177f
- Mediastinal lymphosarcoma,
 chemotherapy for, 200
- Mediastinal mass, clinical signs of, 175
- Medical management
 for calcium oxalate uroliths, 190–191
 with chemotherapy, for meningioma,
 260
 for ureterolithiasis, 205
- Megacolon, 63, 65
 clinical examination, 61–63
 diagnostic test results of, 63–64, 63f
 discussion of, 65, 65f
 investigation for, 62
 postoperative complications, 64
 response to treatment, diagnosis, and
 outcome of, 64–65
 signalment, clinical history and clinical
 examination findings on, 61
 treatment of, 63–64
- Melatonin supplement, 341
- Meloxicam, 313, 314, 354
 for feline pyothorax, 151
 for mycobacterial infection, 9–10
 for pain relief after surgical removal of
 cystolith, 195
- Meningiomas, 261
 diagnosis, response to treatment and
 outcome of, 261
 diagnostic test results of,
 259–260, 260f
 differential diagnoses for, 258
 discussion of, 261
 investigation for, 259
 physical examination of, 258–259
 signalment and clinical history
 of, 258
- Mesenteric lymph nodes, enlarged, 307
- Metastatic digital carcinoma, 354
- Methocarbamol, 296
- Methylprednisolone
 for eosinophilic granuloma complex,
 50–51
 for mosquito bite hypersensitivity, 3
- Metoclopramide
 for hepatic lipidosis, 84
 for low grade lymphocytic intestinal
 lymphoma, 107
 for oesophagitis, 74
- Metronidazole
 for feline pyothorax, 152
 for IBD, 101, 232
 for low grade lymphocytic intestinal
 lymphoma, 110
 for pancreatitis, 114
- Miconazole and chlorhexidine shampoo,
 for dermatophytosis, 8
- Microcytosis, 255
- Microsporum canis*, and dermatophytosis,
 6, 7f
- Mid-caudal abdominal mass, differential
 diagnoses for, 92
- Midazolam, 275–296
- Middle ear flushing, for central and
 peripheral vestibular disease, 251
- ‘Mik’ antigen, 121
- Mirtazapine, for pancreatitis, 80
- Miscellaneous disorders, 300–359
 chronic feline gingivostomatitis,
 300–359
 feline infectious peritonitis (FIP),
 305–309, 355–359
 feline mast cell tumours, 325–331
 feline odontoclastic resorptive lesions
 (FORLs), 316
 feline orofacial pain syndrome,
 343–349
 glomerulonephritis, 317–322
 hypercalcaemia, 322–325
 mammary fibroadenomatous
 hyperplasia, 340–343
 metastatic digital carcinoma,
 349–355
 peracute toxoplasmosis, 331–334
 polycystic kidney disease (PKD),
 335–340
 thromboembolism, 300–305
- Monoclonal gammopathy, 307

Index

- Morphine, 345b
- Mosquito bite hypersensitivity, 5
 - clinical examination findings on, 1–2
 - diagnostic testing of, 3–4
 - differential diagnoses for, 2
 - discussion of, 5
 - management of, 2
 - outcome of case, 4, 4f
 - results of further diagnostics of, 3
 - results of therapeutic trials of, 3
 - signalment and clinical history of, 1
- Mucous membranes, pale, 121f
- Multifocal pruritic skin lesions, differential diagnoses for, 244
- Multimodel environmental modification (MEMO), for FLUTD, 209b
- Muscle fasciculations, 296, 298
 - mild, 293
- Muscularis hypertrophy, 232, 232f
- Myasthenia gravis
 - case information, 271–272
 - case outcome, 272
 - diagnostic test results of, 270–271, 270f
 - discussion of, 272–273
 - examination findings on, 269–270
 - investigations for, 271
 - management of, 272
 - signalment and clinical history of, 269
- Mycobacterial infection, 173b
 - clinical examination of, 10, 12f–13f, 170
 - diagnostic test results of, 170–173, 171f–172f
 - differential diagnoses for, 10
 - discussion of, 13, 174
 - investigation for, 10, 172
 - management of, 12
 - response to treatment, diagnosis, and outcome, information on, 173, 174f
 - signalment and history of, 9–10, 9f and clinical examination findings on, 170
 - treatment options for, 11
- Mycobacterium microti*, 174
- Mycoplasma haemofelis*, 123
- Mycotic dermal granuloma, 19
- Mydriasis, bilateral, 293
- Myringotomy, bilateral, for central and peripheral vestibular disease, 251
- N**
 - Nasal bridge, localized infections of, 18f, 20
 - Nasal catheters, placement of, for tick paralysis, 268
 - Nasal dermatitis, 1f
 - Nasal discharge
 - in nasal lymphoma, differential diagnoses for, 185
 - in nasopharyngeal stenosis, 152, 153f
 - Nasal disease, investigation of, radiographic views for, 153
 - Nasal lymphoma, 187b
 - clinical examination of, 185–186
 - diagnosis of, 187–188
 - discussion of, 188
 - investigations for, results of, 186, 188f
 - prognosis for, 188
 - radiographs of, 186, 187f
 - signalment and clinical history of, 184
 - treatment options for, 187, 199
 - Nasal swelling, 9f
 - Nasopharyngeal stenosis
 - case information, 154–156, 154f–156f
 - clinical examination of, 152–154, 153f
 - investigation for, 153
 - signalment and history of, 152
 - treatment and outcome of, 157
 - treatment options for, 156
 - Neoplasia, and bilateral renomegaly, 198
 - Neostigmine, for myasthenia gravis, 272
 - Nephrectomy, 136f
 - Neurological deficits, and muscle weakness, 336
 - Neurological disorders, 249–273
 - meningiomas, 258–261
 - myasthenia gravis, 269–273
 - peripheral vestibular disease, 249–252
 - PSS, 252–257
 - snake bite envenomation, 261–265
 - tick paralysis, 265–269
 - Neurological examination
 - central *versus* peripheral vestibular disease, 250
 - for meningioma, 258
 - Neuromuscular weakness, 272–273
 - Neutral protamine hagedorn (NPH) insulin, 233, 233b
 - Neutropenia, feline pyothorax and, 150

- Nodules, cutaneous, in cryptococcosis, differential diagnosis for, 36
- Non-healing wounds, differential diagnosis for, 43
- Non-steroidal anti-inflammatory drugs (NSAIDs), 290, 293
- dental procedure, 314
- Non-tuberculous opportunistic mycobacteria (NTM), in mycobacterial infection, 13
- Noncardiogenic pulmonary oedema, 269
- NTM. *see* Non-tuberculous opportunistic mycobacteria (NTM).
- Nursing care, for tick paralysis, 268
- Nystagmus, vertical, central vestibular disease and, 250, 252
- O**
- Obstipation, 63
- factors that may contribute to, 61
- Obstructive shock, 278
- Ocular conjunctiva, pale, 120f
- Oesophagitis, 74
- discussion of, 74, 79f
- investigation for, 72, 73f
- results of diagnostic tests for, 73–74
- signalment, clinical history and clinical examination of, 71–72
- treatment and outcome of, 74
- Oesophagostomy
- tube, 85
- Oliguria, 292
- Omega-3 fatty acid supplementation, 321
- Omeprazole, for oesophagitis, 73
- Opioid(s), 278, 304, 345b
- during dental procedure,
- Opioid analgesia, for pancreatitis, 114
- Oral prednisolone therapy, for nasopharyngeal stenosis, 157
- Orthopnoea, 128
- Osteoarthritis, and chronic kidney disease, 214b
- Osteotomy, bilateral ventral bulla, for central and peripheral vestibular disease, 251–252
- Otitis media/interna, feline peripheral vestibular disease and, 252
- Ovulation, manual stimulation of, 341
- Oxyglobin transfusion, 126
- P**
- Palliative therapy, for meningioma, 260
- Pancreas, hypoechoic, 79f
- Pancreatic enzyme supplementation, for EPI management, 70
- Pancreatitis, 321
- analgesia for, 80
- antiemetic therapy for, 80
- chronic, 231–232
- clinical examination of, 75–80
- discussion of, 81
- investigations for, 76, 76t–78t
- nonspecific clinical presentation of
- approach for, 112, 113t
- case information, 113–114
- discussion of, 116
- follow-up for, 114–115, 115f
- management of, 114
- signalment, clinical history and examination findings on, 112–113
- nutritional support for, 80
- outcome of, 80
- signalment and history of, 75
- treatment of, 79, 321
- Panniculitis, 17
- differential diagnoses for, 14
- discussion of, 16–17
- investigation for, 15
- outcome of case, 16
- results of, 15–16
- signalment, clinical history, and clinical examination of, 14–15, 14f
- treatment and results of, 16
- Paracentesis, 139
- Paralysis tick, 266, 267f
- Parathyroid hormone (PTH)
- in hypercalcaemia, 323
- level, in primary hyperparathyroidism, 241
- Parathyroid hormone related peptide (PTHrp), 323
- Parathyroidectomy, 242
- Parenteral cobalamin supplementation, for IBD, 233
- Partial seizures, 254b
- Pathogens, obligate, in mycobacterial infection, 13
- PCR. *see* Polymerase chain reaction (PCR).

Index

- Pemphigus foliaceus, 30
 - diagnostic test results of, 28–30, 29f
 - differential diagnoses for, 26
 - discussion of, 30
 - investigation for, 28
 - management of, 29
 - signalment, clinical history, and clinical examination of, 26–28, 26f–27f
- Penrose drains, 281
- Pentoxifylline, for Ehlers-Danlos syndrome, 34
- Percutaneous antegrade pyelography, for calcium oxalate uroliths, 190
- Perinephric pseudocysts, and bilateral renomegaly, 198
- Peripheral lymphadenopathy, in eosinophilic granuloma complex, 49
- Peripheral vestibular disease
 - versus* central vestibular disease, 250
 - differential diagnoses for, 249
 - discussion of, 252
 - investigation for, 250, 251f
 - signalment, clinical history and clinical examination findings on, 249–251, 249f
 - treatment, diagnosis and outcome of, 251–252
- Peritoneopericardial diaphragmatic hernia (PPDH), 160
 - case information, 158–160, 158f–159f
 - differential diagnoses for, 158
 - discussion of, 160–161
 - investigation for, 158
 - management of, 160
 - signalment, clinical history, and clinical examination of, 157–158
 - surgery for, 160
 - complications and precautions of, 160
 - treatment and outcome of, 160
- Peritonitis, septic, 285
- Permethrin, 298
 - intoxication, 293, 297f–298f
 - clinical signs associated with, 295
 - complications, 297
 - mortality of, 298
- Petechiae, 128, 128f
- Phaeohyphomycosis
 - diagnostic test results of, 19, 20f
 - discussion of, 20–21
- Phaeohyphomycosis (*Continued*)
 - investigation for, 18
 - signalment, clinical history, and clinical examination of, 17–19, 18f
 - treatment options for, 19
- Pharmacological diuresis, 292
- Phenobarbitone, 132, 296
- Phosphorus supplementation, for diabetic ketoacidosis, 235
- Piroxicam, for squamous cell carcinoma, 47
- Platelet count, low, 138
- Pleural effusion
 - causes of, 149
 - in DCM, differential diagnosis for, 180
 - dyspnoea and, 175
 - in feline pyothorax, 150f
- Pleural space disease
 - peritoneopericardial diaphragmatic hernia and, 158
 - tachypnoea and systolic heart murmur and, 144
- Pneumothorax, feline pyothorax and, 151
- Polychromasia, 129
- Polyclonal gammopathy, 307
- PKD, 340, 340f
 - and bilateral renomegaly, 198
 - clinical examination, 335–336, 335f, 336b
 - differential diagnosis and, 335
 - haematology, 338t
 - investigation for, 337–339
 - outcome, 339–340
 - potassium supplement rates, 339t
 - serum biochemistry, 337t
 - signalment and history, 335
 - ultrasound appearance of kidney, 338f
 - urinalysis, 337t
- Polycythaemia, 134
- Polymerase chain reaction (PCR)
 - for feline herpesvirus 1, 41
 - for panniculitis diagnosis, 15
 - for phaeohyphomycosis, 19
- Polyneuropathy, generalized, tick paralysis and, 269
- Polyprenyl immunostimulant, for FIP, 97
- PSS
 - clinical examination of, 252–257, 253f
 - discussion of, 257

- PSS (*Continued*)
 investigations for, 254, 254t–256t, 255b, 256f–257f
 signalment and clinical history of, 252
 treatment and outcome of, 257
 treatment options for, 256
- Posaconazole, for phaeohyphomycosis, 19
- Postrenal azotaemia, 189
- Potassium, 339
 for correction of hypokalaemia in pancreatitis, 80
 supplement rates for intravenous use, 339t
- Potassium citrate, supplemental, for idiopathic hypercalcaemia, 197
- Potassium gluconate, for primary hyperaldosteronism, 218
- Pradofloxacin, 124
 for nasopharyngeal stenosis, 157
- Prednisolone, 127, 324–325, 356
 administration, after adrenalectomy, 224
 for atopic dermatitis, 245
 for eosinophilic granuloma complex, 50–51
 for FIP, 97
 for gastric lymphoma, 104
 for hypercalcaemia, 242
 for IBD, 101, 233
 immunosuppressive, 123
 for meningioma, 260
 for mosquito bite hypersensitivity, 3
 for myasthenia gravis, 272
 oral, for nasopharyngeal stenosis, 157
 for pemphigus foliaceus, 29–30
 for renal lymphosarcoma, 201–202
 side effects of, 105, 111
- Primary amyloidosis, and bilateral renomegaly, 198
- Primary brain injury, 287
- Primary hepatic amyloidosis, 141, 141f
- Primary hyperaldosteronism, 216, 218
 case information, 217, 217f
 diagnostic test results of, 215–216, 215t
 discussion of, 218
 due to adrenal tumour with concurrent hyperthyroidism, 217
 investigations for, 215
 signalment, clinical history and clinical examination findings on, 215
 treatment of, 218
- Primary hyperparathyroidism, 243
 discussion of, 243
 investigations for, 240–242, 240t–241t
 physical examination of, 238–240, 239t
 treatment and outcome of, 242–243
- Primary idiopathic seizures, 132
- Primary polycythaemia rubra vera, 134
- Primary pulmonary carcinoma, 354
- Progestogens, 341
 duration of effect, 341
 potential adverse effects, 341
- Prokinetics, for oesophagitis, 74
- Proligestone, 340–341
- Propofol, 314, 296
- Proptosis, of the right eye, 285, 286f, 289f
- Protein-losing enteropathy (PLE), 318–320
- Protein-losing nephropathy (PLN), 305, 318–320
 biochemistry results, 319t
 investigations for, 320
 urinalysis results, 320t
- Protein-restricted renal diet, 321
- Proteinuria, 307, 320
 in chronic kidney disease, 339
 pre-renal, 320
- Proton-pump inhibitors, for oesophagitis, 73
- Pseudocysts, perinephric, and bilateral renomegaly, 198
- Ptyalism, marked, 293
- Pulmonary haemorrhage, 130
- Pulmonary oedema, 304
- Punch skin biopsy, for mosquito bite hypersensitivity, 3
- Pyoderma, 245
 secondary to pemphigus foliaceus, 29
- Pyogranulomatous inflammation, 15
- Pyogranulomatous vasculitis, 126, 127f
- Pyridostigmine, for myasthenia gravis, 272
- R**
- Radiation treatment, for acromegaly, 229b
- Radiography, bulla and nasopharyngeal, for central and peripheral vestibular disease investigation, 250
- Radiotherapy, for meningioma, 260
- Ranitidine, 329–330
- Rapidly growing mycobacteria (RGM), 16–17

Index

- Recombinant feline interferon omega, for feline herpesvirus 1, 41
 - Refractometer, in determining urine specific gravity, 193, 194t
 - Refractory leucopenia, 136
 - Regurgitation, 71, 86
 - differential diagnoses for, 71
 - Relative polycythaemia, 134
 - Renal amyloidosis, and bilateral renomegaly, 198
 - Renal carcinoma, 136f
 - Renal lymphosarcoma, 199
 - case description, 198
 - chemotherapy for, 200
 - diagnosis of, 199–201
 - investigation for, 198, 199f
 - treatment and outcome of, 201–202, 201f
 - Renal replacement therapy, 275–276
 - Renomegaly, unilateral/bilateral, causes of, 336
 - Repellants, insect, for mosquito bite hypersensitivity, 3
 - Resource map, for FLUTD, 209, 209f
 - Respiratory disorders, 143–188
 - Bordetella* infection, 166–169
 - DCM, 178–184
 - feline pyothorax, 149–152
 - hypertrophic cardiomyopathy, 143–148
 - lymphoplasmacytic laryngitis, 161–166
 - mediastinal lymphoma, 174–177
 - mycobacterial infection, 170–174
 - nasal lymphoma, 184–188
 - nasopharyngeal stenosis, 152–157
 - peritoneopericardial diaphragmatic hernia, 157–161
 - Respiratory distress, localization of, 161
 - Reticulocyte count, 125
 - Reticulocytosis, 129
 - Retroflexed pharyngoscopy, in nasopharyngeal stenosis, 155
 - Retroflexed rhinoscopy, in nasal lymphoma, 186
 - Retrograde ureteropyelography, for calcium oxalate uroliths, 190
 - Retroviral testing
 - for pancreatitis investigation, 77t
 - for renal lymphoma, 198
 - RGM. *see* Rapidly growing mycobacteria (RGM).
 - Rifampicin, for mycobacterial infection, 11–13
 - Rivalta test, 95, 95b
 - Rodenticide anti-coagulants, 131
 - Rodenticide toxicity, 130
 - prognosis for, 131
 - Ronidazole, for *Tritrichomonas foetus* infection, 117–118, 118b
- ## S
- Saline, hypertonic, 288, 288b
 - SCC. *see* Squamous cell carcinoma (SCC).
 - Second-generation anti-coagulants, 131
 - Secondary amyloidosis, and bilateral renomegaly, 198
 - Secondary brain injury, 287
 - Secondary polycythaemia, 134
 - Sedation, for tick paralysis, 268
 - Sediment examination, in investigation for feline uroliths, 194
 - Seizure(s), 254b, 293, 297–298
 - anaesthetic agent to control, 294f
 - causes of,
 - how to control, 296
 - Seizure disorders, 132, 133t
 - Selamectin
 - for flea hypersensitivity, 50
 - for mosquito bite hypersensitivity, 3
 - Sepsis, 281
 - Septic effusion, 283, 283f–284f
 - Septic peritonitis, 285
 - Serum alpha-1 acid glycoprotein, measurement of, 308t
 - Serum cobalamin concentration, in histiocytic ulcerative colitis diagnosis, 52
 - FCoV antibodies, measurement of, 308t
 - Serum protein electrophoresis, 305–306, 356
 - Shock, 278
 - Skin lesions, multifocal pruritic, differential diagnoses for, 244
 - Skin scrape, for dermatophytosis
 - investigation, 6
 - Slide agglutination test, 125
 - Snake antivenom, for snake bite, 268
 - Snake bite envenomation
 - clinical examination of, 261–262
 - follow-up for, 265
 - management of, 264
 - possible consequences of, 264

- Snake bite envenomation (*Continued*)
 signalment and history of, 261
 stabilization of, 262–265
Sodium bicarbonate, 288
Sodium lactate, for diabetic ketoacidosis, 234–235
Soft tissue injuries, 280f
Spinosad, for flea hypersensitivity, 50
Spironolactone, 304
 for primary hyperaldosteronism, 218
Splenomegaly, 326
Squamous cell carcinoma (SCC), 47
 clinical examination of, 43–44, 43f
 diagnostic test results of, 44–45, 44f–46f
 discussion of, 47
 investigation for, 44
 metastases, 45
 risk factors for, 44
 signalment, clinical history, and clinical examination findings on, 42–43
Stenosis, nasopharyngeal
 case information, 154–156, 154f–156f
 clinical examination of, 152–154, 153f
 investigation for, 153
 signalment and history of, 152
 treatment and outcome of, 157
 treatment options for, 156
Steroids, 289
Sertor
 in nasal lymphoma, 185
 in nasopharyngeal stenosis, 152, 157
Streptokinase, 304
Stress, and feline idiopathic cystitis, 208, 210
Stridor, lymphoplasmacytic laryngitis and, 161
Struvite crystals in feline idiopathic cystitis, 207
Struvite uroliths
 epidemiology of, 197
 recurrence of, 197
Sucralfate, 292
 for oesophagitis, 74
Sudden onset oral pain, differential diagnoses for, 344
Supportive treatments, for snake bite envenomation, 264
Surgery
 for meningioma, 259–260
 for removal of calcium oxalate uroliths, 197
Surgery (*Continued*)
 for removal of ureterolith, 191
 for ureterolithiasis, 206
Surgical adrenalectomy, for primary hyperaldosteronism, 218
Surgical biopsy, 141
Survey radiographs
 abdominal
 for detection of uroliths, 197
 in investigation for feline uroliths, 194
 for assessment of megacolon, 62
Swelling
 in Ehlers-Danlos syndrome, differential diagnoses for, 31
 nasal, in MN British Shorthair cat, 9f
Systolic blood pressure (SBP), in chronic kidney disease, 212b
Systolic heart murmur, left base, causes of, 143–144
- T**
- Tachycardia, 124
Tachypnoea, 177
 acute onset, 128
 causes of, 143
 episodic, 143
 extra-thoracic causes of, 144
 mild resting, 137
 moderate, 120
 treatment/further investigation for, 122–123
Tachyzoites, 334
Tape strip, for dermatophytosis
 investigation, 6
Temporary oestrus control, options for, 341
Tepoxalin, for squamous cell carcinoma, 47
Tetracosactrin, for iatrogenic hyperadrenocorticism, 24
Therapeutic diet, for calcium oxalate uroliths, 197
Thoracic drain, placement of, in feline pyothorax
 bilateral, 152
 location for, 151
Thoracic radiography
 for diagnosis of FIP, 96
 for feline pyothorax, 151, 151f
 for hypertrophic cardiomyopathy evaluation, 144, 145f

Index

- Thoracic radiography (*Continued*)
 for investigation of oesophagitis, 72
 for myasthenia gravis, 270, 270f
 for mycobacterial infection, 171, 171f
 for peritoneopericardial diaphragmatic hernia, 158f–159f, 159–160
 interpretation of, 159
 for squamous cell carcinoma, 45, 45f–46f
 for thromboembolism, 302f
 for tick paralysis, 267
- Thoracocentesis, 332
 for feline pyothorax management, 150
 for cranial mediastinal mass, 271
- Thorax, lateral, hyperpigmentation and comedones on, 24f
- Thrombocytopaenia, 138, 142
- Thromboembolism, 304, 321
 aortic, 304
 clinical examination findings on, 300–301
 response to treatment, diagnosis, and outcome, 304
 signalment and clinical history, 300
 brachial, 301f
 problem list, 300
- Thrombolytic therapy, 304
- Tick antiserum, for tick paralysis, 266
- Tick paralysis
 clinical examination of, 265–267
 follow-up for, 269
 management of, 266, 267f
 progression of case, 267–268
 signalment and clinical history of, 265
- Tick removers, 267f
- Tiger snake envenomation test, 263–264
- Tissue, cutaneous, hyperextensibility of, 34
- Tissue hypoxia, global, 278
- Tissue plasminogen activator, 304
- Tissue samples
 for mycobacterial infection diagnosis, 11
 for phaeohyphomycosis diagnosis, 19
 for squamous cell carcinoma, 44
- Tooth resorption, classification based on severity of lesion, 311
- Toxic ibuprofen dose, 290
- Toxicity, 274–299
- Toxoplasmosis
 antemortem diagnosis of, and limitations of, 334
 peracute, 334
- Toxoplasmosis (*Continued*)
 haematology and, 332
 investigation and stabilization, 331–332
 outcome, 333–334
 signalment, clinical history, and clinical examination findings on, 331–332
- Trachea, rupture of, during dental procedure, 314
- Tracheostomy tubes, for tick paralysis management, 268
- Tramadol, 345b
- Trauma, 274–299
 acute, 285
 facial, 285, 286f
 head, 286–287
- Tremors, 293
- Triamcinolone, for pemphigus foliaceus, 29–30
- Trichogram, for dermatophytosis investigation, 6
- Trilostane, for adrenal gland tumour, 223
- Tritrichomonas foetus*, 117
 infection, 118–119
 asymptomatic, management of, 118
 case information, 117–118
 history of case, 116
 physical examination for, 116
 treatment of, 117
 typical features of, 117
- Tumours
 adrenal gland, 224
 clinical examination of, 219–220, 219f
 with concurrent hyperthyroidism, primary hyperaldosteronism due to, 217
 discussion of, 224
 follow-up for, 224
 investigation for, 220, 222, 223t
 laboratory results of, 220–224, 220t–221t, 222f
 management of, 223, 223t
 signalment and history of, 219
 gastrointestinal, 199–200
 lymphoblastic *versus* lymphocytic, 200
 mast cell
 abdominal ultrasound of, 329
 blood results in, interpretation of, 326

- Tumours (*Continued*)
- blood test results, 327t–328t
 - clinical examination, 326
 - cutaneous, 326
 - dermal, well-differentiated, 325
 - differential diagnosis for, 326
 - investigations for, 326, 329
 - management of, 330
 - signalment and history and, 325
 - urinalysis results, 327t
- U
- Ulcerating and crusting dermatitis, in
FHV-1 infection, differential
diagnoses for, 40
- Ultrasound-guided paracentesis, 140
- Ultrasound-guided Tru-cut biopsy, 141
- Unilateral adrenomegaly, 222
- Upper motor neurone disorders, 336
- Ureteral stents, for management of feline
ureteral obstruction, 192
- Ureterolithiasis, 206
- clinical examination of, 202–204, 203t
 - diagnostic test for, 204–206,
204f–205f
 - dietary modification for, 206
 - medical management of, 205–206
 - minimally invasive procedures for, 206
 - signalment, clinical history and clinical
examination findings on, 202
 - surgical management of, 206
 - treatment options for, 205, 206b
 - urinalysis for, 204
- Ureteroneocystostomy, for calcium oxalate
uroliths, 191
- Ureterotomy, for calcium oxalate
uroliths, 191
- Urinary acidifiers, 323
- Urinary catheter
- in facilitating retrograde flushing of
bladder, 195
 - indwelling, 292b
- Urinary tract disorders, 189–214
- calcium oxalate uroliths, 189–192
 - chronic kidney disease, 211–214
 - feline idiopathic cystitis, 207–210
 - feline uroliths, 192–198
 - renal lymphosarcoma, 198–202
 - ureterolithiasis, 202–206
- Urination, inappropriate, differential
diagnoses for, 23
- Urine bacterial culture, for chronic kidney
disease, 213b
- Urinary tract infection, 226b
- Urine protein:creatinine ratio
(UPCR), 320
- interpretation and investigation, 320
- Urocystoliths, double contrast cystography
for detection for, 194
- Urohydropulsion techniques, for
uroliths, 197
- Urokinase, 304
- V
- Vestibular disease
- central
 - differential diagnoses for, 250
 - versus* peripheral, 250
 - peripheral
 - differential diagnoses for, 249
 - discussion of, 252
 - investigation for, 250, 251f
 - outcome of, 252
 - signalment, clinical history and
clinical examination findings on,
249–251, 249f
 - treatment, diagnosis and outcome of,
251–252
- Vincristine, 105b
- for renal lymphosarcoma, 201–202
 - side effects of, 105
- Vitamin B12 injections
- for EPI management, 70
 - for hepatic lipidosis, 82–84
- Vitamin D
- metabolites, 323
 - supplementation, oral, for postoperative
hypocalcaemia, 242
 - toxicosis, 325
 - sources of, 323
- Vitamin K deficiency, 129–130
- Vitamin K1 treatment, 130
- Vomiting, 86, 91
- case information, 87t–88t, 89, 90f, 91
 - clinical examination of, 86–88
 - differential diagnoses for, 76–79
 - in cat with pancreatitis, 112
 - discussion of, 91

Index

- Vomiting (*Continued*)
 - interpretation of laboratory results of, 88
 - investigation for, 89
 - management of, 89
 - signalment and history for, 86
- W
- Warfarin, 303
- Water intake, for calcium oxalate uroliths, 197
- Weakness, in cat, differential diagnosis for, 262, 269
- Weight loss, 317, 325
 - differential diagnoses for, 106
- Wet diet, for calcium oxalate uroliths, 197
- Wood's lamp, for dermatophytosis investigation, 6, 6b
- Wounds, non-healing, differential diagnosis for, 43