NOVARTIS

INTERNAL PARASITES OF DOGS AND CATS

DIAGNOSTIC MANUAL

Developed with Dr. Byron Blagburn
College of Veterinary Medicine
Auburn University

Throughout this manual, you will find icons that indicate the species affected by individual parasites (see definitions for the species icons below), plus drawings that provide relative size comparisons. In each key, a simple drawing of the parasite being discussed will be shown next to a *Toxocara* spp. egg drawing.

Indicates the parasite infects dogs.

Indicates the parasite infects cats.

Indicates the parasite infects raccoons.

Indicates that one or more stages in the life cycle of the parasite can infect humans.

Parasitology is a fascinating field, especially when exploring the intricate mechanisms by which parasites propagate. In the fast-paced veterinary clinic environment, the study of parasitology too often becomes routine and mundane—we simply perform yet another fecal examination and dutifully record the results.

We invite you to step out of this routine and rediscover the amazing life cycles of these remarkable organisms. Challenge yourself to not only identify a hookworm egg by genus alone, but by species. Explore the complex relationships between parasites and their intermediate and definitive hosts.

This diagnostic manual is designed to be an informative source for the identification and exploration of internal parasites. To be of most benefit to veterinarians and technicians, the manual was designed to be convenient and easy to use. As you'll see, the parasites described in this manual have been divided into two groups according to the material (i.e., feces or blood) tested for infection. Additional sections are devoted to pseudoparasites, parasite life cycles and practical, time-saving diagnostic procedures. In addition, you will find guidelines for parasite prevention in dogs and cats developed by the Companion Animal Parasite Council, plus a handy index.

All of the information provided here is brief and to the point. Wherever possible, symbols are used to convey key information (see the key at left).

We would like to acknowledge Professor Byron Blagburn, Department of Pathobiology, College of Veterinary Medicine, Auburn University, for providing astute technical assistance and one-of-a-kind illustrative material for this manual.

Novartis is pleased to provide you with this laboratory manual to assist with diagnosis of common parasites in dogs and cats. We hope it will further aid your fecal examinations and parasite identification. Please use this manual to help educate your clients on the risks and prevention of internal parasites. We are honored to work with you toward the most important goal: a happy, healthy pet.

Jason Drake, DVM
Director of Professional Services
Novartis Animal Health US, Inc.

Dr. France Gagné
National Director, Professional Services
Novartis Animal Health Canada Inc.

Parasites found in blood 5
Nematodes 6

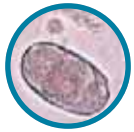

Parasites found in feces 9
Parasites of the gastrointestinal tract
Cestodes 10
Nematodes 16
Protozoa 24
Parasites of the respiratory tract
Nematodes 28
Trematodes 29
Parasites of the urinary tract
Nematodes 30

Pseudoparasites 31

Parasite life cycles 37
Feline 38
Canine 45

Parasite prevalence 57

Diagnostic techniques 61
Direct smear 62
Sedimentation 63
Flotation 64
Centrifugation 65

Companion Animal Parasite Council (CAPC) guidelines 69

Index 72

CONTENTS

Vet-ebooks.com

NOVARTIS

PARASITES FOUND IN **BLOOD**

Nematodes

Acanthocheilonema (Dipetalonema) reconditum 6
Dirofilaria immitis 7

Vet-ebooks.com

Acanthocheilonema (Dipetalonema) reconditum

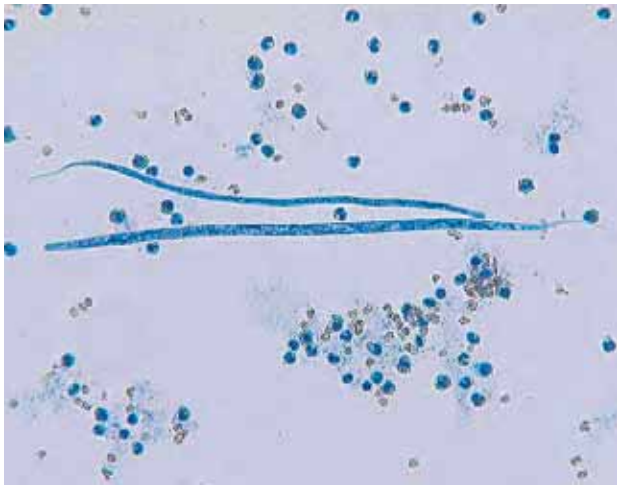

Note the characteristic smaller size and blunt anterior end of microfilariae of *A. reconditum* (top) and the characteristic tapering anterior end of microfilariae of *D. immitis* (bottom).

Characteristics of microfilariae of D. immitis and A. reconditum

	Dirofilaria immitis	*Acanthocheilonema reconditum*
Length	307–322 µm (310 µm average)	246–293 µm (280 µm average)
Width (⅓ of length from anterior end)	6.1–7.2 µm	4.7–5.8 µm
Shape of head	Tapered	Blunted
Cellularity of anterior end	Cellular	Clear space
Condition of tail	Straight	Button hook shaped in some (artifact of formalin fixation)
Motility in direct smear of anticoagulated whole blood	Stationary	Progressive (tends to move out of field of view)

Vet-ebooks.com

Dirofilaria immitis

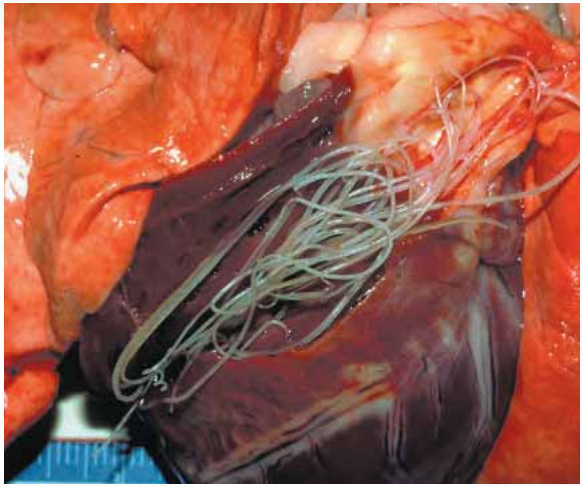

Adult *D. immitis* in the right ventricle of the heart.

Dirofilaria immitis

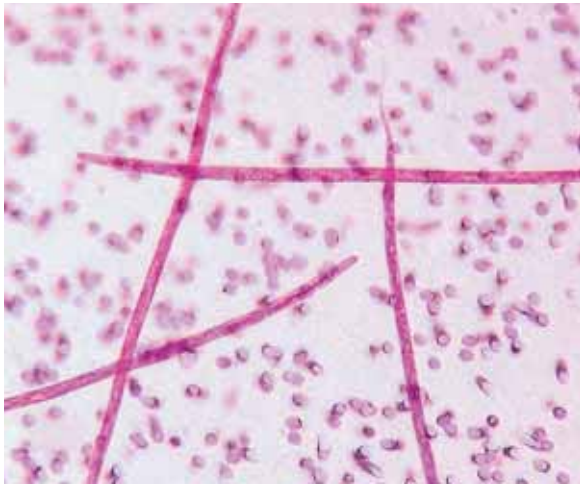

Microfilariae of *D. immitis* as seen on a membrane filtration test. Note: Circulating microfilariae are very rarely observed in the cat.

Vet-ebooks.com

Vet-ebooks.com

NOVARTIS

PARASITES FOUND IN **FECES**

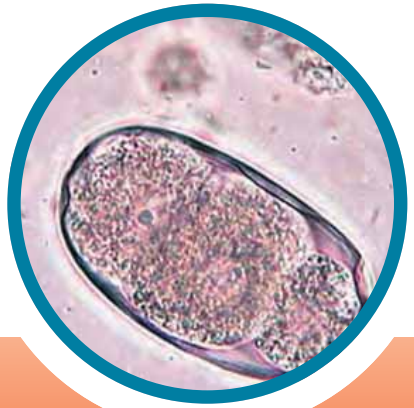

PARASITES OF THE GASTROINTESTINAL TRACT

Cestodes

Dipylidium caninum 10
Echinococcus spp. 14
Taenia spp. 15

Nematodes

Ancylostoma caninum 16
Ancylostoma tubaeforme 17
Uncinaria stenocephala 18
Physaloptera spp. 20
Toxascaris leonina 21
Toxocara canis 21
Toxocara cati 21
Baylisascaris procyonis 22
Trichuris vulpis 23

Protozoa

Giardia spp. 24
Isospora (Cystoisospora) spp. 25
Toxoplasma gondii 27
Cryptosporidium spp. 27

PARASITES OF THE RESPIRATORY TRACT

Nematodes

Aelurostrongylus abstrusus 28
Eucoleus (Capillaria) aerophilus 28

Trematodes

Paragonimus kellicotti 29

PARASITES OF THE URINARY TRACT

Nematodes

Pearsonema (Capillaria) feliscati 30
Pearsonema (Capillaria) plica 30

Vet-ebook3.com

PARASITES OF THE **GASTROINTESTINAL TRACT** – CESTODES

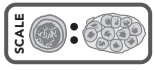

Dipylidium caninum

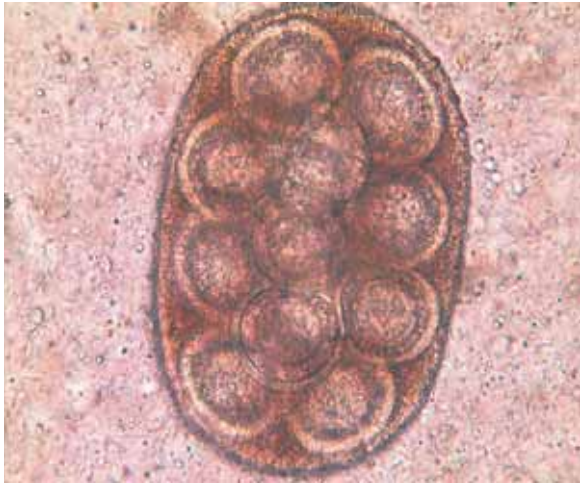

Egg packet of *D. caninum*

Dipylidium caninum

Comparison of adult *D. caninum* with a canine roundworm.

Vet-ebooks.com

Dipylidium caninum

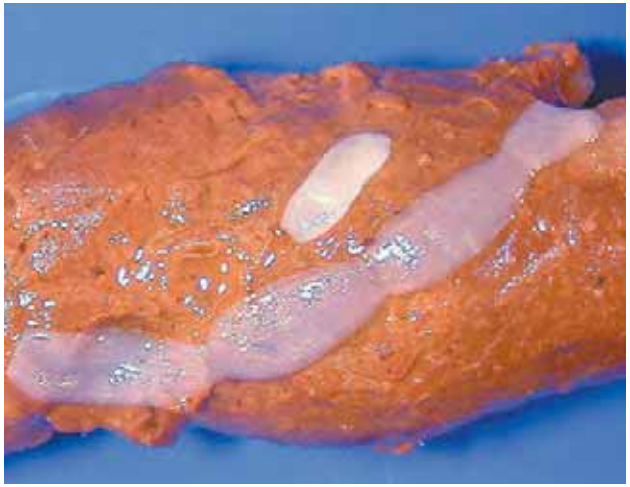

Adult *D. caninum*. Note that the segments are longer than they are wide. Dried proglottids (segments) are sometimes brought in for identification by pet owners.

Dipylidium caninum

Dried *D. caninum* segments; sometimes found by pet owners.

Vet-ebooks.com

Comparison of common tapeworms in dogs and cats

	Dipylidium caninum	*Taenia pisiformis**
Common name	Cucumber seed tapeworm	Dog - Rabbit tapeworm
Definitive host	Dog, cat, rarely humans	Dog
Intermediate host	Fleas, lice	Rabbits
Size	Small; 0.2–0.8 meters (0.6–2.6 feet)	Large; 0.6–2 meters (1.9–6.6 feet)
Structure of head	Small rostellum (attachment device) armed with many small hooks; rostellum is surrounded by 4 suckers	Large rostellum with a double row of large hooks; rostellum is surrounded by 4 suckers
Structure of mature/ gravid proglottids (tapeworm segments)	Oblong (resemble cucumber seed), with two sets of reproductive organs opening into bilateral pores; proglottids are often motile. Dried proglottids resemble rice grains.	Mature proglottids are square to rectangular, with a single set of reproductive organs opening into alternating unilateral pores. Gravid proglottids tend to be rectangular and more elongated.
Structure of eggs	Individual eggs consist of a hexacanth (6-hooked) embryo within a thin embryophore (shell); individual eggs are contained in packets of 3–30 eggs. Egg packets (200–300 µm) are passed in feces or retained within proglottids.	Individual eggs consist of a hexacanth embryo within a radially striated embryophore. Eggs (30–40 µm) are usually passed individually in feces. Eggs of *T. pisiformis* cannot be distinguished from eggs of other *Taenia* spp., or from those of *Echinococcus* spp.
Zoonotic potential	Yes, usually small children	No
Disease potential in dogs or cats	Both *Dipylidium* and *Taenia* tapeworms are generally nonpathogenic to dogs or cats. Rarely, heavy infections can cause soft or diarrheic feces, restlessness, abdominal pain, dull coat, and excessive grooming of the perineum due to pruritus. *Dipylidium caninum* can infect humans, particularly small children, resulting in similar clinical signs.	

*A similar tapeworm, *Taenia* (syn. *Hydatigera*) *taeniaeformis* infects cats. It resembles *T. pisiformis*.

Vet-ebooks.com

Selected tapeworms of veterinary importance

Tapeworm Species	Definitive Hosts*	Intermediate Hosts	Larval Stage; Site of Larval Tapeworm Development
Dipylidium caninum	Canids, felids, rarely humans	Flea, louse	Cysticercoid; body cavity of insects
Taenia pisiformis	Canids	Rabbits	Cysticercus; abdominal cavity and liver of rabbits
Taenia hydatigena	Canids	Livestock	Cysticercus; abdominal cavity and liver of livestock
Taenia ovis	Canids	Sheep, goats	Cysticercus; musculature of intermediate hosts
Taenia multiceps	Canids	Sheep, cattle, humans	Coenurus; brain and spinal cord of intermediate hosts
Taenia serialis	Canids	Rabbits, rodents, rarely humans	Coenurus; connective tissue of rabbits, rodents and rarely humans
Taenia taeniaeformis	Felids	Rodents	Strobilocercus; liver of rodents
Mesocestoides spp.	Canids, felids	Coprophilic insect or mite (1st host); mammals, reptiles, frogs, birds (2nd host)	Tetrathyridium in insect or mite and in abdominal cavity and liver of vertebrates
Echinococcus granulosus	Canids	Livestock, humans	Unilocular hydatid cyst; liver, lungs
Echinococcus multilocularis	Canids, rarely felids	Rodents, humans, rarely pig, horse	Multilocular hydatid; liver, lungs
Spirometra mansonoides	Felids, canids, raccoons	Copepods (1st host); many verterbrates except fish (2nd hosts)	Procercoid (body cavity of copepods); plerocercoid (body musculature and subcutaneous fascia of vertebrates)
Diphyllobothrium latum	Humans, canids, felids, porcids	Copepods (1st host); fish (2nd host); several paratenic hosts	Procercoid (body cavity of copepods); plerocercoid (abdominal cavity, musculature of fish)

*All tapeworms inhabit the small intestine of the definitive host.

Vet-ebooks.com

Parasites of the **GASTROINTESTINAL TRACT –** CESTODES

Echinococcus spp.

Eggs of *E. granulosus*

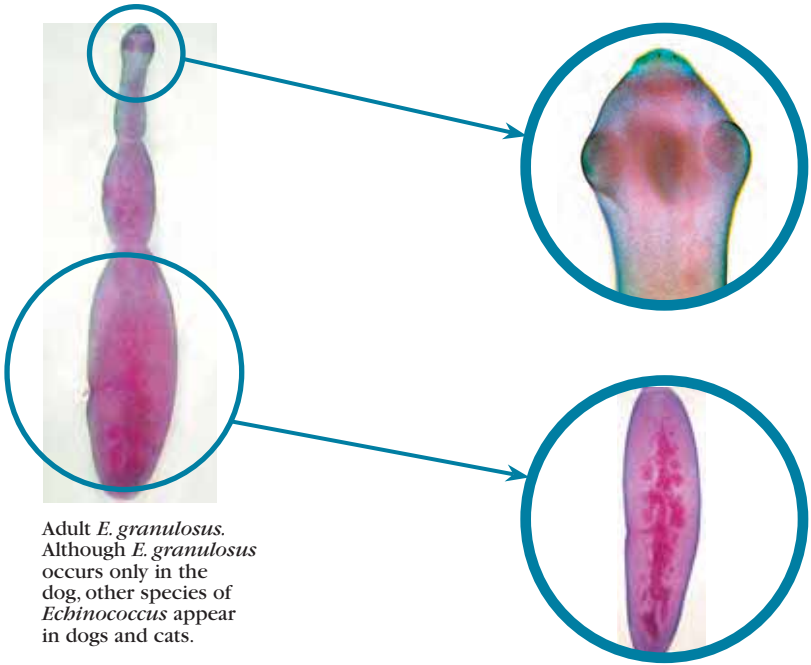

Adult *E. granulosus*. Although *E. granulosus* occurs only in the dog, other species of *Echinococcus* appear in dogs and cats.

Vet-ebooks.com

Taenia spp.

Eggs of *T. pisiformis*
Note: Cats are host to other *Taenia* spp.

Adult *T. pisiformis.*
Note the difference in segment shape compared to adult *D. caninum.*

Vet-ebooks.com

Parasites of the **GASTROINTESTINAL TRACT –** NEMATODES

Ancylostoma caninum

Egg of *A. caninum*

Ancylostoma caninum

Anterior end of adult *A. caninum*.
Note the three pairs of ventral teeth.

Vet-ebooks.com

Ancylostoma tubaeforme

Egg of *A. tubaeforme*

Vet-ebooks.com

Parasites of the **GASTROINTESTINAL TRACT –** NEMATODES

Uncinaria stenocephala

Egg of *U. stenocephala*

Uncinaria stenocephala

Note the differences in size between *U. stenocephala* (upper right) and *A. caninum* (lower left).

Vet-ebooks.com

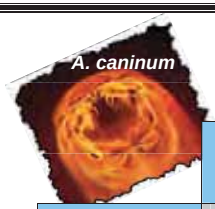

CANINE HOOKWORMS[1,2]

	Ancylostoma caninum	Uncinaria stenocephala	Ancylostoma braziliense
Infection	➢ Ingestion of 3rd stage larvae from contaminated environment ➢ Larval penetration of the skin ➢ Ingestion of other vertebrate hosts with infective larvae in their tissues ➢ Transmammary transmission of larvae is an important route of infection for *A. caninum*		
Prepatent Period	14 to 21 days (nursing puppies may shed eggs in 10 to 12 days)	13 to 27 days	13 to 27 days
Occurrence	Common	Uncommon (1%)[3]	Uncommon
Locations	Worldwide	Colder climates (northern US, Canada, Europe)	Warm, coastal areas (also sub and tropical Central & South America & Caribbean
Pathogenic	Very pathogenic: anemia	Rarely pathogenic	Cutaneous larva migrans
Blood per worm per day	adult female: ~40µl; adult male: ~13µl	0.3µl	1 to 2µl
Mouthparts	3 pairs of teeth	cutting plates	1 pair of large; 1 pair of small

[1] www.capcvet.org
[2] Bowman, DD. Hookworm Parasites of Dogs and Cats. Compend Contin Educ #2. Vol 14, No. 5, May 1992
[3] Prevalence of Canine Parasites Based on Fecal Flotation. Blagburn BL *et al*. Compend Contin Educ Pract Vet 18: 483-509, 1996

NOVARTIS ANIMAL HEALTH

CAPC

Vet-ebooks.com

Parasites of the **GASTROINTESTINAL TRACT** – NEMATODES

Physaloptera spp.

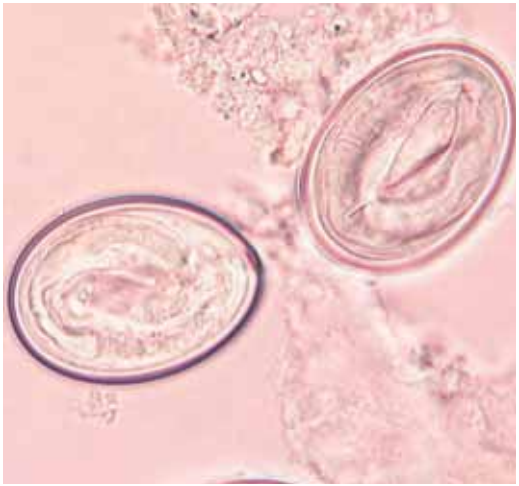

Embryonated eggs of *Physaloptera* spp. (stomach worm)

Vet-ebooks.com

Parasites of the **GASTROINTESTINAL TRACT** – NEMATODES

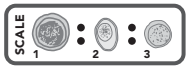

1: *T. canis*
2: *T. leonina*
3: *T. cati*

Toxascaris leonina

Egg of *T. leonina*

Toxocara canis

Egg of *T. canis*

Toxocara cati

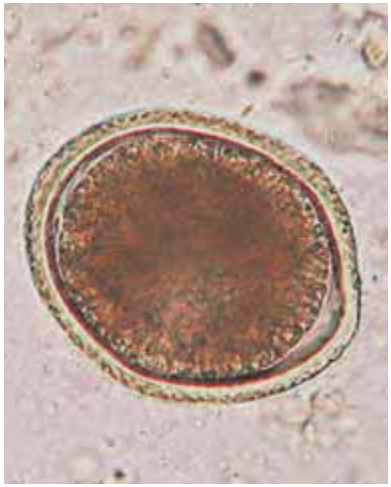

Egg of *T. cati*
Note the size is about 10 percent smaller than the *T. canis* egg.

Vet-ebooks.com

Parasites of the **GASTROINTESTINAL TRACT –** NEMATODES

1: *B. procyonis*
2: *T. canis*

Baylisascaris procyonis

Egg of *B. procyonis*

Toxocara canis

Egg of *T. canis*

Note the similarities.
Differentiation can be made based on size and color, as the egg of *B. procyonis* is roughly three-quarters the size of *T. canis* and typically appears darker.

Vet-ebooks.com



Trichuris vulpis

Egg of *T. vulpis*

Trichuris vulpis

Adults of *T. vulpis* Note how the whip-like anterior ends are laced through the mucosa.

Vet-ebooks.com

Parasites of the **GASTROINTESTINAL TRACT** – PROTOZOA

1: *trophozoite*
2: *cyst*

Giardia spp.

Motile trophozoite of *Giardia* spp. (iodine stain)

* certain assemblages may infect humans

Giardia spp.

Cyst of *Giardia* spp. (iodine stain)

Vet-ebooks.com

1: *I. canis*
2: *I. ohioensis*

Isospora (Cystoisospora) spp.

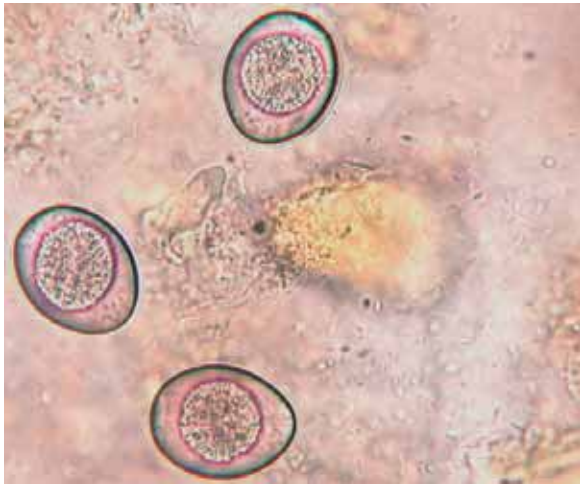

Nonsporulated oocysts of *I. canis*

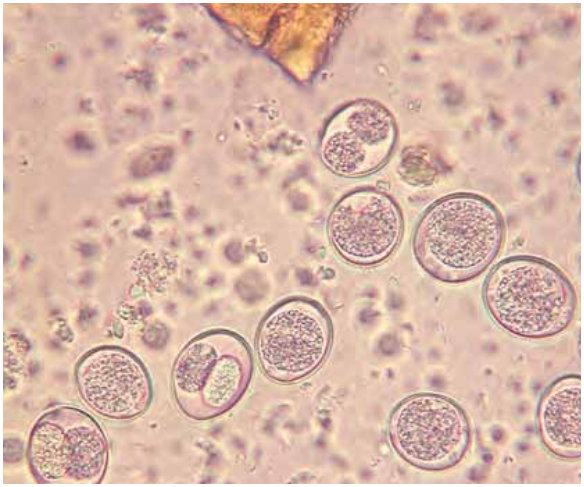

Nonsporulated oocysts of *I. ohioensis*

Vet-ebooks.com

Parasites of the **GASTROINTESTINAL TRACT** – PROTOZOA

1: *I. felis*
2: *I. rivolta*

Isospora (Cystoisospora) spp.

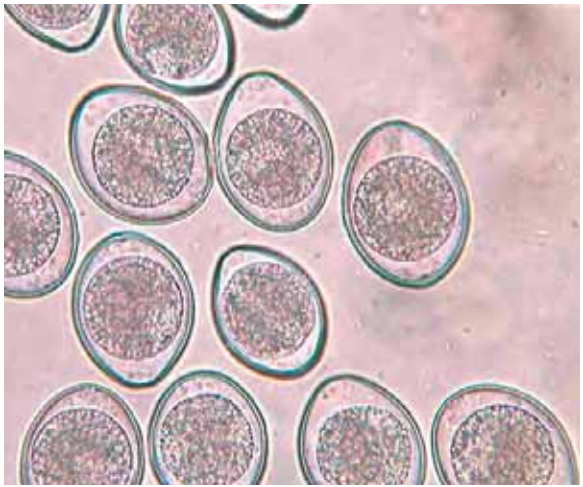

Nonsporulated oocysts of *I. felis*

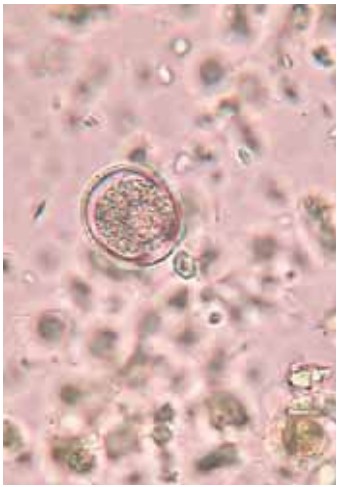

Nonsporulated oocysts of *I. rivolta*

Vet-ebooks.com

1: *T. gondii*
2: *Cryptosporidium* spp.

Toxoplasma gondii

Nonsporulated oocysts of *T. gondii*
Compare the size of *T. gondii* to *I. felis* in the background.

Cryptosporidium spp.

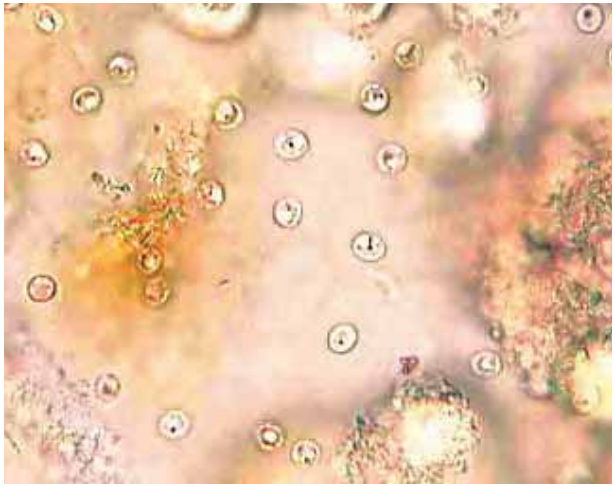

Sporulated oocysts of *Cryptosporidium* spp.

Vet-ebooks.com

Parasites of the **RESPIRATORY TRACT** – NEMATODES

1: *A. abstrusus*
2: *E. aerophilus*

Aelurostrongylus abstrusus

Larva of *A. abstrusus*
Note dorsal appendage on tail of larva.

Eucoleus (Capillaria) aerophilus

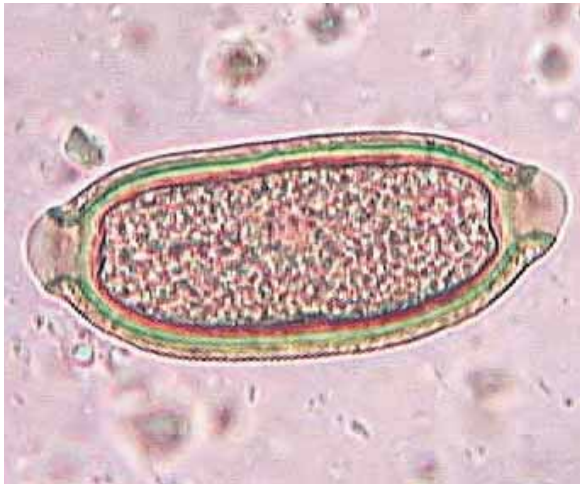

Egg of *E. aerophila*

Vet-ebooks.com

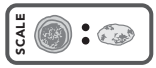

Paragonimus kellicotti

Egg of *P. kellicotti*. Note the collar surrounding the operculum.

Vet-ebooks.com

Parasites of the **URINARY TRACT –** NEMATODES

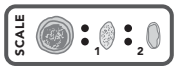

1: *P. feliscati*
2: *P. plica*

Pearsonema (Capillaria) feliscati

Stained egg of *P. feliscati* from urinary sedimentation

Pearsonema (Capillaria) plica

Egg of a *P. plica* from urinary sedimentation

Vet-ebooks.com

PSEUDOPARASITES

Pseudoparasites

Alternaria spp. 32
Free-living nematode 33
Grain mite egg 34
Planarian 34
Pollen granules 35

Spurious parasite

Monocystis lumbrici or *Rhyncocystis pilosa* spore 36

Pseudoparasites are specimens found in feces or blood that are mistaken for parasites. (For the purpose of this manual, only examples of pseudoparasites found in feces are included.) Pseudoparasites can be differentiated from spurious parasites, which are parasites of a host other than the host under examination. For example, dogs and cats often consume feces of other vertebrate animals or consume invertebrates and will sometimes excrete stages of parasites unique to their prey. *Monocystis lumbrici* is an example of a spurious parasite. While it is a true parasite of earthworms, dogs and cats can ingest earthworms, causing *M. lumbrici* to appear in fecal examinations.

Vet-ebooks.com

Alternaria spp.

These conidia are common environmental fungal contaminants.

Vet-ebooks.com

Free-living nematode

These pseudoparasites are often recovered from feces collected from the ground. Note the bulbed esophagus.

Vet-ebooks.com

Grain mite egg

Dogs and cats ingest these eggs by eating mite-infested food. Eggs are often recovered during fecal flotation.

Planarian

This free-living flatworm is not a parasite but crawls into water dishes kept outside. It can then be ingested and is sometimes regurgitated by dogs and cats.

Vet-ebooks.com

Pollen granules

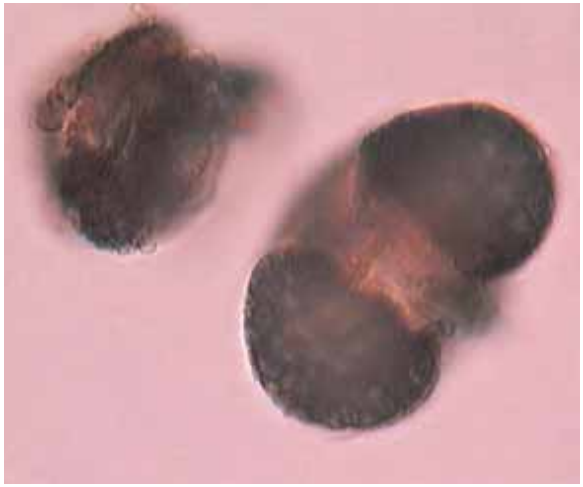

Pine pollen

Pollen granules

Tree pollen

Vet-ebooks.com

Monocystis lumbrici or *Rhyncocystis pilosa* spores

These spurious parasites often infect earthworms; dogs and cats may ingest earthworms. In fecal flotations, the spore is similar in appearance to eggs of *T. vulpis*, although much smaller.

Vet-ebooks.com

NOVARTIS

PARASITE **LIFE CYCLES**

Feline

Aelurostrongylus abstrusus 38
Ancylostoma tubaeforme 39
Dirofilaria immitis 40
Taenia spp. 41
Toxascaris leonina 42
Toxocara cati 43
Uncinaria stenocephala 44

Canine

Ancylostoma caninum 45
Baylisascaris procyonis 46
Dipylidium caninum 47
Dirofilaria immitis 48
Echinococcus granulosus 49
Echinococcus multilocularis 50
Taenia spp. 51
Toxascaris leonina 52
Toxocara canis 53
Trichuris vulpis 54
Uncinaria stenocephala 55

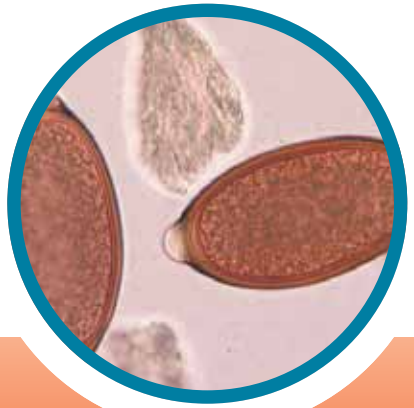

Vet-ebooks.com

AELUROSTRONGYLUS ABSTRUSUS

Prepatent period: 7-9 weeks
Patent period: several years

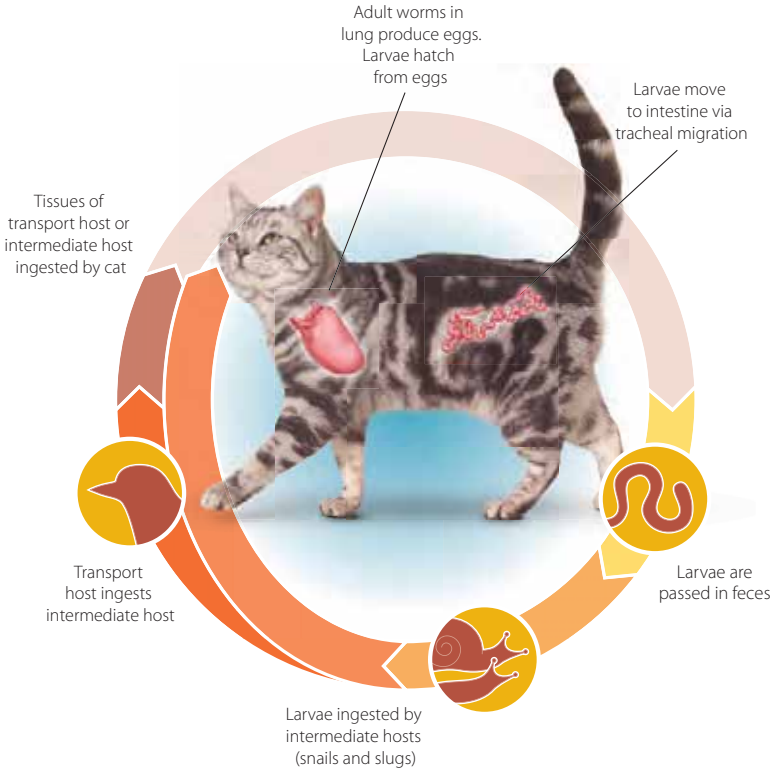

Vet-ebooks.com

ANCYLOSTOMA TUBAEFORME

Prepatent period: 2-3 weeks
Patent period: can be prolonged depending on immune status

A. tubaeforme: The principal routes of transmission are through ingestion and skin penetration. Parateric transmission occurs rarely, if at all

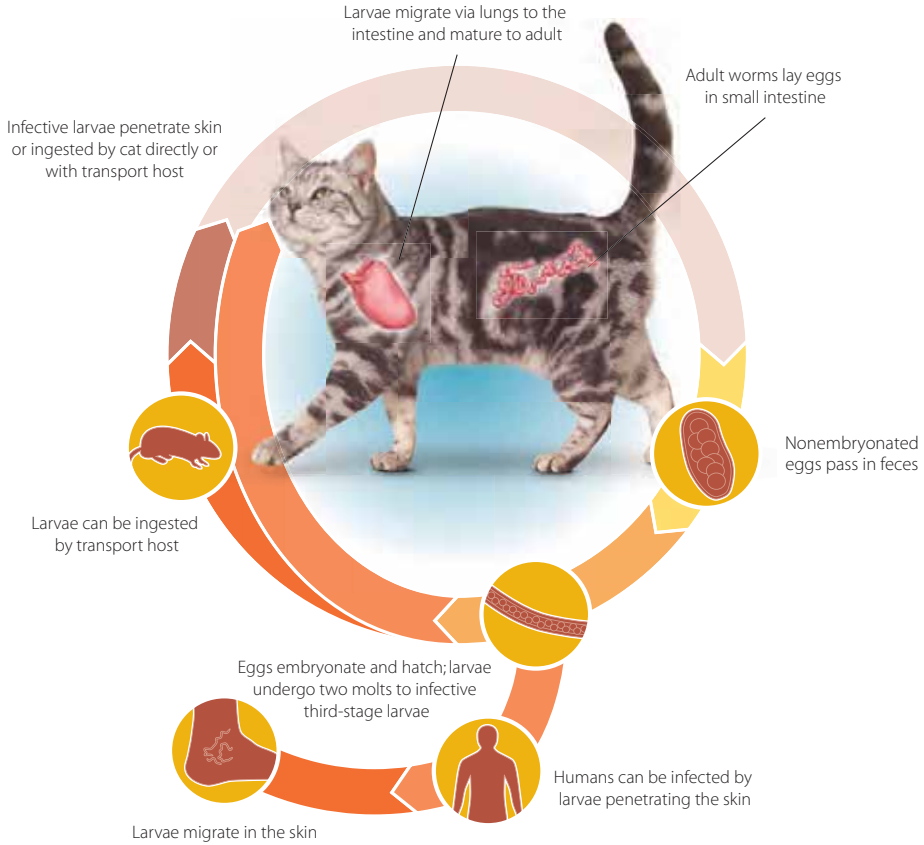

Vet-ebooks.com

DIROFILARIA IMMITIS

Prepatent period: 6-8 months
Patent period: usually short

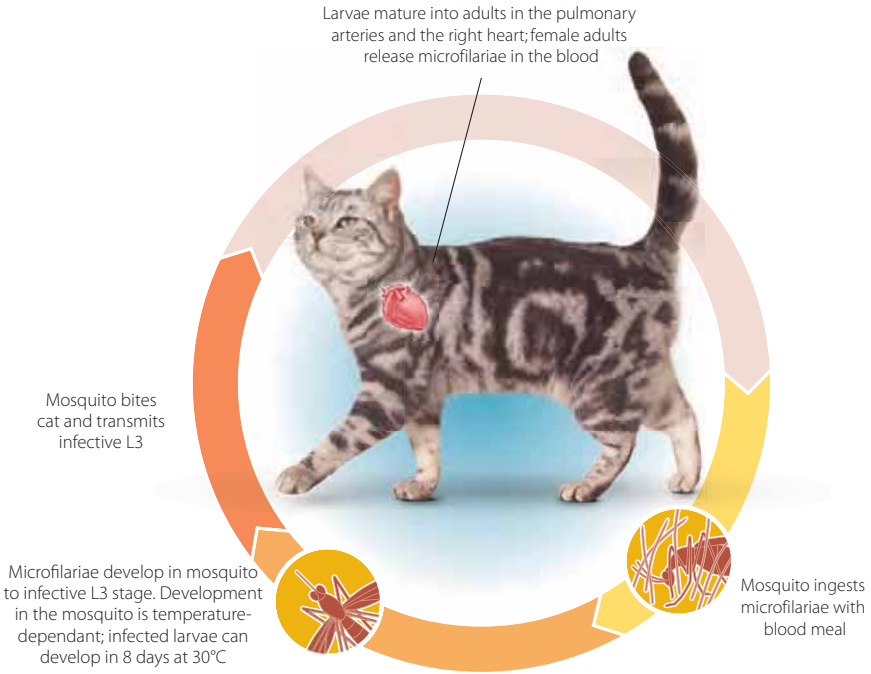

Vet-ebooks.com

TAENIA spp.

Prepatent period: 4-11 weeks
Patent period: several years

Cats mainly: *Taenia taeniaeformis*

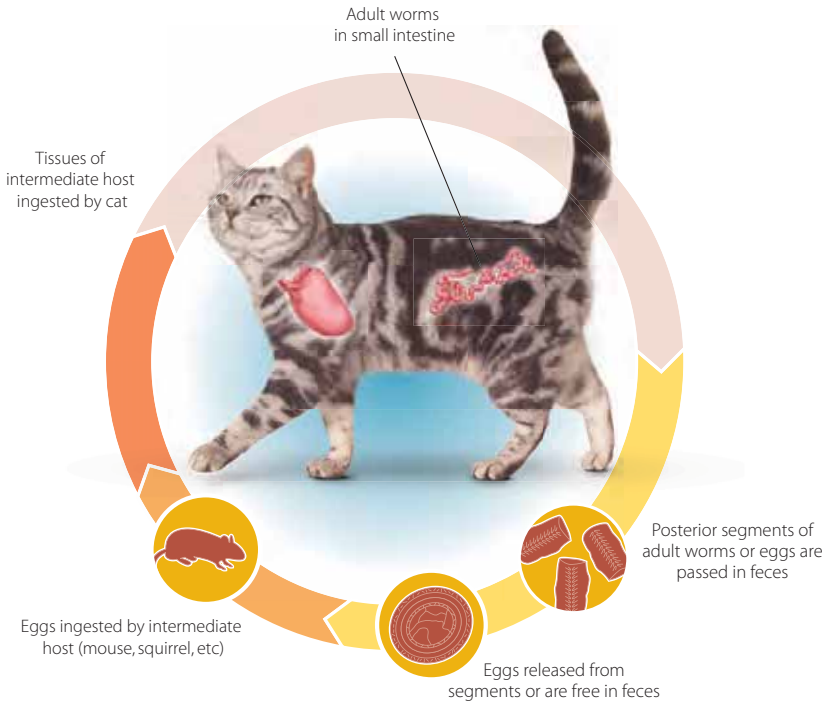

Vet-ebooks.com

TOXASCARIS LEONINA

Prepatent period: 13 weeks
Patent period: 4-6 weeks

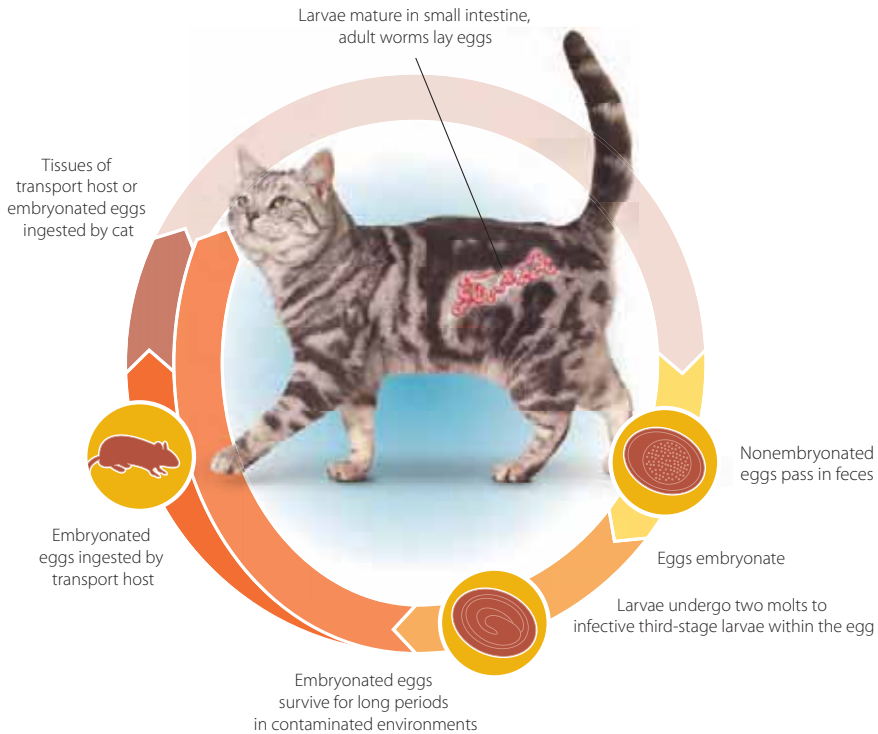

Vet-ebooks.com

TOXOCARA CATI

Prepatent period: 3-6 weeks
Patent period: 4-6 months

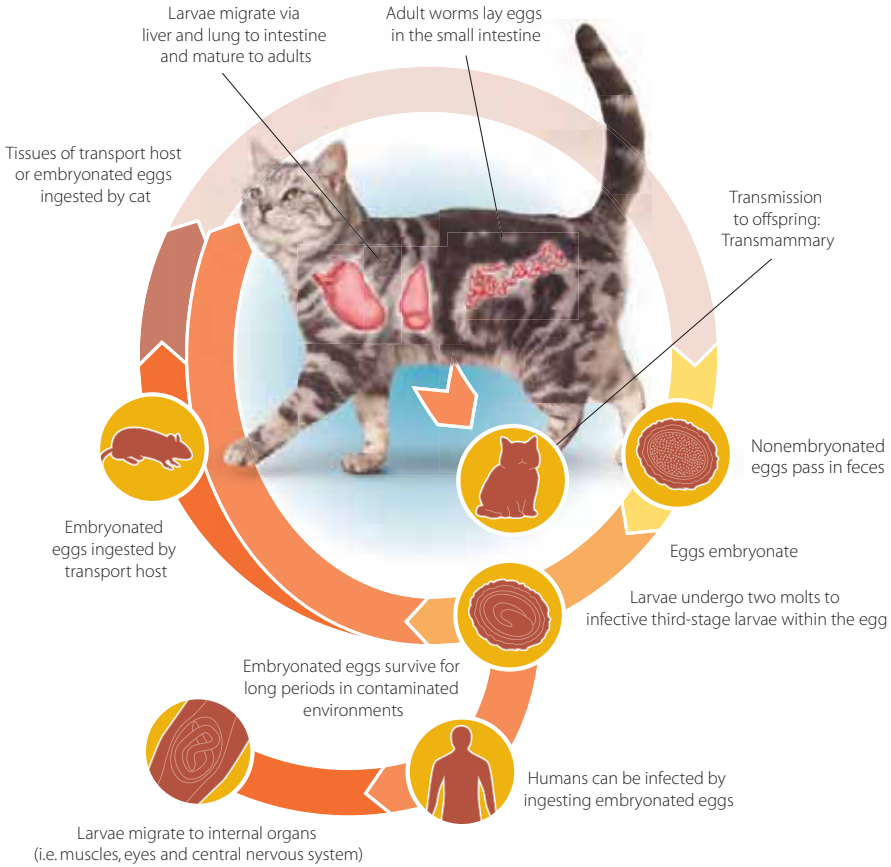

Vet-ebooks.com

UNCINARIA STENOCEPHALA

Prepatent period: 3-4 weeks
Patent period: can be prolonged depending on immune status

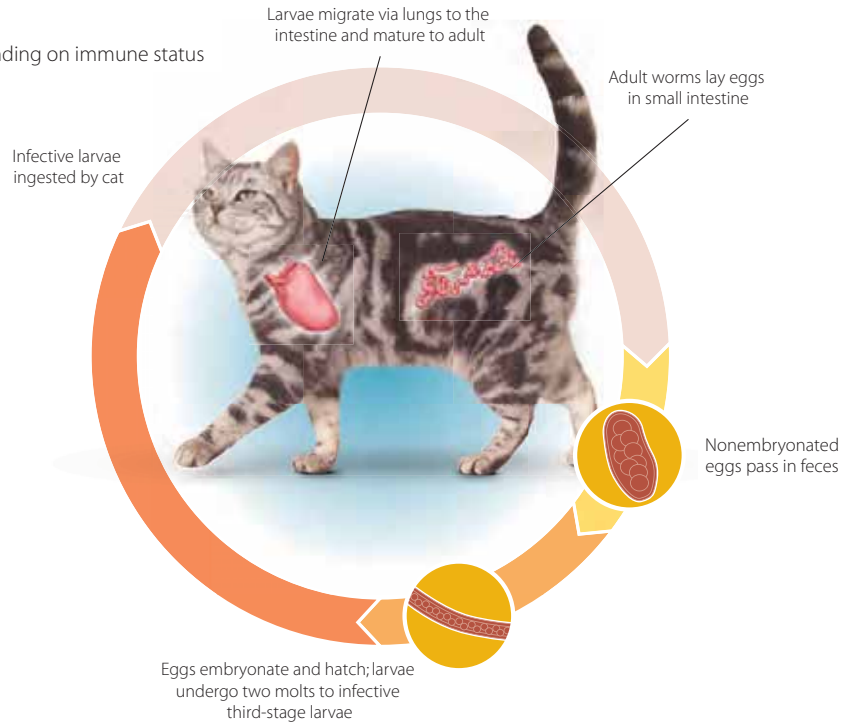

Vet-ebooks.com

ANCYLOSTOMA CANINUM

Prepatent period: 2-3 weeks
Patent period: 7 months to 2 years, can be prolonged depending on immune status

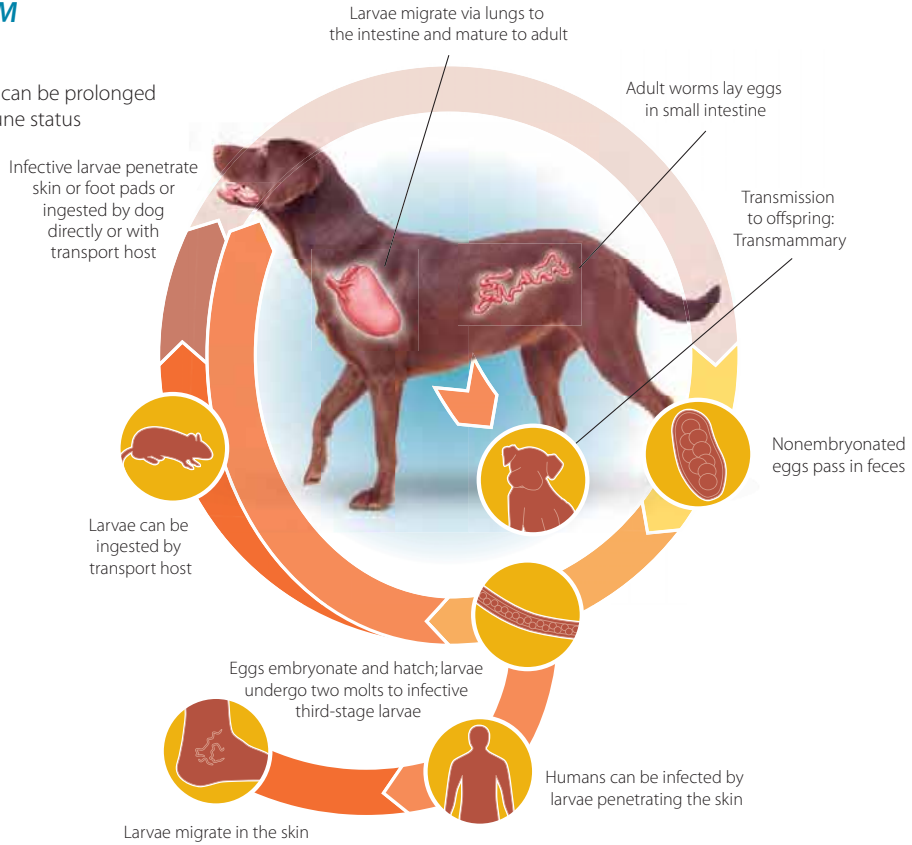

Vet-ebooks.com

BAYLISASCARIS PROCYONIS

Prepatent period: 8 weeks
Patent period: 4-6 months

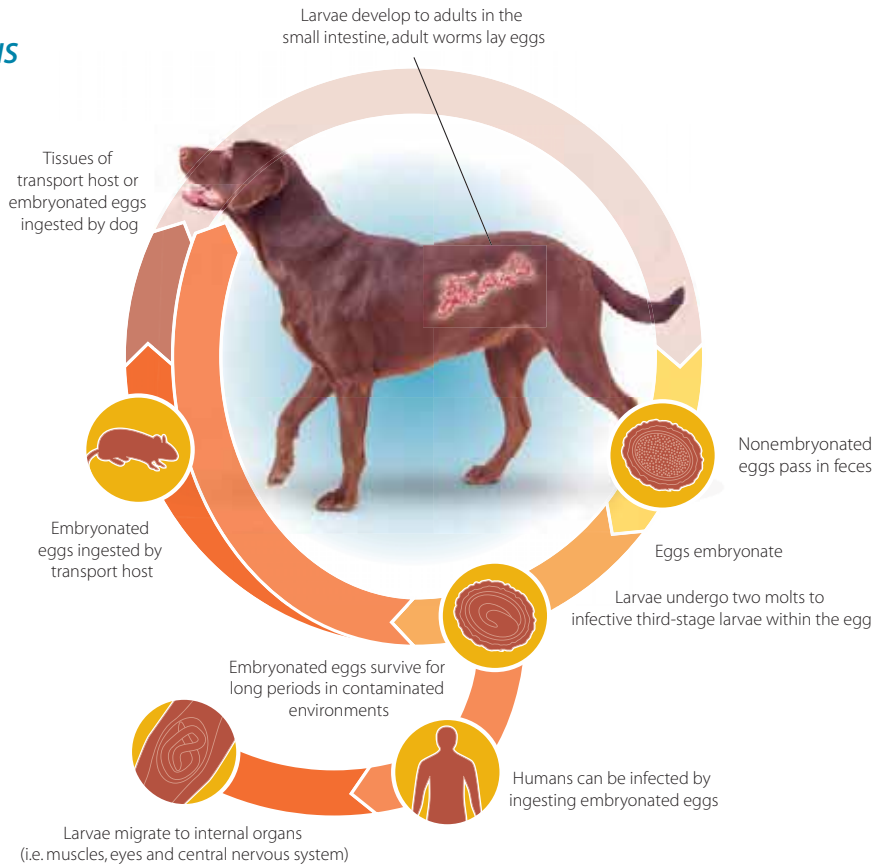

Vet-ebooks.com

DIPYLIDIUM CANINUM

Prepatent period: 2-3 weeks
Patent period: several months

*On occasion: dog biting lice *Trichodectes canis*

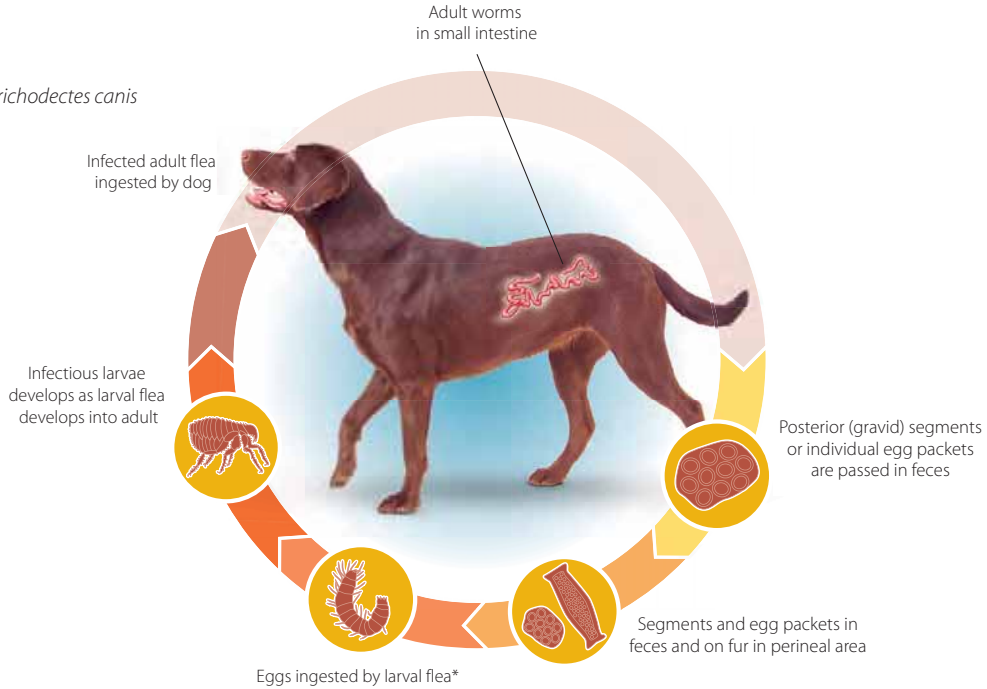

Vet-ebooks.com

DIROFILARIA IMMITIS

Prepatent period: 6 months
Patent period: several years

Effects of immature heartworms:

Disease associated with ***Dirofilaria immitis*** may not be limited to mature adult worms. Advancement of L_4 to immature adult heartworm (L_5) begins at 50 days post infection. By day 58 approximately half of the L4 have become immature adults, and by day 70 all L4 are now immature adults. These small worms (approx. 1.5 cm) are carried by the flow of blood to the pulmonary arteries. Inflammatory events associated with these and maturing later stages include peri-arteritis, interstitial edema and inflammatory interstitial disease. These immature worms in the pulmonary vessels are not detectable by veterinarians with available heartworm tests.

Effects of adult heartworms:

Presence of adult worms in the right heart and pulmonary arteries results in the more commonly observed disease syndrome. The physical presence of adult worms can lead to inflammation and proliferation of the arterial walls (villous endarteritis). Death of adult worms and resulting embolic worm fragments can trigger a cascade of inflammatory events leading to thrombosis and decreased blood flow to the lungs. In severe, long- standing infections, ventricular hypertrophy and classical right heart failure are observed.

Note: Infective larvae reach the heart and lungs about 3 months after being transmitted to the animal by a bite from a carrier mosquito. A positive blood test will be achieved after 6–6.5 months, when infective larvae have matured into adult heartworms.

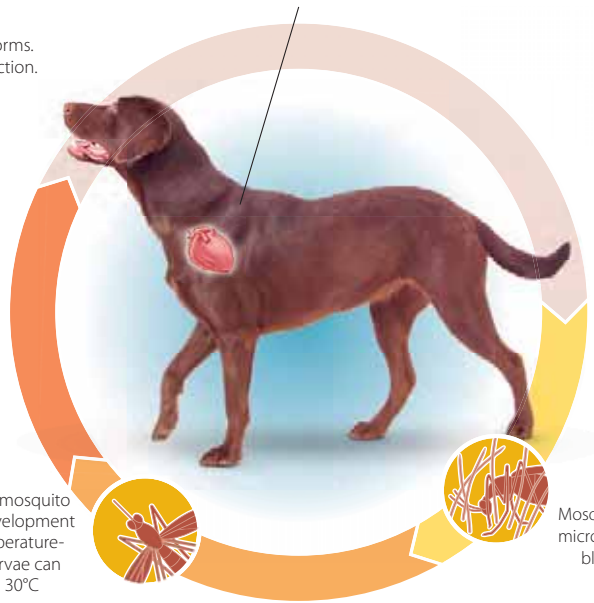

Vet-ebooks.com

ECHINOCOCCUS GRANULOSUS

Prepatent period: 45 days
Patent period: several months

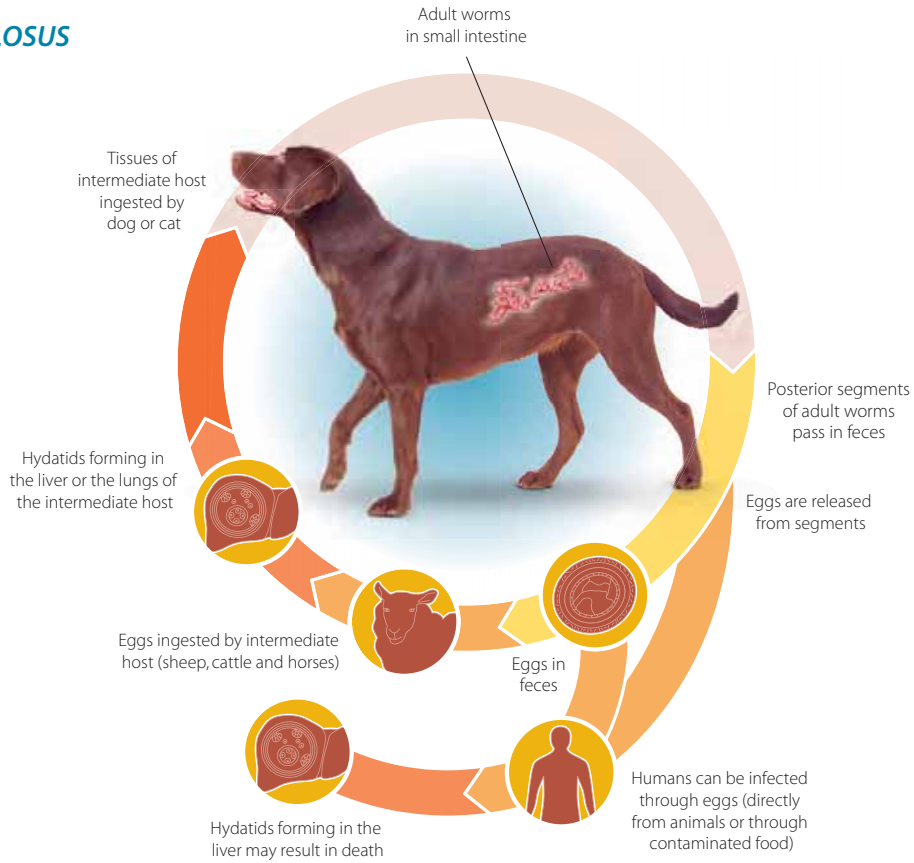

Vet-ebooks.com

ECHINOCOCCUS MULTILOCULARIS

Prepatent period: 28 days
Patent period: several months

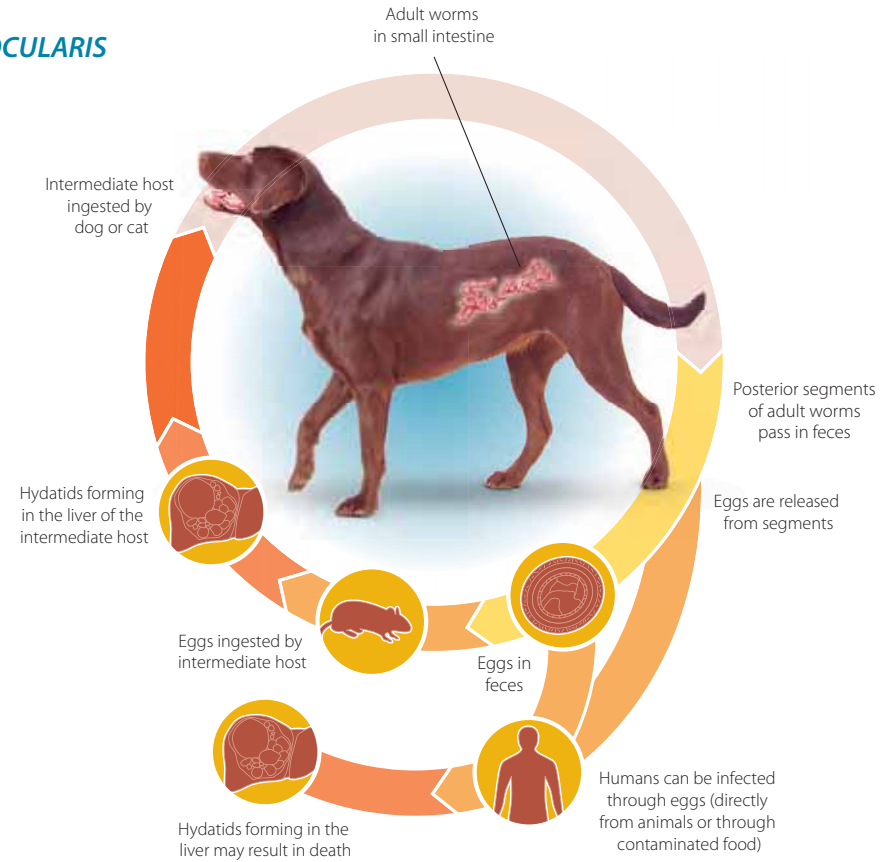

Vet-ebooks.com

TAENIA spp.

Prepatent period: 4-10 weeks
Patent period: 1 month to several years

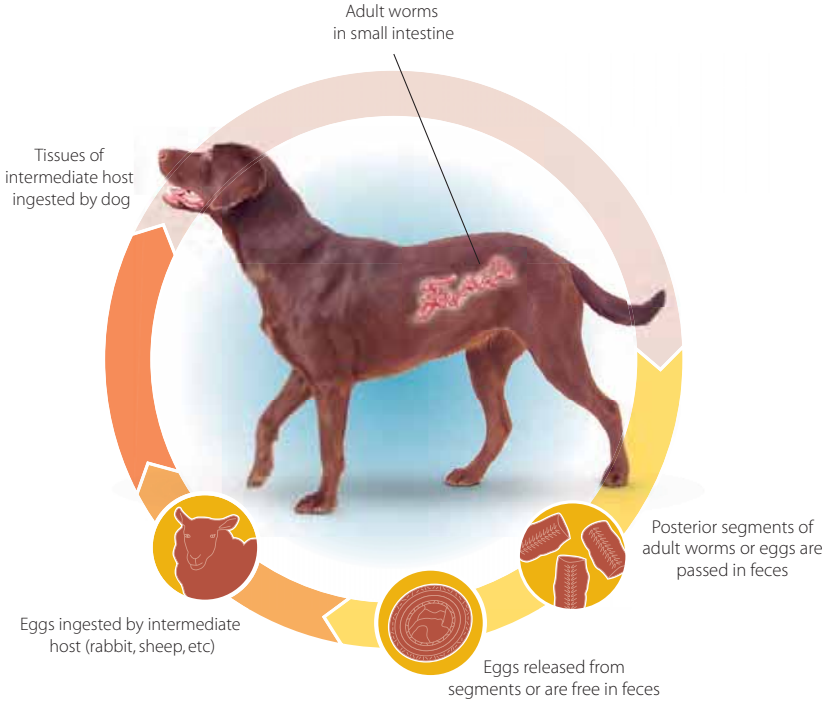

Vet-ebooks.com

TOXASCARIS LEONINA

Prepatent period: 8 weeks
Patent period: 4-6 months

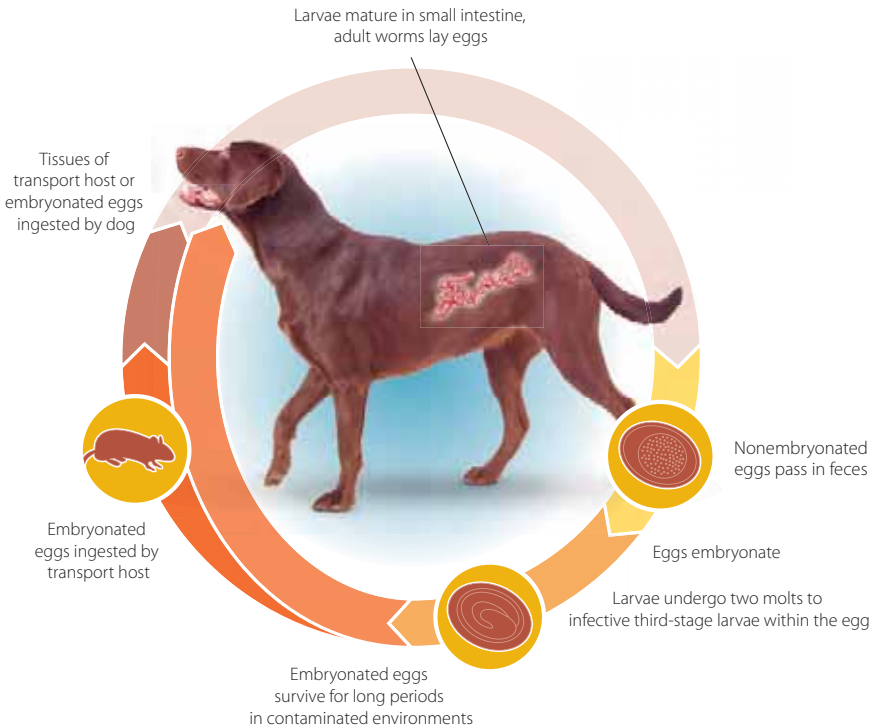

Vet-ebooks.com

TOXOCARA CANIS

Prepatent period: 21 days after transplacental infection
27-35 days after lactogenic infection
3-4 weeks after egg infection
Patent period: 4-6 months

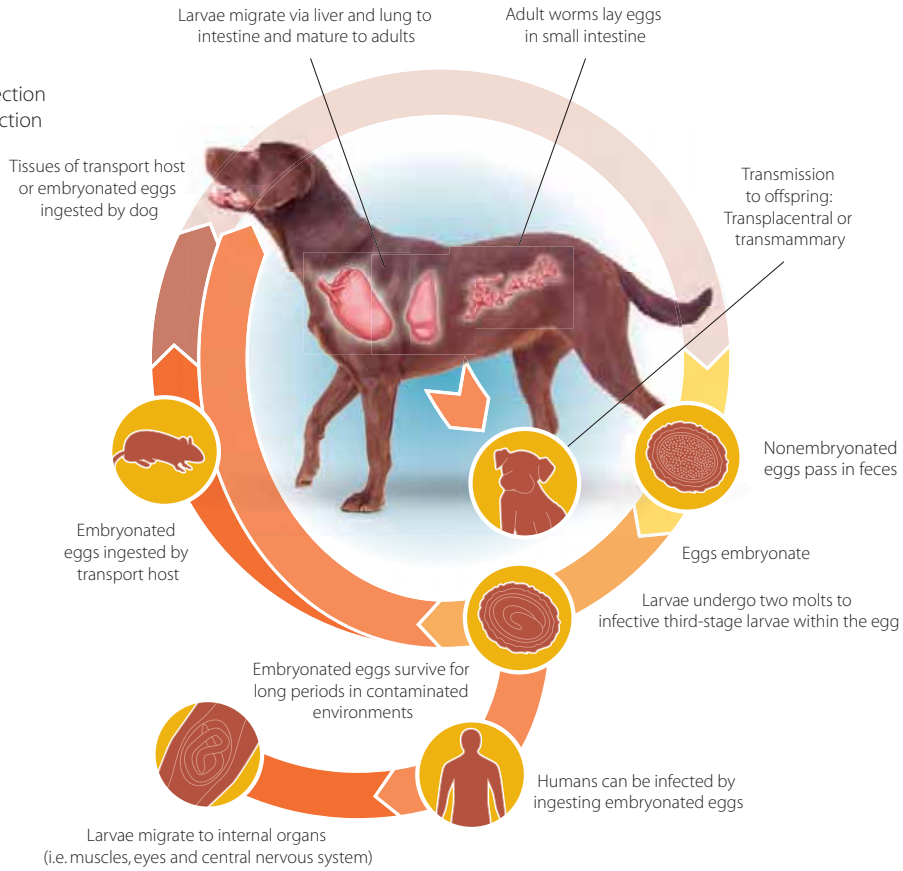

Vet-ebooks.com

TRICHURIS VULPIS

Prepatent period: 8 weeks
Patent period: up to 18 months

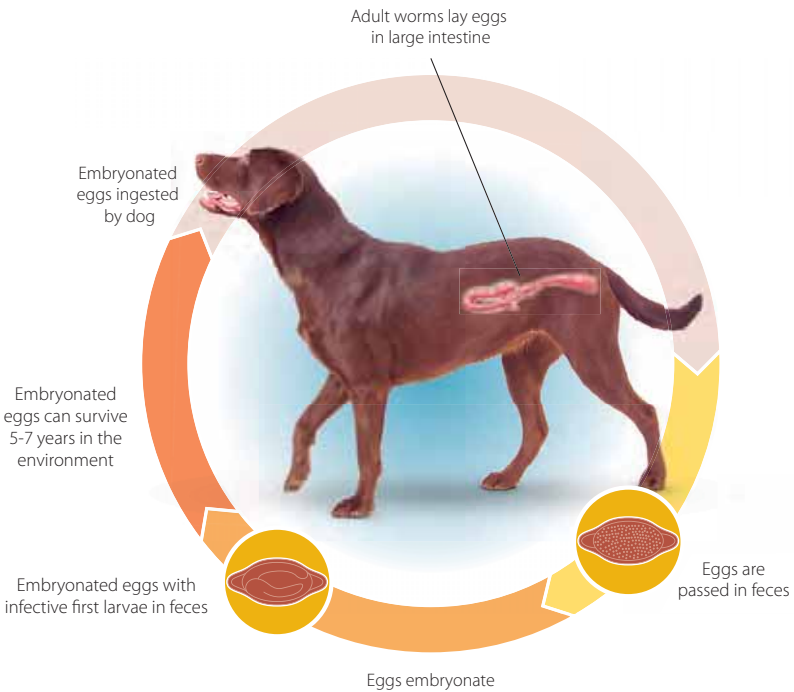

Vet-ebooks.com

UNCINARIA STENOCEPHALA

Prepatent period: 3-4 weeks
Patent period: can be prolonged depending on immune status

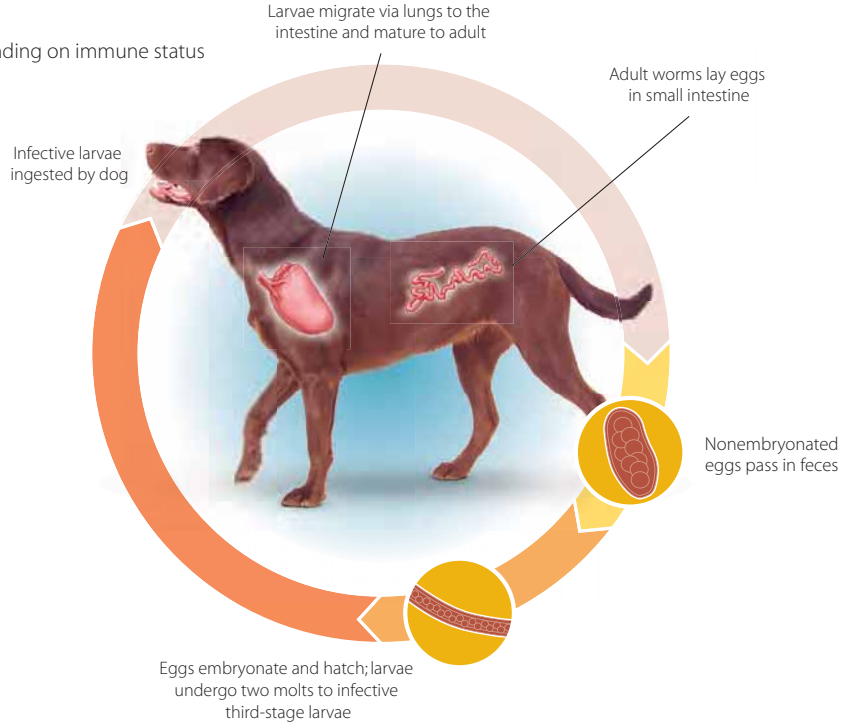

Vet-ebooks.com

Vet-ebooks.com

NOVARTIS

PARASITE PREVALENCE

- Intestinal parasites are present in all regions of the United States
- How prevalent are the most common canine and feline parasites?

Vet-ebooks.com

2009 US Canine Parasite Prevalence Survey (n=4,015)

Are you seeing parasite prevalence similar to the national prevalence demonstrated below?

Parasite	National Prevalence[1]
Hookworm *A. caninum*	33.3%
Roundworm *T. canis*	13.2%
Whipworm *T. vulpis*	19.4%

Note that the National Prevalence of whipwoms is greater than that of roundworms

Intestinal parasites are prevalent in all regions of the United States.

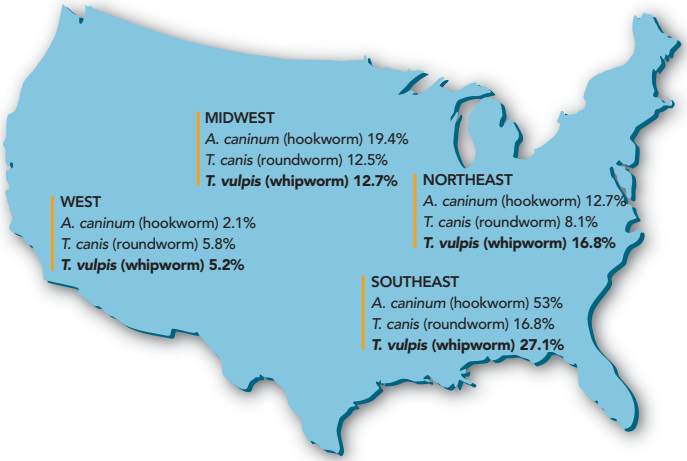

[1] Blagburn BL: World Association for the Advancement of Veterinary Parasitology, Calgary, CANADA, August 9-13, 2009. Sponsored by Bayer Animal Health

Vet-ebooks.com

2009 US Feline Parasite Prevalence Survey (N=1,808)

Are you seeing parasite prevalence similar to the national prevalence demonstrated below?

Parasite	National Prevalence[1]
Roundworm *Toxacara cati*	21.6%
Hookworm *Ancylostoma tubaeforme*	8.6%

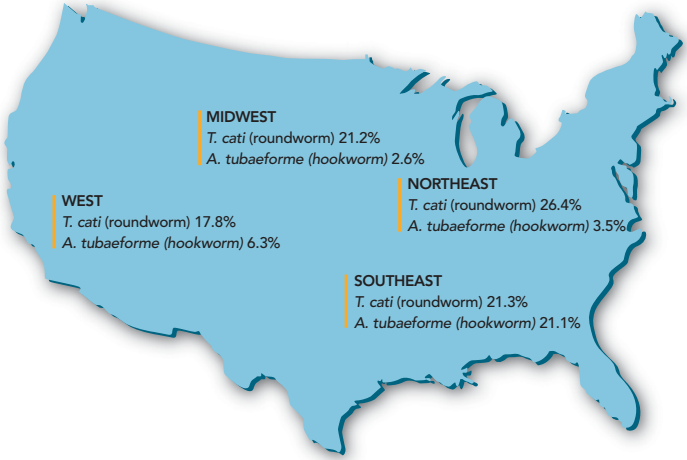

[1] Blagburn BL: World Association for the Advancement of Veterinary Parasitology, Calgary, CANADA, August 9-13, 2009. Sponsored by Bayer Animal Health

Vet-ebooks.com

Vet-ebooks.com

NOVARTIS

DIAGNOSTIC TECHNIQUES

Direct smear	62
Sedimentation	63
Flotation	64
Centrifugation	65

Do not underestimate the importance of accurately conducting fecal examinations. Internal parasites that can be detected by fecal examination remain prevalent in U.S. dogs and cats; some of these are important zoonotic agents.

The following descriptions will help you choose the most appropriate diagnostic procedure. You will also find guidelines and techniques to help achieve the greatest success while conducting these procedures.

Vet-ebooks.com

Direct smear

The direct smear technique is most appropriate when:

- You suspect protozoa that can be demonstrated as active motile stages (e.g., *Giardia* or trichomonads).
- You suspect a parasite that passes motile larval stages in feces.
- Flotation solution might distort the parasite stages you wish to detect.

Notes:
Many larvae also can be recovered in a flotation procedure.

The direct smear procedure is convenient and fast, but has low sensitivity due to the small amount of feces used and the amount of debris on the slide.

Direct smear procedure:

1. Apply a small amount of fresh feces to water or saline solution on a slide and mix thoroughly.
2. Add a coverslip.
3. Examine the entire slide. Thickness of the smear should allow reading newsprint placed beneath it.

Note:
Iodine can be added to the direct smear at the coverslip margin to stain motile protozoa, cysts or larvae—or for flotation techniques, the coverslip can be added to a drop of iodine already placed on the slide.

Vet-ebooks.com

Sedimentation

The sedimentation procedure is most appropriate when:

- Parasite stages are too heavy to float in standard flotation solutions (e.g., heavy operculated fluke eggs or larvae of lungworms).
- Flotation solutions may distort the parasite stages you wish to detect.

Notes:

Centrifuging sedimentation samples can increase test speed and improve performance.

Some larvae can be recovered in a flotation procedure.

A sedimentation preparation can be difficult to read due to large amounts of debris on the slide.

Sample preparation for sedimentation

Simple straining procedures can separate large debris from parasites and from smaller debris.

1. Mix feces thoroughly with water in a clean disposable cup.
2. Pour the mixture through a metal strainer (preferred) or gauze sponges into a second clean cup.
3. Add the strained mixture to a tube.

Sedimentation procedure:

1. Centrifuge or let preparation stand until sediment forms.
2. Remove most of the liquid above the sediment.
3. Place a drop of the sediment on a slide, then add a coverslip and examine.

Vet-ebooks.com

Simple flotation

Flotation solution guidelines

- Desired specific gravity of a fecal flotation solution is 1.18–1.20, measured with a hydrometer.
- Common parasite eggs have specific gravities between 1.06 and 1.20.
- Remember that simple flotation may underestimate or misdiagnose low parasite burdens.

Sample preparation for flotation

Simple straining procedures can separate large debris from parasites and from smaller debris.

1. Mix feces thoroughly with flotation solution in a clean disposable cup. Try to use at least 1 gram of fresh feces (a cube about ½ inch on each side; a fecal loop sample is about 0.1 gram).
2. Pour the mixture through a metal strainer (preferred) or gauze sponges into a second clean cup.
3. Add the strained mixture to a tube.

Simple flotation is most appropriate when:

- You want better sensitivity than can be provided in a direct smear.
- A centrifuge is not available or feasible.

Notes:

Simple flotation improves sensitivity over direct smear when a small amount of feces is being tested.

Simple flotation provides less sensitivity than flotation using centrifugation.

Simple flotation procedure:

1. Mix feces and flotation solution (see sidebar at left) and pour into a tube.
2. Add flotation solution to form a meniscus.
3. Add coverslip and wait 15 minutes.
4. Remove coverslip, place on slide and examine.

Vet-ebooks.com

Centrifugal Flotation

[1]Dryden MW et al. "Comparison of common fecal flotation techniques for the recovery of parasite eggs and oocysts." Veterinary Therapeutics. 2005: 6(1): 15-21.

Comparison of Common Fecal Flotation Techniques for the Recovery of Parasite Eggs and Oocysts

M.W. Dryden, P.A. Payne, R. Ridley, and V. Smith

A variety of procedures are available to detect parasite eggs or oocysts in feces. This study compared the efficacy of simple flotation, a commercial assay, and various centrifugation techniques and three common flotation solutions. Results indicate that centrifugation consistently recovered more eggs than other methods. Proper technique is critical, including ensuring that the specific gravity of the flotation solution is correct and allowing the sample to stand for a sufficient amount of time before examining the coverslip. Because of the zoonotic health risks of many companion animal parasites, veterinarians and their staff should better utilize fecal examinations in their routine diagnostic plan.

Veterinary Therapeutics Vol. 6, No. 1, Spring 2005

Intestinal parasites can be difficult to diagnose.

In a recent study[1] comparing direct smear, Ovassay, and centrifugation techniques, the results showed a wide disparity in how often each test failed to detect the eggs:

Technique	Whipworm false negatives	Roundworm false negatives	Hookworm false negatives
Direct smear	92.61%	85.38%	72.82%
Ovassay	32.02%	25.88%	4.85%
Centrifugation	4.93%	10.53%	0.97%

Note the reduction of whipworm false negatives when comparing direct smear to centrifugation..

Vet-ebooks.com

Centrifugal flotation

Flotation solution guidelines

- Desired specific gravity of a fecal flotation solution is 1.18–1.20, measured with a hydrometer.
- Common parasite eggs have specific gravities between 1.06 and 1.20.

Sample preparation for flotation

Simple straining procedures can separate large debris from parasites and from smaller debris.

1. Mix feces thoroughly with flotation solution in a clean disposable cup. Try to use at least 1 gram of fresh feces (a cube about ½ inch on each side; a fecal loop sample is about 0.1 gram).
2. Pour the mixture through a metal strainer (preferred) or gauze sponges into a second clean cup.
3. Add the strained mixture to a tube.

Centrifugal flotation is most appropriate when:

- Sensitivity is the most important criteria in selecting a fecal examination procedure.

Notes:

Increased test sensitivity will improve accuracy in recovering fecal stages from animals with low parasite burdens.

Centrifugal flotation is the most sensitive fecal concentration procedure available to the veterinarian.

Centrifugal flotation procedure with a swinging bucket centrifuge:

1. Mix feces and flotation solution (see sidebar at left) and pour into a centrifuge tube.
2. Place sample in centrifuge tube holder.
3. Add flotation solution to form a meniscus and place a coverslip on the tube.
4. Spin at 1,200 rpm for 10 minutes.
5. Stop centrifuge, remove coverslip, place on slide and examine.

Centrifugal flotation procedure with a fixed-angle centrifuge:

1. Mix feces and flotation solution (see sidebar at left) and pour into a centrifuge tube, filling to within 1/2 to 1 inch of the top.
2. Place sample in centrifuge tube holder.
3. Spin at 1,200 rpm for 5 minutes.
4. Stop centrifuge, place sample upright in a tube holder and add flotation solution to form a meniscus.
5. Add a coverslip and let stand for 10 minutes.
6. Remove coverslip, place on slide and examine.

Vet-ebooks.com

Common fecal flotation solutions

Flotation	Specific Gravity	Preparation (hot water)	Comments
Water	1.00 (standard for comparison)	Not applicable	Not applicable
Sodium chloride	1.20	approx. 400 g/liter	Inexpensive; forms crystals on slide.
Sodium nitrate	1.18–1.20	approx. 400 g/liter	Good all-purpose solution; forms crystals on slide.
Zinc sulfate	1.18–1.20	approx. 371 g/liter	Good all-purpose solution; excellent for protozoa. Best general-purpose specific gravity = 1.18–1.20; forms crystals on slide.
	1.29	approx. 700 g/liter	Will levitate heavy debris and parasites. Forms crystals more rapidly.
Magnesium sulfate	1.27	approx. 500 g/liter	Good all-purpose solution. Will levitate heavy debris and parasites.
Sheather's sucrose	1.27	approx. 1,278 g/liter	Excellent all-purpose solution; Add 6 ml phenol or formaldehyde to inhibit microbial growth; sticky solution attracts flies and other pests; this viscosity requires longer incubation time in simple flotation. Does not crystallize or distort specimens if samples are held.

Vet-ebooks.com

Specific gravities of selected parasites of companion animals*

Parasite	Common Name	Specific Gravity
Ancylostoma spp.	hookworm	1.06
Physaloptera spp.	stomach worm	1.24
Taenia spp.	taeniid tapeworm	1.23
Toxocara canis	canine roundworm	1.09
Toxocara cati	feline roundworm	1.10
Trichuris vulpis	canine whipworm	1.15

*Modified from Payne PA and Dryden MW. *DVM Best Practices*, March 2003, pp. 8–11.

Vet-ebooks.com

NOVARTIS

CAPC GUIDELINES

CAPC
Companion Animal Parasite Council

The Companion Animal Parasite Counsel (CAPC) is an independent counsel of U.S. veterinary, governmental, and association thought leaders brought together to create guidelines for optimal control of internal and external parasites. These guidelines have been developed to protect the health of pets, enhance the safety of the public, and preserve the bond between pets and people. Veterinarians and pet owners must take measures to protect pets from parasitic infections. Veterinarians, pet owners, and physicians should work together to reduce the risks associated with zoonotic transmission of parasitic diseases. Important preventive measures include:

practicing good personal hygiene; controlling pet parasite infections through internal and external parasite treatment and control; minimizing exposure of children to potentially contaminated environments; cleaning up pet feces regularly to reduce environmental contamination with infective parasite stages; and understanding and communicating parasitic infection risks and effective control measures.

For more information on CAPC, go to www.capcvet.org.

Vet-ebooks.com

GUIDELINES FOR CONTROLLING PARASITES IN DOGS AND CATS

Administer year-round treatment with broad-spectrum heartworm anthelmintics that have activity against parasites with zoonotic potential.

Administer preventive flea and/or tick products as soon after birth as possible (consistent with label claims) for the life of the pet.

- Conduct annual physical examination with complete history.
- Conduct periodic (annual is ideal) heartworm infection testing in dogs and periodic testing in cats.
- Feed pets cooked or prepared food (not raw meat) and provide fresh, potable water.
- Conduct fecal examinations two to four times during the first year of life and one to two times per year in adults, depending on patient health and lifestyle factors.
- Administer anthelmintic treatment of puppies at 2, 4, 6 and 8 weeks of age, followed by administration of a monthly preventive.
- Administer biweekly anthelmintic treatment of kittens between 3 and 9 weeks of age, followed by administration of a monthly preventive.
- Treat nursing bitches and queens along with their offspring.
- Tailor parasite prevention programs to geographic, seasonal and lifestyle factors.

CAPC
Companion Animal Parasite Council

Vet-ebooks.com

In the absence of optimal year-round heartworm preventive/intestinal parasite combination products, use the following protocol:

- Deworm puppies and kittens at 2, 4, 6 and 8 weeks of age and then again monthly until 6 months of age.
- In kittens, begin biweekly anthelmintic treatment between 3 and 9 weeks of age and then treat monthly until 6 months of age.
- Conduct fecal examinations two to four times a year in adult pets, depending on patient health and lifestyle factors, and treat with appropriate parasiticides.
- Test for heartworm status yearly in dogs and/or before starting preventive medications.

For additional resources please visit the following websites:

www.students.novartis.us

www.growingupwithpets.com

www.ah.novartis.com

www.heartwormsociety.org

www.capcvet.org

www.cdc.gov

CAPC
Companion Animal Parasite Council

Vet-ebooks.com

Parasites	Identification	Life Cycles
Acanthocheilonema (Dipetalonema) reconditum	6	
Aelurostrongylus abstrusus	28	38
Ancylostoma caninum	16	45
Ancylostoma tubaeforme	17	39
Baylisascaris procyonis	22	46
Cryptosporidium spp.	27	
Dipylidium caninum	10	47
Dirofilaria immitis	7	40,48
Echinococcus granulosus	14	49
Echinococcus multilocularis	14	50
Eucoleus (Capillaria) aerophila	28	
Giardia spp.	24	
Isospora (Cystoisospora) spp.	25	
Paragonimus kellicotti	29	
Pearsonema (Capillaria) feliscati	30	
Pearsonema (Capillaria) plica	30	
Physaloptera spp.	20	
Taenia spp.	15	41,51
Toxascaris leonina	21	42,52
Toxocara canis	21	53
Toxocara cati	21	43
Toxoplasma gondii	27	
Trichuris vulpis	23	54
Uncinaria stenocephala	18	44,55

Pseudoparasites	Identification
Alternaria spp.	32
Free-living nematode	33
Grain mite egg	34
Planarium	34
Pollen granules	35

Spurious Parasite	Identification
Monocystis lumbrici or *Rhynococystis pilosa* spore	36

Vet-ebooks.com

Vet-ebooks.com

©2010 Novartis Animal Health US, Inc.

COR 100001A

Vet-ebooks.com